



CLINICAL METHODS IN MEDICINE

CLINICAL SKILLS AND PRACTICES



SN Chugh
Eshan Gupta

SECOND EDITION

CLINICAL METHODS IN MEDICINE

Clinical Skills and Practices

CLINICAL METHODS IN MEDICINE

Clinical Skills and Practices

Second Edition

SN Chugh

MD MNAMS FICP FICN FIACM FIMSA FISC FICA

Senior Professor and Pro-Vice Chancellor
Pt BD Sharma University of Health Sciences
Rohtak, Haryana, India

Eshan Gupta

MD DM (Cardiology Student)

Govind Ballabh Pant Hospital
New Delhi, India



The Health Sciences Publishers

New Delhi | London | Philadelphia | Panama



Jaypee Brothers Medical Publishers (P) Ltd.

Headquarters

Jaypee Brothers Medical Publishers (P) Ltd.
4838/24, Ansari Road, Daryaganj
New Delhi 110 002, India
Phone: +91-11-43574357
Fax: +91-11-43574314
E-mail: jaypee@jaypeebrothers.com

Overseas Offices

J.P. Medical Ltd.
83, Victoria Street, London
SW1H 0HW (UK)
Phone: +44-20 3170 8910
Fax: +44(0) 20 3008 6180
E-mail: info@jpmmedpub.com

Jaypee-Highlights Medical Publishers Inc.
City of Knowledge, Bld. 237, Clayton
Panama City, Panama
Phone: + 507-301-0496
Fax: + 507-301-0499
E-mail: cservice@jphmedical.com

Jaypee Medical Inc.
The Bourse
111, South Independence Mall East
Suite 835, Philadelphia, PA 19106, USA
Phone: + 267-519-9789
E-mail: jpmmed.us@gmail.com

Jaypee Brothers Medical Publishers (P) Ltd.
17/1-B, Babar Road, Block-B, Shaymali
Mohammadpur, Dhaka-1207
Bangladesh
Mobile: +08801912003485
E-mail: jaypeedhaka@gmail.com

Jaypee Brothers Medical Publishers (P) Ltd.
Bhotahity, Kathmandu, Nepal
Phone: +977-9741283608
E-mail: Kathmandu@jaypeebrothers.com

Website: www.jaypeebrothers.com
Website: www.jaypeedigital.com

© 2015, Jaypee Brothers Medical Publishers

The views and opinions expressed in this book are solely those of the original contributor(s)/author(s) and do not necessarily represent those of editor(s) of the book.

All rights reserved. No part of this publication may be reproduced, stored or transmitted in any form or by any means, electronic, mechanical, photocopying, recording or otherwise, without the prior permission in writing of the publishers.

All brand names and product names used in this book are trade names, service marks, trademarks or registered trademarks of their respective owners. The publisher is not associated with any product or vendor mentioned in this book.

Medical knowledge and practice change constantly. This book is designed to provide accurate, authoritative information about the subject matter in question. However, readers are advised to check the most current information available on procedures included and check information from the manufacturer of each product to be administered, to verify the recommended dose, formula, method and duration of administration, adverse effects and contraindications. It is the responsibility of the practitioner to take all appropriate safety precautions. Neither the publisher nor the author(s)/editor(s) assume any liability for any injury and/or damage to persons or property arising from or related to use of material in this book.

This book is sold on the understanding that the publisher is not engaged in providing professional medical services. If such advice or services are required, the services of a competent medical professional should be sought.

Every effort has been made where necessary to contact holders of copyright to obtain permission to reproduce copyright material. If any have been inadvertently overlooked, the publisher will be pleased to make the necessary arrangements at the first opportunity.

Inquiries for bulk sales may be solicited at: jaypee@jaypeebrothers.com

Clinical Methods in Medicine: Clinical Skills and Practices

First Edition: 2008

Second Edition: 2015

ISBN: 978-93-5025-039-6

Printed at

Dedicated to

My parents

*Late Shri Chhabil Dass Chugh and Sanwari Devi Chugh
and my wife Dr Kiran Chugh*

and

My children

*Dr Anshul Chugh (Son)
Dr Ashima Chugh (Daughter)
and my all students and teachers*

SN Chugh

Preface to the Second Edition

After the success of first edition of this book, I am delighted to introduce the revised second edition on the request of my students. I am fully aware that in the present era, the clinical medicine has got back seat. The driving seat in medicine is occupied by highly sophisticated investigations which are marred with false-negative and false-positive results.

The student in medicine, who has to make up his career, must be acquainted with the skills and interpretation of clinical signs. What you see or elicit is more reliable than what you do not see? Student has to appear in the examination with proper skills and interpretations of the clinical signs.

I being a clinician is of the opinion that a student must learn the history taking and master the technique of interpreting and eliciting the clinical signs. The history and clinical signs prepare road map to the clinical and differential diagnoses.

A large number of books in clinical medicine written by Indian as well as Foreign authors are available, but no book is perfect, i.e. some are deficient in substance while others are deficient in elaboration of signs. Keeping these deficiencies in mind, I have prepared the second edition of this book.

Clinical Methods in Medicine: Clinical Skills and Practices consists of two sections—*Section 1: History Taking and Physical Examination* (Chapters 1 to 10) concentrates on History Taking and Review of System (Unit I) and Physical Examination (Unit II). I have written this as separate section because in examinations, short cases/spot cases are kept only for general physical examination. *Section 2: Systemic Examination* (Chapters 11 to 20) and *Appendices* is written on Systemic Examination (Unit III), which is comprehensive and gives explanation of each abnormal finding and Unit IV on Appendices.

This book is written for students of medicine, both for undergraduates and postgraduates. Even the clinicians will find it useful in their day-to-day practice. I have attempted to include all the available information in the literature to update this book. However, if there is an error in interpretation of a clinical sign or there is under- or over-interpretation, I may be informed personally. I shall be obliged for this gesture.

I am thankful to M/s Jaypee Brothers Medical Publishers (P) Ltd, New Delhi, India, who have made first edition successful and now has taken sincere effort to bring the colourful edition of the book.

Any suggestion from my students and teachers will be appreciated with open heart.

SN Chugh

Preface to the First Edition

Medicine is a fast-changing subject, is nowadays dominated by investigations instead of clinical skills in making the clinical diagnosis. There is no doubt that with fast development of science and availability of new techniques for investigations, the diagnosis can be made accurately but at exuberant cost. In the present era, the practice of medicine is changing; clinical skills have been pushed to back seat. I must say that clinical skills make up the clinical sense of the students/physicians thus cut short the demand of unnecessary investigations. The human mind is a computer, can see and interpret the clinical signs on the bedside and can give provisional diagnosis instantaneously. A good bedside examination can narrow down the differential diagnosis and provide you a concise approach for investigations and thus curtail the cost of investigations. The developing countries cannot afford such costly investigations just for pretty ailments/diseases, for example CT scan for just headache.

I being a clinician, is of the opinion that a student must learn the technique of history taking and master the interpretation of clinical signs so as to become a good physician. If you cannot see and interpret clinical sign, your mind will not think of the diagnosis and differential diagnosis. If you cannot make a provisional diagnosis, you cannot order the appropriate investigations; hence, history taking, clinical skills and methods and investigations are interlinked. Keeping this concept in mind, I am delighted to bring the first edition of this book.

A large number of books are available on clinical examination in the market, but none of them is complete. Most of them are written by foreign authors from the developed countries, lay more emphasis on the investigations than the physical signs. Our students by reading such books are not able to interpret the clinical signs and are becoming investigations-oriented which is not accepted by our society. Our patients are poor, cannot afford so much on investigations, require cheap diagnosis which can be provided by the accurate and better interpretations of clinical signs and symptoms.

This book on *Clinical Methods in Medicine* will provide the students an opportunity to get acquainted with the secrets of history taking and clinical examination and then take the help of appropriate bedside investigations so as to plan the management. The basic aim of the book is to describe the various skills in taking a history and step by step clinical examination including general physical and systemic examination. Unit I is devoted to history taking and analysis of the symptoms pertaining to various systems. Unit II concentrates on the clinical examination, includes first ten chapters on detailed general physical examination while next ten chapters of Unit III deals with the proper systemic examination. The approach of this book is basic, i.e. to start with the history taking and then proceed to analyse the symptoms and discuss their significance and then find all what is normal or what is abnormal on physical examination. The examination sequence is detailed, abnormal findings to be noted on inspection or palpation also detailed and relevance of abnormal findings discussed simultaneously. Throughout the book, the "key points" are highlighted in the boxes.

The book is primarily intended for the undergraduate students but the postgraduate students and even the physicians will also find it useful in day today clinical practice. The postgraduate students who are preparing for the examination and especially those who are planning to pursue higher study will also be benefitted. I have attempted to include all the available information in the literature so as to make the book presentable both for undergraduates and postgraduates. However, if there is an error in interpretation of a clinical sign or under- or over-interpretation, I may be informed personally. I will like suggestions from my teacher colleagues on this book so that I can improve on my deficiencies.

I extend my sincere thanks to M/s Jaypee Brothers Medical Publishers (P) Ltd, who have taken sincere and dedicated efforts to bring the first colourful edition of this book. I must say that best look and face to the book is provided by the publisher.

I am grateful to my family who have supported me in this endeavour.

At last, I request the readers to forward any suggestion or comment on this book to the publisher or to me.

SN Chugh

Contents

SECTION 1 *History Taking and Physical Examination*

Unit I: History Taking and Review of System

1. History Taking 3

- History Taking 3
- Review of Systems/Presenting Symptoms 11

2. Analysis of Systemic Symptoms 19

- Analysis of Systemic Symptoms 19
- Gastrointestinal Symptoms 19
- Symptomatology Related to Liver and Gallbladder 24
- Cardiovascular Symptoms 25
- Respiratory Symptoms 28
- Symptoms Related to Blood Disorder 35
- Urinary Symptoms 37
- Neurological Symptoms 40
- Endocrinal Symptoms 44
- Symptoms Pertaining to Genital System 46
- Symptoms of Rheumatic Diseases 49

Unit II: Physical Examination

3. General Physical Examination 51

- General Observations 51

4. The Head, Scalp, Skin and Hair 62

- Head and Scalp 62
- The Skin 66
- The Nails 67
- The Hair 77

5. The Eyes 83

- The Eyes 83
- Investigations for a Case with Eye Disorder 100

6. The Mouth and the Pharynx 104

- The Mouth and the Pharynx 104

7. The Ear, Nose, Sinuses and Throat 113

- The Ear 113
- Examination of the Ear 116
- Investigations for a Case with the Disease of Ear 120
- The Nose and Paranasal Sinuses 121
- Examination of the Nose and Nasal Sinuses 122
- Examination of the Throat 124

8. The Neck 126

- The Neck 126
- Examination of Neck 126
- The Thyroid Gland 132
- Investigations of a Patient with Thyroid Disease 134
- The Trachea 134
- The Carotid Arteries and Jugular Veins 135

9. The Breast and the Axillae 136

- The Breast and the Axillae 136
- Investigations for Breast Disease 143

10. The Extremities 144

- Examination of Extremities 144
- The Hands and the Nails 144

SECTION 2 *Systemic Examination and Appendices*

Unit III: Systemic Examination

11. The Cardiovascular System 161

- The Cardiovascular System 162
- Examination of Cardiovascular System (CVS) 164
- Investigations for a Case with Cardiovascular Disease 187
- Peripheral Vascular System 196
- Occlusive Arterial Disease 198
- Investigations of Peripheral Vascular Disease 205
- Venous System 206
- Examination of Venous System 206

12. The Respiratory System 211

- The Respiratory System 212
- Examination of Chest 220
- Investigation of a Patient with Respiratory Disease 238

13. The Abdomen 245

- The Abdomen 246
- Examination of the Groins and Back 273
- The Anus, Rectum and Prostate 276
- Investigations of Gastrointestinal System 278
- Investigations of Hepatobiliary System 282

14. The Urogenital System and Sexually Transmitted Diseases 293

- The Urinary System 294
- The Genital System 295
- Investigations of a Case with Renal Disease 302
- Examination of Genitalia 313

15. The Nervous System 324

- The Nervous System 325

16. The Examination of Unconscious Patient 414

- Unconsciousness or Coma 415

17. The Locomotor System 425

- The Locomotor System 426
- Examination of Locomotor Disorders 431
- Examination of Individual Joints 440
- The Ankle and the Foot 461
- Investigations for Rheumatological Disorders 464

18. The Blood 469

- The Blood 470
- Investigations for a Haematological Case 481

19. The Psychiatric Assessment 488

- The Psychiatric Assessment 489
- Case Histories 495

20. The Endocrinal System 504

- The Endocrine System and Metabolism 505
- Brief Synopsis of Few Common Endocrinal Disorders 519

Unit IV: Appendices

Appendix I 529

- Sample Collection 529
- Venipuncture 529
- Microbial Tests 530
- Serological Test 530
- Chemical Analysis of the Urine 533
- Semen Analysis 536

Appendix II 537

- Centigrade and Fahrenheit Scale 537
- SI Units 537
- Normal Values (Reference Values) 538

Index 547

SECTION 1

History Taking and Physical Examination

Unit I: History Taking and Review of System

1. History Taking
2. Analysis of Systemic Symptoms

Unit II: Physical Examination

3. General Physical Examination
4. The Head, Scalp, Skin and Hair
5. The Eyes
6. The Mouth and the Pharynx
7. The Ear, Nose, Sinuses and Throat
8. The Neck
9. The Breast and the Axillae
10. The Extremities

1

CHAPTER

History Taking

INTRODUCTION

A student while posted in medicine has to learn the clinical medicine with following aims:

- One should learn the art of taking a detailed informative history. History taking is an important aspect of medicine.
- One has to know the method of detailed physical examination to be carried out. Both the important positive and negative physical signs are to be noted so as to reach some conclusion at the end of examination.
- The exact terminology used in medicine has to be followed. Terminology based on science is the foundation for the solution to many clinical problems.
- The practice of medicine combines both science and art. The dazzling advances in biochemical methodology and in biophysical imaging techniques that allow access to the remotest recesses of the body are the products of science. So, too are the therapeutic manoeuvres which increasingly are major products of medical science. One has to learn the skill in the most sophisticated application of laboratory technology or use of the latest therapeutic modality.
- The ability to extract items of crucial significance from a mass of contradictory physical signs and from the printouts of laboratory data, when a clinical sign is worth pursuing or when to dismiss it as 'red herring' and to estimate in any given patient whether a proposed treatment entails a greater risk than the disease are all involved in the 'decision-making'. This combination of medical knowledge, intuition and judgement is termed the art of medicine, which one has to learn.
- **The patient-doctor relationship:** It may be emphasised that students/physicians need to approach patients not as 'cases' or 'diseases' but as 'individuals' whose problems/symptoms are to be heard sympathetically. Most patients are anxious and frightened. Often, they go to extreme ends to convince themselves that illness does not exist or unconsciously develop false belief or perception about benign disease as life threatening illness. Some patients

may use illness to gain attention, or to serve as a crutch to extricate themselves from an emotionally stressful situation; some even feign physical illness. Without this knowledge, it is difficult for the physicians to gain rapport with the patient or to develop insight into the patient's illness. The patient-doctor relationship must be based on thorough knowledge of the patient and on the mutual trust and the ability to communicate with one another. A strong personal relationship with the patient is essential in order to sustain the patient during stressful situation.

HISTORY TAKING

The Skills

The written history of a patient should contain all the facts of medical significance in the life of the patient. The history should be recorded in a chronological order. The recent events should be given most attention. A problem-oriented approach should be adopted while recording the history; the problems that are clinically dominant should be listed first. Ideally, patient should be allowed to narrate his/her history in his/her own way and language without any interruption. However, few patients have sufficient power of observation or recall to give a history without some guidance from the physician. A physician/student must be careful not to suggest the answers to the questions being posed. A physician/student should hear the history with patience, often a symptom which has concerned a patient most may have little significance, while an apparently minor complaint may be of considerable importance. Therefore, the physician must be constantly alert to the possibility that any event narrated by the patient, however, trivial or apparently remote, may be the key to the solution of the medical problem.

NB: History taking is not a mere records of some questions and answers between the doctor and the patient. Remember the dictum—"Listen to the patient, he/she is telling you the diagnosis".

An informative history is more significant than orderly recorded symptoms. Something is always gained by listening to the patient and noting the way in which he/she expresses the symptoms. Inflections of voice, facial expression and attitude may betray important clues to the meaning of the symptoms to the patients. In listening to the history, physician/student discovers not only something about the disease but also something about the patient.

Unless patient is known, clinicians should introduce themselves by name and explain their position. If appropriate, the patient identity must be confirmed along with that of any accompanying person. The patient may be interviewed alone or in the presence of an accompanying person. This may allay anxiety and may be necessary in some situations such as memory impairment and language difficulty or an unconscious patient. The accompanying person or third person or a family member may be involved during discussion after the clinical examination as this may improve patient's subsequent understanding of the information given by the doctor.

Interview Technique

It includes:

- **What to ask about?** It is useful to think about questions to be asked which are multilayered. A positive response leads to further questioning; whereas negative response moves the clinician on to the next question.
- **How to ask?** The patient needs to understand what is being said. Generally speaking, technical words should be avoided. The public is becoming increasingly aware of medical terms or medical matters through the internet and mass media, but this does not necessarily mean they understand the terms, therefore, certain terms having different meanings may be clarified if used by the patient.

There are two main types of enquires—*open* (*how, what* and *why* type of questions) and *closed* (*who, when, where* types of questions). Examples of inquiries and there purpose is depicted in the Box 1.

Pitfalls in History Taking

With experience, the following pitfalls in history—taking have become apparent.

- What the patients relate for the most part consists of subjective phenomenon and they obviously differ widely in their responses to the same stimuli and in their interpretation. Their attitude is variably influenced by fear of disability and death and by concern over the consequence of their illness to their families.
- Accuracy of the history is affected by language or sociological barriers.
- History is also influenced by intellectual powers which interfere with recall. This is the reason that, sometimes narration by the patient may be difficult due to failing intellectual powers, hence, in such a situation it is narrated by the accompanying person which, in itself, may not be true representation of patient's symptoms.
- History taking in unconscious patient is difficult. It is difficult to collect factual data and physician is forced to proceed with objective evidence of the disease.

It is in obtaining the history that the physician's skill, knowledge and experience are most helpful.

Parts of History Taking/Recording

It consists of the following parts:

- Name, age, sex, father's name, marital status, full address, occupation, socio-economic status.
- Chief complaints.
- History of present illness.
- Past history of illness.
- Treatment (drug) history.
- Family history.
- Personal history:
 - Occupational or socio-economic history.
 - Dietary history.
 - Menstrual history in females.

Box 1

Examples of inquiries, techniques and their purpose

Type	Questions	Purpose
Open	<ul style="list-style-type: none"> • Tell me about your illness • What happened next? 	What effects has this illness on your life Such questions give them an opportunity to say what they want to say
Closed	<ul style="list-style-type: none"> • When did this begin? • Have you had chest pain? • Has anyone in your family had a similar trouble? • Do you smoke? 	They are mainly used to expand the patient's story and to clarify specific points

Chief Complaint(s)

Ask the patient regarding the main complaint for which he/she is seeking medical consultation. Most of the patients have mainly one or two complaints which are recorded in chronological order easily (see Box 2) but sometimes because of nervousness, anxiety, apprehension and fear, they may exaggerate the symptoms to gain sympathy and make a list of complaints that are recorded in an order in which the most troubling complaint becomes the presenting complaint.

The question of duration of a complaint is difficult especially in old people and in uneducated people. Majority of patients do not remember the exact duration of complaints. In such a situation, approximate duration may be asked. The duration of complaints gives a rough idea of duration of disease whether acute, subacute or chronic and its progression. The onset of complaints may help to make the diagnosis in the absence of objective evidence. For example, to satisfy the definition of chronic bronchitis, history of intermittent cough for three months in a year for two years is sufficient for diagnosis.

Remember: Make every attempt to quote the patient's own words.

How to Write the Chief Complaints?

The format is to ask the patient “*what is your main complaint?*” And then “*when were you last in your usual state of health?*” This leads to the request; please tell me what has happened to you since then. The format of chief complaint(s) in chronological order is given in the Box 2.

The History of Present Illness

Ask the patient to tell the detailed story of his/her illness from the day it started till today, giving the details of treatment, if taken. Ideally, patient should not be interrupted while narrating the history. During history, patient may tell the things or statements which are of no consequence; these should be ignored. Sometimes, patient may describe the complaints in medical terms such as they may use rheumatism for joint pains and migraine for headache. The patient here will be asked to tell what actually happens

during these complaints or he/she should give full details of the symptoms. While listening to the history, a student/physician can ask the patient to give more details about that specific symptom. Sometimes, symptoms and signs appear and disappear spontaneously and one should try to confirm whether they are related to relapse or remission of the disease.

When a student/doctor has understood the story of illness, he should proceed with each main complaint turn by turn and examine it in details. The first step in history is to make sure that you and patient are talking about the same thing. Sometimes, patient may use certain words which may have many meanings or may have different interpretation. In such a situation, one should clearly ask what does it mean actually. For example, a patient may say wind in the abdomen that moves from abdomen upwards into the brain and causes headache. Ask the patient directly whether he/she means that wind does not pass down and instead it goes up and causes discomfort.

Aims of Present History

- To keep history flowing by asking so what happened next?
- To identify those aspects of history which are incomplete and require further questioning.
- To pick up clues about the patient's reaction to the complaints, emotional and mental state of the patient.

Analysis of a Symptom

Perhaps the most common complaint is a pain which brings the patient to a doctor. The way in which a symptom is to be analysed is illustrated with the example of pain. Ask about the following points.

- **Site:** Where is the pain? Note the way by which the patient illustrates the site, either he/she will use his/her finger or spreads his/her hand over the chest.
- **Radiation:** Is it static or moves from one place to another?
- **Severity:** How severe is it? Is it variable in severity from time to time? It depends on an individual's perception of pain. Patient may use exaggerated terms such as agonising or tearing to seek sympathy of the doctor or to overcome socio-psychological distress.
- **Timing:** Note the time or any diurnal variation of symptom.
- **Occurrence or its exaggeration:** Note what brings the pain. How does it get relieved? Are there any precipitating factors? Is it related to exertion? Does it occur at rest? Is there any relation to food, etc.?
- **Relief:** What makes it better? Does it get relieved with the change in position? Is it relieved by food, by defaecation or by passage of wind? Cardiac pain is brought by exertion and is relieved by rest.

Box 2

Chronological order of chief complaints

Presenting of complaint(s)	Chronological order
• Headache off and on	For the last 2 years
• Breathlessness (shortness of breath)	For the last 2 months
• Chest pain	Since today

Box 3

Enquiries for symptom of thirst

Thirst is a prime symptom of loss of body water which may be due to vomiting, diarrhoea, diminished intake, fever, polyuria and haemorrhage. Simple questions will uncover its immediate cause.

If, for example, polyuria is the cause of thirst then it could be due to compulsive water drinking, diabetes insipidus, diabetes mellitus, hypercalcaemia, diuretic therapy and renal failure (nephrogenic diabetes insipidus). Specific enquiries about other symptoms of the disease may be made, such as whether polyuria or polyphagia or both are associated with thirst or not. This will make clinical distinction between diabetes insipidus and mellitus.

Confirm whether it is physiological due to excessive tea or coffee before embarking on the diagnosis.

- **Effect of treatment:** The effect of drugs may have diagnostic value.

It is, however, possible to explore other symptoms, for example, thirst, by asking the relevant questions. The enquiries to be made for thirst are given in the Box 3. This is an urge to drink water. It occurs in variety of disorders.

Similarly, other symptoms analysis may be done according to the systemic symptoms discussed under the symptoms of systemic disorders. Towards the end of present illness, besides positive complaints of the patient, one must ask certain relevant questions about symptoms which the patient has not complained. This is important from following points of view:

- Patient may not like to include it as main complaint but that may be important for diagnosis.
- Presence and absence of symptoms not told by the patient may help in making the diagnosis and to exclude other similar conditions.
- Other information relevant to the symptoms may be necessary such as risk factors for coronary artery disease in a patient with chest pain or current medications in patients with syncope.

Remember: It is important to include “pertinent positive” and “pertinent negative” symptoms while recording the history of present illness.

There are two important points about history-taking which must be mentioned here:

- Under each system, the absence of the most important symptoms, i.e. dyspnoea and cough in case of respiratory system, dyspnoea on exertion or cardiac pain in case of the cardiovascular system and paralysis or headache or fits in the case of nervous system must be recorded. Their absence influences the diagnosis. The positive symptoms

and important negative symptoms on history may give indication of specific involvement of a system.

- Secondly, the history does not end with the first examination. Continuous notes should be made regarding the disappearance of symptoms or the appearance of new ones, or any other relevant fact.

Course of the illness must be ascertained whether it is acute or insidious onset. How did it progress, i.e. worsened quickly or slowly? Whether there have been relapses or remissions of illness, which would give the intermittent nature of the disease. Sudden events are due to trauma or vascular accidents, etc. Painful disorders and fever indicate infections and neoplasms. Progressive or chronic nature of the disorders points to degenerative origin of the disease. Exaggeration and chronicity of symptoms without any ill effect may be due to psychological reasons.

History of Past Illness

The previous or past history should include all events since infancy. Patient may give ready-made diagnosis of his/her illness that occurred in the past. In that eventuality, it must be verified by asking what actually happened during that illness so as to conclude whether diagnosis is likely or less likely. At times, it may be necessary to communicate with doctors or hospitals that have treated the patient in the past.

Patients are usually not interested to tell the past events. They may or may not remember minor events of the past. The relevant past history pertaining to the present symptoms is to be asked by the physician and recorded. For example, history of acute rheumatic fever in cases with rheumatic heart disease is quite relevant. Jaundice in the past, in case of liver disease, may point to the aetiopathogenesis of symptoms of liver disease in the present history.

To ask past history of diabetes in a patient, who is suffering from diabetes mellitus, is not relevant because it is incurable disease and once it manifests, it continues. Therefore, in such a situation, past history should be asked about the age of onset, its progression and any complications during the past. Some relevant past history to be asked and recorded is as follows:

- *Childhood illnesses*, e.g. measles, rubella, mumps, whooping cough, chicken pox, rheumatic fever and polio and history of immunisation such as DPT, polio, tetanus, hepatitis B, measles must be asked.
- *Adult medical illnesses*, e.g. diabetes, hypertension, tuberculosis, asthma, hepatitis, HIV disease must be asked.
- In a patient with rheumatic valvular disease, past history of acute rheumatic fever, joints pain, sore throat is helpful, while history of hypertension is to be recorded in a patient with ischaemic heart disease.

- History of jaundice, haematemesis, melena, disturbed consciousness are to be asked in a case with liver disease. Drug treatment is to be asked if jaundice is present. Past history of amoebic dysentery in a case with liver abscess is important.
- Past history of chronic bronchitis (cough occurring 3 months in a year for two consecutive years) is relevant to COPD (chronic obstructive pulmonary disease). Similarly, history of episodes of acute breathlessness with wheeze is important in a case with bronchial asthma. Past history of exanthematous fever, respiratory sinus infection, sore throat are important points to be asked in a respiratory case. Long history of fever with cough, haemoptysis is important for tuberculosis of lung.
- Prolonged history of diarrhoea is relevant to a patient with an intestinal disorder. Episodic pain in abdomen in the past related to meals is relevant to peptic ulcer.
- Past history of trauma head is significant in a case with neurological disorder.

Importance of Past History

Certain illnesses in the past may produce complications in the present, for example, childhood infectious illness may produce pulmonary complications in adulthood. Similarly adult illness in the past may have important bearing on the symptoms of present illness. Obstetric/gynaecological past history (menstrual history, birth control, and sexual function) carry significance in a female presenting with gynaecological complaints. The past history relevant to various systems is depicted in the Table 1.1.

Difficulties in History Taking

Taking a history from a patient may pose problem for a number of reasons discussed below. Patient may not at all be at fault. The difficulty is created by circumstances, hence, one should bear this in mind and remain objective (rely on signs) and professional throughout. The circumstances that lead to difficulty and their remedial measures given in the Box 4.

NB: Person should narrate the history himself/herself unless, otherwise indicated.

Family History

Note the patient's position in the family, the ages of the children and record of their health, important illnesses and cause of death of immediate relatives. If, however, there is question of hereditary disorder, one should enquire about all the relatives and attempt to construct a family tree showing those affected and those who are not affected (Fig. 1.1). The family history serves several functions. First, in rare single

gene defects, a positive family history of a similarly affected individual or a history of consanguinous marriage may have important diagnostic implications. Second, in diseases of multifactorial aetiology that have a family aggregation, it may be possible to identify the patients at risk for the disease and to intervene prior to development of overt manifestations. For example, a recent history of weight gain is a more ominous development in a woman who has a family history of diabetes than in one who does not. Ask the family history of each of the following conditions and record if they are present or absent in the family; hypertension, coronary artery disease, hyperlipidaemia, stroke, diabetes, thyroid or renal disease, cancer (specify type), arthritis, asthma, tuberculosis, headache, seizure disorder, mental illness, suicide, alcohol or drug addiction and allergies.

The symbols used in construction of a family tree (pedigree chart) are illustrated in Figure 1.1. The genetic basis is most striking in certain autosomal dominant (Huntington's disease) or X-linked disorders (haemophilia, myopathy). The pattern of inheritance is less apparent in autosomal recessive disorders as sblings just have a 1 in 4 (25%) chance of developing the disorder.

In many common disorders such as hypertension or coronary artery disease, the mode of inheritance is complex and variable under the environmental influences such as diet and smoking. Apparently a common pathological process such as atheroma may present in unrelated manner in a family for example one relative may present with a heart attack and another with stroke. Therefore, environmental factors may emerge through family proximity. For example, a life-long non-smoking woman with a bronchogenic carcinoma may have had a smoker husband who died due to smoke-related illness.

The Social, Personal and Occupational History

This history actually deals with the patient's physical and emotional environment, the surroundings both at home and at work, habits, mental attitude to life and to work. Therefore, ask about the followings:

- **Exact nature of work/occupation:** Ask the type and nature of work being done by the patient. You can ask him about former occupations, if any. One should also ask about the attitude towards work, employer and fellow-workers. Try to find out financial worries.
- **Domestic and marital relations:** Ask about the marital status. In men, particularly if unmarried, remember the possibility of homosexuality. Both in males and females, homosexuality is frequently associated with personal and social stresses.

TABLE 1.1 Past history relevance to review of systems

<i>System</i>	<i>Ask past history of</i>	<i>For/Purpose</i>
<i>Cardiovascular</i>	<ul style="list-style-type: none"> • Joint pain (fleeting in nature) during childhood or adolescence • Rubella infection (maternal) • HT, and diabetes • Risk factors, e.g. obesity, smoking, lack of exercise, family history of heart attacks, etc. • Drug treatment, if any 	<p>Rheumatic fever, rheumatism</p> <p>Congenital heart disease</p> <p>Coronary artery syndromes</p> <p>Coronary artery disease</p> <p>Congestive heart failure, arrhythmias</p>
<i>Respiratory</i>	<ul style="list-style-type: none"> • Viral exanthems, polio, influenza • Allergy/asthma • Tuberculosis • Status of immunisation • Epilepsy/convulsion • Ear, nose, throat infection • Surgery over upper respiratory tract 	<p>Predispose to respiratory disease</p> <p>Respiratory allergic disorders and asthma</p> <p>Reactivation or reinfection or post-tubercular complications</p> <p>Partial immunisation or unimmunisation predispose to disease</p> <p>Aspiration of secretion and predisposition to infection</p> <p>May complicate to involve respiratory tract</p> <p>Inhalation of infected secretion and predisposition to respiratory infection</p>
<i>GI tract</i>	<ul style="list-style-type: none"> • Recurrent pain abdomen, vomiting, diarrhoea • Haematemesis and/or malena • Prolonged diarrhoea • Expulsion of worms 	<p>Recurrent pancreatitis, cholecystitis, erosive gastritis, parasitic infection</p> <p>Peptic ulcer, erosive gastritis, cirrhotic portal hypertension, Mallory-Weiss syndrome</p> <p>Chronic diarrhoea/malabsorption/steatorrhoea</p> <p>Round worm infestation</p>
<i>Hepatobiliary</i>	<ul style="list-style-type: none"> • Alcohol intake • Haematemesis and malena • Jaundice • Drug treatment • Recurrent biliary colic 	<p>Alcohol related disorders</p> <p>Cirrhotic and non-cirrhotic portal hypertension</p> <p>Cirrhosis, hepatitis</p> <p>Cirrhosis, drug induced hepatitis</p> <p>Stone in biliary system</p>
<i>Urinary system</i>	<ul style="list-style-type: none"> • Recurrent renal/ureteric colic • Recurrent fever with chills and rigors • Any change in frequency or colour of the urine • Instrumentation/catheterisation 	<p>Stone in renal or urinary tract, urinary tract infection, obstructive nephropathy</p> <p>Urinary tract infection (UTI)</p> <p>UTI, haematuria, haemoglobinuria, drugs</p> <p>Predisposition to infection</p>
<i>Obstetric/ Gynaecological</i>	<ul style="list-style-type: none"> • Menstrual history • Birth control (medications) • Sexual history • Alcoholism and smoking • Difficult labour 	<p>Endocrinal disorder</p> <p>Oral contraceptive related disorder</p> <p>Sexually transmitted diseases</p> <p>Delivery of low birth weight children</p> <p>Injury to urinary tract and predisposition to infection</p>
<i>Endocrinal and metabolism</i>	<ul style="list-style-type: none"> • Childhood diarrhoea/malabsorption • Candida infection (mouth, GI tract, nails) • Drug history (e.g. antidiabetic, steroids, hormone replacement therapy) • Profuse postpartum bleeding • Diabetes 	<p>Coeliac disease, hypopituitarism</p> <p>Candida endocrinopathy</p> <p>Osteoporosis</p> <p>Seehan's syndrome</p>
<i>Neurological</i>	<ul style="list-style-type: none"> • Recurrent, headache, visual disturbance, vertigo • Repeated convulsions • Head trauma • Muscular weakness • Chronic diarrhoea/malabsorption • Alcohol use 	<p>Migraine-related disorders</p> <p>Epilepsy</p> <p>Subdural haematoma, head injury related brain disorder</p> <p>Myopathies</p> <p>Nutritional deficiency disorders including peripheral neuropathies</p> <p>Alcohol related neurological diseases</p>

Contd...

Contd...

System	Ask past history of	For/ Purpose
Haematological	<ul style="list-style-type: none"> Any bleeding in the past or recurrent episodes Family history of deep tissue bleeding/joint bleeding Dietary history Chronic diarrhoea Excessive bleeding from any site 	Bleeding disorders (vascular or thrombocytopenic) Haemophilia A and B Anaemia and nutritional disorders Parasitic infestation and anaemia Bleeding/coagulation disorder, anaemia

Box 4

Difficulties in history taking and their remedial measures

Circumstances	Remedial measures
<ul style="list-style-type: none"> Patient too unwell (triage, severe pain, profuse bleeding, vomiting, severe breathlessness, agitation, distress) 	<ul style="list-style-type: none"> Treat the patient Obtain history from a third party/ accompanying person Review in detail when the patient becomes fit enough
<ul style="list-style-type: none"> Mental incapacity (coma, confusion, acute psychosis, severe learning disability) 	<ul style="list-style-type: none"> Ascertain what, if any, history can be obtained from the patient Seek history from a third party or parties, relatives, friends, neighbours or professionals who have full knowledge of the disease of the patient
<ul style="list-style-type: none"> Communication difficulties <ul style="list-style-type: none"> Does not know English language (foreigner), or a regional language (illiterate, labourer) Sensory deficit (deafness, mutism) Expressive difficulty (dysphasia, dysarthria, stammering) Emotionally disturbed (angry, abusive/threatening) 	<ul style="list-style-type: none"> Establish competence to understand the uncommon people considerably more than they can express If accompanied, ask whether the friend or relative could act as an interpreter. Proceed if the patient agrees to this If alone, or involving a friend or relative unacceptable, seek an interpreter Check the hearing and establish a means of communication Obtain a history through written questions, lip reading, involving a relative or someone who is acceptable and can communicate with the patient Establish the nature of the problem and proceed accordingly, e.g. the patient can communicate in writing or via a relative Ascertain the nature of problem and try to establish the basis of the reaction Try to correct any misunderstanding If appropriate, either offer an alternative appointment or talk to the relative, friend or third party to get the requisite information

Try to find out his/her relation with other family members/friends. The life study of the patient should be explored by asking his/her hobbies, interests, fear, hopes, games played or other source of entertainment, etc.

- Home surroundings:** Ask about his house whether it is made of mud (kuccha house) or bricks and cemented (pucca). Ask about the sanitary conditions, any possibility of overcrowding or loneliness. What pets are kept?

Habits

Smoking, alcohol drinking and abusing drugs contribute to the disease, hence, inquiries into these habits is often necessary. Patient may be defensive and may deny or minimise their substance use, in such a situation questioning should be tactful, firm and persistent to get the full information either from him or from a relative.

Tobacco

- Determine status of smoking of the patient, e.g. smoker, an ex-smoker or a life-long non-smoker.
- If patient is smoker, then determine;
 - Form of smoking (cigarettes, bidi, cigars, pipe), quantity (number of cigarettes/bidi/cigar smoked/day) and duration of smoking.
- If the patient is ex-smoker, note the length of time since the patient stopped smoking.

Remember: Staining on the fingers or teeth should raise strong suspicion that patient is or until recently was a heavy smoker.

In smoker, the possibility of tobacco related disease should be considered (Fig. 1.2). It must be remembered that tobacco related diseases are common in both active as well as passive smokers (who just inhale smoke).

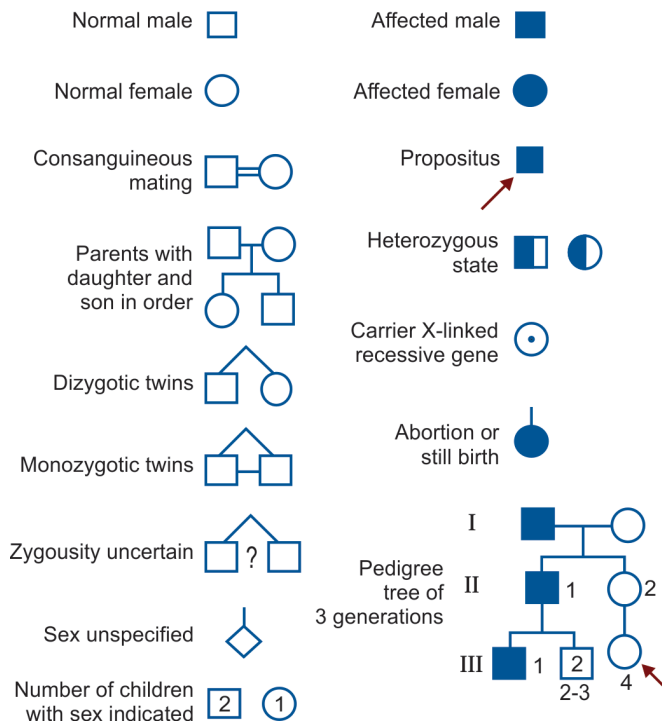


FIGURE 1.1 Symbols used for construction of a pedigree charts. First of all draw up a family tree with affected person first found to have trait. Thereafter, relevant informations regarding siblings and all maternal and paternal relatives are included

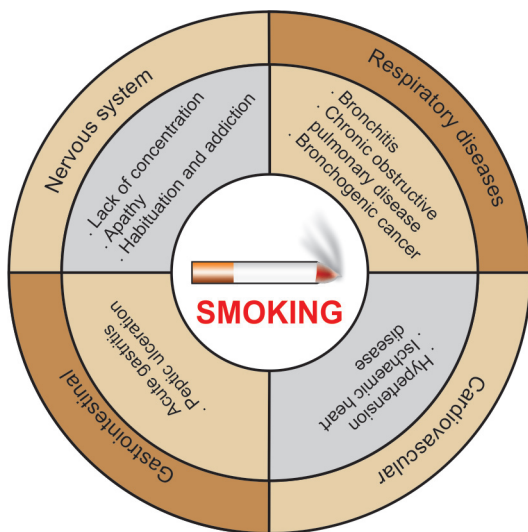


FIGURE 1.2 Bad effects of smoking

Alcohol

- Ask whether the patient is tea-totallar or drinks alcohol, with the approximate weekly amount (quantity in units).
- A past or recent history of an alcohol related problem must be noted. Repeated hospital admissions or consultations must be noted.

- The quantity of alcohol consumed in an week should be calculated. Normally in Indian setting, a small pack of alcohol means 20–30 mL and large back consists of 40–60 mL.

There are two ways of calculating the units of alcohol consumed.

Rough Estimate

Standard measure = one glass of wine, one half pint of beer, one shot of spirits = 1 unit of alcohol.

Calculation of accurate alcohol strength, i.e. 1 unit = 10 mL of pure alcohol × percent proof = units of alcohol/L. For example, 40 percent proof contains 400 mL pure alcohol or 40 units/L so one standard bottle of 750 mL contains 30 units of alcohol. For beer, 4 percent beer contains 40 mL of pure alcohol or 4 units/L, so one large 500 mL bottle can contain 20 units of alcohol.

Recommended limits for 'Safe' drinking

For men	24 units/week
For women	14 units/week

- The detailed history of alcohol intake becomes important;
- When a man drinks heavily in a binge and could be a suspect of alcohol-induced problem.
- When excessive drinking is suspected either currently or in the recent past.
- When an alcohol dependence syndrome exhibiting withdrawal symptoms such as “Shakes” develop.
- When symptoms are suggestive of alcohol-related disorder. A further questioning relate to assessing the presence of different aspects of alcoholism (Box 5).

Illicit Drug Use

The significance of alcohol intake and its related disorder are depicted in Box 6.

In modern era where illicit drug consumption is rising rapidly, one should not hesitate to ask about it if there is any doubt. However, enquiries should be made in a tactful manner with no adverse effect on patient-doctor relationship.

If illicit drugs are being suspected or have been used; the followings should be noted:

- The type(s) of drug involved
- The frequency and duration of use
- Intravenous use and whether needle-sharing occurred. The needle-related disorders are depicted in Figure 1.3
- Whether drug dependence developed
- Any mental, physical or social problem arising from drug use (e.g. indulging in other illegal activities).

Box 5

The contents of alcohol history

- Drinking habits
- Quality and quantity of drink
- Daily/weekly pattern (especially binge drinking and morning drinking)
- Usual place of drinking (home, outside), alone or in a company

Box 6

Alcohol related disorders

- **CNS related**
 - Withdrawal convulsions
 - Delirium tremens
 - Alcoholic dementia
 - Subdural haematoma
 - Wernicke's and Korsakoff's syndromes
 - Proximal myopathy and peripheral neuropathy
- **GI tract related**
 - Oesophagitis and Mallory—Weiss syndrome
 - Gastritis and peptic ulceration
 - Pancreatitis
- **CVS related**
 - Cardiomyopathy
 - Hypertension
- **Liver related**
 - Stenosis
 - Cirrhosis
 - Alcoholic hepatitis
- **Genitourinary related**
 - Impotence
 - Infertility
 - Foetal alcohol syndrome

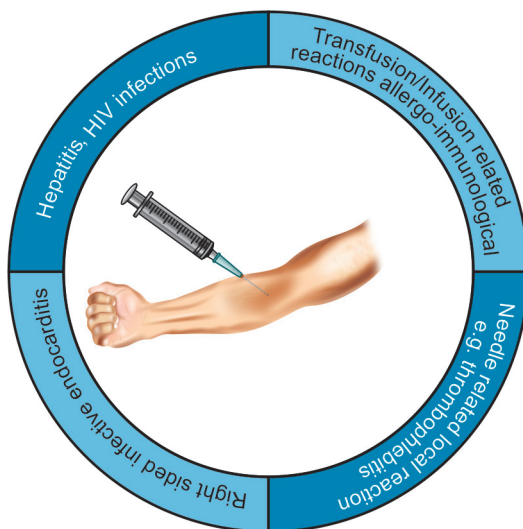


FIGURE 1.3 Needle sharing disorders

Remember: Past history of intravenous drug use or misuse or IV transfusion becomes important if a patient is suffering from chronic hepatitis or hepatitis B or C infection

While asking about substance misuse, it is necessary to advise the patient that medical confidentiality affords protection of patient and even if he/she refuses to disclose details of illicit drug-taking, this should be noted.

The social history and its relevance is depicted in Table 1.2.

REVIEW OF SYSTEMS/PRESENTING SYMPTOMS

While taking/recording the history, the doctor/student has to ask certain questions pertaining to his/her presenting complaints. What sorts of questions are to be asked is most challenging task for the students. In fact, the review of systems covers the questions pertaining to symptoms, but on occasions, some physicians also include diseases like tuberculosis, pneumonia, epilepsy, diabetes in the present or past history (if the patient is intelligent, educated and remember important illnesses as you ask questions within the *Review of Systems*, you can record or present such illnesses as a part of present illness or past history).

The details of questions varies according to state of the patient, nature and severity of illness and relevance of the information sought to the problem/illness under consideration. Always begin with general questions pertaining to various systems in easy understandable language. These focusses the patient attention and enable you to gain confidence of the patient so that you can shift to more specific questions about the system in question.

Under Review of Systems questions may uncover certain problems that the patient has overlooked, particularly in areas unrelated to present illness.

Remember: “Major health events should be moved to the present illness or past history in your write-up”

Some physicians do the “Review of Systems” during the physical examination, asking about questions as they examine them. If the patient has only a few symptoms, this combination can be efficient, but if there are multiple symptoms, then the flow of both history and the examination is disrupted and necessary note-taking becomes awkward.

A standard series of review-of-system questions are listed in the Table 1.3.

TABLE 1.2 The social history and its relevance

<ul style="list-style-type: none"> • Upbringing <ul style="list-style-type: none"> – Birth injury – Parental attachments and disruptions – Schooling, academic interest and achievements—difficulties if any – Behavioural problems • Domestic life <ul style="list-style-type: none"> – Emotional, physical or sexual abuse – Experience of death and illness – Interest and attitude of parents – Other occupants of house—any problem, e.g. violence, health and bereavement • Marital status <ul style="list-style-type: none"> – Married or unmarried – Quality of relationship and any problem of homosexuality – Spouse’s occupation • House and surroundings <ul style="list-style-type: none"> – Type of house—size, owned or rented – Problems with the house – Relationship with neighbours 	<ul style="list-style-type: none"> • Education <ul style="list-style-type: none"> – Status of education – Higher education and further training • Occupation <ul style="list-style-type: none"> – Current and previous – Exposure to hazard, e.g. chemicals, accidents, foreign travel etc. – Employment (employed or unemployed—duration and reason) • Finance <ul style="list-style-type: none"> – Financial position (sound or weak) – Any loss of income or debts • Community and family support <ul style="list-style-type: none"> – Supporting friends or family • Leisure activities <ul style="list-style-type: none"> – Habits – Use of alcohol, tobacco, caffeine, illicit drugs – Deitary restrictions/eating habit
--	--

TABLE 1.3 Systemic symptoms

<i>Symptoms</i>	<i>Questions</i>
<i>Weight</i>	<ul style="list-style-type: none"> • Is it increasing, decreasing or stationary? • Is change in weight of recent onset
<i>Sleep</i>	<ul style="list-style-type: none"> • Has the pattern of sleep changed? • Is there difficulty in getting to sleep or there is early awakening? • Does the patient feel sleep during the day? • Does the patient take any medication for it?
<i>Energy</i>	<ul style="list-style-type: none"> • Is there any tiredness? • Is there any fatigability? • Is there any general malaise?
GASTROINTESTINAL SYSTEM A. Upper GI Symptoms <i>Upper abdominal pain</i>	<ul style="list-style-type: none"> • What is the site of pain? • How severe is it? • Is it continuous or intermittent? • Does it radiate to any site or direction? • What is duration of pain? • Are there any pain-free intervals, if yes, what is their duration? • Is pain related to meal? • Does it disturb sleep at night? • What are the aggravating factors? • What are relieving factors (e.g. food, vomiting or antacid)?
<i>Appetite</i>	<ul style="list-style-type: none"> • Is it increased or decreased? • If reduced, is appetite poor or the patient is afraid of taking food due to pain?

Contd...

Contd...

Symptoms	Questions
<i>Vomiting</i>	<ul style="list-style-type: none"> • What is its frequency? • Does vomiting relieve pain? • What is the colour of the vomitus? • Does it contain blood, residues of food taken the day before? • When does it occur, i.e. morning or evening?
<i>Flatulent dyspepsia</i>	<ul style="list-style-type: none"> • Does the wind move downwards or upwards? • Does either relieve symptoms?
<i>Water brash</i>	<ul style="list-style-type: none"> • Does patient get excessive secretion of saliva into the mouth?
<i>Heart burn</i>	<ul style="list-style-type: none"> • Does patient feel any pain or burning behind the sternum? • Does it appear especially after lying down? • Does sitting up has any effect?
<i>Dysphagia</i>	<ul style="list-style-type: none"> • Is there any difficulty in swallowing? • Is there any sticking of the food during swallowing? • Is it worse with solids or liquids? • Is swallowing painful? • Is there any associated symptom, i.e. dysphonia or vomiting?
<i>Sour eructations</i>	<ul style="list-style-type: none"> • Does patient experience acid taste in the mouth? • Does it have any relation to type of food? • Does it occur during lying down? • Is any relieving factor known?
B. Lower GI Symptoms <i>Diarrhoea</i>	<ul style="list-style-type: none"> • What is the frequency of stools? What is the duration of diarrhoea? • At which part of the day is it more? • What is their relation to meals or to special articles of food? • What is the colour of stool? • Are stool formed (solid) or unformed (liquid) or porridge—like frothy or watery • Do they float or stick to lavatory pan and difficult to wash them away? • Has the patient ever passed any blood? • Is there pain during defecation? • Is there any incontinence or involuntary passage of stool? • Any other associated symptoms?
<i>Constipation</i>	<ul style="list-style-type: none"> • What is the patient usual bowel habit? • Has there any recent change in the habit, if yes, then is change related to change in diet, medicines etc.? • Does constipation alternate with diarrhoea? • Is there any colicky pain? • Is there any blood in the stools?
<i>Lower abdominal pain</i>	<ul style="list-style-type: none"> • What is the localisation, character, and radiation of pain? • Is it persistent or intermittent? • Where is it felt worst? • Is it relieved by defecation or by passage of flatus?
<i>Abdominal distension</i>	<ul style="list-style-type: none"> • Is there any increase in the abdominal girth? • Is there any flatulence or dyspepsia? • Is distension more after taking meals? • Does the patient has any diarrhoea or constipation? • Has the patient any psychiatric illness?
<i>Lower GI bleed</i>	<ul style="list-style-type: none"> • What is the colour of stool? Is the stool black-tarry coloured? • Are stools mixed with fresh blood? • Is it painful or painless?

Contd...

Contd...

Symptoms	Questions
HEPATOBIILIARY SYSTEM <i>Jaundice</i>	<ul style="list-style-type: none"> • Has the patient noticed any yellowness of eyes or skin? Is there any change in colour of the urine and/or stool? • What is the colour of the stool, i.e. pale or dark? • Does the skin itch (pruritus)? • Have there been any case of jaundice among family, friends or locality? • Has there any history of injection/pin prick during the past three months? • Has the patient visited abroad recently? • Is there any history of alcoholism. If yes, ask the amount and duration? • Is the patient a drug addict?
<i>Pain</i>	<ul style="list-style-type: none"> • Where the pain is? • Has the patient experienced severe attack of pain coming on suddenly and lasting for few hours? If so, did the pain radiate and in which direction? • Is pain associated with jaundice or jaundice is painless and progressive? • Did the pain radiate to shoulder or middle of back? • Is there any history of steatorrhoea (pale, frothy stools)?
<i>Haematemesis</i>	<ul style="list-style-type: none"> • What is its duration? • Is blood in the vomitus dark-coloured or red coloured (fresh)? • When did the first episode of haematemesis occurred if it is recurrent? • What is the amount of blood lost? • Is there associated tarry-coloured stool? • Is there any past history of jaundice?
CARDIOVASCULAR SYSTEM <i>Dyspnoea</i>	<ul style="list-style-type: none"> • How short of breath is the patient? • When does it occur, i.e. at rest or on exertion? • What degree of exertion is necessary to produce it? • Are there any attacks of dyspnoea at night (PND)? • Does the patient sleep with many pillows behind the head (orthopnoea)?
<i>Pain/discomfort/tightness</i>	<ul style="list-style-type: none"> • What is its exact site? • What is its character, i.e. dull, severe, stabbing, tearing, etc.? • Is there any radiation of pain to the left arm, neck, shoulder or interscapular region? • What precipitates it? And what relieves it? • Is pain present at rest or occurs during exertion? • Is it relieved by rest or sublingual medication?
<i>Palpitation</i>	<ul style="list-style-type: none"> • What brings on palpitation and how long does it last? • Is it paroxysmal or intermittent? • Is it induced or relieved by exercise? • Is the heart rate regular or irregular and whether patient experiences any missing of the beat? • Does the heart give an occasional thump now and then?
<i>Cough oedema</i>	<ul style="list-style-type: none"> • Ask about cough and expectoration and haemoptysis as detailed under respiratory system? • Do the feet or ankle swell? • Are the clothes or shoes tight? • Is there any associated symptom, e.g. dyspnoea, pain abdomen, cyanosis or abdominal swelling (ascites)?
<i>Other symptoms</i>	<ul style="list-style-type: none"> • Is there a past history of rheumatic fever, joint pain or chorea (John's major criteria) • Is there any coldness, blueness or redness of the extremities?

Contd...

Contd...

Symptoms	Questions
RESPIRATORY SYSTEM	
<i>Cough</i>	<ul style="list-style-type: none"> • Is it dry or productive? • Is it paroxysmal or constant? • At what time is it worst? • Is it become worse with cold, dust, smoke or pollen? • Is it painful or not?
<i>Sputum</i>	<ul style="list-style-type: none"> • What is its quantity? • At what time is it more pronounced? • What is its colour, odour and consistency? • Is it purulent or not? • Is it ever blood-stained (haemoptysis), if, so whether blood comes in streaks or clots and on how many occasions?
<i>Dyspnoea</i>	<ul style="list-style-type: none"> • Is patient dyspnoeic? • Does dyspnoea occur in paroxysms? • Does dyspnoea occur at rest or after exercise? • What sort of activity provokes it, e.g. walking upstairs, running for a bus etc.?
<i>Wheezing</i>	<ul style="list-style-type: none"> • When does wheezing occur? • Is it constant or intermittent? • Does anything provoke it, e.g. smoke, dust, pollens? • Is it worst at any particular time of the day or night? • What is the occupation of the patient?
<i>Pain chest</i>	<ul style="list-style-type: none"> • What is its exact site, i.e. central or peripheral? • Is it aggravated by deep breathing or coughing? • Is it associated with increase in cough, sputum or dyspnoea? • Whether is it acute in onset?
<i>Haemoptysis</i>	<ul style="list-style-type: none"> • Is there any blood in the sputum? • Is it fresh or altered colour? • How often does it occur and for how long? Is the blood seen alone, or is it accompanied by purulent sputum?
<i>Other symptoms</i>	<ul style="list-style-type: none"> • Ask the occupation and exposure to toxic substances and allergans at home or at work place? • Is patient smoker?
HAEMOPOIETIC SYSTEM (BLOOD)	
In patients with blood disorders, history carries much significance in addition to symptoms	
Lassitude, dyspnoea and palpitation	<ul style="list-style-type: none"> • Ask about these symptoms
Fever	<ul style="list-style-type: none"> • Is there history of fever? Ask the characteristics of fever?
Pallor	<ul style="list-style-type: none"> • Does the patient look pale?
<i>Blood loss</i>	<ul style="list-style-type: none"> • Is there any history of bleeding from any site, i.e. gums, epistaxis, GI tract, respiratory tract or skin? • Is there any menstrual disturbance in females? • Is there any easy bruising?
History	<ul style="list-style-type: none"> • Diet history including meat and green vegetable consumption? • Past history of excessive bleeding following dental extraction/minor procedure • Family history of bleeding/clotting disorders (haemophilia) • History of drug intake for aplasia of bone marrow • Exposure to chemicals • Any enlargement of glands (lymph nodes)

Contd...

Contd...

Symptoms	Questions
<p>URINARY SYSTEM <i>Urinary symptoms (pertaining to urine)</i></p>	<ul style="list-style-type: none"> • How much urine do you pass at a time? • Does the patient get up at night to pass urine (nocturia)? • Is the patient continent? • Is the stream of urine normal or thin? • Is the urine altered in colour? • Is it clear or turbid when passed? • Is there any blood in it (haematuria), if so, at what part of micturition is it present? • Is there any increased frequency or burning micturition? • Do you get up at night? How often? • Is frequency associated with increased thirst (polyuria and polydipsia)? • Is there any pain during micturition? Is it before, during or after the act? What is its character? And where is it felt? • Is there any retention of urine with overflow incontinence? Do you ever leak any urine? or wet yourself involuntarily?
<p><i>Symptoms of renal failure</i></p>	<ul style="list-style-type: none"> • Is there any history of loin pain? Does the patient has any attack of pain shooting down into the groin or testes? • Have any of the symptoms being noticed by the patients, i.e. headache, vomiting, drowsiness, fits, diminished vision, dyspnoea, alteration in urine volume? • Does the face ever look puffy or oedematous in the morning? • Are the ankles swollen? (pedal oedema)? • What is the state of the bowel?
<p>NERVOUS SYSTEM</p>	
<p><i>Stroke, e.g. weakness, sensory loss or visual disturbance on one side of the body (hemiplegia, hemianaesthesia, hemianopia)</i></p>	<ul style="list-style-type: none"> • Is it transient (TIA—transitory ischaemic attacks recover within 24 hours)? • Is it persistent >48 hours and then starts recovering (reversible ischaemic neurological deficit)? • Was headache, vomiting associated with the onset? • Is there any history of risk factors for cerebrovascular disease, e.g. hypertension, heavy smoking, diabetes or hyperlipidaemia or positive family history? • Is there any history of heart disease especially vascular disease (for cerebral embolism)?
<p><i>Epilepsy (seizures consisting of repetitive and even stereotyped convulsions)</i></p>	<ul style="list-style-type: none"> • What was your age at first attack? Describe the first attack. • How frequent do these attacks occur? What is the shortest and longest interval between the attacks? • Do they occur at night during sleep? • Is there any aura or warning? • What is the nature of aura? • Does the patient become unconscious during attack (complex-partial seizure) or not (simple partial)? • Does the patient bite the tongue during attack? Examine the tongue for injury. • Is patient incontinent (involuntary passage of urine and stool) during attack? • Is there any postictal phenomenon, e.g. headache, somnolence, automatism or Todd's paralysis? • Is the patient on treatment? Take treatment history. • Ask about predisposing or precipitating events, e.g. head trauma, ear infection, brain injury, fever and family history.

Contd...

Contd...

Symptoms	Questions
<i>Other symptoms, e.g. dizziness, speech disturbance, disturbance in memory, proximal or distal weakness and numbness of extremities</i>	<ul style="list-style-type: none"> • In each instance, ask about the mode of onset, circumstances of onset of symptoms, its progression and specific precipitating and relieving factors. • Did it follow an injury or viral infection? • Is dizziness induced by moving the head or by a particular posture? • Is there any history of systemic disease responsible for neurological complications? • Is there an evidence of inherited neurological disorder or congenital malformation? • Is there any history of exposure to toxic substances?
<i>Headache</i>	<ul style="list-style-type: none"> • Is it intermittent or continuous? • Is visual disturbance associated with it (migraine) or not? • Is there any family history (migraine)? • What is the site and localisation of headache? Does it remain on one side or occurs on both sides? • What are the aggravating or relieving factors, if any? • Is there any neurological deficit?
ENDOCRINAL AND METABOLIC SYSTEM <i>Excessive thirst and excessive urine output</i>	<ul style="list-style-type: none"> • These symptoms may occur in diabetes mellitus, hyperparathyroidism, diabetes insipidus and may be psychogenic. Ask about the other associated features of the disorders mentioned below.
<i>Weight loss or weight gain</i>	<ul style="list-style-type: none"> • How much weight have you gained or lost? • Is weight loss associated with good appetite (hyperthyroidism) or poor appetite (malignancy, hypopituitarism)? • What is duration of weight loss? A long duration of low body weight in young girls indicate anorexia nervosa. • Is there any associated menstrual irregularity? • Weight gain indicates obesity which has its consequences on various systems, i.e. joint, heart, metabolism, respiratory and neurological. Ask about their involvement, if any. • Is weight gain associated with moon-facies, camel's hump, abdominal striae, truncal obesity (Cushing's syndrome) or associated with slow mental and physical activity, constipation and change in voice (hypothyroidism)?
<i>Cold/heat intolerance</i>	<ul style="list-style-type: none"> • Ask about them. Cold intolerance indicates hypothyroidism and heat intolerance indicates hyperthyroidism. • Ask about other feature of these disorders.
<i>Sweating, palpitation</i>	<ul style="list-style-type: none"> • Are they episodic or continuous? Episodes indicate phaeochromocytoma while constant symptoms indicate hyperthyroidism, anxiety. • Does sweating occur after meals? Gustatory hyperhydrosis indicates autonomic neuropathy. • Is sweating associated with flushing (carcinoid syndrome)? • Do they occur during fasting (hypoglycaemia)?
<i>Tremors</i>	<ul style="list-style-type: none"> • Do they occur at rest (hyperthyroidism)? • Do they occur during action (Parkinsonism, cerebellar disease)? • Are they relieved with alcohol? Alcohol relieves benign essential tremors?
<i>Sexual and menstrual symptoms (e.g. impotence, amenorrhoea, polymenorrhoea, galactorrhoea, hirsutism, gynaecomastia)</i>	<ul style="list-style-type: none"> • Read genital system.
<i>Pigmentation and depigmentation</i>	<ul style="list-style-type: none"> • Excessive pigmentation occurs in Cushing's syndrome, hence, ask for other features. • Depigmentation (vitiligo) occurs in autoimmune endocrine disorders and vitamin B₁₂ deficiency.

Contd...

Contd...

Symptoms	Questions
Family history	<ul style="list-style-type: none"> Family history is important in certain endocrinal disorders, e.g. diabetes mellitus, thyroid disorders (autoimmune, dyshormonogenesis), hyperparathyroidism, multiple endocrinal neoplasia).
GENITAL SYSTEM In male	<ul style="list-style-type: none"> Is there any urethral discharge, swelling of the penis and scrotum? When does it occur, i.e. at the initiation or end of micturition? Is there any history of sexual contact with a women other than his wife? Is the micturition painful?
In female • Urethral/vaginal discharge	<ul style="list-style-type: none"> Ask the similar question in female as described above? Are menses scanty? Is menstruation painful?
• Menstrual irregularity Sexual functional complaints, e.g. impotence, premature ejaculation, infertility, impotence, anxiety about masturbation or homosexuality.	<ul style="list-style-type: none"> These aspects are to be asked while recording menstrual history in females. These are discussed in psychiatric assessment Chapter 20.
THE SKIN Skin disorders may be primary or secondary. The questions to be asked in a case with skin disorders are briefly described here.	<ul style="list-style-type: none"> Is there any occupational or other exposure to chemicals or other irritants? Ask about recent drug history. Does the eruption itch? If so, when does it itch? Did the eruptions appear as a single lot or in crops? Is there history of allergy, e.g. asthma, hay fever, etc.? Is there any family history? Is there any contact with animals, insects or plants? What skin medication or application is being used? Is there any history of loss of hair (alopecia) or excessive hair (hirsutism)? Is there any patch of depigmentation with loss of sensation? Is there any present or past history of tuberculosis?
LOCOMOTOR SYSTEM	
• Symptoms of joint disease, e.g. pain, swelling and stiffness.	<ul style="list-style-type: none"> Is there pain in a joint or joints? Is pain constant or episodic? Are there any recurrent attacks of joint pain? Is the joint visibly swollen? Is there any history of fever, bowel disturbance (inflammatory bowel disease) or urethritis (Reiter's syndrome)? Does the pain move from one joint to another (fleeting joint pains of rheumatic fever and gonococcal arthritis). Therefore ask other features of these disorders. What is the distribution of joint pain, i.e. whether involves small (rheumatoid arthritis) or large joints (osteoarthritis)? Is there any family history of gout or other rheumatic disorders? Has the patient been exposed to rubella? Is there any gait/posture abnormality?
• Soft tissue symptoms such as pain, tenderness and swelling of soft tissue.	<ul style="list-style-type: none"> What is the site of these symptoms? Is there any history of trauma or overuse during sport? What is the occupation of the patient? What are the aggravating or relieving factors?
• Symptoms of bone disease, e.g. fracture, dislocation, deformity, swelling, pain etc.	<ul style="list-style-type: none"> Is there any pain associated with bony enlargement? Is there any history of trauma or a stress? Is there congenital or family history of bone disorder? Is the patient suffering from immunodeficient state?

2

CHAPTER

Analysis of Systemic Symptoms

ANALYSIS OF SYSTEMIC SYMPTOMS

The symptoms pertaining to various systems have been briefly described in “Review of Systems”. These systemic symptoms are analysed with respect to their causes, pathogenesis, clinical significance and their relevance.

GASTROINTESTINAL SYMPTOMS (Box 1)

Box 1

Symptoms related to GI tract

- Pain abdomen
- Dyspepsia or flatulence
- Heart burn
- Anorexia
- Vomiting
- Dysphagia
- Diarrhoea
- Constipation
- Bleeding per rectum
- Abdominal distension

Pain Abdomen

- **Duration and pattern of pain** help to determine the nature and severity of pain. Abdominal colicky pain is acute severe crampy pain during which patients cry in discomfort or toss in the bed.
 - *Mid-line pain* is usually visceral pain due to distention of a hollow viscus and localises poorly.

- *Pain around the umbilicus* is usually due to intestinal diseases, e.g. acute intestinal obstruction.
- *Somatic pain* (due to peritoneal involvement) is usually sharper and is localised to the diseased region, e.g. right iliac fossa in appendicitis, right hypochondrium due to stretching of capsule of liver in acute hepatomegaly and to the loin in renal disorders. The causes of pain in different abdominal quadrants are given in the Fig. 2.1.

- **Radiation of pain:** Pain originating from specific organs radiates to the specific sites, i.e. to right shoulder (in hepatobiliary diseases and diaphragmatic pleurisy), to left shoulder (splenic disease), to mid-back (pancreatic disease), to the flank (urinary tract disease) and to the groin (genitourinary tract diseases).
- **Precipitating and relieving factors:** The aggravating or relieving factors in relation to various diseases, are given in the Box 2.
- **Associated symptoms**
- Fever and chills indicate inflammatory/infective diseases or infarction.
- Weight loss suggests malignancy, malabsorption, tuberculosis, inflammatory and/or ischaemia.

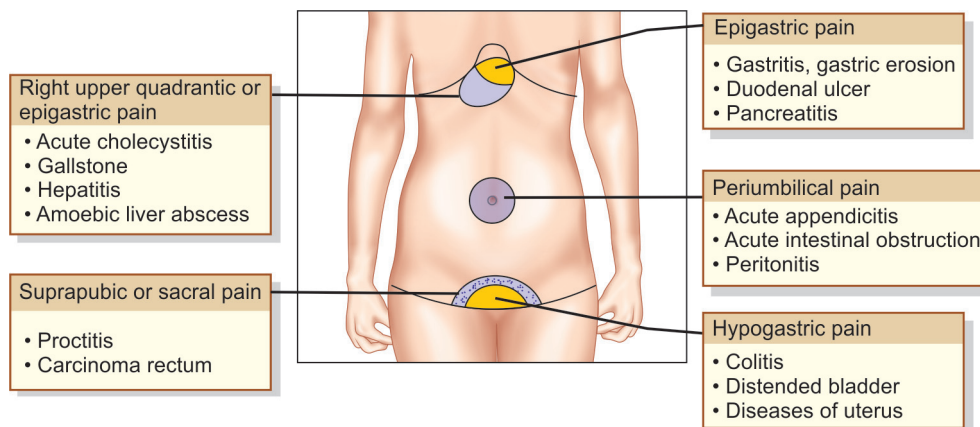


FIGURE 2.1 Causes of pain in various quadrants of abdomen

Box 2

Precipitating and relieving factors for abdominal pain

Factor	Disorders
• Eating	• Upper GI tract, biliary, pancreatic, ischaemic bowel disease
• Defaecation	• Colorectal
• Urinary	• Genitourinary or colorectal
• Respiratory	• Pleuropulmonary and hepatobiliary
• Position	• Pancreatic, gastroesophageal reflux, musculoskeletal, menstruation, tubo-ovarian, endometrial
• Exertion	• Coronary, intestinal ischaemia, musculoskeletal
• Medication or specific drug	• Motility disorders, food intolerance, gastro-esophageal reflux, porphyria, adrenal, insufficiency, ketoacidosis and toxins
• Stress	• Motility disorders, nonulcer dyspepsia, irritable bowel syndrome.

- Nausea/vomiting indicates obstruction, infection, inflammatory disease or metabolic disease.
- Dysphagia or odynophagia suggests oesophageal disease.
- Haematemesis indicates oesophageal, gastric and duodenal disease.
- Jaundice is either due to haemolytic or hepatobiliary disorders.
- Diarrhoea indicates either malabsorption or infection, inflammation of bowel or secretory tumours (Zollinger-Ellison's syndrome).
- Dysuria/haematuria suggests urinary diseases.
- Vaginal/penile discharge indicates genitourinary disorders.
- Hematochezia indicates colorectal disease.
- Skin/joint/eye involvement indicates inflammatory bowel disease.

Causes

The causes of pain are given in Table 2.1 and its differential diagnosis in Table 2.2.

TABLE 2.1 Causes of abdominal pain

<i>Intra-abdominal</i>	<i>Extra-abdominal</i>
<ul style="list-style-type: none"> • Distension/stretching/obstruction <ul style="list-style-type: none"> – Intestinal, e.g. tumour, hernia, volvulus, adhesions/intussusception, faecal impaction – Biliary, e.g. stone, tumour, stricture, parasite (round worm) – Ureteric, e.g. stone, clot colic, obstruction – Renal, e.g. stone, tumour, hydronephrosis, pyonephrosis, blood clot. – Urinary bladder, e.g. stone, tumour, blood clot – Hepatic, e.g. hepatitis, tumour, CHF, Budd-Chiari syndrome – Pancreatia, e.g. stone, carcinoma of ampulla – Appendix, e.g. faecal impaction, foreign body – Uterine, e.g. dysmenorrhoea, displacement, retained products of conception, carcinoma – Fallopian tube, e.g. adhesions, ectopic pregnancy – Spleen, e.g. infarction, spontaneous rupture, trauma • Inflammation <ul style="list-style-type: none"> – Peritonitis, e.g. perforated viscus (peptic ulcer, diverticulum), appendicitis, diverticulitis (colonic, Meckle's), pancreatitis, cholecystitis, salpingitis, abscess – Mesenteric lymphadenitis – Inflammatory bowel disease – Urinary infection, e.g. pyelonephritis, pyonephrosis, ureteritis, cystitis – Genital infection, e.g. endometritis, salpingitis • Ischaemia <ul style="list-style-type: none"> – Mesenteric angina, e.g. thrombosis, embolus – Renal infarction (thrombus, embolus) – Spleen infarction, e.g. sickle cell anaemia – Torsion, e.g. ovarian cyst – Tumour necrosis, e.g. hepatoma 	<ul style="list-style-type: none"> • Neurological, e.g. herpes zoster, spinal cord and peripheral nerve tumours, spinal arthritis. • Haematological, e.g. sickle cell disease, paroxysmal nocturnal haemoglobinuria, hereditary spherocytosis, haemorrhagic diathesis. • Metabolic, e.g. diabetic ketoacidosis, hypercalcaemic crisis, uraemia, porphyria, hyperlipidaemia. • Immunological, e.g. angioneurotic oedema. • Toxins, e.g. food poisoning, strychnine. • Psychogenic, e.g. depression, anxiety, stress, hypochondriasis, Munchausen's syndrome. • Referred pain from <ul style="list-style-type: none"> – Heart and blood vessels, e.g. pericarditis, myocardial infarction, aortic dissection – Pleura, e.g. pleurisy, pleural effusion – Dorsal spine, e.g. trauma, fracture – Oesophagus, e.g. oesophagitis, neoplasia, rupture, motility disorders

TABLE 2.2 Differential diagnosis of acute abdominal pain (Fig. 2.1)

	<i>Acute appendicitis</i>	<i>Acute diverticulitis</i>	<i>Perforated intestine</i>	<i>Intestinal obstruction</i>	<i>Acute pancreatitis</i>	<i>Acute cholangitis</i>	<i>Renal colic</i>	<i>Acute salpingitis</i>
Location	Centre of abdomen, then right iliac fossa	Lower abdomen, usually left iliac fossa	Upper abdomen, then generalised	Centre of abdomen then generalised	Upper abdominal quadrant, then generalised	Right upper quadrant	Lumber region (loin)	One of iliac fossa
Radiation	No	No	No	No	Back	Shoulder	Back or along the groin	No
Intensity	Moderate	Moderate	Severe	Severe	Severe	Moderate	Severe	Moderate
Character	Constant	Constant	Constant	Colicky	Constant	Constant	Colicky	Constant
Exacerbating factors	Movement, coughing	Movement, coughing	Movement, coughing	Food	Movement, coughing	Inspiration	Intermittent, movements	No
Onset	Gradual	Gradual	Sudden	Gradual	Sudden	Gradual	Acute	Acute
Other symptoms	Anorexia, fever	Fever, change in bowel habit	Shock, fever	Vomiting if high small bowel, constipation	Vomiting, shock	Vomiting, jaundice	Occasional vomiting, haematuria	Fever

Predisposing Factors

- Family history may be positive in polyposis, inflammatory bowel disease and pancreatitis.
- Hypertension, smoking, old age, atherosclerosis predispose to ischaemic colitis.
- Diabetes mellitus predisposes to disorders of motility, ketoacidosis, connective tissue diseases predispose to motility disorders and serositis; while depression may predispose to motility disorders and functional disorder, e.g. irritable bowel syndrome.

Dyspepsia/Flatulence

It is a loosely applied term to all upper GI symptoms, e.g. vague abdominal pain, heart burn, nausea, vomiting, abdominal distension or bloating, flatulence and aerophagy. The causes of dyspepsia are given in the Table 2.3.

Flatulent dyspepsia is the term applied to symptoms of bloating and belching without abdominal pain. *Ulcerative dyspepsia* is due to acid-peptic disease; while *nonulcer dyspepsia* refers to acid-peptic symptoms but there is no demonstrable ulcer either on endoscopy or on radiology. The differences between ulcerative and nonulcerative dyspepsia are summarised in the Box 3.

Heart Burn

It refers to burning sensation in the epigastrium in retrosternal region. The causes are:

- *GI tract diseases*, e.g. gastroesophageal reflux disease, peptic ulcer, Zollinger-Ellison’s syndrome, hiatus hernia
- *Drugs and alcohol*

TABLE 2.3 Causes of dyspepsia

<i>Organic</i>	<i>Functional</i>
<ul style="list-style-type: none"> • Peptic ulcer • Gastroesophageal reflux disease • Crohn’s disease • Cardiac, hepatic, renal failure • Drugs, e.g. NSAIDs, analgesic, antibiotics • Alcohol abuse • Gallbladder disease • Pregnancy 	<ul style="list-style-type: none"> • Anxiety • Depression • Non-ulcer dyspepsia • Irritable bowel syndrome

Box 3

Differentiation between nonulcer dyspepsia and peptic ulcer

<i>Character</i>	<i>Nonulcer dyspepsia</i>	<i>Peptic ulcer/ulcerative dyspepsia</i>
Site of pain	Diffuse all over abdomen, no recognised or fixed pattern	Epigastric- patient points pain with a finger (finger-pointing present)
Pain frequency	Daily/nonepisodic for long periods	Episodic
Relation to food/meal	Unrelated, lasts the whole day	Food/meal relieves pain
Response to antacids	No relief	Relief in pain
Nocturnal pain awakening the patient	Rare	Common
Vomiting	No effect	Reduces pain

- *Functional*, e.g. faulty dietary habits, sleeping immediately after taking food, spicy food
- *Psychogenic*, e.g. anxiety neurosis, nonulcer dyspepsia.

Sour Eructation

It refers to water brashes or acid taste in the mouth. Causes are:

- *GI tract disorders*, e.g. Gastritis, peptic ulcer, hiatus hernia, Zollinger-Ellison's, cholecystitis, nonulcer dyspepsia, gallstones, irritable bowel syndrome
- *Smoking, alcohol, pan-masala, chewing gums*
- *Faulty dietary habit*, e.g. large meal, spicy food
- *Psychogenic*.

Vomiting

- Early morning vomiting without retching is seen in pregnancy and uraemia. Alcoholic gastritis produces retching with early morning vomiting.
- Vomiting occurring during or immediate after eating is either psychogenic or due to peptic ulcer with pylorospasm.
- Vomiting occurring after 4–6 hours of eating with expulsion of large quantities of gastric contents is seen in pyloric obstruction or gastroparesis or cardia achalasia or Zollinger-Ellison's syndrome.
- A projectile vomiting indicates raised intracranial pressure.
- A long history of vomiting with little or no weight loss is psychogenic in nature.
- Associated symptoms such as tinnitus, vertigo indicate vestibular involvement.
- Relief of abdominal pain with vomiting is typical of peptic ulcer.
- The presence of blood (haematemesis) indicates bleeding from the oesophagus, stomach or duodenum.
- Associated fever with vomiting indicates inflammatory or infective disorder.
- History of drug intake indicates drug-induced vomiting

Differential diagnosis: A large number of causes that give rise to vomiting are given in the Table 2.4.

Dysphagia

Dysphagia means difficulty in swallowing. *Odynophagia* means painful swallowing usually results from oesophagitis due to gastrointestinal reflux disease or candidiasis. *Globus hystericus* means a sensation of lump in the throat without any organic cause, occurs in anxious or hysterical patients. The causes of dysphagia are given in the Table 2.5. The differential diagnosis is given in the Box 4.

Diarrhoea

Diarrhoea refers to more than 3 stools/day. Quantitatively, it is defined as stool content more than 200 g/day when dietary fibre content is low.

TABLE 2.4 Common causes of vomiting

• Gastrointestinal	
– <i>Mechanical obstruction</i>	
– Gastric outlet obstruction following peptic ulcer or malignancy	
– Small intestinal obstruction, e.g. volvulus, adhesions, malignancy	
– <i>Motility disorders</i>	
– Gastroparesis due to diabetes, drugs, postvagotomy or idiopathic	
– <i>Inflammation</i>	
– Bacterial food poisoning	
– Appendicitis	
– Acute pancreatitis	
– <i>Gastrointestinal irritants</i>	
– Alcohol and drugs	
• Hepatobiliary	
– Hepatitis A and B	– Acute cholecystitis
– Portal hypertension	– Gallstones
• CNS disorders	
– Vestibular, e.g. labyrinthitis, Meniere's disease, motion sickness	
– Raised intracranial pressure, e.g. tumors, hydrocephalus, subdural haematoma, subarachnoid haemorrhage, meningitis, encephalitis	
• CVS	
– Acute MI	– CHF
• Renal	
– Renal failure	
• Endocrinal	
– Diabetes, hypo or hyperparathyroidism, thyrotoxic crisis, adrenal crisis	
• Systemic causes	
– Infection	– Pregnancy
• Psychogenic	
• Radiation therapy	
• Postoperative	

Acute diarrhoea means less than 2 weeks duration, is rapid in onset, occurs in otherwise healthy person and may lead to dehydration and shock. It is usually infective in origin (Table 2.6).

Chronic diarrhoea is more than 2 weeks to few months duration, insidious in onset, may be constant or intermittent, may be associated with malnutrition/deficiency signs of nutrients. It is either a symptom of functional disorder or a manifestation of systemic illness (Table 2.7). *Malabsorption* refers to chronic diarrhoea of more than 3 months duration.

Constipation

Constipation is defined as infrequent passage of hard stool. Patient may complain of straining, a sensation of incomplete evacuation. Associated symptoms include diarrhoea alternating with constipation or suspicious diarrhoea or pain abdomen. The causes of constipation are given in the Table 2.8.

TABLE 2.5 Causes of dysphagia

- **Mechanical (obstructive) dysphagia or oesophageal dysphagia**
 - *Intrinsic (obstruction within oesophagus)*
 - Congenital atresia of oesophagus
 - Stomatitis, glossitis, pharyngitis, oesophagitis
 - Oesophageal/pharyngeal web (Plummer-Vinson's syndrome)
 - Benign and malignant tumours
 - Oesophageal stricture or ulceration
 - *Extrinsic (oesophageal compression from outside)*
 - Retropharyngeal mass or abscess
 - Large goitre
 - Left atrial enlargement in mitral stenosis
 - Aortic aneurysm
 - Posterior mediastinal mass
- **Motor dysphagia/oropharyngeal dysphagia/neuromuscular dysphagia**
 - Lower cranial nerves (9th, 10th) palsy due to poliomyelitis, motor neuron disease, systemic sclerosis
 - Myasthenia gravis
 - Oesophageal myopathy
 - Paralysis of oesophageal sphincter due to cardia achalasia, diffuse oesophageal spasms, Chagas' disease

Box 4

Differential diagnosis of dysphagia

Characteristic	Cause(s)
• Dysphagia to solids worst than liquids	• Mechanical dysphagia (e.g. stricture, oesophagitis, oesophageal tumours, dysmotility)
• Dysphagia to liquids worst than solids	• Motor dysphagia (e.g. neuromuscular diseases)
• Progressive dysphagia	• Oesophageal tumours
• Transient, painful dysphagia	• Inflammatory diseases e.g. glossitis, stomatitis, candidiasis, viral (herpes) infection
• Dysphagia with chest discomfort and heart burn	• Hiatus hernia, GERD, diffuse oesophageal spasms
• Dysphagia with dysphonia/ nasal regurgitation	• Bulbar or pseudobulbar palsy
	• Left recurrent nerve palsy due to mitral stenosis

TABLE 2.6 Causes of acute diarrhoea

<i>Small bowel diarrhoea (large loose watery stools without blood or mucus)</i>	<i>Large bowel diarrhoea (small viscid stools usually with blood and pus cells)</i>
<ul style="list-style-type: none"> • Infective <ul style="list-style-type: none"> – Viral, e.g. Rota, Norwalk, Adeno, corona – Bacterial, e.g. <i>E. coli</i>, <i>V. cholerae</i>, <i>Yersinia</i> – Parasitic, e.g. <i>Giardia</i> – Fungal, e.g. <i>Candida</i> • Drugs, e.g. laxative, digitalis, ampicillin • Traveller's diarrhoea • Consumption of fish, shell fish 	<ul style="list-style-type: none"> • Nonviral • Bacterial e.g. <i>Shigella</i>, <i>Salmonella</i>, <i>E. coli</i>, <i>Campylobacter</i> • Fungal • Pseudomembranous colitis (antibiotic-induced diarrhoea) • Food poisoning • Spurious diarrhoea (faecal impaction) • Traveller's diarrhoea • Pelvic inflammatory disease • Consumption of fish, shell fish

The onset, duration and characteristics are important.

- Acute onset indicates either acute obstruction or acute inflammatory cause such as acute appendicitis, perforation or colics.
- Neonatal onset suggests Hirschsprung's disease; while a recent change in bowel habits in middle age suggests colonic carcinoma.
- Pain and rectal bleeding suggest irritable bowel syndrome.
- Alternate diarrhoea and constipation suggest ileocaecal tuberculosis or irritable bowel syndrome.

Abdominal Distension/Swelling

Ask about:

- Is there an increase in abdominal girth, i.e. tightness of clothes or belt? Is it related to meals? Does the bowel move regularly? Is there history of pregnancy in the female? Is the distension progressive? Is there any history of tapping of fluid?

The causes of distension of abdomen are: denoted by 4 F, i.e.

- *Fluid*, e.g. ascites, ovarian cyst, distended bladder
- *Foetus*, e.g. pregnancy
- *Faeces and flatus*, e.g. acute intestinal obstruction, adynamic ileus or paralytic ileus.
- *Fat*, e.g. truncal obesity due to any cause, fatty hernia.

Bleeding Per Rectum

Ascertain the followings:

- Is blood comes in streaks or in spurts? Is patient constipated? Is bleeding painful? Is blood mixed with loose stool? Is there history of drug intake? Is there any change in bowel habits? Is there bleeding from any other site?

TABLE 2.7 Classification of chronic diarrhoea

Mechanism	Causes	Clinical features
<ul style="list-style-type: none"> Inflammatory: Mucosal and sub-mucosal inflammation, mucosal damage, impaired intestinal absorption and excessive secretion 	<ul style="list-style-type: none"> Ulcerative colitis Regional ileitis (Crohn's disease) Radiation enteritis Eosinophilic gastroenteritis and AIDS associated enteritis 	Fever, abdominal pain, blood and/or WBC in stools
<ul style="list-style-type: none"> Osmotic: Non-absorbed or non-digested hypertonic solute in the intestinal lumen 	<ul style="list-style-type: none"> Pancreatic insufficiency Coeliac sprue Bacterial contamination Disaccharide (lactose) intolerance 	Improvement of diarrhoea with fasting, bulky, greasy, foul smelling stools, weight loss, nutritional deficiencies, weakness and fatigue
<ul style="list-style-type: none"> Secretory: Excessive secretion of electrolytes and water 	<ul style="list-style-type: none"> Carcinoid syndrome Zollinger-Ellison syndrome VIP-secreting tumours in WDHA syndrome (Water diarrhoea hypokalaemia, achlorhydria) Medullary carcinoma of thyroid 	Watery diarrhoea that also persists during fasting, dehydration, other systemic effects of hormones depending on the cause
<ul style="list-style-type: none"> Abnormal: Rapid transit and associated sometimes bacterial overgrowth 	<ul style="list-style-type: none"> Irritable bowel syndrome Neurogenic diseases Faecal impaction 	Alternating diarrhoea and constipation and neurogenic symptoms, e.g. bladder involvement weakness
<ul style="list-style-type: none"> Factitious: Self-induced 	Laxative abuse	Common in women, watery diarrhoea, oedema, dehydration and weakness

TABLE 2.8 Causes of constipation

Gastrointestinal	Others
<ul style="list-style-type: none"> Dietary, e.g. lack of fibres and/or fluid intake Motility disorders <ul style="list-style-type: none"> Irritable bowel syndrome Acute intestinal obstruction Chronic intestinal pseudo-obstruction Structural/organic <ul style="list-style-type: none"> Colonic carcinoma Diverticular disease Stricture Hirschsprung's disease Painful anorectal conditions <ul style="list-style-type: none"> Piles (haemorrhoids) Anal fissure Faecal impaction 	<ul style="list-style-type: none"> Drugs <ul style="list-style-type: none"> Opiates Anticholinergics Calcium antagonists Iron supplements Aluminium—containing antacids Neurological <ul style="list-style-type: none"> Multiple sclerosis Spinal cord compression CVA Parkinsonism Endocrinal/metabolic <ul style="list-style-type: none"> Diabetes mellitus Hypothyroidism Hypercalcaemia Pregnancy General <ul style="list-style-type: none"> Old age Depression Immobility or bed-ridden

The causes are:

- Painful anorectal conditions**, e.g. anal fissure, piles fistula, proctitis, foreign body, neoplasm.
- Colonic**, e.g. dysentery (amoebic or bacillary), ulcerative colitis, diverticulitis, polyposis, carcinoma, pseudomembranous colitis.

- Haematological**, e.g. leukaemias, coagulation disorders, anticoagulant therapy.
- Renal**, e.g. uraemia.

SYMPTOMOLOGY RELATED TO LIVER AND GALLBLADDER

The symptoms of the liver disease are divided into two groups (Box 5).

Nonspecific Symptoms

- Fatigue:** It is described as lethargy, weakness, listlessness, malaise, lack of stamina, arises after activity or exercise, is intermittent and variable in intensity and suggests chronic liver disease.
- Nausea:** It occurs with more severe liver disease. It is again a nonspecific symptoms and usually accompanies fatigue or vomiting. Vomiting is rarely persistent in liver disease.
- Poor appetite with weight loss:** It occurs commonly in acute liver disease but is rare in chronic disease. Diarrhoea (steatorrhoea) is uncommon in liver disease except with severe jaundice. On the other hand constipation may commonly occur and may exacerbate the symptoms of end-stage hepatic disease such as encephalopathy.
- Right upper quadrant pain:** It occurs in many liver diseases and is usually marked by tenderness in

Box 5

Symptoms pertaining to hepatobiliary system

- **Constitutional or nonspecific symptoms**
 - Fatigue
 - Weakness
 - Nausea, vomiting
 - Anorexia or poor appetite
 - Malaise
- **Specific symptoms** (i.e. they are liver-specific, suggest the cause such a hepatitis or cirrhosis and/or complications such as end-stage liver disease or encephalopathy)
 - Jaundice
 - Dark coloured urine, light coloured stools
 - Abdominal distension—(ascites)
 - Swelling or oedema feet
 - Feter hepaticus
 - Flapping tremors
 - Encephalopathic features (disturbed consciousness, disturbed speech and sleep pattern, bizarre hand-writing)
 - Abdominal pain
 - Bloating
 - Haematemesis and malena
 - Pruritus

this area. The pain arises due to stretching or irritation of *Glisson's capsule* which surrounds the liver and is a pain sensitive structure due to rich in nerve endings. Severe pain due to liver involvement is seen in liver abscess, severe venoocclusive disease, Budd-Chiari syndrome and acute hepatitis. Occasional colicky pain in right hypochondrium indicates biliary colic (stricture, stone, tumour). Pain radiating to shoulder is due to involvement of diaphragmatic pleura (pneumonia) or liver (liver abscess or malignancy liver) or due to subphrenic abscess.

- **Pruritus (itching):** It occurs in acute liver disease appearing early in obstructive jaundice somewhat later in hepatocellular jaundice (acute hepatitis). Itching also occurs as a presenting symptom in certain chronic liver diseases, i.e. primary biliary cirrhosis or cholestatic jaundice of pregnancy and sclerosing cholangitis.
- **Haematemesis and malena:** In liver disease it occur from rupture of oesophageal varices by passage of hard bolus of food in patients with portal hypertension or due to coagulation disorders.
- **Symptoms of hepatic insufficiency or end-stage liver disease:** It includes progressive jaundice, haematological alterations (anaemia, thrombocytopenia, pancytopenia, bleeding tendencies) symptoms of portal hypertension (ascites, feter hepaticus, caput medusae, haematemesis), endocrinal changes (gynaecomastia, testicular atrophy, breast atrophy in female) and pigmentation.

- **Mass abdomen:** Mass abdomen refers to intra-abdominal masses in relation to various viscera in the abdomen. Mass abdomen may produce fullness of abdomen or visible swelling, dragging sensation in abdomen, pain abdomen or may just be asymptomatic, i.e. patient is not aware of it. Malignant masses or tumours produce decreased/loss of appetite or weight loss. The possible sites of masses in the abdomen and specific to right hypochondrium are discussed under the examination of abdomen Chapter 13.
- **Jaundice:** Jaundice is yellowness of sclera, mucous membranes and skin, occurs due to raised serum bilirubin. Normal serum bilirubin is 0.3–1.5 mg%. Jaundice appears when serum bilirubin is ≥ 2.5 mg%. Serum bilirubin less than 2.5 mg but more than normal indicate subclinical jaundice. The clinical jaundice may be progressive or may appear intermittently. Work-up of a patient with jaundice is given in the Table 2.9. Ask about certain features which will give you presumptive diagnosis.

Jaundice is the hallmark of liver disease and perhaps the most reliable marker of severity. Patient usually report darkening of the urine before they note the scleral icterus. In obstructive jaundice, the stools are clay-coloured while urine is dark-coloured. Jaundice without dark urine usually indicates unconjugated (indirect) hyperbilirubinaemia and is typical of haemolytic jaundice and genetic disorder of bilirubin conjugation (Gilbert's syndrome and Crigler-Najjar syndrome). In these genetic disorders, the jaundice is more noticeable during fasting and with stress.

CARDIOVASCULAR SYMPTOMS

The symptoms pertaining to cardiovascular system (CVS) are many and their interpretation varies from patient to patient. The common symptoms are given in the Box 6.

Dyspnoea

It is defined as consciousness of breathing which normally does not occur except during severe exertion, emotional stress or during anxious events. It can be cardiac or respiratory origin. Here dyspnoea as a cardiovascular symptom will

Box 6

Symptomatology of cardiovascular system

- | | | |
|--------------|---------------|------------|
| • Dyspnoea | • Palpitation | • Fatigue |
| • Pain | • Syncope | • Cyanosis |
| • Oedema | • Cough | |
| • Chest pain | • Haemoptysis | |

TABLE 2.9 Clinical work-up of a case with jaundice

Features (ask about them in history)	Tentative diagnosis
<ul style="list-style-type: none"> • Jaundice with fever, abdominal pain, anorexia, distaste to food and smoking • Jaundice in haemophiliacs, IV drug abuser and male homosexual • Jaundice with dark-coloured urine and stool • Pruritus (itching) with jaundice, acholic white-coloured stool, xanthomatous • Abdominal pain with fluctuating jaundice • Painless progressive jaundice with palpable gallbladder • Jaundice, ascites with prominent abdominal veins and history of haematemesis • Jaundice with pregnancy • Recurrent jaundice 	<ul style="list-style-type: none"> • Viral or drug induced hepatitis or liver abscess • Acute transfusion hepatitis B or C, chronic active hepatitis if duration of jaundice is >6 months • Haemolytic jaundice due to any cause • Cholestatic (obstructive) jaundice (intra or extrahepatic cholestasis) or biliary cirrhosis • Bile duct stone or stricture, pancreatitis • Carcinoma of pancreas • Portal hypertension (cirrhotic, noncirrhotic, Budd-Chiari syndrome) • Hepatic or cholestatic jaundice of pregnancy • Congenital hyperbilirubinaemia or recurrent benign cholestasis

TABLE 2.10 New York Heart Association Functional Classification

Grade	Description
I.	Patients with cardiac disease but without limitation of physical activity. There is no dyspnoea on ordinary physical activity
II.	Patients with cardiac disease resulting in slight limitation of physical activity. They are comfortable at rest but become dyspnoeic on ordinary physical activity
III.	Patients with cardiac disease resulting in marked limitation of physical activity. They are comfortable at rest. Less than ordinary physical activity causes dyspnoea
IV.	Patients with cardiac disease resulting in inability to carry on any physical activity without discomfort. Dyspnoea is present at rest and increases with mildest exertion

be analysed and discussed though respiratory disease may coexist if there is some common aetiological factor such as smoking. The grading/class of dyspnoea is described in the Table 2.10.

Dyspnoea on exertion: It is a physiological phenomenon but becomes a symptom of disease if it occurs at exercise at levels below than normal or expected for the patient's age and degree of previous fitness. Exertional dyspnoea is a presenting symptom of left heart failure irrespective of its cause. It indicates increased work-load on the heart. The condition in which dyspnoea is a presenting symptom are:

- *Systemic hypertension* (accelerated or malignant)
- *Valvular heart disease* (mitral, aortic valve stenosis or regurgitation or both)
- *Cardiomyopathies* (dilated, hypertrophic and restrictive)

- *Myocardial diseases*—acute MI (papillary muscle dysfunction) or myocarditis
- *Arrhythmia* such as atrial fibrillation.

Orthopnoea: Dyspnoea in recumbent (lying flat) position is termed as *orthopnoea*. The patients with orthopnoea usually try to lie propped up position by using extra-pillows at night. Sometimes, the symptom is so distressing that the patient prefers to sleep upright in a comfortable chair. These patients usually have disturbed sleep at night due to frequent awakenings as their head may slip off the pillows. Orthopnoea indicates advanced heart disease and may or may not be associated with effort (exertional) dyspnoea. The orthopnoeic patients often experience paroxysmal nocturnal dyspnoea (PND).

Paroxysmal nocturnal dyspnoea: The term refers to attacks of breathlessness which generally occur at night and awaken the patients from sleep. The patient with PND or orthopnoea usually sits upright gasping in the bed or sitting on the edge of the bed with legs hanging from the bed. Occasionally, patient may even come out of the bed to open the windows in an attempt to relieve the discomfort/distress. All these positions relieve PND and orthopnoea, but patients with PND characteristically have cough and wheezing and bring out frothy sputum streaked with blood. The mechanisms of PND are:

- Increased venous return during supine position (recumbency)
- Shift of oedema fluid from extravascular to intravascular compartment
- Reduced adrenergic drive during sleep
- Heart rate increases during REM sleep
- Vital capacity is reduced in supine position.

Box 7

Causes of dyspnoea at rest

- **Cardiovascular**
 - Acute left heart failure (acute pulmonary oedema)
 - Massive pulmonary embolism (acute cor pulmonale)
- **Respiratory**
 - Acute severe asthma
 - Tension pneumothorax
 - Acute bronchopneumonia
 - ARDS (Adult respiratory distress syndrome)
 - Acute laryngeal oedema
- **Others**
 - Diabetic ketoacidosis
 - Lactic acidosis
 - Salicylate poisoning
 - Uraemia with fluid overload.

Dyspnoea at rest: It indicates an advanced stage of cardiac dyspnoea and occurs in the presence of severe heart failure. Its presence is preceded by worsening effort dyspnoea, orthopnoea and PND, and ankle oedema. These patients have all signs and symptoms of left heart failure—which is a cause of cardiac dyspnoea. The causes of dyspnoea at rest are given in the Box 7.

Dyspnoea at rest (acute dyspnoea) is an emergency.

Palpitation

Palpitation is the awareness of heart beat in the chest. Patients describe it by using different terms such as thumping, pounding, fluttering, jumping, racing and bumping of the heartbeat. It may be due to heightened awareness of the heart beating during sinus rhythm (e.g. after exertion, excessive use of tea and coffee, anxiety, hyperthyroidism and due to catecholamine excess) or due to irregular heart beating or an arrhythmia (e.g. ventricular ectopics, atrial fibrillation, ventricular tachycardia, atrial tachycardia). Irregularity of heart beat is described by the patient as missing of a beat or jumping or fluttering of heart, is seen in VPCs and atrial fibrillation.

- Palpitation associated with polyuria indicate supraventricular tachycardia. Patient describes it as racing or fluttering of the heart.
- Palpitation with breathlessness indicates either atrial fibrillation or ventricular tachycardia. Ventricular tachycardia may present with syncope rather than palpitations.

Cough, Sputum and Haemoptysis

These are discussed under respiratory symptoms.

Peripheral Oedema (Read also the Examination of Extremities Chapter 10)

It is collection of fluid in the interstitial tissues. Pitting pedal oedema is demonstrated clinically by applying pressure with thumb on the ankles or feet which produces a pit at the site of pressure. The pit stays for some time (about 10–15 sec) and then slowly disappears. Peripheral oedema is seen on the ankles or over feet in ambulatory patients; while it appears on the sacrum and thighs in recumbent position or while in bed (bed-ridden patients). Oedema appearing on the face early in the morning is its example and is seen commonly in nephrotic syndrome. The different sites of oedema in different positions represent the effect of gravity. Oedema may be unilateral or bilateral.

Peripheral oedema is associated with ascites and/or pleural effusion in severe congestive heart failure. The causes of oedema are summarised in the Box 8. Non-pitting peripheral oedema is seen in hypothyroidism (myxoedema).

Chest Pain

Pain in chest of cardiac origin (originating from myocardium, pericardium, blood vessels etc) is called *cardiac chest pain*. Noncardiac chest pain also occurs due to a variety of extracardiac disorders and may simulate cardiac chest pain from which it has to be differentiated. Here we will discuss cardiac chest pain. The causes of cardiac chest pain with their characteristics are given in the Table 2.14.

Syncope

It is loss of consciousness due to fall in BP (hypotension) leading to decreased cerebral perfusion. The feeling of

Box 8

Causes of peripheral pitting oedema

<i>Unilateral</i>	<i>Bilateral</i>
<ul style="list-style-type: none"> • Lymphatic obstruction, e.g. filariasis, pressure due to growth • Venous obstruction (thrombosis) or insufficiency (varicose vein) • Infection, e.g. cellulitis, carbuncle • Traumatic, e.g. fracture/sprains • Hereditary, e.g. Milroy's disease 	<ul style="list-style-type: none"> • Congestive heart failure • Constrictive pericarditis • Nephritic or nephrotic syndrome • Cirrhosis of liver, portal hypertension • Hypoproteinaemia • Beriberi • Inferior vena cava obstruction • Angioneurotic oedema • Epidemic dropsy • Drug induced, e.g. pioglitazone, amlodipin

impending loss of consciousness is called *presyncope*. Both syncope and presyncope may be of cardiac origin, occur due to either decreased cardiac output or decreased peripheral resistance or both. It may be a symptom of neurological disorder (Read syncope as a symptom of nervous system).

Other Symptoms of Cardiac Disease

Fatigue

Fatigue or tiredness is a common complaint of patients with heart failure, coronary artery disease, persistent cardiac arrhythmia, hypertension and cyanotic heart disease. It is due to poor cerebral perfusion and oxygenation. It can occur in patients with bacterial endocarditis.

Nocturia

Nocturia means excessive urination of night, can occur due to congestive heart failure. Oliguria can also occur in heart failure.

Cardiovascular Disease Presenting with Noncardiac Symptoms

- *Stroke* may be a presenting feature of cerebral embolism from an intracardiac thrombus or atrial fibrillation, endocarditis and hypertension.
- *Anorexia, nausea, abdominal pain and jaundice* can occur due to liver congestion in patients with heart failure or mesenteric embolism.

RESPIRATORY SYMPTOMS

The symptoms which point to the disease of respiratory system are given in the Box 9. Special attention has to be given while taking history of a patient with respiratory disease. Always ask about the following:

- *Family history* of tuberculosis, allergies, asthma.
- **Occupational history:** Do the symptoms relate to his occupation? Stone cutters, asbestose workers, woollen industries workers have their symptoms increased when at work.

In case symptoms indicate involvement of respiratory system, then proceed to ask questions regarding family history of allergy, asthma and tuberculosis. History of smoking in the

present and past is also an important point to be asked. If the disease is episodic like asthma or allergy, then ask whether attacks of breathlessness are spontaneous or induced. What brings about these attacks? Is there any relation of an attack with the dust or exercise or occupation?

Cough

Cough is defined as violent expiratory effort to clear the tracheobronchial secretion and is produced by rise in intra-bronchial or intratracheal pressure against closed glottis. With opening of the glottis, the pressure is released with throwing of secretions out of trachea with production of sound of cough. The cough is the most frequent symptom of respiratory disease for which patient usually seeks medical advice. It is produced by stimulation of the sensory nerves of the mucosa of the pharynx, larynx, trachea and bronchi (smaller bronchi) by inflammatory, mechanical, chemical and thermal stimuli. Rarely, it may arise due to irritation or stimulation of the pleura during the aspiration of a pleural effusion.

The characteristics of cough depend on the site and the nature of the lesion as follows:

- Post-nasal discharge into pharynx resulting from rhinitis or sinusitis, acute lower respiratory infection produces dry persistent cough
- Laryngeal involvement (e.g. laryngitis, tumour, whooping) produces harsh, barking, painful persistent cough with stridor (loud sound)
- Tracheitis produces painful coughing
- The characteristics of cough originating at various levels of respiratory tract is given in the Box 10
- Cough with wheezing occurs in chronic obstructive pulmonary disease (COPD) and asthma. The wheezing is nocturnal and reversible in asthma; while it is irreversible, persistent in COPD. Prolonged bouts of coughing may give rise to syncope
- Single vocal cord paralysis usually the left gives rise to prolonged low-pitched inefficient and *bovine cough* which is accompanied by hoarseness
- Cough may be intermittent/episodic (asthma) or persistent (COPD).

Sputum

The abnormal tracheobronchial secretion is called *sputum*. If history of sputum production is positive, then enquire about its *amount, character, viscosity and colour* or *taste*. Sputum characteristics in various respiratory diseases are given in the Table 2.11.

Box 9

Symptoms of respiratory system

- | | |
|---------------|------------|
| • Cough | • Dyspnoea |
| • Sputum | • Wheeze |
| • Haemoptysis | • Stridor |
| • Chest pain | |

Box 10

Characteristics of cough in diseases of the bronchi and small airways

Disease	Nature of cough
Bronchitis	Dry or productive, worse in the mornings
Asthma	Dry or productive, worse at night
Bronchial carcinoma	Persistent, usually with haemoptysis
Pneumonia	Initially dry, later productive with or without blood tinge
Bronchiectasis	Productive, copious in amount, postural relationship (change in posture induces sputum production)
Pulmonary oedema	Productive with pink frothy sputum, often at night, associated dyspnoea, orthopnoea, PND and crackles
Interstitial lung disease	Dry, irritant and distressing cough

TABLE 2.11 Sputum characteristics and their causes

Type	Character/nature	Cause
Serous	Clear, watery, frothy may be pink	<ul style="list-style-type: none"> Acute pulmonary oedema Bronchoalveolar carcinoma
Mucoid	Clear, grey, white, may be frothy or black (soot)	<ul style="list-style-type: none"> Chronic bronchitis COPD Bronchial asthma Asthmatic bronchitis
Mucopurulent or purulent	Yellow, green, brown	<ul style="list-style-type: none"> All types of bacterial bronchopulmonary infections Pulmonary eosinophilia
Rusty	Rusty, golden yellow	<ul style="list-style-type: none"> Pneumococcal pneumonia

- Quantity:** It is difficult to assess the quantity of sputum because most of the children and some adults swallow it and do not expectorate it. The quantity can be assessed as large or copious by teacupful/day or very small (one or two spits) by teaspoonful/day. Some patients deny cough while admitting the presence of sputum saying that they bring it up by clearing the throat. The large amount of sputum occurs in bronchiectasis, bronchitis, resolving lung abscess or a cavity. Small amount is seen in asthma, COPD and interstitial lung diseases.
- Character/appearance:** The four main types of sputum include *serous*, *mucoïd*, *mucopurulent* or *purulent* and *rusty*. Haemoptysis means coughing up blood in the

sputum. The term dirty sputum is misleading as it may either refer to purulent sputum or to mucoid sputum containing black (soot) particles. The appearance of sputum and their causes are listed in the Table 2.11. The specimen of sputum may be inspected for nature wherever possible.

- Viscosity:** Mucoid sputum is more viscous than purulent sputum, hence, is more difficult to cough up. Mucoid viscous sputum occurs in pneumonia and asthma. Serous sputum is watery with low viscosity.
- Taste or colour:** The sputum is foul tasting/smelling (fetid) in bronchiectasis, lung abscess or anaerobic (bacteroides) infection of the lung. The clinician’s own sense of smell should be used to assess the odour of sputum.
- Postural relation:** Diurnal and postural variation in cough and sputum is characteristic of lung abscess and bronchiectasis.

Haemoptysis (Fig. 2.2)

The coughing up blood in the sputum is called *haemoptysis*. It may be in the form of drops or streaking of the sputum (pneumonia) or there may be frank blood in the sputum (bronchiectasis or bronchial adenoma or carcinoma). It may be recurrent or may be just an occasional episode. Although, most patients know whether blood has been coughed up or vomited, yet haemoptysis is occasionally confused with haematemesis. The distinguishing features between the two are listed in the Box 11.

Causes: Some important causes of haemoptysis are given in the Table 2.12.



FIGURE 2.2 Haemoptysis. Note the red colouration of the sputum

Box 11

Differentiation between haemoptysis and haematemesis

<i>Haemoptysis</i>	<i>Haematemesis</i>
Blood in the sputum	Blood in the vomitus
The prodromal symptom is either irritation of throat or cough	The prodrome is either nausea or abdominal discomfort
Blood is bright red or frothy	Blood is magenta-coloured or brownish-black due to formation of acid haematin
Blood in sputum is alkaline in reaction	Reaction of blood is acidic
It is mixed with sputum	It is mixed with food particles

TABLE 2.12 Causes of haemoptysis

<i>Common</i>	<i>Uncommon</i>	<i>Rare</i>
<ul style="list-style-type: none"> • Pulmonary infection • Bronchial carcinoma • Tuberculosis • Bronchiectasis • Lung abscess • Bronchitis (acute or chronic) • Mitral stenosis 	<ul style="list-style-type: none"> • Bronchial adenoma • Aspergilloma • Secondaries in the lungs • Laryngeal tumour • Connective tissue diseases • Goodpasture's syndrome • Blood dyscrasias and anticoagulation 	<ul style="list-style-type: none"> • Foreign body inhalation • Chest trauma • Iatrogenic, e.g. after bronchoscopy or biopsy (transbronchial or transthoracic)

CLINICAL TIPS

- Recent frank haemoptysis or blood streaking of mucoid sputum, sometimes in the mornings for a week along with anorexia and weakness suggests a diagnosis of bronchial carcinoma
- Recurrent episodes of haemoptysis over many years usually associated with purulent sputum occur in bronchiectasis
- Clinical setting is an important consideration, for example, in a patient with deep vein thrombosis, haemoptysis is due to pulmonary embolism unless proved otherwise
- When no cause is found out, the oropharynx should be examined to find out the source of bleeding.

Chest Pain as Respiratory Symptom

Any type of pain in the chest is called '*chest pain*' which may arise from:

- The structures covering the chest (skin, nerves, muscles)

TABLE 2.13 Causes of chest pain

<i>Central (retrosternal)</i>	<i>Peripheral</i>
<ul style="list-style-type: none"> • Cardiac <ul style="list-style-type: none"> – Angina – Myocardial infarction – Myocarditis and pericarditis • Aortic <ul style="list-style-type: none"> – Aortic aneurysm – Aortic dissection • Oesophageal <ul style="list-style-type: none"> – Diffuse oesophageal spasm – Gastroesophageal reflux disease (GERD) – Oesophageal tear (Mallory-Weiss syndrome) • Mediastinal <ul style="list-style-type: none"> – Compression due to tumour – Mediastinitis – Tracheitis • Functional <ul style="list-style-type: none"> – Anxiety (cardiac neurosis) 	<ul style="list-style-type: none"> • Lungs/pleura <ul style="list-style-type: none"> – Pulmonary infarct (small peripheral vessel) – Pneumonia – Pneumothorax – Tuberculosis – Malignancy – Connective tissue disorders • Musculoskeletal <ul style="list-style-type: none"> – Rib injury/fracture – Intercostal muscle injury – Direct invasion of chest wall by tumour or metastases – Costochondritis (Teitz syndrome) – Epidemic myalgia (Coxsackie B infection) – Bronholm disease • Neurological <ul style="list-style-type: none"> – Spinal nerve root involvement in Pott's disease (tuberculosis of spine) or vertebral disease or prolapsed disc – Post-herpetic neuralgia – Thoracic outlet syndrome

- The bony cage/chest wall
- The pleura or lungs
- The heart (pericardium) or the blood vessels.

Therefore, chest pain is a common complaint of both cardiac and respiratory disease for which the patient usually seeks medical advice. Localisation of chest pain helps in making the clinical diagnosis. In general, pain originating from the lungs, pleura or chest wall tends to be peripheral; while pain arising from the centrally situated structures, i.e. heart, aorta, trachea, mediastinum, oesophagus is retrosternal. The causes of chest pain depending on the location are given in the Table 2.13. Pain from other organs may also get referred to the chest (referred pain). It can also be psychogenic Table 2.14.

Characteristics of Chest Pain due to the Diseases of the Lung and Pleura

There are four major types of chest pain due to pleuro-pulmonary disease:

1. Central or retrosternal chest pain due to repeated coughing is seen in tracheobronchitis or chronic bronchitis/COPD. It is actually chest discomfort rather than pain.

TABLE 2.14 Differential diagnosis of chest pain/discomfort

Disorder	Mechanism	Site	Quality, severity and timing	Aggravating factor(s)	Relieving factor(s)	Associated symptom(s)
Cardiovascular Angina pectoris	Reversible myocardial ischaemia due to atherosclerosis of coronary artery	Retrosternal or across the anterior chest, radiating to the arms (left), neck, shoulders, lower jaw, or upper abdomen	Pressing, squeezing, tightness or heaviness in chest usually of mild to moderate intensity, perceived as discomfort rather than pain. Duration is short, i.e. 1–3 minutes (may be upto 10 minutes)	Exertions, cold, heavy meals, psychological stress act as precipitating factors	Rest and nitroglycerine	Nausea, vomiting, sometimes dyspnoea
Myocardial infarction	Irreversible prolonged myocardial ischaemia resulting in muscle damage/necrosis	—same as above—	—same as above— —except pain is more severe and prolonged (20 minutes to several hours)	No aggravating factor	No relieving factor	Nausea, vomiting, perspiration, exhaustion
Pericarditis	Irritation of pericardium and of adjacent pleura	Precordial, may radiate to the tip of shoulder and to the back	Sharp, cutting (knife-like) often severe and persistent	Breathing, change in posture, coughing, lying down	Forward bending or sitting forward may give some relief	Fever and symptoms of underlying illness, pericardial rub is present
Aortic dissecting aneurysm	Formation of a dissecting channel within layers of aortic wall allowing the passage of blood	Anterior chest radiating to the neck, back or abdomen	Tearing pain which is severe and persistent. Abrupt onset	Hypertension	No relieving factor	Of the underlying cause. Syncope, hemi-plegia, paraplegia. Aortic diastolic murmur of aortic regurgitation may appear
Pulmonary Acute bronchitis	Inflammation of large bronchi and trachea	Upper sternum or on either side of the sternum	Burning, mild to moderate intensity	Coughing	Sputum expulsion	Of the underlying cause
Pleuritis	Inflammation of parietal pleura	Anterior chest wall overlying the area of pleurisy	Sharp, cutting (knife-like) often severe and persistent	Breathing, coughing, movement of the trunk	Lying on the involved side may relieve it	Of the underlying cause
Gastrointestinal Reflux oesophagitis	Inflammation of the oesophageal mucosa	Retrosternal, may radiate to the back	Burning or squeezing pain, mild to moderate	Large meal; bending	Antacids and nitrates, lying down	Heartburn, Sour eructation, acid taste in mouth
Diffuse oesophageal spasm	A motility disorder of oesophagus	Retrosternal, may radiate to the back, arms, and jaw	Burning or squeezing of mild to moderate intensity	Swallowing of food, cold liquid, emotional stress	Antacids and nitrates	—do—
Myalgia/Teitz's syndrome	Variable, unclear	Often below the left breast or along the costal cartilage or elsewhere	Stabbing, sticking or dull aching of fleeting nature. Severity variable	Movements of chest, trunk, arms aggravate it. There may be local tenderness	—	—
Psychogenic Anxiety neurosis (cardiac neurosis)	Unclear	Precardial, below the left breast or across the anterior chest	Stabbing, sticking or dull aching. Variable intensity, fleeting nature	May follow stress or effort	Mental rest and anxiolytics psychotherapy	Hyperventilation, palpitations, weakness, anxious look

Box 12

Characteristics of pleural chest pain

- Sharp, stabbing pain
- Pain is related to respiration (maximal towards the end of inspiration) and coughing
- It is associated with rapid shallow breathing and sometimes patient may hold breaths
- It may get referred to shoulder if there is involvement of diaphragmatic pleura
- It may be associated with a scratchy sound called *pleural rub/friction* which is due to friction between the two layers of pleura, hence is intermittent and, disappears with development of pleural effusion
- There is no localised tenderness which differentiates it from rib fracture

2. Central chest discomfort/heaviness is felt in mediastinal compression due to a tumour or lymph node enlargement or spontaneous pneumothorax.
3. Unilateral sharp, stabbing chest pain which is made worse by coughing and breathing, is characteristic of pleuritis or chest wall disease (myalgia, fibromyalgia, rib fracture). Sometimes, a patient of pleuritis may hold breath or take shallow respiration due to pain. The characteristics of pleural pain are given in the Box 12.
4. Constant dull or sharp persistent pain is felt in malignant lung tumours. It is neither related to coughing nor breathing.
5. Atypical chest pain with no localisation or relation to coughing or breathing is characteristic of anxiety neurosis. These patients have anxious look.

Dyspnoea due to Respiratory Disease

Dyspnoea is subjective awareness of the sensation of breathing, may be due to cardiac or respiratory disease, but sometimes it may occur as a result of disorders of other system, e.g. diabetic ketoacidosis, anaemia, thyrotoxicosis. Patients with dyspnoea complain of shortness of breath. The principle contributory factors to breathlessness are:

- **Increased work of breathing:** The work of breathing is increased by increased airflow resistance, decreased compliance of the lungs (stiff or noncompliant lungs) and restricted chest expansion. The causes of increased work cost of breathing are given in the Box 13.
- **Increased ventilatory drive:** An increase in physiological dead space (ventilation/perfusion mismatch) and hyperventilation may cause an increase in respiratory drive either singly or in combination leading to

Box 13

Causes of increased work of breathing

<i>Increased airway resistance</i>	<i>Restricted chest expansion</i>
• Asthma	• Ankylosing spondylitis
• COPD	• Kyphoscoliosis
• Tracheobronchitis	• Respiratory muscle paralysis
<i>Decreased pulmonary compliance</i>	
• Pulmonary oedema	
• Pulmonary fibrosis	
• Extrinsic allergic alveolitis	

breathlessness. Hyperventilation may result from stimulation of respiratory centre in response to chemical or neural stimuli (Table 2.15).

- **Respiratory muscle dysfunction:** Neuromuscular paralysis may impair the function of respiratory muscles and diaphragm leading to breathlessness. The causes include Guillain-Barre syndrome, cervical cord injury, muscular dystrophy, myasthenia gravis, organophosphorus poisoning.

Points to be Asked on History of Breathlessness

- *Mode of onset*—acute or insidious
- *Exercise tolerance*—daily physical activities
- *Associated symptoms* such as
 - Cough, sputum, haemoptysis
 - Wheeze, chest pain
- *Past history of allergy, cardiac or respiratory disorder*
- *Occupational history*—exposure to dust, pollens, animals, chemical
- *Personal history*—history of smoking (past and present)
- *Recent travel abroad.*

CLINICAL TIPS

- Breathlessness with unilateral chest pain (pleurisy) occurs in pneumonia, pulmonary infarction, rib fracture, pneumothorax
- Breathlessness without chest pain, cough and wheeze is seen in pulmonary embolism, tension pneumothorax, shock and metabolic acidosis
- Breathlessness with cough and wheeze but with no chest pain indicates left heart failure, asthma, pneumothorax.

TABLE 2.15 Causes of increased ventilatory drive responsible for dyspnoea

Cause/mechanism	Disease
• Acidemia ($\uparrow H^+$ ion concentration) causing Kussmaul breathing	• Diabetic ketoacidosis, lactic acidosis
• $\uparrow PaCO_2$ (respiratory acidosis)	• Chronic obstructive pulmonary disease
• $\downarrow PaO_2$ (arterial hypoxaemia) stimulates chemoreceptors	• Cyanotic congenital heart disease, asthma, COPD, anaemia, shock, pneumonia
• Increased central arousal (sympathetic activity)	• Exercise, anxiety, thyrotoxicosis, phaeochromocytoma, fever
• Pulmonary 'J' receptors discharge	• Pulmonary oedema

Causes of Dyspnoea

Depending on the onset, dyspnoea may be divided into acute (within minutes to hours) and chronic (days to months or years). Acute dyspnoea presents with prominent symptoms at rest while chronic dyspnoea occurs on exertion. The causes are given in the Table 2.16. The differential diagnosis of acute severe dyspnoea is tabulated (Table 2.17).

Dyspnoea Characteristics

Mode of onset, duration and progression: Dyspnoea may be of acute or sudden onset (pulmonary oedema, pulmonary embolism, pneumothorax) or slow insidious onset (chronic congestive heart failure, interstitial lung disease, COPD), may be continuous and progressive (diffuse interstitial lung disease, occupational diseases) or intermittent/episodic (asthma). Mode of onset, duration and progression help in arriving at the diagnosis.

Aggravating and relieving factors: Diurnal variation of symptoms is characteristic of bronchiectasis, lung abscess. Dyspnoea which improves at weekend or on holidays (rest) suggests occupational asthma or extrinsic allergic alveolitis. Some diseases such as asthma may be provoked by coughing or laughing or exertion or following exposure to allergans/irritants.

Nocturnal dyspnoea which may awaken the patient from sleep is a typical feature of nocturnal asthma, pulmonary oedema and COPD. Orthopnoea may be seen in heart failure and severe COPD and such patients may have to sleep in the sitting position propped up by pillows.

Associated symptoms: The symptoms associated with dyspnoea include cough, wheeze, sputum, haemoptysis and chest pain. Their significance has been discussed in the Table 2.14.

TABLE 2.16 Causes of dyspnoea

System	Dyspnoea at rest (acute)	Dyspnoea on exertion (chronic)
C.V.S.	• Acute left ventricular failure • Myocardial infarction	Chronic heart failure
Respiratory	• Acute severe asthma • Acute exacerbation of COPD • Pneumonia • Tension pneumothorax • Pulmonary embolism • ARDS • Lobar collapse • Laryngeal oedema (anaphylaxis)	• Chronic asthma • COPD • Bronchial carcinoma • Interstitial lung disease • Chronic pulmonary thromboembolism • Large pleural effusion • Lymphatic carcinomatosis
Miscellaneous	• Metabolic acidosis (e.g. diabetic ketoacidosis, lactic acidosis, uraemia, salicylate poisoning, ethylene-glycol poisoning) • Psychogenic hyperventilation	• Severe anaemia • Obesity

Severity: Though grading systems exist to assess the cardiac and respiratory disabilities (*see* Table 2.10 NYHA classification) but simple questions like breathlessness on daily activities may provide an effective functional assessment of the severity of dyspnoea.

Apnoea: Apnoea is defined as cessation of breathing, can occur in following conditions:

- Voluntarily holding of breathe for sometimes
- Cheyne—stokes breathing in which apnoea alternates with hyperventilation
- Sleep—apnoea syndrome (Read from the textbook).

Wheeze

Wheezing is described by the patients as whistling or musical sounds produced in the chest. It is due to narrowing of the bronchi as a result of mucus plugging or bronchoconstriction. It is heard in asthma and COPD. Many patients may become so accustomed to wheeze that they cease to be aware of its presence.

Stridor

It is loud sound produced by partial obstruction of a major airway (e.g. laryngeal oedema, tumour, an inhaled foreign body).

TABLE 2.17 Differential diagnosis of acute severe dyspnoea

Condition	History	Signs	Chest X-ray	Arterial blood gas	ECG	Other tests
<ul style="list-style-type: none"> Left ventricular failure (Pulmonary oedema) 	<ul style="list-style-type: none"> Previous cardiac disease or chest pain, orthopnoea PND and palpitation. There is pink frothy sputum 	<ul style="list-style-type: none"> Central cyanosis JVP-normal or raised Sweating Cold extremities End-inspiratory crackles at bases 	<ul style="list-style-type: none"> Cardiomegaly Upper lobe veins engorgement Pulmonary oedema Pleural effusion 	<ul style="list-style-type: none"> ↓PaO₂ ↓PaCO₂ 	<ul style="list-style-type: none"> Sinus tachycardia Myocardial ischaemia/infarction Arrhythmias 	<ul style="list-style-type: none"> Echocardiography shows depressed left ventricular function
<ul style="list-style-type: none"> Massive pulmonary embolism 	<ul style="list-style-type: none"> Recent surgery or other risk factors Chest pain Haemoptysis Deep vein thrombosis 	<ul style="list-style-type: none"> Central cyanosis ↑JVP Signs of shock Unilateral oedema Calf tenderness Pleural rub may be heard 	<ul style="list-style-type: none"> Prominent hilar vessels with oligaemic lung fields 	<ul style="list-style-type: none"> ↓PaO₂ ↓PaCO₂ 	<ul style="list-style-type: none"> Sinus tachycardia S₁Q₃T₃ pattern Inverted T(V₁-V₄) RBB Block 	<ul style="list-style-type: none"> Echocardiography Lung scan Angiography
<ul style="list-style-type: none"> Acute bronchial asthma 	<ul style="list-style-type: none"> History of previous episode History of asthma medication Wheeze 	<ul style="list-style-type: none"> Tachycardia Pulsus paradoxus Cyanosis (late) JVP normal Diffuse bronchi (rales), sonorous 	<ul style="list-style-type: none"> Hyperinflation Pneumothorax if complicated 	<ul style="list-style-type: none"> ↓PaO₂ N or ↓PaCO₂ (late) 	<ul style="list-style-type: none"> Sinus tachycardia 	
<ul style="list-style-type: none"> Acute exacerbation of COPD 	<ul style="list-style-type: none"> Long duration of history of cough Repeated hospital admissions History of smoking Mucoid or mucopurulent sputum 	<ul style="list-style-type: none"> Cyanosis Signs of COPD (barrel shaped chest, intercostal indrawing, pursed lips breathing) Signs of CO₂ retention (warm extremities, bounding pulse, flapping tremors) Bilateral crackles and rales 	<ul style="list-style-type: none"> Hyperinflation Increased lung translucency Tubular heart Low flat diaphragm Bullae may be seen 	<ul style="list-style-type: none"> ↑PaO₂ ↑PaCO₂ Acidosis 	<ul style="list-style-type: none"> Signs of right ventricular hypertrophy if cor pulmonale develops 	
<ul style="list-style-type: none"> Pneumonia 	<ul style="list-style-type: none"> Fever, cough chest pain and haemoptysis 	<ul style="list-style-type: none"> Raised temperature Signs of consolidation Pleural rub may be present Cyanosis, if wide-spread disease 	<ul style="list-style-type: none"> Pneumonic homogenous opacity in the lung involved 	<ul style="list-style-type: none"> ↓PaO₂ ↓PaCO₂ 	<ul style="list-style-type: none"> Tachycardia 	
<ul style="list-style-type: none"> Psychogenic (Anxiety) 	<ul style="list-style-type: none"> Previous episodes Acute anxious events precipitate it 	<ul style="list-style-type: none"> No cyanosis No signs of heart or lung disease Hyperventilation Anxious looks Carpopedal spasm 	<ul style="list-style-type: none"> Normal 	<ul style="list-style-type: none"> Normal PaO₂ ↓PaCO₂ Alkalosis may be present 		

Abbreviations:

A-absent; N-normal; ↓-decreased ↑-increased

TABLE 2.18 Symptoms pertaining to upper respiratory tract

Nose and nasopharynx	Larynx	Trachea
<ul style="list-style-type: none"> Nasal discharge with frequent sneezing (e.g. rhinitis respiratory catarrh, nasal allergy) 	<ul style="list-style-type: none"> Horseness or dysphonia 	<ul style="list-style-type: none"> Pain Cough Stridor Dyspnoea
<ul style="list-style-type: none"> Intermittent nasal obstruction (e.g. adenoids enlargement, deflected nasal septum or polyps), bilateral nasal obstruction may result in mouth breathing in children 	<ul style="list-style-type: none"> Dry barking cough in laryngeal oedema and bovine cough in laryngeal paralysis Stridor—a high-pitched crowing sound occurring during inspiration 	
<ul style="list-style-type: none"> Epistaxis (bleeding from the nose). It may give rise to haemoptysis if blood from posterior nares is first inhaled and then coughed up 	<ul style="list-style-type: none"> Laryngeal pain (e.g. acute laryngitis, tubercular laryngitis and laryngeal carcinoma) 	

Symptomatology of Upper Respiratory Tract

The symptoms originating from upper respiratory tract (nose, nasopharynx, larynx and trachea) are summarised in the Table 2.18.

Clinical Clues

- Cough causing sleep disturbance is common in asthma than COPD
- Small repeated episodes of frank haemoptysis suggest bronchial carcinoma or adenoma
- Pleuritic pain suggests underlying pneumonia or malignancy.

Significance of History

- Past history:** Past history of tuberculosis, pneumonia, measles and whooping cough, chest injury, epileptic attacks or surgery under general anaesthesia, pregnancy may be asked in a patient with respiratory disease.
- Personal social history:** Certain pets (mammals, birds) may be the cause of rhinitis, asthma, allergic alveolitis and psittacosis pneumonia, hence, history of keeping pets must be asked.

Cigarette smoking is an incriminating factor for bronchial carcinoma and COPD, therefore, history of active or passive smoking in nonsmokers must be asked. In smokers, one should enquire about the age at which smoking started, average number of cigarettes/cigar per day and duration of smoking. (Read Habits in Chapter 1).

Cardiac Versus Respiratory Dyspnoea

Dyspnoea may be a symptom of a cardiovascular or a respiratory disease but sometimes both may coexist in the same patient when it becomes difficult to decide how much is contributed by individual cardiac and respiratory disorder.

In some patients, it may be possible to pinpoint whether dyspnoea is cardiac or respiratory origin; while in others it is rather difficult. The salient differentiating features between cardiac and respiratory dyspnoea are given in the Table 2.19.

SYMPTOMS RELATED TO BLOOD DISORDER

The symptoms and appearance (pallor) that point to a disorder of haemopoietic system are given in the Box 14.

Lassitude, dyspnoea and palpitation: They are nonspecific symptoms, can occur in hypoxia due to any cause. Anaemia is a common cause of these symptoms. They appear when haemoglobin concentration is reduced so that oxygen delivery to the tissue is affected.

Pallor is often the complaint of the friends or relatives rather than the patients themselves. The degree of pallor does not correspond with degree of anaemia. The degree of pallor is difficult to assess in dark-coloured people or patients with thick skin.

The anaemia is discussed in details in examination of haemopoietic system Chapter 17.

Infections: In patients with blood disorders, the infections (bacterial, viral, fungal, etc.) are common due to agranulocytosis (leucopenia), aplastic anaemia, leukaemias, lymphomas, hypersplenism. The presence of fever in blood disorders indicates infection. In addition, there may be excoriation and ulceration of the mouth or fauces, white plaques of oral candidiasis (mouth thrush). These lesions are often associated with cold sores on the lips due to herpes simplex infection. There may be anorectal ulceration.

Bleeding: Bleeding is a common symptom of either a haemostatic disorder or a local anatomic defect (trauma, surgery, stress), the latter has to be differentiated from former. One clue to local cause of bleeding following common hemostatic stresses such as dental extraction, delivery or

TABLE 2.19 Distinction between cardiac and pulmonary dyspnoea

	<i>Cardiac dyspnoea</i>	<i>Pulmonary dyspnoea</i>
<i>History</i>	<ul style="list-style-type: none"> • History or evidence of heart disease • Acute or sudden onset • Associated symptoms, include chest pain, orthopnoea, palpitation, diaphoresis (sweating) etc. • A previous history of left ventricular failure • Paroxysmal attacks of dyspnoea (PND) are common, relieved by sitting or recumbent position • Wheezing less frequent • Dyspnoea is marked with less troublesome unproductive cough 	<ul style="list-style-type: none"> • History or evidence of respiratory disease • Gradual onset except when there is an acute exacerbation of COPD or acute asthma • Associated symptoms such as cough, wheeze, haemoptysis, stridor are common • Previous history of repeated attacks of asthma or chronic bronchitis • PND is less common, is relieved by cough and expectoration • Wheezing is marked and even audible • Dyspnoea is marked with productive cough
<i>Signs</i>	<ul style="list-style-type: none"> • Tachycardia, tachypnoea, cyanosis, (both central and peripheral) • Percussion note may be dull at bases • Trachea central and normal in length • There is no retraction of supraclavicular fossae or no activity of extra respiratory muscles • Crackles (crepitations) at the bases with few rhonchi (wheezes) • Apex beat is normal or displaced • Breath sounds normal • 3rd heart sound may be present (gallop rhythm) 	<ul style="list-style-type: none"> • Tachypnoea, tachycardia and central cyanosis are less marked • Hyper resonant note may be present • Trachea central but palpable part is decreased • Retraction of supraclavicular fossae, indrawing of ribs, barrel-shape chest and over activity of extra respiratory muscles prominent • Diffuse wheezes and crackles (crepitation's) • Apex beat may not be visible or normal • Breath sounds with prolonged expiration • No 3rd heart sound
<i>Chest X-ray</i>	<ul style="list-style-type: none"> • Heart size enlarged, diffuse haze from hilum to periphery of lungs, Kerley's B lines may be present. Hydrothorax present in some cases 	<ul style="list-style-type: none"> • Heart size normal or may be tubular, there is increased translucency of lungs and low flat domes of diaphragm. Bullae may be seen in emphysema
<i>ECG</i>	<ul style="list-style-type: none"> • Myocardial ischaemia/infarction, left ventricular hypertrophy, conduction defects and arrhythmias 	<ul style="list-style-type: none"> • Sinus tachycardia and right ventricular hypertrophy if cor pulmonale develops
<i>Echocardiogram</i>	<ul style="list-style-type: none"> • Left ventricular ejection fraction depressed at rest and may decline during exercise 	<ul style="list-style-type: none"> • Right ventricular ejection fraction are low at rest and may decline with exercise
<i>Arterial blood gas</i>	<ul style="list-style-type: none"> • PaO₂ low • PaCO₂ low 	<ul style="list-style-type: none"> • PaO₂ low • PaCO₂ normal or raised

Box 14

Symptoms of disorders of blood

- | | |
|---|--|
| <ul style="list-style-type: none"> • Lassitude, dyspnoea and palpitation • Infections at various sites • Bleeding from different sites, e.g. nose (epistaxis), gums, rectum, per vagina, and urinary tract | <ul style="list-style-type: none"> • Blood loss • Skin and joint bleeding (purpura, ecchymosis, haemarthrosis) • Glandular swellings (lymph node enlargement), splenomegaly |
|---|--|

birth or minor surgery. Severe bleeding from multiple sites that cannot be linked to trauma or surgery also suggests a systemic disorder. Family history of bleeding indicates an inherited haemostatic disorder.

Bleeding if occurs due to blood disorders indicate either defects of primary haemostasis (platelet disorders) or secondary haemostasis (coagulation disorders). Platelet disorders produce bleeding into superficial structures, e.g. skin and mucous membrane, comes on immediately after trauma or surgery and can be readily controlled by local measures. On the other hand, coagulation defects produce bleeding in deeper structures (muscles, joints or body cavities), comes late (hours to days) after injury and local measures cannot control it.

Bleeding into the anus and rectum can occur in thrombocytopenia as well as in coagulation disorders. The causes of bleeding per rectum are discussed under GI tract symptoms.

Box 15

Causes of bleeding gums

- **Haematological**
 - Leukaemias (monocytic or monomyelocytic)
 - Aplastic anaemia
 - Idiopathic thrombocytopenic purpura (ITP)
 - Thromboasthenia
 - von Willebrand's disease
 - Coagulation disorders, e.g. haemophilia, Christmas disease, Vitamin K deficiency, liver disease, anticoagulants, afibrinogenaemia, etc.
 - Hypersplenism
 - DIC (disseminated intravascular coagulation)
- **Diseases of the gums**
 - Gingivitis
 - Periodontitis
 - Herpes infection
 - Vincent's infection
- **Systemic disorders**
 - Scurvy (Vitamin C deficiency)
 - Phenytoin toxicity (gum hypertrophy)
 - Pregnancy
 - Henöch-Schönlein purpura
 - Connective tissue disorders

Bleeding into nose (epistaxis), sputum (haemoptysis), vomitus (haematemesis), urine (haematuria) are discussed in the appropriate sections. The causes of bleeding gums are given in the Box 15.

Terms Used in Relation to Bleeding

- **Purpura and petechiae:** These are tiny pin-point haemorrhages into the skin which do not blanch on compression with a glass slide. They indicate platelet disorders.
- **Echymoses:** These are superficial haemorrhages larger than petechiae and are more often confluent.
- **Bruises:** These are confluent areas of blood deposition, become multicoloured in appearance as they resolve and are sometimes associated with an obvious swelling (haematoma).

Blood loss: Blood loss may be due to haemorrhage which may be acute or chronic, internal (e.g. GI tract oesophageal varices, gastric carcinoma, a ruptured spleen, trauma or massive haemorrhage into body cavities or retroperitoneal space) or external (epistaxis, piles, haematemesis, haemoptysis, menorrhagia).

Acute blood loss leads to compensatory adjustment such as increase in O₂ delivery to the tissues, cardiovascular mechanisms and an increase in erythropoiesis in the bone

TABLE 2.20 Symptoms and signs of blood loss

Percentage blood loss (volume lost)	Symptoms and signs
<20% (<1000 mL)	Restlessness, vasovagal reaction
20–30% (1000–1500 mL)	Anxiety, orthostatic hypotension, exertional tachycardia (palpitation)
30–40% (1500–2000 mL)	Syncope on sitting or standing, orthostatic hypotension, tachycardia at rest
40–50% (>2000 mL)	Confusion, shortness of breath, shock, poor perfusion

marrow (increased erythropoietin production). The signs and symptoms of blood loss occur relative to the volume of the blood loss (volume depletion) and the time frame over which the haemorrhage occurs (Table 2.20). With larger blood losses, blood volume redistribution is not adequate to maintain normal BP, hence, initially there may be hypotension during standing, followed by hypotension during sitting and lying down position and eventually shock.

Glandular swellings (lymph nodes enlargement): These are discussed under examination of neck (Chapter 8) as well as haemopoietic system.

URINARY SYMPTOMS

The main functions of the kidneys and urinary system are formation of urine, excretion of waste products and to maintain water and pH balance, therefore, changes in the urine or retention of waste products and disturbance of water and pH indicate renal system involvement. Renal disease especially chronic renal failure may be totally asymptomatic, detected incidentally by presence of hypertension, proteinuria or raised blood urea or creatinine concentrations. The symptoms which most often bring the patient to a doctor are given in the Box 16 and discussed below:

Box 16

Common urinary symptoms

- Pain and dysuria
- Polyuria and/or nocturia
- Oliguria/anuria
- Red coloured (haematuria) or dark coloured urine (haemoglobinuria, porphyria)
- Increased frequency, burning micturition
- Hesitancy, retention of urine, retention with overflow, urinary incontinence
- Puffiness of face and oedema
- Symptoms of uraemia, e.g. nausea, vomiting, pallor

Box 17

Pain due to urinary system disorders

Site	Disorder
Loin pain/flank pain	<ul style="list-style-type: none"> Renal disorders, e.g. renal colic (e.g. stone, clot, tumour). Constant pain with fever occurs in acute pyelonephritis or perinephric abscess. Dull, dragging flank pain occurs due to large kidneys or polycystic kidney disease <i>Radiation:</i> Pain of perinephric abscess may radiate upwards to chest or may track over psoas muscle Pelvi-ureteric/ureteric obstruction/spasm due to impaction of a stone or tumour or clot. Labium pain radiates round the groin and often limited to the labium in the sensory distribution of L₁
Suprapubic/hypogastric pain and dysuria Perineal/rectal pain	<ul style="list-style-type: none"> Urinary bladder disorders (calculous, infection), urethral disorders (stricture, infection) Prostatic hypertrophy or infection

Pain

The pain due to acute bladder or urethral inflammation is called *dysuria/stangury*. This is a burning or tingling sensation felt at urethral meatus or in suprapubic area during the act of micturition. The site of pain and their respective disorder are given in the Box 17.

Abnormal Urine Volumes

Polyuria: It refers to urine output >3L/day, provided the patient is not on high fluid intake. *Nocturia* means excessive amount of urine passed at night. Polyuria differs from increased frequency of micturition in the former urine volume is more while in the latter patients goes for micturition many times but amount of the urine passed in a day is normal or less, hence, 24 hour urine output differentiates the two. The causes of polyuria are given in the Table 2.21.

Normal urine output is 800–2500 mL/day in temperate climate. It varies with the diet and fluid intake.

Oliguria: It refers to urine output <500 mL/day in an average adult. The oliguria may also arise due to error of judgement as it is difficult to collect the urine without spilling, and is difficult to measure when urine flow rates are low.

Oliguria is invariably a symptom/sign of acute renal failure but can occur in acute on chronic renal failure. The causes of oliguria are the causes of acute renal failure (Table 2.22).

TABLE 2.21 Causes of polyuria

- **Physiological**
 - Primary psychogenic polydipsia or excessive fluid intake
- **Osmotic diuresis**
 - Chronic renal failure
 - Diabetes mellitus
 - Mannitol infusion
- **Nephrogenic diabetes insipidus (tubules insensitive to ADH)**
 - Congenital (polycystic disease)
 - Tubulointestinal diseases, e.g. pyelonephritis, multiple myeloma, hypercalcaemia, drug/toxins induced, amyloidosis
- **Natriuresis (loss of salt along with water)**
 - Salt-losing nephropathy
 - Diuretics

TABLE 2.22 Causes of oliguria

- **Prerenal causes**
 - Hypovolaemia (blood or fluid loss) and shock
 - Heart failure
 - Renal vascular disease (renal artery stenosis/occlusion)
- **Renal causes**
 - Glomerular diseases
 - Interstitial diseases of kidney
 - Drug/toxin/sepsis
- **Postrenal (obstructive uropathy)**
 - Stone, tumour, retroperitoneal fibrosis

Anuria: It refers to urine output <20 mL/day or patient may not pass urine at all in 24 hours. It must be ensured that urinary bladder does not contain urine on catheterisation before labelling a patient anuric. The causes are:

- Complete bilateral urinary tract obstruction
- Total renal arterial/venous occlusion
- Bilateral renal cortical necrosis
- Rapidly progressive acute glomerulonephritis (RPGN)
- Severe shock.

Abnormal Colouration of Urine

Red coloured urine is due to presence of RBCs (haematuria) while dark coloured urine (brownish discolouration) is due to haemoglobinuria or myoglobinuria; the two can be distinguished by microscopic examination of urine which shows RBCs in the former not in the latter. The causes of high coloured urine are given in the Box 18. Haematuria which does not produce red-colouration is called microscopic haematuria. The causes of haematuria are tabulated in Table 2.23.

Increased Frequency of Micturition

It refers to how many times a patient go for micturition. In this condition, urine output remains normal or low. It often

Box 18

Causes of high coloured (dark) urine

- Loss of blood in urine (*haematuria*).
- Loss of haemoglobin in urine (*haemoglobinuria*). Urine gives positive test for Hb but there are no RBCs under microscope. This suggests intravascular haemolysis
- Loss of muscle pigment in urine (*myoglobinuria*). No RBCs present in urine. Chemical tests for haemoglobin are positive. Myoglobin is distinguished from haemoglobin by spectrophotometry
- Loss of porphobilinogen in urine (*porphyria*). In this condition, freshly voided urine is normal-coloured which becomes dark-coloured (Bragandy-wine) on standing
- Excretion of drugs in urine such as rifampicin and phenolphthalein.

TABLE 2.23 Causes of haematuria

- **Renal**
 - Glomerular diseases, e.g. glomerulonephritis (primary or secondary)
 - Interstitial renal disease
 - Cystic renal disease (polycystic kidneys)
 - Renal stones/tumours/trauma
- **Ureter**
 - Stone
 - Neoplasm
- **Urinary bladder**
 - Cystitis
 - Neoplasm
 - Stone
 - Trauma
 - Schistosomiasis
- **Urethra**
 - Urethritis, injury to urethra (catheter)
- **Prostate**
 - Prostatitis
 - Benign enlargement of prostate (BEP)
 - Neoplasm
- **Disorders of haemostasis**
 - Bleeding or coagulation disorders
 - Anticoagulant therapy

goes undetected during the day, because during the day micturition is determined as much by habit and social factors as by necessity. Increased frequency at night if regular is much more easily recognised as an abnormal and brings the patient to the physician. It may be due to loss of concentration ability of the tubules (tubular disorders), urinary infection, bladder obstruction (infection/injury), benign enlargement of prostate or prostatitis or neurological disease affecting the urinary bladder. It could be psychogenic also.

Hesitancy, retention of urine, retention with overflow:

These are common symptoms of benign enlargement of prostate past middle age. Characteristically, the stream of the urine produced during micturition is thin and poor, and the patient complains of difficulty in initiation of micturition (hesitancy) and in stopping it (terminal dribbling). Acute retention may follow with overflow. These symptoms can also be seen in spinal cord lesions (acute, complete lesion).

Urinary Incontinence

It refers to the inability to retain urine in the bladder. Young women in child-bearing age may complain of involuntary passage or leakage of urine during coughing, sneezing and laughing. This is called *stress incontinence*. Some old patients with cognitive or neurosensory deficits complain of involuntary passage of urine because they do not sense the bladder fullness. Upto 30% older patients are concerned about urinary incontinence that is socially embarrassing or cause problem with hygiene. The causes of incontinence are given in the Table 2.24. Some old persons with mental derangement wet their trousers before reaching the bathroom.

Enuresis

It is involuntary passage of urine at night or during sleep. It is also called *nocturnal enuresis* or *night bed-wetting*.

Bed-wetting is normal upto 2 years of age. In some children, bed-wetting persists upto 3 years due to delayed acquisition of the bladder control. Majority of the bed-wetters become dry at the age of puberty. Enuresis may be organic or psychogenic. The organic enuresis occurs both during the day and night. The causes include UTI, obstructive uropathy,

TABLE 2.24 Causes of urinary incontinence

- **Neurogenic incontinence**, e.g. CVA, dementia, neoplasm, hydrocephalus, spinal cord compression, pelvic tumours, uterine prolapse
- **Stress incontinence**
 - Postmenopausal parous women
- **Overflow incontinence**
 - Bladder neck obstruction
 - Urethral stricture
 - Benign enlargement of prostate
- **Mechanical incontinence**
 - Congenital abnormality of urinary bladder
 - Transurethral resection of prostate with damage to sphincters
- **Functional incontinence**
 - Anxious children
 - Neuropsychiatric or mental derangement
 - Musculoskeletal disorders
 - Immobility

utrovesical dysfunction and polyuria. The psychogenic enuresis is common in young children.

Pneumaturia

It refers to passing air bubbles in the urine. It is caused by a colovesical fistula due to diverticular abscess or malignant disease.

Puffiness of Face and Oedema

Morning puffiness of face, periorbital oedema and pitting pedal oedema are characteristic features of renal diseases (nephritic and nephrotic syndrome) and renal failure due to any cause.

NEUROLOGICAL SYMPTOMS

Headache

(Discussed in examination of cranium Chapter 3)

Involuntary Movements

Neurological disorders especially involving the basal ganglia and extrapyramidal system manifest with certain involuntary or unintended movements (Box 19). These involuntary movements are not disease specific. They are discussed under nervous system examination.

Epilepsy/Seizure

The epilepsies or seizure disorders comprise a group of clinical disorders of cerebral functions characterised by chronic, recurrent, paroxysmal nonsynchronous discharge of cerebral neurons. *Seizure* is defined as an episode of neurological dysfunction. Convulsions are seizures accompanied by motor manifestations, i.e. limb jerking, incontinence of urine or faeces or both etc. Seizures need not be always convulsive, it may be manifested by other changes in the neurological functions, i.e. sensory, cognitive, emotional events etc.

Box 19

Various involuntary movements

- Epilepsy
- Myoclonus
- Tremor/asterixis
- Athetosis
- Chorea
- Hemiballismus
- Fasciculations
- Dystonia
- Dyskinesia
- Torticollis
- Tics
- Myokymia
- Tetany
- Cramp

Note: An isolated nonrecurrent seizure occurring in an otherwise healthy individual for no obvious reason should not be labelled as epilepsy.

The questionnaire for convulsions are given in the Box 20 and Table 1.3 on systemic symptoms. These questions not only help to categorise the epilepsy into partial or focal seizures (simple or complex) and generalised form but also suggest the status of epilepsy.

The epilepsy starts from one area of the brain and may remain limited to that area or may become generalised (secondary generalisation of focal seizures). In focal epilepsy, if consciousness is preserved, it is called *simple partial* and; if lost then it is called *complex partial seizures*.

Different terms are used by the patients for different involuntary movements such as ‘fits’ for epilepsy, shaking or trembling of hands for tremors, dancing movements for chorea and muscle twitchings for fasciculations.

Vertigo or Dizziness (Read Chapter 7 Also)

Dizziness is a common and often vexing symptom that patients use to describe a variety of sensations such as light-headedness, faintness, spinning, giddiness etc. The symptomatic enquiries for dizziness are given in the Box 21 and Table 1.3.

Box 20

Enquiries for convulsions

- Are convulsions present?
- Are they generalised or focal?
- Where from do they begin or end?
- Does the patient fall?
- Has the patient ever hurt himself/herself?
- Does he/she bite his/her tongue?
- Does the patient micturate or defaecate during the fit?
- Are there any after-symptoms (postictal symptoms)— automatism, sleep, headache or paralysis?
- Is there any mental disturbance associated with it?

Box 21

Symptomatic enquiries for dizziness

- Is it intermittent?
- Does it relate to change in head posture?
- Is there a history of deafness?
- Is there a history of trauma?
- When does it become worse?
- Are there any associated symptoms such as ataxia, speech disturbance, double vision, facial weakness?

Vertigo is an illusory or hallucinatory sense of self or environmental movement, most commonly due to a disturbance in the vestibular system. The causes of vertigo have been discussed in Chapter 7.

Nystagmus is a common concomitant of vertigo. Vertigo may be peripheral (labyrinthine and vestibular causes) or central (brain-stem and cerebellar lesions). The vertigo is analysed as follows:

- The distinction between true vertigo and dizziness is by provocative tests (read ENT examination as separate Chapter 7).
- Once it has been established that it is true vertigo rather than dizziness, then find out whether it is central or peripheral (*see* Table 7.2).
- The time course and duration of vertigo also help in the diagnosis. Recurrent episodes of brief positional vertigo (lasting less than a minute) indicate benign positional or post-traumatic vertigo. It can be psychogenic. On the other hand, recurrent spontaneous vertigo lasting for minutes/hours indicates Meniere's disease, vertebrobasilar insufficiency, migraine or autoimmune disease. Spontaneous attacks of prolonged vertigo lasting for a day or longer suggest labyrinthitis, multiple sclerosis or an infarction in the vertebrobasilar artery territory.
- Vascular cause (vertebrobasilar insufficiency) is suspected in elderly patients with predisposing factors such as hypertension, CVA, IHD, smoking, diabetes, hyperlipidaemia.
- Patients with central vertigo can neither stand or walk and direction of fall is variable. Vertical nystagmus (up beat or down beat) is pathognomonic of central vertigo. Most common cause of central vertigo is vascular insufficiency of brain stem (ischaemia/infarction) or basilar artery insufficiency supplying the cerebellum.
- A peripheral cause is suspected when there is history of ear discharge or pain, unilateral deafness or tinnitus. It is unidirectional nystagmus with slow component (phase) towards the affected ear and fast component away from (opposite to) the side of lesion. It is commonly due to labyrinthine disorders.

Syncope

Syncope refers to loss of postural tone, inability to maintain erect posture followed by unconsciousness. It is a symptom of decreased cerebral perfusion (Table 2.25). It occurs commonly in standing position due to postural drop in BP but it can occur in sitting position in conduction defects called Stokes-Adam attacks. The loss of consciousness is briefer than an epileptic fit (Table 2.26). Syncope has been discussed as a symptom of cerebrovascular disease (Read neurology). The three common syncope are compared in Table 2.27.

TABLE 2.25 Causes of syncope

<ul style="list-style-type: none"> • Decreased cerebral perfusion <ul style="list-style-type: none"> – <i>Inadequate vasoconstrictive mechanisms</i> <ul style="list-style-type: none"> - Vasovagal (vasodepressor) - Postural hypotension (autonomic neuropathy) - Carotid sinus hypersensitivity - Antihypertensive drugs (hydralazine, alpha-methyl dopa) – <i>Hypovolaemia</i> <ul style="list-style-type: none"> - Fluid or blood loss - Addison's disease – <i>Reduction in venous return</i> <ul style="list-style-type: none"> - Cough and micturition syncope - Mediastinal compression - Straining during defaecation - Valsalva manoeuvre – <i>Reduction in cardiac output</i> <ul style="list-style-type: none"> - Left ventricular outflow tract obstruction, e.g. valvular heart disease, hypertrophic cardiomyopathy - Right ventricular or pulmonary outflow obstruction, e.g. pulmonary stenosis, pulmonary hypertension, pulmonary embolism 	<ul style="list-style-type: none"> - Myocardial disease (infarction, inflammation) - Cardiac tamponade (pericardial effusion) – <i>Arrhythmias</i> <ul style="list-style-type: none"> - Sinoatrial and AV blocks - Supraventricular/ventricular arrhythmias - Ventricular asystole • Other causes <ul style="list-style-type: none"> – <i>Altered state of blood</i> <ul style="list-style-type: none"> - Hypoxia - Anaemia - Hypoglycaemia - Hyperventilation - Prolonged bed rest – <i>Cerebrovascular disturbance</i> <ul style="list-style-type: none"> - TIAs - Vertebrobasilar insufficiency - Hypertensive encephalopathy
--	--

TABLE 2.26 The distinction between syncope and an epileptic fit

Feature	Syncope	Epilepsy
Precipitating factors	Emotional, painful or stressful stimuli	Unusual or recognised
Position	Upright	Any position
Diurnal pattern	Day time	Day and night
Onset	Subacute or gradual	Acute
Aura	Absent	Present
Motor symptoms and signs	Motionless, flaccid, may have few clonic jerks	Often tonic or tonic-clonic, or clonic jerks
Colour of the skin	Pale or ashen-gray	Pale or flushed
Cyanosis	Absent	May be present
Breathing	Slow, shallow	Stertorous
Urinary and /or faecal incontinence	Rare	Usual
Tongue biting	Rare	Common
Injury	Rare	Common
Postictal	Rare	Confusion, headache, drowsiness, sleep
Period of unconsciousness	Brief (few seconds)	Short (few minutes)

TABLE 2.27 Salient features of common syncope

Feature	Cardiac syncope	Vasovagal syncope	Neurogenic syncope
Premonitory symptoms	Light headedness, palpitation, chest discomfort, dyspnoea, and convulsions may occur	Nausea, perspiration, pallor, light-headedness	Headache, confusion, hyperexcitability, visual or auditory hallucinations and aura
Period of unconsciousness	Extreme, death like pallor present	Pallor with ashen-grey skin	Prolonged unconsciousness (>1 min), motor-seizure activity, urinary incontinence, tongue biting
Recovery	Rapid or fast	Slow recovery with nausea and light-headedness	Recovery with prolonged headache or focal neurologic deficit

Weakness or Paralysis

Weakness means reduction in normal power of one or more muscles. Paralysis and the suffix “*plegia*” implies weakness that is severe and complete or nearly complete. On the other hand, *paresis* implies partial weakness. The prefix “*hemi*” refers to one half of the body, “*para*” to both the lower limbs and “*quadri*” to all the four limbs. The enquiries about the weakness are given in the Box 22.

Analysis: (Basic patterns of weakness have been discussed in nervous system examination).

Episodic Weakness

Weakness whether true or perceived, may be due to disorders of the central or peripheral nervous system. Weakness from CNS disorders is usually accompanied by disturbance in the level of consciousness, or cognition, and with hypertonia

Box 22

Enquiries about weakness/paralysis

- Is there any inability to move the limb/part or side of the body?
- Did the weakness start slowly or suddenly?
- Is it stationary or has progressed? if, yes, then how it progressed?
- Which area of the body is involved?
- Does the weakness affect one or both sides?
- What movements are affected?
- Is there any difficulty in combing hair, trying to reach high shelf or difficulty in getting out of a chair, or taking a high step up?
- Does the weakness increase with effort and improve after rest?
- Are there any associated sensory or other symptoms?
- Is there any difficulty in opening a jar or cane or using hand tools (e.g. scissors, screw driver)?

TABLE 2.28 Common causes of episodic weakness

- **Electrolyte disturbances**
 - Hypo or hyperkalaemia due to any cause
 - Hypercalcaemia and hypocalcaemia (tetany)
 - Hyponatraemia
 - Hypophosphataemia
- **Neuromuscular junction disorders**
 - Myasthenia gravis
 - Myasthenia-myopathic syndrome. (Lambert-Eaton syndrome)
- **Muscle diseases**
 - Periodic paralysis
 - Myotonias
 - Metabolic defects of muscles
- **CNS disorders**
 - Cataplexy and narcolepsy
 - Multiple sclerosis
 - TIAs
- **Miscellaneous**
 - Hyperventilation (alkalosis)
 - Hypoglycaemia

(increased tone or spasticity) and exaggerated tendon reflexes, and often with alteration of sensations. Intermittent or episodic weakness with normal mental function is a characteristic of neuromuscular disorders. The common causes of episodic weakness are electrolyte disturbance, neuromuscular disorders or muscle disorders and due to CNS and metabolic causes (Table 2.28). The questionnaire for episodic weakness given in the Box 23.

Terminology for Motor and Sensory Symptoms

One must be clear regarding the terminology to be used for various motor and sensory symptoms. The patient may interpret them in different ways but a doctor/student should use correct term listed for motor symptoms (Box 24) and sensory symptoms (Box 25).

Sensory Symptoms

The different types of sensory loss are discussed under neurological examination Chapter 15.

The Gait

The normal gait and its abnormalities are discussed in examination of nervous system.

Acute confusional state, dementia are discussed in psychiatric case examination Chapter 20. The coma or unconsciousness is discussed as a separate Chapter 19.

Box 23

Enquiries about episodic weakness

- Hypokalaemic periodic paralysis occurs at rest after immediately after cessation of exercise. Diarrhoea, high carbohydrate diet, diuretics, steroids, and hyperthyroidism are its important causes. Therefore ask the history of these precipitating factors/illnesses
- Hyperkalaemic period paralysis occurs in the setting of renal or Addison's disease. Ask the history for clinical features of these diseases
- Sodium loss occurs from GI tract (diarrhoea, vomiting, burns, excessive sweating, pancreatitis) or through kidneys (diuretics, salt wasting nephropathy, hypoaldosteronism). Ask for these conditions/illnesses
- Tetany may be hypocalcaemic, alkalotic, hypokalaemic and hypomagnesaemic. In case of tetany, try to explore the underlying cause of electrolyte disturbance
- Episodic weakness may occur in metabolic muscle disorders characterised by muscle pain and muscle weakness
- Hyperventilation may produce recurrent attacks of weakness but these patients have normal strength when tested
- Episodes of hypoglycaemia may produce transient subjective weakness
- Patients with narcolepsy, cataplexy and sleep paralysis may have sudden loss of strength and tone during the attack

Box 24

Clinical terminology used for symptoms referable to muscles (motor symptoms)

- **Spasms:** It refers to brief, unsustained contractions of a muscle or muscles. It results from abnormal electrical activity of CNS, motor neurons or muscle(s) itself. Flexor or extensor spasms result from UMN lesions
- **Cramp:** It refers to paroxysmal, spontaneous, painful and prolonged contraction of a muscle or muscles
- **Stiffness:** It refers to rigidity or spasm
- **Asthenia:** It refers to muscle pain associated with fatigue
- **Myalgia:** It is a muscular pain in the absence of muscle weakness, is usually viral in origin (influenza, coxsackie virus). *Fibrositis*, *fibromyalgia* and *fibromyositis* are synonyms for a disorder associated with muscle pain/tenderness. Myalgia may be *polymyalgia rheumatica* (occurs over age 50 and is characterised by pain, stiffness in shoulder and hip muscles) or may be a symptom of other rheumatological disorders (rheumatoid arthritis, SLE, PAN, scleroderma and mixed connective tissue syndrome)

Box 25

Terminology used for abnormal sensations

- **Paraesthesia:** It is a positive symptom, denotes the abnormal sensation perceived without an apparent stimulus
- **Dysaesthesia:** It is also a symptom used to denote all types of positive sensations whether a stimulus is evident or not
- **Hypoaesthesia:** It means reduction of cutaneous sensation to a specific stimulus for testing such as pressure, light touch and warm or cold stimuli
- **Anaesthesia:** It means loss of skin sensations of all types
- **Hypoalgesia:** It means loss of pain sensation only
- **Hyperalgesia:** It means an exaggerated response to a noxious stimulus such as squeezing of calf produces pain in a patient with peripheral neuropathy
- **Hyperaesthesia:** It means exaggerated perception of sensations in response to mild stimuli (light touch or stroking of the skin)
- **Allodynia:** It is a condition in which nonpainful stimulus once perceived, is experienced as painful. For example, a vibrating tuning fork may be perceived as painful stimulus
- **Hyperpathia:** It is a broad term used to include hyperaesthesia, allodynia and hyperalgesia, seen in thalamic lesions
- **Sensory ataxia (loss of position sense):** It is characterised by imbalance particularly with the eyes closed or in the dark, clumsiness or precision movements and unsteadiness of gait. It indicates posterior column involvement. Romberg's sign is used to test the sense of position (read examination of nervous system)

Box 26

Common endocrinal symptoms

- **Body size and shape**
 - Alteration in stature (short or tall)
 - Weight gain/loss
- **Metabolic effects**
 - Tiredness, weakness
 - Change in appetite (increased/decreased)
 - Polydipsia (excessive thirst)
 - Polyuria and nocturia
 - Tremors, palpitations, sweating
- **Local effects**
 - Headache, visual disturbance
 - Prominence of eyes
 - Bone or muscle pain
 - Swelling in the neck
- **Reproduction and sex**
 - Impotence/loss of libido
 - Oligomenorrhoea/amenorrhoea
 - Infertility
 - Galactorrhoea
 - Gynaecomastia (breast enlargement in males)
 - Delayed puberty
 - Precocious puberty
- **Skin**
 - Hirsutism and thinning of hair
 - Pigmentation, dryness of skin

ENDOCRINAL SYMPTOMS

There are certain symptom complexes that particularly suggest an endocrinal or metabolic disorder are discussed and analysed in this section. The symptoms are given in the Box 26.

Excessive Thirst (Polydipsia) and Excessive Urination (Polyuria)

The polyuria as an isolated symptom has been discussed under urinary symptoms.

Polyuria, polydipsia and polyphagia is a characteristic triad of type I diabetes mellitus. The polyuria is due to osmotic diuresis induced by glucosuria and other two symptoms in the triad are obligatory. Polyuria and polydipsia may occur in:

- **Central or neurogenic diabetes insipidus** due to deficiency of secretion of ADH by posterior pituitary.
- **Nephrogenic diabetes insipidus** in which there is a failure of action of ADH on distal tubules. This may be inherited or acquired secondary to impairment of ADH action by hypercalcaemia (hyperparathyroidism) or hypokalaemia.

- **Primary or psychogenic polydipsia:** It is due to compulsive water drinking leading to excessive fluid intake resulting in polyuria and polydipsia.

The differentiation between *psychogenic polydipsia* and *diabetes insipidus* is important. Generally nocturnal polyuria is not a feature of psychogenic polydipsia. The absolute differentiation needs water deprivation (Table 2.29) in addition to other tests to find out the cause. Vasopressin test differentiates between cranial diabetes insipidus from nephrogenic diabetes.

Vasopressin Test

It is performed as a second part of 8 hours water deprivation test to differentiate cranial diabetes insipidus from nephrogenic diabetes insipidus. Rise in urine osmolality >900 mOsm/kg of pretest level is diagnostic of cranial diabetes insipidus; while no rise or insignificant rise may occur in nephrogenic diabetes insipidus.

Weight Loss

It is a physical sign rather than symptom, hence, discussed in general physical examination (Read the Chapter 3).

TABLE 2.29 Distinction between diabetes insipidus and psychogenic polydipsia

Test	Diabetes insipidus				Psychogenic polydipsia			
	Plasma osmolarity		Urinary osmolarity		Plasma osmolarity		Urine osmolarity	
	Initial	Final	Initial	Final	Initial	Final	Initial	Final
Water deprivation test (no fluid for 8 hours)	High	Rises further	Low	No rise	Low	Raised	Low	Raised

Weight loss in endocrinal disorders is either due to increased metabolism (increased energy expenditure) seen in hyperthyroidism and pheochromocytoma; or increased energy loss such as type I diabetes mellitus or due to diminished food intake, i.e. anorexia nervosa, hypercalcaemia and adrenal insufficiency. Weight loss with increased appetite is invariably seen in hyperthyroidism and diabetes mellitus, while weight loss with poor appetite is characteristic of anorexia nervosa.

Weight Gain

Weight gain is a symptom of certain endocrinal and metabolic disorders. The causes of weight gain in different endocrinal disorders are given in Table 2.30.

Muscle Weakness/Myopathy

Many endocrinal disorders cause muscle weakness and symmetrical proximal myopathy characterised by difficulty in climbing up-stairs, rising from a sitting position and boarding a train or bus. The proximal groups of muscles involved are the hip and shoulder girdle muscles, hence, resemble girdle myopathy. This can be subclinical but can be demonstrated by Gower’s sign by asking the patient to rise from the sitting position. The endocrinal and metabolic causes of myopathy are listed in the Box 27. The painful myopathy of endocrinal causes can be confused with polymyositis, polymyalgia rheumatica as well as spinal motor root/plexus disease.

Temperature Intolerance (Heat or Cold)

Thyroid disorders predispose the patients to temperature intolerance due to change in basal metabolic rate.

Cold intolerance is a feature of hypothyroidism in which a patient feels abnormal sensation of cold which is out of proportion to that experienced by normal individuals. This is due to low metabolic rate (hypometabolism). This symptoms is different from coldness of hands due to vasospasm seen in Raynaud’s phenomenon (e.g. a tricolour response with coldness of hands).

Heat intolerance, a symptom of thyroid over activity is commonly seen in patients with hyperthyroidism. It is

TABLE 2.30 Cause of weight gain in endocrinal disorders

Cause	Disorder
Low metabolic rate resulting in low energy expenditure	Primary hypothyroidism
Redistribution of fat in central areas (truncal obesity) with paradoxical thinning of extremities	Cushing’s syndrome
Energy intake more than expenditure	Simple obesity (Read Chapter 3 also)
Genetic predisposition to weight gain	<ul style="list-style-type: none"> Prader-Willi syndrome Laurence-Moon-Biedle syndrome (autosomal recessive) Alstrom, Cohen and Carpenter syndromes (autosomal recessive, cause childhood obesity) Frolich’s syndrome

Box 27

Conditions associated with myopathy

Painless	Painful
<ul style="list-style-type: none"> Hyperthyroidism Cushing syndrome Acromegaly Hyperparathyroidism 	<ul style="list-style-type: none"> Vitamin D deficiency Osteomalacia
<ul style="list-style-type: none"> Steroid-induced myopathy 	<ul style="list-style-type: none"> Hypothyroidism (e.g. Debre-Kocher-Semelaigne syndrome, in children and Hoffman’s syndrome in adults) Diabetic myopathy (ischaemia or infarction of muscles)
<ul style="list-style-type: none"> Conn’s syndrome (primary hyperaldo-steronism) 	<ul style="list-style-type: none"> Hypoparathyroidism (generalised tetany)

characterised by inability of the patient to tolerate heat or high temperature. The thyrotoxic patients feel comfortable at ambient temperature which others find unpleasantly cold. This is due to a high metabolic rate (hypermetabolism).

Increased sweating (hyperhidrosis) is a symptom of thyrotoxicosis, (excess of thyroid hormones) or hyperaldrenalism/phaeochromocytoma (excess of catecholamine), acromegaly (excess of GH), autonomic neuropathy (gustatory hyperhidrosis) and anxiety neurosis.

Loss of sweating (anhidrosis) or reduced sweating is a symptom of

- Hypothyroidism
- Hypothermia
- Autonomic neuropathy
- Acute or subacute dysautonomia
- Hypoadrenalism
- Anticholinergics
- Vitamin A deficiency
- Sjögren's syndrome.

Postural Instability

It means a sensation of faintness or giddiness on standing (syncope) occurs due to a fall in diastolic blood pressure on standing (postural hypotension) as a result of reduced cardiac output or blood volume. If a patient complains of this symptom, one must measure the BP in lying and standing positions. The causes of postural hypotension are:

- Reduced blood volume (hypovolaemia) due to bleeding or fluid loss
- Adrenal insufficiency (Addison's disease)
- Autonomic neuropathy especially in long-standing diabetes (microvascular complications), beri-beri and amyloidosis
- Antihypertensive therapy and vasodilators
- After sympathectomy
- Prolonged bed rest or recumbancy in elderly.

The various accompanying symptoms with postural hypotension are given in the Box 28. The history of these accompanying symptoms or signs and drug history must be recorded.

Visual disturbance: Several endocrinal disorders produce visual symptoms:

- I. **Graves' disease ophthalmopathy:** The proptosis or exophthalmos in Grave's disease may cause decreased

Box 28

Accompanying symptoms/signs of postural hypotension

- Loss or diminished lacrimation, sweating, and salivation
- Loss of pupillary reflexes
- Compensatory tachycardia, pallor or nausea may or may not occur
- Impotence
- Paresis of bladder and bowel

visual acuity, ophthalmoplegia and congestive oculoopathy characterised by chemosis, conjunctivitis, diplopia, periorbital swelling, optic neuritis and optic atrophy. This is a mechanical complication occurring due to compression of optic nerve in the orbital space.

- II. **Pituitary tumours:** The optic chiasma is located anterior to the pituitary stalk above the diaphragma sella. The lateral walls of sella turcica abut on the cavernous sinuses which contain internal carotid arteries and III, IV, V and VI cranial nerves. Therefore, a pituitary tumour may compress optic chiasma and optic nerve by suprasellar extension leading to visual field defect. By lateral extension, it may compress the cranial nerves in cavernous sinus leading to diplopia. It may compress the optic radiation by infrasellar extension leading to quadrantic field defect.

Macropsia (apparent magnification of vision) can occur in hypoglycaemia and migraine.

Symptoms of Sympathetic Overactivity (e.g. Tachycardia, Tremors, Perspiration)

These symptoms occur spontaneously due to excessive sympathetic drive, are seen in thyrotoxicosis, phaeochromocytoma, acromegaly, diabetic ketoacidosis and anxiety neurosis. If these symptoms occur in fasting state, then they are mostly due to hypoglycaemia which can be induced by:

- Insulinoma (insulin secreting tumour)
- Drugs, e.g. inappropriate insulin or excess of oral hypoglycaemic agents especially sulphonylureas administration in diabetic patients
- Hypopituitarism (e.g. corticosteroid deficiency with or without thyroxine deficiency—Schmidt's syndrome)
- Primary adrenal failure
- Hepatic failure (rare cause)
- Paraneoplastic syndrome, e.g. tumours secreting insulin-like hormone/peptide.

Dysphagia

Dysphagia in endocrinal disorders is due to mechanical compression of oesophagus by either diffuse goitre (Graves' disease), simple large goitre or multinodular goitre. Motor dysphagia may occur due to reversible pharyngeal muscle weakness in severe hyperthyroidism.

SYMPTOMS PERTAINING TO GENITAL SYSTEM

Impotence

It is defined as the failure to achieve penile erection, ejaculation or both. Men with sexual disorders present with a variety of

complaints either singly or in combination such as loss of libido (desire), inability to maintain an erection, ejaculatory failure, premature ejaculation or inability to achieve orgasm. Impotence can result due to:

- Systemic illness or its treatment
- Specific disorders of urogenital and endocrinal systems
- Psychological disturbance.

Note: It was previously thought that the majority of men with erectile dysfunction had a psychological cause, but it has now become clear that most impotent men have a component of underlying organic disease.

Failure of erection (erectile impotence) may be due to a variety of causes (Table 2.31). *Premature ejaculation* seldom has an organic cause.

Absence of emission is produced by retrograde ejaculation, sympathetic denervation, androgen deficiency or drugs. If libido and erectile functions are normal, the absence of orgasm is almost always due to a psychiatric disorder.

Loss of libido/desire may be due to androgen deficiency, psychological disturbance or to some types of habitually abused drugs.

TABLE 2.31 Causes of erectile impotence in men

- **Endocrinal causes**
 - Testicular failure (primary or secondary)
 - Hyperprolactinaemia
- **Drugs**
 - *Antiandrogens*, e.g. H₂-blockers, spironolactone, ketoconazole
 - *Antihypertensives*, e.g. sympatholytics (clonidine, methyldopa), betablockers, thiazides
 - *Anticholinergics*
 - *Antidepressants*, e.g. MAO inhibitors, tricyclic
 - *Antipsychotics*
 - *Anxiolytics and sedatives*
 - *Toxic*, e.g. alcohol, smoking
- **Penile diseases**
 - Ischaemia due to atherosclerosis
 - Penile trauma
 - Previous priapism
- **Neurologic diseases**
 - Temporal lobe lesion
 - Diseases of spinal cord
 - Diseases of nerve roots, e.g. tabes dorsalis, radiculopathy
 - Polyneuropathies especially diabetic autonomic neuropathy
- **Vascular disease**
 - Aortic dissection (Leriche syndrome)
 - Atherosclerotic occlusion or stenosis of pudendal arteries
- **Psychological**
 - Anxiety
 - Emotional disorders
 - Depression

Priapism: It refers to persistent painful erection of penis, often unrelated to sexual activity. Priapism differs from normal erection by the absence of tumescence of the glans penis. The causes of priapism are given in the Box 29.

Infertility

It means failure to conceive. Around 10% of couples have difficulty in conceiving children. One third of cases are attributed to infertility in female, other third to male and remaining one third belong to idiopathic group. Infertility is a common presenting symptom in female but the couple has to be assessed for it. It must be stressed that one must ensure that the couple is having intercourse when the woman is likely to be fertile (between 10 to 14 days after start of menstruation). The causes of male infertility are given in the Table 2.32.

Box 29

Causes of priapism

- Idiopathic
- Sickle cell anaemia
- Chronic myeloid/granulocytic leukaemia
- Spinal cord injury
- Injection of vasodilator agents (such as alprostadil) into the penis

TABLE 2.32 Causes of infertility in males

- **Hypothalamic-Pituitary**
 - Panhypopituitarism
 - Isolated gonadotropin deficiency
 - Hyperprolactinaemia
 - Haemochromatosis
 - Congenital adrenal hyperplasia
- **Testicular**
 - *Developmental and structural defect*
 - Klinefelter's syndrome
 - Cryptorchidism
 - Varicocele
 - Immobile cilia syndrome
 - *Acquired defect*
 - Infection, e.g. orchitis
 - Trauma, radiation
 - Drugs, e.g. spironolactone, ketoconazole, cyclophosphamide
 - Granulomatous disease
 - Associated with systemic diseases, e.g. liver diseases, renal failure, sickle cell diseases, AIDS
 - Neurological disease, e.g. paraplegia, myotonia dystrophica
- **Obstruction to sperm transport**
 - Obstruction to epididymis or vas deferens, e.g. cystic fibrosis

Infertility in Females

Infertility in female refers to the failure to become pregnant after 1 year of unprotected intercourse. The causes are given in the Table 2.33.

Menstrual Irregularities

Amenorrhoea: An acceptable definition of amenorrhoea is failure of menarche by age of 16 irrespective of the presence or absence of secondary sexual characteristics or the absence of menstruation for 6 months in a woman with previous normal menses. It is a common complaint among women. The common endocrinal causes are:

- Hypothalamic-pituitary dysfunction, e.g. tumour (prolactinomas may produce galactorrhoea-amenorrhoea syndrome).
- Ovarian failure (primary or secondary), e.g. gonadal dysgenesis, deficiency of P₄₅₀, resistant ovarian syndrome etc.
- Thyroid dysfunction, e.g. thyrotoxicosis
- Defects in lower genital tract development, e.g. imperforate hymen, transverse vaginal septa, cervical stenosis, intrauterine adhesions, absence of vagina or uterus etc.

Precocious Puberty

This is a symptom among girls. Puberty is said to be precocious if breast budding begins before age 8 or if menarche occurs before age 9. It can be isosexual or heterosexual. The causes are given in the Table 2.34.

TABLE 2.33 Causes of infertility in females

- **Hypothalamic-pituitary-ovarian dysfunction**
 - Panhypopituitarism
 - Hypogonadotropic hypogonadism (Kallmann's syndrome)
 - Craniopharyngioma
 - Pituitary tumours, e.g. hyperprolactinoma
 - Anorexia nervosa
 - Chronic debilitating diseases, e.g. renal failure, malignancy, malabsorption etc.
- **Genital (ovarian/uterine/tubal/cervical) dysfunction**
 - Primary ovarian failure (polycystic ovarian syndrome, Turner's syndrome 46XO, enzyme deficiency syndromes-17 alpha-hydroxylase, resistant ovarian syndrome)
 - Tumours of ovaries (granulosa-theca cell tumours, Brenner's tumour, cystadenomas, Krukenberg tumour)
 - Anovulatory cycles (dysfunctional uterine bleeding)
 - Tubal diseases, e.g. salpingitis, irradiation, trauma
 - Endometriosis
 - Congenital defects of vagina, i.e. imperforate hymen, transverse vaginal septae, mullerian agenesis (the Mayer-Rokitansky-Kuster-Hauser syndrome), hypoplasia of vagina

Isosexual precocious puberty means developing sexual characteristics are appropriate for the genetic and gonadal sex, i.e. feminization in girls and virilization in boys.

Heterosexual precocious puberty refers to sexual characteristics not in accordance with the genetic sex, namely virilization in girls or feminization in boys.

Gynaecomastia

Enlargement of the breast due to proliferation of breast tissue in males is called gynaecomastia. It can be physiological, i.e. mild breast enlargement in the male may occur during puberty and may persist for several years. Growth of the breast in men, as in women, is mediated by oestrogen, hence, results from disturbed normal ratio of active androgen to oestrogen (Table 2.35).

Galactorrhoea

Galactorrhoea means nonpuerperal or inappropriate lactation in a female. No breast secretions whatsoever are detectable in normal regularly menstruating nulligravid women but breast secretions can be demonstrated in 25% of normal females who have been pregnant in the past. Occasionally, lactation may persist after breastfeeding following child-birth has ceased. The causes of galactorrhoea have been discussed in Chapter 9.

TABLE 2.34 Causes of sexual precocity

- **Isosexual precocity**
 - *True precocious puberty* (premature appearance of sexual characters due to excessive secretion of gonadotrophins/LHRH).
 - Constitutional
 - Congenital adrenal hyperplasia
 - Organic brain diseases
- **Precocious pseudopuberty (enhanced oestrogen formation)**
 - Ovarian tumours
 - Adrenal tumours
 - Hypothyroidism
 - Russell-Silver syndrome (short stature, and precocious feminization)
 - McCune-Albright syndrome (Cafe-au-lait spots, cystic fibrous dysplasia of bones and sexual precocity)
- **Incomplete isosexual precocity (i.e. premature development of a single pubertal event)**
 - Premature thelarche (premature breast budding only)
 - Premature adrenarche and pubarche (appearance of axillary and/or pubic hair without any secondary sexual character development)
- **Heterosexual precocity**
 - Ovarian tumours
 - Adrenal tumours
 - Congenital adrenal hyperplasia

TABLE 2.35 Causes of gynaecomastia (See Figs 9.7 and 9.8)

- **Increased oestrogen/testosterone ratio**
 - Chronic liver disease (cirrhosis)
 - Hyperthyroidism
 - Malnutrition
 - Adrenal disease
 - Phenytoin toxicity
 - Oestrogen secreting tumour of testis
 - Human chorionic gonadotrophin secreting tumours of testes
- **Androgen receptors antagonists:**
 - Spironolactone, digoxin
 - Anti-androgen therapy for prostate carcinoma
 - Cimetidine
- **Androgen receptors defects** (inherited or acquired)
 - Testicular feminization syndrome
 - Hypogonadism
 - Primary, e.g. Klinefelter syndrome mumps orchitis, haemochromatosis, tuberculosis, chemotherapy or irradiation, cryptorchidism and autoimmune gonadal failure
 - Secondary, e.g. Hypopituitarism, Kallmann's syndrome, hyperprolactinoma

Hirsutism (Excessive Hair Growth)

Hirsutism refers to excessive growth of thick terminal hair in an androgen-dependent distribution in women (upper lip, chin, chest, back, lower abdomen, thigh, forearm). It is most common presentations in endocrine disease. It differs from hypertrichosis which is generalised excessive growth of vellus hair. The causes of hirsutism are given in the Chapter 4 (Read Chapter 4).

Cryptorchidism

Cryptorchidism refers to undescended testes. It occurs in otherwise normal boys but may be the presenting feature of hypogonadism. High retractile testes, particularly in the obese boy, may be mistaken for cryptorchidism. In cryptorchidism, the testes may remain in the inguinal canal, retroperitoneally or in the pelvis. In this condition, secondary sexual characters development may remain normal.

Proptosis (Exophthalmos)

Proptosis is an abnormal forward protrusion of eyeball. It can be unilateral or bilateral. It is measured by using a Hertel exophthalmometer. The causes have been discussed in Chapter 5.

SYMPTOMS OF RHEUMATIC DISEASES

The patients of musculoskeletal or rheumatological disorders present with a variety of complaints given in the Box 30. These may pertain to joint or periarticular soft tissue or bone.

Box 30

Common rheumatic symptoms

- Pain/tenderness joint
- Stiffness
- Swelling
- Weakness/disuse atrophy
- Joint deformity
- Nonspecific symptoms

Note: These have been dealt with in details in Chapter 17. (The locomotor system examination)

TABLE 2.36 Differentiation between articular (joint) and periarticular lesion

<i>Sign</i>	<i>Joint</i>	<i>Periarticular (soft tissue rheumatism/ extra-articular lesion)</i>
Tenderness and pain	Diffuse over the joint (joint line)	Localised around the joint (away from joint line)
Restricted movement	Active and passive movement affected equally	Active more restricted than passive
Resisted active movement	Not painful	Painful
Swelling	Capsular pattern	Localised, periarticular
Crepitus	Coarse or fine	Fine

Box 31

Differentiation between synovitis vs joint damage

<i>Feature</i>	<i>Synovitis</i>	<i>Joint damage</i>
• Stiffness (early morning, inactivity)	+++	±
• Increased warmth	+	-
• Stress pain	+	-
• Swelling of soft tissue	+	-
• Joint effusion	+++	±
• Crepitus	-	+++
• Deformity	-	+
• Instability	-	+

Analysis of Rheumatic Complaints

The analyses of musculoskeletal complaint in terms of history and physical examination have been discussed.

The symptoms and signs that differentiate articular (joint) and periarticular diseases are given in the Table 2.36.

Features that differentiate inflammatory joint disease (synovitis) from noninflammatory joint damage are summarised in the Box 31.

Box 32

Causes of arthritis

<i>Acute</i>	<i>Chronic</i>
<ul style="list-style-type: none"> • Infectious arthritis • Gout • Pseudogout • Reiter's syndrome • Acute presentation of chronic arthritis 	<ul style="list-style-type: none"> • Mono/oligoarthritis <ul style="list-style-type: none"> - Indolent infection - Psoriatic - Reiter's syndrome - Pauciarticular juvenile arthritis • Polyarthritis <ul style="list-style-type: none"> - <i>Symmetric</i> (small joints) <ul style="list-style-type: none"> - Rheumatoid arthritis - Collagen vascular disorders, e.g. SLE, Scleroderma, polymyositis - <i>Asymmetric</i> <ul style="list-style-type: none"> - Psoriatic - Reiter's syndrome - <i>Large joints arthritis</i> <ul style="list-style-type: none"> - Osteoarthritis - Charcot arthritis - Ankylosing spondylitis

Box 33

Causes of polyarthralgia

- Viral infections
- Depression
- Fibromyalgia or soft tissue rheumatism
- Rheumatic fever
- Bursitis or tendinitis
- Hypothyroidism and hyperthyroidism
- Metabolic bone disease
- A symptom of many systemic diseases

Arthritis

It is inflammation of the joint characterised by pain, swelling, stiffness, warmth and restricted movement. It can be acute (<6 weeks) or chronic (>6 weeks). The causes of acute and chronic arthritis are given in the Box 32.

The causes of polyarthralgia where pain occurs around the joint but without involving it are given in the Box 33.

3

CHAPTER

General Physical Examination

GENERAL OBSERVATIONS

The general observation starts as soon as the patient enters the doctor's room. The physician/student tries to assess his/her general appearance which includes demeanour, personal cleanliness/hygiene and the nature and state of clothing. The things to be noted are given in the Box 1.

Box 1

Observations at a glance

- Note facial appearance, built, complexion, state of clothing
- Observe and define any abnormality of mental state, consciousness, gait, posture and movement
- Identify any abnormal sound or odour
- Assess the state of hydration, nutrition and oedema
- Observe any change in colour of skin and mucous membrane
- Measure the height and weight

1. **Facial appearance/expression.** Look at face for expression.

- Expressionless face is seen in parkinsonism.
- A startle look or staring look is seen in Grave's disease.
- Apathy or blunt expression is seen in depression.
- Agitation indicates hypomania.
- Toxic look with swinging temperature indicates septicaemia or toxemia.

The typical gross facial appearances that pinpoint the diagnosis are given in the Table 3.1.

The recognition of looks of pain, fear, anxiety, anger and grief alert the physician to explore the possibility of underlying psychiatric disorder.

2. **Complexion:** Note whether patient has dark or fair complexion. Abnormalities of complexion may be noticed by the friends, relatives and even by the patient. The colour of the skin or face depends on the variation in haemoglobin, melanin and to a lesser extent on carotene. The unusual skin colours are described in the Chapter 4.3. **State of clothing and personal hygiene:** Just inspection of clothing gives information about the personality and state of mind.

- Patients with dementia are shabbily dressed and may have faecal soiling of underwear.
- Excessive clothing may reflect the cold intolerance of hypothyroidism, or to hide the skin rash/disease or needle marks.

4. **Mental state/consciousness:** Is the patient conscious and co-operative?

Patient's conscious level should be observed. Examination of unconscious patient is described separately (Read Chapter 16). Note whether patient is co-operative and answer your questions or noncooperative and avoids or overlook your questions. Other higher mental functions are discussed in the examination of nervous system.

5. **Posture, gait and abnormal movements:** The posture of the patient may give valuable information. Severely ill patients are not comfortable in bed and adopt uncomfortable attitudes/postures.

Patients of congestive heart failure or cor pulmonale may sit up on the bed with legs hanging down the bed due to orthopnoea (Fig. 3.2). Patients with asthma are dyspnoeic at rest. Patients with abdominal colic are restless and toss in the bed in agony.

Patients with neurological disorders produce characteristic posture, for example, neck retraction is seen in meningitis. Abnormalities of gait, posture and abnormal movements are either due to a neurological disorder or locomotor disorder, hence, are discussed in respective sections (Read Chapter 17).

6. **Sounds/voice/speech:** Normal speech is produced by coordination of the tongue, lips, palate, nose and voice box in the larynx. The speech disturbances are discussed under the examination of nervous system. However, some non-neurological causes may produce disturbance in speech such as cleft palate, nasal obstruction, loose

TABLE 3.1 Face as a clue to diagnosis

Rounded moon-faces with red cheeks indicate Cushing's syndrome (Fig. 3.1A).

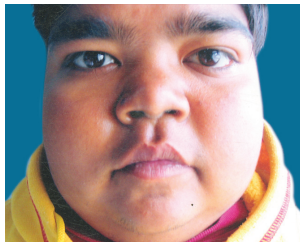

FIGURE 3.1A Moon-facies in Cushing's syndrome

Large facies, elongated protruding jaw, coarse facial appearance, thick lips, elongated head, short stubby finger and stout built indicate acromegaly (Fig. 3.1B).



FIGURE 3.1B Acromegaly

Dull puffy facies with non-pitting periorbital oedema. The hair on the eye brows are dry, coarse and loss of hair on outer third of eye brows indicate myxoedema (Fig. 3.1C).

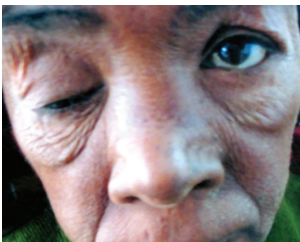

FIGURE 3.1C Myxoedema

Periorbital oedema with puffy eyelids in the morning (on getting up) making the eyes to look slit-like indicate renal oedema due to nephritic or nephrotic syndrome (Fig. 3.1D).

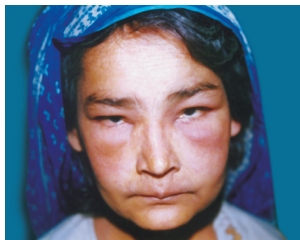

FIGURE 3.1D Nephrotic syndrome

Bilateral asymptomatic parotid glands enlargement indicates mumps, if acute, painful and tender (Fig. 3.1E).



FIGURE 3.1E Bilateral parotids enlargement

A mask-like face with decreased facial mobility, infrequent blinking and vacant look indicate Parkinsonism (Fig. 3.1F).



FIGURE 3.1F Mask like face of Parkinsonism

Disfigured scar red face due to superficial facial burns (Fig. 3.1G).

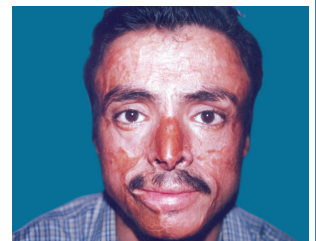

FIGURE 3.1G Disfigured charred face following burns

There is small, flat face, upward slanting eyes, small nose with depressed bridge and protruded furrowed tongue with idiotic look. There was an accessory breast on right side, simian crease in hand with short stubby finger, short 5th metacarpal, clinodactyly and wide gap in 1st and 2nd toes with prominent longitudinal crease. Features are suggestive of Down's syndrome (Fig. 3.1H).

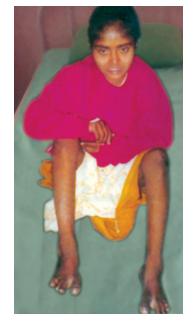

FIGURE 3.1H Mongolism in Down's syndrome

Box 2

Common causes of round/moon like face

- Cushing syndrom
- Pseudocushing syndrome (alcoholism)
- Myxoedema
- Angioneurotic oedema
- Nephritic/nephrotic syndrome

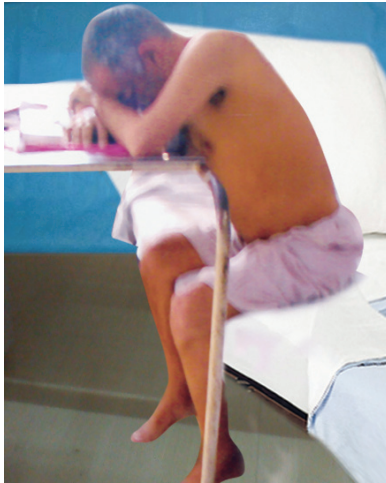

FIGURE 3.2 COPD with cor pulmonale. A patient of COPD with acute exacerbation and cor pulmonale adopts a typical posture to relieve breathlessness and oedema. The patient is sitting along the edge of the hospital bed with legs hanging and arms supported on the cardiac table, so as to reduce increased work cost of breathing as well as venous return from the legs

denture and dryness of mouth. Hoarseness of voice may be due to local cause (laryngitis) or a neurological disorder. The low-pitched, slow deliberate speech which sounds thick is characteristic of myxoedema due to myxomatous deposition in voice box.

Some other sounds may help in the diagnosis. Wheezing, rattling or stridor help in differentiation of dyspnoea. Sounds during coughing may be characteristic of some disorders such as *whooping cough* is suggestive of pertussis, *brassy cough* indicate bronchial obstruction (adenoma), *barking cough* suggest tracheobronchitis. A *cry* may be heard during an epileptic fit.

Audible noises of cardiovascular and alimentary systems are discussed in appropriate sections. Abnormalities of speech are discussed in examination of nervous system.

7. **Smell/odour:** *Normal smell* or odour from the body is due to sweat. *Pungent smell* may be due to excessive sweating and poor personal hygiene. *Malodour* (odour of dirty and soiled clothing and smell of dried-out urine) occurs

in elderly or physically disabled/bed ridden patients or those with dementia. The *offensive/faecal* smell from the body occurs in gastrocolic fistula. Some characteristic odours that help in the diagnosis are given in the Box 3.

Halitosis means malodorous breath which often goes unrecognised by the patient but is offensive to others. It occurs due to a variety of reasons/causes given in the Box 3.

8. **Built/physique:** Note whether height and weight are according to his/her chronological age. Is he/she tall or short, thin or muscular, asthenic or hypoasthenic? Are there any obvious deformities? Measure the height and body proportions if patient is too tall for his/her age.
9. **Measurement of height and weight:** Measurement of height and weight is important for their immediate value and for future reference. Measurements such as span, sitting height and pubis to ground height are made only where a more precise evaluation of growth and development is required especially in infants and young children (pre-pubertal). The significance of height is given in the Box 4 while causes of disorders of height are given in the Table 3.2. The normal height is equal to arm span (one fingertip to another finger-tip of outstretched arms) and twice the lower body segment (pubis to heel). For disturbance of these body proportions, read, "Bed side medicine without tears by Prof. SN Chugh".

Changes in weight: Change in weight results from changes in body tissues or body fluid. Weight gain occurs when caloric intake exceeds caloric expenditure over a prolonged period of time or may be due to an abnormal accumulation of body fluids (oedema, ascites, etc.).

Take the weight by a weighing machine adjusted at O. Weight should be measured with clothing (*pajama* and *kurta*, and *salwar* and *kameez*), wherever necessary body mass index (BMI) may be calculated.

Box 3

Abnormal smell from breath

• Malodorous breath (<i>Halitosis</i>)	Bronchiectasis, lung abscess, oral sepsis (stomatitis, gingivitis), extensive caries, atrophic rhinitis, smoking and idiopathic
• A fishy odour (feter hepaticus)	Hepatic failure
• Ammonical or urinary smell	Uraemia/azotaemia
• A sweet or fruity odour	Diabetic or starvation ketoacidosis

Box 4

Analysis of height

- Assess any abnormality in stature
- Measure height on vertical scale with rigid adjustable arm piece with patient standing erect without shoes

<i>Increased</i>	<i>Decreased</i>
<ul style="list-style-type: none"> • Gigantism (Fig. 3.3) • Hypogonadotrophic hypogonadism (Kallmann's syndrome, Laurence-Moon-Biedl syndrome) • Chromosomal abnormalities, e.g. Klinefelter's syndrome • Marfan's syndrome 	<ul style="list-style-type: none"> • Hereditary, e.g. constitutionally short • Genetics, e.g. Down's syndrome, Turner's syndrome and achondroplasia (Fig. 3.6) • Nutritional, e.g. protein energy malnutrition, rickets, intra-uterine growth retardation • Systemic disease, e.g. CRF, Steatorrhea • Endocrinal, e.g. hypothyroidism (cretinism, juvenile), hypopituitarism, craniopharyngioma • GI tract, e.g. malabsorption (coeliac disease Crohn's disease, cystic fibrosis) • Cardiorespiratory, e.g. congenital heart disease, suppurative lung disease • Locomotor, e.g. severe scoliosis

TABLE 3.2 Measurement of height in various disorders

<i>Measurement of body proportions</i>	<i>Disease</i>	<i>Other associated features</i>
Total height , upper and lower segments of body increased.	Gigantism (\uparrow GH) (Fig. 3.3)	Coarse facial features, thick lips, prognathism, sturdy body.
Eunuchoidism (the sitting height from top of head to pubic symphysis is less than half of total height during standing (top of head to floor)).	<ul style="list-style-type: none"> • Kallmann's syndrome (hypogonadotrophic hypogonadism) • Klinefelter's syndrome (47 XXY). 	Anosmia or parosmia. Gynaecomastia, small testes, loss of axillary and pubic hair, talkativeness.
• Arm span (the span of extended arms) will exceed the standing height or will be twice or more of sitting height.	• Marfan syndrome (Fig. 3.4).	Long slender fingers (arachnoidactyly), webbing of fingers, high arched palate, ectopia lentis (slit lamp examination), dilatation of ascending aorta, positive thumb protrusion sign.
Short stature. The actual height is less than the expected height according to his/her age and weight. The built is stocky and short in achondroplasia (Fig. 3.6).	It may be hereditary (selective failure of GH) or genetic or chromosomal disorders (Turner's syndrome (45X0), chronic renal failure, coeliac disease (Fig. 3.5).	Features of associated or underlying condition will be present. In Turner's syndrome, there is low hair-line and webbing of the neck in the girls. Features of renal failure or malabsorption may be present. Endocrinal disorders may have their characteristic manifestation, e.g. cretinism, juvenile hypothyroidism and panhypopituitarism.

Obesity is a clinical condition in which there is excessive amount of body fat. In an adult of 70 kg male, the total body water accounts for 60–65% (45 kg) of weight while fat accounts for 10 kg of weight. In clinical practice, the body weight is considered indirectly the measurement of fat in a normal hydrated patient. The causes and consequences of obesity are given in Table 3.3.

The Framingham study demonstrated that 20% excess over desirable weight should be considered as obesity as this weight imparts a health risk. A National Institute of Health Consensus Panel on obesity agreed with this definition, which is now widely accepted.

An alternative method of estimating obesity and undernutrition is **body mass index (BMI)** and **waist-hip ratio**.



FIGURE 3.3 Gigantism: Note the height (8 feet 2 inches). The hands and feet are large. The built is stout

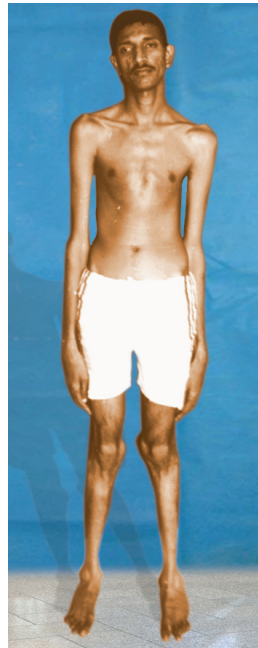

FIGURE 3.4 Marfan's syndrome: Note the tall stature. The height of patient is 6' and 1.5". Arm span 6' and 6"; upper segment: lower segment is 0.75

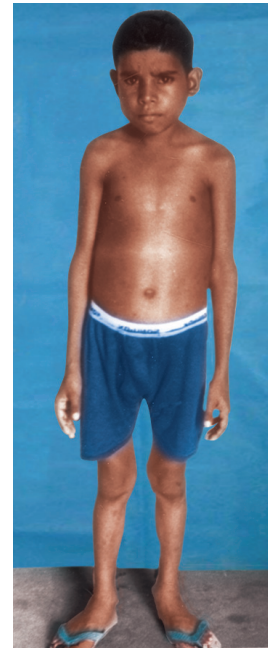

FIGURE 3.5 Dwarfism: The child has coeliac disease



FIGURE 3.6 Achondroplasia: An active mentally sound dwarf male with well-developed sexual features. He has full-fledged family

Other parameters of obesity determination include *skin fold thickness measurement, body fat scan, dual energy X-rays, CT scan* and *MRI*. Now a days, body fat percentage may be a better measure of weight-related diseases than BMI.

$$\text{BMI} = \frac{\text{Body weight (kg)}}{\text{Height (metre)}^2} = \text{kg/m}^2$$

Waist-hip ratio: It is determined in the erect position by measuring the abdominal girth at the level equidistant

TABLE 3.3 Causes and consequences of obesity

Causes	Consequences
<ul style="list-style-type: none"> • Primary <ul style="list-style-type: none"> – Psychological – Socioeconomic reasons – Hereditary (genetic predisposition) – Physical inactivity – Drug induced, e.g. steroids, insulin, oral contraceptives, phenothiazines. • Secondary <ul style="list-style-type: none"> – <i>Endocrinal</i> <ul style="list-style-type: none"> - <i>Physiological</i>, e.g. puberty, pregnancy, menopause. - <i>Pathological</i>, e.g. thrombosis hypothyroidism, Cushing's syndrome, Frohlich's syndrome, Laurence-Moon-Biedl syndrome, Prader-Willi syndrome 	<ul style="list-style-type: none"> • Metabolic <ul style="list-style-type: none"> – Type 2 DM – Impaired glucose tolerance (IGT) – Gallstones – Hyperuricaemia (gout) • Mechanical <ul style="list-style-type: none"> – Osteoporosis – Hernias (abdominal, diaphragmatic) – Varicose veins and diaphragmatic) • Respiratory <ul style="list-style-type: none"> – Pickwickian syndrome – Sleep-apnoea syndrome • Cardiovascular <ul style="list-style-type: none"> – Atherosclerosis and IHD – Hypertension • Neurological <ul style="list-style-type: none"> – Stroke – Accident-prone • Gastrointestinal <ul style="list-style-type: none"> – Hiatus hernia

Box 5

Facts and figures about abdominal obesity*Waist circumference indicating abdominal obesity*

- Men > 90 cm (as opposed to 102 cm according to international guidelines)
- Women > 80 cm (as opposed to 88 cm as per international guidelines)

Facts

- Experts say 6–8 crore Indians will benefit from the new guidelines
- Absolute mortality due to chronic heart diseases in India will increase to 2.03 million/year by 2010. It will reach 2.58 million by 2020
- The number of patients with diabetes in India (presently 41 million) is expected to increase by 170% in the next 20 years
- Figures indicate that every second person in Delhi is obese. Nearly 25% of the adolescents suffer from metabolic syndrome

between costal margins and iliac crest and at the level of greater trochanter. It indicates abdominal obesity—an ingredient of metabolic syndrome [waist circumference ≥ 102 cm (> 90 cm in Indian) in men and ≥ 88 cm (≥ 80 cm in Indian)] in women indicates abdominal obesity (Box 5).

Depending on the percentage of weight reduction and BMI, the malnutrition is graded as **mild**, **moderate** and **severe** (see the Box 6). The two common types of protein-energy malnutrition are compared in the Table 3.4.

Weight loss: Weight loss is an important symptom that has many causes and explanations. Patients with weight loss present with history of loosening of clothes, belt, bra, undergarments and also complain of fatigue and weakness.

In normal persons, weight is stable over long periods because food intake is matched with energy expenditure by neural activity in the hypothalamus. Because the system is usually effective, hence weight loss brings the patient to the physician.

Weight loss may be “physiological” due to dieting, exercise, starvation or the decreased nutritional intake which accompanies old age.

It is difficult to define weight loss in clear terms. In general, a reduction of 5% of body weight or 5 Kg is considered significant if lost over a period of 6 months.

Weight loss with poor food intake is due to psychiatric illness (anorexia nervosa), chronic infections, cardiac, pulmonary or renal failure or malignancy. On the other hand, weight loss with relatively high food intake suggests hyperthyroidism, diabetes mellitus, malabsorption or binge eating (bulimia).

Box 6

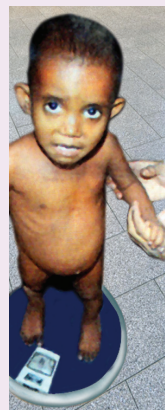Obesity and BMI (Kg/m²)

	WHO criteria	Indian criteria
Normal	18–25	18–23
Overweight	< 30 (26–29)	≤ 25
Obesity	> 30 (30–39) (Fig. 3.7)	< 25
Morbid obesity	> 40	≥ 32.5

Undernutrition and BMI

Severity or grade	Body weight reduction 95% of international standard	BMI reduction (Kg/m ²)
Mild	From 90% to 81%	From 20 to 18
Moderate	80% to 71%	18 to 16
Severe	< 70%	< 16

Note: Nutritional intervention will be needed if BMI is less than 18 or if weight loss during an illness is greater than 10%.

FORCES draft report on state of children in India

- Malnourished children under 3 years has increased from 15.5% to 19.1%
- Children aged 6–35 months who are anaemic has increased from 74.2% to 79.2%
- India has 47% underweight children as compared to 29% in sub-saharan Africa

TABLE 3.4 Comparison of two common types of protein energy malnutrition (PEM)

Parameter	Kwashiorkor	Marasmus (Fig. 3.8)
• Growth retardation	Mild to moderate	Severe
• Deficit in weight for height	Mild	Marked
• Body weight as % of international standard	60–80	<60
• Oedema	Present	Absent
• Wasting, skin and hair changes	Skin and hair changes present	Wasting is marked
• Serum albumin	Low	Normal
• Physical state	Child is miserable	Child is alert

Symptoms associated with weight loss often pinpoint the cause as does a good psychological history. Poverty, old age, social isolation, physical disability, emotional or mental



FIGURE 3.7 Indian scenario of metabolic syndrome/obesity (facts and figures)

- Overweight if the BMI (Body Mass Index) is 23 kg/m^2 or more. The international standard is 25 kg/m^2
- Obese if the BMI is 25 kg/m^2 or more as opposed to 30 kg/m^2 as international standard
- An Indian needs drug therapy for obesity if BMI is 25 kg/m^2
- An Indian qualifies for bariatric surgery for obesity if the BMI is 32.5 kg/m^2 as opposed to 35 kg/m^2 for international patients

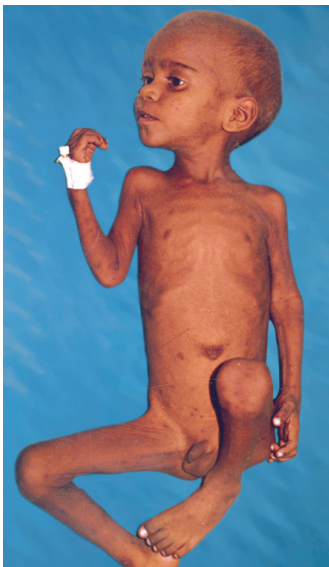

FIGURE 3.8 Marasmus—protein energy malnutrition (PEM)

impairment, lack of teeth or ill-fitting dentures, alcoholism and drug abuse increase the chances of malnutrition and weight loss.

Weight loss occurring as an isolated symptom is seldom associated with serious organic disease.

Nutritional Status

Assessment of nutritional state of a patient is an important part of clinical examination because nutritional depletion may eventually result in malnutrition which has its functional consequences such as reduced immune response, muscle weakness, oedema, confusion or neuropathy etc. It is easy to detect gross malnutrition but lesser degree may be difficult to detect especially when oedema is present.

Parameters of assessment are:

- **Dietary history:** In the history one should ask about the diet the patient has been taking. Is he/she taking diet regularly or has omitted any major meal? Is the appetite good? Is there any difficulty in eating? Ask about history of diarrhoea, vomiting or steatorrhoea. Is patient alcoholic or drug addict? Is there any history of psychiatric or neurological illness that interferes with his/her food intake? Has the patient lost weight recently? Does the patient avoid certain food stuffs for any reason?

Significance of Dietary History

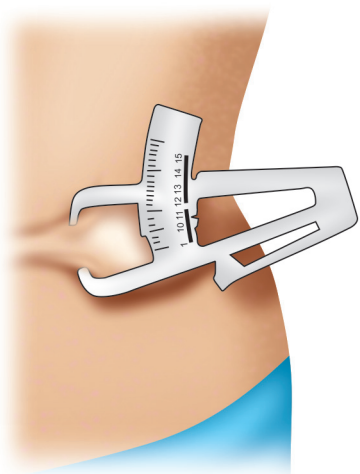
- In *anorexia-bulimia*, a disorder usually affecting young women, there are cyclic changes in appetite and food intake.
- Patients having dysphagia or other gastrointestinal disorders or cirrhosis may develop malnutrition.
- Patients with gluten sensitivity will avoid wheat products and in lactase deficiency will avoid milk because they have been advised to do so.
- A strict vegetarian diet or vegan diet may lead to vitamin B_{12} deficiency.
- Purdah muslims ladies are more prone to get vitamin D deficiency.
- Low fibre diet is associated with constipation and gall stones.
- **Clinical assessment:** Wasting or thinness of muscles, oedema, pallor, weakness, loss of skin elasticity, and other signs of nutrients and vitamins deficiency are pointers towards poor nutrition or malnutrition. The primary illness may obscure or confuse signs of malnutrition.
- **Anthropometry:** Measurement of body weight, measurement of subcutaneous fat and muscles by *mid-arm* circumference with a tape or measurement of *skin-fold* thickness by special calipers (Harpender or Hotain calipers) are used for nutritional assessment in hospitalised patient. Serial measurements are essential.

The reference standards of mid-arm circumference are given in the Table 3.5.

Skin fold thickness (Fig. 3.9): The measurement of triceps skin fold thickness midway between acromion and olecranon is the preferred site. The measurement is

TABLE 3.5 Mid-arm circumference in mm

Age	Men percentile			Women percentile		
	50th	10th	5th	50th	10th	5th
19–24	308	272	262	265	230	221
25–34	319	282	271	277	240	233
35–44	326	287	278	290	251	241
45–54	322	281	267	299	256	242
55–64	317	273	258	302	254	243
>65	307	263	248	299	252	240

**FIGURE 3.9** Skin fold thickness measurement**TABLE 3.6** Skin fold thickness measurement (mm)

	Standard	80%	60%
Adult male	12.5	10.0	7.5
Adult female	16.5	13.0	10.0
Nutritional status	Normal	Moderate	Poor

Note: The 80% and 60% ranges are associated with moderate and severe nutritional depletion.

done in vertical plane with arms hanging by the side in relaxed position. Normal values and 80% and 60% values indicating moderate and poor nutrition are depicted in the Table 3.6. Among Asians 20–20% body fat is normal for women and 17% for men.

- **Biochemical assessment:** Biochemical tests are done in hospitalised patients to assess the nutritional status and micronutrients deficiencies. The various tests are:
 - **Blood protein.** Estimation of serum proteins is sensitive parameter to detect undernutrition and to monitor nutritional repletion.

- **Serum albumin** (half-life 14 days) is the most useful predictor.
- **Serum transferrin, retinol binding protein, etc.**

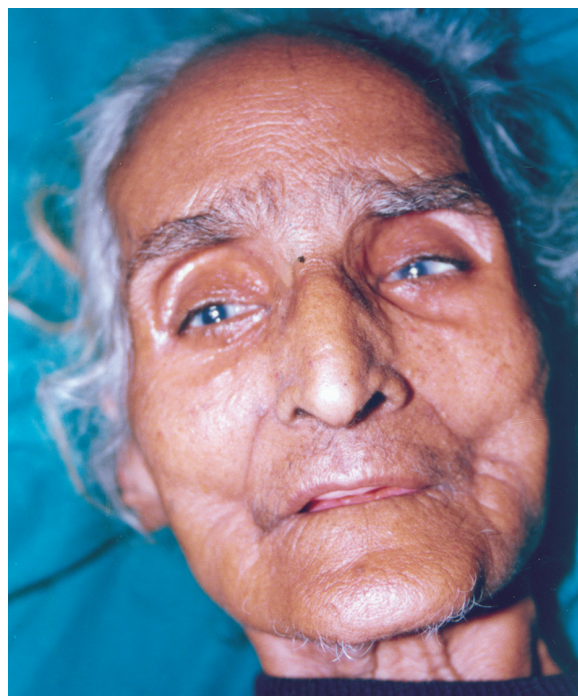State of Hydration

In an adult of 70 kg, the body fluid is 45 litres (60–65% of the body weight) out of which two-thirds (30L) is intracellular; of the remainder, two-third is interstitial (10L) and rest 5L constitutes the circulating blood volume.

Parameters of Assessment

The state of hydration is assessed by:

- **Skin elasticity:** It is demonstrated by pinching up a fold of skin and then released. It remains as a ridge and subsides slowly if skin elasticity is lost otherwise it returns immediately to its normal position. Loss of elasticity is not true index of hydration as it is lost in old age and due to loss of collagen in the skin.
- **Intraocular tension:** Low tension indicates dehydration. In dehydration, the eyeballs are soft and shrunken (Fig. 3.10).
- **Recording of BP:** Low blood pressure and postural drop in BP indicates dehydration and is a useful index of intravascular volume depletion due to diarrhoea, vomiting, excessive sweating and polyuria.

**FIGURE 3.10** A dehydrated patient. Note: the sunken cheeks and eyeballs with dry tongue. Her systolic BP was < 90 mmHg. The skin was dry, wrinkled with loss of elasticity

Box 7

Causes of dehydration

- | | |
|---|---|
| I. Gastrointestinal loss <ul style="list-style-type: none"> • Diarrhoea • Vomiting • Gastroenteritis (food poisoning) | III. Renal loss <ul style="list-style-type: none"> • Diabetes mellitus • Diabetes insipidus • Diuretics |
| II. Cutaneous loss <ul style="list-style-type: none"> • Burns • Perspiration | IV. Internal sequestration <ul style="list-style-type: none"> • Acute pancreatitis • Acute intestinal obstruction • Ascites |

- **Dry tongue and mouth:** A dry tongue and mouth may indicate dehydration but are commonly seen in smokers and mouth-breathers, hence, these signs may be deceptive.
- **Measurement of weight:** A recent loss of weight may be a sign of dehydration if previous weight is known.
- **Haemoconcentration:** Rise in haemoglobin, PCV and plasma osmolality provide evidence of severity of dehydration. The serial readings will indicate the replacement of effective fluid volume.
- **Jugular venous pulse and pressure (JVP):** The jugular venous pressure is low in volume depletion, hence veins are collapsed and not visible.
The causes of dehydration are given in the Box 7.

Vitals

Look for vitals, i.e. pulse, BP, temperature and respiration.

The pulse: Count the pulse for at least 15 seconds if the rhythm and heart rate appear to be normal, multiply the reading by 4 to get the pulse rate or heart rate in beats/min (bpm). If the rate is too slow or too fast, then count the pulse for full one minute. The pulse should be analysed for **rate, rhythm, character, volume** and **presence or absence of radio-femoral delay**. When the rhythm is irregular, the heart rate should be evaluated by cardiac auscultation to know the pulse deficit. The **pulse deficit** (difference between heart rate and pulse rate) is because of nonconduction of weak cardiac beats to peripheral pulse.

Heart rate <60/min is called **bradycardia** and more than 100/min is called **tachycardia**. The causes of decreased and increased heart rate are given in the Box 8.

The rate of pulse varies from 60 to 90 bpm during activity in a normal healthy individual.

Blood pressure: Blood pressure is measured using a Sphygmomanometer cuff wrapped around the upper arm. The method of measurement, a checklist for measurement are discussed in CVS examination. It is important to use

Box 8

Causes of change in heart rate

<i>Bradycardia</i>	<i>Tachycardia</i>
<ul style="list-style-type: none"> • Physiological, e.g. vagotonic individuals, athlete, during sleep and induced by carotid sinus compression. • Hypothyroidism • Hypothermia 	<ul style="list-style-type: none"> • Physiological, e.g. anxiety, excessive use of tea, coffee, exercise, smoking etc. • Hyperthyroidism • Arrhythmia
<ul style="list-style-type: none"> • Obstructive jaundice • Sick sinus syndrome 	<ul style="list-style-type: none"> • Acute pulmonary embolism • CHF, hypertension
<ul style="list-style-type: none"> • Hyperkalaemia/hypermagnesaemia 	<ul style="list-style-type: none"> • Drug-induced, e.g. adrenaline, thyroid medications, nicotine or alcohol, atropine, caffeine, amyl nitrate, nifedipine
<ul style="list-style-type: none"> • Drugs, e.g. b-blockers, calcium channel blockers • Second and third degree (complete) AV blocks • Raised intracranial pressure • Poisoning, e.g. organo-phosphorous, aluminium phosphide, scorpion sting bite. 	<ul style="list-style-type: none"> • Congenital heart disease, valvular heart disease, thyrotoxic heart disease • Pheochromocytoma (catecholamine excess)

the correct size of the cuff. The length of inflatable bladder of the cuff should be 30–35 cm and width should be 12.5 cm (12–14 cm) for an average adult.

Blood pressure should be taken in both the arms at least once. Normally there may be difference of <10 mmHg in both the arms. Subsequent readings should be repeated on the arm with high pressure difference.

An internationally recognised JNC VIII classification which defines the normal and abnormal blood pressure is depicted in Box 9.

Respiration: Count the respiratory rate for a full half minute and multiply it by 2 to get respiratory rate per minute. This should be counted when patient's attention is diverted elsewhere for example count the respiratory rate when you are counting the pulse rate. Tachypnoea implies respiratory rate more than normal. The causes are given in the Box 10.

Normal respiratory rate in adults is 14–18 breaths/min.

Temperature: The warmth of the skin felt with back of the hand over covered body part (neck, chest, abdomen) provides a good indication of fever, but the skin of a patient with a

Box 9

JNC VIII Classification of hypertension

Category	Systolic (mmHg)	Diastolic (mmHg)
Normal	<120	<80
Prehypertension (previous term used in JNC VI as high normal replaced)	120–139	80–89
HYPERTENSION		
Stage 1	140–159	90–99
Stage 2	≥ 160	≥ 100
JNC VIII has not changed the definitions of JNC VII. They have addressed treatment goals mainly.		

Box 10

Causes of tachypnoea

- Physiological, e.g. strenuous exercise, anxiety, nervousness
- Fever
- Hypoxia due to pulmonary disease
- CHF (congestive heart failure)
- Pleuritis, pneumothorax
- Cerebral disturbance/hypoxia
- Metabolic acidosis
- Hysterical hyperventilation

normal temperature may feel cold and an apparently normal temperature does not exclude hypothermia.

Fever or pyrexia refers to an elevated resting body temperature (>37.2° or > 99°F). The average oral temperature is usually quoted as 37.1°C (98.6°F). It may fluctuate considerably, i.e. in early morning, it may fall as low as 35.8°C (96°F) and in the evening it may rise to 37.2°C (99.0°F). *Rectal temperature* is higher than oral temperature by an average of 0.4 to 0.5°C (0.7 to 0.9°F) approximately. In contrast, the axillary temperature is lower than oral temperature by approximately 1°C, hence, is considered less accurate than other two measurements.

Choice of site for recording: Most patients prefer oral to rectal temperatures. Oral temperature recording is not recommended in an unconscious patient or restless/violent patients as recordings may be less accurate and thermometer is likely to be broken.

Method: For oral temperature you may choose either a glass or electronic thermometer. When using a glass thermometer,

wash the mercury end of thermometer and then shake it down to 35°C (98°F) or below. Now insert it into the mouth under the tongue and ask the patient to close the mouth. Read the thermometer after 1 minute. This will tell the temperature of the patient.

Types of fever (Fig. 3.11): Fever may be *continuous*, *remittent* and *intermittent*. It is said to be *continued (continuous)* when it does not fluctuate >1°C (1.5°F) during 24 hours and at no time touches the normal. If fluctuations (swings) exceed 2°C, it is called *remittent* and when fever manifests only for several hours in a day, it is called *intermittent*. The intermittent fever may appear daily (*quotidian*), on alternate days (*tertian*) and on every third day (*quartan*). Now-a-days, in era of antibiotics and other effective drug therapy, these types of fever are infrequently seen.

Note: Transient rise in temperature may occur due to a recent hot drink or a bath and even after smoking. In such situations, it is best to defer the measurement for 10 to 15 minutes.

Conventionally it is called *low grade* (<101°F or 38°C), *moderate grade* (<103°F) and *high grade* (>103°F).

Hyperthermia/Hyperpyrexia: It refers to extreme elevation in temperature above 41°C (106°F). It could be due to heat stroke, heat exhaustion or malignant hyperpyrexia (an inherited abnormality).

Hypothermia: It refers to an abnormally low temperature below 35°C (95°F) rectally. Low-reading clinical rectal thermometers are available and should be used when hypothermia is suspected. Temperatures as low as 27°C are not uncommon and core body temperatures below 20°C have been recorded in patients who subsequently survived. The causes of hypothermia are tabulated—(Table 3.7).

TABLE 3.7 Causes of hypothermia

- **Excessive heat loss**
 - Prolonged environmental exposure at low temperature, e.g. accidental, iatrogenic, unconsciousness
 - Increased continuous blood loss (heat loss), e.g. burn, psoriasis, toxic epidermal necrolysis (TEN)
- **Inadequate heat production**
 - Inadequate metabolism, e.g. malnutrition, starvation, hypothyroidism, Addison's disease, hepatic failure, diabetic ketoacidosis and hypoglycaemia
 - Altered thermoregulation, e.g. sepsis, uraemia, head trauma, stroke, tumour, spinal cord injury and Shapiro's syndrome (episodic spontaneous hypothermia with hyperhidrosis)
 - Drug-induced, e.g. barbiturates, phenothiazines, opiates, lithium, benzodiazepines, alcohol

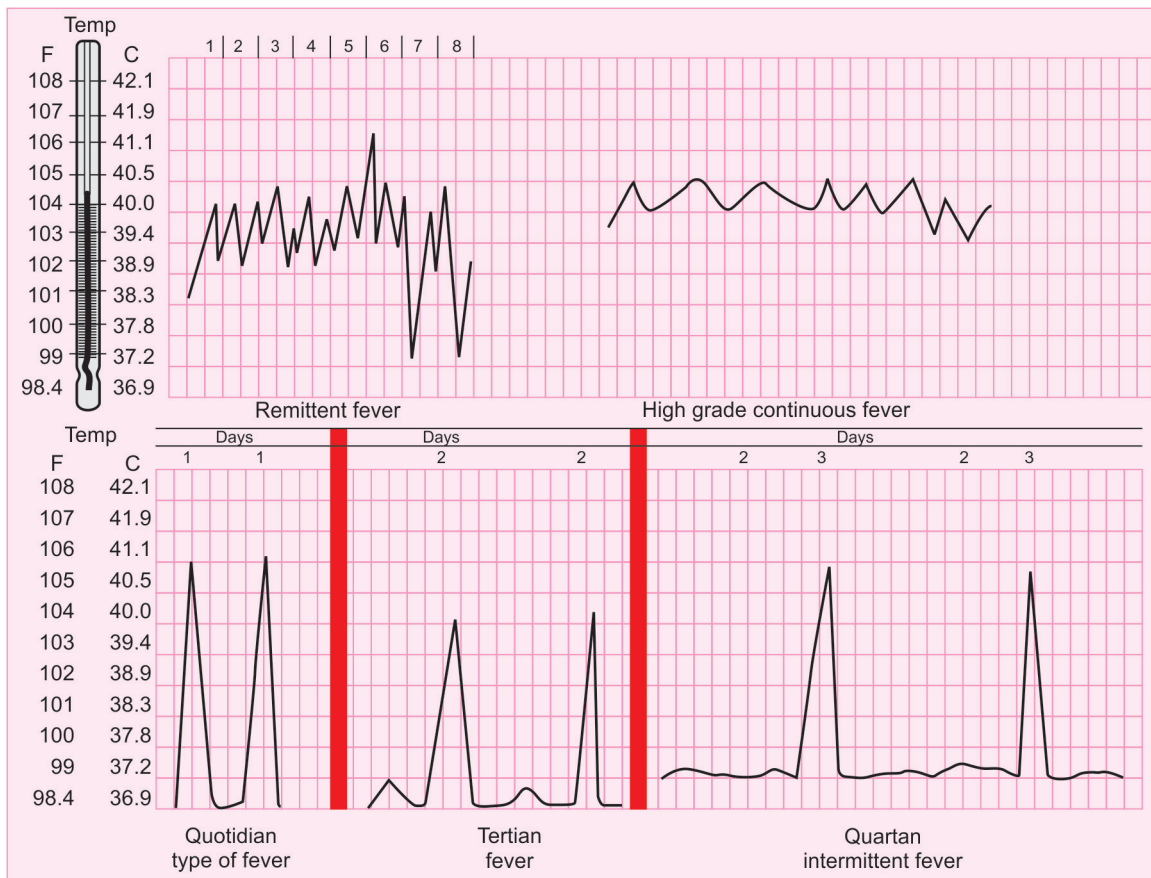


FIGURE 3.11 Types of fever

Compilation of Statement

After going through the general physical examination, one has to make statement as follows:

- Is patient conscious/semiconscious/unconscious?
- Is he/she cooperative or uncooperative?
- Is he/she lying or sitting comfortably or is patient uncomfortable?
- Comment about normal/abnormal physical appearance, built, complexion, personal hygiene.
- Comment about any abnormal sound/voice, abnormal smell/odour.
- Is patient well-nourished/poorly nourished?

- Is patient well hydrated/dehydrated?
- Is oedema present or absent?
- Vital signs, e.g. pulse, BP, temperature and respiration normal or abnormal.

Comment as follows

On general examination, the patient is fully conscious, cooperative and lying/sitting comfortably. He/she is having normal built, physical appearance and maintaining good personal hygiene. He/she is well nourished and well hydrated. There is no oedema. The pulse, BP, temperature and respiration are normal.

4

CHAPTER

The Head, Scalp, Skin and Hair

HEAD AND SCALP

Applied Anatomy and Physiology

Regions of the head derive their names from the underlying bones of the skull (e.g. frontal, parietal, temporal and occipital area), knowledge of anatomy helps to locate and describe the clinical findings.

Common Presentations

- Headache
- Abnormalities of the skull
- Hydrocephalus.

HISTORY

Headache is an extremely common complaint that always requires careful evaluation, since a small fraction of headache arise from life-threatening conditions. Ask about the following attributes of headache:

- **Location:** Where is it? Does it radiate? Is it unilateral or bilateral?
- **Quality:** What is it like? Is it steady or throbbing? Is it continuous or comes and goes?
- **Severity:** How severe is it?
- **Timing:** When did (does) it start? How long did (does) it last? How often did (does) it come? Does headache recur at the same time every day?
- **Setting** in which it starts. Ask about environmental factors, personal activities, emotional reactions or other contributory circumstances.
- **Aggravating or relieving factors:** Does anything make it better or worse? Ask whether coughing, sneezing or changing the position of the head have any effect (better, worse, or no effect) on headache.
- **Associated symptoms:** Have you noticed anything else that accompanies it such as nausea, vomiting and neurological symptoms such as change in vision or motors/sensory deficits?

Common Clinical Conditions Related to Cranium

Headache

It means all aches and pains localised to head. It is a common symptom of a variety of both benign and malignant conditions, hence, carries dual significance and keeps the physicians alert. Fortunately, in most circumstances, it is benign either due to tension or fatigue and is reversible.

Pain results due to stretching of the pain sensitive areas/ structures inside or outside head such as:

- *Skin, subcutaneous tissue, muscles, arteries and periosteum of the skull.*
- *Intracranial dural venous sinuses or veins.*
- *Tissues of eyes, ear and nasal sinuses.*
- *Durameter at the base of brain and the arteries within dura and pia-archnoid mater.*

Pathogenesis: Headache occurs due to:

- *Distortions, inflammation, distension, traction, displacement of large intracranial extracranial vessels and/or dural sinuses.*
- *Compression, traction and inflammation of cranial and spinal nerves.*
- *Muscle spasms (voluntary or involuntary) or trauma to cranial or cervical muscles.*
- *Meningeal irritation and raised intracranial pressure.*

Causes: The classification of headache is elaborate one but its practical version is given in the Table 4.1. Some common forms of headache encountered in clinical practice are enumerated in Fig. 4.1.

A careful detailed history is the most important tool in the headache diagnosis. Moreover, headache is complaint, where, symptoms outweigh the signs and abnormal investigations are obligatory not the rule.

Analysis of Symptom of Headache

Onset, duration and progress

- Acute onset of severe headache commonly suggests subarachnoid haemorrhage and meningitis.

TABLE 4.1 A practical classification of headache

- **Acute primary headaches (unknown cause)**
 - Migraine
 - Tension-type
 - Benign exertional headache
 - Cluster headache
- **Secondary headache (secondary to some cause)**
 - *Intracranial causes*
 - *Vascular disorders*, e.g. embolic, thrombotic (arterial or venous), haemorrhagic, acute dissection
 - *Infections*, e.g. meningitis, encephalitis, brain abscess
 - *Inflammation*, e.g. vasculitis, arteritis
 - *Tumors*, e.g. benign and malignant (primary, metastatic)
 - *Miscellaneous*, e.g. benign intracranial hypertension, postspinal and post-traumatic-headaches
 - *Extracranial causes*
 - Involvement of eye, ear, sinuses, teeth, neck and temporomandibular joint
 - *Systemic illnesses and acute intoxications*
- **Neuralgias**
 - Trigeminal
 - Glossopharyngeal
 - Occipital

- Progressively worsening headache suggests raised intracranial pressure or uncontrolled systemic disease. Focal or lateralizing signs make the diagnosis easier.
- A **chronic recurrent headache** or **chronic nonprogressive daily headache** represents a primary headache such as migraine, cluster headache or tension-type headache.
- The headache that develops over weeks or months (**slowly evolving recurrent headache**) may have a benign cause such as migraine or tension type headache or it could even be due to a serious underlying cause (unruptured aneurysm).
- Some headaches may show nocturnal frequency and awaken the patient at night or may occur at the same time of the day (**cluster headache**) or at specific occasion such as during menstruation or may increase towards the evening such as tension-type (**psychogenic**) headache.

The age of the patient is also a prime importance as migraine generally begins at a younger age, tension headache is more common in middle age and headache originating in older persons are usually due to organic causes.

The frequency and duration of headache also help to differentiate the episodic headaches from chronic progressive headaches. Many attacks of headache of short duration in the day would favour the diagnosis of cluster headache or chronic proxysmal hemicrania (a variant of cluster headache).

Site and quality of pain

- Unilateral pulsating or throbbing headaches are usually vascular such as migraine and cluster headaches (occur at the same location unilaterally).
- Bilateral diffuse dull headache is usually of tension-type headache.
- With secondary headaches of organic cause, the nature, location and severity of headache vary according to cause and mechanism of production.

Associated symptoms

- Associated features such as nausea, vomiting, hypersensitivity to light and noise along with headache suggest migraine but one should also consider the underlying organic cause in the absence of such associated symptoms.
- *Fever, arthralgia* and *malaise* suggest a systemic illness or meningitis.
- *Transient visual symptoms (auras)* are characteristic of migraine but can occur in transient ischaemic attacks, vascular anomalies or focal epilepsy secondary to space occupying lesions.
- *Behaviour following an acute attack* of headache distinguishes migraine (patient tries to sleep undisturbed in a dark room) from cluster headache in which a patient is up and moving about.

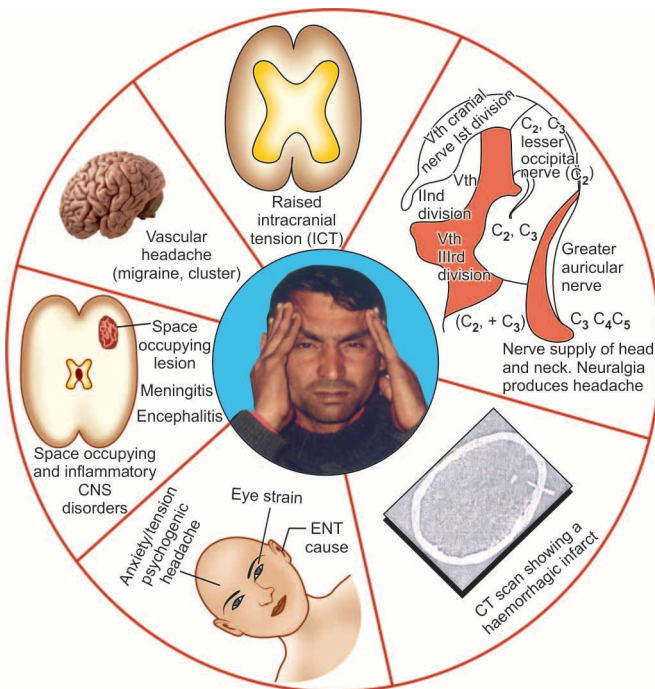


FIGURE 4.1 Common headaches

Box 1

Provoking factors for migraine

Food item	Cheese, dairy products, fruits, chocolates, etc.
Food additives	Caffeine (coffee), nitrates
Alcohol	Beer, red wine
Hormonal changes	Menstruation, pregnancy, ovulation
Visual triggers	Bright lights, glare
Auditory triggers	Noise and music
Olfactory triggers	Perfumes, odours
Others	Sleep, hunger, headache and neck trauma, stress and anxiety

- **Headache** may be related to *menstruation*, more common in morning (hypertensive) and worst on bending (sinusitis related), may occur towards the evening (eye strain headache) or follow a period of inactivity (cervical pain).

Provoking and relieving factors

Primary headaches such as migraine can be triggered by various stimuli including food items (Box 1). Headache due to intracranial pathology or raised intracranial tension worsens during coughing, straining or adopting the head in low posture.

EXAMINATION

The scalp: Separate the hairs at several places and look for scaliness, naevi or other lesion.

Redness and scaling occurs in seborrhoeic dermatitis and psoriasis.

Box 2

Abnormalities of skull

Anencephaly means absence of cranial vault, scalp and cerebral hemispheres. The brain is a compact mass of neurones, glial cells, nerve fibres and blood vessels.

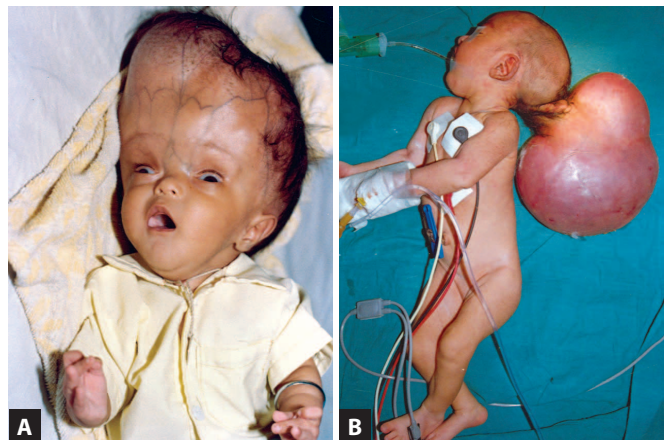
Microcephaly refers to small cranium and brain. It is seen as a part of many syndromes and also secondary to premature closure of the cranial sutures.

Macrocephaly or large skull is seen in hydrocephalus (Fig. 4.3A). There is enlargement of skull in Paget's disease. **Encephalocoele** (Fig. 4.3B) refers to failure of midline defect resulting in evagination of brain tissue outside the skull.

Localised bony bossing is seen over meningioma. **Skull tenderness** is seen following trauma or temporal arteritis.

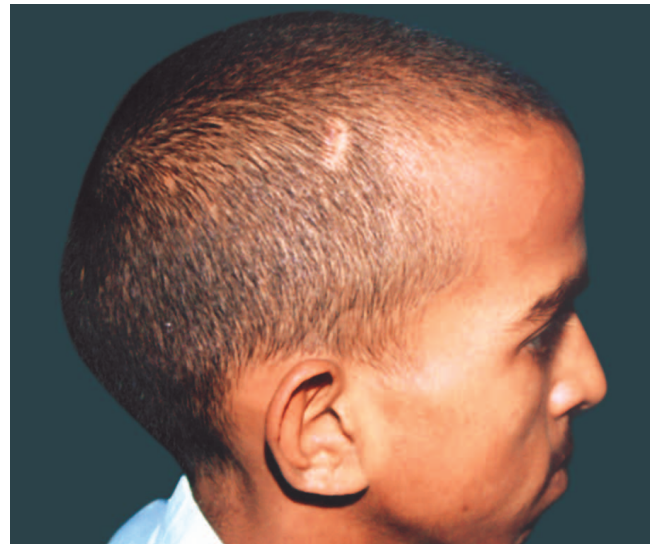

FIGURE 4.2 Large head according to his age



FIGURES 4.3A and B Macrocephaly: (A) With evidence of congenital hydrocephalus. Note the large head with sun-setting sign and bulging fontanelle; (B) Encephalocoele

The skull (cranium): Note the size and contour. Look for any *deformity, depression, lump* or *tenderness*. The abnormalities are given in the Box 2. Some children may have larger head than normal according to his/her age (Fig. 4.2).

General Physical Examination (GPE)

- **The physical examination** should evaluate vital signs (pulse, BP), the cardiac status, the extracranial structure (to palpate over the head and neck for detection of tender trigger-points, to auscultate over the skull, carotid vessels for bruit, to palpate the temporal artery for pulsation) and cervical spine for pain and limitations of movements. Examine the nose and sinuses, the teeth and temporomandibular joint, the ear and throat.
- **A short neurological examination includes:**
 - Mental status and level of consciousness.
 - Cranial nerve examination including optic fundi.
 - Motor system examination, e.g. power, tone, reflexes, etc.
 - Look for neck stiffness and other signs of meningitis.

Common Types of Headache

Migraine

It is characterised by episodic, hemicranial or unilateral throbbing headache and often associated with nausea, vomiting and visual disturbances. In many patients, headache is bimodal and generalised and there may not be any visual disturbances or focal neurological signs. It occurs in childhood, adolescent and adult life, more common in females than males (3:1). Family history may be positive in 60% patients.

Pathogenesis: The symptoms of migraine are associated with changes in the cerebral blood flow secondary to changes in the vessels calibre. In migraine with aura (classical migraine), the prodromal phase and neurological symptoms are due to arteriolar constriction of cerebral vessels leading to oligoemia particularly in the occipital and parietal lobes. During the phase of headache, there is dilatation of extracranial vessels which may be related to fluctuations in blood 5-hydroxytryptamine levels.

Dietary factors including chocolate, coffee, tea, cheese and alcohol may precipitate attacks (Box 1). Some patients describe exposure to sunlight, exercise, tension, oral contraceptives, menstruation as increasing the frequency and severity of attacks. Stress and anxiety may initiate or lead to perpetuation of headache. Stress and migraine frequently co-exist.

About 50% patients of migraine have an affected relative suggesting a genetic predisposition.

The principal forms of migraine are depicted in Table 4.2.

Note: The clinical interview of an acute headache patient should be quick and systematic including onset, location of

pain, the character, severity, duration of pain, precipitating and relieving factors. Past history of similar episodes, history of trauma, exertional aspect of headache, physical tests done earlier, any treatment taken earlier and relief obtained therefrom should be noted.

Headache due to Raised Intracranial Pressure

The raised intracranial pressure (ICP) produced by mass lesions leads to headache, the mechanism of which has already been described but full discussion is beyond the scope of this book. Here, the benign raised intracranial tension which produces headache resembling migraine or tension headache will be briefly discussed.

Benign Raised Intracranial Tension

It is a benign condition seen in young obese women, in which raised intracranial tension occurs without space occupying lesion or hydrocephalus, hence, called *pseudotumour cerebri*. The **aetiology** is unknown but the condition is precipitated by drugs such as steroids, oral contraceptives or tetracyclines. The **symptoms** include: headache, nausea, vomiting, visual blurring and papilloedema. The **diagnosis** is confirmed by the exclusion of an intracranial mass or a meningeal tumour. Fundus examination reveals papilloedema. CT scan shows normal ventricular system. CSF examination is normal. The **treatment** is aimed at prevention of visual defects and other intractable symptoms by reducing CSF pressure by repeated lumbar punctures. This is the raised intracranial tension where lumbar puncture can be performed without herniation of brain. The offending or precipitating factors

TABLE 4.2 Principal forms of migraine

Type	Symptoms and signs
<i>Classical migraine</i> (migraine without aura)	Visual and sensory symptoms precede or accompany headache.
<i>Common migraine</i> (migraine with aura)	Headache, nausea, vomiting, photophobia. No visual disturbance.
<i>Hemiplegic migraine</i>	Prolonged headache (hours or days) followed by transient hemiparesis, which recovers completely with time.
<i>Basilar migraine</i>	Occipital headache preceded by vertigo, diplopia and disturbance in speech. Visual or sensory disturbances may or may not occur.
<i>Cluster headache</i> (migraineous neuralgia)	Affects males, episodes of severe headache and pain occur around one eye associated with tears and nasal congestion.

must be sought and removed. Patients refractory to above treatment may benefit from acetazolamide, frusemide or short-term corticosteroids therapy. The outlook for most patients is excellent but less than 5–10% patients may be left with permanent or recurrent visual defects.

Tension or Psychological Headache

Tension (stress or anxiety induced) headache is usually bilateral and extends to top of the head. Occipital, nuchal (nape of neck) or bifrontal localisation is also common. It is characterised by dull ache rather than headache or there may be sensation of fullness of head, pressure over head or there may be constricting band around the head. The onset is gradual but pain may continue for weeks or months without interruption. The severity of headache varies and patient can usually continue normal activities.

There is no associated vomiting or photophobia during an attack of headache. The attack usually occurs when the patient is being observed and is less noticeable when patient is self-occupied. Local tenderness over skull vault may be elicitable in some patients. The characteristic features in comparison to migraine are summarised in the Table 4.3.

Investigations (Read Nervous System)

Certain features in the history or examination should raise the suspicion of ominous disease warranting investigations. These signals are listed in the Box 3.

THE SKIN

Anatomy and Physiology

The skin is a large organ of the human body covering an area of 2 m² and forms a major interface between man and his environment. It has three layers (Fig. 4.4):

- i. *The epidermis*
- ii. *The dermis*
- iii. *The hypodermis*

The Epidermis

It is outer avascular epithelial layer consisting of two types of cells.

Box 3

Danger signals warranting testing

- First severe headache ever
- Subacute worsening or progressive over days and weeks
- Disturbs sleep or presents immediately after awakening
- Abnormal neurological examination
- Fever, nausea, vomiting or other systemic signs
- Headache precipitated by Valsalva manoeuvre (cough, sneeze, bending, straining, position change, exercise and sexual activity)
- New-onset headache in adult life (>40 years) or a significant change in a long-standing headache problem.

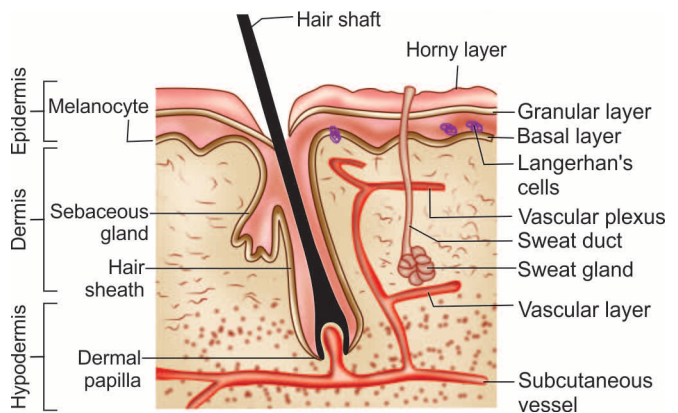


FIGURE 4.4 Structure of the skin

TABLE 4.3 Characteristics of two common types of headache

	<i>Migraine</i>	<i>Tension (psychogenic)</i>
Site	Unilateral, hemicranial, bilateral or bitemporal	Generalised
Duration	Episodic	Constant
Character	Throbbing and/or dull ache	Non-throbbing and/or dull ache or pressure on head
Diurnal variation	Usually on awakening or later in the day	Continuous, throughout the day, varying intensity
Provoking factors	Bright light, noise, tension, alcohol, food articles and colours	Fatigue and nervous strains
Associated features	Nausea, vomiting, prostration, photophobia and visual disturbances	Anxiety, depression, nervousness, insomnia, etc.
Relieving factors	Sleep or dark room	None
Life profile	Occurs at irregular intervals of weeks to months, tends to disappear as age advances	Occurs at an interval of a month or months and continues for years.

- **Keratinocytes:** These make up 90% of the epidermal cells and synthesise insoluble proteins-keratins which constitute the horny character of the epithelium.

Genetic abnormalities of keratin have been demonstrated in epidermolysis bullosa complex, where clumping of abnormal keratin filaments is followed by cytolysis of basal cells which follows minor trauma to the skin. Similarly microscopic changes occur in another genetic disease of Keratin-epidermolytic hyperkeratosis where clumping is seen in suprabasal cells.

- **Dendritic cells:** Two types of dendritic cells i.e. *melanocytes* and *Langerhan's cells* make up most of the remaining epithelial cells.

The melanocytes are present in basal cell layers, contain an enzyme-tyrosinase which synthesise melanin from phenylalanine. Melanin is normally formed in the deepest layer of the epidermis and colours the skin brown or black. The amount of melanin is largely determined by hereditary influences. The pigment increases or decreases in amount with exposure to, or withdrawal from ultraviolet light.

The Langerhan's cells are immunogenic cells that originate in the bone marrow and circulate between local lymph nodes and the skin. They are capable of presenting antigen to lymphocytes and are antigen-trapping cells and can elicit an immune response. The T cells and keratinocytes of the skin and draining lymph nodes form the skin-associated lymphoid tissue (SALT) that maintain immuno-surveillance. Thus, these cells play an important part in immunosurveillance of viral and tumour antigens.

The Dermis

The dermis is supporting layer to epidermis and is separated from it by a basement membrane. It contains blood vessels, nerves, glands and hair. It has three principal components, i.e.

1. *Cells* (mainly fibroblasts and a few mononuclear phagocytes, lymphocytes, mast cells, and Langerhan's cells).
2. *Fibres* (collagen, reticulin and elastin).
3. *Amorphous ground substance* (mostly glycosaminoglycans, hyaluronic acid and dermatan sulphate).

Two types of glands are *sweat glands* and *sebaceous glands*. The *sweat glands* are of two varieties, i.e. *eccrine glands* and *apocrine glands*. The eccrine glands are distributed all over the skin particularly the palm, but not present in mucous membrane. The glands are situated in the dermis and secrete a watery fluid rich in chloride, lactic acid, fatty acid, urea, glycoproteins and mucopolysaccharides. The *apocrine glands* are large sweat glands whose duct open into the hair follicles, hence, are present in hairy skin areas, i.e. axillae, anogenital areas, nipple, areolae and scalp. They do not function until puberty. These glands produce wax in the ears.

The sebaceous glands are distributed all over the skin except on the palms and soles. They are most numerous on the scalp and face. Meibomian glands on the eyelids are modified sebaceous glands. They have no lumen. They secrete *sabum* which consists of fatty acids and cholesterol and is discharged into pilosebaceous follicle.

Functions of the Skin

- **Physical barrier:** It provides a formidable barrier to antigens or bacteria.
- **Preservation of a balanced internal environment:** It prevents excessive absorption or loss of water, electrolytes.
- **Protection:** It protects against chemicals, particles and ultraviolet rays.
- **Shock absorber**
- **Temperature regulation**
- **Synthesis:** The vitamin D is synthesised in the epidermis by sunlight.
- **Sensations:** It contains receptors of specialised nerve endings of pain, touch and temperature, hence, these sensations can be distinguished.
- It is involved in immunological reactions.

THE NAILS

Nails are hard, translucent plates of keratin and grow from beneath the nail fold. A finger nails takes up to 6 month to replace itself and its growth is affected by malnutrition and disease.

HISTORY

A complete history should be taken with special emphasis on the following points:

- **Symptoms associated with lesions**, e.g. itching, pain, burning or numbness. Ask about these symptoms as they form clues to clinical diagnosis. Itching is the most common dermatological symptom. In some diseases, i.e. scabies, it is particularly worst at night. The causes of itching are given in the Box 4. Some skin disorders are not itchy (e.g. rash of secondary syphilis, xanthomas). Loss of sensation is prominent in leprosy.
- **Evaluation of the lesions:** Ask about:
 - Site of involvement
 - Duration of lesions
 - Manner in which the lesion progressed or spread
 - Associated aggravating or relieving factors
 - Period of resolution or improvement in chronic skin lesions
- **Drug history:** Ask in details about the medicines taken already and medicines being taken or being applied locally.

Box 4

Causes of pruritus (itching)

- **Common skin disorders**
 - Scabies (Fig. 4.5)
 - Atopic eczema, allergic contact dermatitis (Fig. 4.6)
 - Candidiasis
 - Urticaria (Fig. 4.7)
 - Insect bites (e.g. flea, bed bug)
- **Systemic diseases with or without skin involvement**
 - Metabolic diseases
 - Hypothyroidism, carcinoid syndrome
 - Neoplastic diseases
 - Chronic lymphatic leukaemia (CLL)
 - Lymphomas and other carcinomas
 - Haematological disease
 - Polycythaemia vera
 - Renal failure
 - Uraemia
 - Liver diseases
 - Cholestasis particularly primary biliary cirrhosis
 - Miscellaneous
 - Senile, psychogenic
 - Drug-induced
 - Carcinoid tumour

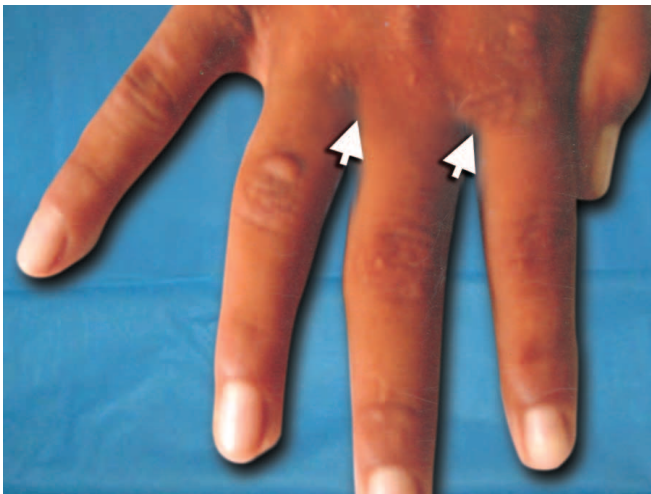


FIGURE 4.5 Scabies. Note the burrows caused by the mite in the interdigital region (arrow head)

In our country self-applied remedies often cause irritant contact dermatitis.

- **Associated systemic symptoms**, e.g. fever for infection and autoimmune condition, malaise, arthralgia (e.g. psoriatic arthropathy, pemphigus).
- **Past history:** Ask about ongoing illnesses or past illnesses.
 - A history of same condition in the past may be a clue to the diagnosis (e.g. recurrent herpes simplex, fixed drug eruptions).

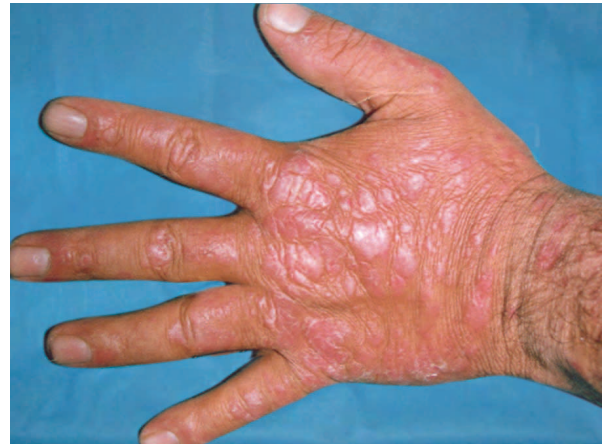

FIGURE 4.6 Allergic contact dermatitis

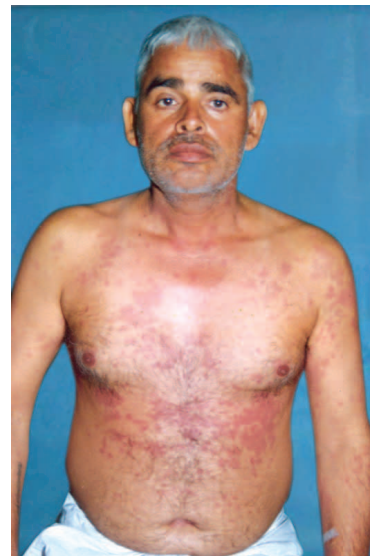

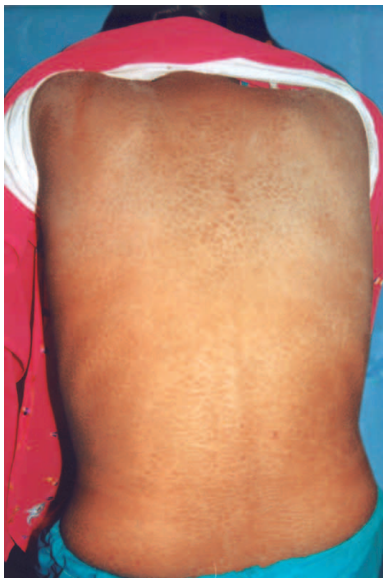FIGURE 4.7 Urticarial rash/wheals

- **Family history:** Family history is relevant in atopic skin conditions, psoriasis, genetic disorders such as ichthyosis (Fig. 4.8), infections (e.g. impetigo and dermatophyte infections) and infestations (e.g. scabies, pediculosis). A history of the same genital condition in the sexual partner may be obtained in conditions like genital candidiasis and other sexually transmitted diseases.
- **Personal history:** Ask about place of work, hobbies or recreational activities, use of cosmetics and ornaments and sexual exposure.

- Work contacts may produce irritant or allergic contact dermatitis
- Ornaments and cosmetics are incriminated in contact dermatitis
- Sexual exposure is important for diagnosis of sexually transmitted diseases, HIV
- History of photosensitivity in photodermatitis

TABLE 4.4 Review of skin lesions and systemic disorders

<i>Skin eruptions</i>	<i>Associated</i>	<i>Enquire about</i>
<i>Erythema nodosum</i> (Fig. 4.9)	• Sarcoidosis, tuberculosis, post-streptococcal infections, connective tissue disorders, drugs	• Cough and expectoration • Dyspnoea • Sore throat • Joint pains • Drugs
<i>Pyoderma gangrenosum</i> (Fig. 4.10)	Ulcerative colitis, rheumatoid arthritis	Rectal bleeding and joint pains
<i>Acanthosis nigricans</i>	Carcinoma stomach, DM and endocrinopathies	• Symptoms of weight loss, asthenia and loss of appetite • Endocrine disease (e.g. DM, thyroid, adrenal and pituitary)
<i>Dermatitis herpetiformis</i> (Dry, itchy vesicles/plaques)	Gluten-induced enteropathy	Family history and change in bowel habits
<i>Generalised purpura</i>	Idiopathic thrombocytopenic purpura, dengue and other blood disorders	Family history, haematuria, fever and weight loss
<i>Dermatitis artefacta</i>	Personality disorders	Stresses or anxieties

**FIGURE 4.8** Ichthyosis

Note the dry scaly lesions of the skin on the back

- **Review of systems:** Some examples of skin lesions and systemic diseases are reviewed in the Table 4.4.

EXAMINATION

Dermatology is the branch of medicine where the correct diagnosis primarily depends on the careful inspection of the skin. A careful examination of the whole skin should be made as clues to the diagnosis may be evident on distant sites. The diagnosis of the skin is based on morphology, distribution and nature/character/configuration of the lesion. If the diagnosis of skin disease is not apparent, a full general physical

examination should be performed as the skin disorder may be a manifestation of a systemic disorder.

Sequence of Examination

- Ask the patient to remove any dressing, wigs or make up
- Before inspecting any rash or lesion, inspect the **colour of the skin**
- Examine the lesion using uniform bright light over the undressed part of patient according to the spread of the lesion.
- Inspect the **distribution of the lesion**, e.g. symmetrical or asymmetrical, centripetal or centrifugal, etc.
- Note the **morphology of the lesion**, using a lens if necessary. Palpate the lesion. Note whether lesion is smooth or rough, dry or moist and is there any sweating?
- **Note the configuration/shape** (a tumour, Fig. 4.11 or ulcer) and arrangement of the lesion

Abnormalities of Skin Colour and Pigmentation

The normal skin colour varies depending on lifestyle, light exposure as well as constitutional and ethnic factors. The abnormal skin colouration is depicted in Box 5.

Pallor denotes paleness; can be transient due to haemorrhage or shock and intense emotional upset, or in patients with atopy—an inherited susceptibility to develop hay fever, asthma and eczema. It must be remembered that pallor does not mean anaemia, yellowness or jaundice. A pale skin is also seen in hypopituitarism and hypogonadism (Kallmann's syndrome).

Loss of normal pigmentation (melanin) in the skin is usually congenital—called **albinism** (Fig. 4.15); if it is localised,

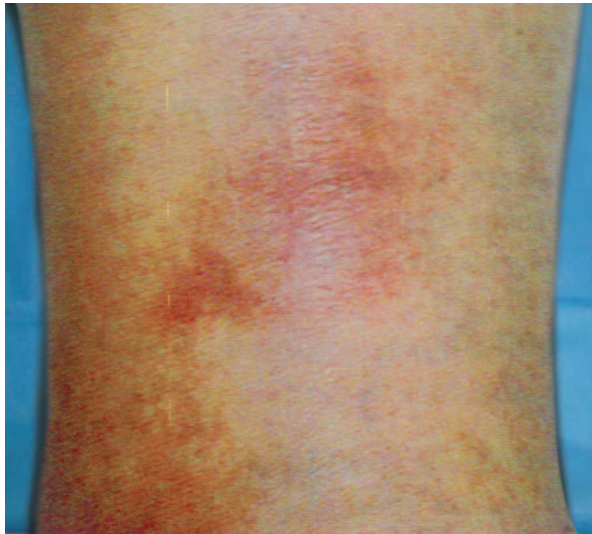

FIGURE 4.9 Erythema nodosum

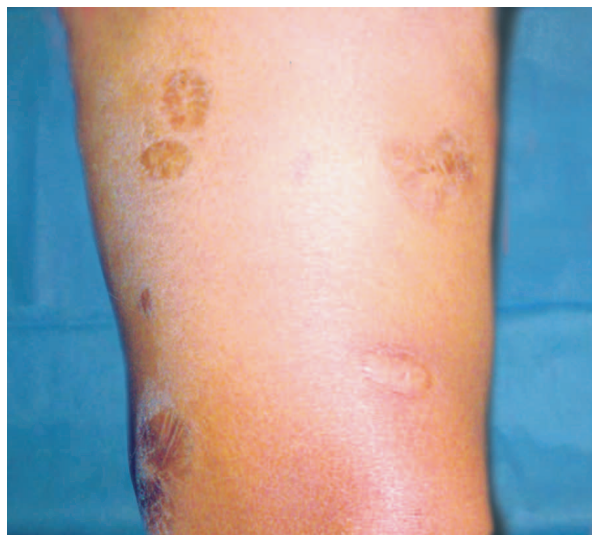


FIGURE 4.10 Healed lesions of pyoderma gangrenosum

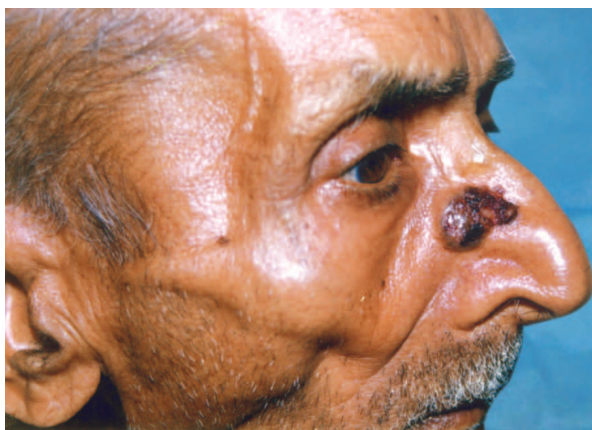

FIGURE 4.11 Basal cell carcinoma. Note the brownish pigmented macule at the side of the nose

Box 5

Abnormal skin colouration

Colour	Disorder/state
• Shallow brownish discolouration	Uraemia
• Bluish tinge or abnormal discolouration	Cyanosis produced by abnormal haemoglobin (Sulph or methaemoglobin). It has been discussed under CVS and respiratory system examination
• Pink discolouration	Carbon monoxide poisoning
• Yellow discolouration (Fig. 4.12)	Mepacrine, jaundice (discussed under examination of abdomen)
• Red discolouration	Clofazemine, rash (Fig. 4.13)
• Slate grey discolouration of exposed parts	Phenothiazines
• Loss of normal colour/pigment	Vitiligo (patchy Fig. 4.14), albinism (total absence Fig. 4.15)
• Brown pigmentation of skin, mucous membrane and creases of the palm and scars	Addison's disease or hypopituitarism, idiopathic (Fig. 4.16)
• Blotchy pigmentation of the face, "melasma or chloasma"	Pregnancy, postpartum (Fig. 4.18)
• Pallor of skin and mucous membrane	Anaemia
• Black pigmentation of skin	Haemochromatosis, kala-azar
• Pink, plethoric complex	Polycythaemia, alcoholism, Cushing's syndrome (see Fig. 3.1A)

it is called *piebaldism*. Patches of white and dark pigmented skin is seen in *vitiligo* (Fig. 4.14). Vitiligo is an autoimmune disorder of the skin characterised by a complete absence of melanocytes and is associated with other autoimmune disorders and positive family history.

Hyperpigmentation refers to excess of pigmentation of the skin which is mostly due to melanin, but occasionally may be due to other pigments i.e. brawny pigmentation could be either drug induced (see the Box 6) or haemosiderosis of skin (e.g. chronic venous insufficiency). Orange discoloration suggests carotenaemia and a bronze colour of the skin is seen in haemochromatosis and chronic arsenic poisoning.



FIGURE 4.12 Yellow discolouration of skin due to jaundice



FIGURE 4.15 Albinism. There is congenital widespread loss of pigment. Note the heterochromia (loss of pigment in the iris)

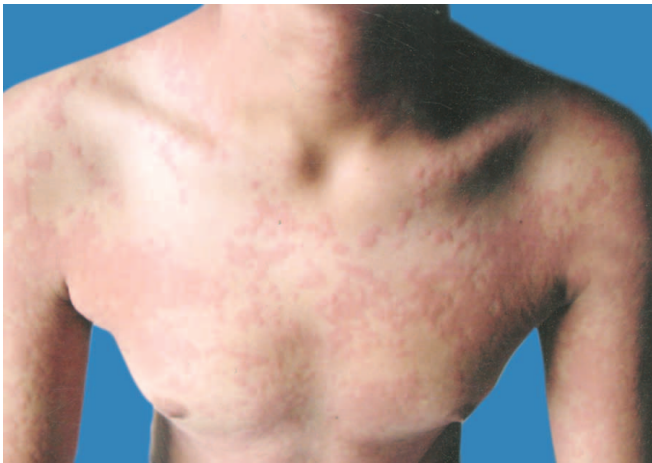

FIGURE 4.13 Rash. A rash of viral fever producing reddish discoloration

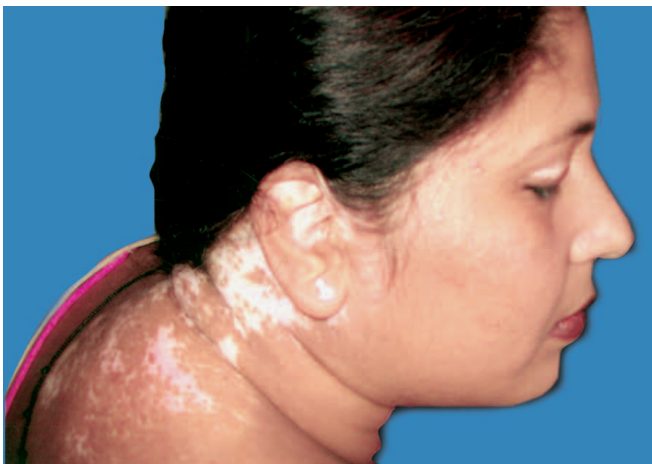

FIGURE 4.14 Vitiligo. Note the patchy loss of skin pigmentation

A different slate-grey hair is seen in argyria and in cachexia of advanced malignancy. Pigmentation may also occur with chronic infestation by body lice. Hyperpigmentation may be

Box 6

Drug-induced pigmentation

Drug	Pigmentation
Amiodarone (class III anti-arrhythmic)	Slate-grey, seen on exposed parts
Arsenic	Diffuse bronze with superimposed rain drop depigmentation
Bleomycin and Busulfan	Brown pigmentation
Chloroquine	Blue-grey pigmentation on exposed parts
Mepacrine	Yellow
Clofazemine	Red
Minocycline	Slate-grey, seen in scars, temples, shins and sclera
Phenothiazines	Slate-grey on exposed parts
Psoralens	Brown, seen on exposed parts

localised or generalised. *Erythema ab igne*—a reticular pattern of pigmentation of legs is seen in women who habitually sit near the fire, can be seen on the back or belly with use of hot-water bottle.

Localised hyperpigmentation: Patchy hyperpigmentation commonly is brown (epidermal) or bluish-black (dermal) following healing of an inflammatory disease (post-inflammatory). The causes of localised or patchy pigmentation are given in the Box 7. Localised pigmentation may be seen in pellagra and in scars of various kinds. It can be idiopathic (Fig. 4.16).

Generalised hyperpigmentation: Diffuse/generalised hyperpigmentation over sun-exposed areas commonly occurs due to exposure to sunlight. Diffuse pigmentation is classically seen in Addison's disease (see Fig. 20.24).

Box 7

Causes of localised or patchy hyperpigmentation

Chloasma (Fig. 4.17)	A mask-like pigmentation of face associated with pigmentation of nipples and of linea alba. It is seen in pregnant women and women taking oral contraceptives
Melasma	A similar condition to chloasma, is seen in Asian and African males
Brown coloured naevoid lesion	Light brown discolouration of skin over trunk, buttocks, and thighs is seen in Albright's syndrome
Café-au-lait spots	Brown patches as localised lesions or as a manifestation of neurofibromatosis (more than 5 spots of >1.5 cm ² area are diagnostic)
Freckles or (ephelides) (Fig. 4.18)	Sharply defined light-brown macules seen on face or exposed sites in fair-skinned persons or are seen in xeroderma pigmentosum
Lentigines	Macules larger than freckles are seen on palms, soles and genitalia. Solar lentigines are seen over sun-exposed area.
Post-inflammatory hyperpigmentation	Following eczema and dermatophytosis, drug eruptions, lichen planus.
Congenital melanocytic naevi (Fig. 4.19)	Any part of the body may be involved
Melanoma	A single patch of variegated colour



FIGURE 4.17 Facial pigmentation chloasma persisting in a postpartum female

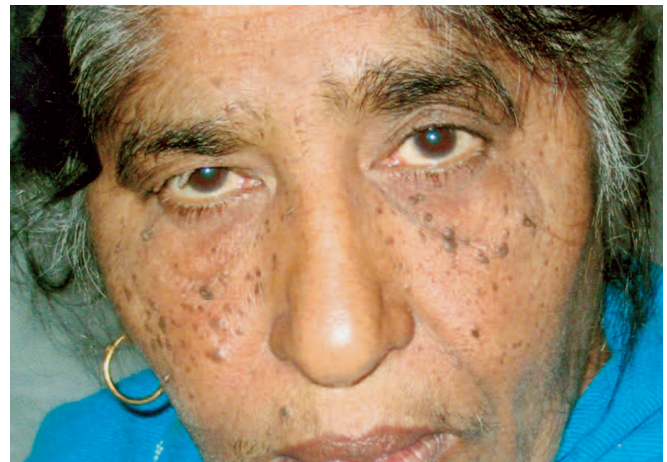

FIGURE 4.18 Freckles (ephelides). Note the hyperpigmented macules over the face in a fair complexioned woman



FIGURE 4.16 Idiopathic pigmentation of face, and hand in a young adult

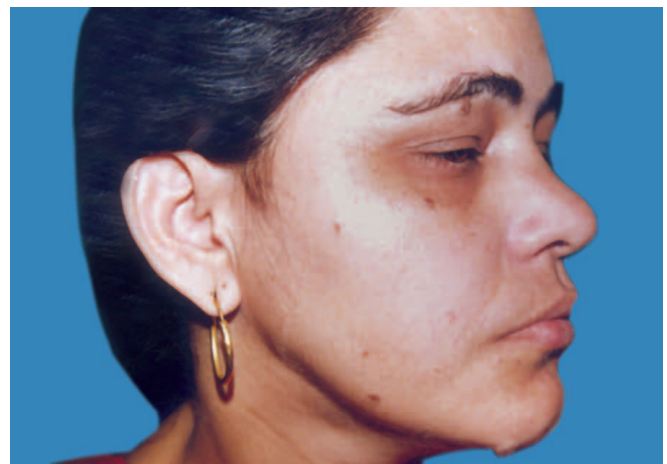

FIGURE 4.19 Congenital melanocytic naevi over the face

The diffuse dark brown pigmentation of Addison's disease is accentuated over sun-exposed areas, flexures, bony prominences, mucosal, mucocutaneous junctions, nipples, palmer creases and genitalia. Previously pigmented lesion or scars also become darker. Addison's like pigmentation is observed in many other conditions (Table 4.5).

Abnormal redness of skin may be due to, flushing (deep red or violaceous erythema of neck and face) occurs in carcinoid syndrome, systemic mastocytosis, in menopause as a reaction to alcohol or glutamates, may be due to chlorpropamide, calcium channel blockers and nicotinic acid.

- Cherry-red colour in carbon-monoxide poisoning
- Overheating (erythema ab igne-dusk discolouration of skin seen on the front of lower legs in a person who sits near open fire places or on abdomen or back due to hot water bottle)
- Extreme exertion.

Cyanosis refers to bluish discolouration of skin, produced by presence of reduced haemoglobin >5 g either locally, as in impaired peripheral circulation, or generally, when oxygenation of the blood is defective. The presence of abnormal haemoglobin such as methaemoglobin or

sulphaemoglobin may lead to cyanosis. The causes of methaemoglobin are given in the Box 8. Carboxyhaemoglobin in carbon-monoxide poisoning leads to cherry-red colour of the skin and cyanosis called red cyanosis.

Jaundice refers to various shades of yellow colouration of the skin and mucous membrane of conjunctivae by presence of increased bilirubin >2.5 mg%. The level of bilirubin <2.5 mg% produce subclinical jaundice which may not be detected. The lemon yellow colouration of skin may be seen in haemolytic anaemia while deep yellow to orange or yellowish-green colouration is seen in obstructive jaundice (Fig. 4.12). Orange-yellow colouration to the skin may be due to carotenaemia from which jaundice has to be differentiated by examining the conjunctivae which are also orange-yellow in jaundice but not in carotenaemia.

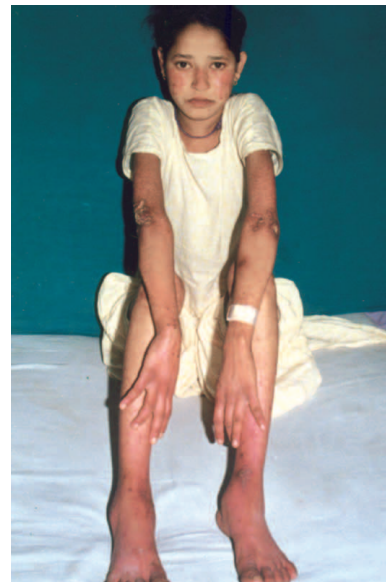

FIGURE 4.20 Diffuse pigmentation of skin in a patient with SLE. Note the butterfly rash (heliotrophic rash) over the face starting from the nose extending over the cheeks

TABLE 4.5 Causes of diffuse generalised pigmentation

• Increased ACTH (MSH) production	
– Addison's disease (see Fig. 20.24)	
– ACTH/MSH producing pituitary adenoma or ectopic	
– ACTH producing tumour	
– Bilateral adrenalectomy (Nelson's syndrome)	
– Cushing's syndrome, acromegaly	
• Collagen vascular diseases	
– SLE (Fig. 4.20)	– Dermatomyositis
• Drugs and metals	
– Heavy metals	
– Cancer chemotherapy	
• Debilitating diseases	
– HIV infection	– Alcohol abuse
– Kala azar, malaria, tuberculosis	– Hepatic failure, biliary cirrhosis
– Advanced malignancies	– Chronic renal failure
– Megaloblastic anaemia	
• Metabolic diseases	
– Haemochromatosis	– Porphyrria
• Neurofibromatosis (Fig. 4.21)	
– Sunburn or photosensitivity	
– Erythroderma (e.g. exfoliative dermatitis) in which majority of the skin surface is red, could be due to skin conditions, drugs (Fig. 4.22)	
– In febrile illness, exanthematous skin disease	
– Inflammatory skin disease	
– Local redness may be due to telangiectasia or disseminated intravascular coagulation and purpura (Fig. 4.23).	

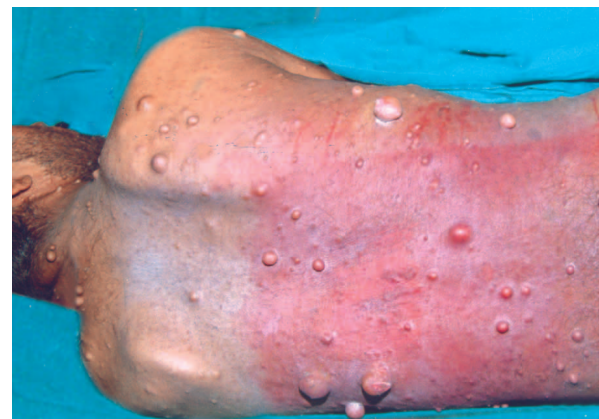

FIGURE 4.21 Neurofibromatosis. Note the multiple small swellings on the skin with diffuse pigmentation

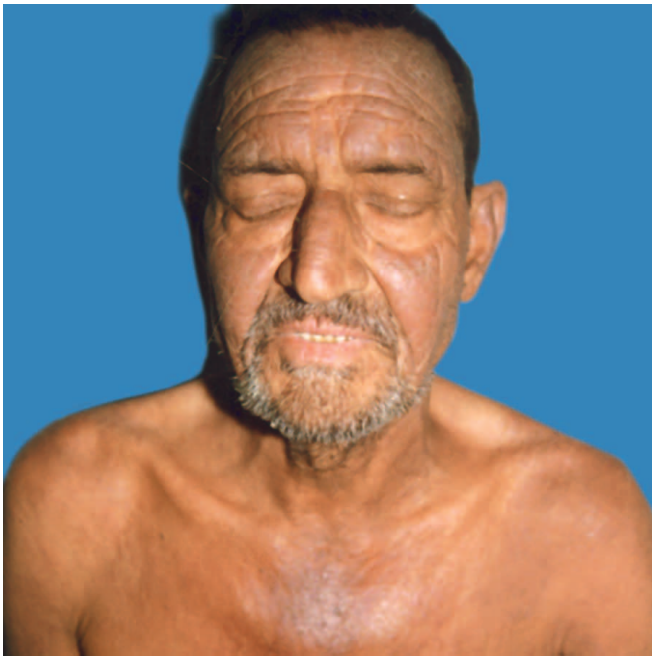

FIGURE 4.22 Erythroderma (exfoliative dermatitis) induced by a drug. Note the diffuse erythema and exfoliation of skin

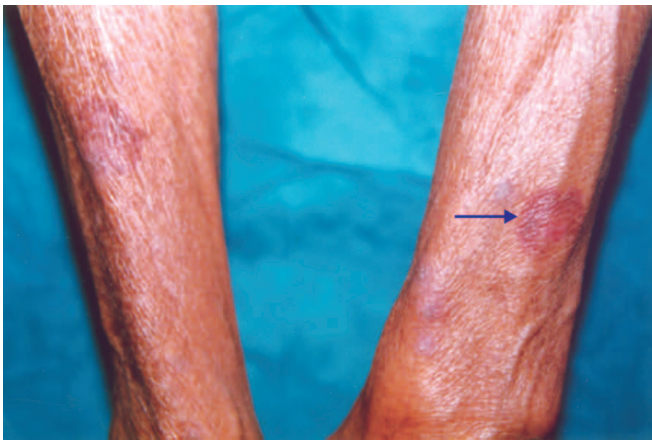


FIGURE 4.23 Redness of skin. Large purpuric or ecchymotic patches (Devil's pinches) indicated by an arrow in an old patient due to senility called senile purpura

Box 8

Causes of methaemoglobin

Oxidising agents and drugs

- Aniline and its derivatives
- Chlorates
- Local anaesthetic (e.g. benzocaine)
- Antimalarial (e.g. primaquine)
- Dapsone
- Phenazopyridine
- Sulphonamides

Common Abnormal Skin Lesions

Distribution of the Lesion as a Clue to the Diagnosis

Skin disorders are generalised, localised or regional. Recognition of the characteristic distribution facilitates the diagnosis greatly by narrowing down the diagnostic possibilities. The questions to be asked about distribution of the lesion are given in the Box 9.

Universal, symmetric vs asymmetric lesion

- Localised distribution of lesion is seen in contact dermatitis e.g. necklace, ear-rings, lip-stick dermatitis
- Universal and symmetrical eruptions favour the systemic or constitutional cause
- Asymmetrical eruptions spreading from a single focus favour fungal, bacterial, rickettsial or viral infections

Anatomical pattern of central vs peripheral distributions

- Dermatomal distribution (Fig. 4.24) of the rash favours the diagnosis of herpes zoster infection. Some common diseases such as chicken pox (Figs 4.25A and B) and pityriasis are centripetal in distribution; while erythema nodosum, erythema multiforme and small pox are centrifugal (peripheral) in distribution.

Special sites or areas of predilection

- **Photodermatitis** involves sun-exposed areas and spares shielded areas (Fig. 4.26).
- **Atopic dermatitis** in children frequently involves the antecubital and popliteal fossae e.g. flexor surfaces; while psoriasis in adults involves extensor surfaces (Fig. 4.27).
- **Psoriasis** involves the extensor surfaces of joints (elbow, knee) scalp, natal cleft and nails.
- **Cutaneous candidiasis** produces maceration of the skin in body folds especially in the obese, induces erosion and intertrigo (Fig. 4.28). In infants, napkin may encourage candida infection.

Box 9

Questionnaire for distribution of the lesions

- Is the lesion/rash localised, universal, symmetrical?
- Does the lesion/rash follow an anatomical (dermatomal) pattern or central/peripheral distribution?
- Does it affect special sites (flexor or extensor areas)?
- Are areas/regions of predilection for some skin disorder involved?
- Are there other clues to the diagnosis at distant sites?
- Are there any incidental findings e.g. genitalia involved?

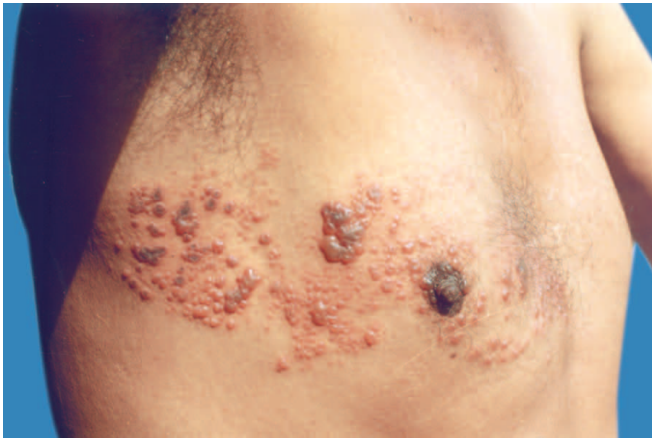

FIGURE 4.24 Herpes zoster infection. Note the distribution of skin lesion along the dermatome

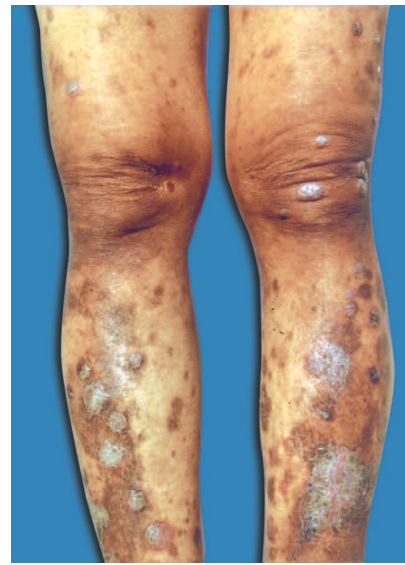
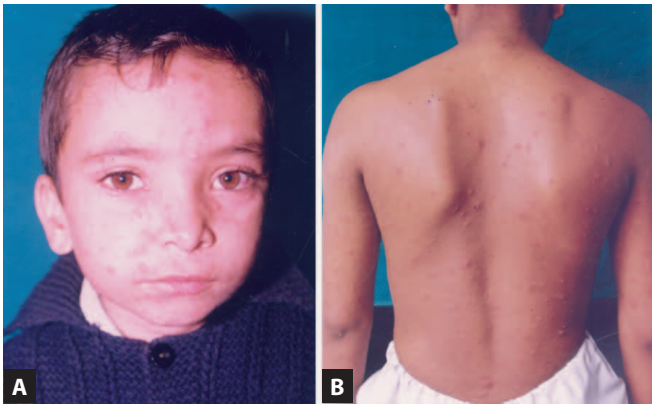
FIGURE 4.27 Psoriasis. Note the dry scaly pruritic lesions over the extensor surface of the legs



FIGURES 4.25A and B Chicken pox. Note the centripetal distribution of the skin eruptions in two brothers: (A) Lesions over the face; (B) Lesions over the back. Simultaneous infection in two brothers indicates direct transmission of infection

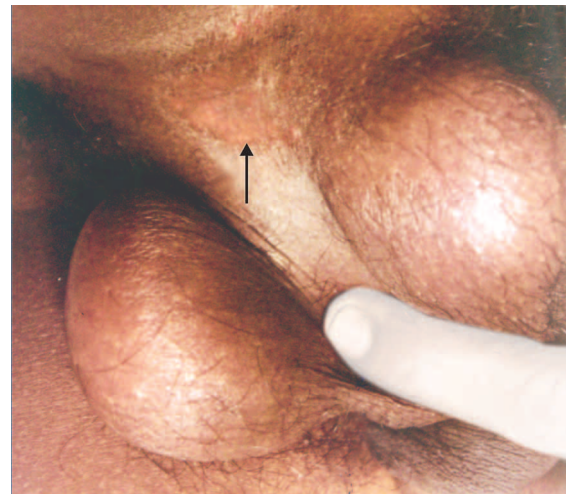


FIGURE 4.28 Cutaneous candidiasis. Note the maceration of the skin in the body folds (e.g. sacral folds) inducing erosions and intertrigo

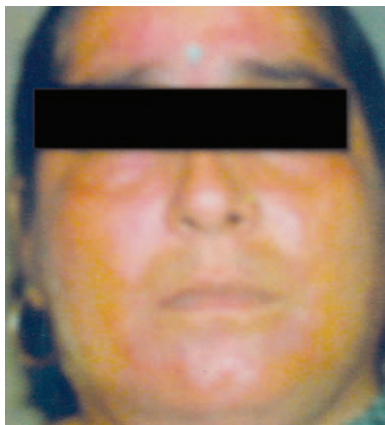

FIGURE 4.26 Photodermatitis

- **Seborrhoeic dermatitis** is seen in areas where there is high density of sebaceous glands, i.e. scalp, forehead, eye brows, nasolabial folds, presternal areas, etc.
- **Acne** involves cheek (Fig. 4.29) forehead, shoulder and back.

- **Ring worm** (Fig. 4.30) involves groin (*tinea cruris*) feet (*tinea pedis*), scalp (*tinea capitis*) and beard (*tinea barbae*).
- **Lipoatrophy** (loss of subcutaneous fat) producing disfiguring excavations and depressed areas (pits) due to insulin are seen on thighs, buttocks, arms and abdomen.
- Swelling around the eyelids without redness indicates acute nephritic or nephrotic syndrome or trichinosis; whereas irritation around eyes indicates contact dermatitis.

Morphology of Skin Lesions due to Diagnosis

Skin lesions are said to be **primary** when they arise *de novo* as the first manifestation of skin disorder.

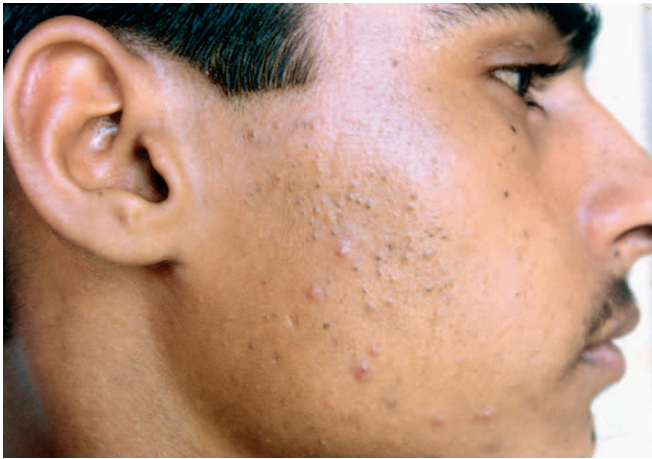

FIGURE 4.29 Acne vulgaris—a chronic skin condition manifesting as comedones or black heads due to blockage of pilosebaceous glands commonly involves the face, chest and back where glands are present in abundance. The condition occurs commonly in adolescent males and females

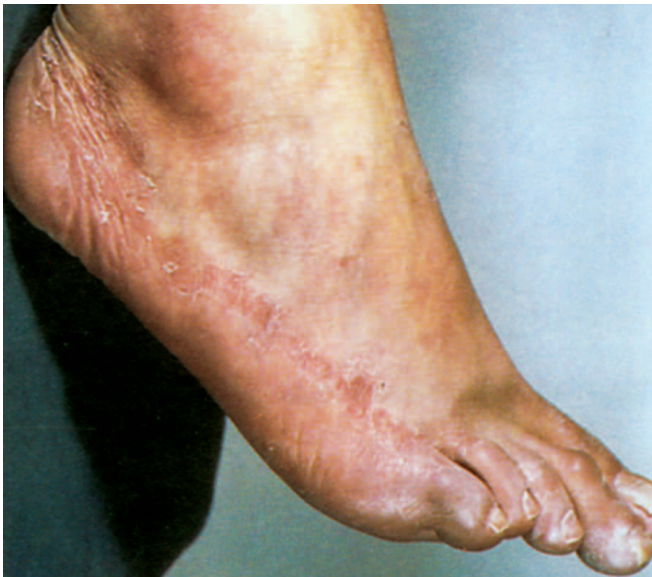

FIGURE 4.30 Tinea pedis (ring worm infection of foot). A moccasin distribution of a red rash with scales; note clear line of demarcation

Secondary lesions: Secondary lesions arise from the changes in the primary lesions. They trace the evolutionary course of the primary into secondary lesions and are thus helpful to the clinical diagnosis. After the distribution of the lesion, the morphology of the lesion should be defined. Most lesions (primary as well as secondary) have special names (Table 4.6) which should be used to describe the skin lesion. Sometimes early primary lesion may be obscured by scratch marks, crusting and ulceration, therefore, these must be sought and when found, inspected closely.

TABLE 4.6 Terminology used in skin lesions

<i>Skin lesion</i>	<i>Description</i>
I Primary lesions	
<i>Papule</i>	A circumscribed, raised solid area of skin, less than 0.5 cm in diameter
<i>Plaque</i>	An elevated area of skin greater than 2 cm in diameter, can result from coalescence of papules
<i>Macule</i>	A flat circumscribed area of altered colour or texture
<i>Vesicle</i>	A small vesicle (<0.5 cm in diameter)
<i>Bulla</i>	A large vesicle (>0.5 cm in diameter)
<i>Pustule</i>	A pus-containing blister
<i>Abscess</i>	Collection of pus in a cavity, more than 1 cm in diameter
<i>Wheal (urticaria)</i>	A transient elevated reddened area associated with scratching and dermal swelling
<i>Angioedema</i>	A diffuse swelling or oedema that extends into the subcutaneous tissue (Fig. 4.31)
<i>Nodule</i>	A raised solid skin mass greater than 0.5 cm in diameter
<i>Papilloma</i>	A nipple-like mass projecting from the skin
<i>Petechiae</i>	Small pin-head size (<3 mm in diameter) macules containing blood. It occurs due to extravasation of blood into the skin
<i>Purpura</i>	Extravasation of blood into skin producing large macule or papule that does not blanch on pressure
<i>Ecchymosis</i>	A large petechiae (> 3 mm) is called ecchymosis
<i>Haematoma</i>	A localised collection of blood producing a swelling
<i>Burrow</i>	A linear or curved tract (particularly caused by a burrowing scabie mite)
<i>Comedome (the black head)</i>	A plug of keratin and sebum wedged in a dilated pilosebaceous orifice. It is a characteristic lesion in acne vulgaris
<i>Telangiectasia</i>	Dilatation of small cutaneous blood vessels
<i>Annular lesions</i>	Ring-shaped lesions
II Secondary lesions	
<i>Scales</i>	Dried flakes of dead skin arising from the horny layer
<i>Crust</i>	Dried exudate (blood or fluid) on the skin looking like a scale
<i>Erosion</i>	A denuded area of skin with loss of epidermis
<i>Ulcer</i>	A denuded area of skin with loss of epidermis and a part of dermis
<i>Excoriation</i>	Linear marks or erosions produced by scratching
<i>Fissure</i>	A slit in the skin
<i>Sinus</i>	A channel or cavity that permits the discharge of fluid or pus
<i>Scar</i>	The healed area of the skin in which normal skin has been permanently replaced by fibrous tissue
<i>Keloid scar</i>	Excessive scar formation
<i>Atrophy</i>	Thinning of the skin
<i>Striae</i>	A streak-like linear, atrophic pink or white skin lesion caused by a change in connective supporting tissue

The clinician/student should study the lesions carefully, if necessary by a lens and should ask the following questions and described them as per terminology used (Table 4.6)

1. What are their shapes?
2. What are their sizes?
3. What is their colour?
4. What are the characteristics of their margins and surfaces?

Most skin lesions vary in colour, i.e.

- Violaceous scaly discrete flat-topped papules are seen in lichen planus.
- Yellow coloured hue or tubercles are seen in xanthomatosis (Fig. 4.32).
- Slat grey colour of skin is seen in drug-induced pigmentation.
- Depigmented or reddened anaesthetic skin lesions are seen in leprosy (Hansen's disease—Fig. 4.33). The lesions are located in the skin that is normally cooler than body temperature.
- Rose spots (Fig. 4.34) make up a faint salmon coloured maculopapular, blanching rash over the trunk and chest, is seen in enteric fever due to *S. typhi* and *paratyphi*.
- A pink heliotropic rash over the cheeks is seen in dermatomyositis and SLE (see Fig. 4.20).
- Ash-leaf depigmented (Shagreen patch) lesion on the trunk and adenoma sebaceum on the face indicate tuberous sclerosis (Fig. 4.35).
- Port-wine stain (a tumour consisting of dilated capillary vessels) may be associated with Sturge-Weber syndrome (Fig. 4.36). A salmon-coloured patch due to capillary plexus may be seen as capillary naevus (naevus flammeus—Fig. 4.37).
- Cavernous haemangioma (Strawberry naevus—Fig. 4.38) de Morgan's spots (Fig. 4.39) are cherry-angiomas.
- Painless black crusted eschar surrounded by erythematous halo is seen in Rickettsial infection at the site of mite bite (Fig. 4.40).

Configuration of the Lesions as Clue to the Diagnosis

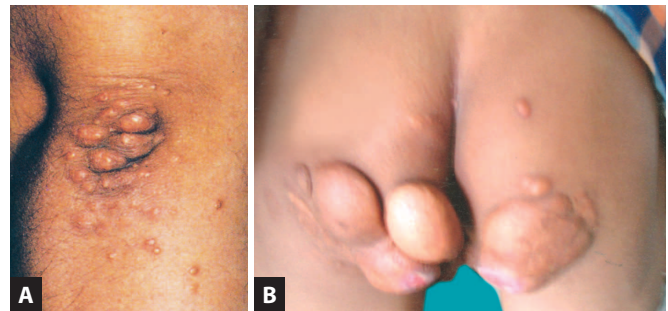
Once the morphology of the individual lesions and their distribution has been established, it is useful to describe their configuration on the skin. The terminology used in relation to the configuration of the lesion are given in the Table 4.7.

THE HAIR (Fig. 4.41)

The hair consists of hair follicles which house the hair shaft. The germinal part of hair shaft is in the hair matrix. The melanocytes migrate into the matrix and give different colour to the hair by producing melanin.

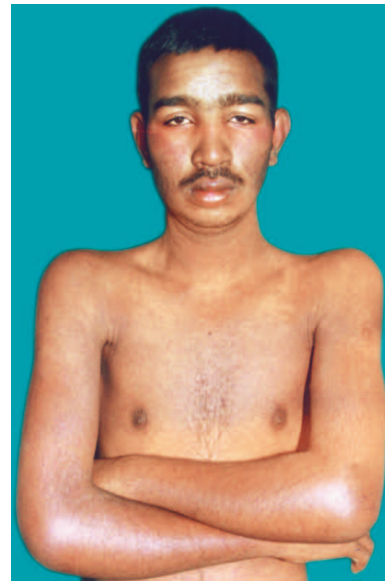

FIGURE 4.31 Angioedema. Note the diffuse swelling over the body due to oedema of subcutaneous tissue including face



FIGURES 4.32A and B Tuberoeruptive xanthomata: (A) On the elbow of a patient with dyslipidemia; (B) On the buttocks

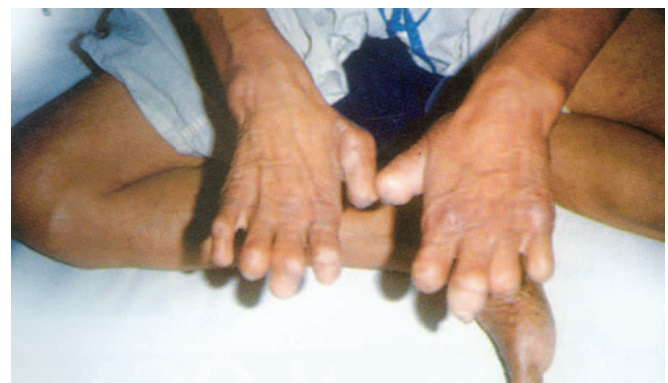

FIGURE 4.33 Hansen's disease (leprosy)

Types of hair—There are three types of hair:

- i. *Terminal*—coarse medullated hair, e.g. scalp, moustaches, beard, eyebrows, pubic.
- ii. *Vellus-nonmedullated*, fine, short downy hair e.g. on the face of women and prepubertal boys.
- iii. *Lanugo*—hair covering the foetus.

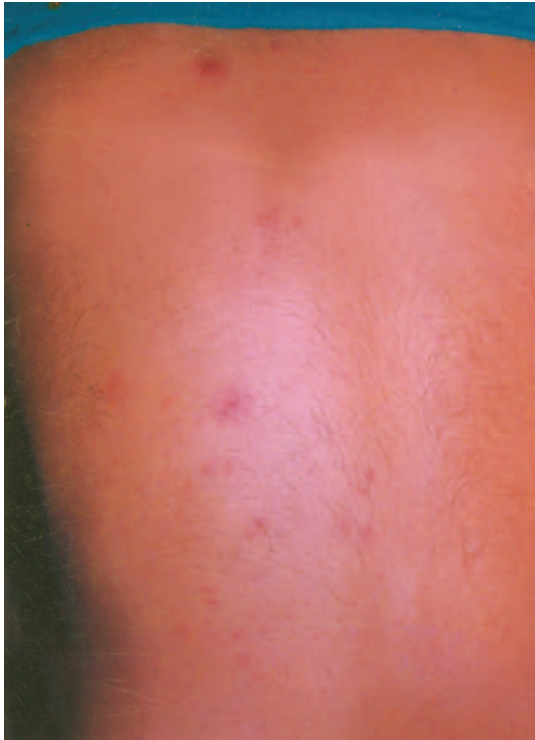
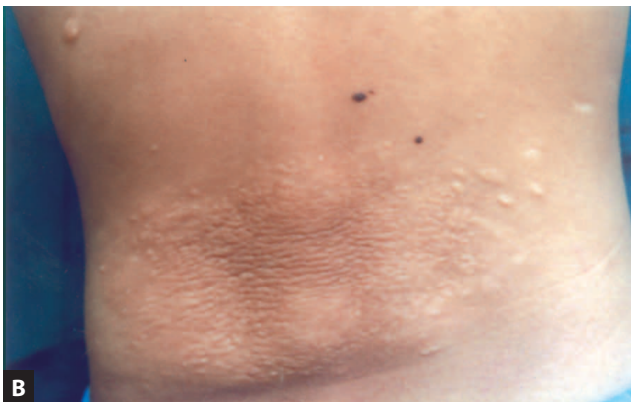
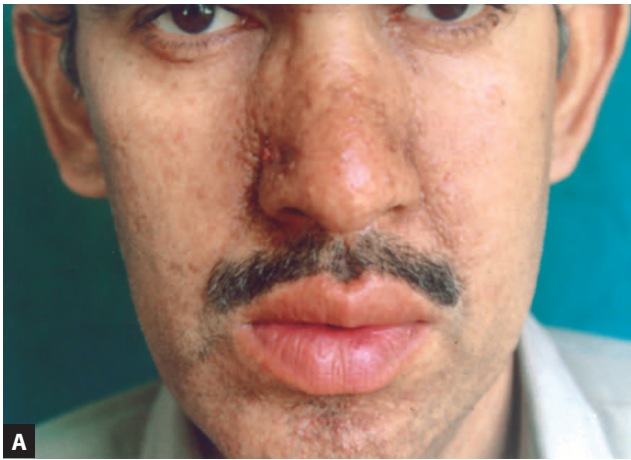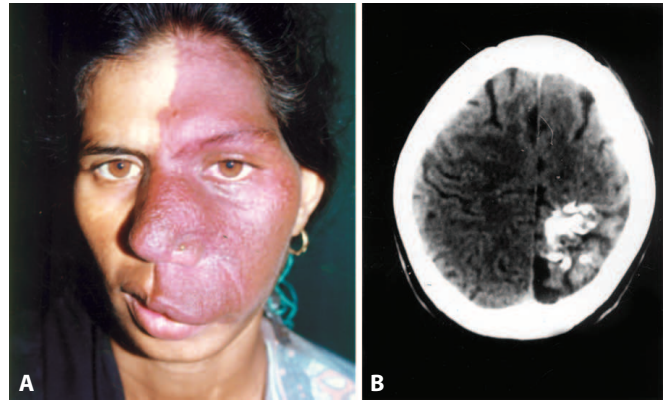FIGURE 4.34 Rose spots. The rash of typhoid fever in a patient



FIGURES 4.35A and B Tuberous sclerosis: (A) Adenoma sebaceum over the face; (B) Shagreen (ash-leaf depigmented lesion) patch over the back



FIGURES 4.36A and B Sturge-Weber syndrome: (A) Port-wine stain (capillary haemangioma) of left side of face; (B) CT scan of the patient shows gyral calcification in the same patient. Patient had epilepsy for more than 10 years

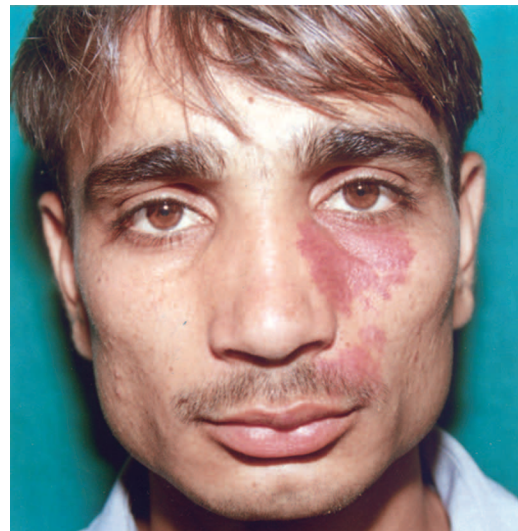

FIGURE 4.37 Capillary naevus (naevus flammeus). Note the salmon—coloured patch on the left side of the face

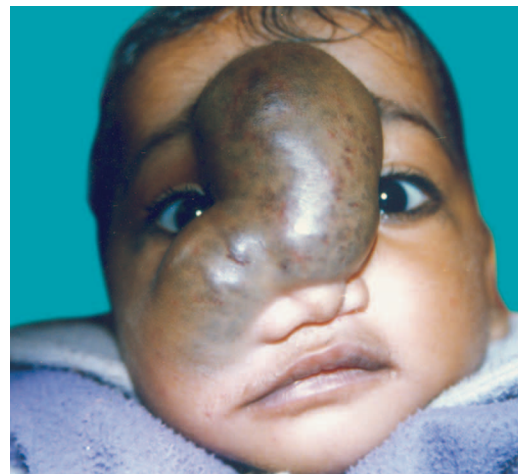

FIGURE 4.38 Cavernous haemangioma (strawberry naevus) in a child. Note the well demarcated round, lobulated growth on the face at the base of the nose and obstructing both the eyes

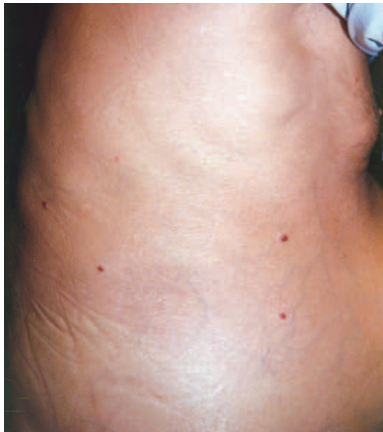

FIGURE 4.39 de Morgan's spots. Note the pinpoint pinkish spots (cherry angiomas) over the side of the chest

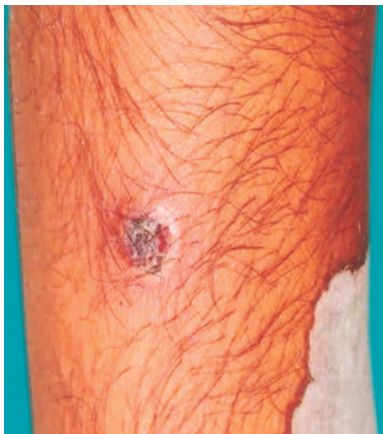

FIGURE 4.40 Eschar at the site of mite bite in a patient with scrub typhus

The growth of hair like other epithelial structures occurs by mitosis. The growth of hair is cyclic and continues throughout life and passes through alternating phases of active growth (anagen) and resting/shedding (telogen). The duration of these phases varies in different regions of the body. The anagen phase of scalp hair may last for upto 5 years, but this phase is shorter and the telogen phase is longer in eyebrow and sexually determined hair. The length of anagen phase determines the length of hair, hence, is longer in the regions where the hair are longer. Normally 85% of scalp hairs are in anagen and 15% in telogen stages. The catagen is the conversion phase from active to resting phase and usually lasts for few days.

Secondary sexual hair begins to appear at puberty and has characteristic male and female patterns. The hair growth occurs earlier in girls (average age 11.5 years) than in boys (average age 13.5 years). The development of pubic hair is related to androgen production (adenarache) in the absence of gonadotrophin secretion. This is the reason that in isolated

Lesion	Description	Significance
Nummular/ discoid	Ring or coin shaped	Nummular eczema, nummular/guttate psoriasis, discoid lupus erythematosus
Annular	Ring-like	Tinea corporis or by coalescence of adjacent lesions (annular granuloma annulare)
Circinate	Circular	Fixed drug eruptions
Arcuate	Curved	Scabies (curved burrows of scabies mite)
Gyrate/ serpiginous	Wave-like	Urticaria
Linear	In a line	Seen in insect bites, scratching (Koebner phenomenon) linear psoriasis, photodermatitis, linear warts
Grouped	Clustered	Grouping of vesicles is seen in herpes simplex infection, typical of bug-bites
Reticular	Net-like or Web-like	Allergic conditions, drug induced, photodermatitis. Livedo reticularis (e.g. vasculitis, SLE, Snedden's syndrome)

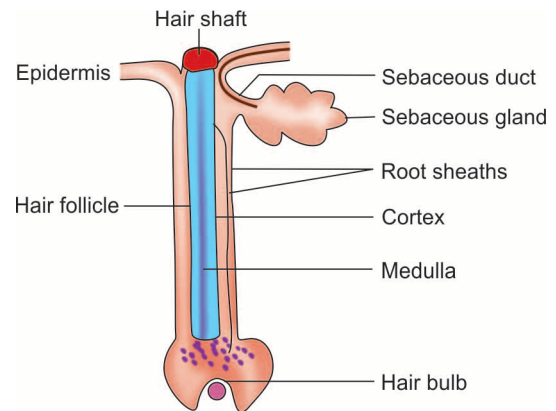


FIGURE 4.41 Structure of hair

gonadotrophin deficiency, the pubic hair are present but signs of puberty are absent. The axillary hair appear about 2 years later than the start of pubic hair, and, in boys, coincides with the development of facial hair. Last of all, body hair develops and its extent increases throughout the years of sexual maturity, with slight variations in its pattern.

Hair colour, amount and texture have familial and racial characteristics that are genetically determined. Asians tends to have straight hair, Negroids to have black curly hair and Europeans to have wavy hair. Mongoloids have sparse facial and body hair. Mediterranean people have more hairs than northern Europeans.

EXAMINATION

Examination Sequence

First of all, inspect the scalp hair followed by body and secondary sexual hair for:

- Lustre, calibre, structure, strength and density
- Note the absence or loss of hair. If present, determine its cause
- For fungal infection, nits and lice
- Nature and distribution.

Abnormalities of Hair

- Too little hair.
- Too much hair.

Too Less Hair and Hair Loss

- **Temporal recession:** Certain follicles of the scalp regress with age to produce fine vellus hair instead of coarse terminal hair. This leads to thinning of hair and temporal baldness-called temporal recession. This pattern of baldness is androgen dependent, hence seen in males and not in females. In females, this pattern suggests virilisation.
- **Premature male-pattern baldness:** Vertical thinning is seen in association with marginal recession in both the sexes, indicates androgen excess called androgenic alopecia.
- **Thinning or loss of hair** over frontal region may be seen in myotonia dystrophica and also in systemic lupus erythematosus. Diffuse thinning of hair is seen in hypothyroidism, hyperthyroidism, hypopituitarism, HIV infection and deficiency of protein, iron, biotin and zinc.
- **Alopecia** is the term used to describe hair loss which may be localised (e.g. scarring and nonscarring) or diffuse. There are many causes and patterns (Table 4.8).

In nonscarring alopecia, the hair shafts are gone but hair follicles are preserved. Primary cutaneous disorders such as telogen effluvium, androgenic alopecia, alopecia areata, tinea capitis and trauma are most common causes of localised or diffuse nonscarring alopecia. In women androgenic alopecia indicates virilisation, therefore, others signs such as deepening of voice and enlarged clitoris may be sought and the possibility of an ovarian or adrenal tumour should be considered.

Drugs also can produce diffuse hair loss (*see* Box 10) by inducing a telogen effluvium.

In systemic lupus erythematosus, both scarring (discoid lupus) and nonscarring forms (lupus hair) of alopecia are seen. The lupus hairs are multiple short hairs, mostly seen in frontal scalp region in SLE (Fig. 4.43). In secondary stage of syphilis, scattered, poorly circumscribed patches of alopecia with a “moth-eaten” appearance may be seen.

TABLE 4.8 Classification of alopecia

• Localised (patchy)
– <i>Nonscarring</i>
– Tinea capitis
– Alopecia areata (Fig. 4.42)
– Androgenic alopecia
– Traumatic (trichotillomania, traction, cosmetic)
– <i>Scarring</i>
– Idiopathic
– Developmental defects
– Discoid lupus erythematosus
– Herpes zoster
– Pseudopelade
– Tinea capitis/kerion
• Generalised (diffuse)
– <i>Non-scarring</i>
– Drug-induced (<i>see</i> the Box 10)
– Telogen effluvium
– Androgenic
– Metabolic, e.g. diabetes mellitus
– Thyroid disorders, e.g. hypo and hyperthyroidism
– Hypopituitarism
– Nutritional deficiency
– HIV infection/disease
– Liver disease, e.g. cirrhosis of liver
– Postpartum
– Syphilis
– <i>Scarring</i>
– Discoid lupus erythematosus, sarcoidosis
– Radiotherapy
– Lichen planus pilaris
– Folliculitis decalvans
– Cutaneous metastases

Remember that nonscarring alopecia is reversible

In scarring alopecia, there is inflammation, fibrosis and loss of hair follicles resulting in nonreversible form of alopecia. Scarring alopecia is most frequently the result of primary skin disorders such as lichen planus pilaris, folliculitis decalvans, and cutaneous discoid lupus.

Alopecia areata

This is nonscarring alopecia which occurs in both the sexes and all races and is usually seen in young adults or children. There is often a personal or family history of atopy. It occurs in association with other autoimmune diseases, i.e. thyrotoxicosis, Addison’s disease, pernicious anaemia, vitiligo, atopy and Down’s syndrome.

There are sharply defined non-inflamed patches of baldness seen usually on the scalp (Fig. 4.42) but may involve eyebrows and beard. Patches tend to regrow over the course

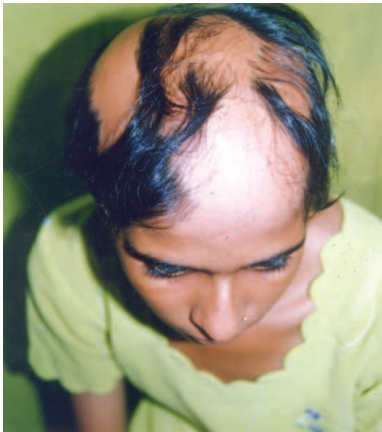

FIGURE 4.42 Alopecia areata. Note the patchy loss of hair over the scalp

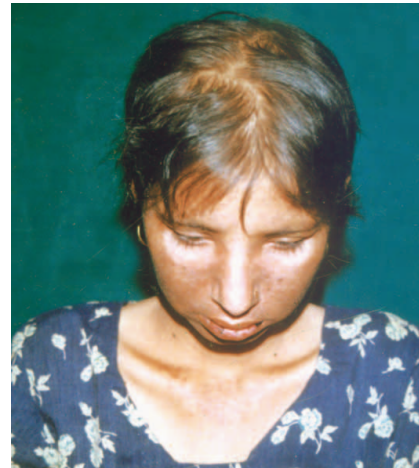

FIGURE 4.43 Lupus hairs in a patient with SLE. There is nonscarring patchy hair loss with lupus hairs (multiple short hairs) over the scalp and forehead

Box 10

Drug-induced alopecia

- Anticoagulants
 - Warfarin
 - Heparin
- Antithyroid
 - Prophylthouracil
 - Carbimazole
- Antimitotic
 - Daunorubicin
- Vitamin A
- Betablockers
- Antidepressants e.g. lithium
- Colchicine
- Amphetamines

of several months. Children with an atopic background may lose all scalp hair (alopecia totalis), which is less frequent in adults. Loss of hair from all body sites (alopecia universalis) may occur by extension from other sites but can also occur acutely. The extension of hair loss starts in peripheral fashion, at the advancing edge, the broken hair (exclamation mark hairs) provide evidence of disease activity.

Androgenic alopecia (Male-Pattern Baldness)

Recession of hair margin is an ageing process. Androgenic alopecia (male-pattern baldness), is physiological in men over 20 years of age though rarely it may be extensive and develop acutely in late teens. It also occurs in females most obviously after menopause. The male-pattern baldness includes bitemporal recession of hair line and then loss of hair over the crown. This is attributed to increased 5α -reduction of testosterone to dihydrotestosterone (DHT) in frontal but not in occipital hair follicles. DHT is responsible for miniaturization of hair follicles, fine hair growth ensues and there is shortening of anagen phase of hair growth.

- Premature male-pattern baldness refers to early onset of hair loss both in males and females, indicates androgen excess. In females, androgen excess suggests virilisation.

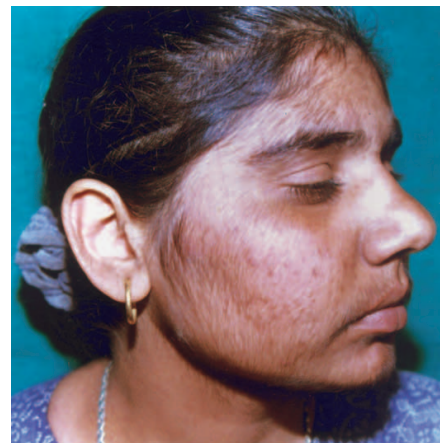

FIGURE 4.44 Hirsutism. Note the excessive growth of hairs over the face, beard and moustache in a young female

- Secondary sexual hair on the face in the male and in the axillae and on the pubis in both sexes may fail to develop in hypogonadism, may diminish in old age or be lost in hypopituitarism.
- **Eyebrows:** The amount of hair in the eyebrows varies widely. Thinning of hairs on outer third of the eyebrow is common in normal persons and abnormally seen in hypothyroidism and obstructive jaundice.

Too Much Facial and Body Hair

Hirsutism

It is the excessive growth of coarse terminal hair in a male pattern (androgenic distribution) in a female. Therefore, hirsutism in females involves those areas which have hairs in the male (male pattern), i.e. face (Fig. 4.44), trunk and limbs. The pubic hair spreads from its normal flat-topped distribution up towards umbilicus-called *male escutcheon*.

TABLE 4.9 Differential diagnosis of hirsutism

Condition	Clinical presentation	Menstruation
<ul style="list-style-type: none"> • Hirsutism without virilisation <ul style="list-style-type: none"> – Familial: Family history often long history, Normal positive, beginning after menarche – Idiopathic: Long history, beginning Normal after menarche – Mild polycystic ovarian syndrome: Long history, beginning after Normal to menarche chaotic – Late-onset congenital adrenal hyperplasia: Often before menarche, often short stature, sometimes acne or greasy skin • Hirsutism with virilisation (e.g. enlarged clitoris, deepening of voice, male phenotype, greasy skin, acne) <ul style="list-style-type: none"> – Polycystic ovarian long history, beginning chaotic or syndrome (severe) after menarche amenorrhoea – Ovarian neoplasm short history, an adult Amenorrhoea – Congenital adrenal infancy or childhood – Hyperplasia • Drug-induced hirsutism (e.g. androgens, phenytoin, diazoxide, minoxidil, cyclosporine) 		

Hirsutism is often racial (e.g. Mediterranean, Asians, Caucasians) and familial. Some degree of facial hair growth (hirsutism) is common after menopause. The hirsutism may or may not be associated with virilisation (Table 4.9). The causes of hirsutism are given in the Box 11.

Box 11

Causes of hirsutism (see Fig. 4.42)

Causes	Clinical characteristics
Idiopathic	<ul style="list-style-type: none"> • Often familial • Asian background
Polycystic ovarian syndrome (Stein-leventhal-syndrome)	<ul style="list-style-type: none"> • Obesity • Oligo or amenorrhoea • Infertility
Congenital adrenal hyperplasia (21-hydroxylase deficiencies)	<ul style="list-style-type: none"> • Pigmentation • History of salt-wasting in childhood • Ambiguous genitalia or adrenal crisis when stressed. • Jewish background.
Exogenous androgen administration	<ul style="list-style-type: none"> • Athletes • Virilisation
Androgen-secreting tumour of the ovary or adrenal cortex	<ul style="list-style-type: none"> • Rapid onset • Virilisation • Clitoromegaly, deep voice, balding, breast atrophy.
Cushing syndrome	<ul style="list-style-type: none"> • Clinical features of Cushing's syndrome (moon faces, truncal obesity, striae).

Hypertrichosis

It is an excess growth of terminal coarse hair which does not follow an androgen-induced pattern (a distinguishing feature from hirsutism). It may be due to drugs (minoxidil, cyclosporin), trauma and cutaneous porphyria.

5

CHAPTER

The Eyes

THE EYES (Fig. 5.1)

Applied Anatomy and Physiology

The organs of vision are the eyes. Each eye is situated in the orbit—a bony cage. It consists of upper and lower eyelids, the upper eyelid covers a portion (one-eighth) of the cornea but does not overlap the pupil. The space between the two-eyelids is called *palpebral fissure*. The white colour of sclera on the sides of the cornea looks somewhat buff-coloured at its extreme periphery. Do not confuse this colour for jaundice, which is deeper yellow.

The *conjunctiva* is a clear mucous membrane with two visible components. The first component, the bulbar conjunctiva covers most of the anterior eye ball adhering loosely to the underlying tissue. It meets the cornea at the *limbus*. The other component, the palpebral conjunctiva lines the eyelids. The two parts/components merge in a folded recess that permits the eyeball to move.

Within the eyelids lie tarsal plates—firm strips of connective tissue. Each plate contains a parallel row of *meibomian glands*, which open on the lid margin. The *levator palpebrae superioris* muscle raises the upperlid and

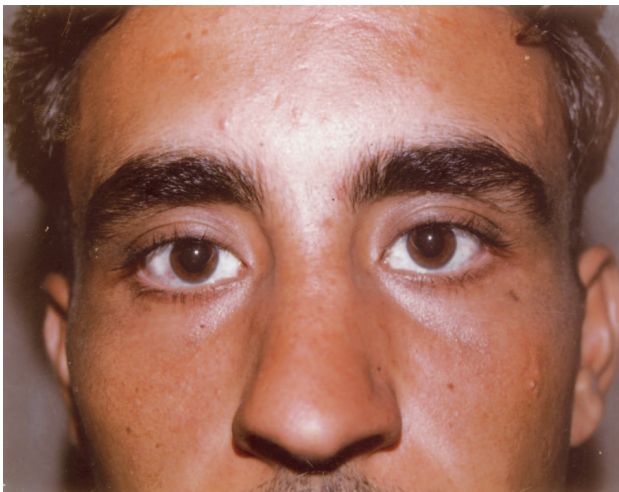

FIGURE 5.1 The eyes

is innervated by 3rd cranial nerve. Smooth muscle innervated by the sympathetic nervous system also contributes to raising this lid. This is the reason that the upper lid droops both in 3rd nerve and sympathetic paralysis (Horner's syndrome).

A clear fluid called *tear fluid* protects the conjunctiva and cornea from drying, has anti-microbial action and gives a smooth optical surface to the cornea. This fluid comes from three sources, i.e. meibomian glands, conjunctival glands, and the lacrimal gland. The lacrimal gland lies within the orbit, above and lateral to the eyeball. The tear fluids after spreading through the eye drains into *lacrimal sac* and further into the nose through nasolacrimal duct.

The eyeball is a spherical structure that focusses light on the retina. The size of the pupil is controlled by the muscles of the iris. Muscles of the ciliary body control the thickness of the lens allowing the eye to focus on near or distant objects.

The *aqueous humour* a clear fluid produced by the ciliary body, circulates from the posterior chamber through the pupil to anterior chamber, and drains out through the *canal of Schlemm*. The circulatory system helps to control pressure inside the eye (intraocular tension).

The posterior part of the eye that is seen through an ophthalmoscope is often called the *fundus* of the eye. Structures here include the retina, choroid, fovea, macula, optic disc and retinal vessels. The optic nerves with retinal vessels enter the eyeball at optic disc. Lateral and inferior to the disc, there is a dark circular area with a central depression—called *fovea centralis*, marked for central vision. The fovea is surrounded by macula which does not reach the optic disc. The eyeball behind the lens is filled by a transparent gelatinous material—called *vitreous body* that maintains the shape of the eye.

THE HISTORY

The present *ocular history* should concentrate on the following symptoms:

- **Disturbance of vision:** It may be sudden or gradual, may involve one or both the eyes. The patients may complain

of halos around bright lights, flashes, floaters or may experience visual hallucinations. Objects may appear smaller (*micropsia*) or larger (*macropsia*).

- **Diplopia or blurring of vision:** These result due to disordered ocular movements.
- **Pain in the eye:** It may be felt like a foreign body sensation, often increased by eye movements. A deep seated pain within eye, or sometimes associated photophobia occurs in *iritis*. Severe ocular pain with vomiting may indicate an acute glaucoma. Migraine may present with visual symptoms and headache and pain may be referred to the eye from neighbouring structures.
- **Dryness or excessive watering of the eyes:** There may be abnormal secretions from the eye such as mucus or pus. In tear insufficiency, the eye feels dry. Excessive tear production (*lacrimation*) may indicate local ocular disease; while over-flow of tears (*epiphora*) suggests defective lacrimal drainage.
- **Redness of eyes**
- **Protrusion of the eyeball** (exophthalmos, proptosis).

In addition to ocular history as discussed above, a routine general medical and surgical history is essential so as to know whether ocular symptoms pertain to local eye disease or eye involvement is part of a systemic disorder. **Past history** should include enquiries about presence of squint in childhood, a previous injury or wearing of glasses at any time. The **family history** may reveal a history of glaucoma, squint or the presence of neurological disease associated with visual loss.

Symptomatic Inquiries and Their Analysis

Start your inquiry about eye and vision problem with following question:

- *How is your vision?*
- *Have you had any trouble with your eyes?*

Refractive errors most commonly explain blurring. Hyperglycaemia may also cause blurring.

If the patient reports a change in the vision, pursue the related details as follows:

Is the onset sudden or gradual? The causes of visual loss are given in the Box 1. Sudden loss of vision is mostly unilateral and often results from vascular disease.

Sudden visual loss suggests retinal detachment, vitreous haemorrhage, occlusion of central artery of retina.

Is the problem of vision worst during close work or at distances?

Box 1

Causes of visual loss

<i>Acute or sudden and transient</i>	<i>Chronic and progressive</i>
• Amaurosis fugax (TIA of retina)	• Cataract
• Hypertensive crisis (vasospasm of retinal arterioles)	• Glaucoma
• Retinal vein occlusion	• Macular degeneration
• Occlusion of central artery of retina (embolism of retinal vessels)	• Diabetic retinopathy
• Optic neuritis (retrobulbar neuritis)	• Intraocular tumour
• Leber's hereditary optic atrophy	• Retinitis pigmentosa
• Toxic optic atrophy	• Macular hole
• Papilloedema	
• Vitreous degeneration or haemorrhage	
• Retinal detachment	
• Transient ischaemic attacks or stroke	
• Factitious (functional)	

Difficulty with close work suggests *hypermetropia* (far-sightedness) or *presbyopia* (aging vision); with distances, *myopia* (near-sightedness).

Is there blurring of the entire field of vision or only parts of it? If the visual defect is partial, is it central, peripheral, or only on one side?

Slow *central* loss of vision occurs in nuclear cataract and macular degeneration; *peripheral* loss is seen in advanced open-angle glaucoma; and one side loss in *hemianopia* and quadrantic defects.

Are there specks in the vision or areas where patient cannot see (scotomas)? If so, do they move around in the visual field with shift in gaze or are they fixed.

- Moving specks or strands suggest vitreous floaters
- Fixed defects (scotomas) suggest lesions in the retinal and visual pathways.

Has the patient seen or sees light flashing across the field of vision? This symptom may be accompanied by vitreous floaters.

Flashing lights or new vitreous floaters suggest detachment of retina, warrants prompt eye consultation.

Box 2

Causes of red or painful eye

- Trauma (blunt or penetrating)
- Corneal abrasion/exposure (5th, 7th nerve palsy)
- Foreign body
- Chemical exposure
- Contact lens (e.g. overuse or infection)
- Subconjunctival haemorrhage (Fig. 5.2)
- Conjunctivitis
- Episcleritis
- Ulceration of cornea
- Herpes keratitis and herpes zoster ophthalmicus
- Sjögren's syndrome (dry eyes)
- Dacryocystitis
- Blepharitis
- Iritis/iridocyclitis
- Endophthalmitis
- Acute close-angle glaucoma
- Pterygium
- Proptosis due to any cause (e.g. orbital cellulitis, cavernous sinus thrombosis (Fig. 5.3) retrobulbar tumour, Grave's disease)

Does the patient wear glasses? Note the number. Ask about pain in or around the eyes, redness, and excessive tearing or watering. The causes of red eyes are given in the Box 2. Ask about headache. What is its character? Is it around the eyes? Does it radiate?

The characteristics of headache with eye disorders (e.g. error of refraction) are:

- It occurs around and over the eyes, may radiate to occipital area
- It is dull, aching in character. It is steady/constant
- Gradual onset
- Variable in duration
- It is probably caused by the sustained contraction of extraocular muscles, and possibly of the frontal, temporal and occipital muscles
- It may be associated with eye fatigue, "sandy" sensation in the eyes, redness of the conjunctiva
- It is relieved by rest to the eyes?

Ask about double vision or diplopia. Check for the presence of diplopia or double vision. If present, find out whether the images are side by side (horizontal diplopia) or on top of each other (vertical diplopia). Does diplopia persist with one eye closed? Which eye is affected? True double vision becomes single when one eye is closed.

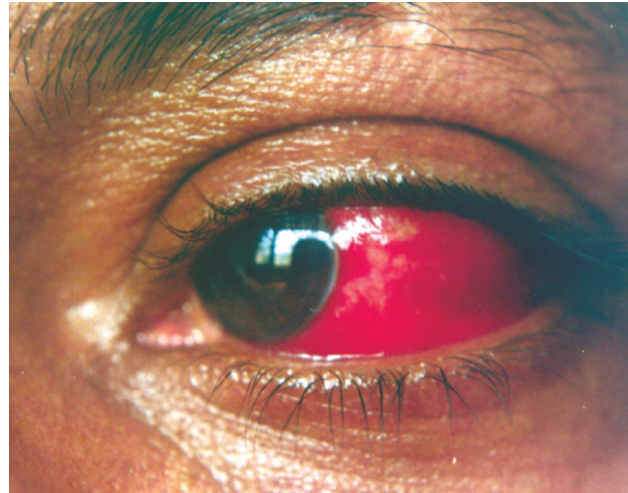


FIGURE 5.2 Subconjunctival haemorrhage producing redness of the eye

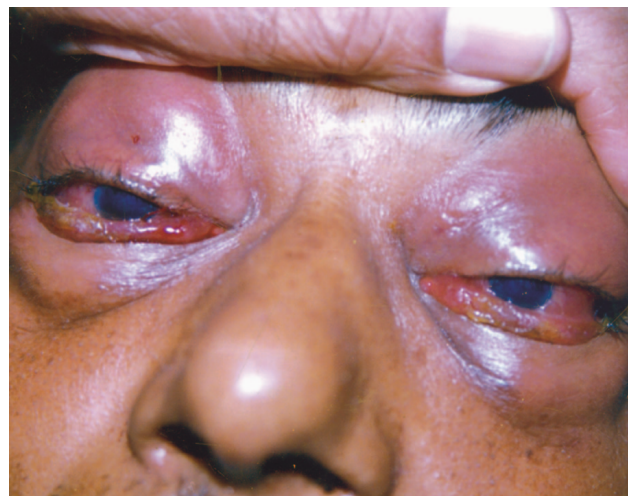

FIGURE 5.3 Bilateral red eyes due to bilateral cavernous sinus thrombosis following orbital cellulitis. Note the suffusion of face chemosis of conjunctivae, periorbital oedema and bilateral proptosis. There was proptosis also

- Diplopia in adults may occur either due to lesions of the *brain stem, cerebellum* or from weakness or paralysis of one or more extraocular muscles
- Horizontal nystagmus is due to palsy of 3rd and 6th cranial nerve while vertical nystagmus results from palsy of 3rd and 4th cranial nerves
- In *monocular diplopia*, the double vision (diplopia) persists in either eye after covering the other eye, results due to intrinsic eye disease, e.g. corneal aberrations (e.g. keratoconus, pterygium), uncorrected refractive error, cataract or foveal traction. Occasionally it may be due to malingering
- Diplopia alleviated by covering one eye is *binocular diplopia* and is caused by disruption of ocular alignment. The binocular diplopia is caused by a lesion of the 3rd, 4th or 6th cranial nerves (or a combination of these) or their nuclei

Box 3

Causes of diplopia

- **Damage to 3rd, 4th and 6th cranial nerves**
 - Brain-stem involvement
 - Haemorrhage
 - Infarction
 - Demyelination
 - Tumour
 - Meningeal involvement
 - Meningitis
 - Raised intracranial pressure
 - Aneurysms
 - Cerebellopontine angle tumour
 - Trauma
 - Cavernous sinus involvement
 - Infection, thrombosis
 - Carotid artery aneurysm
 - Superior orbital fissure
 - Tumour-meningioma
 - Granuloma
 - Orbit involvement
 - Cellulitis
 - Tumour
 - Trauma
 - Vascular (diabetic)
- **Diseases of myoneural junction**
 - Myasthenia gravis
- **Diseases of the ocular muscles**
 - Exophthalmic ophthalmoplegia (Grave's disease)
 - Ocular myopathies
 - Orbital myositis

or disease of neuromuscular junction (myasthenia gravis) or the ocular muscles (see Box 3) or due to ocular causes (refractory errors, incorrect spectacles, media opacities or macular disease).

Is there any evidence of squint? If so, whether paralytic or nonparalytic. The paralytic squint may be convergent (lateral rectus palsy) or divergent (medial rectus palsy).

Squint is an abnormality of ocular movement, results when the visual axes do not meet at the point of fixation or there is failure of the normal co-ordination of the ocular axes. It may be paralytic (paralysis of one or more extraocular muscles) or nonparalytic [no paralysis of extraocular muscles (read Table 5.6)].

Note whether diplopia is present.

Diplopia is present in paralytic squint as image on the paralysed side does not fall on the macula, hence, double vision. However, on the other hand, in nonparalytic squint the image formed by the defective eye is either rejected or suppressed by the occipital cortex.

EXAMINATION

The examination of the eye is an integral component of the clinical examination. The willingness of patient to maintain eye-to-eye contact may give valuable informations. It is also necessary to develop a routine for examination of the eye. This chapter describes an effective sequence; the common abnormal findings in the eye examination are given in the Box 4.

The overview of eye examination is given in the Box 5. It includes:

General inspection of eye, e.g. the eyelids, eyeballs, lacrimal glands, sclera, conjunctiva, cornea to overview the external appearance.

Internal examination of the eyes using torch or slit lamp, e.g. cornea, iris, size of pupil.

Testing of visual functions, e.g. measurement of visual acuity, visual field and colour vision. These are best performed before dazzling the eye with lights.

Checking of ocular movements: This involves checking of eye movements binocularly and unocularly in all positions of gaze and carrying out cover/uncover test.

Ophthalmoscopy: This includes ophthalmoscopic examination of fundus after dilatation of pupil. This is carried out if indicated.

Box 4

Common abnormal findings on eye examination

- Reduced visual acuity
- Abnormal visual field
- Red eyes
- Hazy media
- Diplopia
- Squint
- Abnormal pupil reaction
- Retinal haemorrhage and exudates
- Optic atrophy
- Papilloedema

Box 5

Overview of eye examination sequence

- General inspection of various components of eye
- Tests for visual functions, e.g. visual acuity, visual field and colour vision
- Internal examination/inspection with torch light
- Checking of various ocular movements
- Fundus examination

General Inspection

First of all, look at the face and head for general appearance before making a detailed inspection of the eyes.

- An abnormal head posture suggests problems with ocular motility
- Asymmetry of face or head or facial dysmorphism indicates development abnormality
- Eczema can suggest the likelihood of associated allergic eye disease.

Sometimes, observation of behaviour may suggest the clinical problem.

- Patients with severe ocular pain or photophobia wear dark glasses
- Patients with diplopia (double vision) may close one eye
- Patients with hemianopia may bump into objects on the blind side
- When central vision is lost, person may not make eye-to-eye contact but looks to one side of the person whom he/she is addressing.

Now carry out the gross inspection of various components of the eye. For example:

- 1. The eyeball (position and alignment):** Stand in front of the patient and survey the eyes for position and alignment with each other.

Protrusion of the eye ball is called proptosis or exophthalmos seen in Grave's disease. For causes and further details, read page 88.

- 2. The eyebrows:** Inspect the eyebrows for any scales on the skin and eyelashes.

- Scales are seen in seborrheic dermatitis
- Sparseness of hair in lateral third of eyebrow is seen in hypothyroidism.

- 3. The eyelids:** Note the position of the lids in relation to eyeballs. Inspect the palpebral fissure, position of the upper lid, any oedema of the lids, xanthelasma (Fig. 5.4) and redness of eyes. Evert both lids to examine the palpebral conjunctiva and the fornix.

- Pull down the lower lid while patient looks up.
- To evert the upper lid ask the patient to look down, grasp the eye lashes, press gently on the upper border of tarsal plate with a cotton tip and swing the lashes up (Fig. 5.5).

- Palpebral fissure is wide due to retraction of lids, seen in Grave's disease
- The eyeball may be displaced inwards and becomes deeply set, called *enophthalmos* is seen in Horner's syndrome and *phthisis bulbi* or *microphthalmia*. It may be due to aging (physiological)
- Narrow palpebral fissure is due to drooping of the upper lid (ptosis). Later due to gross drooping of the upper lid, palpebral fissure may get obliterated. The ptosis may be congenital or acquired due to 3rd nerve palsy, ocular muscle weakness and

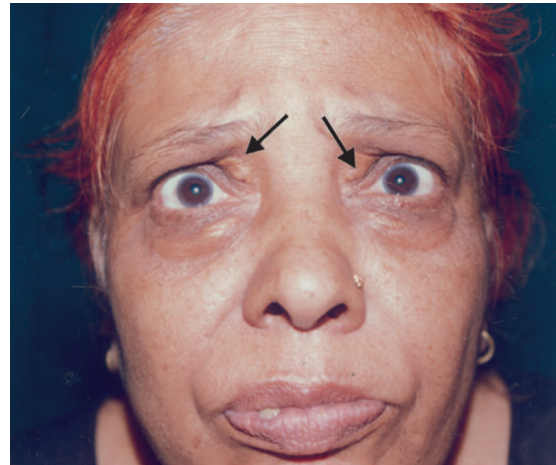

FIGURE 5.4 Xanthelasma of upper eyelids at inner canthus. These are seen in patients with hyperlipidaemia

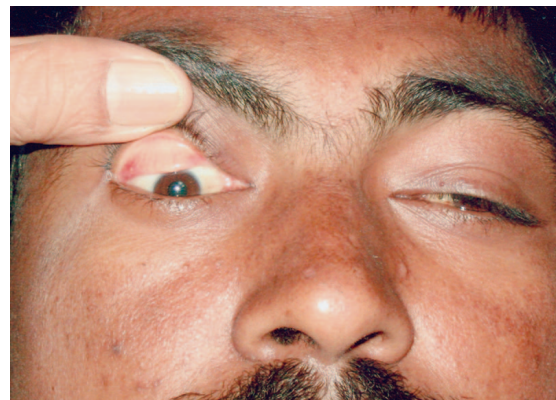

FIGURE 5.5 Method of eversion of the upper eyelid for examination

cervical sympathetic paralysis (Read the causes of ptosis in the Box 6)

- Blepharitis is an inflammation along the lid margins often with crusting or scaling.

Common Ocular Abnormalities Related to Medicine

1. Exophthalmos (Proptosis)

It is defined as forward protrusion of one or both the eyes with the result a portion of white sclera is clearly visible above and below the cornea. Previously, it was defined as visibility of lower sclera of more than 2 mm when the patient looks straight.

Methods of testing

1. Stand in front of the patient and ask him/her to look straight forward. Observe the visibility of upper and lower sclera.

The visibility of the lower sclera is more important than upper in proptosis. Both are clearly visible in moderate to severe proptosis (Fig. 5.6).

2. Another method is to stand behind the patient. Tilt the patient's head backwards. Look vertically down the

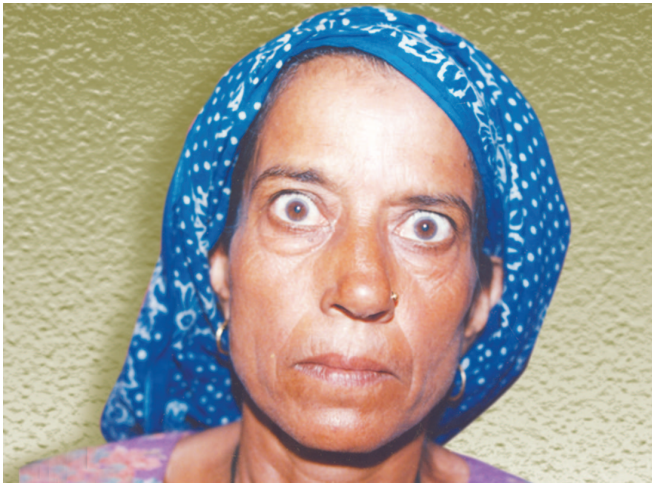

FIGURE 5.6 Bilateral exophthalmos. Note the visibility of both upper and lower sclera with staring look. The palpebral fissures are wide

slanting forehead in the plane of superciliary ridges. Protrusion/visibility of the globe indicates proptosis.

- It is measured using a Hertel exophthalmometer—a hand held instrument that records the position of anterior corneal surface relative to lateral orbital rim.

Types

- Unilateral
- Bilateral.

Causes: The causes of unilateral and bilateral exophthalmos are given in the Table 5.1. Exophthalmos is a common sign of Grave's ophthalmopathy (For detailed discussion, Read Grave's disease or hyperthyroidism as a case discussion in "Bedside Medicine without Tears by Prof. SN Chugh").

Consequences of exophthalmos

Exophthalmic ophthalmoplegia: It refers to weakness of extraocular muscles due to increase in interstitial fluid volume and increase in retrobulbar pressure.

Malignant exophthalmos: Progressive bulging of the eyeballs, conjunctival oedema, corneal ulceration and visual loss are its clinical hallmarks.

2. Ptosis

Drooping of the upper eyelid is called *ptosis*. In complete ptosis, palpebral fissure is obliterated.

Types

- Congenital or acquired
- Complete and partial
- Unilateral or bilateral

Causes: Congenital ptosis may be unilateral or bilateral, results from dysgenesis of the levator palpebrae superioris or from abnormal insertion of its aponeurosis into the lid. Acquired ptosis can be unilateral 3rd nerve palsy and

TABLE 5.1 Common causes of exophthalmos

Unilateral	Bilateral
<ul style="list-style-type: none"> • Early thyrotoxicosis (i.e. eyes are not necessarily involved) • Retrobulbar tumour. Painless, progressive exophthalmos • Cavernous sinus thrombosis (Proptosis, chemosis, 3rd, 4th, 6th cranial nerve palsy) • Orbital pseudotumour (pain, limited eye movements and proptosis) • Orbital cellulitis (i.e. pain, lid erythema, proptosis and conjunctival chemosis— Fig. 5.3) • Carotid cavernous fistula (i.e. proptosis, diplopia, glaucoma, redness of eye and a bruit may be heard on auscultation of head or orbit. It is called pulsating exophthalmos) 	<ul style="list-style-type: none"> • Thyrotoxicosis (Fig. 5.8) • Superior vena cava syndrome (Raised JVP, congestion, chemosis and proptosis) • Craniostenosis • Bilateral cavernous sinus thrombosis • Cushing's syndrome

Box 6

Common causes of ptosis

- **Unilateral**
 - 3rd nerve palsy (Fig. 5.7)
 - Horner's syndrome (partial or pseudoptosis; Fig. 5.8)
 - Mechanical ptosis (enlargement or deformity of upper lid due to infection, trauma, swelling on it)
- **Bilateral**
 - Tabes dorsalis
 - Myasthenia gravis (Fig. 5.9)
 - Chronic progressive external ophthalmoplegia (due to mutations of mitochondrial DNA)
 - Myotonia dystrophica
 - Oculopharyngeal myopathy
 - Congenital (uncommon)
 - Snake bite
 - Botulism
 - Periodic paralysis
 - Senile ptosis (seen in old persons)

Horner's syndrome but is usually bilateral in tabes dorsalis, myasthenia gravis, snake bite and periodic paralysis etc. The common causes of ptosis are given in the Box 6.

Testing for ptosis

Stand in front to the patient (face to face).

Ask the patient to look upwards or elevate the upper eyelid voluntarily.

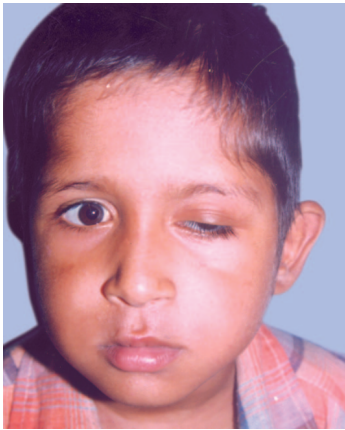

FIGURE 5.7 Ptosis due to 3rd cranial nerve paralysis on left side

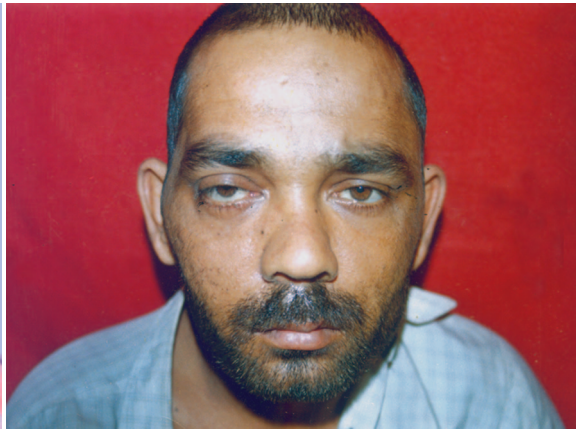

FIGURE 5.8 Ptosis of right eye due to Horner's syndrome (pseudoptosis)

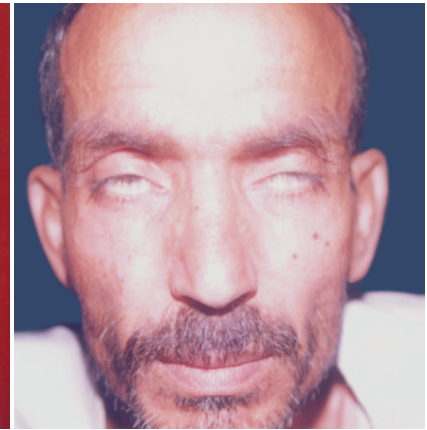

FIGURE 5.9 Bilateral ptosis due to myasthenia gravis

In ptosis, patient cannot elevate the eyelid voluntarily but sometimes he elevates the lid by exerting the frontal belly of occipitofrontalis, therefore, to rule it out, now push down the frontal belly of occipitofrontalis by your left hand and ask the patient to look upwards. Now if he/she cannot do so, ptosis is present.

Pseudoptosis: It refers to partial drooping of the upper lid. It is seen in Horner's syndrome (Fig. 5.8).

The differences between ptosis (3rd nerve palsy) and pseudoptosis or partial ptosis due to sympathetic involvement (Horner's syndrome) are summarised in the Table 5.2.

Note any redness of the eye, if any. The causes of red and painful eye (Figs 5.2 and 5.3) have already been listed in Box 2.

Oedema of the lids or periorbital oedema (puffiness of face) is a part of generalised oedema (Read oedema feet). The puffiness of face especially in the morning is a characteristic feature of nephrotic syndrome.

Inspection of lacrimal apparatus: Look at the regions of lacrimal glands by everting the upper lid (lateral part) and lacrimal sac (lies between medial canthus and the nose) for swelling. Look for excessive watering or dryness of eyes.

- Lacrimal gland may enlarge in viral infections (e.g. mumps), sarcoidosis, lymphoma and carcinoma
- Excessive watering may be due to increased tear production (conjunctival inflammation), or impaired drainage (ectropion and nasolabial duct obstruction)
- Blockage of nasolabial duct causes watering, sticky discharge and may result in dacryocystitis with abscess formation in the lacrimal sac
- Medical conditions associated with dryness of eyes include: dehydration, side-effect of anticholinergics and antidepressants, vitamin A deficiency and Sjogren's syndrome (Sicca syndrome).

The conjunctiva and the sclera: Ask the patient to look up as you depress both lower lids with each thumb, exposing the

TABLE 5.2 Ptosis in 3rd nerve palsy and Horner's syndrome

3rd cranial nerve palsy	Horner's syndrome
<ul style="list-style-type: none"> • Usually complete ptosis (palpebral fissure is obliterated) • Pupil dilated on involved side • Squint (paralytic, horizontal and vertical) • No enophthalmos • Ciliospinal reflex present • Extraocular muscle palsy present • No loss of sweating on the side involved 	<ul style="list-style-type: none"> • Partial or pseudoptosis (palpebral fissure is narrowed) • Pupil constricted • No squint • Enophthalmos present • Ciliospinal reflex absent • Extra-ocular muscles are normal but there is paralysis of Muller's muscles • Anhidrosis on affected side present

sclera and conjunctiva. Note their *colour, vascular pattern, any swellings or nodules*. For better view of the sclera and bulbar conjunctivae (not palpebral conjunctiva) of the upper lid, ask the patient to look to each side and down. For seeing jaundice, this is a better view because yellowness is better seen against white background.

- Conjunctivae are pale in severe anaemia
- Yellow discoloration of conjunctivae and sclera indicate jaundice (Read Jaundice in Bedside Medicine by Prof. SN Chugh). Yellowness of mucous membrane is seen on undersurface of tongue and soft palate. In severe Jaundice skin, palms and soles may be yellowish in colour.
- Redness of conjunctiva (Read red painful eyes in the Box 2).
- Pinguecula are triangular yellow deposits beneath the conjunctiva between the canthus and the edge of the cornea. They develop with the advancing age, are of no significance
- Foreign body stuck under the upper lid may cause irritation and photophobia. They are easily removed on everting the lid.

Normal sclera is white in colour, its yellow colouration indicates jaundice. In osteogenesis imperfecta the sclera are thin and appear blue. Inflammation (scleritis) causes a dusky red colour with pain. It is a characteristic feature of rheumatoid arthritis, SLE and other connective tissue disorders. White spots (Bitot's spots) are seen at the sclera near the lateral part of cornea near the angle of the eye (Fig. 5.10) in chronic vitamin A deficiency. Scleritis may progress to *scleromalacia* and rarely to perforation.

Commentary about jaundice (Fig. 5.11) (Read jaundice as a symptom of liver diseases in examination of abdomen) Normal serum bilirubin is 0.2 to 1.2 mg%.

Subclinical jaundice occurs with serum bilirubin between 1.2 and 2.5 mg.

Clinical jaundice, i.e. the jaundice manifests clinically when serum bilirubin is >2.5 mg.

Unconjugated hyperbilirubinaemia is said to be present if unconjugated bilirubin exceeds 80% of the total bilirubin.

Conjugated hyperbilirubinaemia is said to be present if conjugated bilirubin exceeds 50% of the total bilirubin. Upper conjunctivae and sclera are best sites to see jaundice as they provide white background.

- Always look for jaundice in a bright day light in upper conjunctivae and sclera by everting the both upper lids while patient looks downward (Fig. 5.13).
- Do not comment on jaundice at night as torch light gives yellow reflection. In emergency situation, torch light covered with blue cellophane paper can be used to examine the jaundice at night

The Cornea and the Lens: Normal cornea is transparent with blood vessels at the junction between cornea and conjunctiva—called *limbus*. Inspect the cornea for any *opacity, scar, ulcer, abrasion* etc. Look at the lens for opacity.

The common abnormalities are:

- **General loss of transparency** occurs in corneal oedema, trauma with foreign body, herpes simplex infection, acute glaucoma. Acute severe damage to corneal epithelium occurs in exophthalmos, chemical corneal injury leading to abrasion and ulceration. Damage to the epithelium is difficult to see, but can be detected by instilling yellow fluorescein drops, which stains the affected area.
- **Vascular pattern:** The blood vessels around the limbus dilate in response to a corneal disease or an injury, and is called ciliary congestion/flush.
- **Corneal arcus:** It is a greyish-white arc or ring near the outer margin of the cornea. It is normally seen in older people. In younger people, it suggests hypercholesterolaemia.

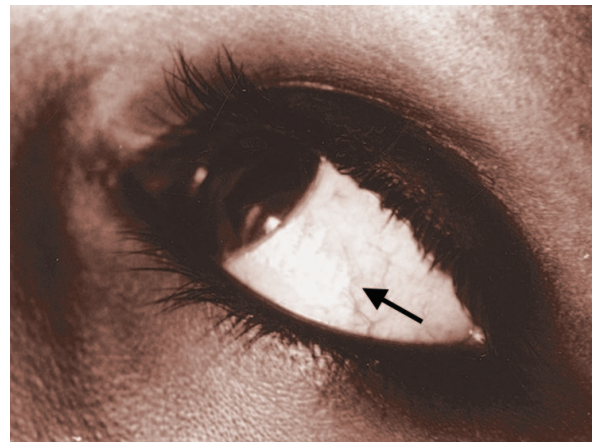


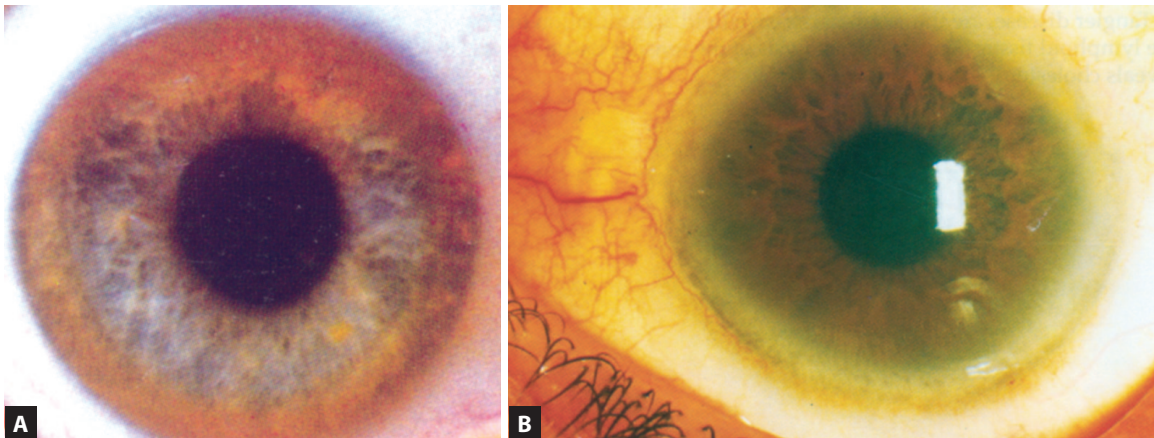
FIGURE 5.10 Bitot's spots. Note the white spots (←) at the sclera near the lateral angle of the eye

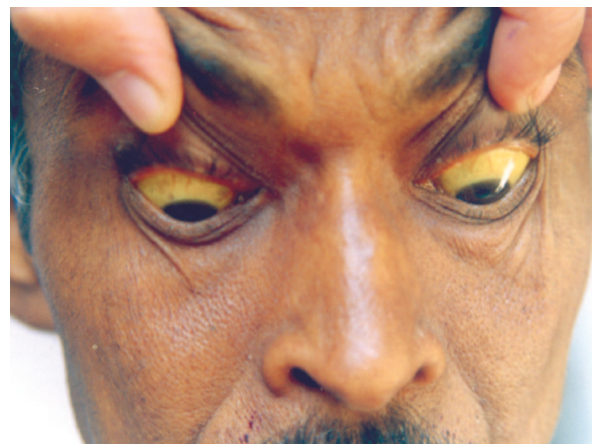

FIGURE 5.11 Jaundice. Note the yellowness of sclerae

- **Corneal scar:** A corneal scar is a superficial greyish-white opacity in the cornea secondary to an old injury or inflammation.
- **Kayser-Fleischer ring** is yellow or brown deposits of copper at the periphery of cornea seen in Wilson's disease (Fig. 5.12A).
- **Corneal calcification** suggests long-standing hypercalcaemia or hyperparathyroidism. Corneal opacification is seen in familial lecithin-cholesterol acetyl transferase deficiency (Fig. 5.12B).
- **Dryness of cornea** occurs in Vitamin A deficiency, severe dry eye syndrome (Sicca syndrome or Sjogren's syndrome), and use of anticholinergics.
- **The 5th cranial nerve palsy** leads to loss of corneal sensation and predisposes the cornea to injury and infection.

The normal lens is not visible on inspection. Advanced cataracts can be seen as chalky (milky) whiteness in the central hole of cornea (Fig. 5.13).



FIGURES 5.12A and B (A) A Kayser-Fleischer ring. It is seen in Wilson's disease; (B) Opacification of the cornea is a striking clinical feature of patients with familial lecithin : cholesterol acyltransferase deficiency. The corneal opacification reflects the loss of reverse cholesterol transport from tissues of these patients

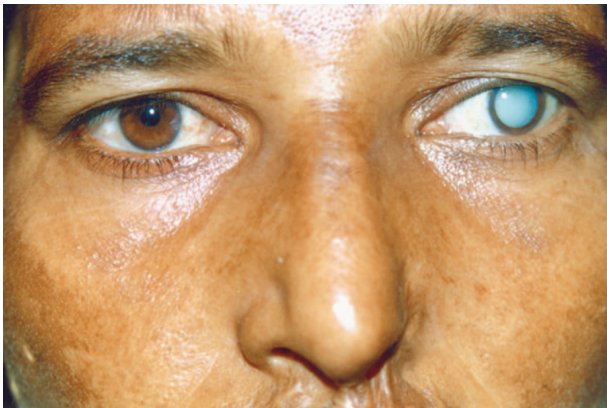

FIGURE 5.13 Cataract (lens opacity) left eye

Testing of the Visual Function

The visual function tests are performed before any detailed eye examination.

Visual Acuity

- I. Tests for distant vision:** Distant visual acuity (VA) should be tested using distance spectacles (if worn) with a Snellen's chart at 6 meters (Fig. 5.14). This test chart has a series of letters of varying sizes constructed so that the top letter is visible to the normal eye at 60 m (hence 60 is written at the top of the letter), and subsequent lines at 36, 24, 18, 12, 9, 6 and 5 m. The numbers on the lines represent the distance in meters at which a normally sighted person can read that line. The visual acuity is written as:

$$VA = \frac{\text{Distance between the patient and the chart, i.e. 6 m}}{\text{The letter/the line patient can read at 6 m distance}}; \text{ for example}$$

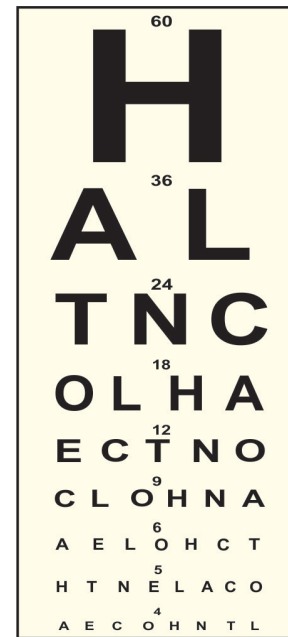

FIGURE 5.14 Testing for distant vision. The lines, from above downwards, should be read at 60, 36, 24, 18, 12, 9, 6, 5, 4 m, respectively. At these distances the letters subtend a visual angle of 5 m

The 6/6 is normal VA, which means a person can read the line having letters written at the top as 6 while standing at a distance of 6 meter.

- Normal visual acuity is 6/6
- Subnormal VA is 6/9
- Vision needed for driving licence is 6/9 or 6/12 legal
- Blindness is defined as vision of less than 3/60, which means an individual cannot see the line at 3 meters which a normally sighted person could read at 60 meters.

Other methods of testing for VA are available for children and people who cannot read.

Steps of Examination

- Test each eye separately. Patient wear the distance glasses (if he/she has one). The other eye should be totally occluded during examination.
 - If possible, use a line rather than single letters; and use different letters for each eye, as patient/children can memorise them quickly.
 - If vision is abnormal, check it again using a pinhole which partially corrects optic errors.
 - If vision is less than 6/60, repeat the test with chart 3 meters away as 3/60 etc.
 - If the vision is still less than 3/60, resort to finger counting at 1 meter distance from the face, to detect a moving hand or perceive light.
- II. Tests for near vision:** Near vision is measured using standard near charts with the patient wearing reading glasses. If no near charts are available, use a newspaper and record the smallest print seen/read.

Colour Vision

Colour vision examination assesses the function of retinal cones and optic nerve. *Ishihara plates* are most commonly employed for this purpose. They consist of a series of plates in which coloured spots contain shapes which the patient is asked to pick out. Error will be made if patient's colour vision is defective. The causes of abnormalities of colour vision are depicted in Box 7.

Visual Field

Testing visual field assesses the function of the peripheral and central retina, the optic pathways and the cortex. (Read Chapter 15 on nervous system).

Measurement of intraocular tension (Fig. 5.15): The rough estimate of intraocular tension can be made by fluctuating the eye gently with the index fingers. Accurate measurement is done with a *tonometer*.

Internal Examination with Light

The iris: Examine the iris with torch light for any colour change (discolouration). Normally the iris is black in colour

Box 7

The causes of abnormalities of colour vision seen

- Congenital red/green colour blindness (sex-linked X chromosomal)
- Age-related macular disease/degeneration
- Optic nerve disease

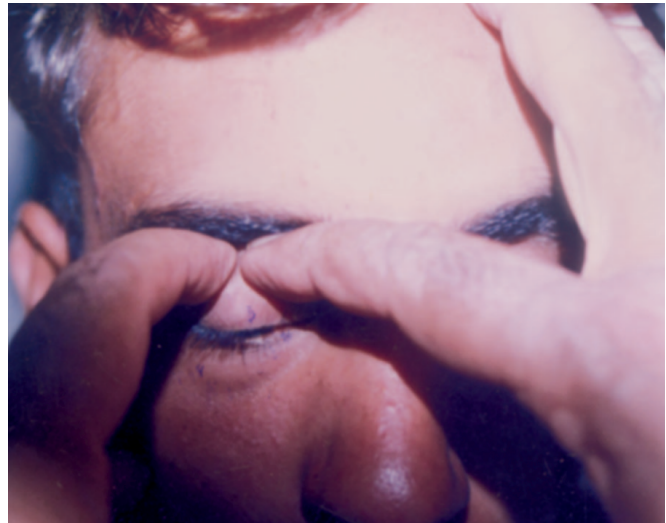

FIGURE 5.15 Measurement of intraocular tension

and a circular hole in the centre is called the *pupil*. Heterochromia refers to different colours of the iris, indicates intraocular disease or albinism. In inflammation (*iritis*), the iris looks muddy with a small pupil and there is ciliary flush (congestion). Iritis may be a manifestation of rheumatoid arthritis; connective tissue disease or a manifestation of other systemic disease such as sarcoidosis.

The pupils: *Inspect the pupils for size, shape and symmetry.*

If the pupils are large (> 5 mm), small (3 mm) or unequal on two sides, measure them with a card with black holes of varying sizes. Pupillary inequality of less than 0.5 mm (anisocoria) is considered as normal.

Assess the pupillary reactions to light (direct and consensual) and accommodation.

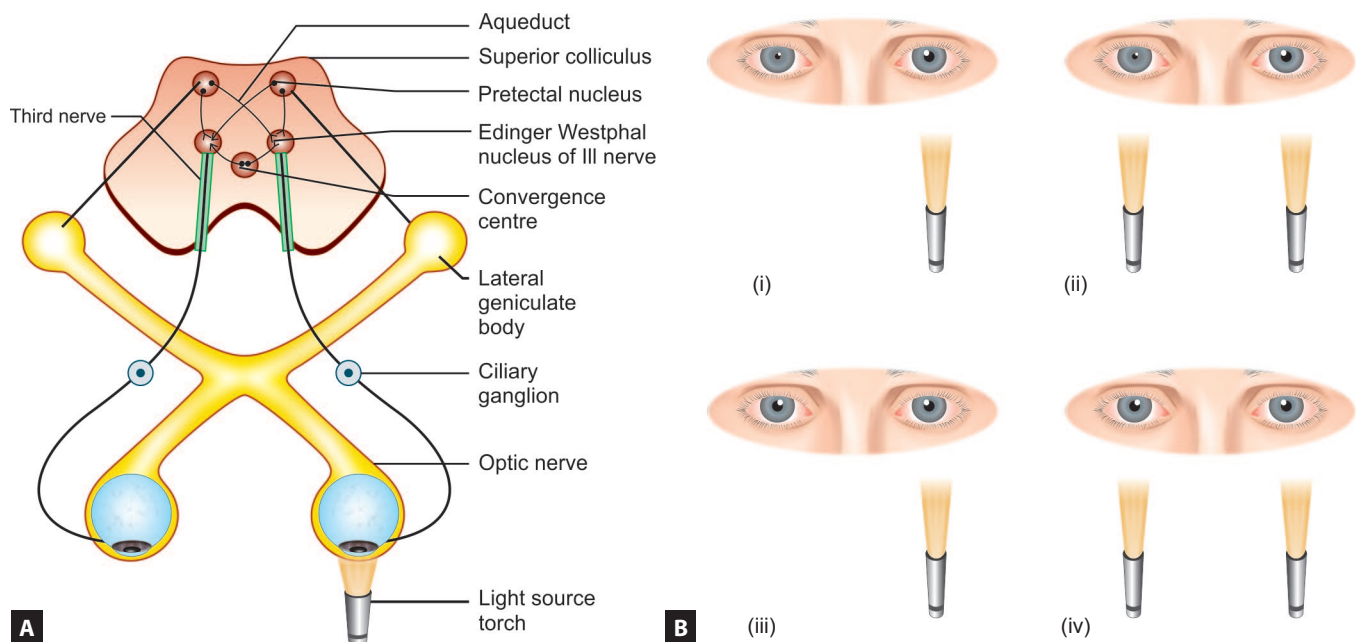
Methods: Ask the patient to look at a distant object and shine a bright light or pin-torch obliquely into each pupil in turn. Note the following:

- Pupillary constriction in the same eye indicates direct reaction
- Pupillary constriction of the opposite pupil indicates consensual reaction.

The light reflex pathways and interpretation of direct and consensual light reflex are presented in Figs 5.16A and B.

Warning: Always darken the room and use a bright light before labelling that a light reflex is absent.

If reaction to light is impaired or questionable, then test for *near reaction* or *accommodation reaction* in normal room light.



FIGURES 5.16A and B The light reflex: (A) Pathways; (B) Direct and consensual light reflex and its interpretation. (A) Pupillary light reflex and its afferent and efferent pathways. Some fibres concerned with light reflex can bypass the lateral geniculate body to pretectal nucleus. (B) Direct and consensual constriction of pupils to light. Step 1: Shine a light source into the pupil in question. (i) No direct constriction, consensual intact indicate topical mydriatics or Argyll Robertson pupil; (ii) No direct or consensual constriction indicates monocular blindness, Step 2: After 5 seconds, shine the light into the contralateral pupil; (iii) No direct constriction, but direct constriction of the contralateral pupil suggest topical mydriatics, Argyll Robertson pupil, or monocular blindness; (iv) No direct constriction of either pupil indicates death or profound brainstem damage

Method

To test the reaction to accommodation, ask the patient first to look into the distance and then at an object (finger or pencil) held at 10 cm distance from the face. Watch for pupillary constriction with near object (Fig. 5.17).

Bilateral pupillary constriction on convergence of the eyes to near object is called accommodation reflex.

Normal pupils are often described in the case notes by mnemonics *PERLA* (pupils equal and reactive to light and accommodation).

In Argyll-Robertson's pupil, the light reflex is absent and accommodation reflex (near reaction) is retained (Remember mnemonics AR pupil as Accommodation Retained).

In Adie's pupil, the light reflex is absent but accommodation reflex is slow.

Common Abnormality of Pupil (Table 5.3 and Fig. 5.18)

Unequal pupils (Anisocoria)

Approximately 10–12% of normal individuals have a slight but clinically evident pupillary inequality. Such physiological unequal pupils react normally to light. Pathological pupils

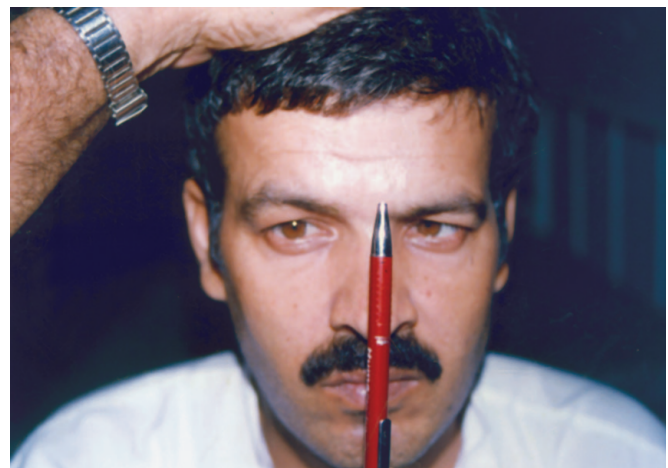

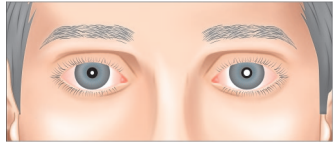
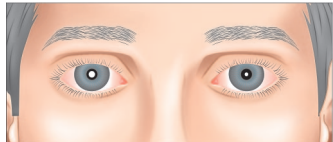
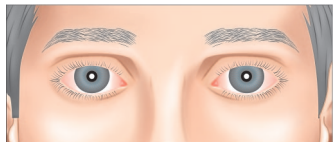
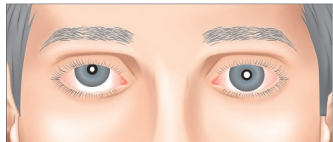
FIGURE 5.17 Testing for convergence

(variation >0.5 mm between two pupils) dilate and constricts abnormally. In the absence of local disease of the eye, the causes of constriction (meiosis) and dilatation (mydriasis) of pupil are given in the Table 5.4.

Test

From about 2 feet directly in front of the patient, shine a torch on to the patient's eye and ask the patient to look at it. Inspect

TABLE 5.3 Pupillary abnormalities in common disorders

Disorder	Size of pupil (Fig. 5.18)	Reaction
<i>III cranial nerve paralysis or parasympholytic agents use</i>	 <p>Normal Abnormal</p> <p>A. Abnormal > normal side</p>	<ul style="list-style-type: none"> Efferent pupil defect Light or accommodation reaction absent on the affected side Normal side reacts consequently
<i>Ciliary ganglion lesion (Adie's myotonic pupil)</i>	 <p>Abnormal Normal</p> <p>B. A tonic pupil</p>	<ul style="list-style-type: none"> Light reaction absent on side affected Accommodation reaction is slow and sustained
<i>Retinal/optic nerve disease</i>	— do — Abnormal > normal side	<ul style="list-style-type: none"> Afferent pupil defect Poor direct light reflex, normal consensual reflex (reaction) and normal accommodation reaction on the affected side Reduced consensual reflex on the normal side
<i>Neurosyphilis (pretecal lesion) Argyll Robertson pupil</i>	 <p>C. Small, irregular, unequal pupil</p>	<ul style="list-style-type: none"> Light reflex absent Accommodation reflex present
<i>Sympathetic lesion (Horner's syndrome) It consists of meiosis, ptosis, enophthalmos, anhydrosis, loss of ciliospinal reflex</i>	 <p>Abnormal Normal</p> <p>D. Abnormal > normal side</p>	<ul style="list-style-type: none"> Reaction to light and accommodation present Does not dilate with cocaine drops

the reflections in the cornea. Normally they should be visible slightly nasal to the centre of the pupils.

Asymmetry of the corneal reflections indicate a deviation from the normal ocular alignment (conjugate position)—called squint.

A *cover-uncover* test (Table 5.5) may reveal a slight or latent muscle imbalance not seen otherwise.

Squint

Deviation of eyes from their normally conjugate position is termed as *strabismus* or *squint*.

Classification

- Paralytic:** It is caused by weakness or paralysis of one or more extraocular muscles.

Divergent: Due to paralysis of medial rectus.

Convergent: Due to paralysis of lateral rectus (Fig. 5.19A).

- Non paralytic (concomitant).** There is no paralysis of extraocular muscles. It is caused by an imbalance in ocular muscle tone (Fig. 5.19B).

The differences between paralytic and nonparalytic squints are given in the Table 5.5 and represented in Fig. 5.20 and Table 5.6.

Testing of Ocular Movements

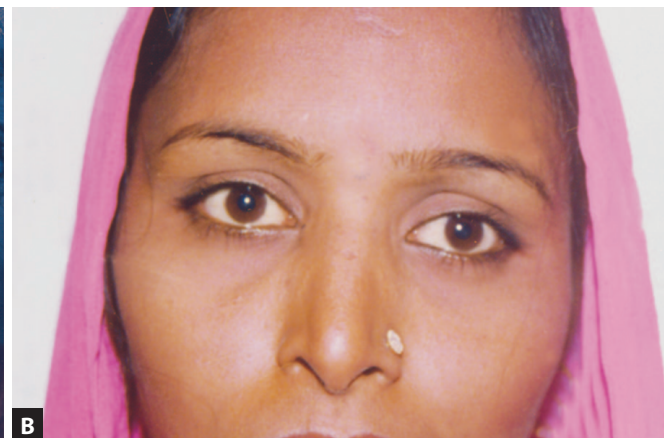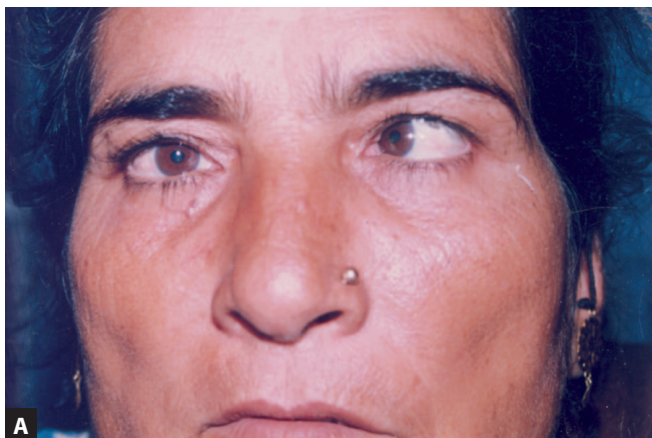- Testing movement in all directions of gaze is discussed in nervous system examination (read cranial nerves examination). Both eyes should move symmetrically with no diplopia. If diplopia is present, the most peripheral double vision is the one from the paretic eye.

TABLE 5.4 Causes of constriction and dilatation of pupils

<i>Small pupil (constricted pupil)</i>	<i>Large pupil (dilated pupil)</i>
<ul style="list-style-type: none"> • Sympathetic nerve fibres involved. Could be due to local eye disease or drug induced 	<ul style="list-style-type: none"> • 3rd cranial nerve or ciliary ganglion is involved. It can be due to local disease of the eye or drug induced
Causes	Causes
<ul style="list-style-type: none"> • Old age (senility) • Cervical sympathetic compression in lymphomas (Horner's syndrome) • Brain-stem involvement (pontine haemorrhage) • Posterior inferior cerebellar artery infarction-lateral medullary syndrome • Neurosyphilis (Argyll Robertson's pupil) • Local ocular disease, e.g. iritis, iridocyclitis • Parasympathomimetic agents, e.g. organophosphorous compounds, morphine, heroin etc. 	<ul style="list-style-type: none"> • 3rd cranial nerve palsy in midbrain (nuclear) or outside it in cavernous sinus (cavernous sinus thrombosis) • Parasympatholytic agents/drops (atropine, scopolamine, hyocin) • A tonic pupil (Holmes-Adie pupil) • Ciliary ganglion lesions (herpes infection, trauma, ischaemia due to diabetes) • Ocular diseases e.g. acute glaucoma, retinal or optic nerve disease • Deep coma, death

TABLE 5.5 Differentiation between two types of squint

<i>Feature</i>	<i>Paralytic</i>	<i>Non-paralytic</i>
<i>Cause</i>	Paralysis of one or more extraocular muscles; may be convergent or divergent	<ul style="list-style-type: none"> • No paralysis of the muscles • It is due to imbalance in ocular muscle tone, hence, mostly hereditary
<i>Onset</i>	Acute, acquired in later life	Slow, present since childhood
<i>Movements</i>	Restricted in the direction of paralysed muscle	Good in all the directions
<i>Diplopia</i>	Present	Absent
<i>Associated symptom and signs</i>	Long-standing paralytic squint often results in abnormal head posture with the head turned or tilted to minimize diplopia	As diplopia is absent in this type of squint (diplopia is centrally suppressed but amblyopia-lazy eye may result. There is no abnormal head posture

**FIGURES 5.19A and B** Squint: (A) Paralytic (convergent squint due to 3rd nerve palsy); (B) Nonparalytic (concomitant)

- **The cover/uncover test (Fig. 5.20):** The cover/uncover test is particularly useful in detecting small concomitant squints in children.

Method (Fig. 5.20)

- Ask the patient to look at a distant object
- Cover one eye




















TABLE 5.6 Analysis of paralytic and nonparalytic squint																															
Nonparalytic squint (imbalance of ocular muscle tone)	Paralytic squint (weakness of one or more extracocular muscles)																														
<p>Convergent Divergent</p>  <p>Cover Uncover test It is helpful to diagnose monocular nonparalytic squint (for example right) as described below:</p>  <p>Corneal reflections asymmetric</p>  <p>← Cover The right eye moves outwards to fix on the light. The left eye is not seen but moves inward to same degree</p>  <p>← Uncover The left eye moves outward to fix on the light. The right eye deviates.</p> <p style="text-align: center;">A</p>	<table border="0"> <tr> <td></td> <td>Looking to the right</td> <td>Result</td> </tr> <tr> <td></td> <td></td> <td>Eyes are conjugate</td> </tr> <tr> <td>Left VIth CN palsy</td> <td>Looking straight</td> <td>Squint appears</td> </tr> <tr> <td></td> <td></td> <td></td> </tr> <tr> <td></td> <td>Looking to the left</td> <td>Squint is maximum</td> </tr> <tr> <td></td> <td></td> <td></td> </tr> <tr> <td>Left IV CN paralysis</td> <td>Looking down and to the right</td> <td>The left eye cannot look down turned inwards. Deviation is maximum in this direction</td> </tr> <tr> <td></td> <td></td> <td></td> </tr> <tr> <td>Left IIIrd CN paralysis</td> <td>Looking straight a hand</td> <td>The eye is pulled outward by the action of VIth nerve. Upward, downward and inward movements are lost. Ptosis and delated pupil present.</td> </tr> <tr> <td></td> <td></td> <td></td> </tr> </table> <p style="text-align: center;">B</p>		Looking to the right	Result			Eyes are conjugate	Left VIth CN palsy	Looking straight	Squint appears					Looking to the left	Squint is maximum				Left IV CN paralysis	Looking down and to the right	The left eye cannot look down turned inwards. Deviation is maximum in this direction				Left IIIrd CN paralysis	Looking straight a hand	The eye is pulled outward by the action of VIth nerve. Upward, downward and inward movements are lost. Ptosis and delated pupil present.			
	Looking to the right	Result																													
		Eyes are conjugate																													
Left VIth CN palsy	Looking straight	Squint appears																													
																															
	Looking to the left	Squint is maximum																													
																															
Left IV CN paralysis	Looking down and to the right	The left eye cannot look down turned inwards. Deviation is maximum in this direction																													
																															
Left IIIrd CN paralysis	Looking straight a hand	The eye is pulled outward by the action of VIth nerve. Upward, downward and inward movements are lost. Ptosis and delated pupil present.																													
																															

FIGURE 5.20 Deviation of the eyes due to squint: (A) Cover and uncover test for nonparalytic squint; (B) Paralytic squint due to 6th, 4th and 3rd nerve paralysis. CN means cranial nerve

- Closely observe uncovered eye for any movements. If it moves to take up fixation, that eye is squinting
- Repeat the sequence for the other eye
- Tests for paralytic squint. Determine the direction of gaze that maximizes the deviation.
The paralysis of left VI, IV and III are diagrammatically represented in Fig. 5.20B.

Ophthalmoscopy

The ocular fundus

Examination of the ocular fundus constitutes an important part of complete medical examination. Fundus is seen with the help of an ophthalmoscope (Fig. 5.21). Valuable informations can be gathered about the state of the optic nerve head, and of the arteries and veins of the retina, in addition to the detection of local eye disorders.

In general, one should examine the fundus without dilating the pupil but it needs expertise and you can not see the peripheral parts very well. To see the more peripheral structures, to evaluate the macula well or to investigate unexplained visual loss, ophthalmologists or internists dilate the pupil with some mydriatic drops unless contraindicated (see Box 8).

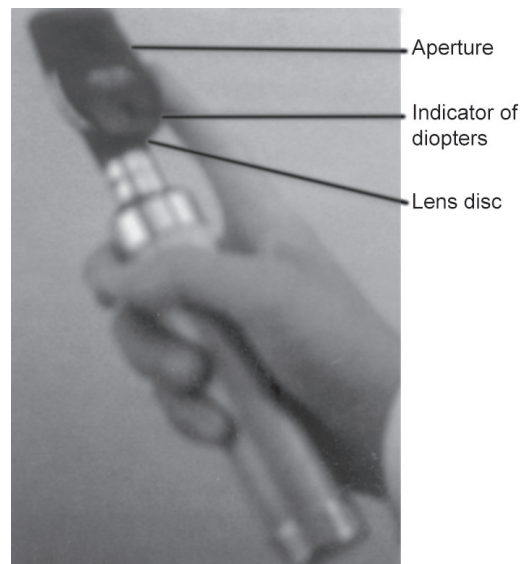


FIGURE 5.21 Ophthalmoscope

Steps of examination

- The patient should be examined either sitting or lying down in a darkened room

Box 8

Contraindications for mydriatic drops

- Head injury and coma, in which continuing observations of pupillary reactions are essential
- Any suspicion of narrow-angle glaucoma (i.e. ask whether they have ever seen halos, i.e. coloured rings around lights or the presence of shallow anterior chamber)

- Ask the patient to look straight at a distant object and blink and breath normally
- Stand or sit on the side to be examined at an arm's length from the patient and keep the eyes level with that of the patient
- To look at the right eye, hold the ophthalmoscope with lenses at zero in the right hand (Fig. 5.21)
- Use your right eye to examine the patient's right eye and vice-versa (left eye for patient's left eye)

In case, if the examiner has difficulty using the nondominant eye, examine the patient from above while the patient is looking at a distant object.

- Switch on the instrument and shine it at pupil. The ophthalmoscope should then be brought as close as possible to the patient's eye and the light is directed slightly nasally
- If the eye closes, open it gently
- Demonstrate the red reflex of the fundus and note the nature of any opacities in the media

Opacities in the media of the eye (cornea, anterior chamber, lens, vitreous will appear as black specks or lines against the red glow.

- Keeping the beam pointing in the abovementioned direction and the red reflex in view, move close to the patient, stopping just clear off the lashes
- In this way, optic disc can be found because of angle of approach. If, instead of disc, retinal vessels are in focus (seen), follow them to reach the fundus
- If the optic disc is not in focus, the strength of the lenses of the ophthalmoscope should be gradually reduced until the disc becomes sharply focussed
- *Examine the fundus systematically for:*
 - Optic disc (*shape, colour, physiological cup, margins etc*)
 - Retinal blood vessels
 - Macula
 - The periphery of the fundus.
- Note any abnormality considering the fundus as a clock with the disc at the centre. The disc diameter (1.5 mm)

is used as a unit of measurement; for example you can say haemorrhage seen at 3 o'clock position at two disc diameter distance from the disc.

Uses of ophthalmoscopy including fundoscopy

1. **To detect opacities in the media:** The ocular media (cornea, lens and vitreous) are normally clear. Note any opacity while observing the red reflex. Dense opacities completely obscure the reflex (e.g. cataract). The depth of the opacity can be determined by moving the ophthalmoscope.

- Corneal opacities move in opposite direction
- Lens opacity stay stationary
- Vitreous opacities move in the same direction of ophthalmoscope.

2. **Refractory errors** (e.g. myopia, hypermetropia, astigmatism).
 - *Myopia:* Minus (concave) lenses are required. Sometimes, it may not be possible to focus on the retina unless patient wears his/her glasses. The myopic disc often looks larger and pale with surrounding chorioretinal atrophy.
 - *Hypermetropia:* Plus (convex) lenses are required. The hypermetropic disc appears pink and swollen (pseudopapilloedema)
 - *Astigmatism:* The radii of curvature of the cornea in different planes are not regular. When severe, refractory errors cannot be corrected with ophthalmoscope. The disc may look distorted.
3. **To examine the fundus:** The steps of fundus examination have already been described. Here, the normal and abnormal fundi are highlighted.

A. Normal Fundus**i. The optic disc**

Shape: Round or slightly oval (Fig. 5.22).

Colour: Pink with slight temporal pallor.

Physiological cup: A depression in the central part, is more pale than the surrounding disc and from it retinal vessels enter and leave the eye. It varies in depth and size but diameter should not exceed 50% of the disc.

Edge (margin) of the disc: Quite commonly, there is a surrounding white scleral ring, a dark pigmented ring or a stippled choroidal ring.

The retinal blood vessels: They radiate from the disc, dividing dichotomously into many branches as they pass towards the periphery. The arteries or arterioles have a smaller calibre than the veins, and have a bright red colour. Healthy vessel walls are not visible. Note the normal and abnormal pulsations.

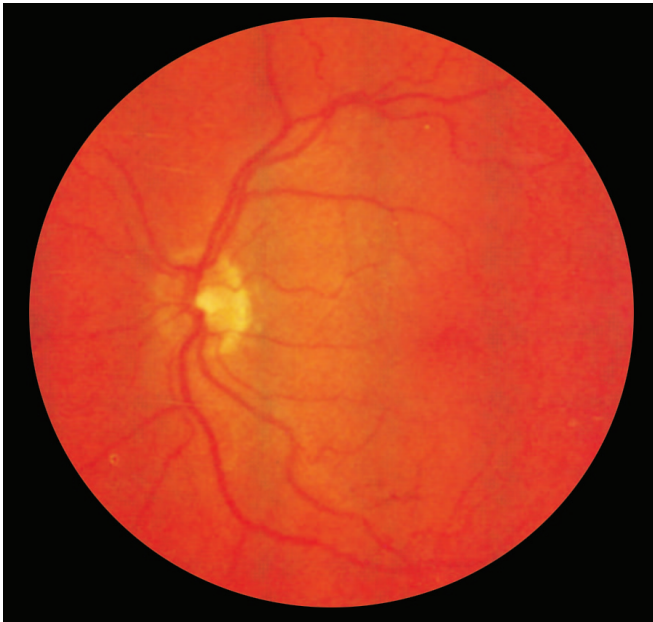


FIGURE 5.22 Normal fundus

Spontaneous venous pulsation is a normal finding; while spontaneous retinal artery pulsations are abnormal and occurs in glaucoma and aortic regurgitation.

- ii. **Macular region:** It is a portion of the posterior retina containing xanthophilic pigment (hence, macula lutea) and two or more layers of ganglion cells. The *fovea* (5.5 mm in diameter) lies at the centre of macula and is devoid of blood vessels. Macular involvement produces greater reduction of the vision than similar changes in any other part.

Periphery of the fundus: It is examined only when pupil is dilated with a mydriatic (tropicamide 0.5% drops). Certain disease processes, i.e. retinal tears and retinitis pigmentosa can be diagnosed.

B. The Abnormalities of the Fundus (Figs 5.23 to 5.30)

- i. **Retinal atrophy:** Old injuries and inflammation may result in atrophic scars. White patches of atrophic retina occur in congenital coloboma, high myopia and retinal degeneration.
- ii. **Abnormal pigmentation:** *Macular degeneration* (Fig. 5.23) occurs in old persons (age related process) in which retinal pigment epithelial changes cause hypopigmentation and pigment clumping at the macula. Central vision is poor.

Melanomas: Benign choroidal melanomas are flat dark lesions while malignant melanomas are raised, enlarge progressively and often metastasize.

Retinitis pigmentosa is associated with pigment deposits like bony spicules, seen in Laurence-Moon-Biedle Syndrome.

iii. Abnormal exudates (Table 5.7)

- iv. **Optic atrophy:** It is defined as atrophy or death of optic nerve fibres leading to reduction or loss of tiny blood vessels. In this condition, the disc is paler than normal, and may even be white (Fig. 5.24).

In optic atrophy, the number of capillaries that cross the disc margin is reduced from normal 10 to 7 or less (Kestenbaum's sign).

The classification of optic atrophy into *primary* (disc is flat, chalky-white in colour with clear cut margins), *secondary* (atrophy follows papilloedema) and *consecutive* (glucomatous) is confusing, hence, avoided.

Causes: They are given in the Box 9.

- v. **Papilloedema:** It is bilateral optic disc swelling from raised intracranial pressure. All other forms of optic disc swelling, e.g. from inflammation of optic nerve (optic neuritis) or ischaemic optic neuropathy should be called "optic disc oedema" rather than papilloedema. This convention is arbitrary but serves to avoid confusion. Disc changes in papilloedema are given in the Box 10 and Fig. 5.26.

Calculation of papilloedema in diopters: The elevated disc of papilloedema can be measured by noting the differences in diopters of the two lenses used to focus clearly on the disc and on uninvolved retina (Fig. 5.27).

Causes: They are given in the Table 5.8.

- vi. **Optic neuritis:** It results from inflammatory, demyelinating or vascular disease leading to marked loss of vision. There may be retrobulbar involvement (retrobulbar neuritis in which neither the doctor sees any abnormality of the fundus nor the patient sees anything, i.e. vision is lost. The difference between optic neuritis and papilloedema are summarised in the Box 11. Optic neuritis is frequently followed by optic atrophy, with residual reduction in visual acuity and scotomas (central or peripheral). It may occur alone, bilaterally (Devic's disease) or during the course of multiple sclerosis.

- vii. **Retinal haemorrhages:** *Superficial retinal haemorrhage* are flame-shaped because of tracking of the blood along

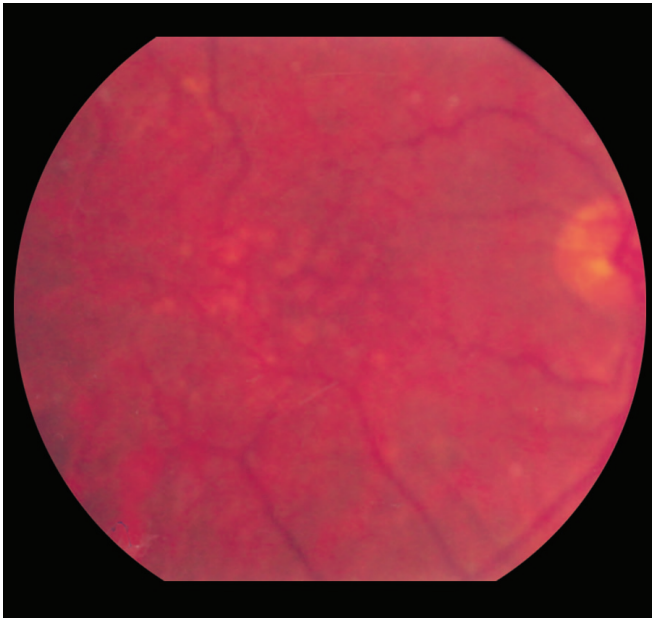


FIGURE 5.23 Age related macular degeneration. Note the accumulation of drusen within macula. They appear as scattered yellow subretinal deposits

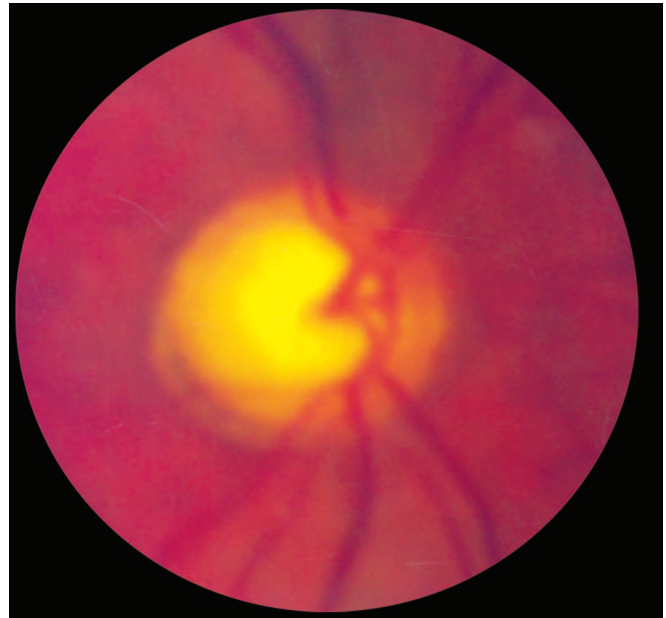


FIGURE 5.25 Glaucomatous optic atrophy. The physiological cup is enlarged. The disc is pale. The retinal vessels are displaced nasally because of angulation of the optic cup

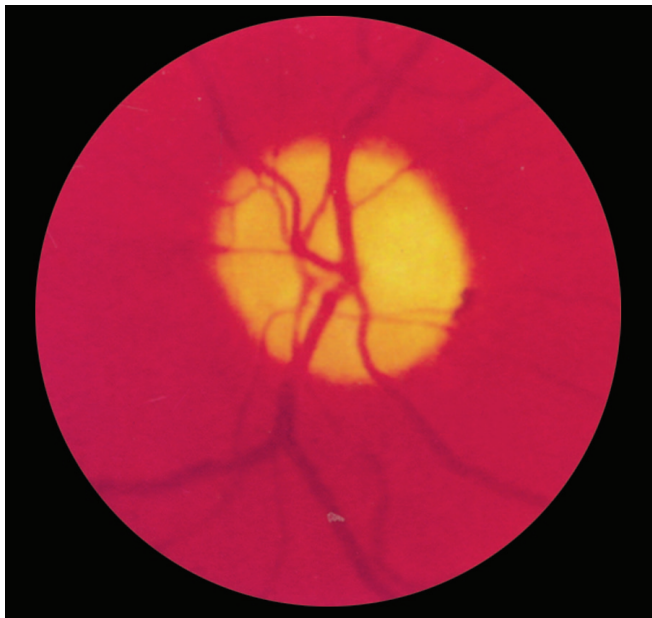


FIGURE 5.24 Fundus photograph of a patient with optic atrophy. Note the pallor of disc with arteriolar narrowing

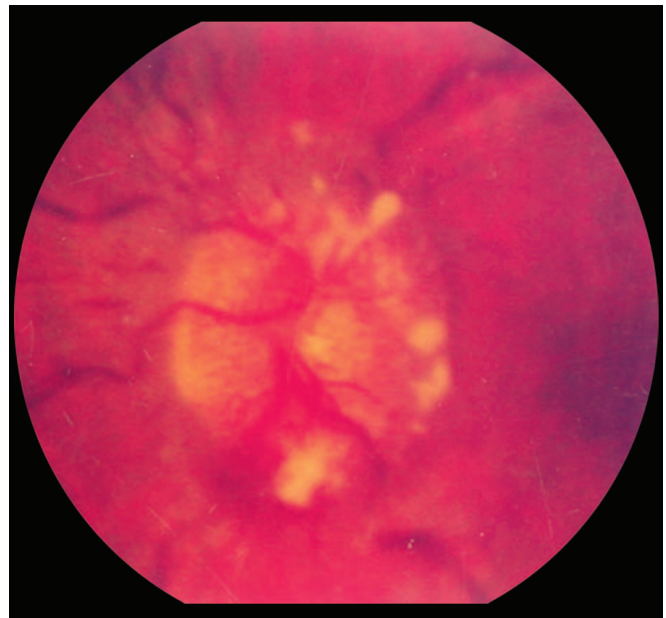


FIGURE 5.26 Papilloedema. The fundus photograph was taken from a patient with raised intracranial pressure. Note the disc oedema, haemorrhage and cotton wool exudates

the horizontally arranged nerve fibres. They occur in hypertension.

Deep haemorrhages are round blotches and spots contained by vertically arranged deep retinal layers. Microaneurysms also look very similar. Both occur in the dots (aneurysms) and blots (haemorrhage) of diabetic retinopathy.

Subhyloid haemorrhages, situated in front of retina, are occasionally very large round haemorrhage obscuring the underlying retina. They may occur following subarachnoid haemorrhage or follow bleeding from new retinal vessels in diabetic retinopathy.

Vitreous haemorrhage: The fundus is hidden by a dark haze of blood. The blood may be distributed diffusely

TABLE 5.7 Abnormal deposits on the retina

Character	Hard exudates (Fig. 5.30)	Soft exudates (Fig. 5.29)
Site	They are deep	They are superficial
Margins	Well defined, deep seated (hence hard)	Irregular or ill-defined, superficial (hence soft)
Arrangement	They are often arranged in rings. At the macula, they may arrange in a star (macular star)	They look like deposits of cotton-wool
Pathogenesis	They are caused by leakage of proteins through an abnormal permeable blood vessel	They occur around areas of infarcted retina and may be associated with other features of retinal ischaemia (venous dilatation, haemorrhage, new blood vessels). They are due to swelling of optic nerve fibre layer.
Causes	They are seen in hypertension, diabetes, and following retinal vascular occlusions.	They are seen in retinal artery ischaemia put it infarction due to hypertension or retinal vein occlusion

Box 9

Causes of optic atrophy

- Inherited, e.g. Leber's optic atrophy
- Toxic, e.g. ethambutol, methyl alcohol, carbonmonoxide and ethylene glycol (antifreeze)
- Glaucoma (Fig. 5.25)
- Extensive retinal disease
- Ischaemic optic atrophy
- Demyelinating disease, e.g. multiple sclerosis, Devic's disease
- Trauma, e.g. avulsion of optic nerve
- Tumours, e.g. pituitary adenoma, craniopharyngioma

through the vitreous gel or form clots which cause tadpole-like floaters. It is an important cause of sudden loss of vision.

Causes: They are given in the Box 12.

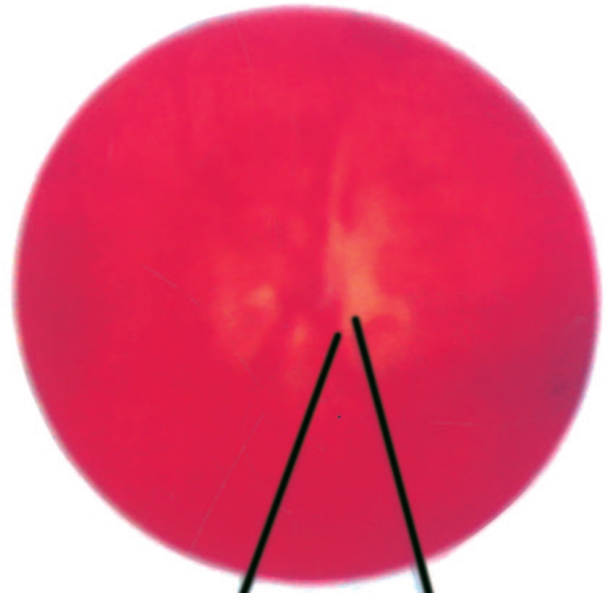
viii. Occlusion of central artery of retina (Fig 5.28): It refers to sudden, and often total loss of vision. It is characterised by:

- Pale and swollen optic disc and surrounding retina
- A cherry-red spot at the macula
- The retinal arteries are narrow and thread-like. It is due to embolic occlusion of retinal vessels from an atheromatous plaque.

ix. Retinal vein occlusion: In central vein occlusion a little vision is retained. It is characterised by:

- Large flame-shaped haemorrhages and cotton-wool spots splashed over the fundus (Fig. 5.29)
- Swelling of the optic disc
- Gross venous dilatation.

x. Retinopathy: The two common types of retinopathy seen are hypertensive and diabetic. The fundus changes are given in the Box 13.



Clear focus here (periphery) at -1 diopter clear focus here (disc) at +2 diopters

Calculation of papilloedema
 $+2 - (-1) = 3$, therefore disc
 is elevated by 3 diopters,
 hence, papilloedema is 3d (Diopters)

FIGURE 5.27 Calculation of papilloedema in diopters (read the text)

INVESTIGATIONS FOR A CASE WITH EYE DISORDER

- **Refraction test:** It is done to ascertain the optical power of an eye. This is performed subjectively by placing neutralising lenses in front of the eye and simultaneously assessing the visual acuity. An objective refraction is also performed in conjunction with a retinoscope.

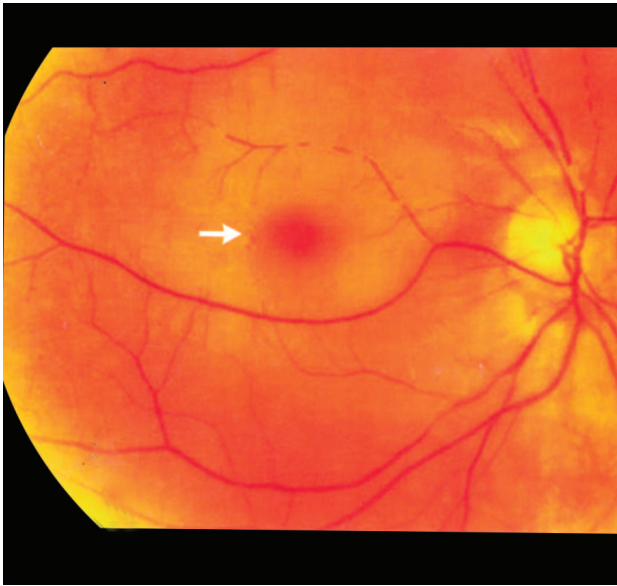


FIGURE 5.28 Occlusion of central artery of retina. Ophthalmoscopic examination revealed diffuse retinal whitening, constriction of the arteriole and venule with segmentation and a cherry-red spot in the macula (arrow)—all signs compatible with the diagnosis of central retinal artery occlusion.

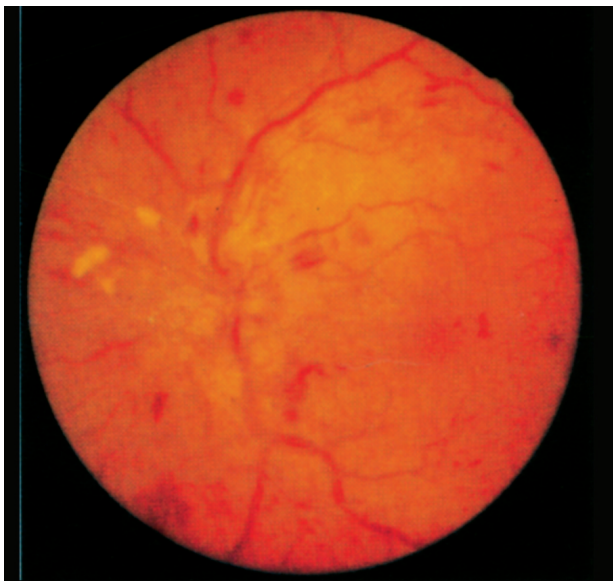


FIGURE 5.29 Central retinal vein occlusion. The veins are tortuous and enlarged, and haemorrhages of varying shapes are scattered throughout. The optic disc is obscured completely. A few cotton wool spots exudates can be seen on nasal side

- **Measurement of intraocular tension** (see the method, Fig. 5.5). It is measured by tonometry.
- **Ophthalmoscopy:** It has already been discussed.
- **A slit lamp examination:** It consists of a binocular microscope mounted on a table with an adjustable beam

Box 10

Optic disc in papilloedema (Fig. 5.26)

- The swollen disc is pink and hyperemic
- Disc vessels clearly visible, more numerous, curve over the borders of the disc. There is venous dilatation and loss of venous pulsations
- The margins are blurred
- The physiological cup is not visible, i.e. cup is lost and full

TABLE 5.8 Causes of papilloedema

- *Raised intracranial pressure* due to tumours, abscesses, meningitis, obstructive hydrocephalus, subdural haematoma, subarachnoid haemorrhages, dural sinus thrombosis and idiopathic.
- *Cerebral oedema*
- *Accelerated or malignant hypertension* (hypertensive crisis)
- *Haematological disorders*, e.g. anaemia, leukaemia, polycythemia
- *Respiratory diseases*, e.g. emphysema, carbon dioxide narcosis, mediastinal compression (SVC obstruction)
- *Vitamin A deficiency or excess*
- *Hypoparathyroidism*
- *Optic nerve tumour* (Foster-Kennedy syndrome) in which there is ipsilateral optic atrophy and contralateral papilloedema
- *Pseudopapilloedema* is congenitally elevated disc due to drusen (optic nerve drusen are refractile hyaloid deposits within substance of the optic nerve head) or hyperopia.
- *Papillitis*

of light. This provides a magnified optical section of the various structures of the eye to be examined.

- **Fundus photography and fluorescein angiography:** They are useful adjunct to the diagnosis of retinal and choroidal disorder. The fluorescein angiography is superior to plain fundus photography because a detailed assessment of retinal and choroidal vasculature is possible after injection of sodium fluorescein—a dye. The blue filter of fundus camera excites fluorescence as the dye circulates.
- **Ultrasonography:** It is used to detect retinal detachments and intraocular or orbital tumours.
- **Dacrycystography:** A contrast study is used to identify the obstruction in lacrimal drainage system.
- **CT scan and MRI:** They are also useful in the diagnosis of orbital disease.
- **Electrophysiological study:**
 - **Visual evoked potential (VEP):** If a stimulus is applied, for example, to the eye, it would normally be impossible to detect small EEG response evoked by

Box 11

Differentiation between optic neuritis and papilloedema

<i>Optic neuritis</i>	<i>Papilloedema</i>
• Usually unilateral	Bilateral
• Eye movements are painful	They are painless
• Ocular tenderness on compression	No such tenderness
• In papillitis, there is hyperaemia and some swelling of the disc	Marked swelling of the disc with loss of cup (e.g. cup is full)
• Severe visual loss	Minimal visual impairment
• There may be signs of inflammation, e.g. hazy vitreous and retinal exudates	No signs of inflammation

Box 12

Causes of retinal haemorrhages

- Hypertension
- Diabetes
- Trauma
- Blood disorders, e.g. anaemia, sickle cell disease, leukaemia, bleeding diathesis
- Anticoagulants
- Subarachnoid haemorrhage
- Retinal vein occlusion
- Age-related macular disease

Box 13

Fundus changes in two common retinopathy

<i>Hypertensive retinopathy</i> <i>Fig. 5.30</i>	<i>Diabetic retinopathy</i> <i>Fig. 5.31</i>
<ul style="list-style-type: none"> • Diffuse or segmental narrowing of arterioles/arteries and thickening of their walls, <i>venous nipping</i>. The thick walled arterioles compress the veins at crossings giving “silver wiring” appearance 	<ul style="list-style-type: none"> • <i>Microaneurysms</i>. Capillary microaneurysms are the earliest abnormality detected in background retinopathy
<ul style="list-style-type: none"> • Flame-shaped haemorrhages 	<ul style="list-style-type: none"> • Dots and blots haemorrhage
<ul style="list-style-type: none"> • Hard exudates. Sometimes star-shaped exudates around the macula (macular star) 	<ul style="list-style-type: none"> • Both hard and soft exudates (cotton-wool)
<ul style="list-style-type: none"> • Papilloedema may occur especially in malignant hypertension 	<ul style="list-style-type: none"> • Neovascularisation—new vessels extend into vitreous and may bleed, are seen in proliferative diabetic retinopathy <ul style="list-style-type: none"> – Pre-retinal and vitreous haemorrhage – Fibrosis, retinitis proliferans and retinal detachment

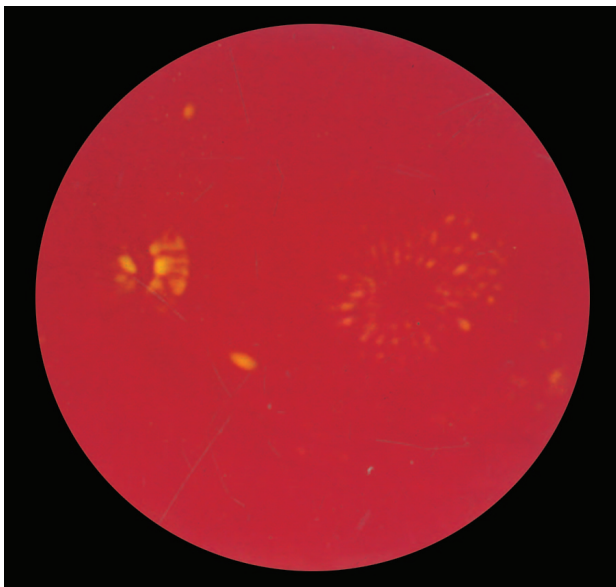


FIGURE 5.30 Hypertensive retinopathy with macular star. Note the punctate hard exudates forming a macular star. Note also the flame-shaped haemorrhage and two small soft exudates

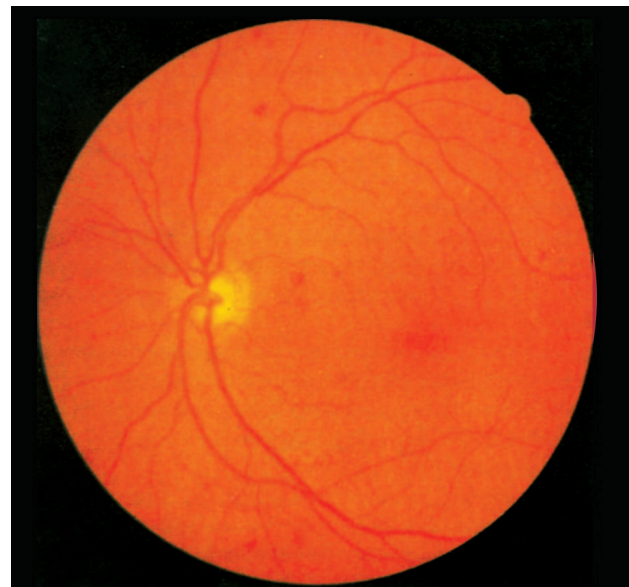

FIGURE 5.31 Diabetic background retinopathy. Note the blot haemorrhages in different stages of resolution, microaneurysm dots and a few hard exudates in the lateral part of retina. This is a characteristic appearance as dot and blot appearance of fundus in diabetic background retinopathy

it over the occipital cortex as the signal will be lost in background noise. However, if EEG data from repeated stimuli (100–1000) are averaged electronically and the noise is removed then an evoked potential can be recorded whose latency (time interval between stimulus onset and its maximum positive wave of the evoked potential, P100 wave) and amplitude can be measured.

The abnormalities in evoked potential occur in the form of either conduction delay (increased latency) or reduction in amplitude of the wave form or both.

It is useful for diagnosis of lesion of the visual pathways, usually demyelinating optic neuritis (retrobulbar neuritis) seen in multiple sclerosis, compressive lesion of the optic pathway, toxic and nutritional amblyopias, Leber's optic atrophy and hereditary ataxia.

VEP can be used to distinguish hysterical from cortical blindness.

Electroretinograms are used in assessing the patients with hereditary or acquired retinal degenerations.

6

CHAPTER

The Mouth and the Pharynx

THE MOUTH AND THE PHARYNX (Fig. 6.1)

The mouth is an open cavity. The lips are muscular folds that form the opening of the mouth. When mouth is opened, the gums (gingivae) and teeth are visible. Note the scalloped shape of the gingival margins and the pointed interdental papillae. The gingiva is firmly attached to the teeth and to the bone (maxilla or mandible) in which they are seated. In the lighter-skinned people, the gingiva is pale to coral pink and lightly stippled; while in darker-skinned persons, it may be diffusely or partly brown. A midline fold called *labial frenulum* connects each lip with the gingiva.

Each tooth, composed mostly of dentine, lies rooted in a bony socket with only its enamel-covered crown exposed. Small blood vessels and nerves enter the teeth through its apex and pass into the pulp. The adult has 32 teeth (16 in each jaw). Each half of upper and lower jaw, thus, has 8 teeth (2 incisors, one canine, two premolars and 3 molars).

The dorsum of the tongue is covered with papillae giving it a rough surface. Some of these papillae look like red dots on the thin white coat that often covers the tongue. The under surface of the tongue has no papillae. Note the midline *lingual frenulum* that connects the tongue to the floor of the mouth.

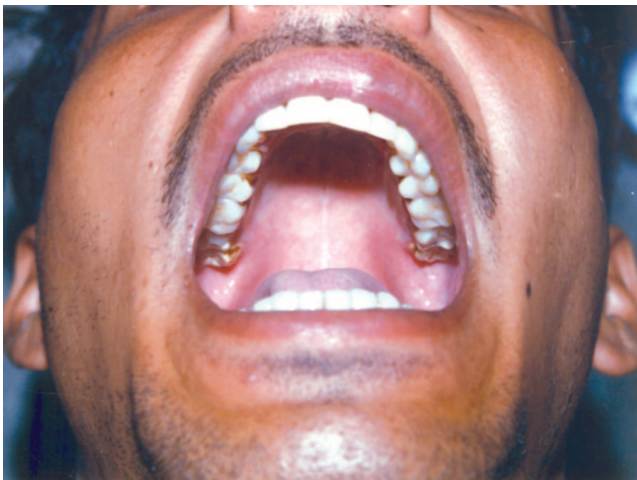

FIGURE 6.1 The oral cavity—an inner view

At the base of the tongue, the duct of *submandibular glands* (*Wharton's ducts*) passes forwards and medially to open on papillae that lie on each side of the lingual frenulum.

Each *parotid duct* (*Stensen's duct*) empties into the mouth near the upper 2nd molar where its location is marked by a small papilla. *The buccal mucosa* lines the cheeks.

Above and behind the tongue, there is an arch formed by the *anterior* and *posterior pillars*, *soft palate* and *uvula*. The tonsils lie between anterior and posterior pillars on each side. In the adult, the tonsils are often small or absent. A meshwork of blood vessels may web the soft palate. Between the soft palate and the tongue, the pharynx is visible (Fig. 6.1).

EXAMINATION

The examination of mouth and pharynx is conducted with the patient sitting up comfortably either in bed or in a chair. A torch light, a tongue depressor (spatula) and a pair of gloves are essential. The examination sequence includes:

- **Inspection** of the lips, teeth, gums, tongue, palate and oropharynx
- **Palpation** of the sides of the tongue, floor of the mouth and tonsillar regions.

Inspection

The lips

The parts of the lips to be examined for their clinical significance are depicted in the Table 6.1.

The teeth

Ask the patient to show the teeth. If the patient has a denture, ask him/her to remove it and open the mouth widely. With the help of tongue depressor, retract first the lips and then the cheek so as to have a glimpse of all the teeth. Count the number of teeth present.

Look for any decay (caries)

- Dental caries is visible as chalky white area in the enamel surface of the teeth.

TABLE 6.1 Inspection of lips

Site	Look for	Significance
Philtrum (the shallow depression running from nose to upper lip)	Any scar	Tell-tale scar indicates repaired cleft-lip (Fig. 6.2), therefore, if present inspect the palate for signs of a cleft
Angles or corners of the mouth	Cracks or fissures	Their presence indicate angular stomatitis. The cracks are reddish-brown superficial linear ulcers radiating from the angles of the mouth. The causes are: - Infection (perleche) in children - Ill-fitting or deficient denture in old persons - Severe iron deficiency anaemia - Vitamin B ₂ (riboflavin) deficiency
Lips	Desquamation or inflammation of the lips (cheilitis)	Desquamation is common in cold weather Grouped vesicles on the lips on a red base with crusted lesions are seen in inflammation due to <i>herpes simplex labialis</i> (Fig. 6.3) Recurrent cheilitis with small blisters and exfoliation (a premalignant condition) is seen in fishermen and farmers exposed to sun and the wind
	Any ulcer	Carcinoma (epithelioma) occurs as an indolent ulcer on the lower lip with heaped up and indurated margins
	Any nodule	A keratoacanthoma (molluscum sebaceum) is a nodular lesion, commonly occurs on the upper lip due to overgrowth of stratum granulosum of the skin. It is a benign lesion, heals spontaneously.
	A granuloma	Pyogenic granuloma—a soft red raspberry like nodule on the upper lip occurs due to trauma
	An extragenital chancre	A small rounded, indurated lesion on the upper lip indicates secondary syphilis
	A crack	A crack in middle of lower lip seen in cold weather, is of no significance
	Any pigmentation	<i>Circumoral pigmentation</i> (multiple small brown or black spots on the skin around the mouth; may extend on to the lip and buccal mucosa) is seen in <i>Peutz-Jeghers syndrome</i> (inherited small bowel polyposis)
	Any telangiectasia Aphthous ulceration (Fig. 6.4)	Their presence may signify the existence of others elsewhere in the small bowel Grasp and evert the lower or upper lip with the index finger and thumb of both the hands to display the mucous membrane of the lip. <i>Aphthous ulcers</i> are small superficial painful ulcers with a white or yellow base and a red narrow halo of hyperemia. Such ulcers are seen on the tongue, buccal mucosa and palate. Severe chronic aphthous ulceration may be seen in ulcerative colitis, Crohn's colitis, coeliac disease, malabsorption and Behçet's syndrome Behçet's syndrome is characterised by recurrent oral and genital ulcerations with gastrointestinal and neurological manifestations.
Any cysts	Retention cysts of the mucous glands of the lower lips may be seen as rounded, bluish or white swellings.	

Caries: A common dental disease, occurs due to bad oral hygiene and is bacterial induced progressive destruction of mineral and organic constituents of enamel and dentin.

Caries is related to lack of fluoride, hence to prevent teeth decay, most of the dental pastes contain optimal amount of fluoride.

Count the number of teeth present. Note any absence of teeth.

- The tooth most common missing is an impacted unerupted third mandibular molar (wisdom tooth)
- Missing teeth are most commonly molars as these are used for grinding rather than biting; their absence is associated with indigestion and other GI tract diseases.

Look for any change in colour

- Tartar deposits (brown deposits) occur on incisors and canine teeth in smokers.
- Reddish brown discolouration of teeth may be seen in chewers of betel nuts.
- Staining of permanent and deciduous teeth in the form of yellow-grey bands is seen in children (<8 years) treated with tetracyclines. Children of expectant mothers are also at risk of staining after 14 weeks of pregnancy if treated with tetracyclines.
- The teeth may be pitted or mottled yellow-brown (Maldon teeth) in fluorosis (Fig. 6.5).

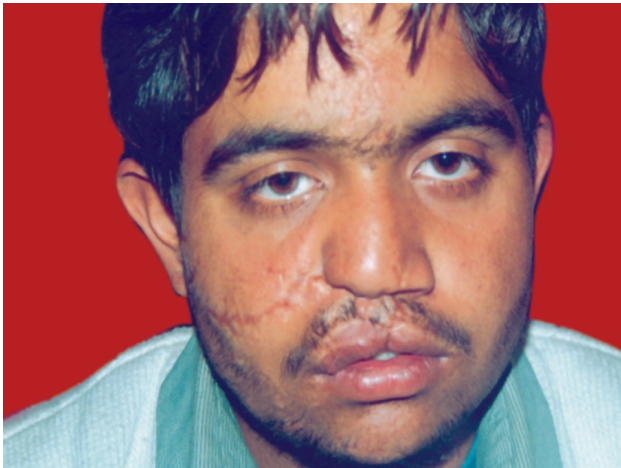

FIGURE 6.2 Stitched and repaired cleft lip. Note the characteristic scar

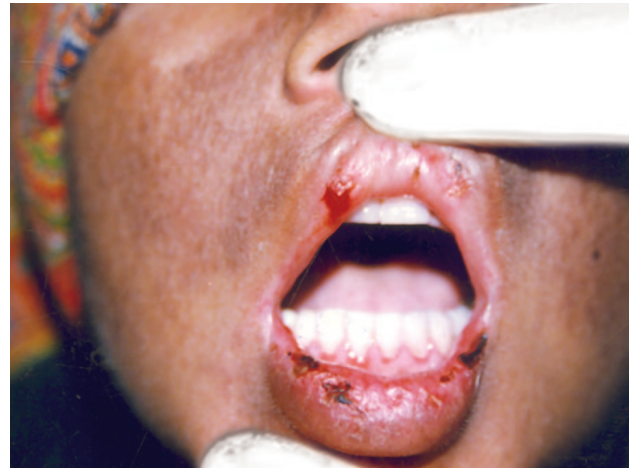

FIGURE 6.4 Aphthous ulceration. Note the superficial ulcers on inner aspects of both lips with hyperaemia. The ulcers have whitish base

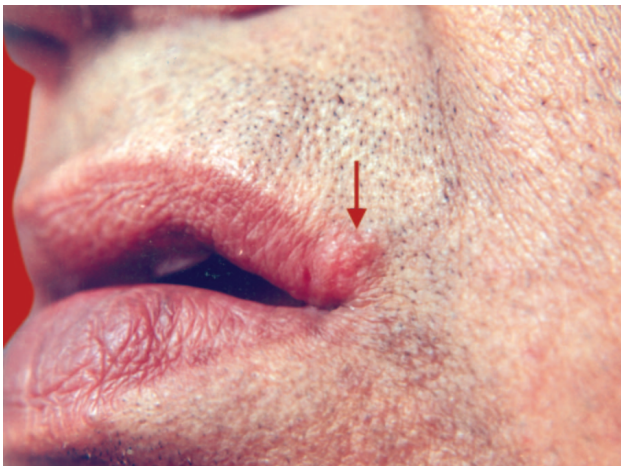

FIGURE 6.3 Herpes labialis. Note the grouped vesicles on the upper lip with red base (↓)

Look for shape of the teeth

- Notching of incisors is common in those who persistently bite their nails or hold hair clips between their teeth.
- Notched, separated and peg-shaped upper incisors are seen in congenital syphilis (*Hutchinson's teeth*).
- The two central upper incisors are sometimes lost in *leprosy*.
- Teeth are poorly developed in *juvenile hypo-thyroidism*.
- Eruption of teeth may be delayed and transverse ridging is sometimes seen in *scurvy* and *rickets*.
- Enlargement of lower jaw (prognathism) in acromegaly leads to alteration of biting line so that lower teeth may close outside the upper ones.
- Attrition of teeth. Teeth are worn down by repetitive use in old persons leading to the recession of gums—called attrition. This process leads to apparent increase in the length of teeth.
- *Look for any erosion.* Teeth may be eroded by chemical action of the acid. Erosion of incisors in children may be a sign of gastro-oesophageal reflux disease (GERD).

The gums

Inspect the gum along with teeth at the same time and note the followings:

- Normally, pink, healthy gums (gingivae) adhere firmly and closely to the teeth (Fig. 6.6).
- Blue line at gum may sometimes be seen in lead poisoning, bismuth and mercury poisoning.
- *Attrition of teeth-recession of gums.* With increasing age teeth become worn down and there is recession of the gums from the teeth so that the teeth appear longer and are prone to infection.
- Look for signs of inflammation (*redness, pain or tenderness, exudation of the pus on gentle pressure and swelling of interdental papillae*) and any plaque (*a soft white film/line of salivary salts, proteins and bacteria that covers the teeth and leads to gingivitis*).
- **Gingivitis** is inflammation of the gums. In *chronic marginal gingivitis*, the gingival margins are red and swollen.
- *Brushing the teeth often makes the gums bleed.*
- *Plaque* is not readily seen. Sometimes pus can be squeezed from them, (*pyorrhoea alveolaris*).
- **Acute herpetic gingivostomatitis** due to herpes simplex virus producing small vesicles on the gums is common among infants and children. The vesicles also appear on the lips, tongue, palate and cheeks.
- **Acute necrotising ulcerative gingivitis (Vincent's infection) and periodontitis.**
It is an infection due to fusiform spirochaetes characterised by painful tender gums which bleed on pressure. There is gingival necrosis and ulceration. Breath is foul smelling (*halitosis*) and there is regional tender lymphadenopathy.
- In *chronic gingivitis and periodontitis*, the teeth become loose as the gum margins recede. A calculus (mineralised bacterial plaque) may be seen as hard cream coloured deposits on teeth and predispose to infection. The bacterial infection (*streptococcal viridans*) may predispose to bacterial endocarditis in patients suffering from congenital or valvular heart disease and in those having valve prosthesis.

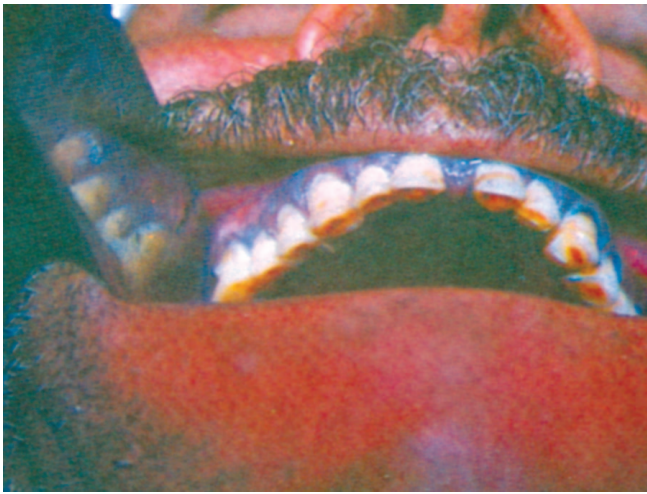

FIGURE 6.5 Teeth in fluorosis. Note the brownish mottled appearance and pitting of teeth

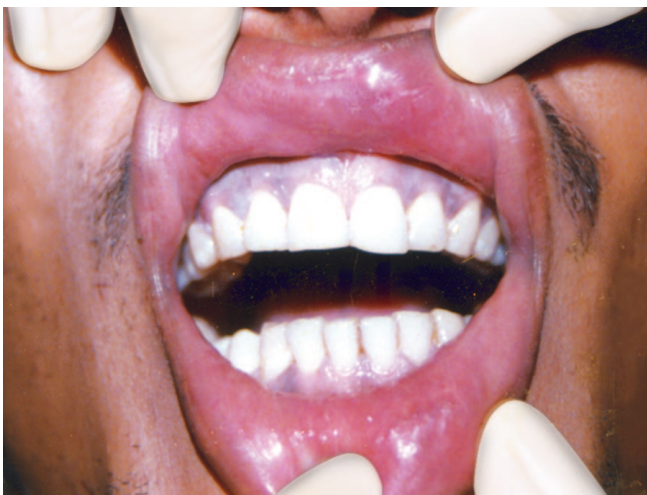

FIGURE 6.6 Inspection of the gum and teeth

Look for hypertrophy or bleeding

The gums may be involved in (gum-hypertrophy) systemic disorders (Box 1). Gingival hyperplasia is also seen during puberty and pregnancy. It is also caused by phenytoin toxicity, scurvy and acute monocytic leukaemia.

Look for a granuloma or a ulcer

Ill-fitting denture can produce a granuloma or an ulcer on the gum at the point of pressure. A carcinomatous ulcer (*in situ*) may arise in the gum, has to be differentiated from a traumatic ulcer of ill-fitting denture. *Epulis* or *pyogenic granuloma* is a localised gingival enlargement like a tumour originating on interdental papilla. It is red and soft and usually bleeds easily. This is common during pregnancy (pregnancy tumour).

Box 1

Gums in systemic disorders

Alteration	Disease/Condition
Firm, hypertrophied gums (Fig. 6.7)	Phenytoin therapy, cyclosporine, nifedipine.
Soft, spongy haemorrhagic gums	Scurvy
Hypertrophied and haemorrhagic gums (Fig. 6.8)	Thrombocytopenic purpura and acute myelomonocytic leukaemia
Spongy and haemorrhagic gums	Cyanotic congenital heart disease
A punctate/stippled blue line on gums	Chronic lead poisoning (common); Bismuth and mercury poisoning (uncommon)

The tongue (Fig. 6.9)

Look at the tongue. Ask the patient to protrude the tongue. Inability to protrude (*ankyloglossia*) is seen in infants due to *tongue-tie* (a congenitally short frenulum linguae) or in advanced malignancy of tongue involving the floor of the mouth. In painful conditions of tongue, patient protrudes it slowly with a great difficulty.

Examine the tongue for following abnormalities:

- Deviation or asymmetry
- Size of the tongue
- Fasciculations and tremors
- Colour
- Moistness
- Fur
- Atrophy or hypertrophy of papillae.

1. **Asymmetry or deviation of tongue:** The deviation of the tongue may be due to asymmetry of the jaws, hemiplegia and XII cranial nerve paralysis (Read cranial nerve examination in nervous system).
2. **Size of the tongue:** The tongue is large (*macroglossia*) in acromegaly, cretinism, myxoedema, amyloidosis, Down's syndrome and lymphangioma, haemangioma and lingual duct cyst.

Patient is said to have **macroglossia** when resting tongue protudes beyond the teeth or alveolar ridge. Relatively enlarged tongue due to a small mandible is called pseudomacroglossia seen in Down's syndrome and cerebral palsy.

3. **Fasciculations and tremors:** In early stage of XII cranial nerve or its nucleus involvement (infranuclear or nuclear

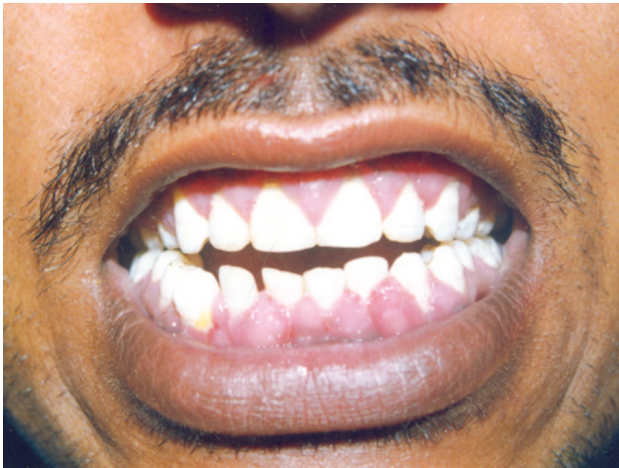

FIGURE 6.7 Gum hypertrophy. Note the firm hypertrophied gums due to phenytoin toxicity

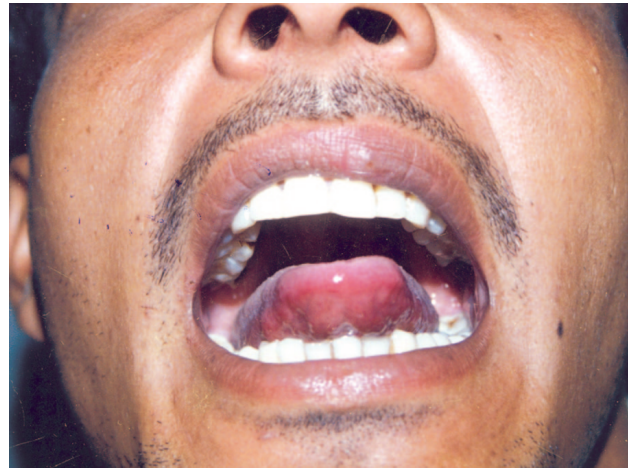

FIGURE 6.9 Examination of the tongue. Inspect the tongue in the oral cavity and then ask him to protrude the tongue

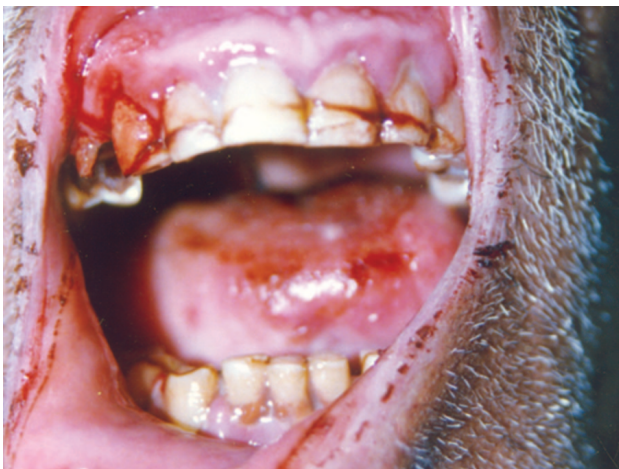

FIGURE 6.8 Bleeding gums. There was hypertrophy and bleeding from the gums in a patient with acute leukaemia

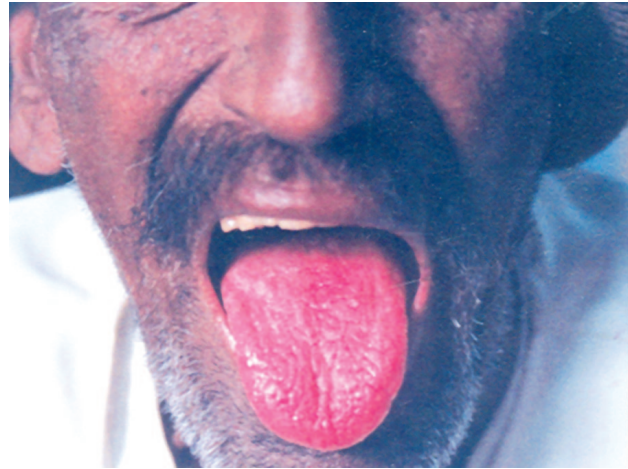

FIGURE 6.10 Magenta-coloured tongue. Red, raw, painful tongue is seen in vitamin B complex deficiency

paralysis of XII nerve), there may be fasciculations on the affected side of the tongue followed by wasting and atrophy. Fasciculations of tongue is a diagnostic feature of motor neuron disease.

Tremors of the tongue may be due to anxiety, thyrotoxicosis, delirium tremens and parkinsonism.

- 4. Colour:** Is the tongue pale, red or discoloured? Pale and *bald tongue* is seen in iron deficiency anaemia, *magenta coloured* in vitamin B₁₂ deficiency (Fig. 6.10). A *clean tongue with prominent papillae* can result from antibiotic treatment. *Discolouration of tongue* (Fig. 6.11) is most often due to the ingestion of coloured foods, e.g. red wine or coloured sweets or pan chewers; and may also be due to quantitative or qualitative changes in haemoglobin. *Central cyanosis* can best be assessed clinically by

inspection of the tongue (Fig. 6.12). Glossitis may produce *red, raw and painful tongue* (Fig. 6.13).

- 5. Moistness:** Is the tongue dry or wet? The state of hydration of the tongue is an indicator of hydration of the body provided the patient is not mouth breather. The causes of dry tongue are given in the Box 2. A dry, brown furred tongue may be found in severe illness, uraemia and acute intestinal obstruction.
- 6. Fur:** *Is there any abnormal coating of the tongue?* Furring of the tongue is of little significance, is often seen in persons with bad oral hygiene (Fig. 6.14), can occur with oral iron therapy especially syrup and heavy smokers (Fig. 6.15).

A black hairy tongue is seen in infection by fungi or chromogens. The *Strawberry tongue* (bright red papillae standing out of a thick white fur) is seen in scarlet fever. *Hairy leukoplakia* is characteristic feature of HIV infection.

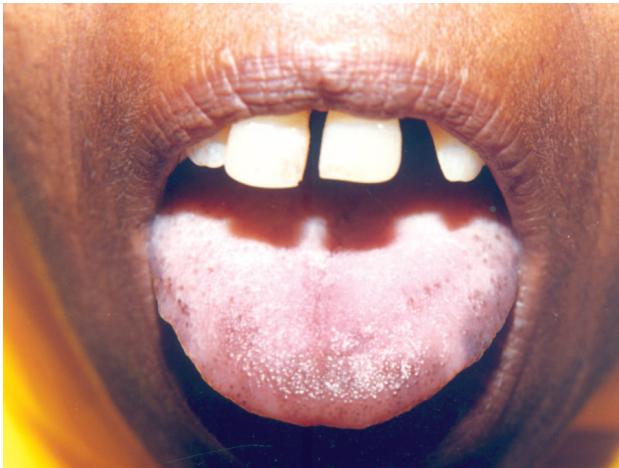

FIGURE 6.11 Discolouration of the tongue

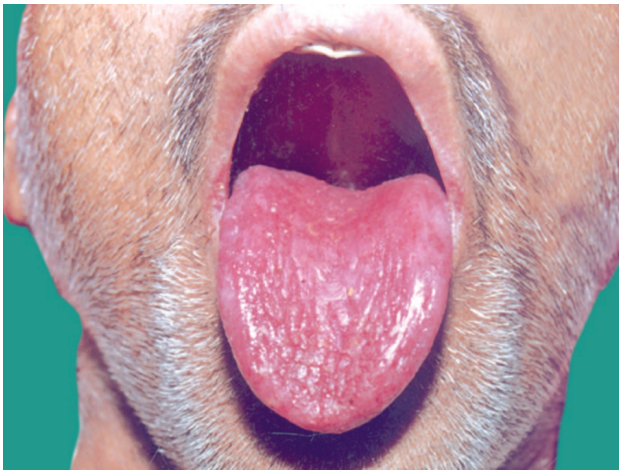

FIGURE 6.12 Central cyanosis. Note the bluish colouration of the tongue

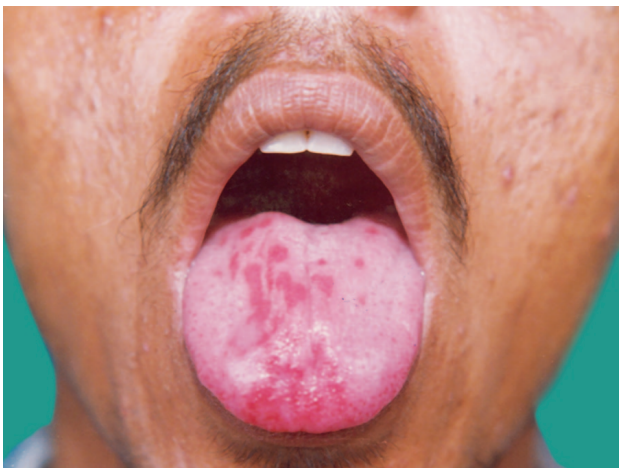

FIGURE 6.13 Glossitis. Note the red, raw and rough tongue. The tongue was painful. There are cracks along the angles of the mouth (cheilosis)

Box 2

Causes of dryness of the tongue

- Mouth breathers
- Dehydration
- Vitamin A deficiency (xerosis)
- Anticholinergics
- Sjögren's syndrome (Sicca syndrome)

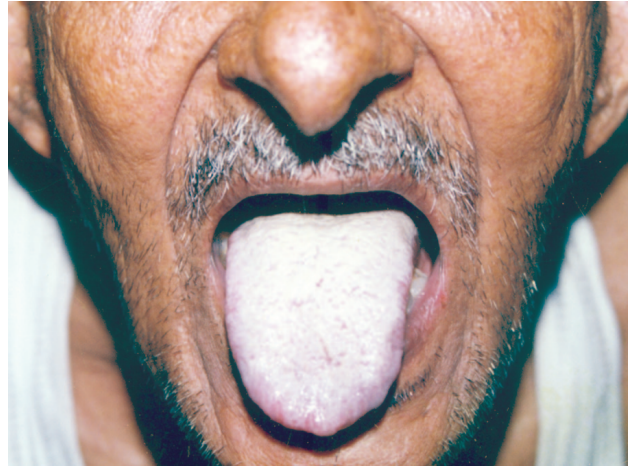

FIGURE 6.14 Coated furred tongue in a person with bad oral hygiene

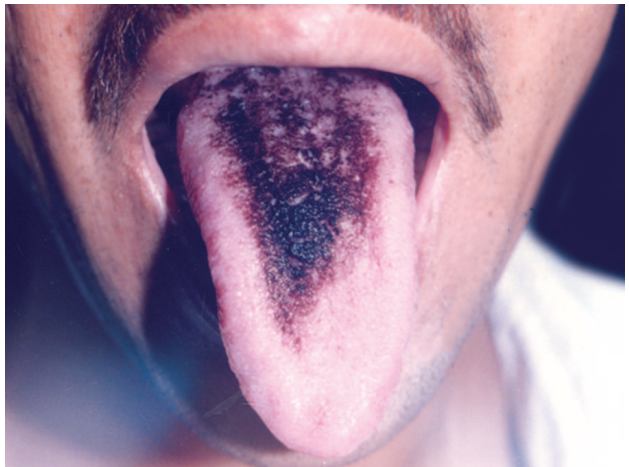

FIGURE 6.15 Black tobacco staining in a smoker. Note the black staining which can also occur in patients receiving oral iron therapy especially the syrups

White mucous patches (mouth thrush) are seen in candidiasis (Fig. 6.16) in patients with diabetes, neutropenia, HIV, polyendocrinal deficiency syndrome (*Candida* endocrinopathy) and following prolonged use of antibiotics (tetracycline) or immunosuppressive therapy and leukaemias and chronic leukoplakia (Fig. 6.17) of the tongue which is a precancerous condition.

Any ulcer or growth on the tongue (Fig. 6.18) indicate carcinoma of the tongue, hence, must be biopsied.

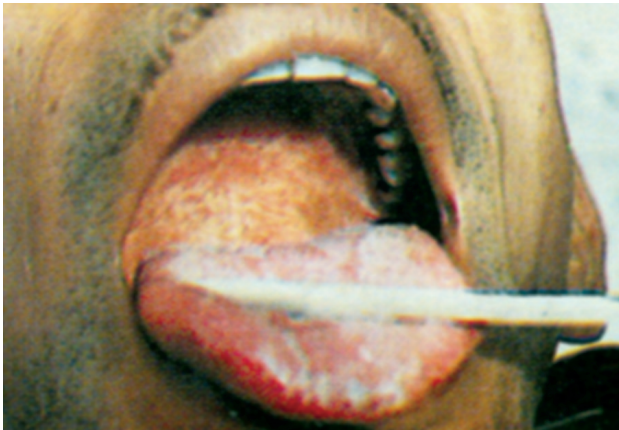

FIGURE 6.16 Mouth thrush. Curdy white patches are seen over the tongue due to superinfection by *Candida albicans* in a patient receiving anti-cancer therapy

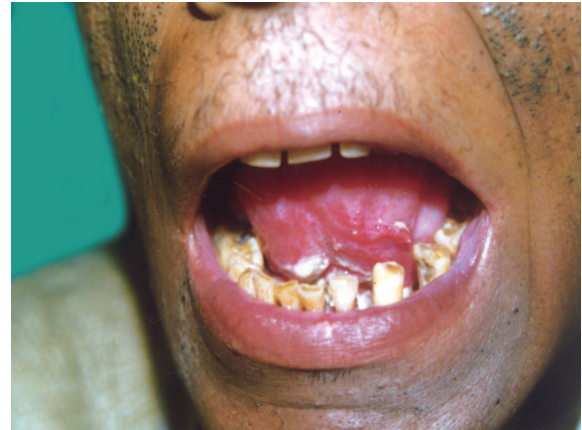

FIGURE 6.18 Carcinoma of the tongue. Note the irregular growth with ulceration

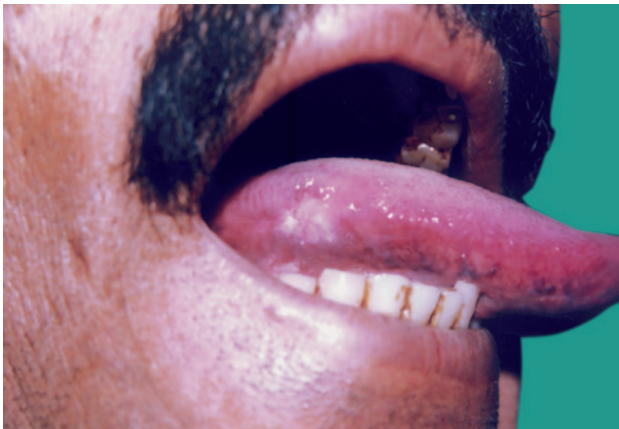

FIGURE 6.17 Leukoplakia of tongue. Note the white smooth patches with firm margins on the side of the tongue

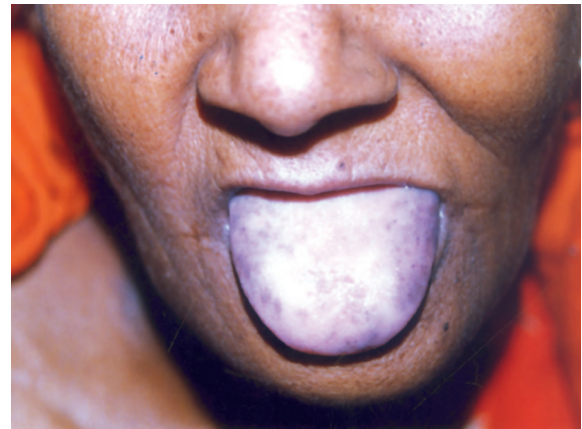

FIGURE 6.19 Bald (atrophic) tongue. Pale, smooth, pigmented tongue with loss of papillae seen in the patient with iron deficiency anaemia

7. The papillae: *Is there atrophy or hypertrophy of the papillae?*

Bald tongue (generalised atrophy of the papillae) is seen in vitamin B₁₂ deficiency and severe iron deficiency anaemia (Fig. 6.19), coeliac disease, malabsorption and pellagra.

Fissuring of the tongue (surface is interrupted by several horizontal folds) is seen in chronic superficial glossitis and congenital fissuring of the tongue. In *rhomboid glossitis*, there is a lozenge-shaped area of loss of papillae and fissuring is seen in midline. It is of no consequence but has to be distinguished from carcinoma and lingual thyroid (both are situated posterior to foramen caecum in contrast to rhomboid glossitis situated anterior to it).

Geographical tongue: It is characterised by denuded red patches wandering across the tongue due to papillary loss and its renewal giving the appearance of a map. This is asymptomatic condition seen in certain geographical areas/regions, hence, is inconsequential.

False geographical tongue: It appears similar to geographic tongue but is seen in children with fever.

The Floor, Sides and Roof of the Mouth

Ask the patient to open the mouth as wide as he/she can and protrude out the tongue fully to one side. Retract the cheek with a spatula. Now inspect the side and lateral surface of the mouth. Some patients may find difficulty to do so, then wrap a gauze piece around the tip of the tongue and with index finger and the thumb of left hand gently pull the tongue out and to one side. This will expose the side and lateral under surface of the mouth.

Examine these areas for any ulcer

Benign ulcers on the side or floor of the mouth are either inflammatory or traumatic (ill-fitting denture or broken carious teeth) in origin. In older persons, any ulcer at this site must be considered malignant until proved otherwise on biopsy. However, the malignant ulcer is a hard, indurated ulcer with raised everted margins (Fig. 6.18).

Now to inspect the under surface of the tongue and floor of the mouth, ask the patient to retract the tongue fully and elevate the tip to touch the roof of the widely opened mouth. Note the frenulum linguae and orifice of the submandibular duct opening on either side of the base of the frenulum. A stone or calculus formed in the submandibular salivary gland may be seen or felt at this site. The calculus is seen as a white or yellow bleb distending the ampulla.

Look for any ulcer on the frenulum

A small ulcer on the frenulum is sometimes seen in persistent coughing in children (e.g. whooping cough)

Look at the floor for any cyst

A *ranula*—retention cyst due to blockage of a mucous gland and *sublingual dermoid cyst* are common at this site.

The oral mucosa

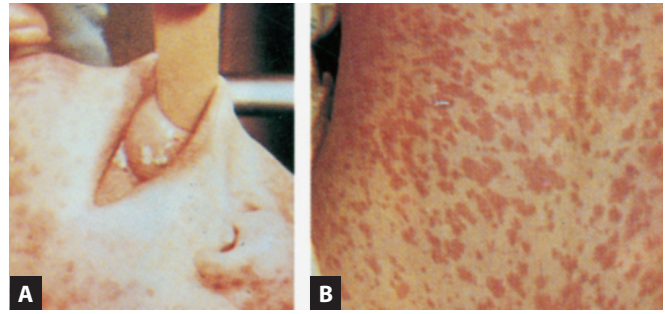
Retract the cheek with a spatula to inspect the buccal mucosa. Note the opening of the parotid duct as a tiny swelling opposite the second molar teeth. The opening will be red, and oedematous in *parotitis*.

Now inspect the oral mucosa for discoloured spots, dots, ulcers, cysts

- **Koplik's spots (Fig. 6.20):** There are bluish-white spots surrounded by a red areola, may be seen on buccal mucosa against the molar teeth in children suffering from *measles*. These spots appear in the catarrhal stage before the appearance of rash.
- Dots of slate-grey or blue pigmentation on buccal mucosa are seen in Addison's disease, Peutz-Jeghers syndrome Hemochromatosis etc.
- Mouth ulceration either aphthous or larger may be seen in variety of disorders (Box 3) including inflammatory bowel disease (e.g. Crohn's disease). Mouth ulcers in association with genital ulcers indicate Behçet's syndrome.
- White opalescent patches may be seen in leukoplakia, Lichen planus while white patches/mouth thrush adherent to the mucosa may be seen in *Candida* infection. White milk curds are small patches seen in infants and children are of no consequence. The causes of thrush are given in the Box 4.

The roof (e.g. palate, fauces), tonsils and pharynx

Method of examination: Make the patient sit comfortably. Ask the patient to put head right back and keep the mouth wide open. Inspect the hard and soft palates and note the position of uvula. Instruct the patient to speak 'ah' which will raise the soft palate and will increase the visibility of fauces, tonsils and oropharynx. To have a good view of these structures, one can use a spatula to depress the tongue and another spatula to retract the anterior pillar of the fauces.



FIGURES 6.20A and B A child suffering from measles: (A) Koplik's spots and rash over face; (B) Measles rash over trunk on 2nd day

Box 3

Common causes of oral ulcers

- Inflammatory bowel disease, e.g. Crohn's disease
- Behçet's syndrome (e.g. orogenital ulceration with GI tract and neurological involvement)
- Leucoplakia (a premalignant ulcer)
- Lichen planus
- Thrush (Candidiasis)
- Idiopathic aphthous ulceration
- Koplik's spots (measles)
- Malignant ulcer

Box 4

Common causes of mouth thrush (oral candidiasis)

- Debilitated children
- Poor oral hygiene and unclean denture
- Patients receiving cytotoxic or immunosuppressive drugs
- Immunocompromised state, e.g. diabetes, AIDS
- Postoperative sepsis
- Patients being treated with broad spectrum antibiotics

Look once again for any ulcer, erythema or vesicles.

- Vesicles due to herpes zoster infection of maxillary division of Vth cranial nerve may be seen on one side of the hard palate. These are oval and painful. Similarly herpes zoster infection of IXth (glossopharyngeal) cranial nerve produces vesicles in the oropharynx.
- Malignant ulcers can be present on the hard palate, but less frequently and present the same appearance.
- A *hole* in the hard palate indicate:
 - Imperfect closure of cleft palate
 - Tertiary syphilis with gumma formation
 - Radionecrosis of bone following radiotherapy for local carcinoma
- A high arched palate is a congenital abnormality seen in *Marfan's syndrome*.
- Petechiae on the hard palate are common in glandular fever, thrombocytopenia, rubella and streptococcal tonsillitis.
- A slit in the palate indicate cleft palate.

Examine the tonsils for exudate

- A white exudate over the tonsils is seen in glandular fever while yellow punctate follicular exudate is seen in streptococcal tonsillitis. Exudate with membrane formation, white to green in colour starting from the tonsils and spreading to fauces and pharynx is seen in *diphtheria*. If this condition is suspected, a swab should be taken for bacteriological examination.
- Finally examine the posterior wall of pharynx for any swelling, vesicles, ulcers or pus.
- *Small lymphatic nodules are normally common on the posterior wall of pharynx.*
- In *chickenpox (herpes varicella)*, there is erythema of pharyngeal and buccal mucosal followed by vesicles which progress to round or oval ulcers with a white slough. In *coxsackie virus infection (herpangina)* similar lesions may be present on the pharynx and soft palate.
- In the *common cold* (infection of nose or sinuses) mucus or pus may be visible trickling down the back of the throat. *Peritonsillar abscess (quinsy)* and *retropharyngeal abscess* are now-a-days less common.

Palpation

Palpation is a part and parcel of systemic examination but can be done during physical examination of any part. Palpation of mouth is essential in a patient with a solitary nodule or ulcer in the oral cavity. Bimanual palpation provides much information about such things as swellings in the floor of the mouth.

Method: First of all explain the patient about the procedure and ensure him/her that examination will be gentle. Put on a

disposable glove or finger cot. Ask the patient to remove any denture and open the mouth widely and elevate the tongue. Put the index finger of your right hand underneath the tongue on one side of frenulum and sweep it back along the floor of the mouth. This will help to palpate a small stone or calculus in any part of submandibular duct. Now come forwards sweeping the finger along the lingual side of the tongue to the midline and return on the buccal side of the tongue towards the lower molar teeth. Examine the palatal and buccal aspects of the gums of the upper jaw by moving the finger up the mucosa covering the ascending ramus of the jaw (mandible).

If an ulcer is found, try to decide whether induration is present or not, for which the bimanual palpation is performed. With the right index finger already inside the mouth, put your finger tips of your left hand flat below the mandible or over the cheek outside the jaw. Palpate the ulcer between your index finger and finger tips of the left hand by gentle pressure.

Now palpate the tongue (dorsum, lateral and under surface) by the index finger. In case of atrophy of the one side of tongue, the bulk of the tongue can be palpated by asking the patient to protrude the tongue and hold it in a gauge between finger and thumb of left hand and perform bimanual palpation of one side with index finger and thumb of right hand.

Posterior third of the tongue, fauces and tonsils are examined last of all. Feel for any abnormality such as a swelling and study it for irregularity, ulceration and induration so as to detect a small or hidden carcinoma.

7

CHAPTER

The Ear, Nose, Sinuses and Throat

THE EAR

Anatomy and Physiology

The ear has three compartments; the *external ear* (auricle and ear canal), the *middle* (air filled cavity containing the three bony ossicles) and the *internal ear* (cochlea, utricle and three semi-circular canals).

Functions

I. The ears are concerned with hearing: Vibrations of sound pass through the air of the external ear and are transmitted through the ear drum and ossicles of the middle ear to the cochlea of inner ear. The cochlea senses and codes these vibrations and sends them up as nerve impulses to the brain through cochlear division of VIIIth cranial nerve. This pathway of hearing has two phases:

- i. *Conductive phase* (from external ear to middle ear) and *sensorineuronal phase* (cochlea and cochlear nerve). The involvement of conductive phase produces conductive hearing loss while that of sensorineuronal phase produces sensorineural or nerve type of hearing loss.
- ii. *Air conduction* describes the normal first phase in the hearing pathway. An alternative pathway, known as *bone conduction* bypasses the external and the middle ear and is used for testing purposes. *In bone conduction* a vibrating tuning fork is placed on the head, sets the bone of the skull into vibrations and stimulates the cochlea directly.

In normal person, air conduction is better than bone conduction (AC > BC).

II. To maintain equilibrium: The labyrinth within the inner ear senses the position and movements of the head and thus helps to maintain balance.

Symptomatology of Ear Disease

The main symptoms of ear diseases are:

- Aural pain (*otalgia*)

- Ear discharge (*otorrhoea*)
- *Deafness* (hearing loss)
- *Tinnitus* (the sensation of sound in the absence of an appropriate auditory stimulus)
- *Vertigo* (sensation of abnormal movements).

Otalgia

The pain in the ear (*otalgia*) may be due to involvement of pain sensitive structures, i.e. external ear canal, tympanic membrane and middle ear. The pain may be referred to ear from other structures, i.e. larynx and pharynx which share the sensory innervation. The sensory innervation of ear is 5th, 9th and 10th cranial nerves and branches of greater auricular and lesser occipital nerves. Since division of these cranial nerves also supply larynx, pharynx, temporomandibular joints and teeth, therefore primary involvement of these structures may give rise to referred ear pain. The causes of *otalgia* are given in the Box 1.

Box 1

Causes of otalgia

- **Diseases of the skin and auricular cartilage**
 - Infection (furunculosis)
 - Trauma due to cotton buds used to remove the wax from ear canal or by using other articles
 - A squamous-cell or basal cell carcinoma of external ear
 - Perichondritis
 - Subperichondrial haematoma due to external blunt trauma
 - Polychondritis helix (tender nodules on helix)
 - Tophaceous gout (gouty tophi on the helix)
- **Diseases of middle ear**
 - Acute suppurative otitis media secondary to upper respiratory or sinus infection in children
 - Chronic suppurative otitis media
 - Dural infection
 - Malignancy within middle ear
- **Referred pain**
 - Disease of larynx, pharynx and base of the lung
 - Temporomandibular arthritis
 - Maloccluded teeth

Otorrhoea

It is defined as discharge (purulent, sanguinous or serous) from the ear. The ear discharge may be acute, intermittent or chronic.

- Acute onset of ear discharge with pain indicates either an *otitis externa* or *acute suppurative otitis media* with perforation of tympanic membrane. The discharge of pus (mucopus) indicates the involvement of mucous secreting glands in the middle ear cleft.
- Intermittent, profuse and offensive ear discharge suggests the tympanic membrane perforation with passage of infection from the nasopharynx into the eustachian tube (tubo-tympanic disease). Such an infection is unlikely to involve the meninges.
- Chronic offensive ear discharge indicates serious middle ear infection (chronic suppurative otitis media) which may travel to meninges (causing meningitis), brain (encephalitis) and may involve the cranial nerves leading to their paralysis. From the middle ear, infection may involve internal ear leading to vertigo and deafness.
- **Blood-stained discharge:** In chronically discharging ear, the onset of bleeding indicates malignant change within the middle ear.

Trauma (a blow) may cause perforation of the tympanic membrane resulting in pain, bleeding, ear discharge and hearing loss. More severe trauma may cause a dural tear and fracture of the tegmen tympani resulting in bleeding and subsequently CSF discharge from the external ear.

Deafness (Hearing Loss)

A loss of hearing can result from lesions in the external auditory canal, middle ear, inner ear or central auditory pathways. Lesions of external auditory canal, middle ear or tympanic membrane cause *conductive type* of deafness, while lesions of the inner ear or eight nerve (cochlear division) or central auditory pathways cause *perceptive* or *sensorineural type* of deafness. The two types of deafness are compared in the Table 7.1 and causes of deafness are listed in the Box 2.

Normally, a tone is heard louder by air conduction than by bone conduction. With a *conductive* deafness the bone conduction stimulus is perceived louder than the air conduction stimulus. With perceptive or sensorineural deafness, both air and bone conduction perceptions are reduced but the air conduction stimulus is perceived louder as in normal hearing.

Tinnitus

It is defined as the perception of a sound when there is no sound in the environment. It is associated with a conductive or sensorineural (perceptive) deafness. The causes of tinnitus can usually be determined by finding the cause of deafness. Most cases of tinnitus complain of a ringing, rushing or

Box 2

Causes of deafness

Conductive deafness	Sensorineural deafness
<ul style="list-style-type: none"> • Obstruction of external auditory canal <ul style="list-style-type: none"> – Wax, debris and foreign body – Otitis externa (swelling of lining of the canal) – Canal stenosis – Neoplasm • Middle ear or tympanic membrane <ul style="list-style-type: none"> – Chronic otitis media (perforation of tympanic membrane) – Disruption of ear ossicles by trauma or infection – Otosclerosis (fixation of the ossicles) – Neoplasm of the middle ear 	<ul style="list-style-type: none"> • Ageing • Noise-induced deafness (occupational, loudspeakers, personal stereo) • Viral infections, e.g. mumps, intrauterine rubella • Ototoxic drugs, e.g. aminoglycosides, gentamicin, frusemide, cytotoxic (cisplatin), betablockers, aspirin and quinine • Trauma (fracture of temporal bone) • Meningitis • Cochlear otosclerosis • Meniere's disease • Acoustic neuroma or other cerebellopontine angle tumour

TABLE 7.1 Comparison of two types of deafness

Type	Site of lesion	Feature		
		Conductive tests	Auditory acuity	Speech discrimination
Conductive deafness	External ear, middle ear or tympanic membrane	Air conduction is impaired (thresholds for air conduction elevated) but bone conduction is normal	Retained	Normal
Perceptive or sensorineural deafness	Inner ear, cochlear nerve, central neural pathway	Both air and bone conduction are impaired (thresholds for both conduction elevated)	Impaired or fluctuates	Impaired

hissing sound in the ear. Tinnitus must be distinguished from *autophony*—an abnormal perception of patient’s own voice as well as the breath sounds. Autophony is similar to the sensation experienced when holding a sea shell to the ear. The most common cause is patulous eustachian tube.

Vertigo

Vertigo is defined as a hallucinations of self or environment movements, most commonly perceived as a feeling of rotation, usually due to a disturbance in the vestibular system. The vestibular system is one of three sensory systems involved in spatial orientation and maintenance of posture. The other two systems are visual system and sensory (somatosensory) system.

The vertigo may be *central* (lesions of brain stem or cerebellum) or *peripheral* (labyrinthine in origin). Acute peripheral lesions cause vertigo of sudden onset, severe in nature, usually unilateral lasting for a few *seconds or a few days and is often recurrent* and associated with tinnitus. On the other hand, a central vertigo is chronic and mild in nature, often bidirectional and associated with other central abnormalities (Table 7.2). The common causes of vertigo are given in the Box 3.

The most common cause of pathological vertigo is vestibular dysfunction. The vertigo is frequently accompanied by nausea, jerky nystagmus, postural instability and gait ataxia. Since vertigo increases with rapid head movements, patients tend to hold their head still.

Labyrinthine dysfunction causes severe rotational or linear vertigo. When rotational, the hallucinations of movement whether of self or environment, is directed away from the side of the lesion. The fast phase of nystagmus is also directed away from the side of the lesion, and tendency to fall is towards the side of the lesion.

Positional vertigo is precipitated by recumbent head position either to the right or to the left. It may be benign paroxysmal positional vertigo following head trauma or idiopathic, or may be central positional vertigo due to lesions in and around the fourth ventricle. The differences between the two are summarised in the Table 7.3.

Box 3

Common causes of vertigo

<i>Peripheral</i>	<i>Central</i>
<ul style="list-style-type: none"> • Hereditary • Acquired <ul style="list-style-type: none"> - Physiological <ul style="list-style-type: none"> - Motion sickness - Height vertigo - Space vertigo - Pathological <ul style="list-style-type: none"> - Infection, e.g. Labyrinthitis, meningitis, vesibular neuronitis - Benign paroxysmal positional vertigo - Meniere’s disease - Posttraumatic - Drug induced, (e.g. diuretic, aminoglycosides, cytotoxic) - Cerebellopontine angle tumour (e.g. acoustic neuroma, meningioma) - Vascular compression of vestibular nerve - Toxic, e.g. alcohol 	<ul style="list-style-type: none"> • Brain-stem ischaemia or infarction • TIAs (transient ischaemic attacks) • Multiple sclerosis • Vertebro-basilar insufficiency • Acute cerebellitis • Posterior fossa (cerebellum) tumour • Migraine (basilar artery) • Epilepsy (temporal lobe focus)

TABLE 7.2 Differentiation between central and peripheral vertigo

Feature	Peripheral vertigo	Central vertigo
Postural instability (imbalance)	Mild	Severe
Direction of nystagmus	Undirectional, fast phase opposite to lesion	Bidirectional or unidirectional
Pure horizontal nystagmus	Uncommon	Common
Vertical nystagmus	Never occur	May be present
Visual fixation	Attenuates or inhibits nystagmus and vertigo	No change
Direction of spin	Towards fast phase of nystagmus	Variable
Direction of fall	Towards slow phase	Variable
Nausea and vomiting	Severe	Mild to moderate
Tinnitus and/or deafness	Common	Rare
Onset of symptoms	Acute	Usually slow
Duration of symptoms	Finite (minutes, days, weeks)	Chronic
Neurological	Rare	Common

TABLE 7.3 Distinguishing features between benign paroxysmal positional vertigo (BPPV) and central positional vertigo

Features	BPPV	Central
Occurrence	Common	Uncommon
Latency (time between attaining head position and onset of symptoms)	3–4 sec.	None, immediate vertigo and nystagmus
Fatiguability (disappearance of symptoms with maintenance of offending position)	Yes	No
Habituation (lessening of symptoms with repeated trials)	Yes	No
Intensity of vertigo	Severe	Mild to moderate
Reproducibility (reproduction of symptoms during each examination)	Variable	Good

Psychogenic vertigo, usually a concomitant of agoraphobia (fear of large open spaces or crowd) should be suspected in patients distressed by their symptoms so much that they remain confined to the house (house bound status). It differs from the *organic vertigo* in which despite discomfort patients attempt to work. Organic vertigo is invariably accompanied by the nystagmus but psychogenic is not.

The time course and duration of vertigo also help in the diagnosis.

- Recurrent episodes of brief positional vertigo (lasting less than a minute) indicate benign positional or post-traumatic vertigo. It can also be psychogenic.
- Recurrent spontaneous vertigo lasting for minutes or hours indicate Meniere's disease, vertebrobasilar insufficiency, migraine or autoimmune disorder.
- Vertigo, progressive hearing loss and tinnitus suggest Meniere's disease.
- Spontaneous prolonged attacks of vertigo lasting for a day or longer suggest labyrinthitis, multiple sclerosis, brain stem infarction.

Clinical Work-up of a Patient with Vertigo

It includes:

- Careful history
- Checking of BP in standing position for orthostatic hypotension. Duplication of symptoms during orthostatic hypotension indicates cerebral ischaemia.
- *Valsalva manoeuvre* exacerbates vertigo in patients with cardiovascular disease.
- The simplest provocative test for vestibular dysfunction is *rapid rotation and abrupt cessation of movement in a swivel chair*. This manoeuvre always induces vertigo, differentiating it from false vertigo (e.g. dizziness).

- In patients with perilymphatic fistula coughing or sneezing will induce vertigo. In patients with a fistula in the lateral semicircular canal, vertigo occurs in response to loud sounds (*Tullio's phenomenon*).
- Hyperventilation causes dizziness (false vertigo), blunting of consciousness and light headedness in many anxious patients, is most important cause of dizziness and not of true vertigo. Forced hyperventilation for 1 minute is employed for this purpose.

EXAMINATION OF THE EAR (Fig. 7.1)

- **The auricle:** *Inspect each auricle and surrounding tissues for deformities, lump(s) or skin lesions.* Causes of lump(s) on or around the ear are given in the Box 4. The deformities of pinna are:
 - **Anotia**—absence of pinna
 - **Microtia**—incomplete development of pinna
 - **Macrotia**—a large pinna (bat-ear deformity)
 - **Melotia**—Displacement of pinna from its normal position.

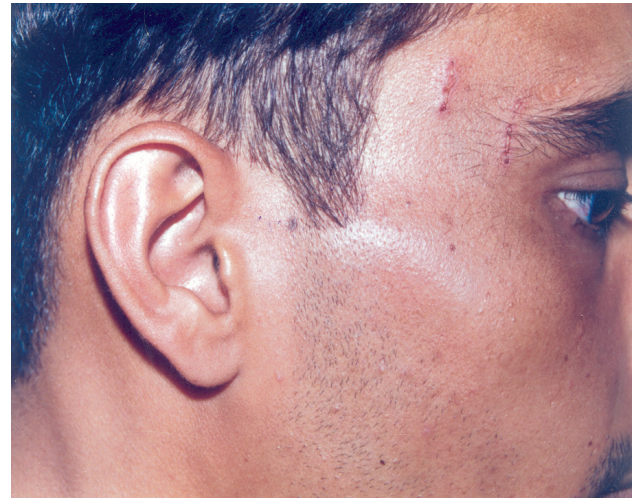

FIGURE 7.1 Inspection of the ear

Box 4

Lumps on or around the ear

- Chondrodermatitis helices (painful tender nodule/papule on helix)
- Epidermoid cyst
- Squamous cell or basal cell carcinoma
- Gouty tophus/tophi
- Rheumatoid nodules
- Keloid
- Lepromatous leprosy
- Preauricular lymphadenopathy

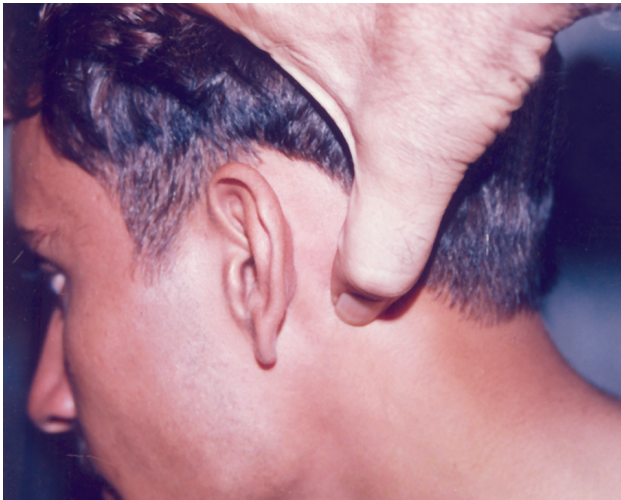

FIGURE 7.2 Elicitation of mastoid tenderness

If pain, discharge or inflammation is present, move the auricle up and down, press the tragus, and press firmly just behind the ear (Fig. 7.2).

- Movement of the auricle and tragus (*the tug test*) is painful in acute *otitis externa* but not in *otitis media*; while tenderness behind the ear may be present in *otitis media*.

Now look at the postauricular region for signs of a scar (previous surgery) or a nodule.

- **Ear canal and drum:** *Examine the external auditory canal either with an auriroscope (otoscope) or with a head mirror using reflected light.*

The steps of examination are as follows:

- Select a speculum of appropriate length with the largest diameter that will comfortably fit into the ear canal.
- Gently retract the pinna upwards and backwards in adults and only backwards in children to straighten the external auditory meatus and ear canal, thereby facilitating the insertion of the speculum.
- Hold the auriroscope like a pin between thumb and index finger of right hand resting gently against the patient's head.
- Inspect the external meatus and ear canal for wax, keratin debris, pus or mucopus and any foreign body. Note any redness of the skin. Foreign bodies in the ear canal may be found in children and in patients with psychological illness. In *otitis externa*, the skin of ear canal is red, swollen and tender.

The lumen of ear canal may be congenitally narrow or may be narrowed due to recurrent bouts of *otitis externa*. Bony osteoma may rarely occlude the meatus.

- *Now inspect the ear drum noting its colour and contour.* If the vision of the ear drum is obscured by wax, remove this by using a wax hook or by syringing with warm water. The water accumulates behind the wax and forces it out of the meatus. Syringing is contraindicated if there is history of pain and discharge from the ear since perforated membrane will be further damaged or infected.

Red bulging drum is seen in acute purulent *otitis media*.

- *Identify the ear drum and handle of the malleus noting its position and inspect the short process of malleus.*

- An unusually short prominent process and a prominent handle that looks more horizontal suggest a retracted membrane.
- The retracted membrane is due to negative pressure in the middle ear. If negative pressure persists, this may lead to thinning and either hypermotility or hypomotility of membrane. Retraction into attic region of the middle ear and antrum may result in the formation of a *cholesteatoma*.

Mobility of the ear drum can be evaluated with a pneumatic otoscope.

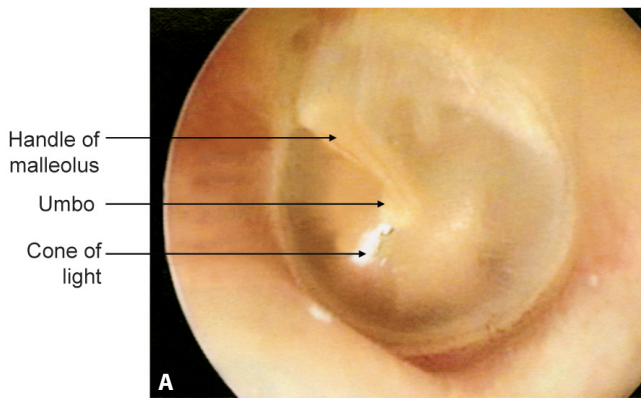
Note any perforation of the ear drum (Figs 7.3A to C).

Perforation of the pars tensa are classified as marginal or central. Marginal defects extend to the annulus whereas the central perforations have a rim of membrane between the defect and the annulus. If the perforation involves most of the tympanic membrane it is called *subtotal*.

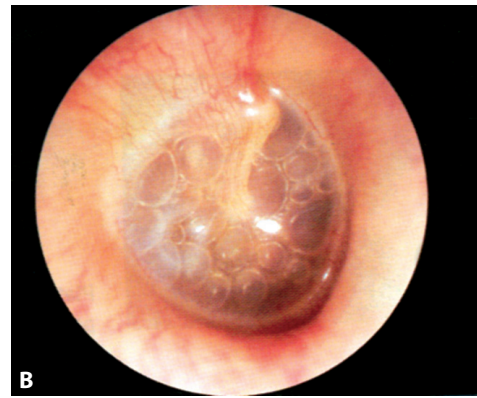
Assessment of Hearing

Auditory acuity: It is possible to make a preliminary assessment of the severity of hearing impairment by:

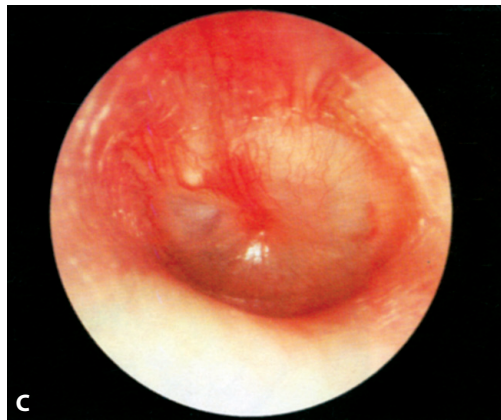- **Clinical history:** Ask the patient whether he/she can hear the doorbell or telephone (sound outputs around 60 dB) and ask if conversation in a quiet environment can be heard (normal levels about 40 dB). For example, if the patient prefers a loud voice in a quiet environment, this implies a hearing loss of 70-80 dB in the speech frequencies.
- **Clinical testing (Free-field voice testing):** It can be performed by asking the patient to repeat word spoken at varying intensities. This testing employs phonetically balanced words (e.g. baseball), number combinations (e.g. 9-4) or combinations of numbers and letters (e.g. 6-M-4). In such testing, one ear is tested at a time. The examiner stands to the side of the ear to be tested and occludes the other ear using tragal movement or a finger. The test starts with a whispered voice at 60 cm (2 feet) and proceeds with a whispered voice at 15 cm (6 inches).



A Normal tympanic membrane. Note that the tympanic membrane is gray, pale and translucent. The umbo and triangle shaped cone of light are normal



B Serous otitis media. Note that the tympanic membrane is retracted, fluid and air bubbles are seen behind membrane. The cone of light is absent



C Purulent otitis media. Note the bulging of the tympanic membrane with a red circumference of red. The umbo and cone of light are not demonstrable

FIGURES 7.3A to C Tympanic membrane (A) Normal; (B) and (C) Abnormal

If necessary (e.g. no response to conventional voice at 60 cm) increase the intensity of your voice to a medium whisper, a loud whisper, and then soft, medium and loud voice. Note the response to voice in each ear. When auditory acuity on the two sides is different, this gives an idea of impaired hearing on one side. However responses in such a type of testing is difficult to quantify for which audiometry is necessary.

- **Air and bone conduction:** Further information about hearing may be obtained at the bed side by using a vibrating tuning fork. A tuning fork of frequency 512 Hz or 1024 Hz may be employed for such a purpose because forks with lower frequency may lead to overestimating bone conduction and can also be felt as vibrations.

Tuning fork test is used to distinguish between conductive and perceptive (sensorineural) deafness.

In clinical practice two tests are used:

- **Rinne test (It compares air conduction and bone conduction):** It is performed by placing the base of a

vibrating tuning fork (set the tuning fork into vibrations by striking it between thumb and index finger or by tapping it on your knuckles and place it on the mastoid process, behind the ear at level with the canal (See Figure examination of VIII cranial nerve). When patient can no longer hear the sound, quickly place the fork close to the ear canal and ascertain whether the sound can be heard again. Remember, here the “U” of the fork should not be touched and should face forward, thus maximizing its sound for the patient. Note which conduction (air or bone) is better. In conductive deafness, sound is heard through the bone as long as or longer than it is through the air ($BC = AC$ or $BC > AC$). Reverse happens in sensorineural deafness.

- If air conduction is better than bone conduction ($AC > BC$), the Rinne test is said to be positive. In normal persons air conduction is better than bone conduction and this response is also found in perceptive deafness (sensorineural deafness), therefore, in both the conditions, Rinne test is positive.
- In conductive deafness, Rinne test is negative.
- Rinne's test is less specific because false negative and positive results are common.

- **Weber test (Test for lateralisation):** Place the base of a vibrating tuning fork firmly on the top of the patient's head or on the mid-forehead. Ask whether the patient hears it; on one side or both sides. Normally the sound is heard in the midline or equally in both ears (no lateralisation). If nothing is heard, try again, pressing the fork now more firmly on the head.

In unilateral conductive deafness, the sound is heard into (lateralised) the affected ear; while in unilateral sensorineural deafness sound is heard in the normal ear (lateralised to normal ear).

Audiometry

For quantitative assessment, audiometry is useful. It is also helpful in assessing the likely site of pathology in the auditory pathways.

Assessment of Vestibular Function

Balance and orientation of body in space depends on the sensory inputs from:

- Vestibular system
- The eyes
- Muscles, joints and skin receptors (somatosensory system).

This information is integrated and modulated in the brainstem and cerebellum. *Imbalance* or *unsteadiness* is defined as impaired ability to maintain postures in the intended orientation of the body in space. It generally manifests as difficulty in maintaining an upright posture while standing or walking; a severe imbalance may also affect the ability to maintain posture while seated. The imbalance results from disorder of spinocerebellar or vestibular sensory inputs. Vestibular input is composed of informations from the utricular maculae and the semicircular canals. The utricular maculae respond to changes in gravity and to linear acceleration whereas semicircular canals respond to the angular acceleration. This information is then integrated so as to allow compensatory eye movements through central pathways. These include vestibulo-ocular reflex and postural adjustments.

Abnormalities of Vestibular Function

Testing for Nystagmus

It is voluntary, conjugate ocular movements with rhythmical oscillations of the eye. The direction of quickest movement decides the side of nystagmus. Nystagmus is either induced or spontaneous, may be pendular (seen in refractory error/macular disease) or Jerky/phasic (seen in cerebellar and vestibular disease).

Generally, in vestibular disturbance, nystagmus is enhanced by movement of the eyes in the direction of fast

phase and diminished movement in the opposite direction. In the destructive vestibular lesion, the contralateral vestibular system dominates being intact and drives the eyes to the side of the lesion. This movement to the side of the lesion will be slow phase and opposite to the lesion will be the fast phase. The nystagmus will be maximal when looking in the direction opposite to lesion. **Causes** of vestibular nystagmus are:

- I. **Peripheral lesion (Labyrinth or vestibular nerve)**
 - Labyrinthitis Meniere's disease, acoustic neuroma, otitis media, head injury etc.
- II. **Central (Vestibular nuclei)**
 - Stroke, multiple sclerosis, tumours and alcoholism.

In vestibular destructive lesion, nystagmus will be on the opposite side to the lesion.

- **Visual fixation:** Vestibular nystagmus is enhanced without visual fixation, i.e. visual fixation attenuates or inhibits nystagmus and vertigo. Nystagmus should also be assessed by using Frenzel's glasses which have a 20 dioptre lens and, therefore, abolishes fixation.

Persistent positional nystagmus occurring with ocular fixation implies central lesion (brainstem disease and lesions in the region of fourth ventricle).

- The penular nystagmus on central gaze in which the oscillations are equal in speed and amplitude is seen in severe refractory error or a macular disease. The Jerky or phasic nystagmus (fast component on one side or both sides on horizontal movement to lateral gaze) is seen in lesions of cerebellum, vestibular apparatus or their connections in the brainstem.
- **Electronystagmography** is a graphic recording of eye movements which can be measured. As the eye acts as a dipole (the cornea as a positive and retina as a negative), eye movement results in an altered potential difference between the two electrodes on a moving paper strip. In this way, one can measure the velocity, amplitude and frequency of eye movements or nystagmus and permanent record can be obtained.
- **Dix and hallpike method:** Positional vertigo is precipitated by a recumbent head position either to the left or to the right. Positional vertigo is elicited by making the patient to sit on a couch and fix the eyes on the centre of the forehead of the examiner. The patient's head is turned 45 degrees to the left or right and then is rapidly lowered to 30° below the horizontal. The patient has to keep the eyes open during this procedure so that examiner can observe the nystagmus. The patient is instructed to report vertigo or dizziness during this procedure. The nystagmus is induced within the latent period of 2-5 seconds and disappears within few seconds.

This is most important sign of benign paroxysmal positional vertigo (BPPV). The nystagmus has fast component directed towards the lower most ear.

The repetition of the test will produce little abnormality (adaptation). Whatever may be the cause, the benign nature of this syndrome is characterised by disappearance of the symptoms with time in most of the cases. Alcohol abuse and psychotropics may induce transient positional vertigo.

- **Romberg's sign** (discussed in detail in CNS examination): This is a sign of proprioception. Patients with uncompensated unilateral labyrinthine lesion show instability to the side of the lesion with their eyes closed which becomes more marked when their eyes are open. Patients with posterior column disease (sensory ataxia), will sway or fall with the eyes closed but will stand normally with the eyes open. Patients with central lesions sway to both sides with eyes open or shut.
- **Caloric test:** This is most frequently employed test to assess the performance of vestibular end-organ. The test is performed by making the patient in recumbent position (lying down) and head is flexed at 30° in order to bring the lateral semicircular canal in vertical position. The patient is instructed to fix on a point in the central gaze. The ear canal is irrigated with water at 30°C and then at 44°C for 30–40 seconds respectively. The test is based on the principle that a thermal gradient across the temporal bone by cold and hot water produce convection current within endolymph and thus induces nystagmus. Normally, cold water induces nystagmus away from the ear being irrigated and the warm water induces nystagmus towards the ear being tested. Each ear is tested at both temperatures with a suitable gap between each test. The evoked nystagmus may be recorded and analysed using electronystagmography.

A diminished response to caloric test on one side indicates peripheral vestibular lesion (canal paresis), whereas central lesions (brainstem) produce diminished response with directional preponderance of the nystagmus to one direction than the other. Visual fixation abolishes the caloric induced nystagmus in peripheral lesions.

Gait abnormalities: These are discussed in examination of nervous system.

INVESTIGATIONS FOR A CASE WITH THE DISEASE OF EAR

Radiological Examination

- X-ray neck (lateral view) for any soft tissue swelling or a foreign body in postnasal space.
- Barium swallow for pharyngeal webs/pouch. Endoscopy is preferred investigation in such a case.

Audiometry

- **Pure tone audiometry:** In this test, the threshold for pure tone sounds introduced into each ear is measured for different frequencies. The threshold responses for air and bone conduction are recorded for evaluation of conductive or perceptive deafness. In perceptive (sensorineural) deafness, the air conduction thresholds and bone conduction thresholds are equal whereas in conductive deafness bone conduction thresholds exceed those for air. The difference between these thresholds called air-bone gap, measures the degree of conductive hearing loss.
- **Speech audiometry:** Speech audiogram is recorded for speech discrimination. In this test, patient is asked to repeat the words arranged in groups of 12 and delivered at different intensities to the test ear from a taped recording. A normal person can achieve a 100% discrimination at a sound intensity of 45–55 dB.

Patients with pure conductive deafness can achieve 100% discrimination like a normal one but only at much higher intensities; whereas patients with perceptive or sensorineural deafness are unable to achieve 100% discrimination at any intensity.

- **Impedance audiometry:** It is done to determine the state of tympanic membrane (thin or thick) and its mobility and compliance.

Evoked Response of Audiometry

In this test evoked responses in the brain are recorded as a waveform with 7 peaks following a sound applied to the ear. The averaged response displayed on an oscilloscope include a waveform with 7 peaks:

First peak: From cochlear hair cells

Second peak: Cochlear nucleus

Third peak: Superior olivary nucleus

Fourth and fifth peak: Inferior colliculus

Sixth peak: Medial geniculate body

Seventh peak: Auditory cortex

It is usual to measure the time taken for the impulse to travel from peaks 1 to 5 (I–V latency). The delay of the impulse as it travels along the nerve with increased I–V latency is seen in:

- Compressive lesions of acoustic (VIII cranial) nerve
- Brain-stem tumours
- Multiple sclerosis.

Electrocochleography

This is done to assess the presence of endolymphatic hydrops which occurs in Meniere's disease.

Caloric Testing

This has already been discussed.

THE NOSE AND PARANASAL SINUSES

Applied Anatomy and Physiology

About upper third of the nose is supported by bone and lower two thirds by cartilage. Air enters the nasal cavity by way of an opening called *anterior nares* on each side. The medial wall of nasal cavity is formed by nasal septum covered by a mucous membrane well supplied with blood.

Laterally, curving bony structures, the turbinates covered with a highly vascular membrane protrude into the nasal cavity. Below each turbinate, there is a groove or meatus, each named according to turbinate above it. The nasolacrimal duct opens into the inferior meatus while the most of the paranasal sinuses drain into the middle meatus. These opening are not usually visible.

The anterior nares (external opening of the nose) leads to a large widened area called *vestibule* which further leads through nasal passages to nasopharynx.

The paranasal sinuses are air-filled cavities within the bones of the skull. They are lined by mucous membrane. Only the frontal and maxillary sinuses are readily accessible to clinical examination.

The nasal cavities or mucosa performs the following functions:

- Cleansing of air
- Humidification of air
- Temperature control of inspired air
- Protection against entry of foreign material.

Symptoms of Nasal Disease

The principal symptoms of nasal disease are:

- Nasal obstruction (blockage of the nose)
- Sinus pain
- Nasal discharge (rhinorrhoea), running nose
- Sneezing
- Disturbance of smell (Read olfactory nerve in CNS examination)
- Symptoms due to involvement of adjoining structures, e.g. orbital pain, proptosis, diplopia, periorbital swelling and conjunctival chemosis may develop if the infection spreads to the orbit (orbital cellulitis) from the adjacent paranasal sinuses.

Nasal Obstruction

Blockage of the nasal passages is often associated with local discomfort, nasal discharge, and causes difficulty in breathing, may lead to mouth breathing and dryness of the mouth, persistent sore throat and snoring. Acute nasal obstruction may be secondary to trauma leading to subperichondrial haematoma or to deviated nasal septum. Vasomotor rhinitis or seasonal allergic rhinitis with swollen intranasal mucosa is the common cause of nasal blockage of varying severity. Long standing nasal obstruction suggests either persistent deflected nasal septum or a nasal polyp. Nasal obstruction may be unilateral or bilateral, and seasonal or perennial.

Nasal Discharge (Rhinorrhoea)

It is a common symptom of acute inflammation or infection of the nose, may be watery (nasal catarrh), mucoid, purulent or blood-stained. The discharge is often bilateral but may be unilateral. A unilateral blood-stained discharge with nasal obstruction indicates nasal or sinus malignancy.

Epistaxis means bleeding from the nose, can occur due to pathology in the nose or may be due to extra nasal causes. The causes of epistaxis are given in the Box 5.

A bilateral watery or mucoid (whitish) discharge suggests a vasomotor or allergic rhinitis. A purulent discharge may be secondary to a foreign body in the nose or sinus infection. Postnasal discharge is common in sinus infection.

Box 5

Causes of epistaxis

- **Nasal disease**
 - Rhinitis
 - Trauma
 - Tumours
 - Sinusitis
 - Diphtheria
- **Haematological disorders**
 - *Due to thrombocytopenia*
 - Leukaemia
 - Idiopathic thrombocytopenic purpura (ITP)
 - Aplastic anaemia
 - *Qualitative platelet defects*
 - von Willebrand's disease
 - Glanzmann's disease
 - *Coagulation disorders*
 - Haemophilia
 - Afibroginaemia/hypofibroginaemia
 - *Miscellaneous*
 - Hypersplenism
- **Systemic disorders**
 - *Infection*
 - Typhoid, malaria, measles
 - Hypertension
 - High altitude
 - Collagen diseases

Pain

Nasal pain is a uncommon symptom, occurs during acute severe infection of the nose or may be secondary to infiltration of the anterior maxillary nerves as they pass along the nasal floor and lateral nasal wall.

Persistent localised pain centered over a sinus suggests sinus infection. Tenderness can be elicited over the involved sinus. Pain of trigeminal neuralgia or migraine may be referred to nose.

Sneezing

It is a protective expulsive reflex initiated by irritation of nasal airways. It helps to clear the nasal passages off irritants. Excessive sneezing is associated with vasomotor rhinitis or allergic rhinitis due to release of histamine and other mediators.

EXAMINATION OF THE NOSE AND NASAL SINUSES

- **Inspect the anterior and inferior surfaces of the nose (Fig. 7.4A)**

Note any asymmetry or deformity of the nose.

- Saddle-shape deformity of the nose may follow destruction of the bony septum from syphilis and the cartilaginous septum following tuberculosis or leprosy or, following trauma, septal haematoma or septal abscess.
- The nasal septum may be depressed in other destructive conditions, e.g. midline granuloma or Wegener's granulomatosis.
- Deviation of the nasal septum is a common deformity visible (Fig. 7.4B).

Gentle pressure on the tip of the nose with your thumb will widen the nostrils (Fig. 7.4B), and now with the help of a

penlight or otoscope light, you can have a partial view of each nostril. If tip of the nose is tender, then manipulate the nose more gently and as little as possible.

- The tip of nose may be red in chronic alcoholics
- Tenderness of the nasal tip or alae suggests local infection such as furunculosis (Fig. 7.5), erysipelas, etc.
- Skin malignancy may involve the skin over the nose.

- **Test for the patency of nasal airway:** It may be assessed either by pressing on each *ala nasi* and occluding the front of each nostril in turn and asking the patient (child or adult) to sniff, or by holding a Lack's tongue depressor, beneath each nostril and comparing the surface misting of the depressor on the two sides.

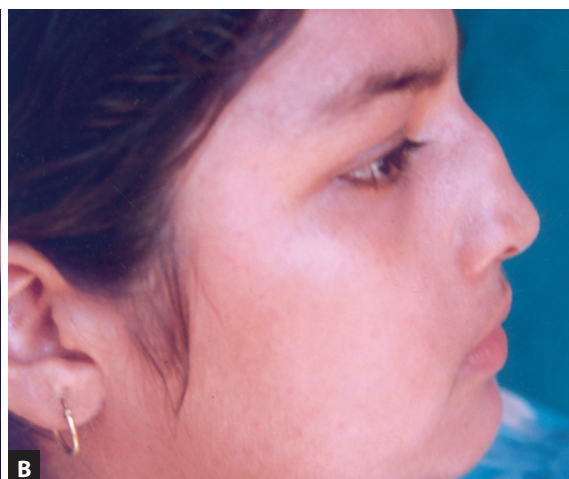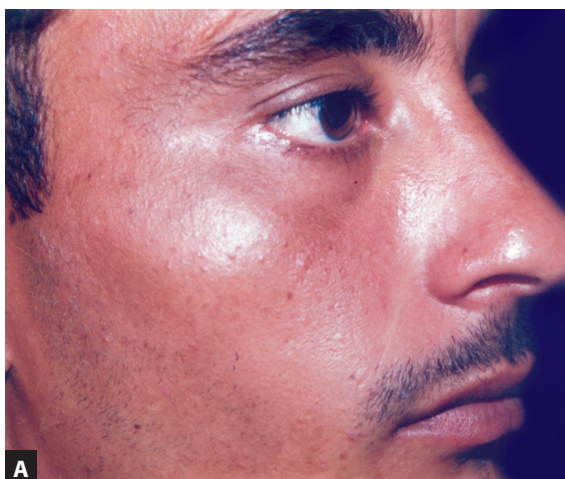Patency of the nasal passage is occluded by a variety of causes as listed under the symptom of nasal obstruction.

- **Inspect the inside of the nose** with the help of a biphong nasal speculum and reflected illumination from a head mirror.

Look at the nasal mucosa that covers the septum and turbinates. Note its colour, any swelling, bleeding or exudate. The atrophic rhinitis or Ozena is characterised by atrophied mucosa overlaid by foul-smelling dry crusts (Greek-Ozein, "Stench").

- In viral rhinitis, the mucosa is red and swollen; in allergic rhinitis, it may be pale, bluish or red.
- The most common disorder of vestibule (nasal cavity) is *furunculosis* and *vestibulitis*. In the later condition, the vestibule becomes crusted and excoriated as a result of infection usually secondary to repeated trauma from rubbing or cleaning the nose.

Look at the nasal septum for any area of granulation and for a septal perforation.



FIGURES 7.4A and B Inspection of the nose: (A) External appearance; (B) Visible deformity of the nasal septum

Klebsiella rhinoscleromatis causes *rhinosclerotoma*—a granulomatous disease of upper respiratory tract. *Black eschars* in diabetics may be seen in nasal cavity in mucormycosis.

- Fresh blood from the nose may be seen in epistaxis. Causes of septal perforation include trauma (nose pricking) surgery and intranasal use of cocaine or amphetamines or inhalation of industrial products, e.g. nickel and chrome.

Note any abnormalities on the lateral wall of the nasal cavity, e.g. hypertrophy of nasal turbinate or a nasal polyp or an ulcer or a mass.

- When the air space is large, the inferior turbinate may undergo hypertrophy. In allergic rhinitis, it is hypertrophied and red.

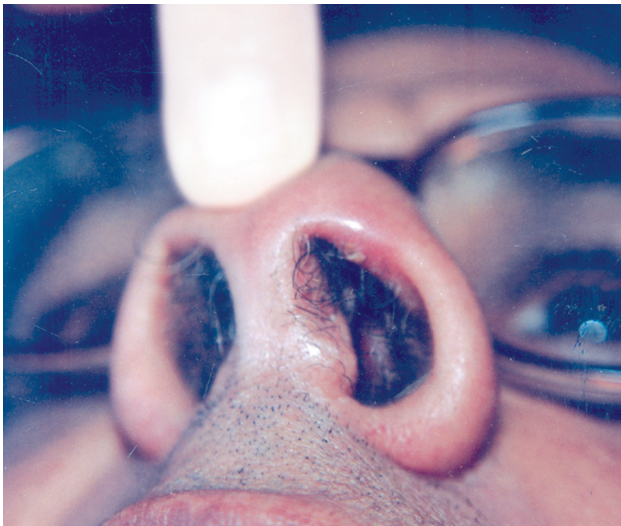

FIGURE 7.5 Furunculosis of the nose

- *Nasal polyps* are pale, semitranslucent masses that usually come from the middle meatus. The polyp is nontender, hence, can be differentiated from hypertrophied inferior turbinate that is tender.
- Ulcer may result from nasal use of cocaine or other drugs, e.g. pituitary preparations and blastomycosis (*Blastomyces dermatitidis*).

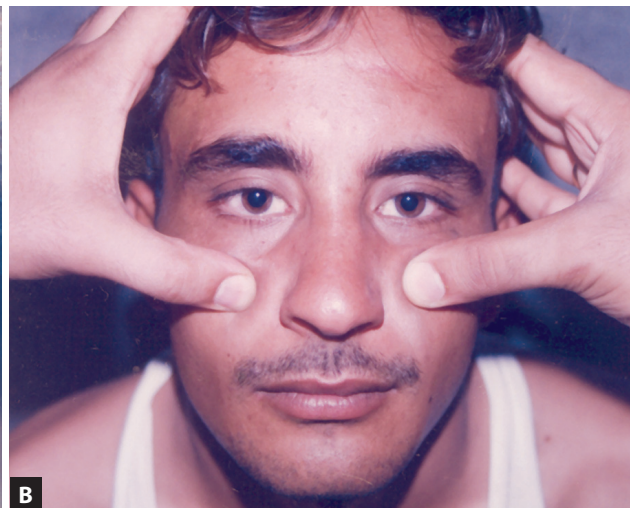- **Examine the postnasal space with the help of a small postnasal mirror:** The manoeuvre is best performed with the patient leaning forward, with mouth opened and the tongue firmly depressed with a tongue depressor. A postnasal mirror is warmed over the flame of a spirit lamp and passed into the mouth over the upper surface of the tongue until it lies in the space between the uvula, the tongue, and the faucial pillars.

Note the hypertrophy or any polyp in this space.

The site is common for:

- Carcinoma
- Antrochoanal polyp—a benign polyp arising from the nasal septum and protruding through the middle meatus.
- Hypertrophy of the posterior end of the inferior turbinate (*mulberry turbinate*)
- **Palpation for sinus tenderness:** Press up on the *frontal sinuses* from under the bony brows, avoiding pressure on the eyes (Fig. 7.6A). Then press up on the *maxillary sinuses* (Fig. 7.6 B).

Local tenderness together with pain, fever and rhinorrhoea suggest *acute sinusitis* involving the frontal or maxillary sinuses. Transillumination may be useful for diagnosis. Absence of glow on one or both sides on transillumination suggests either a thickened mucosa or secretion in the sinus involved.



FIGURES 7.6A and B Elicitation of sinus tenderness: (A) Frontal sinus tenderness; (B) Maxillary sinus tenderness

EXAMINATION OF THE THROAT

The throat comprises of the mouth, the oropharynx, the nasopharynx and the laryngopharynx. The oropharynx opens anteriorly into the mouth, is bounded above by the soft palate and below by the epiglottis. The second and third cervical vertebrae form its posterior wall, and the tonsils are situated in its lateral wall between anterior and posterior pillars of the fauces. The laryngopharynx opens into larynx and is bounded above by the epiglottis and below by the cricoid cartilage. The 3rd to 6th cervical vertebrae form its posterior wall.

Clinical Manifestations/Presentations

Patient may present with one or more of the followings:

- Sore throat
- Stridor
- Hoarseness of voice
- Dysphagia (difficulty in swallowing)
- A lump in the neck.

Sore Throat

The mouth being an open cavity and the tonsils being the policemen of the mouth, are likely to be involved in a variety of conditions but the sore throat is the most common presenting complaint. A sore throat due to tonsillitis may be associated with systemic manifestations such as fever and chills in children, may also be associated with dysphagia and formation of an abscess at different sites such as peritonsillar area (*quinsy or peritonsillar abscess*), or retropharyngeal space (*retropharyngeal abscess* presenting as a bulge on posterior pharyngeal wall) or parapharyngeal area (e.g. parapharyngeal abscess presenting as a swelling around the angle of the mandible). A *grey membrane* in the area of tonsils and covering it is formed in *diphtheria*.

The ulceration due to *herpes zoster*, *glandular fever* and *rubella* may be seen in this area as already discussed in examination of the mouth and pharynx. Ill-fitting dentures or trauma may also result in ulceration.

Note: A throat swab should always be taken for culture and sensitivity in a child/adult suffering from acute tonsillitis.

Stridor

Stridor (a noisy sound) occurs due to narrowing of the laryngeal airway, is common in children due to narrow diameter of larynx, results commonly due to acute infections within laryngopharynx and upper respiratory tract. Stridor is a common symptom of acute laryngitis, acute tracheobronchitis (croup) and acute epiglottitis. These acute infections of upper respiratory tract may be due to viruses

(*rhinovirus, influenza and parainfluenza virus, coxsackie virus, adenovirus or respiratory syncytial virus*) and bacterial (*Streptococcal, M. Catarrhalis*) infections. These infections are characterised by fever, pharyngeal pain, drooling of saliva from the corner of the mouth, stridor (airway obstruction), dyspnoea and dysphonia (hoarseness of voice).

Dysphonia (Hoarseness)

The hoarseness of voice results from involvement of vocal cord either locally or its paralysis due to damage to recurrent laryngeal nerve or the main trunk of the vagus. The hoarseness may be acute (irritation or inflammation of the cord) or chronic (nodule, papilloma or polyp of the cord). The causes of hoarseness are given in the Box 6.

Dysphagia

The diseases of the oropharynx that produce dysphagia are:

- Squamous cell carcinoma of distal oropharynx
- A pharyngeal pouch—a pulsion diverticulum consisting of mucosa interposed between two parts of inferior constrictor muscles. The pouch presents frequently on the left side.
- Involvement of hypopharynx by inflammation, webs (pharyngeal web-postcricoid web), stricture and tumours. The other causes of dysphagia are discussed under GI tract symptoms.

Box 6

Causes of dysphonia (hoarseness of voice)

- **Local**
 - Acute, e.g. smoke inhalation, exposure to dust
 - Chronic
 - Laryngeal oedema (chronic laryngitis)
 - A vocal cord nodule (hyperkeratosis)
 - Papilloma of the cord
 - Foreign body
 - A polyp
 - Carcinoma of larynx
- **Neurological**
 - Recurrent laryngeal nerve palsy
 - Thyroid disorders, e.g. neoplasia, thyroid surgery
 - Neoplasia of oesophagus
 - Neoplasia of apex of the lung (pancoast tumour)
 - Aortic aneurysm
 - A left atrial hypertrophy in mitral stenosis
 - Involvement of main trunk of vagus
 - Juglar bulb involvement
 - Infiltrative nasopharyngeal carcinoma/bronchial carcinoma
- **Systemic illness**
 - Myxoedema
 - Angioneurotic oedema.

Lump in the Neck

Certain deep cervical lymph nodes may get enlarged and palpable in the neck due to diseases of the pharynx. The most commonly enlarged lymph node is jugulo-digastric which becomes enlarged in upper respiratory tract infection especially tonsillitis and in neoplasm of the pharynx.

In patients with enlarged lymph nodes at the angle of the mandible, the nose and throat should be examined before a fine needle aspiration biopsy of the node is taken and sent for cytological examination.

Examination

- The anterior oropharynx should be examined with a head light or with a head mirror. First check the lips, teeth, and gums, floor of the mouth and opening of submandibular duct and the buccal mucosa (Read Chapter 6).
- The more distal portion of oropharynx and larynx can be inspected only with a laryngeal mirror or fibre-optic laryngoscope.
- Examination of the neck (It is discussed as separate in Chapter 8).

8

CHAPTER

The Neck

THE NECK

The structures to be examined in the neck are:

- The skin. It is to be examined as usual for any lesion
- The lymph nodes
- The salivary glands
- The trachea and the thyroid
- Neck movements (read Chapter 15 on Nervous System Examination)
- Carotid and subclavian pulsations—Read peripheral vascular system examination under CVS examination
- Jugular veins (Read CVS examination).

EXAMINATION OF NECK

The neck should be inspected and palpated. Physical abnormalities in the neck are common. Swellings in the neck are usually palpated best from behind.

Inspection

- Inspect the neck, noting its length (Figs 8.1A and B), symmetry and any mass(es) or swelling(s)

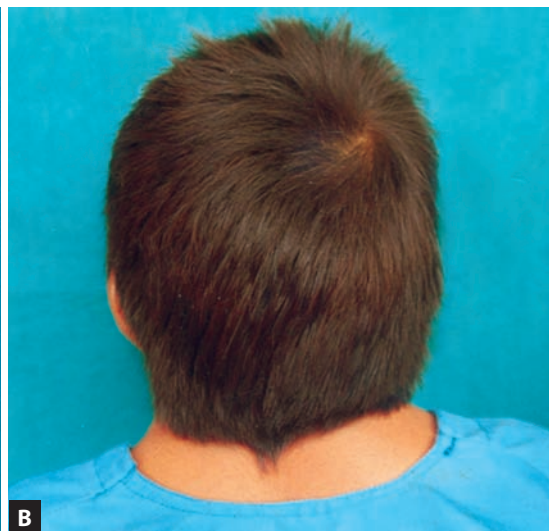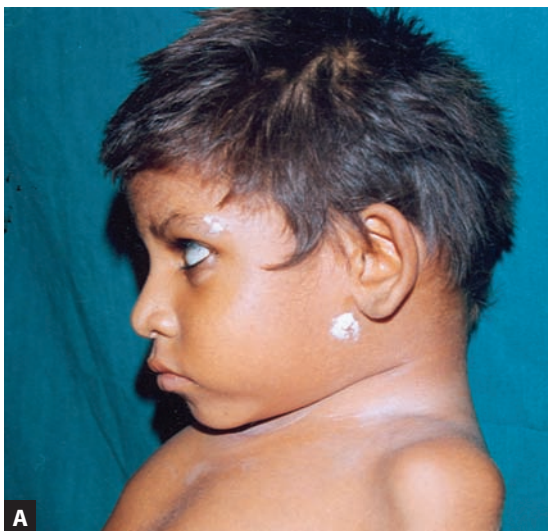- Look for enlargement of parotid or submandibular glands, and note any visible swelling or lymph node(s)
- Note any swelling in the region of the thyroid and any deviation of the trachea. If trachea is markedly deviated to one side, the sternomastoid muscle stands prominent on that side (Trail's sign)
- Note any visible pulsations in the neck
- Note any deviation of neck to any side (Fig. 8.2).

Palpation

Palpate the lymph nodes. The important groups of lymph nodes available for palpation are diagrammatically represented in Figure 8.3.

Sites of lymph nodes in the neck:

- **Preauricular**—In front of the ear
- **Posterior auricular**—Superficial to mastoid process behind the ear.
- **Occipital**—Below the occiput at the base of skull.
- **Tonsillar**—At the angle of the mandible.
- **Submandibular**—Midway between the angle and the tip of the mandible.



FIGURES 8.1A and B Abnormalities in the length of neck: (A) A child with short neck as a congenital deformity; (B) A young female with flat chest, short neck and low hair line suggestive of Turner's syndrome

- **Submental**—In the midline, a few centimeters behind the tip of the mandible.
- **Superficial cervical**—Superficial to the sternomastoid.
- **Posterior cervical**—Along the anterior edge of the trapezius.
- **Deep cervical lymph node chain**—Deep to the sternomastoid and often inaccessible to examination. Hook your thumb and fingers around either side of sternomastoid muscle to find them.
- **Supraclavicular**—Deep in the angle formed by the clavicle and sternomastoid.



FIGURE 8.2 Torticollis (Wry neck) due to drug toxicity. Note the tilting of neck to one side due to muscular spasm

Examination Sequence

In clinical practice, the lymph nodes are often examined in piece meal and regionally. Here they are described together to avoid confusion.

Some glands can only be assessed by investigations, for example—a chest X-ray may reveal hilar (Fig. 8.4) or paratracheal lymphadenopathy and CT scan abdomen may disclose para-aortic lymphadenopathy.

In healthy subjects palpable glands can usually be detected especially in the axilla and the groin. They are usually less than 1 cm in diameter. Lymph nodes > 2 cm in groin are considered abnormal and pathological and biopsy should be taken for diagnosis of the cause.

The examination involves not only the detection of lymphadenopathy but also an assessment of its significance and the various features described in the Box 1. The causes of lymphadenopathy are listed in the Table 8.1.

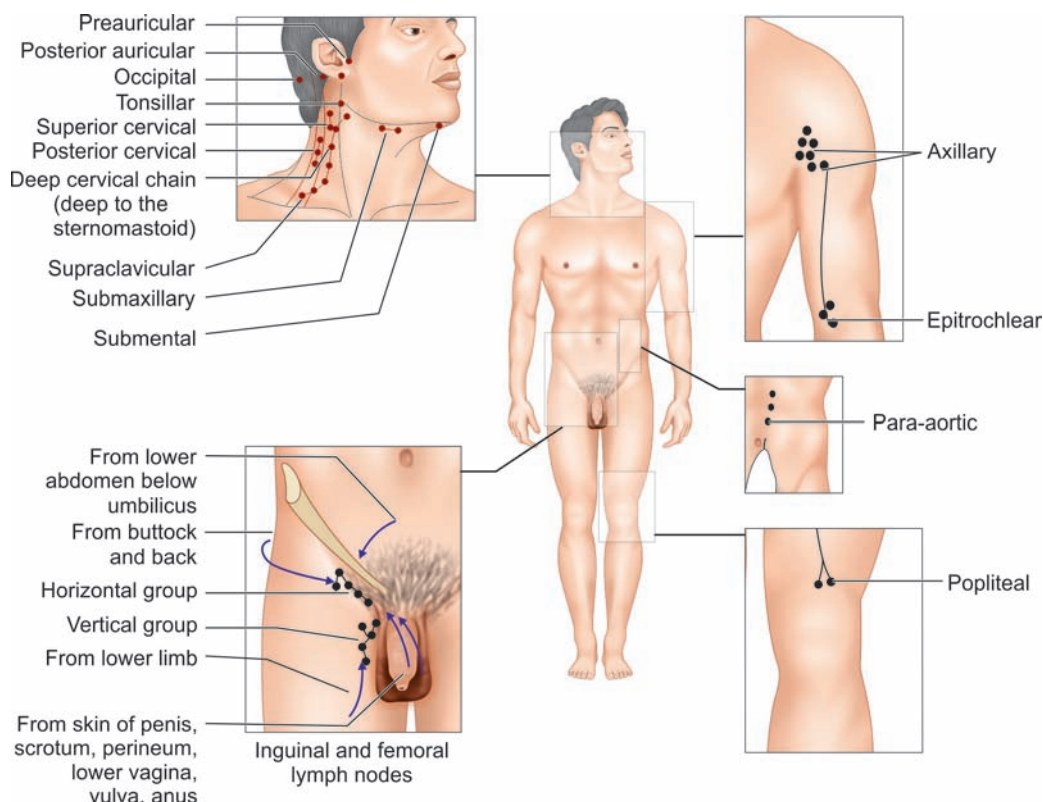


FIGURE 8.3 Lymphadenopathy—Distribution of palpable lymph nodes throughout the body. Scalene node—an important gland has not been shown in the figure

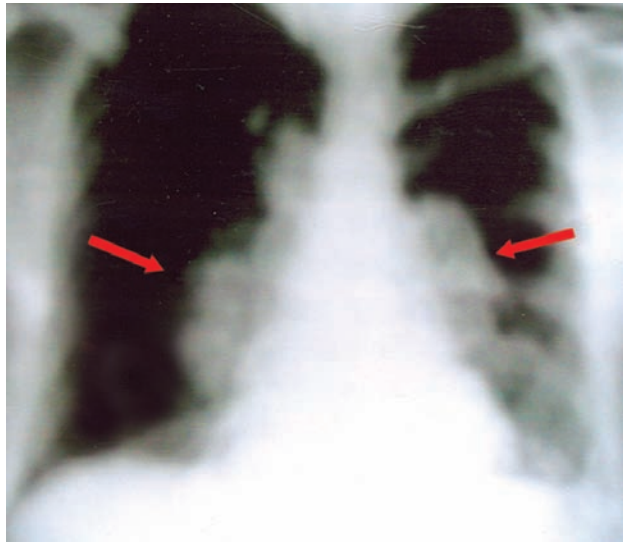


FIGURE 8.4 Chest X-ray (PA view) showing bilateral hilar lymphadenopathy due to sarcoidosis

Box 1

Examination of a lymph node mass or any swelling

- Inspect the mass carefully, noting change in colour or texture of the overlying skin.
- Elicit any tenderness by gentle palpation. Note any change in skin temperature by palpation with dorsum of the fingers.
- Define the size, shape of the mass.
- Keep the hand on the mass to determine whether it is pulsatile.
- Assess the consistency, surface, texture and margins of the mass.
- Try to pick up a fold of the skin between fingers and thumb over the swelling to determine fixation to the skin.
- To determine fixation to the deeper underlying structures, try to move the mass in different planes relative to the surrounding structures.
- Look for *fluctuation* by compressing the swelling or mass suddenly with one finger, using another finger to determine if a bulge is produced. Positive fluctuation means a bulge is created.
- Confirm the presence of fluctuation in two planes.
- Auscultate the mass for vascular bruits and other sounds to differentiate between lymph node mass and any other vascular mass.
- Elicit transillumination in the dark. Press the lighted end of the torch into one side of the swelling (mass). A cystic mass will light up if the fluid is translucent provided that the covering tissues are not too thick. A solid lymph node mass is negative to transillumination.

Method of palpation of different groups of lymph nodes

- **Preauricular (Fig. 8.5):** Using the pads of the 2nd and 3rd fingers, palpate the preauricular nodes with a gentle rotatory motion.

TABLE 8.1 Common causes of lymphadenopathy

- **Infective**
 - *Bacterial*
 - Streptococcal, brucellosis, tuberculosis, syphilis, leprosy, glanders, plague, diphtheria
 - *Viral*
 - Epstein-Barr, HIV, infectious mononucleosis
 - *Protozoal*
 - Toxoplasmosis, filariasis, leishmaniasis, trypanosomiasis
 - *Fungal*
 - Histoplasmosis, coccidioidomycosis
- **Neoplastic**
 - *Primary*
 - Leukaemias (acute and chronic lymphatic leukaemia), lymphomas (Hodgkin's and Non-Hodgkin's)
 - *Secondary*
 - Lung, breast, thyroid, stomach
- **Connective tissue disorders**
 - Rheumatoid arthritis
 - SLE
- **Others**
 - Lipid storage diseases (Gaucher's, Niemann-Pick), sarcoidosis, amyloidosis, histiocytosis X.
- **Drug-induced**
 - Phenytoin (pseudolymphoma), gold, hydralazine, allopurinol.

Note: Localised lymphadenopathy is common with acute and chronic (viral, bacterial) infections and metastases (secondaries).

- **Posterior auricular and occipital lymph nodes:** Palpate them in similar manner as described above by standing in front of the patient (Fig. 8.6).
- **Cervical lymph nodes:** Examine the cervical lymph nodes with the patient sitting. Palpate the anterior cervical chain, located anterior and superficial to the sternomastoid (Fig. 8.7). Standing in front of or behind the patient palpate the submental, submandibular glands (Fig. 8.8) and supraclavicular (Fig. 8.9) and scalene node (Fig. 8.10). For palpation of **Virchow's node**, instruct the patient to rotate the head to the right actively and concurrently perform the valsalva manoeuvre for 5–10 seconds. Palpate the left supraclavicular area for a nodule, if present, it is enlarged Virchow's node.
- **Axillary lymph nodes:** Sit or stand in front of the patient, supporting the arm on the side under examination. Palpate the right axilla with left hand and vice versa (Fig. 8.11). Insert the finger tips into the vault of the axilla and then draw them downwards while palpating the medial, anterior and posterior axillary wall in turn.
- **Epitrochlear lymph node:** Support the patient's left wrist with the right hand and grasp the partially flexed elbow with the left hand and use the thumb to feel for the epitrochlear lymph node (Fig. 8.12).



FIGURE 8.5 Preauricular node

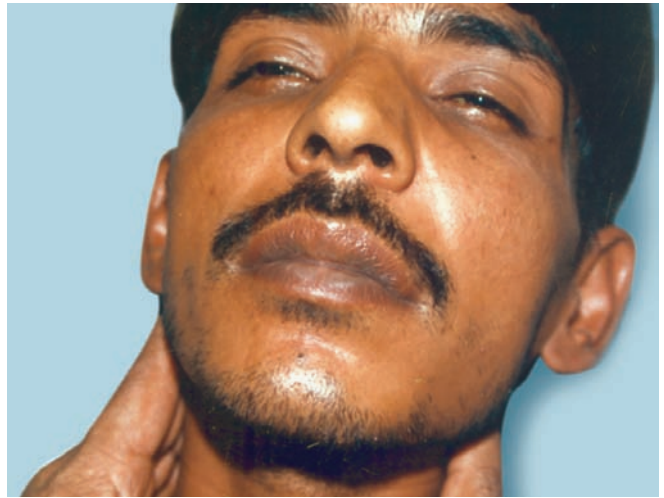

FIGURE 8.8 Palpation of submandibular lymph nodes

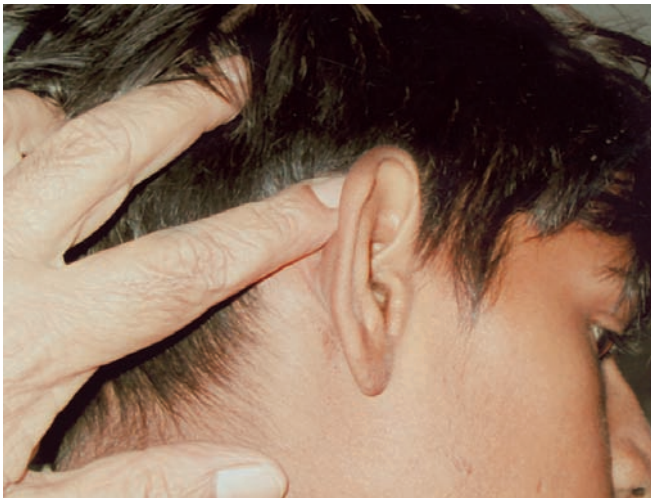

FIGURE 8.6 Posterior auricular lymph node

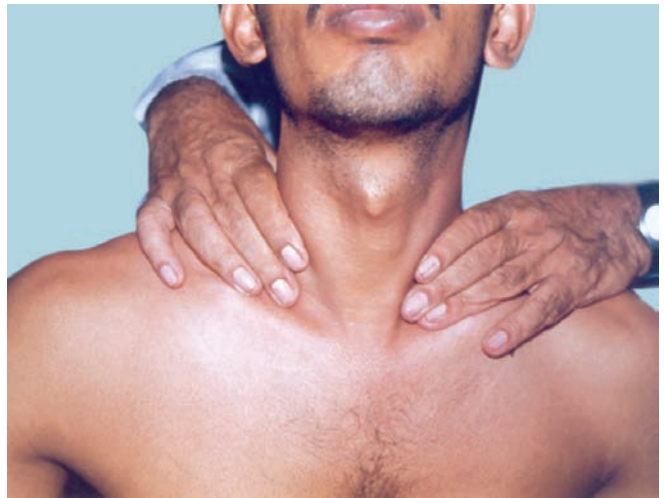

FIGURE 8.9 Palpation of supraclavicular lymph nodes

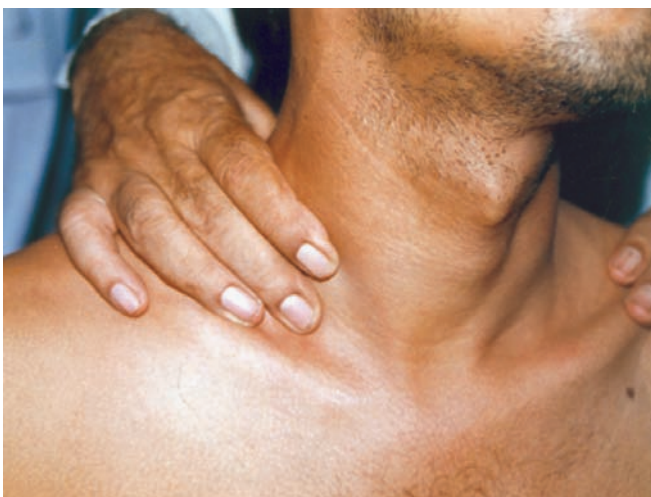

FIGURE 8.7 Palpation of cervical lymph nodes in anterior cervical chain

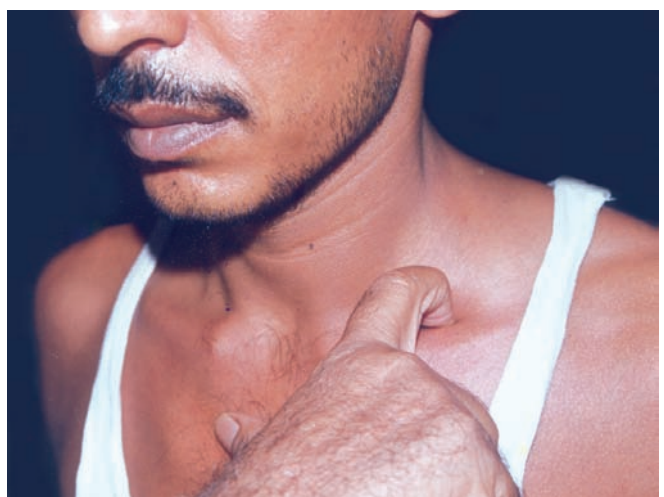

FIGURE 8.10 Palpation of scalene lymph node

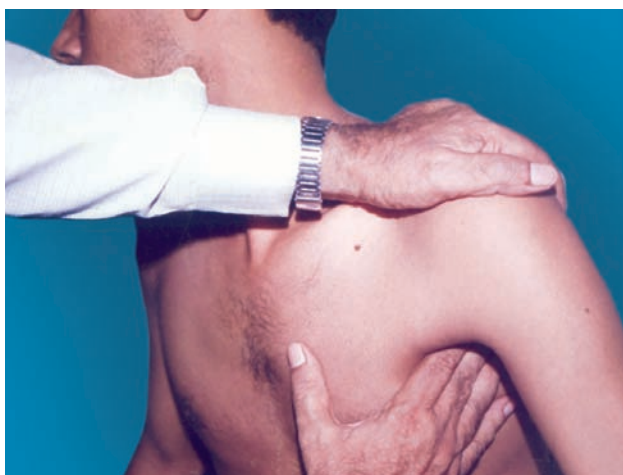

FIGURE 8.11 Palpation of axillary lymph nodes

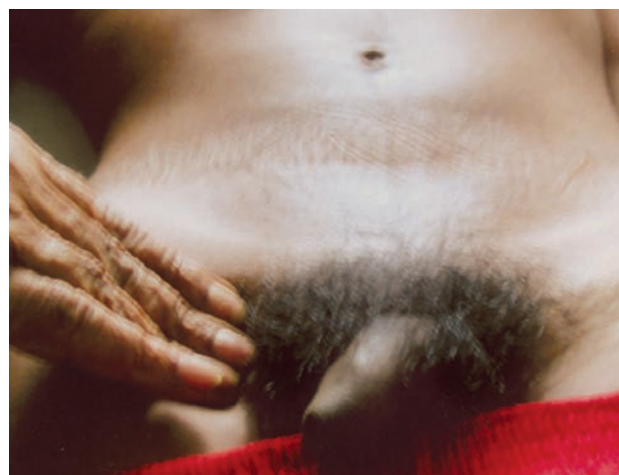


FIGURE 8.13 Palpation of inguinal lymph nodes



FIGURE 8.12 Palpation of epitrochlear lymph node

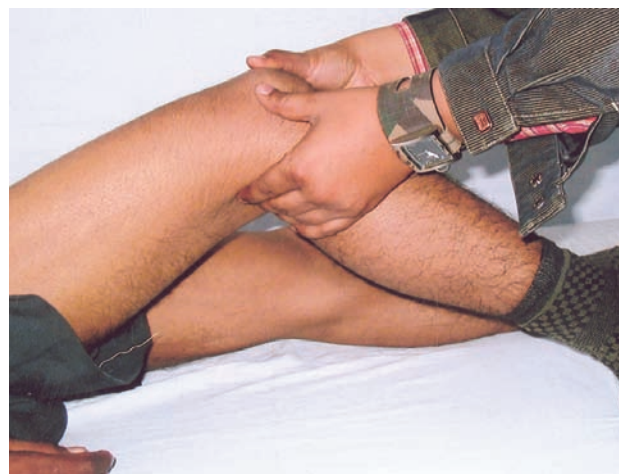

FIGURE 8.14 Palpation of popliteal lymph node

- **Inguinal lymph nodes (Fig. 8.13):** Let the patient lie down for examination of inguinal and popliteal lymph nodes. Palpate in turn over the horizontal chain, which lies just below the inguinal ligament, and then over the vertical chain along the saphenous vein.
- **Popliteal lymph nodes (Fig. 8.14):** Use both hands to examine the popliteal fossa with the knee flexed to less than 45°. Occasionally, a lymph node may be mistaken for a band of muscle or an artery. To differentiate between them, roll the mass or node in two directions; up and down; and side to side. The lymph node moves in both the directions; while muscle or an artery moves from side to side only.

If enlarged or tender lymph nodes found, proceed for:

- Re-examination of the region they drain.
- Careful assessment of lymph nodes elsewhere so that you can distinguish between regional and generalised lymphadenopathy.

- Look for the presence or absence of enlargement of the liver and spleen to determine whether the cause of lymphadenopathy is infection or primary malignancy.
- Look for any haematological manifestations, e.g. bruising, purpura or petechiae.

Differential Diagnosis of Lymphadenopathy Depending on its Characteristics

- **Consistency:** The consistency of the lymph nodes may provide the following informations.
 - In Hodgkin's disease, the lymph nodes are "rubbery" soft and may be matted.
 - In tuberculosis, the lymph nodes are firm and may be matted. There may be discharging sinus or involvement of skin (scrofuloderma Fig. 8.15).
 - In metastatic carcinoma, they feel hard or "craggy", calcified nodes feel stony hard.

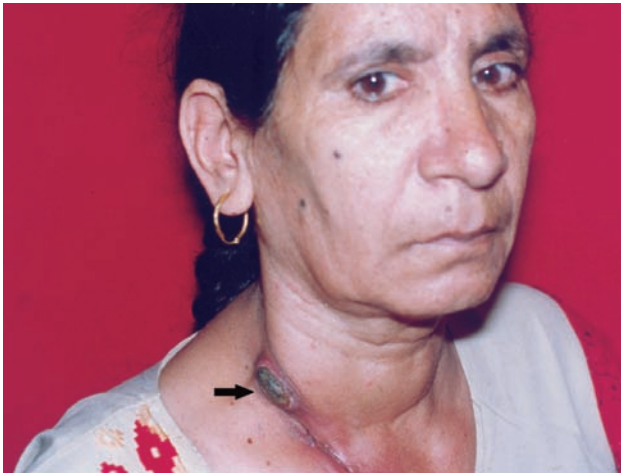

FIGURE 8.15 Tubercular lymph node enlargement with extension into the skin (scrofuloderma →)

- **Tenderness:** Tenderness of the nodes is a feature of acute infection. Therefore, if the lymph nodes are acutely tender, look for the evidence of infection in the region they drain, for example, the possibilities for tender cervical lymphadenopathy include: dental sepsis, tonsillitis and mastoiditis. In acute leukaemia, the lymph nodes are tender. Nodes in lymphoma and metastatic cancer are nontender. Mobile, tender and recent enlargement of nodes indicates reactive lymphadenitis.
- **Fixation:** The lymph nodes which are fixed to the underlying or overlying structures are usually malignant.
- **Site of involvement:**
 - Supraclavicular nodes enlargement occurs in tuberculosis, sarcoidosis, toxoplasmosis, metastatic cancer (*Virchow's gland*—enlarged left supraclavicular).
 - Axillary lymphadenopathy is common due to injuries, infection in the upper extremities.
 - Inguinal lymphadenopathy is due to:
 - Infection of lower limbs, plague
 - Trauma to lower extremities
 - Sexually transmitted diseases, e.g. syphilis, lymphogranuloma venereum, chancroid, genital herpes.
 - Lymphomas
 - Metastases from genital or rectal or lower limb malignancy.
 - Mediastinal (hilar) lymphadenopathy is due to:
 - Sarcoidosis (bilateral)
 - Tuberculosis (unilateral)
 - Primary lung cancer (in smoker)
 - Lymphomas

- Metastatic carcinoma
- Fungal infection
- **Intra-abdominal or retroperitoneal**
 - Lymphomas
 - Tuberculosis (tabes mesenterica)
 - Metastatic.

Work up of a Patient with Lymphadenopathy (see Box 2)

Symptoms of Lymph Nodes Enlargement

Lymph node enlargement may be asymptomatic and an incidental finding:

- **Acute lymphadenopathy** may present with fever, pains, sore throat, cough, indicate infection or inflammation as the cause. The cause may be found on ENT examination.
- **Superficial lymphadenopathy** presents with visible or palpable mass or masses in cervical, axillary or inguinal regions. This may present as a discharging sinus or sinuses in these regions.
- **Nonsuperficial presentations** (thoracic or abdominal) of lymphadenopathy are:
 - May be detected on routine chest X-ray or during work up of superficial lymphadenopathy.
 - May present as a lump or lumps in the abdomen (mesenteric or para-aortic).
 - May present with pressure symptoms:
 - Cough and wheezing from airway obstruction
 - Hoarseness and bovine cough from recurrent laryngeal nerve involvement
 - Dysphagia from oesophageal compression
 - Swelling of neck, face or arms due to compression of superior vena cava or subclavian vein
 - Paraplegia from spinal cord compression.

The sudden onset of lymphadenopathy with rapid progression indicates malignancy involving the lymph node. The three common conditions, e.g. lymphoid leukaemia, non-Hodgkin's and Hodgkin's lymphoma are compared in the Table 8.2.

Acute Lymphadenitis

- Enlarged, tender and fixed lymph nodes
- Overlying skin may be red, hot and indurated
- Primary infective focus may be found.

Chronic Lymphadenitis

Two common groups of diseases are compared in the Table 8.3.

TABLE 8.2 Lymphoid leukaemia and lymphomas

Features	Chronic lymphocytic leukaemia (CLL)	Non-Hodgkin's lymphoma	Hodgkin's lymphoma
<ul style="list-style-type: none"> Cellular derivation Age Site of the disease <ul style="list-style-type: none"> Localised Nodal spread Nodal characteristics <ul style="list-style-type: none"> Common groups involved Mediastinal (pressure symptoms e.g. superior vena cava, bronchus, spinal cord compression) Abdominal Extranodal involvement Bone marrow involvement B. symptoms (e.g. fever, weight loss, night sweats) Chromosomal defects Curability 	80% B, 20% T cells Older persons Uncommon Common, non-contiguous lymph nodes involved Discrete, painful, soft Cervical and axillary groups Common Uncommon Uncommon Always Common Common (translocations, deletion) Trisomy 12 common 40–60%	90% B; 10% T Young age Uncommon Discontiguous nodes involved Painless, discrete lymph nodes, soft to firm Involvement of Waldeyer's ring, Epitrochlear node Common Common Common Uncommon Common (translocations, deletion) 30–40%	Unresolved Older males Common Contiguous nodes involved, nontender Rubbery consistency Cervical group is involved early, but later all groups may be involved Common Uncommon Uncommon Uncommon Common Common (aneuploidy) 75–85%

Box 2

Lymphadenopathy clinical work-up

- Medical history:** It includes:
 - Patient's age, sex, occupation, exposure to pets, sexual behaviour and use of drugs
 - Ask for symptoms of cough, fever, sore throat, night sweats, fatigue, weight loss, pain in the nodes
- Physical examination**
 - Look for the site and size of lymph nodes, texture, presence or absence of tenderness, signs of inflammation over the node, skin lesions (petechiae, purpura) and splenomegaly
 - A thorough ear, nose and throat (ENT) checkup
- Laboratory tests**
 - Complete blood count for infections, leukaemia
 - Serological tests for EBV, CMV, HIV, SLE, toxoplasmosis, brucella
 - Chest X-ray for tuberculosis, sarcoidosis, lymphoma, lung cancer or metastatic cancer
- Biopsy** lymph node is indicated when:
 - Lymph node size is >2 cm in diameter
 - Recent onset, rapid progression
 - Location e.g. supraclavicular or cervical
 - Age >40 years
 - Hard, nontender lymph nodes
 - ENT cause is excluded.

TABLE 8.3 Chronic infective lymphadenitis (septic vs tubercular)

Septic	Tubercular
<ul style="list-style-type: none"> Lymph nodes are discrete, firm, slightly tender and non-matted Symptoms of sepsis may be present, e.g. high temperature, tachycardia, tachypnoea, sweats Abscess formation common, hence, fluctuation in the centre is common Rupture is uncommon 	<ul style="list-style-type: none"> Lymph nodes may or may not be tender, firm and often matted may be adherent to skin Fever, weight loss, night sweats and respiratory symptoms present Occasionally caseation may lead to cold abscess formation The lymph nodes may extend to involve skin and may burst forming tuberculous ulcer or sinus

**THE THYROID GLAND
(READ ALSO ENDOCRINE SYSTEM)**

Applied Anatomy and Physiology

The normal thyroid gland—an endocrine gland is made up of two lobes connected by an isthmus in the middle. It lies in the anterior part of the neck just below the thyroid cartilage. Occasionally, the gland may extend into superior

mediastinum or may be entirely retrosternal. Rarely, the gland may be located along the line occupied by the thyroglossal duct. When situated near the origin on the dorsum of tongue, it is called *lingual thyroid*. The normal thyroid is palpable in about 50% of females and 25% of male. It is divided into pseudolobules which are further divided into thyroid follicles lined by cuboidal epithelium and contain a protein called *thyroglobulin*. The thyroid hormones are synthesised and stored in thyroglobulin. Parafollicular or 'C' cells present around the follicles secrete another hormone—*calcitonin* which plays role in calcium homeostasis.

Thyroid hormones are:

- T₃ (Triiodothyronine)
- T₄ (Tetraiodothyronine)
- Calcitonin.

Steps of Hormogenesis

- *Uptake of iodine* by the thyroid in the form of iodide.
- *Formation of iodotyrosine* (MIT and DIT) from oxidation of iodides and its subsequent combination with tyrosyl group of thyroglobin to produce monoiodotyrosine (MIT) and di-iodotyrosine (DIT).
- *Coupling reaction* occurs between these iodotyrosines. One molecule of diiodotyrosine combines with one molecule of moniodotyrosine to form triiodothyronine (T₃) and two molecules combine to give tetraiodothyronine (T₄) respectively.
- *Release of T₃ and T₄* by proteolytic enzymes, i.e. proteases and peptidases.

The hormone T₄ is produced in the thyroid whereas T₃ is mainly produced in the peripheral tissue by conversion of T₄ to T₃ by deiodination. About 20% T₃ is also produced in the thyroid gland also.

Functions of Thyroid Hormones

- They control the general metabolism by regulating the rate of oxidation and production of energy. They maintain the basal metabolic rate (BMR) of the body.
- They promote growth of body tissues and development of mental functions during infancy and childhood.
- They sensitize the tissues to the action of endogenous catecholamines. Therefore, excess of these hormones lead to symptoms and signs of sympathetic overactivity especially seen in hyperthyroidism.

Clinical Presentations

Disorders of the thyroid gland present in three different ways:

1. Symptom and signs of excess of thyroid hormone (Thyrototoxicosis read Case Discussion in Bedside Medicine without Tears by Prof. SN Chugh).

2. Symptom and signs of thyroid hormone deficiency (Hypothyroidism read Case Discussion in Bedside Medicine without Tears by Prof. SN Chugh).
3. Enlargement of thyroid (goitre or thyromegaly).

Goitre: The enlargement of thyroid gland is called *goitre*. It may be physiological (puberty) or pathological. It may be diffuse (Grave's disease, Hashimoto's thyroiditis, iodine deficiency, congenital or dysmorphogenesis) or nodular (single nodular or multinodular toxic or nontoxic goitre).

By definition, the lateral lobes of the thyroid have a volume in excess of the terminal phalanges of the thumbs of the subject. Goitre is noticed as a cosmetic defect by the patient, friends or relatives but many subjects are unaware of it. The vast majority are asymptomatic. Tenderness is associated with various forms of thyroiditis (viral, autoimmune) and acute pain may occur following bleeding into a thyroid cyst. Dysphagia can occur if there is marked enlargement of thyroid; its presence may suggest malignant process. The causes of goitre are given in the Box 3.

Box 3

Causes of goitre

- **Physiological**
 - Puberty (Fig. 8.16A)
 - Pregnancy
- **Autoimmune**
 - Grave's disease (see Fig. 20.4)
 - Hashimoto's disease (Fig. 8.16B)
- **Thyroiditis**
 - Acute (de Quervain's thyroiditis)
 - Chronic fibrotic (Riedel's thyroiditis)
- **Iodine deficiency goitre**
- **Dysmorphogenesis**
- **Goitrogens (e.g. sulphonylureas)**
- **Multinodular goitre (Fig. 8.16C)**
- **Diffuse goitre (unknown cause)**
 - Colloid
 - Simple
- **Cysts and tumours**
 - Adenoma
 - Carcinoma
 - Lymphoma
- **Miscellaneous**
 - Sarcoidosis
 - Tuberculosis

There is a WHO grading of goitre:

Grade 0: Neither palpable nor visible goitre

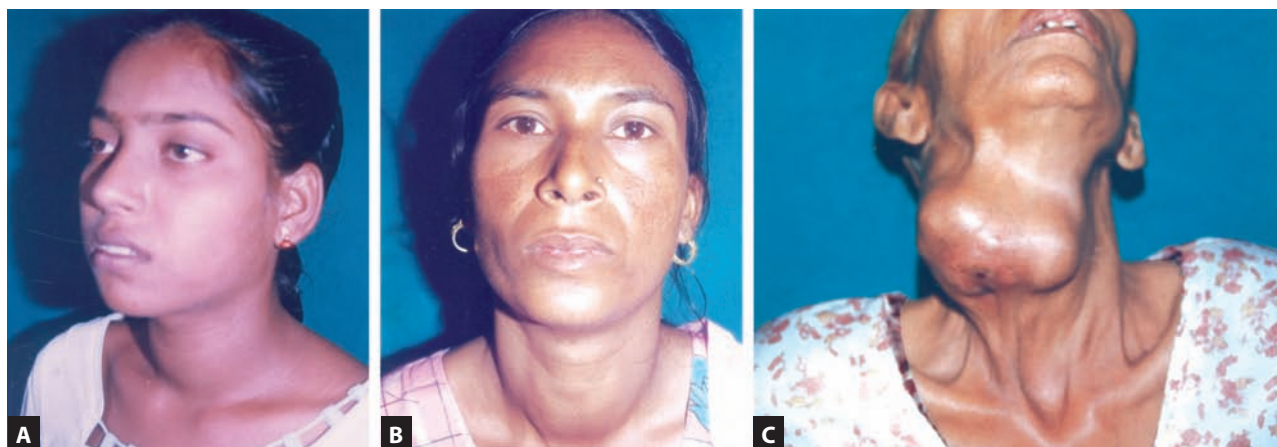Grade 1: Palpable goitre

A: Goitre detectable only on palpation.

B: Goitre palpable and visible with neck extended

Grade 2: Goitre visible with neck in normal position

Grade 3: Large goitre visible from a distance



FIGURES 8.16A to C (A) Puberty goitre (physiological). The thyroid is mildly enlarged in a 14 year girl; (B) Hashimoto's thyroiditis. The thyroid is diffusely enlarged; (C) Multinodular goitre. *Note:* The multiple thyroid nodules causing enlargement of the thyroid

Examination of Thyroid (Read Chapter 20)

It includes inspection, palpation and auscultation.

Abnormalities and their Interpretations

- **Shape:** The regular, smooth, symmetric enlargement of thyroid occurs in Grave's disease and thyroiditis; while irregular enlargement is seen in multinodular goitre.
- **Size:** Large goitres are usually autoimmune, multinodular or malignant in origin whereas small goitres are seen during puberty, pregnancy, thyroiditis and dysmorphogenesis.
- **Mobility:** Most goitres move upwards with swallowing except very large goitre occupying the all available space in the neck. However, absence of mobility indicates invasive thyroid carcinoma leading to fixation of thyroid gland.
- **Consistency:** The goitre is soft in Grave's disease, firm in Hashimoto's thyroiditis, and hard in malignancy.
- **Surface:** The surface is smooth in Grave's disease, thyroiditis (Hashimoto's or viral) and iodine deficiency or puberty goitre. It is nodular in multinodular goitre or malignancy of thyroid.
- **Tenderness:** Diffuse tenderness indicates infection or inflammation of thyroid (thyroiditis) while localised tenderness may occur following bleeding into a cyst.
- **Bruit and a thrill:** A palpable thrill or an audible vascular bruit may be associated with Grave's disease, indicates increased blood flow through the thyroid gland (murmur), must be distinguished from a murmur arising in the carotid artery or transmitted from the aorta and from a venous hum originating in the internal jugular vein.
- **Other features:** The goitre may or may not be associated with systemic features. All the systemic features may not

be present in a patient with toxic goitre. It is, therefore, necessary to look for other signs of hyperactivity or hypoactivity of the thyroid in a patient presenting with goitre. It is made clear that facial appearance and some systemic features are excellent guide to the diagnosis. The systemic features of both hyper and hypothyroidism are described in Case Discussion in Bedside Medicine without Tears by Prof. SN Chugh.

INVESTIGATIONS OF A PATIENT WITH THYROID DISEASE

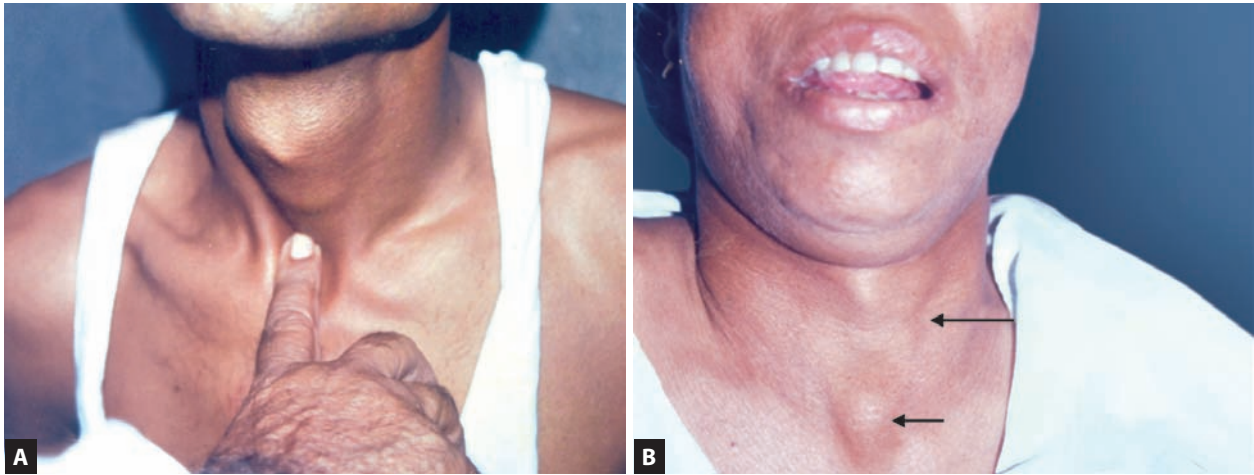
(Read Chapter 20—The Endocrine System)

THE TRACHEA

To orient yourself to the neck, identify the thyroid and cricoid cartilages and the trachea lies below them.

Steps of Examination

- Inspect the trachea from the front for any deviation from its usual midline position.
- Now *palpate it for any deviation* (Fig. 8.17A). For this, place your finger along one side of the trachea with neck slightly flexed to accommodate the finger. Note the space between it and the sternomastoid muscle. Compare it with the other side. Normally, the spaces should be symmetric and equal. A small space on one side indicates shift of trachea to that side.
- The prominence of sternomastoid muscle on one side may suggest tracheal shift (Trail's sign; Fig. 8.17B) which may be confirmed on palpation.



FIGURES 8.17A and B (A) Palpation of trachea; (B) Trail's sign. The sternomastoid muscle stands out prominently on the side of the trachea is shifted (left side in this case ←)

- Masses in the neck may shift the trachea to the opposite side.
- Tracheal deviation may also signify mediastinal shift—an important problem in the thorax. For separate mediastinal shift and concomitant shift of trachea—Read examination of respiratory system.

THE CAROTID ARTERIES AND JUGULAR VEINS

You will prefer to defer the examination of these vessels until the patient lies for cardiovascular examination (Read Cardiovascular Examination).

9

CHAPTER

The Breast and the Axillae

THE BREAST AND THE AXILLAE

Applied Anatomy and Physiology

The female breast lies against the anterior chest wall extending from the 2nd rib down to the 6th rib, and from the sternum across the midaxillary line. Its surface is rectangular rather than circular. The breast overlies the pectoralis major.

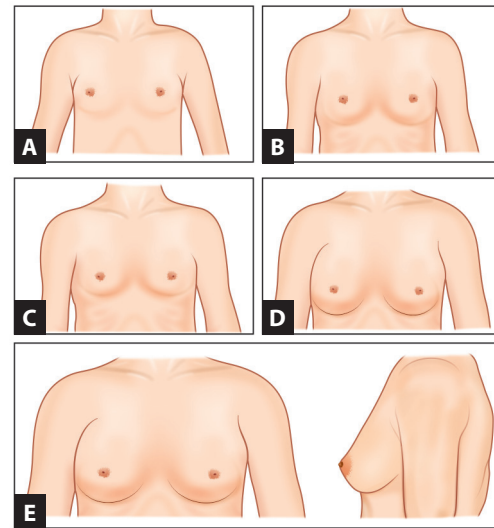
The stages in the development of the female breast are diagrammatically illustrated (Figs 9.1A to E). The most common site for nipple development is the 4th intercostal space on the midclavicular line, but accessory breast/nipple tissue may develop anywhere down the nipple line (*axilla to groin*).

To describe the clinical findings, the breast is often divided into the nipple, the areola and four quadrants based on the horizontal and vertical lines crossing at the nipple (Fig. 9.2). The nipple consists of erectile tissue covered with pigmented skin, which also covers the axilla. The opening of the lactiferous ducts may be seen near the apex of the nipple.

Alternatively, instead of quadrants, finding can be localised as the time on the face of a clock (e.g. 6 o'clock) and the distance in centimeters from the nipple.

The size and shape of the female breast vary widely and are influenced by hereditary factors, sexual maturity and the phase of menstrual cycle, parity, pregnancy and lactation and the general state of nutrition. The amount of fat and stroma surrounding the glandular tissue largely determines the size of the breast except during lactation (e.g. breast enlargement is glandular).

The breast is hormonally sensitive tissue, responsible to the changes of monthly cycling and ageing. In premenopausal women, its consistency may vary considerably in response to fluctuations in oestrogen and progesterone levels during menstrual cycle and in pregnancy. Swelling and tenderness due to fluid retention and prominence of the glandular elements of the breast are more common in premenstrual phase. With advancing age, there is a reduction in the



FIGURES 9.1A to E Stages of development of female breast (diag). (A) Pre-pubertal breast; (B) Breast budding (initial stage); (C) Enlargement (primary mount); (D) Secondary mount formed by areola; (E) Contour of breast and areola

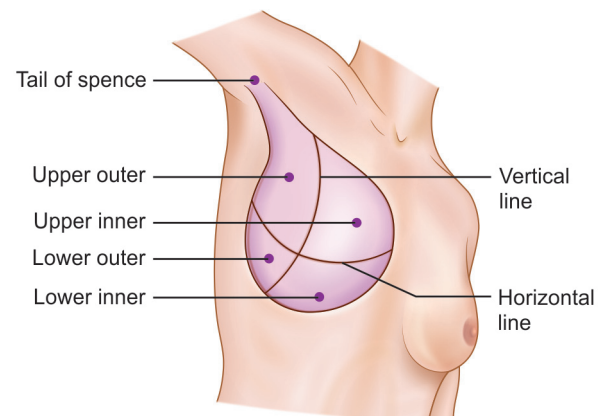


FIGURE 9.2 Various quadrants of the breast

amount of glandular tissue with a corresponding increase in the amount of fat. Therefore, the breasts become softer in consistency and more pendulous. The breasts of lactating mothers are swollen and engorged with milk, hence, are best examined after breast-feeding or milk expression.

Each male breast consists chiefly of a small nipple and areola. It overlies a thin disc of undeveloped breast tissue that may not be distinguishable clinically from the surrounding tissues. A firm button of the breast tissue 2 cm or more in diameter has been described in one-thirds of adult men. The limits of normal adult male breast have not yet been established.

Clinical Presentations

The common symptoms of the breast disease are:

- Breast lump or mass
- Breast pain or discomfort
- Nipple discharge
- Nipple retraction
- Skin changes
- Galactorrhoea (milk ejection)
- Men may present with gynaecomastia.

Breast Lump

The common causes of breast lump include: carcinoma of breast, fibrocystic change, fibroadenomas, cysts and breast abscesses. The most common cause of breast lump varies with age (Table 9.1).

Carcinoma of breast

This is one of the most common malignancy in the women and its incidence increases with age. It is customary to regard

TABLE 9.1 Palpable masses of the breast

Age (in years)	Lesion	Characteristics
15–25	Fibroadenoma	Usually fine, soft to firm in consistency, round, mobile and tender. It is well demarcated from surrounding tissue, retraction sign absent
25–50	Cysts	Usually single, soft, round, mobile, often tender, retraction sign absent
	Fibrocystic changes	Nodular, rope like, bilateral changes (lumps), firm
	Carcinoma	Irregular in outline, stellate, firm to hard, not clearly demarcated from surrounding tissue, may be fixed to skin and underlying tissue. Retraction sign may be present
Over 50	Carcinoma unless proved otherwise	—As above
Pregnancy/lactation	Lactating adenomas, cysts, mastitis (abscess) and carcinoma	—As above

any mass in the breast as potentially malignant until proven otherwise on histopathology. Cancer of the male breast is uncommon and there is strong genetic factor.

Characteristically carcinoma are solid masses with an irregular outline, often painless but firm or hard in consistency and can not be delineated clearly from the surrounding tissue. The tumour may be localised within breast tissue or extend into the overlying structures such as skin or, pectoral fascia, pectoral muscle or metastasise to regional lymph nodes through lymphatics or spread to distant organs through systemic circulation. When a tumour is fixed to the chest wall, it is immobile when the pectoral muscle is relaxed. When tethered to the pectoral fascia, but not muscle, it will be mobile when pectoral muscle is relaxed and adherent when the muscle is tensed. The current TNM (tumour, nodes, metastases) classification of breast tumour is given in the Table 9.2.

Risk Factors for Breast Cancer

- **Age:** Advanced age is a risk factor. More than three-fourths breast cancer cases occur in women 50 years or

TABLE 9.2 TNM classification of breast cancers

Tumour (T)	
T _x	Can not be assessed
T ₀	No evidence of primary tumour
T _{is}	Carcinoma <i>in situ</i> , intraductal carcinoma, lobular carcinoma <i>in situ</i> , Paget's disease of the nipple
T ₁	Tumour <2 cm in greatest dimension <ul style="list-style-type: none"> a. < 0.5 cm b. > 0.5 to 1 cm c. > 1 cm to 2 m
T ₂	Tumour >2 cm to <5 cm in greatest dimension
T ₃	Tumour > 5 cm in greatest dimension
T ₄	Direct extension into the chest wall or skin irrespective of the size <ul style="list-style-type: none"> a. Extension to chest wall b. Oedema including <i>peau d'orange</i> or ulceration of overlying skin c. 4a + 4b d. Inflammatory carcinoma
Nodes (N)	
N _x	Regional lymph nodes can not be assessed
N ₀	No lymph node metastasis
N ₁	Metastases with movable ipsilateral axillary nodes
N ₂	Metastases to ipsilateral axillary nodes fixed to one another or to other structures
N ₃	Metastases to ipsilateral internal mammary nodes
Metastases (M)	
M _x	Presence of distant metastases can not be assessed
M ₀	No distant metastases
M ₁	Distant metastases including supraclavicular nodes
Note: This classification is also applicable for classification of other primary malignancies.	

older; more than half in women older than 65. For women between ages of 35 and 55 years without major risk factors, the chance of developing breast cancer is approximately 2–5%.

- **Family history:** Risk from familial breast cancer falls into two patterns: (i) family history of breast cancer and (ii) genetic predisposition. First degree relatives, namely a mother or sister with breast cancer establish a “positive family history”. The first degree relatives with breast cancer who are premenopausal with bilateral disease confers the highest risk. Inherited disease (genetic predisposition) in women carrying mutations in the breast cancer susceptibility genes BRCA1 and BRCA2 accounts only 5–10% of breast cancer. However, these genes confer a 50% risk of the disease in women under 50 which increases further to 80% by age of 65.
- **Menstrual history and pregnancy:** Early menarche, delayed menopause, and first live birth after 35 or no pregnancy, all raise the risk of breast cancer two to three folds.
- **Associated conditions/diseases:**
 - **Breast conditions and diseases:** Benign breast disease with biopsy findings of atypical hyperplasia or lobular carcinoma *in situ* carry significantly increased risk.

Fibrocystic disease of the breasts

This is another cause of breast lump in the young women (35–50 years), is characterised by irregular nodularity of the breast especially in the upper outer quadrant. Usually the tissue is rubbery in consistency and varies in size with the hormonal cycle, being the largest premenstrually. These changes are bilateral.

Fibroadenomas

These are the abnormalities of normal development and involution due to outgrowth of elements derived from terminal ductal lobules. These present as small, round, smooth mobile discrete rubbery lumps in young women (<35 years of age). The distinction between a juvenile fibroadenoma and phylloides tumour (giant fibroadenoma) is made on distinct histopathological grounds and both are regarded as distinct pathological entities.

Breast cysts

These are a feature of the involuting breast which is still subject to hormonal stimulation. They are the most common cause of lump in women between the ages of 35–50 (Table 9.1). Their clinical picture depends on the intracystic tension. They present as smooth lumps, which may be soft and fluctuant when intracystic tension (pressure) is low, become hard and painful when the cyst is under high tension or pressure.

Cysts may occur in multiple clusters. Occasionally, a cyst may represent a malignant change.

Any cyst in which aspirate is blood-stained or there is residual mass following aspiration or which recurs after several aspiration should be excised and subjected to histopathology to exclude malignancy.

Breast abscess

The two distinct types of breast abscess are:

1. **Lactational abscess(es).** These occur in women who are breast-feeding or lactating and are usually peripheral in distribution.
2. **Nonlactational abscess(es).** These occurs as an extension of periductal mastitis and have a classical distribution at the edge of the nipple, often associated with nipple inversion. They are common among young women smokers. Occasionally, a nonlactating abscess may rupture spontaneously forming a fistula to the exterior at areolocutaneous border.

Skin Changes

- **Skin dimpling** may be just a benign simple skin dimpling due to retraction of the skin or may be as a result of indrawing of the skin due to infiltration of the dermis by tumour. The differentiating feature between the two is mobility of the skin. In simple dimpling, the skin remains mobile over the tumour but in malignancy, the tumour is fixed to the skin and is immobile. Similarly if the tumour is tethered to the chest wall (pectoral fascia), the tumour appears solid with the chest wall when pectoral muscle is contracted but it is possible to move it when the muscle is relaxed. In contrast, the tumours which infiltrate the chest wall become fixed when the pectoral muscle is both relaxed and contracted.
- **Lymphoedema of the breast** is another skin change produced by obstruction of the intramammary lymphatics by the tumours. The skin is attached to the hair follicles but is swollen in between, giving the appearance of the skin of an orange (*peau d'orange*—Fig. 9.3).

Eczematous changes of the nipple may be a part of a generalised skin disorder. Localised eczematous changes around the nipple raise the possibility of Paget's disease of the nipple. There may be fulgurating growth of the breast producing disfigurement (Fig. 9.4).

Nipple Changes

- **Nipple inversion:** The nipple retraction may be benign (due to shortening of the nipple ducts due to inflammation and fibrosis) in which the nipple retraction is symmetrical

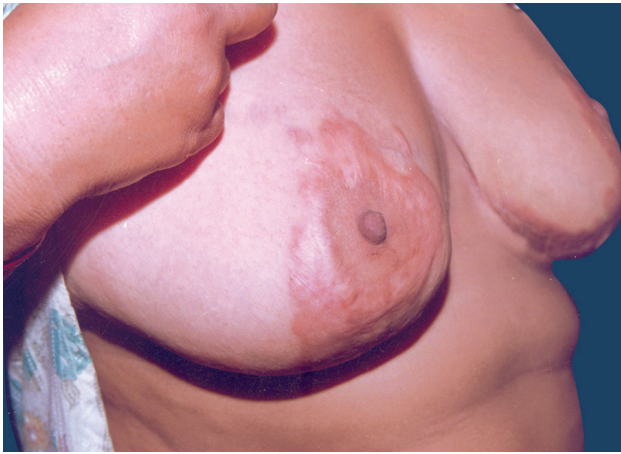

FIGURE 9.3 Peau d'orange of the breast. The intramammary lymphatic obstruction by the tumour results in swollen (lymphoedema) breast and typical appearance like skin of an orange (Peau d'orange)

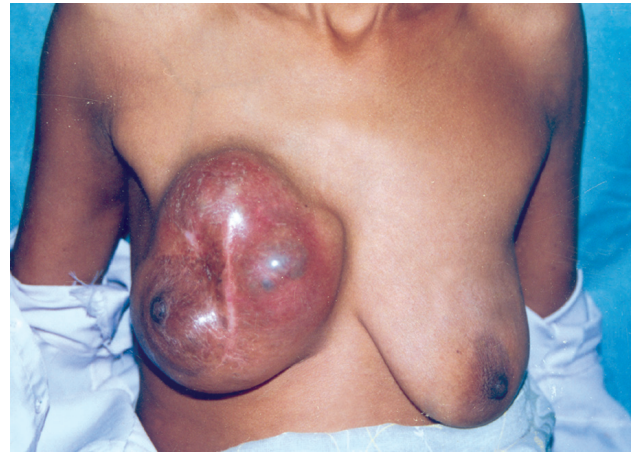

FIGURE 9.5 Fulgurating growth causing disfigurement of breast (right) and displacement and retraction of the nipple

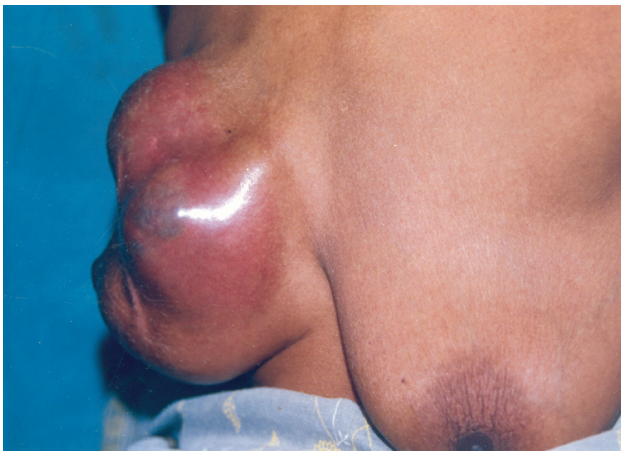

FIGURE 9.4 Disfigurement of breast due to a fulgurating growth

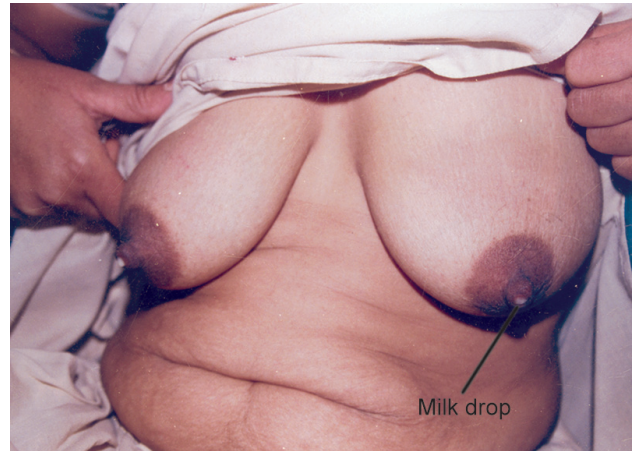

FIGURE 9.6 Galactorrhoea. Note the drops of milk coming out of the breasts in a nonlactating mother due to hyperprolactinaemia. A white drop of milk attached to the left breast is visible

and slit-like. Nipple retraction due to malignant disease is asymmetrical and disfiguring pulling the nipple away from the central position (Fig. 9.5).

- **Nipple discharge:** A small amount of clear fluid from the breast on massage is normal. Persistent single duct discharge or blood-stained (macroscopic or microscopic) is abnormal should be investigated. A milky discharge from multiple ducts in non-lactating mother is called *galactorrhoea* (Fig. 9.6). The causes of galactorrhoea are given in the Box 1. It is commonly associated with hyperprolactinaemia.

Abnormalities of the Breasts in Males

Gynaecomastia (Figs 9.7 and 9.8)

Gynaecomastia refers to enlargement of breast in the males, occurs in about 50% of pubertal boys probably due to elevated

oestradiol levels. Growth of the breast in men, as in women, is mediated by oestrogen and results from disturbances of the normal ratio of the active androgen to oestrogen. Growth of

Box 1

Common causes of galactorrhoea

- Prolactin secreting pituitary tumour
- Hypothalamic-pituitary stalk lesions
- Drug-induced (phenothiazines, dopamine antagonists and dopamine depleting agents)
- Ectopic production of prolactin, e.g. hydatidiform moles, choriocarcinoma, lung cancer, hypernephroma
- Primary hypothyroidism
- Sucking reflex and breast trauma
- Renal failure
- Idiopathic.

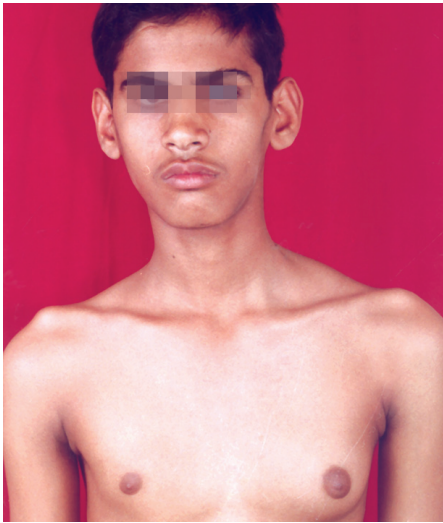

FIGURE 9.7 Gynaecomastia in an adolescent male, more on the left than the right. It appears physiological (to be investigated)

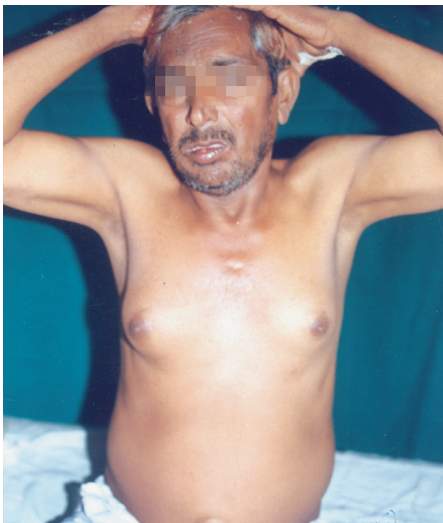

FIGURE 9.8 Gynaecomastia in a patient with cirrhotic portal hypertension. Note the ascited with inverted umbilicus

the breast ensues in men when the normal ratio decreases as a result of diminished testosterone production or action, enhanced oestrogen formation, or both processes occurring simultaneously.

Enlargement of the male breast can be a normal physiological phenomenon at certain times of life (puberty) or the result of several pathological states (Table 9.3).

Examination of Breasts

The clinical breast examination is an important part of women's health case; it enhances detection of breast cancers that may otherwise go undetected and also provides an opportunity to demonstrate techniques for self-examination to the patient. Clinician is advised to adopt a more standard

TABLE 9.3 Common causes of gynaecomastia

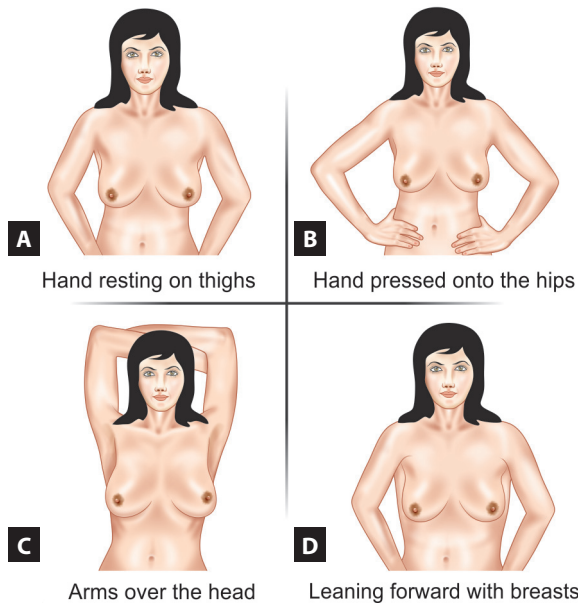
- **Physiological gynaecomastia**
 - Newborn
 - Adolescents (Fig. 9.7)
 - Ageing
- **Pathological gynaecomastia**
 - *Deficient testosterone production or action*
 - Klinefelter's syndrome, testicular feminisation and Reifenstein's syndrome
 - Orchitis (viral)
 - Trauma
 - Defects of testosterone synthesis
 - Congenital anorchia
 - *Increased production of oestrogen*
 - Testicular tumours
 - Carcinoma of lung or other tumours producing hCG
 - Adrenal disease
 - Cirrhosis of the liver
 - Thyrotoxicosis
 - Malnutrition
 - *Drug-induced*
 - Oestrogen used for treatment of prostate cancer
 - Diuretics, e.g. spironolactone
 - Acid suppressants, e.g. cimetidine, omeprazole
 - Antimitotic drugs, e.g. busulfan, cisplatin
 - Antihypertensive, e.g. methyldopa, calcium channel blockers, angiotensin-converting enzyme inhibitors
 - *Idiopathic*

approach especially for palpation and to use a systemic and thorough search pattern, varying palpation pressure and a circular motion with the finger pads.

Examination includes **inspection** and **palpation** of breasts in different positions as described below:

Steps

- As you begin the examination of the breasts, be aware that women and girls may feel apprehensive. Reassure the patient and adopt a gentle and courteous approach.
- Before you begin, explain to the patient that you are about to examine her breasts. Explain the purpose for the examination also.
- An adequate inspection requires full exposure of the chest. Ask the patient to sit upright on a well-illuminated chair/couch, undressed to the waist and with the hands resting on the thighs, so that the pectoral muscles are relaxed (Fig. 9.9A).
- Sit facing the patient and *look for the size, symmetry, contour, local swelling and changes in the skin. Inspect the nipples also for size, shape, direction in which they point (Fig. 9.10), any rash or ulceration or any discharge.*



FIGURES 9.9A to D Examination of the breast in different positions

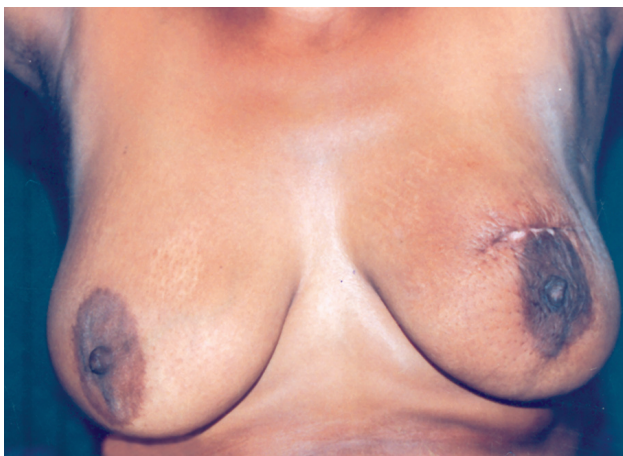

FIGURE 9.10 Elevation of nipple in underlying carcinoma breast. The scar of biopsy is visible above the left nipple. Left nipple is elevated and facing medially, while right nipple is directed laterally

- Redness of a breast may be due to mastitis (local inflammation or inflammatory carcinoma).
- Thickening and puckering of the skin may suggest infiltrating carcinoma. Flattening of the normally convex breast, skin dimpling, peau d'orange and blood-stained, nipple discharge suggest breast (s) carcinoma.
- Asymmetry of direction in which nipple points suggests an underlying cancer. Rash or ulceration of nipple occurs in Paget's disease of the nipple.

- Repeat the inspection with the patient's *hands pressed firmly on hips* (Fig 9.9B) thereby contracting the pectoral muscles, then with arms raised above head (Fig. 9.9C) to stretch the pectoral muscles and the skin over the breasts, and finally leaning forward so that the breasts become

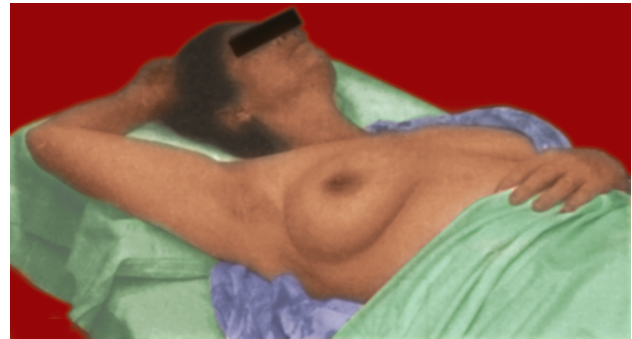

FIGURE 9.11 Positioning for palpation of the right breast

pendulous (Fig 9.9D). Such actions expose the whole breast and exacerbate skin dimpling.

- Ask the patient to lie supine with the head supported on one pillow and with the hand on the side to be examined under the head (Fig. 9.11). Breast tissue gets flattened in this position.
- With the hand held flat to the skin, palpate the rectangular area extending from the clavicle to the bra line, and from the midsternal line to the posterior axillary line and well into the axilla for the tail of the breast. Use the fingerpads of middle 3 fingers (2nd, 3rd, 4th) keeping them slightly flexed and compressing the breast tissue gently against the chest wall.
- To localise the lesion, consider the breast as a face of a clock and carefully examine each hour of the clock from outside towards the nipple, not forgetting the tissue directly under the nipple. Compare the texture of one breast with that of other.
- Define the following characteristics of a mass, if found:
 - *Location*—by quadrant or clock, with centimeters from the nipple
 - *Size*—in centimeters
 - *Shape*—round, or cystic, disc like, or irregular in outline
 - *Consistency*—soft, firm, hard
 - *Limits/extent*—well circumscribed or not
 - *Tenderness*—present or absent
 - *Mobility*—in relation to the skin, the pectoral fascia and the chest wall. Gently move the breast near the mass and watch for dimpling. Next try to move the mass itself by holding it between thumb and forefingers while the patient relaxes her arm and then while she presses her hands against her hip to contract the pectoral muscle.

Hard, irregular, poorly circumscribed nodule or nodules, fixed to the skin or underlying tissues strongly suggest malignancy (Fig. 9.12)

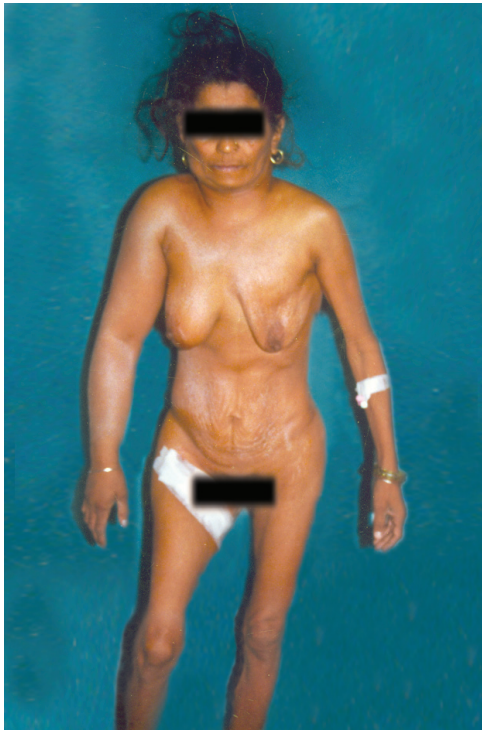

FIGURE 9.12 Carcinoma of right breast producing an irregular hard poorly defined nodule in the breast. There is an associated lymphoedema of right upper and lower limbs due to metastases in the axillary and inguinal lymph nodes (biopsy has been taken)

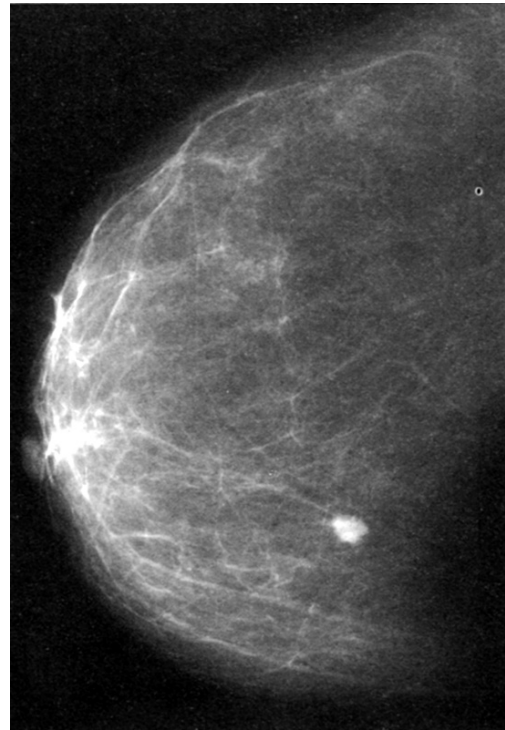


FIGURE 9.14 Mammographic image of a breast cancer

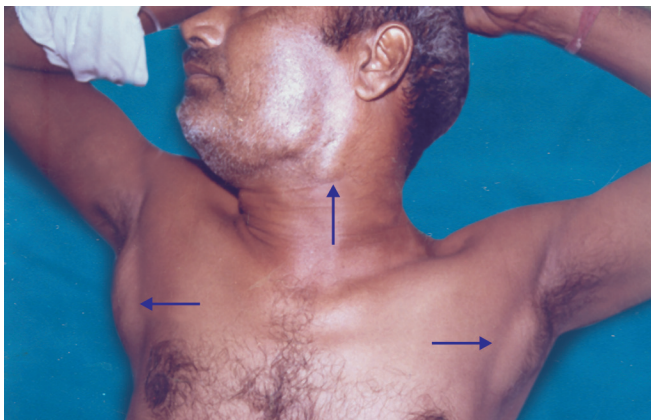


FIGURE 9.13 Enlargement of axillary and neck lymph nodes (↑)

Note: Because breasts tend to swell and become more nodular before menses as a result of oestrogen stimulation, the best time for examination is 5–7 days after the onset of menses.

- Examine the axillary tail between the thumb and finger as it extends towards the axilla.
- Palpate each nipple by holding it gently between index finger and thumb and note its elasticity and try to express any discharge.

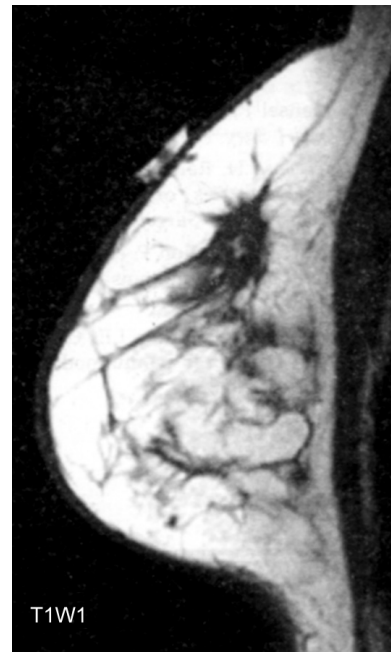

FIGURE 9.15 MRI of patient with breast cancer. Note the suspicious mass—speculated borders

- To examine the lateral portion of the breast, ask the patient to roll onto the opposite hip, placing her hand on her forehead but keeping the shoulders pressed against the bed or examining table. This flattens the lateral breast

tissue. Now start the palpation from the axilla and move towards bra line. To examine the medial portion of the breast, ask the patient to lie with her shoulders flat against the bed or examining table, placing her hand behind her neck and lifting up her elbow until it is even with her shoulder. Palpate in a straight line down from the nipple to the bra line.

- Complete the examination by palpating the regional lymph nodes, including the supraclavicular group.

Examination of the Axillae

Examine the axillae with the arm relaxed in order to expose the apex of the axilla.

Inspection

Inspect the skin of each axilla for any rash or infection or unusual pigmentation.

Deeply pigmented, velvety axillary skin suggests *acanthosis nigricans*, one form of which is associated with internal malignancy.

Palpation

Palpate the axillary region for any nodule or lymph node enlargement (Fig. 9.13) by asking the patient to alternately contract and relax the pectoral muscles by pressing her hands on to the hip.

Nodules in the tail of the breast are sometimes mistaken for enlarged lymph nodes.

INVESTIGATIONS FOR BREAST DISEASE

- **Fine-needle aspiration** for histopathological examination
- **Trucut biopsy** for confirmation of diagnosis
- **Mammography** (Fig. 9.14). It is useful to detect a lesion before it becomes palpable
- **Ultrasound** to differentiate cystic from solid lesion and to discriminate between benign and malignant lesion.
- **MRI:** Breast MRI is increasingly being used in the assessment of breast cancers. Its sensitivity is high (as 100%) but specificity is low resulting in high false positive results. It has a role in specific situation such as a suspicious mass on clinical examination with negative findings on USG and mammogram (Fig. 9.15).

10

CHAPTER

The Extremities

EXAMINATION OF EXTREMITIES

After examination of head and neck, axillae and breasts, now turn to the examination of extremities. The formal physical assessment often begins with examination of hands followed by feet.

THE HANDS AND THE NAILS

Applied Anatomy and Physiology

The hand is a well-developed structure and its cortical (cerebral) representation occupies a larger area (Remember, the smaller parts have wider cortical representation). The examination of hands begins with inspection for gross abnormality and then examination of individual structures on an anatomical basis.

The keratinous nail plate is produced mainly in the nail matrix which lies in the nail fold on the back of the terminal phalanx of each digit. The matrix runs from the end of the floor of the nail fold to the distant margin of the lunula (“half moon”), and from it, the nail plate grows forward covering the nail bed. A small part of the nail and the under surface are formed from the cells in the nail bed. Nail grows throughout life. Finger nails grow faster than foot nails, the growth in the finger nails being approximately 1 cm in 3 months.

Examination of the Hands

Steps of examination

- Inspect the general features of the dorsal and palmar aspects of the both hands. The abnormalities are given in the Box 1.
- Now shake hand with the patient and note the temperature, sweating and grip strength (Box 2).
- Note the specific changes in the nails (Box 3), fingers (Table 10.1), tendons and joints.

Examination of the Nails

Growth is slowed by acute illness and ischaemia. It is increased in psoriasis. Injury is the most common cause of

Box 1

Hand as a diagnostic tool

Morphological feature	Diagnosis
Flexed posture of hand and arm	Hemiplegia (Fig. 1.33th in Bedside Medicine without Tears by Prof. SN Chugh)
Large hands and palms	Gigantism (see Fig. 3.3), Marfan's syndrome (see Fig. 3.4)
Short spade-like hands	Acromegaly (Fig. 10.1)
Wrist drop	Radial nerve palsy, lead neuropathy, other peripheral neuropathies
Ulnar deviation of hand	Rheumatoid arthritis
Main De'accoucheur or obstetric hand	Tetany (Fig. 10.2A)
Deformity (Prayer's hand)	Trauma, rheumatoid arthritis (Fig. 10.2B)
Claw hand (main-en-griffe)	Paralysis of interossei and lumbricals (Fig. 10.2C)
Oedema of hands	May be part of generalised oedema, may be due to local venous or lymphatic obstruction or disuse in hemiplegia

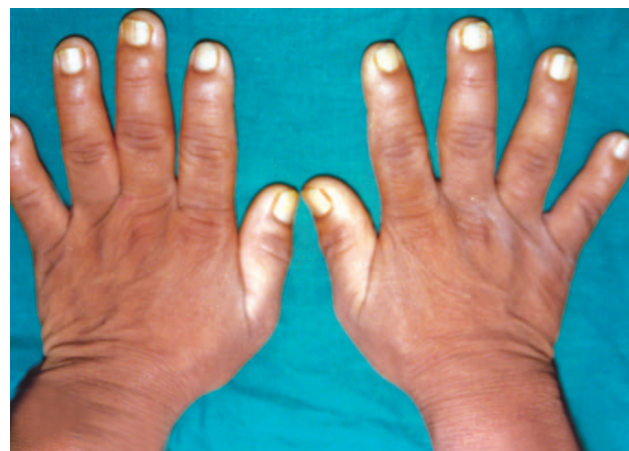
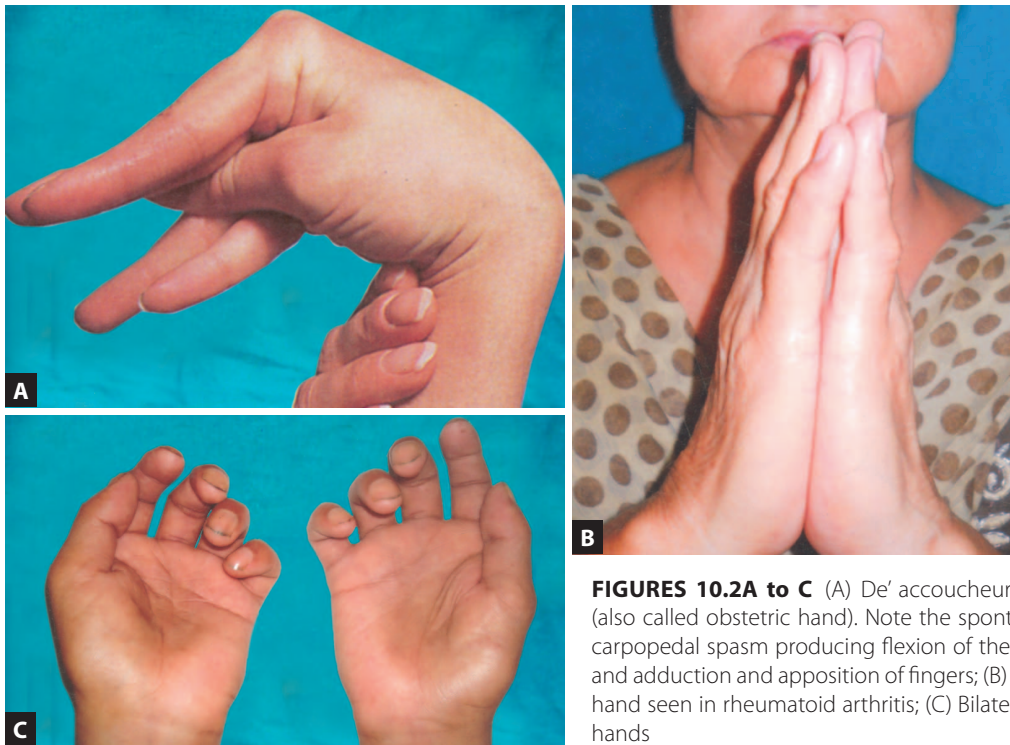
FIGURE 10.1 Acromegalic hands. Note the short hand with short stubby stout fingers



FIGURES 10.2A to C (A) De' accoucheur's hand (also called obstetric hand). Note the spontaneous carpedal spasm producing flexion of the thumb and adduction and apposition of fingers; (B) Prayer's hand seen in rheumatoid arthritis; (C) Bilateral claw hands

Box 2

Information gathered from hand shake

Feature	Condition
Temperature (warm, cold hands)	<ul style="list-style-type: none"> • Warm, moist hands in hyperthyroidism, high output states, cor pulmonale, respiratory failure • Cold but moist hands in anxiety, low cardiac output (e.g. CHF), acromegaly • Cold, dry and rough hands in myxoedema
Weak hand grip	Weakness of small muscles of hand or flexors of hand
Inability to relax the grip	Myotonia
Thick, rough palm	Hyperkeratosis (vitamin A deficiency) tylosis, occupational (Fig. 10.3), arsenic poisoning, myxoedema

nail deformity. Some important changes in the nails are depicted in the Table 10.2.

Abnormalities of the Nails

Clubbing

Definition: It is bulbous enlargement of soft tissue of the terminal phalanges with both transverse and longitudinal curving of the nails due to increase in anteroposterior and

Box 3

Change in the nail colour as a clue to diagnosis

Change	Diagnosis
Pale	Anaemia
Orange or lemon yellow	Carotenaemia, mepacrine toxicity
Yellow	Jaundice
Bluish	Cyanosis (see Fig. 10.18)
Red	Palmar erythema (Fig. 10.4), carbon-monoxide poisoning, polycythaemia, embolic lesions of subacute bacterial endocarditis, vasculitis (Fig. 10.5)
Black (melanin)	Read the causes of pigmentation (Fig. 10.6)
Petechiae, purpura, ecchymosis	Bleeding or coagulation disorders
Rash	Disease or drug-induced

transverse diameters of the nails. The soft tissue swelling is due to interstitial oedema and dilatation of arterioles and capillaries.

Method of Examination

Bring the patient's finger at your eye level and look tangentially (see Fig. 10.17). Look at the *onychodermal angle* (angle formed

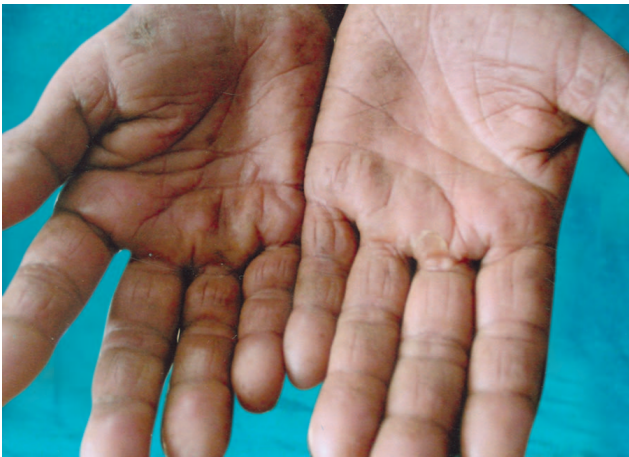

FIGURE 10.3 Hyperkeratosis of palms in a maid servant

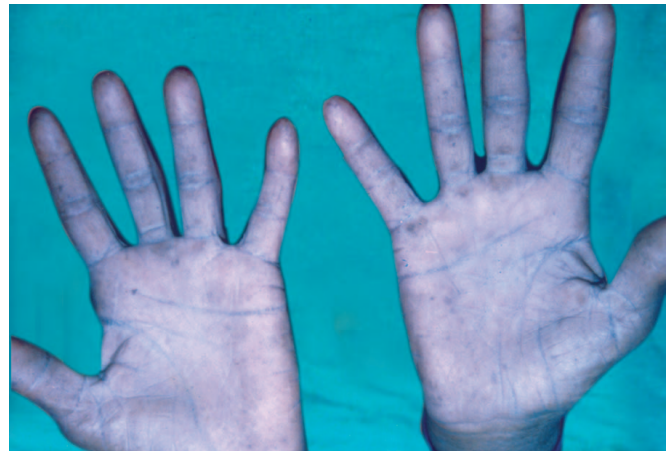

FIGURE 10.6 Pigmentation of hands and creases of the palms in pellagra

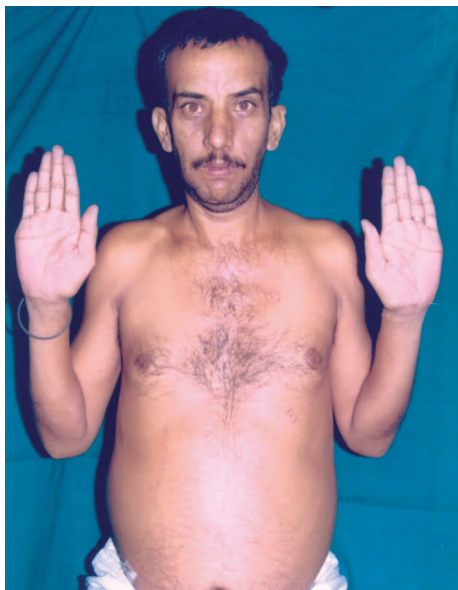

FIGURE 10.4 Palmar erythema in a patient with cirrhotic portal hypertension. Note the redness of palms

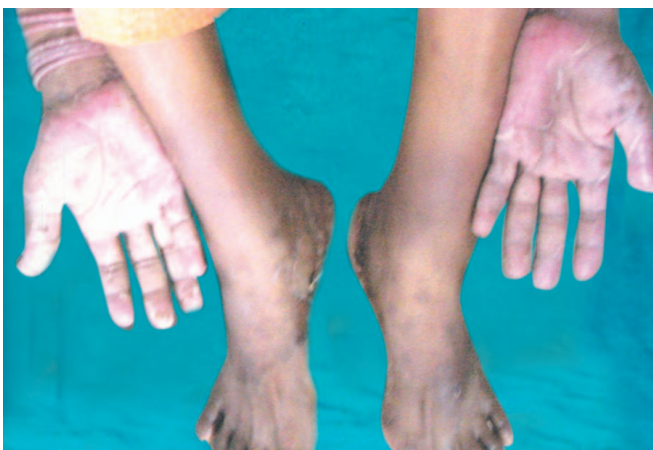

FIGURE 10.5 Vasculitic changes in the skin

between the nail bed and the adjacent skin fold); if it is more than 180° or more (angle is lost), clubbing is said to be present.

Normal onychodermal angle is about 160° , clubbing appears when either the angle is lost or is $\geq 180^\circ$

Now look for the fluctuation of the nail bed (*see* Fig. 10.18). Fluctuation is due to softening of the nail bed. It is observed by gentle pressure over the base of the nail by tip of right index finger while holding the patient's finger (say middle finger) between the thumb and index finger of left hand and supporting the pulp of the finger over the pulp of the right thumb.

Alternative Method (Schamroth's Window Test)

Approximate the nails of two fingers preferably the thumb of both hands and look for the normal lozenge-shaped gap between the two nails and the proximal nail folds. In clubbing, this diamond/lozenge shape gap is either reduced or obliterated (*see* Fig. 10.19).

Causes: They are given in the Box 4.

Grades

- I. Softening of nail bed with obliteration of onychodermal angle.
- II. **Grade I plus** increased AP and transverse diameters of nails as well as nails become tense, shiny with loss of longitudinal ridges.
- III. **Grade II plus** increase in pulp tissue resulting in Parrot's beak or drumstick appearance.
- IV. **Grade III plus** hypertrophic osteoarthropathy.

Unilateral clubbing: Clubbing is mostly bilateral but may be unilateral due to:

- Presubclavian coarctation of aorta
- Cervical rib
- Pancoast's tumour

TABLE 10.1 Finger deformities as a sign of disease	
Deformity	Disease/condition
Arachnodactyly (long, slender fingers—Fig. 10.7)	Marfan's syndrome, Kallmann's syndrome (hypogonadotrophic hypogonadism)
Polydactyly (an extra finger, 6th finger Fig. 10.8A)	Laurence-Moon-Biedl syndrome, congenital heart disease
Syndactyly (United or jointed fingers Fig. 10.8B)	Poland's syndrome, congenital heart disease
Sclerodactyly (tight skin over phalanges. Fig. 10.9)	Scleroderma
Broad, short, stubby, stout fingers (Fig. 10.1)	Acromegaly, pseudohypoparathyroidism
Short metacarpals, i.e. brachydactyly (short fingers)	Down's syndrome (Fig. 10.10), Turner's syndrome, mucopolysaccharidosis
Clubbing of the fingers	Read finger clubbing discussed below

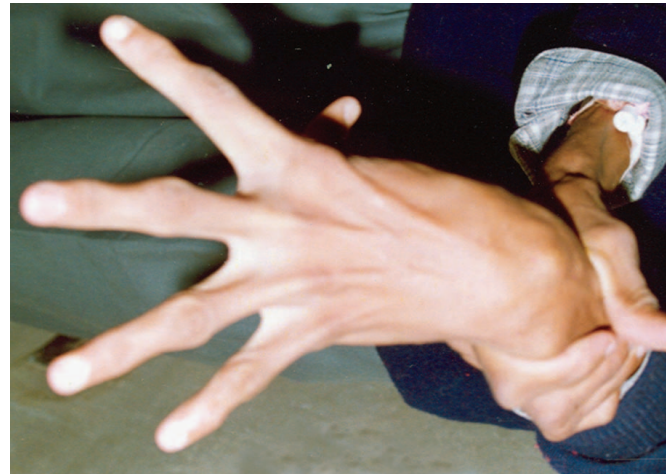
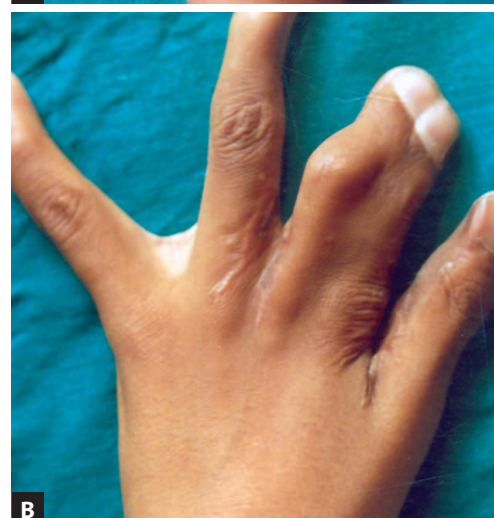
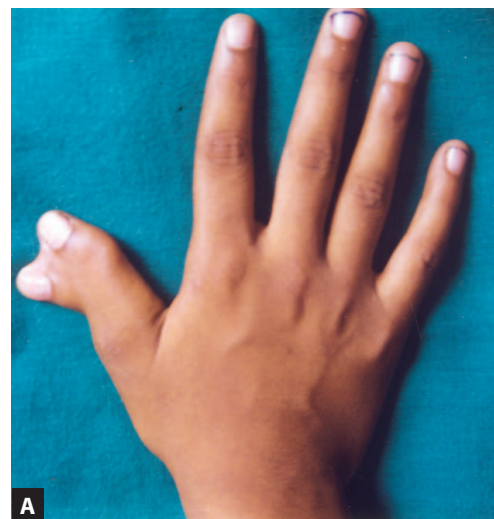FIGURE 10.7 Arachnodactyly. Note the long slender fingers from a patients with Marfan's syndrome. Webbing of fingers is present. Thumb protrusion sign is positive

TABLE 10.2 Important changes in the nails	
Change	Association
Bitten nails (Fig. 10.11)	Personality disorder
Splinter haemorrhages (see Fig. 11.3)	Minor trauma, systemic vasculitis, SABA
Pitting of nails	Psoriasis, eczema
Koilonychia (Fig. 10.12)	Chronic iron deficiency anaemia
Onycholysis	Trauma, psoriasis, lichen planus, ring worm infection
Platynychia (flat nails) (Fig. 10.13)	Hereditary, iron deficiency
White nails or Terry's nails [(leukonychia (Fig. 10.14)]	Hypoalbuminaemia, chronic liver disease, other wasting diseases
Transverse ridging	Acute illness, Zn deficiency
White line (transverse across the nails, i.e. <i>Beau's lines</i> Fig. 10.15)	Systemic illness, malnutrition, trauma, chemotherapy for cancer, peripheral vascular disease
Absent nail	Nail-patella syndrome
Fungal infection (thickening, crumbling and discoloration) (Fig. 10.16)	Candidiasis, ring worm
Red half-moons (<i>red lunula</i>)	Congestive heart failure
Blue half-moons (<i>blue lunula</i>)	CuSO ₄ poisoning, Wilson's disease
'Half and half' nails (see Fig. 14.8)	Chronic renal failure (CRF)
Mee's lines (punctate or linear discoloration)	Arsenic poisoning

- Aneurysm of a subclavian artery
- Erythromelalgia
- AV fistula involving brachial vessels.



FIGURES 10.8A and B Deformities of fingers: (A) Polydactyly (an extra thumb); (B) Syndactyly

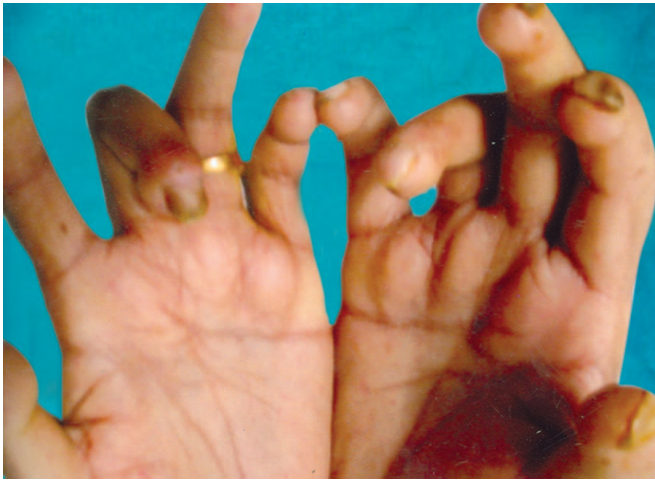

FIGURE 10.9 Sclerodactyly

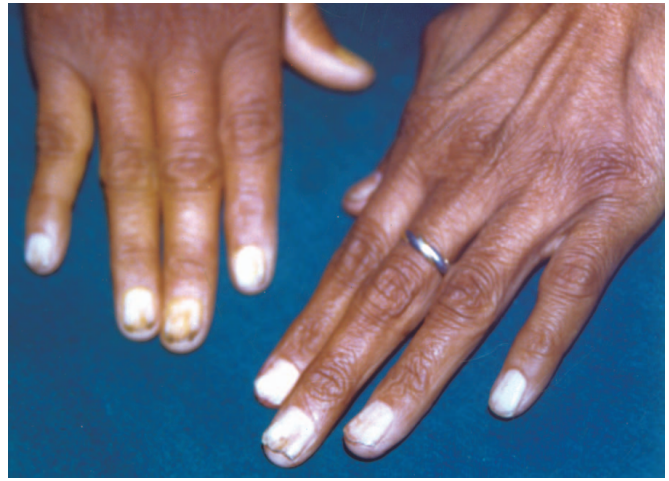

FIGURE 10.12 Koilonychia. Note the spoon-shaped nails

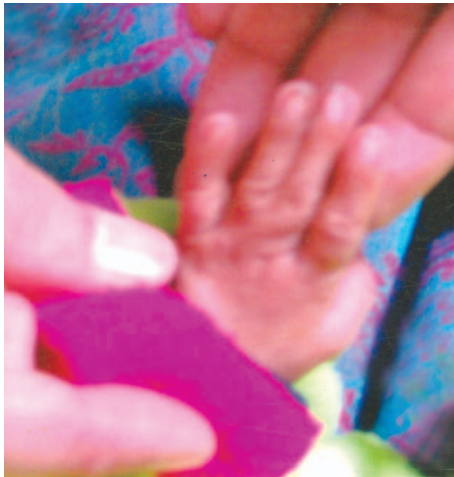

FIGURE 10.10 Down's syndrome. Note clinodactyly (hypoplasia of middle phalanx of little finger resulting in incurving of it)

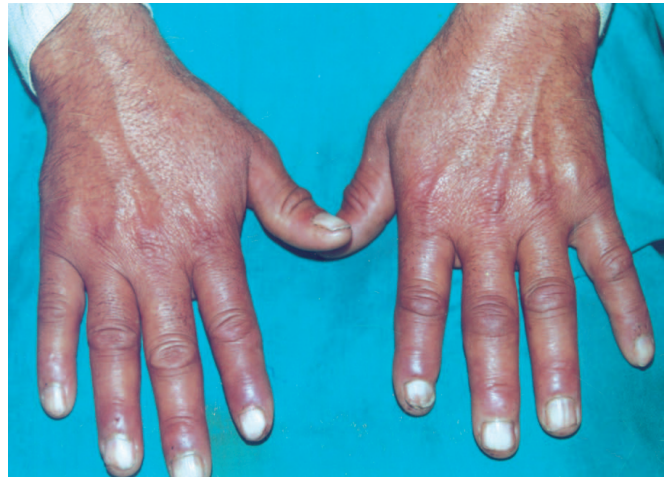

FIGURE 10.13 Platynychia (flat nails)

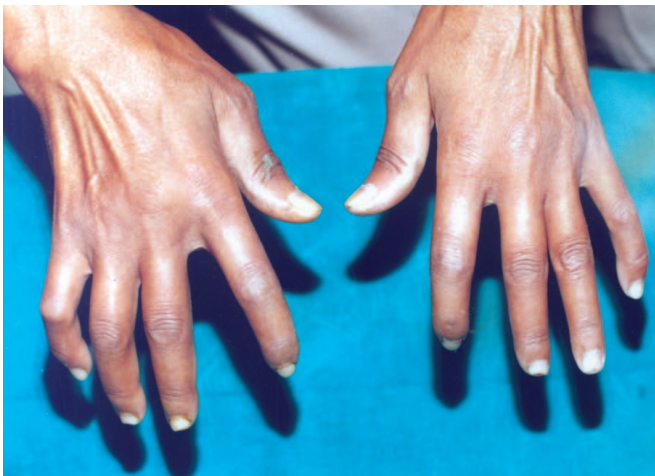

FIGURE 10.11 Thimbling of nails in nail biters

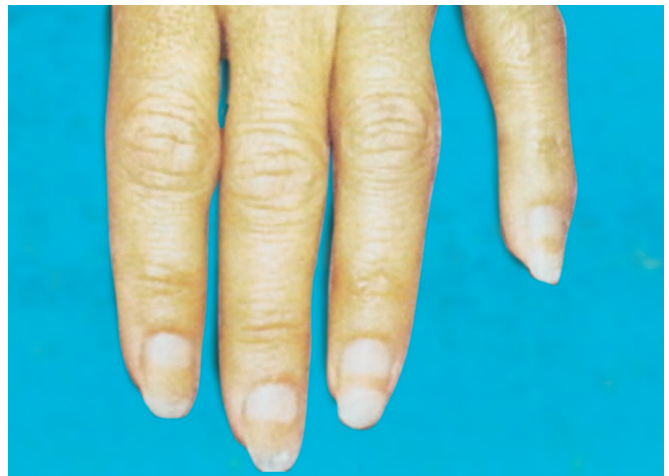

FIGURE 10.14 Terry's Nail: Note brownish-red distal transverse band, occurs normally in elderly and cirrhosis, CHF

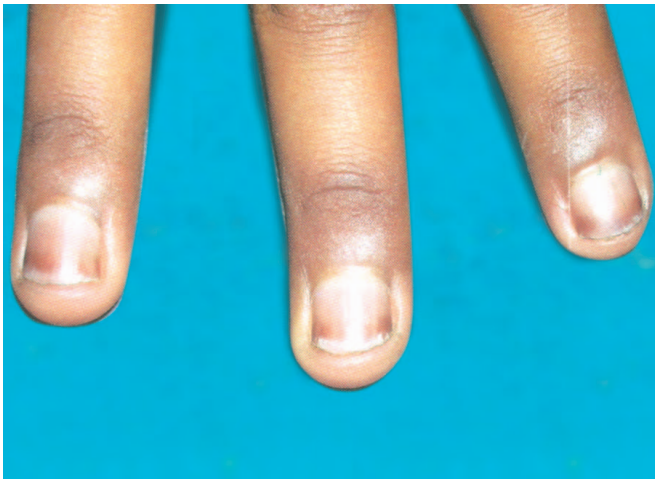

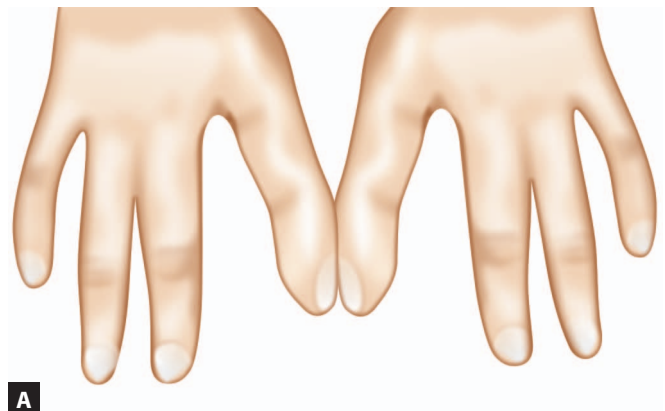
FIGURE 10.15 Beau's line. These are pigmented horizontal lines with transverse grooves across the nails

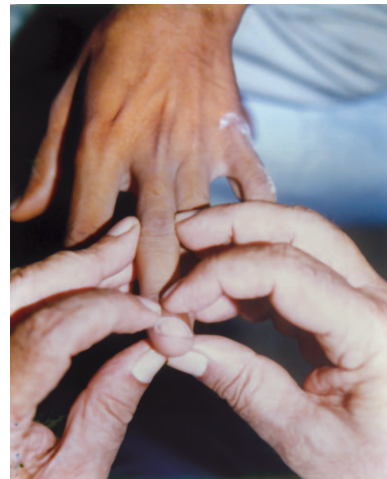

FIGURE 10.18 Elicitation of fluctuation of the nail bed (e.g. fluctuation sign for clubbing is positive)

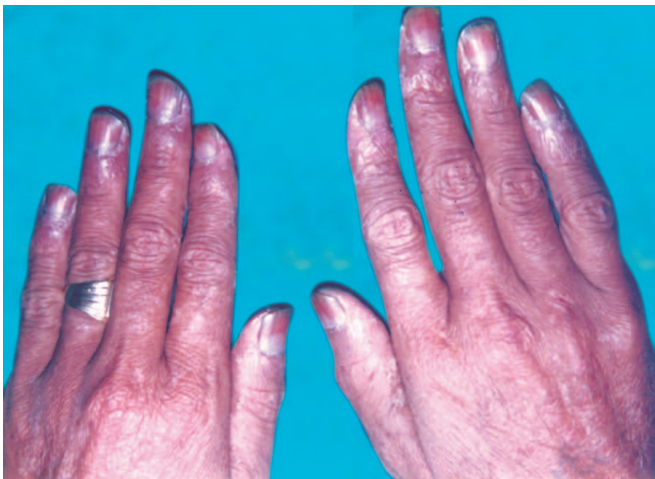

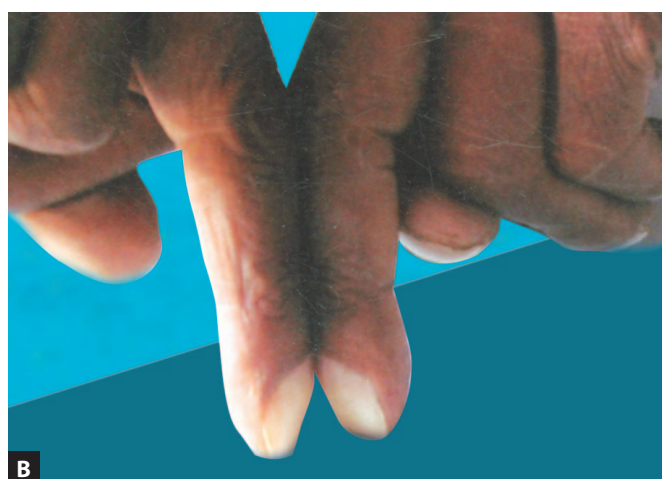
FIGURE 10.16 Nail changes in HIV disease (e.g. fungal infection of nails with seborrheic dermatitis)



A

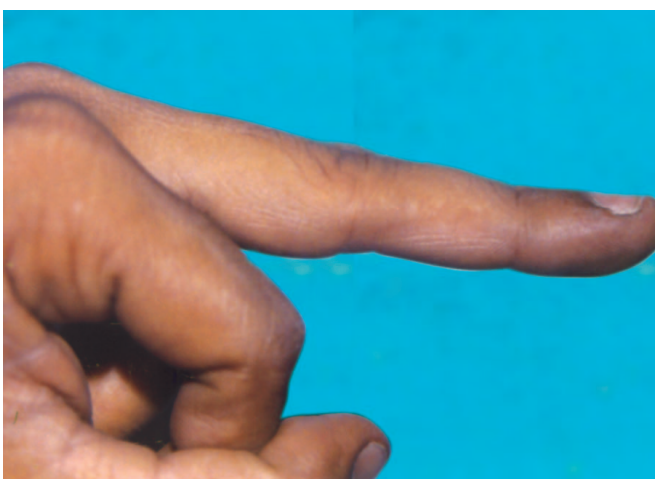

FIGURE 10.17 Position of the finger for inspection for clubbing. Hold the finger in front of your eye for onchodermal angle at base of the nail



B

FIGURES 10.19A and B Schamroth's window sign for clubbing (an alternative method for clubbing): (A) Diagrammatic illustration showing normal lozenge—Shaped gap; (B) Positive sign in clubbing of fingers

Differential clubbing: Clubbing may be limited to the upper limbs in chronic obstruction of the veins (phlebitis of upper extremities as seen in IV drug users) or may be present in the lower limbs only in infected abdominal aortic aneurysm and PDA with reversal of shunt (Eisenmenger's syndrome).

Box 4

Causes of clubbing

- Cardiac
 - Congenital cyanotic heart disease (Fallot's tetralogy) (Fig. 10.20A)
 - Subacute infective endocarditis
 - Atrial myxoma
 - Eisenmenger's syndrome
- Respiratory
 - Bronchiectasis (Fig. 10.20B)
 - Lung abscess
 - Bronchogenic carcinoma
 - Empyema thoracis
 - Mesothelioma
 - Fibrosing alveolitis
 - Pulmonary arteriovenous communication
 - Rarely fibrocaceous tuberculosis
- GI tract
 - Ulcerative colitis
 - Crohn's disease
 - Malabsorption
 - Polyposis
- Hepatobiliary
 - Biliary cirrhosis
 - Hepatocellular failure
- Genetic
 - Familial

Pathogenesis

Clubbing may appear acutely in acute lung suppuration but usually it is of slow onset. The exact pathogenesis is not known but hypotheses are:

- Anoxaemia due to any cause leading to vasodilatation and proliferation of subcutaneous tissue of nail bed. There is increase in capillary permeability leading to interstitial oedema.
- **Toxaemia:** Clubbing in SABA is considered due to this factor and hormonal influence.
- **Metabolic and hormonal:** Clubbing seen in endocrine disorders, e.g. hyperthyroidism, acromegaly, hyperparathyroidism.
- Pressure changes between radial and digital arteries.
- Reduced ferritin by escaping oxidation in the lungs leads to dilatation of AV anastomosis.
- *Hereditary.*

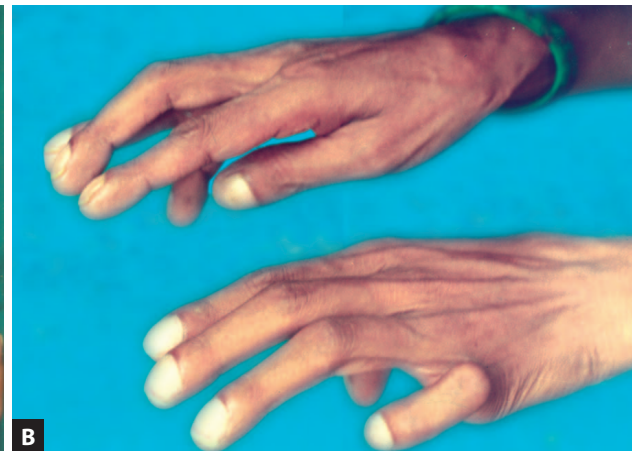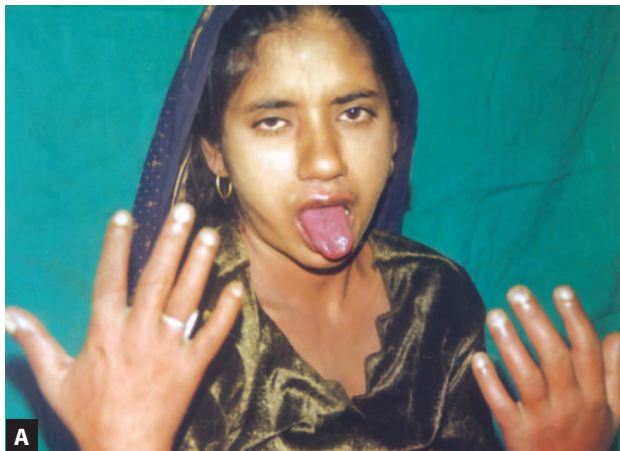Tip: Drumstick clubbing in combination with cyanosis in an adult indicates cyanotic congenital heart disease, commonly Fallot's tetralogy Fig. 10.20A.

Examination of Nail Folds

Examination of the nail folds should accompany examination of nails but here they are described separately. *Paronychia* or *whitlow* refers to inflamed, bolstered and swollen nail folds.

The causes are:

- Poor peripheral circulation
- Persons involved in wet-work
- Diabetes
- Persons overenthusiastic in manicuring their cuticles.



FIGURES 10.20A and B Clubbing of fingers: (A) Clubbing (drumstick appearance) with cyanosis in a patient with cyanotic congenital heart disease; (B) Clubbing of fingers without cyanosis. This was recorded from a patient with bronchiectasis

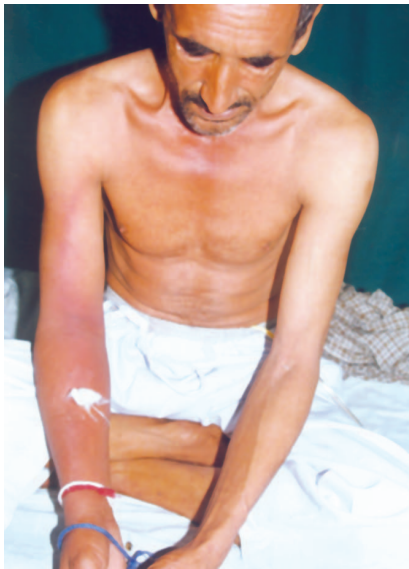

FIGURE 10.21 Thrombophlebitis of right forearm vein following IV cannulation (Branula has been removed)

Abnormalities of Vascularity and Pulsations

- **Palmar erythema:** It is a mottled, bright-red cutaneous vasodilation seen mainly on the thenar and hypothenar eminences. It is normally found in some persons, but is also a sign of liver cell failure.
- **Arteritis** may cause small necrotic lesions at the base of the nail and on the pulps, is seen in endocarditis, SLE and connective tissue disorders.
- **Capillary pulsations** are seen by putting the tip of a pintorch under the pulp. They are characteristically seen in aortic incompetence.
- **Raynaud's phenomenon:** Read peripheral vascular examination.
- **Venous abnormalities** are seldom seen, but the linear marks or phlebitis (Fig. 10.21) caused by intravenous injection of drugs in addicts ('mainliners') are characteristics.
- **Absent pulsation** (radial or digital) is seen in embolisation to small vessels.

The hands

Swellings: Look for any swelling. The different swellings and their significance are discussed in the Box 5.

Deformities: Look for any deformities. Deformities of the hands may occur due to involvement of the joints, muscles, tendons, bones and nerves (Table 10.3).

Palmar creases: Look at the palmar creases for paleness, pigmentation or any other abnormality. Palmists can predict the future by examining these lines but clinicians have to be careful to examine these lines for any abnormality (Box 6).

Involuntary movements: Read neurological examination.

Box 5

Significant swellings in the hands

Swelling	Significance
• Osler nodes (tender papules on the pulp of the fingers)	Subacute bacterial endocarditis
• Heberden's nodes (hard bony nodules on dorsum of distal interphalangeal joints Fig. 10.22)	Osteoarthritis (see also Fig. 17.10)
• Bouchard's nodes (hard nodules on dorsum of proximal interphalangeal joints Fig. 10.22)	Osteoarthritis (see also Fig. 17.10)
• Rheumatoid nodules (firm painless subcutaneous nodules) (see Fig. 17.9)	Rheumatoid arthritis

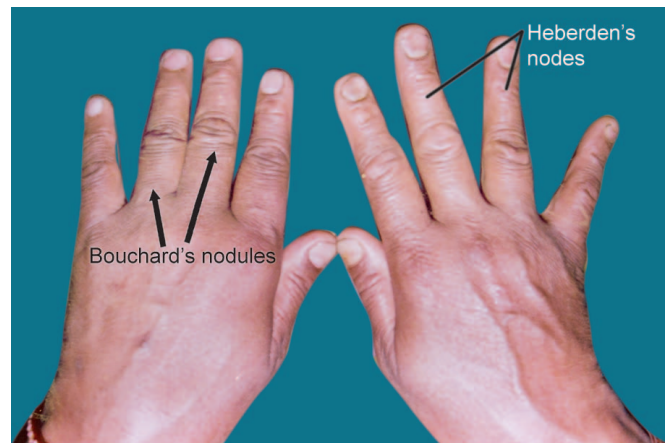


FIGURE 10.22 Heberden's and Bouchard's nodes on the fingers

Box 6

Palmar creases aid to diagnosis

Creases/line	Disease/condition
• Pale creases	Anaemia
• Red creases	Polycythaemia
• Pigmented creases (Fig. 10.6)	Addison's disease
• A single palmar crease (Simian crease)	Down's syndrome (Mongolism)

The Feet and the Legs

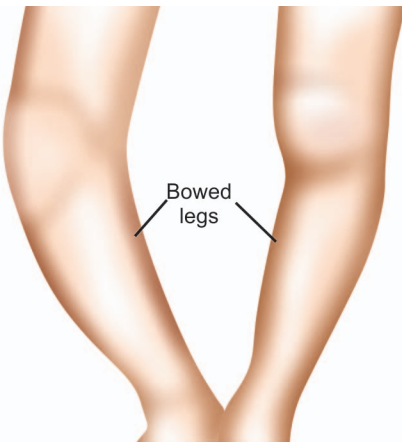
The examination of feet is done by *inspection* and *palpation*. The examination of feet is just similar to examination of hands.

Inspection: Look at the feet for:

- **Deformity**, e.g. *pes cavus* or *pes planus*. *Pes cavus* (Fig. 10.24) is a fixed deformity where both feet are more or less symmetrically high-arched which can

TABLE 10.3 Analysis of hand deformities

Deformities	Significance
<ul style="list-style-type: none"> • Joints <ul style="list-style-type: none"> – Spindle shaped (swelling of PIP joints) – Swan-neck (hyperextended PIP joints and flexed DIP joints, (see Fig. 17.18), and Boutonniere' or button-hole deformity (flexed PIP and hyperextended DIP joints—see Fig. 17.18) – Volar subluxation with ulnar deviation of hand, Z-deformity of thumb – Swelling of distal interphalangeal joints (DIP) – Claw hand (hyperextension of metacarpophalangeal joints and flexion of PIP and DIP) – Jaccoud's arthritis 	<ul style="list-style-type: none"> • Rheumatoid arthritis, scleroderma • Rheumatoid arthritis Fig. 17.15 • Rheumatoid arthritis • Osteoarthritis, psoriatic arthropathy • Paralysis of interosseous and lumbricals • Very rarely seen in rheumatic arthritis
<ul style="list-style-type: none"> • Subcutaneous tissue <ul style="list-style-type: none"> – Dupuytren's contracture (thickening and shortening of palmar fascia resulting in flexion deformities of the 4th and 5th fingers) 	<ul style="list-style-type: none"> • Repeated trauma, alcoholic cirrhosis, phenytoin therapy, diabetes mellitus and working with vibrating tools
<ul style="list-style-type: none"> • Tendons <ul style="list-style-type: none"> – de Quervain's tenosynovitis (swelling over the tendon sheath) and trigger finger or thumb flexor tendon 	<ul style="list-style-type: none"> • Excessive use of the tendon
<ul style="list-style-type: none"> • Muscles <ul style="list-style-type: none"> – Flattening of palm, prominent knuckles and hollow interosseous spaces – Carpal tunnel syndrome 	<ul style="list-style-type: none"> • Wasting of small muscles of the hand (read the causes in case discussion in Bedside Medicine by Prof. SN Chugh). • Rheumatoid arthritis, Disuse atrophy, diabetes, amyloidosis, autoimmune hypothyroidism, acromegaly, pregnancy
<ul style="list-style-type: none"> • Bones <ul style="list-style-type: none"> – Tapering and conical finger tips with or without trophic changes – Bone deformity due to pathological fractures or bowed legs 	<ul style="list-style-type: none"> • Hyperparathyroidism, leprosy • Paget's disease of the bone (Fig. 10.23), surgical conditions, trauma
<ul style="list-style-type: none"> • Nerves <ul style="list-style-type: none"> – Trophic changes, e.g. ulcerations, burns 	<ul style="list-style-type: none"> • Peripheral neuropathies

**FIGURE 10.23** Deformities (bowed legs) in Paget's disease of the bone

be demonstrated by observing the arch of foot when patient stands on the floor (there is exaggeration of the longitudinal arch in *pes cavus*) or by taking a foot-print on a white paper after painting the foot with some colour or after immersion of the feet in water and asking the patient

to walk barefooted. The *pes cavus* (claw foot) results from wasting of small muscles (interossei and lumbricals) of foot due to polio myelitis, spina bifida, Friedreich's ataxia, syringomyelia, peroneal muscle atrophy (Charcot-Marie-Tooth disease), familial peripheral neuropathies (Refsum's disease) and may be idiopathic. *Talipes equinus varus* (Fig. 10.25) is a congenital abnormality seen in infants/children. There may be supernumerary toe or under developed toes (Fig. 10.26).

- **Posture:** Plantar flexion of the foot occurs in hemiplegia, which may be associated with extension and adduction of lower limb. Foot drop is seen in sciatic or common peroneal nerve palsy or peripheral neuropathies.
- **Size:** Feet are large and broad in acromegaly. There is increase in the size of the shoes. Oedema feet also causes increase in feet dimensions.
- **Colour:** By and large changes in the colour of the skin of the feet are similar to those of the skin in general. Read changes in skin colour. The trophic changes (varicose ulcer, black-staining) at or around the ankle are seen in

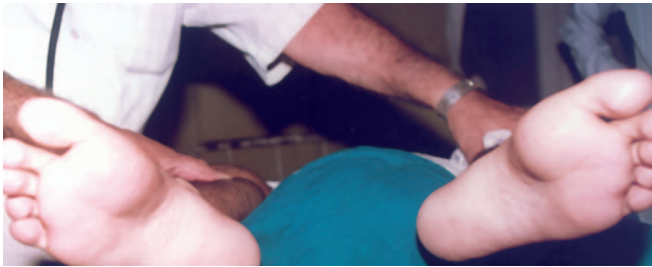

FIGURE 10.24 *Pes cavus*. Note the high arching of both the feet leading to hollowness of soles

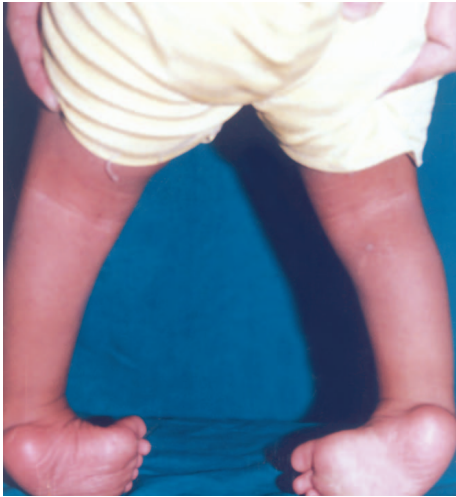

FIGURE 10.25 Talipes equinus varus—a congenital abnormality of the feet

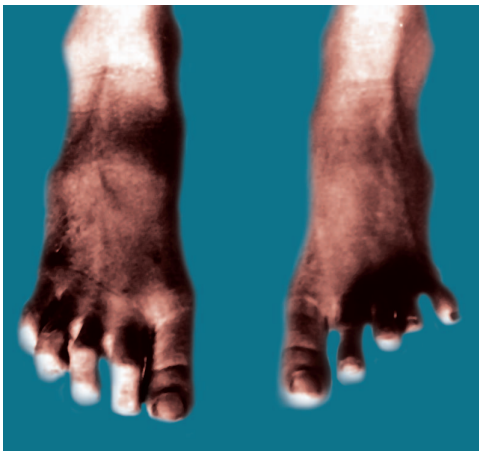

FIGURE 10.26 Underdeveloped and maldeveloped toes of left foot

varicosity of veins or venous insufficiency (Fig. 10.27). There is central pallor with atrophy and erythematous borders of plaques seen in necrobiosis lipoidica diabetorum (Fig. 10.28).

- **Nails:** Changes in nails are similar to nails of hands. (Fungal changes in nails Fig. 10.29). Paronychia (whitlow)

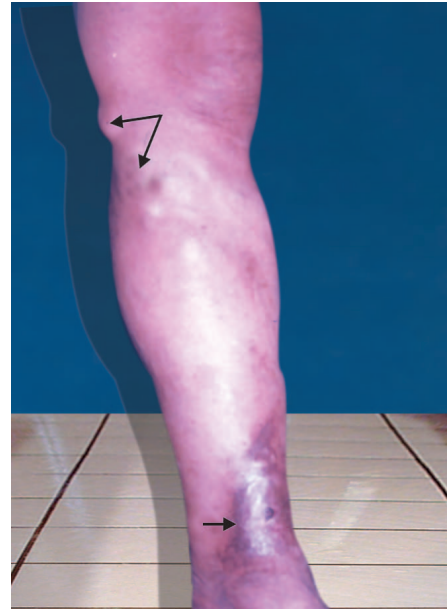

FIGURE 10.27 Varicose veins (↙↘) with varicose ulcer (→). Note the brown pigmentation around the ankle (→)

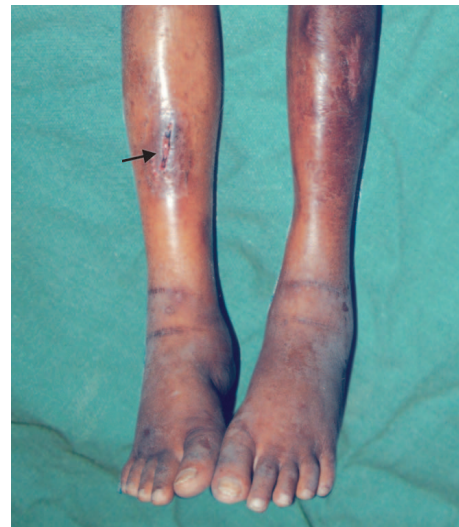

FIGURE 10.28 Necrobiosis lipoidica diabetorum. Note the plaques with central pallor, atrophy and erythematous border

occurs due to infections of nail folds leading to bolstered and swollen nail folds (Fig. 10.30).

- **Temperature:** The feet are warm or cold similar to hands (Read examination of temperature of hands). The toes become cold, red and then blue due to chilblain (cold injury) (Fig. 10.31) producing pain due to vasospasm.
- **Vessels and pulsations:** Veins stand out prominently over the calf and the ankle in varicosity and venous thrombosis. Pulsations may be absent in embolisation to the vessels or arteritis (pulseless disease or Takayasu's arteritis, Buerger's disease). Digital gangrene may occur due to arterial obstruction. Vasculitis (palpable purpura,

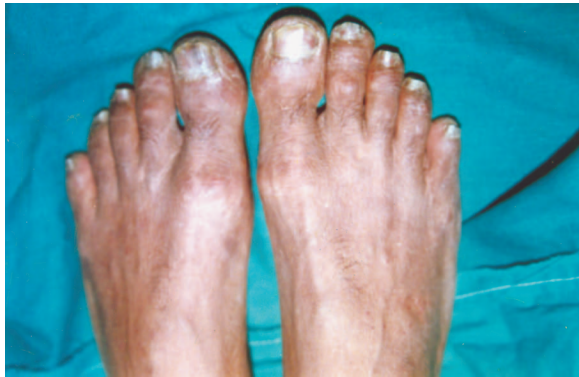

FIGURE 10.29 Fungal infection of nails

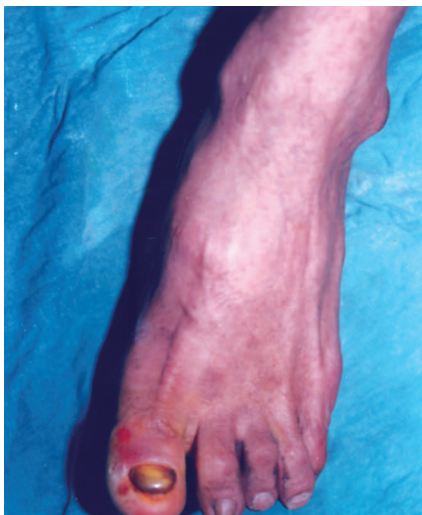

FIGURE 10.30 Paronychia (whitlow) of great toe (left)

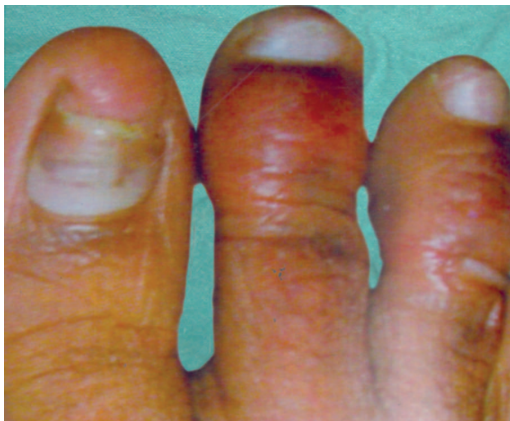

FIGURE 10.31 Chilblain. Note the red erythematous plaques over the toes due to cold injury

urticarial rashes, maculopapular eruptions) may be seen in SLE, infections and may be due to drugs.

- **Joints:** Arthritis may involve small joints of the foot in rheumatoid arthritis and psoriasis. The ankle may be involved in osteoarthritis. Swelling of ankle may be due to trauma or bleeding into joints (hemarthrosis) in

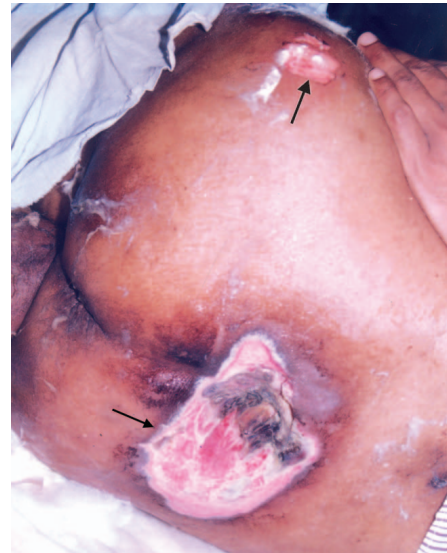

FIGURE 10.32 Pressure sores over the sacrum (→) and iliac crest (↑) formed in a patient who was lying in an unconscious state for a long period

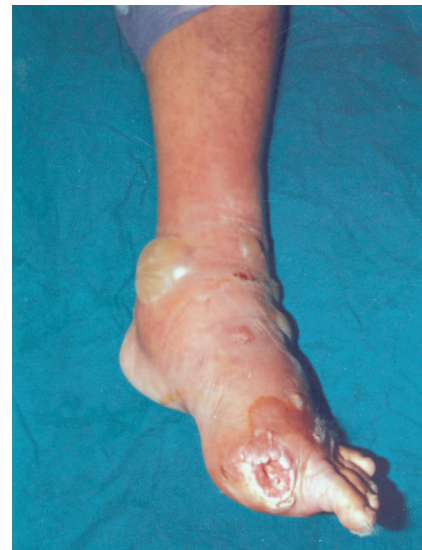

FIGURE 10.33 Diabetic foot. There is blistering of the skin with amputation of left big toe. There is impending gangrene of other toes

coagulation disorder, e.g. haemophilia. Painful swelling of joints of big toe is seen in gout (podagra).

- **Nerves:** Neuropathy may involve the peripheral parts and the joints. Neuropathic joint (Charcot joint) commonly involves the knee, hip and ankle producing painless huge swelling of the joint with presence of loose bodies in the joint. Crepitus may be felt over the joint.
- **Trophic ulcers** may be seen in neuropathy commonly in diabetic neuropathy at pressure points, i.e. sacrum (Fig. 10.32), heel and pad of great toe. In diabetic foot (Fig. 10.33), there is vasculopathy, neuropathy and dermopathy, and there may be loss of digit(s).

Neuropathic ulcers are seen in progressive sensory neuropathy, tabes dorsalis, leprosy, amyloidosis and porphyria.

- **Oedema (Fig. 10.34):** Look at the feet for oedema. Oedema means collection of fluid in the interstitial tissue as a result of either increased hydrostatic pressure (e.g. CVS disease) or reduced oncotic pressure (e.g. hypoproteinaemic states) or due to increased capillary permeability or local venous or lymphatic obstruction.

Clinical Evaluation of a Case with Oedema

Ankle Oedema

Inspection of the feet for the swelling

It is checked by applying firm pressure with the right thumb (e.g. till the nail blanches) for at least 5–10 second not exceeding 30 seconds at the ankle above the medial malleolus, lower end of tibia or upper part of shin bone and then the pressure is released. Presence of a pit staying for >30 seconds indicates pitting oedema (Figs 10.35A and B).

- The extent of oedema is assessed by spread over the tibia; in the medial thigh, in sacral area and abdominal wall.

Sacral Oedema

It is demonstrated by putting pressure with the right thumb over the subcutaneous tissue in sacral area while the patient is lying prone or on one side. Presence of a pit indicates oedema (Fig. 10.36). Otherwise also, pitting of sacral area may be seen in oedematous patients confined to bed for prolonged period.

Abdominal Wall Oedema (Parietal Oedema)

Usually oedema is demonstrated by the presence of a pit by applying firm pressure over subcutaneous tissue in an area against the hard surface usually the bone.

- Oedema of abdominal wall or thigh can be demonstrated by pressing the chest piece of the stethoscope (Fig. 10.37A) or the tips of the fingers of right hand and looking for the pit.
- It can also be demonstrated by pinching the skin between the thumb and index finger for few seconds (Fig. 10.37B) and then released. Presence of pits at the sites of pressure indicate oedema.

Types

Pitting oedema

- **Generalised oedema:** It is present throughout the body; is due to disorders of heart, kidney, liver, gut, etc. It can be nutritional or idiopathic. It may be associated with ascites or hydrothorax.

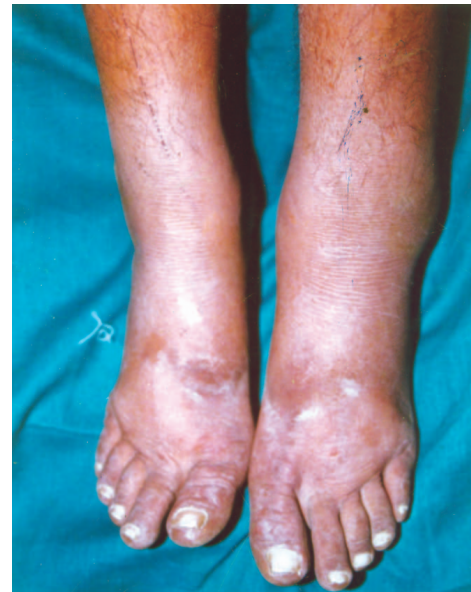
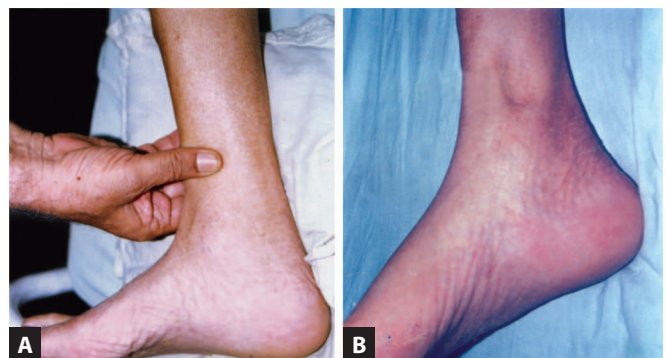
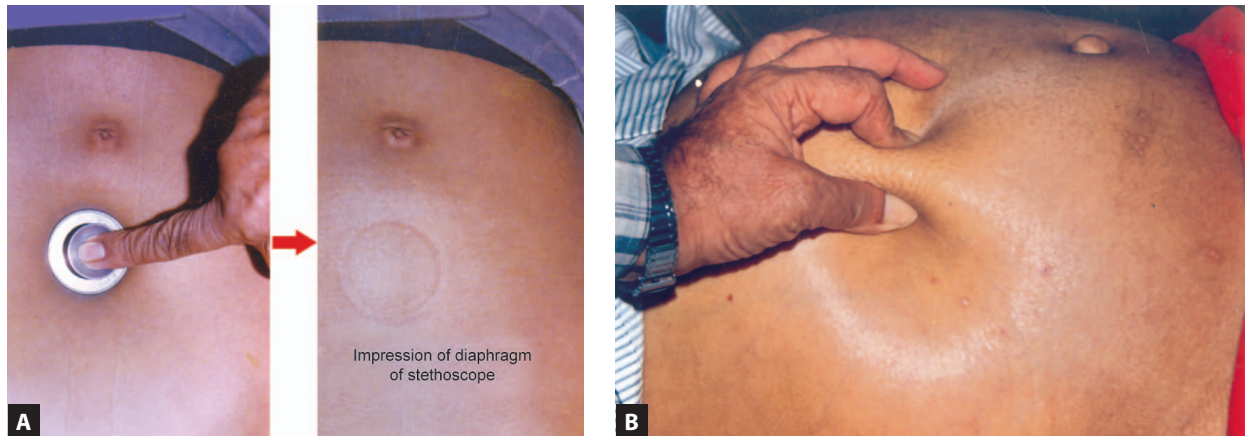
FIGURE 10.34 Oedema of feet and legs



FIGURES 10.35A and B Demonstration of pitting ankle oedema. (A) Pressure by the thumb above medial malleolus; (B) Production of a pit after thumb removal

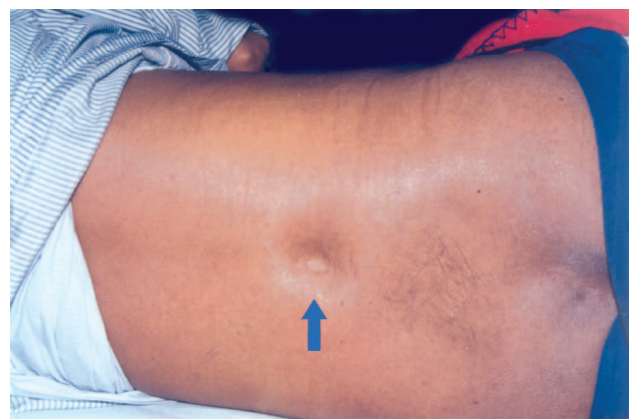

FIGURE 10.36 Oedema over the back near or at sacral area. Pressure over the skin and subcutaneous tissue with the thumb against the vertebral column left behind a pit (↑)



FIGURES 10.37A and B Detection of abdominal wall oedema: (A) Pressure by diaphragm of stethoscope leaves behind a circular impression on the wall after withdrawal of stethoscope; (B) Pinching of the abdominal wall will leave behind the pits at the sites of pressure by the thumb and index finger

- **Localised oedema:** It involves a part of the body, is due to venous obstruction, allergy or inflammation. It is unilateral.
- **Postural oedema:** It may occur due to prolonged standing, old age, hemiplegia but is unimportant.
- **Unilateral oedema:** Cyclical oedema may be unilateral.
- **Nonpitting oedema:** Occurs in lymphatic obstruction, i.e. lymphoedema (Figs 10.38A and B) or myxoedema (Table 10.4).

Distribution of Oedema

When oedema is due to fluid retention, then its distribution is governed by gravity. This is the reason that oedema first appears in dependent parts such as legs, back of thighs and sacral region in the semirecumbent position. If the patient lies flat, it may involve face and hands; for example oedema due to renal disease appears first on the face early in the morning just getting up from the bed, then subsequently gets distributed over the legs when patient is ambulatory.

The cardinal sign of subcutaneous oedema is pitting of the skin. Pit appears with application of firm pressure of the thumb due to displacement of extracellular fluid which disappears after release of pressure due to return of displaced fluid.

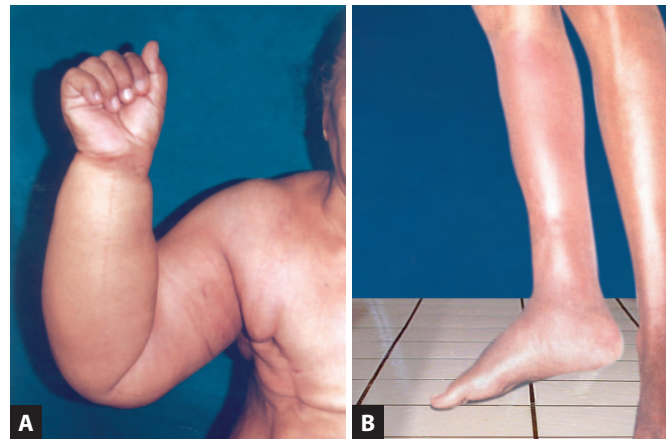
Causes

See Table 10.4.

Pathogenesis of Generalised Oedema

It is also called *anasarca*.

- **Increased hydrostatic pressure** results in transduction of fluid from intravascular to interstitial compartment resulting in oedema. The causes are given in the Table 10.4.
- **Reduced oncotic pressure:** The oncotic pressure depends on the plasma proteins. The conditions associated with



FIGURES 10.38A and B (A) Unilateral lymphoedema. Note the huge swelling, thickening and induration of skin of upper extremity. The lymphoedema occurred due to removal of lymph nodes during surgery for carcinoma of the breast. Note the scar of mastectomy; (B) Bilateral lymphoedema of legs due to filaria called elephantiasis of legs

hypoproteinaemia result in oedema as a result reduced oncotic pressure (for causes read the Table. 10.4).

- **Renin-angiotensin system:** Stimulation of renin-angiotensin-aldosterone system (cirrhosis and renal diseases) results in retention of sodium and H_2O and may contribute to oedema.

The renal excretory capacity may be reduced by the disease of the kidneys or by extra-renal factors. For sake of example, in the early stages of CHF, there is fall in renal blood flow due to reduced stroke output leading to fall in GFR and stimulation of *renin-angiotensin-aldosterone* system resulting in secondary hyperaldosteronism. The rise in aldosterone secretion increases the reabsorption of Na^+ and Cl^- . Secondary

TABLE 10.4 Causes of oedema

<ul style="list-style-type: none"> • Pitting oedema <ul style="list-style-type: none"> – Increases hydrostatic pressure <ul style="list-style-type: none"> - Congestive heart failure or cor pulmonale - Pericardial effusion - Constrictive pericarditis - Budd-Chiari syndrome – Reduced oncotic pressure <ul style="list-style-type: none"> - Cirrhosis of the liver - Nephrotic syndrome - Hypoproteinaemia (nutritional, malabsorption, protein losing enteropathy) – Increased vascular permeability/vasodilatation <ul style="list-style-type: none"> - Beri-beri - Epidemic dropsy - Drugs, e.g. nifedipine/amlodipine – Retention of salt and H₂O <ul style="list-style-type: none"> - Cushing syndrome or corticosteroids use - Oral contraceptives (e.g. oestrogen) - Liquorice – Venous obstruction 	<ul style="list-style-type: none"> • Nonpitting oedema <ul style="list-style-type: none"> – Myxoedema. It may become pitting if CHF is superadded over myxoedema – Lymphatic oedema, e.g. filariasis or lymph node removal. It is recurrent and intractable oedema, lymphogranuloma venereum, radiation, malignancy, congenital abnormalty – Angioneurotic oedema – Scleroderma (painless oedematous induration)
---	---

Box 7

Differential diagnosis of oedema

<i>Cirrhotic</i>	<i>Renal</i>	<i>Cardiac</i>	<i>Angioneurotic</i>	<i>Lymphoedema (Fig. 10.38A and B)</i>	<i>Venous oedema</i>
<ul style="list-style-type: none"> • Oedema appears on the legs with ascites • Signs or stigmata of chronic liver disease may be present • Signs of portal hypertension, e.g. caput medusae, ascites, fetor hepaticus and splenomegaly may be present • Past history of jaundice or hepatitis 	<ul style="list-style-type: none"> • Oedema starts on the face (puffiness of face) then on the legs • Oedema is usually noticed in the morning • Ascites is common • Sacral oedema in nonambulatory patients • Evidence or history of a renal disease in the past • Urine shows massive albuminuria • Other features of hypoproteinaemia and hypercholesterolaemia may be present 	<ul style="list-style-type: none"> • Oedema appears first on legs then on face • Patient will be dyspnoeic • Raised JVP, cyanosis • Tender hepatomegaly • Signs of RVH may be present • Evidence of a cardiac disease, e.g. cardiomegaly, 3rd heart sound, murmurs, etc. • Ascites may also be present 	<ul style="list-style-type: none"> • It is solid or non-pitting oedema • Results from hypersensitivity, involves eye-lids, tongue, lips, face etc. • It is acute in onset • Associated with itching • Congenital variety due to C₁ esterase deficiency • May become life-threatening emergency if glottis is involved 	<ul style="list-style-type: none"> • Oedema is soft in early stage, becomes indurated, hard and nonpitting • Mostly unilateral, may be bilateral • Skin thickening present • Oedema involves legs, feet and toes • Caused by lymphatic obstruction due to tumour, fibrosis, inflammation, radiation and lymph node removal • Congenital variety is due to hypoplasia of lymph vessels, (Milroy's disease) • Oedema is intractable and recurrent 	<ul style="list-style-type: none"> • Soft pitting ankle oedema • Skin thickening may be present • Ulceration and pigmentation over ankle and foot common • Usually unilateral, occasionally bilateral • Caused by venous obstruction or vulvular incompetence of the deep veins

hyperaldosteronism also occurs in patients with hepatic cirrhosis and nephrotic syndrome also.

- **Release of ADH:** Reduction in effective fluid volume result in release of ADH to conserve water.
- **Stimulation of antinatriuretic hormone or peptide (ANP):** In CHF, there is stimulation of antinatriuretic

hormone from the distended right atrium which inhibits salt loss and conserves Na⁺ and H₂O.

Differential Diagnosis of Oedema

The characteristic features of oedema due to various causes/ conditions are given in the Box 7.

SECTION 2

Systemic Examination and Appendices

Unit III: Systemic Examination

11. The Cardiovascular System
12. The Respiratory System
13. The Abdomen 245
14. The Urogenital System and Sexually Transmitted Diseases
15. The Nervous System
16. The Examination of Unconscious Patient
17. The Locomotor System
18. The Blood
19. The Psychiatric Assessment
20. The Endocrinal System

Unit IV: Appendices

Appendix I

Appendix II

11

CHAPTER

The Cardiovascular System

HISTORY**Symptoms**

- Dyspnoea, orthopnoea, PND, cough and sputum
- Palpitations
- Chest pain, haemoptysis
- Syncope, fatigue, tiredness
- Oedema.

Present History

Detailed history of present illness.

Past History

- Rheumatic fever, HT
- IHD, diabetes, CHD.

Family History

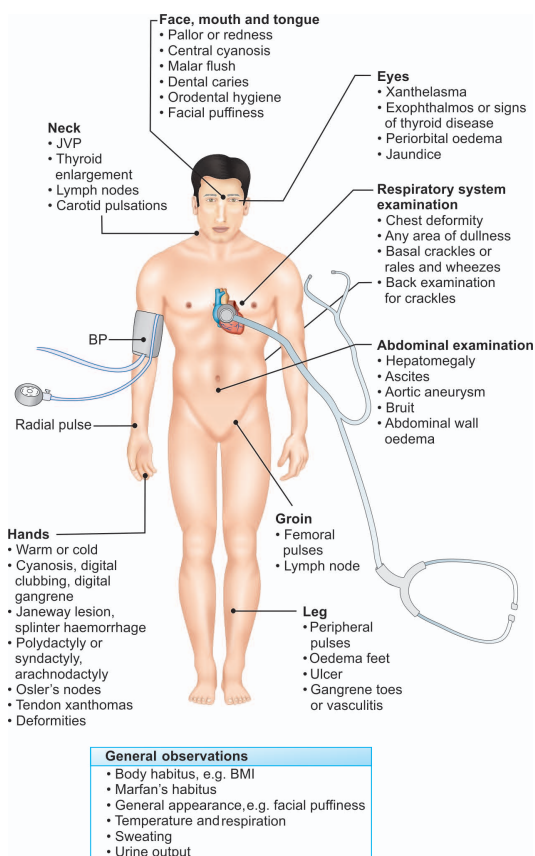
HT diabetes, TB, similar illness.

Personal History

- Habits, nutrition, smoking, alcohol.

GENERAL PHYSICAL EXAMINATION

- **Head, scalp, hair**, e.g. deformity, loss of hair
 - **Face**, e.g. pallor, redness, puffiness, bluishness, malar flush, oedema
 - **Mouth, oral mucosa, tongue, lips**, e.g. dryness, cyanosis, orodental hygiene
 - **The skin**: Rash, purpura or bleeding spots
 - **The eyes**, e.g. xanthelasma exophthalmos, jaundice, oedema, fundus examination
 - **The ear, nose, paranasal sinus, throat** for discharge, infection, tenderness
 - **The neck**, e.g. JVP, thyroid enlargement, pulsations, lymph nodes, etc.
 - **The axillae**, for lymph node
 - **The hands and upper extremity**
 - **The legs and lower extremity**
 - **The genitalia** for oedema, hydrocoele.
- NB:** Examine the above structures and record your findings.

**The Cardiovascular System (CVS) Examination****SYSTEMIC EXAMINATION****Inspection**

- Chest deformity/spinal deformity
- Shape of chest/precordium
- Trachea
- Visible pulsations, e.g. apex beat, left sternal, epigastric, suprasternal
- Scars, dilated veins, sinuses.

Palpation

- Apex beat, e.g. note its site, rate, character
- Parasternal heave
- Palpable pulsations, e.g. epigastric, suprasternal, pulmonary, arterial
- Other palpable sounds/thrills/pulsations in any other area of precordium
- Venous hum.

Percussion

- Cardiac dullness, e.g. percuss right and left borders of the heart
- Percuss 2nd left intercostal space
- Percuss for upper border of liver dullness and define liver span.

Auscultation

- **Mitral area** for S_1 and S_2 (loud, muffled absent), murmurs and other sounds
- **Tricuspid area**, e.g. S_1 and S_2 , murmurs and other sounds
- **Aortic area** (A_1 and A_2) for S_2 , murmurs, other sounds. Hear splitting of S_2 (normal, narrow, wide, paradoxical) and auscultate other big vessels, e.g. carotid, femoral, renal arteries for bruit.

Other Systems Examination

- Respiratory system
- Abdomen
- CNS.

Investigations

- EGG, stress tests, Holter's monitoring, radiology and other specialized investigations.

THE CARDIOVASCULAR SYSTEM (Fig. 11.1)

The Applied Anatomy and Physiology

Understanding cardiac anatomy and physiology is important in the examination of the cardiovascular system.

Surface projection of heart and great vessels: The human heart consists of 4 chambers (two atria and two ventricles). The right ventricle occupies most of the anterior cardiac surface, lies behind and to the left of sternum. Pulmonary artery arises from it at the level of sternum or base of the heart—a clinical term that refers to the right and left 2nd interspaces close to the sternum. The inferior border of the right ventricle lies below the junction of the sternum and the xiphoid process. Enlargement of right ventricle produces parasternal lift (heave) and pulsations in the epigastrium.

The left ventricle forms the left border of the heart, lies behind the right ventricle and to the left. Its tapered inferior tip forms the cardiac apex. It is clinically important because it produces *apical impulse* (*apex beat*), sometimes called *the point of maximal impulse*. This impulse is located in the precordium, within 10 cm left to midsternal border beyond which it is considered as shifted. The left ventricular enlargement shifts the apex beat down and out.

The right border is formed by right atrium, the chamber which is not identifiable on physical examination. The left atrium is situated posteriorly, hence, can not be examined directly. However, its small atrial appendage may make up a segment of left border of heart between pulmonary conus and the left ventricle, becomes visible prominently in mitralised heart. The left atrial enlargement may compress trachea, oesophagus and recurrent laryngeal nerve.

The positions of the great vessels, e.g. pulmonary artery, aorta, superior and inferior vena cavae and circulation through them are depicted in the Figure 11.1. The mitral valve (bicuspid) and tricuspid valves are called *atrioventricular valves*. The aortic and pulmonary valves are called *semilunar valves* (three cusps constitute a shape like a half-moon). As the heart valves close, the heart sounds are produced by vibrations emanating from the leaflets, the adjacent cardiac structures and the flow of the blood.

Cardiac cycle and its events (Fig. 11.2): The heart serves as a muscular pump and generates varying pressures during contraction and relaxation. Systole is the period of ventricular contraction and augmentation of pressure from 5 mmHg in resting stage to a normal peak of 120 mmHg. Diastole is the period of ventricular relaxation and fall of pressure to below 5 mmHg and flow of blood from the atrium to the ventricle. During systole, aortic and pulmonary valves open and blood flows into aorta and pulmonary artery while mitral valve

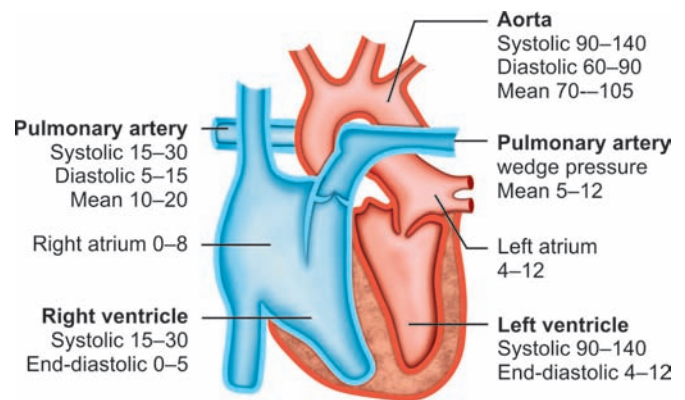


FIGURE 11.1 The cardiovascular system

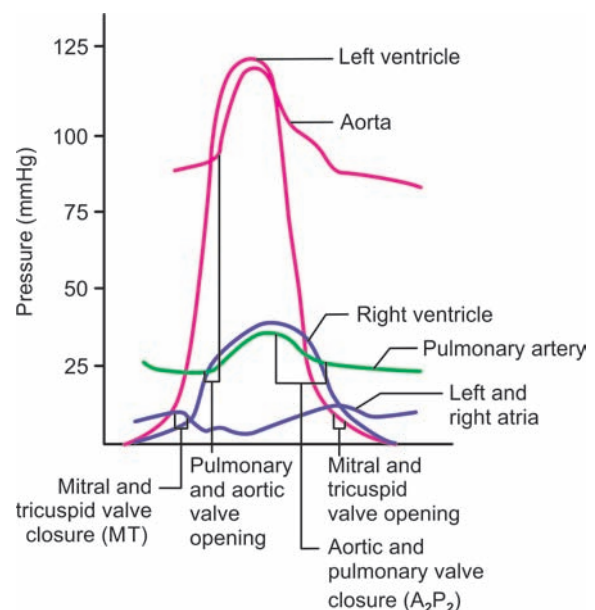


FIGURE 11.2 Events in a cardiac cycle. Normally the left ventricular system precedes the onset of pressure rise in the right ventricular system, the mitral valve, thus, closes before the tricuspid valve. Because the pulmonary artery diastolic pressure is lower than aortic diastolic pressure, the pulmonary valve opens before the aortic valve. It means pulmonary ejection sound occurs closer to the S₂ than do the aortic ejection sound. During systole pressure in the ventricles slightly exceeds the pressure in the greater vessels. Towards the end of systole, the pressure in the ventricle falls below the pressure in great vessels and when diastolic pressure is reached, the semilunar valves close. Producing S₂ (A₂P₂). Normally aortic valve closure precedes pulmonary valve closure. The mitral and tricuspid valves open at the point at which ventricular pressure falls below the corresponding atrial pressure

and tricuspid valves are closed to prevent regurgitation of blood from the ventricles to atria. In contrast, during diastole, the aortic and pulmonary valves get closed to prevent regurgitation of blood from the aorta and pulmonary artery back to ventricles. The mitral and tricuspid valves allow the blood to flow from atria to ventricles.

Understanding the interrelationship of the pressures into these chambers—left atrium and ventricle, aorta and pulmonary artery together with the position and movement of the valves is fundamental to understanding of the heart sounds. These changing pressures and the sounds that result are traced here through one cardiac cycle (Fig. 11.2).

Cardiac Murmurs

Heart murmurs result from vibrations set up in the blood stream and the surrounding heart and great vessels as a result of turbulent blood flow, the formation of eddies and cavitations (bubble formation as a result of sudden decrease in pressure). Heart murmurs are distinguishable from heart sounds by their longer duration. They may be “benign” or “innocents” when cardiac output is increased such as in fever, exercise, pregnancy. These are called *flow murmur*, heard across the pulmonary and aortic valves in the second left or right 2nd intercostal spaces respectively.

Abnormally, they may arise across a stenotic valve that obstructs the blood flow or across an incompetent valve that allows the regurgitation of blood or blood flows through an abnormal communicating channel (VSD, PDA). The features of the murmur to be observed are given in the Box 1.

Box 1

Characteristics of a murmur

- Timing of murmur, i.e. systolic or diastolic
- Radiation
- Duration
- Intensity or loudness
- If associated with thrill or not
- Site where it is best heard
- Quality/character

Types of Murmurs

Depending on the timing, they can be *systolic*, *diastolic* and *continuous murmur*.

The main differences between systolic and diastolic murmur are given in Table 11.1.

Whether a murmur is *systolic* or *diastolic* is decided by its timing with apex beat or carotid pulse. Therefore, while hearing the murmur, fingers must be put on carotid pulse to time it. Carotid pulse normally coincides with first heart sound. A *systolic murmur* is heard between 1st and 2nd heart sounds. A diastolic murmur is heard between 2nd and 1st heart sound, i.e. during diastole. A *continuous murmur* is heard both in systole and diastole. The loudness or intensity of murmurs is graded on a scale of 1–6. The murmur associated

TABLE 11.1 Distinguishing features of two commonly encountered murmurs

Systolic	Diastolic
<ul style="list-style-type: none"> • Soft and blowing • Crescendo-decrescendo • Shows radiation. Mitral murmurs radiate to left axilla and aortic to neck vessels • Are ejection systolic, midsystolic, pansystolic and late systolic • Appears between 1st and 2nd heart sound 	<ul style="list-style-type: none"> • Rough and rumble (mitral) or blowing (aortic and pulmonary) • Decrescendo in character • Nonradiating • Early and mid-diastolic • Appears between 2nd and 1st heart sound.

with thrill is graded IV loud murmur. Grade I is difficult to hear and Grade VI is heard with stethoscope without touching the chest, i.e. by lifting the stethoscope for a smallest distance from the chest. The location of a murmur and direction of radiation reflect the direction of turbulent flow. The grading of murmur is as follows:

Grade	Systolic murmurs	Diastolic murmurs
I	Very soft (heard only in good circumstances)	Very soft (heard only in good circumstances)
II	Soft	Soft
III	Moderate	Moderate
IV	Loud	Loud or associated with palpable thrill
V	Very loud	—
VI	Very loud (no stethoscope needed) or associated with palpable thrill	—

Systolic murmurs

The ejection or midsystolic murmurs are associated with ventricular outflow obstruction, occur in early or midsystole and possess crescendo-decrescendo character. Pansystolic murmurs extend from 1st heart sound throughout systole and maintain a constant intensity. Late systolic murmurs occur during the end of systole.

Diastolic murmurs

Mid-diastolic murmurs occur due to turbulent flow across mitral and tricuspid valves. *Early diastolic murmur* occurs due to regurgitation of blood flow from aortic and pulmonary valves into the heart. They are decrescendo and blowing in character.

Benign (physiologic) murmurs

They do not occur beyond early or midsystole. The characters of these murmurs are given in the Box 2.

Box 2

Characteristics of a benign or innocent murmur

- They are soft and musical
- Mostly mid-systolic or ejection systolic
- Heard at the left sternal edge
- They do not radiate
- Not associated with thrill
- No other cardiac abnormality

Continuous murmurs

These usually result from combination of systolic and diastolic flow across a communicating channel between heart and a vessel or between two vessels having different pressures. These murmurs start with the onset of systole, pass through the systole with increasing intensity and, then pass through 2nd heart sound to enter into diastole (Waxing and waning character). There is constant gradient during systole and diastole. They are heard in patients *with patent ductus arteriosus, aorto-pulmonary window and an arteriovenous communication, coronary arteriovenous fistula and communication between sinus of valsalva and right side of the heart.*

Effects of Certain Physiological and Pharmacological Interventions on Heart Murmurs

Certain manoeuvres that increase or decrease the blood flow across the valves alter the intensity of the murmur (Table 11.2). Right sided murmur increases due to increase in venous return to the heart (e.g. inspiration). The systolic murmurs of hypertrophic cardiomyopathy (HCM) and mitral valve prolapse (MVP) become louder with valsalva manoeuvre and during standing.

The types of murmurs, their location and conditions in which they are produced are given in Table 11.3.

Cardinal Symptoms of Cardiovascular Disease (Read Chapter 2.1)

The **presenting symptoms** once again are enumerated here.

- Dyspnoea, orthopnoea, paroxysmal nocturnal dyspnoea (PND)
- Increase in heart beat (palpitations)
- Chest pain; exertional in ischemic heart disease (IHD), tearing in aortic dissection and dull or sharp continuous and central in pericarditis that increases with movement and change in posture.
- Swelling of the legs (peripheral oedema). It is a common symptom of congestive heart failure.
- Syncope, tiredness or fatigue are symptoms of those cardiovascular diseases which produce low cardiac output and CHF.

TABLE 11.2 Effects of certain manoeuvres on heart murmurs

Manoeuvre	Effect
Respiration	Right sided murmurs of TR, PS, TS and PR increase during inspiration. Left sided murmurs become louder during expiration
Valsalva manoeuvre. This procedure helps to differentiate murmur of hypertrophic cardiomyopathy (HCM) from aortic stenosis. It helps to identify a prolapsed mitral valve.	Most murmurs decrease in length and intensity. Two murmurs that become louder include systolic murmurs of HCM and mitral valve prolapse (MVP). The systolic murmur of aortic stenosis decreases which differentiates it from HCM.
Positional change	With standing (decreased venous return i.e. preload) and decreased vascular resistance most murmurs diminish but systolic murmur of HCM, becomes louder while that of MVP increases in length and intensity (click moves earlier in systole and murmur lengthens). With squatting (increased venous return as well as peripheral vascular resistance) there is decrease in the intensity of murmur of HCM and MVP but increase in the intensity of murmur of aortic stenosis.
Exercise	Murmurs due to rapid blood flow across normal or obstructed valves (e.g. MS, PS) become louder with both isotonic and isometric (handgrip) exercise.
Pharmacological interventions	During amyl nitrate inhalation (hypotensive response), the murmurs of MR, VSD and AR decrease while murmur of aortic stenosis increases. The response in MVP is biphasic (first softer and then louder than normal) The phenylephrine (vasoconstrictor) tends to produce opposite effects.

- Nocturia is a symptom of congestive heart failure (CHF)
- Anorexia, nausea, vomiting are symptoms of CHF (congestive hepatomegaly and gastroenteropathy) or digitalis toxicity.

EXAMINATION OF CARDIOVASCULAR SYSTEM (CVS)

A clinical approach to a patient with cardiovascular disease include:

- **General physical examination:** It is important to note certain peripheral signs of a cardiovascular disease or its

TABLE 11.3 Murmurs, their location and characters

Timing of murmurs	Location	Radiation
Systolic murmurs		
<i>Ejection systolic (crescendo-decrescendo) murmurs</i>		
Aortic stenosis	2nd right space (A ₁ area)	To neck vessels
Pulmonary stenosis	2nd left space (pulmonary area)	None
Hypertrophic cardiomyopathy	At lower left sternal border	None
Falot's tetralogy	At pulmonary area	None
Atrial septal defect	At pulmonary area	None
<i>Pansystolic</i>		
Mitral regurgitation	At apex	Radiation towards left axilla
Tricuspid regurgitation	Left sternal edge	Radiation towards left axilla
Ventricular septal defect (low pitched, harsh, rasping)	4th space left sternal edge	Across the sternum
<i>Late systolic</i>		
Mitral valve prolapse	Apex	Radiates to left axilla
Hypertrophic cardiomyopathy	Apex	None
Diastolic murmurs		
<i>Early diastolic murmurs</i>		
Aortic regurgitation	Left sternal edge	
Pulmonary regurgitation (Graham-Steell's murmur)	Left sternal edge	
<i>Mid-diastolic murmurs</i>		
Mitral stenosis	Apex	
Austin-Flint due to aortic regurgitation	Left sternal edge	
Continuous murmurs		
Patent ductus arteriosus	Upper left sternal edge below left clavicle	
Aorto-pulmonary window	Upper left sternal border	

complications (e.g. CHF, endocarditis, rheumatic activity, arrhythmia, thromboembolism, etc.)

- **Systemic examination:** It includes examination of heart (precordium)
 - Inspection
 - Palpation
 - Percussion
 - Auscultation
- **Examination of vascular system (arteries and veins).**

General Physical Examination (GPE)

After taking the history and before proceeding to examination of the heart, following points given in the Box 3 are to be observed on general physical examination.

Cyanosis

Bluish discolouration of skin and mucous membrane is called *cyanosis*. It may be peripheral or central or mixed.

Peripheral cyanosis

It occurs due to extraction of O₂ from the blood when circulation is slow either due to congestive cardiac failure or

Box 3

Points to be noted on general physical examination

- Cyanosis (e.g. central or peripheral or mixed)
- Painful fingertips (Osler's nodes)
- Oedema (pitting or nonpitting)
- Palmar erythema (Janeway lesion)
- Anaemia
- Splinter haemorrhage
- Extremities (cold or warm, gangrene of toes or fingers)
- Jaundice
- Clubbing of the fingers
- Lymphadenopathy
- Malar flush over cheeks
- Pulse, BP and temperature

due to shock or vasospasm (Raynaud's phenomenon leading to vasoconstriction. It can occur in healthy persons when extremities are too cold, and warmth abolishes it. It is seen on lips, nails, tip of nose, ear lobe, etc.

Central cyanosis

It is due to poor oxygenation of blood in the lungs due to interference in exchange of gases (O₂ and CO₂) such as in

respiratory failure or pulmonary oedema. It is also seen in certain congenital heart disease where unoxygenated or deoxygenated blood from right side mixes with oxygenated blood from the left, brings down the oxygen saturation of blood, i.e. cyanotic congenital heart disease. Central cyanosis is seen on the under surface of the tongue, mucous membrane of oral cavity and palate.

Mixed cyanosis

A combination of peripheral and central cyanosis is seen in congestive cardiac failure.

Clubbing of Fingers (See Fig. 10.18)

Clubbing of fingers in a cardiovascular patient indicates cyanotic congenital heart diseases or subacute bacterial endocarditis.

Splinter Haemorrhages (Fig. 11.3)

These are flame-shaped or linear haemorrhages under the nail bed, seen in infective endocarditis.

Painful Finger-Tips/Toes

It is seen in infective endocarditis (Fig. 11.4) due to embolisation of peripheral vessels. There can be gangrenous fingers or toes due to impaction of an embolus.

Janeway Lesion (Palmer Erythema)

Redness of hypothenar or thenar prominence occurs due to vasculitis in infective endocarditis.

Temperature of Extremities

Cold extremities in warm environment indicates congestive cardiac failure. Warm moist palms on the other hand, indicate anxiety or thyrotoxicosis.

Malar Flush

A blush hue is seen over cheeks in fair complexed person in mitral stenosis (MS) due to low cardiac output.

Oedema

Compare one foot and leg with the other, noting their relative size and the prominence of veins, tendons and bones.

Oedema causes swelling that may obscure the veins, tendon and bony prominences.

Check for pitting oedema: (Read examination of extremities).

If you suspect oedema, measurement of the legs may help you to identify it and to follow its course. A difference of more

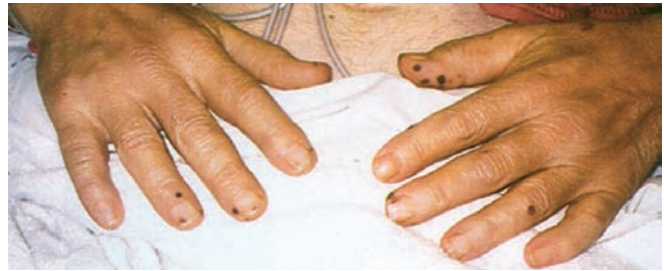

FIGURE 11.3 Splinter haemorrhages. Multiple purple lesions and splinter haemorrhages in the finger nails due to endocarditis

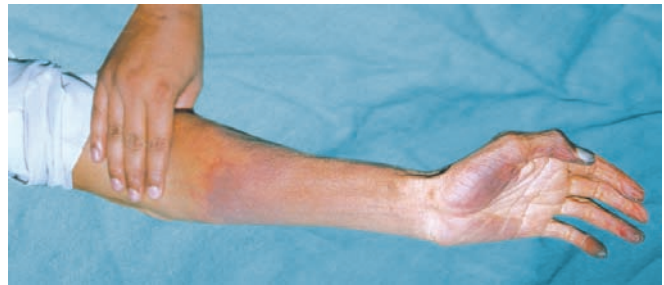

FIGURE 11.4 Painful finger-tips in a patient with RHD with endocarditis. This was due to embolisation of the brachial artery. There was loss of radial pulse

than 1 cm just above the ankle or 2 cm at the calf is unusual in normal persons and suggests oedema.

The Arterial Pulse

With each contraction, the left ventricle ejects a volume of the blood into the aorta and then into the arterial system. The ensuing pressure wave moves rapidly through the arterial system, where, it is felt as the arterial pulse. The radial pulse is palpated for analysis (Fig. 11.5). Method of examination of various pulses is demonstrated in peripheral vascular system examination.

The pulse is observed for (i) *rate* (ii) *rhythm* (iii) *character* (iv) *volume*, (v) *radioradial and radiofemoral delay* and (vi) *condition of the vessel wall*. All the peripheral pulses should be examined.

Rate: To assess the rate, radial pulse is frequently used as it is superficially placed. Count the beats for at least half a minute if pulse is regular and multiply it by two to get the rate in beats per minute (bpm). If pulse is irregular, count the pulse for full one minute to get the approximate rate.

If pulse is irregular, then also count the heart rate with stethoscope for one minute and calculate the pulse deficit.

Pulse deficit = Heart rate minus pulse rate. Note: Vice versa is not true because pulse rate can never be faster than heart rate. The pulse deficit is due to non-conduction of feeble heart beats to the pulse resulting in their non-palpability,

hence, the deficit. The pulse deficit >10 beat/min occurs in atrial fibrillation and less than 10 beats/min in ventricular ectopics but this is not a hard and fast rule.

A normal resting pulse rate is between 60–100 bpm in an adult and 80–200 bpm in a child. Pulse rate (heart rate) less

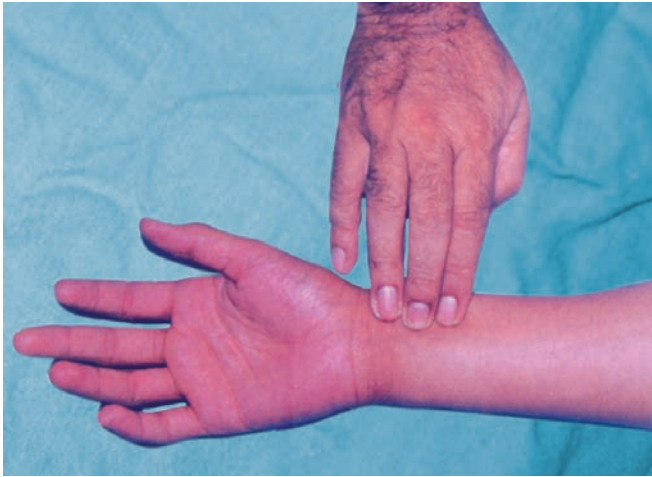

FIGURE 11.5 Method of examination of radial pulse. The patient should sit or lie on the bed or couch. The arm should be by the side, elbow slightly flexed and forearm mid-pronated so as to avoid kinking of artery and to have proper transmission of pulse wave. Use three fingers for palpation. Use fingers of the right hand for palpation of patient's right radial pulse

than 60/min is called bradycardia and more than 100/min as tachycardia. The causes of fast and slow pulses are given in the Box 4.

Rhythm: The normal rhythm of the heart originates from the SA node, hence, called sinus rhythm. Sinus rhythm is seldom completely regular because heart rate increases during inspiration and decreases during expiration, a condition called sinus arrhythmia. The sinus arrhythmia is most obvious in children, young adults and athletes.

When the pulse is irregular, it is important to identify the nature of irregularity and to determine whether it is present continuously or intermittently. Some common causes of irregular pulse are enumerated in the Box 5. An occasional irregularity is caused by ectopic beats or extrasystoles which can be atrial or ventricular. Frequently the pulse wave produced is too weak to be felt at the wrist resulting in missing of a beat. In case of irregularity or missing of beat, pulse deficit may be calculated.

The multiple ventricular ectopics produce regularly irregular pulse. Ventricular ectopics do not penetrate the SA node, hence, do not reset it, therefore, a compensatory pause results following an ventricular ectopic which is seen on ECG. Sometimes, ectopic beats occur regularly, i.e. an ectopic alternates with a sinus beat regularly called pulsus bigemini and may give an erroneous impression of a very slow pulse.

Box 4

Causes of fast and slow pulse rate (e.g. heart rate)

Bradycardia (HR < 60/min)

Sinus bradycardia

- Sleep
- Athletic heart
- Hypothyroidism
- Hypothermia
- Second degree AV block
- Raised intracranial pressure
- Obstructive jaundice
- Drugs, e.g. betablockers, calcium channel blocker, digoxin, etc.
- Poisoning, e.g. OP compounds

Tachycardia (HR > 100/min)

Sinus tachycardia

- Physiological, e.g. exercise, fever, use of tea, coffee, etc.
- Pain
- Anxiety/excitement
- Thyrotoxicosis
- Heart disease, e.g. CHF, congenital heart disease
- Drugs, e.g. sympathomimetics, vasodilators
- Pheochromocytoma

Arrhythmic bradycardia

- Carotid sinus hypersensitivity
- Sick sinus syndrome
- Complete heart block

Arrhythmic tachycardia

- Atrial fibrillation
- Atrial flutter
- Supraventricular tachycardia (SVT)
- Ventricular tachycardia (VT)

Box 5

Causes of irregular pulse

- | | |
|---|--|
| <p><i>Irregularly irregular pulse</i></p> <ul style="list-style-type: none"> • Sinus arrhythmia (respiratory or non respiratory) • Atrial ectopics (extrasystoles) • Ventricular ectopics (extrasystoles) • Atrial fibrillation with variable response • Second degree AV block with variable response | <p><i>Regularly irregular pulse</i></p> <ul style="list-style-type: none"> • Ventricular ectopics in bigeminus or trigeminus pattern • Atrial flutter with fixed AV conduction |
|---|--|

TABLE 11.4 Causes of atrial fibrillation

Common	Uncommon
<ul style="list-style-type: none"> • Rheumatic heart disease (e.g. MS and MR) • Thyrotoxicosis • Coronary artery disease • Cardiomyopathy • Myocarditis 	<ul style="list-style-type: none"> • Constrictive pericarditis • Cor pulmonale • Congenital heart disease (e.g. ASD, Ebstein’s anomaly) • Wolff-Parkinson-White (WPW) syndrome • Left atrial myxoma • Heart surgery • Idiopathic (lone AF)

Atrial fibrillation (AF) causes a totally random heart rhythm leading to a pulse which is irregular in both timing and volume. This is often described as an “irregularly irregular pulse”. The pulse deficit is more in atrial fibrillation than in ventricular ectopics. The causes of atrial fibrillation are given in the Table 11.4.

Volume: It is the amplitude of the pulse that is judged by the palpating finger. It depends on the pulse pressure and graded as *good or high volume* (high pulse pressure > 60 mmHg) or *normal* (pulse pressure between 30–60 mmHg) and *low volume* (pulse pressure <30 mmHg). The method to decide volume of pulse is given Box 6.

A *good volume or bounding or collapsing pulse* (read collapsing pulse) occurs due to diastolic “run off” the blood from aorta (aortic regurgitation, PDA) or from the left ventricle (MR, VSD) or high output states or vasodilatation. The causes of high volume pulse are given in the Box 7.

Low volume pulse is characterised by small amplitude, is due to either low systolic pressure or raised diastolic pressure resulting in low pulse pressure. The causes of low volume pulse are also given in the Box 7.

Box 6

Method to decide volume of the pulse

- Pulse volume is decided by the amplitude by which the finger is displaced during palpation with each beat.
- Normally, pulse is felt without lifting of the fingers.
 - Pulse volume is said to be good or high if lifting of fingers occurs
 - If pulse is felt with difficulty, it is said to be low volume pulse.

Box 7

Causes of change in volume of the pulse

Good volume pulse (augmented stroke output)	Low volume pulse (reduced stroke volume)
<p><i>Physiological</i></p> <ul style="list-style-type: none"> • Exercise • Emotion, anxiety • Heat • Pregnancy 	<ul style="list-style-type: none"> • Valvular stenosis (aortic, mitral, tricuspid and pulmonary) • Tachycardias • Left ventricular outflow obstruction (fixed) • Shock
<p><i>Pathological</i></p> <ul style="list-style-type: none"> • Fever • Thyrotoxicosis • Anaemia • Peripheral AV shunts • Paget’s disease of the bone • Beriberi • Cor pulmonale • Vasodilators • Aortic regurgitation • Mitral regurgitation • Left to right shunt (PDA, VSD) 	<ul style="list-style-type: none"> • Pump failure following massive acute myocardial infarction • Congestive heart failure • Peripheral vascular disease. • Dilated cardiomyopathy

A *varying volume pulse* is either a *pulsus alternans* or *pulsus paradoxus*.

Pulsus alternans is a regular pulse but alternate beats are strong and weak. It is difficult to appreciate *pulsus alternans* by the palpating fingers, but is diagnosed while measuring the blood pressure. When the mercury is being lowered, the stronger beats are heard first and on further lowering, the weaker beats also become audible, thus, suddenly doubling the number of audible beats.

Pulsus alternans is a sign of severe myocardial disease, resulting in left heart failure.

Pulsus paradoxus describes a pulse that increases in volume during expiration and decreases in inspiration—an

exaggeration of normal phenomenon. Technically, the term is a misnomer because this variation (BP fall of <10 mmHg on inspiration) is physiological, is most accurately assessed using an appropriate, blood pressure cuff to measure the difference in systolic pressure between inspiration and expiration; a difference of >10 mmHg or a fall > 10 mmHg in BP during inspiration is pathological and confirms pulsus paradoxus.

Pulsus paradoxus is seen in conditions associated with restricted diastolic filling of right side of the heart during inspiration (e.g. constrictive pericarditis, cardiac tamponade or massive pericardial effusion), increased respiratory effort in severe asthma during inspiration or lowered left ventricular stroke volume in shock.

Character: The normal character of the pulse is fairly rapid rise, rounded peak and fairly rapid fall. The waveform consists of “*a percussion wave, a tidal wave, a dicrotic wave and a notch*”.

It is usually not possible to detect slight variations from the normal, but in certain diseases the character of the arterial pulse is detectably abnormal. Some classical pulses seen in certain conditions and their characteristics are given in the Table 11.5 and Figure 11.6.

Radiofemoral delay: Delay of femoral as compared to radial pulse is seen in coarctation of aorta and occlusive aortic disease. The coarctation of aorta is nothing but constriction or narrowing of a part of aorta resulting in slow transmission of pressure wave, hence, the delay.

Radioradial delay: One radial pulse usually the left is delayed in preductal coarctation.

Arterial wall: The aorta and large arteries stiffen with age as they become atherosclerotic. As the aorta becomes less distensible, a given stroke volume causes a greater rise in systolic blood pressure; systolic hypertension with a widened pulse pressure often ensues. Peripheral arteries tend to lengthen, become tortuous and feel harder, hence, vessel wall becomes palpable.

Water hammer pulse is better appreciated in the big vessel, e.g. better in the brachial than the radial.

Normally vessel wall is not palpable due to resilient arteries but becomes palpable in old age and in hypertensives due to stiffness and hardening of arteries (arteriosclerosis and atherosclerosis).

Blood Pressure

This is the pressure at which blood is flowing in the arterial system. It is due to pressure exerted by the intravascular blood volume laterally on the vessel wall. Systolic blood

pressure (BP) depends on the cardiac output and diastolic BP depends on peripheral resistance.

In western societies, the systolic BP tends to rise from childhood through old age. Diastolic BP stops rising, however, roughly around the sixth decade.

Clinically the BP is measured by a mercury sphygmomanometer or instrument. To measure the BP accurately, one must choose a cuff of appropriate size, i.e.

- Width of standard cuff should be about 40% of upper arm circumference (about 12–14 cm for an average adult)
- The length of the cuff should be about 80% of upper arm circumference (almost long enough to encircle the arm)
- If aneroid instrument is used, recalibrate periodically before use because it becomes inaccurate with repeated use.

Note: Cuff that are too short or too narrow may give falsely high readings. Using a regular-size cuff on an obese arm may lead to a false diagnosis of hypertension. For children, a variety of cuffs of different widths are available for use.

Technique (Fig. 11.8): While assessing the BP, you must take following steps to make sure that your measurement is accurate. The examination sequence is as follows:

- Ideally ask the patient to avoid smoking or drinking caffeinated beverages for 30 minutes before BP is measured, and person should rest for at least 5–10 minutes.
- Support the arm comfortably at about heart level.
- Remove all the clothing from the arm.
- Apply the cuff to the arm and identify the brachial pulse.
- Inflate the cuff until the pulse is impalpable. Note the pressure on the manometer which is rough estimate of systolic pressure.
- Now inflate the cuff another 20–30 mmHg above and listen through the stethoscope over the brachial artery.
- Deflate the cuff slowly until the regular heart sounds (called Korotkoff sounds) can be heard. This is systolic pressure which should be measured to the nearest 2 mmHg.
- Continue to deflate the cuff slowly until the sounds disappear.
- Record the point at which the sounds just disappear or get muffled. It is diastolic BP. Usually as the sphygmomanometer cuff is deflated the Korotkoff sounds get gradually louder, then suddenly become muffled just before they disappear.

Occasionally the muffled sounds persist, in which case, the point at which they first become muffled gives the diastolic BP. A checklist for BP measurement is given in the Table 11.6.

In some people, muffling point and the disappearance point are further apart. Occasionally as in the regurgitation,

TABLE 11.5 Characteristic pulses and the conditions associated with them

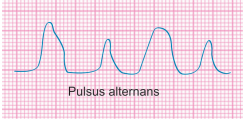
Pulse	Characteristic (Figs 11.6A to I)	Condition(s)
Normal: It has a fairly rapid rise, rounded top and fairly steep fall	 <p>Normally seen (Fig. 11.6A)</p>	Normal pulse wave P = Percussion wave T = Tidal wave N = Notch D = Dicrotic wave VS = Ventricular systole
Anacrotic: It is a slow rising, small volume, well-sustained pulse. It is now-a-days called pulsus tardus. An anacrotic notch (AN) between percussion and tidal wave is present.	 <p>(Fig. 11.6B)</p>	Aortic stenosis: It is due to obstruction to ejection of left ventricle leading to delayed and small peak.
Collapsing or Water Hammer or Corrigan's pulse: It is characterised by a rapid upstroke (forceful, high percussion wave) which gives a tap to the palpating finger similar to feeling of a water-hammer, and rapid downstroke or descent producing collapsing character due to sudden disappearance of the pulse wave from the palpating hand. The method of palpation of water hammer pulse is described in Figure 11.7	 <p>(Fig. 11.6C)</p>	This is found in <i>aortic regurgitation, PDA, AV fistula</i> and other <i>high output states</i> (Read good volume or bounding pulse)
Pulsus parvus: It is low volume ill-sustained pulse, differs from pulsus tardus where pulse is low-volume but well sustained.	 <p>(Fig. 11.6D)</p>	It is seen in <i>mitral stenosis</i> . Low stroke volume produces malar flush.
Pulsus bisferiens: It is double peak pulse. The first peak is due to quick rising percussion wave and second peak is due to delayed tidal wave, with a notch in between, thus both the peaks have same amplitude	 <p>(Fig. 11.6E)</p>	It is seen in <i>aortic regurgitation alone, combined aortic stenosis and aortic regurgitation and hypertrophic cardiomyopathy (HCM)</i>
Dicrotic pulse: It is characterised by two palpable waves, one in systole and one in diastole, separated by an accentuated normal dicrotic notch.	 <p>(Fig. 11.6F)</p>	It is frequently seen in patients with a low stroke volume particularly <i>dilated cardiomyopathy</i> . It is also seen in <i>high grade fever</i> .
Pulsus alternans: Large and small volume pulses alternate due to alternation of stroke volumes.	 <p>(Fig. 11.6G)</p>	It is seen in <i>CHF</i> and <i>dilated cardiomyopathy</i>
Pulsus bigeminus or trigeminus or quadrigeminus: The pulse is regularly irregular and is due to fixed unifocal extrasystoles coming after every normal beat or after every two or three normal beats with the usual pause after the extrasystole	 <p>(Fig. 11.6H)</p>	It is seen in patients with <i>multiple unifocal ectopics</i> with fixed pattern.
Pulsus paradoxus: Volume of pulse decreases during inspiration and increases during expiration	 <p>(Fig. 11.6I)</p>	<i>Pericardial effusion, shock, acute asthma</i>

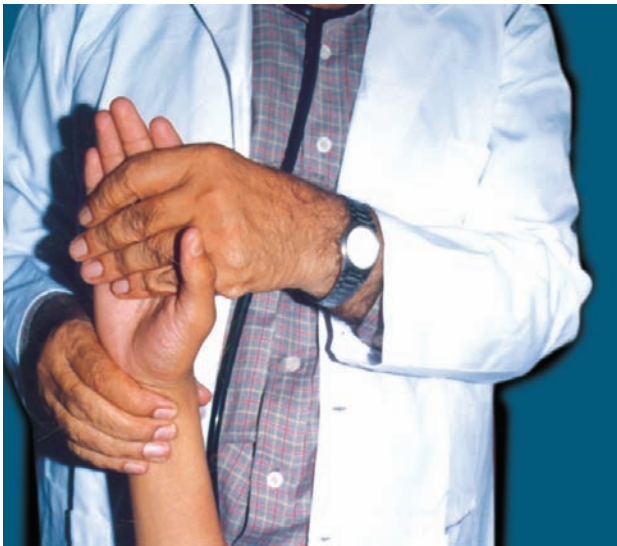

FIGURE 11.7 Method of palpation for water-hammer pulse. The patient should lie or sit on a couch/bed. Raise the patient's arm above the head to bring radial and brachial artery in line with aorta for better palpation of the pulse wave. Hold the patient's right hand with your left hand. Put the three fingers of your right hand either on the radial or brachial artery. Feel for the rapid upstroke and rapid downstroke of the pulse

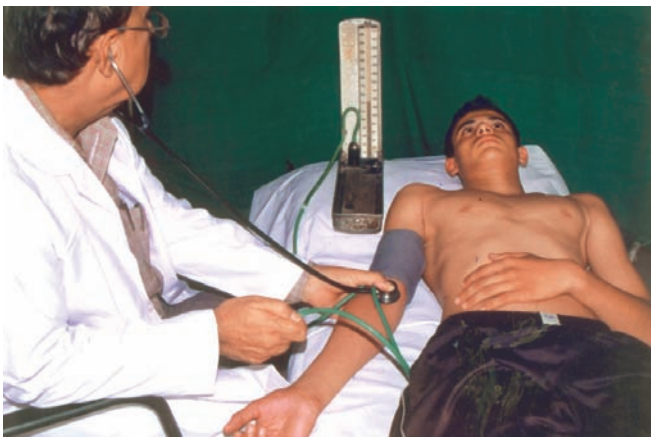

FIGURE 11.8 Measurement of blood pressure

TABLE 11.6 Checklist for measurement of blood pressure

Patient	Relaxed, arm supported at heart level. All clothings removed from the arm
Cuff	Neatly applied—appropriate size for arm. No leaks
Manometer	Well supported, upright, if aneroid, calibrated regularly
Doctor/Student	Check systolic pressure by palpation. Release pressure slowly. Avoid parallax error (eye at same level as manometer). Avoid end-digit preference (record to nearest 2 mmHg)

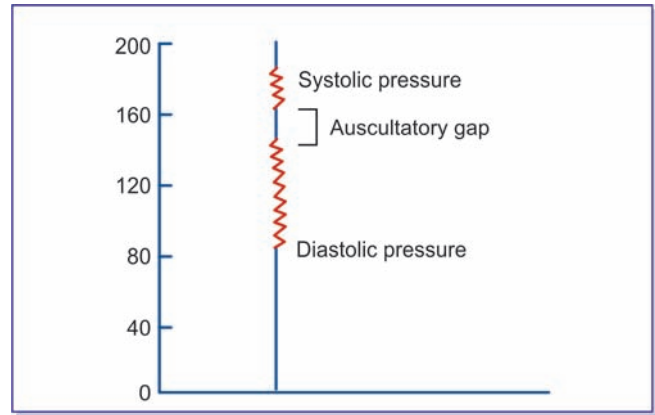


FIGURE 11.9 The Korotkoff sounds and an auscultatory gap. If you find an auscultatory gap, record your finding as follows; BP—130/90 with an auscultatory gap from 160–150 mmHg

the sounds never disappear. If there is more than 10 mmHg difference in muffling and disappearance point, record both figures as 150/80/68.

Note: An unrecognised gap on auscultation (Fig. 11.9) may lead to serious underestimation of systolic BP (e.g. 140/90 mm in the example below) in such a situation, record your findings completely (e.g. 200/90 with an auscultatory gap from 160 to 140 in the example below).

How to write BP? The blood pressure is written as systolic/diastolic, for example 140/90 mmHg means 140 mm is systolic and 90 mmHg is diastolic BP.

Blood pressure should be taken in both arms at least once. Normally there may be a difference of 5 mmHg and sometimes upto 10 mmHg, beyond this, it is abnormal hence, repeated measurements are to be taken in case of abnormality.

Definitions of normal and abnormal level

Blood pressure varies with excitement, stress and environment. Repeated measurements are required before a patient should be identified as hypertensive. In some patients, the measurement of just BP by the doctor as soon as the patient approaches the doctor cause BP to rise-called white coat hypertension. This may come to normal after sometime when the patient is relaxed and as soon as he/she comes out of doctor's chamber. Ambulatory BP monitoring helps to distinguish these patients from those with sustained hypertension.

The 7th joint national committee (JNC VII) report on prevention, detection, evaluation and treatment of hypertension, has defined normal and abnormal values of BP (Box 8). According to it, 120/80 mmHg is taken as upper limit of normal. This report has been superseded by JNC VIII report in which 120/80 mmHg had been retained as normal. The normal pulse pressure (difference between systolic and diastolic) is around 20–40 mmHg.

Box 8

JNC VIII classification of hypertension

Category	Systolic (mmHg)	Diastolic (mmHg)
Normal	<120	<80
Prehypertension (previous term high normal replaced)	120–139	80–89
Hypertension		
• First stage	140–159	90–99
• Second stage	> 160	> 100

In patients taking antihypertensive treatment or elderly patients or patients with symptoms of faintings or syncope, or patients with depletion of blood volume, take the BP in *supine*, *sitting* and *standing* positions (unless contraindicated). Normally, as the patient rises from the horizontal to a standing position, systolic pressure drops slightly or remains unchanged, while diastolic pressure rises slightly. Another measurement after 1 to 5 minutes of standing may identify orthostatic hypotension missed by earlier readings. The repetition is especially useful in elderly. A fall in systolic BP ≥ 20 mmHg especially when accompanied by symptoms indicates *orthostatic (postural) hypotension*.

In suspected coarctation of aorta, it is useful to compare the systolic BP in the arm with that in the leg; the patient lies prone and an 18 cm cuff is used above the knee to measure the systolic BP over the popliteal artery.

Special problems and the remedial measures

Some specific problems may produce difficulty as well as erroneous record of BP. The problems and the remedial measures are given in the Table 11.7.

Jugular Venous Pulse and Pressure

The neck veins (internal and/or external jugular veins) are used to analyse the venous waveforms and to estimate the jugular venous pressure (JVP). In most patients, the right internal jugular vein is the best for both the purposes because:

- There are no valves between right atrium and the internal jugular vein. It follows that degree of distension of the veins is directly proportional to the pressure in the right atrium and there is direct transmission of waveforms of right atrium to internal jugular vein, hence, venous waveforms, provide valuable information about cardiac function.
- Because of its deep position, the internal jugular vein can only be examined when the neck muscles are relaxed. Only a diffuse pulsation can be seen if the vein is not

TABLE 11.7 Specific problems related to blood pressure and their remedial measures

Problem/Condition	Measure(s)
<i>Anxious or apprehensive patient.</i> There may be a high reading during an initial visit.	<ul style="list-style-type: none"> • Try to relax the patient • Repeat your measurements later • Some patients will say their BP is only elevated in the office or just during recording (white-coat hypertension), they need to have their BP checked several times at home or in a community setting
<i>The obese or very thin arm</i>	<ul style="list-style-type: none"> • For obese arm, use a wide cuff (15 cm). If the circumference of the arm exceeds 41 cm, then use thigh cuff (18 cm wide) • For the very thin person, a pediatric cuff may be used.
<i>Weak leg pulses and pressure.</i> A femoral pulse that is weak (smaller) and comes later than radial pulse indicates coarctation of aorta or occlusive aortic disease.	<ul style="list-style-type: none"> • Compare the volume and timing of the radial and femoral pulses. • Compare the BP in the arm and leg. BP is lower in the legs than in the arms in these conditions. • To rule out coarctation of the aorta, two observations must be made at least once in the hypertensive patient. • Use thigh cuff (18 cm) for recording of BP in the leg.
<i>Weak or inaudible Korotkoff sounds.</i> The causes are: <ul style="list-style-type: none"> • Erroneous placement of stethoscope • Failure to make full contact with the bell. • Venous engorgement of the patient’s arm from repeated inflations of the cuff. • Patient in shock. 	<ul style="list-style-type: none"> • To intensify the Korotkoff sounds, one of the following method may be useful: <ul style="list-style-type: none"> – Raise the patient’s arm before and while you inflate the cuff. Then lower the arm and take the BP. – Inflat the cuff. Ask the patient to make a fist several times and then take BP. • When you cannot hear the Korotkoff sounds at all, estimate the BP by palpation method or alternatively by Doppler technique.
<i>Arrhythmias:</i> Irregular rhythms produce variations in pressure and therefore, unreliable measurement.	<ul style="list-style-type: none"> • Ignore the effects of an occasional extrasystole • With frequent VPCs or atrial fibrillation, determine the average of several observations.

visible. The external jugular vein is visible but it is not routinely examined because it is prone to kinking and partial obstruction as it traverses deep fascia of the neck.

- The venous pulsations in the neck when the veins are not visible cause confusion with carotid pulsations. The differentiating features between the two are tabulated (Table 11.8).

TABLE 11.8 Distinctions between jugular and carotid artery pulsations

Internal jugular pulsations	Carotid pulsations
<ul style="list-style-type: none"> • Not palpable • They have rapid inward movement • Two peaks per heart beat in sinus rhythm • Pulsations can be diminished or obliterated by pressure at root of the neck • Level of pulsations changes with position, i.e. drops as the patient becomes more upright • Level of pulsations usually descends with inspiration • Veins can be made prominent with abdominal pressure (abdomino-jugular reflux) 	<ul style="list-style-type: none"> • Palpable • Rapid outward movement • A vigorous thrust with a single peak per heart beat • Pulsations unaffected by such pressure. • Position does not have any effect • Pulsations not affected by inspiration. • Abdominal pressure has no effect

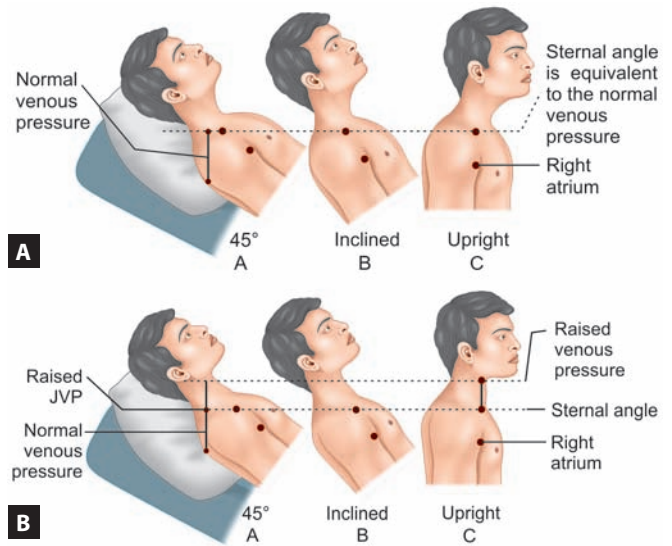
Normal jugular venous pressure (JVP)

The normal mean right atrial pressure is < 9 cm of H₂O or < 8 mmHg. Since the sternal angle (angle of Louis) is approximately 5 cm above the right atrium, therefore, the normal jugular venous pulse should not extend beyond 4 cm above the sternal angle (Figs 11.10A and B). When a normal person sits upright the pulse is hidden behind the clavicle and sternum. When the patient is reclined to 45°, the top of the pulsations is normally just at the level of the clavicle. If pulsations are not seen at this inclination, then a normal right atrial pressure is confirmed by applying pressure over the centre of the abdomen for 5–10 seconds (abdominojugular reflux). This manoeuvre increases the venous return to right side of the heart and leads to transient rise in right atrial pressure of 1–3 cm which is reflected in the height of jugular venous pulse.

A hypovolemic patient may have to lie flat before you see the veins; while normally venous pulsations are visible just above sternal angle when reclined at 45°. In contrast, when jugular venous pressure is raised, reclination upto 60° or even 90° may be required to see the pulsations which may be hidden behind the angle of the jaw. In all these positions, the sternal angle usually remains about 5 cm above the right atrium as illustrated in the diagram (Fig. 11.10).

Waveform: Identification of the jugular venous pulse waveform requires experience. It has two positive waves; a wave and v wave, and two descents x and y. There is a third positive wave called 'c' wave is not visible (Fig. 11.11).

The 'a' wave or first positive wave occurs due to right atrial contraction just before the first heart sound.



FIGURES 11.10A and B Jugular venous pulsations and jugular venous pressure: (A) Normal jugular venous pressure. In normal subjects, when body is inclined to 45° to the horizontal, (A) the venous pulsations are just visible in the internal jugular vein just above the clavicles (B). As patient tries to adopt upright position, the distance between the right atrium and sternal angle remains constant, regardless of the position of the thorax. However, in sitting (upright) position (C), the venous pulsations, become hidden behind the clavicle which is just situated equivalent to the sternal angle. Therefore, for JVP, the inclination of 45° is must to see the venous pulsations; (B) *Raised jugular venous pressure* (↑JVP). When JVP gets elevated, the internal jugular vein becomes full and venous pulsations appear in the neck which can be appreciated. To differentiate them from carotid pulsations, perform hepatojugular reflux which not only makes the veins prominent but also gives an idea of upper column of pulsations. The JVP is measured as vertical distance between top of the pulsations and sternal angle. When JVP is markedly elevated the venous pulsations get hidden behind the angle of jaw, hence, it is beyond measurement

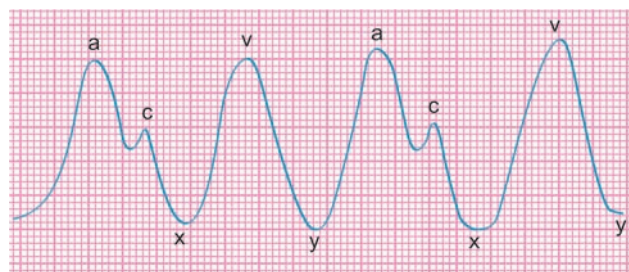


FIGURE 11.11 The waveforms of jugular venous pulse

- The 'a' wave becomes prominent in pulmonary hypertension, pulmonary stenosis, and tricuspid stenosis. Giant 'a' wave (Cannon wave) occurs due to forceful atrial contractions against closed tricuspid valve, is seen in complete heart block, supraventricular (junctional) tachycardia and ventricular tachycardia.
- The 'a' wave is absent in atrial fibrillation.

The 'c' wave, often not observed in the JVP is a positive wave produced by bulging of the tricuspid valve into right atrium as right ventricular pressure rises.

The 'v' wave is the third positive wave produced by the increasing volume of blood into the right atrium during ventricular systole when the tricuspid valve is closed. Tricuspid regurgitation causes the v wave to be more prominent while tricuspid stenosis diminishes it.

The x descent is the first negative wave that follows 'a' wave (c is not visible). This is produced by atrial relaxation. It is accentuated in constrictive pericarditis but is diminished in right ventricular dilatation and obliterated in tricuspid regurgitation.

The combination of a prominent 'v' wave and obliteration of 'x' descent results in a single large positive systolic wave, characteristically seen in tricuspid regurgitation.

The 'y' descent is the second negative wave (trough), produced by the opening of the tricuspid valve and the subsequent rapid inflow of the blood into the right ventricle.

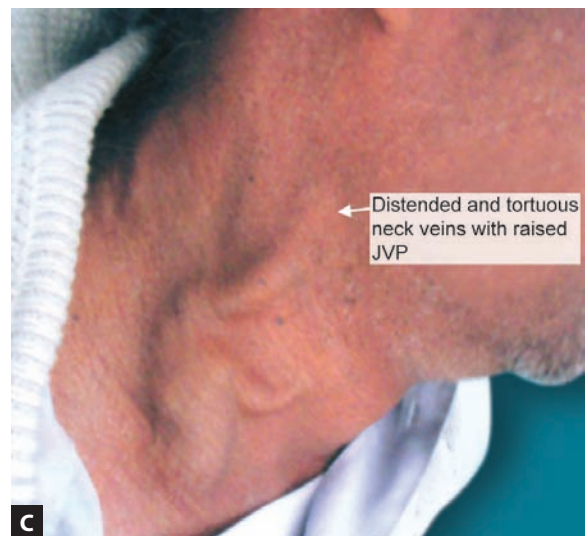
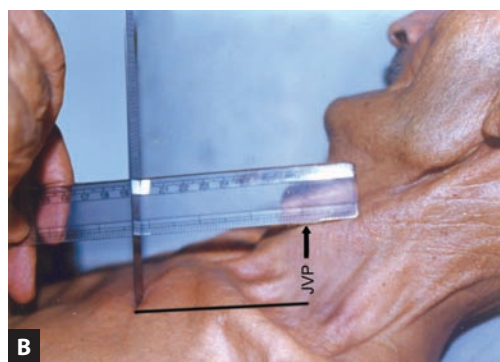
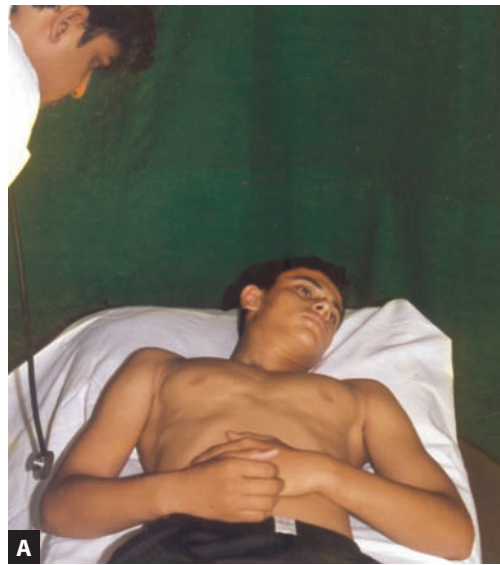- A sharp y descent is seen in patients with constrictive pericarditis, or with right-sided heart failure.
- A slow y descent indicates obstruction to the right ventricular filling, is seen in patients with tricuspid stenosis or right atrial myxoma.

The absent venous pulsations with prominent dilated neck veins and raised JVP are characteristically seen in superior mediastinal compression or superior vena cava obstruction.

Examination of jugular venous pulse and measurement of jugular venous pressure

The steps for assessing the jugular venous pulse are as follows:

- Make the patient comfortable with the head resting on a pillow to relax the sternomastoid muscles.
- Raise the head of the patient to 45° in supine position by putting the pillows behind the head or by raising the head of the bed or examining table.
- Turn the patient's head slightly away from the side you are inspecting. Use good light for examination.
- Look at the neck veins from the side of the patient (Fig. 11.12A).
- Identify the internal jugular pulsations especially on the right side. Focus on the pulsations and note the highest point of pulsations, if necessary, by means of abdominojugular reflux.
- Measure the JVP (Fig. 11.12B) by vertical distance in centimeter between the top of venous pulsation and the sternal angle. This distance measured in centimeters above the sternal angle is the JVP. Sometimes JVP may be raised beyond the angle of JAW, then say JVP is beyond measurement (Fig. 11.12C).



FIGURES 11.12A to C Measurement of JVP: (A) Looking at the neck veins for JVP; (B) Actual measurement at 45°; (C) JVP raised beyond measurement, say, JVP is raised up to the angle of jaw and above

- Now readjust the position of the patient, if necessary, to make the waveforms clearly visible.
- Now identify the pattern of waveforms of venous pulsation and note any abnormality.

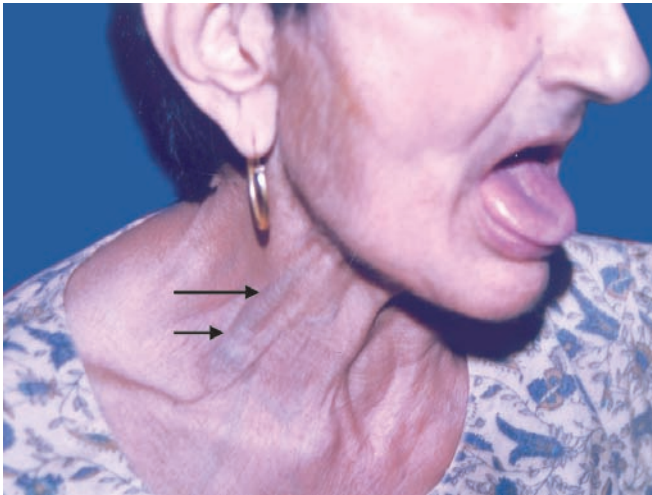

FIGURE 11.13 Raised JVP with cyanosis in a patient with CHF. Note the distended pulsatile neck veins (⇨)

Increased jugular venous pressure suggests:

- Right sided heart failure due to any cause or congestive cardiac failure (Fig. 11.13)
- Constrictive pericarditis
- Tricuspid stenosis
- Superior vena cava obstruction (JVP is raised but pulsations may be absent).

Effect of respiration on JVP: Normally, the JVP decreases during inspiration, the paradoxical rise of JVP during inspiration (opposite to normal decrease) is called Kussmaul's sign, is most often caused by constrictive pericarditis, severe right-sided failure or right ventricular infarction.

In patients with chronic obstructive lung disease (COPD), venous pressure may be elevated on expiration only. The veins collapse on inspiration. This finding does not indicate congestive heart failure.

Unilateral distension of the external jugular vein is usually due to local kinking or obstruction.

Even though students may not see clinicians making these measurements very frequently in clinical settings, practicing exact technique for measurement is important. With experience, the physicians and cardiologists come to identify the JVP and estimate its height visually.

Abdominojugular reflux test/manoeuvre: In patients suspected of having right ventricular failure who have a normal JVP at rest, the abdominojugular reflux test may be helpful. It is performed by applying firm pressure with the palm of the hand over the abdomen for 10 seconds or more. In normal persons, this manoeuvre does not alter JVP significantly but when incipient or compensated right heart

failure is present, the upper level of the pulsations usually increases, hence, positive test.

The Carotid Pulse

After measuring the JVP, move on to assessment of carotid pulse in the neck. The carotid pulse is useful for detecting stenosis or regurgitation of the aortic valve and in evaluation of a case with stroke. Assess the quality of carotid upstroke, its amplitude and contour, and presence or absence of any thrill or bruit.

Method: To assess the amplitude and contour, the patient should be lying comfortably on the bed with the head of bed elevated to 30°. Inspect the neck for carotid pulsations. These may be visible just medial to sternomastoid muscles. Then place your right index and middle fingers (or left thumb) on the right carotid artery in the lower third of the neck, press posteriorly and feel for pulsations (Figs 11.14A to C).

Caution: Avoid pressing on the carotid sinus which lies at the level of the top of the thyroid cartilage. Pressure on the carotid sinus may cause reflex bradycardia or hypotension. Never press both carotids simultaneously as this may reduce blood supply to the brain and induce syncope.

Abnormalities

- A tortuous or kinked carotid artery may produce a unilateral pulsatile bulge
- Delayed carotid pulsations may be seen in cardiac pump failure or in atherosclerotic narrowing or occlusion of the artery
- Small thready carotid pulse is seen in cardiogenic shock
- Delayed carotid upstroke occurs in aortic stenosis.

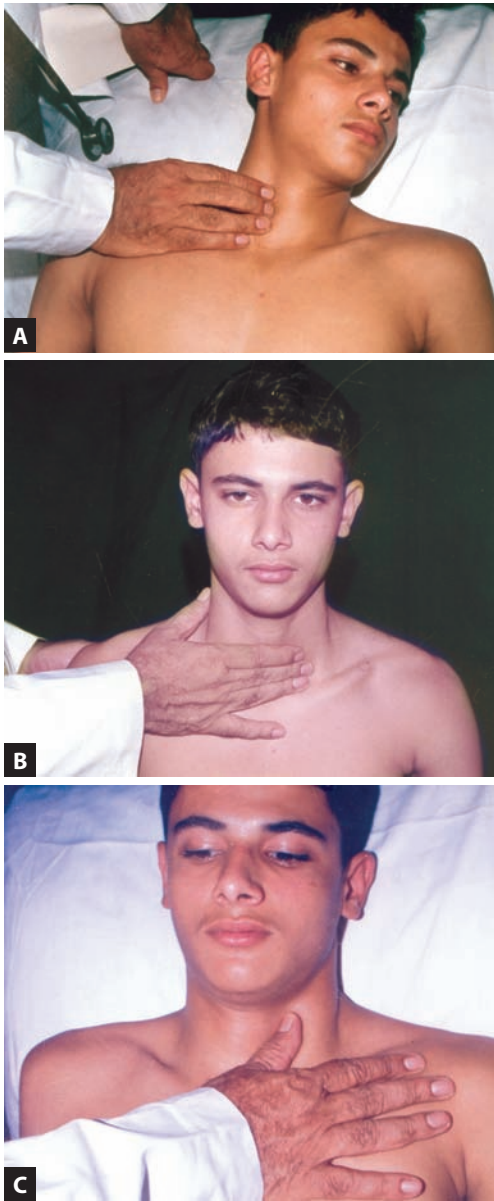Feel for thrills and hear for bruits: A carotid bruit with or without thrill in a middle aged or older person suggests arterial narrowing. An aortic ejection systolic murmur may radiate to the carotid artery and sound like a thrill.

Conditions of Other Peripheral Pulses

Look for the various peripheral arterial pulses as discussed under examination of peripheral vascular system. Pain or diminished pulses suggest arterial insufficiency, hence, look for postural colour changes (Read examination of peripheral vascular system).

1. Jones Criteria

Rheumatic fever is a multisystem disorder that typically follows an episode of sore throat (streptococcal) and usually presents with fever, anorexia, joint pains and lethargy. Arthritis is common presentation, occurs in 75% of patients; other features include skin rashes, carditis and neurological changes. The Jones criteria for diagnosis are given in the Box 9.



FIGURES 11.14A to C Method of palpation of carotid pulse: (A) Palpation by index and middle fingers; (B) Palpation of the opposite carotid; (C) Palpation of left carotid with left thumb

Clinical Significance

In a patient suspected of rheumatic heart disease, past history of sore throat, joint pains (fleeting character), fever and skin rash must be asked. For evidence of rheumatic fever one should look for:

- **Sore throat, lymphadenopathy, fever**
- **Swelling of large joint(s) if any**
- **Erythema marginatum**, i.e. red macules with pale centre (appear as red rings). They are seen on the trunk and extremities (Fig. 11.15). They may not be visible in dark-complexioned persons.

Box 9

Jones diagnostic revised criteria for rheumatic fever

Major	Minor
<ul style="list-style-type: none"> • Carditis • Polyarthritits • Chorea • Erythema marginatum 	<ul style="list-style-type: none"> • Fever • Arthralgia • Previous history of rheumatic fever or rheumatic heart disease • Raised ESR, or positive C-reactive protein • Leucocytosis • First degree or second degree AV block on ECG

Interpretation: The diagnosis is suggested by:

- Two or more major criteria *plus*
 - One major and two or more minor criteria *plus*
- Evidence of preceding streptococcal infection is also required such as increased ASO titre, positive throat culture for group A streptococci or other antistreptococcal antibodies or echocardiographic evidence of endocarditis.

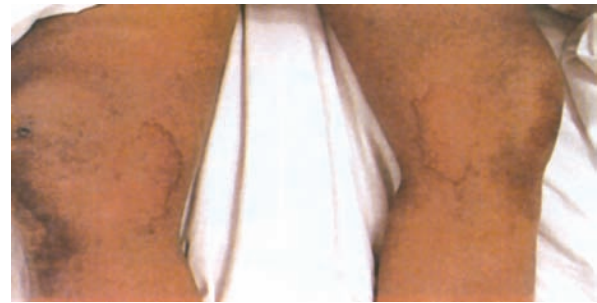

FIGURE 11.15 Erythema marginatum in a patient suspected to be a case of acute rheumatic fever. Note the red macules with serpiginous borders over the swollen knee joints

- **Subcutaneous nodules:** Palpate for small painless nodules over the bony prominences and tendons on the extensor surface of forearms and legs. These nodules are smaller than those of rheumatoid arthritis.
- **Involuntary movements (chorea):** Look for wide flung dancing irregular movements of extremities. These are quasi-purposive and usually recover and may be accompanied or followed by rheumatic carditis.
- **Arthralgia:** A migratory polyarthritits involving one or two large joints at a time is common presentation. A common corollary about acute rheumatic fever “*it licks the joint and bites the heart*”, is true and widely accepted.

2. Acute Rheumatic Activity

A patient of chronic rheumatic heart disease is prone to either another attack of rheumatic fever (if not previously protected by penicillin) or to infective endocarditis. Rheumatic activity

in a patient with chronic rheumatic valvular disease should be suspected in the presence of fever with one or two manifestations of Jones criteria. Therefore examination of Jones criteria is mandatory in patients suffering with chronic valvular heart disease.

3. Peripheral Manifestations of Infective Endocarditis (Read Case Discussion on Infective Endocarditis in Bedside Medicine without Tears by Prof. SN Chugh)

Infective endocarditis is a microbial infection of mural endocardium, a heart valve or valves (native or prosthetic) or lining of a blood vessel or a congenital defect (septal defect). The infection may develop insidiously or suddenly, may pursue a fulminant or prolonged course and is fatal unless treated.

The clinical manifestations are highly variable and occur as a result of:

- **Infection** such as fever, nausea, vomiting, night sweats, weight loss, headache and weakness
- **Immune complex vasculitis**, e.g. splinter haemorrhages, Janeway lesion (palmar erythema), haematuria (glomerulonephritis), etc.
- **Septic embolisation** to peripheral vessels (loss of pulse(s) or gangrene, Osler's node), to viscera, e.g. lung (haemoptysis, pleuritic pain), spleen (splenomegaly) to the eyes (Roth's spot) and to the brain (e.g. hemiplegia or monoplegia)
- **Anaemia and its consequences:** Anaemia develops due to infection and haematuria. This along with toxemia or septicemia may produce change in the previous murmur or appearance of new murmurs.

Therefore, in a patient with rheumatic or congenital heart disease or having prosthetic valve, always look for the following signs of infective endocarditis:

- Record pulse and temperature for tachycardia and fever.
- Look for peripheral pulses for diminished or absent pulsations. Examine peripheral parts for gangrene. Look for anaemia.
- See the nails and fingers for clubbing, splinter haemorrhages, Osler's node, Janeway lesion
- Examine skin for haemorrhages and purpuric spots
- Examine eyes for subconjunctival haemorrhage. Look at the fundus and retina with ophthalmoscope for Roth's spot, optic atrophy or haemorrhage.
- Examine the abdomen for liver and spleen enlargement.

Systemic Examination (Examination of the Precordium)

The part of anterior chest overlying the heart is called precordium. Examination of the precordium is the main

component of clinical cardiology and reflects indirect examination of heart and great vessels.

Surface anatomy of the heart: A knowledge of surface anatomy of the heart is important for:

- Radiological outline of the heart on chest X-ray (Read Radiology of the Heart—Bedside Medicine by Prof. SN Chugh)
- **Auscultation of the heart in different areas (Fig. 11.16):** The auscultatory areas do not correspond with the markings of the heart valves. The locations on the chest wall where you hear heart sounds and murmurs help to identify the valve or chamber where they originate. Sounds and murmurs arising from the various valves are best heard in certain areas as depicted in the Table 11.9.

These areas usually overlap, hence, one will need to correlate the auscultatory findings with other parts of cardiac examination to identify the sounds and murmurs.

Examination Sequence

1. Inspection
2. Palpation
3. Percussion
4. Auscultation

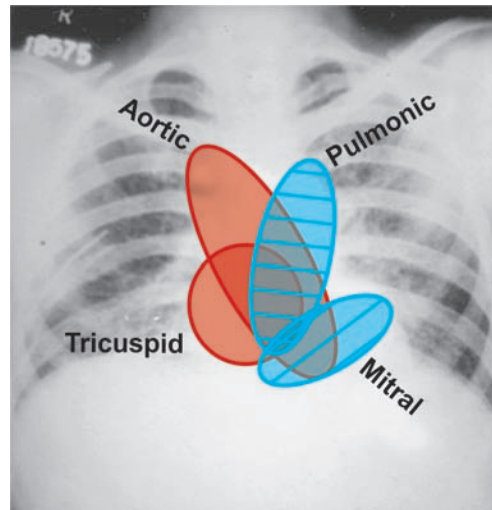
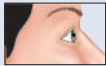

FIGURE 11.16 Surface anatomy of the heart valves for auscultation of different areas

TABLE 11.9 Surface anatomy of heart valves for auscultation	
Valve	Surface projection (Fig. 11.16)
Mitral	At and around the cardiac apex
Tricuspid	Lower left sternal border
Pulmonary	2nd left interspace close to the sternum
Aortic	Right 2nd intercostal space. Aortic murmurs may be heard anywhere from this space to the apex. Left third space is called second aortic area (A ₂) for auscultations of aortic events
NB: These areas are not applicable in a patient with dextrocardia.	

Inspection



Procedure: Inspect the precordium with patient resting 45° on the bed or couch with shoulders horizontal (Fig. 11.17). Look for chest deformity, any scar, and pulsations in the parasternal area (*parasternal lift*), *suprasternal notch* and *epigastrium*.

Now look for the *apex beat* which is the lowest and outermost point of the cardiac pulsations seen. Note its position and character. This can be confirmed on palpation.

Normal apex beat lies in the 5th intercostal space (the space below the 5th rib) within 10 cm from the midsternal line or within the midclavicular line in an adult in the sitting or lying down position.

Normal apex beat may not be visible in a patient with asthma or COPD due to hyperinflation, obesity or thick chest or when it lies behind the rib or in pericardial effusion. It may sometimes be hidden behind the pendulous breasts in females.

Common abnormalities on inspection may include:

- Any **localised bulge** (Fig. 11.18) or **depression**
- **Chest deformities**, e.g. *pectus excavatum* (Fig. 11.19) *pectus carinatum*, and *barrel shaped chest*.
- **Scars** (e.g. *midline sternotomy scar* of coronary bypass surgery or *valvotomy*—Figs 11.20A and B or *scar at antecubital fossa* for cardiac catheterisation). A *mark of needle prick* may be seen at the site of tapping of pericardial effusion. This will be recognised either by attached cotton fibres or a scab. Note any keloid or hypertrophied scar (Fig. 11.20C).
- **Pulsations:** Prominent pulsations may be seen in suprasternal notch in anxiety, in aortic incompetence, high output states and aortic aneurysm. The epigastric pulsations may be visible in thin persons, in right ventricular dilatation, aneurysm of the descending aorta and hepatic venous pulsation of tricuspid regurgitation. The pulsations of dilated pulmonary artery in pulmonary hypertension may be seen in 2nd left intercostal space. With severe degree of cardiac enlargement, the whole pericardium may be shaky. In coarctation of aorta, pulsations may be felt and even seen overlying the scapulae on posterior chest wall. These are due to collaterals formation. A localised pulsatile bulge may occur due to long-standing aortic aneurysm (Fig. 11.18).
- **Apex beat:** Displacement of apex beat may be seen to the same side or to the opposite side. It may be displaced because of mediastinal shift in which trachea is also deviated. The causes of displaced apex beat are discussed under palpation because apex beat is better felt than seen.

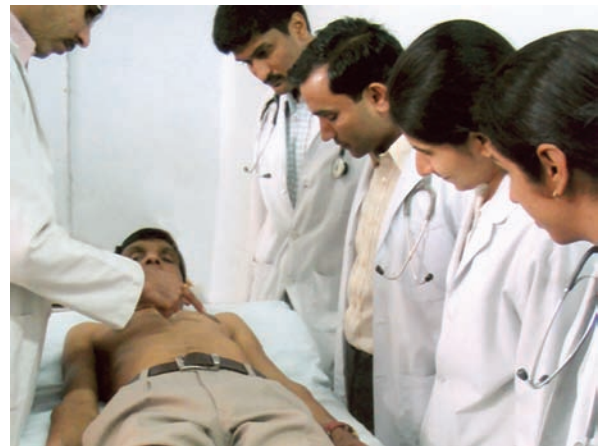

FIGURE 11.17 Inspection of the apex beat. The consultant is pointing the apex beat to the students with the help of index finger

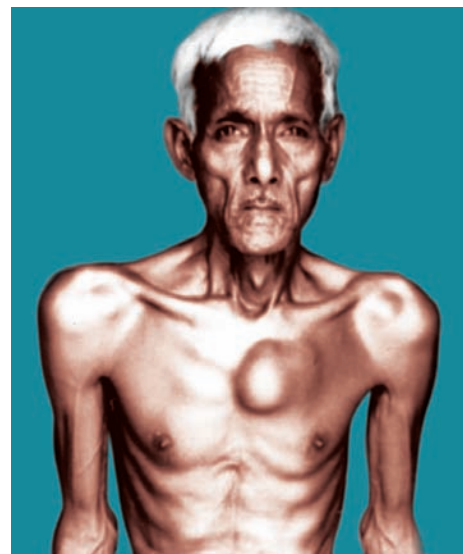
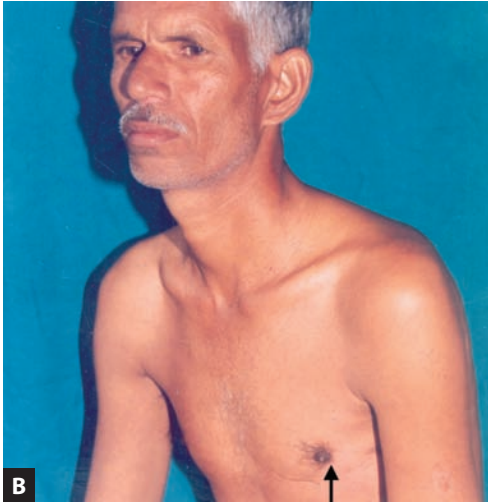
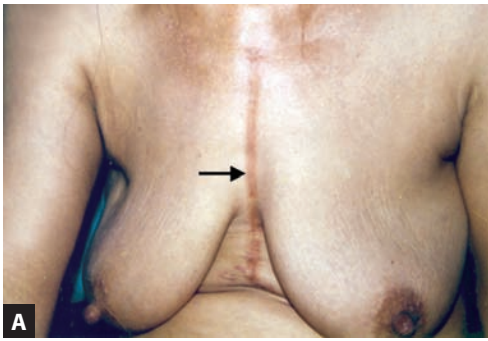


FIGURE 11.18 A localised bulge at 2nd left space due to long-standing aortic aneurysm in a patient

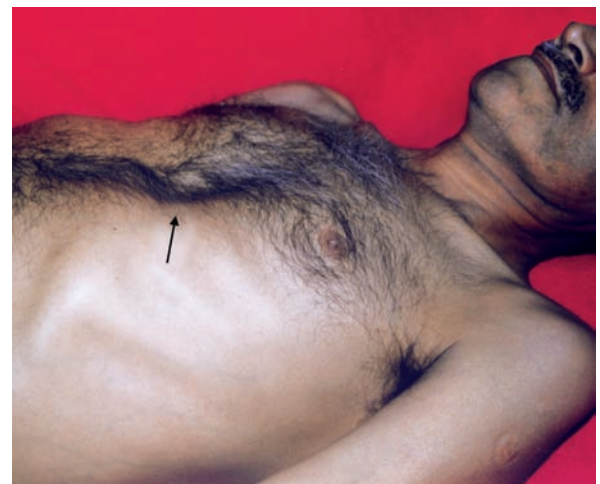
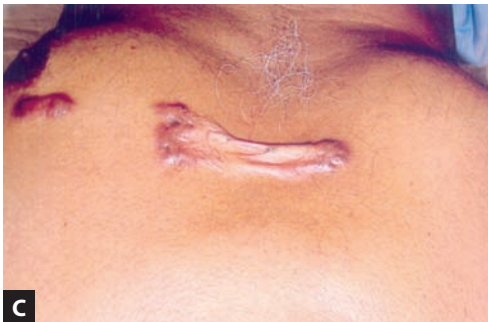
FIGURE 11.19 Pectus excavatum. Note the central mid-sternal depression (↑)



FIGURES 11.20A to C Scars: (A) Mid-Sternotomy vertical scar of valve replacement; (B) Scar of coronary bypass surgery; (C) A keloid

In *dextrocardia*, the apex beat is normally seen on the right side. If you do not see the apex beat on the left, try to see it on the right side also.

Palpation



It is just to confirm the findings seen on inspection.

Method: The best way of palpation of heart is put flat of right hand on the precordium to get a general impression of cardiac activity (Fig. 11.21).

Now localise the apex beat (Fig. 11.22) if necessary, ask the patient to roll on to the left side.

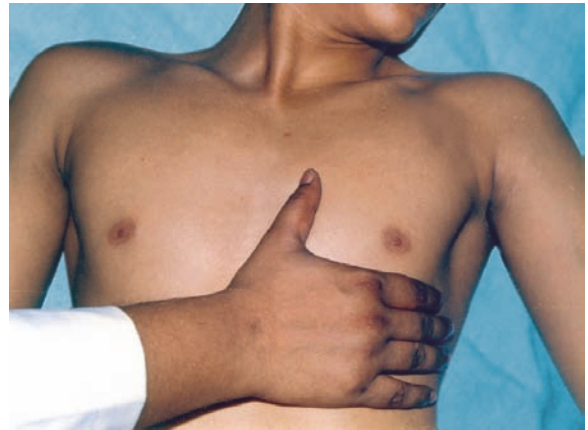

FIGURE 11.21 Palpation of the apex beat

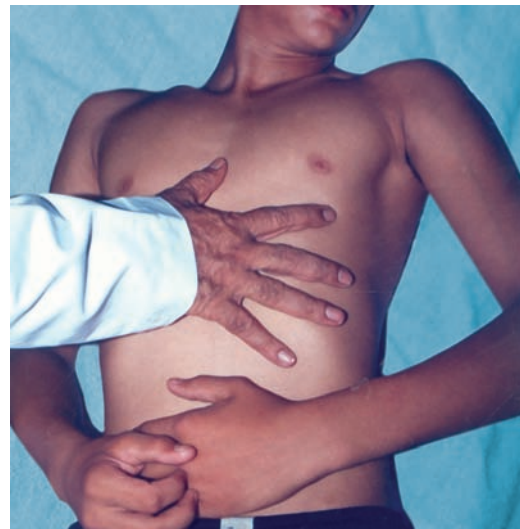

FIGURE 11.22 Localisation of apex beat

Apex beat on palpation is the outermost and lowest point of cardiac impulse where the finger is lifted during systole (i.e. definite impulse or thrust is felt). It lies within 10 cm from the midline or just inner to midclavicular line.

The apex beat may be deviated to the same side due to pull or to the opposite side due to push. The causes of displaced apex beat are given in the Box 10.

The apex beat is neither visible nor palpable on the left side in:

- Extreme obesity or thick chest
- Large pericardial effusion
- Apex beat hidden behind the rib or behind pendulous breast in a female
- Asthma or COPD
- Dextrocardia.

Character of the apex beat: The character of the apical impulse is more important than its location.

Box 10

Causes of displaced apex beat

To the same side	To the opposite side
<ul style="list-style-type: none"> • Left ventricular hypertrophy/enlargement • Due to pull in pulmonary conditions such as lung fibrosis, collapse or removal of the lung 	<ul style="list-style-type: none"> • Pleural effusion when it is massive • Large pneumothorax

- A forceful and sustained apex beat is seen in left ventricular hypertrophy (pressure overload) due to HT and aortic stenosis
- Diffuse apex beat which is less forceful, is felt in left ventricular dilatation (dilated cardiomyopathy) and ischaemic heart disease (ischaemic cardiomyopathy)
- *Tapping apex* beat is found in mitral stenosis. Actually, it is nothing but a palpable first heart sound
- A *double apex beat* is characteristic of hypertrophic cardiomyopathy where left ventricle is divided into two chambers by hypertrophied septum. The first thrust comes in lower space followed by second upper thrust due to pulsations in upper spaces. It also occurs in left ventricular aneurysm.

Palpate for parasternal heave, any palpable sound or thrill and pulsations at apex, and on either side of the sternum and aortic (A_1 and A_2) and pulmonary area.

Heaves: These are palpable impulses from either the right or left ventricle which lift the examiner's hand from the chest. The left parasternal heave is usually abnormal in adults and indicates of right ventricular hypertrophy, i.e. pulmonary stenosis or pulmonary hypertension. The method of palpation of parasternal heave and its grading is depicted in the Figure 11.23.

Epigastric pulsations: They are palpated by the method described in the Figures 11.24A and B. In right ventricular hypertrophy, pulsations indicate pulmonary hypertension/stenosis while ill sustained right ventricular pulsations occur in left to right shunt. Epigastric pulsations may be normal due to aorta in thin persons, but can occur abnormally due to aortic aneurysm.

Pulsations of pulmonary (left 2nd interspace) and aortic vessels (right 2nd interspace) are felt in haemodynamic circulation, e.g. high output states due to anaemia, thyrotoxicosis, fever, etc.

Sounds: The heart sounds normally are not palpable but may become palpable in certain conditions, i.e. first sound may become palpable in mitral stenosis and second sound in pulmonary hypertension.

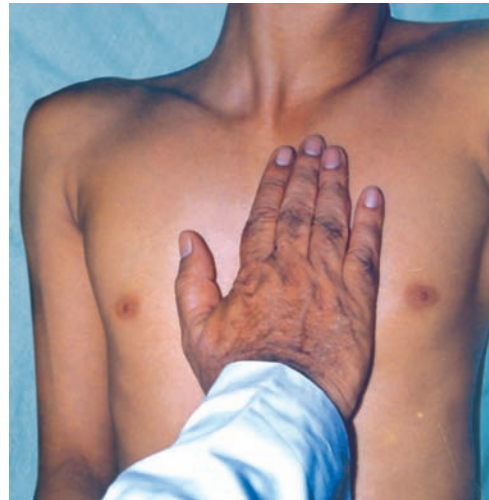
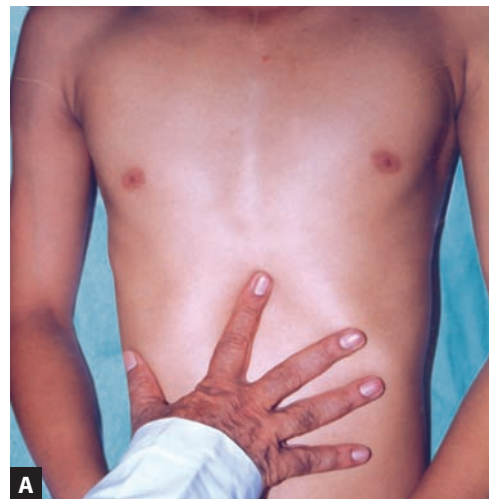
FIGURE 11.23 Grading of parasternal heave. Put the ulnar border of right hand or hypothenar eminence over the left sternal border. It is graded into: Grade I (parasternal left may just be palpable but not visible), grade II (parasternal left palpable as well as visible and grade III (parasternal lift is visible from a distance)



FIGURES 11.24A and B Epigastric pulsations: (A) It is palpated by keeping one finger below xiphisternum and pressing it a little backwards and upwards; (B) Alternative method for right ventricular pulsations

Box 11

Common thrills and associated conditions

Thrill	Condition(s)
<ul style="list-style-type: none"> • A systolic thrill at apex • A diastolic thrill at apex, best felt in left lateral position (Fig. 11.25) • A systolic thrill across the lower part of sternum • A systolic thrill in 2nd right intercostal space, may be transmitted to carotid vessels in the neck • A diastolic thrill in 2nd right intercostal space 	<ul style="list-style-type: none"> • Mitral regurgitation • Mitral stenosis • Ventricular septal defect (VSD) • Aortic valvular stenosis • Acute aortic regurgitation, dissection of aorta and rupture of aortic valve cusps (trauma, endocarditis)

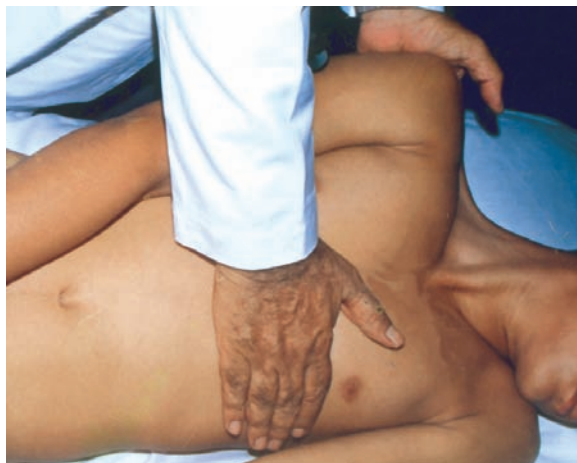
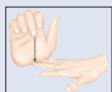
FIGURE 11.25 Palpation for diastolic thrill in left lateral position. Roll the patient to left side and put flat of right hand over the mitral area

Thrills: Thrills are palpable murmurs which impart vibrations to the examiner’s hand like purring of a cat. Usually loud murmurs are associated with thrills. Low pitched vibrations are better heard than felt. The important thrills and the associated conditions are given in the Box 11.

Percussion



In most cases, chest X-ray and echocardiogram have replaced percussion in the estimation of heart size. When you cannot feel the apical impulse, however, percussion may suggest where to search for it. Under these circumstances, cardiac

dullness often occupies a large area. Starting from the left on the chest, percuss from resonant towards dull area in the 3rd, 4th and 5th and possible 6th space from the anterior axillary line towards sternum so as to define the left border of the heart. The second space on the left as well as on the right may also be percussed for any dullness (normally they are resonant). To define the right border, percuss right 4th space from resonant to dull area (normally right border of the heart lies just right to right sternal border).

- Undue dullness on the left side beyond apex and on the right side beyond right sternal border indicates pericardial effusion.
- Cardiac dullness is masked or lost in patients with chronic obstructive lung disease (obstructive emphysema) and left side pneumothorax.

Auscultation



Auscultation of the heart is a rewarding and an important skill of examination that leads directly to several clinical diagnoses. An understanding of the events of the cardiac cycle (see Fig. 11.1) is a useful basis for auscultation. It is essential to identify the systole and diastole correctly. Palpation of the carotid artery provides a systolic time reference and it is wise for the beginners to feel the carotid artery while auscultation. The first heart sound precedes the carotid pulse; the second sound follows it.

The auscultation of the heart is done with the use of a stethoscope fitted with both bell and a diaphragm.

- High pitched sounds such as aortic diastolic murmur, all systolic murmurs, both the heart sounds (S_1 and S_2) and opening snap are heard with the diaphragm firmly pressed against the chest. Low-pitched sounds such as third (S_3) and fourth (S_4) heart sounds and mitral diastolic murmur are heard with the bell loosely applied on the chest wall.

Auscultatory Areas

The auscultable areas of the precordium are customarily named according to the valve from which sounds or murmur arise (see Table 11.9). They are mitral (M), tricuspid (T), aortic (A_1 are a lies in 2nd right interspace and A_2 left 3rd interspace) and pulmonary (P) area. They have already been represented in Figure 11.16.

Some authorities discourage the use of these names. Since murmurs of more than one origin may occur in the given area and a murmur originating from a valve may not be best heard in that area; for example, systolic murmur originating from aortic valve (aortic stenosis) is best heard at the apex (mitral area).

Auscultation involves identifying and describing the followings:

- The heart sounds (first and second)
- Extra heart sounds (third and fourth)
- Additional sounds (clicks, snaps and rub)
- Splitting of the sound (second heart sound)
- Murmurs

Method: It is advisable to have a fixed pattern for auscultation (Fig. 11.26). Listen to the heart with your stethoscope placed first in the right 2nd intercostal space close to the sternum, then along the left sternal border in each interspace from 2nd through the fifth and lastly at the apex. This will form a 'Z' shape pattern (Fig. 11.26). Recall that upper margins of the heart are, sometimes, termed the base of the heart. Some clinicians begin auscultation at the apex, and others at the base. Either pattern is satisfactory. One should listen on an area where you detect a murmur and then listen in areas adjacent to murmurs to determine its origin (loudest at the site of production).

Listen over the precordium first with the diaphragm with the patient supine. Use the bell at the apex, then move along the left sternal border to hear S_3 and S_4 and mid-diastolic murmur if present. Remember, the bell should be lightly placed on the chest because pressing the bell firmly on the chest makes it function like the diaphragm by stretching the underlying skin and with this technique the S_2 and S_4 (low-pitched sounds) may disappear, hence, may be missed.

Steps of Examination

- With the patient sitting semirecumbent, auscultate all the areas over precordium, listening in turn at the base of the heart, right and left sternal edges and apex (Fig. 11.27) with both bell and diaphragm. Also auscultate, over the carotids and where appropriate into the axilla.
- At each site, identify the S_1 and S_2 and assess the intensity, character and splitting of these sounds.
- Then listen for added heart sounds and murmurs.
- Roll the patient to left lateral position and hear for the diastolic murmur of mitral stenosis (Fig. 11.28).
- Make the patient sit and lean forward and hear for the murmur of aortic stenosis or incompetence in left 2nd interspace with diaphragm.
- Note the features of the murmur if present.

Effect of Positions

- *Auscultate the patient is sitting and lying down position.*

Mid-diastolic murmur or tumor plop of atrial myxoma is characteristically heard during sitting position, disappears or become attenuated during lying down.

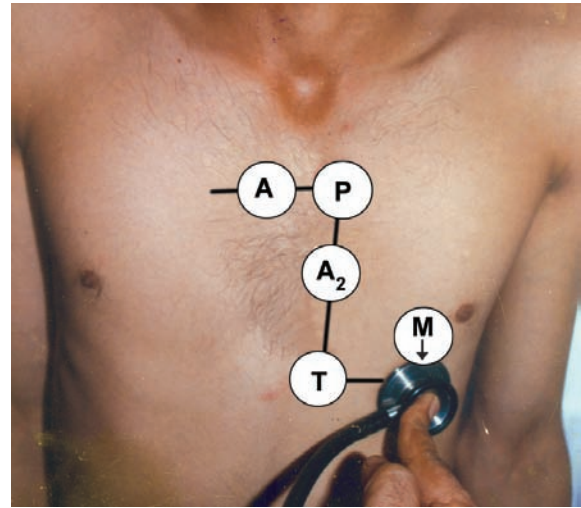


FIGURE 11.26 Method of auscultation of precordium. Start either from aortic (A_1) area or mitral (M) area and proceed auscultation in Z shape manner

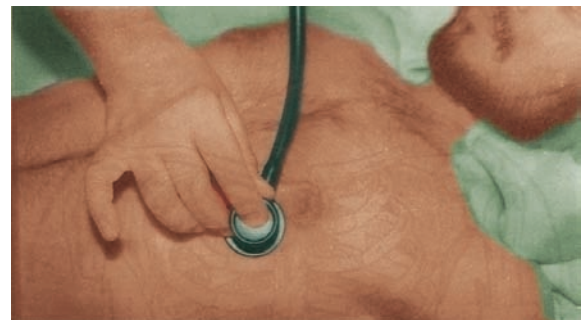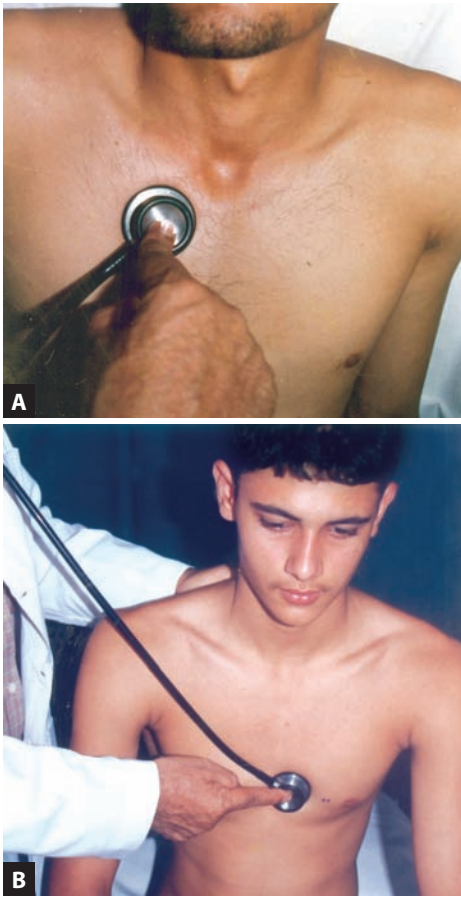


FIGURE 11.27 Auscultation at the apex for mitral events. Put the diaphragm at the apex with the patient lying comfortably on the bed/couch and time it with carotid pulse

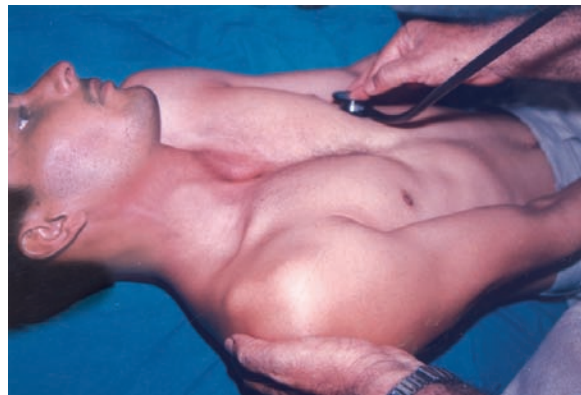

FIGURE 11.28 Position for mitral diastolic murmur. Roll the patient to left lateral position with stethoscope at mitral area

- *Left lateral decubitus position: Ask the patient to roll partly onto the left side. The left lateral decubitus position brings the left ventricle close to the chest wall. Auscultate the heart with bell of stethoscope.*



FIGURES 11.29A and B Auscultation of aortic areas (A_1 and A_2). Ask or make the patient to bend forward and hold her/his breath in expiration. Hear for the aortic murmurs at: (A) Aortic (A_1) area in 2nd right interspace; (B) Aortic (A_2) area in 3rd left interspace

This position accentuates S_3 and S_4 and mid-diastolic murmur of mitral stenosis.

- Ask the patient to sit up, lean forward, exhale completely and stop breathing in expiration. Auscultate the chest with diaphragm along the left sternal border and at the apex (Figs 11.29A and B).

This position accentuates or brings out aortic murmurs (soft diastolic murmur of aortic regurgitation) which is likely to be missed unless you use this position.

Effect of Respiration

- Right sided murmurs (pulmonary and tricuspid) increase during inspiration (i.e. held inspiration).
- Left sided murmurs (aortic and mitral) increase during expiration (i.e. held expiration).
- Perform valsalva manoeuvre if systolic murmur of left side involvement (AS, MVP, HOCM) is heard. Note the effect. Murmurs of HOCM and MVP become louder while murmur of AS diminishes in intensity.

Heart Sounds

Listen the heart sounds, note their intensity and splitting.

Normal heart sounds

The closure of the valves produce sounds called heart sounds. The opening of valves do not produce any sound.

The first heart sound (S_1): It is produced due to closure of mitral and tricuspid valves at the start of ventricular systole. It is best heard at the apex.

The second heart sound (S_2): It is produced by the closure of pulmonary and aortic valves at the end of ventricular systole and best heard at the left sternal edge. It is louder and higher pitched than the first heart sound. Normally, its both components are audible; the aortic component is louder than pulmonary with a narrow normal split.

The third heart sound (S_3): It is low pitched sound heard with the bell of stethoscope at the apex. It is due to rapid filling phase, heard after the second sound as lub-dub-dum'. It normally occurs in children, young adults and during pregnancy.

Abnormalities of the heart sounds

The following abnormalities may be noted:

- The sounds may have a different intensity, i.e. either decreased or increased and quality (metallic heart sounds of prosthetic valve)
- The sound may exhibit abnormal splitting
- Low frequency heart sounds (extra-heart sounds) in diastole-third or fourth sounds may be heard
- Additional high-pitched sounds (click, snaps) may be heard.

Changes in the Intensity

Heart sounds are feebly audible in individuals with thick chest wall, obesity and in those with COPD (emphysema). This is due to the fact that production of the sounds is normal but conduction through chest wall is decreased. Conversely, in the presence of severe heart disease, the sounds may be quite normal. Thus, it becomes clear that alternations in the intensity of the heart sounds should be considered significant only when other features of the heart disease corroborate them. **The abnormalities of first heart sound are given in the Box 12.**

The abnormalities of the second heart sound are listed in the Table 11.10.

The aortic component (A_2) of second heart sound is muffled or reduced in intensity in calcific aortic stenosis and aortic regurgitation and pulmonary component (P_2) in pulmonary stenosis. Second heart sound is loud both in systemic and pulmonary hypertension.

Box 12

Alterations in intensity of first heart sound

Loud	Quiet/Feeble	Variable
<ul style="list-style-type: none"> • High cardiac output and large stroke volume (e.g. high output states) • Mitral stenosis • Atrial myxoma • Short P-R interval (WPW syndrome) • Tachycardias • Atrial septal defect 	<ul style="list-style-type: none"> • Low cardiac output • Poor left ventricular function, e.g. LVF • First degree AV block • Mitral regurgitation 	<ul style="list-style-type: none"> • Atrial fibrillation • Extrasystoles • Complex AV block

TABLE 11.10 Alterations in the intensity of second heart sound

Loud	Quiet/Feeble
<ul style="list-style-type: none"> • Systemic hypertension (A_2 is loud) • Pulmonary hypertension (P_2 is loud) 	<ul style="list-style-type: none"> • Low cardiac output • Calcific aortic stenosis • Aortic incompetence • Pulmonary stenosis (pulmonary component is quiet)

Splitting

First sound: The mitral valve closes slightly earlier than tricuspid and this gives rise to split first sound. Normally, first heart sound splitting is difficult to detect because the two components (M_1 and T_1) are separated by a short interval. When it is present, it does not indicate a heart disease and is not of any significance except it may be confused with an ejection click. It is a sign of right bundle branch block (RBBB). **Second sound:** The splitting of second sound is easier to appreciate because the two components (aortic A_2 and pulmonary P_2) are widely separated. Aortic component (A_2) is louder and audible in all the areas while pulmonary component (P_2) is normally audible in the pulmonary area and for a short distance down the left sternal edge. When P_2 is loud, then it becomes also audible over a wider area of the precordium.

Note: Normal splitting of the second sound is best heard at and close to the pulmonary area, i.e. 2nd left interspace close to the sternum.

Normally P_2 follows A_2 (physiological splitting); is widest during inspiration and narrowest in expiration. The normal and pathological splitting are depicted in Figure 11.30 and causes of pathological splitting are given in the Table 11.11.

The third heart sound (S_3): The third heart sound is pathological after the age of 40 years. Its presence usually indicates impairment of LV function, AV valve regurgitation (MR or TR) or other conditions that increase the rate or volume of ventricular filling. It is often associated with heart failure and disappears with its treatment. The triple or gallop rhythm is the term used for the presence of S_1 , S_2 and S_3 in a patient with congestive heart failure associated with tachycardia. It is so called because it is said to resemble the sound of a galloping horse. The causes of third heart sound are given in the Box 13.

The third heart sound may originate from the left side (rapid left ventricular filling in MR or LVF), is best heard at the apex while right-sided S_3 originating from RVF or TR is heard at left sternal border with the bell of stethoscope.

The fourth heart sound (S_4): It is a low pitched sound, produced by forceful atrial contractions during presystole, is best heard with bell of stethoscope. The sound is absent in atrial fibrillation. The S_4 is pathological, occurs when there is increased resistance to ventricular filling forcing the atria to contract forcibly, hence, it is present in patients with hypertension, aortic stenosis, hypertrophic cardiomyopathy, IHD and acute mitral regurgitation. Most patients with an acute MI and sinus rhythm have an audible S_4 . The right-sided S_4 is present in right ventricular hypertrophy secondary to pulmonary stenosis or pulmonary hypertension and accompanies a prominent 'a' wave of jugular venous pulse.

Added Sounds (Figs 11.31A to G)

Listen for added sounds, e.g. clicks, opening snap, metallic sounds, pericardial rub and murmurs. These have to be distinguished from normal heart sounds (Fig. 11.31A) described above.

Ejection clicks (Fig. 11.31B): These are high pitched sounds occurring in early systole and closely follow the first heart sound, occur in the presence of semilunar valve stenosis or dilatation of aorta or pulmonary artery (Box 14). Remember, the click will become absent in aortic stenosis if valve is calcified (calcific aortic stenosis) because the cusps become rigid and non pliable.

Non-ejection or midsystolic clicks (Fig. 11.31C): They occur late in systole with or without late systolic murmur; often denote prolapse of one or both leaflets of the mitral valve (MVP—click murmur syndrome). They may also occur in tricuspid valve prolapse. They probably result from prolapse of mitral or tricuspid valve due to redundant chordae tendinae which are functionally abnormal. Systolic clicks may be single or multiple. These clicks are high pitched sounds best heard either at the apex or along the lower left sternal border and are

TABLE 11.11 Normal and pathological splitting of second heart sound

Splitting	Diagram (Fig. 11.30)	Cause(s)
Normal or physiological split. Split widens during inspiration and narrows during expiration	<p>Normal splitting</p>	Seen in normal individuals. A single sound (S_2) in inspiration is normal in adults.
Fixed splitting of second heart sound. The splitting does not change during inspiration and expiration.	<p>Wide and fixed splitting</p>	Wide and fixed splitting is characteristic of atrial septal defect (ASD)
	<p>Narrow splitting</p>	Wide but not fixed splitting occurs in right ventricular hypertrophy due to pulmonary stenosis and right bundle branch block.
Reversed or paradoxical splitting (e.g. splitting occurs maximally in expiration and decreases during inspiration. Even in inspiration, splitting is so narrow that it may appear as single S_2 as shown in diagram)	<p>Paradoxical splitting</p>	In pulmonary hypertension, splitting may be normal, narrow or wide, depending on its cause and pulmonary vascular resistance. Reversed splitting occurs in left ventricular outflow obstruction, a large aorto-pulmonary shunt, systolic hypertension, left bundle branch block.

Box 13

Causes of third heart sounds

Physiological	Pathological
<ul style="list-style-type: none"> • Healthy young adults • Athletes • Pregnancy 	<ul style="list-style-type: none"> • CHF • Large poorly contracting left ventricle • Fever • Mitral regurgitation

influenced by certain manoeuvres which have been already discussed.

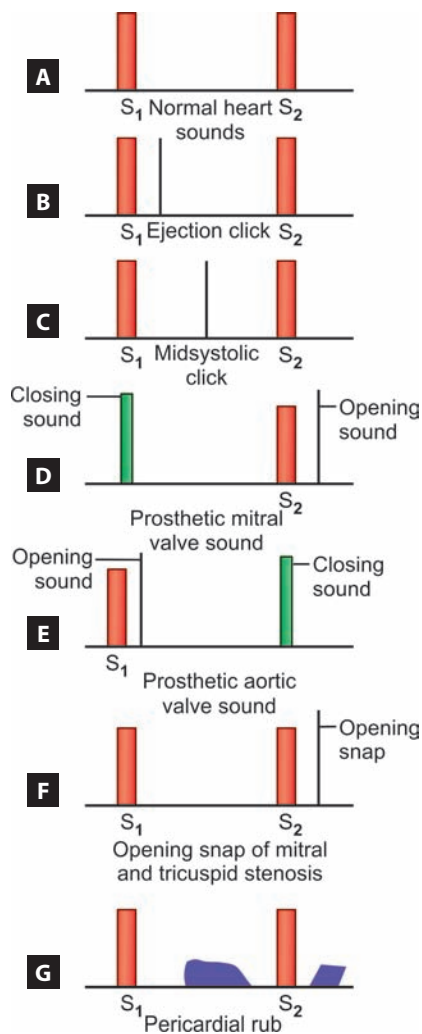
Metallic sounds: These are high pitched sounds produced by mechanical heart valves both during closing and opening. They are commonly palpable and often audible without a stethoscope. A mechanical mitral valve replacement makes a metallic first heart sound and a sound like a loud opening snap (Fig. 11.31D); a mechanical aortic valve produces loud, metallic

second heart sound, and an opening sound like an ejection click (Fig. 11.31E). They are associated with a flow murmur.

Opening snap (OS): It is a brief, high pitched, early diastolic sound which is usually due to stenosis of mitral valve and rarely tricuspid valve (Fig. 11.31F). It is best heard at the apex or left sternal border in case of mitral stenosis. It is produced by restricted opening of stenosed valve. It only occurs when the valve is stenosed but mobile, hence, is likely to disappear in calcific or fenestrated valve.

Opening snaps occur in early diastole, just after the second heart sound (S_2). A_2 -OS interval is inversely proportional to severity of mitral stenosis, i.e. the near the OS to second heart sound, the severe is the stenosis.

Pericardial rub and knock: It is high pitched superficial scratching sound having both systolic and diastolic components (Fig. 11.31G), is best heard at the left sternal



FIGURES 11.31A to G Added sounds on cardiac auscultation

Box 14

Causes of ejection clicks

Aortic	Pulmonary
<ul style="list-style-type: none"> • Aortic stenosis • Aortic regurgitation • Dilatation of aorta • Site: It is best heard at apex or second right intercostal space just near to sternum (aortic area) 	<ul style="list-style-type: none"> • Pulmonary stenosis • Pulmonary regurgitation • Idiopathic dilatation of pulmonary artery • Site: It is heard in second left interspace or upper left sternal border (pulmonary area)

border with the diaphragm of the stethoscope with the patient sitting and leaning forward during expiration. It is a characteristic sign of acute pericarditis. Like the pericarditis, its intensity may alter from time to time as well as with the position the patient.

Pericardial knock is an intermittent knocking sound, occurs due to sudden stretching of adherent pericardium

during early diastole. It is to be differentiated from 3rd heart sound.

A *pericardial rub* has to be distinguished from *pleuropericardial rub*. In both, the sounds coincide with the cardiac cycle but the pleuropericardial rub is also influenced by respiration and is pleural in origin.

Murmurs: As already discussed in the beginning of this chapter that murmurs arise flow due to turbulent flow across a narrowed valve or rapid large flow across a normal valve or across an abnormal communication within the heart. It follows that loudness of a murmur depends on the size of the orifice or defect, i.e. smaller the orifice or defect, the louder is the murmur. In large orifices such as large VSD, MR or AR, the murmurs are soft. Therefore, one should not make deductions about the importance of the murmur from its loudness.

Not all murmurs are produced by a structural heart disease, some of them may arise due to abnormal rapid flow across a normal valve. These are called *flow murmurs*. These are benign in nature. Their characteristics have already been discussed (Read innocent murmurs).

Flow murmurs are most commonly seen in children, young adults, athletes and in the elderly. They also occur in high output states.

Points to be noted about the murmur have already seen listed in the Box 1.

The classification of murmurs (Figs 11.32A to H)

- **Systolic**
 - Ejection systolic
 - Midsystolic
 - Pansystolic
 - Late systolic
- **Diastolic**
 - Early diastolic
 - Mid-diastolic
- **Continuous, i.e. both systolic and diastolic.**

Causes: The causes of various types of murmurs are tabulated (Table 11.12).

Mammary souffle: Many women have a murmur heard both in systole and diastole during late pregnancy and during lactation. These are secondary to increased blood flow in their breasts. It can be heard over the breast but is best heard in the 2nd and 3rd interspace on either side of the sternum.

Venous hum: These are continuous murmur heard both in systole and diastole, soft in character, heard above the medial third of clavicle. They arise from the jugular veins commonly in children and young adults, hence, can be obliterated by pressure on the jugular veins.

Arterial bruits: Murmurs occurring at the site of arterial occlusion are called bruits.

TABLE 11.12 Causes of murmurs

I. Systolic murmurs

- **Ejection systolic (Fig. 11.32A)**
 - Normal or reduced flow through stenotic valve
 - Aortic valvular stenosis
 - Pulmonary valvular stenosis
- Abnormal rapid flow through normal valves (*innocent flow murmurs*)
 - Fever
 - Athletes
 - Pregnancy
 - High cardiac output states, e.g. beriberi, thyrotoxicosis, Paget's disease, AV fistula, etc.
 - Atrial septal defect (pulmonary flow murmur)
- Other causes
 - Hypertrophic cardiomyopathy (obstruction of left ventricular outflow—subvalvular stenosis)
 - Acute aortic regurgitation (aortic flow murmur)
- **Midsystolic murmur (Fig. 11.32B)**
 - Mitral valve prolapse. There is associated midsystolic click.
- **Pansystolic (Fig. 11.32C)**

These are caused by a systolic leak from a high to lower pressure chamber:

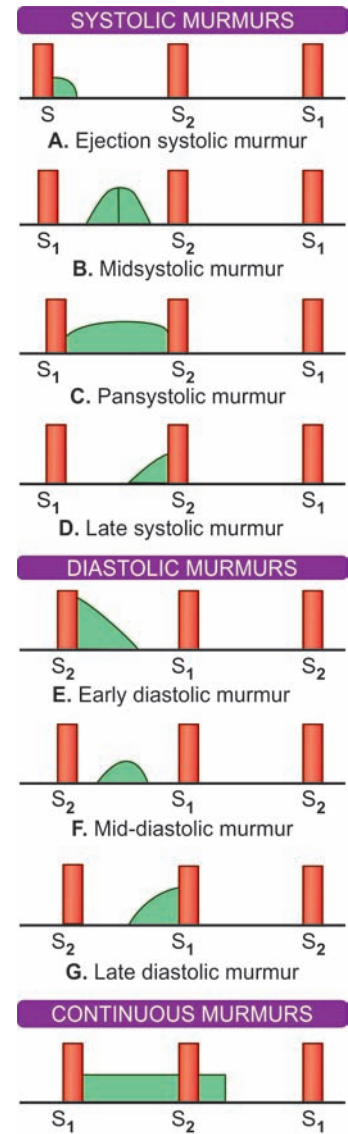
 - Mitral regurgitation
 - Tricuspid regurgitation
 - Ventricular septal defect
 - Leaking mitral or tricuspid prosthesis
 - Mitral valve prolapse
 - Rupture of cordae tendinae in acute MI
- **Late systolic murmur (Fig. 11.32D)**
 - Papillary muscle dysfunction

II. Diastolic murmurs

- **Early diastolic (Fig. 11.32E)**
 - Aortic regurgitation
 - Pulmonary regurgitation (Graham-steele's murmur)
- **Mid-diastolic (Fig. 11.32F)**
 - Mitral stenosis
 - Tricuspid stenosis
 - Austin Flint murmur of functional mitral stenosis caused by a jet of blood in aortic regurgitation.
 - Carrey-Comb's murmur of mitral valvulitis.
- **Late diastolic or presystolic (Fig. 11.32G)**
 - Presystolic murmur may be heard in mild MS, while presystolic accentuation of MDM indicates moderate to severe MS

III. Continuous murmur (Fig. 11.32H)

- PDA
- Aortopulmonary window
- Rupture of sinus of Valsalva into right atrium
- Coronary arteriovenous fistula



FIGURES 11.32A to H Classification of murmurs

INVESTIGATIONS FOR A CASE WITH CARDIOVASCULAR DISEASE

- Conventional procedures
 - Electrocardiogram (ECG)
 - Chest X-ray and fluoroscopy
 - Echocardiogram and colour Doppler study.

- Specialised procedures
 - Nuclear scanning
 - Computerised tomography (CT)
 - Magnetic resonance imaging (MRI).

Electrocardiography

It is defined as recording of electrical potentials generated in the heart on a paper with the help of a machine. The

fundamental basis of ECG is that electrical activation of heart muscle causes its depolarization, which is propagated along the length of whole muscle fibre or adjoining cells. This wave of depolarisation passes through the heart and sets up electrical currents/potentials which are detected by surface electrodes, which are amplified and displayed as waveforms on the electrocardiogram. Depolarisation is followed by a wave of repolarisation, therefore, each lead of ECG represents summation of depolarisation and repolarisation across the heart.

Standard 12-lead electrocardiogram

The standard 12-leads consists of:

- **Frontal plane leads**
 - Leads I, II, III, called '*Limb leads*'.
 - Leads aVR, aVL, aVF, called '*Augmented limb leads*'.
- **Horizontal plane leads**
 - Leads V1-V6 are called '*Chest leads*'

These reflect electrical activation of the heart from various positions in the horizontal plane.

The electrocardiographic symbols and abbreviations used are depicted in Figure 11.33, showing an ECG complex.

Pathway of electrical activation of the heart (Fig. 11.34)

Normally, SA node is the pacemaker that generates a wave of excitation. It has an intrinsic property to produce it, the

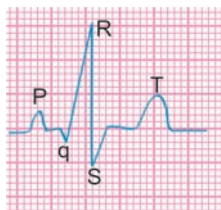


FIGURE 11.33 An ECG complex

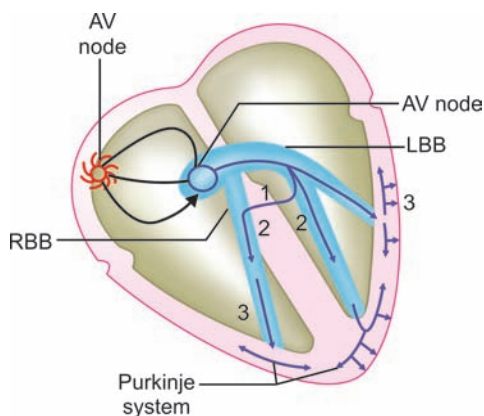


FIGURE 11.34 Electrical excitation of heart by passage of an impulse from SA node to AV node through internodal of pathways; (1) Septal activation from left to right; (2) Ventricular excitation through bundle branches; (3) Ventricular depolarisation through Purkinje system

mechanism of which is not known. This wave of excitation is not recorded on ECG. The wave of excitation (depolarisation) then spreads to atria through internodal conduction pathways producing an upright 'P' wave in all leads except aVR (P wave is negative). From atria, it reaches AV node where slight normal delay occurs and conduction through AV node is slow. It then rapidly goes to bundle of His, travels through its right and left branches to reach ventricles, which are activated to produce QRS complex in all the leads. The time taken by the wave to reach AV node from atria is called P-R interval. The QRS complex is dominated by 'R' wave, which is an actual ventricular depolarisation wave of left ventricle. 'S' wave of QRS complex is produced when depolarisation wave, after activating the septum and ventricles, gets deflected to basal part of left ventricle producing its activation. Therefore, it will be seen dominantly in those leads which are not facing (away from) the depolarisation wave. The leads are I and aVR where 'S' wave is prominent. The frontal plane QRS axis is the mean frontal plane vector of QRS and is determined roughly by seeing which frontal plane leads (I, II, III, aVR, aVL, aVF) have the biggest 'R' wave. Normally, it lies between 0°–90°. The axis is determined as follows:

- 0° = 'R' wave is largest in lead I with smallest 'S' wave. The aVF shows a small complex or an equiphasic complex.
- 90° = 'R' wave is largest in lead aVF with smallest 'S' wave. The lead I shows a small complex or an equiphasic (RS) complex.

In left axis deviation the QRS complex is upright in lead I and negative in lead III and by placing the lead III below lead I, the complexes of leads drift apart from each other.

Conventions used in ECG: These are given in the Box 15.

Calculation of heart rate on ECG

It is calculated as follows:

$$\text{HR/minute} = \frac{1500}{\text{R-R interval (mm) in any lead}}$$

For example, if Rb - R is 20 mm, then

$$\text{HR/min is } 1500 \div 20 = 75/\text{min.}$$

Indications of ECG

It is useful in following situations:

- **Atrial and/or ventricular hypertrophy**
- **Myocardial ischaemia and infarction:** The success of thrombolytic therapy for acute myocardial infarction is governed by it
- **Diagnosis and management of cardiac arrhythmias and conduction defects:** It is a gold standard test.
- **Myocardial and pericardial diseases, e.g. myocarditis, pericarditis**
- **Effects of drugs, electrolytes and poisons on the heart.**

Box 15

ECG conventions

- Upright wave means positive deflection from baseline, e.g. the P, R and T waves are positive
- Downward wave means negative deflection from baseline, e.g. the Q and S waves
- If a wave in QRS complex is, > 5 mm in any lead, it is written in capital letters, i.e. QRS while less than 5 mm is written as small letters, i.e. qrs.
- Standardisation or sensitivity is 10 mm = 1 mV.
- Paper speed = 25 mm second
- Each small square = 1 mm = 0.04 sec.
- Each large square = 5 mm = 0.2 sec.

- **Detection of efficiency of various cardiac intervention procedures**, e.g. angioplasty, bypass surgery
- **More advanced ECG technology** include *stress ECG* to diagnose asymptomatic coronary artery disease. *Holter monitoring* is used to relate symptoms to ECG. *Signal-average ECG* is used to determine the prognosis of arrhythmias.
- **For pacemaker functioning/dysfunctioning.**

Normal and abnormal ECGs: Normal ECG is depicted in Figure 11.35. For ECG Abnormalities—read *Bedside Medicine* by Prof. SN Chugh.

Stress (Exercise) Electrocardiography

Unfortunately, the diagnosis of ischaemic heart disease is often difficult to establish especially in those patients who are asymptomatic for the disease, and in those who have atypical chest pain associated with normal resting ECG. In such a situation, early diagnosis is mandatory to plan medical versus surgical therapy before permanent damage occurs.

Types of stress tests

- Exercise tests
- Pharmacological stress tests, e.g. adenosine, dipyridamole and dobutamine. These tests are done when exercise test is not feasible due to disability or due to some other reason.

Stress (exercise) test is a noninvasive method to evaluate myocardial function. It has become popular in early detection of ischaemic heart disease but its major drawback is its higher false-positive and false-negative results. Since, it is simple and safe method of study, it can be repeated to assess the functional progress of the heart disease as well as to judge the efficacy of therapy. The indications and contraindications are given in the Table 11.13.

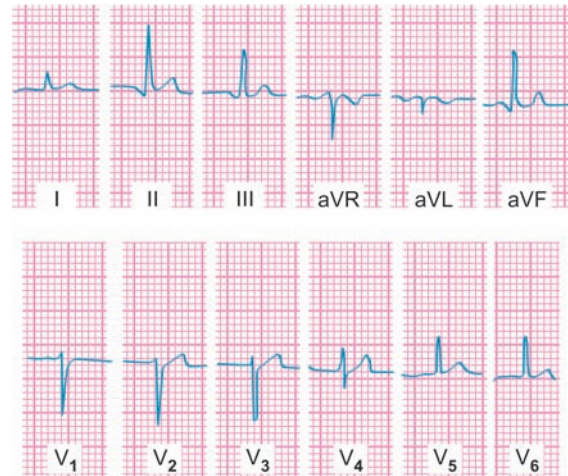


FIGURE 11.35 Normal ECG

TABLE 11.13 Indications and contraindications of stress (exercise) testing

Indications	Contraindications
<ul style="list-style-type: none"> • To confirm the diagnosis of angina • To evaluate stable angina and post-myocardial angina. • To assess prognosis following myocardial infarction. • To test effectiveness of coronary revascularisation, e.g. coronary angioplasty and bypass surgery • To diagnose and evaluate the treatment of exercise induced arrhythmias 	<ul style="list-style-type: none"> • Unstable angina with recent chest pain. • Advanced AV blocks • Uncontrolled hypertension • Severe congestive heart failure • Left main coronary artery disease. • Severe aortic stenosis • Hypertrophic cardiomyopathy • Acute associated disease, e.g. systemic illness, pulmonary or renal insufficiency, diabetes or thyrotoxicosis • Ventricular aneurysm.

Method

A 12-lead ECG is recorded during exercise on a treadmill (Fig. 11.36) or bicycle. The limb leads are placed on the shoulders and hips rather than the wrist and ankles. The most frequent protocol used for treadmill test is Bruce protocol which employs a relatively higher initial workload with greater subsequent work increments. The subject starts at 1.7 mph speed on a 10% incline (gradient). Bruce protocol is given in the Box 16.

Result of stress test

- **Normal exercise electrocardiogram:** When heart rate increases during exercise, certain predictable changes occur in normal ECG. The P-R, QRS and QT intervals shorten, the P wave becomes taller and atrial

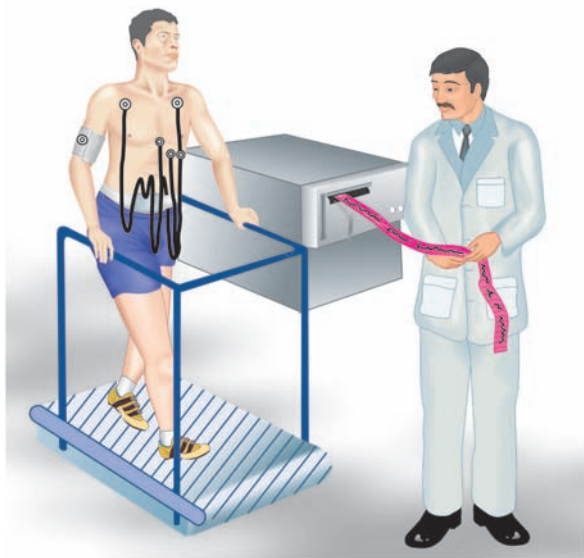


FIGURE 11.36 Exercise treadmill test

Box 16

Brouce protocol for treadmill

Stage	Speed (mph)	Gradient (% incline)
1	1.7	10
2	2.5	12
3	3.4	14
4	4.2	16
5	5.0	18

Note: Each stage lasts for 3 minutes

depolarisation wave (Ta wave) becomes prominent causing depression of PR segment. This results in depression of J point for a short period of 0.04 sec. The normal ST segment with exercise is upsloping and slightly convex in form and returns to baseline within 0.04 to 0.06 sec. after J point.

- **Abnormal or positive test (Fig. 11.37):** The test is said to be positive for provokable ischaemia when there is depression of J point >1 mm with horizontal ST segment ≥ 1 mm persisting for 0.08 sec (two small squares) from the J point in three successive beats.

End points for termination of stress tests: Exercise tests are terminated when the patient develops symptoms and signs of myocardial ischaemia as given in the Table 11.14.

Pitfalls

The results of an exercise test are inconclusive due to false negative and false positive results. Exercise testing is an unreliable screening method because in low-risk population

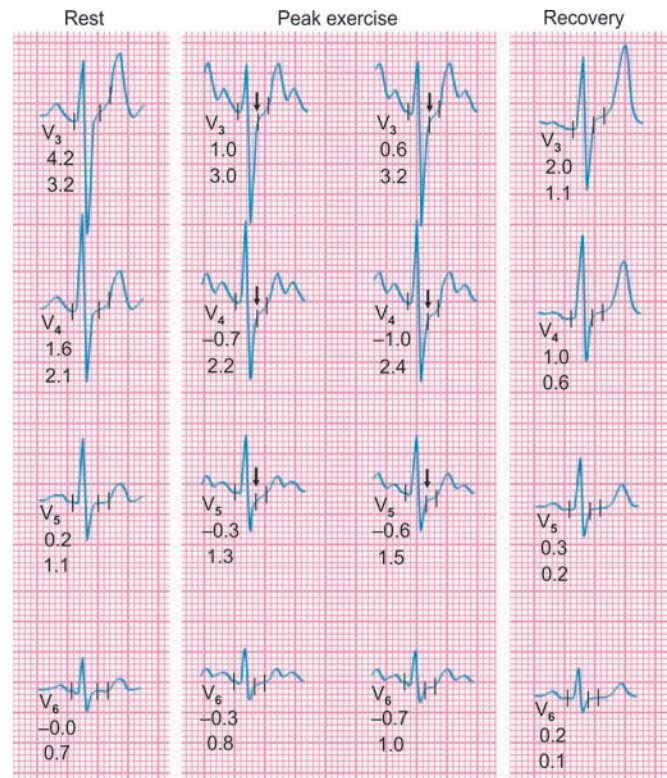


FIGURE 11.37 Positive stress test (Leads V₃-V₃ depicted). Resting ECG is normal. The ECG during exercise showed depression of J-point and ST segments > 2 mm staying for > 80 msec (2 small squares) which reverses during the recovery period

TABLE 11.14 Indications for termination of the stress test

- **Symptoms and Signs**
 - Anginal pain
 - Dyspnoea
 - Dizziness/syncope
 - Unsteady gait
- **Arrhythmias, e.g. bradyarrhythmias and tachyarrhythmias, e.g. multiform VPCs or VT**
- **Abnormal ECG**
 - Abnormal ST segment depression (> 1 mm) or elevation (> 1 mm) in non-q wave leads
 - Hypotension in presence of pain or abnormal ECG.
- **Blood pressure abnormalities**
 - Systolic BP > 250 mmHg
 - Hypotension
- **Heart rate, e.g.**
 - Decreasing heart rate.

(e.g. asymptomatic middle aged women) an abnormal response is more likely to represent a false positive than a true positive test. Nevertheless, certain findings on exercise testing are predictive of severe underlying disease called high risk change (Box 17).

Box 17

High risk finding on stress ECG

- Low threshold of ischaemia, e.g. ischaemic changes appear within stage 1 or 2 of Bruce protocol
- Fall in BP on exercise
- Widespread, marked or prolonged ischaemic ECG changes
- Exercise induced arrhythmias

Continuous Ambulatory Electrocardiographic Recording (Holter Monitoring)

Continuous ambulatory ECG recording (Holter monitoring) is a method of recording one or more leads of ECG for extended period of time (24 hours Holter monitoring) by attaching a small portable solid state tape recorder to the patient (Fig. 11.38). This technique is useful because ECG is recorded when patient is up and about performing normal activities. It is especially useful for detecting transient episodes of arrhythmias or ischaemia which are likely to be missed on 12-leads routine ECG recording (Figs 11.39A and B).

A variety of hand-held or implantable patient-activated devices are available to record the ECG during symptomatic episodes (called event-recorders). These are suitable for investigating those patients who have infrequent but potentially serious symptoms. Many of these devices also have the facility to transmit ECG recording to a cardiac centre through the telephone.

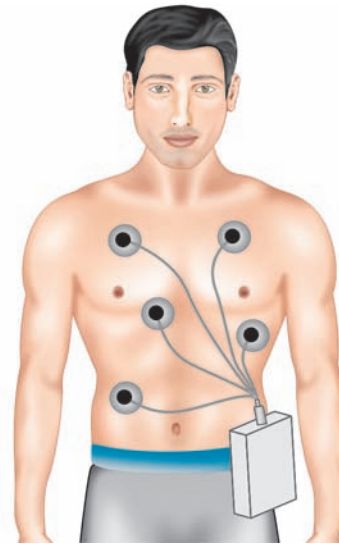
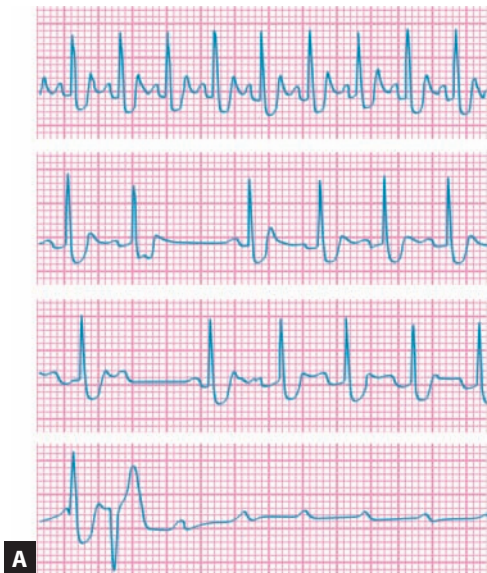

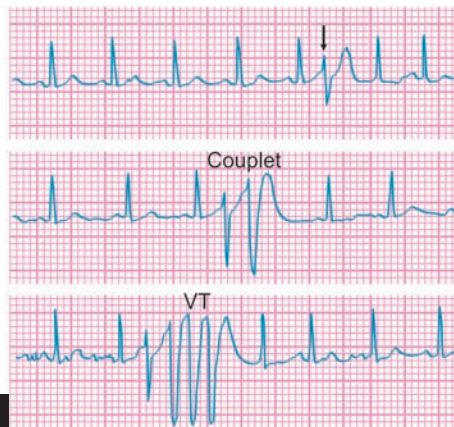
FIGURE 11.38 Holter monitoring. Placement of electrodes on the body surface for continuous recording of one or two leads of ECG over a period of hours (24 hr) or days

Chest X-ray

A postero-anterior (PA) chest X-ray renders most information regarding the size and shape of the heart, state of pulmonary vasculature and lung fields. Antero-posterior (AP) chest X-ray is not preferred because it magnifies the cardiac shadow by divergence of radiographic beam and may give false impression of cardiomegaly when it does not exist. It is done only in bed-ridden patients.



A
Top strip shows sinus rhythm with normal AV conduction
Second strip shows sinoatrial block and third strip also shows second degree SA block—both these episodes were asymptomatic.
Bottom strip shows a ventricular extrasystole followed by complete heart block with ventricular standstill. The patient lost consciousness due to this Stokes-Adams attack.



B
 Samples from three separate 24-hour records made at weekly intervals
Top strip shows sinus rhythm with an ectopic (↓)
Second record shows a couplet (pair) of ventricular extrasystoles (no symptoms noted)
Third record shows a short run of ventricular tachycardia, which corresponded to the patient's complaint of palpitations.

FIGURES 11.39A and B Holter's monitoring: (A) From a patient with Stokes-Adams attacks; (B) From another symptomatic patient of syncope

An estimate of heart size is determined by 'cardiothoracic ratio', which is ratio of the heart size to the maximum transthoracic diameter.

The cardiothoracic ratio >0.5 ($>50\%$) indicates cardiomegaly.

The Normal Cardiac Shadow/Silhouette

In standard PA view of the chest (Fig. 11.40), the heart is interposed between two translucent lungs as a flask-shaped shadow with one-third of its area to the right and two-thirds to the left of the midline. The apex is internal to the mid-line.

The right border of normal heart shadow is constituted by two curves from above downwards:

- The upper curved portion consists of superior vena cava with ascending aorta.
- The lower convexed portion consists of right atrium the lower margin of which lies on the diaphragm.

The left border is constituted from above downwards by:

- Aortic knuckle produced by arch of the aorta
- Straight line of the pulmonary conus (pulmonary artery)
- Left atrial appendage
- The wide sweep of the left ventricle ending as apex where it rests on the diaphragm.

Indications of Chest X-ray

- The overpenetrated PA film can visualise the left atrium very well if enlarged and aorta is particularly seen for calcification. Calcification of pericardium as well as of the valves can also be better seen.

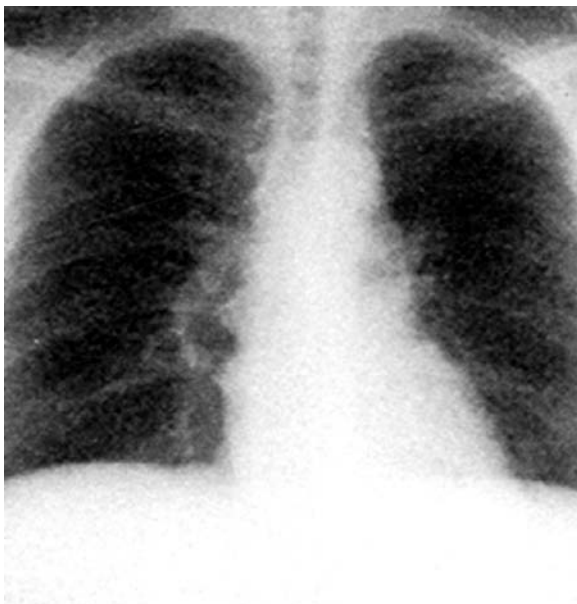


FIGURE 11.40 Normal cardiac shadow on chest X-ray (PA view)

- The right lateral view is of value in localising right ventricular hypertrophy (RVH) when the anteriorly placed right ventricle is seen closer to the sternum than normal.
- For detection of common alterations in diseases of heart such as:
 - **Displacement of the heart in the chest:**
 - To the opposite side, i.e. pleural effusion, pneumothorax
 - Shift to the same side abnormally, i.e. collapse of the lung, atelectasis, fibrosis and removal of a part or whole lung. In scoliosis, the heart is shifted to the left with convexity towards right.
 - In narrow chests and in patients with COPD, the heart lies centrally and seems smaller and tubular.
 - **Abnormal shape and size of the heart:**
 - Cardiomegaly (heart is enlarged and shadow is enlarged)
 - Valvular heart disease such as aortic, mitral (mitralised heart), pulmonary and tricuspid valves diseases.
 - Hypertension
 - Dilated cardiomyopathy, myocarditis
 - Ventricular aneurysm
 - No cardiomegaly but heart shadow is enlarged
 - Pericarditis with effusion or cardiac tamponade
 - Cardiac rupture
 - Secondaries in pericardium
 - Mediastinal obstruction leading to widening of heart shadow by widening the mediastinum.
 - Dilatation of individual cardiac chamber can be assessed by the alterations they cause to the cardiac silhouette (heart shadow):
 - Left atrial enlargement results in prominence of shadow of left atrial appendage on the left border of heart and a double cardiac shadow to the right of sternum. These changes are characteristically seen in patients with mitral stenosis (Read Mitral Stenosis in Bedside Medicine by Prof. SN Chugh).
 - Right atrial enlargement produces prominence and enlargement of right border of the heart towards right lower lung field.
 - Left ventricular dilatation causes prominence of left border of heart and enlargement of cardiac shadow (Fig. 11.41).
 - Right ventricular dilatation increases heart size and displaces the apex upwards.
- Detection of abnormalities of shape and size of great vessels and pulmonary vasculature.
 - **Aorta:**
 - Dilatation of ascending aorta* occurs due to Marfan's syndrome, cystic medial necrosis,

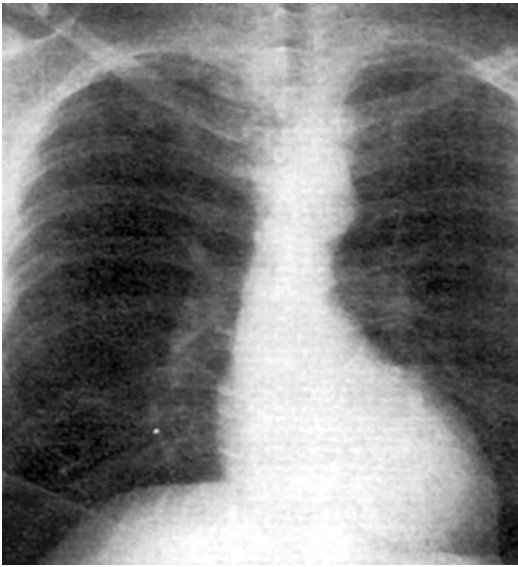


FIGURE 11.41 Left ventricular enlargement. Note the boot shaped heart

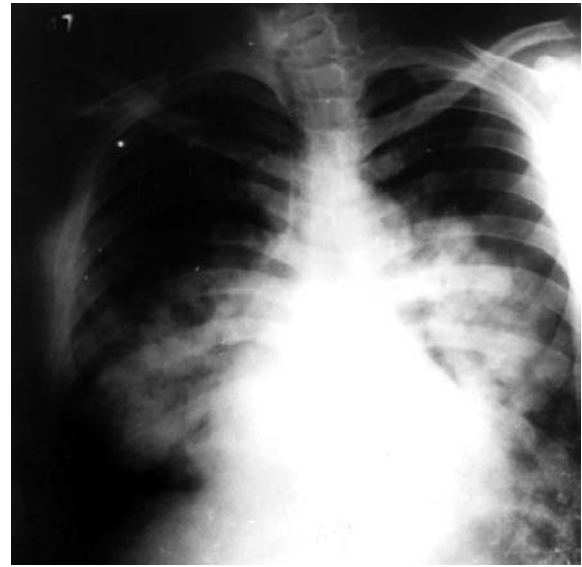


FIGURE 11.42 Heart failure. Chest X-ray (PA view) shows enlarged cardiac shadow with nonhomogenous opacification of the lungs from hila to periphery (pulmonary oedema)

- aneurysm of aorta, syphilis, atherosclerosis and acute dilatation occurs in aortic dissection. Post-stenotic dilatation is seen in severe aortic stenosis,
- ii. Unfolding of aorta (both ascending and descending aorta may be involved) is seen in patients with hypertension and old age.
- *Prominent superior vena cava shadow*: It is seen in the upper part of right border of the heart in patients with:
 - i. Right ventricular failure.
 - ii. Superior vena cava obstruction.
- *Prominent pulmonary artery (conus)*: The enlargement of pulmonary artery causes prominence of pulmonary conus in patients with:
 - i. Pulmonary hypertension due to any cause
 - ii. Post-stenotic dilatation in pulmonary stenosis
 - iii. Idiopathic dilatation of pulmonary artery.
- *Prominent pulmonary vasculature*: The pulmonary vasculature becomes prominent in raised left atrial pressure producing congestion in the lungs characterized by:
 - i. Prominent hilar shadows
 - ii. Kerley's B lines. These are short horizontal lines extending out to the lung edges or the bases of lung
 - iii. Prominence of upper lobe veins
 - iv. Interstitial pulmonary shadowing either as diffuse haziness or a bat-wing appearance of acute severe pulmonary oedema (haziness from hilum extending towards periphery).

- *Pulmonary plethora*: The main branches of the pulmonary arteries are dilated and engorged. This occurs in:
 - i. Left to right shunt (e.g. ASD, VSD, PDA). This is best seen on fluoroscopy (screening) discussed below.
- *Pulmonary oligoemia*: The pulmonary vasculature is inconspicuous in:
 - i. COPD where there is pruning of peripheral vessels due to compression by the hyperinflated alveoli.
 - ii. Fallot's tetralogy.

Radiographic Findings in Heart Failure

Characteristic radiological findings are observed on chest X-ray in patients with left heart failure. These are mainly due to elevation of pulmonary venous pressure and interstitial oedema. These are:

- Abnormal distention of upper lobe pulmonary veins.
- Vasculature of lung fields is increased and pulmonary artery is dilated.
- Kerley's 'B' lines become evident at costophrenic angles due to interstitial oedema. These lines represent thickened interalveolar septa and dilated lymphatics.
- More advanced cases show non-homogenous opacification spreading from the hilar regions to periphery (Fig. 11.42).
- There may be interlobar effusion and hydrothorax.

The abnormal cardiac conditions and their radiological features have discussed in Bedside Medicine by Prof. SN Chugh.

Fluoroscopy for Hilar Dance

Hilar dance is a radiological finding seen in congenital heart disease with moderate left to right shunt pulmonary vascular markings are prominent and pulmonary artery is dilated. Pulmonary arteries show increased pulsations from hilum to periphery which can easily be seen on fluoroscopy of chest. This is due to increased blood flow through pulmonary vessels.

Screening of the heart is primarily of value in visualising the calcification and in detecting a left ventricular aneurysm.

Echocardiography

Echocardiography is ultrasound imaging of heart and great vessels. Ultrasound is reflected at interfaces between blood and solid tissues because velocity of sound is constant in body tissues. These sounds are then gathered and they collectively give the anatomical dimensions of the structure to be studied. Therefore, it is useful in studying the blood flow, the structure of the heart and movements of valves and cardiac muscles. It is done by placing a transducer on the chest (*trans-thoracic echo*) or in the oesophagus (*transoesophageal echo*). **Transoesophageal echo** gives better images quality and resolution as transducer is very close to the heart and there is less interference with the ultrasound beam. It is better than **transthoracic echo** in examining the posterior parts such as LA appendages, descending aorta and pulmonary veins. In echocardiography, the transducer passes sounds and collects the reflected sounds which are displayed and studied. The normal values of echocardiogram varies with height, age, sex and exercise.

The normal values in an adult are depicted in Table 11.15.

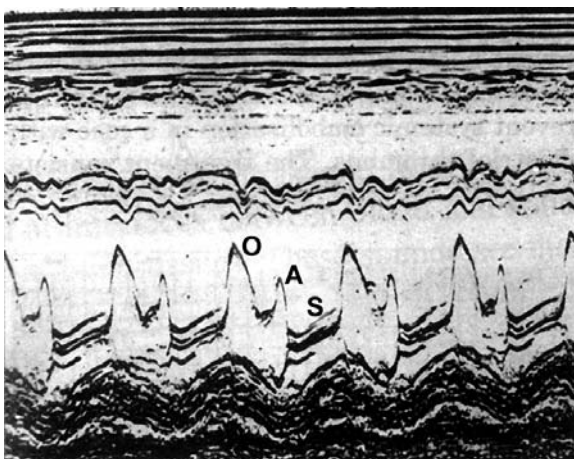
Type of Studies

Three types of study are performed:

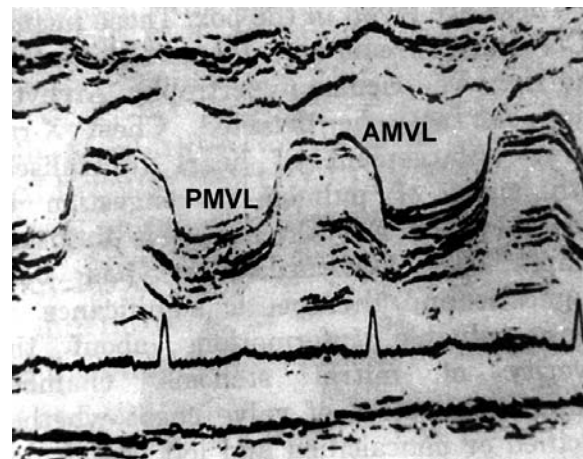
1. **M-mode echocardiography:** A single transducer along a single line provides an 'ice pick' view of heart. The ECG is recorded simultaneously permits accurate measurement of the timings of cardiac events including opening and closing of valves. Characteristic patterns are seen in mitral stenosis and pericardial effusion (Fig. 11.43).
2. **Two-dimensional echocardiography:** It produces an image in two distant dimensions by swinging the ultrasound beam rapidly back and forth over an area or sector. The information is collected and displayed on a television screen and it can be synthesized into two

TABLE 11.15 Normal echocardiographic values in an adult

Left ventricle			
Internal diameter	End-systolic		2.0–4.0 cm
	End-diastolic		3.5–5.6 cm
Wall thickness	Diastolic	Septum	0.6–1.2 cm
		Posterior wall	0.6–1.2 cm
	Systolic	Septum	0.9–1.8 cm
		Posterior wall	0.9–1.8 cm
Fractional shortening			30–45%
Ejection fraction			50–85%
Left atrium (LA)			
Diameter			2.0–4.0 cm
Aortic root			
Diameter			2.0–4.0 cm
Right ventricle (RV)			
Diameter (systolic-diastolic)			0.7–2.3 cm

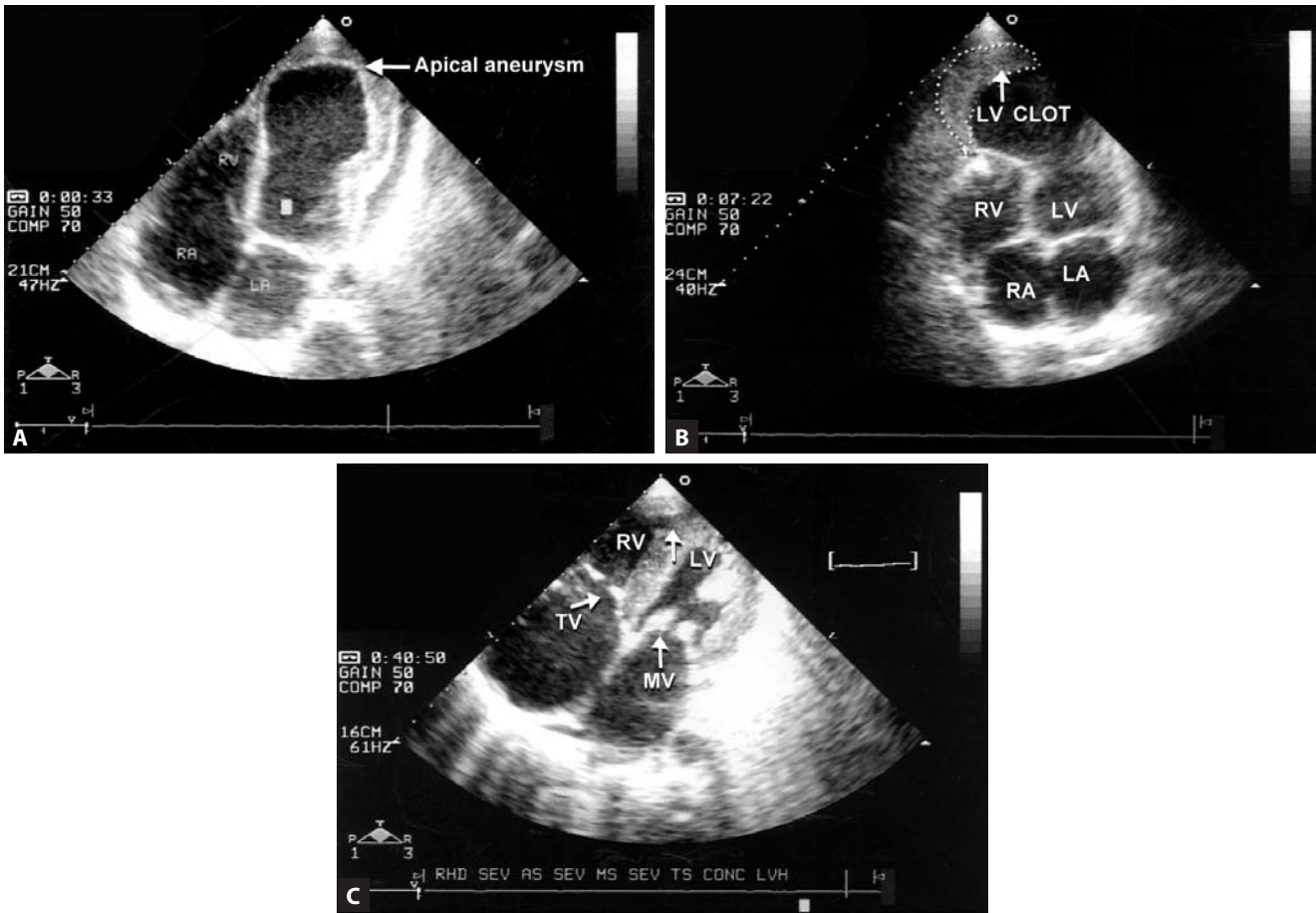


Pericardial effusion



Mitral stenosis

FIGURE 11.43 Echocardiogram



FIGURES 11.44A to C Two dimensional echocardiogram. The four chamber view shows: (A) An apical aneurysm; (B) A ventricular clot; (C) Ventricular septal defect

dimensional map also. The structures shown will depend on the position and orientation of the ultrasound probe. This type of echocardiography is practically helpful in detecting an aneurysm (Fig. 11.44A), intra-cardiac masses such as clots, thrombus (Fig. 11.44B), tumour or vegetations, etc. It is specially useful in congenital heart diseases such as atrial septal defects, ventricular septal defects (Fig. 11.44C) etc.

3. **Doppler echocardiography:** The basic principle of Doppler studies is that sound waves reflected from moving objects such as RBCs in blood, undergo frequency shift. The speed and direction of movement of RBCs in blood can be detected in the heart chambers and great blood vessels. The information is presented as a colour overlay on a two dimensional real time echo picture (colour flow Doppler). It is useful to detect abnormal direction of flow of blood through valves (aortic and mitral regurgitation; Fig. 11.45), through septal defects (ASD, VSD) and in measuring pressure gradient across a stenosed valve. Three commonly used Doppler echo techniques are:

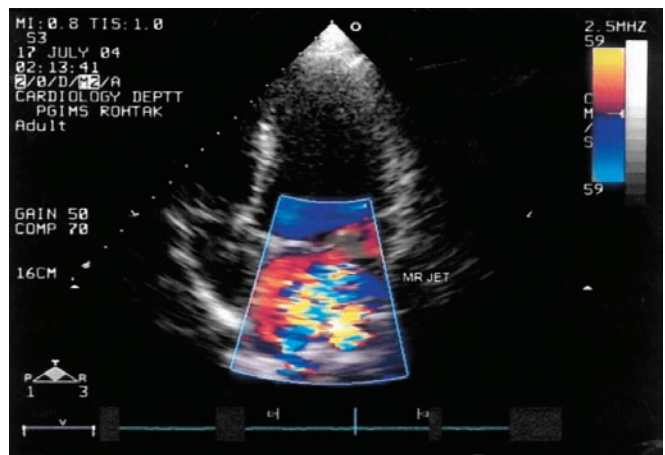


FIGURE 11.45 Colour Doppler study showing regurgitant jet across mitral valve in mitral regurgitation (MR)

- i. **Continuous wave Doppler:** Two crystals are used—one transmitting continuously and other receiving continuously.

Box 18

Echocardiographic modalities and their main uses

2-D echo	<ul style="list-style-type: none"> • Anatomy • Ventricular and valvular movement
M-mode echo	<ul style="list-style-type: none"> • Measurement of dimensions • Timing cardiac events
Pulse wave Doppler	<ul style="list-style-type: none"> • Normal valve flow patterns • LV diastolic function • Stroke volume and cardiac output
Continuous wave Doppler	<ul style="list-style-type: none"> • Severity of valvular stenosis by calculating gradient • Severity of valvular regurgitation • Velocity of flow in shunts
Colour flow mapping	<ul style="list-style-type: none"> • Assessment of regurgitation and shunts

- ii. **Pulse wave Doppler:** A single transducer is used to transmit as well as to receive an ultrasound signal, used to localise disturbance in flow or blood velocity from a small region measured.
- iii. **Colour flow mapping:** It is an automated 2D version of pulsed wave Doppler. It calculates blood velocities and direction at multiple points. The velocities and directions of blood flow are colour encoded. Velocities away from the transducer are in blue, those towards it are in red. This is known as BART convention (Blue away, Red towards). The summary of echocardiographic modalities and their uses are given in the Box 18.

Radionuclide Scanning

This is a noninvasive technique to study the cardiac functions by using a gamma-emitting radionuclides with a short half-life. The gamma rays are detected by means of a scanner or a tomographic camera that permits the images of the heart to be reconstituted. There are two techniques:

1. **Blood pool scanning:** The isotope is injected intravenously and mixes with the blood. The gamma camera detects the amount of isotope emitting blood in the heart at different phases of cardiac cycle and also the size and shape of cardiac chambers. By linking gamma camera to the ECG, information over multiple cardiac cycles are collected and then 'gated' to the systolic and diastolic phases of the cardiac cycle. This type of scanning gives an accurate information of left ventricular functions. It is most useful to detect ventricular aneurysms.
2. **Myocardial scanning:** This technique uses gamma camera scintigraphy. Radioactive thallium or tracers

are used to distinguish ischaemic from non-ischaemic myocardium. Radioactive pyrophosphate is used to distinguish between normal and infarcted segment.

Stress Radionuclide Scanning

Single photon emission tomography (SPECT) with Technetium 99-labelled transforming stress testing (Fig. 11.46) is used to detect reversible ischaemia. The image taken at rest and during exercise are compared to detect an ischaemic segment/area. 99 TC-Sesambi or 301 TI perfusion images detect myocardial infarction as a perfusion defect (cold area). This is sensitive test but, cannot detect age of infarct.

Invasive Cardiac Investigations

Cardiac Catheterisation and Angiocardiology

This is an invasive investigation in which a catheter is introduced through a vein or an artery and manipulated through the heart under fluoroscopic guidance. Cardiac catheterisation is used for this purpose. The indications and contraindications of cardiac catheterisation and angiography are given in the Table 11.16.

Coronary Angiography

It is a procedure of opacification of the coronary arteries by injecting a radio-opaque material through a catheter which is passed either through the brachial or femoral artery (a common route). These catheters are preshaped, hence, entry to the coronary vessel is easy. Generally Judkin's catheters are used for coronary angiography.

Indications: These are given in the Table 11.17.

Contraindications

- Gross CHF
- Uncontrolled cardiac arrhythmias
- Incurable noncardiac disease, renal failure and bleeding diathesis.

Complications

- Myocardial infarction
- Arrhythmias
- Cerebrovascular disease
- Death (incidence is low $\leq 0.1\%$). It is now-a-days considered as a safe procedure.

PERIPHERAL VASCULAR SYSTEM

Historical background: In developed countries and in people belonging to high socioeconomic status, the peripheral artery disease is common after the age of 60 years. Underlying atherosclerosis involving the large and

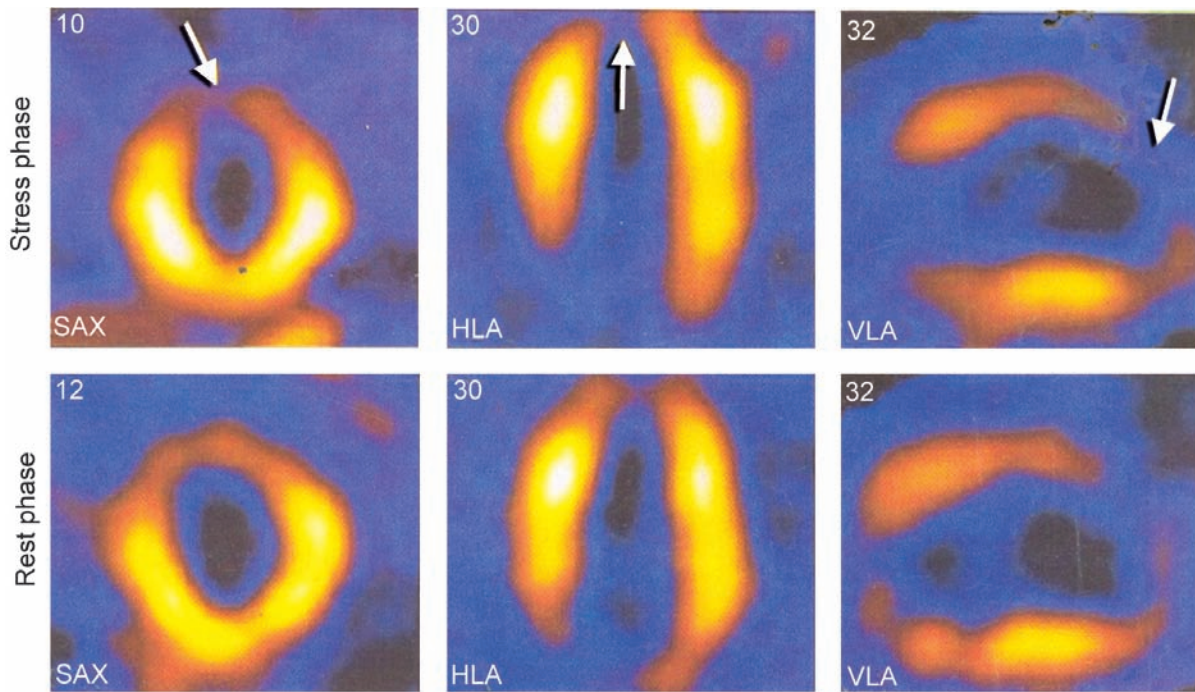


FIGURE 11.46 Single photon emission computed tomography (SPECT) image of LV and LA with ⁹⁹Tc tetrofosmin tracer. There is moderate to large defect in the anterior wall and apex of left ventricle during stress (top image, defect indicated by arrows). The defect is partially reversible during rest (bottom row). Tomographic veins are labelled in the left lower corner of each image. *Abbreviations:* HLA = Horizontal long axis image; VLA = Vertical long axis image

TABLE 11.16 Indications, contraindication and complications of cardiac catheterization and cardiac angiography

Indications	Contraindications
<p>A. Diagnostic</p> <ul style="list-style-type: none"> • To study cardiovascular anatomy in patients with congenital or acquired heart disease. • To study intracardiac/intravascular pressures and to measure flow, e.g. cardiac output and regional blood flow • To determine gradient across a valve and to identify and quantify valvular regurgitation • To assess ventricular function • To perform coronary angiography • A Swan-Ganz catheter is used in ICU to monitor pulmonary capillary wedge pressure • To perform endomyocardial biopsy <p>B. Therapeutic</p> <ul style="list-style-type: none"> • For administration of thrombolytic agents • For selective therapeutic embolisation of vessels • For performing balloon dilatation (valvular or vascular) or related procedures, e.g. stenting • For cardiac pacing (temporary or permanent) • For nonsurgical closure of ASD, VSD, PDA • For nonsurgical destruction of foci of cardiac arrhythmias and pathways of aberrant conduction in patient with re-entrant arrhythmias 	<ul style="list-style-type: none"> • Refusal of the study by the patient • Ventricular instability with risk of VT or VF • Electrolyte disturbances • Digitalis toxicity • Severe systemic hypertension • Concurrent systemic illness, e.g. systemic infections, pulmonary or renal insufficiency, severe anaemia • Gross CHF (untreated) • Gross LV dysfunction <p>Complications</p> <p>A. Systemic</p> <ul style="list-style-type: none"> • Myocardial infarction • Cerebrovascular disease • Hypotension and arrhythmias • Embolisation (systemic and pulmonary) <p>B. Local</p> <ul style="list-style-type: none"> • Arterial damage and perforation of heart and great vessel • Vasovagal and pyrogen reactions • Local infection

TABLE 11.17 Indications for coronary angiography

- Unexplained chest pain with high degree of suspicion of coronary artery disease (Figs 11.47A and B).
- To detect the presence, site and severity of coronary artery disease in patients with symptomatic angina.
- Prior to coronary angioplasty and bypass surgery. It is repeated after angioplasty (stenting done) to study the re-establishment of circulation and for postoperative study of bypass grafts and native circulation.
- Prior to intracoronary thrombolytic therapy
- Strongly positive stress test at low level of exercise.
- Patients with equivocal symptoms, ECG and stress testing but with high risk occupations, e.g. pilots. It is also done to clarify the coronary status for life insurance purpose
- Patient suspected to have coronary AV fistula.

medium sized arteries is the common cause in majority of the patients. The risk factors for peripheral artery disease include diabetes, smoking, hyper-lipidaemia, sedentary habits, hypertension, obesity and familial aggregation. The general history should accordingly focus on the family history of premature arterial disease and on the risk factors associated with atherosclerosis/atheroma. Diabetes is specifically important in this regard. Furthermore, the clinical manifestations of diabetic arterial disease are frequently exacerbated by co-existing peripheral neuropathy and microangiopathy.

About two thirds of patients with clinically detectable peripheral arterial disease (PAD) may be asymptomatic, hence, early diagnosis is mandatory because of following reasons:

- The initial manifestation of peripheral arterial disease (PAD) may be with life-threatening complication.

- Evidence of PAD is a marker for premature cardiovascular and cerebrovascular death.
- The presence of PAD may affect the outcome of medical and surgical treatment for a range of other conditions. For example, beta-blockers should not be prescribed in patients with PAD as they may precipitate the onset of claudication. Likewise, cardiac surgery (bypass surgery) may lead to stroke in patients with severe but asymptomatic carotid artery stenosis.

Classification

Peripheral arterial disease occurs as a result of any of the following three processes:

- Occlusive arterial disease (most common type)
- Vasospastic disorders
- Aneurysmal disease.

OCCLUSIVE ARTERIAL DISEASE

An aetiological classification of occlusive PAD is given in the Table 11.18.

Clinical Presentations

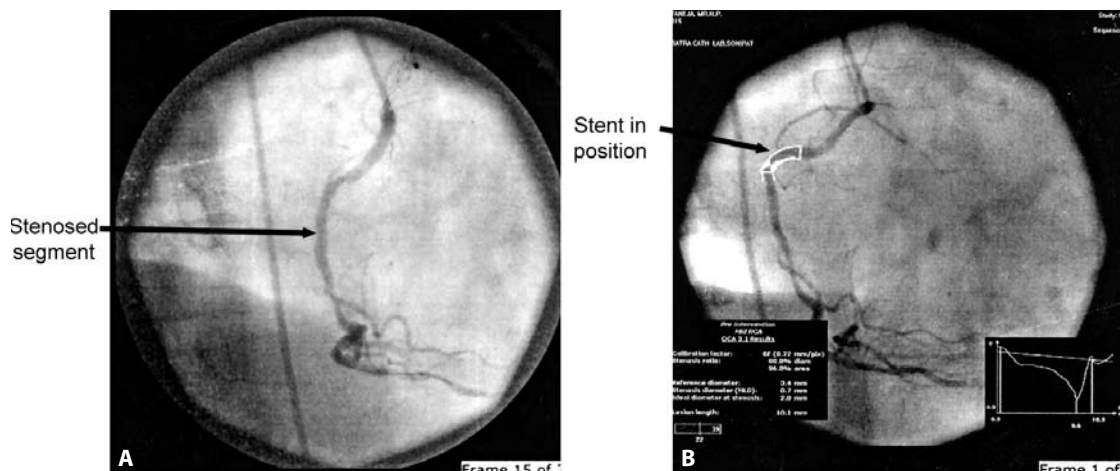
The PAD may manifest in four major ways:

1. Limb symptoms.
2. Neurological symptoms.
3. Abdominal symptoms.
4. Vasospastic symptoms.

Limb Symptoms

A. Lower limb symptoms

- Acute lower limb ischaemia manifests with *pain, paraesthesias, paralysis, pallor, pulselessness* and



FIGURES 11.47A and B Coronary angiography in a patient with angina: (A) Before angioplasty. There is narrowed segment in one of the branches of coronary artery (→); (B) After angioplasty and stenting, the coronary circulation is resumed

TABLE 11.18 Aetiological classification of occlusive peripheral arterial disease

- **Acute arterial ischaemia**
 - *Thrombotic*, e.g. atherosclerotic obliterans, thromboangitis obliterans (Buerger’s disease), arteritis (connective tissue disease, giant cell and Takayasu’s arteritis), myeloproliferative diseases (polycythaemia) and hypercoagulable status
 - *Embolic*, e.g. cardiac origin (valvular disease, prosthetic valve, AMI, AF with atrial thrombus, infective endocarditis, cardiomyopathy, left atrial myxoma); atherosclerotic plaques (in aorta or big vessels), trauma and arterial spasm.
- **Chronic arterial disease**
 - Atherosclerotic obliterans
 - Thromboangitis obliterans
 - Arteritis, e.g. connective tissue disorders, temporal arteritis (giant cell) and Takayasu’s disease .
 - Miscellaneous, e.g. trauma, entrapment, congenital arterial narrowing

perishingly cold limb (denoted by 6 Ps). There may be pain on squeezing the muscles (calf tenderness). Any one or all of them may be present. Any “cold limb” with suspected acutely ischaemia must be discussed immediately with vascular surgeon because a few hours can make the difference between amputation and complete recovery of the limb function. Differentiation of acute embolic from thrombotic occlusion is important (Table 11.19) because treatment and prognosis are different.

B. Chronic ischaemia of limb

- Lower limb symptoms. There are four well defined stages of lower limb ischaemia, i.e.
 - Asymptomatic
 - Intermittent claudication
 - Rest pain
 - Tissue loss (ulceration/gangrene).

Asymptomatic lower limb ischaemia is identified by a reduced ankle brachial pressure index (ABPI). It is common in middle aged and elderly. Such patients are also at high risk of developing complications.

Intermittent claudication refers to cramp like muscle pain in calf, buttock or thigh on walking which is rapidly relieved by taking rest.

Male patients with gluteal claudication, due to internal iliac disease, are almost invariably impotent. Enquiry into sexual activity should be made if not told by the patient.

The term claudication just denotes pain in the leg on walking, could also be due to neurological and musculoskeletal disorder of the lumbar spine (neurogenic claudication) and due to venous outflow obstruction from the leg (venous claudication). However, all these claudications are much less common than arterial claudication and can easily be distinguished on history and examination (Table 11.20). The questions to be asked for intermittent claudication are given in the Box 19.

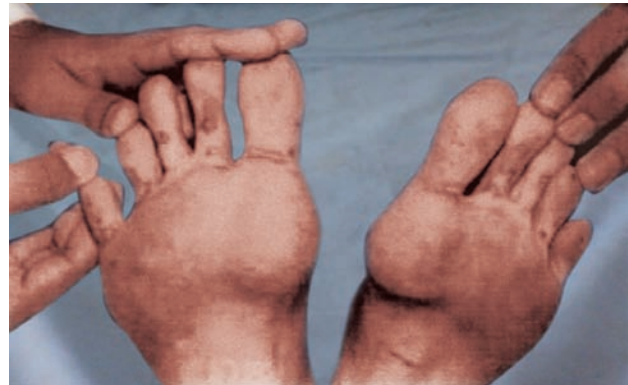

FIGURE 11.48 Feet in a patient with bacterial endocarditis. Note digital embolisation

TABLE 11.19 Acute limb ischaemia (thrombosis vs embolism)

Clinical feature	Embolism (Fig. 11.48)	Thrombosis
• Onset	Sudden (seconds or minutes)	Hours
• Severity	Complete (no collaterals)	Incomplete (collaterals)
• Embolic source	Yes (atrial fibrillation common)	No
• Previous claudication	Absent	Present
• Central pulses present	Yes	No
• Upper limb affected	Commonly (25%) leg: arm (3:1)	Rare Leg: arm (10:1)
• Palpation of artery	Soft, tender	Hard, calcified
• Bruits	Absent	Present
• Contralateral leg pulses	Present	Absent
• Multiple sites	Upto 15% (sometimes)	Rare
• Diagnosis	Clinical	Angiography
• Treatment	Embolectomy, warfarin	Thrombolysis
• Prognosis	Loss of life > loss of limb	Loss of limb > loss of life

TABLE 11.20 The clinical characteristics of arterial, neurogenic and venous claudication

Feature	Arterial	Neurogenic	Venous
Cause	Stenosis or occlusion of major limb arteries	Lumbar nerve root or cauda equina compression (spinal canal stenosis)	Obstruction to the venous outflow of the leg due to iliofemoral venous occlusion
Site of pain	Calf, but may involve thigh and buttock	Ill-defined. Whole leg pain, may be associated with numbness and tingling	Whole leg pain, bursting in nature.
Lateralisation	Unilateral, can be bilateral	Often bilateral	Nearly always unilateral
Onset	Gradual, occurs after walking some distance	Often immediate after walking or even standing up	Gradual, often from the moment walking starts
Relieving factors	Cessation of walking abolishes pain immediately	Relief is achieved on bending forwards and stop walking. May have to sit to obtain full relief	Elevation of leg relieves discomfort
Colour	Normal or pale	Normal	Normal or increased
Temperature	Normal or low (cold)	Normal	Normal or increased
Oedema	Absent	Absent	Present
Straight leg raising	Normal	May be limited	Normal

Box 19

Questionnaire for intermittent claudication

- Have you ever had any pain or cramping in your legs on walking or exercise?
- How far can you walk without pain?
- Does the pain get better with rest?
- Ask also about coldness, numbness, or pallor in the legs or feet or loss of hair over the anterior tibial surfaces

Night/rest pain: It may be the first manifestation of PAD. The patient goes to bed and is woken up after 1–2 hours by pain in the foot, usually in the step. This is due to loss of beneficial effects of gravity on limb perfusion on recumbency. Sleep also causes reduction in heart rate, BP and cardiac output. Patients usually get relief by hanging their leg out of bed or by getting up and walking around. When the patient returns to bed symptom recurs. Rest pain usually indicates the presence of multi-level disease.

Tissue loss (ulceration and/or gangrene): It is frequently caused by critical limb ischaemia. In such cases, trivial injury will fail to heal and provide a portal of entry for bacteria leading to gangrene and/or ulceration. Without revascularisation, the ischaemia will rapidly progress.

Examination**The physical examination**

The general physical examination includes looking for:

- Anaemia and cyanosis.
- Signs of cardiac failure
- Direct or indirect evidence of vascular disease (Box 20 for signs and their related vascular disease).

Box 20

Signs suggestive of vascular disease

Sign	Suggested vascular disease
<ul style="list-style-type: none"> • Hands and arms <ul style="list-style-type: none"> – Nicotine stains – Purple discolouration of finger tips – Pits and healed scars on finger pulps – Cyanosis and visible nail-fold capillary loops – Wasting of small muscles of the hand • Face and neck <ul style="list-style-type: none"> – Corneal arcus and xanthelasma – Horner's syndrome – Hoarseness of voice and bovine cough – Prominent veins in the neck and over shoulder and anterior chest • Abdomen <ul style="list-style-type: none"> – Epigastric/umbilical pulsation – Mottling of abdomen – Evidence of weight loss 	<ul style="list-style-type: none"> • Smoking • Atheroembolism from a subclavian aneurysm • Secondary Raynaud's phenomenon • Scleroderma and the CREST syndrome • Thoracic outlet syndrome • Hypercholesterolaemia • Carotid artery dissection or aneurysm • Recurrent laryngeal nerve palsy from a thoracic arch aneurysm • Axillary/Subclavian vein occlusion • Aortoiliac aneurysm • Ruptured abdominal aortic aneurysm or saddle embolism occluding aortic bifurcation • Visceral ischaemia

A thorough search should be made for these signs in addition to the detailed examination of arterial pulses.

Areas of Examination

Assessment of the peripheral vascular system relies primarily on inspection of the arms and legs, palpation of pulses, and a search for oedema or an arterial bruit (Box 21).

Examination Sequence

Inspection

Inspect both the arms (hands, finger tips, nail beds, skin) and legs (feet, toes) for size, symmetry, change in temperature, colour of the skin and nail beds. Note any area of pigmentation, rashes, scales, ulcer (Fig. 11.48) or gangrene.

Palpation

- Palpate upper limb vessels
 - Palpate lower limb vessels
- Measure the blood flow or grade the volume of the pulse as follows:

Normal	+
Reduced	±
Absent	-
Aneurysmal	++

Note: If the examiner is in any doubt about which pulse is being felt (i.e. his or her own or patient's pulse), it is useful for the clinician to palpate his or her own pulse at the same time. Lack of synchronisation implies that it is the patient's pulse.

Now palpate for the lymph nodes (axillary, epitrochlear, cervical and inguinal) for any enlargement.

Palpate the feet for pitting or nonpitting oedema.

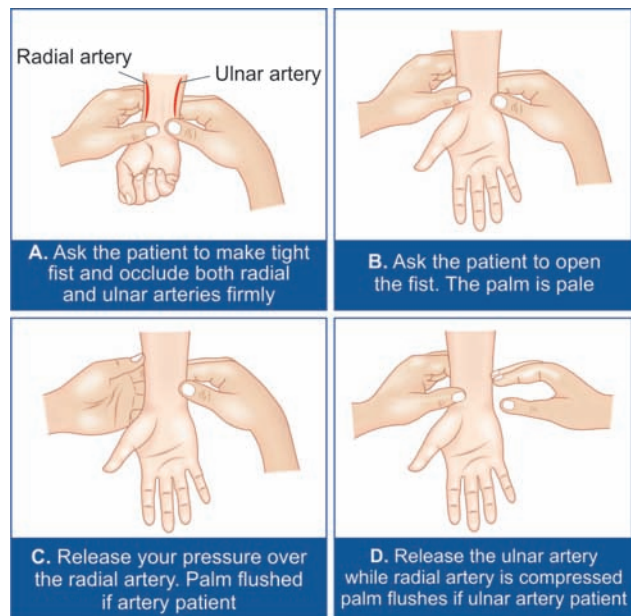
Box 21

Important areas of examination

The extremities	Systemic examination
<ul style="list-style-type: none"> • The arms <ul style="list-style-type: none"> – Size, symmetry, skin colour, nail beds and skin texture – Pulses, e.g. radial and brachial – Epitrochlear lymph nodes, axillary or cervical lymph nodes • The legs <ul style="list-style-type: none"> – Size, symmetry, skin colour, nail growth, texture of skin, hair loss – Pulses, e.g. femoral, popliteal, dorsalis pedis, posterior tibial – Inguinal lymph nodes – Peripheral (pedal) oedema – Any pigmentation, rashes, scales, ulcer, gangrenous toe 	<ul style="list-style-type: none"> • Heart and vessels <ul style="list-style-type: none"> – Look for the evidence of valvular heart disease or ischaemic heart disease. – Record systolic BP in the upper (brachial BP) and lower limb (ankle BP on posterior tibial or dorsalis pedis artery). Calculate the ankle/brachial systolic BP ratio or index – Auscultate the abdominal aorta or other major vessels for any bruit • Nervous system examination <ul style="list-style-type: none"> – Look for the evidence of any neurological deficit

Special Techniques to Test Arterial Supply of Hands

- **The Allen test for patency of ulnar and radial artery:** Ask the patient to make a tight fist of one hand. Compress both the radial and ulnar arteries between your thumb and fingers at the wrist. Now ask the patient to open the hand into a relaxed and slightly flexed position. The palm becomes pale in this position (Figs 11.49A and B).
- Patency of the radial artery may be tested by releasing the radial artery while still compressing the ulnar (Fig. 11.49C).
- Release your pressure over the ulnar artery. If artery is patent the palm flushes within 3–5 seconds (Fig. 11.49D). Persisting pallor indicates occlusion of ulnar artery or its distal branches.
- **Adson's test:** This is performed for presence of subclavian artery compression by a cervical rib or scalenus anticus (*thoracic outlet syndrome*). While the patient is sitting, palpate the radial pulse on the affected side (i.e. there is pain or diminished pulse on that side). Then patient is asked to inhale and hold the breath and turn his chin upwards and towards the affected side. A decrease in or absence of radial pulse indicates positive test for subclavian artery compression.
- **Postural colour changes for chronic arterial insufficiency (Buerger's test):** If pain or diminished pulses suggest arterial insufficiency, look for postural colour changes. Raise both the legs while the patient lying supine to about 60° until maximal pallor of the feet develops usually within 60 seconds. In this position, a slight pallor is normal response, but marked pallor suggests arterial insufficiency.



FIGURES 11.49A to D The Allen test for patency of the vessel

Now ask the patient to sit up with legs dangling down. Compare both feet, noting the time required for return of normal pink colour (usually returns within 10 seconds) and filling of veins of the feet (normally fills within 15 seconds).

The abnormal response indicates arterial insufficiency.

Persistence of rubor (dusky redness) on dependency indicates positive test for arterial insufficiency.

Normal responses accompanied by diminished arterial pulsations indicate that a good collateral circulation has developed around the arterial occlusion.

Colour changes may be difficult to see in darker-skinned persons.

Palpation of Various Peripheral Pulses

Palpate the various pulses of upper and lower limbs for pulsations (normal, increased, diminished or absent).

The arterial pulses are detected by gently compressing the vessel against some firm underlying structure such as bones. The method of palpation of various pulses is illustrated in the Figures 11.50A to E in the Box 22.

Box 22

Palpation of various pulses

- **The brachial artery** is palpated in the antecubital fossa by compressing it against the humerus. The examiner should use the index, middle fingers or thumb of opposite hand. With your free hand, flex the elbow to varying degree to get optimal palpations (see Fig. 11.14).

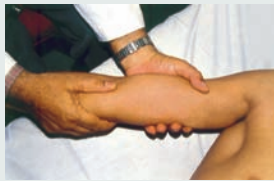

FIGURE 11.50A Examination of brachial pulse with thumb

- **The carotid artery** is palpated in the neck by gently compressing it against the transverse process of cervical vertebrae when the patient is resting on the bed or couch. Use the left thumb for right carotid and vice versa.
- **The femoral pulse** is palpated in the thigh between the iliac crest and the pubic ramus by compressing the artery against the underlying femur

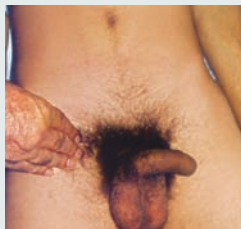

FIGURE 11.50B Palpation of femoral artery pulsations

- **The dorsalis pedis:** It is palpated on the dorsum of foot by compressing it against tarsal bone. The left dorsalis pedis is palpated with fingers of right hand and vice versa.

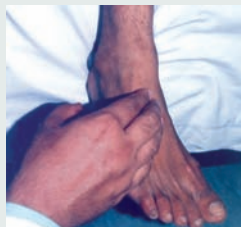

FIGURE 11.50E Palpation of dorsal is pedis artery pulsations

- **The popliteal artery** is palpated in the popliteal fossa. With the knee flexed at an angle of 120°. The finger tips are used to palpate the artery while the thumb rests on the patient's patella.

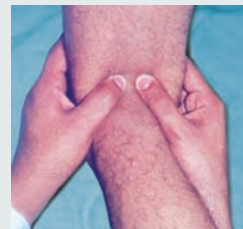


FIGURE 11.50C Palpation of popliteal artery pulsations

- **The posterior tibial** is palpated behind the medial malleolus of the tibia with the foot relaxed between plantar and dorsiflexion.

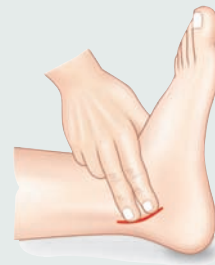

FIGURE 11.50D Palpation of posterior tibial artery

Other Areas of Examination

The Heart

- Examine the heart for any evidence of valvular heart disease or ischaemic heart disease that predispose to atrial or mural thrombosis which may lead to systemic embolisation (Fig. 11.51).
- Record systolic blood pressure in the upper and lower limbs to calculate the ankle/brachial pressure index or ratio (ABPI)
- Auscultate the abdominal aorta or any other major vessel, i.e. carotid artery for any bruit (Fig. 11.52).

The Abdomen

Look at the abdomen for aortic pulsations and auscultate for any bruit.

Note: Auscultate all the major vessels for bruit if there is an evidence of diminished pulsations.

The Nervous System

Examine the nervous system for any neurological deficit. Vascular disease may present with transient ischaemic attacks (TIA), stroke or multi-infarct dementia,

A significant proportion of strokes and TIAs are due to atheroemboli originating from a tight atherosclerotic stenosis or the origin of internal carotid artery. The signs of internal carotid artery occlusion include ocular (loss of vision in the ipsilateral eye—called *amaurosis fugax*) often described by the patient as a curtain coming across the field of view lasting for few minutes. Less commonly there may be permanent monocular blindness and cerebral/hemispheric signs such as hemiplegia, hemianaesthesia and dysphasia (if dominant hemisphere is affected).

Vertebrobasilar arterial insufficiency presents with giddiness, collapse, with or without loss of consciousness, transient occipital blindness or complete loss of vision in both the eyes.

Patients with subclavian artery stenosis or occlusion proximal to the origin of the vertebral artery may experience vertebrobasilar symptoms, as part of the *subclavian steal syndrome*. This happens when the arm is exercised. The increased blood supply to the arm is met by stealing the blood from posterior cerebral circulation producing symptoms and signs of vertebrobasilar insufficiency. Signs of this include asymmetry of pulses and BP in the arms and sometimes a bruit over the subclavian artery in the supraclavicular fossa may be heard.

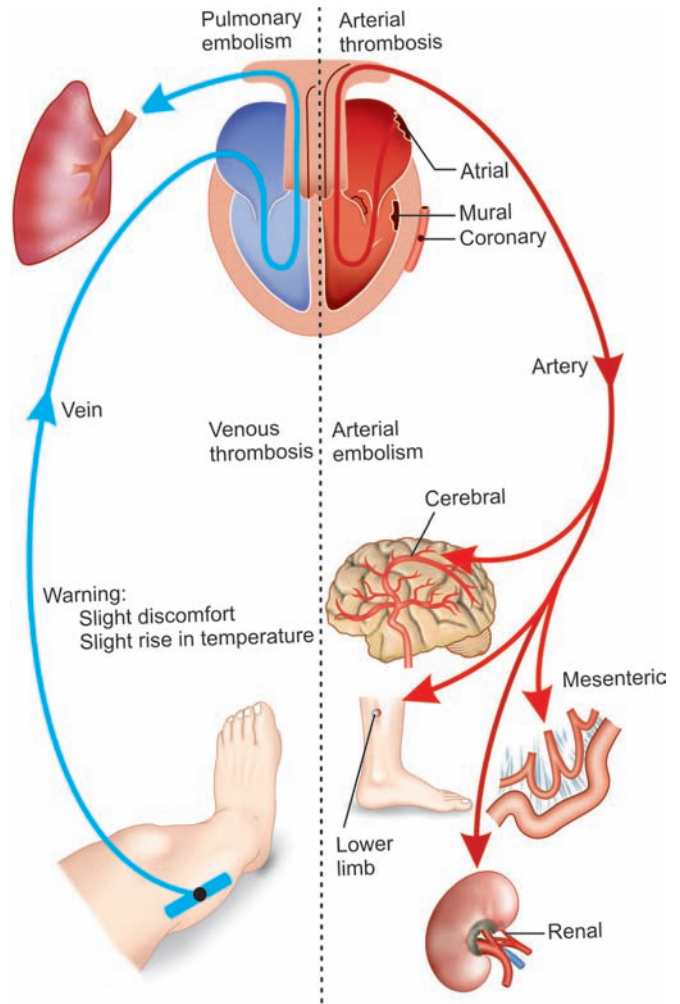


FIGURE 11.51 Thrombosis and embolism

1. Right side of figure shows venous thrombosis of leg and its embolism
2. Left side of figure shows arterial thrombosis (mural left ventricular or atrial) and its subsequent embolism

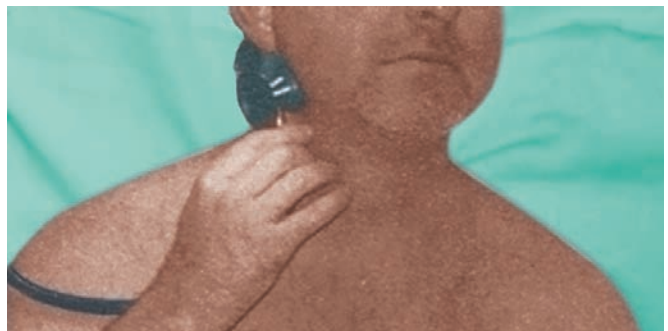

FIGURE 11.52 Carotid artery auscultation for bruit. Note that the bell of the stethoscope is placed gently on the skin overlying the angle formed by the sternocleidomastoid muscle and the lower jaw

Disorders of Peripheral Vessels

Buerger's Disease (*Thromboangiitis Obliterans*)

This is an inflammatory obliterative arterial disease different from atherosclerosis. It presents in young (<30 years) male smokers and characteristically affects the peripheral arteries giving rise to intermittent claudication in the feet or rest pain in the fingers and toes. This disease has a strong genetic basis.

The condition also affects the veins, and superficial thrombophlebitis is common. Wrist and ankle pulses are usually absent but brachial and popliteal pulses are characteristically palpable, arteriography shows narrowing or occlusion of arteries below the knee with relatively healthy vessels above that level. The conditions usually remits if patient stops smoking. In severe disease, there may be ulceration and gangrene of the toes (Fig. 11.53).

Vasospastic Disorders

Vasospastic disorders involve the small vessels (arteries and arterioles), hence, are characterized by changes in the skin colour and temperature rather than intermittent claudication and gangrene. The various vasospastic conditions are given in the Box 23.

- **Raynaud's phenomenon (Fig. 11.54):** It is the most common vasospastic disorder characterized by brief, intermittent triphasic colour response, i.e. pallor, cyanosis and redness of the digits due to constriction followed by dilatation of small vessels (arteries, arterioles) precipitated by exposure to cold or emotional stress. This could be:
 - *Primary* (idiopathic, Raynaud's disease) owing to vasospasm of digital vessels of unknown cause.
 - *Secondary* (Raynaud's syndrome) is due to digital artery obstruction caused by:
 - Immunologic or connective tissue diseases, i.e. systemic sclerosis (most common), SLE, RA, MCTD, etc.
 - Vibration injury (secondary to use of power tools), cold injury (handling frozen commodities)
 - Atheroembolism from subclavian artery aneurysm, or obliterative arterial disease (thoracic outlet syndrome, cervical rib)
 - Drugs and chemicals, e.g. beta blockers, bromocryptine, ergot alkaloids, sulphasalazine—vinyl chloride.
 - Miscellaneous, e.g. cold agglutinins and dyoglobulins
 - Idiopathic
 - **Initial evaluation** includes:
 - History of tricolour response precipitated by cold and emotion

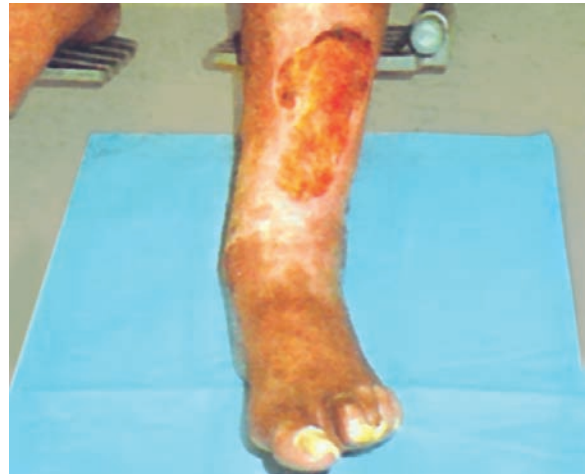

FIGURE 11.53 Buerger's disease

Box 23

Common vasospastic conditions

- **Raynaud's phenomenon**
 - Primary (Raynaud's disease)
 - Secondary due to connective tissue disease, occlusive arterial disease, hypothyroidism, pheochromocytoma
- **Livedo reticularis**
 - Primary
 - Secondary to connective tissue disease, vasculitis, myeloproliferative disorders
- **Acrocyanosis**
- **Chronic pernio syndrome (chilblains)**
- **Reflex sympathetic dystrophy**

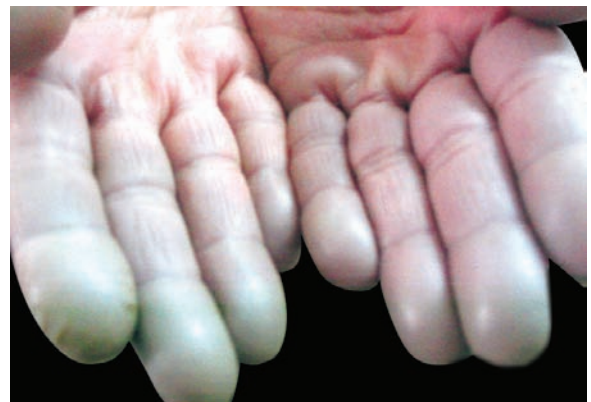

FIGURE 11.54 Raynaud's phenomenon. Note the bluish discoloration of finger tips

- Drug history includes intake of betablockers and ergot preparation
- Allen's test
- Look for thoracic outlet compression.
- **Livedo reticularis:** It is purplish mottling of skin due to spasm of the dermal arterioles, seen commonly in lower

extremities and is more prominent in cold weather. Recurrent ulceration around the ankle may occur in primary livedo reticularis.

- **Acrocyanosis:** It is characterized by coldness and cyanosis (bluish discolouration) of the acral parts (hands, fingers, feet and toes). It is always a primary and commonly occurs in women. Cyanotic heart disease and methaemoglobinaemia must be excluded before making the diagnosis.
- **Chronic pernio syndrome:** It results from cold injury and is characterized by abnormal reaction of the blood vessels to changes in environmental temperature. There are often erythematous, cyanotic, haemorrhagic or ulcerative lesions of the toes during the colder months, and they disappear in warm weather.

Reflex sympathetic dystrophy: It is probably a neurological disorder that occurs following trauma, characterized by pain, oedema, warmth, hyperhidrosis, coldness and colour changes.

Vascular occlusion by embolism or vasculitis: There may be involvement of big vessels due to embolism (*see* Fig. 11.51) and small vessels in vasculitis.

Aneurysmal Disease
(Abdominal Aortic Aneurysm—AAA)

Aortic aneurysm is commoner in men than in women, occurs after the age of 65 years. The presenting complaints include abdominal and/or back pain or pulsations. Many patients may remain asymptomatic until aneurysm ruptures. There is usually a mural thrombus in the aneurysm often leading to complete thrombosis and distal embolisation.

In the extremities, the most common aneurysms encountered are in the femoral, popliteal and subclavian artery.

Clinically abdominal aortic aneurysm presents with a pulsatile mass in the epigastrium. A pulsatile mass below the umbilicus suggest an iliac artery aneurysm.

The diagnosis of ruptured aortic aneurysm is made by the classical features of abdominal and/or back pain, pulsatile abdominal mass and hypotension.

True arterial aneurysms are defined as 50% increase in the normal diameter of the vessel.

Atheroembolism may arise from abdominal arch aneurysm and lead to “blue leg toe syndrome” characterized by purple discolouration of the toes/forefoot.

INVESTIGATIONS OF PERIPHERAL VASCULAR DISEASE

For peripheral vascular disease, one should choose an investigation which is cheap and provides the most

TABLE 11.21 Investigations for peripheral arterial disease

Test	Indications and uses
Plain X-ray abdomen	• Calcification of the vessel wall or aneurysm of aorta
Doppler ultrasound	• For calculation of ankle brachial pressure index (ABPI) • Pulse waveform analysis
B-mode ultrasound	• Abdominal aortic aneurysm • Popliteal artery aneurysm
Duplex ultrasound	• Occlusion/stenosis of limb arteries, carotid arteries, renal arteries • Surveillance of limbs after venous bypass graft or angioplasty
Computed tomography (CT)	• CT abdomen for abdominal aortic aneurysm • CT head for cerebral infarct/haemorrhages • Spiral or helical CT scanning is useful in imaging of cerebral, carotid and abdominal arteries.
Plethysmography	• For stenotic or occlusive vascular lesions
Magnetic resonance angiography (MRA)	• AV malformations • Carotid artery stenosis
Angiography	• Acute or chronic limb ischaemia • Carotid artery stenosis

information and least risk to the patient. Ultrasound has replaced invasive angiography in many instances. The various investigations for PAD are given in the Table 11.21.

Measurement of ankle/brachial pressure index (ABPI): Measurement of ABPI is useful in assessing the severity of chronic lower limb ischaemia. This index has predictive value in the healing of the ischemic ulcers.

It is performed using a hand-held Doppler and a Sphygmomanometer. The probe is held over the three pedal arteries (posterior tibial, dorsalis pedis, perforating peroneal) in turn while a BP cuff wrapped round the ankle is inflated. The pressure at which Doppler signal disappears gives the systolic BP in that artery. The ratio of the highest pedal artery pressure to highest brachial artery pressure is ABPI.

Normally the ABPI index is ≥ 1.0 in supine position (ankle systolic BP is equal to or higher to brachial systolic BP) while in patients with various types of occlusive PAD, the index is below 0.9 and in some cases below 0.5.

In diabetics, crural arteries are hard and incompressible, hence, may falsely raise the pedal pressures, and thus, the ABPI. In such circumstances, an alternative is to “isonate” the artery while elevating the foot. The height above the bed in centimeters at which the Doppler signal disappears is approximately equal to the perfusion pressure in mmHg.

VENOUS SYSTEM

General Considerations

The venous system can be classified as either superficial or deep. The superficial venous system is thick walled and muscular that lies underneath the skin. Deep venous system, on the other hand, is thin-walled and less muscular. Both systems are interconnected by perforating veins. The presence of venous valves regulates the blood flow. Alterations in the function of valves cause venous disorders.

Clinical Presentations

Venous disease is much more common in the legs than in the arms. It usually presents in one of the four following ways:

1. Deep vein thrombosis (DVT)
2. Superficial thrombophlebitis
3. Varicosity of veins
4. Chronic venous insufficiency.

Clinical Assessment

The clinical assessment is primarily concerned with:

- Determining the nature and severity of any venous problem
- Identifying any underlying or precipitating factor(s).
The assessment include; history, physical examination and investigations.

THE HISTORY

The patients usually present with one or more of the four cardinal symptoms of the venous disease (Box 24). The common area of involvement is lower limbs.

1. Pain of deep vein thrombosis is deep seated and associated with oedema below the level of obstruction. The superficial venous thrombophlebitis produces a red, painful area overlying the vein involved.

Patient with uncomplicated varicose vein may complain of an aching pain/discomfort in the leg, itching and a feeling of swelling due to prominence of venous system. Symptoms are aggravated by prolonged standing and are worst towards the end of the day. Varicose ulceration is

painless, but if pain occurs, it is relieved by elevation of the limb.

2. **Swelling:** It is associated invariably with deep vein thrombosis and deep venous reflux. It may be present with varicose veins.
3. **Discolouration:** Deep blue/black to purple or even red discolouration may be complained on the medial aspect of the lower part of the leg by the patients suffering from chronic venous insufficiency. The discolouration is due to deposition of haemosiderin in the skin leading to lipodermatosclerosis.
4. **Ulceration:** A venous ulcer occurs on the lowest dependent part especially the ankle in patients with varicose vein. This is associated with pigmentation around it. Patients with venous ulceration may not seek medical attention for many years. Bleeding from the ulcer and secondary infection at the site of ulcer are common.

Ask about the followings in a patient with venous system disease.

- Recent bed rest or operation on the leg or pelvis
- Recent travel (e.g. long air flight)
- Prolong forced immobilisation, especially following bone fracture, trauma, plaster of Paris splintage.
- Pregnancy or history of taking oral contraceptive
- Previous deep vein thrombosis
- Family history of thrombosis
- Recent central vein catheterisation, injection of drugs or prolonged IV drip through a cannula in the upper limb (for superficial thrombophlebitis)
- History of weight loss (if patient has recurrent thrombophlebitis, due to suspected malignancy).

EXAMINATION OF VENOUS SYSTEM

It is done under two heads:

1. Inspection
2. Palpation.

Inspection

- Examine the legs with the patient standing and then lying supine
- Expose the limbs adequately and inspect it for *swelling*, any *superficial venous dilatation* and *tortuosity*. Look the skin for any colour change or ulcer.

Palpation

- Palpate for any differences in the temperature
- Elevate the limb to about 15° above the horizontal and note the rate of venous emptying.
- If appropriate, perform the Trendelenburg test.

Box 24

Cardinal symptoms of venous disease

- | | |
|------------|------------------|
| • Pain | • Discolouration |
| • Swelling | • Ulceration |

Specific Conditions

Deep Vein Thrombosis

Deep vein thrombosis (DVT) commonly involves the legs (Fig. 11.55) but can also involve the arm (axillary vein thrombosis). The precipitating and predisposing factors for deep vein thrombosis are given in the Table 11.22. The incidence of deep vein thrombosis is increasing because of greater utilization of indwelling central venous catheters.

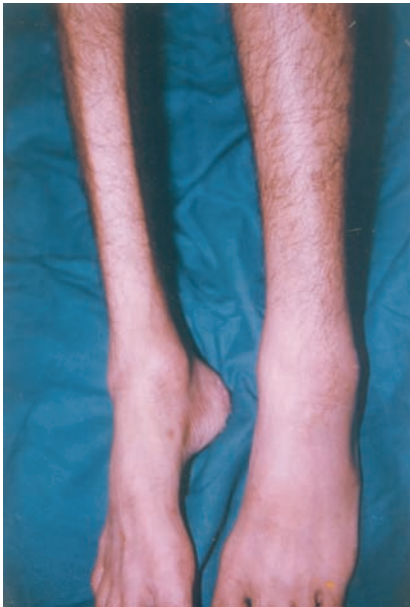

FIGURE 11.55 Deep vein thrombosis of leg. Note the swelling over the foot and leg on left side

Clinical features

The clinical features of DVT of lower limb (leg) and upper limb (arm) are given in the Table 11.23.

Homan's sign (Fig. 11.56)

It is unreliable diagnostic sign of DVT of leg where increased resistance or pain occurs during dorsiflexion of foot. It is now-a-days not performed due to risk of dislodgement of thrombus.

Investigations

- *Duplex venous ultrasonography* (B-mode, i.e. two dimensional, imaging and pulse wave Doppler interrogation) is quite accurate in the diagnosis of deep vein thrombosis.
- *Impedance plethysmography (Fig. 11.57)*: It measures the rate of venous return from the lower extremities. It detects

TABLE 11.22 Deep vein thrombosis; predisposing and precipitating factors

Predisposing factors	Precipitating factor(s)
<ul style="list-style-type: none"> • Venous stasis • Oral contraceptives • Prolonged bed rest or immobilization • Hypercoaguable state • Old age • Smoking • Pregnancy • Dehydration 	<ul style="list-style-type: none"> • Congestive heart failure • Orthopedic procedure (total hip replacement) • Malignancy (e.g. pancreas, lung, ovary, testes) • Nephrotic syndrome • SLE and antiphospholipid syndrome • Inflammatory bowel disease • Polycythaemia • Protein C and S deficiency • Homocystinuria

TABLE 11.23 Clinical manifestations of deep vein thrombosis of leg and arm

Feature	DVT of leg	DVT of arm
Veins involved	Iliac, femoral or popliteal	Subclavian or axillary vein
Pain	Calf pain, increases during walking	Arm pain exacerbated by activity especially occurs on holding the arms above the head.
Tenderness	Calf tenderness on squeezing the calf	Arm tenderness on squeezing
Swelling	Unilateral leg oedema	Unilateral arm oedema
Warmth	Present	Present
Increased tissue turgor	Present	Present
Skin colour	In some patients, a cyanotic hue present due to deoxygenated haemoglobin in stagnant vein—a condition called <i>phlegmasia cerulea dolens</i> . In others, there may be pallor due to increased interstitial tissue pressure—a condition called <i>phlegmasia alba dolens</i> .	The skin is often cyanosed and mottled especially on dependency.
Visible distended veins	Distention of superficial veins over the calf and around the ankle or over foot	Superficial distended veins acting as collaterals are seen in the upper arm, over the shoulder and anterior chest wall.
Palpable vein	A cord may be felt in the calf region	A cord may be felt in the arm region.

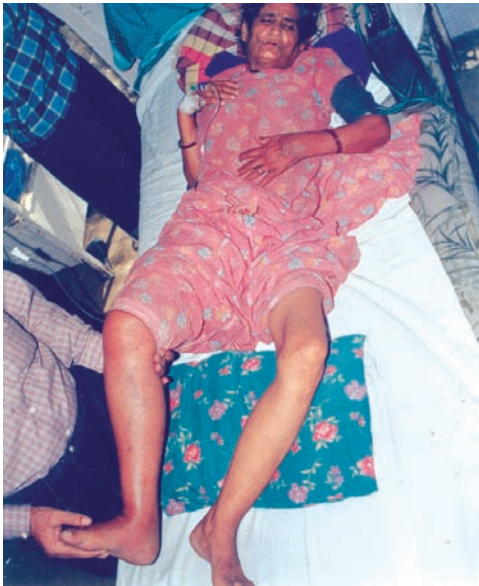

FIGURE 11.56 Homan's sign

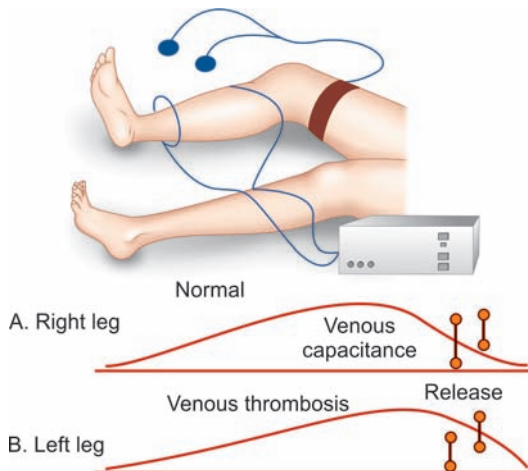


FIGURE 11.57 Impedance plethysmography. In venous occlusion, there is increased venous outflow resistance in venous capacitance

the increased venous resistance in the deep veins of proximal lower extremities. Venograms are occasionally used now-a-days, because they have been currently replaced by ultrasonography and magnetic resonance imaging—a noninvasive method.

Differential diagnosis

DVT must be differentiated from a variety of disorders that cause unilateral leg pain or oedema such as:

- Muscle rupture
- Muscle haematoma due to trauma or haemorrhage
- A ruptured popliteal cyst
- *Lymphoedema*: The skin over the oedema is thickened, indurated and pigmented (brawny). The oedema is non-pitting.

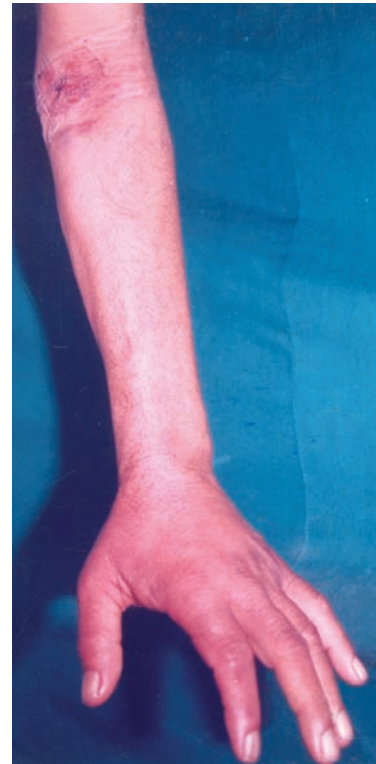

FIGURE 11.58 Superficial venous thrombophlebitis

- *Postphlebitic syndrome*: It results from acute recurrent deep vein thrombosis.

Complications

- Chronic venous insufficiency and ulceration
- **Pulmonary embolism**: It can occur even without symptoms of venous thrombosis (see Fig. 11.51).

Superficial Venous Thrombophlebitis (Fig. 11.58)

This is a usually sterile inflammation of superficial veins, may be associated with intraluminal thrombosis. The most common cause is central indwelling catheters or needles used for intravenous fluids. Sometimes, it is secondary to trauma or carcinoma of pancreas (recurrent superficial thrombophlebitis). Primary superficial venous thrombosis is often seen in pregnancy, postpartum state and in thromboangiitis obliterans.

The clinical features include dull aching pain, swelling, erythema and induration along the vein involved. There may be associated fever and chills as constitutional symptoms.

Varicose Veins and Chronic Venous Insufficiency

Varicose veins are defined as abnormally dilated, tortuous superficial veins of the lower extremities involving commonly the saphenous vein and its branches.

Trendelenburg Test (Figs 11.59A and B)

It is done to assess the valvular competence in both the communicating veins and saphenous venous system.

Method

- Start with the patient lying supine
- Elevate the limb to empty the superficial veins by “milking” the leg
- With the leg still elevated, the upper end of the vein is then occluded by finger pressure on the saphenous opening. The saphenous opening lies 2–3 cm below and 2–3 cm lateral to pubic tubercle.
- While the examiner maintains this pressure, the patient stands
- If the valves (saphenofemoral junction) are incompetent the veins will fill rapidly from above (retrograde filling) when the pressure is released.

Results

- Rapid filling of the superficial veins while the saphenous vein is occluded indicates incompetent valves in the communicating system.
- Positive Trendelenburg test indicates sapheno-femoral junction incompetence.

Types

- **Primary:** The incompetency of venous valves is of unknown cause. This may be inherited. Incompetent valves of the perforating veins in the thigh and lower limbs, communicate the pressure from the deep veins to superficial veins and make them to swell elongated and tortuous. Pregnancy and prolonged standing (e.g. in policemen, farmers) are common precipitating factors.
- **Secondary:** This is due to damage to the venous valves due to neoplasms or thrombophlebitis.

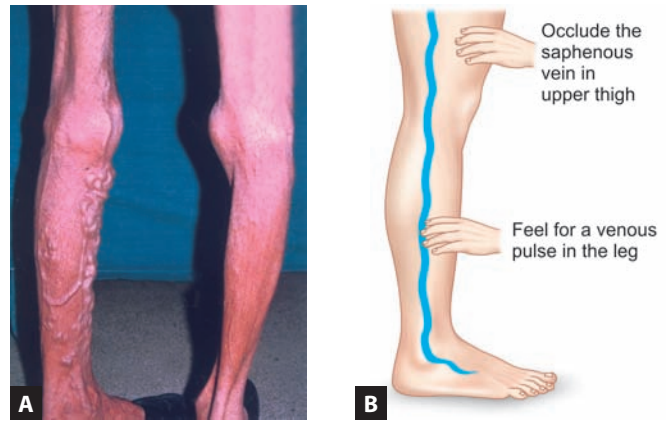


FIGURE 11.59 Varicose veins: (A) The dilated and tortuous veins of the left leg indicate varicose vein; (B) Trendelenburg’s test for valve incompetence

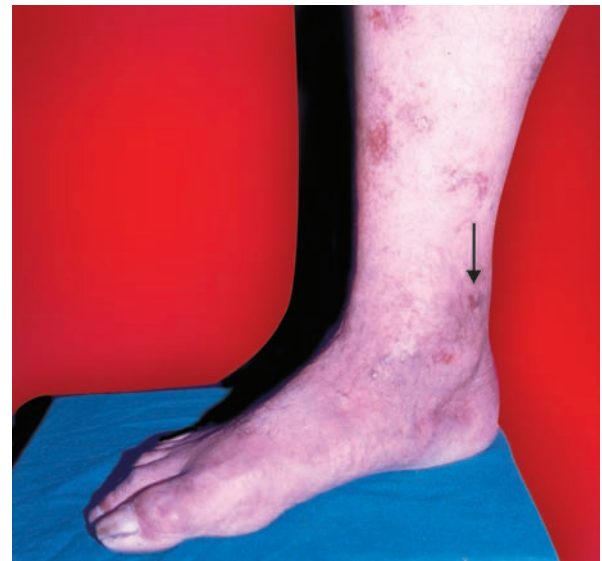

FIGURE 11.60 Chronic venous ulcerations and pigmentation. Note the oedema of leg, venous ulceration (↓) and pigmentation of right foot and leg

TABLE 11.24 Differentiation between various trophic ulcers

Feature	Arterial insufficiency	Chronic venous insufficiency	Neuropathic ulcer
Site	Toes, feet or in areas of trauma	Around the ankle	Pressure points in areas with diminished sensation, as in diabetic neuropathy
Skin around the ulcer	No callous, excess of pigment, may be cold and atrophic. Loss of hair, thickened nails	Pigmented, white atrophy with scar.	Calloused
Pain	Intermittent claudication or severe pain unless neuropathy present	Not severe	Absent, hence, ulcer often goes unnoticed
Associated gangrene	May be present	Absent	Absent in uncomplicated ulcer
Other signs	Decreased pulses, pallor of the foot on elevation, dusky rubor on dependency, sluggish filling of toes capillary	Oedema, pigmentation, stasis, dermatitis	Decreased sensation and absent ankle jerk

- **Symptoms and signs:** The varicosity of veins may be asymptomatic, but if symptoms occur, then patients usually complain of a dull ache or pruritus. The involved veins are dilated and tortuous (Fig. 11.59). In long standing cases, chronic venous insufficiency develops producing skin changes in the lower leg, e.g. varicose eczema, lipodermatosclerosis (brownish discolouration and in duration), venous ulcerations due to sustained venous stasis and increased pressure.

Chronic Leg Ulceration

Deep vein thrombosis are common causes of chronic venous insufficiency, and varicosity of veins and leg ulceration (Fig. 11.60). The ulcers are located around the ankle. There is surrounding dermatitis and excoriation, white atrophy with scars, and presence of varicose veins, if they are the cause. Vast majority of the leg ulcers can be ascertained by clinical examination (Table 11.24).

12

CHAPTER

The Respiratory System

HISTORY

Symptoms

- Cough and expectoration
- Haemoptysis
- Pain chest
- Dysphagia, hoarseness of voice.

Present History

Detailed history of present illness.

Past History

Measles, whooping cough during childhood, diabetes, TB, HT, pneumonia, chest injury, epilepsy, pregnancy and exposure to STD and HIV.

Family History

Allergy (e.g. hay fever, asthma), TB, etc.

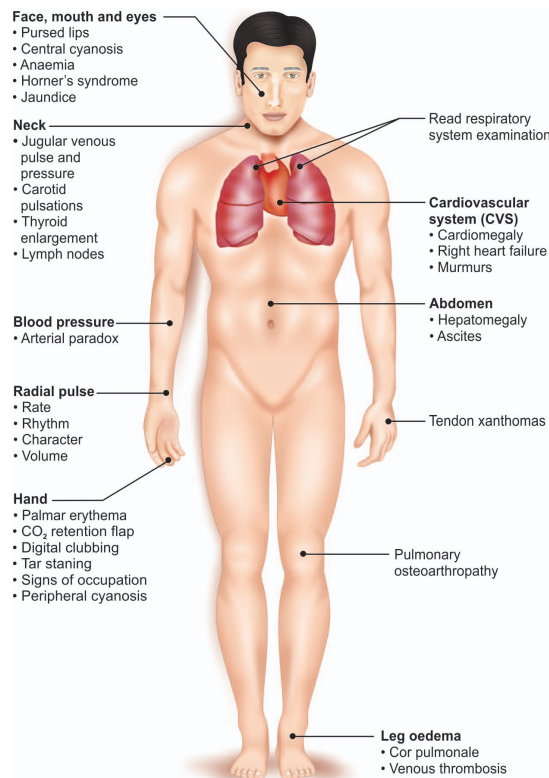
Personal History

Record occupation and menstrual history in female. Take drug history.

- Habits, e.g. smoking, alcoholism.

GENERAL PHYSICAL EXAMINATION (GPE)

- *Built, nutrition, consciousness*
- *Facial appearance*, e.g. puffiness, pallor, bluishness, dyspnoea
- *Skin*, e.g. pallor, purpuric spots
- *The eyes*, e.g. for jaundice, anaemia, suffusion, periorbital oedema
- *The ear, nose, throat*, e.g. sinus tenderness, tonsils enlargement or for any septic focus
- *Mouth, pharynx and posterior pharyngeal wall* for any septic focus and foul breath
- *Lips and tongue* for pursed-lip breathing, cyanosis
- *Neck*, e.g. lymph nodes, JVP
- *Carotid pulsations, thyroid, trachea and activation of extra-respiratory muscles*
- *Hands and feet*, e.g. clubbing, cyanosis, oedema.



General observations
• Respiratory rate
• Cachexia, fever, rash
• Sputum, e.g. Mucoid/purulent, haemoptysis
• Fetor or smell from breath

The Respiratory System Examination

SYSTEMIC EXAMINATION

Inspection

- Deformity (e.g. pectus excavatum)
- Scars
- Intercostal indrawing/recession
- Symmetry of chest expansion
- Paradoxical/abnormal movements
- Movements of extra-respiratory muscles
- Apex beat, e.g. visible or not, displaced or normal.

Palpation

Cervical lymphadenopathy
Trachea: Central or displaced
Cardiac apical impulse: Displaced or normal
Chest expansion (measurement)
Intercostal spaces (wide, narrow, normal)
vocal fremitus (e.g. normal or abnormal).

Percussion

- Percussion note (resonant, dull, stony dull)
- Define cardiac dullness and liver dullness (increased, normal/masked/shifted).

Auscultation

- Breath sounds (e.g. normal, bronchial, louder or softer)
- Added sounds, e.g. wheezes, crackles, rub
- Vocal resonance: Absent (effusion) increased (consolidation), normal
 - *Bronchophony* (if vocal resonance is increased)
 - *Whispering pectoriloquy* (if vocal resonance is increased).

Other Systems Examination

- The cardiovascular system
- The abdomen
- The CNS.

Provisional Diagnosis

- Anatomical (site of lesion)
- Pathological (type of lesion)
- Aetiological (cause of lesion)
- Complications, if any.

Differential Diagnosis and Investigations

THE RESPIRATORY SYSTEM

Applied Anatomy and Physiology

The chest is a bony cage bounded anteriorly by sternum, laterally by the ribs on both sides and posteriorly by the vertebral column, contains heart and great vessels; lungs and the pleura.

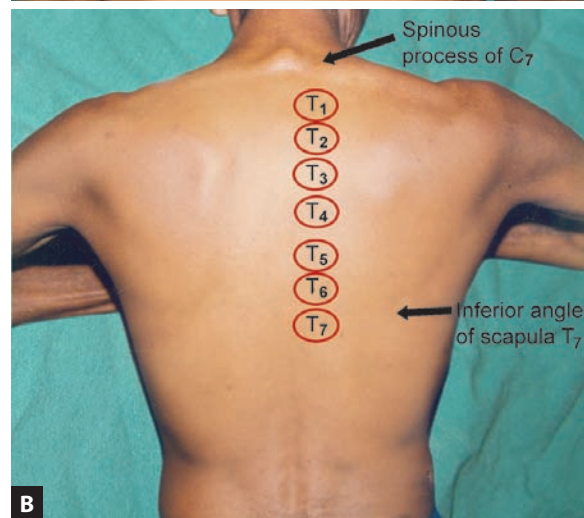
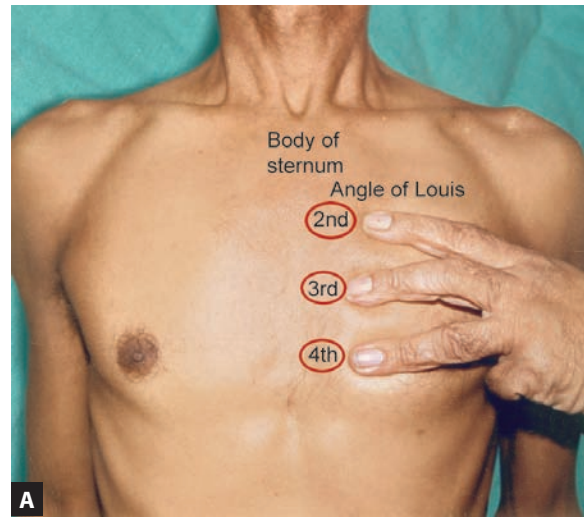
Important Landmarks

The lungs and its covering pleura are well protected within the thoracic cage; however, the approximate location of the underlying lobes can be deduced from the surface markings. The abnormalities of the chest are described in relation to certain landmarks in two dimensions:

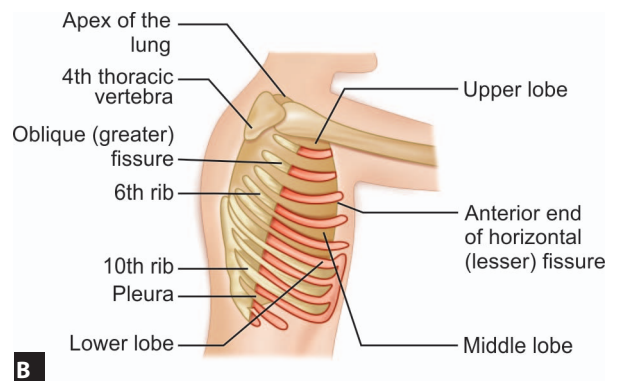
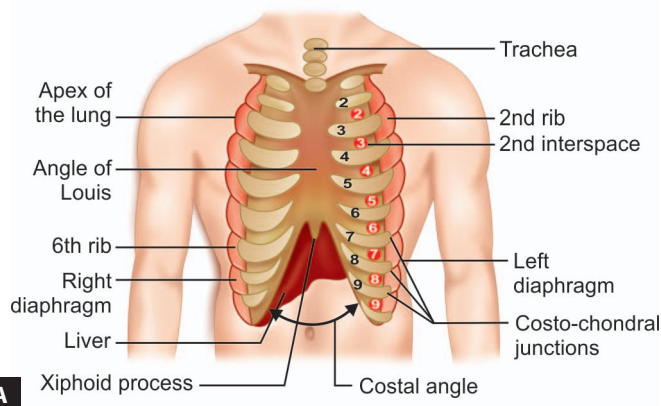
- To make vertical locations, one must be able to locate the sternal angle (*angle of Louis*) which is considered the best guide.

To locate this, place your finger in the hollow curve of suprasternal notch, then move your finger down 5 cm to the horizontal bony ridge joining the manubrium to the body of the sternum. This is *sternal angle*, adjacent to 2nd rib and costal cartilage. Second intercostal space is below the 2nd rib. From here, you can count down the spaces using two fingers, one space at a time on an oblique line illustrated by red circles with numbers inside, e.g. 2, 3 to 9 (Figs 12.1 and 12.2A). Do not try to count interspaces along the lower edge of the sternum as ribs are too crowded there. In a woman, count the spaces by displacing the breast laterally or palpate a little more medially.

Posteriorly, the 12th rib is an important surface mark for counting the ribs and interspaces. It helps to locate the findings on the lower posterior chest and provides an option when anterior approach is unsatisfactory. With fingers of



FIGURES 12.2A and B Important landmarks on the chest: (A) Location of the sternal angle (angle of Louis) and counting down the interspaces below it as 2nd, 3rd and 4th by fingers; (B) Surface marking on the back of chest



FIGURES 12.1A and B Surface anatomy of respiratory system: (A) Front view; (B) Lateral view

one hand, press in and up against the lower border of the 12th rib, then “walk up” the interspaces numbered in red circle (Fig. 12.2B) or following a more oblique line up and around to the front of the chest. The other important anatomical landmarks are given in the Box 1.

Localisation around the Circumference of the Chest

A series of vertical lines are used for localization of lesion on the circumference of the chest. The *midsternal* and *vertebral* lines are precise; the others are estimated.

Box 1

Important anatomical landmarks on posterior wall of chest (Fig. 12.2B)

- The inferior tip of the scapula lies at the level of 7th rib or interspace.
- *Spinous processes of vertebra*: They are useful landmarks. When the neck is flexed forward, the most protruding process is spine of C₇ vertebra; and if there are two prominent processes, then they are spines of C₇ and T₁. You can palpate them and count the spinous process below them for vertebral localisations.

Note: First 7 ribs articulate with the sternum, the cartilages of 8th, 9th and 10th ribs articulate with costal cartilages just above them, and the 11th and 12th ribs—called “floating ribs” have no anterior attachments.

Anteriorly, the three lines are (Fig. 12.3A):

- *Midsternal line* drops vertically in middle of sternum.
- *Midclavicular line* drops vertically from the midpoint of the clavicle.
- *Anterior axillary line* drops vertically along the anterior axillary fold.

Laterally (Fig. 12.3B), the three lines represents the axillary area of the chest:

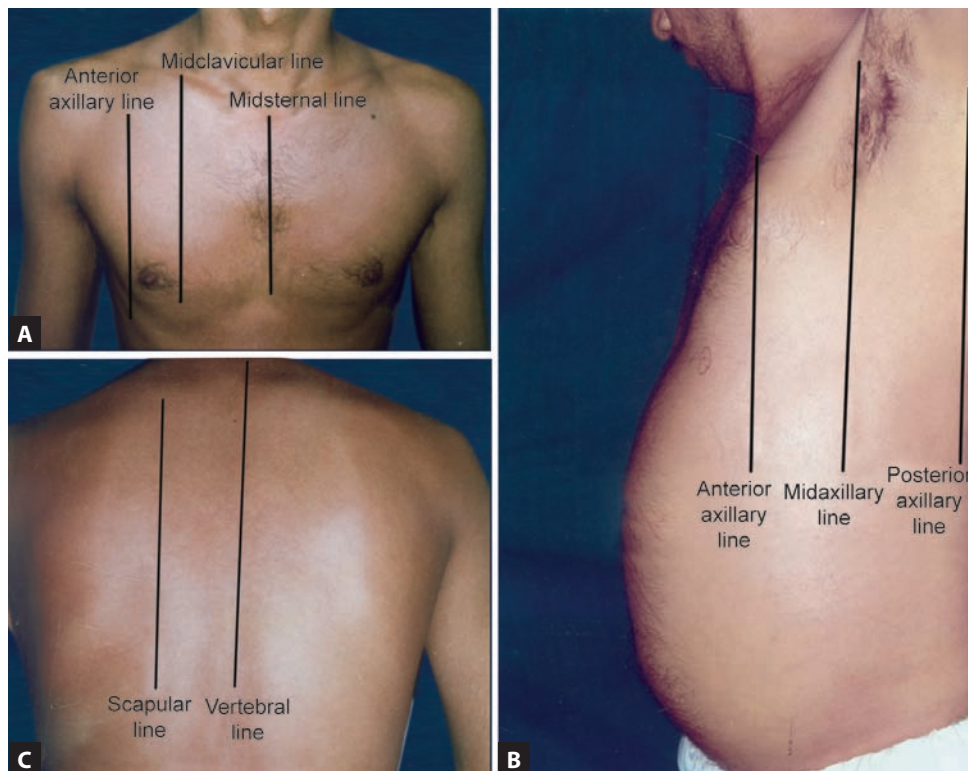
- Anterior axillary line along anterior axillary fold
- Posterior axillary line along posterior axillary fold
- Midaxillary line drops vertical from apex of the axilla.

Posteriorly: The two vertical lines are (Fig. 12.3C):

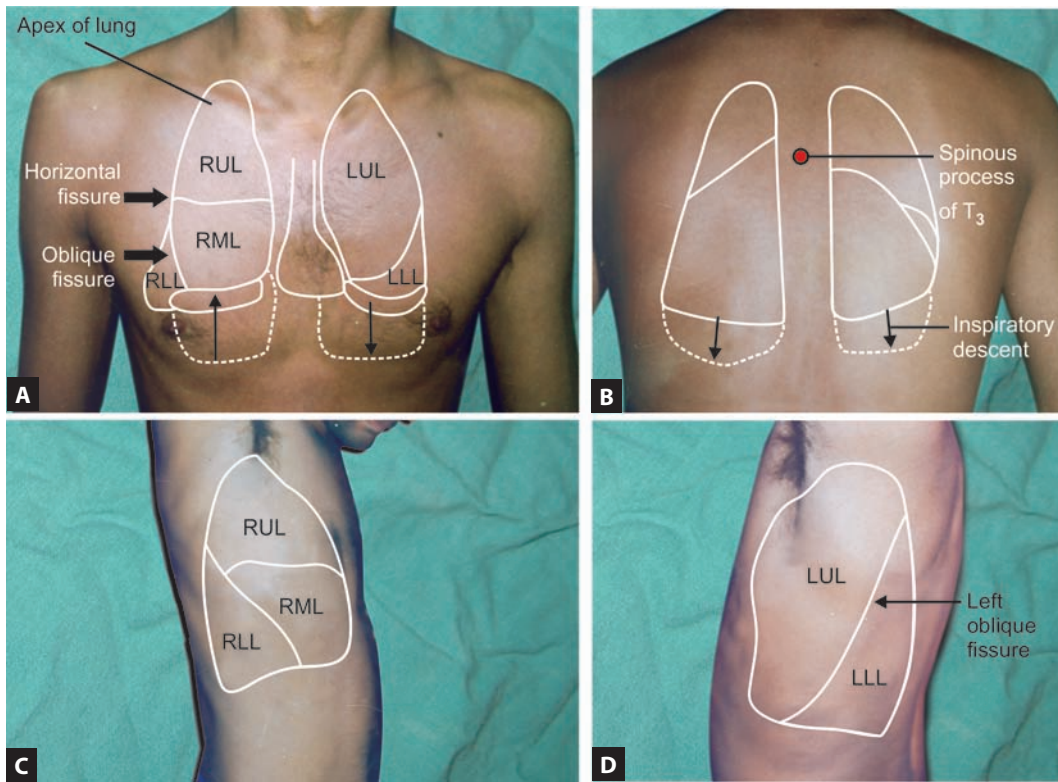
- *Vertebral line* overlies the spinous process of the vertebrae
- *Scapular line* passes across the inferior angle of scapula.

Lungs, Fissures and Lobes

The upper respiratory tract includes the nose, the nasopharynx and larynx. It is lined by vascular mucous membranes with ciliated epithelium. The lower respiratory tract includes trachea and bronchi which further divides and subdivides to form terminal bronchioles and thus form an interconnecting tree of conducting airways. The terminal bronchioles with alveoli form *acini*. The lower respiratory tract is lined by ciliated epithelium upto the terminal bronchioles. The larynx



FIGURES 12.3A to C Important landmarks around the circumference of the chest for localisation of the lesion



FIGURES 12.4A to D Surface markings of the lungs in different views: (A) Anterior view (front of chest); (B) Posterior view (back of chest); (C) Right lateral view; (D) Left lateral view. Read the division of lungs into lobes by the fissures from the text

and bronchi are supplied with sensory receptors involved in the cough reflex.

An *acinus* is the basic fundamental functional unit of the lung. The alveoli are lined by flattened epithelium on inner side and are supplied by pulmonary capillaries on outer side, thus form an *alveolar-capillary* membrane through which gaseous exchange occurs.

Surface markings of the lung (Figs 12.4A to D): Anteriorly, the apex of each lung rises about 2–4 cm above the inner third of the clavicle. The lower border of the lung crosses the 6th rib at the midclavicular line and the 8th rib at midaxillary line. Posteriorly, the lower border of the lung lies at about the level of T₁₀ spinous process, and on inspiration, it descends further (Fig. 12.4 posterior view).

Lobes of the lungs: Each lung is divided into two halves by an oblique (major interlobar) fissure. This fissure can be represented by a line from the second thoracic spine (T₂) running obliquely down and around the chest to the 6th rib in the midclavicular line. The left lung has only this fissure and thus has two lobes: upper and lower. As the posterior end of this fissure is higher than anterior, the upper lobes lie largely above and in front of the chest (Fig. 12.4 anterior view). This landmark is clinically important because upper lobe lesions

produce physical signs on front of the chest while lower lobe mainly on the back.

The right lobe has three lobes due to presence of two fissures: The oblique and the transverse. The right oblique fissure as described above separates the lower lobe from rest of the lung. The transverse fissure can be represented by a horizontal line from the sternum at the level of the 4th costal cartilage, drawn to meet the line of the oblique fissure thus, marks the boundary between the upper and middle lobes (Fig. 12.4 anterior view). The middle and upper lobe on the right similar to upper lobe on the left occupy most of the area on front of the chest. In the axillary regions, parts of all the lobes are accessible (Fig. 12.4 lateral and oblique views).

The bronchial divisions, bronchopulmonary segments of various lobes of both lungs are represented in the Figs 12.5A to D.

Remember: A knowledge of the anatomy of the bronchial tree is essential while performing bronchoscopy and interpreting the findings.

Locations on the chest: One must be familiar with the terms used to locate chest findings (Box 2).

You may derive conclusion about what part(s) of the lung(s) are affected by the disease/lesion. Signs in the right

upper lung field, for example, almost certainly originate in the right upper lobe. Signs in the right middle lung field laterally, however, could come from any of the three different lobes.

Box 2

Important regions on the chest (Figs 12.6A and B)

<i>Supraclavicular</i>	above the clavicles
<i>Infraclavicular</i>	below the clavicles
<i>Infrascapular</i>	below the scapula
<i>Interscapular</i>	between the scapulae
<i>Suprascapular</i>	above the scapula
<i>Bases of the lungs</i>	the lowermost portions of upper, middle and lower lung fields

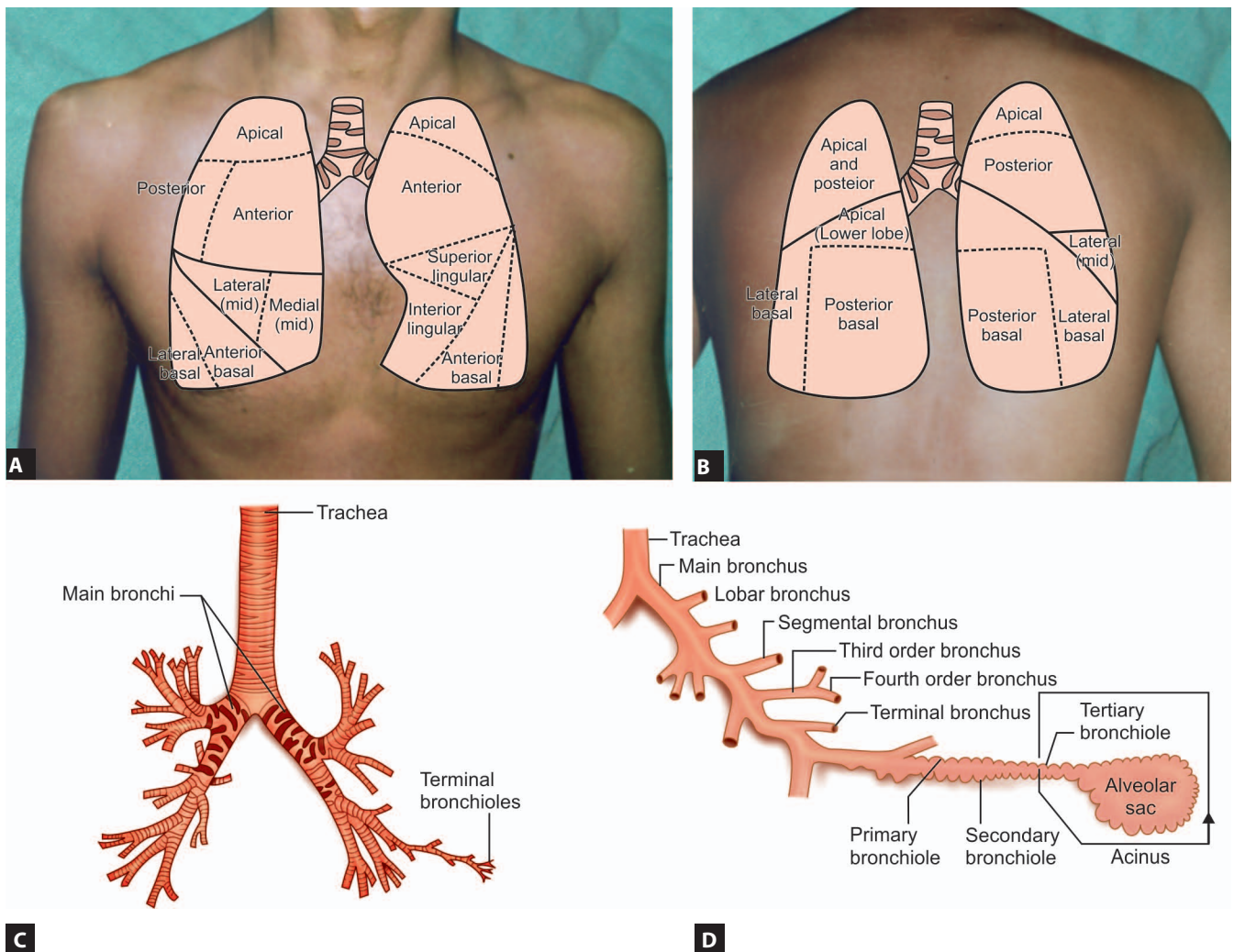
Presenting Symptoms of Respiratory Disease

- Symptoms of upper respiratory tract (nose, paranasal sinuses, pharynx, larynx and trachea have been discussed in Unit II Chapter 7 Read the ENT examination and also summarised in Unit I, Chapter 2).
- Symptoms pertaining to lower respiratory tract (bronchi, bronchioles and lung parenchyma have already been described and analysed in Unit-I, Chapter 2. Read symptoms pertaining to various systems and their analysis). However, for reference sake, they are given in the Box 3.

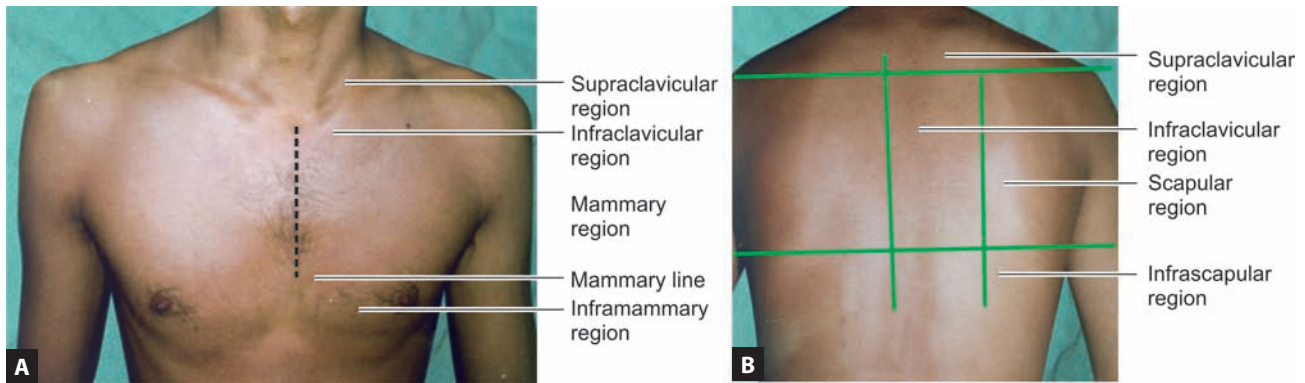
HISTORY

Present History

Describe according to symptoms in chronological order.



FIGURES 12.5A to D Bronchopulmonary segments of the lungs. The continuous lines show the interlobar fissures while dotted lines represent the bronchopulmonary segments: (A) Front of the chest; (B) Back of the chest; (C and D) Diagrammatic illustration of tracheobronchial tree and distal airway



FIGURES 12.6A and B Important areas on the chest: (A) Front; (B) Back

Box 3

Symptomatology of respiratory tract

Upper respiratory tract (nose, sinuses, pharynx, larynx and trachea)	Lower respiratory tract (bronchi, bronchioles and lung parenchyma (i.e. alveoli))
<ul style="list-style-type: none"> Nose and nasopharynx, e.g. nasal discharge, nasal obstruction, sneezing, headache, epistaxis. Pharynx, e.g. sore throat, fever, cough Larynx, e.g. hoarseness, cough, stridor, pain Trachea, e.g. pain, cough, stridor and dyspnoea and symptoms of mediastinal compression (dysphonia, dysphagia) 	<ul style="list-style-type: none"> Cough Sputum (expectoration) Haemoptysis Pain chest Breathlessness (dyspnoea). The differential diagnosis of an acute severe dyspnoea has been discussed. Apnoea Wheeze

Box 4

Occupational asthma

Cause	Source
Non-Ig E mediated	
Isocyanates	Varnishes and industrial coating soldering and electronic industry
Colophony fumes	
Ig E-mediated	
Animals and insects allergens	Laboratories
Allergens from flour and grain	Farmers, millers and grain handlers
Proteolytic enzymes	Manufacturers of biological washing powder
Platinum salts	Metal refining
Acid anhydrides and polyamine, hardening agents	Industrial coatings

Past History

In respiratory case, history of past illness is valuable in diagnosis, prognosis and planning the treatment. If there is history of same respiratory illness in the past and X-ray of chest has been done, summon the previous X-ray since comparison with the previous films or at least the reports, help to reach at the correct diagnosis easily. Important consequences of some common previous disorders/events are highlighted in the Table 12.1.

Family History

Ask about the following respiratory diseases in the family.

- Tuberculosis:** It is not a familial condition but may be transmitted from one person to another. Any history of contact with the infected person in the family or in neighbourhood is, of course, important than the family relationship.

- Certain allergic disorders, e.g. asthma, eczema and hay fever have familial or inherited predisposition.
- Chronic bronchitis is not again a familial disease but several members of a family are likely to suffer if there are poor living conditions and smoking habits in a family.

Personal and Occupational History

- Habits,** e.g. alcohol, smoking. Always record smoking habits. Cigarette smoking is the single most important cause of chronic lung disease such as chronic bronchitis and emphysema, hence, can be relevant to current problems, even if the patient gave up smoking some years ago. Lung cancer is also associated with smoking.
- Occupation:** A detailed history of past and present occupations is essential. Numerous chemicals, moulds, organic dust and animal proteins can cause occupational asthma (see Box 4) and extrinsic allergic

TABLE 12.1 Significance of past history

History	Relevance and consequences
Tuberculosis	<ul style="list-style-type: none"> • May have relapsed • Reactivation of past lesion • Development of tubercular bronchiectasis or a fungal ball (aspergilloma) in a tubercular cavity in a patient with past lesion
Pneumonia (pleurisy)	<ul style="list-style-type: none"> • May have caused bronchiectasis • Recurrent pulmonary infections is common in bronchiectasis, bronchial tumour, aspiration of gastric or pharyngeal contents, alcoholism, AIDS, hypogammaglobulinaemia
Measles and whooping cough during childhood	Can be complicated by pneumonia, bronchitis and bronchiectasis
Allergic rhinitis	May lead to bronchial allergy (nasobronchial allergy) or asthma
Chest injury	Trauma to the chest may lead to haemothorax. Multiple fractures of ribs may lead to <i>flail chest</i> . Thickening of pleura following resolution of haemothorax may splint the lung (“frozen chest”)
Recent general anesthesia or loss of consciousness	Inhalation (aspiration) of nasopharyngeal secretions or a foreign body (e.g. tooth) during anaesthesia or epileptic fit may lead to pneumonia or lung abscess
Pregnancy, prolonged immobilization, surgery, drugs such as oral contraceptives	May lead to deep vein thrombosis (DVT) and pulmonary embolism

TABLE 12.2 Extrinsic allergic alveolitis

Disease	Cause/Source	Antigen
Farmer’s lung	Mouldy hay or any other mouldy vegetable material	<i>Aspergillus fumigatus</i> and micropolyspora faeni
Bird fancier’s lung	Handling pigeons	Avian excreta, proteins and feathers
Malt worker’s lung	Turning germinating barley (moulty maltings)	<i>Aspergillus clavatus</i>
Humidifier fever	Contamination of air-conditioning	Thermophilic actinomycetes
Cheese worker’s lung	Mouldy cheese	<i>Aspergillus clavatus</i>
Maple bark stripper’s lung	Bark from stored maple	Cryptostroma corticale

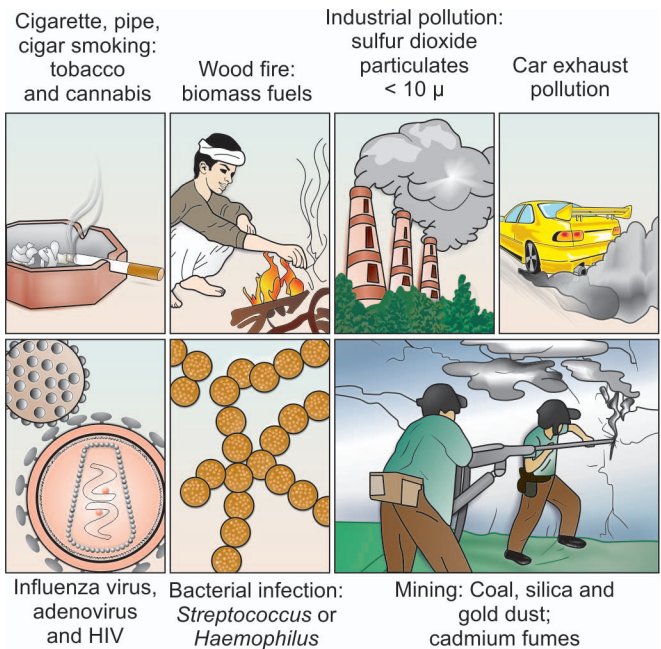


FIGURE 12.7 Risk factors for COPD: Environmental factors

alveolitis (Table 12.2). Nonorganic particles such as silica, coal dust and asbestos are important causes of pneumoconiosis and malignant diseases (Table 12.3). Exposure to coal, silica and gold dust, welding fumes and chemical at work increases the risk of COPD (Fig. 12.7).

- **Drug history:** Full details of drugs already been taken or are being taken should be asked, because certain drugs may precipitate the asthma (e.g. penicillins, sulphonamides, aspirin, NSAIDs, contrast agents), may induce lung injury (amiodarone, hexamethonium, paraquat, continuous O₂,

TABLE 12.3 Occupational lung diseases caused by exposure to inorganic dust

Cause	Occupation	Disease
Coal dust	Coal mining	Coal worker’s pneumoconiosis
Silica	Mining, quarrying, stone dressing, metal grinding, pottery, boiler scaling	Silicosis
Asbestos	Demolition, ship-breaking, fireproof insulating material and brake-pads, pipe	Asbestosis or asbestos related diseases, interstitial fibrosis, pleural disease/calcification, carcinoma of bronchus
Beryllium	Aircraft, atomic energy and electronic industries	Berylliosis

busulphan, bleomycin) or predispose to opportunistic lung infections (corticosteroids, cytotoxic drugs). ACE inhibitors are known to produce benign intractable cough.

General Physical Examination (GPE)

General assessment should be made by making the patient resting on a bed inclined at an angle of 45° and supported by pillows. In this chapter physical signs related to respiratory system are enumerated, which have already been detailed in Unit II on general physical examination. The points to be noted are:

- *General appearance, rate and nature of breathing.*

Normal breathing is quiet with larger inspiration than expiration. The respiratory rate is about 14–20/minutes in normal adults. The various abnormal breathing patterns seen in various respiratory disorders are given in the Box 5.

- *Note whether patient is comfortable or dyspnoeic at rest (Fig. 12.8). Note the grade of dyspnoea. Also inspect whether alae nasi or accessory muscles of respiration working.*

Activity of alae nasi, contractions of extrarespiratory muscles, e.g. scalenei and sternomastoids on inspiration indicate severe airflow obstruction.

- *Note the form, physique, state of nutrition and hydration. Record the weight.*
- *Note any cough, wheeze (audible inspiratory wheeze), stridor and hoarseness. Note any smell in breath.*
(long inspiratory whoops in whooping cough, loss of expiratory character of cough—bovine cough is seen in recurrent laryngeal nerve palsy)

Foul smelling breath indicates lung sepsis or bronchiectasis. Wheeze audible both to the patient and doctor occurs in cardiac and bronchial asthma.

- Stridor (loud sound) occurs in laryngeal and tracheal obstruction.
- Hoarseness indicates laryngitis, vocal cord paralysis (recurrent laryngeal nerve paralysis).
- *Examine the face, mouth, lips and tongue for anaemia, polycythemia, central cyanosis.*

Pursed-lip breathing suggests severe COPD (Fig. 12.9). This is often associated with overactivity of extra respiratory muscles and intercostals recession during inspiration indicating severe airway obstruction and non-compliant lung.

- *Examine the eye as it is likely to be involved in many respiratory disorders:*

Box 5

Breathing patterns in respiratory disorders

Pattern	Disorder
• <i>Rapid shallow breathing (tachypnoea)</i>	• Restrictive lung disease • Elevated hemidiaphragm
• <i>Slow breathing (bradypnoea)</i>	• Respiratory depression • Narcotic poisoning
• <i>Kussmaul's breathing (deep and rapid respiration)</i>	• Ketoacidosis (diabetic, alcoholic and starvation)
• <i>Cheyne-Stokes breathing (periods of hypernoea alternate with periods of apnoea)</i>	• Uraemia (renal failure) • Normal in children • Respiratory failure • Left ventricular failure • Raised intracranial pressure
• <i>Biot's breathing (ataxic, irregular breathing)</i>	• Narcotic poisoning • Respiratory depression • Meningitis
• <i>Deep, stertorous breathing (rattling noise breathing)</i>	• Raised intracranial pressure • Deep coma • Deep sleep
• <i>Sighing respiration</i>	• Dying patients • Hyperventilation, hysteria

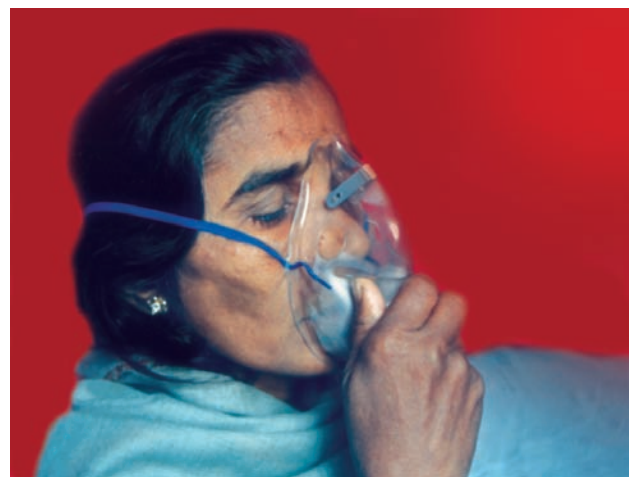


FIGURE 12.8 Dyspnoea at rest in a patient with respiratory disease

- Phlyctenular keratoconjunctivitis suggests primary tuberculosis
- Iridocyclitis may be a manifestation of tuberculosis or sarcoidosis.
- Horner's syndrome may occur due to involvement of cervical sympathetic in lung carcinoma or a tubercular lymph node mass.
- Conjunctival chemosis, suffused face, retinal vein dilatation and papilloedema may be seen in type II respiratory failure or superior vena cava obstruction.



FIGURE 12.9 Pursed-lip breathing in COPD. Note the sprouting of the lips during inspiration

- *Examine the neck for the followings* (Read also the Chapter 8)

Look excavation of the suprasternal and supraclavicular fossae.

Excavation of the suprasternal and supraclavicular fossae during inspiration occurs in COPD, suggests advanced airflow obstruction.

Look for carotid pulsations.

Bounding carotid pulsations are seen in hypoxia and hypercapnia (type II respiratory failure).

Look for Jugular venous pulse and pressure (For this, read CVS examination)

However, raised JVP and distended neck veins indicate right ventricular failure (cor pulmonale) or superior vena cava obstruction. The differences between the two are given in the Table 12.4.

Cervical lymphadenopathy: Palpate for enlargement of lymph nodes in supraclavicular fossa, cervical and axillary regions (Read Chapter 8 examination of neck). The scalene node in particular be examined by dipping the palpating finger behind the clavicle through the clavicular insertion of sternomastoid muscle (see Fig. 8.10). The enlarged lymph nodes have a variety of causes (Read Lymphadenopathy as Case Discussion in Bedside Medicine without Tears by Prof. SN Chugh) but infection (e.g. tuberculosis) and malignancy (lung cancer) need special mention. If malignancy lung is suspected, the abdomen should be examined for liver enlargement (secondaries liver).

Cervical nodes >1 cm in diameter are considered as abnormal, need further evaluation.

TABLE 12.4 Differential diagnosis of distended neck veins

<i>Superior vena cava obstruction</i>	<i>Right ventricular failure</i>
Distended neck veins with absent venous waveforms or pulsations	Distended veins with prominent V and Y collapse
The face is swollen, plethoric with conjunctival chemosis	Swollen face without suffusion or chemosis
Prominent veins over chest	Visible veins on the chest
Associated features such as stridor (due to tracheal obstruction) or dysphagia (oesophageal obstruction) may be present	Other associated features of CHF such as cyanosis, pitting peripheral oedema hepatomegaly and ascites may be present

Look for a swelling in the neck.

In *subcutaneous emphysema* and *mediastinal emphysema*, the air usually escapes into the neck leading to localise or diffuse swelling of neck which gives crackling sensation on palpation.

Inspect and palpate the trachea: *Note the position, palpable length above suprasternal notch and ‘tracheal tug’* Normally the trachea is either central or slightly to the right. Normally a good length of trachea is palpable in the neck. The method of palpation of trachea has been demonstrated in examination of the neck Chapter 8 in Fig. 8.17.

A reduction in palpable length of trachea and tracheal tug indicate severe airflow obstruction.

Examine the hands and feet (Read Chapter 10). The hands should be examined for *pallor* (anaemia), *redness* (polycythaemia, CO₂ narcosis), *peripheral cyanosis* and *clubbing of the fingers*. The feet are examined for *pitting oedema*.

Examine the skin: Skin examination as a whole is important for respiratory system. Some of the skin and subcutaneous lesions associated with respiratory diseases are listed in the Box 6.

Vital signs. Look for temperature, pulse, BP and respiration.

Now look for the signs of complications respiratory disease In a patient of respiratory disease, one should look for the signs of complications such as:

- Low grade fever, weight loss and malaise indicate tuberculosis and cachexia of malignancy. High grade intermittent or remittent fever, toxic look, finger clubbing, coated tongue and white eyes indicate empyema thoracis.
- Peripheral signs of right ventricular failure, e.g. orthopnoea, raised JVP, cyanosis, pitting oedema and hepatomegaly.

Box 6

Skin lesions as an aid to diagnosis of respiratory disease

Lesion	Associations
<i>Erythema nodosum (painful, tender erythematous nodules)</i>	May be a manifestation of tuberculosis and sarcoidosis
<i>Cutis vulgaris, scrofuloderma</i>	May indicate tuberculosis elsewhere
<i>Scar and sinus</i>	May be due to ruptured cold abscess or actinomycetes of lymph node
<i>Bruises/purpuric spots</i>	Bleeding disorder
<i>Cutaneous sarcoids and pernio</i>	May be associated with intrathoracic malignancies
<i>Herpetic vesicular eruptions (painful)</i>	May indicate the cause of unilateral chest pain
<i>Skin metastases or subcutaneous nodules</i>	May indicate malignancy lung
<i>Enlarged vascular (arterial) anastomotic channels on chest</i>	Coarctation of aorta
<i>Distended veins on the chest wall</i>	Superior vena cava obstruction
<i>Diffuse swelling of the chest wall, neck and face with crackling sensation on palpation</i>	Subcutaneous emphysema (air leakage into subcutaneous tissue—a complication of intercostal tube drainage or a pneumothorax or acute severe asthma)

- Peripheral signs of type II respiratory failure (CO₂ narcosis) should be sought because these patients may not appear distressed despite being critically ill.
- Look for level of consciousness (response to command and ability to cough) and signs of CO₂ retention (warm extremities, bounding/collapsing pulses and flapping tremors on outstretched hands).
- Look for signs of anaemia (pale conjunctivae, tongue, mucous membrane, nails and palmar creases) and polycythaemia (suffused face, cyanosis).

EXAMINATION OF CHEST

Examination of chest includes examination of anterior (including lateral) and posterior chest. It is described under four heads:

1. **Inspection**—looking at the chest.
2. **Palpation**—confirming the findings of inspection.
3. **Percussion**—to define resonant and dull areas on the chest.
4. **Auscultation**—to hear normal and abnormal sounds.

Examination of Anterior Chest Including Lateral Chest

The patient should be examined in the supine position with arms somewhat abducted. A patient, who is having difficulty in breathing on lying down, should be examined in the sitting position or with the head of the bed elevated to a comfortable level.

Persons with severe COPD prefer to sit leaning forward, with lip-pursed during expiration and arms supported on their knees or a table (Fig. 12.9).

Inspection



1. Shape of the chest: Observe the following:

- Symmetry
- Antero-posterior (AP) and transverse diameter
- Hollowing, flattening or bulging
- Subcostal angle
- Position of shoulders and spine.

The normal shape of the chest is described in the Box 7 and abnormalities/deformities of the chest are given in the Table 12.5 and demonstrated in Fig. 12.10.

Unilateral prominence of the chest: One side of the chest may become prominent or protuberant in pleural effusion, pneumothorax tumours, aneurysm and empyema necessitans. Localised bulge may occur in aortic aneurysm (see Fig. 11.19), pericardial effusion, liver abscess etc.

Unilateral or localized depression of the chest: Chest may be unilaterally depressed in fibrosis, collapse, thickened pleura and unilateral muscle wasting of chest.

Flat chest: The AP diameter is decreased and chest becomes flat. It is seen in children due to adenoid/lymphoid hypertrophy, rickets and advanced tuberculosis.







2. **Respiratory rate and rhythm:** Observe for any abnormality. The adult respiratory rate is 14–20 minutes and respiratory rhythm is regular with inspiration longer than expiration. Abnormal respiratory pattern have already been given in the Box 5.

Box 7

Normal shape of the chest and its dimensions

- Normal chest is bilaterally symmetrical with smooth contours and slight recession in infraclavicular regions.
- It is wider than it is deep. Its transverse diameter is more than the AP diameter, the ratio being 7:5. On cross section, it is ellipsoidal.
- The subcostal angle is acute (<70°)
- The interspaces are oblique; wider anteriorly than posteriorly.

TABLE 12.5 Deformities of the chest

Deformity	Fig. 12.10
<p>Barrel shaped chest: The A.P. diameter is increased, becomes equal or more than transverse. The subcostal angle is wide (obtuse). The sternum is more arched, spines become unduly concave forwards. The ribs become less oblique. This shape is normal during infancy but abnormally seen in COPD (emphysema)</p>	
<p>Funnel chest: (Cobbler's chest, pectus excavatum). There is hollowing of the sternum. Compression of heart and great vessels may cause murmurs. Due to sternal depression, the normal heart shadow may appear enlarged on chest X-ray (Pomfret's heart). This may be a congenital, or an occupational deformity in cobbler's.</p>	
<p>Pigeon chest: (Keel chest, pectus carinatum). The sternum is displaced anteriorly, increasing the AP diameter and leading to depression on either side of sternum. This is characteristically seen in rickets. Other signs of rickets (<i>rickety rosary</i>—beading of costochondral junctions, Harrison's sulcus—a transverse groove passing outwards from the xiphisternum to the mid-axillary line) may be present.</p>	
<p>Traumatic flail chest: The side of the chest is depressed due to fracture of multiple ribs resulting in paradoxical movement of the thorax, i.e. the injured area moves inwards during inspiration and outwards during expiration.</p>	
<p>Dumbbell shape chest: The chest is protuberant anteroposteriorly at its middle and the heart is placed obliquely in it.</p>	
<p>Kyphoscoliosis: There is backwards bending (kyphosis) due to thoracic convexity and lateral bending (scoliosis) due to lateral and rotatory curvature of thoracic spines. This deformity may be congenital and associated with hereditary ataxias. The asymmetry of the chest may decrease the size of thoracic cage and restrict lung expansion.</p>	

3. **Type of breathing movements:** *Note the type of breathing and the presence of any abnormal inspiratory or expiratory movements.*

- In majority of the males and some females, the normal breathing is *abdominothoracic* (mainly abdominal because men rely more on the diaphragm for respiration).
- In majority of females, the normal breathing is *thoracoabdominal* (mainly thoracic as females rely on intercostals muscles than diaphragm for respiration).

Abnormal breathing movements are:

- **Thoracic breathing:** The respiratory movements are exclusively thoracic. This occurs when diaphragmatic movements are inhibited either by paralysis or by abdominal pain or restricted by raised intra-abdominal pressure caused by ascites, gaseous distension of the bowel, a large ovarian cyst or pregnancy.
 - **Abdominal breathing:** The respiratory movements are exclusively abdominal with minimal thoracic movements. It occurs when there is restriction of chest movements either by ankylosing spondylitis or paralysis of intercostals muscles or pleural pain.
4. **Lesion on the chest wall (skin and subcutaneous tissue):** *Look for cutaneous* (e.g. eruptions, purpuric spots, bruises, scars, sinuses) *and subcutaneous lesions* (e.g. inflammatory swelling, subcutaneous tumour or empyema necessitans, nodule, sebaceous cyst, sarcoid nodules, vascular anomalies). These have already been highlighted during general physical examination. For lesion of the breasts (Read Chapter 9).
5. **Movements of the chest (expansion of the chest):** *Observe the chest movements and compare the range of chest movements on the two sides during normal and deep breathing.*
- To compare the range of movements in the infraclavicular regions, position the patient supine, shoulders relaxed and symmetrical with the head resting on a pillow and the head and trunk in a straight line. Then ask the patient to take deep steady breaths while inspecting the infraclavicular regions tangentially.
 - Assess lower anterior chest movements by inspecting the patient semirecumbent and breathing deeply.
 - Note the intercostals recession or indrawing of the intercostals spaces during movements of the chest.
 - Observe the prominence of accessory muscles of respiration.

Normally both sides of the chest move more uniformly without any indrawing of intercostals spaces. Accessory muscles of respiration are usually not required for act of breathing, hence, are not prominent. The alae nasi are not active.

TABLE 12.6 Causes of diminished movement/expansion of the chest

<i>Unilateral diminished movements/expansion</i>	<i>Bilateral diminished movements/expansion</i>
<ul style="list-style-type: none"> • Massive collapse of the lung (a foreign body, bronchial adenoma/carcinoma) • Consolidation • Consolidation collapse • Fibrosis of the lung • Thickened pleura • Pleural effusion • Pneumothorax or hydropneumothorax 	Bronchial asthma COPD Extrinsic allergic alveolitis Bilateral pulmonary fibrosis (idiopathic, drug induced) Guillain-Barre syndrome Respiratory muscle paralysis Poisonings, e.g. narcotics

Common causes of intercostal secession/suction include: asthma, COPD foreign body within larynx and trachea, diphtheria, laryngeal oedema, anaphylaxis, bronchitis and bilateral diaphragmatic paralysis.

During the movements of the chest, there is usually expansion of the chest, hence, both are interchangeably used. The causes of diminished movements or expansion of the chest are given in the Table 12.6.

There can be diminished movements/expansion of the chest in a localized part due to underlying lung or pleural disease such as fibrosis, collapse of the lung, localised pleural effusion.

A good test of the diaphragm is to ask the patient to sniff vigorously; patient with diaphragmatic paralysis is unable to do so.

In normal movements of the chest, the lower parts move first followed by the upper part, but in COPD (emphysema) with barrel-shaped chest, the chest moves as a whole (en bloc).

• *If the patient is breathless, examine him/her in semirecumbent or sitting position. Note any abnormality of inspiratory or expiratory movement.*

- Abnormal inspiratory movements produced by contractions of accessory muscles of respiration (sternomastoids, scapular and trapezii) are seen in patients with gross over distension of lungs (emphysema or severe asthma Fig. 12.11). More violent inspiratory movements of similar character are seen in laryngeal or tracheal obstruction. The intercostal recession or indrawing of the ribs, excavation of supraclavicular fossae and suprasternal notch and widening of the subcostal angle invariably accompany these movements in patients with COPD (Fig. 12.12).

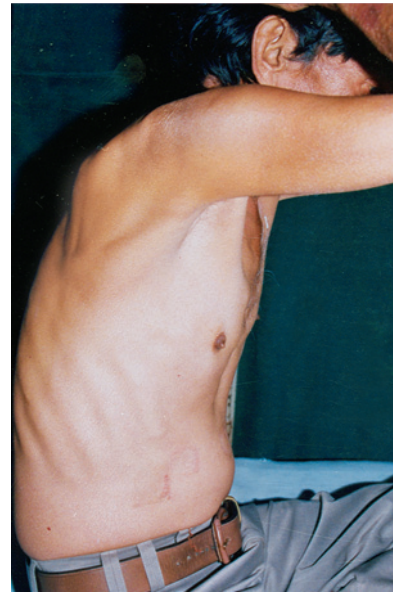

FIGURE 12.11 Severe asthma in a young person. Note the presence of indrawing or recession of intercostal spaces and contraction of extrarespiratory muscles of respiration

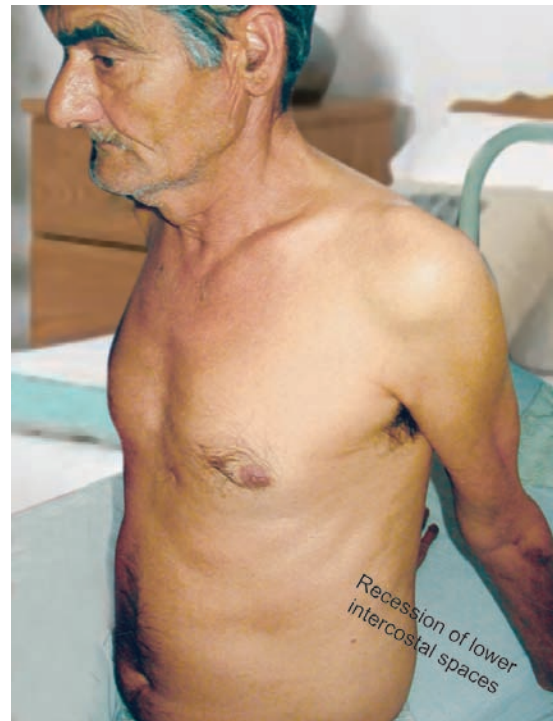

FIGURE 12.12 Chronic obstructive pulmonary disease (COPD). Note the barrel shaped chest, excavation of the supraclavicular fossae, prominence of sternomastoid and recession of intercostal spaces

- Paradoxical movements of chest occur in flail chest (read abnormalities of chest).
- Abnormal expiratory movements are produced by contractions of abdominal muscles and latissimus

dorsi. These are observed when either the compliance of the lung (elastic recoil of the lung) is reduced (e.g. emphysema) or there is severe airway obstruction (bronchitis or bronchial asthma). Such patients prefer to sit upright, gasping on a bed table or the back of a chair. Many patients have purse-lip breathing. (see Fig. 12.9). Such patients recruit accessory muscles of respiration into action.

Alae nasi, sternomastoid, scalani, lathismus, dorsi, trapezius, pectoralic major, serrotus anterior, abdominal muscles are accessory muscles of respiration.

6. **The cardiac apex, trachea and mediastinum:** *Look at the position of the apex beat*—(Read CVS examination).
7. **The trachea:** *Look at the trachea for any deviation.* This finding has to be confirmed on palpation (the method of palpation has been discussed under examination of neck-thyroid and trachea Chapter 8).

On inspection, sternomastoid muscles becomes unduly prominent on the side to which trachea has been shifted. This is called Trail's sign (Fig. 8.19).

- *Look for mediastinal shift. The position of the mediastinum is decided by the position of the trachea and that of cardiac impulse (apex beat). The mediastinal shift occurs in a variety of diseases given in the Box 8.*

Palpation



Palpation has four potential uses:

1. Identification of tender areas.
2. Assessment of observed abnormalities (e.g. to confirm the findings of inspection).
3. Further assessment of chest expansion by measurements.
4. Assessment of tactile vocal fremitus.

Steps of Examination

Palpate the chest wall for any swelling or bony prominences

- Fluctuation sign is positive in an abscess on the chest wall
- A cystic reducible swelling, becoming more prominent after coughing (positive cough reflex) indicates empyema necessitans
- Rickety rosary or scorbutic rosary produces swelling of costochondral junctions
- Bony swelling is a hard mass
- A crepitus (crackling sound) will be produced on palpation of subcutaneous emphysema
- Identify the site of tenderness so as to find out the cause of pain. The causes of pain and tenderness are given in the Box 9.

Box 8

Position of the mediastinum in respiratory diseases

Central	Pulled to the same side	Pushed to the opposite side
<ul style="list-style-type: none"> • Bronchitis • Asthma • Pulmonary suppuration, e.g. lung abscess, bronchiectasis • Consolidation • Emphysema • Interstitial fibrosis 	<ul style="list-style-type: none"> • Collapse • Fibrosis • Thickened pleura • Pneumonec-tomy or lobectomy 	<ul style="list-style-type: none"> • Pleural effusion • Pneumothorax • Hydropneumothorax or pyopneumothorax

Box 9

Causes of pain and tenderness of chest

- A recent chest wall injury
- Inflammatory myositis
- Fibromyalgia—musculoskeletal pain where, as a rule, localised tender spots can be discovered on pressure.
- Secondaries in the ribs
- Herpes zoster intercostal neuralgia
- Pleurisy (a pleural rub may be palpated)
- Pericarditis (a pericardial rub may be palpated).

Note the position of cardiac impulse. Palpate the trachea for any deviation.

Displacement of cardiac impulse alone may occur in chest deformities such as scoliosis (the commoner form, with convexity to the right causing displacement of the cardiac impulse to the left and vice versa) and funnel chest central depression (displaces the cardiac impulse to the left). The displacement may be due to cardiovascular causes (Read CVS examination) and respiratory causes (Read displacement of the apex beat under inspection of anterior chest).

The shift of the trachea and the mediastinum may be due to pull or push. The causes of mediastinal shift have already been discussed in Box 7.

Assess the other abnormalities seen on inspection.

Confirm the findings of inspection by palpation such as skin lesion, pulsations, venous hum or thrill.

The observed asymmetrical expansion of the chest must be confirmed by palpation. The method is described in the Box 10. Measurement of expansion is done by a tape measure (Fig. 12.14).

Record with a tape measure the maximum inspiratory/ expiratory difference in the lower chest (at the level of nipple in males and 4th or 5th intercostal space in females). This gives you actual total expansion not expansion of each hemithorax.

Box 10

Measurement of expansion by palpation (Figs 12.13A and B)

Place your thumbs along a costal margin, your hands along the chest wall laterally. Shift the tips of the thumbs a bit medially so that they meet in the centre. Ask the patient to inhale deeply. Observe how far your thumb diverge as the thorax expands. The distance between the thumbs indicate degree of chest expansion. If one thumb remains closer to the midline, this confirms the diminished expansion on that side. This gives you an idea of expansion of each side as well as total chest expansion. Repeat the process on the back.

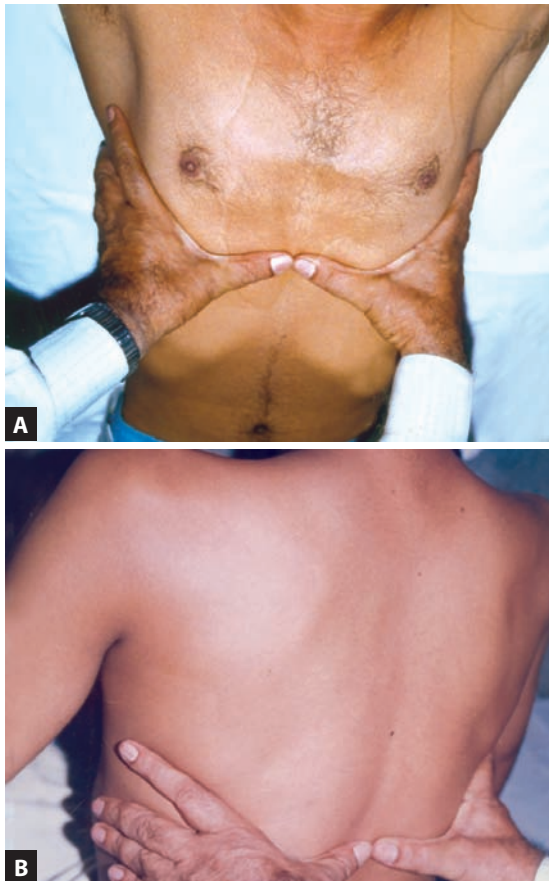


FIGURE 12.13A and B (A) Manual measurement of chest expansion on the front. Note the placement of hands for this measurement; (B) Manual measurement of chest expansion on the back

For expansion of each hemithorax (differential expansion), measure expansion from midsternal line to the spinal column on each side and decide which side is moving less and how much.

In young male, chest expansion is > 5 cm. In persons above 40 years > 4 cm is taken as normal while in persons above 60 years, 3 cm expansion is accepted as normal.

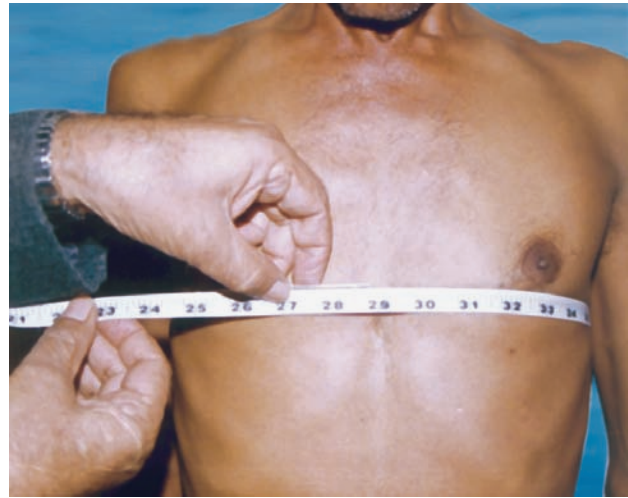

FIGURE 12.14 Measurement of expansion of the chest by measuring tape. Encircle the tape around the chest at the level of nipple in the males and below the breast in females. Confirm that the tape is at the same level all around. Note the reading of the tape during quiet breathing. Ask the patient to take breath as deep as he can while you let loose the tape. Now note the reading during full inspiration. The difference between the two reading indicates expansion of chest

Palpation of intercostals spaces: *In case of abnormal chest, palpate the intercostal spaces with pulp of the fingers on each side at corresponding levels to know any widening or narrowing.*

Narrowing or overcrowding of intercostal spaces on one side occurs in atelectasis, collapse, fibrosis, thickened pleura, pneumonectomy/lobectomy.

Bilateral narrowing is seen in interstitial lung diseases or bilateral pulmonary fibrosis.

Widening of spaces on one side occurs in pleural effusion and pneumothorax; and on both sides in emphysema (COPD).

Assessment of tactile vocal fremitus: *Assess the vocal fremitus on both sides.* Tactile vocal fremitus refers to perception of vibrations transmitted to chest wall from the voice box (larynx) via the tracheobronchial tree during the act of phonation.

Mechanism: During production of sound, vibrations are produced from the larynx (voice box) which get transmitted from the larynx to trachea, bronchi, lungs and then to the chest wall and set the chest wall to vibrate. These vibrations may be detected by palpation with the palm of the hand placed flat on the chest.

Variations: The tactile vocal fremitus is diminished or absent in females because the fundamental frequency of female voice is often higher than that of the lungs. On the other hand, vocal fremitus can be better appreciated in children than in adults because fundamental frequency though also high in children but corresponds to fundamental frequency of small lungs.

Method (Figs 12.15A and B)

Vocal fremitus is detected and compared on both sides of the chest using the ball or ulnar surface of the hand when patient is asked to repeat some words, say, *ninety-nine* or *one-one-one*. The examining hand perceives distinct vibrations. Points to be noted in tactile vocal fremitus are given in the Box 11. The causes of increased, decreased or absent tactile vocal fremitus are listed in the Table 12.7. The sites of vocal fremitus are given in Fig. 12.3C.

Box 11

Points to be noted during tactile vocal fremitus

- Intensity of the sound perceived, i.e. increased, decreased or absent.
- To determine whether change in intensity is localized or generalized. This is done by comparing the vocal fremitus in corresponding areas on the two sides of the chest (Figs 12.15A and B).
- Do not include cardiac area for comparison of vocal fremitus on the corresponding area on the other side as it is normally diminished in this area.
- Vocal fremitus on percussion corresponds with the vocal resonance on auscultation.

TABLE 12.7 Abnormalities of tactile vocal fremitus

Increased	Decreased	Absent
<ul style="list-style-type: none"> • Consolidation • A large superficial cavity • Bronchopleural fistula 	<ul style="list-style-type: none"> • <i>Bronchopulmonary diseases</i>, e.g. <ul style="list-style-type: none"> – Bronchial asthma – Emphysema – Pulmonary fibrosis – Lung collapse with obstructed bronchus • <i>Pleural disease</i>, e.g. <ul style="list-style-type: none"> – Thickened pleura 	<ul style="list-style-type: none"> • Pleural effusion • Pneumothorax • Hydro or pyopneumothorax

Palpate for Other Palpable Vibrations

Normal lung does not produce any vibrations during breathing, but sometimes can be felt in certain diseases:

A palpable pleural friction rub: It is produced due to rubbing of the parietal pleura against visceral pleura towards the end of inspiration or during beginning of expiration. It occurs in pleurisy due to any cause, e.g. pleurodynia, consolidation, pulmonary infarction, early pleural effusion. It is felt over the area of pleura involved.

Palpable crackles or rales: Coarse crackles or rales may become palpable in bronchiectasis and pulmonary fibrosis.

Palpable wheeze/rhonchi: Wheeze may be audible as well as palpable in bronchial asthma and in acute exacerbations of COPD.

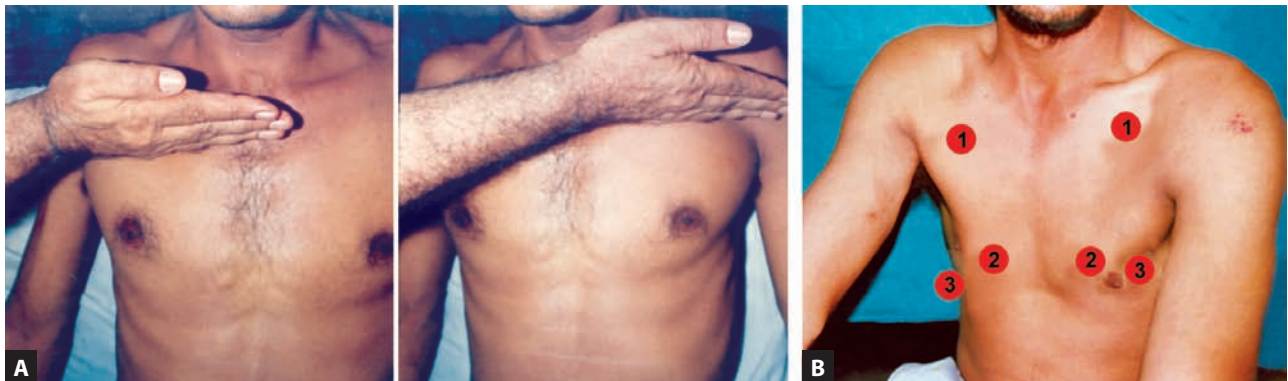


The aim of percussion is to compare the degree of resonance over equivalent areas on the two sides of the chest and to define any area of abnormality on percussion note. A small lesion < 2 cm in diameter does not produce change in percussion note.

Normal Areas of Resonance and Dullness

The regions of the thorax where a resonant percussion note is normally found correspond approximately to the surface marking of the lungs. The heart normally produces an area of dullness to the left of the sternum from the 3rd to 5th space. Percuss the left lung lateral to it. The liver dullness starts from the 5th intercostal space downwards on the right side.

Mechanism: Percussion of the chest sets the chest wall and underlying tissues into motions, producing audible sounds and palpable vibrations called percussion note. Percussion



FIGURES 12.15A and B Vocal fremitus: (A) Comparison is made on the both sides at corresponding areas from above downwards toward lower part of chest; (B) Sites for palpating vocal fremitus

note helps you to establish whether the underlying tissues are air-filled (pneumothorax), fluid filled (pleural effusion) or solid (tumour). It penetrates only about 5–7 cm into the chest, therefore, will not help to detect the deep seated lesions.

Note: “Practice makes the man perfect”. Percussion is a crude method of examination, can be rather uncomfortable to the patient if performed repeatedly and inexpertly. Therefore, at first percussion can be practiced on any surface. As you practice, listen to different percussion notes at different area of material and different parts of the body.

Method: The technique of percussion is illustrated in the Fig. 12.16. The steps of percussion are discussed in the Box 12.

With your plexor or tapping finger, deliver the lightest percussion that produces a clear note (Fig. 12.16). A thick chest wall may need heavier percussion than a thin one. However, if a louder note is needed, apply more pressure with the pleximeter finger (this is more effective for increasing the percussion note volume than tapping harder with the plexor finger).

While percussing the lower posterior chest, stand somewhat to the side rather than directly behind the patient. This allows you to place your pleximeter finger more firmly on the chest and your tapping is more effective, making a better percussion note.

While comparing two areas, use the same percussion technique in both areas. Percuss or strike twice in each locations (Fig. 12.17). It is easier to detect differences in percussion notes by comparing one area with another than by striking respectively in one place.

Rules of Percussion

- Always percuss from resonant to dull area over one side of the chest. The vice versa is not true.
- Compare the corresponding areas on two side of the chest simultaneously.

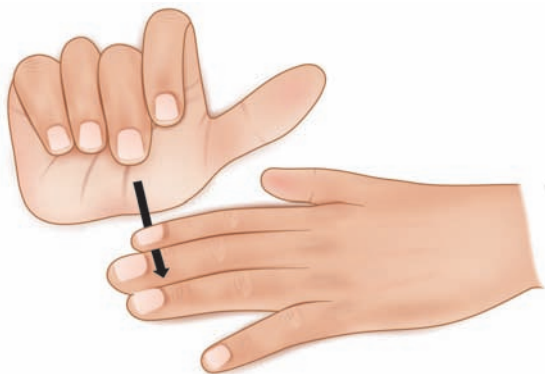

FIGURE 12.16 Method to deliver the stroke with plexor (tapping finger on pleximeter finger). The corresponding areas to be percussed are labelled in Fig. 12.17

While the patient keeps both arms crossed in front of the chest, percuss the chest in a symmetric fashion from above (apices) to below (bases of the lung). Percuss first one side of the chest and then the other at each level and at similar locations marked in Figure 12.17. Omit the areas over the scapulae as thickness of the muscles and bones alter the percussion note over the lungs.

Identify and locate the area of any abnormal percussion note.

Box 12

The method of percussion for right handed doctor/student (Fig. 12.16)

- The middle finger (pleximeter finger) of the left hand is placed on the part to be percussed usually an intercostal space and others fingers of the hand are slightly separated from the middle finger.
- Make a good contact of the middle finger by pressing the finger firmly.
- Strike the back of middle phalanx with the tip of the right middle finger held at right angle. The movement should be at the wrist rather than at elbow so as to produce ‘hammer effect’.
- As soon as the blow is delivered, the striking finger must be raised each time.
- Compare the note obtained from identical sites on two sides.
- Map out the area of impaired dullness (including cardiac and hepatic) by percussing from a resonant to a dull area but not otherwise.
- In woman, to enhance percussion, gently displace the breast with your left hand while percussing with the right.

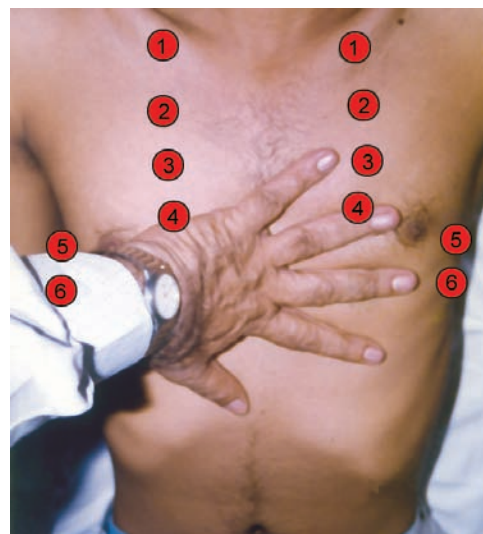


FIGURE 12.17 Percussion of the front of the chest. Note the placement of fingers parallel to intercostal spaces. The areas to be percussed are labelled and encircled

Learn to identify five percussion notes: You can practice few of them on yourself. Normal lungs are resonant. The other percussion notes are described along with illustrations in Fig. 12.18 given in the Box 13.

Normally the lungs are resonant due to air in alveoli. Normal lung resonance is replaced by dullness when fluid or solid tissue is interposed between air containing lungs and the chest wall beneath your percussing fingers, for example.

- Dull note over consolidation is due to solidification of the lung as the alveoli are filled with fluid and blood cells. Similarly dull note on percussion is elicited in a solid growth (tumour) or collapse (airless alveoli) and fibrosis of the lung.
- Stony dull note (a marked resistance to pleximeter finger on percussion) is elicited when either the fluid (pleural effusion) or blood (hemothorax) or pus (empyema) occupies the pleural space.

Now define liver dullness and liver span (Figs 12.19A and B)

Percuss for liver dullness on the right side from above downwards in midclavicular line and mark the point of dullness. Now percuss from below (right lumbar region) upwards and make the point of dullness. The distance between two points indicates liver span. The normal liver dullness lies in the right 5th intercostal space in mid-clavicular line, in the 7th space in anterior axillary line and in the 9th space in scapular line.

Liver dullness is pushed up (e.g. 4th intercostal space or above) in mid clavicular line in amoebic and pyogenic abscess of the liver, collapse of the lower lobe of the lung, diaphragmatic paralysis and eventration of right dome of diaphragm. It may be pushed down to 6th space in emphysema and right-sided pneumothorax and right-sided subphrenic abscess.

Box 13

Percussion note

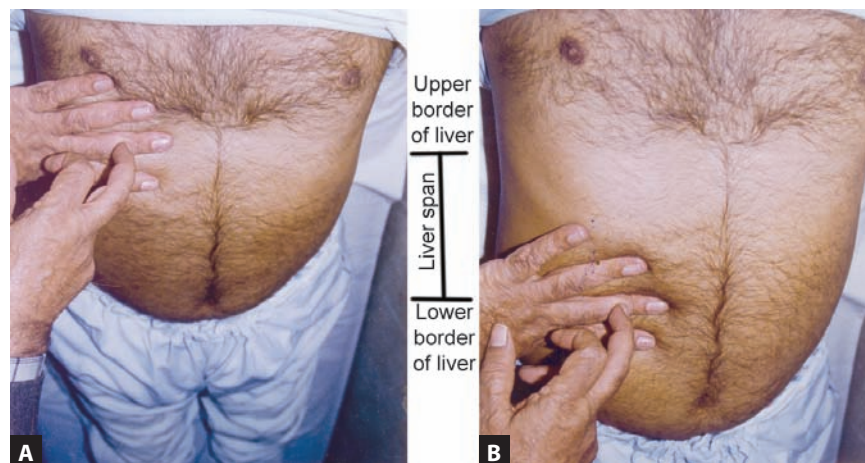
Type (Fig. 12.18)	Detected over
Tympanic (drum-like resonance)	Stomach or air filled hollow viscus, pneumothorax, superficial empty cavity
Resonant	Normal lung
Hyper-resonant	Pneumothorax, emphysema, asthma, air filled large bulla or a thin walled cavity, eventration of diaphragm
Impaired/dull note	<ul style="list-style-type: none"> • Consolidation • Collapse • Fibrosis
Stony dull	Thickened pleura Pleural effusion, empyema

Normal liver span is 10–14 cm in midclavicular line. Liver is said to be shrunken if span is <10 cm and enlarged if span is >14 cm. Liver span is reduced in acute fulminant hepatitis and enlarged in hepatomegaly due to any cause. However, change in liver span elicited on percussion must be confirmed on USG of liver because reduction of liver span carries prognostic and therapeutic significance.

Now define area of normal cardiac dullness

The normal cardiac dullness is defined in the 3rd and 4th left interspace along the parasternal line and 5th space upto midclavicular line by starting percussion from anterior axillary line (i.e. the lowest cardiac dullness corresponds to the apex beat).

The cardiac dullness is masked or obliterated in severe obstructive emphysema or left sided pneumothorax. It may be increased in cardiomegaly and pericardial effusion. It may get merged with dullness of left pleural effusion, if fluid is massive.



FIGURES 12.19A and B Normal liver dullness and liver span

Define normal Traube's area of resonance (Fig. 12.20)

It is bounded above by the lung resonance, below by the costal margins, on the right by left border of the liver dullness and on the left by normal splenic dullness. Percussion note is resonant because normally stomach occupies this area (tympanic note). It becomes dull in left-sided pleural effusion. Fluid or solids in the stomach or colon may also produce dullness in this area. This area is known for splenic dullness but normally splenic dullness is hidden within dullness of other posterior tissues. Tympanic note of the Traube's area is also lost in splenomegaly.

Causes of dullness in Traube's area are:

- Left sided pleural effusion
- Splenomegaly
- Solid tumor of stomach or splenic flexure.

Note: This area is obliterated in situs inversus (liver is present in this area instead of stomach) and cardiac achalasia.

Identification of descent of diaphragm or diaphragmatic excursion by tidal percussion

First, define the level of diaphragmatic dullness on anterior chest in midclavicular level or on posterior chest at scabular line during quiet respiration. You can infer the probable location of the diaphragm from the level of dullness.

To estimate the extent of diaphragmatic excursion, one has to determine the distance between the level of dullness on full expiration and the level of dullness on full inspiration. Tidal percussion is used for this purpose but this procedure is of little practical value. This estimate usually does not correlate well with the radiological assessment of diaphragmatic movement.

Normal diaphragmatic excursion is 5–6 cm. An abnormal high level of diaphragmatic dullness suggests subpulmonic pleural effusion, or a high diaphragm as in atelectasis or diaphragmatic paralysis. Paradoxical resonance (dull note on inspiration becomes resonance during expiration) is seen in diaphragmatic palsy while constant dull note both during inspiration and expiration indicates either pleural effusion or basal consolidation.

Abnormalities of Percussion Note

The various abnormal percussion notes and the conditions in which they can be elicited have been listed already in the Box 13.

When an abnormality of the percussion note is due to lung consolidation or collapse, it is usually possible to identify the lobe or lobes involved by reference to the surface marking of the fissures but unless a lobe is totally solidified (consolidated), the area over which the percussion note is impaired is often much smaller than would be expected from the surface marking. This is even more striking when a lobe is collapsed.

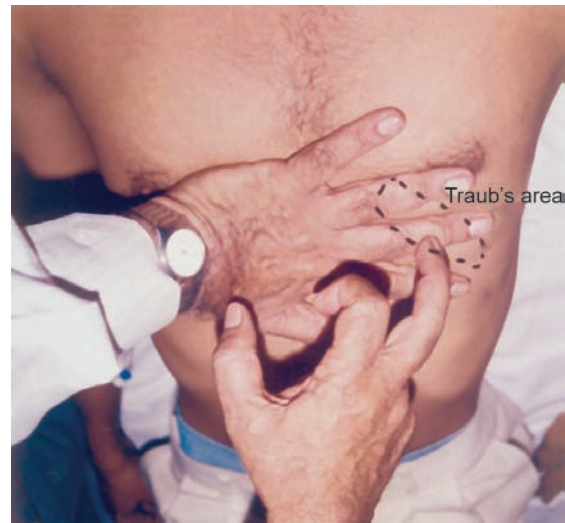

FIGURE 12.20 Percussion for the Traube's area

Box 14

Pitfalls of percussion

Do not rely too much on percussion note alone in localizing the pulmonary or pleural lesion. Percussion combined with auscultation for breath sounds and voice sound are more rewarding. However, small lesions, such as areas of segmental collapse or consolidation and deep-seated lesions may not produce any abnormal physical signs. Even with larger lesion, the signs may be partly or completely obscured if the lungs are emphysematous. Generalized hyper-resonance on both sides is rarely of diagnostic significance.

- A small lesion may not cause any change in percussion note.
- Pleural fluid <200 mL may not be detected on percussion, needs USG for confirmation.

Dullness in pleural effusion: In pleural effusion the area of stony dull note is unrelated to the surface anatomy of the lobes. In localized effusion, however, the area of dullness is limited while in small effusion, dullness occur over the lower part of the hemithorax. Large effusions may have dullness that rises in the axilla (**rising dullness**) but this sign is lost in case fluid is replaced by pus (empyema thoracic) or it gets loculated. Pleural effusion of considerable size may not be detected during examination of anterior chest when the patient is in a semirecumbent position because gravity causes the pleural fluid to accumulate posteriorly. When there are no pleural adhesions, the chest X-ray shows an effusion to have a curved upper border.

The pitfalls of percussion are discussed in the Box 14.

Shifting dullness: The dullness in the pleural effusion is due to fluid but there is no shifting dullness because there is no space for the fluid to shift. In case of hydropneumothorax in sitting position, the upper area occupied by the air is

hyper-resonant, while the lower area occupied by free fluid is dull/stony dull. On changing the posture to lying down (supine), this area of dullness changes along the lower part of the whole anterior chest as fluid splashes over a wider area by displacing the air. This is called *shifting dullness*, is characteristic of hydropneumothorax or a large cavity or a cyst containing both air and fluid.

How to elicit the horizontal fluid level in hydropneumothorax: Patient is made to sit comfortably with arms above the head and chest fully exposed.

Percussion is done from above downwards in the front along midclavicular line, lateral chest wall along midaxillary line and back (along scapular line) in the conventional way. During such percussions a point of dullness is reached on the front, lateral chest wall and back where these points are marked with skin pencil. These three points are joined transversely and horizontal line is drawn encircling the affected chest wall. This is upper border of fluid level.

At the upper border of fluid level in hydropneumothorax, there is stony dull area but above it there is hyper resonant area due to air. The transition between the two different notes gives a clear cut horizontal level.

Percussion myokymia: It is noticed during percussion in chronically ill debilitated cachexic patients where a percussion stroke over the front of chest causes a transient twitchings of the muscles, more marked on the affected side. This may be seen in an advanced case of pulmonary tuberculosis.

Hyper-resonance: A percussion note having pitch in between normal resonance and tympany is taken as hyper-resonant. It can normally be elicited over the normal lung tissue when the chest is held in full inspiration. Pathologically, it occurs in pneumothorax, emphysema, a large cavity or cyst or bullae and in eventration of the diaphragm (see Box 13).

A hyper-resonant note with a boxy quality is elicited just above the level of pleural effusion. This is called *skodaic resonance*.

A band of lung resonance (*Kronig's isthmus*) 5–6 cm in width is present in the lower part of the neck connecting the anterior and posterior aspects of side of the chest. It is bounded medially by neck muscles and laterally by shoulder muscles. Its absence on either side indicate apical pulmonary fibrosis while its increased width bilaterally suggest voluminous lungs of emphysema.

Auscultation



Auscultation of the lungs is the most important examining technique for assessing the airflow through the

Box 15

Points to be noted on chest auscultation

- Breath sounds
 - Vesicular
 - Bronchovesicular
 - Bronchial
- Vocal resonance (increased or decreased). If increased, then hear the transmitted sounds.
 - Bronchophony
 - Whispering pectoriloquy
 - Aegophony
- Adventitious (added) sounds
 - Crackles (crepitation word has been replaced)
 - Wheezes (rhonchi)
 - Pleural rub

tracheobronchial tree. Together with percussion, it also helps to assess the condition of the surrounding lungs and pleural space. It is extremely valuable for diagnosis of most of the pulmonary as well as pleural lesions. In contrast, auscultation is unhelpful in the early diagnosis of pulmonary tuberculosis, which may reach an advanced stage before any abnormality can be detected. Auscultation involves:

- Listening to the sounds generated by breathing (breath sounds)
- Listening for any added or adventitious sounds
- If abnormality is suspected, listening to the sounds of the patients spoken or whispered voice (words) as they are transmitted through the chest wall.

The points to be noted on auscultation are given in the Box 15.

Method of Auscultation (Fig. 12.21)

- The patient should be in the usual position for examining the chest.
- Listen with diaphragm of a stethoscope after explaining the patient to breathe deeply through an open mouth. You can switch on to hear with the bell of stethoscope if you suspect abnormal sounds being produced by the diaphragm, sounds from bed clothes, gowns and chest itself.
- Pattern of auscultation is similar to percussion, moving from one side to the other and comparing corresponding areas of the lungs (see Fig. 12.17).
- If you hear or suspect abnormal sounds, auscultate adjacent areas so that you can fully describe the extent of any abnormality.
- Listen to at least one full breathe in each location.
- Auscultate in two stages: compare first the amplitude of the breath sounds and then vocal resonance.

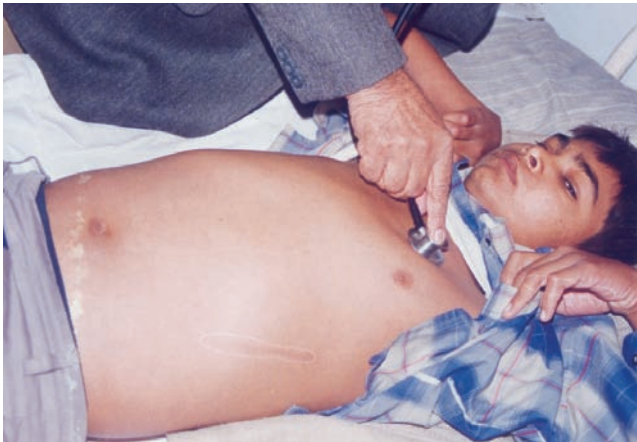

FIGURE 12.21 Auscultation of the anterior chest

Avoid prolonged deep breathing as it may cause giddiness or tetany and also avoid auscultation with 2–3 cm of the midline.

Auscultate anteriorly from above the clavicle down to 6th rib, laterally from the axilla to the 8th rib and posteriorly down to the level of the 11th rib.

While listening to the breath sounds:

- Note the quality and amplitude of inspiration and expiration.
- Identify if there is a silent gap between inspiration and expiration.
- Listen for added (adventitious) sounds.

Intensity of breath sounds may decrease when airflow is decreased or when transmission of the sound to the chest is poor.

A gap suggests bronchial breath sounds.

Added sounds are discussed further in this chapter.

Auscultation in Special Situations

- If there is difficulty in distinguishing between coarse crackles and a pleural rub, repeat auscultation after the patient has been asked to cough forcefully.

Forceful coughing changes the character or intensity of crackles but not of pleural rub.

- Do not ask the patient with a severe pleuritic pain (consolidation) to take frequent deep breaths or to cough. Test the vocal resonance first, if an area of increased vocal resonance is found, then ask the patient to take one or two deep breaths, and now bronchial breathing will be audible in the same area.
- When the abnormal breath sounds are heard, define the extent of the area by moving the stethoscope with each breath from the normal to abnormal zone and note the level at which the intensity of breath sounds changes sharply.

Breath sounds

Breath sounds are produced by passage (rushing) of the air through tracheobronchial tree. The breath sounds have intensity and quality. The intensity of breath sounds may be normal, reduced or increased (see Box 16). Since the intensity and quality of breath sounds being variable from patient to patient and in different situations, it is only by repeated auscultations of the chest of many patients one becomes familiar with normal variations and learns to recognize the abnormalities.

Classification

Breath sounds are classified into three main types, e.g. vesicular, bronchial and bronchovesicular. Normally when

Box 16

Intensity of breath sounds

Diminished	Increased	Absent breath sound
<ul style="list-style-type: none"> • Decreased airflow <ul style="list-style-type: none"> – Localised airway obstruction – COPD – Paralysis of respiratory muscles • Extensive destruction of the lung, e.g. interstitial fibrosis • Poor transmission of the sounds <ul style="list-style-type: none"> – Obesity (thick chest wall) – Oedematous chest wall – Thickening of pleura – Pleural effusion/empyema – Pneumothorax – Emphysema 	<ul style="list-style-type: none"> • Thin chest persons • Bronchovesicular or bronchial breath sounds are louder than vesicular breath sounds (Read the causes of bronchial sounds) but this is not hard and fast rule. It is possible for bronchial sounds to be much quieter than the vesicular sounds heard elsewhere in the chest as, for example, when there is a pleural effusion overlying consolidation (synpneumonic effusion) • Fibrocavitary lesions or bronchiectasis 	<ul style="list-style-type: none"> • Large pneumothorax • Massive pleural effusion • Collapsed of the lung with obstructed bronchus

TABLE 12.8 Characteristic of breath sounds

Type	Character	Intensity	Duration	Gap between inspiration and expiration
Vesicular Fig. 12.22A (produced by passage of air in and out of alveoli)	Rustling (sound like dry leaves blown by the wind or rustling of hair in front of ear)	High pitched, low intensity sound, heard normally all over the chest	Expiration is louder and longer than inspiration	No gap (i.e. continuous sound)
Bronchial Fig. 12.22B (Alveolar part is cut off, bronchial part intact)	Blowing or hollow	Low or high pitched, high intensity. Inspiration being active is louder than passive expiration. It is an abnormal sound	Intermediate Inspiratory phase is equal or shorter than expiratory phase	Definite silent gap present (discontinuous sound)
Bronchovesicular	Harse vesicular	Intermediate between vesicular and bronchial	Expiration is slightly longer, may be normal or abnormal	Gap may or may not be present

person breathes, air enters through the tracheobronchial tree and the breathing remains bronchial upto tertiary bronchioles (air passes through conduit pipes), gets filtered by the alveoli and converted into vesicular which is heard over the chest. This is the reason, that we have a normal loud bronchial breathing over trachea. Any disease process that either causes collapse of the alveoli or destroys the alveoli, or solidifies the alveoli produces bronchial breathing (as heard in collapse, consolidation, etc.) because the filtering effect of alveoli is abolished.

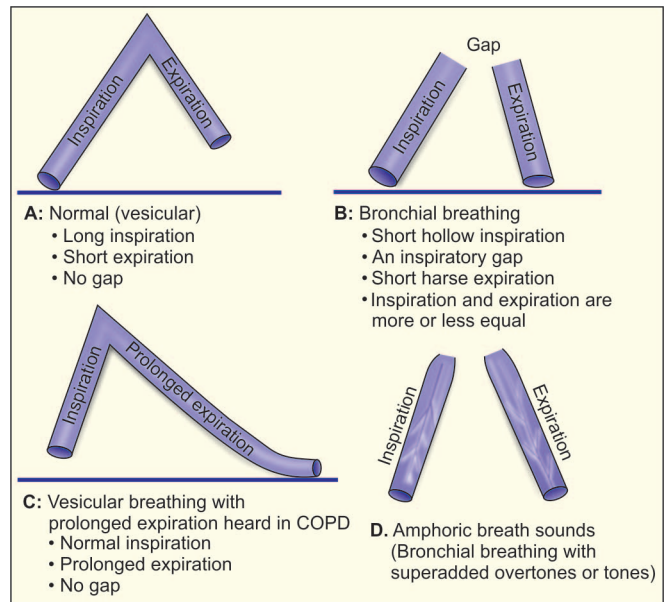
The type of breath sound depends on the *intensity*, *pitch* and the *relative duration of their inspiratory and expiratory phases* (Table 12.8).

Vesicular Breath Sound (Fig. 12.22A)

It is the sound produced by passage (rushing) of air in and out of the alveoli. Normally the alveoli of the lung selectively filter out or dampen the higher frequency sounds but transmit the lower frequency sound, hence the breath sounds are quieter and vesicular in type. It is normally heard all over the chest.

Variations: Common variations are:

- **Diminished vesicular sound:** The causes have already listed in the Box 16.
- **Vesicular breath sounds with prolonged expiration (Fig. 12.22C):** This is due to increased airway resistance during expiration either due to spasm or obstruction resulting in prolongation of expiration which becomes equal to inspiration. The causes are:
 - Bronchial asthma
 - Chronic bronchitis and emphysema (COPD)
- **Harsh vesicular:** In this intensities of both inspiration and expiration are increased. It is heard in compensatory emphysema.



Note: The width of bar indicates intensity

FIGURES 12.22A to D Respiratory breath sounds (diagram)

Bronchial Breath Sound (Fig. 12.22B)

It is the sound produced by passage of the air through larger airways (bronchi and bronchioles), and the lung between these airways and the chest wall is airless with the result sound is conducted from the bronchial tree to the chest wall without undergoing the process of filtration by alveoli (alveolar part of inspiration is cut off resulting in a gap between inspiration and expiration). The causes of bronchial breathing are given in the Table 12.9.

Note: The confirmatory sign of bronchial breath sound is increased vocal resonance with whispering pectoriloquy over the area of bronchial breathing.

TABLE 12.9 Causes of bronchial breath sounds

<i>High-pitched bronchial sound (also called tubular breathing)</i>	<i>Low-pitched bronchial sound (also called cavernous and amphoric breathing)</i>
<ul style="list-style-type: none"> • Pneumonic consolidation • Large superficial pulmonary cavity • Collapsed lung or lobe when surrounding large bronchi are patent • Above the level of pleural effusion (effusion compresses the lung alveoli and brings the patent bronchus near the chest) • Tension pneumothorax (sometimes) 	<ul style="list-style-type: none"> • Localised areas of pulmonary fibrosis, e.g. chronic pulmonary tuberculosis, chronic suppurative pneumonia (lung abscess) • Amphoric (Fig. 12.22D). It is low-pitched bronchial breathing with superadded tones and overtones, or with a metallic tone. The sound resembles the whistling sound produced by blowing air across the mouth of a narrow neck glass bottle. It is produced in: <ul style="list-style-type: none"> – Bronchopleural fistula (open pneumothorax) – A big thin-walled cavity connected with a narrow patent bronchus

Vocal resonance

Vocal resonance refers to listening of the vocal sounds (laryngeal vibrations) with the help of stethoscope as the patient repeats some words such as “*ninety-nine, one-one-one*”. Normally, the ear perceives not the distinct syllables but a resonant sound, the intensity of which depends on the loudness and depth of the patient’s voice and the conductivity of the lungs.

Palpation for local fremitus is closely allied to listening for vocal resonance. High-pitched sounds which are not easily palpable can be heard as vocal resonance. The vocal resonance like vocal fremitus has to be compared on each side of the chest. Each point examined on one side must be compared with corresponding point on the other side. Normal vocal resonance gives the impression of being produced near the chest piece of stethoscope. If it seems to be near to the ear than the stethoscope, the resonance is said to be increased. If the intensity of the sound is diminished, then it is designated as decreased vocal resonance. The causes of increased or decreased vocal resonance are tabulated (Table 12.10). Remember, the causes are more or less same as discussed in tactile vocal fremitus.

Once the vocal resonance is found to be increased, proceed further to decide whether it is:

- **Bronchophony:** This is increased vocal resonance where spoken sounds are clearly audible but the words are indistinguishable. It conveys the impression that the sound is being produced near the ear piece of stethoscope rather than chest piece. This is heard in consolidation.

TABLE 12.10 Causes of variations in vocal resonance

<i>Increased</i>	<i>Decreased</i>	<i>Absent</i>
<ul style="list-style-type: none"> • Consolidation • A cavity communicating with bronchus • Bronchopleural fistula • At the apex (just above) of pleural effusion posteriorly • Fibrosis of the lung 	<ul style="list-style-type: none"> • Thickened pleura • Emphysema 	<ul style="list-style-type: none"> • Pleural effusion • Pneumothorax • Collapse of lung due to obstructed bronchus

- **Whispering pectoriloquy:** It is the further increase in vocal resonance where even the whispered sound (voice) or words are not only clearly and loudly audible but are clearly distinguishable. It conveys the impression that they are being uttered directly into the examiner’s ear.

It is heard in:

- A cavity communicating with bronchus.
- A large consolidation where both bronchophony and whispering pectoriloquy are present.
- **Aegophony:** When the nasal or bleating character is imparted to the spoken sound, it is called *aegophony*. It is heard in:
 - Open pneumothorax
 - At the apex of pleural effusion on posterior chest.

Note: At any site where vocal resonance is increased bronchial breathing should be present and vice versa is also true.

Added (adventitious) sounds: Listen for the added sounds.

The sounds which are superimposed on or added to the usual breath sounds are called *added or adventitious or extrasounds*. They may arise in the pleura or in the lung. Certain extraneous sounds which resemble the added sounds and cause confusion in the diagnosis are:

- Sound resembling crackles may be produced by movement of the stethoscope on hairy skin of the patient. The shaving of chest or wetting of the hair may eliminate the error.
- Sounds resembling pleural rub may be produced by movements of the stethoscope on the patients’ skin. This error is eliminated by firmly pressing the stethoscope on the chest.
- Sounds of muscular contractions in a shivering patient makes the auscultation difficult and useless. Change in the position may eliminate the noise.

Types of Adventitious/Added Sounds

- **Lung sounds**
 - **Discontinuous:** These are intermittent, nonmusical and brief sounds such as *crackles* or *rales*.

- **Continuous sounds:** These are musical sounds that persist in most of the respiratory cycle or throughout the cycle (both inspiration and expiration). These include *wheezes* (high-pitched sound) or *rhonchi* (low-pitched) sounds.
- *Pleural sound*
 - **Pleural rub:** It may be continuous or discontinuous.
- *Other sounds.*

Crackles or Rales

These are short, discontinuous explosive sounds often described as bubbling or clicking noises.

Mechanisms of Production

- They may result from a series of tiny explosions when small airways deflated to residual volume during expiration open during inspiration. This gives rise to fine crackles.
- They may result from air bubbles flowing through the secretions or lightly closed airways during respiration (both inspiration and expiration). This mechanism explains coarse crackles or rales of bronchiectasis or a cavity.

The types of crackles and their causes are illustrated in the Table 12.11 and Fig. 12.23.

Wheezes and Rhonchi

These are continuous sounds produced by air buzzing through large airways. They occur due to narrowing of the airways either by spasm or by secretions or by extraneous compression. The causes of wheezes have been enumerated in the Table 12.11. There are two types of wheeze:

- **Monophonic:** This a single pitched localised musical sound arising from fixed, persistent, localized narrowing of a single bronchus by a tumour or a foreign body. It may be inspiratory, expiratory or both and may not change in intensity with position.
- **Polyphonic:** Widespread polyphonic wheezes are the most common type, particularly heard during expiration, contain several notes of different pitches. They are heard in bronchial asthma, cardiac asthma, tropical pulmonary eosinophilia (TPE) and chronic bronchitis. These wheezes are probably due to dynamic compression of the several bronchi, which is accentuated in expiration when airway narrowing is present.

Note: *Rhonchi (wheeze) sometimes may be heard only in few respiratory cycles instead of all cycles called occasional rhonchi/wheeze.*

Occasionally, in severe COPD, the patient is no longer able to force enough air through the narrowed bronchi to produce wheezing. The absence of wheezing leads to silent chest. This is

a cause of immediate concern and should not be mistaken for improvement, actually is a bad prognostic sign.

Pleural Rub

A continuous rubbing or creaking sound generated by rubbing of roughened surfaces of both parietal and visceral pleura is called *pleural friction/rub*. It differs from crackles (Table 12.12).

Stridor (Fig. 12.23E)

It is a loud monophonic wheeze associated with laryngeal spasm or tracheal stenosis (Read it as a respiratory symptom). The noise is often inspiratory and expiratory.

Other Sounds

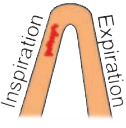


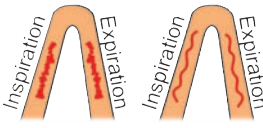
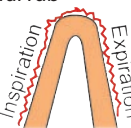


There are certain sounds heard following some manoeuvres.

- **Succussion splash (Fig. 12.24):** It is a splashing sound produced by movement of fluid in a cavity or hollow viscus containing both fluid and air so as to allow the movement of fluid.

Method: Define the upper border of dullness in lateral chest wall along the mid-axillary line in sitting position. Now place the diaphragm of stethoscope at this point and shake the patient vigorously from side to side. A splashing sound is audible with every jerk. Sometimes this sound can be heard without stethoscope. The causes are:

- Hydropneumothorax
- A large cavity containing thin fluid and air
- Eventration of diaphragm with herniation of stomach into the thorax on left side or pyloric obstruction or cardia achalasia (air and fluid in oesophagus)
- Absence of this sign does not exclude the presence of fluid and air, as in presence of, too small, too large or thick fluid (pus), the splash may not be audible. To avoid splashing sound of stomach, the test should be performed atleast 4 hours after a meal or water.
- **Post-tussive suction:** When signs of a lung cavity are present, then patient is asked to cough violently. A sucking inspiratory sound heard over the chest following coughing is called *post-tussive suction*, suggests that the cavity is thin-walled and compressible. It carries no significance.
- **Post-tussive crackles/rales:** The crackles which are not heard during normal respiration, but are heard following coughing are called *post-tussive crackles*. They signify that the cavity is filled with secretions which are dislodged during coughing allowing the air to bubble through the fluid/secretions, producing the crackles/rales.
- **Coin test (Fig. 12.25):** In hydropneumothorax, at the junction of air and fluid, the metallic quality of the sound

TABLE 12.11 Causes of different crackles/rales

Figs 12.23A to E	Phase of respiration	Character	Aetiology
<p>A. Crackles</p> 	<p>End-inspiratory or late inspiratory crackles: They begin in mid-inspiration and continue into late inspiration</p>	Profuse, fine and persist from breath to breath	They are heard at the bases of the lungs, spread upwards as the condition worsens. They shift to dependent region with changes in posture. They are heard in early congestive heart failure (pulmonary oedema) and interstitial lung disease or lung fibrosis
	<p>Early inspiratory crackles: They are heard in early part of inspiration</p>	Scanty, coarse in nature	They occur in chronic bronchitis and asthma
	<p>Mid-inspiratory and expiratory crackles: They are heard during middle of inspiration and throughout expiration</p>	Coarse and profuse	Heard in bronchiectasis, a cavity and in lung abscess
<p>B. Wheezes and rhonchi</p> 	<p>Wheezes are high pitched sounds having hissing or shrill quality. Rhonchi are low pitched sounds with snoring quality. They are heard either in expiration or in both phases of respiration</p>	Musical sounds produce by air buzzing past the airways. Rhonchi suggest secretions in large airways	Causes include bronchial asthma, bronchitis, COPD, cardiac asthma (LVF), localized obstruction due to malignancy, carcinoid syndrome, recurrent thromboembolism, anaphylaxis, eosinophilic lung disease (tropical pulmonary eosinophilia)
<p>C. Pleural rub</p> 	<p>Pleural rub: It is heard in both phases of respiration, does not change its character with coughing. It is accentuated by increased pressure over the chest.</p>	<ul style="list-style-type: none"> • Rubbing or creaking superficial continuous sound • Disappears on holding the breath 	It occurs in pleuritis due to any cause such as pleurodynia, pulmonary consolidation, pulmonary infarction and following pleural biopsy
<p>D. Mediastinal crunch</p> 	<p>Mediastinal crunch has no relation to respiration but is synchronous to heart beat. Best heard in the left lateral position</p>	Precordial crackling or crunching sound produced by compressing the sternum	It occurs in mediastinal emphysema (pneumomediastinum)
<p>E. Stridor</p> 	<p>Stridor is a loud inspiratory wheeze or sound produced by closure of glottis</p>	Wheezing sound	It occurs in partial obstruction of trachea (tracheal stridor) or larynx (laryngeal stridor)

produced by striking one coin over another placed on the chest can be heard appreciably at the diametrically opposite side of the chest wall.

Examination of the Posterior Chest

It has to be carried out in similar fashion as examination of anterior chest. Therefore, the specific findings pertaining to the posterior chest wall will be highlighted here only.

Inspection

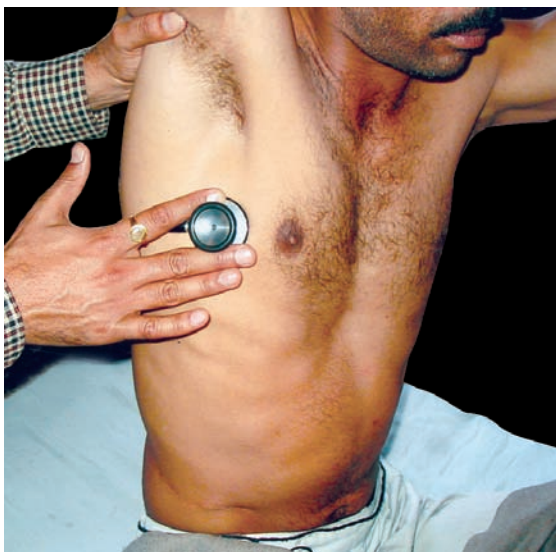Inspect from the midline position behind the patient:

- Observe the shape of the chest for asymmetry or deformities.

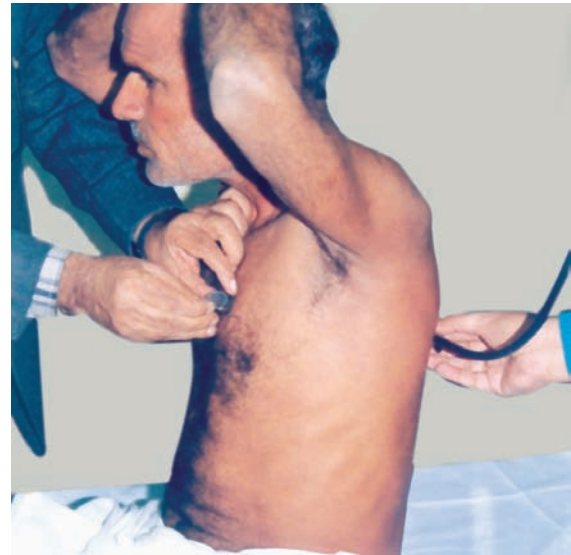In addition to the deformities mentioned under the examination of anterior chest, note any deformity of the spine (e.g. gibbus, scoliosis), prominence of scapulae (scoliosis, winging of scapulae in myopathy).

TABLE 12.12 Differences between pleural rub and coarse crackles

<i>Pleural rub</i>	<i>Coarse crackles</i>
• Rubbing or creaking sound	• Bubbling or clicking sound
• Audible and have same intensity during both phases of respiration	• May be inspiratory or expiratory, usually louder during inspiration
• Usually confined to a smaller area of chest wall	• Audible over a large area or heard diffusely over the chest
• Not altered by coughing	• May change its character or intensity on coughing
• Accentuated by firmly pressing the chest piece of stethoscope over the chest wall	• No accentuation
• Associated with pain and tenderness	• Usually not associated
• Caused by rubbing of roughened pleural surfaces	• Caused by tiny explosions produced by sudden opening up of smaller airways deflated during expiration or due to air bubbles flowing through secretions
• It is associated with pain	• Not associated with pain

**FIGURE 12.24** Elicitation of succussion splash

- Observe skin and subcutaneous tissue for swelling or nodules, purpuric spots and bruises.
- Observe the type of breathing. Note abnormal retraction of the intercostal spaces during inspiration.
- Observe the respiratory movements and expansion of the chest. Note any abnormality on one side or both sides of the chest.

**FIGURE 12.25** Coin test. Place the coin on the anterior chest and strike the coin with another coin. Place the stethoscope on posterior chest diametrically opposite to the coin to hear the metallic sound

Palpation

As you palpate the chest, focus on areas of tenderness and abnormalities in the overlying skin, respiratory movements and chest expansion. Compare the tactile vocal fremitus on both sides and note any abnormality either on one side or on both the sides.

Note: Any widening or narrowing of the intercostal spaces on either side of the chest.

Percussion

For percussing the lower posterior chest, stand somewhat to the side rather than behind the patient. This will allow you to place your pleximeter finger more firmly on the chest and your plexor will be more effective and will make a better percussion note.

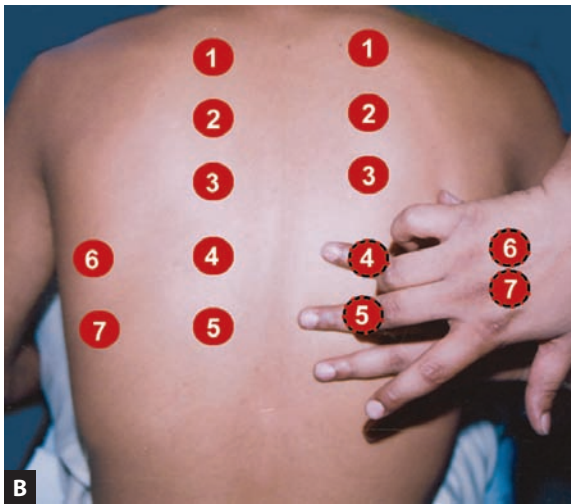
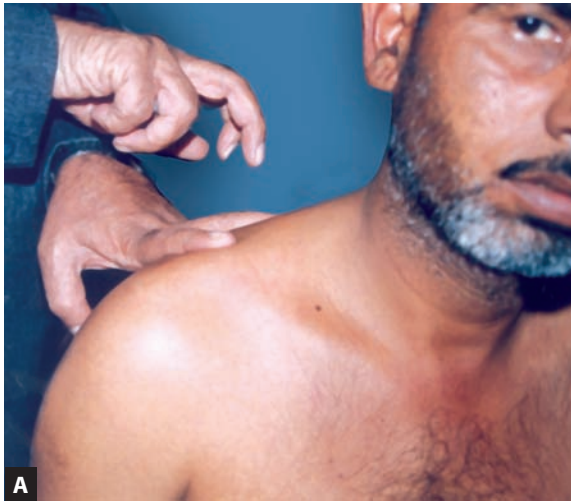When percussing the two areas, use the same percussion technique and compare the corresponding areas on both sides. Percuss or strike twice in each location (Fig. 12.26A). It is easier to detect differences in percussion note by comparing one area with another rather than by percussing the same area repetitively.

Percuss one side of the chest and then the other at same level. Omit the areas over the scapulae. Identify and locate the area and quality of any abnormal percussion note.

The sites for percussion are represented in Fig. 12.26B.

Auscultation

The areas to be auscultated are same as used for percussion (Fig. 12.26B).



FIGURES 12.26A and B Percussion: (A) Method and point of start of percussion and auscultation on the back; (B) Final stages of percussion and areas to be percussed and auscultated are labelled

Points to be noted are same as discussed in auscultation of anterior chest, i.e. breath sounds, vocal resonance and added sounds.

Examination of Other Systems

- **CVS examination:** It is to be examined for any evidence of chronic cor pulmonale or associated pericardial effusion (polyserositis—Meig’s syndrome, a complication of pneumonia or as a complication of anasarca).
- **GI tract and hepatobiliary system:** It is examined for:
 - Ascites
 - Hepatosplenomegaly or hepatomegaly for chronic cor pulmonale or may be palpable in obstructive emphysema, or ruptured amoebic liver abscess into pleural space.
 - Any abdominal mass, e.g. para-aortic lymphadenopathy in patients with tuberculosis and lymphoma.

- **Nervous system:** Neurological complications such as meningitis, brain abscess and raised intracranial tension (due to type 2 respiratory failure) are common. Therefore, look for:
 - *Neck stiffness/rigidity* may be present in meningism in pneumonia and tubercular meningitis. Patient may have other signs of meningitis.
 - *Higher function* may be altered in encephalopathy (type 2 respiratory failure, meningitis or encephalitis)
- Any neurological deficit* for brain abscess.

Physical signs in common respiratory disorders: They are briefly discussed in Table 12.13.

Bedside Respiratory Function Test

If a person is having respiratory failure at rest, the poor lung functions are self-evident, but when a person is not having clinical evidence of respiratory failure, he/she may be having poor pulmonary reserve which can be assessed by following bedside tests:

- **Exercise tolerance**
 - If a person is performing his outdoor activities without any discomfort, then his/her respiratory functions are taken as normal.
 - If a person can climb 20 steps/stairs (8"-9") at reasonable speed (20 sec) without breathlessness or tachypnoea (increase in RR < 5/min) or he/she can walk fast for 100 m without dyspnoea or tachypnoea, then he/she has good pulmonary function.
- **Expansion of chest:** Chest expansion >5 cm upto 60 years or >4 cm after 60 years indicates good lung functioning.
- **Single breath count:** Ask the patient to count in a single breath without interruption.

Counting >40 is good lung function
Counting between 25 and 40 is fair lung function
Counting <25 is poor lung function

- **Breath holding time:** Ask the patient to hold breath after taking deep inspiration.

More than 35 sec—normal function	
25–35 sec	Good function
15–25 sec	Satisfactory function
<15 sec	Poor function

- **Match-stick test:** Light the match stick/candle and let it burn for 15 sec. Now keep the match stick/candle 15 cm (6") away from the person and ask him/her to blow it with widely open mouth. Normally a person can blow it. If a person can not blow it then reduce the distance to 12 cm,

TABLE 12.13 Important differential physical signs in various respiratory disorders

<i>Sign</i>	<i>Lobar consolidation</i>	<i>Lobar collapse</i>	<i>Fibrosis/ bronchiectasis</i>	<i>Cavity or lung abscess</i>	<i>Pleural effusion</i>	<i>Pneumo-thorax</i>	<i>Acute or chronic bronchitis</i>	<i>Bronchial asthma</i>	<i>Emphysema</i>
Shape of the chest	N	Retraction on the side involved	Retraction on the side involved	N or slight retraction on the side involved	N	N	N	N	Hyper-inflated or barrel shaped
Chest wall movement	Reduced on the side involved	Reduced on the side involved	Reduced on the side involved	Slightly reduced on the side involved	Reduced or absent on the side involved	Reduced or absent on the side involved	N	Bilateral diminished	Bilateral diminished
Expansion of chest	Reduced on the side involved	Reduced on the side involved	Reduced on the side involved	Slightly reduced on the side involved	Reduced or absent on the side involved	Reduced or absent on the side involved	N	B/L reduced	B/L reduced
Activity of extra-respiratory muscles	A	A	A	A	A	A	P	P	P
Position of trachea and mediastinum	N	Shifted to the side involved	Shifted to the side involved	Shifted to the side involved	Shifted to opposite side	Shifted to opposite side	N	N	N
AP and transverse diameter	N	N	N	N	N	N	N or abnormal	N	Abnormal AP > T
Vocal fremitus	Increased on the side involved	Reduced or absent on the side involved	Increased over the area involved	Increased over the area involved	Reduced or absent on the side involved	Reduced or absent on the side involved	N	N	N or reduced on both sides
Percussion note	Dull on the side involved	Dull on the side involved	Impaired over the area involved	Impaired over the area involved	Stony dull on the side involved	N or hyper-resonant on the side involved	N	N or hyper-resonant	Hyper-resonant
Breath sounds	High-pitched bronchial over the area involved	Diminished or absent over the area involved	Low pitched bronchial over the area involved	Amphoric bronchial over the area involved	Absent or diminished over the area involved	Absent or diminished on the side involved	B/L vesicular with prolonged expiration	B/L vesicular with prolonged expiration	B/L vesicular with prolonged expiration
Intensity of breath sounds (vocal resonance)	Increased over the area involved. <i>Bronchophony</i> and <i>whispering pectoriloquy</i> present	Decreased over the area involved	Increased over the area involved	Increased over the area involved <i>whispering pectoriloquy</i> present	Decreased over the area involved	Decreased on the side involved	N	N	N or diminished
Added sounds	Fine crackles early, coarse crackles later on the area involved	None	Coarse crackles on the area involved	Coarse crackles on the area involved	Pleural rub in some cases over the area involved	None	Rhonchi with some coarse crackles on both the sides	Rhonchi/ wheezes mainly expiratory and high-pitched	Expiratory rhonchi/ wheezes

Abbreviations: N = normal; B/L = bilateral; P = present; A = absent; AP = anteroposterior

10 cm, 7.5 cm and 5 cm and 2.5 cm and see the distance at which person can blow it.

Blowing match stick at 15 cm	Good function
Blowing match stick at 10 cm	Fair function
Blowing match stick between 5–10 cm	Poor function
Blowing match stick <5 cm	Very poor function

- **Forced expiratory time:** Normal person takes 3 sec for full expiration, after maximal inspiration. If a person takes more than 4 seconds for full expiration, then he/she is having small airway obstruction due to asthma, bronchitis or COPD or tropical pulmonary eosinophilia.
- **Inspiration/expiration time ratio:** It is easily calculated by spirometry on the bed side, it can be calculated by counting the numbers one, two, three and so on during one inspiration and note how much have you counted during one inspiration and during one expiration. Repeat the process for 5 inspirations and expirations and take the mean of the counting. Calculate the inspiratory and expiratory counting ratio which is roughly the inspiratory/ expiratory time ratio. Normally expiratory time is one-third or half of inspiration, i.e. ratio is $< 1 : 3$; ratio more than $1 : 3$ means the expiration is prolonged indicating expiratory obstruction. Reversal of ratio, i.e. $1 : 1$ indicates inspiratory obstruction.
- **Respiratory rate reserve:** Normal respiratory rate (RR) is 14–18/min which can be increased to 3 times by voluntary efforts. This voluntary rise is lost if person has poor respiratory reserve. Count the respiratory rate during quiet and rapid breathing (breathe as fast as he/she can) and see the rise in RR; rise in rate by 3 times is normal but less than 2 time indicates decreased reserve.

INVESTIGATION OF A PATIENT WITH RESPIRATORY DISEASE

Routine Haematological and Biochemical Tests

- Haemoglobin, to detect the presence of anemia or secondary polycythaemia
- TLC and DLC for evidence of an infection or to detect eosinophilia
- Packed cell volume (PCV) for secondary polycythaemia which occurs in COPD
- Routine biochemistry, e.g. sugar, urea, electrolytes, creatinine
- Other blood investigations sometimes required include:
 - α_1 -antitrypsin deficiency for emphysema

- IgE to specific allergen (RAST: radioallergosorbent test)
- Aspergillus antibodies.

Sputum Examination

- **Sputum should be inspected for gross appearance:**
 - Mucoid sputum (clear, whitish, sticky) is characteristic of chronic bronchitis
 - Yellow-green indicates infection or allergy
 - Black sputum indicates bronchopulmonary aspergillosis
 - Purulent, fetid sputum suggest bronchiectasis or lung abscess
 - Pink-frothy sputum indicates pulmonary oedema
 - Blood in sputum is called *haemoptysis* (read the causes of haemoptysis)
 - Thick, viscid rusty sputum occurs in lobar pneumonia
 - Anchovy-sauce appearance of sputum indicates rupture of amoebic lung abscess into the lung.
- **Microscopic examination:**
 - Pus cells
 - Organisms
 - Fungal hyphae
 - Dumb-bell shaped asbestos bodies
- **Microbial examination:**
 - Gram's staining for cocci and bacilli
 - Acid-fast staining for AFB (Fig. 12.27)
 - For malignant cells if carcinoma lung is suspected.
- **Culture and sensitivity:**
 - For bacteria, virus and fungi
 - For acid-fast bacilli.

Fluoroscopy of the Chest

It is valuable in detecting pulsatile lesions such as aortic aneurysm and hilar pulsations (hilar dance) in left to right

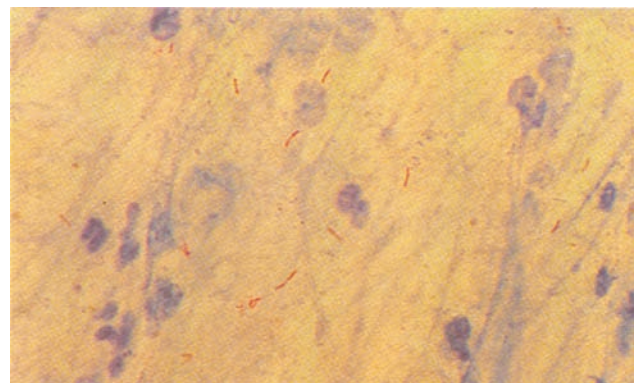


FIGURE 12.27 Sputum examination for AFB. AFB are seen as pink rods in the specimen of sputum

shunts. It is also done to see the movements of diaphragm in patients with diaphragmatic paralysis.

Chest X-ray

(Read Radiology Section of Bedside Medicine without Tears by Prof. SN Chugh). The points to be noted on chest X-ray are enumerated in the Box 17. The importance of X-ray in evaluation of respiratory disorders is depicted in Figs 12.28A to E.

Computed Tomography (CT Scan)

Conventional CT scan is useful in evaluation of hilar and paratracheal lymph nodes enlargement, to differentiate localised collection of fluid from a tumour (Fig. 12.29), to determine the position and size of pulmonary nodule and in pre-operative assessment of lung cancer to detect mediastinal spread. Enhanced CT (contrast CT) is done by injecting a contrast media to enhance the outlines of mediastinal vessels to differentiate vascular mediastinal lesions. CT scan is also useful to make the site for pleural aspiration.

Microbial Examination

Sputum, pleural aspirate, bronchial washings obtained through bronchoscope must be subjected to isolation of bacteria, fungi and viruses and also for culture and sensitivity. Isolation of acid fast bacilli from these specimens is diagnostic of pulmonary tuberculosis. The microbial findings must be interpreted in conjunction with clinical and radiological findings so as to reach to a conclusive diagnosis.

Box 17

Examination of chest X-ray

Points to be noted

- Position of trachea, mediastinum and domes of diaphragm
- Homogenous/non-homogenous opacity or opacities
- Area /areas of reduced or increased translucency of lungs
- Cavity with well-defined margins
- Cavity with any fluid level
- Obliteration of costo or cardiophrenic angles
- Nodule/s or coin-shaped shadows
- Multinodular lesions
- Infiltration; localised or diffuse
- Honey comb appearance
- Hilar lymphadenopathy
- Cardiovascular markings
- Thoracic cage abnormalities such as scoliosis, widening or narrowing of intercostal spaces and fracture or tumours of the ribs

Histopathological and Cytological Examination

The biopsy material or bronchial lavage obtained through transbronchial route by bronchoscope must be subject to histopathological examination as they may yield valuable information regarding suspected malignancy of lung in some cases.

The exfoliated cells in the sputum and other specimens (pleural fluid and bronchial washings) are examined cytologically for malignancy and inflammatory disorders. Pleural fluid is studied biochemically to confirm its nature, i.e. exudate or transudate. These specimens can also be used for microbial culture and sensitivity.

Skin Tests

Tuberculin (Mantoux) test is useful for diagnosis and detection of tuberculosis. Kveim test is meant for sarcoidosis. Skin tests are also employed to find out an allergan or allergans in allergic disorders.

Serological Tests

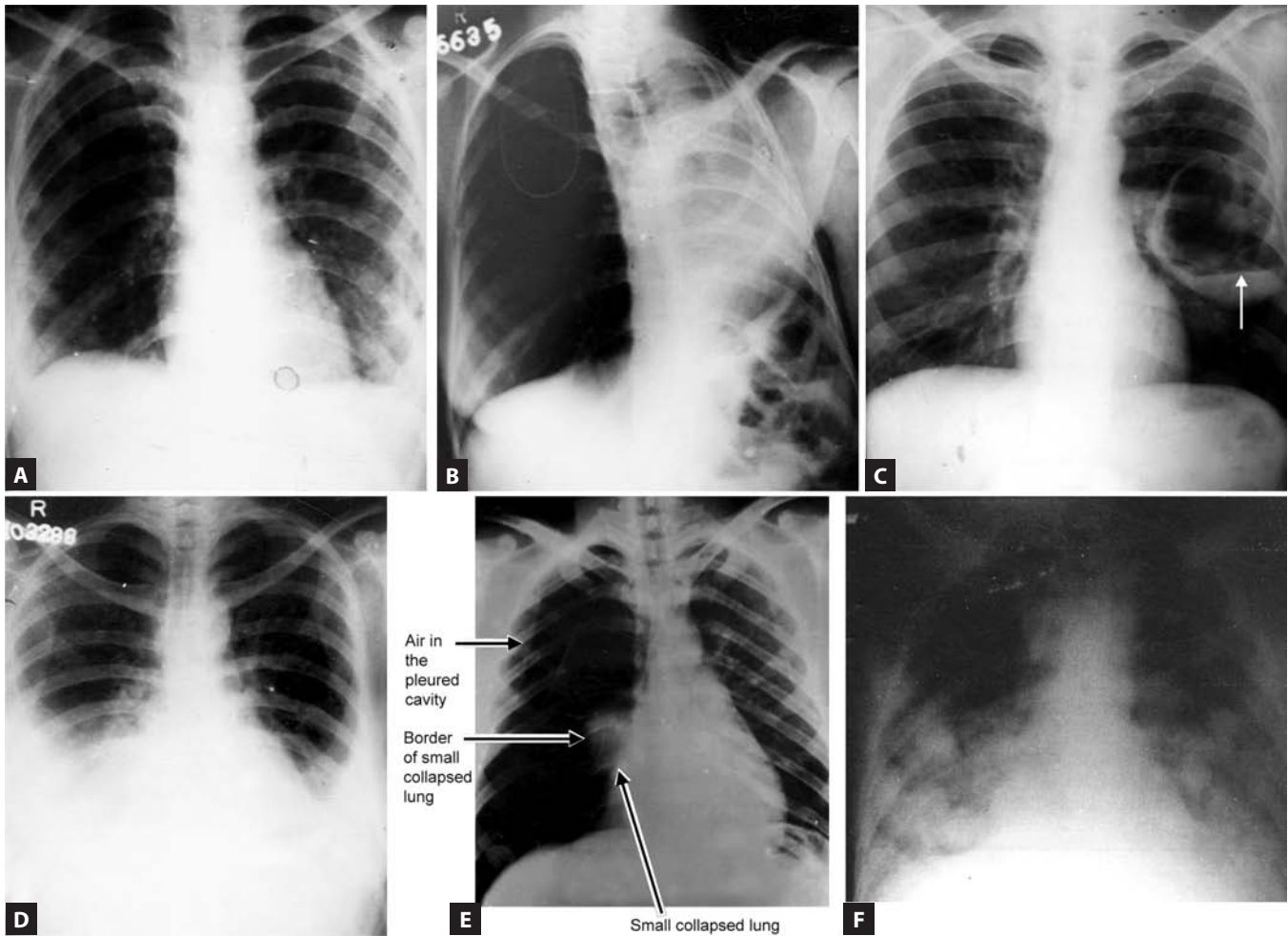
They are based on detection of either antigens or antibodies in the blood or sputum. The detection of pneumococcal antigen by counter-immunoelectrophoresis establishes the diagnosis of pneumococcal pneumonia. Higher titres of the antibodies in the serum may help in diagnosis of microbial infections of lungs.

Pulmonary Function Tests

These tests aid to assess functional impairment, effect of treatment and progress of the disease.

Tests for Ventilation

- **Spirometry:** The forced expiratory volume in one second (FEV_1), forced vital capacity (FVC) or vital capacity (VC) and their ratio FEV_1/VC are important parameters to assess ventilation. These are recorded by spirometer (Fig. 12.30A) after maximum forced and relaxed expiration. The volume of air exhaled between 0.25 sec. and 0.75 sec. (middle half second) on spirometer graph constitutes peak expiratory flow volume (Fig. 12.30B). For interpretation of results, the values obtained in spirometer are compared with predicted values based on age, sex, height and body constitution. Two types of defects are noticed (Table 12.14). The FEV_1 and FVC in normals and lung disorders are present in Figures 12.31A to E.

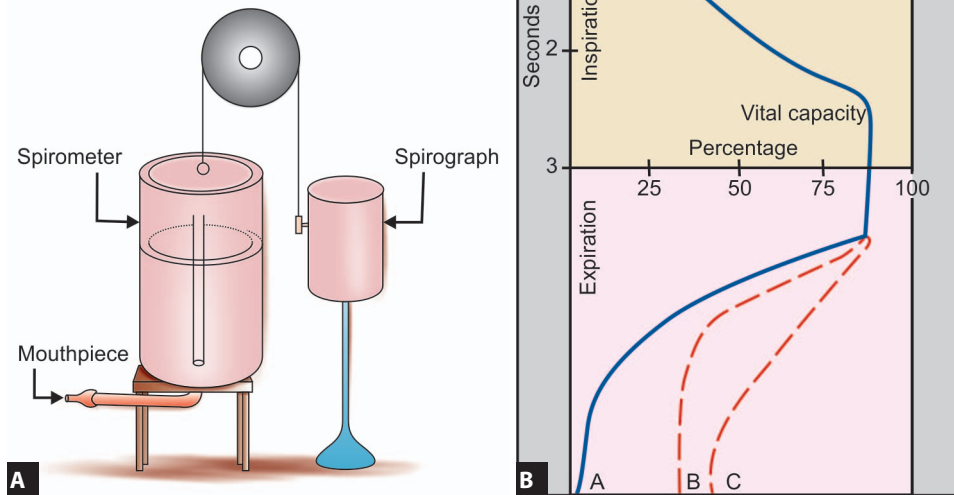


FIGURES 12.28A to F Chest X-ray (PA) view in different parenchymal lung disease: (A) Chronic obstructive lung disease; (B) Collapse of the left lung due to malignancy; (C) Lung abscess (left lung); (D) Bilateral pleural effusion; (E) Pneumothorax; (F) Cannonball secondaries in the lungs

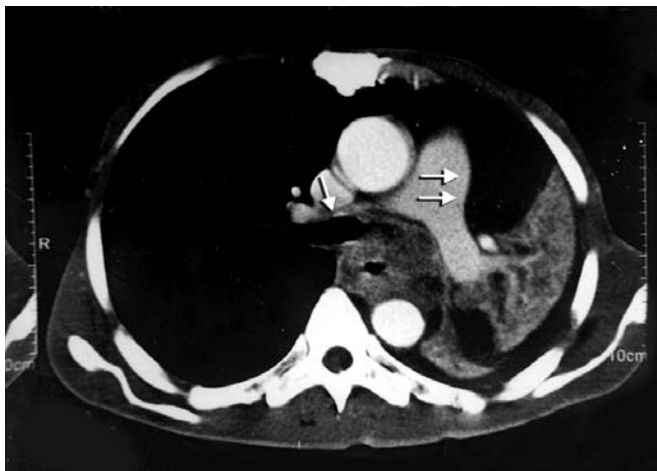

FIGURE 12.29 CT scan showing bronchogenic carcinoma (→) and pleural effusion (⇨)

- **Obstructive ventilatory defect (Fig. 12.31B):** FEV_1 is reduced, vital capacity (VC) remains normal or is slightly reduced. Their ratio FEV_1/VC is reduced. On the basis of airway obstruction, chronic obstructive pulmonary disease can be graded for severity by GOLD criteria. Common causes include: asthma, COPD and chronic bronchitis.
- **Restrictive ventilatory defect (Fig. 12.31C):** FEV_1 is reduced, VC is also reduced but their ratio FEV_1/VC is increased or may sometimes be normal. The causes include: parenchymal lung diseases (e.g. sarcoidosis, lungfibrosis, drugs, pneumoconiosis), neuromuscular involvement of chest (myasthenia, Gullaine-Barre syndrome) chest wall deformities (i.e. kyphosis) and obesity.



FIGURES 12.30A and B (A) Spirometer; (B) The expiratory spirogram

TABLE 12.14 Pulmonary function tests in obstructive and restrictive ventilatory defects

Test	Obstructive lesion	Restrictive lesion
FEV ₁	Markedly reduced	Slightly reduced
VC	Reduced or normal	Markedly reduced
FEV ₁ /VC	Reduced	Increased or normal
PEF	Reduced	Normal
FRC	Increased	Reduced
RV	Increased	Reduced
TLC	Increased	Reduced
T _{co} & D _{co}	Normal	Low
PaO ₂	Decreased	Decreased
PaCO ₂	Increased	Low or normal
Causes	Asthma, COPD, broncholitis	Sarcoidosis, lung fibrosis, pneumoconiosis, drugs

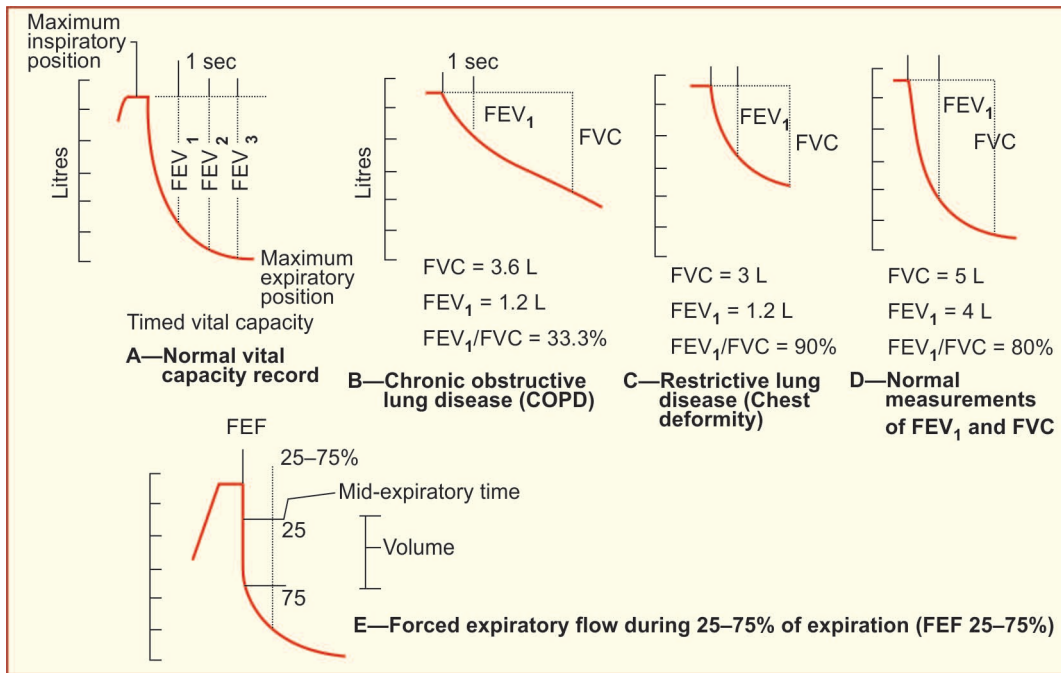
Abbreviations

- FEV₁ = Forced expiratory volume during one second
 - VC = Vital capacity
 - PEF = Peak expiratory flow
 - FRC = Functional residual capacity
 - RV = Residual volume
 - T_{co} = Gas transfer factor for carbon monoxide
 - TLC = Total lung capacity
 - D_{co} = Diffusing capacity for carbon monoxide
 - PaO₂ = Partial pressure of oxygen in arterial blood
 - PaCO₂ = Partial pressure of CO₂ in arterial blood.
- FRC and residual volume (RV). Both are increased in obstructive ventilatory defect and decreased in restrictive ventilatory defect (Table 12.14).

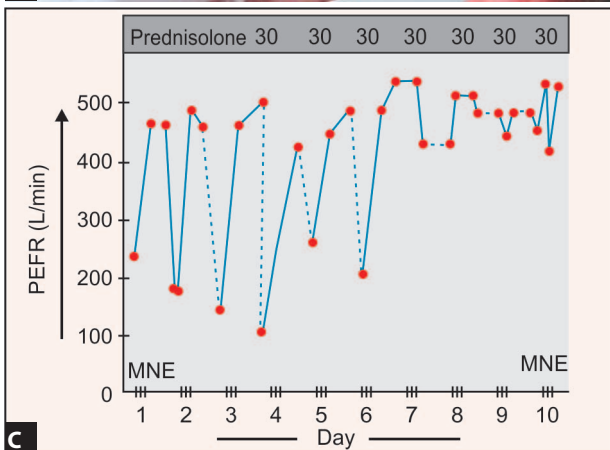
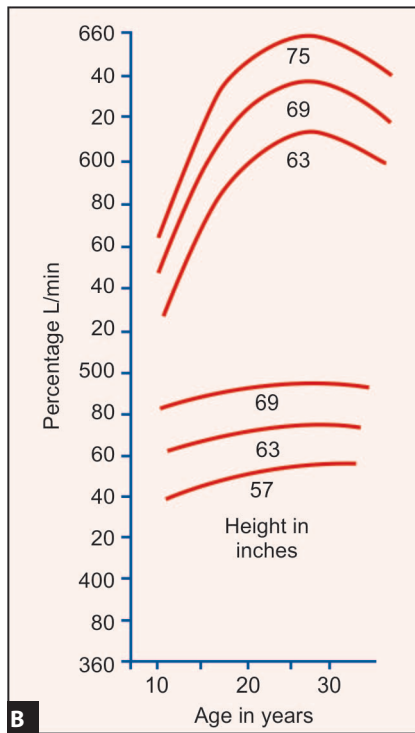
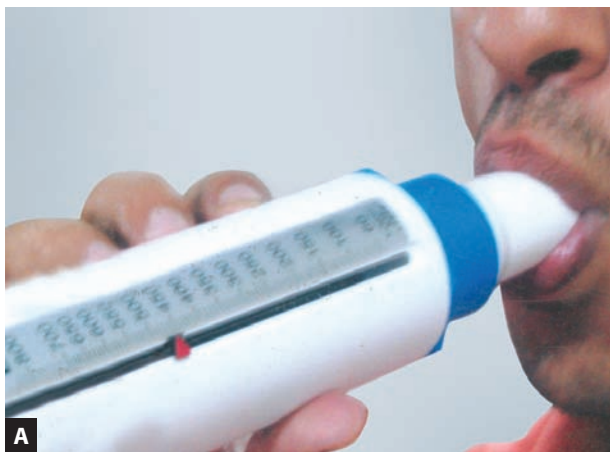These tests of ventilation are repeated in reversible obstructive pulmonary diseases after full doses of bronchodilators to monitor the response to therapy in cases of bronchial asthma and early cases of chronic bronchitis.

- **Peak expiratory flow (Figs 12.32A to C):** It is measured during forced expiration by a simple flow meter. It is useful to detect airflow obstruction, response to treatment and reversible changes. It has supplementary role to spirometry in obstructive lung diseases. It has no role in restrictive lung disorders.
- **Flow-volume loops:** The measurement of flow rates against volume (flow volume loops) enables to analyse the site of airflow limitation within the lung. In subjects with healthy lung, there is no flow limitation on maximal flow rates; while in COPD limitation of expiratory flow occurs even during tidal breathing at rest. Due to smaller airway obstruction, expiratory flow rates at 50% or 25% of the vital capacity are reduced disproportionately when compared with flow rates at larger lung volumes (Fig 12.31E).

The measure of volume that can be forced in from the residual volume in one second (FIV₁) will always be greater than which can be forced out from total lung capacity in one second (FEV₁). Thus the ratio of FIV₁ to FEV₁ is >1. This ratio becomes <1 in extrathoracic obstruction of large airways. When obstruction of large airways occurs



FIGURES 12.31A to E Measurement of forced expiratory volume (FEV₁) forced vital capacity (FVC) and maximum mid-expiratory flow (MEF_{25–75%}) in normal individuals and in various lung disorders



FIGURES 12.32A to C Peak expiratory flow: (A) Simple flow meter; (B) Graph showing normal values; (C) Diurnal variation in asthma. Note the morning dipping and response to prednisolone therapy. M: Morning, N: Noon, E: Evening

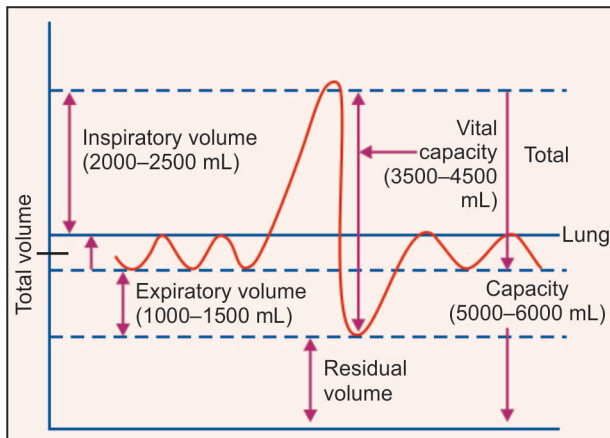


FIGURE 12.33 Normal pulmonary air volumes

within the thorax (lower end of trachea or main bronchi) expiratory flow is impaired more than inspiratory flow but a characteristic plateau is seen in expiratory flow rates.

- **Lung volumes:** (Normal lung volumes are given in Fig. 12.33).

The values of these lung volumes (TLC, RV) are obtained either by diluting inert gas helium into the gases (helium dilution method) in the lungs or by whole body plethysmography. The values are compared with normals. The commonly measured lung volumes are functional residual capacity.

Test for Diffusion

Exercise Tests

Asthma induced on exercise is called *exercise induced asthma* which will become evident by these tests.

A simple 6 minute walking test is widely employed reproducible and useful test to assess disability and response to treatment in patients with exercise induced asthma and chronic bronchitis.

Exercise test incorporating assessment of both heart and lung function are useful in evaluation of a case with dyspnoea. Such tests are sophisticated enabling measurement of O_2 uptake (VO_2), work performed, heart rate, BP and serial ECGs. They are used mainly to distinguish between lung and heart disease, to detect early heart or lung disease and in assessment of physical fitness.

Forced Expiratory Time

The test assesses the expiration which is typically prolonged in COPD. Ask the patient to take a deep breath in and then breath out as quickly and completely as possible with

mouth open. Listen over the trachea with diaphragm of the stethoscope and note the time for expiration.

A forced expiration time of 6 or more seconds suggests COPD.

Invasive Procedures

Laryngoscopy

It is done by Otolaryngologist and the instrument used is fiberoptic bronchoscope or laryngoscope which gives magnified views of larynx to detect small lesions.

Bronchoscopy

The instrument used to have direct and magnified view of bronchi is called *bronchoscope*. Two types of bronchoscope are available, fiberoptic and rigid. The fiberoptic bronchoscope is best suited for lesions in small bronchi and bronchioles. Structural changes are seen through bronchoscope in the form of obstruction or distortions of airways. Through bronchoscope, one can collect bronchial secretions, bronchial washings or lavage and brushings (exfoliative cytology) for histopathological and cytological examination. The biopsy of the lesion can be taken under direct vision through bronchoscope and studied for histopathological changes.

Mediastinoscopy

It is an important procedure. Mediastinoscope is passed through the suprasternal notch into mediastinum to have its direct view. It is performed in mediastinal lesions such as lymphadenopathy and bronchial carcinoma.

Thoracentesis or Pleural Aspiration (Fig. 12.34)

Pleural fluid is aspirated with the help of an aspiration needle or by an intercostal tube/catheter introduced into the pleural cavity through one of the intercostal spaces overlying effusion or empyema. The fluid is removed and sent for cytological, biochemical and microbial examinations to find out the cause of pleural effusion.

Ventilation Perfusion Scan

These are actually two scans performed simultaneously; one by inhalation of radioisotope ^{133}Xe gas (ventilation scan) and another by intravenous injection of radio-isotope $^{99\text{m}}\text{Tc}$ labelled macroaggregates of albumin (perfusion scan). The corresponding areas are compared both on perfusion and ventilation scan for pulmonary thromboembolism. A defect on perfusion scan with normal

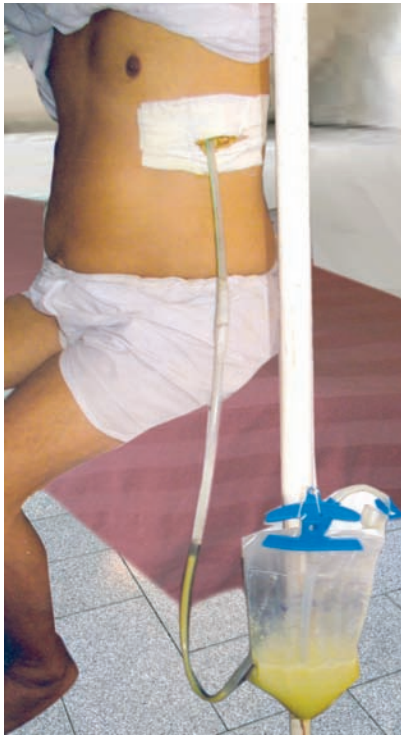

FIGURE 12.34 Drainage of empyema thoracis. Note the greenish creamy coloured pus

ventilation scan indicates pulmonary thromboembolism. The small filling defects which match on perfusion and ventilation scans indicate distortion of blood vessels and lung parenchyma, are seen in COPD and interstitial lung diseases.

Pulmonary Angiography

This is done by pushing the dye into main pulmonary artery via a catheter introduced through one of the femoral veins and advanced into main pulmonary artery through right side of the heart. The digital subtraction angiography (DSA) is a better, useful and sensitive technique to obtain high quality images. The angiography is valuable for diagnosis of pulmonary thromboembolism. If an embolism is detected, the catheter used for angiography can be employed to instill streptokinase for thrombolysis.

Lung Biopsy

Transbronchial biopsy taken through bronchoscope is studied for bronchial lesions. Transthoracic needle biopsy of the lung is done under CT guidance for peripheral pulmonary lesions. In some cases, open needle biopsy is recommended for peripheral lesions.

13

CHAPTER

The Abdomen

HISTORY

Symptoms

General, e.g. fever, loss of weight, fatigue, lassitude.

Upper GI symptoms, e.g. dysphagia, heart burn, vomiting, haematemesis.

Lower GI symptoms, e.g. pain abdomen, diarrhoea, abdominal distension, rectal bleeding, weight loss.

Hepatobiliary symptoms, e.g. jaundice, mass abdomen, ascites, haematemesis, etc.

Present History

Ask about time of onset of symptoms, progression, relation to meals, aggravating and relieving factors, history of prior surgery and medication, etc.

Past History

DM, HT, past surgery, history of jaundice, haematemesis, drug, etc.

Family History

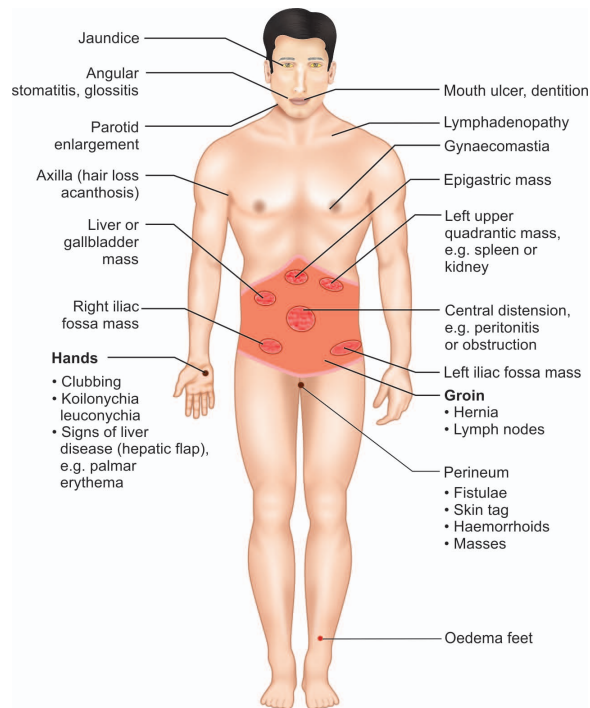
Hereditary polyposis, Wilson's disease, haemochromatosis, biliary cirrhosis and cancer, etc.

Personal History

- Habits, e.g. alcohol, smoking.

GENERAL PHYSICAL EXAMINATION (SEE FIGURE ALSO)

- **Face**, e.g. expression, agony, pallor, pigmentation
- **Eyes**, e.g. jaundice, pallor, xanthelasma
- **Mouth**, e.g. ulceration, cracks at the angle, fissuring of lips, vesiculation.
- **Teeth and gums** for discolouration, staining, gum bleeding, erosion
- **Tongue** for asymmetry, coating, dehydration, pigmentation, atrophy
- **Neck** for JVP, carotid bruit, lymph nodes enlargement



General observations

- Distressed/in pain
- Fever
- Dehydrated
- Habitus
- Abdominal distension
- Signs and symptoms or chronic stigmata of liver disease/cirrhosis, portal hypertension and hepatic encephalopathy

The Abdominal Examination

- **Skin**, e.g. bleeding spots, telangiectasia, pigmentation, scratch mark
- **Hands and feet**, e.g. clubbing, koilonychia, platynychia, oedema (pedal, sacral), signs of liver disease (palmar erythema leukonychia, hepatic flap).

SYSTEMIC EXAMINATION

Inspection

- Shape, symmetry and movements of abdomen
- Umbilicus, e.g. position, contour, inflammation, hernia
- Any abdominal pulsation
- Hernial sites, groin, scrotum
- Skin of abdomen for scar, striae, veins, pigmentation, bleeding, rash.

Palpation

- Feel for tenderness, rebound tenderness, rigidity or guarding
- Palpate for any enlarged viscera/mass
- Palpate for abdominal pulsations
- Elicit the fluid thrill if ascites is suspected
- Palpate for divarication of recti.

Percussion

- Percussion note of abdomen, i.e. normal/abnormal (dull note or hyperresonant note)
- Percuss over the mass, flanks for dullness
- Define upper and lower borders of liver and calculate the liver span
- Elicit shifting dullness for ascites if suspected.

Auscultation

Hear bowel sounds, any venous hum, bruit or rub (hepatic or splenic).

Examination of other systems

Diagnosis and Differential diagnosis

Investigations

THE ABDOMEN

It includes

- *Gastrointestinal system*
- *Urinary system*—it is dealt separately as a Chapter 14.
- *Hepatobiliary system.*

Applied Anatomy and Physiology

For descriptive purposes, the abdomen is conveniently divided into 9 regions by intersection of imaginary planes; two horizontal and two sagittal. The upper horizontal plane is transpyloric, lies at the level of L1 vertebra, midway between the suprasternal notch and the symphysis pubis. The lower plane passes through the upper borders of the iliac crests. The sagittal planes are indicated on the surface by lines drawn vertically from the mid-inguinal points towards the midclavicular points (Fig. 13.1).

The resultant regions are artificial but are used to localise the mass lesions. An alternative method is to divide the abdomen into 4 quadrants by imaginary lines crossing at the umbilicus, forming the right upper, right lower, left upper and left lower quadrants (Fig. 13.2).

Normal Palpable Structures in the Abdomen (Fig. 13.3)

While examining the abdomen, you may be able to feel several normal structures. Sigmoid colon is palpable as firm tube in the left lower quadrant; while the caecum and part of the ascending colon forms a soft wider tube in the right lower quadrant. Portions of transverse and descending colon may also be palpable. None of these structures should be mistaken for tumour.

The liver is difficult to be felt through the abdominal wall but its lower margin or edge descends 1–3 cm during deep inspiration, hence, often becomes palpable in the right upper quadrant. Also in the right upper quadrant, but usually at a deeper level lies the lower pole of the right kidney. It can also become palpable in thin individuals with relaxed abdomen. The normal left kidney is less often palpable.

Pulsation of abdominal aorta are frequently visible and as well as palpable in the upper abdomen, while pulsations of the iliac arteries may sometimes be felt in the lower quadrants.

The abdominal cavity extends up under the rib caged to the domes of the diaphragm. The spleen lies against and posterior to the left mid-axillary line. It is lateral to and behind the stomach and just above the left kidney. The tip of the normal spleen is not palpable below the left costal margin.

The gallbladder lies deep to the liver, cannot be distinguished separately. The duodenum and pancreas lie deep in the upper abdomen, hence, are not palpable.

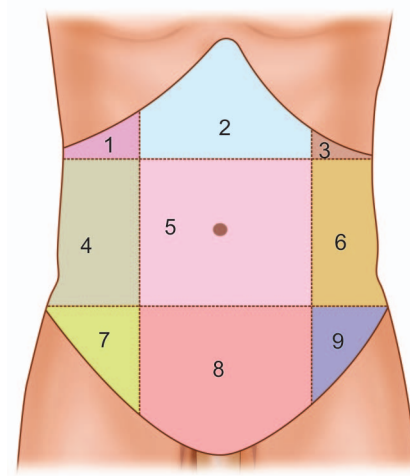


FIGURE 13.1 Regions of the abdomen (diagram). 1. Right hypochondrium, 2. Epigastrium, 3. Left hypochondrium, 4. Right lumbar, 5. Umbilical, 6. Left lumbar, 7. Right iliac, 8. Hypogastrum, 9. Left iliac

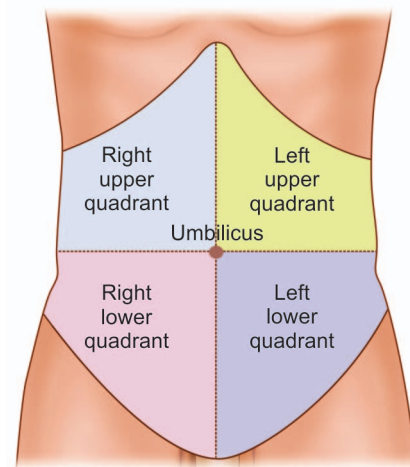


FIGURE 13.2 The quadrants of abdomen

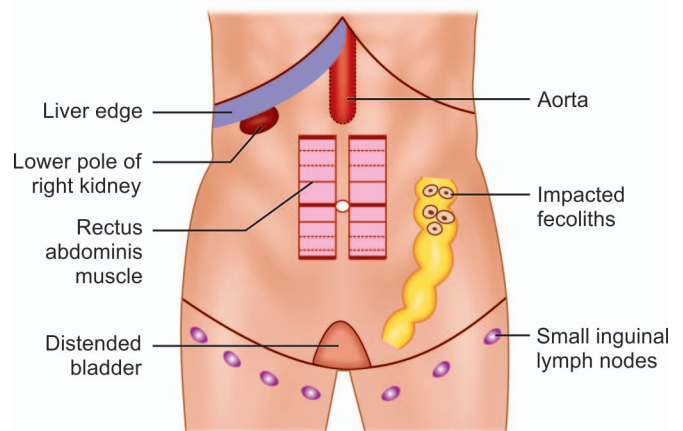


FIGURE 13.3 Normally palpable structures in the abdomen

A distended urinary bladder may be palpable above symphysis pubis.

Other structure that becomes palpable in the lower abdomen include the uterus enlarged by pregnancy or fibroids, may rise above symphysis pubis and the sacral promontory, the anterior edge of the first sacral vertebra.

The kidneys are retroperitoneal structures and lie along the vertebrae. The costophrenic angle (the angle formed by the lower border the 12th rib and the transverse process of the upper lumbar vertebrae) defines the region to be assessed for renal tenderness. Quiet respiration is mainly diaphragmatic particularly in males, so that the abdominal wall moves out during inspiration.

Anatomical Landmarks and their Significance

The anatomical landmarks of the abdomen help to localize the disease in one of the region, from which it becomes easier to diagnosis the disease and to differentiate it from other conditions as illustrated in the Figure 13.4. For differential diagnosis, one should know the abdominal structure(s) present in that region.

Presenting Symptoms (Read Unit I, Chapter 2)

The GI tract and hepatobiliary symptoms have already been listed and discussed in appropriate section (Chapter 2) For ready reference, they are again listed below; (Box 1).

THE HISTORY

Gastrointestinal System

The present illness should be described according to the symptoms arranged in chronological orders. The history of the patient with suspected GI disorders have a bearing on the clinical diagnosis, i.e.

- **Timing (onset) of symptoms:** Symptoms timing can suggest specific aetiology
 - Symptoms of short duration, i.e. acute onset suggests acute infection, toxins exposure and an abrupt inflammation or ischaemia.
 - Long-standing symptoms indicate underlying chronic inflammatory or neoplastic condition or a functional bowel disorder.
- **Relation to meal:** Some GI symptoms are either aggravated or relieved after taking food, i.e.
 - Peptic ulcer symptoms are relieved by taking food or antacids.
 - Conversely meal ingestion worsens the symptoms of mechanical obstruction, ischaemia, irritable bowel syndrome (IBS) and functional bowel disorders.

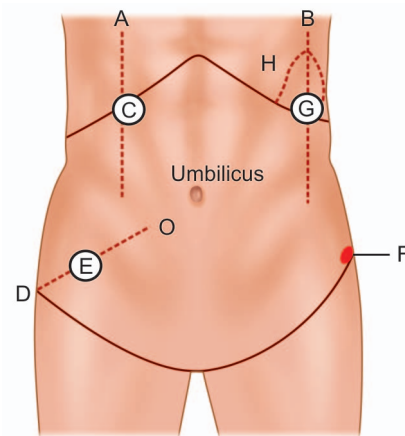


FIGURE 13.4 Anatomical landmarks of the abdomen. A. Right mid clavicular line (MCL) used to assess the liver, B. Left axillary line (AAL) used to assess spleen, C. Murphy's point at the intersection of right MCL and the 10th rib, D. Mc Burney's line between anterior superior iliac spine (ASIS) and the umbilicus, E. Mc Burney's point, 3 cm medial to ASIS on the line used to assess appendix, F. Anterior superior iliac spine, G. Traube's area a space formed by the left costal margin, 7th rib and AAL, is used to assess spleen

Box 1

Symptoms of gastrointestinal system

Symptoms of upper GI tract

Symptoms of disease of mouth, pharynx oesophagus and stomach

- | | |
|--|---|
| <ul style="list-style-type: none"> • Dryness of mouth • Painful lips, tongue and mouth • Bad breath (halitosis) • Heart burn and acid reflux • Retrosternal chest pain • Nausea, vomiting • Haematemesis and malena | <ul style="list-style-type: none"> • Excessive salivation • Disturbance of taste i.e. altered (dysgeusia) or foul taste (cacogeusia) • Feeling of lump in throat (globus) • Dysphagia and odynophagia (painful swallowing) • Hiccups • Dyspepsia, belching and flatulence • Anorexia |
|--|---|

Symptoms of lower GI tract

- | | |
|---|---|
| <ul style="list-style-type: none"> • Abdominal pain • Diarrhoea • Rectal bleeding (Haematochezia) • Weight loss | <ul style="list-style-type: none"> • Abdominal distension • Constipation • Black tarry stools (malena) |
|---|---|

Note: There is no clear cut demarcation between upper and lower GI symptoms

- **Pattern and duration of symptoms:**
 - Ulcer pain is intermittent, spasmodic, nocturnal and last for minutes to hours; pain of acute pancreatitis or acute inflammation lasts for days to weeks or for months.

- Biliary colic (e.g. stone) is of acute onset and lasts for several hours.
- **Relation to fasting and stress:**
 - Diarrhoea from malabsorption improves with fasting while secretory diarrhoea persists without oral intake.
 - Meals elicit diarrhoea in some cases of inflammatory blood diseases (IBD) and irritable bowel syndrome (IBS).
 - Stressful situations exacerbate the symptoms of functional bowel disorders.
- **Relation to defaecation:**
 - Bowel evacuation or defaecation relieves the symptoms of IBD and IBS.
- **History of prior surgery:**
 - Obstructive symptoms with prior abdominal surgery suggest adhesions, whereas loose stools after gastrectomy or gallbladder excision suggest dumping syndrome or just cholecystectomy diarrhoea.
- **Recent travel:**
 - Symptoms onset after recent travel suggest enteric infection (Traveller’s diarrhoea).
- **Medications/drugs:**
 - Medications/drugs produce pain, altered bowel habits or GI bleeding.
- **Upper GI bleeding** results from the diseases of oesophagus and stomach. Lower GI bleeding likely results from diseases of colon (neoplasm, diverticula or vascular lesions) or IBD or anorectal abnormalities (fissure, piles, proctitis, etc.)
- **Sexual contact:**
 - A sexual contact raise the suspicion of sexually transmitted disease or immunodeficiency.
- **Rome criteria:**
 - The most widely accepted symptom based criteria is “Rome criteria” for IBS (Box 2) which improves diagnostic accuracy and obviates the need for unnecessary investigations.

Hepatobiliary System

The clinical history should focus on the symptoms of the liver disease—their nature, pattern of onset, progression and the potential risk factors.

The presenting symptoms (Box 3) should be analysed in a chronological manner with regards to onset, duration of symptoms, their pattern and progression, their relation to meals or defaecation, any known aggravating or relieving factors and other associated symptoms referable to hepatobiliary system or other systemic disorders presenting with hepatobiliary symptoms. The change in colour of stool and urine must be asked.

Box 2

Rome II criteria for IBS

- Symptom duration of at least 12 weeks in preceding 12 months such as abdominal pain or discomfort with any of the two of three features;
 - Relieved by defaecation
 - Onset associated with change in frequency
 - Onset associated with change in stool form

Box 3

Symptoms of hepatobiliary system

<ul style="list-style-type: none"> • Nonspecific symptoms or constitutional symptoms: They neither point out the cause nor they are specific to liver or gallbladder disease. <table border="1"> <tr> <td>- Fatigue</td> <td>- Weakness</td> </tr> <tr> <td>- Nausea, vomiting</td> <td>- Poor appetite</td> </tr> <tr> <td>- Malaise</td> <td>- Pain abdomen</td> </tr> </table> • Liver specific symptoms: These symptoms relate to hepatitis and/or cirrhosis (portal hypertension and end stage liver disease) <table border="1"> <tr> <td>- Haematemesis</td> <td>- Malena</td> </tr> <tr> <td>- Jaundice</td> <td>- Ascites</td> </tr> <tr> <td>- Hepatomegaly (mass in right hypochondrium)</td> <td>- Oedema (swelling feet)</td> </tr> <tr> <td>- Change in colour of the stool or urine</td> <td>- Pruritus/itching</td> </tr> <tr> <td>- Mental features (hepatic encephalopathy)</td> <td></td> </tr> </table> 		- Fatigue	- Weakness	- Nausea, vomiting	- Poor appetite	- Malaise	- Pain abdomen	- Haematemesis	- Malena	- Jaundice	- Ascites	- Hepatomegaly (mass in right hypochondrium)	- Oedema (swelling feet)	- Change in colour of the stool or urine	- Pruritus/itching	- Mental features (hepatic encephalopathy)	
- Fatigue	- Weakness																
- Nausea, vomiting	- Poor appetite																
- Malaise	- Pain abdomen																
- Haematemesis	- Malena																
- Jaundice	- Ascites																
- Hepatomegaly (mass in right hypochondrium)	- Oedema (swelling feet)																
- Change in colour of the stool or urine	- Pruritus/itching																
- Mental features (hepatic encephalopathy)																	

Present History

The following points to be noted in the present history in a patient with GI/hepatobiliary disease:

- **Alcoholism**
- **Smoking**
- **Medications**, e.g. NSAIDs, oral contraceptives, laxative, steroids, immunosuppressive drugs.
- **Arthritis** (peripheral, ankylosing spondylitis) is associated with IBD.
- **Eye symptoms** of conjunctivitis (red eye, watering of eyes), uveitis/irritis, blurring of vision, episcleritis (e.g. ocular pain, photophobia, blurred vision, headache) must be noted.
- **Skin manifestations**, (e.g. erythema nodosum and pyoderma gangrenosum) are common in IBD (ulcerative colitis and Crohn’s disease).
- **Psychiatric symptoms**, e.g. anxiety, apprehension and depression may be symptoms associated with functional bowel disorders. Stress is related to peptic ulcer and functional disorders of intestine.

- **History of expulsim of worms:** Patient may complain of it or even may bring the worm (round worm) to the clinician for inspection.

Past History

Ask for the followings:

- **Past history of similar symptoms.**
- **Surgery:** Any gastrointestinal surgery may lead to adhesions (pain abdomen), diarrhoea or malabsorption due to resection of the gut (small bowel syndrome) or bacterial overgrowth or dumping syndrome.
- **Diabetes:** It may lead to gastroparesis, malabsorption and predispose to GI infection and vascular insufficiency
- **Hypertension** may predispose to vascular disease (ischaemia) of intestine
- **Drugs:** Past history of oral contraceptive and NSAIDs may predispose to GI tract and hepatobiliary diseases (veno-occlusive disease)
- **Alcohol and cigarette smoking** are important for peptic ulcer disease as well as for IBD.
- **Blood transfusion, tattooing or body piercing.**

Family History

Although many GI diseases result from environmental factors, other exhibit hereditary components, therefore, family history is important for the followings:

- Family members of inflammatory bowel disease (IBD) patients show a genetic predisposition to disease development themselves.
- Colonic and oesophageal malignancies arise in certain inherited disorders (e.g. polyposis).
- Hereditary pancreatitis is caused by mutation in the cationic trypsinogen gene.
- Familial clustering is even observed in functional bowel disorders but is not proved.
- A family history of hepatitis, liver disease and liver cancer is important. Familial α_1 -antitrypsin deficiency causes liver disease (Wilson's disease)
- Congenital or hereditary syndromes of bilirubin metabolism (Gilbert's, Crigler-Najjar and Dubin-Johnson) are well known.
- Haemochromatosis—a disorder of iron metabolism runs in families.

Personal History

- **Dietary history:** History of eating shelfish (for hepatitis)
- **History of smoking, alcohol, drug abuse, blood transfusion.**
- **Sexual contact history** for sexual related disorders.

EXAMINATION

General Physical Examination (GPE)

Examination of mouth and pharynx (Read Chapter 6).

Look at the lips for:

- Desquamation or inflammation (cheilitis)
- Any ulcer
- Nodule/granuloma
- Extragenital chancre
- Any crack
- Pigmentation
- Telangiectasis
- Aphthous ulceration

Look at the teeth for:

- Decay (caries)
- Any missing teeth
- Change in colour/staining
- Shape of the teeth
- Any erosion

Inspection and palpation of the gums for:

- Recession of gums
- Redness or hypertrophy
- Bleeding (spontaneous or on gentle pressure)
- Granuloma/ulcer
- Tenderness
- Exudation of pus from the gums on gentle pressure

Inspection and palpation of the tongue for:

- Deviation or asymmetry
- Size
- Fasciculations/tremors
- Colour, moistness
- Fur
- Atrophy/hypertrophy

Look at the oral mucosa for:

- Discoloured spots/dots/ulcers/cysts

Inspect the roof (palate, fauces), tonsils and pharynx:

- Ulcer/erythema or vesicles
- Any hole or abnormal arching of the palate
- Exudation from the tonsils or pharynx.

Examination of throat

When there is complaint of dysphagia, watch for the act of swallowing to solids and liquids. This may reveal the organic cause and the site of the lesion.

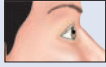
If swallowing is followed by distressing cough, then either a neuromuscular disturbance (bulbar or pseudobulbar palsy) or a fistula between the trachea and oesophagus is the likely possibility.

Examination of neck for JVP, carotid pulsations and lymph node enlargement (Read Chapter 8).

Examination of extremities (*see* Fig. 13.1).

Systemic Examination of the Abdomen

Inspection



Sequence of Examination

Position: The patient should be lying in comfortable supine position with arms by the side and the head and neck supported by one or two pillows in order to relax the abdomen. Use extra pillows to support a patient with severe kyphosis.

Do not ask the severe breathless patient to lie flat. A sagging mattress make the palpation difficult, hence, use a good non-sagging mattress.

Light and exposure: Make sure that there is good light, the room is warm and your hands are also warm. A shivering patient cannot relax the abdomen and makes the palpation difficult.

While examining the patient in bed, pull down all the clothes except the upper sheet. The clothing should be drawn upto xiphisternum and sheet is folded down across the upper thighs so as to have a good look of the groins and genitalia. This position facilitates the good inspection of the whole abdomen. Once inspection of groin and genitalia has taken place, the sheet may be pulled upto the level of symphysis pubis. The point to be observed on inspection are given in the Box 4.

The Skin of Abdomen

Look at the skin for swelling, texture, striae, scars, dilated veins, rash, pigmentation, spider angiomas, etc.

- **Swelling:** In elder patients *seborrhoeic warts* (pink, brownish or black) and *haemangiomas* (*Campbell de Morgan spots*) are common.

- **Texture:** *Smooth and glossy skin* indicates abdominal distension; whereas *wrinkled skin* suggests old distension that may be disposed of as normal changes.
- **Striae:** These (*atrophic* or *gravidarum*) are white or pink wrinkled stretch marks on the abdominal wall produced by any condition that stretches the abdominal wall abnormally and causes the rupture of elastic fibres and indicate recent change in size of the abdomen.

Ascites, pregnancy or postpartum (Fig. 13.6A), wasting diseases or severe dieting and Marfan's syndrome can cause silver striae on the abdomen.

Box 4

Points to be noted on inspection

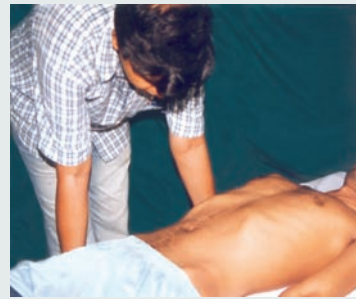
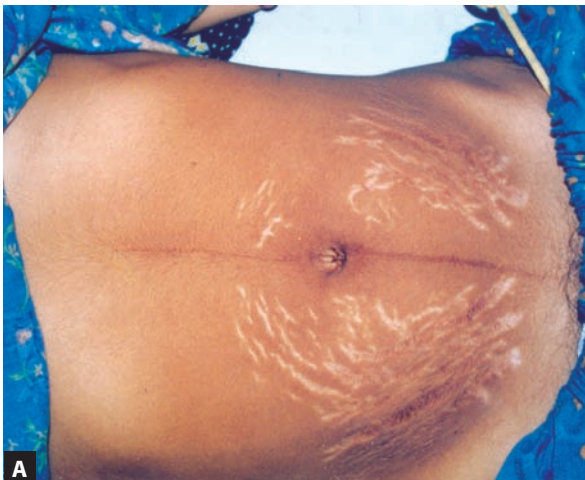
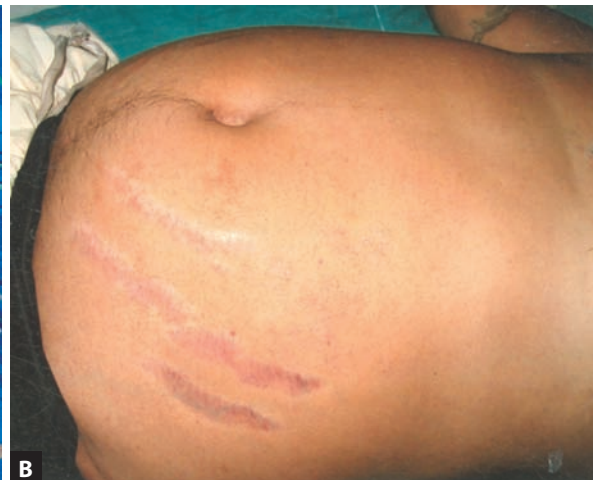FIGURE 13.5 Inspection of the abdomen

Method: Stand on the right side of the patient (Fig. 13.5) and inspect for the followings:

- *The skin* for scars, striae, dilated veins, rashes and pigmentation
- The *umbilicus* for its contour and location, any signs of inflammation and hernia
- *Shape of the abdomen* including its symmetry
- *Movements of the abdominal wall and peristalsis*
- *Any abdominal pulsations*
- *Hernial sites*, e.g. groins and scrotum.



A



B

FIGURES 13.6A and B Abdominal striae: (A) White silvery striae in a postpartum female; (B) Wide pink-purple striae

- *Wide, pink-purple striae* (Fig. 13.6B) are characteristics of Cushing's syndrome or prolonged steroids therapy.
- Striae over shoulder and buttocks may be seen in Marfan's syndrome.
- Striae alba are linear white or normal coloured. These are seen in wasting disease or debility.

- **Scars:** Note any surgical scars and identify whether they are old (white) or recent (red/pink), linear or stretched. This is important because surgical scars may be weak and bulge under raised intra-abdominal pressure resulting in hernias called *incisional hernias*. The common examples of various surgical incisions are illustrated in Figure 13.7 and Box 5.
- **Dilated superficial veins:** The three common sites are given in the Box 6. The method to detect the flow of blood in a vein is illustrated in the Figures 13.8A to D.
- **Any rash/lesion or pigmentation:** Note any rash (drug induced, viral, vasculitic) or lesion (vesicular or vesicopapular or papular) or pigmentation (linea nigra or erythema ab igne).

Linea nigra—a pigmentation in the midline below the umbilicus is a sign of pregnancy.
 Erythema ab igne—a brown mottled pigmentation produced by heat to the skin (e.g. hot water bottle or heat pad)

- **Spider angiomas:** Look for spider like capillary dilatation or pin-head size red macules over the upper abdomen and thorax (Fig. 13.10A). The spider or macular lesion blanches with pressure by the head of pin (Fig. 13.10B).

The Umbilicus

Look at the umbilicus and observe its contour, location, signs of inflammation or hernia:

- Umbilicus may be pulled up and down in lower abdominal and upper abdominal muscles paralysis respectively.
- A mass may distort the position of the umbilicus
- Umbilicus is slit transversely (smiling umbilicus) due to stretching by the distended flanks (ascites), anterioposteriorly in central abdominal distension (pregnancy, distended bladder, any central mass), obliquely in pressure from one side (ovarian cyst).
- A swelling ground the umbilicus (umbilical/paraumbilical hernia) may evert it.
- Umbilicus is red or erythematous in inflammation or sepsis.
- Frequently a concentrate of inspissated desquamated epithelium and other debris (amphalolith) may be seen in the umbilicus of elder women.

Normally umbilical is retracted and inverted, but may get everted, pushed up and down, slit (transversely/ anterioposteriorly or obliquely in different conditions).

Shape of the Abdomen

Note whether abdomen is of normal contour, full or distended. Is it sunken (scaphoid)? Do the flanks bulge or is there any local bulge? Is the abdomen symmetrical? Are there any visible organs or masses?

Normal shape of the abdomen is boat-shaped or slightly scaphoid, i.e. the abdominal wall sinks within the bony margins of the abdominal surface and receding towards the centre.

Box 5

Common surgical scars

- Non specific incisions
 - Midline (upper, lower) — ① and ④
 - Paramedian (right) — ②
 - These are vertical incisions used for general access.
- Specific incisions
 - Subcostal (Kocher's) for gallbladder — ③
 - Suprapubic for bladder, prostate, gynaecology — ⑤
 - Mc Burney's point for appendix — ⑥
 - Inguinal for hernia — ⑦
 - Laparoscopic incisions are usually below the umbilicus and may be difficult to see.
- Surgical stomas
 - An ileostomy mark — ①
 - A colostomy mark — ②
 - A loop colostomy mark.

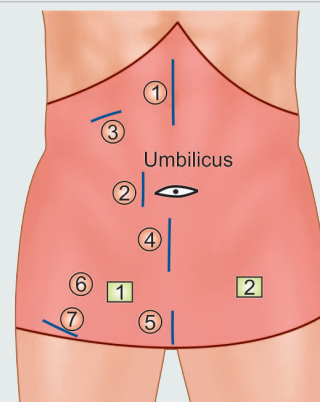
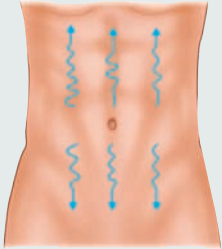
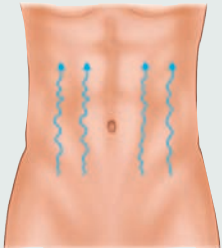
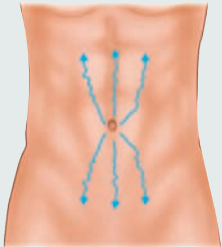
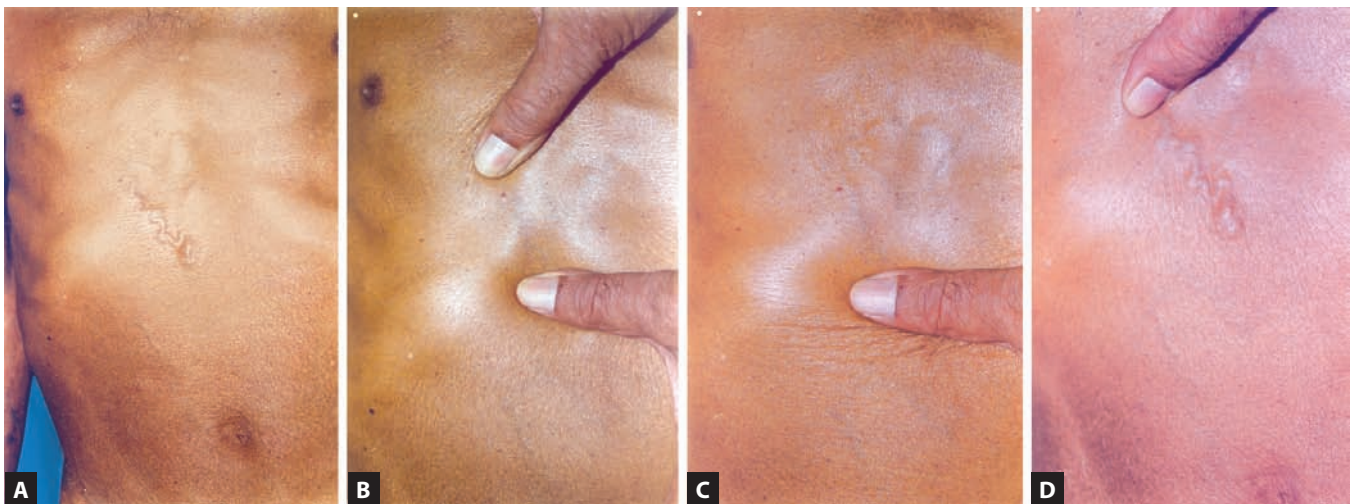


FIGURE 13.7 Common sites of scars produced by abdominal incisions. The common sites of surgical stomas are illustrated in small boxes, i.e. ① and ②

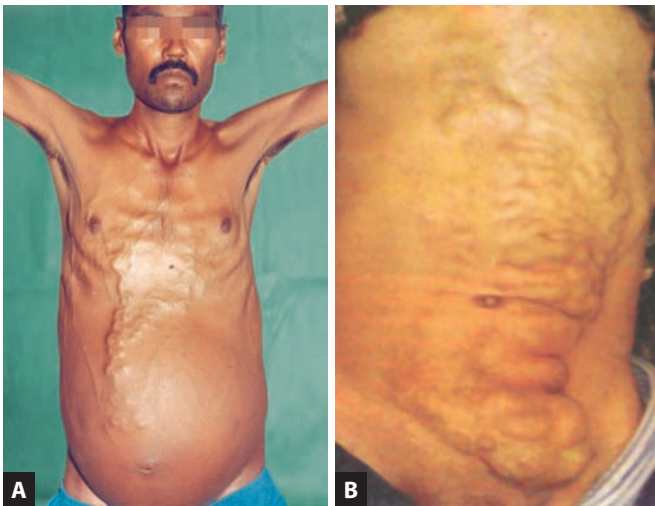
Box 6

Dilated veins over the abdomen and direction of flow

Site	Significance	Flow	Figure
<ul style="list-style-type: none"> Small thin veins over the costal margin and abdomen 	No significance	Normal (away from umbilicus)	 <p>Normal</p>
<ul style="list-style-type: none"> Distended veins on the abdominal wall and chest wall with oedema of limbs, buttocks and groins 	Inferior vena cava obstruction (Fig. 13.9A)	Below upwards	 <p>IVC obstruction</p>
<ul style="list-style-type: none"> Distended veins around the umbilicus (<i>caput medusae</i> Fig. 13.9B) <p>The other signs of portal hypertension should also be seen (e.g. splenomegaly, fetor hepaticus and oesophageal varices)</p>	<p>Portal hypertension (cirrhotic or noncirrhotic) leading to formation of anastomotic channels between portal and systemic veins. Other sites are:</p> <ul style="list-style-type: none"> Oesophagus Rectum Behind the kidney and liver Lungs 	Away from the umbilicus	 <p>Caput medusae</p>



FIGURES 13.8A to D Demonstration of direction of flow of blood through dilated tortuous veins around the umbilicus (caput medusae). The flow of blood is away from the umbilicus in cirrhotic portal hypertension: (A) Dilated tortuous veins in epigastrium and around the umbilicus; (B) Empty the veins with the pressure of the thumbs; (C) First release the pressure of the upper thumb and note the filling of veins. The vein does not fill; (D) Now repeat the same procedure again and release the lower thumb. The vein fills indicating the direction of blood flow from below upwards (away from the umbilicus)



FIGURES 13.9A and B Dilated and tortuous veins over the abdomen and chest: (A) In a patient with inferior vena cava obstruction; (B) Caput medusae in a patient with cirrhosis of liver

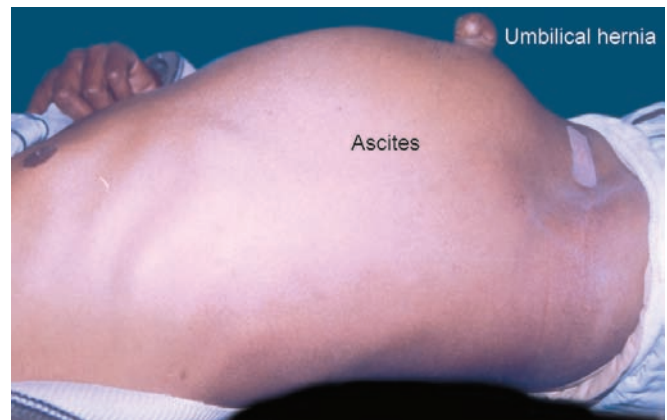
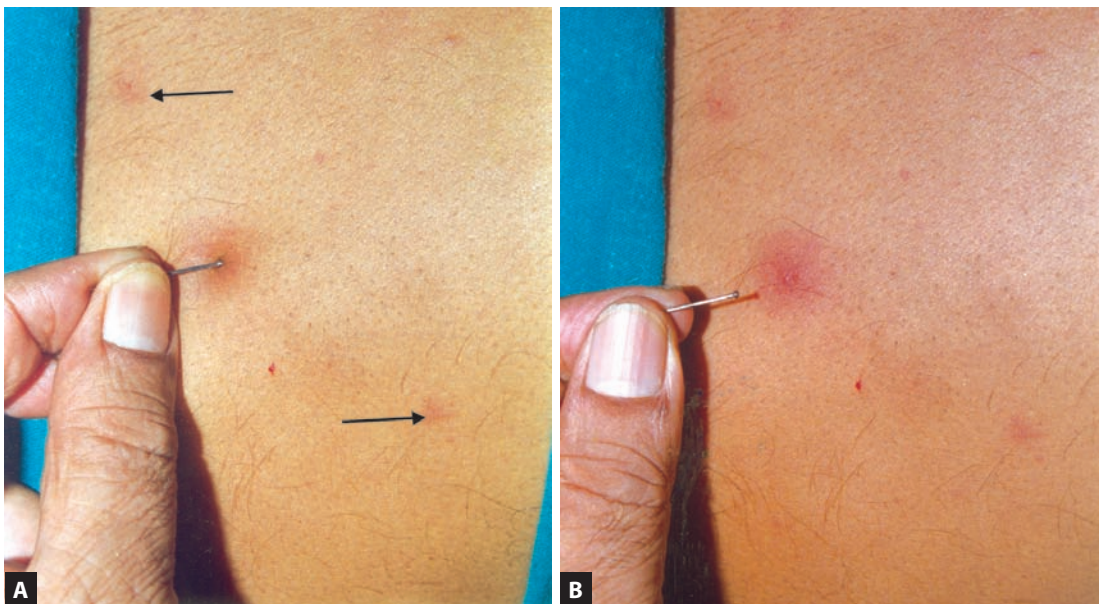


FIGURE 13.11 Ascites.
Note the central distension and an umbilical hernia



FIGURES 13.10A and B Spider angiomata: (A) A red macule with spider leg appearance; (B) It blanches on pressure with pin-head and reappears after release of pressure

Common abnormalities

- **Generalised distension/fullness** is indicated by 5 F's i.e. fat, flatus, fluid, foetus, faeces.
 - **Fatty abdomen (obesity):** Fat is the most common cause of generalised protuberant abdomen due to fatty, thick abdominal wall. The umbilicus may be everted (sunken).
 - **Fluid (ascites):** Fluid collects in the flanks during lying down, hence distension is either in the flanks (mild to moderate ascites) or generalised with protruding flanks in massive ascites (Fig. 13.11). In sitting or

standing position, the distension is central or lower abdominal as fluid gravitates into lower abdomen. The percussion note is dull.

- **Flatus (gas):** Gaseous distension may be localised or generalised depending on the site of intestinal obstruction, is invariably generalised in paralytic ileus. The percussion note is tympanitic.
- **Foetus (pregnancy):** Pregnancy causes central distension, tympany in the flanks and palpable foetal parts per abdomen.

- **Faeces:** Impacted faeces (faecoliths) in the colon during severe constipation cause generalised distension with tympanitic percussion note.
- **Localised distension**
 - Visible enlargement of the bladder, uterus or ovary (ovarian tumour or cyst) may be evident as a characteristic swelling arising from the pelvis. The swelling is predominantly central than peripheral.

Full distended bladder produces a suprapubic bulge which is cystic, rounded, dull on percussion and disappears after micturition.

- Visible bulges may also be due to gross enlargement of viscera (liver, spleen, kidney) or to large tumours, for example an ovarian tumour produces bulge in the lower abdomen thereby increasing the distance between umbilicus and symphysis pubis than between xiphisternum and the umbilicus. Hepatomegaly and massive splenomegaly may produce a bulge in right and left hypochondrium (Fig. 13.12) respectively.

Distension of stomach in pyloric obstruction produces a localised bulge in the upper part of abdomen with positive succussion splash and visible peristaltic waves from left to right.

- **Sunken abdomen (or scaphoid abdomen)** may be seen in undue starvation or wasting diseases such as malignancies.
- **Divarication of the recti (diastasis recti):** Divarication of the recti (Fig. 13.13) is separation of the two recti through which abdominal contents bulge in the midline as a ridge when the patient raises head and shoulders. It may either be a congenital defect or due to raised intra-abdominal pressure as a result of repeated pregnancies, ascites, obesity and chronic lung disease.

Abdominal Movements

Look for abdominal movements and for any abnormality.

Normally the abdominal wall bulges during inspiration and falls during expiration. The movements are free and equal on both sides.

In *generalised peritonitis*, the abdominal movements become diminished or absent to limit the spread of infection and peritoneal irritation/pain.

In *diaphragmatic paralysis*, the abdomen bulges during expiration (paradoxical abdominal movements).

Peristalsis

Look at peristalsis.

Note any abnormality in peristaltic movements.

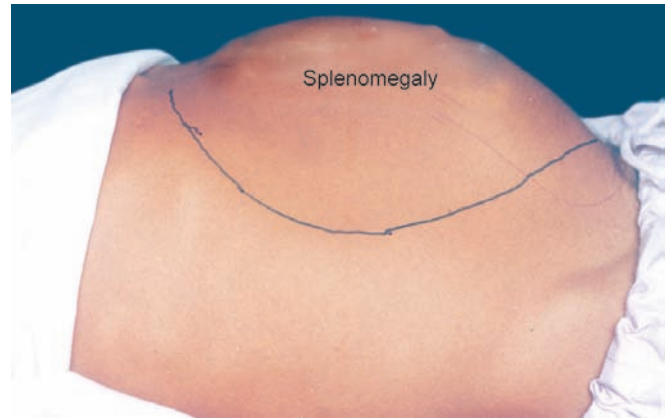


FIGURE 13.12 Splenomegaly. Note the bulge in left hypochondrium

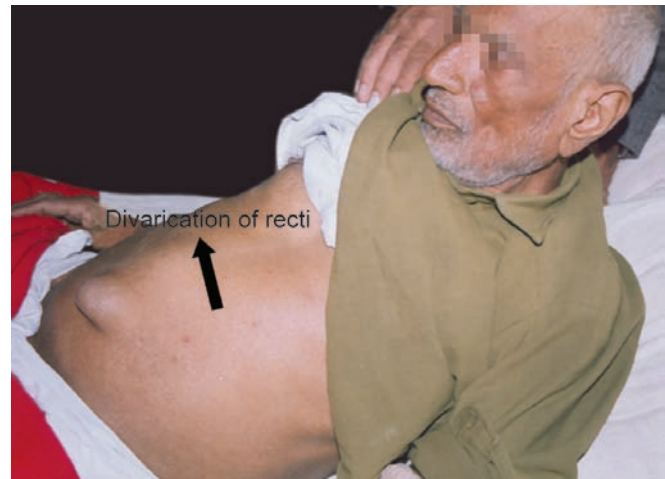

FIGURE 13.13 Divarication of the recti. Note the midline ridge or linear bulge (↑) when the patient raises his head and shoulders. This is due to ascites (e.g. note the generalised distension of the abdomen and umbilical hernia in this patient)

Peristalsis is best observed by watching the abdomen for some time. If it is not visible, an attempt should be made to visualise it either by asking the patient to swallow some fluids or by applying a sharp tap with fingers over the abdomen.

Small intestinal peristalsis may be seen through a thin abdominal wall, or if there is divarication of the recti abdominis or an incisional hernia. It is normal finding, hence, of no consequence. Peristaltic waves may be seen passing across the upper abdomen from left to right i.e. from epigastrium to right hypochondrium in pyloric stenosis (congenital or acquired). Peristalsis waves due to large intestinal obstruction (transverse colon) are also seen in the same region but moving from right to left.

Peristaltic waves in distal small gut obstruction (ileocaecal region being the commonest site) are seen in the centre of the abdomen in a "step-ladder pattern" with distended coils of the gut with "hyper-resonant note."

Pulsations

Look at abdominal pulsations.

Note any pulsation in the epigastrium or other abdominal regions.

Normally pulsations are not visible over the abdomen except epigastric pulsations of abdominal aorta in thin anxious patients or in anaemic patients:

- **Abnormal pulsations** seen in epigastrium or right hypochondrium are:

Aortic aneurysm produces expansible pulsations in the epigastrium in any position.

Transmitted pulsations may be seen in the same region in patients having a tumour overlying the aorta. These pulsations arise from the aorta, are transmitted to the surface through the tumour hence, disappear when the patient adopts a "knee-elbow" position in which tumour falls away from the aorta.

Right ventricular pulsations are seen and felt over the right hypochondrium corresponding with the apex beat in patients with tricuspid regurgitation.

Even congested liver, sometimes, in addition, produces pulsations posteriorly, in tricuspid regurgitation.

Hernias

Look at the following sites for hernias (Fig. 13.14)

- Incisional scar (Fig. 13.15)
- Umbilicus (Figs 13.11 and 13.13)
- Abdominal wall (ventral hernia Figs 13.16A and B and multiple lipomas)
- Groin/Inguinal region (Fig. 13.17A)
- Femoral hernia (Fig. 13.17B).

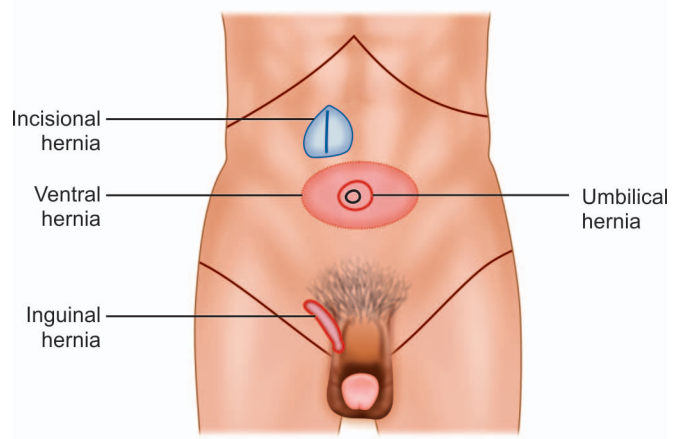
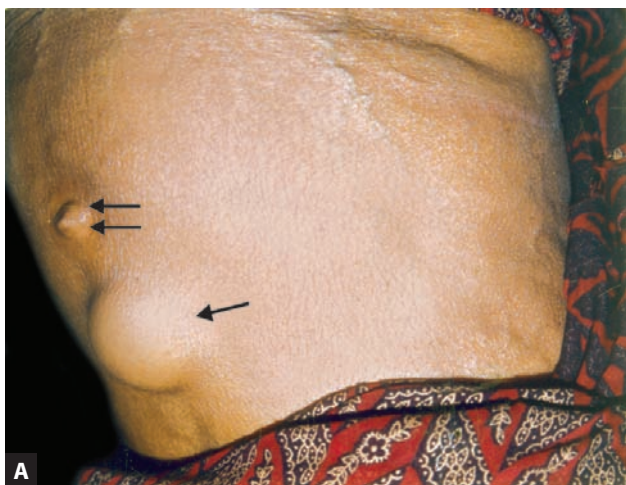


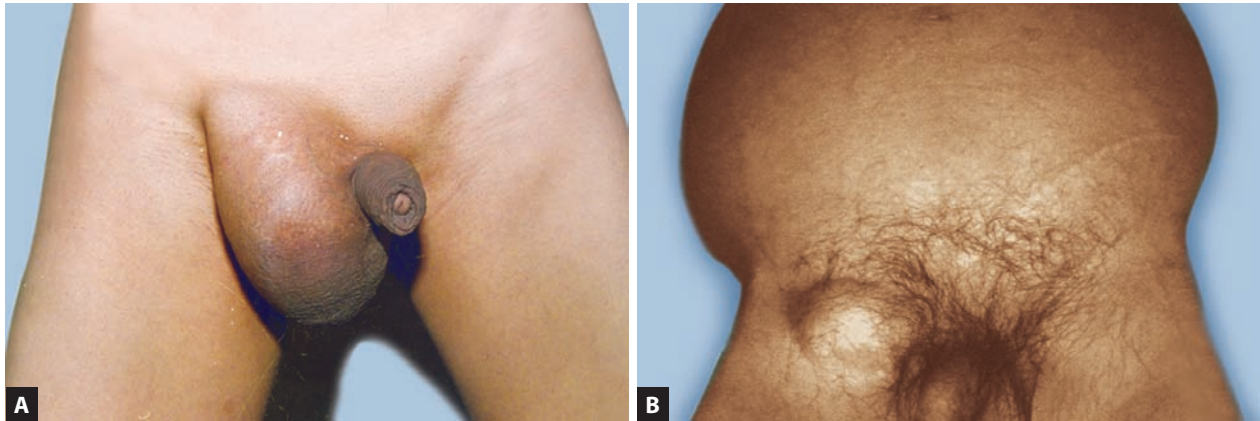
FIGURE 13.14 Sites for hernias

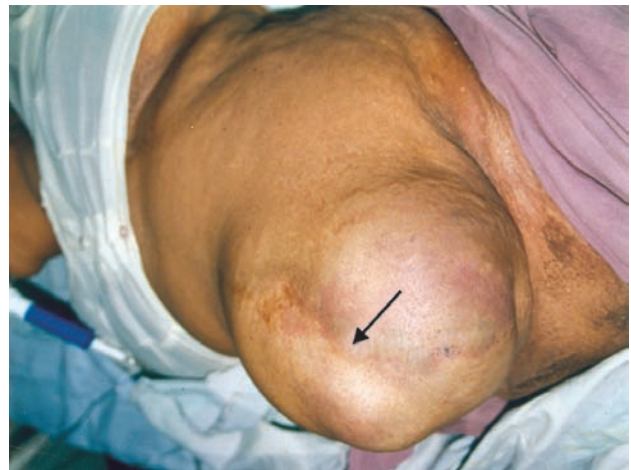
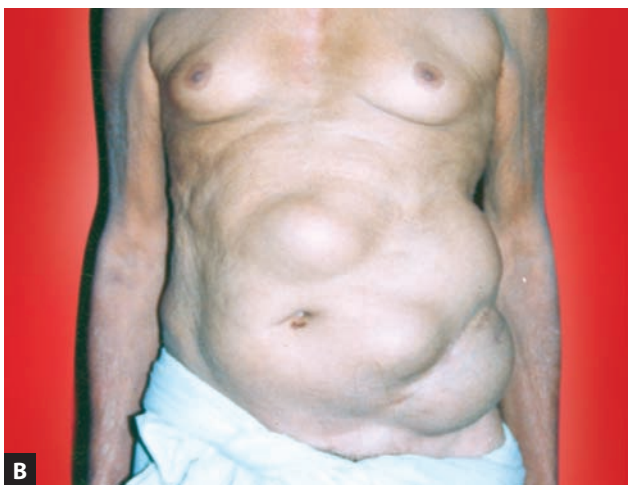
FIGURE 13.15 Incisional ventral hernia. Note the incisional scar (←) and protuberance around the scar (e.g. ventral hernia)



FIGURES 13.16A and B (A) Non incisional ventral hernia. Note a localised bulge of anterior abdominal wall due to ventral hernia (←). There is a small umbilical hernial also (↔); (B) Abdominal wall multiple lipomas



FIGURES 13.17A and B (A) Inguinal hernia. It lies above and medial to pubic tubercle; (B) Femoral hernia

If there is no swelling, the patient is asked to stand up, turn his head to one side and cough. The positive impulse (protuberance on coughing) suggests hernia.

To differentiate between femoral and inguinal hernia, the index finger of the examiner is placed on the pubic tubercle (traced up along the tendon of adductor longus to inguinal canal) and the patient is asked to cough. If the impulse is medial and above the index finger, it is *inguinal hernia*. If the impulse tends to bulge straight through the posterior wall of the inguinal canal, it is *direct*, whereas, if it travels obliquely along the inguinal canal, it is *indirect inguinal hernia*.

Ventral hernia (e.g. epigastric hernia) is a small midline bulge through a defect in the *linea alba*, some where between the xiphisternum and the umbilicus. Ask the patient to raise both head and shoulders off the table or bed or couch, if hernia is present, a central bulge will appear.

Palpation



Palpation forms the most important part of the abdominal examination and is divided into three phases:

1. Light.
2. Deep.
3. Palpation during respiration.

Instruct the patient to relax as best as they can and to breath quietly. Assure him that you will be as gentle as possible. Enquire about the site of any pain. Make your hands warm by rubbing them against each other. All these points will be helpful in gaining the confidence of the patients.

The *dipping* technique/method may be employed during deep palpation in patients with marked ascites to detect the enlargement of liver or spleen that might otherwise be missed because of the ascites. The sudden displacement of the fluid gives a tapping sensation over the surface of liver or spleen.

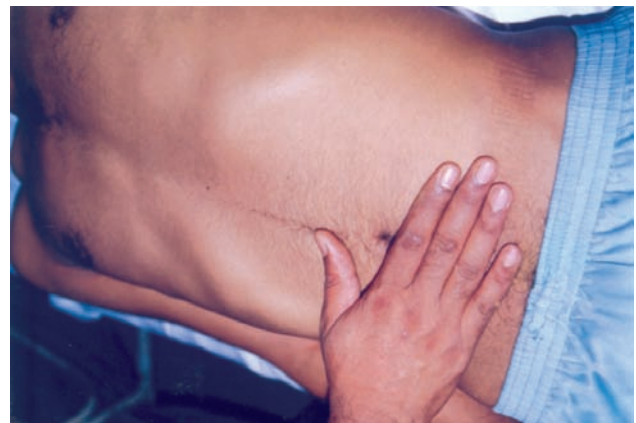

FIGURE 13.18 Superficial (light) abdominal palpation. Put the hand lightly into abdomen after warming it by rubbing the hands against each other. Explain the procedure to the patient so that he/she voluntarily relaxes the abdomen

Superficial Palpation (Fig. 13.18)

It is done to elicit tenderness and guarding/rigidity. Temperature over the abdomen is felt with back of the palm.

- Ask the patient to place the arms alongside the body to help relax the abdominal muscles.
- Place the examining hand on the abdomen and thereafter maintain the continuous contact with the patient's abdominal wall.
- Ask the patient to report any tenderness elicited during palpation and observe the patient's face for any grimace/wince indicative of local pain/discomfort.
- Enquire about the site of any pain and examine that region last.
- Test the muscle tone by light dipping movements over symmetric areas commencing at a point away from the site of any pain. Guarding is local or generalised rigidity encountered as resistance due to increased muscle tone.

- To elicit rebound tenderness, press the examining hand gently but firmly into the abdomen and then suddenly release the pressure. Observe for any grimacing/wincing of face due to pain. Sudden withdrawal causes pain due to movement of the inflamed organ.

Deep Palpation (Fig. 13.19)

It is done to palpate the mass, and liver, spleen and kidney enlargement.

- Palpate the abdomen more deeply and firmly with the flat of the hand. The predominant use of finger tips should be avoided as it is likely to induce muscular spasm or resistance.
- You can use both hands one over the other for deeper palpation if necessary
- Examine each region in turn, starting away from any area of tenderness; start preferably from the left iliac fossa and proceed anticlockwise as follows:
 - feel for the left kidney
 - next feel for the spleen
 - feel for the right kidney
 - feel for the liver
 - feel for the urinary bladder
 - feel for aortic pulsations and para-aortic glands.
 - Feel also the femoral vessels/pulses

If a swelling is palpable, spend some time in eliciting its features, i.e. size, shape, outlines, tenderness,

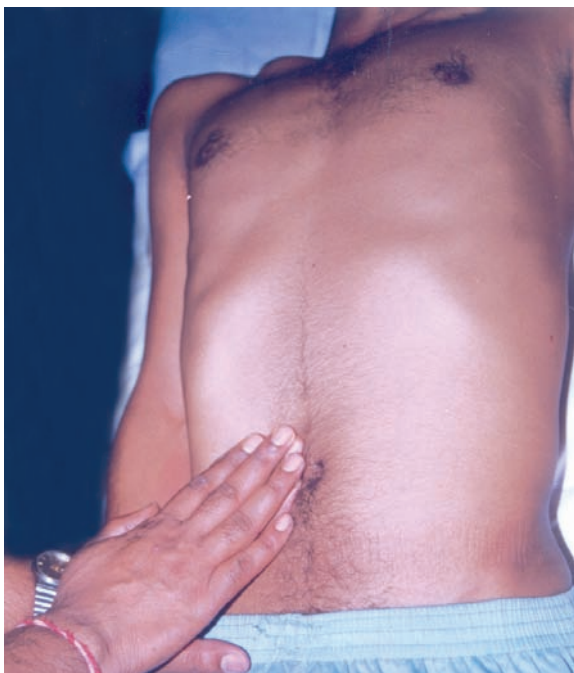

FIGURE 13.19 Deep abdominal palpation

adherence to underlying or overlying structures, movements and expansion.

Now palpate both groins and examine the external genitalia.

Method

Start by placing the right hand flat on the abdominal wall in left iliac fossa with the wrist and forearm in the same horizontal plane. Do not hold the hand rigid but mould it to the abdominal wall. Palpate gently with firm pressure with the fingers held straight with slight flexion at the metacarpophalangeal joints.

Avoid sudden poking with fingertips which is likely to induce muscle spasm and making the palpation rather difficult. Palpate the each quadrant of the abdomen. Note any area of tenderness and rigidity. If necessary, repeat the palpation using both hands; putting the left hand over the right to exert increased pressure so as to facilitate palpation in an obese or muscular patients.

In patients who are unable to relax their abdominal muscles, the best way of examination is to ask them to breathe deeply, bend their knees up and distract their attention by talking to them.

Note: A little will be gained from palpation of a poorly relaxed abdomen, hence, every attempt must be made to relax it by bending their knees up and talking to them while palpation.

Common Abnormalities

• Feel of the abdomen

Doughy feel indicates plastic type of tubercular peritonitis.

- **Tenderness:** Tenderness means pain on pressure. Resistance accompanies tenderness, indicates inflammatory lesions of the underlying viscera and the surrounding peritoneum (*see* Box 7).

Rebound tenderness may reveal deep-seated inflammation (parietal peritonitis) where local guarding may not be present.

- **Guarding:** Guarding is the resistance offered by the patient during palpation. It is a protective or defense mechanism against pain in which abdominal muscles contract resulting in increased tone. It is commonly seen in anxious patients who are unable to relax their abdomen. This finding can be confirmed by reduction in resistance during the early phase of respiration and when the patient is in a comfortable position and his/her attention has been distracted by talking and explaining that no undue pain will be caused by the examination.

Box 7

Pain and tenderness as a clue to diagnosis

Site	Condition
• Epigastrium	Peptic ulcer
• Right hypochondrium (intercostal tenderness)	Hepatitis, (Fig. 13.20) liver abscess, cholecystitis (gall stone)
• Spine	Pott's disease
• McBurney's point or right iliac fossa	Appendicitis
• Lumbar region/lion	Renal colic

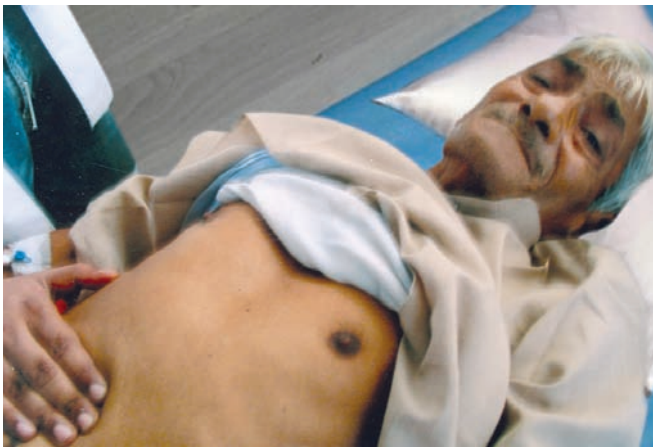

FIGURE 13.20 Elicitation of tenderness in right hypochondrium in a patient with hepatomegaly. The liver is tender as with firm pressure over right hypochondrium, the patient winces due to pain

- **Rigidity:** Rigidity is a protective mechanism similar to guarding but can not be, voluntarily, relaxed.
 - *Generalised 'board-like' rigidity* invariably indicates peritonitis due to any cause. In peritonitis, abdomen does not move during respiration and bowel sounds are absent but rebound tenderness is present. The causes of localised (limited to one side according to the organ affected) and generalised rigidity are given in the Box 8.

The various structure which are normally palpable during the abdominal examination and likely to be misinterpreted as enlarged, are illustrated in the Figure 13.3.

- **Skin elasticity or turgor:** The elasticity of the skin provides clue to state of hydration; *loss of turgor* indicates dehydration, on the other hand, *redundant skin folds* indicate weight loss. *Laxity of skin* may be seen with advancing age, after child birth and ascitic tap.

Box 8

Causes of rigidity of abdomen

- Perforation of a hollow viscus
- Acute pancreatitis, cholecystitis, salpingitis
- Peritonitis (generalised rigidity)
- Intestinal strangulation
- Superior mesenteric artery thrombosis
- Ruptured ectopic gestation
- Twisted ovarian (cyst) or torsion of a fibroid.

Palpation of various viscera during deep inspiration.

The liver, gallbladder, spleen and kidneys are palpated in turn during deep inspiration because they lie at some point with the contact of diaphragm.

- **Palpation of viscera.**

The Liver*Method*

The patient must be lying in supine position with hips and knees flexed. Place both hands side-by-side flat on the abdomen in the right subcostal region with the fingers pointing towards the ribs. If resistance is encountered, move the hands further down until no resistance is felt. Now ask the patient to breath as deeply as can and at the height of inspiration, press the fingers firmly inwards and upwards to feel the lower edge. If liver is palpable it will be felt as a sharp, firm edge during inspiration. Try to locate the liver edge both laterally and medially. Once you feel the liver edge, lighten the pressure of your palpating hand(s) slightly so that liver can slip under your finger pads and you can feel its anterior surface.

Conventional method is to place the right hand below and parallel to right subcostal margin. Palpate the edge of the liver with radial border of the index finger of right hand during deep inspiration which will be felt as something striking your hand (Fig. 13.21).

The *'hooking technique'* may be useful in obese persons. Stand on the right side of the patient, place both hands, side by side, on the right abdomen below the costal margin. Press in with your fingers and up towards costal margin (Fig. 13.22). Ask the patient to take deep breath. The liver edge becomes palpable with the fingerpads of both hands.

The liver is often palpable in normal persons without being enlarged. Hepatomegaly is described in centimeters below the right costal margin in midclavicular line.

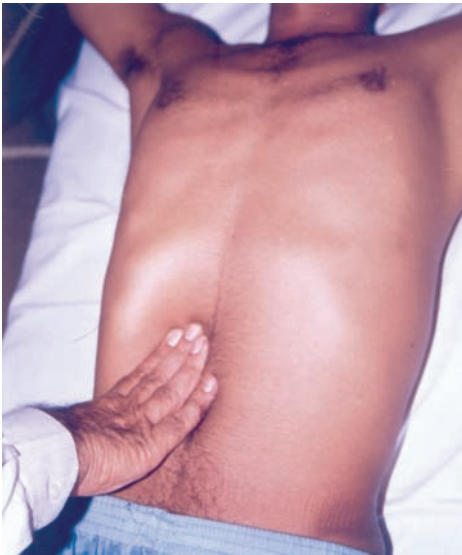

FIGURE 13.21 Palpation of liver (conventional method)

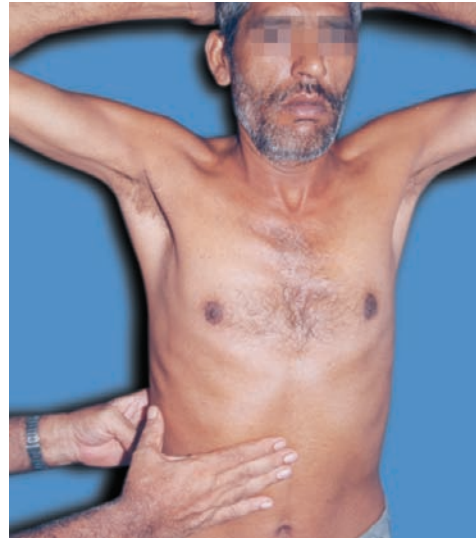

FIGURE 13.23 Method to elicit pulsatile liver. Make the patient sit. Position the hands as if you are bimanually palpating the liver. Note the separation of hands during quiet breathing

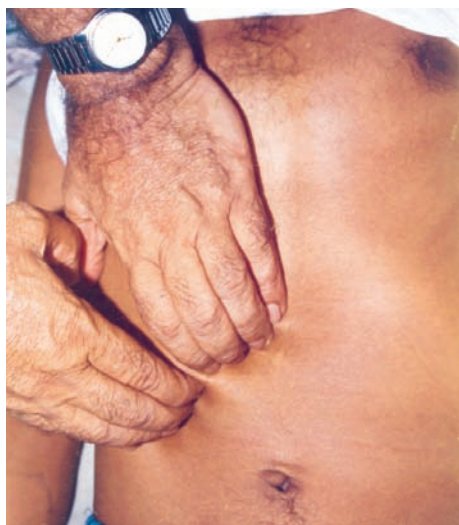

FIGURE 13.22 Palpation of liver by hooking method

Describe the liver enlargement as follows:

- *Enlarged* by so many centimeters
- *Surface*: Rough or smooth, tender or nontender
- *Consistency*: Soft, firm or hard
- *Tenderness* present or not
- Bimanually palpable or not (liver is bimanually palpable)
- Ballotable or not (liver is not ballotable)
- Movement with respiration (liver moves freely with respiration)
- Pulsatile or not (Fig. 13.23)
- Fingers can or cannot be *insinuated* behind the costal margin (Finger cannot be insinuated behind the liver mass).

The characteristics of liver mass are discussed in Box 9.

Box 9

The characteristics of liver mass and its differentiation from right kidney mass

Feature	The liver	The right kidney
• Direction of enlargement	Above downwards	Below upwards
• Surface	Smooth	Smooth
• Consistency	Firm	Soft to firm
• Bimanual palpation	Bimanually palpable but not ballotable	Bimanually palpable and ballotable
• Movements with respiration	Moves freely with respiration	Restricted movements with respiration
• Percussion note	Percussion note is dull	Percussion note shows band of resonance of intestine over the kidney
• Finger insinuation	Finger cannot be insinuated behind it	Finger can be easily insinuated between kidney and ribs
• Renal angle	Empty	Full

Abnormalities

Differential features of enlarged liver

- Liver is smooth, soft and tender in hepatitis, congestive heart failure, Budd-Chiari syndrome, and fatty infiltration
- Liver is firm and regular in obstructive jaundice and cirrhosis

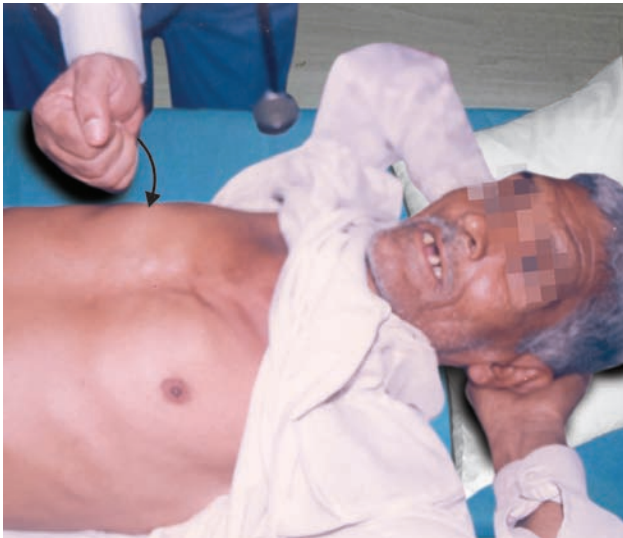

FIGURE 13.24 Thumping sign for intercostal tenderness. Note the wincing following a gentle thump with fist of right hand

- Painless, hard, nodular liver indicates malignancy of liver (primary or secondary)
- Liver is pulsatile in tricuspid regurgitation
- Riedle's lobe enlargement is characteristic of Budd-Chiari syndrome.
 - *Assessing the tenderness of a nonpalpable liver:* Place your left hand flat on the lower right rib cage and then gently strike your hand with the ulnar surface of your right fist. Ask the patient to compare the sensation with that produced by a similar strike on the left side.
 - *Thumping sign* (Fig. 13.24): Strike your right fist over the lower right rib cage and note whether the patient winces/grimaces or feel pain. Tenderness by this manoeuvre indicates inflamed liver.

Causes of hepatomegaly (Read case discussion on Hepatomegaly in Bedside Medicine by Prof. SN Chugh).

The Gallbladder

The gallbladder is a pear-shaped organ lying under the right lobe of the liver with its fundus located anteriorly behind the tip of the 9th costal cartilage. Its body and neck pass posteromedially towards the porta hepatis. Its cystic duct joins the common hepatic duct to form the common bile duct.

The gallbladder is palpated in the same way as the liver.

Method

Place the examining fingers over the gallbladder area and ask the patient to take a deep breath. Gallbladder if palpable is felt as a firm, smooth, rough or globular swelling with distinct

TABLE 13.1 Distinctive features between palpable gallbladder and right kidney

Feature	Gallbladder	Right kidney
• Shape of mass	Globular, firm, smooth	Boat-shaped, firm, smooth
• Movements with respiration	Free movement	Restricted movements
• The upper border of the mass defined or not	Not defined, merges with the liver	Defined
• Ballotability	Not ballotable	Ballotable
• Bimanually palpable	No	Yes
• Percussion note over the mass	Dull	Colonic resonance over the renal mass present sometimes

borders, just lateral to the edge of rectus abdominis near the tip of 9th costal cartilage. Its upper border merges indistinctly with the lower border of the right lobe of the liver or disappears underneath the costal margins so that its only fundus and a part of the body is palpable when it gets enlarged.

When the liver is enlarged or the gallbladder gets grossly distended, the latter may be felt not in the hypochondrium but in the right lumbar region or even as low down as the right iliac fossa.

Once the gallbladder is palpable, note its shape, surface, consistency, tenderness and percussion note.

The Characteristics of Gallbladder Mass/Palpable Gallbladder

- The gallbladder mass is rounded or globular structure with well-defined margins.
- It moves freely with respiration similar to liver
- It is superficially placed, dull on percussion
- It is neither ballotable nor bimanually palpable
- The upper border of the mass cannot be reached.
- The renal angle on the back is not full.

The differences between palpable gallbladder and palpable right kidney are given in the Table 13.1.

Common Abnormalities

- 1. Tenderness over gallbladder area (Murphy's sign):** In acute cholecystitis, the gallbladder gets inflamed, swollen, painful and tender. Often, an extremely tender gallbladder can be palpated as an indefinite mass. Ask the patient to take deep breath and palpate for the gallbladder in the normal way. At the height of the inspiration, the breath is arrested with a gasp as the mass is felt. This represents *Murphy's sign*. This sign is not found in chronic

cholecystitis or uncomplicated gallstones. Hepatic tenderness may also increase with this manoeuvre but is usually not localised.

2. **Enlargement of the gallbladder** causes the gallbladder becomes enlarged and palpable in the following conditions:

- **Carcinoma of the head of the pancreas or any other cause of malignant obstruction of the common bile duct:** The gallbladder and biliary duct become dilated painlessly and progressively leading to deep jaundice with palpable gallbladder (*Courvoisier's sign*)
- **A stone in common bile duct (CBD):** If a stone is present in CBD, then there is intermittent colic, intermittent jaundice and fever with chills and rigors. By Courvoisier's law, gallbladder is not palpable but becomes palpable in an impacted stone, stricture or fixed luminal obstruction.
- **Mucocoele of the gallbladder:** Occasionally, the inflammation may be mild and subsides quickly sometimes leaving a gallbladder distended by mucocoele. In this condition, there is pain with palpable gallbladder.
- **Empyema of gallbladder:** It is a complication of acute cholecystitis, where the infection involves the whole wall of the gallbladder giving rise to localised peritonitis and acute pain. Occasionally, the gallbladder may become distended with pus (an empyema).
- **In carcinoma of the gallbladder:** The gallbladder will be felt as a stony hard, irregular swelling unlike the firm and regular swelling of the above two mentioned conditions.
- **Porcelain gallbladder:** The gallbladder wall may get calcified due to chronic inflammation. It may become palpable.
- **Emphysematous gallbladder:** Especially seen in diabetics and following hepatic artery embolisation. This is severe form of cholecystitis with gas forming organisms. On plain X-ray abdomen, air within gallbladder wall may be identified.
- **Mirizzi's syndrome:** This consists of obstruction of common hepatic duct or common bile duct by a stone impacted in the cystic duct with surrounding inflammation. (*Mirizzi's type I*). In *Mirizzi's type II*, the stone erodes into the common bile duct creating a fistula (*calculous cholecystitis*).
- **Chronic cholecystitis and cholelithiasis:** It is characterised by pain in the right hypochondrium radiating to inferior angle of the scapula, aggravated by a fatty meal and relieved by frequent belching or vomiting.

The gallbladder may become palpable and *Murphy's sign* may be positive.

The Spleen

When the spleen enlarges, it expands anteriorly, downwards and medially, often replacing the tympany of the stomach and colon with the dullness of a solid organ in *Traube's region* (Fig. 13.25). It then becomes palpable below the costal margin.

Spleen can be palpated by the following methods:

- **Bimanual method (Figs 13.26A and B):** The examiner's left hand is placed on the lower rib cage so as to pull the skin towards the costal margin, allowing the fingertips of the right hand to feel the tip of the spleen as it descends while the patient inspires quietly and deeply. Palpation is begun with the right hand in the left lower quadrant with gradual upwards movement towards the left costal margin thereby identifying the lower edge of the enlarged spleen. Once the splenic tip is felt, the finding is recorded by measuring the enlargement in centimeters below the left costal margin at some fixed point i.e. *left midclavicular line*, the *xiphisternal junction* or *from midpoint of umbilicus*. Bimanual examination can be done in supine or right lateral position.
- **Hooking method (Fig. 13.27):** The patient is put in right lateral position and the examiner stands on the left side behind the patient, hook your both hands over the left costal margin. The tip of the spleen can be felt striking the pulp of fingertips when the patient takes deep breath.
- **Dipping method (Fig. 13.28):** This method is used to palpate the spleen in presence of ascites where other methods are likely to displace the spleen. Stand on the right side of the patient. Palpate the spleen starting from the

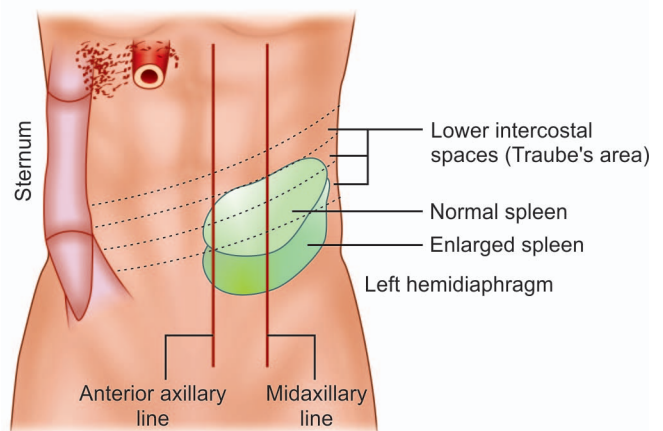
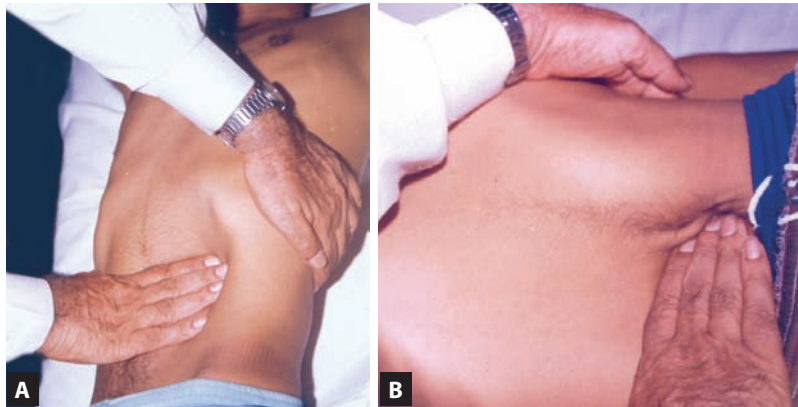


FIGURE 13.25 Traube's area/region (diagram). It lies underneath the lowest intercostal spaces (9th to 11th). Normally, this area is resonant, becomes dull on percussion in splenomegaly and left-sided pleural effusion



FIGURES 13.26A and B (A) Palpation of spleen by bimanual method for mild splenomegaly. Tip of the spleen will strike the fingertips of palpating hand; (B) Palpation of spleen by bimanual method for massive splenomegaly. Start palpation from the right iliac fossa and proceed towards the umbilicus obliquely

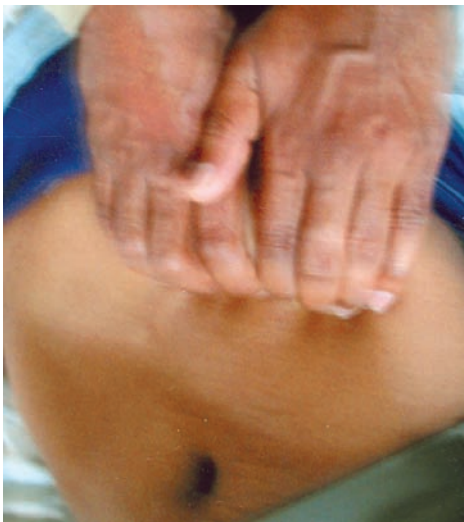

FIGURE 13.27 Palpation of spleen by hooking method

right iliac fossa moving towards the left hypochondrium. Dip your fingers into the abdomen with each palpation so as to displace the fluid to the side. If spleen is enlarged, it will strike back your hand, following each dip. By this method you can just judge the enlargement only while other characteristics are difficult to judge.

Note: Spleen is normally not palpable. It can become palpable only when it has enlarged two to three times its usual size.

Common Abnormality

Splenomegaly

Palpable spleen does not mean enlargement as it may be pushed down by the low descending diaphragm in emphysematous patients. Therefore to define its extent of enlargement, its upper and lower borders have to be defined and span of the spleen may be measured. The spleen enlargement may be graded as mild (1–2 cm), moderate (3–7 cm) and severe (7 cm or more).

Causes (For causes, read case discussion on Splenomegaly in Bedside Medicine by Prof. SN Chugh) However, common causes include infections (hepatitis, malaria, kala azar, typhoid, endocarditis), congestion (pericardial effusion, CHF, portal vein or hepatic vein thrombosis) haemolytic anaemias, collagen vascular disease (SLE) and infiltrative disorders (lymphomas and leukaemias).

The characteristics of splenomegaly are described in the Table 13.2.

The Kidneys

Adult kidneys are 11–14 cm (three lumbar vertebral bodies) in length, lie retroperitoneally on either side in lumbar region. The right kidney is usually a few centimeters lower because liver lies above it. Both kidneys rise and descend with respiration because the upper pole of each kidney is in contact with diaphragm.

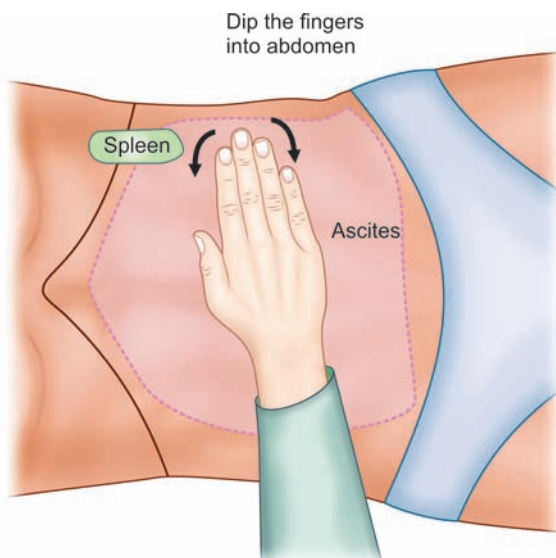


FIGURE 13.28 Palpation of spleen in the presence of ascites (dipping method)

TABLE 13.2 Distinguishing features between palpable spleen and left kidney

Feature	Spleen	Kidney
Mass is smooth and regular in shape	More likely	Mass is irregular
Mass moves with respiration	Yes, moves superficially and obliquely The movements are free	Yes, moves deeply and vertically movements are restricted (e.g. slight movement possible)
Able to insert fingers between the mass and costal margins	No	Yes
Palpable notch on the medial surface	Yes, if enlarged massively	No
Bilateral masses palpable	No	Sometimes (e.g. polycystic disease)
Percussion note over the mass	Dull usually	Resonant usually
Direction of the mass	Anterior, downwards and obliquely towards right	Anteroposterior
Mass extends beyond midline	Sometimes, if massively enlarged	Never (except with horseshoe kidney)
Renal angle	Empty	Full
Ballotability	No	Yes

Kidneys are usually not palpable but the lower pole of the right kidney unlike the left may be palpable bimanually in thin patients as a smooth, rounded swelling which descends on inspiration. The kidneys being retroperitoneal structure enlarge anteroposteriorly in the lumbar region filling the costovertebral angle (renal angle).

Method

- A bimanual method is used to palpate the kidneys.

Palpation from the Same Side (Bimanual Method)

- **Left kidney**
 - Move to the patient’s left side. Place your right hand posteriorly just below the costal margins with your fingertips just reaching the costovertebral angle (renal angle). Place your left hand anteriorly in the left upper quadrant.
 - Push the two hands together firmly but gently as the patient breathes out.
 - Feel for the lower pole as it moves down between the hands (i.e. try to capture the kidney between your hands) as the patient breathes in deeply. The lower pole of the kidney, when palpable, is felt as a rounded solid swelling between two hands, i.e. bimanually palpable.
 - **Test for ballotability:** Kidney can be pushed from one hand to the other. Push the kidney from back to the front with one hand and feel its movement with the other. This is known as *balloting*.

Kidney is a ballotable structure.

- Assess the *size*, *surface* and *consistency* of a palpable kidney.

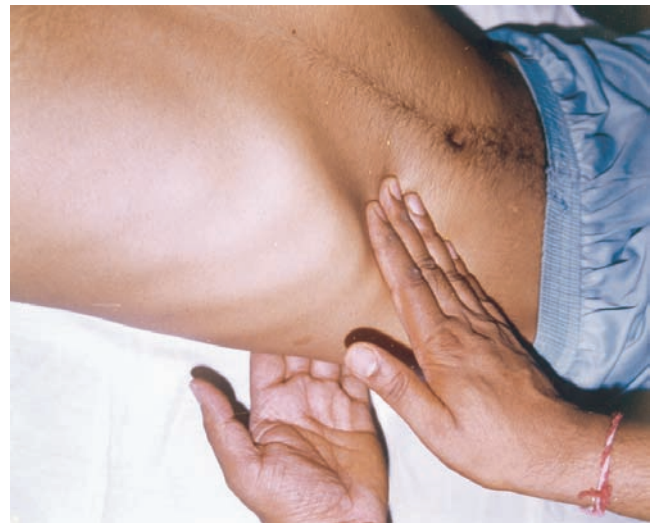

FIGURE 13.29 Palpation of the right kidney by bimanual method from the same side

- **Right kidney (Fig. 13.29)**
The method of palpation is same. Now you have to stand on the right side and repeat the above process in the manner described above. Now use the left hand posteriorly and right hand anteriorly.

Palpation from the Opposite Side

A kidney can be palpated from the opposite side by standing on the right side as follows:

- The left kidney can be palpated by placing the left hand posteriorly in the left loin and right hand anteriorly on the left upper quadrant. Feel the kidney’s lower pole between two hands as described above.
- The right kidney can also be palpated by placing left hand in right loin and right hand anteriorly over the right

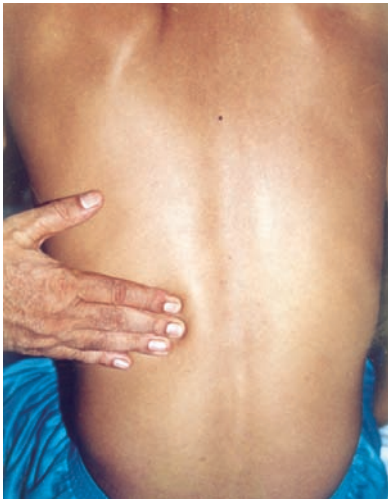

FIGURE 13.30 Elicitation of renal tenderness

quadrant. Feel the kidney's lower pole between two hands as described above.

Elicitation of tenderness of the kidney (Fig. 13.30): The tenderness of the kidney is elicited posteriorly by gently tapping the renal angle using a fist or fingertips with the patient sitting forward.

Common Abnormalities

- **Congenital horseshoe kidney:** The two kidneys are joined at their lower poles and may be palpable straddling the midline.
- **Enlarged kidney(s):** Owing to the varying degree of thickness of the abdomen, kidney enlargement is difficult for the inexperienced to assess unless there is gross enlargement. Irregularity of the surface or an abnormal consistency is more easily appreciated. The causes of enlargement are given in the Box 10.
The characteristics of the renal mass: The salient features of the renal mass and its differentiation from liver on right side and spleen on left side have already been described in the Tables 13.1 and 13.2 respectively.
- **Small kidneys:** The kidneys are smaller and naturally *nonpalpable* in chronic renal disease (e.g. chronic renal failure) where the diagnosis is suggested on the history rather than from the clinical examination. Ultrasound confirms the diagnosis.
- **Tenderness over the renal angle** may be elicited in inflammatory disease of the kidneys or in musculo-skeletal disorder.

Urinary Bladder

The bladder normally cannot be examined unless it is full or distended above the symphysis pubis.

Box 10

Causes of enlargement of kidney(s)

Unilateral	Bilateral
<ul style="list-style-type: none"> • Renal tumour • Hydronephrosis, pyonephrosis • Unilateral cystic disease (medullary cystic disease, medullary spongy kidney) • Compensatory hypertrophy of one kidney due to renal agenesis or hypoplasia affecting the other kidney or following nephrectomy 	<ul style="list-style-type: none"> • Polycystic kidneys • Lower urinary tract obstruction with hydronephrosis, pyonephrosis • Acute pyelonephritis in children • Amyloidosis • Diabetic nephropathy • Acromegaly

The Characteristics

- Distended bladder produces a globular swelling in the hypogastrium arising from the pelvis and extending to the umbilicus. Its lateral and upper borders can be made out but it is not possible to feel its lower border.
- The lump is smooth and tender.
- Pressure over the lump may produce sensation of urination.
- It is dull on percussion
- The mass disappears after micturition or catheterisation.

Abnormality

- Bladder distension occurs from outlet obstruction due to urethral stricture, prostate enlargement, drugs and medications and also from neurological disorders such as stroke, multiple sclerosis as well as in spinal cord compression.
- *Suprapubic* tenderness indicates cystitis.

Aortic and Other Pulsations

Aortic pulsations are not readily felt but can easily be made out with practice on deep palpation a little above and to the left of umbilicus. In older patients particularly women with marked lumbar lordosis and in thin individuals, the aortic pulsations are more easily palpable.

Method

- Fingertips are used as a means of palpation.
- Palpation is done to detect the pulsations and to assess the width of the aorta
- Press the extended fingers of both the hands, held side by side deeply into the upper abdomen on each side of aorta as illustrated (Fig. 13.31). Make out the left wall of the aorta on that side and note its pulsations.

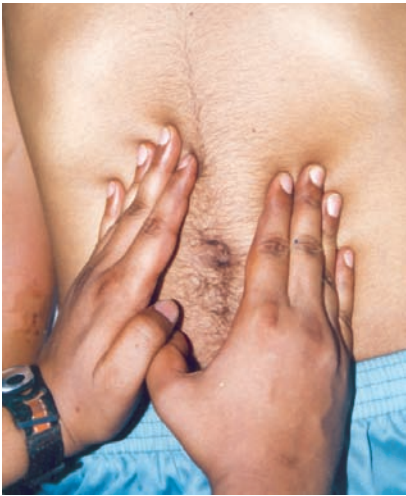

FIGURE 13.31 Palpation of aortic pulsations (e.g. aortic aneurysm)

- Remove both hands and repeat the procedure slightly to the right of the midline in upper abdomen. Make out now the right wall of the aorta by noting its pulsations.
- The width of the aorta, in this way, is assessed by measuring the distance between pulsations on either side of midline. Increased width more than normal suggests either a merely tortuous aorta or an aortic aneurysm (a pathologic dilatation of the aorta), hence, an ultrasound is a means to distinguish between the two.

Roughly, a normal aorta is 1–3 cm (average 2.5 cm) wide in adults; increase in width suggests an aneurysm.

Femoral vessels: (Palpation of femoral vessels is described under CVS examination in Chapter 11).

An Abdominal Lump, If Any

When a mass or a swelling is palpable in the abdomen, first of all make sure that it is not a normal structure. The normal palpable structures are already depicted in the Figure 13.3.

Next consider whether it could be due to enlargement of liver, spleen, right or left kidney, gallbladder, urinary bladder, aorta or para-aortic lymph nodes. The mass in relation to these structures as well as other masses in the abdomen are discussed further in this chapter.

Now palpate the mass carefully again and localise it to one of the anatomical regions and try to study the pathological nature of the mass. The points to be described about a mass include its *site, size and shape, surface, edge and consistency, mobility and adherence*, and whether it is *bimanually palpable or ballotable* or *expansile*. If the mass is expansile, then decide whether pulsations are intrinsic to the mass or are transmitted aortic pulsations.

Physical examination of an abdominal lump/mass

- **General**
 - *Appearance*, anaemic or pale, emaciated or jaundiced.
 - *Lymph nodes* at different sites especially supra-clavicular
 - *Pedal oedema*.
- **Local**
 - *Inspection (look at)*
 - Site
 - Size and shape
 - Surface, edge
 - Movements with respiration
 - Skin overlying the mass
- **Palpation (to elicit and define)**
 - Tenderness
 - Rigidity
 - Confirm the findings of inspection regarding size, shape, edge and surface
 - *Margins*, i.e. ill defined or well defined.
 - Notch present or not
 - *Consistency*, i.e. soft, firm or hard. Hard swelling are usually malignant. Soft swellings are usually cystic. A solid undefined, tender mass suggests an inflammatory mass.
 - **Abdominal (parietal) or intra-abdominal position:** To determine whether the mass lies in the abdominal wall or inside the abdomen, ask the patient to lift his/her head while you press firmly against the forehead. Now feel the swelling and decide whether it disappears or becomes prominent or does not change.

If swelling becomes less prominent or disappears it is intra-abdominal.

If it becomes more prominent, it is extra-abdominal.

If it remains the same, it must be within the layers of the abdominal wall.

- *Mobility or adherence: Move the mass in all directions, i.e. from side to side and above downwards.*

A mass arising from the small bowel, transverse colon, cysts in mesentery and large secondary deposits in the omentum move freely in all directions.

Fibroid uterus or pregnant uterus move from side to side that differentiates it from bladder and ovarian mass.

A fixed mass indicates either an adherent inflammatory mass or infiltration of malignant tumour into the abdominal wall and surrounding structures or the mass is situated retroperitoneally (e.g. pancreas).

- *Boundaries or limits: If the mass lies in the upper abdomen, feel the upper border and decide if it is*

possible to “get above it”. Similarly, if the mass lies in the lower abdomen decide whether one can “get below it”.

If one cannot get above the mass (i.e. disappears under the costal margins), a hepatic, splenic, renal or gastric origin of the mass must be suspected.

If one cannot get below it (i.e. arising from the pelvis), a bladder, uterus, ovary or rectal origin should be suspected.

– *Movements on respiration*

Swellings arising from the structures that lie in contact with diaphragm, i.e. liver, spleen, kidneys, gallbladder and distal stomach descend on inspiration.

Swellings originating from structures that have a mesenteric or other broad base of attachments do not move with respiration.

- *Pulsations, if present:* Feel the pulsations and decide whether these are intrinsic (expansile mass) or extrinsic (transmitted aortic pulsations) to the mass. Put two fingertips at some distance over the mass and look what happens to them during systole. If fingers are separated while being lifted, it is expansile swelling, (e.g. aneurysm), and if just lifted not separated, it is transmitted pulsation. Secondly, disappearance of the pulsations in knee-elbow position (mass is off the aorta) suggests transmitted aortic pulsations.
- *Bimanual palpation and ballotability.*

Renal mass is bimanually palpable and ballotable while a gallbladder mass may only be bimanually palpable. Actually, any mass that can be caught between two hands is bimanually palpable.

Fluctuation if present: Tap the mass from one side after fixing it between the fingers and thumb, if not already fixed, feel the impulse on the other side. Cystic mass and distended urinary bladder shows fluctuation positive.

Measurement of abdominal girth: Abdominal girth is measured with a tape at the level of umbilicus. It is increased in conditions associated with generalised distension of the abdomen.

- **Percussion:** Light percussion should be employed.
 - *Decide whether mass is resonant or dull.*

Masses originating from liver and spleen are dull on percussion while renal mass may be resonant.

- **Auscultation:** *Auscultate over the mass for rub* (hepatic or splenic) *or an arterial bruit* (hepatic haemangiomas, renal artery stenosis). The areas of auscultation over the abdomen are diagrammatically represented (see Fig. 13.39).

Differential Diagnosis of a Mass in Abdomen

1. Mass in the Abdominal Wall (e.g. Cold Abscess)

- A cystic swelling with no signs of inflammation (cold)
- Fluctuation sign is positive
- Swelling becomes prominent when patient is asked to raise head and shoulder against resistance (i.e. abdominal muscles contract and make the swelling prominent)
- There may be irregularity in the affected rib or a gibbus or deformity of the spine (i.e. it usually arises from the caries of the spine or the rib).

2. Intra-Abdominal Mass (e.g. Mass in Right Hypochondrium)

The differential conditions producing a mass in right hypochondrium are detailed in the Box 11.

3. Mass in Epigastrium (see Box 12)

4. Mass in the Left Hypochondrium

The splenic mass has been differentiated from the left kidney (see Table 13.2).

5. Mass in Right and Left Lumbar Regions (See Box 13)

6. Periumbilical Mass

It could be either due to peritonitis or intestinal obstruction, their characteristics have been highlighted in Table 13.6.

7. Mass in Right Iliac Fossa

The masses in the right iliac fossa are related to either appendix, caecum, ileocaecal junction, ascending colon, iliopsoas sheath, uterus and its appendages. Transplanted kidney is also placed in one of the iliac fossa.

• **Appendicular mass—characteristics**

- An irregular firm, tender mass initially fixed, may show slight mobility later on.
- Tympanitic note on percussion.
- History of severe pain around the umbilicus, settling down to the right lower quadrant.
- Early voluntary guarding may be replaced by involuntary muscular rigidity.
- Rebound tenderness suggests peritoneal inflammation around the appendix.
- *A positive Rovsing’s sign:* Pain in the right lower quadrant during left-sided pressure suggests appendicitis (Rovsing’s sign). So does the right lower quadrant pain on sudden withdrawal (*referred rebound tenderness*).

Box 11

Differential diagnosis of a mass in right hypochondrium

Liver	Gallbladder	Subphrenic abscess	Gastric or duodenal	Hepatic flexor of colon
<ul style="list-style-type: none"> • It moves with respiration (descends during inspiration) but is not mobile from side to side • It has a sharp edge • Fingers cannot be insinuated between it and the costal margins • It is dull on percussion. Dullness of the mass is continuous with liver dullness • Bimanual palpable but nonballotable mass • Liver span is increased (> 10 cm) 	<ul style="list-style-type: none"> • Pear-shaped or globular swelling of the size of an egg • Cystic and smooth • Upper border is not reachable (hidden behind liver) • Moves with respiration • Can be moved from side to side but cannot be pushed down to the loin like kidney 	<ul style="list-style-type: none"> • A diffuse tender swelling with fever and signs of toxæmia, e.g. sweating, tachycardia, rigors and chills and tachypnoea • Shallow respiration due to pain with frequent breath holding • Pain in right hypochondrium referred to shoulders • Fluoroscopy shows raised and fixed diaphragm with gas under it 	<ul style="list-style-type: none"> • An irregular, firm lump that fully moves with respiration • Patient is anorectic, emaciated with weight loss • If pyloric obstruction, present, peristalsis is visible from left to right • Succession splash is positive • Percussion note is tympanitic • Enlarged supraclavicular gland, if malignant • Barium meals may show a filling defect 	<ul style="list-style-type: none"> • Carcinoma of colon occurs in old age, produces alternate diarrhoea and constipation. The lump is firm and irregular, poorly moves with respiration. Stools are positive for occult blood • Barium enemas shows a filling defect • <i>Intussusception</i>. It occurs commonly in children, produces curved sausage-shaped lump in the line of colon with its convexity towards umbilicus. There is sudden intermittent pain and vomiting. Absolute constipation present without faecal odour. The lump may harden with screaming. Barium enema is diagnostic

Box 12

Differential diagnosis of mass in the epigastrium

Ventral hernia	Stomach and duodenum (e.g. pyloric stenosis)	Pseudopancreatic cyst	Aortic aneurysm
<ul style="list-style-type: none"> • A small midline swelling in the abdominal wall due to defect in linea alba, lies between xiphoid process and the umbilicus • Dragging pain or discomfort after food resembles peptic ulcer 	<ul style="list-style-type: none"> • A well-defined lump felt in the epigastrium in an infant • Projectile vomiting and wasting • Visible peristalsis from left to right 	<ul style="list-style-type: none"> • It is a collection of fluid in the lesser sac of peritoneal cavity due to trauma or pancreatitis • The mass/swelling is smooth, rounded, cystic fluctuation sign positive • USG and barium meal study will show the mass posterior to the stomach (in the bed of stomach) 	<ul style="list-style-type: none"> • An expansile mass situated in the midline • It can be differentiated from transmitted pulsations by knee elbow position in which transmitted pulsations will disappear

- *A positive psoas sign*: This can be elicited in different ways;
 - Place your hand just above the patient's right knee and ask the patient to raise it against resistance.
 - Or
 - Ask the patient to turn onto left side. Now extend the patient's right leg at the hip.
- *A positive obturator sign*: Flex the patient's right thigh at the hip, with the knee bent, and rotate the leg internally at the hip. This manoeuvre stretches the internal obturator muscle and produces pain.
- **Ileocaecal mass**
 - *Hyperplastic ileocaecal tuberculosis*
 - An irregular, firm, tender mass that slips under your fingers.
 - Intermittent subacute intestinal obstruction (i.e. vomiting, distension).

Increased pain on either manoeuvre constitutes a positive psoas sign indicating irritation of psoas muscle by an inflamed appendix.

Box 13

Differential diagnosis of lumbar region mass

<i>Umbilical hernia</i>	<i>Desmoid tumour of the rectus sheath</i>	<i>Tabes mesenterica</i>	<i>Retroperitoneal tumour (sarcoma)</i>
<ul style="list-style-type: none"> • Swelling is around the umbilicus • Impulse expansion on coughing present • Swelling is reducible • Common in multiparous women after the age of 40 years 	<ul style="list-style-type: none"> • It is a fibroma arising from rectus muscle either spontaneously or following surgery • Firm, round swelling which recurs after surgery • Recurrent growth becomes malignant 	<ul style="list-style-type: none"> • An irregular, ill-defined mass of lymph nodes and mesentery seen in children and young adults • Mass can be moved along the line of mesentery (a line passing from right hypochondrium to left anterior superior iliac spine) • There may be signs of subacute intestinal obstruction • Evidence of tuberculosis either in the lung or lymph node 	<ul style="list-style-type: none"> • Young patient • Firm, nodular mass attached to the posterior wall of the abdomen • Oedema feet if there is pressure on inferior vena cava

- Caecum is pulled up (may be detected on USG)
- Other manifestations of tuberculosis of lung or abdomen (lymph nodes).
- Barium meal study shows pulled up caecum and a filling defect.
(**Note:** Barium meal study should not be done in subacute intestinal obstruction).

- *Carcinoma of caecum or ascending colon*

- An irregular firm lump
- Change in bowel habits, e.g. alternate diarrhoea or constipation
- Occult blood in the stool
- Patient is anaemic and emaciated
- Age above 45 years
- Filling defect on barium enema

- *Amoebic typhlitis*

- An irregular, firm, tender lump
- History of amoebic dysentery (present or past)
- Stools are positive for *E. histolytica*

- *Impaction by a bunch of round worms*

- Irregular lump
- History of intermittent abdominal colic
- History of passage of a large worm

• **Iliopsoas abscess**

- It may be appendicular (read appendicular lump).
- It may be infection of a haematoma in the traumatised iliopsoas muscle producing pain, tenderness, guarding, rigidity, etc.
- It may be a cold abscess gravitating down deep to the inguinal ligament into the thigh, fluctuation on either side of the inguinal ligament is positive. There may be Pott's disease of the spine (e.g. gibbus or spinal deformity).

• **Gallbladder**

- A huge distended gallbladder with hepatomegaly may be palpable in this region as discussed (Read gallbladder mass).

• **Unascended kidneys**

- Read characteristics of renal mass.

• **Undescended testis**

- When palpable, it is pathological (i.e. atrophic)
- Hard, irregular lump
- Absence of testis in the scrotum.

• **Uterus or tubo-ovarian mass**

- Usually a midline swelling extending into the right iliac fossa (uterine mass) or localised in the iliac fossa (tubo-ovarian).
- One cannot get below the mass.
- Mass moves from side to side.
- Menstrual disturbances are usual accompaniments.
- Vaginal examination will confirm the diagnosis.

8. *Mass in the Hypogastrium*

- Distended urinary bladder (Read the characteristic of bladder mass as already discussed).
- Uterus and its appendages
 - A spherical midline mass arising from the pelvis lower limit cannot be reached.
 - Firmer than urinary bladder
 - Moves from side to side, not above downwards
 - Menstrual irregularity present.
 - Catheterisation will differentiate it from bladder mass (disappears after catheterization).
- Tubo-ovarian (salpingitis, ovarian cyst or tumour)
 - Mass arising from one side of the pelvis, may become central later on.

- Pain, fever and tenderness present in salpingitis due to surrounding pelvic peritonitis.
- Menstruation normal or scanty
- Ovarian cyst or tumour is dull on percussion but flanks remain resonant, i.e. a feature that distinguishes it from ascites.
- Vaginal examination confirms the diagnosis.
- Pelvic abscess
 - It may follow acute appendicitis, salpingo-oophoritis and puerperal sepsis.
 - Constitutional symptoms, i.e. fever, pain abdomen, nausea
 - Copious discharge of mucus per rectum due to irritation of rectum.
 - Increased frequency of micturition due to irritation of bladder.
 - Rectal examination shows bulging of anterior part of rectum.

9. Mass in the Left Iliac Fossa

- Normally palpable masses (*see* Fig. 13.3)
 - Thickened sigmoid or descending colon
 - Impacted faeces.
- Abnormal masses
 - *Cold abscess of abdominal wall.* (A) parietal swelling, may present in any quadrant.
 - *Carcinoma of sigmoid colon*
 - Increasing constipation
 - Loaded colon proximal to obstruction, signs of malignancy, i.e. anaemia, weakness, cachexia.
 - Sigmoidoscopy/colonoscopy is diagnostic.
 - Barium enema shows a filling defect.
 - *Diverticulosis/Diverticulitis*
 - Evidence of diverticulosis, e.g. history of recurrent pain, flatulent distension of lower abdomen, diarrhoea or constipation. Barium enema is diagnostic, i.e. shows saw-tooth appearance of the colon.
 - Diverticulitis evidence of inflammation, e.g. pain, fever, altered bowel habits, tender colon. Confirmation is done by CT after opacification of bowel.
 - *Iliopsoas mass*—already discussed above
 - *Undescended testis*—already discussed above
 - *Unascended kidney*—already discussed above.

Percussion



The aim of abdominal percussion is to define liver and splenic dullness and distinguish between resonant (gaseous

distension) and dull (ascites, solid or cystic mass) percussion note. Normal percussion note is resonant over whole of the abdomen.

Fluid gravitates into flanks during lying down, hence, flanks are dull on percussion in ascites. Percussion is tympanitic in gaseous distension, e.g. ileus and intestinal obstruction, intussusception. Solid (tumour or gravid uterus) and cystic (ovarian cyst) masses in the abdomen are dull.

Method

- Percussion is done from resonant to dull area. Start percussion in the centre and move to the periphery of the abdomen.
- Place the percussing finger on the abdomen parallel to the anticipated change in the percussion note.
- Percuss lightly for superficial structures such as lower border of the liver and firmly for the deeper structure, e.g. upper border of the liver. Measure the vertical span of the liver dullness (Fig. 13.32) by mapping out the upper border of the liver dullness by percussing the chest starting from 4th intercostal space downwards in midclavicular line, and lower border by percussing the upper abdomen starting from the umbilicus towards right hypochondrium in midclavicular line. The distance between the upper border of dullness and lower border of dullness is the vertical span of liver dullness. Normal liver span is 10–14 cm.

The span of liver dullness is increased when the liver is enlarged, e.g. amoebic liver abscess, malignancy liver.

The span of liver dullness is decreased when liver is small and shrunken (fulminant hepatitis) and liver dullness is obliterated when free air collects below the diaphragm (perforation of a hollow viscus) right sided pneumothorax, visceroptosis (drooping of organs including liver) or interposition of the colon between the liver and diaphragm—*Chilaiditi's syndrome*; serial observations may show a decreasing span of dullness with resolution of hepatitis, CHF or less commonly, with progression of fulminate hepatitis.

Liver dullness may be displaced downwards by the low diaphragm in COPD (emphysema).

Abnormalities on Percussion

Distention of Abdomen

Three common causes of diffuse distension of abdomen are:

1. Ascites.
2. A large ovarian cyst.
3. Obstruction of the large bowel, distal small bowel or both.

Percussion distinguishes between the above three mentioned conditions (Figs 13.33A to C).

A protuberant abdomen with bulging flanks suggests the possibility of free fluid in the peritoneum (ascites) while gas filled intestines float to the top (in the centre), therefore, percussion note is dull in flanks and resonant in the centre in ascites (Fig. 13.34A) while the whole abdomen is tympanic in intestinal obstruction with increased peristalsis (Fig. 13.33C).

Elicitation of Signs of Ascites

Two important techniques help to confirm the presence of ascites, although both may be misleading unless there is sufficient free fluid present to give generalized enlargement of the abdomen.

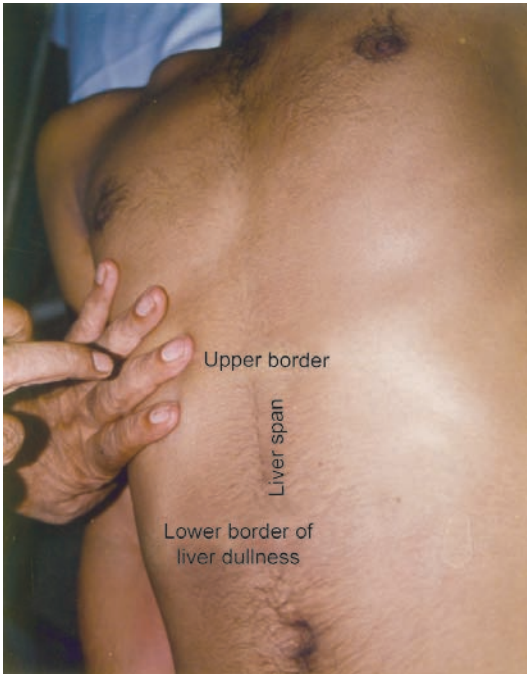


FIGURE 13.32 Percussion for upper and lower borders of liver dullness and measurement of liver span (Remember the best way to define liver span is ultrasound)

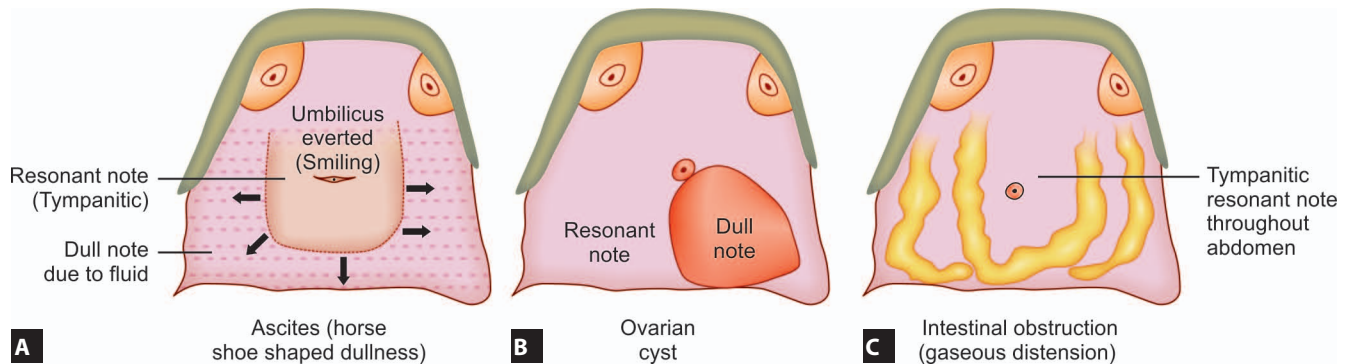
- Shifting dullness (Figs 13.34A to D):** Ask the patient to lie supine. Percuss from the centre outwards towards one of the flank; say right flank keeping the fingers in the longitudinal axis, until dullness is detected. Normally the dullness is detected over the lateral abdominal musculature; while flanks are dull in ascites. Then keeping the hand on the abdomen, asks the patient to roll away from you on to the left side. Percuss again in the new position, if the previously dull note has now become resonant then ascitic fluid is probably present. To confirm its presence, repeat the manoeuvre on the left side of the abdomen.

The sign is positive in moderate ascites but may become absent when fluid is either too small or too large (no space to shift the fluid).

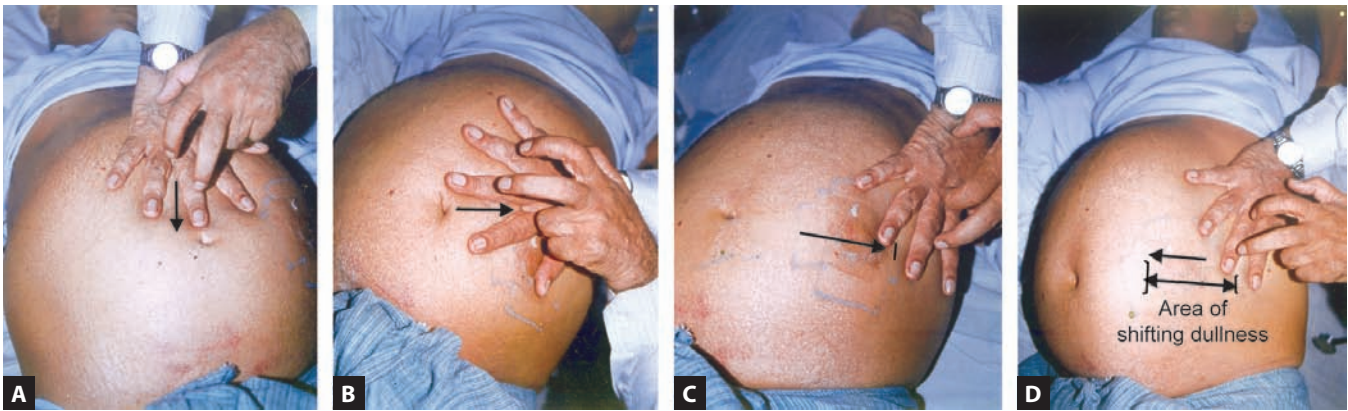
- Fluid thrill (Fig. 13.35):** Ask the patient or an attendant to put the edge or side of the hand in the midline of the abdomen and press firmly as shown in Figure 13.35. This pressure will stop the transmission of waves or thrill through the fat in the abdominal wall. Place your one hand flat in one of the flank to detect the impulse while you tap or flick the opposite flank with your other hand (Fig. 13.35) for an impulse or thrill which will be transmitted to the receiving hand if fluid is present. Fluid thrill just suggests fluid under tension either in a cavity (peritoneal) or a cyst (ovarian).

Presence of fluid thrill indicates tense ascites. It may be absent in mild ascites.

- Horse-shoe shaped dullness:** This can be demonstrated in ascites by mapping out dullness from the umbilicus outwards in different directions (Fig. 13.34A). Dull area accumulates in the dependent parts and the resonant intestines float up in centre.
- Pudal’s sign (dullness in knee-elbow position):** The centre of the abdomen is percussed as the patient adopts



FIGURES 13.33A to C Importance of percussion in a patient with distended abdomen. Percussion can distinguish the resonant structures from dull structures inside the abdomen. Fluid (A) solid mass or cyst (B) can easily be distinguished from gaseous distension (C)



FIGURES 13.34A to D Elicitation of shifting dullness. Start percussing from resonant (A) area towards dull area (B) till you reach a dull area (C). Now while keeping the finger over dull area ask the patient to turn to the other side, now the area which was dull earlier on percussion becomes resonant due to shift of fluid, hence, shifting dullness is present (D). To further define the area of shifting dullness, now start percussion again from this newly found resonant area toward umbilicus to know where the dullness has shifted. Mark the line of demarcation at the start of dull area now. The length of the space between the previous resonant area in D and newly found dull area on change of position indicates the area of shifting dullness, i.e. the space over which fluid has shifted (indicated between arrows by arrows head \longleftrightarrow in Fig. 13.34D)

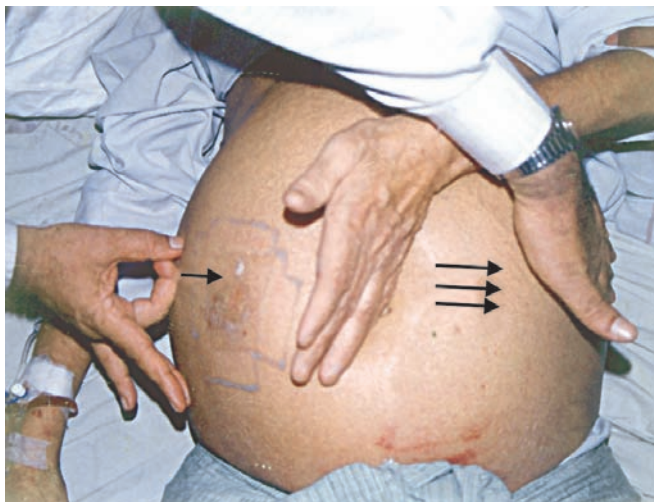

FIGURE 13.35 Elicitation of fluid thrill

a knee-elbow position. The fluid collects (gravitates) in the centre in this position, making it dull on percussion.

Puddle's sign demonstrates minimal or mild detectable ascites (Fig. 13.36).

Cirrhosis of the Liver

Flapping tremors (asterixis): Look for the presence of flapping tremors (Fig. 13.37) in a patient with cirrhosis of the liver with ascites. Ask the patient to outstretch his/her hands with widened fingers if patient is conscious. Note the flaps of the hands. In unconscious patient, hold the wrist with one hand and dorsiflex the patient's hand with your other hand and feel for the flap with palm of your hand.

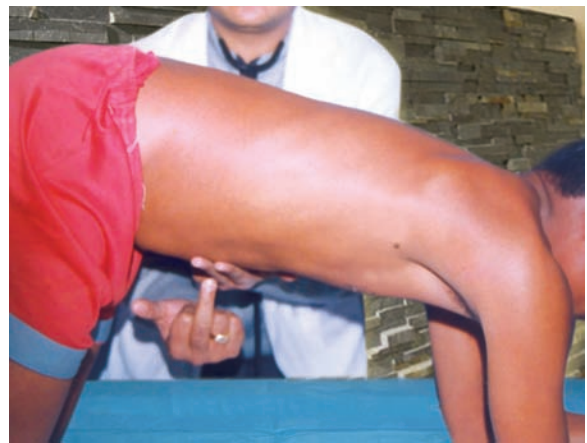

FIGURE 13.36 Puddle's sign for mild ascites

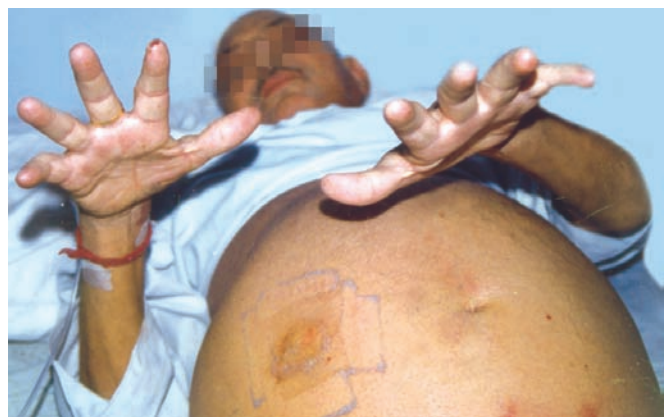

FIGURE 13.37 Demonstration of flapping tremors in a patient with cirrhosis of liver and ascites. This should be demonstrated in sitting position in conscious patients, if not able to sit then in lying down position

Hydatid Thrill/Sign

It is elicited by placing 3 fingers over the swelling and percussing the middle finger. After thrill will be felt by other two fingers. This sign was used to demonstrate a hydatid thrill in the liver or in other abdominal structures, but is now-a-days not practised because of doubtful significance.

Percussion for Splenic Dullness

It is accomplished with any of the three techniques described by Nixon, Castell, or Barkiun.

- **Nixon method:** The patient is placed on the right side so that the spleen lies above the colon and stomach. Percussion begins at the lower level of lung resonance in the posterior axillary line and proceeds diagonally along a perpendicular line towards mid and anterior axillary lines.

Normally, the upper border of dullness is 6–8 cm above the costal margin. Dullness >8 cm in an adult indicates splenomegaly.

- **Castell's method:** With the patient supine, percussion in the lowest interspace in anterior axillary line (8th or 9th) produces a resonant note during deep inspiration if spleen is normal in size. A dull percussion note on full inspiration suggests splenomegaly.
- **Percussion of Traube's semilunar space:** The borders of the Traube's space are 4th rib superiorly, the left midaxillary line laterally, and left costal margin inferiorly. The patient lies supine with left arm abducted. During normal breathing, the space is percussed from medial to lateral margins, yielding a normal resonant sound. A dull percussion note suggests splenomegaly.

Note: All these techniques are less reliable in obese patients and in patients with full or distended stomach.

Percussion is of limited value in determining the size and position of the spleen as this can only be roughly assessed from the percussion note. However dull note over the left hypochondriac mass is invariably splenic in origin.

Splenic area of dullness may be masked by expanding left lung in COPD (emphysema).

Auscultation

The areas to be auscultated are represented in Figure 13.38.

- *Auscultate peristalsis bowel sounds for at least 3 minutes before deciding that they are absent.* However, normal peristaltic activity of the gut produces a characteristic gurgling sound which may be heard from time to time by the unaided ear (borborygmi). Normal peristaltic sounds
- *Listen for a vascular bruit over the aorta or other vessels and liver:* Place the stethoscope lightly on the abdominal wall over the aorta in epigastrium above and to the left of the umbilicus and listen for bruit. For renal bruit, place the stethoscope similarly just above and to the side of

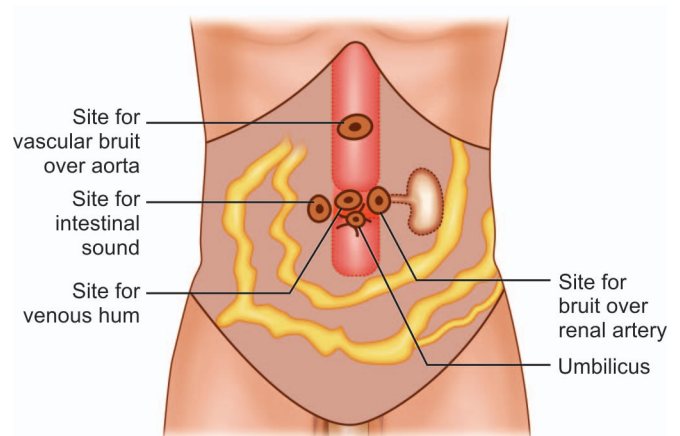


FIGURE 13.38 Sites for auscultation over the abdomen

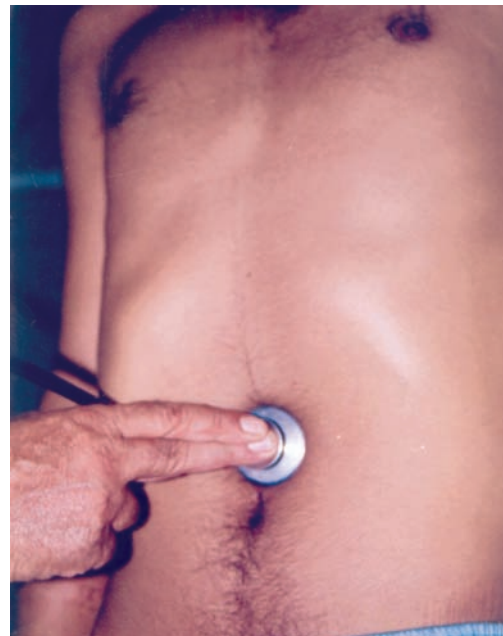

FIGURE 13.39 Auscultation for the bowel sounds

can be heard with stethoscope placed just above the umbilicus on either side. The sounds appear at an interval of 8–10 seconds though the interval varies greatly and they occur more frequently after meals.

Place the stethoscope preferably in the centre just right to the umbilicus and keep it pressed there until sounds are heard (Fig. 13.39). Normal bowel sounds are heard as intermittent low and medium pitched gurgles at a rate of 3–5/min with an occasional high-pitched noise.

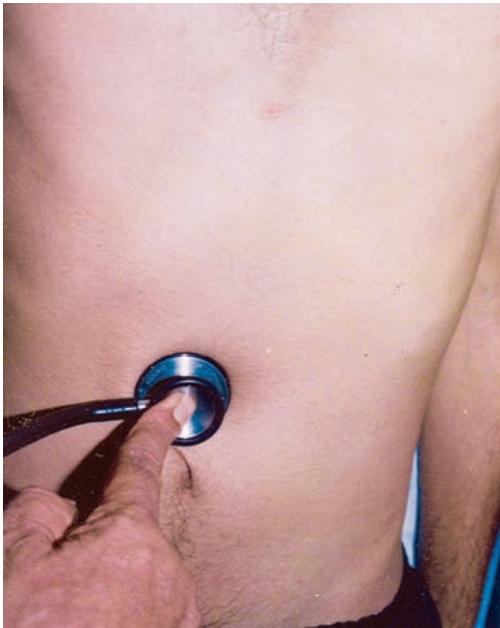

FIGURE 13.40 Site for auscultation for a bruit over the renal artery in a patient with renal artery stenosis

umbilical (Fig. 13.40). Listen for bruit in the corresponding iliac fossae, and over the common femoral arteries in each groin.

Listen for a bruit or venous hum or rub in right hypochondrium over the liver.

- **Venous hum:** A humming sound may be heard between xiphisternum and the umbilicus in portal hypertension.
- **Friction rub:** Auscultate over the splenic and hepatic area for any rub (friction sound).

Listen for succession splash if pyloric obstruction is suspected

- **Succession splash:** A splashing sound like shaking a half-filled bottle is termed as *succession splash*.

To elicit a succession splash in stomach, place one hand over the lower ribs and shake the patient quickly and rhythmically from side to side and auscultate over the epigastrium.

Abnormalities on Auscultation

- **Abnormal bowel sounds:** Increased and exaggerated bowel sounds (borborygmi) are heard in mechanical small gut obstruction. If associated with bouts of colicky pain abdomen, then they are pathognomonic of it.
 - High-pitched tingling sound may be heard after every 10–30 seconds in a dynamic obstruction (paralytic ileus). This represents the fluid spilling over one distended gas or fluid filled loop to another. Later on the peristalsis ceases and, bowel sounds become absent.

- *Silent abdomen* (absence of bowel sounds) occurs in;
 - Generalised peritonitis
 - Paralytic ileus.
- **Vascular bruits:** Arterial bruits (harsh systolic murmurs) in the abdomen may arise from the aorta, or any other narrowed or partially obstructed vessel (renal artery stenosis in renovascular hypertension). Rarely, a systolic bruit may be heard over the liver in hepatoma (due to increased vascularity).
- **Venous hum:** It is heard over well-developed collateral circulation in portal hypertension (**Cruveilhier-Baumgarten syndrome**).
- **Friction rub** over hepatic area indicates perihepatitis due to embolism, hepatoma or may occur following a liver biopsy. A splenic rub indicates perisplenitis due to splenic infarct(s) in embolisation and sickle cell anaemia.
- **Succession splash:** This can be produced in normal stomach upto 2 hours after food or drink. Abnormally, it occurs in pyloric obstruction, advanced intestinal obstruction with grossly dilated loops of gut and in paralytic ileus.

EXAMINATION OF THE GROINS AND BACK

Anatomy of the Groin

Because hernias are relatively common in this region, it is important to understand the anatomy of the groin. The basic landmarks are anterior superior iliac spine, the pubic tubercle, and the inguinal ligament that runs between them. Find these on yourself and a colleague.

The inguinal canal (a common site for hernia) lies above and parallel to the inguinal ligament, is a tunnel having an external opening called *external inguinal ring* and an internal opening called *internal inguinal ring* (Fig. 13.41) which lies just above the midpoint of inguinal ligament. Neither the canal nor internal inguinal ring is palpable through the abdominal wall normally. When loops of gut force their way through weak areas of inguinal canal, *inguinal hernias* appear and ring(s) become dilated and palpable.

Another potential site is femoral canal which lies below the inguinal ligament. Although you cannot see it, you can estimate its site by placing your index finger, from below, on the right femoral artery, your middle finger then overlies the femoral vein and your ring finger on the femoral canal. Femoral hernias protrude here.

Inspection and Palpation

A. The Groin

Inspection of the groin for the hernial sites has been described during examination of abdomen. Look for cough impulse

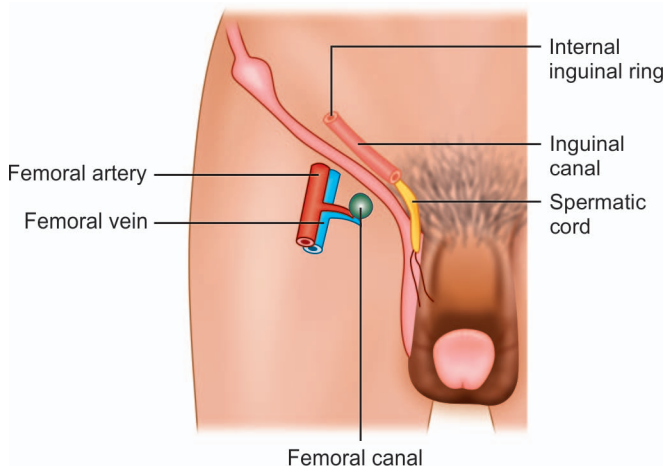


FIGURE 13.41 Anatomy of inguinal canal

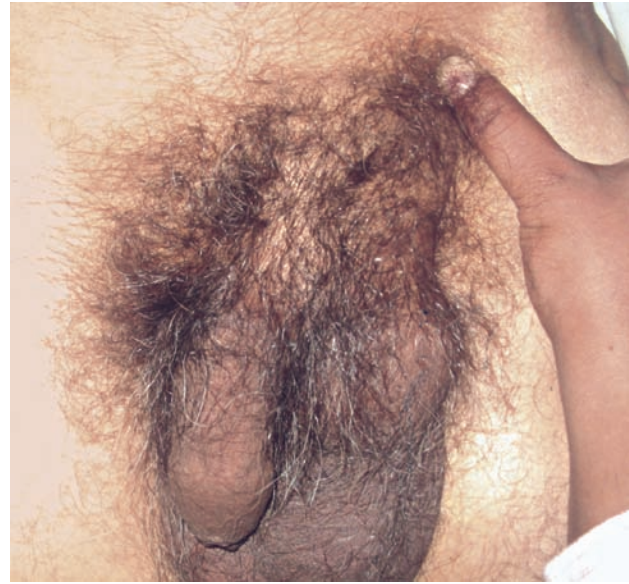
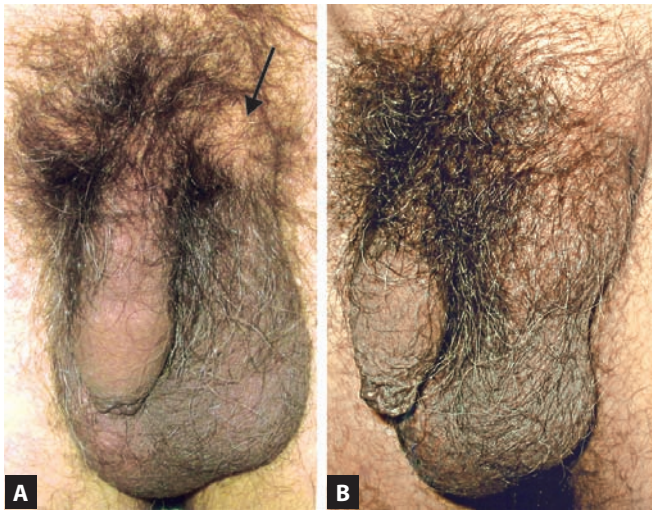
FIGURE 13.43 Palpation for left inguinal hernia. The inguinal hernia is direct



FIGURES 13.42A and B Inguinal hernia: (A) Note the swelling in the left inguinal region due to hernia (arrow). It is reducible. Patient can reduce the hernia himself; (B) Cough reflex. The hernia reappears on standing and coughing. It increases in size and becomes prominent during coughing

while asking the patient to turn his/her head to one side and cough. If no bulge is apparent on inspection, then proceed to palpation. Place the left hand in left groin so that the fingers overlie and are in line with the inguinal canal; place the right hand similarly in the right groin. Now ask the patient to cough (strain) and feel for any bulge (expansive impulse) with each hand. A positive impulse indicates hernia. Normally, when patient coughs and raises the intra-abdominal pressure, a nonexpansive impulse is transmitted to the palpating hand which may be confused with small reducible inguinal hernia in inexperienced hand.

A bulge that appears on straining (coughing) suggests a hernia (Figs 13.42A and B).

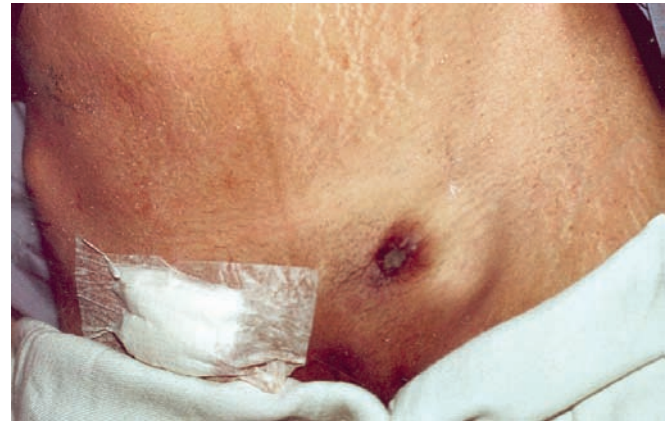

FIGURE 13.44 Inguinal lymph nodes. The biopsy of the lymph node has been done on right side and the wound is dressed. The left inguinal region shows a mass with discharging sinus (↓)

Palpate for an inguinal hernia by placing your fingers or thumb on the anterior thigh in the region of the femoral canal (Fig. 13.43). Ask the patient to cough or strain down again. Note any thrust imparted to the fingers/thumb.

The difference between inguinal and femoral hernia has already been discussed (Read hernias under inspection of abdomen).

Palpations of the femoral arteries have already been discussed (read CVS examination Chapter 11). Auscultation of femoral artery for any bruit has also been described.

Now palpate for inguinal lymph nodes (Fig. 13.44) for any enlargement along the femoral artery, medially beneath the inguinal ligament towards perineum. Repeat this examination on the other side also.

When the patient complains of a lump in the groin, he/she should be examined lying down and standing up.

B. The Back

Inspect the back of abdomen for any swelling, skin lesion or deformity of the spine or a tuft of hair (spina bifida).

Palpate the spine and ribs for any deformity and tenderness.

A gibbus indicates Pott's disease of the spine.

Abnormalities of the Groin

- Swelling, e.g. hernia
- Mass, e.g. lymph nodes.

The hernia

Examination of genitalia have been discussed separately (Chapter 14). However, genital examination is also important when patient presents with abnormalities of the groin or acute or subacute intestinal obstruction (disease of genitalia may lead to abdominal symptoms such as pain or tenderness).

Most of the complains pertaining to the groin include a lump in the groin. Most lumps in the groin are either hernias or enlarged inguinal lymph nodes. The inguinal hernias are more common than femoral.

Examination of the groins and scrotum also constitute a part of general examination. Lymphadenopathy in the groin may be a part of a generalised disorder such as lymphoma, leukaemia, hence, the lymph nodes should be examined as a whole throughout the body including cervical, axillary, etc. not in isolation.

Method

Ask the patient to stand up in front of you, turn him to one side and inspect the site of swelling noting that it descends into the scrotum or not. Now ask him to cough loudly and look for cough impulse (expansile impulse) and try to decide whether it is above or below the inguinal ligament. If a cough impulse produces a bulge on inspection, it suggests hernia, so move to that side where the lump is present in the groin and stand by the side and a little behind the patient. If right groin is being examined, support the patient by putting left hand on the right buttock, and fingers of the right hand being placed over the inguinal canal. Ask the patient to strain (cough) and feel for an expansile impulse, if present, indicates hernia.

If hernia is confirmed to be inguinal, then proceed to decide.

- Whether it is direct (Fig. 13.43) or indirect (this has also been discussed in inspection of abdomen-Hernias)
- *Is the hernia fully reducible or not?* It is clinically important because nonreducible hernias are prone to strangulation.

The best way to demonstrate it is to ask the patient to lie down; if protuberance disappears, hernia is reducible. You can also ask the patient about its reducibility, and if need to be confirmed, then ask the patient to reduce it himself.

- *What are the contents of hernial sac?* The gut produces gurgle, is soft and compressible on palpation; while omentum in the sac feels firmer and doughy.

Differential Diagnosis of Inguinal Hernia

The conditions that mimic inguinal hernia include:

- A large hydrocoele of tunica vaginalis
- A large cyst of the epididymis
- An undescended testis (scrotum will be empty in this condition)
- A lipoma or a hydrocoele of the spermatic cord.

Differential Diagnosis of Femoral Hernia

In addition to inguinal hernia, the other conditions to be kept in its differential diagnosis include:

- A lipoma in femoral triangle
- A pulsatile aneurysm of the femoral artery
- A sphenovarix is a swelling containing varicose sphenous veins, hence, a bluish tinge is imparted to the swelling. The swelling disappears on lying down and a venous hum may be heard over it.
- A psoas abscess (mass is fluctuant and compressible)
- An enlarged lymph node. Look for any evidence of infection in the areas it drains, i.e. feet, legs, thigh, scrotum, pudendal or perianal areas. If inflammatory in origin, it may be tender and skin temperature be raised (acute lymphadenitis).

Differential Diagnosis of a Scrotal Swelling

The three ways used for accurate diagnosis and differential diagnosis of a scrotal swelling are:

1. *Inspection* (Fig. 13.45).
2. *Palpation*.
3. *Transillumination*.

- Expose the groin and scrotum fully. Look for any abnormality or swelling.
- If a swelling is present, proceed to determine the following characteristics on palpation.

1. *Can one get above the swelling?* To decide it, palpate the neck of the scrotum between fingers and thumb and determine:
 - Whether finger and thumb can be approximated or not. If they can be approximated (nothing is felt in between them) then the swelling is limited to

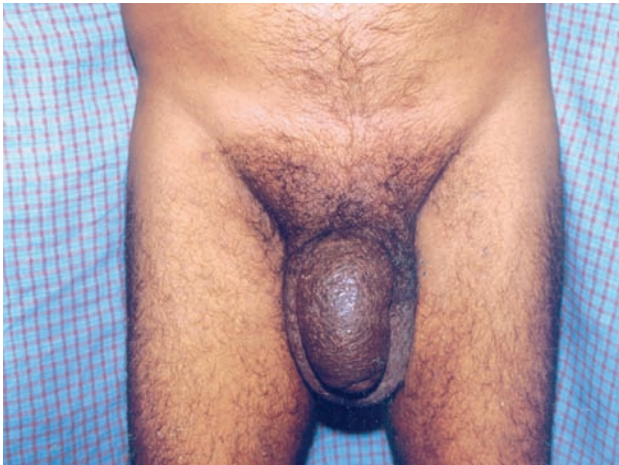

FIGURE 13.45 Normal scrotum. Exposure of the patient for inspection of scrotum

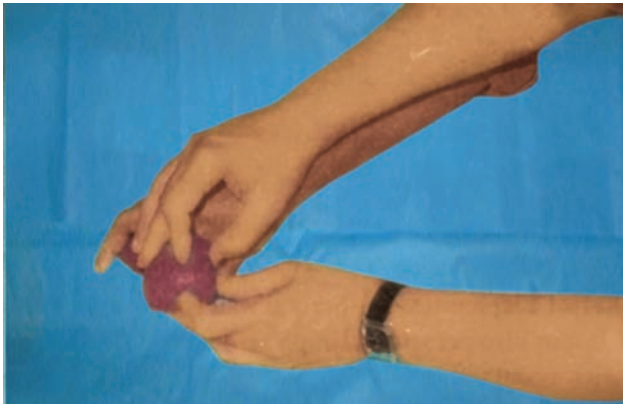

FIGURE 13.46 Fluctuation test in a cystic scrotal swelling. Hold the swelling with fingers and thumb of both hands at two opposite ends. Now compress (or tap) the swelling on one side by one index finger (displacing finger) and feel the impulse on the other end by another index finger (watching finger)

spermatic cord (i.e. one can get above the swelling). If cannot be approximated due to presence of cord between the thumb and finger, then swelling is arising from the above, i.e. groin, and may be inguinoscrotal hernia (one cannot get above the swelling).

2. *Is the swelling cystic or solid?* This is decided by palpation (fluctuation test Fig. 13.46) as well as by transillumination.
3. Whether *transillumination* is positive? To decide it, first make the scrotal swelling tense by gently holding it, and place a bright pin-torch just behind the swelling. Transillumination of light across the swelling indicates it to be cystic in nature (i.e. an epididymal cyst or a hydrocoele of tunica vaginalis see Fig. 14.36B). If the swelling is non-transilluminant, then it is solid, hence, palpate it again to decide whether it is epididymis (epididymitis produces a painful swelling) or testis (orchitis produces a painful swelling while malignancy is usually painless).

4. **A postural relation:** A swelling that is inapparent on lying down but it becomes apparent on standing could be a varicocele. If swelling is cystic and feels like palpating a bag of worms, it is a varicocele.

The various abnormalities on scrotal swelling are discussed under the examination of urogenital system Chapter 14.

Female genitalia

(Read Chapter 14).

THE ANUS, RECTUM AND PROSTATE

Applied Anatomy

The gastrointestinal tract terminates in a short segment called the *anal canal*. The anal canal is usually kept in closed position by muscular action of the voluntary external anal sphincter and involuntary internal anal sphincter. The anal canal is directed along a line roughly between anus and umbilicus. The anal canal is demarcated from the rectum superiorly by anorectal junction which can be seen on proctoscopic examination as a stout band of muscle above which rectum balloons out and turns posteriorly into the hollow of coccyx and the sacrum.

The prostate gland surrounds the urethra, has two lateral lobes and one median lobe. The seminal vesicles, shaped like rabbit ears above the prostate are not normally palpable.

In female, the uterine cervix can usually be felt through the anterior wall of the rectum.

Common Presenting Symptoms of Anorectal and Prostate Disorders

- Change in bowel habits (occur in cancer)
- Blood in the stool (polyps, cancer, piles, GI bleed)
- Pain during defaecation, rectal bleeding and rectal prolapse
- Anal warts or fissures (*fissure in ano*)
- Thinning of stream of the urine (prostate enlargement or urethral obstruction)
- Increased frequency and burning during micturition (urinary infection).

Examination

The examination includes inspection of the perianal area, anus (Fig. 13.47) and digital (per rectum) examination of anal canal and rectum.

Method

Make the patient to lie in left lateral position with knees drawn well up and buttocks projecting over the side of bed/couch.

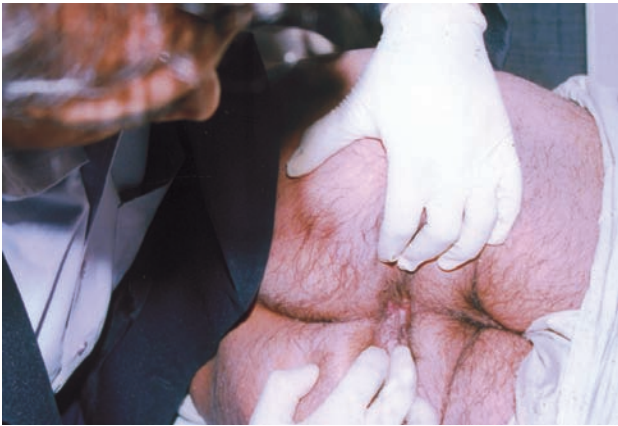

FIGURE 13.47 Examination (inspection) of anus

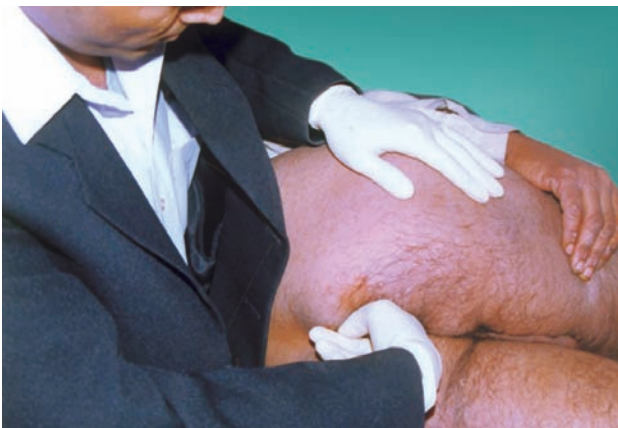

FIGURE 13.48 Digital (per rectal) examination

A good source of light should be used for inspection. Put a disposable glove on the right hand and stand behind the patient's buttocks facing the patient's leg (Fig. 13.48). Explain the procedure to the patient and assure him that you will be as gentle as possible.

Inspection

After separating the buttocks, inspect the anus and perianal area for any abnormality such as:

- *Inflammation of skin or dermatitis or rashes or excoriations.*
- *Anal skin tags* (occur in severe pruritus or prolapsed piles).
- *Anal warts (condylomata acuminata)* which are sessile or pedunculated papillomata with red base and white surface and are numerous.
- Note any *hole or dimple* near the anus with a tell-tale bead of pus or granulation (*Fissure-in-ano*).
- A *sentinal pile* is a tag of skin which is pathognomonic of anal fissure. The fissure can easily be demonstrated by drawing apart the anus to reveal the linear tear in

the lining of anal mucosa. Anal fissures are common in proctitis and Crohn's disease.

- *A perianal haematoma* (thrombosed external pile).
- *Prolapsed strangulated piles* (prolapsed pile which is deep red or purple is surrounded by oedema of the anus and perianal skin).
- **An abscess:** A tender fluctuant swelling which deforms the outline of the anus is perianal abscess—a point that distinguishes it from ischiorectal abscess where anal outline is maintained.
- *Note the presence of any ulceration.*
- **Rectal prolapse:** If rectal prolapse is suspected, ask the patient to bear down and note whether any pink rectal mucosa or bowel comes out through the anus.
- **Perineal bulge:** Note whether the perineum bulges itself downwards.

Downward bulging of the perineum during straining or coughing indicates weakness of pelvic floor muscles usually due to denervation of these muscles. This sign is also seen in women after childbirth, in women with urinary—faecal incontinence or in patients with severe constipation.

Palpation (Digital Examination)

Lubricate your gloved right index finger and place it flat on the anus. As the sphincter relaxes, gently insert the fingertip into the anal canal, in a direction pointing towards the umbilicus (Fig. 13.48). If severe pain is elicited by this manoeuvre then further examination must be stopped and now spread the anus with the fingers and examine it for any anal fissure which might explain this tenderness or pain.

If no pain or discomfort is elicited, then proceed further,

- **Note the sphincter tone of the anus:** Normal tone of sphincter grips the finger.

Sphincter tightness occurs in anxiety, inflammation or scarring. Sphincter is lax in neurological diseases.

- Rotate the finger through 360 degrees in the anal canal and feel for any *induration, thickening or irregularity of the wall of anorectum.*

Induration may be due to inflammation, scarring or malignancy. The irregular border or nodularity of border indicates rectal cancer.

To bring the lesion (nodularity, irregularity or induration) within a reach of palpating finger, first take out the finger and ask the patient strain down and palpate again.

- Try to visualize the anatomy of the rectum which can be assessed by sweeping movements of the finger at 2, 5, 8 cm inwards or until the finger cannot be pushed

further anymore into the rectum. Repeat these movements as the finger is being withdrawn. In this way, one can detect malignant ulcer, nodular or stenosing carcinomas, polyps and villous adenomas.

- Palpate also the hollow of sacrum and coccyx posteriorly and walls of the pelvis laterally for any abnormality.
- In men, one should feel anteriorly the *rectovesical pouch*, *seminal vesicles* and the *prostate*. Normally, rectovesical pouch and seminal vesicles are not palpable. Abnormally, pus may collect in this pouch producing swelling (pelvic abscess) or it may contain malignant deposits which may be felt as hard nodules. Infection of the seminal vesicle produces a tender tubular swelling on one side of midline above the prostate.
- **Palpation of prostate gland:** It is felt as a rubbery firm swelling about the size of a large chestnut. Move the finger over each lateral lobe which is normally smooth, regular and has rubbery consistency. Between the two lateral lobes is a palpable median sulcus (a faint depression running vertically between lateral lobes). Assess the prostate for enlargement and any other abnormality.

Benign prostatic hypertrophy produces smooth enlargement of prostate. Its consistency and median sulcus are preserved. In carcinoma, the gland becomes hard, nodular, the lateral lobes tends to become irregular and nodular and there is distortion or loss of median sulcus.

In women, the cervix is felt as a firm, rounded mass projecting back into the anterior wall of the rectum. Above the cervix, there is rectouterine pouch (*pouch of Douglas*) which is a common site of abnormality in females. Thus, rectal examination is an essential part of pelvic examination in females.

The body of the retroverted uterus, a fibroid mass, ovarian cyst, malignant nodule or a pelvic abscess, all can be palpated in the pouch of Douglas—a common site of abnormality.

- Gently withdraw your finger and wipe out the patient's anus or give him/her tissues or a piece of gauze to do it. *Inspect your finger for mucus, blood or pus on the glove and test it for occult blood.*

INVESTIGATIONS OF GASTROINTESTINAL SYSTEM

Radiological Examination

Plain X-ray of Abdomen

This is a simple and cheap investigation. This yields important informations, such as radio-opaque stones anywhere in the

tract and gas and fluid levels. Normally gas in the intestine acts as contrast media to assess the distribution of small intestine in the abdominal cavity. There may be a fluid level normally seen in the stomach because it contains both gas and fluid. In obstruction, there may be excessive gas and fluid in the bowel above the obstruction, films taken with the patient erect will demonstrate fluid levels. More than 3 levels in ascending manner (*step-ladder pattern*) indicate *acute intestinal obstruction*. The chest X-ray will show the position of diaphragm. Gas under the right dome of diaphragm indicates *perforation of a hollow viscus (stomach, colon, intestine)*. A gas and fluid level below the right dome of diaphragm will indicate *subphrenic abscess*. Raised right dome of diaphragm may occur with large *amoebic liver abscess* or *phrenic nerve palsy*.

Barium Meal Studies

The radio-opaque barium can visualise a break in the continuity of the outline of the gut mucosa, abnormalities in the appearance of mucosa and disorder of motility. The normal mucosa seen on barium meal study is shown in Figure 13.49.

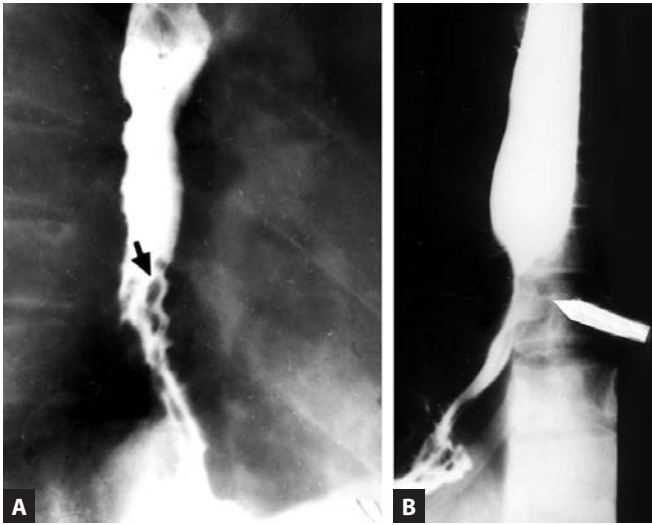
Barium swallow

The oesophagus can be studied easily with barium being swallowed. The procedure will show disorder of motility, a filling defect(s) caused by varices (Fig. 13.50A) or a tumour, a stricture (Fig. 13.50B), hiatus hernia or a diverticulum.

Barium meal examination by a double contrast study in which a small amount of barium is used together with introduction of gas to distend the stomach will show an ulcer

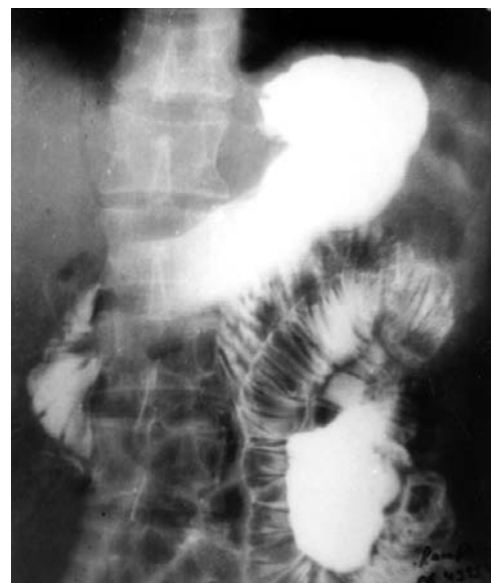

FIGURE 13.49 Barium meal study of small intestine showing normal pattern of mucosa



FIGURES 13.50A and B Barium swallow: (A) There are irregular filling defects in barium filled oesophagus due to oesophageal varices; (B) There is an oesophageal stricture (←)

as a small collection of barium with radiating folds of gastric mucosa. The ulcer and the mucosal pattern can be studied in double contrast study. Barium meal follow through study is useful to delineate the diseases of small intestines.

Barium enema is uncomfortable and exhaustive procedure, sometimes may induce arrhythmias in old persons. It is used to delineate the lower GI tract (rectum, colon and terminal ileum). Double contrast barium study is more useful than simple barium. Before barium enema, the patient is fully cleared of gas and faecal matter by taking laxative at night and a cleansing enema just before the barium enema. Barium alone or, for double contrast study, barium and air are introduced into the bowel through a self-retaining catheter. Radiographs are taken with colonic mucosa coated with barium and lumen of intestine filled with air. In this way colonic mucosa can be studied for motility disorder, inflammatory bowel disease (Fig. 13.51), polyposis and tumours of colon.

Computed Tomography (CT) and Magnetic Resonance Imaging (MRI)

The usefulness of CT scan and MRI is comparable in diagnosing gastrointestinal disorders. They are useful for intra-abdominal diseases involving the inaccessible organs or regions such as pancreatitis, pancreatic tumours or abscess (Fig. 13.52), retroperitoneal masses such as lymph nodes, etc.

Angiography (Coeliac Axis or Mesenteric Artery)

It is done in upper and lower GI tract bleed.

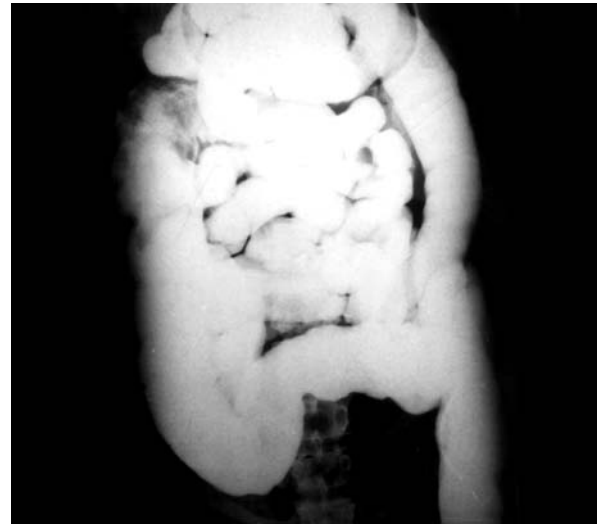

FIGURE 13.51 Barium enema. There is loss of haustration and stem-pipe appearance of the colon indicating ulcerative colitis

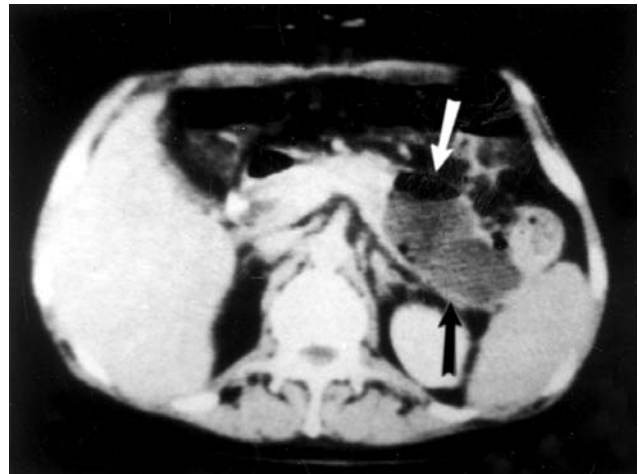


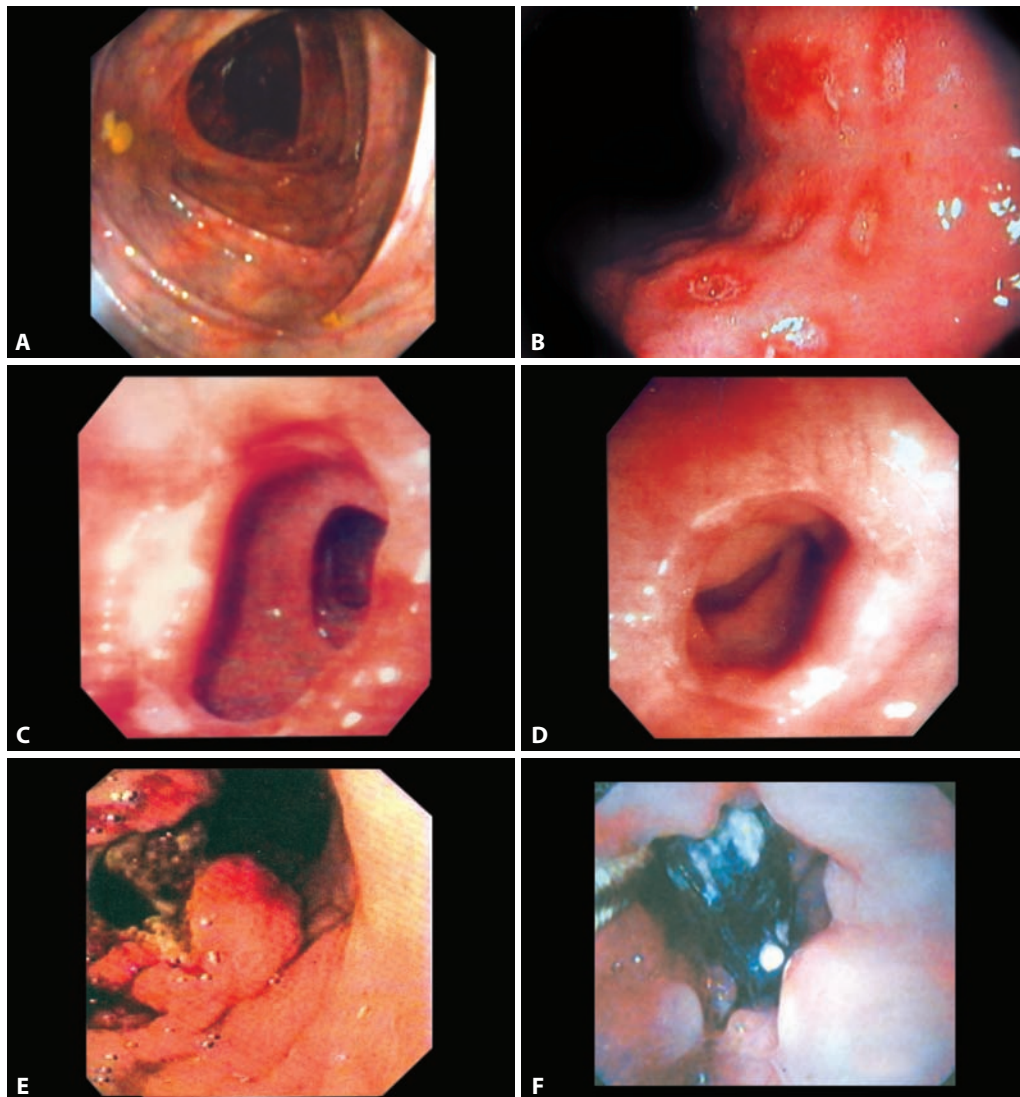
FIGURE 13.52 Pancreatic abscess. CT scan shows a mass (arrow) containing fluid and gas arising from the tail of the pancreas

Endoscopy

It is done by a flexible instrument called *endoscope* which is passed through the mouth in upper GI tract endoscopy and through anus in lower GI endoscopy. The instrument can also be used for therapeutic purposes such as for taking a biopsy and removal of a stone or a polyp.

Upper GI Endoscopy

This is done on both outpatients and inpatients. This is done on elective as well as on emergency basis. An outpatient with 12 hours fast is sedated with diazepam and pharynx is anaesthetised with local xylocaine. The fiberoptic instrument



FIGURES 13.53A to F Upper GI endoscopy: (A) Normal gastric mucosa; (B) Gastric erosions; (C) Duodenal ulcer; (D) Healing of duodenal ulcer after anti-ulcer therapy; (E) Adenocarcinoma of the stomach; (F) Impacted tooth at lower end of oesophagus

is passed into pharynx and patient is encouraged to swallow it gently. Where possible, the oesophagus, stomach and duodenum are also inspected (Fig. 13.53A) at the same examination because multiple lesions are not uncommon. This is particularly important in patients with haematemesis and malena where there may be more than one source of bleeding. In therapeutic endoscopy, the bleeding point or lesion is directly coagulated. The complications of the procedure include perforation of oesophagus or stomach, inhalation of secretions, cardiac arrhythmias and arrest. These complications are common when the precautions are ignored.

Oesophagoscopy and **gastrosocopy** are part of upper GI tract endoscopy, done for diagnosis of oesophageal lesions such as oesophagitis, varices, motility disorder, and gastric

lesion, such as erosions (Fig. 13.53B), ulcer, malignancy of the stomach (Figs 13.53A to F) respectively. Therapeutic procedures such as dilatation of an oesophageal stricture and injection of sclerosing material into oesophageal varices, removal of an impacted foreign body (Fig. 13.53F) can be carried out. Follow-up of healing of a gastric or a duodenal ulcer can be done by serial endoscopy (Figs 13.53C and D). Biopsy can be taken from a space occupying lesions in the stomach (Fig. 13.53E).

Endoscopic Retrograde Cholangio-Pancreatography (ERCP)

This investigation is most useful in liver disease. In addition to liver disease, it is useful in diagnosis of pancreatic diseases such as pancreatitis and pancreatic carcinoma. A stone or a

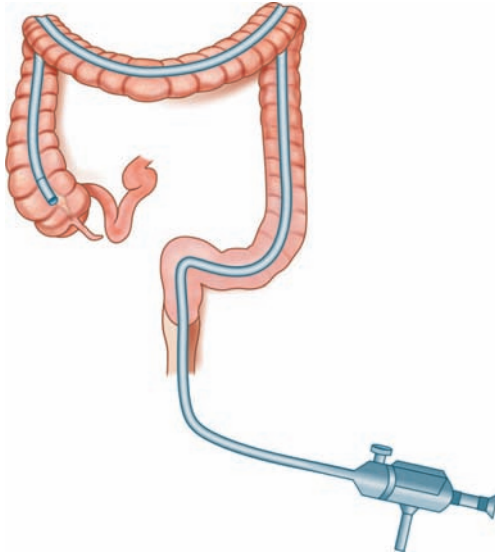


FIGURE 13.54 Colonoscopy

tumour in the common bile duct producing obstruction can be visualised, and endoscopic papillotomy of *sphincter of Vater* (sphincterotomy) can be performed to allow removal of a stone or stones (Fig. 13.54).

Lower GI Endoscopy

Sigmoidoscopy and proctoscopy: These simple procedures, can be carried out on outpatient basis. These are done in patients with symptoms referred to lower GI tract (anus, rectum and sigmoid colon), proctoscopy visualizes anus and 2–3 cm of rectum while sigmoidoscopy examines the rectum and lower few centimeters of pelvic colon. Digital examination should always be done before lower GI tract endoscopy to confirm that rectum is empty. Proctoscopy is used to demonstrate piles (haemorrhoids) and for injection of the piles. Sigmoidoscopy is useful to demonstrate polyps, cancer of rectum, ulcerative colitis or proctitis. Biopsy of the lesion can be obtained.

Colonoscopy (Fig. 13.54): It permits the visualization of whole colon but the procedure is little difficult. Most often short colonoscopes are used for lesions of sigmoid colon or left side of colon where most of the lesions occur. Before colonoscopy, the bowel must be carefully prepared. During colonoscopy, it is possible to carry out polypectomy (Removal of polyps) or biopsy of the lesion.

Warning: These invasive procedures should not be carried out during acute phase of inflammatory bowel disease because mucosa is friable and there are more chances of perforation.

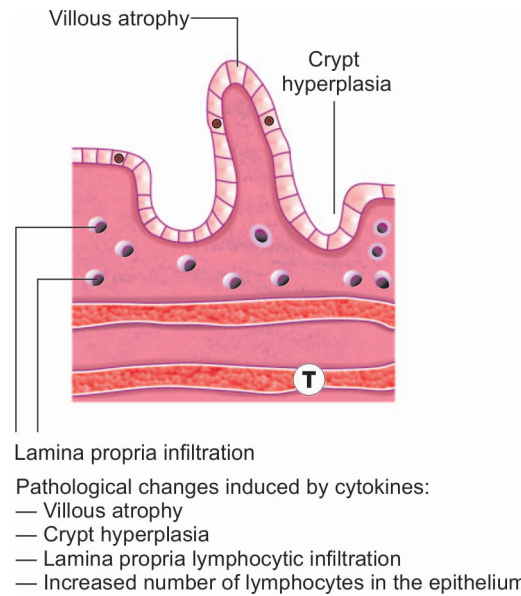


FIGURE 13.55 Histopathological changes in coeliac disease

Other Procedures

Biopsy of Small Intestine (Fig. 13.55)

This can be done in a patient with malabsorption syndrome. This is carried out by passing the *Crosby capsule* through mouth into the intestine, the procedure is time-consuming, hence, duodenal biopsy through endoscope may serve this purpose.

Secretory Studies

The pentagastrin test: The basal and maximal acid output of stomach are studied in response to pentagastrin. The patient is prepared before the test by stopping H_2 receptors antagonists at least 2–3 days before the test and omeprazole (a proton pump inhibitor) at least 7 days before the test. The fasting gastric contents of stomach are aspirated and their volumes are measured and discarded; then the secretions are collected continuously for one hour. This is called *basal acid output*. Pentagastrin is injected subcutaneously and then the gastric acid secretions are collected for further one hour. This acid output during this one hour is called *maximal acid output*.

A large volume of fasting gastric juice indicates gastric outlet obstruction.

A very high basal acid output indicates *Zollinger-Elison's syndrome*.

Pentagastrin fast achlorhydria indicates gastric atrophy or pernicious anaemia.

Insulin test: This is used to evaluate the completeness of vagotomy in patients who had undergone gastric surgery.

Tests for Exocrine Pancreatic Function

These tests are carried out in patients having diarrhoea or steatorrhoea due to exocrine pancreatic insufficiency. The basis of these tests is to stimulate pancreas either exogenously (secretin-cholecystokinin test) or endogenously (Lundh test).

In secretin-cholecystokinin test, the hormones are injected intravenously and the pancreatic juice is collected for one hour for analysis for bicarbonate and enzymes (amylase or lipase). A special double lumen tube is used to collect gastric and pancreatic secretions separately so as to prevent neutralisation of bicarbonate by HCl of stomach juice.

Lundh test is simple and tests the efficiency of pancreas in response to a liquid meal of fixed composition which is given orally. The duodenal aspirate is collected for analysis for enzymes (*trypsin and amylase*).

Both these tests are used to confirm the exocrine pancreatic insufficiency present in chronic pancreatitis and cystic fibrosis.

Malabsorption Tests (See Table 13.3)

Biochemical Test

Examination of stool: The importance of stool examination has been described at the end of this chapter. The stools should be examined for trophozoites, cysts and parasites also.

Occult Blood in Stool

Tests for occult blood using the *guaiac test* (Fig. 13.56) or immunological techniques detect small amounts in the stool and are performed for several successive days because bleeding is intermittent in GI disorders. Guaiac test is available as commercial kits. It is positive in bleeding at any level in GI tract while immunological test detects bleeding only from the colon.

INVESTIGATIONS OF HEPATOBILIARY SYSTEM

The diversity of the liver function tests and involvement of liver in diverse disorders precludes the use of any single test as reliable measure of overall liver functions while others may remain unaffected. Since no battery of tests is universally applicable, hence they should be selected appropriate to a given clinical problem, their diagnostic value and risks considered and the results obtained must be interpreted in the light of clinical findings.

Aims of investigations are:

- To detect hepatic abnormality.
- To measure the severity of the disease. Serial tests must be done during follow-up to evaluate the evolution and course of the disease.
- To find out of the cause of underlying disease.
- To investigate the consequences (sequelae or complications) of liver disease such as portal hypertension, ascites and hepatic encephalopathy.

Urine Tests

Normally, bilirubin being mainly unconjugated, is not excreted in the urine as it is not water soluble. In a patient with jaundice, absence of bilirubin in urine indicates unconjugated hyperbilirubinaemia. The unconjugated hyperbilirubinaemia leads to passage of increased amount of urobilinogen in the urine. Unconjugated hyperbilirubinaemia with increased amount of urobilinogen and absent bilirubinuria are found in haemolytic diseases and with any cause leading to hepatic uptake dysfunction. On the other hand, bilirubinuria indicates conjugated hyperbilirubinaemia and points to hepatobiliary disease or biliary obstruction.

Biochemical Tests

Biochemical investigations are useful in revealing or confirming that liver is diseased, in indicating whether liver cells are primarily involved, in giving an indication of the extent of liver damage and in assessing the progress.

Bilirubin

The rise in bilirubin more than normal irrespective of type of bilirubin is called *hyperbilirubinaemia*. There are two fractions of bilirubin, *unconjugated* and *conjugated*, their estimation in the blood is necessary for evaluation of a case with jaundice.

The unconjugated hyperbilirubinaemia without any abnormality of liver function tests may result from haemolysis (Figs 13.57A and B) or ineffective erythropoiesis or from defective uptake of bilirubin by the liver cells such as *Gilbert's syndrome* and *Crigler-Najjar syndrome* (congenital unconjugated hyperbilirubinaemia). It may also occur in newborns due to immaturity of an enzyme *glucuronyl transferase*. The normal serum bilirubin is 0.3–1.2 mg out of which 20% is conjugated. Unconjugated bilirubin is not excreted in the urine, hence, bilirubinuria is absent in unconjugated hyperbilirubinaemia.

The conjugated hyperbilirubinaemia becomes significant only when conjugated fraction becomes equal or more than unconjugated bilirubin (i.e. 50% or more of

TABLE 13.3 Biochemical tests and other investigations for malabsorption

Test	Normal values	Malabsorption (non tropical sprue)	Maldigestion (pancreatic insufficiency)
Fat absorption			
• Faecal fat (24 hours excretion)	<6.0 g/day	>6.0 g/day	>6.0 g/day
• Fat in stools (g%)	<6	<9.5 and >6	>9.5 (steatorrhoea)
Carbohydrate absorption			
• D-xylose absorption (25.0 g oral dose)	5 hours urinary excretion >4.5 g (>20% of dose)	Decreased	Normal
• Hydrogen breath test (oral 50.0 gm lactose and breath hydrogen measured every hour for 4 hours)	Less than 10 ppm above baseline in any sample	Increased	Normal
Protein absorption			
• Faecal clearance of endogenous α_1 -antitrypsin measured in three days collection of stools	Absent in stools	Increased	Increased
• Nitrogen excretion (3–5 days collection of stools)	< 2.5 g/day	>2.5 g/day	>2.5 g/day
Vitamins absorption			
• Radioactive B ₁₂ absorption test (0.5 μ g of labelled Vitamin B ₁₂ is given orally followed 2 hours later by 1000 μ g of non-labelled B ₁₂ given by i.m. injection. Radioactivity in the urine is seen after 24 hours)	>16% radioactivity in urine	Frequently decreased	Frequently decreased
Other test			
• <i>Breath test</i>			
– Breath ¹⁴ CO ₂ (14 _C xylose)	– Minimal amount	Decreased	Normal
– Bile salt breath test (radioactive)	– <1% of dose excreted ¹⁴ CO ₂ in 4 hours	Decreased	Normal
• <i>Blood test</i>			
– Serum calcium	9-11 mg/dL	Frequently decreased	Normal
– Serum albumin	3.5-5.5 g/dL	Frequently decreased	Normal
– Serum iron	80-150 μ g/dL	Decreased	Normal
– Serum vitamin A	>100 IU/dL	Decreased	Decreased
Miscellaneous			
Bacteria (culture)	<10 ⁵ organisms/mL	Normal but abnormal in blind loop syndrome	Normal
Secretin test	Volume (1.8 mL/kg/hr) and bicarbonate (>80 mmol/L) concentration in duodenal aspirate	Normal	Abnormal
Barium study (follow through)	Normal pattern	Flocculation and segmentation of barium (malabsorption pattern—see text)	Normal
Small intestine biopsy	Normal mucosa	Abnormal	Normal

total bilirubin). The conjugated hyperbilirubinaemia in the absence of any abnormality of liver cell functions, may occur in congenital disorders such as *Dubin-Johnson* and *Rotor syndromes*.

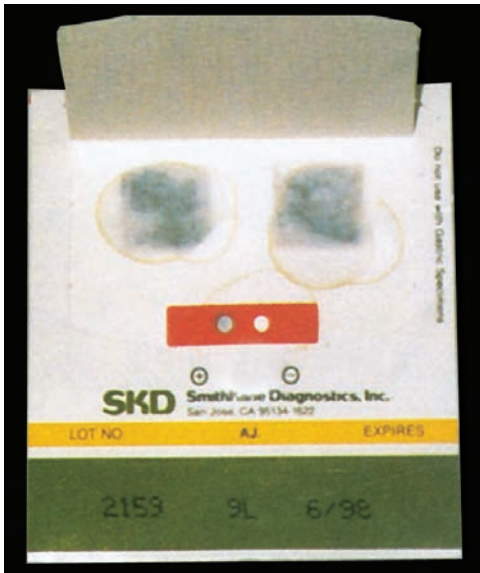

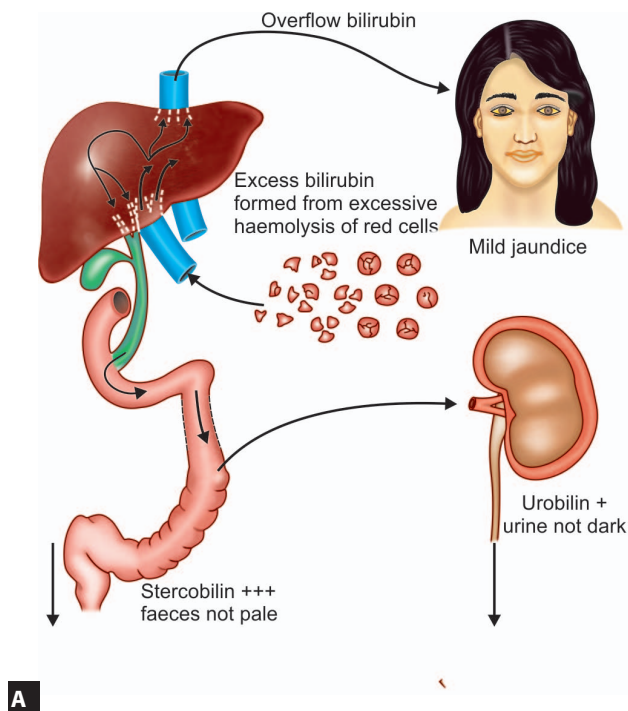
FIGURE 13.56 Guaiac-positive. Blue colour indicates organified iron, that is, haemoglobin

Hyperbilirubinaemia in hepatobiliary disease is predominantly conjugated and bilirubinuria is present. The bilirubin stains the reticulin and produces yellowness of sclera. Which is visible if bilirubin is 72.5 mg%.

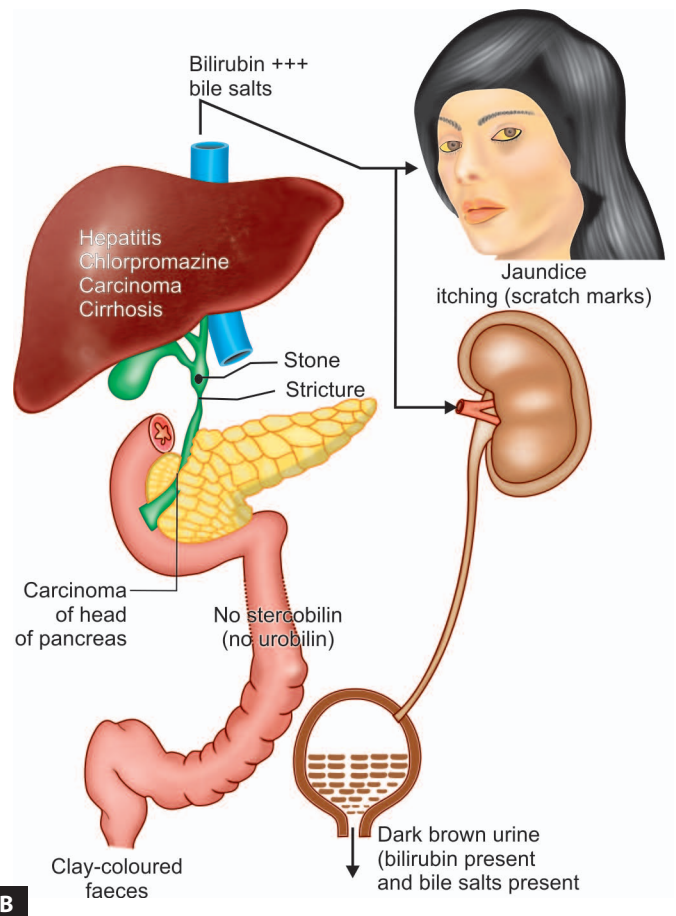
Enzymes

Liver cells contain many enzymes which are released into circulation during hepatocellular injury and their serial elevations may indicate liver disease. But there are certain limitations to enzymes elevation because these are raised in certain non-hepatic disorders, hence, only careful and proper interpretation may yield valuable informations. However, in practice, maximal information is obtained by measuring the activity of relatively a few enzymes. None of the enzymes is specific to the liver and alternative origins should be considered particularly where abnormalities have been detected incidentally.

Levels of SGOT (serum-glutamic-oxalo-transaminase) and SGPT (serum glutamic-pyruvo-transaminase) are raised in an acute liver damage but they have no prognostic significance in acute and chronic liver disease. The activity of SGOT and SGPT is greatly increased (10–100 times of



A



B

FIGURES 13.57A and B Pathogenesis of jaundice and urinary and stool findings: (A) Haemolytic jaundice; (B) The main causes and features of cholestasis

normal value) in early phase of hepatitis after which activity falls rapidly. Equally high levels of these enzymes are also seen in drug-induced hepatitis and in exacerbations of chronic active hepatitis. High values of the enzymes (100–500 times than normal values) have been observed in paracetamol induced hepatotoxicity, while only mild rise (5 times than normal) may occur in alcoholic hepatitis and hepatitis due to infectious mononucleosis, cytomegalovirus infection and cirrhosis of the liver. In obstructive jaundice mild rise of these enzymes (2–5 times) may also be seen.

Alkaline Phosphatase

Alkaline phosphatase arises from bone, intestine, liver and placenta. A number of different assays have been developed which utilise different substrates. The widely used methods are expressed in international units (normal 30–120 U/I), Bodansky units (normal 3–13 units). Normally serum alkaline phosphatase rises after meals and is of intestinal origin. In liver disease alkaline phosphatase rise is mild and does not signify the disease. However, in obstructive jaundice, its diagnostic accuracy is undisputed. A greatly increased serum alkaline phosphatase (>30 K.A. units or Bodansky units) indicate biliary obstruction but it does not provide any information about the site of obstruction.

This enzyme is not liver specific. Sometimes a raised plasma alkaline phosphatase activity is found incidentally and is the sole abnormality. Even in the presence of hepatobiliary disease, it is important to ensure that the alkaline phosphatase has no *extrahepatic* origin. Therefore, if gamma-glutamyl transferase which is specific to liver is raised along with alkaline phosphatase, then possibility of liver disease is very high. Other causes of raised alkaline phosphatase activity include rickets, Paget's disease, hyperparathyroidism, bone metastases, multiple myeloma, pregnancy and normally in adolescence.

Gamma-Glutamyl Transference (γ -GT)

It is a microsomal enzyme. Increased plasma γ -GT activity is sensitive index of liver damage. Moderate rise is seen in acute and chronic liver disease but highest levels are seen in biliary tract obstruction. Gamma-glutamyl transferase in liver disease carries same diagnostic value as occupied by transaminases and alkaline phosphatase. It has high diagnostic value in alcoholic liver disease because alcohol is microsomal enzyme inducer.

Serum Proteins

Albumin

It has long half-life (20–26 days) and its concentration does not change much in acute liver cell injury but prolonged or

chronic liver cell damage leads to hypoalbuminaemia which results in oedema and ascites of liver disease. Albumin is mainly synthesised in the liver, hence, decreased synthesis resulting in low plasma levels form an important diagnostic tool for chronic liver disease such as cirrhosis of the liver.

Globulins

Hyperglobulinaemia is associated with hypoalbuminaemia due to liver disease. It tends to persist once it rises. The causes of hyperglobulinaemia are not well understood, but rise is due to increased synthesis of immunoglobulin due to increased activity of immune system. Individual plasma immunoglobulins are variably increased in various liver disorders, i.e. IgG rise in autoimmune hepatitis, Ig in primary biliary cirrhosis and IgA in alcoholic liver disease.

Albumin and Globulins Ratio

Decrease in albumin and rise in globulins in liver disease changes or reverses the normal albumin and globulins ratio, but this carries no diagnostic significance other than individual variation in albumin and globulin concentration, hence, obsolete now-a-days.

Coagulation Factors

Liver synthesises important coagulation factors, such as factors II, V, VII, IX, X and needs vitamin K to activate these factors. Prothrombin time (PT) tests the integrity and activity of these factors. PT gets prolonged when the plasma concentration of any of these factors is below 30% of normal. Prolonged PT indicates severe liver disease. As coagulation factors have very short half-life, hence, changes in PT occurs quickly when liver damage occurs. PT gets prolonged both in acute and chronic liver disease. The PT has most prognostic value in acute fulminant hepatitis. An increased prothrombin time indicates severe liver disease and an increasing value indicates worse prognosis. The normal blood prothrombin time is 11–16 sec and index is 100%. The prothrombin index is calculated:

$$\text{PTI (\%)} = \frac{\text{Normal PT}}{\text{PT of the patient}} \times 100$$

For example, if PT of the patient is 20 seconds against 14 seconds of normal person, then PTI of the patient is 70%.

Blood Ammonia

Blood ammonia level rises in liver disease. Normally, ammonia is detoxified to urea. Rise in ammonia indicates severe liver disease, especially hepatic encephalopathy. But there is no correlation between ammonia levels and severity of encephalopathy.

Serum Lipids and Cholesterol

Abnormalities in serum lipids or lipoproteins are sensitive but non-specific indicators of liver disease. Acute parenchymal disease is associated with rise in serum triglycerides and decrease in cholesterol esters. In cholestasis, the situation is different. Serum unesterified cholesterol increases along with serum phospholipids. Lipoprotein X, a distinctive lipoprotein is encountered in cholestasis due to any cause.

Other Biochemical Tests

Ferritin

Increased serum ferritin levels (>1000 µg/L) indicates haemochromatosis but cannot, establish the diagnosis of its own because alcoholic liver disease may have such an increased concentration (>1000 µg/L) of ferritin.

Alpha 1-Antitrypsin

This is an α_1 -globulin produced by the liver. The alpha 1-antitrypsin deficiency is associated with liver disease and pulmonary disease (emphysema). Increased loss in stools indicates protein malabsorption.

Ceruloplasmin and Copper

Ceruloplasmin is copper binding globulin produced by the liver. Low levels of ceruloplasmin are seen in Wilson's disease, fulminant hepatic failure, severe liver disease and protein-losing enteropathy. High serum concentration occurs in pregnancy, biliary obstruction, inflammatory and neoplastic diseases. Copper levels are very high in Wilson's disease, cholestasis and primary biliary cirrhosis. Urinary excretion of copper is high in these diseases.

Bromsulphalein (BSP) Clearance

It is used now-a-days only in the diagnosis of *Dubin-Johnson's syndrome* (congenital conjugated hyperbilirubinaemia) where its excretion is delayed.

Serological Test for Viral Hepatitis

(Read Case Discussion of Hepatitis in Bedside Medicine without Tears by Prof. SN Chugh)

Only one antigen is present against which an individual infected with HAV (hepatitis A virus) makes an antibody (anti-HAV), hence, anti-HAV (IgA and IgM type) appears in the incubation period and titres of this antibody fall to low levels within 3 months of recovery. IgG type of antibody also appears in HAV infection but has no diagnostic value and persists for years after infection, hence, is used to measure the

prevalence of illness in the population. IgG antibody provides immunity to HAV infection.

Hepatitis B Virus (HBV) Antigens and Antibodies

The hepatitis B virus commonly contains three antigens; a surface (s), a core (c) and an envelope (e) antigen. These antigens and their antibodies are important in identifying HBV infection.

Acute infection

Hepatitis surface antigen and antibody (HbsAg and anti-HBs).

The hepatitis B surface antigen (HBsAg) is a reliable marker of HBV infection. It appears in the blood late in incubation period, persisting for few days and disappearing even before jaundice appears; but it usually lasts for 3–4 weeks and may persist upto 6 months. Therefore, it should be sought early in infection. Antibody to HBsAg (anti-HBs) usually appear after 3–6 months and persists for many years or perhaps permanently. Presence of this antibody indicates past infection to HBV or person is immunised against HBV infection.

Hepatitis B Core Antigen and Antibody (HBcAg and Anti-HBc)

The hepatitis B core antigen (HBcAg) is not found in the blood but antibody to it (anti-HBc) appears early in the course of illness, rapidly rises to high titres and then subsides gradually and persists. The early antibody is of IgM type which reveals an acute HBV infection when HBsAg has disappeared and anti-HBs have not developed, hence, indicates established infection. IgG antibody appears late and persists during convalescence from hepatitis B infection.

Hepatitis B Envelope Antigen (HBeAg) and Antibody (Anti-HBe)

The hepatitis B 'e' antigen appears transiently during illness, and is followed by production of antibody (anti-HBe). The HBeAg indicates active replication of virus particles in the liver.

Chronic infection

The chronic HBV infection is marked by the presence of HBsAg and anti-HBe (IgG type) in the blood. Usually HBeAg or anti-HBe is also present; the HBeAg indicates continued active virus replication in the liver and anti-HBe implies that replication is occurring at lower rate and viral DNA is incorporated into host hepatocytes DNA. Hence, anti-HBe indicates chronicity of liver disease. Polymerase chain

reaction (PCR) can show HBV-DNA in the blood and indicates ongoing viral replication.

Hepatitis C Virus Antibodies

The hepatitis C virus contains several antigens, against which antibodies appear and form a diagnostic tool for this infection. Current laboratory diagnosis depends not only to detect antibody against single antigen but to detect against several viral antigens in initial screening and then subject them to confirmation by polymerase chain reaction which can show HCV-RNA in the blood.

Hepatitis D-Antigen and Antibody

The hepatitis D virus (HDV) contains a single delta antigen against which an individual produces antibodies (anti HDV). Delta antigen appears transiently in the blood and in practice, diagnosis depends on detecting anti-HDV. Simultaneous infection with HBV and HDV followed by full recovery is associated with the appearance of low titres of anti-HDV which generally disappears within 2 months after recovery. Superinfection by HDV of patients with HBV infection leads to production of high titres of anti-HDV and these patients then pass on to chronic infection by both viruses and ultimately to cirrhosis of the liver.

Hepatitis E Virus Antibody

Individuals infected with hepatitis E virus (HEV) produces anti-HEV which is used in making the diagnosis of hepatitis E.

Autoantibodies

Antinuclear antibody (ANA), anti-mitochondrial antibody (AMA) and anti-smooth muscles antibody are done for the diagnosis of various autoimmune disorders of the liver. Titres of these antibodies is low in normal persons. Antinuclear and antimitochondrial antibodies in high titres indicate connective tissue diseases and autoimmune thyroiditis, etc. Anti-smooth muscles antibody has been reported in infectious mononucleosis and in a variety of malignant disorders. Auto antibodies are important in chronic liver disease rather than acute viral hepatitis. High titres are found in autoimmune hepatitis, cryptogenic cirrhosis and primary biliary cirrhosis. None of these autoantibodies damage the liver tissue, hence, have no aetiological significance.

Diagnostic Procedures

Radiology

- **Imaging:** Imaging techniques determine the site and general nature of the structural lesion of the liver and biliary tract.

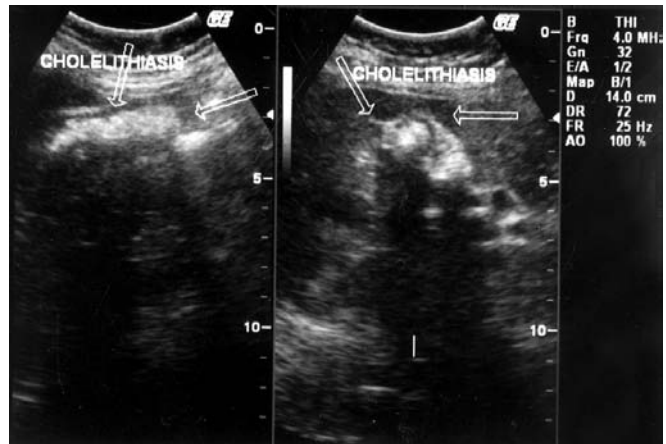
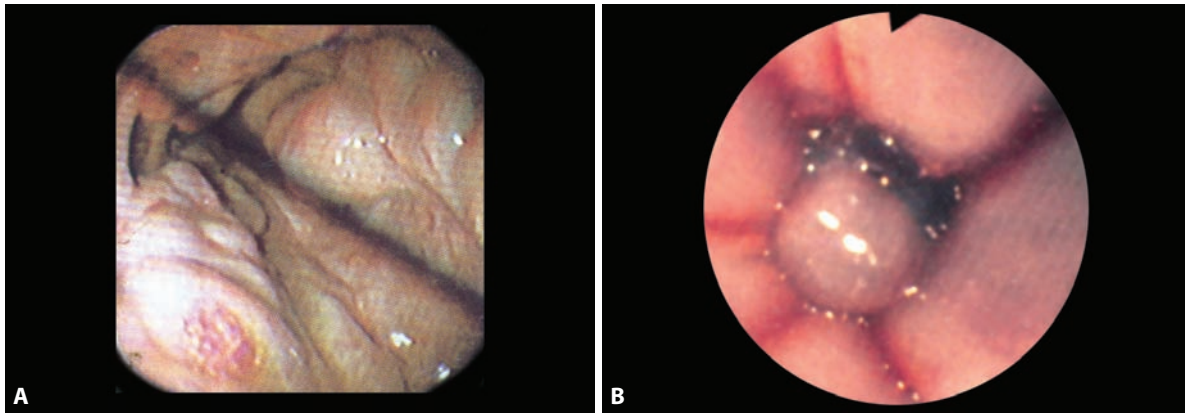


FIGURE 13.58 Ultrasound of the gallbladder showing gallstones

- **Ultrasound:** It is a noninvasive procedure. It detects gall stones, (Fig. 13.58), tumours of the liver, gallbladder and biliary tract, abscesses and cysts in the liver. It is a useful method for evaluation of a patient with jaundice. Dilatation of biliary system proximal to the site of obstruction indicates obstructive jaundice. Diffuse diseases of the liver parenchyma such as fatty liver, cirrhosis of liver, chronic active hepatitis are difficult to diagnose on ultrasound. Colour Doppler ultrasound will detect lesions of hepatic vessels such as Budd-Chiari syndrome, portal hypertension and venous invasions by tumours.
- **Abdominal X-ray:** A plain X-ray of abdomen will detect radio-opaque gall stones (20%), can visualise soft tissue mass of inflamed gallbladder or gas in the biliary tract. It can pick up calcification in tumours, cysts and areas of infarction.
- **Barium swallow and meal examination:** Varices in the oesophagus and stomach can be revealed by barium swallow and meal examination. Presence of varices (see Fig. 13.50A) indicates portal hypertension.
- **Upper GI endoscopy:** It is done to see the oesophageal/gastric varices, erosions (gastropathy), and also used for treatment of varices to prevent bleeding (Figs 13.59A and B).
- **Computed tomography (CT):** CT scan has same diagnostic significance as that of ultrasound except that it can detect smaller lesions. Contrast CT is more helpful in demonstrating the cause of the liver or biliary system disease. It is less helpful in diffuse parenchymal liver disease and gallbladder disease (Fig. 13.60). **Colour Doppler study** may show flow reversal in portal and splenic veins in portal hypertension.



FIGURES 13.59A and B Upper GI endoscopy. (A) Upper gastrointestinal endoscopy showing large, oesophageal varices with red colour signs; (B) Oesophageal variceal band ligation. Note the blue 'O' ring on one of the varix

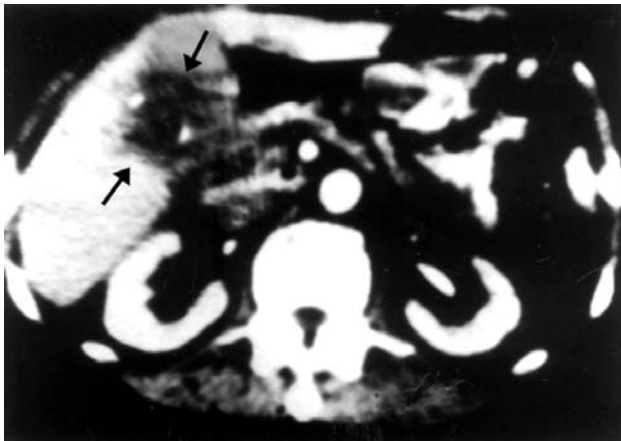


FIGURE 13.60 Carcinoma of the gallbladder. CT scan shows a gallbladder carcinoma (→) that obliterates the normal landmarks of the gallbladder

- **Magnetic resonance imaging (MRI):** It has same place in diagnosing focal lesions which is occupied by ultrasound and CT scan. It is not superior to them.
- **Radionuclide imaging:** Technetium (^{99m}Tc) sulphur colloid as taken up by monocyte-macrophage system, is used to image the liver and the spleen. It can detect focal liver lesions, diffuse liver disease and portal hypertension, but is less commonly used for this purpose now-a-days.
- **Cholecystography:** This is now-a-days less commonly used than ultrasound, but is effective in demonstrating gallbladder functions and diseases. This is done by iodinated compounds given orally after preparation of the patient. These compounds are concentrated in gallbladder and excreted in the bile. The gallbladder gets opacified on cholecystography. Non-opaque gall stones and adenomas produce filling defects in the opacified

gall bladder. Failure of the gallbladder to opacify is frequent in gallbladder disease and the gallbladder is said to be 'non-functional', which may be due to cystic duct stone or patient has not absorbed the tablets either due to vomiting, diarrhoea or malabsorption. Occasionally, normal gallbladder may fail to opacify for unknown reasons in some patients (20%), where the test is repeated with the same dose of contrast now given for 2 consecutive days. If under these circumstances, it is still not opacified then it is definitely diseased.

- **Endoscopic retrograde cholangio-pancreatography (ERCP):** The endoscope is passed into the duodenum and this allows direct examination of ampulla of Vater, where lesions such as carcinoma of ampulla can be biopsied under direct vision and contrast media can be injected for radiological examination of biliary tract and pancreatic duct. It is valuable in assessing a case of cholestasis of unknown origin. The procedure can be adopted for papillotomy at ampulla of Vater and removal of stones from the common bile duct. Dilatation of benign strictures of common bile duct can be carried out through this procedure. Complications of the procedure include pancreatitis (1-3%) and cholangitis (rare).
- **Percutaneous transhepatic cholangiography (PTC):** This is done by injecting the contrast material through a needle passed percutaneously into an intrahepatic duct. Excellent delineation of biliary tree (Fig. 13.61) is obtained but the technique is less useful than ERCP. Complications are uncommon, include bleeding and leakage of bile from the liver. This is invasive cumbersome procedure, uncommonly employed now-a-days if facility of ERCP is available.

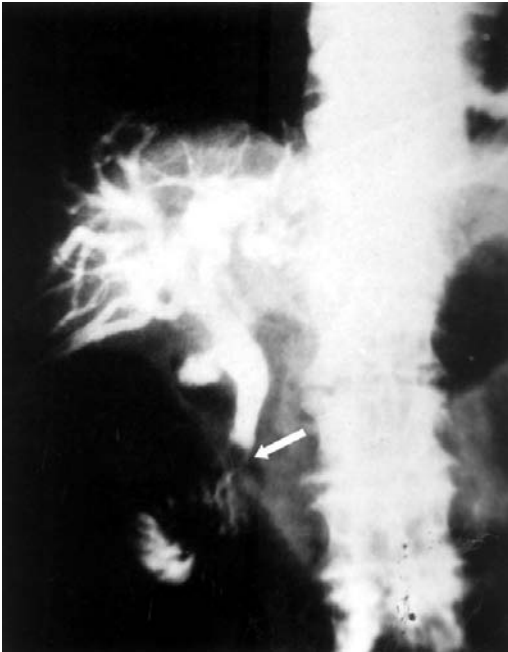

FIGURE 13.61 Percutaneous transhepatic cholangiography showing a common bile duct stone (arrow) obstructing the biliary tract and leading to dilatation of intrahepatic and extrahepatic biliary system above the obstruction

- **Arteriography:** Hepatic arteriography is useful for localizing lesions such as tumour in the liver before surgery. Hepatocellular carcinomas and highly vascular tumours in contrast to metastatic tumours, can be diagnosed easily. This is employed only before planning the surgery on the liver.
- **Portal venography:** This is most useful investigation for the portal hypertension of unknown origin. It is also essential before portosystemic shunt surgery in patients with portal hypertension, though such surgery is done infrequently now-a-days.

Endoscopy

Upper GI tract endoscopy is superior to barium meal examination in diagnosis of oesophageal and gastric varices because small varices can easily be differentiated from mucosal folds on endoscopy. Endoscopy is also a valuable means of diagnosing congestive gastropathy of portal hypertension.

Abdominal Paracentesis (Removal of Ascitic Fluid)

The ascites can be tapped by passing a wide bore needle through the skin into peritoneal space (Fig. 13.62). The fluid removed is analysed biochemically and cytologically. The fluid

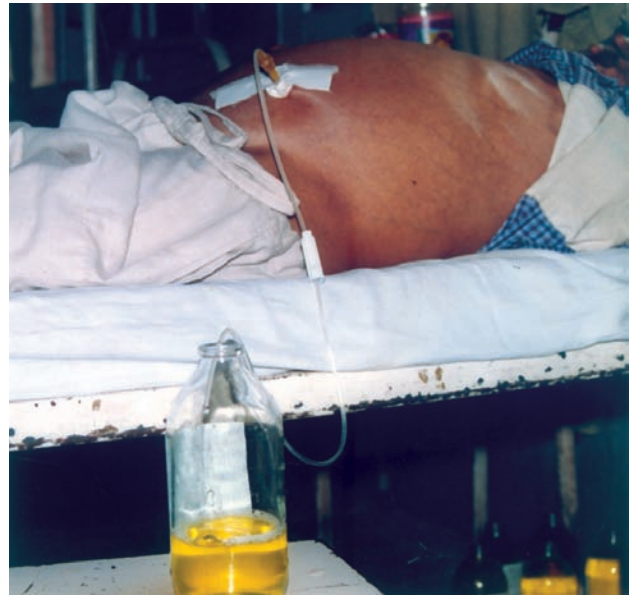


FIGURE 13.62 Abdominal paracentesis. The ascitic fluid is being drained. The fluid should be sent for biochemistry and cytology




FIGURE 13.63 Ascitic fluid characteristic: Straw coloured fluid; Chylous (milky) fluid; Pus (greenish) sticky, creamy fluid

is clear (transudate) in cirrhosis, its protein content is less than 3.0 g/L and cell content is less than 250 polymorphonuclear leucocytes/mm³. Blood stained ascites indicate malignant infiltration of peritoneum or tubercular peritonitis. *Chylous (milky) ascites* indicates obstruction of lymphatic ducts (Fig. 13.63). *Exudative ascites* (protein > 3.0 g/L) occurs most frequently in tuberculosis, malignancy, peritoneal infection, pancreatitis and hepatic vein obstruction. Amylase activity is high in ascites due to pancreatitis. Infections such as

spontaneous bacterial peritonitis has polymorphonuclear leucocyte counts above $250/\text{mm}^3$ and positive bacteriological examination. The cytology of ascitic fluid can show malignant cells in malignancy but negative examinations do not exclude malignant disease.

Liver Biopsy

This is performed by a special needle passed through an intercostal space under local anaesthesia. The patient should be assessed for haemostasis by bleeding, clotting and prothrombin time before biopsy. Biopsy yields only a small piece of liver and consequently the best results are obtained with diffuse liver disease. The procedure is essential for diagnosis of chronic hepatitis and to distinguish persistent, active or aggressive and lobular forms. It can also be essential in cases of cirrhosis to establish its cause such as alcohol induced or haemochromatosis. Focal diseases such as malignancy are first diagnosed by ultrasound or by laparoscopy, then subjected to biopsy for histopathological examination. Operative biopsy is useful for staging the lymphoma.

Liver Aspiration (Figs 13.64A and B)

Aspiration biopsy is done by using a fine bore needle (20–22 gauge) usually guided by ultrasound, has become the initial method of choice for investigation of focal lesions such as abscesses, tumours and cysts (except hydatid cyst). This can be done satisfactorily without any risk. Diagnostic and therapeutic aspiration is attempted for large left lobe (>10 cm) amoebic abscess which threatens to rupture.

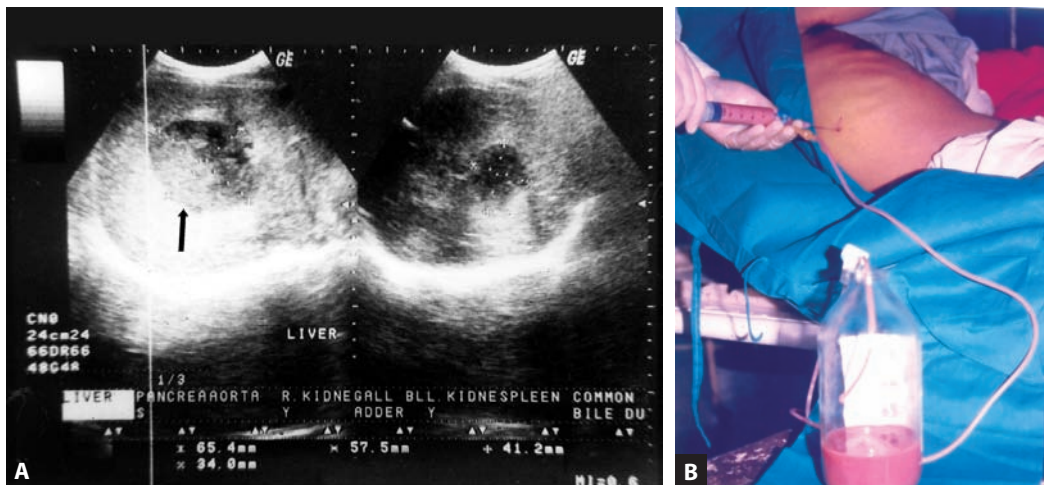
Aspirated material is sent for cytological, histopathological and bacteriological examination.

Laparoscopy

Modern laparoscopes of relatively small size can now be used under sedation and local anaesthesia. They provide excellent view of the inferior and anterior surfaces of the liver. The spleen, prominent blood vessels of portal hypertension and evidence of peritoneal disease may also be seen. Biopsies can be taken directly from diseased areas which is valuable in focal disorders especially malignant disease. The main contraindications are; marked ascites, haemostatic abnormalities and peritoneal adhesions of previous surgery.

Portal Pressure

This can be measured directly by passing needles or catheters into the spleen, the portal vein or the hepatic parenchyma (sinusoids), but these methods are invasive, hence, rarely, used now-a-days. The pressure recorded by a catheter wedged in a hepatic vein (wedged hepatic venous pressure) reflects the portal venous pressure via the hepatic sinusoids. The portal venous pressure is calculated as the difference between the wedged hepatic venous pressure and the free hepatic venous pressure and is normally 3–5 mmHg and more than 6 mm indicates portal hypertension. Normal portal pressure measured indirectly through spleen is 10–15 mmHg. Pressure more than normal indicates portal hypertension. It is now-a-days an obsolete investigation.



FIGURES 13.64A and B Amoebic liver abscess: (A) Ultrasound of the liver showing a big liver abscess in right lobe of the liver (\uparrow); (B) Drainage of the abscess. Note the anchovy-sauce appearance of the pus

TABLE 13.4 Character of vomit as a clue to diagnosis

<i>Character</i>	<i>Diagnosis</i>
<ul style="list-style-type: none"> • Copious, sour smelling vomitus containing food eaten many hours before • Dark red blood in the vomitus. Clots may be present. • Altered (dark brown colour) blood in vomitus or coffee coloured appearance. • Bright red/fresh unaltered blood in vomitus • Brown feculent vomitus like vanities tea. It has faecal odour • Vomit containing fecal matter 	<ul style="list-style-type: none"> • Pyloric stenosis • Gastric ulcer, gastric erosions, Mallory-Weiss syndrome • Haematemesis due to any cause where haemoglobin is converted into haematin in the stomach by HCl • Intake of iron or red wine may produce similar appearance • Epistaxis where the blood may be ingested • Bleeding from nose or oropharynx • Advanced intestinal obstruction. • Gastrocolic fistula

TABLE 13.5 The abnormality of the stool on inspection and its significance

<i>Abnormality</i>	<i>Diagnostic significance</i>
<ul style="list-style-type: none"> • <i>Amount</i> <ul style="list-style-type: none"> – Copious and foul smelling, porridge-like and frothy – Scanty stool (pellets of faeces) 	<ul style="list-style-type: none"> • Steatorrhoea • Irritable bowel syndrome
<ul style="list-style-type: none"> • <i>Colour</i> <ul style="list-style-type: none"> – Black-tarry stool – Red currant jelly – Pale stools (acholuric stool) – Bright red colour 	<ul style="list-style-type: none"> • High intestinal bleeding or gastric haemorrhage. Iron or bismuth ingestion • Intussusceptions • Obstructive jaundice, acute diarrhoea, steatorrhoea • Anorectal bleeding (piles)
<ul style="list-style-type: none"> • <i>Odour</i> <ul style="list-style-type: none"> – Offensive – Odourless – Odour like that of semen 	<ul style="list-style-type: none"> • Massive duodenal bleed with rapid transition, jaundice • Cholera • Acute bacillary dysentery, amoebic dysentery
<ul style="list-style-type: none"> • <i>Consistency</i> <ul style="list-style-type: none"> – Watery stool – Rice-water stool – Purulent or pus containing stool (viscid) may be mixed with blood – Slimy stools (white mucus mixed with stool) 	<ul style="list-style-type: none"> • Diarrhoea and use of purgatives • Cholera • Severe dysentery or functional bowel disorder • Large bowel disorder

TABLE 13.6 Differential diagnosis of acute abdomen

<i>Condition</i>	<i>History</i>	<i>Clinical examination</i>
Perforated peptic ulcer with acute peritonitis	Vomiting at onset followed by acute severe abdominal pain, previous history of dyspeptic symptoms, ulcer disease, NSAIDs or cortico-steroids therapy	Shallow breathing with diminished abdominal movements, generalised abdominal tenderness, guarding, board-like rigidity, distension of abdomen with absent bowel sounds
Acute pancreatitis	Anorexia, nausea, vomiting, epigastric pain radiating to back, previous alcohol abuse or cholelithiasis	Fever, periumbilical bruising (Cullen's sign), loin bruising (Grey Turner's sign), epigastric tenderness, variable guarding or absent bowel sounds
Ruptured aortic aneurysm	Sudden onset of tearing, severe back/lion/abdominal pain, circulatory collapse, history of peripheral vascular disease and/or hypertension	Shock and hypotension, pulsatile tender epigastric mass with an overlying bruit, asymmetrical femoral pulses, sometimes hypertension due to renal artery ischaemia

Contd...

Contd..

Condition	History	Clinical examination
Acute mesenteric insufficiency	Anorexia, nausea, vomiting, bloody diarrhoea, constant abdominal pain in an old person (>60 yrs), previous history of cardiovascular disease	Atrial fibrillation, cardiac failure, asymmetrical peripheral pulses, absent bowel sounds, variable tenderness and guarding
Acute intestinal obstruction (strangulated hernia)	Central colicky abdominal pain, nausea, vomiting and constipation	Surgical scars, abdominal mass, hernia, distension, exaggerated visible peristalsis, increased bowel sounds (borborygmi)
Acute appendicitis	Nausea, vomiting, central abdominal pain settling into right iliac fossa	Fever, tenderness, guarding in right iliac fossa, a mass in right iliac fossa, pelvic peritonitis (rebound tenderness)
Ruptured ectopic pregnancy	Premenopausal, delayed/missed menstrual period, feeling of fainting, circulatory collapse, unilateral iliac fossa pain or shoulder tip pain, vaginal discharge—'Late period', like prune juice	Suprapubic tenderness, periumbilical bruising (Cullen's sign), pain/tenderness on vaginal examination, swelling/fullness in the fornix on vaginal examination
Pelvic inflammatory disease (PID)	Sexually active female, previous history of STD/PID, recent gynecological procedure, pregnancy or use of intrauterine contraceptive device, irregular menses, dysuria, dysprunia, lower or central abdominal pain, backache, pleuritic right upper quadrant pain (Fitz-Hugh-Cutis syndrome)	Fever, vaginal discharge, pelvic peritonitis, right upper quadrant tenderness (perihepatitis), pain and/or tenderness on vaginal examination (cervical erosions), swelling/fullness in the fornix on vaginal examination

Examination of Vomit

The character of the vomit varies with nature of food ingested and absence or presence of bile or blood (Table 13.4).

Examination of Faeces

The faeces in bedpan is ideal for examination because white surface of bedpan provides a contrast background for the detection of blood, pus and mucus. The abnormality of the stool and its significance is depicted in the Table 13.5.

Acute Abdomen

The term '*acute abdomen*' is applied to conditions in which patient presents with acute distress related to an abdominal complaint/disorder. Patients with acute upper GI bleed present with acute abdomen and may require urgent management. Diagnosis and management of acute abdominal disorders depends on the history and clinical examination (Table 13.6).

14

CHAPTER

The Urogenital System and Sexually Transmitted Diseases

HISTORY

Symptoms

- Polyuria, oliguria, increased frequency, dysuria, nocturia
- Mass abdomen
- Hesitancy, precipitancy, incontinence, dribbling, swelling of face and abdomen
- Sex related complaints, e.g. sexually transmitted disease
- Menstrual complaints, discharge per vagina.
- Nausea, vomiting, fatigue

Present History

Detailed history of present illness.

Past History

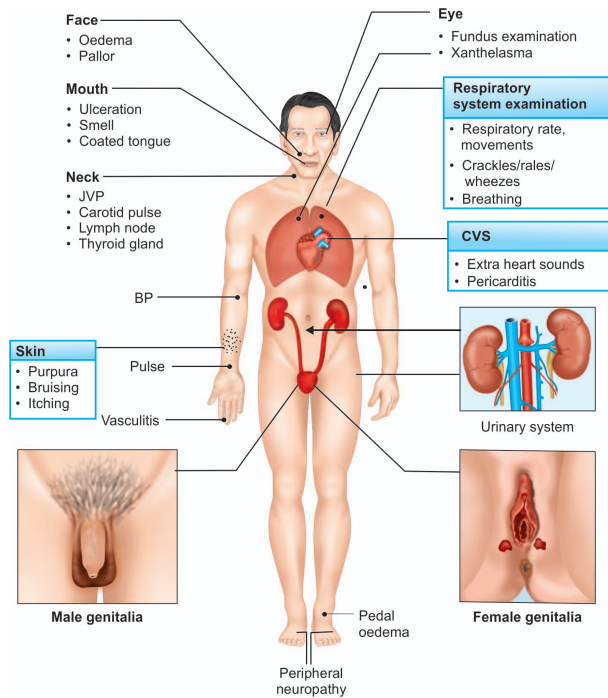
DM, HT, colic arthritis, etc.

Family History

Family history of any heredo-familial diseases.

GENERAL PHYSICAL EXAMINATION

- *Face*—puffiness, pallor
- *Eyes*—oedema, xanthelasma
- *Mouth, oral mucosa, tongue*
- *Ear* for tophi
- *Neck* for JVP for fluid overload, carotid pulsations
- *Skin*—purpura, bruising, pruritus, uraemic frost
- *Extremities* for oedema, clubbing, peripheral neuropathy.



General observations
• Fatigue, tiredness
• Yellow complexion
• Urine output
• Skin temperature
• Signs of dehydration, i.e. loss of skin turgor
• Features of advanced renal failure

The Examination of Genitourinary System

SYSTEMIC EXAMINATION

Abdominal Examination

- **Inspection** for any local bulge
- **Palpation** for enlarged kidneys, urinary bladder
 - Local tenderness in renal angle
- **Percussion** over the palpable kidneys/mass
- **Auscultation** for renal or other arterial bruit

Genitalia Examination

Male Genitalia

- **Inspect** the penis and scrotum for infection, ulceration, rash, excoriation, abnormality of prepuce, penis, urethra for any discharge. Inspect scrotum for swelling, oedema, hernia
- **Palpation** of penis and scrotum for discharge, epididymus and spermatic cord (tenderness, sensation), prostate enlargement.

Female Genitalia

- **Inspection** of cervical os, uterus, adnexa for any abnormality
- **Palpation** for any mass in relation to uterus, cervix, vagina and adnexa, papsmear examination.

Provisional Diagnosis

Differential Diagnosis

Investigations

THE URINARY SYSTEM (Figs 14.1A to C)

Applied Anatomy and Physiology

The kidneys are 11–14 cm in size, bean-shaped organs, placed in the retroperitoneal paravertebral space in relation to three thoracic vertebrae. Nephron is the fundamental, structural and functional unit of the kidneys. The kidneys are supplied by a pair of renal arteries, each arising from the abdominal aorta. The glomerulus is a bunch of capillaries placed in the Bowman's capsule, the afferent of which receives blood from the systemic circulation and passes it through the glomerulus to the efferent arteriole, which arborises to supply blood to the proximal and distal convoluted tubules and collecting ducts (see Fig. 14.2). The medulla is supplied by arterioles arising from the glomeruli in the deeper regions of the cortex. The glomerulus and a part of proximal and distal convoluted tubules lie in the renal cortex and rest of the nephron is placed in the medulla. Juxtaglomerular apparatus (JGA), a collection of specialised cells, lies in the cortex near the junction of afferent arteriole and distal convoluted tubules and secretes *renin*.

Glomerular filtration is a process of diffusion of water and solutes across the glomerular capillary membrane. It occurs due to pressure gradient of 10–12 mmHg across the

membrane. The glomerular filtrate resembles chemically to plasma, except that it has no fat and contains little proteins. This glomerular filtrate while passing through the renal tubules undergoes modification by process of tubular reabsorption and tubular secretion and ultimately excreted as the urine.

Renal Functions

- The kidneys maintain volume and composition of body fluids by regulating the secretion of ADH.
- The kidneys retain certain useful substances by maintaining the threshold called *renal threshold* which may get altered in renal diseases.
- The kidneys excrete waste products (urea, uric acid, creatinine) which get retained in renal failure.
- They play a role in homeostasis of electrolytes (K^+ , Mg^+), minerals (calcium and phosphorous), anions and cations (H^+ , HCO_3^-), salt and water through renin-angiotensin-aldosterone system. Hydroxylation of Vitamin D_3 to 1–25 dihydroxycholecalciferol occurs in the kidney.
- Kidneys perform metabolic and hormonal functions as follows:
 - Secrete renin which converts angiotensinogen to angiotensin.

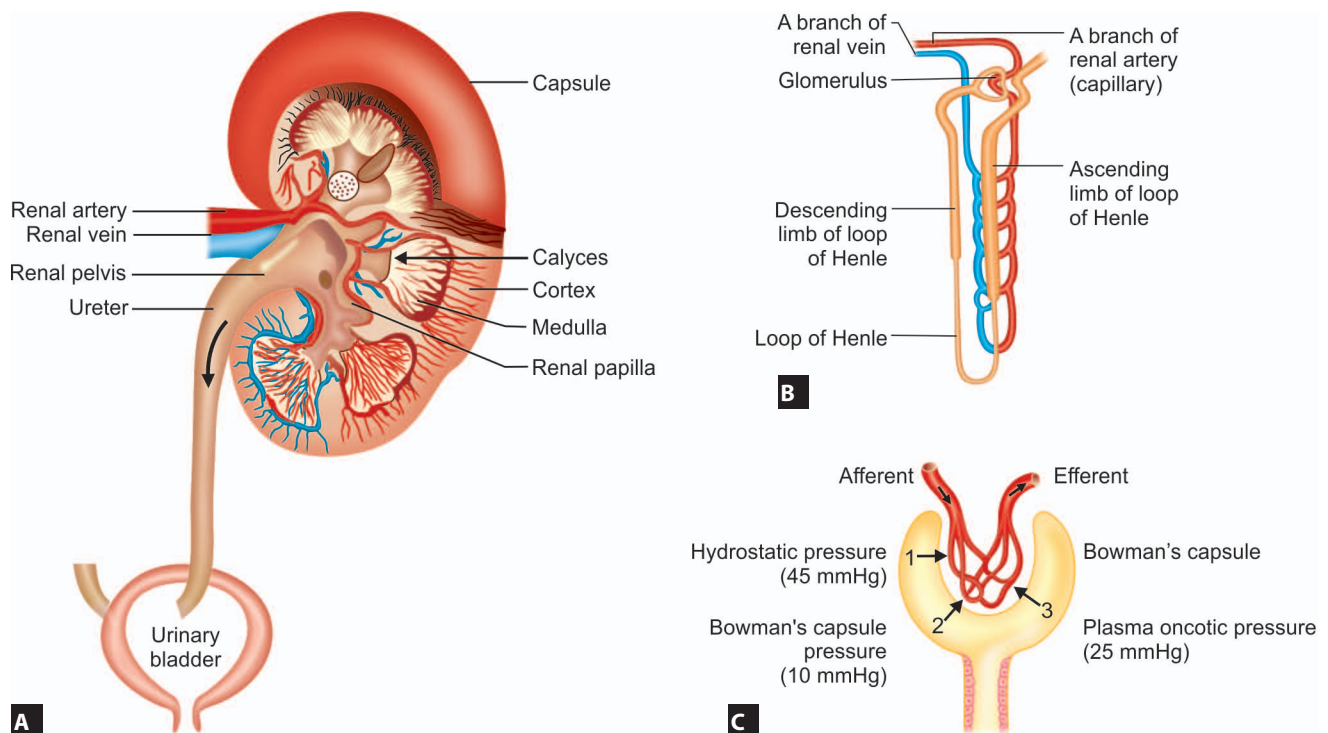


FIGURE 14.1 The urinary system, the nephron and the glomerulus. The pressures controlling the rate of formation of GFR have also been depicted. (A) Pelviureteric system; (B) The nephron; (C) Glomerulus

- Secrete *erythropoietin*—a hormone that stimulates erythropoiesis. Decreased production of erythropoietin is an important factor in pathogenesis of anaemia in chronic renal failure.
- Reduced hydroxylation of vitamin D₃ to 1-25 dihydroxycholecalciferol explains hypocalcaemia and osteodystrophy in renal failure.
- They produce vasodilators (prostaglandins) and an enzyme (Kallikrein) which influence blood flow.

The ureters: These are conduit pipes which transmit urine from the kidneys to the urinary bladder, thus, maintain urine flow. They lie retroperitoneally, likely to be pushed or pulled or compressed or stenosed by certain masses and in retroperitoneal fibrosis.

The urinary bladder: It is situated in suprapubic region and collects urine. It is placed in front of uterus in females. It opens into urethra.

THE GENITAL SYSTEM

The Male Genitalia

The penis: The shaft of the penis is composed of three columns of erectile tissue; the *corpus spongiosum*, containing the urethra and two *corpora cavernosa*. The corpus spongiosum ends in a cone-shaped *glans*. In uncircumcised men, the glans is covered by a fold of skin—the *prepuce*. The urethra runs through the shaft of the penis. The urethra opens into a vertical opening called *urethral meatus* at the tip of the glans.

The scrotum: It is a pouch divided into two compartments, each containing a testis. The testes are ovoid, somewhat rubbery structures, about 4.5 cm in length (3.5–4.5 cm) in an adult, the left lies somewhat lower than the right. On the posterolateral surface of each testis is the softer, comma-shaped epididymis. It is most prominent along the superior margin of the testis. The epididymus may be anteriorly placed in some persons (6–7%). Surrounding the testis is a serous membrane enclosing the potential cavity called *tunica vaginalis*—a site for hernia.

The *vas deferens*, a cord-like structure, begins at the tail of epididymis runs upwards through scrotal sac and passes through the external inguinal ring on its way to abdomen and pelvis. A duct from the seminal vesicle joins it behind the bladder and then it opens into the urethra within the prostate gland. Sperms formed in the testes pass through this passage into the urethra. Secretions from the vas deferens, the seminal vesicles, and the prostate, all contribute to the semen. Within the scrotum, each vas is closely associated with blood vessels, nerves and muscle fibres. These structures constitute the *spermatic cord*.

Functions

The testes produces spermatozoa and testosterone. Testosterone stimulates the pubertal growth of the male genitalia, prostate and seminal vesicles. It also stimulates the development of secondary sexual characters (the beard, body hair, musculoskeletal development and enlargement of larynx with the associated change in voice).

Clinical Significance

Male sexual function depends on the normal levels of testosterone, adequate arterial blood supply, and intact neural innervation from α -adrenergic and cholinergic pathways.

Erection from venous engorgement of the corpora cavernosa results from the visual stimuli and tactile stimuli. Both sets of stimuli increase levels of nitric oxide and cyclic GMP resulting in local vasodilatation and erection of penis.

The Female Genitalia

The external female genitalia (vulva) include the *mons pubis* (a hair covered fat pad overlying symphysis pubis), the *labia majora* (rounded folds of adipose tissue), the *labia minora* thinner pinkish red folds that extend anteriorly to form prepuce and the clitoris. The *vestibule* is a boat-shaped fossa between the labia minora. In its posterior portion lies the vaginal opening (introitus), which in virgins may be hidden by the hymen. The term *perineum* is used to denote the tissue between the introitus and the anus.

The urethral meatus opens into vestibule between the clitoris and the vagina. The openings of *Bartholin's* glands are located posteriorly on either side of the vaginal opening, but are not usually visible. Bartholin glands themselves are situated more deeply.

The *vagina* is a hollow tube extending upwards and posteriorly between the urethra and rectum. Its upper third terminates in the cup-shaped *fornix*. The vaginal mucosa is thrown into folds called *rugae*.

The uterus sits over the vagina at right angle. The uterus has two parts, i.e. the body (corpus) and the cervix which are joined together by the *isthmus*. The convex upper surface of the body is called *fundus* of the uterus. The lower part of the uterus, the *cervix*, protrudes into the vagina, dividing the fornix into anterior, posterior and lateral fornices. The vaginal surface of the cervix is seen easily with the help of a speculum. At its centre is a rounded, oval or slit-like depression called the *external os* of the cervix which marks the opening of endocervical canal. The cervix is covered by columnar (surrounding the os) and squamous epithelium merging with vaginal epithelium. The *Pap* smear is used for diagnosis of *cervical dysplasia*.

A fallopian tube connects the uterus to the ovary on each side. The two ovaries are almond-shaped structures that vary in size from adulthood through menopause. The ovaries are palpable on pelvic examination in roughly half of the women during reproductive years. Normally, fallopian tubes can not be felt. The term *adnexa* (meaning appendages) refers to the ovaries, tubes and supporting tissue.

The parietal peritoneum extends downwards behind the uterus into a *cul de sac* called the *rectouterine pouch (pouch of Douglas)*. You can reach this area on rectovaginal examination, and is a common site of collection of pus in pelvic inflammations and nodules for malignancy of pelvic organs.

The pelvic organs are supported by a sling of tissues, composed of muscle, ligaments, and fascia, through which the urethra, vagina and rectum all pass.

Functions

The ovaries produce ova and hormones, e.g. oestrogen, progesterone and testosterone. Increased hormonal production during puberty stimulates the growth of sexual as well as secondary sexual characters. The levels of the hormones fall during menopause.

Genitourinary Symptoms

- Symptoms pertaining to genitourinary tract have already been discussed in Chapter 2. They are summarised in the Box 1 and Fig. 14.2.
- **Associated symptoms:** For example fever, anorexia, nausea, malaise, weakness.
- **Symptoms due to uraemia:** Most of the diseases of urinary system are complicated by uraemia (raised blood urea, nitrogen, creatinine). They are given in the Fig. 14.3.

Clinical Patterns of Renal Disorders

The following clinical syndromes are seen in association with renal disease. No symptom or sign is specific for renal disease.

- **Acute renal failure:** The occurrence of recent decline of renal functions over days leading to oliguria or anuria constitute syndrome of *acute renal failure*. In contrast, when functional decline is noted over weeks instead of days, the renal failure is categorised as rapidly *progressive renal failure*. In addition to reduced GFR, oedema, hypertension, abnormal electrolytes and urinary sediments may be noted but are not specific to this syndrome. It is caused by pre-renal, renal and postrenal disorders.
- **Acute nephritic syndrome:** It is characterised by acute onset of oliguria, haematuria (microscopic or macroscopic), proteinuria (< 3 g/day), hypertension,

Box 1

Symptomatology of genitourinary tract

1. Symptoms and signs related to urinary system

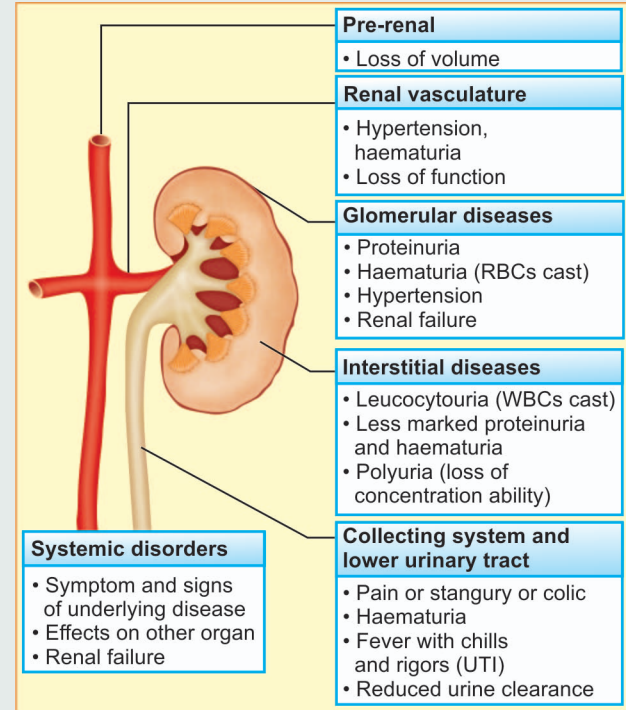


FIGURE 14.2 Renal disorders and their clinical presentation

2. Symptoms related to genital tract

- **Female**
 - Stress urinary incontinence
 - Menstrual irregularities
 - Obstetric complaints
 - Bleeding per vagina (e.g. intrauterine erosions, polyps, malignancy)
 - Vaginal discharge, e.g. sexually transmitted diseases or vaginal infection
 - Altered sexual function, i.e. dyspareunia (painful intercourse) or inactivity (loss of desire)
- **Male**
 - Delay in initiating micturition (hesitancy)
 - Thinning of urinary stream
 - Impaired urinary flow
 - Post-micturition dribbling
 - Urethral discharge (e.g. sexually transmitted disorder)
 - Altered sexual function/activity (e.g. impotence)

oedema and azotaemia with urine of high specific gravity and smoky in appearance. It invariably indicates acute glomerulonephritis due to any cause.

- **Nephrotic syndrome:** It is defined as massive proteinuria (> 3.5 g/day), hypoalbuminaemia, periorbital or pitting pedal oedema, hyperlipidaemia and lipiduria (passage of fat globules in urine) and coagulopathy or hypercoagulable

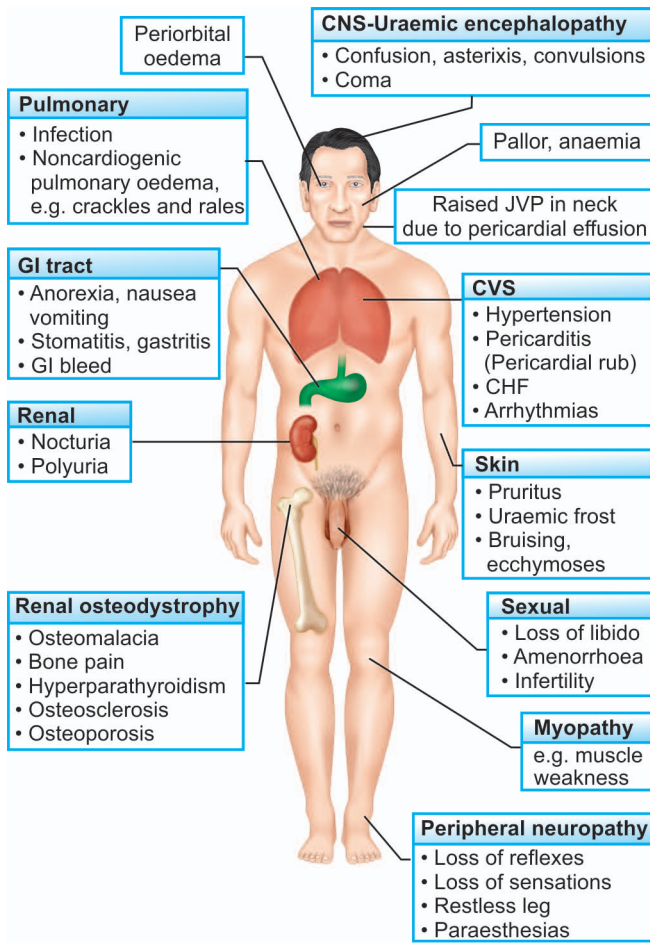


FIGURE 14.3 Symptoms and signs of chronic renal failure (CRF)

state due to urinary losses of antithrombin C and S and hyperfibrinogaemia.

- **Chronic renal failure:** It is a clinical syndrome of uraemia occurring as a result of slow insidious irreversible deterioration of renal functions manifested by excretory, metabolic, neurological, haematological and endocrinal abnormalities. The diagnosis is made by documentary evidence of uraemia (raised blood urea and creatinine) for more than 3 months, small contracted kidneys on radiology or USG, renal bone disease and renal biopsy evidence of chronicity of the disease.

The occurrence of recent acute renal failure (e.g. oliguria, hypotension) in the presence of a previously compensated chronic renal failure has been termed as *acute on chronic renal failure*.

Anaemia, hypertension, hypocalcaemia, hyperphosphataemia; UTI, GI symptoms, electrolyte disturbance and renal osteodystrophy are some of the important clinical features of CRF in addition to low fixed specific gravity of urine and presence of broad hyaline casts (renal failure casts).

- **Asymptomatic urinary abnormalities:** Detection of isolated haematuria, proteinuria or unexplained pyuria during screening procedures or routine medical check-up for employment or life insurance purposes constitutes *asymptomatic urinary abnormalities*. Many cases of asymptomatic glomerular disease are diagnosed from these abnormalities. Most asymptomatic glomerular haematuria is due to IgA nephropathy (*Berger's disease*) or thin basement membrane (TBM) disease (benign haematuria). A rare but, more ominous cause of isolated haematuria is hereditary nephritis (*Alport's syndrome*).

Between 0.5 and 10% of the population have isolated proteinuria, a radiologically normal urinary tract and the absence of known renal disease. Majority of these patients excrete proteins of < 2 g/day, and more than 80% have an excellent prognosis (benign isolated proteinuria). A minority (10–25%) are found to have *persistent isolated proteinuria*, some of whom develop progressive renal insufficiency over a period of one to two decades.

Asymptomatic bacteriuria is defined as colony count > 10⁵/mL in mid-stream urine sample of approximately healthy asymptomatic individual. About 1% children, 1% school girls, 0.03% school boys and men, about 1% nonpregnant women and 5% pregnant women have asymptomatic bacteriuria. Otherwise, such colony count in urine indicates urinary infection.

- **Urinary tract infection:** A mid-stream urine sample, appropriately collected under aseptic conditions, with colony counts > 10⁵/mL indicates urinary infection in symptomatic patients. Under certain conditions, colony counts between 10² and 10⁴/mL in mid-stream sample or suprapubic aspiration of bladder may indicate urinary infection, needs further evaluation.

Fever, dysuria, increased frequency of micturition, leucocytouria or pyuria, burning micturition suggest upper urinary tract infection.

- **Renal tubular defects:** Renal tubular defects (anatomical or functional) are either inherited or acquired. Anatomical defects such as cystic diseases (polycystic and medullary cystic) and medullary sponge kidney, are usually identified during investigations for haematuria, bacteriuria, flank pain or azotemia. USG and radiological diagnostic techniques confirm the diagnosis.

Functional renal tubular defects results in impaired secretion or resorption of electrolytes, H⁺, HCO₃⁻ or organic solutes or decreased urinary concentrating and diluting activity. Polyuria, nocturia, metabolic acidosis, disorders of fluid and electrolyte balance are its clinical manifestations. Diagnosis is dependent on individual tubular functions.

Tubular syndromes cause pyuria, calculous disease, calcinosis, renal bone disease or renal failure.

- **Nephrolithiasis:** Renal colic, painful haematuria, unexplained pyuria, dysuria and urinary frequency raises the suspicion of a renal stone. Passage of stone, visualisation of a stone on X-ray or on removal at surgery or on cystoscopy confirms the diagnosis of stone disease. Stones detected on X-ray include calcium containing and cysteine stones, while uric acid stones are radiolucent.
- **Urinary tract obstruction:** Oliguria, anuria, polyuria, nocturia, urinary retention, azotemia, slowing of the urinary stream, enlarged prostate, large kidneys, flank pain or tenderness, a full bladder after voiding are some of the diagnostic clues to urinary tract obstruction which is confirmed on investigations and radiology.

Anuria is almost always associated with complete bilateral urinary tract obstruction. A palpable bladder after voiding is caused by lower urinary tract obstruction (e.g. due to urethral stricture, tumour, stone, neurogenic cause and prostate hypertrophy). Nocturia, increased frequency and outflow incontinence, hesitancy also suggest outflow obstruction. Upper urinary tract obstruction may, at times, be asymptomatic especially when it is incomplete or unilateral.

NB: Syndromes in nephrology as discussed above serve to narrow down the diagnostic possibilities, and thus, limit the time and effort spent in arriving at the aetiological diagnosis.

HISTORY

Present History

Certain points in the **present history** act as clue(s) to diagnosis:

- Dysuria, frequency and urgency suggest the disorders of the lower urinary tract (bladder, prostate, and urethra). Commonly, it is due to urinary tract infection, tumour, calculi and urinary tract obstruction.
- Dysuria with urethral discharge indicates gonorrhoea.
- Dysuria with stangury indicates acute bladder neck obstruction due to a stone or blood clot.
- Painless haematuria in an adult is usually due to benign bladder papilloma or a renal, bladder or prostatic carcinoma.
- Change in colour of the urine after standing (fresh voided urine is of normal colour) indicates acute intermittent porphyria.
- Polyuria alone is due to renal disease, polyuria, polydipsia and polyphagia indicate diabetes, polyuria and polydipsia suggest diabetes insipidus and psychogenic polydipsia. Polyuria and nocturia suggest cardiac failure.

- Reduced force of urinary stream and thinning of urinary stream in males suggest bladder outlet obstruction (prostate enlargement, urethral stricture).
- Hesitancy, double voiding (need to pass urine again within few minutes of micturition), dribbling after micturition, increased frequency and nocturia due to incomplete bladder emptying or complete urinary retention are symptoms of prostatic outflow obstruction.
- Stress incontinence (leakage of urine in response to coughing, sneezing, or laughing) occurs in multiparous women due to weakness of pelvic floor muscles.

Past History

Ask about:

- Renal colic (intermittent colic due to stone or clot due to haematuria)
- Polyarthrits (gout, rheumatoid arthritis, SLE)
- Hypertension and diabetes (diabetic nephropathy)
- Long history of chronic suppurative lung disease or tuberculosis (tuberculosis of kidney, amyloidosis)
- Malaria or filarial infection (nephrotic syndrome, chyluria)
- Poisoning, snake bite or insect stings and bites
- Surgery
- Sexually transmitted disease.

Family History

In certain heritable and developmental renal disorders which get transmitted from parent to offsprings, the family pedigree chart provides an important clue to presence of some or many of the manifestations in the index patient and in other members of the family. These disorders are:

- Cystic renal diseases, e.g. *polycystic kidney disease* (autosomal dominant or autosomal recessive), *tuberous sclerosis*, *von Hippel-Lindau disease* and *medullary sponge kidney* or *medullary cystic disease*.
- Hereditary nephritis (*Alport's syndrome*)
- Hereditary metabolic disorders, (e.g. *Bartter's syndrome*, *Alport's syndrome*, *familial urate nephropathy*).
- Hereditary renal tubular defects.
- Hereditary systemic disorders with involvement of kidneys, e.g. diabetes, Wilson's disease, familial mediterranean fever, sickle cell disease.

Drug History

The kidneys play a major role in the excretion of many drugs, and has rich vascular supply, hence, is susceptible to the effects of various drugs/toxins. Exposure to these toxins may be accidental or deliberate. The drugs causing nephrotoxicity are given in the Box 2, their history of intake must be asked in each and every case of renal disease.

Box 2

Nephrotoxic drugs/toxins**Drugs**

- *Antibiotics*, e.g. Aminoglycosides, penicillins, cephalosporins, vancomycins, tetracyclines
- *Sulphonamides*
- *Antifungal*, e.g. amphotericin
- *Antiviral*, e.g. acyclovir
- *Antimitotics*, e.g. cyclosporine, cisplatin, cyclophosphamide, methotrexate, cytosine arabinoside, thioguanine, 5-fluorouracil
- *NSAIDs*, or aspirin or phenacetin (analgesic nephropathy)
- *Diuretics*
- *Rifampicin*
- *Pentamidine*
- *Lithium*
- *Heroin-induced nephropathy*

Toxins

- *Heavy metals*, e.g. lead, mercury, cadmium, gold, pencillamine
- *Chemical and plant toxins*, e.g. CuSO_4 , mushroom poisoning
- *Metabolic toxins*, e.g. hyperuricaemia, hypercalcaemia, hyperoxaluria, cystinosis, Fabry's disease

Sexual History

Sexual dysfunction and sexually transmitted diseases are common (see Box 3). Two aspects of sexually transmitted diseases are important. First, an infected individual/patient indicates that at least one other person (partner) is also infected, therefore, treatment in isolation will not control the spread of the disease. Second, a patient may harbour more than one sexually-transmitted disease. Remember that babies, innocent partners and victims of rape and sexual abuse can also be infected.

The sexual history is important for sexual dysfunction as well as for sexually transmitted diseases in young adults. Although such topics are often avoided by patients because of embarrassment, it is particularly important to interview and examine the patient in privacy and with confidentiality. The staff should be sympathetic, without a disapproving or moralistic attitude.

The history should explore the two important aspects:

- **Sexual function and activity:** Ask about sexual activity and whether they have any of the disorders known to predispose to sexual dysfunction, i.e. diabetes, alcoholism, chronic renal failure, marital difficulty or psychological disorder.
- **To explore the possibility of sexually transmitted disease** as listed in the Box 3. The points to be asked are listed in the Box 4.

Box 3

Sexually transmitted diseases (Causative agents)**Bacterial**

- Syphilis (*T. pallidum*)
- Gonorrhoea (*N. gonorrhoeae*)
- Lymphogranuloma venereum (*Chlamydia trachomatis*, LGV 1–3 serovars)
- Chancroid (*H. Ducreyi*)
- Granuloma inguinale (*Calymmatobacterium granulomatis*)
- Bacterial vaginosis
- Shigellosis, Salmonellosis
- Nonspecific genital infection (*ureaplasma*, *Mycoplasma*)

Viral

- Genital herpes (*Herpes simplex virus I and 2*)
- Genital warts (*Human papilloma virus*)
- Molluscum contagiosum (*Molluscum contagiosum virus*)
- AIDS and related disease (*Human Immunodeficiency virus*)
- Hepatitis (*Virus A, B, C and delta viruses*)

Fungal

- Thrush/moniliasis/candidiasis

Ectoparasites

- Pediculosis pubis (*Phthirus pubis*)
- Scabies (*Sarcoptes scabiei*)

Protozoal

- Trichomoniasis (*T. vaginalis*)
- Amoebiasis (*E. histolytica*)
- Giardiasis (*G. lamblia*)

Nematode

- Enterobiasis (*E. vermicularis*)

Box 4

Points to be asked in sexual history

- How many sexual partners have you had in the last 12 months?
 - How many of your partners have been males and how many females?
 - How many of your partners have casual relationship?
 - Do you use condom most of the time, all of the time, or not at all?
 - Have you ever suffered from a sexually transmitted disease?
- Males:** Ask for any problem with sexual drive, erection, penetration, ejaculation or orgasm?
- Females:** Ask for any problem with sexual drive, pain during intercourse or orgasm?

The *incubation period* of infection—a pointer towards the cause of the disease, may be assessed from the date of exposure to the onset of symptoms. A history of intercourse with homosexual or bisexual men, IV drug users or with persons living in or from an area of high HIV endemicity may suggest AIDS as the cause.

The type of sexual practice must be asked such as:

- Straight sex (penovaginal intercourse)
- Oral sex (oro-penile intercourse)
- Gay sex (oro-anal sex) or (peno-anal intercourse)

Hepatitis B and HIV infection are common in those practising peno-anal intercourse.

Menstrual and Obstetrics History

Ask about the followings:

- Age of menarche
- Age of menopause, if appropriate
- Use of contraceptive drugs or device, or hormone replacement therapy
- Date of the first day of last menstrual period
- Frequency, duration and regularity of menses
- Blood loss during menses, i.e. scanty or heavy.

The normal age of menarche varies from the ages 10–15 years. Failure to menstruate at all by this age indicates primary amenorrhoea.

The normal age of the menopause varies 45–55 years. Secondary amenorrhoea may be due to pregnancy, systemic illness, hyperprolactinaemia, androgens excess or hypopituitarism. It could be psychological also.

The obstetric history includes details of all pregnancies, successful or otherwise, and any problem experienced during pregnancy such as hypertension or urinary infection (see Box 5). If a woman has never conceived, it is appropriate to ask whether this was by choice or whether difficulties in conceiving have been experienced.

If a female complains of vaginal discharge, then ask about its *colour*, *consistency* and *odour* (foul smell indicates anaerobic infection).

Vaginal bleeding following intercourse could be due to cervical erosions, polyp or carcinoma.

The presence of vaginal discharge, or intermenstrual, postcoital or postmenopausal bleeding is an indication for gynaecological assessment and examination.

Box 5

Obstetric history

- Number of pregnancies and live births, miscarriages and termination.
- Any health problem during pregnancies or after delivery?
- Were the previous deliveries vaginal or caesarean?
- Were forceps or episiotomy used?
- Ask about medical disorders complicating pregnancy such as anaemia, hypertension, diabetes mellitus, thyroid disease or urinary infection.

EXAMINATION

It includes:

- General physical examination
- Examination of the abdomen
- Examination of genitalia.

General Physical Examination

- *Look for consciousness. Is there any disturbance in consciousness?*

Consciousness may be disturbed due to uraemic encephalopathy as a result of retention of waste substances or toxins.

- *Look for anaemia at different sites.*

Anaemia in renal disorders may occur due to gross haematuria, bleeding or coagulation defect or reduced production of erythropoietin in CRF or hypoplasia of marrow due to uraemic toxins or shortened span of RBCs (haemolysis).

- *The mouth and tongue: Note, any abnormality.*

Buccal mucosa is pale in anaemia.

Tongue and mucous membrane are dry in dehydration

White deposits and ulceration of the mouth are seen in severely ill patients or patients receiving steroids or immunosuppressive drugs, indicate bacterial, viral or fungal infections.

- *The skin: Look for any abnormality.*

Facial puffiness may denote nephrotic syndrome.

Dry, pale and flaky skin is seen in uraemia. *Uraemic frost* (dirty brown appearance of skin) looks like dandruff on the forehead and is due to crystallisation of urea from the sweat. It is seen in terminal uraemia.

Bruises or purpura suggest bleeding or coagulation defect.

A butter-fly rash over face indicate SLE (Fig. 14.4).

Scratch marks or excoriation of skin indicates pruritus.

The lustre and laxity of the skin can be demonstrated by pinching the skin between finger and the thumb. *Skin turgor* or *lustre* is lost in dehydration.

Subcutaneous calcium deposits in skin may occur due to hyperparathyroidism which may ulcerate.

Scars of vascular access surgery may be seen in forearms or ankles and the veins over dorsum of the hands may be dilated as a result of arteriovenous anastomosis constructed in the forearm in patients undergoing dialytic therapy (haemodialysis). Scars of lithotripsy for crushing of stone may be noticed (Fig. 14.5).

Pitting oedema of the ankles, scrotum and oedema of the genitalia may be present. This is due to hypoproteinaemia in renal disorders (e.g. nephrotic syndrome).

Wart and skin cancers are common in immunosuppressed patients with renal transplant.

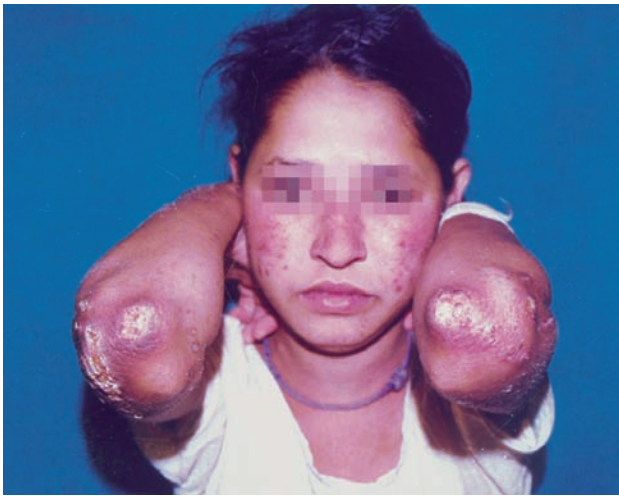

FIGURE 14.4 Puffiness of face (periorbital oedema) due to SLE induced nephrotic syndrome

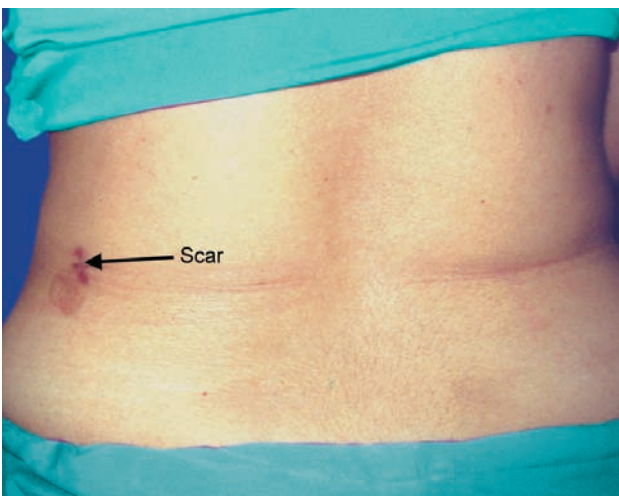


FIGURE 14.5 A lithotripsy scar in left renal area

- *The growth and development to be examined especially in children.*

The growth is retarded and puberty delayed in children suffering from chronic renal failure.

- *Deformity: Note, if present.*

The renal rickets may cause valgus or varus deformity of the knees ('knock knees' or 'bow legs' Fig. 14.6), ankles swelling or beading of costochondral junctions (*rickety rosary*) and proximal muscle weakness so that patient is not able to get up from squatting position without levering up with the arms.

Shortening of distal phalanges: Shortening of fingers due to shortening of terminal phalanges may occur as a result of resorption of bone secondary to hyperparathyroidism in chronic renal failure. There may be softening of the vertebrae with consequent curvature of the spine and loss of height may cause a rounded shoulder appearance.

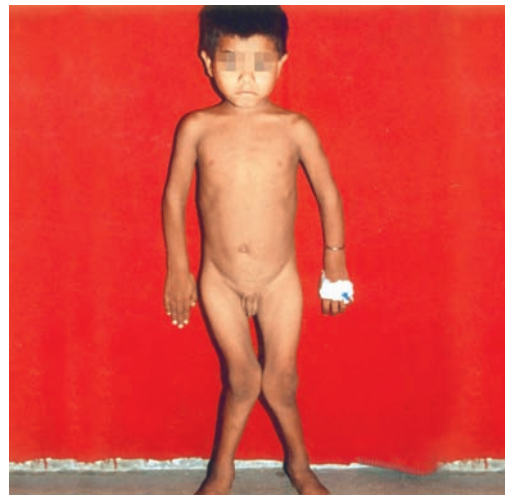

FIGURE 14.6 Knocked knees in a child with renal rickets. Note the bowing of the legs also

- *The extremities: Note, any abnormality.*

Flapping tremors of outstretched hands may be seen in uraemia (uraemic flaps). Other conditions that produce these flaps include hepatic encephalopathy and respiratory failure (CO₂ retention). There may be sporadic twitchings of the limbs and muscle cramps.

Restless leg—a uncontrolled desire to move their legs continuously may be seen in patients with CRF undergoing dialysis.

- *The nails: Note, any abnormality.*

White and opaque nails (leuconychia) are sometimes seen in nephrotic syndrome or CRF.

Beau's transverse lines are seen in severe illness or malnutrition. *Splinter haemorrhages* in the nail beds suggest vasculitis or endocarditis.

Nail dysplasia with multiple osseous abnormalities (elbow and knees, i.e. patella) are seen in Nail-Patella syndrome—an autosomal dominant disorder of kidney (hereditary nephropathy).

Half and half nails. Lower half white and upper half brown of a nail called *half and half syndrome* is seen in chronic renal failure (Fig. 14.7).

- *The eyes: Note, any abnormalities in the eyes.*

Pain and redness from conjunctivitis may be caused by local deposits of calcium due to hyperparathyroidism. Yellow deposits in the sclerae may also be seen. Thin curved white lines in corneoscleral junction may occur due to hyperparathyroidism. Haemangioblastomas of retina occur in von-Hippel-Lindau disease. Blurring of vision or visual loss may occur due to hypertensive retinopathy or retinal vascular thrombosis.

Macular flecks and recurrent corneal erosions are seen in Alport's syndrome.

Retinal changes (exudates, haemorrhage-retinopathy) may occur due to hypertension, diabetes and vascular disorders.

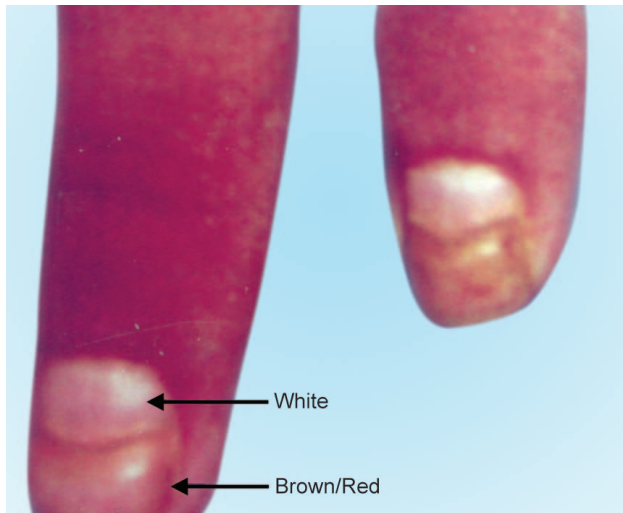


FIGURE 14.7 Half and half nails' in a patient with chronic renal failure

- **The ears:** Note any abnormality.

Sensorineural deafness may be present in patients with *Alport's syndrome* (consisting of proteinuria, haematuria, renal failure and ocular abnormalities) and other forms of hereditary renal disease.

The Abdomen (Read Chapter 13)

Inspection

Read Chapter 13.

Palpation

Normal kidneys, especially right one which is lower than the left due to presence of liver, may sometimes be felt in thin persons with relaxed abdomen. The palpable, enlarged kidneys are always abnormal, except compensatory hypertrophied kidney in response to removal of the other kidney.

The causes of enlargement of kidneys as well as palpation of a renal lump and its differential diagnosis has already been discussed in Chapter 13.

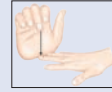The characteristics of distended bladder due to delayed micturition, outlet obstruction or neuropathy (neurogenic bladder) has also been discussed in Chapter 13.

Fullness of renal angle and tenderness of kidneys (renal area) or bladder (suprapubic area) have been described already.

Remember: It should be remembered that a transplanted kidney lies in the iliac fossa, where it can be felt as a firm swelling underneath the skin and anterior abdominal musculature.

Diffuse oedema of the abdominal wall which indents or pits on finger pressure, sacral and pedal oedema have also been described, may be caused by salt and water retention, hypoproteinaemia due to nephrotic syndrome and chronic renal failure.

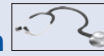Percussion



Percussion in urinary system disorders is done:

- To diagnose pulmonary complications such as pneumonia and pleural effusion.
- To diagnose ascites (perform fluid thrill and shifting dullness) in nephrotic syndrome.

Auscultation



Auscultation in urinary system is not limited to the kidneys (renal vasculature) but also of the heart and lungs.

- **Arterial bruits:** These may be heard over the kidneys posteriorly (renal angle) or anteriorly in the midline on either side of umbilicus by pressing the stethoscope in relaxed abdomen (*see* Fig. 13.40). Presence of bruit in patients with hypertension indicates renal artery stenosis. Iliofemoral bruit implies the presence of atherosclerosis and increases the possibility of renal artery stenosis when no bruit is heard in renal area.
- **Pericardial and pleural rubs:** These may be heard in patients undergoing dialysis, and sometimes in conditions, such as systemic lupus erythematosus and vasculitis where kidney, heart and lungs are involved as a part of multisystemic involvement.

INVESTIGATIONS OF A CASE WITH RENAL DISEASE

Urine Examination

The urine should be tested routinely in any medical illness because testing of urine often leads to discovery of unsuspected disorders such as diabetes mellitus, diabetes insipidus or chronic renal failure, jaundice or hypertension.

Urine passed into a clean vessel is suitable for chemical examination which should be carried out immediately on uncentrifuged and if necessary on centrifuged urine. Antiseptic or detergents may not be used during collection of urine for culture as they may cause false results. Mid-stream sample of urine should be collected for bacteriological and microscopic examination.

Physical Characteristics

- **Volume:** Normal urine output per day is 800–2500 mL. Markedly decreased or no urine output may be due to urinary retention, oliguria or anuria. Oliguria indicates acute renal failure or acute on chronic renal failure, may be due to salt or water depletion resulting from diarrhoea, vomiting, fever, heat stroke, excessive burns, shock, severe heart failure or acute diffuse disease of the kidney, i.e. acute glomerulonephritis or acute nephritic syndrome. Urinary retention differs from anuria where urine formation occurs resulting in distention of urinary bladder. Polyuria refers to daily urine output of 3 litres, and differs from increased frequency of micturition where patient passes small amount of urine frequently, but patient’s total output of urine remains normal polyuria results from tubulo-interstitial disorders, excessive water intake, increased diuresis and may be drug induced. Nocturnal polyuria indicates chronic renal failure.
- **Colour and transparency:** Urochrome and uroerythrin are pigments which give the normal colour (light yellow) to the urine. The exact tinge varies. Urine darkens on standing due to oxidation of colourless urobilinogen to coloured urobilin. The urine is abnormally pale when it is very dilute and in renal failure.

Abnormal colouration of urine occurs due to presence of blood in the urine called *haematuria* which may be microscopic or macroscopic, has to be differentiated from other coloured pigments in the urine (see Box 6). A small quantity of blood gives the urine a smoky appearance (see in acute nephritic syndrome); larger quantities make it brownish or red.

Urine is normally quite transparent and clear when freshly passed but pus, bacteria, precipitated urates and phosphates may make it *cloudy*. If cloudiness persists after filtration, it is due to bacteria. Stale or unrefrigerated urine often appears hazy or musky because of bacterial proliferation which occurs at body temperature.


Phosphate and urates may precipitate in normal urine. Phosphate produces a white deposit in alkaline urine and warming increases their deposition because urine becomes more alkaline due to loss of CO₂. Phosphate dissolves easily with acidification with acetic acid. Clear urine becomes cloudy at room temperature due to precipitation of urates which dissolves on rewarming or adding NaOH. Urate excretion increases in myeloproliferative disorders and in gout when purine breakdown is augmented.

- **Urine concentration or osmolality:** Urine osmolality (mOsm) is determined by the number of solute particles/kg of H₂O. This is tested by water deprivation for 8–12 hours or administration of vasopressin. Normally, after 8 hours of water deprivation, urine osmolality reaches 800 mOsm/kg. The weight of patient should be recorded before and after the test. If weight loss is more than 3% of body weight, the test should be abandoned. Normal urine osmolality is 70–1200 mOsm/kg H₂O.
- **Specific gravity of urine:** It is the measure of the quantity of the solutes (urea and sodium) in solution, approximately measures the urine osmolality. It is measured either by commercially available reagent strip or by urinometer. For urinometer, a sufficient quantity of urine is required to dip it, if quantity is not sufficient, then dilute the urine with equal amount of distilled water and the last two figures of urinometer reading doubled. The normal specific gravity varies from 1.002–1.025, is proportional to the urinary concentration of urea and sodium. It depends on the hydration of the patient and time of the day. It is greatest on arising in the morning. After 12 hours of water deprivation, it is more than 1.025 normally. Urine of low specific gravity (1.004) is passed in *diabetes insipidus*, in patients with *compulsive water drinking* and in certain disorders affecting the tubular function of the kidney (tubulointerstitial disorders) called *nephrogenic diabetes insipidus*. The specific gravity is low

Box 6

Abnormalities of the urine colour (Figs 14.8A to D)

Orange-brown	Bilirubin (unconjugated) Rhubarb, senna Normal concentrated urine (dehydration)
Red-brown	Blood, myoglobin, haemoglobin Porphyrins, rifampicin, nitrofurantoin phenolphthalein, desferrioxamine Beet root, black berries
Brown-black	Bilirubin, melanin, methaemalbumin, L-dopa, homogentisic acid (alkaptonuria)



FIGURES 14.8A to D Abnormal colouration of the urine: (A) Normal; (B) Urine from a patient with Jaundice; (C) Haematuria; (D) Patient on rifampicin

and fixed in chronic renal failure. The specific gravity is high in acute nephritic syndrome. If a random or pre-breakfast sample of urine is found to have specific gravity of 1.020 or more; it is presumed that kidney had normal concentrating capacity.

- **Urine dilution:** It is tested by asking the patient to drink one litre of water and the urine is collected one hourly for next 4 hours. At least 750 mL of urine should be excreted normally during this period and osmolality of one of the samples should be less than 100 mOsm/kg. A number of conditions interfere with diluting ability of the kidneys such as tubulointerstitial diseases.

Chemical Examination

Many of the chemical tests for routine urine examination are done by commercial tablets, or reagent 'stick' or 'strip'. It is imperative to follow the manufacturer's instructions in order to avoid false results. The strips should be kept dry in their closed containers and indicator ends of the strips are not handled. The reagent strip has to be dipped into the urine and its edge is wiped off by running it against the rim of the urine container. The colour change noted after a specified period of reaction between the reagent and the urine is compared with the colour chart of the manufacturer's drawn on the strip container. Most strips test several constituents of the urine. Try to read the strip at the specified time.

The pH

The pH of the urine is tested by commercial reagent strips. Normal fresh urine is slightly acidic except shortly after meals. Alkalinisation of the urine may be done for therapeutic purposes (forced alkaline diuresis in salicylate poisoning) by administering drugs. However, impairment of tubular acidification indicate tubular defect which can be confirmed by acidification test described below:

- **Reaction of the urine and acid excretion:** Normal pH of urine varies from 4.3 to 8.0. Urea splitting organisms raise the pH beyond 8.0. It is an important diagnostic clue to infection by these organisms. The acidification of urine occurs when kidneys are not able to excrete sufficient amount of NH_4^+ . This can be tested by acidification test.

Procedure for test

- Give NH_4^+Cl , 1.0 g/kg in capsules orally
- Collect urine every hourly for 8 hours in a container having some amount of liquid paraffin to prevent its exposure
- Measure urine pH, total NH_4^+ and total titrable acid in each sample
- During testing, patient should eat normally and drink sufficient amount of fluids (200 mL/hr).

Failure to reduce the pH of urine to less than 5.3 indicates renal tubular acidosis or chronic renal failure with metabolic acidosis.

Urinary Constituents Abnormalities

I. Proteinuria

Normal adult passes upto 150 mg of proteins in the urine daily, which is not detected by ordinary tests. Hence, we say, normally, there is no proteinuria. Proteinuria more than 150 mg is called pathological proteinuria which may be *microalbuminuria* (30–300 mg/day or albumin excretion rate of 20–200 $\mu\text{g}/\text{min}$) or *overt proteinuria* (> 500 mg/day). Microalbuminuria is detected by special tests only. Overt proteinuria can be detected by conventional tests. Normally, 10–15% of urinary proteins is albumin derived from plasma, rest of proteins are tubular in origin (*Tamm-Horsefall mucoproteins*) or some other fractions of plasma proteins. Albumin being a large molecule is usually not filtered normally, but in pathological conditions involving glomeruli, it is filtered in variable amount, constituting *nephritic* and *nephrotic syndrome*. In clinical practice, albuminuria is interchangeably used for proteinuria.

Consequences of proteinuria: Plasma proteins maintain plasma oncotic pressure, which falls in patients with albuminuria leading to retention of fluids. The retention of fluids in extravascular compartment, reduces effective blood volume and effective renal perfusion leading to stimulation of *renin-angiotensin-aldosterone cascade*, resulting in Na^+ and water retention and oedema formation. Loss of urinary proteins, if not compensated by the synthetic capacity of the liver, results in hypoalbuminaemia and lowered oncotic pressure. There is rise in serum lipids in patients with massive albuminuria. A hypercoagulable state frequently accompanies severe proteinuria (nephrotic syndrome) due to urinary losses of antithrombin III, reduced serum levels of proteins S and C and hyperfibrinoginaemia. Therefore, consequences of massive albuminuria are: *hypoalbuminaemia, oedema, ascites, hyperlipidaemia, lipiduria and hypercoagulable state*.

Tests for proteinuria

- **Heat coagulation method (conventional method):** It is done by heating upper portion of urine in a test tube. The white coagulum at the top indicates proteinuria.
- **Dip stick test:** This is available as a bed side test and can be done by the patient himself, if his/her eyesight or colour vision is normal. The change in colour of the strip is compared to the colour on the bottle which quantifies the loss of proteins.
- **Electrophoresis of proteins:** It is done to detect globulins in the urine (Fig. 14.9).

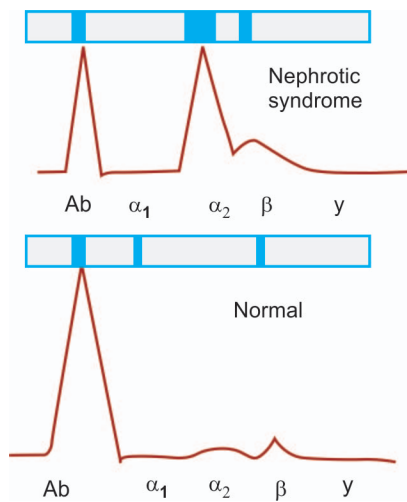


FIGURE 14.9 Serum paper electrophoresis in normal person and in a patient with nephrotic syndrome. Note the reduced albumin and increased globulins (α and β) in a patient with nephrotic syndrome.

- **Immunoelectrophoresis:** It is done to identify the various fragments of immunoglobulins when there is a monoclonal peak on routine urine paper electrophoresis.
- **24 hours urine for proteinuria:** It is carried out to separate cases of nephrotic syndrome (massive proteinuria > 3.5 g/day) from other causes of proteinuria, where it is mild to moderate (1–2 g/day).

Aetiopathogenesis of proteinuria

Tubular proteinuria: The disease producing damage more to tubules than to glomeruli has proteinuria ranging from 1–3 g/day, consists of only small molecular proteins but not albumin. In this type of proteinuria, oedema and hyperlipidaemia do not occur as there is no loss of albumin in the urine. There is no abnormal cell in the urine.

Glomerular proteinuria: Glomerular injury to basement membrane leads to albuminuria which, if persists, can also lead to filtration of large molecular proteins, such as globulins. Therefore, selectivity of proteinuria varies with the extent of glomerular damage. In selective proteinuria, the larger molecular proteins are absent but albuminuria present; in non-selective proteinuria, they are present in significant amounts along with albumin. The clinical utility of differentiating selective proteinuria from nonselective proteinuria has not been well defined, but it has been observed that patients with selective proteinuria respond to treatment better and have better life span than those with non-selective proteinuria.

Asymptomatic proteinuria: It is defined as chance detection of proteinuria during routine urine examination. It is frequently seen in younger persons who are undergoing medical examination for employment or insurance purposes. The proteinuria is considered as benign and it may be

orthostatic (postural) or exercise induced. The renal biopsy is indicated if proteinuria exceeds 2 g/day or there is associated hypertension, haematuria and impaired renal functions.

Orthostatic (postural) proteinuria: Some children, adolescents and healthy persons pass small amounts of proteins in the urine in relation to assuming the upright posture. This is again a benign condition without demonstrable renal disease. In such patients, urine formed during recumbent position, i.e. morning sample of urine on rising is free from proteins. Urine formed during daytime activities or after vigorous exercise contains proteins. Other investigations are not required if renal disease is not suspected. Follow-up studies of such patients indicate that the condition is benign.

Microalbuminuria: The term is used to denote mild albuminuria (30–300 mg/day or albumin excretion rate of 20–200 $\mu\text{g}/\text{min}$) which is not detected by conventional methods. Special radioimmunoassay methods are used to detect it. Interpretation of results is very difficult because albumin excretion will increase with exercise as well as in certain other disorders. Nonetheless it is a useful diagnostic test for the detection of early diabetic nephropathy provided other causes of an increased urinary excretion of albumin have been excluded. Diabetic nephropathy is suspected when two of three samples collected at 2–3 months intervals are positive for microalbuminuria.

Bence-Jones proteinuria: These are light chain immunoglobulins (Bence-Jones proteins—a paraprotein) that appear in the urine in patients with monoclonal gammopathies. These proteins can be identified by immunoelectrophoresis of urine.

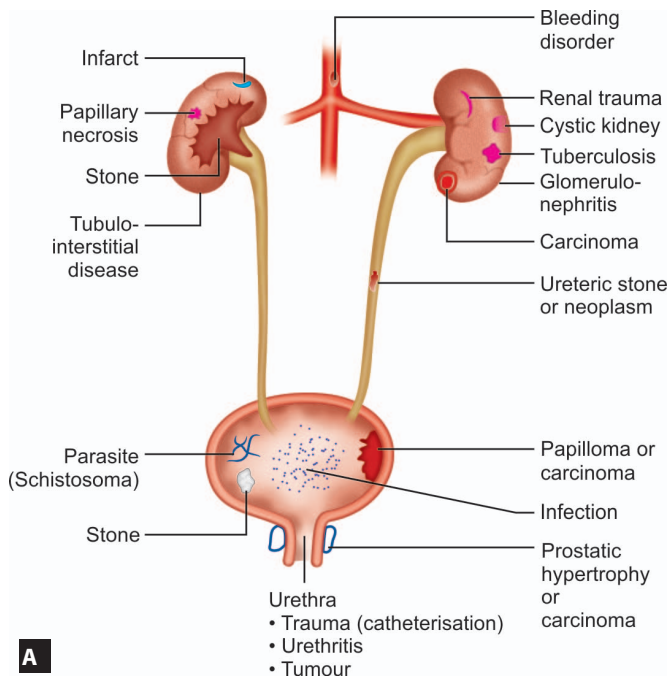
2. Haematuria

Blood or RBCs in the urine is called haematuria. Isolated haematuria occurs in bleeding anywhere in genitourinary tract (Fig. 14.10A). In such a situation, blood is mixed with urine giving it a red colour (Fig. 14.10B) or detected on microscopy by RBCs called microscopic haematuria. Bleeding in the beginning or at the end of micturition indicates prostatic or urethral disease.

Tests for blood in urine

The haematuria (passage of intact RBCs in urine) and haemoglobinuria (passage of free haemoglobin in urine) give positive tests for blood in the urine, hence, can only be differentiated by presence of RBCs in urine on microscopy in haematuria not in haemoglobinuria.

Reagent strips: The blood in urine is quickly tested in bedside laboratory by reagent strips. The reaction is based on *haemoglobin* or *myoglobin* which produces a patchy discolouration. *False-positive* results may be produced by stale or infected urine because peroxides are produced



A



B

FIGURES 14.10A and B Haematuria: (A) Causes and sites (diagram); (B) Urinary bag contains urine mixed with blood, collected from a patient suffering from haematuria

by proliferating bacteria in the urine. Similarly, presence of other oxidants (e.g. sodium hypochlorite or antiseptic solution) may also give false-positive results. Other pigments, i.e. haemoglobin and myoglobin also produce false positive results. Reducing agents (e.g. vitamin C) may give *false-negative results*. Therefore, one must test the freshly voided urine for blood.

Clinical Significance

- Menstrual bleeding is the most common cause of blood in the urine, hence, non-menstrual fresh urine should be examined if some renal disorder is suspected.
- Microscopic examination of urine for RBCs not only separates haematuria from haemoglobinuria but also points to the site of injury, i.e. RBCs in glomerular diseases



FIGURE 14.11 Haemoglobinuria: Black-brown colouration of urine due to haemoglobinuria. The sample was taken from a patient with black-water fever (Falciparum infection). Urine was positive for haemoglobin

are distorted because they pass through the tubules while they are undistorted if bleeding is from lower urinary tract.

Haemoglobinuria may occur:

- Following strenuous exercise in normal persons.
- Haemolysis due to any cause (Fig. 14.11)

Myoglobinuria can occur due to:

- Strenuous exercise.
- Crush injuries damaging the muscles.
- Metabolic myopathies.

- Urine containing blood or haemoglobin invariably contains some protein usually in trace amounts that does not exceed 0.5 g/L in any case. This should be kept in mind in patients with haematuria.

3. Glucosuria/ketone uria

Sugars in Urine

The kidneys retain certain useful substances, i.e. fats, proteins and glucose by maintaining threshold called *renal threshold* for that specific substance. The substance will appear in the urine if its concentration exceeds its renal threshold, for example, glucose appears in the urine when its plasma concentration exceeds 180 mg% (renal threshold for glucose).

Presence of glucose in the urine is called *glycosuria*, which may result from raised blood glucose levels (*diabetes mellitus*), defective renal tubular reabsorption (*renal glucosuria*) or GI tract disorders (*alimentary glucosuria*).

Several reducing sugars, i.e. glucose (most common and important), lactose, fructose, pentose and galactose may be

found in the urine and may give positive result with Benedict's reagent or clinitest. *Lactosuria* occurs in late pregnancy, and during lactation. *Pentosuria* may be caused by eating large quantities of certain fruits such as *plums, cherries and grapes*. Galactosuria and fructosuria occur usually due to a rare inborn error of metabolism.

NB: Sucrose is not a reducing sugar, hence, deliberate loading the urine (foul-play) with this substance does not produce positive clinitest but only raises the specific gravity of the urine—a diagnostic clue.

Reducing substances other than sugars, if found in the urine, may give *false positive results*. These include homogentisic acid (present in alkaptonuria—a rare disorder), ascorbic acid (vitamin C), cephalosporins, nalidixic acid, probenecid or aspirin used for treatment.

Tests for Reducing Sugars

Reagent strips: These strips tests are specific for glucose, and non-glucose reducing sugars give negative results. False positive reactions may be given by strong oxidising agents (e.g. hypochlorite, antiseptics, bleaches and detergents) and reducing agent (ascorbic acid).

Clinitest and Benedict's test: The clinitest is a convenient modification of Benedict's test (a solution) in a tablet form. It is nonspecific and less sensitive for glucose than the reagent strips.

Tests for Ketones

Ketonuria: Ketones (e.g. acetoacetic acid and acetone) may appear in the urine of patients with severe diabetes mellitus (more common in type 1 than type 2), following starvation (starvation ketosis), or prolonged vomiting, diarrhoea and alcoholism.

Reagent strips: These utilise a modification of Rothera's nitroprusside test and are semi-quantitative. A *mauve* colour denotes the presence of acetoacetic acid. Acetone and hydroxybutyric acid do not react in this test.

False-positive results will occur if urine contains; bromsulphalein, phenylketones, benzopyridines and metabolites of L-dopa.

Acetest: This is a modification of Rothera's test.

Gerhardt test (Ferric chloride test): Severe ketonuria is implied if this test is positive.

Remember that the urine must be fresh and unboiled when used for testing for ketones because acetoacetic acid (a ketone body) is easily decomposed by proliferating microorganism or heat.

Tests for bilirubin and bile pigments

Bile pigments: Bile pigments are passed in the urine in a patient suffering from jaundice, make the urine yellowish or brownish in colour and shaking the test tube containing urine may yield the formation of a stable yellow froth.

Bilirubin: It is an end-product of haem metabolism. It is conjugated in the liver by an enzyme *glucoronyl transferase*. The unconjugated bilirubin is fat-soluble, strongly bound to protein and is not excreted in the urine. Unconjugated hyperbilirubinaemia is a characteristic feature of haemolytic process. On the other hand, conjugated bilirubin is water soluble, less bound to albumin and can be excreted in the urine.

The bilirubinuria in a patient with jaundice suggests either hepatocellular damage or obstructive jaundice. This could also be due to congenital hyperbilirubinaemia with bilirubinuria (*Dubin-Johnson syndrome*).

- **Ictotest:** This is based on coupling of bilirubin with a diazonium salt.
- **Reagent strips:** These are less sensitive than ictotest.

NB: Chlorpromazine or phenopyridine in the urine may give a false-positive result in both strips and tablet tests; while ascorbic acid gives false-negative results.

Urobilinogen and urobilin: Urobilinogen is formed in the intestine by the action of intestinal bacteria on bilirubin excreted by the liver into the intestine. Some of the urobilinogen formed enters into the enterohepatic circulation to be transported to the liver for excretion again, while a small amount reaches the systemic circulation to be excreted in the urine. The colourless urobilinogen gets oxidised to urobilin on standing and imparts normal light yellow colour to the urine. Urine becomes deep-yellow or orange coloured if urobilinogen is passed in excessive amount as in a patient with haemolytic jaundice.

Urobilinogenuria in a patient without jaundice imply that urobilinogen is being formed in large amount and normal liver is unable to cope with it or that a damaged liver is unable to excrete the normal amount of urobilinogen being presented to the liver via enterohepatic circulation as in cirrhosis or early infective hepatitis.

Presence of excessive urobilinogen in urine followed by its disappearance subsequently in a patient with infective hepatitis indicates recovery.

Ehrlich's Aldehyde Test and its Commercial Modification into Reagent Strips

Ehrlich's aldehyde test or reagent strips are used to test the urobilinogen in the urine. The test is performed with freshly

voided urine because as already discussed, the urobilinogen gets oxidised to urobilin on standing spontaneously, and does not give the reaction.

Porphobilinogen (excreted in the urine in intermittent porphyria or certain other porphyrias) is also converted into porphobilin which on standing imparts a burgundy-wine or portwine colouration to the urine (Figs 14.12A and B), also gives positive test result (a red colour), which does not disappear with alcohol extraction.

The commercial strips also give similar results as aldehyde test for urobilinogen and porphobilinogen. The false positive (e.g. sulphonamides, salicylates) and false-negative (contamination with formaline) results for urobilinogen may also be obtained by these tests.

Microscopic Examination

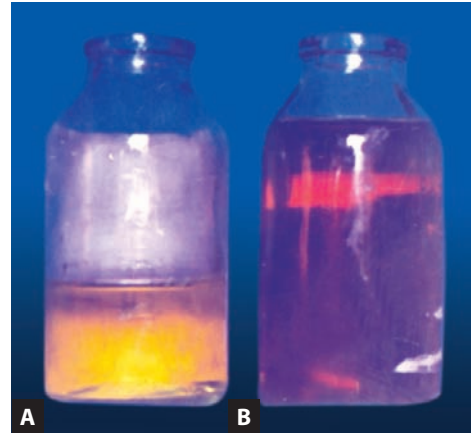
(For example, RBCs, WBCs, cells and casts).

The cells, and the casts may be disrupted on prolonged standing and on rapid centrifugation, hence, it is essential to examine a fresh uncentrifuged specimen for this purpose. High-power magnification is necessary to distinguish RBCs from WBCs, yeasts and small crystals. Phase contrast microscopy is

used to identify the casts and to assess red cell morphology. Polarised light can be used to identify urinary crystals.

Cells

Abnormal cellular elements in the urine are described in the Table 14.1.



FIGURES 14.12A and B Porphobilinogen in urine: (A) Freshly passed urine is normal in colour; (B) Dark-brown (burgundy-wine) urine on standing

TABLE 14.1 Various types of cells in the urine

RBCs	WBCs	Epithelial cells
<p>RBCs in urine appear as a small (7 µm approx.) rounded cells without nucleus. Dysmorphic RBCs (irregular in size and shape) indicate glomerular involvement rather than lower urinary tract. Phase-contrast microscopy is best to demonstrate them.</p>	<p>They are larger than RBCs and have round shape, bilobed nucleus and refractile granular cytoplasm. They are best seen in acidified urine which causes the RBCs to disintegrate. They can be differentiated from epithelial cells by phase-contrast microscopy. When numerous, they disintegrate rapidly, hence, urine should be fresh for their examination.</p>	<p>Epithelial cells arise from the renal tubule, are larger than WBCs and have oval nuclei. They are present in urinary tract infection and to lesser extent in inflammatory conditions such as tubulointerstitial nephritis and glomerulonephritis. Transitional epithelial cells from bladder or ureters appear as large oval cells with single nucleus. Polygonal cells, sometimes in sheets, come from the urethral or vaginal secretions, if they are present in large numbers, the specimen is contaminated.</p>
<p>Normal urine contains not more than 3 RBCs/mm³ of uncentrifuged urine or less than 1 per high power field of centrifuged urine</p> <p>Red cells may be confused with oil droplets (catheter lubricant) but latter are variable in size, have high refractile index and are more circular than RBCs. Yeast cells can be differentiated from RBCs by variability in the size and presence of budding forms.</p>	<p>More than 3 cell/mm³ in men are abnormal. In women, 10 cells/mm³ in uncentrifuged mid-stream urine is abnormal and 3 to 10 cells/mm³ are of doubtful significance.</p> <p>Increased excretion of WBCs in urine indicates either active urinary tract infection for which urine should be cultured for confirmation. However, sterile pyuria (pus cells are present in urine but culture is sterile) indicates either tuberculosis of the kidney or patient is of UTI on antibiotic therapy. A commercial strip test is also available which becomes positive if urine contains 10 or more cells/mm³. False-positive (nitrofurantoin) and false-negative (high specific gravity, glycosuria, and presence of tetracyclines, cephalosporins and oxalic acid) results are common with these strips.</p> <p>Mid-stream sample showing pyuria indicates urethritis or prostatitis.</p>	

Casts

These are cylindrical structures formed in the renal tubules.

Hyaline casts: These are relatively clear, homogenous cylindrical structures formed by the precipitation of Tamm-Horsfall mucoproteins in the renal tubules. It is unusual to see more than one cast per low-power field in health. A large number of them are seen:

- Following strenuous exercise
- In febrile illnesses
- In severe essential hypertension
- In chronic renal disease.

RBCs, WBCs and epithelial casts: These are formed by the precipitation of the tubular (mucoproteins) on the cells from which they derive their names, i.e. RBC cast (precipitation of protein on RBC), WBC cast (precipitation of protein on WBC) and epithelial casts (precipitation of protein on epithelial cells).

RBCs casts (Fig. 14.13) indicate haematuria of glomerular origin and are most often seen in acute glomerular disease such as diffuse proliferative glomerulonephritis.

WBC casts indicate acute renal infection or inflammation, are most often seen in acute pyelonephritis.

Granular casts: These are hyaline casts which in addition contain granules of albumin and immunoglobulins. They may also contain disintegrated cellular debris to varying degrees in the form of fine or coarse granules (granular and cellular casts). They are pathological and found in glomerulonephritis, hypertension, diabetic nephropathy.

Very broad casts (*renal failure casts*) are nothing but hyaline or granular casts formed in large dilated surviving tubules of the kidney, hence, are so shaped and named.

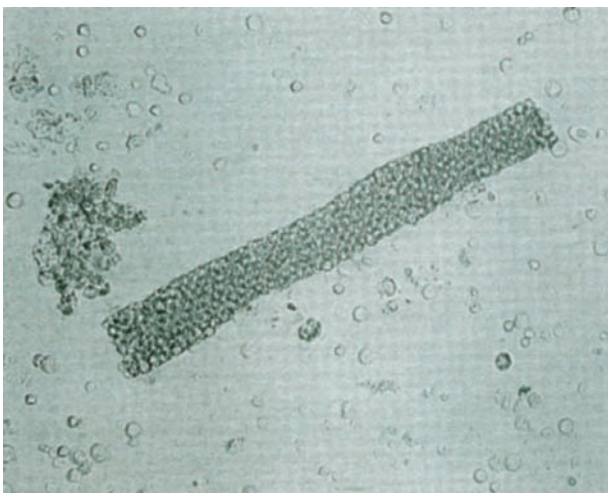


FIGURE 14.13 Red cells (RBCs) casts in the urine. Note the red cells aggregation as a cast of the tubule

Casts are easily missed if microscopic illumination is too bright and they disintegrate if the urine has been centrifuged too rapidly or for too long. They should be looked for towards the edges of the coverslip.

Crystals

These will form in any urine if left to stand for more than an hour. Crystals in fresh urine may indicate disease. Alkaline urine often contains 'coffin-lid' shaped crystals of ammonium magnesium phosphate (triple phosphate). Conversely an acidic urine may show envelop-shape crystals of calcium oxalate. Uric acid crystals occur in normal urine and may crystallize out in various shapes. Crystals are usually of no pathological significance unless passed in large numbers. Occasionally, they may be of diagnostic importance, i.e. urate crystals in gout or urate nephropathy, oxalate crystals in hyperoxaluric stone disease, cysteine crystals in cystinuria.

Micro-organisms

Bacteria, if motile, may be seen under high-power in uncentrifuged and unstained urine but are easily seen in Gram-stained centrifuged specimen. Their presence indicate that the urine is infected.

Trichomonas vaginalis (a pear-shaped or round parasite about twice the size of WBC with a unipolar flagellae) may be seen in the urine of woman either as a contamination of urine with vaginal secretion or due to trichomonas vaginitis in patients with uncontrolled diabetes. Yeasts may also contaminate urine.

Ova of *Schistosoma haematobium* are best looked for in the last few millimeters of a stream of urine passed in *mid-morning*. A spine projects at one pole of the ova. The ova of *S. mansoni* are less often found in the urine.

Microbiological Examination

Urine for culture: For all suspected bacterial infection, a fresh, clean-voided mid-stream urine sample is most suitable for culture. The method of collection of mid-stream urine sample is given in the Box 7.

NB: The most satisfactory sample for culture is the first one collected after arising from the sleep because the bacteria in the bladder at night have sufficient time to multiply undisturbed for several hours. Urine should either be cultured within 2 hours of collection, or refrigerated at 4°C immediately in order to prevent contamination, if delay in transportation to the laboratory is anticipated.

In conscious patients or patients with retention of urine, a catheterised sample should be cultured quantitatively.

Occasionally, it may be important to obtain a sample free from urethral contamination. This is obtained by suprapubic

Box 7

Collection of mid-stream sample of urine in female**In female**

- The patient's bladder should be full
- The patient removes undergarments and stands over the toilet pan
- The labia are separated with the left hand
- The vulva is cleansed front to back with sterile swabs
- The patient voids downward into the toilet and continues until "half-done"
- Without stopping the urine flow, the sterile container is plunged into the stream of the urine with right hand
- Collect about 10 mL of urine
- The patient then completes voiding into the toilet.

In male

- The patient bladder should be full
- The foreskin (prepuce), if present, should be retracted
- The glans is cleansed with a sterile swab
- The patient voids into the toilet until "half-done"
- Without stopping the urine flow, the sterile container is plunged into the stream of urine to collect about 10 mL of urine
- The patients then completes the process of passage of urine.

aspiration of urine by inserting a sterile needle in suprapubic region after shaving and cleaning the skin with swabs soaked in water. Needle aspiration is to be attempted after confirming the distension of bladder by percussion.

Bacteriuria: In general, the findings of more than 10^5 bacteria/mL or 10^8 bacteria/L in a mid-stream sample of urine indicates urinary tract infection. However, contamination can also lead to high bacterial counts which should, therefore, be interpreted with caution in the absence of pyuria. Sometimes, lower counts may be encountered in urinary tract infection in patients passing large amount of urine. Lower bacterial counts may also be encountered in the patients with urinary tract infection receiving antibiotic therapy.

Bacterial count of 10^2 – 10^4 /mL in urine is of no clinical significance in asymptomatic women.

Usually, the urine becomes infected with only one species or serotype of bacteria, hence, detection of more than one kind of bacteria or serotypes indicate contamination, but this is not a rule. In doubtful cases, a suprapubic aspirate may be cultured.

Blood Biochemistry

Urea: The concentration of urea in the blood depends on a balance between its production in the liver from ammonia, and its excretion by the kidneys. Its level varies with the

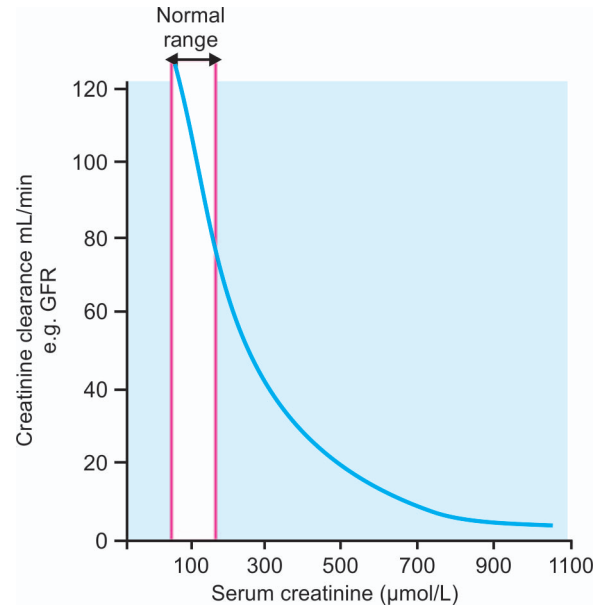


FIGURE 14.14 Creatinine clearance curve. Note that serum creatinine does not rise above the normal range until the glomerular filtration rate (GFR) falls below 50–60%

protein intake, may be raised in catabolic state such as fever and GI haemorrhage. In spite of so many factors that influence urea level, still it is used as an indicator of renal function and high levels correlate fairly well with the clinical syndrome of uraemia. Normal blood urea is 15–40 mg/dL (2.5–6.6 mmol/L).

Creatinine: It is derived mainly from the endogenous sources. Its blood concentration correlates well with the glomerular filtration rate (GFR) because it is neither secreted nor reabsorbed in the tubules. Therefore, creatinine clearance rate is actually the GFR. The normal serum creatinine level is 0.7–1.4 mg/dL (62–124 μmol/L). However, in patients with severe renal failure, a small change in GFR causes a large rise in blood urea and creatinine levels (Fig. 14.14).

Renal clearance or glomerular filtration: GFR is calculated by creatinine clearance by collecting 24 hours urine sample and a blood sample at the end of collection. Reduction in GFR parallels reduction in renal functions.

$$\text{GFR in mL/minute} = \frac{\text{Urinary creatinine (U)} \times \text{Volume of urine (V)} \times 1440}{\text{Plasma creatinine (P)}}$$

Radiology and Renal Imaging

Plain radiograph of abdomen is done to detect radiopaque stones (Fig. 14.15) or areas of calcification within the urinary tract. A radiograph from a well prepared patient gives enough idea of shape, size and position of the kidneys. This information now-a-days is best obtained by ultrasound and intravenous pyelography.

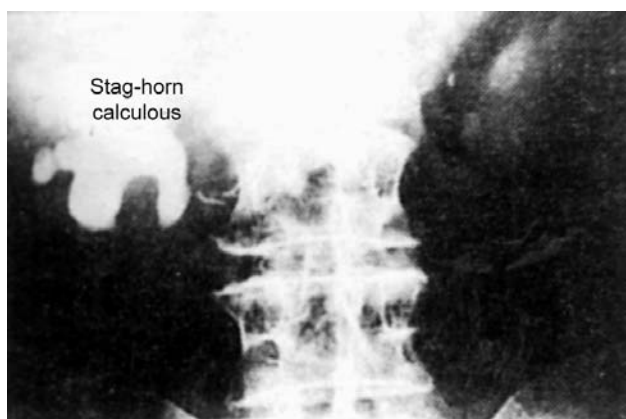

FIGURE 14.15 Plain X-ray abdomen showing a stag-horn calculous

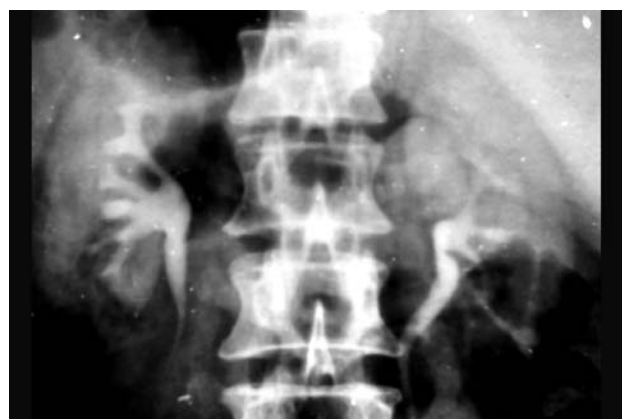

FIGURE 14.17 Normal intravenous pyelogram

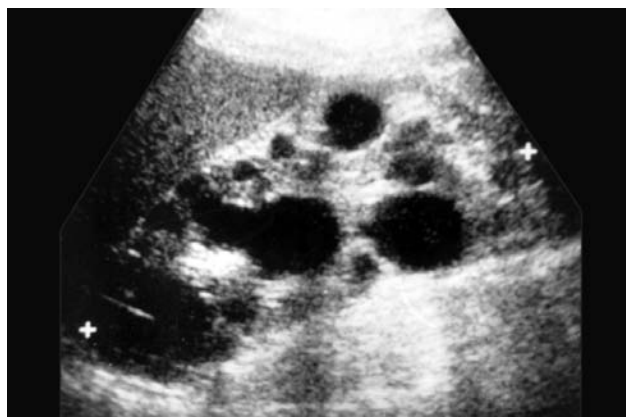

FIGURE 14.16 Ultrasound of kidney showing polycystic kidney disease (multiple cysts in the kidney are seen)

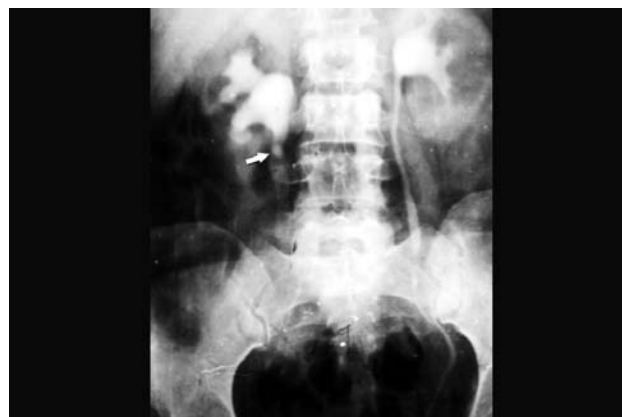

FIGURE 14.18 Hydronephrosis of right kidney. Note the dilated renal pelvis with clubbed calyces

Ultrasonography: Ultrasound is a quick, non-invasive, inexpensive and harmless method employed:

- To assess renal size, shape, position and thickness of renal cortex.
- To detect solid tumours and their extension, cysts and polycystic disease (Fig. 14.16), stones and calculi, dilatation of pelvicalyceal system and haematoma.
- To evaluate residual urine volume to detect bladder neck obstruction or enlargement of prostate. Prostate size, volume, mass can also be calculated.
- To carry out certain procedures as cyst puncture and renal biopsy.
- To detect metastasis from renal carcinoma into the lymph nodes and liver.

Intravenous pyelography: It is done by injecting a radiopaque material and following its concentration and excretion through the kidneys. Following the injection, films are taken at timed intervals. First of all, the dye is concentrated in the renal tubules increasing the radiographic density of renal parenchyma (nephrogram) by which shape and size of the kidneys can be studied. Within minutes, contrast is excreted

into pelvicalyceal system and making their outlines clear to study them for any abnormality (Fig. 14.17).

In adults, kidneys differ from each other by less than 1.5–2.0 cm. They have smooth texture and outline. Usually each kidney is seen to possess 2–3 major calyces, each has further 3–4 minor calyces and they give concave or cup-like opacification on intravenous pyelography.

Abnormalities on intravenous pyelography and their interpretations are given below:

- Nephrogram may reveal irregular cortical scars of pyelonephritis, irregular small contracted kidneys, tumours or localised masses.
- In diffuse renal parenchymal disease, the nephrogram will be faint and its appearance will be delayed.
- An increased opacification of the kidney on the affected side occurs in renal artery stenosis. The affected kidney is smaller by more than 1.5 cm from the opposite kidney.
- Clubbed or dilated calyces with slow excretion of the dye indicates urinary tract obstruction and hydronephrosis (Fig. 14.18).
- Bilateral kidneys enlargement with stretched and spidery calyces indicate polycystic disease of kidneys.

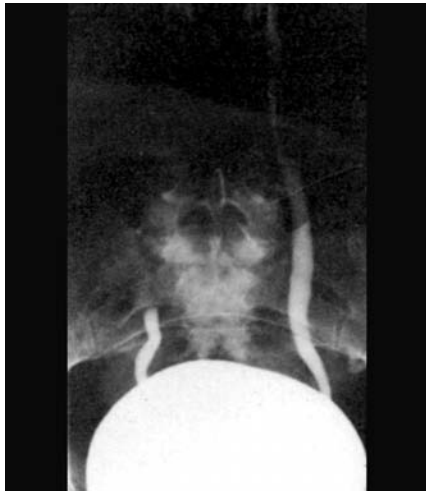

FIGURE 14.19 Micturating cystogram showing vesicoureteric reflux. Note the distended bladder with free reflux into both the ureters

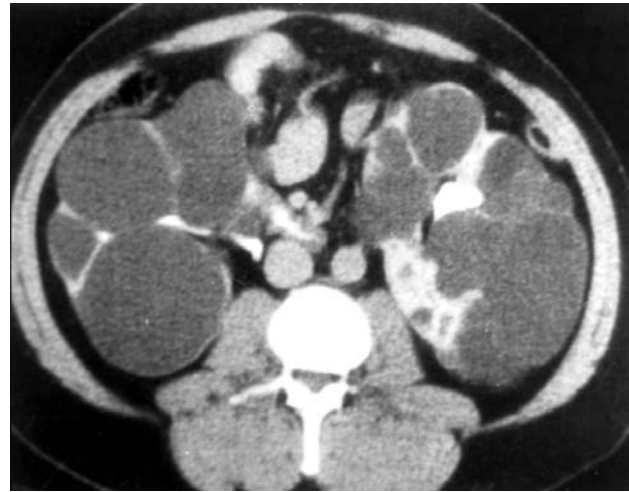


FIGURE 14.21 CT scan kidney's showing bilateral multiple cysts indicating polycystic kidney disease

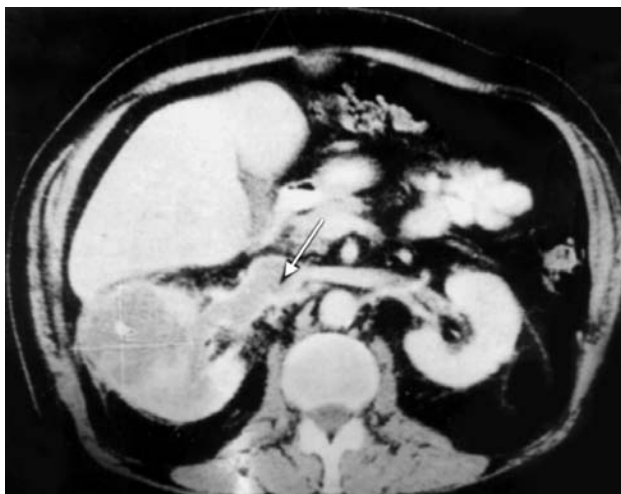


FIGURE 14.20 CT scan showing renal cell carcinoma (←)

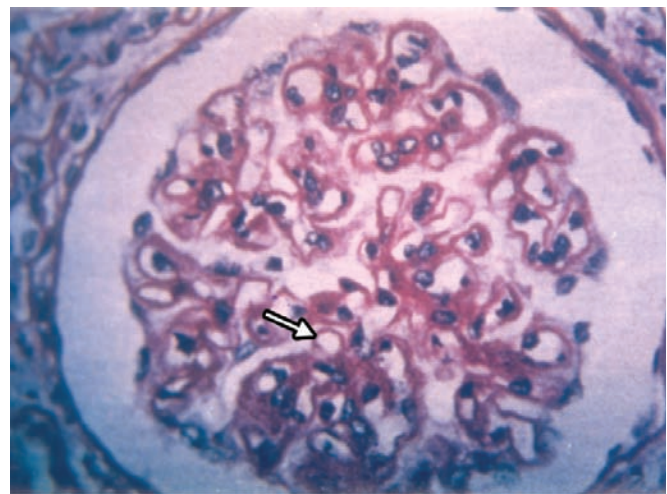


FIGURE 14.22 Membranous glomerulonephritis. There is thickening of basement membrane

- Non-opacification of one kidney by the contrast medium indicates non-functioning kidney.

Micturating cystogram: It is done in children to reveal abnormalities of bladder outflow tract and to find out vesicoureteric reflux (Fig. 14.19).

Renal angiogram: It is used to demonstrate the anatomy of the renal arterial tree. It is useful to find out renal artery stenosis, arteriovenous malformations and persistent bleeding after trauma. Nowadays it has been superseded by ultrasound and computed tomography.

Computed tomography (CT scan): It is done to detect masses (Fig. 14.20) and cysts (Fig. 14.21) in and around the kidneys. This information obtained can be enhanced by contrast CT. Extension of renal tumours and extent of renal trauma are better assessed by it.

Radionuclide studies: These are carried out by injecting radio-active compounds which are concentrated and excreted by the kidneys. Radioactivity in the kidneys is recorded by gamma camera. This is also useful to define size, shape, position and function of the kidneys and to detect tumours and abscesses in the kidneys and their effect on renal functions.

Renal biopsy: It is performed percutaneously by a needle (Vim Silverman's needle or trucut needle). This is useful in diagnosis of patients with proteinuria of unknown origin, an unexplained renal failure with normal sized kidneys and in systemic diseases associated with abnormal urinary constituents. The biopsy specimen is subjected to light, electron and immunofluorescence microscopic studies. This technique has increased our knowledge and better understanding of glomerular diseases (Figs 14.22 and 14.23).

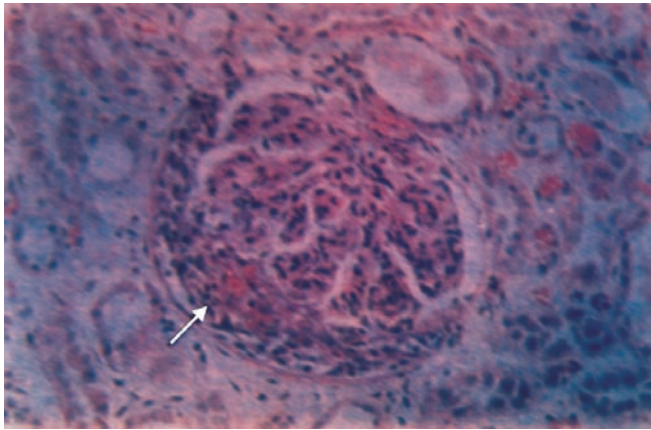


FIGURE 14.23 Glomerulonephritis with crescents formation. There is an epithelial crescent at the periphery of the glomerulus

EXAMINATION OF GENITALIA

The patient is examined in a well-lit room after proper exposure. The examination includes inspection and palpation. Gloves should be worn before examination.

Male Genitalia

Penis

Inspection



Look at the penis for any abnormality

Note the size of the penis, the presence or absence of the prepuce and the position of the external urethral meatus. Examine the penile shaft for warts, ulcers, burrows and excoriated papules of scabies and rashes. The abnormalities of penis are given in the Table 14.2.

- **The prepuce (foreskin)**, if present, retract it or ask the patient to retract it. This step is essential for detection of many chancres and carcinoma. Smegma, a cheesy whitish material may accumulate normally under the prepuce.

Phimosis (Fig. 14.28). It refers to tight prepuce that cannot be retracted over the glans.

Paraphimosis (Fig. 14.29). It refers to tight prepuce that, once retracted, cannot be returned. Painful oedema of glans ensues.

- **Look at the glans for any ulcer, scar, nodule or signs of inflammation.**

Balanitis is inflammation of the glans leading to pain and redness. Balanoposthitis (Fig. 14.28) means inflammation of both the glans and prepuce.

- *Check the skin around the base of the penis for excoriation or inflammation. Look for nits or lice at the base of the pubic hair.*

TABLE 14.2 Abnormalities of the penis

Venereal warts: (Condyloma acuminata—Fig. 14.24. Venereal warts are rapidly growing excrescences that are moist and often malodorous. They result from infection by papilloma virus.

Genital herpes: A cluster of small vesicles followed by painful non-indurated ulcers on red bases, suggests a herpes simplex infection. The lesion may occur anywhere on the penis.

Syphilitic chancre: A syphilitic chancre (Figs 14.25A and B) usually appears as an oval or round, dark red painless erosion or ulcer with an indurated base. Nontender enlarged inguinal lymph nodes are typically associated. Chancres may be multiple and may become painful due to secondary infection. Chancres are infectious.

Chancroid (Fig. 14.26): It is sexually transmitted disease caused by *H. ducreyi*, produces multiple tender ragged ulcers which bleed on manipulation.

Donovanosis (Fig. 14.27): It is called granuloma venereum in-guinale a sexually transmitted disease produces a singular or multiple ulcers with granulation tissue. There is associated lymphadenopathy.

Hypospadias: It is a congenital displacement of the urethral meatus to the inferior surface of the penis. A groove extends from the actual urethral meatus to its normal location on the tip of the glans.

Peyronie's disease: In this disease, there are palpable non-tender hard plaques just beneath the skin, usually along the dorsum of the penis. The patient complains of crooked, painful erections.

Carcinoma of the penis: Carcinoma may appear as an indurated nodule or ulcer that is usually nontender, common to men who are not circumcised in childhood and it may be masked by the prepuce. Any persistent penile ulcer must be suspected as malignant.

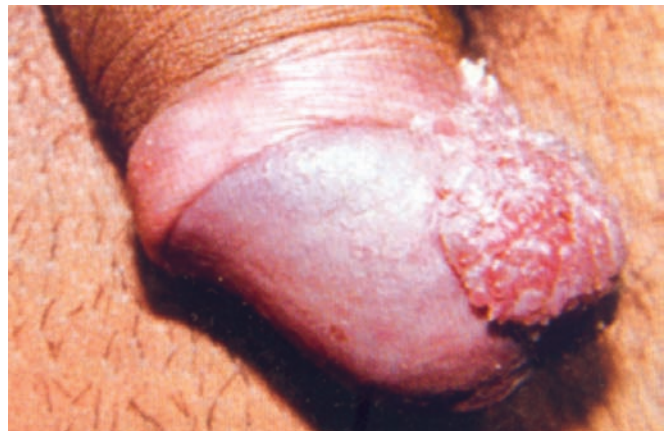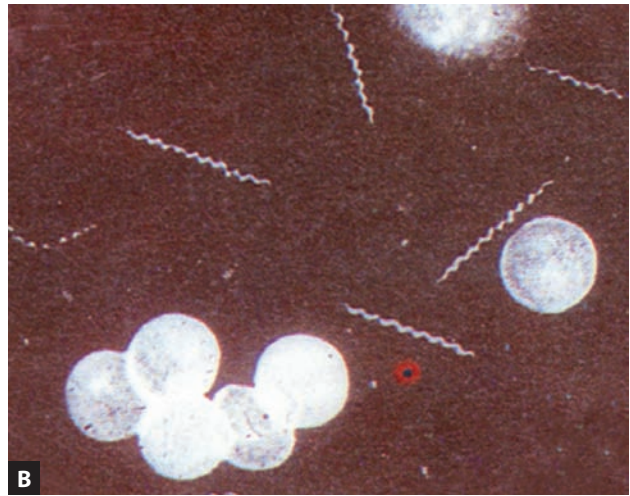

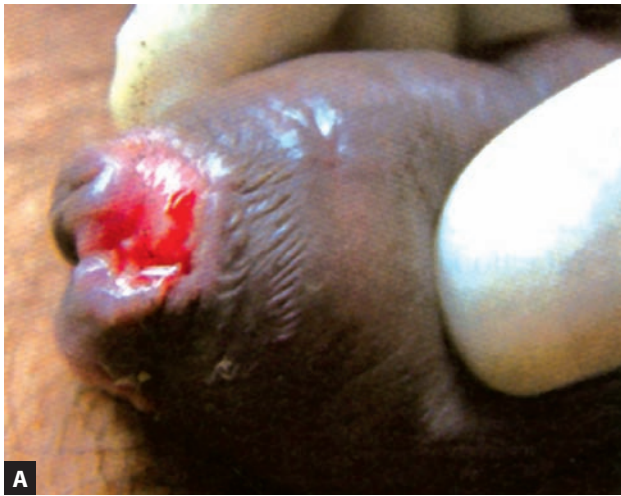
FIGURE 14.24 Venereal wart (condyloma accuminata)

Pubic or genital excoriations suggest the possibility of lice or scabies.

- *Note the site of urethral meatus—normal or displaced.*

Hypospadias is a congenital, ventral displacement of the meatus on the penis.



FIGURES 14.25A and B Primary syphilis: (A) Chancre on glans penis; (B) Direct field microscopy of urethral discharge demonstrates the thread like *treponema pallidum*—spirochaetes. There are large number of pus cells also seen

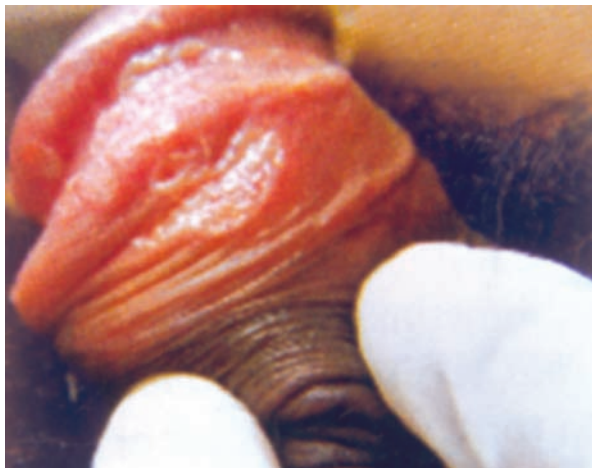

FIGURE 14.26 Chancroid. Note multiple, tender, dirty looking (ragged) ulcers which bleed on manipulation

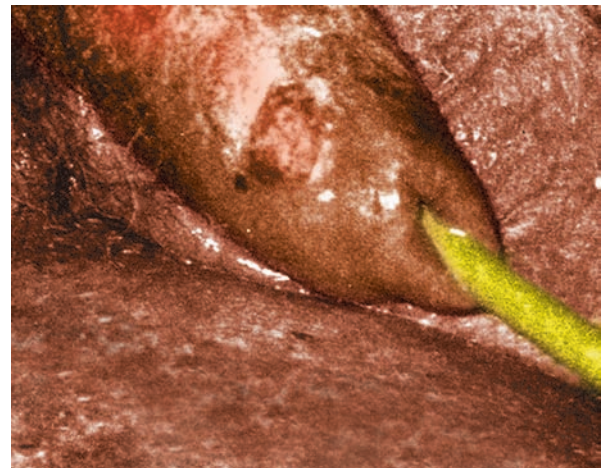


FIGURE 14.28 Balanoposthitis, phimosis. Note the significant erythema and swelling; Foley's catheter was placed to relieve the obstruction

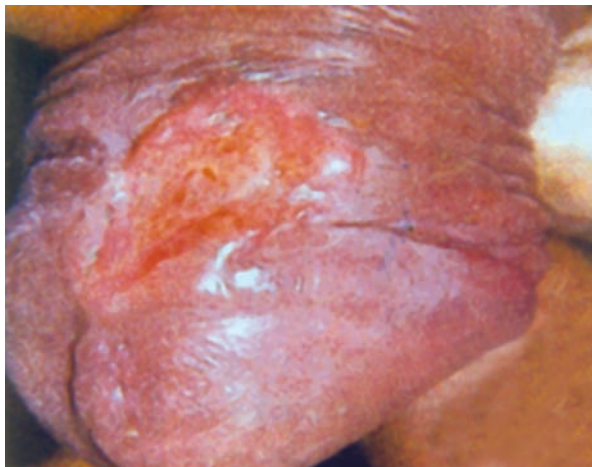

FIGURE 14.27 *Donovanosis*. Note the red ulcer with lot of granulation tissue at the base

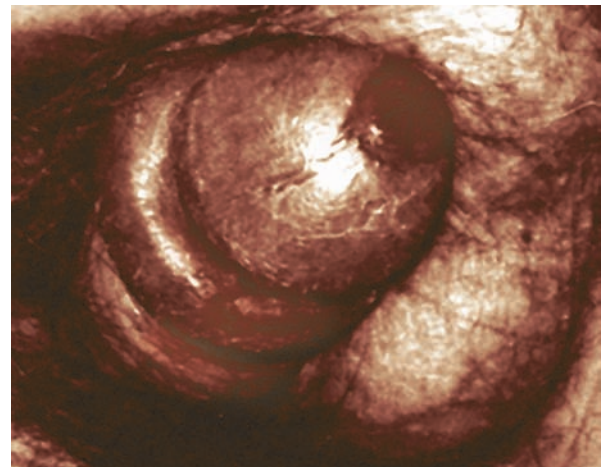


FIGURE 14.29 Paraphimosis. Severe-oedema of the glans as the result of retraction a phimotic foreskin so that the glans is ischaemic

- Compress the glans gently between your index finger and the thumb. This manoeuvre will open the urethral meatus. Look at the meatus for inflammation, urethral discharge, narrowing (stricture) and warts. Normally, there is no discharge per urethra.

Profuse yellow discharge occurs in gonococcal urethritis (Fig. 14.30); white or clear discharge occurs in nongonococcal urethritis. Definite diagnosis requires Gram's stain (Fig. 14.31) and culture.

- If the patient reports a discharge but you do not see any, in such a situation, ask him to strip and milch the shaft of the penis from its base to the glans. Alternatively, you can do it yourself. This manoeuvre may bring the discharge out of the meatus for examination. *Have this discharge on glass slide for examination as well as for culture.*

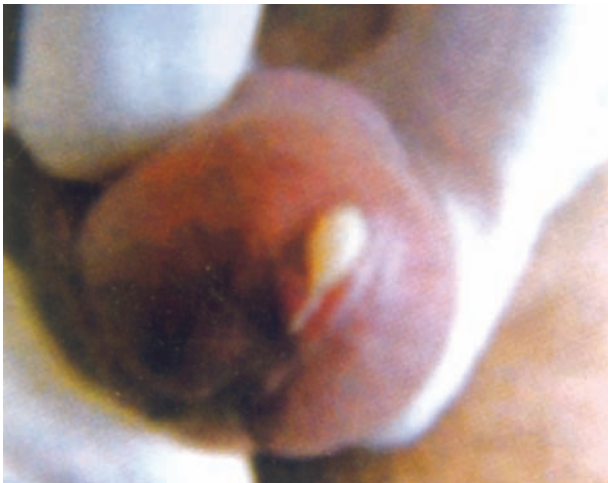

FIGURE 14.30 Gonococcal urethritis. Note the thick white or creamy discharge coming out of the urethral meatus

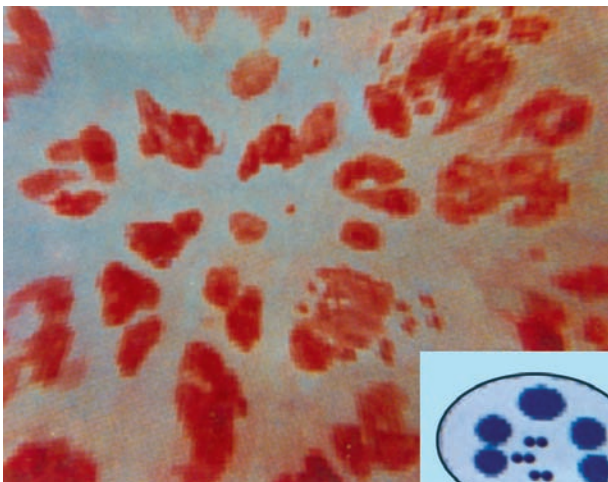
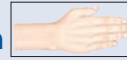

FIGURE 14.31 Gram's stain of the urethral discharge showing Gram-negative intracellular and extracellular diplococci (gonococci)

Palpation



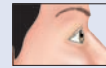
Now palpate the penis between your thumb and first two fingers for any tenderness or induration. Palpation of the shaft may be omitted in a young asymptomatic male patient.

Induration along the ventral surface of the penis suggests a urethral stricture or possibly a carcinoma. Tenderness of penis suggests periurethral inflammation secondary to urethral stricture.

If you retract the foreskin, replace it before proceeding on to the examination of scrotum.

The Scrotum and Its Contents

Inspection



- Look at the scrotal skin for any redness, swelling or ulcer. Lift up the scrotum so that you can see its posterior surface.

Tiny dark red papules of angiokeratoma may be seen
 Round, firm whitish nodules suggest sebaceous cysts
 Scabies causes erythematous nodular lesions on the scrotum and glans penis
 Ulceration can result from a gumma or from fungation of an underlying tumour of the testes.
 Thickening and white scaly lesion over scrotum indicates seborrhoeic dermatitis (Fig. 14.32).

Palpation



The testes

Method

- Place the right hand below the scrotum and palpate both the testes separately.
 - Now fix each testis between the hands and the fingers (Fig. 14.33); support the posterior aspect of the testis with middle, ring and index fingers of both the hands, the right hand being inferior. Palpate the anterior surface of the testis with the index finger and thumb of each hand, lateral border with index finger and medial border with the thumb.
- Note:* The size, shape, consistency, tenderness. Feel for any nodules or irregularities. Pressure on the testis normally produces a deep visceral pain.
- Now gently palpate the upper pole of the testis by approximating the index finger and the thumb of the left hand, pushing the testis inferiorly.
 - Next move the testis upwards by reversing the movements of the hands and gently approximating the index finger and the thumb of the right hand. This will allow you to palpate the lower pole of testis.

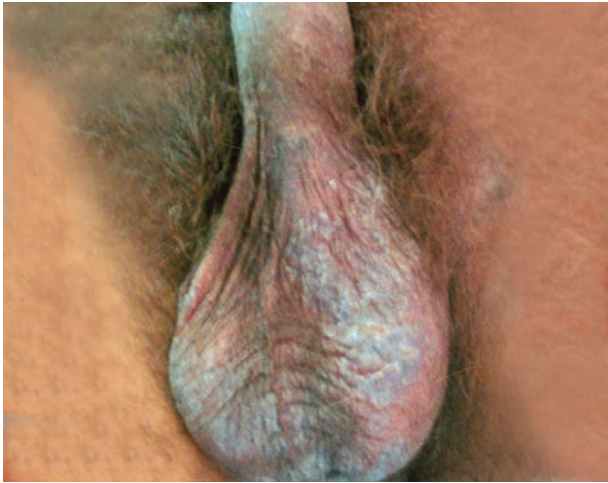

FIGURE 14.32 Seborrhoeic dermatitis of the scrotum

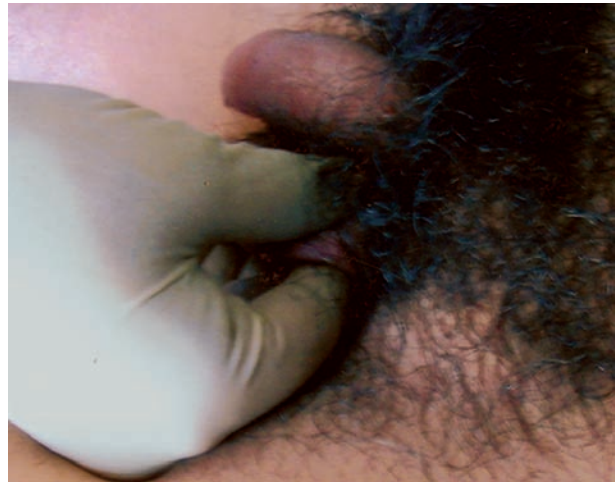

FIGURE 14.34 Palpation of spermatic cord

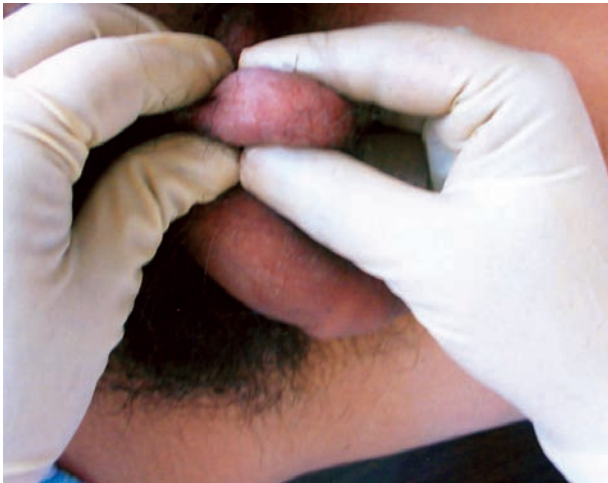

FIGURE 14.33 Palpation of testis

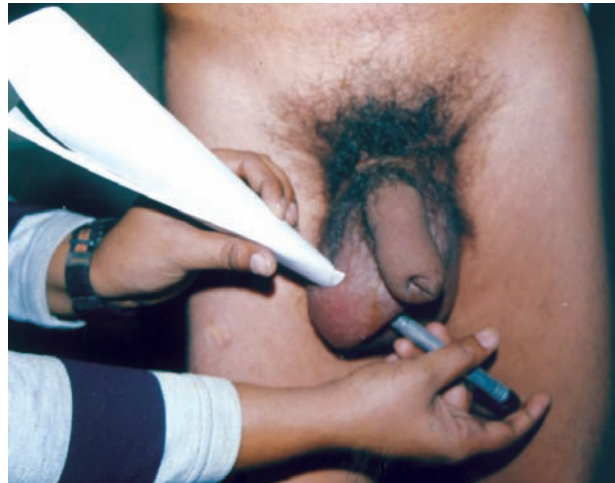

FIGURE 14.35 Transillumination test in a patient with hydrocoele. The test is positive

Normal testes are equal in size, varying between 3.5–4 cm in length, soft in consistency.

The epididymis and spermatic cord

Palpate the epididymus and spermatic cord as follows:

- Palpate the epididymis at the upper pole of the testis posteriorly. The head is felt between the left thumb anteriorly and the index and middle fingers posteriorly. It is soft and nodular structure of about 1 cm in length.
 - Palpate the tail of epididymis at the inferior pole of the testis. It is felt between the thumb and fingers of the right hand. The tail is also soft, coiled tubular structure.
- Note:** Occasionally epididymis may be situated anteriorly.
- Finally palpate the spermatic cord with the left hand. Then exert gentle downward traction on the testis by

placing the fingers of right hand behind the scrotum and the thumb placed anteriorly. Palpate the spermatic cord including the vas deferens inside it between your thumb and fingers of the left hand from the epididymis to the superficial inguinal ring (Fig. 14.34). Note any nodules or swelling.

The vas deferens feels like a thick piece of string inside the spermatic cord.

- Repeat the process on the other side to palpate epididymus and spermatic cord of other side.

Transillumination test (Fig. 14.35): Any swelling in the scrotum other than the testicles can be evaluated by transillumination. After darkening the room, shine the beam of a strong flashlight from behind the scrotum though the mass.

- Look for transillumination of light across the mass as a red glow.

In cystic swellings or swellings containing fluid as in hydrocoele, the transillumination test is positive; while in swellings containing blood or tissue, such as normal testis, a tumour or most hernias, the test is negative.

Abnormalities of Scrotum and its Contents

Read Table 14.3.

Female Genitalia

Vaginal examination is not a routine. An informed consent and presence of a female attendant is mandatory during the examination. The vaginal examination should be avoided if the hymen is intact (unmarried girls) particularly as the information required can be gathered by digital examination of the rectum. Vaginal examination of a minor requires a written consent of a parent or guardian.

Indications for Vaginal Examination

- For cervical carcinoma surveillance
- Vaginal discharge
- A pelvic mass
- Symptoms of uterine prolapse

- Unexplained urinary tract obstruction
- Suspected tubal pregnancy
- Postmenopausal bleeding
- Evaluation of rape victim irrespective of age.

Method

The important areas of examination are given in the Box 8. The tools for the examination are given in the Figs 14.40A to F.

External Examination

Inspection

- Ask the patient to empty the bladder
- Position the patient comfortably on her back, with head and shoulders slightly elevated, arms at the sides or folded across the chest to reduce tightening of the abdominal muscles, hips and knees flexed and thighs abducted.
- Use a good source of light for illumination of the genitalia
- Use suitable gloves and lubricate the examining fingers
- Examine the perineum, vulva, labia majora and minora for discharge, redness, swelling, excoriation, ulcers (syphilitic chancre), warts (venereal warts) and other lesions (genital herpes—Fig. 14.41). In rape and sexual abuse cases, look for signs of trauma.

Excoriation or itchy, small red maculopapules suggest pediculosis pubis.

TABLE 14.3 Abnormalities of the scrotum and its contents

Normal testes (Fig. 14.36A)

Hydrocoele (Fig. 14.36B)

A hydrocoele is a nontender, fluid filled mass within tunica vaginalis. It transilluminates and the examining fingers can get above the mass within the scrotum. Hydrocoele may be unilateral or bilateral.

Spermatocoele or cyst of epididymus (Fig. 14.36C)

A painless moveable cystic swelling in the epididymus above the testis may be spermatocoele or other cyst. Both transilluminate; are prone to infection often in association with urinary tract infection. Spermatocoele contains sperms. Both are indistinguishable.

Scrotal hernia

A hernia within the scrotum is an indirect inguinal hernia. It comes through the external inguinal ring, so, the examining fingers cannot get above the mass.

Orchitis or epididymo-orchitis (Fig. 14.36D)

In orchitis, the testis is acutely inflamed, painful, tender and swollen. It may be difficult to distinguish it from epididymitis. In epididymitis, the epididymus is inflamed, tender and painful. The scrotum may be reddened. It may be unilateral or bilateral, commonly seen in mumps and tuberculosis.

Tumour of the testis (Fig. 14.36F)

Usually appears as a painless, firm to hard nodule within the testis, which grows and spreads to replace the entire organ. The testis characteristically feel heavier than normal.

Varicocele (Fig. 14.36E)

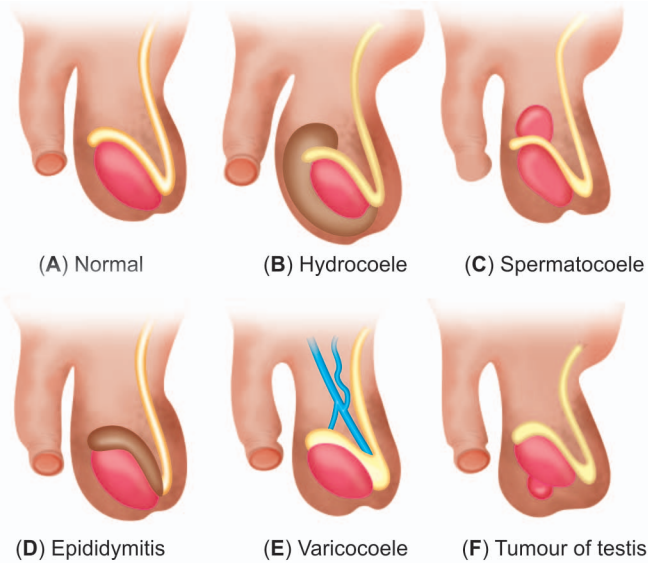
Varicocele refers to varicose veins of the spermatic cord, usually found on the left. It feels like a soft “bag of worms” separate from the testis, and slowly collapses when the scrotum is elevated in the supine position. Infertility may be associated.

Small testis (Fig. 14.37)

In adults, the length of testis is usually 3.5–4 cm. In *Klinefelter’s syndrome*, the testes are small (< 2 cm) and firm. Small soft testes suggesting atrophy are seen in cirrhosis, dystrophic myotonia, use of oestrogens, hypogonadism and hypopituitarism.

Cryptorchidism (Fig. 14.38)

In cryptorchidism, the testis is atrophied and may lie in the inguinal canal or the abdomen, resulting in an undeveloped scrotum. There is no palpable testis and epididymus in scrotum. Cryptorchidism markedly raises the risk of testicular cancer.



FIGURES 14.36A to F Differential diagnosis of scrotal swelling (Read the Table 14.3)

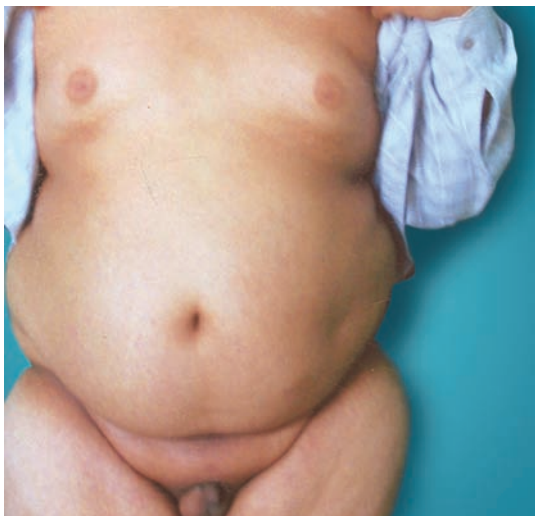

FIGURE 14.37 Small testes in a patient with adipsogenital syndrome. Note the gynecomastia and scanty pubic hair

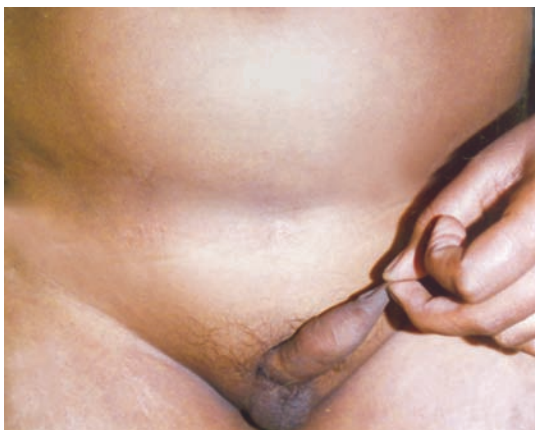

FIGURE 14.38 Cryptorchidism. Note the empty scrotum on the right side

Box 8

Areas of examination

External examination (Fig. 14.39A)	Internal examination (Fig. 14.39B)
• Mons pubis	• Vagina and its wall
• Labia majora and minora	• Cervix (cervical os)
• Urethral meatus, clitoris	• Uterus and ovaries
• Vaginal introitus	• Pelvic muscles
• Perineum	• Rectovaginal wall

- Look for nits or lice at the bases of pubic hair.

Redness and swelling of the vulva with excoriation is seen in vaginal thrush and trichomoniasis. Condyloma lata, e.g. papular lesions in intertriginous areas may erode to form lesions (Fig. 14.42) in secondary syphilis. Pearly white umbilicated papules around the anogenital region are seen in molluscum contagiosum (Fig. 14.43).

- Separate the labia minora with the forefinger and thumb of the left hand, bringing into view the clitoris anteriorly, then the urethra, the vagina and the anus posteriorly.

Clitoromegaly occurs in masculinizing conditions.

- Inspect for any evidence of discharge, ulceration, tumour or abnormalities of Bartholin's glands (normally they are not felt).

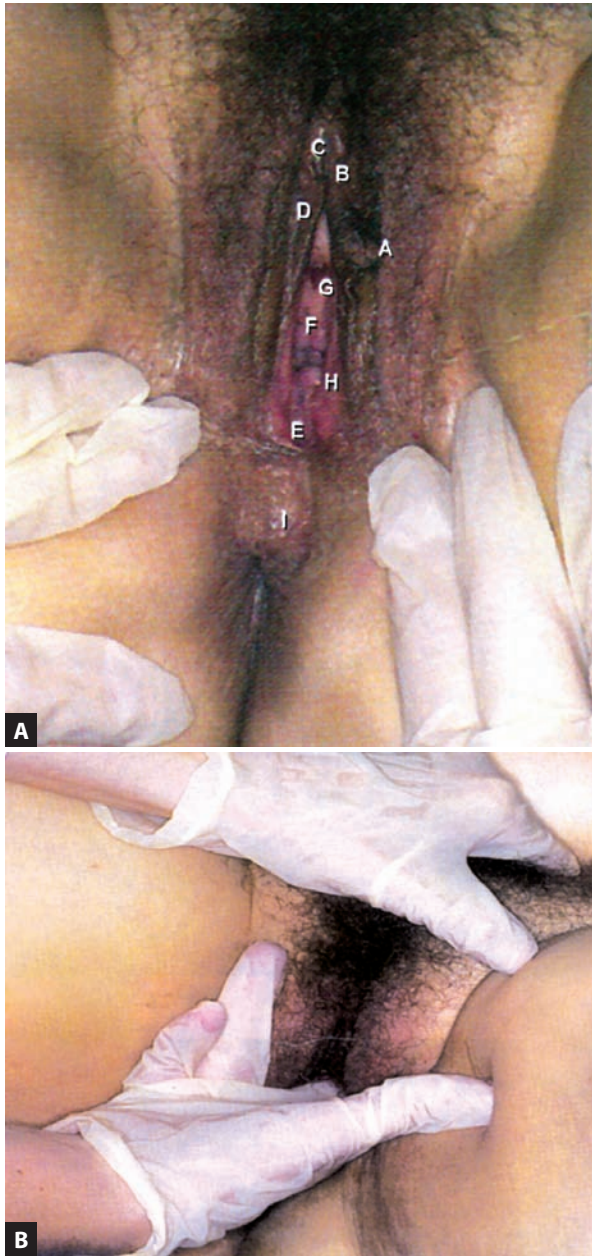Urethral caruncle is a small, red benign tumour visible at the urethral meatus.

Prolapsed urethral mucosa forms a red swollen ring around the urethral meatus.

Bartholin's gland abscess (Fig. 14.44) is acutely formed hot, tender swelling caused by its infection with gonococci, chlamydia trachomatis, etc. Look for the evidence of pus coming out of the duct or erythema around the duct opening.

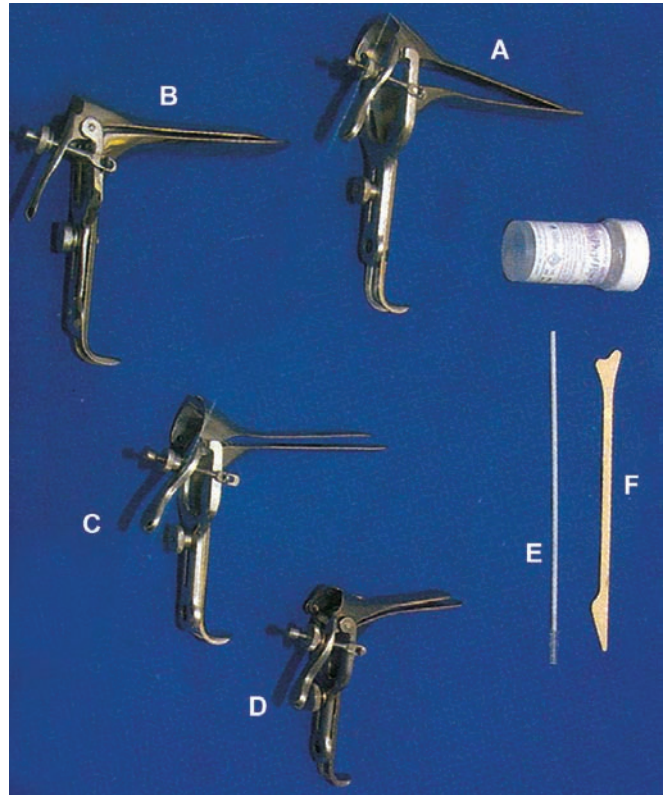
- Inspect the vaginal walls for any bulge or swelling or prolapse by asking the patient to strain down and then to cough.
- Note the position and degree of any vaginal prolapse and the occurrence of any involuntary urinary incontinence on coughing.

A cystocele is a bulge of the anterior vaginal wall together with bladder above it and results from weakened supporting tissues. The upper two-thirds of the vaginal wall is involved.



FIGURES 14.39A and B Examination of female: (A) External examination B. Internal (vaginal examination). External genitalia. A. Labia majora. B. Labia minora. C. Clitoris. D. Urethra. E. Fourchette. F. Vagina, G. Skene's adenitis, H. Bartholin's glands, I. Anus, (B) Bimanual examination: The lubricant is applied by fingers which are inserted to palpate the cervix/proximal vagina, other hand used to palpate using a "hooking" manoeuvre to feel the uterus, then left and right lower quadrant to feel the adnexa

A cystourethrocele is a bulge that involves the entire anterior vaginal wall together with the bladder and the urethra. A groove sometimes defines the border between urethrocele and cystocele, but not always present.
 A rectocele is a herniation of the rectum into the posterior wall of the vagina resulting from a weakness or defect in the endopelvic fascia.



FIGURES 14.40A to F Various tools for pelvic examination: (A) Pederson's speculum (narrow bill); (B) Grave's speculum (wider bill); (C and D) Paediatric and adolescent specula; (E) Cytobrush; (F) Cervical spatula

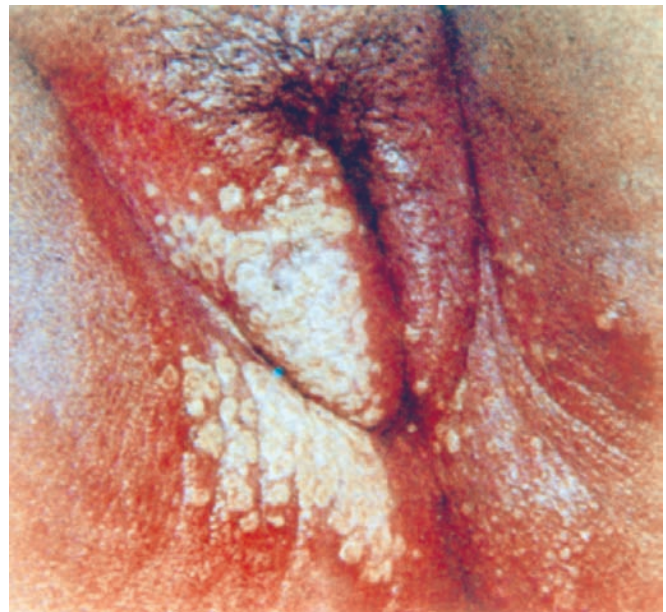

FIGURE 14.41 Primary herpes genitalis. It is a sexually transmitted disease caused by herpes simplex type 2 virus (less commonly by type 1). Multiple painful small grouped vesicles are present in the labia majora in females giving appearance of a white plaque

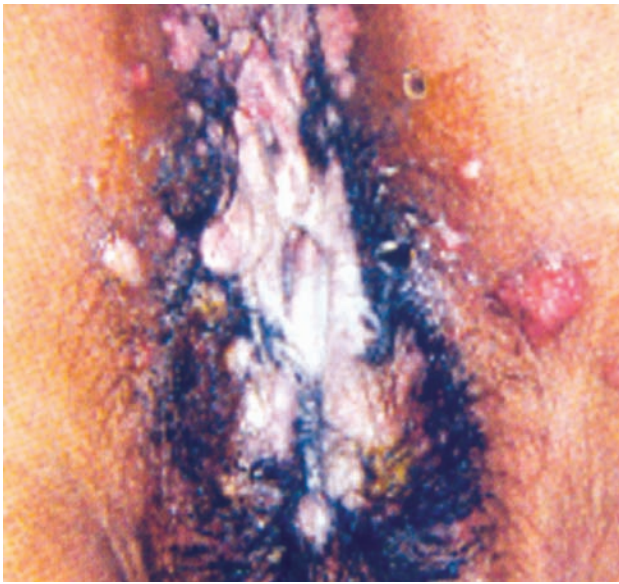


FIGURE 14.42 Secondary syphilis. Note the condyloma lata in the intertriginous areas as papules eroding the skin. Mucocutaneous lesions are characteristic of secondary syphilis

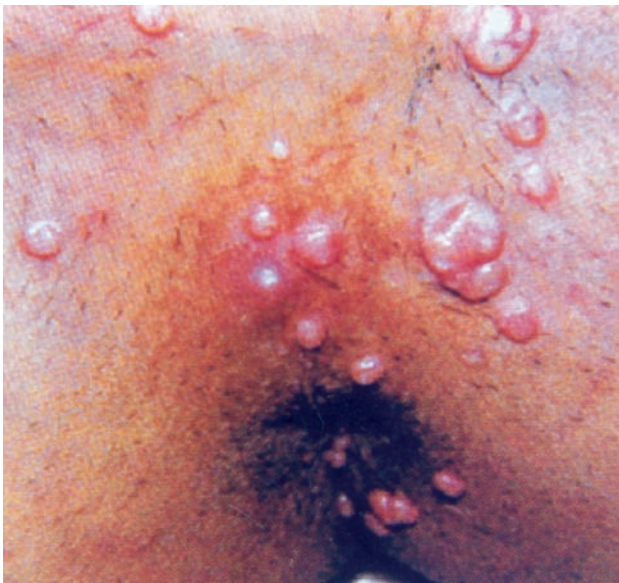

FIGURE 14.43 Molluscum contagiosum is caused by molluscum contagiosum virus may spread by endogenously from the GI tract in immunocompromised patients or sexually transmitted from one partner to other. It produces pearly white umbilicated papules

Palpation

- Insert the index and middle finger of the right hand into the vagina and rotate the palm-upwards. Use only one finger if vaginismus (spasm of the vaginal muscles) or atrophic vaginitis makes the examination painful.
- *Palpate the cervix and note any tenderness on movements of the cervix.*

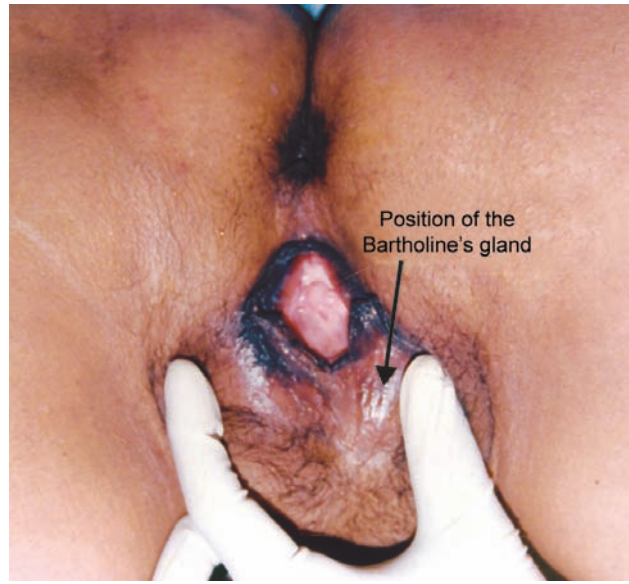


FIGURE 14.44 Bartholin's gland abscess

Normal cervix points downwards and slightly backwards and feels like the tip of the nose.

- *Now perform bimanual palpation (Fig. 14.39B) to identify the uterus between the hands and note its characteristics (size, position, surface). For this put two fingers in the anterior fornix, place the left hand flat on the abdomen above the pubis.*

Abnormalities of the Uterus

Uterine Fibroids

Myomas of the uterus (fibroids) are benign tumours, may be single or multiple, project from the surface as a swelling or swellings (nodules) which are firm and irregular in outline. Occasionally, a myoma projecting laterally may be confused with an ovarian tumour, a nodule projecting posteriorly can be mistaken for a retroflexed uterus. Submucous myoma project towards the endometrial cavity.

Uterine Prolapse

Prolapse of the uterus occurs due to weakness of pelvic floor muscles, and is often associated with a cystocele and rectocele. In progressive stages, uterus becomes retroverted and descends down into the vaginal canal to the outside.

In first degree prolapse, the cervix is still well within vagina.
 In second degree, cervix is at the introitus
 In third degree prolapse (14.45), the cervix and vagina are outside the introitus.

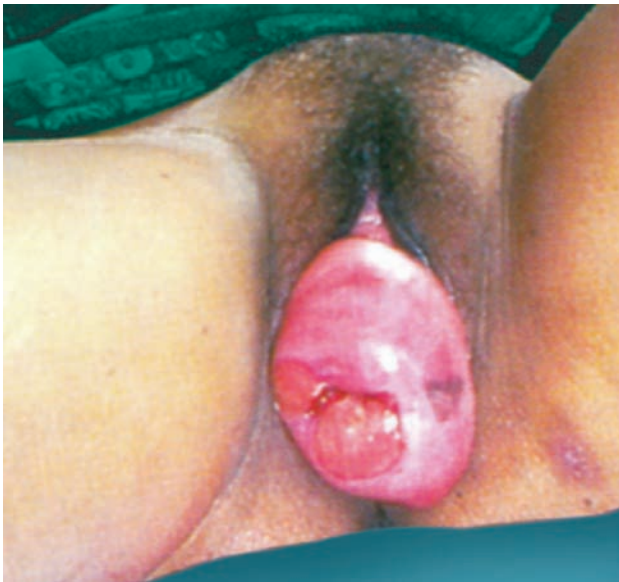

FIGURE 14.45 Uterine prolapse

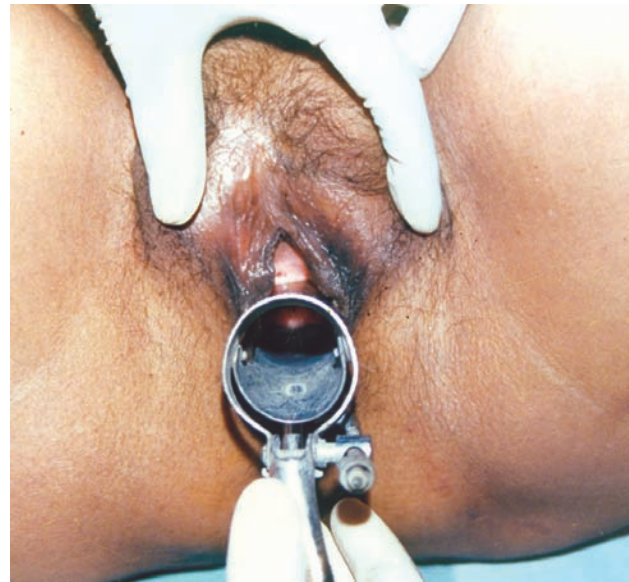

FIGURE 14.46 Cusco's speculum used to have internal view of vagina. Rotate it to 90° to have internal view of cervix

Retroversion of the Uterus

It refers to falling (tilting) backwards of the entire uterus, occurs normally in 1 out of 5 women. In mild cases, pelvic examination shows a cervix that faces forwards and uterus can not be felt by bimanual examination. In marked retroversion, the body can be felt posteriorly either through the posterior fornix or through the rectum. A retroverted uterus is mobile and asymptomatic.

- *If the uterus is not palpable; palpate with the fingers in the posterior fornix as uterus may be retroverted (read retroversion of the uterus).*
- *Palpate each lateral fornix in turn bimanually. Note any tenderness or swelling of the fallopian tubes or ovaries (Adnexal masses—Table 14.4), the bladder anteriorly and the pouch of Douglas posteriorly.*

Infection of fallopian tubes and ovaries may follow delivery of a baby or gynaecological surgery

- *Supplement digital examination by inspection of the vagina and cervix by a vaginal speculum.*

Internal Examination by a Vaginal Speculum and Taking a Cervical Smear (Figs 14.46 and 14.47)

- Gently insert a lubricated and warmed speculum into the vagina. Do not use a lubricant other than water if a cervical smear is to be taken.
- Rotate the blades through 90° pointing the handle anteriorly if the patient is supine and posteriorly if in left lateral position.
- Open the blades of speculum and identify the cervix (Fig. 14.46).

TABLE 14.4 Adnexal masses

Ovarian cysts and tumours

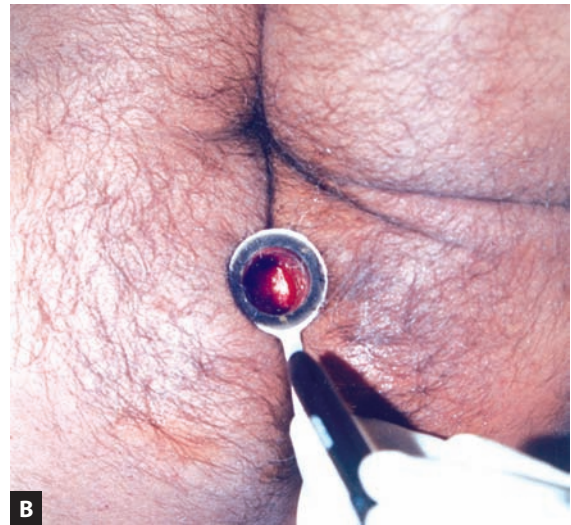
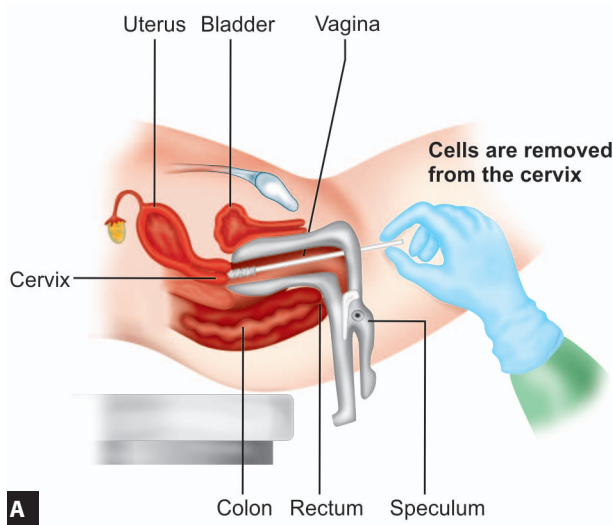
Ovarian cyst or a tumour presents as an adnexal mass arising from one side or both sides of pelvis, may extend out of pelvis. Cysts are smooth and compressible; while tumours are more solid and often nodular. Uncomplicated cysts and tumours are nontender. Polycystic ovarian disease (Box 9) is characterised by irregular menses, obesity, excessive hair growth and insulin resistance (Fig. 14.48).

Ruptured tubal pregnancy

A ruptured tubal pregnancy spills blood into the peritoneal cavity, causing severe abdominal pain and tenderness. Guarding and rebound tenderness are sometimes associated. A unilateral adnexal mass may be palpable and tender. Fainting, syncope, nausea, vomiting, tachycardia and shock may be associated reflecting the haemorrhage. There will be prior history of amenorrhoea or other symptoms of pregnancy.

Pelvic inflammatory disease (PID)

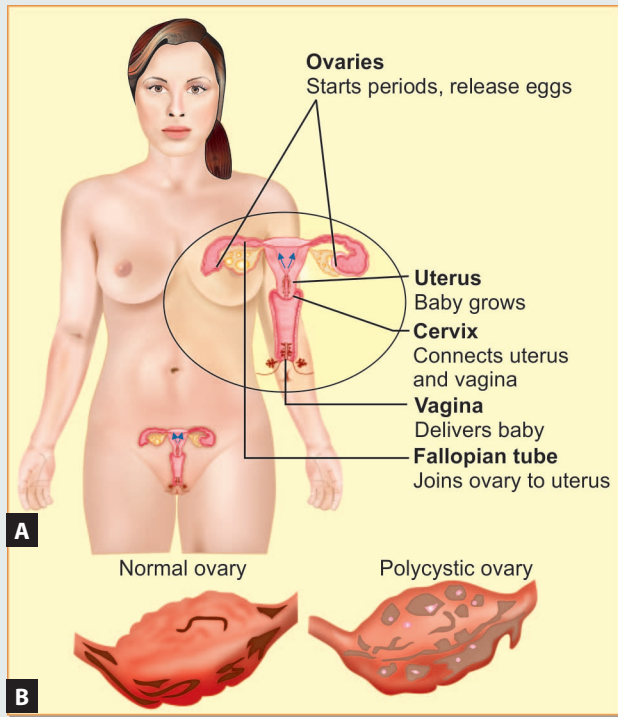
PID is most often a result of sexually transmitted infection of fallopian tubes (salpingitis) or of tubes and ovaries (salpingo-oophritis). It is caused by *N. gonorrhoea*, *chlamydia trachomatis* and other organisms. Acute disease is often associated with painful, tender adnexal masses with protective muscles spasm which usually make it impossible to demarcate them. Movement of cervix produces pain. If not treated, a tubo-ovarian abscess may ensue.



FIGURES 14.47A and B (A) Method of taking the Papanicolaou (Pap) smears; (B) Cusco's speculum used to display the cervix for Pap smear as well as for examination

Box 9

Polycystic ovarian syndrome (Figs 14.48A and B)



FIGURES 14.48A and B Polycystic ovarian disease (diag)

Polycystic ovarian syndrome (PCOS) is a condition most often characterised by irregular menstrual periods, excess hair growth and obesity, but it can affect women in a variety of ways. Irregular or heavy periods may signal the condition in adolescence, or PCOS may become apparent later when a woman has difficulty in becoming pregnant.

The signs and symptoms

Disruption in the reproductive cycle, which normally culminates each month with the release of an egg from an ovary (ovulation). The name polycystic ovary syndrome comes from the appearance of the ovaries in some women with the disorder—large ovaries studded with numerous cysts (polycystic). These cysts are follicles, fluid-filled sacs that contain immature eggs

Why obese women suffer from PCOS?

Many women with polycystic ovary syndrome are obese. The distribution of fat seems to affect the severity of symptoms. One study found that women who have central obesity—fat in the midsection or trunk of the body—have higher androgen, sugar and lipid levels than women who have accumulated fat in their limbs.

- Women with body mass index higher than 28 kg/m² are at increased risks of PCOS and it is fast becoming the most common cause of female infertility in India.
- Most women with PCOS have ovulatory dysfunction or absent ovulation. Weight loss through exercise is single most important counter measure against PCOS.

- Use the notched end of the spatula and rotate through 360° to scrape off a cytological sample from the cervical os (Figs 14.47A and B).
 - Spread the smear on the glass slide and fix it immediately with 50/50 mixture of alcohol and ether.
 - Swab any discharge from the urethra, vagina and cervix. Wipe the cervix and examine it for discharge, erosion, cervicitis, warts and ulcers.
 - Send one specimen for culture. Take another smear for direct microscopy; unstained smears are helpful to confirm trichomonal infection and stained smears to confirm gonorrhoea or thrust.
- Warts on the cervix appear either as flat or papilliferous lesions. Take the smear for cervical cytology to detect dysplasia and cancer of the cervix. This is because there is strong association of cervical cancer with genital warts.*
- Remove the speculum after completion of the examination.

15

CHAPTER

The Nervous System

HISTORY

Symptoms (Read Chapter 2)

- **Symptoms of higher function**, e.g. change in mood, memory, orientation, consciousness, insight, etc.
- Headache-vertigo, syncope
- Stroke, epilepsy, cranial nerve palsy
- **Motor**, e.g. paralysis, weakness, atrophy, involuntary movements
- **Sensory symptoms**, e.g. abnormal or loss of sensations, paraesthesia.

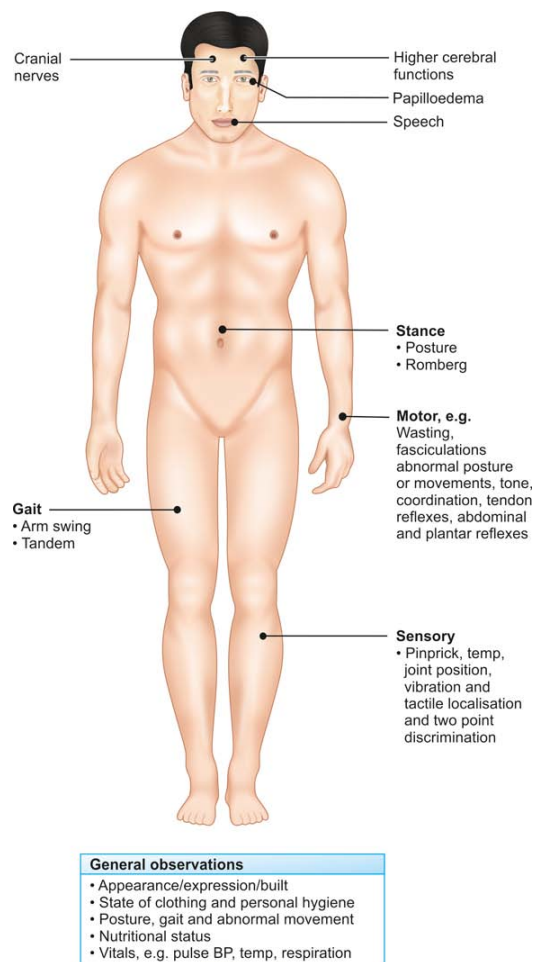
GENERAL PHYSICAL EXAMINATION

- **Head and scalp**, e.g. size, shape and neck stiffness
- **The skin**, e.g. naevus, haemangioma, sebaceous adenoma bleeding spots, infection (herpes, HIV)
- **The eyes** including fundus
- **Mouth and oral cavity**
- **Ear, nose and paranasal sinus**
- **Neck** for lymph nodes, thyroid disease and carotid bruit
- **Axillae** for lymph nodes
- **Extremities**, e.g. posture, spasm, cramps, deformities, wrist and foot drop, wasting, abnormal movements, oedema
- **Fingers and nails**
- **Back-scoliosis**, winging of scapula, tuft of hair, gibbus or spinal deformity.

SYSTEMIC EXAMINATION

Higher Cerebral Functions

- Appearance, mood and behaviour
- Emotional status
- Memory, intelligence



The Nervous System Examination

- Orientation, insight delusions and hallucinations
- Consciousness
- Released reflexes.

Speech and Language Cranial Nerves (I to XII) Motor Function

- Wasting, fasciculations
- Abnormal movements
- Tone, strength (power)
- Coordination
- Reflexes (superficial, deep, plantar and primitive).

Sensory System (Sensations)

- Pinprick, light touch, temperature
- Deep touch, position, vibration, stereognosis
- Tactile localization, two-point discrimination.

Autonomic Functions

- Standing test for postural hypotension
- Handgrip and Valsalva test
- Other tests.

Gait and Posture

- Arm swing
- Tandem (heel-toe)
- Romberg's test.

Diagnosis

- Site of lesion (anatomical)
- Neurological deficit, i.e. tracts involved (physiological lesion)
- Cause of the disease (Pathological lesion).

Differential Diagnosis Investigations

CSF, EEG, EMG nerve conduction, VEP and radiological (X-ray, CT scan and MRI).

THE NERVOUS SYSTEM

Applied Anatomy and Physiology

The nervous system consists of (i) *central nervous system* (brain and the spinal cord) and (ii) *peripheral nervous system* (12 pairs of cranial nerves, spinal and peripheral nerves). Most of the peripheral nerves contain both the motor and sensory fibres.

The Central Nervous System

The Brain

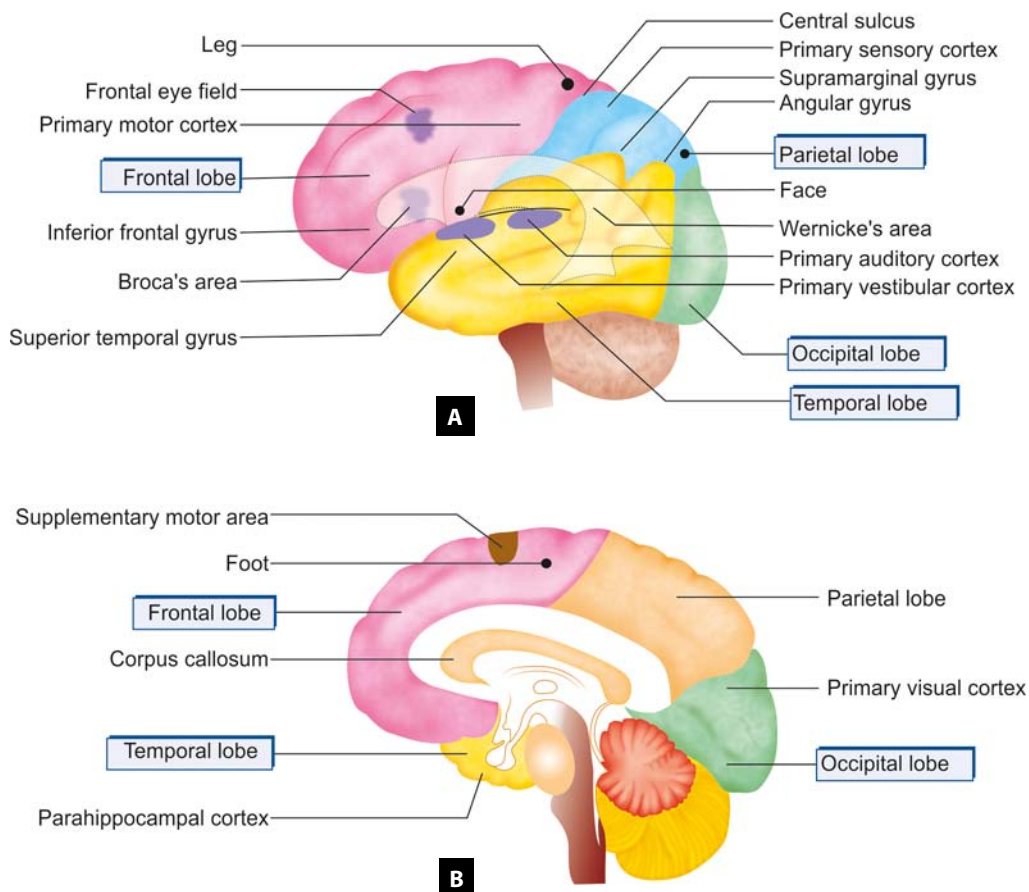
The brain has four regions (i) the *cerebrum* consisting of two cerebral hemispheres, (ii) the *diencephalon* (thalamus and hypothalamus), (iii) the *brainstem* (midbrain, pons and medulla) and (iv) the *cerebellum* consisting of two cerebellar hemispheres connected by an isthmus. The cerebral hemispheres constitute the major bulk of the brain. Each hemisphere is subdivided into *frontal, parietal, temporal* and *occipital lobes* (Figs 15.1A and B).

The brain has a network of interconnecting nerve cells called *neurons*. These consists of *cell bodies (cytones)* and

their *axons*—single long fibres that conduct impulses to other parts of the nervous system.

The brain tissue consists of *gray and white matter*. The *gray matter* containing the neuronal cell bodies, constitutes a rim that runs over the surface of the cerebral hemispheres forming the cerebral cortex. *White matter* consists of neuronal axons that are coated with myelin which imparts it white colour. The myelin sheaths conduct the impulses more rapidly. Deep in the brain lie additional clusters of gray matter, *the basal ganglia* (globus pallidus, caudate nucleus, putamen, substantia nigra and subthalamic nuclei) which is concerned with movements, tone and posture, and the *thalamus* and the *hypothalamus* constituting the *diencephalon*. The thalamus receives the sensory impulses and relays them to the cerebral cortex. The hypothalamus regulates the heart rate, blood pressure, thirst, and temperature. The hypothalamus affects the endocrine system (produces trophic hormones which stimulate the pituitary) and governs emotional behaviour such as anger and sexual drive.

Deep inside the crebral cortex lies the *internal capsule*—a white matter structure where white myelinated fibres from all parts of cortex converge, condense and then descend into the brainstem. The brainstem connects the upper part of the brain



FIGURES 15.1A and B Major areas and divisions of the brain: (A) Lateral view; (B) Medial view

with the spinal cord, has three structures, the midbrain, pons and the medulla. Consciousness depends on a system called *reticular activating (arousal) system* which interacts between the cerebral hemisphere and projects from the diencephalon and upper brainstem.

The *cerebellum* lies at the base of the brain, is concerned with tone, coordination of all movements and helps maintain the body upright in space.

The spinal cord

The spinal cord is a cylindrical mass of nerve tissue that runs within the bony vertebral column, extending from the medulla to the L₁ or L₂ vertebra, is surrounded or ensheathed by three meninges, e.g. dura mater, arachnoid mater and pia mater from outside to inside. There is a *subarachnoid space* between the arachnoid and pia mater that contains cerebrospinal fluid (CSF).

The spinal cord contains important motor and sensory nerve pathways that enter and exit the cord via posterior (sensory) and anterior (motor) nerve roots and spinal and peripheral nerves. The spinal cord also mediates reflex activity of deep tendon reflexes (spinal reflex arc). Motor and sensory systems are further discussed separately.

The five spinal cord regions (Fig. 15.2) and the nerve roots contained are:

1. Cervical (C₁-C₈).
2. Thoracic (T₁-T₁₂).
3. Lumbar (L₁-L₅).
4. Sacral (S₁-S₅).
5. Coccygeal.

Remember that the spinal cord is not as long as the vertebral column. The levels of nerve roots exiting the cord do not correspond with their vertebral levels. The lumbar and sacral roots travel the longest intraspinal distance. These roots fan out like a tail of the horse at L₁-L₂ giving rise to the term *cauda equina*.

Peripheral Nervous System

The Cranial Nerves

Twelve pairs of cranial nerves emerge from within the skull, cranial nerves III through XII arise from the brain stem as follows:

- III and IV from midbrain
- V through VIII from pons
- IX through XII from medulla.

Cranial nerves I and II are actually fibre tracts emerging from the brain. Some cranial nerves are motor, some are sensory and rest are mixed as follows:

Sensory cranial nerves—I, II and VIII

Motor cranial nerves—III, IV, VI, XI, XII

Mixed, e.g. V, VII, IX, X.

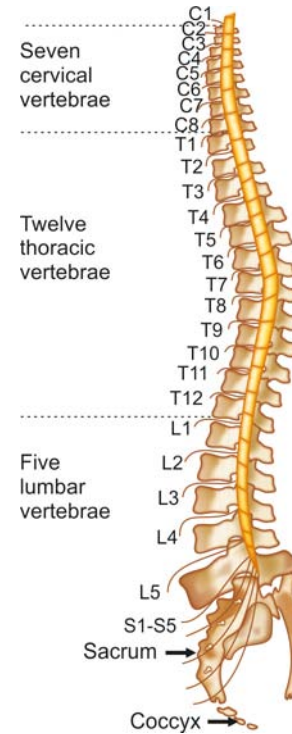


FIGURE 15.2 The spinal cord, and its segments (lateral view)

The functions of the cranial nerves most relevant to physical examination are summarised in the Box 1.

The Peripheral Nerves

In addition to cranial nerves, the peripheral nervous system also includes spinal and peripheral nerves that carry impulses to and from the cord. Thirty-one pairs of nerves attach to the spinal cord: *8 cervical, 12 thoracic, 5 lumbar, 5 sacral* and *1 coccygeal*. Each nerve has an anterior motor root and posterior sensory root containing sensory fibres. The posterior root has a dorsal ganglion. The anterior and posterior roots unite to form a spinal nerve. Spinal nerve fibres combine with similar fibres from other levels to form peripheral nerves. Most peripheral nerves contain both sensory (afferent) and motor (efferent) fibres.

Like the brain, the spinal cord has an inner H-shaped core of gray matter and outer white matter (Fig. 15.3). Nuclei of gray matter containing the nerve cells bodies are surrounded by white tracts of nerve fibres connecting the brain to the peripheral nervous system.

The Motor System

The motor system consists of (i) *pyramidal system* (upper motor neurons), (ii) the *basal ganglia* (extrapyramidal system), (iii) the *cerebellum* and (iv) *neuromuscular system* (lower motor neurons).

Box 1

Cranial nerves and their functions

Name	Function
Olfactory	Sense of smell
Optic	Vision
Oculomotor	Pupillary constriction, opening the eye, and most extraocular movements
Trochlear	Downward and inward movement of the eye
Trigeminal	<ul style="list-style-type: none"> • Motor—temporal and masseter muscles (jaw clenching), also lateral movement of the jaw • Sensory—the face through three divisions; <i>ophthalmic</i>, <i>maxillary</i> and <i>mandibular</i>
Abducens	Lateral deviation of the eye
Facial	<p>Motor—facial movements including those of facial expression, closing the eye, and closing the mouth</p> <p>Sensory—<i>taste</i> on the anterior two-thirds of the tongue</p>
Vestibulocochlear	<i>Hearing</i> (cochlear division) and <i>balance</i> (vestibular division)
Glossopharyngeal	<p>Motor—pharynx</p> <p>Sensory—posterior portion of ear canal, the pharynx and the posterior third of the tongue including taste</p>
Vagus	<p>Motor—palate, pharynx and larynx</p> <p>Sensory—pharynx and larynx</p>
Spinal accessory	Motor —the sternomastoid and upper part of trapezius
Hypoglossal	Motor —tongue

The normal motor pathways contain upper motor *neurons* that synapse in the brainstem and spinal cord with lower motor neurons. The nerve cell bodies of upper motor neurons (UMNs) lie in the precentral gyrus of the cerebral cortex and in several brainstem nuclei, their axons synapse with motor nuclei in the brainstem (cranial nerves nuclei) and in the spinal cord (peripheral nerves). Lower motor neurons (LMNs) have their cell bodies in the anterior horn cells (AHC); their axons transmit impulses through the anterior roots into peripheral nerves terminating at the neuromuscular junction.

Three kinds of motor pathways imprint on the anterior horn cells; *the corticospinal tract, the basal ganglia system,*

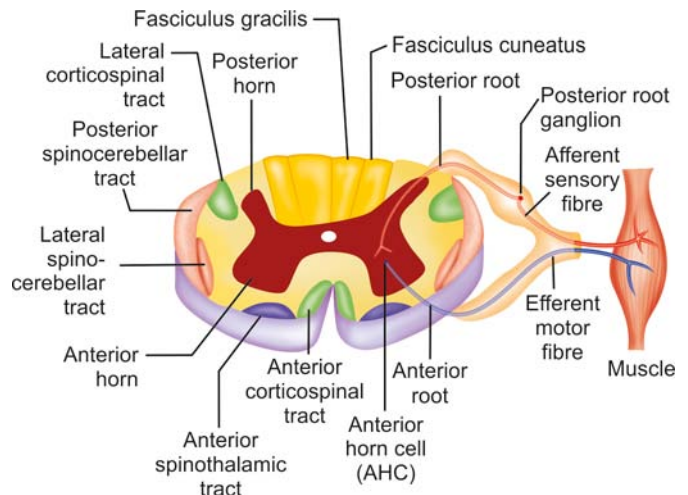


FIGURE 15.3 Cross section of spinal cord

and the *cerebellar system*. There are additional pathways originating in the brainstem that mediate flexor and extensor tone in limb movement and posture, most notable in coma. All these higher motor pathways affect movement through the LMNs—so called the “final common pathway”.

The movement whether initiated voluntarily in the cortex, “automatically” in the basal ganglia or reflexly in the sensory receptors, must ultimately be translated into action via anterior horn cells. A lesion in any of the above mentioned area will affect movement or reflex activity.

Three principal motor pathways are:

1. **The corticospinal (pyramidal) tract:** The corticospinal (pyramidal) tracts mediate voluntary movement and integrate skilled, complicated, or delicate movements of selected muscular actions and inhibit others. They also carry impulses that inhibit tone, hence, their lesion results in hypertonia.

The corticospinal fibres originate in the cerebral cortex (precentral motor cortex—Fig. 15.4) pass through the corona radiata and condense in the internal capsule, pass through its posterior limb and travel down through midbrain, pons and come down into the lower medulla, where they form an anatomical structure resembling a pyramid. There most of the fibres cross to the opposite or contralateral side of the medulla, pass downwards and synapse with the anterior horn cells or with internuncial neurons. Tracts synapsing in the brainstem with motor nuclei of the cranial nerves are termed *corticobulbar fibres (tract)*.

2. **The basal ganglia system:** It includes motor pathways between the cerebral cortex, basal ganglia, brain stem and spinal cord. It controls tone, posture and body movements especially gross “automatic” movements such as walking.

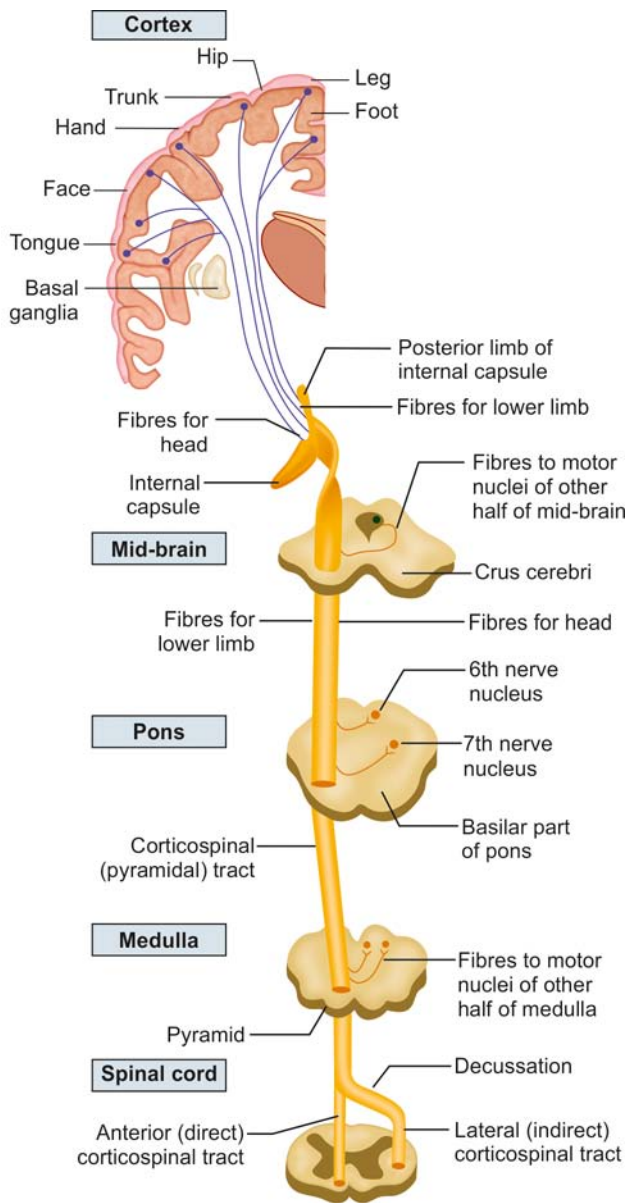


FIGURE 15.4 Body parts representation of motor cortex and internal capsule. The principal motor pathway (pyramidal tract) is depicted

3. **The cerebellum:** It receives both sensory and motor inputs and controls and co-ordinates the motor activity, maintains equilibrium and controls posture.

Body Parts Representation in Motor Cortex (Fig. 15.4) and Internal Capsule

The body parts are represented in contralateral hemisphere in a characteristic fashion, i.e. *lower limb* occupies upper position, *face* occupies lower most, *arm and trunk* occupy middle position. The smaller parts of the body occupy a larger area. Similarly, the parts of the body capable of performing delicate movements have largest cortical representation.

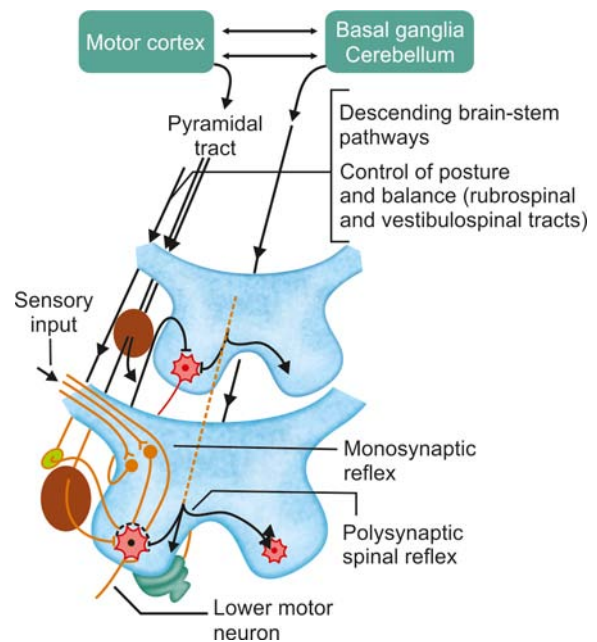


FIGURE 15.5 Hierarchies of control of motor system. In addition to direct descending pathways from the cerebral motor cortex, motor neurons in the anterior horn are influenced by descending pathways controlling balance and posture as well as monosynaptic and polysynaptic spinal reflex pathways

In internal capsule, the representation of the parts is reversed. The upper limbs, trunk and lower limbs occupy upper, middle and lower parts of the posterior limb of the internal capsule.

Hierarchy of The Motor Control (Fig. 15.5)

Movement of a body part requires changes in the posture and alteration in the tone of many muscles, some quite distant from the part being moved. The motor system consists of hierarchy of control mechanisms that maintain body posture, baseline muscle tone upon which a specific movement is superimposed. The lowest order of the hierarchy lies in the gray matter of spinal cord which controls the muscle tone in response to stretch and the reflex withdrawal response to noxious stimuli.

Above the spinal cord, circuits between basal ganglia and the motor cortex constitute the extrapyramidal system which controls background muscle tone and body posture, and gates the initiation of movement (Fig. 15.5).

The cerebellum coordinates the targeted movements accurately and acts as an on-line guidance computer to fine-tune goal directed movements initiated by the motor cortex. In addition, cerebellum through its reciprocal connections with the thalamus and cortex, participates in the planning and learning of skilled movements (Fig. 15.5).

Symptomatology of Motor System

- **Negative symptoms** include weakness, lack of coordination, lack of stability and stiffness.
- **Positive symptoms** include involuntary movements such as tremors, chorea, athetosis, hemiballismus, tics, dystonia and myoclonus. When the lower limbs are affected, characteristic pattern of gait disorder may result.

Motor System Lesion (Motor Deficit)

- **Upper motor neuron (UMN) lesions:** The corticospinal tract (UMN) as the name suggests, extends from the cortex to the spinal cord, when damaged or destroyed, its functions are reduced or lost below the level of the lesion.
 - When UMNs are damaged above the crossover of its tracts in the medulla, motor impairment develops on the opposite or contralateral side (*contralateral hemiplegia*).
 - In damage below the crossover, motor impairment occurs on the same or ipsilateral side of the body (*ipsilateral hemiplegia*).

In upper motor neuron lesions, the spinal cord is disconnected from the modulating influence of the higher motor hierarchies, comes under the uninhibited direct influence of the spinal reflex mechanisms. The affected limbs become weak or paralysed, and show reflex patterns of movement like flexion withdrawal to noxious stimuli and spasms of extension, the skilled, complicated or delicate movements are performed especially poorly when compared to gross movements. A UMN lesion, therefore, manifests clinically:

- **Weakness of a limb or limbs** (monoplegia, hemiplegia, quadriplegia or paraplegia).
- **Brisk tendon stretch reflexes and loss of superficial reflexes.**
- *Hypertonia*, i.e. spastic increase in tone greater in the extensors of the lower limbs and the flexors of the upper limbs—a characteristic pattern of hemiplegia. Spasticity is ‘*clasp-knife*’ type, takes some time to develop and may not be present for weeks after the onset of an upper motor lesion (a state of spinal shock in acute UMN lesion). Spasticity will be exacerbated by increased sensory input to reflex arc, as may be caused by a bed sore or urinary tract infection in a patient with spinal cord lesion.
- **Extensor plantar responses (positive Babinski’s sign).**
- The weakness is more pronounced in the extensors of the upper limbs and flexors of the lower limbs—opposite to spasticity.
- **Little or no wasting of muscles.**

- **Lower motor neuron (LMN) lesions:** Lower motor neuron consists of anterior horn cells, nerve roots, peripheral nerves and myoneural junctions. Groups of muscle fibres innervated by a single anterior horn cell (lower motor neuron) form a *motor unit*, hence, LMN lesions will cause loss of function of these *motor units* and muscle fibres innervated by them resulting in weakness, flaccid paralysis, atrophy and wasting the muscles, and these muscle fibres depolarise spontaneously producing fibrillations, which except in the tongue are only perceptible on EMG. Reinnervation from neighbouring intact motor neurons may occur but the neuromuscular junctions of these so formed enlarged motor units are unstable and depolarise spontaneously causing *fasciculations* (twitches of muscles due to contraction of a muscle bundle) which are visible. *Fasciculations*, therefore, imply chronic partial denervation.

Signs of lower motor neuron lesion

- Weakness or loss of movements
 - Wasting of muscles leading to atrophy
 - Decreased tone (hypotonia-flaccid paralysis)
 - Loss of tendon and superficial reflexes
 - Fasciculations
 - Contractures of muscles
 - Trophic changes in skin and nails in neuropathies.
- **Extrapyramidal lesions:** Disease of the basal ganglia or extrapyramidal system does not cause paralysis but produces an increase in tone (*rigidity*—continuous increase in tone throughout the range of movement), disturbances in posture and gait, a slowness or lack of spontaneous and automatic movements termed *bradykinesia*, and a variety of involuntary movements.
 - **Cerebellar lesions:** A lesion in the cerebellar hemisphere leads to:
 - **Lack of co-ordination on the same side of the body:** The initial part of movement is normal but as the target is approached the accuracy of movement deteriorates resulting in “*intention tremor*”. The distances of the targets, are misjudged (*dysmetria*), resulting in ‘*past-pointing*’. The ability to produce accurate, regularly alternating movements is impaired—called “*dysdiadochokinesis*”. The jerks tends to diminish due to rigidity.
 - **Impairment of gait, equilibrium and postures:** Lesions involving the cerebellar hemisphere lead to ataxic gait (patient tends to fall towards the side involved); while involvement of central vermis leads to *truncal ataxia* (patient has difficulty in sitting up, or standing).

- **Decrease in muscle tone (hypotonia)** due to involvement of red nucleus. The hypotonia combined with incoordination lead to “pendular jerks” in cerebellar lesions.
- **Paralysis is not a feature of cerebellar disease.**

The clinical signs of different motor system disorders are summarised in Table 15.1 and pattern of motor loss according to site of lesion is depicted in Box 2.

Spinal Reflex Arc (Fig. 15.6)

The deep tendon or muscle stretch reflexes are relayed over structures of both the central and peripheral system. A reflex is a stereotype involuntary response that may involve as few as two neurons, one afferent (sensory) and other efferent (motor), across a single synapse. The deep tendon jerks in the arms and legs, thus, are monosynaptic reflexes. They illustrate the simplest unit of sensory and motor function.

To elicit a deep tendon reflex, briskly tap the tendon of a partially stretched muscle. For the reflex to fire, all the components of the reflex arc, i.e. sensory nerve fibres, spinal cord synapse, motor nerve fibres, neuromuscular junction and muscle fibres, must be intact. Tapping the tendon activates special sensory fibres in the partially stretched muscle, triggering a sensory impulse that travels to the spinal cord via peripheral nerve. The stimulated sensory fibres synapse directly with anterior horn cells innervating the same muscle. When the impulse crosses the neuromuscular junction, the muscle suddenly contracts, completing the reflex arc.

The Sensory System (Figs 15.7A and B)

It consists of:

- **Sensory receptors** giving rise to sensory impulses.
- **Sensory pathways** through which cutaneous and proprioceptive sensations are carried to sensory cortex or thalamus.

- **Cortical (postcentral gyrus) and subcortical (thalami) sensory centres** where they reach to conscious level, are integrated and interpreted.

Sensory impulses not only participate in reflex activity but also give rise to conscious sensation, calibrate body position in space and help regulate internal autonomic functions like blood pressure, heart rate and respiration.

Box 2	
Pattern of motor loss according to site of the lesion	
Upper motor neuron lesion	
<i>Clinical presentation</i>	<i>Site</i>
Contralateral monoplegia Contralateral hemiplegia	<ul style="list-style-type: none"> • Cerebral cortex • Corona radiata • Internal capsule • Mid brain • Pons • Upper medulla above decussation of pyramidal tracts
Ipsilateral hemiplegia	<ul style="list-style-type: none"> • Lower medulla below decussation • Unilateral spinal cord lesion above C₅
Quadriplegia paraplegia	<ul style="list-style-type: none"> • Lower cervical cord below C₅ • Thoracic cord • Lumbar cord above L₁-L₂
Lower motor neuron lesion	
<ul style="list-style-type: none"> • Monoplegia, paraplegia, quadriplegia • Radiculopathy • Peripheral neuropathy • Myopathy 	<ul style="list-style-type: none"> • Anterior horn cells • Anterior (motor) root • Peripheral nerves • Myoneural junction, muscles

TABLE 15.1 Clinical signs in different motor system disorders

Sign	UMN lesion	LMN lesion	Extrapyramidal lesion	Cerebellar lesion
Power	Weak • Extensors weak in upper limbs • Flexors weak in lower limbs	Weak	No weakness	No weakness
Wasting and atrophy	Absent	Present, after an interval	None	None
Fasciculations	None	Yes, after interval	None	None
Tone	Spasticity, clonus may be present	Flaccidity	Rigidity (Cog-wheel)	Normal/reduced
Deep tendon reflexes	Exaggerated	Reduced/absent	Normal	Normal/pendular
Superficial reflexes	Lost	Lost	Normal	Normal
Plantar response	Extensor	Flexor	Flexor	Flexor
Coordination	Reduced due to weakness	Reduced due to weakness	Normal but slow	Impaired

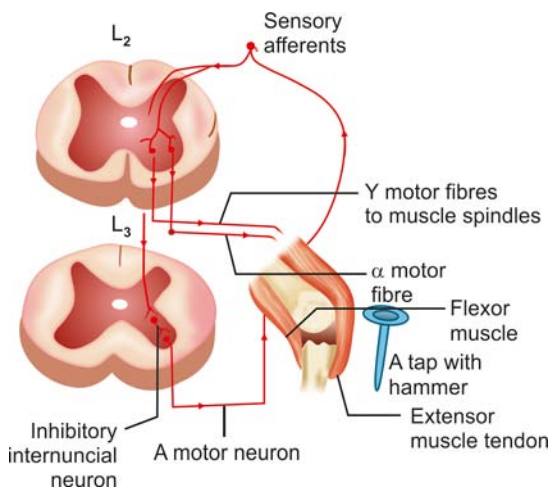
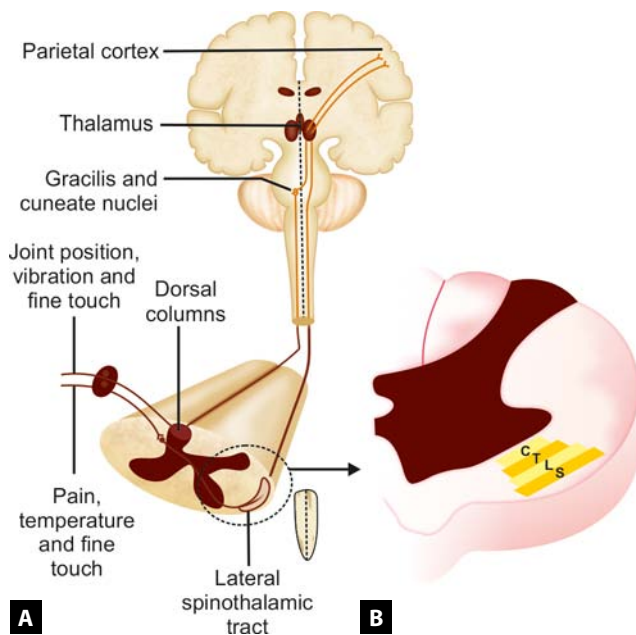


FIGURE 15.6 Spinal reflex arc of knee jerk



FIGURES 15.7A and B The sensory pathways-spinothalamic tract and posterior column: (A) The main sensory pathways; (B) Spinothalamic tract to show its layering in the cervical region. C—represents fibres from cervical region, T—from thoracic, L—from lumbar and S—from sacral region

A complex system of sensory receptors relays impulses from the skin, subcutaneous tissue, mucous membranes, deeper structures (muscles, tendons, joints) and viscera. Sensory fibres carrying the sensation of touch, pain, temperature, position, joint and vibration pass through the peripheral nerves and posterior (dorsal) roots and enter the spinal cord.

Diseases of the first order neuron, i.e. peripheral nerves, posterior roots involve all modalities of sensation.

After they have entered the spinal cord, sensory impulses reach the sensory cortex via one of the two pathways: the *spinothalamic tracts* or *posterior columns*.

- **The spinothalamic tracts (lateral and anterior):** Within one or two spinal segments from their entry into the spinal cord, the group of smaller, slower-conducting fibres carrying the sensation of pain, crude touch and temperature pass into the posterior horn of the spinal cord and synapse with secondary neurons. The secondary (second-order neurons) neurons then cross to the opposite side either immediately or within a few segments up and continue into the lateral and anterior columns of the cord and ascend to the brainstem as the *lateral* and *anterior spinothalamic tracts* to reach the thalamus where they relay. The fibres from the lower parts are arranged laterally while those from the upper part move medially in these tracts.
- **Posterior columns:** It is other group of different large-fast conducting fibres subserving the sensations of fine touch, position, pressure, joint and vibration that do not relay in spinal cord but pass directly into the posterior columns (*tract of gracilis* or *cuneate*) of the cord and travel upwards to the medulla on the same side together with the fibres of *fine touch* (touch concerned with localisation and discrimination). The fibres synapse in the gracile and cuneate nuclei of the caudal medulla. Fibres arising from the nuclei (secondary neuron or second order neuron) cross to the opposite side at the medullary level and continue on to the thalamus as *medial lemniscus*. Higher in the brainstem, the spinothalamic tracts and medial lemnisci are joined by second neuron fibres from cranial nerve nuclei on each side.

Remember that at any level of spinal cord, there are two groups of fibres carrying the sensations, i.e. spinothalamic tract carrying sensation of pain, crude touch and temperature from the opposite side, and posterior column carrying sensation of position, fine touch, vibration, and other discriminatory sensation from the same side, therefore, a unilateral lesion of the spinal cord (Brown-Sequard syndrome) will therefore cause loss of pain and thermal sensibility below the level of the lesion on the opposite side of the body; while on the side of the lesion (ipsilateral), there is, disturbance of sense of position, movement, vibration, stereognosis and tactile localisation and discrimination.
NB: The thalamus does not have power of localisation and differentiation which are interpreted in parietal sensory cortex (Read below)

- **Cortical and subcortical centres (higher centres) for sensation:** At the thalamic level (subcortical level), the general quality of sensation is perceived (e.g. pain, cold, pleasant, unpleasant) but fine localisations and

distinctions are not made. Thalamus also receives sensations, from the lateral and medial geniculate bodies that are concerned with vision and hearing respectively. Thalamus also receives visceral sensations via autonomic fibres that pass along the posterior columns. For full perception, a third group of sensory neurons (third order neuron) sends impulses from the thalamus to the sensory cortex as thalamocortical fibres.

The *somatosensory centre* that lies in the postcentral gyrus of the cerebral cortex is concerned with not only perception of sensation but is able to localise, recognise the nature of stimuli applied and can discriminate between two simultaneously applied stimuli. Representation of the body parts in the sensory cortex corresponds topographically to that in the motor cortex.

- A lesion involving the sensory pathway below thalamus or in the thalamus will impair all the sensory modalities with hyperpathia (*thalamic syndromes*).
- A cortical lesion will cause loss of those sensations which reach consciousness in the cortex such as sense of position, joint sense, vibration, tactile localisation and discrimination graphesthesia, stereognosis and sensory attention (phenomenon of extinction).

Symptomatology of Sensory System

- **Hypoesthesia (decreased sensation):** The sensations of pain, touch and temperature are diminished when compared with normal limbs. A patient may inadvertently burn the fingers or toes if pain and temperature sensations are disturbed (for example in syringomyelia and peripheral neuropathies).
- **Paraesthesias and dysaesthesias:** These are positive symptoms where paraesthesia denotes altered sensation perceived spontaneously (without an apparent object) and dysaesthesia refers to altered sensation elicited by touch or other stimuli. These may be in the form of pins and needles, tightness or constriction, feeling of tingling or crawling of ants, and feeling of warmth or coldness.
- **Pain:** Pain can result from inflammation or compression of any pain sensitive structures, i.e. skin, nerve root, muscle or an organ. In some diseases, such as trigeminal neuralgia (V nerve distribution), glossopharyngeal neuralgia (IX nerve distribution, post-herpetic neuralgia) and discogenic radiculopathies (compression of nerve root by disc prolapse), the description of pain and its distribution is diagnostic. In most cases, however, symptoms of pain do not conform to standard dermatomal or peripheral nerve distribution, while in some cases, pain is referred to other sites (referred pain). In thalamic infarct (a thalamic syndrome), the pain often is perceived inappropriately (e.g. touch felt as pain); this phenomenon is called *hyperpathia*. In discogenic radiculopathy the nerve root pain corresponds to the dermatome involved, increases with manoeuvres that increase intra-abdominal or intraspinal pressure such as coughing, sneezing, straining at stool, etc.
- **Numbness:** The word '*numbness*' can have many meanings; when a patient says that a limb is *numb*, he or she may mean that the sensation in that part is abnormal but sometimes, this means weakness or heaviness to some people rather than loss of feeling.

Clinical Signs/Terms

- **Anaesthesia** means loss of sensation.
- **Analgesia** refers to loss of pain sensation.
- **Thermoanaesthesia** means loss of thermal sensation.
- **Hyperaesthesia** means exaggerated perception of sensation in response to mild stimuli (touch or pinprick).
- **Hyperalgesia** denotes an exaggerated response to a noxious stimulus.
- **Hyperpathia** is an inappropriate perception of sensation, encompasses all the phenomenon described such as hyperaesthesia, allodynia and hyperalgesia.
- **Allodynia** describes a phenomenon in which an ordinary nonpainful stimulus once perceived, is experienced as painful stimulus. An example is painful sensation felt during an application of vibrating tuning fork.
- **Romberg's sign:** It is an important sign of impaired sensation of position and joint sensation in the lower limbs (sensory ataxia). Normally the person does not sway on standing either with eyes closed or open, hence, Romberg's sign is negative. Positive Romberg's sign means swaying on standing with eyes closed (posterior column involvement) not on eyes open (cerebellar and labyrinthine diseases), hence, can differentiate sensory ataxia (posterior column involvement) from cerebellar ataxia.
- **Lhermitte's sign:** In a lesion of posterior column in the cervical cord, sudden flexion or extension of the neck sends an 'electric-shock' like sensation down the trunk to lower limbs. This is seen in multiple sclerosis, cervical spondylosis (spondylitic myelopathy), syringomyelia and cervical cord tumour.

Patterns of Sensory Disturbance

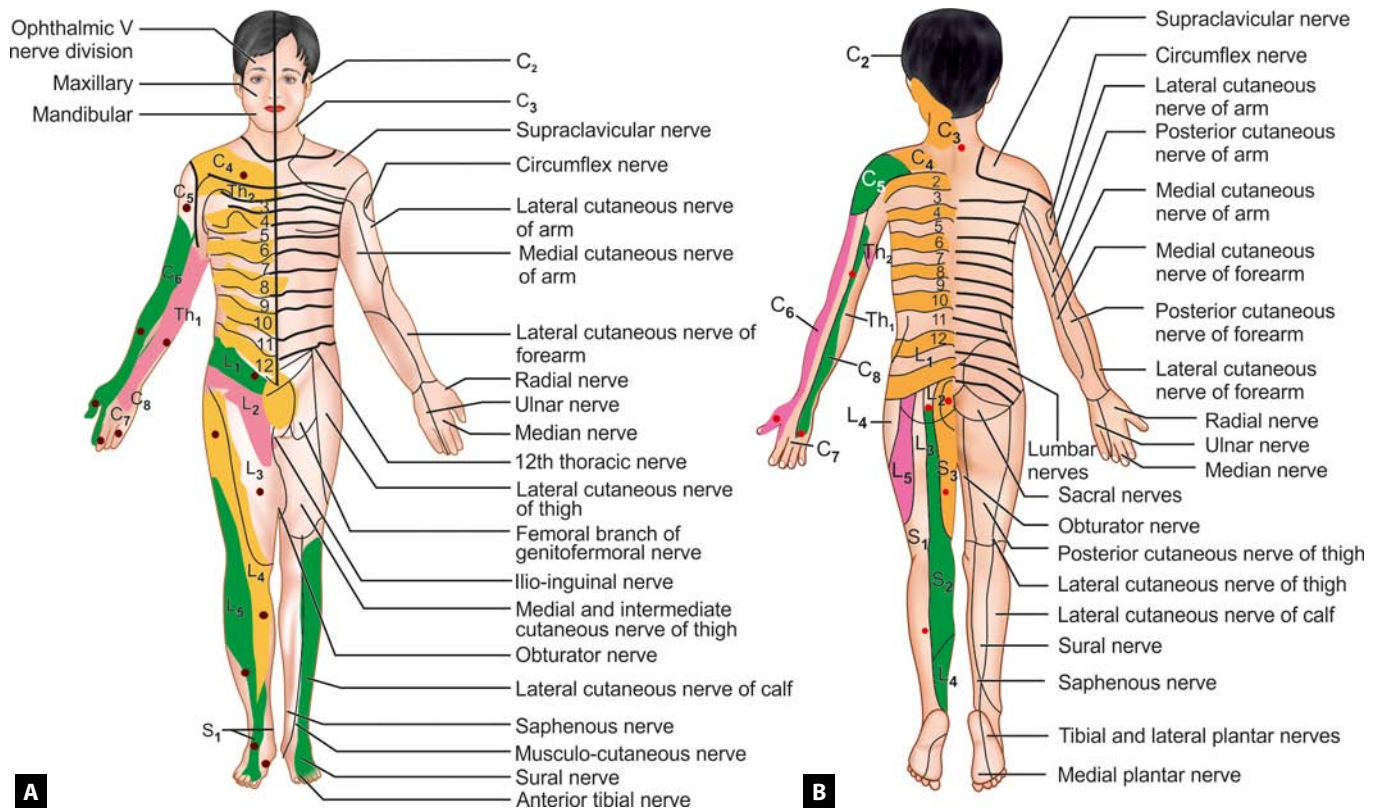
In the history, the most useful features are the anatomical distribution and mode of numbness, paraesthesia or pain. Certain patterns at the onset of sensory symptoms can be recognised, for example, during a migrainous attack, the *aura* may consist of tingling sensation followed by numbness which takes 20–30 minutes to spread over one half of the body,

splitting the tongue. Sensory loss due to a vascular lesion, on the other hand, will occur over the whole territory of the lesion more or less instantaneously. The rare, unpleasant paraesthesia of sensory epilepsy 'shoots' down one side of the body within seconds. The numbness and paraesthesia of spinal cord lesions often ascend one or both lower limbs to a level on the trunk over hours or days. Sensory symptoms of tingling and numbness can be of 'functional' or 'nonorganic' origin as a manifestation of anxiety or as a part of a conversion disorder. In these circumstances, the pattern of sensory symptoms do not conform to any known anatomical distribution or known pattern of sensory involvement in organic disease. Therefore, caution must be exercised to avoid misdiagnosing an unusual organic sensory impairment as a functional disorder.

Examination of the sensory system needs to be approached with caution since confusing false positive results may occur because of inescapably subjective nature of the sensory testing. Lesions of different sites in the sensory pathways produce different kind of sensory loss. Pattern of sensory loss combined with associated motor findings help to identify the site of lesion, for example, a lesion in the sensory cortex may not impair the perception of pain, touch and position but does impair tactile localisation and

discrimination. A person so affected can not appreciate the size, shape or texture of an object by feeling it (astereognosis) and therefore can not identify it. Loss of sensation of position, vibration and movement (joint) with preservation of other sensations points to disease of posterior columns. The loss of all sensations from the waist down, together with spastic paraplegia and exaggerated tendon jerks in the legs, indicates spinal cord transection or compression. Crude or light touch are often preserved despite partial damage to the cord because impulses originating on one side of the body travel up both sides of the cord.

A knowledge of *dermatomes* also helps in localising the lesion. A *dermatome* is defined as a band or an area of the skin innervated by the sensory root of a single spinal segment. The spinal cord is organised in segments from each of which a pair of anterior (motor) and posterior (sensory) nerve roots arise. Dermatomes are mapped out in Figures 15.8A and B. Their levels are considerably more variable than the diagram suggests because there is overlapping among dermatomes. The sensory nerves from each side of the body also overlap slightly across the midline. The distribution of a few main peripheral nerves is also depicted in the same figure on the left.



FIGURES 15.8A and B Dermatomal mapping and peripheral nerve innervation of the body. The points for testing the sensations are indicated by red dots (•). By testing the sensations at these marked points you can calculate the dermatomal and peripheral nerve involvement

Spinal Dermatomes

The spinal cord extends from the foramen magnum to interspace between T₁₂ and L₁; the meninges continue down as far as the body of S₂ vertebra creating a space called *cul-de-sac*. This is the space containing CSF where lumbar puncture is usually done. There is also a cervical enlargement extending from C₅-C₇. The lumbar segments lie opposite to the T₁₀ and T₁₁ spine and the next interspace.

The spinal segments do not correspond exactly with the vertebral bodies overlying them. This is clinically important while assessing the level of compression in a patient suffering from spinal cord disease. To determine which spinal segment is related to which vertebral body, the given formula is detailed in the Box 3.

How to Count the Vertebra?

The spine of C₇ vertebra is prominent at the level of shoulder from which you can palpate the upper dorsal vertebrae down. On the front of the body, there is a line of demarcation between the T₂ and C₄ at the level of clavicle. The nipple lies at the level of T₆; the xiphisternum at T₈, the umbilicus at T₁₀ and inguinal ligament at T₁₂. However in the lower dorsal region on the back the tip of a spinous process marks the level of the body of the vertebra below. Similarly the line between anterior iliac spines passes in the interspace between L₁ and L₂. The spinous process above this line is L₁ vertebra and below it is L₂ vertebra. This also constitute a land mark to count the diseased vertebra.

The vertebra involved or diseased is decided clinically by deformity/gibbus/tenderness and radiologically by destruction and/or reduction of interspace, then correlation is made.

Box 3

Calculation of spinal segment in relation to vertebrae

Vertebrae	Spinal segment
For cervical vertebrae	Add 1 (1+)
For T ₁ to T ₆	Add 2 (2+)
For T ₇ -T ₉	Add 3 (3+)
T ₁₀ vertebra	Overlies L ₁ and L ₂
T ₁₁ vertebra	Overlies L ₃ and L ₄
T ₁₂ vertebra	Overlies L ₅
L ₁ vertebra	Overlies sacral and coccygeal segments

NB: If vertebral level is known, then addition is done for calculation of spinal segment level. If spinal segment has been calculated from the sensory loss or loss of jerk, then number given within the bracket is subtracted to calculate the vertebra.

In the spinal cord compression/disease, after determining the segments involved, the radiology/imaging of the vertebrae is ordered keeping the approximately calculated vertebral level in the centre and including one or two vertebrae above and one to two vertebrae below. For example, if segments involved are T₁-T₆ (loss of upper abdominal reflexes), then vertebral body will be T₆ minus 2 = T₄ level, which means upper thoracic vertebrae are to be X-rayed or scanned. Similarly you can calculate other vertebral level.

Spinal Myotomes

The myotomes are motor spinal segments similar to dermatomes which are sensory spinal segments. The myotomes supply the muscles of the upper limbs (Fig. 15.9A) and lower limbs (Fig. 15.9B). The significance of the myotome lies in calculation of motor level in case of compression and to determine the group of muscles involved in myopathies. For example, loss of biceps tendon reflex indicates compression of C₅-C₆ segments.

Blood Supply of the Brain (Cerebrum)

An understanding of normal arterial anatomy and the likely sites of the atheromatous plaques and stenotic lesions is important. Embolic lesions are more frequent in the left than in the right cerebral hemisphere.

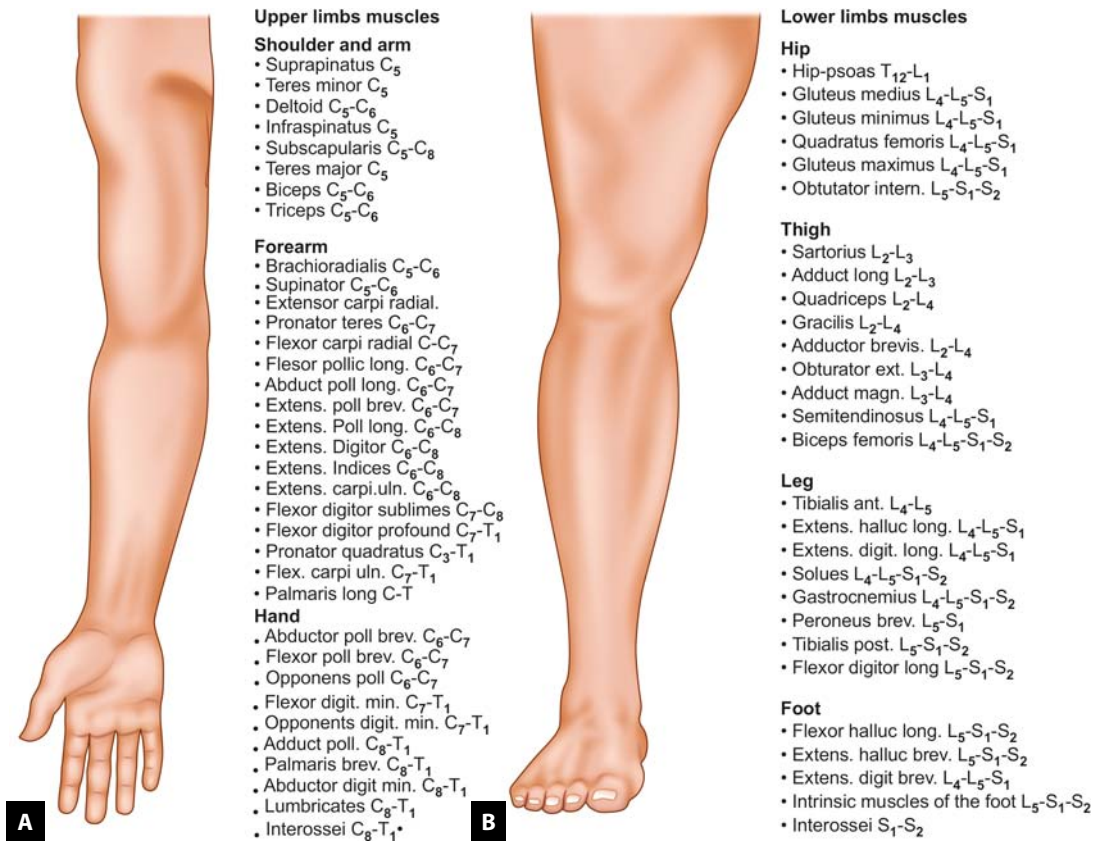
The circle of Willis (Figs 15.10A and B) is supplied by the two internal carotid arteries and by the basilar artery which is formed by the union of two vertebral arteries. Proximal to the circle, the following sites are common for atheromatous plaques and stenoses (Fig. 15.10B):

- The origins of common carotid artery
- The origins of internal carotid artery
- Vertebral artery
- Subclavian vessels.

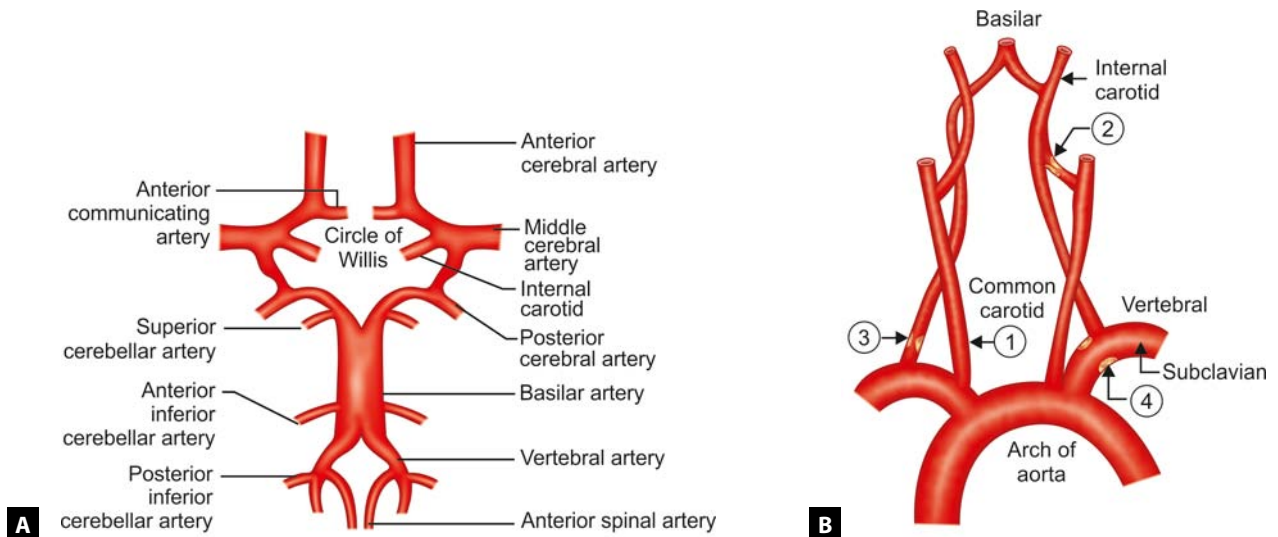
Anatomy of Cerebral Circulation

Anterior cerebral artery: It is a branch of internal carotid artery and gives off the following branches:

- Basal branches, one of which is important recurrent branch (*Heubner's artery*) that supply internal capsule, a part of caudate nucleus and putamen.
- Anterior communicating artery which unites the two anterior cerebral arteries.
- Cortical branches to frontal and parietal lobes—supply 2–2.5 cm strip of cortex on lateral surface extending from frontal to parietal lobe.
- A paracentral cortical branch that supplies paracentral lobule containing leg area of motor cortex.



FIGURES 15.9A and B Segmental innervation of the muscles (myotomes) of (A) Upper limbs; (B) Lower extremities



FIGURES 15.10A and B (A) Arterial supply of the brain through circle of Willis and spinal cord; (B) The principal sites of atheroma

The middle cerebral artery: It is main branch of internal carotid artery, is commonly involved in embolism from the heart. It gives off:

- *Cortical branches, i.e. orbital, frontal* (supply inferior and middle frontal gyri and precentral gyrus), *parietal* which supply postcentral gyrus and superior parietal lobule,

inferior parietal lobule, and temporal branches to supply superior and middle temporal gyri.

- *Central branches-striate arteries (lenticulostriate, lenticulo-optic)* supply the white matter of the brain and the basal ganglia. These are particularly involved with hypertensive cerebral haemorrhage.

Posterior cerebral arteries: These are terminal branches of basilar artery and gives off branches to supply the visual cortex (occipital lobe), lower part of the temporal lobe, the uncus, two third of crux cereberi, red nucleus, third and fourth ventricles, posterior part of the posterior limb of the internal capsule, occlusion of this artery at its origin will therefore involve the visual cortex and the sensory fibres but sometimes the calcarine branch supplying the visual area may be involved in isolation.

Clinical Significance of Cerebral Circulation

- The partial occlusion of carotid arterial system leads to transient ischaemic attacks (TIAs).
- The circle of Willis is the site of congenital aneurysm at the bifurcation of its major arteries due to congenital deficiency of intima and media at these points. The rupture of an aneurysm may lead to haemorrhage.
- The thrombosis of anterior cerebral artery, if it is single (unpaired) leads to paraplegia of cortical origin—a rare phenomenon.
- The middle cerebral artery is the main culprit vessel in a patient of hemiplegia in majority of patients.
- The occlusion of small branch due to lipohyalinosis or proliferation of internal elastic lamina leads to a small area of an infarction which may not be picked up on CT scan—called *lacunar* infarct. For example, a lacunar infarct of a branch of middle cerebral artery may lead to pure motor or pure sensory hemiplegia.
- A branch of middle cerebral artery supplying the internal capsule is the common site of haemorrhage leading to hemiplegia.

Specific Vascular Syndromes of Brain (Stroke)

Cerebrovascular disease is the third most common cause of death after heart disease and cancer in the developed countries. The incidence of stroke is 1–2 per 1000 population per annum in Europe and USA. It is uncommon below the age of 40 years and more common among the males.

For stroke—Read “Case Discussion on Hemiplegia in Bedside Medicine without Tears” by Prof. SN Chugh

Classification and Causes of Stroke (Table 15.2)

- **An ischaemic stroke:** It results from acute occlusion of an intracranial cerebral vessel either due to thrombosis or embolism. An infarction will occur if blood supply is critically reduced (< 16 mL/100 g of brain tissue/min.) while in ischaemia without infarction only transient symptoms will occur. Tissue surrounding the core region of infarction/ischaemia—called ischaemic penumbra

TABLE 15.2 Causes of stroke (cerebrovascular accidents)

• Ischaemic stroke

- With cerebral infarction
 - Cerebral thrombosis
 - Cerebral embolism
 - Small vessel infarct (lacunar infarct)
 - Cerebral arteritis, e.g. tuberculosis, collagen vascular diseases, Takayasu’s syndrome etc
 - Dissecting aneurysm of brachiocephalic vessels
 - Prolonged hypotension or shock.
- With cerebral ischaemia
 - Transient ischaemic attacks (TIAs)
 - Hypotension due to bleed
 - Cardiac arrhythmias, e.g. atrial fibrillation, complete heart block
 - Migraine
- Miscellaneous
 - Drugs and oral contraceptives
 - DIC
 - Cerebral malaria
 - Hyperviscosity syndromes, paraproteinaemia
 - Hypercoagulable states, e.g. pregnancy, puerperium.

• Haemorrhagic stroke

- Hypertension
- Ruptured aneurysm (saccular, mycotic)
- Trauma
- Blood dyscrasias such as purpura, leukaemia and bleeding diathesis
- Anticoagulants.

• Strokes of undermined origin

- Moyamoya disease
- Fibromuscular dysplasia
- Aortic arch syndrome.

can be imaged by perfusion—diffusion imaging with MRI. The saving of this ischaemic penumbra is the goal of thrombolytic therapy now-a-days otherwise ischaemic penumbra will eventually lead to infarction/brain death.

- **A haemorrhagic stroke:** It is caused by intracerebral bleed/haemorrhage. It produces neurological symptoms by mass effect and the toxic effects of blood itself. Ruptured aneurysm is the cause of stroke in young while hypertension in the elderly.
- **A small vessel stroke (lacunar infarct):** The term lacunar infarction refers to lipohyalinotic occlusion of a small perforating artery in the brain. Now-a-day, the small vessel stroke is the preferred term.

Syndrome of Transient Ischaemic Attacks (TIAs)

They are defined as episodes of focal neurological deficit lasting for <24 hours, hence, are reversible by definition. The episodes may be isolated and infrequent or may occur many

TABLE 15.3 Features of transient ischaemic attack

Anterior circulation (carotid system)	Posterior circulation (vertebrobasilar system)
<ul style="list-style-type: none"> • Amaurosis fugax • Aphasia • Hemiparesis • Hemisensory loss • Hemianopic visual loss 	<ul style="list-style-type: none"> • Diplopia: vertigo, vomiting, choking and dysarthria • Ataxia • Hemisensory loss • Hemianopic visual loss • Transient global amnesia • Quadriparesis • Loss of consciousness (rare)

times a day and tend to be consistent in their symptomatology in affected individuals suggesting the recurrent ischaemia consistently involves the same side of the brain.

The clinical features of TIA involving anterior and posterior circulation are given in the Table 15.3. Hemiparesis, vertigo or aphasia are the most common complaints.

The embolisation of platelet—fibrin clot formed over the atheromatous plaques within a great vessel is the most common cause (90%) of TIA.

Syndrome of Internal Carotid Artery Occlusion

The clinical picture of internal carotid occlusion varies depending on the cause of ischaemia, i.e. thrombus, embolism or low flow. The cortex supplied by the middle cerebral artery (MCA) territory suffer the most, hence, symptoms are identical to syndrome of MCA territory (Read below) but feeble internal carotid, poor pulsation of retinal vessels with or without optic atrophy, dilated pupil on the side of the lesion and presence of bruit in cervical region over carotid vessels may help in the diagnosis of internal carotid occlusion.

Bilateral carotid occlusion, (an old lesion on one side with fresh lesion on the other side may) lead to *double hemiplegia* with coma.

Syndrome of Middle Cerebral Artery (MCA)

The areas supplied by it include sensory-motor cortex, speech centre (motor, sensory), auditory area and optic radiation. The penetrating branch supply the posterior limb of internal capsule, genu, globus pallidus and putamen.

The clinical picture is variable and depends on the area involved (Box 4).

Syndrome of Anterior Cerebral Artery

The cortical branches mainly supply the medial and superior surface of frontal lobe, the parietal lobe including paracentral

Box 4

Syndrome of middle cerebral artery

Symptoms and signs	Area involved
<ul style="list-style-type: none"> • Contralateral hemiplegia or hemiparesis with UMN signs 	<ul style="list-style-type: none"> • Motor area
<ul style="list-style-type: none"> • Contralateral hemianaesthesia and analgesia (loss of pain, touch, temperature, position, vibration, tactile localisation, stereognosis, two point discrimination) 	<ul style="list-style-type: none"> • Sensory area
<ul style="list-style-type: none"> • Motor aphasia 	<ul style="list-style-type: none"> • Motor speech area of dominant hemisphere
<ul style="list-style-type: none"> • Paralysis of conjugate gaze to opposite side 	<ul style="list-style-type: none"> • Frontal contraversive field
<ul style="list-style-type: none"> • Homonymous hemianopia 	<ul style="list-style-type: none"> • Optic radiation
<ul style="list-style-type: none"> • Central aphasia, word deafness, alexia, acalculia, finger agnosia, etc. 	<ul style="list-style-type: none"> • Parieto-occipital cortex of dominant hemisphere
<ul style="list-style-type: none"> • Anosognosia, apraxia, visual agnosia 	<ul style="list-style-type: none"> • Non-dominant parietal lobe lesion (areas correspond to area 6 of dominant hemisphere)

Note: In middle cerebral artery lesion, there will be contralateral hemiplegia, hemianaesthesia, motor aphasia, paralysis of conjugate gaze, visual field defect, alexia, acalculia, finger agnosia if dominant hemisphere is involved. Apraxia and visual agnosia, anosognosia will replace motor and central aphasia if non-dominant hemisphere is involved.

lobule, anterior limb of internal capsule and part of caudate nucleus.

The clinical picture depends on the areas involved (Box 5).

Syndrome of Posterior Cerebral Artery

Thrombotic occlusion of this artery results in:

- **P1 syndrome** (e.g. infarction of ipsilateral subthalamic nucleus, medial thalamus, ipsilateral cerebral peduncle and midbrain). This is due to occlusion of the proximal PCA. The clinical picture is summarised in the Box 6. Bilateral proximal PCA occlusion produces coma, unreactive pupils, bilateral pyramidal signs and decerebrate rigidity.
- **P2 syndrome:** Occlusion of distal PCA leads to infarction of medial temporal and occipital lobes (Box 7).

Bilateral infarction of distal PCA produces cortical blindness (blindness with preserved pupillary reflexes). The patient is often unaware of the blindness and may even deny it (*Anton's syndrome*).

Box 5

Syndrome of anterior cerebral artery

Symptoms and signs	Area/structure involved
Paralysis of opposite lower limb	Motor lower limb area
A lesser degree of paresis of opposite arm	Involvement of corticospinal fibres descending in corona radiata
Cortical type of sensory loss (e.g. position, two point discrimination and tactile localisation)	Sensory area for lower limb
Urinary incontinence	Paracentral lobule
Grasp reflex, sucking reflex, paratonic rigidity	Supplementary motor area
Akinetic mutism (abulia)	Cingulate gyrus, medial portion of frontal, parietal and temporal lobes
Gait apraxia	Frontal cortex near motor leg area

Box 6

Clinical picture of P1 syndrome

Signs	Structure involved
Benedikt's syndrome	Red nucleus (Read Table 15.4)
Claude's syndrome (a 3rd nerve palsy with contralateral ataxia)	Red nucleus, midbrain
Weber's syndrome (a 3rd nerve palsy with contralateral hemiplegia)	Cerebral peduncle, mid-brain
Contralateral hemiballismus	Subthalamic nucleus
Thalamic syndrome (contralateral hemisensory loss followed later by an agonising or burning pain in the affected areas)	Thalamus

**Brainstem Infarction
(Vertebrobasilar Artery Syndrome)**

Infarction in the brainstem causes complex pattern of dysfunction depending on the site of the lesion and its relationship to the cranial nerve nuclei, long tracts and brainstem connections (Table 15.4).

Box 7

Clinical picture of P2 syndrome

Signs	Structure involved
Contralateral homonymous hemianopsia with macula sparing. Patient may be aware of visual field defect	Calcarine cortex (occipital lobe)
Acute memory loss (amnesia) which may clear as memory is bilaterally represented Visual agnosia for faces, objects, mathematical symbols and colours may develop if dominant hemisphere is involved. There may be alexia without agraphia	Medial temporal and hippocampal involvement

TABLE 15.4 Syndromes of brainstem infarction

- **Weber's syndrome (already described)**
- **Benedikt's syndrome (midbrain lesion)**
 - Ipsilateral 3rd nerve palsy
 - Contralateral involuntary movements, e.g. tremors, chorea and athetosis.
- **Nothnagel's syndrome (midbrain, cerebellar peduncle)**
 - Unilateral 3rd nerve palsy
 - Ipsilateral cerebellar ataxia.
- **Claude syndrome (already described)**
- **Parinaud syndrome (dorsal midbrain infarction)**
 - Vertical gaze palsy
 - Convergence disorder
 - Convergence retraction
 - Nystagmus
 - Pupillary and lid disorders
- **Millard-Gubler syndrome (Ponto-medullary junction involved)**
 - Ipsilateral 6th nerve palsy
 - Ipsilateral 7th nerve palsy
 - Contralateral hemiplegia
- **Lateral medullary (Wallenberg) syndrome (lower lateral medulla involved)**
 - Ipsilateral 5th, 9th, 10th and 11th nerve palsy
 - Ipsilateral Horner's syndrome
 - Ipsilateral cerebellar signs
 - Contralateral spinothalamic sensory loss (pain, touch, temperature)
 - Vestibular disturbance (nystagmus, vertigo)
- **Locked-in syndrome (upper brain-stem infarction)**
 - Patient is conscious but can not speak, swallow or move the limbs
- **Bulbar and pseudobulbar palsy** (read lower cranial nerve lesions)

TABLE 15.5 Common lacunar syndromes

Sign	Site of infarction
• Pure motor hemiparesis	Posterior limb of the internal capsule or basis pontis
• Pure sensory stroke	Ventrolateral thalamus
• Ataxic hemiparesis	Base of pons
• Dysarthria and a clumsy hand or arm	Base of pons or in the genu of internal capsule
• Pure motor hemiparesis with motor (Broca's) aphasia	Genu and anterior limb of internal capsule and white matter of corona radiata
• Pseudobulbar	Corticobulbar tract

Lacunar Syndromes (Small Vessel Stroke)

The most common lacunar syndrome occurs due to single lacunar infarct (<300 μm) in the brain at different sites (Table 15.5).

Blood Supply of Spinal Cord and Spinal Artery Syndromes

The anterior and posterior spinal arteries arise from the vertebral artery and travel downwards in the anteromedian fissure and two latter pass along side the posterior nerve roots. These spinal arteries receive radicular tributaries at each spinal level. The anterior spinal artery supplies anterior two-thirds of the spinal cord; while posterior spinal artery supplies the posterior one-third of the cord containing posterior horns and posterior columns. Both these arteries function as anastomotic vessels linking the radicular feeding vessels.

Infarction of the cord may occur due to occlusion of anterior or posterior spinal artery resulting in respective **anterior and posterior spinal artery syndrome** (Box 8). The primary cause of infarction may be atherosclerosis, dissecting aneurysm, thromboembolism, meningovascular syphilis, polyarteritis nodosa or AV malformations. The onset of symptom is sudden acute back pain. The intermittent claudication may occur due to foramina stenosis. The vascular malformations may produce spinal bleed.

Venous Drainage of Brain and Dural Sinus Thrombosis

The cerebral veins and venous sinuses have no valves, therefore, blood flows in them in either direction. The **superior sagittal sinus** is the largest of venous sinuses (Fig. 15.11), receives blood from the frontal, parietal and occipital superior cerebral veins and the diploic veins, which communicate with the meningeal veins. Bacterial meningitis is a common cause

Box 8

Features of spinal artery syndromes

Anterior spinal syndrome	Posterior spinal syndrome
• Anterior two-thirds of the cord involved	• Posterior one-third of cord involved
• Spinothalamic and corticospinal tracts involved	• Posterior column and corticospinal tract involved
• Paraplegia/quadruplegia with loss of pain, touch, temperature. Vibration and position sense preserved	• Paraplegia/quadruplegia with loss of posterior column sensation (loss of position and vibration sense)

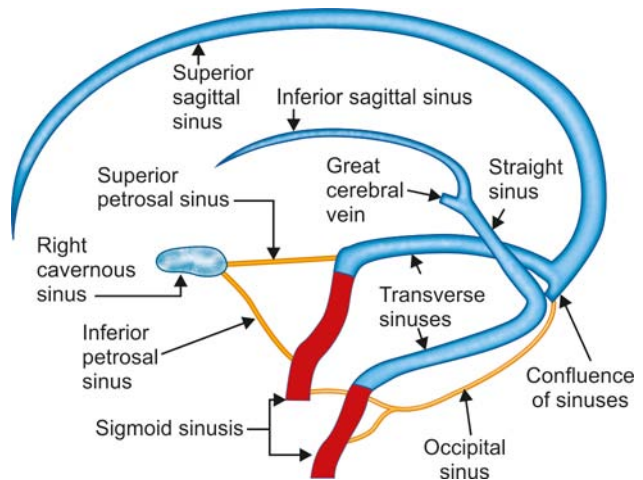


FIGURE 15.11 Dural venous sinuses

for septic thrombosis of superior sagittal sinus. Infection can spread to superior sagittal sinus from nearby subdural empyema or epidural abscess. The predisposing conditions for venous sinus thrombosis including the superior sagittal (common) are given in the Box 9.

The **superior sagittal sinus** drains into the **transverse sinuses** (paired sinus). The transverse sinuses also receive venous drainage from small veins from both middle ears and mastoid cells. The transverse sinus becomes sigmoid sinus before draining into internal jugular vein. Septic transverse/sigmoid sinus thrombosis can be a complication of acute or chronic otitis media or mastoiditis. Infection spreads from the mastoid air cells to the transverse sinus via the emissary veins or by direct invasion.

The **cavernous sinuses (a pair)** are inferior to superior sagittal sinus at the base of the skull. The cavernous sinuses receive blood from the facial veins via superior or inferior ophthalmic veins, hence are likely to be involved in orbital cellulitis or orbital infection or facial infection. Bacteria in ethmoid sinuses or sphenoidal sinuses can spread to the

Box 9

Causes of cerebral venous thrombosis

General	Local
• Pregnancy and postpartum state	• Sinusitis, mastoiditis
• Sepsis	• Otitis
• Dehydration or hypotension	• Pyogenic meningitis
• Oral contraceptive use	• Subdural empyema
• Polycythaemia, sickle cell anaemia, leukaemia	• Facial infection
• Hyperviscosity syndrome	• Trauma or head injury
• Antiphospholipid syndrome, deficiency of protein C and S	• Jugular venous catheterisation
• Debilitating states or malignancy	
• Postoperative	
• Cyanotic heart disease	

cavernous sinuses via the small emissary veins. **The sphenoid and ethmoid sinuses** are the most common sites of primary infection in septic cavernous sinus thrombosis.

The clinical manifestations of common venous sinus thrombosis are given in the Table 15.6.

Presenting Complaints and Symptoms Pertaining to Nervous System

(Read Front Page of this Chapter and Chapter 2 also).

THE HISTORY

The symptoms of neurological disorders are so vague that detailed history and execution of clinical signs will enable the physician to come to some definite conclusion because established principles of anatomy and physiology help to localise the site of the neurological lesion and to narrow down the differential diagnosis. In structural disease of the nervous system (e.g. vascular, tumours, multiple sclerosis), significant changes are often found as localising signs which are taken as clues to the diagnosis. On the other hand, disorders of neuronal function (e.g. epilepsy, migraine) may produce no abnormal signs on examination, hence, the history taking is of paramount importance.

The presenting symptoms of patients with neurological disorders are variable and depend on the site of involvement. In most instances, the diagnosis can be based on detailed analysis of the symptoms, hence, elaborate history as detailed below is important. The general principles of history-taking apply as outlined in Chapter 1.

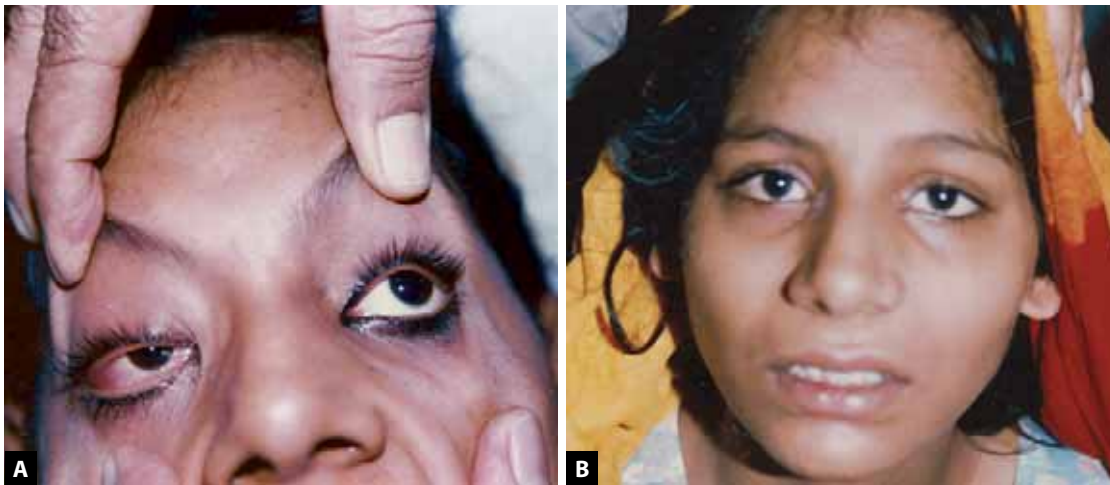TABLE 15.6 Clinical manifestations of cerebral venous sinus thrombosis

Sinus involved	Features
• Cavernous sinus thrombosis —(3rd, 4th, 6th and first division of V cranial nerve involved) (Figs 15.12A and B)	<ul style="list-style-type: none"> • Chemosis, proptosis, ptosis, ophthalmoplegia (internal and external), papilloedema, retinal haemorrhage, reduced sensation in ophthalmic division of V cranial nerve • Involvement may be unilateral or bilateral. Patient is ill with fever, headache, frontal and retro-orbital pain and diplopia
• Superior sagittal sinus thrombosis	<ul style="list-style-type: none"> • Fever, headache, nausea, vomiting, confusion, focal or generalised seizures, stupor, coma, papilloedema • Weakness of lower extremities (paraplegia) with bilateral plantar extensors or quadriparesis with predominant lower limbs involvement • Sensory focal deficits may be present • Neck rigidity and signs of meningitis present if it occurs as a complication of meningitis
• Transverse sinus	<ul style="list-style-type: none"> • Otitis media, 6th nerve palsy, retroorbital or facial pain (<i>Gradenigo's Syndrome</i>) • Headache, hemiparesis, convulsions and papilloedema
• Jugular foramen or jugular vein	<ul style="list-style-type: none"> • Since transverse sinus thrombosis extends to jugular vein, hence, its features may be present in addition to 9th, 10th and 11th cranial nerve palsies

Present History

In the history, emphasis should be laid on:

- **Time relationship of symptoms**, i.e. onset, progression or regression, frequency, duration, etc.
- **Localisation**—e.g. Which part of the body is affected the most. Is involvement symmetrical or asymmetrical?
- **Precipitating factors**, e.g. Are the symptoms increase by any specific activity, e.g. exercise, sleep, posture, reading, eating, coughing, micturition, sexual activity or by external stimuli, e.g. sound, smell, heat or cold?
- **Associated symptoms**: Are there other associated or accompanying symptoms in addition to presenting symptoms? i.e.
 - Numbness, tingling, paraesthesias, cold, or warmth (sensory disturbance)



FIGURES 15.12A and B Right cavernous sinus thrombosis in a postpartal female: (A) There is chemosis, lid oedema, conjunctival congestion and external ophthalmoplegia (immobile right eye) due to 3rd, 4th and 6th nerve palsy; (B) The same female patient after recovery

- Weakness, clumsiness, stiffness, unsteady gait (motor system disturbance)
- Headache, nausea, vomiting, seizures (symptoms of raised intracranial pressure)
- Visual disturbances, e.g. diminution of vision, diplopia, scintillating spots
- Disturbance in consciousness, e.g. confusion, delirium, stupor
- Psychological disturbance, e.g. depression, euphoria, agitation, somnolence, appetite disturbance, change in libido.

Past History

- Past history of diabetes, hypertension, renal disease or dialytic therapy, alcoholism, smoking, tuberculosis must be asked
- Any past history of diarrhoea or malabsorption or acute respiratory infection
- Some neurological disorders (e.g. epilepsy, hydrocephalus) may present many years after the causative event. It is therefore important to ask about:
 - Pregnancies (length of term, intrauterine problems)
 - Delivery (normal, assisted or operative)
 - Neonatal health (severe jaundice, respiratory difficulty, infections and convulsions)
 - Problems during infancy (e.g. convulsions, trauma, infection).
 - *Childhood and adulthood* (e.g. trauma to head or spine, infections such as meningitis, encephalitis, surgical operation).

Drug History

- Ask about the drug being taken or has been taken in the past such as antitubercular, antiepileptics, anticoagulants, antipsychotics, oral contraceptives, nitrofurantoin, vincristine.
- History of intake of poison, e.g. organophosphorus compounds.
- History of vaccination, e.g. predisposition to AIDS, hepatitis and demyelinating disorders, etc.

Family History

- Many neurological disorders have a genetic component, some may be strictly genetic disorders (e.g. hereditary ataxias, muscular dystrophies, myotonias, Huntington's chorea and hereditary neuropathies).
- In some neurological disorders, genetic factors appear to influence the development of the disease (e.g. epilepsy, multiple sclerosis, migraine, stroke, dementia).

Social and Personal History

- **Occupation:** Patient's occupation may be relevant in the causation or triggering of neurological disorders.
 - Exposure to toxic chemicals (toxic neuropathies or encephalopathies) such as lead, mercury, industrial solvents, OP compounds, etc.
 - Recurrent overuse of certain joints predisposing to entrapment neuropathy (e.g. carpal tunnel syndrome).
 - Prolonged visual work (tension headache, migraine).
 - History of recent travel.

- Occupation requiring prolonged stay outside home, e.g. *Sadhu* or *saint*, *sailors*, *truck driver* are predisposed to sexually transmitted disorders.
- **Diet**, e.g. vegetarian or non-vegetarian (neurocysticercosis), alcohol intake, quality of diet.
- **Marital status**: Marriage, divorce, bereavement and change in occupation are important precipitating factors for tension headache, migraine and depression, may also trigger attacks of multiple sclerosis and epilepsy.
- **Sexual contact**: History of contact with unknown partner must be asked to explore any possibility of sexually transmitted disease.

EXAMINATION

A neurological examination requires to be systematic. It includes:

- General physical examination
- Proper neurological examination
 - Higher mental functions
 - Speech and language
 - Gait and cerebellar functions
 - Cranial nerves
 - Motor system
 - Sensory system
 - Other associated/involved system.

General Physical Examination

- **Head (cranium)**: Look for any abnormality of the skull:
 - Large skull with protruding jaw (Gigantism)
 - Hyperostosis (Paget's disease)
 - Microcephaly
 - Irregularity of the surface, e.g. localised bony swelling or erosion, fractures
 - Tenderness of skull
 - Intracranial bruits to be heard with bell of stethoscope on frontal region, lateral occipital region and on each closed eyeball for angiomas, carotid cavernous fistula, tumours of Glomus Jugulare (best heard over mastoid or jugular vein).
- **Skin**: Following points are to be noted:
 - *Café-au lait* spots, subcutaneous and plexiform neurofibromas.
 - *Cutaneous angiomas (Port-wine stain)*: Facial nevi may occur in Sturge-Weber syndrome, telangiectasia of skin may be associated with intracranial telangiectasia.
 - *Adenoma sebaceum* may be present with tuberous sclerosis.

- *Herpes zoster infection* (papulovesicular eruption) may be associated with neuralgias.
- *Any rash*, e.g. exanthematous rash or butterfly rash over face in SLE.
- *Thick tight skin* occurs in systemic sclerosis.
- *Signs of nutritional deficiencies*, e.g. angular stomatitis, cheilosis, pellagrous skin, anaemia.
- *Scar marks, injection marks*, may be present in drug addicts. Burn marks are seen in neuropathies. Gangrene of the phalanges or painful finger tips may be seen in embolic phenomenon. *Bed sores* indicate prolonged illness or unconsciousness or paraplegia.
- *Tuft of hair* over the spine may be seen in spina bifida.
- *Skin tumours*, e.g. melanoma.
- **Eyes**: Detailed examination of the eyes is discussed under cranial nerve examination. However, *look for the following on general physical examination*:
 - Unilateral proptosis, conjunctivitis, chemosis, keratitis or corneal ulceration.

• Ear, nose and throat

Look at the ear for:

- Otitis externa.
- Chronic suppurative otitis media for 7th cranial nerve palsy and meningitis.
- Mastoid tenderness for mastoiditis associated with jugular foramen syndrome.

Look at the nose for:

- Depressed bridge of the nose may occur in tertiary syphilis, relapsing polychondritis, leprosy and Wegener's granulomatosis, Gummatous lesion may be present on nasal septum.

Look at nasopharynx for evidence of any malignancy (nasopharyngioma).

Look at the oral cavity for dental abscess, tonsillar abscess, gum hypertrophy, etc.

• Neck

- Look for cervical lymphadenopathy which may occur as a part of generalised lymphadenopathy. Therefore, examine the lymph nodes at other sites also, e.g. axillary and inguinal.
- Palpation or auscultation of cervical carotid bruit.
- Thyroid for enlargement. Look for the signs of thyrotoxicosis or hypothyroidism if present (these signs are discussed in Case Discussion in Bedside Medicine without Tears by Prof. SN Chugh).
- Neck stiffness and signs of meningitis.

- **Breast**: Examine the breast for any lump. Carcinoma of the breast is a common source of distant metastasis including brain.

- **Look for vitals:**
 - **Pulse:** Bradycardia may occur in raised intracranial tumour, Stokes-Adam attacks and hypothyroidism. Tachycardia may indicate an infection, arrhythmias (atrial fibrillation) or thyrotoxicosis. Arrhythmia in valvular heart disease is a common cause of cerebral embolisation.
 - **Blood pressure:** Hypertension may predispose to encephalopathy, lacunar infarct and atherothrombogenesis.
 - **Temperature:** Fever indicates infective or inflammatory brain disorders. Both hyperthermia and hypothermia are associated with neurological symptoms.
 - **Respiration:** Respiratory irregularities (e.g. Cheyne-Stokes respiration, irregular slow respiration) may occur in raised intracranial pressure.

Systemic Neurological Examination

Three important questions govern the neurological examination.

- **Mental status:** Is it intact?
- **Symmetry or asymmetry of findings:** Are the right-sided or left sided findings symmetric?
- **If the findings are asymmetric or otherwise abnormal:** Does the lesion lie in the central nervous system or peripheral nervous system?

In this section, you will learn the techniques for a practical and comprehensive examination of the nervous system. One should master these techniques. At first, these techniques may appear difficult but with time and experience, one feels comfortable evaluating the neurological symptoms and signs. You should be dedicated and active in learning.

The details of an appropriate neurologic examination varies widely. With experience, one can go through the neurological examination quickly in patients not suspected of neurological disease. When you detect abnormal findings, your examination will become more comprehensive. Be aware that neurologists may use many other techniques in specific situations. Nonetheless the neurologist approach to the mental state examination is similar to that taken by the psychiatrist, although with a difference in emphasis that reflects the different symptom complexes of organic and functional brain syndromes.

For efficiency; you should integrate certain portions of neurological examination with other parts of examination. Observe the mental status and speech during the process of *history taking*. Similarly you can assess some of the cranial nerves during examination of head and neck, and inspect the

arms and legs for neurologic abnormalities while you observe the peripheral vascular and musculoskeletal systems.

As always in neurology, the history-taking is of utmost importance and influence the subsequent investigation of symptoms. For example, if the patient memory is impaired, the patient's description of illness will be limited. If the patient is comatosed, confused, or unable to understand speech or language, any attempt to examine the sensory system is likely to be frustrated. If for any reason, the patient is not able to give the history himself/herself, it is essential to obtain history from relatives or friends.

Rapid bed side protocol for mental state testing can be used to quantify roughly the deficit. Detailed neurological examination can follow later on.

Testing for Higher Mental Functions

The essential elements of mental status examination are:

- Appearance, behaviour and communication
- Speech and language
- Mood/emotional status
- Thoughts and perceptions (delusions and hallucinations)
- Cognitive functions, e.g. memory, intelligence, attention, information, vocabulary, calculations, and abstract thinking and constructional ability.

1. **Appearance and behaviour:** First of all note whether there is any disturbance in consciousness such as confusion, stupor or coma. Level of consciousness primarily reflects the patient's capacity for arousal or wakefulness. It is determined by the level of activity that the patient can be aroused to perform in response to escalating stimuli from the examiner (Table 15.7).

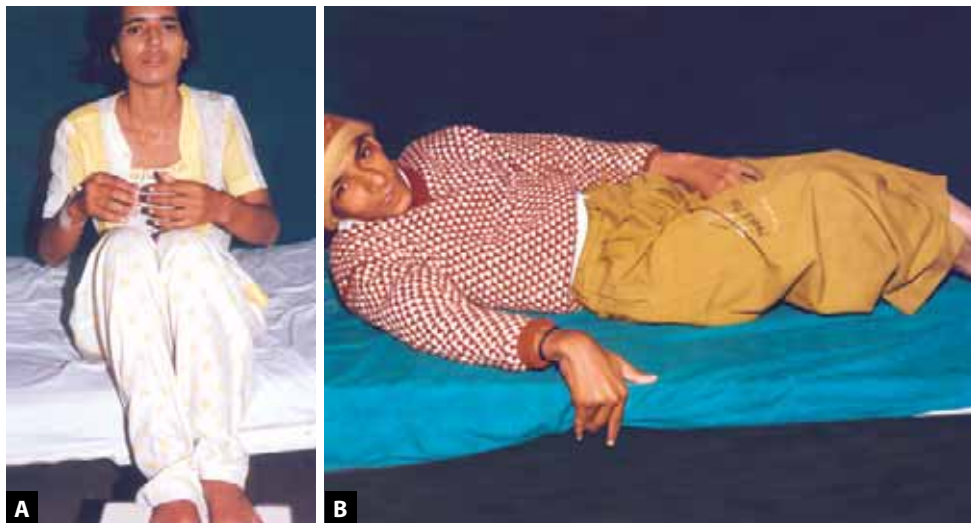
- **Facial expression:** Observe the patient at rest and while interacting with others. Is patient anxious, depressed or apathetic?

Facial immobility or expressionless face is seen in parkinsonism.

- **Posture and motor behaviour:** Look for any unusual features in the behaviour, e.g. facial tics, fidgetiness of anxiety, crying, hand-winging of agitated depression, slowed movements of depression, singing, dancing movements of a manic episode. There may be abnormal posture in schizophrenia, encephalitis and cerebral palsy (Figs 15.13A and B).
- **Dress, grooming, personal cleanliness:** How is the patient dressed? Is clothing clean, pressed and properly fastened? Note the patient's hair, nails, teeth, skin and beard if present. How are they groomed? Compare the dress, grooming and personal hygiene with other people of comparable age, lifestyle and socioeconomic status.

TABLE 15.7 Assessment of level of consciousness

Level	Technique	Abnormal response
Alertness	Speak to the patient in normal tone of voice. An alert patient responds, i.e. opens the eyes, looks at you and answers the questions appropriately (arousal intact)	Inattentive patient or patient with disturbed consciousness may not respond to command or questions
Lethargy	Speak to the patient in a loud voice. Ask "How are you?" "What is your name?"	A lethargic patient appears drowsy but opens the eyes and looks at you, responds to the questions and then falls asleep
Obtundation	Shake the patient gently as if awakening a sleeper	An obtunded patient opens the eyes and looks at you, but responds slowly and is somewhat confused. Alertness and interest in the surroundings is less
Stupor	Apply a painful stimuli: For example, pinch a tendon, rub the sternum or roll a pencil across a nail bed. No stronger stimuli needed	A stuporous patient arouses from sleep only after painful stimuli. Verbal responses are slow or even absent. The patient lapses into an unresponsive state when the stimulus ceases. There is minimal awareness of self or environment
Coma	Apply repeated painful stimuli	A comatosed patient remains unarousable with eyes closed. There is no evident response to inner need or external stimuli



FIGURES 15.13A and B (A) Catatonic posture following encephalitis (postencephalitic); (B) Dystonic posture in a patient with cerebral palsy

Grooming and personal hygiene may deteriorate in depression, schizophrenia and dementia.

One sided neglect may result from a lesion in the opposite parietal cortex, usually the nondominant side.

2. **Mood or emotional state:** It is important to evaluate the patient mood during the interview exploring the patient's own perceptions of it. Note:

- Is the patient appear happier than normal (elated or euphoric) or filled with despair or dismay (depression) or angry?
- Is there any flattening or blunting of emotion during conversation, e.g. family or financial success is described without pleasure or patient laughs after relating a misfortune or breaks into tears after narrating a pleasant news?

- Does the patient enjoys life or fed up with life?
- Is there any suicidal intent or tendency?
- Is there any sense of depersonalisation or derealisation by asking whether things seem as real as they should be or whether they seem changed in some mysterious way.

Feelings of depersonalisation-derealisation occurs in psychotic disorders.

Mood disorders may be either depressive or bipolar. A bipolar disorder includes manic or hypomanic features as well as depressive features.

3. **Thought and perceptions:** Are there any flight of ideas, loosening of associations (person shifts from one subject to other), neologisms (use of invented or distorted words), incoherence, confabulations (fabrication of facts or events to fill in the gap in an impaired memory), preservation

(persistent repetition of words) echolalia (repetition of the words and phrases of others) are common in psychiatric disorders, hence, discussed in examination of psychiatric patient Chapter 19.

- Delusions are false beliefs which continue to be held despite evidence to contrary. Examples include: delusions of persecution, grandiose delusions, delusional jealousy and delusions of reference.

Delusions are most often associated with psychotic disorders, may occur in delirium, severe mood disorders and dementia.

- **Illusions:** Illusions are misinterpretations of real external stimuli, may occur in grief disorders, delirium, acute or post-traumatic stress disorders and schizophrenia.
- **Hallucinations** are false subjective sensory perceptions in the absence of relevant external stimuli. Hallucinations may be *auditory, visual, olfactory, gustatory, tactile* or *somatic*.
Note: Does the patient perceives hallucinations of any type?

Hallucinations of taste and smell are characteristic of temporal lobe epilepsy (partial seizures).

Hallucinations of small animals or insects crawling through the room, or on the walls, or bed are particularly associated with delirium tremens (alcohol withdrawal syndrome).

In occipital lobe lesions, visual hallucinations may occur.

Hallucinations may occur in post-traumatic stress disorders and schizophrenia.

4. **Insight and judgement:** One should assess whether the insight into the illness is intact or not. This can be assessed by asking “What brings you to the hospital?” “What seems to be the trouble?” “What do you think is wrong?” Note whether the patient is aware of himself/herself and the surroundings.

Patients with psychotic disorders often lack insight into their illness. Denial of impairment may accompany some neurological disorder.

Judgement can be assessed by noting the patient’s response to family situations, jobs, use of money or interpersonal conflicts. Who will look after your financial affair while you are in the hospital? “If your husband starts abusing you again, what will you do”?

Poor judgement is seen in dementia, delirium, mental retardation and psychotic states. Judgement is affected by anxiety, mood, intelligence, education, socio-economic status.

5. Cognitive functions

- **Orientation to time, place, person:** In order to assess patient’s ability to recognise place, time or person, the following questions can be asked:
 - **Time** (you can ask about the time of day, day of the week, month, season, date and year, duration of hospital stay).
 - **Place** (Ask about patient’s residence, names of the hospital, city and state).
 - **Person:** (You can ask the patient’s own name, and the names of the relatives and friends).

Disorientation occurs especially when the memory or attention is impaired as in delirium.

- **Memory:** Memory consists of the ability to grasp and retain the new information, requires adequate processing of input, followed by registration and then appropriate recall. To test the recent memory, inquire about the events of the day including the day’s weather, today’s appointments and medications or diet taken today. Ask the patient to recall informations such as what has been taken in the breakfast or dinner? What have you read in the paper or seen on the television? In framing questions, one should keep in mind the patient’s educational qualification, background and their likely personal interests. Those questions should be asked whose answers can be checked from other sources for confirmation so that, you can know whether or not the patient is confabulating (cooking up facts to compensate for a defective memory).

Recent memory is impaired both in delirium and dementia. Amnesic disorders also impair memory but they do not have other features of dementia or delirium.

Anxiety, depression, and mental retardation may also impair recent memory.

To test remote memory (short-term or long-term memory), inquire about birth days, anniversaries, numbers, name of the schools attended, jobs held, or past historical events such as wars.

For short-term memory, you can ask for the events happened a few seconds or minutes past.

Loss of memory is called amnesia. Short-term memory loss is characteristically impaired in Wernicke-Korsakoff syndrome and in many patients with Alzheimer-type dementia. The degree to which the recent memory is lost is an index of severity of organic brain disorder.

- **Intelligence:** It is a higher cognitive function. Information and vocabulary, when observed clinically, provide a rough estimate of a person's intelligence. Assess them during the history-taking. The educational level reached before leaving school, inquiries about person's work or hobbies, reading, favourite television programmes or current events, give a rough and ready estimate of intelligence.

Frequent change of mind or jobs may indicate mental defect or personality disorder.

Frequent changes of work or employment after an accident or a serious illness in patients with a previously good work record suggests brain damage.

- **Calculating ability** is another cognitive function and tests the memory and reasoning, indicates more serious and specific defect. Ask the patients simple, arithmetic questions, i.e. ("what is $4 + 3?$ - - -), "what is $5 \times 6?$ - - . The task can be made more difficult by asking to subtract 7 from 100 (i.e. 93, 86, 79 - - -). You can ask to spell a five-letter word "W-O-R-L-D" backwards.

Poor performance may be a sign of dementia or may accompany aphasia, but it must be tested in terms of patient's intelligence and education.

- **Constructional ability:** The task here is to copy figures of increasing complexity onto a piece of blank unlined paper. Show each figure one at a time and ask the patient to copy it (Fig. 15.14).

If vision and motor ability are intact, poor constructional ability suggests dementia or parietal lobe damage (hepatic encephalopathy).

Released Reflexes/Return of Primitive Reflexes

In organic brain disorders (diffuse degenerative disorders) certain reflexes released from the control of higher centre may be elicited. Some may be elicited even in focal lesions such as grasp reflex in frontal lobe disease. All these are primitive reflexes and their presence or absence in infancy is used as a part of developmental assessment, hence, they appear during infancy, disappear during childhood and adulthood, reappear or released during damage to higher centres by diffuse organic disease. The important higher level reflexes are:

- Grasp and avoiding reflexes
 - Palmomental reflexes
 - Snout and sucking reflexes
 - Glabellar tap reflexes
- } All these reflexes are under higher control, get released when the higher control centres, e.g. frontal lobe(s) is diseased or damaged.

Grasping and avoiding reflexes: *Grasp reflex* is elicited by stroking the palmar surface of the patient's hand on its lateral aspect by firmly moving a stimulus (pencil or examiner's finger) distally between the patient's thumb and forefinger




FIGURE 15.14 Constructional apraxia

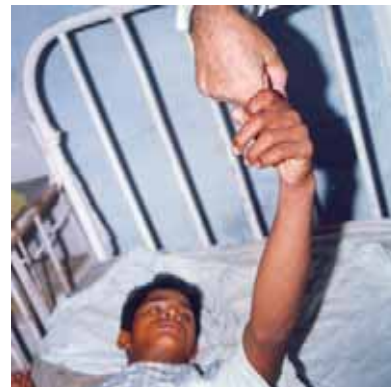

FIGURE 15.15 Grasp reflex. The patient tries to grasp the finger of examiner hand

(Fig. 15.15). The patient's hand grasps the object or move towards examiner's hand to grasp it. This grasp reflex is not inhibited even if the patient's attention is diverted, for example, by asking his/her address. If observer tries to pull the object or his/her finger (used as a stimulus) against the patient's flexed fingers, the patient tries to oppose with an equivalent force.

The avoiding response (reflex) is a tendency on the part of the patient to move away his/her hand from palmar or dorsal contact. It is usually elicited by applying the stimulus on the ulnar side of the hand.

Both grasping and avoiding reflexes or responses are elicited in patients with contralateral frontal lobe disease, e.g. Alzheimer's disease.

Palmomental reflex: Stroke the skin of the palm near the thenar eminence, there is contraction of ipsilateral mentalis (a subcutaneous muscle) causing puckering of the chin.

Snout and sucking reflexes: Apply gentle pressure by your knuckles against the patient's lips, there is puckering of the orbicularis oris (forming a snout). Similarly, the reflex can be elicited by tapping the finger placed on the lips with a tendon hammer or with finger of other hand, there is contraction of facial musculature.



FIGURE 15.16 Elicitation of glabellar sign

Sucking reflex is an anticipatory opening of the mouth in response to visual stimuli, e.g. shining the mental end of a tuning fork or just touching cheeks near the corner of the mouth.

Glabellar tap (Fig. 15.16): A series of finger tap at the glabella normally produces two or three blinks and then response is inhibited, but in *Parkinsonism* or *diffuse degenerative disorders*, the response is not inhibited, i.e. each glabellar tap is followed by a blink.

Speech and Language

Much can be learnt about the patient's speech during history-taking. Speech disorders are mainly of two types:

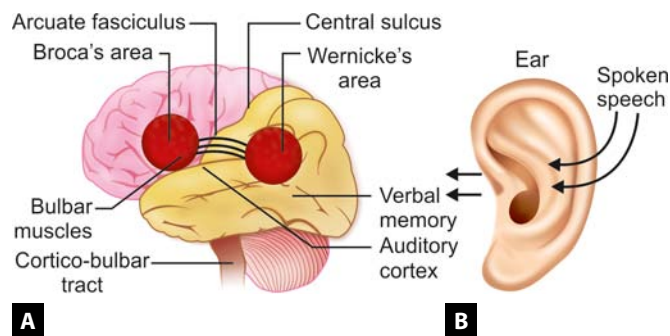
1. Disorders of articulation (*dysarthria*) and phonation (*dysphonia*).
2. Disorders of the structure and organisation of language (*dysphasia*).

If a deficit in speech is noticed, then a thorough careful examination of speech and language should be undertaken so as to explore and localise the causative lesion.

Applied anatomy: The language areas are situated in the dominant hemisphere. The dominance of hemisphere is decided by handedness of a person. In the vast majority of right-handed persons the left hemisphere is dominant. About a third of left-handers have a dominant right hemisphere; the others have either left-sided or bilateral language representation. The main language areas and their association fibres are shown in Figs 15.17A and B.

Speech functions of cerebral hemispheres

Dominant hemisphere	Nondominant hemisphere
<ul style="list-style-type: none"> • Formation of speech • Right-left orientation • Finger identification • Calculation 	<ul style="list-style-type: none"> • Drawing ability, construction • Dressing, facial recognition • Awareness of body and space



FIGURES 15.17A and B The diagrammatic representation of main language areas and their associations and the mechanism of speech. The spoken words pass from the ear of the listener's (B) to auditory cortex (A) and then to Wernicke's area (arrows)

- **Broca's area:** It lies in the posterior region of the inferior frontal gyrus of the dominant hemisphere. It is concerned with generation of motor programmes for production of words or parts of words (phonemes). The motor commands generated in the Broca's area pass to the cranial nerve nuclei in the pons and medulla, as well as the anterior horns of the spinal cords, thus nerve impulses reach the lips, tongue, palate, pharynx, larynx and respiratory muscles via the facial nerve and cranial nerves 9th, 10th and 12th.
- **Wernicke's area:** It lies in the posterior temporal lobe and the adjoining parietal region and is concerned with the comprehension of language and the selection of words to convey meaning.

The decoding of speech sounds (phonemes) is a function of posterior temporal lobe. The perception of these sounds as meaningful language, as well as the formulation of the language required for the expression of ideas and concepts (speech comprehension) is the function of Wernicke's area. The Broca's and Wernicke's areas are connected by an arcuate fasciculus (Figs 15.17A and B). The language information generated in the Wernicke's area to the spoken speech is passed anteriorly via the arcuate fasciculus to Broca's area for motor commands.

Mechanism of Speech Production (Fig. 15.17B)

The spoken words (language) are detected by a listener in whom the nerve impulses are passed from the ears to the auditory cortex in the temporal lobe to the Wernicke's area where the speech is comprehended. In dominant hemisphere the language information so generated is passed to Broca's motor area of speech via arcuate fasciculus. From the Broca's area, the motor commands pass to parts concerned with articulation and phonation (e.g. lips, tongue, pharynx, palate, larynx and respiratory muscles) via the cranial nerves 7th, 9th, 10th and 12th for production of ordered sounds known as speech. In this way, the speech and language are controlled by the cerebral cortex.

Examination Sequence

Spontaneous speech is assessed by *fluency* (rate, flow and melody of speech and the content and use of words) during conversations. The area of fluency of speech lies around central fissure (Box 10). *Paraphasias* means the words are either malformed (“*I write with a den*”), wrong or inappropriate (“*I write with a bar*”), or invented (*I write with a dar*). If the patient speech lacks fluency, proceed with further testing as outlined in the Table 15.8.

If *dysarthria* is suspected ask the patient to repeat a phrase which requires precise articulation, e.g. British Constitution or artillery. The causes of dysarthria and their characteristics are given in the Table 15.9.

Dysarthria may be caused by mechanical factors such as ill-fitted dentures, but invariably occurs due to weakness or impaired co-ordination of the muscles of speech (orolingual

muscles). Dysarthric speech is indistinct and difficult for listener to discern. However, in dysarthria, the grammatical construction of speech is normal and the patient’s comprehension of spoken speech and written language is preserved. Elevation of soft palate is used to close off the nasopharynx for production of

Box 10	
Site of lesion of spoken speech	
Speech output	Site of lesion
<ul style="list-style-type: none"> • Fluent, i.e. normal to increased number of words (>10/sec) are produced 	Fluent aphasia indicates lesion posterior to central fissure
<ul style="list-style-type: none"> • Nonfluent aphasia, i.e. verbal output is reduced (<10 words/sec) 	It indicates lesion anterior to central fissure

TABLE 15.8 Testing for aphasia	
• <i>Word comprehension</i>	Ask the patient to follow a one-stage command, such as “point to your nose” or “put out your tongue”. Try a two-stage command “Point to your mouth, then your knee”
• <i>Repetition</i>	Ask the patient to repeat a phrase of one syllable words “Today is Tuesday”. Repetition failure occurs in conduction aphasia
• <i>Naming</i>	Ask the patient to name a shown object (e.g. a comb or pen). The test can be made difficult by asking the patient to name the components of a watch
• <i>Reading comprehension</i>	Ask the patient to read a paragraph loudly. This may reveal an associated dyslexia
• <i>Writing</i>	Ask the patient to write a sentence. This can not be assessed if the patient has a motor deficit of writing hand. Errors of form, grammar and sentence indicate dysphasia. A person who can write a correct sentence does not have <i>aphasia</i>

TABLE 15.9 Causes of dysarthria			
Type	Mechanism	Characteristic	Associated features
Myopathic	Weakness of muscles of face and tongue	Poor articulation, indistinct speech	Weakness of muscles of neck
Myasthenic	Motor end plate	Indistinct, with fatigue and dysphonia, fluctuating severity. This can be tested by asking the patient to count upto 50; speech become indistinct due to fatigue after sometime	Ptosis, diplopia, facial and neck muscles
Bulbar	Lower motor neuron lesion of brainstem (9th, 10th and 11th cranial nerves palsy)	Indistinct, slurred often nasal. Ask the patient to speak “egg”, he/she will pronounce it as “eng”	Dysphagia, diplopia, ataxia
Scanning	Cerebellum	Slurring, impaired timing and cadence, sing-song quality. This can be tested by asking the patient to say “artillery”; it will be pronounced as “ar-til-ler-y” meaning thereby each word is scanned	Ataxia of the limb and gait, tremors of head/limbs
Spastic	Bilateral pyramidal tracts above the pons (pseudobulbar palsy)	Indistinct, explosive, high pitched, hot potato speech, imprecise pronunciation, breathy, mumbling. This can be tested by asking the patient to pronounce “British Constitution; it will be pronounced as “Britzf Conshishushon”	Increased/exaggerated reflexes, bilateral plantar extensor response and jaw jerk is present
Parkinsonism	Basal ganglia	Indistinct, rapid, stammering, quiet, slurred and monotonous	Tremors, rigidity, slow shuffling gait

TABLE 15.10 Differentiation between two common types of aphasias

Feature	Wernicke's aphasia (posterior)	Broca's aphasia (anterior)
Qualities of spontaneous speech	Fluent, often rapid and effortless. Articulation is good. Sentences lack meaning and words are malformed (paraphasias) or invented (neologisms). Speech may be totally incomprehensible	Nonfluent, slow with few words, laborious effort. Articulation is impaired but words are meaningful with nouns, transitive verbs and important adjectives. Small grammatical words are often dropped
Word comprehension	Impaired	Fair to good
Reading comprehension	Impaired (dyslexia)	Good
Repetition	Impaired	Impaired
Naming	Impaired	Impaired, though patient recognises objects
Writing	Impaired	Impaired
Gesture language	Impaired	May be impaired
Associated lesion	No associated hemiparesis as pyramidal tracts are spared	Often associated hemiparesis due to pyramidal tract involvement
Site of lesion	Posterior in temporal lobe	Anterior in frontal lobe

explosive consonants (b and g). Weakness of palate (bulbar palsy) or anatomical defects in palate cause 'nasal' speech with failure to produce these sounds correctly. For example, such a patient will pronounce 'egg' as 'eng'.

Dysphonia: It is defined as disturbed phonation. The production tones in speech is achieved by movements of expired air through the larynx. Vibrations of the vocal cords generate frequency changes used in speech and singing. Poor vocal cords movements and poor respiratory function may cause dysphonia, but characteristically it is caused by laryngeal involvement such as recurrent laryngeal nerve palsy or laryngitis.

Dysphasia or aphasia: Dysphasia or aphasia is a disorder of language content of speech. It can occur with lesions over a wide area of the dominant hemisphere. The term, *aphasia*, rather than *dysphasia* is preferred term to be used to designate any degree of spoken language deficit. Aphasia is detected by the patient inability to produce the correct word (*anomia*). When patients are asked to name objects or parts of objects, if *anomia* is present either no word will be produced or the wrong word or a nonsense word will be produced (paraphasia). Two common types of aphasia (Broca's and Wernicke's) are compared in the Table 15.10.

Conduction dysphasia is produced by lesions involving the association fibres (arcuate fasciculus) between Broca's and Wernicke's areas. In this disorder, the patient is unable to repeat phrases or chords spoken by the examiner.

Global aphasia: Patients with large lesions in middle cerebral artery territory over which speech areas are not testable or there are elements of both anterior (Broca) and posterior

(Wernicke) dysphasias are said to have "global aphasia". Such patients have no language production.

Speech Disorders

Apraxia

The term '*apraxia*' means inability to perform certain acts or movements when asked to do so. Before testing apraxia, make sure that there is no sensory or motor deficit or ataxia. This can be tested by asking the patient to use objects to make or initiate certain movements. For instance, when given a pen and asked to write with it, the apraxic patient may fail to open the pen or to write with it or may show an inability to recognise the end to be used for writing. It is important to be sure that patient understands the command.

Apraxia results from damage to either the dominant hemisphere (left parietal cortex) or to parietal white matter of left or of both hemispheres, or from the disease of association fibres through the corpus callosum. When corpus callosum is involved, apraxia is limited to left side since the dominant left hemisphere has been disconnected from right side, but usually it is more commonly a bilateral disorder.

The different types of apraxia are:

- **Dressing apraxia** (Inability to dress when asked to put on clothes)
- **Gait apraxia** (Inability to walk though patient has normal leg movements while in bed)
- **Ideomotor apraxia** (Inability to perform movements on command although he/she performs those movements automatically)
- **Constructional apraxia** (Inability to copying designs/figures etc.)

Dyslexia means difficulty in reading despite conventional instruction adequate intelligence and opportunity to learn.

Examination of Neck and Cervical Spine Movements

The examination of neck has been dealt at different places, i.e. general physical examination (Chapter 8), cardiovascular system (Chapter 11) and locomotor system examination (Chapter 17).

In neurology, the neck is tested for active and passive movements especially flexion and side rotation. The cervical movements are restricted in degenerative arthrosis of cervical spine (cervical spondylosis), a common disorder in the middle-aged and elderly. In addition to neck pain, stiffness and restricted movements are also present. These patients may develop radicular symptoms and long tract signs due to compression (spondylotic myelopathy). The neck movements have been discussed under testing of neck muscles.

Signs of Meningeal Irritation

In patients suspected of meningitis (e.g. fever, disturbed consciousness, neck stiffness), the following signs may be elicited:

- Neck stiffness (rigidity)
- Kernig's sign
- Brudzinski's sign

Neck stiffness is not specific to meningitis, indicates spasm of the paravertebral muscles, may be seen in cervical spine disease or meningeal irritation (e.g. inflammation of the meninges in meningitis or irritation of the meninges by blood in subarachnoid haemorrhage). Neck stiffness is a protective mechanism, occurs to reduce the pain during neck flexion in conscious patients, therefore, is lost in patients with deep coma. The neck stiffness occurs both in meningitis and meningism (Table 15.11).

Neck stiffness, Kernig's and Brudzinski's signs occur due to protective muscular spasms, are lost in patients who lapse into deep coma or may not present in the early evolution of meningitis or subarachnoid haemorrhage.

TABLE 15.11 Difference between meningism and meningitis	
Meningitis	Meningism
• Neck pain and rigidity both present	Only neck rigidity
• Kernig's sign more pronounced	Less pronounced
• Convulsions and coma common	Rare
• Cranial nerve palsies common	Rare
• Turbid CSF with cellular changes	Clear CSF with no cellular change

Method

- **Neck stiffness:** Ask the patient to lie supine and to relax the head onto a single pillow.
 - Support the occiput with both hands and gently flex the neck until chin touches the chest (Fig. 15.18)

Neck rigidity or stiffness is said to be present if bending of neck produces pain and spasm of the neck muscles or it may be difficult to bend the neck or bending of neck produces lifting of the whole body like a log of wood.
- **Brudzinski's sign:** As you flex the neck to test neck stiffness, watch the hips and knees in reaction to this manoeuvre. Normally they remain relaxed and motionless. In meningitis, there will be reflex flexion of hip or knee on one side or both sides. Similarly while flexing the thigh of one limb (leg sign) there is reflex flexion of other thigh to overcome pain in meningitis.
- **Kernig's sign** (Figs 15.19A and B)
 - Ask the patient to lie supine with both legs exposed and fully extended.
 - Passively flex one leg at the hip and the knee.
 - Now passively extend the knee while keeping the hip in flexion (Fig. 15.19A). Observe the other limb for

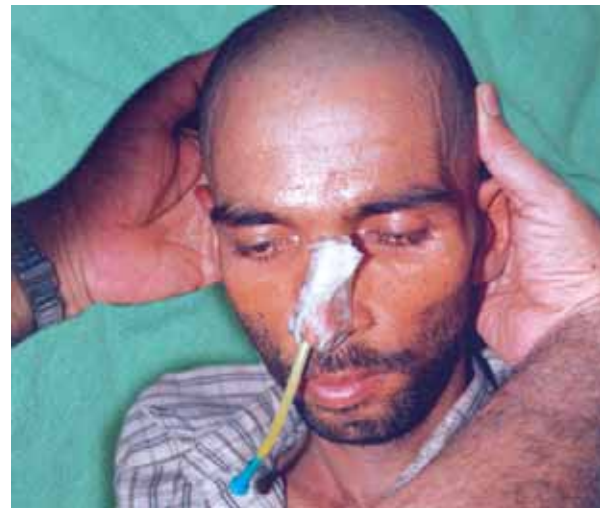
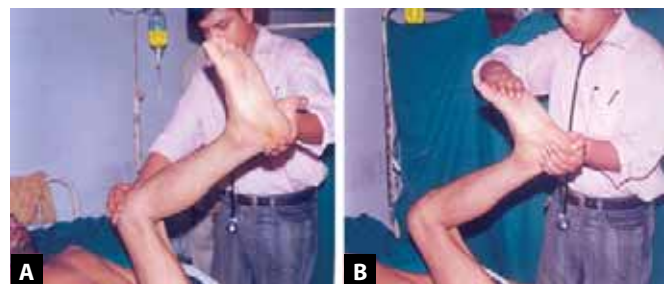
FIGURE 15.18 Method to test the neck stiffness



FIGURES 15.19A and B Testing for Kernig's sign

reflex flexion—the Kernig’s sign (positive sign means reflex flexion of opposite limb).

- Pain and increased resistance to extending the knee or flexion of the opposite limb indicate meningeal irritation.
- If conventional Kernig’s sign is negative, you can further augment it by dorsiflexing the foot (Fig. 15.19B) and observing for the similar response. In some cases this manoeuvre may cause positive Kernig’s sign.

Examination of Gait and Balance

Before starting the formal neurological examination it is often possible to obtain a useful information by observing the patient’s gait and balance. Additional information can be obtained from general physical examination.

Observe the patient’s gait, posture, balance as soon as he/she walks across the room to come for examination. Analysis of patient’s gait is an important element of disability. Patterns of weakness, lack of co-ordination and loss of proprioceptive sensations produce a range of abnormal gaits. Neurogenic gait disorders need to distinguished from skeletal disorder, the latter are usually characterised by pain producing an antalgic gait or limb.

As the gait depends on the muscle tone and co-ordination, hence, its examination is discussed under motor system examination.

Examination of Cranial Nerves

The olfactory (first) cranial nerve

It is concerned with sense of *smell* which is carried through sensory fibres from the nose (olfactory epithelium) to the olfactory bulb through the cribriform plate and subsequently relayed in the olfactory area of the cerebral cortex, the uncus and parahippocampal gyrus. Thus, in temporal lobe epilepsy (uncinate fits), hallucinations of smell constitute an *aura*.

Testing the Sense of Smell (Fig. 15.20)

- First of all, check that nasal passages are clear
- Each nostril is to be tested separately
- Occlude each nostril by gentle pressure
- Ask the patient with eyes closed to sniff and identify in turn the test substances
- Use familiar and nonirritating odours. Commonly used test substances include vials of peppermint, vanilla, coffee, almond oil. Common bedside substances such as *soap, fruit or scent* can be used.

A normal person perceives odour on each side, and can identify it.

Abnormalities

Anosmia means loss of sense of smell, can occur normally due to obstruction of nasal passage (e.g. catarrh), hence,

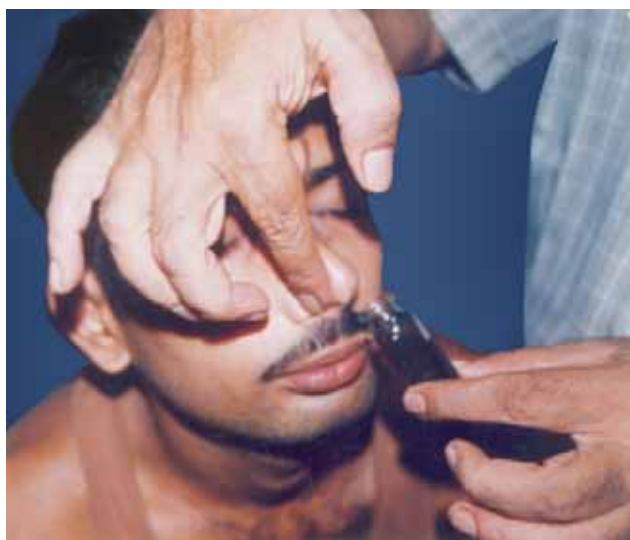

FIGURE 15.20 Testing for the sense of smell

must be excluded before labelling it to be due to neurologic cause.

The causes of anosmia are:

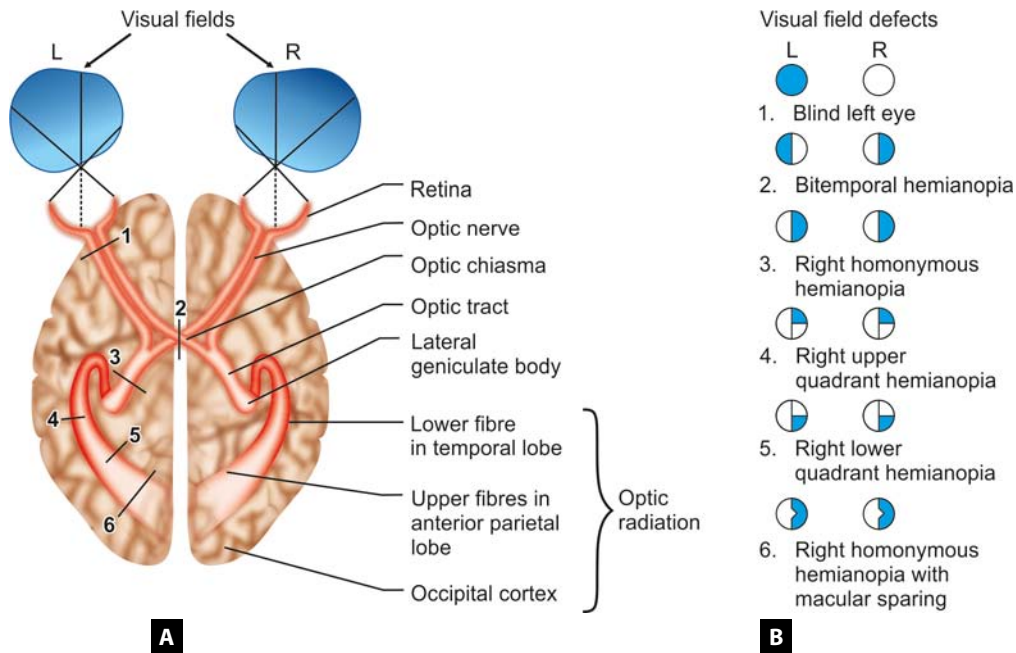
- Smoking, ageing and use of cocaine
- Trauma or head injury causing damage to cribriform plate and subsequently the olfactory tract
- Nasopharyngeal tumour (meningioma of olfactory groove)
- Carcinoma of paranasal air sinus
- Kallmann’s syndrome (hypogonadotropic hypogonadism).

Parosmia refers to perversion/alteration of smell, i.e. pleasant odours seem offensive. It is sometimes of psychological origin but may occur following partial recovery of olfactory nerve from trauma. Certain drugs and sinus infection can cause it.

NB: Olfactory hallucinations are characteristic of temporal lobe epilepsy, are often associated with involuntary smacking movements of lips and unusual feelings in the epigastrium.

The optic (second) cranial nerve

The optic nerves consist of axons of retinal ganglion cells, begins at the back of eye globe and each passes through the optic canal of the sphenoid bone to meet the opposite optic nerve to form optic chiasma. In the optic chiasma, the fibres from the medial half (nasal half) of each retina representing the temporal field cross; while those from the lateral (outer) half representing the nasal field remain on the same side. In this way, a optic tract consisting of fibres from outer half of the retina on the same side and inner half of the retina of opposite side is formed. Each optic tract then passes posteriorly to the lateral geniculate bodies of the same side. The optic radiation starts from the lateral geniculate bodies to the thalamus on



FIGURES 15.21A and B Visual pathways (A) and visual field defects (B). Read the description from Table 15.12

each side, passes through the posterior limb of the internal capsule and project to primary visual cortex (calcarine cortex) in the occipital lobe. The fibres representing the upper visual fields pass through the white matter of the temporal lobe; whilst those representing the lower field pass through the parietal lobe. In this way, the left half of the field of vision is represented in the cortex of the right hemisphere and vice versa (Figs 15.21A and B).

The impulses from the two homologous fields of the two eyes are represented in adjacent columns of neurons. The most peripheral part of the visual fields is represented anteriorly and macular field in the occipital hole.

Visual field defects are called *homonymous* if the same part of the visual field is affected in both the eyes. The lesions distal to optic chiasma produce *homonymous field defects*. The field defect may be *hemianopic* (i.e. one half of the visual field is lost) or *quadrantropic* (one quadrant of the visual field is lost). Such field defects may be upper or lower depending on the fibres affected. If the visual field loss is not identical in both eyes, it is termed *incongruous*, this type of defect is seen in lesions of the optic tract. Homonymous hemianopia due to occipital lobe lesion tends to spare the central part of vision (*macular sparing*). When sensory inattention is present, the patient will be able to detect single targets on both sides but will ignore objects on one side when two fields are stimulated simultaneously.

Testing of Second Nerve

The visual acuity and visual fields must always be tested. Other aspects of visual perception including colour vision,

visual localisation and visual recognition may also be tested if appropriate. It is hereby stressed that while testing the second nerve for vision, any refractory error if present must be corrected and there should not be any evidence of other ocular disease that might impair vision. Each eye must be tested separately.

- Visual acuity
 - Colour vision
 - *Pupillary reflexes* (read examination of eye)
- Read Chapter 3

Testing for the Field of Vision

The visual field means the extent of the vision when we look at an object. This field is limited both by area of retina and by the margins of the orbit, nose and the cheek. Therefore, to test the field of vision, the position of the eye carry utmost significance. The extent of field of vision varies as follow:

- Larger the stimulus used the larger is the field of vision and vice versa.
- Bright illuminated objects have larger field than dim object.
- Moving objects used for field of vision are better perceived than stationary objects.

The visual field can be assessed by many methods but the simplest and the best though gives a rough estimate is *confirmation method* (Fig. 15.22). This method tests the field of vision of the patient with that of examiner, hence the field of vision of the examiner should be normal. Both eyes are tested together for binocular vision and test each eye separately for

TABLE 15.12 Clinical manifestations of visual field loss

Site	Causes	Symptoms	Visual field loss	Associated physical signs
Optic disc	<ul style="list-style-type: none"> • Vascular disease (vasculitis) • Glaucoma • Inflammation 	Partial or complete loss of vision depending on site	<ul style="list-style-type: none"> • Altitudinal field defect • Arcuate scotoma 	<ul style="list-style-type: none"> • Reduced acuity • Visual distortion • Abnormal retinal appearance
Optic nerve (1)	<ul style="list-style-type: none"> • Optic neuritis • Sarcoidosis • Tumour • Leber's optic atrophy 	Partial or complete visual loss in one eye Often painful eye Central vision particularly affected	<ul style="list-style-type: none"> • Central scotoma • Paracentral scotoma • Unilateral blindness 	<ul style="list-style-type: none"> • Reduced acuity • Reduced colour vision • Loss of direct light reflex • Optic atrophy may be seen
Optic chiasma (2)	<ul style="list-style-type: none"> • Pituitary tumours • Craniopharyngioma • Sarcoidosis 	<ul style="list-style-type: none"> • May be none • Rarely diplopia 	Bitemporal hemianopia	Pituitary function abnormalities
Optic tract (3)	<ul style="list-style-type: none"> • Tumour • Inflammatory disease 	Disturbed vision to one side of midline	Incongruous contralateral homonymous hemianopia	
Temporal lobe (4)	<ul style="list-style-type: none"> • Stroke • Tumour • Inflammatory disease 	Disturbed vision to one side of midline	<ul style="list-style-type: none"> • Contralateral homonymous upper quadrantanopia 	Memory/language defect
Parietal lobe (5)	<ul style="list-style-type: none"> • Stroke • Tumour • Inflammatory disease 	<ul style="list-style-type: none"> • Disturbed vision to one side of midline. Bumping into things 	<ul style="list-style-type: none"> • Contralateral homonymous lower quadrantanopia 	<ul style="list-style-type: none"> • Contralateral sensory disturbance • Optokinetic nystagmus
Occipital lobe (6)	<ul style="list-style-type: none"> • Stroke • Tumour • Inflammatory disease 	<ul style="list-style-type: none"> • Disturbed vision to one side of midline. Bumping into things • Reading difficulty 	Homonymous hemianopia with macular sparing	Damage to other structures supplied by posterior cerebral circulation

monocular vision so as to exclude a field defect involving a part of the visual field of one eye only.

Method (Fig. 15.22)

- Sit in front of the patient at one meter distance.
- To test the right eye of the patient, ask him/her to close his/her left eye with the left hand, and look steadily at your left eye.
- Cover your right eye with your right hand and look steadily at patient's right eye.
- Hold your left hand to the side at an arm's length in a plane midway between patient and yourself.
- Keep moving the index finger of left hand and bring it nearer until you yourself can see its movements. Now ask the patient whether he/she also sees the movements, making sure at the same time that patient is steadily fixing the gaze on your eye.
- If the patient is unable to see the finger, keep bringing it nearer until he/she does see it.
- Test the field in this way in every direction, i.e. upwards, downwards and sideways (right and left) using the extent of your own field for comparison.



FIGURE 15.22 Testing of visual field (confrontation methods)

- Map out peripheral fields by moving the finger across the visual field.
- *Red pin test*: This outlines the central field. This test can be performed by using a red pinhead held up in the field of vision of the patient in the same manner as described above. A central scotoma (central area of impaired vision) can be recognised by this method because the

red or white pinhead cannot be perceived in the area of impaired vision (scotoma). This method allows the patient's field as well as the size of the physiological blind spot to be compared precisely with the examiner field. A good rough method used in preliminary assessment is to ask the patient to compare the contour and colour of the palm of the examiner's hand held up in the right, left and central fields of each eye separately.

The normal binocular visual field extends 160° horizontally and 130° vertically with a blind spot 15° from fixation in the temporal field.

The physiological blind spot is situated on the temporal side of the central point of the visual field. It corresponds to the point of entry of optic nerve into the retina (optic disc) found slightly to nasal side of the macula when seen with ophthalmoscope. The blind spot sometimes appears to be absent in an uncooperative patient or if the patient is attempting to mislead the examiner. Defects in the visual field are described as central or peripheral. A scotoma is a field defect surrounded by a seeing area.

The causes of visual field defects include: glaucoma, retinitis pigmentosa, the age related macular disease, cerebrovascular disease, carotid vascular disease, brain tumours and trauma. Central scotomas involve fixation, occurs due to involvement of macula.

Ring scotomas are characteristics of retinitis pigmentosa (Laurence-Moon-Biedl syndrome)

Arcuate scotomas are diagnostic of glaucoma.

Altitudinal of hemianopia is loss of upper or lower field in one eye, common in vascular disease of the optic nerve.

Perimetry

It means mapping out of field of vision by perimeter as a permanent record. Several types of perimeters are available which utilise the same principle. The patient is seated comfortably with chin placed on a chin rest adjusted so that the eye under test is oriented at the centre of hemispherical, lighted field upon which spots of lights of varying intensities, colours or sizes are projected or moved so as to detect the limits of the field and its intensity in various parts. In sophisticated modern perimeter, the examiner can see the patient's eye in order to detect any movement of the patient's eye away from fixation on the central point of hemispheric field. Simple perimeter consists only of a hemisphere arm along which stimulus is moved by a mechanical method. Stationary, rather than moving, targets can be used for perimetry in the control field, using special perimeters with targets of variable luminance.

Perimetry charts out the limits of perception, hence, surveys the monocular field of vision. The central point on the chart corresponds to the point of fixation (Fig. 15.23). Around this point are arranged a series of more or less concentric lines each of which denotes equal visual acuity—an isopter.

Since the fixation point is not exactly central, hence the outer and inner fields are unequal. With an object of 5 mm

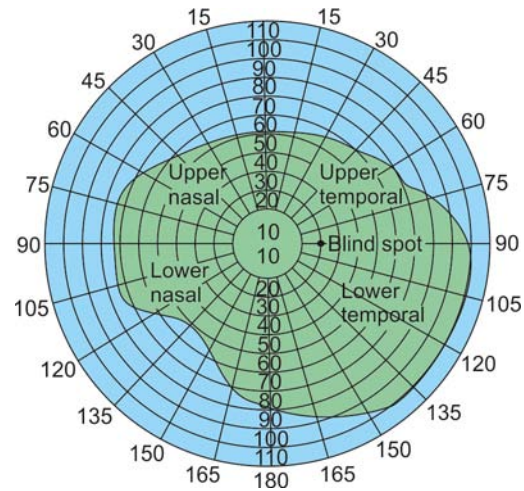


FIGURE 15.23 The normal right field of vision using a white object of 5 mm diameter. The field is mapped out on a perimeter at a distance of 330 mm. Note the restriction of lower nasal field by the bridge of nose

diameter, the extent of average field of vision is 100° laterally, 60° superiorly and medially and 75° inferiorly. The field chart is depicted in the Figure 15.23.

The area within 30° from fixation is tested either with a sophisticated perimeter having first corrected any refractory error with lenses or by presenting objects against a 2 m² well-mounted black screen (Bjerrum's screen) at a distance from the patient of 1 or 2 meters. In the latter method the patient is sealed comfortably with head and chin on the head rest while object of 1 cm in diameter is fixed to the screen on a level with the patient's eye. The blind spot is mapped out first using a white object of 10 mm; at a distance of 2 m the field should be round or circular and extend to about 25° to the edge of 2 m² screen. With a smaller or red object areas of blindness or defective perception should be sought around the blind spot especially between this area and the macula (the centrocaecal area), and in horizontal meridian which subsequently is transformed to a chart for recording in the patient's history sheet.

The visual pathways and their field defects have already been depicted in Fig. 15.21.

The oculomotor (III), the trochlear (IV) and the abducens (VI) cranial nerves

The 3rd, 4th and 6th cranial nerves are called motor nerves for eye movements and also control the size of the pupils.

The Third Nerve

The oculomotor (III) nerve nucleus lies in the midbrain anterior to the preaqueductal gray matter. The nerve passes between the cerebral peduncles, then come in close contact with posterior communicating artery and enters the lateral wall of cavernous sinus. It then enters the orbital fossa

through the *superior oblique fissure* where it subdivides into its terminal branches. The nerve innervates the *superior rectus* (SR), *medial rectus* (MR), *inferior rectus* (IR), the *inferior oblique* (IO) and *levator palpebral superioris muscles* (LPS). These muscles open the upper lid (LPS), move the eyeball upwards (SR, IO), downwards (IR) and medially (MR).

The parasympathetic fibres of the 3rd nerve arise from the *Edinger-Westphal nucleus* (rostral part of main 3rd nerve nucleus) and supply the sphincter muscles of the iris which cause constriction of pupil, and the ciliary muscle, which is responsible for focusing the lens for near vision.

The Fourth Nerve

The trochlear (4th) nerve arises from the nucleus in the caudal midbrain. The fibres decussate before leaving the midbrain just below the inferior colliculus. The nerve passes forward and laterally in relation to the rostral pons. It comes out of the free edge of tentorium and enters the cavernous sinus and then pass forwards to superior oblique fissure to enter the eye where it innervates the superior oblique (SO) muscle, contraction of which causes downward movement of the eyeball. Tilt the head to same side, the affected eyeball will intort if 4th nerve is intact.

The Sixth Nerve

The abducens (6th) nerve originates from the nucleus situated in the midline in the caudal part of the pons. It hooks around the facial nerve nucleus and comes out between medulla and pons. It has a long intracranial course, hence, is liable to get compressed under the effect of raised intracranial pressure producing diplopia on lateral gaze. After exit from the pons, it enters the cavernous sinus and lies in direct relation to the internal carotid artery before it enters the eye through superior oblique fissure to supply the lateral rectus (LR) muscle, the contraction of which causes abduction of the eye.

The ocular motility is dependent on:

- **Integrity of 3rd, 4th and 6th cranial nerves.**
- **Medial longitudinal fasciculus (MLF)** which interconnects the nuclei, also receives impulses from the vestibular nuclei, cerebellum and para-abducens nucleus—also called *the nucleus of the paramedian pontine reticular formation (PPRF)*. The MLF lies in the brainstem, provides a mechanism by which the optical axes remain parallel or conjugate when the eyes are turned to one side or when there is movement of the head.
- **Supranuclear connections (Fig. 15.24):** These connections control the upward, downward and lateral gaze. The

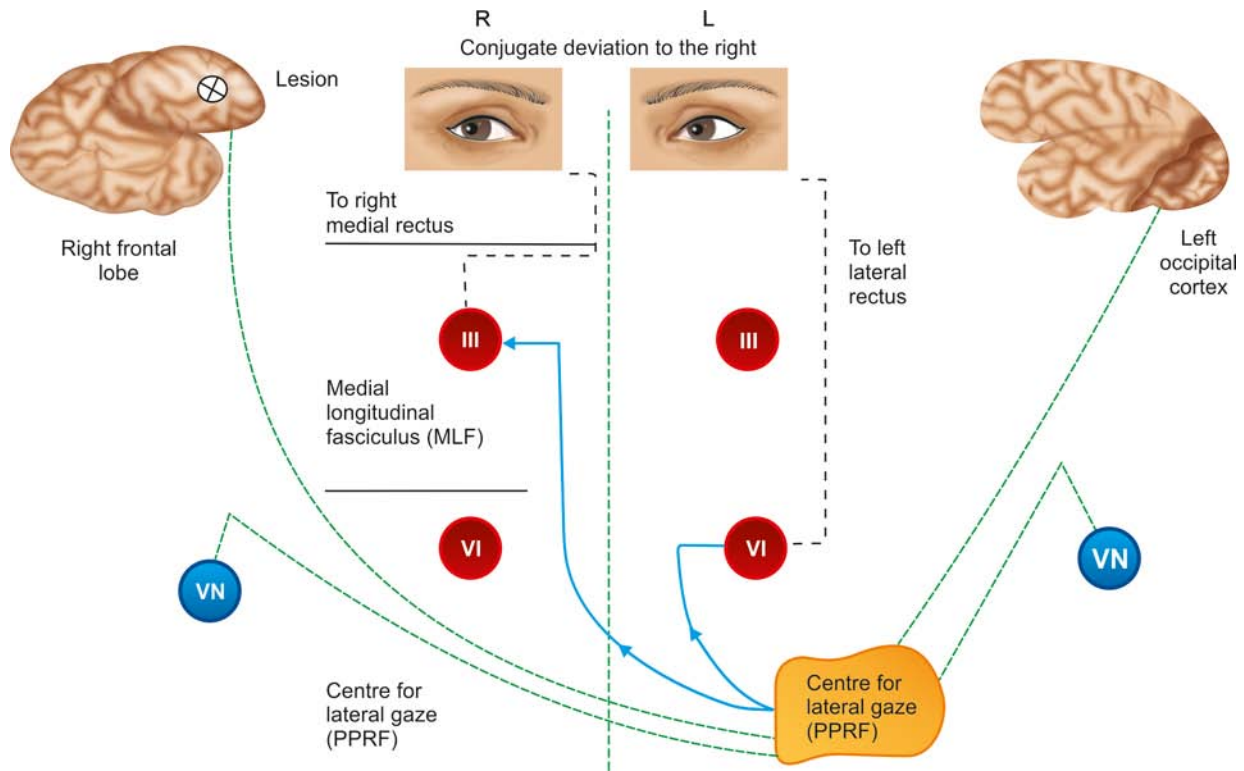
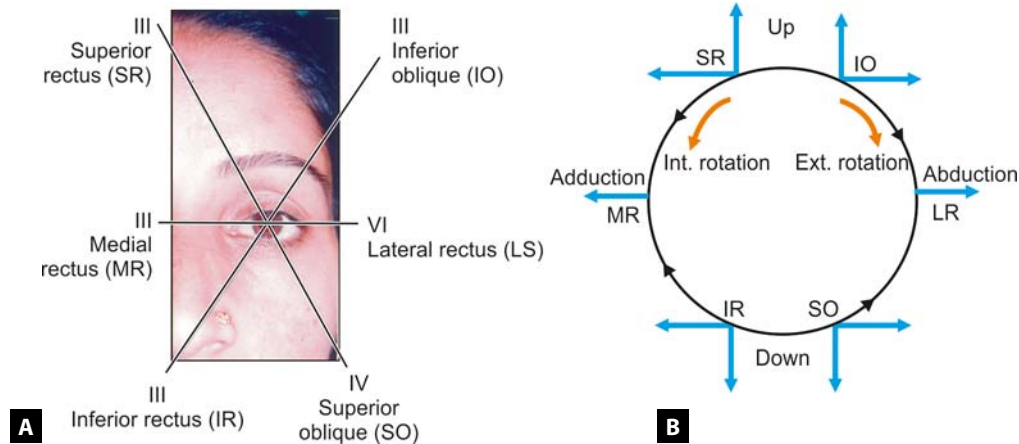


FIGURE 15.24 Conjugate lateral gaze (A) Central pathway (diagram). Impulses from right frontal cortex drive the left centre for lateral gaze situated in paramedian pontine reticular nuclei (PPRN) and also from the occipital cortex and vestibular nuclei. Destructive frontal lobe lesion produces conjugate deviation of eyes to the side of lesion, because impulses thus generated from one side of cortex for lateral gaze pass to both ipsilateral VI nerve nucleus and contralateral 3rd nerve nucleus through medial longitudinal fasciculus



FIGURES 15.25A and B Functions of external ocular muscles (left eye). The superior rectus and inferior rectus act as elevator and depressor alone when eye is in abduction and inferior oblique and superior oblique act in similar way when the eye is in adduction

gaze means movement of both the eyes in one direction (conjugate gaze). The involvement of these connections leads to paralysis of conjugate gaze.

Sympathetic fibres which dilate the pupils and innervate the LPS also, arise as preganglionic fibres from the hypothalamus. They pass through the brainstem to emerge through the ventral roots of the first 2 or 3 segments of thoracic spinal cord and ascend through the sympathetic chain to the superior cervical ganglion. Post-ganglionic fibres ascend in carotid neural plexus and pass through the cavernous sinus into the orbit with the ophthalmic artery to terminate in the dilator muscle of the pupil. In the area 8 of the frontal lobe, there is frontal eye field (FEF). When this area is stimulated, the eyes turn conjugately away from the side of stimulation.

Testing of Ocular Movements

The six external ocular muscles move the eyeball in different directions (Figs 15.25A and B).

Method

- Inspect the eye for any abnormality
- Hold the head of the patient in neutral position and test for ocular movements with both the eyes open
- Look for squint and nystagmus
- Test the movement by asking the patient to look up and down and to the right and left from the mid-position of gaze. Test the up and down movements in full adduction and in full abduction also.

The eyes normally move 50° medially, 30° upwards and 50° downwards.

- Now ask the patient to fix gaze on the examiner's finger and to report if double vision occurs while following the movement of the finger held at 60 cm away.

- Move the finger up and down, then to the right and up and down, and then to the left and up and down. If necessary, repeat the examination, one eye at a time, to distinguish muscle paralysis and gaze paralysis.
- Record the direction of diplopia if present and where maximal separation of the images occurs.
- If diplopia is present, ask the patient to close one eye at a time to identify which eye is producing the false image.
- To test convergence, bring the finger from a distance towards the tip of the nose and ask the patient to focus on it.
- Look for nystagmus while testing the ocular movements.
- Record the direction of nystagmus (vertical, horizontal, rotatory) and the direction of gaze in which it is most marked.
- Note the direction of fast component of nystagmus, whether it changes direction with direction of gaze and whether the degree of nystagmus is different in each eye.

Common Abnormalities

Abnormalities of palpebral fissures

Normally the palpebral fissures are symmetrical.

Narrowing of the palpebral fissure occurs due to ptosis (3rd nerve palsy or Horner's syndrome) or due to local lid disorders (Box 11).

Widening of fissures occur in Grave's disease or exophthalmos due to any cause.

Inequality of size of pupils (anisocoria)—Read Examination of the Eyes (Chapter 5).

Disorders of ocular movements: There are many neurological causes of disordered eye movements such as ocular myopathies and diseases of myoneural junction (myasthenia gravis), metabolic encephalopathies (toxicity of phenytoin and carbamazepine). The classification of disorders of ocular

movements based on the type of neurological involvement is given in the Table 15.13 and causes of 3rd, 4th and 6th cranial nerve involvement are depicted in Table 15.14.

Third nerve palsy (Figs 15.26A to C): It produces:

- **Unilateral ptosis:** It means drooping of the upper eye lid on the side involved due to paralysis of levator palpebral superioris leading to narrowing of palpebral fissure.
- **Dilated and fixed pupil** on the side involved due to involvement of parasympathetic fibres.
- **External strabismus:** The eye is displaced downward and laterally due to paralysis of superior, medial and inferior recti and inferior oblique. Only movements possible are lateral (due to intact lateral rectus) and downward (due to intact superior oblique).

Box 11

Causes of ptosis

<i>Unilateral</i>	<i>Bilateral</i>
<ul style="list-style-type: none"> • Third nerve palsy • Horner's syndrome • Congenital • Myasthenia gravis • Lid disorders 	<ul style="list-style-type: none"> • Myasthenia gravis • Dystrophic myotonia • Ocular or oropharyngeal myopathy • Tabes dorsalis, syringomyelia • Snake bite

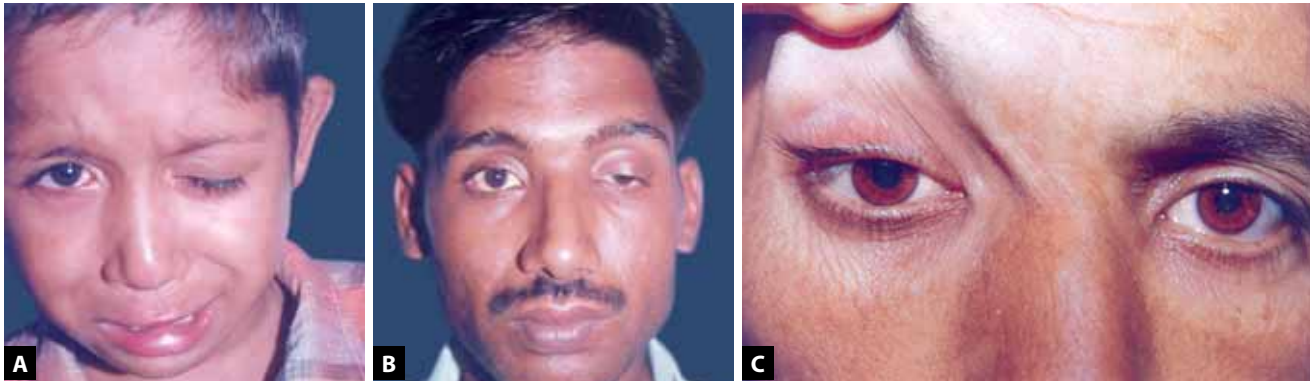The common causes of an isolated 3rd nerve palsy include: diabetes, posterior communicating artery aneurysm, pituitary or other tumours, trauma and vascular disease. The third nerve lesion may be incomplete depending on the location and type of lesion. Lesions due to diabetes or vascular disease tend not to involve the pupil, in contrast to compressive lesions (e.g. aneurysm).

TABLE 15.13 Classification of disorders of eye movements based on the site of neurological involvement

- Nuclear and infranuclear lesions (individual nerve paralysis)
 - 3rd nerve palsy
 - 4th nerve palsy
 - 6th nerve palsy
- Supranuclear lesions (above the brainstem or cerebellar or basal ganglia lesion)
 - Conjugate gaze palsy
 - Lateral gaze palsy
 - Upward gaze palsy
 - Downward gaze palsy
 - Internuclear gaze palsy
 - Complex supranuclear gaze palsies
 - Convergence nystagmus
 - Cerebellar diseases
 - Nystagmus
 - Basal ganglia lesions
 - Slowed and interrupted smooth pursuit movements

TABLE 15.14 The site, pathology and associated features of 3rd, 4th and 6th nerve palsies

<i>Site</i>	<i>Common pathology</i>	<i>Nerve(s) involved</i>	<i>Associated features</i>
Brain stem	Infarction	3rd (mid-brain)-Weber's syndrome	Contralateral pyramidal signs
	Haemorrhage	6th (ponto-medullary junction)	Ipsilateral lower motor neuron 7th palsy (ponto-medullary junction)
	Demyelination Intrinsic tumour	Millard-Gubler-Foville syndrome	Other brain-stem/cerebellar signs
Intracranial course	Meningitis (infective/malignant)	3rd, 4th and/or 6th	Signs of meningitis
	Raised intracranial pressure	3rd (uncal herniation)	Signs of raised ICT
	Aneurysms	3rd (posterior communicating artery)	Pain
	Cerebello-pontine angle tumour	6th (basilar artery)	Features of subarachnoid haemorrhage
Superior orbital fissure	Tumour (e.g. sphenoid wing meningioma), Granuloma	3rd, 4th and/or 6th	8th, 7th, 5th nerves involvement
	Infection/thrombosis	3rd, 4th and/or 6th	Ipsilateral cerebellar signs
	Carotid artery aneurysm	3rd, 4th and/or 6th	Other features of trauma
Orbit	Corticocavernous fistula	(see Fig. 15.16)	May be 5th cranial nerve involvement also
	Tumour (e.g. sphenoid wing meningioma), Granuloma	3rd, 4th and/or 6th	Pupil may be fixed, mid-position (sympathetic plexus on carotid may also be affected)
Orbit	Vascular (e.g. diabetes, vasculitis)	3rd, 4th and/or 6th	May be proptosis, chemosis
	Infections	3rd, 4th and/or 6th	Pain
	Tumour	3rd, 4th and/or 6th	Pupil often spared in vascular 3rd nerve palsy
	Granuloma	3rd, 4th and/or 6th	
Orbit	Granuloma	3rd, 4th and/or 6th	
	Trauma	3rd, 4th and/or 6th	



FIGURES 15.26A to C Left third cranial nerve palsy: (A) Complete: Note the marked ptosis producing closure of the eye; (B) Partial: There is drooping of upper eyelid covering a part of cornea; (C) The ptosis is true (eyelid can not be lifted completely due to right 3rd nerve palsy)

Fourth (trochlear) nerve palsy: It produces:

- **Impaired downwards movement:** On attempting to look downwards in mid-position of gaze the eyeball is rotated outwards by the unopposed action of inferior rectus.
- **Diplopia** is the main complaint particularly on looking down and during reading. There is rarely a visible squint. The patient will often adopt a compensatory head tilt away from the side of the lesion.

Isolated lesions of 4th nerve palsy are uncommon and include diabetes, hypertension, and head trauma. Damage to the nerve may occur in superior oblique tendon through which it passes following head injury, ENT surgery and in patients with rheumatoid arthritis.

Sixth (abducens) nerve (Fig. 15.27) palsy: It produces:

- **Inability to move the eye outwards** (laterally) and diplopia (double vision) occurs on looking laterally.
- **Convergent squint** visible because of unopposed action of the medial rectus innervated by 3rd nerve.

Isolated 6th nerve palsy is common due to its long intracranial course (a false localising sign, i.e. the nerve is displaced or compressed without actual involvement). The paralysis may be complete or partial. The common causes include, head injury, diabetes, chronic SOM (Gradenigo's syndrome).

The 6th nerve palsy may be a false localising sign in raised intracranial pressure due to any cause.

As already discussed, in addition to isolated lesions, the 3rd, 4th and 6th cranial nerve may be involved in combinations (Table 15.14) and are usually associated with other features.

Supranuclear 3rd, 4th and 6th Nerve Lesions

- **Conjugate gaze paralysis:** Normally the movements of the two eyes are symmetrical, so that the visual axes meet at a point of fixation of the eyes. This is called *conjugate*

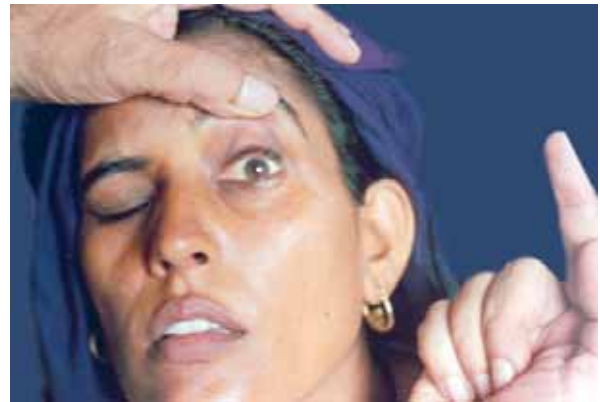

FIGURE 15.27 Abducens nerve (VI CN) palsy on left side. Note that left eye can not be abducted beyond midline

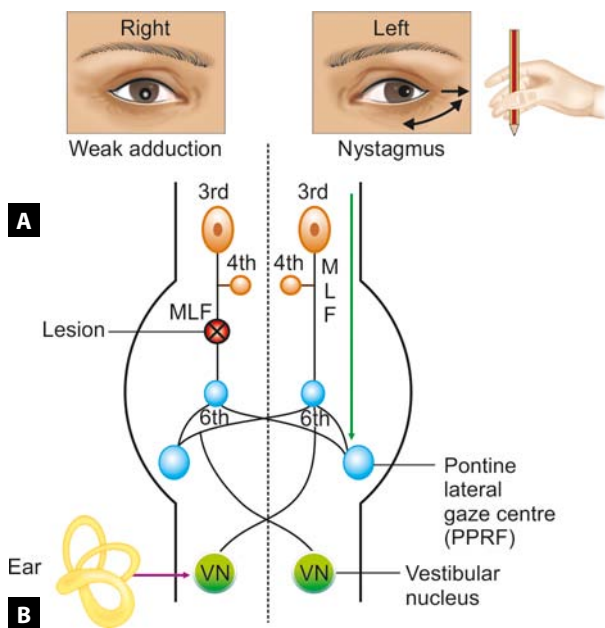
ocular movements. Supranuclear (upper motor neuron) lesions leads to paralysis of conjugate movement of the eyes. The causes of gaze palsy are given in the Box 12.

- **Other saccadic and pursuit gaze movements:** The *saccadic* (rapid, programmed conjugate fixation movements) and *pursuit* (following) gaze movements can be tested separately by asking the patient to move his/her eyes rapidly from fixation on one finger to another held about 30° away in horizontal plane and by asking him/her to follow a slowly moving finger across visual space in the same or in the vertical plane. In *Huntington's Chorea* and *Parkinsonism*, pursuit movements are slowed or interrupted by slowed saccades.
- Optokinetic system involves restoration of gaze despite movements from the outside world, e.g. when a subject is sitting in a train and looking out of window, the eyes move slowly as the train moves, to be followed by a rapid corrective movement back to initial position of gaze. Vestibulo-ocular reflex eye movements (Doll's head manoeuvre) are preserved in supranuclear palsy. Coloric test is used to test vestibulo-ocular reflex.

Box 12

Common causes of gaze palsy

Gaze palsy	Causes
• Upwards and downwards gaze	• Space occupying lesions around the pineal gland and tectal region • Aqueductal stenosis
• Upwards and downwards gaze with Parkinsonism or dystonia	• Hydrocephalus
• Failure of upward gaze with loss of light reflex but preservation of accommodation reflex	• Steele-Richardson-Olszewski syndrome • Parinaud's syndrome (e.g. lesion of pineal gland or ventral midbrain)
• Lateral gaze	Lesions of frontal eye field (FEF) in pons. – Destructive lesions (haemorrhage) cause conjugate eye deviation towards the side of lesion (patient looks towards his lesion) – Irritative lesions (e.g. epileptic fit) cause deviation of eyes and head opposite to the side involved (healthy side)
• Internuclear ophthalmoplegia (Figs 15.28A and B)	Lesion of the <i>medial longitudinal fasciculus</i> (MLF) in the midbrain or upper pons. On attempting lateral gaze to one side there is weakness of adducting eye (3rd nerve involvement) and nystagmus of abducting eye. Causes include multiple sclerosis, vascular disorders, inflammatory lesion and tumours of the brainstem and drugs (phenytoin)
• One-and-a-half syndrome	A lesion involving the PPRF (parapontine reticular formation) and the MLF on the same side. There is failure of lateral conjugate deviation in one eye and adduction of the same eye on the side of the lesion. There is nystagmus on abduction (lateral movement) of the opposite eye. Thus as the name indicates one eye will not move at all horizontally and the other eye only in abduction, i.e. one-and-a-half movements are paralysed



FIGURES 15.28A and B Right internuclear ophthalmoplegia: (Diagrammatic illustration). (A) On attempted lateral gaze to the left produces weak adduction of right eye and left abducting eye shows nystagmus. The lesion ⊗ lies in right medial longitudinal fasciculus (MLF). A lesion in or ear to the PPRF causes impaired conjugate lateral gaze to the same side; (B) Inter-connection of 3rd, 4th and 6th cranial nerves with the PPRF via MLF

- **Nystagmus:** Read Examination of Ear (Chapter 7).
- **Squint (Strabismus):** Read Chapter 5.

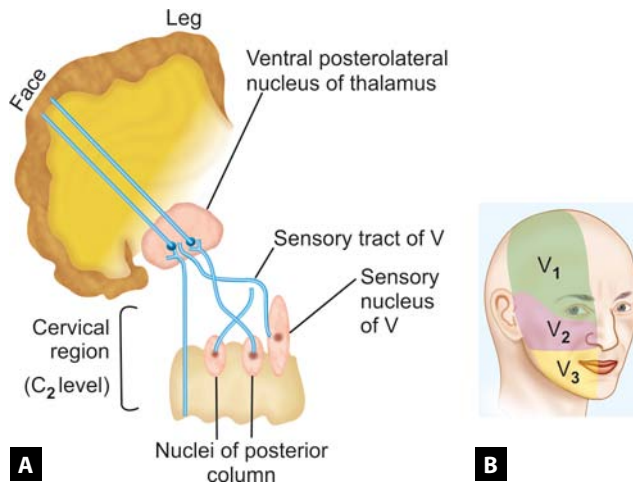
The fifth (trigeminal) cranial nerve

The trigeminal nerve is mainly sensory but contains motor fibres for muscles of mastication, hence, is a mixed nerve.

The *sensory root* takes origin from the nerve cells in the *trigeminal (Gasserian) ganglion* and enters the lateral surface of the pons at its middle. The principal sensory nucleus and the motor nucleus of the fifth nerve lie in the pons near the floor of the 4th ventricle; the sensory nucleus is lateral to motor and receives fibres for the sensations of touch, joint position sense and two point discrimination sense. An another sensory nucleus (bulbospinal nucleus or tract) extends from the pons through the medulla to second cervical segment (C₂) of the spinal cord before ascending in the medial lemniscus. This nucleus receives fibres for the sensation of pain and thermal sensation. Owing to inversion of the fibres going through this nucleus, the upper part of face is represented in the caudal part of nucleus (upside—down representation).

The motor fibres arise from the motor nucleus in the upper pons and join the mandibular branch to supply the muscles of mastication (masseter and pterygoid muscles).

Immediately distal to trigeminal ganglion, the nerve divides into three separate divisions (Figs 15.29A and B)



FIGURES 15.29A and B Fifth cranial nerve: (A) Sensory nucleus of Vth nerve extending upto C₂ (cervical cord); (B) Peripheral distribution of Vth nerve to the face

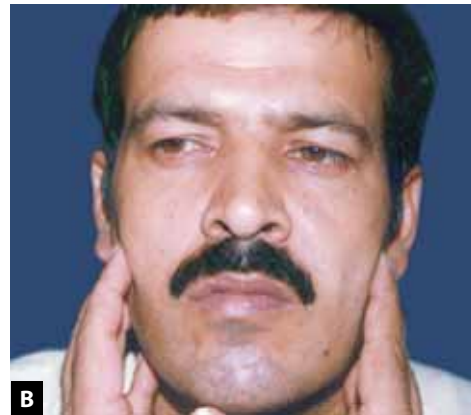
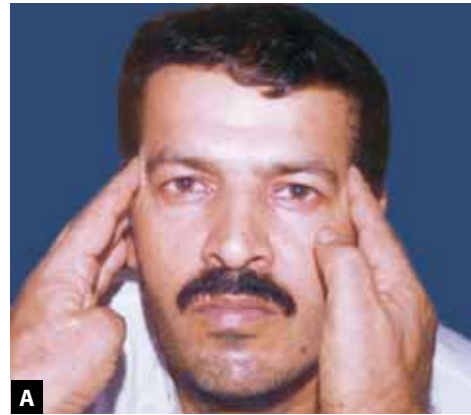through which sensations are transmitted from the face, mouth, lips, eyes, forehead and anterior part of the scalp as well as dura of the anterior and middle cranial fossae.

The first (ophthalmic) division after arising from *Gasserian ganglion* passes through the cavernous sinus and superior orbital fissure, supplies sensations to the skin of upper nose and eyelid, forehead and scalp (Fig. 15.30B) as well as the cornea, conjunctiva, lacrimal gland, parts of mucosa of the frontal, sphenoidal and ethmoidal sinuses and upper part of nasal cavity. The lesion of the ophthalmic branch results in loss of sensations from the areas described above. There is loss of corneal sensation and corneal reflex. Trophic changes in the cornea may develop in the lesion called *neuropathic keratitis*.

The second (maxillary) division (V₂) arising from the *Gasserian ganglion* comes out of the base of skull through foramen rotundum to supply the cheek, skin of temple, the side of nose, upper lip, mucous membrane of mouth, roof of pharynx, gums, teeth and palate of the upper jaw on same side. The lesion of this division leads to loss of sensations from the areas described above as well as loss of palatal reflex.

The third (mandibular) division (V₃) after arising from the *Gasserian ganglion* comes out of the skull through foramen ovale and supplies sensations to teeth and gums of the lower jaw, mucosa of cheek, floor of the mouth, anterior two-thirds of the tongue, temporomandibular joint, external and internal ear, and the skin of lower lip and jaw on the same side. It supplies the parasympathetic fibres to the salivary glands through its lingual branch to chorda tympani of VII nerve.

The motor branch of the 5th nerve passes through the mandibular division (V₃) and innervates muscles of mastication (the masseters, temporalis, medial and lateral pterygoids, the anterior belly of digastric) on same side. It also supplies the mylohyoid, tensor palatini and tensor tympani muscles.



FIGURES 15.30A and B Testing the motor part of Vth cranial nerve: (A) Palpation of both temporalis muscles for tone; (B) Palpation of both masseters for tone. Tone is tested during contraction of these muscles during clenching of teeth

Testing of the 5th Nerve

The sensations

The sensations from the peripheral parts supplied by the 5th nerve are tested in the usual way:

- Test light touch and pain sensation by using wisp of cotton wool and pin-prick respectively. The temperature sensation can be tested by using test tube containing warm and cold water.
- Two point discrimination on the upper and lower lips is tested by using calipers. Normally a separation of 3–4 mm can be detected.
- Check sensations in each divisions of the nerve separately comparing both the sides, i.e. the right with the left.

The motor function

- Inspect the muscles of mastication for wasting above zygomatic arch for temporalis and below for masseters.
- Palpate the masseters (Fig. 15.30A) and temporalis (Fig. 15.30B) for tone, bulk and symmetry as the patient clenches the teeth.
- Ask the patient to open the jaw against resistance (hand is placed below the jaw to resist opening). Difficulty

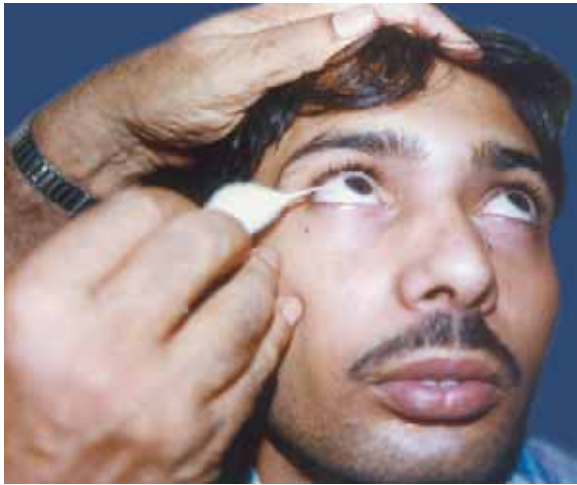

FIGURE 15.31 A unilateral stimulus to cornea produces bilateral blinking

in opening the jaw indicates weakness of pterygoids, mylohyoid and anterior belly of digastric.

The reflexes

- **Corneal reflex** (Fig. 15.31)
 - Make the patient to sit comfortably. Ask him to look at the ceiling or into the distance or to the opposite side.
 - Twist a light wisp of cotton into a fine hair and lightly touch the lateral margin of the cornea.
 - Observe the presence of direct and consensual corneal reflex. If the reflex is present, the patient blinks.

Touching of the cornea in a normal person produces brisk contraction of the orbicularis oculi (e.g. blinking). A unilateral stimulus produces bilateral reflex blinking, i.e. the direct and consensual responses due to bilateral innervation of the reflex through Vth nerve.

- **The jaw jerk:** The jaw jerk similar to deep tendon jerk, is elicited by tapping with percussion hammer.
 - Ask the patient to half-open the mouth.
 - Put your left index finger over the lower jaw.
 - Tap the finger with percussion hammer and observe for the closure of the jaw. This is often not elicitable in young persons.

The positive response normally is brisk contraction of the jaw muscles producing closure of the jaw. Both afferent and efferent pathways are subserved by the Vth nerve. A brisk jaw jerk indicates bilateral UMN lesion above the level of pons (e.g. multiple sclerosis, motor neuron disease).

Common Abnormalities

The Signs of Trigeminal Nerve Lesion

- Diminution of the corneal reflex may often be the first sign of a fifth nerve lesion.

TABLE 15.15 Trigeminal nerve disorders

Brainstem (nuclear or infranuclear)

- Multiple sclerosis
- Stroke
- Glioma
- Syringobulbia

Cerebellopontine angle (VII and VIII nerve functions also involved)

- Acoustic neuroma
- Meningioma
- Secondaries

Apex of the petrous temporal bone (Gasserian ganglion lesions)

- Trigeminal neuroma
- Chronic SOM (the combination of Vth and VIth with mastoiditis is called *Gradenigo's syndrome*)
- Herpes zoster

Cavernous sinus (3rd, 4th and 6th cranial nerves are also involved)

- Aneurysm of internal carotid artery
- Extension of a pituitary neoplasm
- Cavernous sinus thrombosis
- Secondary neoplasm

Peripheral nerve lesions (patchy sensory loss or loss of sensations over a branch of a division or a division of 5th may be involved)

- Nasopharyngeal carcinoma
- Trauma
- Leprosy
- Sarcoidosis
- Guillain-Barre syndrome
- Collagen vascular diseases
- Idiopathic trigeminal neuropathy

- A complete fifth nerve lesion produces:
 - Unilateral sensory loss on the face, tongue and buccal mucosa.
 - The jaw deviates to the side of the lesion when the mouth is opened due to unilateral pterygoid weakness. When patient tries to move the jaw from side to side there is difficulty in moving it to contralateral side.

Note: Facial asymmetry resulting from VII nerve palsy may give rise to apparent deviation of jaw which is differentiated from 7th nerve lesion by preservation of side to side movement of the jaw.

- Central (brain stem) lesion of the lower trigeminal nerve nuclei produces a characteristic circumoral sensory loss with other signs of brainstem involvement.
- When spinal nucleus of the Vth nerve alone is involved, the sensory loss is limited to pain and temperature on the side of the face involved but touch is preserved (dissociated sensory loss).

Causes of trigeminal nerve lesions (Table 15.15).

Facial Pain

Trigeminal nerve is a sensory nerve for face, therefore, irritative lesions of 5th cranial nerve or its branches may

lead to facial pain (trigeminal neuralgia). Sometimes, pain may be referred from other sites such as from teeth, temporomandibular joint (rheumatoid arthritis), ears (otitis externa) etc. Atypical facial pain can occur without any reason. The causes of facial pains are:

- Trigeminal neuralgia
- Migrainous neuralgia
- Post-zoster neuralgia
- Psychogenic (atypical facial pain)
- Temporomandibular arthritis (rheumatoid arthritis)
- Otitis externa
- Malocclusion of teeth.

Trigeminal Neuralgia (Tic Douloureux)

It is characterised by facial pain of idiopathic origin. In some cases, an aberrant loop or artery may press the rootlets of trigeminal nerve as they emerge from the pons. It is common in middle aged and elderly.

Facial pain is the *hallmark* of the disease which occurs in bouts or paroxysms, is sharp or lancinating in character and radiates to territory of one or more sensory divisions of a trigeminal nerve or may be limited to a branch of a division such as infra-orbital branch etc. (branch trigeminal neuralgia). The pain disturbs routine activity, is triggered by touching, washing of face, brushing of teeth, shaving, cold breeze, eating, talking and application of lotions and cosmetics. Paroxysms of the pain are transitory and last for few seconds. The course of the diseases is marred by relapses

and remissions which become less frequent as the disease advances.

The second and third divisions are affected most followed by first. There is no sensory loss.

If there is sensory loss or motor symptoms or signs accompanying trigeminal neuralgia, then it is secondary to certain neurological diseases such as multiple sclerosis or meningioma of trigeminal nerve. The characteristics of other causes of facial pain are summarised in the Table 15.16.

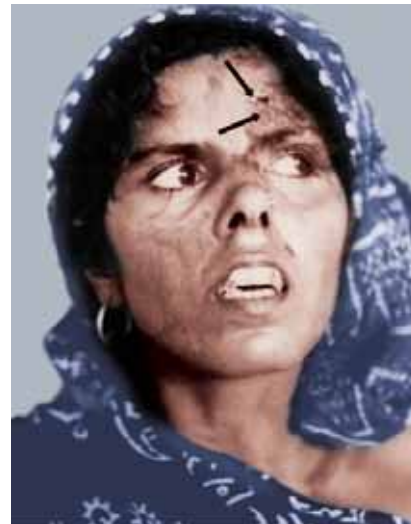

FIGURE 15.32 Post-zoster neuralgia.

Note the typical lesion (arrow) that was associated with severe pain

TABLE 15.16 Differential diagnosis of trigeminal neuralgia

Cause of facial pain	Characteristics
• Trigeminal neuralgia	Already discussed
• Migrainous neuralgia (cluster headache)	<ul style="list-style-type: none"> • Unilateral bouts of pain around one eye, cheek or forehead. The pain is throbbing, severe, and disturbing and may show nocturnal frequency. It is common in males of middle age. • Lacrimation and nasal congestion, conjunctiva is injected on the affected side. • The neuralgia occurs in clusters (repeated for a number of weeks, followed by a respite for a number of months before another cluster occurs).
• Atypical facial pain	<ul style="list-style-type: none"> • Dull, boring ache or pain over the face which is ill-defined and non-localised • May be unilateral or bilateral • Occurs either in too anxious or too depressed patients.
• Temporomandibular arthritis (Costen's syndrome)	<ul style="list-style-type: none"> • Common in elderly females • Pain is severe, aching, gets intensified by chewing or movements of the jaw • Mostly unilateral and limited to temporomandibular joint. It is due to rheumatoid arthritis.
• Malocclusion of teeth	<ul style="list-style-type: none"> • Pain over the face and jaw, may be referred to other areas • Intensified by chewing or movements of the jaw • Dental examination will reveal malocclusion.
• Post-zoster neuralgia (Fig. 15.32)	<ul style="list-style-type: none"> • History of severe facial pain or burning of the face. The pain is increased by contact or movement • History of herpes zoster infection over the face with typical vesiculopapular eruptions • Dermal scars of herpetic lesions may be present • It is unilateral, may involve any division of the Vth nerve • Sensory disturbances such as paraesthesias or slight sensory loss may be present.

The seventh (facial) cranial nerve

Anatomy and Physiology

The facial nerve is a *mixed nerve*.

- It innervates the muscles of face concerned with expression.
- It forms an efferent limb of corneal reflex (afferent being the Vth nerve) and also the palmomental reflex, the pout or snout reflex, the nasopalpebral reflex (glabellar tap) and the efferent limb of stapedius reflex. These reflexes have also been discussed under primitive reflexes.
- It supplies secretory motor fibres (parasympathetic fibres) to the lacrimal glands (producing tears) and submandibular glands (producing saliva).
- It carries taste sensation from the anterior two-thirds of the tongue through the chorda tympani branch.

The motor nucleus of the 7th nerve lies in the pons, its fibres hook around the 6th nerve nucleus in the pons, and then comes out of lateral pontomedullary junction.

The *nervus intermedius* contains parasympathetic fibres (secretomotor) from the superior salivary nucleus and taste fibres which have their cell bodies in geniculate ganglion and synapse centrally with nucleus solitarius (gustatory nucleus). It comes out of pons along with 7th nerve, travels in between 7th and 8th nerve to internal auditory meatus. The facial nerve along with *nervus intermedius* pass through the facial canal

of the temporal bone in the middle ear, emerges from the skull at stylomastoid foramen. In the middle ear, it gives off a branch to the stapedius muscle (which dampens all tympanic vibrations, hence its involvement produces hyperacusis). After leaving the skull, the 7th nerve supplies fibres for the corneal reflex and the other reflexes. The secretomotor branch passes to the pterygopalatine ganglion and supplies the lacrimal gland through the greater petrosal nerve and tongue through the chorda tympani.

Sites of Involvement of VIIth Nerve

The sites of involvement and their features are summarised in Table 15.17.

Symptoms and Signs of Facial Nerve Palsy

These are summarised in Table 15.18.

Examination of VIIth Nerve

The VIIth nerve can only be tested at the face (testing of facial muscles only Table 15.19, Fig. 15.33). The taste sensation is tested from anterior two-thirds of the tongue.

Secretomotor function of the lacrimal gland is only tested by ophthalmologists doing a *Schirmer test*. Testing of decreased saliva production owing to the denervation of submandibular gland is not performed clinically.

TABLE 15.17 Causes of facial weakness depending of the site involved

Site	Causes	Features
Pons	<ul style="list-style-type: none"> • Tumours • Vascular lesion • Demyelination 	<ul style="list-style-type: none"> • 6th, 7th cranial nerve with contralateral hemiplegia (Millard-Gubler syndrome) • Pin-point pupil on the side involved • Ataxic nystagmus • Internuclear ophthalmoplegia
Cerebellopontine angle	<ul style="list-style-type: none"> • Acoustic neuroma • Meningioma 	<ul style="list-style-type: none"> • 7th and 8th nerve palsy on the side involved • Loss of sensation over anterior 2/3rd of tongue due to involvement of <i>nervus intermedius</i>
Internal acoustic meatus (petrous temporal bone)	<ul style="list-style-type: none"> • Bell's palsy • Trauma • Otitis media • Ramsay Hunt syndrome • Tumour 	<ul style="list-style-type: none"> • 7th nerve palsy • 8th nerve palsy • Hyperacusis (e.g. sound appear louder than normal) due to involvement of stapedius muscle • Loss of taste from anterior 2/3rd of tongue
Stylomastoid foramen or within the face	<ul style="list-style-type: none"> • Parotid gland tumour • Mumps • Sarcoidosis • Trauma • Guillain-Barre syndrome • Bell's palsy • Trauma 	<ul style="list-style-type: none"> • Paralysis of all the muscles of the face • Taste and lacrimation is preserved

TABLE 15.18 Symptoms and signs of facial nerve paralysis

Symptoms	Signs
Dribbling or drooling of saliva from the angle of the mouth on the affected side	Angle of the mouth droops on the affected side on clenching the teeth. Facial asymmetry present due to paresis of facial muscles
Creases of face or skin folds are effaced or blunted on affected side	Nasolabial fold is effaced on the affected side when patient is asked to show his/her teeth
Forehead is unfurrowed (expressionless)	Patient is unable to make furrows on the affected side on looking upwards
Difficulty in closing the affected eye. There may spasms of facial muscles	Cornea is visible on affected side as patient is asked to close the eyes, hence, is liable to exposure keratitis
Food collects between teeth and cheeks on the side involved	Patient has difficulty to blow out the cheeks

Testing of Taste Sensation

- Instruct the patient not to speak or retract the tongue during examination as this will dissipate the liquid substance onto the opposite side of the tongue as well as to its posterior one-third.
- Now gently hold the protruded tongue with a swab.
- Put a drop of testing substance (e.g. sweet, salt, bitter or sour) on the anterior two thirds of each side of the tongue in turn.
- Ask the patient to identify the substance by pointing to the appropriate word written on a piece of paper/or card.

Testing for Lacrimation (Schirmer's Test)

Put a piece of special blotting paper under the lower eyelid and remove it after 5 minutes. Normally at least 10 mm of blotting paper will be dampened (wet) by evoked tear secretion. In facial nerve palsy, there is diminished or absence of tear secretion.

Common Abnormalities

Upper motor neuron vs lower motor neuron lesion of 7th nerve (are discussed in the Table 15.20 and Figs 15.34A and B).

Facial weakness: It could be due to 7th nerve paralysis or diseases of myoneural junction or muscle (myopathy). It may be unilateral or bilateral. The causes of facial weakness are given in the Table 15.21.

Idiopathic (Bell's) Palsy (Figs 15.35A and B)

It is the most commonly seen palsy of 7th nerve affecting the patients of all age groups and both the sexes. It is mostly unilateral, can be bilateral. The cause is unknown. The site of the lesion is compression of facial nerve within facial canal or at stylomastoid foramen due to oedema or swelling of the nerve or nerve sheath at these sites. The precipitating factors include vascular damage, viral infections, trauma or cold exposure.

It is characterised by acute or subacute onset of pain behind a ear or on one side of the face followed by LMN paralysis of all the muscles of face leading to asymmetry of the face. Patient may complain of paraesthesias over the face but there is no objective sensory loss. Occasionally, taste sensation may be involved. Hyperacusis occurs if nerve to stapedius is involved. Severe lesion may cause loss of salivation and tears formation.

Taste and lacrimation will be preserved if the lesion is distal to or at the stylomastoid foramen.

Hemifacial Spasms

Hemifacial spasms occur commonly in middle aged women, are characterised by narrowing of the palpebral fissure on the affected side, and the facial muscles contract to pull the angle of the mouth upwards. The cause is unknown but compression of 7th nerve by loops of cerebellar arteries or by AVM (AV malformation) or cerebellopontine tumour is implicated.

The vestibulocochlear (VIII) nerve

The vestibulocochlear nerve, as its name suggests has two components:

1. Vestibular.
2. Cochlear.

Applied Anatomy and Physiology

The *cochlear* branch is concerned with hearing. The *vestibular* branch is concerned with maintenance of correct posture, eye coordination and movement.

The *vestibular* apparatus consists of three *semicircular canals*, the *utricle* which senses the tilting of the head and the *sacculle* which senses the angular acceleration of the head. The fibres carrying impulses from this apparatus form the *vestibular nerve*. It enters the cranium through the internal auditory meatus, traverses the cerebellopontine angle and enters the brainstem at pontomedullary junction. In the brainstem, the vestibular fibres terminate in the four vestibular nuclei (superior, inferior, lateral and medial).

TABLE 15.19 Testing of the facial nerve (Figs 15.33A to E)






Figure	Method
 <p>FIGURE 15.33A Normal person can clench the teeth without any abnormality of angles</p>	<ul style="list-style-type: none"> Ask the patient to clench the teeth <p>In facial nerve palsy, the angle of the mouth droops on the affected side.</p>
 <p>FIGURE 15.33B A normal person can make furrows</p>	<ul style="list-style-type: none"> Hold the head of the patient. Ask the patient to look upwards (e.g. make furrows over the forehead.) <p>A patient with facial paralysis can not make furrows over the forehead on the affected side.</p>
 <p>FIGURE 15.33C Normal closure of the eyes against resistance. Eyes can not be opened normally</p>	<ul style="list-style-type: none"> Ask the patient to close both the eyes as tightly as possible. <p>The eyelids on the affected side do not cover the eye ball properly and firmly.</p> <p>Now try to open the eyes with the fingers (Fig. 15.33C)</p> <p>In facial nerve palsy, eye on the affected side can be opened without any resistance as compared to healthy side.</p>
 <p>FIGURE 15.33D Normal person can blow out the cheeks. Air does not leak on pressure applied with fingers on both the sides</p>	<ul style="list-style-type: none"> Ask the patient to blow out his/her cheeks. <p>In facial palsy, the affected side will not blow out due to leakage of air through the angle of the mouth on the involved side or he/she incompletely blows out the affected cheek as compared to healthy side.</p> <ul style="list-style-type: none"> Now ask the patient to hold the cheeks in fully blown out position. Press both the cheeks between index finger and thumb of your both hands (Fig. 15.33D). <p>In facial palsy, the muscle of the cheek on the involved side is weak and flabby, air leaks out on pressure applied on the involved side.</p>
 <p>FIGURE 15.33E A normal person can whistle</p>	<ul style="list-style-type: none"> Ask the patient to whistle (Fig. 15.33E). <p>In facial palsy, patient is not able to whistle.</p>

TABLE 15.20 Facial nerve paralysis/palsy upper motor neuron (Fig. 15.34A) lower motor neuron (Fig. 15.34B)

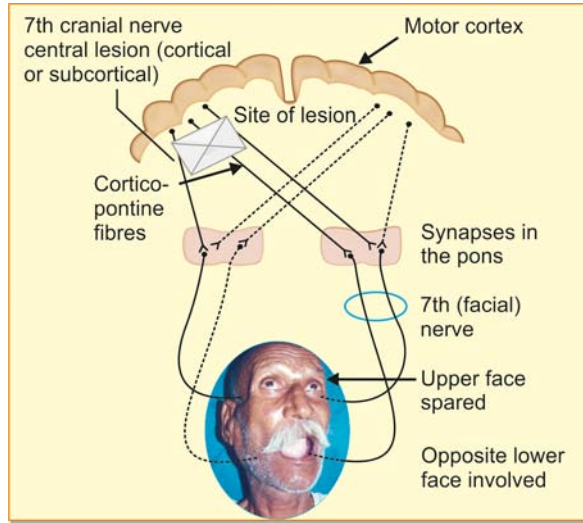


FIGURE 15.34A Upper motor neuron paralysis of VII cranial nerve. Pathways of innervation and site of lesion (rectangle with crossed bars). Upper face uninvolved due to bilateral representation, opposite lower face involved

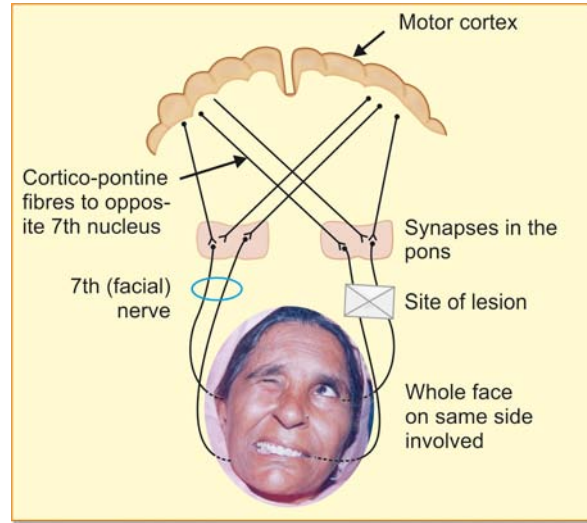


FIGURE 15.34B Lower motor neuron paralysis of VII cranial nerve. Pathway of innervation of face and site of lesion (square with crossed bar)

Upper motor neuron

- Lesion is above the pons
- Corticonuclear fibres are involved
- Facial palsy/paralysis is limited to lower part of the face, the upper part is spared due to its bilateral representation
- Patient can make furrows on forehead on looking upwards
- The eye closure though paretic is well preserved while corner of the mouth will droop, saliva may dribble and the nasolabial fold is flattened on the affected side of the face
- Smiling is preserved
- Taste is normal
- It is invariably associated with uncrossed hemiplegia (supranuclear 7th palsy and hemiplegia are on the same side) due to involvement of contralateral cortical or subcortical pathways
- Usually secondary to some cause, e.g. vascular, multiple sclerosis, tumour, etc.

Lower motor neuron

- Lesion is in the pons or below the pons
- 7th nerve itself or its nucleus is involved
- Facial paralysis involves all the muscles of the face
- Furrows are lost on forehead on the affected side
- The patient is unable to close the eye; and impaired blinking, loss of nasolabial folds and drooling of saliva from the mouth is present
- Smiling is involved because of paresis of emotional facial movements
- Taste to anterior two-thirds of tongue is impaired if the chorda tympani branch is damaged
- Associated with crossed hemiplegia (Millard-Gubler's syndrome) in which 7th nerve palsy is opposite to the side of hemiplegia
- Usually idiopathic (cause unknown)

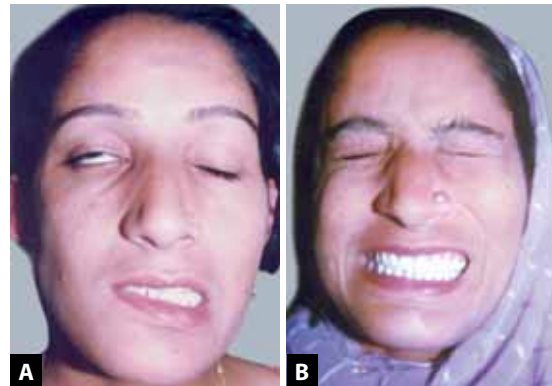TABLE 15.21 Common causes of 7th nerve palsy

Upper motor neuron lesion

Unilateral	Bilateral
<ul style="list-style-type: none"> • Usually vascular • Cerebral tumour • Multiple sclerosis 	<ul style="list-style-type: none"> • Often vascular • Motor neuron disease

Lower motor neuron lesion

<ul style="list-style-type: none"> • Bell's palsy • Parotid tumour • Head injury 	<ul style="list-style-type: none"> • Sarcoidosis • Myasthenia gravis • Guillain-Barre syndrome or polyneuropathies • Myopathies (e.g. myotonic dystrophy)
---	---



FIGURES 15.35A and B Bell's palsy (right side): (A) A full blown LMN paralysis of 7th nerve; (B) Recovery of the same patient

Through fibres in the medial *longitudinal fasciculus (MLF)* it is interconnected and with the III, IV and VI cranial nerves. Other fibres project to the cerebellum, while others descending to the spinal cord form vestibulospinal tracts. Ascending fibres from the brainstem relay through the medial geniculate body to the posterior temporal lobe.

The vestibular part of VIII nerve forms the afferent limb of both the oculocephalic (doll's eye reflex) and oculovestibular (caloric) reflexes.

The *oculocephalic reflex* involves conjugated movements of the eyes in response to changes in head position.

The *oculovestibular reflex (caloric test)* involves elicitation of eye movements following irrigation of external ear canal by either cold or warm water.

The cochlear nerve originates from the *organ of corti* which is a spiral tube containing receptor hair cells and a cavity filled with fluid. Sound waves are transmitted through the fluid to the hair cells which are further transmitted through the fibres of cochlear nerve which accompanies the vestibular nerve in the internal auditory meatus to enter the brainstem at pontomedullary junction. The fibres then synapse in the cochlear nuclei (dorsal, ventral). From the cochlear nuclei, second order fibres ascend to the superior olivary and trapezoid nuclei. Central fibres then ascend up the lateral lemniscus, and synapse in the inferior colliculus and medial geniculate body before entering the auditory cortex in the superior temporal gyrus (area 41 and 42). The ascending auditory pathways decussate at several places so that each cortical region receives impulses from both the ears.

Testing of VIII Nerve

Hearing (Cochlear functions)

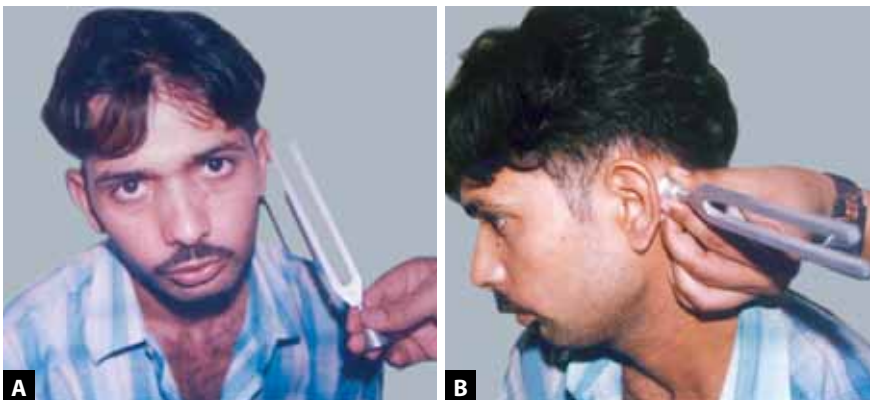Whispering numbers or words tests hearing for higher frequencies in particular. Rinne's test (Figs 15.36A and B) determines whether air conduction is better than bone conduction or vice versa. Normally and in sensorineural deafness; air conduction (AC) is better than bone conduction (BC). In middle ear deafness or conductive deafness $BC > AC$ (bone conduction better than air conduction).

The Weber's test (Fig. 15.37)—a lateralising hearing test provides additional information about the nature of any hearing impairment. Normally, sound arises in the midline and heard equally in both the ears when a vibrating tuning fork (256 or 512 Hz) is placed over the vertex or forehead. In *sensorineural deafness*, fork is heard better on healthy side and in *conductive deafness* on the diseased side.

In clinical practice, deafness or impaired hearing is best studied using audiometry and brain-stem evoked potentials to determine the precise aetiology.

Equilibrium (Vestibular functions)

- *Gait and Stance.* The patient may get imbalance of gait. Patients tend to fall to the side of the lesion.
- Coloric test (oculovestibular reflex) has already been described in examination of ear (ENT examination Chapter 7).
- Movements of eyeballs in relation to head rotation (oculocephalic reflex) can be tested. It has also been described in ENT examination.
- Testing for positional nystagmus (Read Chapter 7).



FIGURES 15.36A and B Rinne's test: (A) Bring the vibrating tuning fork in front of ear (say left). Ask the patient to report as soon as vibrations stop. When patient notices that the vibrations have stopped, put the tuning fork on the mastoid process; (B) Ask whether now vibrations are audible or not, to decide whether air conduction is better than bone conduction or vice versa

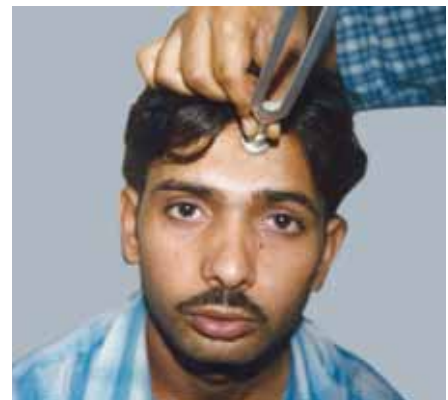

FIGURE 15.37 Weber's test: Put the vibrating tuning fork over the middle of forehead. Ask the patient on which side the vibrations are best audible to decide on which side bone conduction is better

Common abnormalities of VIII nerve (Read Chapter 7).

The glossopharyngeal (ix), vagus (x) and accessory (xi) nerves

These nerves are considered together, being related anatomically, functionally and in terms of clinical examination.

Applied Anatomy and Physiology

The *glossopharyngeal*, *vagus* and *accessory nerves* arise as a series of rootlets in an order from above downwards from the posterolateral sulcus of medulla in the floor of the 4th ventricle.

The spinal part of the XI (*accessory nerve*) emerges from the lateral column of the cord, perhaps beginning as low as the sixth cervical root. It ascends up through the foramen magnum to meet its second medullary part to form the accessory nerve. All the three nerves (IX, X, XI) pass through the jugular foramen. The medullary part of the XI nerve separate and join the *vagus* (X) nerve to supply motor fibres to the larynx and pharynx. The spinal portion of XIth nerve supplies *sternomastoid* and upper portion of the *trapezius* muscles.

The parasympathetic fibres of IX nerve arise from the inferior salivary nucleus and relay in the otic ganglion. They supply parotid gland. The parasympathetic fibres of X nerve supply all the viscera.

The sensory, motor and parasympathetic innervations of *glossopharyngeal* and *vagus* are given in the Table 15.22.

Symptoms of IX and X Nerve Palsy

- **Nasal regurgitation of fluids:** The patients may complain of regurgitation of fluids through the nose during swallowing. This is common symptom in total paralysis of soft palate due to defective elevation of the palate during swallowing.
- The voice may have nasal quality due to inability to pronounce certain words which require complete closure

of nasopharynx. Thus egg is pronounced as 'eng', "rub" becomes "rum" and so on.

- Lesions of IX and X nerves cause dysphagia, dysphonia and loss of gag reflex.

IX Nerve Palsy

Isolated involvement is rare, hence, other signs of brainstem dysfunctions are present. The unilateral paralysis is suggested by:

- Unilateral loss of palatal, tonsillar or pharyngeal sensation.
- Absent or depressed gag reflex (afferent limb of the reflex is involved).

Glossopharyngeal neuralgia is idiopathic like trigeminal neuralgia where brief attacks of lancinating pain occur over the side of throat radiating down to the neck and back of jaw. These attacks are precipitated by swallowing or protruding the tongue. There is no paralysis of the nerve.

X Nerve Palsy

- The voice may sound hoarse or may have nasal quality. The patient can not cough clearly (*bovine cough*) due to recurrent laryngeal nerve paralysis.
- Bilateral paralysis may produce stridor or even respiratory obstruction because the paralysed cords lie in partial adduction, thus, partially blocking the airway.

Testing of IX and X Nerves

- Observe the movements of the palate by asking the patient to open the mouth as wide as he/she can. Depress the tongue with a tongue depressor while patient facing the light (natural or torch). Note the position of uvula at rest. Now ask the patient to say 'AAH' and note whether both sides of the palate arch upwards (Figs 15.38A to D).

TABLE 15.22 Sensory and motor innervation of IX, X and XI cranial nerves

Nerve	Motor innervation	Sensory innervation	Parasympathetic innervation	Reflex
IX (glossopharyngeal)	Stylopharyngeus muscle	Mucosa of pharynx, tonsils, soft palate, conveys taste fibres to posterior third of the tongue, lining of tympanic cavity and Eustachian tube	Parotid gland	It constitutes an afferent limb of the <i>gag reflex</i>
X (vagus)	Muscles of upper pharynx, soft palate, all the intrinsic muscles of larynx and cricothyroid muscle	Duramater of posterior cranial fossa, some part of skin of external auditory meatus	All the abdominal and thoracic viscera	<ul style="list-style-type: none"> • It constitutes an efferent limb of gag reflex • It is involved in oculocardiac and carotid sinus reflexes
XI (accessory)	Sternomastoid and trapezius muscles	Nil	Nil	Nil

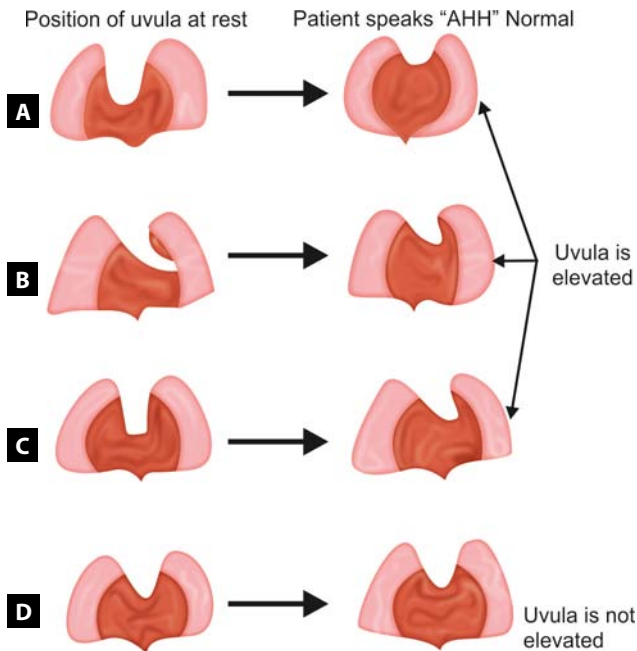


FIGURE 15.38A to D Testing of cranial nerves IX and X: (A) *Normal uvula*—is in the midline at rest, and elevated in the midline with “AHH.”; (B) *Right CN IX and X paralysis*—Uvula is deviated to nondiseased (left) side at rest and elevated and deviated to the left with “AHH.”; (C) *Left CN IX and X paralysis*—Uvula is in the midline at rest, get elevated and deviated to the nondiseased (right) side with “AHH.”; (D) *Bilateral CN IX and X paralysis*—Uvula is in the midline at rest and there is no movement with “AHH.”

In unilateral paralysis, the involved side remain flat and immobile and the median raphe will be pulled to the healthy side (Figs 15.38A to D).

In bilateral paralysis the whole palate is immobile.

- Remember that minor degree of asymmetry of palate and of tongue can occur in hemiplegia with UMN VII nerve palsy. It differs from palatal palsy which is LMN type of paralysis.
- Assess the tonsillar, palatal and pharyngeal tactile sensation using a dampened swab stick and tongue depressor. Test the taste sensation over posterior third of the tongue as described under 7th nerve.

Sensations are lost over these regions in IX nerve palsy.

- The gag reflex may be elicited by touching either the tonsil or pharynx which is followed by contraction of pharyngeal muscles. Test each side separately. It is unpleasant and difficult to test the gag reflex, hence, to be performed only when there is other evidence of IX or X nerve palsy.

Gag reflex is absent or diminished in IX (afferent limb) and X (efferent limb) or both nerve palsy.

- Assess the volume and quality of the patient’s speech, noting if the voice is hoarse or has a bleating or nasal character.

In unilateral X nerve palsy, the speech is blurred and ineffectual. Bilateral palsy produce stridor or respiratory obstruction.

- Ask the patient to cough to determine whether this is more nasal or bovine than normal.

Bovine cough is a characteristic feature of recurrent laryngeal nerve palsy.

- To test the palatal closure of nasopharynx ask the patient to puff out the cheeks.

Normally, both sides of palate elevate in a symmetric fashion and the uvula remains in the midline. In order to puff out the cheeks, the palate must elevate and occlude nasopharynx. If palatal movement is weak, air will escape audibly through the nose.

Causes of IX and X Nerves Palsy (Box 13)

Box 13

Common causes of IX and X cranial nerve palsy

Unilateral IX and X

- Fracture of base of skull
- Neoplasm of base of skull (meningioma)
- Recurrent laryngeal nerve (branch of X nerve) palsy is due to:
 - Bronchial carcinoma
 - Mediastinal tumour (lymphoma)
 - Aortic arch aneurysm
 - Dilated left atrium in mitral stenosis

Bilateral X

- Progressive bulbar palsy (motor neuron disease)
- Pseudobulbar palsy (bilateral UMN lesion in CVA or multiple sclerosis).

Testing of Accessory (XI) Nerve

It is a pure motor nerve.

- Inspect the trapezius muscle from behind and sternomastoid from the front for any wasting or atrophy. Palpate these muscles to assess tone and bulk. In XI nerve palsy, the shoulder will appear dropped and the arm will appear lower than the healthy side.
- To test the trapezius, ask the patient to shrug his/her shoulder while the examiner presses downward on them (Fig. 15.39A) or ask the patient to shrug the shoulder and maintain them elevated, then apply pressure downward on the shoulder.

Normally, a person can shrug the shoulder against resistance, but can not do so if XI nerve is paralysed.



FIGURES 15.39A to C Testing for the accessory (XIth cranial) nerve: (A) Testing of both the trapezius muscles; (B) Testing of right sternomastoid; (C) Testing of bilateral sternomastoids. Note the prominence of the muscles on both sides. Compare one side with the other for any weakness

- To test the right sternomastoid ask the patient to rotate the head to the right side while a hand is placed against the left side of the chin to stop rotation of the chin (Fig. 15.39B). Normally, the muscle stands out prominently during the manoeuvre.

Paralysis of sternomastoid (XI nerve palsy), causes weakness of rotation of the chin to the opposite side.

- You can examine the left sternomastoid by placing left hand on right side of chin of the patient.
- You can test both sternomastoids simultaneously by asking the patient to flex the neck against resistance applied by the examiner on the forehead (Fig. 35.39C) or to depress the examiner's hand placed below the chin while examiner try to resist it.

Common Abnormalities

- In the cervical region, the spinal component of XI nerve may be involved in syringomyelia, poliomyelitis, motor neuron disease and spinal cord tumours.
- In the intracranial course, it may be a part of jugular foramen syndrome (glomus jugulare tumour producing IX, X and XI nerve palsy).

The hypoglossal (XII) nerve

It is a pure motor nerve.

Applied Anatomy and Physiology

The fibres of XII nerve originate from the hypoglossal nucleus in the medulla in the lower part of the 4th ventricle close to midline. The nerve travels the medulla between the pyramid and the olive. It runs a short course in posterior cranial fossa. It leaves the skull through hypoglossal canal or foramen. It courses downwards and forwards to reach the root of the tongue where it divides into branches which innervate the

muscles of the tongue (e.g. genioglossus, styloglossus and the hypoglossus).

Testing of XII Nerve

- Look for wasting and fasciculations of the tongue in the resting position (tongue lying inside the mouth).
- Ask the patient to protrude the tongue; observe the symmetry of movements and its deviation.

In XII nerve palsy, the tongue is pushed to the paralysed side instead of being protruding straight. The median raphe is convex towards healthy side (Fig. 15.40). Apparent deviation of the tongue occurs in facial palsy and loss of teeth on one side (Fig. 15.41) which is distinguished from true deviation (XII nerve palsy) by twisting of the tongue as well as angle of the mouth to the paralysed side while the median raphe is normal.

- Assess the movements from side to side; observe whether this can be done freely.
- Ask the patient to lick each cheek with the tongue; feel the strength by pressing the cheek against the tongue with a finger as the patient protrudes it into each cheek in turn. Also palpate the muscle bulk of tongue between thumb and fingers for tone (tongue is flabby on paralysed side).
- Assess the hypokinesia of tongue movements by asking the patient to say "ah, ah, ah" as quickly as possible, and to make rapid in-and-rapid out and side to side movements of the tongue.

Signs of Unilateral XII Nerve Palsy

Lower motor neuron type (nuclear or infranuclear)

- There is atrophy or wasting of the tongue on the side involved. Fasciculations may be present which are best seen when the tongue lies in the mouth in resting position.
- The tongue tends to deviate on the side of the lesion.
- The tongue can not be moved freely from side to side.

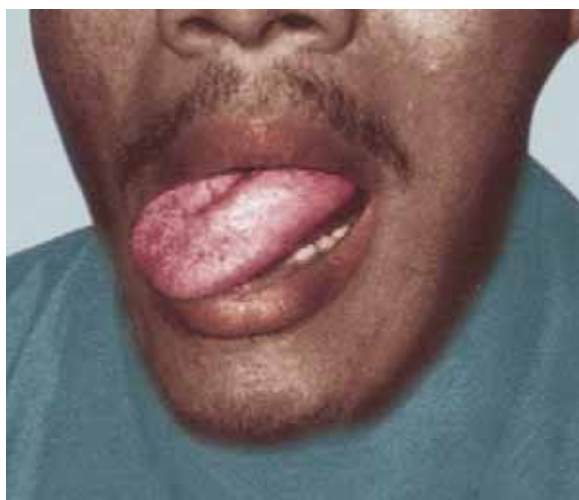


FIGURE 15.40 Right hypoglossal (XII cranial nerve) palsy. Tongue deviates to right on protrusion indicating an ipsilateral LMN lesion

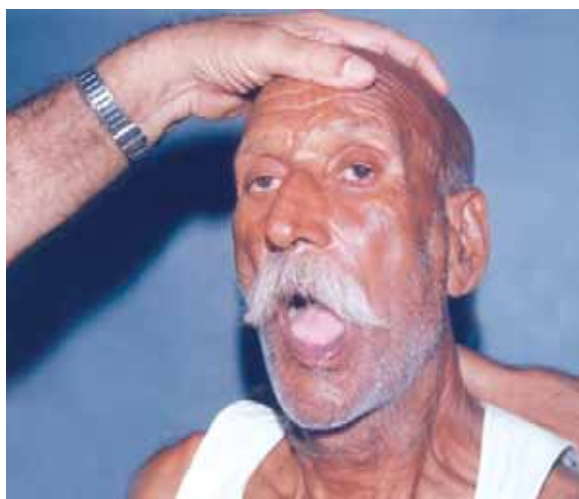

FIGURE 15.41 Facial palsy showing false deviation of tongue, i.e. median raphae due to loss of teeth on left lower jaw. This is called *pseudo deviation* of the tongue

- The bulk of the muscle mass is reduced on palpation of the protruded tongue on the side involved.

Upper motor neuron (supranuclear) paralysis

Unilateral UMN lesion of XII nerve produces deviation of the protruded tongue to paralysed side without atrophy or fasciculations.

Bilateral XII Nerve Palsy

In LMN paralysis, the tongue is flat, atrophic lying listless in the mouth with loss of movements. In UMN lesion, the tongue is spastic and shrivelled up.

Common Abnormalities

- Tremors of the tongue are seen in Parkinson's disease, either when the tongue is at rest or protruded.
- The lower cranial nerves, IX, X, XI and XII are frequently affected bilaterally producing dysphagia, dysarthria and nasal regurgitation (a characteristic triad). The lower cranial nerves may be affected in the jugular foramen (IX, X and XI) or at the base of skull along with XII nerve and sympathetic innervation to the eye (Horner's syndrome). The syndromes of lower cranial nerves palsy are depicted in the Table 15.23. The causes may be neoplastic (skull base tumour), vascular (medullary infarct, vertebral artery aneurysm) or traumatic.
- Bilateral lower motor neuron lesions of lower cranial nerves are often components of bulbar palsy, result either at nuclear or fascicular level in the medulla or from bilateral lesions of the lower cranial nerves outside the brainstem. The causes of bulbar palsy include genetic, i.e. Kennedy's disease (X-linked bulbospinal neuronopathy), vascular (infarction of medulla), degenerative (motor neuron disease, syringobulbia), inflammatory infective (myasthenia, Guillain-Barre, poliomyelitis, lyme disease, vasculitis) and neoplastic (brainstem glioma and neoplastic meningitis). The differences between bulbar and pseudobulbar palsy are summarised in the Box 14.
- A '*pseudobulbar palsy*' arises from an upper motor neuron lesion of the bulbar muscles due to lesions of the corticobulbar tracts. The causes include bilateral cerebral lacunar infarcts, motor neuron disease, multiple sclerosis and brainstem tumour. The features are summarised in the Box 14.

The Motor System

The examination of the motor system includes:

- Inspection and palpation of muscle groups (atrophy/wasting; hypertrophy or bulk of the muscles or contractures).
- Assessment of tone.
- Testing of muscle strength or power.
- Elicitation of reflexes (e.g. deep tendon, superficial and visceral)
- Testing of co-ordination and gait.
- Involuntary movements (spontaneous or induced).

The motor system pathways (corticospinal tracts) have already been outlined in Fig. 15.5. The symptoms of motor system involvement are varied and include:

- Paralysis or weakness (UMN or LMN)
- Impairment of co-ordination (ataxia)

TABLE 15.23 Common syndromes involving the lower cranial nerves outside the medulla

Syndrome	Cranial nerves affected	Site of involvement	Causes
Vernet	IX, X and XI	Jugular foramen inside the skull	Metastases, meningioma, epidermoid, carotid body tumour (Glomus jugulare tumour), pharyngeal carcinoma, fracture base of skull, Paget's disease, neurofibroma
Collet-Sicard	IX, X, XI and XII	Jugular foramen just outside skull	Metastases, meningioma, epidermoid, carotid body tumour, pharyngeal carcinoma, basal meningitis, Paget's disease
Villaret	IX, X, XI, XII and sympathetic (Horner's syndrome)	Posterior retropharyngeal space near carotid artery	Carotid dissection, meningioma, metastases, epidermoid, carotid body tumour, Paget's disease, basal meningitis
Isolated XII	XII	Hypoglossal canal (skull base)	Metastases, meningioma, epidermoid

Box 14

Differentiation between bulbar and pseudobulbar palsy

Bulbar	Pseudobulbar
<ul style="list-style-type: none"> LMN lesion (cranial nerve nuclei in medulla involved) 	<ul style="list-style-type: none"> UMN lesion (corticobulbar tract involved)
<ul style="list-style-type: none"> Tongue is wasted, flabby (due to decreased muscle mass) and immobile. Fasciculations are present 	<ul style="list-style-type: none"> Tongue is small, conical in shape, spastic and moves slowly
<ul style="list-style-type: none"> Tone of tongue decreased 	<ul style="list-style-type: none"> Tone is increased (spastic, shrivelled tongue)
<ul style="list-style-type: none"> Pharyngeal, palatal reflexes absent 	<ul style="list-style-type: none"> Preserved
<ul style="list-style-type: none"> Jaw jerk absent 	<ul style="list-style-type: none"> Jaw jerk brisk

- Changes in tone and posture (dystonia)
- Involuntary movements (dyskinesia or hyperkinesia)
- Slowness of movements and activity (hypokinesia and bradykinesia)
- Loss of learned movement patterns (dyspraxia).

(i) Inspection and palpation for bulk of muscles

The patient should be examined in underwear only so as to observe the limbs and muscles clearly in a good light. The muscle bulk and power varies considerably between normal subjects depending on the age and occupation. In health, normally the lower limb muscles are symmetrical and well developed. In the upper limbs, the musculature on the dominant side (the limb used more) is often well developed, as in the racquet arm of tennis player.

The causes of muscle weakness according to site of lesion are described in Table 15.24.

The change in bulk of muscles may be either atrophy/weakness or hypertrophy (e.g. occupational, muscular

dystrophy-Duchenne type) (Box 15). In order to determine the anatomical cause of atrophy, it is necessary to know the distribution of weakness, whether focal or diffuse, primarily proximal or distal and whether it involves a peripheral nerve or a spinal segment. Assessment of weakness is given in the Box 16. When muscle wasting is accompanied by fibrosis, the muscles become hard, inelastic and shortened due to contractures. Contractures may develop due to prolonged hypertonia.

Proximal vs distal type of weakness: The causes are given in the Table 15.25.

(ii) Assessment of tone of muscles

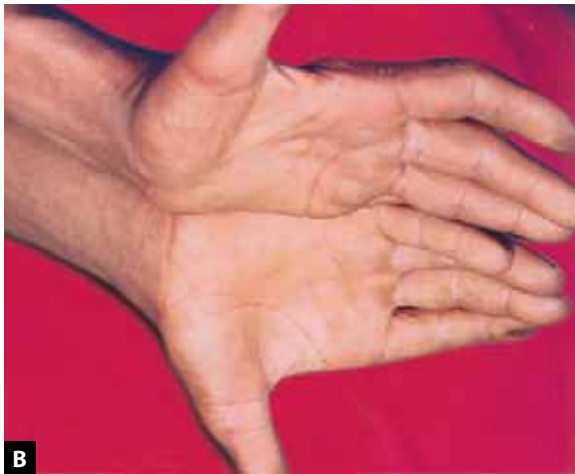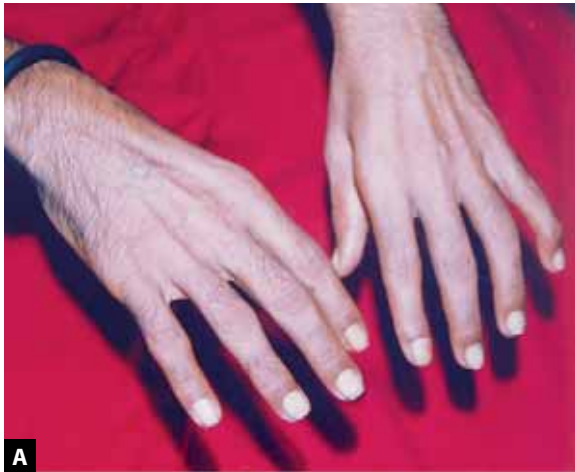Muscular tone is a state of contraction or tension found in healthy muscles, is gauged by the resistance felt when a joint is moved passively through its range of movement. In normal person, there is slight 'elastic' type of resistance from the adjacent muscles.

Testing of the Tone

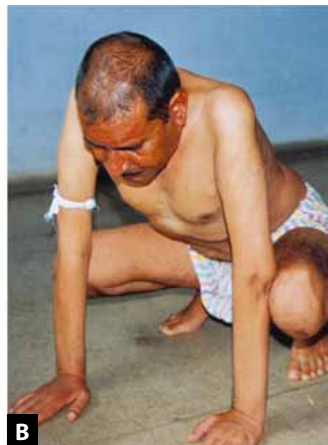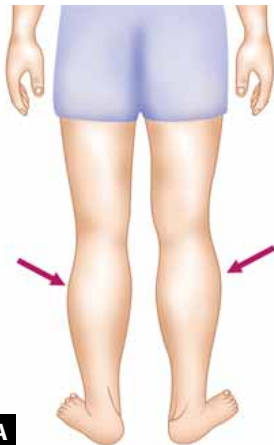
- Ask the patient to relax.
- Passively flex and extend each joint in turn; do this slowly at first, then more rapidly to get a feel of muscle resistance.
- In the upper limbs, tone is tested at bigger joints, i.e. shoulder, elbow and wrist.
- In the lower limbs, test the tone at the hip by internally and externally rotating the resting leg and by briskly raising the patient's knee off the bed and observing whether the ankle is also raised off the bed. Test the tone in knee muscles by flexing and extending the knee (Fig. 15.47). Similarly test the tone at ankle by dorsiflexion and plantarflexion of foot against resistance.
- If the patient is unable to relax, distract his/her attention by instructing him or her to tap the contralateral hand on the thigh.

TABLE 15.24 Causes of muscle weakness

Anatomical site and type	Accompanying features	Common aetiologies
Upper motor neuron	<ul style="list-style-type: none"> No muscle wasting Weakness of a group of muscle or a limb or limbs or one side of the body Hypertonia (spastic paralysis) Hyperreflexia (exaggerated deep tendon jerks) and loss of superficial reflexes Hypokinesia of movements 	<ul style="list-style-type: none"> CVA (e.g. hemiplegia), Spinal cord disease or injury (paraplegia or quadriplegia) Multiple sclerosis
Lower motor neuron	<ul style="list-style-type: none"> Muscle atrophy Loss of movements or muscle weakness Hypotonia (flaccid paralysis) Fasciculations Absent reflexes (deep tendons as well as superficial) Contractures of muscles Trophic changes 	<ul style="list-style-type: none"> Peripheral neuropathies Radiculopathies Anterior horn cell damage (e.g. poliomyelitis) Motor neuron disease
Peripheral neuropathy (Figs 15.42A and B)	<ul style="list-style-type: none"> Symmetrical distal weakness and wasting Symmetrical distal sensory loss disturbance Loss of tendon reflexes Trophic changes 	<ul style="list-style-type: none"> Genetic (hereditary, motor, sensory) Metabolic (diabetes, renal failure) Toxic (alcohol, drugs) Inflammatory (G.B. syndrome, leprosy) Deficiency, e.g. B₁, B₁₂ Other, e.g. paramalignant
Myopathies (Figs 15.43A and B)	<ul style="list-style-type: none"> Muscle wasting usually proximal Hypotonia with diminished/absent reflexes Tenderness (polymyositis) 	<ul style="list-style-type: none"> Hereditary (e.g. various muscular dystrophies) Alcohol and other toxins Collagen vascular disorder (polymyositis)
Myasthenic (Fig. 15.44)	<ul style="list-style-type: none"> Abnormal fatigability of muscles The extraocular muscles, proximal muscles, muscles of mastication, speech and facial expression are commonly affected Movements initially are strong but weakens with exercise or continued action Worsening of symptoms towards the end of the day The reflexes are preserved initially, may be lost later on No sensory loss 	<ul style="list-style-type: none"> Thymic dysplasia (70%) or thymic tumour (10%) Associated with other autoimmune disorders Drug-induced, e.g. D-penicillamine, lithium, propranolol Paraneoplastic-myasthenic myopathic syndrome (Eaton-Lambert syndrome) due to oat cell carcinoma Snake-bite
Psychogenic	<ul style="list-style-type: none"> Inconsistent weakness No associated feature 	<ul style="list-style-type: none"> Stress or anxiety Compensation claims
Myotonic (inherited or acquired)	<ul style="list-style-type: none"> Continued muscle contraction after cessation of voluntary effort, e.g. relaxation is impaired after muscular contraction (persistent hand grip after relaxation (see Fig. 15.50)) Myotonia is accentuated by rest and cold, is best demonstrated in hands, tongue and other muscles The patient has well-developed muscles in spite of weakness The jerks are preserved 	



FIGURES 15.42A and B Wasting of small muscles of hands: (A) In peripheral neuropathy. Note the bilateral wrist drop; (B) Motor neuron disease. Note wasting of the thenar and hypothenar muscles



FIGURES 15.43A and B Muscular dystrophy: (A) Duchenne's muscular dystrophy with pseudo-hypertrophy of calf and thigh muscles; (B) Becker's muscular dystrophy showing difficulty in rising from sitting position

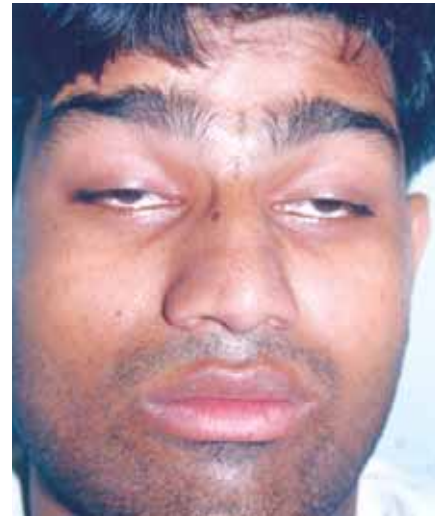

FIGURE 15.44 Myasthenic weakness of extraocular muscles leading to bilateral ptosis

Box 15

Hypertrophy of muscles-types and causes

<i>Pseudohypertrophy</i>	<i>True hypertrophy</i>
<ul style="list-style-type: none"> • Muscles are bulkier than normal. They are weak 	<ul style="list-style-type: none"> • Muscles are large, elastic to feel, hard and globular. They are stronger than normal
<ul style="list-style-type: none"> • The calf, glutei infraspinate, quadriceps, deltoid are commonly affected. 	<ul style="list-style-type: none"> • Facial and muscles of the hand are affected
Causes are:	Causes are:
<ul style="list-style-type: none"> • Duchenne muscular dystrophy (DMD), hypothyroidism, glycogen storage disease 	<ul style="list-style-type: none"> • Manual labourers, myotonia cysticercosis in the muscles (sometimes)

Box 16

Assessment of muscle weakness

- Distribution
 - A few muscles
 - A limb (monoplegia)
 - Both lower limbs (paraplegia)
 - Both limbs on one side (hemiplegia/hemiparesis)
- Type of weakness
 - UMN
 - LMN
- Onset and evolution of weakness
 - Sudden and improving (acute)
 - Gradually worsening over days or weeks (subacute)
 - Evolving over months or years (chronic)

TABLE 15.25 Causes of proximal and distal weakness

Proximal weakness	Distal muscle weakness
(difficulty in climbing upstairs, standing from sitting position, Gower's sign positive Fig. 15.45)	<ul style="list-style-type: none"> • Polyneuropathy • Distal myopathy • Myotonic dystrophy • Charcot-Marie-tooth disease
<ul style="list-style-type: none"> • Muscular dystrophy (Fig. 15.46) • Polymyositis • G.B. syndrome • Porphyria • Thyrotoxic or other endocrinal (Cushing) myopathies • Metabolic myopathies, e.g. diabetic amyotrophy • Periodic paralysis (e.g hypokalaemia) • Steroid-induced • Malignancy-paraneoplastic. 	

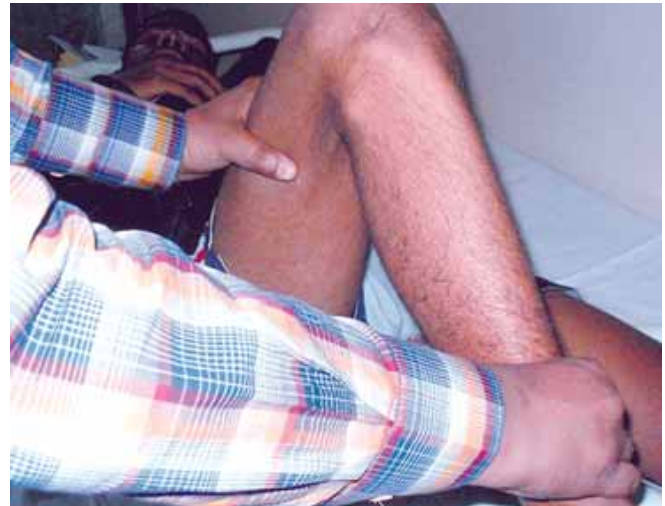

FIGURE 15.47 Testing the tone of muscles at knee



FIGURE 15.45 Positive Gower's sign in Duchenne's muscular dystrophy

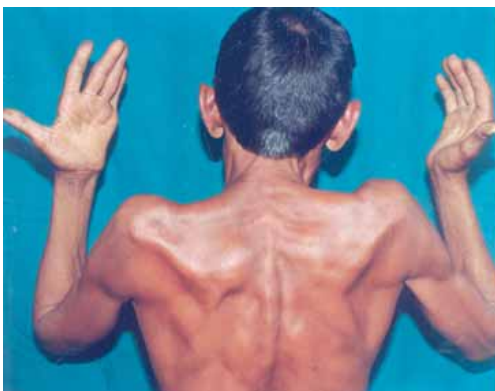

FIGURE 15.46 Fascioscapulohumeral (limb girdle) myopathy. Note the weakness/wasting of the shoulder girdle muscles and winging of the scapulae. Winging is more pronounced when patient attempts to push against a resistance, e.g. a wall or otherwise

Clonus (rhythmic series of muscle contractions in response to sudden stretch).

- If there is hypertonia, elicit the clonus at knee (patellar clonus) and ankle (ankle clonus). It is discussed along with deep tendon jerks.

Common Abnormalities (Fig. 15.48)

Tone may be increased (hypertonia) or decreased (hypotonia). Tone is maintained by the spinal reflex arc modulated by cerebellum and basal ganglia.

Hypotonia refers to decreased tone, is demonstrated by loss of resistance when a limb is moved passively or when an upper limb is released from a distance falls on the bed without any resistance or when a leg is shaken, the foot moves without resistance. It occurs due to involvement of afferent or efferent limb of internuncial neuron. The causes are listed in the Fig. 15.48. Hypotonic muscles are soft on palpation. Due to hypotonia, the upper limb may assume a characteristic posture on outstretching, i.e. hyperextension at elbow with over-pronation of forearm, wrist flexed and fingers hyperextended at metacarpophalangeal joints.

Hypertonia manifests either as spasticity or rigidity. The *spasticity* is characterised by building-up of resistance during the early part of the passive movement, then there is sudden lessening of the resistance. It may be *clasp-knife* type where the resistance is encountered either in the beginning or at the end of a passive movement. It is seen in pyramidal lesions, e.g. hemiplegia, paraplegia, quadriplegia. Spasticity in the upper limb is infrequently more obvious on attempting extension; whereas in the lower limb it is more obvious with attempted flexion. It is associated with other signs suggestive of pyramidal lesion (*UMN signs*).

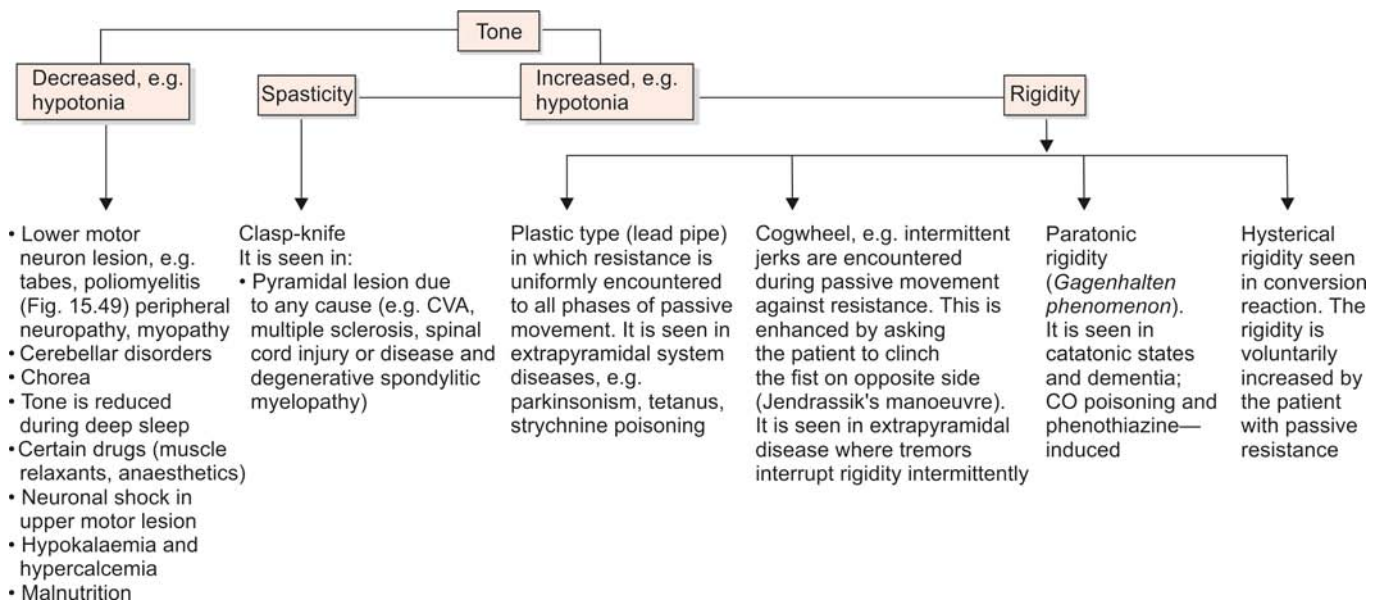


FIGURE 15.48 Alterations in the tone of muscles and their causes

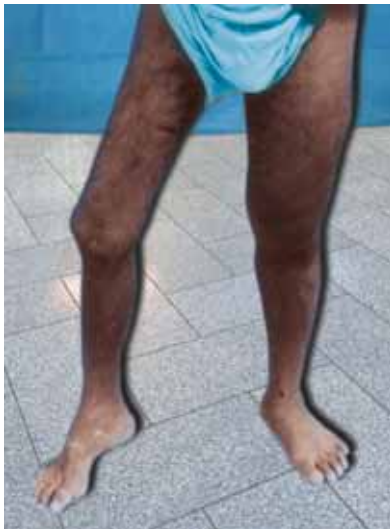

FIGURE 15.49 Postpolio paralysis of right lower limb with contracture at the ankle. Patient walks on the toes due to contracture of Achilles

Rigidity means sustained resistance encountered throughout the range of passive movement. It may be *lead-pipe type* in which resistance is uniform throughout the passive movement or *cog-wheel type* in which continuous resistance is broken by rhythmic jerks (jerky feel), hence, denotes rigidity with interspersed tremors. It can be enhanced by asking the patient to clinch the fist on the opposite side (*Jendrassik's manoeuvre*). *Decerebrate rigidity* (cerebral or brain-stem lesions) is characterised by typical posture in which the limbs are stiff, extended, head is erect and jaw is closed. The righting reflexes are abolished but tonic neck and labyrinthine reflexes remain intact and the deep tendon jerks are exaggerated. It is

due to release of vestibular nuclei from the higher pyramidal control. *Hysterical rigidity* is ill-defined and ill-sustained where the resistance increases proportionately with increasing force or passive movement of the limb. It is usually of long duration, precipitated by alarm, excitement or fatigue.

Reflex rigidity refers to muscle spasm in response to pain, e.g. board-like rigidity of abdomen in peritonitis, neck rigidity in meningitis.

Paratonic rigidity (Gegenhalten phenomenon) refers to stiffening of a limb in response to contact and a resistance to passive changes in posture or position. The strength of antagonists increases as one increases the force to change the position of the limb. It is seen in catatonic states and in patients with clouded or confused consciousness due to any cause especially dementia.

Differences between spasticity and rigidity are enumerated in the Box 17.

Myotonia (Figs 15.50A and B): Refers to increased tone where tonic muscular contraction is followed by slow relaxation. Sudden movement may be followed by marked spasm and inability to relax. Repetition of movement brings about ease of relaxation and gradual decrease in hypertonicity. Percussion myotonia can be elicited by sudden tapping the thenar eminence with a percussion hammer which is followed by apposition of the thumb that stays for several seconds before relaxation begins. It can be elicited by tapping on the extended tongue, deltoid or other muscles where a 'dimple' is produced that relaxes slowly. Shake the hand with the patient and then let it go—produces persistence of the grip that relaxes slowly (Fig. 15.50). Similarly forcible closure of the eyes followed by sudden opening results in graded opening of the eyes.

Box 17

Differentiation between spasticity and rigidity

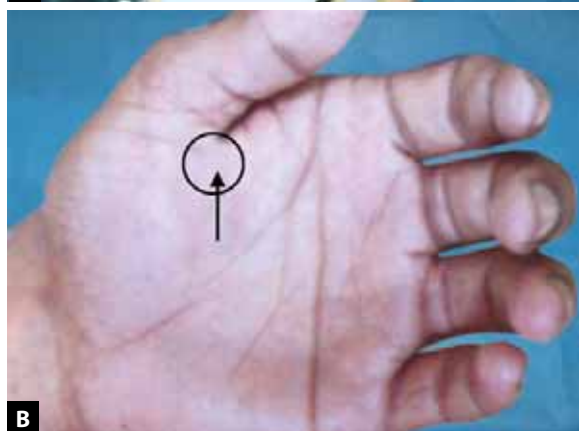
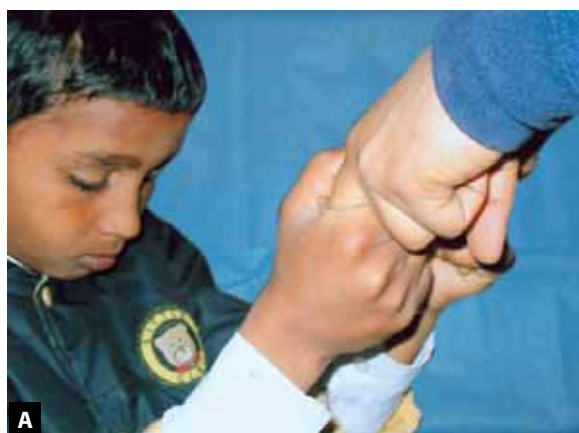<i>Spasticity</i>	<i>Rigidity</i>
• Seen in pyramidal lesions	Seen in extrapyramidal lesions
• Resistance is encountered either in the beginning or at the end of passive movement	Resistance is continuous throughout passive movement either uniform or intermittent
• It is stretch sensitive phenomenon. It is proportional to the speed of the applied stretch	It is stretch-uniform, remains constant with application of varying stretch
• Involves only anti-gravity muscles, e.g. extensors of the lower limbs and flexors of the upper limbs	Involves all groups of muscles (agonists and antagonists) to equal extent
• Deep tendon jerks are exaggerated	Deep tendon jerks are either normal or diminished

(iii) Testing of muscle strength and power

Strength and muscle power can be judged quickly by watching the patient walking, standing from lying down or sitting position, during dressing and undressing and while jumping or hopping. These movements require proximal and distal strength and co-ordination of various movements and much can be learnt by observing them carefully.

There are two methods by which muscle power can be determined, isometric and isotonic. Isometric testing is more sensitive in detecting subtle degree of weakness. The muscle power grading by Medical Research Council (UK) is given in the Box 18. Using this system which is clinically based, paresis/paralysis occurs within the grade 5 range; this can be subdivided into 4⁺ (movement against moderate resistance) and 4⁻ (movement against slightest resistance) to give greater precision of muscle strength.

The muscle power is tested in a group of muscles acting on a joint (*see* Box 19) in case of paralysis and in individual muscle in case of myopathy, mononeuritis or compression of motor root(s). The testing of individual muscle is described separately.



FIGURES 15.50A and B Myotonia: (A) Slow relaxation of hand grip; (B) Percussion test. Note the dimple (→) that returns to normal slowly

Box 18

Medical Research Council (UK) grading of power

- Grade 0 : No muscle contraction visible (no power)
- Grade 1 : Flicker of muscle contraction but no movement of joint
- Grade 2 : Movement with gravity eliminated
- Grade 3 : Movement against gravity
- Grade 4 : Movement against gravity and some resistance
- Grade 5 : Normal power (movement against full resistance)

Box 19

Testing of muscle power in a group of muscle acting on a joint

Test muscle power in proximodistal direction

- Upper limb muscles. Test power in:
 - Abductors and adductors of shoulder
 - Flexors and extensors of shoulder
 - Flexors and extensors of elbow
 - Flexors and extensors of wrist
 - Spinators and pronators of forearm
 - Extensors of fingers at both the metacarpophalangeal and interphalangeal joints
 - Finger and thumb flexors, extensors, adductors and abductors
- Test the strength of the abdominal muscles as a whole by asking the supine patient to raise the head against resistance.
- Lower limb muscles. Test power in:
 - Hip flexors and extensors, adductors and abductors
 - Knee flexors and extensors
 - Foot dorsiflexors, plantarflexors, inverters and everters.

Method of Testing

- Examine individual muscle groups in both limbs alternatively, or in some instances simultaneously, so that the strength of right and left can be compared directly.
 - Either ask the patient to contract a group of muscles as possible and then to maintain the contracted position while the examiner tries to overpower the muscle group being tested. This is called *isometric testing*.
- Or
- Ask the patient to move the joint while examiner attempting to halt the movement. This is called *isotonic testing* of strength.

Common Abnormalities

- By testing a group of muscle, one can identify the type of weakness in a group of muscle or muscles, or a limb or one half side of the body. The causes of such weakness have already been discussed in Table 15.24. If such a weakness is found, a more detailed examination of muscles peripheral nerve or spinal segment should be undertaken as detailed below.

Testing of the Muscles of Upper

Lower Limb (Table 15.26 and Fig. 15.51)

It is useful to test the individual muscle(s) in myopathy and radiculopathy.

(iv) The reflexes

Tendon reflexes (jerks): These are phasic, monosynaptic stretch reflexes involving only two neurons and a particular spinal segment. They are based on the principle that a sudden stretch of a tendon excites a volley of afferent impulses that travel along the afferent side of spinal reflex arc and reach the muscle via the efferent side of the arc and causes it to contract briefly which can be seen and felt. Thus, it tests the integrity of afferent, efferent pathways and their interconnections in the anterior horn cells in the spinal segment supply of that muscle (see Fig. 15.6). The examination of deep tendon reflexes provides a reliable information about the central and peripheral nervous system. It is, therefore, important to become trained in the technique of eliciting these reflexes.

Precautions

- Always use same type of hammer.
- Always examine these reflexes in the same manner.
- Always stand on the side of the bed.
- Always make sure that patient is warm and comfortable.
- Reassure the patient that hammer is soft, will not cause any harm. Let the patient should feel it or examine it.
- The patient should be asked to be relaxed, i.e. "let the muscles go to sleep".

- Expose the part to be examined properly by putting off the clothes. In the lower limb examination, the genitalia to be properly covered and protected.
- The reflexes can easily be tested with the patient supine on a couch/bed, but some neurologists prefer to elicit the jerks with the patient sitting on the edge of the couch facing the examiner.
- Strike the tendon only since mechanical stimulation of a muscle belly may produce contraction of that muscle which is not dependent on that reflex arc.



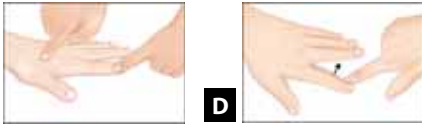

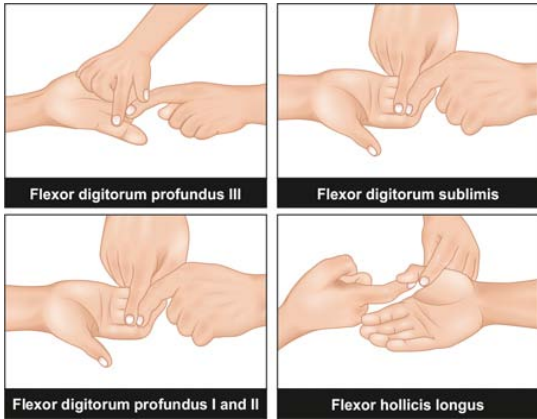

Upper Limb Reflexes

- **Biceps (C₅-C₆):** Flex the elbow to right angle and place the forearm in mid-prone position. Place your thumb or index finger on the biceps tendon in anti-cubital fossa and tap the tendon with the hammer. The biceps contracts and flexes the elbow (Fig. 15.52).
- **Supinator (C₅-C₆):** Place the forearm in mid-prone position. Tap the styloid process of the radius. The supinator contracts followed by flexion and supination of forearm (Fig. 15.53).
 - *Inversion of biceps and triceps:* This means brisk finger flexion following elicitation of biceps or supinator jerks. It indicates C₅-C₆ lesion with loss of biceps and supinator reflexes. This is due to hypertonicity of finger flexors muscles.
- **Triceps (C₆-C₇):** Flex the elbow and allow the forearm and the hand to rest over the patient's chest. Support the forearm with your hand and tap the triceps tendon just above olecranon. The triceps contracts which can be seen or felt (Figs 15.54A and B).
- **Finger flexion (C₇-C₈):** Ask the patient to semiflex the fingers. Place your middle and index fingers on the palmar surface of the hand. Sudden tap over the fingers will cause flexion of the fingers and the thumb (Fig. 15.55).
- **Hoffman's sign (Fig. 15.56):** The patient's hand is pronated and observer holds the index or middle finger of the patient between his/her thumb and index finger of left hand. Briskly flick down the patient's finger tip with the right thumb and release it suddenly. Observe the movement of the thumb.

A positive response results in adduction and flexion of the thumb and flexion of fingers.




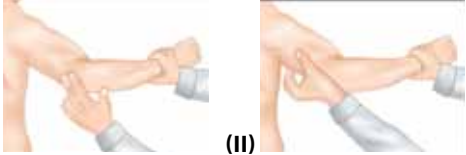
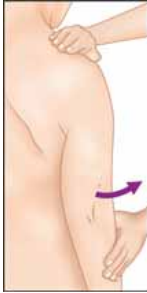


- **Wartenberg's sign (Fig. 15.57):** Hold the patient's fingers except the thumb with your right hand. Try to pull the fingers with your hand. Observe the movement of the thumb. Normally, the thumb abducts and extends with this manoeuvre, but flexion and adduction of the thumb indicates positive response. It carries same significance as the Hoffman's sign.

TABLE 15.26 Testing of the muscles (Figs 15.51A to CC)

Figure	Root value	Muscle testing
 <p>FIGURE 15.51A Testing the abductor pollicis brevis</p>	C ₆ , C ₇	Abductor pollicis brevis: The patient is asked to abduct the thumb at right angle to the palmar surface of the index finger (Fig. 15.51A) against resistance of the examiner's thumb. The muscle normally is seen and felt to contract during this manoeuvre but fails to do so if median nerve is involved (e.g. carpal tunnel syndrome) or there is atrophy of the small muscles of the hand.
 <p>FIGURE 15.51B Testing the opponens pollicis</p>	C ₆ , C ₇	Opponens pollicis: Instruct the patient to touch the top of the little finger with the top of the thumb. Oppose this movement with your thumb or index finger (Fig. 15.51B). Feel for the resistance; failure to do so indicates paralysis.
 <p>FIGURES 15.51C and D (C) Testing the first dorsal interosseus muscle; (D) Testing the first palmar interosseus muscle</p>		Testing the interossei muscles (First dorsal interosseus Fig. 15.51C): Instruct the patient to separate the thumb from the fingers. Now ask him/her to abduct the index finger against your resistance. Failure to do so indicates paralysis of ulnar nerve or atrophy of small muscles of hand. First palmar interosseus (Fig. 15.51D). Ask the patient to adduct the index finger of pronated hand against resistance.
 <p>FIGURE 15.51E Claw hand (left) due to ulnar nerve palsy as a result of fracture at elbow</p>		Testing of other interossei and lumbricals Test the ability of the patient to flex their <i>metacarpophalangeal</i> joint and extend the distal interphalangeal joints. The interossei are adductors (palmar interossei) and abductors (dorsal interossei) of fingers. A claw-hand deformity is produced if they are paralysed such as ulnar nerve palsy. This is due to retention of power in the long flexors and extensors of the two fingers (Fig. 15.51E). The first phalanges are overextend and the distal two are flexed. There is separation of the fingers.
 <p>FIGURE 15.51F Testing the long flexors of the fingers</p>		Testing of long flexors of fingers (e.g. flexor digitorum profundus I, II and III and flexor digitorum sublimis). The long flexors are individually tested by flexion at the interphalangeal joints as demonstrated in the Fig. 15.51F. The long flexors are simultaneously tested by asking the patient to squeeze your fingers. Allow the patient to squeeze only your index and middle fingers; this is sufficient to assess strength of hand grip (Fig. 15.51G).
		 <p>FIGURE 15.51G Testing the power of the small muscles of the hand</p>






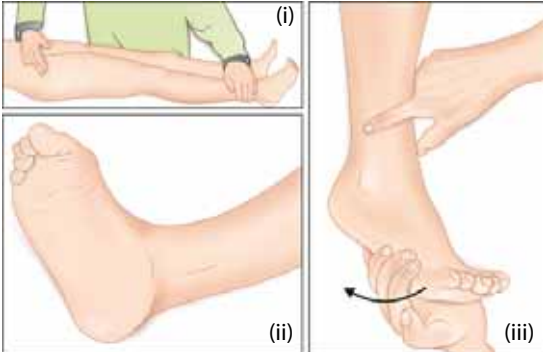
Contd...

Contd...

Figure	Root value	Muscle testing
 <p>FIGURE 15.51H Testing the extensor carpi radialis longus</p>		<p>Flexors and extensors of the wrist: Ask the patient to make the fist. This results in forcible contraction of both the flexors and extensors of the wrist.</p> <p>To test the extensors of the wrist (Fig. 15.51H), ask the patient to extend the wrist against resistance. If the extensors are weak, then he/she can not do so. If extensors are weak, the wrist becomes flexed leading to wrist drop as occurs in radial nerve paralysis.</p>
 <p>FIGURE 15.51I Testing the flexor carpi radialis</p>		<p>To test the flexors of wrist, ask the patient to squeeze your fingers. The grip will be weak, if flexors are weak. Now ask the patient to make the fist and try to overcome the wrist-flexion by your hand (Fig. 15.51I). Failure to do so indicate paralysis of wrist flexion</p>
 <p>FIGURE 15.51J Testing the biceps</p>	<p>C₅C₆</p> <p>C₅C₆</p>	<p><i>Flexors of the elbow</i></p> <p>Biceps: It is tested by asking the patient to bend the supine forearm against resistance. The muscle contracts and stands out prominently (Fig. 15.51J).</p> <p>Brachioradialis: Place the forearm midway between prone and supine positions. Now direct the patient to flex the forearm against resistance. The muscle is seen to contract and stands out prominently at the upper part of forearm.</p>
 <p>FIGURES 15.51K (I) and (II) Testing the triceps: (i) Long head; (ii) The whole muscle</p>	<p>C₇C₈</p>	<p><i>Extensor of the elbow.</i></p> <p>Triceps: It is tested by asking the patient to extend the forearm against resistance [Figs 15.51K(i) and (ii)]. The muscle is seen to contract and stands out prominently at the back of arm.</p>
 <p>FIGURE 15.51L Testing the supraspinatus (e.g. abduction between 0 to 30°)</p>  <p>FIGURE 15.51M Testing the deltoid (e.g. abduction between 30° to 90°)</p>		<p><i>Abductors of the shoulder.</i></p> <p>Supraspinatus and deltoid: These are abductors of shoulder. The first 30° movement (0–30°) is carried out by the supraspinatus and rest 60° (30° to 90°) is carried out by deltoid.</p> <p>Method: Ask the patient to abduct the forearm against resistance. The first 30° is tested for supraspinatus (Fig. 15.51L). Now ask the patient to abduct the arm to 30° and now further abduct the arm against resistance. The deltoid contracts and is seen and felt (Fig. 15.51M).</p> <p>Abduction becomes weak if these muscles are paralysed.</p>
 <p>FIGURE 15.51N Testing the infraspinatus</p>		<p>Infraspinatus is an external rotator at shoulder. It is tested by asking the patient to keep the arm along the side of the chest and flex the forearm at right angle (Fig.15.51N). Now ask the patient to rotate the limb externally against your resistance, the elbow being kept along the side throughout the manoeuvre. The muscle belly can be seen and felt by keeping your hand below the spine of scapula.</p>








Contd...

Contd...

Figure	Root value	Muscle testing
 <p>FIGURE 15.51O Testing the pectoralis major</p>  <p>FIGURE 15.51P Testing the serratus anterior</p>		<p>Pectoralis: Pectoralis major is flexor of the shoulder. It can be tested by asking the patient to outstretch the arms in front and then to clap the hands together while you resist the movement and try to hold them apart (Fig. 15.51O). The muscle is seen and felt to contract and stands out prominently in front of chest.</p> <p>Serratus anterior: This is the scapular muscle which keeps the scapula tight to the chest, hence, its paralysis produces separation of the scapula from the vertebral column called “winging of the scapula” and patient is unable to lift the arm above a right angle. The muscle is tested by asking the patient to push against a wall, the muscle contracts and keeps the scapula bound to chest (Fig.15.51P), paralysis produces winging of scapula.</p>
 <p>FIGURE 15.51Q Testing the latissimus dorsi</p>  <p>FIGURE 15.51R Testing the trapezius</p>		<p>Latissimus dorsi: Stand behind the patient. Ask the patient to clasp the hands behind their back. Offer resistance to the backward and outward movement. The muscle bellies stand are prominently as the posterior axillary folds which can be seen and felt (Fig. 15.51Q). Alternately the muscles can be tested by asking the patient to cough forcibly. The muscles contract and make the posterior axillary fold prominent.</p> <p>Trapezius: Ask the patient to shrug his or her shoulder while the examiner opposes this movement (Fig. 15.51R).</p>
 <p>FIGURE 15.51S Testing of rectus abdominis</p>		<p>Muscles of the trunk</p> <p>Abdominal muscles: Rectus abdominis is the muscle supplied by ventral rami of T₇-T₁₂. The upper portion (above the umbilicus) is supplied from T₇ to T₉ and lower portion from T₁₀-T₁₂. The main action of the muscle is flexion of the spine.</p> <p>Testing: Ask the patient to lie supine and elevate his/her body from the pillow without support or against resistance. You can see and feel the contractions of rectus abdominis on both the sides (Fig.15.51S) and umbilicus is central. In case of paralysis on one side, the umbilicus will be pulled to the other side by the unopposed action of nonparalysed muscle.</p> <p>Paralysis of a portion of anterior abdominal muscle will displace the umbilicus either upwards (lower abdominal muscles paralysis) or downwards (upper abdominal muscle—paralysis). This is called <i>Beevor's sign</i>, helps to localise the lesion in spinal cord disease.</p>
 <p>FIGURES 15.51T (I) to (III) Testing the muscles of foot: (i) Tibialis posterior (e.g. invertor of foot); (ii) Peroneus longus and peroneus brevis (main evertors of the foot); (iii) Small muscles of the sole</p>		<p>Muscles of the lower limbs</p> <ol style="list-style-type: none"> Testing the small muscles of the foot: The small muscles of the foot are tested for adduction, abduction of toes and great toe similar to the small muscles of the hand. Interossei are again adductors and abductors in the foot. Paralysis of the interossei produces foot deformity. Similarly foot deformity occurs in a patient with hemiplegia. 'Pes cavus' is hollowing of the sole, occurs in familial peripheral neuropathy Dorsiflexion and plantarflexion of toes and the feet are tested by asking the patient to elevate or depress the part against resistance. The invertors and evertors are tested as given in the Fig. 15.51T. Extensors and flexors of knee: The extensor (quadriceps) of the knee is tested by bending the knee of the patient with your hand and then asking the patient to extend it against your resistance. Contraction of this muscle can be seen and felt in the thigh (Fig. 15.51U).

Contd...

Contd...

Figure	Root value	Muscle testing
 <p>FIGURE 15.51U Testing the quadriceps femoris</p>  <p>FIGURE 15.51V Testing the hamstring muscles</p>  <p>FIGURE 15.51W Testing the extensors of hip</p>  <p>FIGURE 15.51X Testing the flexors of hip</p>		<p>Flexors of the knee (<i>biceps femoris</i>, <i>semitendinosus</i>, <i>semi membranosus</i>) are tested by asking the patient to lie prone. Now flex the knee against resistance. The muscles can be seen and felt on lateral side (<i>biceps</i>) and medial side (<i>semimembranosus</i>) respectively (Fig. 15.51U)</p> <p>4. Extensors of the hip: (e.g. <i>gluteus maximus</i> and <i>hamstrings</i>). Ask the patient to lie supine with knees extended. Lift the foot off the bed and keep the palm of your hand below the foot. Ask him/her to push it down against your resistance (Fig. 15.52W). Judge the power in the extensors of the hip by estimating the resistance.</p> <p>5. Flexors of the hip (e.g. <i>iliacus</i>, <i>psoas major</i> and <i>psoas minor</i>). Ask the patient to lie supine with legs extended. Ask the patient to raise the leg (flex the leg) off the bed against resistance (Fig. 15.51X). Assess the resistance to decide power in the muscles.</p> <p>“Babinski’s rising up sign”: In the abdominal muscles weakness, patient is not able to rise from the bed with out support. <i>Babinski’s rising up sign</i> is elicited by asking the patient to lie supine with legs extended and rise up without support. Normally the legs do not rise. In spastic paralysis (UMN paralysis) of a leg such as in hemiplegia, the affected limb will rise first, but in hysterical paralysis or malingering, this does not occur, hence, this sign differentiates hysterical weakness from spastic weakness.</p> <p>Erector spinae: The erector spinae and back extensors are tested by asking the patient to lie prone and lift the head from the bed by extending the neck and back. Normally, they can be seen standing out and prominently during manoeuvre.</p>
 <p>FIGURE 15.51Y Testing the neck extensors</p>  <p>FIGURE 15.51Z Testing the lateral bending</p>  <p>FIGURE 15.51AA Testing the adductors of hip</p>		<p>Neck muscles</p> <p>Neck flexors (e.g. <i>longus collis</i> C₂-C₆, <i>longus capitis</i>—C₁ to C₃; <i>rectus capitis anterior</i> C₁ to C₂, <i>sternomastoid</i>—C₂-C₃, and XI cranial nerve, <i>scalenus anterior</i>; C₄-C₆) are tested by asking the patient to flex the neck while you resist this movement by placing your hand at the forehead. Note the amount of resistance which you have to apply for this.</p> <p>Neck extensors (e.g. <i>semispinalis capitis</i>, <i>longissimus capitis</i>, <i>rectus capitis posterior major</i> and <i>minor</i>) are tested similarly as flexors. Ask the patient to extend neck against your resistance (Fig. 15.51Y). Assess the amount of resistance used.</p> <p><i>Neck rotator</i> (e.g. <i>sternomastoid</i>) testing has been discussed in examination of XI cranial nerve.</p> <p>Lateral bending of the neck (e.g. <i>sternomastoid</i>, <i>scalenus anterior</i>, <i>splenius cervical is</i>, <i>rectus capitis lateralis</i>) is tested by asking the patient to bend the neck laterally against resistance (Fig. 15.51Z) or first bend the neck laterally and then try to counteract this bending to assess the power to be used.</p> <p>Adductors of hip: (e.g. <i>adductor longus</i>, <i>adductor brevis</i>, <i>adductor magnums</i>, <i>gracilis</i> and <i>pectineus</i>). Adductors are flexor of thigh also. Ask the patient to lie supine with legs separated but straight. Now ask the patient to move the limb towards midline against resistance (Fig. 15.51AA). Assess the power in the muscles from the resistance offered.</p>

Contd...

Contd...



Figure	Root value	Muscle testing
 <p>FIGURE 15.51BB Testing the abductors of the thigh (hip)</p>  <p>FIGURE 15.51CC Testing the medial (internal) rotation of hip</p>		<p>Abductors of the hip: (e.g. gluteus medius and gluteus minimus). Place the patient's legs together while the patient is supine. Ask him/her to separate them against resistance (Fig. 15.51BB). Assess the power in the muscles.</p> <p>Rotators of the hip</p> <p>Lateral or external rotators (e.g. obturator internus, quadriceps femoris) Medial rotators (e.g. obturator externus): To test the rotators, ask the patient to lie supine with limbs extended. Now ask him/her to roll the limb outwards (lateral rotation) or inwards (medial rotation) against resistance (Fig. 15.51CC).</p>

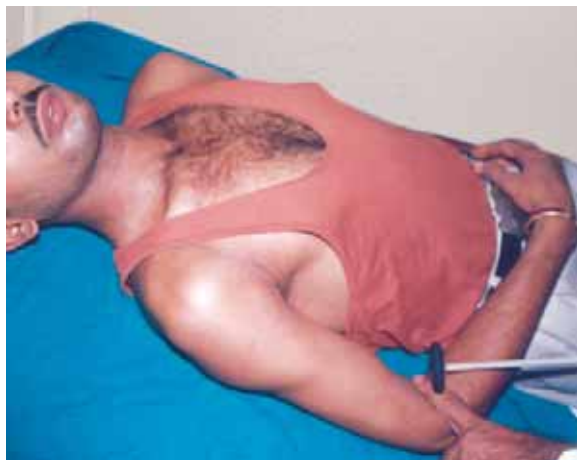

FIGURE 15.52 Biceps jerk

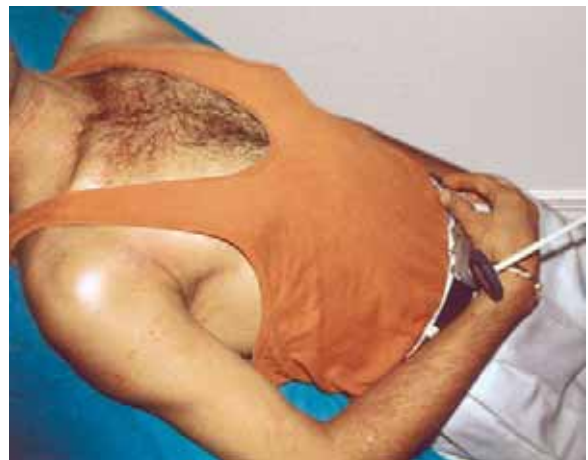
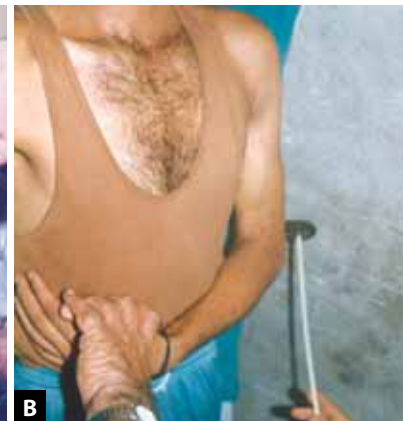
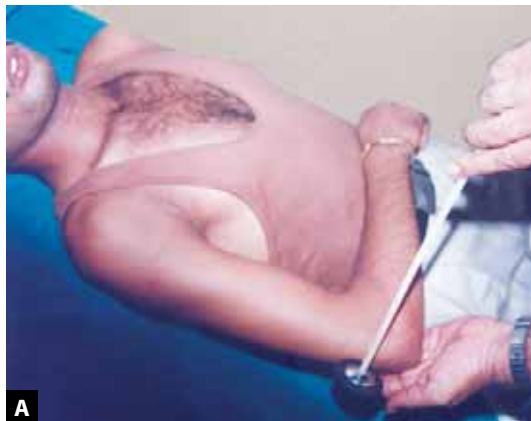FIGURE 15.53 Supinator jerk



FIGURES 15.54A and B Elicitation of triceps jerk: (A) During lying down; (B) During sitting

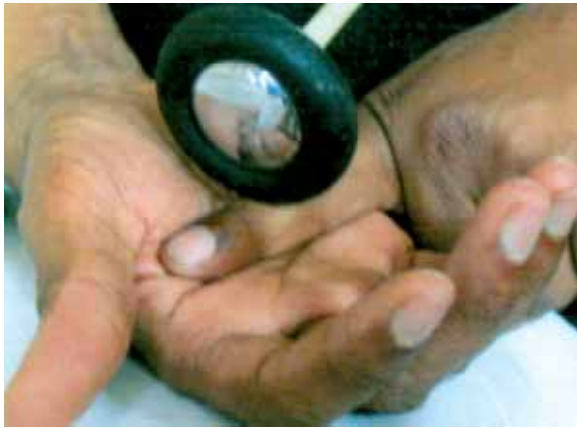

FIGURE 15.55 Finger flexion jerk

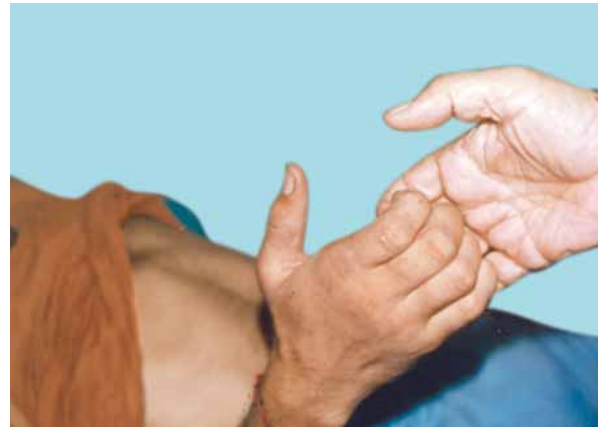

FIGURE 15.57 Wartenberg's sign



FIGURE 15.56 Hoffman's sign

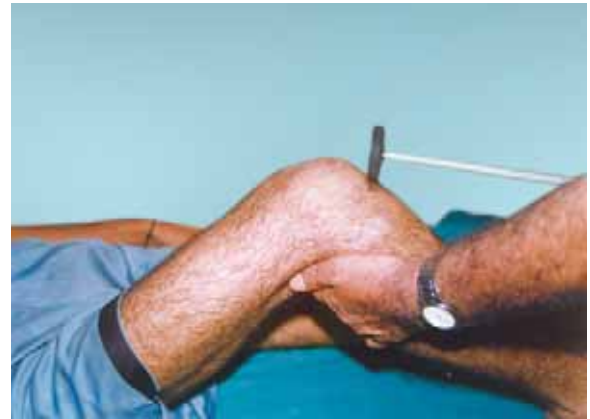

FIGURE 15.58 Knee jerk

- **Jaw jerk (Vth cranial nerve):** It has been discussed under examination of Vth cranial nerve.
- **Pectoral reflex (C₇):** This reflex may sometime be useful in localisation of the lesion. It is not elicited but can be employed if needed. Place the extended index and middle fingers on the lateral border of the pectoralis muscle and tap them with percussion hammer. The muscle contracts.
- **Deltoid reflex (C₅):** The upper fibres of deltoid are supplied by XI cranial nerve and lower fibres by C₅. Place the finger across the tip of shoulder and tap it. The deltoid contracts.
- **Ankle jerk (S₁-S₂):** Place the lower limb on the bed so that it lies everted and slightly flexed. Stretch the Achilles tendon slightly by dorsiflexing the foot (Figs 15.59A and B) with the other hand. Now, tap the tendon on its posterior surface of the ankle. Observe the contraction of the calf muscles as well as plantarflexion of ankle.
Alternatively, the reflex can be elicited when the patient is kneeling on a chair.

Lower Limb Reflexes

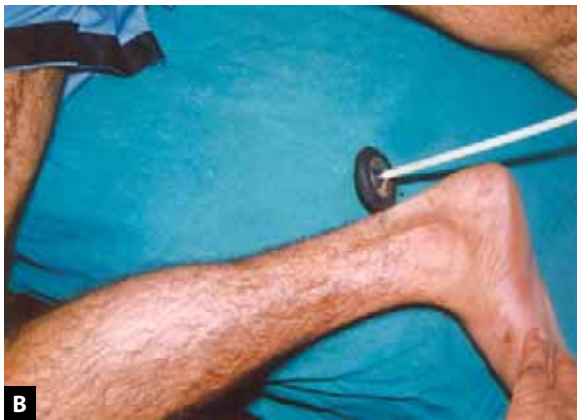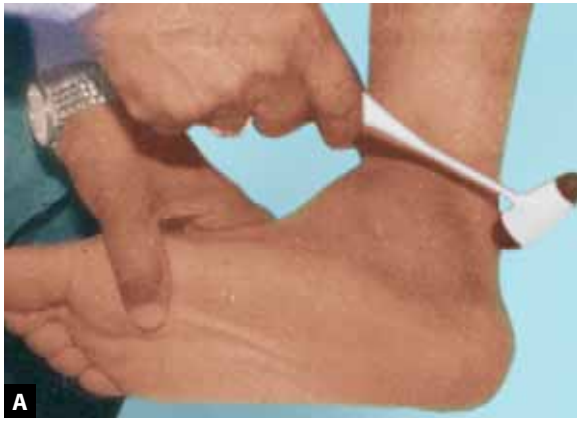- **Knee jerk (L₃-L₄):** It is tested with patient supine. Place your hand under the knee (Fig. 15.58) to be tested and may be placed on the opposite knee so that legs do not come in contact with each other and knee rests on the observer's hand. Strike the tendon just below the patella and observe for the contraction of quadriceps muscle in the thigh as well as extension of the knee.

Alternatively, the reflex can sometimes be tested easily with the patient sitting up, the legs hanging freely over the edge of the bed.

Reinforcement (Fig. 15.60): It is a manoeuvre used to elicit the tendon reflexes when either they are not elicitable or barely elicitable. It is based on the principle that motor activity can be enhanced by contracting another muscle thereby increasing the activity of gamma efferent system. In this manoeuvre, patient is asked to clench the teeth or clench the hands or pull the flexed fingers of two hands against each other (*Jendrassik's manoeuvre*).

Remember: Once the deep tendon reflexes are found to be exaggerated, then proceed to elicit the clonus.

For *knee clonus*, sharply push the patella towards the foot while patient lies supine with knees extended. Give sudden jerk to the patella initially, followed by sustained pressure with



FIGURES 15.59A and B Elicitation of the ankle jerk: (A) Conventional method; (B) Alternative method

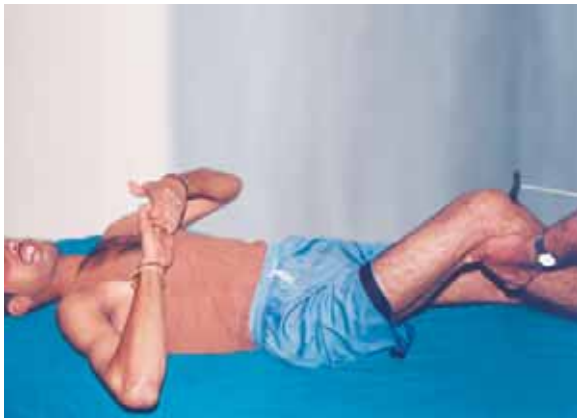

FIGURE 15.60 Reinforcement phenomenon (Jendrassik's manoeuvre)

the thumb and index finger in a downward direction on the patella (Fig. 15.61). Feel for the intermittent jerky movements due to muscle contractions.

For *ankle clonus* (Fig. 15.62), support the flexed knee with one hand in the popliteal fossa so that ankle rests gently on the bed. Dorsiflex the foot briskly with the other hand and sustain the pressure. Inspect and feel for sustained movements of

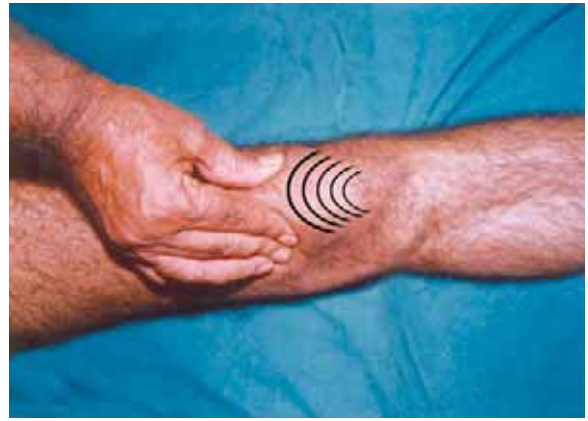

FIGURE 15.61 Patellar clonus

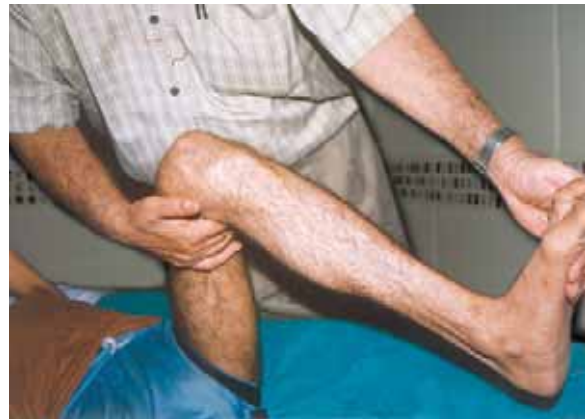

FIGURE 15.62 Ankle clonus

foot due to involuntary muscle contractions of hypertonic muscles.

For *wrist clonus*, have patient lie supine and rest. Grasp the hand and passively flex/extend at the wrist joint 3 times, the last time in full extension for several seconds. Feel for any involuntary movements of hand.

Movements of hands >2 times in the extended posture indicates clonus.

NB: A few beats of clonus are present in a normal person particularly tense or anxious persons having normal plantar response—hence called ill-sustained clonus or unsustained clonus.

Grading of Reflexes

The tendon reflexes are graded as below:

- Grade 0 : Absent
- Grade I : Present (a normal jerk)
- Grade II : Brisker than normal.
- Grade III : Very brisk (exaggerated).
- Grade IV : Associated with clonus in case of knee or ankle jerk.

Abnormalities of Tendon Jerks

The tendon reflexes may be increased, decreased or absent, and sometimes may have pendular quality. Normal jerk is initiated by sudden contraction followed by sudden relaxation. The causes of abnormal jerks are given in the Table 15.27.

The Superficial Reflexes

The superficial reflexes have, in addition to a local spinal reflex arc, a superimposed cortical pathway—a cerebral arc. Impulses ascend through the spinal cord and brainstem to the sensory parietal cortex, jump to the motor cortex through cerebral connections. The efferent impulses from the motor cortex pass down the pyramidal tracts to the anterior horn cells of the brainstem and spinal cord at each level. Hence, a lesion of the reflex arc or an upper motor neuron lesion involving pyramidal tract will abolish these superficial reflexes. This is a paradox in the UMN lesion where the deep tendon jerks are exaggerated but the superficial reflexes are absent.

1. The superficial abdominal reflex (upper T₆-T₉ and lower T₁₀-T₁₂)

- Position the patient supine with relaxed upper limbs by the side of the body.
- Stroke the upper and lower quadrants of the abdominal wall on each side lightly with a key or a wooden stick preferably from outside towards centre as indicated by arrows in Figure 15.63. It does not matter much whether you stroke from outside inwards or inwards to outwards.
- Observe any muscle contraction.

Normally, following a stimulus there is reflex homolateral contraction of the anterior abdominal muscles, retraction of linea alba and the umbilicus towards the quadrant stimulated.

Significance: In disease of the thoracic spine, the loss of these reflexes indicate segmental localisation of the lesion. The causes of absent abnormal reflexes are:

- Lesions of the reflex spinal arc involving segmental innervation of these reflexes.
- UMN lesion above their spinal level (T₆-T₁₂).
- Marked obesity or over distended abdomen such as ascites.
- Multiparous women with lax abdomen, pregnancy
- In anxious and elderly patients.

2. Cremasteric reflex (L₁-L₂)

- Position the patient with thigh externally rotated and legs separated (abducted)
- Scratch the skin of the upper thigh with a stick (Fig.15.64) from below upwards.
- Observe the movement of the ipsilateral testicle.

TABLE 15.27 Abnormalities of jerks

Increased (hyper-reflexia)

It means the jerks are brisk or exaggerated as compared to normal or if one side is involved, then brisker than the other side. The causes are:

- Upper motor neuron lesion due to any cause at all levels. In spinal cord compression, the jerks are increased below the level of compression due to loss of UMN control over LMN.
- Anxiety or nervousness.
- Thyrotoxicosis.
- Tetanus.
- Hysteria.
- Strychnine poisoning.
- Fright.
- Tetany.

Decreased (hyporeflexia) or absent (areflexia)

- Lower motor neuron lesion involving the local reflex arc.
- Neuronal/spinal shock in UMN lesion.
- Muscle contractures due to marked spasticity/rigidity.
- Normal individual who are unable to relax.

Pendular jerks

- Cerebellar disease. This is due to combination of ataxia and hypotonia in cerebellar disease.
- Chorea.

Myotonic jerks (hung-up reflex)

In this type of jerks, contraction and the relaxation phase of the jerks is prolonged, i.e. the jerks are slower than normal with prolonged relaxation.

These are seen in:

- Myxoedema (delayed relaxation is typical)
- Hypothermia

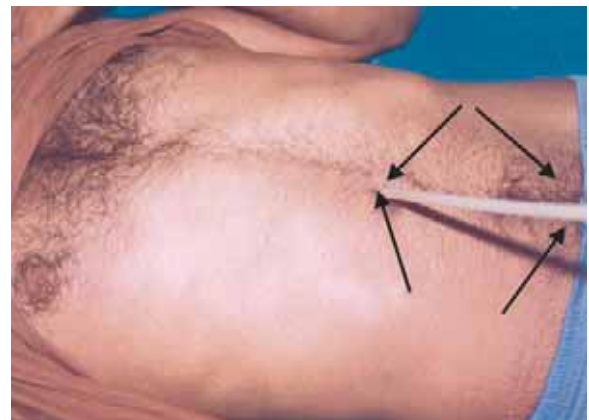


FIGURE 15.63 Abdominal reflexes

Normal response is the contraction of the cremasteric muscle with elevation of ipsilateral testicle.

The causes of absent cremasteric reflex are:

- Lesions involving the spinal dermatome L₁-L₂.
- Pyramidal lesion.
- Hydrocoele.
- Hernia.

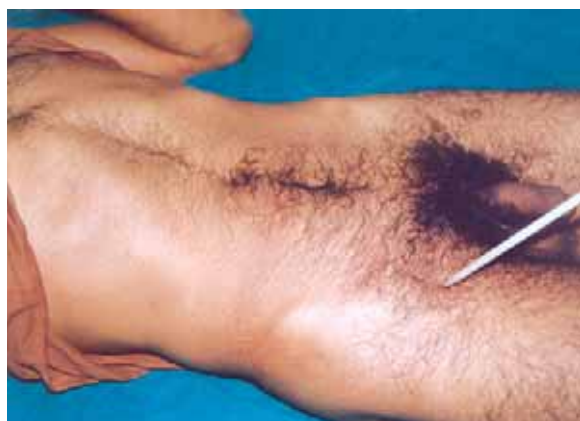

FIGURE 15.64 Cremasteric reflex

The absent reflex has a localising value. Its absence indicates either the lower motor neuron lesion involving L₁-L₂ segments or UMN lesion of the cord above this level.

The superficial reflexes are *exaggerated* in chorea, parkinsonism and amyotrophic lateral sclerosis, anxiety or hysteria (as a part of general hyper-reflexia). It has been believed that lesion involving the red nucleus is associated with increased superficial reflex.

3. The plantar reflex

It is also a superficial reflex. The method of elicitation is described in the Box 20 with illustration (Fig. 15.65).

Normally, there is flexion of all the toes including great toe with plantarflexion of foot.

Normal vs Abnormal Response

The plantar reflex is never completely absent in the healthy subjects. However a stronger stimulus or an irritating stimulus in an hypersensitive patient may evoke withdrawal of the limb (e.g. initial flexor response is quickly followed by extension of toes and withdrawal of leg).

Babinski's response (an abnormal extensor plantar response). Positive Babinski's sign indicates always an upper motor neuron lesion and is considered pathognomonic of it when present.

A positive Babinski's sign means dorsiflexion (extension) of the big toe and fanning of the other toes with slight dorsiflexion of the ankle and flexion of knee and hip. It is actually considered as generalised flexor response of the lower limb.

If plantar reflex is not elicited by any method, the reinforcement (*Jendrassik's manoeuvre*) method (clinch the fists) may be employed to evoke a response. Other means employed to evoke a response in such a case are:

- Application of warmth to the cold skin or rubbing the sole of the foot to make the skin sensitive.

Box 20

The plantar reflex (L₅-S₁)

- Place the patient supine in relaxed position with knees extended.
- Just hold the ankle with left hand above the foot or over the knee so as to prevent withdrawal of the foot.
- Gently scratch the outer edge of the sole of the foot by a key or a stick from the heel towards little toe and then medially across the metatarsus.

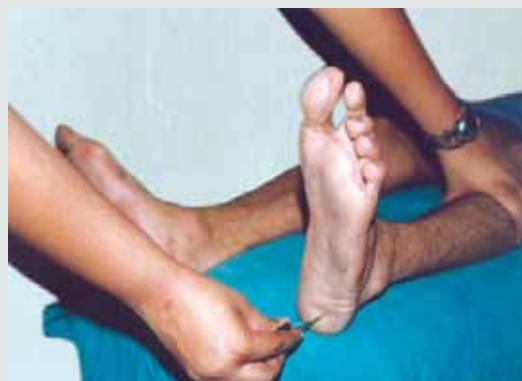

FIGURE 15.65 Methods of eliciting plantar response

- Turn the patient's head to opposite side to divert the attention of the patient.
- A different stimulus may be used.

In case of *amputated* great toe, the fanning of lateral four toes, dorsiflexion (extension of the ankle) and eversion of the foot is taken as a positive response, while if the foot is amputated, then strong contraction of fascia lata and flexion of knee and hip is taken as positive response on scratching the stump with a key or a stick (*Brissaud's reflex*).

The causes of plantar extensor response (Babinski's positive) are:

- Physiological
 - In infants below 1 year of age.
 - Deep sleep.
- Pathological
 - Pyramidal (corticospinal tract) lesions.
 - Deep coma or following anaesthesia.
 - Hypoglycaemia.
 - Following an epileptic fit (post-seizures)
 - Metabolic encephalopathy.
 - Neuroleptics.

The causes of absent plantar response are:

- Loss of sensation over the foot (L₅-S₁), e.g. prolapsed disc or peripheral neuropathy.
- Paralysis of extensor hallucis.
- Thickened (hyperkeratotic) skin.

- Cauda equina lesions.
- Flexor and extensor spasms

Extensor spasms refer to extension of the whole limb during plantar extensor response indicate severe corticospinal tract lesion without posterior column involvement.

Flexor spasms refer to sudden flexion of the whole lower limb (withdrawal response) during plantar extensor response.

The causes of these spasms include:

- Spinal cord disease/compression
- Bilateral UMN lesions at higher level
- More common in combined involvement of corticospinal tracts and posterior column (e.g. multiple sclerosis, subacute combined degeneration)
- Presence of bed sore or UTI in patients with cord lesion.

Both flexor and extensor spasms are abnormal and indicate nothing but an exaggerated plantar extensor response (Read paraplegia—a case discussion in Bedside Medicine without Tears by Prof. SN Chugh).

Other Methods to Elicit Plantar Reflex

In extensive corticospinal tract damage, the area from which the extensor plantar reflex can be elicited (receptive field) enlarges, spreading first inwards and over the whole sole and then upwards along the leg to the knee and even higher, therefore, other tests are based on this enlargement of receptive area, also called *plantar equivalence* (Box 21).

4. **Corneal reflex:** Read Examination of Eye Chapter 5.
5. **Palatal reflex:** Read Examination of Cranial Nerves IX and X.
6. **Anal reflex (S₃-S₄):** Stroking or scratching the skin near anus in a circular manner produces contraction of anal sphincter.

Box 21

Plantar equivalence

- **Oppenheim sign:** Stroking with heavy pressure by the thumb and index finger from above downwards along the shin (anterior surface of tibia) evokes an extensor response.
- **Gordon's reflex (Schaefer's sign):** Pinching the achilles tendon evokes plantar extensor response.
- **Chaddock's sign:** Scratching the skin around the lateral malleolus in a circular fashion evokes plantar extensor response.
- **Strinsky's sign:** Passive abduction of the 5th digit evokes a response.
- Other signs such as *Bing sign*, *Gonde sign*, *Moniz sign* are just similar to the above 4 signs, are not practised usually.
- **Rossolimo's sign:** It is similar to Hoffmann's sign in UMN lesion where there is flexion of all the five toes (the greater toe is plantarflexed rather than dorsiflexed).

7. **Bulbocavernosus reflex (S₃-S₄):** Pinching dorsum of the glans penis produces contraction of bulbocavernosus muscle.
8. **Scapular reflex (C₅-T₁):** Stroking the skin in interscapular region produces contraction of scapular muscles. This becomes absent in high cervical UMN lesion or LMN lesion involving lower cervical segments.

Anal and bulbocavernosus reflexes become absent involving S₃-S₄ spinal segments (cauda equina lesion) or UMN lesions of the cord.

Primitive reflexes (Read testing of higher mental function in the beginning of the chapter).

Visceral Reflexes

These reflexes pertain to visceral functions such as swallowing, defecation, micturition and sexual activity.

Swallowing (deglutition): Ask the patient about any nasal regurgitation of food through the nose. Also ascertain whether there is any difficulty in swallowing (dysphagia).

Dysphagia in neurological disorders (motor dysphagia) pertains to liquids more than solids, whereas mechanical dysphagia (obstruction in the oesophagus or pharynx) is limited to solids only.

Cough reflex: Ask the patient to cough. Normally on coughing one should have sharp voice and you can feel movement air in front of mouth. In poor cough reflex voice becomes hoarse, feeble and there is hardly any movement of air in front of mouth. Cough reflex is absent or poor in bulbar paralysis, diaphragmatic palsy, intercostal muscles paralysis and IX and X cranial nerves palsy. Cough reflex is also lost in deep coma (Read the Examination of Unconscious Patient Chapter 16).

Defecation: Ask the patient about any difficulty with defecation or continence. Ask also about any abnormal anorectal sensations.

Tone of the voluntary anal sphincter can be tested by introducing the lubricated gloved finger into the anus and noting any laxity or paralysis (toneless) or spasm of the sphincter. The degree of tension of anal sphincter during a voluntary squeeze by asking—“tighten on my finger”—should be noted. It can be further tested by *anal reflex* and *cough reflex* (anal sphincter contracts briskly in response to sudden cough).

Damage to innervation of pelvic floor musculature produces relaxation of anal sphincter leading to incontinence of urine and faeces during stress (stress incontinence).

Micturition: Ask about any difficulty in controlling or initiating micturition and whether bladder and urethral sensations are normal. Retention, incontinence or urgency of micturition should be noted.

Neurological disorders with atonic distended urinary bladder produce overflow incontinence due to loss of bladder sensation. This is associated with distended bladder in the suprapubic region. Urge incontinence (incontinence occurs at regular intervals reflexly as it fills, in response to sudden noise, to movement or to exposure to cold), is an early feature of intrinsic spinal cord lesions.

Sexual activity: When incontinence is associated with neurological disease, sexual functions (e.g. penile erection, ejaculation in male) or orgasm in both sexes may be affected, hence, may be asked.

Mass reflex: In this situation, widespread response is seen to a localised stimulus; for example, stroking a thigh may produce flexor spasms of the leg with incontinence of faeces and urine. This is seen in chronic spinal cord compression with paraplegia-in-flexion.

(v) Co-ordination and gait

Co-ordination means smooth recruitment, interaction and co-operation of separate muscles or a group of muscles during a movement (motor act). The co-ordination depends on:

- Afferent impulses from the muscles and joints.
- Cerebellar functions.
- Tone of the muscles.

Testing of co-ordination indirectly refers to testing of the cerebellar function provided tone of the muscles is normal. The cerebellum plays an important role in the co-ordination of voluntary, automatic, and reflex movements. The cerebellum has a central vermis which is concerned with maintenance of the body posture, and two lateral cerebellar hemispheres which control the limb movement on its own side. *Ataxia* means instability due to incoordination of the muscles, may be due to cerebellar disease (cerebellar ataxia) or due to disordered sense of position or joint sense (sensory ataxia) as a result of posterior column involvement such as *tabes dorsalis*. When, however, there is loss of sense of position of a limb or joint (sensory ataxia), the sensory defect can be compensated by vision, hence, ataxia becomes apparent only when the eyes are closed or when the patient is in the dark. In cerebellar disease, the ataxia occurs even when the eyes are open.

Tests of Co-ordination

A. Eyes

Jerky or phasic nystagmus on lateral gaze to one side or both sides or downbeat or upbeat nystagmus. Upbeat nystagmus on looking up is characteristic of lesion of vermis of cerebellum.

B. Upper limbs and trunk

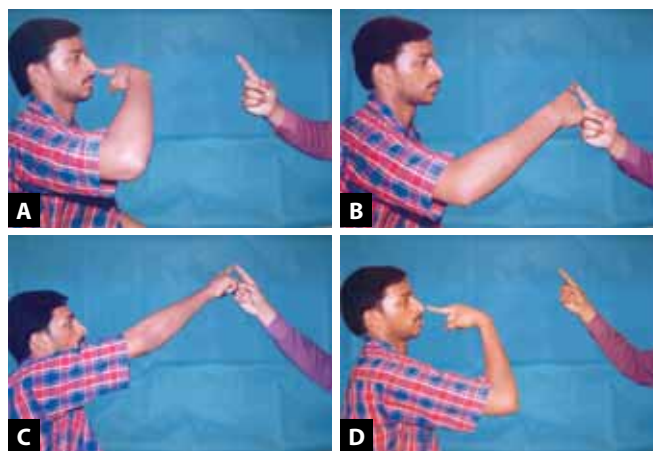
A useful method is to watch the patient dressing or undressing, handling a book or picking of pins or a glass of water, since these movements are more complex and practised daily,

the disturbance of these movements indicates disturbed co-ordination.

- **Finger-nose test:** Ask the patient to hold one arm outstretched, and then with the tip of the index finger, alternately touch the tip of the nose and the examiner's fingertip held in space as accurately as possible (Figs 15.66A to D).
 - Perform the test with patient's eyes open and test each arm in turn.
 - Make the test more discernible by moving the examiner's finger tip in space so that the patient has to adjust 'aim'.
 - To test sensory ataxia, repeat the procedure with the eyes closed.

In *sensory ataxia*, the patient may carry out the act without much difficulty with eyes open, but becomes unstable (ataxic) when the eyes are closed. In *cerebellar ataxia*, the patient is unable to perform the act with the eyes open. In addition, there may either be intention tremors, dysmetria and dyssynergia. In *dysmetria* the patient may either stop before he or she reaches the nose (hypometria) or may overshoot (hypermetria). In *dyssynergia*, the act or movement is not carried out smoothly but is broken into its constituent parts. *Intention tremors* mean tremors appear, become more marked and coarse as the finger approaches the nose. This is best appreciated during finger-nose test when the finger sways from one side to other as it approaches the nose.

- **Finger to finger test (Fig 15.67):** The patient is asked to outstretch both the arms to a horizontal level and then bring in the tips of index fingers in a wide circle to approximate them exactly in the midline.



FIGURES 15.66A to D Finger nose test for coordination: (A) Ask the patient to touch the tip of nose while you hold your finger in front of him/her; (B) Ask the patient to touch your finger (e.g. the examiner); (C) Move the finger from one position to another and ask the patient to touch it every time; (D) The patient touches the finger alternately while the examiner, moves the finger backwards and side to side. The patient touches the examiner's finger first and his/her tip of the nose later alternately



FIGURE 15.67 Finger to finger test in cerebellar ataxia. Note the past-pointing with eyes closed

In the unilateral cerebellar lesion, the finger on the side involved is ataxic, will either undershoot or overshoot the finger on the normal side. There may be past pointing of the fingers.

Rapid alternating movement (diadochokinesis): The patient is asked to perform alternately pronation and supination (Figs 15.68A to C).

In cerebellar lesion, there is slowness and irregularity in performing the movement on the side involved due to loss of rhythm of movement as a result of incoordination called *dysdiadochokinesis*.

Similarly you can ask the patient to close and open the fist on both sides as rapidly as patient can or pat his knees with palms and dorsa of the hands. The slowness of movements indicate cerebellar disease.

Postural instability: The patient is asked to hold the outstretched arms in horizontal position in front of him. Observe for any deviation.

In unilateral cerebellar lesion, the arm falls slowly and deviates laterally on the side involved.

Rebound phenomenon/test: Normally, contraction of antagonistic muscles occurs immediately after the relaxation of the agonists due to co-ordination between antagonist and agonists; the loss of co-ordination leads to rebound test/phenomenon as discussed below.

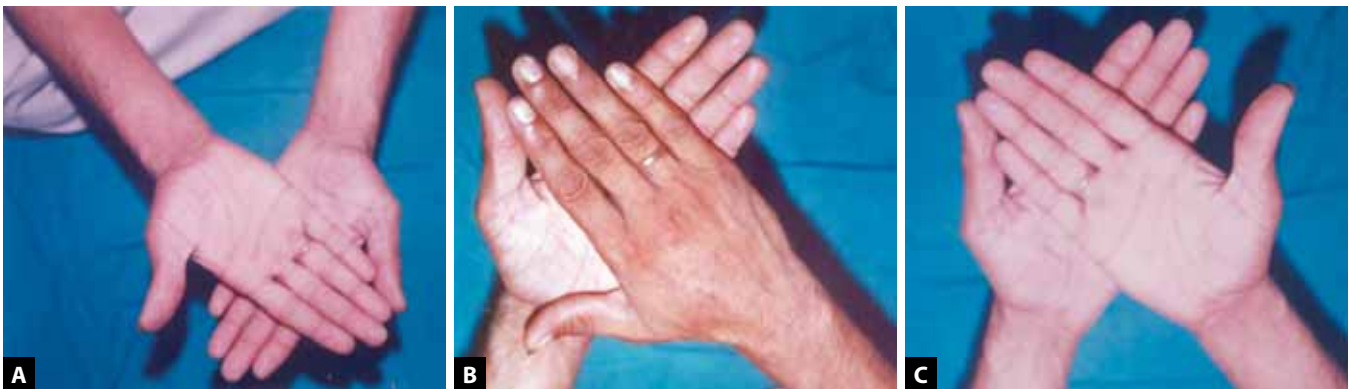The patient is asked to flex the upper limb at shoulder and elbow with clenched fist. The examiner pulls the wrist against resistance and then suddenly releases it. Normally, the contraction of triceps against resistance will stop the tendency towards flexion, but in cerebellar disease, this tendency is lost leading to exaggeration of flexion and overshooting of the forearm due to unopposed flexion.

Truncal ataxia: Normally the vermis of cerebellum controls the balance and checks the shift of the body from midline. In cerebellar disease, the patient is unable to maintain balance when sitting. The patient sways to one side or the other or may fall forwards or backwards when made to sit on the bed/chair.

C. Lower limbs

Knee-heel test [the heel-shin test (Fig. 15.69)]

- Ask the patient to raise one leg at the hip and place the heel of the flexed leg on the opposite knee and run the heel down along the shin (anterior surface of the tibia) towards the ankle and then lift it again and repeat the process again.
- To render the test more complex, ask the patient first to raise the leg and touch the examiner's finger held in a suitable position in space with the great toe before placing the heel on the knee. Still to make it more complex, the finger can be moved from one place to another.
- Observe for any irregularity in the speed and direction of movement, for intention tremors or dysmetria and dyssynergia as observed in the finger-nose test.



FIGURES 15.68A to C Testing the rapid alternating movement (diadochokinesis). Patient is explained the test by the examiner performing the movement himself/herself. Now patient is ask to perform supination (A) and pronation (B) and again supination (C) quickly as far as possible. Note any slowness of movement or its irregularity called dysdiadochokinesis.

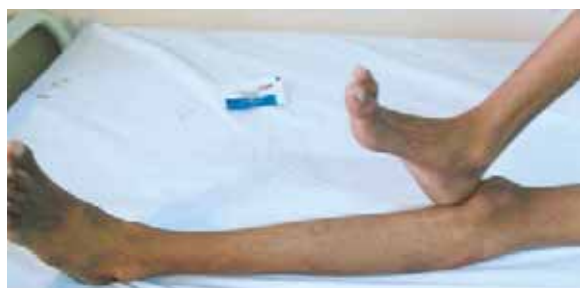

FIGURE 15.69 Knee-heel test (the heel-shin test)

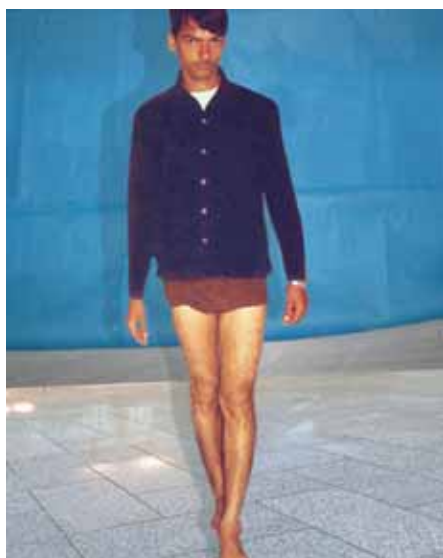

FIGURE 15.70 Tandem walking

- The test is repeated with eyes open and closed.

In cerebellar lesion, characteristic irregular side-to-side series of error occur both in speed and direction of movement with eyes open. In addition, there may be intention tremors, dysmetria and dyssynergia.

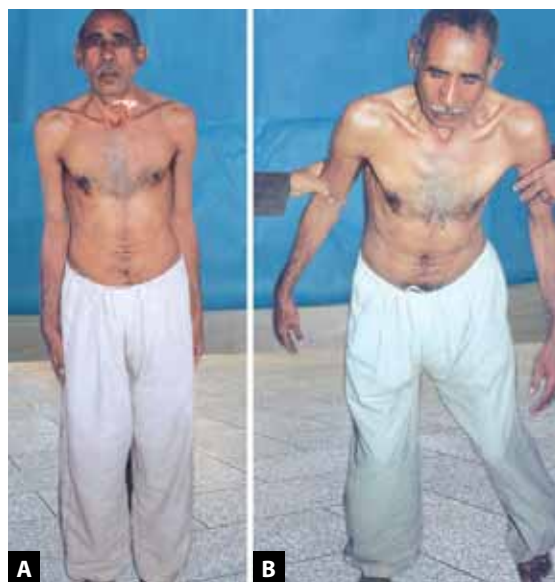Alternate test is to ask the patient to draw a large circle in the air with toes or forefinger. Normally, the circle will be drawn smoothly and accurately but irregularity will be noted in the cerebellar disease due to ataxia.

Tandem walking [the heel-toe test of gait (Fig. 15.70)]

The patient is asked to walk in a straight line on the floor either bare-footed or wearing fleet-shoes, placing one heel directly in front and above the opposite toes. Observe the gait in general, and in particular note any tendency to stagger and the side to which the patient preferentially falls.

Repeat the process with eyes open and with eyes closed.

- In unilateral cerebellar lesion, patient tries to deviate towards the side of lesion.
- In *sensory ataxia*, patient may walk fairly well with eyes open, but on closing his eyes he sways and staggers.



FIGURES 15.71A and B Romberg's sign for sensory ataxia: (A) Patient does not deviate during standing with feet close together and the eyes open; (B) Tends to fall (becomes ataxic) when asked to close the eyes

Romberg's test (Figs 15.71A and B)

It is a test for loss of position sense (sensory ataxia) in the legs. It is not a test of cerebellar function.

The patient is asked to stand with feet close together, and, if this can be done then to stand in this posture with the eyes closed. Observe for any swaying or tendency to fall.

In sensory ataxia, the Romberg's sign is positive (i.e. the patient is able to maintain the upright position when the eyes are open, but tends to sway or fall when the eyes are closed). It patient who is ataxic with eyes open but becomes more ataxic with eye closed is also positive for Romberg's sign. Patients with cerebellar or labyrinthine lesions tend to sway or fall towards the side of lesion with the eyes open which does not increase or increases a little when the eyes are closed (Romberg's sign is negative)

In hysteria, there may be a false positive Romberg's sign. There is marked unsteadiness both with eyes open and closed with swaying at the hip not at the ankle, first on one side, then on the other.

Causes of ataxia are given in the Box 22 and signs of cerebellar disease are tabulated (Table 15.28).

(vi) Examination of gait

Gait being an important element of assessing the disability, seeing a patient walking can be rewarding for neurological diagnosis. Patterns of weakness, loss of co-ordination, and proprioceptive (posterior column) sensory loss produce a range of abnormal neurological gaits. Neurogenic gait disorders need to be distinguished from those due to skeletal abnormalities, which are characterised by pain producing an

Box 22

Causes of ataxia

- Cerebellar
 - Cerebrovascular disease (infarction, haemorrhage)
 - Multiple sclerosis
 - Cerebellar tumour or abscess
 - Cerebellar degeneration (alcoholic, idiopathic)
 - Hereditary ataxias (spinocerebellar degenerations)
 - Drugs, e.g. alcohol, phenytoin, carbamazepine
 - Paraneoplastic syndrome (nonmetastatic manifestation of malignancy)
- Sensory
 - Tabes dorsalis
 - Subacute combined degeneration of cord
 - Peripheral neuropathy
 - Parietal lobe disease
- Functional
 - Hysterical
- Vestibular
 - Acute labyrinthitis
 - Meniere's disease
 - Drugs, e.g. streptomycin
 - Vascular lesion in medulla

TABLE 15.28 Signs of cerebellar involvement

Cerebellar vermis	Cerebellar hemisphere (ipsilateral signs)
<ul style="list-style-type: none"> • Truncal ataxia (patient has difficulty in maintaining balance while sitting and unassisted walking) • Gait ataxia (wide-based unsteady gait) 	<ul style="list-style-type: none"> • Abnormal finger-nose, adiadochokinesis, and abnormal heel-shin test on the side of lesion • Horizontal phasic nystagmus towards the side of lesion. • Intention tremors with pastpointing, dysmetria and dyssynergia.

analgesic gait, or limb. Gaits that do not fit either pattern may be due to “functional” or nonorganic disorders and are usually incompatible with any anatomical and physiological deficit.

Procedure/Sequence of Examination

The patient is asked to walk away from the observer, to turn round at a given point and then to come back. Note the following points:

- Is the patient able to walk or not?
- If unable, how much help does he/she need?

If the patient is able to walk without help, then ask him to walk along a straight line (*tandem walking*), and note whether he/she sways or tends to fall on any side.

To decide whether the gait conforms to any of the well-recognised gait disorder, note the posture, tone and arms

swinging during walking (for parkinsonism), the base on which patient walks (narrow, or broad), movements of the foot (high-steps or circumduction), etc. The various gaits are briefly discussed in the Table 15.29. Before labelling the gait disorder, exclude the musculoskeletal disorders.

Gait Apraxia

In an apraxic gait, there is normal power in legs with no abnormal cerebellar signs or proprioception loss, yet the patient can not formulate the motor act of walking. This is a higher cerebral dysfunction in which feet appear to be glued (stuck) to the ground and patient can not walk in spite of normal movements in bed.

(vii) Involuntary movements

These are unintended extra-movements that occur either at rest or during voluntary act or movement, mostly are due to diseases of the basal ganglia and extrapyramidal system.

Involuntary movements may be rhythmical (tremors) and irregular (chorea, athetosis, dystonia, hemiballismus, tics and myoclonus).

Tremors: These are regular, rhythmical, repetitive oscillatory movements of a part of body around a fixed point resulting from alternate contractions and relaxation of groups of muscles along with their antagonists.

They are classified in two ways, i.e. depending on the position or posture of a limb and according to amplitude (Box 23).

Static tremors are present at rest, intention, flapping and action tremors are absent at rest, present on actively maintaining a position and exaggerated by movement or action. The characteristics of various types of tremors, associated features and their causes are tabulated (Table 15.30).

Flapping tremor is the result of intermittent failure to maintain a posture (Table 15.30).

Chorea: These are brief, rapid, jerky, irregular, non-repetitive, quasi-purposive movement involving the face, head, and limbs. They occur at rest, often appear less obvious during voluntary movement and are increased by nervousness or anxiety.

Chorea literally means ‘a dance’, hence, choreiform movements are dancing movements occurring at various joints.

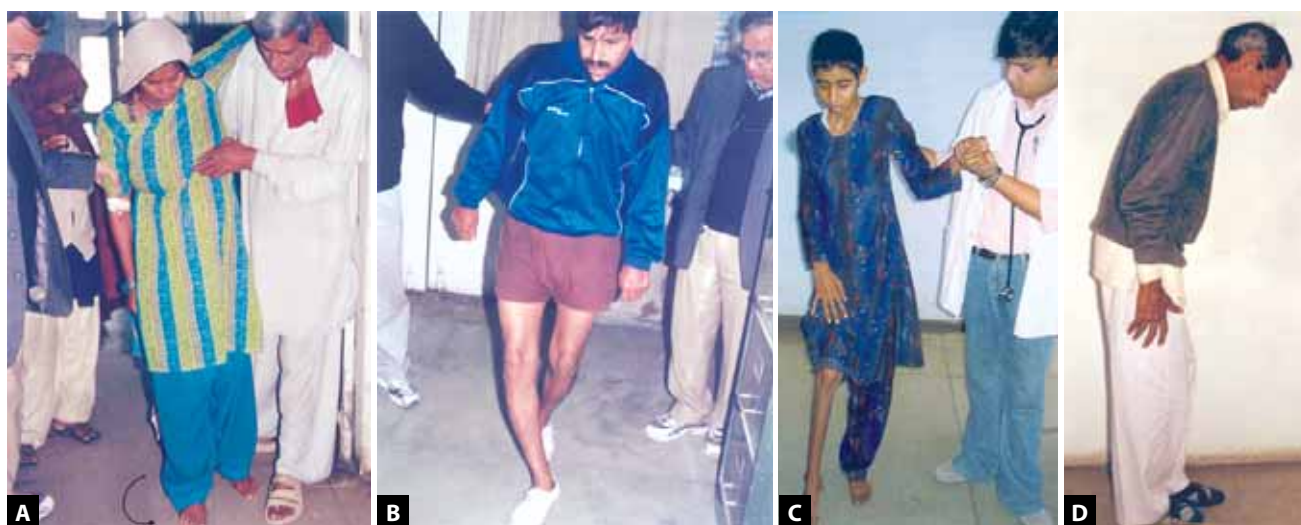The causes of chorea are given in Box 24.

Method of Demonstration

Ask the patient to outstretch the upper limbs in front of him/her and maintain this posture. If chorea is present, the patient will start to have rapid jerkings of the upper limbs and can no longer hold the limbs for some time, i.e. there is instability to maintain a posture (Fig. 15.73A).

TABLE 15.29 Various types of gaits

1. Spastic gait (hemiplegic gait): It is seen in patients with stroke (e.g. hemiplegia) <ul style="list-style-type: none"> In this type, one arm is held immobile and close to the side with elbow, wrist and phalangeal joints flexed. The leg is extended with plantarflexion of the foot. During walking, patient either drags the foot, often scraping the toe or move the leg outward and forward in a circle (circumduction gait (Fig. 15.72A).
2. Scissors gait (Fig. 15.72B): It is seen in paraplegia/quadriplegia with bilateral spastic lower limbs. <ul style="list-style-type: none"> The limbs are stiff. Each leg is advanced slowly and the legs (thighs) tend to cross forward on each other at each step like a scissor. This is due to spasticity of adductors of hips. The steps are short.
3. High Steppage or slapping gait (Fig. 15.72C): It is seen in sensory neuropathy or foot drop (LMN lesion) or dorsal column lesion. <ul style="list-style-type: none"> These patients either drag their feet along the ground or lift them too high to clear the ground and then bring them down with a slap on the floor. They are unable to walk on their heels. The high steppage gait may be unilateral or bilateral.
4. Fascinate or short shuffling gait: It is seen in Parkinsonism (Fig. 15.72D) <ul style="list-style-type: none"> In this gait, patient adopts a stooped posture, with head and neck forward and hips and knees flexed. The patient walks with short, rapid steps in shuffling manner so as to appear as if the patient is trying to catch the centre of gravity. Arms swings are decreased. Axial tone is increased and patient turns around stiffly "all in one piece". Postural instability is evident on anteropulsion/retropulsion. In some cases, if the patient is suddenly pulled backwards or pushed forwards, he walks in that direction and is unable to stop.
5. Cerebellar gait (drunken or reeling gait): It is seen in patients with a cerebellar or associated tracts involvement. <ul style="list-style-type: none"> The gait is ataxic (staggering), unsteady, and wide-based with exaggerated difficulty on the turns. These patients can not stand steadily with feet together, whether their eyes are open or closed.
6. Rapid tapping gait (magnetic gait): It is seen in bilateral corticospinal lesions deep in the cerebral hemisphere (frontal lobe lesion) due to cerebrovascular disease. <ul style="list-style-type: none"> The gait is wide-based, short-stepped but rapid tapping called <i>marche a petits pas</i> resembling the rapid steps of a ballet dancer on her points. There are usually bilateral UMN's signs, i.e. bilateral plantar extensor response and exaggerated jaw jerk.
7. The waddling gait: It is seen in proximal myopathy, muscular dystrophy and osteomalacia. <ul style="list-style-type: none"> The gait is like the gait of a duck. The body is tilted backwards with an increase in lumbar lordosis; the base is wide and the body sways from side to side with each step. Note: Bilateral hip disease produces a similar gait (Trendelenburg's sign)
8. Hysterical gait <ul style="list-style-type: none"> Bizarre or irregular gait which does not fit into any of the above described patterns. It is seen in hysteria. Miraculously, the patient does not fall. Asiata-Abasia is a typical hysterical gait disorder in which patient has normal co-ordination of leg movements in bed while sitting, but is unable to stand or walk without assistance. If attention is diverted, stationary balance is sometimes maintained and several steps are taken normally followed by a dramatic demonstration of imbalance, and tendency to fall towards examiner's arm or a nearby bed.



FIGURES 15.72A to D Abnormal gaits: (A) Hemiplegic (arc-shaped or circumducting). The patient makes an arc while putting the hemiplegic lower limb forward; (B) Paraplegic gait (scissoring gait). The lower limbs cross when patient walks. This is due to adductor spasm of lower limbs, indicates *paraplegia-in-flexion*; (C) High-steppage gait. A patient with peripheral neuropathy demonstrating the high steppage gait. Note the foot drop while the patient is lifting the foot-off the ground; (D) Parkinsonism. Note the characteristic gait (e.g. short-shuffling or fascinating) and stooped posture

The other characteristics of chorea are:

- **Hypotonia**
- **Pendular jerks (hung-up reflex):** It is due to hypotonia and choreiform movement superimposition.
- **Pronator sign (Fig. 15.73B):** There is tendency towards pronation of the forearms when the upper limbs are raised above the head with hands opposing each other.

Box 23

Classification of tremors

- **According to posture**
 - Static tremors
 - Action tremors
 - Intention tremors
 - Flapping tremors
- **According to amplitude**
 - *Fine*, i.e. more frequency (7–10/sec) less amplitude.
 - *Coarse*, i.e. less frequency (4–5/sec) more amplitude.

- **Milkmaid's grip (waxing and waning of the grip):** Ask the patient to grasp or squeeze the examiner's finger or hand, there is waxing and waning of the grip.
- **Reptile tongue:** Ask the patient to protrude the tongue and keep it in that position. The patient protrudes it momentarily and takes it back into the oral cavity with a reptile speed.
- **Dinner-fork deformity:** The patient is asked to outstretch the hands and spread the fingers. He/she adopts a characteristic posture, i.e. hyperextended limb with hyperpronation of forearm, flexion of wrist, extension of metacarpophalangeal joints with separation of fingers, i.e. dinner-fork deformity.

The differences between two types of chorea are tabulated (Table 15.31).

Athetosis: Athetoid movements are slow, rhythmic, twisting and writhing movements having a large amplitude and involve face and distal extremities. Athetosis is usually

TABLE 15.30 Characteristics and causes of common tremors

Type	Characteristics	Causes	Associated features
Action or postural (most common type)	Fine (8–10/sec) Absent at rest Present during posture and movement. They can be seen when patient is asked to outstretch hands in front of him/her or can be demonstrated by putting a paper on outstretched hands	Physiological	Fatigue and stressed persons
		Familial (essential)	Present in other members of the family
		Anxiety	Anxious looking patients with tachycardia
		Hyperthyroidism	Signs of thyrotoxicosis may be present
		Post-alcoholic	History of alcoholism and its abstinence
Intention	Coarse (4–5/sec) Absent at rest Present during posture Increased by movement	Drug induced	Drugs (salbutamol, terbutaline), history of asthma with intake of beta-agonists
		Phaeochromocytoma	Signs of sympathetic overactivity
Resting	Coarse (<5/sec) Present at rest Reduced by posture or voluntary movement. Sometimes, a pin-rolling character may be noticed in which thumb moves across the tips of all fingers	Cerebellar	Other signs of cerebellar disease
		Multiple sclerosis	Paralysis, diplopia, nystagmus, slurred speech, internuclear ophthalmoplegia
Flapping (asterixis)	Coarse (<5/sec) Present at rest Reduced by posture or voluntary movement. Sometimes, a pin-rolling character may be noticed in which thumb moves across the tips of all fingers	Parkinsonism	Other features of parkinsonism
		Senile	Old age
Flapping (asterixis)	Fine (7–10/sec) Present in outstretched or extended hands or during action in conscious patient In unconscious patient, it is demonstrated by passively dorsiflexing the hand of the patient Hold the one hand of the patient with your left hand above the wrist, dorsiflex it with your right hand and maintain the same posture for seconds. Movements of the hand of patient indicate asterixis	Wilson's disease	Keyser-Fleischer's ring, cirrhosis of liver
		Hepatic encephalopathy	Other signs of hepatic encephalopathy
		Uraemia	Other features of chronic renal or respiratory failure
		Respiratory failure	Presence of features of CNS disease
		Raised intracranial pressure	History of intake and features of poisoning
Poisoning with hypnotics, phenytoin toxicity			
Acute vascular parietal lesions			

Hemiballismus ‘*Ballism*’ is derived from the Greek word meaning “to throw”. These movements have wide excursions like chorea, are flinging in character and affect the proximal parts of the body. When confined to one side of the body, they are referred to as *hemiballism*. These movements are absent during sleep. They occur due to involvement of subthalamic nucleus of Luys. Causes include; birth injury, tumour and vascular lesion of basal ganglia. They can be congenital.

Myoclonus: It is a brief, shock-like muscular contractions that may involve the whole limb or a muscle or a small number of muscle fibres. Soft palate may be involved (palatal myoclonus). The contractions may be too weak to cause any movement or may be too strong to cause violent movements as a result one may fall from standing position and even from the cot. It may occur during sleep but often occurs in response to extraneous stimuli such as loud noise, light, pinprick or touch. It can occur spontaneously. The site of the lesion is either olivo-dentate system or cerebral cortex.

The classification based on aetiology is given in Table 15.33.

Dystonia: It is an abnormally increased tone in the axial muscles (trunk and limbs), the contraction of which results in fixed abnormal posturing or shifting postures. The dystonias are closely related to choreoathetosis. The term *dystonia* is used to include all involuntary movements accompanied

by increased tone and abnormal postures. Dystonia is due to extrapyramidal dysfunction usually involving the basal ganglia. It may be focal, segmental, generalised or hemidystonia. The causes are:

- *Primary torsion dystonia* (Figs 15.74A and B).
- *Secondary generalised dystonia*
 - Cerebral anoxia, kernicterus
 - Trauma, tumour, vascular lesions
 - Encephalitis
 - Drugs (phenothiazines), toxic (copper)
- *Secondary focal dystonia*
 - Spasmodic torticollis (wry neck), i.e. frequent turning of neck to one side
 - Writer’s cramp/violinist cramp/barbar cramps, etc.
 - Spastic facial dystonia (oromandibular dystonia)

TABLE 15.33 Aetiological classification of myoclonus

- Physiological
 - Sleep jerks, hic cup
 - Benign infantile myoclonus
- Essential myoclonus
 - Hereditary
 - Sporadic
- Epileptic myoclonus
 - Epilepsia partialis continua
 - Photosensitive myoclonus
 - Infantile spasms
 - Juvenile myoclonic epilepsy
 - Galtic myoclonus
- Symptomatic myoclonus
 - Storage disease, e.g. Lafora body disease
 - Basal ganglia disease, e.g. Wilson’s disease
 - Subacute sclerosing panencephalitis
 - Mitochondrial disease
 - Creutzfeldt-Jacob disease
 - Metabolic encephalopathy
 - Toxic, e.g. bismuth, heavy metals
 - Drugs, e.g. L-dopa, tricyclics
 - Post-hypoxic myoclonus (Lance-Adams syndrome)
 - Focal CNS damage, e.g. tumour, trauma, stroke



FIGURES 15.74A and B Dystonia: (A) Torsion dystonia. Note the increased tone and fixed posture of right upper and lower limb. There is inversion and plantar flexion of right foot. Patient walks on toes on right side; (B) Focal dystonia (oromandibular dystonia) involving face (oral cavity and mandible). Patient has persistently opened mouth and unable to protrude the tongue

- Blepharospasm (frequent opening and closing of eyes). Meige syndrome is combination of blepharospasm, oromandibular dystonia and cranial dystonia.
- Metabolic disorders, e.g. homocysteinuria.
- Oromandibular dystonia (involuntary opening and closing of mouth, pouting, snouting, frequent licking of lips, etc.)
- Hemiplegic dystonia.

Fasciculations and fibrillations: *Fibrillations* are contractions of a single muscle fibre or a group of muscle fibres, hence, are not seen usually except in the tongue. They are recorded on the EMG.

Fasciculations are subcutaneous twitches overlying the muscle bellies when the muscles are at rest, result from contractions of a group of muscle fibres or a fascicle (muscle bundle) i.e. the whole motor unit. They may be absent at rest, but can be induced by mechanical stimulation, fatigue and cold. Fasciculations are seen in actively degenerating muscles but not in degenerated muscles, hence, disappears when the muscles are totally degenerated. Recurrent fasciculations are followed by weakness and wasting.

Method of examination/elicitation

They may be visible spontaneously over the muscle underneath the skin as ripples. They can be induced by tapping the muscle belly with tips of the fingers such as thigh and calf muscles.

They signify the involvement of anterior horn cells. The *causes* are:

- Motor neuron disease
- Spinomuscular dystrophy (peroneal muscular atrophy)
- Syringomyelia/syringobulbia
- Poliomyelitis (recovery phase)
- Intramedullary tumours (root compression)
- Peripheral neuropathy (early or recovery phase)
- Peroneal muscular atrophy
- Hypoxia, hypoglycaemia
- Poisoning-organophosphorous
- Cervical spondylosis (limited to upper limbs)
- Diabetic or syphilitic amyotrophy (limited to lower limbs)
- *Benign*, e.g. fasciculations are present without muscle wasting, seen in anxiety and fatigue states. They are common among students.

Myokymia: They are transient or persistent quivering or flickering movements which affect a few muscle bundles within a single muscle but are not sufficient to cause a movement of a joint. Thus, they are larger and widespread than fasciculations. They are not associated with weakness and wasting. Myokymia commonly involves orbicularis oculi. The *causes* are:

- It may occur as a benign phenomenon in fatigued or stressed muscles in anxious patients.
- It may be due to lesion of the facial nerve or its nucleus.
- It may occur as a generalised myokymia (*Isaac's syndrome*).

Tics and habit spasms: They are brief, repetitive, stereotyped, co-ordinated movements occurring at irregular intervals. These movements increase with anxiety and stress and get abolished during relaxation and during sleep. Example includes motor tics, i.e. repetitive winking, grimacing and shoulder shrugging. Tics may be vocal (simple or complex).

The *causes* are:

- *Gille de la Tourette's* syndrome.
- Drugs, e.g. phenothiazines and amphetamines.

Oro-facial dyskinesias: They are rhythmic, repetitive, bizarre movements that involve the face, mouth, jaw and tongue producing grimacing, pursing of the lips, protrusions of the tongue, opening and closing of the mouth and deviations of the jaw.

The *causes* are:

- Psychotropic drugs such as phenothiazines produce tardive (late) dyskinesias.
- May occur in long standing psychosis.
- Occasionally in elderly and edentulous persons.
- Facial spasm/dyskinesia occur due to irritation of facial nerve (VII nerve) at CP angle or as a part of epilepsy.

Muscle spasm and muscle cramps: Tetanic spasms are characterised by sudden intermittent forceful involuntary contractions of small muscles of hands and feet (*carpopedal spasm*). The hands in carpopedal spasm adopt a peculiar posture in which the fingers and thumbs are adducted and there is flexion at metacarpophalangeal joints and extension at interphalangeal joints and there is apposition of thumb (*main d' accoucheur hand*—see Fig. 10.2A). Pedal spasms are less frequent. Tetany is due to neuromuscular excitability resulting from hypocalcaemia or alkalosis or both. Tetany can be latent or manifest. In latent tetany, these spasms can be provoked by certain manoeuvres:

- **Trousseau's sign:** Raising the blood pressure above systemic level by inflation of sphygmomanometer cuff produces characteristic carpal spasm within 3–5 minutes (Fig. 15.75).
- **Chvostek's sign:** A tap at facial nerve at angle of jaw produces twitchings of facial muscles.

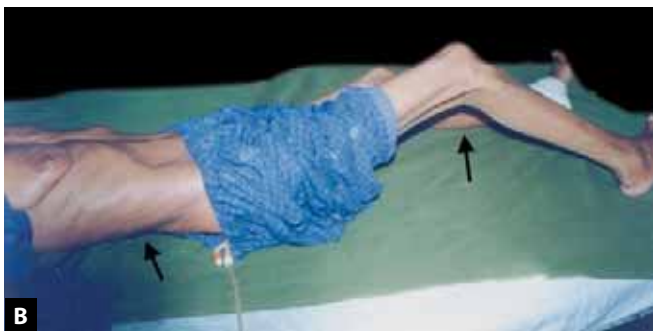
The *tetanus spasm* is sudden violent sustained contraction of agonists and antagonists muscles due to loss of central inhibition. In tetanus, there are generalised spasms of skeletal and smooth muscles involving the jaw (*lock jaw* or *trismus*), neck and shoulder muscles producing pain and stiffness, face (*risus sardonicus* Fig. 15.76A), back muscles (*opisthotonos*

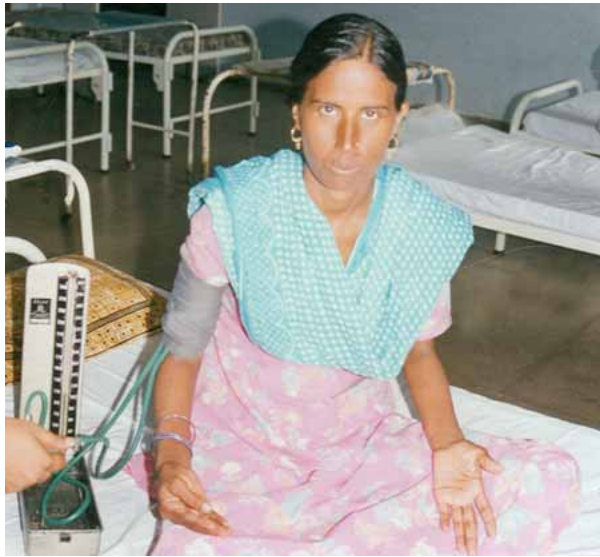
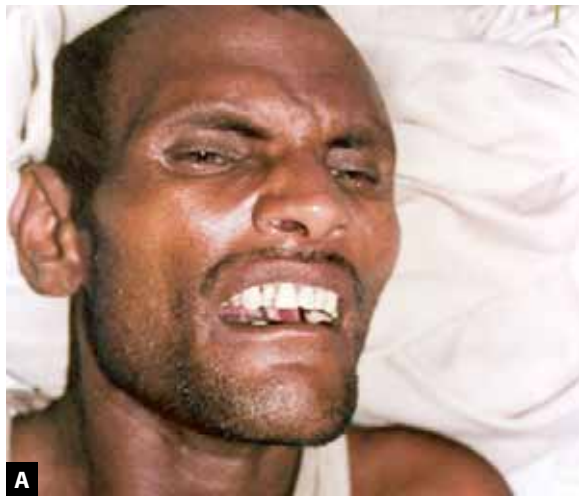
FIGURE 15.75 Trousseau's sign



A



B

FIGURES 15.76A and B Tetanus: (A) Risus sardonicus; (B) Opisthotonos (arching of back and legs indicated by arrows)

Fig. 15.76B), laryngeal, oesophageal and respiratory muscles. The muscles of hands and feet are spared. Rigidity is associated with spasms. Autonomic dysfunction may also occur in tetanus. In tetanus, spasms may occur spontaneously or provoked by noise, light and handling of the patient, i.e. just



FIGURE 15.77 Muscle cramp. Person is trying to relieve it

putting the hand over the abdomen may induce abdominal spasm.

Flexor and extensor spasms (They have already been discussed)

Muscle cramp (Fig. 15.77) is painful spasm of a part or whole of the muscle, especially of the calf muscles, is common in normal people. It is common in electrolyte disturbance, i.e. hyponatraemia, hypokalaemia, hypomagnesaemia. It is due to hypercontraction of muscle fibres and is relieved by passive stretch of the affected muscle.

The Sensations

General Principles

- Sensory examination depends on the subjective patient's response, therefore, patient must be alert, motivated and intelligent enough to respond promptly to the stimulus. The procedure of testing must be explained to the patient. In an unconscious patient, it is not possible to test the sensations. In obtunded patients, sensory examination is reduced to observing the briskness of withdrawal and the complexity of defensive movements of the patients in response to a pinch or other noxious stimulus. In the alert but uncooperative patient, it is often possible to have some idea of proprioceptive function by noting the patient's best performance of movements requiring balance and precision.
- Sensory examination should not be imposed if the patient is fatigued. A limited survey or examination will suffice

until a detailed examination is carried out when the patient has taken rest.

- Sensory examination such as pain, touch and vibration testing in the hands and the feet *plus* examination of stance and gait including the Romberg's sign will suffice in a patient who has no neurological deficit.
- Patient's eyes must be closed or covered during examination of sensations because the results of sensory testing will be affected if the patient is actually watching the procedure. Explain the process of testing the sensation with the eyes open remembering that a sudden pin-prick may evoke a frightening response and may damage the patient's confidence in the examiner. Once patient has observed the procedure of testing the sensation and has accustomed to pin-prick and other modes of testing, then the sensations may be tested with eyes closed.
- Compare the findings with the abnormalities, if any, described by the patient as part of neurological history. Most persons are usually aware of sensory abnormality and may even complain except perhaps in the case of

temperature sense which may be lost without patient being aware of it especially if area affected is around the shoulders (as in syringomyelia) rather than hands and feet.

- Try to define the upper limit of sensory loss and whether it corresponds with the spinal dermatome [often seen in cord compression (Fig. 15.35D)] or anatomical landmarks like knee, ankle, elbow or wrist as seen in peripheral neuropathy (Fig. 15.35B). Try to define the lower limit of sensory loss if possible to define dermatomal distribution (cap distribution in syringomyelia). If more than one sensations involved, find out whether they have same or different levels. Try to find out also whether sensory loss is complete or partial.

Testing of the primary sensations and their pathways are given in the Table 15.34.

If history of root pain is present, then try to find sensory loss or motor deficit (loss of a Jerk). This is important in localising the lesion.

TABLE 15.34 Testing of primary sensations

Sensation	Test device	Nerve endings	Pathways
Sensations carried by spinothalamic tracts			
Pain	Pinprick (Fig. 15.78B)	Cutaneous naked nerve endings (nociceptors)	Smaller, slower conducting axons and spinothalamic tracts
Temperature (heat)	Test tube filled with warm water (Fig. 15.78D)	Cutaneous thermoreceptors for heat	— do —
Temperature (cold)	Test tube filled with cold water (Fig. 15.78D)	Cutaneous thermoreceptors for cold	— do —
Crude touch	Pulp of finger	Cutaneous mechanoreceptors	Smaller slower-conducting fibres and spinothalamic tracts
Sensations carried by posterior column			
Fine touch	Cotton wisp, fine brush (Fig. 15.78A)	Cutaneous mechanoreceptors with naked nerve endings	Large fast-conducting axons, dorsal (posterior) column, medial lemniscus
Joint position sense (JPS)	Passive movements of joints (Fig. 15.79A)	Joint capsule, muscle spindles, and tendons	— do —
Vibration	Tuning fork 128 Hz (Fig. 15.79B)	Mechanoreceptor (Pacinian corpuscles)	— do —
Sensations of parietal lobe (cortical sensations)			
Stereognosis	Palpation of objects with hand (Fig. 15.79E)	Mechanoreceptors	Large fast conducting axons, posterior columns, medial lemniscus and thalamocortical projections to the parietal lobe.
Barognosis	Recognition of weight of an object by keeping it in hand	Mechanoreceptors	— do —
Tactile localisation and two point discrimination	Two point discriminator (cliper) or an opened up clip (Fig. 15.79D)	Mechanoreceptors	— do —
Graphaesthesia (letter or number identification)	To draw letters or numbers on various parts of the body with a blunt object or finger tip (Fig. 15.79E)	Mechanoreceptors	— do —

Testing Sequence

Touch (Fig. 15.78A)

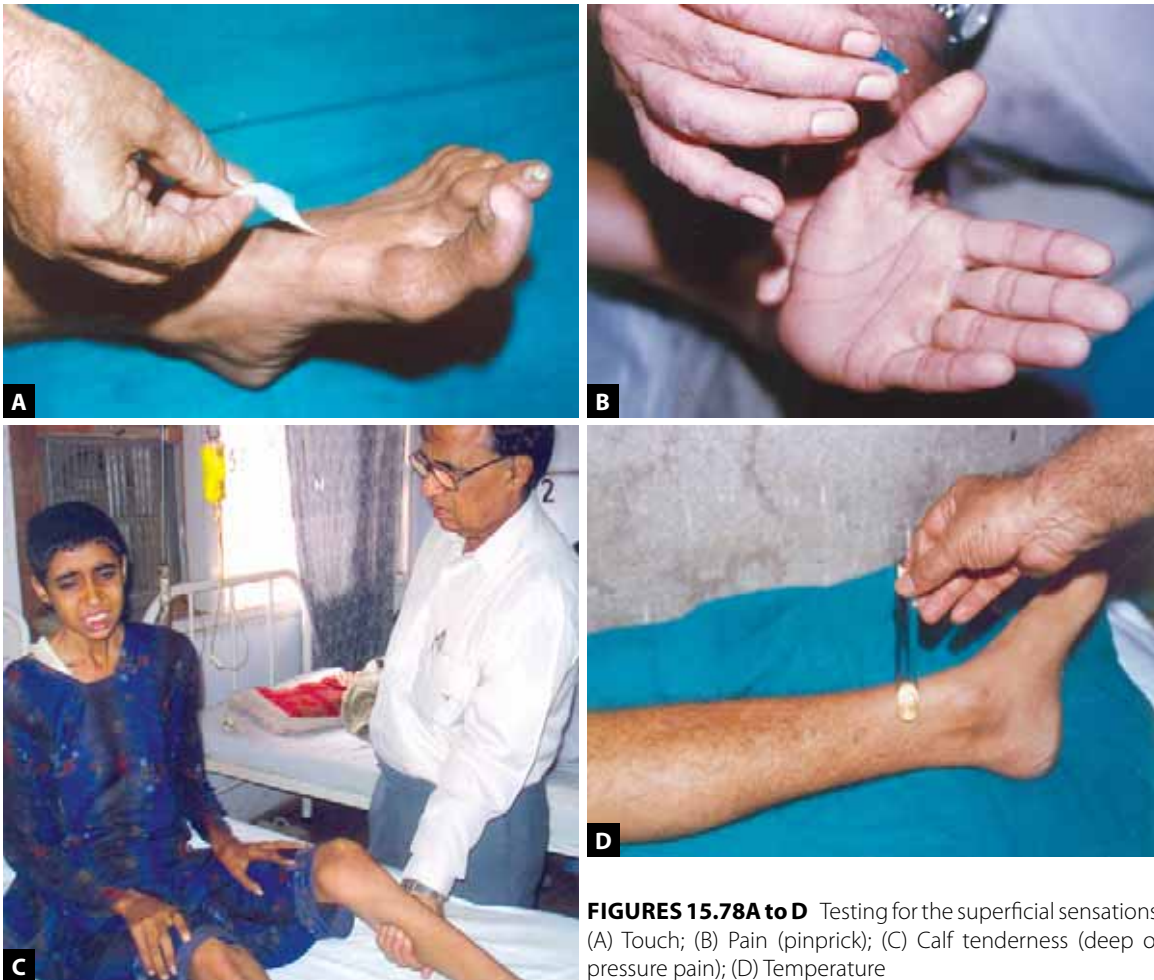- Ask the patient to close the eyes and to respond verbally as “yes” to each touch.
- Touch the skin with a small piece of cotton wool. The tissue paper and fine hair brush are alternative stimuli used.
- Avoid regularly timed stimuli so that patient does not anticipate the stimulus.
- The stimulus for touch should be applied on non-hairy part of skin.
- Examine the spinal segments sequentially (e.g. in the upper limb start on the outer border of the arm (C₅), then proceed downwards to lateral border of forearm and thumb (C₆) and then fingers (C₇), etc.
- Compare the sensation on each limb for symmetry. Touch the part on each limb exactly similarly.
- Map out the abnormal area of sensation by testing from the hypoaesthetic area towards normal.
- If the patient complains of dysaesthesia (an abnormal feeling) map from the normal to the abnormal area.

Pain (Fig. 15.78B)

- The point of a pin should be used as the stimulus.
- Use a new dress making or sterilised ordinary domestic pin or a disposable pin to avoid the risk of transmission of hepatitis and HIV. Avoid the use of a hypodermic needle which is too sharp.
- Establish the baseline for sharpness (e.g. sternal area) before examining the limb.
- Test pin-prick sensation down each limb and over the trunk.
- Ask the patient to report if there is change in the quality of sensation from normal to blunt (hypoaesthesia) or feeling sharper or more painful (hyperaesthesia).
- Touch each dermatome in turn.
- If any area of abnormal sensation found, map out its outlines.

Deep (Pressure) Pain

- Squeeze the muscle bellies, i.e. calf (Fig. 15.78C), biceps or triceps or apply firm pressure over the patient's finger nail and toe-nail beds.



FIGURES 15.78A to D Testing for the superficial sensations: (A) Touch; (B) Pain (pinprick); (C) Calf tenderness (deep or pressure pain); (D) Temperature

- Ask the patient to report as soon as the sensation becomes painful.

Temperature warm and cold (Fig. 15.78C)

- Ask the patient to close the eyes.
- Touch the patient's skin with a test tube filled with water of desired temperature (i.e. at 35 or 36° for warm sensation; and 28° to 32° for cold sensation).
- Both cold and warm sensations should be tested separately as each stimulates different receptors in the skin.
- Sensation can be tested in each dermatome in turn similar to pain.
- For improved discrimination, fill the two test tubes (or serum bottles or vials) one with warm and the other with cold water. Ask the patient to close the eyes and to distinguish between warm and cold while applying the container to the skin in a random sequence.

Most of normal persons can distinguish temperature difference by 1°C.

Joint position sense (JPS)

- Start testing sensation from the distal parts to the proximal part of the limb. In the upper limb, first test at the distal interphalangeal joint of the index finger. In the lower limb, test the joint sensation in the great toe.
- Explain the patient the intended movements of the joint and name them (e.g. "that is up" and "that is down").

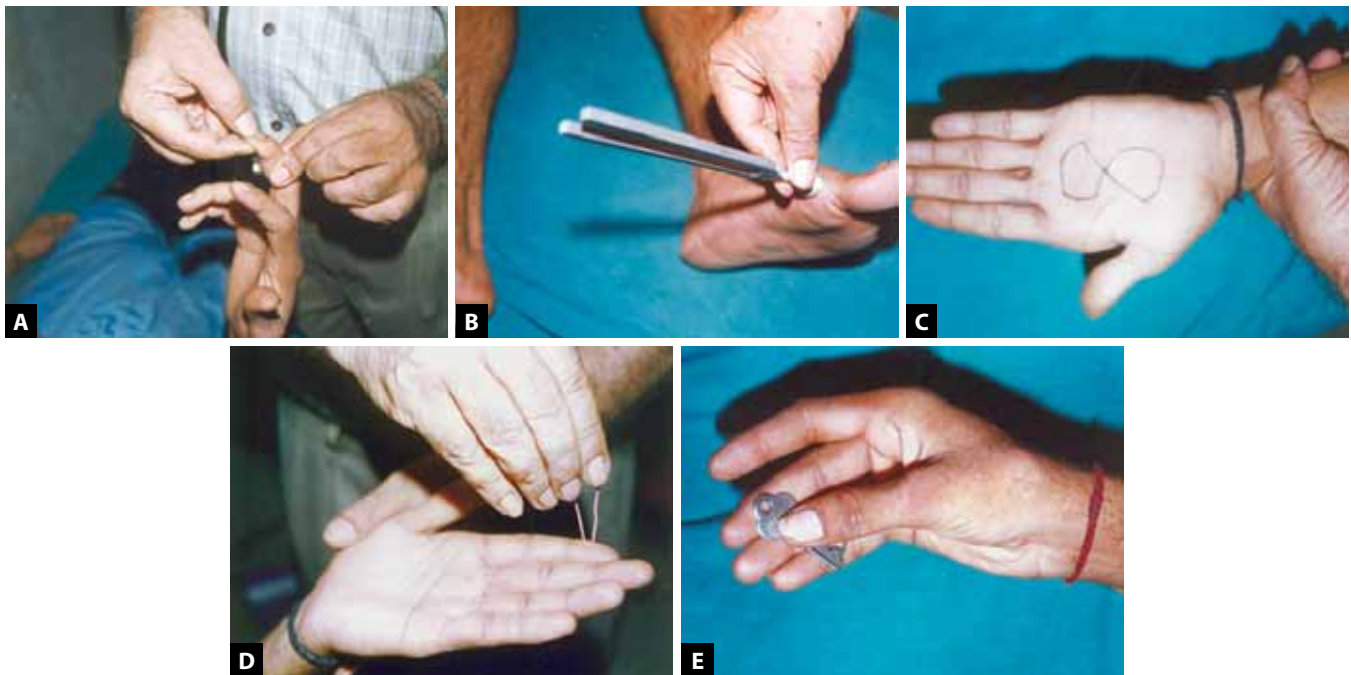
- Ask the patient to shut the eyes so as to avoid guessing.

A. Testing of joint position sense in upper limb

- Hold the middle phalanx of a finger (e.g. index finger) with one hand (left hand) while holding the distal phalanx of the same finger between your thumb and index finger of other hand (right hand).
- Move the distal phalanx up and down, down and up in a random sequence and ask the patient to identify the direction of movement (Fig. 15.79A).
- Then test the other upper limb in similar fashion.
- If there is any abnormality of joint position sense (JPS) at the distal small joints, move to the proximal joints and progressing to wrist and elbow if joint position remained impaired.

B. Testing of joint position sense in lower limbs

- In the lower limb, start testing at the interphalangeal joint of the big toe.
- Hold the big toe with left hand between the thumb and index finger; and grasp the proximal phalanx in the other hand (right hand). Move the distal phalanx up and down as described above.
- Ensure that the examiner's fingers do not rub against the patient's other toes.
- If there is impaired sensation, proceed to examine the metatarsophalangeal joint and, if necessary, the ankle and knee.



FIGURES 15.79A to E Testing the sensations carried by posterior column: (A) Testing for position sense in middle finger; (B) Testing the sensation of vibration by tuning fork 128 Hz in the lower limb; (C) Testing of graphaesthesia (figure or number identification) in the upper limb; (D) Testing the sensation of two point discrimination in the upper limb by a discriminator/divider; (E) Testing for stereognosis (e.g. object identification)

Most normal persons can identify the slightest movement at the joint. **Remember** a patient with loss of position sense in the part being tested will have a 50% error rate because only two choices (yes or no) are available. Answers greater than 50% errors should be taken indicative of the absence of position sense.

Vibration sense

- Show the patient the tuning fork and make him/her acquainted with vibrations. Explain the whole procedure to the patient with the eyes open.
- Now ask the patient to close the eyes.
- To set the tuning fork into vibrations, strike it against the palm or any other soft object.
- First hold the vibrating tuning fork (128 Hz) over the sternum so that the patient identifies the sensation.
- Start testing over the base of thumb, then proceed over the bony prominences at wrist, elbow and shoulder.

In the lower limbs

- Start testing from the big toe (Fig. 15.79B). If necessary, next move proximally in turn to the medial or lateral malleolus (ankle joint), tibial shaft and ischial tuberosity and the anterior iliac crest (i.e. put the tuning fork at bony prominences from below upwards).
- **Stereognosis (Fig. 15.79E):** It is an ability to recognise the shape and size of an object by palpation with eyes closed. For testing stereognosis, touch and sense of position/movement must be normal. Put an object (pen, pencil, key or a coin) in his hand and ask him to recognise it by palpation (feeling it). A normal person can recognise it. In case of involvement of posterior column person either cannot recognise it or takes longer time to recognise it.
- **Graphaesthesia (topognosis):** This is ability to appreciate figure, letters or numbers drawn on the skin of a hand. To test it, ask the patient to close the eyes. Now with a blunt object (posterior end of pencil/pen) write numbers like 1, 4 on the palm or at other parts (thigh, abdomen) and ask the patient to identify. Inability to recognise the letters/figures indicate parietal lobe lesion (Fig 15.79C).

Abnormalities of sensations: (Read Table 15.35 and see Fig. 15.80)

Sensory vs Cerebellar Ataxia

(It has already been discussed).

Common Abnormalities of a Single Nerve Lesion (Mononeuritis)

The identification of the sensory abnormalities resulting from peripheral nerve lesions or from the lesions of the brachial and lumbosacral plexuses can easily be done from a knowledge of cutaneous distribution of various peripheral nerves and components of the plexuses.

Common entrapment neuropathy, i.e. single nerve lesion and their features are given in the Table 15.36.

Entrapment Neuropathies

Entrapment means trapping of a single nerve in a tight anatomical compartment resulting in the compression of the nerve. The various entrapment neuropathies are given in the Box 25.

Autonomic Nervous System

Applied anatomy and physiology

The autonomic nervous system consists of afferent and efferent postganglionic sympathetic and parasympathetic neurons in the periphery and preganglionic components of these systems lie in the spinal cord, brainstem and cerebral hemispheres. This neuronal system is autonomous.

The autonomic nervous system (ANS) is concerned with:

- Modulation of CVS and GI tract system.
- Temperature regulation.
- Sexual reflexes.
- Bladder and bowel reflexes
- Pupillary and respiratory reflex control

Causes the disorders of ANS are given in Table 15.37.

Symptomatology of autonomic nervous system disorders:

The clinical manifestations of autonomic dysfunction depend on the organs involved and the normal balance between sympathetic-parasympathetic innervation, the nature of the underlying disease and the stage of progression. The common symptoms are given in the Box 26. Postural hypotension, sexual impotence, nocturnal diarrhoea, constipation, urinary incontinence, impaired sweating are some of the common presenting symptoms.

Diagnosis of autonomic dysfunction depends on the clinical history, examination and tests of autonomic functions.

The history should include an adequate drug review. (e.g. diuretics, antihypertensives, phenothiazines, alcohol, narcotics, insulin, barbiturates, beta-blockers and calcium channel blockers) and diseases which produce autonomic dysfunction, e.g. diabetes mellitus, alcoholism, Parkinsonism, etc. The relationship of symptoms to meals and awakening in the morning must be sought.

Tests for Cardiovascular Functions

Parasympathetic

- **Beat to beat variation (R-R intervals on ECG):** Subject takes deep breaths 6 per minute. The difference between mean of the shortest and longest R-R intervals on ECG is calculated for heart rate variations.

Normal differences – 15 bpm
Abnormal – 10 or less bpm.

TABLE 15.35 Sensory abnormalities at various level (Figs 15.80A to H)

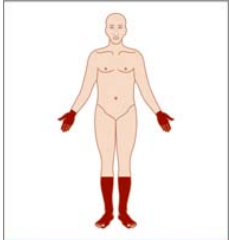
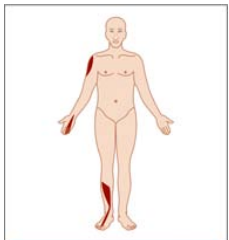
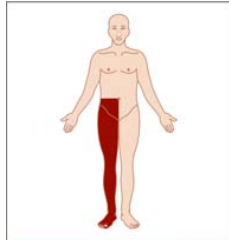
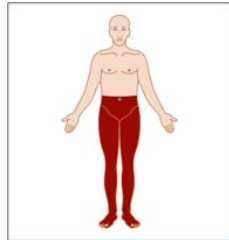
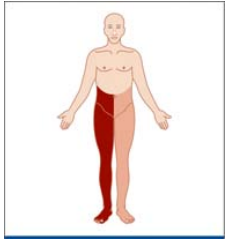
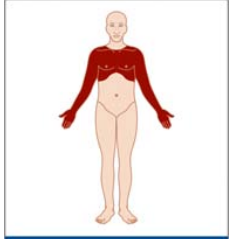
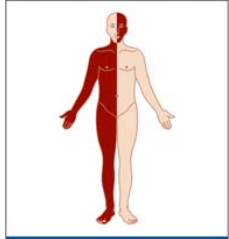
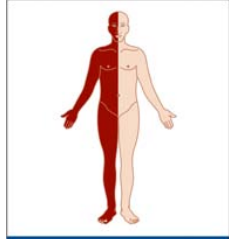
 <p>A Generalised peripheral neuropathy</p>	 <p>B Sensory roots</p>	 <p>C Single dorsal column lesion</p>	 <p>D Transverse thoracic spinal cord lesion</p>
<ul style="list-style-type: none"> • Longest fibres being affected first, the sensory loss occurs in “glove and stocking” pattern (Fig. 15.80A). • If the smaller nerve fibres are preferentially affected (e.g. in alcoholic polyneuropathy), pain, temperature sensations are lost whilst modalities served by large-fibres (joint position, vibration) may be spared. On the other hand, the latter are particularly affected in demyelinating (e.g. G.B. syndrome) neuropathy. • Calf tenderness may be present 	<ul style="list-style-type: none"> • Root pain in the distribution of a nerve root is a characteristic feature. • Dermatomal pattern of sensory loss occurs (Fig. 15.80B) although this is often smaller than expected because of the overlap of sensory territories. 	<ul style="list-style-type: none"> • Loss of proprioceptive sensations (joint position sense, vibration, two-point, discrimination, stereognosis etc.) while pin-prick pain and temperature sensations are preserved (Fig. 15.80C). • Dorsal (posterior) columns alone are affected in multiple sclerosis. • Unpleasant tight feeling over the limb involved. 	<ul style="list-style-type: none"> • Loss of all sensory modalities below that level of segmental compression on the trunk (Fig. 15.80D) although the level obtained clinically will vary by two or three segments because spinothalamic fibres do not cross at the same level but cross 2–3 segments below or above the level. • Very often at the top of the area of sensory loss, there is a band of paraesthesia or hypoesthesia.
 <p>E Unilateral cord lesion (Brown-Sequard)</p>	 <p>F Central cord lesion</p>	 <p>G Mid-brain stem lesion</p>	 <p>H Hemisphere (thalamic) lesion</p>
<p>Lesion damaging one side of the cord [hemisection-Brown-Sequard syndrome (Fig. 15.80E)] produces.</p> <ul style="list-style-type: none"> • Contralateral loss of pain and temperature sensation (spinothalamic tract involvement). • Ipsilateral (same side) loss of joint position and vibration sense due to posterior columns involvement 	<p>Lesion in the centre of the cord (syringomyelia) produces cape distribution of the spinothalamic sensory loss (loss of pain and temperature) by involving the spinothalamic fibres crossing the cord from both sides over the length of the lesion (Fig. 15.80F).</p> <ul style="list-style-type: none"> • Posterior column sensations are spared, hence, the sensory loss is dissociated in terms of modalities affected. 	<ul style="list-style-type: none"> • Sensory loss affecting all the modalities occur on the contralateral (opposite) side of the body due to involvement of crossed spinothalamic tract. • Ipsilateral sensory loss on the face due to involvement of spinal nucleus of the Vth cranial nerve. 	<p>Lesions in the cerebral hemisphere or thalamus produce loss of all forms of sensations on opposite side of the body (hemisensory loss) due to involvement of both spinothalamic and posterior columns involvement.</p> <ul style="list-style-type: none"> • Lesions of the sensory parietal cortex produce contralateral loss of cortical sensations (joint position, vibration, two-point discrimination and stereognosis) while pain and temperature may or may not be involved.

TABLE 15.36 Symptoms and signs of single nerve lesion (entrapment neuropathy)

Nerve involved	Symptoms	Signs	
Median at wrist (carpal tunnel syndrome)	Distressing pain and paraesthesia on the palmar aspect of the palm, waking the patient at night	Motor (muscle weakness, wasting) of adductor pollicis brevis (Fig 15.81A)	Sensory loss over palmar aspects of three and half fingers, i.e. thumb, index middle and half ring fingers
Ulnar at elbow	Paraesthesia on medial border of hand. Weakness of hand muscles	Wasting and weakness of all hand muscles except abductor pollicis brevis	Palmar aspect of one and half fingers, i.e. little finger and half ring finger
Radial	Weakness of extension of wrist [(wrist drop (Fig. 15.81)) and fingers. Often precipitated by sleeping in chair with arms above the back of chair	Wrist and finger extensors (Fig. 15.81B), supinator are affected	Base of the dorsum of thumb shows sensory loss.
Peroneal	Foot drop, trauma to head of fibula	Dorsiflexion and evtor of foot are weak	Nil or dorsum of foot may show sensory loss
Meralgia prosthetica	Tingling and paraesthesia on the lateral border of thigh	Nil	Lateral border of thigh shows sensory loss

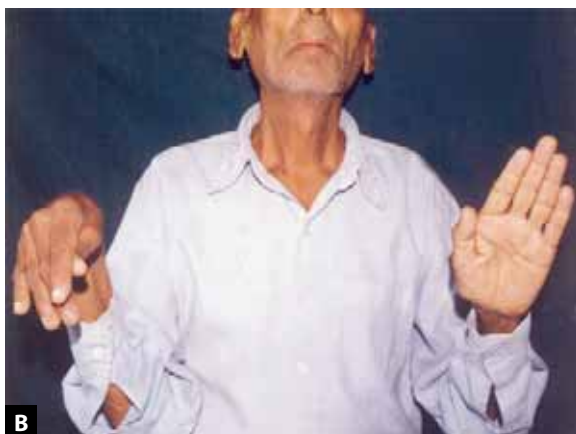
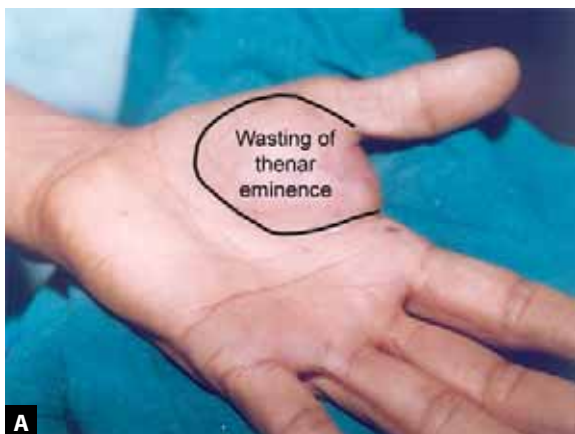
Box 25

Entrapment neuropathies

Syndrome/condition	Nerve compressed/involved
Carpal tunnel syndrome	Median nerve trapped by palmar aponeurosis
Meralgia paresthetica	Lateral cutaneous nerve of the thigh trapped under inguinal ligament
Elbow tunnel syndrome	Ulnar nerve trapped in cubital tunnel
Common peroneal nerve entrapment	Trapped at the head of fibula
Morton's metatarsalgia	Trapped medial and lateral plantar nerves
Tarsal tunnel syndrome	Posterior tibial nerve is trapped

TABLE 15.37 Aetiology of autonomic nervous system disorders

Central ANS disorders	Peripheral ANS disorders	Focal ANS disorders
<p><i>With CNS signs</i></p> <ul style="list-style-type: none"> – Shy-Drager syndrome – Olivopontocerebellar degeneration – Parkinsonism – Huntington's chorea – Hypothalamic disorders 	<ul style="list-style-type: none"> – Diabetes mellitus – Spinal cord disorders – Peripheral neuropathies (amyloid, porphyria, alcoholism) 	<p><i>Without CNS signs</i></p> <ul style="list-style-type: none"> – Guillain-Barré syndrome – Chronic idiopathic anhydrosis – Raynaud's syndrome – Familial dysautonomia (Riley-Day syndrome) – Tetanus (occasional) – Guillain-Barré syndrome – Tables dorsalis – Lambert-Eaton syndrome – Innervation anomalies (e.g. crocodile tears)



FIGURES 15.81A and B Single nerve lesions: (A) Carpal tunnel syndrome; (B) Wrist drop due to radial nerve palsy

Box 26

Symptoms of autonomic dysfunctions

Cardiovascular, e.g. postural hypotension, resting tachycardia, supine hypertension, fixed heart rate, arrhythmias and cardiac arrest.

Gastrointestinal, e.g. dysphagia, abdominal distension, nocturnal diarrhoea, constipation.

Genitourinary, e.g. hesitancy, retention and incontinence of urine and sexual impotence.

Sudomotor, e.g. Gustatory sweating, anhidrosis.

Vasomotor, e.g. cold extremities, dependent oedema.

CNS, e.g. syncope, light headedness, diminished vision, diaphoresis, pallor.

Pupillary, e.g. miosis (constricted pupil), resistance to mydriatics.

- **Valsalva manoeuvre (heart rate response):** Subject blows into an anaeroid BP instrument to maintain uniform BP of 40 mm for 15 secs. The ECG is recorded and measured for R-R interval immediately during manoeuvre and 15 seconds after release. The ratio of longest R-R interval (following release) and shortest (during manoeuvre) is calculated.

Normal = 1.21

Abnormal = ≤ 1.00

- **Immediate heart rate response to standing.** Subject lies supine. The ECG leads are placed and machine is kept on running. The subject gets up quickly unaided to standing position. The R-R interval at 15 and 30 seconds is measured and heart rate calculated as ratio of 30:15.

Normal = 1.4

Abnormal = ≤ 1.0

Sympathetic

- **BP response to standing:** Blood pressure (BP) is recorded while supine and then on standing for at least 1 minute. Fall in systolic BP is noted.

Normal = Upto 10 mmHg

Abnormal = > 30 mmHg

- **BP response to sustained hand grip:** Hand grip maintained at 30% of maximal capacity upto 5 min. BP measured once every minute. Increase in diastolic BP is noted.

Normal = 16 mmHg

Abnormal = < 10 mmHg

- **BP response to cold pressure test:** One hand of the subject immersed in ice water (1–4°C) and BP measured at 30 seconds and 1 minute. The rise in BP is noted.

Normal = 10–20 mmHg

Abnormal = < 10 mmHg

Sudomotor Function

- **The quantitative sudomotor axon reflex test for acetylcholine-induced sweating:** A reduced or absent response indicates a lesion of the post-ganglionic sudomotor axon.
- **Thermoregulatory sweat test (regional sweat response to elevation of temperature):** An indicator powder placed on the anterior chest on both sides changes its colour with sweat production during temperature elevation. The pattern of colour changes is a measure of regional sweat abnormality, may suggest a peripheral or central lesion. A unilateral decrease over half of the body suggests a central lesion.

Reflex Function

- **Cilio-spinal reflex:** Stroking the skin on the side of neck produces dilatation of pupil on the same side, called cilio-spinal reflex. It tests the integrity of central sympathetic fibres. This reflex is lost in stellate ganglion lesion and involvement of cervical sympathetic (Horner's syndrome).
- **Pilomotor reflex:** It is simple to test this reflex. Take a dry cold object (0 degree) and touch it at any part for 1 minute. Normally at the site of touch, there is erection of hairs and skin becomes rough (goose skin) which becomes normal in few minutes. These changes are lost in autonomic neuropathy.

Nervous System at a Glance

The signs of lesion in different parts of the brain and the paths involved are summarised in the Table 15.38.

Quick Neurological Examination

A detailed neurological examination may not be necessary in each and every case. The symptoms in neurology may pertain to specific area of involvement. Detailed examination in a patient who is not suffering from a neurological disease is time-consuming, boring and unwanted. Otherwise also, a short-cut neurological examination is performed by the physician in patients not suspected of neurological disease in order to exclude major neurological disability.

General Physical Examination

- Examine the skull, posture and spinal movements.
- Look for cutaneous nevi or burn mark, pigmentation or depigmentation.
- Listen for bruits in the neck and palpate the carotids.

TABLE 15.38 Signs of lesions in different parts and the paths involved

<ul style="list-style-type: none"> • Upper motor neuron lesion <ul style="list-style-type: none"> – Weakness or paralysis of movement – No wasting or atrophy – Hypertonia-clasp-knife spasticity – Exaggerated tendon jerks – A plantar extensor response (Babinski's sign positive) – Loss of superficial reflexes • Lower motor neuron lesion <ul style="list-style-type: none"> – Weakness and paralysis of muscles – Wasting and atrophy of muscles – Fasciculations may be present – Hypotonia – Diminution or loss of tendon and superficial reflexes • Basal ganglia (extrapyramidal lesion) <ul style="list-style-type: none"> – Resting tremors of hands, especially pin-rolling movements – Rigidity-cogwheel or lead pipe – Bradykinesia or akinesia (slowness of movements) – Expressionless (mask-like) face – Festinant gait • Cerebellar lesions <ul style="list-style-type: none"> – Ataxia (truncal and limb) – Intention tremors of hands (limbs) – Jerky nystagmus – Staccato or scanning speech – Dysmetria – past-pointing, dyssynergia, adiadochokinesis – Hypotonia and pendular jerks – Smooth movements are replaced by jerky movements • Peripheral neuropathies <ul style="list-style-type: none"> – Loss of all sensory modalities affecting the distal parts of the limbs in “glove-stocking fashion” – Loss of tendon jerks – Hypotonia of distal muscles 	<ul style="list-style-type: none"> • Lesion of later spinothalamic tract <ul style="list-style-type: none"> – Impaired or loss of pain and temperature sensation • Posterior column involvement <ul style="list-style-type: none"> – Sensory ataxia (Romberg's sign positive) – Impaired joint sense position – Diminished or loss of vibration sensation • Muscle disorders (myopathy) <ul style="list-style-type: none"> – Wasting and weakness of muscles (may be proximal or distal) – Hypotonia and loss of tendon jerks – Pseudohypertrophy (Duchenne's type of myopathy) – Gower's sign positive (difficulty in rising from sitting position) • Parietal lobe dysfunction <ul style="list-style-type: none"> – Dysphasia and dyscalculia – Right and left orientation – Astereognosis, sensory inattention (extinction) – Apraxia – Amnesia and cognitive disorders – Homonymous visual field defect – Hemiparesis, monoparesis • Frontal lobe lesion <ul style="list-style-type: none"> – Personality change – Emotional change – Antisocial behaviour – Impaired memory – Expressive dysphasia – Incontinence – Impaired smell – Contralateral hemiparesis – Primitive release reflexes – Seizures
---	---

Mini-mental state examination: Screening for the cognitive functions or dementia can be done during history taking and physical examination. No specific questions need usually be asked. Observe the patient while patient is giving the history or talking to the examiner. Assess mental function quickly as follows:

- Is the history given by the patient accurate, concise and with insight? Or is the patient vague or concrete?
- Is patient's behaviour and memory normal?
- Is the patient well-dressed or cared for? Note the dress, hair-style, shoes, etc.
- Is the patient aphasic or dysarthric?
- Is the patients fully conscious or confused?

Gait

Observe the patient while walking towards examiner and note:

- Is there any abnormality of gait? If yes, is it spastic, hemiparetic, ataxic or parkinsonian or hysterical?
- Is there any neurological deficit? Weakness of a part of the body or half side of the body should be looked for. Is there any foot drop?

Cranial Nerves

- Test the ocular movements and look for squint or nystagmus.
- Test for facial movements.
- Test movements of tongue and soft palate.
- Test for visual fields. Is there a hemianopia? If yes, is it homonymous, bitemporal or unilateral? Is *central vision normal*? Can patient read newspaper or small prints with or without glasses?
- Look at the optic fundi for *papilloedema* or optic atrophy. Are there any changes in the fundus such as hypertensive, uraemic, diabetic or bleeding disorder?

Motor Function

- Have a hurried look for the tone of the muscle (normal, spastic or rigid or flaccid).
- Look for any weakness, wasting of the distal or proximal muscles.
- Look for ataxia in the limbs. If present, decide whether Romberg's sign is positive or negative. Then proceed further for detailed cerebellar or sensory functions.
- Elicit one or two tendon reflexes such as biceps in the upper limb and knee jerk in the lower limb. Note whether present or absent, normal or exaggerated. Elicit the plantar response.
- Can the patient get up from the floor normally? Is there any difficulty in getting up from the low chair and climbing the stairs?

Sensory

- Test the pin-prick and light touch in all the four limbs from the periphery to the centre. Test sensations over the face also.
- Test one or two posterior column sensations especially the joint position sense in the upper and lower limbs. If necessary vibration sense may also be tested.

Note: After having the quick assessment of nervous system, one can proceed further for detailed neurological examination depending on the neurological complaints/deficit.

INVESTIGATIONS

Biochemical

The routine biochemical test performed and their diagnostic significance is summarised in the Table 15.39.

TABLE 15.39 The value of some biochemical tests in neurological disorder

Test	Significance
Urinalysis	Glycosuria (polyneuropathy), ketones (coma), Bence-Jones proteins (cord compression due to myeloma)
Blood	Raised MCV (B_{12} deficiency), high ESR (giant cell arteritis)
Serum electrolytes	Hyponatraemia, hypokalaemia (periodic paralysis)
Blood glucose	Hypoglycaemia (coma), diabetes mellitus related neurological disorders
Serum calcium	Hypocalcaemia (tetany)

Radiological

A. **Skull X-rays:** Plain X-ray should not be done routinely. Diagnostic important changes seen are:

- Fractures and lesions of the vault or base of skull (e.g. metastasis).
- Enlargement or destruction of the pituitary fossa called *sella turcica* (e.g. pituitary tumours, raised intracranial pressure)
- Intracranial calcification (e.g. tuberculoma, cysticercosis, oligodendroglioma, wall of an aneurysm)
- Pineal calcification (to show midline shift)
 - Spinal X-rays:** These show fractures and degenerative, destructive and congenital bone lesions.
 - Chest X-rays:** These may show bronchial carcinoma, spinal or rib lesions, thymoma.

B. **Imaging**

- Computed tomography (CT scan):** The difference in CT attenuation between bone, brain and CSF makes it possible to distinguish normal and infarcted tissue (hypodense), tumour, extravasated blood (hyperdense) and oedema.

The image can be enhanced with IV contrast media to show areas of increased blood supply and oedema more clearly. Additional information about the subarachnoid space and the cerebral ventricles is obtained by scanning after the intrathecal injection of water-soluble contrast media (e.g. metrizamide) or air. The method is safe (apart from occasional systemic reaction to contrast); the irradiation involved is small.

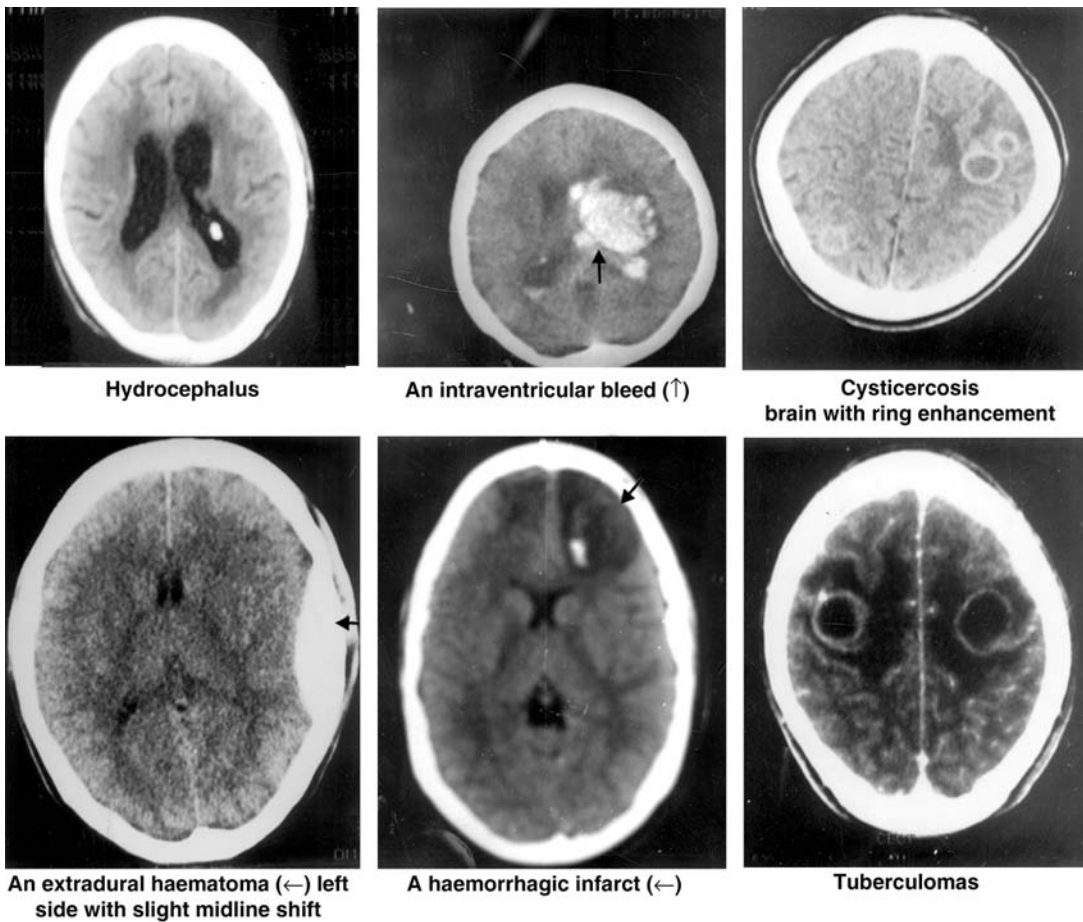
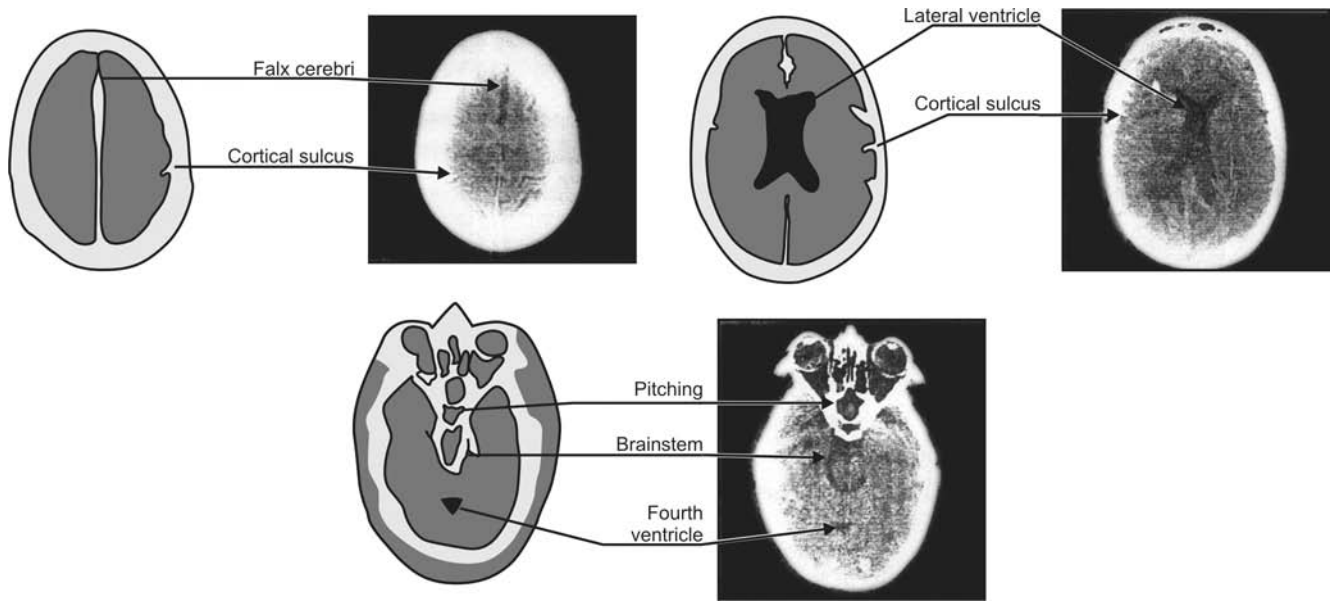
Indications: In general, lesions greater than 1 cm in diameter can be visualised on CT scans. CT scan is useful for the diagnosis of the conditions given in the Box 27.

Box 27

Diagnostic value of CT scan

Cerebral tumour

- Subdural and extradural haematoma (Fig. 15.82)
- Lateral shift of mid-line structures and displacement of ventricular system
- Cerebral atrophy
- Pituitary lesions
- Intracerebral bleed or infarction (Fig. 15.82)
- Subarachnoid haemorrhage
- Raised intracranial pressure or hydrocephalus (Fig. 15.82)
- Space-occupying lesions, e.g. tuberculoma, cysticercosis (Fig. 15.82)
- Spinal lesions (with CT myelography)



B

FIGURES 15.82A and B CT scan brain: (A) Normal CT scan (transverse section at three different levels); (B) CT scan in different CNS disorders

Limitations:

- Lesions under 1 cm in diameter may be missed. That is why, some lacunar infarcts are usually not picked up on CT scan.
- Lesions with attenuation close to that of bone may be missed if they are near the skull.
- Lesions with attenuation similar to that of brain may be difficult to diagnose (e.g. 'isodense' subdural haematoma).
- The results are poor when the patient does not cooperate—a general anaesthesia may occasionally be necessary.

A normal CT scan pictures are depicted against abnormal CT scan in (Figs 15.82A and B).

b. Magnetic resonance imaging (MRI): This technique uses properties of protons (hydrogen nucleus) aligned in a strong magnetic field. The protons are bombarded with radiofrequency waves at right angles to generate images. The protons resonate and spin, then revert to normal alignment. As they do so, images are taken at different phases of relaxation called T₁, T₂ and T₂ STIR—diffusion weighted imaging (DWI). The equipment is expensive and still restricted to specialised centres.

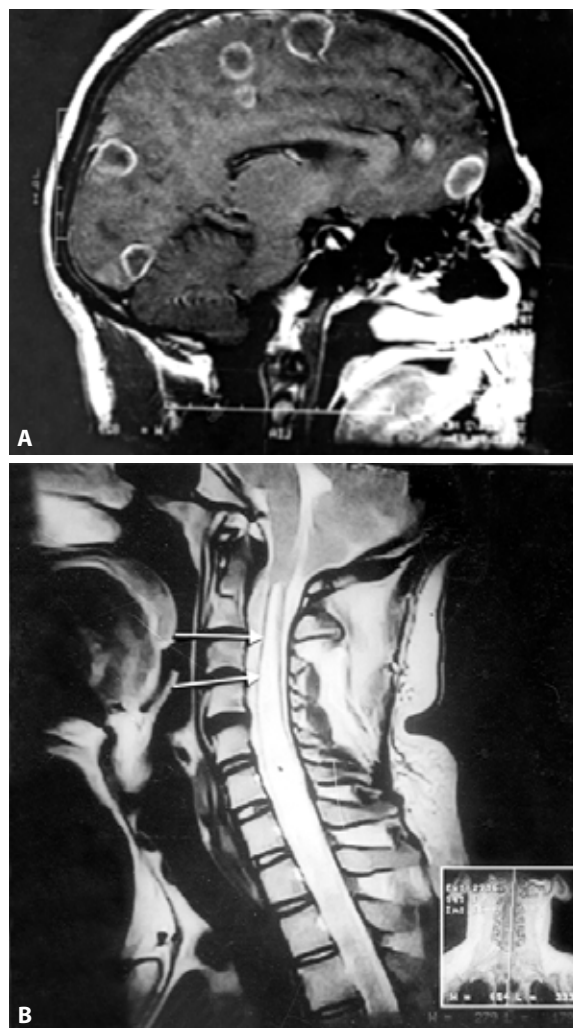
Advantages of magnetic resonance imaging

- MRI has higher resolution than CT scan
- It can distinguish between white and grey matter, hence, better than CT scan in neurology.
- It can image spinal cord and its roots directly.
- No radiation exposure.
- Magnetic resonance angiography images the blood vessels without contrast
- It is useful to evaluate the deep seated structures such as pituitary.
- It is useful in muscle disease.

Limitations

- Expensive and time-consuming.
- Patients do not co-operate. Claustrophobia is biggest handicap, but now open machines are available.
- Patients with pacemaker or metallic bodies in the brain cannot be imaged
- MRI imaging for some days after lumbar puncture frequently, shows meningeal enhancement with gadolinium.

MRI scan can distinguish between white matter and grey matter in the brain. Brain tumours or space occupying lesion (Figs 15.83A and B), syringomyelia, demyelinating plaques of multiple sclerosis and lesions in the posterior fossa and at the foramen magnum are demonstrated well. It has replaced myelography in spinal cord lesions such as spinal tumours, cord compression and vascular malformations.



FIGURES 15.83A and B Magnetic resonance imaging (MRI): (A) Cerebral space occupying lesion. An enhanced MRI shows multiple tuberculomas in the brain; (B) In spinal cord lesion, MRI (T₂ image) shows a syrinx extending over few segments indicated by arrows

c. Cerebral angiography or MR angiography digital imaging: This demonstrates the cerebral arterial and venous systems. Contrast is injected intra-arterially or intravenously (Fig. 15.84).

Carotid and vertebral angiography is used for demonstrations of aneurysms, AV malformation and venous occlusions. Films of aortic arch and the carotid and vertebral arteries demonstrate, stenosis, occlusion and atheromatous plaques. For AV malformations of spinal cord, spinal angiography is done.

Conventional angiography is invasive and requires general anaesthesia. It carries a mortality of about 1% and a 1% risk of stroke.

Digital subtraction angiography (DSA) using a computerised subtraction technique is superseding traditional

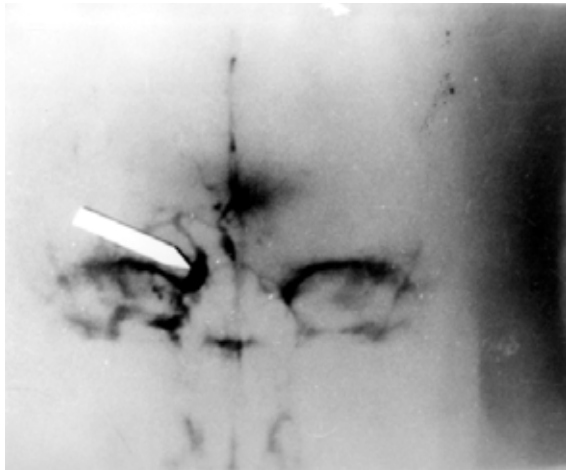


FIGURE 15.84 Cerebral angiography. There is an aneurysm of anterior communicating artery (↑)

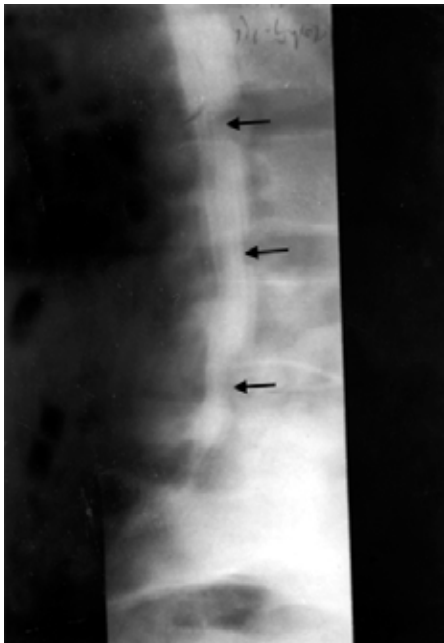


FIGURE 15.85 CT myelography. It shows multiple levels of indentations (↑) due to multiple disc prolapse

angiography. Contrast is injected intravenously or intra-arterially. No anaesthesia is required.

- d. **Myelography:** A water-soluble contrast media is injected intrathecally into subarachnoid space and viewed by conventional X-rays or CT. This is used in patients with spinal cord compression (Fig. 15.85) and spinal tumours.
- e. **Isotope brain and bone scanning:** A radioisotope (^{99m}Tc) pertechnetate is injected intravenously to detect.
 - Vascular tumours
 - AV malformations
 - Cerebral infarcts
 - Subdural haematoma

Box 28

Waveforms and their frequency discharge

Alpha	7–13 H/sec	Theta	4–6 H/sec
Beta	>13 H/sec	Delta	<4 H/sec.

Box 29

The EEG changes in disease states

Disease	EEG pattern
Cerebral tumour	Focal theta/delta
Cerebral abscess	Focal delta
Cerebral infarct	Focal theta/delta
Encephalitis	Theta/delta sharp waves, generalised
Hypoglycaemia	Diffuse theta/delta
Hepatic coma	Theta/delta sharp waves, generalised
Subdural haematoma	Reduced amplitude of waves on the side of lesion
Epilepsy (Fig. 15.86)	Focal or generalised spikes, sharp waves, sharp-wave complexes

Electrophysiological Tests

- a. **Electroencephalography (EEG):** It is recording of electrical discharges or signals across the skull arising from the cerebral cortex with the help of scalp electrodes on 16 channels for 10–30 minutes. Rhythmical waveforms can be detected depending on their frequency. Slow frequencies tend to predominate in the very young, during sleep and in diseased states. The frequency discharge of various waveforms are given in the Box 28.

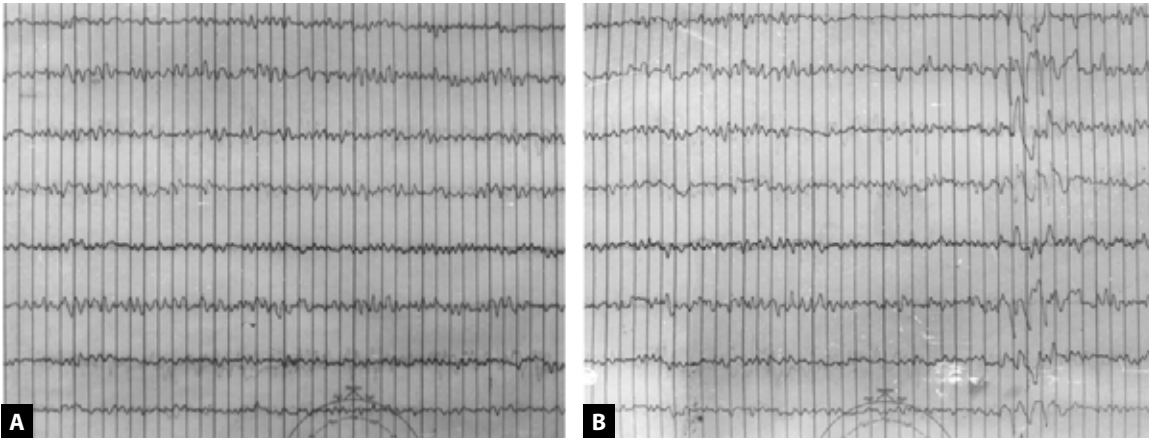
In alert adults alpha activity dominates especially when eyes are shut, and is found best over posterior quadrants. In disease states, slow activity (theta and delta) may be seen either as focal (Figs 15.86A and B) or generalised.

Indications:

- Detection and characterisation of epileptic disturbances
- Diffuse brain lesion
- Brain death. The isoelectric EEG record indicates brain death.

The EEG changes in disease states are summarised in the Box 29.

- b. **Electromyography (EMG) studies:** Electromyography means recording of muscle potentials through a concentric recording, can be seen on an oscilloscope and heard through a speaker. The following EMG pattern can be demonstrated:
 - *Normal interference*



FIGURES 15.86A and B Electroencephalography (EEG) in epilepsy showing focal discharge (lateralisation of electrical potential)

- *Denervation and reinnervation*: Spontaneous fibrillation potentials of about 1 ms in duration and 50–200 MV in amplitude are seen, and are evidence of reinnervation.
- *Myopathic*: When the muscle is weak, the normal interference pattern is reduced. Short duration ‘spiky’ fibrillation is occasionally recorded.

In myotonia, there is high frequency activity that varies repeatedly to cause a characteristics sound on the loudspeaker (dive - bomber sound).

In myasthenia gravis, a characteristic decrement in the evoked muscle action potential follows stimulation of motor nerve. The reverse is seen (an increment in repetitive response) in myasthenic-myopathic syndrome (Eaton-Lambert syndrome) which may accompany bronchial carcinoma.

- c. **Nerve conduction** means recording of action potentials by needle electrodes (Fig. 15.87). After electrical stimulation of a peripheral nerve trunk, compound action potentials varying from 5–30 MV can be recorded over the nerve’s course. These potentials elicited by motor nerve stimulation are much larger (1–20 MV) and more readily recorded because the muscle amplifies the response. Many peripheral nerves can be stimulated and conduction velocities of motor and sensory fibres can be calculated separately. Velocity and amplitude help to determine the type and severity of polyneuropathies and may define the site of nerve compression as in the carpal tunnel syndrome.

Four measurements are principal value in the diagnosis of neuropathies and nerve impairment:

- *Mean conduction velocity*, e.g. motor and sensory (see Fig. 15.87)
- Distal motor latency

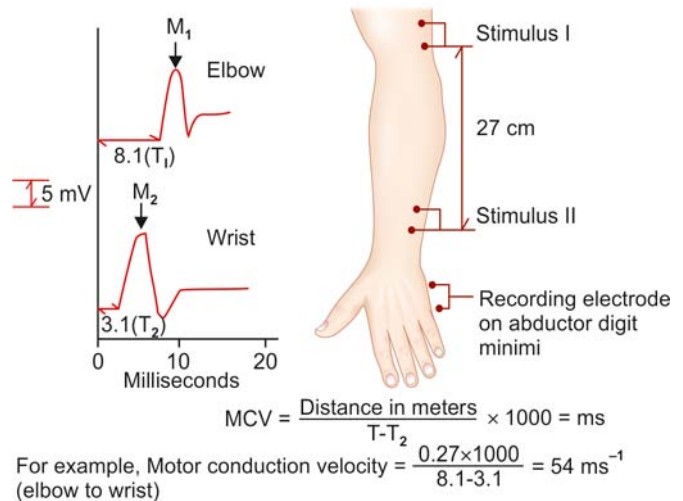


FIGURE 15.87 Measurement of motor conduction velocity of the ulnar nerve. M_1 is motor action potential from stimulus I, M_2 is motor action potential of stimulus 2. T_1 is time from elbow to electrode and T_2 is time from wrist to electrode

- Sensory action potentials
- Muscle action potentials.

Comments:

- Demyelination of peripheral nerve causes reduction in conduction velocity.
- Primary axonal degeneration is associated with reduction of motor and sensory action potential amplitude with little or no reduction in velocity.

- d. **Evoked potential recording:** Visual evoked potential (VEP) records the time taken for the response to a retinal stimulus to travel to the visual occipital cortex. The dominant response wave from a normal eye is a positive wave peaking at about 100 ms. Lesions of retina, optic nerve, chiasma, optic tract and visual occipital cortex

may all disrupt or delay the response, but demyelination of optic nerve causes marked delay with relatively good preservation of the *waveform*.

A delayed VEP in a patient with multiple sclerosis is diagnostic even in the presence of normal vision.

Sensory motor evoked potential (SSEP) recorded from the brachial plexus, cervical spine and contralateral parietal region when median or ulnar nerve is electrically stimulated help to detect lesion in sensory pathway. Similar responses may be produced over the lumbar and a dorsal spine and vertex by stimulation of posterior tibial nerve in the leg. SSEP is less useful than VEP for detecting subclinical demyelination. They may be helpful in localising the lesions of brachial plexus, spinal root and cord.

Lumbar Puncture

Cerebrospinal fluid (CSF) examination: A lumbar puncture is done to draw the CSF for examination. The indications and contraindications of lumbar puncture are given in the Box 30. The diagnostic significance of CSF due to its alteration in composition are given in the Table 15.40.

Meticulous attention should focus on microbiology and polymerase chain reaction (PCR) or ELISA to identify the organism in CNS infections. Sometimes repeated CSF examination may be necessary in chronic infection such as tubercular meningitis.

f. Miscellaneous test

- Estimation of serum enzymes released from the muscles (CPK, aldolase, transaminases). The elevated levels of these enzymes are seen in acute polymyositis and muscular dystrophies.
- Estimation of serum copper and ceruloplasmin in Wilson's disease.
- Estimation of antibodies to acetylcholine receptors protein in myasthenia gravis.
- Anticardiolipin and lupus anticoagulant antibodies and detailed coagulation studies are done in patients with stroke in young.
- Blood lactate levels in McArdle's disease (failure to rise on exercise).
- Genetic analysis in Huntington's chorea and hereditary sensorimotor neuropathy.

Biopsy

- Muscle biopsy is useful in diagnosis of inflammatory muscle disorders and muscular dystrophies. Biopsy is subjected to light and electron microscopy and biochemical analysis (enzymes)

Box 30

Lumbar puncture

Indications

- Infections, e.g. meningitis (Fig. 15.88) encephalitis.
- Subarachnoid haemorrhage if CT scan is negative or not available.
- Inflammatory conditions, e.g. multiple sclerosis, sarcoidosis, acute polyneuritis, neurosyphilis
- Infiltrative disorders, e.g. carcinomatous meningitis, lymphoma, leukaemia
- To confirm raised intracranial pressure when CT scan excludes the danger of brainstem herniation, e.g. benign raised intracranial pressure, and cerebral venous sinus thrombosis
- Intrathecal administration of drugs, e.g. antimitotic, antibiotics, or spinal anaesthesia
- Instillation of contrast media or isotopes for myelography and cisternography
- Removal of CSF therapeutically in benign intracranial hypertension

Contraindications

- Suspicion of a mass lesion in the brain or spinal cord: Caudal herniation of cerebellar tonsils (coning) may occur if an intracranial mass is present
- Papilloedema due to raised intracranial pressure from any cause
- Local infection at the site of lumbar puncture
- Congenital lesion in the lumbosacral region (e.g. meningomyelocele)
- Thrombocytopenia or abnormal haemostasis: Dry tap (no CSF comes out). It may be due to (i) faulty technique and (ii) due to obliteration of subarachnoid space by mass lesion of cord or chronic adhesive arachnoiditis.

Dry tap

No CSF comes out of LP needle. Causes are:

- Faulty technique, i.e. needle is not in the space
- Obliteration of the space by the tumour
- Chronic adhesive arachnoiditis.

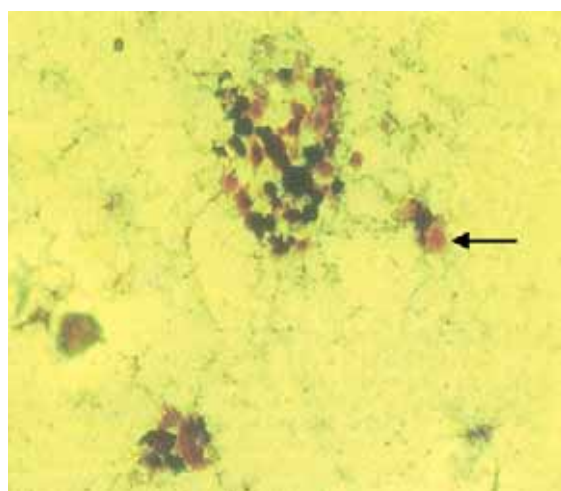
When LP is not possible as the proper place, it can be done once space higher.

Side-effects

- Postspinal headache
- Dissemination of demyelination
- Cerebellar coning/herniation if papilloedema has not been suspected
- Introduction of infection
- Arachnoiditis on repeated LP.

TABLE 15.40 The cerebrospinal fluid changes in various neurological conditions

Condition	Colour	Pressure (mmHg)	Cells (mm ³)	Protein (mg/dL)	Glucose (mg/dL)	Culture
Normal	Clear	50–180	<5 (all mononuclear)	20–50 IgG <15% of total No oligoclonal band protein	40–70 (or 2/3 to 1/4 of blood sugar)	Sterile
Tubercular meningitis	Clear or straw coloured (cob-web may occur on standing)	Elevated	>400 mostly mononuclear	Elevated	Moderately reduced (<40 mg/dl or ½ of blood sugar)	Difficult to isolate the organism on Zn stain or culture
Pyogenic meningitis	Turbid	Elevated	>1000 mostly polymorphs	Elevated	Markedly reduced, e.g. <30 mg/dL (1/3 of blood sugar)	Organisms may be isolated on Gram's stain or culture
Cryptococcal meningitis	Clear	Elevated		Elevated	Normal	Organism seen in India ink preparation (Fig. 15.88)
Aseptic meningitis	Clear	Elevated	Marked lymphocytosis	Normal	Normal	Culture sterile
Subarachnoid haemorrhage	Haemorrhagic or xanthochromic	Elevated	Markedly increased all types of cells including RBCs seen	Elevated	Reduced or normal	Sterile
Multiple sclerosis	Clear	Normal	Increased (mononuclear cells)	Elevated proteins and IgG levels. Oligo-monoclonal band may be seen	Normal	Not indicated
Encephalitis	Clear	Normal	Normal or slightly increased	Elevated mildly	Normal	Sterile

**FIGURE 15.88** Cerebrospinal fluid (CSF) showing *Cryptococcus neoformans* in India ink preparation in a patient of AIDS with meningitis

- Sural nerve biopsy is done in certain polyneuropathies. (e.g. vasculitis)
- Brain biopsy, a invasive procedure, is rarely employed to diagnose inflammatory and degenerative brain disease. CT and MR-guided stereotactic biopsy of an intracranial mass is the standard procedure.

Psychomotor Assessment

Psychomotor testing is valuable for measuring the cognitive function. Preservation of verbal IQ (a measure of past attainments) in the presence of decline in performance IQ (a measure of present attainments) suggests decline of cognitive function for example in dementia.

16

CHAPTER

The Examination of Unconscious Patient

HISTORY

Symptoms

Patient is brought in unconscious state.

Present History

Ask for

- Mode of onset of coma
- Details of neurological symptoms before falling unconscious, e.g. T₁A
- History of vomiting, diarrhoea (volume depletion)
- History of trauma, detail of illicit drug/poison or alcohol
- History of exposure to hot environment.

Past History

- Ask for liver and kidney disease, HT, diabetes, endocrinal disease, cardiovascular disease or arrhythmias or epilepsy, etc.

Family History

Diabetes, HT, CVA, epilepsy.

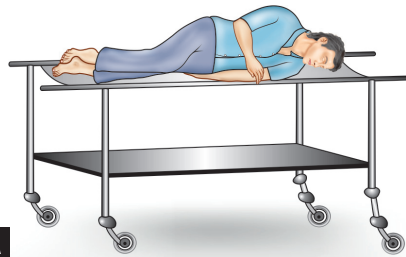Personal History

Alcoholism, drug intoxication.

GENERAL PHYSICAL EXAMINATION

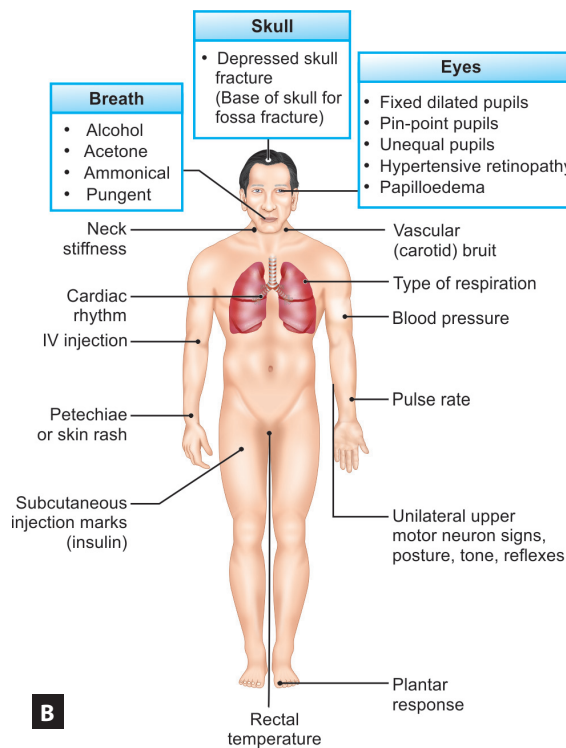
First of all assess for vital signs, e.g. patent airway, injury to cervical spine, pulse, BP, respiration, convulsions. Record temperature (rectal):

- Start the management if vital parameters are disturbed and perform examination later on
- **Examination of the skull**, e.g. for trauma
- **Eyes** for haemorrhage, ptosis, pupils for size and reaction
- **Face** for pallor, asymmetry, injury
- **Mouth**, e.g. bleeding, tongue bite, smell, debris
- **Ear, nose** for bleeding



A

An unconscious patient on trolley



B

Examination of unconscious patient including basic neurological examination

Examination of Comatosed Patient in Accident and Emergency Department

- **Skin** for bleeding, scratch marks
- **Neck** for neck rigidity, lymph nodes, thyroid enlargement.

SYSTEMIC EXAMINATION

Nervous System

- Level of consciousness, posturing
- Neck stiffness, cranial nerves
- Check the size, shape and reaction of pupils to light. Note any conjugate deviation
- Look for brainstem reflexes
- Doll's eye movements, oculovestibular reflex, corneal reflex
- Look for presence of focal neurological signs or motor paralysis. Elicit the deep tendon jerks for asymmetry.

Cardiovascular System

- Look for cardiomegaly
- Auscultate for carotid bruit
- Auscultate the heart for cardiovascular disease or arrhythmia.

Respiratory System

- Note the rate, type and pattern of breathing. Look for chest injury
- Auscultate for crackles, rales and wheezes or any respiratory problem or aspiration.

Abdominal Examination

Look for the abdominal distension, rigidity, ascites, hear the intestinal sounds, look for signs of hepatic, renal insufficiency.

Endocrinal System

Assess for any endocrinal disturbance especially thyroid.

Diagnosis

Coma, Cause?

Investigations

UNCONSCIOUSNESS OR COMA

Definition

Coma or unconsciousness is defined as persistent loss of consciousness in which the subject lies with eyes closed and shows no understandable response to external stimulus or inner need. The coma may vary in degree; and in its deepest stage no reaction of any kind, i.e. corneal, pupillary, pharyngeal is obtainable. The tendon and plantar reflexes are absent. With lesser degree of coma, pupillary reflexes, reflex ocular movements and other brainstem reflexes are preserved and there may or may not be rigidity of the limbs and extensor plantar response.

The term 'stupor' refers to that state when an individual responds to only the vigorous painful stimuli by groaning, opening the eyes or with irregular respiration.

Coma Like Syndromes

Coma is characterized by complete unarousability. Several other syndromes render the patients apparently unresponsive or insensate, are considered separately because of their special significance.

- **Vegetative state:** This is state of coma in which the eyelids have, after a time, opened giving the appearance of wakefulness. There is an absolute absence of response to commands and an inability to communicate. This is also called '*awake coma*'. There may be yawning, grunting and random movements of limbs and head. There are accompanying signs of extensive bilateral cortical damage, i.e. Babinski signs, decerebrate or decorticate limb posturing and absent response to visual stimuli. Autonomic nervous system functions are preserved. The vegetative state results from global damage to the cerebral cortex most often following cardiac arrest or head injury.
- **Akinetic mutism:** It refers to the state of partial or full wakefulness in which patient lies immobile with eyes open and is unable to talk. It results from hydrocephalus, mass in the region of third ventricle, bilateral frontal lobe lesions.
- **Locked-in-state:** It is a state of pseudocoma in which patient appears to be unconscious, immobile and unresponsive but can open and move the eyes on command. Often these patients communicate with movements of eyes, a form of '*sign language*'. These individuals are thus "*locked in, or imprisoned within their own bodies.*" It results from infarction or haemorrhage of ventral pons due to basilar artery occlusion.
- **Coma vigil:** It indicates a state of impaired consciousness with muttering. The unconsciousness is not such as to

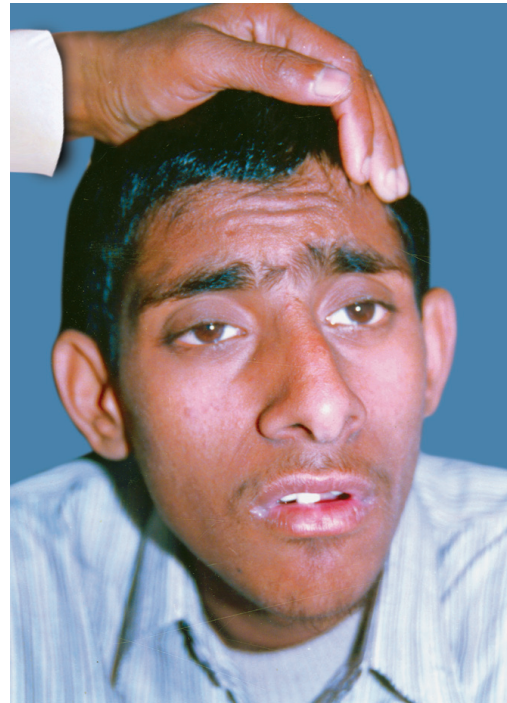

FIGURE 16.1 Catatonia: A patient with hypomobile face and vacant look. He appears to be distressed and makes no responsive movements

amount coma. It is observed in infectious fevers such as typhoid, dengue or pneumonia.

- **Catatonia (Fig. 16.1):** It is hypomobile syndrome associated with major psychosis. In its typical form, the patients appear awake with eyes open but make no voluntary or responsive movements, although they blink spontaneously and may not appear distressed. The characteristic feature is that the limbs maintain their posture when lifted or moved by the examiner.
- **Hysterical pseudocoma:** It indicates voluntary attempt to appear comatosed. Patients resist to examination. Eyelid elevation is actively resisted. Blinking occurs to visual threat when the lids are held open. The eyes move concomitantly with head rotation. All these signs belie brain damage.

Pathophysiology and Causes of Coma

A normal level of consciousness depends on the activation of the cerebral hemispheres by neurons located in brainstem reticular activating system (RAS). Both these components and the connections between them must be preserved for maintenance of normal consciousness. The principal mechanisms of coma therefore are:

- Widespread damage to both hemispheres (i.e. disease, ischaemia, trauma)

Box 1

Common causes of coma

- **Brainstem lesions**
 - Infarction
 - Tumour
 - Haemorrhage
 - Trauma
 - Infections, e.g. encephalitis, brain abscess, meningitis
 - Cerebellar infarction or haemorrhage
 - **Lesions of cerebral hemisphere with oedema and brainstem compression**
 - Infarction
 - Haemorrhage
 - Encephalitis, meningitis
 - Tumour
 - Status epilepticus
 - Cerebral malaria
 - Trauma (subdural, extradural)
 - Hydrocephalus, hypertensive encephalopathy
 - **Metabolic abnormalities**
 - Diabetes mellitus
 - Respiratory failure
 - Hepatic failure
 - Adrenal crisis
 - Renal failure
 - Hypopituitarism
 - Cardiac failure
 - Hypothyroidism
 - Hyponatraemia (severe)
 - Hypoxia
 - Hypokalaemia
 - Hyper and hypocalcaemia
 - Vitamin deficiencies (e.g. B₁, nicotinic acid, B₁₂)
 - **Drugs and physical agents**
 - Anaesthetic agents
 - Drug overdose and alcohol ingestion. Hyper and hypothermia
 - **Psychogenic**, e.g. hysteria
- Depression of cerebral functions by drugs (hypnotics), toxins (poisons), hypoxia or metabolic derangements (diabetes, hypoglycaemia, liver cell or renal failure)
 - Brainstem lesions (subtentorial neoplasms) involving RAS.

The causes of coma are depicted in the Box 1.

Clinical Evaluation of a Patient with Coma

Whenever possible an account of events preceding coma must be obtained directly from the friends or relatives and supplemented by any other information from the third personnel/ambulance personnel/eye witness, etc. It is imperative to establish when the patient was last seen alert

and conscious because the possible diagnosis is influenced by the rate of onset of coma.

HISTORY

In many cases, the cause of coma is immediately evident (e.g. trauma, cardiac arrest or known drug ingestion); while in others information has to be gathered from third party regarding the:

- **Mode of onset of coma:** The cerebrovascular episodes, drug abuse or intoxication, hypo-glycaemia, a life-threatening infection (septicaemia) or postictal condition may develop suddenly; whereas coma associated with diabetic ketoacidosis, chronic renal failure (uraemia) or hepatic encephalopathy develops insidiously.
- **Details of preceding neurological symptoms:**
 - A history of headache before coma indicates intracranial space occupying lesion of any cause.
 - Seizures of recent onset whether focal or generalised indicate intracranial tumour, brain abscess, encephalitis or brain haemorrhage.
 - Dizziness, diplopia before coma indicate transient vascular episodes which may occur due to cerebral vasospasm.
 - A history of trauma with concussion followed a few days later by fluctuating consciousness, confusion, stupor and coma indicate subdural haematoma.
 - A history of trauma followed by a brief lucid interval before lapsing into coma suggests extradural haemorrhage.
- **Use of medications, illicit drugs or alcohol:** Patients with drug-induced coma may be known or identified by neighbours, family, medical attendants or the ambulance driver or recovery of drug containers or alcohol from their homes by the attendant.
- **A history of depression or suicidal tendencies** must be taken into account in unexplained coma.
- **A thorough search of the patient** may reveal hospital outpatient attendance card, unfilled prescriptions, drugs or even syringes. *Diabetics or hypertensives or epileptics* often carry some form of identification either in their clothing (pocket) or as a wrist band or necklace.
- **History of liver, kidney, lung, heart disease or other medical illness** such as *diabetes, hypothyroidism, Addison's disease* must be sought. *Hypoglycaemia* is characterised by stupor or coma with signs of sympathetic overactivity (pallor, sweating, tachycardia, seizures) can be aroused easily by IV 25% glucose in case of doubt of diabetic vs hypoglycaemia coma before blood or urine sample is taken for examination.

EXAMINATION

General Physical Examination

Proper management of a case of coma depends on the recognition of the cause of coma, an interpretation of certain clinical signs such as brainstem reflexes, proper use of diagnostic tests. It is a common practice that acute respiratory and cardiovascular problems should be attended to on priority basis than neurological examination. Therefore, vital signs must be maintained such as clear airway (Fig. 16.2), pulse, BP before subjecting the patient to further evaluation; otherwise appropriate resuscitative measures should be adopted immediately. The immediate basic assessment will guide series of investigations and immediate remedial measures (Table 16.1).

- *Note the general appearance, nourishment, dress and cleanliness.*

Note the general features of the patient with coma as they may constitute important clues to the diagnosis.

- *Note for any evidence of trauma or exposure. Note any marks of injection or superficial thrombophlebitis.*

Signs of external trauma may be associated with fractures and intracranial bleeding. Marks of injections or thrombophlebitis indicate drug abuse/overdose.

- *Look for pallor or signs of shock.*

Pallor and shock indicate blood loss (internal or external) if trauma is suspected. It may indicate fluid loss in a patient with diarrhoea and vomiting.

- *Always look for the important clues (Table 16.2) so as to reach the aetiological diagnosis.*

The clinical signs of two important comas, e.g. neurological vs metabolic are given in the Box 2.

- *Note the body temperature and perspiration.*

High body temperature 42°C or above associated with dry skin indicate heat stroke or anticholinergic drug intoxication. Hypothermia is observed in alcoholics, barbiturate, sedative or phenothiazine intoxication; causes coma if temperature falls below 31°C.

- *Count the pulse and heart rate. Measure BP.*

In patients with severe raised intracranial pressure and signs of cerebral herniation, there will be bradycardia as well as hypertension (Cushing response).

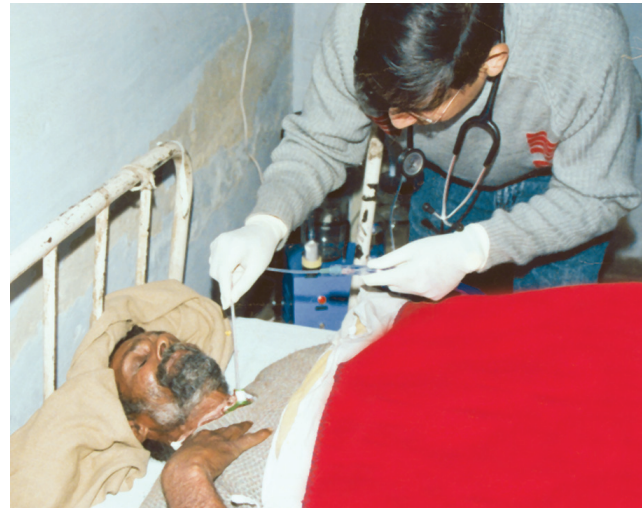

FIGURE 16.2 Maintenance of patent airway is mandatory in coma assessment and management. To maintain patent airway, tracheostomy has been done. The suction is being done by a resident doctor. Arterial blood gas sample has been sent

TABLE 16.1 Immediate assessment of coma and remedial measures

Assess	Check	Remedy
• Is the airway patent?	Blood gases	Intubate and give O ₂
• Is the patient convulsive?	EEG/blood glucose	IV glucose, O ₂ and diazepam
• Are there signs of head or face injury?	CT scan	Neurological examination
• Is the neck fractured?	X-ray	Splint neck
• Is there major haemorrhage?		Maintain BP and circulation
• Is there an evidence of diabetes mellitus?	Blood/urine sugar	Give glucose if hypoglycaemia, otherwise treat appropriately
• Is there an evidence of drug overdose or misuse such as needle pricks?	Pupils and respiration	Naloxone or other appropriate antidote

- *Note bleeding from any site.*

Petechiae suggest thrombotic thrombocytopenic purpura, meningococemia, bleeding diathesis.

Systemic Examination

Neurological Examination

Systemic assessment of the unconsciousness patient: It is an important part of neurological examination. An application

TABLE 16.2 Clinical clues to the cause of coma

<i>Finding</i>	<i>Diagnostic clues to</i>
Smell of breath	Diabetic ketoacidosis, uraemia, alcohol, hepatic encephalopathy, aluminium phosphide poisoning
Seizure	Meningitis, encephalitis, cerebral malaria, brain haemorrhage, status epilepticus.
Pyrexia	Septicaemia, meningitis, encephalitis, thyroid crisis, vasculitis
Jaundice	Hepatic coma (Fig. 16.3)
Sympathetic overactivity	Anxiety, phaeochromocytoma, thyrotoxic crisis
Bradycardia	Stokes-Adams, myxoedema coma, OP poisoning, raised ICP
Tachycardia	Hyperthyroidism, shock, CHF, infections
Hypotension	Shock, Addisonian crisis, AMI, drug intoxication, internal haemorrhage
Hypertension	Hypertensive encephalopathy, raised ICP (intracranial pressure)
Tachypnoea	Diabetic coma, metabolic acidosis, infection (pneumonia), respiratory failure (see Fig. 16.7)
Rapid, shallow breathing	Alcohol intoxication, acidosis, diabetes
Dilated pupils	Autonomic hyperactivity
Papilloedema	Hypertensive encephalopathy, brain tumour, subarachnoid haemorrhage
Neck rigidity	Meningitis, subarachnoid or intracerebral haemorrhage, meningoencephalitis, meningism (typhoid, malaria)
Tongue/cheek bite	Status epilepticus
Cardiomegaly	CHF, hypertensive heart disease
Arrhythmias	AMI, CHF
Pulmonary rales/crackles	Pulmonary oedema, CHF, pneumonia
Hepatomegaly	CHF, hepatic failure
Asymmetric deep tendon reflexes	CVA, subdural haematoma, mass lesion
Plantar extensor	Raised intracranial pressure, hypoglycaemia
Primitive reflexes present	Dementia, frontal lobe lesions

Box 2

Clinical features of two important comas

<i>Feature</i>	<i>Neurological coma</i>	<i>Metabolic coma</i>
State of consciousness	Coma usually with agitation	Silent coma (no agitation or resistance)
History of trauma	May be present. There may be signs of injury, e.g. bruising, bleeding	No history or evidence of trauma
Focal neurological deficit/neck stiffness	Present	Absent
Brainstem reflexes	Doll's head ocular movements are lost on one side or both sides	Doll's head eye movements are preserved usually except in deep metabolic coma. They are always preserved in drug-induced coma
Physical signs	Neck stiffness, plegia/paresis of limb(s), seizures, abnormal posture and reflexes, and signs of raised intracranial pressure (headache vomiting, papilloedema) indicate neurological disorders as the cause	Hyperpyrexia, abnormal smell, air hunger flapping tremors indicate metabolic disorder as the cause
Breathing	Deep, stertorous	Slow and shallow
Pupils	Unequal pupils or unilateral pupillary involvement indicates neurological disorder	Bilateral small pupils occur in drug induced (opiate, barbiturates and other drugs) coma
Ocular fundi	Abnormal	Normal
Common cause	Meningitis, encephalitis, subarachnoid or intracerebral haemorrhage, status epilepticus, brain tumour and infarction	Hypo or hyperglycaemia, uraemia, liver cell failure, hypothermia, respiratory failure, drug overdosage, endocrinal and electrolyte imbalance

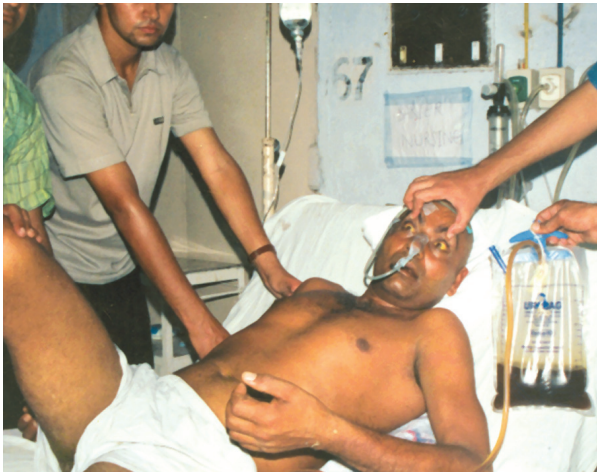

FIGURE 16.3 Hepatic coma: Presence of jaundice, dark coloured urine in presence of unconsciousness indicate hepatic coma

Box 3

Glasgow coma scale

Scale	Score
Eye opening (E)	
• Spontaneous	4
• To loud voice	3
• To pain	2
• Nil	1
Best motor response (M)	
• Obeys	6
• Localises	5
• Withdraws (flexion)	4
• Abnormal flexion	3
• Extensor response	2
• Nil	1
Verbal response (V)	
• Oriented	5
• Confused, disoriented	4
• Inappropriate words	3
• Incomprehensible sounds	2
• Nil	1
Coma score (E + M + V)	
• Minimum	3
• Maximum	15

Note: Patients with head trauma scoring 3 or 4 have an 85% chance of death or vegetative state; while scores above 11 indicate only 5–10% chance of death or vegetative state and 85% chance of moderate disability or good recovery. Intermediate scores have intermediate prognosis.

of **Glasgow coma scale** not only provides a grading of coma by numerical scale but also allows serial comparisons to be made for prognostic information particularly in traumatic coma (Box 3). This scale should be applied in each and every

Box 4

Fundamentals of neurological examination in coma

- Assess the level of consciousness according to Glasgow scale.
- Look for the signs of head injury, e.g.
 - Local bruising
 - Penetrating wounds and fracture
 - Bleeding from nose, ear or other site
 - *Neck stiffness*: The causes are given in the Table 16.2
- Check the size, shape and reaction of the pupils to light
- Look for ocular movements (spontaneous, following and to doll's head if no voluntary response)
- See the limbs for posture, tone and movement
- Elicit reflexes (tendon, primitive, plantar response)
- Pattern of respiration
- Examine ocular fundus

patient under observation and should be charted out from time to time for comparison.

This can be charted by nursing or medical staff. It is important to note the degree of unconsciousness to external stimuli. If the patient is not arousable by conversation, calling the patient's first name, a sudden loud noise, then increasingly intense stimuli are used to determine the threshold for arousal and the optimal motor response of each side of the body. Tickling the nostrils with a cotton wisp is a modest stimulus to arousal—all but deeply stuporous or comatose patients will move the head away and rouse to some degree and may use the hand to remove the offending stimulus. Responses to noxious stimuli (squeezing the achilles tendon, sternal pressures, supraorbital pressure with thumb) should be appraised critically. Stereotyped posturing indicates severe dysfunction of corticospinal system. Abrupt withdrawal movement elicited by the above-mentioned stimuli denotes an intact corticospinal system.

The fundamentals of neurological examination are summarised in the Box 4 and discussed in the text.

Look for abnormal posturing

The patient posture should be observed first without intervention.

- Decorticate rigidity or posturing describes stereotyped arm and leg movements either occurring spontaneously or induced by sensory stimulation. It is characterised by flexion of elbows and wrists and arm supination against the rigid body; suggests bilateral cerebral damage above the midbrain.
- Decerebrate rigidity (Fig. 16.4) or posturing describes extension and adduction of elbows and wrists with pronation; suggest corticospinal damage in the midbrain or caudal to diencephalon.
- Arms extension with flaccid legs or leg flexion have been associated with low pontine lesions.

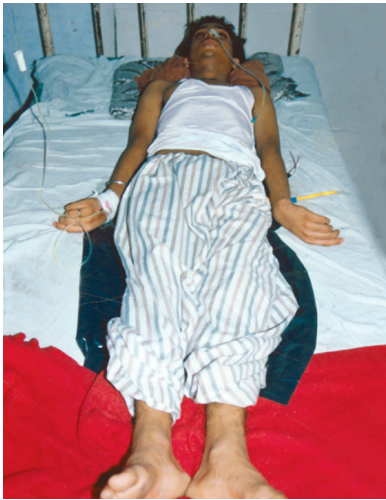

FIGURE 16.4 Decerebrate rigidity in a patient with coma due to encephalitis

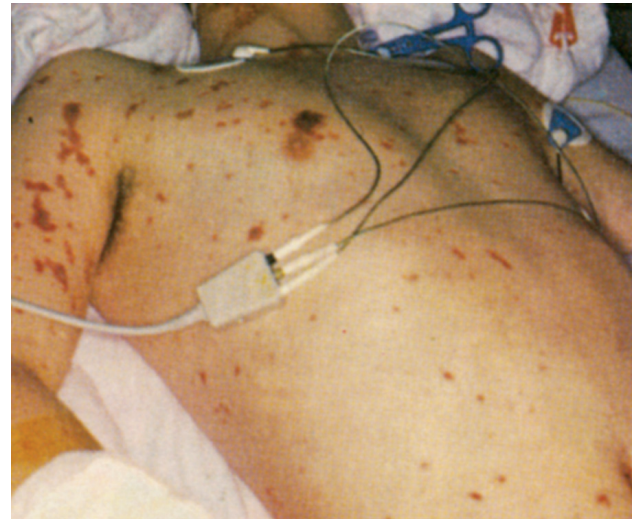

FIGURE 16.6 Meningococcal meningitis: The patient had meningococcal rash over the trunk and extremities with neck rigidity

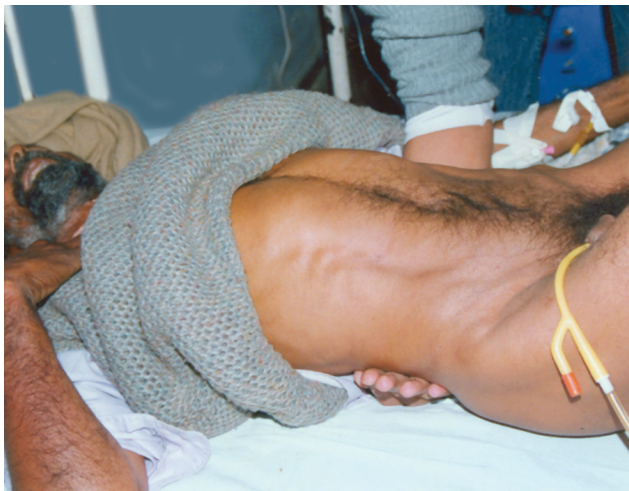

FIGURE 16.5 Unconscious patient presenting with abdominal rigidity, trismus and provoked muscle spasms. He appears to be a case of tetanus. The arching of the back is demonstrated by putting the hand behind the back

- Total flaccidity of all the four limbs and hypotonia indicate the involvement of pontomedullary junction.
- Multifocal myoclonus is almost always an indication of a metabolic disorder (e.g. uraemia, anoxic encephalopathy, drug intoxication).
- In a drowsy and confused patient bilateral asterix (flapping tremors) is a certain sign of metabolic encephalopathy or drug intoxication.
- An unconscious patient with rigidity and opisthotonos position indicates either strychnine poisoning or tetanus (Fig. 16.5).

Look for signs of head injury, e.g. bruising, hematoma, penetrating wound, bleeding from nose, ear and other sites.

Note: Acute lesions of any type frequently cause limb extension regardless of location, and almost all extensor posturing become flexion as the time passes, so posturing alone cannot be utilised to pinpoint the anatomical site of the lesion.

Look for signs of head injury

Scalp oedema and haematoma (local swelling) can easily be palpated while “battle sign” (bleeding/bruising of skin behind pinna “suggest basal skull fracture.” Similarly bleeding from the ear is a sign of trauma and fracture.

Neck stiffness: Neck stiffness due to spasm of nuchal muscles is protective mechanism, indicates meningeal irritation either due to blood in CSF or infection. It may disappear in deep coma.

Causes of coma with neck rigidity

- Subarachnoid haemorrhage
- Meningitis, e.g. bacterial (Fig. 16.6), viral, fungal, etc.
- Encephalitis
- Intracranial bleed
- Posterior cranial fossa lesion (e.g. tumour, haemorrhage)
- Cerebral malaria.

- Purpura and neck stiffness indicate meningococcal meningitis or septicaemia.
- Fever, meningism, convulsions, jaundice oliguria indicate cerebral malaria.

Note the pattern of breathing

Respiration patterns though received much attention in the coma diagnosis, but are of little help in localisation of the lesion.

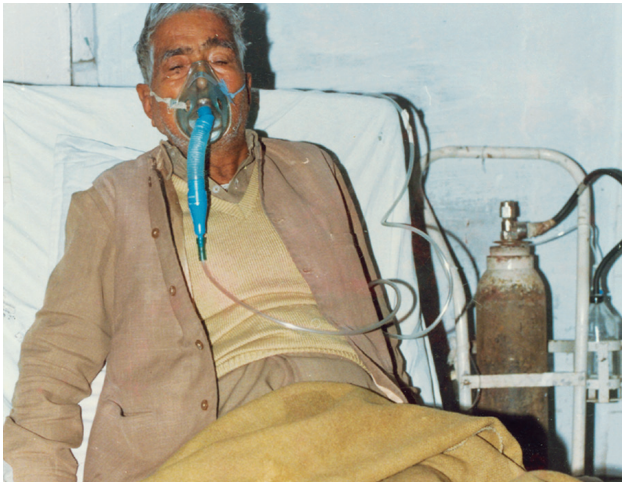

FIGURE 16.7 Respiratory failure (type 2) with CO₂ narcosis. The patient had cyanosis, tachypnoea, tachycardia, flapping tremors. He is being shifted to respiratory intensive care unit (RICU)

Hyperventilation (rapid breathing) indicates hypoxia, acidosis, poisoning, infection and psychogenic.

Slow, shallow, regular breathing suggest metabolic or drug effect. The presence of cyanosis, activation of extrarespiratory muscles, flapping tremors, intercostal recession indicate type 2 respiratory failure (Fig. 16.7).

Rapid, deep (Kussmaul) breathing suggests metabolic acidosis, but can occur in pontomesencephalic lesions.

Cheyne-Stokes breathing in classic cyclic form ending with a brief apnoea (hyperpnoea alternates apnoea) suggests bihemispherical damage or metabolic coma.

Agonal gasps (gaspings respiration) is a terminal respiratory pattern, suggests bilateral lower brainstem damage.

- *Examine the pupils for size and reaction.*

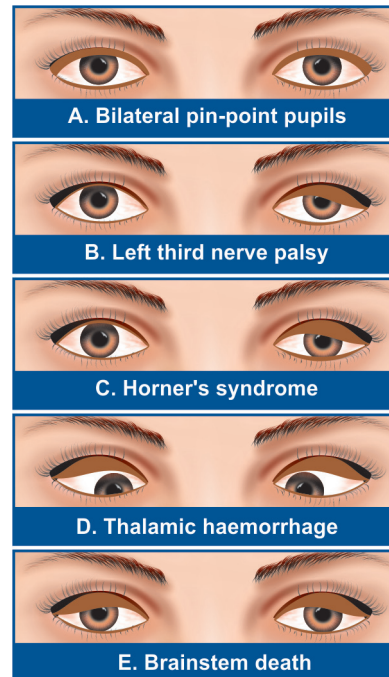
Pupillary size and reaction: The size, equality and inequality of pupils and their reaction to light provide valuable information regarding the site of lesion in an unconscious patient (Figs 16.8A to E).

The small pupils (1 to 2.5 mm) that react to light indicate metabolic encephalopathy or bilateral cortical lesions (hydrocephalus or thalamic haemorrhage).

With early midbrain lesion, the pupils become mid-dilated and non-reactive to light. As the damage to the midbrain increases, the pupils become dilated and fixed. The ciliospinal reflex is also lost at this stage. The use of mydriatic eye drops by a previous examiner, self-administration by a patient or direct ocular trauma may cause misleading pupillary enlargement.

Very small pin point (<1 mm) pupils with reaction to light characterize narcotic or barbiturate poisoning. In bilateral pontine lesions (haemorrhage) pupils are small pin-point but unreactive to light (Fig. 16.8A). The response to naloxone and the presence of reflex eye movements distinguishes the two.

Unilateral 3rd nerve palsy (Fig. 16.8B) causes unilateral pupillary enlargement (< 6 mm) which could be due to ipsilateral lesion



FIGURES 16.8A to E Various pupillary abnormalities: (A) Bilateral pinpoint pupils occur in opiate and hypnotic poisoning, pontine haemorrhage and brainstem lesions; (B) Left third nerve palsy (ptosis, mydriasis, absent light reflex) occurs in midbrain lesion, cavernous sinus thrombosis; (C) Horner's syndrome (ptosis, meiosis, anhidrosis, enophthalmos, loss of ciliospinal reflex) occurs due to cervical or brainstem sympathetic involvement; (D) Thalamic haemorrhage produces deviation of eyes towards the nose and pupils are small, later become large and unreactive; (E) Brain death with fixed, dilated, unreactive pupils with eyes closure

(mass lesion of midbrain) or due to contralateral compression of 3rd nerve in midbrain against the opposite tentorial margin (contrecoup effect).

Unilateral small pupil of a Horner's syndrome (16.8C) is detected by failure of the pupil to enlarge in the dark, is seen in cerebral haemorrhage that affects the thalamus (sympathetic system).

- *Examine the movements of eye balls.*

Eye movements: These are cornerstones of physical diagnosis in coma because they allow a large portion of the brainstem to be analysed (Fig. 16.9).

The eyes are first observed by elevating the lids and noting the resting position and spontaneous movements of the globes. Horizontal divergence of the eyes at rest is normally observed in coma. An adducted eye at rest indicates lateral rectus palsy due to 6th nerve in the pons; and when bilateral, it is often a sign of raised intracranial tension. An abducted eye with pupillary dilatation indicates 3rd nerve palsy in the midbrain. Skew deviation, i.e. vertical separation of the eyes (ocular axes), sometimes with elevation of one eye and depression of the other results from pontine or cerebellar lesions. Spontaneous ocular movements may be observed in structural lesions in the posterior fossa.

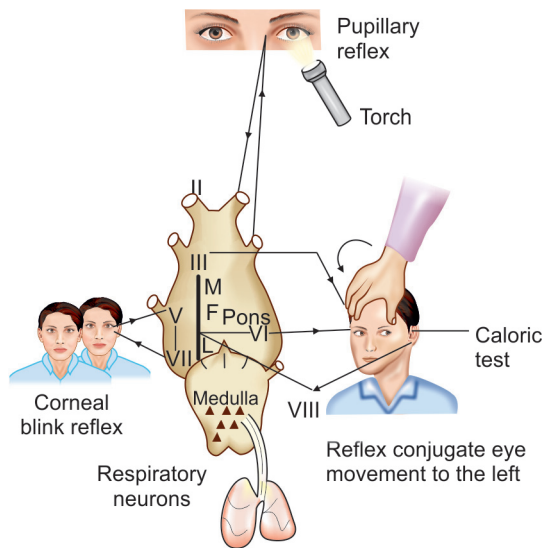


FIGURE 16.9 Brainstem reflexes in coma examination (read the text)

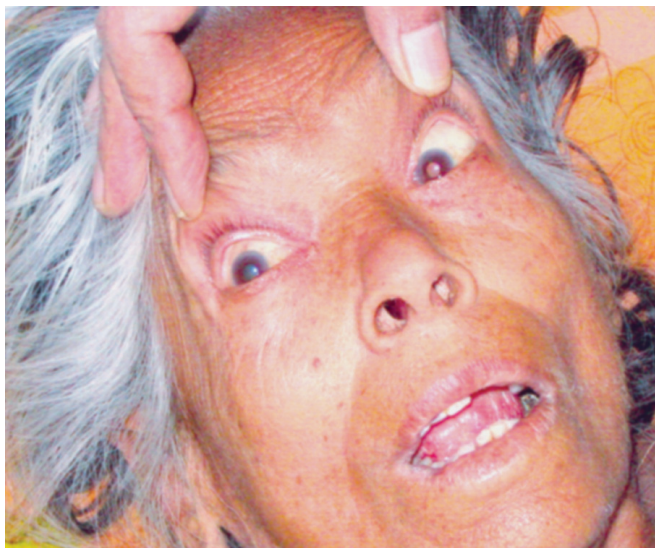

FIGURE 16.10 Conjugate horizontal ocular deviation in an unconscious patient at rest indicates either pontine or frontal lobe lesion

Conjugate horizontal ocular deviation at rest indicate damage to the pons on the side of paralysis of gaze or frontal lobe lesion on the opposite side (Fig. 16.10).

Oculocephalic reflex (Doll's eye movements): The oculocephalic reflexes depend on the integrity of the ocular motor nuclei and their interconnecting tracts that extend from the midbrain to the pons and medulla. On vertical or horizontal rotation of the head, the conjugate deviation of the eyes (evoked doll's eye movements) to the opposite side, signifies the intact brainstem and implies that the coma originates from damage to cerebral hemisphere. The

opposite—absence of doll's eye movements signifies damage within the brainstem but can be produced infrequently by profound overdoses of certain drugs. Spontaneous conjugate horizontal deviation in a comatose patient indicates pontine damage on the same side or frontal lobe damage on opposite side. Oculocephalic reflex test must not be attempted if there is little doubt about trauma to the cervical spine.

Oculovestibular reflex (caloric test): It tests the integrity of pathway from labyrinth in the ear to the midbrain via medial longitudinal fasciculus (Fig. 16.9) which connects the 6th and 8th cranial nerves to contralateral 3rd nerve. The test is performed by irrigating the external auditory canal with cold water in order to produce convection currents in the labyrinth. After a brief period, there is deviation of both eyes to the irrigated side and nystagmus occurs to the opposite side. *Nystagmus* is the response to be seen in this test, therefore, medical students can remember the acronym (COWS—cold water opposite, warm water same) which will remind them the direction of nystagmus to cold and warm water. The absence of nystagmus despite conjugate deviation of the eyes indicate hemispherical lesions. The loss of conjugate deviation indicates brainstem damage.

Corneal blink reflex (corneal reflex): The corneal reflex tests the integrity of pontine pathways between 5th and 7th cranial nerves which form the afferent and efferent pathway of this reflex respectively. The loss of corneal reflex indicate brainstem damage. CNS depressants diminish or eliminate the corneal responses soon after reflex eye movements are paralysed but before the pupils become unreactive to light. The corneal and pharyngeal response may be lost for sometime on the side of an acute hemiplegia.

Ocular bobbing describes a brisk downward and slow upwards movements of the eyes, indicates cerebellar tumour or haemorrhage.

Ocular dipping describes a slower downward and faster upward movements of the eyes, denotes anoxic damage to the cerebral cortex.

Rapid ocular *oscillations* may occur especially after poisoning with tricyclic antidepressants.

Rapid conjugate lateral movements should suggest focal motor seizure originating in contralateral frontal lobe.

In thalamic infarct, the eyes are pushed downwards and medially as if patient is looking at his/her own nose (Fig. 16.8D). Oculogyric crisis (tonic deviation of eye balls upwards or to one side for minutes to hours) is seen in encephalitis lethargica or Japanese B. encephalitis (it is a rare phenomenon now (Fig. 16.11).

Cough reflex: Cough reflex test the integrity of IX and X cranial nerves, diaphragm and intercostal muscles. In unconscious patient it is tested by touching the pharynx by a blunt object (suction catheter, ryle's tube) and, patient

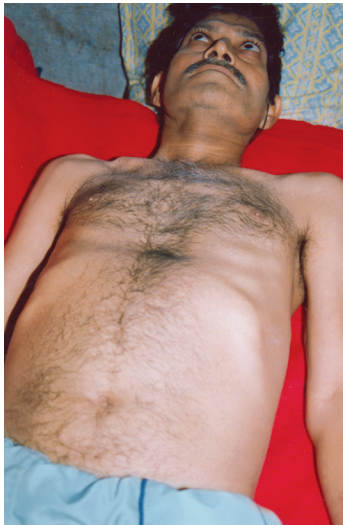

FIGURE 16.11 Oculogyric crisis: Note the tonic deviation of eyeballs upwards, occurs intermittently in a patient with encephalitis (idiopathic encephalitis) is rarely seen now-a-days

Box 5

Causes of coma without neurological signs or neck rigidity

- Hyper or hypoglycaemia
- Hypothermia
- Renal failure
- Hepatic failure
- Respiratory failure (type II with CO₂ narcosis)
- Endocrinal cause, e.g. myxoedema coma, pituitary apoplexy
- Electrolyte imbalance
- Drug poisoning producing respiratory depression.

responds by coughing. This response is lost in deep coma, bulbar paralysis diaphragmatic palsy, IX and X cranial nerve palsy and during general anaesthesia.

- *Examine the ocular fundi by ophthalmoscope*

Ocular fundus examination (Read chapter 5, Examination of eyes): The fundoscopic examination can detect subarachnoid haemorrhage (subhyaloid haemorrhages), hypertensive encephalopathy (exudates, haemorrhage, vessel crossing changes, papilloedema) and increased intracranial pressure (papilloedema).

Now elicit the motor response for paralysis

Motor responses: Presence of focal signs or unilateral paralysis indicates focal structural damage to the brain.

While its absence indicate metabolic or drug—induced coma (Box 5).

The only evidence of paralysis may be abnormal flaccidity on the affected side. In case of hemiplegia in

unconscious patient, the paralysed limb falls suddenly with a thud when both upper limbs are raised and then released suddenly. Facial asymmetry indicates 7th nerve palsy. Alteration of deep tendon jerks and plantar extensor response on the paralysed side indicate contralateral corticospinal involvement; but in deep coma, plantar reflexes lose their significance because they may become extensor on both the sides.

Other Systems Examination

- **Cardiovascular system (CVS) examination** for cardiomegaly, murmurs and carotid artery bruit.
- **Respiratory system examination**, e.g. crackles/rales or abnormal breath sounds for any underlying respiratory disorder.
- **Abdominal examination** for any mass, signs of hepatic or renal insufficiency, ascites, rigidity, etc.

Brain Death Testing

The widespread utility of mechanical ventilation has improved survival of patients with severe brain damage but functioning cardiovascular system. The clinical diagnosis of brain death is now an inevitable aspect of practice in intensive care units on patients receiving ventilatory support. Prior to testing for brain death, it is necessary to confirm that the cause of the irreversible brain damage has been established (e.g. intracranial bleed, encephalitis) and reversible causes (hypothermia, drug intoxication and metabolic defects) have been excluded. The diagnosis of brain death depends on meeting a set of preconditions, all of which must be present, and then apply a series of clinical tests (Table 16.3). The brain death tests should be performed by two experienced physicians either together or separately. The tests are then repeated after an interval of 6–24 hours before labelling “brain death”.

INVESTIGATIONS

Laboratory Investigations

Blood sugar, urea, creatinine, electrolytes and acid-base.

Specialised Investigations

- **CT scan and MRI:** The CT scan and MRI give valuable informations regarding radiologically detectable lesions, e.g. haemorrhage, tumours, hydrocephalus, etc. These investigations are not useful in toxic or metabolic causes of coma, but are done to exclude the radiological evident lesion.

TABLE 16.3 Diagnosis of brain death and its testing

<i>Preconditions for brain death</i>	<i>Brain death tests (all brainstem reflexes are absent)</i>
<ul style="list-style-type: none"> • Deeply comatosed patient • Exclusion of reversible causes of coma: <ul style="list-style-type: none"> – There must be no suspicion that coma is due to depressant drugs, e.g. narcotics, hypnotics, tranquillisers – No evidence of hypothermia (rectal temperature >35°C) – No profound abnormality of electrolytes and acid-base disturbance – No metabolic or endocrinal cause of coma • Establish the cause for severe irreversible brain damage There should be no doubt that patient is suffering from irreversible brain damage (intracranial haemorrhage, encephalitis and others causes) 	<ul style="list-style-type: none"> – The pupils are fixed, dilated, and unreactive to light – The corneal reflexes are absent – The vestibulo-ocular reflexes are absent, i.e. there is no eye movement following an injection of 20 mL of ice-cold water into ear in turn. – There is no motor response to adequate stimulation within cranial nerve distribution – No gag reflex and no response to suction – No spontaneous respiratory movement when the patient is disconnected from the ventilator

The CT scan and MRI are also useful to detect mass effect of the lesion by midline shift of the pineal body (a calcified lesion).

- **The ECG:** It gives valuable informations:

- i. Diffuse slowing of EEG indicates encephalopathy
- ii. Predominant high-voltage slowing (delta waves) in the frontal regions is typical of metabolic coma (hepatic coma).

iii. Alpha-coma (8 to 12 Hz activity) indicates high pontine or diffuse cortical damage.

- **CSF examination** is done in those cases where CT scan has ruled out mass lesion(s) or raised intracranial tension. It is valuable in the diagnosis of meningitis, encephalitis, subarachnoid haemorrhage (xanthochromic CSF), etc. It has already been discussed in nervous system examination.

17

CHAPTER

The Locomotor System

HISTORY

Important Musculoskeletal Symptoms

- Pain
- Swelling
- Non-specific symptoms of systemic illness.
- Stiffness
- Deformity
- Weakness

Present History

Ask about:

- Mode of onset
- Pattern of joint involvement
- Number of joints involved
- Morning stiffness
- Time relationship, e.g. duration, frequency of attacks
- Ask about non-articular manifestations
- Aggravating and relieving factors
- Drugs being taken or have been taken.

Past History

For example, enteritis, sore throat, psoriasis, sexual contact with a women other than wife, intercurrent illness, tuberculosis, gout, surgery.

Family History

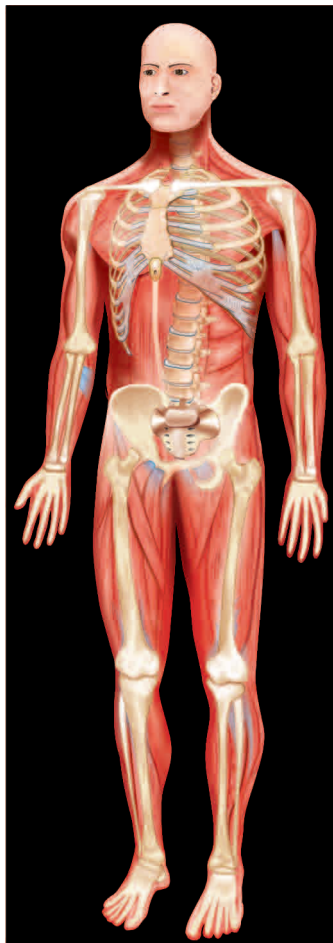
Osteoarthritis, ankylosing spondylitis and gout.

Social and Occupational History

Overuse syndrome, repetitive, stress syndrome, stress related to neck-shoulder-limb and spine disorders, chronic arthritis, sleep disturbance.

GENERAL PHYSICAL EXAMINATION

- **Appearance**, e.g. depressed/in agony
- **Face**, e.g. heliotropic rash, puffiness, pallor, etc.
- **Eyes**, e.g. redness, dryness
- **Mouth and buccal mucosa**, e.g. buccal ulcers, pallor, bleeding
- **Neck**, e.g. lymphadenopathy, thyroid enlargement, erythema nodosum, haemorrhage
- **Skin**, e.g. nodules, purpura, petechiae, rash, photosensitivity, Raynaud's phenomenon, livedo reticularis
- **Hair**, e.g. Alopecia, lupus hair
- **Finger and nails**, e.g. clubbing, nail pitting, splinter haemorrhage, vasculitis, dactylitis, infarct, gangrene
- **Legs and feet**, e.g. oedema, ulcer.



General observations

- General appearance
- Posture and gait
- Deformity/deformities
- Pulse, BP, temperature and respiration

The Locomotor System Examination

SYSTEMIC EXAMINATION

The gals screening for the locomotor system.

Examination of the Joint(s)

Inspection

- Position or posture of limb
- Note the type of involvement, e.g. symmetric or asymmetric
- Note any swelling, deformity, redness or erythema of overlying skin, muscle wasting, range of active movements of joints.

Palpation

- Palpate for signs of inflammation (active disease), e.g. tenderness, warmth
- Palpate the swelling if present
- Feel for joint crepitus, nodules on the bony prominences
- Measurement of passive movement of the joints.

Examination of the Spine

Inspection

- Look for cervical, thoracic, lumbar curves
- Look for alignment of shoulders, iliac crests and the skin creases below the buttocks
- Look for skin masses, tuft of hair, tag of skin
- Look for active movement at cervical and dorsolumbar spine
- Inspection of gait and stance.

Palpation

- Perform passive movement and note its range.
- Perform special tests, e.g. straight leg raising, sciatic nerve root stretch tests, femoral nerve stretch tests
- Tests for structures around the joint, e.g. tendons, carpal tunnel syndrome.

Examination of the Other Systems

CVS: Examine for murmurs, sounds and pericardial rub

- **Nervous system**
- **Alimentary system** for enteritis
- **Genitourinary system** for sexually transmitted disease and urethritis.

Diagnosis and Differential Diagnosis

Investigations

THE LOCOMOTOR SYSTEM

Rheumatology is a branch of science that deals with medical disorders of the locomotor system which can be divided into three categories: *arthritis*, *back pain* and *soft tissue rheumatism*.

Applied Anatomy and Physiology

There are three primary types of joint articulation—*synovial*, *cartilaginous* and *fibrous*—allowing various degrees of joint movement (Box 1).

The Normal Synovial Joint

The structure of typical synovial joint is shown in Fig. 17.1. The joint consists of two articulating bones, each covered with articular cartilage, and a fibrous capsule lined by synovium. The space within the joint is filled with synovial fluid which acts as a lubricant. Inflammation of above structures is called *arthritis* while *arthropathy* is sometimes used to describe joint disease of any type. The joint is surrounded by

Box 1

Types of joints and extent of movements

Type	Extent of movement	Example
Synovial	Freely movable	Shoulder, knee
Cartilaginous	Slightly movable	Joints between vertebral bodies of spine, symphysis pubis
Fibrous	Immovable	Skull sutures

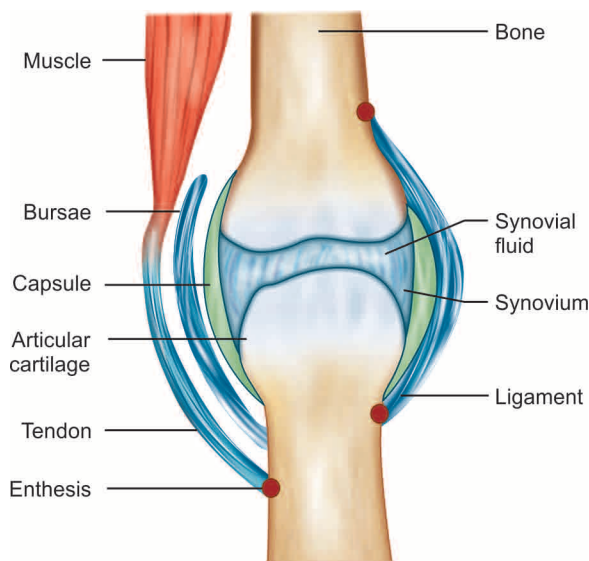


FIGURE 17.1 Structure of a synovial joint

“soft-tissues” including tendons, ligaments and bursae. The specialised junction of tendon and bone is called “*enthesis*”; which can also become inflamed. The types of synovial joints are given in the Table 17.1.

In cartilaginous joints, fibro cartilaginous discs separate the bony surfaces. At the centre of each disc is the *nucleus pulposus* (Fig. 17.2)—fibro cartilaginous material that serves as a cushion or shock absorber between bony surfaces.

Non-articular structures: They include ligaments, tendons, bursae, muscles, fascia and bone. *Ligaments* are rope-like bundles of collagen that connect bone to bone.

Tendons: They are collagen fibres connecting muscle to bone. Another type of collagen matrix forms the *cartilage* that overlies bony surfaces.

TABLE 17.1 Types of synovial joints

Type	Articular shape	Movement	Example
Ball and socket	Convex surface in a concave cavity	Flexion, extension, abduction, rotation and circumduction	Hip and shoulder
Hinge	Flat, planar	Motion in one plane, i.e. flexion, extension	Inter-phalangeal joints of hands and feet, elbow
Condylar	Convex or concave	Movement of two articulating surfaces not dissociable	Knee, temporomandibular joint

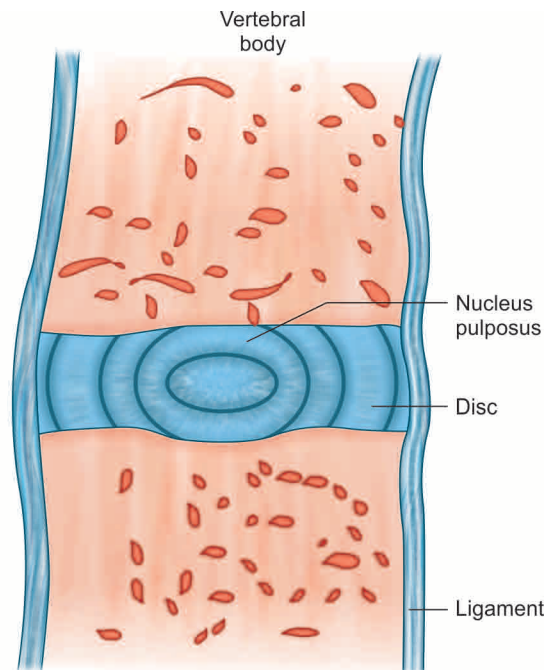


FIGURE 17.2 Structure of a cartilaginous joint

Bursae: The bursae ease joint action, are disc-shaped synovial sacs filled with fluid that allow adjacent muscles or muscle and tendons to glide over each other during movement. They lie between the skin and the convex surface of a bone or joint (i.e. prepatellar bursa of knee) or in areas where tendons or muscles rub against bone, ligaments or other tendons or muscles (as in subacromial bursa of the shoulder).

Major Symptoms of Rheumatic Disorders

Rheumatic symptoms are common, may reflect primary rheumatological disorders or an underlying systemic disorder; for example, bleeding into a large joint (haemarthrosis) may be the presenting symptom of a coagulation disorder—haemophilia. The various symptoms of joint disease are given in the Box 2. The first aim of clinical assessment of the locomotor system is to determine whether symptoms are derived from bone, joint, muscle or other soft tissue structures.

Terminology used: The main terms used in rheumatology are listed in the Box 3.

HISTORY

Present History

Main features in the present history of a patient with rheumatological problem to be recorded are:

- Background information, e.g. age, sex
- Major complaints in chronological order
- Pain, e.g. onset, site, duration, severity, radiation, character, diurnal variation, aggravating or relieving factors
- Other associated symptoms such as swelling, stiffness (early morning), tenderness
- Resultant problems, e.g. deformity
- Pattern of joint involvement, e.g. single or multiple joints, symmetric or asymmetric involvement, small joints or large joints or both. Some common anatomical patterns of rheumatic diseases are summarised in the Box 4.
- Time relationships, e.g. duration, frequency of attacks.

Background information: This may be helpful in assessing the type of arthritis.

- **Age and gender of the patient:** Juvenile idiopathic arthritis is restricted to children, haemophilia to boys; reactive arthritis most common in young men, gout in middle aged men while pseudogout in older women and osteoarthritis occurs in old age.
- **Race:** Some arthropathies (e.g. sickle cell disease) occur in particular races.

Box 2

Major symptoms of rheumatic disorders

- **Pain**
 - *Usage pain*—worst on use, relieved by rest (mechanical strain, damage)
 - *Rest pain*—worst after rest, improved by movement (inflammation)
 - *Night or 'bone' pain*—mostly at night, poorly related to movement
- **Stiffness** (subjective feeling or inability to move freely)
 - stiffness that can be “*worn off*” suggest inflammation
- **Swelling**
 - Fluid, soft tissue, bone
- **Weakness/wasting**
 - Primary—myopathy
 - Secondary to joint disease, e.g. overuse, disuse
- **Deformity**
 - Joint, bone
- **Nonspecific symptoms reflecting acute phase response**
 - Reduced appetite, weight loss
 - Fatigue, mood disturbance
 - Night sweats, chills
 - Feeling ill, low, irritable

Box 3

Rheumatological terms

Term	Description
<i>Monoarticular</i>	Single joint affected
<i>Polyarticular</i>	Many joints affected
<i>Oligoarticular or pauciarticular</i>	Two, three, or four joints affected
<i>Migratory</i>	Fleeting, e.g. arthritis moving from one joint to another
<i>Arthralgia</i>	Joint pain without swelling
<i>Arthritis</i>	Inflammation of the joint (e.g. pain, swelling)
<i>Small joints</i>	Joints of hands and feet
<i>Large joints</i>	Any other joint except hands and feet
<i>Seropositive</i>	Rheumatoid factor positive
<i>Seronegative</i>	Rheumatoid factor negative

- **Occupation:** It is important in soft-tissue rheumatism or osteoarthritis.
- **Joint pain:** A combination of *pain*, *swelling* and *stiffness* causing loss of function is a frequent presenting symptom of joint disease, however, pain and swelling can also result from the overuse of normal joint. Usually one component predominates, i.e. swelling in inflammation and pain in mechanical joint problems, hence, ask specific questions

Box 4

Some common anatomical patterns of rheumatic diseases

I. Inflammatory disorders (synovitis)

Patterns of joints involved (Figs. 17.3A to D)

- Polyarticular
 - MCP, PIP, and MTP joints
 - DIP joints
- Girdle joints
- Oligoarticular
 - Asymmetrical large joints or dactylitis (sausage digit)
- Monoarticular
 - Acute
 - Chronic
- Axial, sacroiliac, girdle joints

Diseases

- RA, SLE, psoriasis
- Psoriasis
- Polymyalgia rheumatica, RA
- Reactive arthritis, Reiter's syndrome, psoriasis or AS
- Gout, pseudogout, infection, psoriasis
- Psoriasis, RA, AS, chronic infection (tuberculosis)
- AS

II. Degenerative disorders (bony swelling ± synovitis)

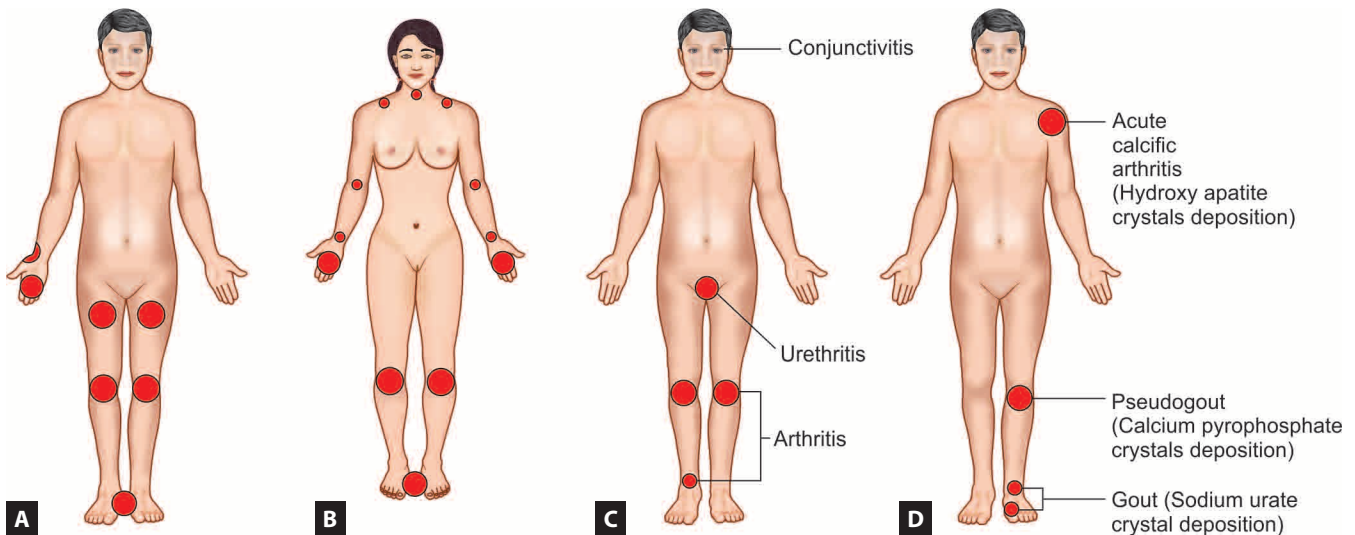
- Polyarticular
 - DIP, or PIP joints and/or first -CMC joint
- Monoarticular
 - Chronic
- Axial joints

- Nodal OA
- OA
- Spondylosis (cervical or lumbar)

Abbreviations

- MCP = Metacarpophalangeal joint
- DIP = Distal interphalangeal joint
- CMC = Carpometacarpal joint
- RA = Rheumatoid arthritis
- OA = Osteoarthritis

- PIP = Proximal interphalangeal joint
- MTP = Metatarsophalangeal joint
- SLE = Systemic lupus erythematosus
- AS = Ankylosing spondylitis



FIGURES 17.3A to D Patterns of joints involvement in various types of arthritis: (A) Osteoarthritis; (B) Rheumatoid arthritis; (C) Reiter's syndrome; (D) Crystal deposition disease

to establish whether symptoms are mechanical (e.g. degenerative joint disease) or inflammatory (rheumatoid arthritis or gout).

- Ask whether joint pain is recurrent (involves the same joint every time)
- Is joint pain episodic?
- Is joint pain fleeting (moves from one joint to other)?

The features of mechanical (degenerative or meniscal tear) and inflammatory joint disease are given in the Box 5. The other features in the history have been brought out under the differential diagnosis of anatomical patterns of rheumatic diseases. The musculoskeletal pain is often referred to other sites (somatic referral) as depicted in the Table 17.2. The severity of pain is judged by the presence of night pain and

Box 5

Features of two common types of joint disease

Mechanical	Inflammatory
• Pain on activity that improves on rest	• Rest pain that improves on activity
• Inactivity stiffness of joint disappears on activity	• Early morning stiffness persists for more than 30 minutes
• No signs of inflammation	• Signs of inflammation, i.e. pain redness, warmth swelling and tenderness present
• Joints involved include large joints of hip, knee ankle, shoulder and spines	• Any joint may be involved but commonly the smaller joints of big toe (gout), small joints of hand and feet (RA), interphalangeal joint in reactive or psoriatic arthritis
• Loose bodies in the joint may be present	• No loose body
• No periarticular involvement	• Periarticular inflammation e.g. erythema, soft tissue swelling and dactylitis present
• No triggering factor except old age	• Triggering factors include dysentery or new sexual contact, intercurrent illness, sore throat and surgery

TABLE 17.2 Sites of radiation of joint pain

Site of origin	Referred site
Cervical pain	Head and/or shoulder
Lumbar pain	Buttocks/posterior thigh
Shoulder	Lateral aspect of upper arm
Elbow	Forearm
Hip	Anterior thigh or knee or both

sleep disturbance. Persistent pain is also frequently associated with anxiety, depression, hence, one should be careful while interpreting the joint pain.

Soft tissue rheumatism: Symptoms of soft tissue rheumatism include pain, dull ache, tenderness or swelling. In elderly, these symptoms often appear spontaneously, but, in younger persons, there is history of trauma or overuse especially as a result of occupation, for example, tenosynovitis of long flexor tendons of hand in labourers, or achilles tendinitis in athletes. Therefore, define:

TABLE 17.3 Symptoms and signs of rheumatism depending on the structures involved

- **Tendon (e.g. tenosynovitis, tendinitis, tendon rupture etc.).**
 - Localised pain/tenderness at attachment (enthesitis) or in tendon substance
 - Swelling, pain and crepitus along the line of sheath in tenosynovitis
 - Pain on resisted action
 - Complete loss of active movements with preservation of passive movements in tendon rupture
 - Sometimes pain on stretching (e.g. Achilles)
 - Formation of contracture
- **Ligament and joint capsule**
 - Localised pain/tenderness at attachment or in ligament substance or joint capsule in incomplete tear of joint capsule or ligament (sprain)
 - Pain on stretch and movements is limited by muscle spasm
 - Instability and swelling, if major tear or ruptured ligament
 - Passive movements are painful
- **Bursa**
 - Localised tenderness
 - Swelling
 - Pain on stretching the adjacent structures
- **Muscle**
 - Localised or diffuse pain and tenderness
 - Pain on resisted action
 - Pain on stretching (e.g. hamstring)

- Exact site of symptoms, e.g. joint, tendon, ligament, bursa, muscle (Table 17.3). Soft tissue rheumatic disorders are diagrammatically represented in Figure 17.4.
- Aggravating and relieving factors.

The bone pain: The bone pain is deep-seated and localised. The spontaneous bone pain may suggest Paget's disease of the bone (with bony enlargement, e.g. skull or tibia), or metastatic deposits, infection must be considered in younger patients or immunocompromised hosts. In case of pain due to fracture, there is always a history of trauma/injury. In athletes, fracture may be due to overuse (stress fracture of tibia in runners). Certain congenital and familial disorders act as predisposing factors, e.g. multiple osteochondromata, osteogenesis imperfecta.

Assessment of joint pain: The severity, type of onset (acute or insidious), diurnal variation and relation to physical activity should be assessed as follows:

- Pattern of joint involvement (see Box 4)
- Variation with time
- Effect of activity
- Site and distribution
- Night pain/sleep disturbance

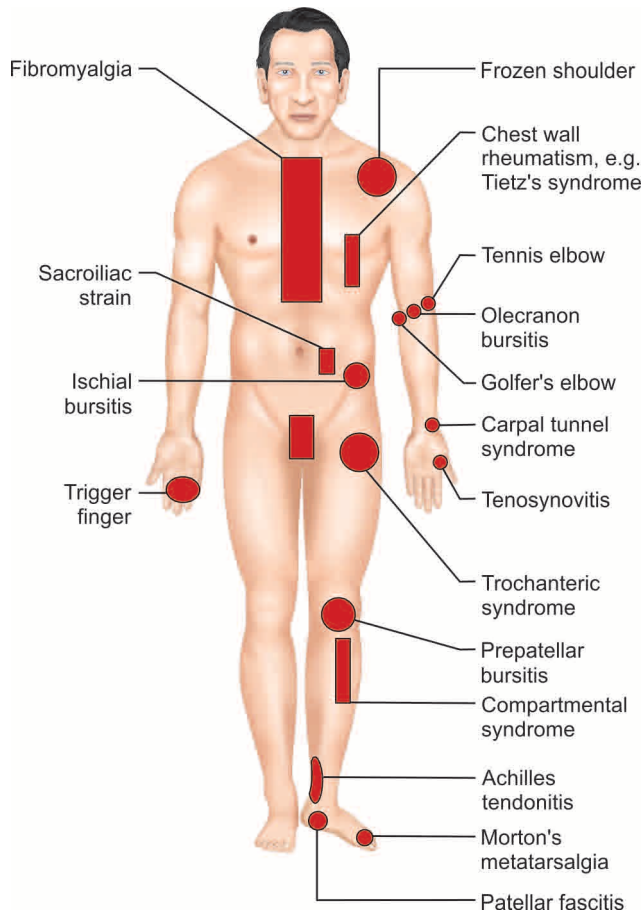


FIGURE 17.4 Soft-tissue rheumatism

- Mood disturbance
- *Extra-articular manifestations:* These are often crucial in making a correct diagnosis of inflammatory joint disease, hence, should be sought in the history as well as on the examination. Depending on the pattern of joint involvement, certain extra-articular or systemic manifestations to be sought are given in the Table 17.4 and diagrammatically represented in Figure 17.5.

Past Medical History

A history of trauma or of some other disease like psoriasis, sore throat and enteritis may be sought. History of new sexual contact (for reactive arthritis), intercurrent illness or surgery (for crystal synovitis) must be asked in the past history.

Family History

Some conditions run in families, e.g. osteoarthritis, ankylosing spondylitis and gout. Patients with psoriatic arthritis do not necessarily have psoriatic skin lesions but may give a family history of psoriasis. Psoriatic genes may be expressed in either skin joints or both in any order and at any time.

There is a common genetic basis to some common arthritis. HLA-B₂₇ is found frequently in ankylosing spondylitis and reactive arthritis (Fig. 17.6) than other spondyloarthropathies (psoriatic arthropathy, enteropathic arthritis due to inflammatory bowel disease).

Family history may be positive in patients with hypermobile joints (e.g. Marfan's syndrome, Ehlers-Danlos syndrome, benign familial hypermobility).

TABLE 17.4 Extra-articular manifestations associated with rheumatic disease (Fig. 17.4)

Disease	Extra-articular or systemic features
<ul style="list-style-type: none"> • Symmetric polyarthritis <ul style="list-style-type: none"> – Rheumatoid arthritis – Systemic lupus erythematosus (SLE) 	<p>Subcutaneous nodules, Raynaud's phenomenon, Sicca syndrome, pleurisy, episcleritis, fever, hepatosplenomegaly, pleuropericarditis, fibrosing alveolitis</p> <p>Raynaud's phenomenon, serositis, alopecia, photosensitivity, rash, fever, episcleritis, hepatosplenomegaly, haematuria, proteinuria, pleuropericarditis fibrosing alveolitis</p>
<ul style="list-style-type: none"> • Asymmetrical oligoarthritis <ul style="list-style-type: none"> – Psoriatic arthritis – Reactive arthritis including Reiter's syndrome – Ankylosing spondylitis 	<p>Psoriatic nail dystrophy</p> <p>Urethritis, conjunctivitis, fever, ulcer penis, rash, iritis, mouth ulcers, diarrhoea, enthesitis (e.g. Achilles tendonitis, plantar fascitis)</p> <p>Iritis, enthesitis, cardiac valvular lesions</p>
<ul style="list-style-type: none"> • Monoarthritis <ul style="list-style-type: none"> – Gout – Septic arthritis 	<p>Tophi, obesity, renal impairment</p> <p>Fever, malaise, source of infection (e.g. skin, throat etc.)</p>

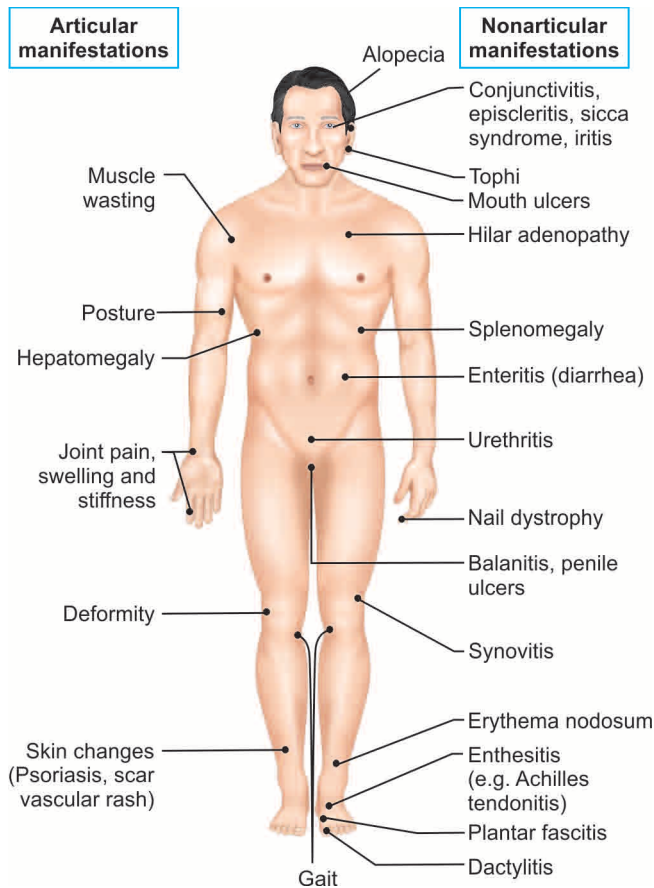


FIGURE 17.5 Articular and nonarticular manifestations of musculoskeletal disorders

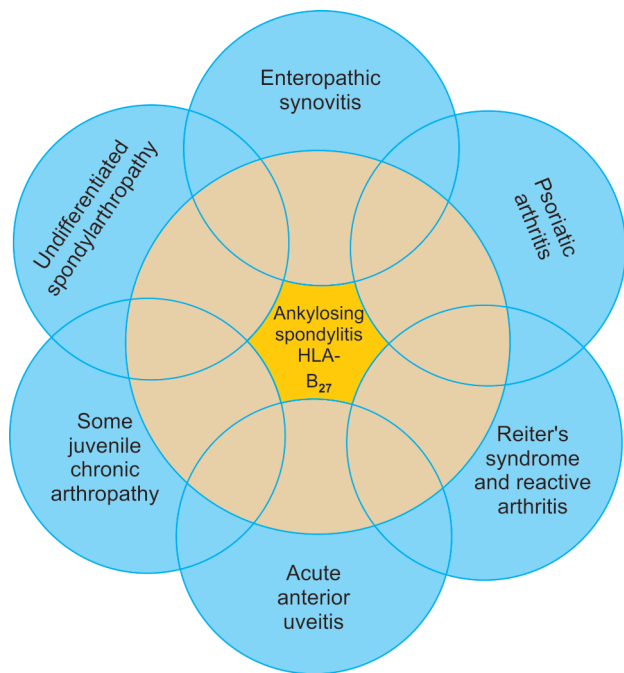


FIGURE 17.6 HLA-B₂₇ linked spondyloarthropathy family. Ankylosing spondylitis has strong association than other arthropathies

Social or Occupational History

The occupation of the patient may have a bearing on the arthritis. Soft tissue rheumatism may be related to physical stress and such forms are known as “*overuse syndrome*” or “*repetitive, stress syndrome*”. The booming computer industry requiring prolonged sitting and bad human postures have unleashed a variety of stress related neck-shoulder-limb and spine disorders. In addition, the development of a chronic arthritis may lead to mood and sleep disturbance. Inability to hold a pen or tools, to kneel, stand for long periods or to use ladders may have profound social and economic consequences.

Drug History

A record of the previous treatment tried must be sought because their success or failure is important for future management. Diuretics may precipitate gout. NSAIDs are commonly prescribed drugs.

EXAMINATION OF LOCOMOTOR DISORDERS

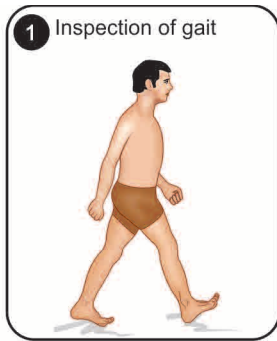
The symptoms of musculoskeletal disorders are so vague that first aim of clinical assessment of the locomotor system is to determine whether symptoms relate to a rheumatological disease or symptoms related to joint are a part and parcel of systemic disorder, hence, a full clinical assessment be made rather than examination limited to the apparent site of symptoms. Even in the absence of major musculoskeletal symptoms, basic examination of joints, muscles and tendons should be done as a routine general examination. The clinical assessment includes:

- Screening for locomotor abnormality and disability
- General physical examination
- Examination of joints including individual joint.

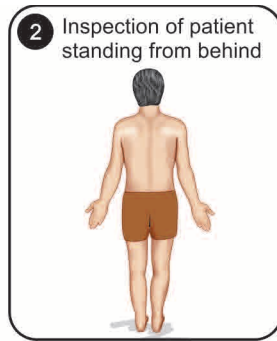
Screening System for Locomotor Abnormality and Disability (Fig. 17.7)

Ask the following three screening questions:

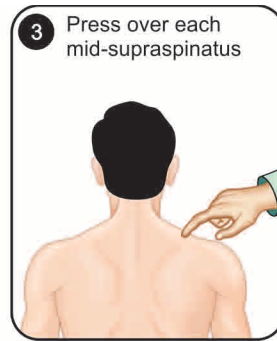
<p>The three screening questions</p> <ul style="list-style-type: none"> • Do you have any pain or stiffness in your muscles, joints or back? • Can you dress yourself completely without any difficulty? • Can you walk up and down stairs without any difficulty? <p>Normal joints should be asymptomatic, look normal, assume a normal resting position and move smooth through their range of movement.</p>	<p>The GALS (gait, arms, legs, spine) screen is a validated screening system for locomotor abnormality and disability with respect to activities of daily living (Fig. 17.7) Doherty M, Dacre J, Dieppe P, Snaith M. The ‘GALS’ locomotor screen. <i>Ann Rheum Dis.</i> 1992;51:1165-9; Plan MJ, Linton S, Dodd E, et al. The GALS locomotor screen and disability. <i>Ann Rheum Dis.</i> 1993;52:886-90.</p>
---	---



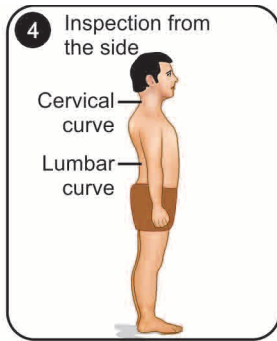
- 1** Inspection of gait
- Symmetry, smoothness of movement
 - Normal stride length
 - Normal heel-strike, stance, toe-off, swing-through able to turn quickly



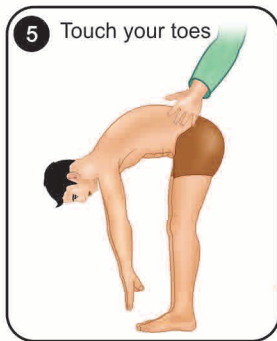- 2** Inspection of patient standing from behind
- Straight spine
 - Muscle bulk/symmetry of paraspinal, shoulder and gluteal muscles
 - Level iliac crests
 - No hindfoot swelling or deformity



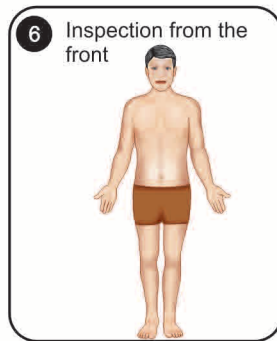
- 3** Press over each mid-supraspinatus
- Hyperalgesia of fibromyalgia



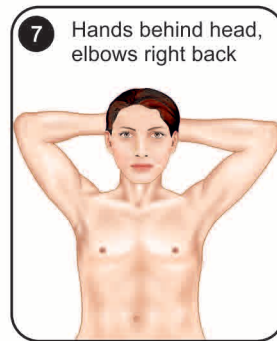
- 4** Inspection from the side
- Normal cervical and lumbar lordosis
 - Normal thoracic kyphosis



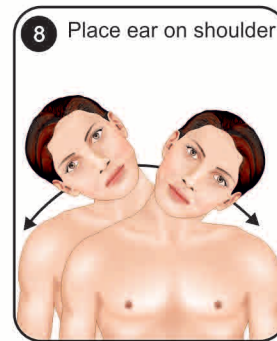
- 5** Touch your toes
- Normal lumbar spine (and hip) flexion



- 6** Inspection from the front
- Full elbow extension
 - Shoulder and quadriceps muscle bulk, symmetry
 - No knee swelling or deformity
 - No forefoot or midfoot deformity
 - Normal arches



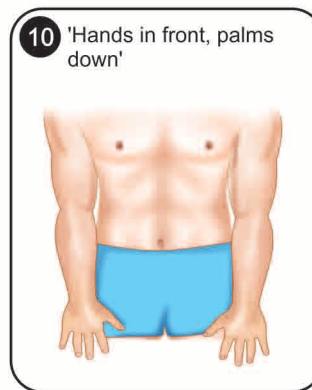
- 7** Hands behind head, elbows right back
- Full shoulder abduction, external rotation
 - Normal acromioclavicular and sternoclavicular movement
 - Full elbow flexion



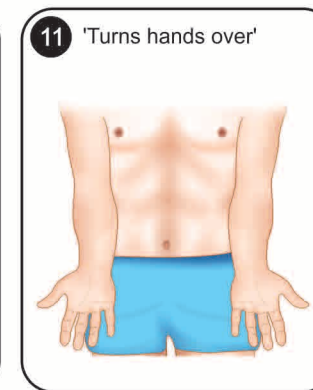
- 8** Place ear on shoulder
- Normal pain-free cervical lateral flexion



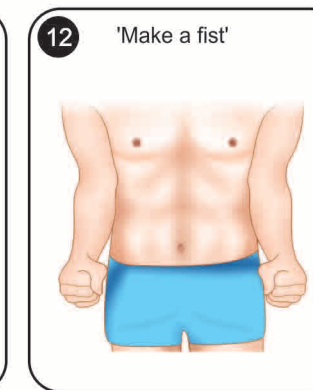
- 9** 'Open jaws, move side to side'
- Normal temporomandibular movement



- 10** 'Hands in front, palms down'
- No swelling or deformity of hands/wrists
 - Able to extend fingers



- 11** 'Turns hands over'
- Normal supination (wrist, distal radio-ulnar joint)
 - Normal palms



- 12** 'Make a fist'
- Strong power grip

FIGURE 17.7 GALS screening tests (Contd...)

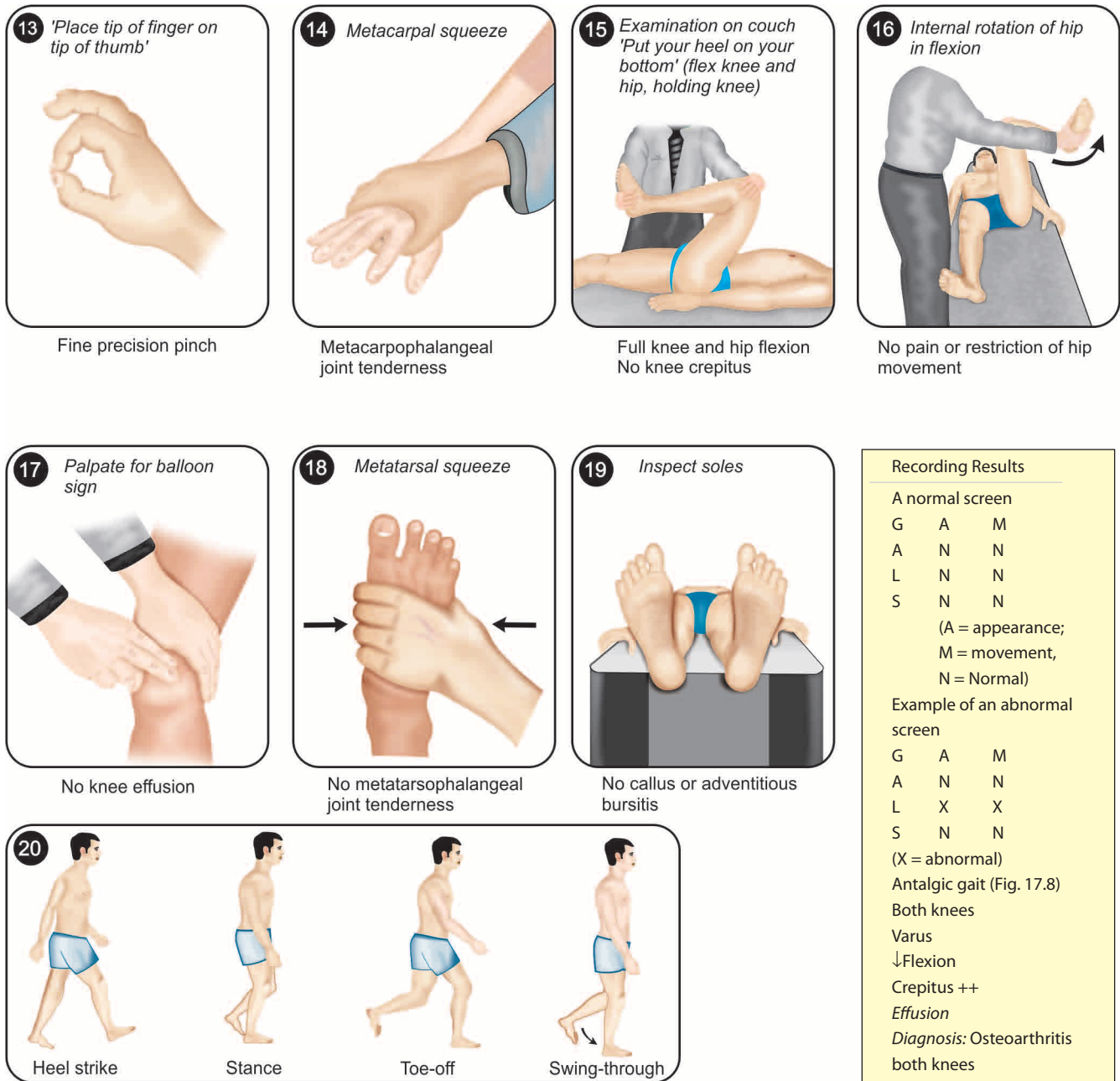


FIGURE 17.7 (.....Contd) GALS screening tests

General Physical Examination

Aims of the Examination

- To identify the site and type of pathology, i.e. articular or nonarticular, inflammatory or degenerative (non-inflammatory).
- To assess the loss of function by examining range of movements and specific functions (e.g. walking, rising, power grip).

- To identify associated complications, e.g. deformity, instability, muscle wasting, calluses, extra-articular features.

The examination begins with the observation of the patient entering the room (see Box 6). Abnormalities of gait and posture may provide clues that can be pursued in history-taking. The patient may be asked to stand and walk, even when it is obvious that this may not be possible. This will give an idea about the help the patient requires from others

Box 6

General observations of locomotor system

- Gait
- Posture
- Mobility
- Deformity
- Muscle wasting
- Long bones
- Fractures
- Joints
- Tendons
- Skin

or from sticks, crutches, etc. Observation of any difficulty in undressing, getting out of the chair and getting on to the examination couch will further help in assessing the patient. The locomotor system examination includes not only of the joints but also of the soft-tissue structures (muscles, tendons, ligaments, bursae, etc.). A look for any muscle wasting which could either be due to a primary muscle disease e.g. polymyositis, myopathy or secondary to a painful joint (disuse—*Suddack's atrophy*). Examinations of muscles have already been discussed in nervous system examination (Chapter 16).

Gait: Abnormal gaits due to musculoskeletal disorders may be divided into two types- painful (antalgic) or painless.

Painful gait (antalgic gait Fig. 17.8): It is jerky asymmetric gait with less time spent on weight bearing on painful leg or foot on the ground; with more severe pain the whole limb is held flexed and the foot is placed delicately on the ground for very short periods. The patient requires support to walk.

Painless gait: In a painless gait, the normal smooth rhythm is disturbed either because of a short limb, a deformed or stiff joint or weak muscles. The effect of muscle weakness will depend on the site and degree of muscle pathology.

Trendelenburg gait: Unilateral weakness of hip abductors produces pelvis drop on the opposite side during stance phase on affected side.

Waddling gait: Bilateral Trendelenburg gait (paralysis of glutei muscles) is waddling gait.

Examination of eyes, skin, mucous membrane, hair, nails, and fingers is an important integral part of physical examination in a rheumatological case for extra-articular or systemic manifestations (Table 17.5).

Examination of the Joints and Bones

The fundamental principal for examining the joints is to proceed in “head to toe” manner (e.g. the temporomandibular joint, cervical spine, shoulder girdle, upper limb, thoracic and lumbar spine and then the joints of pelvis and lower limbs) so that inconspicuous but important joints such as sternoclavicular, sacroiliac, symphysis pubis may not be missed. Compare the corresponding joints on the two sides



FIGURE 17.8 Painful (antalgic) gait. Note that patient adopts a flexed positive, places both hands on the legs which are placed delicately on the ground due to pain

of the body. Always be careful not to cause any discomfort to the patient during examinations. The steps of examination include;

- Inspection of the joint (*look at the joint*)
- Palpation of bony landmarks and soft tissue structures (*feel and palpate the joint*).
- Assessment of range of motion or the direction of joint movement (*move the joint*)
- Special manoeuvres to test joint function.

Inspection



(To look at the joint)

You should look at the joint at rest as well as during movement.

Inspection at Rest

- Note symmetry of involvement (see Fig. 17.4). Is there a symmetric change in joints on both sides of the body or is the change only in one or two joints?
 - Monoarthritis (involvement of one joint) indicates trauma, sepsis (Fig. 17.14), tuberculosis or gout as the cause.
 - Symmetric involvement of many joints especially of the extremities indicate rheumatoid arthritis (Fig. 17.15).
 - Asymmetric involvement of joints (pauci-arthritis) is seen in reactive arthritis, psoriatic arthritis, Reiter's syndrome, ankylosing spondylitis.

Swelling: Note any swelling of the joint or periarticular tissue. Local oedema is sometimes seen over the inflamed joint.

- Joint swelling indicates synovitis (Figs 17.16A and B).
- Periarticular swelling may be due to tendonitis, bursitis, muscle tear.

TABLE 17.5 Important physical signs and their related rheumatological disorders

Look at	Disease associated
<ul style="list-style-type: none"> • Eyes for <ul style="list-style-type: none"> – Redness (conjunctivitis, iritis, episcleritis) – Dryness of eyes (sicca syndrome) • Mucous membrane for <ul style="list-style-type: none"> – Buccal ulcers – Anaemia, leucopenia, pancytopenia • Skin for <ul style="list-style-type: none"> Nodules Nodes on bony prominence Petechiae Palpable purpura Erythema nodosum Haemorrhagic pustules Rash (butterfly on face) Photosensitivity (sun-sensitivity rash) Raynaud's phenomenon Livedo reticularis • Hair <ul style="list-style-type: none"> Alopecia • Nails <ul style="list-style-type: none"> Clubbing of finger nails Nails pitting Splinter haemorrhages, nail fold vasculitis • Fingers <ul style="list-style-type: none"> • Dactylitis, cutaneous infarct, gangrene • Neck <ul style="list-style-type: none"> Lymphadenopathy • Extremities <ul style="list-style-type: none"> Leg ulcers 	<ul style="list-style-type: none"> • Rheumatoid arthritis, reactive arthritis, spondylarthritis, Sjögren's syndrome SLE, Reiter's syndrome, Behçet's syndrome Still's disease, Rheumatoid arthritis, SLE, Felty syndrome RA (Figs 17.9A and B), gout, amyloidosis, sarcoidosis, rheumatic arthritis Osteoarthritis (Fig. 17.10) SLE, ITP Vasculitis (Fig. 17.11) Sarcoidosis, reactive arthritis Gonococcal arthritis SLE, dermatomyositis SLE SLE, systemic sclerosis Antiphospholipid syndrome SLE Hypertrophic osteoarthropathy Psoriatic arthritis (Fig. 17.12) Vasculitis, SLE, and polyarteritis nodosa Vasculitis (Fig. 17.13), rheumatoid arthritis, SLE RA, Felty's syndrome, sarcoidosis, tuberculosis Rheumatoid arthritis, vasculitis, Felty's syndrome

Note any joint deformity or malalignment of bones. Look for any alterations in shape or outline or shortening of bone.

- Dupuytren's contracture (Fig. 17.17) is flexion contracture of the ring and little fingers.

- The term *valgus* is used to describe deviation of a limb distal to the joint away from midline (knock knee) and *varus* to describe deviation towards the midline (e.g. bow-leg).
- Bowing of femur and tibia is seen in Paget's disease of the bone. (see Fig. 10.21 in Chapter 10).
- Alteration in the shape of bones (bowing of legs) occurs in rickets. Deformity of the chest in rickets (*ricketty rosary*) is due to osteochondral enlargement.
- Swan-neck, ulnar deviation of hand, Boutonniere and Z-shape deformities are seen in rheumatoid arthritis (Figs 17.18A to D).

Note any muscle wasting.

- Global wasting of the shoulder muscles may occur in glenohumeral arthritis—called disuse atrophy.
- Arthritis or a splinted joint may cause disuse atrophy.
- Wasting of the small muscles of the hand may occur in rheumatoid arthritis.
- Wasting of thenar muscle may be due to carpal tunnel syndrome.

Note the position or posture of the limb.

- Guarded posture—held in loose-pack position for capsule (adduction, internal rotation for shoulder) is characteristic of joint problem.

Note any redness or erythema of the overlying skin.

- Redness over a joint suggests septic or gouty arthritis or possibly rheumatoid arthritis

Inspection of joint for range of motion: Ask the patient to perform movements. Note any limitations in range of motion or increased mobility (*hypermobility*) or joint instability from excessive mobility of the joint ligaments (*ligamentous laxity*).

Decreased ranges of movements (*restricted movements*) occur in arthritis, inflammation of periarticular tissue, fibrosis in or around a joint, or bony ankylosis (*fixation*).

Hypermobility of the joint is seen in Marfan's syndrome and Ehlers-Danlos syndrome, neuropathic joint (*Charcot's joint*).

Pain on usage (*stress pain*) if occurs in all directions (*universal*) indicates synovitis while selective stress pain (*one plane only*) indicates periarticular lesion.

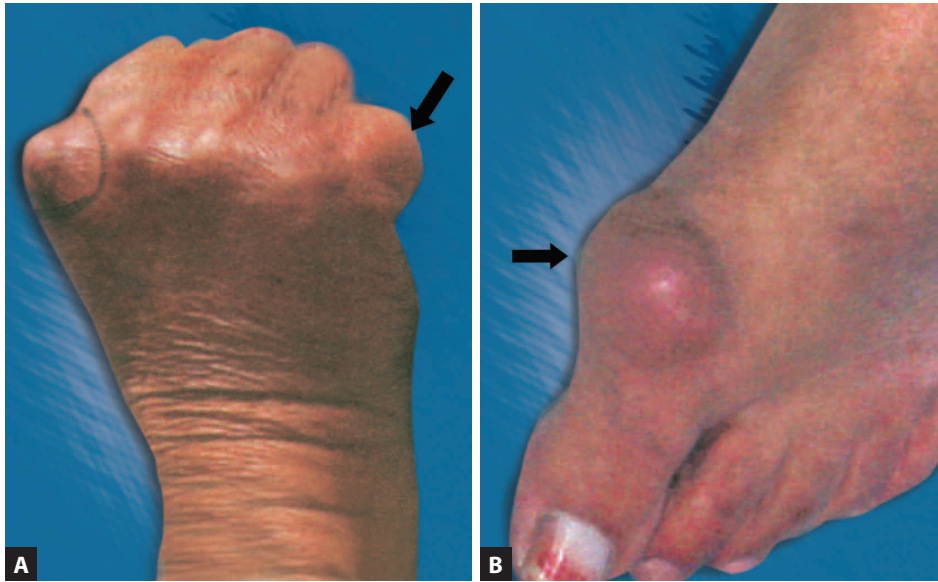
Note: Restriction of movements in one plane or direction indicates periarticular lesion; while restriction of all movements indicate joint problem.

Palpation (Feel and move the joint)

Palpate for the signs of inflammation of the joint.

- **Swelling:** Palpable swelling may involve:
 - Synovial membrane which can feel boggy or doughy.

Palpable bogginess or doughiness of the synovial membrane indicates synovitis, which is often accompanied by effusion (Fig. 17.16A).



FIGURES 17.9A and B Rheumatoid nodules. Note the cystic swellings over the bony prominences (knuckles) of hand (A) and great toe (B)



FIGURE 17.10 Heberden's nodes and Bouchard's nodes in osteoarthritis

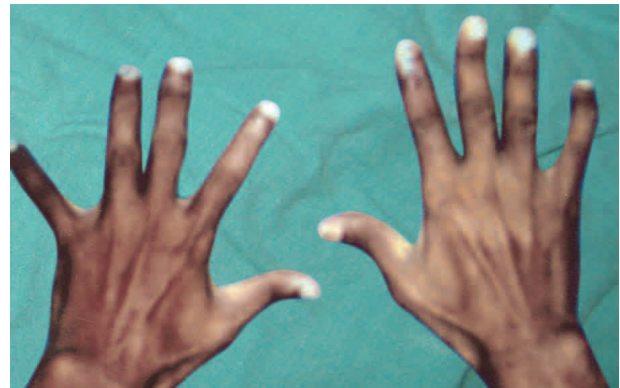

FIGURE 17.12 Psoriatic arthritis involving PIP and DIP joints with nail changes (pitting of the nails)

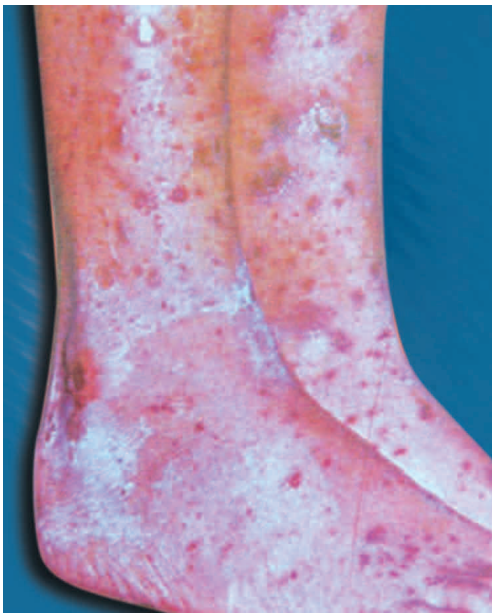

FIGURE 17.11 Henöch-Schönlein purpura. Note the palpable purpura over both the legs. Patient also had arthritis

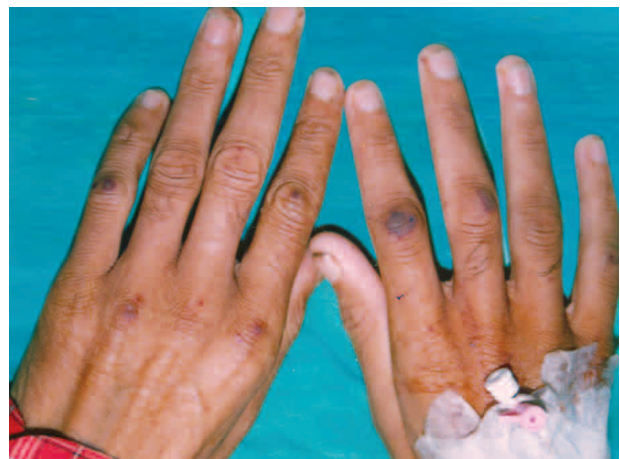

FIGURE 17.13 Changes in the skin and nails in a patient with vasculitic arthritis

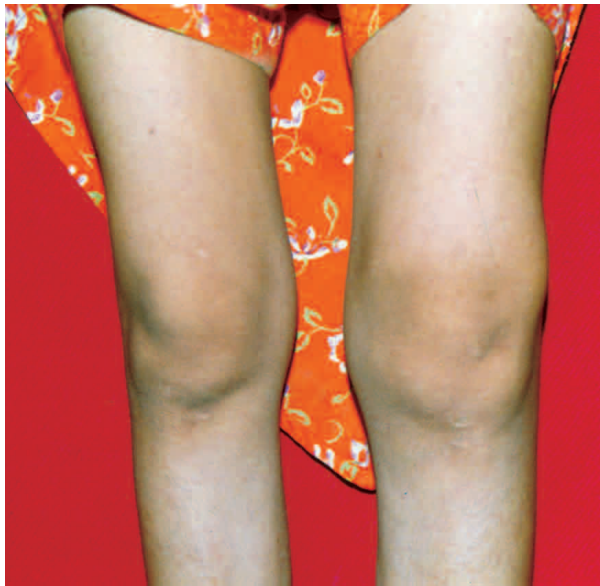
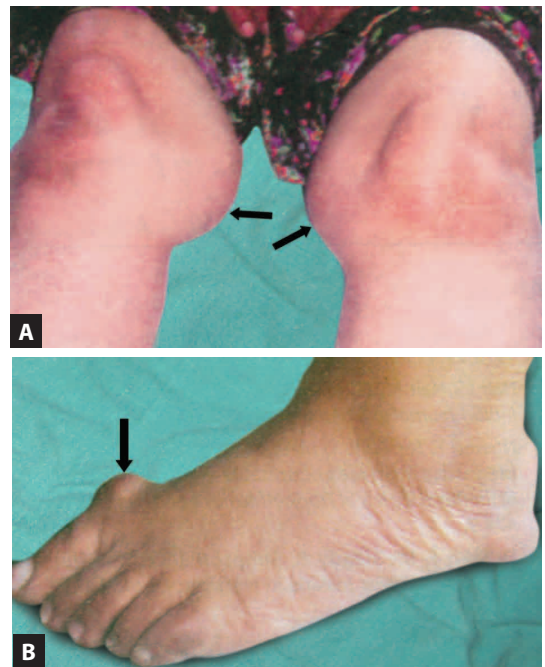


FIGURE 17.14 Acute infective monoarthritis of left knee. Note the soft tissue swelling

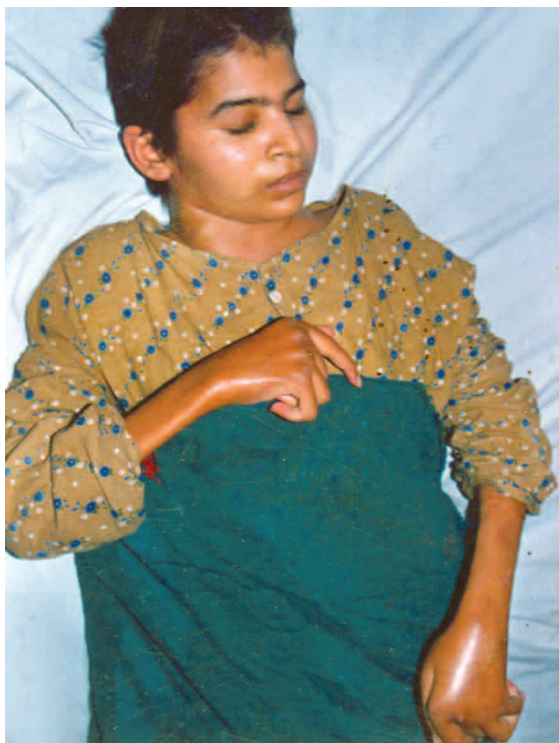

FIGURE 17.15 Rheumatoid arthritis. Note bilateral symmetrical involvement of small joints of both hands, wrists, elbows and shoulders. There are associated deformities of the joints (deforming arthritis)

- Joint effusion from excess synovial fluid within joint space (fluctuation test is positive) soft tissue structures such as bursae, tendons and tendon sheaths. Tendon sheath effusions are distinguished from joint swelling by their location in association with tendons.



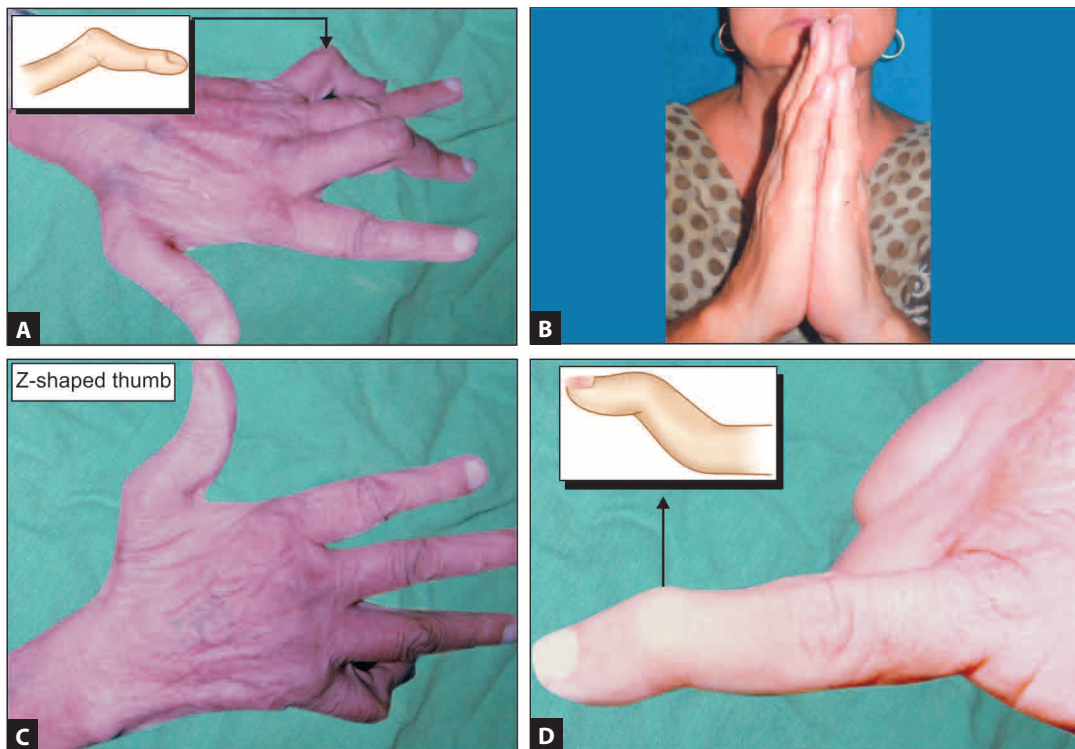
FIGURES 17.16A and B Synovitis due to rheumatoid arthritis. Note the boggy swellings (joint effusion) of both knees: (A) There is a rheumatoid nodule over the bony prominence of metatarsophalangeal joint of great toe (↓) in figure (B)

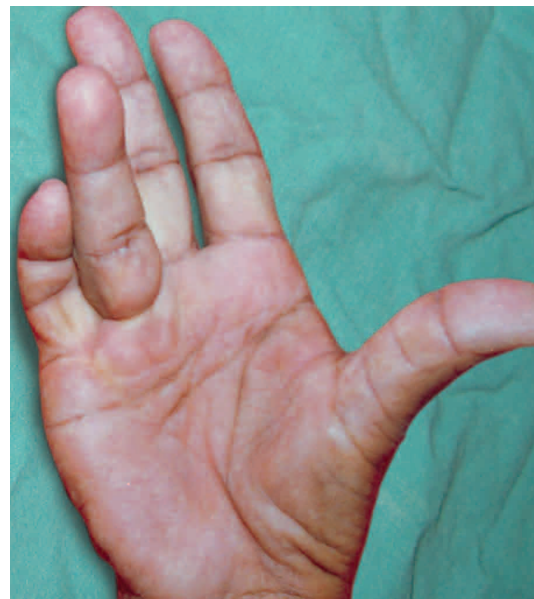

FIGURE 17.17 Dupuytren's contracture of right hand

Swelling and tenderness over the tendon sheath or bursa indicate tendonitis or bursitis.

- Enlarged subcutaneous bursae may be found over pressure areas (olecranon bursa at elbow). Deep bursitis may only produce tenderness.



FIGURES 17.18A to D Deformities of hand in deforming rheumatoid arthritis: (A) Boutonniere deformity; (B) Prayer's hand seen in rheumatoid arthritis; (C) Ulnar deviation of hand and Z-shaped thumb; (D) Swan-neck deformity

Box 7

Assessment of joint tenderness

- Grade
1. The patient says the joint is tender.
 2. The patient winces due to pain.
 3. The patient winces and withdraws the affected part.
 4. The patient does not allow the joint to be touched.

NB: Grade 4 tenderness occurs only in septic arthritis, crystal arthritis and rheumatic arthritis.

- Localised swellings of long bones may be caused by infection (osteomyelitis), cysts or tumours or fracture. Spontaneous fractures of bones may occur in carcinoma, multiple myeloma, hyperparathyroidism, osteogenesis imperfecta.
- **Warmth:** Use the backs of your fingers to compare the warmth of the involved joint with its unaffected contralateral joint, or with nearby tissues if both joints are involved.

Warmth indicates arthritis, tendinitis, bursitis, osteomyelitis.
- **Tenderness:** Joint tenderness may be graded (*see* Box 7) on the patient's response to firm pressure on the joint by holding it between finger and thumb.

If tenderness is present, localise it as accurately as possible and determine whether it arises in the joint or in the neighbouring structures, e.g. in the supraspinatus or bicipital tendon rather than the shoulder joint.

Feel for the Tendon Sheath Crepitus or Joint Crepitus

Tendon sheath crepitus is felt as a grating or creaking sensation when patient is asked to contract the muscle tendon involved. It is particularly common in tenosynovitis in the hand.

Joint crepitus is palpable crunching detected by feeling the joint with palm of one hand while it is moved passively with the other hand (Fig. 17.19). This may indicate osteoarthritis or loose bodies (cartilaginous fragments) in the joint space, but should be differentiated from nonspecific clicking of joints.

Palpate for Subcutaneous Nodules

Palpate for subcutaneous nodules by running the finger/thumb over the bony prominences or between thumb and finger if present in soft tissue. The various subcutaneous nodules and their site for palpation are given in the Box 8.

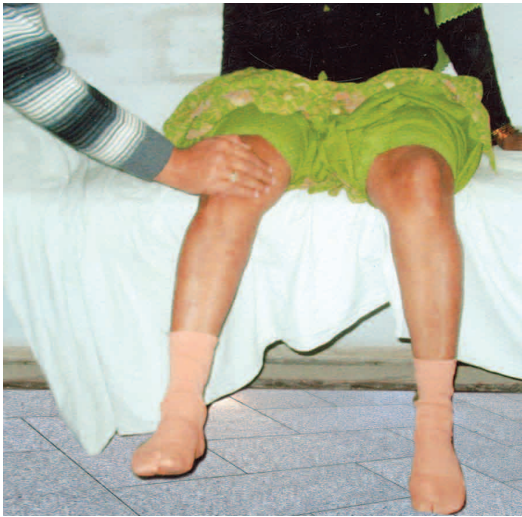

FIGURE 17.19 Method of elicitation of joint crepitus

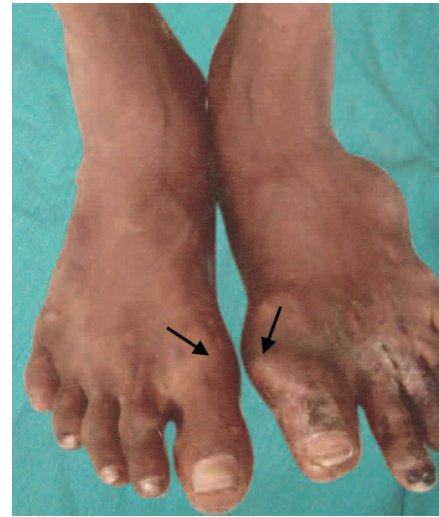

FIGURE 17.20 Chronic tophaceous gouty arthritis. Note the presence of tophi over the joints of big toes

Box 8

Subcutaneous nodules

Type	Site
Gouty tophi (Fig. 17.20) seen in gout	Helix of the ear, overlying the joint or in finger pulps.
Rheumatoid nodules in rheumatoid arthritis (Fig. 17.9)	Firm, nontender nodules present at pressure points or frictional sites such as bony prominences, indicate seropositive aggressive arthritis
Nodules in SLE	Tendons of the hand
Rheumatic nodules in rheumatic fever	Present over the tendons on extensor surfaces of forearm, legs
Xanthomatous deposits in hypercholesterolaemia	Xanthomas may be present over joints, tendons etc.
Neurofibromatosis (see Fig. 4.21)	Small, superficial, subcutaneous nodules over the side of neck and back

The cutaneous neurofibromas (see Fig. 4.21) are small swellings (Read Box 8) arising from the sensory nerve twigs producing subcutaneous nodules or from the peripheral nerve trunks (plexiform neurofibromatosis). The subcutaneous nodules of neurofibroma can be pushed back through the defect (Button-hole sign).

Measurement of Range of Movements

Note the movements and their range of motion.

Some joints such as the subtalar joint of foot which have limited movement can be tested passively. Relatively immobile joints (sternoclavicular, acromioclavicular,



FIGURE 17.21 Location and palpation of temporomandibular joint

manubriosternal, costochondral and sacroiliac) have to be examined by palpation or stressing manoeuvres to evoke pain.

The neutral zero method of recording movement is recommended. All joints are considered to be in the neutral position when the body assumes classical anatomical position except joints of hands and feet.

In examining joints for range of movement, estimate the degree of limitation by comparing with the normal side. For accurate measurement, a *goniometer* (protractor) is used. Both active and passive movements should be assessed.

Limitation of movements in a joint may be due to pain, muscle spasm, inflammation, increased thickness of the capsule; fibrous ankylosis, contractures, effusion into the joint, bony overgrowth, bony ankylosis, mechanical factors (meniscal tear).

Remember painful active movements will give a poor estimate of true range of movement because of muscle spasm, hence, other findings should be corroborated for diagnosis. Be gentle and careful during examination of painful joints.

EXAMINATION OF INDIVIDUAL JOINTS

Temporomandibular Joint

Inspection and palpation: Inspect the joint for *swelling* or *redness*. Swelling may appear as a rounded bulge anterior to external auditory meatus.

Swelling, tenderness and restriction of movement indicate an inflamed joint.

Swelling may also occur in subluxation or dislocation of the joint due to trauma.

For location and palpation of the joint, place the tips of your index fingers just in front of the tragus of each ear (Fig. 17.21) and ask the patient to open his or her mouth. The finger tips should drop into the joint space as the mouth opens. Check for the smooth range of movements. Note any swelling or tenderness. Snapping or clicking may be felt or heard in normal people.

Palpable crepitus or clicking may occur in poor occlusion, meniscal injury or synovial swelling due to trauma.

- **Range of movements:** There are three types of movements at this joint;
 - (i) **Opening and closing of the jaw:** Ask the patient to demonstrate this movement.
 - (ii) **Protrusion and retraction of jaw:** This can be demonstrated by jutting the jaw forward and backwards. Ask the patient to follow you as you demonstrate the protrusion and retraction of the jaw.
 - (iii) **Side to side or lateral movements:** Ask the patient to move the jaw from side to side.

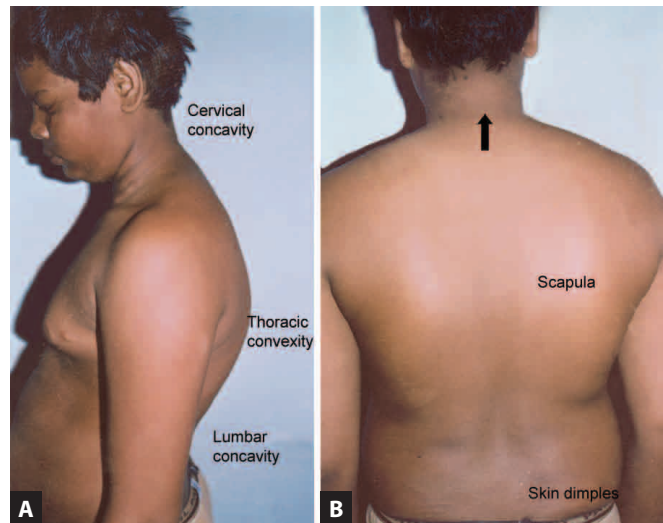
- Normally as mouth is opened wide, three fingers, can be inserted between incisors.
- During normal protrusion of the jaw, the bottom teeth can be placed in front of the upper teeth.

NB: Any deviation from the normal indicate joint involvement.

The Spine (Joints of Vertebral Column)

Applied Anatomy and Physiology

The vertebral column or spine is a central supporting structure of the body. It has two concavities; one of the cervical and other of lumbar spines, and two convexities, i.e. of thoracic and sacrococcygeal spines (Fig. 17.22A). These curves help



FIGURES 17.22A and B Important anatomical landmarks and curves: (A) Patient's lateral view for various curves; (B) Patient's back for important landmarks

- Spinous process of C_8-T_1 (\uparrow) is prominent during forward bending
- Scapulae stand out prominently
- Both shoulders are at same level.
- Skin dimples above the belt indicates posterior superior iliac spine. A line drawn above the posterior superior iliac spine crosses the spine of L_4 . A lumbar puncture is done just above this line

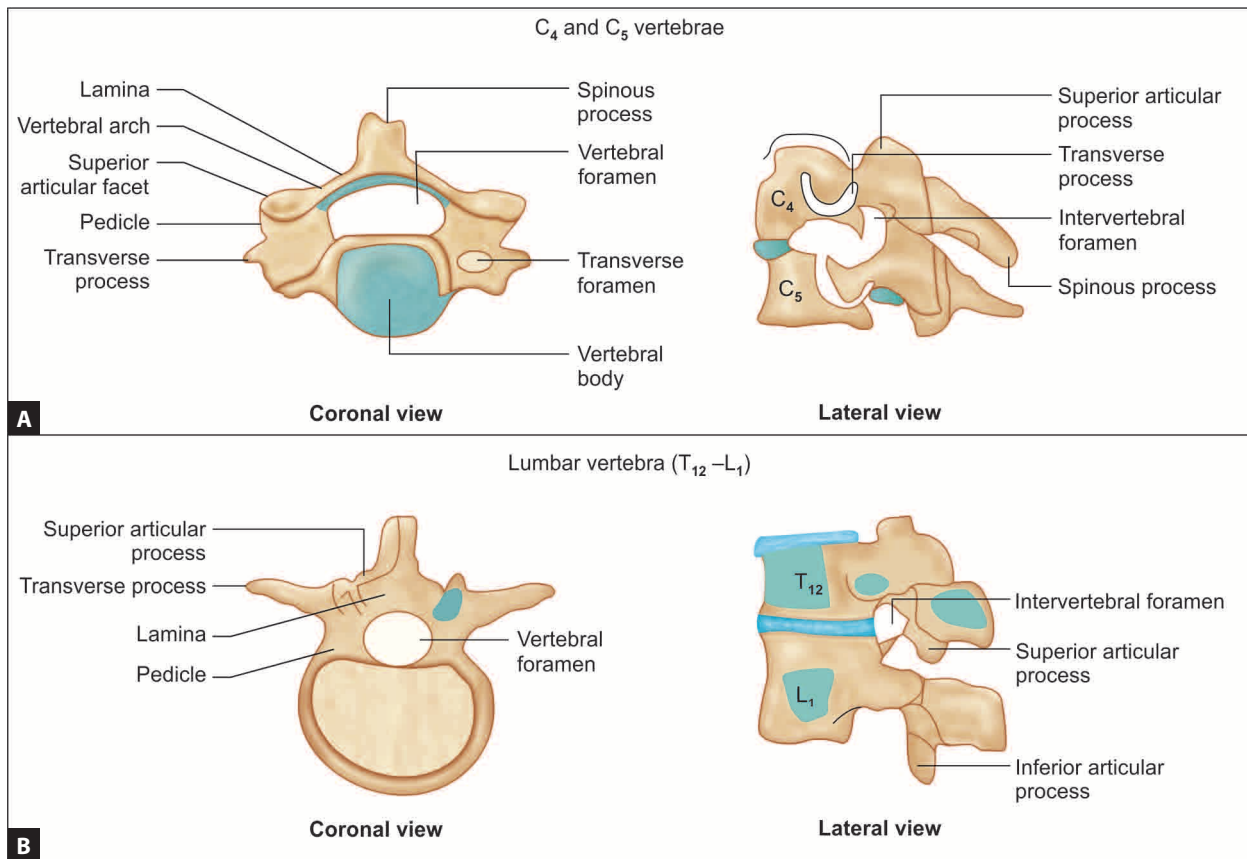
to distribute upper body weight to the pelvis and lower limbs and also cushion the concussive effect of walking or running.

The vertebral column consists of vertebrae, intervertebral discs, an interconnecting system of ligaments, large superficial and deeper intrinsic muscles and muscles of abdominal wall.

Important landmarks: Viewing from the behind, the important landmarks visible are depicted in Fig. 17.22B.

Bony structures: The vertebral column has 24 vertebrae stacked on the sacrum and coccyx. The typical structure of cervical and thoracic vertebrae is depicted in the Figures 17.23A and B. A typical vertebra consists of:

- **The spinous process projecting** in the midline posteriorly and transverse processes standing out at the junction of the pedicle and the lamina. Muscles attach at these processes.
- **Two articular processes** on each side of the vertebra, one facing up and another facing down at the junction of the pedicles and lamina. These are articular facets for joint articulations.
- **The vertebral foramine** is a large central space through which spinal cord passes. The smaller foramina—called *intervertebral foramina* formed by the inferior and superior articular processes of adjacent vertebrae, create a space for exit of the spinal nerve roots; and in the cervical vertebrae, the transverse foramen is for the vertebral artery.



FIGURES 17.23A and B Bony structure of: (A) Cervical vertebrae (C₄ and C₅); (B) Lumbar vertebrae (T₁₂-L₁)

The proximity of the spinal cord and spinal nerve roots to the vertebral bodies and to the intervertebral discs makes them vulnerable to compression by disc herniation, trauma and impingement from degenerative changes in the vertebrae.

Joints: The spinal column has slightly movable cartilaginous joints between the vertebral bodies as already described in the beginning.

The Movements and Muscle Groups

The cervical spine

- Nodding of the head occurs at atlanto-occipital joint (C₁)
- Rotational neck movements occur mainly at atlantoaxial joint (C₁-C₂)
- The flexion (sternomastoid, scalene, paravertebral muscles), the extension (splenius capitis, trapezius, small neck muscles) and lateral bending (scalene and small intrinsic neck muscles) occur at the mid-cervical (C₃-C₅) level.

Symptoms

- Neck pain and difficulty in turning the head. Pain may be referred to the arm. The causes of referred pain are given in Box 9.
- Neck stiffness.

Box 9

Causes of referred pain to the arm

- Cervical spondylosis
- Cervical rib
- Apical lung neoplasm (Pancoast's tumour)
- Hiatus hernia
- Cardiac ischaemia
- Diffuse oesophageal spasms

Compression of nerve roots (radiculopathy) and cord (myelopathy) may lead to quadriparesis, difficulty in walking, loss of sensation and sphincter control.

- The patient may also report paraesthesias or pain due to nerve root irritation at different sites at different level of involvement (Table 17.6). Thus, any patient with neck pain should be subjected to detailed history; neurological examination and investigations.

The thoracic spine

This segment of the spinal cord is least mobile and maintains a kyphosis throughout life. Movements in the thoracic spine

TABLE 17.6 Radiation of pain in cervical spine involvement

Site of involvement	Radiation of pain
• Upper cervical spine affecting atlantoaxial joint	Pain radiating to occiput in distribution of the C ₂ nerve root
• Mid-cervical spine	Pain radiating into the upper border of trapezius, interscapular region or into arms, often associated with local tenderness
• Lower cervical spine (C ₆ -C ₇)	Widely referred pain into the interscapular region or into radial fingers and thumb
• C ₈ involvement	Pain on the ulnar side of forearm and into ring and little fingers

Box 10

Causes of pain in thoracic spine involvement

- *Adolescents/adults*
 - Scheuermann's disease
 - Ankylosing spondylitis
 - Disc protrusion
- *Middle age and elderly*
 - Osteoporosis
 - Degenerative change
 - Aortic aneurysm
- *Any age*
 - Tumour
 - Trauma
 - Infection

are mainly rotational with little flexion, extension and lateral bending.

Symptoms

The presenting symptoms of thoracic spine disease are:

- Localised spinal pain or pain radiating round the chest wall, mimicking cardiac or pleural disease.
- **Progressive stooping and loss of height:** The patient with osteoporosis may complain of becoming progressively stooped (*Dowager hump*) with loss of height but without neurological features.
- **Symptoms and signs of spinal cord compression,** e.g. paraplegia, sensory loss and loss of bowel and bladder control.

The causes of pain due to involvement of the thoracic spine are given in the Box 10.

Lumbar spine

The lumbar spine has a smooth lordosis which may be lost in certain disorders, i.e. ankylosing spondylitis and disc protrusion. The main landmarks in lumbar region of vertebral

column are the spinous process of L₄/L₅, which are level with the pelvic brim and the “*Dimples of Venus*” which lie over the sacroiliac joint.

Symptoms

Low backache or low back pain is the presenting symptom. Most adults will have experienced it by the time they are middle-aged. An important objective of the history is to distinguish low back pain due to mechanical cause (disc protrusion, spinal canal stenosis, osteoporotic fractures) from pain due to irritation of nerve root (root pain) and inflammatory pain (ankylosing spondylitis, infection). The characteristics of various types of back pain are discussed below.

Acute low back pain in young associated with bending or lifting weight is characteristic of acute lumbar disc protrusion. Sudden movement and coughing will increase it. In addition, there may be compression of nerve roots (*cauda equina syndrome*). If sacral nerve roots are involved, there may be loss of sphincter control and perianal sensations. These acute episodes may be superimposed on previous disc degeneration. Acute back pain in middle and old age may be due to osteoporotic fracture and is not associated with neurological symptoms. This type of pain is increased by spinal flexion but is relieved on lying down.

Inflammatory or infective pain is associated with systemic features, e.g. malaise, weight loss, night sweats, usually indicates tuberculous or pyogenic infection of the spine. The patient feels difficulty in moving the spine. The infection may involve intervertebral disc (caries), adjacent vertebrae, and at times it may tract into psoas muscle (*psoas cold abscess*) presenting as a swelling in the groin or may lead to painful flexed hip. Malignant disease involving the vertebral bodies produces continuous, unremitting spinal pain of acute onset, which disturbs the patient's sleep as well as the mood. There may be associated symptoms of malignancy such as anorexia, weight loss, night sweats.

Intermittent pain or discomfort in the lumbar region occurring over a long period of time in an old person is typical of wear and tear of the spine as a result of degenerative disc disease. The characteristic pain and stiffness occur in the morning or after immobility, relieved by gentle activity but recur with or after excessive activity.

Diffuse pain in the buttocks/thighs brought on by prolonged standing or walking is indicative of lumbar canal stenosis. The pain may be associated with paraesthesias. Typically, the pain is relieved by rest and flexion of the spine. Narrowing of the lumbar spinal canal or exit foramina is caused by degenerative pathology in the discs and facet joints.

The common causes of low back pain/lumbar pain and referred back pain are illustrated in Box 11.

Box 11

Common causes of low back pain

- Vertebral compression fracture
- Infection of the intervertebral disc space
- Tumour of the vertebral body
- Spondylolisthesis of vertebral body
- Spondylosis of posterior intervertebral joints
- Prolapsed intervertebral disc

Causes of referred back pain

Genitourinary and aorta	Gastrointestinal
<ul style="list-style-type: none"> • Kidney <ul style="list-style-type: none"> – Stone – Tumour – Infection – Hydronephrosis • Uterus and ovaries <ul style="list-style-type: none"> – Dysmenorrhoea – Pelvic inflammation – Tumours of uterus and ovaries – Ovarian cyst • Aorta <ul style="list-style-type: none"> – Aortitis – Aortic aneurysm 	<ul style="list-style-type: none"> • Oesophagus <ul style="list-style-type: none"> – Oesophagitis – Hiatus hernia – Carcinoma • Stomach and duodenum <ul style="list-style-type: none"> – Peptic ulcer – Carcinoma • Pancreas and gallbladder <ul style="list-style-type: none"> – Pancreatitis – Carcinoma – Cholecystitis • Gut <ul style="list-style-type: none"> – Diverticulosis – Abscess

Range of movements

The principal movements are flexion, extension, lateral flexion and rotation. Most patients will be able to bring the tips of the fingers at least to the level of the knee in forward flexion and lateral bending.

Extension is variable from 10–20°. In flexion, the upper segments moves first, followed by lower segments to produce a smooth lumbar curve. Even with a rigid lumbar spine, if hips are mobile, the patient may be still able to touch his/her toes.

Spinal cord ends at the level of L₁, therefore injury above this level may damage the cord while below this will damage the nerve roots only (cauda equina).

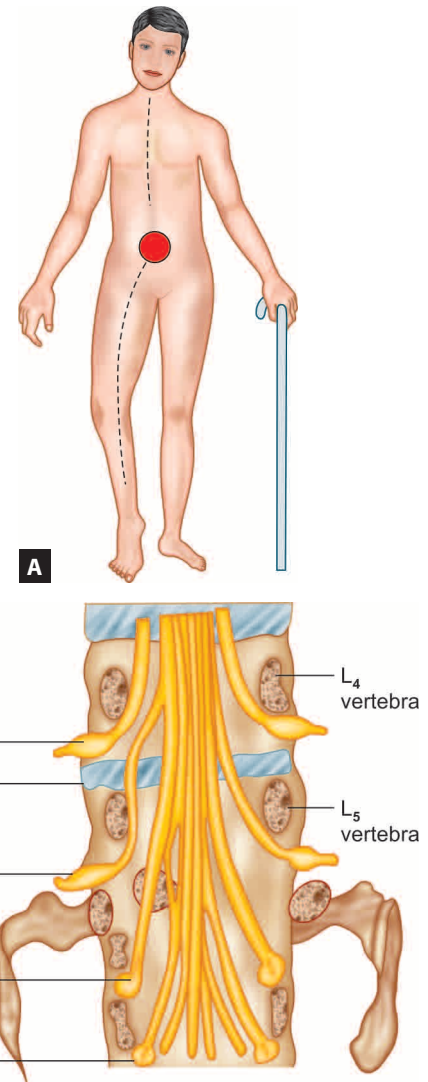
Protrusion of disc occurs mostly at the level of L₄/L₅ and L₅/S₁ (Figs 17.24A and B).

Examination of the Spine

In clinical practice, the spine is examined in its entirety not in isolation.

Inspection

- Begin by observing the posture including the position of both neck and trunk when patient is entering the room.
- Assess the patient for erect position of the head, smooth, coordinated neck movements. Note the posture of the neck.



FIGURES 17.24A and B Compression of lumbosacral nerve roots by herniation of disc: (A) Clinical presentation with site and radiation of pain to the leg (diagram). There is compensatory scoliosis; (B) Common site of prolapse of the disc (diagram)

- Expose the patient's back for complete inspection. Patient should stand in erect posture in natural standing position—with feet together and arms hanging at the sides. The head should be in midline in the same plane as sacrum, and the shoulders and pelvis should be in the same plane.
- Inspect the patient from the side for spinal curvatures. Note any curvature of the spinal column whether as a whole or of part of it. The curvature may be in an anterior, posterior or lateral direction. Common abnormalities are given in the Box 12.

Anterior curvature is termed *lordosis*. There are natural lordotic curves in cervical and lumbar regions. Loss of lordosis occurs in acute disc prolapse.

Box 12

Common abnormalities related to spine

- Neck stiffness indicates arthritis, muscle strain
- Torticollis (wry neck) indicates sternomastoid spasm or contracture
- Cock-Robin position indicates lateral flexion of neck due to erosion of atlas in rheumatoid arthritis.

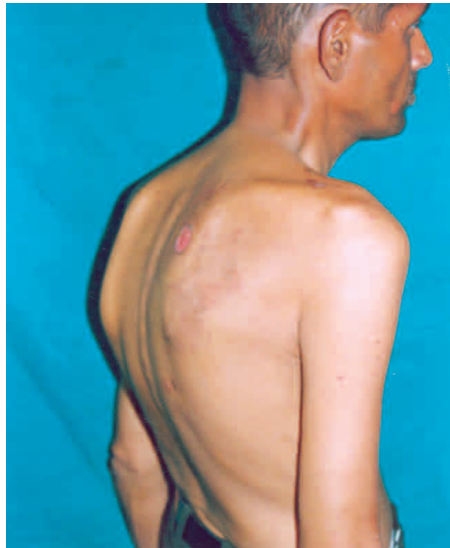

FIGURE 17.25 Kyphosis

General posterior curvature is termed *kyphosis* (Fig. 17.25). The thoracic spine exhibits a slight kyphosis normally, which increases with age. *Gibbus* is a localised angular deformity caused by fracture, Pott's disease (spinal tuberculosis) or by secondaries in the spines. The abnormalities of spines and their causes are tabulated (Table 17.7).

Scoliosis means lateral curvature of the spine and may be towards either side. It is associated with rotation of the bodies of the vertebrae.

In scoliosis due to acute disc protrusion:

- If lateral to nerve root—patient bends away from lesion
- If medial to nerve root—patient bends towards lesion.

When scoliosis is due to unequal leg lengths, it disappears on sitting because the buttocks then come at same level. Scoliosis secondary to skeletal anomalies shows in spinal flexion a 'rib-hump' due to rotation. Kyphosis and scoliosis are often combined and called *kyphoscoliosis* (Fig. 17.26) which is an idiopathic spinal deformity beginning in adolescence.

Palpation

- In sitting or standing position, palpate the spinal processes of each vertebra by rolling the thumb over them and to note any tenderness.

Tenderness suggests fracture or disc prolapse, infection or arthritis.

TABLE 17.7 Inspection of other spine for deformity and their causes

View of patient inspection	Focus	Causes of abnormal spinal curvature	Comment
From the side	<p>Cervical, thoracic, and lumbar curves</p> <p>Alignment of the shoulders, the iliac crests, and the skin creases below the buttocks (gluteal folds).</p> <p>Skin markings, tags and masses</p>	<ul style="list-style-type: none"> • Osteoporosis • Infection • Tumour • Prolapsed intervertebral disc (Fig. 17.24) • Inflammatory disorders 	<p>Kyphosis (increased AP diameter) occurs with ageing. In children a correctable structure deformity should be pursued.</p> <p>Unequal shoulder heights seen in Sprengel's deformity of the scapula in "winging" of the scapula (from loss of innervation of the serratus anterior muscle by the long thoracic nerve) and in contralateral weakness of the trapezius. Unequal heights of the iliac crests, or tilt, suggest unequal lengths of the knee and disappear when a block is placed under the short leg and foot. Scoliosis and hip abduction or adduction may also cause a pelvic tilt. "Lifting" of the trunk to one side is seen with a herniated lumbar disc.</p> <p>Birthmarks, port wine stains, hairy patches, and lipomas often overlie bony defects such as spinal bifida. Café-au-lait spots (discoloured patches of skin), skin tags and fibrous tumour occur in neurofibromatosis.</p>

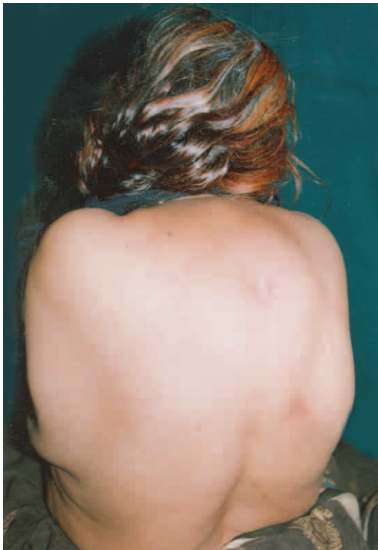

FIGURE 17.26 Kyphoscoliosis

- In the neck, also try to palpate the facet joints which lie deep to trapezius muscle, hence, may not be palpable, but tenderness over the joints occurs in arthritis.
- In the lumbar region, check for any vertebral “step-off” to determine if one spinous process seems either unusually prominent or recessed in relation to one above it. Identify any tenderness.

Step-off occurs in spondylolisthesis, in which forward slippage of one vertebra may compress the spinal cord. Vertebral tenderness is suspicious for fracture or infection.

- Palpate over the sacroiliac joint, often identified by the dimple overlying the posterior superior iliac spine.

Tenderness over sacroiliac joint occurs commonly in ankylosing spondylitis.

- If needed, use light percussion with the fist or tendon hammer to elicit spinal tenderness.

Pain on percussion may arise from osteoporosis, infection or malignancy.

- Palpate the paravertebral muscles for tenderness and spasm. Muscles in spasm feel firm and knotted.

Spasms occur in disc protrusion, myositis, prolonged abnormal posture and anxiety.

- Elicit sciatic tenderness in sciatic notch. With the hip flexed and patient lying on the opposite side, palpate the sciatic nerve between greater trochanter and the ischial tuberosity as it leaves the pelvis, i.e. in sciatic notch.

Sciatic nerve roots compression (L_4 , L_5 , S_1 , S_2 and S_3) suggests a herniated disc or mass lesion irritating the nerve roots.

- Palpate for tenderness in any other area that is suggested by the patient’s symptoms.
- Perform a detailed neurological check-up noting any sensory or motor deficit in the limbs.
- Test the active and passive movements at various joints and note their range to identify any limitation or hypermobility.

Testing of Cervical Movements

Flexion—Ask the patient to touch chin to chest

Extension—Ask the patient to look up at the ceiling

Rotation—Ask the patient to turn the head to each side, looking directly over the shoulder

Lateral bending—Ask the patient to tilt the head sideways and try to touch the shoulder with the ear without raising the shoulder.

Note any pain or paraesthesias in the arm reproduced by neck movement, suggesting nerve root involvement. If indicated, perform neurological examination of neck and upper extremities for radicular or spinal cord involvement.

In patients with rheumatoid arthritis involving atlantoaxial joint or in patients with cervical injury, never try to elicit range of motion of the neck. Take the help of investigations such as X-rays for diagnosis.

Testing the Movements at Thoracic and Lumbar Spine

The thoracic spine permits mainly rotation whilst the lumbar spine can flex, extend and bend laterally. The movements are tested as follows:

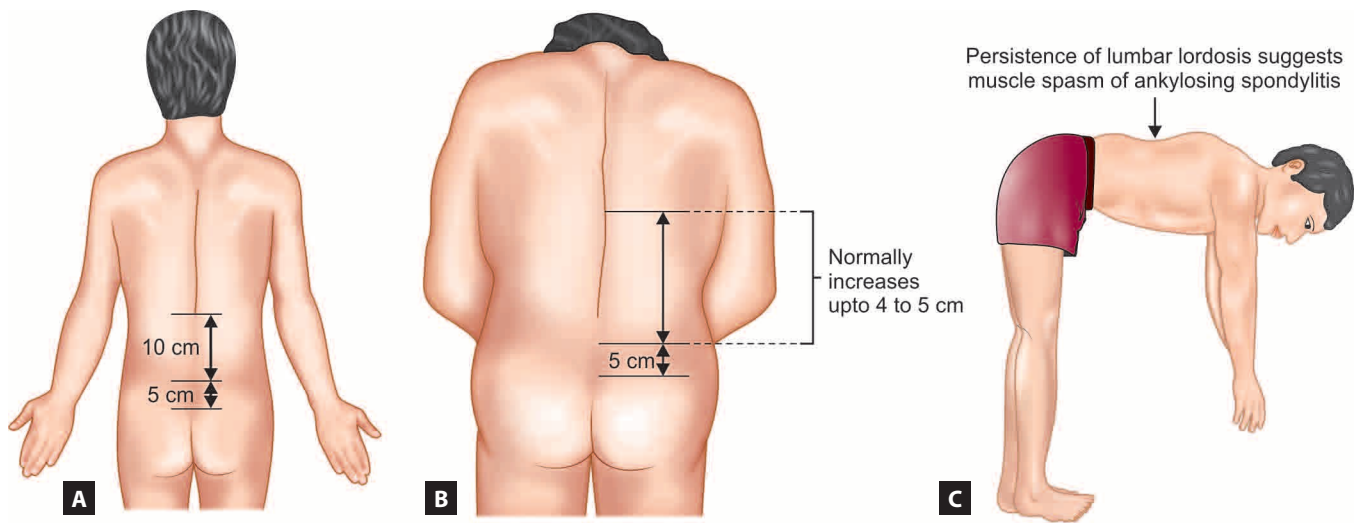
Flexion: Ask the patient to touch the toes without bending at the knees. Note the smoothness, symmetry and range of movement and the lumbar curve. As flexion proceeds, the lumbar concavity should flatten out.

Persistence of lumbar lordosis suggests muscle spasm or ankylosing spondylitis (Fig. 17.27C).

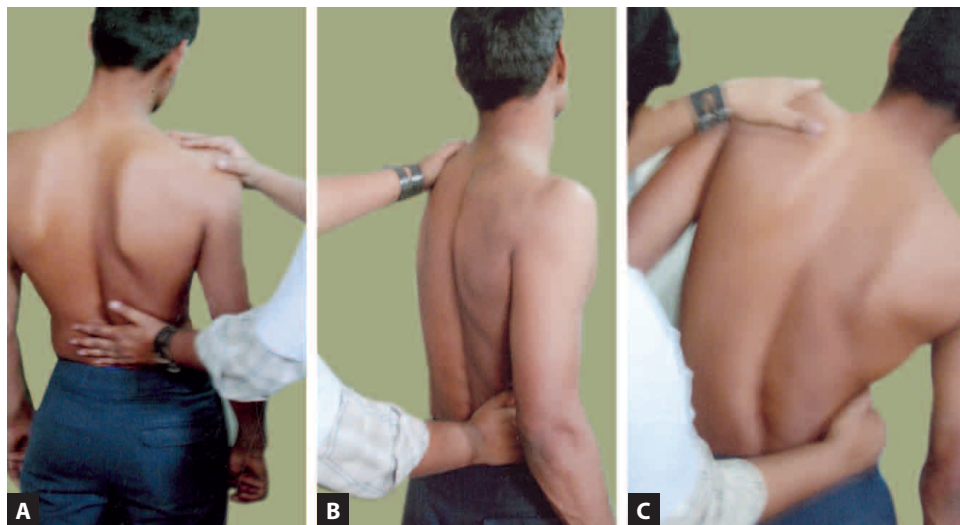
To measure the degree of flexion, first mark the spine at lumbosacral junction, then mark 10 cm above and 5 cm below this point (Fig. 17.27A) in standing position. Ask the patient to bend forwards. A 4 cm increase between the two upper marks (10 cm mark + 4 cm) is normally seen (Fig. 17.27B). The distance between two lower marks remains same (5 cm).

Extension: Place your hand on posterior superior iliac spine (Fig. 17.28A). Ask the patient to bend backwards as far as possible.

Rotation: Stabilize the pelvis by placing one hand on the patient’s hip and the other on the opposite shoulder. Now rotate the trunk by pulling the shoulder and then the hip



FIGURES 17.27A to C Schober's test, measuring forward bending (flexion) of spine



FIGURES 17.28A to C Testing for the thoracic and lumbar spine: (A) Extension; (B) Rotation; (C) Lateral bending

posteriorly (Fig. 17.28B). Repeat the manoeuvre on the opposite side.

Lateral bending: Support the patient at the pelvis and at the shoulder, ask the patients to bend sideways as far as possible (Fig. 17.28C).

Decreased spinal movements occur in osteoarthritis, ankylosing spondylitis and other painful musculoskeletal conditions.

Testing the Movements of Costovertebral Joints

Chest expansion: It is a measure of costovertebral movement and should be recorded using a tape measure with patient's hands behind their head.

Reduced chest expansion occurs in pulmonary disease (emphysema) and ankylosing spondylitis.

Tests for Nerve Root Compression

Prolapse of intervertebral disc is common at L₄/L₅ or L₅/S₁ level producing compression of the L₅ and S₁ nerve roots respectively (Fig. 17.24). *Straight-leg raising* test is used to stretch these roots. Normally about 90° of flexion at the hip is possible (varies from 70–120°) without producing pain. When the root is stretched over a prolapsed disc, the straight leg raising will be restricted due to pain which will be felt in the lumbar region, not just in the leg.

Straight Leg Raising Test (Fig. 17.29A)

- Make the patient lying supine and both legs extended.
- With knee extended, raise the leg on unaffected side by lifting the heel with one hand while preventing knee flexion with the other. Note the range of movement.
- Now repeat this manoeuvre on the affected side directing the patient to report as soon as pain is felt. Ask the patient to localise the pain or paraesthesia felt (Fig. 17.29A).
- When this limit is reached, augment the stretching of nerve roots by dorsiflexion the ankle (Bragard test—Fig. 17.29B).

Straight leg raising is limited by stretching of the sciatic nerve roots in sciatica pain due to any cause.

Bowstring Sign (Figs 17.30A to C)

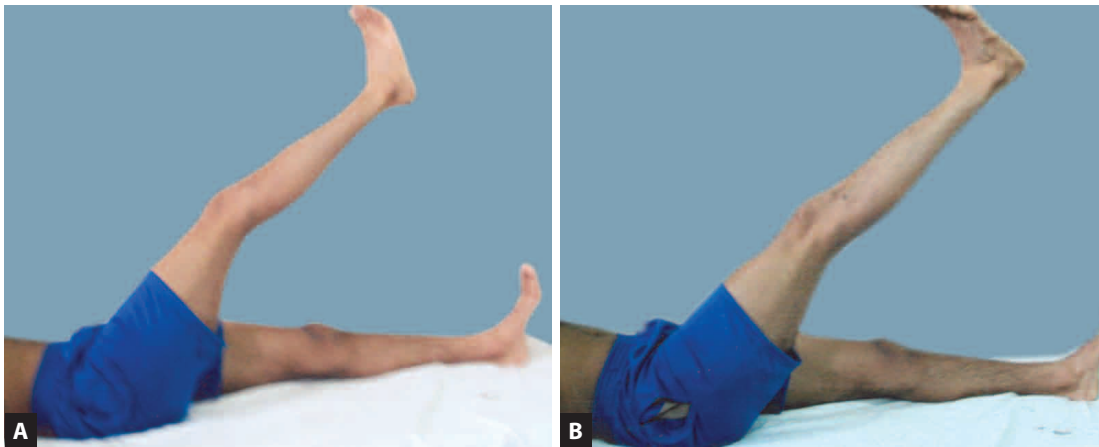
- Perform the straight leg raising test as described above in Figure 17.29A. When limit is reached, flex the knee to reduce the tension on sciatic nerve roots (Fig. 17.31A)
- Now further flex the hip.

- Now gently extend the knee until pain is reproduced once again (Lassegue's sign (Fig. 17.31B)).
- The posterior tibial nerve is now stretched like a bowstring across the popliteal fossa. Firm pressure is then applied with the thumb, first over the hamstring nearest the examiner, then over the nerve in the middle of popliteal fossa and finally over the other hamstring tendon. Ask the patient which manoeuvre exacerbated pain (Fig. 17.31C).

The test (sign) is positive if the second manoeuvre is painful and if the resultant pain radiates from the knee to the back.

Flip test (Fig. 17.31): It is used (to distinguish between sciatic nerve root irritations from malingering).

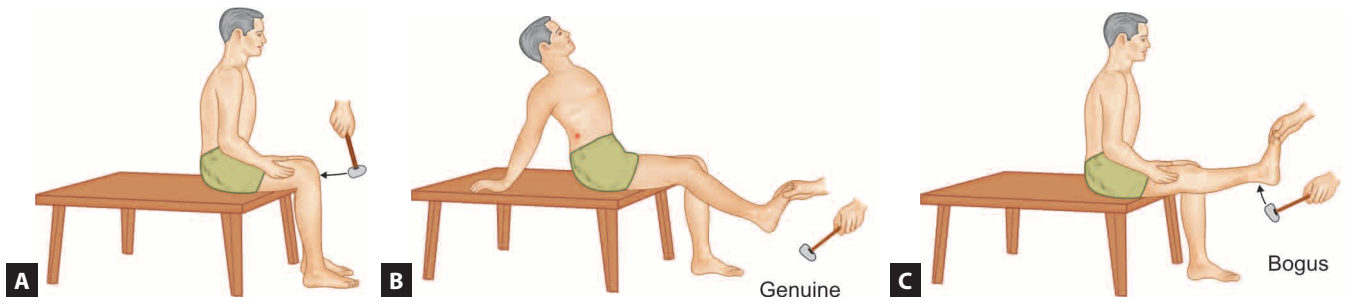
- The patient is made to sit on the edge of couch with the hips and knees flexed to 90°. Test the knee reflexes (Fig. 17.31A)
- Now extend the knee to an extent to elicit the ankle jerk (Fig. 17.31B)
- If there is no irritation, then patient will flip backwards to relieve tension on the nerve roots (Fig. 17.31B).



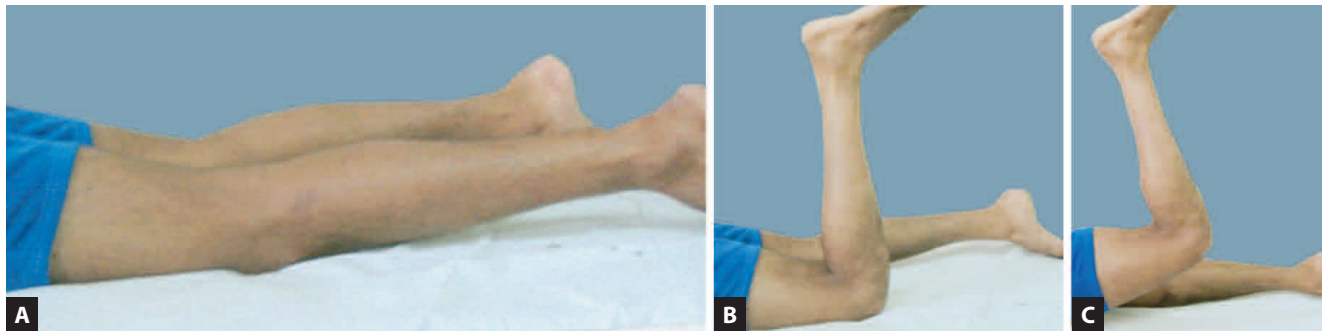
FIGURES 17.29A and B Stretch tests for sciatic roots: (A) Straight leg raising test; (B) Bragard test-tension increased by dorsiflexion of foot



FIGURES 17.30A to C Bowstring sign: (A) Root tension relieved by flexion at the knee; (B) With knee extension over prolapsed disc causing pain radiating to the back (*Lassegue's sign positively*); (C) Pressure over centre of popliteal fossa bears on posterior tibial nerve which is "bowstringing" across the fossa causing pain locally and radiation into back



FIGURES 17.31A to C Flip test. In the “flip” test, when attention is diverted to the tendon reflexes, the genuine patient will not permit full extension of the leg



FIGURES 17.32A to C Femoral nerve stretch test: (A) patient lies prone and is free from pain because femoral roots are slack; (B) When femoral roots are tightened by flexion of the knee, pain may be felt in the back; (C) If still no pain, femoral roots are further stretched by extension of the hip

- In the absence of nerve root irritation, the patient’s attention distracted to the ankle jerk, may allow full extension of the knee, i.e. to 90° (Fig. 17.31C).
- With the patient supine, fully flex the hip and knee and with firm pressure, adduct the thigh to stress the ipsilateral sacroiliac joint.

Painful joint on stress manoeuvre indicates sacroiliitis.

Femoral Nerve Stretch Test (Figs 17.32A to C)

- Make the patient to lie prone, in case of flexion deformity of the hip to lie on the unaffected side.
- Flex the knee slowly, asking the patient to report the onset of pain. If pain does not occur in the thigh or back, gently extend the hip with the knees remaining flexed (Fig. 17.32C).

Testing the Sacroiliac Joints

Pain arising from the sacroiliac joints may radiate into buttocks and posterior aspect of the thighs, but, unlike sciatica, does not go beyond knee. There is no reliable test to elicit tenderness of sacroiliac joint because both false positive and false negative results are common. In case of inflammation of sacroiliac joint, stressing of the buttocks to reproduce pain may be useful. To test the sacroiliac joints;

- Ask the patient to lie prone on a firm surface and apply firm pressure with palm of the hand over the sacrum. Or

Upper Limb Joints

The Shoulder

The lateral end of the clavicle and the acromion can easily be identified. With your fingers, trace the clavicle laterally. Now from behind, follow the bony spine of the scapula laterally and upwards until it becomes the *acromion*, the summit of the shoulder. Identify the manubrium and *sternoclavicular* joint. The tip of the coracoid process of scapula can be palpated 1 inch below the clavicle under the anterior edge of the deltoid. The three bony points—acromion, the greater tubercle of humerus and coracoid process are important anatomical landmarks in structure of the shoulder. Three different joints articulate at the shoulder.

1. **Glenohumeral joint**—a ball and socket joint allowing the arm its wide arc of movements, e.g. flexion, extension, abduction, adduction, rotation and circumduction.

2. **Sternoclavicular joint**—between medial end of clavicle and upper sternum.
3. **Acromioclavicular joint**—between lateral end of the clavicle with acromion process of scapula.

The shoulder derives its mobility from a complex structure of these joints supported by strong muscle groups, ligaments and bursae, often referred to as *shoulder girdle*. The important group of muscles—scapulohumeral group extends from the scapula to the humerus and includes the muscles inserting directly on the humerus known as *SITS muscles*—*supraspinatus (S)*, *infraspinatus (I)*, *teres minor (T)* and *subscapularis (S)* of the rotator cuff. This group rotates the shoulder laterally (infraspinatus and teres minor are external rotator) and supraspinatus stabilises the shoulder and allows the deltoid muscle to abduct the arm and is main component of rotator cuff. The rotator cuff muscles surround the glenohumeral joint and are inserted into a fibrous capsule lining the joint. The capsule is lined by synovial membrane with two outpouchings, i.e. subscapular bursa and the synovial sheath of the tendon of the long head of the biceps. Therefore, the rotator cuff, the related subacromial bursa and the tendon of the long head of the biceps are important sites of pathology in the shoulder.

Examination of the Shoulder

Inspection

Inspect and compare the shoulder girdle from the front, scapulae and related muscles from behind. Note any muscle *wasting*, *soft tissue swelling* or *difference in bony contour* on the two sides.

Muscle atrophy points to a lesion in cervical nerves. In scoliosis, there is elevation of one shoulder facing towards convexity. The shoulder contour gets flattened in its dislocation; in anterior dislocation, lateral aspect is flattened while in posterior dislocation, anterior aspect is flattened.

Look for swelling of the joint capsule anteriorly or a bulge in the acromial bursa under deltoid muscle.

A significant amount of fluid may collect in the synovial cavity producing outpouching of bursa.

Survey the entire upper extremity for colour change, skin alteration or abnormal positioning.

Stand behind the patient and observe the overall range of movements by asking the patient to place the hands at the base of the neck with elbow pointing sideways.

Next ask the patient to put the arms down and to reach behind the back in-between the shoulder blades.

Box 13

Causes of painful shoulders

- Rotator cuff—tendinitis, tears, degeneration, tendon rupture
- Subacromial bursa—calcific bursitis, arthritis
- Capsule—Adhesive capsulitis (frozen shoulder)
- Head of humerus—tumour deposit, osteonecrosis, fracture/dislocation
- Joints—synovitis, osteoarthritis, dislocation

Proceed further only if pain, swelling or limitation of movements is present.

Palpation

If there is history of shoulder pain (*see* Box 13), ask the patient to point to the painful area.

The location of pain is important for the diagnosis such as:

- Top of the shoulder, radiating towards neck—acromioclavicular joint
- Lateral aspect of shoulder radiating towards deltoid insertion—rotator cuff
- Anterior shoulder—bicipital tendon.

Testing for range of movements at shoulder

The neutral position is with the arm to the side, elbow flexed to 90° with forearm pointing forwards. Because the scapula is mobile, true shoulder (glenohumeral) movement can be assessed only when the examiner immobilises the scapula between the thumb and the finger on the posterior chest wall.

The movements to be tested are:

- Flexion and extension (Fig. 17.33)
- Abduction (Fig. 17.33)
- Rotation in abduction (Fig. 17.33)
- Rotation in neutral position (Fig. 17.33)
- Rotation in neutral adduction
- Elevation.

In clinical practice, internal rotation can best be compared by recording the height reached by each thumb up the back (*internal rotation and adduction*). This is tested by “asking the patient to scratch the back” or undo the bra strap (Fig. 17.34 Apley test). Similarly external rotation can be tested by asking the patient to place both hands behind the neck with elbows out to the side (tests external rotation and adduction Fig. 17.35 Apley test).

- **Note any pain during the range of movement:** In supraspinatus tendinitis (rotator cuff), a full passive range of movement is found, but there is a painful arc on abduction, with pain exacerbated on resisted abduction (Figs 17.36A to D in Table 17.8).

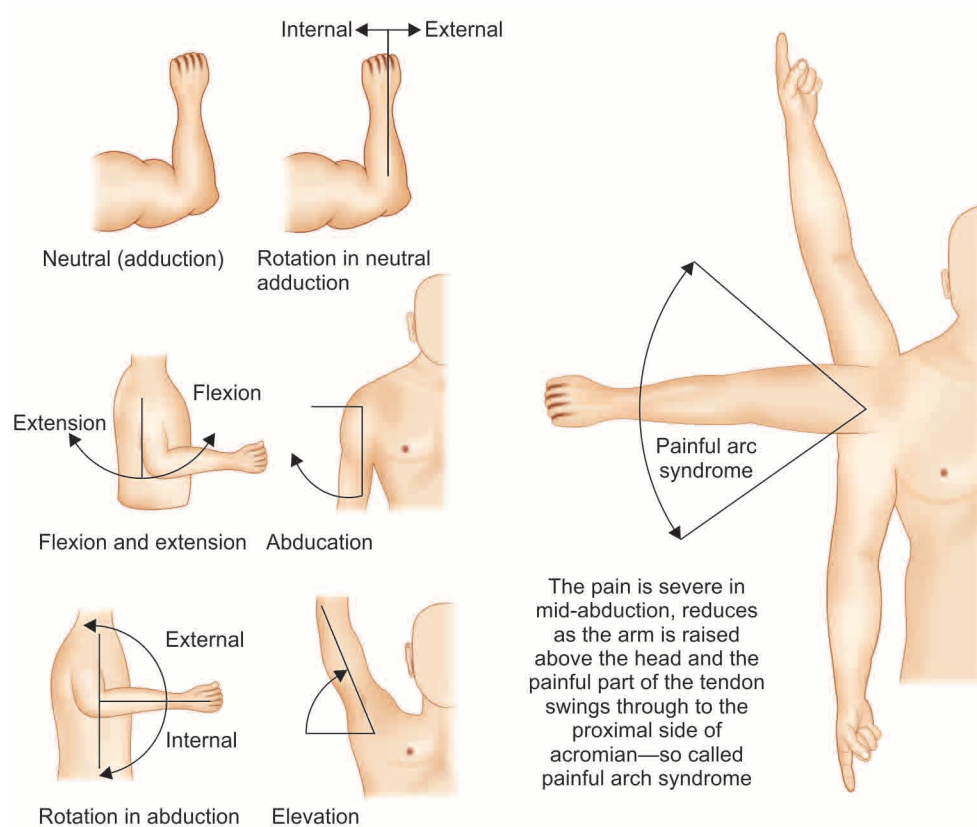


FIGURE 17.33 Movements at the shoulder. The movements are tested against resistance. Stand in front of the patient and test the range of following movements at shoulder by asking the patient to;

- (i) Abduction: Raise the arm to shoulder level 90° with palms facing down. This tests glenohumeral movement only.
- (ii) Elevation: Raise the arms to 0° vertical position above the head with palms facing each other. This tests initial 60° scapulothoracic movement
- (iii) Place both hands behind the neck with elbows stretched out to the side. This tests external rotation and abduction
- (iv) Place both hands behind the small of the back. It tests internal rotation and adduction
- (v) Move the forearm forwards (flexion) and backwards (extension)

Painful arc syndrome
 Inability to perform these movements results in painful arc syndrome which is due to involvement of soft tissue around shoulder such as bursitis, capsulitis, rotator cuff tears or sprains or tendinitis

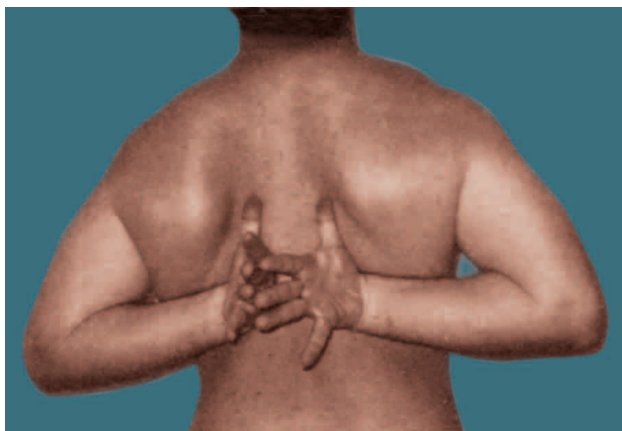


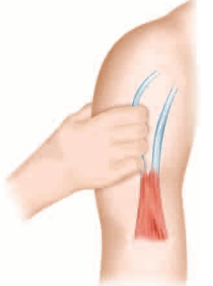


FIGURE 17.34 Apley from below. Functional test of the subscapularis, that is, internal rotation. Here examination findings are normal

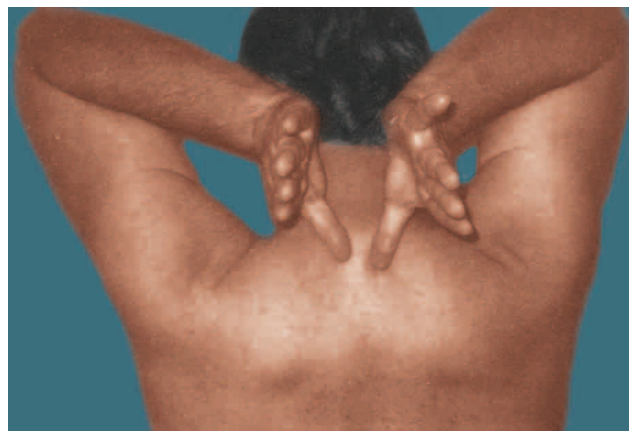

FIGURE 17.35 Apley from above. Functional test of the infraspinatus and teres minor, that is, external rotation. Here the findings are quite normal

TABLE 17.8 Testing of the acromioclavicular joint and structures in and around shoulder joint

Structure	Test
<p>A Acromioclavicular joint</p> 	<p><i>Cross over test:</i> Ask the patient to adduct the arms across the chest.</p> <p>Localised tenderness during the manoeuvre suggests arthritis of acromioclavicular joint.</p>
<p>B Subacromial and subdeltoid bursitis</p> 	<p>Passively extend the shoulder by lifting the elbow posteriorly. Palpate over the subacromial and subdeltoid bursae.</p> <p>Tenderness over the area of subacromial or subdeltoid bursae indicates bursitis or calcific deposits in the rotator cuff; while swelling suggests bursal tear.</p>
<p>C Rotator cuff</p> 	<p>SITS (Supraspinatus, Infraspinatus, Teres minor and subscapularis) muscle insert anteriorly at the shoulder, hence palpate them on the greater tuberosity of the humerus with the patient's arm hanging at the side.</p> <p>These muscles can also be tested (Fig. 17.36) by passively extending the shoulder by lifting the elbow posteriorly. This manoeuvre brings the rotator cuff on to the acromion. Palpate these muscles at the greater tuberosity of the humerus</p> <p>Tenderness over SITS muscles indicate sprains, tears or tendon rupture of the rotator cuff.</p> <p><i>Drop-arm sign</i> (ask the patient to abduct the arm fully upto 90° and then lower it slowly) if positive (inability to hold the arm abducted at shoulder lines) indicates "rotator cuff tear"</p>
<p>D Bicipital groove and tendon</p> 	<p>Rotate the arm and forearm externally to localise the biceps muscle distally near the elbow. Along the anterior aspect of the humerus lies the bicipital groove. Palpate the biceps tendon in the groove. Note any tenderness on calling the tendon in the groove. Finally, hold the patient's elbow against the body with forearm flexed to 90°. Ask the patient to supinate the forearm against resistance.</p> <p>Pain or tenderness during flexing of lessow against resistance occurs with bicipital tendinitis or tendon rupture.</p>

FIGURES 17.36A to D

Subacromial (Fig. 17.36) painful arc syndrome impingement due to bursitis or rotator cuff abnormality may produce severe pain at the end of abduction blocking the full elevation.

Acromioclavicular joint pain is always localised and is typically felt in last 10° of elevation (170–180° arc).

Testing for bicipital tendinitis

Ask the patient to flex the elbow against resistance or ask the patient to supinate the forearm against resistance

(Fig. 17.36D). Pain during these manoeuvres indicates bicipital tendinitis.

The Elbow

The elbow helps to position the hand in space and stabilises the lever action of the forearm. The joint is formed by the humerus and two bones of the forearm, the radius and the ulna. The three bony prominences, at the elbow are: two epicondyles (medial and lateral) of the humerus and tip

Box 14

Movements at the elbow

Movement	Muscle group(s)
Flexion	Biceps and brachioradialis
Extension	Triceps
Pronation	Pronator teres
Supination	Supinator

of the olecranon which forms an equilateral triangle. The subcutaneous bursa overlying the olecranon is visible and palpable only when inflamed. The movements and the muscles involved are given in the Box 14.

Examination of Elbow**Inspection and palpation**

- Support the patient's forearm with your opposite hand and flex the elbow to about 70°. Identify the medial and lateral epicondyles and the *olecranon* process of the ulna. Inspect the contours of the elbow including the extensor surface of the ulna and the olecranon process. *Note any nodule or swelling.* The causes of swollen elbow are given in the Box 15.
- Palpate the olecranon process and press on the epicondyles for tenderness. Note any displacement of olecranon.

Medial (*golfer's elbow*) and lateral (*tennis-elbow*) epicondylitis are the common causes of pain and tenderness of elbow.

- Palpate the *groove* between epicondyles and the olecranon, noting any *swelling* or *tenderness*. The synovium is most commonly accessible in this region if there is synovitis (normally neither synovium nor bursa is palpable). The sensitive ulnar nerve can also be palpated posteriorly between the olecranon process and the medial epicondyle.

Testing for movements at elbow joint: The neutral position is with the forearm in extension. The following movements are tested.

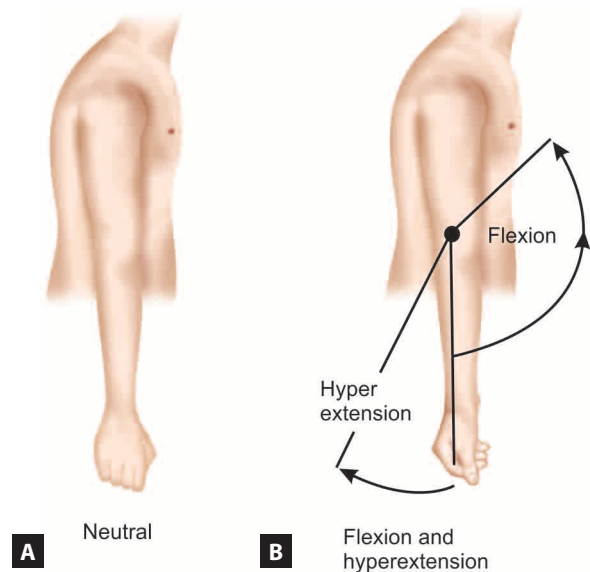
Flexion and extension (Figs 17.37A and B): To test these movements ask the patient to bend (flex) and straighten (extend) elbow.

Supination and pronation (Fig. 17.38): With the patient sitting with arms at the sides and elbows flexed to minimize shoulder movement, ask the patient to supinate (turn up the palms) and pronate (turn down the palms).

Box 15

Swollen tender elbows

- Olecranon bursitis
- Arthritis
- Epicondylitis
- Rheumatoid nodules



FIGURES 17.37A and B Movements at elbow (e.g. flexion, hyperextension)

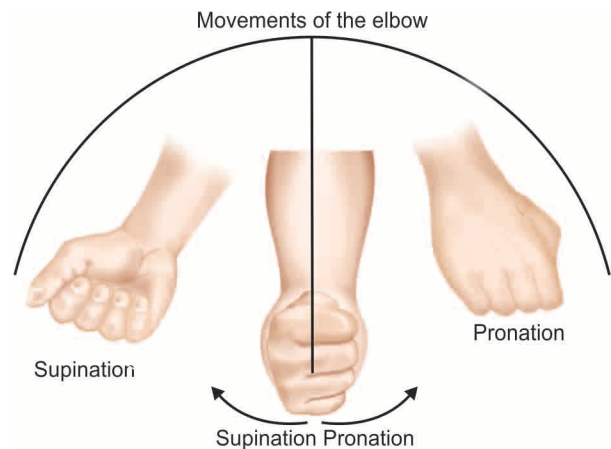
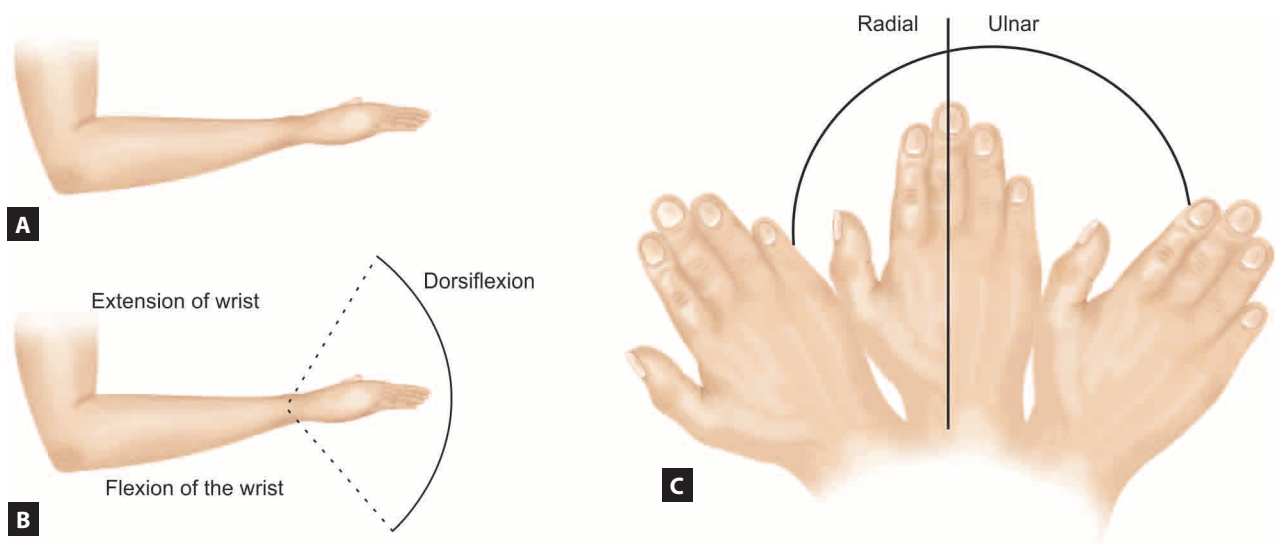


FIGURE 17.38 Movements of the forearm/elbow (supination and pronation)

The Wrist and Hands

The wrist includes the distal radius and ulna and 8 small carpal bones. At wrist, the bony tips of the radius and the ulna can be identified.



FIGURES 17.39A to C Movements of the wrist: (A) Neutral; (B) Flexion and extension of the wrist; (C) Deviation

The numerous joints of the wrist and hand lend unusual dexterity to the hands. The wrist joints include the *radiocarpal* or wrist joint, the distal *radioulnar joint* and *intercarpal joints*. On the dorsum of the wrist, there is groove of the radiocarpal joint.

The joints of the hands include *metacarpophalangeal* joints (MCPs), the proximal interphalangeal joints (PIPs) and the distal interphalangeal joints (DIPs). Flex the hand and you will find the groove marking the MCP joint of each finger. It is distal to the knuckles and is best felt on either side of the extensor tendon on dorsal aspect of hand.

The movements at the wrist are described in Figures 17.39A to C.

The pronation and supination of the wrist result from respective muscle contraction in the forearm (already discussed).

Soft tissue structures especially the tendons and tendon sheaths are extremely important in the wrist and the hand.

- **Flexor retinaculum:** It is a transverse ligament that holds the tendons and tendon sheath in place. The median nerve lies between the flexor retinaculum and tendon sheaths, provides sensation to the palm and the palmar surface of most of the thumb, the index, middle and inner half of ring fingers. It also supplies thumb muscles of flexion, abduction and apposition.
- **Carpal tunnel (see Fig. 17.44):** It is a canal or tunnel beneath the flexor retinaculum. The canal contains the sheath and flexor tendons of the forearm muscles and the median nerve.

Examination

Inspection

The neutral position of wrist joint (at rest) is with the hand in line with the forearm, and palm down.

- Observe the position of the hands in motion to see if the movements are smooth and natural.

The movements are tested in neutral position, i.e. hand in line with the forearm (Fig. 17.39A).

Flexion: Ask the patient to flex the wrist against gravity, then again resistance (Fig. 17.39B).

Extension: Ask the patient to extend the wrist against gravity, then again graded resistance.

Ulnar and radial deviation: With palms down, ask the patient to move wrist laterally and medially (Fig. 17.39C).

- Inspect the hands and wrists (palm and dorsum) carefully for *swelling* over the joints.

Diffuse swelling of hand(s) and wrist(s) is seen in arthritis and acute infection.

Localised swelling or ganglia arise from cystic enlargement.

- Look specifically for *skin* and *nail* changes, *muscle wasting*, *joint deformity* (ulnar or radial deviation). The abnormalities of the hand associated with rheumatic diseases are depicted in the Table 17.9.
- Observe *contours* of the palm, namely the thenar and hypothenar eminences.

Thenar atrophy indicates median nerve compression. Hypothenar atrophy indicates ulnar nerve compression.

TABLE 17.9 Visible abnormalities of the hands in rheumatic disease

Abnormality	Physical appearance	Site	Disease(s)
Heberden's nodes (Fig. 17.10)	Small bony nodules	DIP joints	OA
Bouchard nodules (Fig. 17.10)	Small bony nodules	PIP joints	OA
Rheumatoid nodules (Fig. 17.9)	Fleshy and firm	Extensor surface of knuckles	RA
Tophi (Fig. 17.20)	White subcutaneous swellings	Juxta-articular	Gout
Calcific deposits	White subcutaneous deposits	Finger pulp	Scleroderma, dermatomyositis
Dilated capillaries	Redness	Nail folds	Scleroderma, dermatomyositis, SLE

OA = Osteoarthritis, RA = Rheumatoid arthritis, SLE = Systemic lupus erythematosus

- Note any thickening of the flexor tendons or flexion *contractures* in the finger.

Flexion contractures of 3rd, 4th and 5th fingers or Dupuytren's contractures arise from thickening of the palmar fascia.

Palpation

- Palpate the wrist joint with your thumbs on the dorsum of the wrist and fingers beneath it (Fig. 17.40). *Note any swelling or tenderness.*

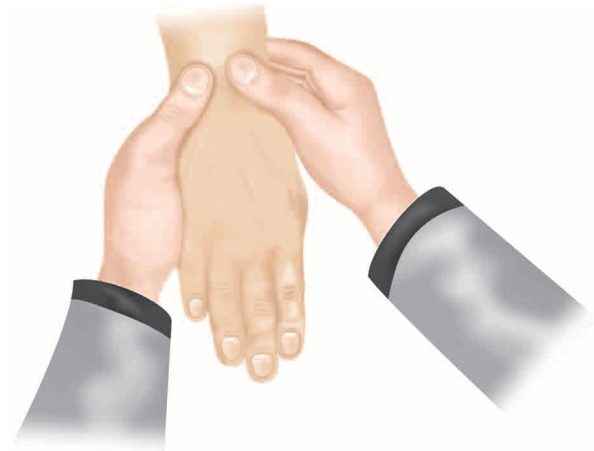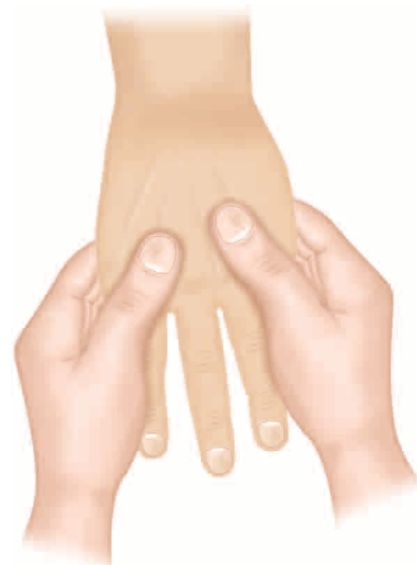Tenderness over distal radius occurs in Colles' fracture. Any tenderness or bony step-off indicates fracture. Swelling and tenderness of joints indicate rheumatoid arthritis if bilateral or gonococcal infection if unilateral arthritis.

- Palpate the anatomical *snuff box* (a hollowed depression just distal to radial styloid process).

Tenderness over snuff box suggests a scaphoid fracture.

- Compress the MCP joints by squeezing the hand from each side between the thumb and fingers (is equivalent to shaking hands). Alternatively use your thumb to palpate each MCP on each side of knuckles as your index finger feels the head of the metacarpal in the palm (Fig. 17.41). Note any swelling or boggy or tenderness.

Shaking hands is painful in synovitis of MCP.

**FIGURE 17.40** Palpation of wrist joint**FIGURE 17.41** To palpate and elicit tenderness at each metacarpophalangeal joint

- Palpate the PIP joints between your thumb and index finger. *Note for swelling or enlargement or tenderness (see Table 17.7).* Using the same technique, examine DIP joints.
- Palpate the flexor tendons and tendon sheaths inserted on the thumb and fingers with your index finger for any *swelling or tenderness.*

Swelling and tenderness along the tendons indicate tenosynovitis.

Testing of the Movements

At wrist joint

They have already been described (Fig. 17.39).

At the finger joints

The movements are tested in relation to neutral position. The neutral position is with the fingers in extension.

Flexion and extension can be tested by asking the patients to make a tight fist with each hand, thumb across the knuckles, and then extend and spread the fingers. The fingers should open and close smoothly and easily. Test flexion and extension of MCP, PIP and DIP joints against gravity and against resistance (Figs 17.42A to C).

Abduction and adduction. Ask the patient to spread the fingers apart (abduction) and back together (adduction). Check for smooth coordinated movements.

At the thumb (Figs 17.43A to C)

Movements are tested in relation to neutral position (thumb alongside the index fingers and extended). The movements tested are:

Flexion and extension: Ask the patient to touch the base of little finger with the thumb (flexion) and then to move the thumb back across the palm and away from the fingers to test extension (Fig. 17.43).

Abduction and adduction: Ask the patient to place the fingers and thumb in neutral position with the palm up, now ask the patient to move the thumb anteriorly away from the palm (abduction) and then back to same position (adduction).

Opposition: Ask the patient to touch the thumb to each of the other finger tips (Fig. 17.43).

Assessment of hand function

Fine pinch: Ask the patient to perform the pinch grip (between the thumb and index finger).

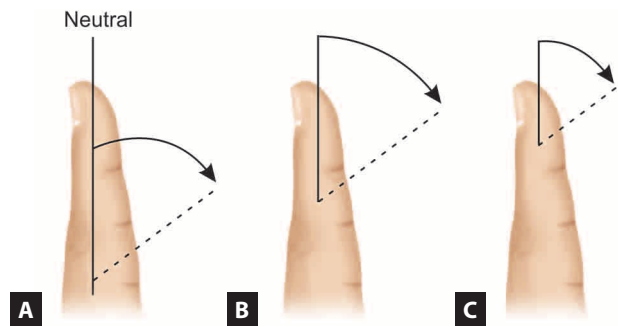
It may be decreased in the line of action of thumb metacarpal particularly in scaphoid fracture.

Hand grip: Note the grip strength by asking the patient to grip two or three fingers of the examiner's hands. If the range of movements of the joints is not full, then patient will not be able to grip the fingers tightly.

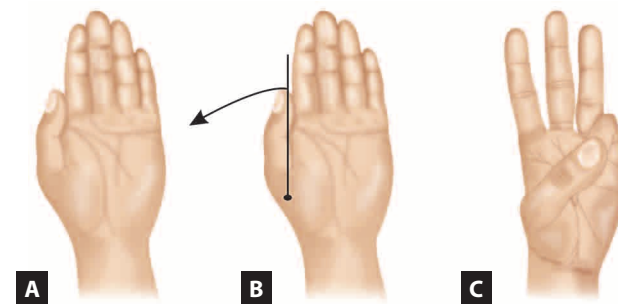
Test for Sensations

At the end, test the sensation in the fingers. Test median, ulnar and radial nerve sensation in the hand as discussed in nervous system examination.

Pain and numbness and objective loss of sensations on the ventral surface of first three and half fingers but not the palm along with weakness of abduction of the thumb indicates carpal tunnel syndrome which is confirmed by the following tests.



FIGURES 17.42A to C Movement of the fingers. The movements are tested against gravity and against resistance: (A) Flexion; (B) Proximal IP joint; (C) Distal IP joint



FIGURES 17.43A to C Movements of the thumbs: (A) Neutral; (B) Extension; (C) Opposition

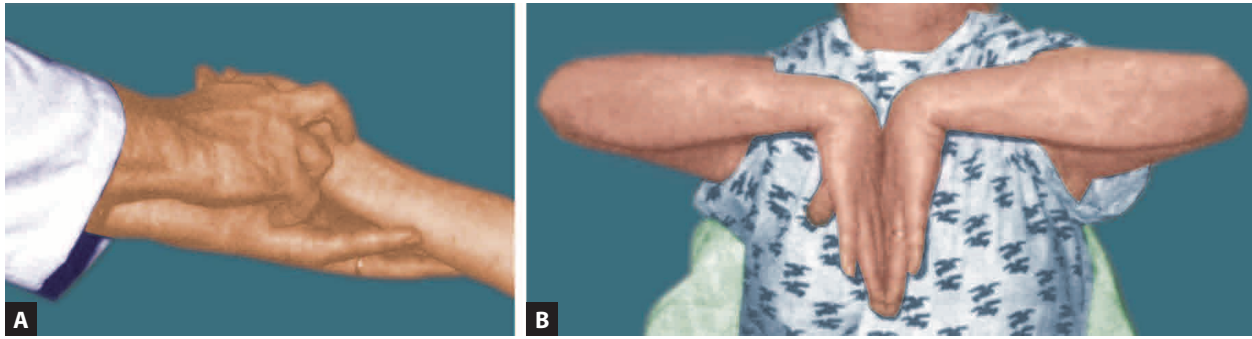
Tests for Carpal Tunnel Syndrome

Thumb abduction test: To test the abductor pollicis, ask the patient to raise the thumb perpendicular to the palm against resistance applied on the distal phalanx.

Inability to do so, indicates weakness of adductor pollicis.

Tinel's sign (Fig. 17.44A): Percuss lightly with your finger at the spot on the carpal tunnel (encircled Fig. 17.45). Tingling or electric sensations in the distribution of the median nerve constitute positive test and confirms the diagnosis of carpal tunnel syndrome.

Phalen's manoeuvre: The manoeuvre is performed to compress the median nerve tunnel. The test is performed either by holding the wrists of the patient in acute flexion for one minute or ask the patient to press the back of the both hands (see Fig. 17.44B) together at right angle. The appearance of numbness or tingling within a minute over the distribution of median nerve (palmar surface of lateral three and half fingers) indicates that the sign is positive, suggesting carpal tunnel syndrome.



FIGURES 17.44A and B Tests for carpal tunnel syndrome: (A) Tinel's sign; (B) Phalen's manoeuvre

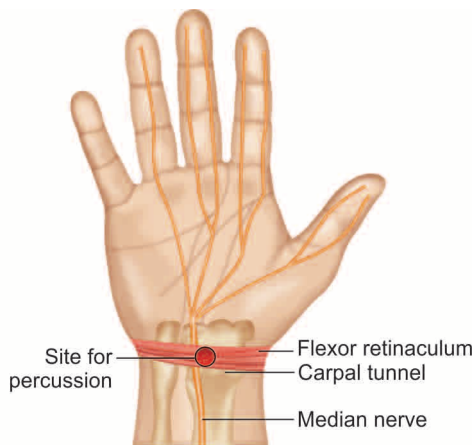


FIGURE 17.45 Carpal tunnel lying behind the flexor retinaculum contains median nerve. The tests for carpal tunnel syndrome (median nerve compression) are discussed

Wrist extension sign: The patient is asked to extend his wrists for 1 minute; this should produce tingling or numbness in the distribution of median nerve.

Tourniquet test: The symptoms are produced when the BP cuff is inflated above the systolic pressure.

Luthy' sign: If the skinfold between thumb and index finger does not close tighten around a bottle or cup because of thumb abduction paresis, this test is considered as positive.

Durkan's sign: Direct pressure over the carpal tunnel produces tingling over the distribution of median nerve. This carpal compression test is more sensitive and specific than Tinel's and Phalen's signs.

Lower Limb Joints

The Hip

The hip joint—a synovial joint is deeply embedded in the pelvis, and is notable for its length, stability and wide range of motion. The stability of joint is due to fitting of the head of the femur into the *acetabulum*, its strong fibrous capsule and

powerful muscles crossing the joint and inserting below the head.

Four powerful groups of muscles move the hip, i.e. flexors (e.g. mainly iliopsoas), extensors (mainly gluteus maximus), adductor and abductor (gluteus medius and minimus). These muscles help to stabilize the pelvis during the stance phase of gait.

A strong dense capsule extending from the acetabulum to the femoral neck, encases and strengthens the hip joint, reinforced by three overlying ligaments and is lined with synovial membrane. There are three principal bursae at the hip, i.e. *iliopsoas*, *trochanteric* and *ischio-gluteal*.

Important landmarks

On the anterior aspect of the hip, identify the iliac crest as the rim of pelvis at the level of L4. Follow the downward curve to locate iliac tubercle (widest point of crest) and then anterior superior iliac spine.

On the posterior aspect, the posterior superior iliac supine lies directly under the dimple just above the buttocks. Next locate the greater trochanter laterally with your fingers at the level of gluteal fold.

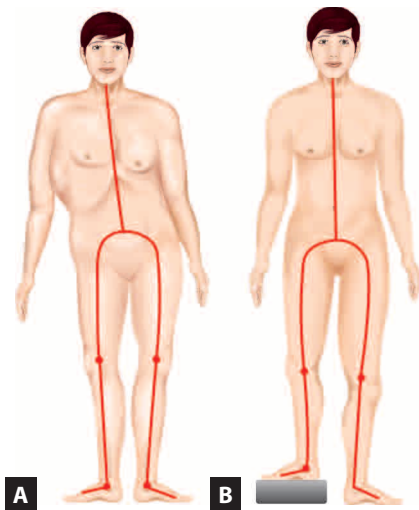
Symptoms of hip disease

- **Hip pain:** It may be reported in the groin, anterior thigh or knee. The pain is worst during activity and limits walking. There is often troublesome pain at night which disturbs the sleep and awakens the patient while turning over during sleep.
- **Stiffness:** Pain is associated with stiffness to some extent which results in limitation of movements especially flexion and causing difficulty in putting on socks or shoes or cutting the toe nails. There may be difficulty getting in and out of the bath or sitting on a low chair.

Examination of hip joint

Inspection-standing

- Inspect the hip when standing and walking. Observe the gait while patient entering the room. *Note any abnormality of gait.*



FIGURES 17.46A and B Effect of true shortening right leg on posture: (A) Causes pelvic tilt and scoliosis; (B) Pelvic tilt and scoliosis are fully corrected by providing a shoe base

- Observe the patient from behind for *scoliosis* and *pelvic tilt* which may conceal a hip deformity or true shortening of one leg (Figs 17.46A and B). If *pelvic tilt* occurs, measure the leg lengths.
- Inspect the anterior and posterior surface of the hip for any *muscle wasting* or *bruising*.

Testing for stability of the hip (Trendelenburg's test)

Ask the patient to stand first on one leg and then on the other, and observe any change in pelvic tilt on the non-weight bearing side (Figs 17.47A and B).

Inspection in supine position

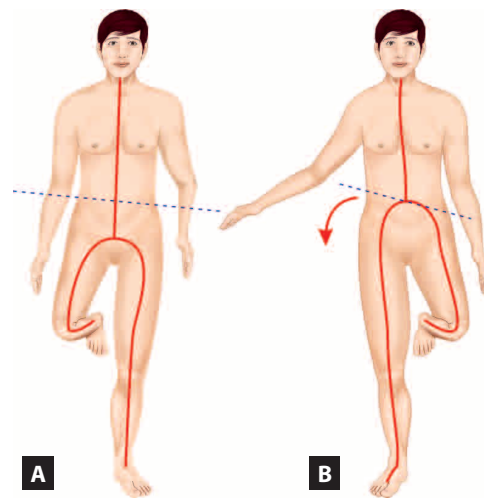
- Make the patient to lie supine with pelvic brim at right angle to the spine.
- Note the posture of each leg and look for any deformity, *swelling* or other signs of *inflammation*, *muscle wasting* or *asymmetry*.

Palpation

- Palpate for local *tenderness* over the front of the hip and over the greater trochanter.
- Measurement of 'true' and 'apparent' shortening.
 - For measurement of apparent shortening place the legs parallel with the patient lying supine. The length of the leg is measured from a fixed point, i.e. xiphisternum or umbilicus to the tip of medial malleolus on each side, provided there is no true shortening of one leg.

Apparent shortening is due to tilting of the pelvis, indicates adduction deformity of hip (Fig. 17.48A).

- For true shortening, measure the distance from anterior superior iliac supine to medial malleolus



FIGURES 17.47A and B Trendelenburg's test for testing the gluteal muscles: (A) Powerful gluteal muscles maintain the position normally on standing on the left leg; (B) Weakness of gluteal muscles on right side causes pelvic tilt on standing on the right leg

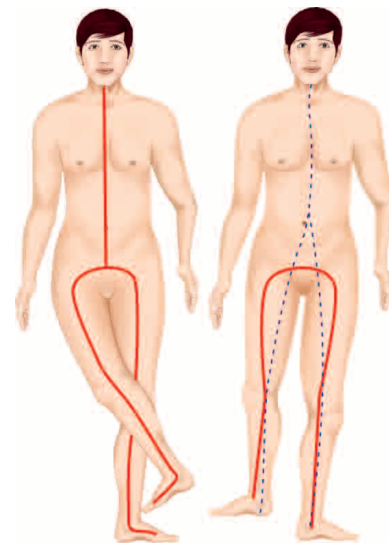


FIGURE 17.48A Measurement for apparent shortening of the leg caused by adduction deformity of the right hip

and compare it with the other side. Any difference is termed '*true*' shortening.

True shortening results either from the disease of hip joint (Fig. 17.48B), i.e. dislocation or neck of the femur or fracture (Fig. 17.48C). Fracture of the neck is common after fall but may occur with trivial injury in a patient with osteoporosis or tumour infiltration. Posterior dislocation of hip is common in dash-board knee injury in patients sitting in the front seat in a car. The limb will be shortened and internally rotated.

Testing of movements

The movements are measured in neutral position (i.e. hip in extension, and patella pointing forwards). Ensure that the

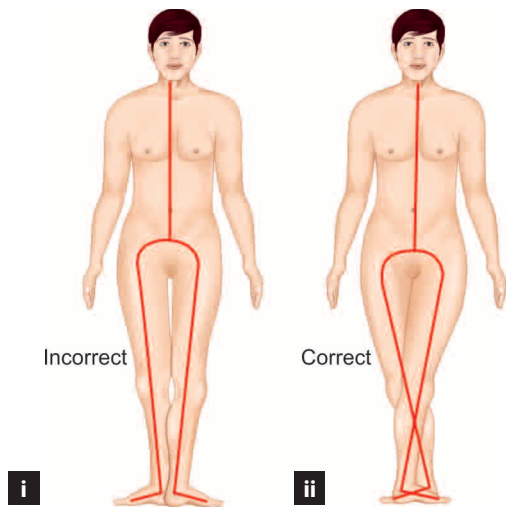


FIGURE 17.48B Measurement for true shortening of the leg. The patient has an adduction deformity of the right limb. On placing the normal limb in the same position of adduction, the leg lengths are the same, excluding true shortening. (i) Incorrect because legs are not in a comparable position; (ii) Correct because the legs are in comparable position of adduction

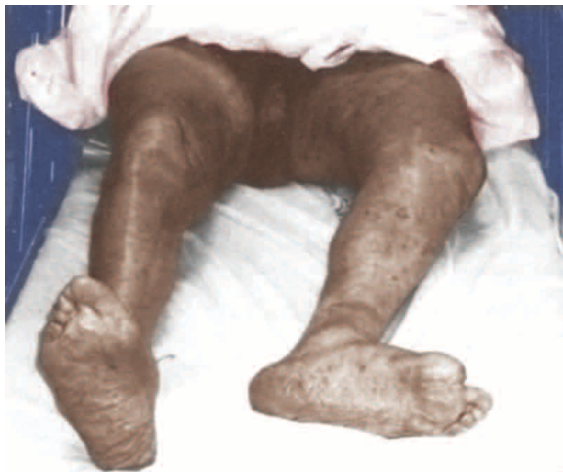

FIGURE 17.48C True shortening of left leg due to fracture neck of femur in a patient with diabetes (left big toe is amputated)

pelvis does not tilt by placing one hand over the pelvis, while examining the hip with the other. The following movements are tested:

Flexion: With one hand stabilising the iliac crest in a patient lying supine, use the other hand to flex each hip and note the range of flexion (0–120°).

Thomas’ test for flexion deformity of hip: Flexion deformity of the hip may be concealed or masked by the presence of compensatory lordosis, therefore, Thomas’ test is performed first on one side and then on the other in, order to unmask it.

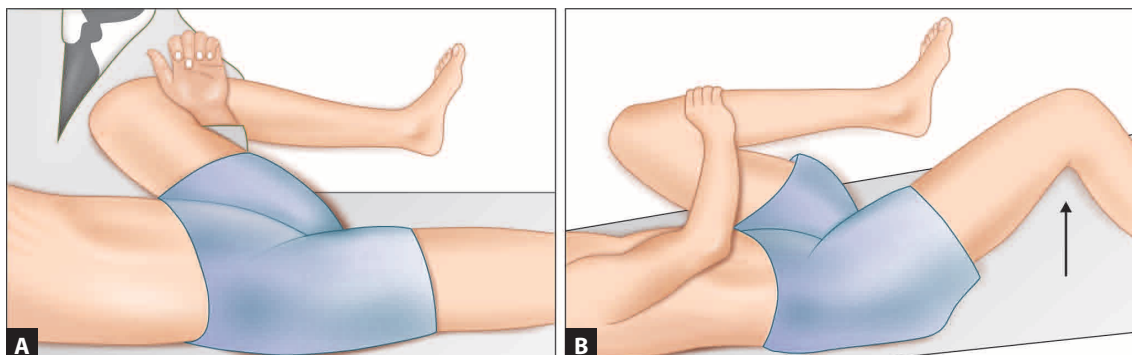
- Place one hand between the patient’s lumbar spine and the examination couch with the patient lying supine.
- Ask the patient to bend each knee in turn upto the chest and pull it firmly against the abdomen. Normally, as the lumbar lordosis is obliterated, the examining hand is quashed between the patient’s spine and the examination couch. Further flexion involves the hip joint itself, therefore, if flexion deformity is present, then as the unaffected hip is flexed with the thigh against the chest, the affected hip does not allow full leg extension, hence, the leg on that side gets flexed (Figs 17.49A and B).

Extension: Try to stabilise the pelvis with one hand while the patient is lying in a lateral position. Attempt to extend the hip backwards by the other hand.

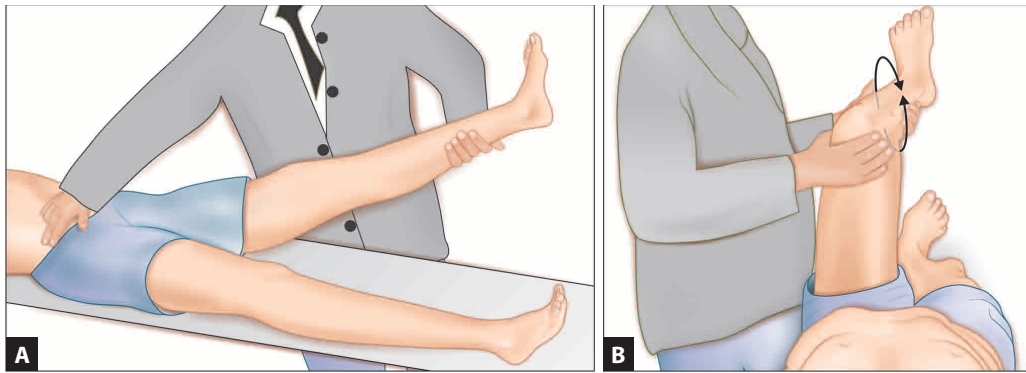
Abduction (Fig. 17.50A): Stabilise the pelvis by grasping the opposite iliac crest with one hand. With the other hand grasp the ankle and abduct the extended leg (variable minimum 45°) until you feel the iliac spine move. This movement marks the limit of hip abduction.

Restricted hip abduction is common in osteoarthritis.

Adduction (Fig. 17.50A): With the patient supine, stabilise the pelvis, hold one ankle and move the leg medially across the body and over the opposite extremity.



FIGURES 17.49A and B Thomas’ test for flexion deformity: (A) Hip flexion and flattening of lumbar lordosis; (B) In flexion deformity of the hip, the affected leg gets flexed (↑)



FIGURES 17.50A and B Movements of the hip joint: (A) Testing the abduction and adduction of hip; (B) External (medial) and internal (lateral) rotation of the hip

Rotation (Fig. 17.50B): Flex the leg to 90° at hip and knee, stabilise the thigh with one hand, hold the ankle with the other, and swing the lower leg—medially for external rotation at the hip and laterally for internal rotation.

Rotation movements are restricted in hip arthritis.

Analysis of Lower Back Pain by Fabere (Patrick's Test) (Fig. 17.51)

Method

For the FABERE (flexion, abduction, external rotation) test, have the patient lie supine. Passively flex, abduct, and externally rotate the lower extremity at the hip so that the lateral malleolus touches the contralateral patella. Then apply downward force on the ipsilateral knee (Fig. 17.51). Repeat on the contralateral side for control.

If there is pain in the lateral lumbar area with radiation into the leg: *radicular low back pain*.

If pain in the midline back over a specific site:

- Compression fracture

If pain in the SI joint: *ankylosing spondylitis, ipsilateral*

If pain in the affected hip: *hip degenerative joint disease*

If no exacerbation of pain: *normal or another aetiology*.

The Knee

The knee joint is the largest joint in the body. It is formed between three bones; the *femur*, the *tibia* and the *patella* (knee cap) with three articular surfaces. The joint is most vulnerable to injury because of no inherent stability of the joint combined with lever action of the femur on tibia and lack of protection from fat or muscle.

Important landmarks of knee

- Medial and lateral epicondyles are bony prominences on the medial and lateral aspects of the joint situated on the top of medial and lateral border of the tibia.

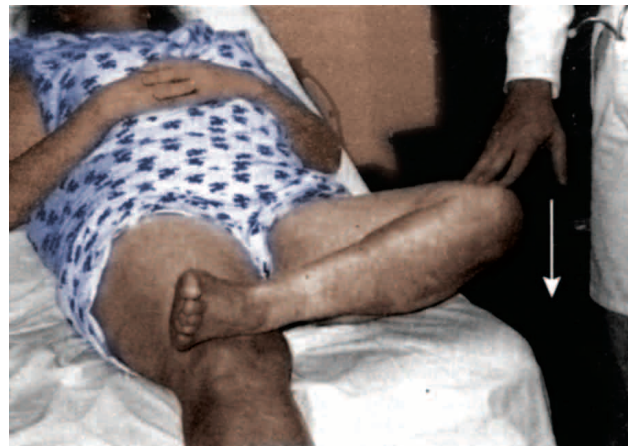

FIGURE 17.51 FABERE test. Patient lies supine with passive flexion, abduction, external rotation of the lower extremity. Here the left leg is being assessed. Excellent test to assess the function of the hip thus, helps to confirm and exclude the disease of the hip

- A third bony-prominence is tibial tuberosity situated at the anterior border of the tibia just below the joint line. The two condyles and tibial tuberosity are equidistant from each other and form two arms of an isosceles triangle.
- The patella rests on the anterior articulating surface of the femur midway between two epicondyles. It is covered by the tendon of quadriceps muscle which is inserted on tibial tuberosity.

Muscles: Two powerful muscle groups move and support the knee. The quadriceps covers the anterior, medial and lateral aspects of the thigh and extends the knee; while the hamstrings situated on the posterior aspect of thigh flex it.

The joint is supported by a network of ligaments; a pair of *collateral ligaments* (medial and lateral), a pair of *cruciate ligaments* (anterior and posterior) and a pair of *menisci* (medial and lateral). The menisci are crescent-shaped fibrocartilaginous discs which provides a cup—like surface, thus, cushion the action of femur on the tibia.

The two important bursae are; *prepatellar bursa* lying between the patella and the skin and *semimembranosus bursa* that communicates with the joint cavity, lies on the posterior and medial surfaces of the knee.

Examination of the knee and lower leg

Inspection

- Observe the gait for smooth, rhythmic movements as the patient enters the room. The knee should be extended at heel strike and flexed at all other stages of swing and stance.

Stumbling or pushing the knee into extension with the hand during heel strike suggests quadriceps weakness.

- With the patient standing, note the presence of bow legs (*genu varum*) and knock-knees (*genu valgum* Fig. 17.52).
- With the patient supine, inspect the limb alignment and note any *deformity, bony contour, loss of muscle bulk, erythema or swelling*.

A large effusion is seen as ‘horse-shoe’ swelling just above the patella.

A synovial swelling in popliteal fossa indicates Baker’s cyst.

- Look for *muscle wasting*.

The quadriceps especially its medial part near the knee, rapidly wastes in disease of the knee joint.

- Check the apparent height of the patella and watch if it deviates to one side in flexion or extension of knee.

Palpation

- With the knee flexed, palpate the joint line to elicit *tenderness*.
- Palpate the *ligaments, tendons and borders of menisci* for any *tenderness*.

Tenderness over the tendon or inability to extend the leg suggest quadriceps (patellar) tendon tear.

- If quadriceps wasting is suspected, record and compare the muscle girth at a selected level above the patella (say 10 cm) in both thighs.

The Patellar Tap Test for a Large Effusion (Fig. 17.53)

- With knee extended, apply pressure with the hand to empty any fluid within suprapatellar pouch into the retropatellar space. If there is large amount of fluid, this will distend the joint and will lift the patella off the underlying femoral condyle.

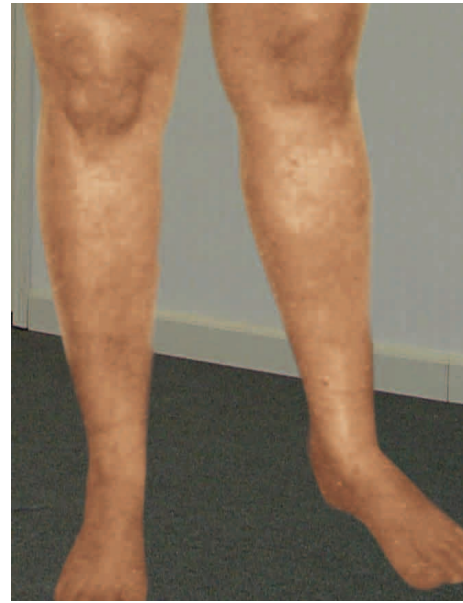

FIGURE 17.52 Genu valgus or valgum. Patient standing, tibial axis pointing lateral relative to the femoral axis. This is particularly evident in patient’s left leg

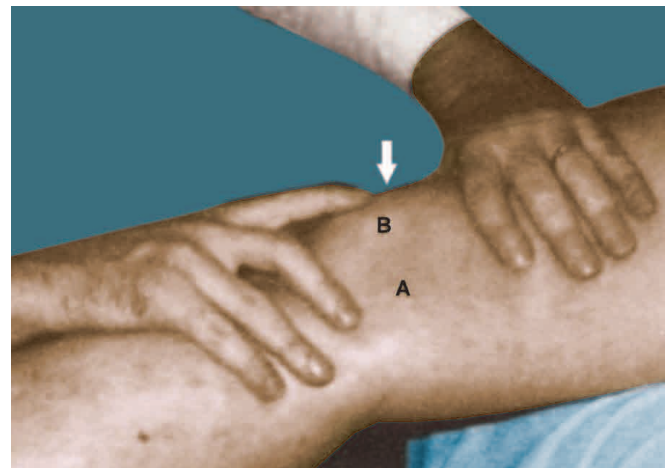
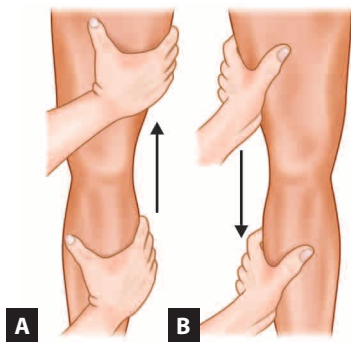


FIGURE 17.53 Examination for knee effusion. Leg at knee in extension and parallel to floor: (A) Site of potential bulge of an effusion—posterior to patella, over joint line; (B) Application of pressure on patella to attempt ballottement

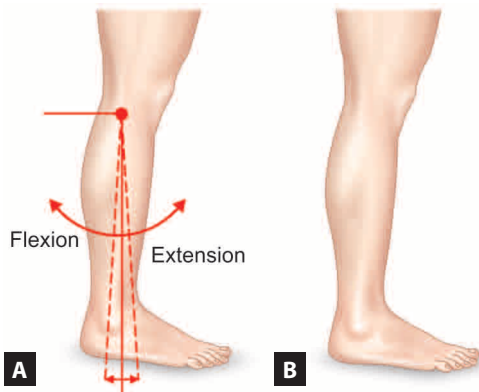
- With the finger of the opposite hand, press down on the patella and fluctuation may be noticed. If this is performed with more brisk downward pressure on the patella, a tapping sensation may be felt as the patella hits the femur. In tense effusion, the patellar tap will be absent.

Bulge Sign (The Massage Test Figs 17.54A and B) for a Small Effusion

- With the knee extended, place the left hand above the knee and apply pressure on the suprapatellar pouch displacing



FIGURES 17.54A and B Massage test (bulge sign) for a small effusion: (A) Massage (milk) any fluid away from the medial side of the knee; (B) Apply firm downward pressure on the lateral side of the knee and observe for the bulge or fluid displacement



FIGURES 17.55A and B Movements of the knee joint. The movements are tested against gravity and against resistance: (A) Movements of flexion and extension; (B) Neutral position during sitting

or “milking” fluid downward. Stroke downward on the medial aspect of the knee and apply pressure to force fluid into the lateral area. Tap the knee on the lateral margin of the patella with right hand for any *fluid wave* or *bulge*.

A fluid wave or bulge on the medial side between the patella and the femur is considered as positive sign and indicates a small effusion.

Movements of the Knee Joint

The principal movements of the knee are:

- **Flexion and extension (Figs 17.55A and B)**

- Ask the patient to flex and extend the knee while sitting.

Or

Knee flexion and extension can also be assessed by asking the patient to squat and stand upto provide support if needed to maintain balance.

- **Rotation:** To check internal and external rotation, ask the patient to rotate the foot medially and laterally.

Testing for Joint Stability (See Table 17.10)

The ligaments stabilise and the menisci maintain the stability of the knee joint hence, any injury to these structure destabilise the joint. The tests and their method of elicitation are given in the Table 17.10 along with Figs 17.56A to F.

- Palpate the *gastrocnemius* and *soleus* muscles on the posterior surface of the lower leg. Their common tendon, the achilles, is palpable from about the lower third of the calf to its insertion on the calcaneus.

Tenderness and swelling occurs in ruptured Achilles tendon.

Tenderness, thickening of the tendon above the calcaneus with protuberant posterolateral bony process of calcaneus occurs in achilles tendinitis.

Tenderness of achilles tendon at its insertion on calcaneous (enthesopathy) is common in ankylosing spondylitis and Reiter's syndrome.

- To test the integrity of the *achilles tendon*, ask the patient to kneel on a chair. Squeeze the calf and watch for plantar flexion at the ankle (Fig. 17.57).

Absence of plantar-flexion is a positive test, indicates rupture of Achilles tendon. Patients on steroid therapy are prone to this rupture.

THE ANKLE AND THE FOOT

The total weight of the body is transmitted through the ankle to the foot. Despite thick padding along the toes, sole, and heel and stabilising ligaments at the ankles, the ankle and the foot are frequent sites of sprain and bony injury.

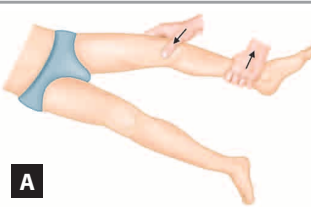

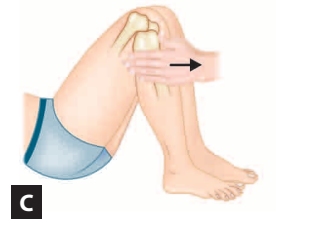
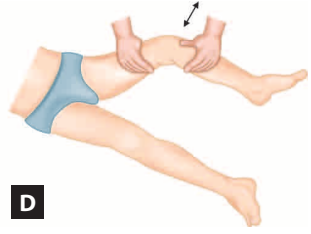

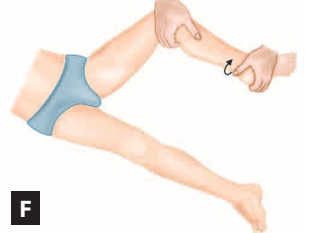
The ankle is a hinge joint formed by the *tibia*, the *fibula* and the *talus*. The three bony landmarks at the ankle are; the medial malleolus at the distal end of the tibia, the *lateral malleolus* at the distal end of the fibula and *calcaneus* – the heel is lodged under the talus. An imaginary line, the longitudinal arch spans the foot, extending from the calcaneus along the tarsal bones of the midfoot. The heads of the metatarsals are palpable in the ball of the foot.

Muscles and Additional Structures

Movements at the ankle joint are; *dorsiflexion* being carried out by anterior tibialis muscle and toe extensors situated anteriorly and the *plantar flexion* being carried out by the *gastrocnemius*, the posterior tibial muscle and the toe- flexors situated posteriorly. The strong Achilles tendon inserts on the heel posteriorly.

The *deltoid ligament* fans out from the inferior surface of the medial malleolus to the talus and proximal tarsal bones, protects against stress from eversion (ankle bows inward).

TABLE 17.10 Knee joint stability test

Structure	Figures 17.56A to F	Method	Comment
Medial collateral ligament (MCL)		Abduction stress test: With the patient lying supine and the knee slightly flexed, move the thigh about 30° laterally to one side of the table. Place one hand against the lateral knee to stabilize the femur and the other hand around the medial malleolus. Push medially the knee and pull laterally at the ankle to open the knee joint on the medial side (<i>valgus stress</i>).	Pain or a gap in the medial joint line suggests ligamentous laxity and a partial tear of the <i>medial collateral ligament</i> . Most injuries occur on the medial side.
Lateral collateral ligament (LCL)		Adduction stress test: Now, with the thigh and knee in the same position, change the position of your hands; place one hand against the medial surface of the knee and the other around the lateral ankle. Push medially at the knee and pull laterally at the ankle to open the knee joint on the lateral side (<i>varus stress</i>).	Pain or a gap in the lateral joint line points to the ligaments laxity and partial tear of the <i>lateral collateral ligament</i> .
Anterior cruciate ligament (ACL)		Anterior drawer sign: With the patient supine, both hips and knees flexed to 90° and feet flat on the table, cup your hands around the knee with the thumbs on the medial and lateral joint line and the fingers on the medial and lateral insertions of the hamstrings. Draw the tibia forward and observe if it slides forward (like a drawer) from under the femur. Compare the degree of forward movement with that of the opposite knee.	A few degrees of forward movement are normal if equally present on both the sides. A forward jerk showing the contours of the upper tibia is a <i>positive anterior drawer sign</i> and suggests a tear of the ACL.
		Lachman test: Place the knee in 15° of flexion and external rotation. Grasp the distal femur with one hand and the upper tibia with the other. With the thumb of the tibial hand on the joint line, simultaneously move the tibia forward and the femur backward. Estimate the degree of forward excursion.	Significant forward excursion points to an ACL tear.
Posterior cruciate ligament (PCL)		Posterior drawer sign: Position the patient and place your hands in the positions described for the anterior drawer test. Push the tibia posteriorly and observe the degree of backward movement in the femur.	A backward jerk with positive contour of upper tibia is a positive sign of PCL tear which is rare.
Medial meniscus and lateral meniscus		Mc Murray test: If a click is felt or heard at the joint line during flexion and extension of the knee, or if tenderness is noted along the joint line, further assess the meniscus for a posterior tear. With the patient supine, grasp the heel and flex the knee. Cup your other hand over the knee joint with fingers and thumb along the medial and lateral joint line. From the heel, rotate the lower leg internally and externally. Now push on the lateral side to apply a valgus stress on the medial side of the joint. At the same time, rotate the leg externally and slowly extend it.	A click along the medial joint with valgus stress, external rotation, and leg extension suggests a probable tear of the posterior portion of the medial meniscus.

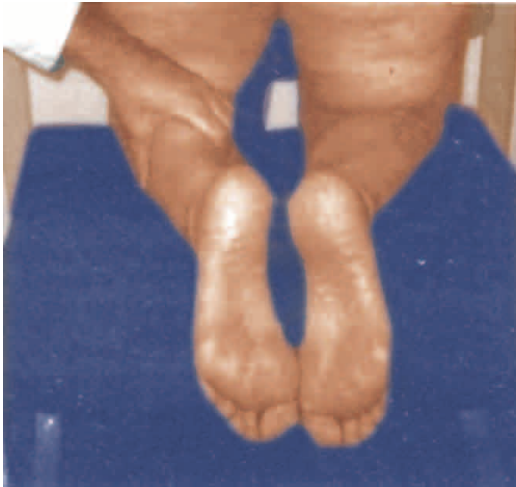


FIGURE 17.57 Thompson's test. Squeeze the gastrocnemius muscle to assess the integrity of the Achilles tendon. Here foot is plantarflexed with the test and thus is normal

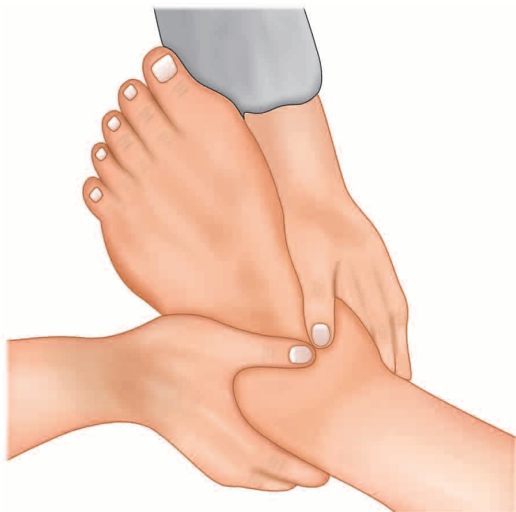

FIGURE 17.58 To elicit tenderness at ankle joint in arthritis

Examination of the Ankle and Foot

Inspection

Inspect all surfaces of the ankles and feet, noting any *deformities*, *nodules* or *swellings* and any *calluses* or *corns*. Note the conditions of the nails and skin, and the presence of *callosities* or *swelling*.

Palpation

- With your thumbs, palpate the anterior aspect of each ankle joint, noting any *swelling* or *tenderness* (Fig. 17.58).
- Feel the Achilles tendon for *nodules* and *tenderness*.
- Palpate the heel especially the posterior and inferior calcaneus, and the plantar fascia for *tenderness*.

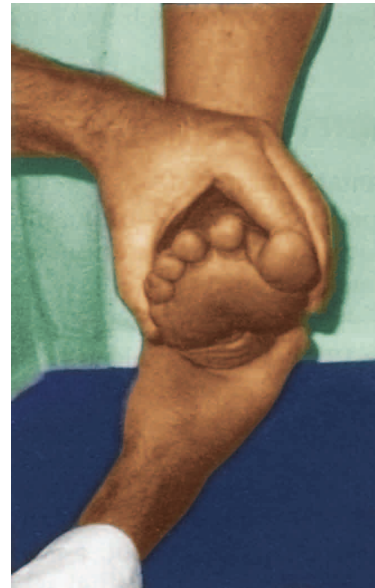

FIGURE 17.59 Transverse arch squeeze test. To elicit the tenderness on metatarsophalangeal joint. Examiner squeezes the forefoot to accentuate the transverse arch. Pain from metatarsalgia or Morton's neuroma will increase on the plantar and dorsal aspects, respectively

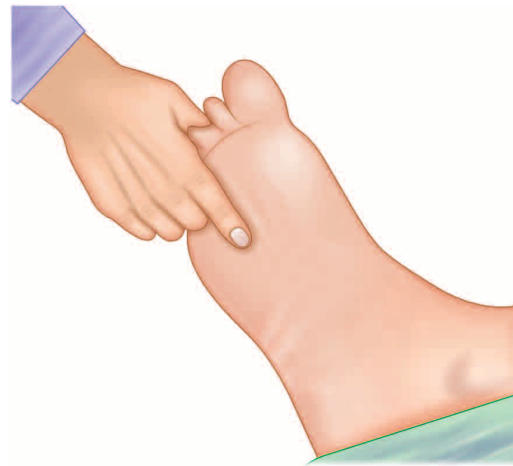

FIGURE 17.60 To elicit tenderness on metatarsals. Metatarsalgia occurs in trauma, arthritis and vascular insufficiency

- Palpate the metatarsophalangeal joints for tenderness. Compress the forefoot between the thumb and fingers (Fig. 17.59). Exert pressure just proximal to the heads of the 1st and 5th metatarsals. Tenderness on metatarsals is an early sign of rheumatoid arthritis. Pain and tenderness of first metatarsophalangeal joint is seen in acute gouty arthritis.
- Palpate the heads of 5 metatarsals and the grooves between them with your thumb and index finger for tenderness (Fig. 17.60). Place your thumb on dorsum of the foot and your index finger on the plantar surface.

Box 16

Causes of pain/tenderness in the heel and foot

The heel and hind foot	The forefoot
<ul style="list-style-type: none"> Plantar fasciitis 	<ul style="list-style-type: none"> Stress fracture of neck of second metatarsal
<ul style="list-style-type: none"> Calcaneus fracture, posterior bony prominence (pump heel) 	<ul style="list-style-type: none"> Synovitis involving MTP joints
<ul style="list-style-type: none"> Degenerative arthritis or gouty arthritis 	<ul style="list-style-type: none"> Plantar nerve—Morton's neuroma
<ul style="list-style-type: none"> Tenosynovitis—Achilles tendonitis or partial tear from trauma 	<ul style="list-style-type: none"> Clawing or hammer toe deformity due to soft tissue contractures
<ul style="list-style-type: none"> Retrocalcaneal bursitis 	

The cause of pain and tenderness in the heel and foot are given in the Box 16. The abnormalities of heel and toe are given in the Table 17.11 and Figures 17.61A to H.

Testing of Movements of Ankle

The movements that occur at the ankle include flexion and extension at the ankle joint and inversion and eversion of the foot at subtalar and transverse talar joints.

Dorsiflexion and plantar flexion (Fig. 17.62): Ask the patient to move the foot upwards (dorsiflexion) and down-wards (plantar flexion) against gravity and resistance.

Inversion and eversion: Stabilise the ankle with one hand, grasp the heel with the other, and invert and evert the foot (Figs 17.63A and B). These movements occur at tibiotarsal joints.

Metatarsophalangeal and interphalangeal flexion and extension (see the illustration Figures 17.64A and B).









Hyperextensibility of Joints (Fig. 17.65)

It occurs in Ehlers-Danlos syndrome. The method of hyperextensibility of is demonstrated in Fig. 17.65.

INVESTIGATIONS FOR RHEUMATOLOGICAL DISORDERS

Investigations are often unnecessary in many patients with rheumatic conditions as diagnosis is easily made on the basis of history and clinical examination, for example tennis elbow. There are no diagnostic tests in osteoarthritis and tests are usually and only required either to know the extent or severity

TABLE 17.11 Abnormalities of feet and toes

Deformity	Figures 17.61A to H
Acute gouty arthritis: It is characterised by a very painful, tender, hot dusky swelling involving metatarsophalangeal joint especially of the big toe (see Fig. 17.20).	
Hallux valgus: The great toe is abnormally abducted	
Flat foot: When the patient stands, the longitudinal arch flattens so that the sole touches the floor	
Hammer toe: It is characterised by hyperextension at metatarsophalangeal joint with flexion at the proximal interphalangeal joint	
Mallet toe: Flexion at the terminal interphalangeal joint	
Claw toe: An abnormal curvature due to fixed flexion of all toes at interphalangeal joint	
Corn: A painful conical swelling due to thickening of the skin occurring over bony prominences resulting from recurrent pressure on normally thin skin. It occurs in a region where the skin is normally thick such as sole. It is painless	
Plantar wart: A swelling due to thickened skin of the sole with characteristic small dark spots that give a stippled appearance to a wart	
Neuropathic ulcer: In neuropathy (especially diabetic), the loss of sensation results in formation of an ulcer at pressure points called neuropathic ulcer. They are deep, infected, indolent and painless. Callus formation about the ulcer is diagnostically helpful	

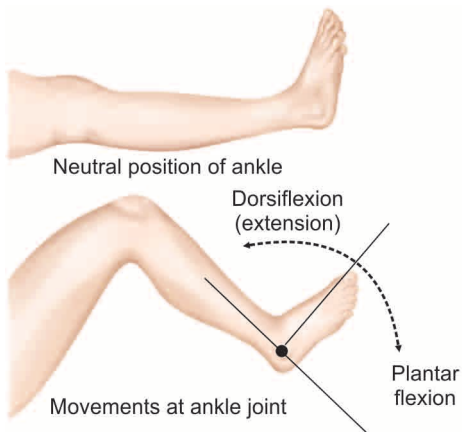
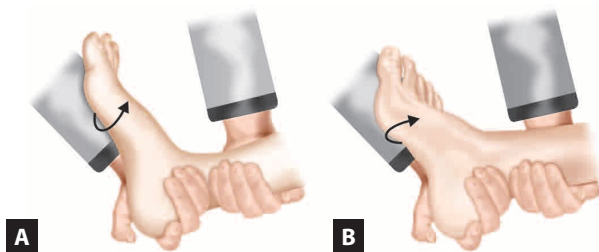
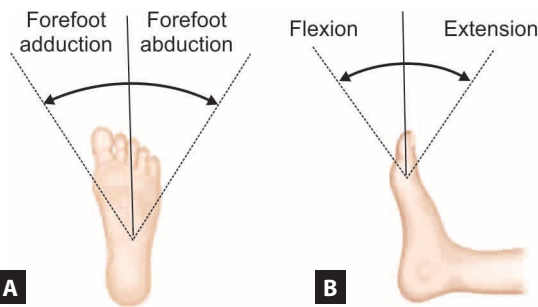


FIGURE 17.62 Movements at the ankle joint. These movements are tested against gravity and against resistance



FIGURES 17.63A and B Movements at tibiotarsal joint



FIGURES 17.64A and B Movements at: (A) Mid-tarsal joints; (B) Metatarsophalangeal joints

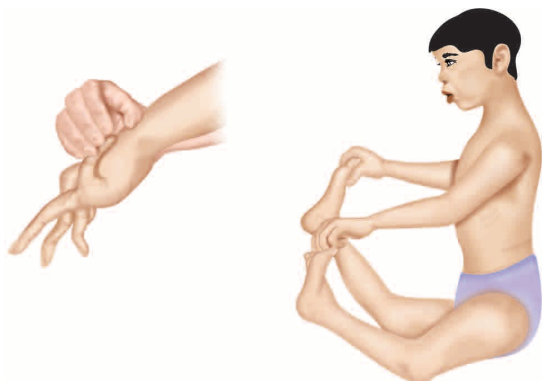


FIGURE 17.65 Test for hyperextensibility of the digits and joints in Ehlers-Danlos syndrome

Box 17

Diagnostic tests in skeletomuscular disorders

Useful tests

- ESR/CRP. Rheumatoid factor (RF)
- Antinuclear antibodies (ANA)
- Serum uric acid
- Synovial fluid examination
- X-rays

Occasionally useful tests

- WBC count
- HLA-B₂₇
- Serum alkaline phosphatase
- ASO titre – in rheumatic fever
- Protein electrophoresis, immunoglobulins, urinalysis for **Bence-Jones protein, bone marrow for multiple myeloma**
- Serum complement
- ANCA
- Anticardiolipin antibodies
- Arthroscopy and if necessary synovial biopsy
- Arthrogram
- Bone scan/MRI scan

Abbreviations

- ANCA = Anti-neutrophil cytoplasmic antibodies
- ESR = Erythrocyte sedimentation rate
- CRP = C-reactive protein
- ASO = Antistreptolysin
- MRI = Magnetic resonance imaging

of the disease or to exclude some other conditions when there is lack of response to therapeutic agents. Blood batteries of diagnostic tests and radiological procedures that can be done are given in the Box 17.

Tests for Rheumatoid Factor

Rheumatoid factors are IgM class autoantibodies directed against Fc portion of IgG. They are detected in serum in dilution of 1 : 20 or 1 : 40, more than this titre is considered as abnormal. They are detected by agglutination of either large particles (The **Rose-Waller test**) or **sheep red cells agglutination test (SCAT) test**. The latex test is quicker and easier to perform; it is more sensitive, and therefore more often positive, but is less specific than sheep red cells test. The rheumatoid factor is positive in 70–75% cases of rheumatoid arthritis.

Citrullinated Cyclic Peptide (CCP) Antibodies

They are measured by ELISA and are highly specific for RA (90%). They are helpful in diagnosis of early disease and can distinguish RA from synovitis.

Antinuclear Antibodies

Antinuclear antibodies (ANA) in the serum are detected using immunofluorescent staining of the nuclei of a tissue such as rat liver or human cells in tissue culture. A low titre of less than 1 : 40 is weakly positive and is of little significance. Conditions in which antinuclear antibodies are found in higher titres are given in the Box 18.

Antibodies to other Nuclear Antigens

A variety of antinuclear antibodies have been described with particular disease associations that are depicted in Table 17.12. It seems likely that pattern of the disease is determined by the nature of autoantibodies produced.

- **Antibodies against double stranded DNA (dsDNA):** These antibodies can be detected using a radio-immunoassay measuring percentage antibody binding of added labelled dsDNA (*Farr test*). Antibodies are found in about 50% cases of SLE but seldom in any other conditions. They are, therefore, much more specific test than antinuclear antibody. They are also associated with more severe disease and renal involvement.
- **Antibodies against extractable nuclear antigen (ENA):** These are IgG class antibodies against soluble nuclear antigen, characteristically seen in mixed connective tissue disease, but are also found in patients with SLE.
- **Anticardiolipin antibodies and lupus anticoagulant:** They are found in antiphospholipid syndrome, characterised by arterial and venous thrombosis, recurrent abortions, CNS manifestations (chorea, migraine and epilepsy), accelerated atherosclerosis and cutaneous manifestations.
- **Antineutrophil cytoplasmic antibodies (ANCA):** These are detected by immunofluorescence and by enzyme linked immunosorbent assay (ELISA) in the serum and are of two types.
 1. **cANCA (cytoplasmic staining)** is directed against proteinase 3, now called PR3-ANCA.
 2. **pANCA (perinuclear staining)** is mainly directed against myeloperoxidase, now called MPO-ANCA.

The PR3-ANCA is seen in Wegener's granulomatosis with specificity of about 90%. It is found in 50% of early cases and about 100% of cases with full blown systemic disease. It disappears with treatment and rising titres may predict relapse, hence, a good marker to determine the progress of the disease. It is occasionally seen in other types of vasculitis.

The MRO-pANCA antibodies is much less specific and is found in, vasculitis, glomerulonephritis and RA.

- **Anti-RNA polymerase antibodies, I, II and III:** These antibodies (I, II, III) are found in 20–25% patients with diffuse cutaneous systemic sclerosis.

Box 18

Conditions associated with ANA

Common	Uncommon
• Systemic lupus erythematosus (SLE 95%)	• Autoimmune chronic active hepatitis
• Systemic sclerosis (80%)	• Primary biliary cirrhosis
• Sjögren's syndrome (60%)	• Infective endocarditis
• Polymyositis/dermatomyositis (30%)	• Normal elderly people
• Still's disease (30%)	

TABLE 17.12 Antinuclear antibodies and associated conditions

Antibody	Clinical association
Double stranded DNA (dsDNA)	SLE
Extractable nuclear antigen (ENA); ribonucleoprotein	Mixed connective tissue disease and SLE
Ro (SS-A)*	SLE and primary Sjögren's syndrome
La* (SS-B)	Primary Sjögren's syndrome
S _m *	SLE
Nucleolus	Systemic sclerosis
Anti-topoisomerase 1 (Sci-70)*	Systemic sclerosis
Centromere	CREST syndrome
Jo-1*	Polymyositis/dermatomyositis
Anticardiolipin	SLE and antiphospholipid syndrome
Anti-UI-RNP	SLE and overlap syndrome

* Fractions of nuclear material

- **Immune complexes measurement** by ethylene glycol precipitation method. Immune complexes and low levels of complement are seen in autoimmune diseases.

Serum Uric Acid

Raised serum uric acid indicates gout but is not diagnostic of it. A low level of uric acid excludes gout. In known cases of gout, monitoring of uric acid is helpful in deciding the treatment.

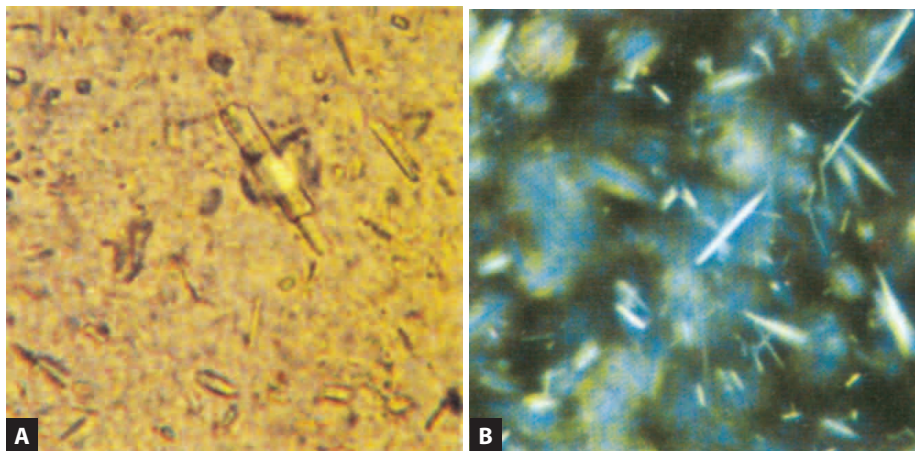
Synovial Fluid Examination

The synovial fluid removed by joint puncture is subjected to biochemical, microbiological and cytological examination. The characteristics of synovial fluid in normal and diseased joints are summarised in the Table 17.13.

Polarized light microscopy reveals the presence of negatively birefringent crystals in gout (Fig. 17.66A). In

TABLE 17.13 Synovial fluid changes in common joint disorders

Condition	Gross appearance	WBCs ($\times 10^5$ /litre)	Crystals	Culture
Normal	Clear viscous fluid	<200 mononuclear	None	Sterile
Osteoarthritis	Increased volume viscosity retained	3000 mononuclear	5% have pyrophosphate	Sterile
Rheumatoid arthritis	Sometimes turbid yellow or green in colour, viscosity lost	30,000 neutrophils	None	Sterile
Gout	Clear, low viscosity	10,000 neutrophils	Needle shaped negatively birefringent	Sterile
Septic arthritis	Turbid, low viscosity	50,000–100,000 neutrophils	None	Positive
Pyrophosphate arthropathy	Clear, low viscosity	10,000 neutrophils	Brick-shaped positively birefringent	Sterile



FIGURES 17.66A and B Synovial fluid examination by polarised light microscopy: (A) Crystals of calcium pyrophosphate, which tend to be rather brick-shaped; (B) Needle-shaped crystals of uric acid. They react with nitric acid and ammonium hydroxide to give a purple colour (*murexide test*)

pyrophosphate arthropathy, crystals of calcium pyrophosphate which are weakly positive birefringent are seen (Fig. 17.66B). The electron microscopy is used to detect crystals of hydroxyapatite, because the crystals being too small are not seen in polarised light microscopy. Gram stain is used to identify the organism in septic arthritis, but fluid should be sent for culture.

Radiology and Imaging Techniques

X-rays of joints has been a valuable tool in diagnosis and staging of articular disorders. However, in most inflammatory disorders, early radiography (X-rays) is rarely helpful in establishing the diagnosis and may only reveal soft tissue swelling or juxta-articular demineralisation. As the disease progresses, calcification (of soft tissue, cartilage, or bone), joint space narrowing, erosion, bony ankylosis, new bone formation (sclerosis, osteophytes formation or periostitis) or

subchondral cysts may develop and suggest specific clinical entities.

Ultrasonography: It is inexpensive, noninvasive, easily performed technique used in the detection of soft tissue abnormalities, synovial (Baker's) cysts, rotator cuff tears and various tendon injuries.

Radioisotope bone scan: It is useful in demonstrating malignant deposits and evaluation of Paget's disease. Increased uptake also occurs in osteoarthritic joints and also in inflammatory arthropathies, but these abnormalities can easily be distinguished from malignant disease.

CT scan: It is useful to detect herniated intervertebral disc, spinal stenosis, spinal trauma and sacroiliitis.

MRI scan: MRI scanning is useful for the detection of mechanical problems in joints, for example, a torn meniscus or ruptured cruciate ligament in the knee or rotator cuff tear in the shoulder. It is useful to detect avascular necrosis for

example in the hip joint and is replacing myelography for detection of spinal diseases.

Positron emission tomography (PET): This scanning uses radio-nuclide which decays by emission of positrons. Fluorine 18 deoxyglucose is used for this and areas of increased glucose uptake detected (vascular tumour). It is helpful to locate tumour and to demonstrate large vessel vasculitis. It can be used with CT/ MRI.

Arthrogram: It can also be used to visualise the meniscus or to determine knee-joint structure.

Bone density: Bone density, i.e. thickness of cortex can be measured by densimeter in diseases associated with osteoporosis.

Other ancillary investigations.

WBC count: It is useful in infections and leukaemia presenting with arthritis.

Histocompatibility Antigen HLA-B₂₇ is found in 96% cases with ankylosing spondylitis and 5% of normal people. In addition, about 60% of patients with Reiter's disease are B₂₇ positive.

18

CHAPTER

The Blood

HISTORY

Symptoms and Signs

- Anaemia
- Polycythaemia
- Bleeding
- Thrombosis.

GENERAL PHYSICAL EXAMINATION

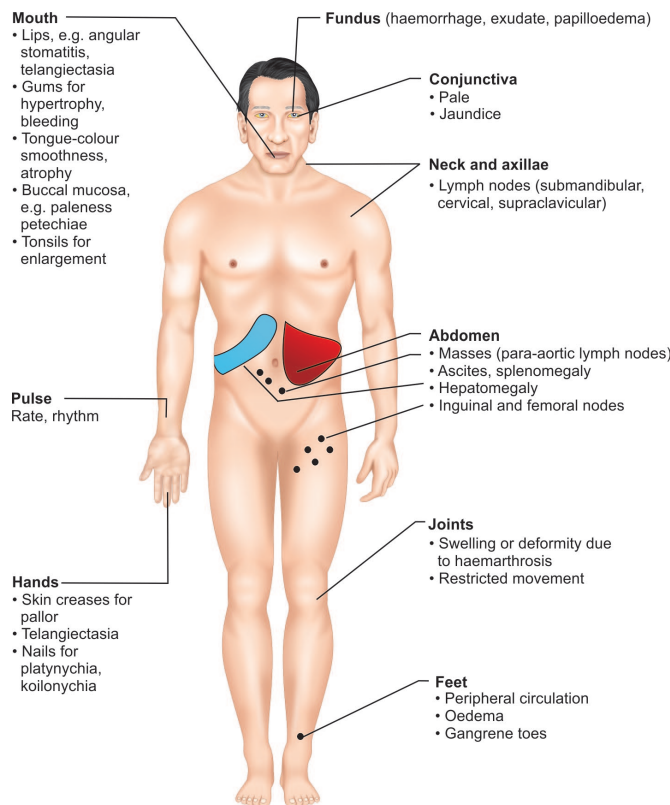
- **General observation**—pale look
- **The face for pallor, hair, skin** (purpura, petechial)
- **The eyes including ocular fundi, conjunctiva for pallor**
- **The mouth, tongue, the buccal mucosa** for ulceration, bleeding, infection and excoriation
- **The neck, i.e. thyroid, JVP** and lymph nodes
- **The axillae and groins** for lymph nodes
- **Hands and feet** for oedema, pale creases palm
- **Nails** for platonychia and koilonychia
- **Joints** for synovitis and arthritis
- **Vital, e.g. pulse, temperature, B.P. and respiration**

SYSTEMIC EXAMINATION

Abdomen

(Read Chapter 13)

Inspection: Any localised swelling



General observations

- Well being or nourishment
- Colour, e.g. pale or plethoric
- Bleeding, e.g. purpura or bruising
- Breathlessness

Clinical Examination in Blood Disorders

Palpation for liver and spleen or abdominal lymph nodes or any other mass or ascites

Percussion over the mass if palpable

Auscultation for bruits, hum or rub

CVS

Inspection for apex beat

Palpation for apex beat, thrill, rub, etc.

Percussion for cardiomegaly

Auscultation for abnormal sound and murmurs.

Respiratory System

Auscultation for crackles or wheezes or any other abnormality.

CNS

- Higher mental functions
- Cranial nerves
- Motor and sensory system.

Joints (For evidence of bleeding)

Diagnosis

Differential Diagnosis

Laboratory Investigations

- Peripheral blood examination
- Bone marrow
- Coagulation profile
- Other specific tests.

THE BLOOD

Blood diseases cover a wide spectrum of illnesses ranging from anaemias, the most common disorders affecting mankind to other relatively uncommon disorders encountered in clinical practice, i.e. leucaemias and coagulation defect. Haematological change may occur as a consequence of disease affecting any system and measurement of haematological parameters is an important part of routine clinical assessment.

Clinical Manifestations

- Anaemia
- Leucopenia, leucocytosis, leucaemia
- Myelomatosis
- Polycythaemia
- Lymphadenopathy, hepatosplenomegaly
- Bleeding
- Thrombosis
- Pancytopenia.

Anaemia

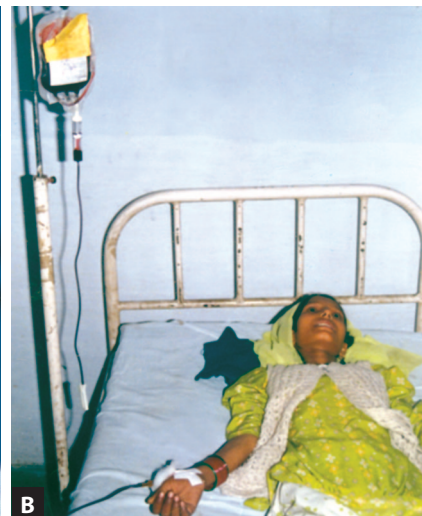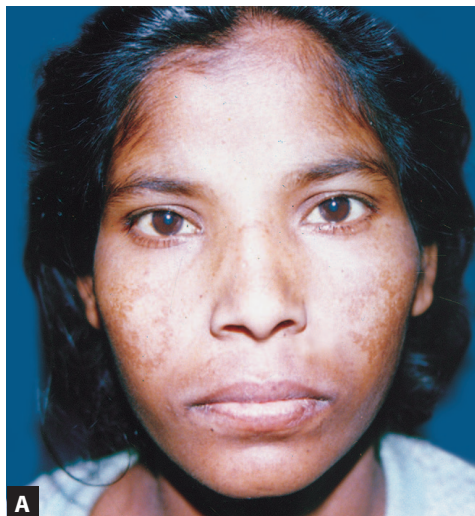It is a laboratory diagnosis and is said to be present if haemoglobin level is below the normal range of age and sex of the individual. A haemoglobin level of 12 g/dL is taken as anaemia in males and less than 11 g/dL in females. Normally adult males have higher haemoglobin level (about 2 g/dL) than the females. The symptoms and signs depend on the speed of onset, severity of anaemia and age of the patient. Rapid onset of anaemia will give rise to severe symptoms than slow onset. The younger patients tolerate anaemia better than old (Fig. 18.1A). The patients with cardiovascular disease will have symptoms of anaemia at higher haemoglobin levels

than those with normal cardiorespiratory function. Patient with severe anaemia (Hb < 4 g%) may pose an emergency requiring blood transfusion (Fig. 18.1B). The symptoms and signs of chronic severe anaemia are given in the Box 1.

Box 1

Symptoms and signs of anaemia

Symptoms	Signs
<ul style="list-style-type: none"> • General <ul style="list-style-type: none"> – Lassitude, fatigue • CVS <ul style="list-style-type: none"> – Exertional dyspnoea or dyspnoea at rest – Palpitation – Throbbing in head and ears – Precipitation of angina, intermittent claudication and vascular insufficiency • CNS <ul style="list-style-type: none"> – Headache, dizziness, vertigo – Insomnia – Numbness and tingling of hands and feet • Genitourinary <ul style="list-style-type: none"> – Amenorrhea/menorrhagia, loss of libido • GI tract <ul style="list-style-type: none"> – Anorexia, nausea, flatulence – Weight loss 	<ul style="list-style-type: none"> • Pallor of skin, mucous membrane, conjunctivae and creases of the palm • Tachycardia and collapsing pulse • Raised JVP • Flow/haemic murmurs, e.g. midsystolic across the aortic and pulmonary valves • Cardiomegaly and congestive heart failure in chronic severe anaemia • Ankle oedema



FIGURES 18.1A and B (A) Severe anaemia in postpartum female; (B) A patient of severe anaemia (Hb < 4.0 g) receiving emergency blood transfusion

Clinical Evaluation of Anaemia

- Iron deficiency anaemia is the most common type of anaemia worldwide. A thorough gastrointestinal history (anorexia, diarrhoea, worm infestation, haematemesis, melena, piles) must be recorded. Menorrhagia is a common cause of anaemia in females still menstruating, hence, a woman must be asked about her periods.
- **Dietary history:** A dietary history must assess the intake of iron and folate which may become deficient in comparison to needs (e.g. in pregnancy, lactation, during periods of growth). Malnutrition due to diarrhoea and malabsorption may result in anaemia.
- **Past medical history:** Ask about:
 - Previous surgery (resection of the stomach or small bowel).
 - Past history any blood loss, e.g. pills, haematemesis, menorrhagia, epistaxis, PPH etc.
 - Any history of chronic infection (e.g. tuberculosis) or acute infection (malaria).
 - Past history of chronic illness, e.g. liver or kidney disease or rheumatoid arthritis, endocrinal problem.
- **Family history:** Haemolytic anaemias such as the haemoglobinopathies and hereditary spherocytosis may be suspected from the family history. Pernicious anaemia may also be familial.
- **Drug history:** Drugs are known cause blood loss (aspirin, NSAIDs), haemolysis (antimalarial in G6PD deficiency) or hypoplasia or aplasia of the bone marrow, hence, drug already taken or are being taken should be recorded.

Causes of Anaemia (Table 18.1)

In a case of anaemia; one has to find out its cause. No symptom and sign is diagnostic of a specific type of anaemia, but there may be specific findings related to the cause of anaemia, for example, a mass in the abdomen such as in right iliac fossa may suggest caecal carcinoma. A patient having jaundice as well as anaemia is either due to cirrhotic portal hypertension with haematemesis or haemolytic anaemia. Anaemia with neurological signs such as peripheral neuropathy, dementia or subacute combined degeneration indicate vitamin B₁₂ deficiency as its cause. Sick cell anaemia may result in pain crises and leg or digital ulceration.

Morphological classification of anaemia: Based on the red cell size, haemoglobin content and red cell indices, anaemias are classified into:

- **Microcytic hypochromic anaemia** (e.g. MCV, MCH, MCHC all are reduced). Examples include iron deficiency anaemia (Fig. 18.2A), sideroblastic anaemia, thalassemia (Fig. 18.3B).

TABLE 18.1 Aetiological classification of anaemia

<ul style="list-style-type: none"> • Blood loss <ul style="list-style-type: none"> – Post-haemorrhagic – Chronic blood loss, e.g. piles, haematemesis, menorrhagia – Worm infestation, e.g. hookworm
<ul style="list-style-type: none"> • Deficiency of haemopoietic factors <ul style="list-style-type: none"> – Iron deficiency – Folate and vitamin B₁₂ deficiency – Protein deficiency, e.g. diarrhoea, malabsorption
<ul style="list-style-type: none"> • Hypoplasia or aplasia of marrow <ul style="list-style-type: none"> – Pure red cell aplasia – Aplastic or hypoplastic anaemia
<ul style="list-style-type: none"> • Anaemia due to systemic disorders or chronic infections <ul style="list-style-type: none"> – Anaemia of chronic infection, e.g. tuberculosis – Anaemia of chronic renal disease, e.g. CRF – Anaemia of chronic hepatic disease, e.g. cirrhosis – Anaemia of disseminated malignancy – Anaemia of endocrinal disease, e.g. hypothyroidism
<ul style="list-style-type: none"> • Anaemia of bone marrow infiltration (dyshaematopoietic anaemia) <ul style="list-style-type: none"> – Leucaemias, lymphomas, myelofibrosis or myelosclerosis – Multiple myeloma – Congenital sideroblastic anaemia
<ul style="list-style-type: none"> • Anaemia due to haemolysis <ul style="list-style-type: none"> – Intracorpuscular defect (hereditary or acquired) – Extracorpuscular defect (acquired)

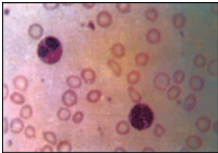
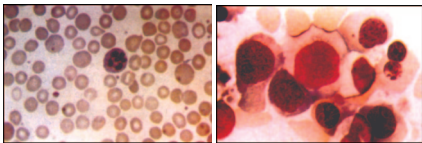
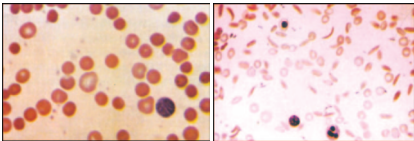
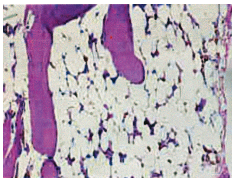
- **Macrocytic** (MCV is raised, MCH and MCHC are reduced relative to size of RBC). Examples include megaloblastic anaemia (folic acid and vitamin B₁₂ deficiency (Fig. 18.2B)).
- **Normocytic normochromic** (e.g. MCV, MCH, MCHC are normal). Examples include anaemia of blood loss, haemolytic anaemia (Fig. 18.2C), aplastic anaemia (Fig. 18.2D) etc.
- **Dimorphic:** When two populations of red cells (microcytes as well as macrocytes) are seen on peripheral blood examination, anaemia is said to be dimorphic due to combined deficiency of iron as well as folic acid/vitamin B₁₂.

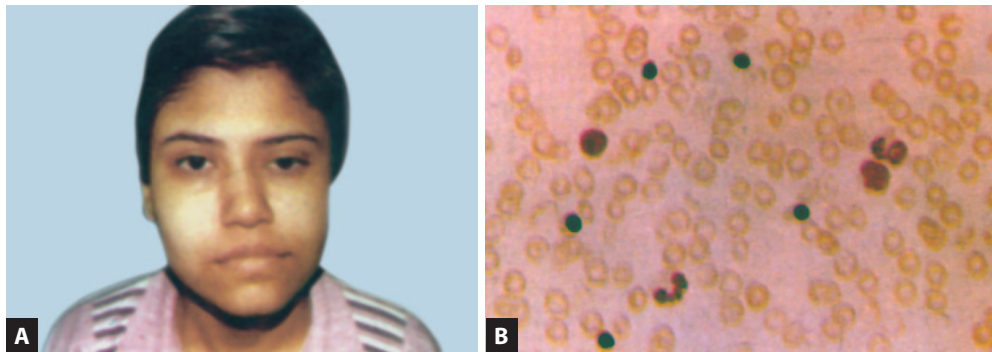
Symptoms and Signs Specific to Certain Anaemia (See Table 18.2)

Leucopenia and neutropenia

The leucocytes especially the neutrophils are phagocytic cells, provide strong defence against micro-organisms. The leucopenia refers to low leucocyte count. Neutropenia means neutrophils count $<1.5 \times 10^9/L$. Virtual absence of granulocytes in peripheral blood is called *agranulocytosis*. The major consequence of neutropenia is infection, which in patients with blood disorders may be severe and lead to fatal septicaemia. Fever and pneumonia are common presentations.

TABLE 18.2 Specific symptoms and signs of some important anaemias

Anaemia (Figs 18.2A to D)	Specific symptoms and signs	Cause(s)
Iron deficiency  <p>FIGURE 18.2A: Peripheral blood film showing iron deficiency anaemia. The red blood cells are smaller than normal (microcytosis), and their central area of pallor is expanded (hypochromia) so that the cells appear to have thin rim of haemoglobin</p>	<ul style="list-style-type: none"> • Glossitis with papillary atrophy (bald tongue) • Angular stomatitis (cheilosis)—fissuring at the angles with sore tongue • Dysphagia (Peterson-Kelly or Plummer-Vinson's syndrome) • Koilonychia or platynychia 	<ul style="list-style-type: none"> • Strict vegetarian diet • Diarrhoea or malabsorption, gastrectomy • Chronic blood loss from uterus (menorrhagia, dysfunctional uterine bleeding), GI tract (e.g. NSAIDs, bleeding peptic ulcer, piles, varices, gastritis, colitis and hookworm disease), renal (e.g. haematuria), nose (epistaxis), lungs (haemoptysis) • Increased demands, e.g. growing children, pregnancy, lactation
Vitamin B₁₂ deficiency  <p>FIGURE 18.2B Macrocytic anaemia with megaloblastic bone marrow. Upper peripheral blood film shows larger RBCs with poor haemoglobinisation. Lower bone marrow examination shows megaloblasts</p>	<ul style="list-style-type: none"> • Mild jaundice • A lemon yellow tinge to skin, grey hair • Red-smooth (magenta coloured) sore tongue • Tinglings and paraesthesias • Weight loss • An abnormal gait • Skin pigmentation • Mental features, e.g. poor memory, lack of concentration, depression, personality change and hallucinations • Optic atrophy and subacute combined degeneration 	<ul style="list-style-type: none"> • Inadequate dietary intake (vegetarian diet) • Malabsorption (diarrhoea) • Autoimmune gastritis resulting in loss of intrinsic factor • Previous surgery (gastrectomy)
Folic acid Deficiency—same as above	<ul style="list-style-type: none"> • Same as above except neurological features 	<ul style="list-style-type: none"> • Increased demand (pregnancy) • Poor intake (diet lacking in green vegetables) • Infection • Haemolytic anaemia due to any cause • Malabsorption
Haemolytic anaemia  <p>FIGURE 18.2C: Haemolytic anaemia. Upper: Abnormal shape of the cells (hereditary spherocytosis) and lower abnormal haemoglobin (sickle-cell-HbS)</p>	<ul style="list-style-type: none"> • Symptoms and signs of anaemia • Mild jaundice • Dark coloured urine and stool, e.g. smoky urine due to haemoglobinuria, or frank bloody or even black (black-water fever) • Abnormal facies with frontal bossing (Fig. 18.3A) • Skin ulceration of legs or gangrenous toes or dactylitis (sickle cell anaemia) • Hepatosplenomegaly • Pigmented gallstones (biliary colics) 	<ul style="list-style-type: none"> • Congenital or hereditary defect [spherocytosis, thalassaemia (Figs 18.3A and B), G6PD deficiency] • Drug induced (e.g. analgesics, antimalarial, antibiotics) • Autoimmune • Infections (malaria)
Hypoplastic or aplastic  <p>FIGURE 18.2D Hypoplastic anaemia. Bone marrow examination reveals just fat and fibrosis with no cellular element</p>	<ul style="list-style-type: none"> • Neutropenia results in infections, necrotic mouth ulcerations, throat ulcers • Thrombocytopenia results in bleeding in skin, mucous membrane, epistaxis, haematuria or intracranial bleed • Symptoms and signs of anaemia 	<ul style="list-style-type: none"> • Irradiation • Drugs • Chemicals • Infection • Autoimmune disease



FIGURES 18.3A and B Thalassemia: (A) patient with abnormal face and frontal bossing; (B) Peripheral blood film showing microcytic hypochromic picture

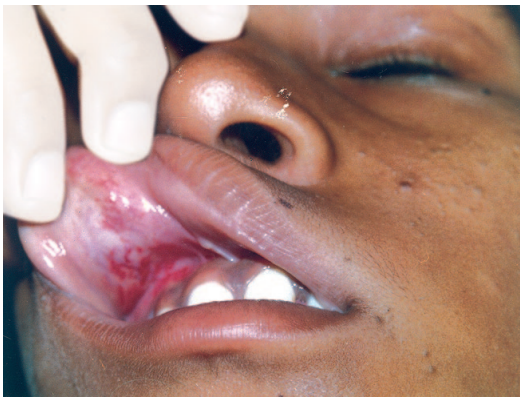

FIGURE 18.4 Neutropenia. Note the mouth ulceration in a patient with neutropenia

Patients with neutropenia may develop opportunistic infections with unusual organisms such as fungi and viruses, i.e. herpes zoster and herpes simplex infections.

As a general rule; neutropenia is associated with bacterial infection while *lymphopenia* is associated with virus and other exotic infections, e.g. *pneumocystis carinii* and toxoplasma.

Presenting symptoms

- Clinical manifestations may vary from asymptomatic to overwhelming infection. The risk of bacterial infection is related to degree of neutropenia, with counts $<0.5 \times 10^9/L$ conferring the highest risk.
- Fever, sore throat, mouth ulceration (Fig. 18.4), anal ulceration and skin infection are common presentation.
- If untreated, patients may become septicaemic and shocked within few hours if immediate antibiotic therapy is not given.

Causes of neutropenia

They have already been described in Chapter 2.

Leucocytosis and leukaemoid reaction

An increase in total leucocyte count more than $11,000/dL$ is called *leucocytosis*. This is usually due to an increase in a

Box 2

Differentiation between leukaemoid reaction and leucaemia

<i>Leukaemoid reaction</i>	<i>Leucaemia</i>
• Count is between 30,000 to 50,000 cells/ μL	• Count is $>50,000$ cells/ μL
• Mostly mature cells. Immature cell may be present but are less than 25%	• Immature cells are present in all forms and account $>30\%$ of all cells. It is low
• Leucocyte alkaline phosphatase content is normal or increased	

specific type of WBC, i.e. neutrophils, basophils, eosinophils, monocytes or lymphocytes. Sometime an increase in one type of leucocyte may not cause rise in total leucocyte count.

Neutrophilic or neutrophilic leucocytosis is a normal response to infection or injury and is often associated with symptoms of the disorder which have led to it. The causes of neutrophilic leucocytosis have already been described in Chapter 2.

Symptoms and signs: The symptoms and signs depend on the cause, for example, a patient with neutrophilic leucocytosis with pneumonia will have fever, shaking chills, cough, sputum, haemoptysis, etc; while a patient with infectious mononucleosis will have fever, malaise, sore throat, lymphadenopathy and lymphocytosis.

Leukaemoid reaction: Leucocytosis with cell count of 10,000 to 25,000/mL occurs in response to infection and acute inflammation and results from release of mature WBCs. Persistent neutrophilia or leucocytosis with cell count of 30,000 to 50,000/ μL is called *leukaemoid reaction*. This term is used to distinguish this degree of leucocytosis from leucaemia. The differentiation between the two is given in the Box 2.

The causes of leukaemoid reaction are:

- Severe infection
- Tuberculosis
- Malignant infiltration of the bone marrow
- Occasionally, following a severe haemorrhage or haemolysis.

Leucoerythroblastic Anaemia

Results in appearance of nucleated red cells and WBC precursors in peripheral blood. Causes include, marrow infiltration with metastatic carcinoma, myelofibrosis, osteopetrosis, myeloma, lymphoma and occasionally severe haemolytic or megaloblastic anaemia.

Leucaemias

(Read Bedside Medicine by Prof. SN Chugh)

Leucaemias, lymphoma and myeloma are malignant disorders of myeloproliferative and lymphoproliferative system. Leucaemias are a heterogenous group of diseases characterised by malignant proliferation or apoptosis of the blood cells resulting in infiltration of the blood, bone marrow and other tissues. If mature differentiated cells are involved, the cells will have a low growth rate and produce indolent neoplasms such as low grade lymphoma or chronic leucaemia. The differentiation between acute and chronic leucaemia are summarised in the Table 18.3.

Myelomatosis

Multiple myeloma represents a malignant proliferation of plasma cells derived from a single clone, is characterised by the presence of a paraprotein (an immunoglobulin) in the serum which can be demonstrated by monoclonal dark-staining band on protein electrophoresis.

In multiple myeloma, the malignant plasma cells appear in the peripheral blood in a small numbers but majority of them remain in the bone marrow (Fig.18.7). These cells elaborate cytokines which stimulate osteoclasts and result in lytic lesions due to bone resorption. The resulting lytic lesions produce bone pain, fractures and hypercalcaemia. Anaemia and pancytopenia result due to bone marrow involvement. Renal failure is common. Soft tissue infiltration is uncommon (Table 18.4).

It is a disorder of old age, may present with solitary plasmacytoma of bone or extramedullary plasmacytoma.

Polycythaemia (High Haemoglobin and PCV)

A haemoglobin level greater than upper limit of the normal (adult females 16.5 g/dL, adult males 18 g/dL) may be due to an increase in the number of red blood cells (true polycythaemia) or a reduction in the plasma volume (relative or apparent polycythaemia) due to dehydration, diuretic use or alcohol consumption. True polycythaemia (*polycythaemia rubra vera*) is a myeloproliferative disorder involving the RBCs in the bone marrow. Polycythaemia may also occur secondary to increased erythropoietin production either as a consequence of chronic hypoxaemia (COPD, congenital heart disease) or because of inappropriate erythropoietin secretion, e.g. lung and renal tumours etc.

A clinical history and examination will provide clues to the underlying cause. Polycythaemia in the early stages may go unnoticed due to no symptoms. Relatives and friends may be the first to notice the red complexion or plethora of polycythaemia. The patient may complain of headache, tinnitus, a feeling of fullness in the head. As the PCV is very high in polycythaemia, hence, the patients are more at risk of developing heart attack, stroke and peripheral vascular disease. In true polycythaemia, the patient, in addition to above features, have pruritus (itching)

TABLE 18.3 Differentiation between acute and chronic leucaemias

Feature	Acute leucaemia	Chronic leucaemia
Onset	Acute	Subacute or chronic
Age	Involves young age	Middle or old age
Blood count	Varies in thousands from 50,000 onwards	Varies in lacs from one lac onwards
Immature cells	Mostly blast cells (>25%), involves pleuropotential stem cells (Fig. 18.5)	Mostly mature differentiated cells (myelocytic, metamyelocytic promyelocytic) are involved (Fig. 18.6)
Course	Rapid growth rate	Low growth rate
Clinical presentation	Fever, bleeding, lymphadenopathy or splenomegaly and acute infections. Bone pain and tenderness, gum hypertrophy and DIC also occur	Massive splenomegaly, lymphadenopathy, tissue infiltration, symptoms and signs of anaemia are its presentation. Bone tenderness may or may not be present
Treatment and prognosis	Poor response to treatment, hence, prognosis is few months to 2 years	Response to treatment is good, prognosis is better than acute; varies from few years to many years

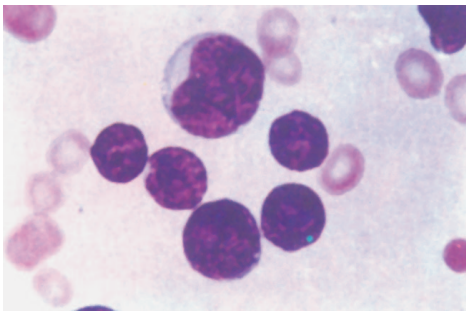


FIGURE 18.5 Acute lymphocytic leukaemia

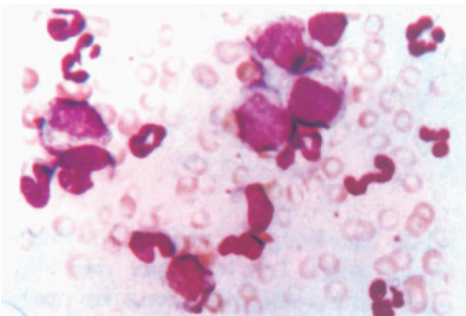


FIGURE 18.6 Chronic myeloid (granulocytic) leukaemia

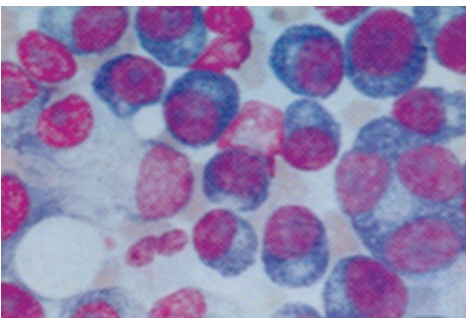


FIGURE 18.7 Multiple myeloma. Bone marrow examination shows cells with characteristic morphologic features of plasma cells (round or oval cells with an eccentric nucleus composed of coarsely clumped chromatin, a density basophilic cytoplasm and a perinuclear clear zone). Binucleate and multinucleate malignant plasma cells are also seen

especially while taking a hot bath, gout due to high red cell turnover and hepatosplenomegaly. Due to high thrombocyte count in true polycythaemia, the patients are at an increased risk of developing thrombotic episodes or paradoxically, a bleeding tendency.

Lymphadenopathy

(Read Examination of Neck Chapter 8)

Examination of lymph nodes at different sites and the causes of enlargement of lymph nodes have already been discussed under examination of neck. Here lymph nodes enlargement secondary to haematological disorders will be discussed. Lymphadenopathy in haematological malignancy is more often painless, generalised, and associated with hepatosplenomegaly and other manifestations of the underlying cause. Weight loss and drenching sweats which may require a change of night clothes are associated with haematological malignancies, particularly lymphoma.

The lymph nodes in lymphatic leukaemia are diffusely enlarged, firm, discrete and painless, involves the cervical, axillary and inguinal regions.
The lymph nodes in Hodgkin's disease are painless, discrete and rubbery in consistency while they are firm in non-Hodgkin's lymphoma. Systemic symptoms, extranodal involvement (bone, brain or skin), compression symptoms, e.g. gut obstruction, ascites, superior vena cava obstruction and spinal cord compression are common in non-Hodgkin's lymphoma.

Splenomegaly or Hepatosplenomegaly

(Read Abdominal Examination Chapter 13)

The spleen is a lymphoreticular organ, is capable of assisting the host in adapting to its hostile environment. It discharges following functions:

- Clearance of bacteria and particulates from the blood.
- The generation of immune response to certain invading pathogens.

TABLE 18.4 Symptoms and signs of myelomatosis

<i>Pathogenic mechanism</i>	<i>Effect</i>	<i>Symptoms and signs</i>
Malignant plasma cell proliferation	<ul style="list-style-type: none"> • Bone erosion • Pathological fractures • Hypercalcaemia • Bone marrow failure 	<ul style="list-style-type: none"> • Bone pain • Severe local pain • Thirst, lethargy, polyuria, weakness, depression, confusion • Tiredness, weakness
Excessive production of paraprotein	<ul style="list-style-type: none"> • Renal damage • Hyperviscosity 	<ul style="list-style-type: none"> • Asymptomatic until uraemia • When severe, produces blurred vision, headache, vertigo, stupor and coma
Reduction in number of normal immunocompetent plasma cells	<ul style="list-style-type: none"> • Immunodeficiency 	<ul style="list-style-type: none"> • Susceptibility to infection especially respiratory and urinary

- Reticuloendothelial activity (destruction of RBCs and other formed elements).
- Extramedullary erythropoiesis when the marrow is unable to meet the needs (e.g. myeloproliferative disorders). This is a recapitulation of the blood forming function the spleen plays during gestation. The spleen gets enlarged when its normal functions are exaggerated. The causes of enlargement of spleen have been discussed in case discussion of Splenomegaly in Bedside Medicine by Prof. SN Chugh.

Clinical Assessment

Symptoms pertaining to splenomegaly

- Abdominal discomfort and dragging sensation due to a mass itself.

Acute enlargement of spleen may produce pain due to stretching of its capsule.

- Back pain and abdominal bloating due to stomach compression.
- Severe abdominal colicky pain radiating to the left shoulder tip, associated with splenic rub due to splenic infarct (perisplenitis), commonly seen in myeloproliferative disorders and sickle cell anaemia.
- Rupture of the spleen, either from trauma or infiltrative disease that breaks the capsule, may result in intraperitoneal bleeding, shock and death. The rupture itself may be painless.

Examination

Normally, the spleen is not palpable. A palpable spleen is the major physical sign that warrants investigations because spleen becomes palpable when it has already enlarged two to three times than normal. It is stressed here that enlarged palpable spleen does not mean a disease because in certain tropical countries like New Guinea, the incidence of asymptomatic splenomegaly in normal population is very high.

The spleen is examined under four heads:

1. **Inspection:** Inspection may reveal a fullness in the left hypochondrium that descends on inspiration, a finding associated with massive splenomegaly (Fig. 18.8).
2. **Palpation:** The spleen can be palpated by bimanual, ballottement method and palpation from above (Middleton manoeuvre). Splenomegaly is just palpable as its tip descends during deep inspiration in right lateral position.
 - Bimanual methods of palpation is as good as other methods. This method has already been described in examination of the abdomen.

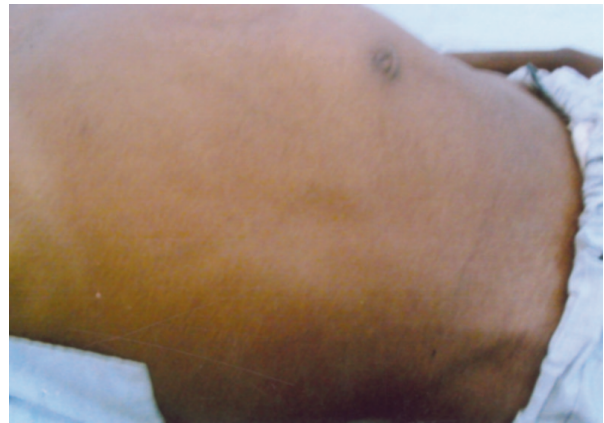

FIGURE 18.8 A visible lump in left hypochondrium in a patient with chronic myeloid leucaemia

3. **Percussion** for splenic dullness (read examination of abdomen).
4. **Auscultation:** A splenic rub may be heard in the splenic area in splenic infarct leading to perisplenitis.

Other Methods of Splenic Detection

On ultrasonography, radionuclide scan, the spleen has a maximum cephalocaudal diameter of 13 cm, the increased diameter indicates splenomegaly.

Bleeding

Bleeding usually results from a breach of the vessel wall due to specific insult (e.g. trauma, peptic ulcer) or from haemostatic failure. The haemostasis is a complex process, involves interactions between vessel wall, platelets and coagulation factors. Haemostatic failure may be *primary* (e.g. due to vessel wall abnormalities, qualitative or quantitative disorders of platelets) or *secondary* (a coagulation defect). Thus, bleeding may result from deficiency of one or more of the coagulation factors, thromboasthenia, thrombocytopenia or occasionally from excessive fibrinolysis which most often arises following therapeutic fibrinolytic therapy with streptokinase or with tissue plasminogen activator (tPA).

Certain elements of the history are particularly useful in determining whether bleeding is caused by an underlying haemostatic disorder or by a local anatomical defect. One clue is a history of bleeding following common haemostatic stresses such as dental extraction, childbirth or minor surgery. A history of recurrent bleeding following each stress suggests a haemostatic defect. It is important to consider the following points on the history:

- **Site of bleed:**
 - Muscle or joint bleeds (haemarthrosis) indicates a coagulation defect.

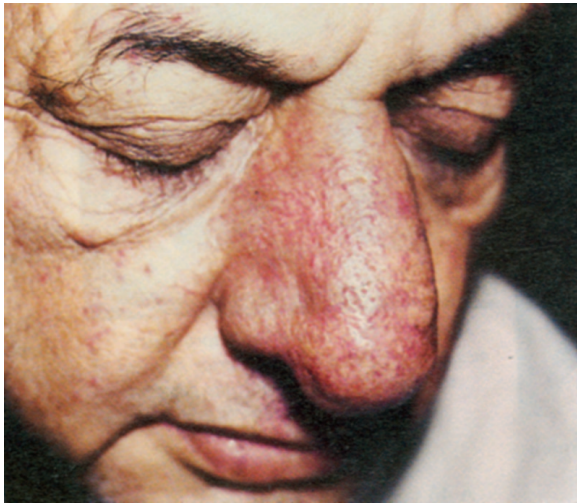

FIGURE 18.9 Osler-Weber-Rendu disease. Note the multiple telangiectasia as red spots due to capillary dilatation. This is also called hereditary haemorrhagic telangiectasia

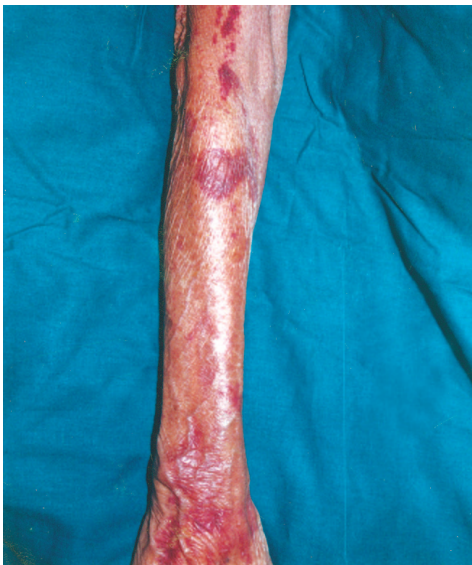

FIGURE 18.10 Senile purpura
(Note the bruising resembling devil's pinches)

- **Duration of history:** It may be possible to assess whether the patient has a congenital or acquired disorder. A long history of bleeding episodes indicate a congenital disorder. Certain congenital conditions, such as haemophilia usually become obvious in early childhood but may be misdiagnosed as non-accidental injury. Milder bleeding disorders may go undetected for long time even upto old age.
 - **Precipitating factors:** Bleeding occurring spontaneously indicate a severe haemostatic defect than bleeding arising only after trauma.
 - **Surgery:** Enquiries should be made about all the operations specifically dental extraction, tonsillectomy and circumcision as these are all stressful tests of haemostatic system. Bleeding that starts immediately after surgery indicates defective platelet plug formation; whereas that comes on after several hours indicates failure of platelet plug stabilisation by fibrin due to a coagulation defect.
 - **Family history:** It is important to question the patient about previous incidents involving excessive bleeding in childhood so as to establish pattern of inheritance. A family history of bleeding indicate both bleeding or coagulation disorder, hence, interview the relatives, if necessary. Since bleeding sometimes can be mild, lack of family history of bleeding does not exclude an inherited haemostatic disorder.
 - **Systemic illness:** Bleeding from multiple sites that cannot be linked to trauma or surgery suggest a systemic disorder. It is particularly important to consider the possibility of hepatic, or renal failure, paraproteinaemia or a connective tissue disorder.
 - **Drugs:** Drugs can produce bleeding either by depressing bone marrow function with consequent thrombocytopenia or by interacting with coagulation factors (warfarin. NSAIDs inhibit platelet function).
 - **Occupation:** Contact with dangerous chemicals may produce thrombocytopenia.
- Purpura, epistaxis, prolonged bleeding from superficial cuts, GI bleed, menorrhagia suggest primary haemostatic failure due to a platelet defect, thrombocytopenia, *von Willebrand's disease*.
- Recurrent bleeding at a single site suggest a local structural abnormality (hereditary haemorrhagic telangiectasia, i.e. Osler-Weber-Rendu disease; Fig. 18.9).
- Spontaneous bruising or following minor trauma resembling devil's pinches in an old person with normal BT, CT indicate senile purpura (Fig. 18.10).

Examination of bleeding site can differentiate platelet defect (primary haemostatic defect) from haemostatic defect (secondary haemostatic failure) as shown in the Table 18.5.

Thrombosis

Arterial and venous thrombosis may be presenting features of hypercoagulable or prethrombotic state. Swelling of one leg or both legs is common due to deep vein thrombosis (DVT). The DVT causes pain, swelling, an increase in temperature and dilatation of superficial veins. The thrombotic disorders are given in the Box 3.

TABLE 18.5 Differentiating features between primary and secondary haemostatic defects

Feature	Defects of primary haemostasis (platelet defect Fig. 18.11)	Defects of secondary haemostasis (secondary haemostatic defect Fig. 18.13)
Onset of bleeding following trauma	Immediate	Delayed for hours or days
Site of bleeding	Superficial, e.g. skin, mucous membrane, nose, GI tract and genitourinary tract	Deep, e.g. joints, muscles, retroperitoneal etc.
Sex of the patient	More common in females	80–90% are males
Physical signs	<ul style="list-style-type: none"> • Purpura—collection of blood in the skin • Patechiae—pinpoint haemorrhages into dermis (Fig. 18.12) • Ecchymosis—large subcutaneous collection of blood (Fig. 18.11) 	<ul style="list-style-type: none"> • Haematomas into muscles • Haemarthrosis (joint swollen, tender due to bleed)
Family history	<ul style="list-style-type: none"> • Autosomal dominant 	<ul style="list-style-type: none"> • Autosomal or X-linked recessive
Response to treatment	<ul style="list-style-type: none"> • Immediate, local measures effective 	<ul style="list-style-type: none"> • Requires sustained systemic therapy

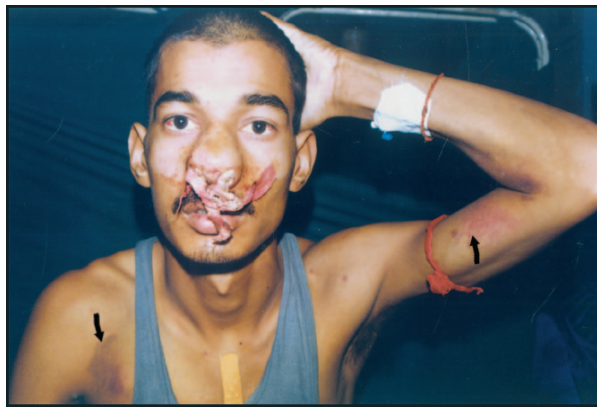

FIGURE 18.11 Thrombocytopenic purpura. Epistaxis is present. Nasal packing is visible. There is an ecchymotic patch over the left forearm (↑) and another on right upper chest (↑)

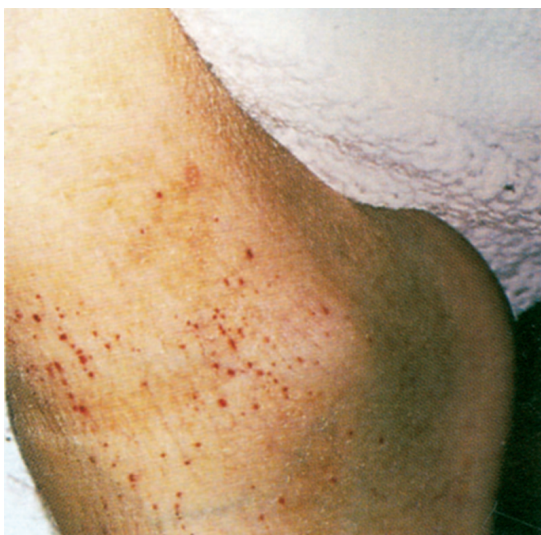

FIGURE 18.12 Petechiae. Skin of the left ankle shows multiple non-palpable, nonblanching purple lesions, all < 1 cm



FIGURE 18.13 Joint swelling (right knee) due haemarthrosis following trivial trauma in young haemophilic

Pancytopenia

Pancytopenia refers to the combination of anaemia, leucopenia and thrombocytopenia.

Pancytopenia with hypocellular or acellular marrow: It is due to reduced production of blood cells as a consequence of bone marrow suppression or infiltration.

Pancytopenia with hypercellular marrow: It is due to peripheral destruction or splenic sequestration of mature cells, seen in hypersplenism.

The patients with pancytopenia present with acute infections, bleeding and signs and symptoms of anaemia.

Box 3

Thrombotic disorders

<i>Inherited</i>	<i>Acquired</i>
<p>A. Defective inhibitors of coagulation factors Antithrombin III deficiency, Protein S and C deficiency, factor V Leiden deficiency</p> <p>B. Impaired clot lysis Dysfibrinogenaemia, plasminogen deficiency and/or tPA deficiency</p> <p>C. Uncertain Homocystinuria</p>	<p>Diseases</p> <ul style="list-style-type: none"> • SLE (lupus anticoagulant) • Malignancy • Myeloproliferative disorders • Thrombotic Thrombocytopenic purpura <p>• Oestrogen treatment</p> <p>• Hyperlipidaemia</p> <p>• Diabetes</p> <p>• Hyperviscosity</p> <p>• Nephrotic syndrome</p> <p>• CHF</p> <p>• Paroxysmal nocturnal haemoglobinuria</p> <p>• Physiologic states</p> <p>• Pregnancy, postpartum</p> <p>• Obesity, old age</p> <p>• Postoperative</p> <p>• Immobilisation</p>

EXAMINATION**General Physical Examination (GPE)**

The points to be examined in a patient with haematological disorder are depicted in Figure (page 469) on front page of the chapter.

1. General appearance

- *Pale looking*—anaemia
- *Plethoric facies*—polycythaemia
- *Mongoloid facies* (thalassaemia), frontal bossing, 'Hair on end' appearance
- *Emaciation*—anaemia, malnutrition, malignancy
- *Puffy face*—hypoproteinaemia

2. Conjunctivae

- *Look for pallor and jaundice*: Suffused conjunctivae are seen in polycythaemia or mediastinal compression

3. The mouth

- *Look for glossitis and angular stomatitis*.

Cracking of the skin at the corner of the mouth (angular cheilosis) is due to iron deficiency anaemia.

- *Look at the tongue and oral mucosa for any abnormality* (see Box 4).

- *Inspect the lips for vesicles, ulceration, cyanosis etc.*

Cold sores (vesiculation of the lips) is seen in herpes simplex infection which is associated with certain blood disorders.

Box 4

Oral manifestations of haematological disorders

<i>Oral lesion</i>	<i>Disease</i>
<ul style="list-style-type: none"> • Gingival hypertrophy, gum bleeding, necrosis, petechiae and ulceration of oral mucosa • Multiple petechiae and ecchymosis • Wide spread ulceration involving gums, buccal mucosa, tongue, pharynx, larynx, palate • Atrophic papillae with red smooth sore tongue • Reddening of oral mucosa and tongue (magenta – coloured) with or without ulceration, swelling • Petechiae in oral mucosa and swollen bleeding gums • Bald tongue (atrophy or loss of papillae) • Cyanosis of lips and tongue • White patches (mouth thrush) 	<ul style="list-style-type: none"> • All types of leucaemias especially acute monocytic type (Fig. 18.14) • Thrombocytopenias due to any cause • Agranulocytosis, leucopenia (neutropenia Fig. 18.4) • Iron deficiency combined with vitamin B complex deficiency • Vitamin B complex deficiency (see Fig. 6.10) • Scurvy • Pernicious anaemia, iron deficiency (see Fig. 6.9) and pellagra • Methaemoglobinaemia • Oral candidiasis (see Fig. 6.6). It is seen in blood disorders

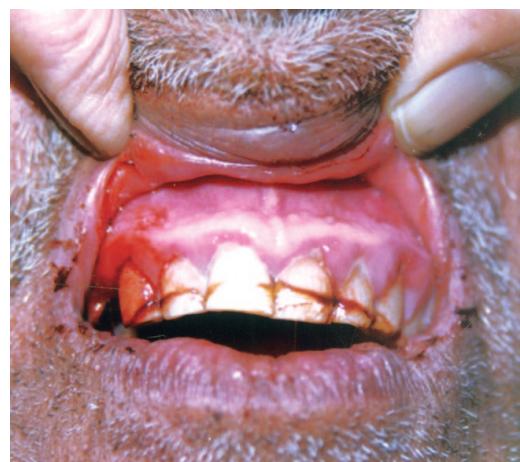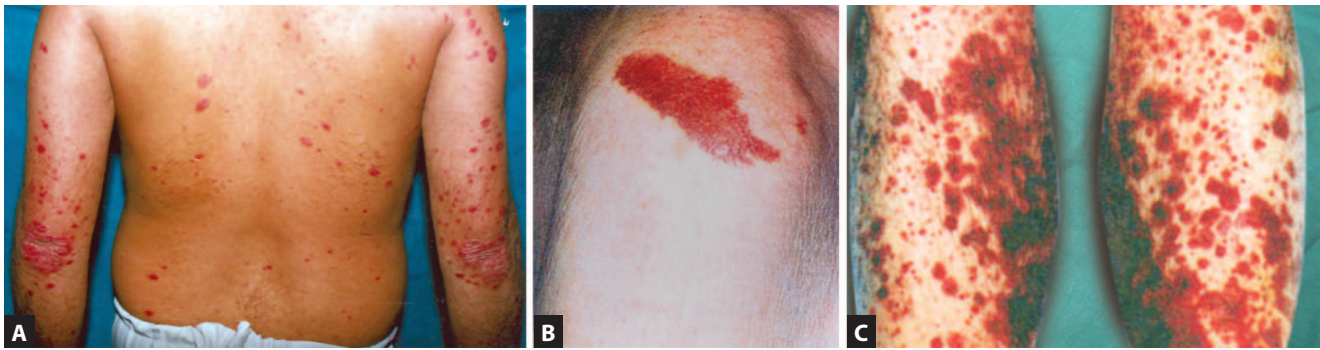


FIGURE 18.14 Bleeding gums in a patient with acute leukaemia

4. The skin

The skin surface may be infected, ulcerated or infiltrated by tumour (leukaemia, lymphoma) but the effect of haemorrhage is important.

- *Look at the skin and subcutaneous tissue for bleeding*.



FIGURES 18.15A to C Idiopathic thrombocytopenia: (A) Visible purpura due to thrombocytopenia. Note the pin head size spots on the back of upper limbs and trunk; (B) Larger purpuric spot or ecchymotic patch. There is a large nonpalpable nonblanching purple patch of haemorrhage on the skin of right shoulder; (C) Palpable purpura. Skin of the lower extremities, reveals quite advanced and confluent purpuric spots in a patient with vasculitis

The bleeding points are classified as follows:

- i. Purpura (Fig. 18.15A) and petechial haemorrhages**—tiny pinpoint haemorrhages into the skin which do not blanch on compression with a glass slide.
- ii. Ecchymotic patches** are larger haemorrhages than petechiae (Fig. 18.15B).
- iii. Bruises** are larger areas of haemorrhages resulting as a result of confluent deposition of blood, often multicoloured in appearance as the bruise resolves.

Purpuric spots, petechial haemorrhages, ecchymotic patches and bruises indicate a bleeding disorder due to platelet dysfunction.

Thrombocytopenic purpura is prominent in dependent areas most commonly on the front of lower legs but may be seen anywhere on the skin and in ocular fundi.

Henoch-Schönlein purpura (anaphylactoid purpura) on the other hand is distributed over the backs of the legs and the buttocks. It is due to circulating immune complexes.

Bruises often have no haematological significance but if they are large, extensive with an obvious firm haematoma beneath them, then they may indicate a coagulation defect.

- iv. Telangiectasias (Fig. 18.16)** are small dilated blood vessels which may be visible on the skin surface particularly the lips. They blanch on pressure.
- v. Vasculitis:** It is a clinicopathological entity characterised by inflammation and damage to blood vessels of various organs including skin. Skin lesions in vasculitis may be in the form of a rash (papulovesicular) or palpable purpura (Fig. 18.15C), ulcers or subcutaneous nodules.

Telangiectasia and vasculitis are not blood disorders, indicate vessel wall abnormalities but are important because sometimes they may be a source of severe haemorrhage.

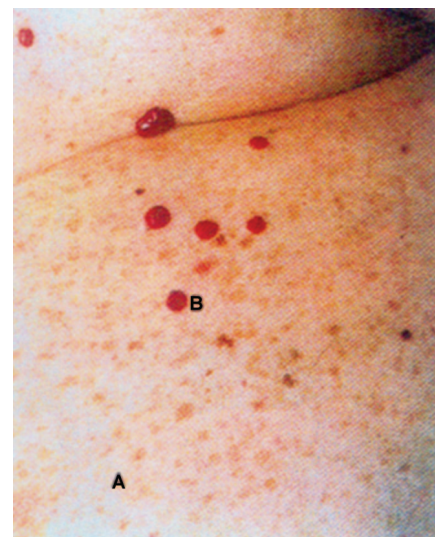


FIGURE 18.16 Telangiectasia: A. Macules—freckles and B. Papules—telangiectasia on the skin of the right upper chest

- Note the colour of the skin, pigmentation and depigmentation.

- Bright red skin (*Phomme rouge*) may be seen in dermatitis, sometimes associated with lymphoma.
- Dusky pigmentation (deposition of iron and melanin) is seen in haemochromatosis and haemosiderosis.
- Dark pigmentation of the skin of the legs is seen in varicosity of veins with eczema.
- Patchy depigmentation (vitiligo) is a feature of pernicious anaemia but often has no clinical significance.

5. Ocular fundi

Examine the fundus

Fundal haemorrhages are often visible in:

- Thrombocytopenia
- Hyperviscosity syndrome due to macroglobulinaemia and promyelocytic leukaemia. Papilloedema may also be present.

6. The muscle and joints

Examine the muscles and joints for swelling and tenderness.

Bleeding into the muscles (intramuscular haematoma) or in between muscles and into the joints (haemarthrosis) indicate a coagulation disorder. The muscles and joints involved are swollen, hot and tender.

7. The lymph nodes (Read chapter 8)

The lymph nodes in a patient suspected of a lympho-reticular disorder must be examined as a whole not in isolation. *Note the following points on the lymph node examination:*

- Size and the group involved (location)
- Consistency (soft, firm, hard, rubbery)
- Are they discrete or matted or confluent?
- Are they mobile or fixed to the underlying or overlying structure
- Are they tender or non-tender?

Under normal conditions in adults, the inguinal lymph nodes may be palpable, 0.5 to 2.0 cm in size, hence, large lymph nodes >2 cm in diameter are considered as abnormal. Smaller lymph nodes elsewhere may be palpable due to past infection. Therefore, new lymph nodes enlargement more than 1 cm in size anywhere except in inguinal region is considered as abnormal and needs further evaluation.

Causes, differential diagnosis and associated features in lymphadenopathy have been discussed in case discussion of Lymphadenopathy in Bedside Medicine by Prof. SN Chugh.

The method of palpation of various groups of lymph nodes has been described in Examination of Neck Chapter 8.

Abdominal Examination

Abdomen should be examined for:

- Liver enlargement (read Palpation of Liver in Chapter 13).
- Spleen enlargement (Read Chapter 13).
- Para-aortic lymph node. They are difficult to palpate unless patient has thin abdomen or lymph nodes are sufficiently large.

NB: The thoracic lymph node cannot be palpated at all. Their enlargement is suspected when there are symptoms and signs of mediastinal compression. They are detected on X-ray or CT scan of chest.

The Anus

The anus should be examined because it is lined by mucosa which is vulnerable to infection, ulceration and bleeding similar to oral mucosa in patients with leucopenia, pancytopenia or agranulocytosis.

INVESTIGATIONS FOR A HAEMATOLOGICAL CASE

Blood Count

This test is very popular and most frequently used by the physicians and is done in their side laboratory by automatic analyser. Anticoagulated blood is processed for this purpose. A variety of techniques are used to measure haemoglobin, red cells count, to estimate haematocrit and to measure red cell indices. Total and differential white cells count is also performed. An automatic analyser has the ability to provide full differential count. A platelet count is also done. It is simple but rich in providing information. The reference values for common haematological parameters in adults are given in Table 18.6.

Peripheral Blood Film (PBF) Examination

Most of the information provided by the peripheral blood examination can be obtained from modern full blood count (Table 18.6). The PBF examination (Fig. 18.17) renders useful information regarding the type of anaemia, bone marrow response (reticulocytosis) and abnormal WBCs such as premature cells (blast cells or others) or abnormality of RBCs shape (spherocytes, elliptocytes, sickle cells) and contents (Howell-Jolly bodies, basophil stippling, malarial parasite (Figs 18.18A and B) and autoagglutination of RBCs (Fig. 18.19).

TABLE 18.6 Reference range of haematological parameters

Hb g/dL	11.5–16.5 (female)	13.0–18.0 (male)
RBC $\times 10^9/L$	3.8–5.8 (female)	4.5–6.5 (male)
ESR in mm 1st hour	0.7 (female)	0–5 (male)
MCV (fl)	78–98	
MCH (pg)	27–32	
MCHC (g/dL)	30–36	
Platelets $\times 10^9/L$	150–400	
WBC $\times 10^9/L$	4.0–11.0	
PCV	0.37–0.47 (female)	0.40–0.54 (male)
Differential leucocyte count (DLC)		
Neutrophils	2000–7500 $\times 10^6/L$	(40–75%)
Lymphocytes	1500–4000 $\times 10^6/L$	(20–50%)
Monocytes	200–800 $\times 10^6/L$	(2–10%)
Eosinophils	40–400 $\times 10^6/L$	(1–6%)
Basophils	10–100 $\times 10^6/L$	(<1.0%)
Reticulocyte count	10–100 $\times 10^9/L$	(0.5–2.5%) of red cells
Serum ferritin	14–150 $\mu g/L$ (in females)	17–300 $\mu g/L$ (in males)
Red cell mass	20–30 mL/kg (females) 65 mL/kg (female)	23–35 mL/kg (males)
Blood volume	1.5–20.6 $\mu g/L$	70 mL/kg (male)
Serum folate	95–570 $\mu g/L$	
RBC folate	130–770 pg/mL	
Serum vitamin B ₁₂		

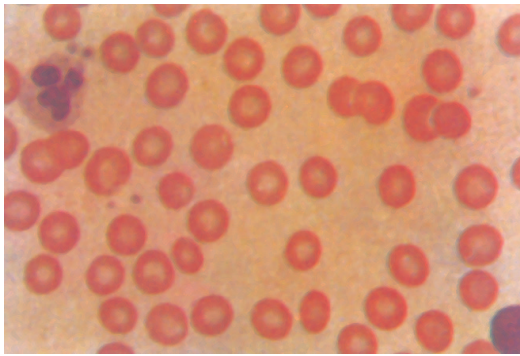
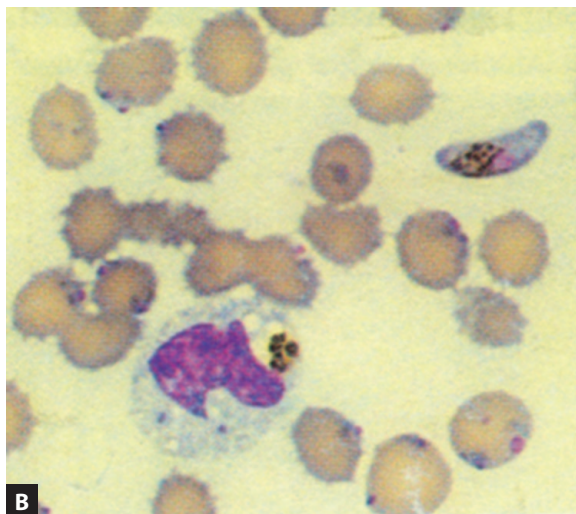
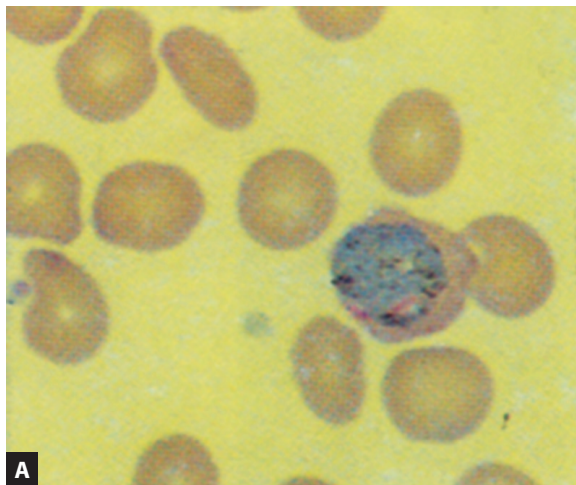


FIGURE 18.17 Normal peripheral blood film



FIGURES 18.18A and B Peripheral blood smear showing malarial parasite in different stages

The terms used for peripheral blood film examination are given in Table 18.7.

Bone Marrow Examination

The bone marrow is obtained either by aspiration of marrow or by trephine biopsy from sternum or posterior iliac

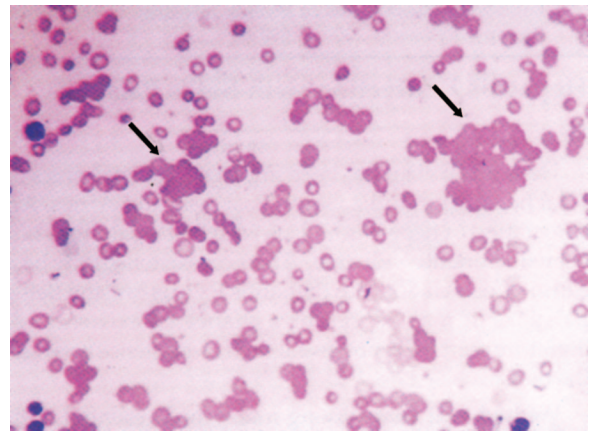


FIGURE 18.19 Peripheral blood smear showing autoagglutination of red blood cells (arrows) in autoimmune haemolytic anaemia

crest. Marrow is examined not only for its morphological appearances but for cell marker studies, karyotyping and molecular biological studies are performed for accurate diagnosis and assessment of malignant diseases.

The marrow film provides assessment of cellularity, details of developing blood cells. The indication of bone marrow are given in the Box 5. The bone marrow gives information regarding cells (i.e. normoblasts or megaloblasts, myeloid, lymphoid, macrophages and megakaryocytes), ratio between erythroid and myeloid cells, assessment of iron stores and ring sideroblasts (Fig. 18.22), storage diseases and for the presence of marrow infiltration by secondary carcinoma, granulomatous conditions, fungi (e.g. histoplasmosis) and parasites (e.g. malaria, leishmania, trypanosomiasis). Marrow can also be sent for culture in cases of suspected tuberculosis or typhoid fever.

Coagulation Profile

A. Coagulation pathways: The coagulation cascade (mechanism) is activated in two ways and there is also a common pathway of activation (Fig. 18.23).

I. *Intrinsic (blood) pathway:* This is activated by contact with collagen of exposed endothelial surface, that leads to activation of factor XII and the sequential activation of factors XI, IX, VIII and finally activate the factors in the common pathway.

II. *Extrinsic (tissue) pathway:* Tissue damage results in the release of a tissue factor or thromboplastin. Tissue factor on interaction with factor VII activates factor X of common pathway.

III. *Common pathway:* It begins when both intrinsic and extrinsic pathways converge to activate the factor X which forms a complex with factor Va and platelet factor 3 in the presence of calcium. This complex activates prothrombin (factor II) to thrombin (IIa)

TABLE 18.7 Meaning of the terms used to describe abnormal peripheral blood film examination and their significance

Term	Description	Significance
<i>Microcytosis</i>	The average size and mean cell volume (MCV) of red cells is reduced	<ul style="list-style-type: none"> • Found in iron deficiency anaemia • Sideroblastic anaemia • Thalassemia
<i>Macrocytosis</i>	The average size of red cells is greater than normal. MCV will be increased	<ul style="list-style-type: none"> • Macrocytic anaemias • Megaloblastic anaemias
<i>Hypochromia</i>	Red cells have less than normal amount of haemoglobin and show central pallor. Mean corpuscular haemoglobin concentration (MCHC) is below normal	<ul style="list-style-type: none"> • Microcytosis and hypochromia are commonly associated, hence causes are same as for microcytosis
<i>Anisocytosis</i>	Variation in size of red cells	<ul style="list-style-type: none"> • Found in many forms of anaemia • Prominent in megaloblastic anaemia
<i>Poikilocytosis</i>	Variation in the shape of red cells	<ul style="list-style-type: none"> • It is always present with anisocytosis, reflects dyserythropoiesis
<i>Elliptocytosis or ovalocytosis</i>	Elliptical red cells or oval red cells	<ul style="list-style-type: none"> • Megaloblastic anaemias • Iron deficiency anaemia • As a hereditary disorder (dominant type), does not have significance
<i>Target cells</i>	These are red cells which are flat, have a central mass of haemoglobin surrounded by an inner ring of pallor and outer ring of again haemoglobin	<ul style="list-style-type: none"> • Liver disease • After splenectomy • Haemoglobinopathies
<i>Polychromasia and reticulocytosis</i>	Young red cells with basophilic cytoplasm; are seen in large number with normal pink coloured red cells	<ul style="list-style-type: none"> • Accelerated erythropoiesis
<i>Howell-Jolly bodies</i>	Nuclear remnants left in red cells after nucleus is extruded	<ul style="list-style-type: none"> • Absent spleen • Megaloblastic anaemias
<i>Punctate basophilia (basophilic stippling)</i>	Damaged young red cells with scattered blue dots in cytoplasm	<ul style="list-style-type: none"> • Severe anaemia • Chronic lead poisoning • Beta-thalassaemia
<i>Nucleated red cells (normoblastosis)</i>	Large number of normoblasts (early, intermediate, late) found in blood	<ul style="list-style-type: none"> • Accelerated erythropoiesis • Leucaemias • Infiltration by a secondary tumor
<i>Leucoerythroblastosis</i>	Primitive erythroblasts and granulocytes present in blood film	<ul style="list-style-type: none"> • Malignant infiltration of marrow • Myelofibrosis • Reactionary-secondary to excessive blood loss or haemolysis

Box 5

Chief indications for bone marrow examination

- | | |
|--|---|
| <ul style="list-style-type: none"> • Infiltrative disorders <ul style="list-style-type: none"> – Leucaemias – Lymphomas – Myelofibrosis (Fig. 18.20) • Parasitic diseases <ul style="list-style-type: none"> – Leishmania (Fig. 18.21) – Malaria – Trypanosomiasis | <ul style="list-style-type: none"> • Cytopenic disorders <ul style="list-style-type: none"> – Neutropenia – Thrombocytopenia – Anaemias – Pancytopenia • Infection disorder <ul style="list-style-type: none"> – Suspected tuberculosis – Suspected typhoid |
|--|---|

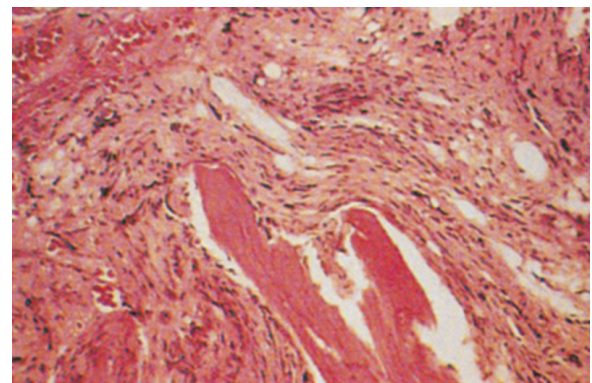


FIGURE 18.20 Myelofibrosis. Bone marrow section shows the replacement of marrow cavity with fibrosis in a patient with myelofibrosis. When this fibrosis is due to primary haematological process, it is termed as *myelofibrosis*; while fibrosis secondary to a tumour or a granulomatous process, it is termed as *myelophthisis*

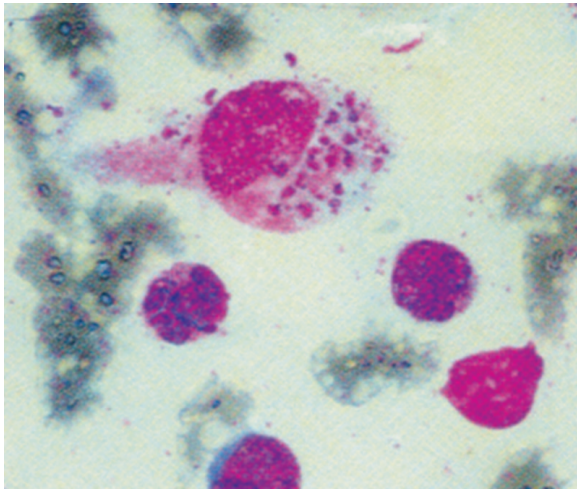


FIGURE 18.21 Bone marrow examination shows a histiocyte loaded with *Leishmania donovani* bodies in the cytoplasm

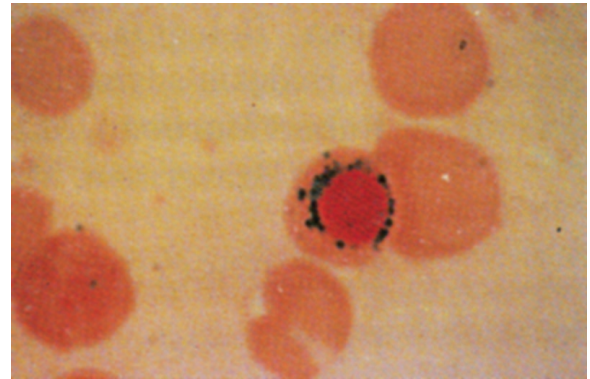


FIGURE 18.22 Ringed sideroblast. The bone marrow (Prussian blue stain) shows an orthochromatic normoblast with a collar of blue granules surrounding the nucleus. The blue granules represent iron-laden mitochondria. The presence of ring sideroblast indicates sideroblastic anaemia or myelodysplastic syndrome (refractory anaemia with ring sideroblasts)

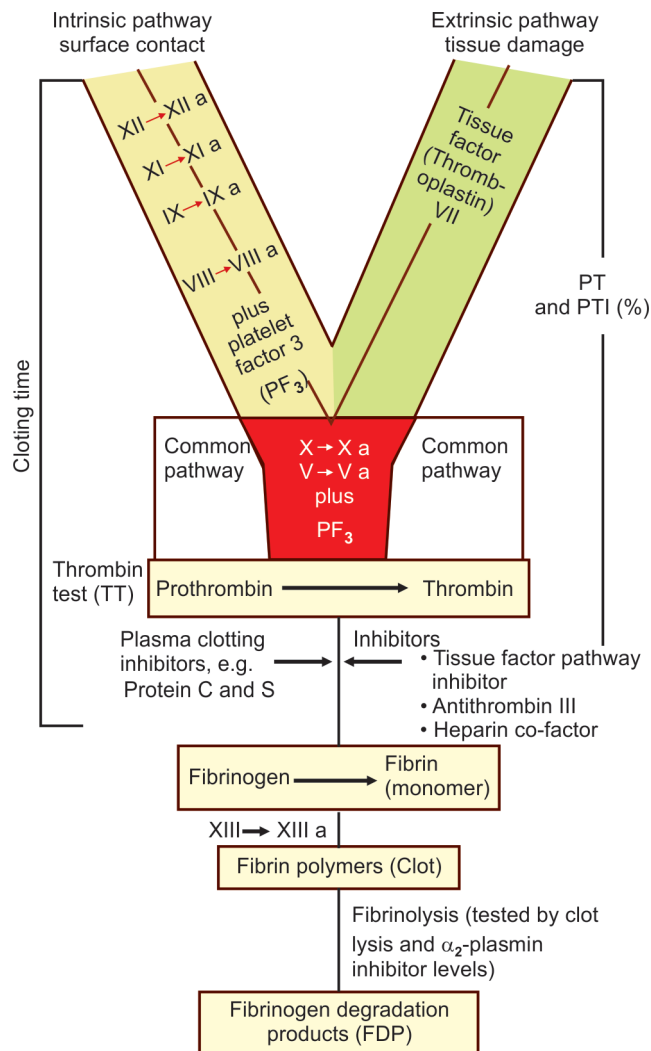


FIGURE 18.23 A schematic representation of coagulation cascade

which, in turn, converts fibrinogen into fibrin (monomer). The monomer fibrin polymerises to form insoluble fibrin under the activation of factor XIII.

Deficiency of one or more coagulation factors result in bleeding diathesis. The deficiency may be congenital or acquired. Haemophilia is an example of coagulation disorders. The test to be done in a case with bleeding are given in the Table 18.8.

B. Fibrinolytic system: Fibrinolysis is a process of dissolution of fibrin clot (haemostatic plug) and thrombus by activating tissue thromboplasminogen activator released from the endothelial cells. This converts fibrin bound plasminogen into plasmin which hydrolyses the fibrin into fibrin degradation products (FDP). The FDP themselves are weak anticoagulants and their detection in high concentration forms a diagnostic test for abnormal fibrinolysis.

Laboratory Diagnosis of Bleeding Disorder

Presumptive diagnosis based on the laboratory tests is depicted in the Table 18.9.

6. Specific tests for a patient with leucaemias and multiple myeloma: The laboratory findings of acute leucaemia are given in the Box 6.

Investigations for a patient with chronic leucaemia are given in Box 7.

Investigations for multiple myeloma are given in Box 8.

Inhibitor Syndromes or Circulating Anticoagulants

These are antibodies that impair coagulation activity and may infrequently cause bleeding. Inhibitors are likely when screening test abnormalities (prolonged PT and PTT) cannot be reversed by adding normal plasma to the patient plasma. Antibodies to specific coagulation factor may develop in postpartum women, patients with autoimmune diseases (SLE), patients taking drugs, e.g. penicillin, streptomycin and healthy old persons. Haemophiliacs who have received multiple blood transfusions may also develop them. Patients with such anticoagulants as lupus-like anticoagulant manifest as anticardiolipin antibody syndrome characterised by increased risk of thromboembolism rather than bleeding.

TABLE 18.8 Tests for assessment of a case with bleeding

Investigation	Result	Normal range	Bleeding disorder
Platelet count	↓	1,50,000–400,000 per cubic millimeter	• Thrombocytopenia (congenital or acquired)
Bleeding time (BT)	↑	2–7 min (dry method)	• Thrombocytopenia • Thrombopathy (aspirin, von Willebrand's disease)
Prothrombin time (PT) <i>It screens the extrinsic (tissue) pathway of coagulation</i>	↑	12–14 seconds	• Deficiency of factors II, V, VII, X • Liver disease • Anticoagulant therapy • Disseminated intravascular coagulation (DIC)
Activated partial thromboplastin time (PTTK). <i>It screens the intrinsic pathway</i>	↑	30–40 seconds	• Deficiency of factors II, V, VIII, IX, X, XI, XII • Haemophilia A and B • von-Willebrand's disease • DIC
Thrombin time (TT)	↑	About 12 seconds	• Hypofibrinogenaemia, afibrogenaemia • Dysfibrinogenaemia
Fibrinogen	↓	1.5–4.0 g/L	• Hypofibrinogenaemia
FDP	↑	<2.5 mg/L	DIC

Note: Correction tests are used to differentiate prolonged times in PT, PTTK and TT due to coagulation factor deficiencies and inhibitors of coagulation. Prolonged PT, PTTK or TT due to coagulation factor deficiencies are corrected by addition of normal plasma to the patient's plasma, while no correction occurs in case of an inhibitor(s) of coagulation being present

↑ means increased; ↓ means decreased

TABLE 18.9 Differential diagnosis of bleeding disorders

Platelets	Bleeding time	Clotting time	PT	aPTT	TT	Presumptive diagnosis
N	N	↑	N	↑	N	Factor VIII, IX or rarely factor XI, XII deficiency, lupus anticoagulants, acquired factor inhibitors
N	↑	Variable↑	N	↑	N	von Willebrand's factor inhibitors
N	N	Variable↑	↑	↑	N	Deficiency of factor II, V, X, Vitamin K deficiency, liver disease, warfarin therapy
N	N	N	↑	N	N	Deficiency of factor VII
N	↑	↑	↑	↑	↑	Fibrinogen disorder (e.g. afibrinogenemia/hypofibrinogenemia)
N	N	N	N	N	N	With clinical evidence of bleeding; factor XIII deficiency or mild coagulation defect
N	↑	N	N	N	N	Platelet function (adhesion or aggregation) defect, Glanzmann's thrombasthenia
↓	↑	N	N	N	N	Thrombocytopenia, platelet factor defect, Bernard-Soulier syndrome, Wiscott-Aldrich syndrome
↓	↑	↑	↑	↑	↑	Liver disease, DIC

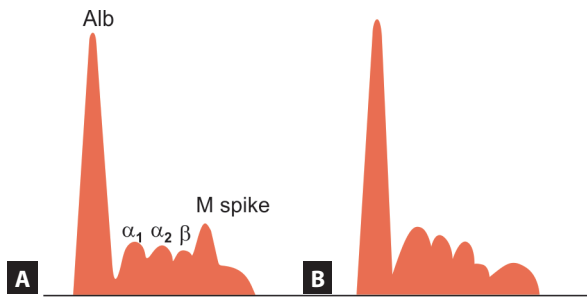
N—Normal, ↑—increased, ↓—decreased

Box 6

Laboratory findings in acute leukaemias

- **Haemoglobin**—Low.
- **Platelet count**—Low.
- **WBC count**—Markedly high (50,000–1,00,000 etc.).
- **Reticulocyte count**—High.
- **Blood film** shows large number of blast cells.
- **Bone marrow examination** shows hypercellularity with leukaemic blast cells (>30% of cells). The presence of Auer rods in the cytoplasm of blast cells indicate myeloblastic leukaemia. Erythropoietic and megakaryotic cells are reduced.
- **Cytochemical stains** differentiate different types of cells, i.e. myeloperoxidase and sudan black stains give positive reaction with myeloid series of cells.
- **Immunophenotyping**: The recent development of monoclonal antibodies as well as advances in flow cytometry have made immunophenotyping easy. It is useful to define definite lineage (B cell vs T cells), helps to differentiate acute leukaemia from other non-haematological disorders.
- **Chromosomal abnormalities**: Three major techniques of molecular analysis such as Southern blot analysis (commonly used), the PCR and fluorescent *in situ* hybridisation demonstrate chromosomal abnormalities in acute leukaemia.
- **LDH, uric acid and alkaline phosphatase** levels are elevated in acute leukaemia indicating rapid turnover of the cells.
- **Coagulation profile**: DIC may be seen in acute promyelocytic leukaemia (M₃)
- **CSF examination** is mandatory in all patients of ALL to evaluate CNS involvement at presentation and during follow-up
- **X-ray chest** for any mediastinal mass which may be seen in T-Cell ALL.
- **Renal functions**, e.g. urea and creatinine.

NB: Some patients present with pancytopenia and have a few blast cells in peripheral blood (subleukaemic leukaemia) or no blast cell (aleukaemic leukaemia). Both these conditions now-a-days are included under myelodysplastic syndromes.



FIGURES 18.24A and B Serum protein electrophoresis: (A) There is 'M' spike in beta-gamma interzone indicating multiple myeloma (monoclonal gammopathy); (B) A control for normal reference

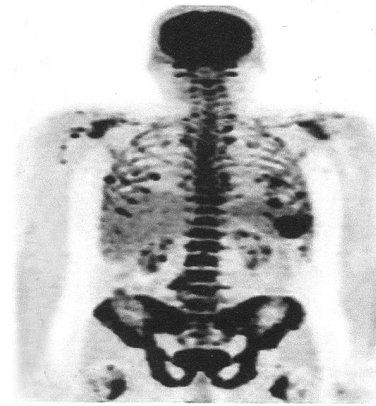


FIGURE 18.25 Bone scan showing multiple lytic lesions

Investigations for a patient with chronic leucaemia (Box 7)

Box 7

Laboratory findings in chronic leucaemias

- **Haemoglobin** is low. There is normocytic normochromic anaemia.
- **WBC count** is high usually more than a lac, but varies greatly from 50,000/ μ L to many lacs.
- **Platelet count** is high initially but becomes low later on. It is low during acute blastic crisis in chronic leucaemia.
- **Peripheral blood film examination:** In CML there is full range of granulocyte precursors (promyelocytes, myelocytes and metamyelocytes >30% and myeloblasts < 10% indicate CML). There is increase in eosinophil and basophil counts. Blast cells >30% indicate blastic crisis. In CLL, there is lymphocytosis with atypical lymphocytes.
- **Bone marrow:** It is done for cytogenetic studies [Philadelphia (Ph⁺) chromosome]. The Ph⁺ chromosome is present in 90% cases of CML. DNA analysis is done to demonstrate the presence of *Chimeric Abelson*—BCR gene in CML.
- **Other investigations**
 - Neutrophil alkaline phosphatase
 - Low in CML
 - Plasma Vitamin B12 levels
 - High in CML
 - LDH levels
 - Elevated in CML

Investigations for multiple myeloma (Box 8)

Box 8

Investigations for multiple myeloma

- **Full blood counts and reticulocyte count** to determine the degree of bone marrow failure:
 - Hb normal or low
 - WBC count normal or low
 - Platelets normal or low
 - ESR almost always high.
- **Blood film** shows normocytic normochromic anaemia and plasmablast and plasma cells. There may be rouleaux formation.
- **Urea and electrolytes, creatinine, urate.** Their levels are elevated in presence of renal failure.
- **Serum calcium** is usually raised but can be normal.
- **Serum alkaline phosphatase**—usually normal.
- **Total serum protein**—normal or raised.
- **Serum albumin**—normal or low.
- **Serum β_2 -microglobulin** is increased and acts a single most prognostic indicator.
- **Protein electrophoresis** shows a monoclonal band (Fig. 18.24)
- **Immunoelectrophoresis** will reveal nature of immunoglobulin (e.g. IgG, IgA etc.) production.
- **Serum M components** (IgM, IgG, IgA) is usually >3 g/dL.
- **Skeletal survey**, e.g. X-ray of bones may show characteristic lytic lesions, most easily seen in the skull and bone scan. Pathological fractures may be seen. CT scan, MRI and PET are used to diagnose plasmacytomas.
- **Blood viscosity**—normal or increased.
- **Urine is positive** for Bence-Jones protein (light-chain excretion) in one-third cases.
- **Bone marrow aspirate** (Fig. 18.25) shows characteristic infiltration by plasma cells (>10%). Amyloid may be found.

19

CHAPTER

The Psychiatric Assessment

HISTORY

Symptoms and Signs

- Headache, dizziness
- Vomiting, functional dyspepsia (nonulcer dyspepsia), irritable bowel syndrome
- Dyspnoea, hyperventilation
- Atypical chest pain, palpitations
- Tinnitus, vertigo
- Low back pain, myalgia,
- Chronic fatigue
- Fibromyalgia
- Associated with psychiatric symptoms, e.g. anxiety, depression, irritability, abnormal behaviour, sleep disturbance, etc.

History of Present Illness

Detailed history of present complaints.

Past Medical History and Psychiatric History

- History of diabetes, thyroid and adrenal disorders, cancer, epilepsy
- Neurological or surgical illness head injury.

Family History

For example plotting of family tree, socioeconomic status, and history of any psychiatric illness in the family.

Personal History

- Alcoholism
- Menstrual and obstetric history
- Developmental history, e.g. developmental milestones



General observations

- Appearance, behaviour, dress and cloths, facial expression, grooming, personal hygiene
- Drug/substance abuse

The Psychiatric Assessment

PHYSICAL AND PSYCHOLOGICAL EXAMINATION

- **Mental status examination**
 - General appearance and behaviour
 - Speech
 - Mood and affect
 - Thought
 - Perception and abnormal beliefs
 - Cognition
 - Insight
 - Judgement
- **Cognition (neuropsychiatry) assessment**
 - Consciousness
 - Orientation
 - Attention and calculation
 - Registration and recall
 - Language
 - Memory
- **Psychological tests**
 - Objective tests, e.g. personality and intelligence tests
 - Projective tests
 - Neuropsychological tests
 - Diagnostic psychological tests
 - Rating scales.

Investigations

- Medical screen
- Toxicological screen/levels
- Electrophysiological tests
- Imaging studies
- Neuroendocrine studies.

THE PSYCHIATRIC ASSESSMENT

The prevalence of psychiatric illness in our society is so high that every doctor must be able to carry out a psychiatric assessment. Familiarity with the technique of psychiatric assessment is important not only for the psychiatrist but also for a medical specialist or practitioner, since a large percentage (more than one-third) of medical patients have psychiatric disorders.

Medically Unexplained Symptoms and their Clinical Presentations

Some physical symptoms cannot be explained when one does not find a definite physical disease as a cause, one labels them as medically unexplained symptoms. These are most common and often most frustrating to the primary care physicians. Typically, these symptoms are chronic in duration and many of them may pertain to different organ systems. The patients with common medically unexplained symptoms without physical signs presenting to different specialties are given in the Box 1. Patients with these symptoms must be subjected to various investigations before labelling them as psychiatric symptoms.

In some patients, the physical or psychiatry illness may coexist or there may be a direct casual relationship between the two (Table 19.1), for example, a depressed patient may take overdose of a drug or the elderly man develop confusional state in postoperative period. Sometimes, the physical and psychiatric illness are unrelated, i.e. a schizophrenic patient with a brain tumour. Lastly, each patient's reaction to illness will be influenced by their emotional state and it will affect the course of the disease. As the diagnosis and treatment of psychiatric disorder is mainly based on psychiatric assessment only, hence, detailed history and psychiatric examination are essential.

- A consistent scheme should be used each time for recording the interview, although the interview need not follow fixed and rigid method.
- Whenever possible, the patient should be seen first. When the account of present (or past) history given by the patient and the attendants is different, record both of them.
- During the interview, the patient should be put at ease and in a warm environment.
- In psychiatric assessment, history taking and mental status examination should not be always conducted separately (although, they may be recorded separately). During the history taking session, the interviewer must observe the abnormalities in verbal and non-verbal communication and make a note of them.

Box 1

Common unexplained symptoms without underlying organic cause

Symptom	Specialty
• Headache, dizziness	Neurology
• Vomiting, irritable bowel functional dyspepsia	Gastroenterology
• Dyspnoea, hyperventilation	Pulmonology
• Atypical chest pain, palpitations	Cardiology
• Tinnitus	Otorhinolaryngology
• Low backache	Orthopedic
• Pelvic pain, premenstrual tension, vaginal discharge	Obstetric and gynaecology
• Chronic fatigue	Internal medicine
• Fibromyalgia	Rheumatology

TABLE 19.1 Psychiatric symptoms commonly associated with physical illness

Symptom	Physical illness
Anxiety	Hyperthyroidism, phaeochromocytoma, hypoglycaemia, seizures, alcohol abuse and withdrawal
Depression	Diabetes, infections, cancer, thyroid disorders, adrenal disorders, neurological disorder (Fig.19.1)
Irritability	Head injury, premenstrual tension, hypoglycaemia
Fatigue	Anaemia, sleep disorders, cancer, infections
Behaviour disturbance	Epilepsy, toxic states, dementia porphyria
Sleep disturbance	CNS disorders (e.g. degenerative disorder), COPD, sleep apnoea syndrome, left-heart failure, gastroesophageal reflux disease etc.

- It is helpful to record the patient's responses *verbatim* rather than naming them (e.g. rather than writing delusion of persecution, it is better to write verbatim, "my brother and my nephew are trying to poison me with arsenic"). It is best done in the patient's own spoken language, wherever possible.
- It is useful to ask open-ended and non-directive questions (e.g. how are you feeling today?) rather than asking direct leading questions (e.g. are you feeling sad at present?).
- The most important interview skill is listening and showing that you are interested in listening. Remember, listening is an active, and not a passive, process.

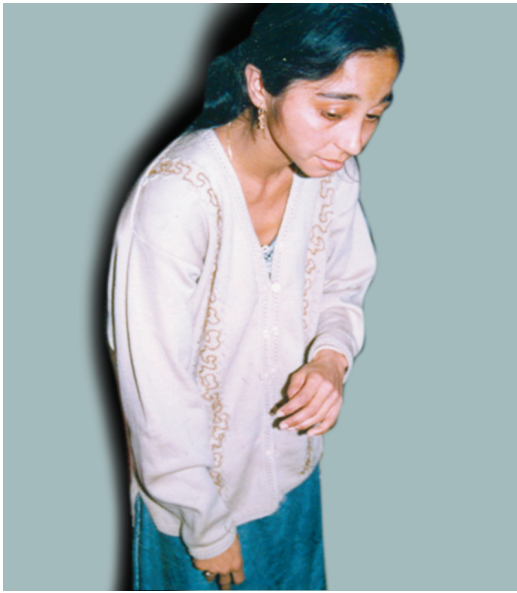

FIGURE 19.1 Depression due to physical illness. Note the depressed mood and facial expression

- Confidentiality must always be maintained. However, in cases of suicidal/homicidal risk and child abuse, an exception may follow.

A complete psychiatric interview may often require more than one session.

The psychiatric assessment can be discussed under the following headings:

Psychiatric History

It consists of:

- Reason for referral
- Presenting/chief complaints
- History of present illness
- Past medical history and psychiatric history
- Family history
- Personal history
 - Childhood
 - Schooling
 - Occupation
 - Psychosexual and marital experience
 - Drugs and substance abuse
 - Premorbid personality
 - Social circumstances.

General Information

It is best to start the interview by obtaining general information, i.e. name (including aliases and pet name), age, sex, marital status, education, occupation, income, residential and office address(es), religions and socio-economic

background. It is useful also to record the source of referral of the patient. In medicolegal cases, in addition, two identification marks should also be recorded.

Second Hand Information

Since sometimes the history, provided by a psychiatric patient may be incomplete, due to factors like confusion, absent insight or uncooperativeness, it is important to take the history from the patient's relatives or friends who are acting as informers.

Their identification data should be recorded along with their relationship to the patient, whether they stay with the patient or not, and the duration of stay together.

Finally, a comment should be made regarding the reliability of the information provided. The parameters of reliability are:

- Relationship with patient
- Intellectual and observational ability
- Familiarity with the patient and length of stay with the patient
- Degree of concern regarding the patient.

The source of referral may also provide valuable information regarding the patient's condition.

Presenting/Chief Complaints

Presenting complaints and/or reasons for consultation should be recorded. Both the patient's and the informant's or attendant's version should be recorded separately. If the patient says that he has no complaints, this should also be recorded.

Use the patient's own words and note the duration of each presenting complaint in chronological order.

THE HISTORY

History of Present Illness

Ask the followings:

- When the patient was last well should be noted.
- The time of onset of illness/symptoms.
- The symptoms of the illness from the earliest time at which a change was noticed until the present time should be recorded in a chronological order.
- The presenting chief complaints should be detailed.
- Any disturbances in the sleep, appetite, and sexual functioning should be inquired. Always inquire about the presence of suicidal intent.
- Important negative points on history should be recorded (e.g. no history of head injury before the onset of illness).
- A life chart provides a valuable display of the course of illness and episodic sequence, polarity (if any), severity,

frequency, and relationship (if any) to stressors and response to treatment.

The points to be noted in present history are given in the Box 2.

The chief symptoms of anxiety and depression with clues to the diagnosis are given in the Box 3.

Box 2

History of present illness

- The complaint itself
- Date and time of onset of illness
- Aggravating and relieving factors
- Duration and course of illness
- Precipitating factors including life stressors
- Consistency of the symptoms
- Associated symptoms
- Site and radiation of physical symptoms

Box 3

Symptoms of two common psychiatric

<i>Symptoms of anxiety (Fig. 19.2)</i>	<i>Symptoms of depression (Fig. 19.3)</i>
A. Mental symptoms	
<ul style="list-style-type: none"> • Worry • Feeling nervous • Lack of concentration • Sleep disturbance 	<ul style="list-style-type: none"> • Disturbance of mood (sad mood) • Loss of interest or pleasure • Disturbed sleep • Loss of self-confidence, feeling of guilt
B. Physical symptoms	
<ul style="list-style-type: none"> • Restlessness • Headaches • Tremors • Inability to relax 	<ul style="list-style-type: none"> • Tiredness, lethargy • Agitation (agitated depression) or slowness of movements
C. Autonomic symptoms	
<ul style="list-style-type: none"> • Dizziness • Perspirations • Palpitations • Dry mouth • Pain abdomen 	<ul style="list-style-type: none"> • Decreased or loss of appetite • Suicidal tendencies • Poor concentration • Loss of libido/sexual drive
Clues to the diagnosis of anxiety or depression	
<ul style="list-style-type: none"> • The physical complaint has been present for > 3 months. • Three or more symptoms pertaining to different organ systems (described above) are present for at least 2 weeks. • History of multiple consultations or advice or investigations. • Physical examination and routine investigations are normal. • History of stressful life event(s). 	

Past Medical and Psychiatric History

History of similar or any other psychiatric illness in the past, if present, should be obtained. Past history of psychotropic medication, alcohol and drug abuse or dependence and psychiatric hospitalisation should be asked for.

Past history of any serious medical, neurological or surgical illness, surgical procedure, accident and hospitalisation should be obtained. The nature of treatment received, if any, should be ascertained. Past history of head injury, convulsions, unconsciousness, diabetes mellitus, hypertension, coronary artery disease, acute intermittent porphyria, syphilis and HIV positivity (or AIDS) should be particularly looked for.

Treatment History

The treatment given in the present episode and the previous episodes should be asked in details along with the response to treatment.

Family History

Family history usually includes the ‘family of origin’ (i.e. the patient’s parents, siblings, grandparents, uncles, etc). However, the ‘family of procreation’ (i.e. the patient’s spouse, children and grandchildren) can also be recorded here instead of under personal history. Family history includes:

Family structure: Plotting of a ‘family tree’ (pedigree chart) helps in recording all the relevant information’s in a concise manner and is easily readable. A typical pedigree chart is plotted in Fig. 19.4. It should be noted whether the family is nuclear or joint family. If consanguineous relationship is present, it should be recorded. Age and cause of death (if any) of the family members should be asked.

Family history of similar or other psychiatric illnesses, major medical illnesses, alcohol or drug dependence and suicide should be recorded.

Family socioeconomic status: Home circumstances, per-capita income, socio-economic status, leader of the family (normal as well as functional) and current attitude of the family members towards the patient’s illness should be noted.

The communication patterns in the family, range of affectivity, cultural and religious values and social support system should be inquired about, when relevant.

Personal History

The younger the patient, it is possible to give more attention to details. In older patients, there may be considerable retrospective falsification. Parents, if alive, can often provide much additional information regarding the past personal history.

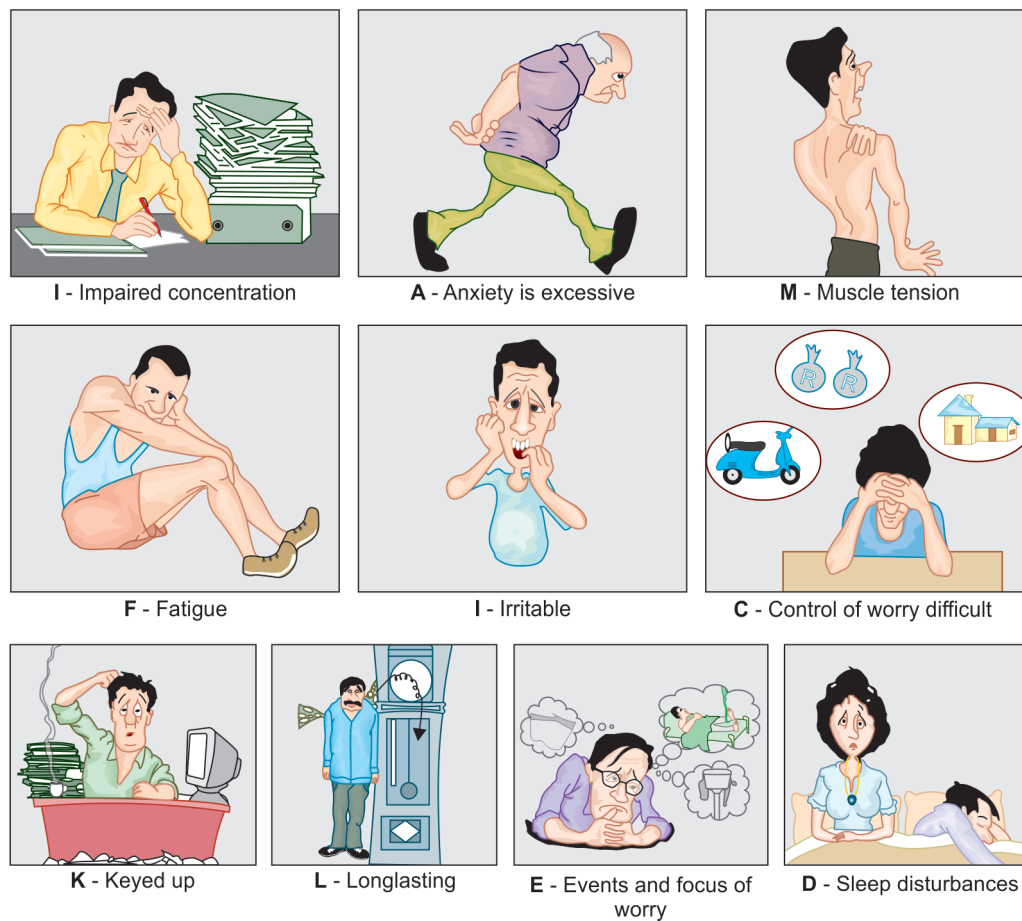


FIGURE 19.2 Some common clinical features of anxiety disorder. The word “I AM FICKLED” explains these unexplained symptoms

Personal history can be recorded in the following headings:

- **Perinatal history:** Any febrile illness; medications, drugs and/or alcohol use; trauma to abdomen and any physical or psychiatric illness during pregnancy (particularly in the first three months of gestation) should be asked. Other relevant questions are: whether the patient was a wanted or unwanted child; date of birth; whether normal or abnormal delivery; any instrumentation; where born (hospital or home); any perinatal complications (cyanosis, convulsions, jaundice); APGAR score (if available); birth cry (immediate or delayed); any birth defects; any prematurity.
- **Childhood history:** Whether the patient was brought up by mother or someone else; breastfeeding; weaning; any history suggestive of maternal deprivation, should be asked.

The age of passing each important developmental milestone should be noted. The age and ease of toilet training should be asked.

The occurrence of neurotic traits should be noted. These include stuttering, stammering, tics, enuresis, encopresis,

night terrors, thumb sucking, nail biting, head banging, body rocking, morbid fears or phobias, somnambulism, temper tantrums, and food fads.

- **Schooling:** The age of beginning and finishing formal education, academic achievements and relationships with classmates and teachers, should be asked.

Any school phobia, non-attendance, truancy, any learning difficulties and reasons for termination of studies (if occurred prematurely) should be noted.

Further questions to be asked are, what games were played at what stage, with whom and where? Relationships with peers, particularly the opposite sex, should be recorded.

- **Puberty:** The age at menarche, and reaction to menarche (in females), the age at appearance of secondary sexual characteristics, nocturnal emissions (in males), masturbation and any anxiety related to puberty changes should be noted.

- **Menstrual and obstetric history:** The regularity and duration of menses, the length of each cycle, any abnormality, the last menstrual period, the number of

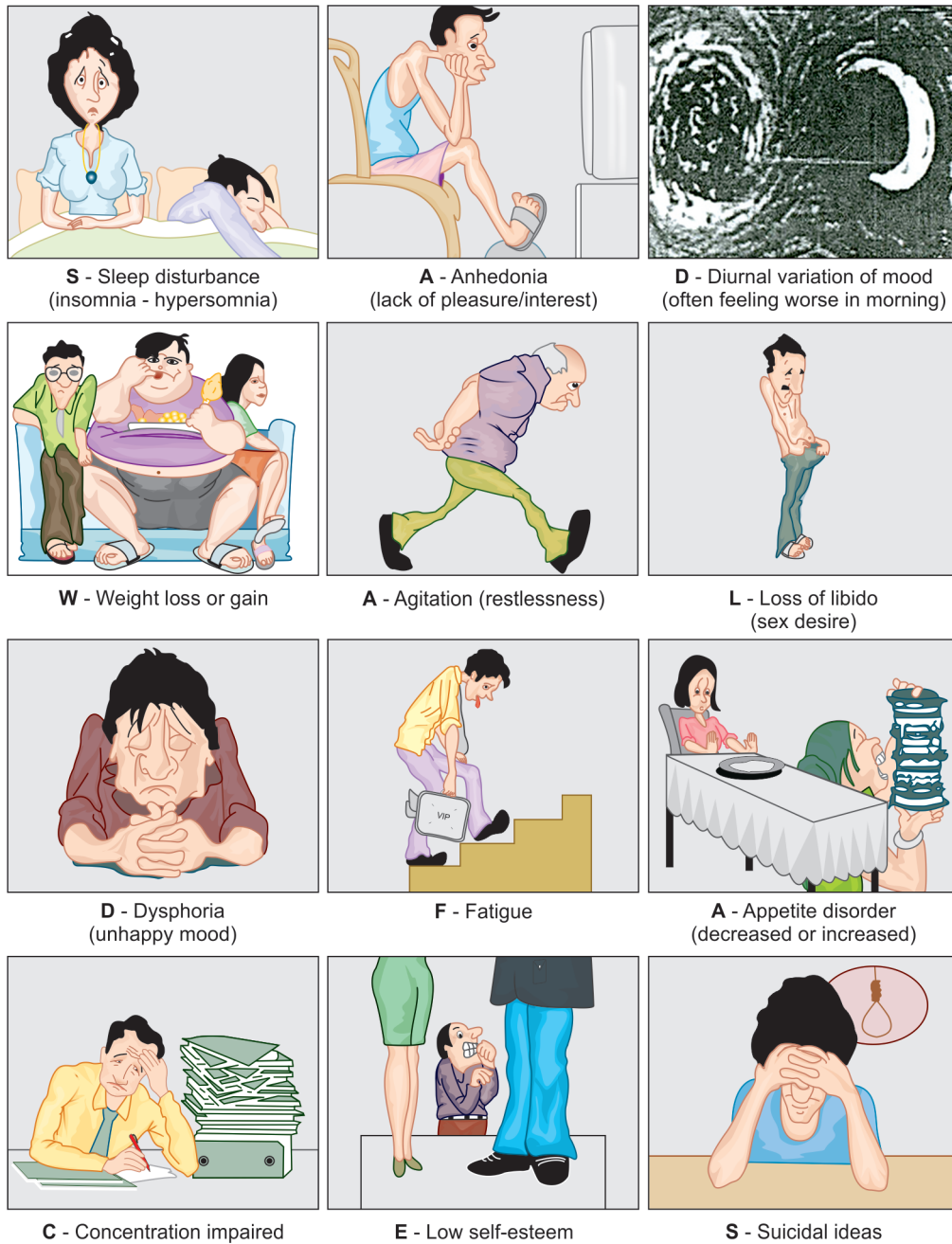

FIGURE 19.3 Some common clinical features of depression. The word “SAD WALD FACES” explains the symptoms

children born, termination of pregnancy if any, should be asked for.

- **Occupational history:** The age at starting work; jobs held in chronological order; reasons for changes; job satisfactions; ambitions; relationships with authorities, and subordinates; present income; and whether the job is appropriate to the educational and family background, should be asked.
- **Psychosexual history:** Sexual information, how acquired and of what kind; masturbation (fantasy and activity); sex

play, if any; adolescent sexual activity; premarital and extramarital sexual relationships, if any; sexual practices (normal and abnormal); and any gender identity disorder, are the areas to be inquired about.

The duration of marriage; whether known or unknown partner before marriage; marriage arranged by parents with or without consent or love marriage number of marriages, divorces or separation; interpersonal and sexual satisfaction; mode and frequency of sexual activity.

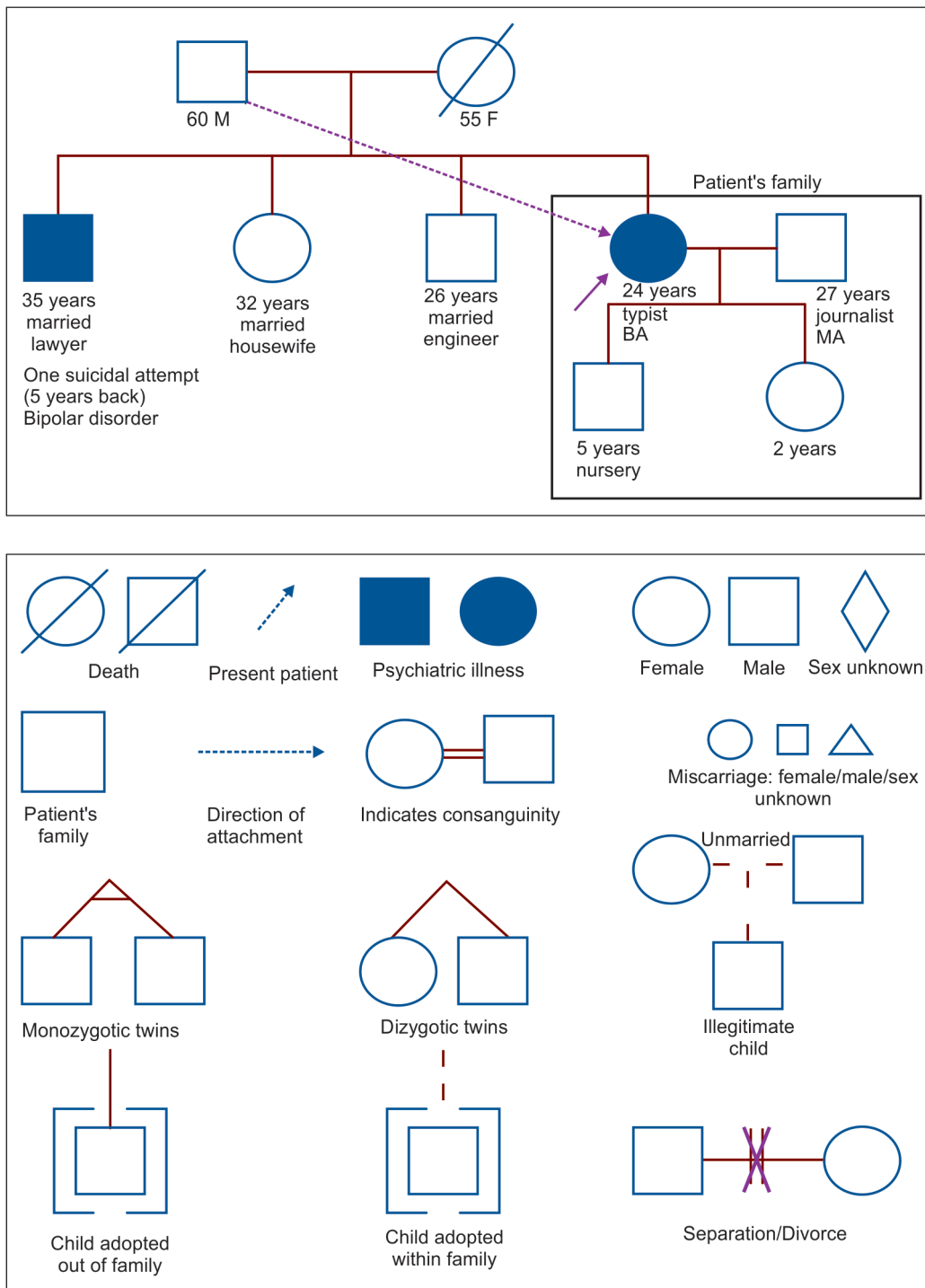


FIGURE 19.4 A typical pedigree chart and symbols used

Predisposing and Precipitating Factors

Predisposing factors often operate from early life, determine the vulnerability of the patient to psychological disease. These include:

- Genetic predisposition—strong genetic association is seen in psychoses

- Environment in utero.
- **Personality:** Certain personalities are believed to be particularly prone to develop certain disorders.
- Childhood trauma.

Precipitating factors occur shortly before the onset of a disorder and appear to be the cause of disorder. They may be physical, psychological or social (Table 19.2).

TABLE 19.2 Precipitating factors for a psychiatric illness**Physiological factors**

- Hypothyroidism
- Tumours
- Metabolic disorder
- Drugs (steroids, alcohol, antihypertensives)

Psychological factors

- Loss of self-esteem due to misfortune or financial loss

Social factors

- Moving job
- Job difficulties
- Family disturbance

Forensic History

Any and all confrontations with law as a result of juvenile delinquency and antisocial behaviour should be recorded. Details of offences committed and punishment received should be noted.

Premorbid Personality (PMP)

It is important to elicit details regarding the personality of the individual (temperament, if the age is less than 16 years). Rather than giving labels like schizoid or histrionic, it is more useful to describe the personality in some detail as follows:

- **Interpersonal relationship:** Interpersonal relationship with family members, friends, work-mates and superiors; introverted/extraverted; ease of making and keeping social relations.
- **Extracurricular activities:** Hobbies, interests, intellectual activities, critical faculty, energetic/sedentary.
- **Mood:** Optimistic/pessimistic, stable/prone to anxiety, cheerful/despondent, reaction to stressful life events.
- **Attitude to self and others:** Self-confidence level, self-criticism, self-consciousness, selfish/thoughtful of others, self-appraisal of abilities, achievements and failure.
- **Attitude to work and responsibility:** Decision making, acceptance of responsibility, flexibility, perseverance, foresight.
- **Religious beliefs and moral attitudes:** Religious beliefs, toleration of others' standards and beliefs, conscience, altruism.
- **Fantasy of life:** Sexual and nonsexual fantasies day-dreaming—frequency and content, recurrent or favourite day-dreams, dreams.
- **Habits:** Food fads, alcohol, tobacco, drugs, sleep.

The most reliable method of premorbid personality assessment is, interviewing an informer/friend/relative familiar with the patient prior to the onset of illness.

CASE HISTORIES

Case histories of some medically unexplained symptoms with their analysis and differential diagnosis are discussed as Case No. 1 to 7.

Case No. 1: Chest Pain*Clinical Presentations*

- Intermittent, sharp knife like cutting pain of long duration or precordial aching or tightness or heaviness or discomfort
- Preoccupation with pain and sighing respiration
- Increased by psychological distress (stress precipitant)
- No relation to exertion/activity
- Complains that pain is “coming from heart”, i.e. it is heart pain
- Associated complaints of palpitations, dizziness, shortness of breath are present
- Associated fear of having a heart attack
- Family history of similar pain. One of my relative had such pain died due to heart attack is a common complaint.

Case history: A 45-year-old male patient complained of persistent chest pain and tightness around the chest. He felt very anxious and reported that “pain was coming from his heart”.

On inquiry he reported that he was worried about his daughter's marriage which was due after a month and he had borrowed money for that event. About a month back he was operated for strangulated hernia which had resulted in unexpected expenses. He also reported that he was not sleeping well, had lost interest in activities which he enjoyed previously. He had also lost his appetite and lost 3 kgs of weight. Physical examination and investigation including ECG and stress test were normal.

Provisional diagnosis: Cardiac neurosis*Differential diagnosis*

- Angina pectoris or MI
- Esophageal motility disorder or reflux oesophagitis
- Musculoskeletal pain
- Pneumonitis
- Pleuritis
- Mitral valve prolapse.



*Investigations***Routine**

- Physical examination
- ECG
- X-ray chest.

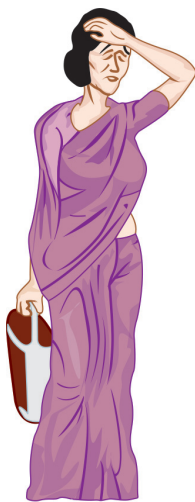Special (if cardiac aetiology is suspected)

- Stress test
- 2D ECHO
- Angiography—to be done in patients above 40 years.

Case No. 2: Chronic Fatigue*Clinical Presentations*

- Feeling weak and tired “all the time”
- Lack of energy to do daily activities
- Loss of enthusiasm in work and social engagements
- Feeling lethargic
- Wanting to lie down the whole day
- Difficulty in concentration
- Complaints of aches and pains
- Sleep problems.

Case history: A 58-year-old lady complained of feeling extremely tired and fatigued all the time. Her symptoms began more than a year ago. Nothing seemed to make her feel better. On inquiry, it was found out that her husband had suddenly died the previous year. Her children have all grown up and left home for better employment opportunities. She had started experiencing poor sleep and loss of appetite soon after her husband died. Later, she began to get headaches, tiredness and other physical discomforts which led her to consult the local hospital. There she was told she was alright but was prescribed tonics and vitamins. She felt better immediately, particularly because her sleep improved. However, within two weeks, her sleep got worse and she felt tired all the time. She was given sleeping pills and vitamin injections. This went on for months, until she decided to see another doctor.

**Provisional diagnosis: Chronic fatigue syndrome***Differential diagnosis*

- Anaemia
- Ischaemic heart disease
- Chronic infections or inflammatory diseases
- Neoplastic disorder
- Hypothyroidism.

*Investigations***Routine**

- Haemoglobin
- Full blood count
- Blood chemistry for liver and renal disease
- Chest X-ray
- Urinalysis.

Special

- Thyroid function test
- ECG.

All these investigations were normal.

Case No. 3: Chronic Headache*Headache Characteristics*

- **Intensity:** Mild to severe
- **Duration:** Months to years
- **Episode:** Lasts for an hour or continuous
- Increased tightness and tenderness of neck and jaw muscles
- Generalised or bi-occipital distribution
- No nausea, no vomiting, no photophobia.

Case history: A 35-year-old housewife came to the doctor with complaints of persistent headache. The headaches were present since her marriage, about 12 years back. She would daily take 1 to 2 tablets of paracetamol. Frequently the headaches were so severe that they incapacitated her. She had consulted neurologists and had gone through CT scans and MRI of the brain. A physical examination and all her investigations including blood biochemistry were normal.



On inquiry she mentioned that there were frequent alterations with her mother-in-law. The headaches were bilateral and the pain was throbbing. She also felt a tightening band around her temporal regions. She felt a little better when somebody massaged the back of her neck or when she took analgesics. She was known to be tense and anxious. Recently she had become depressed and lost interest in her household activities.

Provisional diagnosis: Chronic headache (psychogenic)*Differential diagnosis*

- Migraine
- Cluster headaches
- Cranial arteritis.

Investigations usually prescribed/done

Special (if intracranial lesion is suspected)

- CT scan
- MRI scan.

Case No. 4: Chronic Backache

Clinical Presentations

- Persistent backache of long duration
- Preoccupation with pain and discomfort
- Restriction of social activities
- No localization
- No tenderness
- Straight leg raising test—normal
- No motor weakness or sensory loss
- Knee and ankle jerks normal.

Case history: A 45-year-old male patient complained of persistent backache for 10 years. He attended his work with great difficulty and had given up practically all social activities. He mentioned that he had also lost interest in sex and felt very fatigued and tired. He had visited several specialists. He had several X-rays and scans of the spine, all of which were normal. He was advised analgesics and physiotherapy. He generally took more analgesics than what was prescribed and gave up physiotherapy as he felt fatigued and unmotivated. He said that the backache had started when he was moving furniture in his new house about 10 years ago. He had to move into his own house following a quarrel with his elder brother. He was very close to his mother and he wanted his parents to stay with him. They opted to stay with his brother and he had felt very hurt. His mother had suffered from depression and also complained of backache. His maternal uncle had committed suicide.



Provisional diagnosis: Chronic low back pain

Differential diagnosis

- Osteoporosis of spine
- Spondylosis/herniated intervertebral disc
- Infections of spine
- Carcinoma.

Investigations done

Routine

- X-ray spine.

Special (if cardiac aetiology is suspected)

- MRI spine
- CT scan spine.

Case No. 5: Sleep Disturbances

Clinical Presentations

- Difficulty in falling asleep
- Early morning awakening
- Daytime drowsiness
- Feeling tired
- Difficulty in concentration
- Forgetfulness
- Diminished performance at work
- Irritability
- Preoccupation with sleep.

Case history: A 30-year-old female patient working as a clerk complained of difficulty in falling asleep. In addition, she frequently woke up at 3.00–4.00 AM and could not get back to sleep. She started having sleep problems after the delivery of her second child.

On inquiry she revealed that she had a very difficult pregnancy and was very tense during the last month. She could not concentrate on her work, and was worried that she may lose her job. She had consulted the company doctor—who had prescribed her sleeping pills. These had helped her for a week but the sleep problem returned and her tension worsened.



Provisional diagnosis: Insomnia

Differential diagnosis

- Medical conditions causing pain or discomfort
- Drug and alcohol abuse
- Obstructive sleep apnoea syndrome.

Investigations done/required

- Routine blood tests.

Case No. 6: Abdominal Pain

Clinical Presentations

- Long duration of symptom
- Irregular bowel movements associated with flatulence and bloating sensation often diffuse or localised to lower abdomen

- Pain may be relieved by passage of flatus or defaecation
- No weight loss or weight gain
- No disturbance of appetite
- Abdominal examination normal.

Case summary: A 35-year-old male patient came with complaints of persistent pain in abdomen for several years. The pain was dull aching. He complained of “a lot of gas and irregular bowel habits. The pain had started following some financial stress and illness of his wife. The pain persisted in spite of detailed investigations and treatment.

He had not lost any weight. He had no disturbance of appetite. He complained that he had difficulty in falling asleep and sometimes woke-up early in the morning.

He had lost interest in social activities and avoided religious functions in the family.



Provisional diagnosis: abdominal neurosis

Differential diagnosis

- Peptic disease
- Reflux oesophagitis (GERD)
- Amoebic colitis
- Irritable bowel syndrome.

Investigations done/required

Routine

- Blood examination
- Stool examination.

Special (if organic cause is suspected)

- Ultrasound abdomen
- Endoscopic examination.

Case No. 7: Panic Attacks

Panic attacks are attacks of extreme anxiety and fear. The following is the description of a typical panic attack:

- It comes out suddenly without any warning.
- If extreme with some severe physical symptoms such as palpitations or difficulty breathing, the person is terrified that he may die or collapse or go mad.
- The attack lasts for a few minutes to half an hour.
- It disappears spontaneously as it started.



Panic attacks are quite common. Many persons will have one or two panic attacks sometime during their lives. However, sometimes, panic attacks become more frequent. When they occur regularly, for example, once or twice a week, then this is called as *Panic disorder*. It is most often misdiagnosed as an acute myocardial episode.

Examination

- Physical examination
- Psychological examination.

Physical examination

A detailed general physical examination (GPE) and systemic examination is must in each patient. Physical disease which is etiologically important (for causing the psychiatric symptoms) accidentally may be coexistent or signs caused by the condition are often present and can be detected by a good physical examination. Anxious patients may have signs of thyrotoxicosis. Liver disease must be suspected in alcoholism. Needle marks on the body indicate drug abuse and predispose to HIV infection.

Although conventionally the details of the ‘family of procreation’ are recorded here, they can also be recorded in the family tree.

Psychiatric or mental state examination (MSE)

Mental status examination is a standardised format (Table 19.3) in which the clinician records the psychiatric signs and symptoms present at the time of the interview.

TABLE 19.3 Mental status examination format

- | | |
|--|-------------------|
| • General appearance and behaviour | |
| – General appearance | – Motor activity |
| – Attitude towards examiner | – Social manner |
| – Comprehension | – Rapport |
| – Gait and posture | |
| • Speech | |
| – Rate and quality | – Flow and rhythm |
| – Volume and tone | |
| • Mood and affect | |
| • Thought | |
| – Stream and form | |
| – Content | |
| • Perception and abnormal beliefs | |
| • Cognition (higher mental functions) | |
| – Consciousness | |
| – Orientation | |
| – Attention | |
| – Concentration | |
| – Memory | |
| – Intelligence | |
| – Abstract thinking | |
| • Insight | |
| • Judgement | |

MSE should describe all areas of mental functioning that may arise from the history, e.g. mood and affect in depression, cognitive functions in delirium and dementia.

General appearance and behaviour

A good deal of information can be elicited from general appearance and behavior. While examining, it is important to remember the socio-cultural background and personality of the patient.

Understandably, general appearance and behavior needs to be given more emphasis in the examination of an uncooperative patient.

General appearance

Note the followings:

- Physique and body habitus (built)
- Physical appearance (approximate height, weight, and appearance)
- **Looks:** Anxious, depressed
- Physical health
- Grooming, hygiene, self-care
- Dressing (adequate, appropriate, any abnormalities)
- Facies (non-verbal expression of mood)
- Effeminate/masculine.

Attitude towards the examiner

- Cooperation/guardedness/evasiveness/hostility/combativeness/naughtiness
- Attentiveness
- Appears interested/disinterested/apathetic
- Any ingratiating behaviour
- Perplexity.

Comprehension

- Intact/impaired (partially/fully).

Gait and posture

Normal or abnormal (way of sitting, standing, walking, lying).

Motor activity

- Increased/decreased
- Excitement/stupor
- Abnormal involuntary movements like tics, tremors, akathisia
- Restlessness/ill at ease
- Catatonic signs (mannerisms, stereotyped posturing, waxy flexibility, negativism, ambitendency, automatic obedience, stupor, echopraxia, forced grasping)
- Conversion and dissociative signs (pseudoseizures, possession states)
- Social withdrawal, autism
- Compulsive acts, rituals or habits (e.g. nail-biting)
- Reaction time.

Social manner and non-verbal behaviour

- Increased, decreased, or inappropriate
- Eye contact (gaze aversion, staring vacantly, staring at the examiner, hesitant eye contact, or normal eye contact).

Rapport

Whether a working and empathic relationship can be established with the patient, should be mentioned.

Hallucinatory behaviour

Smiling or crying without reason, muttering or talking to self (non-social speech) and odd gesturing in response to auditory or visual hallucination.

Speech

Speech can be examined under the following headings:

- **Rate and quantity of speech**
 - Whether speech is present or absent (mutism)
 - If present, whether it is spontaneous
 - Productivity is increased or decreased
 - Rate is rapid or slow (its appropriateness)
 - Flow of speech or poverty of speech.
- **Volume and tone of speech**
 - Increased/decreased (its appropriateness)
 - Low/high/normal pitch.
- **Flow and rhythm of speech**
 - Smooth/hesitant, blocking (sudden)
 - Dysprosody, stuttering/stammering/cluttering, any accent
 - Circumstantiality, tangentiality
 - Verbigeration, stereotypes (verbal)
 - Flight of ideas, loose associations.

Mood and affect

Mood is the pervasive feeling which is sustained (lasts for some time) and colors the total experience of a person. Affect, on the other hand, is the outward expression (objective) of the immediate (cross-sectional) experience of emotion at a given time.

The assessment of mood includes testing the quality of mood, which is assessed subjectively ('how do you feel') and objectively (by examination). The other components are stability of mood (over a period of time), reactivity of mood (variation in mood with stimuli), and persistence of mood (length of time the mood lasts).

The affect is similarly described under quality of affect, range of affect or emotional changes displayed over time, depth or intensity of affect (normal, increased or blunted) and appropriateness of affect (in relation to thought and surrounding environment).

Mood is described as general warmth, euphoria (mild happiness), elation, exaltation and/or ecstasy in mania;

anxious and restless in anxiety and depression; sad, irritable, angry and/or despaired in depression; shallow, blunted, indifferent, restricted, inappropriate and/or labile in schizophrenia.

Anhedonia may occur in both schizophrenia and depression.

Thought

Normal thinking is a goal directed flow of ideas, symbols and associations initiated by a problem or a task, characterized by rational connections between successive ideas or thoughts, lead towards a reality oriented conclusion. Therefore, thought process that is not goal-directed, or not logical, or does not lead to a realistic solution to the problem at hand, is not normal.

Traditionally, in the clinical examination, thought is assessed (by the content of speech) under the four headings of *stream*, *form*, *content* and *possession* of thought. However, since there is widespread disagreement regarding this subdivision, 'thought' is discussed here under the following two headings.

1. Stream and form of thought

'Stream of thought' overlaps with examination of 'speech'. Spontaneity, productivity, flight of ideas, prolixity, poverty of content of speech, and thought block should be mentioned here.

Continuity of thought is assessed whether the thought processes are relevant to the questions asked. Any loosening of associations, tangentiality, circumstantiality, illogical thinking, perseveration, or verbigeration is noted.

2. Content of thought

- Any preoccupations
- Obsessions (recurrent, irrational, intrusive, ego-dystonic, ego-alien ideas)
- Contents of phobias (irrational fears)
- Delusions (false, unshakeable beliefs) or over-valued ideas
- Explore for delusions/ideas of persecution, reference, grandeur, love, jealousy (infidelity), guilt, nihilism, poverty, somatic (hypochondriacal) symptoms, hopelessness, helplessness, worthlessness, and suicidal ideation.

Delusions of control, thought insertion, thought withdrawal, thought broadcasting are *Schneiderian first rank symptoms* (SFRS of Schizophrenia). The presence of neologisms should be recorded here.

Perception

Perception is the process of being aware of a sensory experience and being able to recognise it by comparing it with previous experiences.

Perception is assessed under the following headings:

- **Hallucinations:** The presence of hallucinations should be noted. Whether hallucinations are auditory, visual, olfactory, gustatory or tactile should be asked.

Auditory hallucinations are most common type of hallucinations in non-organic psychiatric disorders. Clarify whether they are elementary (only sounds are heard) or complex (voices heard). It should be further inquired what was heard, how many voices were heard, in which part of the day, male or female voices, how interpreted and whether second person or third person hallucinations (i.e. whether the voices were addressing the patient or were discussing him with third person); enquire about command (imperative) hallucinations.

Enquire whether the hallucinations occurred during wakefulness, or were they hypnagogic (occurring while going to sleep) and/or hypnopompic (occurring while getting up from sleep) hallucinations.

- **Illusions and misinterpretations:** Whether visual, auditory, or in other sensory fields; whether occur in clear consciousness or not; whether any steps taken to check the reality of distorted perceptions.
- **Depersonalisation/derealisation:** Depersonalisation and derealization are abnormalities in the perception of a person's reality.
- **Somatic passivity phenomenon:** Somatic passivity is the presence of strange sensations described by the patient as being imposed on the body by 'some external agency', with the patient being a passive recipient. It is one of the Schneider's first rank symptoms.
- **Others:** Autoscopy, abnormal vestibular sensations, sense of presence should be noted here.

Cognition (Neuropsychiatric) Assessment

Cognitive or higher mental functions are an important part of the MMSE (Table 19.4). Their significant disturbance commonly points to the presence of an organic psychiatric disorder.

- **Consciousness:** The intensity of stimulation needed to arouse the patient should be indicated to demonstrate the level of alertness, e.g. by calling patient's name in a normal voice, calling in a loud voice, light touch on the arm, vigorous shaking of the arm, or painful stimulus.

Grade the level of consciousness; whether conscious/confused/somnolence/clouding/delirium/stupor/coma. Any disturbance in the level of consciousness should ideally be rated on Glasgow Coma Scale, where a numeric value is given to the best response in each of the three categories (eye opening, verbal, motor).

TABLE 19.4 Higher mental function in mini-mental state-examination

Orientation —1 point for each correct answer	
What is the:	
time	
date	
day	
month	
year	5 points
What is the name of this:	
ward	
hospital	
district	
town	
country	5 points
Registration	
Name three objects	
Score 1, 2, 3 points according to how many are repeated	
Re-submit list until patient word perfect in order to use this for a later test of recall	
Score only first attempt	3 points
Attention and calculation	
Ask the patient to subtract 7 from 100 and then from the result a total of five times. Score 1 point for each correct subtraction	5 points
Recall	
Ask for three objects used in the registration test, one point being awarded for each correct answer	3 points
Language	
1 point each for two objects correctly named (pencil and watch)	2 points
1 point for correct repetition of 'No ifs, and buts'	1 point
3 points if three-stage commands correctly obeyed 'Take this piece of paper in your right hand, fold it in half, and place it on the floor'	3 points
1 point for correct response to a written command such as 'close your eyes'	1 point
Can the patient write a sentence. Award 1 point if the sentence is meaningful, has a verb and a subject	1 point
Test the patient's ability to copy a complex diagram of two intersected pentagons	1 point
Total score	30

Note any amnesia (anterograde/retrograde), or confabulation, if present

- **Orientation:** Whether the patient is well oriented to time (test by asking the time, date, day, month, year, season, and the time spent in hospital), place (test by asking the present location, building, and city) and person (test by asking his own name and can he identify people around him and their role in the setting). Disorientation in time usually precedes disorientation in place and person.
- **Attention:** Is the attention easily aroused and sustained? Ask the patient to repeat digits forwards and backwards (digit span test; digit forward and backward test), one at a time (e.g. patient may be able to repeat 5 digits forward and 3 digits backwards). Start with two digit numbers, increasing gradually up to eight digit numbers or till failure occurs on three consecutive occasions.
- **Concentration:** Can the patient concentrate? Is he easily distractible? Ask to subtract serial sevens from hundred (100-7 test), or serial three from forty (40-3 test), or to count backwards from 20, or enumerate the names of the months (or days of the week) in the reverse order.
- **Memory:**
 - *Immediate retention and recall (IR and R):* Use the digit span test to assess the immediate memory; digit forwards and digit backwards subtests (also used for testing attention; are described under attention).
 - *Recent memory:* Ask how did the patient come to the room/hospital; What he ate for dinner the day before or for breakfast the same morning? Give him/her an address to be memorised and ask him/her to recall 15 minutes later or at the end of the interview.
 - *Remote memory:* Ask the date and place of a marriage, name and birthdays of children, any other relevant questions from the person's past.
- **Intelligence:** Intelligence is the ability to think logically, act rationally, and deal effectively with the environment. Ask questions about general information, keeping in mind the patient's educational and social background, his experiences and interests, e.g. ask about the current and the past Prime Ministers and Presidents of India, the capital of India, and the name of the various states. Test for reading and writing. Give simple tests of calculations.
- **Abstract thinking:** Abstract thinking is characterised by the ability to:
 - assume a mental set voluntarily
 - shift voluntarily from one aspect of a situation to another
 - keep in mind simultaneously the various aspects of a situation
 - grasp the essentials of a 'whole' (e.g. situation or concept), and
 - to break a 'whole' into its parts.
 Abstract thinking testing assesses patient's concept formation. The methods used are:
 - **Proverb testing:** The meaning of simple proverbs (at least 3) should be asked.

TABLE 19.5 Clinical rating of insight

Insight is rated on a 6-point scale from one to six.

1. Complete denial of illness.
2. Slight awareness of being sick and needing help, but denying it at the same time.
3. Awareness of being sick, but it is attributed to external or physical factors.
4. Awareness of being sick, due to something unknown in self.
5. **Intellectual insight:** Awareness of being ill and that the symptoms/failures in social adjustment are due to own particular irrational feelings/thoughts; yet does not apply this knowledge to the current/future experiences.
6. **True emotional insight:** It is different from intellectual insight in that the awareness leads to significant basic changes in the future behaviour and personality.

- Similarities (and also the differences) between familiar objects should be asked, like: table/chair; banana/orange; dog/lion; eye/ear.

The answers may be concrete or abstract. Appropriateness of answers is judged. Concretisation of responses or inappropriate answers may occur in schizophrenia.

Insight

Insight is the degree of awareness and understanding that the patient has regarding his illness.

Ask the patient's attitude towards him, present state; whether there is an illness or not; if yes, which kind of illness (physical, psychiatric or both); is any treatment needed, is there hope for recovery; what is the cause of illness? Depending on the patient's responses, grade the insight (Table 19.5).

Judgement

Judgement is the ability to assess a situation correctly and act appropriately within that situation. Both social and test judgement are assessed.

- i. Social judgement is observed during the hospital stay and during the interview session. It includes evaluation of personal judgement.
- ii. Test judgement is assessed by asking the patient what he would do in certain test situations, like 'a house on fire' or 'a man lying on the road', or a sealed, stamped addressed envelope lying in a street'. Judgement is rated as Good/Intact/Normal or Poor/Impaired/Abnormal.

INVESTIGATIONS

After a detailed history and examination, investigations (laboratory tests, diagnostic standardised interviews, family

interviews and/or psychological tests) are carried out based on the diagnostic and etiological possibilities. Some of these investigations are discussed below:

Medical Screen

The following tests may be useful in screening for the medical disorders causing psychiatric symptoms:

- *Haemoglobin:* It is done as a routine.
- *Total and differential leucocyte counts (TLC, DLC):* It is done for follow up. Treatment with antipsychotics (e.g. clozapine), lithium, carbamazepine.
- *Peripheral smear* for mean corpuscular volume (MCV): It is increased in alcohol dependence.
- *Urinalysis* done to monitor the treatment with lithium.
- *Liver function tests* done to monitor treatment with carbamazepine, valproate, benzodiazepines, alcohol dependence.
- *Serum sodium and potassium* for SIADH, due to antipsychotic, drugs.
- *Blood glucose for diabetes*
- *Thyroid function test* for refractory depression, rapid cycling mood disorder, treatment with lithium, carbamazepine.
- *Electrocardiogram (EKG)* taken during treatment with lithium, antidepressants, and before ECT.
- *HIV testing* done in intravenous drug users, suggestive sexual history, AIDS dementia.
- *VDRL* for suggestive sexual history.
- *X-ray chest and skull:* Age >35 years, treatment with ECT.
- *CPK:* It is increased in neuroleptic malignant syndrome.

Toxicology Screen

Useful when substance use is suspected, e.g. alcohol, cocaine, opiates, Cannabis, phencyclidine, benzodiazepines, barbiturates.

Drugs levels: Drug levels are indicated for therapeutic and toxic blood levels, and for testing drug compliance. The common drug levels monitored include lithium (0.6-1.6 meq/L), carbamazepine (6-12 mg/mL), valproate (50-100 mg/mL), haloperidol (8-18 ng/mL), tricyclic antidepressants (nortriptyline 50-150 ng/mL; imipramine 200-250 ng/mL), benzodiazepines, barbiturates.

Electrophysiological Tests

EEG (Electroencephalogram) for seizures, dementia, pseudoseizures vs. seizures, episodic abnormal behavior. **BEAM** (Brain electrical activity mapping) provides topographic imaging of EEG data. **Video-telemetry EEG.** *Evoked potential:* Research tool. *Polysomnography/sleep studies:* Sleep disorders, seizures (occurring in sleep). The various components in sleep studies include EEG, EKG, EOG, EMG, airflow measurement, penile tumescence, oxygen

saturation, body temperature, GSR (Galvanic skin response), and body movement. **Holter EKG** for panic disorder.

Imaging Studies

Computed tomography (CT) scans: To differentiate between organic and functional disorder, e.g. dementia, delirium, seizures, first episode psychosis. *Magnetic Resonance Imaging (MRI) or higher resolution CT Scan:* Dementia *Single Photon Emission Computed Tomography (SPECT) Scan:* Research tool. *Magnetic Resonance (MR) angiography* for cerebral disease, if indicated.

Neuro-endocrine Studies

Dexamethasone suppression test (DST): Research tool in depression (response to antidepressants or ECT). If plasma cortisol is more than 5 mg/100 mL following administration of dexamethasone (1 mg, given at 11 PM the night before and plasma cortisol taken at 4 PM and 11 PM the next day).

TRH stimulation test: Lithium-induced hypothyroidism, refractory depression. If the serum TSH is more than 35 mU/mL (following 500 mg of TRH given IV), the test is positive.

Serum prolactin levels: Seizures vs pseudo-seizures, galactorrhea with antipsychotics.

Serum 17-hydroxycorticosteroid: Organic mood (depression) disorders.

Biochemical Tests

(5-HIAA and catecholamine levels). They are done in organic anxiety disorder (e.g. pheochromocytoma).

Genetic Studies

Cytogenetic work-up is useful in some cases of mental retardation.

Tests for Sexual Disorders

Papaverine test: Male erectile function disorder (intracavernosal injection of papaverine is sometimes used to differentiate organic from non-organic male erectile disorder).

Nocturnal penile tumescence and Doppler: Male erectile disorder.

Serum testosterone: Sexual desire disorders (loss of libido), male erectile disorder.

Miscellaneous Tests

Lactate provocation test: Panic disorders (in about 70% of patients with panic disorders, sodium lactate infusion can provoke a panic attack).

Drug assisted interview (Amytal interview): Useful in catatonia, unexplained mutism, and dissociative stupor.

- CSF examination for meningitis.

Box 4

Face/Hand test

The face/hand test is also useful in differentiating organic brain disorders from functional brain disease, e.g. psychoses. The patient sits with their eyes closed and their hands on their knees. The examiner strokes the patient's cheek and, at the same time, one hand. Alternate combinations of face and hand may be touched in random sequence and, each time, the patient is asked to report the contacts. Incorrect answers are associated with organic brain disease.

Psychological Tests

- **Objective tests:** These are pen and paper, objective tests for personality and intelligence in a person.
 - Objective personality tests:** Some examples of objective personality tests are MMPI (Minnesota multiple personality inventory) and 16-PF (16-personality factors).
 - Intelligence tests:** Some commonly used tests of intelligence are WAIS (Wechsler adult intelligence scale), Standard-Binet test and Bhatia's battery of intelligence.
- **Projective tests:** In projective tests, ambiguous stimuli are used which are not clear to the person immediately. Some commonly used projective tests of personality are Rorschach inkblot test, TAT (Thematic appreciation test), DAPT (Draw-a-Person test), sentence completion test and face and hand test (*see* Box 4).
- **Neuropsychological tests:** Some of the commonly used neuropsychological tests are Wisconsin card sorting test, Wechsler memory scale, GI memory scale, BG test (Bender Gestalt test), BVRT (Benton visual retention test), Luria-Nebraska neuropsychological test battery, Halstead-Reitan neuropsychological test battery, and PGI battery of brain dysfunction.
- **Rating scales:** Several rating scales are used in psychiatry to quantify the psychopathology observed. Some of the commonly used scales are *BPRS* (Brief psychiatric rating scale), *SANS* (Scale for assessment of negative symptoms), *SAPS* (Scale for assessment of positive symptoms), *HARS* (Hamilton's anxiety rating scale), *HDRS* (Hamilton's depression rating scale), and *YBOCS* (Yale Brown obsessive-compulsive scale).
- **Diagnostic standardised interviews:** These instruments make the diagnostic assessment more standardised. These include *PSE* (Present state examination), *SCAN* (Schedules for Clinical Assessment in Neuropsychiatry), *SCID* (Structured Clinical Interview for DSM-IV), and *IPDE* (International Personality Disorder Examination), among many others.

20

CHAPTER

The Endocrinal System

HISTORY

Symptoms

- Alteration in height, e.g. increase or decrease
- Weight gain or loss
- Polyuria and polydipsia
- Menstrual irregularity
- Thyroid swelling with or without signs of thyrotoxicosis
- Hypothyroidism or its features
- Gynaecomastia
- Hirsutism
- Myopathy or muscle weakness.

Present History

- Chronological order of symptoms
- Mode of onset, their progression and course
- Drugs treatment being taken, e.g. replacement therapy or oral contraceptives.

Past History

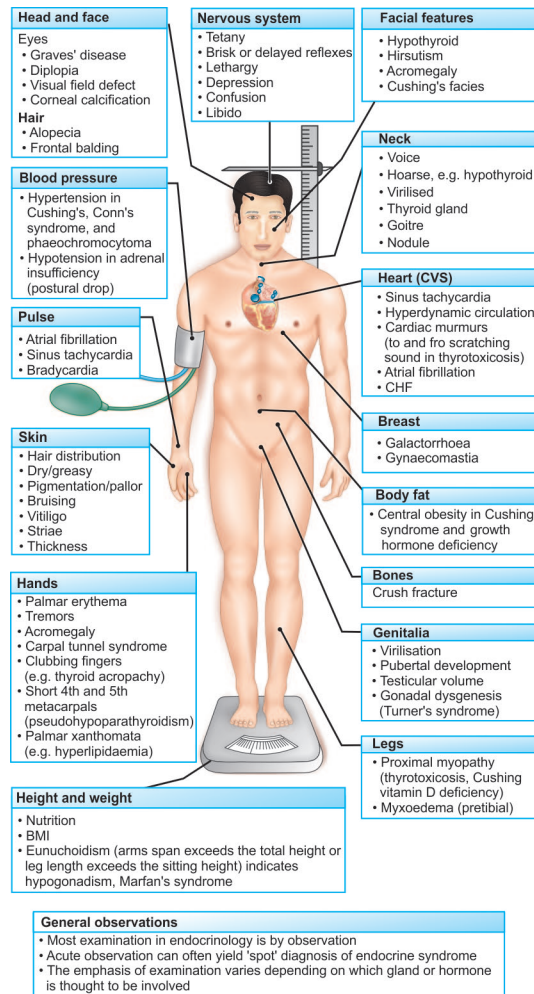
Details of pregnancies or PPH in females, previous surgery, radiation to neck or gonads and developmental milestones in children.

Family History

DM or any other endocrinal or autoimmune disease.

General Physical Examination

- **Appearance, built, height, weight BMI and body proportions**
- **Face**, e.g. periorbital oedema, moon-facies, prognathism, etc.
- **Eyes**, e.g. exophthalmos, proptosis, signs of Grave's ophthalmopathy, visual acuity
- **Ear**, e.g. deafness
- **Mouth**, e.g. large protruding tongue, thick lips, etc.
- **Neck**, e.g. goitre, carotid, pulsations/bruit, JVP.



Examination of Endocrine System

- **Breast**, e.g. atrophy in female, gynaecomastia and galactorrhoea
- **Skin and hair**, e.g. dry, wet, hair loss, hirsutism, striae, pigmentation, thin or thick skin, necrobiosis lipoidica diabetorum
- **Extremities**, e.g. long/short, hands (long/short/extra finger), ulceration, oedema feet, pressure sores or loss of fingers etc.

Systemic Examination

- **Cardiovascular**
 - Look for cardiomegaly
 - Auscultate for change in heart rate, rhythm, murmur or any other abnormal sound
- **Nervous system**
 - Look for higher function, cranial nerve, speech
 - Look for abnormal movements
 - Motor system examination for brisk or delayed jerks or myopathy
 - Sensory system examination for neuropathy including carpal tunnel syndrome
- **Genitalia and breast**
 - Look genitalia for hyper or hypogonadism
 - Virilisation
 - Breast development, atrophy and galactorrhoea.
- **Bone and joints**
 - Look for osteoporosis, crush fractures or arthropathy
- **Psychiatric assessment for depression or anxiety or abnormal behaviour.**

Diagnosis and Differential Diagnosis Investigations

THE ENDOCRINE SYSTEM AND METABOLISM

The *endocrine system* comprises of following glands:

- Pituitary—a master endocrine gland
- Thyroid
- Parathyroid
- Adrenals
- Gonads
- Pancreatic islet cells.

Metabolic disorders result due to:

- Biochemical abnormality
- Enzymatic defect
- Abnormal receptor mechanism.

Diabetes mellitus, hyperlipidaemia, hyper and hypocalcaemia are some examples of disorder carbohydrate, fat and calcium metabolism.

Applied Anatomy and Physiology

Endocrinology is a branch of science that deals with the control and coordination of various endocrine glands within the human body so as to maintain healthy milieu interior.

The term '*hormone*' derived from Greek word means to 'excite' or '*to arouse*', but today the fact is that all hormones are not excitatory, a few are inhibitory as well.

The '*endocrine effect*' means the hormone is released from the site of origin enters the circulation and reaches the target site to exert its effect.

Hormone receptors: These are the specific receptor sites on the cell membranes called *hormone receptors* which recognise the hormones and translate them into biochemical effect.

Nature of the hormones: The hormones are either (i) *polypeptide* and *glycoproteins* or (ii) *amino acid analogues* and their derivatives and (iii) *steroids* in nature.

Functions of Hormones

- Growth, development and cell differentiation
- Development and differentiation of sex organs
- Control of reproductive function
- Metabolic functions such as control of carbohydrates, proteins and fat metabolism
- Regulation of water, electrolyte and mineral metabolism
- Adaptation to stress.

Level of Hormonal Production and their Sites of Actions (Fig. 20.1)

The hormones are produced at three levels, i.e. hypothalamus (releasing hormones), pituitary (trophic or stimulating

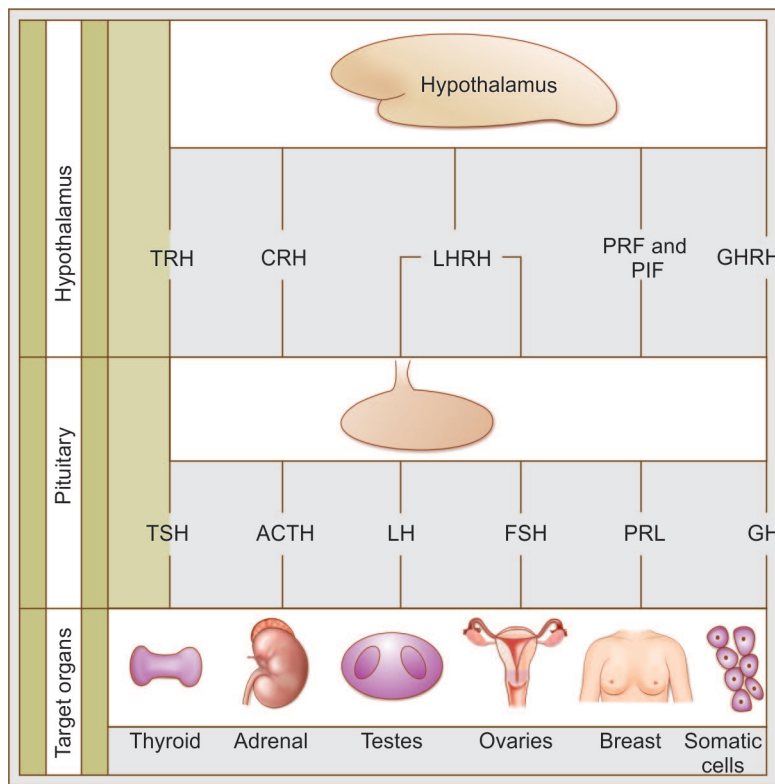


FIGURE 20.1 Hierarchy of endocrine system

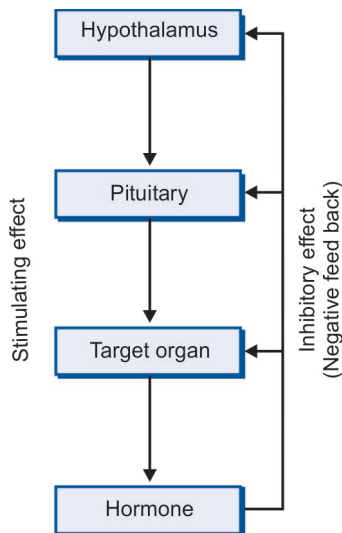


FIGURE 20.2 Feedback system of hormone regulation

hormones) and target organ such as thyroid, parathyroid, adrenals, gonads etc. (active hormones or prohormones).

Feedback system (Fig. 20.2): In endocrinology, there is a feedback system of regulation of secretion of various hormones. Each hormone feeds back on the cell producing or releasing a stimulatory hormone which either enhance or suppress its own secretion and secretion of other glands (negative feedback).

The inter-relationship between target hormones and trophic hormones: For diagnostic work-up of a case with endocrine disease, it is necessary to understand the relationship of target hormones and trophic hormones. The various hormones operate through hypothalamus-pituitary-target organ axis in which there are possibilities on hormone measurement (Fig. 20.3).

Clinical Presentation

- The manner in which patients with endocrine disease present is extremely varied, reflecting the protein effects of hormone excess or deficiency.
- Most patients with endocrine disease present with non-specific symptoms. Often patients are first referred to other specialist clinics—for example, dermatology (pruritus of hyperthyroidism), cardiology (dysrhythmia of hyperthyroidism or pheochromocytoma), and diabetes (glycosuria of Cushing's syndrome).
- Duration of symptoms before diagnosis is also variable. The average duration of symptoms before consultation in Graves' thyrotoxicosis is 6 months; young patients often present more acutely. Most endocrine syndromes are insidious in onset, and are often diagnosed by chance

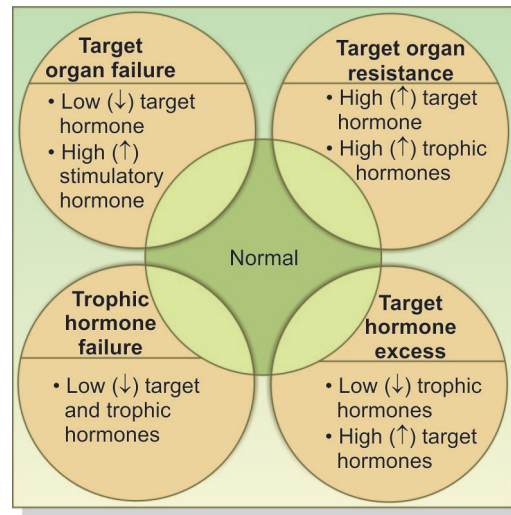


FIGURE 20.3 The relationship between target hormones and their trophic (stimulatory) hormones. The unshaded lined areas show borderline or subclinical states

(e.g. routine blood tests may detect hypercalcaemia or hypothyroidism), or when a change in appearance is noted by a friend or relative who has not seen the patient for some time (e.g. acromegaly or Cushing's syndrome), or when an acute complication arises (e.g. a hypoadrenal 'crisis' in Addison's disease or hypopituitarism, or pain following bleeding into a nodule in multinodular goitre).

- Apart from thyroid disease and diabetes mellitus, endocrine disease is relatively rare. So, although headache may be presenting complaint in patients with pituitary tumours, not every patient with headache is harbouring a macroadenoma stretching the diaphragma sellae. Similarly, obesity is much more likely to be idiopathic than to be caused by hypothyroidism or Cushing's syndrome.

Asymptomatic Endocrine Disease

This may be detected as a result of screening or indiscriminate biochemical testing; the most common being.

- Subclinical hypothyroidism (raised serum TSH, normal T_4)
- Hyperglycaemia (e.g. impaired glucose tolerance)
- Mild primary hyperparathyroidism with serum calcium concentrations between 2.70 and 2.90 mmol/L.

Influence of Gender

- Endocrine disease is more common, and often more obvious, in women. Hyperprolactinaemia causes galactorrhoea, amenorrhoea/oligomenorrhoea and infertility in the female and, as these symptoms usually prompt an early visit to the general practitioner, any underlying pituitary tumour (prolactinoma) is likely to be small.

- In the male the only symptom of hyperprolactinaemia may be impotence and, because of embarrassment or an acceptance that the problem may be age-related, any pituitary tumour is usually large at the time of presentation with headache, features of hypopituitarism or compression of surrounding structures, such as the optic chiasma.

History

Present History

Maximum information can be gathered on the history in a patient with endocrinal disease. The patients of endocrinal disorders present with multiplicity of symptoms pertaining to various system, hence, symptomatic enquires are essential for differential diagnosis of the symptoms. Similarly endocrinopathy may involve one gland or multiple glands simultaneously, subsequently needs a high degree of suspicion on the history. This is because treatment of one condition may cause worsening of other and because familial endocrinal syndromes do occur, hence, it is mandatory to take detailed history for systemic effects of the disease. In the present history, ask for:

- Chronological order of the symptoms and do their analysis (Table 20.1)
- Onset of symptoms, their progression and course
- Full drug history including oral contraceptive pills and replacement hormonal therapy.

Past History

- Details of previous pregnancies (case of conception, postpartum haemorrhage—PPH)
- Previous surgery (e.g. thyroidectomy or orchidopexy)
- Radiation to neck, gonads, thyroid
- Drug treatment, e.g. chemotherapy, oral contraceptives
- In children—ask for developmental milestones and growth.

Family History

Ask about family history of:

- Autoimmune disease
- Endocrine disease
- Essential hypertension
- Diabetes mellitus.

Take family details of:

- Height and weight
- Body habitus
- Hair growth
- Age of sexual development.

TABLE 20.1 Common presenting symptoms of endocrinal disorders

Symptom	Most likely endocrine disorder(s)
<i>Lethargy and depression</i>	Hypothyroidism, diabetes mellitus, hyperparathyroidism, hypogonadism, adrenal insufficiency, Cushing's syndrome
<i>Weight gain</i>	Hypothyroidism, Cushing's syndrome, adiposogenital syndrome, obesity
<i>Weight loss</i>	Hyperthyroidism, adrenal insufficiency, diabetes mellitus (type 1), hypopituitarism, anorexia nervosa
<i>Amenorrhoea oligomenorrhoea</i>	Menopause, polycystic ovarian syndrome, hyperprolactinaemia, hyperthyroidism, premature ovarian failure, Cushing's syndrome
<i>Polyuria and polydipsia</i>	Diabetes mellitus, diabetes insipidus, hyperparathyroidism, Conn's syndrome
<i>Heat intolerance</i>	Hyperthyroidism, menopause
<i>Palpitations</i>	Hyperthyroidism, pheochromocytoma, Conn's syndrome
<i>Thyroid nodule</i>	Solitary thyroid nodule, dominant nodule in multinodular goitre
<i>Generalised thyroid enlargement</i>	Graves' disease, Hashimoto's thyroiditis
<i>Pain over thyroid</i>	Haemorrhage into nodule, de Quervain's thyroiditis, rarely Hashimoto's thyroiditis
<i>Prominence of eyes</i>	Graves' disease
<i>Hirsutism</i>	Idiopathic, polycystic ovarian syndrome congenital adrenal hyperplasia, Cushing's syndrome, androgen secreting ovarian and adrenal tumours
<i>Galactorrhoea</i>	Hyperprolactinaemia (due to tumour, hypothyroidism, drug-induced, idio-pathic)
<i>Impotence</i>	Hyperprolactinaemia, hypogonadism, diabetes mellitus
<i>Visual dysfunction</i>	Pituitary tumour, Grave's disease (e.g. <i>exophthalmic ophthalmoplegia</i>).
<i>Headache</i>	Acromegaly, pituitary tumour, pheochromocytoma
<i>Muscle weakness (usually proximal)</i>	Hyperthyroidism, Cushing's syndrome, hypokalaemia (e.g. Conn's and iatrogenic steroid therapy syndrome), hyperparathyroidism, hypogonadism, acromegaly, vitamin D deficiency and osteomalacia
<i>Paraesthesiae and tetany</i>	Hypoparathyroidism
<i>Recurrent ureteric colic</i>	Hyperparathyroidism
<i>Coarsening of features</i>	Acromegaly, hypothyroidism

Social History

- Details of alcohol intake
- Details of occupation, e.g. access to drugs, chemicals
- Diet, e.g. salt, iodine, liquorice
- Menstrual history particularly in young women.

General Physical Examination (GPE)

The physical signs in endocrinal diseases arise either locally such as thyroid enlargement and its local effects, or due to systemic effects of the hormones (Table 20.2).

- *Observe the general appearances. Assess the state of hydration. Measure the height, weight and calculate the BMI (kg/m²).*

The various external appearances in various disorders have already seen described in Chapter 3.

Normal body mass index (BMI) in men is 20–25 and in women is 18–24. The BMI > 30 kg/m² is labelled as *obesity*. Obesity in endocrinal disorder is associated with Cushing's syndrome, hypothyroidism, Adiposogenital syndrome etc.

The causes of weight loss have been described in Table 20.1.

Tall stature is seen in endocrinal diseases, e.g. Gigantism, Kallmann's syndrome (hypogonadotrophic hypogonadism), Laurence-Moon-Biedl syndrome, Klinefelter's syndrome, and connective tissue diseases (e.g. Marfan's syndrome).

Short stature (dwarfism) may be seen in heredofamilial disorders (Down's syndrome, Turner's syndrome), metabolic disorders (Rickets, osteomalacia, PEM, chronic renal failure), endocrinal disorders (hypothyroidism, hypopituitarism) and GI disorders (e.g. coeliac disease, Crohn's disease, steatorrhoea, cystic fibrosis).

TABLE 20.2 Physical signs of endocrinal diseases

<p>I. General</p> <ul style="list-style-type: none"> • Appearance/look/external features • Stature (short or tall) • Eunuchoidism (measure upper and lower body segment and calculate their ratio) • Weight (increased or reduced) • Temperature (high or low) • Pulse rate (high/low) • Respiration (rate/rhythm) • Blood pressure (lying down and standing) <p>II. Local signs</p> <ul style="list-style-type: none"> • Neck swelling • Thyroid enlargement, e.g. note size, shape temperature, nodularity, tenderness and bruit <p>III. Signs due to systemic effects</p> <p><i>(i) Cardiovascular</i></p> <ul style="list-style-type: none"> • Look for postural drop of BP • Signs of autonomic dysfunction • Arrhythmias (irregularly irregular pulse due to atrial fibrillation or VPCs). • Signs of congestive heart failure <p><i>(ii) Eyes</i></p> <p>Look for:</p> <ul style="list-style-type: none"> • Xanthelasma • Corneal calcification-band keratopathy • Proptosis/exophthalmos (unilateral/bilateral) • Ophthalmoplegia (external/internal/complete) • Lid retraction • Lid lag sign • Failure of furrows on looking up • Visual acuity/field defect • Fundus examination for retinopathy or optic atrophy 	<p><i>(iii) Neurological</i></p> <ul style="list-style-type: none"> • Generalised muscle wasting • Proximal myopathy • Peripheral neuropathy • Carpal tunnel syndrome • Gait abnormalities/ataxia • Tendon reflexes (exaggerated/delayed/absent) • Induction of tetany in a patient with hypocalcaemia <p><i>(iv) Reproduction and sex</i></p> <ul style="list-style-type: none"> • Failure of appearance of secondary sexual characters • Gynaecomastia • Delayed puberty • Galactorrhoea • Precocious puberty • Enlargement of clitoris <p><i>(v) Skin</i></p> <p>Look for the followings:</p> <ul style="list-style-type: none"> • Hirsutism • Thin and sparse hair • Skin thickening/thinning (localised, generalised) • Dry/wet skin • Pigmentation (localised, generalised, mucous membrane) • Striae (pink/white) • Palmar erythema • Necrobiosis lipoidica diabetorum <p><i>(vi) Extremities</i></p> <ul style="list-style-type: none"> • Long or short • Long/short hands and longer fingers • Spade like hands • Finger clubbing • Short 4th and 5th metacarpals • Subcutaneous nodules (xanthomatosis), gangrene of fingers or toe(s) • Ulceration or pressure sores • Loss of finger(s) or toes • Oedema of feet (pitting or nonpitting)
--	--

- *If person is tall, measure body proportions. In case of obesity, note the redistribution of fat.*

Eunuchoidism is confirmed by measurement of body proportions (e.g. lower body proportion or leg length measured from the ground to symphysis pubis) exceeds the upper body proportion or sitting height (symphysis pubis to top of head). It can also be confirmed by measuring the arm span (distance between middle fingers of extended arms of both upper limbs) that exceeds total height (ground to top of the head). Eunuchoidism is a feature of hypogonadism and Marfan's syndrome (see Fig. 3.4).

Truncal obesity is seen in patients with Cushing's syndrome, adiposogenital syndrome and obese type 2 diabetes mellitus.

- *Look for the vital signs, e.g. pulse, BP, temperature and respiration.*

Tachycardia is seen in hyperthyroidism, phaeochromocytoma and Conn's syndrome.

Bradycardia is seen in hypothyroidism.

Hypertension is seen in hyperthyroidism, hypothyroidism, phaeochromocytoma, Conn's syndrome.

Hypotension is seen in Addison's disease.

Rise in temperature is seen in hyperthyroidism while low body temperature occurs in hypothyroidism.

Respiration may be increased in thyrotoxicosis, slow in hypothyroidism.

Examination of the Skin

- Examine the skin for *hair* (thin, sparse, hirsutism or loss) *moistness* (dry or wet), *thickness* (rough and thick or fine and thin), *pigmentation* (localised, generalised, mucous membrane), *striae* (pink, white) and for any *erythema* (redness of palms) and *nodules*.

Androgenetic alopecia or frontal baldness (miniaturisation of hair follicle) is seen in males and females due to androgen excess.

Diffuse hair loss is seen in both hyperthyroidism and hypothyroidism.

Thin, shiny hair are seen in hyperthyroidism; while sparse hair are seen in hypothyroidism.

Thick (toad-like Fig. 20.4), rough and dry skin is seen in hypothyroidism while skin is fine and moist in hyperthyroidism and phaeochromocytoma. Localised thickening particularly on the anterior aspect of the leg (pretibial myxoedema) is one of the features of Grave's disease (dermopathy).

Marked thinning of skin (skin atrophy) with ulceration in the anterior tibial region may be due to necrobiosis lipoidica diabetorum seen in diabetes mellitus.

Generalised pallor occurs in panhypopituitarism. In hyperthyroidism, the skin is wet, hot not flushed while in hypothyroidism, it is dry, pale-yellow and there is loss of hair on the lateral third of eyebrows.

Diffuse skin pigmentation (palmar creases, exposed parts of the body) with buccal and circumoral pigmentation is seen in Addison's disease. Excessive pigmentation occurs in Cushing's syndrome.

Patches of depigmentation or vitiligo may also be seen in Addison's disease and autoimmune hyperthyroidism or prolonged steroid therapy.

Pink or violaceous striae are seen in Cushing's syndrome.

Multiple small subcutaneous nodules/xanthomas are seen in hyperthyroidism or hyperlipidaemia seen in patients with diabetes mellitus or familial hyperlipidaemia. There may be associated xanthelasmas.

For hirsutism read case discussion in Bedside Medicine without Tears by Prof. SN Chugh.

- *In a patient with diabetes, look for the skin lesions common in diabetics*

- **Skin infections:** For example, boils, carbuncle, cellulitis, abscesses, mucocutaneous candidiasis, gangrene
- **Necrobiosis lipoidica diabetorum:** Erythematous plaques with brown waxy discoloration followed by atrophy and scarring of the skin in front of shin (pretibial region)
- **Diabetic dermopathy:** Hyperpigmented atrophic skin due to microangiopathy.
- **Diabetic stiff hands:** (e.g. cheiroarthropathy). There is stiffness of small joints with tight waxy skin over the dorsum of fingers.
- **Scleroderma-like thickening of skin:** Starting from neck and trunk, may become generalised.
- **Diabetic bullae:** Blistering and bullae formation on the skin of hands and feet without trauma. This is associated with polyneuropathy.
- **Granuloma annulare:** The condition is similar to necrobiosis lipoidica. In this, fleshy coloured annular, crescentic skin lesions are seen on the skin of extensor surface of fingers, hands, wrist, toes and ankles.
- **Eruptive xanthomas:** These are yellow coloured papules on the knee, elbow, back and buttocks due to associated hyperlipidaemia in diabetes.

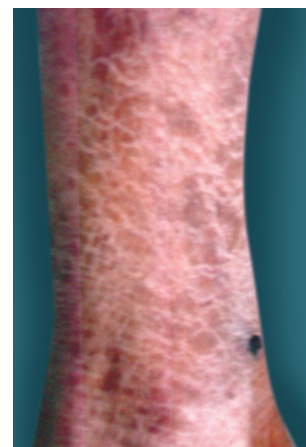

FIGURE 20.4 Skin in hypothyroidism the skin is dry, thick, rough with fine demarcations (toad-like). There is diffuse hair loss

- **Diabetic foot:** Foot ulceration at pressure points, digital necrosis, gangrene and infection are its components. It is due to neuropathy combined with vasculopathy and ultimately bone may be involved leading to osteomyelitis.

Examination of the Eyes

- *Look at the eyebrows, eyelids, eyelashes, eyeball, cornea, conjunctivae for any abnormality.*

Lid retraction leading to exposure of cornea is seen in Grave's disease.

Unilateral or bilateral exophthalmos (proptosis) is common in Grave's disease.

Oedema of lids or periorbital oedema with thickening of skin and loss or sparsity of hair is seen in hypothyroidism.

Recurrent styes, chalasion or blepharitis, conjunctivitis is common due to infection in diabetics. Xanthelasmas are seen in diabetes, hypothyroidism and hyperlipidaemia.

Paralytic squint occurs due to cranial nerve involvement in diabetes and, external ophthalmoplegia in Grave's disease.

Exposure keratitis, corneal ulceration may be seen in Grave's disease.

Corneal calcification is seen in hypercalcaemia due to hyperparathyroidism.

- *Test for visual acuity, visual field and ocular movements.*

Visual acuity is reduced in exophthalmic goitre (Grave's disease), hypothalamic-pituitary space occupying lesions and diabetes. Visual field defects are seen in pituitary tumours.

Visual loss is seen in diabetes and rapidly enlarging pituitary tumours.

Examine the ocular fundus for optic atrophy or retinopathy.

Optic atrophy is seen in compression due to pituitary tumour.

Retinopathy is seen in hypertension associated with endocrinal diseases and retinopathy due to diabetes (read diabetic retinopathy).

Look for various eyes signs (Read Synopsis of thyrotoxicosis later in this chapter) in case of thyrotoxicosis.

Examination of Neck

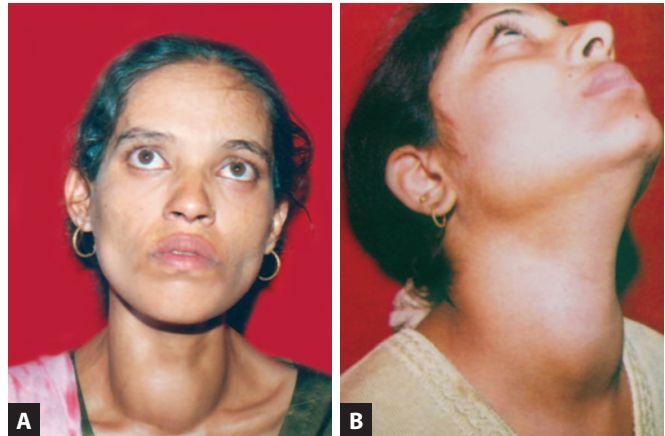- *Look for pulsations in the neck.*

Pulsations of carotid vessels and of other neck vessels are visible in thyrotoxicosis.

Inspection of Thyroid

Look at the thyroid region for the enlargement of thyroid (Fig. 20.5A). If thyroid is enlarged, look at the right and left lobes for their shape, size and presence nodule. Next see the isthmus for any nodule. Note the movement of the swelling on deglutition.

Thyroid enlargement causes swelling in the neck which encroaches the suprasternal notch and tries to obliterate it. The swelling moves with deglutition.



FIGURES 20.5A and B Inspection of thyroid: (A) Note the huge enlargement of thyroid with the obliteration of supraclavicular fossa. There is exophthalmos with visible sclera both above and below the cornea; (B) Pizzalo's method of demonstration of mild enlargement of thyroid

The causes of thyromegaly are:

- Goitre, e.g. simple or puberty, diffuse toxic (Grave's disease) and nontoxic and nodular (single or multiple nodules) toxic and nontoxic goitre
- Thyroiditis, e.g. viral, postpartum and autoimmune (Hashimoto's thyroiditis)
- Malignancy of thyroid.

If thyroid swelling is mild, then Pizzalo's method of inspection is used which makes the thyroid swelling more prominent (Fig. 20.5B).

- *In case of thyroid swelling, look for the distension of neck veins and veins over the upper thorax.*
Neck veins and veins over the upper thorax are distended and visible in retrosternal goitre.

- *If veins are prominent, try to establish the retrosternal extension of the goitre by asking the patient to raise both arms over the head and keep it there for a while.*

Suffusion of the face and increased dilatation of the veins over the chest during this manoeuvre indicates retrosternal goitre. This is due to obstruction of veins at thoracic inlet by the goitre.

- *In case of localised nontoxic thyroid swelling in the neck in a young person, ask the patient to protude the tongue to differentiate thyroid nodule from thyroglossal cyst.*

Thyroglossal cyst also produces midline swelling in the neck in thyroid region. Thyroid swelling and the thyroglossal cyst both move upwards on deglutition, but thyroglossal cyst also moves upwards with protusion of the tongue while thyroid swelling does not—a differentiating feature.

Palpation of Thyroid

The thyroid gland is easier to feel in a long slender neck than in a short stocky one. In shorter necks, added extension of neck may help. In some persons, thyroid is not amenable to physical examination because it is substernal. The steps for palpation of thyroid gland are given in the Box 1.

The temperature over the thyroid swelling is noted by placing back of the fingers over the swelling (Figs 20.6A and B). Tenderness is elicited by gentle pressure during palpation. Surface is judged by rolling the fingers over the thyroid. Fixity of the thyroid swelling is tested by moving the swelling from side to side and from above downwards.

Auscultation of Thyroid

Auscultate over the lateral lobes with bell of the stethoscope for a bruit (Fig. 20.7) if thyroid is enlarged.

One can auscultate the closed eyes for bruit. Ask the patient to close both the eyes. Place the bell of the stethoscope over each eye one by one for auscultation for bruit, the presence of which either in one eye or both the eyes indicates Grave's disease or cavernous arteriovenous fistula.

Abnormalities of the thyroid gland (Read also the Chapter 8).

Normally the thyroid gland is neither visible nor palpable. Goitre means thyroid enlargement the causes of which have already been discussed.

Thyroid enlargement is mild in simple goitre (see Fig. 8.16), moderate in thyroiditis (see Fig. 8.16B), a single thyroid nodule and in benign tumour and some cases of carcinoma, large in Grave's disease (see Fig. 20.4A) and multinodular goitre (Fig. 20.8). Goitre is soft in Grave's disease, firm in Hashimoto's thyroiditis and hard in thyroid malignancy and Riedel's thyroiditis.

Thyroid tenderness is seen in thyroiditis.

Thyroid temperature is raised in Grave's disease, multinodular goitre.

A localised systolic or continuous bruit may be heard in hyperthyroidism.

A single focal nodule suggests either a cyst or an adenoma or thyroid carcinoma.

- If thyroid is enlarged, note for its pressure effects, e.g. dysphagia (pressure on oesophagus), dysphasia or stridor (pressure on trachea) or hoarseness of voice (recurrent laryngeal nerve involvement) or Horner's syndrome (sympathetic trunk involvement).

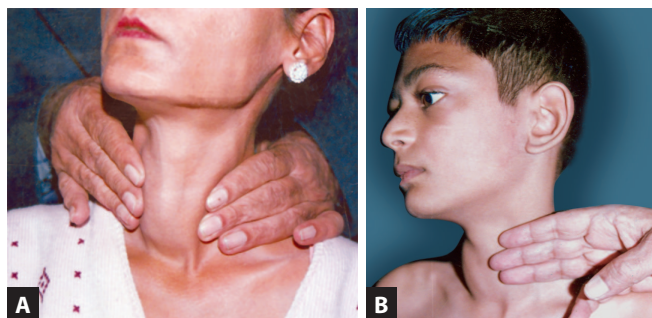
Pressure on the trachea can be confirmed by Kocher's test, i.e. pushing the trachea from one side will compress the lateral lobe and subsequently the trachea leading to stridor.

- Note the toxic manifestations. These are discussed under thyrotoxicosis. Fine tremors can be seen on extending hands in front of the body.

Box 1

Method of palpation of the thyroid gland (Figs 20.6A and B)

- The patient is made to sit comfortably. The examiner should stand behind the patient.
- Ask the patient to flex the neck so as to relax sternomastoid muscles.
- Place the fingers of both hands on the patient's neck so that your index fingers lie just below the cricoid cartilage.
- Ask the patient to sip some water or perform act of deglutition. Feel for the isthmus of thyroid moving up under your finger pulps (pads). It is often but not always palpable.
- Now try to displace the thyroid to one side with the fingers of the hand of other side. Palpate one lateral lobe of the thyroid. Now perform the same act on the other side and palpate the other lobe.
- Try to define the lower limit of the thyroid.
- Alternatively, Lahey's method for palpating each lobe from the front instead of the back may often be more helpful.
- *Note the size, shape, temperature, tenderness, consistency, nodularity and fixation of the thyroid swelling.*
- To get below the thyroid place your index finger over the lower border of thyroid and now ask the patient to swallow. The thyroid swelling moves up and you can reach the lower limit. You cannot reach the lower limit in retrosternal and large goitres.



FIGURES 20.6A and B Palpation of the thyroid: (A) Method of palpation; (B) Testing for the warmth/temperature of thyroid

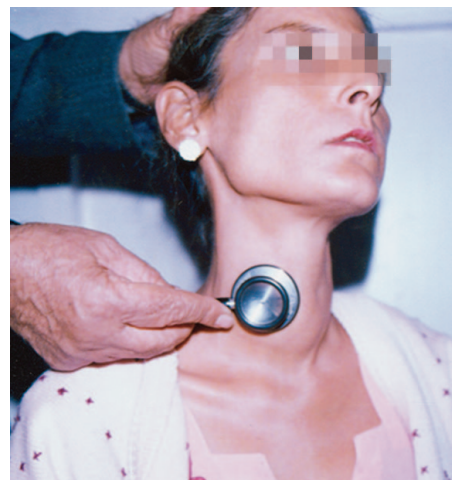


FIGURE 20.7 Auscultation of thyroid for a bruit




FIGURE 20.8 Multinodular goitre with retrosternal extension (patient had stridor)

- Ascertain whether there are features of hypothyroidism (read hypothyroidism).
- To complete the examination of neck, palpate the cervical lymph nodes.

Palpable and enlarged cervical lymph nodes with goitre indicate malignancy of thyroid.

- Measurement of thyroid swelling. It is difficult to measure the thyroid gland in isolation, however, measurements of neck at the most prominent part of the swelling is employed to assess the increase or decrease in the size of the thyroid swelling during treatment.

Examination of Breast

The examination of breast and axillae has been discussed under chapter 9. Examine the breast for endocrinological point of view as follows:

- *Examine the male breast for gynaecomastia* (Read chapter 9 also and see Figs 9.7 and 9.8).

Gynaecomastia means enlargement of male breast similar to female. This can be detected by palpation with palm of the hand or palpation of breast tissue with fingers for any nodule.

The presence of subareolar nodule >0.5 cm in diameter suggests gynaecomastia which may be physiological or pathological.

Pathological gynaecomastia must be suspected when the glandular tissue or nodule is >4.0 cm in diameter or is gradually progressive.

Gynaecomastia must be distinguished from subareolar fat deposition by texture and shape of the breast. Comparison of the breast with nearby subcutaneous tissue provides a definite diagnosis.

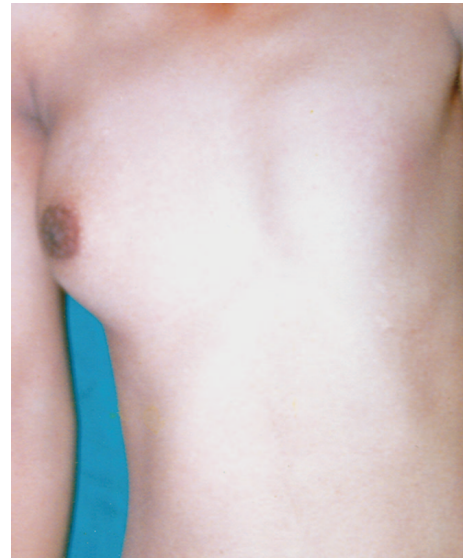

FIGURE 20.9 Gynaecomastia (right breast)

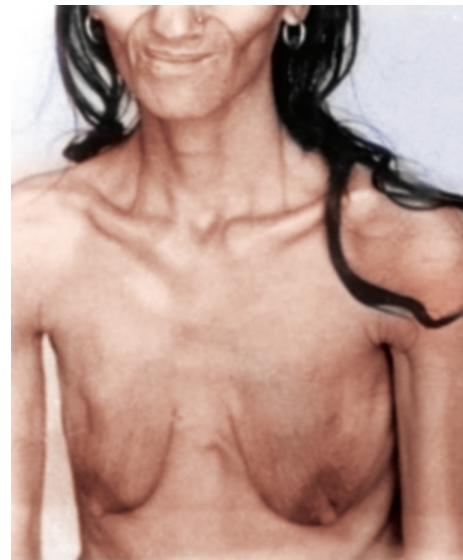

FIGURE 20.10 Sheehan's syndrome. Note the atrophy of the breasts with failure of lactation

- *Note whether gynaecomastia is unilateral* (Fig. 20.9) or bilateral.
- *Note whether breast enlargement is associated with generalised adiposity. Note the consistency and tenderness.*

True gynaecomastia is hard and tender (Read the causes of gynaecomastia in Table 9.3, Chapter 9).

Mammoplasty is soft gynaecomastia occurs following oestrogen therapy:

- *Examine the female breast for atrophy* (Fig. 20.10).

Breast atrophy in females is seen in Addison's disease, Sheehan's syndrome and panhypopituitarism.

- Also ask about any discharge from the nipples and when it occurs. Does it occur on squeezing the nipple or is spontaneous.

Inappropriate secretion of milk in a nonlactating female is called *galactorrhoea*, may be *physiological*, i.e. occurs only after squeezing the nipple or *pathological* (i.e. occurs spontaneously and can be seen as wetting of bra or night clothes without local stimulation).

- Try to demonstrate galactorrhoea by compressing the areola with your index finger placed in radial position around the nipple.

Milky discharge in nonlactating female (see Fig. 9.6 in chapter 9) should be investigated. It could be due to hormones or drugs.

- Is it unilateral or bilateral?

Galactorrhoea invariably is either due to hyperprolactinaemia (prolactin secreting tumour, hypothyroidism, drugs, idiopathic) or due to increased sensitivity to prolactin.

Examination of Genitalia

The genital examination has already been discussed under the examination of abdomen genitourinary system examination (Chapter 14). Here, the examination of testes and ovaries being a part of endocrine system will be discussed.

Inspection of testes and secondary sexual characters.

- Look at the amount and distribution of body hair including beard growth, axillary hair and pubic hair. Note the presence of male pattern baldness. Note the presence of gynaecomastia and galactorrhoea as already described.

The failure of development of secondary sexual character indicates prepubertal hypogonadism (Fig. 20.11A). While loss of libido and impotence suggest post-pubertal hypogonadism (Fig. 20.11B).

Appearance of primary and secondary sexual characters in a male or female before 7 years of age is called *isosexual precocious puberty* (Fig. 20.12).

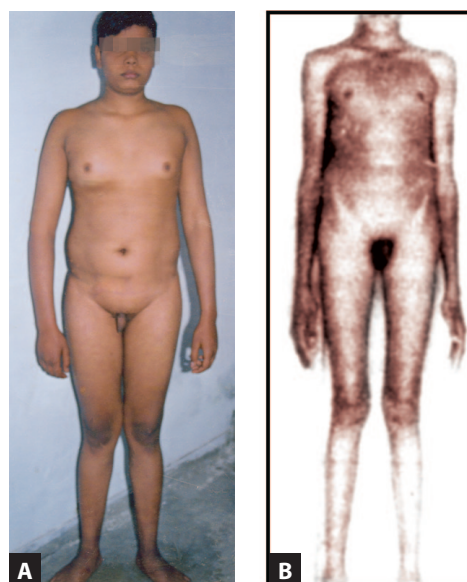- Note the presence or absence of testes in the scrotum. Absence of testes in the scrotum is called *anorchia* while hidden testes with empty scrotum is called *cryptorchidism*. (see Fig. 14.38).

Assess the testicular volume by palpation as well measure its volume by *prader orchidometer*.

Prepubertal testicular volume is < 4 mL. Increased volume implies pubertal gonadotropin stimulation.

The approximate ranges of testicular size are as follows:

Age	Testicular volume	Testicular length in cm	Testicular width in cm
Prepubertal	3–4	<3	<2
Postpubertal	4–15	3–4	2–3
Adult	20–30	4.5–5.5	2.8–3.3



FIGURES 20.11A and B (A) Prepubertal hypergonadotrophic hypogonadism (Klinefelter's syndrome—46 XXY). Note the small penis with very small testes which are firm on palpation. Note bilateral gynecomastia and Eunuchoidism; (B) Hypogonadotrophic hypogonadism (Kallmann's syndrome). Note the tall stature with small testes and penis. The patient had associated *anosmia*

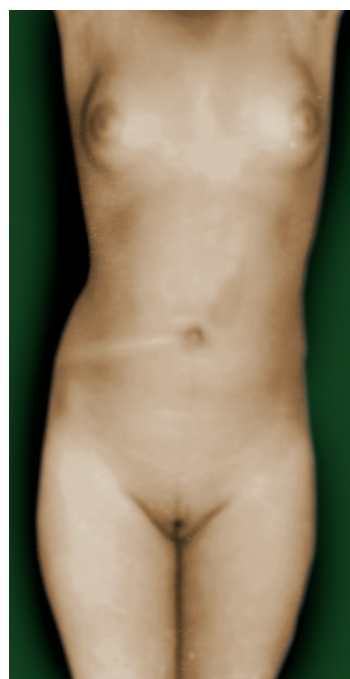

FIGURE 20.12 Isosexual precocious puberty in a 7 years sold girl. Note the enlarged breasts and genital parts resembling an adult female

- Note the consistency of the testes.

The testes are small and firm in Klinefelter's syndrome (Fig. 20.11A) and prepubertal hypogonadism (Fig. 20.11B). The testes are soft and small in acquired hypogonadism or postpubertal hypogonadism.

- Inspect the external genital parts in female. Note the signs of virilisation.

Enlargement of clitoris is a feature of androgen excess. The signs of virilization are deepening of the voice, temporal balding, clitoromegaly and increased muscle mass.

Hypogonadism

Hypogonadism means hypofunctioning of the gonads which manifests either by deficiency in gametogenesis and/or secretion of gonadal hormones. Symptoms of hypogonadism depend primarily on the age of the patient at the time of development. Hypogonadism is seldom recognised before the age of the puberty unless it is associated with growth retardation or other anatomic or endocrine abnormalities. The features of hypogonadism in males and females are given in the Table 20.3. The causes of hypogonadism are listed in Table 20.4. The *primary* hypogonadism means involvement of gonads *while secondary* is due to hypothalamic pituitary disease. The primary hypogonadism may be hypergonadotrophic (↑gonadotrophin) or hypogonadotrophic (low gonadotrophins) hypogonadism.

Examination of the Extremities

- Look at the hands, fingers, feet and toes for any abnormality in shape and size of fingers or any other abnormality.

Systemic Examination

The main systems involved in endocrinological disorders are, cardiovascular and nervous system. The examination of both these systems has been dealt as separate chapters. The same steps of examination are applied here. However, the findings in the system are summarised in Table 20.5:

- In case of carcinoma thyroid, always look for the metastatic manifestations in the lungs, liver and bone both clinically and on investigations.
- In case of anaplastic carcinoma of thyroid, even nonmetastatic manifestations may occur. These should be looked and patient should be investigated.

Investigations of a Case with Endocrinal Disorders

Most diagnosis in endocrinology are based on results of biochemical investigations. A clear understanding of these tests is crucial, guided by the principles outlined in the Box 2.

Stimulation and Suppression Tests Used in Endocrinology

General

Different laboratories have slightly different reference ranges for and even slightly different protocols for these tests. Always

TABLE 20.3 Clinical features of hypogonadism

• Prepubertal hypogonadism (Fig. 20.11)	
<ul style="list-style-type: none"> <i>In male</i> <ul style="list-style-type: none"> Scanty pubic and axillary hair Eunuchoidism Reduced muscle mass and strength Gynaecomastia Persistent high-pitched voice Small testes, phallus and prostate 	<ul style="list-style-type: none"> <i>In female</i> <ul style="list-style-type: none"> Scanty pubic and axillary hair Eunuchoidism Reduced muscle mass Small atrophic breasts Change in voice Small atrophic uterus and tubes
• Postpubertal hypogonadism	
<ul style="list-style-type: none"> Loss of libido Impotence Progressive decline in muscle mass Oligospermia or azospermia 	<ul style="list-style-type: none"> Loss of libido Infertility Dry vagina and dyspareunia Primary amenorrhoea

TABLE 20.4 Causes of hypogonadism

• Hypothalamic-pituitary disease	
<ul style="list-style-type: none"> Hypopituitarism Kallmann's syndrome (hypogonadotrophic hypogonadism (Fig. 20.15)) Hyperprolactinaemia 	
• Primary gonadal disease (Congenital)	
<ul style="list-style-type: none"> <i>In male</i> <ul style="list-style-type: none"> Anorchia/Leydig cell agenesis Klinefelter's syndrome (46XXY) Enzyme defect -5 reductase deficiency 	<ul style="list-style-type: none"> <i>In female</i> <ul style="list-style-type: none"> Absent uterus, imperforate hymen Turner's syndrome (XO) Steroid biosynthetic defect
• Primary gonadal disease (Acquired)	
<ul style="list-style-type: none"> Testicular torsion Cryptorchidism Castration Chemotherapy/irradiation toxicity Infections, e.g. orchitis due to mumps Systemic diseases <ul style="list-style-type: none"> Renal failure, hepatic failure (cirrhosis) sickle cell disease Drugs and alcoholism 	<ul style="list-style-type: none"> Partial ovarian failure, e.g. resistant ovarian syndrome or polycystic ovarian syndrome Premature ovarian failure Ovariectomy Chemotherapy/irradiation toxicity Oophoritis or salpingo-oophoritis leading to blockage of fallopian tubes Partial ovarian failure, e.g. resistant ovarian syndrome or polycystic ovarian syndrome Systemic disorders <ul style="list-style-type: none"> Renal failure, cirrhosis liver, drugs

TABLE 20.5 Systemic examination in endocrinal disorders

CVS	Nervous system
<ul style="list-style-type: none"> Bounding pulses and wide pulse pressure indicate hyperthyroidism. Hypertension occurs in Conn's syndrome, Cushing's syndrome, thyrotoxicosis, phaeochromocytoma, thyrotoxicosis, hypothyroidism while hypotension occurs in Addison's disease Postural hypotension indicates autonomic dysfunction common in diabetics and hypoglycaemia. Arrhythmias (e.g. atrial fibrillation) are common in thyrotoxicosis Hyperdynamic circulation with flow murmurs occur in thyrotoxicosis. Ischaemic heart disease and CHF may occur in thyrotoxicosis, hypothyroidism and diabetes. 	<ul style="list-style-type: none"> Proximal myopathy with positive Gower's sign is seen in Cushing's syndrome, thyrotoxicosis and diabetic amyotrophy Periodic muscle paralysis is seen in Conn's syndrome Peripheral neuropathies with loss of tendon jerks are seen in diabetes Hyper-reflexia is seen in thyrotoxicosis and phaeochromocytoma while delayed relaxation of Jerks is seen in myxoedema Carpal-tunnel syndrome or entrapment neuropathy is seen in hypothyroidism, pregnancy etc. Ataxia or gait abnormalities are common due to peripheral neuropathy, myopathy, and osteomalacia

consult your own laboratory before performing complex, expensive and inconvenient tests. Also check what specimen is required (e.g. serum, plasma, urine) and whether any special handling is required (e.g. freezing).

The recent introduction of multichannel endocrine analysers by a number of different manufacturers increases the need for reference to local laboratory ranges and guidelines.

Date, time and sampling conditions (plus date of last menstrual period where appropriate) should always be noted on the request form as they are critical for interpretation.

Gonadal Axis

Basal Levels

Basal levels are often sufficient to indicate the site of the problem; they may also indicate the stage of the menstrual cycle or of puberty.

The international standard for I.U. may change during the publication of this book with resultant changes in reference ranges—please check your own laboratory for their new values. Basal levels of sex hormones are displayed in Box 3.

Box 2

Principles of endocrine investigation

Timing of measurement

- Release of many hormones is rhythmical (e.g. pulsatile, circadian or monthly), so random measurement may be invalid and sequential or dynamic tests may be required.

Choice of dynamic biochemical tests

- Abnormalities are often characterised by loss of normal regulation of hormone secretion
- If hormone deficiency is suspected, choose a stimulation test
- If hormone excess is suspected, choose a suppression test
- The more the tests available to choose from, the less likely is that any single test is infallible, so do not interpret one result in isolation.

Imaging

- Secretory cells also take up substrates, which can be labelled
- Most endocrine glands have a high prevalence of 'incidentalomas', so do not scan unless the biochemistry confirms endocrine dysfunction or the primary problem is a tumour.

Biopsy

- Many endocrine tumours are difficult to classify histologically (e.g. adrenal carcinoma and adenoma).

Box 3

Basal levels of sex hormones

Adult male

Testosterone	10–35 nmol/L
Luteinizing hormone (LH)	1–10 U/L
Follicle-stimulating hormone (FSH)	1–7 U/L

Adult female

	Follicular	Mid-cycle	Luteal	Post menopausal
LH (U/L)	2.5–21	25–70	1–10	>50
FSH (U/L)	1–10	6–25	0.3–21	>25
Oestradiol (pmol/L)	<110	500–1100	300–750	<150
Progesterone (nmol/L)	<12	–	>30	<3
Testosterone (nmol/L)	0.5–3.0			

LHRH Test

The 100 µg of luteinizing hormone releasing hormone (LHRH) is given intravenously via an indwelling catheter at time 0; samples are taken at time 0, +20 and +60 min for LH and FSH. Normal responses are:

Normal response	20 min	60 min
<i>Female (follicular phase)</i>		
LH (U/L)	15–42	12–35
FSH (U/L)	1–11	1–25
<i>Male</i>		
LH (U/L)	13–58	11–48
FSH (U/L)	1–7	1–5

Sperm counts/seminal fluid analysis

Volume	2–6 mL
Density	20–200 × 10 ⁶ mL ⁻¹
Motility	>60% motile

Full assessment of normal and abnormal forms is needed for fertility work.

Prolactin

Stress can affect prolactin levels. To establish a definite abnormality several samples should be taken, ideally through an indwelling venous catheter.

Normal levels are <400 mU per litre in most laboratories. The significance of minor increases (400–600 mU/L) is disputed. Levels of 2000–5000 mU/L are strongly suggestive of a prolactinoma but can occur with other tumours/stalk disconnection.

Growth Axis

Basal Levels

Growth hormone (GH) release is episodic; however, an undetectable or very low level (<1 mU/L) on a random sample excludes acromegaly.

Acromegaly

In normal subjects, GH levels are suppressed to below 1–2 mU/l during an oral glucose tolerance test, but there is no effect in acromegaly.

GH Deficiency

In children, exercise and arginine are often used to stimulate GH secretion; a level above 20 mU/L is a normal response. The insulin induced hypoglycaemia test is, however, the optimal test for adults and children.

The insulin induced hypoglycaemia test should only be used for children when essential and must only be performed in expert centres with considerable expertise and constant medical supervision.

Insulin Test for GH Reserve

After an overnight fast, a rapid-acting human insulin is administered at 9 AM via an indwelling intravenous catheter. The dose is usually 0.15 U/kg body weight but should be 0.1 U/kg for hypopituitarism and 0.2–0.3 U/kg in cases of insulin resistance (e.g. acromegaly, Cushing's syndrome). Clinical hypoglycaemia and a blood glucose <2.2 mmol/L should be produced; if not, repeat the dose at 45 min. Samples are collected at 0, 30, 45, 60, 90 and 120 min.

The test should not be used in patients with epilepsy, heart disease or profound hypopituitarism—a normal ECG and a cortisol result > 150 nmol/L should be seen before the test. Syringes loaded with 50% dextrose and hydrocortisone must always be kept by the side during the test.

This test is also used to measure ACTH reserve (see below).

Thyroid Axis

Basal Levels

Levels of the thyroid hormones vary little by hour or day unless patients are acutely ill; basal levels thus are usually suffice. Normal thyroid profile is given in the Box 4.

TRH Test—now Much Less Used

The 200 µg of thyrotropin-releasing hormone (TRH) is given via an indwelling intravenous catheter at time 0 after a basal sample is collected; subsequent samples are taken at 20 and 60 min. Normal responses (levels of TSH) are given in the Box 5.

Box 4

Normal thyroid profile

Total serum thyroxine (T ₄)	60–160 nmol/L
Free serum thyroxine (fT ₄)	13–30 pmol/L
Total serum tri-iodothyronine (T ₃)	1.2–3.1 nmol/L
Free serum tri-iodothyronine (fT ₃)	3.8 pmol/L
Thyroid-stimulating hormone (TSH)	0.3–3.5 mU/L

Box 5

Normal TSH response to TRH

0 min	0.3–3.5 mU/L
20 min	3.4–20 mU/L
60 min	<20 mU/L
Increment	>20 mU/L

An excessive response indicates hypothyroidism; an inadequate one indicates either primary hyperthyroidism or pituitary disease.

Adrenal Axis

All cortisol values here refer to specific assay methods, e.g. radioimmunoassay, and not to fluorimetry.

Basal Levels

Adrenocorticotrophic hormone (ACTH) and cortisol levels vary episodically and with a circadian rhythm; single timed values are thus of limited use except at 9 AM exactly, the peak of the circadian rhythm, when cortisol values are predictive of response to a stimulatory test:

The cortisol < 100 nmol/L is highly predictive of adrenal/pituitary failure.

The cortisol > 500 nmol/L is highly predictive of intact adrenal/pituitary axis.

Intermediate values are essentially of little value. The basal levels of adrenal hormones are given in the Box 6.

Intravenous Synacthen Test

This is now frequently used as a safer and easier surrogate for the insulin test, though it tests only adrenal reserve. A basal cortisol sample is taken at 0 min, followed by intravenous Synacthen 250 mg, and a further sample taken at 30 min. A cortisol value >550 nmol/L is normal.

Short ACTH Stimulation Test

This test is used to exclude Addison's disease. After taking a first sample for cortisol, 0.25 mg of tetracosactrin is given at time 0. Further samples are taken at 30 and 60 min. Normal values are:

30 min	550–1160 nmol/L
60 min	690–1290 nmol/L
Increment	330–850 nmol/L

Box 7

Dexamethasone suppression tests

	Normal value		Comment
<ul style="list-style-type: none"> Overnight (Give 1–2 mg dexamethasone at bed time) 	Cortisol 9 AM	<100 nmol/L	<ul style="list-style-type: none"> • Screening test only • Confirm with low dose test
<ul style="list-style-type: none"> Low dose (48 hrs) Give 0.5 mg dexamethasone 6 hourly for 48 hours (8 doses) 	9 AM on day 0 and 2	< 50 nmol/L at the end of test	For diagnosis and differential diagnosis of Cushing's syndrome
<ul style="list-style-type: none"> High dose test, i.e. 2 mg 6 hourly for 48 hours (8 doses) 	-do-	-do-	

Dexamethasone Suppression Tests

These are used to exclude Cushing's syndrome. It is described in the Box 7.

Insulin Test

This can be used to measure ACTH reserve (read investigation of a reserve). It should be performed where morning cortisol is ≥ 150 nmol/L. A normal response to hypoglycaemia (<45 mg%) produces cortisol level ≥ 550 nmol/L.

Endocrinology of Blood Pressure and Thirst

Aldosterone (and plasma renin activity) should be measured at least 30 min of recumbency and possibly 4 hrs of ambulation. Normal response is given in the Box 8.

Thirst

As a screening test, measure osmolality of the plasma and urine (see Box 9).

Water Deprivation Test

Ask the patient to have free fluid intake at night. Start the test in the morning at 8.00 AM. Advise light breakfast, no coffee tea or smoking.

Box 6

The reference ranges of adrenal hormones

Reference ranges	0900 hours	2400 hours
	(must be asleep)	
Cortisol (nmol/L)	180–700	<150
ACTH (ng/L)	10–80	<10

Box 8

Normal values of aldosterone

Lying	100–500 pmol/L
Standing	200–1000 pmol/L

Box 9

Normal values of osmolality

• Plasma	275–290 mosm/kg
• Urine	above 600 mosm/kg

Maintain dehydration for 8 hrs with no access to fluids. Dry food is permitted. Plasma osmolality, urine osmolality and volume of the urine are measured hourly. Record the weight hourly also. Abandon the test if weight falls by > 3% of the body weight.

After 8 hours, give 2 mg desmopressin IM; continue urine collection hourly (2–4 samples are sufficient). Patient may drink but intake over 12 hours restricted to 1.5 L × volume excreted in dehydration period.

Results

- Normal person will maintain plasma osmolality. Urine osmolality rises due to urine concentration to > 800 mosm/kg during dehydration, unenhanced by desmopressin.
- In cranial diabetes insipidus (DI) urine will fail to concentrate during dehydration (e.g. urine osmolality does not rise); while plasma osmolality rises; this will be corrected by desmopressin with a urine osmolality > 800 mosm/kg. Persons with nephrogenic DI. Behave as cranial DI initially but do not concentrate urine after desmopressin.
- Patients with psychogenic polydipsia respond generally normally. Overlaps are, however not infrequent.

Endocrinal Imaging

- **Plain X-ray head for pituitary fossa** (AP and lateral view) may be helpful in detecting abnormal calcification and its enlargement due to pituitary tumour (Fig. 20.13).
Plain X-ray abdomen may show renal calcification, e.g. nephrocalcinosis in patients with long standing hypercalcaemia or renal tubular acidosis.
X-ray of soft tissue for heel pad (>23 mm) in case of acromegaly.
- **Ultrasonography:** It is useful to detect nodularity and enlargement of thyroid, to detect adrenal mass, to detect polycystic ovarian disease and to evaluate the genital organ in hypogonadism.

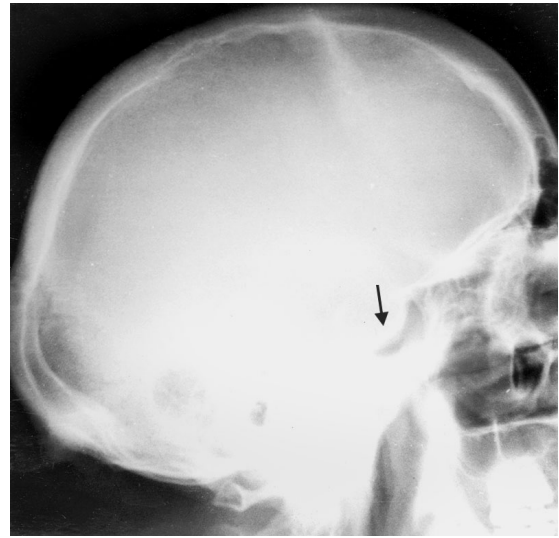
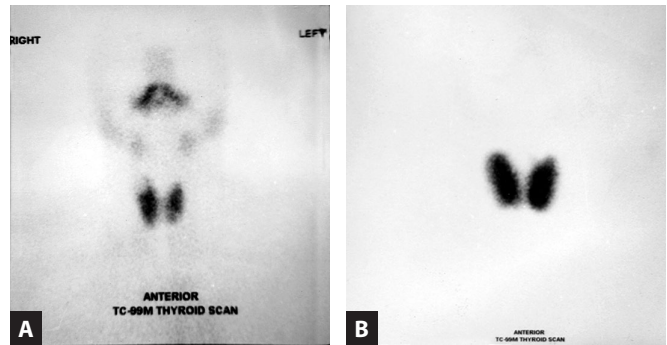


FIGURE 20.13 X-ray skull showing enlargement of pituitary fossa (↓) with destruction of clinoid processes



FIGURES 20.14A and B Isotope imaging of thyroid: (A) Normal thyroid scan; (B) Hyperthyroidism

- **CT scan:** It is useful in assessing the pituitary fossa (micro or macroadenoma), adrenal glands and thorax.
- **MRI of pituitary** offers definite advantage over CT scan as it not only detects the pituitary tumour but its intrasellar and suprasellar extensions also.
- **Isotope imaging:** It is particularly useful for demonstrating autonomous function within endocrine tumours. This technique is useful and done by different isotopes for different glands, i.e. radio-labelled pertechnetate for thyroid (Figs 20.14A and B). The adrenal cortex is scanned by radio-labelled solano cholestrol and adrenal medulla by radio-labelled meta-iodobenzylguanidine.

Serological Tests

- Antibodies can be produced in autoimmune endocrine disorders which can be detected by different serological tests or radioimmunoassay. Anti-peroxidase antibodies are present in higher titres in autoimmune thyroiditis.

BRIEF SYNOPSIS OF FEW COMMON ENDOCRINAL DISORDERS

Thyrotoxicosis (Table 20.6 and Fig. 20.15)

Clinical Presentations

- Patients usually present with goitre (swelling in the neck) with symptoms of thyrotoxicosis (listed in the Fig. 20.15). These are cases of Grave's disease and nodular goitre.
- Patients may present with unexplained weight loss inspite of good appetite, without any diarrhoea or malabsorption.
- Patients may present with arrhythmias (atrial fibrillation) especially old patients.
- The young patients present with symptoms of sympathetic overactivity, i.e. palpitations, nervousness, sweating, insomnia, tremulousness, weakness, menstrual irregularity (in females).
- Patients may present with psychiatric manifestations, e.g. irritability, anger, hyperactivity, depression.

Note: Patient present in variety of ways because thyrotoxicosis disturbs the general metabolism in such a way that every system is affected and patient may present with symptoms related to any system (Fig. 20.15).

Definitions

Thyrotoxicosis implies a state of hyperthyroidism in which the thyroid hormone is toxic to the tissues producing clinical features; while hyperthyroidism simply implies excessive thyroid function. However, both are not synonymous, yet are used interchangeably.

Grave's disease: It is an autoimmune disorder characterised by hyperthyroidism, diffuse goitre, ophthalmopathy and dermopathy (pretibial myxoedema) and thyroid acropachy (clubbing fingers). A thyroid scan and antithyroid antibodies (TPO, TRAb) are diagnostic.

Causes of Thyrotoxicosis (Box 10)

Methods of Demonstration

Lid Lag and Lid Retraction

Lid retraction means the upper eyelid is pulled higher up than the lower leading to exposure of the upper cornea (Fig. 20.4A).

Box 10

Causes of thyrotoxicosis

Common (> 95%)	Less common (3–5%)	Rare (< 1%)
<ul style="list-style-type: none"> • Grave's disease • Multinodular goitre • Autonomously functioning solitary thyroid nodule 	<ul style="list-style-type: none"> • Thyroiditis, e.g. subacute (de Quervain's) and postpartum • Drug induced (e.g. amiodarone, radioactive contrast media or iodine prophylaxis programme) • Factitious (self-induced) • Struma ovarii 	<ul style="list-style-type: none"> • Pituitary or ectopic TSH • Thyroid carcinoma

TABLE 20.6 Clinical manifestations of thyrotoxicosis


Symptoms		Signs	
Weight loss Increased appetite Irritability/behaviour change Restlessness Malaise Muscle weakness <i>Tremulousness</i> Vomiting Diarrhoea Eye complaints Goitre (diffuse, nodular) Oligomenorrhoea Loss of libido Gynaecomastia Onycholysis Tall stature (in children)		I. CNS Irritability Psychosis <i>Hyperkinesia</i> Tremors II. CVS Systolic hypertension Cardiac failure Tachycardia or atrial fibrillation Warm vasodilated peripheries Onycholysis Palmar erythema To and fro murmur	III. Eyes (Fig. 20.15) Exophthalmos Lid lag, lid retraction Conjunctival oedema Ophthalmoplegia IV. Thyroid gland Thyroid acropachy Pretibial myxoedema Goitre, bruit Weight loss V. Nervous system Insomnia Proximal muscle wasting (shoulder and hips) Peripheral neuropathy

FIGURE 20.15 Grave's disease. Note the diffuse goitre with exophthalmose. There were symptoms and signs of thyrotoxicosis in this patient. Note the presence at the baseline, of visible sclera between upper eyelid and upper limbus lower eyelid and lower limbus (Dalrymple sign)

It is due to overactivity of smooth muscles inserted into levator palpebrae superioris. In exophthalmos, the lower eyelid is also retracted exposing the lower sclerae (Fig. 20.15).

Lid lag means the upper lid cannot cope with the movements of the eyeball when patient looks downward following an examination finger moving downwards from above.

Both lid retraction and lid lag are not synonymous with exophthalmos. They are part of exophthalmos.

Exophthalmos (Proptosis)

It simply means protusion of the eyeballs within the orbit due to push from behind due to increase in retrobulbar fat or oedema or cellular infiltration. This results in the prominence of the eyeball, staring look, retraction of the eyelids, and clear visibility of the upper and lower sclera. Note the following signs:

One should look for the various eye signs (Box 11).

Method to Examine for Exophthalmos

Using direct light, look at the surface of cornea from the side relative to supraorbital and intraorbital rims. If the corneal surface extends anterior to the level of the bony orbital rims, then exophthalmos is present otherwise it is absent.

Ophthalmoplegia: This means weakness of extraocular muscles due to oedema or cellular infiltration leading to ptosis (Fig. 20.19) as a result of involvement of levator palpebrae superioris, inward eyeball movement (lateral rectus palsy) or outward deviation of the eyeball (medial rectus palsy). These muscles palsy result in diplopia and prevents the patient looking upwards and inwards.

Chemosis: It means oedema of the conjunctivae which become oedematous, thickened and wrinkled. It is due to venous and lymphatic obstruction of conjunctivae by proptosis.

Bruit: Auscultate with the bell of stethoscope over goitre for bruit. One can also auscultate for bruit over closed both eyes one by one. Bruit is present in Grave's disease.

Classes of Eye Signs in Thyrotoxicosis

Many scoring systems have been used to gauge the extent and activity of orbital changes in Grave's disease. As a mnemonic, the NO SPECS scheme is used to class the eye signs as follows:

- 0 = No sign or symptom
- 1 = Only sign (lid lag or retraction), no symptoms
- 2 = Soft tissue involvement (pretibial myxoedema)
- 3 = Proptosis (> 22 mm)
- 4 = Extraocular muscle involvement (diplopia)
- 5 = Corneal involvement
- 6 = Sight loss

Pretibial myxoedema: A sign of Grave's disease.

The name justifies the site of skin changes, i.e. over the anterior and lateral aspects of the lower leg. The typical skin change is noninflamed, indurated, pink or purple colour plaque giving an 'orange-skin' appearance. Nodular involvement can uncommonly occur.

Differential Diagnosis of Thyrotoxicosis

The two common conditions causing thyrotoxicosis are compared in the Table 20.7.

Hypothyroidism (Table 20.8 and Fig. 20.20)

Definitions

Hypothyroidism is clinical condition reflecting hypo-functioning thyroid gland, characterised by low levels of circulating thyroid hormones. It is called *primary* when the cause of it lies in the thyroid gland itself. It becomes *secondary* when hyperthyroidism occurs due to disease of anterior pituitary or hypothalamus.

Goitrous hypothyroidism means enlargement of thyroid gland associated with hypothyroidism.

Subclinical hypothyroidism means biochemical evidence of hypothyroidism (normal T₃ and T₄ but raised TSH) without any symptoms of hypothyroidism (asymptomatic hypothyroidism). The cause of subclinical hypothyroidism is same as described under transient hypothyroidism. It may persist for many years. Treatment with replacement therapy with small dose of thyroxine is indicated.

Transient hypothyroidism refers to a state of reversible thyroid function, often observed.

- During the first 6 months after subtotal thyroidectomy or ¹³¹I treatment of Grave's disease.
- Post-thyrotoxic phase of subacute thyroiditis
- Postpartum thyroiditis, i.e.
- In some neonates, transplacental passage of TSH receptors-binding antibodies (TRABs) from the mother with Grave's disease or autoimmune thyroid disease may cause transient hypothyroidism.

Congenital hypothyroidism is asymptomatic state detected during routine screening of TSH levels in blood spot samples obtained 5–7 days after birth. It results either from thyroid agenesis, ectopic hypoplastic glands or from dysmorphogenesis. Early detection and early treatment with replacement thyroxine therapy is mandatory to prevent irreversible brain damage.

Causes of Hypothyroidism

Read case discussion in Bedside Medicine without Tears by Prof. SN Chugh.

Box 11

Various eye signs in thyrotoxicosis

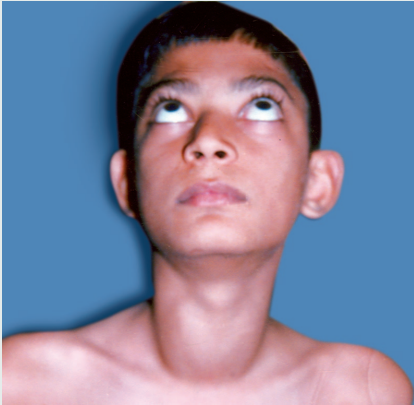

FIGURE 20.16 Loss of furrows on looking up — Joffroy's sign positive

Joffroy's sign: Slightly flex the neck with face looking downwards. Now ask the patient to make wrinkles over forehead by looking up. Absence of wrinkling indicates the sign is positive (Fig. 20.16).

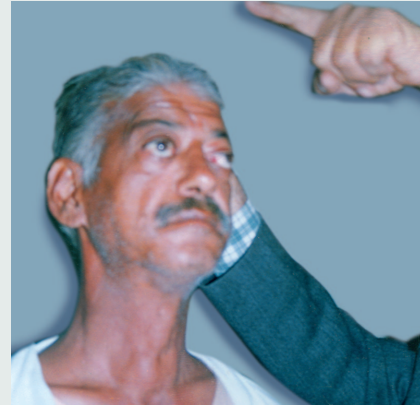

FIGURE 20.17 Failure of elevation of upper eyelids on looking upwards due to inactivity of levator palpebral superioris. The upper lid does not move due to levator palpebral muscle paralysis. In such a case lid lag sign cannot be elicited, i.e. negative

Von Graefe's sign (Lid lag, Fig. 20.17): Ask the patient first look straight. Bring your index finger in front of one eye. Now instruct the patient to follow the movements of the finger which is moved slowly from above downwards. The upper eyelid lags behind the eyeball which is easily appreciated.

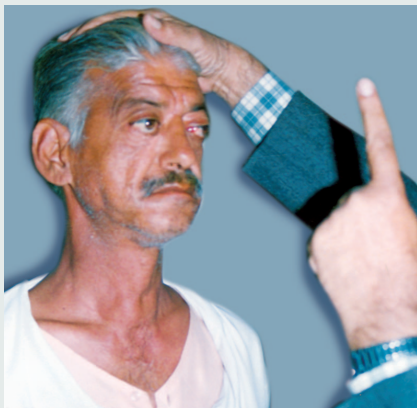

FIGURE 20.18 Failure of accommodation (internal ophthalmoplegia) in a patient of exophthalmos (moebius sign positive)

Moebius sign: This means inability or failure to converge the eyeball (Fig. 20.18) when a finger is brought in front of the eyes

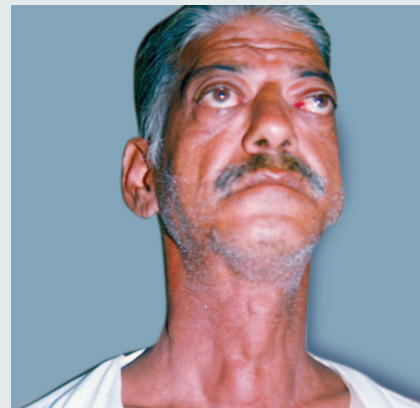


FIGURE 20.19 Lower palpebral conjunctiva is clearly visible in a patient of thyrotoxicosis with bilateral ptosis (external ophthalmoplegia). In a patient with ophthalmoplegia with ptosis, the visibility of the lower sclera indicates lid retraction

Darympie's sign (lid retraction): This means the visibility of lower or upper sclera due to retraction of the upper or lower eyelid (Fig. 20.19 and Fig. 20.15). Ask the patient to look straight, the visibility of lower or upper sclera indicate positive sign (see Fig. 20.15)

TABLE 20.7 Differential diagnosis of thyrotoxicosis

Feature	Grave's disease	Toxic multinodular goitre
Age	Young age	Old age
Sex	Common in females	Common in females
Goitre	Diffuse, firm, smooth. Bruit is heard commonly	Nodular, firm to hard, irregular surface. No bruit.
Eye signs	Common	Uncommon
Dermopathy (pretibial myxoedema)	May occur	Does not occur
Severity of thyrotoxicosis	Moderate to severe	Mild to moderate
Atrial fibrillation	Common	More common
Compression symptoms	Uncommon	Common
Cause	Autoimmune, may be associated with other autoimmune diseases	Autonomous
Treatment of choice	Drug therapy	Surgery or radioactive iodine

TABLE 20.8 The symptoms signs of adult hypothyroidism

Symptoms		Signs	
Tiredness/malaise	 <p>FIGURE 20.20 Clinical manifestations of hypothyroidism</p>	Mental slowness	Large tongue
Weight gain		Psychosis/dementia	Periorbital oedema
Anorexia		Ataxia	Deep voice
Cold intolerance		Poverty of movement	Goitre (sometime)
Poor memory		Deafness	
Change in appearance			
Depression		'Peaches and cream' complexion	Dry skin
Psychosis		Dry thin hair	Mild obesity
Coma		Loss of eyebrows	Myotonia
Deafness			Muscular hypertrophy
Poor libido/loss of libido		Hypertension	Proximal myopathy
Goitre in some cases		Hypothermia	Slow-relaxing reflexes
Puffy eyes or periorbital swelling		Heart failure	
Dry, brittle, hair		Anaemia	
Bradycardia		Pericardial effusion	
Dry, coarse skin			
Arthralgia		Cold peripheries	
Myalgia		Carpal tunnel syndrome	
Constipation		Oedema	
Menorrhagia or oligomenorrhoea in women			
A history from a relative is often rewarding			
Symptoms of other autoimmune disease may be present			

Simple goitre versus goitrous hypothyroidism: The difference between simple diffuse goitre and Hashimoto's thyroiditis are given in the Table 20.9.

Clinical Presentations

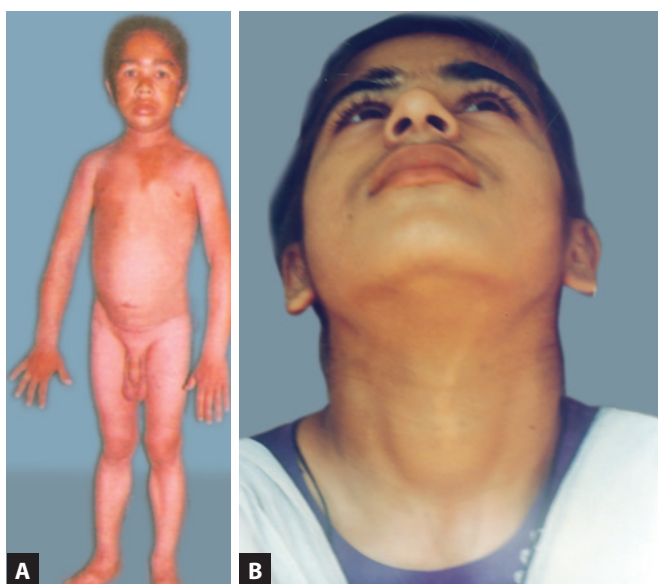- Infants (< 1 year) present with mental retardation, pot belly, large protruding tongue (macroglossia), flat nose, dry skin, sparse hair and delayed milestones of development,

other features of hypothyroidism are present. The condition is called *cretinism* (Fig. 20.21A).

- The adolescents with hypothyroidism, e.g. juvenile hypothyroidism (Fig. 20.21B) present with short stature, retarded growth, poor performance at school, delayed puberty and sexual maturation. Other features of adult hypothyroidism are present.

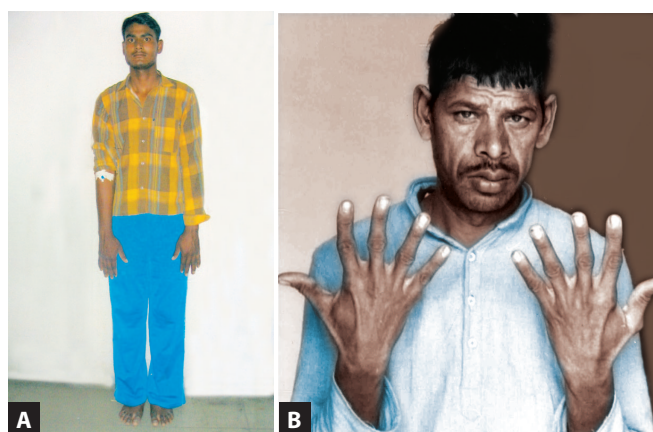TABLE 20.9 Differentiation between two common causes of diffuse goitre

Feature	Simple diffuse goitre (see Fig. 8.16A)	Goitre due to hashimoto thyroiditis (see Fig. 8.16B)
Age	Common in young girls (15–25 years) or during pregnancy	Common in young females (20–50 years)
Thyroid enlargement	Mild, tends to be noticed by friends and relative	Large
Goitre	Soft, nontender	Firm, tender
Prevalence	Endemic or sporadic	Sporadic
Symptoms	Asymptomatic or there is a tight sensation in neck.	Pain radiating to jaw or neck, increased during swallowing coughing and neck movement.
Cause	Suboptimal dietary iodine intake and minor degrees of dysmorphogenesis	Autoimmune disease.
Thyroid status	Normal become later on	25% cases are hypothyroid at presentation, others
Thyroid antibodies (TPO antibodies)	Negative	Positive (95% cases)



FIGURES 20.21A and B (A) Cretinism. A child showing short stature, retarded growth with coarse features (e.g. oedematous face, thick dry skin, thick lips etc.). He had mental retardation. He developed these features at the age of one year; (B) Juvenile hypothyroidism in a 16 year girl. She had short stature and retarded growth. She had not started menstruating. Secondary sexual characters are not developed. Note the coarse features on the face, i.e. thick lips, oedematous and wrinkle free face.

- The adult patients present with symptoms and signs illustrated in Fig. 20.20. Usual presentation is myxoedema in which features of hypothyroidism are associated with myxomatous changes in skin (dry, toad-like skin, puffiness of face, hands and feet, larynx (hoarseness of voice) tongue (slurred speech), and ear (leading to deafness)). They may complain of carpal tunnel syndrome (entrapment neuropathy).



FIGURES 20.22A and B (A) Gigantism (GH excess before the fusion of epiphyses). Note the tall stature, strong muscular built, long Tall, ears, lips and long hands with stout large fingers; (B) Acromegaly (excess of GH after the epiphyses have fused). Note the stout stock built with spade-like hands and short stubby fingers

- Majority of the women present with rapid increase in weight, menstrual irregularity, mental feature (depression) or slowness of activity and generalised ache and pains.

Gigantism and Acromegaly (Fig. 20.22 and Table 20.10)

Gigantism is a disorder due to excess of GH before fusion of epiphyses resulting in tall stature with stout muscular built; while GH excess after fusion of epiphyses results in normal stature with enlargement of acral parts (hands and feet), a condition called *acromegaly*. If GH excess occurs during puberty before fusion of epiphyses and continues after that will lead to a clinical picture of Giganto-acromegaly. The most common cause is a pituitary tumour or prolactinoma.

The effect of excess of GH is visible on all tissues (soft), bones, hands and feet (Figs 20.22A and B). In addition, compression effects of the pituitary tumour may be noticeable if present. The symptoms and signs of GH excess are given in the Table 20.10.


Cushing Syndrome (Table 20.11 and Fig. 20.23)

Cushing’s syndrome is a clinical condition characterised by increased levels of free circulating glucocorticoids and their effects on the various systems of the body. It occurs most

TABLE 20.10 Clinical manifestations of GH excess

System	Symptoms	Signs
General	Fatigue, perspiration, heat intolerance and weight gain.	Stout built, overweight and coarse facial features.
Skin and soft tissues	<ul style="list-style-type: none"> • Large hands and feet leading to increase in size of shoes and gloves • Oily skin • Hypertrichosis 	<ul style="list-style-type: none"> • Moist, warm, stout hand with doughy hand shake, increased heel pad (>23 mm) • Skin tags • Increased heel pad • Acanthosis nigricans
Head	Headache. Large head with increase in size of hat	• Frontal bossing, parotid enlargement
Eyes	Decreased vision	• Visual field defects
Ears and para nasal sinuses	Large ears and sinusitis	• Large ears and paranasal sinuses
Oral cavity and mouth	Large tongue, voice change, malocclusion of teeth, large thick lips	• Enlarged furrowed tongue with teeth indentation on it.
CVS	Congestive heart failure	• Widely spaced teeth
Genitourinary system	Decreased libido, impotence, oligomenorrhoea,	• Hypertension, cardiomegaly
Neurological muscles	Paraesthesias, hypersomnolence, weakness	• Infertility
Skeletal system	Joint pains (shoulder, knees)	• Carpal tunnel syndrome, proximal myopathy,
		• Osteoarthritis

TABLE 20.11 The clinical features of Cushing’s syndrome

Symptoms		Signs
<ul style="list-style-type: none"> • Weight gain (94%) • Obesity • Hirsutism • Fatigue, muscle weakness and backache (85%) • Psychological changes and depression • Blackening of skin • Increased chances of fever, cough and other symptoms of infection • Menstrual irregularity, i.e. amenorrhoea (70%) • Polyuria, polydipsia (25%) 	 <p>FIGURE 20.23 Cushing’s syndrome. Note the presence of moon-facies, truncal obesity and pink striae</p>	<ul style="list-style-type: none"> • Hirsutism (80%) • Oedema (60%) • Hypertension (80%) • Truncal or centripetal obesity (97%) • Camel hump • Moon-facies • Acne • Scanty menses • Cutaneous striae (65–70%) • Easy bruisability (55–60%) • Back pain, fracture and osteoporosis • Emotional lability and personality changes (60%) • Pigmentation • Hypokalaemic alkalosis • Predisposition to infection • Clitoromegaly (15%)
<p>Note: The incidence of some symptoms and signs is indicated within bracket</p>		

often following the therapeutic administration of synthetic steroids or rarely a pituitary tumour or adrenal hyperplasia. It may be *primary* (e.g. adrenal disease) or *secondary* (hypothalamic-pituitary disease). Cushingoid features (Pseudo-Cushing's syndrome) may be due to obesity or alcohol consumption.

Causes

- **Adrenal hyperplasia secondary to hypothalamic-pituitary involvement**
 - Pituitary-hypothalamic disorder
 - ACTH secreting tumour
 - Nonendocrine ACTH/CRH secreting tumours (paraneoplastic syndromes)
- **Adrenal nodular hyperplasia**
- **Neoplasm of the adrenals**
 - Adenoma
 - Carcinoma
- **Iatrogenic**
 - Prolonged use of corticosteroids, prolonged use of ACTH.

Addison's Disease (Fig. 20.24 and Table 20.12)

It is a clinical condition characterised by hypoadrenal state and its related effects. All the three adrenal hormones, e.g. glucocorticoids, mineralocorticoids and androgens are reduced. It may be *primary* (adrenal atrophy) or *secondary* (hypothalamic-pituitary disease).

Causes

They are as follows:

- Primary Addison's disease
 - Surgical removal
 - Infection, e.g. tuberculosis, fungal, viral, AIDS
 - Haemorrhage
 - Metastatic deposits
 - Autoimmune destruction
 - Congenital defects in hormone biosynthesis
- Secondary Addison's disease (involvement of hypothalamus or pituitary)
 - Hypopituitarism
 - Hypothalamic-pituitary disease
 - Hypothalamic-pituitary axis suppression by exogenous or endogenous steroids.

TABLE 20.12 Clinical manifestations of Addison's disease

Symptoms and signs

- **Glucocorticoids insufficiency**
 - Weight loss
 - Malaise
 - Nausea and
 - Anorexia vomiting
- **Mineralocorticoids insufficiency**
 - Hypotension
 - Salt loss
 - Syncope
- **Loss of androgens**
 - Loss of axillary and pubic hair in females
 - Sparse body hair
- **Increased ACTH secretion**
 - Hyperpigmentation of sun-exposed areas, elbow, knees, creases of palm, knuckles, mucous membrane of mouth, scars etc.
- **General**
 - Fatigue
 - Asthenia or generalised weakness
 - Sunken eyeballs, cheeks, thin legs and oedema

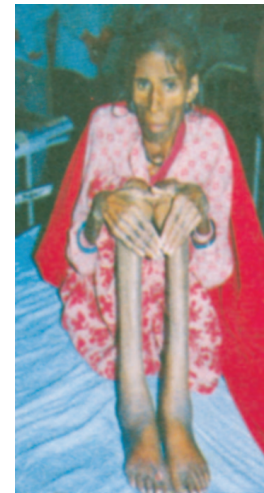

FIGURE 20.24 A patient of Addison's disease. Note sunken cheeks, eyeballs, dry pigmented skin and mucous membrane. Patient had long duration of diarrhoea and developed pedal oedema. Such a patient is likely to develop acute crisis during sepsis or surgery

Hypopituitarism (Fig. 20.25 and Table 20.13)

It means deficiency of more than one pituitary hormones. The manifestations due to deficiency of each hormone are presented in the Table 20.13 with Figure 20.25.

Causes

The causes are listed in Table 20.14.

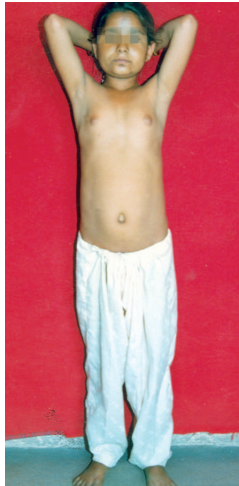

FIGURE 20.25 An adolescent girl (16 years female) with panhypopituitarism. Note the stunted growth, failure of secondary sexual characters, no menarche, thick skin, cold intolerance, weight loss

TABLE 20.13 Clinical manifestations of hypopituitarism	
Deficiency of hormone	Manifestations
GH deficiency	<ul style="list-style-type: none"> • Short stature or growth failure in children • Fine wrinkling around the eyes and mouth, muscle mass decreased.
Gonadotropin deficiency	<ul style="list-style-type: none"> • <i>In males:</i> Decreased libido, decreased beard and body hair and preservation of scalp hair line • <i>In females:</i> Amenorrhoea and infertility, loss of axillary and pubic hair
TSH deficiency	<ul style="list-style-type: none"> • Hypothyroidism features, e.g. fatigue, cold intolerance, thick puffy skin, no goitre
ACTH deficiency	<ul style="list-style-type: none"> • Fatigue, decreased appetite, weight loss, decreased skin and nipple pigmentation, hypotension. No hyperpigmentation, hyperkalaemia or potassium loss-these are features of primary Addison's disease
Prolactin	<ul style="list-style-type: none"> • Failure of lactation in postpartum female.
ADH deficiency	<ul style="list-style-type: none"> • Diabetes insipidus with polyuria and polydipsia.

Diabetes Mellitus (Fig. 20.26)

It is a metabolic disorder characterised by hyperglycoemia, glycosuria due to either lack of insulin (type 1) or insulin resistance (type 2). Diabetes mellitus (DM) may be *primary* (type 1 and type 2) or *secondary* due to pancreatic disease, endocrinopathies, drugs or genetic disorders. Type 1 diabetes is HLA-linked autoimmune insulinitis with destruction of Langerhans cells in the pancreas while type 2 is related to insulin resistance due to several factors. The diagnostic criteria are given in the Box 12.

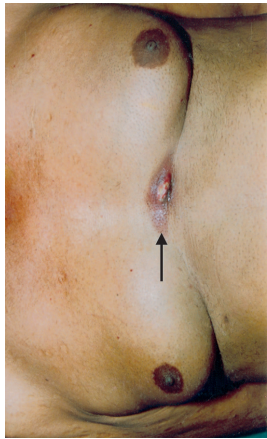
Box 12

Diagnostic criteria (ADA and WHO) for DM

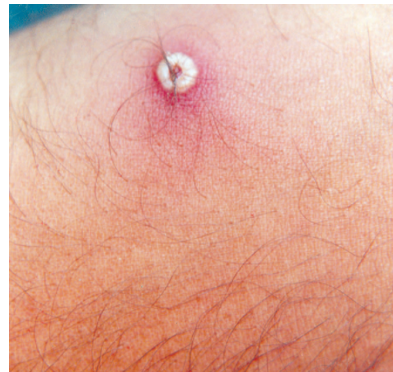Condition	Venous plasma glucose in mg% (mmol/L)		
	Fasting	Postprandial (2 hrs GTT)*	HbA1c (%)
Normal	< 110 (6.1)	< 140 (7.3)	4–6
DM	> 126 (7.0)	> 200 (11.1)	≥ 6.5
Impaired fasting glycaemia (IFG)	> 110 and < 126	< 140	5.8–6.4
Impaired glucose tolerance (IGT)	< 126	> 140 and < 200	5.8–6.4

* 2 hours GTT means following 75 g of oral glucose

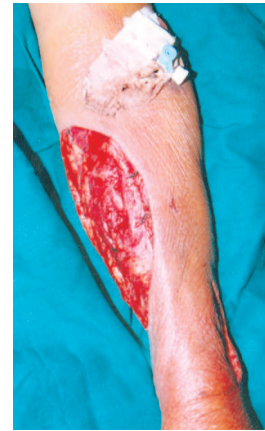TABLE 20.14 Causes of panhypopituitarism	
• Hypothalamic	
– Congenital	<ul style="list-style-type: none"> - Gonadotropin releasing hormone (LHRH) deficiency, i.e. Kallmann's syndrome (Fig. 20.11B) - Isolated GH deficiency
– Acquired	<ul style="list-style-type: none"> - Tumours such as craniopharyngioma - Radiation - Head injury - Tuberculosis or sarcoidosis - Histiocytosis 'X'
• Pituitary	
– Tumours	
– Surgery	
– Radiotherapy	
– Head injury	
– Postpartum necrosis (Sheehan's syndrome)	
– Autoimmune	
– Haemorrhage	



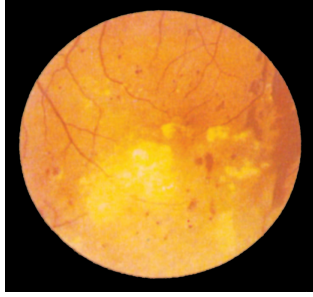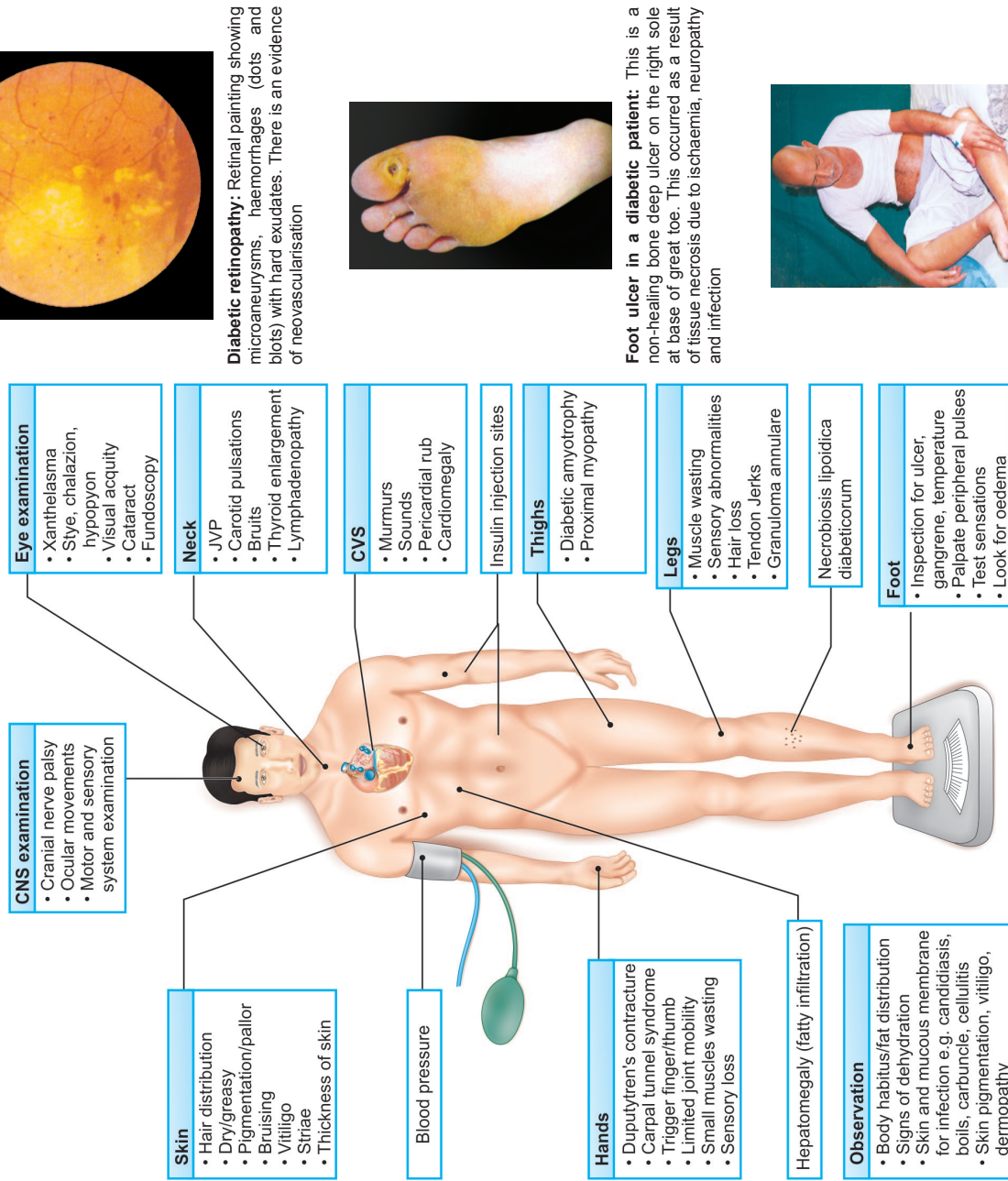
Carbuncle (→)



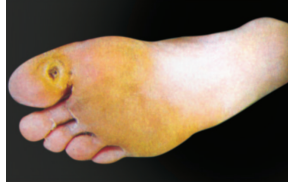Furuncle/boil (→)



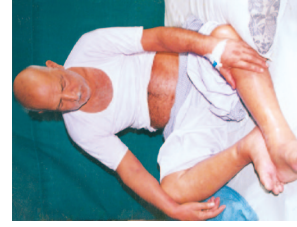Cellulitis—debridement done



Diabetic retinopathy: Retinal paining showing microaneurysms, haemorrhages (dots and biots) with hard exudates. There is an evidence of neovascularisation



Foot ulcer in a diabetic patient: This is a non-healing bone deep ulcer on the right sole at base of great toe. This occurred as a result of tissue necrosis due to ischaemia, neuropathy and infection



Diabetic nephropathy bilateral oedema feet and legs

FIGURE 20.26 Complete examination of a patient with diabetes mellitus

Box 13

Clinical presentations of type 2 DM

Organ/system involved	Features
<ul style="list-style-type: none"> • Eye • Urinary tract • GI tract • Genital tract • Cardiovascular • Nervous system • Skin • Respiratory • Immunity 	<p>Recurrent styes, chalazion, anterior uveitis (hypopyon), refractory errors with frequent change of glasses, cataract, keratitis, conjunctivitis and retinopathy, ocular nerve palsy</p> <ul style="list-style-type: none"> • Urinary tract infection, acute pyelitis, or pyelonephritis, acute papillary necrosis, sterile pyuria, stone formation, nephrotic syndrome (diabetic nephropathy—Fig. 20.26) • Chronic diarrhoea, malabsorption, gastroparesis, adynamic ileus, GI infections <p><i>In females:</i> Pruritus vulvae, vaginal discharge, menstrual irregularities, recurrent abortions, infertility <i>In males:</i> Loss of libido, impotence, urethritis</p> <p>Ischaemic heart disease (silent angina or acute coronary syndrome), hypertension, peripheral vascular disease (cold extremities, digital gangrene, (Fig. 20.26) diabetic foot (Fig. 20.26)</p> <ul style="list-style-type: none"> • TIA, recurrent strokes, peripheral neuropathies, autonomic neuropathy, mononeuritis multiplex, diabetic amyotrophy, cranial nerve palsy. The classification of neuropathy in diabetes is presented in Table 20.15 • Multiple boils, carbuncle, abscesses, cellulitis (Fig. 20.26) pressure sores (Fig. 20.26) • Pneumonias, lungs abscess, tuberculosis <p>Diabetes is an immunocompromised state, predisposes to infection at each and every site/system</p>

TABLE 20.15 Classification, clinical features of neuropathy

Classification	Symptoms and signs
<ul style="list-style-type: none"> • Somatic <ul style="list-style-type: none"> – Symmetric sensory and distal polyneuropathy – Asymmetric, motor, proximal (diabetic amyotrophy) neuropathy • Mononeuropathy <ul style="list-style-type: none"> – Mononeuritis (cranial or spinal) – Mononeuritis multiplex • Autonomic (visceral) <ul style="list-style-type: none"> – Cardiovascular – Gastrointestinal – Genitourinary – Sudomotor and vasomotor – Eye (Pupils) 	<ul style="list-style-type: none"> • Tingling or burning sensation in the extremities (hands and feet), nocturnal pain in limbs, numbness and coldness of extremities. • Glove and stocking type of anaesthesia. • Loss of tendon reflexes and muscle wasting. • Disorganisation of joints (Charcot's joints). • Abnormal gait (wide based, thumping gait). • Nerve conduction velocity delayed in distal parts. • Lower motor neuron paralysis with wasting of muscles. • Hyper or hypoesthesia may be present on anterior aspect of things. • Lower limbs are commonly involved than upper limbs. • Tendon reflexes are lost on affected side. • Lumbosacral area is the site of involvement. • 3rd and 6th cranial nerves involvement common producing diplopia and loss of eye movements. • Carpal tunnel syndrome with ulnar and median nerve involvement (wrist drop) • Vertigo, giddiness and blurring of vision due to postural hypotension resting tachycardia and fixed heart rate. • Nausea, vomiting, abdominal distension, nocturnal diarrhoea, constipation due to colonic atony, gastroparesis, dysphagia due to oesophageal atony. • Loss of libido, impotence, urinary incontinence, difficulty in micturition (atony of bladder) • Abnormal or gustatory sweating, anhidrosis, fissuring of feet, cold extremities, dependent oedema. • Constriction of pupils, absent or delayed light reflex.

Clinical Presentations of Diabetes Mellitus

- **Type 1 diabetics** present with a triad of symptoms of hyperglycaemia, e.g. polyuria, polydipsia and polyphagia and there is associated weight loss. In some cases, the disease is heralded by the appearance of ketoacidosis during an intercurrent illness or following surgery.
- **Type 2 diabetics** present to different specialists and superspecialists with features pertaining to various organs/system (Box 13).

Appendix—I

- Sample collection and venipuncture
- Sample collection for microbial and serological tests
- Collection of samples for other tissues
- Examination of various specimens
- Chemical analysis of urine
- Semen analysis

SAMPLE COLLECTION

Correct sample collection and correct type of container are essential for laboratory investigations. Specimens taken/obtained are taken to the laboratory by the ward boy as soon as they are obtained. If they are to be sent by post, then they should be suitably packed and labelled “*Handle with care*’ and “*pathological specimens*”. Such samples/specimen are first sealed in the inner container and placed in a secure carton containing sufficient absorbent material so as to dry up all the liquid contents spilled if the inner container is broken.

Local and International regulations for the transmission of pathological material must be adhered to strictly.

Suitable containers are usually provided by the laboratory that is going to analyse the sample/specimen. All the container must be clean and sterile for microbial examinations; while the container for blood sample must be perfectly dry. They should have properly fitting cap or lid.

It is essential to use correct container for each investigations, for example, anticoagulant may be necessary for certain investigations while coagulated blood may be needed for others. It is also essential that suitable amount of the blood should be put into the container.

It is also mandatory that the nurse/doctor taking the blood sample must use the sterilised/disposable type of syringe and needle.

VENIPUNCTURE (Fig. A.1)

This is to make a puncture in the vein to collect the sample. The site selected is the vein in the antecubital fossa or any other prominent superficial vein.

The steps of venipuncture are:

- Make the vein prominent by a tourniquet (use a piece of rubber tubing, dupatta, a sling or by manual squeezing of arm, etc) applied over the middle of the arm.
- Clean the area to be punctured by alcohol/spirit/savlon or any other antiseptic solution.

- Stretch the skin at the elbow with your left hand.
- The patient is asked to make fist. Introduce the needle in the vein and move it upwards further in the direction of the vein.
- The blood will enter automatically into the syringe. The venous blood is dark in colour. Take the required amount of the blood in the syringe. Remove the tourniquet, before the needle is withdrawn.
- Alternatively, you can remove the tourniquet as soon as the needle enters the vein so that free flowing blood is withdrawn as in shocked patients.
- As soon as the needle is withdrawn, a swab is placed on the punctured site and the patient is asked to bend the elbow so that forearm presses over the swab against the arm for one minute or so.

- NB:**
1. Occasionally, a vein may not be visible at the elbow. In that case, you can collect the sample from any other superficial vein over the forearm or wrist remembering that procedure at these sites is painful.
 2. A vein which can be felt easily, can be entered easily than the vein which is just seen.

- Collect the blood sample in the appropriate container for the test required. Remove the needle first from the syringe and then push the blood into the container, since forcing of the blood through the needle may cause haemolysis.

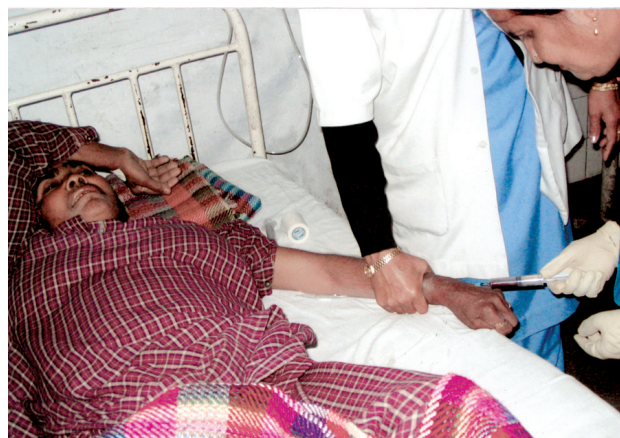

FIGURE A.1 Blood sample collection by nurse

- Heparin and EDTA are the commonly employed anticoagulants. EDTA can be used for most haematological investigations and heparin for most simple chemical tests.
- For blood group and serological investigation, blood should be taken into a dry sterile bottle or tube. If specimen has to be sent to the laboratory by post, it is best to wait till the blood has clotted. Some serum should then be removed with a sterile needle and syringe and this serum is sent separately together with blood clot.

Other Specimens

Urine, faeces, peritoneal fluid, pleural fluid, pericardial fluid, gastric and pancreatic juice, arterial blood, semen, nasal secretions, CSF and fluid aspirated from the cyst (cyst puncture) and pus may be also be collected and sent to the laboratory. The method of collection of these samples has been discussed in the appropriate chapters.

Making the Best Use of the Result

All the tests are subject to the errors of performance. The clinician must inform back the pathologist in case of 'rougue' result which does not correspond with the clinical data. All results will depend on the precision of the method and the variability of the quality measured among the healthy population.

In nonquantitative test such as cytology, there may be false-positives and false-negatives. The laboratory should be able to say with what frequency these may occur. For instance, in cases of bronchial carcinoma, the finding of malignant cells in the sputum is diagnostic, and detected most often but in a very small number of examinations, apparently malignant cells in the sputum may be reported when there is no evidence of bronchial carcinoma. The clinician should consider such finding in the light of his clinical data. If patient is middle aged smoker, the report of malignant cell would be likely to be true positive as bronchial carcinoma is prevalent in such cases without symptoms. On the other hand, such a positive sputum for malignant cells in a young non-smoking girl is unacceptable and is likely to be false, hence require reassessment. *Precision* is the measure of repeatability of determination. This is employed in quantitative biochemical or haematological tests. The precision of measurement has to be linked to the variations of the true value in the healthy population. Therefore it is conventional to express the normal range as the mean value plus or minus 2 SD (standard deviations). Although 95% of all normal results will fall within this range, and 5% will fall out of this range. Therefore a value just outside this range does not necessarily indicate abnormality.

MICROBIAL TESTS

Successful microbial culture depends on the viability of the organisms. The overgrowth of the normal flora can hinder in the detection of the pathogens. It is, therefore, necessary to collect the sample for microbial culture properly and by proper technique as careless collection of such samples can cause cross-contamination with the organisms present on the skin surface or in the environment.

The organisms in the specimen can either be detected directly or by the antibody response to the infecting organism (antigen). Direct examination of the stained smear of the sample under light (Fig. A.2) or electron microscope will visualise the organism directly. Success of such examination depends on the presence of a large number of the organisms in the specimen, for example, in the pus. If fewer organisms are present, a sensitive technique is required to demonstrate them, hence, in such a situation culture techniques are employed by allowing the organisms to multiply.

Most modern methods such as PCR (polymerase chain reaction) have been developed to detect gene or gene products specific to the organism, allowing direct detection even when only a small number of the organisms are present. Although these newer techniques are very sensitive, unless meticulous care is taken both during collection of the specimen and during performance of the test contamination with other antigens or proteins is a problem that reduces the specificity of the result. In addition, specificity may not be much because antigens are shared amongst the organisms and between the patient's tissue and the organism etc. but specificity is important.

SEROLOGICAL TEST

Usually antibodies are detected so far in the serum. Now technique are available to detect the antigen also, therefore,

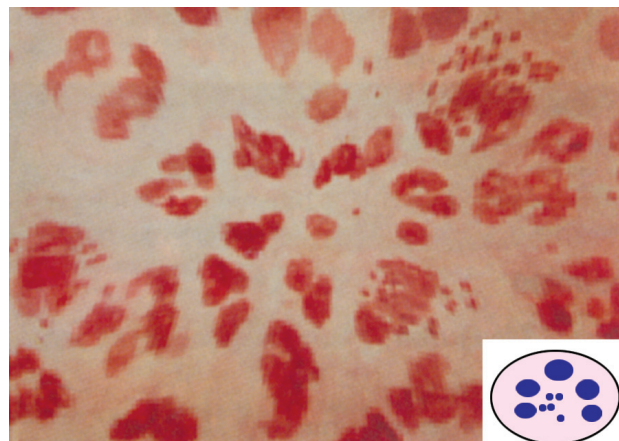


FIGURE A.2 Gram Stain of urethral discharge showing Gram-negative intracellular and extracellular diplococci

serological test depends on the detection of either antigen or antibody or both. Now-a-days you can perform these serological tests not in the blood but in other samples also such as saliva, CSF and ascitic/pleural fluid etc. The total antibody response or specific IgM or IgG titres can be assessed. The total antibody response and IgG response are used to study the prevalence of the disease in a community. For active disease, it is necessary to demonstrate four fold rise in the IgM level specific to the organism in the specimen studied during the course of the illness.

Collection of the Samples of Other Tissues (CSF, Pus, Fluid)

A sufficient amount of the material must be supplied to the laboratory for analysis. Generally about 10–15 g of the tissue or discharge and up to 25 mL of the fluid are necessary. If only very small amounts of the material are available the material should be sent in a sterile container containing isotonic saline never in the formal saline available. In such a situation where the material is small, it is best to summon the laboratory personnel to the bedside to make culture there.

If it is not possible to send the sufficient required material for culture, then a swab may be taken and sent. Ensure that the correct swab supplied by the laboratory is used as swabs vary according to which pathogen is sought (Box 1).

Blood Culture

Blood cultures are done for isolation of bacteria or viruses.

Bacterial Pathogens

Blood culture for bacterial pathogens is useful in the investigation of almost all infections. Bacteria are often present in blood in only very low concentrations, and their

Box 1

Swabs for culture

- **Plain swab without transport medium:** They are used for hardy microorganisms only.
- **Plain swab with transport medium:** They are useful for general bacteriology
- **Swab with charcoal (black) transport:** Useful for *Neisseria gonorrhoeae*, and other delicate bacteria
- **Plain swab with virus transport medium:** Essential to gently squeeze swab in transport medium. Virus transport medium contains antibiotics and is not suitable for bacterial culture
- **Chlamydial swab with transport medium:** Used for detection of *Chlamydia trachomatis* antigen by immunoassay. Designed for urogenital and ophthalmic specimens only
- **Wire swab with transport medium:** It is used for nasal pertussis infection

viability and growth potential may be inhibited by antibiotic treatment. Since so many infections accompanied by septicaemia may be caused by many organisms (mixed infections). It is important to inoculate bottles containing a variety of different culture media. The media used should be suitable for aerobic and anaerobic pathogens, and for fastidious species such *Brucella spp.*, *Mycobacteria spp.*, *Leptospira spp.*, and for non-bacterial pathogens such as fungi. Antibacterial substances present in the patient's blood can be inactivated by dilution (at least 1:10), by the addition of specific enzymes, e.g. penicillinase, or by absorption by resins.

Before taking blood sample the patient's skin and the bottle cap should be cleaned with antiseptic solution and allowed to dry. At least three sets of blood cultures should be taken, preferably before antibiotic therapy is started. Occasionally, particularly if endocarditis is suspected, it may be necessary to take up to six sets of cultures before a negative result can be declared.

Viral Pathogens

Sterile heparinized blood sample should be sent to the laboratory for virus studies.

Serology

Clotted blood in a container without additives is required for serology.

Urine Culture

Urine specimens (Box 2) should be transferred to the laboratory within 1 hour of voiding, unless specific precautions are taken to prevent bacterial multiplication before cultures are set up. Urine specimens may be stored overnight at 4°C. If this is not possible then a commercial kit for culture of the specimen at the bedside should be used. Several commercial 'chemical' kits are available, but experience in their sensitivity and specificity is limited at present.

Box 2

Urine sample for culture and sensitivity

- **Catheter specimen of urine (CSU):** Aspirate the urine, via a 21 gauge needle and syringe, from the rubberized part of the tubing connecting the catheter to the collection bag. Do not collect urine from the tap outlet to the bag.
- **Early morning urine (EMU):** Send the entire first-voided specimen, usually about 250 mL, to the laboratory in the large sterile container provided. Three consecutive morning specimens should be taken.
- **Mid-stream urine (MSU):** A urine specimen is taken during mid-micturition by the patient, after instruction, or with the assistance of a nurse, after the labia or penile orifice have been cleaned with chlorhexidine.

Mid-stream (MSU) or suprapubic aspiration techniques are suitable for general bacterial and viral culture of urine, but are unsuitable for typhoid or tuberculosis. In the diagnosis of the latter infection three early morning urine (EMU) specimens should be submitted to the laboratory. For the diagnosis of schistosomiasis the terminal 5 mL of a freshly voided specimen is required.

Examination of Faeces

Bacterial Pathogens

Human faeces contain approximately 10^{11} organisms/g wet weight as normal flora, but gut bacterial pathogens rarely exceed 10^5 organisms/g. Because of the relative scarcity of bacteria in faecal specimens examination of a Gram-stained smear of faeces is not usually done. However, occasionally in infections caused by *Campylobacter* spp. the typical seagull-shaped Gram-negative bacteria are present in sufficient numbers to be identifiable in a directly stained smear of a faecal specimen.

The definite diagnosis of bacterial infections of the gut is by culture. Correct collection and transportation of the specimen to the laboratory is, therefore, important, since incorrect technique can lead to the death of the pathogen or to overgrowth by normal gut flora.

Collection of the Specimen

Approximately 20 mL of stool should be collected on three different occasions as early as possible in the illness and placed in three separate, sterile containers. For immediate transport to the laboratory dry sterile containers are suitable but, if there is a delay in transfer to the laboratory, the faecal specimen should be placed in a suitable preservative, for example in 0.0033 M phosphate buffer mixed with an equal volume of glycerol, at pH 7.0. If possible, include any mucus or blood passed in the faeces in the specimen submitted.

As there are a large number of bacterial species causing diarrhoea, the laboratory will use many different selective culture media in order to isolate them. It is essential to note on the accompanying request form any relevant clinical detail or data to enable the laboratory staff to seek the most likely pathogens. Important information includes a history of travel to potential endemic areas, prior antibiotic therapy, any known outbreak of sporadic disease, possible contamination of food, and any associated immune suppressive disease.

Viral Pathogens

Many of the viruses which cause diarrhoea can be cultured. Diagnosis is therefore often made by immunological

techniques, or by electron microscopic identification of the virus.

Collection of Specimens

In contrast to the techniques used for collection when viral pathogens are suspected, chemical preservatives should not be used. Specimens should be taken into a dry sterile container and sent to the laboratory promptly, or frozen at -20°C (-70°C is normal but rarely available). For direct detection of viral particles by electron microscopy many particles must be present. Electron microscopy is a specific but not very sensitive technique.

Parasitic Infections

For detection of *Entamoeba histolytica* infestation the faecal specimen must be kept at body temperature until can be examined. Other cysts and ova can be detected by examination of stool sent in a plain sterile container.

The Respiratory Tract

Material may be taken for detection of bacterial and viral infections. Specimens can be taken from throat, the nasopharynx, sputum or by bronchoalveolar lavage, as appropriate.

Throat Swabs

Vigorously swab the tonsillar areas, the pharynx, and any areas of visible inflammation exudation, ulceration or membrane formation. For bacterial cultures, use a plain swab with transport medium. For viral detection, use a plain swab with viral transport medium. The specimen should be sent immediately to the laboratory, or stored at 4°C and should not be frozen.

Nasopharynx

Specimens of nasopharyngeal secretions are used principally for diagnosis of pertussis infection—an uncommon disorder in developed countries where immunization programmes have been largely effective in a preventing whooping cough.

The specimen is obtained using a wire nasal swab. The swab is passed gently along the base of the nostril into the nasopharynx, rotated, removed and placed into transport medium. The laboratory may need prior warning of the arrival of the specimen so that appropriate culture media can be prepared.

For detection of viral pathogens from the nasopharynx an aspirated specimen is obtained using a suction catheter.

Sputum

For best results an early morning freshly expectorated sputum specimen should be collected in a dry, sterile bottle, preferably with the help of a physiotherapist. For isolation of mycobacteria three consecutive morning specimens should be obtained.

Bronchoalveolar Lavage

This technique may be helpful when lower respiratory tract infection is suspected, e.g. *Legionella* spp., *Nocardia* spp., *Pneumocystis carinii*, *Mycobacterium* spp. and *Cytomegalovirus* infections.

The Genital Tract

Different methods are used for particular genital infection (Box 3).

The Skin

Dermatophytes and Candida albicans

Keratinized specimens, e.g. hair, skin scrapings or nail cuttings, should be sent enclosed in black paper, for ease of recognition. Do not use sticky tape.

Virus Detection

There are certain methods to detect virus in the skin scrapings.

Box 3

Microbiological investigation of the genital tract

- **Neisseria gonorrhoeae** infection
 - Urethral and/or endocervical (not high vaginal), rectal or throat swabs
 - Use charcoal transport medium
- **Chlamydia trachomatis**
 - Endocervical (not high vaginal) or urethral specimen
 - Inoculate in transport medium
 - Abnormal specimens will contain pus cells
 - Specimen can be stored at 2–8°C
- **Candida spp. and Trichomonas spp.**
 - High vaginal swab in plain transport medium
- **Herpes simplex virus (HSV)**
 - Most successful in first 3 days of infection
 - Use plain sterile swab to collect vesicular fluid into viral transport medium
 - Air-dried smears of scrapings from base of vesicles can be used for direct examination by immunofluorescence
- **Pelvic inflammatory disease**
 - Send endocervical swabs or pus in charcoal transport medium

The Eyes

There are methods for detection of bacterial and viral pathogens.

Bacterial Pathogens

Conjunctival Infection

Using a firm action, thoroughly swab the inner surface of the lower and then the upper eyelid, using a separate swab for each eye. Use a plain swab and a transport medium. For gonorrhoeal infection use a charcoal transport medium.

Intraocular Infection

Bedside inoculation of tiny quantities of aspirated material can be performed by the ophthalmologist.

Viral Pathogens

A swab moistened with sterile saline is used to collect secretions from the palpebral conjunctiva; this is inserted into a transport medium.

Scrapings from cornea or conjunctiva can be collected by the ophthalmologist.

Chlamydia Infection

Specimens should contain as many epithelial cells as possible, but should not consist of pus. See above for special precautions.

CHEMICAL ANALYSIS OF THE URINE

The urine is analyzed for proteins, sugar, ketones and urobilinogen. However, the commercial reagent strip tests are available for bedside analysis of the urine. However, the chemical tests are reliable, cheap and use commonly available reagents, they are, therefore, still useful when reagent strip tests are not available.

Proteinuria

The Boiling Test

The test is simple. Fill the two-third of test tube with urine. If urine is alkaline, make it acidic (pH5) by adding 10% acetic acid drop by drop and mixing it thoroughly. The pH is measured by indicator paper (litmus paper). Boil the top 2 cm of the tube over a flame while holding the bottom of the tube. Examine the test tube for cloudiness against a dark background. A cloudiness indicates presence of either the protein or phosphate in the urine. Phosphate will dissolve

and cloudiness will disappear after adding few drops of more acid. If turbidity/cloudiness persists despite addition of acid, then it is due to protein precipitation and urine is said to be positive for protein. This is a qualitative test. The boiling test is positive only when patient has overt proteinuria. The microalbuminuria is not detected by this test.

The false positive results are given by penicillins, tolbutamide, radiocontrast medium, sulphonamides, PAS and when urine contains a lot of uric acid.

The Salicylsulphonic Acid Test

Take 5 mL of urine in a test tube. Add 20% salicylsulphonic acid drop by drop till a cloudy precipitate is formed or till 25–30 drops have been added. If precipitate is formed, continue to add salicylsulphonic acid until no more precipitate is formed. Express the amount present as haze, (1⁺), cloud (-2⁺) or granular precipitate (3⁺). In general, haze indicates 20 mg protein/100 mL. A heavier deposit or precipitate is allowed to settle down for half an hour or one hour. Now the quantity is expressed as the proportion of the urine, i.e. volume occupied by the precipitate/deposit. If this proportion is one half, then the urine contains 10 g protein/litre.

False positive results are similar to the boiling test.

Dipstick Test

This is available as a bedside test and can be done by the patient himself, if his eye sight and colour vision is normal. The end of the strip containing the chemical incorporated into the strip is dipped into the urine for a specified period. The change in colour of the strip compared to the colour on the bottle which quantifies the loss of proteins.

Urine for 24 Hour Proteinuria

The urine is collected in a container and volume of the urine is noted during 24 hours. The quantitative analysis of urine by Esbach's albuminometer in measured quantity of urine is done and then proteinuria is calculated depending on the amount of urine passed. It is expressed in grams/day. The test separates the patients with asymptomatic urinary abnormalities (proteinuria is <1 g/day) from nephrotic syndrome (subnephrotic range of proteinuria, i.e. < 3 g%) from nephrotic syndrome (>3.5 g/day proteinuria).

Tests for Urine Sugar

Benedict's Test for Reducing Sugars

Take 5 mL of Benedict's reagent in a test tube. Add 8 drops of the urine, boil for 2 minutes and allow the test tube to cool. If a reducing substance is present, a precipitate will appear

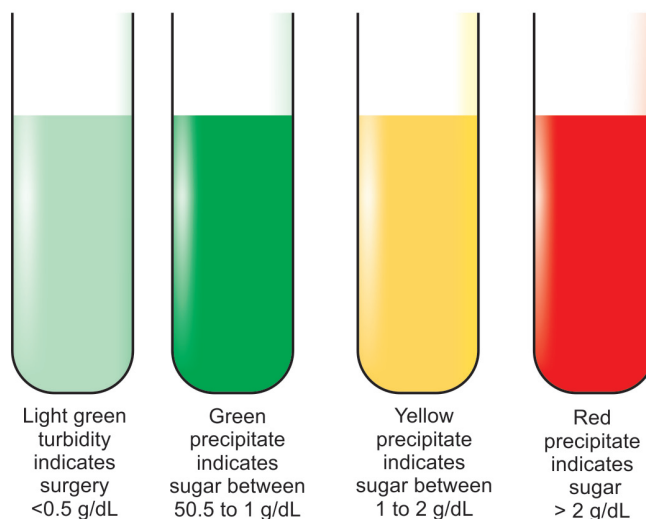


FIGURE A.3 Benedict's test

varying from light green colour turbidity to red coloured precipitate (Fig. A.3). The test is not specific for glucose and a positive reaction is given by any reducing substance present in the urine. Therefore, vitamin C and aspirin may give false positive results.

If colour change is due to sugar only then the test gives appropriately quantitative results (Fig. A.3).

Test for Bence-Jones Protein's

Bence Jones Protein's are light chains, secreted in multiple myeloma and light chain myeloma. Take 5 mL of urine in a test tube and heat the urine with thermometer inside. At 45°C, Bence-Jones Protein appears in the urine as a precipitate and remains in the urine up to 58°C. If heating is continued beyond it, the precipitate dissolves. Now cool the urine. The precipitate will reappear on cooling at 60°C.

If the amount of light chain in the urine is low, then immunoelectrophoresis of the urine is the method of choice.

Test for Microalbuminuria

It is detected by immunometric assay.

Dipstick Test (Uristix-Test—Fig. A.4)

Urine for glycosuria is employed for screening the public or individual for presence of diabetes. Glycosuria does not mean diabetes could be innocuous as renal glycosuria or alimentary glycosuria or could be due to diabetes renal glycosuria is an inherited condition in which the renal threshold for glucose is reduced resulting in appearance of glucose in urine at a level which is lower than renal threshold, i.e. < 180 mg%). On the other hand, glycosuria in diabetes occurs when glucose levels are higher than renal threshold.

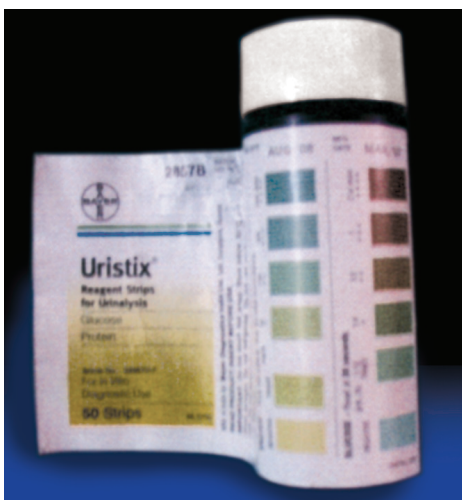

FIGURE A.4 Uristix test for sugar

The Clinistix test is bedside dip test in which a strip impregnated with chemical is dipped in the urine for a specified period (10 sec/30 sec) as per manufacturer's instruction. The colour obtained on the strip is compared with the colour code provided on the bottle by the manufacturer for quantification. In this way, glycosuria can be detected immediately. The dipstick method a glucose-oxidase method, detects glucose in the urine, hence, is specific.

Urine for Ketone Bodies

Rothera's Test

Take 10 mL of urine in a test tube. Saturate the urine with an excess of ammonium sulphate crystals. Now add 3 drops of freshly prepared strong solution of sodium nitroprusside and 2 mL of strong ammonia solution is added further. A deep purple colour over the top of the solution indicates positive test for ketone bodies (acetone and acetoacetic acid). If Rothera's test is negative; ketones are absent.

Ferric chloride (Gerhardt's) Test

Take 5 ml of urine in a test tube. Add drop by drop 10 % ferric chloride solution. A precipitate of ferric phosphate usually forms which dissolves when more ferric chloride is added. Brownish-red colouration of the solution indicates positive test and detects the presence of only acetoacetic acid not the acetone.

NB: Aspirin and other salicylates, phenothiazines, phenol and some drugs give a positive colour reaction with ferric chloride. Boiling the urine for 5 minutes before addition of ferric chloride will destroy the acetoacetic acid but not the other substances, hence, if ferric chloride test is positive even after boiling the urine, then it is positive due to other substances than the acetoacetic acid.

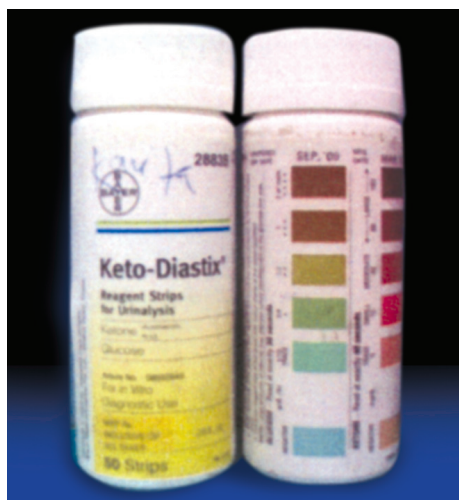

FIGURE A.5 Ketostix test for ketone bodies

Ferric chlorides test becomes positive for ketones if considerable amount of acetoacetic acid is present. If Rothera's test is positive but ferric chloride test is negative, then the ketone bodies are present in small amount. If both the tests are positive then the patient is severely ketotic and requires urgent treatment.

Ketostix Test

Acetotest tablets or ketostix test papers utilising nitroprusside reactions are employed to detect ketone bodies in the urine. Ketostix test is simple bedside strip test in which the end of strip containing the reagent incorporated is dipped for the specified period. The colour obtained is matched with colour on the container for quantification (Fig. A.5).

Ketonuria is not pathognomonic of diabetes as starvation, prolonged fasting state, high fat diet and repeated vomiting may result in ketosis, therefore, ketonuria with glycosuria indicates diabetes.

Urobilinogen and Porphobilinogen

Ehrlich's Aldehyde Test

Take 1 mL of fresh urine in a test tube. Add 1 mL of Ehrlich's aldehyde reagent. After one and half minutes add 2 mL of saturated aqueous sodium citrate and mix the solution. Now add 2 mL of 3:1 (v/v) mixture of amyl alcohol and benzyl alcohol. The test tube is stoppered and its contents are shaken gently for one minute. Two phases in the solution are formed, i.e. upper (alcohol) phase and lower (aqueous) phase. The red colouration of the upper phase indicates urobilinogen while a similar colour in the lower phase indicates porphobilinogen. Chloroform may be used as alternative to amyl and benzyl alcohols.

Normal fresh urine contains enough urobilinogen to produce a weakly positive reaction. A strong reaction indicates excess of urobilinogen suggesting haemolysis.

Test for Bile Salts

Take 10 mL of urine in a test tube and sprinkle sulphur powder over its surface, watch for 5 minutes. Sulphur powder sinks to the bottom of test tube in the presence of bile salts in the urine. This test is positive in obstructive jaundice.

Test for Blood and Haemoglobin

Benzidine Test

Take 2 mL of urine in a test tube. Add 2 mL of Benzidine reagent and mix. Blue colour indicates the presence of Hb/blood in urine.

Dipstick Test

The reagent area of the strip is dipped in the urine for specified period. The colour obtained is matched with the colour index provided on the container.

Microscopic Examination of The Urine

(Read investigations of genitourinary system).

SEMEN ANALYSIS

Collection of the Sample

Patient is asked to collect the specimen by masturbation following one week's abstinence. Specimen should be collected in a clean, wide mouthed plastic/glass container. Specimen must be received in the laboratory at the earliest possible but not later than 2 hours after collection.

Gross Examination

Freshly ejaculated semen is an opaque and viscid fluid. It liquefies spontaneously within 1/2 hour. In case liquefaction does not take place within 1/2 hour, it needs further investigation.

- Volume** – 2–5 mL.
Postcoital studies suggest that volumes less than 2 mL may result in poor penetration of cervical mucus by sperms.
- Colour** – Following liquefaction, semen is a translucent, viscous fluid.
- pH** – Alkaline 7.5–7.8.

Microscopic Examination

Sperm Count

Count is carried out in a Neubauer chamber using a Thoma pipette in a dilution of 1 in 20 (as for TLC).

Normal count

- = 40–140 million/mL.
<20 million indicates oligospermia

Motility

Motility of sperms helps in penetration of cervical mucus and migration of sperms into fallopian tube.

Method

Take a drop of the liquefied seminal fluid on a slide; place a coverslip on top of it and examine it under high power objective and assess at least 300 sperms for motility (motile/non-motile).

Calculate % of motile sperms.

Normal range

- Within 1 hour motility is 70–90%
Within 2 hours motility is 40–70%
Within 6 hours motility is 25–50%.

Sperm Morphology

To study sperm morphology, a thin smear is made from the semen and is fixed in 95% ethanol. Carry out the Pap staining. Examine the smears under oil immersion for:

- Morphology of sperms—normal and abnormal (Fig. A.6)
- Presence of RBCs and pus cells
- Epithelial cells
- Abnormal sperms have double and pointed head/double head, etc.

Indications for Semen Analysis

- Infertility
- Medicolegal utility—in rape case vaginal pool smear for sperms is taken.

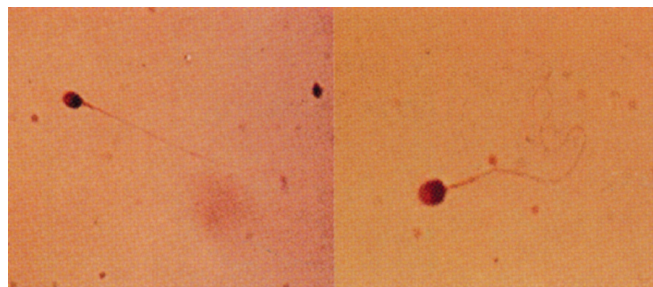


FIGURE A.6 Normal sperms

Appendix—II

- Temperature scales and conversion from Fahrenheit scale to Centigrade scale
- SI units
- Normal values
- Conversion chart
- Greek alphabets
- Table for surface area for different heights and weights
- Ideal body weights and heights of different age groups
- Tables for values useful in pulmonology, haemodynamic monitoring and echocardiography

CENTIGRADE AND FAHRENHEIT SCALE

The centigrade (Celsius) scale is preferred. Table A.1 shows the relationship of the centigrade and Fahrenheit scales, as far as is likely to be required in clinical work.

TABLE A.1 The Centigrade and Fahrenheit scales

Centigrade	Fahrenheit	Centigrade	Fahrenheit
110	230	36.5	97.5
100	212	36	96.8
95	203	35.5	95.9
90	194	35	95
85	185	34	93.2
80	176	33	91.4
75	167	32	89.6
70	158	31	87.8
65	149	30	86
60	140	25	77
55	131	20	68
50	122	15	59
45	113	10	50
44	111.2	5	41
43	109.4	0	32
42	107.6	-5	23
41	105.8	-10	14
40.5	104.9	-15	5
40	104	-20	-4
39.5	103.1	—	—
39	102.2	0.54	1
38.5	101.3	1	1.8
38	100.4	2	3.6
37.5	99.5	2.5	4.5
37	98.6		

To convert Fahrenheit to Centigrade:

$$^{\circ}\text{F} - 32 \times 5/9 = ^{\circ}\text{C}$$

To convert Centigrade to Fahrenheit:

$$^{\circ}\text{C} \times 9/5 + 32 = ^{\circ}\text{F}$$

SI UNITS

In this book the Systeme International (SI) d'Unites has been used as far as possible. This system aims to derive all

measurements from seven basic units and to express all measurements as decimal fractions or multiples of these. Of the seven basic units the four which appear in this book are:

Physical quantity	Name of SI unit	Symbol
Length	metre	m
Mass	kilogram	kg
Time	second	s
Amount of substance	mole	mol

and the prefixes indicating the decimal fraction and multiples are:

Fraction	Prefix	Symbol
10^{-1}	deci-	d
10^{-2}	centi-	c
10^{-3}	milli-	m
10^{-6}	micro-	μ
10^{-9}	nano-	n
10^{-12}	pico-	p
10^{-15}	femto	f

1 fluid ounce (fl oz)	=	28 mL
1 gallon UK (gal)	=	4.5 L
1 grain (do not abbreviate)	=	65 mg
1 inch (in)	=	25.4 mm
1 foot (ft)	=	0.3 m
1 ounce (oz)	=	28 g
1 pound (lb)	=	0.45 kg
1 calorie (cal)	=	4.2 J
1 kilocalorie (medical calorie, Cal)	=	4.2 kJ

The litre (= 1 dm³) is also recognized as the unit of volume. It follows that with the adoption of SI, certain familiar terms are no longer used, as is the case with measures of volume. A cubic centimetre (cc, cm³) is replaced by the millilitre (mL) and the cubic millimetre (cmm, mm³) by the microlitre (μ L). In linear measure the micron (μ) should no longer be used; the correct unit is the micrometre (μ m). Blood, intra-uterine and intra-ocular pressure are measured in millimetres of mercury (mmHg) and intrathecal pressures in centimetres of cerebrospinal fluid (cm CSF). It is recommended that the medical calorie kilocalorie should now be converted to the joule (1 kcal = 4186.8 J).

Further information on SI units may be obtained from The Use of SI Units, Publication PD 5686 of the British Standard Institution, and useful information on the SI units commonly used in medicine and biology is available in Units, Symbols and abbreviations: A Guide for Biological and Medical Editors Authors, published by the Royal Society of Medicine.

Multiple	Prefix	Symbol
10	deca-	da
10 ²	hecto-	h
10 ³	kilo-	k
10 ⁶	mega-	M

NORMAL VALUES (REFERENCE VALUES)

P = plasma; B = blood; S = serum; E = erythrocyte; U = urine; CSF = cerebrospinal fluid; pg = picogram; ng = nanogram; µg = microgram; mg = milligram; d = day.

The normal values, in different samples are depicted in Table A.2.

Analyte	Sample	Units	SI units
Ammonia	P/S	< 50 µg/dL	
Acetoacetate	S	0.3–1 mg/dL	
Acid phosphatase (ACP), Total	P/S	0.5–4 KAU/dL	2.5–12 IU/L
Acid phosphatase (tartrate labile)	P/S	<0.9 KAU/dL	<1 IU/L
ACTH (corticotropin)	P	2.5–10 ng/dL	2–10 pmol/L
Alanine aminotransferase (ALT/SGPT) Male:	S	13–35 IU/L	
Female:		10–30 IU/L	
Albumin	S	3.5–5 g/dL	35–50 g/L
Albumin	CSF	10–30 mg/dL	100–300 mg/L
Aldolase	S	1.5–7 IU/L	
Aldosterone, standing	S	6–20 ng/dL	0.17–0.6 nmol/L
Alpha-1-acid glycoprotein	S	55–140 mg/dL	13.4–34 µmol/L
Alpha-1-antitrypsin	S	75–200 mg/dL	0.75–2 g/L
Alkaline phosphatase (ALP)		S3–13 KAU/dL	40–125 IU/L
Alpha fetoprotein (AFP)	S	5–15 ng/mL	5–15 µg/L
Amino acids, Total	P/S	30–50 mg/dL	
Amylase	S	80–180 S U/dL	50–120 IU/L
	U		0–375 IU/L
Angiotensin converting enzyme	S		10–50 IU/L
Angiotensin-I	P	1.8–8 ng/dL	
Angiotensin-II	P	1–6 ng/dL	
Anti-diuretic hormone (ADH) (arginine vasopressin)	P	1–13 pg/mL	
Ascorbic acid (vitamin C)	P	0.4–1.5 mg/dL	23–85 µmol/L
Aspartate aminotransferase (AST/SGOT)	S	8–20 IU/L	
Bicarbonate (HCO₃)	S	22–26 mEq/L	22–26 mmol/L
Bilirubin, total	S	0.2–1 mg/dL	4–17 µmol/L
Calcium	S	9–11 mg/dL	2.1–2.5 mmol/L
Calcitonin	S	0–20 pg/mL	0–20 ng/L
Calcitriol (1,25-dihydroxy vitamin D)	S	1.5–6 µg/dL	50–160 pmol/L
Epinephrine	P	10–100 pg/mL	10–500 pmol/L
	U	2–22 µg/day	10–100 nmol/day

Contd...

Contd...

Analyte	Sample	Units	SI units
Ceruloplasmin	S	25–50 mg/dL	
Chloride	S/P	96–106 mEq/L	96–106 mmol/L
Chloride	CSF	120–130 mEq/LU	120–130 mmol/L
			10–200 mmol/L
Cholesterol, Total	S/P	150–200 mg/dL	4–6 mmol/L
(HDL fraction) Male:	S	30–60 mg/dL	0.75–1.58 mmol/L
Female:		35–75 mg/dL	0.98–1.95 mmol/L
(LDL fraction) 20–29 years		60–150 mg/dL	
30–39 years		80–175 mg/dL	
40–60 years		90–200 mg/dL	
Cholinesterase	B	2–12 IU/mL	
Chorionic gonadotropin, (beta-hCG)(non-pregnant)	S	<10 mU/mL	<10 U/L
Complement C3		80–120 mg/dL	
Complement C4		25–40 mg/dL	
Complement-1-esterase		5–10 mg/dL	
Complement-1-esterase inhibitor	S	10–25 mg/dL	
Copper	P	70–150 µg/dL	16–30 µmol/L
Cortisol 9 AM	P	5–25 µg/dL	130–600 nmol/L
Midnight	P	2–5 µg/dL	30–130 nmol/L
C-reactive protein (CRP)		0.5–1 mg/dL	
Creatine	S	0.2–0.4 mg/dL	15–30 µmol/L
Creatine kinase (CK)			
Female:	S		10–80 U/L
Male:	S		15–100 U/L
Creatinine	S	0.7–1.4 mg/dL	60–125 µmol/L
	U	15–25 mg/kg/d	0.15–0.2 mmol/kg/d
Cyanocobalamin (vitamin B ₁₂)	S	20–80 ng/dL	150–600 pmol/L
Electrophoresis	S	Alb: 55–65%	3.5–4.7 g/100 mL
		α ₁ : 2–4%	0.2–0.3 g/dL
		α ₂ : 6–12%	0.4–0.9 g/dL
		Beta: 8–12%	0.5–1.0 g/dL
		Gamma: 12–22%	0.7–1.5 g/dL
Estradiol			
Female (Midcycle)	S	10–50 ng/dL	0.3–2 nmol/L
Male:		<5 ng/dL	<180 pmol/L
Ferritin Male:	S	3–30 µg/dL	30–300 µg/L
Female:		2–12 µg/dL	20–120 µg/L
Fibrinogen	P	200–400 mg/dL	5.8–8.5 µmol/L
Folic acid	S	5–20 ng/mL	10–40 nmol/L
FSH Male:	S		4–10 IU/L
Female (midcycle)	S		10–20 IU/L
Gamma glutamyl transpeptidase (GGT)	S		10–30 IU/L
Globulins	S	2.5–3.5 g/dL	25–35 g/L
Glucagon	S	2–10 ng/dL	
Glucose (Fasting)	P	70–110 mg/dL	4.0–6.1 mmol/L
	B	65–100 mg/dL	3.5–5.6 mmol/L
	CSF	50–70 mg/dL	2.8–4.2 mmol/L

Contd...

Contd...

Analyte	Sample	Units	SI units
Glucose-6-phosphatedehydrogenase (GPD)	E		6–12 U/g Hb
Glutamic acid	S	8–10 mg/dL	
Glutathione	E	20–40 mg/dL	2 mmol/L
Growth hormone (GH)	S		2–6 ng/L
Haptoglobin	S	40–175 mg/dL	400–1750 mg/L
Hemoglobin Male:	B	14–16 g/dL	2.17–2.4 mmol/L
Female:	B	13–15 g/dL	
Hemoglobin A2	E	2–3% of total	
HbA1c (glycohemoglobin)		4–6% of total	
Hemopexin	S	50–100 mg/dL	
17-hydroxy corticosteroids			
Female:	U	2–8 mg/d	5.5–22 µmol/d
Male:	U	3–10 mg/d	8–28 µmol/d
5-hydroxy indole acetic acid (HIAA)	U	2–9 mg/d	10–47 µmol/d
Immunoglobulins	S		
IgG		800–1200 mg/dL	
IgM		50–200 mg/dL	
IgA		150–300 mg/dL	
IgD		1–10 mg/dL	
IgE		1.5–4.5 µg/dL	
Immunoglobulins	CSF	4–5 mg/dL	
Insulin	S	5–15 µU/mL	30–100 pmol/L
Iodine	S	5–10 µg/dL	
Iron	B	5 mg/dL	
Iron	S	100–150 µg/dL	20–30 µmol/L
Iron binding capacity	S	250–400 µg/dL	44–70 µmol/L
17-ketogenic steroids			
Female	U	3–15 mg/d	10–15 µmol/d
Male	U	5–23 mg/d	17–80 µmol/d
17-ketosteroids	U		
Up to 1 year		<1 mg/d	
1–4 years		<2 mg/d	
5–8 years		<3 mg/d	
8–12 years		3–10 mg/d	
13–16 years		5–12 mg/d	
Male, adult		8–20 mg/d	
Female, adult		6–15 mg/d	
Lactic acid	P	4–20 mg/dL	0.4–2.0 mmol/L
Lactate dehydrogenase (LDH)	S		100–200 IU/L
LH Male	S		1.5–7 IU/L
Female (midcycle)	S		20–50 IU/L
Lipase	S		50–175 IU/L
Lipids-Total	S	400–600 mg/dL	4–6 g/L
Lipoproteins Alpha	S	40 mg/dL	
Beta		180 mg/dL	

Contd...

Contd...

Analyte	Sample	Units	SI units
Magnesium	S	1.8–2.2 mg/dL	0.7–0.9 mmol/L
Nonesterified fatty acids (NEFA)(FFA)	P	10–20 mg/dL	0.3–0.7 mEq/L
Norepinephrine	P	70–700 pg/mL	1–4 nmol/L
	U	15–80 µg/day	100–500 nmol/day
Nucleotide phosphatase (NTP) (5'-Nucleotidase)	S		2–10 IU/L
Osmolarity	S		280–296 mosmol/kg 280–296 mmol/kg
Parathyroid hormone (PTH)	S		10–25 ng/L
pCO ₂ , arterial	B	35–45 mmHg	
pH	B	7.4 (7.36 – 7.44)	[H⁺] = 40 nmol/L
Phenylalanine	S	0.75–1.15 mg/dL	0.05–0.1 mmol/L
Phosphate	S	3–4 mg/dL	1–1.5 mmol/L
	U	1 g/day	32 mmol/day
	B	40 mg/dL	
Phospholipids		150–200 mg/dL	2–2.5 mmol/L
Placental lactogen (HPL)-pregnant	S	0.5–10 mg/L	20–500 nmol/L
Plasminogen	S	10–30 mg/dL	
pO ₂ arterial	B	90–100 mmHg	150–220 ml/L
Potassium	S	3.5–5 – 5.5 mEq/L	3.5–5 mmol/L
Pre-albumin (Transthyretin) (TBPA)	S	25–30 mg/dL	
Progesterone Male	S	12–30 ng/dL	0.3–0.9 nmol/L
Female (after midcycle)	S	0.6–3 µg/dL	19–95 nmol/L
Prolactin Male	S		10–15 µg/L
Female normal	S		10–20 µg/L
Pregnancy	S		90–400 µg/L
Prostaglandin E	P	2.5–20 ng/dL	70–550 pmol/L
Prostate specific antigen (PSA) Male	S	100–500 ng/dL	1–5 ng/L
Proteins—Total	S	6–8 g/dL	60–80 g/L
	CSF	10–30 mg/dL	
Prothrombin	P	10–15 mg/dL	
Pseudocholinesterase		8–18 ID/mL	
Retinol binding protein		3–6 mg/dL	
Secretin	S	3–4.5 ng/dL	
Selenium	S	50–100 ng/dL	0.5–1 µmol/L
Serotonin	B	4–36 mg/dL	0.2–2 µmol/L
Sodium	S	136–155 mEq/L	136–145 mmol/L
Sulfate	S	0.5–1.5 mEq/L	
T ₃ (Tri iodothyronine)	S	120–190 ng/dL	1.8–3 nmol/L
rT ₃ (reverse T ₃)	S	10–25 ng/dL	0.15–0.4 nmol/L
T ₄ (thyroxine)	S	5–12 µg/dL	65–150 nmol/L
Testosterone, male, morning	S	300–1000 ng/dL	10–38 nmol/L
female, morning	S	25–45 ng/dL	1–1.5 nmol/L
Thyroglobulin (Tg)	S	3–5 ng/dL	3–50 µg/L
TRH	S		5–60 ng/L
TSH	S	0.5–5 nU/mL	0.5–5 mU/L

Contd...

Contd...

Analyte	Sample	Units	SI units
Thyroxine binding globulin		1–2 mg/dL	
Transcortin	S	3–3.5 mg/dL	
Transferrin	S	200–300 mg/dL	23–35 $\mu\text{mol/L}$
Transketolase	B		150–200 U/L
Transthyretin	S	25–30 mg/dL	
Triglycerides, fasting, Male:	S	50–200 mg/dL	0.5–2.3 mmol/L
Female:		40–150 mg/dL	0.4–1.6 mmol/L
Troponin I	S		1–10 ng/L
Urea	S	20–40 mg/dL	2.4–4.8 mmol/L
Urea nitrogen	S/P	8–20 mg/dL	3–9 mmol/L
Uric acid Male:	S/P	3.5–7 mg/dL	0.21–0.4 mmol/L
Female:	S/P	3.0–6 mg/dL	0.18–0.35 mmol/L
Children:	S/P	2.0–5.5 mg/mL	0.12–0.32 mmol/L
Vanillylmandelic acid (VMA)	U	2–6 mg/d	7–32 $\mu\text{mol/d}$
Vitamin A	S	15–50 $\mu\text{g/dL}$	0.5–2 $\mu\text{mol/L}$
Vitamin C (Ascorbic acid)	P	0.4–1.5 mg/dL	23–85 $\mu\text{mol/L}$
Vitamin Ds (Calcitriol)	S	1.5–6 $\mu\text{g/dL}$	50–160 pmol/L
Vitamin E	S	0.5–1.8 mg/dL	12–42 $\mu\text{mol/L}$
Zinc	S	50–100 $\mu\text{g/dL}$	8–16 $\mu\text{mol/L}$

The conversion units of length are depicted in Table A.3.

TABLE A.3 Conversion chart	
Units of length	
1 megametre	(M) = 10^6
1 kilometre	(km) = 10^3
1 metre	(m) = 1
1 centimetre	(cm) = 10^{-2} m
1 millimetre	(mm) = 10^{-3} m
1 micrometre	(μm) = 10^{-6} m
1 nanometre	(nm) = 10^{-9} m
1 angstrom	(\AA) = 10^{-10} m
1 picometre	(pm) = 10^{-12} m
1 femtometre	(fm) = 10^{-15} m
Units of mass	
1 Megagram	(Mg) = 10^6 g
1 kilogram	(kg) = 10^3 g
1 gram	(g) = 1
1 centigram	(cg) = 10^{-2} g
1 milligram	(mg) = 10^{-3} g
1 microgram	(μg) = 10^{-6} g
1 nanogram	(ng) = 10^{-9} g
1 picogram	(pg) = 10^{-12} g
1 femtogram	(fg) = 10^{-15} g

The alphabets used are shown in Table A.4.

TABLE A.4 Greek alphabet (Commonly used letters as symbols)		
Letters	Capital	Small
Alpha	A	α
Beta	B	β
Gamma	Γ	γ
Delta	Δ	δ
Epsilon	E	ϵ
Zeta	Z	ζ
Eta	H	η
Theta	Θ	θ
Kappa	K	κ
Lambda	Λ	λ
Mu	M	μ
Xi	Ξ	ξ
Pi	Π	π
Rho	P	ρ
Sigma	Σ	σ
Phi	Φ	ϕ
Chi	X	χ
Psi	Ψ	ψ
Omega	Ω	ω

The surface areas according to different heights and weight are depicted in Table A.5.

TABLE A.5 Surface area for different heights and weights					
<i>Height in cm</i>	<i>Weight in kg</i>	<i>Surface area in square meters</i>	<i>Height in cm</i>	<i>Weight in kg</i>	<i>Surface area in square meters</i>
75	15	0.52	155	45	1.40
80	20	0.62		50	1.46
85	25	0.70		55	1.52
90	30	0.80		60	1.57
95	32	0.85	160	50	1.50
100	34	0.90		55	1.55
105	35	0.95		60	1.60
110	37	1.00		65	1.65
115	39	1.05		70	1.72
120	40	1.10	165	60	1.65
125	41	1.15		65	1.70
130	42	1.20		70	1.75
135	44	1.25		75	1.81
140	45	1.30		80	1.88
145	40	1.25	170	72	1.85
	45	1.32	175	75	1.90
	50	1.38	178	78	1.95
	55	1.45	180	80	2.00
150	40	1.30			
	45	1.35			
	50	1.42			
	55	1.47			

The height and weight of Indians are depicted in Table A.6.

TABLE A.6 Ideal body weight and height of different age groups (Adapted from the Indian Council of Medical Research)				
<i>Age</i>	<i>Males</i>		<i>Females</i>	
	<i>Height in cm</i>	<i>Weight in kg</i>	<i>Height in cm</i>	<i>Weight in kg</i>
1	75	10.0	74	9.5
2	85	11.0	85	10.0
3	95	13.5	93	13.0
4	100	15.0	98	14.0
5	105	16.5	102	15.5
10	139	32.0	139	33.5
12	149	39.0	150	42.5
15	165	48	155	45.0
20	168	59	158	50.0
30	168	62	158	55.0
40	168	65	158	55.0
50	168	65	158	55.0

The various values in pulmonary physiology used are shown in Table A.7.

TABLE A.7 Values useful in pulmonary physiology			
Pulmonary mechanics	Symbol	Values	
		Male	Female
• Spirometry-volume time curves			
– Forced vital capacity	FVC	4.8 L	3.3 L
– Forced expiratory volume in one second	FEV ₁	≥ 3.8 L	≥ 2.8 L
– FEV ₁ /FVC	FEV ₁ %	76%	> 77%
– Maximum mid-expiratory flow	MMF (FEF 25–27)	≥ 4.8 L/sec	≥ 3.6 L/sec
– Maximal expiratory flow rate	MEFR (FEF 200–1200)	≥ 9.4 L/sec	≥ 6.1 L/sec
• Spirometry-flow-volume curves			
– Maximal expiratory flow at 50% of expired vital capacity	V _{max} 50 (FEF 50%)	≥ 6.1 L/sec	≥ 4.6 L/sec
– Maximal expiratory flow at 75% of expired vital capacity	V _{max} 75 (FEF 75%)	≥ 3.1 L/sec	≥ 2.5 L/sec
• Resistance to airflow			
– Airway resistance	Raw	< 2.5 cm H ₂ O/s per litre	
• Lung compliance (Static)			
– Lung + thorax compliance	C (L+T)	0.1 L/cm H ₂ O	
• Maximal static respiratory pressure			
– Maximal inspiratory pressure	MIP	> 90 cm H ₂ O	> 50 cm H ₂ O
– Maximal expiratory pressure	MEP	> 150 cm H ₂ O	> 120 cm H ₂ O
• Lung volumes			
– Total lung capacity	TLC	6.4 litres	4.9 litres
– Functional residual capacity	FRC	2.2 litres	2.6 litres
– Residual volume	RV	1.5 litres	1.2 litres
– Inspiratory capacity	IC	4.8 litres	3.7 litres
– Expiratory reserve volume	ERV	3.2 litres	2.3 litres
– Vital capacity	VC	1.7 litres	1.4 litres

The haemodynamic values are depicted in Table A.8.

TABLE A.8 Haemodynamic values	
Pressures (mmHg)	
Systemic arterial	
Peak systolic/end-diastolic	100–140/60–90
Mean	70–105
Left ventricle	
Peak systolic/end-diastolic	100–140/3–12
Left atrium (or pulmonary capillary wedge)	
Mean	2–12
Pulmonary artery	
Peak systolic/end-diastolic	15–30/4–14
Mean	9–17
Right ventricle	
Peak systolic/end-diastolic	15–30/2–7
Right atrium	
Mean	2–6
Resistances [(dynes)/cm⁵]	
Systemic vascular resistance	700–1600
Total pulmonary resistance	100–300
Pulmonary vascular resistance	20–130
Flows	
Cardiac index or cardiac output (litres/min/m ²)	700–1600
Stroke index (mL/beat/m ²)	30–65
Oxygen consumption (litres/min/m ²)	100–150
Arteriovenous oxygen difference (mL/litre)	30–50

The echocardiographic values in normal population are shown in Table A.9.

TABLE A.9 Normal values of echocardiographic measurements in adults

	<i>Mean</i>	<i>Range</i>
Body surface area (m ²)	1.8	1.45–2.22
RVD (cm) measured at the base in apical	3.5 ± 0.4 cm	2.6 to 4.3 cm
LVID (measure in the parasternal long)	4.7 ± 0.4 cm	3.7–5.6 cm
Posterior left ventricular wall thickness	0.9 ± 0.4 cm	0.6–1.1 cm
IVS wall thickness (cm)	0.9 ± 0.4 cm	0.6–1.1 cm
Left atrial dimension (cm), anteroposterior dimension	2.9 ± 0.3 cm	2.3–3.8 cm
Aortic root dimension (cm)	2.4 ± 0.4	2.0–3.5 cm
Aortic cusp separation	1.9 ± 0.4	1.5–2.6 cm
% of fractional shortening	36%	34–44%
Ejection fraction	67%	55–78%

Abbreviations:

RVD = Right ventricular dimension; LVID = Left ventricular internal diameter;
 TVS = Interventricular septum; d = end-diastole;
 s = end-systole;
 Calculation of fractional shortening % = $\frac{\text{LVIDd} - \text{LVIDs}}{\text{LVIDd}} \times 100$

Index

Page numbers followed by *f* refer to figure, *t* refer to table and *b* refer to box

A

- Abdomen 246
acute 292
differential diagnosis of 291*t*
auscultation 272*f*, 272
common abnormalities 253, 257
dilated veins 252*b*
general physical examination 249
inspection 250
palpable structures 246*f*, 246
palpation 256
deep 257*f*, 257
superficial 256
percussion abnormalities 269
regions of 246*f*
shape of 251
- Abdominal aorta 246
aneurysm 205*t*
- Abdominal distension 19*b*, 23, 247*b*
- Abdominal lump 265
physical examination of 265
- Abdominal movements 254
- Abdominal pain 28, 247*b*
causes 20*t*
precipitating factors 20*b*
relieving factors 20*b*
- Abdominal paracentesis 289
- Abdominal pulsations 250
- Abdominojugular reflux 174
- Abductor pollicis brevis 379*t*
- Abnormal bowel sounds 273
- Abscess 237*t*
- Acanthosis nigricans 69*t*
- Accessory muscles of respiration 221, 222
abdominal muscles 223
alae nasi 223
latissimus dorsi 223
pectoralis major 223
scalani 223
serrotus anterior 223
sternomastoid 223
trapezius 223
- Achondroplasia 54*t*, 54*b*
- Acne vulgaris 76*f*
- Acoustic neuroma 114*b*, 119
- Acrocyanosis 204*b*, 205
- Acromegaly 45*b*, 52*f*, 52*t*, 73*t*, 144*b*, 147*t*,
150, 152*t*, 506, 516, 523*f*, 523
- Acromioclavicular joint 449
- ACTH 517
deficiency 526*t*
- Actinomycetes 220*b*
- Added sounds 184, 186*f*, 211, 229, 232
types of 232
- Addison's disease 41*t*, 46, 60*t*, 70*b*, 71, 73*t*,
151*b*, 416, 506, 509, 512, 525*f*,
525*t*, 525
- Addisonian crisis 418*t*
- Additional sounds 182
- ADH deficiency 526*t*
- Adie's pupil 93
- Adiposogenital syndrome 507*t*
- Adnexal masses 321
- Adrenal axis 517
- Adrenal crisis 22*t*
- Adrenal disease 140*t*
- Adrenalectomy 73*t*
- Adson's test 201
- Agranulocytosis 35
- AIDS 47*t*, 217*t*, 299*b*
associated enteritis 24*t*
- Albinism 69, 71*f*, 92
- Alcohol related disorders 11*b*
- Alcoholic dementia 11*b*
- Alcoholic hepatitis 11*b*
- Alcoholism 70*b*
- Alkaline phosphatase 285
- Allen test 29*f*, 201, 204
- Allergic alveolitis 35
- Allergic contact dermatitis 68*b*
- Allergic rhinitis 217*t*
- Allodynia 44*b*, 332
- Alopecia 18*t*
areata 80, 80*t*, 81*f*
classification of 80*t*
- Alpha 1-antitrypsin 286
- Alport's syndrome 297, 298, 301, 302
- Alveolitis 217
- Amaurosis fugax 84*b*, 203, 337*t*
- Amblyopia 95*t*
- Amenorrhoea 17*t*, 44*b*, 300
- Amnesia 338*b*
- Amoebiasis 299*b*
- Amoebic dysentery 7
- Amoebic liver abscess 19*f*
- Amyloidosis 152*t*, 155, 435*t*
- Anaemia 9*t*, 25, 32, 41*t*, 151*b*, 177, 180, 200,
218, 220, 295, 297, 300, 470,
471, 489*t*
aplastic 35, 37*b*, 121*b*
causes of 471*t*, 471
deficiency 472*t*
dimorphic 471
folic acid 472*t*
haemolytic 262, 472*t*
hypoplastic 472*t*
iron deficiency 472*t*
leucoerythroblastic 474
macrocytic 471
hypochromic 471
megaloblastic 73*t*
normocytic normochromic 471
pernicious 479*b*
symptoms and signs of 470*b*
vitamin B₁₂ deficiency 472*t*
- Anaesthesia 44*b*, 332
- Anal fissure 24, 24*t*, 277
- Anal skin tags 277
- Anal warts 276, 277
- Analgesia 332
- Androgen receptors
antagonists 49*t*
defects 49*t*
- Androgenic alopecia 80*t*
- Aneurysmal disease 205
- Angina pectoris 31*t*
- Angiography, pulmonary 244
- Angioneurotic oedema 53*b*, 157*t*
- Angiotensin-aldosterone system 156
- Angiotensin-converting enzyme inhibitors
140*t*
- Angle of louis 212
- Angular stomatitis 342
- Anhydrosis 94*t*
- Anisocoria 93
- Ankle and foot, examination of 463
- Ankle 461
jerk 384
testing of movements of 464
- Ankle/brachial pressure index 203
measurement of 205
- Ankylosing spondylitis 32*b*, 50, 248, 434,
442, 442*b*
- Anorectal disorders 276
- Anorexia 19*b*, 25, 247*b*

- Anorexia nervosa 17*t*, 45, 48*t*, 56
 Anorexia-bulimia 57
 Anosmia 54*t*, 351
 Anotia 116
 Anterior axillary line 213*f*, 213
 Anterior cerebral artery, syndrome of 337, 338*b*
 Anthropometry 57
 Antinatriuretic hormone 157
 Antineutrophil cytoplasmic antibodies 466
 Antinuclear antibodies 466
 Anti-RNA polymerase antibodies 466
 Antithrombin III 304
 Anuria 38, 298
 Anus 276
 inspection 277
 palpation 277
 Anxiety 489*t*
 Anxiety neurosis 31*t*, 32
 Aorta 192
 Aortic aneurysm 30*t*, 178, 255, 265, 267*b*, 442*b*
 Aortic diastolic murmur 31*t*, 181
 Aortic dissecting aneurysm 31*t*
 Aortic dissection 20*t*, 30*t*, 181*b*
 Aortic ejection systolic murmur 175
 Aortic regurgitation 165*t*, 168*b*, 170*t*, 183, 186, 187, 195
 acute 19*f*
 Aortic stenosis 164*t*, 165*t*, 170, 175, 180, 184, 186*b*
 Aortic valves 162, 177*t*, 181
 Aortic valvular stenosis 181*b*, 187*t*
 Aortoiliac aneurysm 200*b*
 Aortopulmonary window 165*t*, 187*t*
 Apex beat 178, 179
 causes of displaced 180*b*
 character of 179
 localisation of 179*f*
 palpation of 179*f*
 APGAR score 492
 Aphasia 337*t*, 349
 global 349
 Broca's 349*t*
 testing for 348*t*
 Wernicke's 349*t*
 Apical impulse 162
 Apical lung neoplasm 441*b*
 Apnoea 33, 216*b*
 Apocrine glands 67
 Appendicitis 19, 20*t*, 258*b*
 acute 19*f*, 21*t*
 Appendicular mass, characteristics 266
 Apraxia 349
 constructional 349
 dressing 349
 gait 349
 ideomotor 349
 Aqueductal stenosis 359*b*
 Aqueous humour 83
 Arachnodactyly 147, 148*f*, 148*t*
 Arachnoid mater 62, 326
 Arachnodactyly 54*t*
 ARDS 27*b*
 Argyll-Robertson's pupil 93, 94*t*, 95
 Arrhythmias 26, 172*t*, 197
 Arterial bruits 186
 Arterial insufficiency 209*t*
 Arterial pulse
 anacrotic 170*t*
 arterial wall 169
 character 166
 characteristic 170*t*
 Corrigan's pulse 170, 171*f*, 171*t*
 dicrotic pulse 170*t*
 irregularly irregular pulse 168*b*
 normal 170*t*
 pulse rate 167*b*
 pulsus
 alternans 170*t*
 bigeminus 170*t*
 bisferiens 170*t*
 paradoxus 170*t*
 radiofemoral delay 166, 169
 rate 166
 regularly irregular pulse 168*b*
 rhythm 166, 167
 volume 168
 Arteriosclerosis 169
 Arteriovenous anastomosis 300
 Arteritis 199
 Arthralgia 427*t*
 Arthritis 50, 175, 426, 427*t*, 444*b*
 causes of 50*b*
 Arthrogram 468
 Arthropathy 426
 Articular processes 440
 Asbestosis 217*t*
 Ascending aorta 192
 Ascites 14*t*, 25*b*, 26*t*, 53, 157*b*, 219*t*, 236, 248*b*, 253, 269, 304
 fluid thrill 270, 271*f*
 horse-shoe shaped dullness 270, 271*f*
 Pudal's sign 270, 271*f*
 shifting dullness 270, 271*f*
 Aspergilloma 30*t*, 217*t*
 Asthenia 43*b*
 Asthma 6, 8*t*, 18, 28, 29*b*, 32, 33, 34*t*, 35, 69, 178, 179, 211, 217, 217*t*, 222, 223*b*, 240, 241*t*
 acute 36*t*
 bronchial 7, 218, 223, 225, 225*t*, 231, 233, 237
 cardiac 233, 234*t*
 chronic 33*t*
 occupational 216*b*
 Asymmetrical oligoarthritis 430*t*
 Ataxia 371
 causes of 392*b*
 Atelectasis 224
 Atheroembolism 204
 Atheroma 335*f*
 Atherosclerosis 55*t*, 169, 193, 198, 302
 Atherosclerotic obliterans 199
 Athetosis 40*b*, 395*t*
 Atlantoaxial joint 442*t*
 Atopic eczema 68*b*
 Atrial fibrillation 26, 27, 167*b*, 168, 184
 causes of 168*t*
 Atrial flutter 167*b*
 Atrial myxoma 184*b*, 199
 Atrial septal defect 165*t*, 184*b*, 187, 193, 195, 197
 Atrial thrombus 199
 Atrioventricular fistula 198*t*
 Atrioventricular malformations 205*t*
 Atrioventricular valves 162
 Audiometry 119, 120
 pure tone 120
 speech 120
 Auditory acuity 117
 Auricle examination 116
 Auscultation, method of 229, 230*f*
 Automatism 16*t*
 Autonomic dysfunctions, symptoms of 405*b*
 Autonomic hyperactivity 418*t*
 Autonomic nervous system 402
 aetiology of 404*t*
 disorders 402
 Autosomal recessive disorders 7
 AV block first degree 184*b*
 Axillae 137-143
 examination 143
 inspection 143
 palpation 143
 Axillary nodes 137*t*
 Axons 325
 Azotemia 298

B

- Babinski's response 387
 Babinski's sign 329, 382*t*, 387
 Back 275
 Bacteriuria 310
 Balanitis 313
 Balanoposthitis 313
 Barium meal studies
 barium
 enema 279
 swallow 278
 Barrel shaped chest 178, 221*t*
 Bartholin's gland abscess 318
 Bartter's syndrome 298
 Basal cell carcinoma 70*f*
 Basal ganglia 325, 326, 375, 406*t*
 Becker's muscular dystrophy 374*f*
 Behçet's syndrome 435*t*
 Bell's palsy 364, 366*t*, 366
 Bence-Jones protein's, test for 534

- Benedict's syndrome 338t
 Benedict's test 307, 534
 Benign cholestasis 26t
 Benign intracranial hypertension 63t
 Benign prostatic hypertrophy 278
 Benzidine test 536
 Berger's disease 297
 Beri-beri 157t
 Berylliosis 217t
 Beta blockers 47t, 198, 204, 402
 Biceps 380t
 Bilateral diaphragmatic paralysis 222
 Bile pigments, tests for 307
 Bile salts, test for 536
 Biliary cirrhosis 26t, 68b, 73t, 150b
 Bilirubin 90, 282, 307
 tests for 307
 Bimanual palpation 259b
 Biot's breathing 218b
 Bird fancier's lung 217t
 Bitot's spots 90, 90f
 Bleeding 35
 causes of 37b
 disorders 9t
 gums 37
 per rectum 19b, 23
 Blepharitis 85b, 87, 510
 Blood 470
 Blood culture 531
 Blood in urine, tests for 305
 Blood loss signs and symptoms 37t
 Blood pool scanning 196
 Blood pressure 169
 checklist for 169
 diastolic 169
 specific problems related to 172t
 systolic 169, 203
 BMI 53–55, 56b
 Boiling test 533
 Bone density 468
 Bone marrow
 aplasia 15t
 examination 482
 chief indications for 483b
 Bone pain 429
 Bone scanning 410
 Bony ankylosis 435, 439
 Bouchard's nodes 151b, 151f
 Bowel sounds, auscultation of 272f
 Bowman's capsule 294
 Bowstring sign 447f, 447
 Brachial pressure index 199
 Brachioradialis 380t
 Bradycardia 59b, 167b
 arrhythmic 167b
 sinus 167b
 Brain 325
 abscess 63t, 236
 blood supply 334
 death 421f
 diagnosis of 424t
 testing 423
 Brainstem 325, 356, 422
 infarction 116
 tumours 120
 Brainstem reticular activating system (RAS) 415
 BRCA1 138
 BRCA2 138
 Breast 137–143
 abscess
 lactational abscess (ES) 138
 nonlactational 138
 atrophy 25
 carcinoma 137
 risk factors 137
 TNM classification 137t
 cysts 138
 examination of 140, 512
 fibroadenomas 138
 fibrocystic disease 138
 lump 137t, 137
 lymphoedema 138
 stages of development 136f
 Breast disease
 investigations 143
 fine-needle aspiration 143
 mammography 143
 MRI 143
 trucut biopsy 143
 ultrasound 143
 symptoms 137
 Breath sounds 230
 bronchial 231f, 231t, 231
 bronchovesicular 231t
 characteristic of 231
 intensity of 230b
 vesicular 231f, 231t, 231
 Breathing abdominal 221
 Breathing patterns, in respiratory disorders 218b
 Breathin
 bronchial 231, 232t
 causes of 232t
 slow 218b
 thoracic 221
 Breathlessness 32, 216b
 Brisk tendon stretch reflexes 329
 Brissaud's reflex 387
 Broca's area 347
 Bromsulphalein (BSP) clearance 286
 Bronchial adenoma 30t
 Bronchial asthma acute 34t
 Bronchial carcinoma 29b, 30t, 33
 Bronchial tree 214
 Bronchiectasis 29b, 30t, 150b, 217t, 218, 223b, 225, 234, 237t
 Bronchitis 7, 10f, 29b, 30t, 222, 223, 223b, 237t
 acute 31t
 chronic 30, 231, 234t, 240
 Bronchogenic carcinoma 10f, 150b
 Broncholitis 241t
 Bronchophony 229b, 232
 Bronchopleural fistula 225t, 232
 Bronchopneumonia acute 27b
 Bronchopulmonary aspergillosis 238
 Bronchoscopy 243
 Bronholm disease 30t
 Brudzinski's sign 350f, 350
 Bruises 37
 Bruit 520
 Budd–Chiari syndrome 20t, 25, 26t, 157t, 260
 Buerger's disease 153, 199, 204f, 204
 Buerger's test 201
 Bulbar conjunctivae 89
 Bulbar palsy 23b, 338t, 369b, 371
 Bulge sign 460
 Bursae 427
 Bursitis 50b
- C**
- Café-au lait spots 342, 444t
 Calcitonin 133
 Calcium channel blockers 140t, 167b
 Caloric test 120, 121
 Campbell de Morgan spots 250
 Canal of Schlemm 83
Candida albicans 533
Candida spp 533b
 Candidiasis 23b, 68b, 147t
 cutaneous 74
 Capillary naevus 78f
 Caput medusae 25
 Carboxyhaemoglobin 73
 Carcinoid syndrome 17t, 24t, 68b, 234t
 Carcinoid tumour 68b
 Carcinoma 140t
 bronchus 217t
 penis 313
 rectum 19f
 stomach 69t
 Cardiac achalasia 22, 23t, 228, 233
 Cardiac arrhythmias 188
 Cardiac catheterisation 196
 Cardiac cycle 162f, 162, 163
 Cardiac disease 28
 Cardiac dullness 161, 227
 Cardiac ischaemia 441b
 Cardiac murmurs 163
 Cardiac rupture 192
 Cardiac tamponade 41t
 Cardiomegaly 157b, 227, 470b
 Cardiomyopathy 11b, 26, 168t, 199
 Cardiovascular symptoms 25
 Cardiovascular system 162f, 162
 general physical examination 164, 165
 investigations 187
 systemic examination 161
 Carditis 176b

- Carotenaemia 70
 Carotid artery 135, 173*t*, 175
 dissection 200*b*
 stenosis 205*t*
 Carotid pulse 126, 163, 173*t*, 175, 211, 219, 249
 palpation of 176*f*
 Carpal tunnel syndrome 152*t*, 524*t*
 Carpometacarpal joint 428*b*
 Carrey-Comb's murmur 187*t*
 Cataract 84*b*
 Catheterization
 complications 197*t*
 contraindication 197*t*
 indications 197*t*
 Cauda equina 326
 Cauda equina syndrome 442
 Caudate nucleus 325
 Cavernous haemangioma 77
 Cavernous sinus 339, 356, 361*t*
 thrombosis 85*f*, 88*t*, 95
 Central artery of retina 100
 Cerebellar ataxia 389, 402
 Cerebellar lesions 406*t*
 Cerebellopontine angle 361*t*
 Cerebellum 325, 326, 328
 Cerebral abscess 410*b*
 Cerebral angiography 409
 Cerebral artery
 anterior 334
 middle 335
 posterior 336
 Cerebral cortex 330*b*
 Cerebral embolism 28
 Cerebral hemispheres 347
 Cerebral infarcts 410
 Cerebral lacunar infarcts 371
 Cerebral malaria 420
 Cerebral tumour 410*b*
 Cerebral venous sinus thrombosis
 causes of 340*b*
 clinical manifestations 340*t*
 Cerebrospinal fluid 326
 Cerebrovascular disease 197
 Cerebrum 325
 Cervical carcinoma 317
 Cervical lymphadenopathy 211, 219
 Cervical rib 441*b*
 Cervical smear 321
 Cervical spondylosis 441*b*
 Chaddock's sign 388*b*
 Chagas' disease 23*t*
 Chancroid 299*b*, 313, 314*f*
 Charcot arthritis 50*b*
 Charcot's joint 435
 Charcot-marie-tooth 152
 Cheese worker's lung 217*t*
 Chemosi 520
 Chest examination 220-244
 anterior chest 220
 auscultation 229-235
 inspection 220-223, 234
 palpation 223-225, 235
 percussion 225-229, 235
 lateral chest 220
 posterior chest 234-236
 Chest pain 27, 28*b*, 30, 33
 atypical 32
 causes of 30*t*
 differential diagnosis of 31*t*
 pleural 32*b*
 Chest wall
 lesion 221
 posterior 212*f*, 213*b*
 anatomical landmarks 213*b*
 Chest
 deformities 221*t*
 fluoroscopy of 238
 important regions on 215*b*, 216*f*
 movements of 221
 normal shape of 220*b*
 X-ray 191
 of 239*b*
 indications of 192
 Cheyne-stokes breathing 218*b*, 421
 CHF 165, 219*t*, 262, 479*b*
 Chicken pox 6, 76*f*, 74
 Chilaiditi's syndrome 269
Chlamydia trachomatis 533*b*
 Cholangitis, acute 21*t*
 Cholecystitis 8*t*, 22*t*, 258*b*, 443*b*
 acute 19*f*, 22*t*
 chronic 261
 Cholelithiasis 261
 Chorea 392, 395*t*
 causes of 395*b*
 Huntington's 395*t*
 Sydenham's 395*t*
 Christmas disease 37*b*
 Chronic intestinal pseudo-obstruction 24*t*
 Chvostek's sign 397
 Chyluria 298
 Ciliary body 83
 Ciliospinal reflex 94*t*
 Circle of willis 335*f*, 334
 Cirrhosis of liver 8*t*, 11*b*, 49*t*, 80*t*, 140*t*, 157*t*, 271
 Citrullinated cyclic peptide (CCP) antibodies 465
 Claude syndrome 338*t*
 Claudication 200*t*
 arterial 199, 200*t*
 neurogenic 199, 200*t*
 venous 199, 200*t*
 Claw foot 152
 Claw hand 144*b*
 Clinitest 307
 Clonus 375
 Close-angle glaucoma acute 85*b*
 Clubbing 145, 150, 177, 211, 219
 causes of 150*b*
 differential 150
 Coagulation pathways 482
 Coal worker's pneumoconiosis 217*t*
 Coarctation of aorta 169, 172*t*, 178, 220*b*
 Coccyx 440
 Cochlear nuclei 367
 Cochlear otosclerosis 114*b*
 Coeliac disease 8*t*, 54*t*, 55*f*, 508
 Coeliac sprue 24*t*
 Coin test 233
 Colic 20*t*
 Colitis 19*f*
 Collagen diseases 121*b*
 Collagen vascular disorders 50*b*
 Collateral ligaments 459
 Colonic carcinoma 24*t*
 Colonoscopy 281
 Colour vision 92
 abnormalities of 92*b*
 Coma examination, brainstem reflexes 422*f*
 Coma like syndromes 415
 akinetic mutism 415
 catatonia 415
 coma vigil 415
 hysterical pseudocoma 415
 locked-in-state 415
 vegetative state 415
 Coma scale, Glasgow 419*b*
 Coma 415
 abnormal posturing 419
 causes of 415
 clinical
 cause of 418*t*
 evaluation of a patient 416
 common causes of 416
 due to encephalitis 420*f*
 eye movements in 421
 general physical examination 417
 head injury 420
 hepatic 419*f*
 immediate assessment of 417*t*
 investigations 423
 metabolic clinical features 418*b*
 neurological
 clinical features 418*b*
 examination 417
 ocular fundus examination 423
 pupillary size and reaction 421
 without neurological signs 423*b*
 Complete heart block 167*b*, 173
 Conduction defects 188
 Conductive deafness 114
 Congenital adrenal hyperplasia 48*t*
 Congenital heart disease 8*t*, 54*b*, 59*b*, 150*f*, 150, 167*b*, 168*t*, 194
 Congenital hyperbilirubinaemia 26*t*
 Congestive cardiac failure 33, 161, 164, 168*b*, 175*f*, 175, 184
 Conjugated hyperbilirubinaemia 282
 Conjunctiva 83, 86, 89
 Conjunctival chemosis 218, 219*t*
 Conjunctivitis 85*b*, 301, 510

- Conn's syndrome 509, 515*t*
 Consciousness 344
 Consolidation 225, 225*t*
 Constipation 19*b*, 22, 24, 247*b*, 402
 Constrictive pericarditis 157*t*, 168*t*, 174, 175
 Constructional apraxia 346*f*
 Convulsions 40*b*
 COPD 7, 30, 32*b*, 33, 33*t*, 34-36, 178, 179, 183, 192, 193, 217-220, 222, 225, 233, 234*t*, 240, 241, 244
 risk factors for 217*f*
 COR pulmonale 168*b*, 168*t*, 219
 Cornea 83, 86, 90
 Corneal arcus 200*b*
 Corneal blink reflex 422
 Corneal oedema 90
 Corneal reflex 361
 Corneal ulceration 85*b*
 Coronary angiography
 complications 196, 197*t*
 contraindications 196, 197*t*
 indications 196, 197*t*, 198*t*
 Coronary arteriovenous fistula 164, 187*t*
 Coronary artery disease 7, 8*t*, 168*t*, 198*t*
 Corticobulbar fibres 327
 Corticospinal tract 327
 Costochondritis 30*t*
 Costophrenic angle 247
 Costovertebral joints 446
 Cough 28, 216*b*
 barking 53
 brassy 53
 characteristics of 29*b*
 reflex 422
 whooping 53
 Courvoisier's law 261
 Crackles 211, 229*b*, 232, 233
 causes of 234*t*
 coarse 235*t*
 early inspiratory 234*t*
 expiratory 234*t*
 mid-inspiratory 234*t*
 palpable 225
 Cranial nerves 62, 65, 113, 326, 406
 abducens 327*b*, 354, 355
 nerve palsy 358
 accessory 368, 369
 common abnormalities 370
 motor innervation 368*t*
 parasympathetic innervation 368*t*
 reflex 368*t*
 sensory innervation 368*t*
 examination of 351
 facial 327*b*, 363
 nerve paralysis 366*t*
 palsy 363, 365*f*
 functions 327*b*
 glossopharyngeal 327*b*
 common abnormalities 370
 motor innervation 368*t*
 nerve palsy 368, 369
 neuralgia 368
 parasympathetic innervation 368*t*
 reflex 368
 sensory innervation 368*t*
 hypoglossal 327*b*, 370
 nerve palsy unilateral 370, 371
 nerve palsy, bilateral 371
 oculomotor 327*b*, 354
 palsy 89*t*, 95, 421
 olfactory 327*b*, 351
 optic 327*b*, 351
 spinal accessory 327*b*
 trigeminal 327*b*, 359
 mandibular 360
 maxillary 360
 nerve disorders 361*t*
 ophthalmic 360
 palsy 90
 trochlear 327*b*, 354, 355
 nerve palsy 358
 vagus 327*b*
 common abnormalities 370
 motor innervation 368*t*
 nerve palsy 368
 parasympathetic innervation 368*t*
 reflex 368*t*
 sensory innervation 368*t*
 vestibulocochlear 327*b*, 364
 cochlear functions 367
 vestibular functions 367
 Craniopharyngioma 48*t*, 54*b*, 100*b*, 353*t*, 526*t*
 Creatinine 310
 Crest syndrome 200*b*
 Cretinism 54
 Cricoid cartilage 511*b*
 Crigler-Najjar syndrome 25, 282
 Crohn's disease 24*t*, 54*b*, 150*b*, 248, 508
 Cruciate ligaments 459
 Cruveilhier-Baumgarten syndrome 273
 Cryptorchidism 47*t*, 49*t*, 49, 317, 318*f*, 318*t*, 513, 514*t*
 CSF examination 424
 CT scan, diagnostic value of 407*b*
 Cushing's syndrome 17*t*, 45*b*, 45*t*, 52*t*, 53*b*, 55, 70*b*, 73*t*, 88, 157*t*, 251, 506, 507*t*, 509, 515, 524*t*, 524*f*, 524
 Cutis vulgaris 220*b*
 Cyanosis 14*t*, 34*t*, 73, 157*b*, 165, 165*b*, 200, 204, 211, 218, 219
 central 36*t*, 165, 166
 mixed 166
 peripheral 165, 219
 Cyanotic heart disease 205, 340*b*
 Cyst of epididymis 317*t*
 Cystic fibrosis 47*t*, 54*b*, 508
 Cystic medial necrosis 192
 Cystic renal diseases 39*t*, 298
 Cystitis 20*t*, 39*t*, 264
 Cystocele 318
 Cystourethrocele 319
- D**
- Dacryocystitis 85*b*, 89
 Deafness 114
 causes of 114*b*
 conductive 367
 sensorineural 367
 Debre-Kocher-Semelaigne syndrome 45*b*
 Deep tendon reflexes 330*t*, 330
 Deep vein thrombosis 34*t*, 206, 207*f*, 207, 210, 217*t*
 clinical manifestations of 207*t*
 complications 208
 differential diagnosis 208
 investigations 207
 of arm 207*t*
 of leg 207*t*
 Degenerative disorders 428*b*
 Dehydration 59*b*
 Deltoid ligament 461
 Deltoid reflex 384
 Demyelinating optic neuritis 103
 Dendritic cells 67
 Depression 489, 490*f*, 490*t*
 Dermatitis artefacta 69*t*
 Dermatitis herpetiformis 69*t*
 Dermatome 333
 Dermatomyositis 73*t*
 Dermatophytes 533
 Dermis 66, 67
 Descending aorta 178
 Dexamethasone suppression test 503, 517*b*, 517
 Dextrocardia 179
 Diabetes insipidus 6*b*, 17*t*, 44, 45*t*, 59*b*, 303
 nephrogenic 6*b*, 44, 303
 Diabetes mellitus 6, 6*b*, 7, 8*t*, 16, 17*t*, 18, 24*t*, 38, 56, 59*b*, 80*t*, 161, 198, 298, 300*b*, 306, 416, 506, 526, 528, 527*f*
 diagnostic criteria 526*b*
 type 2 528*b*
 clinical presentations 528*b*
 Diabetic coma 418*t*
 Diabetic dermopathy 509
 Diabetic foot 154*f*, 528*b*
 Diabetic ketoacidosis 20*t*, 32, 33, 416
 Diabetic myopathy 45*b*
 Diabetic nephropathy 309
 Diabetic retinopathy 84*b*, 102*b*, 102*f*, 102
 Diadochokinesis 390
 Diaphragmatic paralysis 254
 Diaphragmatic pleurisy 19
 Diarrhoea 19*b*, 20, 22, 24, 43*b*, 247*b*
 Diarrhoea acute, causes of 23*t*
 Diarrhoea chronic, classification of 24*t*
 Diarrhoea nocturnal 402

- Diastasis recti 254*f*, 254
 Diastolic murmur 182
 Diencephalon 325
 Differential leucocyte count 481
 Diffuse proliferative glomerulonephritis 309
 Dilatation acute 193
 Dilated cardiomyopathy 168*b*, 170*t*, 180, 192
 Dilated pupils 418*t*
 Dinner-fork deformity 394
 Dip stick test 304
 Diphtheria 124, 222
 Diplopia 84, 85, 87, 88*t*, 95, 121, 394*t*
 binocular 85
 causes of 86*b*
 monocular 85
 Dipstick test 534, 536
 Disc protrusion 442
 Discoid lupus erythematosus 80*t*
 Distal interphalangeal joints 428*b*, 453
 Distant vision, tests for 91
 Diuretic therapy 6*b*
 Diverticular disease 24*t*
 Diverticulitis 20*t*, 21, 24
 acute 21*t*
 Diverticulosis 269, 443*b*
 Dix and Hallpike method 119
 Doll's eye reflex 367
 Donovanosis 313, 314*f*
 Double apex beat 180
 Dowager hump 442
 Down's syndrome 52*f*, 52*t*, 54*b*, 147*t*, 148*f*,
 151*b*, 508
 Drum examination 117
 Dry eye syndrome 90
 Dry tongue 59
 Dubin-Johnson syndrome 307
 Duchenne muscular dystrophy (DMD)
 374*b*, 374*f*, 375
 Duodenal ulcer 19*f*
 Duodenum 267*b*
 Duplex venous ultrasonography 207
 Dupuytren's contracture 435, 437*f*
 Dura mater 326
 Dural sinus thrombosis 101*t*, 339
 Durkan's sign 456
 Dwarfism 508
 Dysaesthesia 44*b*, 332
 Dysarthria 347
 causes of 348*t*
 Dysdiadochokinesis 329
 Dysgonadotropinism 18*t*
 Dysmenorrhoea 20*t*
 Dyspepsia 19*b*, 247*b*
 causes 21*t*
 nonulcer 20*b*
 Dysphagia 19*b*, 20, 22, 46, 124, 211, 216*b*,
 219*t*, 247*b*, 511
 causes 23*t*
 differential diagnosis of 23*b*
 mechanical 23*b*
 motor 23*b*, 23*t*
 neuromuscular 23*t*
 oropharyngeal 23*t*
 Dysphasia 347, 349
 Dysphonia 124, 216*b*, 347, 349
 causes of 124*b*
 Dyspnoea 14*t*, 15, 15*t*, 16, 25, 26, 28*b*, 32, 35,
 36*b*, 161, 164, 216*b*
 at rest 27
 cardiac 35, 36*t*
 causes of 27*b*, 33, 33*t*
 characteristics 33
 due to respiratory disease 32
 pulmonary 36*t*
 Dystonia 40*b*, 396
 Dystrophic myotonia 317*t*, 357*t*
 Dysuria 37*b*, 38, 293, 298
- E**
- Ear 113-121, 116*f*
 canal examination 117
 examination of 116
 functions 113
 Ecchymosis 36*b*, 37, 478*t*
 Ecchymotic patches 480*f*, 480
 Eccrine glands 67
 ECG
 conventions 189*b*
 indications of 188
 Echocardiographic values, normal 194*t*
 Echocardiography 187, 194
 Doppler 195*f*, 195
 colour flow mapping 196
 continuous wave Doppler 195
 pulse wave Doppler 196
 M-mode 194*f*, 194
 stress 189
 two-dimensional 194, 195*f*
 Eczema 69
 Edinger-Westphal nucleus 355
 Ehlers-Danlos syndrome 435, 464
 Ehrlich's aldehyde test 307, 535
 Eisenmenger's syndrome 150, 150*b*
 Ejection clicks 184, 186*b*, 186*f*
 causes of 186*b*
 Elbow 451
 examination of 452
 joint
 movements testing at 452
 tunnel syndrome 404*b*
 Electroencephalography (EEG) 410
 Electromyography (EMG) 410
 Electronystagmography 119
 Electrophoresis of proteins 304, 305*f*
 Electroretinograms 103
 Embolisation 197
 Emphysema 36*t*, 101*t*, 223, 223*b*, 224, 225*t*,
 232, 237, 269
 subcutaneous 220*b*
 Empyema 220
 Encephalitis 63*t*, 114, 416, 418*b*, 420, 423,
 424
 Encephalitis lethargica 422
 Encephalocoele 64*b*
 Endocarditis 165, 181*b*, 262
 bacterial 199*f*
 Endocrinal diseases
 common presenting symptoms of 507*t*
 general physical examination (GPE) 508
 physical signs of 508*t*
 systemic examination in 515*t*
 Endocrinal imaging 518
 Endocrine system 505
 Endometritis 20*t*
 Endophthalmitis 85*b*
 Endoscopic retrograde cholangio-
 pancreatography (ERCP) 280,
 288
 Endoscopy 279, 289
 lower GI 281
 upper GI 279
 Enophthalmos 87
 Enterohepatic circulation 307
 Entrapment neuropathies 402, 404*b*
 Enuresis 39
 nocturnal 39
 Eosinophilic gastroenteritis 24*t*
 Epidemic myalgia 30*t*
 Epidermis 66
 Epididymis 316
 Epididymo-orchitis 317*t*
 Epigastric pulsations 178, 180*f*, 180
 Epiglottis 124
 Epilepsy 8*t*, 40, 40*b*, 211, 340, 410*b*
 Epileptic fit 42*t*
 Epiphora 84
 Episcleritis 85*b*
 Epistaxis 37, 35*t*, 121
 causes of 121*b*
 Erector spinae 382*t*
 Erosive gastritis 8*t*
 Eruptive xanthomas 509
 Erysipelas 122
 Erythema marginatum 176, 176*b*, 176*f*
 Erythema nodosum 69*t*, 70*f*, 220*b*, 248, 435*t*
 Erythropoietin 295
 Ethmoidal sinuses 360
 Eunuchoidism 54*t*, 509, 513*f*
 Eustachian tube 114
 Exanthematous fever 7
 Exocrine pancreatic function 282
 Exophthalmic ophthalmoplegia 86*b*, 88,
 507*t*
 Exophthalmos 84, 87, 88*f*, 90, 510, 520
 bilateral 88
 causes 88*t*
 unilateral 88
 Extension 445
 Extensor plantar responses 329

External auditory canal 117
 External auditory meatus 117
 External blunt trauma 113*b*
 External jugular vein 172, 175
 External ocular muscles, functions 356*f*
 External strabismus 357
 External urethral meatus 313
 Extramedullary erythropoiesis 476
 Extraocular muscles, paralysis 86
 Extrapyrmidal lesions 329
 Extra-respiratory muscles 211, 218
 Extremities, examination of 144-157
 Extrinsic allergic alveolitis 217*t*
 Eye 83-103
 examination 86, 510
 abnormal findings 86
 general inspection 87
 internal examination 92
 iris 92
 pupils 92

F

Faecal impaction 24*t*
 Faeces, examination of 532
 Fallot's tetralogy 150, 165*t*, 193
 Familial urate nephropathy 298
 Farmer's lung 217*t*
 Fasciculations 397
 Fatigue 28
 Fatty abdomen 253
 Feet, examination 151
 Felty's syndrome 435*t*
 Femoral nerve stretch test 448*f*, 448
 Ferric chloride 535
 Fetor hepaticus 25, 25*b*, 252*b*
 Fever 60
 types of 61*f*, 60
 Fibrillations 28, 397
 Fibromyalgia 50*b*, 223*b*
 Fibromyositis 43*b*
 Fibrosing alveolitis 150*b*
 Fibrosis 220, 224, 237*t*
 lung 232*t*
 Fibrositis 43*b*
 Fibrous ankylosis 439
 Filariasis 157*t*
 Finger
 clubbing of 165*b*, 166
 deformities 147*t*
 joints 455
 Finger to finger test 389
 Finger-nose test 389
 Fistula 24
 Flapping tremors 271*f*, 271, 301
 Flat chest 220
 Flatulent dyspepsia 13*t*
 Flexion 445
 Flexor retinaculum 453
 Flexors/extensors, wrist 380*t*

Flip test 447, 448*f*
 Floating ribs 213*b*
 Fluoroscopy 194
 Foetal alcohol syndrome 11*b*
 Foot 461
 Forced expiratory
 time 243
 volume 242*f*
 Fornix 87
 Foster-Kennedy syndrome 101*t*
 Fovea centralis 83
 Frenzel's glasses 119
 Friction rub 273
 Friedreich's ataxia 152
 Frohlich's syndrome 45*t*, 55*t*
 Frontal lobe lesion 406*t*
 Frontal sinuses 123*f*, 123
 Fructosuria 307
 FSH 515*b*
 Fundus
 abnormalities of 98
 normal 97
 Funnel chest 221*t*
 Furunculosis 122

G

GB syndrome 375*t*
 Gag reflex 368
 Gait 43, 351, 434
 antalgic 434
 apraxia 392
 examination of 391
 painless 434
 trendelenburg 434
 types of 393*t*
 waddling 434
 Galactorrhoea 17*t*, 44*b*, 48, 139*f*, 139, 506, 513
 common causes of 139*b*
 Gallbladder 267*b*, 268
 palpation 260
 Gallstones 55*t*
 GALS screening tests 432*f*
 Gastric carcinoma 37
 Gastritis 11*b*, 19*f*
 acute 10*f*
 Gastroesophageal reflux disease 20*b*, 23*b*, 30*t*, 489*t*
 Gastrointestinal system 247
 investigations of 278
 symptoms 19, 247*b*
 lower GI tract 247*b*
 upper GI tract 247*b*
 Gastroscopy 280
 Gaze palsy 359*b*
 General physical examination 51
 built 53
 complexion 51
 facial appearance 51
 gait 51
 measurement
 of height 53
 of weight 53
 mental state 51
 nutritional status 57
 odour 53
 personal hygiene 51
 speech 51
 state of hydration 58
 vitals 59
 blood pressure 59
 pulse 59
 respiration 59
 temperature 59
 Generalised purpura 69*t*
 Genital herpes 299*b*, 313*t*
 Genital system 46
 Genital warts 299*b*
 Genitalia 295
 female
 external examination 317
 inspection 317
 internal examination 321
 palpation 32
 related symptoms 296*b*
 male 295
 examination 313
 related symptoms 296*b*
 Genito urinary system
 examination of abdomen 300, 302
 auscultation 300, 302
 inspection 302
 palpation 302
 percussion 302
 examination of genitalia 300, 513
 general physical examination 300-302
 Genitourinary symptoms 296
 Genu valgum 460
 Genu varum 460
 Gerhardt test 307
 GH deficiency 516, 526*t*
 Giardiasis 299*b*
 Gibbus 444
 Gigantism 54*b*, 54*t*, 55*f*, 144*b*, 342, 523*f*, 523
 Gilbert's syndrome 25, 282
 Gille de la Tourette's syndrome 397
 Gingivitis 37*b*
 Glabellar tap reflexes 346, 347*f*, 347
 Glanzmann's disease 121*b*
 Glaucoma 84, 84*b*, 88*t*, 95, 97*b*, 100, 353*t*, 354
 acute 90
 Glenohumeral arthritis 435
 Glenohumeral joint 448
 Glisson's capsule 25
 Globulins 304
 Glomerular diseases 38*t*
 acute 309
 Glomerular filtration 294, 310

- Glomerulonephritis 39t, 177, 303, 308b, 309
 Glomus jugulare tumour 372t
 Glossitis 23b, 23t
 Glucoronyl transferase 307
 Glucosuria 306
 alimentary 306
 renal 306
 Glycosuria 308t, 506
 Goitre 133, 511, 519t, 522
 causes of 133b
 hashimoto 523t
 simple diffuse 523t
 WHO grading of 133b
 Gonadal axis 515
 Gonadotropin deficiency 526t
 Gonadotropin releasing hormone 526t
 Gonococcal arthritis 18t, 435t
 Gonococcal urethritis 315f
 Gonorrhoea 298, 299b
 Goodpasture's syndrome 30t
 Gordon's reflex 388b
 Gout 50b, 439b
 Gouty tophi 439b
 Gower's sign 375f, 515t
 Gradenigo's syndrome 340t
 Granulomatous disease 47t
 Graphaesthesia 402
 Grasp reflex 346f
 Grasping and avoiding reflexes 346
 Grave's disease 46, 51, 87, 133, 507t, 510, 511, 519, 519b
 Gray matter 325
 Groins
 abnormalities of 275
 examination of 273
 Growth axis 516
 Guillain-Barre syndrome 32, 366t, 371
 Gustatory hyperhidrosis 17t
 Gynaecomastia 17t, 25, 44b, 48, 54t, 140f, 139, 512, 513f, 519t
 causes of 49t, 140t
- H**
- Haemangioblastomas 301
 Haemangiomas 250
 Haemarthrosis 36b, 427, 476, 478t
 Haematemesis 7, 8t, 14, 14t, 22, 25b, 26t, 30b, 37, 247b, 248
 Haematological case, investigations for 481-487
 Haematological disorders, oral manifestations of 479b
 Haematomas 478t
 Haematuria 8t, 16, 37, 37b, 38, 39, 297, 302, 303, 305, 306, 306f, 309
 causes of 39t
 Haemochromatosis 47t, 70, 70b, 73t
 Haemodialysis 300
 Haemoglobin 305, 502, 536
 Haemoglobinopathies 471
 Haemoglobinuria 8t, 37b, 38, 39, 305, 306
 Haemolysis 300, 306
 Haemophilia 7, 15t, 37b, 121b, 154
 Haemophilia A 9t
 Haemophilia B 9t
 Haemoptysis 7, 14t, 15t, 27, 28b, 29f, 29, 30, 30b, 32, 33, 36t, 37, 211, 216b, 238
 causes of 30t
 Haemorrhage 6b, 101t
 Haemostasis 39t
 primary 36
 secondary 36, 478t
 Haemothorax 217t
 Hair 77
 abnormalities of 80
 types of 77
 Half and half syndrome 301, 302f
 Halitosis 53, 53b, 247b
 Hallucinations 345
 Hand deformities, analysis of 152t
 Hands 144, 452
 examination of 144
 Hashimoto's disease 133, 134f, 134b
 Hashimoto's thyroiditis 133, 507t, 510, 511, 522
 Hay fever 18t
 Head 62
 Headaches 40, 62, 64
 classification of 63t
 primary 63t
 secondary 63t
 Hearing, assessment of 117
 Heart
 auscultation of 177f, 177
 surface anatomy 177
 Heart burn 19b, 21, 247b
 Heart failure
 chronic 33t
 radiographic findings 193
 Heart sounds 182, 183
 abnormalities of 183
 first heart abnormalities 183, 184b
 S1 181
 S2 181
 S3 181
 S4 181
 second heart sound abnormalities 183, 184t
 splitting 184, 185t
 Heat coagulation method 304
 Heaves 180
 Heberden's nodes 151b
 Hemarthrosis 154
 Hematochezia 20
 Hemiballismus 396
 Hemifacial spasms 364
 Hemiparesis 337t, 374b
 Hemiplegia 31t, 144b, 177, 373t, 374b
 contralateral 329, 330b
 ipsilateral 329, 330b
 Hemothorax 227
 Henöch-Schönlein purpura 37b
 Hepatic encephalopathy 248b, 301
 Hepatic failure 60t, 416, 418t, 423b
 Hepatic flexor of colon 267b
 Hepatic venous pulsation 178
 Hepatitis 6, 11f, 19f, 20t, 258b, 266, 299b, 300
 chronic active 26t
 drug induced 8t, 26t
 Hepatitis A 22t
 Hepatitis B 6, 26t
 Hepatitis B core antigen and antibody 286
 Hepatitis C virus antibody 287
 Hepatitis D-antigen and antibody 287
 Hepatitis E virus antibody 287
 Hepatitis infective 307
 Hepatobiliary diseases 19
 Hepatobiliary system 248
 investigations of 282
 symptoms of 248b
 Hepatomegaly 19, 157b, 248b, 418t
 Hepatosplenomegaly 475
 Herberdon's nodes 151f
 Hereditary spherocytosis 20t
 Hernia 20t, 255, 275
 femoral 256f, 255
 differential diagnosis of 275
 incisional scar 255f, 255
 inguinal 255, 256f, 256, 273
 differential diagnosis of 275
 umbilicus 255
 Herpes keratitis 85b
 Herpes simplex infection 90
 Herpes simplex virus (HSV) 533b
 Herpes zoster 80t, 124, 342
 Herpes zoster ophthalmicus 85b
 Herpetic vesicular eruptions 220b
 Heubner's artery 334
 Hiatus hernia 23b, 55t, 441b
 Hip 456
 Hip disease, symptoms of 456
 Hip joint, examination of 456
 Hippel-Lindau disease 298
 Hirschsprung's disease 24t
 Hirsutism 17t, 18, 44b, 49, 81
 causes of 82b
 differential diagnosis of 82t
 HIV 6, 11f, 68, 80t, 299, 300, 491
 HOCM 183
 Hodgkin's disease 130, 131, 132, 475
 Hoffman's sign 378, 384f
 Hoffman's syndrome 45b
 Holmes-Adie pupil 95
 Holter monitoring 191
 Homan's sign 207, 208f
 Homonymous hemianopia 353t
 Hormones, functions of 505

- Horner's syndrome 83, 87, 88*b*, 89, 89*t*, 94, 95, 200*b*, 218, 357*t*, 371, 421*f*
- Human chorionic gonadotrophin 49*t*
- Humidifier fever 217*t*
- Huntington's disease 7
- Hydatid thrill 272
- Hydrocephalus 22*t*, 62, 64*b*, 101*t*, 359*b*, 416 congenital 64*f*
- Hydrocoele 317*t*, 386
- Hydronephrosis 20*t*
- Hydropneumothorax 229, 233, 223*b*
- Hyperaesthesia 44*b*, 332
- Hyperalgesia 44*b*, 332
- Hyperbilirubinaemia 25, 307 conjugated 90 unconjugated 90
- Hypercalcaemia 6*b*, 24*t*, 38*t*, 43, 45, 474
- Hypercalcaemic crisis 20*t*
- Hypercholesterolaemia 157*b*, 200*b*, 439*b*
- Hyperglycaemia 84, 506
- Hyperkalaemia 43*t*, 59*b*
- Hyperkeratosis 145*b*
- Hyperkinesia 519*t*
- Hyperlipidaemia 7, 16*t*, 20*t*, 198, 304, 479*b*, 509, 510
- Hypermagnesaemia 59*b*
- Hyperparathyroidism 17*t*, 18, 22*t*, 45*b*, 150, 152*t*, 297*f*, 301, 438, 506
- Hyperpathia 44*b*, 332
- Hyperphosphataemia 297
- Hyperpigmentation 70 causes of 72*b*
- Hyperprolactinaemia 47*t*, 139, 300, 506, 514*t*
- Hyper-resonance 229, 254
- Hypersplenism 35, 37*b*
- Hypertension 6, 7, 10*f*, 11*b*, 16*t*, 37, 55*t*, 59*b*, 121*b*, 192, 198, 297, 298, 300, 300*b*, 309, 418*t* cirrhotic 8*t* classification of 60*b* JNC VIII classification of 172*b* pulmonary 183, 184*t* systemic 26, 184*t* systolic 169
- Hypertensive crisis 84*b*
- Hypertensive encephalopathy 41*t*, 416
- Hypertensive retinopathy 102*b*, 102*f*, 102, 301
- Hyperthermia 60
- Hyperthyroidism 17*t*, 27, 43*b*, 45, 45*b*, 49*t*, 50, 56, 59*b*, 80*t*, 150, 394*t*, 489*t*, 507*t*, 509
- Hypertonia 375
- Hypertrichosis 82, 524*t*
- Hypertrophic cardiomyopathy (HCM) 41*t*, 164, 164*t*, 165*t*, 170*t*, 180, 184, 187
- Hypertrophic osteoarthropathy 435*t*
- Hyperuricaemia 55*t*
- Hyperviscosity syndromes 336*t*
- Hypoaesthesia 44*b*, 332
- Hypoalbuminaemia 147*t*, 304
- Hypoadosteronism 43*b*
- Hypoalgesia 44*b*
- Hypocalcaemia 295, 297
- Hypochromia 483*t*
- Hypodermis 66
- Hypogammaglobulinaemia 217*t*
- Hypogonadism 49*t*, 317*t*, 507*t*, 514 causes of 514*t* clinical features of 514*t* postpubertal 513 prepubertal 512, 513*f*
- Hyponatraemia 43*t*, 416
- Hypoparathyroidism 45*b*, 101*t*, 395*b*, 507*t*
- Hypophosphataemia 43*t*
- Hypopituitarism 8*t*, 49*t*, 54*b*, 80*t*, 300, 416, 506, 508, 514*t*, 525, 526*t*, 526*f*, 526
- Hypoproteinaemia 157*b*, 157*t*, 300
- Hypospadias 313
- Hypotension 197, 418*t* orthostatic 37*t*, 172
- Hypothalamic-pituitary dysfunction 48
- Hypothalamic-pituitary-ovarian dysfunction 48*t*
- Hypothalamus 56, 325
- Hypothermia 46, 59*b*, 60 causes of 60*t*
- Hypothyroidism 17*t*, 24*t*, 45*b*, 46, 48*t*, 50*b*, 54*b*, 55*t*, 59*b*, 60*t*, 68*b*, 87, 139*b*, 167*b*, 204*b*, 342, 374*b*, 416, 495*t*, 508, 509, 510, 515*t*, 520, 522, 523 autoimmune 152*t* causes of 520 goitrous 522 juvenile 54*t*, 522, 523*f* primary 45*t* subclinical 506, 520 symptoms and signs 522*t* transient 520
- Hypotonia 330, 375, 394 flaccid paralysis 329

I

- Idiopathic thrombocytopenic purpura (ITP) 37*b*, 121*b*
- Ileocaecal mass 267
- Iliopsoas abscess 268
- Illusions 345
- Immobile cilia syndrome 47*t*
- Immune complex vasculitis 177
- Impaired fasting glycaemia (IFG) 526*b*
- Impaired glucose tolerance 5*t*, 526*b*
- Impedance audiometry 120
- Impedance plethysmography 207, 208*f*
- Impotence 17*t*, 46, 47*t*
- Infectious arthritis 50*b*

J

- Janeway lesion 166, 177
- Jaundice 6, 7, 14*t*, 20, 24, 25, 28, 70*b*, 71*f*, 73, 89, 90, 90*f*, 165*b*, 248*b*, 420, 472*t* cholestatic 26*t* clinical work-up 26*t* haemolytic 25, 26*t*, 307 hepatocellular 25 in haemophilics 26*t*
- Jaw jerk 361, 384
- Jaw, protrusion and retraction of 440
- Jendrassik's manoeuvre 376, 384, 387
- Jerks, abnormalities of 386*t*
- Joffroy's sign 521*f*
- Joint crepitus 438
- Joint disease, features of 429*b*
- Joint examination spine 440, 441 cervical 440, 441

lumbar spine 440, 442
sacrococcygeal spines 440
thoracic 440, 441

Joint pain, assessment of 429

Joint

examination

temporomandibular joint 440

inspection 434

palpation 435

Joints and bones, examination of the 434

Jones criteria 175, 177

Jugular veins 126, 135, 340*t*, 342

Jugular venous pressure 34*t*, 59, 157*b*, 172,
173, 219, 249

measurement of 174*f*, 174

raised 173*f*, 175, 175*f*

Jugular venous pulse 59, 172

examination of 174

waveforms 173*f*

Juxtaglomerular apparatus 294

K

Kala azar 70*b*, 73*t*

Kallmann's syndrome 49*t*, 54*b*, 54*t*, 69, 147*t*,
351, 508, 513*f*, 514*t*, 526

Kayser-Fleischer ring 90, 91*f*

Kennedy's disease 371

Keratinocytes 67

Keratoconjunctivitis, phlyctenular 218

Keratoconus 85

Kernig's sign 350*f*, 350, 351

Ketoacidosis 218*b*

Ketonuria 306, 307

Ketostix test 535

Kidneys 294

causes of enlargement of 264*b*

common abnormalities 264

congenital horseshoe 264

enlarged 264

palpation 262

left kidney 263, 263*t*

right kidney 263*f*, 263

small 264

Klebsiella rhinoscleromatis 123

Klinefelter's syndrome 47*t*, 49*t*, 54*t*, 140*t*,
317*t*, 508, 513, 513*f*, 514*t*

Knee jerk 384

Knee joint

movements of 461

stability test 462

Knee 459

examination of 460

Knock knees 301, 301*f*, 435

Kocher's test 511

Koilonychia 147, 148*f*, 148*t*, 472*t*

Korotkoff sounds 169, 171*f*, 172*t*

Korsakoff's syndromes 11*b*

Kronig's isthmus 229

Krukenberg tumour 48*t*

Kussmaul breathing 218*b*, 421

Kyphoscoliosis 32*b*, 221*t*, 444, 445*f*

Kyphosis 441, 444, 444*f*, 444*t*

L

Labrinitis 22*t*, 116

Labyrinthitis Meniere's disease 119

Lacrimal apparatus, inspection of 89

Lacrimal glands 83, 86, 89

Lacrimal sac 83

Lacrimation 84

Lactate provocation test 503

Lactic acidosis 33*t*

Lactosuria 307

Lacunar infarct 336

Lacunar syndromes 339, 339*t*

Lambert-Eaton syndrome 43*t*

Langerhan's cells 67

Laparoscopy 290

Large bowel obstruction 269

Large intestinal obstruction 254

Laryngeal carcinoma 35*t*

Laryngeal oedema 33

Laryngitis 28, 218

acute 35*t*

Laryngopharynx 124

Laryngoscopy 243

Larynx 113

Lassitude 15*t*, 35, 36*b*

Lateral bending 445

Latissimus dorsi 381*t*

Laurence-Moon-Biedl syndrome 45*t*, 54*b*,
55*t*, 147*t*, 354, 508

Lead 442

Leber's hereditary optic atrophy 84*b*

Leber's optic atrophy 100, 353*t*

Left atrial enlargement 192

Left atrial myxoma 168*t*

Left iliac fossa, mass in 269

Left ventricular aneurysm 180

Left ventricular dilatation 192

Left ventricular failure (pulmonary) 34*t*

Left ventricular failure, acute 33*t*

Left ventricular hypertrophy 180, 180*b*

Leg ulceration chronic 210

Legs, examination 151

Lens 90

Lens opacity 97

Leprosy 155

Leucaemias

acute laboratory findings in 486*b*

chronic laboratory findings in 487*b*

Leucocytosis 470, 473

Leucoerythroblastosis 483*t*

Leuconychia 301

Leucopenia 471

Leukaemia 35

Leukaemoid reaction 473, 473*b*

Leukemia 473*b*, 474

acute 474*t*

chronic 474*t*

Levator palpebrae 83

Lhermitte's sign 332

Lichen planus 147*t*

Ligaments 426

Light reflex 93*f*

Lipiduria 304

Livedo reticularis 204, 204*b*

Liver 267*b*

abnormalities 259

abscess 25, 220

aspiration 290

biopsy 290

disease 37*b*

acute 25

dullness 227

enlargement 259

mass, characteristics of 259*b*

palpation 258

span 227*f*, 227

Lobar collapse 237*t*

Lobar consolidation 237*t*

Lobar pneumonia 238

Locked-in syndrome 338*t*

Locomotor abnormality, screening system
for 431

Locomotor disorders, examination of 431

Locomotor system 426

Long flexors, testing of 379*t*

Lordosis 443

Low back pain, common causes of 443*b*

Lower limb

muscles of 381*t*

reflexes 384

Lower motor neuron 366*t*, 370, 373

lesion 330*b*, 329, 406*t*

paralysis 366*f*

Lower urinary tract 308*t*

Lumbar lordosis 264, 432*f*

Lumbar region mass, differential diagnosis
of 268*b*

Lumbricals, testing of 379*t*

Lung abscess 30*t*, 217*t*, 223*b*, 234

biopsy 244

collapse 225*t*, 232*t*

fibrosis 180*b*, 241*t*

parenchyma 244

sepsis 218

volumes 243

Lungs

bronchopulmonary segments of 215*f*

lobes of 214

surface markings of 214*f*, 214

Luteinizing hormone 515*b*

Luthy' sign 456

Lymph nodes 481

enlargement 249

palpation 128

axillary 128, 130*f*

cervical 128, 129*f*

epitrochlear 128, 130*f*

inguinal lymph nodes 130*f*, 130

- occipital lymph nodes 128, 129f
 popliteal lymph nodes 130f, 130
 posterior auricular 128, 129f
 preauricular 128, 129f
 scalene node 128, 129f
 submandibular glands 128, 129f
 supraclavicular 128, 129f
- Lymphadenitis
 acute 131, 275
 chronic 131, 132t
 septic 132t
 tubercular 132t
- Lymphadenopathy 131, 132b, 165b, 176, 475
 common causes of 128t
 differential diagnosis of 130-132
 hepatosplenomegaly 470
 para-aortic 127
 paratracheal 127
- Lymphatic carcinomatosis 33t
- Lymphatic leukaemia chronic 68b
- Lymphocytes 67
- Lymphocytic leukaemia chronic 132t
- Lymphoedema 156, 156f, 157, 208
- Lymphoid leukaemia 131
- Lymphomas 35
- Lymphopenia 473
- M**
- Macrocephaly 64b, 64f
- Macrocytosis 483t
- Macrotia 116
- Macula 97
- Macular degeneration 84, 84b, 98
- Macular flecks 301
- Macular sparing 352
- Magnetic resonance imaging (MRI) 409
 advantages of 409
- Malabsorption tests 282, 283t
- Malar flush 166
- Malena 7, 8t, 25b, 247b, 248b
- Malignancy 30t
- Malignant hypertension 101t, 102b
- Mallory-Weiss syndrome 8t, 11b, 30t
- Malocclusion, teeth 362
- Malt worker's lung 217t
- Mammary souffle 186
- Maple bark stripper's lung 217t
- Marasmus 57f
- Marfan's syndrome 54t, 54b, 55f, 144b, 147t, 192, 250, 251, 435
- Mass in abdomen, differential diagnosis of 266
- Mass in right hypochondrium, differential diagnosis of 267b
- Mass in the epigastrium, differential diagnosis of 267b
- Massive pulmonary embolism 34t
- Mast cells 67
- Match-stick test 236
- Maxillary sinuses 121, 123f, 123
- Mayer-Rokitansky-Küster-Hauser syndrome 48t
- Mccune-Albright syndrome 48t
- Measles 6
- Mediastinal compression 101t
- Mediastinal crunch 234t
- Mediastinal shift 223b, 223
- Mediastinitis 30t
- Mediastinoscopy 243
- Medulla oblongata 326
- Medullary cystic disease 298
- Medullary infarct 371
- Medullary sponge kidney 298
- Meibomian glands 67, 83
- Melanin 67
- Melotia 116
- Memory 345
- Meniere's disease 22t, 41, 114b, 116
- Meningeal irritation, signs of 350
- Meninges 114
- Meningioma 64b, 369b, 372t
- Meningism 350t
- Meningitis 63t, 101t, 236, 350t, 416, 418t, 420, 424
 meningococcal 420
 neoplastic 371
- Meningoencephalitis 418t
- Mesenteric lymphadenitis 20t
- Metabolic acidosis 297, 418t, 421
- Metabolic bone disease 50b
- Metacarpophalangeal joints (MCPs) 152t, 428b, 453
- Metallic sounds 185
- Methaemoglobin 73, 74
- Methaemoglobinaemia 479b
- Microalbuminuria 304, 305
 test for 534
- Microbial tests 530
- Microcytosis 483t
- Microphthalmia 87
- Microtia 116
- Micturating cystogram 312f, 312
- Micturition 16t, 38, 388
- Midaxillary line 213f, 213
- Midbrain 326
- Midclavicular line 213f, 213
- Mid-diastolic murmur 182, 183
- Middle cerebral artery, syndrome of 337b, 337
- Middleton manoeuvre 476
- Midsternal line 213f, 213
- Midsystolic clicks 184, 186f
- Migraine 64b, 65, 66t, 340
 principal forms of 65t
- Migrainous neuralgia 362t
- Milkmaid's grip 394
- Millard-Gubler syndrome 338t
- Millard-Gubler-Foville syndrome 357t
- Milroy's disease 157b
- Mirizzi's syndrome 261
- Mitral regurgitation 165t, 168b, 181b, 184, 187, 195
 acute 184
- Mitral stenosis 23t, 30t, 165, 166, 180-183, 184b, 185, 187t, 194, 369b
- Mitral valve 162, 177t
 prolapse 164, 164t, 165, 187t
- Mixed connective tissue syndrome 43b
- Molluscum contagiosum 299b
- Monoarthritis 430t, 434
 acute infective 437f
- Mononeuritis 402
- Monoplegia 177, 330b, 374b
- Morton's metatarsalgia 404b
- Motion sickness 22t
- Motor control, hierarchy of 328f, 328
- Motor neuron disease 366t, 370, 371, 397
- Motor system disorders 330t
- Motor system, examination of 371
- Multiple endocrinal neoplasia 18t
- Multiple myeloma 38t, 438
- Multiple myeloma, investigations for 487b
- Multiple sclerosis 41, 43t, 116, 119, 120, 340, 366t, 371, 392b, 394
- Mumps 6, 52t
- Murmurs 163t, 165, 177, 182, 187f, 186
 benign 163
 causes 187t, 186
 characteristics of 163b
 continuous 163, 164, 165t, 186
 diastolic 163, 163t, 165, 186
 early diastolic 165t, 186
 ejection systolic 165t, 186
 innocent characteristics 164b
 late systolic 165t, 186
 mid-diastolic 163, 165t, 186
 midsystolic 163, 186
 pansystolic 163, 165t, 186
 systolic 163, 163t, 164, 164t, 165, 181, 186
 types of 163
- Murphy's sign 260
- Muscle cramps 397, 398
- Muscle disorders 406t
- Muscle spasm 397
- Muscle strength, testing of 377
- Muscle testing 379t
- Muscle tone
 common abnormalities 375
 testing 372
- Muscle weakness 45
 assessment of 374b
 causes of 373t
- Muscle, segmental innervation 335f
- Muscles upper limb 378
- Muscular dystrophy 32, 374f, 375t, 375f, 375
- Muscular dystrophy-duchenne type 372
- Myalgia 43b
- Myasthenia gravis 23t, 32, 43t, 86b, 88b, 357t, 366t, 371

- Myasthenia-myopathic syndrome 43t
 Mydriatic drops 96
 contraindications for 97b
 Myelofibrosis 483b
 Myelography 410
 Myelomatosis 470, 474
 symptoms and signs of 475t
 Myeloproliferative disorders 476
 Myocardial disease 41t
 Myocardial infarction 20t, 30t, 31t, 33t, 197
 acute 26, 168b, 188
 Myocardial ischaemia 34t, 36t, 188
 Myocardial scanning 196
 Myocarditis 26, 30t, 168t, 188, 192
 Myoclonus 396
 aetiological classification of 396t
 Myoglobin 39b, 305
 Myoglobinuria 38, 39b, 306
 Myokymia 397
 Myopathy 45, 373t
 proximal 524t
 Myotonia 377f, 376
 cysticercosis 374b
 dystrophica 47t, 88b
 Myxoedema 52t, 52f, 53b, 124b, 145b, 156, 157t, 386t
 Myxoedema coma 423b
- N**
- Nail dysplasia 301
 Nail folds, examination of 150
 Nail-Patella syndrome 147t, 301
 Nails 67, 144
 changes in 147t
 examination of 144
 method of examination 145
 Nasal airway 122
 Nasal disease, symptoms of 121
 Nasal obstruction 121
 Nasal polyps 123
 Nasal sinuses, examination 122, 122f
 Nasolacrimal duct 121
 Nasopharynx 35t, 124, 369
 Nausea 247b, 248
 Neck 126-135
 examination 126, 350
 inspection 126t
 palpation 126
 flexors 382t
 lump in 125
 lymph nodes 126, 127
 cervical 127
 mass examination of 128b
 occipital 126
 posterior auricular 126
 posterior cervical 127
 preauricular 126
 submandibular 126
 submental 127
 superficial cervical 127
 supraclavicular 127
 tonsillar 126
 muscles 382t
 stiffness 236, 350f, 350, 418b, 419b, 420
 Needle sharing disorders 11f
 Neisseria gonorrhoeae infection 533b
 Nelson's syndrome 73t
 Neoplasia 20t
 Nephritic syndrome acute 296, 303
 Nephritis, hereditary 297
 Nephrotic syndrome 52t, 53b, 157t, 296, 298, 300, 301, 304, 479b
 SLE induced 301f
 Nephrotoxic drugs 299b
 Nerve conduction 411
 Nerve root compression 443f, 446
 Nervous system 325
 signs of lesions in 406t
 symptoms 340-342
 Neuralgia 63t
 migrainous 362
 post-zoster 362
 trigeminal 362
 Neurofibromatosis 73f, 73t, 439b
 Neurological disorder, investigations 407
 Neurological examination 405
 general physical examination 342
 systemic 343
 Neuromuscular diseases 23b
 Neuromuscular junction 330
 Neurons 325
 Neuropathic joint 154
 Neuropathic ulcer 209t
 Neuropathy, clinical features of 528t
 Neuropsychiatric assessment 500
 Neutropenia 471, 473, 483b
 Nipple discharge 139f, 139
 Nipple inversion 138
 Nocturia 16t, 28, 37b, 38, 44b, 293, 297, 297f, 298
 Non-ejection clicks 184
 Non-Hodgkin's lymphoma 131, 132t, 475
 Normal thyroid profile 516b
 Nose 121-123
 examination 122, 122f
 Nothnagel's syndrome 338t
 Nystagmus 115t, 359, 394t, 422
 causes 119
 testing for 119
- O**
- Obesity 8t, 54, 56b, 198, 507t
 abdominal 156b
 causes 55t
 consequences 55t
 Obliterative arterial disease 204
 Obstetrics history 300b, 300
 Obstructive emphysema 181, 227
 Obstructive pulmonary disease 28
 chronic 10f, 175
 Obstructive ventilatory defect 240
 Obturator sign 267
 Occlusive peripheral arterial disease 199t
 acute arterial ischaemia 199t
 chronic arterial disease 199t
 Occupational lung diseases 217t
 Ocular fundus 96, 480
 Ocular movements, testing of 94
 Ocular myopathies 86b
 Oculocephalic reflex 367, 422
 Oculovestibular reflex 367, 422
 Odynophagia 20, 22, 247b
 Oedema 155-157, 155f, 166, 211, 219
 abdominal wall 155, 156f
 ankle 155
 causes of 157t
 differential diagnosis of 157b
 distribution of 156
 localised 156
 nonpitting 156, 157t
 pitting 155, 157t
 postural 156
 sacral 155
 unilateral 156
 Oesinophilic lung disease 234t
 Oesophageal myopathy 23t
 Oesophageal spasms, diffuse 23b, 30t, 31, 441b
 Oesophageal tear 30t
 Oesophageal varices 37
 Oesophagitis 11b, 20t, 23t, 23b
 Oesophagoscopy 280
 Oestradiol 515b
 Oligoarthritis 50b
 Oligomenorrhoea 44b, 506, 519t, 524t
 Oligospermia 514t
 Oliguria 38, 293, 298, 303
 causes of 38t
 Onychodermal angle 145
 Onycholysis 147t, 519t
 Opening snap 185
 Ophthalmic artery 356
 Ophthalmic veins 339
 Ophthalmoplegia 520
 internuclear 394t
 Ophthalmoscopy 101
 Opponens pollicis 379t
 Optic atrophy 46, 98, 510
 causes of 100b
 Optic disc 97, 98, 100
 Optic neuritis 46, 84b, 98, 102b, 353t
 Optic pathways 92
 Optokinetic nystagmus 353t
 Orbital myositis 86b
 Orchitis 49t, 140t, 317t, 318f
 Organ of Corti 367
 Oro-facial dyskinesias 397
 Oropharynx 124, 125

- Orthopnoea 26, 33, 164, 219
 Otic stenosis 183
 Osler's node 151*b*, 165*b*, 177
 Osler-weber-rendu disease 477*f*, 477
 Osteoarthritis 18*t*, 50*b*, 428*f*, 428*b*
 Osteochondromata 429
 Osteogenesis imperfecta 429, 438
 Osteomalacia 45*b*, 508
 Osteomyelitis 438
 Osteoporosis 8*t*, 55*t*, 442, 442*b*, 444*t*
 Otalgia 113
 causes of 113*b*
 Otitis externa 117, 362
 Otitis media 113*b*, 114*b*, 117, 119
 Otorrhoea 114
 Ototoxic drugs 114*b*
 Ovarian cysts 20*t*, 269, 321*t*
 Ovarian neoplasm 82*t*
 Overuse syndrome 431
- P**
- Paget's disease 137*t*, 138, 152*t*, 168*b*, 342, 372*t*, 435
 Pain abdomen 19, 19*b*
 Pain chest 216*b*
 Pallor 69, 211, 219
 Palmar erythema 151, 165*b*, 519*t*
 Palmomental reflexes 346
 Palpation sounds 180
 Palpebral conjunctiva 83, 87
 Palpebral fissure 83
 Palpitation 14, 15, 17*t*, 27
 intermittent 14*t*
 paroxysmal 14*t*
 PANCA (perinuclear staining) 466
 Pancreas, carcinoma of the head 261
 Pancreatic disease 19
 Pancreatic insufficiency 24*t*
 Pancreatitis 11*b*, 19*f*, 20, 26*t*, 43*b*, 443*b*
 acute 21*t*, 258*b*
 recurrent 8*t*
 Pancytopenia 25, 483*b*, 470, 9478
 Panhypopituitarism 47, 48*t*, 54*t*, 509, 512
 causes of 526*t*
 Papillary muscle dysfunction 187*t*
 Papillitis 101*t*, 102*b*
 Papilloedema 84*b*, 98, 102*b*, 218, 418*b*, 418*t*
 causes of 101*t*
 optic disc in 99*f*, 101*b*
 Para-abducens nucleus 355
 Paradoxical resonance 228
 Paraesthesia 44*b*, 332, 364
 Paralysis 42, 42*b*
 Paranasal sinuses 121-123
 Paraneoplastic syndrome 46, 392*b*
 Paraneoplastic-myasthenic myopathic syndrome 373*t*
 Paraphimosis 313, 314*f*
 Paraplegia 31, 47*t*, 330, 336, 342, 373*t*, 374*b*
 Parietal lobe dysfunction 406*t*
 Parinaud syndrome 338*t*
 Parkinsonism 17*t*, 51, 52*f*, 52*t*, 371, 394*t*
 Paronychia 150
 Parosmia 54*t*, 351
 Parotid glands enlargement 52*t*
 Paroxysmal nocturnal dyspnoea 26, 164
 Paroxysmal nocturnal haemoglobinuria 20*t*, 479*b*
 Patellar tap test 460*f*, 460
 Patent ductus arteriosus 164, 165*t*, 187*t*, 193, 197
 Patrick's test 469*f*, 459
 Peak expiratory flow 242*f*, 241
 Peau d'orange 137*t*, 138, 139*f*
 Pectoral reflex 384
 Pectus carinum 178
 Pectus excavatum 178*f*, 178, 211, 221*t*
 Pedal oedema 16*t*
 Pediculosis pubis 299*b*
 Pellagra 71
 Pelvic inflammatory disease (PID) 23*t*, 321*t*
 PEM 508
 Pendular jerks 394
 Penile discharge 20
 Penis 295
 abnormalities 313*t*
 inspection 313
 palpation 315
 Pentagastrin test 281
 Pentosuria 307
 Peptic ulcer 7, 8*t*, 10*f*, 11*b*, 248, 258*b*
 Percussion myokymia 229
 Percussion note 259*b*
 abnormalities of 228
 Percussion
 method 226
 rules of 226
 tidal 228
 Percutaneous transhepatic cholangiography 288
 Perforated intestine 21*t*
 Perianal haematoma 277
 Pericardial diseases 188
 Pericardial effusion 157*t*, 170*t*, 179, 194, 220, 227, 262
 Pericardial knock 186
 Pericardial rub 185, 186, 302
 Pericarditis 20, 30*t*, 31*t*, 188, 192, 223*b*
 Pericardium 192
 Perichondritis 113*b*
 Perimetry 354
 Periodontitis 37*b*
 Periorbital oedema 52*t*, 121, 211
 Peripheral arterial disease 198
 aneurysmal disease 198
 occlusive arterial disease 198
 vasospastic disorders 198
 Peripheral blood film (PBF) examination 481
 Peripheral nerve 326, 330*b*
 Peripheral nerve lesions 361*t*
 Peripheral nervous system 326
 Peripheral neuropathies 330*b*, 373*t*, 397, 406*t*
 Peripheral pitting oedema, causes of 27*b*
 Peripheral pulses
 brachial pulse 202*f*
 carotid artery 202*b*
 femoral artery pulsations 202*f*
 palpation of 202
 pedis artery pulsations 202*f*
 popliteal artery pulsations 202*f*
 posterior tibial artery 202*f*
 Peripheral vascular disease, investigations 205
 Peripheral vessels, disorders of 204
 Perisplenitis 476
 Peristalsis 250, 254
 Peritonitis 19*f*, 20*t*, 258*b*
 generalised 254
 Peritonsillar abscess 124
 Pernio syndrome, chronic 204*b*, 205
 Persistent isolated proteinuria 297
 Pertussis 53
 Pes cavus 152, 153*f*
 Petechiae 37
 Petechial haemorrhages 480
 Peyronie's disease 313
 Pheochromocytoma 17*t*, 45, 59*b*, 167*b*, 204*b*, 418*t*, 489*t*, 506, 509, 515*t*
 Phagocytes 67
 Phalen's manoeuvre 455
 Pharyngitis 23*t*
 Pharynx 28
 Phenytoin toxicity 49*t*
 Phimosis 313, 314*f*
 Photodermatitis 74
 Photophobia 66*t*, 87
 Piamater 62
 Pickwickian syndrome 55*t*
 Piebaldism 70
 Pigeon chest 221*t*
 Piles 24*t*
 Pinguecula 89
 Pitting oedema 219
 Pituitary adenoma 100*b*
 Pituitary tumours 46
 Platynychia 148*f*, 147*t*, 472*t*
 Pleural aspiration 243, 244*f*
 Pleural effusion 20*t*, 34*t*, 192, 220, 223*b*, 224-227, 232, 232*t*, 237*t*
 dullness in 228
 shifting dullness 228
 Pleural rubs 32*b*, 225, 229*b*, 232-234, 235*t*, 302
 Pleurisy 32, 223*b*
 Pleuritis 31*t*, 32
 Pleurodynia 225, 234*t*
 Plummer-Vinson's syndrome 23*t*

- Pneumaturia 40
Pneumoconiosis 241*t*
Pneumocystis carinii 473
Pneumonectomy 224
Pneumonia 25, 29*b*, 30, 32, 33, 34*t*, 35, 211, 217*t*, 418*t*
Pneumonic consolidation 232*t*
Pneumothorax 30*t*, 32, 33, 33*t*, 180*b*, 192, 220, 220*b*, 223*b*, 224-227, 232*t*, 237*t*
Poikilocytosis 483*t*
Poland's syndrome 147*t*
Poliomyelitis 6, 8*t*, 23*t*, 370
Polyarthralgia, causes of 50*b*
Polyarthritis 50*b*, 176, 176*b*, 298
 symmetric 430*t*
Polychondritis helix 113*b*
Polycystic kidney disease 298
Polycystic ovarian syndrome 82*t*, 322*b*, 507*t*
Polycythaemia 70*b*, 151*b*, 199, 218, 219, 220, 340*b*, 470, 474
Polydactyly 148*f*, 147*b*
Polydipsia 44, 44*b*, 298, 507*t*
Polymenorrhoea 17*t*
Polymyalgia rheumatic 43*b*, 428*b*
Polymyositis 50*b*, 373*t*
Polyphagia 298
Polyposis 150*b*
Polyuria 6*b*, 27, 37, 38, 44, 44*b*, 293, 297, 297*f*, 298, 507*t*
 causes of 38*t*
 nocturnal 303
Pons 326
Popliteal artery aneurysm 205*t*
Porphobilinogen 308*f*, 308, 535
Porphyria 39*b*, 375*t*
Portal hypertension 22, 25, 26*t*, 248*b*, 252*b*
 non-cirrhotic 8*t*
Portal venography 289
Port-wine stain 77, 78*f*, 342
Positron emission tomography (PET) 468
Posterior axillary line 213*f*, 213
Posterior cerebral artery
 syndrome 337
 p1 syndrome 337, 338*b*
 p2 syndrome 337, 338*b*
Posterior cranial fossa lesion 420
Postictal phenomenon 16*t*
Postmenopausal bleeding 300
Postnasal space, examination 123
Postphlebotic syndrome 208
Post-tussive crackles 233
Post-tussive suction 233
Postural hypotension 41*t*, 402
Post-zoster neuralgia 362*t*
Pott's disease 30*t*, 258*b*, 275, 444
Pouch of Douglas 278
Prader-Willi syndrome 45*t*, 55*t*
Prechordium examination
 auscultation 177, 181, 182
 auscultatory areas 177*f*, 181
 inspection 177, 178
 chest deformities 178
 localised bulge 178
 pulsations 178
 scars 178
 palpation 177, 179
 percussion 177
Precocious puberty 48
Precordium, examination 177
Premorbid personality 495
Pretibial myxoedema 519*t*, 520
Priapism 47, 47*b*
Primary haemostasis 478*t*
Primary haemostatic defect 477
Proctitis 19*f*, 24
Progesterone 515*b*
Prognathism 54*t*
Prolactin 526*t*
Prolactinoma 523
Pronator sign 394
Proptosis 49, 84, 85*b*, 87, 88*t*, 121
Prostate 276
 disorders 276
 enlargement 298
 palpation of 278
Prostatic carcinoma 298
Prostatitis 39*t*
Protein energy malnutrition (PEM) 56*t*
Proteinuria 302, 304, 533
 aetiopathogenesis of 305
 asymptomatic 305
 Bence-Jones 305
 consequences 304
 glomerular 305
 orthostatic 305
 tests 304
 tubular 305
Proximal interphalangeal joints (PIPS) 453
Pruritus 25, 25*b*, 26*t*, 68*b*, 248*b*
Pseudobulbar palsy 23*b*, 338*t*, 369*b*, 371, 372*b*
Pseudocushing syndrome 53*b*
Pseudohypoparathyroidism 147*t*
Pseudomembranous colitis 23*t*, 24
Pseudopancreatic cyst 267*b*
Pseudopapilloedema 101*t*
Pseudoptosis 89
Psoas cold abscess 442
Psoas sign 267
Psoriasis 64, 74, 147*t*, 428*b*
Psoriatic arthritis 434
Psoriatic arthropathy 152*t*
Psychiatric assessment 489
 investigations 502
Psychiatric history 490
Psychogenic hyperventilation 33*t*
Psychogenic polydipsia 44, 45*t*
Psychological tests 503
Psychosis 519*t*
Pterygium 85, 85*b*
Ptosis 88, 96*t*, 357
 common causes of 88*b*
 testing for 88
Puddle's sign 271*f*, 271
Pulmonary arteries 193, 194
Pulmonary consolidation 234*t*
Pulmonary conus 192
Pulmonary embolism 32, 33, 33*t*, 208, 217*t*
 acute 59*b*
Pulmonary fibrosis 32*b*, 225, 225*t*, 232*t*
Pulmonary function tests 239, 241*t*
 obstructive lesion 241*t*
 restrictive lesion 241*t*
Pulmonary hypertension 41*t*, 180, 193
Pulmonary infarction 32, 225, 234*t*
Pulmonary oedema 29, 32*b*, 33, 34*t*, 166, 418*t*
 acute 27*b*
Pulmonary oligoemia 193
Pulmonary rales 418*t*
Pulmonary regurgitation 165, 186*b*, 187*t*
Pulmonary stenosis 41*t*, 165*t*, 180, 184, 186*b*
Pulmonary tuberculosis 229, 239
 chronic 232*t*
Pulmonary valves 162, 177*t*
Pulmonary valvular stenosis 187*t*
Pulse deficit 59, 166
Pulsus alternans 168
Pulsus paradoxus 168, 169
Pupil 83, 92, 96
 common abnormality of 93, 94*t*, 94*f*
 constriction 93, 95*t*
 dilatation 93, 95*t*
Pupillary reflexes 352
Purpura 37, 480*f*, 480
Pursed-lip breathing 219*f*, 218, 223
Pyelonephritis 20, 38*t*, 309
Pyloric obstruction 254
Pyloric stenosis 254
Pyoderma gangrenosum 69*t*, 70*f*, 248
Pyonephrosis 20*t*
Pyopneumothorax 223*b*, 225*t*
Pyuria 298
- Q**
- Quadriplegia 330*b*, 373*t*
Quervain's tenosynovitis 152*t*
- R**
- Radial pulse 167*f*
Radiocarpal joint 453
Radionuclide scanning 196
Radioulnar joint 453
Rapid breathing 218*b*
Rapid left ventricular filling 184
RAS 416

- Raynaud's phenomenon 151, 165, 200*b*, 204*f*, 204, 435*t*
- Reagent strips 307
- Rectal bleeding 247*b*
- Rectal prolapse 276, 277
- Rectum 276
- Recurrent laryngeal nerve palsy 200*b*
- Reducing sugars, tests for 307
- Reflex sympathetic dystrophy 204*b*, 205
- Reflex
- anal 388
 - bulbocavernosus 388
 - cilio-spinal 405
 - corneal 388
 - cough 388
 - cremasteric 386
 - mass 389
 - palatal 388
 - pilomotor 405
 - plantar 387, 387*b*
 - scapular 388
 - superficial 386
 - superficial abdominal 386
 - tendon 385
- Refraction test 100
- Refractive errors 84
- astigmatism 97
 - hypermetropia 97
 - myopia 97
- Reifenstein's syndrome 140*t*
- Reiter's syndrome 18*t*, 50*b*, 428*f*, 434
- Renal angiogram 312
- Renal artery stenosis 38*t*, 302
- Renal biopsy 312
- Renal bone disease 298
- Renal clearance 310
- Renal colic 38*b*, 258*b*, 298
- Renal disease 7
- investigations 302-312
- Renal failure 6*b*, 298, 309, 423*b*
- acute 296
 - chronic 73*t*, 295, 297, 416, 508
 - severe 310
- Renal functions 294
- Renal infarction 20*t*
- Renal oedema 52*t*
- Renal osteodystrophy 297
- Renal rickets 301
- Renal transplant 300
- Renal tubular defects 297
- Renin-angiotensin-aldosterone cascade 304
- Renin-angiotensin-aldosterone system 294
- Reptile tongue 394
- Resonance 225
- Respiratory disease
- investigation 238-244
 - chest X-ray 239
 - computed tomography 239
 - cytological examination 239
 - microbial examination 239
 - routine haematological 238
 - routine sputum examination 238
 - serological tests 239
 - skin tests 239
 - physical signs 237*t*
 - skin lesions in 220*b*
- Respiratory function test 236
- Respiratory muscle dysfunction 32
- Respiratory muscle paralysis 32*b*
- Respiratory reflex 402
- Respiratory sinus infection 7
- Respiratory symptoms 28
- Respiratory system 212
- general physical examination 218
 - surface anatomy of 212*f*
- Respiratory tract, common symptoms 216*b*
- Restrictive lung disease 218*b*
- Restrictive ventilatory defect 240
- Retina 83, 92
- Retinal atrophy 98
- Retinal detachment 84*b*
- Retinal haemorrhages 98
- causes of 102
- Retinal vascular thrombosis 301
- Retinal vein occlusion 84*b*, 100
- Retinitis 102*b*
- Retinitis pigmentosa 84*b*
- Retinopathy 100, 510
- Retrolbulbar neuritis 98
- Retropituitary fibrosis 295
- Retropharyngeal abscess 124
- Retrosternal chest 247*b*
- Reversible ischaemic neurological deficit 16*t*
- Rheumatic arthritis 152*t*, 435*t*
- Rheumatic carditis 176
- Rheumatic diseases 428*b*, 454*t*
- extra-articular manifestations 430*t*
 - symptoms of 49
- Rheumatic disorders 427, 435
- major symptoms of 427*b*
- Rheumatic fever 6, 8*t*, 18*t*, 50*b*, 161, 175, 439*b*
- acute 6
 - criteria 176*b*
- Rheumatic heart disease 6, 168*t*
- Rheumatic nodules 439*b*
- Rheumatic symptoms, common 49*b*
- Rheumatic valvular disease 6
- Rheumatism 8*t*
- soft tissue 429
 - symptoms and signs of 429*t*
- Rheumatoid arthritis 18*t*, 43*b*, 50*b*, 69*t*, 90, 144*b*, 152*t*, 176, 428*b*, 428*f*, 434, 435, 438*f*, 444*b*
- boutonniere 435
 - swan-neck 435
 - ulnar deviation of hand 435
 - Z-shape deformities 435
- Rheumatoid factor 465
- Rheumatoid nodules 151*b*
- Rhinitis 28, 35, 121, 121*b*, 122
- Rhinorrhoea 121
- Rhonchi 233
- Rickets 508
- Rickety rosary 301
- Riedel's thyroiditis 511
- Right atrial enlargement 192
- Right bundle branch block 184
- Right ventricular dilatation 174, 192
- Right ventricular failure 193, 219, 219*t*
- Right ventricular hypertrophy 180, 192
- Rigidity 377*b*
- hysterical 376
 - paratonic 376
 - reflex 376
- Ringed sideroblast 484*f*
- Rinne test 118
- Romberg's sign 120, 332
- Romberg's test 391
- Rome criteria
- for IBS 248
- Rossolimo's sign 388*b*
- Rotation 445
- Roth's spot 177
- Rothera's test 307, 535
- Rovsing's sign 266
- Rubella 6, 8*t*
- Ruptured ectopic gestation 258*b*
- Ruptured tubal pregnancy 321*t*
- Russell-silver syndrome 48*t*

S

- S1, first heart sound 183
- S2, second heart sound 183
- S3, third heart sound 183
- Sacroiliac joints 445, 448
- Sacrum 440
- Saddle embolism 200*b*
- Salicylsulphonic acid test 534
- Salivary glands 126
- Salmonellosis 299*b*
- Salpingitis 20, 48*t*, 258*b*
- acute 21*t*
- Sarcoidosis 69*t*, 89, 132*b*, 239, 241*t*, 353, 366*t*, 435*t*
- Scabies 68*b*, 299*b*, 313
- Scalp 62
- Scalp examination 64
- Scaphoid abdomen 254
- Scapular line 213*f*, 213
- Schamroth's window test 146
- Scheuermann's disease 442*b*
- Schirmer's test 364
- Schistosomiasis 39*t*
- Schmidt's syndrome 46
- Sciatic nerve roots compression 445
- Sclera 86, 89
- Scleritis 90

- Sclerodactyly 147*b*, 149*f*
 Scleroderma 43*b*, 50*b*, 152*t*, 157*t*, 200*b*
 Scoliosis 192, 234, 444
 severe 54*b*
 Scrofuloderma 220*b*
 Scrotal hernia 317*t*
 Scrotal swelling, differential diagnosis of 275
 Scrotum 295
 abnormalities of 317*t*, 318*f*
 inspection 315
 palpation 315
 Scurvy 37*b*
 Sebaceous glands 67
 Seborrhoeic dermatitis 64
 Seborrhoeic warts 250
 Secondary sexual characters 513
 Seehan's syndrome 8*t*
 Semen analysis 536
 indications for 536
 Semilunar valves 162
 Sensations 398-402
 Sensory ataxia 44*b*
 Sensory pathways 330
 Sensory system, examination of 333
 Sentinel pile 277
 Septic embolisation 177
 Serological test 530
 Serratus anterior 381*t*
 Serum lipids 286
 Serum proteins
 albumin 58, 285
 albumin and globulins ratio 285
 globulin 285
 Serum transferrin 58
 Sex hormones 515*b*
 Sexually transmitted diseases 298, 299
 causative agents 299*b*
 SGOT 284
 SGPT 284
 Shallow breathing 218*b*
 Shapiro's syndrome 60*t*
 Sheehan's syndrome 512, 526*t*
 Shigellosis 299*b*
 Short acth stimulation test 517
 Shoulder examination 449
 Sick sinus syndrome 59*b*, 167*b*
 Sickle cell disease 47*t*, 102, 298, 514*t*
 Sighing respiration 218*b*
 Silicosis 217*t*
 Simple diffuse goitre 522
 Single nerve lesion 402
 symptoms and signs of 404*t*
 Single photon emission tomography (SPECT) 196*f*, 196
 Sinus of Valsalva 164, 187*t*
 Sinus rhythm 167
 Sinus tachycardia 34*t*
 Sinus tenderness, palpation for 123
 Sinusitis 121*b*, 123
 Situs inversus 228
 Sjögren's syndrome 46, 85*b*, 89, 90, 435*t*
 Skeletomuscular disorders, diagnostic tests
 in 465*b*
 Skin lesion 76*t*
 Skin pigmentation, abnormalities of 70*t*, 69
 Skin 66
 associated lymphoid tissue (SALT) 67
 examination 69
 functions of the 67
 Skodaic resonance 229
 Skull
 abnormalities 62, 64*b*
 examination 64
 X-rays 407
 SLE 43*b*, 73*t*, 90, 204, 300, 428*b*, 435*t*, 479*b*,
 485
 Sleep apnoea syndrome 55*t*, 489*t*
 Snake bite 88*b*, 357*t*
 Sneezing 122
 Snellen's chart 91
 Snout and sucking reflex 346
 Somnolence 16*t*
 Sore throat 124
 Sour eructation 22
 Spastic paralysis 373*t*
 Spasticity 377*b*
 Spermatic cord 316
 Spermatocoele 317*t*, 318*f*
 Spherocytosis 472*t*
 Spider angiomas 251
 Spinal artery syndromes, features of 339
 Spinal canal stenosis 442
 Spinal cord and spinal artery syndromes 339
 Spinal cord 326
 compression 442
 regions 326*f*, 326
 Spinal dermatomes 334
 Spinal myotomes 334
 Spinal nerves 62
 Spinal reflex arc 330, 331*f*
 Spine
 common abnormalities related to 444*b*
 examination 443
 inspection 443
 palpation 444
 lumbar spine 445
 extension 445
 flexion 445
 rotation 445
 Spinomuscular dystrophy 397
 Spinothalamic tracts 331, 406*t*
 Spinous process 440
 Spirometry 239
 Spleen
 common abnormality 262
 examination 476
 palpation 261
 Splenic disease 19
 Splenic dullness 228
 percussion 272
 Splenomegaly 262, 475, 476
 Splinter haemorrhages 147*t*, 165*b*, 166*f*, 166,
 177, 301, 435*t*
 Splitting of sound 182
 Spondylolisthesis 445
 Sprengel's deformity 444*t*
 Sputum 28, 216*b*
 characteristics 29*t*
 Squint 86, 95*t*, 359
 non paralytic 94, 95*t*, 96*t*
 paralytic 94, 95*t*, 96*t*
 Stapedius reflex 363
 Status epilepticus 416
 Steatorrhoea 24, 54*b*, 57
 Stereognosis 402
 Sternal angle 212
 Sternoclavicular joint 449
 Sternomastoid muscles 174, 219
 Steroid-induced myopathy 45*b*
 Stomach 267*b*
 Stomatitis 23*b*, 23*t*
 Strabismus 94
 Straight leg raising test 447*f*, 447
 Stransky's sign 388*b*
 Stress radionuclide scanning 196
 Stridor 28*b*, 33, 35*t*, 36*t*, 124, 216*b*, 218, 233,
 234*t*
 Stroke 7, 119, 353*t*
 causes of 336*t*, 336
 haemorrhagic 336
 ischaemic 336
 small vessel 336
 Sturge-weber syndrome 78*f*
 Subarachnoid haemorrhage 420, 424
 Subarachnoid space 326
 Subclavian artery aneurysm 204
 Subclavian pulsations 126
 Subclavian steal syndrome 203
 Subclavian vein occlusion 200*b*
 Subconjunctival haemorrhage 85*b*, 177
 Subcutaneous nodules 176, 438, 439*b*
 Subdural haematoma 8*t*, 101*t*, 410, 418*t*
 Subhyloid haemorrhages 99
 Submandibular duct 125
 Submandibular glands 363
 Subperichondrial haematoma 113*b*
 Subphrenic abscess 25, 267*b*
 Substantia nigra 325
 Subthalamic nuclei 325
 Succussion splash 233, 273
 Sudomotor function 405
 Superficial reflexes 330*t*
 Superficial thrombophlebitis 206
 Superficial venous thrombophlebitis 208*f*,
 208
 Superior mesenteric artery thrombosis 258*b*
 Superior sagittal sinus 339
 Superior vena cava 192, 193
 obstruction 175, 193, 219, 219*t*, 220*b*
 Suppurative lung disease 54*b*

- Suppurative otitis media acute 113*b*, 114
 Suppurative pneumonia chronic 232*t*
 Supraclavicular nodes 137*t*
 Supraventricular tachycardia 27, 167*b*, 173
 Surgical scars 251*b*
 Sweat glands 67
 Syncope 27, 28, 41, 42*t*
 causes of 41*t*
 Syndactyly 147*b*, 148*f*
 Synovial fluid examination 466
 Synovial joint 426*f*, 426
 Synovitis 49, 49*b*, 428*b*, 434
 Syphilis 80*t*, 193, 299*b*
 Syphilitic chancre 313*t*
 Syringomyelia 357*t*, 370, 397
 Systemic lupus erythematosus 80, 302
 Systemic sclerosis 23*t*, 435*t*
- T**
- T cells 67
 T3 133, 516*b*, 520
 T4 133, 516*b*, 520
 Tabes dorsalis 155, 357*t*, 392*b*
 Tabes mesenterica 268*b*
 Tachycardia 46, 59*b*, 167*b*, 184*b*
 arrhythmic 167*b*
 sinus 167*b*
 Tachypnoea, causes of 60*b*
 Tactile vocal fremitus 224
 abnormalities 225*t*
 Takayasu's arteritis 153, 199
 Takayasu's syndrome 336*t*
 Tamm-horsfall mucoproteins 304
 Tandem walking 391
 Tarsal tunnel syndrome 404*b*
 Teitz syndrome 30*t*, 31*t*
 Telangiectasias 480*f*, 480
 Telogen effluvium 80*t*
 Temperature intolerance 45
 Temporal arteritis 199
 Temporomandibular arthritis 113*b*, 362*t*,
 362
 Temporomandibular joints 113
 Tendinitis 50*b*
 Tendon jerks, abnormalities of 386
 Tendon reflexes 378
 Tendon sheath crepitus 438
 Tendons 426
 Tension pneumothorax 232*t*
 Tensor tympani muscles 360
 Terminal bronchioles 213
 Terry's nails 147*t*, 149*f*
 Testes 317, 318*f*
 inspection of 513
 palpation 315
 small 317*t*, 318*f*
 tumour of 317*t*, 318*f*
 Testicular atrophy 25
 Testosterone 515*b*
- Tetanus 6
 Thalamic haemorrhage 421*f*
 Thalamic syndrome 338*b*
 Thalamus 325
 Thalasassaemia 472*t*, 479
 Thermoanaesthesia 332
 Thin basement membrane (TBM)
 disease 297
 Thirst 6*b*
 Thomas' test 458
 Thoracic arch aneurysm 200*b*
 Thoracic outlet syndrome 200*b*
 Thrills 181*b*, 181
 diastolic 181*f*, 181*b*
 systolic 181*b*
 Throat swabs 532
 Throat, examination of 124, 249
 Thromboangiitis obliterans 199, 208
 Thromboasthenia 37*b*, 476
 Thrombocytopenia 25, 36, 476, 477, 483*b*
 Thrombocytopenic purpura 478*f*, 480*f*, 480
 Thromboembolism 165, 485
 recurrent 234*t*
 Thrombophlebitis 11*f*, 206
 Thrombosis 470, 477
 arterial and venous 477
 deep vein 477
 Thrombotic disorders 479*b*
 Thumb abduction test 455
 Thyroglobulin 133
 Thyroid axis 516
 Thyroid disease 300*b*, 506
 Thyroid hormones 133
 functions of 133
 Thyroid gland 7, 126, 132-134
 auscultation of 511
 examination of 134
 inspection of 510
 palpation of 511, 511*f*, 511*b*
 Thyroiditis 133*b*, 507*t*, 519*b*
 Thyromegaly 510
 Thyrotoxic crisis 22*t*
 Thyrotoxic heart disease 59*b*
 Thyrotoxicosis 32, 140*t*, 166, 167*b*, 168*t*, 180,
 394*t*, 509, 510, 519, 519*t*, 519*f*
 causes of 519*b*
 clinical manifestations of 519*t*
 differential diagnosis of 520, 522*t*
 eye signs in 520
 TIAS 41, 43*t*
 TICS 40*b*
 Tinea capitis 80*t*
 Tinel's sign 455
 Tinnitus 114, 116, 489*b*
 Todd's paralysis 16*t*
 Tonsillitis 131
 Torticollis 40*b*, 127*f*, 444*b*
 Toxic optic atrophy 84*b*
 Trachea 126, 134, 223
 examination 134
 Tracheal obstruction 222
 Tracheal tug 219
 Tracheitis 30*t*
 Tracheobronchial tree 229
 Tracheobronchitis 30, 32*b*, 53
 Trail's sign 126, 134, 223
 Transient hemiparesis 65
 Transient ischaemic attacks 84*b*, 336
 Transient ischaemic attacks, features of 337*t*
 Transillumination 316*f*, 316
 Transitory ischaemic attacks 16*t*
 Trapezius muscles 368, 444*t*
 Trapezoid nuclei 367
 Traube's area of resonance 228
 Traumatic flail chest 221*t*
 Tremors 392
 characteristics and causes of common
 394*t*
 classification of 394*b*
 Trendelenburg test 209*f*, 209, 457*f*, 457
 TRH stimulation test 503
 Triceps 380*t*
Trichomonas spp. 533*b*
 Trichomoniasis 299*b*
 Tricuspid regurgitation 165, 174, 187*t*
 Tricuspid stenosis 175, 187*t*
 Tricuspid valves 162, 163, 174, 177*t*
 Trigeminal nerve lesion 361
 Trigeminal neuralgia 362
 differential diagnosis of 362*t*
 Trophic ulcers 209*t*
 Tropical pulmonary eosinophilia 233
 Trousseau's sign 397
 Truncal ataxia 329, 390
 Trunk, muscles of 381*t*
 TSH 516*b*, 520
 TSH deficiency 526*t*
 TSH receptors-binding antibodies (TRABs)
 520
 Tubercular laryngitis 35*t*
 Tuberculin test 239
 Tuberculosis 6, 8*t*, 18*t*, 19, 30*t*, 35, 49*t*, 69*t*,
 130, 132*b*, 216, 217*t*, 218-220,
 220*b*, 236, 336*t*, 525, 526*t*
 Tuberos sclerosis 298
 Turner's syndrome 48*t*, 54*b*, 54*t*, 126*f*, 147*t*,
 508
- U**
- Ulcerative colitis 24, 24*t*, 69*t*, 150*b*, 248
 Ulnar deviation 144*b*
 Umbilical hernia 268*b*
 Umbilicus 251
 Unconsciousness 415
 Upper limb reflexes
 biceps 383*f*, 378
 finger flexion 384*f*, 378
 supinator 383*f*, 378
 triceps 383*f*, 378

- Upper motor neuron 366, 373*t*
 lesion 329, 330*b*, 406*t*
 paralysis 366*f*, 371
- Uraemia 33*t*, 37*b*, 68*b*, 218*b*, 296, 300, 301
- Urea 310
- Ureteric colic 8*t*
- Ureteritis 20*t*
- Ureters 295
- Urethral caruncle 318
- Urethral stricture 39*t*, 298
- Urethritis 18*t*, 39*t*, 528*b*
- Uric acid stones 298
- Urinary abnormalities, asymptomatic 297
- Urinary bladder 295
 disorders 38*b*
 palpation 264
- Urinary incontinence 39
 causes of 39*t*
- Urinary system 294*f*, 294-295
 symptoms and signs 296*b*
- Urinary tract infection 8*t*, 297
- Urinary tract obstruction 298
- Urine colour, abnormalities of 303*b*
- Urine culture 531
- Urine
 chemical analysis of 533
 crystals 309
- Urine examination 302-310
 casts
 granular 309
 hyaline 309
 microscopic examination 308
 for culture 309
 micro-organisms
S. mansoni 309
Schistosoma haematobium 309
Trichomonas vaginalis 309
 mid-stream sample of 310*b*
 sugar tests for 534
 tests 282
- Urobilin 307, 308
- Urobilinogen 307, 308, 535
- Urobilinogenuria 307
- Urochrome 303
- Uroerythrin 303
- Urticaria 68*b*
- Uterine fibroids 320
- Uterine prolapse 317, 320
- Uterus
 bimanual palpation 319*f*, 320
 retroversion 321
- V**
- Vaginal examination 317
- Valsalva manoeuvre 66, 164*t*, 405
- Valvular heart disease 26, 59*b*, 192, 203
 chronic 177
- Valvular stenosis 168*b*
- Varicocele 317*t*, 318*f*
- Varicose veins 55*t*, 206, 208
- Vas deferens 47*t*, 316
- Vascular bruits 273
- Vascular disease 200, 200*b*
- Vascular occlusion 205
- Vasculitis 205, 302, 480
- Vasopressin test 44
- Vasospastic disorders 204
- Vegetative state 419*b*
- Venereal warts 313*t*
- Venipuncture 529*f*, 529
- Venous disease, cardinal symptoms of 206*b*
- Venous hum 186, 273
- Venous insufficiency chronic 206, 208,
 209*t*, 210
- Venous system, examination 206
- Ventilation perfusion scan 243
- Ventricular aneurysms 192, 196
- Ventricular ectopics 27, 167
- Ventricular hypertrophy 34, 36*t*, 188
- Ventricular septal defect 165, 181*b*, 187*t*
- Ventricular systole 174
- Ventricular tachycardia 27, 167*b*, 173
- Vertebral artery aneurysm 371
- Vertebral foramine 440
- Vertebral line 213*f*, 213
- Vertebrobasilar arterial insufficiency 41*t*,
 203
- Vertebrobasilar artery syndrome 338
- Vertigo 40, 115
 benign paroxysmal positional 115, 116*t*
 central positional 115, 116*t*
 common causes of 115*b*
 organic 116
 psychogenic 116
- Vestibular function
 abnormalities of 119
 assessment of 119
- Vestibule 121
- Vestibulitis 122
- Video-telemetry EEG 502
- Vincent's infection 37*b*
- Viral exanthems 8*t*
- Viral hepatitis, serological test for 286
- Virchow's gland 131
- Virchow's node 128
- Virilisation 82*t*
- Viscera palpation 258
- Visionfield 352
- Visual acuity 91
- Visual evoked potential (VEP) 101, 411
- Visual field 92
- Visual field loss, clinical manifestations
 of 353*t*
- Visual fixation 119
- Visual function, testing of 91
- Visual loss 84*b*
- Visual pathways 352*f*
- Vitamin
 A 89, 101*t*
 B₁₂ 17*t*
 deficiency 57
 D 67
 deficiency 57
 K deficiency 37*b*
- Vitiligo 17*t*, 70, 70*b*
- Vitreous body 83
- Vitreous degeneration 84*b*
- Vitreous haemorrhage 99, 102*b*
- Vocal cord paralysis (recurrent laryngeal
 nerve paralysis) 218
- Vocal fremitus 225*b*, 225*f*, 225
- Vocal resonance 232
- Volvulus 20*t*
- Vomiting 19*b*, 22, 25*b*
 common causes 22*t*
- Von Willebrand's disease 37*b*, 121*b*, 477
- Von Hippel-Lindau disease 301
- VSD 193, 195, 197
- W**
- Waist-hip ratio 55
- Wallenberg syndrome 338*t*
- Wartenberg's sign 378, 384*f*
- Water deprivation test 517
- WDHA syndrome 24*t*
- Weber's syndrome 338, 357*t*
- Weber's test 119, 367*f*, 367
- Wegener's granulomatosis 342
- Weight changes 53
- Weight gain 45
- Weight loss 56
- Wernicke's area 347
- Wheezes 7, 28*b*, 32, 33, 34*t*, 211, 216*b*, 225,
 229*b*, 233, 234*t*
- Whispering pectoriloquy 232
- White matter 325
- Whooping cough 6, 217*t*
- Wilson's disease 90, 147*t*, 298, 394*t*
- Wolff-Parkinson-White (WPW) syndrome
 168*t*
- Wrist 452
- Wrist drop 144*b*
- Wrist joint 454
- X**
- Xanthelasma 87, 200*b*, 510
- Xanthomatosis 508*t*
- Xiphisternum 254
- Z**
- Zollinger-Ellison syndrome 20, 22, 24*t*