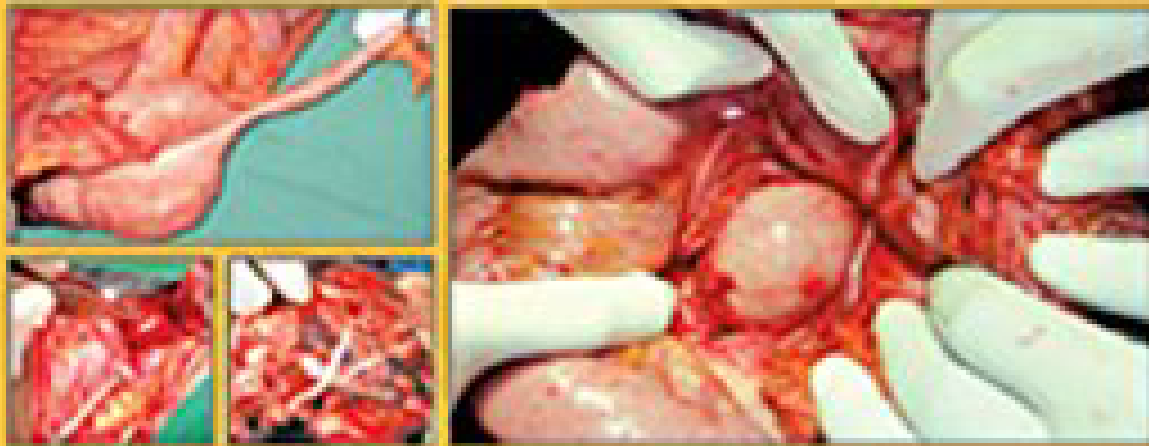


**SRB's**

*More than 1,50,000 Copies Sold*

# Manual of **Surgery**

**5<sup>TH</sup> EDITION**



**Over 3,000 Original Self-explanatory Clinical Photographs**

**Brief Operative Techniques of Relevant Surgeries**

**Special Points are Highlighted as—Notes, Remember Boxes & Tables**

**Best Seller in Overseas Countries**

## **Sriram Bhat M**

*Forewords*

**Prakash Rao**

**Thangam Verghese Joshua**



# Contents

## 1. General Surgery

1

### A. Wounds and Wound Healing 1

Wounds 1; Classification of Wounds 1; Wound Healing 6; Compartment Syndrome 10; Crush Injury 11; Crush Syndrome 11; Degloving injuries 12; Scar 12; Keloid 12; Hypertrophic Scar 13; Problems with Wound Healing 14

### B. Ulcer 15

Ulcer 15; Granulation Tissue 18; Investigations for an Ulcer 9; Management of an Ulcer 20; Traumatic Ulcer 22; Trophic Ulcer (Pressure Sore/Decubitus Ulcer) 22; Ulcer Due to Chilblains 23; Ulcer Due to Frostbite 24; Martorell's Ulcer 24; Arterial/Ischaemic Ulcer 24; Bairnsdale Ulcer 24; Carcinomatous Ulcer (Epithelioma, Squamous Cell Carcinoma) 24; Marjolin's Ulcer 25; Rodent Ulcer 25; Melanotic Ulcer 25; Diabetic Ulcer 26; Meleney's Ulcer (Postoperative Synergistic Gangrene) 27; Lupus Vulgaris 27; Tuberculous Ulcer 28; Bazin's Disease (Erythrocyanosis Frigida/Erythema Induratum) 28; Tropical Ulcer 28; Venous Ulcer (Gravitational Ulcer) 29; Syphilitic Ulcer 29; Soft Chancre/Soft Sore/Ducrey's Ulcer/Chancroid/Bubo 29; Climatic Bubo/Tropical Bubo 29

### C. Sinus and Fistula 31

Sinus 31; Fistula 31; Median Mental Sinus 33; Sequestrum 34; Preauricular Sinus 35

### D. Infectious Diseases 36

Surgical Infection 36; Cellulitis 36; Erysipelas 39; Erysipeloid Disease 39; Lymphangitis 39; Abscess 40; Metastatic and Pyaemic Abscess 45; Bacteraemia 45; Septicaemia 45; Pyaemia 45; Boil (Furuncle) 46; Hidradenitis Suppurativa 46; Carbuncle 47; Pott's Puffy Tumour 48; Pyogenic Granuloma (Granuloma Pyogenicum) 48; Impetigo 49; Erythrasma 49; Scrum Pox 49; Tetanus 49; Gas Gangrene 53; Tuberculosis 55; Leprosy 56; Syphilis (Great Pox) (French Disease) 56; Actinomycosis 57; Madura Foot (Mycetoma Pedis) 58; Rabies (Hydrophobia) 59; Rabies in Dogs 61; Anthrax 62; Nosocomial and Opportunistic Infections 62; Necrotising Fasciitis 63; Acute Pyomyositis 64; Surgical Site infection (SSI) 65; HIV Infection and AIDS 67

### E. Swellings 71

Lipoma 71; Cysts 74; Dermoids 75; Sebaceous Cyst (Wen, Epidermoid Cyst) 78; Glomus Tumour 81; Papilloma 81; Warts 82; Fibroma 82; Bursae 83; Semimembranosus Bursa 85; Marrant Baker's Cyst 85; Lymph Cyst (Lymphatic Cyst) 86; Lymphangioma 86; Calcinosis Cutis 86; Neuroma 87; Neurofibroma 87; Neurilemmoma (Schwannoma) 89; Ganglion 90; Chordoma 90; Epignathus 90

### F. Electrolyte and Nutrition 92

Normal Physiology 92; Water Loss (Volume Loss) 92; Water Excess (ECF Volume Excess) 92; ECF Loss 93; ECF Excess 93; Hyponatraemia 93; Hypernatraemia 94; Hypokalaemia 94; Hyperkalaemia 94; Hypermagnesaemia 95; Hypomagnesaemia 95; Acid-Base Balance 95; Metabolic Alkalosis 96; Respiratory Alkalosis 96; Metabolic Acidosis 96; Respiratory Acidosis 97; Anion Gap 97; Fluid Therapy 97; Nutrition 101; Gastrostomy 102; Jejunostomy 103; Total Parenteral Nutrition (TPN) 104; Refeeding Syndrome 105; Obesity and Morbid Obesity 105; Different Surgeries 106

### G. Shock 110

Shock 110; Stages of Shock 111; Effects of Shock 111; Clinical Features of Shock (Hypovolaemic Shock) 114; Assessment, Investigations and Monitoring 114; Central Venous Pressure (CVP) 115; Pulmonary Capillary Wedge Pressure (PCWP) 116; Systemic Inflammatory Response Syndrome (SIRS) 116; Multiple Organ Dysfunction Syndrome (MODS) 117; Oxygen Therapy 117; Topical O<sub>2</sub> Therapy 117;

Cardiac Arrest 117

### **H. Haemorrhage and Blood Transfusion 119**

Haemorrhage 119; Blood Transfusion 122; Massive Blood Transfusion 124; Autologous Blood Transfusion 124; Artificial Blood 124; Erythropoietin 125; Tourniquets 125; Disseminated intravascular Coagulation 126; Mechanism of Blood Coagulation (Haemostasis) 126

### **I. Burns 128**

Burns 128; Management of Burns 132; Eschar 134; Contracture in Burn Wound 135; Electrical Burns 136; Inhalation injury 137; Chemical Burns 138

### **J. Trauma 139**

Triage 139; Concepts in Trauma Management 141; Spinal Injury 142; Neck injuries 142; Bullet Injuries 142; Blast Injuries 143; Penetrating Injuries 143; Abdominal Trauma 144; Blunt Trauma of Abdomen 146; Duodenal Injury 148; Pancreatic Injury 148; Small Bowel Injury 148; Colonic Injury 149; Liver Injury 149; Splenic Injury 149; Renal Injury 150; Urinary Bladder Injury 150; Abdominal Compartment Syndrome 150; Seat-Belt Injuries 151

### **K. Hand and Foot 152**

Hand 152; Hand Infections 153; Acute Paronychia 156; Chronic Paronychia 156; Apical Subungual Infection 156; Terminal Pulp Space Infection (Felon) 157; Infection of Web Spaces 158; Deep Palmar Space Infection 158; Space of Parona Infection 160; Acute Suppurative Tenosynovitis 160; Compound Palmar Ganglion 161; ORF 161; Milker's Nodes/Nodules (Milkmaid Blisters) 161; Hand Injuries 161; Dupuytren's Contracture 163; Volkmann's Ischaemic Contracture 164; Syndactyly 164; Mallet Finger (Base Ball Finger) 165; Heberden's Nodes 165; Spina Ventosa 165; Foot 165; Callosity 165; Corn 166; Plantar Fasciitis (Policeman's Heel) 166; Ingrowing Toe Nail (Onychocryptosis) 166; Onychogryphosis 167; Onychomycosis 167; Athlete's Foot 167; Hallux Valgus 167

### **L. Arterial Diseases 169**

Surgical Anatomy of Thoracic Outlet 169; Arteries of Upper Limb 169; Arteries of Lower Limb 169; Arterial Diseases 170; Intermittent Claudication 170; Rest Pain 170; Limb Ischaemia 171; Pregangrene 171; Gangrene 171; Different Levels of Arterial Obstruction 172; Other Features of Poor Circulation 173; Investigations for Arterial Diseases 174; Diseases of the Arteries 176; Atherosclerosis 176; Thromboangiitis Obliterans (TAO) Syn. Buerger's Disease 178; Takayasu's Pulseless Arteritis 182; Raynaud's Phenomenon 182; Temporal Arteritis 184; Treatment of Arterial Diseases 184; Subclavian Steal Syndrome 189; Acute Arterial Occlusion 189; Traumatic Acute Arterial Occlusion 190; Embolism 190; Reperfusion Injury 192; Saddle Embolus 193; Embolectomy 193; Fat Embolism 194; Air/Gas Embolism 195; Therapeutic Embolisation 195; Caisson's Disease or Decompression Disease 195; Aneurysm 195; Mycotic Aneurysm 197; Abdominal Aneurysm 197; Abdominal Aortic Aneurysm (AAA) 198; Peripheral Aneurysm 201; Carotid Artery Aneurysm (Extracranial) 202; Dissecting Aneurysm 203; Erythromelalgia (Erythralgia) 204; Livedo Reticularis 204; Polyarteritis Nodosa 204; Scleroderma/Systemic Sclerosis 204; Acrocyanosis (Crurum Puellarum Frigidum) 204; Gangrene 205; Diabetic Foot and Diabetic Gangrene 206; Trophic Ulcer 207; Bedsores (Decubitus Ulcer) (Pressure Sores) 208; Frostbite 208; Ainhum 208; Endovascular Surgeries 208; Upper Limb Ischaemia 209; Arterial Substitutes 211

### **M. Vascular Lesions and Hamartoma 213**

Vascular Anomalies 213; Haemangioma 213; Vascular Malformations 216; Cirroid Aneurysm 217; Arteriovenous Fistula (AVF) 217; Campbell De Morgan Spots 220; Parry-Romberg Disease 220; Hamartomata 220

### **N. Venous Diseases 221**

Anatomy of Veins of Lower Limb 221; Physiology of Venous Blood Flow in Lower Limb 222; Deep Vein Thrombosis 222; Varicose Veins 226; Venous Ulcer (Gravitational Ulcer) 238; Compression Therapy for Varicose Veins 241; Thrombophlebitis 241; Klippel-Trenaunay Syndrome 242; Anticoagulants 242; Heparin (Unfractionated/UFH) 242; Low Molecular Weight Heparin (LMWH) 242; Oral Anticoagulants 242; Warfarin 243; Direct Thrombin Inhibitors 243; Antiplatelet Drugs 243; Pulmonary Embolism 243

### **O. Lymphatics 245**

Surgical Anatomy 245; Lymphangiography 246; Isotope Lymphoscintigraphy 247; Lymphoedema 247; Lymphomas 253; Hodgkin's Lymphoma (HL) 254; Non-Hodgkin's Lymphoma (NHL) 258; Mantle Cell Lymphoma 259; Malt Lymphoma (Maltoma) 259; Burkitt's Lymphoma (Malignant Lymphoma of Africa) 260; Cutaneous T Cell Lymphoma 260; Chylous Ascites 261; Chylothorax 261; Chyluria 261; Sarcoidosis 262

### **P. Peripheral Nerves 263**

Peripheral Nerve Injuries 263; Tinel's Sign 265; Brachial Plexus Injuries 265; Causalgia 265; Median Nerve Injury 266; Carpal Tunnel Syndrome 266; Ulnar Nerve Injury 268; Claw Hand 268; Radial Nerve Injury 269; Common Peroneal Nerve Injury 270; Foot Drop 270; Medial Popliteal Nerve Injury 270; Axillary Nerve Injury 271; Long Thoracic Nerve Injury (Nerve of Bell) 271; Meralgia Paraesthetica 271

### **Q. Neoplasm 272**

Definition 272; Dysplasia 273; Carcinoma In Situ 273; Aetiologic Factors 273; Spread of Malignant Tumours 274; Grading of Tumour 274; Staging of the Tumour 275; Paraneoplastic Syndromes 275; Investigations for Neoplasm 275; Management Strategy for Cancers 280

### **R. Skin Tumours 282**

Anatomy 282; Classification of Skin Tumours 283; Skin Adnexal Tumours 283; Dermatofibroma (Sclerosing Angioma or Subepithelial Benign Nodular Fibrosis) 284; Dermatofibrosarcoma Protuberans 285; Keratoacanthoma (Molluscum Sebaceum) 285; Rhinophyma (Potato Nose) (Bottle Nose) 286; Seborrheic Keratosis (Seborrheic Wart, Basal Cell Papilloma) 286; Squamous Cell Carcinoma (Epithelioma) 287; Marjolin's Ulcer 290; Basal Cell Carcinoma (Rodent Ulcer) 290; Turban Tumour 292; Naevi 292; Melanoma 294

### **S. Sarcomas 302**

Sarcoma 302; Liposarcoma 308; Fibrosarcoma (11%) 308; Malignant Fibrous Histiocytoma (MFH) 310; Leiomyosarcoma 310; Rhabdomyosarcoma 310; Chondrosarcoma 310; Haemangiosarcoma 310; Lymphangiosarcoma 311; Synovial Sarcoma (7%) 311; Malignant Peripheral Nerve Sheath Tumour (MPNST) (3%) 311; Kaposi's Sarcoma 311

### **T. Amputations 312**

Amputation 312; Complications of Amputations 318; Prosthesis 320

### **U. Reconstruction 321**

Graft 321; Skin Grafts 321; Flaps 324; Tendon 330; Tendon Repair 331; Tendon Transfer 331; Tendon Graft 331

### **V. Transplantation 332**

Preoperative Evaluation 332; Organ Procurement 332; Graft Rejection (Transplant Rejection) 333; Immunosuppressive Agents 334; Renal Transplantation 335; Liver Transplantation 336; Bone Marrow Transplantation 338; Pancreatic Transplantation 338; Small Bowel Transplantation 338; Dialysis 339; Cimino Fistula (Cimino-Brescia) 340

### **W. Stings and Bites 341**

Snake Bite 341; Spider Bite 341; Bee Bite 342; Mammalian Bite 342

### **X. Pain 343**

Gate Control Theory 343

## **2. Faciomaxillary Diseases**

346

Diseases of the Palate 346; Orthopantomogram (OPG) 346; Cleft Lip and Cleft Palate 347; Maxillofacial Injuries 350; Primary Care (Early Care) in Maxillofacial Injuries 351; Fracture Middle Third Area 352; Zygomatic Complex Fracture 353; Fracture of the Mandible 355; Dislocation of the Mandible 357; Jaw Tumours 358; Epulis 358; Ameloblastoma (Adamantinoma, Eve's Disease, Multilocular Cystic Disease of the Jaw) 359; Dentigerous Cyst (Follicular Odontome) 360; Dental Cyst (Radicular Cyst, Periapical Cyst) 361; Osteomyelitis of Jaw 361; Alveolar Abscess (Dental Abscess) 362; Fibrous Dysplasia of Bone/Jaw 362; Cherubism 364

## **3. Oral Cavity**

365

Ranula 365; Sublingual Dermoids 366; Stomatitis 367; Cancrum Oris (Noma) 367; Syphilitic Lesions of Oral Cavity 368; Leukoplakia 368; Erythroplakia 369; Oral Submucosal Fibrosis 369; Premalignant Conditions of Oral Cavity 369; Oral and Upper Aerodigestive Cancers 370; Cheek 372; Carcinoma Cheek/Buccal Mucosa 372; Lip 383; Neoplasm of Lip 384; Carcinoma Lip 384; Tongue 387; Tongue Ulcers 388; Benign Tumours of Tongue 389; Tongue Fissure 389; Glossitis 390; Tongue Tie 391; Carcinoma Tongue 391; Carcinoma of Posterior One-third/Base of the Tongue 394; Nasopharyngeal Carcinoma 395; Maxillary Tumours 395; Malignant Tumours of Tonsil 398; Carcinoma Hard Palate 398; Laryngeal Tumours 399; Malignant Tumours of Larynx 399; Trismus 402

#### 4. Salivary Glands

403

Anatomy 403; Saliva 406; Sialography 406; Salivary Calculus and Sialadenitis 406; Sialosis 409; Sialectasis 409; Recurrent Childhood Parotitis 409; Parotid Abscess (Suppurative Parotitis) 409; Parotid Fistula 410; Sjögren's Syndrome 411; Mikulicz Disease 412; Salivary Neoplasms 412; Pleomorphic Adenoma (Mixed Salivary Tumour) 413; Adenolymphoma (Warthin's Tumour, Papillary Cystadenoma Lymphomatosum) 415; Oncocytoma (Oxyphil Adenoma) 416; Basal Cell Adenoma 416; Mucoepidermoid Tumour 416; Adenoid Cystic Carcinoma (10% of Salivary Tumours) 417; Acinic Cell Tumour 417; Malignant Mixed Tumour (MMT) 417; Adenocarcinoma of Salivary Glands 417; Squamous Cell Carcinoma of Salivary Glands 417; Submandibular Salivary Gland Tumours 417; Management of Malignant Salivary Tumours 418; Minor Salivary Gland Tumours 420; Parotid Lymphoma 421; Parotidectomy 421; Frey's Syndrome (Auriculotemporal Syndrome, Gustatory Sweating) 423; Facial Nerve Injury (Lower Motor Nerve Lesion, Surgically Related) 424

#### 5. Neck

426

Anatomy of Lymphatics of Head and Neck 426; Thoracic Outlet Syndrome (TOS) 427; Cervical Rib 428; Branchial Cyst 431; Branchial Fistula 432; Pharyngeal Pouch (Zenker's) 433; Laryngocele 434; Cystic Hygroma (Cavernous Lymphangioma) 435; Ludwig's Angina 436; Parapharyngeal Abscess 437; Retropharyngeal Abscess 437; Subhyoid Bursitis (Retrohyoid Bursa/Boyer's Bursa) 438; Carotid Body Tumour (Potato Tumour, Chemodectoma, Nonchromaffin Paraganglioma) 438; Torticollis (Wry Neck) 440; Sternomastoid Tumour 440; Tuberculous Lymphadenitis 441; Cold Abscess 444; Secondaries in Neck Lymph Nodes 445; Chemotherapy for Head and Neck Cancers 452

#### 6. Thyroid

453

Development 453; Anatomy 453; Physiology 455; Congenital Anomalies 455; Thyroid Function Tests 458; FNAC of Thyroid 458; Classification of Goitre 459; Diffuse Hyperplastic Goitre 460; Multinodular Goitre (MNG) 460; Discrete Thyroid Nodule 462; Solitary Thyroid Nodule 463; Retrosternal Goitre 466; Thyrotoxicosis and Hyperthyroidism 467; Radioactive Iodine 477; Thyroid Neoplasms 478; Differentiated Thyroid Carcinoma (DTC) 478; Papillary Carcinoma of Thyroid (PCT) 480; Follicular Carcinoma of Thyroid (FCT) 482; Anaplastic Carcinoma of Thyroid 485; Medullary Carcinoma of Thyroid (MCT) 486; Malignant Lymphoma 488; Hashimoto's Thyroiditis (Struma Lymphomatosa) 488; De-Quervain's Subacute Granulomatous Thyroiditis 489; Riedel's Thyroiditis (0.5% Common) 489; Thyroid incidentaloma 489; Thyroidectomy 490; Emil Theodor Kocher 495; Kocher's Test 495; Hypothyroidism 495; Recurrent Laryngeal Nerve Palsy 496

#### 7. Parathyroids and Adrenals

499

Anatomy 499; Calcium 499; Hyperparathyroidism (HPT) 500; Parathyroidectomy 503; MEN Syndrome (MEA Syndrome) 505; Apudomas 505; Hypoparathyroidism 505; Tetany 506; Adrenals 507; Adrenal Cortical Tumours 507; Adrenocortical Carcinoma 507; Cushing's Syndrome 508; Conn's Syndrome 508; Virilising Syndrome or Adrenogenital Syndrome 509; Neuroblastoma 509; Pheochromocytoma 510

#### 8. Breast

512

Anatomy 512; Mammography 515; Aberration of Normal Development and Involution (ANDI) of The Breast 516; Fibroadenoma 516; Fibrocystadenosis (Fibrocystic Disease of the Breast/Mammary Dysplasia/Cyclical Mastalgia with Nodularity) 518; Sclerosing Adenosis 519; Phylloides Tumour (Cystosarcoma Phylloides/Serocystic Disease of Brodie) 520; Mastalgia ("Pain in the Breast") 521; Traumatic Fat Necrosis 521; Galactocele 522; Mastitis 522; Antibioma 524; Duct Ectasia 525; Mondor's Disease 525; Tuberculosis of the Breast 525; Breast Cysts 526; Galactorrhoea 527; Gynaecomastia 527;

Duct Papilloma 528; Zuska-Atkins Disease 529; Mammary Fistula of Atkins 529; Carcinoma Breast 529; TNM Staging of Carcinoma Breast 539; Management of Early Carcinoma Breast 553; Advanced Carcinoma Breast 557; Prognostic Factors in Carcinoma Breast 559; Prophylactic Mastectomy 560; Carcinoma of Male Breast 560; Breast Reconstruction 561; Breast Implants 563; Nipple Retraction 564

- 9. Peritoneum 565**  
 Anatomy 565; Physiology 565; Acute Peritonitis 566; Primary Peritonitis 566; Secondary Peritonitis 566; Tertiary Peritonitis 566; Spontaneous Bacterial Peritonitis 572; Sclerosing Peritonitis 573; Biliary Peritonitis 573; Postoperative Peritonitis 573; Other Forms of Peritonitis 573; Pelvic Abscess 574; Subphrenic Spaces and Subphrenic Abscess 575; Mesenteric Cysts 577; Mesenteric Panniculitis 578; Acute Mesenteric Lymphadenitis 578; Mesenteric Malignancy 578; Mesenteric Trauma 579; Peritoneal Malignancy 579; Omental Cyst 580; Omental Torsion 580; Omental Tumour 580
- 10. Abdominal Tuberculosis 581**  
 Abdominal Tuberculosis 581; Ileocaecal Tuberculosis 582; Ileal Tuberculosis 587; Peritoneal Tuberculosis 587; Tuberculous Mesenteric Lymphadenitis 590; Ano-recto-sigmoidal Tuberculosis 591; Tuberculosis of the Omentum 591
- 11. Liver 592**  
 Surgical Anatomy of Liver 592; Liver Function Tests (LFT) 593; Alpha Fetoprotein (AFP) 594; Liver Biopsy 594; Liver injury 594; Infections of Liver 596; Liver Tumours 605; Liver Cysts 613; Congenital Liver Cysts 613; Portal Hypertension 614; Oesophageal Varices 617; Emergency Management in Severe Haemorrhage 619; Portal Hypertensive Gastropathy 624; Ascites 624; Ascites in Portal Hypertension 626; Budd-Chiari's Syndrome 626; Hepatic Failure 627; Hepatic Encephalopathy 627; Hepatorenal Syndrome 628; Hepatic Resection 628; Portal Biliopathy 630
- 12. Gallbladder 631**  
 Surgical Anatomy 631; Oral Cholecystogram (OCG; Graham-Cole Test) 633; IV Cholangiogram 633; Endoscopic Retrograde Cholangio-pancreatography (ERCP) 633; Percutaneous Transhepatic Cholangiography (PTC) 634; Magnetic Resonance Cholangio-pancreatography (MRCP) 634; Radioisotope Scan Study 635; Peroperative Cholangiogram 635; Postoperative T-tube Cholangiogram 635; Congenital Anomalies of Gallbladder 635; Choledochal Cysts 636; Caroli's Disease 638; Biliary Atresia 638; Gallstones 640; Acute Cholecystitis 643; Acute Acalculous Cholecystitis (5%) 645; Mirizzi Syndrome 645; Empyema Gallbladder 646; Mucocele of The Gallbladder 647; Chronic Cholecystitis 647; Murphy's Sign 648; Gallstone Ileus 648; Cholecystoses 649; Dissolution Therapy for Gallstones 650; Choledocholithiasis 650; Sump Syndrome 653; Courvoisier's Law (Sign) 654; Surgical Jaundice (Obstructive Jaundice) 654; CBD Strictures (Biliary Strictures) 657; Sclerosing Cholangitis 658; Gallbladder Polyp 658; Benign Biliary Papilloma 658; Carcinoma Gallbladder 659; Cholangiocarcinoma (Bile Duct Carcinoma) 661; Klatskin Tumour 661; Biliary Fistulas 662; Hemobilia 662; White Bile 663; Cholecystectomy 663; Open Approach Cholecystectomy 663; Laparoscopic Cholecystectomy 664; Single Incision Laparoscopic Surgery (SILS) in Cholecystectomy 665; Bile Duct Injuries 666; Post-cholecystectomy Syndrome (15%) 667; Biliary Dyskinesia 667
- 13. Spleen 668**  
 Surgical Anatomy 668; Functions of the Spleen 668; Splenunculi (30%) 669; Splenic Injury (Rupture Spleen) 669; Splenomegaly 672; Hereditary Spherocytosis 673; Immune Haemolytic Anaemia 673; Thalassaemia (Mediterranean Anaemia/Cooley's Anaemia/Erythroblastic Target Cell Anaemia) 674; Sickle Cell Disease 674; Idiopathic (Immune) Thrombocytopaenic Purpura (ITP) 674; Thrombotic Thrombocytopaenic Purpura (TTP) 675; Splenectomy 676; Overwhelming Post-splenectomy Infection (OPSI) 677; Splenic Artery Aneurysm 677; Splenic Abscess 678; Hypersplenism 678; Splenic Cyst 678; Atraumatic Rupture of Spleen 679
- 14. Pancreas 680**

Anatomy 680; Serum Amylase 681; Serum Lipase 682; Magnetic Resonance Cholangio-pancreatography (MRCP) 682; Pancreatitis 682; Acute Pancreatitis 683; Complications of Acute Pancreatitis 689; Pseudocyst of Pancreas 690; Chronic Pancreatitis 692; Pancreatic Tumours 700; Exocrine Pancreatic Tumours 700; Carcinoma Pancreas 702; Endocrine Pancreatic Tumours 708; Insulinomas 709; Gastrinomas 709; Glucagonomas 710; Zollinger-Ellison Syndrome 711; Cystic Fibrosis 711; Annular Pancreas 711; Ectopic (Accessory) Pancreatic Tissue 712; Pancreatic Divisum 712; Pancreatic Calculus 712; Pancreatic Ascites 713; Pancreatic Fistulae 713; Pancreatic Necrosis 714; Pancreatic Trauma 714; Cystic Lesions of Pancreas 715; Pancreatic Exocrine Insufficiency (Exocrine Pancreatic Disease) 715

## 15. Retroperitoneal Space 717

Anatomy of Retroperitoneum 717; Retroperitoneal Fibrosis 717; Retroperitoneal Swellings 718; Retroperitoneal Tumours 718; Psoas Abscess 722

## 16. Differential Diagnosis of Mass Abdomen 724

Mass in the Right Hypochondrium 726; Mass in the Epigastrium 727; Mass in the Left Hypochondrium 728; Mass in the Lumbar Region 729; Mass in the Umbilical Region 730; Mass in the Right Iliac Fossa 731; Mass in the Left Iliac Fossa 731; Mass in the Hypogastrium 731; Digital Rectal Examination for Prostate and Other Conditions 733

## 17. Abdominal Wall and Umbilicus 736

Diseases of the Umbilicus 736; Omphalitis 737; Umbilical Granuloma 737; Anomalies of Vitellointestinal Duct 738; Umbilical Sinus 738; Umbilical Adenoma (Raspberry Tumour) 739; Umbilical Fistula 739; Patent Urachus 739; Burst Abdomen (Abdominal Wound Dehiscence) (Acute Wound Failure) 740; Abdominal Wall Tumours 742; Desmoid Tumour 742; Exomphalos (Omphalocele) 743; Gastroschisis (Belly Cleft) 744; Rectus Sheath Haematoma 744; Abdominal Wall Abscess 745; Meleney's Progressive Synergistic Bacterial Gangrene of Abdominal Wall 745; Divarication of Recti (Diastasis Recti) 746

## 18. Hernia 747

Aetiology 748; Parts of Hernia 749; Classification of Hernia 750; Inguinal Hernia 751; Surgical Anatomy of Inguinal Canal 751; Classification of Inguinal Hernia (Earlier) 753; Indirect (Oblique) Inguinal Hernia 754; Direct Inguinal Hernia 762; Incarcerated Hernia 768; Strangulated Hernia 768; Sliding Hernia (Hernia-En-Glissade) 770; Pantaloon Hernia (Double Hernia, Saddle Hernia, Romberg Hernia) 771; Femoral Hernia 771; Ventral Hernia 774; Incisional Hernia 775; Umbilical Hernia 778; Paraumbilical Hernia (Supra- and Infraumbilical Hernia) 779; Epigastric Hernia (Fatty Hernia of Linea Alba) 780; Spigelian Hernia 781; Obturator Hernia 782; Richter's Hernia 782; Lumbar Hernia 783; Phantom Hernia 783; Sciatic Hernia 783; Complications of Hernia Surgery 783; Parastomal Hernia 784

## 19. Oesophagus 786

Anatomy 786; Lower Oesophageal Sphincter (LOS) 788; Dysphagia 788; Contrast Study of Oesophagus 789; Oesophagoscopy 790; Oesophageal Endosonography 790; Third Space Endoscopy 790; Gastro-Oesophageal Reflux Disease (GORD/GERD) 790; Hiatus Hernia 795; Rolling Hernia (Paraoesophageal Hernia) 795; Reflux Oesophagitis 796; Barrett's Oesophagus 796; Barrett's Ulcer 797; Oesophageal Motility Disorders 797; Achalasia Cardia (Cardiospasm) 797; Plummer-Vinson Syndrome (Paterson-Kelly Syndrome) 800; Corrosive Stricture of Oesophagus 800; Schatzki's Rings 802; Boerhaave's Syndrome 802; Mallory-Weiss Syndrome 803; Tracheo-oesophageal Fistula (Oesophageal Atresia) 803; Oesophageal Diverticulum 804; Carcinoma Oesophagus 804; Benign Tumours of the Oesophagus 811; Oesophageal Perforation 812

## 20. Stomach 814

Anatomy 814; Blood Supply of Stomach 815; Nerve Supply of Stomach 815; Histology 815; Lymphatic Drainage of Stomach 815; Duodenum 816; Gastric Physiology 816; Gastric Function Tests 817; Gastrin 817; Barium Meal Study 818; Gastroscopy 818; *Helicobacter pylori* 819; Congenital (Infantile) Hypertrophic Pyloric Stenosis 820; Gastritis 822; Acute Peptic Ulcer (Duodenal or Gastric Ulcer) 822;

Gastric Ulcer **823**; Duodenal Ulcer **825**; Pyloric Stenosis Due to Chronic Duodenal Ulcer **828**; Perforated Peptic Ulcer **830**; Bleeding Peptic Ulcer **833**; Haematemesis **836**; Complications of Gastric Surgery **837**; Trichobezoar (Rapunzel Syndrome) **840**; Chronic Duodenal Ileus (Wilkie's Syndrome) **841**; Dunbar's (MALS) Syndrome (Harjola—Marable Syndrome) **841**; Acute Gastric Dilatation **842**; Gastric Volvulus **842**; Gastric Polyp **843**; Menetrier's Disease **843**; Duodenal Diverticula **844**; Carcinoma Stomach **844**; Gastric Lymphoma **855**; Gastric Sarcomas **857**; Gastrointestinal Stromal Tumours (GISTs) **857**; Pyloroplasty **858**; Gastrostomy **858**; Gastrectomy **859**; Gastrojejunostomy (GJ) **860**; Retrograde Jejunogastric Intussusception **860**; Vagotomy **860**

## **21. Small Intestine** **862**

Anatomy **862**; Meckel's Diverticulum **863**; Regional Enteritis (Crohn's Disease) **865**; Surgical Complications of Typhoid **868**; Surgical Complications of Roundworm (*Ascaris lumbricoides*) **869**; Pneumatosis Cystoides Intestinalis **870**; Mesenteric Vessel Ischaemia **871**; Necrotising Enterocolitis **872**; Small Bowel Tumours **873**; Benign Tumours of Small Bowel **874**; Malignant Tumours of Small Bowel **876**; Carcinoid Tumour **877**; Short Bowel Syndrome (Short Gut Syndrome) **879**; Small Bowel Enema (Enteroclysis) **880**; Capsule Endoscopy **881**; Small Bowel Enteroscopy **881**; Enteric/Gastrointestinal Fistula **881**

## **22. Large Intestine** **885**

Anatomy **885**; Hirschsprung's Disease (Congenital Megacolon) **886**; Diverticular Disease of the Colon **888**; Ulcerative Colitis **891**; Ischaemic Colitis **896**; Pseudomembranous Colitis **896**; Surgical Complications of Intestinal Amoebiasis **896**; Tumours of Colon **897**; Benign Tumours/Polyp of the Colon **897**; Juvenile Polyps **898**; Metaplastic/Hyperplastic Polyp **898**; Peutz-Jeghers Polyp **898**; Adenoma of Colon **898**; Familial Adenomatous Polyp (FAP) **899**; Carcinoma Colon **900**; Angiodysplasia of Colon **909**; Ogilvie's Syndrome **909**; Colostomy **910**; Stoma Care **912**; Stoma Appliances **913**; Faecal Fistula **913**; Preparation of Large Bowel for Surgery **914**; Surgical Pouches **915**; Barium Enema **915**

## **23. Intestinal Obstruction** **917**

Intestinal Obstruction: Types **917**; Dynamic Obstruction **918**; Duodenal Atresia **924**; Small Intestine Atresia (Intestinal Atresia) **925**; Malrotation **926**; Meconium Ileus **927**; Intussusception (ISS) **928**; Volvulus **931**; Sigmoid Volvulus (Volvulus of Pelvic Colon) **931**; Paralytic Ileus (Adynamic Intestinal Obstruction) **933**; Adhesions and Bands **933**; Internal Hernias **936**

## **24. Appendix** **937**

Surgical Anatomy **937**; Acute Appendicitis **938**; Incidental Appendicectomy **945**; Appendicular Mass (Periappendicular Phlegmon) **946**; Appendicular Abscess **946**; Faecal Fistula After Appendicectomy **947**; Mucocele of Appendix **948**; Neoplasms of the Appendix **948**; Laparoscopic Appendicectomy **949**

## **25. Rectum and Anal Canal** **951**

Anatomy **951**; Per-rectal Examination (Digital Examination of the Rectum) **952**; Proctoscopy (Kelly's) **953**; Sigmoidoscopy **953**; Colonoscopy **953**; Carcinoma Rectum **954**; Solitary Ulcer Syndrome **960**; Rectal Prolapse **961**; Anorectal Malformations (ARM) **965**; Pilonidal Sinus/Disease (Jeep Bottom; Driver's Bottom) **967**; Piles/Haemorrhoids **969**; Anal Fissure (Fissure-in-Ano) **976**; Anorectal Abscess **978**; Fistula-in-Ano **980**; Anorectal Strictures **985**; Condyloma Acuminata **986**; Anal Intraepithelial Neoplasia (AIN) **986**; Malignant Tumours of Anal Area **986**; Sacrococcygeal Teratoma **987**; Anal incontinence **988**; Descending Perineal Syndrome **988**; Proctitis **989**; Proctalgia Fugax **989**; Hidradenitis Suppurativa of Anal Region **989**; Pruritus Ani **989**; Gastrointestinal Haemorrhage (GI Bleed) **989**

## **26. Urology** **993**

### **A. Kidney 993**

Anatomy of Kidney and Ureter **993**; Kidney—Anatomy **993**; Ureter—Anatomy **994**; Plain X-ray—Kidney, Ureter and Bladder (KUB) **994**; Intravenous Urogram (IVU) **995**; Retrograde Pyelography (RGP) **996**; Renal Angiogram **997**; Micturating Cystourethrography (MCU) **997**; Ascending Urethrogram **997**; Isotope Renography **998**; Cystoscopy **998**; Catheters **999**; Foley's Catheter **1000**; Malecot's Catheter **1000**;



Red Rubber Catheter **1001**; Nephrostomy **1001**; Suprapubic Cystostomy (SPC) **1002**; Haematuria **1002**; Horseshoe Kidney **1003**; Cystic Diseases of the Kidney **1004**; Polycystic Kidney Disease (PCKD) **1004**; Duplication of Renal Pelvis and Ureter **1005**; Retrocaval Ureter **1006**; Ureterocele **1006**; Injuries to Kidney **1007**; Renal Tuberculosis **1008**; Hydronephrosis (HN) **1010**; Pyonephrosis **1014**; Carbuncle of Kidney (Renal Carbuncle) **1014**; Perinephric Abscess **1015**; Renal Calculus **1015**; Ureteric Calculi **1019**; Staghorn Calculus **1021**; Benign Tumours of Kidney **1022**; Wilms' Tumour (Nephroblastoma) **1022**; Renal Cell Carcinoma (RCC) **1024**

### **B. Urinary Bladder 1028**

Anatomy **1028**; Ectopia Vesicae (Exstrophy of the Bladder) **1029**; Urachal Anomalies **1029**; Vesical Calculus **1029**; Cystitis **1031**; Recurrent Cystitis **1032**; Interstitial Cystitis (Hunner's Ulcer, Elusive Ulcer) **1032**; Schistosoma Haematobium (Endemic Haematuria, Urinary Bilharziasis) (Swimmer's Itch) **1032**; Thimble or Systolic Bladder **1033**; Bladder Tumours **1033**; Transitional Cell Carcinoma (TCC) **1033**; Ureterosigmoidostomy **1036**; Rupture Bladder (Bladder Injury) **1037**; Residual Urine **1038**; Malakoplakia **1038**; Neurogenic Bladder **1038**; Vesicoureteric Reflux **1039**; Bladder Diverticula **1039**; Urinary Diversion **1040**; Urinary Fistulas **1041**

### **C. Prostate 1043**

Anatomy **1043**; Acid Phosphatase **1043**; Prostate Specific Antigen (PSA) **1043**; Benign Prostatic Hyperplasia (BPH) **1044**; Prostatitis **1047**; Bladder Outlet Obstruction (BOO) **1047**; Carcinoma Prostate **1048**

### **D. Urethra 1051**

Anatomy **1051**; Urethral Injury **1051**; Rupture of Membranous Urethra and/or Prostatic Urethra (Posterior Urethra) **1051**; Rupture of Bulbous Urethra (Anterior Urethra) **1052**; Stricture Urethra **1053**; Hypospadias **1055**; Epispadias **1056**; Posterior Urethral Valve **1056**; Urethral Calculi **1056**; Urethritis **1057**; Extravasation of Urine **1057**; Retention of Urine **1058**

### **E. Penis 1060**

Phimosis **1060**; Paraphimosis **1061**; Circumcision **1061**; Balanoposthitis **1062**; Chordee (Cordee) **1062**; Priapism **1063**; Peyronie's Disease (Induratio-Penis Plastica) **1063**; Ram's Horn Penis **1063**; Carcinoma Penis **1063**; Buschke-Löwenstein Tumour **1067**

### **F. Scrotum 1068**

Anatomy **1068**; Fournier's Gangrene **1068**; Hydrocele **1069**; Primary Vaginal Hydrocele **1070**; Secondary Vaginal Hydrocele **1071**; Haematocele **1073**; Pyocele **1074**; Cyst of Epididymis **1074**; Spermatocele **1075**; Varicocele **1075**

### **G. Testis 1078**

Anatomy **1078**; Undescended Testis **1078**; Ectopic Testis **1081**; Retractable Testis **1081**; Torsion of the Testis **1081**; Testicular Tumours **1083**; Paratesticular Tumours **1087**; Orchitis **1087**; Epididymitis **1088**

## **27. Neurosurgery**

**1090**

Head Injuries **1090**; Extradural Haematoma **1095**; Subdural Haematoma **1096**; Subarachnoid Haemorrhage (SAH) **1097**; Fracture Skull **1098**; Depressed Skull Fracture **1099**; CSF Rhinorrhoea **1099**; Hydrocephalus **1100**; Intracranial Abscess **1101**; Intracranial Aneurysms **1102**; Intracranial Tumours **1102**; Pituitary Tumours **1105**; Craniopharyngiomas **1106**; Spinal Dysraphism **1106**; Meningocele **1106**; Spina Bifida **1107**; Intervertebral Disc Prolapse (IVDP) **1108**; Tuberculosis of Spine (Caries Spine) **1109**; Spinal Tumours **1111**

## **28A. Thorax**

**1112**

Chest Injuries **1112**; Fracture Ribs **1114**; Flail Chest and Stove in Chest **1115**; Pneumothorax **1116**; Tension Pneumothorax **1116**; Haemothorax **1117**; Pleural Tap **1117**; Bronchoscopy **1118**; Empyema Thoracis **1118**; Empyema Necessitans **1119**; Lung Abscess **1120**; Intercostal Tube Drainage **1121**; Shock Lung (Stiff Lung) **1123**; Pulmonary Embolism (PE) **1123**; Surgical Emphysema **1124**; Lung Cysts **1124**; Mediastinal Tumours **1125**; Thymomas **1127**; Lung Cancers **1127**; Pancoast Tumours (Superior Sulcus Tumour) **1128**; Chest Wall Tumours **1128**; Pericarditis **1129**; Acute Pericarditis **1129**;

Chronic Constrictive Pericarditis (Pick's Disease) 1129; Pericardial Tap 1129; Cardiac (Pericardial) Tamponade 1130; Diaphragmatic Hernia 1130; Pulmonary Complications During Postoperative Period 1133; Surgical Management of Pulmonary Tuberculosis 1133; Video-assisted Thoracoscopic Surgery (VATS) 1133

### **B. Cardiac Surgery 1134**

Anatomy 1134; Preoperative Assessment and Preparation of the Cardiac Patient 1135; Cardiopulmonary Bypass 1135; Congenital Heart Diseases 1136; Patent Ductus Arteriosus (PDA)—10% 1136; Coarctation of Aorta—5% 1136; Atrial Septal Defect (ASD)—7% 1137; Ventricular Septal Defect (VSD)—15% 1137; Pulmonary Stenosis 1138; Transposition of Great Vessels 1138; Tetralogy of Fallot 1138; Acquired Heart Disease 1139; Mitral Regurgitation 1139; Aortic Stenosis 1140; Aortic Regurgitation 1140; Valve Replacement Surgery 1140; Ischaemic Heart Disease (IHD) 1140; Cardiac Pacemakers 1141; Post-operative Care 1141

## **29. Adjuvant Therapy 1142**

Radiotherapy 1142; Chemotherapy 1144; Cell Cycle 1145; Antimalignancy Drugs 1145; Hormone Therapy in Cancer 1145; Immunosuppression 1146; Immunotherapy 1147; Hybridoma 1147; Gene Therapy 1147

## **30. Anaesthesia 1148**

Preoperative Assessment 1148; General Anaesthesia 1149; Anaesthetic Agents 1149; Oxygen 1149; Muscle Relaxants 1149; Reversal Agents 1149; Instruments in Anaesthesia 1149; Complications of General Anaesthesia 1151; Postoperative Care 1151; Monitoring the Postoperative Patient 1151; Regional Anaesthesia 1152; Topical Anaesthesia 1152; Infiltration Block 1152; Field Block 1152; Nerve Block 1152; Intravenous Regional Anaesthesia (Bier's Block) 1152; Spinal Anaesthesia 1152; Saddle Block 1153; Epidural Anaesthesia 1153; Caudal Anaesthesia 1153

## **31. Advanced Imaging Methods 1154**

Ultrasound 1154; Doppler 1156; CT Scan 1156; Magnetic Resonance Imaging (MRI) 1158; Radionuclide Imaging 1159; Positron-Emission Tomography (PET Scan) 1159

## **32. Operative Surgery 1160**

### **A. Asepsis and Sterilisation 1160**

Sterilisation 1160; Disinfection 1160; Antisepsis 1160; Asepsis 1160; Different Methods of Disinfection/Sterilisation 1160

### **B. Instruments 1163**

Cheate's Forceps 1163; Sponge Holding Forceps (Rampley's) 1163; Mayo's Towel Clip 1163; Artery Forceps (Haemostat) 1163; Right Angle Forceps 1164; Kocher's Forceps 1164; Allis' Tissue Holding Forceps 1164; Babcock's Forceps 1164; Lane's Tissue Holding Forceps 1165; Morant-Baker's Appendix Holding Forceps 1165; Volkmann's Retractor 1165; Langenbeck's Retractor 1165; Czerny's Retractor (Hernia Retractor) 1165; Morris' Retractor 1165; Deaver's Retractor 1165; Doyen's Retractor 1166; Self-retaining Retractor 1166; Single Hook Retractor 1166; Plain Non-toothed Dissecting Forceps 1166; Toothed Dissecting Forceps 1166; Surgical Needles 1166; Needle Holder 1167; Joll's Thyroid Retractor 1167; Moynihan's Occlusion Clamp 1167; Payr's Crushing Clamp (Gastric) 1167; Desjardin's Choledocholithotomy Forceps 1167; Bake's Dilator 1167; Sinus Forceps (Lister's) 1168; Scissors 1168; Volkmann's Scoop 1168; Tracheostomy Tube 1168; Drains 1168; Foley's Catheter 1170; Malecot's Catheter 1170; Simple Red Rubber Catheter 1170; Lister's Urethral Dilator 1170; Ryle's Tube 1170; Infant Feeding Tube 1171; Kehr's 'T' Tube 1171; Proctoscope 1171; Flatus Tube 1171

### **C. Suture Materials 1172**

Classification I 1172; Classification II 1173; Classification III 1173; Classification IV 1173; Classification V 1173

### **D. Diathermy (Electrocautery) 1174**

Types 1174

### **E. Operative Procedure 1175**

Abdominal Incisions 1175; Vasectomy 1176; Circumcision 1176; Hydrocele 1177; Inguinal Hernia 1177; Appendicectomy 1178; Thyroidectomy 1178; Tracheostomy 1179; Cryosurgery 1180; Lasers in Surgery 1180; Staplers in Surgery 1181; Nasojejunal Tube Feeding 1182; Gossypiboma 1182

#### **F. Laparoscopic Surgery 1183**

Advantages of Laparoscopic Surgery 1183; Laparoscopic Cholecystectomy 1184; Laparoscopic Appendicectomy 1185; Advanced Laparoscopic Surgeries 1185; Diagnostic Laparoscopy 1185; Retroperitoneoscopy 1186

Natural Orifice Transluminal Endoscopic Surgery (Notes) 1186

#### **G. Dressings and Bandages 1187**

Dressings 1187; Bandages 1187

#### **H. Day Care Surgery 1189**

Day Care Surgery 1189; Surgical Audit 1190; Surgeon and Law 1191

### **33. Miscellaneous**

**1192**

#### **A. Fascinating Signs in Surgery 1192**

#### **B. Triads in Surgery 1201**

#### **C. Misnomers in Surgery 1202**

#### **D. Triangles in Surgery 1203**

#### **E. Drugs at a Glance 1204**

Antibacterials 1204; Sulfonamides 1204; Quinolones 1204; Penicillin 1204; Ampicillin/Amoxycillin/Talampicillin/Pivampicillin 1205; Methicillin 1205; Cloxacillin/Dicloxacillin/Flucloxacillin 1205; Carbenicillin/Ticarcillin 1205; Piperacillin/Azocillin/Mezlocillin 1205; Clavulanic Acid 1205; Sulbactam 1205; Tazobactam 1205; Carbapenem/Imipenem/Meropenem 1205; Lincomycin/Clindamycin 1205; Vancomycin/Teicoplanin 1205; Cephalosporins 1206; Macrolides 1206; Aminoglycosides 1206; Tetracyclines 1206; Chloramphenicol/Thiamphenicol 1207; Drugs for Tuberculosis 1207; Antiamoebic Drugs 1207; Important Anthelmintics 1208; Anticoagulants 1208; Other Drugs 1209

#### *Further Reading*

*1211*

#### *Appendix*

*1213*

#### *Index*

*1217*

# Chapter 1

## General Surgery

### A. Wounds and Wound Healing

*One having a wound in his eyebrow. An ailment which I will treat. Treatment [of a wound in the eyebrow]: Now after thou hast stitched it, [thou shouldst bind] fresh meat upon [it] the first day. If thou findest that the stitching of this wound is loose, thou shouldst draw it together for him with two strips (of plaster), and thou shouldst treat it with grease and honey every day until he recovers.*

—[Anonymous], circa 2500 BC

#### CHAPTER OUTLINE

- ❖ Wounds
- ❖ Classification of Wounds
- ❖ Wound Healing
- ❖ Compartment Syndrome
- ❖ Crush Injury
- ❖ Crush Syndrome
- ❖ Degloving Injuries
- ❖ Keloid
- ❖ Hypertrophic Scar
- ❖ Problems with Wound Healing

#### ■ WOUNDS

##### Wound Definition

A wound is a break in the integrity of the skin or tissues often, which may be associated with disruption of the *structure and function*.

*Wound is simply a disruption of any tissues—soft tissue or bone or internal organs. Ulcer is disruption or break in the continuity of any lining—may be skin, mucous membrane or others. Ulcer is one of the types of wounds.*

#### ■ CLASSIFICATION OF WOUNDS

##### I. Rank and Wakefield classification

###### a. Tidy wounds

- ▶ They are wounds like surgical incisions and wounds caused by sharp objects.
- ▶ It is incised, clean, healthy wound without any tissue loss.
- ▶ Usually primary suturing is done. Healing is by primary intention.

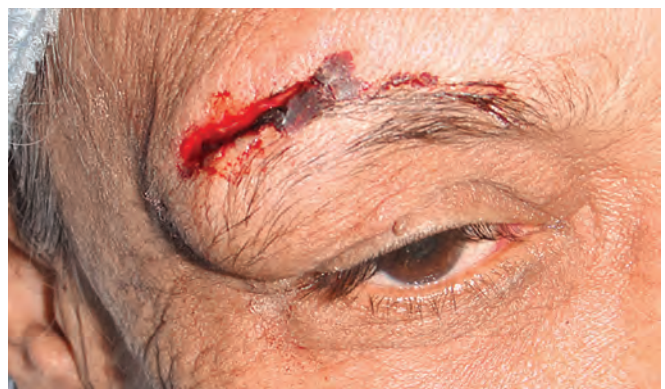

Fig. 1.1A: Tidy wound

### b. Untidy wounds

- ▶ They are due to:
    - Crushing.
    - Tearing.
    - Avulsion.
    - Devitalised injury.
    - Vascular injury.
    - Multiple irregular wounds.
    - Burns.
  - ▶ Fracture of the underlying bone may be present.
- Wound dehiscence, infection, delayed healing are common.
- ▶ Liberal excision of devitalised tissue and allowing to heal by secondary intention is the management.
  - ▶ Secondary suturing, skin graft or flap may be needed.

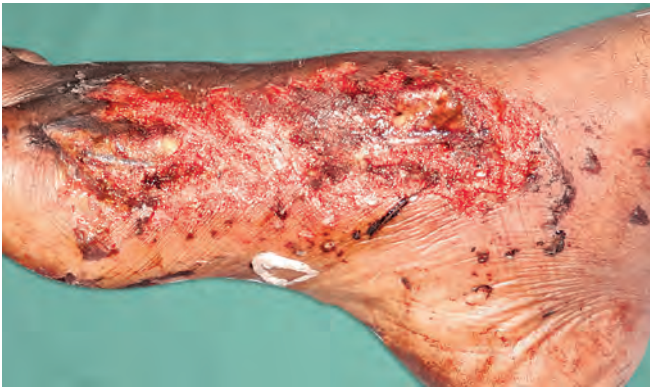

Fig. 1.1B: Untidy wound

## II. Classification based on the type of the wound

**Clean incised wound:** It is a tidy, simple, clean cut wound with linear cut edges; usually due to a sharp object like blade, glass piece or knife. It is treated by primary suturing.

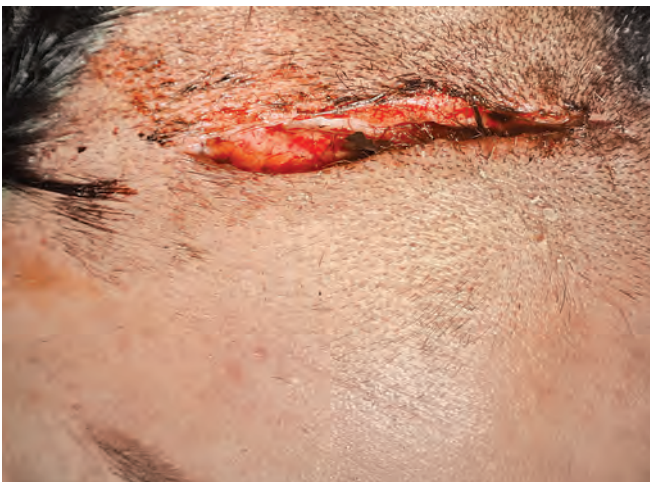
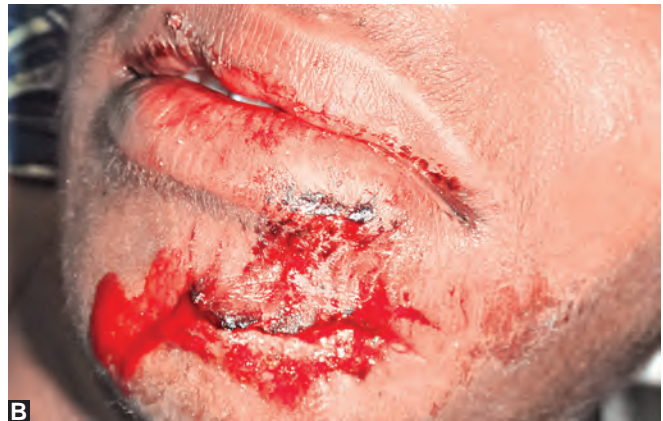
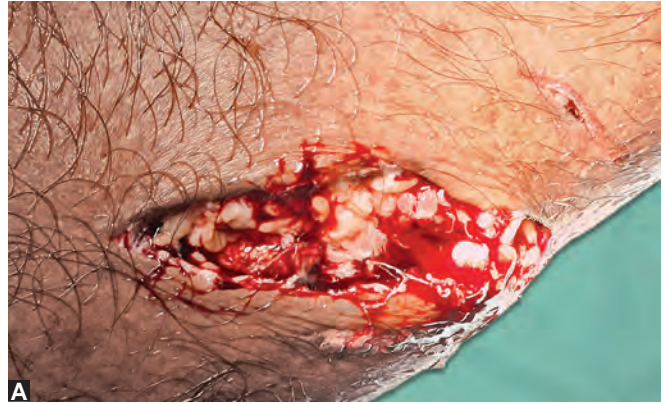Fig. 1.2: Clean incised wound.

**Lacerated wound:** It has ragged edges with some part of the tissues getting devitalized; viability of the tissues may be impaired; depth of the injury and tissue damage should be carefully assessed. Proper adequate wound excision, thorough warm saline wash and suturing of the wound layer-by-layer is required.



Figs 1.3A and B: Lacerated wounds.

**Bruise or contusion:** It is due to blow or blunt force to the skin and tissues underneath wherein blood vessels or capillaries are damaged underneath. There is skin discoloration without breaking of the skin; broken vessels cause seepage of blood underneath; minor soft tissue injury crushes small vessels without breaking the skin accumulating trapped blood underneath. It is more on the skin over the bones; lax area like face, scrotum, eyes; vascular areas; children, old aged, fair skin people.

**Haematoma:** It is a localized collection of blood after blunt trauma or after surgery. Collected fluid blood in few minutes to hours gets clotted; later eventually it gets liquefied and shows discoloured fluid. It may be subcutaneous/intramuscular/subfascial/intra-articular. Large haematoma may get infected to form an abscess; so large haematoma needs drainage under general or regional anaesthesia. Small haematoma usually gets absorbed (like scalp haematoma). Often haematoma contains reddish plasmatic fluid which should be aspirated using wide bore needle. *Complications are*—pressure effects and abscess formation; both needs incision and drainage under anaesthesia. Haematoma causing cosmetic problems may require needle aspiration. Haematoma can occur spontaneously in coagulation disorders (haemophilia) or in individuals who are on anticoagulant drug therapy.

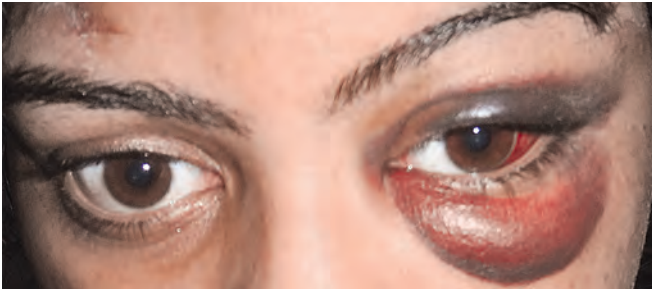

Fig. 1.4: Haematoma of eyelid.

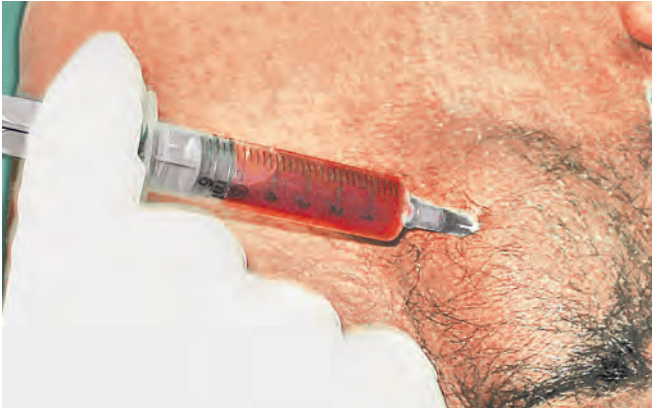

Fig. 1.5: Haematoma in the groin being aspirated. Haematoma may get infected or can compress adjacent structures.

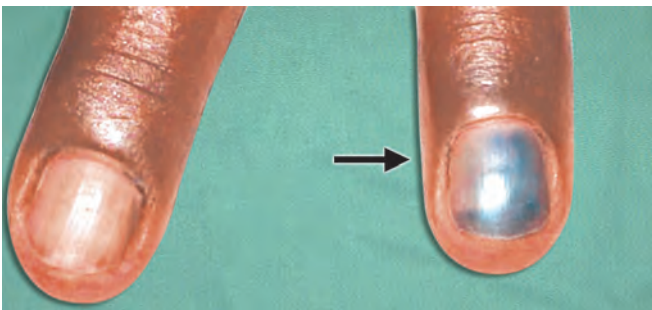


Fig. 1.6: Subungual haematoma. Often nail may need to be removed to evacuate the blood clot.

**Abrasion:** It is superficial injury (scratch/graze/pressure/contact) and is due to shearing of the skin where the surface is rubbed off. This tangential force causes loss of epidermis exposing dermal vessels and nerves leading into profuse painful oozing. Abrasion heals by epithelialisation. Any dirt or foreign body on the abrasion should be removed to avoid formation of poor tattoo like scar.

**Puncture wounds and bites:** It is usually a stab wound with a pointed object; here depth of the wound is more than the width. Deeper vital structures or organs may be injured, so should be assessed; foreign body or object may be present in the depth of the wound. Wound should be explored under general or regional anaesthesia to assess the depth and severity of the injury and sutured layer by layer after through saline wash.

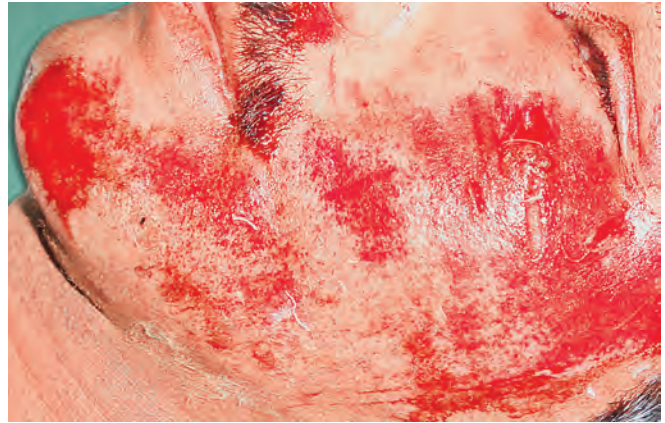

Fig. 1.7: Typical look of abrasion in face.

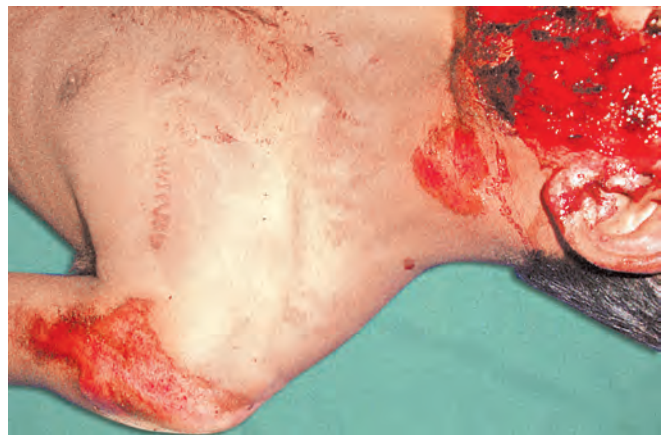

Fig. 1.8: Multiple abrasions.

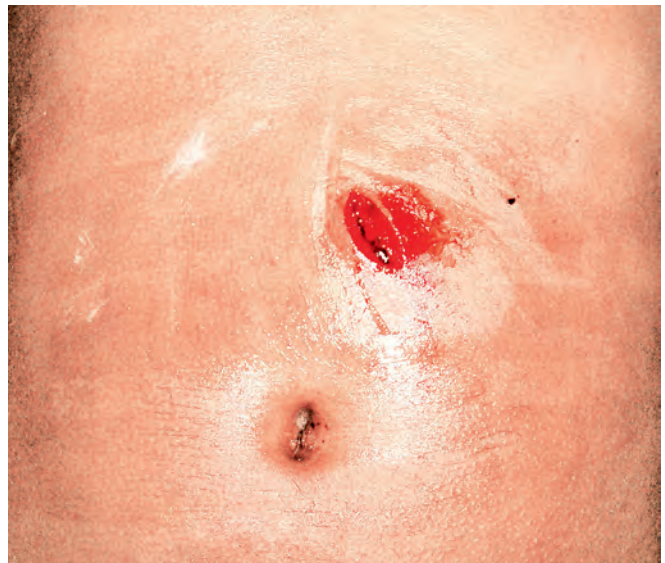


Fig. 1.9: Penetrating wound of the abdomen.

**Penetrating wounds:** They are similar like puncture wounds; due to stab. Abdomen and chest are common sites. Liver, bowel, spleen, major vessels and other visceral organs may be

involved. Ultrasound and CT scan should be done to evaluate deeper organ injuries. Under general anaesthesia wound should be explored properly.

**Traction and avulsion injuries:** These are complex injuries with tissues getting displaced from its normal anatomical position and alignment. It can occur in single plane like in subcutaneous tissue or in multiple planes like in machinery injuries, major injuries or degloving injuries. Ischaemia, bleeding, sepsis, loss of wide tissue area are common problems. Open traction injury occurs on the surface. Closed traction injury can occur in deeper plane like brachial plexus injury or traction bowel injury. After initial resuscitation, definitive treatment like skin graft or nerve repair should be done.

**Crush injury:** It is due to major wounds, war wounds, natural disaster like earth quake injuries, tourniquet injury. It leads into—*compartment syndrome; muscle ischaemia*; loss of tissues; gangrene; sepsis. Muscle will lose its viability which is identified by its *colour* (dark coloured with loss of shining); loss of contractility; turgid, and will not bleed on cutting.

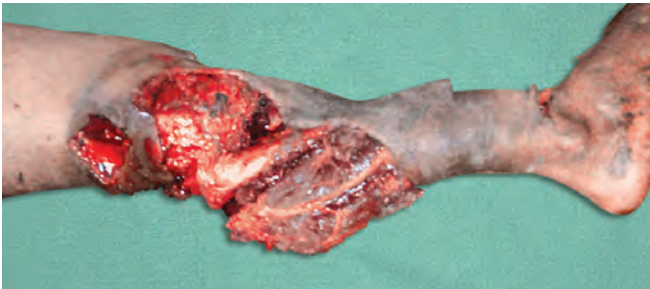

Fig. 1.10: Severe crush injury leg.

**Gunshot injuries:** These injuries may be superficial or deep. Usually entry wound and exit wound will be present. It causes explosive and destructive injuries along with burn injuries in the deeper planes and organs. It can be high velocity injuries with massive bleeding and major organ injuries.

**Injuries to bones and joints:** It is common in all major injuries; should be identified clinically and confirmed radiologically. It needs specialized management like reduction, plating etc.

**Injuries to nerves, arteries, veins (major vessels), deeper organs:** It needs initial resuscitation, later staged management as per individual patient basis depending on the severity and extent of injury and loss of function.

**Closed blunt injury:** It may be due to fall, blunt injury wherein no obvious external injury may be seen but deeper injury occurs; it may be often severe enough to cause major injury like in blunt abdominal injury causing bowel/liver/spleen/renal injuries.

**Note:**

Wound may be *closed* (bruise, haematoma, blunt injury); *open* (abrasion, incised, lacerated, penetrating) or complex (traction/avulsion, crush or gunshot injuries).

### III. Classification based on thickness of the wound

- ◆ **Superficial wound** involving only epidermis and dermal papillae.
- ◆ **Partial thickness** wound with skin loss up to deep dermis with only deepest part of the dermis, hair follicle shafts and sweat glands are left behind.
- ◆ **Full thickness** wound with loss of entire skin and subcutaneous tissue causing spacing out of the skin edges.
- ◆ **Deep wounds** are the one extending deeper, across deep fascia into muscles or deeper structures.
- ◆ **Complicated wounds** are one associated with injury to vessels or nerves.
- ◆ **Penetrating wound** is one which penetrates into either natural cavities or organs.

### IV. Classification based on involvement of structures

- ◆ **Simple wounds** are one involving only one organ or tissue.
- ◆ **Combined/complex wounds** are one involving mixed tissues.

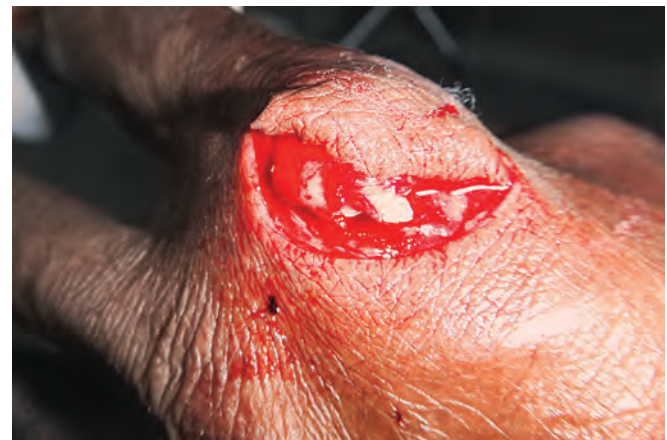

Fig. 1.11: Complex wound exposed tendons.

### V. Classification based on the time elapsed

**Acute wounds** are generally defined as those that progress through the normal phases of healing and typically show signs of healing in less than 4 weeks; examples are—surgical or traumatic or burn wounds; progress through the healing phases in a timely and orderly fashion - haemostasis, inflammation, proliferation, and remodeling or maturation.

**Chronic wounds** are defined as those that do not follow the normal healing process and show no signs of healing in 4 weeks. It fails to progress through the normal phases of healing but with prolonged inflammatory phase. Diabetes, venous/arterial diseases, nutritional deficiencies are the causes. Hypoxia initially is a potent stimulus for fibroblast activity and angiogenesis; persisting hypoxia impedes fibroblast and collagen activity and also allows bacterial invasion to make wounds chronic. Chronic wounds are chronically infected with biofilms which interfere mainly with the inflammatory phase of healing, contributing to the non-healing. A biofilm is a complex structure of microorganisms contained in an extracellular matrix of proteins and polysaccharides that adhere to a surface, creating a protected environment for the organisms. Chronic ulcers are unresponsive to dressing treatment; it requires biopsy, culture study, definitive treatment like wound debridement, VAC (Vacuum Assisted Closure) therapy, skin grafting or flap. Specific conditions like tuberculosis if present should be treated. Malignancy if confirmed is treated by wide local excision and skin graft.

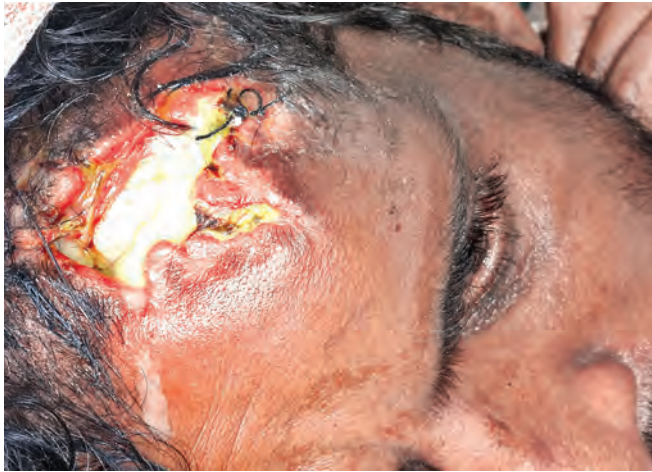

Fig. 1.12: Chronic wounds over the scalp

**VI. Classification of surgical wounds**

**a. Clean wound**

- ▶ Herniorrhaphy.
- ▶ Excisions.
- ▶ Surgeries of the brain, joints, heart, transplant.
- ▶ Infective rate is less than 2%.

**b. Clean contaminated wound**

- ▶ Appendicectomy.
- ▶ Bowel surgeries, gastrojejunostomy.
- ▶ Gallbladder, biliary and pancreatic surgeries.
- ▶ Infective rate is 10%.

**c. Contaminated wound**

- ▶ Acute abdominal conditions.
- ▶ Open fresh accidental wounds.
- ▶ Infective rate is 15–30%.

**d. Dirty infected wound**

- ▶ Abscess drainage.
- ▶ Pyocele.
- ▶ Empyema gallbladder.
- ▶ Faecal peritonitis.
- ▶ Infective rate is 40–70%.

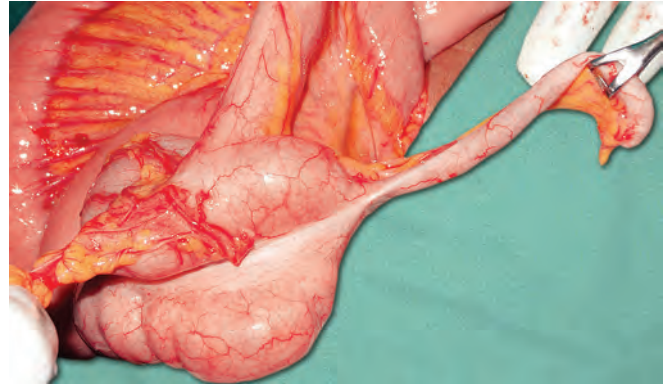


Fig. 1.14: Appendicectomy wound, which is a clean contaminated wound.

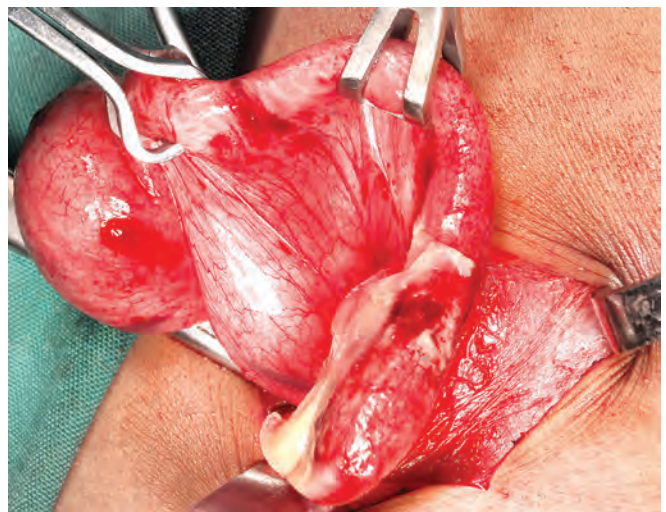


Fig. 1.15: Contaminated wound—burst appendicitis.

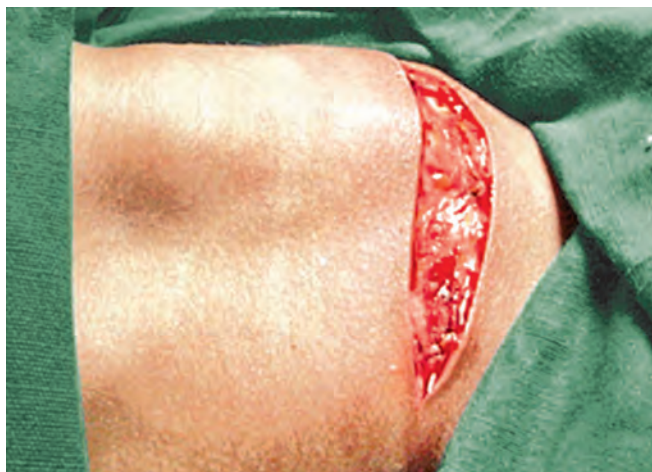

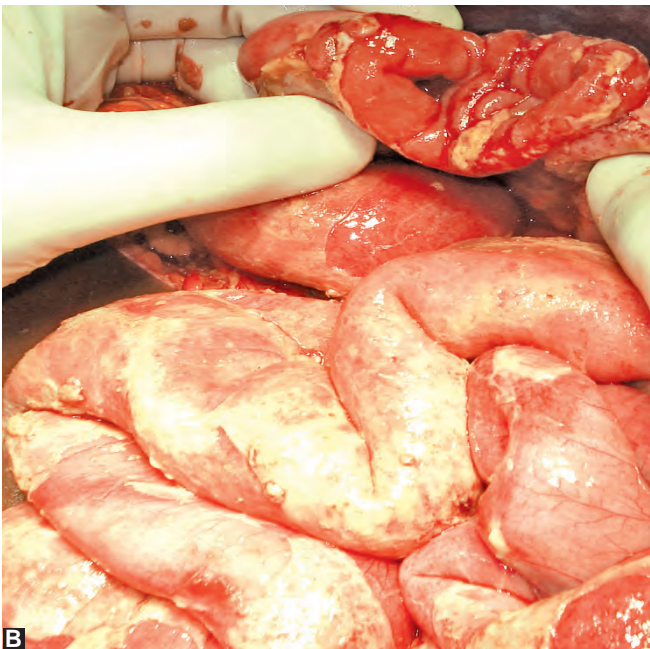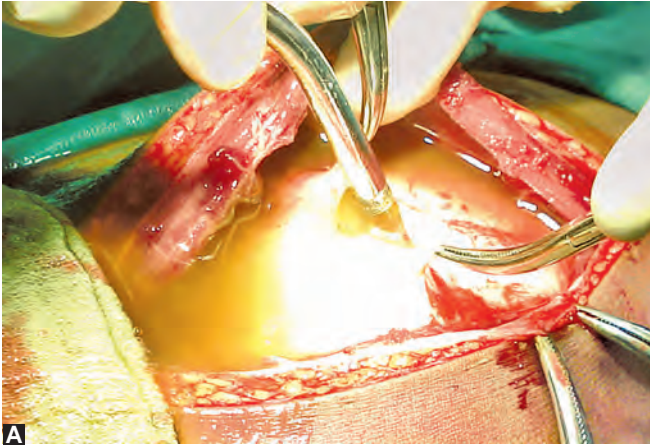
Fig. 1.13: Clean wound of thyroidectomy surgery.

**Wound classifications**

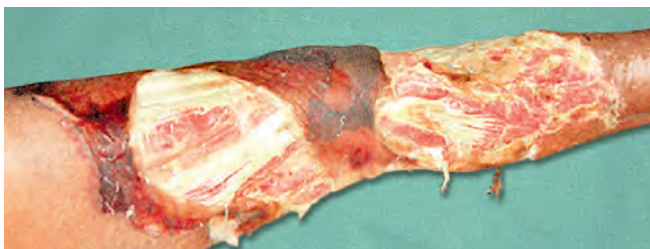• <i>Simple wounds:</i> Only skin is involved	• Tidy wounds
• <i>Complex wounds:</i> Vessels, nerves, tendons or bones are involved	• Untidy wounds
• <i>Closed wounds:</i>	• Clean wound.
– Contusion	• Clean contaminated wound
– Abrasion	• Contaminated wound
– Haematoma	• Dirty wound
• <i>Open wounds:</i>	
– Incised wounds	
– Lacerated wounds	
– Crush injuries	
– Penetrating wounds	

*Start by doing what's necessary, then do what's possible and suddenly you are doing the impossible.*





**Figs 1.16A and B:** Acute peritonitis with frank pus in peritoneal cavity due to bowel perforation is a *dirty wound*.



**Fig. 1.17:** Wound causing extensive skin loss and necrosis.

## WOUND HEALING

*A scab is a beautiful thing—a coin the body has minted, with an invisible motto: In God We Trust. Our body loves us, and, even while the spirit drifts dreaming, works at mending the damage that we do.*

—John Updike, 1984

*Wound healing* is complex method to achieve anatomical and functional integrity of disrupted tissue by various components like neutrophils, macrophages, lymphocytes, fibroblasts, collagen; in an organised staged pathways—haemostasis → inflammation → proliferation → matrix synthesis (collagen and proteoglycan ground substance) → maturation → remodelling → epithelialisation → wound contraction (by myofibroblasts).

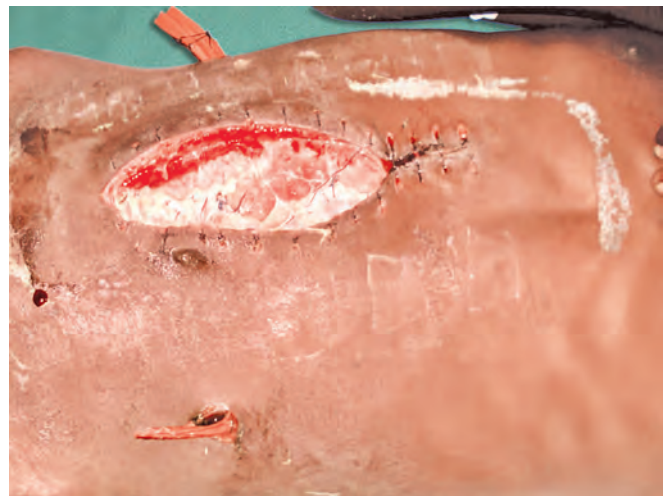### Types of Wound Healing

#### Primary Healing (First Intention)

- ◆ It occurs in a clean incised wound or surgical wound. Wound edges are approximated with sutures. There is more epithelial regeneration than fibrosis. Wound heals rapidly with complete closure. Scar will be linear, smooth, and supple.

#### Secondary Healing (Second Intention)

- ◆ It occurs in a wound with extensive soft tissue loss like in major trauma, burns and wound with sepsis. It heals slowly with fibrosis. It leads into a wide scar, often hypertrophied and contracted. It may lead into disability.
- ◆ Re-epithelialisation occurs from remaining dermal elements or wound margins.



**Fig. 1.18:** Wound in the abdomen healing with second intention which requires secondary suturing once it granulates well. Secondary suturing is done after 10–14 days, once wound granulates well with proper control of infection. Scar in such type is prone to form incisional hernia.

#### Healing by Third Intention (Tertiary Wound Healing or Delayed Primary Closure)

After wound debridement and control of local infection, wound is closed with sutures or covered using skin graft. Primary contaminated or mixed tissue wounds heal by tertiary intention.

### Stages of wound healing

- ❖ Stage of inflammation.
- ❖ Stage of granulation tissue formation and organisation. Here due to fibroblastic activity synthesis of collagen and ground substance occurs.
- ❖ Stage of epithelialisation.
- ❖ Stage of scar formation and resorption.
- ❖ Stage of maturation.

## Phases of Wound Healing

### Inflammatory Phase (Lag or Substrate or Exudative Phase)

- ◆ It begins immediately after formation and lasts for 72 hours.
- ◆ There is initial arteriolar vasoconstriction, thrombus formation, platelet aggregation due to endothelial damage and release of adenosine diphosphate (ADP).
- ◆ Later vasodilatation and increased vascular permeability develops.
- ◆ Here *haemostasis, coagulation and chemotaxis* occur.

#### Note:

Coagulation begins at wound haematoma → formation of platelet fibrin thrombus → release of cytokines, PDGF (platelet-derived growth factor), epidermal growth factor (EGF), transforming growth factor  $\beta$  (TGF- $\beta$ ), platelet activating factor and platelet factor IV, fibrin, serotonin. Chemotaxis causes first neutrophil migration, and then activation of macrophages, lymphocytes leading into phagocytosis, wound debridement, matrix activation, angiogenesis. Chemotaxis factors are complement factors, interleukin-1, TNF- $\alpha$  (tumour necrosis factor- $\alpha$ ) TGF- $\beta$  and platelet factor. Activated macrophages produce free radicals and nitric oxide; release cytokine to activate lymphocytes which release interferon and interleukin (called as lymphokines). These factors attract polymorpho nuclear leucocytes (PMN—poly morphonuclear cells—neutrophils) in 48 hours secreting inflammatory mediators and bactericidal oxygen derived-free radicals. Injured tissues and platelet release histamine, serotonin and prostaglandins which increases the vascular permeability by vasodilatation. These actions are reduced in diabetes mellitus, Cushing's syndrome and immunosuppression increasing the sepsis rate.

- ◆ All these cause *features of acute inflammation*—*rubor, calor, tumour, dolor* and loss of function.

### Proliferative Phase (Collagen/Fibroblastic Phase)

- ◆ It begins from 3rd day and lasts for 3–6 weeks. There will be *formation of granulation tissue and repair* of the wound. Granulation tissue contains fibroblasts, neocapillaries, collagen, fibronectin and hyaluronic acid.
- ◆ (1) *Initial angiogenesis* (growth of new blood vessels) occurs by release of vascular endothelial cell growth factor (VEGF) by keratinocytes; by release of TNF- $\alpha$ , TGF- $\beta$ , PDGF, FGF by macrophages. (2) *Eventual fibroplasia* develops by fibroblast activity with formation of the collagen and ground substance/glycosaminoglycans. Type III collagen is deposited initially in a random fashion. (3) *Later re-epithelialisation* of the wound surface occurs by migration of basal layer of the retained epidermis which proliferates, differentiates and stratifies to form wound closure.

### Remodelling Phase (Maturation Phase)

- ◆ It begins at 6 weeks and lasts for 6 months to 1 or 2 years.
- ◆ There is maturation of collagen by cross linking and realignment of collagen fibers along the line of tension, which is responsible for tensile strength of the scar. There is reduced wound vascularity. Fibroblast and myofibroblast activity causes wound contraction. Type III collagen is replaced by type I collagen causing maturation of the collagen. Ratio of type I collagen to type III collagen becomes 4:1.
- ◆ *Early extracellular matrix* contains fibronectin and collagen type III; eventually it contains glycosaminoglycans and proteoglycans; *final matrix* contains type I collagen.
- ◆ Scar strength is 3% in 1 week; 20% in 3 weeks; 80% in 12 weeks. Final matured scar is acellular and avascular.

#### Note:

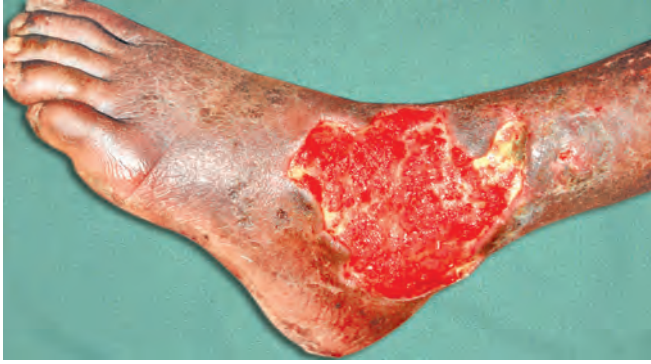Initially fibrin, fibronectin, proteoglycans deposition occurs; later collagen protein develops to form scar. Normal dermal skin contains 80% type I (20% type III) collagen; granulation tissue contains mainly type III collagen; scar contains both type I and III collagen, initially in equal proportion, later becomes 4:1. Basic essential components of collagen are proline and lysine. Hydroxylation of lysine and later glycosylation of this hydroxylysine decides the type of collagen molecule. Hydroxylation of both proline and lysine as essential step needs adequate concentration of vitamin C, iron and  $\alpha$  ketoglutaric acid. Collagen deposition in the wound is assessed by quantity of hydroxyproline excreted in urine. There is a balanced activity of collagen production and degradation of collagen (collagenolysis). Collagen is broken down by collagenase and MMPs (matrix metalloproteinases). Procollagen through procollagenase → collagen fibril → cross linking → collagen fiber → deposition. Deposited collagen → through collagenase → degradation and collagenolysis.

### Points to be remembered

- ❖ PMN cells survive only for 24 hours; so after 48 hours PMNs won't be found in the wound significantly; PMNs are not needed for wound healing.
- ❖ Activated monocytes called macrophages predominate after 48 hours which will persist until completion of the wound healing. Macrophages are the main cells of wound healing. Macrophages secrete TNF- $\alpha$ , interleukin-1, fibroblast growth factor (FGF), proteinases (MMPs – matrix metallo proteinases).
- ❖ B lymphocyte will not have any role in wound healing; T lymphocytes produce stimulatory cytokines like interleukin-1 supporting the fibroblast activity.
- ❖ Collagen and glycosamines are produced by fibroblasts. Tropocollagen is produced which aggregates to form collagen fibrils.
- ❖ Hydroxyproline and hydroxylysine are synthesized by specific enzymes using iron,  $\alpha$  ketoglutarate and vitamin C.
- ❖ Fibroblast requires vitamin C to produce collagen.
- ❖ Granulation tissue and early scar contains type III collagen.
- ❖ Final scar contains type I collagen mainly.
- ❖ Final extra cellular matrix contains type I collagen and proteoglycans.
- ❖ Collagen production decreases after 4 weeks of wound healing (declines in 28-42 days).
- ❖ Eighty per cent of tensile strength of normal skin will be achieved finally but not 100%

*Clinical diagnosis is an art, and the mastery of an art has no end: you can always be a better diagnostician*

—Logan Clending



**Fig. 1.19:** Healing ulcer with healthy granulation tissue which is ready for skin grafting.

### Factors affecting Wound Healing

**Age:** In younger age group wound healing is faster and better. In elderly healing is delayed due to reduction in collagen synthesis, epithelialisation, growth factors and angiogenesis. But final scar will be excellent in old individuals.

**Nutrition:** Adequate vitamin, trace elements, fatty acids and proteins are essential for wound healing. *Vitamin A* deficiency affects monocyte activation, inflammatory phase, collagen synthesis and growth factor actions. *Vitamin K* deficiency affects synthesis of prothrombin (II), factors VII, IX and X. *Vitamin E*, being an antioxidant stabilizes the cell membrane. *Vitamin C* deficiency impairs collagen synthesis, fibroblast proliferation and angiogenesis; increases the capillary fragility and susceptibility for infection. *Zinc* is an essential cofactor for RNA and DNA polymerase; *magnesium* is a co-factor for synthesis of proteins and collagen; *copper* is a required co-factor for cytochrome oxidase, for cytosolic anti-oxidant superoxide dismutase, and for the optimal cross-linking of collagen; *Iron* is required for the hydroxylation of proline and lysine. *Glutamine* is the most abundant amino acid in plasma; is a major source of energy for rapidly proliferating cells such as fibroblasts, lymphocytes, epithelial cells, and macrophages. The serum concentration of glutamine is reduced after major surgery, trauma, and sepsis, and supplementation of this amino acid improves nitrogen balance and diminishes immunosuppression. Glutamine stimulates the inflammatory immune response in early wound healing. Oral glutamine supplementation improves wound breaking strength and of mature collagen. *Arginine* is a semi-essential amino acid that is required in growth, severe stress, and injury. Arginine modulates immune function, wound healing, hormone secretion, vascular tone, and endothelial function. Arginine is a precursor to proline; supports collagen deposition, angiogenesis, and wound contraction. Under psychological stress situations, the metabolic demand of arginine increases, and its supplementation hastens the wound healing. *Serum albumin* level less than 2 g/dl causes prolonged inflammatory phase, decreased fibroplasia, neovascularisation and cell synthesis and wound remodeling and hence decreased wound healing. Wounds in patients who remain in catabolic state will not heal. *Collagen* is the major protein component of connective tissue; it contains mainly glycine, proline, and hydroxyproline. Collagen synthesis requires hydroxylation of lysine and proline, and co-factors such as ferrous iron and vitamin C. *Polyunsaturated fatty acids* which cannot be synthesized *de novo* by mammals, consist mainly of omega-6 (found in soybean oil) and omega-3 (found in fish oil—fatty acids such as eicosapentaenoic acid [EPA] and docosahexaenoic acid [DHA]). They affect pro-inflammatory cytokine production, cell metabolism, gene expression and angiogenesis; improve the systemic immune function of the host, thus reducing infectious complications.

**Wound infection:** Infection prolongs inflammatory phase, releases toxins and utilizes vital nutrients thereby prevents wound epithelialisation. The  $\beta$ -haemolytic streptococci more than  $10^5$  per gram of tissue prevent wounds healing. Formation of biofilms on the wound surface by microorganisms prevents wound healing.

**Anaemia:** Haemoglobin less than 8g % causes poor oxygenation of tissues preventing healing of the wounds.

**Hypoxia:** Hypoxia prevents fibroblast proliferation and collagen synthesis; it also promotes bacterial invasion into the wound. Causes of hypoxia are—arterial diseases, cardiac failure, respiratory causes, hypotension, smoking, tobacco, infection, diabetes mellitus and radiation.

**Radiotherapy:** Both external radiotherapy or ionizing radiation cause endarteritis, fibrosis and delay in wound healing. Radiation may itself cause local tissue necrosis, sepsis and hypoxia.

**Systemic and metabolic causes:** Diabetes mellitus affects all stages of wound healing. Cardiac, renal, hepatic, respiratory diseases prevent wound healing. Tissue oedema impairs wound healing. HIV and immunosuppression of varying causes, malignancy leads into poor wound healing. Jaundice interferes with wound healing. Obesity causes hypoperfusion, reduced microcirculation, increased wound tension and hence prevents wound healing.

**Drugs:** Steroids interfere with activation of macrophages, fibroblasts and angiogenesis in the early phase of healing (proliferative). Non-steroidal anti-inflammatory drugs (NSAIDs) decrease collagen production. Chemotherapeutic agents used in oncology inhibit cellular proliferation, protein synthesis. Alcohol consumption decreases the phagocyte response and pro-inflammatory cytokine release; diminishes host response and thus increasing the infection rate.

#### Local factors

- ❖ Infection
- ❖ Presence of necrotic tissue and foreign body
- ❖ Poor blood supply
- ❖ Venous or lymph stasis
- ❖ Tissue tension
- ❖ Haematoma
- ❖ Large defect or poor apposition
- ❖ Recurrent trauma
- ❖ X-ray irradiated area
- ❖ Site of wound, e.g. wound over the joints and back has poor healing
- ❖ Underlying diseases like osteomyelitis and malignancy
- ❖ Mechanism and type of wound—incised/lacerated/crush/avulsion
- ❖ Tissue hypoxia locally reduces macrophage and fibroblast activity

#### General Factors

- ❖ Age, obesity, smoking, alcohol, stress
- ❖ Malnutrition, zinc, copper, manganese
- ❖ Vitamin deficiency (Vit C, Vit A)
- ❖ Anaemia, hypoxia
- ❖ Malignancy
- ❖ Uraemia
- ❖ Jaundice
- ❖ Diabetes, metabolic diseases
- ❖ HIV and immunosuppressive diseases
- ❖ Steroids and cytotoxic drugs
- ❖ Neuropathies of different causes

## Management of Wounds

### Wound Cleaning

Wound cleaning is needed to optimize the healing environment. It is achieved by removing visible devitalized tissues or dressing materials or excess exudates or crusts.

Absolute aseptic technique should be used while cleaning the wound; warm sterile isotonic normal saline (37°C—this is optimum temperature to support cellular activity) is ideal; normal exudates in the wound should be removed; gentle cleaning of the wound is important to minimize the interference of the wound-healing process. Cleaning agent should be of neutral pH and nontoxic; delipidising agents, antiseptics, alkaline soaps should be avoided. Gentle irrigation of warm saline using a sterile syringe on the wound surface is ideal; rubbing with undue force using cotton or gauze may cause mechanical damage on the process of wound healing.

*Wound is measured* either in two dimensions (length and width) or in three dimensions (length, width and depth).

### Specific Management

- ◆ Wound is inspected and classified as per the type of wounds.
- ◆ If it is in the vital area, then:
  - ▶ The airway should be maintained.
  - ▶ The bleeding, if present, should be controlled.
  - ▶ Intravenous fluids are started.
  - ▶ Oxygen, if required, may be given.
  - ▶ Deeper communicating injuries and fractures, etc. should be looked for.
- ◆ If it is an incised wound then *primary suturing* is done after thorough cleaning.
- ◆ If it is a lacerated wound then the *wound is excised* and primary suturing is done.
- ◆ If it is a crushed or devitalised wound there will be oedema and tension in the wound. So after wound debridement or wound excision by excising all devitalised tissue, the oedema is allowed to subside for 2–6 days. Then *delayed primary suturing* is done.
- ◆ If it is a deep devitalised wound, after wound debridement it is allowed to granulate completely. Later, if the wound is small *secondary suturing* is done. If the wound is large a split skin graft (Thiersch graft) is used to cover the defect.
- ◆ In a wound with tension, *fasciotomy* is done so as to prevent the development of compartment syndrome.
- ◆ Vascular or nerve injuries are dealt with accordingly. Vessels are sutured with 6-zero polypropylene nonabsorbable suture material. If the nerves are having clean cut wounds it can be sutured primarily with polypropylene 6-zero or 7-zero suture material. If there is difficulty in identifying the nerve ends or if there are crushed cut ends of nerves then marker stitches are placed using silk at the site and later secondary repair of the nerve is done.
- ◆ Internal injuries (intracranial by craniotomy, intrathoracic by intercostal tube drainage, intra-abdominal by laparotomy)

has to be dealt with accordingly. Fractured bone is also identified and properly dealt with.

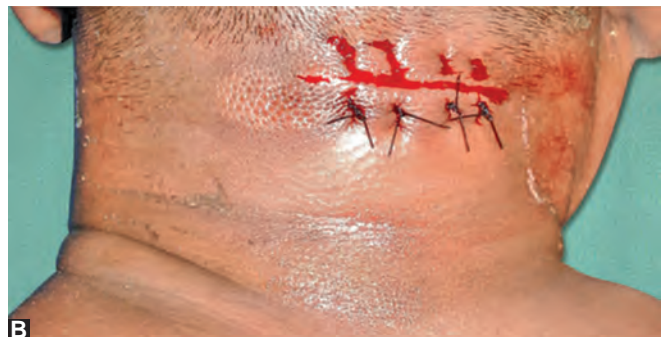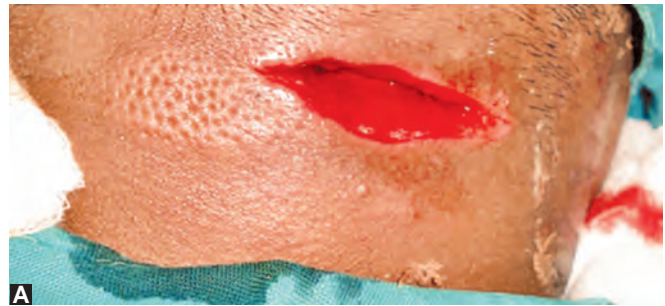
- ◆ Antibiotics, fluid and electrolyte balance, blood transfusion, tetanus toxoid (0.5 ml intramuscular to deltoid muscle), or antitetanus globulin (ATG) injection.

### Later definitive management is done with:

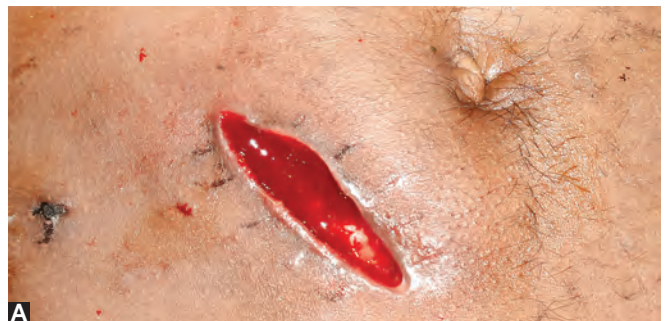*Wound debridement* (wound toilet, or wound excision) is liberal excision of all devitalised tissue at regular intervals (of 48-72 hours) until healthy, bleeding, vascular tidy wound is created.

#### Types of wound suturing

- ◆ *Primary suturing* means suturing the wound immediately within 6 hours. It is done in clean incised wounds.
- ◆ *Delayed primary suturing* means suturing the wound in 48 hours to 10 days. It is done in lacerated wounds. This time is allowed for the oedema to subside.
- ◆ *Secondary suturing* means suturing the wound in 10–14 days or later. It is done in infected wounds. After the control of infection, once healthy granulation tissue appears, secondary suturing is done.



**FIGS 1.20A and B:** Delayed primary suturing is done once oedema over the wound subsides. It is done as single layer interrupted deep sutures using monofilament polypropylene or polyethylene.



**Fig. 1.21A**

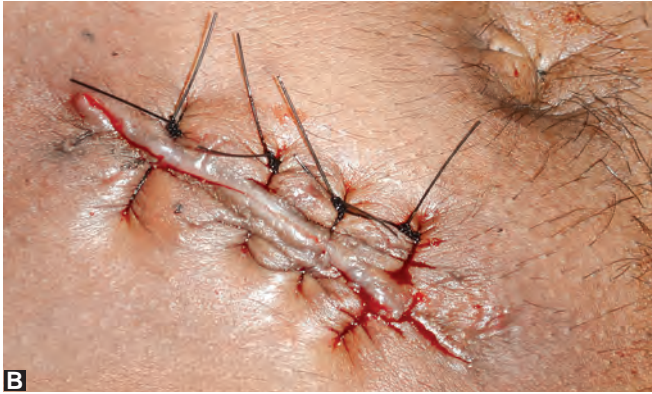

Fig. 1.21B

**Figs 1.21A and B:** Secondary suturing is done once wound is healthy after control of wound infection.

#### Principles of wound suturing

- ❖ Primary suturing should not be done if there is oedema/infection/devitalised tissues/haematoma
- ❖ Always associated injuries to deeper structures like vessels/nerves or tendons should be looked for before closure of the wound
- ❖ Wound should be widened by extending the incision whenever needed to have proper evaluation of the deeper structures—*proper exploration*
- ❖ Proper cleaning, asepsis, wound excision/debridement
- ❖ Any foreign body in the wound should be removed
- ❖ Skin closure if it is possible without tension
- ❖ Skin cover by graft/flap—immediate or delayed
- ❖ Untidy wound should be made tidy and clean before suturing
- ❖ Proper aseptic precautions should be undertaken
- ❖ Antibiotics/analgesics are needed
- ❖ Sutured wound should be inspected in 48 hours
- ❖ Sutures are removed after 7 days

#### Remember

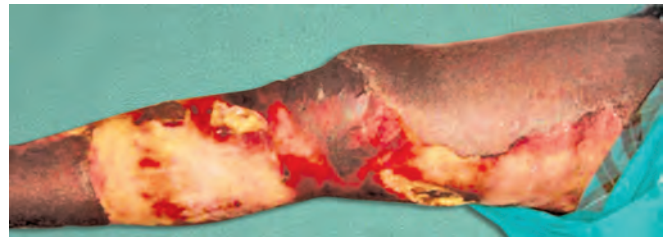- ❖ *Wound toilet* is washing the wound thoroughly using normal saline—ideal
- ❖ *Wound debridement* (french-letting loose) is allowing content to come out by release incisions or fasciotomies. But commonly debridement is used for wound excision
- ❖ *Wound excision* is actually correct terminology for excision of devitalised tissues once or serially
- ❖ *Radical wound excision* is (pseudotumour approach) is excising entire devitalised tissues leaving tissues with visible bleeding from all layers

## COMPARTMENT SYNDROME

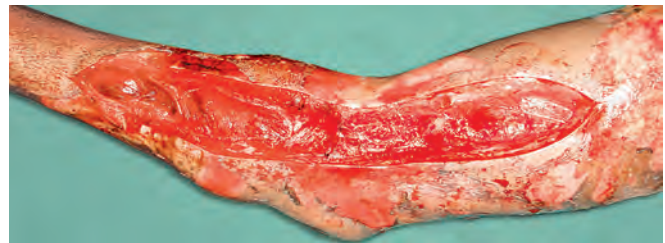
**Compartment syndrome** is a special entity; common in leg, forearm, thigh and arm; is a *syndrome* due to increased intra-compartmental pressure within a limited space area.

**Causes are**—Narrowed space due to tight dressings/plaster cast, lying on one limb in comatous patient; increased content within the compartment due to trauma like fractures, oedema, ischaemic injury, haematoma, positioning after trauma, burn injury, etc.; high pressure injection injuries like gun injury, oil based material injury, extravasation of chemotherapeutic drugs; snake bite.

**Features are**—It compromises circulation and function mainly of muscles and nerves. It often maintains the normal colour and temperature of the fingers and distal pulses may not be obliterated in spite of severe muscle ischaemia. Muscle ischaemia *more than 4 hours* causes muscle death and myoglobinuria. Irreversible nerve damage develops if ischaemia persists for 8 hours. Progressive, persistent severe pain which is aggravated by passive muscle stretching is the *diagnostic sign*. Tense tender regional lymph node is typical. Pulse will be usually normally felt in compartment syndrome; but may become absent if there is associated arterial injury. Compartment pressure more than 30 mmHg is an indication for *fasciotomy*.



**Fig. 1.22:** Necrotizing fasciitis with extensive skin involvement which requires adequate wound excision and eventual skin coverage.



**Fig. 1.23:** Fasciotomy for compartment syndrome should be longitudinal, deep and lengthy and should decompress the compartment to expose the underlying muscle. It should be done early.

It is common in calf and forearm. Closed injuries cause haematoma leading to increased pressure. It is often associated with fracture of the underlying bone which in turn compresses the major vessel further aggravating the ischaemia causing **pallor, pulselessness, pain, paraesthesia, diffuse swelling and cold limb**.

If allowed to progress it may eventually lead to **gangrene** or **chronic ischaemic contracture** with deformed, disabled limb.

#### Problems with the compartment syndrome

- ❖ Infection, septicaemia and abscess formation
- ❖ Renal failure
- ❖ Gangrene of the limb
- ❖ Chronic ischaemic contracture
- ❖ Disabled limb, Volkmann's ischaemic contracture

**Muscle necrosis** releases myoglobin which is excreted in the urine, damages the kidneys leading into renal failure.

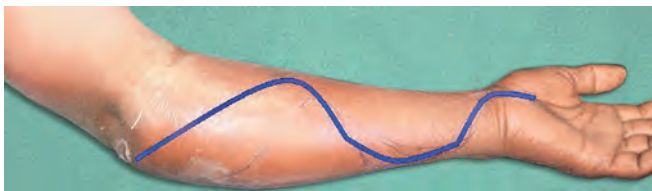#### Note:

Affected muscle when passively stretched worsens the pain—the most reliable clinical sign.

## Treatment

- ◆ Compartment pressure will be persistently more than 30 mm Hg. It can be measured by placing a fine catheter in the compartment and using a pressure monitor. This is an indication for *fasciotomy*. Adequate lengthy incision involving skin, fat and deep fascia should be done until underneath muscle bulges out properly. Multiple incisions should be made if needed. Separate incision in each compartment should be done.

**Fasciotomy** done in forearm anterior compartment is a specific method. Carpal tunnel *should be released by cutting flexor retinaculum*. Incision begins at the junction of the thenar and hypothenar area; extends proximally initially transverse across flexion crease of the wrist at the ulnar border; then across forearm towards radial side of forearm; then in proximal forearm towards medial side creating convex flap towards lateral side. In the elbow it crosses along the medial border to reach the arm where it runs in arm along the medial part of the anterior arm. Injury to major nerves, palmar cutaneous branch of median nerve should be avoided while placing the incision. Incision should be deepened by cutting the deep fascia along the entire length of the incision. *Dorsal fasciotomy* should be added by placing lengthy incision in the midline. Two longitudinal incisions on the dorsum of the hand also should be made.

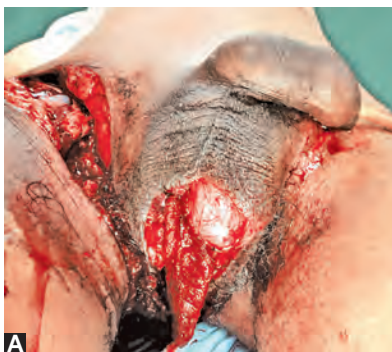

**Fig. 1.24:** Incision for fasciotomy in upper limb begins at flexor retinaculum extending into the forearm with a convex flap towards radial side eventually leading towards medial epicondyle of the elbow joint.

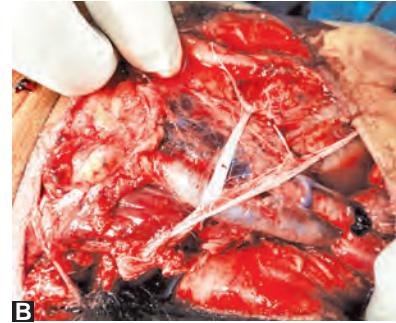- ◆ Antibiotics.
- ◆ Catheterisation.
- ◆ Mannitol or diuretics to cause diuresis, so as to flush the kidney.
- ◆ Fresh blood transfusion.
- ◆ Hyperbaric oxygen.

## CRUSH INJURY

Crush injury is one where a part of the body is being squeezed/compressed between two high force or pressure systems. It causes extensive lacerations, bruising, compartment syndrome, crush syndrome, fractures, haemorrhage, etc. with extensive tissue destruction and devitalisation. Renal failure, hypovolaemic shock and sepsis are the most dreaded problems in crush injuries.



**Fig. 1.25A**



**Fig. 1.25B**

**Figs 1.25A and B:** Traumatic crush injury pelvis exposing testis and iliac vessels. Patient underwent hemipelvectomy.

## CRUSH SYNDROME

It is due to crushing of muscles causing extravasation of blood and release of myohaemoglobin into the circulation leading to *acute tubular necrosis* and *acute renal failure*.

### Causes

- ◆ Earthquakes.
- ◆ Mining and industrial accidents.
- ◆ Air crash.
- ◆ Tourniquet.

Initially tension increases in the *muscle compartment* commonly in the limb, which itself impedes the circulation and increases the *ischaemic damage*. In 3 days, urine becomes discoloured and scanty, patient becomes restless, apathy and delirious with onset of *uraemia*. Crush syndrome is often life-threatening. *Injury* is much worse than initial look.

### Effects of crush syndrome

- ❖ Renal failure
- ❖ Toxaemia
- ❖ Septicaemia
- ❖ Disability with extensive tissue loss
- ❖ Gas gangrene

### Treatment

- ◆ Tension in the muscle compartment is relieved by placing *multiple parallel deep incisions* in the limb so as to prevent further damage—*Fasciotomy*.
- ◆ Rheomacrodex, or mannitol is given to improve the urine output by improving the renal function.
- ◆ Alkalisiation of urine is done by giving sodium citrate or sodium bicarbonate. It increases the solubility of acid haematin in the urine and so promotes its excretion. Urinary pH should be above 6.5 until urine does not show any myoglobin. Mannitol-alkaline diuresis should be 8 litre/day.
- ◆ Initial aggressive volume load using saline about 1-1.5 litres/hour is ideal in these patients.
- ◆ Haemodialysis is done sometimes as a life-saving procedure.

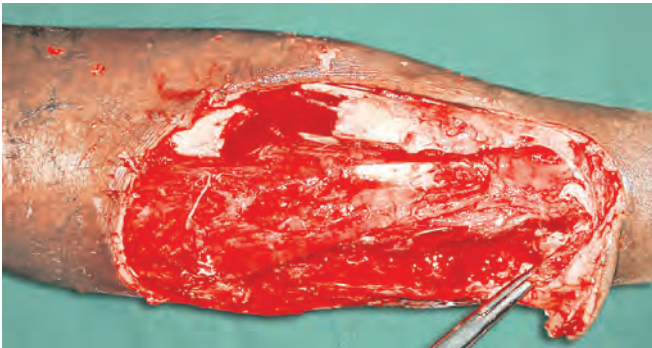
- ◆ Other measures:
  - ▶ Catheterization.
  - ▶ Oxygen therapy.
  - ▶ Antibiotics.
  - ▶ Blood transfusion.
  - ▶ Correction of severe hyperkalaemia.

**Note:**

Doing fasciotomy several days after crush injury may not be safe as it may lead to sudden release of myoglobin causing myoglobinuria and renal failure.

## ■ DEGLOVING INJURIES

- ◆ It occurs due to shearing force between tissue planes as traction—avulsion injury. It usually occurs between subcutaneous tissue and deep fascia or between muscle and bone. It can be localised or circumferential.
- ◆ Avulsion injury strips off the superficial tissues exposing the neurovascular bundle, muscles, tendons, and bone. Degloving injury can be open or closed.



**Fig. 1.26:** Degloving injury wherein skin often with soft tissues gets avulsed off the deeper plane to create extensive raw area which may bleed/get infected.

- ◆ It can be in one plane or multiple planes.
- ◆ It is commonly observed in machinery injuries or major road traffic accidents. It is much more extensive than of on initial presentation.
- ◆ Under anaesthesia fluorescein is injected intravenously and viable skin is visible as fluorescent yellowish—green colour under ultra-violet light. As injection of fluorescein is not fully safer, serial excision is better to look for dermal punctate bleeding.
- ◆ It needs examination under general anaesthesia, wound excision/ radical excision, flap coverage, microflap surgeries, skin grafting, with proper asepsis, and blood transfusion as there is significant blood loss in these injuries.

## ■ SCAR

Initially *immature scar* is formed during remodeling phase; this scar is disorganized contains type III collagen. Such scar is itchy, raised, hard and pink in colour. Over the span of 12 months scar gets matured fully by making disorganised collagen getting aligned along the stress lines and formation of more type I collagen. This matured scar is soft, supple, pale and flat without any itch. Hypertrophic scar and keloid persists to have more type III collagen than type I collagen unlike in matured scar.

### Types of scar

- ❖ A mature scar is paler, acellular, softer, flat, with reduced blood vessels and fibroblasts, without itching (diminishes).
- ❖ An atrophic scar is pale, flat and stretched.
- ❖ A hypertrophic scar is excess scar but will not extend beyond the margin of the scar of the original wound; there is prolonged inflammatory phase of wound healing. It develops in 1 to 3 months after trauma. It improves spontaneously.
- ❖ Keloid is persistent excessive growth of the scar beyond its margin into the adjacent skin; occurs in a triangular area between two shoulder points and xiphisternum. It develops 3 months to years after the trauma; progressive. Presternal area is the commonest site.

**Note:**

- ❖ A linear scar is supple, thin, soft occurs after healing by primary intention.
- ❖ A wide, irregular firm scar occurs after healing by secondary intention or when there is infection

## ■ KELOID: 'Like a claw'

- ◆ Keloid is common in blacks. Common in females.
- ◆ Genetically predisposed. Often familial. Very rare in Caucasians.
- ◆ There is defect in maturation and stabilization of collagen fibrils. Normal collagen bundles are absent.
- ◆ Keloid continues to grow even after 6 months, may be for many years. It extends into adjacent normal skin. It is brownish black/ pinkish black (due to vascularity) in colour, painful, tender and sometimes hyperaesthetic; spreads and causes itching.
- ◆ Keloid may be associated with Ehlers-Danlos syndrome or scleroderma.
- ◆ When keloid occurs following an unnoticed trauma without scar formation is called as *spontaneous keloid*, commonly seen in *Negroes*.
- ◆ Some keloids occasionally become non-progressive after initial growth.
- ◆ *Pathologically* keloid contains proliferating immature fibroblasts, proliferating immature blood vessels and type III thick collagen stroma.

**Site:** Common over the sternum. Other sites are upper arm, chest wall, lower neck in front.

**Differential diagnosis:** Hypertrophic scar.

**Treatment:** Controversial.

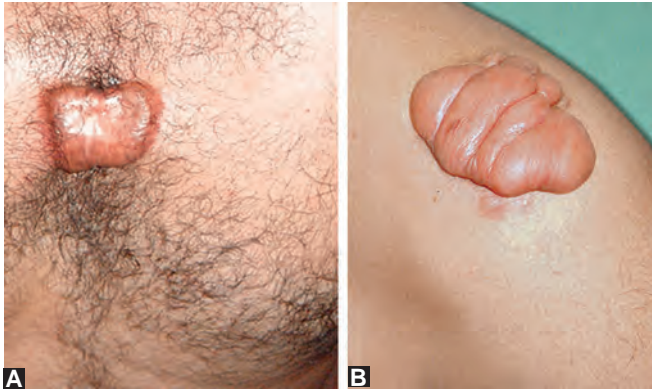
- ◆ Steroid injection—*intrakeloidal triamcinolone*, is injected at regular intervals, may be once in 7–10 days, of 6–8 injections.
- ◆ Steroid injection—excision—steroid injection.
- ◆ Triamcinolone reduces the fibroblast proliferation and collagen synthesis; *it is the first line of therapy* for keloid
- ◆ Methotrexate and vitamin A therapy into the keloid.
- ◆ *Silicone gel sheeting*; topical retinoids.
- ◆ Laser therapy.
- ◆ Vitamin E/palm oil massage.
- ◆ *Intralesional excision* retaining the scar margin may prevent recurrence. *It is ideal and better than just excision.*

- ◆ Excision and irradiation or irradiation alone.
- ◆ Excision and skin grafting may be done.

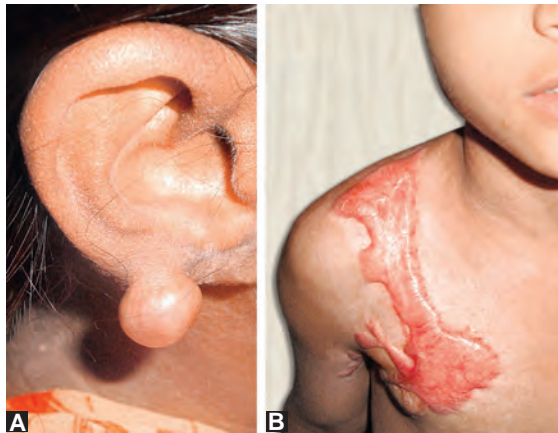
**Note:**

Excision and primary suturing has got high recurrence rate; hence it is not usually practiced.

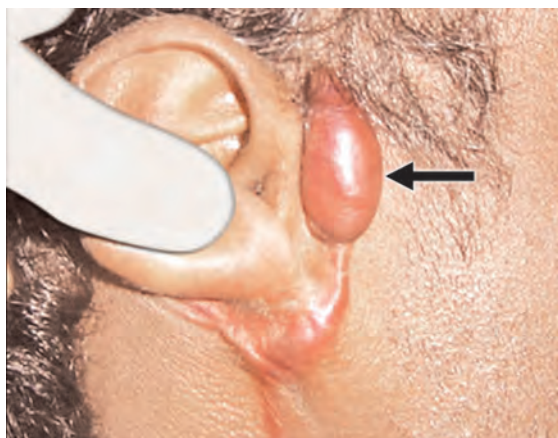Recurrence rate is very high—more than 50%.



**Figs 1.27A and B:** Keloid over the sternum (butterfly shaped; commonest site) and upper part of the arm near shoulder—common sites of occurrence.



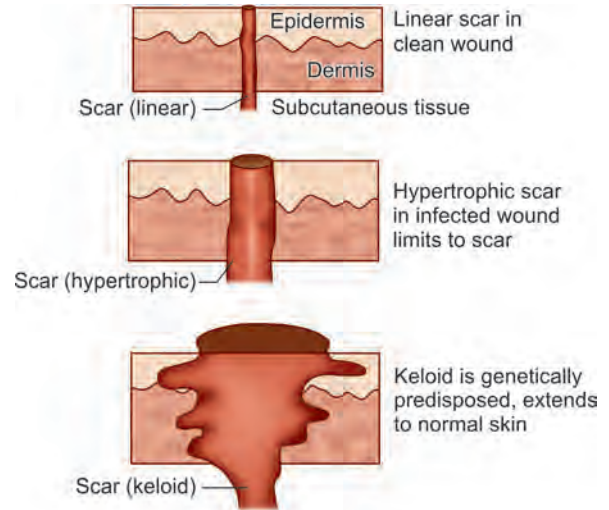
**Figs 1.28A and B:** Keloid in the ear lobule and chest wall near shoulder.



**Fig. 1.29:** Keloid in the upper part of the scar. It is the previous parotidectomy scar.

**■ HYPERTROPHIC SCAR**

- ◆ Occurs anywhere in the body.
- ◆ Not genetically predisposed. Not familial.
- ◆ Growth usually limits up to 6 months.
- ◆ It is limited to the scar tissue only. It will not extend to normal skin.
- ◆ Spontaneous improvement with time occurs commonly.



**Fig. 1.30:** Diagrammatic representation of linear, hypertrophic and keloid scar.

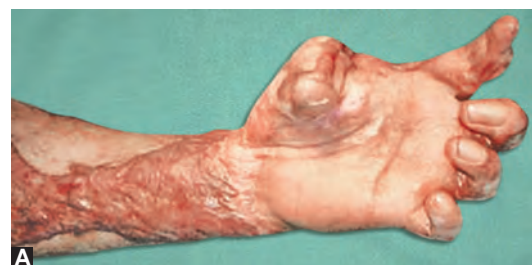- ◆ It is pale brown in colour, not painful, nontender.
- ◆ Often self-limiting also. It responds very well for steroid injection.
- ◆ Recurrence is uncommon.
- ◆ It is common in wounds crossing tension lines, deep dermal burns, wounds healed by secondary intention.

**Complications**

- ◆ Often this scar breaks repeatedly and causes infection, pain.
- ◆ After repeated breakdown it may turn into *Marjolin's ulcer*.

**Treatment**

- ◆ It is controlled by *pressure garments* or often revision excision of scar and closure, if required with skin graft.
- ◆ Triamcinolone injection is the 2nd line of therapy for hypertrophic scar.



**Fig. 1.31A**

*It is not how much we have, but how we enjoy, that makes us happy.*



## Differences between keloid and hypertrophic scar

		<b>Keloid</b>	<b>Hypertrophic scar</b>
a.	Genetic predisposition	Yes	No
b.	Site of occurrence	Chest wall, upper arm, lower neck, ear	Anywhere in the body, common in flexor surfaces
c.	Growth	Continues to grow without time limit	Growth limits for 6 months
		Extends to normal skin	Limited to scar tissue only
d.	Treatment	Poor response	Good response to steroids
e.	Recurrence	Very high	Is uncommon
f.	Collagen synthesis	20 times more than normal skin (Type III thick)	3-6 times more than normal skin (Type III fine collagen)
g.	Relation of size of injury and lesion	No relation. Small healed scar can form large keloid	Related to size of injury and duration of healing
h.	Age	Adolescents, middle age	Children
i.	Sex	Common in females	Equal in both
j.	Race	More in blacks (15 times)	No racial relation
k.	Structure	Thick collagen with increased epidermal hyaluronic acid	Fine collagen with increased alpha actin
l.	Features	Vascular, tender, itching	Not vascular, nontender, no itching
m.	Natural history	Progressive	Shows regression
n.	Problems	Hyperaesthesia, ulceration	Not much

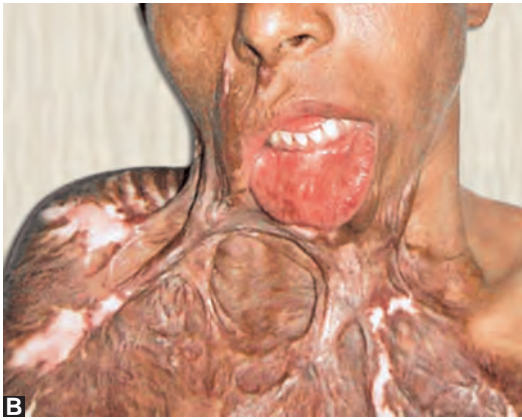
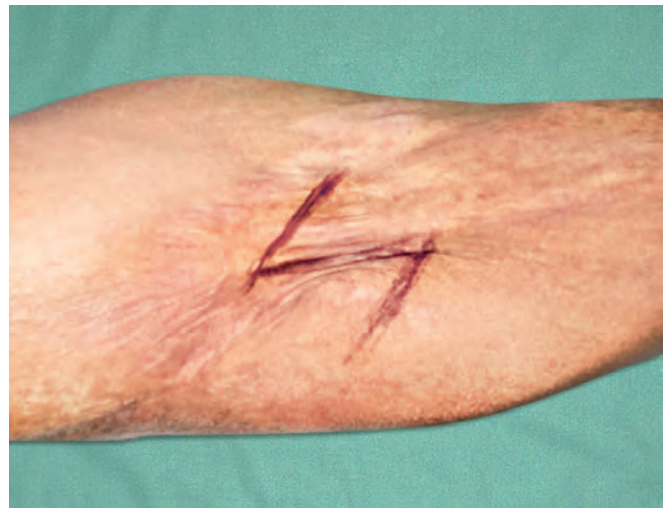
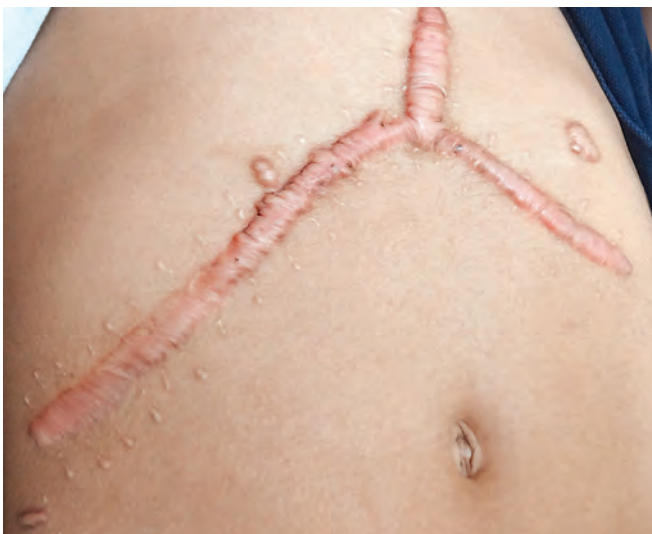Fig. 1.31B

**Figs 1.31A and B:** Different contractures in hypertrophic scars over forearm, finger and neck.



**Fig. 1.33:** 'Z' plasty is very useful method to release small contractures.



**Fig. 1.32:** Hypertrophied scar in the abdominal healed wound

## PROBLEMS WITH WOUND HEALING

- ◆ *Wound infection* is common in devitalized deep difficult wounds. Diabetes, immunosuppression, cytotoxic drugs, anaemia, malnutrition, malignancy increases the chances of wound infection.
- ◆ *Wound dehiscence* is common in all above said adverse factors. Wound suddenly gives away with pain causing copious serosanguineous discharge. After laparotomy when done specially as an emergency in trauma, acute abdomen and also in malignancy, abdominal closed wound may burst in 5–7 days. Usually all layers of abdomen give away causing discharge, occasionally bowel will extrude out. It needs emergency closure of the abdominal wound using specialized sutures or retention sutures.
- ◆ *Hypertrophic scar* or keloid formation due to altered collagen synthesis in the wound healing process. Collagen synthesis is increased 3–6 times in hypertrophic scar and 20 times in keloid.
- ◆ Deeper wound will cause *specified problems* like paraesthesia, ischaemia, paralysis, etc.

## B. Ulcer

### CHAPTER OUTLINE

- ❖ Ulcer
- ❖ Granulation Tissue
- ❖ Investigations for an Ulcer
- ❖ Traumatic Ulcer
- ❖ Trophic Ulcer
- ❖ Ulcer due to Chilblains
- ❖ Ulcer due to Frostbite
- ❖ Martorell's Ulcer
- ❖ Arterial/Ischaemic Ulcer
- ❖ Bairnsdale Ulcer
- ❖ Carcinomatous Ulcer
- ❖ Marjolin's Ulcer
- ❖ Rodent Ulcer
- ❖ Melanotic Ulcer
- ❖ Diabetic Ulcer
- ❖ Meleney's Ulcer
- ❖ Lupus Vulgaris
- ❖ Tuberculous Ulcer
- ❖ Bazin's Disease
- ❖ Tropical Ulcer
- ❖ Venous Ulcer
- ❖ Syphilitic Ulcer
- ❖ Soft Chancre/Soft Sore/Ducrey's Ulcer/Chancroid/Bubo
- ❖ Climatic Bubo/Tropical Bubo

### ■ ULCER

#### Definition

An ulcer is a break in the continuity of the covering epithelium, either skin or mucous membrane due to molecular death.

#### Parts of an Ulcer

- a. **Margin:** It may be regular or irregular. It may be rounded or oval.
- b. **Edge:** Edge is the one which connects floor of the ulcer to the margin. *Different edges are:*
  - Sloping edge.** It is seen in a healing ulcer.
    - Its inner part is *red* because of red, healthy granulation tissue.
    - Its outer part is *white* due to scar/fibrous tissue.
    - Its middle part is *blue* due to epithelial proliferation.
  - Undermined edge** is seen in a tuberculous ulcer. Disease process advances in deeper plane (in subcutaneous tissue) whereas (skin) epidermis proliferates inwards.
  - Punched out edge** is seen in a gummatous (syphilitic) ulcer and trophic ulcer. It is due to endarteritis.
  - Raised and beaded edge** (pearly white) is seen in a rodent ulcer (BCC). Beads are due to proliferating active cells.
  - Everted edge (rolled out edge):** It is seen in a carcinomatous ulcer due to spill of the proliferating malignant tissues over the normal skin.
- c. **Floor:** It is the one which is seen. Floor may contain discharge, granulation tissue or slough.
- d. **Base:** Base is the one on which ulcer rests. It may be bone or soft tissue.

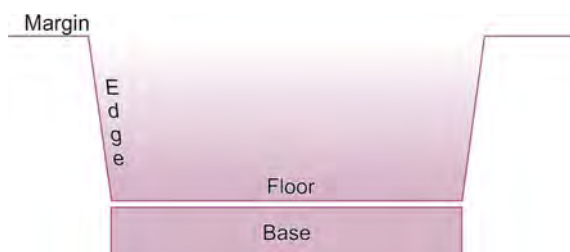


Fig. 1.34: Parts of an ulcer.

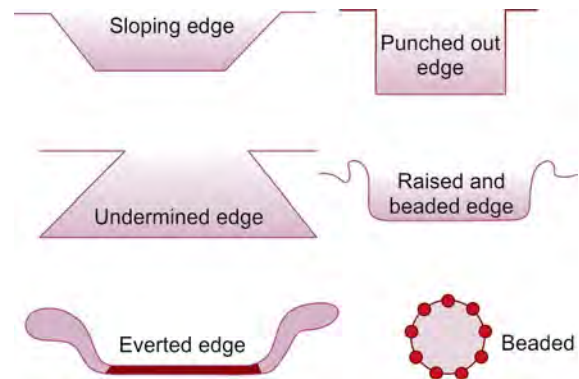


Fig. 1.35: Ulcer edges.

#### Induration of an Ulcer

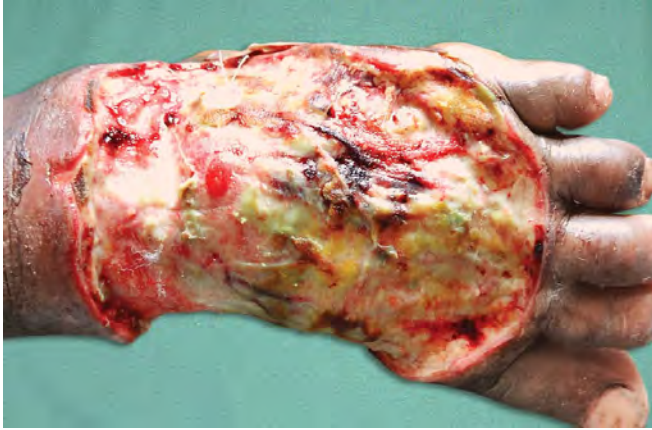**Induration** is a clinical palpatory sign which means a specific type of hardness in the diseased tissue. It is obvious in well-differentiated carcinomas. It is better felt in squamous cell carcinoma. It is also observed in long standing ulcer with underlying fibrosis. It is absent or less in poorly differentiated carcinomas and malignant melanoma. Less indurated carcinoma is more aggressive. Specific types of indurations are observed in venous diseases and chronic deep venous thrombosis. Brawny induration is a feature of an abscess. Induration is felt at edge, base and surrounding area of an ulcer. Induration at surrounding area signifies the extent of disease (tumour). Outermost part of the indurated area is taken as the point from where clearance of wide excision is planned.

#### Classifications

##### Classification I (Clinical)

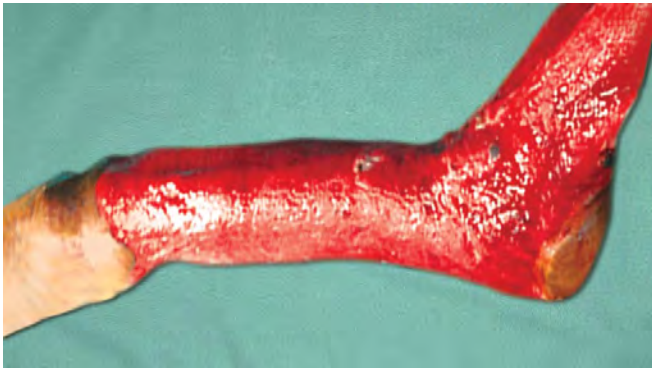1. **Spreading ulcer:** Here edge is inflamed, irregular and oedematous. It is an *acute* painful ulcer; floor does not contain healthy granulation tissue (or granulation tissue is absent) but with profuse purulent discharge and slough; surrounding area is red and edematous. Regional (draining)

lymph nodes are enlarged and tender due to inflammation. There will be associated fever, pain, impairment of functions with local tissue destruction and with little evidence of regeneration.



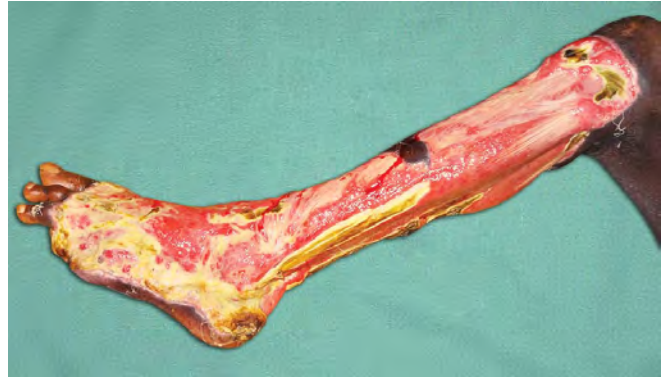**Fig. 1.36:** Spreading ulcer copious purulent discharge with slough.

2. *Healing ulcer:* Edge is sloping with healthy pink/red healthy granulation tissue with scanty/minimal serous discharge in the floor; slough is absent; regional lymph nodes may or may not be enlarged but when enlarged always non-tender. Surrounding area does not show any signs of inflammation or induration; base is not indurated. *Three zones* are observed in healing ulcer. *Innermost red zone* of healthy granulation tissue; *middle bluish zone* of growing epithelium; *outer whitish zone* of fibrosis and scar formation.



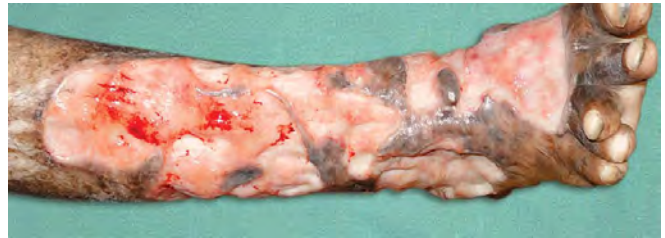**Fig. 1.37:** Healing ulcer with healthy granulation tissue in the floor.

3. *Non-healing ulcer:* It may be a *chronic* ulcer depending on the cause of the ulcer; here edge will be depending on the cause—punched out (trophic), undermined (tuberculous), rolled out (carcinomatous ulcer), beaded (rodent ulcer); floor contains unhealthy granulation tissue and slough, and serosanguineous/purulent/bloody discharge; regional draining lymph nodes may be enlarged but non-tender.



**Fig. 1.38:** Non-healing ulcer with pale unhealthy granulation tissue with slough.

4. *Callous (stationary) ulcer:* It is also a *chronic non-healing ulcer*; floor contains pale unhealthy, flabby, whitish yellow granulation tissue and thin scanty serous discharge or often with copious serosanguinous discharge, with indurated nontender edge; base is indurated, nontender and often fixed. *Ulcer does not show any tendency to heal.* It lasts for many months to years. Tissue destruction is more with absence of or only minimal regeneration. Induration and pigmentation may be seen in the surrounding area. There is no/less discharge. Regional lymph nodes may be enlarged; are firm/hard and nontender. It is callousness towards healing; word callous means—insensitive and cruel; and also it means—hard skinned.



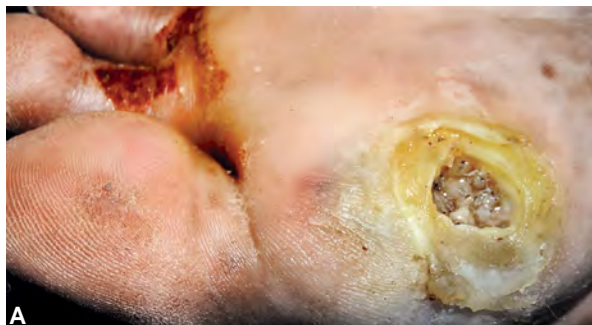**Fig. 1.39:** Callous ulcer without any sign of healing and, without any granulation tissue.

#### Classification II (Based on Duration)

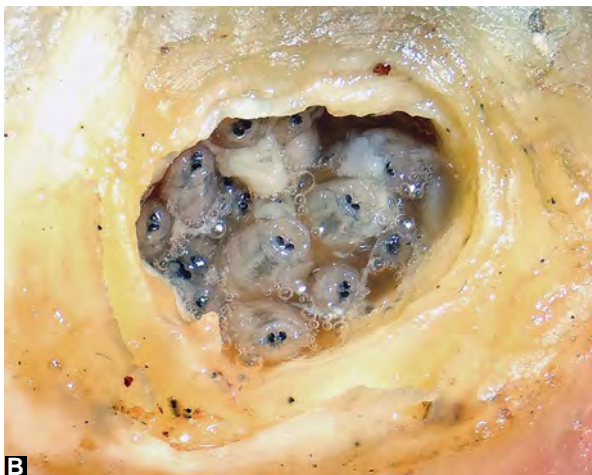1. Acute ulcer—duration is less than 2 weeks.
2. Chronic ulcer—duration is more than 2 weeks (long).

#### Classification III (Pathological)

1. *Specific ulcers:*
  - ▶ Tuberculous ulcer.
  - ▶ Syphilitic ulcer: It is punched out, deep, with “wash-leather” slough in the floor and with indurated base.
  - ▶ Actinomycosis.
  - ▶ Meleney’s ulcer.

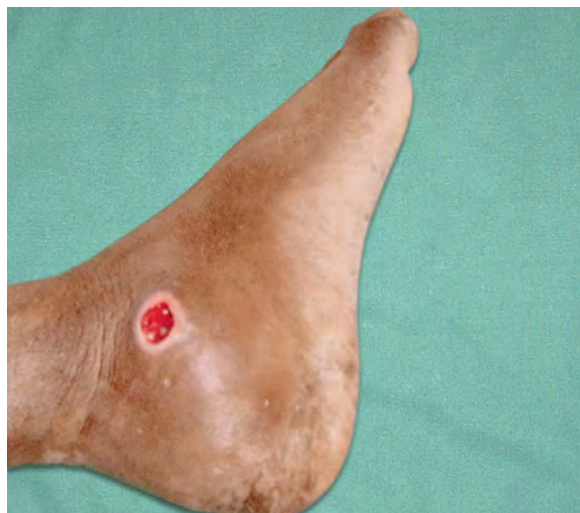

A



B

**Figs 1.40A and B:** Maggots seen in a chronic ulcer



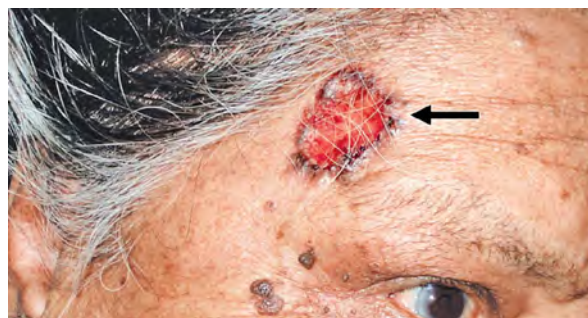**Fig. 1.41:** Tuberculous ulcer ankle area. Note the undermined edge. Discharge study, biopsy and later antituberculous drugs are the treatment. They are usually painless.

## 2. Malignant ulcers:

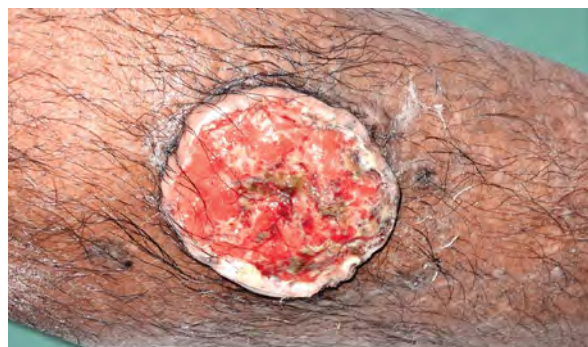- ▶ Carcinomatous ulcer
- ▶ Rodent ulcer.
- ▶ Melanotic ulcer.

## 3. Non-specific ulcers:

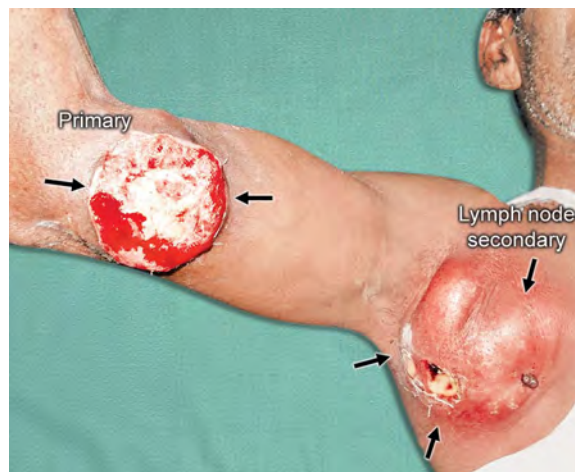
- ▶ *Traumatic ulcer:* It may be mechanical, physical, chemical—common.
- ▶ *Arterial ulcer:* Atherosclerosis, TAO



**Fig. 1.42:** Basal cell carcinoma of face (rodent ulcer). Ulcer edge is raised and beaded in appearance.



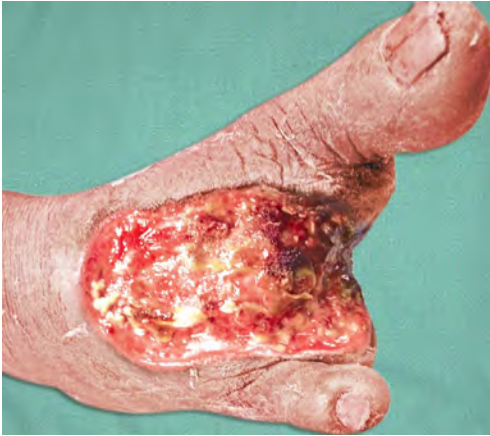**Fig. 1.43:** Squamous cell carcinoma (SCC/epithelioma) leg with typical everted edge. SCC can be ulcerative, ulceroproliferative or proliferative ulcer on clinical look.



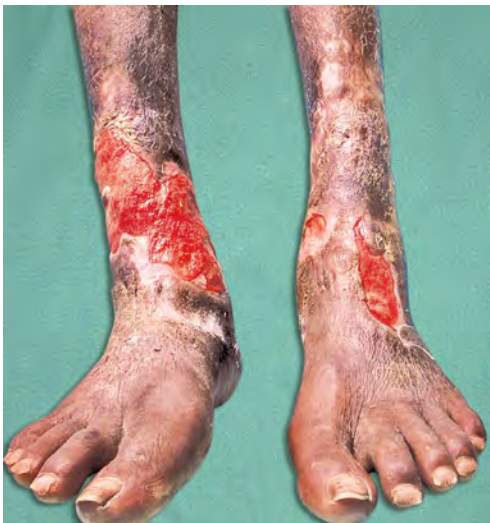**Fig. 1.44:** Squamous cell carcinoma in the arm with secondaries in the axillary lymph node. Friable tumour tissues in the floor cause bleeding after trauma. Secondaries are fixed with ulceration. It is advanced disease.

- ▶ *Venous ulcer:* Gravitational ulcer, post-phlebotic ulcer.
- ▶ *Trophic ulcer/Pressure sore.*
- ▶ *Infective ulcers:* Pyogenic ulcer.
- ▶ *Tropical ulcers:* It occurs in tropical countries. It is callous type of ulcer, e.g. Vincent's ulcer.
- ▶ *Ulcers due to chilblains and frostbite (cryopathic ulcer).*
- ▶ *Martorell's hypertensive ulcer.*

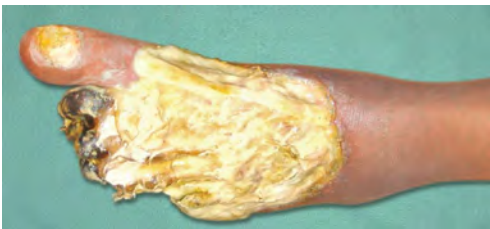- ▶ *Bazin's ulcer.*
- ▶ *Diabetic ulcer.*
- ▶ *Ulcers* due to leucaemia, polycythemia, jaundice, collagen diseases, lymphoedema.
- ▶ *Cortisol ulcers* are due to long-time application of cortisol (steroid) creams to certain skin diseases. These ulcers are callous ulcers last for long time and require excision and skin grafting.



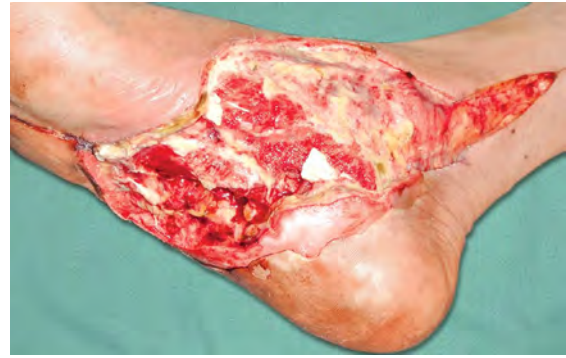**Fig. 1.45:** Ischaemic ulcer foot. Middle three toes are already amputated because of gangrene.



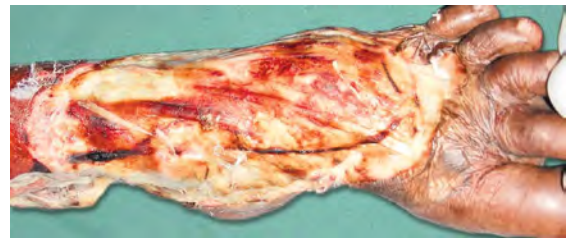**Fig. 1.46:** Venous ulcers in both feet. Site is around ankle (Gaiter's zone). There are healthy granulation tissues. It needs skin grafting and definitive procedure for varicose veins after evaluation.



**Fig. 1.47:** Infective ulcer in the foot. Note the quantity of slough, exposed tendon and gangrenous toes. Patient requires below or above knee amputation.



**Fig. 1.48:** Large ulcer in the foot and leg with exposed tendon.



**Fig. 1.49:** Nonhealing ulcer foot in a diabetic patient with *Pseudomonas* infection. Note the greenish discharge in the wound. *Pseudomonas* infection is commonly hospital acquired.

### Wagner's Grading/Classification of Ulcer

- Grade 0 – Preulcerative lesion/healed ulcer
- Grade 1 – Superficial ulcer
- Grade 2 – Ulcer deeper to subcutaneous tissue exposing soft tissues or bone
- Grade 3 – Abscess formation underneath/osteomyelitis
- Grade 4 – Gangrene of part of the tissues/limb/foot
- Grade 5 – Gangrene of entire one area/foot

#### Stages of ulcer healing

1. *Stage of extension:* Ulcer floor is covered with slough, purulent discharge and inflamed edge and margin.
2. *Stage of transition:* Floor shows separated slough; healthy granulation tissue; serous discharge.
3. *Stage of repair:* Fibrosis, collagen deposition, scar formation occurs.

### ■ GRANULATION TISSUE

It is proliferation of new capillaries and fibroblasts intermingled with red blood cells and white blood cells with thin fibrin cover over it.

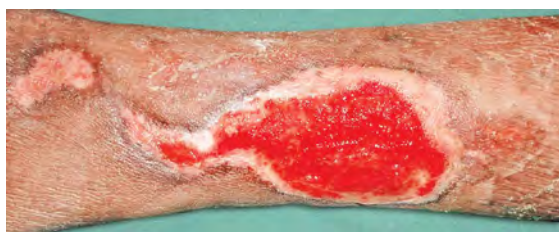
#### Types

- ◆ *Healthy granulation tissue:* It occurs in a healing ulcer. It has got sloping edge. It bleeds on touch. It has got serous discharge. 5 Ps of granulation tissue—*Pink, Punctate haemorrhages, Pulseful,*

*Painless, Pin head granulation.* Skin grafting takes up well with healthy granulation tissue. Streptococci growth in culture should be less than  $10^5$ /gram of tissue before skin grafting.

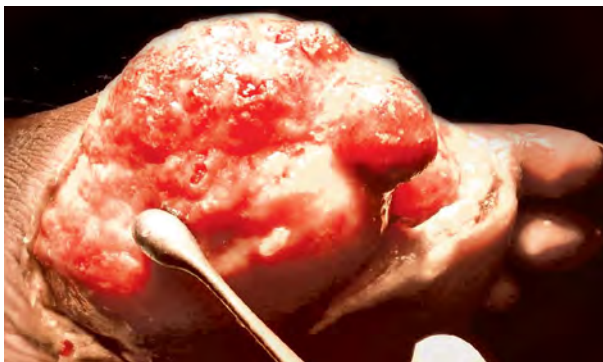#### Different discharges in an ulcer (as well as from a sinus)

- Serous*: In healing ulcer
- Purulent*: In infected ulcer
  - Staphylococci: Yellowish and creamy
  - Streptococci: Bloody and opalescent
  - Pseudomonas*: Greenish colour due to pseudocyanin
- Bloody*: Malignant ulcer, healing ulcer from healthy granulation tissue
- Seropurulent*
- Serosanguinous*: Serous and blood
- Serous with sulphur granules*: Actinomycosis
- Yellowish*: Tuberculous ulcer



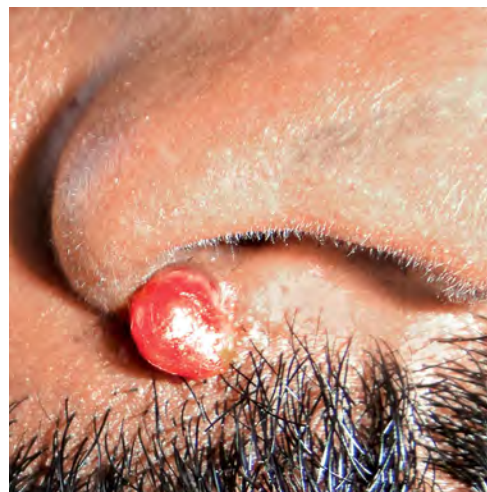**Fig. 1.50:** Healing ulcer with healthy granulation tissue. Note the sloping edge.

- ◆ **Unhealthy granulation tissue:** It is pale with purulent discharge. Its floor is covered with slough. Its edge is inflamed and oedematous. It is a spreading ulcer.
- ◆ **Unhealthy, pale, flat granulation tissue:** It is seen in chronic nonhealing ulcer (callous ulcer).
- ◆ **Exuberant granulation tissue (Proud flesh):** It occurs in a sinus or ulcer wherein granulation tissue protrudes out of the sinus opening or ulcer bed like a proliferating mass. It is commonly associated with a retained foreign body in the sinus cavity.



**Fig. 1.51:** Exuberant granulation tissue (proud flesh) in an ulcer. It should be scooped out using Volkmann's scoop prior to skin grafting.

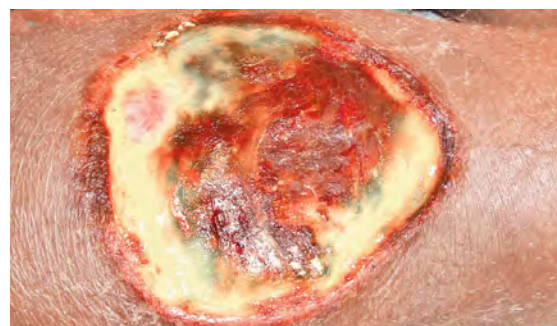- ◆ **Sprouting granulation** tissue of sinus.
- ◆ **Pyogenic granuloma:** It is a type of exuberant granulation tissue. Here granulation tissue from an infected wound or ulcer bed protrudes out, presenting as a well-localised, red swelling which bleeds on touching.  
*Differential diagnosis:* Papilloma, skin adnexal tumours.  
*Treatment:* Antibiotics, excision and sent for biopsy.



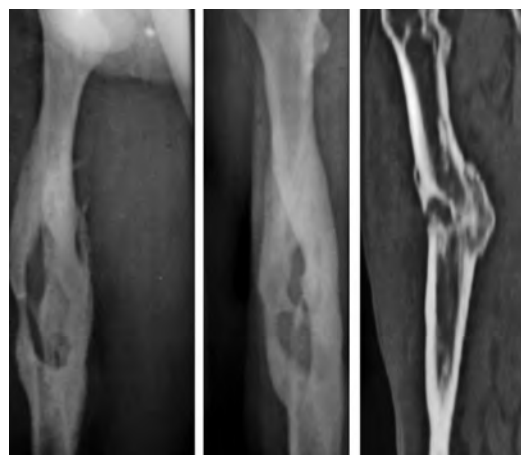
**Fig. 1.52:** Pyogenic granuloma.

## INVESTIGATIONS FOR AN ULCER

- ◆ *Study of discharge:* Culture and sensitivity, AFB study, cytology.



**Fig. 1.53:** Typical greenish coloured ulcer due to *Pseudomonas* infection.



**Fig. 1.54:** X-ray showing osteomyelitis with sequestrum inside. Osteomyelitis prevents ulcer healing. Bone thickening on clinical examination is typical.

- ◆ *Wedge biopsy*: Biopsy is taken from the edge because edge contains multiplying cells. Usually two biopsies are taken. Biopsy taken from the centre may be inadequate because of central necrosis.
- ◆ X-ray of the part to look for periostitis/osteomyelitis.
- ◆ FNAC of the lymph node.
- ◆ Chest X-ray, Mantoux test in suspected case of tuberculous ulcer.
- ◆ Haemoglobin, ESR, total WBC count, serum protein estimation (albumin).

**Note:**

Ulcer will not granulate if haemoglobin is less than 8 gm% and serum albumin is <3 gm%.

#### Assessment of an ulcer

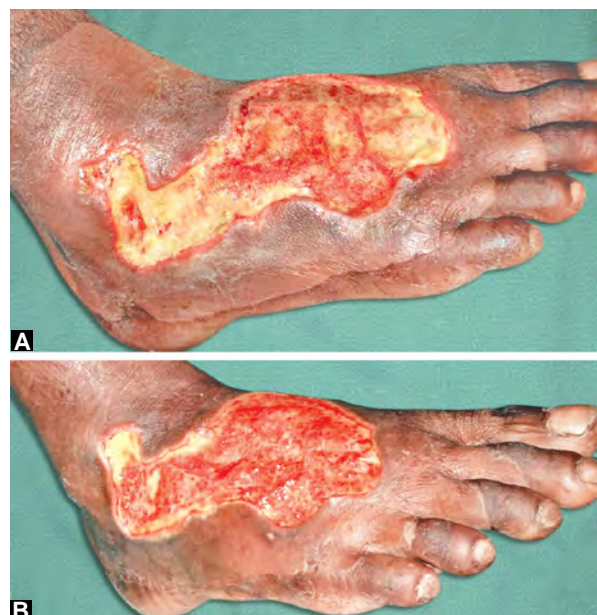- ❖ Cause of an ulcer should be found—diabetes/venous/arterial/infective
- ❖ Clinical type should be assessed
- ❖ Assessment of wound is important—anatomical site; size and depth of the wound; edge of the wound; mobility; fixity; induration; surrounding area; local blood supply. Wound perimeter may be useful in assessing this
- ❖ Wound imaging is done by tracing it on a transparent acetate sheet at regular intervals
- ❖ Presence of systemic features; regional nodal status; function of the limb/part; joint movements; distal pulses; sensations should be assessed
- ❖ Severity of infection should be assessed—culture of discharge
- ❖ Specific investigations like wedge biopsy; X-ray of part; blood sugar; arterial/venous Doppler; angiogram

### MANAGEMENT OF AN ULCER

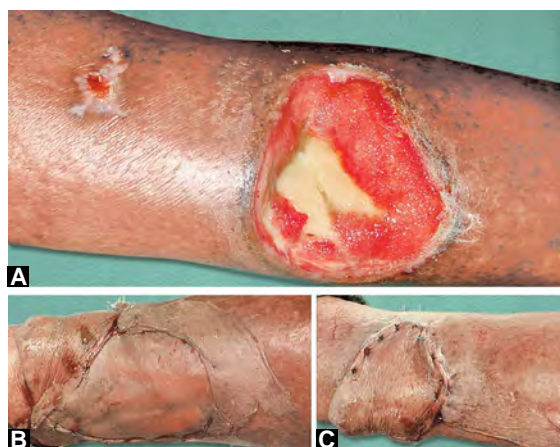
- ◆ Cause should be found and treated.
- ◆ Correction of the anaemia, deficiencies like of protein and vitamins.
- ◆ Proper investigation as needed.
- ◆ Transfusion of the blood if required.
- ◆ Control the pain and infection.
- ◆ *Rest, immobilization, elevation*, avoidance of repeated trauma.
- ◆ Care of the ulcer by debridement, ulcer cleaning and dressing. Desloughing is done either mechanically or chemically. Mechanically it is done using scissor by excising the slough. Hydrogen peroxide which releases nascent oxygen is used as chemical agent. Acriflavine is antiseptic and irritant and so desloughs the area and promotes granulation tissue formation. Eusol (Edinburgh University Solution) which contains sodium hypochlorite releases nascent chlorine which forms a water soluble complex with slough to dissolve it. Use of povidone iodine in ulcer cleaning is controversial (open wound is not suitable; it is mainly for cleaning the surgical field prior to incision). Maggots if present in the wound will cause crawling sensation and are removed using turpentine solution.
- ◆ Removal of the exuberant granulation tissue is also required when present.
- ◆ *Ulcer cleaning and dressing* is done daily or twice daily or once in 2–3 days depending on the type of ulcer and type of dressing used. Normal saline is ideal for ulcer cleaning. Various dressings are available. Films (opsite/semipermeable polyurethane), hydrocolloids (duoderm), hydrogels (polyethylene oxide with water), hydroactives (nonpectin-based polyurethane matrix), foams

(polyurethane hydrophilic or hydrophobic non-occlusive), impregnates (non-adherent fine mesh impregnated with antibacterials), calcium alginates etc.

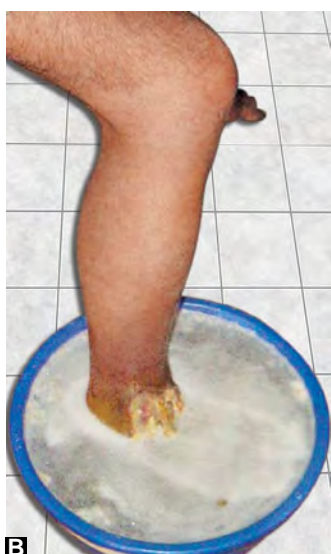- ◆ Topical antibiotics for infected ulcers are not essential but like framycetin, silver sulphadiazine, mupirocin may be used.
- ◆ *Vacuum assisted closure (VAC) therapy*: It is by creation of negative pressure (25–200 mmHg), continuous or intermittent over the wound surface; it causes reduced fluid in the interstitial space, reduces oedema, increases the cell proliferation and protein matrix synthesis, promotes formation of healthy granulation tissue. Sterile foam is placed over the ulcer bed covering widely; tube drain with multiple holes is kept within it and end of the tube comes out significantly away; foam is sealed airtight using a sterile adhesive film. Tube is connected to suction system. Suction is maintained initially continuously later intermittently. Redressing is done only after 4–7 days.
- ◆ Therapy using infrared/short wave/ultraviolet rays to decrease the ulcer size is often used but their benefits are not proved. Amnion to promote re-epithelialisation, chorion to promote granulation tissue formation is also often used.
- ◆ Antibiotics are not required once healthy granulation tissues are formed.
- ◆ *Maggot debridement therapy*: It is used as biotherapy (but not commonly) by placing cultured live disinfected maggots. Maggots are larvae of the green bottle fly, also known as the green blowfly (*Lucilia sericata*). They act by dissolving and engulfing dead necrotic tissues; they may reduce the bacterial content in the wound. They can inhibit many bacteria including MRSA (methicillin resistant bacteria), anaerobic and aerobic bacteria. They secrete proteolytic enzymes to have mechanical effects; secretion of ammonia alters the pH in the ulcer bed which inhibits bacterial growth. They increase the granulation tissue formation also.
- ◆ Once ulcer granulates, defect is closed with secondary suturing, skin graft or flaps.
- ◆ Autologous bone marrow monocytes injection into the ulcer area is new concept by Professor Sribatsa Mohapatra but yet to confirm.



**Figs 1.55A and B:** Ulcer in the foot, initially with slough; later after slough excision and regular dressings. Area requires skin grafting.



**Figs 1.56A to C:** Ulcer leg with exposed bone. Patient underwent local rotation flap to cover. Area from where flap is rotated is covered with split skin graft. When the bone is exposed, skin grafting is not possible.



**Figs 1.57A and B:** Solutions commonly used for ulcer and surrounding area cleaning and dressing—povidone iodine (brownish); EUSOL (colourless); hydrogen peroxide and normal saline. Note the EUSOL bath. Dilute EUSOL solution in a basin is used wherein ulcer foot is dipped and kept in place for 20–30 minutes. EUSOL removes the slough and cleans the ulcer bed. Hydrogen peroxide releases nascent oxygen and helps in removing necrotic material. Povidone iodine is not used for open wound; it is only a surface antiseptic

### Debridement of an ulcer

- ❖ It is removal of devitalised tissue
- ❖ Small ulcers are debrided in the ward
- ❖ Large ulcers are debrided in operation theatre under general anaesthesia
- ❖ All dead, devitalised, necrotic tissues are removed
- ❖ Slough should be separated adequately before debridement
- ❖ Often devitalised tissue separates on its own by autolysis
- ❖ Enzymes like collagenase are used for debridement
- ❖ Hydrotherapy and dressings are mechanical nonselective method of debridement

### Dressing of an ulcer is done

- ❖ To keep ulcer moist
- ❖ To keep surrounding skin dry
- ❖ To reduce pain
- ❖ To soothen the tissue
- ❖ To protect the wound
- ❖ As an absorbent for the discharge

### Note:

Debridement can be surgical, mechanical, autolytic or enzymatic.

### Ulcer dressings

- ❖ Cotton dressing—cheap but traumatic
- ❖ Paraffin dressing
- ❖ Polyurethane dressings used in clean wounds
- ❖ Alginates (seaweed) dressing used when there are heavy exudates
- ❖ Type 1 collagen dressings cause haemostasis, proliferation of fibroblasts and improve the blood supply
- ❖ Foam dressings are highly absorbent, decrease the wound maceration, and reduce the frequency of dressing—hydrophilic polyurethane foam
- ❖ Hydrocolloid dressings help in separation of slough and autolysis of dead tissues
- ❖ Transparent film dressings are waterproof, permit oxygen and water vapour across and prevent contamination
- ❖ Hydrogel dressings used for clean wounds

### Causes of formation of chronic/nonhealing ulcer

#### Local causes:

- ❖ Recurrent infection
- ❖ Trauma, presence of foreign body or sequestrum
- ❖ Absence of rest and immobilization
- ❖ Poor blood supply, hypoxia
- ❖ Oedema of the part
- ❖ Loss of sensation
- ❖ Periostitis or osteomyelitis of the underlying bone
- ❖ Fibrosis of the surrounding soft tissues
- ❖ Lymphatic diseases

#### General/Specific causes:

- ❖ Anaemia, hypoproteinaemia
- ❖ Vitamin deficiencies
- ❖ Tuberculosis, leprosy
- ❖ Diabetes mellitus, hypertension
- ❖ Chronic liver or kidney diseases
- ❖ Steroid therapy locally or systemically
- ❖ Cytotoxic chemotherapy or radiotherapy
- ❖ Malignancy

*Surgery is teamwork which divides the task and doubles the success.*



## ■ TRAUMATIC ULCER

- ◆ Such ulcer occurs after trauma. It may be *mechanical*—dental ulcer along the margin of the tongue due to tooth injury; *physical* like by electrical burn; *chemical* like by alkali injury.
- ◆ Such ulcer is acute, superficial, painful and tender. Secondary infection or poor blood supply of the area make it chronic and deep.
- ◆ *Footballer's ulcer* is a traumatic ulcer occurring over the shin of males due to direct knocks on the shin. It is staphylococcal infection with a chronic and deep ulcer.
- ◆ Traumatic ulcers can occur anywhere in the body due to trauma.

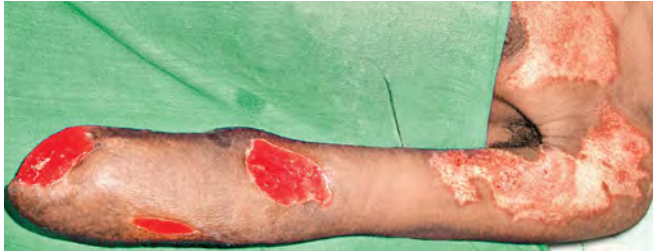

Fig. 1.58: Traumatic ulcers in the upper limb.

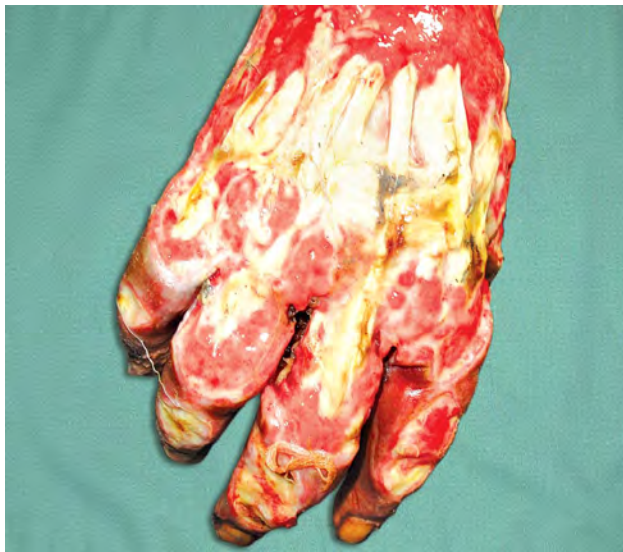

Fig. 1.59: Degloving ulcer with devitalised exposed tendons on the dorsum of the hand.

- ◆ Trauma causes infection, necrosis, fasciitis, crush injury, endarteritis of the skin leading into formation of large/deep nonhealing ulcer.
- ◆ Treatment depends on size and extent of ulcer. Regular dressing, later skin grafting is done.

## ■ TROPIC ULCER (PRESSURE SORE/DECUBITUS ULCER)

Pressure sore is tissue necrosis and ulceration due to prolonged pressure. Blood flow to the skin stops once external pressure becomes more than 30 mmHg (more than capillary occlusive pressure) and this causes tissue hypoxia, necrosis and ulceration. It is more prominent between bony prominence and an external surface.

It is due to:

- ◆ Impaired nutrition.
- ◆ Defective blood supply.
- ◆ Neurological deficit.

### Sites

- ◆ Over the ischial tuberosity.
- ◆ Sacrum.
- ◆ In the heel.
- ◆ In relation to heads of metatarsals.
- ◆ Buttocks.
- ◆ Over the shoulder.
- ◆ Occiput.

Due to the presence of neurological deficit, trophic ulcer is also called as *neurogenic ulcer/neuropathic ulcer*. Initially it begins as callosity due to repeated trauma and pressure, under which suppuration occurs and gives way through a central hole which extends down into the deeper plane up to the underlying bone as *perforating ulcer (penetrating ulcer)*.

Bedsore is trophic ulcers.

### Factors causing pressure sore

- ❖ Normal stimulus to relieve the pressure is absent in anaesthetised patient
- ❖ Nutritional deficiencies worsens the necrosis
- ❖ Inadequate padding over the bony prominences in malnourished patients
- ❖ Urinary incontinence in paraplegia patient causes skin soiling-maceration-infection-necrosis

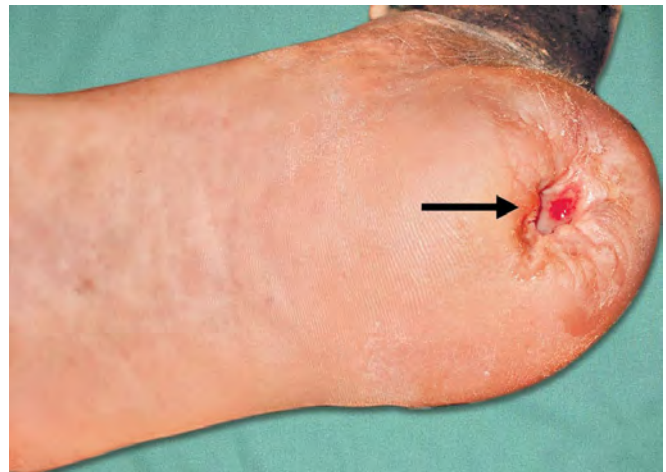
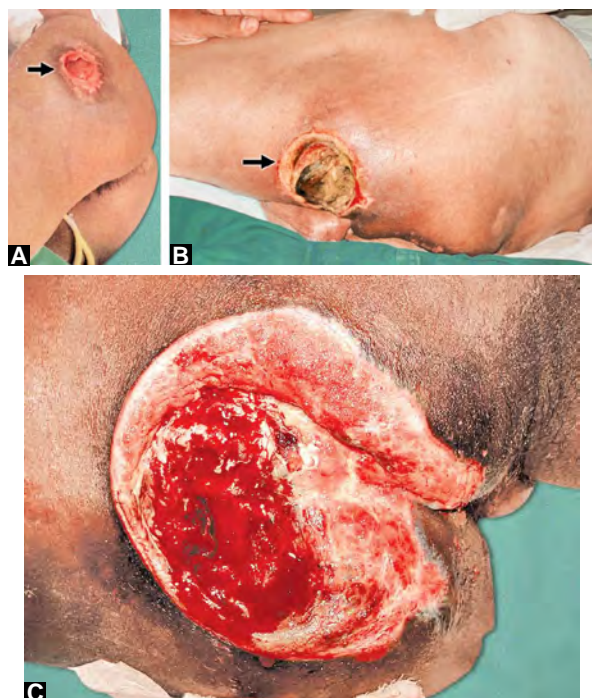


Fig. 1.60: Trophic ulcer—heel. It is deep punched out ulcer. It often requires rotation flap/transposition flap.

### Clinical Features

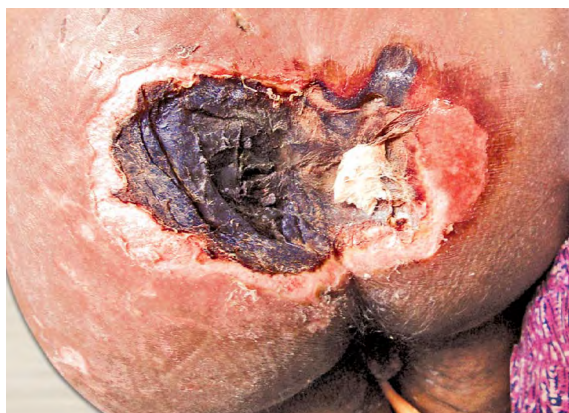- ◆ Occurs in 5% of all hospitalised patients.
- ◆ Painless ulcer which is punched out.
- ◆ Ulcer is non-mobile with base formed by bone.



**Figs 1.61A to C:** Bedsores (decubitus ulcer) over the greater trochanter, ischium and sacrum. Bedsores are trophic ulcers. They usually have a punched-out edge.

#### Neurological causes

- ❖ Diabetic neuropathy
- ❖ Peripheral neuritis
- ❖ Tabes dorsalis
- ❖ Spina bifida
- ❖ Leprosy
- ❖ Spinal injury
- ❖ Paraplegia
- ❖ Peripheral nerve injury
- ❖ Syringomyelia



**Fig. 1.62:** Bedsores over the sacrum with thick black slough on the surface.

#### Investigations

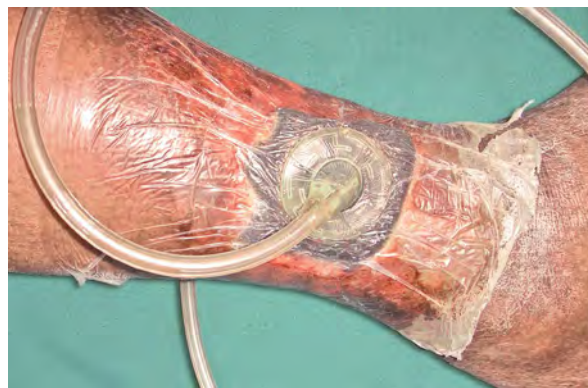Study of discharge, blood sugar, biopsy from the edge, X-ray of the part, X-ray spine.

#### Staging of pressure sore

- ❖ Nonblanching erythema—early superficial ulcer
- ❖ Partial thickness skin loss—late superficial ulcer
- ❖ Full thickness skin loss extending into subcutaneous tissue but not through fascia—early deep ulcer
- ❖ Full thickness skin loss with fascia and underlying structures like muscle/tendon/bone, etc.—late deep ulcer

#### Treatment

- ◆ Cause should be treated.
- ◆ Nutritional supplementation.
- ◆ Rest, antibiotics, slough excision, regular dressings.
- ◆ *Vacuum-assisted closure (VAC)*: It is the creation of intermittent negative pressure of minus 125 mmHg to promote formation of healthy granulation tissue. Negative pressure reduces tissue oedema, clears the interstitial fluid and improves the perfusion, increases the cell proliferation and so promotes the healing. A perforated drain is kept over the foam dressing covered over the pressure sore. It is sealed with a transparent adhesive sheet. Drain is connected to required vacuum apparatus.



**Fig. 1.63:** Vacuum-assisted closure of an ulcer.

- ◆ Once ulcer granulates well, flap cover or skin grafting is done.
- ◆ Excision of the ulcer and skin grafting.
- ◆ Flaps—local rotation or other flaps (transposition flaps).
- ◆ Cultured muscle interposition.
- ◆ *Proper care*: Change in position once in 2 hours; lifting the limb upwards for 10 seconds once in 10 minutes; nutrition; use of water bed/air bed/air-fluid floatation bed and pressure dispersion cushions to the affected area; urinary and faecal care; hygiene; psychological counselling. Regular skin observation; keeping skin clean and dry (using regular use of talcum powder); oil massaging of the skin and soft tissues using clean, absorbent porous clothing; control and prevention of sepsis helps in the management.

#### ULCER DUE TO CHILBLAINS

- ◆ It is due to exposure to intense cold causing blisters and ulcerations in the feet.
- ◆ These ulcers are *superficial*.
- ◆ It is due to excessive cutaneous arteriolar constriction.
- ◆ The condition is also called as *perniosis*.

### ■ ULCER DUE TO FROSTBITE

- ◆ It is due to exposure of a part to wet cold below the freezing point (cold wind).
- ◆ There is arteriolar spasm, denaturation of proteins and cell destruction.
- ◆ It leads to gangrene of the part.
- ◆ Ulcers here are always *deep*.

### ■ MARTORELL'S ULCER (1945)

- ◆ It is seen in *hypertensive* patients often with atherosclerosis.
- ◆ It is seen in *calf*. Often it is *bilateral* and *painful*.
- ◆ Necrosis of calf skin occurs with sloughing away and formation of deep, punched out ulcers extending into the deep fascia.
- ◆ There is sudden obliteration of the arterioles of the calf skin.
- ◆ All *peripheral pulses* are present.
- ◆ *It takes months to heal*.

**Treatment:** Once ulcer granulates well, skin grafting with lumbar sympathectomy is done.

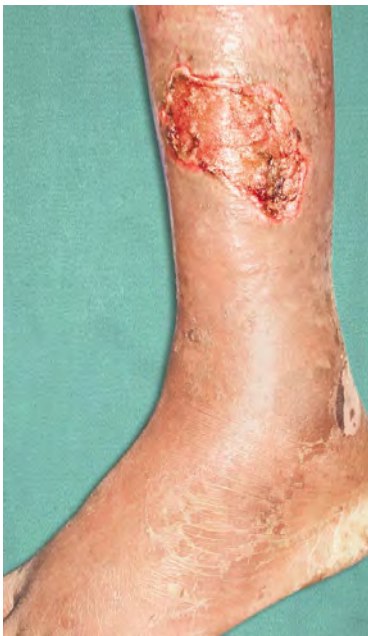

Fig. 1.64: Typical Martorell's ulcer.

### ■ ARTERIAL/ISCHAEMIC ULCER

- ◆ It is common in toes, feet or legs; often can occur in upper limb digits. It is due to poor blood supply following blockage of the digital or medium sized arteries.
- ◆ Atherosclerosis and TAO (Thromboangiitis obliterans) are common causes in lower limb.
- ◆ Cervical rib, Raynaud's phenomenon and vasculitis are common causes in upper limb.
- ◆ Ulcer initially occurs after trauma, soon becomes nonhealing, spreading with scanty granulation tissue.
- ◆ Ulcer is very painful, tender and often hyperaesthetic. Digits may often be gangrenous. Intermittent claudication, rest pain are common. Other features of ischaemia are obvious in the adjacent areas. They are—pallor, dry skin, brittle nail, patchy ulcerations, and loss of hair.
- ◆ Ulcer is usually deep, destructs the deep fascia, exposing tendons, muscles and underlying bone. Dead tendons look pale/greenish with pus over it.

- ◆ **Management:** Specific investigations like arterial Doppler, angiogram, lipid profile, and blood sugar are done. *Treatment* is done accordingly—drugs like vasodilators; arterial surgeries may be needed.

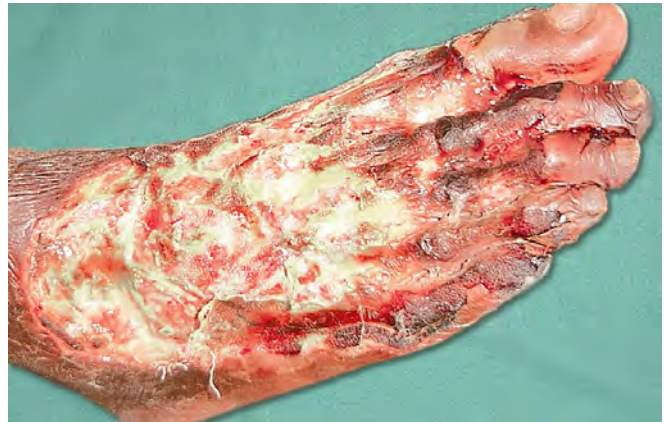

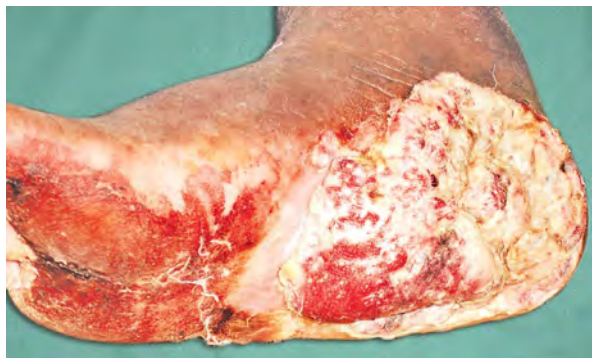Fig. 1.65: Ischaemic ulcer foot with gangrene of toes without evidence of any bleeding with exposed tendons.

### ■ BAIRNSDALE ULCER

- ◆ It is a chronic, irregular, undermined ulcer due to *Mycobacterium ulcerans* infection.
- ◆ Deep severe form, with extensive dermal necrosis is called as '*Buruli ulcer*'.
- ◆ Discharge study will show acid-fast bacilli.
- ◆ Antituberculous drugs resolve the ulcer usually. Skin grafting may be required later.

### ■ CARCINOMATOUS ULCER (EPITHELIOMA, SQUAMOUS CELL CARCINOMA)

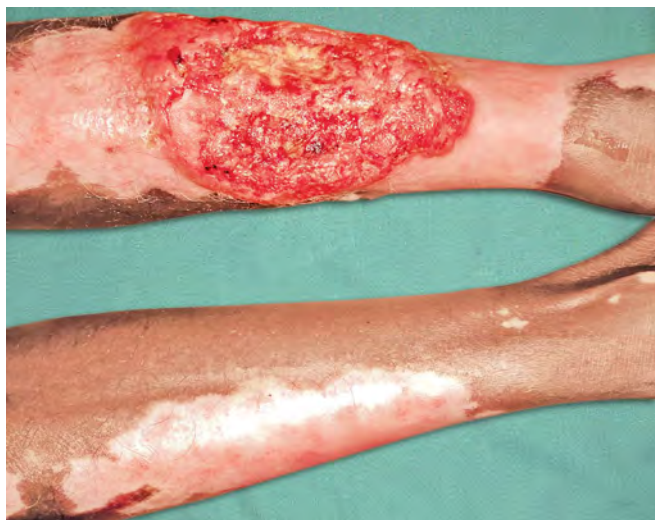- ◆ It arises from prickle cell layer of skin. It may initially begin as a nodule or ulcer; but later forms an ulcerative lesion with rolled out/everted edge. Floor contains necrotic content, unhealthy (tumour) granulation tissue and blood.
- ◆ Ulcer bleeds on touch and is vascular and friable. Induration is felt at the base and edge. It is usually circular or irregular in shape. Initially ulcer is mobile but becomes nonmobile once it infiltrates into deeper tissues. The typical foul smell is due to necrotic material, infection and release of polyamides from the tumour cells.
- ◆ Hard, discrete regional lymph nodes are often palpable, initially mobile but later become fixed. Lymph nodes can fungate eventually. Ulcer and lymph nodes are initially painless; but becomes painful and tender once there is deeper infiltration or secondary infection. Systemic spread is rare. It is a *locoregional malignant* disease.
- ◆ *Verrucous carcinoma* is exophytic, locally malignant well differentiated squamous cell carcinoma without lymphatic spread.
- ◆ **Management:** Wedge biopsy; FNAC of regional lymph nodes are the investigations. Treated with wide local excision with skin grafting and regional lymph node block dissection.



**Fig. 1.66:** Squamous cell carcinoma heel. It is proliferative ulcer. Note the raised and everted edge.

### MARJOLIN'S ULCER (Rene Marjolin, 1828, Paris)

- ◆ It is *slow* growing *locally* malignant lesion—a very well differentiated squamous cell carcinoma occurring in an *unstable scar of long duration*.
- ◆ It is commonly seen in chronic venous ulcer scar. Often it is observed in burns scar and scar of previous snake bite. Lesion is ulcerative/proliferative.
- ◆ Edge may be everted or may not be. It is painless as scar does not contain nerve fibrils. It does not spread into lymphatics as scar is devoid of lymphatics. Induration is felt at the edge and base. There is marked fibrosis also.
- ◆ Once lesion spreads into adjacent normal skin, it can spread into regional lymph nodes behaving like squamous cell carcinoma.
- ◆ *Managed by* wedge biopsy and wide local excision and grafting.

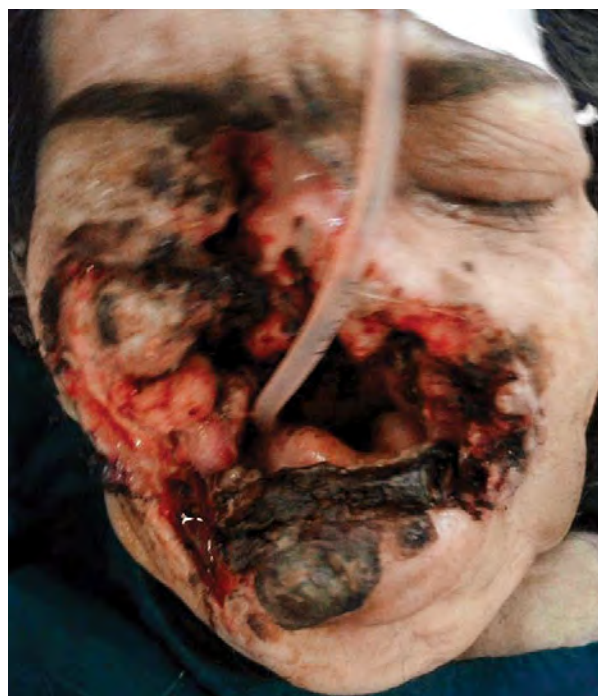

**Fig. 1.67:** Marjolin's ulcer in a *chronic unstable scar* (of long duration) in the leg. It does not spread through lymphatics.

### RODENT ULCER

- ◆ It is ulcerative form of basal cell carcinoma which is common in face.

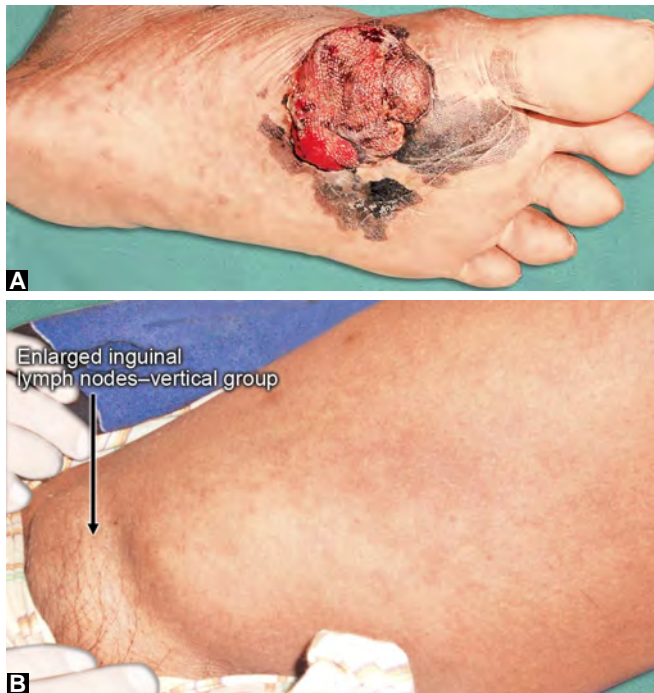
- ◆ Ulcer shows central area of dry scab with peripheral raised active and *beaded* (*pearly white*) edge. Often floor is pigmented. It erodes into deeper plane like soft tissues, cartilages and bones hence the name—*rodent ulcer*.
- ◆ As lymphatics are blocked early in the disease by large tumour cells, it does not spread to regional lymph nodes. Blood spread is absent. It is only *locally malignant*.
- ◆ It is common in face; rarely can it occur over tibia, external genitalia, mucocutaneous junction. It does not occur in mucosa.
- ◆ **Management:** Wedge biopsy, CT scan of the part to see the depth, wide excision.



**Fig. 1.68:** Typical rodent ulcer face causing destruction with deep erosions.

### MELANOTIC ULCER

- ◆ It is ulcerative form of melanoma. It can occur in skin as *de novo* or in a pre-existing mole. Ulcer is pigmented often with a halo around.
- ◆ Ulcer is rapidly growing, often with satellite nodules and '*in-transit*' lesions. It is very aggressive skin tumour arising from melanocytes.
- ◆ It spreads rapidly to regional lymph nodes which are pigmented. Blood spread to liver, lungs, brain, and bones is common. It can occur in mucosa, genitalia, and eye. It is a systemic malignant disease.
- ◆ **Management:** Excision biopsy (usually *incision biopsy is not done*), FNAC lymph node, US abdomen. *Treatment* is wide local excision, regional node block dissection, chemotherapy.



**Figs 1.69A and B:** Melanotic ulcer in the foot with enlarged inguinal lymph nodes.

## DIABETIC ULCER

### Causes

- ◆ Increased glucose in the tissue precipitates infection.
- ◆ Diabetic microangiopathy which affects microcirculation.
- ◆ Increased glycosylated haemoglobin decreases the oxygen dissociation.
- ◆ Increased glycosylated tissue protein decreases the oxygen utilization.
- ◆ Diabetic neuropathy involving all sensory, motor and autonomous components.
- ◆ Associated atherosclerosis.

### Note:

**Diabetic neuropathy** is due to conversion of sugar to sorbitol which causes nerve demyelination; neuropathy is distal, diffuse with a stocking distribution; it takes around 10 years to develop diabetic neuropathy. Glucose forms sorbitol by aldose reductase enzyme and galactose forms galactitol. If sorbitol level raises it gets trapped in peripheral nerves, retina and lens causing neuropathy, cataract and retinopathy. There may be formation of abnormal arteriovenous communications under the skin leads into nerve ischaemia and neuropathy. **Sensory neuropathy** causes loss of vibration sense, sense of position, touch, pain and temperature. Sensation may be absent in the entire sole due to medial and plantar nerve involvement. Foot feels like dead with like walking in the sand and prone for minor repeated traumas which are not noticed by the patient. **Motor neuropathy** causes paralysis of intrinsic muscles of foot leading into claw toes and hammer toe. Longitudinal arch of the foot becomes flat causing loss of foot curvature; loss of joint position and loss of foot muscle strength leads into altered gait and positions of foot leading into the deep seated trophic ulcers over the heads of the metatarsals. **Autonomic neuropathy** causes absence of sweating and loss of skin elasticity making more prone for breakdown and infection. Aut sympathectomy is common in diabetics involving foot area.

**Diabetic angiopathy** may be macro-or micro-angiopathy (thickening of the basement membrane of vessels and capillaries).

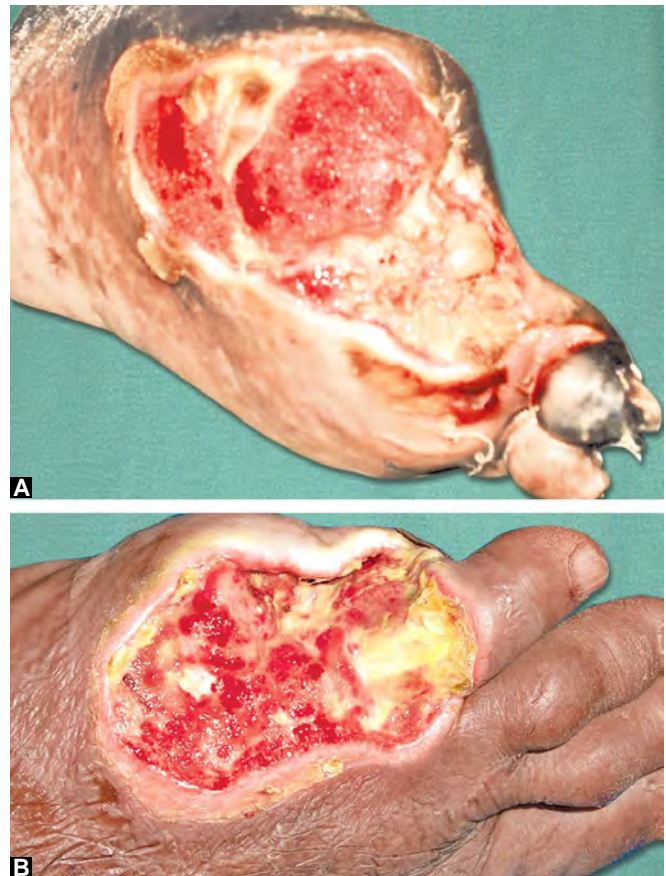
**Sepsis in diabetes:** Cellulitis, deep seated abscess, ulcer formation, gangrene foot, osteomyelitis of metatarsals, septicaemia, multiorgan dysfunction syndrome can occur faster in diabetes. Phagocytic activity in diabetes is reduced significantly; granulocyte mobilization is reduced in diabetic ketoacidosis. Neuropathy, angiopathy, high tissue glucose level, associated smoking, hypertension, hyperlipidaemia, reduced immunity increases the chances of sepsis in diabetics. Polymicrobial and fungal infections are common.

### Sites

- ❖ Foot-plantar aspect—is the most common site
- ❖ Leg
- ❖ Upper limb, back, scrotum, perineum
- ❖ Diabetic ulcer may be associated with ischaemia
- ❖ Ulcer is usually spreading and deep

### Investigations

- ◆ Blood sugar both random and fasting.
- ◆ Urine ketone bodies.
- ◆ Discharge for culture and sensitivity.
- ◆ X-ray of the part to see osteomyelitis.



**Figs 1.70A and B:** Foot is the most common area for diabetic infective problems. It can cause abscess, ulcer, osteomyelitis, gangrene, septicaemia. Initially patient undergoes toe amputation but later eventually land with below knee or above knee amputation.

- ◆ Arterial Doppler of the limb; glycosylated haemoglobin estimation.

#### Problems with diabetic ulcer

- ❖ Neuropathy, in foot—clawing of toes, hammer toe (due to intrinsic muscle paralysis)
- ❖ Multiple deeper abscesses; osteomyelitis of deeper bones are common
- ❖ Reduced leukocyte function; resistant infection; spreading cellulitis
- ❖ Arterial insufficiency
- ❖ Septicaemia; diabetic ketoacidosis
- ❖ Associated cardiac diseases like ischaemic heart disease

### Treatment

- ◆ Control of diabetes using insulin.
- ◆ Antibiotics.
- ◆ Nutritional supplements.
- ◆ Regular cleaning, debridement, dressing.
- ◆ Once granulates, the ulcer is covered with skin graft or flap.
- ◆ *Revascularisation* procedure is done by endarterectomy or thrombectomy or balloon angioplasty or arterial bypass graft. But if distal vessels are involved then success rate is less.
- ◆ Toe/foot/leg amputation.
- ◆ Microcellular rubber (MCR) shoes to prevent injuries; care of foot.



Fig. 1.71: Microcellular rubber (MCR) chappal is used diabetic neuropathy involving foot.

### MELENEY'S ULCER (POSTOPERATIVE SYNERGISTIC GANGRENE)

- ◆ It is commonly seen in *postoperative wounds* in abdomen and chest wall like empyema drainage or after surgery for peritonitis.

- ◆ It is an acute rapidly spreading ulcer with destruction and deep burrowing of subcutaneous tissues.

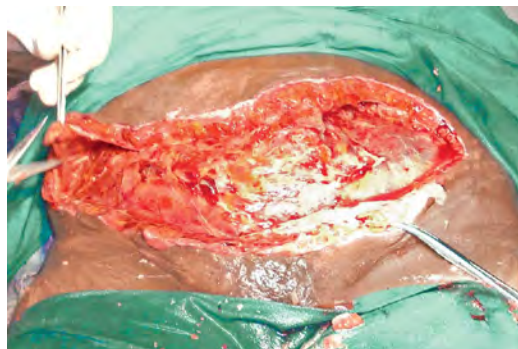


Fig. 1.72: Meleney's ulcer.

- ◆ Occasional symbiotic infection may develop in leg or hand. This can be as *de novo* association of ulcerative colitis or on a pre-existing venous ulcer.

### Aetiology

- ◆ It is common in old age and immunosuppressed individuals and after surgery for infected cases.
- ◆ It is caused by microaerophilic streptococci, *Staphylococcus aureus* and anaerobes.

### Sites

- ◆ It is common in abdomen and thorax. It begins in wound margin and spreads rapidly. It can also occur in other areas of skin.
- ◆ Infection is severe, often with endarteritis of the skin leading to ulcer and destruction.

### Clinical Features

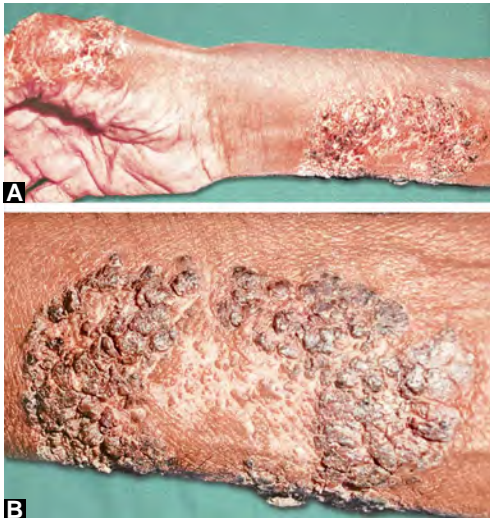
- ◆ Features of toxæmia.
- ◆ Spreading painful ulcer with discharge.
- ◆ Abundant granulation tissue with purple and red zones.

### Management

- ◆ Random blood sugar is checked, if diabetic it has to be controlled.
- ◆ Antibiotics.
- ◆ Blood transfusion, critical care.
- ◆ Adequate excision of dead tissues until it bleeds.
- ◆ Once healthy granulation tissue is formed skin grafting is done.

### LUPUS VULGARIS ('Lupus'—Wolf)

- ◆ It is *cutaneous tuberculosis* which occurs in young age group.
- ◆ Commonly seen on face, hand and forearm; starts as *typical apple-jelly nodule* with congestion of skin around. Eventually a superficial ulcer with *undermined edge* is formed.
- ◆ Glass slide pressed firmly on the diseased area to eliminate the surrounding hyperaemia causes clinically obvious *apple-jelly* appearance.
- ◆ The ulcer is active and destruction occurs at the periphery with healing takes place at the centre.
- ◆ Often lesion extends into nose and oral cavity involving the mucosa.



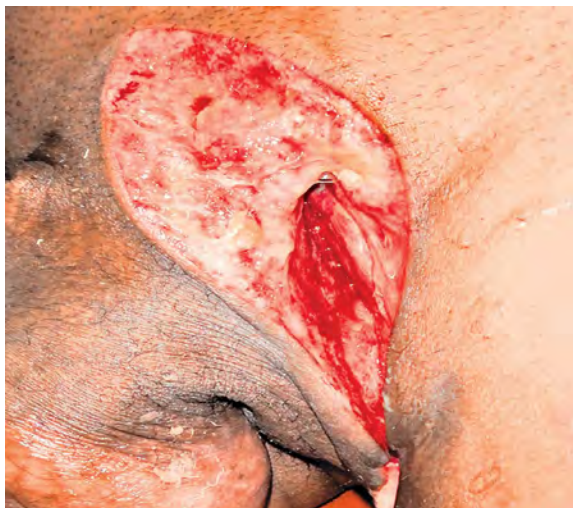**Figs 1.73A and B:** Lupus vulgaris in forearm and thumb. Biopsy confirmed tuberculosis. Patient needs antituberculous drugs (Courtesy: Dr Ashfaque, DNB, Surgeon, KMC, Mangaluru).

- ◆ Due to lymphatic obstruction facial oedema can occur.
- ◆ Long-standing lupus vulgaris can turn into *squamous cell carcinoma*.
- ◆ *Investigation:* ESR, discharge study, biopsy, chest X-ray.
- ◆ *Treatment:*
  - ▶ Antituberculous drugs.
  - ▶ If complete healing does not occur, then **excision and skin grafting** is required.

## ■ TUBERCULOUS ULCER

It is due to *Mycobacterium tuberculosis*. It is usually due to cold abscess later forming ulcer in the neck, chest wall, axilla and groin. It can also be primary tuberculosis of the skin (commonly in face). Ulcer can be single or multiple; oval or rounded; with undermined edge (due to progression of disease outwards underneath and healing inwards by skin), painless with caseating material on the floor. Ulcer is usually not deep. Regional lymph nodes may be enlarged matted, firm, and nontender.

Tuberculous ulcer is usually *painless* except on the tongue.



**Fig. 1.74:** Tuberculous ulcer is typically undermined.

## Management

Discharge study for epithelioid cells (modified histiocytes), AFB; edge biopsy, antituberculous drugs.

## ■ BAZIN'S DISEASE (ERYTHROCYANOSIS FRIGIDA/ERYTHEMA INDURATUM)

(Pierre Bazin, 1850, Paris)

- ◆ It is localised area of fat necrosis with chronic ischaemia of ankle skin affecting exclusively adolescent girls. It may be due to tuberculosis. It is observed in girls with more / thick subcutaneous fat around ankle.
- ◆ Bluish pink leg which becomes bluish mottling in extreme cold season. On warming, skin turns bright red and painful which is typical due to hyperaemia. In these patients perforating arteries perfusing the skin around the ankle are small/poor/not existing causing ischaemia of skin around ankle which becomes hyperaesthetic and sensitive for temperature alteration.
- ◆ Symmetrical, purple nodules develop in ankles and lower leg which later break down forming multiple, small, painful, superficial ulcers often with ankle oedema and pigment scars.
- ◆ Treatment is antitubercular drugs and lumbar sympathectomy.

## ■ TROPICAL ULCER

- ◆ It is endemic in monsoon hit humid tropics with repeated epidemics but sporadic in subtropics. Trauma or insect bite leads into infection exclusively in the lower part of the leg and foot.
- ◆ It is an acute ulcerative lesion of the skin observed in tropical regions like Africa, India and South America. It is associated with lower socioeconomic group, anaemia, and malnutrition and vitamin deficiency.
- ◆ It is commonly caused by *Fusobacterium fusiformis* (Vincent's organisms) and *Borrelia vincentii*.
- ◆ There are abrasions, redness, papule and pustule formation, acute regional lymphadenitis and severe pain.
- ◆ Pustule bursts in 3 days along with necrobiosis and phagedena causing a spreading painful ulcer with an undermined edge, brownish floor and serosanguineous discharge. Spreading stops in few weeks with ulcer persisting for many months to years. Eventually a chronic, large nonhealing/callous ulcer forms with persistent pain, profuse serosanguineous discharge, extremely unpleasant odour, long existing firmly adherent slough in the floor without any obvious constitutional symptoms. During healing it causes a slight pigmented, parchment like round scar.
- ◆ Often destruction is progressive without cessation (*phagedena*) to extend into entire soft tissues of foot and leg inviting amputation. *Phagedena* (Greek—to eat) is also seen in chancroid and cancrum oris.

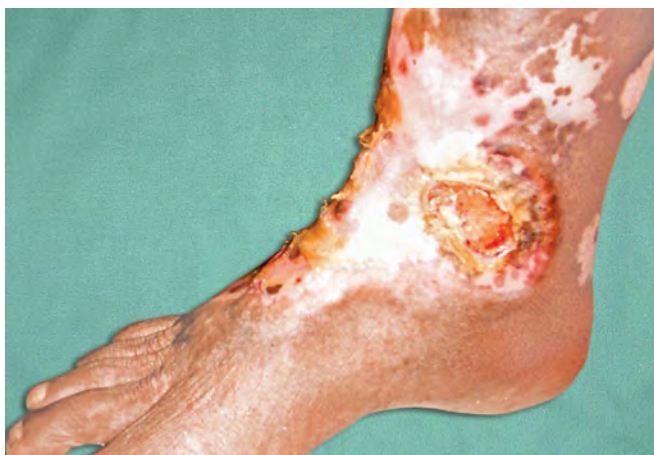### Note:

Phagedena is destruction without proliferation.

- ◆ Occasionally squamous cell carcinoma can develop in it.
- ◆ **Treatment:** Improvement in nutrition, penicillin, metronidazole, Eusol dressing, skin grafting at a later date.

## ■ VENOUS ULCER (GRAVITATIONAL ULCER)

- ◆ It is common around ankle (*gaiter's zone*) due to *ambulatory* chronic venous hypertension. It is due to *varicose veins* (long saphenous vein/short saphenous vein/perforators) or *post-phlebotic limb*.
- ◆ Post-phlebotic limb consists of veins that is been partially recanalised following deep venous thrombosis which causes increased venous pressure around ankle through perforators.
- ◆ Varicose veins are common in *females*. 50% of venous ulcers are due to varicose veins; 50% are due to post-phlebotic limb (previous DVT). Pain, discomfort, pigmentation, dermatitis, lipodermatosclerosis, ulceration, periostitis, ankle joint ankylosis, talipes equinovarus deformity and Marjolin's ulcer are the problems of varicose veins and later of venous ulcer.
- ◆ Ulcer is initially painful; but once chronicity develops it becomes painless. Ulcer is often vertically *oval*; commonly located on the *medial side*; occasionally on lateral side; often on both sides of the ankle; but *never* above the middle third of the leg. Floor is covered with pale or often without any granulation tissue. When well-granulated, edge is sloping. Induration and tenderness is seen often at the base of an ulcer.
- ◆ Venous ulcer is *vertically oval* with sloping edge and *will not penetrate* deep fascia.
- ◆ Inguinal lymph nodes (*vertical group*) are often enlarged. Ulcer often attains very large size which is nonhealing, indolent and callous.
- ◆ Ulcer heals on rest and treatment; but reforms again. Scarring is common due to repeated healing and recurrent ulcer formation. This *unstable scar* of long duration may lead into squamous cell carcinoma (*Marjolin's ulcer*).
- ◆ **Management:** Venous Doppler, regular dressing, skin grafting, specific treatment for varicose veins.



**Fig. 1.75:** Venous ulcer around ankle with skin changes over surrounding area. It is the most common site of venous ulcer.

## ■ SYPHILITIC ULCER

- ◆ Nowadays it is a rare entity. It is caused by *Treponema pallidum* bacterium. It is a sexually transmitted disease. It is named as

'*Syphilis*' after a shepherd named *Syphilus* who acquired the disease as was written in a poem by Francastorius of Verona. Many clinical lesions are observed in different stages of syphilis.

- ◆ *John Hunter* inoculated himself with syphilis organism to study the clinical features and effects. After 24 years of inoculation, he died from rupture of syphilitic aortic aneurysm at the age of 65.
- ◆ Genital chancre (*Hard chancre, Hunterian chancre*) is painless, hard, button like, indurated, nonbleeding ulcer; usually seen in corona or frenum of penis, often on lips, breasts and anal region; appears 4 weeks after initial infection in **first stage** of the disease (**primary syphilis**). Shotty, painless, firm, discrete groin lymph nodes may get enlarged along with genital chancre. Suppuration in these nodes will not occur. Extragenital chancres in lips and breasts show enlarged neck/axillary nodes which are inflamed, painful and also often may be matted.
- ◆ During **second stage** (**secondary syphilis**) white, thickened *mucous patches* appear commonly in the mouth like small, circular, superficial *snail track* ulcers. Also there appears raised, flat, hypertrophied, and warty like epithelium at mucocutaneous junctions (mouth, genitalia) called as *condyloma lata*. Generalised, shotty, hard, discrete, painless lymph nodes are palpable, epitrochlear and suboccipital nodes in particular are enlarged. *Epitrochlear nodes* are felt 1-2 cm above the medial epicondyle (It is also enlarged in non-Hodgkin's lymphoma/NHL). Iritis, arthritis, hepatitis (massive liver in syphilis is called as *hepar lobatum*), meningitis, syphilitic osteitis with '*ivory*' *sequestrum*, *coppery red skin rash*, *moth-eaten alopecia* are other features of second syphilis.
- ◆ In **tertiary/late stage syphilis** *gummatous ulcer* develops. It is deep, punched out, painless, nontender ulcer with *wash leather slough* in the floor, with '*silvery tissue paper*' like scar around and occurs over the subcutaneous bones like tibia, sternum, skull, palate or other area. It also can occur over the tongue, anterior aspect of the scrotum. It is due to delayed hypersensitivity reaction with endarteritis obliterans and vasculitis. Perforation of nasal septum/palate can occur. *Clutton's joint* and *Sabre tibia* are often seen. Lymph nodes are not affected in tertiary syphilis. Neurosyphilis (*tabes dorsalis*), *aneurysm of arch of aorta* are other features of tertiary syphilis.
- ◆ *Tabes dorsalis* presenting as generalized paralysis of insane is often called as **late tertiary or quaternary syphilis**.
- ◆ Long quiescent asymptomatic period from secondary to tertiary is called as **latent syphilis**.
- ◆ Secondary syphilitic stage shows plenty of circulating *Treponema spirochaetes* in blood where as in tertiary stage spirochaetes are less or absent.

## ■ SOFT CHANCER/SOFT SORE/DUCREY'S ULCER/CHANCROID/BUBO

- ◆ These multiple irregular genital ulcers appear 3 days after infection with *Haemophilus ducreyi* as a venereal disease.
- ◆ They are acute painful, tender, nonindurated ulcers. Floor shows yellowish slough with purulent discharge. Edge is oedematous and inflamed. Acute regional lymphadenitis with suppuration presenting as tender, soft or firm swelling is common. Such soft fluctuant inguinal swelling is termed as **bubo**.
- ◆ **Treatment** is by drugs like co-trimoxazole, erythromycin, ciprofloxacin, ceftriaxone; aspiration of **bubo**.

## ■ CLIMATIC BUBO/TROPICAL BUBO

- ◆ It is due to *lymphogranuloma inguinale*, a *venereal* spreading organism (LGV, *Chlamydia* type L1, 2, 3).



- ◆ In LGV, lesion of *primary genital stage* is small, painless and commonly unnoticed.
- ◆ Lesion of *secondary stage* develops in 2 weeks. In males inguinal lymph nodes; in females intrapelvic and pararectal nodes are involved. Suppuration of inguinal nodes eventually occurs leading into discharging sinuses. *Frei intradermal test* becomes positive in 6 weeks and remains positive for life time.
- ◆ In *tertiary stage*, eye, joint, meninges may get involved after many years. Repeated chronic inflammation, lymphatic blockage, scarring can cause rectal stricture and vulval elephantiasis (*esthiomene*) in females.
- ◆ *Treatment* is tetracycline for 3 weeks.
- ◆ *Treponema pertenue* causing *Yaws* (Frambesia) can have multiple painless ulcers in leg and feet due to walking with bare foot (organism enters through abrasion) which heals spontaneously leaving a *tissue paper like scar*.
- ◆ Poor hygiene and dressings can cause multiple, small, red often scabbed *Staphylococcus aureus ulcers* on the skin over the leg and feet which is often recurrent and disturbing.
- ◆ *Buruli ulcer*: It is chronic ulcer caused by *Mycobacterium ulcerans* (acid fast bacillus). Initially it forms a subcutaneous nodule later forming non-caseous necrosis showing slow healing with severe scarring.
- ◆ *Veld sore*: It is cutaneous diphtheria through the skin causing vesicles with a straw coloured fluid; once vesicles rupture chronic tender shallow ulcers will form.
- ◆ *Delhi boil (Oriental sore)*: Here *Leishmania tropica* infection causes indurated papule on the face and exposed body parts causing indolent chronic ulcer which heals producing an ugly pigmented scar.

### OTHER ULCERS

- ◆ Ulcers can occur, in various parts like over shin, legs, feet, face, chest wall, in various diseases like anaemia, polycythaemia, sickle cell disease, hereditary spherocytosis, leukemia, vasculitis, autoimmune diseases like rheumatoid arthritis, Paget's disease of bone (deep, nonmobile, fixed to bone; common in tibia), ulcerative colitis, etc.

## C. Sinus and Fistula

### CHAPTER OUTLINE

- ❖ Sinus
- ❖ Median Mental Sinus
- ❖ Preauricular Sinus
- ❖ Fistula
- ❖ Sequestrum

### SINUS

It is a blind track lined by granulation tissue leading from an epithelial surface into the surrounding tissues.

Sinus means “*hollow*” or “*a bay*” (*Latin*).

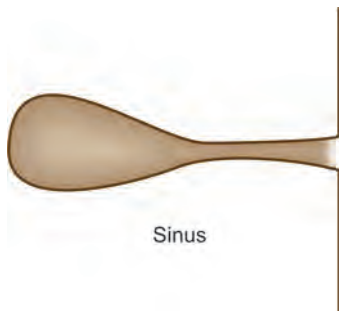


Fig. 1.76: Sinus.

### Causes

*Congenital:* Preauricular sinus.

*Acquired:* Actinomycosis, tuberculosis, pilonidal sinus, chronic osteomyelitis, median mental sinus.

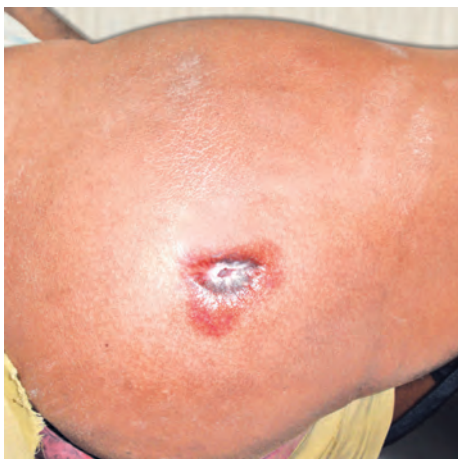

Fig. 1.77: Typical sinus in the thigh due to osteomyelitis of the greater trochanter.

### FISTULA

It is an abnormal communication between the lumen of one viscus to another or the body surface or between the vessels. Fistula means “*flute*” or “*a pipe or tube*.”

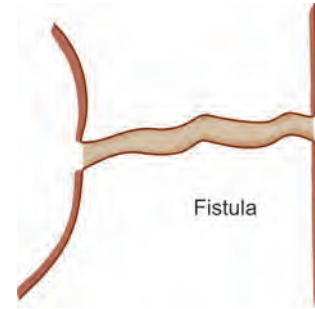


Fig. 1.78: Fistula.

### Causes

*Congenital:*

- ◆ Branchial fistula.
- ◆ Tracheo-oesophageal fistula.
- ◆ Congenital AV fistula.
- ◆ Umbilical fistula (patent vitellointestinal duct).

*Acquired:*

- a. Traumatic:
  - ▶ Following surgery—intestinal fistulas (biliary, pancreatic, faecal).
  - ▶ Following instrumental delivery or difficult labour (vesicovaginal fistula, rectovaginal fistula, ureterovaginal fistula).
- b. Inflammatory—intestinal actinomycosis, tuberculosis.
- c. Malignancy—when the growth of one organ penetrates into the nearby organ (Rectovesical fistulas as in carcinoma rectum, vesicouterine fistulas as in uterine cancer).

#### External fistula

- ❖ Orocutaneous
- ❖ Branchial fistula
- ❖ Thyroglossal fistula
- ❖ Enterocutaneous fistula
- ❖ Appendicular fistula

#### Internal fistula

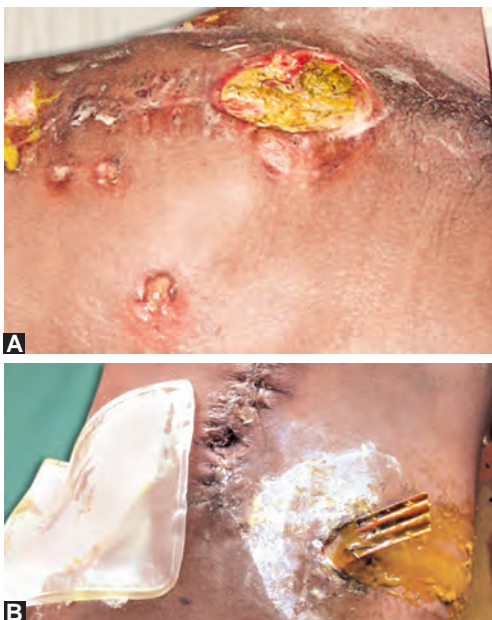- ❖ Tracheo-oesophageal fistula
- ❖ Cholecystoduodenal fistula
- ❖ Colovesical fistula
- ❖ Rectovesical fistula

### Clinical Features of Sinus/Fistula

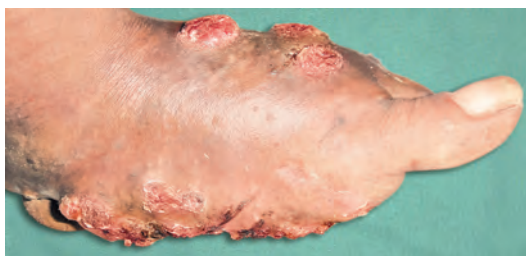
- ◆ Discharge from the opening of sinus.
- ◆ No floor.
- ◆ Raised indurated edge, indurated base, nonmobile.
- ◆ Often *sprouting granulation tissue over the sinus opening*.
- ◆ Bone thickening in osteomyelitis.
- ◆ Surrounding skin may be *erythematous* in inflammatory; *bluish* in tuberculosis; *excoriated* in faecal fistula; *pigmented* in chronic sinuses/fistulas.

*When a man loses his health he begins to take care of it.— John Billings*

- ◆ Discharge typical of the cause will be evident which will be obvious after *applying pressure* over surrounding area.
- ◆ Induration is a feature of all chronic fistulas *except* tuberculosis.



**Figs 1.79A and B:** Faecal fistula through laparotomy wounds. One is through main wound; other is through drain site. It often occurs after surgery for severe peritonitis, tuberculosis, malignancy.



**Fig. 1.80:** Multiple discharging sinus foot. It is commonly due to mycetoma (Madura foot). It could also be due to tuberculosis, chronic pyogenic osteomyelitis or malignancy.

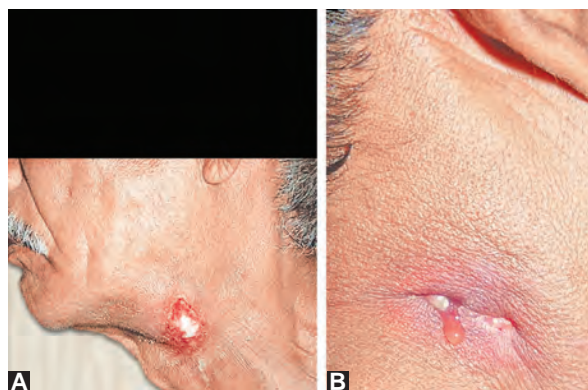- ◆ *Thickening of the bone underneath* on palpation if sinus is adherent to bone or if there is osteomyelitis.
- ◆ Enlargement of *regional lymph nodes* will be evident.
- ◆ Sinus may be single or multiple.

#### Causes of persistence of a sinus or fistula

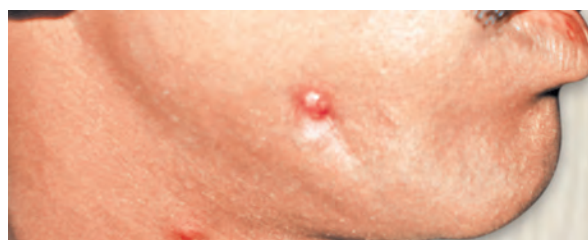- ❖ A foreign body or necrotic tissue underneath, e.g. suture, sequestrum
- ❖ Insufficient or nondependent drainage
- ❖ Persistent obstruction in the lumen, e.g. in faecal fistula, biliary fistula (distal obstruction)
- ❖ Lack of rest, persistent infection
- ❖ Wall become lined with epithelium or endothelium
- ❖ Dense fibrosis prevents contraction and healing
- ❖ Specific infections: Tuberculosis, actinomycosis
- ❖ Presence of malignant disease, post-irradiation

#### Note:

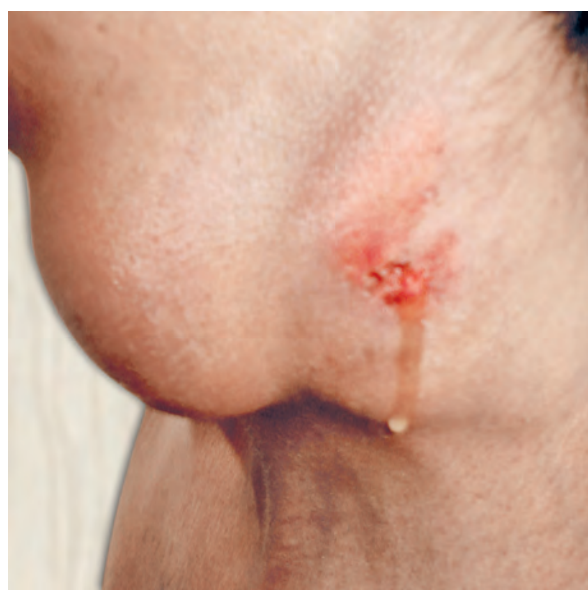The most common cause of sinus in neck is tuberculosis. Commonly it is tuberculous lymphadenitis. It shows yellowish cheesy discharge with bluish margin. Usually tuberculous sinus/ulcer does not show any induration.



**Figs 1.81A and B:** Secondaries in neck causing discharging sinus. (A) and (B) in two different patients.



**Fig. 1.82:** Mandibular sinus. It is usually due to infected tooth causing osteomyelitis of mandible. It also could be due to tumour, trauma, actinomycosis and radiation. X-ray (orthopantomogram), study of discharge and biopsy are relevant investigations. Such sinus should be excised with extraction of the causative tooth.



**Fig. 1.83:** Discharging sinus in the neck due to tuberculosis of lymph nodes with a cold abscess underneath.

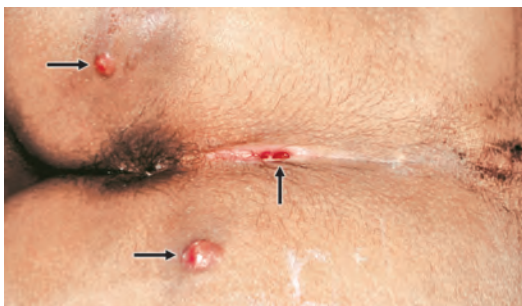

Fig. 1.84: Pilonidal sinus showing primary and secondary sinus.

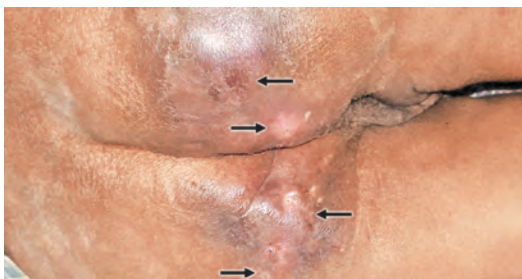

Fig. 1.85: Fistula in ano both sides.

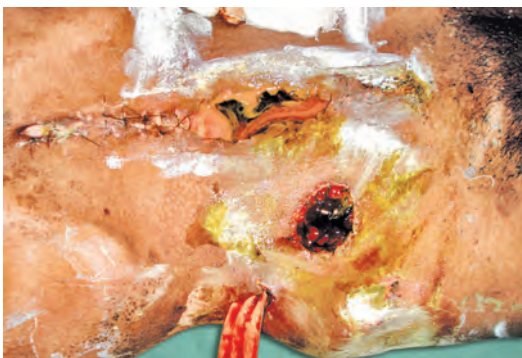

Fig. 1.86: Post-operative gastrointestinal fistula. Note the skin excoriation. It can be controlled by using zinc oxide cream local application.

#### Different discharges in a sinus/fistula

- ❖ Purulent—bacterial infection
- ❖ Caseous—tuberculous
- ❖ Sulphur granules—actinomycosis
- ❖ Mucus—branchial fistula
- ❖ Saliva—parotid fistula
- ❖ Faeces—faecal fistula
- ❖ Bile—biliary, duodenal fistula
- ❖ Bone—osteomyelitis sinus
- ❖ Urine—urinary fistula

#### Note:

- Streptococcal pus is watery with blood stain.
- Staphylococcal pus is yellow and creamy.
- Green or greenish blue pus is due to *Pseudomonas aeruginosa* infection.
- Anchovy sauce pus is seen amoebic liver abscess.
- Gas gangrene produces sickly sweet odour—decayed apple like.
- *E. coli* pus is usually odourless.
- Anaerobic bacteria and proteus vulgaris cause typical odour due

to proteolysis. Bacteroids cause typical *over ripe Camembert cheese* like odour.

- Faecal fistula causes *foul smelling discharge with gas bubble* in it.
- Tuberculous sinus discharges *caseating cheesy* material.

### Investigations

- a. Fistulogram/sinusogram using ultrafluid lipiodol or water soluble iodine dye (Lipiodol is poppy seed oil containing 40% iodine).
- b. Discharge for C/S, AFB, cytology, staining.
- c. Biopsy from the edge for tuberculosis and malignancy.
- d. Chest X-ray; X-ray of the part; MRI (most reliable) of the part.
- e. ESR.
- f. CT sinusogram.
- g. Probing gently with care.
- h. Digital examination of the rectum and proctoscopy in fistula in ano.

### Treatment

- ◆ Treat the cause.
- ◆ **Excision** of sinus or fistulas. Always specimen should be sent for histology.
- ◆ Antibiotics, antitubercular drugs, rest, adequate drainage.

### MEDIAN MENTAL SINUS

It is a chronic infective acquired condition wherein there is infection of roots of one or both lower incisor teeth forming root abscess which eventually tracks down between two halves of lower jaw in the midline presenting as discharging sinus on the point of chin at midline.

### Features

- ◆ Usually painless discharging sinus in the midline on the point of chin.
- ◆ Often incisor infection may be revealed (in many patients clinically tooth looks normal even though root is infected invariably).

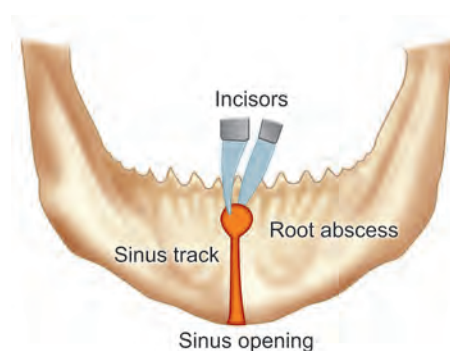

Fig. 1.87: Median mental sinus. Note the origin of the sinus from the root/roots of the lower incisor/incisors.

- ◆ It is often mistaken for infected sebaceous cyst.
- ◆ Osteomyelitis of the mandible is the possible complication.
- ◆ **Differential Diagnosis**
  - ▶ Infected sebaceous cyst.
  - ▶ Tuberculous sinus.
  - ▶ Osteomyelitis.

*The drops of rain make a hole in the stone not by violence, but by oft falling.*

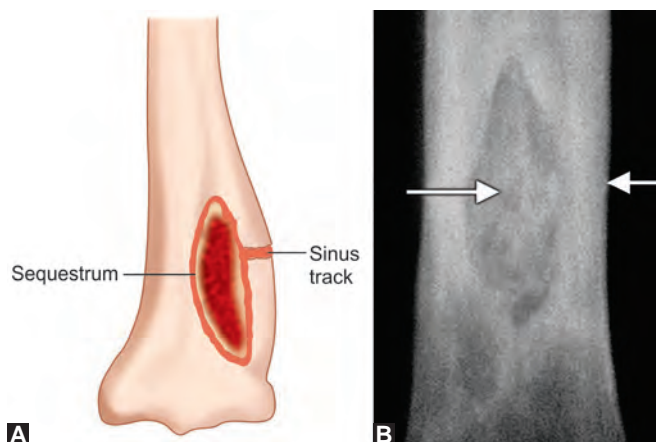
- ◆ **Investigations:**
  - ▶ Dental X-ray is diagnostic (Plain X-ray mandible may not reveal the disease).
  - ▶ Discharge study—C/S, cytology, AFB.
- ◆ **Treatment:**
  - ▶ Antibiotics, after doing discharge study (C/S).
  - ▶ Lay opening and excision of the sinus track with *extraction of incisor tooth/teeth*.

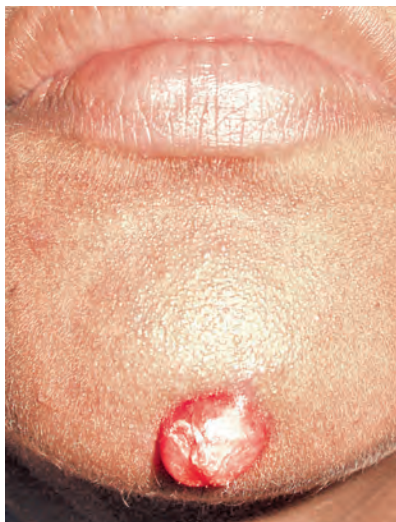

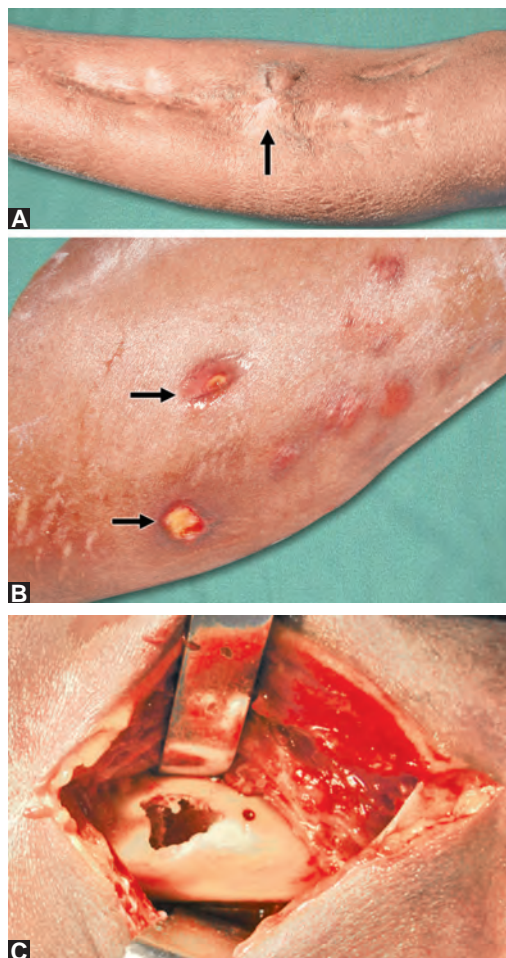
Fig. 1.88: Median mental sinus.

## SEQUESTRUM

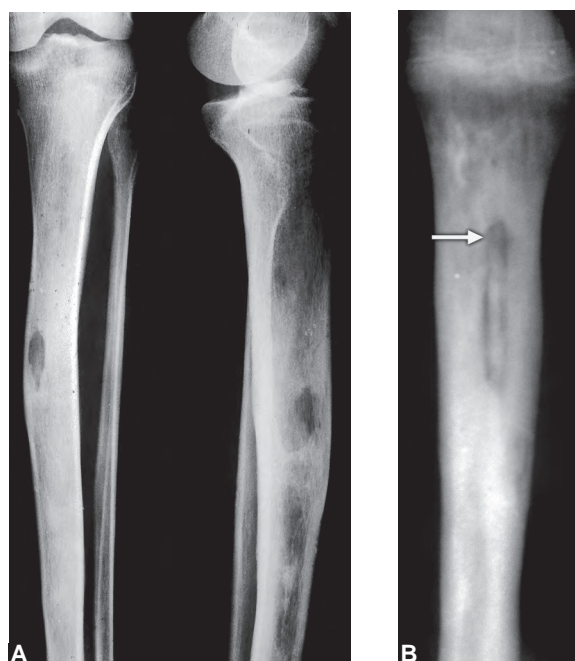- ◆ Sequestrum is dead bone *in situ*.
- ◆ It can be pyogenic, tubercular (feathery), *Salmonella* (granular), syphilitic (ivory), tubular and ring (in amputation stump).
- ◆ It can be *unformed*—means separation between sequestrum and adjacent normal bone has not occurred or *formed*—means there is proper adequate separation between normal bone and sequestrum by forming granulation tissue. Radiologically formed sequestrum shows clear lucent area/zone of demarcation.
- ◆ Sequestrum is denser because of the absence of decalcification in the dead bone as there is no blood supply (*dead bone is dense bone*).
- ◆ Sequestrum should be *formed* prior to surgical intervention—sequestrectomy and saucerisation.



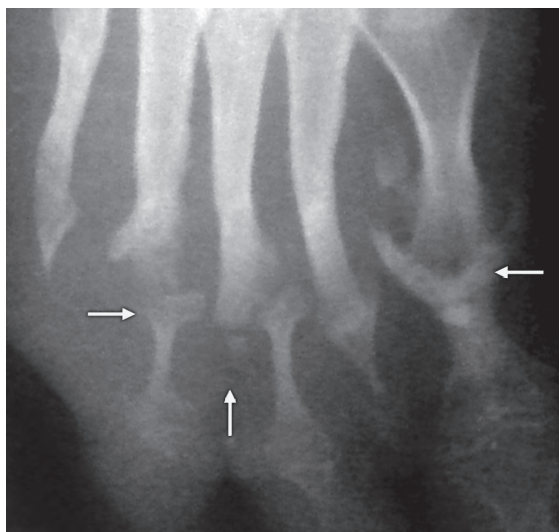
Figs 1.89A and B: Diagram and X-ray showing osteomyelitis with sequestrum and sinus. Sequestrum is dead bone *in situ*.



Figs 1.90A to C: Osteomyelitis patient with scar. Also showing on table photo of sequestrectomy and saucerisation.



Figs 1.91A and B: X-ray pictures showing features of osteomyelitis with sequestrum, sinus, cavity.



**Fig. 1.92:** X-ray of foot showing osteomyelitis of metatarsal bones. Metatarsal osteomyelitis is commonly seen in diabetes mellitus and trauma.

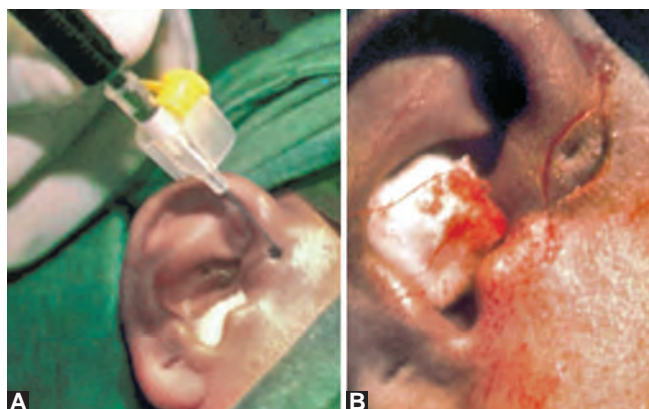
### ■ PREAURICULAR SINUS

It is a *congenital entity* occurring due to imperfect fusion of the six tubercles which form ear cartilage. Sinus opening may be seen at the root of the helix or on the tragus. Track is quiet deep running backwards, slightly upwards towards the helix. It usually ends *blindly*. Outer opening of the sinus often closed causing formation of a cystic swelling (preauricular cyst) which contains fluid which is often infected. Preauricular sinus in *no instance* will communicate with the external auditory meatus. Bursting of this swelling leads into formation of ulcer like lesion. It can be unilateral or bilateral. *Occasionally* multiple sinuses are seen. Opening of the

sinus occurs in a *small triangular area* in front of the ear at the level of the tragus. *Scarring* is common around the opening due to repeated infection.

### Features

- ◆ It is seen since childhood.
- ◆ Often swelling appears and apparently disappears repeatedly.
- ◆ Pain and discharge is common.
- ◆ It causes a cosmetic problem in young individual.
- ◆ Discharge study, ESR, sinusogram to assess the track is needed. MR sinusogram is beneficial.
- ◆ *Differential diagnosis:* Cold abscess, sebaceous cyst.
- ◆ *Investigation:* Sinusogram, discharge study.
- ◆ *Treatment:* Excision under general anaesthesia with removal of entire track is essential. If track is not removed properly recurrence will occur.



**Figs 1.93A and B:** Preauricular sinus. During excision, methylene blue is injected into the track initially and later it is excised using elliptical incision.

## D. Infectious Diseases

*But however secure and well-regulated civilized life may become, bacteria, protozoa, viruses, infected fleas, lice, ticks, mosquitoes, and bedbugs will always lurk in the shadows ready to pounce when neglect, poverty, famine, or war lets down the defenses.*

—Hans Zinsser, 1934

### CHAPTER OUTLINE

❖ Surgical Infection	❖ Carbuncle	❖ Actinomycosis
❖ Cellulitis	❖ Pott's Puffy Tumour	❖ Madura Foot
❖ Erysipelas	❖ Pyogenic Granuloma	❖ Rabies
❖ Lymphangitis	❖ Impetigo	❖ Anthrax
❖ Abscess	❖ Erythrasma	❖ Nosocomial and Opportunistic Infections
❖ Metastatic and Pyaemic Abscess	❖ Scrum Pox	❖ Necrotising Fasciitis
❖ Bacteraemia	❖ Tetanus	❖ Acute Pyomyositis
❖ Septicaemia	❖ Gas Gangrene	❖ Surgical Site Infection
❖ Pyaemia	❖ Tuberculosis	❖ HIV Infection and AIDS
❖ Boil	❖ Leprosy	
❖ Hidradenitis Suppurativa	❖ Syphilis	

### ■ SURGICAL INFECTION

- ◆ Surgical infection is major problem in surgical practice. Asepsis (prevention of entry of organisms) and antisepsis (killing of the bacteria in the skin or tissues) has made a difference in surgical practice. Epithelial surfaces act as mechanical barrier and phagocytes, antibodies; complements, macrophages, leukocytes, opsonins, etc. act as protective mechanisms.
- ◆ Malnutrition, diabetes mellitus, obesity, uraemia, jaundice, malignancy, immunosuppression, radiotherapy, chemotherapy, HIV, ischaemia, foreign body, haematoma are the risk factors for surgical infections. Virulence of organisms, blood supply, body immunity and support of antibiotics are the decisive factors in proper response to control infection.
- ◆ Surgical infection can be *superficial surgical site infection* in the wound or *deep surgical site infection* in deeper fascio-muscular layers or *organ space infection* like abdomen/thoracic cavity, etc.
- ◆ Health care associated infection occurs after hospital admission in intensive unit/postoperative ward, etc.
- ◆ *Southampton wound grading system for healing and infection:*
  - ▶ Grade 0 is normal healing;
  - ▶ Grade 1 is with bruising/mild erythema;
  - ▶ Grade 2 is severe erythema with other features of inflammation at or around wound;
  - ▶ Grade 3 is serous or bloody discharge;
  - ▶ Grade 4 is presence of pus or deep infection or tissue breakdown or significant haematoma.

ASEPSIS wound score system is used to assess the wound infection.

ASEPSIS wound scoring	
Parameters	Score
• Additional treatment	
1. Antibiotics	10
2. Pus drainage	05
3. Wound debridement	10
• Serous discharge—for 5 days of first 7 days of wound infection	0–5 daily
• Erythema—for 5 days of first 7 days of wound infection	0–5 daily
• Purulent fluid—for 5 days of first 7 days of wound infection	0–10 daily
• Separation of deep tissues—for 5 days of first 7 days of wound infection	0–10 daily
• Isolation of bacteria	10
• Stay in the hospital (in-patient) more than 14 days due to infection	05

### ■ CELLULITIS

- ◆ It is **spreading inflammation** of subcutaneous and fascial planes.

- ◆ Infection may follow a small scratch or wound or incision or insect/snake/scorpion bite.
- ◆ It can be superficial or deep. More common superficial type is easier to diagnose.
- ◆ It is common in diabetics, immunosuppressed people and old age.
- ◆ It is common in face, lower limb, upper limb and scrotum wherein subcutaneous tissue is lax.

**Note:**

Cellulitis occurring in children is never primary but secondary to an underlying bone infection—Morison's aphorism (James Morison, 1939—Surgeon, Durham, Newcastle).

**Causative Agents**

- ◆ Commonly due to *Streptococcus pyogenes* and other Gram +ve organisms. Release of streptokinase and hyaluronidase cause spread of infection.
- ◆ Often Gram -ve organisms like *Klebsiella*, *Pseudomonas*, *E. coli* are also involved (usually Gram -ve organisms cause secondary infection).

**Sequelae**

- ◆ Infection can get localised to form *pyogenic abscess*.
- ◆ Infection can spread to cause *bacteraemia*, *septicaemia*, *pyaemia*.
- ◆ Often infection can lead to *local gangrene*.
- ◆ Extensive necrosis of skin and subcutaneous tissue—*necrotizing fasciitis*.

**Clinical Features**

- ◆ Fever, toxicity (tachycardia, hypotension).
- ◆ Swelling is diffuse and spreading in nature.
- ◆ Pain and tenderness, red, shiny area with stretched warm skin.
- ◆ Cellulitis will progress rapidly in diabetic and immunosuppressed individuals.
- ◆ Tender regional lymph nodes may be palpable which signify severity of the infection.
- ◆ No edge; no pus; no fluctuation; no limit.

**Investigations**

- ◆ Total count raises, differential count, platelet count (decreases) to be done.
- ◆ Liver function tests, blood urea and serum creatinine in severe cases.
- ◆ Blood sugar estimation, urine test for ketone bodies, glycosylated haemoglobin estimation.
- ◆ *Deep vein thrombosis* (DVT) often may mimic cellulitis of lower limb. Venous Doppler and ultrasound of soft tissues of the limb may require in such situation.

**Treatment**

- ◆ *Elevation* of limb or part to reduce oedema so as to increase the circulation and bandaging.

- ◆ *Antibiotics*—penicillins, cephalosporins.
- ◆ *Dressing* (often glycerine dressing is used as it reduces the oedema because of its hygroscopic action glycerine magnesium sulphate dressing).
- ◆ *Diabetes* to be treated with insulin. Ketosis if present should be confirmed by assessing urine ketone bodies and treated subsequently with intravenous insulin.
- ◆ Often patient may be in *septicaemia*; patient in such condition should be treated with higher antibiotics, critical care with fluid management, along with maintaining adequate urine output. Catheterization is required; monitoring is done with—renal function tests, haematocrit (platelet count), liver function tests, prothrombin time and serum electrolyte estimation.

**Cellulitis in Special Areas****Orbital Cellulitis**

- ◆ Cellulitis in orbit causes *proptosis*, leading to impairment of ocular movements and blindness.
- ◆ It can spread through ophthalmic veins into cavernous sinus causing *cavernous sinus thrombosis*.
- ◆ It requires admission and immediate aggressive treatment with higher generation antibiotics (Penicillins, cephalosporins).

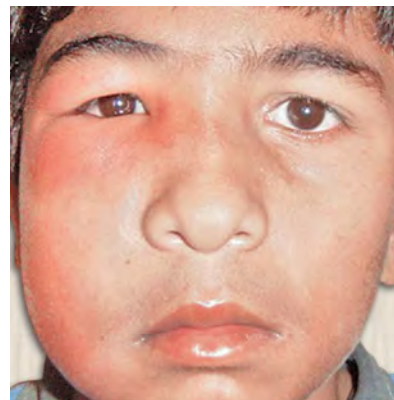
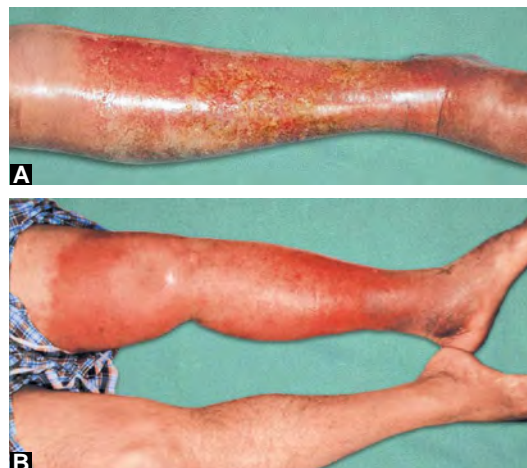
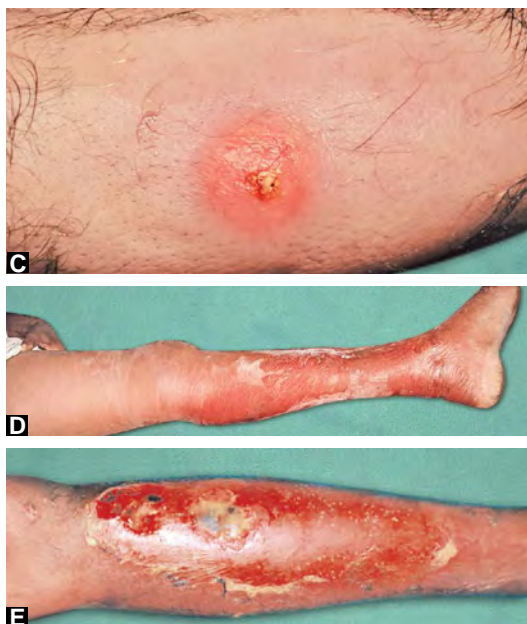
Fig. 1.94: Cellulitis face. Note the oedema of the face and eyelids.



Figs 1.95A and B

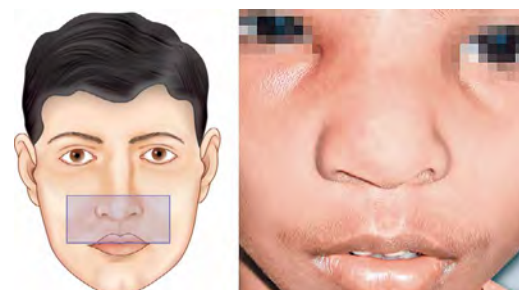
Oedema gives rise to soft pitting, while if pus present, induration can always be felt.—Allan B Kanavel



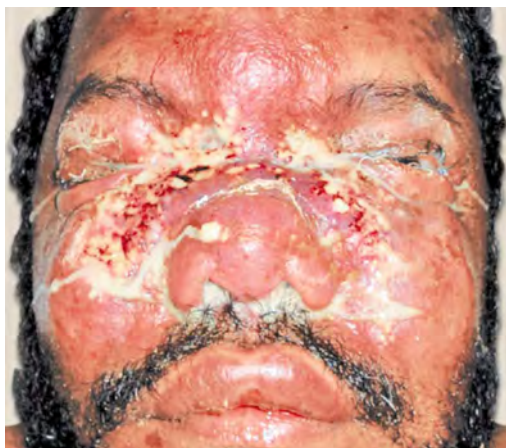

Figs 1.95C to E

**Figs 1.95A to E:** Note the cellulitis in different patients. It is common in lower limbs. There is no edge without any formed pus. It should never be incised with certain exceptions like Ludwig's angina. It is treated by antibiotics. It can cause bacteraemia/septicaemia.



**Fig. 1.96:** Dangerous area of face—area of upper lip and lower part of nose. Infection from this area spreads through deep facial vein → pterygoid plexus → communicating vein → cavernous sinus causing its life-threatening thrombosis.



**Fig. 1.97:** Severe cellulitis face involving nose, eyelids and facial skin. It can cause septicaemia, cavernous sinus thrombosis or intracranial spread of infection. This area is called as *dangerous zone* in face. It needs hospitalisation for treatment.

### Ludwig's Angina (Wilhelm Frederick von Ludwig in 1836)

- ◆ It is a rapidly progressive polymicrobial cellulitis of the sublingual and submandibular spaces involving the floor of the mouth and suprahyoid area on both sides of the neck.
- ◆ Commonest cause is dental infection of 2nd or 3rd molar teeth precipitated by tooth extraction; other causes are submandibular sialadenitis, trauma, peritonsillar abscess, upper respiratory infection, interventions like endotracheal intubation.
- ◆ Predisposing factors are—diabetes mellitus, chemotherapy, oral cancer, alcohol, neutropenia.
- ◆ Commonest organisms are—*Streptococcus viridians*, *Staphylococcus aureus* and anaerobes. Gram negative organisms can also be involved.
- ◆ Cellulitis may extend into the pharyngomaxillary space, retropharynx, and superior mediastinum.

### Features

- ◆ Diffuse painful swelling with woody brawny induration of the mouth and anterior neck. Swelling is non-fluctuant but with redness and tenderness. Bilateral submandibular oedema with marked tenderness on palpation at suprahyoid area with *bull's neck appearance*.
- ◆ Toxic features like fever, tachycardia, tachypnoea is common.
- ◆ Difficulty in speech, earache, drooling of saliva and putrid halitosis.
- ◆ Involvement of connective tissues, muscles and fascial spaces but not glandular structures.
- ◆ Spread via fascial planes in continuity not by lymphatics; no lymph node enlargement.
- ◆ Oedema of the tongue with pushing against palate (elevation) upwards and backwards causing airway obstruction, dysphagia and odynophagia.
- ◆ Stridor, respiratory distress and cyanosis may develop due to oedema of tongue and larynx.
- ◆ Investigations—CT scan or MRI is useful to identify airway block, fluid collection and presence of gas. Ultrasound neck is simpler method to identify same. Total count, blood sugar, chest X-ray and often blood gas analysis (in severe cases) is done.
- ◆ Differential diagnoses are—angioneurotic oedema, sublingual haematoma, sialadenitis, lymphadenitis.

### Complications

- ◆ **Laryngeal oedema** can occur due to spread of inflammation to glottis submucosa via stylohyoid tunnel. It may require emergency tracheostomy to maintain the respiration.
- ◆ **Mediastinitis** due to spread of infection into mediastinum; aspiration pneumonia.
- ◆ **Septicaemia.**
- ◆ Spread of infection into the parapharyngeal space leads to **thrombosis** of the internal jugular vein which may extend above into the sigmoid sinus which may be fatal.
- ◆ Mortality is less than 5% unlike in olden days.

### Treatment

- ◆ Antibiotics (intravenous) like penicillins, piperazillin, tazobactam, clindamycin, metronidazole should be started at the earliest.
- ◆ If patient is in respiratory distress, tracheostomy is required as a life saving procedure.
- ◆ Whenever distress is severe surgical decompression is required. Submental horizontal incision is placed; mylohyoid muscles are cut (both sides); wound may be closed with a loose sutures with a

drain or kept open with a dressing cover until oedema and sepsis subsides and later secondary suturing can be done.

- ◆ Initial steroid therapy (dexamethasone) may be beneficial and is often used to reduce oedema even though it is controversial.

## ■ ERYSIPELAS

*Erysipelas* is (Greek-red skin, Ignis sacer, holy fire, St Anthony fire) an acute spreading inflammation of the upper (outer) dermis and superficial lymphatics; it has got typical skin rash presenting on legs, toes, face and fingers due to acute infection by beta haemolytic *Streptococcus pyogenes*, presenting as raised well demarcated skin rash (rash is due to exotoxin). It is more superficial than cellulitis. In olden days, it was more common in face, now it is common in legs. Infection occurs through a minor trauma. It affects all races; more common in females. There will be always cutaneous lymphangitis with development of **rose pink rash** with cutaneous lymphatic oedema. Vesicles which form eventually will rupture to cause serous discharge.

### Sites

- ◆ Orbit, face and ear lobule—most common.
- ◆ Hands and scrotum.
- ◆ Umbilicus in infants.
- ◆ Decubitus ulcer of lower limb (legs and feet are now becoming more common site).

### Clinical Features

- ◆ **Toxaemia** is always a feature.
- ◆ **Rash** is fast spreading and blanches on pressure.
- ◆ **Rash is raised with sharp margin.**
- ◆ Redness becomes brown and later yellow with vesicles.
- ◆ **Discharge is serous (In cellulitis discharge is purulent).**
- ◆ In the face and orbit it causes severe oedema.
- ◆ **Milian's ear sign** is a clinical sign used to differentiate erysipelas from cellulitis wherein ear lobule is spared. Skin of ear lobule is adherent to the subcutaneous tissue and so cellulitis cannot occur. Erysipelas being a cutaneous condition can spread into the ear lobule (Gaston Milian—dermatologist Paris, 1945).
- ◆ Tender, regional lymph nodes are usually palpable.
- ◆ **Differential diagnoses**—herpes zoster, angioneurotic oedema, contact dermatitis.

### Complications

- ◆ Septicaemia, localized cutaneous and subcutaneous gangrene are dangerous problems.
- ◆ Abscess, pneumonia, meningitis may develop.
- ◆ Lymphoedema of face or eyelid or limbs (when involved) can occur due to lymphatic fibrosis.
- ◆ Glomerulonephritis (not rheumatic fever), septic arthritis, necrotizing fasciitis, can occur occasionally.
- ◆ Recurrence rate is 20%. It causes disfiguring sequelae.

### Treatment

- ◆ Penicillins, clindamycin, erythromycin, roxithromycin.
- ◆ Recurrent erysipelas may require injection benzathine penicillin (long-term penicillin) monthly for 2 years.

## ERYSIPELOID DISEASE

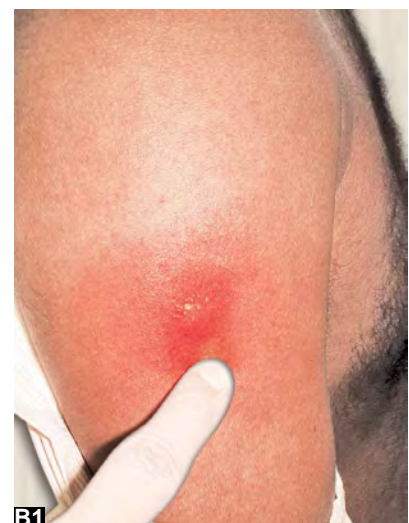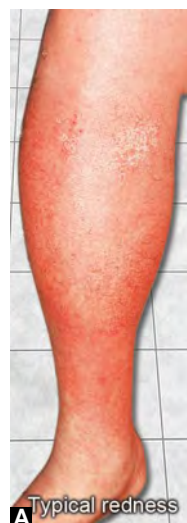- ◆ Also called as 'Fish handler's disease.'
- ◆ Occurs following any cuts or scratches.
- ◆ It has features of both erysipelas and cellulitis.
- ◆ It is self-limiting with relatively mild symptoms.

## ■ LYMPHANGITIS

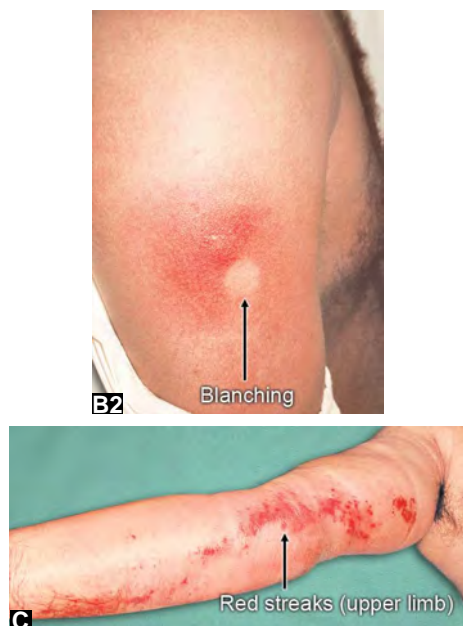- ◆ It is an acute *nonsuppurative* infection and spreading inflammation of lymphatics of skin and subcutaneous tissues due to *beta haemolytic streptococci*, staphylococci, clostridial organisms. It is commonly associated with cellulitis. Erysipelas is a type of lymphangitis.
- ◆ In endemic areas, filariasis is the most common cause (coastal India). It is caused by *Wuchereria bancrofti*. It is transmitted through bites of *Culex* mosquito. Microfilaria reaches the lymph node forming adult worm which blocks the lymph node causing obstruction, fibrosis and lymphangitis.
- ◆ Usually *lymphangitis* due to bacterial infection occurs following a small trauma. Rapidly affected area develops *warmness and redness*.

### Features

- ◆ Streaky redness which is spreading is typical. On pressure area *blanches*; on release redness *reappears*.
- ◆ Oedema of the part, palpable tender *regional lymph nodes* are obvious.
- ◆ Fever, tachycardia, features of toxaemia.
- ◆ Groin lymph nodes are enlarged and tender in *lower limb* lymphangitis. In *upper limb*, as lymphatics are mainly located on the dorsum of hand, oedema and redness develops on the dorsum. Infection in thumb and index finger causes palpable tender axillary nodes; in little and ring finger causes first tender palpable epitrochlear nodes to appear; infection in middle finger causes first deltopectoral nodes to enlarge.
- ◆ Regional lymph nodes (only) may eventually suppurate to form an *abscess*.
- ◆ *Toxaemia, septicaemia* may occur. Rapidity may be more in diabetics and immunosuppressed.
- ◆ *Chronic lymphangitis* occurs due to repeated attacks of acute recurrent lymphangitis leading into acquired *lymphoedema*.



Figs 1.98A and B1

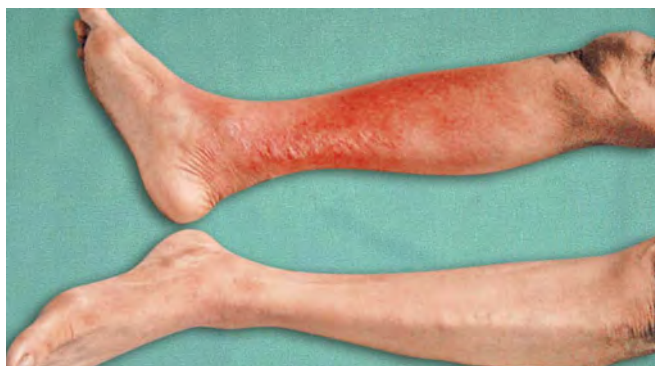

Figs 1.98B2 and C

**Figs 1.98A to C:** (A) Lymphangitis of lower limb showing redness. (B1) Lymphangitis of upper limb; (B2) Blanching is seen immediately after pressure; (C) Typical red streaks in an upper limb lymphangitis.

## Management

- ◆ Blood count, platelet count, renal and liver function tests, peripheral smear and blood culture—are needed investigations.
- ◆ Antibiotics like penicillin, cloxacillin.
- ◆ Elevation, rest, glycerine magnesium sulphate dressing.
- ◆ Management of toxæmia or septicaemia with critical care.



**Fig. 1.99:** Lymphangitis of one leg. Note the typical streaky redness compare to normal side.

## ■ ABSCESS

*If you examine a swelling of pus in any limb of a man and you find it (with) its head raised and it is enclosed and it is rounded, you shall say concerning it: "a swelling of pus, an illness which will be treated by me with the knife treatment. There is something in it like mucus. Something comes forth like wax. It makes a pocket. If anything (remains) in its pocket, it recurs."*

—(Anonymous), circa 1500 BC

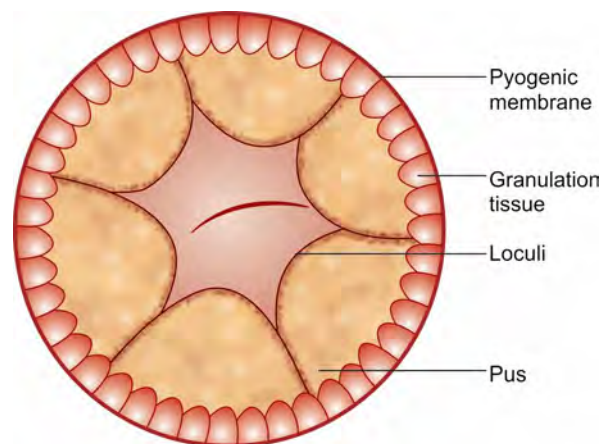
### Types

- ❖ Pyogenic abscess
- ❖ Pyaemic abscess
- ❖ Metastatic abscess
- ❖ Cold abscess due to chronic infection like tuberculosis

## Pyogenic Abscess

It is a **localised collection** of pus in a cavity lined by granulation tissue, covered by pyogenic membrane. It contains pus in loculi. Pus contains dead WBC's, multiplying bacteria, toxins and necrotic material.

- ◆ Protein exudation causes fibrin deposition and formation of pyogenic membrane.
- ◆ Macrophages and polymorphs release lysosomal enzymes which cause liquefaction of tissues leading into pus formation.
- ◆ Toxins and enzymes released causes tissue destruction and pus formation.



**Fig. 1.100:** Pyogenic abscess—parts.

## Mode of Infection

- ❖ Direct
- ❖ Haematogenous
- ❖ Lymphatics
- ❖ Extension from adjacent tissues

## Bacteria Causing Abscess

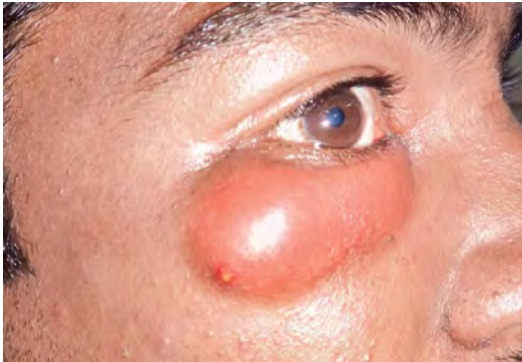- ◆ *Staphylococcus aureus*.
- ◆ *Streptococcus pyogenes*.
- ◆ Gram-negative bacteria (*E. coli*, *Pseudomonas*, *Klebsiella*).
- ◆ Anaerobes.

### Factors precipitating abscess formation

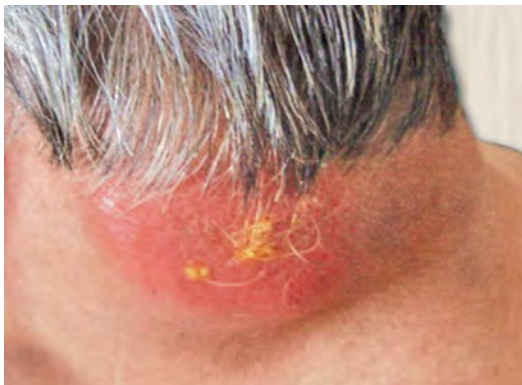- ❖ General condition of the patient: Nutrition, anaemia, age of the patient
- ❖ Associated diseases: Diabetes, HIV, immunosuppression
- ❖ Type and virulence of the organisms
- ❖ Trauma, haematoma, road traffic accidents

**Clinical Features**

- ◆ Fever often with chills and rigors.
- ◆ Localised swelling which is smooth, soft and fluctuant.
- ◆ Visible (pointing) pus.
- ◆ Throbbing pain and pointing tenderness.
- ◆ Brawny induration around.

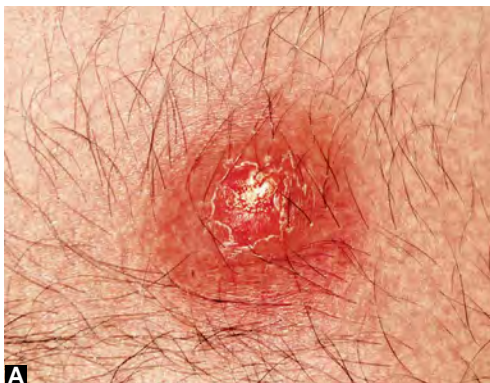

**Fig. 1.101:** Abscess in the face. Note the localisation and redness.

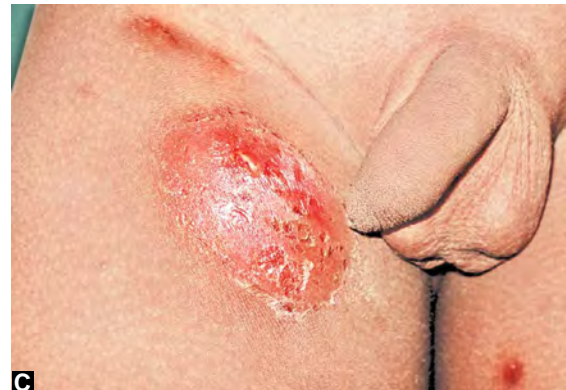
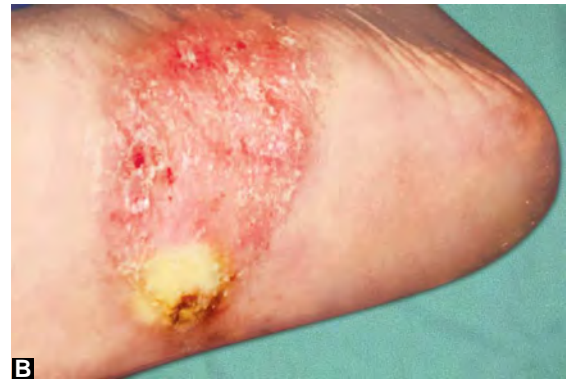
**Fig. 1.102:** Abscess in the nape of the neck—suboccipital region. Note the redness and visible pus. Patient is diabetic.

- ◆ Redness and warmth with restricted movement around a joint.
- ◆ *Rubor* (redness); *dolor* (pain); *calor* (warmness); *tumour* (swelling) and *functiolaesa* (loss of localised and adjacent tissue/joint function) are quite obvious. (Commonly cellulitis occurs first which eventually gets localised to form an abscess.)



**Fig. 1.103A**



**Figs 1.103B and C**

**Figs 1.103A to C:** Pyogenic abscess in different locations in chest wall; in plantar aspect of the foot and in the thigh. Note the redness and visible pus.

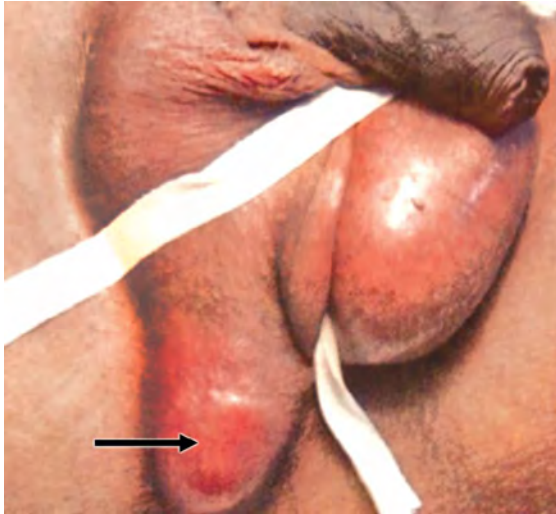
*Visible (pointing) pus, tenderness, fluctuation are the features of formed abscess.*

<b>Cellulitis</b>	<b>Pyogenic abscess</b>
• Diffused—no edge	• Well-localised with clear edge
• Pus not formed—non-suppurative initially	• Formed pus
• Not fluctuant	• Fluctuant
• Spreading—SIRS can occur	
• Blood culture may be negative	• Culture of pus is usually positive
• Never incise; if done danger of bacteraemia. Antibiotics, elevation, dressing—are treatment	• Drainage is essential

**Sites of Abscess**

a. *External Sites*

- ◆ Fingers and hand.
- ◆ Neck.
- ◆ Axilla.
- ◆ Breast.
- ◆ Foot, thigh—here it is deeply situated with brawny induration.
- ◆ Ischiorectal and perianal region.
- ◆ Abdominal wall.
- ◆ Dental abscess, tonsillar abscess and other abscesses in the oral cavity.



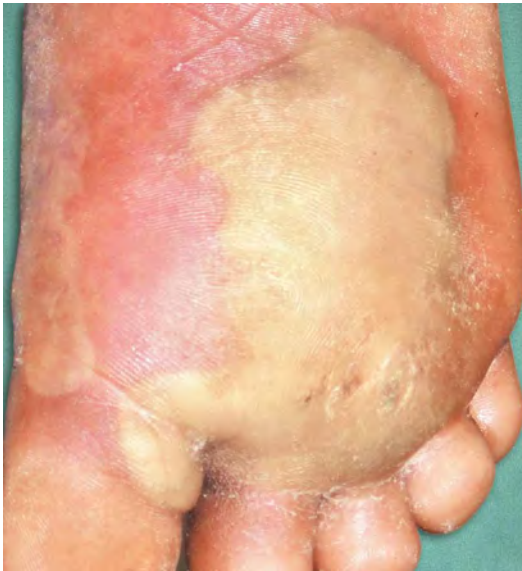**Fig. 1.104:** Perineal abscess.

#### b. Internal Abscess

- ◆ Abdominal: Subphrenic, pelvic, paracolic, amoebic liver abscess, pyogenic abscess of liver, splenic abscess, pancreatic abscess.
- ◆ Perinephric abscess.
- ◆ Retroperitoneal abscess.
- ◆ Lung abscess.
- ◆ Brain abscess.
- ◆ Retropharyngeal abscess.

#### Investigations

- ◆ Total count is increased.
- ◆ Urine sugar and blood sugar is done to rule out diabetes.
- ◆ USG of the part or abdomen or other region is done when required.



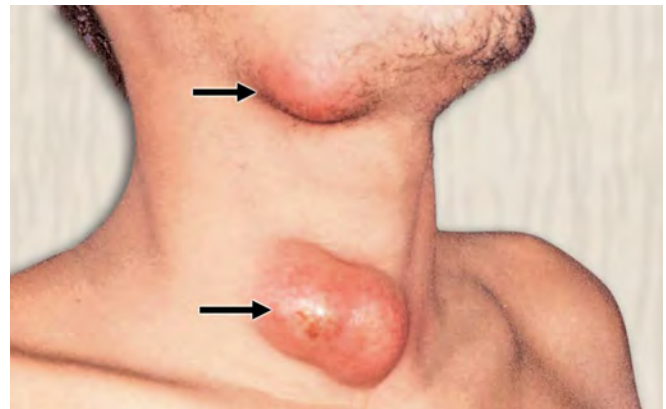**Fig. 1.105:** Abscess in plantar aspect of foot. Note the visible pus.

- ◆ Chest X-ray in case of lung abscess.
- ◆ Gallium isotope scan is *very useful*.

- ◆ CT scan or MRI is done in cases of brain and thoracic abscess.
- ◆ Investigations, relevant to specific types: Liver function tests, PO<sub>2</sub> and PCO<sub>2</sub> estimation, blood culture.

#### Complications of an abscess

- ❖ Bacteraemia, septicaemia, and pyaemia.
- ❖ Multiple abscess formation.
- ❖ Metastatic abscess.
- ❖ Destruction of tissues.
- ❖ *Antibioma formation* (common in breast abscess). Once abscess forms, thick fibrous tissue develops around abscess cavity because of antibiotics. Cavity contains sterile pus as thick flakes. It is nontender, localised, smooth, hard swelling which may mimic carcinoma (in breast—carcinoma breast). It should be differentiated clinically from carcinoma (it is not progressive whereas carcinoma is progressively increasing). FNAC is essential to differentiate. Antibioma should be excised.
- ❖ Sinus and fistula formation.
- ❖ Large abscess may erode into adjacent vessels and can cause life-threatening torrential haemorrhage, e.g. as in pancreatic abscess.
- ❖ Abscess in head and neck region can cause laryngeal oedema, stridor and dysphagia.
- ❖ Specific complications of internal abscess:
  - Brain abscess can cause intracranial hypertension, epilepsy, neurological deficit.
  - Liver abscess can cause hepatic failure, rupture, jaundice.
  - Lung abscess can lead to bronchopleural fistula or septicaemia or respiratory failure or ARDS.



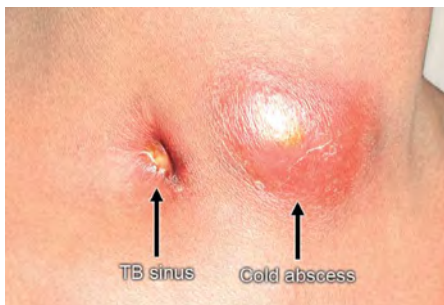
**Fig. 1.106:** Multiple abscesses in neck, chin, face. It is common in HIV, diabetes and immunosuppressed.

#### Differential Diagnosis

- ◆ **Aneurysm:** Especially in popliteal, femoral and axillary regions. So before draining the abscess, presence of pus is confirmed by aspirating with a needle. It should be remembered that thrombosed aneurysm may not be pulsatile but can be warm, soft and tender.
- ◆ **Soft tissue tumours:** Sarcomas may be smooth, soft and warmer.
- ◆ **Haematoma.**
- ◆ **Cold abscess.**

**Differences between pyogenic abscess and cold abscess**

<b>Pyogenic abscess</b>	<b>Cold abscess</b>
a. Red, warm, tender, with signs of acute inflammation	a. No signs of acute inflammation
b. Pyogenic bacteria are nonspecific organisms ( <i>Streptococcus, Staphylococcus</i> )	b. Tuberculous bacteria
c. For drainage, dependent incision is used	c. Nondependent incision is used
d. Suturing of the wound is not done	d. Wound is sutured
e. Drain is placed	e. Drain is not placed (otherwise sinus will form which is difficult to treat)



**Fig. 1.107:** Typical cold abscess and tuberculous sinus in the neck. It does not show signs of acute inflammation. It should be drained (under cover of antituberculous drugs) through *nondependent incision* and incision should be closed without placing a drain.

**Features of a formed abscess**

- ❖ Visible pus
- ❖ Pointing tenderness
- ❖ Fluctuation
- ❖ Excruciating pain

**Treatment of an Abscess**

**Abscess should be formed before draining. Exceptions for this rule are:**

- ❖ Parotid abscess
- ❖ Breast abscess
- ❖ Axillary abscess
- ❖ Thigh abscess
- ❖ Ischiorectal abscess

**Note:**

- Pus anywhere will come to surface; pus anywhere should be drained.
- "Pus is like the truth—you have to let it out."—**Gareth Morris-Stiff**

**Procedure**

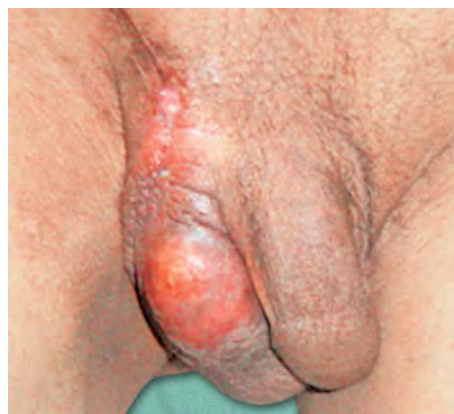**Hilton's method** of draining an abscess.

- ◆ Initially broad spectrum antibiotics are started (depending on severity, extent and site of the abscess).
- ◆ Under general anaesthesia or regional block anaesthesia,\* after cleaning and draping, abscess is aspirated and presence of pus is confirmed.

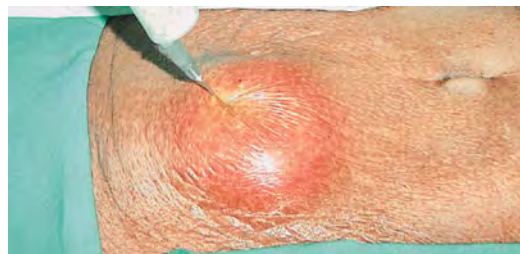\* As the pus is acidic local anaesthetic agent will not act and hence it is not used.

\*\* Sinus forceps do not have lock and has got serrations in the tip. It is called as sinus forceps because it was initially designed and used to pack sinuses.

- ◆ Skin is incised *adequately*, in the line parallel to the neurovascular bundle in the most dependent position.
- ◆ Next, pyogenic membrane is opened using **Sinus forceps**\*\* and all loculi are broken up. Abscess cavity is cleared of pus and washed with saline.
- ◆ A **drain** (either gauze drain or corrugated rubber drain) is placed.
- ◆ Wound is **not closed**. Wound is allowed to granulate and heal.
- ◆ Pus is sent for **culture and sensitivity**.
- ◆ Biopsy should be done in suspected tuberculosis or malignancy.
- ◆ Sometimes *secondary suturing* or *skin grafting* is required.
- ◆ Antibiotics are continued.
- ◆ Treating the **cause** is important.



**Fig. 1.108:** Scrotal abscess, which is well-localised and ready for drainage. Patient has undergone surgery for hernia earlier.



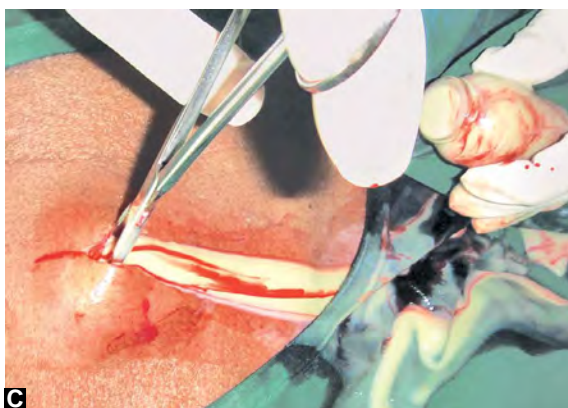
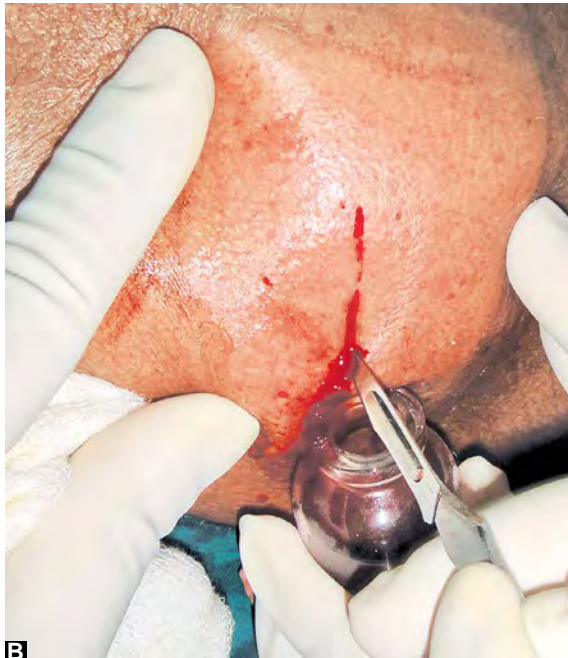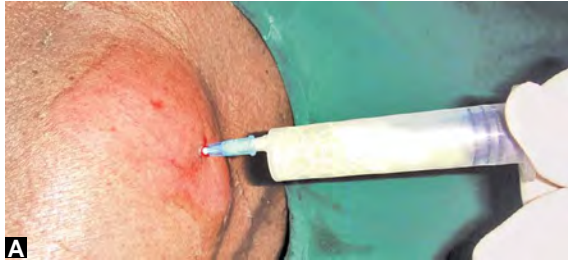**Fig. 1.109:** Abdominal wall abscess being aspirated. Note the aspirated pus in the syringe. Abscess should be aspirated prior to drainage.

**Note:**

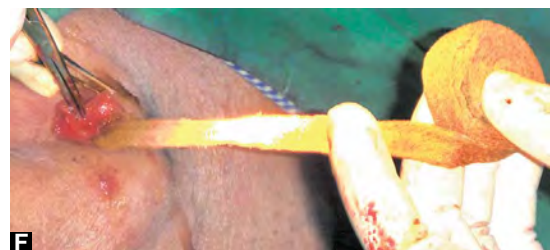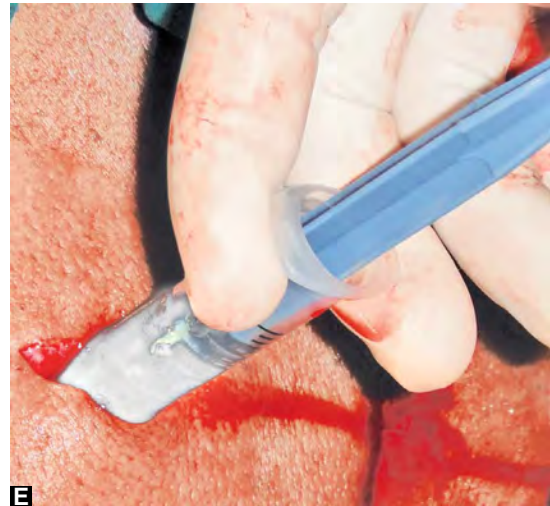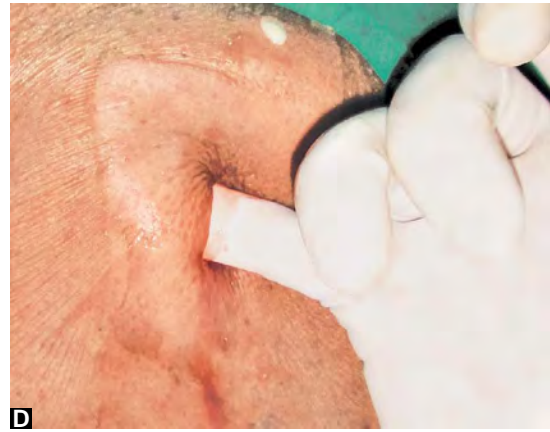- Counter-incision is placed in breast abscess which is placed in upper quadrant.
- Incision should be deeper while draining pus in radial and ulnar bursa, palmar spaces and tenosynovitis.

**Problems in drainage**

- ❖ Improper drainage
- ❖ Bleeding
- ❖ Residual abscess or sinus formation

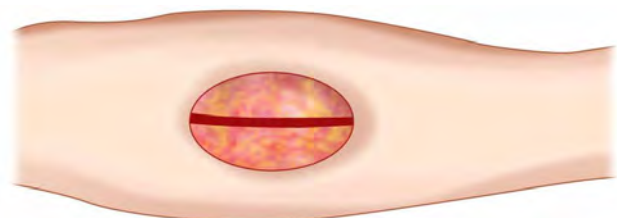


Figs 1.110A to C

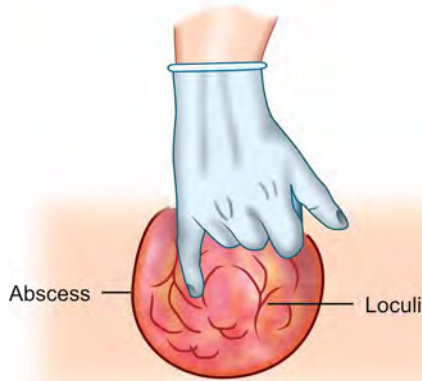


Figs 1.110D to F

**Figs 1.110 A to F:** Technique of incision and drainage of a pyogenic abscess. Abscess should be aspirated first to get pus; No. 11 blade is used to incise; using sinus forceps pyogenic membrane is opened; pus is collected for culture; loculi are broken using sinus forceps and little finger; cavity is irrigated with *normal saline (ideal)*; cavity is packed with roller gauze; wound is not sutured.



**Fig. 1.111:** Incision for draining an abscess by Hilton's method. Note the longitudinal incision.



**Fig. 1.112:** Abscess with loculi and breaking of loculi using finger for drainage.

## ■ METASTATIC AND PYAEMIC ABSCESS

### *Metastatic abscess*

- ◆ It is an abscess which occurs as a spread from other abscess. For example, lung abscess causing metastatic abscess in the brain (common example).
- ◆ Presentation here is of features of focus abscess and of metastatic abscess (localised features).

### *Pyaemic abscess*

- ◆ It is from any infective focus which need not be always from an abscess (from cellulitis or skin infections, etc.) causing pyaemic emboli leading into multiple abscess in different places like brain, kidneys, liver, etc.
- ◆ Presentation here, is mainly of systemic features involving multiple organs with toxicity.
- ◆ These emboli contain bulk of multiplying organisms often derived from infective thrombus or vegetations. Focus may be an abscess, cellulitis, skin infection, acute osteomyelitis, and acute bacterial endocarditis. Acute appendicitis with severe sepsis can cause infective pyaemia in liver called as *pyelphlebitis* or *portal pyaemia*.
- ◆ Pyaemic abscess are multiple, deeper, beneath the fascia or in the internal organs. When it is on the surface, it is less tender without any clear signs of inflammation.
- ◆ Pyaemic abscess carries high mortality with SIRS and MODS.
- ◆ **Management:**
  - ▶ Evaluation for focus of infection, pus for culture, blood culture (three samples), antibiotics, critical care, systemic therapy, drainage of surface abscesses.

## ■ BACTERAEMIA

Presence of bacteria in blood.

## ■ SEPTICAEMIA

Presence of overwhelming and multiplying bacteria in blood with toxins causing SIRS (Systemic inflammatory response syndrome) or MODS (Multiorgan dysfunction syndrome).

## Types

### a. *Gram +ve septicaemia*

It is due to staphylococci, streptococci, pneumococci, etc. It is common in children, old age, diabetics and after splenectomy. After splenectomy, overwhelming post-splenectomy sepsis (OPSI) is not uncommon. Common origin is skin, respiratory infection.

### b. *Gram -ve septicaemia*

It is common in acute abdomen like peritonitis, abscess, urinary infections, biliary infections, postoperative sepsis. It is commonly seen in malnutrition, old age, diabetics, immunosuppressed people. Common bacteria are *E. coli*, *Klebsiella*, *Pseudomonas*, *Proteus*. Condition is also called endotoxic shock. Common focus of Gram-negative sepsis are urinary infection, abscess or infected wounds, biliary sepsis, postoperative wounds.

## Stages of Gram-negative Septicaemia

- a. **Warm stage** is reversible stage. Here existing fever is due to pyrogenic response. Patient is toxic with fever, chills and rigors.
- b. **Cold stage** is irreversible stage. Here fever is not present due to absence of pyrogenic response. Patient is having renal failure, ARDS, liver failure and multiorgan failure.

## Investigations

- ◆ Urine/pus/discharge culture.
- ◆ Blood culture.
- ◆ Haematocrit.
- ◆ Electrolyte assessment.
- ◆ PO<sub>2</sub> and PCO<sub>2</sub> analysis.
- ◆ Blood urea, serum creatinine, liver function tests.

## Treatment

- ◆ Antibiotics like cefoperazone, ceftazidime, cefotaxime, amikacin, tobramycin, metronidazole.
- ◆ Fresh blood transfusion.
- ◆ Adequate hydration.
- ◆ Oxygen supplementation.
- ◆ Ventilatory support.
- ◆ Electrolyte management.
- ◆ Parenteral nutrition (TPN).
- ◆ CVP line for monitoring and perfusion.
- ◆ FFP or platelets in case of DIC.

### Complications of septicaemia

- ❖ Disseminated intravascular coagulation (DIC)
- ❖ ARDS
- ❖ Liver dysfunction
- ❖ Renal failure
- ❖ Bone marrow suppression—thrombocytopenia
- ❖ Multiorgan failure

## ■ PYAEMIA

Presence of multiplying bacteria in blood as emboli which spread and lodge in different organs in the body like liver,

*In tuberculosis arthritis, starting pain at night is very important, as it attracts more attention than occasional discomfort during the day.*

— Royal Whitmann



lungs, kidneys, spleen, brain causing *pyaemic abscess*. This may lead to *multiorgan dysfunction syndrome (MODS)*. It may endanger life if not treated properly.

#### Clinical features

- ❖ Fever with chills and rigors
- ❖ Jaundice, oliguria, drowsiness
- ❖ Hypotension, peripheral circulatory collapse and later coma with MODS

### Common Causes

- ◆ Urinary infection (*most common*).
- ◆ Biliary tract infection.
- ◆ Lower respiratory tract infection.
- ◆ Abdominal sepsis of any cause.
- ◆ Sepsis in diabetics and immunosuppressed individuals like HIV, steroid therapy.

### Investigations

- ◆ Total leucocyte count, platelet count.
- ◆ C reactive protein.
- ◆ Pus, blood, urine culture depending on need.
- ◆ Blood urea, serum creatinine.
- ◆ Liver function tests, prothrombin time.
- ◆ Chest X-ray, USG abdomen.
- ◆ CT chest/abdomen/brain as needed.
- ◆ Arterial blood gas analysis if needed.

### Treatment

- ◆ Monitoring of vital parameters.
- ◆ Antibiotics (ceftazidime, cefoperazone, ceftriaxone sodium).
- ◆ IV fluids, maintenance of urine output.
- ◆ Hydrocortisone—200–600 mg IV.
- ◆ Blood and plasma transfusion.
- ◆ Nasal oxygen, ventilator support, monitoring of pulmonary function.

### ■ BOIL (Furuncle)

It is an acute staphylococcal infection of a hair follicle with perifolliculitis which usually proceeds to suppuration and central necrosis.

- ◆ Often boil opens on its own and subsides (*S. aureus* infection).
- ◆ Furuncle in external auditory canal is very painful because of rich cutaneous nerves. Here skin is adherent to perichondrium.
- ◆ Boil often heals spontaneously; suppuration will not occur in such boil; it is often called as *blind healed dull boil*.
- ◆ Boil is *common* over back, neck, thigh, and forearm even though it can occur anywhere. Boil in eyelash follicle is called as *stye*. Boil can occur in perianal region which can lead into abscess and fistula. Boil can lead into *hidradenitis*, *common in axilla and pubic region*. Boil can cause *cellulitis* of local area. Overlying skin undergoes necrosis. But during healing re-epithelialisation occurs.
- ◆ Boil commonly *subsides* spontaneously often with the support of suitable antibiotics; occasionally it requires incision and drainage. Regional enlarged tender lymph nodes may be palpable due to secondary infection.
- ◆ Systemic features are *not common* unless it is multiple/ recurrent/ severe or in diabetics and immunosuppressed.
- ◆ Multiple/recurrent boils are *common* in diabetics.

### Treatment

- ◆ Antibiotics given if boil is not resolving spontaneously— *cloxacillin/ amoxicillin*.
- ◆ Rarely drainage of boil is needed in severe persistent form.

### Complications

- ◆ Cellulitis.
- ◆ Lymphadenitis.
- ◆ Hidradenitis (*Infection of group of hair follicles*).
- ◆ Boil in dangerous zone in the face, can cause cavernous sinus thrombosis.

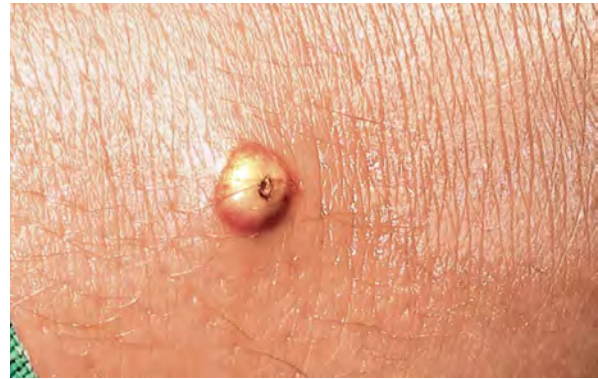

Fig. 1.113: Furuncle/boil are infection of hair follicle with perifolliculitis due to *Staphylococcus aureus*.

### ■ HIDRADENITIS SUPPURATIVA

It is a, *chronic scarring inflammatory acne like* disease of the skin bearing *apocrine* sweat glands. Apocrine sweat glands are coiled glands which open into the hair follicles.

Hidradenitis suppurativa is also known as 'acne inversa'. It occurs commonly in women of menstruating age group; smoking is the important aetiological factor. It may be associated with acne, pilonidal sinus or Crohn's disease.

#### Sites of apocrine sweat glands

- ❖ Axilla
- ❖ Groin
- ❖ Areola
- ❖ Umbilicus
- ❖ Scalp, chest
- ❖ Perineum

### Aetiology

- ◆ Smoking, obesity, poor hygiene, polycystic ovarian disease.
- ◆ Diabetes mellitus, steroid therapy.
- ◆ Genetic causes: It is associated with chromosome 15q24-q25. Multiple members of the family may be affected. It may be associated with pyoderma gangrenosum, acne (PASH syndrome) or/ and pyogenic arthritis (PAPASH syndrome).

#### Note:

Lesion is usually sterile; bacterial infection supervenes in deep abscesses and sinus tracks. *Staphylococcus aureus* and *Propionibacterium acnes* are the common bacteria.

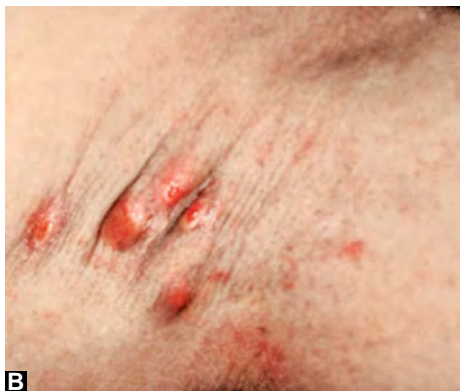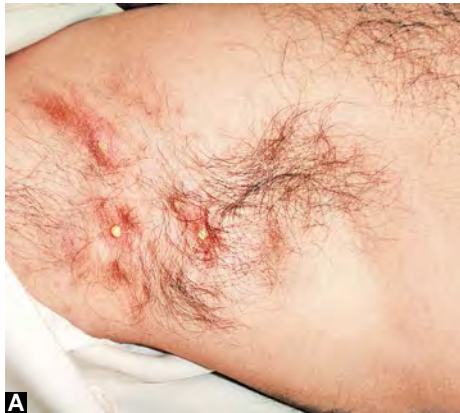**Hurley staging system in hidradenitis suppurativa**

Stage I: Abscess formation, single or multiple, without sinus tracts or scarring.

Stage II: Single or multiple, widely separated, recurrent abscesses with sinus tract formation or scarring.

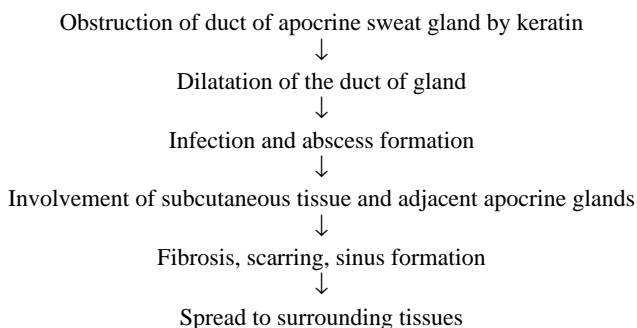
Stage III: Diffuse or near diffuse involvement or multiple interconnected sinus tracts and abscesses across the entire area

**Note:** The Sartorius Hidradenitis Suppurative Scoring is made by counting involved regions, nodules and sinus tracts.



**Figs 1.114A and B:** Hidradenitis suppurativa. It is chronic infection of apocrine sweat glands of the skin. It is common in axilla (Courtesy: Dr Achaleshwar Dayal, MS, Itarsi, MP).

**Pathogenesis**



**Clinical Features**

- ◆ Common in females 4 : 1.
- ◆ The most common site is axilla. Often it is bilateral.
- ◆ Multiple discharging sinuses, with nodules in the skin which is tender.
- ◆ Induration due to fibrosis.

**Note:**

Hidradenitis suppurativa in the anal region rarely may turn into squamous cell carcinoma.

**Investigation**

- ◆ Discharge study—culture/sensitivity and AFB.
- ◆ Biopsy to rule out tuberculosis or malignancy.

**Differential Diagnosis**

- ◆ Tuberculous sinus.
- ◆ Malignancy (squamous cell carcinoma of skin).
- ◆ Lymph node mass in the region which are in *deeper plane*.

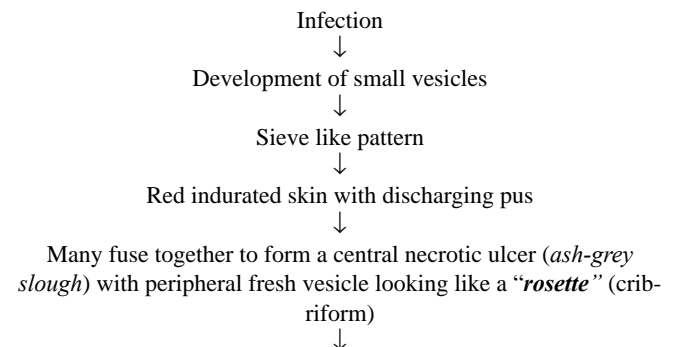
**Treatment**

- ◆ Topical clindamycin 1%; topical resorcinol 15% cream.
- ◆ Oral antibiotics like clindamycin, erythromycin, doxycycline – needs longer course.
- ◆ Infliximab, retinoids (isotretinoin 0.25–0.4 mg/kg) may be used in severe cases.
- ◆ Wide excision (radical excision) of the involved area with skin grafting.
- ◆ Antiandrogen therapy in females using oral estrogen or oral contraceptives or spironolactone or cyproterone acetate or finasteride.
- ◆ Ablative laser (CO<sub>2</sub> or erbium YAG) therapy is an alternate therapy often used

**CARBUNCLE**

Word meaning of carbuncle is **charcoal**.

- ◆ It is an infective gangrene of skin and subcutaneous tissue.
- ◆ **Staphylococcus aureus** is the main culprit.
- ◆ Common site of occurrence is **nape of the neck and back**. Skin in this area is thick. Condition also can occur in shoulder, cheek, hand, forearm.
- ◆ It is common in **diabetics** and after forty years of age.
- ◆ It is common in males.



An external sore may be obvious on external genitalia—hot and tender in gonorrhoea and chancroid, painless and indolent in syphilis. — Angus E.W. McLachlam

Skin becomes black due to blockage of cutaneous vessels



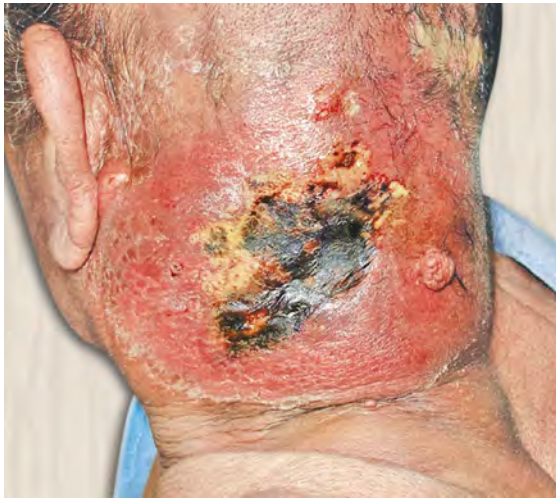Disease spreads to adjacent skin rapidly

Patient is *toxic* and in diabetics they are *ketotic*

In carbuncle, group of hair follicles are involved. Carbuncle is cluster of furuncles connected subcutaneously, causing deeper suppuration and scarring.

### Investigations

- ◆ Urine sugar and urine ketone bodies.
- ◆ Blood sugar.
- ◆ Discharge for C/S.



**Fig. 1.115:** Carbuncle in the nape of the neck—typical site. Note the wide area of involvement and dark area—charcoal like. *Ash-grey slough* is specific.

### Treatment

- ◆ Control of diabetes is essential using insulin.
  - ◆ Antibiotics like penicillins, cephalosporins or depending on C/S is given.
  - ◆ Drainage is done by a cruciate incision and debridement of all dead tissues is done. Excision is done later.
  - ◆ Once wound granulates well, *skin grafting* may be required.
- Renal Carbuncle** is an entity which occurs in kidney due to infection, forming localized infective mass lesion.

### ■ POTT'S PUFFY TUMOUR

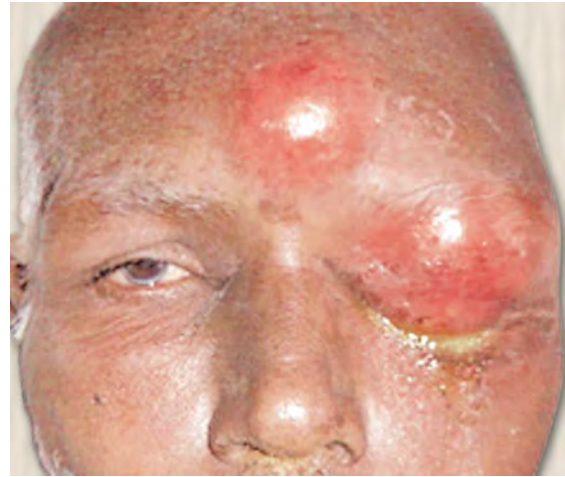- ◆ It is a misnomer. It is not a tumour.
- ◆ It is formation of diffuse external swelling in the scalp due to **subperiosteal pus** formation (abscess) and **scalp oedema**.
- ◆ It originates commonly in frontal region and may extend into other regions.
- ◆ There is acute *osteomyelitis* of frontal bone.

### Causes

- ◆ Chronic frontal sinusitis which eventually suppurates and extends into subperiosteal region.
- ◆ Trauma—subperiosteal haematoma.
- ◆ Chronic suppurative otitis media.

### Features

- ◆ Pain and *boggy swelling in frontal region* which is warm, tender.
- ◆ Toxicity and drowsiness.
- ◆ Pitting scalp oedema is typical.
- ◆ *Investigations:*
  - ▶ Total leucocyte count—increased. ESR—raised.
  - ▶ X-ray skull. CT scan.
- ◆ *Differential diagnosis:* Secondaries in the skull or brain.



**Fig. 1.116:** Pott's Puffy tumour. Note the swelling over the frontal region and eyelid.

### Complications

- ❖ Osteomyelitis of frontal bone.
- ❖ Spread of infection into intracranial cavity leads to intracranial abscess (Extradural or subdural abscess) (dumb-bell abscess). So may present with features of raised intracranial tension like headache, coning and convulsions.
- ❖ Pott's Puffy tumor can be associated with cortical vein thrombosis, epidural brain abscess/subdural empyema. The cause of vein thrombosis is explained by diploic veins in frontal bone, which communicates with the dural venous plexus; septic thrombi can potentially evolve from foci within the frontal sinus and propagate through this venous system.

### Treatment

- ◆ Antibiotics and drainage under general anaesthesia before it spreads into cranial cavity.
- ◆ Once it extends into cranial cavity, it is treated accordingly by formal neurosurgical decompression (often using *Dandy's brain cannula*).
- ◆ Osteomyelitis of skull bones requires radical removal with reconstruction of skull defect.

### ■ PYOGENIC GRANULOMA (GRANULOMA PYOGENICUM)

- ◆ It is a common condition which occurs on the face, scalp, fingers and toes.
  - ◆ It may be due to minor trauma or minor infection.
  - ◆ Infection leads to formation of unhealthy granulation tissue which protrudes through the wound.
- It is also called as acquired lobular capillary haemangioma.

## Clinical Features

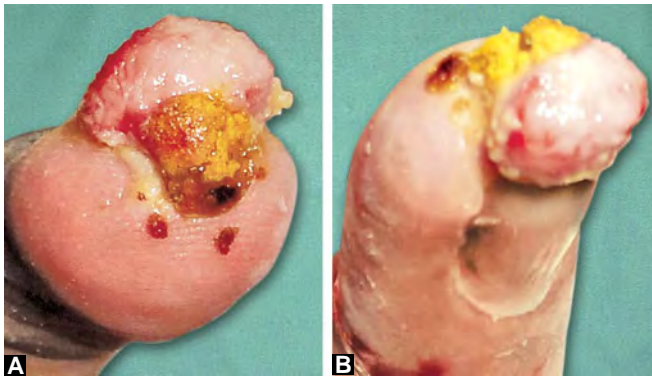
- ◆ Usually single, well localised, red, firm, nodule, which bleeds on touch.
- ◆ May or may not be tender.

### Sites

- ❖ Face
- ❖ Scalp
- ❖ Fingers
- ❖ Toes

## Differential Diagnosis

- ◆ Haemangioma.
- ◆ Papilloma.
- ◆ Skin adnexal tumours.
- ◆ In recurrent cases, haemangioendothelioma and melanoma.



Figs 1.117A and B: Pyogenic granuloma finger.

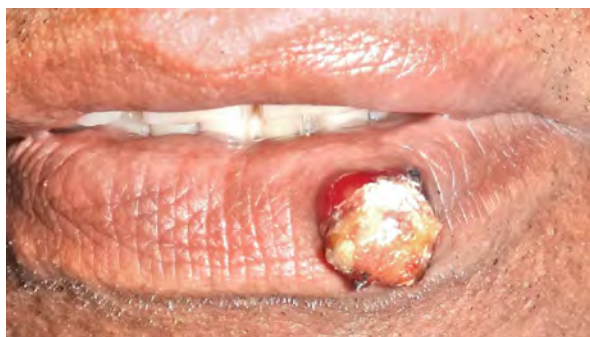

Fig. 1.118: Pyogenic granuloma lower lip.

## Treatment

- ◆ Excision, laser surgery.
- ◆ Tissue to be sent for histopathological study.

## IMPETIGO

- ◆ It is highly infectious superficial skin infection caused commonly by staphylococcus but sometimes by streptococcal organisms.
- ◆ It usually occurs in infants and children with formation of multiple blisters in the face, neck and hands that rupture and coalesce to cover with honey coloured crust.

- ◆ Red sores, itchy rashes, tender regional lymph nodes are typical.
- ◆ Impetigo may be non bullous (impetigo contagiosa, most common, common in nose and mouth); bullous (common in < 2 years, common in body/arms/legs); ecthyma (most serious form involving deeper layer of the skin).
- ◆ *Staphylococcus aureus* causes most nonbullous impetigo and all bullous impetigo.
- ◆ *Ecthyma* is an ulcerative form of impetigo. Ecthyma is characterized by small, purulent, shallow, punched-out ulcers with thick, brown-black crusts and surrounding erythema.
- ◆ For persistent impetigo, culture of the wound (to identify MRSA) and the nose (to identify a causative nasal reservoir) is needed.
- ◆ Treatment is oral antibiotics and topical antiseptics (Mupirocin, fusidic acid).

## ERYTHRASMA

- ◆ It is the infection caused by *Corynebacterium minutissimum* involving *foot*, *groin*, axilla, subumbilical area and perineum mimicking the tinea or intertrigo.
- ◆ It is common in diabetics, obesity; common in females.
- ◆ Superficial scaling, fissuring and maceration are common. In groin, pink brown marginated patch with fine scaling is common.
- ◆ Erythrasma fluoresces a typical coral red color under a wood light. Absence of hyphae in skin scrapings differentiates it from tinea.
- ◆ Treatment is topical and oral erythromycin or clindamycin.

## SCRUM POX

- ◆ *Scrum pox* is a disease seen in *rugby players* (athletes with close contact sports) wherein infection occurs during scrumming. It is usually caused by Herpes rubiorum or Herpes rubgiaforum (Herpes simplex virus type 1).
- ◆ Scrum pox like condition can also be caused by *Streptococcus pyogenes* where it is called as '*scrum strep*'. Similar infection seen in wrestlers caused by Herpes gladiatorum and is called as '*mat pox*'.
- ◆ Rugby players within the scrum (forwards position) are more prone for infection.
- ◆ Vesicular lesions with pain, fever are the usual features.
- ◆ Infection may complicate as keratitis, corneal scarring, sacral ganglionitis and meningitis.
- ◆ Antiviral drug like acyclovir (200 mg 5 times a day for 10 days) is the treatment. Valacyclovir is also used.

## TETANUS

*It is painful for him to open his mouth. His heart beats too slowly (or weakly) for speech. You observe his saliva falling from his lips, but not falling completely....He suffers stiffness in his neck. He does not find he can look at his two shoulders and his breast.*

—(Anonymous), Circa 1500 BC

It is an infective condition caused by *Clostridium tetani* organisms leading to reflex muscle spasm, often associated with tonic clonic convulsions.

*Even if you're on the right track, you'll get runover if you just sit there. — Arthur Godfrey*

## Predisposing Factors for Tetanus

- ◆ Absence of prior tetanus toxoid immunisation.
- ◆ Trauma with lacerations, deep wounds, crush devitalised wounds, presence of foreign body, wounds with anaerobic environment in the tissues.
- ◆ Chronic suppurative otitis media with perforation, caries teeth.
- ◆ Improper sterilisation in the ward, labour (septic abortion) and operation theatre.
- ◆ Tattooing, rusted nails (there is a myth that only rusted instrument will cause tetanus; this is not true), ear lobe prick, colloquial perianal therapies,

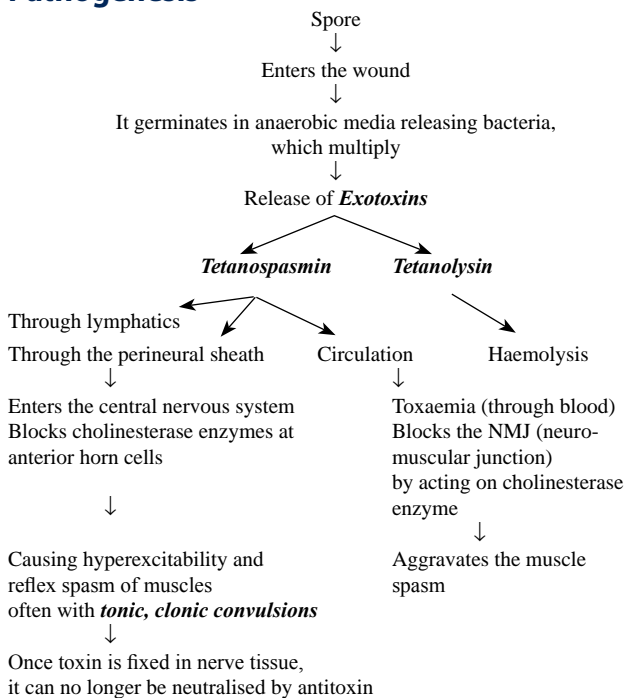
### Note:

**Tetanus** is not communicable from person to person.

## Organism

- ◆ *Clostridium tetani* is a Gram-positive, anaerobic, motile, noncapsulated, organism with peritrichous flagella, and terminal spores (Drum stick/tennis racket appearance).
- ◆ Spore is the infective agent. They are found in soil, manure, dust.
- ◆ Spore can gain entry through any wound, pricks, injuries resulting from road traffic accidents, penetrating injuries.

## Pathogenesis



*Cranial nerves involved in tetanus* – trigeminal (trismus); facial (risus sardonius); vestibulocochlear nerve (hyperacusis); vagus and hypoglossal (dysphagia).

## Toxins

- ◆ Exotoxins released by *Clostridium tetani* are tetanospasmin and tetanolysin (Exotoxin is the one which is released from bacteria without their destruction/death. Endotoxin is the one which is released with death of the bacteria). Tetanus bacteria release only exotoxins.

- ◆ Tetanospasmin, the common exotoxin released by the multiplying bacteria once spore germinates travels along the perineural sheath, lymphatics along the nerve, and through blood to cause various effects.

*Tetanospasmin* is oxygen stable, heat labile exotoxin (zinc dependent metalloproteinase) and is a single polypeptide chain of 150 KDa which gets cleaved into light (fragment A, 50 KDa) and heavy (fragment B, 100 KDa) parts; fragment B part binds to nerve receptors; fragment A blocks neurotransmitter. It blocks the release of inhibitory neurotransmitters glycine and gamma amino butyric acid (GABA). Loss of inhibition alters (increases) the firing rate of  $\alpha$  motor neuron causing rigidity, spasm, sympathetic overactivity. Tetanospasmin rapidly binds to gangliosides at the presynaptic membrane of inhibitory motor nerve endings.

## Clinical Features

### Symptoms

- ◆ Trismus is the most common symptom
- ◆ Jaw stiffness, pain and stiffness in the neck and back muscles
- ◆ Anxiousness, sweating
- ◆ Headache, delirium, sleeplessness
- ◆ Dysphagia
- ◆ Dyspnoea

## Signs

- ◆ Trismus, due to spasm of masseter and pterygoids.
- ◆ Risus sardonius (smiling facies), a rigid smile due to spasm of the facial muscle—zygomaticus major. Looks as if patient is smiling.
- ◆ Neck rigidity.
- ◆ Spasm and rigidity of all muscles.
- ◆ Hyperreflexia.
- ◆ Respiratory changes—due to laryngeal muscle spasm, infection, aspiration.
- ◆ Tonic clonic convulsions.
- ◆ Abdominal wall rigidity often with haematoma formation.
- ◆ Severe convulsion may often lead to fractures, joint dislocations and tendon ruptures.
- ◆ Fever and tachycardia.
- ◆ Retention of urine (due to spasm of urinary sphincter), constipation (due to rectal spasm).
- ◆ Rarely features of carditis are seen due to involvement of the cardiac muscle, which is dangerous, as it often leads to cardiac arrest and death. Here steroids are very useful. It presents with refractory bradycardia.
- ◆ Symptoms will be aggravated by stimuli like light, noise.

### Incubation period

- ◆ Time between the entry of spore and appearance of first symptom
- ◆ Usually 7-10 days
- ◆ Shorter the incubation period worse the prognosis and more severe the course of disease. If it is less than 3 days it is commonly fatal

### Period of onset

- ❖ Time between appearance of first symptom and appearance of first sign
- ❖ Shorter the period of onset worse the prognosis and vice versa. If it is less than 2 days it is commonly fatal

### Effects on Respiratory System

Diaphragm and other muscles of respiration undergo spasm causing tachypnoea, respiratory distress, respiratory infections, aspiration, cyanosis, respiratory failure with altered PO<sub>2</sub> and PCO<sub>2</sub> levels.

### Types of Tetanus

#### Types of tetanus

- ❖ Generalized—commonest
- ❖ Localized—less severe
- ❖ Cephalic—facial nerve muscles
- ❖ Neonatal tetanus

- ❖ **Early tetanus:** It is a severe form with a short incubation period and poor prognosis.
- ❖ **Latent tetanus:** Wound is healed and forgotten. After a long incubation period, may be years later, under favourable environment, spores release bacteria and cause tetanus. It carries better prognosis. Latent tetanus is often called as *delayed tetanus*.
- ❖ **Late tetanus:** Disease develops many months after injury.
- ❖ **Ascending tetanus:** Symptoms and signs progress from below upwards.
- ❖ **Descending tetanus:** Symptoms and signs progress from above downwards.
- ❖ **Cephalic tetanus:** Facial muscles are involved first (3rd, 4th, 6th and 7th cranial nerves can get involved). Facial nerve is commonly involved in this type. Oculomotor nerve—3rd nerve (*ophthalmoplegia*), hypoglossal nerve—12th nerve (*spasm of tongue*) are other cranial nerves involved.
- ❖ **Localised tetanus:** Here muscles adjacent to the wound or muscles of one segment or one area develop spasm. It is due to less virulent toxin or released toxins are of less concentration or only one or few segments of anterior horn cells of the spinal cord are affected.
- ❖ **Bulbar tetanus:** When muscles of deglutition and respiration are involved. Highly fatal.
- ❖ **Tetanus neonatorum** (7th day tetanus): Tetanus occurring in neonates. Spread is through umbilical cord. It carries very high, nearly 100% mortality.
- ❖ **Urban tetanus.** Due to repeated injections in IV drug abusers.
- ❖ **Post-operative tetanus** due to improper sterilisation.
- ❖ Even though it is classified as *acute tetanus* (tetanus develops within 10 days) or *chronic tetanus* (tetanus develops from 10 days to 3 months) it is only of outcome value as therapy will be same in both.
- ❖ **Post-abortion or puerperal tetanus** develops due to practice of improper sterilisation during abortion or delivery.
- ❖ If patient is not given tetanus toxoid during the first attack, he can develop second attack of tetanus at a later period called as *recurrent tetanus* as patient who had once tetanus is not immune for development of second attack of tetanus.
- ❖ In children and adolescents chronic suppurative otitis media (CSOM) with perforation of tympanic membrane can cause tetanus—*otitis tetanus*.

### Different Postures in Tetanus

- ❖ **Opisthotonus:** Posterior muscles are acting more, so *backward bending*.
- ❖ **Orthotonus:** *Straight posture*. Both front and back muscles are acting equally.
- ❖ **Emprosthotonus:** *Forward bending* as front muscles are acting more.
- ❖ **Pleurothotonus:** *Lateral bending* as lateral muscles act more.

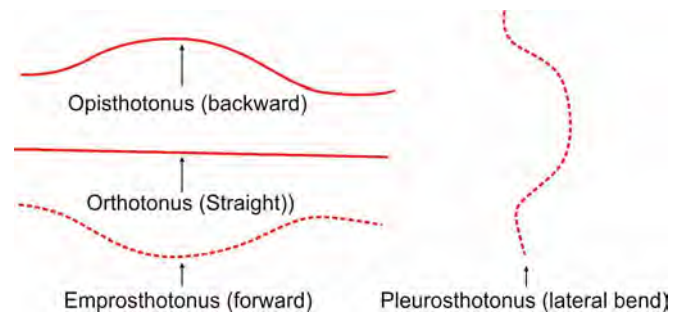


Fig. 1.119: Different types of postures seen in tetanus.

#### Complications of tetanus

- ❖ Fracture bones
- ❖ Haematoma
- ❖ Aspiration pneumonia, respiratory failure, ARDS
- ❖ Carditis, arrhythmias—life-threatening
- ❖ DVT, pulmonary embolism
- ❖ Toxaemia
- ❖ Secondary infection—septicaemia
- ❖ Bedsore, malnutrition, stress gastric ulcers
- ❖ Mortality used to be very high in earlier days up to or more than 50%. It is reduced to 15–20% at present; but it is still higher in children and elderly
- ❖ Repeated uncontrollable convulsions can lead into coma and death.

#### Staging of tetanus

- ❖ Mildly ill: Rigidity, spasm, trismus and different postures.
- ❖ Seriously ill: Spasm, rigidity, severe respiratory infections, dysphagia.
- ❖ Dangerously ill: Cyanosis with respiratory failure and tonic-clonic convulsions, cyanosis.

#### Ablett classification of severity grading of tetanus

- ❖ I Mild: mild to moderate trismus; general spasticity; no respiratory embarrassment; no spasms; little or no dysphagia.
- ❖ II Moderate: moderate trismus; well-marked rigidity; mild to moderate but short spasms; moderate respiratory embarrassment with an increased respiratory rate greater than 30; mild dysphagia.
- ❖ III Severe: severe trismus; generalized spasticity; reflex prolonged spasms; increased respiratory rate greater than 40; apnoeic spells; severe dysphagia; tachycardia greater than 120.
- ❖ IV Very severe: grade III and violent autonomic disturbances involving the cardiovascular system. Severe hypertension and tachycardia alternating.

**Note:** Several other severity grading systems are adapted like of Philips, Dakar, Udawadia, Black, Patel and Jong method.

### Differential diagnosis

- ❖ Strychnine poisoning (here patient is normal in between): Strychnine blocks *synopsis*
- ❖ Trismus due to other causes like—dental, oral, tonsillar sepsis, oral malignancy, temporomandibular joint dysfunction
- ❖ Meningitis
- ❖ Hydrophobia
- ❖ Convulsive disorders
- ❖ Metabolic cause like hypocalcaemia and hypomagnesaemia and hypoglycaemia
- ❖ Drug induced extrapyramidal reaction by metoclopramide, phenothiazines

**Culture media** for *Clostridium tetani* are RCM (Robertson's cooked meat) media and nutrient agar.

## Management of the Tetanus

### Isolation

- ◆ Isolation is advised in a *dark quiet room* to have a faster recovery; ventilator and all supportive critical care facilities should be available. Tetanus *per se* being *not a communicable disease does not essentially require isolation*.

### Eliminating the Source of the Toxin

- ◆ *Clostridium tetani* are sensitive to *penicillins*, metronidazole, *clindamycin*, and erythromycin. Injection crystalline penicillin 20 lac 6th hourly; injection gentamicin and metronidazole are given in secondary infection. Only problem with penicillin is that it is GABA antagonist and may increase the convulsions, but still it is the most commonly used drug. Metronidazole is more effective and choice of drug at present—500 mg intravenously 8th hourly for 10 days.

### Neutralizing the Unbound and Circulating Toxins

- ◆ It is done ideally by *Human Tetanus Immunoglobulin* (HTIG/ATG)—3000–6000 units. HTIG is given intramuscularly usually to deltoid as a single dose or often in 2 or 3 divided doses. HTIG (ATG) has got long half life (40 days). There is no risk of hypersensitivity; it does not interfere with antibody production; there is no preservative. It does not penetrate blood brain barrier. Intrathecal injection of antitoxin is of less value (circulating free toxin in the CSF can be neutralized in first 48 hours during initial development of the spasm). It should not be given intravenously. It is 100 times more potent than anti-tetanus serum (ATS, equinus tetanus antitoxin).
- ◆ When HTIG is not available or financial constraint is the matter then as an alternative, equinus tetanus antitoxin serum (ATS, anti-tetanus serum) can be given. Full dose is 1, 00,000 units; half is given intramuscular and another half is intravenously after initial checking for anaphylaxis by injecting a test dose of 1000 units intravenously.

## Control of Muscle Spasms

- ◆ *Benzodiazepines* are used mainly; they are *GABA agonists* but do not restore glycinergic inhibition. Higher doses of diazepam; lorazepam with a longer duration of action; midazolam with shorter duration of action as infusion (15 mg/hour). Diazepam and lorazepam contains propylene glycol which may cause lactic acidosis; but midazolam does not contain propylene glycol. Diazepam has got cumulative effect by its metabolites oxazepam and desmethyldiazepam.
- ◆ *Phenobarbitones* (anticonvulsants) and *chlorpromazines* are also used.
- ◆ *Therapeutic paralysis* with a nondepolarising neuromuscular blocking agent with mechanical ventilation is often required. Vecuronium and atracurium are used; pancuronium is also used but may cause tachycardia and hypertension. Propofol infusion, dantrolene, baclofen are other agents used. Intrathecal baclofen is also often used (500–200 µg infusion) which is a GABA agonist but is invasive.
- ◆ *Magnesium sulphate infusion* is rapidly emerging as a useful therapeutic technique. It controls the autonomic dysfunction; loading dose of 5 gram in 20 minutes followed by infusion for maintenance should be given; one should observe for hypermagnesaemia by observing ventilation changes.
- ◆ *Centrally acting drugs* like methocarbamol, mephenesin or meprobamate is useful. Methocarbamol which is long acting with high potency does not suppress respiration. It may cause severe gastritis and haemorrhagic cystitis. Mephenesin causes hypotension and haemoglobinuria. Meprobamate causes thrombosis, haemolysis and uraemia but is most potent muscle relaxant.

## Control of Autonomic Dysfunction

- ◆ Autonomic dysfunction in tetanus causes haemodynamic instability. *Fluid therapy* (8 liters/day), morphine (20–180 mg), *phenothiazines* (Chlorpromazine, phenoxybenzamine, phentolamine [ $\alpha$  receptor blocker]), *anticholinergics* (atropine 100 mg hourly),  *$\alpha_2$  adrenergic agonists* (clonidine, dexmedetomidine) contribute to cardiovascular stability. *Beta blockers like propranolol should not be used*. Sodium valproate, angiotensin converting enzyme inhibitor, adenosine are other drugs used for this purpose.
- ◆ *Magnesium sulphate* as presynaptic neuromuscular blocker reduces receptor responsiveness to the catecholamines and also is an anticonvulsant and a vasodilator.

## Managing Respiratory System Complications

- ◆ Aspiration, pneumonia, ARDS (Adult respiratory distress syndrome), respiratory failure are common life-threatening complications. *Ventilator support (IPPR) with endotracheal intubation; paralyzing the patient; tracheostomy*; regular suctioning, respiratory physiotherapy for prevention of bronchopneumonia and ARDS; regular monitoring by doing arterial blood gas analysis (ABG), total count, chest X-ray. Steroids may be beneficial in ARDS and in patients with carditis.

### Active Immunization

- ◆ *Tetanus toxoid* should be given as disease will not give immunity against further infection. To start—1st dose, 2nd dose after one month, 3rd dose after six months.

### Wound Management

*Wound debridement*, drainage of pus when present and injection of HTIG 500 units into wound area to reduce the effects of toxins locally.

### Management of Complications

- ◆ Respiratory (laryngospasm, aspiration, pneumonia, ARDS, pulmonary oedema), renal (infection, failure), cardiac (arrhythmias, failure), gastrointestinal (stasis, ileus, diarrhoea, haemorrhage), fracture bones and vertebrae, muscle and tendon injuries, DVT, thromboembolism, sepsis should be managed accordingly.

### Other Management

- ◆ *Good nursing care*, prevention of bedsore and DVT (deep vein thrombosis), nutrition (enteral through nasogastric tube or parenteral using a central line)—are important. Care of urinary catheter, prevention of urosepsis is important.
- ◆ *Steroids* may be useful in ARDS and carditis.
- ◆ Pyrexia or *hyperpyrexia* should be treated by tepid sponging, intravenous paracetamol or steroids. It is a poor prognostic indicator.
- ◆ *Hyperbaric oxygen* even though routinely not used has got beneficial effects in reversing the symptoms.
- ◆ *Cardiac pacemaker* may be useful in refractory bradycardia and arrhythmias.
- ◆ Following treatment patient may develop muscle spasms or *tics* which can be prevented by giving *oral methocarbamol* for one year.

#### Note:

- Culture media for *Clostridium tetani* is RCM (Robertson's Cooked Meat) media and nutrient agar.
- Serum anti-toxin (antitetanus antibody) level more than 0.01 units/L is protective against tetanus.

#### General measures

- ❖ Isolation
- ❖ Avoid noise and light
- ❖ ATG 3,000 units IM
- ❖ ATS-50,000 IM and 50,000 IV—after test dose
- ❖ Antibiotics like injection penicillin 20 lacs 6th hourly
- ❖ injection tetanus toxoid 0.5 ml IM—to deltoid muscle
- ❖ IV fluids with TPN
- ❖ Urinary catheterisation
- ❖ Nasogastric tube is passed to prevent aspiration initially, later for feeding
- ❖ Regular suction of throat
- ❖ Nasal oxygen when required
- ❖ Prevention of bedsore formation
- ❖ Prevention of DVT by low molecular weight heparin
- ❖ Good nursing care

#### Specific measures

- ❖ IV diazepam 20 mg 6th hourly
- ❖ IV phenobarbitone 30 mg 6th hourly
- ❖ IV chlorpromazine 25 mg 6th hourly
- ❖ Endotracheal intubation and ventilator support
- ❖ Tracheostomy if there is severe respiratory secretions
- ❖ Steroids
- ❖ Bronchodilators like deriphylline
- ❖ Wound care—debridement, drainage, and local injection of ATG

#### Prophylaxis against tetanus

- ❖ In adults, fresh immunisation to start—second in one month, next in 6 months period. Tetanus toxoid 0.5 ml IM. Booster dose should be given once in every 4 years or after any significant trauma
- ❖ In infants—triple antigen (DPT)—6 weeks, 10 weeks, 14 weeks, 18 months, and 5 years
- ❖ To pregnant mother tetanus toxoid injections are given in 4th and 6th months of pregnancy
- ❖ Additional booster dose given in major injuries or high-risk injuries
- ❖ ATG 500–1000 units IM given as a prophylaxis in road accidents, severe burns, crush injuries, war wounds, penetrating wounds and wounds of head and face. Here tetanus toxoid also should be given separately at separate site IM

### Monitoring during Therapy

PCO<sub>2</sub>, PO<sub>2</sub>, haematocrit, blood urea, serum electrolytes, chest X-ray, ECG are done at regular intervals.

#### Cause of death in tetanus

- ❖ Respiratory failure with aspiration pneumonia and ARDS
- ❖ Severe carditis—an ominous sign
- ❖ Mortality is 45–50%—becoming less now in well equipped centers (15%)

## GAS GANGRENE

It is an *infective gangrene* caused by clostridial organisms involving mainly skeletal muscle as *oedematous myonecrosis*. Earlier it was called as *malignant oedema*.

### Source and Predisposing Factors

- ◆ Contaminated, manured or cultivated soil, intestines are the sources. Faecal flora commonly contains clostridial organisms enters the wound; in presence of calcium from blood clot or silica (silicic acid) of soil, it causes infection.
- ◆ It is common in crush wounds, following road traffic accidents, after amputations, ischaemic limb, gunshot wounds, war wounds. Injury or ischaemia or necrosis of the muscle due to trauma predisposes infection.
- ◆ Anaerobic environments in the wound—initial infection with aerobic organism utilises existing oxygen in tissues creating anaerobic environment to cause clostridial sepsis.

### Organisms

- ◆ *Clostridium Welchii* (perfringens): Gram-positive, anaerobic central spore bearing, nonmotile, capsulated organisms, most common—60%.

*Right is right even if everyone is against it, and wrong is wrong even if everyone is for it.*



- ◆ *Clostridium oedematiens*.
- ◆ *Clostridium septicum*.
- ◆ *Clostridium histolyticum*.

Various strains include—A, B, C, D, E.  
'A' strain is most common.

**Note:**

Non-clostridial gas producing organisms like coliforms can also cause gas gangrene.

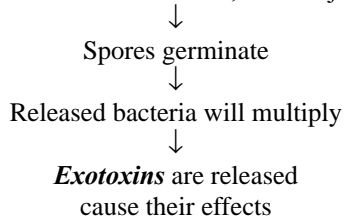
#### Clostridium Welchii produce toxins

- ❖ Alpha (most common)
- ❖ Beta
- ❖ Epsilon
- ❖ Iota
- ❖ Phi toxin—myocardial depressant
- ❖ Kappa toxin—destruction of connective tissue and blood vessels
- ❖ **Bursting factor** and circulating factor

### Exotoxins

- ◆ **Lecithinase** is important toxin which is haemolytic, membranolytic and necrotic causing **extensive myositis**. It splits lecithin into phosphocholine.
- ◆ **Haemolysin** causes extensive haemolysis.
- ◆ **Hyaluronidase** helps in rapid spread of gas gangrene.
- ◆ **Proteinase** causes breaking down of proteins in an infected tissue.

Spores enter through the devitalised tissues commonly in road traffic accidents, crush injury



### Effects

- ◆ Extensive necrosis of muscle with production of gas (hydrogen sulphide; nitrogen; carbon dioxide) which stains the muscle brown or black **anaerobic myositis/myonecrosis**.
- ◆ Usually muscle is involved from origin to insertion.
- ◆ Often may extend into thoracic and abdominal muscles.
- ◆ When it affects the liver it causes necrosis with frothy blood—**foaming liver**, is characteristic.
- ◆ Rapidly spreading infection which is also often fatal.
- ◆ Limbs are commonly involved; but organs like liver can also be affected.
- ◆ Muscle glycogen is broken down into lactic acid, CO<sub>2</sub> and hydrogen. Proteinase released by organism forms amino acids which further releases ammonia and hydrogen sulphide. Acid released earlier is neutralised by ammonia and calcium to progress further multiplication of organisms.

### Clinical Features

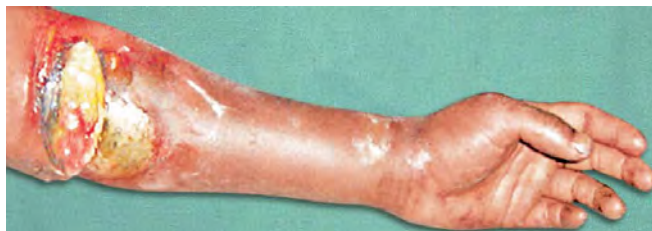*Incubation period* is 1–2 days.

- ◆ Features of toxæmia, fever, tachycardia (*out of proportion* to fever) pallor.
- ◆ Wound is under tension with foul smelling discharge (sickly sweet/*decaying apple* odour).

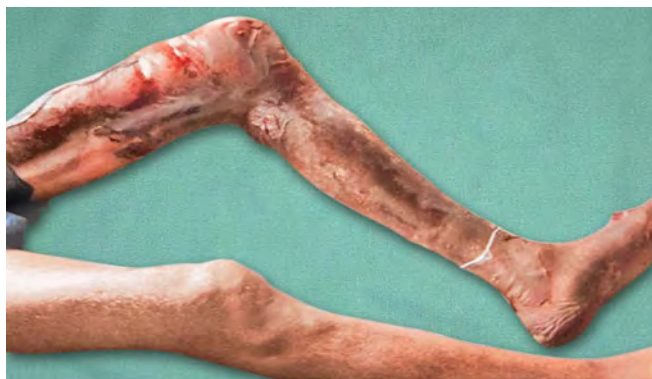- ◆ Khaki brown coloured skin due to haemolysis.
- ◆ **Crepitus** can be felt.
- ◆ Jaundice may be *ominous sign* and also oliguria signifies *renal failure*.
- ◆ *Frequent sites* are adductor region of the lower limb and buttocks and subscapular region in upper limb.  
*Clostridium Welchii* can infect limbs, abdominal wall, appendix, gallbladder, common bile duct, intestine, uterus (during septic abortion).

### Clinical Types

- ◆ **Fulminant type** causes rapid progress and often death due to toxæmia, renal failure or liver failure or MODS or ARDS.
- ◆ **Massive type** involving whole of one limb containing fully dark coloured gas filled areas.
- ◆ **Group type:** Infection of one group of muscles, extensors of thigh, flexors of leg.
- ◆ **Single muscle type** affecting one single muscle.
- ◆ **Subcutaneous type** of gas gangrene involves only subcutaneous tissue (i.e. superficial involvement). It is mainly of *anaerobic cellulitis type* without muscle involvement usually caused by less virulent clostridial organisms other than clostridial welchii. It is usually superficial but may spread and involve fascial planes. It causes necrosis with foul smelling seropurulent discharge.



**Fig. 1.120:** Gas gangrene in upper limb. It is after effect of an assault using an axe by a drunken husband.



**Fig. 1.121:** Gas gangrene involving entire leg extensively. Note the black/khaki coloured area. Patient died of toxæmia.

#### Complications of gas gangrene

- ❖ Septicaemia, toxæmia.
- ❖ Renal failure, liver failure.
- ❖ Circulatory failure, DIC, secondary infection.
- ❖ Death occurs in critically ill patients.

## Investigations

- ◆ X-ray shows gas in muscle plane or under the skin.
- ◆ Liver function tests, blood urea, serum creatinine, total count, PO<sub>2</sub>, PCO<sub>2</sub>.
- ◆ CT scan of the part may be useful especially in chest or abdominal wounds.
- ◆ *Gram's stain* shows Gram-positive bacilli.
- ◆ *Robertson's cooked meat media* is used which causes meat to turn pink with sour smell and acid reaction.
- ◆ *Clostridium Welchii* is grown in culture media containing 20% human serum in a plate. Antitoxin is placed in one-half of the bacteria grown plate sparing the other half. Zone of opacity will be seen in that half of the plate where there is no antitoxin. In the other half part of the plate where there is antitoxin there is no opacity—*Nagler reaction*.

### Prevention of gas gangrene

- ❖ Proper debridement of devitalised crushed wounds
- ❖ Devitalised wounds should not be sutured
- ❖ Adequate cleaning of the wounds with H<sub>2</sub>O<sub>2</sub> and normal saline
- ❖ Penicillin as prophylactic antibiotic.

## Treatment

- ◆ Injection benzyl penicillin 20 lacs 4th hourly + Injection metronidazole 500 mg 8th hourly + Injection aminoglycosides (if blood urea is normal) or third generation cephalosporins or metronidazole.
- ◆ **Fresh blood transfusion.**
- ◆ **Polyvalent antiserum** 25,000 units given intravenously after a test dose and repeated after 6 hours (Welchii 10,000 IU, oedematiens 10,000 IU, and septicum 5,000 IU).
- ◆ **Hyperbaric oxygen** is very useful.
- ◆ Liberal incisions are given. All dead tissues are **excised and debridement** is done until healthy tissue bleeds.
- ◆ Rehydration and maintaining optimum urine output (30 ml/hour) (0.5 ml/kg/hour).
- ◆ Electrolyte management.
- ◆ In severe cases **amputation** has to be done as a **life-saving procedure**—stump should never be closed (*Guillotine amputation*).
- ◆ Often ventilator support is required.
- ◆ *Once a ward or operation theatre is used for a patient with gas gangrene, it should be fumigated for 24–48 hours properly to prevent the risk of spread of infection to other patients especially with open wounds.*
- ◆ Hypotension in gas gangrene is treated with whole blood transfusion.
- ◆ Therapy should be concentrated in managing dehydration, hypotension, infection, toxæmia by hydration, fresh whole blood transfusion, passive immunisation, antibiotics, and hyperbaric oxygen, doing radical wound excision with removal of all dead tissues with foreign body or amputation with critical care.

## TUBERCULOSIS

*Whilst meagre Phthisis gives a silent bow, her strokes are sure, but her advances slow. No loud alarms, nor fierce assaults are shown: She starves the fortress first, then takes the town.*

—Samuel Garth, 1699

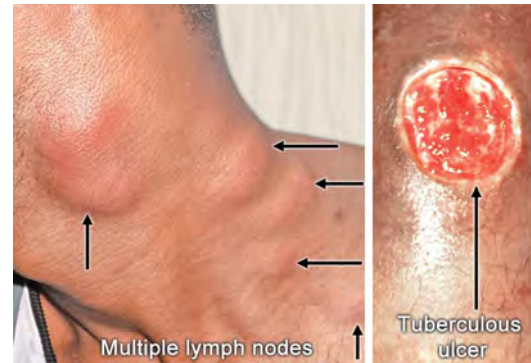


Fig. 1.122: Tuberculous lymphadenitis and tuberculous ulcer.

- ◆ It is commonly caused by *Mycobacterium tuberculosis*; occasionally by *Mycobacterium bovis*, *M. kansasii*, *M. fortuitum*, *M. marinum*, *M. ulcerans*.
- ◆ *M. tuberculosis* is **gram neutral, acid fast, alcohol fast** straight or slightly curved rods.
- ◆ It is prevalent in most of the developing countries and has made its resurgence in the developed countries with the advent of AIDS.

## Pathogenesis

- ◆ The characteristic lesion here is 'tubercle', which is an avascular granuloma composed of a central zone containing giant cells, with or without caseation necrosis, surrounded by a rim of epithelioid cells, lymphocytes and fibroblasts.
- ◆ It can occur in almost all organs in the body. Presentation may vary depending on the individual sites.

## General Features

- ◆ Low-grade fever with evening rise of temperature.
- ◆ Loss of appetite.
- ◆ Decreased weight.

## Investigations

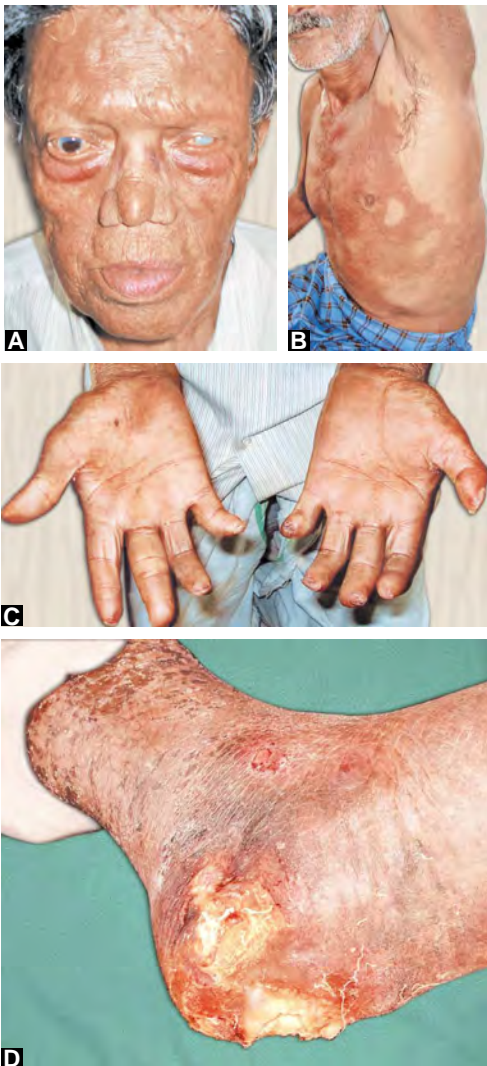- ◆ ESR is often raised; peripheral smear—lymphocytosis.
- ◆ AFB (Acid fast bacillus) staining using Ziehl-Neelsen stain.
- ◆ Chest X-ray is done to rule out pulmonary tuberculosis.
- ◆ Culture of the organism in Lowenstein Jensen media.
- ◆ Mantoux skin test—read after 48 hours of inoculation.
- ◆ Guinea-pig inoculation.
- ◆ Relevant investigations depending on the site of the tuberculosis.

## Treatment

- ◆ Antituberculous drugs are given for 6 months to one year.
- ◆ Specific treatment is given depending on the site of the tuberculosis. (Please refer individual chapters for details about tuberculosis at different locations and also chapter drugs for Anti-tuberculous Therapy.)

## LEPROSY

- ◆ It is caused by *Mycobacterium leprae*. It is a Gram-positive, acid fast bacillus.
- ◆ It mainly involves skin, nasal mucosa and peripheral neural tissues.
- ◆ It involves only the cooler parts of the body (So axilla, gluteal region are not involved). Testicular involvement is seen but not the ovary. It does not involve the vital organs. Though not acutely fatal, the disease leaves the victim severely deformed and crippled for life.



**Figs 1.123A to D:** A leprosy patient with the typical face (leonine); skin patches; hand deformities and trophic changes; trophic ulcer in heel.

## Types

### a. Multibacillary Types

- ◆ **Lepromatous leprosy:** It denotes little or no host resistance. Bacilli are seen in large numbers in the superficial nodular lesions and the patient is highly infective.

- ◆ **Borderline lepromatous.**
- ◆ **Borderline.**

### b. Paucibacillary Types

- ◆ **Borderline tuberculoid.**
- ◆ **Tuberculoid leprosy:** Here strong host resistance is observed. The disease is more localised, but it causes more deformities due to early involvement of nerves. Bacilli are scanty in the lesion and so infectivity is minimal.

## Investigations

- ◆ Regular checking of sensation of the suspected area.
- ◆ Split skin smear, nerve biopsy.

## Treatment

- ◆ Dapsone 100 mg daily.
  - ◆ Rifampicin 600 mg once a month.
  - ◆ Clofazimine 50 mg daily + 300 mg once a month.
- For paucibacillary types, treatment is for 6 months.  
For multibacillary types, treatment is for 2 years or more.

## Surgical Complications in Leprosy

### a. Primary Deformities

- ◆ Leonine facies.
- ◆ Collapsed nasal bridge.
- ◆ Upper branch facial nerve palsy (causes lagophthalmos).
- ◆ Keratitis and blindness.
- ◆ Claw hand either ulnar or combined ulnar and median nerves.
- ◆ Radial nerve palsy—wrist drop (1%).
- ◆ Clawing of toes due to involvement of posterior tibial nerve.
- ◆ Foot drop due to involvement of lateral popliteal nerve. (Medial popliteal nerve which supplies the tibialis posterior is never involved.)

### b. Secondary Deformities

- ◆ Anaesthesia of the part makes it prone to trauma, infection, infective gangrene, destruction, autoamputation and functionless parts.
- ◆ Trophic ulcers in the foot are common.

## Treatment of Complications

- ◆ Reconstructive surgeries.
- ◆ Release of contractures.
- ◆ Tendon transfers.
- ◆ Arthrodesis.
- ◆ Ulcer management.
- ◆ Physiotherapy and rehabilitation.

## SYPHILIS (GREAT POX) (FRENCH DISEASE)

*It is concluded...that this disease which amongst the Italians is called Gallicus, that is to say, the French disease, should now be named Patursa, ...a disease filthy and Saturnall. It is a filthy disease, because it maketh women to be esteemed unchast and irreligious.... There is a twofold kinde of causes.... The first is the only influence or corruption of the aire, from whence we must charitably thinke, that it infected those which were religious. The second is conversation, as by kissing and sucking, as appeareth in children, or by carnall copulation.*

—Juan Almenor, 1502

It is a venereal infection caused by *Treponema pallidum*.

**Early syphilis:**

It lasts for 2 years and the patient is infective during this period.

**Primary syphilis:**

It presents as a *Hunterian chancre* (Hard chancre). It is a shallow, painless, indurated, nonbleeding ulcer usually seen in the genitalia and often on the lips, breasts and anal region. It occurs in 3–4 weeks after the infection. It is confirmed by dark field microscopic study of the discharge for the organism.

**Secondary syphilis:** It occurs in 6–12 weeks.

It presents as:

- ◆ Cutaneous coppery rashes.
- ◆ Snail-track oral ulcers.
- ◆ Condyloma lata: Raised, flat, white lesions seen at the mucocutaneous junctions (mouth, anus vulva).
- ◆ Painless, shotty lymphadenopathy—epitrochlear suboccipital.
- ◆ Moth-eaten alopecia.
- ◆ Hepatitis, arthritis, iritis, meningitis. Massive, enlarged liver in syphilis is called as *hepar lobatum*.
- ◆ Syphilitic osteitis with “ivory” sequestrum.

**Latent syphilis:**

It lasts between 2 years to lifetime. Serum tests are positive.

**Late (tertiary) syphilis:**

- ◆ Painless, punched out, *gummatous ulcers* are seen with “wash leather base” and *silvery tissue paper scar*.
- ◆ It is seen over the tibia, sternum, ulna, skull, scrotum.
- ◆ It is a hypersensitivity reaction occurs as a result vasculitis and obliterative endarteritis.
- ◆ *Neurosyphilis*.
- ◆ *Cardiovascular syphilis*—aneurysm of arch of aorta.

**Investigations**

- ◆ VDRL test; Kahn test.
- ◆ *Treponema pallidum* haemagglutination test (TPHA).
- ◆ *Treponema pallidum* immobilisation test (TPI).

**Treatment**

Penicillin for 15 days is the drug of choice.

Doxycycline 100 mg can be given thrice daily for 15 days.

Others: Erythromycin, tetracycline, cephalosporins.

*Jarisch-Herxheimer* reaction is commonly seen after penicillin, which often requires steroid therapy.

**Congenital Syphilis**

Here the infection is transmitted from the mother to foetus through placenta.

**Early congenital syphilis:** It is seen in newborn.

- ❖ **Features are:**
  - Rash, syphilitic snuffles
  - Nasal discharge, weight loss
  - Periostitis, meningitis, hepatosplenomegaly
  - Pneumonia alba

**Late congenital syphilis:**

- ❖ **Hutchinson's triad:**
  - Interstitial keratitis
  - 8th nerve deafness
  - *Hutchinson's teeth: Peg shaped upper incisors*  
*Moon's molar, molars with cusps*
- ❖ Congenital neurosyphilis
- ❖ Cutaneous, skeletal or visceral gummas
- ❖ Saddle nose
- ❖ Sabre tibia, Clutton's joint
- ❖ Perforated palate

Congenital syphilis is treated with penicillins.

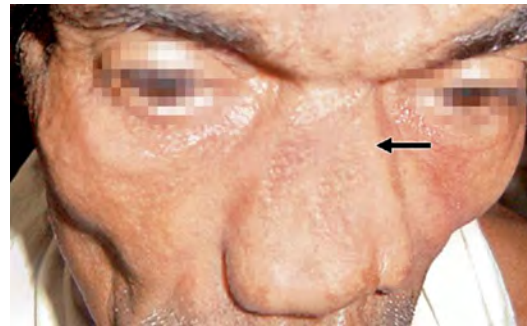

Fig. 1.124: Saddle nose.

**ACTINOMYCOSIS**

- ◆ It is caused by *Actinomyces israelii*.
- ◆ It is an anaerobic Gram-positive *fungus like bacterium*, which is a branching filamentous organism. It is called as “*Ray fungus*” because of *sun-ray* appearance.

**Clinical Types**

- ◆ **Facio-cervical:** It is the most common type. Infection spreads either from tonsil or from adjacent infected tooth. Initially an induration develops. Nodules form with involvement of skin of face and neck. It softens and bursts through the skin as *sinuses* which discharge *pus which contains sulphur granules* (60%).
- ◆ **Thorax:** Lungs and pleura get infected by direct spread from pharynx or by aspiration. Empyema develops. Later chest wall nodules appear leading to sinuses with discharge (20%).
- ◆ **In right iliac fossa:** It presents as a *mass abdomen* with discharging sinus.
- ◆ **Liver** is infected through portal vein (*Honey comb liver*).
- ◆ **Pelvic:** Pelvic actinomycosis can occur due to intra-uterine devices.

**Pathogenesis**

Organism enters through deeper plane of the tissue, causes subacute inflammation with induration and nodule formation. Eventually discharging sinus forms at the surface. Pus collected in a swab or sterile tube will show *sulphur granules*.

**Clinical Features**

- ◆ **Discharging sinus** with induration and nodules.
- ◆ **No lymph nodal involvement.**
- ◆ Through blood spread it may cause pyaemia and endanger life.

*The best rose bush is not the one with the fewest thorns, but that which bears the finest roses.— Jerry Van Dyke*

## Investigations

- ◆ Pus under microscopy shows branching filaments.
- ◆ **Gram's staining** shows **Gram-positive mycelia** in centre with **Gram-negative radiating peripheral filaments**. These clubs are due to host reaction which are lipoid material (antigen-antibody complex).
- ◆ Cultured in brain heart infusion agar and thioglycolate media.

### Differential diagnosis

- ❖ Chronic pyogenic osteomyelitis.
- ❖ Carcinomas at the site
- ❖ Tuberculous disease

## Treatment

- ◆ Penicillins for longer period (6–12 weeks).
- ◆ Tetracyclines, lincomycin, streptomycin.
- ◆ Dapsone and iodides may be useful.
- ◆ Antifungals are often given because it is fungal like bacterium.
- ◆ Surgical debridement is occasionally required.
- ◆ **Welsh regimen**—Injection amikacin 15 mg/kg IV daily for 21 days; such cycle is repeated 3 times at a gap of 15 days—along with tablet trimethoprim (7 mg/kg)—sulfamethoxazole (35 mg/kg) daily for 6 months.

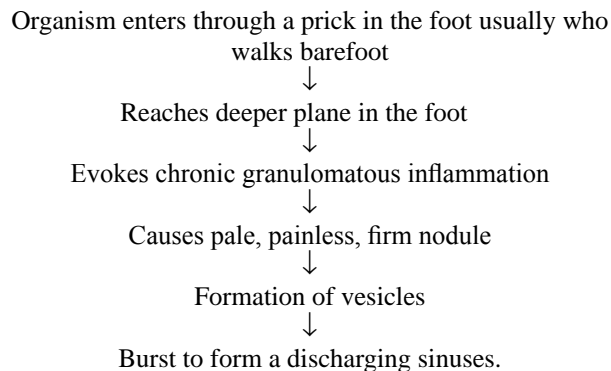
## MADURA FOOT (MYCETOMA PEDIS)

- ◆ It is a chronic granulomatous condition of the foot involving subcutaneous and often deeper tissues causing multiple discharging sinuses.
- ◆ It was first identified in **Madurai, Tamil Nadu (India)** by **Gill** (1842, Madura mycosis).
- ◆ It is common in India and Africa.
- ◆ It is common in Tamil Nadu.
- ◆ It can be *fungal (more common)* or *bacterial origin*.
  - ▶ **Bacterial** can be *Actinomyces* or *Nocardia*. Among bacterial *Nocardia madurae* is most common.
  - ▶ **Bacterial mycetomas** are by *Actinomyces* (*A. israelii* or *A. bovis*) or by *Nocardia* or *Actinomadura* (red granules). Occasionally it can be due to pyogenic bacteria like *Staphylococcus aureus* (*Botryomycosis*). Bacterial mycetoma shows white/yellow/red granules which on smear delineates thin filaments (1 µm). *Nocardia asteroides* can primarily involve lungs later spreading to brain, kidney and other organs as metastatic infection.
  - ▶ **Fungal eumycotic mycetoma** is caused by *Madurella mycetomi* or *Madurella grisa*. Fungal mycetoma causes black granules, crushed smear of which shows thick stout filaments (5 µm).

### Organisms

- ❖ *Nocardia madurae* (most common)
- ❖ *Nocardia brasiliensis*
- ❖ *Nocardia asteroides*
- ❖ *Actinomyces israelii*

## Pathogenesis



- ◆ Discharging granules may be *Black, Red, Yellow*.
- ◆ In black type of Madura foot, infection is mainly subcutaneous.
- ◆ In red and yellow types, it burrows into the deeper plane including bone causing bone necrosis (osteomyelitis). Eventually gross swelling of the limb with multiple discharging sinuses with disability will occur.
- ◆ Muscles and bones are involved.
- ◆ Tendons and nerves are spared until very late.
- ◆ **Regional lymph nodes are not involved.**
- ◆ Condition will deteriorate by secondary bacterial infection.

### Note:

If infection occurs in hand, it is called as **Madura hand**.

### Mycetoma

- ❖ It is a chronic, granulomatous, progressive inflammatory condition involving subcutaneous tissue, skin and deeper tissues
- ❖ It may be bacterial (actinomycetoma or fungal (eumycetoma))
- ❖ Painless subcutaneous tissue; multiple sinuses and seropurulent discharges—triad of mycetoma
- ❖ Causes deformity, disability, destruction
- ❖ 70% occurs in foot; 12% in hands
- ❖ Local hyperhidrosis due to sympathetic over activity can occur
- ❖ Tiny, shotty regional lymph nodes can get enlarged due to secondary infection or as localized immune response
- ❖ Osteomyelitis, Kaposi's sarcoma, carcinoma are the differential diagnoses
- ❖ 'Dot in circle sign' in MRI is characteristic
- ❖ FNAC and biopsy is very useful to confirm
- ❖ Immunoelectrophoresis and ELISA are having diagnostic value.

## Clinical Features

- ◆ Painless diffuse swelling in the foot of long duration.
- ◆ Later multiple discharging sinuses develop on the skin.
- ◆ Lymph node involvement will not occur unless secondary bacterial infection is present.
- ◆ Significant limb disability is common.
- ◆ Common in males.
- ◆ Twenty per cent develop pain—due to secondary infection or bone involvement.

### Differential diagnosis

- ❖ Chronic osteomyelitis
- ❖ Tuberculous osteomyelitis
- ❖ Carcinoma, Kaposi's sarcoma

## Investigations

- ◆ Discharge study will show branching filamentous appearance of the organism.
- ◆ Culture in Sabouroud's dextrose agar medium.
- ◆ Gram stain for actinomycosis will show sun-ray appearance with Gram +ve centre and Gram -ve clubs.
- ◆ X-ray of the foot is done to look for osteomyelitis.
- ◆ FNAC and biopsy is confirmative as eumycetoma or actinomycetoma.
- ◆ Ultrasound of area; MRI are useful. *Dot in circle sign* in MRI is characteristic.
- ◆ Immunoelectrophoresis and ELISA are having diagnostic value showing antibody titre against causative organism.

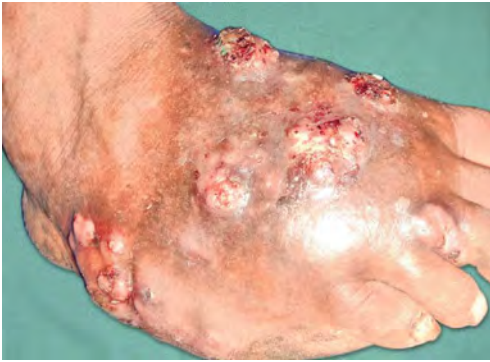
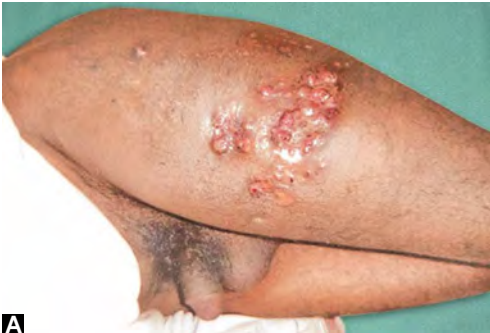
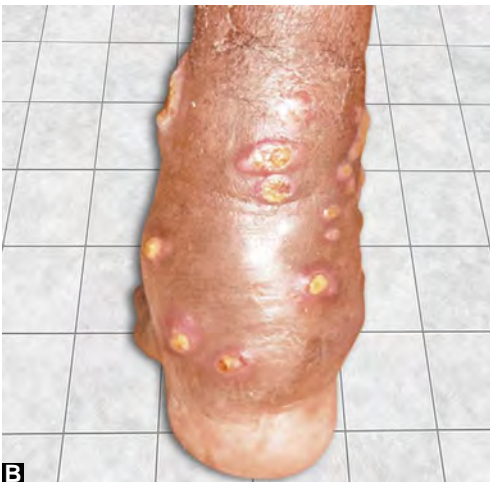Fig. 1.25: Madura foot. Note the multiple sinuses.



A



B

Figs 1.126A and B: Mycetoma thigh and foot in two different patients. Note the discharging sinuses.

## Treatment

### Medical

- ◆ In actinomycetoma, amikacin or streptomycin, co-trimoxazole combined therapy is the first line of treatment (5 weeks therapy). Long-term penicillins are useful. Amoxicillin—clavulanic acid, rifampicin, sulphonamides, gentamicin and kanamycin are second line of drug treatment.
- ◆ In eumycetoma, ketoconazole, itraconazole, voriconazole are the drugs used for long term up to one year.
- ◆ Dapsone and iodides are often used for long term.

### Surgical

- ◆ *Wide surgical excision* should be done after initial proper medical line of treatment. Improper excision will cause recurrence. Recurrence rate is up to 50%. After wide excision, drug therapy has to be continued.
- ◆ Amputation is needed in severe refractory cases as a life saving option. Amputation rate is 10–25%.

## RABIES (HYDROPHOBIA)

It is an *acute fatal encephalomyelitis* caused by a single stranded RNA virus *Lyssa virus type 1*.

- ◆ It is a zoonotic disease transmitted to humans by bite/lick/scratch of infected animals (*commonly dogs*).
- ◆ It is an ancient disease mentioned even in Vedas. Rabies word is derived from Sanskrit word '*Rabhas*' means 'to do violence'.
- ◆ *Celsus* found relation of saliva of infected dog to human disease in 1st century AD. *Louis Pasteur* developed 1st vaccine against Rabies in 1885.
- ◆ Rabies is uncommon in developed countries. It is mainly seen in Indian subcontinent (80%) and Africa. In India, it is not seen in Lakshadweep, Andaman and Nicobar islands. If disease is not seen for 2 years in humans and animals then that area is termed as *rabies free*. Maldives country does not have human or animal rabies.

## Pathogenesis

- ◆ There is no predilection for age or sex even though, it is observed more in children and adult males.
- ◆ Ninety-five per cent of rabies develops due to *bite of rabid dog* occasionally cat (**Urban rabies**). Other animals that can transmit rabies are monkey, horse, fox, cows and buffaloes, donkey, pig, sheep, camel, elephant, mongoose, jackal, bear (**Wild life/sylvatic rabies**). In India, transmission is not observed through bats, rodents and birds. **Bat rabies** (vampire bat) is seen in parts of USA and Latin American countries.
- ◆ Asymptomatic carrier stage occurs only in animals, but they are unlikely to be infective. Only symptomatic animals are considered to be infective.
- ◆ Rabies virus is bullet shaped envelop virus (75 nm × 180 nm) with numerous glycoprotein spikes to help in attachment of virus and also to induce antibodies. Natural occurring rabies virus is called as **street virus** which shows long incubation period of 20–60 days. Serial passage of this virus to brain of rabbits creates **fixed virus** which has got short incubation period of 4–6 days which does not show Negri bodies. This fixed virus which cannot multiply in extraneural tissues is inactivated to prepare vaccine.

- ◆ *Infection* commonly occurs by animal **bite**, often by **licks**, **scratches**. Licks on *abraded skin* and licks on *abraded or unabraded mucosa* can cause infection. Licks are often *ignored* dangerously. Severity of infection depends on *viral load in the animal saliva* and class of wound. **Aerosol** transmission is found in bats or in lab workers. **Person to person** transmission can occur even though it is rare. Rabies may get transmitted through organ/corneal transplantation.
- ◆ Virus multiplies at the site of infection and passes (*ascends*) through the peripheral nerves into the CNS to develop **Negri bodies** in the brain leading into *fatal encephalomyelitis*. From the brain virus *descends* into different tissues like *salivary glands*, muscles, heart, adrenals and skin. It also involves salivary glands to get secreted in the saliva to cause infection.

## Clinical Features

- ◆ Incubation period is 3–6 weeks; but rarely can be up to many years.
- ◆ Prodromal symptoms like fever, headache.
- ◆ Pain, tingling sensation at the site of bite.
- ◆ Hyperexcitability and irritability; increased muscle reflexes and spasms.
- ◆ Increased salivation, sweating, lacrimation.
- ◆ Hydrophobia (fear of water) and **aerophobia** (fear of air) is **pathognomonic**.
- ◆ Mental instability, dilatation of pupils.
- ◆ Symptoms are aggravated by swallowing water or blowing air on them.
- ◆ Once disease starts, patient die in 72 hours.

*Fear of water is seen only in affected human beings, not in animals.*

## Classification of Wounds

**Class I:** Touching or feeding the diseased animal, lick over intact skin or scratches without oozing of blood.

**Class II:** Licks on broken skin, scratches with blood ooze, and all bites except over head, face, palms and fingers. Minor wounds less than five in number.

**Class III:** All bites over head, face, palms and fingers, lacerated wounds, wounds more than five in number, wild animal bites, and contamination of mucous membrane with saliva.

## Indications for Antirabies Vaccination

- ◆ All rabid animal bites.
- ◆ If animal is killed or dies during 10 days of observation period.
- ◆ Bite by an unidentified animal.
- ◆ If lab tests in animal show positive for rabies.
- ◆ All wild animal bites.

## Vaccines for Rabies

### 1. Nervous Tissue Vaccine

(a) **BPL inactivated vaccine:** It is nervous tissue vaccine. It is 5% emulsion of the infected brain of the sheep containing the inactivated fixed virus. It is *Semple vaccine*.

Dosage of Semple vaccine (as recommended by Pasteur Institute, Coonoor)			
	Adult	Children	Duration
Class I	2 ml	1 ml	7 days
Class II	3 ml	3 ml	10 days
Class III	5 ml	3 ml	10 days

**Mode of administration:** Subcutaneously into the abdominal wall using long needle. Joseph Meister received first anti-rabies vaccine (ARV) in 1885. In Olden days, it was given for 15–21 days.

Antibody develops in 7–30 days. Protection lasts only for 6 months. Booster doses are given if needed.

### Side effects

- ◆ Headache, palpitation, allergic reactions.
- ◆ Redness, tenderness and swelling at the site of the vaccination.
- ◆ *Post-vaccinal neuroparalysis*—a dangerous life-threatening complication.
- ◆ During therapy patient *should avoid alcohol and steroids*.

(b) **Nervous tissue vaccine derived from suckling mouse** (less than 9 days old) brain (*Fuezalida vaccine*) is used to reduce neuroparalytic complications as suckling mouse has low myelin neuron. It is given for 10 daily doses then on 20th and 30th day.

### 2. Avian Vaccines—Duck Embryo Vaccine (DEV)

It has got less neuroparalytic side effects. It can cause egg protein allergy. Purified duck embryo vaccine (PDEV-1 ml) is available in India.

### 3. Cell Culture Vaccines

They are more potent and safer.

- ◆ **Human Diploid Cell Vaccine (HDCV-1 ml):** Safest vaccine. It is prepared using fixed virus in human diploid fibroblast cells. But it is costly. It is available in India.
- ◆ *Second generation tissue culture vaccines:* They are potent and cost-effective. They are derived from nonhuman base sources. Examples are chick embryo fibroblast (**Purified Chick Embryo Cell Culture Vaccines—PCECV-1 ml**), foetal bovine kidney, hamster kidney cells, vero cells (**Purified Vero cell Rabies Vaccine—PVRV-0.5 ml**).

*Dosage:* 2.5 IU in one ml. One ml is given IM into the deltoid on 0, 3, 7, 14, 28 and 90 (optional) days.

*Side effects:* Headache, redness at the site, fever. No other serious side effects.

*Second generation tissue culture vaccine* can be given intradermally also. Intradermal dose is one fifth of the intramuscular dose (0.1 ml).

## Wound Treatment

- ◆ *Proper local wound care* reduces the chances of rabies infection by 80%. Immediate cleaning and washing of the wound with running water for 15 minutes is essential to reduce the viral load at the wound site. If soap is available soap water is also used. It is better to wash with warm water if available.
- ◆ Wound should be *cleaned with virucidal agents* like alcohol, tincture, povidone iodine. Savlon or carbolic acid or nitric acid should not be used.
- ◆ Wounds *should not be closed*. ARS should be injected locally. In deep wounds it may be closed only after 48 hours with loose sutures after thorough washing.
- ◆ ARS (horse or human) *should be injected* to all wounds locally.
- ◆ One *should not scrub* the wound.
- ◆ One *should not touch* the wound with *bare hands*. One should wear gloves to touch the wound.

## Passive Immunity

It is used in all severe exposures, class II and class III and in all wild animal exposure. Present recommendation is injection of ARS with vaccine in all exposed patient irrespective of the class.

## Types of Antirabies Serum (ARS)

**Horse antirabies serum** (horse/equine ARS): It is given on first day with a dose of 40 IU/ kg body weight (maximum up to 3000/units). Half is given into the wound and another half given into the gluteal muscle (IM)—single dose. It prevents the multiplication of the virus at the wound site. It also prolongs the incubation period. Passive immunity should always be combined with vaccine therapy. ARS needs test dose prior to injection of full dose. *Side effects*: Serum sickness, anaphylaxis. **Human rabies immunoglobulin (HRIG)**. Dose is 20 units/kg body weight. Part is injected into the wound remaining part into the gluteal muscle (IM)—single dose. Patient should be immunised actively along with serum with additional booster doses. Side effects are rare here.

## Post-exposure Prophylaxis

Cell culture and purified duck embryo vaccines are used as they are safe and efficacious.

All vaccines should be given to deltoid region (never to gluteal region as due to high fat content vaccine would not get absorbed into circulation rapidly and so immune response may not be optimum). Vaccines should be stored at 4–8°C after reconstitution and should be used immediately.

### Mode of Injection

- Intramuscular into deltoid region—**Essen regimen**. It is commonly used and technically easier but higher dose is required compared to intradermal. It is injected at a schedule of 0, 3, 7, 14, and 28 days and booster at 90 days. *First dose should be combined with ARS preferably HRIG*. Multisite IM regime is often used as follows—first dose on day 0 two doses of IM vaccine is injected one on each side deltoid. Later single doses on 7 and 21 days (as 0 {2}, 7 {1}, 21 {1}).
- Intradermal route**: (1) *Two site intradermal method* is used. 1/5th of the IM dose of selected vaccine is used. Two sites on the day 0, 3, 7 and one site on the days 28 and 90. PVRV 0.1 ml; PCECV 0.2 ml; PDEV 0.2 ml. (2) *Eight site intradermal method* is used. On day 0, eight sites intradermal injections at both deltoids, both suprascapular, both thighs, both lower quadrants of abdomen are given. On day 7, on 4 sites—both deltoids, both thighs intradermal injections are given. On days 28 and 90 one dose on each day intradermal vaccine is injected at one site. HDCV 0.2 ml is used. It is like 0 (8); 7 (4); 28 (1); 90 (1). In whatever type, on first day (0) rabies immunoglobulin should be injected locally as well as IM.

**Postexposure vaccination** if individual *has been vaccinated earlier*: Doses on days 0, 3, and 7 are given. But ideally assessed by serum antibody level (should be more than 0.5 IU/ml. Passive immunity is not given in individuals who had vaccination earlier.

## Pre-exposure Prophylaxis

It is given to veterinarians, animal handlers. Dose: 1 ml of cell culture vaccine IM or 0.1 ml intradermally on days 0, 7, 28. Serum titre for antibodies should be assessed after 1 month. If it is less than 0.5 IU/ml then one booster dose is injected. Booster doses are given once in every 2 years.

## RABIES IN DOGS

**Incubation period**: 10 days to 8 weeks.

## Types

- Furious type**: Here dogs are aggressive like a mad dog. Dog changes its behaviour with loss of fear of human beings; bites objects, eat, mud, etc. Running amok, voice change, inability to bark properly, excessive salivation and foaming, paralysis and death.
- Dumb type**: Dog is paralytic and sleepy. There is no aggressiveness at all. Dog sleeps for 3 days and dies. Once symptoms of rabies develop in a dog *it rarely survives more than a week*. Dog brain is sent for study in 50% glycerol-saline solution.

## Laboratory Tests to Confirm Rabies in Dogs/Animals

- ◆ **Fluorescent antibody test (FRA test)**: It is reliable test. If FRA test is negative in brain of animal then even if dog is rabid its saliva does not contain virus. FRA test is positive at any stage of the disease.
- ◆ **Microscopic examination of the brain of the infected dead animal** to look for NEGRI bodies. It is seen in 90% of dead rabid dogs.
- ◆ **Mouse inoculation test** is very sensitive test. 10% brain tissue emulsion in saline is centrifuged at 2000 rpm for 10 minutes; 0.03 ml top fluid is injected intracerebrally into the suckling mouse to demonstrate rabies in 8 days in mouse.
- ◆ Corneal test is simpler but negative result does not rule out the infection possibility.

## Immunisation in Animals

- BPL inactivated nervous tissue vaccine** (20% infected sheep brain suspension): Single dose 5 ml to dogs; 3 ml to cats. Second dose after 6 months. Then once a year regularly.
- Modified live virus vaccine** (33% infected chick embryo suspension): Dose—3 ml single dose which is repeated once in 3 years.
- Oral vaccines** are used successfully to control wild foxes in Canada by placing vaccine in food through baits.

### Remember about rabies

- ❖ Control of stray dogs and immunisation of all dogs will reduce the incidence of rabies
- ❖ Prevention is the only way in rabies. Established rabies cannot be treated—100% mortality
- ❖ HDCV and PCECV dose is 1 ml; PVRV is 0.5 ml—IM into deltoid or anterolateral aspect of thigh in children (NEVER GLUTEAL region)
- ❖ Day 0 is the day of first date of vaccination not day of bite
- ❖ Interchanging of vaccines is even though acceptable but not well recommended and ideally should be avoided
- ❖ Vaccine dose is same in all age groups
- ❖ Reconstituted vaccine should be used immediately
- ❖ Vaccine dose may be doubled in first dose if ARS is not used in bites of face, head, hands and genitals, in malnourished patients, in patients who are on steroids, antimalignancy drugs, antimarialarials; in pregnancy, lactation, infants, elderly, HIV and immunosuppressed individuals
- ❖ Consumption of unboiled milk of a rabid cattle amounts for class III bite and needs prophylaxis vaccine
- ❖ Pet dog should be examined periodically by veterinary doctor. Usual vaccination method used in dog is—at 3rd month of age, 1 month later, and later yearly booster doses. 0, 6 months and then yearly is also used. Pet dog should be prevented from coming into contact with stray dogs
- ❖ Dietary or alcohol restriction is not needed during vaccination as it will not alter immune response

Contd...



Contd...

- ❖ Concomitant other vaccine injection along with rabies vaccine can be done but at different injection site as there is no interference with immune response
- ❖ There is no contraindication for rabies vaccine as it is life-saving method
- ❖ All cases of dog bite should receive initial vaccine and ARS immediately. If the dog remains healthy even after 10 days of observation period vaccine is discontinued. Virus can be present in saliva 3 days before onset; once symptom begins dog cannot live for more than 4 days. Safe period of 3 days is added and so total 10 days is observed
- ❖ Virus can present in semen of a rabid man. So if he had contact with his wife within 5 days prior to symptoms then wife should be vaccinated as class III with HRIG
- ❖ If by mistake vaccine is given to gluteal region, fresh full course of vaccine to deltoid region should be started
- ❖ There are no single shot vaccines available. It is a myth
- ❖ Antiviral drugs are of no use
- ❖ Modern CCVs are very safe and efficacious
- ❖ Intradermal route of 0.1/0.2 ml is the best route
- ❖ Equinus ARS is cheaper and equally effective; but test dose should be given to prevent reaction
- ❖ Rabid dog *will never* have hydrophobia. Rabid dogs can swim through water or can even drink water. Aerophobia and photophobia are present in rabid dog. Hydrophobia is observed *only in human rabies*
- ❖ Bite by cats and cows also should be vaccinated
- ❖ Steroids and antimalarials should be avoided during vaccination as it may alter the immune response

## ■ ANTHRAX

- ◆ It is caused by *Bacillus anthracis*, which is a *Gram-positive*, aerobic, spore forming, capsulated, nonmotile, nonacid-fast bacillus and is *resistant to heat and antiseptics*.
- ◆ Disease is common in cattle and seen in people who handle carcasses, wool, hairs.
- ◆ It is often used in *biological war*.

## Types

- a. **Cutaneous type** (*Hide porter's disease*)
  - ▶ It is the most common type and occurs within 3–4 days after infection.
  - ▶ Indurated papule with black slough surrounded by vesicles—*malignant pustule*. Itching is common in papule—black colour eschar (Anthrax means *charcoal*).
  - ▶ Regional lymph nodes are involved.
  - ▶ *Toxaemia* is common.
- b. **Respiratory type** (*Wool Sorter's disease*) is due to inhalation of spores, causing *haemorrhagic pneumonia*. It is more dangerous and life-threatening.
- c. **Alimentary type** due to ingestion of spores.
  - ▶ Fatal *septicaemia* and meningitis can occur in any type.

## Diagnosis

- ◆ Culture of fluid will show *Medusa head appearance*.
- ◆ It shows positive M'Fadyean's reaction and positive Ascoli's thermoprecipitation test.

## Treatment

- ◆ *Ciprofloxacin*, *doxycycline*, penicillins.
- ◆ Alum precipitated Anthrax toxoid is used in humans.
- ◆ Scalvo's serum prepared by active immunisation of asses are used.

## ■ NOSOCOMIAL AND OPPORTUNISTIC INFECTIONS

### Nosocomial Infection (Hospital-acquired Infection)

It is an infection acquired because of *hospital stay*.

#### Sources

- ◆ Contaminated infected wounds.
- ◆ Urinary tract infections.
- ◆ Respiratory tract infections.
- ◆ Opportunistic infections.
- ◆ Abdominal wounds with severe sepsis.

*Spread* can occur from one patient to another, through nurses or hospital staff who fail to practice strict asepsis.

#### It is more common in:

- ❖ Diabetics
- ❖ Immunosuppressed individuals
- ❖ Patients on steroid therapy and life-supporting machines
- ❖ Instrumentations (indwelling catheter, IV cannula, tracheostomy tube)
- ❖ Patients with artificial prosthesis

#### Organisms

- ◆ *Staphylococcus aureus* is the most common organism causing hospital-acquired wound infection. Others are *Pseudomonas*, *Klebsiella*, *E. coli*, *Proteus*.
- ◆ *Streptococcus pneumoniae*, *Haemophilus*, Herpes, *Varicella*, *Aspergillus*, *Pneumocystis carinii* are the most common pathogens involved in hospital-acquired respiratory tract infection which spreads through droplets.
- ◆ *Klebsiella* is the most common pathogen involved in hospital acquired UTI which is highly resistant to drugs.

#### Management

Most of the time, organisms involved are *multi-drug resistant*, *virulent* and hence, cause *severe sepsis*.

- ◆ Antibiotics.
- ◆ Isolation.
- ◆ Blood, urine, pus for culture and sensitivity to isolate the organisms.
- ◆ Blood transfusion, plasma or albumin therapy.
- ◆ Ventilator support.
- ◆ Maintaining optimum urine output.
- ◆ Nutritional support.

#### Prevention

- ◆ Isolation of patients with badly infected open wounds, severe RTI/UTI.

- ◆ Following strict aseptic measures in OT and in ward by hospital attendants.
- ◆ Proper cleaning and use of disinfectant lotions and sprays for bedpans, toilets and floor.
- ◆ The precipitating causes have to be treated, along with caring for proper nutrition and improving the anaemic status by blood transfusion.

### Opportunistic Infections

They are normally of *low pathogenicity*, occur through therapeutic invasive procedures and are common in immune deficiency status.

#### Immune deficiency may be due to:

- ❖ Diabetes
- ❖ HIV
- ❖ Steroid therapy
- ❖ Radiotherapy
- ❖ Immunosuppressive therapy in transplantation
- ❖ Cytotoxic chemotherapy
- ❖ Starvation and old age

Therapeutic invasive procedures may be in the form of IV cannula, bladder catheter, tracheostomy and other minor surgical procedures which permit the skin organisms like *Staphylococcus epidermidis* to penetrate the skin and invade the deeper tissues.

#### Organisms

**Bacteria:** *Gram-negative:* *E. coli*, *Pseudomonas*, *Klebsiella*, *Proteus*, *Serratia*.

*Gram-positive:* *Staphylococcus epidermidis*, *Streptococcus pneumoniae*.

**Viruses:** *Herpes*, *CMV*, *Varicella zoster*, may cause fatal pneumonia.

**Fungal:** *Candida*, *Aspergillus*, yeast.

**Protozoal:** *Cryptosporidia* (causes diarrhoea), *Pneumocystis carinii*.

Because of the poor defence mechanism, infection is severe and often life-threatening.

#### Investigations

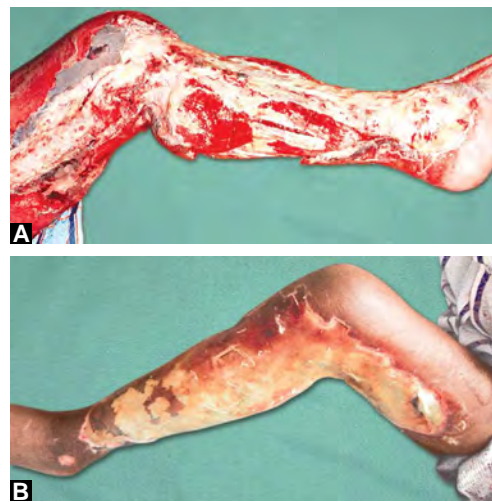- ◆ Swab culture, blood culture, pus culture.

#### Treatment

- ◆ These infections are difficult to treat as they are often *multi-drug resistant*.
- ◆ Combination of broad spectrum antibiotics—cephalosporins, aminoglycosides, metronidazole are given.
- ◆ Depending on culture and sensitivity appropriate antibiotics are given.
- ◆ Often ventilatory support and critical care are necessary.

### ■ NECROTISING FASCIITIS (*Wilson, 1952*)

- ◆ It is spreading inflammation of the skin, deep fascia and soft tissues with extensive destruction, toxæmia commonly due to *Streptococcus pyogenes* infection, but often due to mixed infections like anaerobes, coliforms, Gram-negative organisms.
- ◆ It is common in old age, smoking, diabetics, immunosuppressed, malnourished, obesity, steroid therapy and HIV patients. Trauma is a common precipitating factor/cause—80%.
- ◆ It can occur in limbs, lower abdomen (Meleney's infection), groin, perineum. There is acute inflammatory response, oedema, extensive necrosis and cutaneous microvasculature thrombosis.
- ◆ Muscle is usually *not involved* in necrotising fasciitis.



**Figs 1.127A and B:** Necrotising fasciitis of skin, deep fascia and soft tissues without involvement of muscle.

#### Types

**Type I: Polymicrobial (80%)**—mixed infection; by non-group A streptococci with anaerobes or clostridial or enterobacteriaceae (*E. coli*, *pseudomonas*). It is common in perineum, trunk and postoperative wounds; common in diabetics and immunosuppressed people.

**Type II: Monomicrobial**— is due to group A haemolytic streptococci or methicillin resistant *staphylococcus aureus* (MRSA). It is common in young individual; common in extremities without any comorbid status.

**Type III:** It is Gram-negative rods (*Vibrio vulnificus*) after a minor trauma; associated with chronic liver disease, diabetes, steroid therapy, chronic kidney disease. It is rare.

**Type IV:** It is due to fungal infection; commonly *Aspergillus zygomycetes*. It is also rare.

#### Clinical stages

*It is a clinical diagnosis*

**Stage 1** – Fever, erythema, oedema, warm skin, tenderness.

**Stage 2** – Blisters and bullae formation.

**Stage 3** – Hypoaesthesia or anaesthesia, crepitus, tissue necrosis, haemorrhagic bullae.

## Clinical Features (See Table)

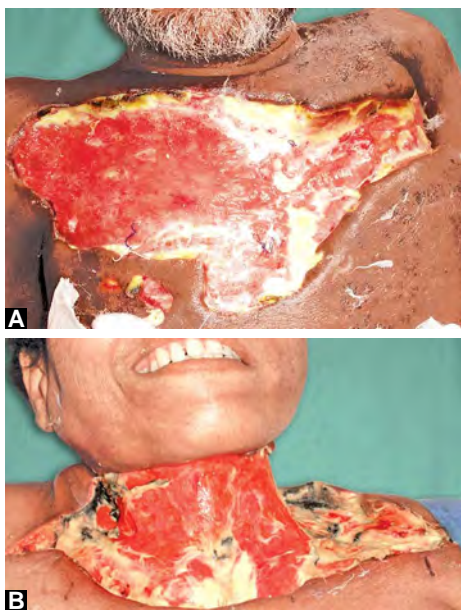
- ◆ Sudden swelling and pain in the part with oedema, discoloration, necrotic areas, ulceration.
- ◆ Foul smelled discharge.
- ◆ Features of toxæmia with high-grade fever and chills, hypotension.
- ◆ Oliguria often with acute renal failure due to acute tubular necrosis.
- ◆ Jaundice.
- ◆ Rapid spread in short period (in few hours).
- ◆ Features of SIRS, MODS with drowsy, ill-patient.
- ◆ Condition if not treated properly may be life-threatening.

### Note:

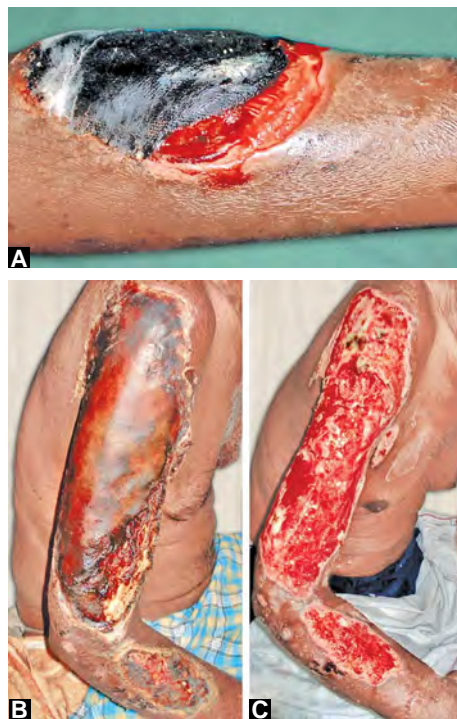LRINEC (Laboratory Risk Indicator for Necrotising Fasciitis) scoring system is very useful to assess the severity. Parameters used are – C-reactive protein (less or more than 150 mg/L); TC (less than 15,000; 15,000 to 25,000; more than 25,000); Hb% (> 13.5 g, 11 to 13.5, < 11); serum sodium (> 135 or less than 135); serum creatinine (less or more than 1.6); blood sugar (less or more than 180 mg). Score > 8 is severe; 6–8 is moderate; < 8 is good.

## Management

- ◆ IV fluids, fresh blood transfusion.
- ◆ Antibiotics depend on C/S or broad-spectrum antibiotics. High dose penicillins are very effective. Clindamycin, third generation cephalosporins, aminoglycosides are also often needed.
- ◆ Catheterisation and monitoring of hourly urine output.
- ◆ Haematocrit, serum creatinine assessment.
- ◆ Pus culture, blood culture.
- ◆ Electrolyte management and monitoring.
- ◆ Control of diabetes, if patient is diabetic.
- ◆ Oxygen, ventilator support, dopamine, dobutamine supplements whenever required.
- ◆ Radical wound excision of gangrenous skin and necrosed tissues at repeated intervals.



**Figs 1.128A and B:** Necrotising fasciitis over chest wall and neck in two different patients.



**Figs 1.129A to C:** The typical necrotising fasciitis showing gangrenous skin. In second photo, arm is extensively involved. Also note the granulating area after extensive wound excision of the necrotic skin (debridement).

- ◆ Vacuum assisted dressing is better.
- ◆ Once patient recovers and healthy granulation tissue appears, split skin grafting is done. As it commonly involves large area, mesh graft (meshing of SSG) is needed.

### Necrotising fasciitis

- ❖ 80% are polymicrobial—*streptococci*, *staphylococci*, *E. coli*, *Pseudomonas*, *Proteus*, *Clostridium*
- ❖ It is a surgical emergency condition as it is very rapidly progressive
- ❖ Lower limb is the most common site—60%
- ❖ Oedema beyond erythema, woody hard texture on palpation
- ❖ Crepitus with subcutaneous emphysema, skin vesicles, dish water pus with grayish discharge are common
- ❖ Lymphangitis is usually absent
- ❖ Pink/orange skin stain and later focal skin gangrene
- ❖ Shock, multiorgan failure
- ❖ Resuscitation, wound excision, antibiotics, critical care (oxygen, intubation, ventilator) is needed
- ❖ Hyperbaric oxygen given in high pressure chamber with 100% oxygen in 2–3 atmospheric pressure reduces the mortality to 10–20%. It is bactericidal and promotes the neutrophil function
- ❖ In spite of adequate therapy mortality is 30–50% or more

### ACUTE PYOMYOSITIS

- ◆ It is infection and suppuration with destruction of the skeletal muscle, commonly due to *Staphylococcus aureus* (90%) and *Streptococcus pyogenes*, occasionally due to Gram-negative organisms.
- ◆ It is common in muscles of thigh, gluteal region, shoulder and arm.
- ◆ Precipitating factors are similar to necrotising fasciitis—trauma, malnutrition, anaemia, and immunosuppression.
- ◆ Pain, oedema, tenderness over the site with apparently normal overlying skin.
- ◆ Induration and muscle spasm is typical.
- ◆ Fever, jaundice, uraemia (*acute renal failure*) are common.

## Management

- ◆ *Creatine phosphokinase* will be very high and signifies acute phase (more than 50,000 units); due to *rhabdomyolysis*.

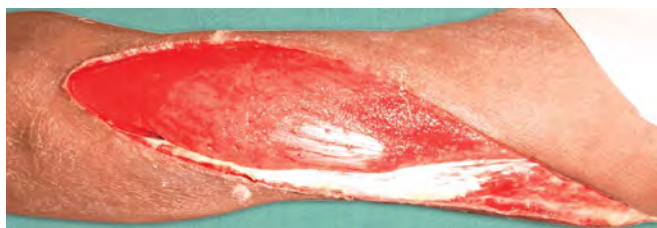

Fig. 1.130: Pyomyositis of thigh muscle.

- ◆ MRI is useful. US guided pus aspiration is also done.
- ◆ *Treatment* is antibiotics, radical wound excision with removal of pus and all necrosed muscle and compartment release. *Haemodialysis* is needed until recovery if there is renal failure. Later secondary suturing or skin grafting is needed.

## ■ SURGICAL SITE INFECTION (SSI)

Surgical site infection is the second most common complication following surgical procedures (*first being postoperative pneumonia*) due to virulent bacterial entry, altered wound microenvironment, and changed host defense. Prevention of SSI can be achieved by better preoperative preparation; proper infection control during surgery; adherence to principles of preventive antibiotic therapy; better surgical techniques to reduce haematoma, tissue injury and foreign bodies within the surgical site; prevention of tissue hypoxia with enhanced oxygen support.

### Common Sources of Infection

- ◆ Surgical wards, wounds, ulcers, catheters, drains, sputum, urine, faeces, open wounds.
- ◆ Operation room without proper ventilation, nurses, surgeons. Operation methods, sterilisation of instruments.

### Organisms Causing SSI

- ◆ Commonly *Staphylococcus aureus*. Any organisms like clostridia, Gram-negative bacteria can cause SSI.
- ◆ Bacteria present in a wound with no signs or symptoms of systemic inflammation is called as *colonization*, usually less than  $10^5$ cfu/ml. Transient exposure of a wound to bacteria (usually less than 6 hours) is called as *contamination* with varying concentration.

### Sequence of Events (in Surgical Wounds)

- ◆ *Activation* of inflammation occurs by cuts, incisions, abrasions, burns. This initiates *inflammation* by protein coagulation, platelet aggregation, mast cell activity, release of complements and bradykinin. *Phase I of inflammation* begins with vasodilatation, increased bulk flow, increased vascularity. Later *Phase II of*

*inflammation* proceeds with phagocytic infiltration and bacterial phagocytosis, removal of dead tissue with release of proinflammatory cytokines. Here tissue injury from incision mobilizes phagocytes before bacterial contamination leading into prior preparation against infection. If contamination is controlled monocytes activate to *regulate wound healing* using myofibrocytes and collagen.

- ◆ If bacterial *contamination is not controlled*, proinflammatory cells release TNF- $\alpha$  to stimulate neutrophils for phagocytosis. It also causes release of reactive oxygen and acid hydrolases from lysosomal vacuoles to result in lipid peroxidation, release of interleukins, evoking acute inflammatory response with creation of space containing pus which contains necrotic tissue, neutrophils, bacteria and proteinaceous fluid with *all signs of inflammation*—*rubor, dolor, calor, tumour*. It is *typical surgical site infection (SSI)*.

### Factors Related to SSI

- ◆ *Bacterial entry* (inoculum) into the wound occurs through air in operation room, through instruments, through surgeons and theatre staffs, patient's endogenous bacteria like perineum, urine, etc.
- ◆ *Bacterial virulence* plays major role in causing SSI.
- ◆ *Microenvironment in the wound* like haemoglobin level at surgical site; presence of necrosis which interferes with phagocytosis; presence of dead space and or foreign body in the wound.
- ◆ *Host defences* both natural (Innate) and acquired, when altered SSI occurs. Acquired causes are—shock, hypoxia, chronic illness, hypoalbuminemia, malnutrition, hypothermia, hyperglycemia, corticosteroids, HIV infection, malignancy and certain drugs.

### Classification of Surgical Wounds

- ◆ *Clean wounds*—operative procedure does not enter into normally colonised viscus.
- ◆ *Clean-contaminated*—operation enters into a colonised viscus but under elective controlled circumstances.
- ◆ *Contaminated wounds*—gross contamination is present at the surgical site in the absence of obvious infection.
- ◆ *Dirty wounds*—surgical procedures performed when active infection is present.

### Risk Classification and Identification System

It is based on three categories of variables—(1) Those that estimate intrinsic degree of microbial contamination at the surgical site. (2) Those that measure the duration of operation. (3) Host susceptibility markers.

### Variables that Influence SSI

Variables that influence SSI	Point
1. An abdominal operation.	1
2. Operation lasting more than 2 hours.	1
3. Surgical site classified as contaminated or dirty/infected.	1
4. Operation performed on a patient with more than three discharge diagnosis.	1
<b>Total index</b>	<b>4</b>

All variables have equal significance. This index twice better at predicting SSI than wound classification. Disadvantage is that it is not operation specific and variables collected at discharge.

## The National Nosocomial Infections Surveillance (NNIS) System as Basic SSI Risk Index

NNIS system	Point
Operation classified as contaminated or dirty.	1
The patient has an ASA (American Society of Anaesthesiology) preoperative assessment score of 3, 4, or 5.	1
Duration exceeds 75th percentile of 'T' point. 'T' point defined as length of time in hours that represents 75th percentile of procedures in NNIS survey.	1

### Note:

T point for common surgical procedures are—coronary artery bypass graft—5; Bile duct, liver or pancreatic surgery, craniotomy, head and neck surgery—4; Colonic surgery, joint prosthesis surgery, vascular surgery—3; Abdominal or vaginal hysterectomy, ventricular shunt, herniorrhaphy—2; Appendectomy, limb amputation, caesarean section—1.

## Physical Status classification

Class I: A patient in normal health.

Class II: A patient with mild systemic disease resulting in no functional limitations.

Class III: A patient with severe systemic disease that limits activity, but is not incapacitating.

Class IV: A patient with severe systemic disease that is a constant threat to life.

Class V: A moribund patient not likely to survive 24 hours.

## Classification of Surgical Site Infection (SSI)

### A. According to the Depth of the Wound Infection

#### 1. Superficial incisional SSI

It occurs within 30 days of operation; involves only skin and subcutaneous tissue; and one of following:

Purulent drainage (culture documentation not required), organisms isolated from fluid/tissue of superficial incision, at least 1 sign of inflammation, wound is deliberately opened by the surgeon, surgeon or attending physician declares that the wound is infected.

A wound is not considered as superficial site infection—if stitch abscess is present; if infection is at episiotomy site; burn wound, SSI extends into the fascia or muscle.

#### 2. Deep incisional SSI

It occurs within 30 days of operation or 1 year if an implant is present; involves deep soft tissues of the incision; and at least one of the following—purulent drainage from the deep incision site without organ/space involvement, fascial dehiscence or deliberate separation by surgeon, deep abscess, identified by—reoperation/histopathology/radiology, surgeon or attending physician declares deep infection present.

#### 3. Organ space infection

It occurs within 30 days or 1 year if an implant is present; involves anatomic structures not opened or manipulated during surgery; and one of the following—pus from a drain placed into organ/space, organism isolated by culture, identification of abscess by direct examination, reoperation, histopathology, radiology, diagnosis by surgeon or attending physician.

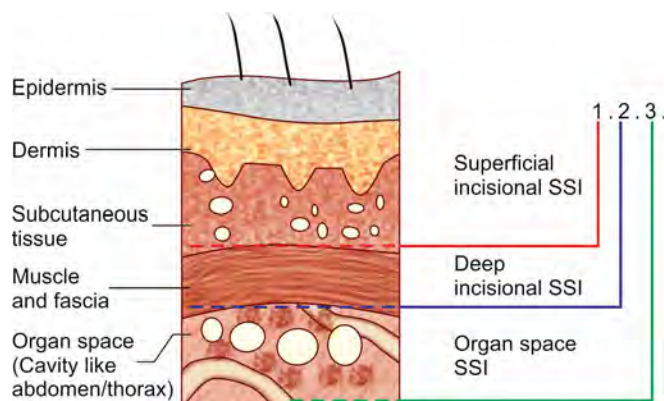
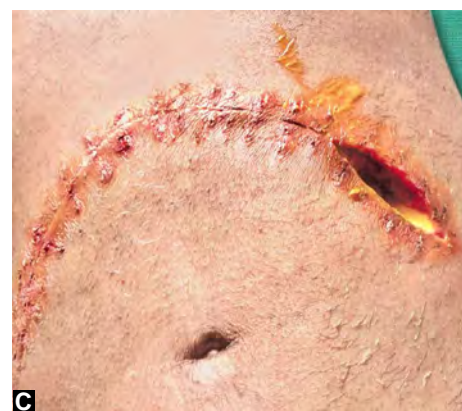
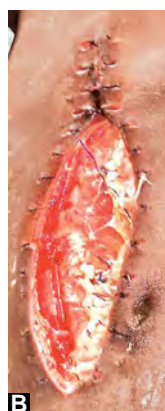
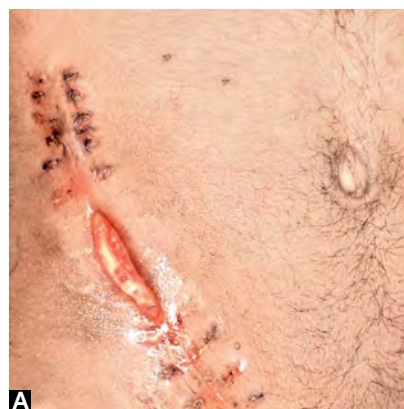Fig. 1.131: Surgical site infection classification as—superficial incisional, deep incisional, organ space.



Figs 1.132A to C: Surgical site infection (SSI) types: (A) Superficial incisional SSI. (B) Deep incisional SSI. (C) Organ space SSI.

### B. Classification of Wound Infection According to the Aetiology

- Primary infection where the wound is the primary site of infection.
- Secondary infection arises following a complication that is not directly related to the wound.

### C. Classification of Wound Infections According to the Time

- An early infection presents within 30 days of a surgical procedure.
- An intermediate infection occurs between 1-3 months afterwards.
- Late infection occurs in more than three months after surgery.

**D. Classification of Wound Infections According to the Severity**

- a. *Minor* wound infection if there is discharge without cellulitis or deep tissue destruction.
- b. *Major* if the discharge of pus is associated with tissue breakdown, partial or total dehiscence of the deep fascial layers of the wound, or if systemic illness is present.

**Note:**

Please refer first page of this Chapter for Southampton wound grading system and Asepsis wound score system.

**Prevention of SSI**

**1. Preoperative**

- ◆ Preoperative cleaning and antiseptic scrub of surgical site. Skin is colonised by various bacteria mainly *Staphylococcus aureus* (50%). Preoperative skin wash using chlorhexidine decreases bacterial colonisation by 80% and so wound contamination.
- ◆ Surgical site to be shaved or clipped in the operation theatre. Shaving should be done in the theatre itself or within 2 hours of beginning of the surgery otherwise infection rate may raise. Clean wound infection after shaving is 2.3%; after clipping it is 1.7%; without shaving or clipping it is 0.9%. However, selective shaving is definitely needed in area like scalp, axilla, groin, and perineum.
- ◆ Surgery should be avoided or postponed if fingers or hand of surgeon has open wounds or infection.
- ◆ Obvious infection in patient if exists should be treated.
- ◆ Prolonged preoperative admission should be avoided for an elective surgery.

**2. Care in the Operation Theatre**

- ◆ One should ensure that sterile caps, masks, gowns and sterile gloves are used.
- ◆ Proper skin cleaning is needed on table after anaesthesia using antiseptics like povidone iodine. One should ensure that all drapes are dry throughout the procedure and all instruments are thoroughly sterilised.
- ◆ Unimpregnated plastic drapes are avoided as it is found that it does not have any advantage.
- ◆ Gentle tissue handling, absolute haemostasis, holding tissues using instruments as much as possible, using appropriate suture materials, avoiding dead space during closure are certain essential on table tips to reduce SSI.
- ◆ One should consider leaving wounds open if it is severely contaminated.

**3. Preventive Antibiotic Therapy**

- ◆ It is used whenever high-risk of infection is associated with the procedure and consequences of infection if possibly severe and if patient has a high NNIS risk index.
- ◆ Antibiotics should be administered as close to the incision time as possible, before induction of anaesthesia.
- ◆ Selected antibiotic should have activity against likely pathogens.
- ◆ Postoperative systemic antibiotics for 24 hours (beyond 24 hours not shown to reduce SSI).
- ◆ Benefit of preoperative antibiotics in NNIS risk 0 index is difficult to assess and quantify.
- ◆ Proper techniques and wound microenvironment are more important than antibiotics.

- ◆ Preventive systemic antibiotics not to be used to prevent nosocomial infections.
- ◆ Oral antibiotic bowel preparation with appropriate mechanical bowel preparation.
- ◆ If systemic antibiotics are to be used antibiotics of longer half-life are to be chosen.
- ◆ Very long procedures should have a redosing strategy during the procedure.

**4. Enhancement of Host Defences**

- ◆ Increased oxygen delivery facilitates phagocytic eradication of microbes.
- ◆ Optimising core body temperature is important as warmer patients resist bacteria better.
- ◆ Blood glucose control is essential even to nondiabetics as well.

**Management of SSI**

- ◆ SSI is managed depending on the type of SSI—superficial, deep or organ space.
- ◆ All infected material and pus should be removed from the wound site—*debridement*.
- ◆ Sutures are removed to allow *free drainage* of infected material.
- ◆ Infected fluid is sent for culture and sensitivity and suitable antibiotics are started.
- ◆ Once wound shows signs of healing by healthy granulation tissue, secondary suturing is done. Often it is allowed to heal by scarring.

Different definitions	
Contamination	Bacteria are on the wound surface. No division is occurring
Colonization	Bacteria are dividing
Topical infection (Critical colonization)	Bacteria are dividing and have invaded the wound surface. There may be an increasing variety of bacteria present; Biofilm may be present
Local infection	Bacteria and/or their products have invaded the local tissue
Regional/Spreading infection/Cellulitis	Bacteria and/or their products have invaded the surrounding tissue
Sepsis	Bacteria and/or their products have entered the blood stream and may have spread to distant sites or organs

**HIV INFECTION AND AIDS (Acquired Immunodeficiency Syndrome)**

*Even if I'd made no money, even if it was the pariah of specialties by virtue of its lack of procedures, an unexpected fringe benefit had become evident with the appearance of AIDS: In those early days, dealing with AIDS made us an elite group, an unexpectedly glamorous group. Even the cardiac surgeons could not approach our kind of heroism. Yes, they dealt with death every day. But it was somebody else's death they had to worry about. Never their own.*

—Abraham Verghese, 1994

*The drops of rain make a hole in the stone not by violence, but by oft falling.*

### History

- ❖ 1983: Discovery of the virus
- ❖ First case of AIDS detected in UK
- ❖ 1984: Development of an antibody test

### Definition of AIDS

Confirmed HIV infection with CD<sub>4</sub> T lymphocyte count  $< 0.2 \times 10^6/L$  with symptoms.

### Human Immunodeficiency Virus

It was discovered by *Barre-Sinoussi and Montagnier in 1983*.

### Types

It is classified under HTLV Type III. HIV is subdivided into Type 1 and Type 2.

They are *retroviruses*.

### Clinical classification of HIV infection

- ❖ Acute infection
- ❖ Asymptomatic but positive HIV
- ❖ Persistent generalised lymphadenopathy
- ❖ AIDS (HIV related diseases)
  - Constitutional diseases like weight loss, fever, diarrhoea
  - Neurological diseases, dementia, neuropathy, myelopathy
  - Opportunistic infections
  - Malignancies. Kaposi's sarcoma, non-Hodgkin's lymphomas, primary cerebral lymphomas
  - Other diseases attributable to HIV infection

### Mode of Transmission

- ◆ Sexual intercourse—vaginal or anal.
- ◆ Needle pricks—using unsterilised needles for injections, in IV drug abusers, careless handling.
- ◆ Mother to child—during birth through vaginal secretion, transplacental, through breast milk.
- ◆ Blood transfusions, organ transplantations.

Disease is common in Africa and Asian countries.

HIV mainly harbours in semen, genital secretions, blood, pus, sputum, saliva and other body fluids.

### Anti-HIV antibody

- ❖ It appears about 3 weeks to 3 months after exposure
- ❖ It always indicates infection
- ❖ It has got weak neutralising capacity
- ❖ It persists throughout the HIV infection

### Tests for HIV

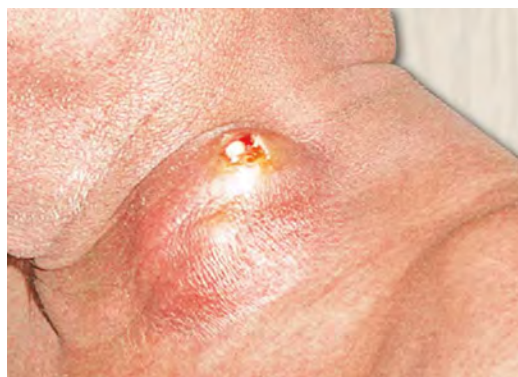1. ELISA test (**screening test**).
2. Western blot test (**diagnostic test**).
3. Polymerase Chain Reaction (PCR).
4. Anti-HIV antibody detection.
5. *Viraemia quantification*—to start treatment and to see the response of antiviral drugs (useful if it is within 0.5 log 10).
6. *CD4+ count*
  - ▶ Normal value  $> 500/mm^3$ .

- ▶ Values between  $200-500/mm^3$  is seen in Kaposi sarcoma, *Candida* infection, *Mycobacterium tuberculosis*.
- ▶ Values between  $50-200/mm^3$  is seen in *Pneumocystis carinii* and *Toxoplasma* infections.
- ▶ Values  $< 50/mm^3$  is seen in atypical mycobacteria, cytomegalovirus, lymphomas.

After HIV infection, there is a time gap for the patient to become reactive to tests. This time gap is called as "*Window period*". This period is variable. But during this period, the individual is infective.

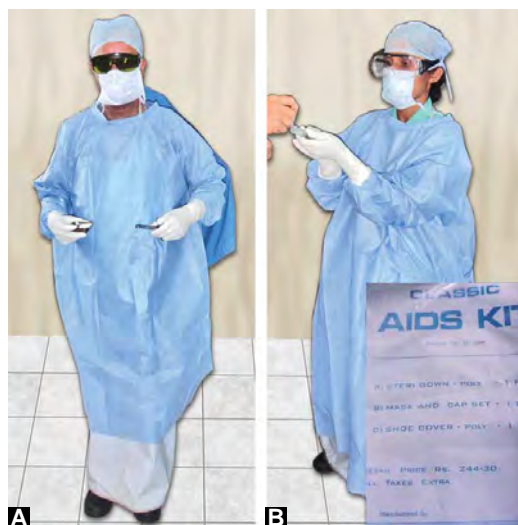### Pathogenesis

Envelope glycoprotein of HIV binds with the surface molecule CD4 of 'T' lymphocytes, monocytes, macrophages, cutaneous Langerhan's cells, dendritic cells of all tissues.



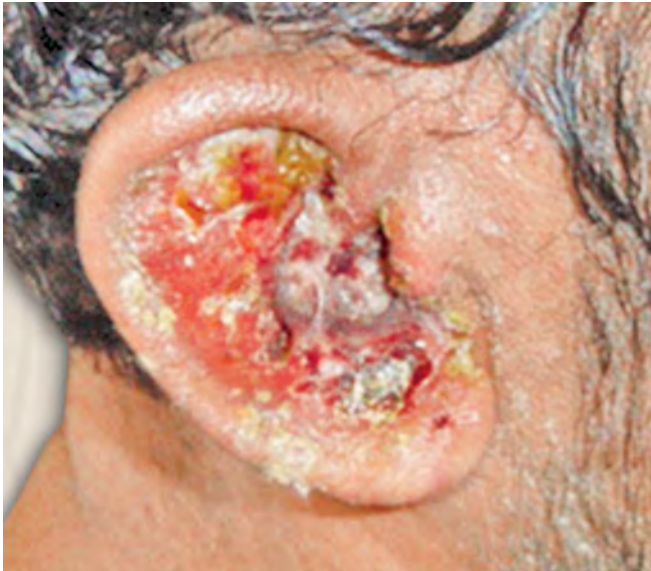**Fig. 1.133:** HIV patient presented with tuberculous cold abscess with discharging sinus.

CD4 of lymphocytes—T helper cells induce and control the normal immune response.

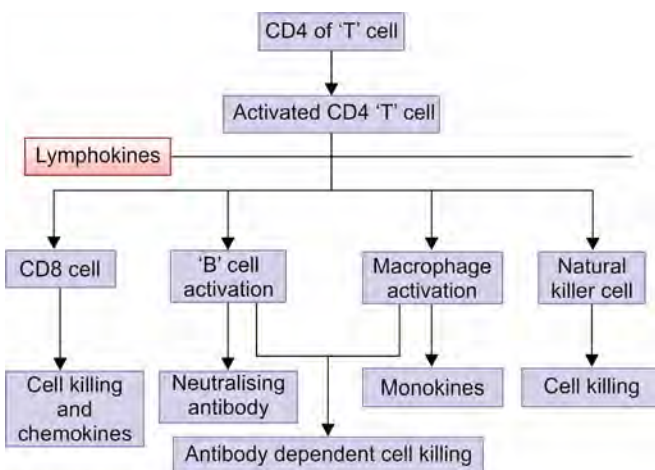


**Figs 1.134A and B:** Picture showing HIV kit and wearing of the HIV kit as a precaution while doing surgery for HIV infected individuals.

HIV suppresses immune response completely directly by suppressing 'T' cell, indirectly by suppressing 'B' cell. Finally it dismantles and destroys the immune system making the individual prone to opportunistic infections.



**Fig. 1.135:** Severe infection of ear cartilage in a HIV infected patient.



After HIV infection, antibodies develop to virus envelope and core proteins which persist throughout life.

### General Features in HIV

- ◆ Weight loss more than 10%.
- ◆ Fever more than 1 month.
- ◆ Diarrhoea more than 1 month.
- ◆ Neuralgia, arthralgia, headache.
- ◆ Lymphadenopathy.
- ◆ Cutaneous rashes, dermatitis, fungal (*Candida*), bacterial, viral (herpes simplex 1 and 2) infection.
- ◆ Dental infection, gingivitis, candidiasis of oral cavity and oesophagus.
- ◆ Varicella zoster infection.
- ◆ Opportunistic infections.
- ◆ Poor healing after surgery, trauma, infection with more complications.

### Tumours in HIV Infection

- ◆ Kaposi's sarcoma—40% common.

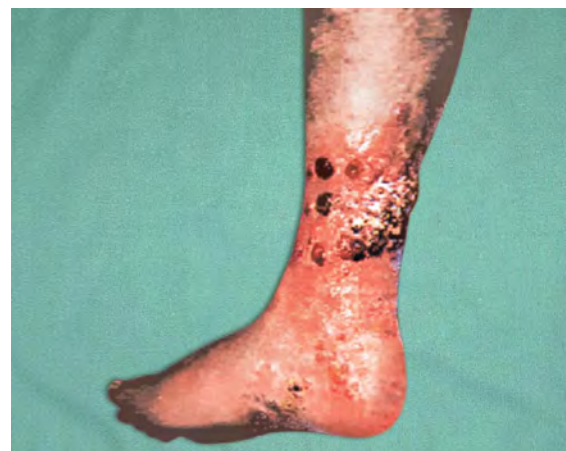- ◆ Lymphomas (NHL common) (3–4%).
- ◆ Cervical cancer.
- ◆ CNS lymphomas.
- ◆ Ano-genital squamous cell carcinoma.
- ◆ Testicular tumours (Germ cell types).
- ◆ Lung cancer.
- ◆ GIT lymphomas and adenocarcinomas.
- ◆ Squamous cell carcinoma of anal canal and cervix.

### Pulmonary Problems in HIV Infection

- ◆ Pneumonia.
- ◆ Tuberculosis.
- ◆ Fungal infections.
- ◆ *Pneumocystis carinii pneumonia*.
- ◆ Cytomegalovirus pneumonia.

### GIT Problems in HIV Infection

- ◆ GIT infections—bacterial, protozoal, viral.
- ◆ Kaposi's sarcoma, lymphomas, adenocarcinomas.
- ◆ Hepatitis ('C' virus), cholestasis.
- ◆ Anorectal diseases.
- ◆ Abdominal tuberculosis.



**Fig. 1.136:** Kaposi's sarcoma.

### Neurological Problems in HIV Infection

- ◆ Encephalitis, aseptic meningitis, myelitis.
- ◆ Neuropathies with demyelination.
- ◆ Opportunistic infections like *Toxoplasma*, *Cryptococcus* causing severe meningitis.
- ◆ Primary CNS lymphomas.
- ◆ CNS tuberculosis (Tuberculomas).
- ◆ Visual problems.

### Management

#### Investigations

- ◆ Tests for HIV.
- ◆ Tests for specific and opportunistic infections.
- ◆ Tests relevant for associated tumours.

#### Treatment

1. Antiviral therapy:



- ▶ *Nucleoside reverse transcriptase inhibitor (NRTI)*: Zidovudine, didanosine, abacavir, lamivudine, stavudine.
  - ▶ *Non-nucleoside reverse transcriptase inhibitor (NNRTI)*: Nevirapine, delavirdine.
  - ▶ *Protease inhibitors*: Ritonavir, indinavir, amprenavir.
2. Treatment of **opportunistic infections**.
  3. Treatment of **tumours**.
  4. Immunotherapy:
    - ▶ Alpha and gamma interferons.
    - ▶ Interleukins.
  5. Bone marrow transplantation.
  6. Anti-CD3 or IL-2 after **HAART (Highly Active Anti-Retroviral Therapy)**.
  7. **Psychotherapy**.
  8. Counselling of HIV patients and their families.
  9. Life-expectancy after initial HIV infection is 8-10 years.

### Prevention

Continues to be our best weapon in combating the menace of HIV infection.

#### Universal precautions against HIV

- ❖ Care in handling sharp objects like needles, blades
- ❖ All cuts and abrasions in an HIV patient should be covered with a waterproof dressing
- ❖ Minimal parenteral injections
- ❖ Equipments and areas which are contaminated with secretions should be wiped with sodium hypochlorite solution or 2% glutaraldehyde
- ❖ Contaminated gloves, cottons should be incinerated
- ❖ Equipments should be disinfected with glutaraldehyde
- ❖ Disposable equipments (drapes, scalpels, etc.) should be used whenever possible
- ❖ Walls and floor should be cleaned properly with soap water
- ❖ Separate operation theatre and staff to do surgeries to HIV patients is justifiable
- ❖ Avoid shaving whenever possible before surgery in HIV patients

*Contd...*

*Contd...*

- ❖ All people inside the theatre should wear disposable gowns, plastic aprons, goggles, overshoes and gloves
- ❖ Surgeons, assistants and scrub nurse should wear in addition double gloves
- ❖ Suction bottle should be half-filled with freshly prepared glutaraldehyde solution
- ❖ Spilled body fluids should be diluted with glutaraldehyde
- ❖ Accidental puncture area in surgeon or scrub nurse should be immediately washed with soap and water thoroughly
- ❖ Theatre should be fumigated after surgery to HIV patient

- ◆ Safe sex. Condom usage reduces the risk of transmission.
- ◆ Health education.
- ◆ Use of disposable needles to prevent infections.

### HIV, hospital and surgeon

- ◆ Isolation per se of HIV patient is not required.
- ◆ Proper care should be taken to prevent transmission of the virus.
- ◆ Open wounds, disposal of excreta, fluids, discharge, pus and other infective materials should be taken care of properly.
- ◆ Risk of HIV infection through needle prick is very less (0.03%). Following measures should be taken while managing HIV patients:
  - ◆ Wearing double gloves.
  - ◆ Wearing proper spectacles (as HIV can get transmitted through eyes directly).
  - ◆ Wearing proper head mask, theatre shoes, apron.
  - ◆ Measures to prevent spread of infection from patient to patient in the hospital.
  - ◆ Disposal of needles through a sharp disposing container.

### Disinfection

- ◆ Autoclave is ideal.
- ◆ Boiling.
- ◆ Sodium hypochlorite solution.
- ◆ 2% glutaraldehyde solution.

## E. Swellings

### CHAPTER OUTLINE

- |                  |                         |                |
|------------------|-------------------------|----------------|
| ❖ Lipoma         | ❖ Fibroma               | ❖ Neuroma      |
| ❖ Cysts          | ❖ Bursae                | ❖ Neurofibroma |
| ❖ Dermoids       | ❖ Semimembranosus Bursa | ❖ Neurilemmoma |
| ❖ Sebaceous cyst | ❖ Marrant Baker's Cyst  | ❖ Ganglion     |
| ❖ Glomus Tumour  | ❖ Lymph Cyst            | ❖ Chordoma     |
| ❖ Papilloma      | ❖ Lymphangioma          | ❖ Epignathus   |
| ❖ Warts          | ❖ Calcinosis Cutis      |                |

*Swelling* means obvious enlargement of a part of the body due to various causes like congenital, inflammatory or neoplastic. *Mass* denotes the lesion with difficulty to define the extent – mass abdomen; *lump* denotes defined lesion within the organ or causing the alteration in the gross nature/shape of the part or organ like – lump in the breast.

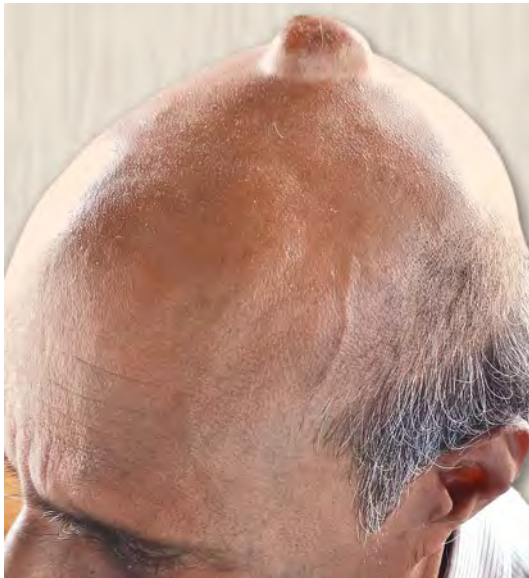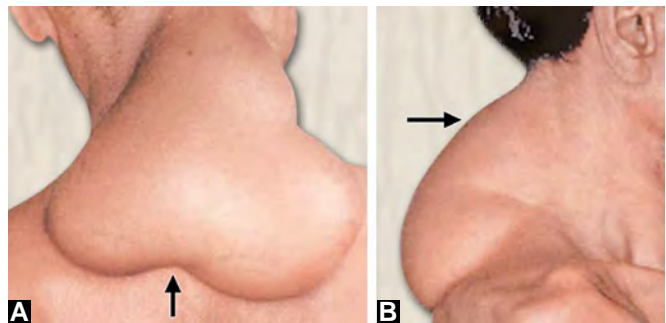


Fig. 1.137: Swelling scalp; could be sebaceous cyst.

### LIPOMA

- ❖ It is a benign neoplasm arising from *yellow fat*. Often it can be hyperplasia or combination of neoplasm and hyperplasia.
- ❖ A lipoma is composed of mature adipocytes and uniform nuclei that are identical to those seen in normal adult fat. The fat in lipoma is considered unavailable for general metabolism.
- ❖ It is the *most common* benign tumour (karyotype 12<sub>q</sub> change). Prevalence is 2.1 per 100 people.

- ❖ It is called as *universal tumour (ubiquitous tumour)* as it can occur anywhere in the body except brain.
- ❖ It can be *localised* (encapsulated) or *diffuse* (nonencapsulated).
  - ▶ Localised lipoma is encapsulated with yellowish orange colour.
  - ▶ Diffuse lipomas are not encapsulated and not localised. It is common in palm, sole, head, neck. It is seen in subcutaneous and intermuscular tissues. It is difficult to remove surgically. Recurrence is high after incomplete removal.
- ❖ Lipoma can be *superficial or deep*.
  - ▶ Superficial lipomas are more common; common in subcutaneous plane. It is common in back, neck, proximal extremities and abdomen. It is commonly less than 5 cm; but can attain large size. There is no gender predisposition.
  - ▶ Deep lipomas are commonly intramuscular, but often may be intermuscular; often both intra- and intermuscular (infiltrating lipoma). They are common in lower limbs (45%), trunk (17%), shoulder and upper limb. They attain large size compared to superficial lipomas. They are more common in men.
- ❖ Lipoma can be single or multiple.
  - ▶ *Single lipoma* is common. It is usually superficial in subcutaneous plane but can be deep also.

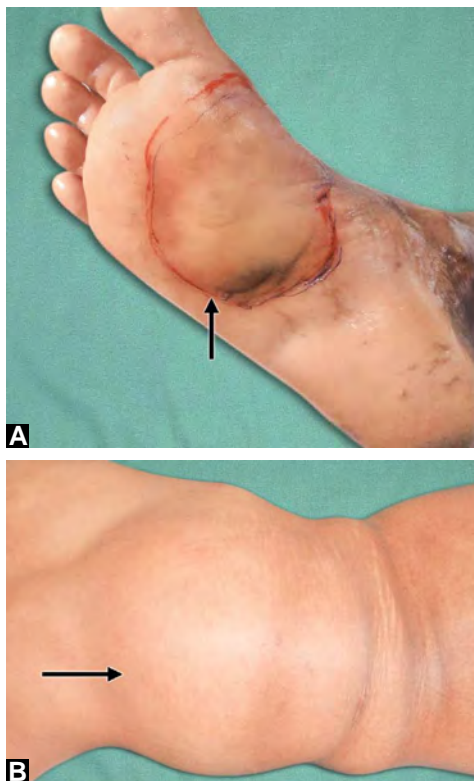


Figs 1.138A and B: Large lipoma in the nape of neck.

- ▶ *Multiple lipomas* are 15% common; common in males (6:1). Common in back, shoulder and upper arm; can be symmetrical. It can be associated with many syndromes like multiple endocrine neoplasia (MEN), Cowden's, Frohlich, Proteus, Bannayan-Zonana syndromes.
- ▶ *Multiple lipomatosis* represents a diffuse overgrowth of mature adipose tissue; involves subcutaneous and muscular planes extensively; common in shoulder and pelvic girdles. It is common in younger age group. 30% of them are familial; *Adiposa dolorosa (Dercum's disease)* is a multiple lipomatosis mainly seen in females (30:1—female to male ratio); there is tender fat deposition especially in the trunk and girdles; it is common in epileptic and psychiatric patients.
- ◆ Benign tumour arising from brown fat is called as *hibernoma* (reddish brown), which has got serpentine vascular elements.
- ◆ Lipoma with fibrous component is called as *fibrolipoma* (most frequent nonlipomatous component in lipoma is fibrous tissue). Fibrolipoma is nonseptal.
- ◆ Lipoma with telangiectasis is called as *naevolipoma*.
- ◆ Neurolipoma (with nerve tissue and is painful), angioliipoma (with vascular element), myoliipoma, chondroid lipoma, spindle cell lipoma, pleomorphic lipoma – are different types depending on the type of nonadipose component associated.
- ◆ *Lipoblastoma* is a benign tumour of immature fat occurring in infant boys in subcutaneous tissue of extremity.
- ◆ Benign lipomatous lesions may occur focally in a joint or tendon sheath or with diffuse villonodular proliferation in the synovium—*lipoma arborescens*. Synovectomy may be needed in this patient.
- ◆ Malignant transformation of lipoma is *non-existent*. Liposarcoma does not arise from mature fat cells but from primitive mesenchymal cells.
- ◆ Mobile, with edges slipping between the palpating fingers (*slip sign*).
- ◆ Skin is free.
- ◆ Lipomas may be pedunculated at times.
- ◆ It is *rare* in children.
- ◆ *Pain* in lipoma may be due to neural element or compression to nerves or adjacent structures. *Angioliipomas* being highly vascular is commonly *tender*.
- ◆ *Trunk* is the most common site; nape of neck and limbs are next common.
- ◆ Clinically lipoma can be single, multiple or diffuse.

**Note:**

A diagnostic criterion used by some clinicians for superficial lipomas is hardening of swelling after application of ice. This test is of less important.



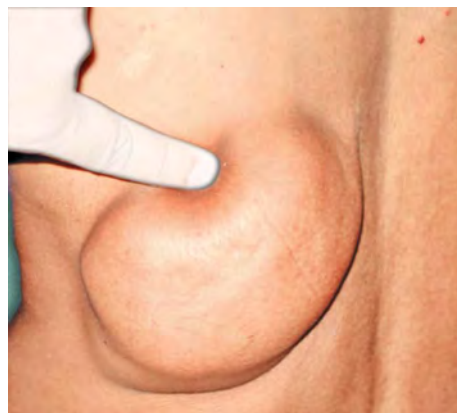**Figs 1.139A and B:** Diffuse lipoma on the plantar aspect of foot and back.

**Sites****Anatomical sites of lipoma**

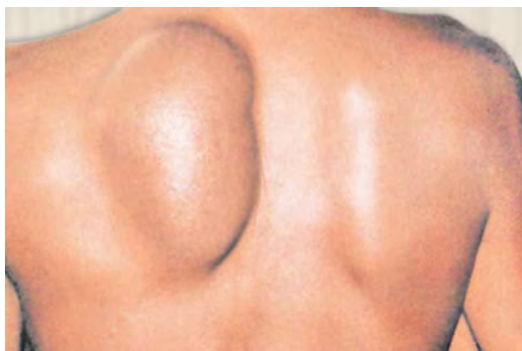- ❖ Subcutaneous.
- ❖ Subfascial.
- ❖ Intramuscular.
- ❖ Intermuscular in anterior abdominal wall.
- ❖ Parosteal.
- ❖ Subserosal.
- ❖ Submucosal (GI tract).
- ❖ Extradural (not intradural).
- ❖ Intra-articular.
- ❖ Subsynovial.
- ❖ Subperiosteal, interosseous.
- ❖ Intraglandular—breast, pancreas, kidney.

**Clinical Features**

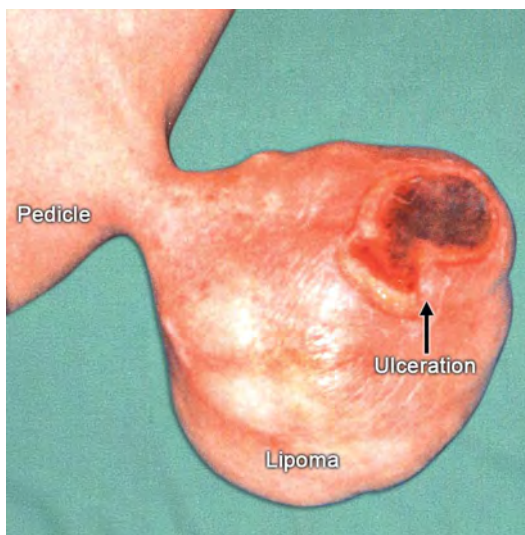
- ◆ Localised swelling, which is lobular (surface), nontender.
- ◆ Often fluctuant like feel but actually not (because fat in body temperature remains soft). It is usually *nontransilluminant*.



**Fig. 1.140:** Slip sign of lipoma.



**Fig. 1.141:** Large lipoma in the back over scapula.



**Fig. 1.142:** Pedunculated lipoma. It is common in axillary region. Lobular surface with narrow pedicle is typical. Often ulceration can occur in the surface due to repeated friction. It often mimics papilloma.

### Differential Diagnosis

- ◆ Neurofibroma – it moves horizontally but not longitudinally along the line of the nerve. Neurofibroma is firmer.
- ◆ Cystic swellings like dermoid, sebaceous cyst.
- ◆ Liposarcoma – all lipomas are benign. Large lipoma should be differentiated from liposarcoma.
- ◆ Other soft tissue tumours.

### Investigations

- ◆ Ultrasound or CT or MR imaging is done in deep or large or intracavitary lipomas.
- ◆ FNAC or incision biopsy is needed in large or deep or intracavitary lipomas to confirm it as benign.

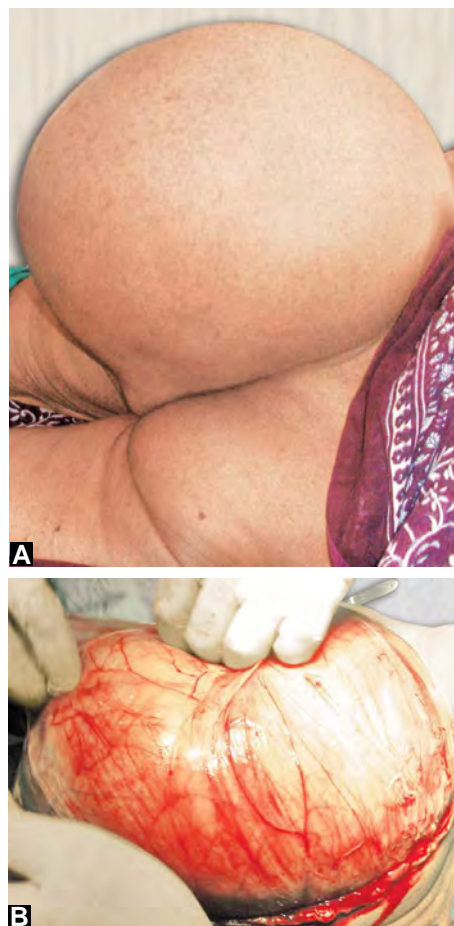### Complications

- ◆ Myxomatous changes—occurs in *retroperitoneal* lipoma.
- ◆ Saponification.

- ◆ Calcification—11% mineralization.
- ◆ Submucosal lipoma can cause intussusception and so intestinal obstruction.

### Note:

It is now considered that all sarcomas are of *de novo* in origin to begin with at mitochondrial level; so benign soft tissue tumour turning into sarcoma is not existing (except of neural origin like neurofibroma).



**Figs 1.143A and B:** Large lipoma in buttock region.

### Liposarcoma

- ❖ Common in retroperitoneum, thigh and back
- ❖ Rapid growth
- ❖ Warm and vascular
- ❖ Dilated veins over the surface
- ❖ Infiltration in to deeper plane with restriction of the mobility
- ❖ Skin fixation and fungation
- ❖ Blood spread to lungs

### Treatment

- ◆ Excision.
- ◆ Small lipoma is excised under local anaesthesia and larger one under general anaesthesia.
- ◆ Recurrence is 11%

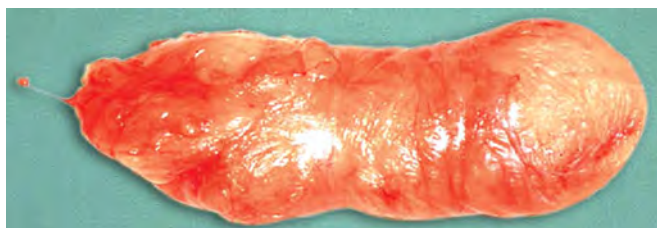

Fig. 1.144: Gross feature of specimen of lipoma.

## ■ CYSTS

Cyst is a collection of fluid in a sac lined by epithelium or endothelium. **Word meaning of cyst is “bladder” (Greek)** (Greek word ‘KUSTIS’ means bladder).

### True Cyst

- ◆ Cyst wall is lined by epithelium or endothelium.
- ◆ If infection occurs, cyst wall also will be lined by granulation tissue.
- ◆ Fluid is usually serous or mucoid derived from the secretion of the lining.

### False Cyst

- ◆ It does not have epithelial lining.
- ◆ Fluid collection occurs as a result of exudation or degeneration.

### Example:

- ◆ Pseudocyst of pancreas.
- ◆ Wall of cystic swelling in tuberculous peritonitis.
- ◆ Cystic degeneration of tumour.
- ◆ After haemorrhage, in a haematoma, RBC's are lysed, gets absorbed and fluid remains as a false cyst.

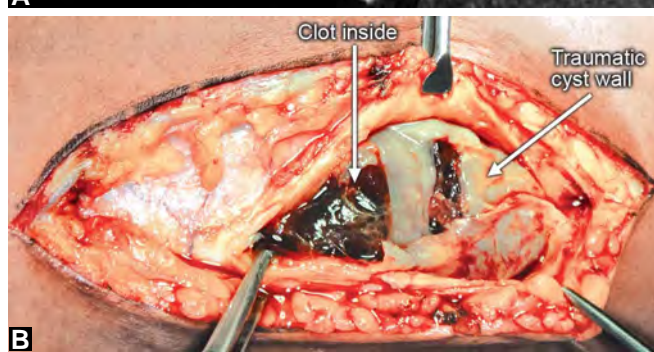
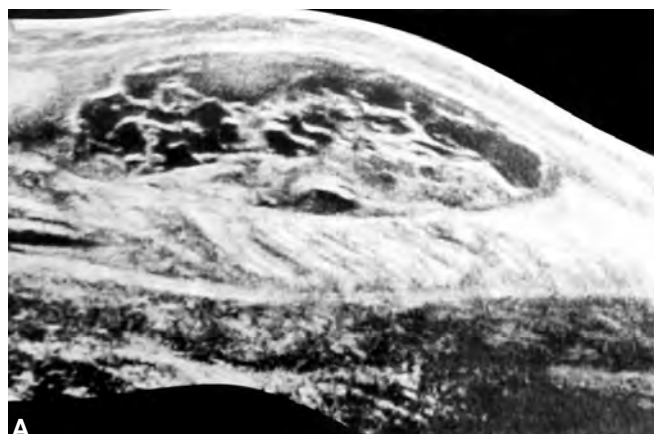
“*Apoplectic cyst*” is formed in brain as a result of ischaemia, causing collection of fluid.

## Classification

- a. *Congenital cyst*
  - ▶ *Dermoids*: Sequestration dermoid.
  - ▶ *Tubulodermoids*: Thyroglossal cyst, postanal dermoid, ependymal cyst, urachal cyst.
  - ▶ *Cysts of embryonic remnants*: Cysts from paramesonephric duct and mesonephric duct, cysts of urachus and vitellointestinal duct.
- b. *Acquired cysts*
  - ▶ *Retention cysts*: They are accumulation of secretions of a gland due to obstruction of the duct, e.g. sebaceous cyst, Bartholin's cyst, cyst of parotid, breast, epididymis.
  - ▶ *Distention cyst*: Lymph cyst, ovarian cyst, colloid goitre.
  - ▶ *Exudation cyst*: Bursa, hydrocoele, pancreatic pseudocyst.
- c. *Cystic tumours*: Dermoid cyst of ovary, cystadenomas.
- d. *Traumatic cyst*: Due to trauma, haematoma occurs usually in thigh, loin, shin. It eventually gets lined by endothelium containing brown coloured fluid with cholesterol crystals.
- e. *Degenerative cyst*: Due to cystic degeneration of a solid tumour (due to necrosis of tumour).
- f. *Parasitic cyst*: Hydatid cyst, trichiniasis, cysticercosis.

## Clinical Features of a Cyst

- ◆ Hemispherical swelling which is smooth, fluctuant, nontender, well-localised.
- ◆ Some cysts are transilluminant.
- ◆ Presentation varies depending on its anatomical location and pathology.
- ◆ Cyst can be single or multiple. Sebaceous cysts are often multiple.



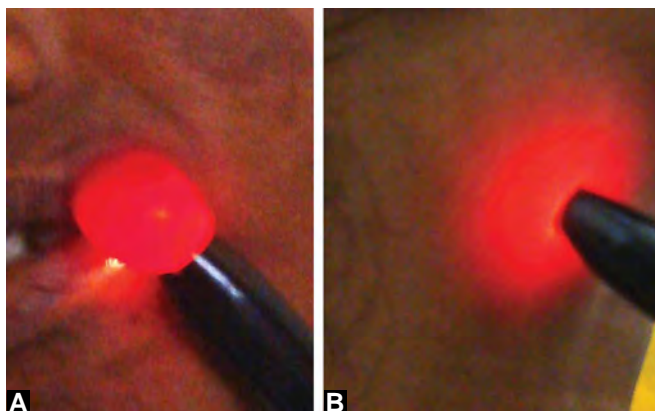
Figs 1.145A and B: Traumatic cyst thigh with false cyst wall with clot inside.

## Effects of a Cyst

- ◆ Compression of adjacent structures (CBD): Choledochal cyst compressing over the CBD.
- ◆ Infection.
- ◆ Sinus formation.
- ◆ Haemorrhage.
- ◆ Torsion, e.g. ovarian cyst.
- ◆ Calcification, e.g. hydatid cyst, cysticercosis.
- ◆ Cachexia: In malignant ovarian cyst patient goes for severe cachexia.

### Swellings which are brilliantly transilluminant

- ❖ Ranula
- ❖ Cystic hygroma and lymph cyst
- ❖ Hydrocoele
- ❖ Epididymal cyst (*Chinese-lantern* pattern)
- ❖ Meningocele



**Figs 1.146A and B:** Brilliantly transilluminant swellings—possibly lymph cyst.

## DERMOIDS

### Types

#### 1. Sequestration Dermoids

- ◆ It occurs at the line of embryonic fusion, due to inclusion of epithelium beneath the surface which later gets sequestered forming a cystic swelling in the deeper plane.
- ◆ It is congenital type.

#### Common sites are

- a. Forehead, neck, postauricular dermoid.
  - b. External angular dermoid.
  - c. Root of nose.
  - d. Sublingual dermoid.
  - e. Anywhere in midline or in the line of fusion.
- ◆ Dermoids occurring in the skull may extend into the cranial cavity.
  - ◆ When it occurs as an external angular dermoid, it extends into the orbital cavity.
  - ◆ It can extend into any cavity in relation to its anatomical location (e.g. thorax, abdomen).

#### Types of angular dermoid

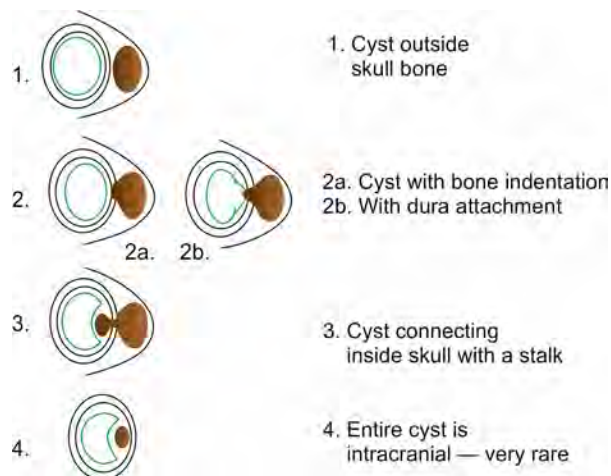
##### a. External angular dermoid:

It is a sequestration dermoid situated over the external angular process of the frontal bone. Outer extremity of the eyebrow extends over some part of the swelling. This typical feature differentiates it from the swelling arising from the lacrimal gland. It may extend into the orbital cavity also (*Frontozygomatic suture*).

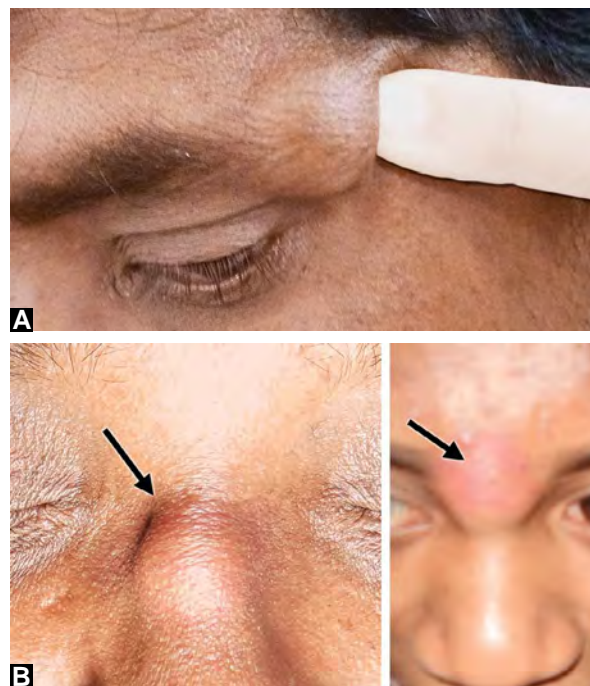
##### b. Internal angular dermoid:

It is a sequestration dermoid cyst in central position near the root of the nose. It occurs in frontonasal suture line. It is rare. It mimics swelling from *lacrimal sac* or *mucocoele* of frontal sinus. *Mucocoele of frontal sinus* is due to blockage of frontonasal duct.

- ◆ Dermoid cyst contains putty like desquamated material, hair follicle, sebaceous and sweat glands. It is lined by both dermal and epidermal components.
- ◆ Dermoid cyst in skull region has different anatomical types as it often may extend into cranial cavity.
  - ▶ Cyst which is located entirely outside the skull bone over suture line but without bone indentation.
  - ▶ Cyst located outside the skull bone but with a bone defect underneath. Bone defect may be either on outer table of skull or through both tables of skull with attachment to dura.
  - ▶ Cyst lying partly outside and partly inside the skull with a connecting stalk between the two like a *dumb bell*.
  - ▶ Cyst is entirely within the skull bone between skull and dura. It is very rare but known.



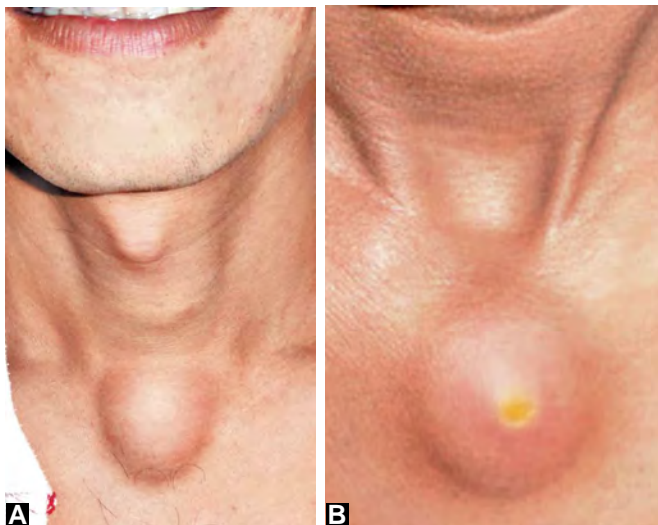
**Fig. 1.147:** Sequestration dermoid in skull—anatomical types.



**Figs 1.148A and B:** Types of angular dermoid. (A) External angular dermoid. (B) Internal angular dermoid (midline).

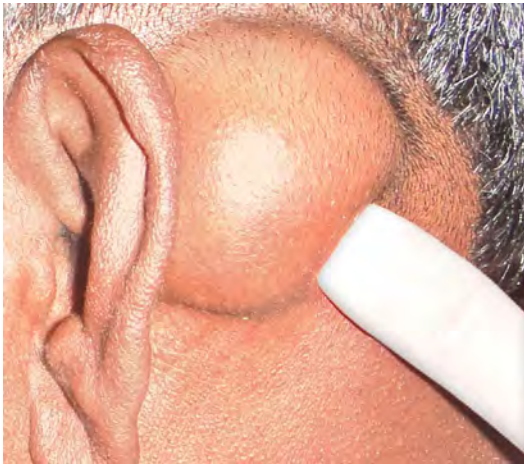

Fig. 1.149: Postauricular dermoid in different patients.



Figs 1.150A and B: Dermoid in the midline—suprasternal space of Burns/sternum. It may extend into deeper plane and so it needs CT chest and evaluation.

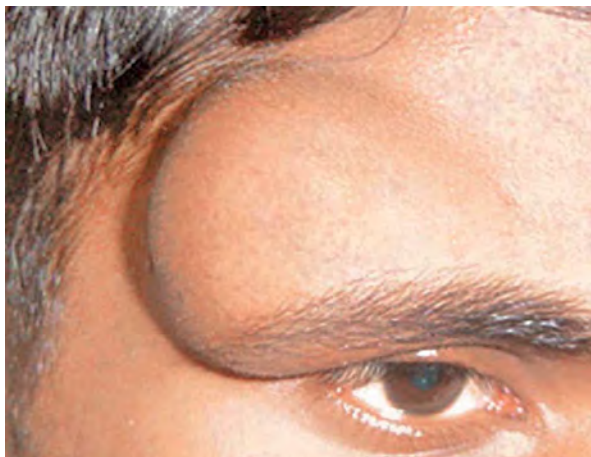

Fig. 1.151: External angular dermoid, right sided.

#### Clinical features

- ◆ Painless swelling in the line of embryonic fusion.
- ◆ Presents in the second or third decade onwards.

- ◆ Smooth, soft, nontender, fluctuant (*Paget's test positive*, i.e. swelling is fixed with two fingers and summit is indented to get yielding sensation due to fluid).
- ◆ Nontransilluminating.
- ◆ Free skin, often adherent into the deeper plane.
- ◆ There will be **resorption and indentation** of the bone beneath.
- ◆ Impulse on coughing may be present only if there is intracranial extension.

#### Differential diagnosis

- ◆ Sebaceous cyst.
- ◆ Lipoma.

#### Investigations

- ◆ X-ray—skull or part.
- ◆ CT scan head or part.

#### Complication of sequestration dermoid

- ❖ Infection
- ❖ Haemorrhage, rupture
- ❖ Surface ulceration
- ❖ Pressure effects if there is intracavitary extension like into cranial cavity or thoracic cavity, etc.
- ❖ Calcification

#### Treatment

- ◆ Excision is done under *general anaesthesia*. Often formal neurosurgical approach is required by raising cranial osteo-cutaneous flaps.

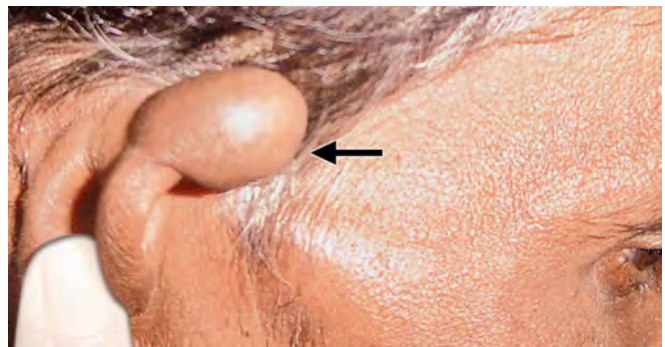

Fig. 1.152: Dermoid in the ear. It arises due to sequestration at the fusion line of the one of the six developmental ear tubercles (Each ear develops from SIX ear tubercles).

#### Submental dermoid

- ❖ It is a congenital sequestration dermoid occurs during fusion of 1st and 2nd branchial arches. It is deep to deep fascia of neck.
- ❖ It presents as soft, cystic, fluctuant, nontransilluminating, swelling in midline in submental region which does not move with deglutition nor moves while protruding the tongue out.
- ❖ It should be differentiated from thyroglossal cyst, cold abscess from submental lymph nodes or sebaceous cyst.
- ❖ It is excised under general anaesthesia with a curvilinear submental incision.

## 2. Tubulodermoids

It arises from the *embryonic tubular structures*; it is due to accumulation of secretions of the lining of the unobliterated portion of congenital ectodermal tube / duct.

*Thyroglossal cyst*—It is due to persistent thyroglossal duct during development of the thyroid gland.

*Ependymal cyst*—They originate from the sequestration of the neuroectodermal cells. They are benign neuroepithelial cysts lined by ependymal cells. They are most commonly located deep in the parenchyma. Ependymal cysts have been postulated to be the entity responsible for the interhemispheric cysts with the Dandy walker cyst and agenesis of the corpus callosum. Large cyst can cause obstructive hydrocephalous.

*Post-anal dermoid*—It develops from post-anal gut, i.e remnant of neuroenteric canal probably as a teratoma; located in front of the sacrum and coccyx. It is symptomless unless attains a large size or infected or causes pressure symptoms. Rectal examination reveals the cyst. It is treated by complete excision. Coccyx may need to be removed to have an easy access.

*Urachal cyst*—It arises from the remnant of the urachus; presents as swelling in the midline at lower abdomen as extraperitoneal mass. It can get infected, or rupture into umbilicus or peritoneal cavity or calculi can form or adenocarcinoma can develop in the cyst.

## 3. Implantation Dermoid

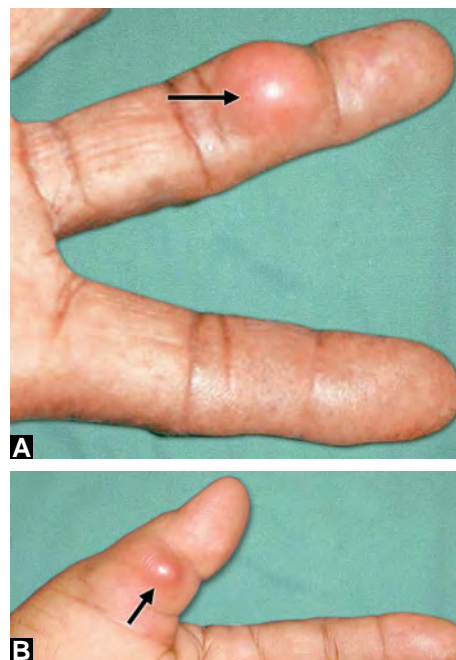
- ◆ Due to minor pricks or trauma, epidermis gets buried into the deeper subcutaneous tissue which causes reaction and cyst formation (trauma is *forgotten often*). It is an *acquired cyst*.
- ◆ It is common in fingers (common in tailors, gardeners), toes and feet.

### Features

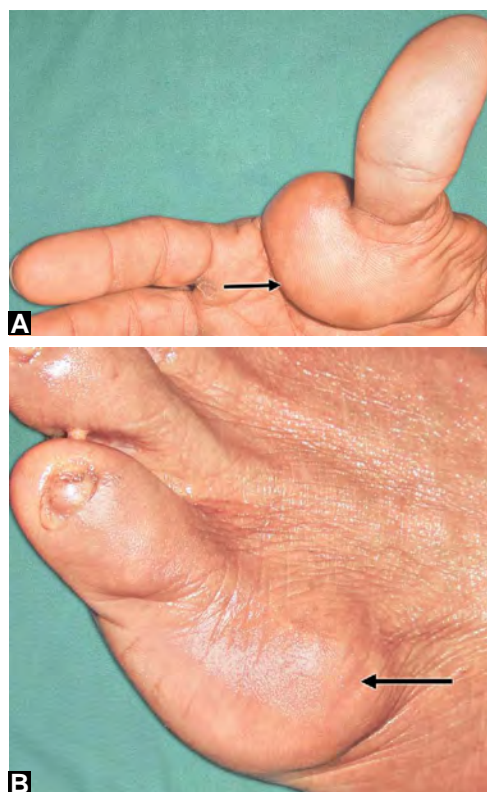
- ◆ Swelling is painless, observed after minor trauma, slowly progressing in fingers or toes.
- ◆ It is smooth, soft, mobile, tensely cystic, non-transilluminating and is often adherent to skin.
- ◆ It contains only squamous epithelium, without hair follicle/sweat or sebaceous glands.
- ◆ Complications are infection, rupture and pressure effect over digital nerves.
- ◆ *Differential diagnosis*: Lipoma, Bursa.
- ◆ *Treatment*: Excision—under local anaesthesia.

## 4. Teratomatous Dermoid

- ◆ It arises from all germinal layers ecto-, meso- and endoderms.
- ◆ It occurs in ovary, testis, retroperitoneum, mediastinum.
- ◆ It contains hair, teeth, cartilage, sebum and muscle.
- ◆ It can be benign or malignant.



**Figs 1.153A and B:** Implantation dermoid finger and thumb—classical site.



**Figs 1.154A and B:** Implantation dermoids in the hand and foot.



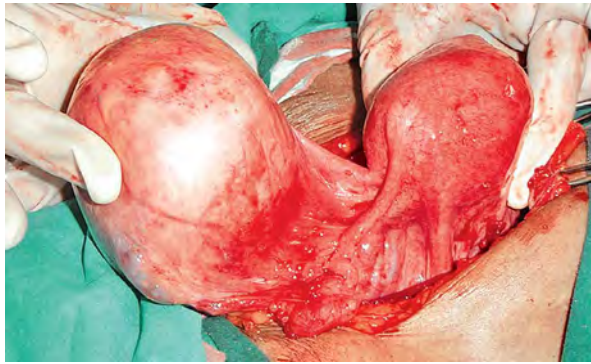


Fig. 1.155: Dermoid cyst ovary right sided.

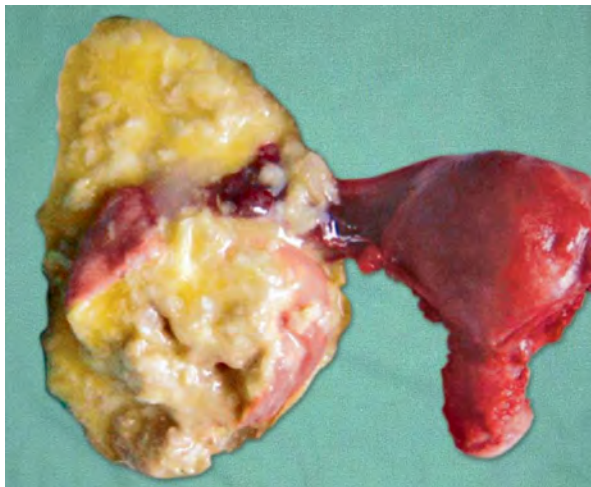


Fig. 1.156: Cut section of dermoid cyst ovary showing sebum.

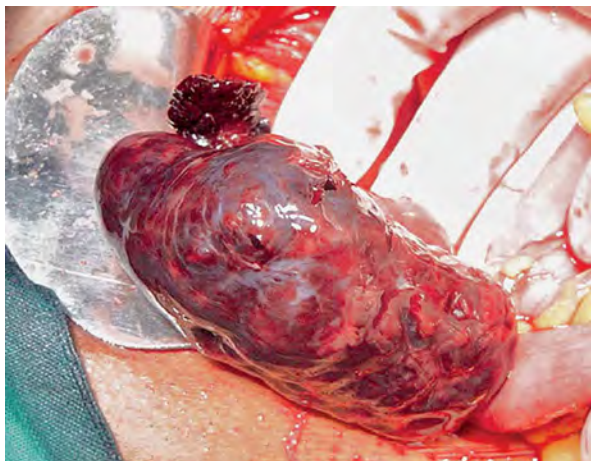


Fig. 1.157: Twisted gangrenous cyst ovary.

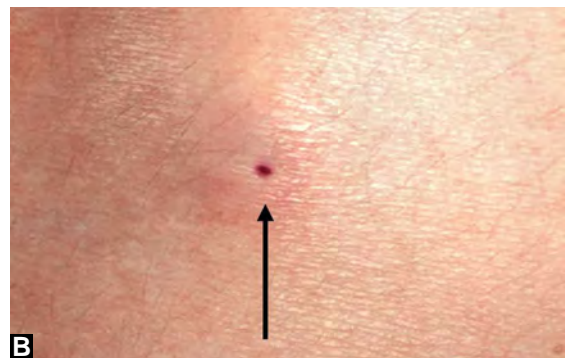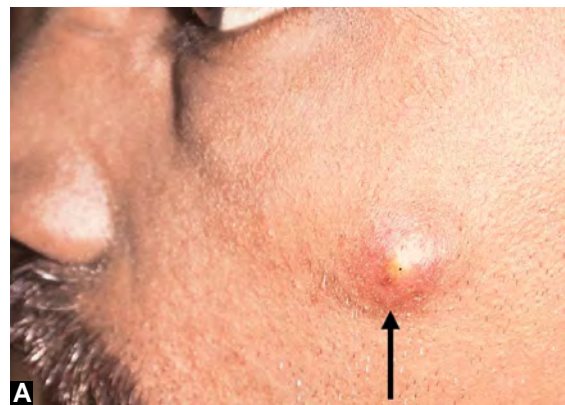## SEBACEOUS CYST (Wen, Epidermoid Cyst)

- ◆ It is a *retention cyst*. It is due to blockage of the duct of sebaceous gland, causing a cystic swelling. Sebaceous glands are situated in dermis which secretes sebum through sebaceous duct which opens either directly to skin surface or in to a hair follicle.

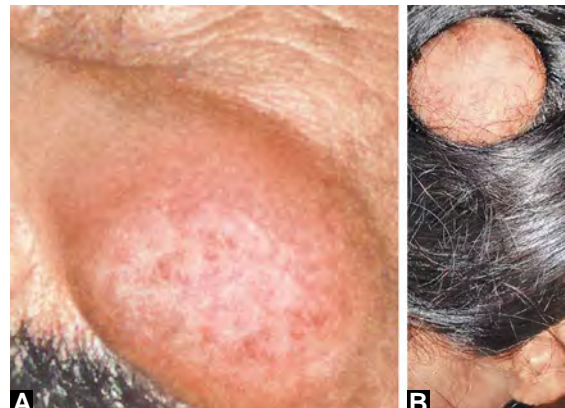
- ◆ It is common in face, scalp, scrotum.
- ◆ It is not seen in palms and soles as there are no sebaceous glands.
- ◆ Sebaceous cyst contains yellowish white cheesy material with fat and epithelium. It has putty like consistency, with a parasite in the wall of the sebaceous cyst—*Demodex folliculorum*. It is lined by only epidermal layer of squamous epithelium.

## Clinical Features

- ◆ Painless swelling which is *smooth, soft, nontender, freely mobile, adherent to skin especially over the summit, fluctuant (positive Paget's test), nontransilluminating with punctum over the summit*.
- ◆ It moulds on finger indentation.

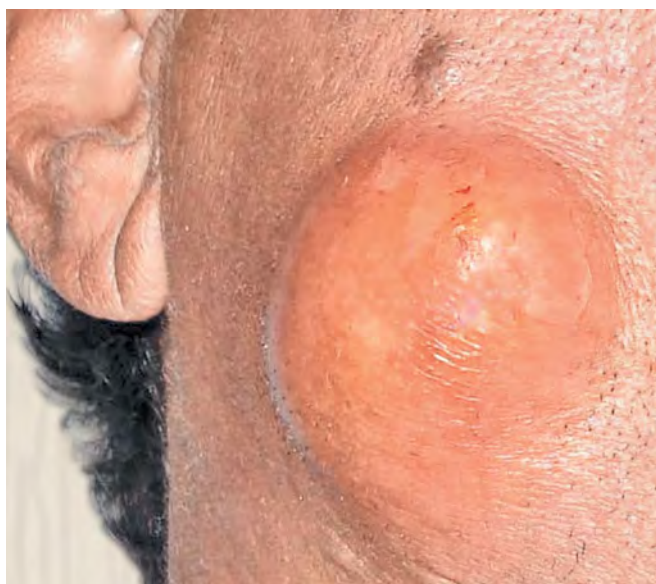

Figs 1.158A and B: Small sebaceous cysts in face and back with typical punctum over the summit.

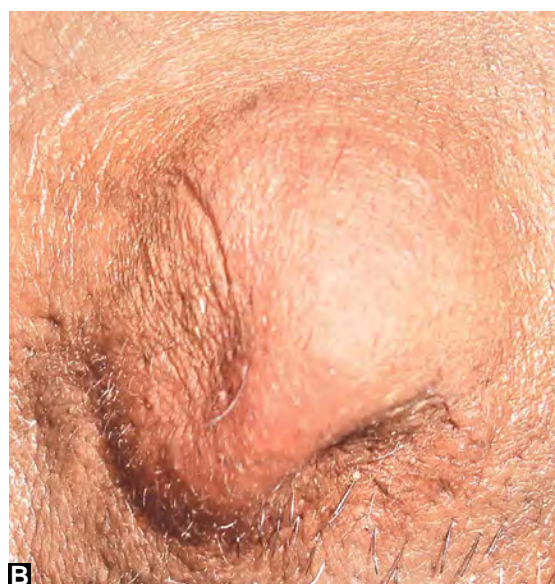

Figs 1.159A and B: Large sebaceous cyst in the face and scalp. Note the hair loss on the surface.

<b>Sequestration dermoid</b>	<b>Sebaceous cyst</b>
• Occurs in the line of fusion	• Occurs anywhere except palm and sole
• Skin is not adherent (free)	• Skin is adherent over summit
• Extends often into deeper plane or cavities through suture line	• Subcutaneous plane—do not extend to deeper plane
• Punctum is absent	• Punctum is present—70% cases
• Bone resorption and indentation is common	• Freely mobile without bone resorption
• With restricted mobility	• Superficial swelling, mobile
• Needs proper evaluation with X-ray/CT scan	
• Excision is done under general anaesthesia	• Excision is done under local anaesthesia

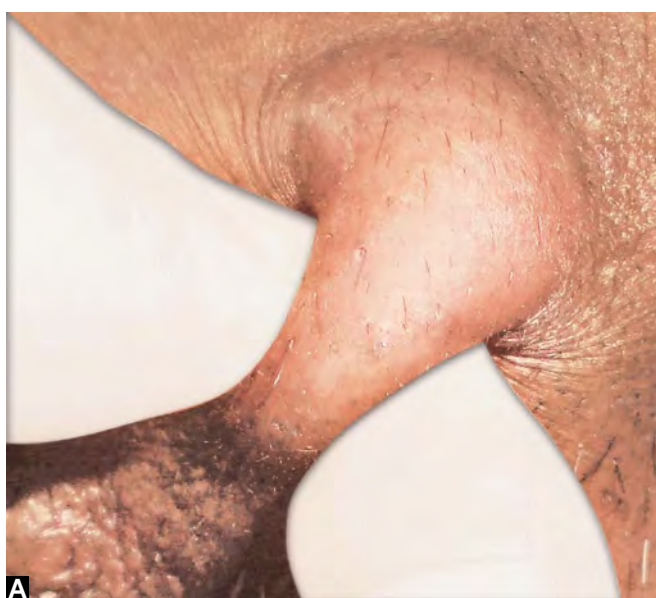


**Fig. 1.160:** Infected sebaceous cyst face.

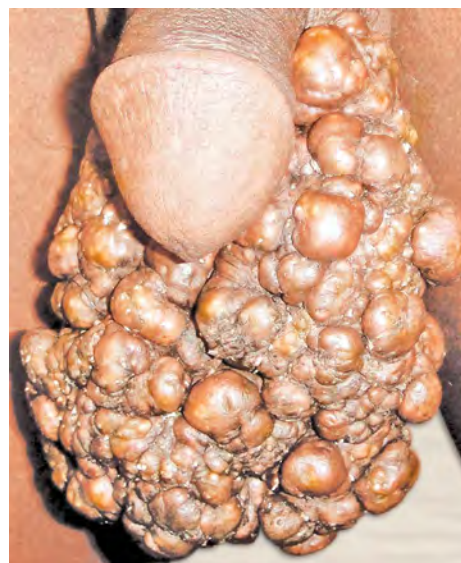

**Fig. 1.161B**

**Figs 1.161A and B:** Sebaceous cyst showing *moulding sign*.



**Fig. 1.161A**



**Fig. 1.162:** *Strawberry scrotum*—multiple sebaceous cysts on the scrotum.

- ◆ **Punctum** is present over the summit in 70% of cases because here sebaceous duct opens directly into the skin which gets blocked. Punctum is depressed black coloured spot over the summit of the sebaceous cyst. Because of the denuded squamous epithelium (keratin), it is black in colour. In 30% cases, sebaceous duct opens into the hair follicle and so punctum is not seen.

(**Fordyce's disease** is heterotopic sebaceous glands in mucosa of the lip and oral cavity).

- ◆ Hair loss over the surface is common due to constant pressure over the roots of the hair follicles.
- ◆ Unpleasant odour of sebum content is typical.

### Complications

- ◆ Infection and abscess formation.
- ◆ Surface gets ulcerated leading to formation of a painful, fungating mass with discharge called as—**Cock's peculiar**

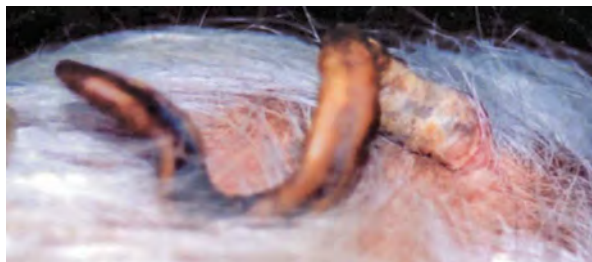

Fig. 1.163: Sebaceous horn scalp.

**tumour**—often resembles epithelioma. It is a misnomer as it is not a tumour. It is a chronic granuloma on an ulcerated surface of a sebaceous cyst.

- ◆ **Sebaceous horn** results from hardening of slowly discharged sebum through the punctum. (Horn is one which has greater length than its base diameter. Cutaneous horn is keratin deposition).

#### Note:

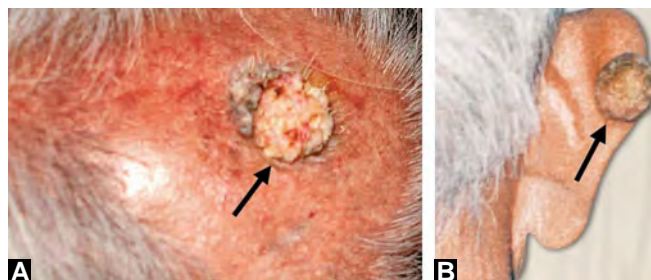
- Multiple sebaceous cysts may be associated with syndromes like Gardner's syndrome.
- Sebaceous cyst in the scrotum is usually multiple, firm and often calcified without any punctum. It is often treated by partial or total scroterctomy. Scrotum with multiple sebaceous cysts is *strawberry* scrotum.

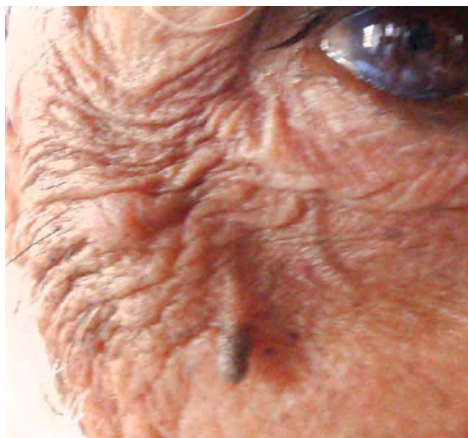

Fig. 1.164: Sebaceous horn face.

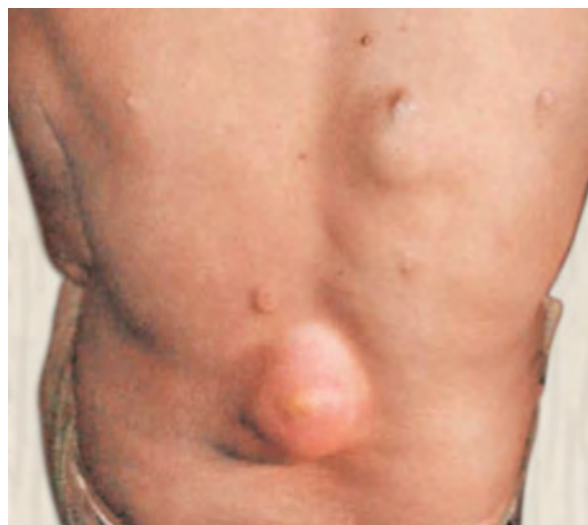

Fig. 1.165: Multiple sebaceous cysts back.



Figs 1.166A and B: Cock's peculiar tumour over scalp and ear.

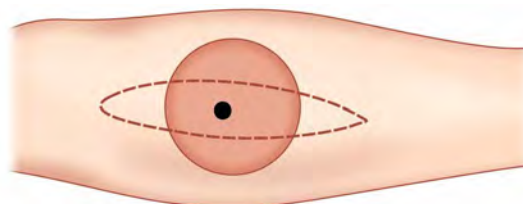


Fig. 1.167: Incision for sebaceous cyst is elliptical which includes punctum.

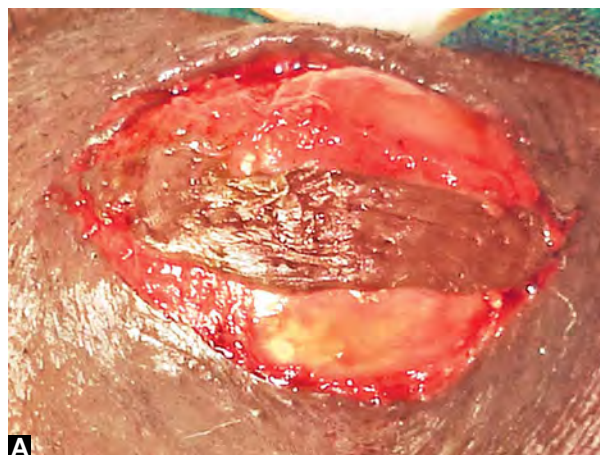


Fig. 1.168A

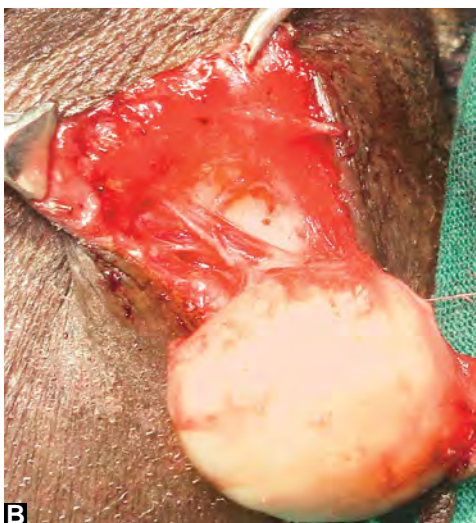

Fig. 1.168B

Figs 1.168A and B: Elliptical incision and removal of sebaceous cyst.

### Treatment

- ◆ Excision including skin adjacent to punctum using elliptical incision—*dissection method*.
- ◆ Incision and avulsion of cyst wall.
- ◆ If abscess is formed, then drainage initially and later excision is done.
- ◆ If capsule is not removed properly the cyst will recur.

### ■ GLOMUS TUMOUR

- ◆ It is also called as *glomangioma*.
- ◆ It arises from the cutaneous glomus composed of a tortuous arteriole which communicates directly into the venule (*Sucquet-Hoyer canal*) and these vessels being surrounded by network of small nerves making this lesion very painful. This communication is called as *Sucquet-Hoyer canal*.
- ◆ Tumour consists of a mixture of blood spaces, nonmedullated nerve tissue, muscle fibres derived from the wall of the arteriole, with large cuboidal glomus cells—*angiomyoneuroma*.
- ◆ They are often seen in limbs and common in nail-beds near the finger tips, as purple red swelling.
- ◆ It is 2–3 mm in size.
- ◆ It does not turn into malignancy.

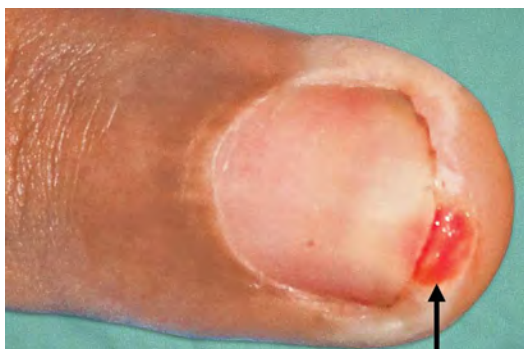

Fig. 1.169: Glomus tumour in finger tip—subungual region.

### Features

- ◆ Severe burning sensation and pain, out of proportionate to the size. The most common site is *nail-bed*.
- ◆ Even the slightest pressure will give rise to severe pain. Dilated vessels compress over nerves.
- ◆ **It is compressible and pain is more when the limb is exposed to sudden changes in temperature (cold stimulus).**
- ◆ On increasing the pressure in the arm above systolic, pain disappears.
- ◆ It looks like a *reddish blue spot* which does not blanch on percussion.
- ◆ *Subungual* type may not be visible but only to cause episodic digital severe pain.
- ◆ It is usually single, but *rarely* multiplicity is observed as familial.
- ◆ *Differential Diagnosis*
  - ▶ Pyogenic granuloma—bleeds on touch.
  - ▶ Subungual melanoma—painless pigmented lesion.
- ◆ *Treatment*: Excision cures the condition.

### ■ PAPILLOMA

- ◆ It is warty swelling from the skin or often from the mucous membrane.
- ◆ It has got a central axis of connective tissue, blood vessels and lymphatics.

### True Papilloma

- ◆ It is a benign tumour with localised overgrowth of *all* layers of the skin. It is commonly pedunculated but rarely can be sessile.
- ◆ It contains sweat glands, sebaceous glands and hair follicles.

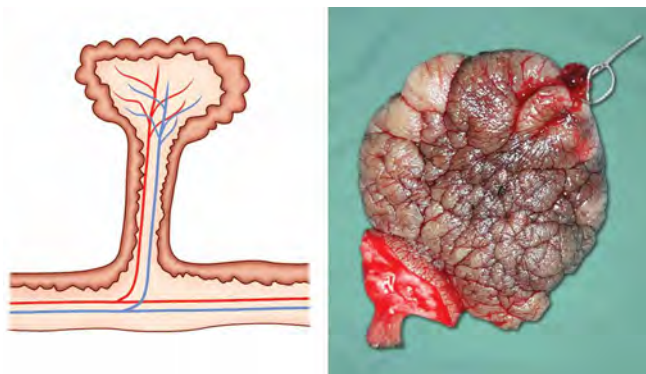


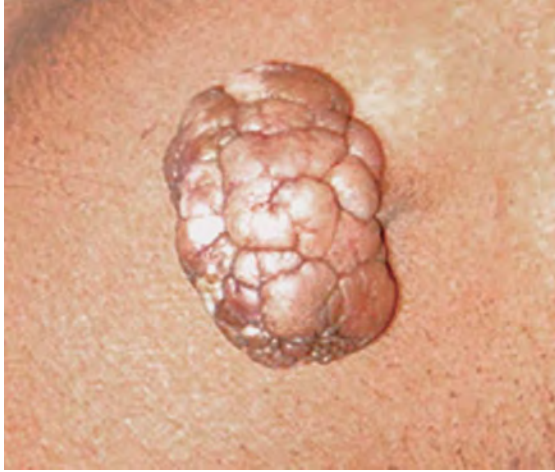Fig. 1.170: Pedunculated papilloma with its pedicle.

- ◆ Pedunculated papilloma is villous with a central axis of connective tissues, blood vessels and lymphatics.
- ◆ Papilloma can be *cutaneous* or *mucosal*. Cutaneous can be *squamous* or *basal* cell type. Squamous cell papilloma can be soft which is seen in eyelids in elderly; or can be *congenital* which can be sessile or pedunculated; single or multiple. Squamous papilloma also occurs in oral cavity. *Basal cell papilloma* is oily semitransparent brownish raised seborrhoeic keratotic lesion in skin around trunk of elderly.

Papilloma may be single.  
multiple.

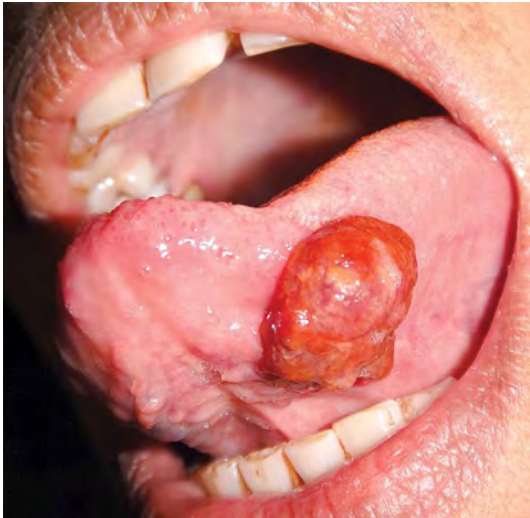Papilloma may be pigmented.  
nonpigmented.

- ◆ True papilloma may turn into squamous cell carcinoma occasionally. There will be sudden increase in size, bleeding or ulceration.



**Fig. 1.171:** Papilloma right waist (sessile). Note the warty surface.

- ◆ Papilloma can occur in the breast called as *duct papilloma* which is the most common cause of bloody discharge from the nipple.
- ◆ Papilloma can occur in mucous membrane like in *oral cavity*, *urinary bladder* (transitional papilloma), in the *rectum* (columnar), in the *larynx*, in the *gallbladder* (cuboidal).



**Fig. 1.172:** Papilloma tongue.

### Infective Papilloma

Infective papilloma is a warty lesion due to infection, e.g. condyloma acuminata.

### Differential Diagnosis

Amelanotic melanoma, pedunculated lipoma, carcinoma.

### Treatment

- ◆ *True papilloma* is excised with its base along with surrounding 1 cm skin margin.
- ◆ *Infective warts* can be treated by excision or CO<sub>2</sub> snow or diathermy coagulation.

### Complications of papilloma

- ❖ Bleeding
- ❖ Malignant transformation
- ❖ Ulceration
- ❖ Mechanical disability like voice change when it occurs in vocal cord

#### Note:

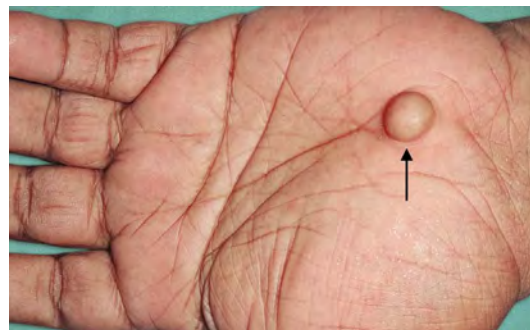
*Fibroepithelial papilloma* also called as skin tags/achrochordon is very common benign skin lesion of usually 5 mm diameter in size; common in adults; common in neck, axilla, thigh and groin. It is a vascularised keratinised squamous epithelium, can cause local irritation and insignificant bleeding. If it causes cosmetic problem it is removed by laser/cautery or excision.

### WARTS

- ◆ They are usually multiple hyperkeratotic skin patches with finger like projections, common in children and adolescents.
- ◆ They are common in finger tips, face, axilla and sole of the feet. It may be familial but often stimulated by virus.
- ◆ They are dry, overgrown projections from the skin of finger often painful, tender and disfiguring. Repeated rubbing may cause infection. It can spread to other fingers and other parts of the body. Kiss lesions can occur.
- ◆ Warts attain their size in few weeks and then persist for many months to years. They may regress spontaneously also.
- ◆ **Plantar wart (*Verruca plantaris*)** is wart in the sole. Speciality of this is it gets pushed into the sole of the foot due to walking. It is common in ball and heel of the foot. It is pearly white in color with brownish haemorrhagic flecks. It is often covered by apparently normal skin because wart is buried into the skin. It looks like a circular pit. It is grey white finger/filiform like strands in the center of the lesion and is soft. Plantar warts can be multiple. It is painful and very tender on pressing (more than callosity or corns). A defined clear lump may not be felt.
- ◆ **Butcher's wart/pathologist's wart/verruca necrogenica** is due to entry of *Mycobacterium tuberculosis* through broken skin which are common in *milkmaids*. It presents as bluish red warty lesion from which fluid oozes out on pressure between projections. It is common over *dorsum of hand*. Lesion is surrounded by pustules.
- ◆ **Senile warts** and **venereal warts** are other types. Venereal warts are same as infective papilloma.
- ◆ **Differential diagnoses** are true papilloma, callosities, neurofibromas.
- ◆ **Treatment** is excision. Salicylic acid, podophyllin cream applications are also used. Laser ablation of warts is commonly advocated.

### FIBROMA

It is a benign tumour arising from fibrous tissue. It is capsulated.



**Fig. 1.173:** Fibroma hand.

## Classification of True Fibroma

1. *Soft fibroma*—contains immature fibrous tissue. Common in face, presents as soft brown swelling.
2. *Hard fibroma*—contains well-formed fibrous tissue.

## Treatment

Treatment of true fibroma is excision.

### Note:

- *True fibroma* is rare and cannot be diagnosed clinically. It is mostly combined with mesodermal tissues like nerve sheath (neurofibroma), fat (fibrolipoma), muscle (fibromyoma).
- An entity called **aggressive fibromatosis** is known to occur as unencapsulated proliferation of fibrous tissue, common in abdominal and chest wall. It is considered presently as *locally malignant*. It does not spread through lymphatics or through blood. *But recurrence is common.*
- **Desmoid tumour** is a variant of aggressive fibromatosis, seen in females, often associated with Gardner's syndrome (Desmos = tendon, eidos = appearance). Refer chapter *Abdominal Wall and Umbilicus*.
- **Recurrent fibroid of Paget's** is a rare type of fibrosarcoma occurring in a scar tissue after many years.

## BURSAE

Bursa is a sac like cavity containing fluid within, which in normal location prevents friction between tendon and bone.

- ◆ Minor injuries and pressure leads into bursitis, which will present as a swelling at the site.
- ◆ Inflammation of this bursa due to friction causes **bursitis**, which commonly presents as swelling, pain, and restricted movements.
- ◆ Bursa secretes *synovia like clear fluid* in a cavity lined by flat endothelium. It reduces the friction at the site between tendon and bone. Normally fluid content is little to cause a swelling. Minor trauma or infection causes sudden increase in fluid secretion of the bursa making it to enlarge and clinically palpable as pathological bursitis. Bursa is common around knee, elbow, heel and hip.
- ◆ Long-standing bursitis leads into thickening of its wall often with calcification making it feel hard with indurated surface. Lining of bursa may become rough or fluid may contain loose fibrinous particles to create *grating sensation (crepitus)* on the surface.
- ◆ Often overlying skin becomes thick, cracked and horny due to repeated friction and inflammation.
- ◆ Bursa may get adherent to deeper tissue as well as overlying skin to make it immobile. Bursa is usually well-localised, smooth, fluctuant, nontender swelling. Often it can be bilateral—in knee or elbow.
- ◆ Joint related should be examined. Bursa *may be* communicating with the adjacent joint.
- ◆ Gout or rheumatoid arthritis can cause bursa. For example, olecranon bursa can develop in gout patient.

- ◆ Bursa should be differentiated from cold abscess, soft tissue tumour, aneurysm, synovial tumour (sarcoma) at different locations.

## Complications of Bursa

- ◆ Infection of bursa can occur due to trauma to overlying skin or through blood.
- ◆ Mechanical disturbances and discomfort.

## Management

- ◆ US of the anatomical site, X-ray of the part or MRI are very useful.
- ◆ Avoiding friction and other aggravating factors may control many bursae.
- ◆ Aspiration and steroid injection may be useful.
- ◆ Bursa which is felt indurated with thick wall or calcified or infected or attained large size or which interferes with joint movement or daily activities needs surgical excision. Subcutaneous bursa can be excised under local anaesthesia; large or deeper bursa requires general anaesthesia for excision.

## Different Types

It can be *anatomical or adventitious*.

### Anatomical

- ◆ *Anatomical bursae* are located normally in a particular anatomical site with a purpose of reducing friction. They are commonly deep and adjacent to a bone or joint.
- ◆ They become *pathological* and clinically significant when it presents with *bursitis*.
- ◆ They are soft, cystic, well localised, nontransilluminating swelling at known anatomical site.
  - ▶ *Subhyoid bursa*: An horizontally oval swelling situated below the hyoid bone and in front of the thyrohyoid membrane.
  - ▶ *Subacromial bursa*: In front and lateral to humeral head in relation to supraspinatus tendon between acromion and greater tuberosity of humerus.
  - ▶ *Bicipitoradial bursa*.
  - ▶ *Olecranon bursa (Student's elbow, Miner's elbow)*: It is subcutaneous bursa in relation to olecranon which becomes distended due to prolonged periods of leaning over elbow. Gout may involve this bursa.
  - ▶ *Psoas bursa*: A tensely cystic swelling situated beneath and below the inguinal ligament, in the lateral aspect of the femoral triangle. But it will not extend above the inguinal ligament in to the iliac region (unlike in psoas abscess which extends above and is *cross fluctuant*). Psoas bursa lies between the psoas tendon and lesser trochanter. When it is enlarged, it causes diffuse swelling over outer part of femoral triangle lateral to femoral vessels. When hip is moved swelling becomes painful. It also should be differentiated from femoral hernia.
  - ▶ *Prepatellar bursa (Housemaid's knee/miner's beat knee)*: It lies subcutaneously in front of lower half of patella and upper half of patellar tendon (upper part) undergoes inflammation in people who do much kneeling. Joint is normal here.

*Look well to this day, for yesterday is but a dream and tomorrow is but a vision. But today, well lived, makes every yesterday a dream of happiness and every tomorrow a vision of hope.*

—Kalidasa

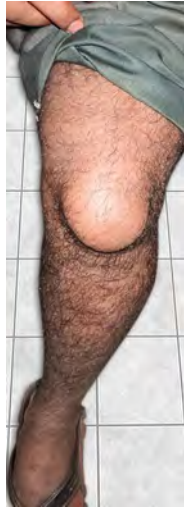

Fig. 1.174: Prepatellar bursa.

- ▶ *Subcutaneous infrapatellar bursa* occurs between skin and lower part of the tibial tuberosity and ligamentum patellae. It is called as *Clergyman's knee*. 'Clergyman' is Christian priest who kneels down during prayer.
- ▶ *Suprapatellar bursitis* is deep to patella and vastus intermedius, in front of lower end of femur. It communicates with knee joint.

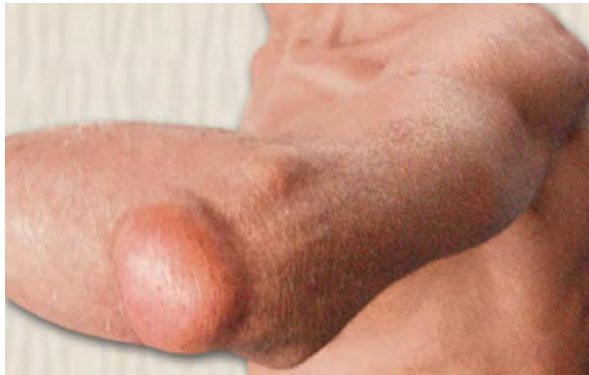

Fig. 1.175: Bursa near elbow joint.

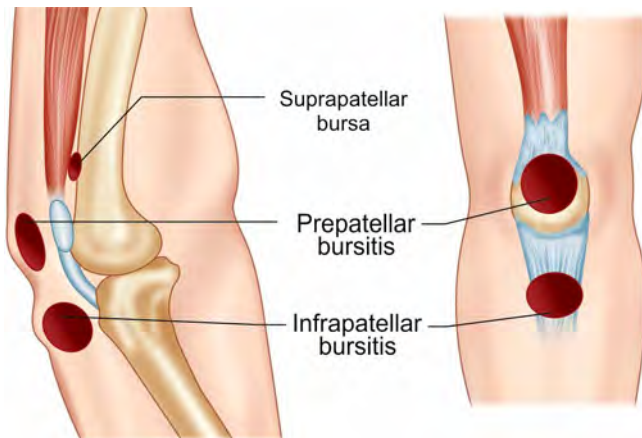


Fig. 1.176: Prepatellar (*Housemaid's knee*) and infrapatellar bursae (*Clergyman's knee*).

- ▶ *Brodie's bursa* lies deep to medial head of gastrocnemius.
- ▶ *Semimembranosus bursa*

- ▶ *Bursa anserina*—under the tendons of Guy ropes (sartorius, gracilis and semitendinosus tendons—*Goose's foot*).
- ▶ *Retrocalcaneum bursa*—between calcaneum and tendo-Achilis.

### Adventitious Bursa

- ◆ Adventitious bursa occurs in an *unusual place/site* due to friction/pressure between two layers of tissue. Once it becomes chronic it may get adherent to overlying skin or tissue underneath.
- ◆ It may get infected, wall gets calcified, and fluid may become thick. It is well-localised, cystic usually nontender swelling. It becomes painful and tender if infected.
- ◆ Lining of bursa may become rough or fluid may contain loose fibrinous particles to create grating sensation/crepitus on the surface.

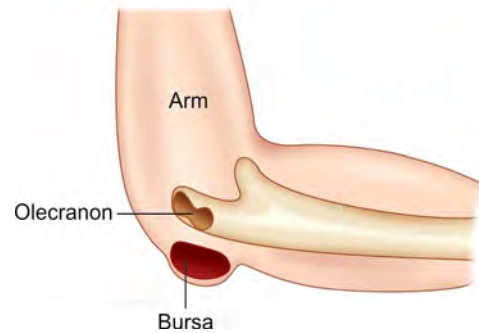


Fig. 1.177: Location of olecranon bursa (*Student's elbow*).

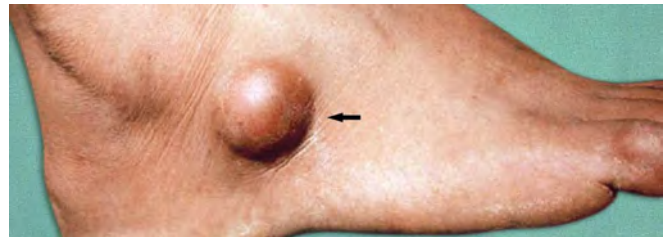

Fig. 1.178: Adventitious bursa over lateral aspect of foot—a common site.

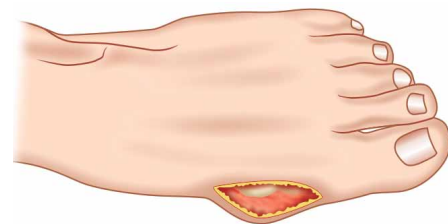


Fig. 1.179: Common site of adventitious bursa (*Bunion*).

### Examples

- ▶ *Bunion* is adventitious bursa in patient with hallux valgus occurring between head of first metatarsal and skin.
- ▶ *Tailor's bursa* occurs between lateral malleolus and skin.
- ▶ *Porter's bursa* occurs between skin over shoulder and clavicle.
- ▶ *Weaver's bursa* occurs between gluteus maximus, ischial tuberosity and skin.

- ▶ *Retro-Achillis bursitis* occurs between skin and Achilles tendon.
- ▶ *Subcalcaneal bursitis* occurs between calcaneum and heel in long distance runners.
- ▶ *Billing gate hump* appears over 7th cervical spine deep to overlying skin in people carrying weight over it. Billing gate is a large *fish market* in London.
- ◆ Condition should be *differentiated* from soft tissue tumour, sebaceous cyst, ganglion (depending on the location of bursa).
- ◆ **Management:**
  - ▶ X-ray of the part and FNAC of swelling should be done.
  - ▶ Later it is excised usually under local anaesthesia.

## SEMIMEMBRANOSUS BURSA

It is a cystic swelling in the *upper medial* aspect of the popliteal fossa under the semimembranosus tendon. It is said to be due to friction under the tendon causing bursitis.

### Features

- ◆ It is located between semimembranosus tendon and femoral condyle *above* the knee joint line.
- ◆ It is *common* in young adult; in *both* sexes. It is *most common* swelling of the popliteal fossa.
- ◆ It is nontender, cystic/tensely cystic (firm) swelling located above and on medial aspect of the popliteal fossa, fluctuant, noncompressible, often transilluminating, often with a fluid thrill. When it enlarges it comes out of semimembranosus tendon to become subcutaneous.
- ◆ Content of bursa *does not* communicate with knee joint. So fluid cannot be reduced into the joint cavity; but often appears *flaccid* on flexion of knee or by firm pressure probably due to displacement of fluid into deeper recesses of the bursa. The swelling becomes *tense* when knee is extended.
- ◆ Knee joint is *normal*.
- ◆ *Differential Diagnosis*
  - ▶ Baker's cyst, popliteal aneurysm.
- ◆ *Management*
  - ▶ Ultrasound of popliteal fossa shows the cystic swelling under semimembranosus tendon.
  - ▶ X-ray knee joint is normal.
  - ▶ Excision is done under general anaesthesia using tourniquet in prone position. Complete excision of the sac is needed to prevent recurrence.

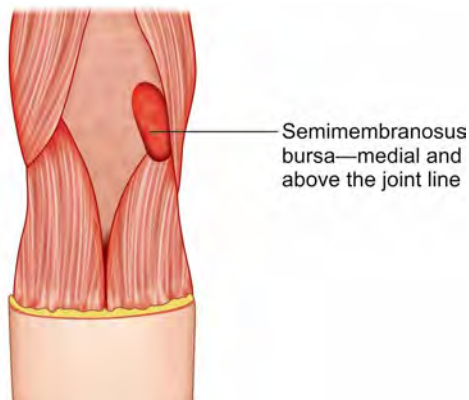
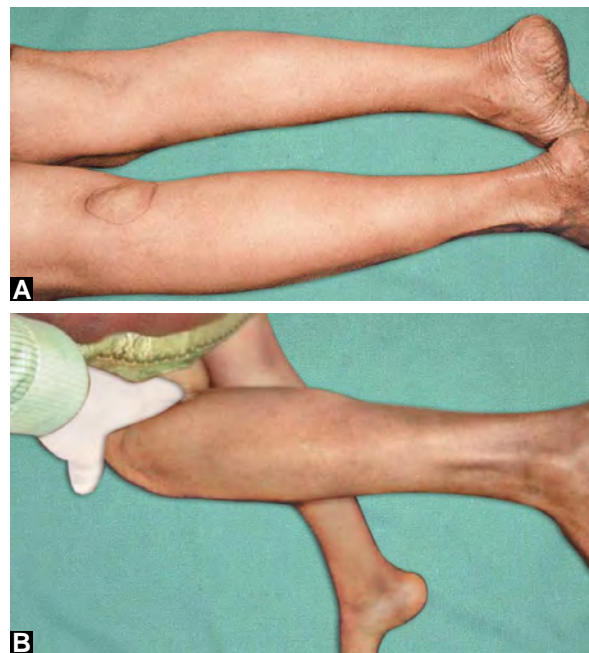


Fig. 1.180: Semimembranosus bursa typical location.



Figs 1.181A and B: Semimembranosus bursa—typical location. On flexion it only becomes flaccid but *does not disappear*.

## MORRANT BAKER'S CYST

It is a cystic swelling containing gel like fluid in the *lower midline* of the popliteal fossa. It occurs due to herniation of the synovial membrane of the knee joint as a result of chronic arthritis.

- ◆ It is *pulsion/pressure diverticulum* of the synovial membrane towards surface under the gastrocnemius through an opening in the joint capsule. It is *below* the joint line.

### Clinical Features

- ◆ It is common in middle-aged individuals.
- ◆ It is smooth, soft and cystic, nontransilluminant, often tender swelling located below (the joint line) and in midline of the popliteal fossa.

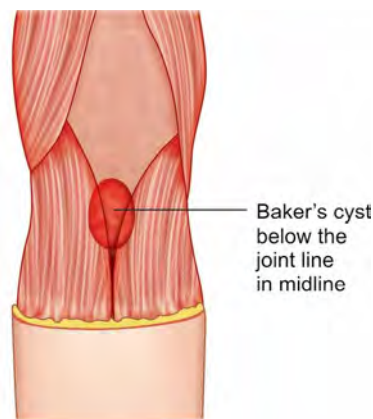
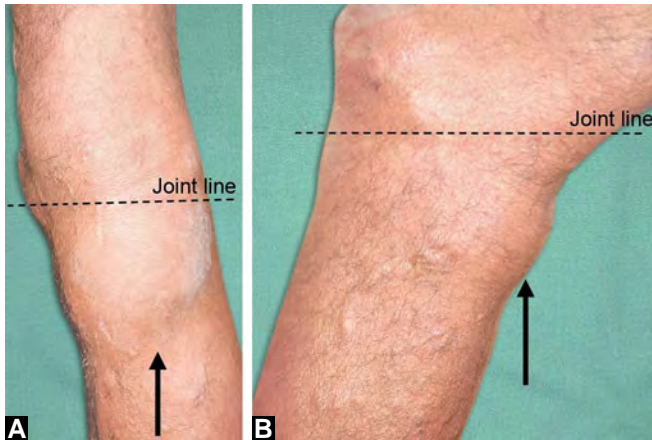

Fig. 1.182: Morrort Baker's cyst—typical location.

*There is only one pretty child in the world, and every mother has it.— Chinese proverb.*



- ◆ On flexion swelling *disappears* and on extension swelling *increases* in size.
- ◆ Pain and tenderness are present in knee joint with effusion showing positive patellar tap.
- ◆ The knee joint movements are painful and restricted.
- ◆ Baker's cyst may *rupture* sometimes causing severe sudden pain and swelling in the calf mimicking *deep vein thrombosis*.



**Figs 1.183A and B:** Baker's cyst. It is below the joint line.

### Differential Diagnosis for Baker's Cyst

- ◆ Semimembranosus bursa.
- ◆ Thrombosed popliteal aneurysm (often bilateral).

### Management

- ◆ X-ray of joint shows arthritic changes.
- ◆ MRI is needed.
- ◆ Arthritis is treated and Baker's cyst is excised under *general anaesthesia in prone* position.

### LYMPH CYST (LYMPHATIC CYST)

- ◆ It is an *acquired type of distension cyst* wherein lymphatics form a localised swelling with a capsule around it.
- ◆ It usually occurs in subcutaneous plane, which is smooth, soft, nontender, mobile, and brilliantly transilluminant. It is usually not adherent to the skin.
- ◆ **Common sites** are neck and limbs.
- ◆ It can get infected and form an abscess.
- ◆ **Differential diagnosis:** Cold abscess, dermoid cyst.
- ◆ **Treatment:** Excision.

### LYMPHANGIOMA

It is congenital localised clusters of dilated lymph sacs in the skin and subcutaneous tissue that has failed to join the normal lymph system during development period.

#### Types

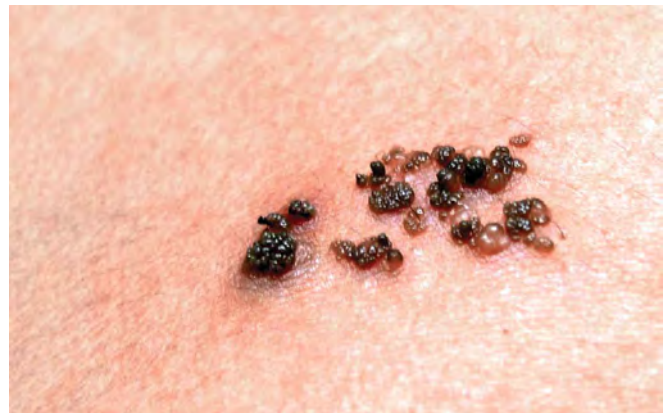##### Capillary Lymphangioma

- ◆ It is simple type which can be present at birth but noticeable skin vesicles often develop in few years.
- ◆ It is common at the junction of body to limbs-like near shoulder, axilla, groin or buttock.

- ◆ Skin vesicles contain clear watery or yellow fluid. Bleeding within the vesicle may turn it into brown or black. Its features includes multiple, indistinct white/brown/black coloured vesicles of 0.5 to 4 mm size at typical locations in children involving around 5–20 cm area of skin in the particular location.
- ◆ If it is less than 5 cm in size it is called as *lymphangioma circumscriptum*.
- ◆ If it is more than 5 cm in size it is called as *lymphangioma diffusum*.
- ◆ If it is with reticulated ridges, it is called as *lymphoedema ab igne*.
- ◆ Area is soft, spongy, often fluctuant with fluid thrill and translucency. It is not compressible. Vesicles will not fade on pressure.
- ◆ Often lesion may get infected to make it painful and tender.
- ◆ Condition will not block the lymph drainage in normal lymphatics and skin oedema is absent.
- ◆ Regional lymph nodes are not enlarged.

##### Cavernous Lymphangioma

- ◆ It is soft, lobulated, fluctuant, *brilliantly transilluminant* larger lymphatic swelling with often multiple communicating lymphatic cysts.
- ◆ It often extends into deeper plane like muscle. It is common in face, mouth, lips (*macrocheilia*), tongue (*macroglossia*).



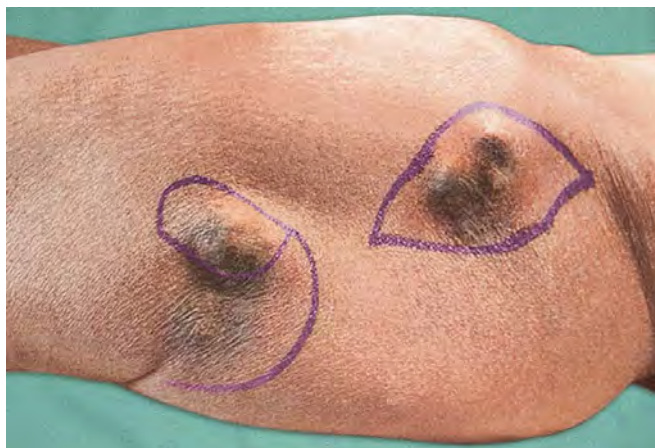**Fig. 1.184:** Lymphangioma circumscripta (Courtesy: Dr Balasaraswathy, DVD, DNB, Consultant Dermatologist, Mangaluru)

##### Cystic Hygroma

It is collection of clustered sequestered lymph sacs (occurring during developmental period *in utero*) presenting in newborn as large swelling which is soft, smooth, fluctuant, brilliantly transilluminant, and *compressible* (For detail refer chapter 5, Neck).

### CALCINOSIS CUTIS

- ◆ It is a type of calcification (*dystrophic*) in or under the skin. Usually presents as a circumscribed lesion in the skin.
- ◆ Commonly seen in females. Common site is in the waist (Fig. 1.188)
- ◆ Usually bilateral.
- ◆ It is said to be due to friction causing degeneration of skin and immediate deeper structure with increased local alkalinity of the tissue causes precipitation of the calcium leading to solid, hard, swelling in the skin. Cut section shows hard, yellowish material.
- ◆ It may mimic calcified lipoma or neurofibroma.
- ◆ **Treatment** is excision and closure of defect often with local flaps.



**Fig. 1.185:** Calcinosis cutis near waist is a common site. It is common in females.

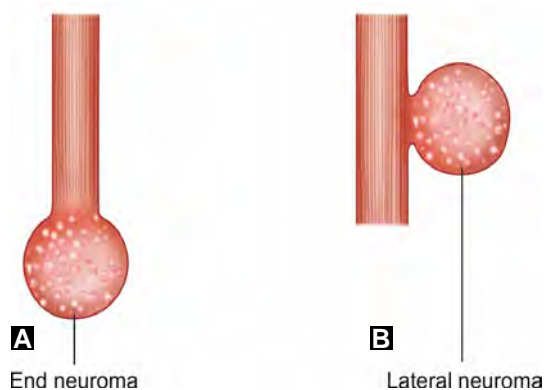
## NEUROMA

Two types of neuromas are found.

- ◆ **False neuroma.**
- ◆ **True neuroma.**

### False Neuroma

- ◆ It occurs due to injury to the nerve either after trauma or amputation which presents as a tender swelling.
- ◆ It arises from the connective tissue of nerve sheath.
- ◆ It contains fibrous tissue with coiled nerve fibres.
- ◆ It can be **end neuroma**, commonly seen in amputation stump as a tender localised firm swelling often adherent to the stump scar. It can cause neuralgia in the stump. It prevents the proper usage of prosthesis. So during amputation, nerve should be pulled down and cut so as to make cut end to retract more proximally, which prevents the formation of neuroma.
- ◆ It can be **lateral (side) neuroma** which is observed after partial nerve injury, usually after trauma. It presents as a tender, firm swelling along the line of the peripheral nerve.



**Figs 1.186A and B:** Types of false neuromas: (A) End neuroma; (B) Lateral neuroma.

## True Neuroma

- ◆ It is a rare tumour.
- ◆ It occurs in connection with sympathetic system, spinal cord.

### Types

#### Ganglioneuroma

- ◆ It contains ganglion cells and nerve fibres.
- ◆ It occurs in connection with sympathetic chain. So it is observed in neck (parapharyngeal mass), thorax, retroperitoneum, adrenal medulla.
- ◆ It is relatively benign and symptomless and often attains a large size.
- ◆ Early complete excision can give a cure.

#### Neuroblastoma

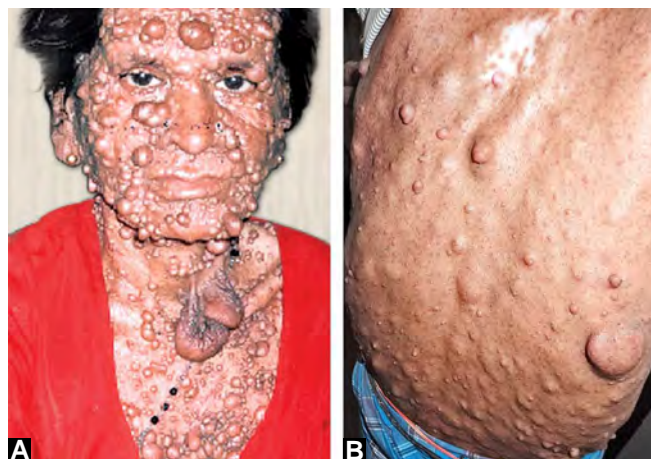- ◆ It is poorly differentiated, aggressive, embryonic type of tumour.
- ◆ It is seen in infants and children.
- ◆ It spreads through blood but can go for spontaneous remission occasionally.

#### Myelinic Neuroma

- ◆ It contains only nerve fibres.
- ◆ Ganglion cells are absent.
- ◆ It occurs in spinal cord or pia mater.

## NEUROFIBROMA

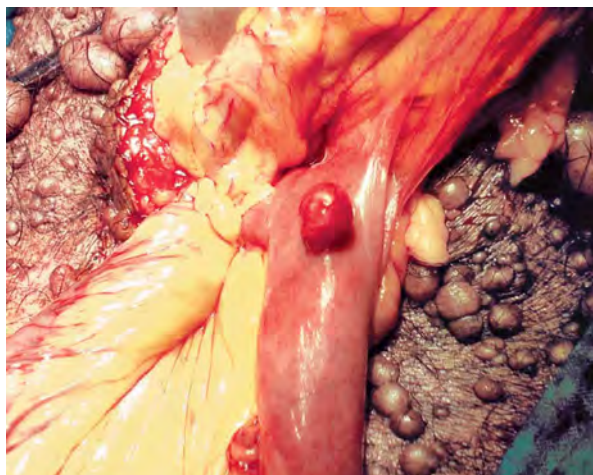
- ◆ **It is a benign tumour arising from connective tissue of the nerve containing ectodermal, neural and mesodermal connective tissue components.**
- ◆ It can be single or multiple. Neurofibromas may be associated with pheochromocytomas, hypertension and few syndromes.



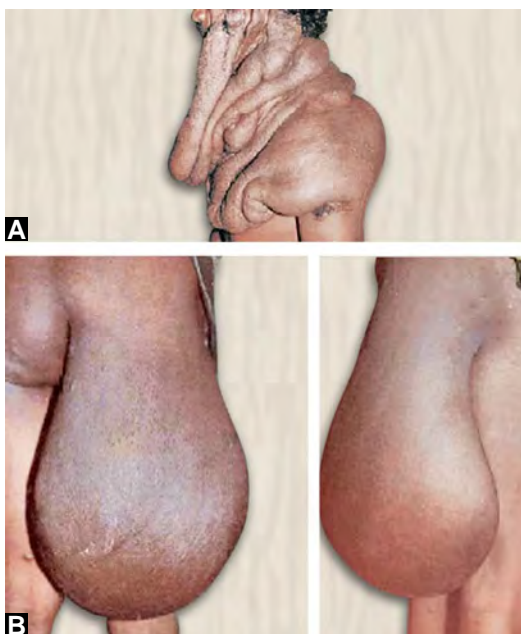**Figs 1.187A and B:** Multiple neurofibroma.

### Sites

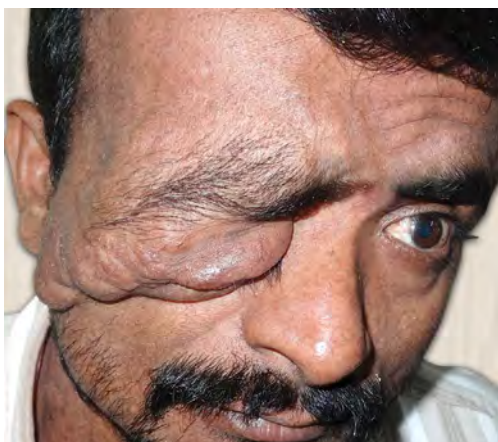
- ◆ Cranial.
- ◆ Spinal. Neurofibroma is the most common intradural extramedullary spinal tumour.
- ◆ Peripheral.



**Fig. 1.188:** Patient with multiple neurofibromatosis underwent laparotomy showing serosal neurofibroma.



**Figs 1.189A and B:** Plexiform neurofibroma in the (A) Face and neck; and (B) Buttock.



**Fig. 1.190:** Plexiform neurofibromatosis involving trigeminal (5th cranial) nerve.

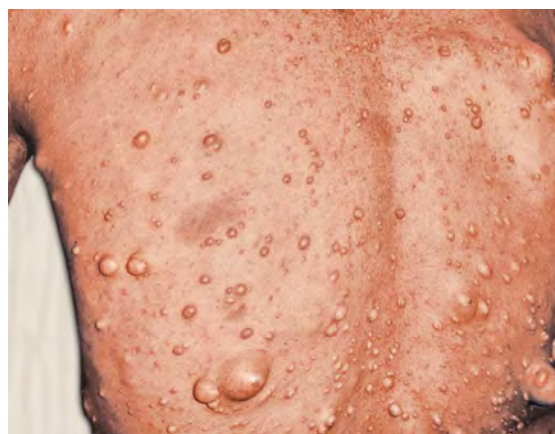## Types

### ◆ *Nodular neurofibroma:*

- ▶ It presents as single smooth, firm, tender (often) swelling which moves horizontally or perpendicular to the direction of the nerve, not in the direction of the nerve.
- ▶ There is pain and hyperaesthesia in the distribution of the nerve.

### ◆ *Plexiform neurofibroma:*

- ▶ It commonly occurs along the distribution of 5th cranial nerve in the skin of face. It often occurs in the cutaneous distribution of the peripheral nerve.
- ▶ It attains enormous size with thickening of the skin which hangs downwards. It causes erosion into the bone, orbit and deeper structure.
- ▶ It may also undergo myxomatous degeneration. It causes cosmetic problem.
- ▶ Paraesthesia along the distribution of the trigeminal nerve (commonly ophthalmic division) is common.
- ▶ **Pachy dermatocele**—a variant of plexiform neurofibroma where neck is involved. There is thickening and oedema of skin, pigmentation, thrombosed veins with enormous proliferation of subcutaneous nerve fibers causing *folded pendulous hanging thickened skin* with tissues. It is *common* along trigeminal (5th cranial) nerve; rarely is it seen in limbs and scalp skin.



**Fig. 1.191:** Multiple neurofibromatosis with café-au-lait spots in the skin.

### ◆ *Generalised neurofibromatosis (von Recklinghausen's disease):* (1:4000 births)

- ▶ It is an inherited autosomal dominant disease wherein there will be multiple neurofibromas in the body—chromosome 17. It is called as type 1 in which more than 50% will be familial. *Type 1*, more commonly, called as *von Recklinghausen's disease*. *Type 2* is *acoustic neurofibromatosis* (mutation of chromosome 22). All layers of nerve with Schwann cells and fibroblasts show tumour proliferation.
- ▶ It may be cranial, spinal or peripheral.
- ▶ It is associated with pigmented spots (coffee coloured) in the skin, commonly seen on the back, abdomen, thigh

(*café au lait spots*). More than 5 in number, with each 1.5 cm or more in size is significant. *Café-au-lait* signifies common neuroectodermal origin of nerve sheath cells and melanocytes.

- ▶ *Axillary/groin freckles and Lisch nodules*, pigmented iris, hamartoma may be present.
- ▶ Neurological disturbance is uncommon.
- ▶ It may be associated with MEN type IIb (Multiple neurofibromas of eyelids, lips, and face; medullary carcinoma of thyroid; pheochromocytoma, hyperparathyroidism), primary brain tumours and bone cysts.
- ◆ **Elephantiatic neurofibromatosis:**
  - ▶ It is of congenital origin. It involves limbs.
  - ▶ Skin of the limb is greatly thickened, dry and coarse.
- ◆ **Cutaneous neurofibromatosis:**
  - ▶ They are small, multiple, firm/hard nodules arising from terminal ends of dermal nerves. Overlying skin is normal without any changes. It commonly occurs all over the body. It can be pedunculated or sessile. It can occur in scalp to result in a *turban tumour*.

## Clinical Features

- ◆ Mild pain or painless swelling usually in subcutaneous or cutaneous plane with tingling, numbness and paraesthesia along the distribution of nerve.
- ◆ Round/oval/fusiform swelling along the peripheral/cutaneous nerves which moves perpendicular to the direction of the nerve but not along the longitudinal direction of nerve fibre with smooth surface and firm consistency. It is nontender or mild tenderness may be present. Skin is free unless it is of cutaneous type. *Cutaneous type is often soft*.

## Complications

- ◆ Cystic degeneration.
- ◆ Haemorrhage into the tissues.
- ◆ Spinal and cranial neurofibromas can cause neurological deficits.
- ◆ Erosion into deeper planes, bone, orbit.
- ◆ Muscle atrophy.
- ◆ Spinal dumbbell tumour can cause compression of spinal cord and paralysis of the limb.
- ◆ *Sarcomatous changes:* Common in generalised type (5%). When it occurs it shows rapid enlargement, warmth, more vascularity with dilated veins. Secondaries in lungs can occur through blood spread.

### Note:

- The most common spinal tumour is neurofibroma.
- von Recklinghausen disease of *primary hyperparathyroidism* is different as it is due to raised PTH level causing *osteitis fibrosa cystica*.
- Familial type of neurofibroma may be associated with *scoliosis*.
- Café-au-lait spots are also seen in *McCune Albright syndrome*.

## Treatment

- ◆ Excision.

### Indications

- ❖ Symptomatic neurofibroma—pain and pressure symptoms
- ❖ Cosmetically problematic lesion
- ❖ Recent increase in size
- ❖ Malignant transformation 5%

### Remember about neurofibroma

- ❖ Neurofibroma is fusiform swelling which has got horizontal mobility but not longitudinal mobility (neurilemmoma has got free mobility in all directions)
- ❖ Café au lait spots signify common neuroectodermal origin of nerve sheath and melanocytes
- ❖ Kyphoscoliosis may be an association in familial variety
- ❖ Pheochromocytoma with hypertension may be an association (20%)
- ❖ *Plexiform neurofibromatosis* commonly involves trigeminal cranial nerve mainly ophthalmic division causing paraesthesia, can obstruct the vision when it is large, have grossly thickened pendulous skin hanging down to various levels
- ❖ Calcification, saponification, myxomatous changes, sarcomatous transformation (fungation, rapid recent increase in size, warmth, dilated surface veins, redness with increased vascularity, fixity, persistent severe pain, immobility, lung spread) and cosmetic problem are the complications
- ❖ Intestinal neurofibroma may precipitate intussusception

## NEURILEMMOMA (SCHWANNOMA)

It is arising from Schwann (neurilemmal cells) cells. They are lobulated, encapsulated, soft, whitish grey in appearance. They displace the nerve from which they arise and can be removed. They are common in acoustic nerve (cerebellopontine angle) but also can occur in a peripheral nerve. Occasionally, they are multiple. Calcification is common. It is *ectodermal* in origin.

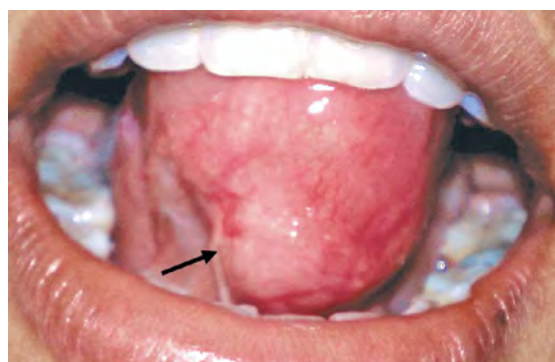


Fig. 1.192: Lingual schwannoma (Courtesy: Dr Harish Rao, Professor in Surgery, KMC, Mangaluru).

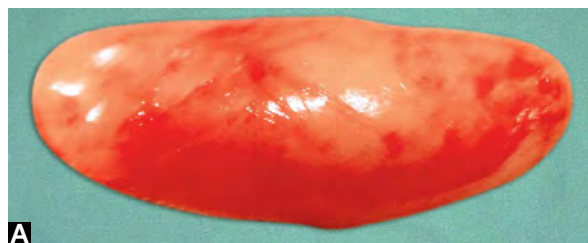


Fig. 1.193A

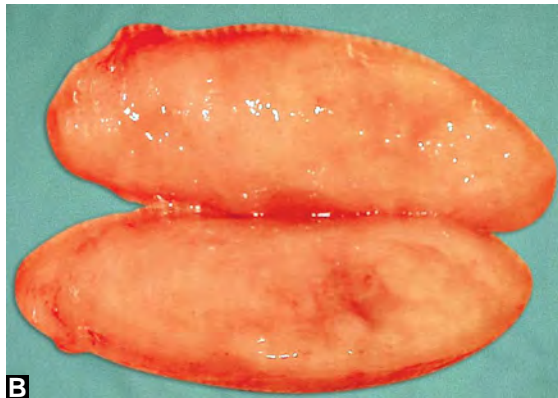

Fig. 1.193B

**Figs 1.193A and B:** Neurilemmoma—gross look and cut section.

*Two types:*

*Anthony A*—Two rows of spindle cells with central acellular area (Verocay bodies).

*Anthony B*—Acellular myloid areas.

Presentation is pain along the distribution of the nerve, hyperaesthesia and tenderness and as, soft or firm, lobulated, well localised mobile swelling.

### Treatment

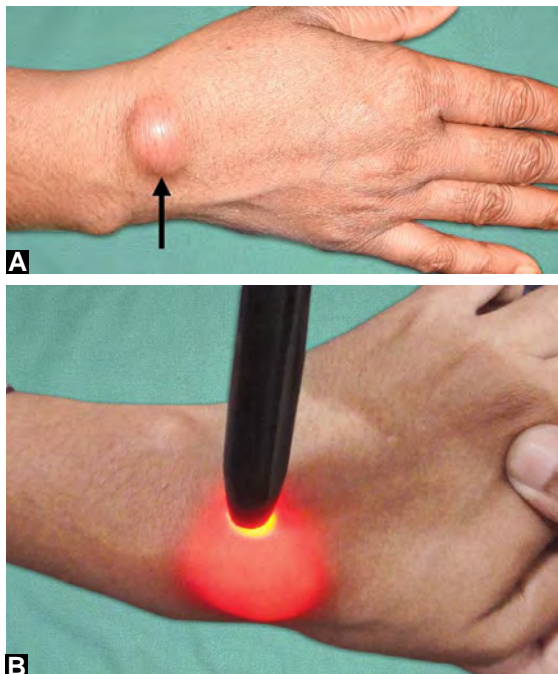
- ◆ Excision—easier without causing neurological damage.

#### Note:

Recurrent schwannoma could be malignant.

## ■ GANGLION

It is a cystic swelling occurring in relation to tendon sheath or synovial sheath or joint capsule. It contains clear gel like fluid.



**Figs 1.194A and B:** Ganglion over the dorsum of the wrist— typical location. It can occur over the flexor aspect also. It can be transilluminant also.

### Common sites

- ◆ Dorsum of wrist (Near scaphoid-lunate articulation)
- ◆ Flexor aspect of wrist
- ◆ Around ankle joint—occasionally

### Pathogenesis

- ◆ Cystic degeneration of the tendon sheath.
- ◆ Leakage of synovial fluid through joint capsule.
- ◆ There are small islets of microspaces in synovial sheath which often fuse together or one of them gets enlarged to form ganglion.

### Clinical Features

- ◆ Well-localised swelling which is smooth, soft, cystic, or tensely cystic, (Paget's test is +ve), nontender, transilluminant. It is mobile but mobility is restricted when tendon is contracted against resistance.
- ◆ Occasionally it is communicating with joint capsule.
- ◆ Often pain, tenderness and restricted joint movement may be the presentation (but rare).

### Differential Diagnosis

- ◆ Lipoma.
- ◆ Lymph cyst.
- ◆ Sebaceous cyst.
- ◆ Small ganglion often mistaken for sesamoid bone or exostoses.
- ◆ Bursa.

### Treatment

- ◆ Asymptomatic ganglion is better left alone because of high recurrence rate.
- ◆ **Excision.** Usually done under local anaesthesia (lignocaine plain 2%). Patient should be explained of **high recurrence rate (30%)**. After excision always it should be sent for histopathology. Firm crepe bandage application for 4 weeks is better in these patients.
- ◆ Aspiration and sclerosant injection may be useful. (In olden days people used to rupture the ganglion using bible book).

## ■ CHORDOMA

Tumour arising from the remnants of notochord.

It is seen in:

- ▶ Sacrococcygeal region.
- ▶ Sphenoid sinus region.
- ▶ Around the foramen magnum.
- ◆ It invades into the surrounding structure like nerves.
- ◆ Resection is difficult.
- ◆ Radioresistant.

## ■ EPIGNATHUS

This is a type of growth anomaly seen in neonates wherein growth from the base of skull protrudes through the mouth.

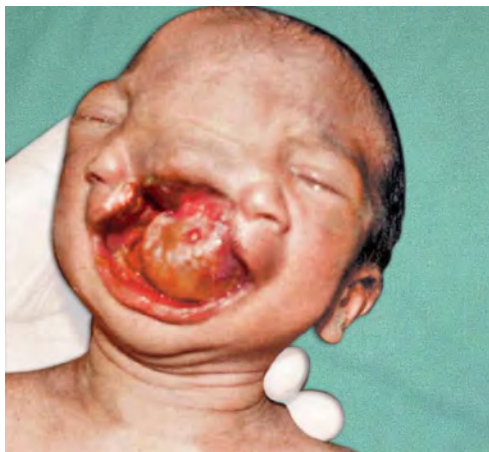

Fig. 1.195: Epignathus.

**Note:**

- *Enucleation* is removal of the swelling within the tissue of origin with normal part of tissue of origin is being retained, e.g. enucleation of prostate in benign prostatic hyperplasia (BPH).
- *Excision* is removal of tissue/tumour entirely with its capsule.
- *Wide excision* is removal of tumour with surrounding tissue margin adequately for clearance.
- *Compartment excision* is removal of tumour/diseased tissue with all adjacent soft tissues in one compartment except neurovascular bundle. It is done in limbs for soft tissue sarcoma as a curative but limb saving procedure.

- *Radical excision/radical block dissection* is removal of tumour widely with adjacent soft tissues with lymph node dissection.

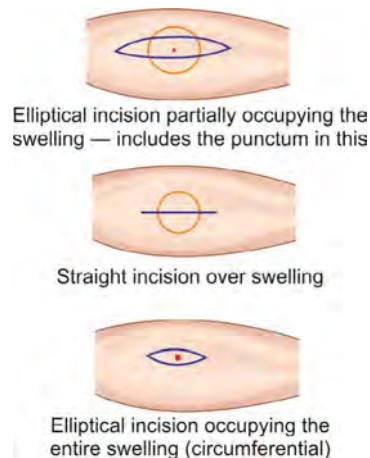


Fig. 1.196: Different incisions used in surgical approaches to remove swelling.

**Swellings which are cross fluctuant**

- ❖ Psoas abscess
- ❖ Bilocular hydrocoele
- ❖ Ranula (plunging)
- ❖ Compound palmar ganglion

## F. Electrolyte and Nutrition

### CHAPTER OUTLINE

- ❖ Normal Physiology
- ❖ Water Loss
- ❖ Water Excess
- ❖ ECF Loss
- ❖ ECF Excess
- ❖ Hyponatraemia
- ❖ Hypernatraemia
- ❖ Hypokalaemia
- ❖ Hyperkalaemia
- ❖ Hyperkalaemia
- ❖ Hypermagnesaemia
- ❖ Hypomagnesaemia
- ❖ Acid-base Balance
- ❖ Metabolic Alkalosis
- ❖ Respiratory Alkalosis
- ❖ Metabolic Acidosis
- ❖ Respiratory Acidosis
- ❖ Anion Gap
- ❖ Fluid Therapy
- ❖ Colloids
- ❖ Nutrition
- ❖ Gastrostomy
- ❖ Jejunostomy
- ❖ Total Parenteral Nutrition
- ❖ Refeeding Syndrome
- ❖ Obesity and Morbid Obesity

### ■ NORMAL PHYSIOLOGY

Total body water is 60% of body weight in males, 50% of body weight in females, i.e. 30 litres.

- ◆ Intracellular water—20 litres (2/3).
- ◆ Extracellular water—10 litres (1/3).
  - ▶ Plasma (1/4) (2.5 litres).
  - ▶ Interstitial fluid (7.5 litres).

Ion	ICF	ECF and plasma
Sodium	10 mmol/L	140 mmol/L
Potassium	150 mmol/L	4.5 mmol/L
Chloride	Trace only	105 mmol/L

ECF volume and osmolality regulation is controlled by three hormones. Aldosterone, ADH, atrial natriuretic hormone.

### ■ WATER LOSS (VOLUME LOSS)

It is decrease in the whole body fluid volume which includes both ECF and ICF. It is usually ECF loss which is more important and assessed. It can be *isotonic volume depletion* with both salt and water loss leading into *hypovolaemia*, or *only water loss* with only minimal loss of electrolytes leading into *dehydration*.

#### Causes and Features

- ◆ *Isotonic volume depletion* occurs due to diarrhoea, vomiting, and excess diuresis. Here normal or decreased sodium is observed. Fluid loss is only of ECF and so early intravascular volume reduction occurs. This causes hypotension and decreased tissue perfusion. Features are—dry tongue, rapid pulse, cold clammy extremities, sunken eyes, hypotension, oliguria, raised blood urea, decreased urinary sodium. Hypovolaemia can be mild (< 2l fluid loss); moderate (2–3 L fluid loss); severe (>3 L fluid loss).
- ◆ *Only pure water loss* occurs due to poor fluid intake and diabetes insipidus. It causes dehydration with proportionate decrease in total body water (2/3rd ICF, 1/3rd ECF). As ECF including intravascular fluid loss is less, hypotension is less. Features here are—severe thirst, confusion and convulsions due to hypernatraemia; blood pressure is relatively normal. Dehydration can be mild (weight loss 5%); moderate (10%); severe (15%).

### Management

- ◆ Evaluation is done by doing serum sodium, urinary sodium, and blood urea.
- ◆ Isotonic volume depletion is corrected by 0.9% normal saline.
- ◆ Pure water depletion is corrected by more water intake/ intravenous 5% dextrose.
- ◆ Monitoring fluid therapy by skin and tongue examination, weight gain, pulse, blood pressure, CVP, PCWP.

### ■ WATER EXCESS (ECF VOLUME EXCESS)

It can be divided into *water and salt excess* or *predominantly water excess* called as *water intoxication*.

*Water and salt excess* occurs in CCF, cirrhosis, nephrotic syndrome, hypoproteinaemia, renal failure, excessive saline infusion.

*Water intoxication* occurs in TURP, excess infusion of 5% dextrose only, SIADH secretion, psychogenic polydypsia. It is managed by stopping fluid infusion or procedure (TURP); fluid restriction, and treating the cause.

### Causes

- ◆ Excessive amount of intravenous dextrose (5%).
- ◆ During colorectal bowel wash for preparation of large bowel for surgery, if water is used instead of saline, especially in children.
- ◆ In TURP (Transurethral resection of prostate) when excess irrigating fluid water or glycine is used (commonly used).
- ◆ In syndrome of inappropriate antidiuretic hormone (SIADH) which is commonly associated with lobar pneumonia, empyema, oat cell carcinoma and head injury.

#### Clinical features

- ❖ Drowsiness, weakness
- ❖ Convulsions and coma
- ❖ Nausea, vomiting
- ❖ Passage of dilute urine
- ❖ Distended neck veins
- ❖ Pedal oedema
- ❖ *Gain in body weight*—most sensitive and consistent sign
- ❖ Circulatory overload—tachycardia, pulmonary oedema, hypertension
- ❖ Bilateral basal crepitations, ascites
- ❖ Raised CVP, PCWP

## Investigations

- ◆ Haematocrit and sodium level (will show fall in level).
- ◆ Low potassium. Low blood urea.

## Treatment

- ◆ Water and salt restriction and observation.
- ◆ Monitoring in ICU.
- ◆ Management of fluid and electrolyte balance.
- ◆ Infusion of hypotonic sodium chloride.

Administration of diuretics and hypertonic saline should be avoided, as it may cause rapid changes in serum sodium and water level which will lead to neuronal demyelination and *fatal outcome*.

## ECF LOSS

- ◆ Here only ECF loss is present with normal ICF.
- ◆ It is seen in vomiting, diarrhoea, intestinal obstruction.
- ◆ Treatment is infusion of normal saline.

## ECF EXCESS

- ◆ Only ECF excess without an ICF excess.
- ◆ Excessive infusion of saline with impaired excretion.
- ◆ Raised JVP (earliest and best clinical sign), cardiac failure and peripheral oedema.
- ◆ Treatment is fluid restriction and diuretics like frusemide.

## HYPONATRAEMIA

Sodium level less than 130 mEq/L. Hyponatraemia is said to be *severe* if serum sodium becomes lesser than 100 mEq/l in acute type; and lesser than 115 mEq/l in chronic type.

It can be due to water overload (dilutional) or sodium loss.

## Types of Hyponatraemia

- ◆ Acute—presents as neurological manifestations.
- ◆ Chronic—causes pontine myelinolysis. It presents as behavioural changes, progressive weakness, and cranial nerve palsies.

### Types also may be:

- ◆ *Hypervolaemic hyponatraemia* wherein rapid absorption of fluid occurs into intravascular compartment leading into pulmonary and cerebral oedema. It is due to decreased osmolality causing movement of ECF into the cells. Serum sodium level lesser than 100 mmol/L is called as severe hyponatraemia, causes convulsions. Here urinary sodium will be less than 15 mmol/L. Acute hyponatraemia is corrected by fluid restriction, hypertonic saline, loop diuretics like frusemide. Monitoring the serum sodium level of the patient is essential. Sodium should be corrected up to above the level of 125 mmol/L. Correction should be slow and gradual at a rate of 2 mEq/L/h with up to 20 mEq/L correction in 24 hours with 4th hourly assessment of serum sodium. Overcorrection of sodium should not be done. Rapid correction can lead into *irreversible myelin lysis of pontine*.
- ◆ *Hypovolaemic hyponatraemia*: It is due to hypovolaemia by

diarrhoea, vomiting, wherein urine sodium level is less than 20 mmol/L; due to diuresis or renal causes wherein urine sodium level is more than 20 mmol/L or it may be due to correction of hypovolaemia using hypotonic fluid like 5% dextrose. Condition can be treated well using isotonic normal saline.

- ◆ *Normovolaemic hyponatraemia*: It may be due to renal failure or syndrome of inappropriate ADH secretion (SIADH). In mild asymptomatic patients it is corrected by fluid restriction (1 L/day will raise the serum Na). Vasopressin antagonist *demeclocycline* which increases the diluting ability of kidney is used in severe cases.
- ◆ *Pseudohyponatraemia*: Plasma osmolality is mainly achieved by serum sodium; but small proportion, i.e. 25% of osmolality is due to other solutes like glucose, lipids, plasma proteins, urea which will not move easily between intracellular and extracellular spaces. When concentration of these molecules raise due to some pathology, proportionately relative concentration of sodium will drop causing pseudo-hyponatraemia. Here condition causing related to specific solutes mentioned above is treated, than hyponatraemia.

## Causes

- ◆ Intestinal obstruction.
- ◆ Intestinal fistulas—biliary, duodenal, gastric, pancreatic.
- ◆ Gastric outlet obstruction with severe vomiting.
- ◆ Ryle's tube aspiration.
- ◆ Severe diarrhoea due to viral cause, in colitis, colorectal polyps.
- ◆ Syndrome of inappropriate antidiuretic hormone (SIADH).
- ◆ Immediately after surgery and trauma, sodium depletion occurs.
- ◆ Stroke.

### Clinical features

- ❖ Dry coated tongue
- ❖ Sunken eyes
- ❖ Dry wrinkled skin
- ❖ Hypotension
- ❖ Dark scanty urine
- ❖ Irritability, disorientation and neurological manifestations
- ❖ Convulsions
- ❖ In chronic hyponatraemia—hypothermia, reduced tendon reflexes, pseudobulbar palsy

## Investigations

- ◆ Serum electrolytes. Urinary sodium is low.
- ◆ Sodium *deficit* is calculated by:  $(125 - \text{present serum sodium}) \times \text{body weight in kg} \times 0.6$ .

## Treatment

- ◆ Intravenous infusion of normal saline as a slow and gradual correction at a rate of 2 mEq/L/hour in acute cases and < 1 mEq/L/hour in chronic cases. Correction should not exceed more than 20 mEq/L/day in acute cases and more than 10 mEq/L/day in chronic cases. Hypertonic saline of 1.6% or 3% also can be used in severe cases. 0.9% normal saline contains 154 mEq of NaCl; 3% saline contains 500 mEq of NaCl.
- ◆ The cause is treated.



## ■ HYPERNATRAEMIA

Serum sodium level > 150 mEq/L. Excess infusion of normal saline causes overload in circulating salt and water. It is usually due to water deficit.

### Causes

- ◆ Renal dysfunction.
  - ◆ Cardiac failure.
  - ◆ Drug induced like NSAID, corticosteroids.
- It may be either primary sodium excess or primary potassium excess or primary water deficit.

### Types of Hypernatraemia

- ◆ *Euvolemic* (pure water loss): It is due to failure of water intake like in comatous patients, bedridden people, post-operative patients and in patients with high fever leading into extrarenal loss of water. It can occur in diabetes insipidus or chronic renal failure as renal loss of water.
- ◆ *Hypovolaemic* (among loss of water and sodium, more water is lost than sodium): It is due to vomiting, diarrhoea, more undue sweating (extrarenal); osmotic diuresis by glucose/mannitol (renal).
- ◆ *Hypervolaemic* (both sodium and water gain but sodium gain is more than water gain) as seen in more salt intake, excess steroids, sodium bicarbonate/hypertonic saline infusion (salt gain).

### Clinical Features

- ◆ Pitting oedema.
- ◆ Puffiness of face.
- ◆ Increased urination.
- ◆ Often dilated jugular veins.
- ◆ Features of pulmonary oedema.

### Investigation

- ◆ Serum electrolytes, plasma and urine osmolality, renal function tests, haematocrit.

### Management

- ◆ Restriction of saline and sodium. Treatment of pulmonary oedema.
- ◆ *Hypernatraemia should be corrected slowly as follows:*
  - ▶ Initial infusion of normal saline, then infusion of half strength saline (0.45%) and later with 5% dextrose, i.e. gradual controlled correction is done. Otherwise cerebral oedema and hyperglycaemia can develop.
  - ▶ Oral and nasogastric administration of water/fluids.

## ■ HYPOKALAEMIA

### Sudden Hypokalaemia

Serum potassium level less than 3.5 mEq/L.

It occurs in patients in diabetic coma treated by insulin and saline infusion.

### Gradual Hypokalaemia

#### Causes

- ◆ Diarrhoea of any causes, villous tumour of the rectum, ulcerative colitis.
- ◆ After trauma or surgery.
- ◆ Pyloric stenosis with gastric outlet obstruction.
- ◆ Duodenal fistula, ileostomy.
- ◆ After ureterosigmoidostomy.
- ◆ Insulin therapy.
- ◆ Poisoning.
- ◆ Drugs like beta agonists.
- ◆ Familial periodic paralysis.

#### Clinical Features

- ◆ Slurred speech.
- ◆ Muscular hypotonia—physical sign.
- ◆ Depressed reflexes.
- ◆ Paralytic ileus.
- ◆ Weakness of respiratory muscles.
- ◆ Cardiac arrhythmias.
- ◆ Inability to produce concentrated urine and so causes nocturia and polyuria.

ECG shows prolonged QT interval, depression of the ST segment and inversion of T wave, prominent U wave.

Often hypokalaemia is associated with *alkalosis*.

Serum potassium will be decreased.

#### Treatment

- ◆ Oral potassium 2 g 6th hourly, 15 ml potassium chloride syrup (20 mmol of K).
- ◆ IV KCl 40 mmol/litre given in 5% dextrose or normal saline *slowly*, often under ECG monitoring [Total dose is 40 mmol (0.2 mmol/kg/hour). Maximum dose per hour is 20 mmol].
- ◆ *Hypokalaemic alkalosis which occurs in pyloric stenosis* should be treated carefully by IV potassium as there will be severe potassium loss.

## ■ HYPERKALAEMIA

Normal range of potassium is 4.0 to 4.5 mEq/L.

Hyperkalaemia manifests when potassium *exceeds 6 mEq/L*.

### Causes

- ◆ Renal failure.
- ◆ Rapid infusion of potassium.
- ◆ Transfusion of stored blood.
- ◆ Diabetic ketoacidosis.
- ◆ Adrenal insufficiency.
- ◆ Potassium sparing diuretics, cyclosporine, beta blockers.
- ◆ Metabolic acidosis.

- ◆ Insulin deficiency.
- ◆ Tissue destruction, burns, trauma, tumour necrosis, crush injury.
- ◆ *In vitro* haemolysis, thrombocytosis, tourniquet application, exercise—pseudohyperkalaemia.
- ◆ Familial hyperkalaemic periodic paralysis.

Potassium excess is a dangerous condition which can cause sudden cardiac arrest.

## Investigations

High serum potassium level. Peak 'T' wave in an ECG.

## Treatment

- ◆ IV administration of 50 ml of 50% glucose with 10 units of soluble insulin, slowly.
- ◆ Infusion of 10% calcium gluconate (as cardioprotection) intravenously.
- ◆ Calcium chloride is given in severe cases as calcium in this form is released immediately without hepatic metabolism.
- ◆ Diuresis using frusemide injection.
- ◆ Haemodialysis when required—very useful.
- ◆ Continuous ECG monitoring is a must.
- ◆ Polyesterene sulphonate ion exchange resin 30 g/hour in 50 ml of 70% sorbitol as an enema.
- ◆ Salbutamol nebulisation or intravenously 0.5 mg in 4 ml of saline/Albuterol nebulisation.
- ◆ IV sodium bicarbonate—shifts potassium in to cells. 7.5%, with 50–100 ml intravenously in 10 minutes.

## HYPERMAGNEAEMIA

It is rare. Serum magnesium > 2.5 mEq/L.

Normal serum magnesium is 1.5–2.5 mEq/L and intra-cellular magnesium which is more (2nd higher) is 26 mEq/L. Magnesium is mainly deposited in bone (60%). It is a cofactor for many enzymes necessary in phosphorylation of glucose in the cell and ATP utilisation in muscle fiber. Daily required dietary intake of magnesium is 0.4 gram. It is reabsorbed well in proximal renal tubule.

## Causes

- ◆ Advanced renal failure treated with magnesium containing antacids, diabetic ketoacidosis.
- ◆ Intentionally produced hypermagnesaemia while treating preeclampsia.

## Clinical Features

- ◆ Loss of tendon reflexes (most common).
- ◆ Neuromuscular depression.
- ◆ Flaccid quadriplegia.
- ◆ Respiratory paralysis.
- ◆ Somnolence.
- ◆ Hypotension.

## HYPOMAGNEAEMIA

- ◆ Serum magnesium < 1.5 mEq/L.

## Causes

- ◆ Malnutrition, alcohol.
- ◆ Large GI fluid loss.
- ◆ Patients on total parenteral nutrition.

## Clinical Features

- ◆ Hyperreflexia.
- ◆ Muscle spasm.
- ◆ Paraesthesia.
- ◆ Tetany.
- ◆ It mimics hypocalcaemia. It is often associated with hypokalaemia and hypocalcaemia.

## Treatment

Two gram (16 mEq) of magnesium sulphate slow intravenously, in 10 minutes. Later maintenance dose of 1 mEq/kg/day as slow continuous infusion is given/oral magnesium is needed.

## ACID-BASE BALANCE

Normal pH (– log 10 of H<sup>+</sup>) is 7.36–7.44.

### Factors which control the pH

- ❖ Buffer system
  - Bicarbonate buffer
  - Protein buffer
  - Phosphate buffer
- ❖ Renal control of pH
- ❖ Respiratory control of pH

### Note:

When H<sup>+</sup> increases pH decreases.

An *acid* is a substance that dissociates water to release hydrogen ion. A *base* is a substance that takes hydrogen ion. A *buffer* is a combination of weak acid and conjugate base. These buffers maintain the H<sup>+</sup> concentration in blood within fine limits. Natural buffers are *extracellular or intracellular*. Bicarbonate/carbonic acid buffer, phosphate buffer and plasma proteins are *extracellular* natural buffers. Haemoglobin and other proteins are *intracellular* buffers. Bicarbonate/carbonic acid buffer is most important as carbonic acid levels are regulated by lungs which eliminates excess of it as CO<sub>2</sub>. Bicarbonate part is separately controlled by kidney.

Acidosis is pH of blood less than 7.35. Alkalosis is pH more than 7.45.

## Henderson Equation (Used to Assess Hydrogen Ion Concentration)

$$H^+ \text{ (nmol/L)} = K \times \frac{H_2CO_3 \text{ mmol/L}}{HCO_3^- \text{ mmol/L}}$$

$$\text{OR } K \times \frac{\alpha \text{ PCO}_2}{\text{HCO}_3^- \text{ mmol/L}}$$

Here constant **K** is 800 (for  $\text{H}_2\text{CO}_3 / \text{HCO}_3^-$  buffer).

Carbonic acid ( $\text{H}_2\text{CO}_3$ ) is solubility coefficient of  $\text{CO}_2$  in blood ( $\alpha$ ) multiplied by partial pressure of  $\text{CO}_2$  ( $\text{PCO}_2$ ).  $\alpha$  is 0.03 ml/mmHg/100 ml of blood;  $\text{PCO}_2$  is 40 mmHg.  $\text{H}_2\text{CO}_3 = \alpha\text{PCO}_2 = 0.03 \times 40 = 1.2$  ml. Normal blood bicarbonate/ $\text{HCO}_3^-$  level is 24 mmol/L. so  $\text{H}^+$  is  $800 \times 1.2$  divided by 24 = 40 mmol/L.

### Henderson-Hasselbalch Equation (Used to Assess pH)

It is used to find out pH of the blood using logarithm. Negative logarithm of constant K (800 for carbonic buffer) is called as pKa. It is 6.1 for  $\text{H}_2\text{CO}_3/\text{HCO}_3^-$  buffer system.

$$\text{pH} = \text{pKa} + \log \frac{\text{HCO}_3^-}{\text{H}_2\text{CO}_3} \text{ means } 6.1 + \log 24 \text{ divided by } 1.2 = 6.1 + \log 20 = 6.1 + 1.3 = 7.4$$

### ■ METABOLIC ALKALOSIS

Primary base excess, i.e.  $\text{HCO}_3^-$ . A standard bicarbonate above 27 mmol/litre.

#### Causes

- ◆ Repeated vomiting due to any cause. Commonly seen in cases of pyloric stenosis. Here *hypokalaemic alkalosis* occurs which is an important aspect for managing the patient.
- ◆ Excess alkali ingestion, e.g. antacids.
- ◆ Cortisol excess either due to over administration or Cushing's syndrome.

#### Clinical Features

- ◆ Cheyne stokes breathing with period of apnoea of 5–30 seconds.
- ◆ *Tetany* due to alkalosis. More often *latent tetany* which is revealed by *Trousseau's sign*.

#### Investigations

Serum electrolytes, arterial blood gas analysis.

#### Treatment

- ◆ Normal saline or double strength normal saline IV infusion, with slow IV potassium chloride 40 mmol/litre in saline, slowly under ECG monitoring.
- ◆ pH more than 7.7 causes life-threatening alkalosis which requires rapid correction by infusing dilute hydrochloric acid or ammonium chloride, however, with care and monitoring.

### ■ RESPIRATORY ALKALOSIS

Arterial  $\text{PCO}_2$  is below normal.

#### Causes

- ◆ Hyperventilation during anaesthesia, due to head injury/severe pain.
- ◆ High altitude.
- ◆ Hyperpyrexia.
- ◆ Encephalitis, hypothalamic tumours, drugs like salicylates, due to cirrhosis of liver.
- ◆ Hysteria.

#### Features and Management

- ◆ Headache, tingling, circumoral anaesthesia, tightness in chest, tetany, arrhythmias are the features.
- ◆ Low  $\text{PaCO}_2$ , low  $\text{HCO}_3^-$ , high alkaline pH are typical. Serum  $\text{HCO}_3^-$  will not fall below 15 mEq/L.
- ◆ It can be acute or chronic.
- ◆ It is managed by oxygen therapy, treating the cause, *acetazolamide* in high altitude.
- ◆ Respiratory suppression due to alkalosis is treated by  $\text{CO}_2$ .

### ■ METABOLIC ACIDOSIS

It is an excess acid or base deficit. A standard bicarbonate below 21 mmol/litre.

#### Causes

*Increase in fixed acid:*

- ◆ Diabetic ketoacidosis.
- ◆ Starvation.
- ◆ Hypoxia.
- ◆ Renal insufficiency.
- ◆ Cardiac arrest.
- ◆ Excessive exercise.
- ◆ Intestinal strangulation. Here anion gap is increased.

*Loss of base:*

- ◆ Diarrhoea.
- ◆ Ulcerative colitis.
- ◆ Gastrocolic fistula.
- ◆ Intestinal fistula.
- ◆ Ureterosigmoidostomy causes hyperchloraemic hypokalaemic acidosis. Here anion gap is normal.

#### Features

- ◆ Rapid, deep, noisy breathing (air-hunger)—*Kussmaul's* breathing.
- ◆ Cold clammy skin, tachycardia, right heart strain, altered level of consciousness.
- ◆ Cardiac arrhythmias, hypotension.
- ◆ Anorexia, muscle weakness, vomiting.
- ◆ pH below 7.2 is dangerous and life-threatening.
- ◆ Capillary stasis.
- ◆ Urine is strongly acidic.
- ◆ Low standard  $\text{HCO}_3^-$  level.
- ◆ Base deficit.

- ◆ It is evaluated by doing arterial blood gas analysis (ABG) which shows low  $\text{HCO}_3^-$ , low pH; anion gap; urinary anion gap (UAG). Normal UAG is zero or positive. In metabolic acidosis due to GI cause, UAG becomes negative due to increased  $\text{NH}_4\text{Cl}$  excretion; if it is due to renal cause, UAG will be positive.

## Treatment

- ◆ Correction of hypoxia.
- ◆ **50 mmol of 8.4% sodium bicarbonate infusion IV.**  
Sodium bicarbonate required in mEq/L = Body weight in kg  $\times$  Base deficit  $\times$  0.3.
- ◆ Correction of electrolytes.
- ◆ Specific treatment for lactic acidosis (*type A* [shock/ respiratory/ $\text{CO}_2$ /cyanide/anaemia]; *type B* [diabetes/hepatic/toxins/ drugs])—only careful use of  $\text{NaHCO}_3$  in severe cases, *dichloracetate* which stimulates pyruvate dehydrogenase to reduce lactate.
- ◆ Specific therapies for diabetic ketoacidosis, alcoholic acidosis, aspirin poisoning, renal causes.

### Astrup formula

Total base excess or deficit = Base excess/base deficit  $\times$  body weight in kg  $\times$  0.3

## RESPIRATORY ACIDOSIS

It is a feature of respiratory failure with high arterial  $\text{PCO}_2$  causing fall in pH.

### Causes

- ◆ During and after anaesthesia.
- ◆ Chronic bronchitis.
- ◆ Emphysema.
- ◆ Thoracic diseases.
- ◆ Upper abdominal surgeries and diseases.
- ◆ Respiratory airway obstruction.
- ◆ Myasthenia gravis.
- ◆ Poliomyelitis.
- ◆ Stroke, infection, obesity, hypoventilation.

### Features and Treatment

- ◆ Features of hypercapnia like dyspnoea, confusion, psychosis, hallucinations, sleep disturbances, tremor, jerks, and personality changes. CNS manifestations are more severe in respiratory acidosis than in metabolic acidosis as lipid soluble  $\text{CO}_2$  crosses blood-brain barrier easily than  $\text{HCO}_3^-$ .
- ◆ Acute respiratory acidosis is managed by oxygen therapy, ventilator support. Oxygen therapy should not be used in chronic hypercapnoea unless it is really indicated as hypoxia stimulated respiration may be suppressed. Alkali therapy

also is not usually used unless acidosis is very severe (below 7.15) or there is severe bronchospasm.

## ANION GAP

- ◆ It is calculated estimation of the undetermined or unmeasured anions in the blood.
- ◆ It is  $(\text{Na}^+ + \text{K}^+) - (\text{HCO}_3^- + \text{Cl}^-)$ .
- ◆ Normal anion gap is 10-16 mmol/litre.
- ◆ Anion gap is charge difference between unmeasured anion and cation. Important unmeasured anions are anionic protein, phosphate, sulphate, organic acids. Unmeasured cations are calcium and magnesium. Albumin is the main component of anion gap. When albumin decreases by one g/dl then anion gap decreases by 2 mEq/L.

Increased anion gap is seen in	Normal anion gap is seen in
• Metabolic acidosis due to ketoacidosis	• Diarrhoea
• Lactic acidosis	• GIT fistulae
• Poisoning	• Hyperchloraemic acidosis
• Renal failure	

## FLUID THERAPY

Osmolality of a solution is assessed by the amount of solute dissolved in a solvent like water measured in weight (kg).

Osmolarity of a solution is assessed by the amount of solute dissolved in a solvent like water measured in volume (litre).

Normal plasma Osmolality is 285 mOsm/kg (275–295).

### Osmolality is calculated by two methods

$$a. \text{Osmolality of plasma} = \frac{0.54}{1.86} \times 10^3 \text{ mOsm/kg}$$

It is based on the fact that solution of 1 mOsmol/kg freezes at  $-1.86^\circ\text{C}$ ; whereas normal plasma freezes at  $-0.54^\circ\text{C}$ .

$$b. \text{Osmolality of plasma} = 2 \times (\text{Na}) + \frac{(\text{Glucose mg\%})}{18} + \frac{(\text{Blood urea mg\%})}{6}$$

It is based on the concentrations of major solutes in plasma. So sodium concentration contributes mainly to the osmolality.

Colloidal osmotic pressure is difference in plasma osmotic pressure and interstitial fluid pressure which is normally 25 mm Hg, which is mainly by plasma albumin concentration. Plasma proteins do not go out of capillary wall into the interstitium.

## Principles of Fluid Therapy

### Indications

- ◆ For rapid restoration of fluid and electrolytes in dehydration due to vomiting, diarrhoea, shock due to haemorrhage or sepsis or burns.
- ◆ Total parenteral nutrition.
- ◆ Anaphylaxis, cardiac arrest, hypoxia.
- ◆ Post-gastrointestinal surgeries.
- ◆ For maintenance, replacement of loss or as a special fluid.

### Advantage

Controlled, accurate and adjustable, rapid and predictable.

*Less you eat, you are malnourished. More you eat, more you are diseased.*

### Problems in Fluid Therapy

- ◆ Needs hospitalisation; costly; needs asepsis.
- ◆ Fluid overload; pulmonary oedema and cardiac failure; infection.
- ◆ Thrombophlebitis; haematoma; cellulitis in local area.
- ◆ Pyrogenic reaction; air embolism; bacteraemia.
- ◆ Discomfort; poor patient acceptance.

Daily requirement of sodium is 100 mEq; potassium is 60 mEq; calcium is 5 mEq; magnesium 1 mEq.

One litre of normal isotonic saline contains 154 mEq of sodium.

Ringer's lactate is the most physiological fluid (*crystalloid*) containing sodium—130 mEq/l; potassium—4 mEq/l; chloride—109 mEq/l; lactate (bicarbonate)—28 mEq/l; and calcium—3 mEq/l. It should be avoided in liver failure patients. As it does not contain glucose it can be used in diabetics.

Other *crystalloid* fluids—normal saline, dextrose saline, 5% dextrose, isolyte P, isolyte G, isolyte M.

*Colloids* are of large molecules which shift the fluid from interstitial compartment to intravascular compartment and are used as plasma expanders. Haemaccel, hetastarch, pentastarch, dextran 40/70 are colloids.

*Special purpose fluids* are sodium bicarbonate 7.5% and 8.4% used in metabolic acidosis, forced diuresis, hyperkalaemia; mannitol 10/20% used as an osmotic diuretic agent; hypertonic saline 1.6%, 3%, 5% and 7.5% used in hyponatraemia of different severity; albumin 4.5% as plasma expander; albumin 20% in severe hypoalbuminaemia.

### Calculation of Drop Rate of IV Fluids

1 ml = 16 drops in usual drip set. For microdrip set one ml = 60 drops.

- a. Quantity of fluid required in liters per day  $\times 10 =$  Drop rate/minute.  
2.5 litres is usually used quantity of fluid/day. So  $2.5 \times 10 = 25$  drops/minute.

- b. Fluid volume in ml to be infused in one hour divided by four = Number of drops/minute. Example: 100 ml/hour means 25 drops/minute.
- c. Number of microdrop/minute = Volume in ml/hour (50 microdrop/minute = 50 ml/hour).

#### Note:

- Weight loss more than 10% of individual's weight in 6 months is called as significant weight loss.
- Body mass index (BMI) is body weight in kilograms divided by height in meters squared. BMI less than 18.5 signifies nutritional impairment and below 15 signifies severe malnutrition.
- Daily fluid loss from kidneys is 1500 ml; from lungs is 400 ml; from skin is 800 ml; from stool is 60–150 ml.
- Energy requirement per day is 20–30 kcal/kg, i.e. around 2000 kcal/day total.
- Glucose requirement is 200 g per day; fat requirement is 200 g per week; nitrogen (protein) requirement is 0.15 g/kg per day. Nitrogen need increases to 0.25 g/kg/day in hypercatabolic status.
- Transit time is rapid in jejunum; three times slower in ileum; still slower in colon.
- Fluid absorption capacity is 40% in jejunum; 70% in ileum; 90% in colon.
- Electrolyte and vitamin B<sub>12</sub> absorption and enterohepatic circulation occurs in ileum and so ileum is more important than jejunum.

### Crystalloids

Crystalloids are aqueous solutions of mineral salts or other water soluble molecules. They are used mainly to improve the volume and electrolyte supplementation.

### Crystalloids Commonly Used

Type	Content	Indications	Contraindications and problems
5% Dextrose	One litre contains 50 gram of glucose. It is hypotonic; pH is 4.5; provides 170 kcal/L	Used in pre- and post-operative fluid therapy; 5% and 10% dextrose is used as protector of liver in obstructive jaundice, pre-operative preparation in biliopancreatic surgeries, clear toxic substances. It is useful in correction of hypernatraemia due to pure water loss like diabetes insipidus, excess use of electrolytes; 5% dextrose is infused with frusemide.	Cerebral oedema as it is hypotonic; cranial surgeries; stroke; hypovolaemic shock as it may cause hyperglycaemia and osmotic diuresis; hyponatraemia; water intoxication; it should not be used for rapid correction of hypernatraemia; diabetes and hyperglycaemia. Note: Intravenous administration of dextrose can cause low potassium, magnesium and phosphate; and causes thrombophlebitis.
Normal saline (isotonic saline—0.9% NaCl/NS).  3% normal saline (hypertonic) contains 513 mEq/litre of sodium; is used in hyponatraemia due to SIADH or water intoxication or severe hyponatraemia	One litre contains 154 mEq each of sodium and chloride.	<ul style="list-style-type: none"> <li>• It mainly exists in ECF to maintain osmolality; it increases the intravascular volume and is so very useful to stabilize the blood pressure in hypovolaemia.</li> <li>• It is used in diarrhoea, vomiting, excessive sweating; in treatment of alkalosis; in hyponatraemia; diabetic ketoacidosis; hypercalcaemia; brain surgery and injuries.</li> <li>• It is used in giving wash to body cavities like peritoneum or any wounds (warm NS).</li> </ul>	<ul style="list-style-type: none"> <li>• It is avoided in hypertension, pre-eclampsia, elderly, dehydration with hypokalaemia.</li> <li>• Large volume infusion may cause sodium retention and hyperchloraemia.</li> </ul>

Contd...

Contd...

		<ul style="list-style-type: none"> <li>• Many drugs are given using NS as vehicle.</li> <li>• It is safer in renal failure as it does not contain potassium.</li> </ul>	
Dextrose (5%) with normal saline (0.9 NaCl), (DNS)	One litre contains 50 grams of glucose, 154 mEq each of sodium and chloride; pH 4.2; osmolarity 585 mOsm/litre.	It corrects hypovolaemia and hyponatraemia. It is used alkalosis due to vomiting and nasogastric aspiration.	It is not used in cardiac and renal failure. Used in shock but not used in severe hypovolaemic shock.
Dextrose with 0.45% normal saline	One litre contains 50 grams of glucose; 77 mEq each of sodium and chloride.	It is commonly used in fluid therapy; treatment of severe hypernatraemia as it corrects it gently; to avoid cerebral oedema. It is used in maintenance therapy and in post-operative period.	It is not used in hyponatraemia, and in diarrhoea and vomiting.
Ringer's lactate (Hartmann's/ balanced salt) solution	One litre contains 130 mEq sodium (as sodium lactate); 109 mEq of chloride; 4 mEq potassium; 28 mEq of bicarbonate; 3 mEq of calcium. It is devoid of glucose.	<ul style="list-style-type: none"> <li>• It is used in corrections of severe hypovolaemia as it expands intravascular volume rapidly.</li> <li>• It is useful in managing metabolic acidosis as lactate in liver is metabolized to bicarbonate.</li> <li>• It is useful fluid for therapy in post-operative period, burns, diarrhoea. It also corrects hypokalaemia. It maintains normal ECF fluid and electrolyte balance.</li> <li>• In diabetic ketoacidosis it provides glucose free fluid.</li> </ul>	<ul style="list-style-type: none"> <li>• It can cause lactic acidosis, so contraindicated in hypoxia, severe shock, liver diseases, in vomiting and nasogastric aspiration, in metabolic alkalosis.</li> <li>• It cannot be used along with blood transfusion as calcium in Ringer lactate can bind with citrate of transfusing blood precipitating clotting of the donor blood. Blood products and RL cannot be infused simultaneously.</li> </ul>
Isolyte M (Maintenance)	One litre contains 50 grams of glucose; 40 mEq sodium; 38 mEq chloride; 35 mEq potassium; 15 mEq phosphate; 20 mEq acetate.	<ul style="list-style-type: none"> <li>• It gives calories, water, electrolytes, pH. Rich potassium in it is useful in correcting the hypokalaemia provided renal function is good. It can correct acidosis also.</li> <li>• It is useful in diarrhoea, bilious vomiting.</li> </ul>	It is not useful in correcting hyponatraemia as sodium concentration in it is low.
Isolyte G (Gastric)	<ul style="list-style-type: none"> <li>• One litre contains 50 grams of glucose, 63 mEq of sodium, 130 mEq of chloride, 17 mEq of potassium, 69 mEq of ammonium.</li> <li>• Gastric juice contains nearly similar contents of Isolyte G. In liver ammonium converts into urea and hydrogen ion. Hydrogen ion neutralizes alkalosis.</li> </ul>	Gastric juice vomiting or continuous nasogastric aspiration which causes hypochlorhaemic, hypokalaemic, metabolic alkalosis which is corrected by Isolyte G.	
Isolyte E (Extracellular replacement)	One litre contains 50 grams of glucose; 140 mEq of sodium; 103 mEq of chloride; 5 mEq of calcium; 10 mEq of potassium; 47 mEq of magnesium; 3 mEq of acetate; 8 mEq of citrate.	It is used mainly to replace extracellular fluid. It contains double the ECF concentrations of potassium and acetate (rest similar). It gives energy, water, magnesium, corrects acidosis.	It is not used in metabolic alkalosis due to vomiting, due to diuretics.
Isolyte P (Paediatric)	One litre contains 50 grams of glucose; 25 mEq of sodium; 22 mEq of chloride; 20 mEq of potassium; 3 mEq of magnesium; 23 mEq of acetate.	It is used in fluid therapy in paediatric age group.	It is not used in hyponatraemia, renal failure, hyperkalaemia, hypovolaemic shock.

## Colloids

Colloids are of up to 20 u sized large molecules, which retain in the intravascular space for longer time and so raise the intravascular volume (3 times > than crystalloids). They improve cardiac output but not oxygen carrying capacity. Colloids should maintain oncotic pressure equal to that of plasma; should be stable and inert; non-toxic, non-antigenic, non-pyrogenic; should be easily sterilisable; should not interfere with blood grouping.

### Colloids Commonly Used

Colloid	Content	Indications	Problems
<p>Albumin (Heat treated human albumin)</p> <p>It maintains 75% of plasma oncotic pressure. It is the vehicle to transport many low molecular substances including drugs.</p>	<ul style="list-style-type: none"> <li>5% human albumin (50 grams/L) has colloid osmotic pressure of 20 mm of Hg (that of plasma pressure); its effects last for 18 hours. It increases the volume 1:1.</li> <li>25% human albumin (250 grams/L) has got colloid osmotic pressure of 70 mm Hg; expands the intravascular volume 5 times more by shifting the fluid from extravascular (interstitial) space to intravascular space; should not be used in hypovolaemia.</li> </ul>	<ul style="list-style-type: none"> <li>It is used - when rapid plasma volume expansion is needed like burns in correcting hypovolaemia sometimes; in plasmapheresis as exchange fluid.</li> <li>500 ml of 5% albumin is infused at a rate of 2 ml per minute.</li> </ul>	<ul style="list-style-type: none"> <li>It is contraindicated in cardiac failure, anaemia.</li> <li>It can cause allergic reactions, nausea, febrile reactions.</li> </ul>
<p>Dextran</p> <p>Bacteria (<i>Leuconostoc mesenteroides</i> and <i>Streptococcus mutans</i>) incubated in sucrose media producing complex branched glucan polymers as dextrans.</p>	<ul style="list-style-type: none"> <li>Dextran is first discovered by Louis Pasteur in wine.</li> <li>It is used to expand intravascular volume.</li> <li><i>Dextran 70</i> has got molecular weight of 70,000. Its excretion through kidney is poorer and so remains in the blood for weeks. It is used as 6% solution.</li> <li><i>Dextran 40</i> has got molecular weight of 40,000. It is used as 10% solution; its action is faster but shorter than dextran 70 due to faster excretion through kidney compared to dextran 70.</li> </ul>	<ul style="list-style-type: none"> <li>It is used as volume expander in hypovolaemia. It increases the blood sugar also.</li> <li>It is also used as antithrombotic agent. Dextran is a plasminogen activator; inhibits erythrocyte aggregation and platelet adhesiveness.</li> <li>It improves microcirculation and blood flow.</li> <li>Dextran 40 is commonly used.</li> </ul>	<ul style="list-style-type: none"> <li>It causes electrolyte disturbances and hyponatraemia.</li> <li>It causes acute renal failure by direct toxicity to glomerulus and tubules and by intraluminal hyperviscosity.</li> <li>It should be used carefully in diabetic patients.</li> <li>It can cause pulmonary and or cerebral oedema also due to hyperosmolarity.</li> <li>It can cause anaphylaxis (being a potent antigenic).</li> <li>It can interfere with blood grouping and cross matching.</li> <li>It prolongs the bleeding time and so may precipitate bleeding.</li> </ul>
<p>Haemaccel</p> <p>500 ml bottle with active ingredient polygeline.</p>	<ul style="list-style-type: none"> <li>1000 ml of <i>hamacel</i> contains polypeptides of degraded gelatin (origin—bovine bone; cross linked via urea bridges), 35 grams (equivalent of 6.3 gram of nitrogen).</li> <li>It also contains sodium and chloride of 145 mmol (0.85 gram); calcium 6.25 mmol (0.25 gram); potassium 5.1 mmol (0.20 gram); traces of phosphate, sulphate and anionic polypeptides. Its molecular weight is 30,000 with 1.7 viscosity.</li> <li>Haemaccel should be stored in 2–25°C.</li> <li>Haemaccel does not induce antibody formation.</li> </ul>	<ul style="list-style-type: none"> <li>It is used as a rapid volume replacement in circulatory collapse like shock, burns and trauma. It is infused rapidly at a rate of 125 drops/minute. H2 blocker like cimetidine or ranitidine should be given along with haemaccel as it releases histamine.</li> <li>It improves the plasma volume rapidly and remains like that for 5 hours.</li> <li>It will not interfere with coagulation, blood grouping and cross matching.</li> <li>It is used also in heart lung machine.</li> <li>Haemaccel can be mixed with other IV fluids and drugs.</li> <li>Haemaccel can be infused up to 2000 ml.</li> </ul>	<p>Rapid histamine release and anaphylactoid reaction.</p>

Contd...

Contd...

<p>Hetastarch (hydroxyethyl starch) It is nonionic starch derivative, which is ethoxylated amylopectins which is a plasma volume expander.</p>	<ul style="list-style-type: none"> <li>• It is a synthetic colloid available as 6% solution in 0.9% normal saline (30 gram hetastarch in 500 ml of isotonic saline). It is administered IV only using infusion pump; 20 ml / kg / hour; it is stored in room temperature. It is enzymatically degraded and causes rise in serum amylase level.</li> <li>• Total dose per day should be 1500 ml only.</li> </ul>	<ul style="list-style-type: none"> <li>• It is used in hypovolaemia— shock, burns, trauma.</li> <li>• It is also used in leukapheresis.</li> <li>• It is nonantigenic; does not interfere with blood grouping.</li> <li>• It shows greater plasma volume expansion for longer period compared to 5% albumin.</li> </ul>	<ul style="list-style-type: none"> <li>• Anaphylactoid reactions can occur.</li> <li>• Renal impairment should be observed.</li> <li>• It has no O<sub>2</sub> carrying capacity; so should not allow haematocrit to fall below 30%.</li> <li>• Impairment of coagulation is possible.</li> </ul>
<p>Pentastarch It is a subgroup of hetastarch with five hydroxyethyl groups with 50% esterification. It is a low molecular weight derivative; it is more effective plasma volume expander.</p>	<p>It is available as 3%, 6% and 10% in normal saline.</p>	<ul style="list-style-type: none"> <li>• It is used in hypovolaemia.</li> <li>• It is useful in cardiac surgeries.</li> </ul>	

## NUTRITION

*We (now) devote more attention to the patient's diet and habits, and more often send him away with good advice than with hastily-written prescriptions.*

—Robert Hall Babcock, 1901

### Principles of Nutrition

- ◆ Avoiding of malnutrition is the basic goal in nutrition therapy as malnutrition increases the morbidity and mortality of the disease process and prevents or delays the recovery. Malnutrition increases the chance of sepsis, prevents wound healing, increases the respiratory complications, and decreases the efficacy and tolerance to radiotherapy or chemotherapy.
- ◆ Whenever possible enteral route of nutrition should be used ideally. If that is not possible then parenteral nutrition is used.
- ◆ Overfeeding should be avoided as it leads into hyperglycaemia, hepatic steatosis, raised BUN, and excess CO<sub>2</sub> production.
- ◆ Timing and type of nutrition is also important.
- ◆ Nutrition therapy reduces protein wasting.
- ◆ Immunomodulators like glutamine, arginine and omega 3 fatty acids are also very useful. *Glutamine* is a nonessential amino acid synthesized in skeletal muscle. It is essential for cell proliferation during tissue repair. Glutamine helps GI mucosal cell proliferation, maintains mucosal integrity, improves immune function and prevents translocation of bacteria. It is useful in inflammatory bowel disease, short gut syndrome, burns, major trauma, and sepsis. Glutamine is used commonly by enteral route even though IV preparations are now available (but it is very unstable in solutions).

*Caloric requirement:*

- ◆ Neonatal 100 kcal/kg/day.
- ◆ Adult 40 kcal/kg/day.
- ◆ Adult with catabolism 60 kcal/kg/day.

*It is given as:*

- ◆ Carbohydrates 50%.
- ◆ Fat 30–40%.
- ◆ Protein 10–15%.

*Caloric values:*

- ◆ Carbohydrate 4 kcal/g.
- ◆ Protein 4 kcal/g.
- ◆ Fat 9 kcal/g.

### Indications for Nutritional Support

- Preoperative nutritional depletion.
- Postoperative complications: Sepsis, ileus, fistula.
- Intestinal fistula: High type wherein output is more than 500 ml/day. It may be duodenal, biliary, pancreatic, intestinal.
- Pancreatitis, malabsorption, ulcerative colitis, pyloric stenosis.
- Anorexia nervosa and intractable vomiting.
- Trauma—multiple fractures, fasciomaxillary injuries, head and neck injuries.
- Burns.
- Malignant disease.
- Renal and liver failure.
- Massive bowel resection causing short bowel syndrome.

#### Assessment

- ❖ Body weight
- ❖ Mid-arm circumference
- ❖ Triceps skin fold thickness
- ❖ Serum albumin
- ❖ Lymphocyte count

**Nutritional requirements:** Carbohydrates, fat, proteins, vitamins (includes fat-soluble vitamins also), minerals, trace elements.

### Methods of Feeding

#### Enteral:

- Gastrointestinal tract is the best route to provide nutrition.*
- Enteral feeding can be delivered by bolus, by gravity or using mechanical pump.*
  - ▶ *By mouth:* Requires:
    - Common sense,
    - Cleanliness,
    - Compassion.

*We will not know unless we begin.*



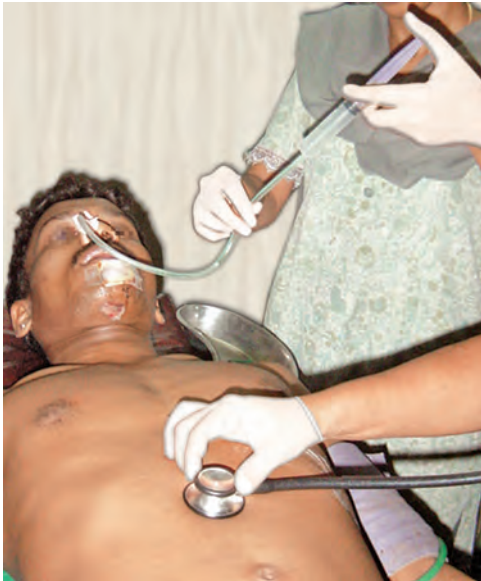- ▶ *By nasogastric tube:* Confirmation of the tube in the stomach is made by injecting 5 ml of air down the tube and listening through a stethoscope for its bubbling entry into the stomach. Feeding rate is 30–50 ml/hours. 5 hours night time gap is given to allow gastric pH to return to normal.

#### Problems with tube feeding are:

- ❖ Blockage
- ❖ Nausea and vomiting, aspiration
- ❖ Hyperosmolarity
- ❖ Diarrhoea
- ❖ Tube discomfort
- ❖ Cholestasis

#### c. *By enterostomy:*

- ▶ Gastrostomy.
- ▶ Jejunostomy.



**Fig. 1.197:** Nasogastric tube passed should be confirmed in place using stethoscope. Tube is used for feeding purpose.

Different preparations and formulas are available for enteral feeding. Soluble fibre containing diets along with nutrients are better to prevent diarrhoea.

#### Complications of enteral feeding

- ❖ Aspiration
- ❖ Wound infection and leak
- ❖ Diarrhoea due to rapid feeding or hyperosmolarity
- ❖ Hyperglycaemia
- ❖ Hypokalaemia
- ❖ Refeeding syndrome due to severe hypokalaemia and hypophosphataemia

#### Advantages of Enteral Nutrition

- ◆ Enteral nutrition preserves mucosal protein, digestive enzymes, IgA secretion; prevents mucosal atrophy and bacterial translocation.
- ◆ It is more physiological as nutrients pass through liver, the first

filter to process and store. Gallstone formation is prevented (unlike long-term TPN) by stimulating gall-bladder motility.

- ◆ It has got less serious complications. It is cost-effective.
- ◆ It supplies glutamine and short chained fatty acids to gut.

#### Contraindications of Enteral Nutrition

- ◆ Intestinal obstruction, GI bleed, paralytic ileus, severe diarrhoea, high output fistula.
- ◆ Low cardiac output, haemodynamically unstable patient.
- ◆ If safe access to enteral feeding is not present.
- ◆ Anticipated complications if thought to be present should be avoided.

#### GASTROSTOMY

It is done if feeding is required for more than *one month*.

#### Indications

- ❖ Severe malnutrition
- ❖ Major surgeries
- ❖ Severe sepsis
- ❖ Trauma
- ❖ Head and neck surgeries

#### Types

##### Based on duration of use:

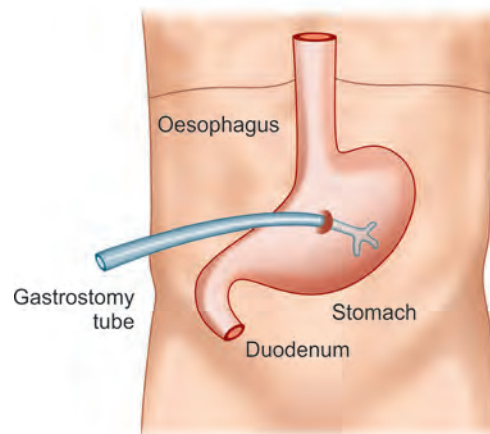
- ◆ Temporary.
- ◆ Permanent.

##### Based on lining:

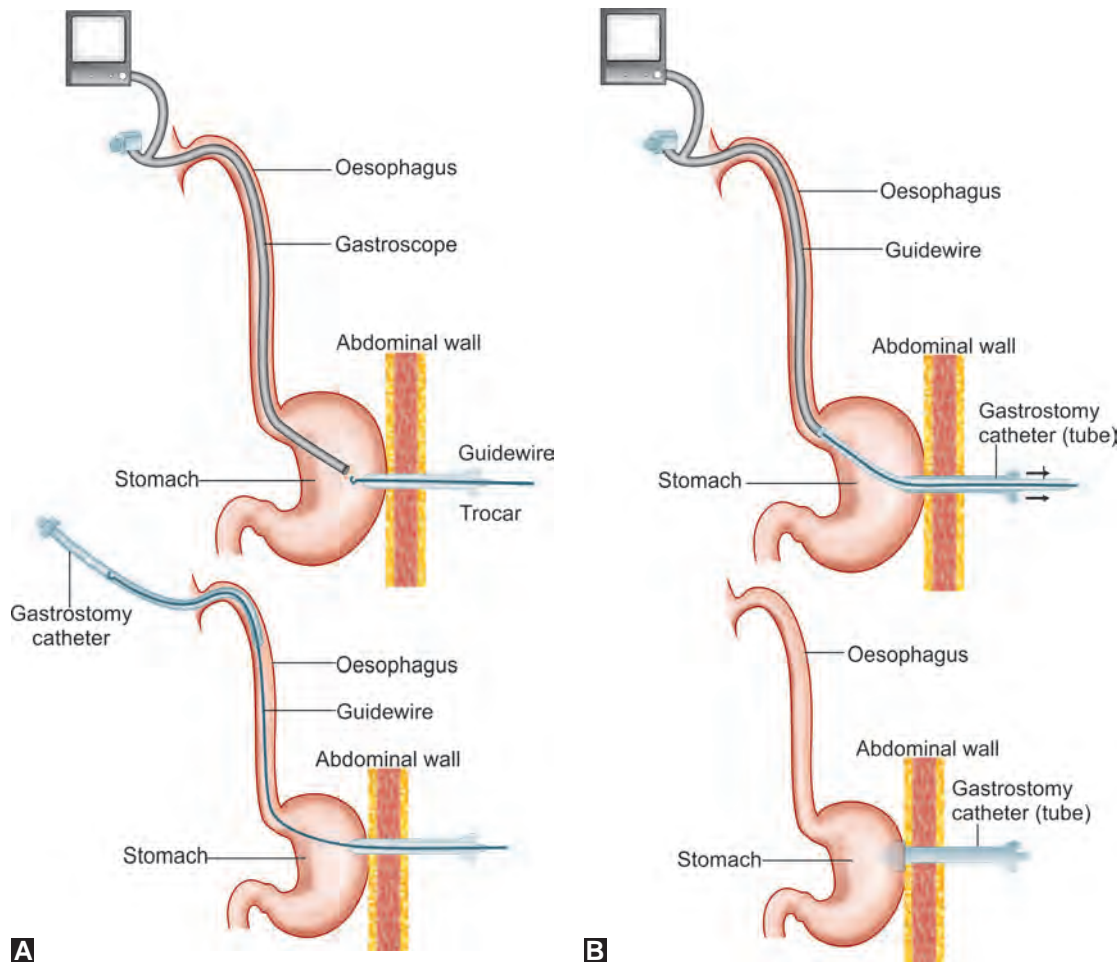
- ◆ Mucus lined (permanent).
- ◆ Serosal lined (temporary).

##### Based on technique:

- a. *Stamm temporary gastrostomy:* After opening the abdomen, anterior wall of the stomach is opened. Feeding tube (Malecot's catheter) is placed in position. Two layers of purse string sutures are put around the tube. Wound is closed.



**Fig. 1.198:** Gastrostomy tube in place for enteral feeding.



**Figs 1.199A and B:** Percutaneous endoscopic gastrostomy (PEG). Guidewire passed through a trocar in the abdominal wall into the stomach is pulled out across the oesophagus and mouth under visualisation using gastroscope. Gastrostomy catheter (tube) is passed along the guidewire and pushed downwards across mouth and oesophagus to reach the stomach. It is further pushed along the abdominal wall through the trocar. Gastrostomy tube is pulled out through abdominal wall and fixed. Trocar is removed. Placement of tip of gastrostomy tube can be confirmed by doing gastroscope.

- b. *Kader-Senn temporary gastrostomy*.  
 c. *Percutaneous endoscopic gastrostomy* (popular)—now becoming common method.  
 d. *Janeway's mucus lined permanent gastrostomy* by creating tunnel in stomach wall.

- ◆ Intestinal obstruction.
- ◆ Gastric outlet obstruction.

## ■ JEJUNOSTOMY

Jejunostomy for enteral nutrition is becoming more popular because of:

- ◆ Its comfort,
- ◆ Easy to do,
- ◆ Can be kept for long time,
- ◆ Lesser complication than gastrostomy.

*Indications* are same as gastrostomy.

## Types

- a. *Witzel jejunostomy*: Site of placing jejunostomy is 30 cm from duodenojejunal junction.
- b. *Needle jejunostomy* using catheter of small gauge.

### Problems in gastrostomy

- ❖ Leak—gastric fistula
- ❖ Infection
- ❖ Aspiration and pneumonia
- ❖ Diarrhoea is common—30%
- ❖ Bloating, abdominal cramps
- ❖ Displacement, blockage of the tube

## Contraindications

- ◆ Previous gastric surgeries.

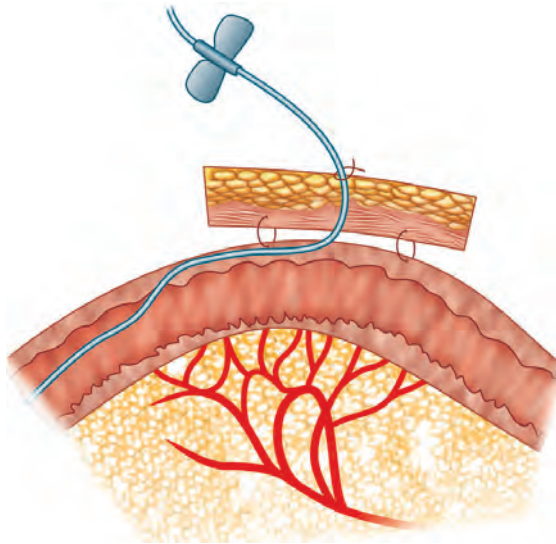


Fig. 1.200: Needle jejunostomy.

## TOTAL PARENTERAL NUTRITION (TPN)

All nutritional requirements are given only through intravenous route, not through gastrointestinal tract. It can be through a central catheter through the subclavian/internal jugular vein where the tip of venous catheter is at distal part of superior vena cava.

It can also be a peripheral (Peripheral parenteral nutrition/PPN) through a peripherally inserted central venous catheter (PICC) or through a formal peripheral venous line.

### Indications

- ❖ Failure or contraindication for any enteral nutrition for 7–10 days
- ❖ High output abdominal fistulas, duodenal, biliary, pancreatic fistulas
- ❖ Major abdominal surgeries of liver, pancreas, biliary, colonic
- ❖ Septicaemia
- ❖ Multiple trauma
- ❖ Short bowel syndrome
- ❖ Severe pancreatitis, bowel ischaemia, peritonitis, ileus
- ❖ Massive GI bleeding, unstable haemodynamically
- ❖ High risk of aspiration
- ❖ Hyperemesis gravidarum
- ❖ Multiorgan failure, head injury, severe burns

About 5% of hospital admissions require TPN.

## Technique

- ◆ Using a needle and guide wire a *Subclavian vein catheter* is passed just below the clavicle and fixed securely to the skin.
- ◆ TPN is given through *central vein* and not through a peripheral vein.
- ◆ Peripherally inserted central catheter (PICC) is also commonly used (PPN).

## Goals, Factors and Assessment in TPN

- ◆ To decrease adverse effects of catabolism; to increase protein synthesis, to reduce protein breakdown, to prevent weight loss.

- ◆ To support ongoing metabolism.
- ◆ To improve immune function, cardiac and respiratory function.
- ◆ To maintain glycogen reserve in cardiac and respiratory muscles.
- ◆ To maintain acid, base and electrolyte metabolism.
- ◆ Age, pre-morbid state, muscle mass, weight, serum albumin should be assessed.
- ◆ Underlying disease, its severity, therapies for the disease, GI function should be assessed.
- ◆ *Fluid requirement* is assessed by—1500 ml for 20 kg weight + 20 ml/kg for additional weight.
- ◆ *Energy needed* is calculated by calculating resting energy expenditure (REE).
  - ▶ By *simple calculation*: REE in kcal/day = 25 × weight in kg.
  - ▶ *Harris Benedict equation*: REE in men = 66 + (13.7 × weight in kg) + (5 × ht in cm) – (6.7 × age in years). In women = 655 + (9.6 × weight) + (1.8 × ht) – (4.7 × age). Activity/disease/thermal factors are also added.
  - ▶ *Indirect calorimetry*: It is more accurate method done using special instrument. REE: = (3.9 × VO<sub>2</sub>) + (1.1 × VCO<sub>2</sub>) – 61.

### Components used in TPN

- ❖ Carbohydrates
- ❖ Fat and amino acids
- ❖ Vitamins and trace elements, electrolytes, minerals

## Components Used in TPN/PPN

**Carbohydrates:** Dextrose is less costly (1 gram dextrose 3.4 kcal); can be used in 50–70% concentration during PN. It supplies calories, stimulates insulin release and glucose oxidation, prevents muscle protein breakdown, has got nitrogen sparing ability. *Problems of carbohydrate/dextrose* are—low calorie value compared to fat, requires large fluid volume to infuse, hyperglycaemia, causes more CO<sub>2</sub> production, because of high osmolality it causes thrombophlebitis in 10% or above concentration. Rate of administration of dextrose is 5 mg/kg/min.

**Fat:** Fat gives high calorie (1 gram—9 kcal), essential fatty acids. It is given as emulsion containing long chain triglycerides. It contains soyabean/sunflower oil with egg yolk phospholipids (emulsifying factor), glycerin (isotonic). Fat has got low osmolality (260 mosm/L); it is available as 10%, 20%, 30% emulsions. *Advantages of fat* in PN are—high calorie, prevents hyperglycaemia, glucose and nitrogen sparing, less CO<sub>2</sub> production, less insulin production; it prevents essential fatty acid deficiency (for this purpose 3 days a week dose is given), reduces thrombophlebitis. *Problems of lipids* in PN are—hypertriglyceridaemia, sepsis, fat embolism, fat overload, hepatic dysfunction, pancreatitis, delayed gastric emptying. Lipid emulsions are avoided in hyperlipidaemia, anaemia, acidosis, obesity. Lipid emulsion is a good culture media for bacteria and fungi; so care should be taken to prevent sepsis. Triglyceride level should be monitored weekly; if more than 400 mg%, infusion is discontinued. Mixture of long and medium chain fatty acids is better tolerated and efficient.

**Amino acids:** They are source of proteins. Calorie value of amino acid is 4 kcal/gram. 6.25 gram protein has 1 gram nitrogen. In PN 20% of energy comes from amino acids; rest from dextrose and fat. Daily protein need is 0.8–1.5 gram/kg. Protein supplement should be less in patients with CRF and hepatic encephalopathy. Its need is more in burns, trauma, enteropathy, sepsis. Protein supplement should not exceed 1.7 gram/kg/day; if so will cause raised urea production. *Uses of amino acids* in PN—in protein anabolism; prevents scatabolism. Proper monitoring by doing BUN or ammonia level is essential during amino acid therapy.

**Vitamins, electrolytes, trace elements and minerals:** Electrolytes like sodium, potassium, magnesium, phosphate, calcium; fat-soluble vitamins like A, D, E, K; water-soluble vitamins; trace elements like chromium, copper, iodine, iron, manganese, selenium, zinc are all used in PN.

#### Monitoring the patient

- ❖ By body weight, fluid balance, blood glucose, electrolytes, blood urea, LFT, serum calcium, magnesium, phosphate should be done at regular intervals.
- ❖ A weight gain more than one kg/day signifies fluid overload.

## Complications

### Technical

- a. Air embolism.
- b. Pneumothorax.
- c. Bleeding.
- d. Catheter displacement, sepsis, blockage.
- e. Infection, thrombosis.

### Biochemical

- a. Electrolyte imbalance: Hyponatraemia, hypokalaemia, hypophosphataemia.
- b. Hyperosmolarity.
- c. Hyperglycaemia—common.
- d. Dehydration.
- e. Altered immunological and reticuloendothelial function.
- f. Azotaemia.

### Others

- a. Dermatitis.
- b. Anaemia and increased capillary permeability.
- c. Cholestatic jaundice: It is common.
- d. Severe hepatic steatosis.
- e. Metabolic acidosis.
- f. Candida infection (candidiasis), staphylococcal infection (10–15%).

#### Contraindications

- ❖ Cardiac failure
- ❖ Blood dyscrasias
- ❖ Altered fat metabolism

Anabolic steroid durabolin 25 mg IM weekly is given to improve nitrogen balance.

#### Home parenteral nutrition

- ❖ It is becoming popular
- ❖ It is commonly used in western countries
- ❖ It is indicated in short bowel syndrome or any other conditions wherein enteral feeding is not possible but patient can be sent home with provision for home parenteral nutrition
- ❖ Patient himself uses the TPN fluids as advised at home. He will be with TPN catheter
- ❖ Patient should attend TPN clinic weekly for follow-up or immediately whenever complications arise
- ❖ Patient will be comfortable psychologically and often can attend his job also

## REFEEDING SYNDROME

- ◆ Refeeding syndrome is occurrence of severe fluid and electrolyte imbalance in severely malnourished individual while starting the proper feeding enteral or parenteral nutrition. It is more common in TPN.
- ◆ It causes hypomagnesaemia, hypocalcaemia and hypophosphataemia leading into myocardial dysfunction, respiratory changes, altered liver functions, altered level of consciousness, convulsions and often death.
- ◆ Gradual feeding and correction of magnesium, phosphate and calcium and other electrolytes is important.
- ◆ Condition is common in chronic starvation, severe anorexia and alcoholic patients.

## OBESITY AND MORBID OBESITY

**Obesity** is weight more than 20% above the normal. Body mass index (BMI) is weight in kilogram divided by height in metres squared [ $\text{wt in kg}/(\text{Ht in meters})^2$ ].

**Morbid obesity** is a condition wherein BMI is more than 40  $\text{kg}/\text{m}^2$ . It is often also defined as weight 100 lbs or more; or 100% over ideal body weight.

Weight more than double the expected weight to that age and height of the individual is also often called as morbid obesity. Body weight exceeding BMI 50  $\text{kg}/\text{m}^2$  is called as *superobesity*.

### Causes of Obesity

- ◆ Familial, hyperinsulinism, hyperadrenocorticism, hyogonadism.
- ◆ Abnormal eating behaviour: Hormones which control eating are—ghrelin from stomach; insulin from pancreas; leptin from fat; PYY 3–36 from colon. Hypothalamus is the center in CNS which controls eating.

Nutritional status	BMI ( $\text{kg}/\text{m}^2$ )
• Underweight	• <18.5
• Normal	• 18.5–24.9
• Overweight (Preobesity)	• 25.0–29.9
• Obesity	• >30
– Class I	– 30.0–34.9
– Class II (Moderate)	– 35.0–39.9
– Class III (Severe / Morbid)	– 40.0
• Superobesity	• >50
• Super superobesity	• >60

Obesity is more common in young women. Child of a normal weight parents has 10% chance to become obese. If both parents are obese then child has got 80% chances to develop obesity.

### Problems with Morbid Obesity

Obstructive sleep apnoea, degenerative joint disease, back pain, hypertension, GERD, gallstones, type II diabetes, hyperlipidaemia, arrhythmias, venous diseases, DVT, skin diseases, urine incontinence, infertility, ventral hernias, obesity hypoventilation syndrome, polycystic ovarian disease, hirsutism, gynaecomastia, steatohepatosis, malignancies—are common problems. All these conditions are called as *comorbidities*.

Infertility is common in married morbid obese women due to improper ovulation, polycystic ovary disease. Urinary incontinence is common in morbid obese women (stress incontinence and detrusor instability). Pregnancy in morbid obese patient is considered as high-risk pregnancy. Gestational diabetes, hypertension, are common. It is better these women to undergo bariatric surgery prior to pregnancy which definitely reduces the complications during pregnancy. Such individual after bariatric surgery needs more iron and vitamin supplements.

*Evaluation of the patient*—cardiac and respiratory assessment; lipid profile; blood glucose; renal and liver status assessment; anaesthesia risk assessment.

## Medical Management

- ◆ General: Diet, life style changes, exercise.
- ◆ *Drugs*: (1) Orlistat is a selective inhibitor of gastric and pancreatic lipases that reduces the absorption of lipids from intestine. (2) Sibutramine is a noradrenaline and 5 HT reuptake inhibitor which act as appetite suppressor.

## Surgical Treatment (Bariatric Surgery)

Bariatric surgery causes long-term durable weight loss. Patient's eating behaviour is reduced to slow ingestion of small boluses of food and or also reducing the absorptive surfaces.

## Types of Bariatric Surgery

- a. *Restrictive* wherein caloric intake is reduced. Purely gastric restrictive procedures are vertical banded gastroplasty (VBG) and laparoscopic adjustable gastric banding (LAGB).
- b. *Malabsorptive* wherein absorption of calories and nutrients from food is reduced. Biliopancreatic diversion (BPD) and biliopancreatic diversion with duodenal switch (BPD-DS) are malabsorptive procedures.
- c. *Combined* wherein both methods are used. Roux-en-Y gastric bypass (RYGB) is both restrictive and malabsorptive types. Gastric bypass reduces GI polypeptide ghrelin level secreted from fundus of stomach and duodenum. Ghrelin acts on specific receptor in CNS—hypothalamus to initiate appetite. This stimulation is reduced to decrease appetite. In restrictive only procedure ghrelin level raises and so appetite stimulation is not controlled.

## Indications for Bariatric Surgery

BMI more than 40 kg/m<sup>2</sup> or BMI more than 35 kg/m<sup>2</sup> with comorbidity is indication for bariatric surgery. American Association of Bariatric Surgery (ASBS) published indications and approved surgeries.

## Contraindications

Patients who are unfit for general anaesthesia (cardiac/renal/respiratory/hepatic causes) or who are unable to adjust post-operative life styles or psychiatric patients are contraindications for bariatric surgery.

## Preoperative Preparations and Evaluation

- ◆ Complete cardiac, respiratory/renal/hepatic evaluation.
- ◆ Lipid profile and blood glucose assessment.
- ◆ Obstructive sleep apnoea in obese patient should be assessed using polysomnography and be treated.
- ◆ Risk assessment for DVT should be done.
- ◆ If GERD symptoms are present gastroscopy should be done.
- ◆ USG abdomen to identify gallstones should be done; if gallstones present it is of usual practice to do cholecystectomy along with bariatric procedure.
- ◆ Nutritional evaluation and dietician advice for preoperative and postoperative diet management.
- ◆ Psychological screening is needed to all patients to counsel their postoperative care and diet.
- ◆ Separate theatre table is needed for morbid obese patient. Equipments should be long and flexible. In laparoscopic surgery, special ports and instruments are needed.

## DIFFERENT SURGERIES

### Vertical Banded Gastroplasty (VBG); Mason (1982)

It is a purely restrictive type with creation of a calibrated stoma in the lesser curvature which is reinforced by an encircled mesh with a proximal gastric pouch. After laparotomy Ewald's stomach tube is passed per orally to place against lesser curve. A 2.5 cm circular window is created in the body of stomach near lesser curvature 8 cm below the *angle of His*. After this, four lines of linear vertical stapling are done from circular opening towards angle of His. This staple line ideally should be divided using another cutting linear stapler to reduce chances of dehiscence. This creates a 50

Complications of obesity	Obesity and surgery	Treatment for obesity
<ul style="list-style-type: none"> <li>• <i>General</i>: Difficulty in work, fatigue, depression, back pain, arthritis and gout</li> <li>• <i>Cardiovascular</i>: Hypertension, stroke, thrombophlebitis, pulmonary embolism</li> <li>• <i>Pulmonary</i>: Hypoventilation, poor respiratory effort</li> <li>• <i>GIT</i>: Hiatus hernia with reflux, changes in liver, pancreatitis, gallstones</li> <li>• <i>Endocrine</i>: Diabetes mellitus</li> </ul>	<ul style="list-style-type: none"> <li>• Hernia and gallstones are more common in obese individual</li> <li>• Burst abdomen, incisional hernia are more common in obesity</li> <li>• Delay in recovering from anaesthesia</li> <li>• Infertility is more common</li> </ul>	<ul style="list-style-type: none"> <li>• <i>General</i>: Dieting, exercise</li> <li>• <i>Drugs</i>: Orlistat, Sibutramine</li> <li>• <i>Surgeries</i>: <ul style="list-style-type: none"> <li>– <i>Restrictive</i> <ul style="list-style-type: none"> <li>◆ Vertical banded gastroplasty</li> <li>◆ Laparoscopic adjustable gastric banding (LAGB)</li> <li>◆ Jaw wiring</li> </ul> </li> <li>– <i>Malabsorptive</i> <ul style="list-style-type: none"> <li>◆ Biliopancreatic diversion (BPD)</li> <li>◆ Biliopancreatic diversion with duodenal switch (BPD-DS)</li> <li>◆ Jejunioileal bypass</li> </ul> </li> <li>– <i>Combined</i> <ul style="list-style-type: none"> <li>– Roux-en-Y gastric bypass (RYGB) open or laparoscopic</li> </ul> </li> </ul> </li> </ul>

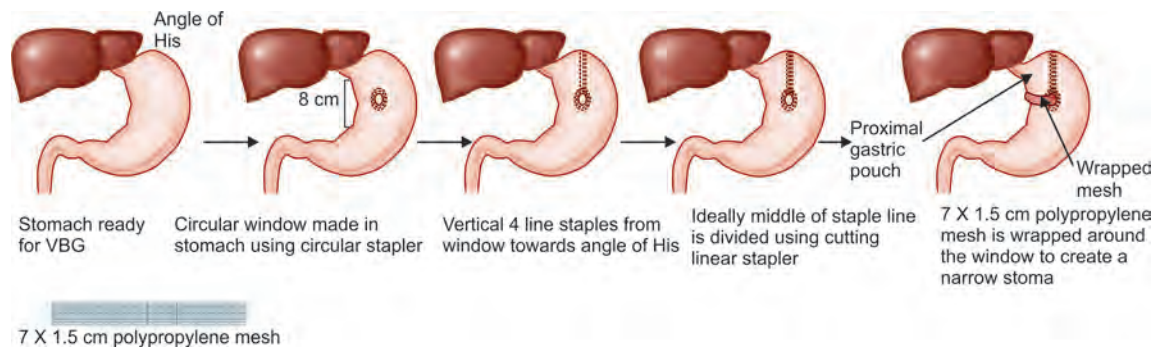


Fig. 1.201: Vertical banded gastroplasty (VBG).

ml proximal gastric pouch. A 1.5 × 7 cm polypropylene mesh is placed around the lesser curve through circular opening and sutured to create a 5 cm collar stoma. *It is not used at present; it is only of historical importance.*

VBG causes only medium term weight loss; its efficacy is less compared to other procedures. *Complications of VBG are*—stricture at stoma (20%), vomiting (30%), reflux (20%), staple line dehiscence (40%), conversion into other procedures. Mortality is 0.3%.

VBG is technically easier to do; it has got very less chances of long-term metabolic and nutritional deficiencies.

## Laparoscopic Adjustable Gastric Banding (LAGB)

It is also a restrictive type (1992, Guy Bernard) to create a narrow stoma just below the OG junction. It is used in adolescents and elderly. It is contraindicated in hiatal and paraoesophageal hernias. It is done using *laparoscopy*.

Under general anaesthesia, with patient in reverse Trendelenburg position six laparoscopic ports are placed. Using pars flaccida method, retrogastric tunnel is created; a silicone band is passed through the tunnel to encircle the cardia just below the OG junction; tail of the band is buckled and locked. Stoma diameter is determined by inserting a calibration tube. Stomach over the band is imbricated using interrupted sutures except the buckle area. Silicone tube end is brought out through the abdominal wall to connect access port. It is used for band volume adjustment by injecting or withdrawing the saline.

Gastrograffin study is done on 1st postoperative day to assess band position and lumen patency. Patient is advised to have liquid diet for one month. Band adjustment is done under fluoroscopic guidance in 2 months. Adjustment is done to achieve weight loss at a rate of 2 kg/week. Efficacy of LAGB is 55%.

*Complications of LAGB are*—spleen/stomach injury; bleeding; band slippage (10%); band erosion (7.5%); tube related complications; vomiting; pouch dilatation; reflux. Conversion rate is 3%; mortality is less than 0.5%.

## Jejunioileal Bypass

It was the first malabsorptive procedure done for obesity. Now this technique is not done due to high incidences of complications.

Proximal jejunum is divided and proximal cut end is anastomosed to distal ileum just proximal to ileocaecal valve to reduce the absorptive surface area of small bowel.

Complication rates were higher and so procedure is not practiced. Colon in these patients absorbs high level of oxalate causing nephrocalcinosis. Bypassed bowel promotes bacterial growth causing endotoxin-induced liver injury, cirrhosis, liver failure. Complications like protein, vitamin K, vitamin B<sub>12</sub> deficiencies; gallstone formation; enteritis and diarrhoea; arthritis, osteoporosis are common.

## Roux-en-Y Gastric Bypass

It is commonly done combined procedure. It can be done by open or laparoscopic method. Proximal stomach is dissected between 1st and 2nd branches of left gastric branches. Vagii nerves and *nerves of Latarjet* are retained carefully. Stomach is transected at this proximal site to create a proximal gastric pouch (15 ml if BMI is > 50; 30 ml if BMI is 40–50). It is usually carried out through linear stapler. Jejunum is transected 45 cm from *ligament of Treitz*. A side to side jejunojejunal anastomosis is done using stapler 75 cm distal to the distal cut end. Proximal Roux part of the distal jejunal cut part (75–150 cm, based on patient's preoperative weight) is brought out through the transverse mesocolon towards the created proximal gastric pouch and gastrojejunostomy is done to this proximal gastric pouch. Mesenteric defect is closed. Stomal integrity is checked on table by air distension and methylene blue infusion. Gastrograffin study is done in 24 hours to assess pouch size, stomal patency and distal obstruction. Oral food is started in 24 hours and patient is discharged in 4 days.

RYGB is more useful in weight loss compared to purely restrictive types. 5 years weight loss is 60–75%. It also prevents progression of noninsulin dependent diabetes mellitus, controls hypertension, sleep apnoea, hyperlipidaemia, asthma, arthritis, GERD.

*Complications are*—Roux obstruction, anastomotic leak, acute distal gastric dilatation, stomal stenosis, marginal ulcer, dumping syndrome, internal hernias, vitamin B<sub>12</sub> deficiency, iron deficiency anaemia. Distal gastric dilatation needs emergency intervention which is usually due to jejunojejunal obstruction.

## Laparoscopic RYGB (1994, Wittgrove, Clark, Trembly)

Technique is similar to open RYGB. Anastomoses are done using endoscopic stapler. GJ between gastric pouch and Roux jejunum is done either using linear stapler through laparoscopic port after making a gastrotomy in the pouch which is later sutured after staple firing; or using circular stapler anastomosis is done wherein anvil is initially passed transorally often under endoscopic guidance across the pouch into the

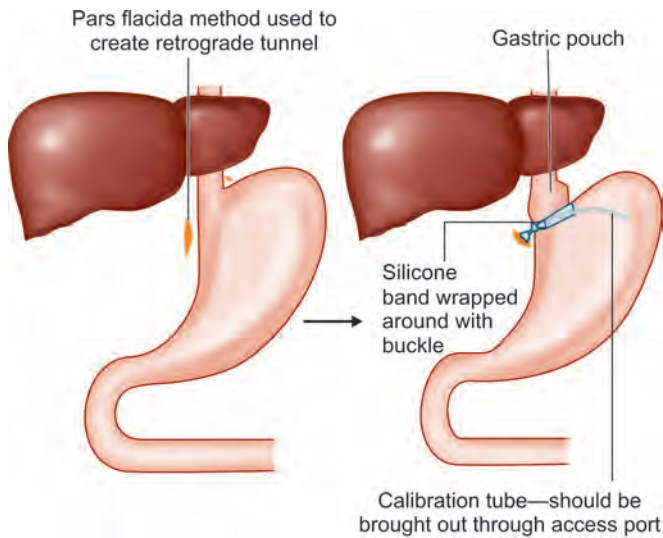


Fig. 1.202: Laparoscopic adjustable gastric banding (LAGB).

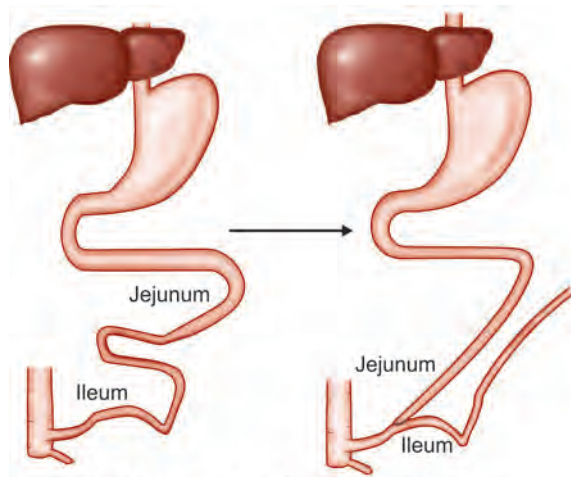


Fig. 1.203: Jejunioileal bypass procedure (JIB).

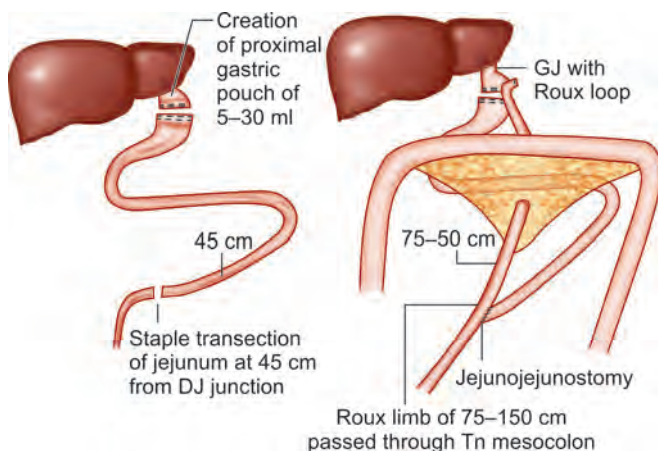


Fig. 1.204: Roux-en-Y gastric bypass procedure (RYBG).

Roux jejunum; or using hand sewing with absorbable sutures. Omentum is released from the colon and is covered over the GJ. Mesenteric defect and *Patterson Brown defect* are closed. A *Bronlin antiobstructive stitch* is placed between Roux and biliopancreatic limbs. Integrity of anastomosis is checked using insufflation of air, methylene blue. *Complications* are similar to open RYBG. Conversion rate is 9%. *Advantages* of LRYBG to open RYBG are—faster recovery, less post-operative pain, less wound related complications, less morbid one. *Disadvantage* of LRYBG is availability of facility, technical expertise, and steep learning curve.

Now technique is modified to antegastric, antecolic one which has become popular (Gagner).

## Biliopancreatic Diversion (BPD) (Nicola Scopinaro, Italy)

It is done in patients who had failed restrictive procedure or who are superobese.

Distal subtotal gastrectomy is done with formation of proximal gastric pouch (of 400 ml in BMI 40–50; 200 ml in BMI >50). Ileum is transected 250 cm proximal to ileocaecal valve; distal ileal segment is brought up to anastomose into the proximal gastric pouch. Proximal biliopancreatic jejunioileal limb is anastomosed into distal ileal segment 50 cm proximal to ileocaecal valve as end to side stoma. Additionally cholecystectomy should be done.

*Modification of BPD with duodenal switch (BPD-DS)* has become more popular. Here sleeve gastrectomy along the greater curvature is done to create gastric reservoir (200 ml) along lesser curve. Duodenum just distal to first part is divided using stapler; proximal cut end is sutured to proximal upward pulled end of the distal ileal segment of earlier transected ileum, 250 cm from ileocaecal valve. Biliopancreatoduodenal with proximal jejunioileal segment is later stapled to distal ileum 50 cm proximal to ileocaecal valve. Duodenal switch reduces the rate of marginal ulcer and dumping syndrome.

*Results of BPD/BPD-DS* are—excellent for weight reduction compared to restrictive procedures. But they need lifelong supplement of vitamins, fat-soluble vitamins, calcium, and iron. Technically BPD is easier to do when compared to BPD-DS.

*Complications of BPD/BPD-DS* are—*anemia* (30%); *protein deficiency* (20%); *dumping syndrome*; *marginal ulcer* (in BPD 10%; in BPD-DS it is 1%); *osteoporosis*; *night blindness*; *biliopancreatic*

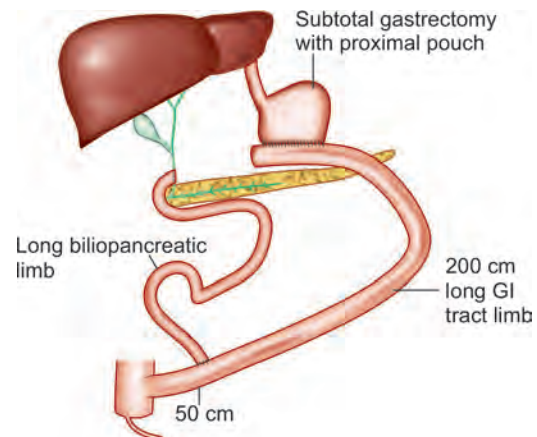
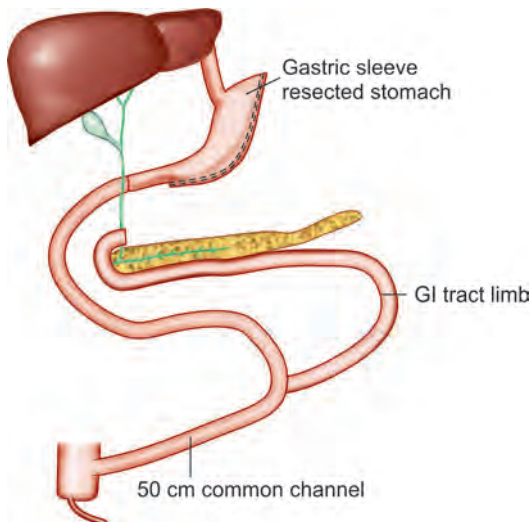


Fig. 1.205: Biliopancreatic diversion procedure (BPD).



**Fig. 1.206:** Biliopancreatic diversion with duodenal switch procedure (BPD-DS).

limb obstruction; staple line leak; staple line bleed; DVT; subphrenic abscess. Vitamin B<sub>12</sub> deficiency is specific.

### Ileal Interposition with Sleeve Gastrectomy

It is done *mainly in type II diabetes*. Often they are associated with obesity, dyslipidaemia, hypertension, nephropathy and neuropathy. Two types of ileal interposition with sleeve gastrectomy are done.

**Type 1:** Sleeve gastrectomy is done. 170 cm of ileum with mesentery is isolated 30 cm from ileocaecal junction. Jejunum is transected 50

cm from duodenojejunal flexure. Isolated 170 cm ileal segment is interposed 50 cm distal to DJ junction with end-to-end anastomosis on both ends.

**Type 2:** After doing sleeve gastrectomy, gastroduodenal junction is transected; cut proximal end of duodenum is closed. 170 cm ileal segment with mesentery is isolated and interposed between cut end of stomach and side of jejunum 50 cm distal to DJ flexure.

### Cholecystolithiasis After Bariatric Surgery

Gallstone formation is common after bariatric surgery (50%). It is due to rapid weight loss. If gallstones are present at the time of bariatric surgery it is essential to do laparoscopic cholecystectomy during bariatric procedure. It is controversial about doing prophylactic cholecystectomy during bariatric surgery even though it is practiced in many places. Advantages are—it prevents future gallstone formation at the time of bariatric surgery (loss of access); it prevents difficulties in approaching CBD in case needed endoscopically due to surgery. Disadvantage is cholecystectomy adds additional 1 hour time for bariatric surgery increasing the risk of immediate complications. Patients who are not having gallstones at the time of bariatric surgery, should receive ursodeoxycholic acid 300 mg twice daily for 6-12 months of post-bariatric surgery period. Often stomach is anchored to abdominal wall as access part to biliary system for future need.

**Note:**

Many of these patients after bariatric surgery require plastic surgery for abdominal contour (panniculectomy, abdominoplasty) after weight reduction due to bariatric surgery.



## G. Shock

*The first noteworthy characteristic of the blood in shock is a high capillary red count... When haemorrhage as a complicating factor tending to reduce the blood count is considered, these high counts are striking. They indicate that in shock a concentration of the blood occurs, at least in the superficial capillaries.*

—Walter Bradford Cannon, J Fraser, AN Hooper, 1918

### CHAPTER OUTLINE

- ❖ Shock
- ❖ Stages of Shock
- ❖ Effects of Shock
- ❖ Clinical Features of Shock
- ❖ Assessment, Investigations and Monitoring
- ❖ Investigations in Shock
- ❖ Central Venous Pressure
- ❖ Pulmonary Capillary Wedge Pressure
- ❖ Systemic Inflammatory Response Syndrome
- ❖ Multiple Organ Dysfunction Syndrome
- ❖ Oxygen Therapy
- ❖ Topical O<sub>2</sub> Therapy
- ❖ Cardiac Arrest

### SHOCK

Shock is a state of poor perfusion with impaired cellular metabolism manifesting with severe pathophysiological abnormalities. It is due to circulatory collapse and tissue hypoxia. Normal *aerobic metabolism* is not maintained due to hypoperfusion. Shock is meant by '*inadequate perfusion*' to maintain normal organ function.

At *cellular level* hypoxia causes change of normal aerobic to anaerobic metabolism causing lactic acidosis. Intracellular potassium is released into circulation. Lysosomes from cells get released into blood causing cell lysis. *Hypoxia and acidosis* through complements release free oxygen radicals and cytokines which damage capillary endothelium. Eventually cardiovascular, respiratory, renal, endocrine and GIT will be affected presenting as *systemic* features.

#### Causes of shock

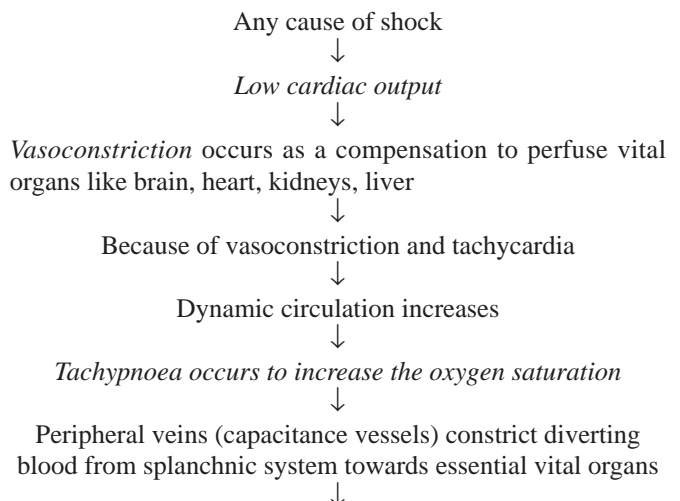
- 1. Hypovolaemic shock**—due to reduction in total blood volume. It may be due to:
  - a. *Haemorrhage*
    - External from wounds, open fractures
    - Internal from injury to spleen, liver, mesentery or pelvis
  - b. *Severe burns*, which results in loss of plasma
  - c. Peritonitis, intestinal obstruction
  - d. Vomiting and diarrhoea of any cause
- 2. Cardiac causes**
  - a. Acute myocardial infarction, acute carditis
  - b. Acute pulmonary embolism wherein embolus blocks the pulmonary artery at bifurcation or one of the major branches
  - c. Drug induced
  - d. Toxaemia of any causes
  - e. Cardiac surgical conditions like valvular diseases, congenital heart diseases
  - f. Cardiac compression causes
    - i. Cardiac tamponade due to collection of blood, pus, fluid in the pericardial space which prevents the heart to expand leading to shock.
    - ii. Trauma to heart
- 3. Septic shock**—is due to bacterial infections which release toxins leading to shock

Contd...

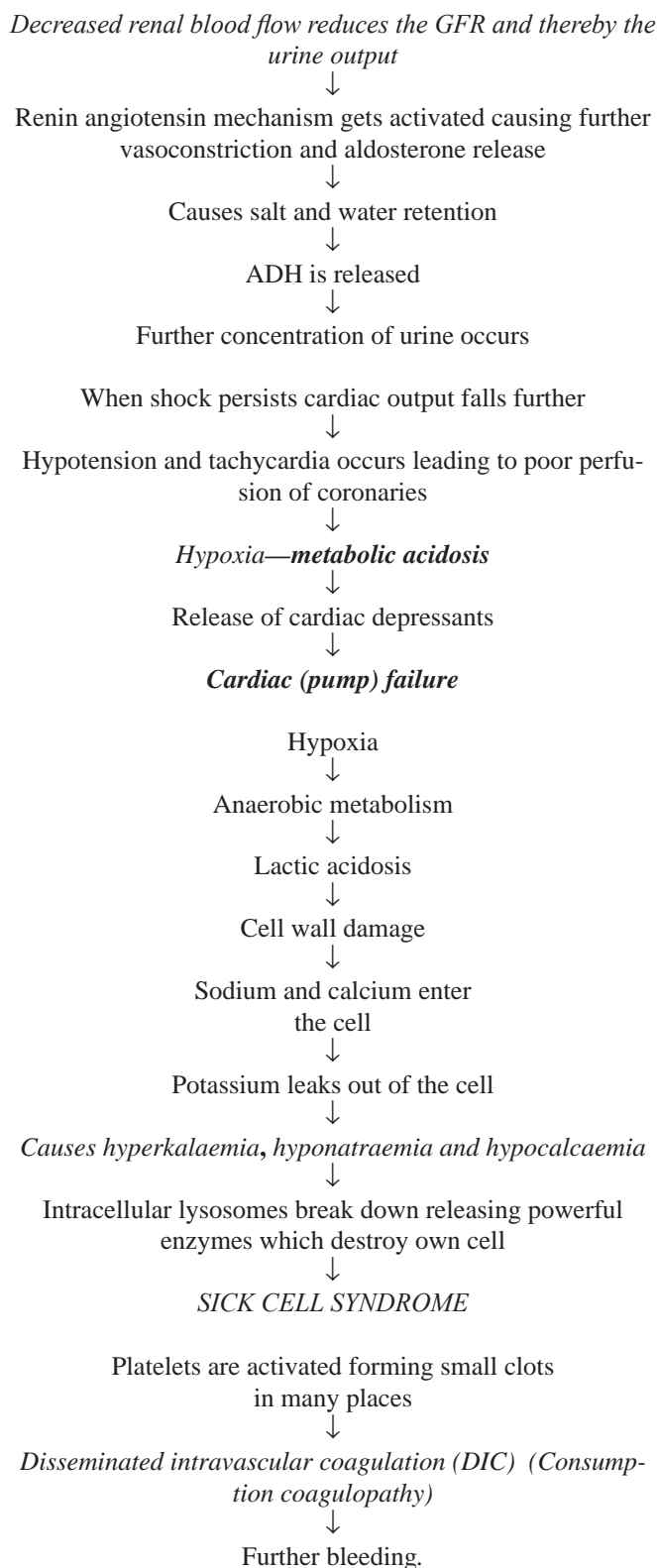
- 4. Neurogenic shock**—due to sudden anxious or painful stimuli causing severe splanchnic vessel vasodilatation. Here, patient either goes for cardiac arrest and dies or recovers fully spontaneously—spinal cord injury/anaesthesia can cause neurogenic shock
- 5. Anaphylactic shock**—is due to Type 1 hypersensitivity reaction
- 6. Respiratory causes**
  - a. Atelectasis (collapse) of lung
  - b. Thoracic injuries
  - c. Tension pneumothorax
  - d. Anaesthetic complications
- 7. Other causes**
  - a. Acute adrenal insufficiency (Addison's disease)
  - b. Myxoedema

Shock may be *hypovolaemic, cardiogenic, obstructive, distributive or of endocrine* variety.

### Pathophysiology of Shock



Contd...



## ■ STAGES OF SHOCK

Factors like infection, trauma, burns, haemorrhage, hypovolaemia

↓

Hypoxia and its effects.

↓

**SIRS** (*Systemic inflammatory response syndrome*) is due to vasodilatation, increased endothelial permeability, thrombosis, leucocyte migration and activation.

↓

All these lead to altered cytokines level, abnormal **NO (nitric oxide)** synthesis, abnormal arachidonic acid metabolism, neutrophil activation, free radical production, altered complement activation, failure to have a localisation of inflammation. It is severe type of **reversible shock**.

↓

Which will lead to established microvascular occlusion, cellular dysfunction, sick cell syndrome, DIC and PUMP failure.

↓

**MODS** (*Multiorgan dysfunction syndrome*) (**Irreversible shock**)—of lungs, kidneys, liver, clotting system and brain.

### Stages of shock

Stage 1	Stage of compensatory shock by neuroendocrine response to maintain the perfusion of the vital organs like brain, heart, kidney, liver.
Stage 2	Stage of decompensatory shock where there is progressive shock causing persistent shock with severe hypotension (with mean arterial pressure < 65 mmHg); oliguria, tachycardia.
Stage 3	Stage of irreversible shock with severe hypoxia and MODS.

### Note:

- *Distributive shock* is one in which there is vasodilatation, decreased vascular resistance, hypotension, altered micro-vascular perfusion with arteriovenous shunting, altered cellular oxygen metabolism. It is seen in septic shock, spinal trauma, adrenal crisis and anaphylaxis.
- *Obstructive shock* occurs due to mechanical impediment of circulation due to pulmonary embolism, tension pneumothorax or cardiac tamponade.

## ■ EFFECTS OF SHOCK

**Heart:** Low perfusion → low venous return → decreased cardiac output → hypotension → tachycardia. Persistent shock causes hypoxia and release of myocardial depressants leading to further cardiac damage.

**Lung:** Interstitial oedema → decreased gaseous exchange → pulmonary arteriovenous shunting → tachypnoea → *Adult/Acute respiratory distress syndrome (ARDS)* and pulmonary oedema.

**Metabolic:** Shock leads to hypoxia, which activates anaerobic metabolism leading to lactic acidosis. Antidiuretic hormone (ADH) is released which increases the reabsorption of water from renal tubules. Other hormones released are ACTH, prostaglandins, histamine, bradykinin, and serotonin to compensate the effects of shock to increase the perfusion of vital organs like heart, brain and lungs.

**Cellular changes** occur in persistent shock due to release of lysosomal enzymes, which alters the cell membrane permeability causing cell death—*sick cell syndrome*.

*Ideas have a short shelf life—that's why we must act before the expiry date.*

**Sympathetic overactivity** alters the microcirculation leading to capillary dysfunction.

**Brain** perfusion, when decreases the patient becomes drowsy. *Brain is the last organ to get underperfused in shock.*

**Kidneys:** GFR decreases and tubular reabsorption of salt and water increases for compensatory response. But in severe cases tubular necrosis sets in leading into irreversible damage.

**Blood:** Alteration in cellular components including platelets leads to *Disseminated intravascular coagulation (DIC)*. It causes bleeding from all organs.

**Gastrointestinal tract:** Mucosal ischaemia develops causing bleeding from GIT with haematemesis and malaena. It is aggravated by DIC. Hepatic ischaemia leads into increased enzyme levels.

## Types of Shock

### 1. Vasovagal Shock

It is sudden dilatation of peripheral and splanchnic vessels causing reduced cardiac output and shock. Often it may be life-threatening due to hypoxia.

### 2. Neurogenic Shock

- ◆ It is usually due to spinal cord injury, which causes dilatation of splanchnic vessels.
  - ▶ This type can safely be treated with vasoconstrictor drugs to bring up the blood pressure. There will be bradycardia, hypotension, arrhythmias, and decreased cardiac output. Blood pressure control, oxygen delivery, maintenance of haemodynamics, airway, fluid therapy, intravenous methylprednisolone therapy should be done. Dopamine and or phenylephrine ( $\alpha$  agonist) can be used.

### 3. Hypovolaemic Shock—Most Common Type

- ◆ Haemorrhage, may be due to injury to the liver, spleen, bone fractures, haemothorax, vascular injury, severe bleeding on table during surgeries of thyroid, liver, portal vein or major vessels.
- ◆ Vomiting, diarrhoea due to any cause.
- ◆ Burns.

#### Types of Hypovolaemia

- a. **Covert compensated hypovolaemia (Mild <15%):** When blood volume is reduced by 10-15%, there will not be significant change in heart rate, cardiac output and splanchnic blood compensates for the same.
- b. **Overt compensated hypovolaemia (Moderate 15-40%):** Here patient has cold periphery, tachycardia, a wide arterial pressure, tachypnoea, confusion, hyponatraemia, metabolic acidosis, but systolic pressure is well-maintained but postural hypotension.
- c. **Decompensated hypovolaemia (Severe >40%):** Here all features of hypovolaemia are present like hypotension, tachycardia, sweating, tachypnoea, oliguria, drowsiness, eventually features of SIRS is seen and often if not treated on time leads to MODS, i.e. irreversible shock.

### 4. Cardiogenic Shock

- ◆ *Cardiogenic shock* is defined as circulatory failure causing diminished forward flow leading into tissue hypoxia in the setting of adequate intravascular volume with systolic blood pressure <90

mmHg for 30 minutes; cardiac index <2.2 L/minute/sq metre; raised PCWP (pulmonary capillary wedge pressure) >15 mmHg. It is commonly seen in acute MI with a mortality >50%.

- ▶ Cardiogenic shock develops within 24 hours of MI. It occurs when 50% of left ventricular wall is damaged by infarction.
- ▶ It leads to pulmonary oedema and severe hypoxia. Ischaemic necrosis of left ventricular wall causes failure of pump thereby decreasing stroke volume.

*Diagnosis* is established by *ECG*, echocardiography, arterial blood gas analysis, *cardiac enzymes*, *PCWP* and electrolyte estimation (hypokalaemia and hypomagnesaemia are common) are the essential investigations.

## Management

- ◆ Proper oxygenation with intubation, ventilator support, cardioversion, pacing, antiarrhythmic drugs, correction of electrolytes, avoiding fluid overload, prevention of pulmonary oedema as immediate measures.
- ◆ Dobutamine ( $\beta_1$  receptor agonist) is used to raise cardiac output provided there is adequate preload and intravascular volume (it is peripheral vasodilator and reduces BP). Dopamine is preferred in patients with hypotension. But it may increase peripheral resistance and heart rate worsening cardiac ischaemia. Often both dopamine and dobutamine combination may be required.
- ◆ Careful judicious use of epinephrine, norepinephrine, phosphodiesterase inhibitors (amrinone, milrinone) are often needed. Anticoagulants and aspirin are given. Thrombolytics can be used.  $\beta$  blockers, nitrates (nitroglycerine causes coronary arterial dilatation), ACE inhibitors are also used.
- ◆ *Intra-aortic balloon pump (IABP)* may need to be introduced transfemorally as a mechanical circulatory support to raise cardiac output and coronary blood flow.
- ◆ Relief of pain, preserving of remaining myocardium and its function, maintaining adequate preload, oxygenation, minimizing sympathetic stimulation, correction of electrolytes should be the priorities.
- ◆ Percutaneous transluminal coronary angioplasty (*PTCA*) and coronary artery bypass graft (*CABG*) are the final choices.

### 5. Cardiac Compression Shock

- ◆ It is probably due to pericardial tamponade of any cause or kinking of great vessels, massive pulmonary embolism, tension pneumothorax, air embolism causes obstructive shock with reduced preload to heart.
- ◆ Acute massive pulmonary embolism from a thrombus or an air embolism (*50 ml of air*), obstructing more than 50% of pulmonary vasculature leads to severe shock and sudden death.
- ◆ Tachycardia, hypotension, pulmonary oedema, raised JVP, gallop rhythm are the features.

### 6. Septic Shock

- ◆ Septic shock may be due to gram-positive organisms, gram negative organisms, fungi, viruses or protozoal origin.
- ◆ Gram-negative septicaemia/gram-negative septic shock is called as *endotoxic shock*. It occurs due to gram-negative bacterial infections, commonly seen in strangulated intestines, peritonitis, gastrointestinal fistulas, biliary and urinary infections, pancreatitis, major surgical wounds, diabetic wounds and crush injuries.

Gram-positive septic shock	Gram-negative septic shock
<ul style="list-style-type: none"> <li>• Due to exotoxin by gram +ve bacteria like <i>Clostridium tetani/welchii</i>, staphylococci, streptococci pneumococci</li> <li>• Fluid loss, hypotension is common; with normal cardiac output</li> </ul>	Gram negative bacteria cause endotoxaemia and its effects. Urinary/gastrointestinal/biliary and respiratory foci are common

### Pathophysiology of septic shock

Toxins/endotoxins from organisms like *E. Coli*, *Klebsiella*, *Pseudomonas*, and *Proteus*



Inflammation, cellular activation of macrophages, neutrophils, monocytes



Release of cytokines, free radicals



Chemotaxis of cells, endothelial injury, altered coagulation cascade—SIRS



*Reversible hyperdynamic warm stage* of septic shock with fever, tachycardia, tachypnoea



Severe circulatory failure with MODS (failure of lungs, kidneys, liver, heart) with DIC



*Hypodynamic, irreversible cold stage* of septic shock.

- ◆ Septic shock is typically a *vasodilatory shock* wherein there is peripheral vasodilatation causing hypotension which is resistant to vasopressors. This is due to toxin induced release of isoform of nitric oxide synthetase from the vessel wall which causes sustained prolonged release of high levels of nitric oxide.
- ◆ Magnitude of infection is quantified as:
  1. *Sepsis* which shows fever, tachycardia, leucocytosis.
  2. *Severe sepsis* which shows low tissue perfusion with organ dysfunction (lactic acidosis, dysfunction of liver, kidney, lungs).
  3. *Septic shock* with systemic hypotension (BP < 90 mmHg in spite adequate fluid therapy), severe organ dysfunction (acute lung, kidney, liver injury), maldistribution of blood flow, shunting in microcirculation.

### Stages of septic shock

#### a. *Hyperdynamic (warm) shock*:

This stage is *reversible stage*. Patient is still having inflammatory response and so presents with fever, tachycardia, and tachypnoea. Pyrogenic response is still intact. Patient should be treated properly at this stage. Based on blood culture, urine culture (depending on the focus of infection), higher antibiotics like third generation cephalosporins, aminoglycosides, metronidazole are started. The underlying cause is treated like draining the pus, laparotomy for peritonitis, etc.

Ventilatory support with ICU monitoring may prevent the patient going for the next *cold stage of sepsis*.

#### b. *Hypodynamic hypovolaemic septic shock (cold septic shock)*:

Here pyrogenic response is lost. Patient is in decompensated shock. It is an irreversible stage along with MODS (Multi-organ dysfunction syndrome) with anuria, respiratory failure (cyanosis), jaundice (liver failure), cardiac depression, pulmonary oedema, hypoxia, drowsiness, eventually coma and death occurs (*Irreversible stage*).

### Treatment of septic shock

- ◆ Correction of fluid and electrolyte by crystalloids, blood transfusion. *Perfusion* is very/most important.
- ◆ Appropriate antibiotics—third generation cephalosporins/aminoglycosides.
- ◆ Treat the cause or focus—drainage of an abscess; laparotomy for peritonitis; resection of gangrenous bowel; wound excision.
- ◆ Pus/urine/discharge/bile/blood culture and sensitivity for antibiotics.
- ◆ Critical care, oxygen, ventilator support, dobutamine/dopamine/noradrenaline to maintain blood pressure and urine output.
- ◆ Activated C protein prevents the release of inflammatory mediators and blocks the effects of these mediators on cellular function.
- ◆ Monitoring the patient by pulse oximetry, cardiac status, urine output, arterial blood gas analysis.
- ◆ *Short-term (one or two doses) high dose steroid therapy* to control and protect cells from effects of endotoxaemia. It improves cardiac, renal and lung functions. Single dose of methylprednisolone or dexamethasone which often may be repeated again after 4 hours is said to be effective in endotoxic shock.

### Septic shock

- ❖ Common causes are biliary, urinary, GIT sepsis (peritonitis, strangulation), respiratory (pneumonia)
- ❖ Common bacteria are *E. coli*, *Klebsiella*, *Pseudomonas*
- ❖ Common pathophysiologies are release of toxins, neutrophil activation, cytokine release, and sick cell syndrome, SIRS, MODS
- ❖ Clinical stages are hyperdynamic and hypodynamic
- ❖ Find out the source of the infection by US, CT scan
- ❖ Do pus/blood/urine culture
- ❖ Start antibiotics of high generations like ceftazidime, amikacin, cefoperazone
- ❖ Dopamine/dobutamine infusion (slow)
- ❖ Monitoring by pulse, BP, respiration, urine output, level of consciousness
- ❖ Ventilator support, ICU management
- ❖ Treat the causes like peritonitis, abscess

### 7. Anaphylactic Shock

Injections—penicillins, anaesthetics, stings, venom, shellfish may be having antigens which will combine with IgE of mast cells and basophils, releasing histamine and large amount of SRS-A (Slow releasing substance of anaphylaxis). They cause bronchospasm, laryngeal oedema, respiratory distress, hypotension and shock. Mortality is 10%.

*Rashes all over the body are commonly observed.*

*Tears shed for self are tears of weakness, but tears shed for others is a sign of strength.*

### Anaphylactic shock

- ❖ Sudden onset
- ❖ Distributive shock
- ❖ Bronchospasm, laryngeal oedema
- ❖ Generalised rashes and oedema
- ❖ Hypotension, feeble pulse
- ❖ Mortality 10%
- ❖ To start adrenaline 100 ug IV, steroids, IV fluids, oxygen with foot end elevation
- ❖ Ventilator in severe cases
- ❖ Cardiac massage, defibrillation

## CLINICAL FEATURES OF SHOCK (HYPOVOLAEMIC SHOCK)

- ◆ *In early stage*—tachycardia, sweating, cold periphery, hypotension, restlessness, air hunger, tachypnoea, oliguria, collapsed veins.
- ◆ *In late stage*—cyanosis, anuria, jaundice, drowsiness.

### Clinically shock may be:

- ◆ *Compensated* with mild tachycardia, normal blood pressure, urine output, normal respiration and mild lactic acidosis.
- ◆ *Mild shock* with mild lactic acidosis, tachycardia, tachypnoea and anxiousness.
- ◆ *Moderate shock* with significant lactic acidosis, decreased urine, tachycardia, tachypnoea, drowsiness, and mild hypotension.
- ◆ *Severe shock* with severe lactic acidosis, anuria, tachypnoea with gasping, severe tachycardia, profound hypotension and unconsciousness.

### Note:

- Shock index is ratio of pulse rate to blood pressure; normal shock index is < 1. In shock it reverses.
- Tachycardia, tachypnoea, oliguria, hypotension are typical features in shock.

### Complications of shock

- ❖ Acute respiratory distress syndrome and respiratory failure
- ❖ Acute renal failure
- ❖ Hypoxia, metabolic acidosis
- ❖ Stress ulcers, ileus, liver failure
- ❖ Disseminated intravascular coagulation (DIC) and thrombocytopenia
- ❖ Systemic inflammatory response syndrome and multiorgan dysfunction syndrome (MODS)

## ASSESSMENT, INVESTIGATIONS AND MONITORING

- ◆ *Regular monitoring* with blood pressure, pulse, heart rate, respiratory rate, urine output measurement (hourly) should be done. Urine output should be more than 0.5 ml/kg/hour. Pulse oximetry should be used.
- ◆ *Central venous pressure (CVP—only have gross assessment), pulmonary capillary wedge pressure (PCWP—an accurate assessment of left ventricular function)* monitoring should be done. ICU care is needed during monitor period. But both CVP and PCWP are not accurate method of assessing tissue perfusion.
- ◆ Complete blood count, ESR, pH assessment, serum electrolyte estimation, chest X-ray (to rule out ARDS/pulmonary problems).

- ◆ Pus/urine/blood/bile/sputum cultures depending on the focus and need in sepsis.
- ◆ *Serum lactate estimation* is an important prognostic factor. Level >2 mEq/L suggest tissue ischaemia.
- ◆ USG of part, CT/MRI of the location of the pathology of the septic focus should be done; often may require repetition of these imaging to assess progress.
- ◆ Blood urea, serum creatinine, liver function tests, prothrombin time (PT), activated partial thromboplastin time (APTT), ECG monitoring are also should be done.
- ◆ All these tests including *platelet count and arterial blood gas analysis (ABG)* should be repeated at regular intervals.

## Treatment of Shock

### Guidelines

- ❖ *To treat the cause*
- ❖ *To improve cardiac function*
- ❖ *To improve tissue perfusion*

### Treatment of shock

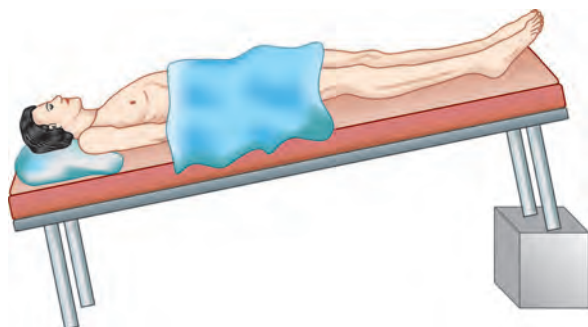
- ❖ First stabilize the patient with initial resuscitation
- ❖ Next evaluate the patient for cause and severity
- ❖ Lastly treat the specific cause to achieve cure

- ◆ Treat the cause, e.g. arrest haemorrhage, drain pus.
- ◆ **Fluid replacement:**
  - ▶ Plasma, normal saline, Ringer's lactate, plasma expander (haemaccel) (maximum 1 litre can be given in 24 hours).
  - ▶ Initially *crystalloids* then colloids are given. Blood transfusion is done whenever required.
  - ▶ *Fluid therapy* is ideally done with crystalloids like normal saline, *Ringer's lactate*, *Hartmann's solution*. Blood loss should be corrected by blood transfusion only. Crystalloids and colloids do not have O<sub>2</sub> carrying capacity. Hypotonic solutions like dextrose are poor volume expanders and so should not be used in shock.
  - ▶ *Dynamic fluid response* is studied by infusing 500 ml of fluid rapidly in 10 minutes. *Responders* show improvement; *transient responders* show improvement temporarily but revert back to original status probably due to still existing fluid/blood loss or still existing fluid shift from intravascular space; *nonresponders* will not respond as fluid loss is severe and persistently ongoing.
- ◆ *Inotropic agents*: Dopamine, dobutamine, adrenaline infusions—mainly in distributive shock like septic shock.

### Note:

- ❖ Dopamine improves renal and splanchnic blood
- ❖ Dobutamine improves the cardiac output
- ❖ Adrenaline/Levaterenol IV in anaphylaxis
- ❖ Amrinone and milrinone are newer inotropic drugs

- ◆ *Correction of acid-base balance*: Acidosis is corrected by using 8.4% sodium bicarbonate intravenously.
- ◆ *Steroid* is often life-saving. 500–1000 mg of hydrocortisone can be given. It improves the perfusion, reduces the capillary



**Fig. 1.207:** Trendelenburg position—head down position, used in patient in shock.

leakage and systemic inflammatory effects.

- ◆ *Antibiotics* in patients with sepsis; proper control of blood sugar and ketosis in diabetic patients.
- ◆ *Catheterisation* to measure urine output (30–50 ml/hour or >0.5 ml/kg/hour should be maintained).
- ◆ *Nasal oxygen* to improve oxygenation or ventilator support with intensive care unit monitoring has to be done.
- ◆ *CVP line* to perfuse adequately and to monitor fluid balance. TPN is given when required.
- ◆ PCWP to monitor very critical patient.
- ◆ Haemodialysis may be necessary when kidneys are not functioning.
- ◆ Control pain-using morphine (4 mg IV).
- ◆ Ventilator and ICU/critical care management.
- ◆ Injection ranitidine IV or omeprazole IV or pantoprazole IV.
- ◆ *Activated C protein* even though costly is beneficial as it prevents the release and action of inflammatory response.
- ◆ *MAST (military antishock trouser)*: Provides circumferential external pressure of 40 mmHg. It is wrapped around lower limbs and abdomen, and inflated with required pressure. It redistributes the existing blood and fluid towards centre. It should be deflated carefully and gradually.

## Remember

- ◆ Response to dynamic fluid therapy can be checked in patient in shock by perfusing 500 ml of fluid rapidly in 10 minutes and patient is checked as nonresponder/transient only initial responder or proper responder.
- ◆ Vasopressor like dobutamine is used only in distributive shock like due to sepsis (not in hypovolaemic, haemorrhagic shock where there is low preload).
- ◆ Intubation and ventilator may be needed in shock.
- ◆ The patient is monitored with ECG, pulse oximetry, blood pressure/invasive blood pressure, CVP/PCWP, urine output, pupillary reaction (dilated or not), serum electrolytes, arterial PO<sub>2</sub> and PCO<sub>2</sub> analysis.

## CENTRAL VENOUS PRESSURE (CVP)

It is a method to measure the right atrial pressure by placing a venous catheter (20 cm) into the SVC (superior vena cava). Commonly for CVP monitoring, a venous catheter is passed through internal jugular vein or infraclavicular subclavian vein

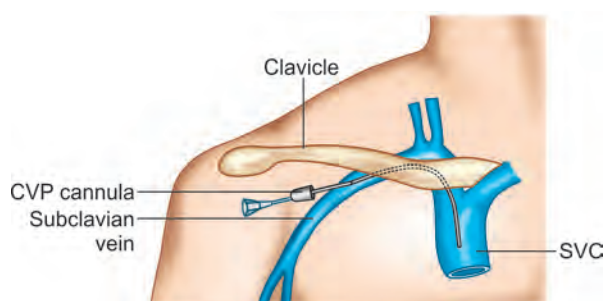
to the SVC (used for TPN purpose). Occasionally a long catheter (60 cm) can be passed through basilic vein (not commonly done). Under radiological guidance, initially a needle is passed 3 cm above the medial end of the clavicle, in the hollow between the two heads of sternomastoid muscles, directing towards the suprasternal notch into the right internal jugular vein. Then through a guide wire, a venous catheter is passed into the SVC through right internal jugular vein, which can also be confirmed by changes in flow during inspiration and expiration.

Catheter is connected to saline manometer, taking manubriosternal angle (angle of Louis) as zero point.

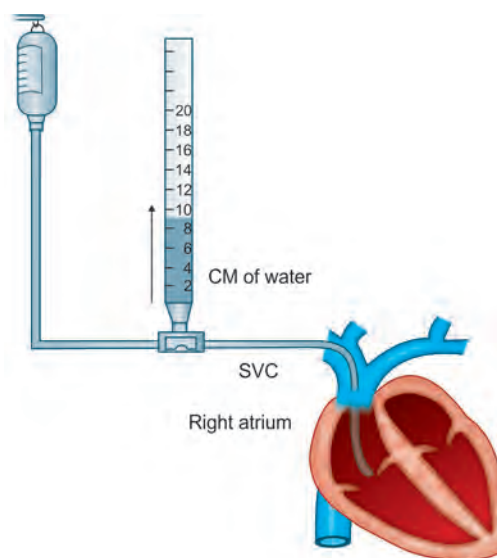
Normal value is 2–10 cm of saline.

If less than 2 cm, more fluid is infused.

If more than 10 cm, fluid infusion should be restricted.



**Fig. 1.208:** CVP cannula. Note the location of tip of CVP line in the SVC (or can be in the right atrium).



**Fig. 1.209:** CVP line for monitoring and perfusing the patient in shock.

### Complications of CVP

- ❖ Pneumothorax
- ❖ Haemothorax
- ❖ Injury to brachial plexus and vessels
- ❖ Bleeding
- ❖ Sepsis
- ❖ Catheter displacement

## PULMONARY CAPILLARY WEDGE PRESSURE (PCWP)

It is a better indicator of circulating blood volume and left ventricular function.

Catheter used is *Swan Ganz* triple channel pulmonary artery balloon catheter.

### It is used to:

- ❖ Differentiate right and left ventricular failure, pulmonary embolus, septic shock
- ❖ To measure and monitor cardiac output during the use of inotropic agents, vasodilators and fluid therapy

## Procedure

Under strict aseptic precaution, using cannula and guide wire, catheter is passed through internal jugular vein, into the right atrium. Balloon is inflated by 1.5 ml of air and then negotiated into pulmonary artery, until it reaches a small branch and wedges it. Pressure at this point is called as *pulmonary capillary wedge pressure*.

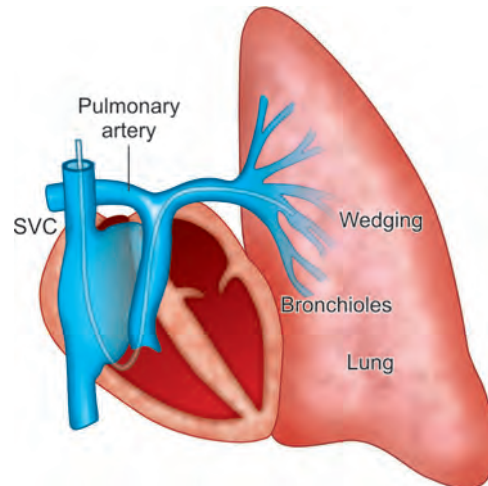
PCWP normally is 8–12 mmHg, considering mid axillary point as zero reference point.

After that, balloon is deflated to get pulmonary artery pressure which is normally 25 mmHg systolic and 10 mmHg diastolic.

PCWP catheter can be kept *in situ* only for 72 hours.

### Complications

- ❖ Arrhythmias
- ❖ Pulmonary artery rupture
- ❖ Balloon rupture
- ❖ Pulmonary infarction
- ❖ Pneumothorax
- ❖ Haemothorax
- ❖ Bleeding, sepsis, thrombosis



**Fig. 1.210:** Pulmonary capillary wedge pressure. Note the wedged balloon in the tip of the venous catheter in the pulmonary arteriole.

## SYSTEMIC INFLAMMATORY RESPONSE SYNDROME (SIRS)

- ❖ *SIRS* is systemic manifestations of inflammation due to variety of causes like infection, pancreatitis, polytrauma, burns, transfusion reaction, and malignancy. So it is often categorised as *infectious cause SIRS* or *noninfectious cause SIRS*. It causes either hyperthermia (>38°C) or hypothermia (<36°C); tachycardia (pulse >90/minute); tachypnoea (>20/minute); total white cell count >12,000/cu mm, or count <4000/cu mm.
- ❖ It is final common pathway in shock due to any cause (trauma, sepsis, endotoxaemia, burns) where there is failure of inflammatory localisation with vasodilatation, increased endothelial permeability with damage, thrombosis, leucocyte migration and activation.
- ❖ It is associated with release of free radicals, abnormal arachidonic acid release, cytokine release, neutrophil sequestration, abnormal NO synthesis, complement activation, DIC.

### Differences between CVP and PCWP

CVP	PCWP
1. Technically easier	1. Requires skilled experts
2. Normal pressure is 2–10 cm of saline	2. 8–12 mmHg
3. Gives gross idea about fluid balance	3. Better and specific
4. Left ventricular function is not assessed	4. Left ventricular function is very well-assessed
5. Not used to differentiate between right and left ventricular function	5. Very well-differentiated
6. Can be kept <i>in situ</i> as long as desired	6. Cannot be kept <i>in situ</i> for more than 72 hours
7. Catheter tip is in SVC	7. Catheter tip is in pulmonary capillary with wedging
8. Plain tip catheter	8. 1.5 ml air filled balloon tip
9. Can be used for TPN, fluid infusion, etc.	9. Can not be used for TPN, or fluid infusion
10. Complications are easy to tackle	10. Often difficult to tackle
11. Not as sensitive and specific as PCWP	11. Sensitive and specific

- ◆ It is a part of severely decompensated *reversible shock* which eventually leads to MODS (Multiorgan dysfunction syndrome), a state of *irreversible shock* wherein patient is anuric, drowsy, cold and terminally ill.
- ◆ SIRS carries poor prognosis.

## MULTIPLE ORGAN DYSFUNCTION SYNDROME (MODS)

- ◆ It is progressively becoming irreversible injury of all tissues like *kidney, lungs, liver, GIT*. Lungs and liver are commonly involved (70%). Next organs to be involved are kidney and GIT. Order of involvement of organs in MODS is—lungs → right ventricular failure → liver → kidney. But mortality is higher if kidney and lungs are involved.
- ◆ It occurs in critically ill patient after severe trauma, burns, acute pancreatitis, bleeding and sepsis.
- ◆ It is more common in elderly, diabetic, smokers, alcoholics, cirrhosis, malnutrition, patients under steroids and cytotoxic drugs, and uraemia.
- ◆ Multiple features related to multiple organ dysfunctions are typical. Oliguria, jaundice, hypotension, drowsiness, respiratory distress are common.
- ◆ Platelet microaggregation, acute pulmonary hypertension, ARDS, DIC, circulatory failure with reduced total oxygen utilization in spite of adequate oxygen supply, impaired defense mechanism are the pathogenetic features.
- ◆ Respiratory, renal, hepatic, circulatory, coagulative and cardiac failure occurs as an end stage MODS.
- ◆ *Primary MODS* is due to a well defined cause like pulmonary contusion, rhabdomyolysis, multiple transfusions.
- ◆ *Secondary MODS* occurs as a result of host response in SIRS.
- ◆ *Management* of MODS is critical care in ICU with ventilator support, haemodialysis, transfusions, antibiotics, proper nutrition in the form of TPN or enteral. MODS stage has got high mortality.

## OXYGEN THERAPY

### Indications

1. Chest injuries, any severe haemorrhage.
2. Gas gangrene with toxic haemolysis.
3. Coal gas poisoning.
4. Over morphinisation.
5. Pulmonary embolism and fat embolism.
6. Spontaneous pneumothorax, pulmonary oedema, cardiac infarction, pneumonia, cor pulmonale.
7. Cardiogenic shock and acute bronchitis.
 

27% oxygen is delivered through ventimask (disposable polythene mask) at a rate of 4–6 litres per minute. Oxygen is also given along with positive pressure ventilation.

## HYPERBARIC OXYGEN

It is administration of oxygen 1 or 2 atmospheres above the atmospheric pressure in a compression chamber. It increases the arterial oxygen saturation so that oxygen perfusion of tissues will be increased.

### Indications

1. Carbon monoxide poisoning.
2. Tetanus, gas gangrene infections.

3. Bedsores, frostbites, necrotising fasciitis.
4. Drenching in paralytic ileus to reduce the nitrogen gas in distended bowel.
5. As a radiosensitizer in the treatment of cancer.

## Complications

- ◆ Cerebral gas embolism.
- ◆ Rupture of tympanic membrane.
- ◆ Visual defects.
- ◆ O<sub>2</sub> toxicity.
- ◆ CO<sub>2</sub> narcosis.
- ◆ Respiratory depression.

## Contraindications

- ◆ Asthma/emphysema.
- ◆ High fever.
- ◆ Chronic sinusitis.
- ◆ Viral infection.
- ◆ Pregnancy.

## TOPICAL O<sub>2</sub> THERAPY

H<sub>2</sub>O<sub>2</sub> to release nascent oxygen in ulcers and abscess.

## CARDIAC ARREST

*It is the cessation of the heart. Heart stops contracting.*

**Causes:** All causes for shock.

### Features of cardiac arrest

- ❖ No palpable pulse
- ❖ Heart sounds not heard
- ❖ Cessation of respiration—cyanosis occurs
- ❖ Development of unconsciousness
- ❖ Pupils start dilating

## Critical Period

Once heart and lungs stop, *brain death occurs in 3 minutes.*

### Immediate measures

- ❖ **A**irway
- ❖ **B**reathing
- ❖ **C**ardiac compression
- ❖ **D**rugs and **D**efibrillator
- ❖ **E**CG, **E**ndotracheal tube and **M**onitor

- a. **External cardiac compression (massage):** Patient is laid flat on a *hard surface (never on soft surface)*. Manual compression is exerted over the lower sternum using both hands one over other without bending the elbow at a rate of 60 to 70 per minute. Rib cage damage during procedure can be very well ignored (Heel of right hand is placed over the sternum 8 cm above xiphoid process and left hand is placed over it).

*Hope puts a smile on our face when the heart cannot manage.*



- b. Another person at the same time should give *mouth to mouth breathing* at a rate of 20 to 30 per minute after clearing the airway by removing froth and dentures. A bag with mask can be used to ventilate using air or oxygen.
- c. Endotracheal intubation and ventilator support.
- d. Injection of 1:10,000 adrenaline and 10% calcium chloride intravenously.
- e. Sodium bicarbonate 8.4% injection, hydrocortisone injection.
- f. Defibrillator, if there is ventricular fibrillation.
- g. Analysis of blood gas ( $PCO_2$  and  $PO_2$ ), and serum electrolytes assessment at repeated intervals.
- h. Urinary catheterization, Ryle's tube insertion.
- i. Monitoring the patient with BP, pulse, respiration, and temperature chart.

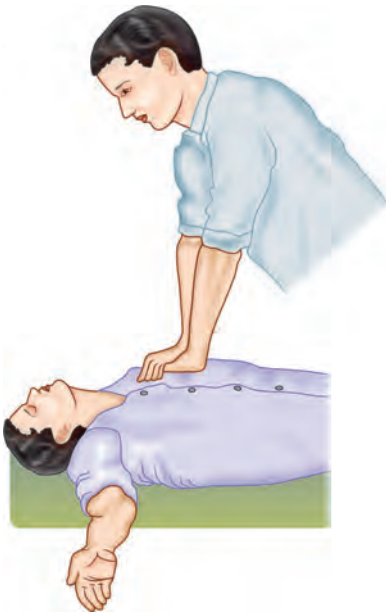

Fig. 1.211: Technique of external cardiac massage.

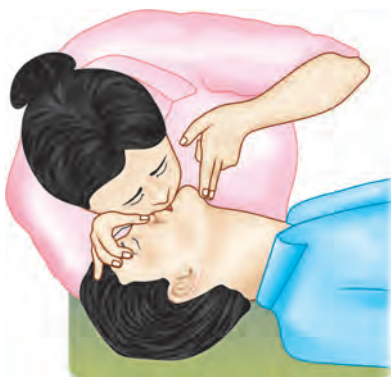

Fig. 1.212: Technique of mouth-to-mouth respiration. Note patient's nose should be held closed with right hand of the doctor/assistant and with left hand lower jaw should be pushed forward.

#### Observations to be made are:

- ❖ Groin pulse
- ❖ Respiration and breath sounds
- ❖ Blood pressure
- ❖ Pupillary reaction
- ❖ ECG activity

Once patient recovers, the cause and sequelae has to be managed properly.

#### Sequelae are due to hypoxia and circulatory collapse

- ❖ Cerebral oedema and permanent brain damage
- ❖ ARDS (Adult respiratory distress syndrome)
- ❖ Renal failure

### Internal Open Cardiac Massage

This method is used when cardiac arrest occurs in the operation theatre during surgery, acute tamponade, and acute bilateral pneumothorax.

Left side thorax is opened through a lengthy incision along 4th or 5th intercostal space. Initially heart with intact pericardium is rhythmically compressed and relaxed using left hand against sternum. Meanwhile costal cartilages above and below are cut with a knife to have a better exposure. Pericardium is opened in front of the phrenic nerve. Direct cardiac massage is undertaken until heart regains its function and later shifted to ventilatory support and critical care.

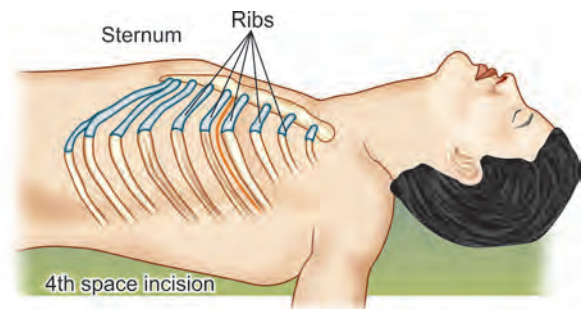


Fig. 1.213: Left thoracotomy for open internal cardiac massage.

### Defibrillation Technique (Cardioversion)

Apply gelly to the site of electrodes. One electrode at the base of heart to the right of the sternum other over the estimated area of the apex of the heart. **Ensure that nobody is in contact with the patient.** Activate the defibrillator. Resume ventilation and ECG monitor immediately. After that, monitor continuously, correct the acidosis, catheterise and observe urine output. Arrange for ICU care.



Fig. 1.214: Defibrillator used in case of cardiac arrest.

## H. Haemorrhage and Blood Transfusion

There are canals (or vessels) in it (the heart) to (every) member. Now if the priests of Sekhmet or any physician put his hands (or) his fingers (upon the head, upon the back of the) head, upon the two hands, upon the pulse, upon the two feet, (he) measures the heart, because its vessels are in the back of the head and in the pulse; and because its (pulsation is in) every vessel of every member.

—(Anonymous), Circa 2500 BC

### CHAPTER OUTLINE

❖ Haemorrhage	❖ Autologous Blood Transfusion	❖ Disseminated Intravascular Coagulation
❖ Blood Transfusion	❖ Artificial Blood	❖ Mechanism of Blood Coagulation
❖ Blood Substitutes	❖ Erythropoietin	
❖ Massive Blood Transfusion	❖ Tourniquets	

### HAEMORRHAGE

#### Classification

I. Based on the source of bleeding:

- Arterial** is bright red in colour, spurting like jet along with pulse of the patient.
- Venous** is dark red, steady and continuous flow. Blood loss may be severe and rapid when bleeding is from femoral vein, jugular vein, other major veins, varicose veins, portal vein, oesophageal varices. Pulmonary arterial blood is dark red in colour and pulmonary venous blood is bright red in colour.
- Capillary**: Here bleeding is rapid and bright red. It is often torrential due to continuous ooze.

II. Based on the time of onset of bleeding in relation to any operative procedure:

- Primary**: Occurs at the time of injury or operation.
- Reactionary**: It occurs within 24 hours after surgery or after injury (commonly in 4–6 hours).

3. **Secondary**: It usually occurs in 14 days after surgery.

Factors	Common causes
Infection	Erosion of carotid artery by cancer (secondaries in the neck)
Pressure by drain or bone	Haemorrhoidectomy
Malignancy	Inguinal block dissection

III. Based on the type of haemorrhage:

Revealed haemorrhage	Concealed haemorrhage	Initially concealed but later revealed
It is visible external haemorrhage	It constitutes internal haemorrhage	Haematuria
		Haematemesis
	• Liver injury	Melaena
	• Spleen injury	
	• Fracture femur	
	• Ruptured ectopic gestation	
	• Cerebral haemorrhage	
	• Haemothorax	

Precipitating factors	Common causes
Coughing	Thyroid surgery
Vomiting	Cholecystectomy
Straining	Major abdominal surgeries
Rise of blood pressure	Circumcision
Restlessness	Hydrocele surgery
Venous refilling during recovery from anaesthesia	Tonsillectomy
Slipping of ligature	
Clot dislodgement	

IV. Based on the duration of haemorrhage:

- Acute haemorrhage**: It is sudden, severe haemorrhage after trauma, surgery.
- Chronic haemorrhage**: It is chronic repeated bleeding for a long period like in haemorrhoids, bleeding peptic ulcer, carcinoma caecum, etc. They present with chronic anaemia with hyperdynamic cardiac failure. They are

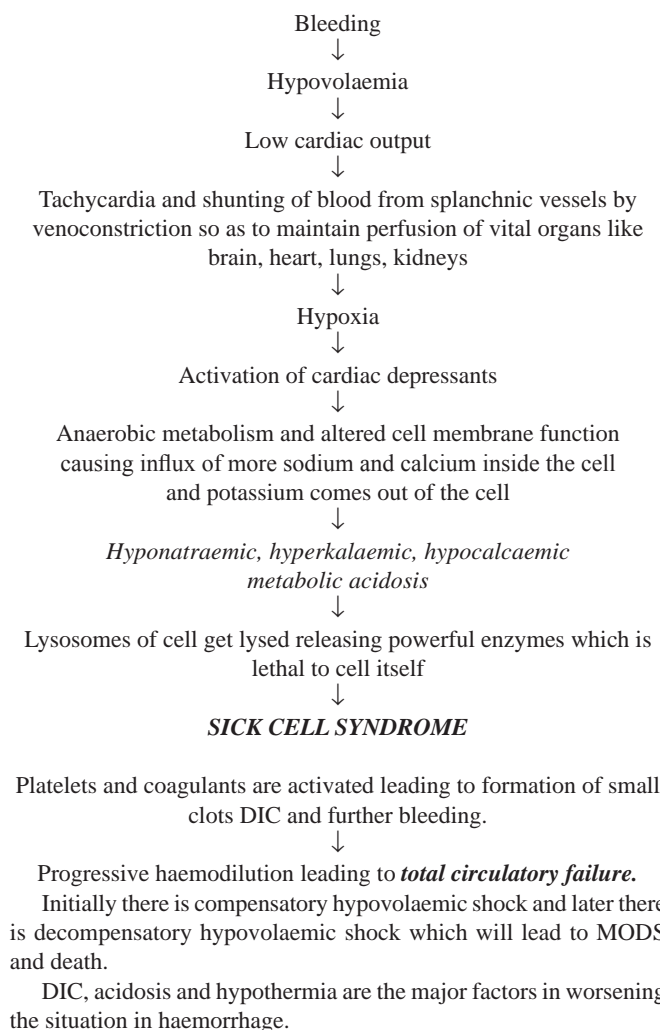
in a state of chronic hypoxia. It is corrected by *packed cell transfusion* not by whole blood itself. Cause has to be treated accordingly.

3. **Acute on chronic haemorrhage:** It is more dangerous as the bleeding occurs in individuals who are already hypoxic, which may get worsened faster.

V. Based on the possible intervention:

1. **Surgical haemorrhage**—can be corrected by surgical intervention.
2. **Nonsurgical haemorrhage**—is diffuse ooze due to coagulation abnormalities and DIC.

## Pathophysiology of Haemorrhage



## Clinical Features of Haemorrhage

- ◆ Pallor, thirsty, cyanosis.
- ◆ Tachycardia, tachypnoea.

- ◆ Air hunger.
- ◆ Cold clammy skin due to vasoconstriction.
- ◆ Dry face, dry mouth and goose skin appearance (due to contraction of arrector pili).
- ◆ Rapid thready pulse, hypotension.
- ◆ Oliguria.
- ◆ Features related to specific causes.

### Signs of significant blood loss

- ❖ Pulse > 100/minute
- ❖ Systolic BP < 100 mmHg
- ❖ Diastolic BP drop on sitting or standing > 10 mmHg
- ❖ Pallor/sweating
- ❖ Shock index (ratio of pulse rate to blood pressure) > 1 (cardiac index)

**Note:** Tachycardia is not a reliable indicator of haemorrhage.

## Measurement of Blood Loss

- ◆ Clot size of a clenched fist is 500 ml.
- ◆ Blood loss in a closed tibial fracture is 500–1500 ml; in a fracture femur is 500–2000 ml.
- ◆ Weighing the swab before and after use is an important method of on-table assessment of blood loss.

## Rains Factor

$$\left. \begin{array}{l} \text{Total amount} \\ \text{of blood loss} \end{array} \right\} \begin{array}{l} \text{Total difference in swab weight} \times 1.5 \\ = \text{or} \\ \text{Total difference in swab weight} \times 2 \\ \text{(For larger wounds and larger operations)} \end{array}$$



**Fig. 1.215:** Mops used during major surgery should be kept in a rack so that quantity of bleeding during surgery can be assessed approximately.

### Classification of haemorrhagic shock (circulatory failure)

Class	Blood loss	Features
I	Up to 15% (< 750 ml)	Normal
II	Blood loss 15–30% (750–1500 ml)	Palor, thirsty, tachycardia
III	Blood loss 30–40% (1500–2000 ml)	Hypotension, tachycardia, oliguria, confusion
IV	Blood loss > 40% (> 2000 ml)	Rapid pulse, low BP, anuria, unconsciousness, MODS

- ◆ Hb% and PCV estimation.
- ◆ Blood volume estimation using radioiodine technique or micro-haematocrit method.
- ◆ Measurement of CVP or PCWP.
- ◆ Investigations specific for cause: U/S abdomen, Doppler and often angiogram in vascular injury, chest X-ray in haemothorax, CT scan in major injuries, CT scan head in head injuries.

### Effects of haemorrhage

- ❖ Acute renal shut down
- ❖ Liver cell dysfunction
- ❖ Cardiac depression
- ❖ Hypoxic effect
- ❖ Metabolic acidosis
- ❖ GIT mucosal ischaemia
- ❖ Sepsis
- ❖ Interstitial oedema, AV shunting in lung—ARDS
- ❖ Hypovolaemic shock—MODS

### Treatment

<b>Stop the blood loss</b>	Pressure; Packing; Position and rest; operative Procedures.
<b>Restoring the lost blood</b>	Fresh whole blood transfusion; plasma expanders.

- ◆ Restoration of blood loss: By blood transfusion, albumin 4.5%, SAG-M blood, saline, haemaccel (Gelatin), dextran, plasma infusions.
 

**Note:** One unit of blood should raise 1 gm% of haemoglobin.
- ◆ Catheterisation, foot end elevation, monitoring.
- ◆ Oxygen support/intubation/ventilator and critical care.
- ◆ Pressure, packing and *head down (Trendelenburg)* position to restore BP and blood supply of brain.
- ◆ Wound exploration and proceeding, i.e. ligation of the small vessel, suturing the wound part, vessel suturing (anastomosis), excision of the tissues.
- ◆ Absolute rest, analgesics, morphine 10–20 mg IM/IV to relieve pain, sedation.
- ◆ ICT placing for haemothorax.
- ◆ Laparotomy for liver or spleen or mesentery or bowel injuries, suturing, splenectomy.
- ◆ Topical applications for local ooze—Oxycel, gauze soaked with adrenaline, bone wax for oozing from bone and other local haemostatic agents (collagen, thrombin).
- ◆ In venous haemorrhage, elevation, ligation of vein or in case of large vein suturing of venous wall, pressure bandaging, packing will be helpful.
- ◆ Tourniquet are often used in operation theatre for control of haemorrhage in limbs. But it is not advisable as a first aid measure.
- ◆ TPN, CVP monitoring, electrolyte management are all equally important.
- ◆ Steroid injection, antibiotics, ventilator support are often required.

**Note:**

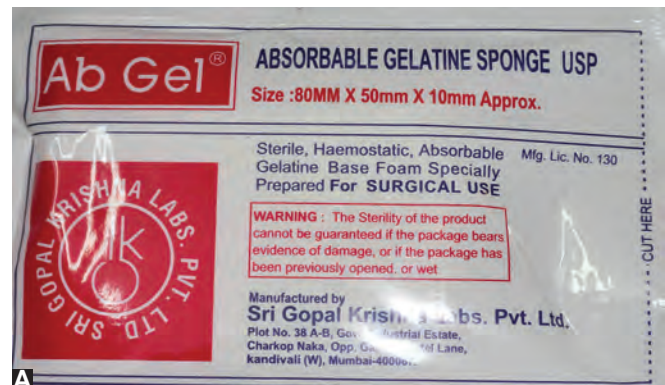Blood transfusion is required if Hb% is < 8 g%.

### Management concepts

- ❖ Confirm shock, hypovolaemia and haemorrhage by clinical assessment
- ❖ Immediate resuscitation by blood, oxygen, fluid
- ❖ Identify site of haemorrhage—ultrasound, endoscopy, CT scan, diagnostic peritoneal lavage (DPL), blood tools
- ❖ Control of haemorrhage—surgery, endoscopic control, therapeutic embolisation
- ❖ Definitive treatment if any
- ❖ Sepsis control
- ❖ Prevention of coagulopathy by FFP, platelet concentrate, fresh blood
- ❖ Critical care management
- ❖ End point resuscitation, fluid and electrolyte management, prevention of organ failure

### Local haemostatic agents

- ❖ Gelatin sponge (Gel foam)
- ❖ Oxidised cellulose (Surgicel)
- ❖ Collagen sponge (Helistat)
- ❖ Microfibrillar collagen powder (Avitene)
- ❖ Topical thrombin
- ❖ Bone wax (derived from bees wax + almond oil)
- ❖ Gelatin matrices (Flo seal)
- ❖ Topical EACA, topical cryoprecipitate



Figures 216A and B

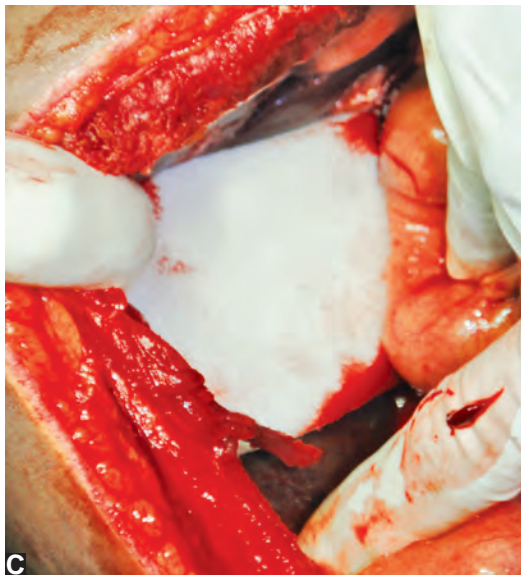


Fig. 216C

**Figs 1.216A to C:** Gel foam (gelatin sponge) is a good haemostatic agent on oozing surface like gallbladder bed after cholecystectomy.



**Fig. 1.217:** Oxidised regenerated cellulose is very good local haemostatic agent; but it is much costlier than gelatin sponge.

## BLOOD TRANSFUSION

*This noon I met with Mr (Robert) Hooke, and he tells me the dog which was filled with another dog's blood at the (Gresham) College the other day, is very well, and like to be so as ever. And doubts not its (i.e. blood transfusion) found being of great use to men.*

—Samuel Pepys, 1666

### Indications

- ◆ Acute blood loss following trauma,  $\geq 15\%$  of total body volume in otherwise healthy individuals (liver, spleen, kidney, GIT injuries, fractures, haemothorax, perineal injuries).
- ◆ During major surgeries—abdominoperineal surgery, thoracic surgery, hepatobiliary surgery.
- ◆ Following burns.
- ◆ In septicaemia.

- ◆ As a prophylactic measure prior to surgery.
- ◆ Whole blood is given in acute blood loss.
- ◆ Packed cells are given in chronic anaemia.
- ◆ Blood fractions are given in ITP, haemophilias.

### Donor Criteria

- ◆ Donor should be fit without any serious diseases like HIV1 and HIV2 and hepatitis infections and malaria.
- ◆ Weight of donor should be more than 45 kg.

### Collection of Blood

- ◆ Blood is collected in a sac containing 75 ml of CPD (Citrate phosphate dextrose) solution and stored in special refrigerators at 4 degree celcius. CPD blood lasts for 3 weeks.
- ◆ Adenosine can be added to increase the storage life of the blood up to 5 weeks; it is called as CPDA solution.
- ◆ In storage period, RBCs lose their ability to release oxygen in 7 days even though RBCs last for 3 weeks; so blood should be transfused within 7 days ideally. WBCs are destroyed in 2 days. Platelets and clotting factors are destroyed very early in 1–2 days.

#### In stored blood

- ❖ RBC's last for 3 weeks
- ❖ WBC's are destroyed rapidly
- ❖ Platelets also get reduced in 24 hours
- ❖ Clotting factors are labile and so their levels fall quickly

*After grouping and cross-matching, 540 ml of blood is transfused in 4 hours (40 drops per minute), using a filtered drip set.*

One litre of blood contains 350 mg of iron. Normal excretion of iron is 1 mg/day. Iron overload can occur after many transfusions. Iron excretion can be increased by desferrioxamine infusion.

### Blood Fractions

#### 1. Packed cells

- ▶ It is obtained by centrifuging whole blood at 2000–2300 g for 15–20 minutes.
- ▶ It is used in chronic anaemias, in old age, in children.
- ▶ It minimises the cardiac overload due to transfusion.
- ▶ It can be stored for 35 days at 1°–6°C.
- ▶ One unit contains 300 ml with haematocrit about 70%. One unit raises Hb% by 1.0 gram.

#### 2. Plasma:

- ▶ This is obtained in the same way as packed cells by centrifugation.
- ▶ It is indicated in *burns, hypoalbuminaemia, severe protein loss.*
- ▶ It can be fractionised into different fragments:
  - a. **Human albumin 4.5%** is obtained after repeated fractionations and can be stored for several months in liquid form at 4°C.
  - b. **Fresh frozen plasma (FFP):** Fresh plasma obtained, is rapidly frozen and stored at –40°C. It contains all coagulant factors. 1 unit of FFP increases the clotting factors levels by 3%. It can be stored for 2 year. Rhesus D positive FFP can be transfused to Rhesus D negative female.

#### Uses:

- Severe liver disease with abnormal coagulation function.
- Congenital clotting factor deficiency.
- Deficiency following warfarin therapy, DIC, massive transfusion.

- To maintain prothrombin time at normal level. Dose of FFP is 15 ml/kg.
- c. **Cryoprecipitate:** When fresh frozen plasma is allowed to thaw at 4°C, visible white supernatant layer develops and is called as cryoprecipitate which is rich in Factor VIII and fibrinogen. It is stored at minus 40°C and can be kept for 2 year. Cryoprecipitate is used to raise fibrinogen level at a dose to make plasma fibrinogen level 150 mg/dl. It is also used in inherited deficiency of Factor VIII, fibrinogen, Factor XIII, von Willebrand's disease.

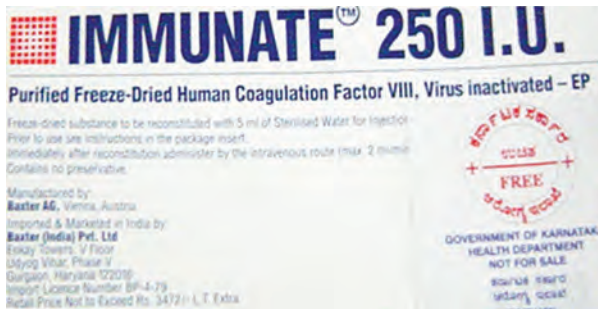


Fig. 1.218: Purified freeze dried human coagulation factor VIII is available for use in haemophilia patients.

- d. **Fibrinogen** is obtained by organic liquid fractionation of plasma and is stored in dried form. It is very useful in DIC and afibrinogenemia. It has risk of transmitting hepatitis.
  - e. **Factor VIII and IX concentrate:** They are freeze dried part from a large pooled plasma used in haemophilia and von Willebrand's disease.
3. **Platelet rich plasma:** It is obtained by centrifugation of freshly donated blood at 150–200 g for 15–20 minutes. Platelet rich plasma contains  $5.5 \times 10^9$ /L platelets in 50 ml plasma. It can be random donor platelet or single donor platelet. Single donor platelet is prepared by plateletapheresis containing  $3 \times 10^9$ /L platelets in 200 ml of plasma. One single donor platelet is equal to 8 units of random donor platelet.
  4. **Platelet concentrate:** It is prepared by centrifugation of platelet rich plasma at 1200–1500 g for 15–20 minutes. Used in thrombocytopenia and drug (aspirin, clopidogrel) induced haemorrhage. Platelet is transfused at a dose of 0.1 unit/kg, when platelet drops below 20,000/or episodes of bleeding. Platelet stored at 4°C should be used within 48 hours; when stored at room temperature can be used up to 5 days. One platelet concentrate can increase up to 10,000 platelet/cumm in one hour.
  5. **Prothrombin complex concentrate (PCC)** are derived from pooled plasma which contains factors II, IX and X; used in emergency reversal of warfarin therapy in uncontrolled haemorrhage.

### SAG-M Blood

A proportion of donations will have plasma removed and will be replaced by crystalloid solution of SAG-M.

- S** — Sodium chloride.
- A** — Adenine.
- G** — Glucose anhydrate.
- M** — Mannitol.

### Advantages

- ❖ This allows good viability of cells
- ❖ But it is devoid of any protein
- ❖ It is very useful in anaemias

### Precautions

- ◆ For every four units of SAG-M blood, one whole blood has to be given.
- ◆ Later for every two units of SAG-M blood, one unit (400 ml) of 4.5% human albumin has to be given.
- ◆ Coagulation status and platelet count should be checked regularly.

### Complications of Blood Transfusions (Please also See Table for Entire List)

**Febrile reactions:** It is the most common complication due to impurities like pyrogens in the blood or in infusion set. Headaches, fever, chills and rigors, tachycardia, nausea are the features. Transfusion is temporarily stopped or the flow is slowed down with administration of antipyretic drug to reduce fever. Often transfusion of that unit needs to be discontinued.

**Allergic reaction (3%):** Urticaria and allergy to specific proteins in the donor's plasma can occur. Usually it is mild and is treated with steroid and antihistaminics. In severe urticaria that unit of blood is discarded; new washed RBC's and platelets are used.

**Acute haemolytic reactions:** It is the most dangerous complication. It is due to ABO incompatibility. Usually it is *nonfatal* but occasionally can be *fatal*. It is commonly due to technical error at different levels. It amounts for criminal negligence in court of law. Intravascular destruction causes haemoglobinemia, haemoglobinuria, acute renal failure and DIC. Dyspnoea, chest pain, sweating, fever with chills, tachycardia, hypotension, and cardiac arrest occurs in fatal type. *Jaundice is a common* feature in nonfatal type. Free haemoglobin level in blood will be above 5 mg/dl. Condition is treated as an emergency in critical care unit/ICU. Transfusion is stopped immediately; blood sample of recipient and transfusing blood is sent immediately for two laboratories for rechecking. *Smoky urine* of the patient is typical. Injection hydrocortisone/dexamethasone IV is given immediately. *Fluid therapy, alkalization of blood* is done using sodium lactate and sodium bicarbonate. Mannitol 20 gram in 100 ml is infused in 5 minutes; furosemide 120 mg is injected intravenously. Haemodialysis is needed if there is renal failure. Often ventilator support, defibrillator if cardiac arrest occurs is needed. Correction of acidosis, electrolytes is needed.

**Transfusion-related acute lung injury:** It is due to donor plasma antibody against HLA and leucocyte specific antigens of recipient. Occasionally it is due to recipient's antibody

against donor's leucocytes. Features are—breathlessness, saturation drop, fever, hypotension which is observed 4 hours after transfusion. Chest X-ray shows bilateral diffuse infiltrate. They need ventilator support for short period with eventual rapid and complete recovery.

**Transfusion-related graft versus host disease (TGVH):** This *very serious*, very rare complication occurs due to recognition and reaction against host tissues by infused donor lymphocytes. It is common in immunosuppressed, lymphoma, leukaemic patients. Any type of blood products including leukocyte reduced blood can cause the condition. Features are—pancytopenia, toxic epidermal necrosis, liver dysfunction with *more than 90%* mortality. It is difficult to treat.

**Congestive cardiac failure (CCF):** It occurs if especially large quantities of whole blood are transfused in chronic severe anaemia, pregnancy, elderly patients, in patients who have cardiac problems.

#### Complications of blood transfusion

- ❖ Congestive cardiac failure
- ❖ Transfusion reactions HBV, HCV
  - Incompatibility: Major and minor reactions with fever, rigors, pain, hypotension
  - Pyrexial reactions due to pyrogenic ingredients in the blood
  - Allergic reactions
  - Sensitisation to leucocytes and platelets
  - Immunological sensitisation
- ❖ Infections
  - Serum hepatitis
  - HIV infection
  - Bacterial infection
  - Malaria transmission
  - Epstein-Barr virus infection
  - Cytomegalovirus infection
  - Syphilis, *Yersinia*
  - *Babesia microti* infection
  - *Trypanosoma cruzi* infection
- ❖ Air embolism
- ❖ Thrombophlebitis
- ❖ Coagulation failure
  - Dilution of clotting factors
  - DIC
  - Dilutional thrombocytopenia occurs in patients with massive blood transfusion
- ❖ Circulatory overload causing heart failure
- ❖ Haemochromatosis in patients with CRF receiving repeated blood transfusions
- ❖ Citrate intoxication causes bradycardia and hypocalcaemia. For every four units of blood 10 ml of 10% calcium chloride or gluconate should be infused intravenously
- ❖ Iron overload

## MASSIVE BLOOD TRANSFUSION

- ❖ It is defined as *replacement or transfusion of blood equivalent to patient's blood volume in < 24 hours corresponding to that particular age (In adult it is 5–6 litres, in infants it is 85 ml/kg body weight.)* Or single transfusion of blood more than 2,500 ml continuously
- ❖ Massive transfusion is used in severe trauma associated with liver, vessel, cardiac, pulmonary, pelvic injuries. Often it is required during surgical bleeding (primary haemorrhage on table) of major surgeries
- ❖ Adverse effects of massive transfusion
  - a. Severe electrolyte imbalance (hypocalcaemia, hyperkalaemia, acidosis)
  - b. Coagulopathy—altered platelet and coagulation factors – Dilutional thrombocytopenia
  - c. Citrate toxicity, hyperammonaemia
  - d. Hypothermia
  - e. Poor oxygen delivery—due to reduced 2,3 DPG
  - f. Infections
  - g. Incompatibility and transfusion reactions
  - h. ARDS, DIC, CCF

## AUTOLOGOUS BLOOD TRANSFUSION

A healthy individual with no infection and haematocrit of  $\geq 30\%$  can pre donate blood few weeks prior to any elective surgeries, which in turn, can be used at the time of surgery.

Autologous blood is used in orthopaedic, gynaecologic and urologic surgeries. Patient donates one unit of blood weekly; last one if at all being 72 hours before the date of surgery.

## Recycled Blood

In major surgeries if there is significant blood loss, then patient's bled blood is carefully sucked out through a sterile system and is filtered and reused again to the patient. This will reduce the number of transfusions.

## ARTIFICIAL BLOOD

1. *Perfluorocarbon (Fluosolea; perfluoro decalin; Fluosol DA)*—abiotic substitute as synthetic oxygen carrier. Its half life is 7 days. It is RBC substitute.
  - ▶ It has got high affinity for  $O_2$ .
  - ▶ It is inert, colourless, odourless, dense, poorly soluble liquid.
  - ▶ It is biocompatible.
  - ▶ It is emulsified with albumin or lipids before infusion. Its emulsion alone injection can cause pulmonary embolism.
  - ▶ It can bind and release oxygen. But as it reduces the  $PPO_2$  quickly, it is a disadvantage. Patient ideally to be kept in hyperbaric place.
  - ▶ It is oily in nature hence has to be emulsified. It releases 1.3 ml of oxygen/100 ml. It should be kept frozen. It can cause anaphylaxis.
2. *Stroma-free haemoglobin*—biomimetic haemoglobin based substitute. It has more affinity for oxygen as it does not contain 2, 3 DPG but has short half life. It is nephrotoxic.
3. *Chelates which reverse bound  $O_2$* .
  - ▶ Intraoperative—salvage of blood: On table blood is collected, washed, filtered and transfused. Used in trauma.

## ERYTHROPOIETIN

- ◆ Injection 1000–3500 units preoperatively also used to increase the RBC count.
- ◆ It is used in CRF patients who are on haemodialysis. It is given twice weekly but it is costly.

### Blood substitutes

#### ❖ **Human albumin 4.5%**

*There is no risk of transmitting hepatitis.*

Plasma fractionation is done using organic liquids and heat to extract albumin which is stored at 4°C for many months. It can be used in patients with cirrhosis, burns, nephrotic syndrome, ovarian hyperstimulation syndrome (occurring after ovarian stimulation with gonadotrophin injections during *in vitro* fertilization (IVF) therapy). One gram of albumin binds with 14 ml of water so it increases the blood volume also. Albumin is infused daily as needed until good response is observed. Albumin is expensive.

#### ❖ **Dextrans** are useful to improve plasma volume. They are polysaccharides of varying molecular weights.

This is derived from *leuconostoc mesenteroides* bacteria after adding yeast. One gram of dextran binds with 20 ml of water to raise the plasma volume.

##### a. **Low molecular weight dextran** (40,000 mol wt) (*Dextran 40*, *Rheomacrodex*).

Dextran 40 is very effective in restoring blood volume immediately. But small molecules are readily excreted in kidney and so effect is transitory. It may be useful in prevention of sludging in kidney and hence renal shut down.

##### b. **High molecular weight dextran** (*Dextran 110* and *Dextran 70*). Less effective but long acting and so useful to have prolonged effect.

#### **Precautions**

1. Blood samples for blood group and cross-matching should be taken before giving dextrans as it interferes with Rouleaux formation of red cells.
  2. Dextrans also interfere with platelet function and so may precipitate abnormal bleeding.
  3. Total volume of dextrans should not exceed 1000 ml.
- ❖ **Gelatin**, in a degraded form of mol. wt. 30,000S, is used as a plasma expander. Up to 1000 ml of 3.4-4% solution containing anions and cations is given intravenously—**Haemaccel**. But it is less effective than dextran and after 4 hours of its infusion, only 30% remains intravascular.
  - ❖ **Hydroxyethylstarch**: It contains starch, sodium hydroxide, ethylene oxide. It is a good plasma volume expander but lasts only for 6 hours.

## TOURNIQUETS

Tourner means to turn (Greek). A tourniquet is used to cut off the blood supply to a limb temporarily so that a bloodless field is created while performing the surgery. Limb should be exsanguinated before applying/inflating the cuff of the tourniquet. It is done using a bandage or pressurized Rhys-Davis exsanguinator. A tourniquet is applied in mid-thigh above the knee joint in lower limb and in mid-biceps level above the elbow in upper limb. It should not be closer to joints. It is not applied over the forearm or leg. It is applied over layers of gauze or cotton, not over a bare skin. Pressure used in upper limb is 250 mmHg; lower limb is 300 mmHg (In children, it is 150 and 250 mmHg for upper and lower limbs respectively).

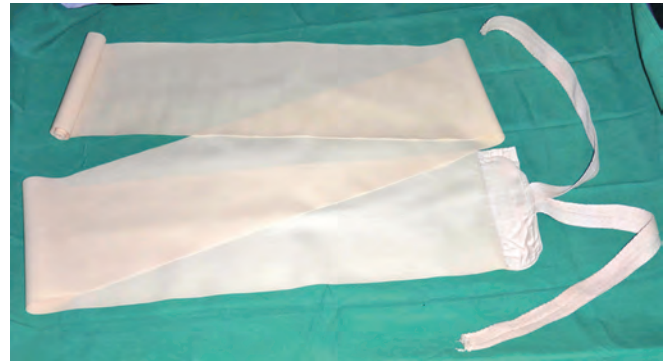


Fig. 1.219: Esmarch rubber tourniquet.

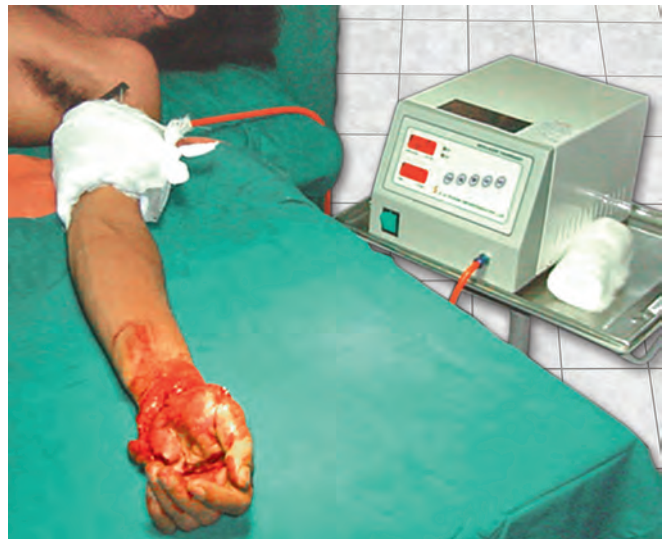

Fig. 1.220: Automatic gauged pressure tourniquet.

## Uses

- ◆ To attain bloodless field in limb surgeries—upper and lower limbs, orthopaedic surgeries, soft tissue tumours, amputations.
- ◆ It is used (rubber tourniquet) to access veins for IV injections and IV sampling.
- ◆ Tourniquet is used in diagnostic tests for varicose veins, purpura (ITP), carpal tunnel syndrome, tetany.
- ◆ It is used as a first aid in bleeding conditions of limbs, snake bite (it is controversial).
- ◆ Tourniquets are often used for small procedures in fingers and toes.

## Types

- ◆ **Rubber tourniquet**: Simple red rubber catheter is used for drawing blood, to have access to veins.
- ◆ Martin's tourniquet made up of India rubber.
- ◆ **Pneumatic tourniquet**: Used in limbs, will give the arterial pressure and also acts as a tourniquet (Sphygmomanometer cuff is simpler and easily available type).
- ◆ Esmarch rubber **elastic bandage tourniquet**.
- ◆ Conn pneumatic tourniquet is manually operated tourniquet where air is pumped up to the required pressure.
- ◆ Specialised sophisticated tourniquets are available which gauge pressure and time accurately—automatic tourniquet.



*Tourniquet time for upper limb is one hour and for lower limb is two hours.*

### Contraindications

- ◆ In all peripheral vascular diseases and atherosclerosis.
- ◆ Infection.
- ◆ Deep venous thrombosis.
- ◆ Crush injuries.
- ◆ Sickle cell disease.

### Complications

- ◆ *Crushing effect* on muscles in thigh occurs leading to crush syndrome.
- ◆ *Tourniquet palsy* in upper limb (radial nerve involvement)—neuropraxia.
- ◆ *Infection.*
- ◆ Improper application of tourniquet leads to more bleeding.
- ◆ *Forgetting the removal of tourniquet* or taking more time to release may compromise the blood supply of the limb leading to severe ischaemia and gangrene. It occurs especially when tourniquet is used in *finger* or *toe*.
- ◆ *Skin blistering* and necrosis.

## ■ DISSEMINATED INTRAVASCULAR COAGULATION

Disseminated intravascular coagulation (DIC) is a manifestation due to wide spread intravascular coagulation resulting in microthrombi formation, consumption of platelets and clotting factors and production of breakdown products eventually leading into severe bleeding and tissue ischaemia.

### Causes

- ◆ Major trauma causes DIC due to release of tissue thromboplastin. Burns, major surgery can also cause DIC.
- ◆ Sepsis is the most common cause of DIC. Common sepsis causing DIC are gram-negative, meningococcal, malarial, histoplasmosis, aspergillosis, etc.
- ◆ Acute pancreatitis can cause DIC by releasing proteolytic enzymes which activate prothrombin and factor X.
- ◆ Septic abortion, abruption, retained dead foetus, amniotic fluid embolism are obstetric causes of DIC.
- ◆ Carcinoma of pancreas, prostate, acute promyelocytic leukaemia often cause DIC.
- ◆ Haemolysis, snake bite, liver dysfunction are other causes.

### Types of DIC

- ◆ *Acute DIC* presents with bleeding in gums, GIT, venepuncture site, haematuria, petechiae, oozing from surgical or traumatic wounds. Massive bleeding also can occur.
- ◆ *Chronic DIC* is a low grade type with thrombotic features.

### Investigations

- ◆ In DIC—bleeding time, platelet counts are reduced. Thrombin time (TT), prothrombin time (PT) and activated partial thromboplastin time (APTT) are prolonged. Fibrin-

- ogen degradation product (FDP), D-dimer test are raised.
- ◆ Complete haematocrit, investigations relevant to cause, renal function tests, LFT, electrolyte estimation, blood/discharge/pus/urine culture.

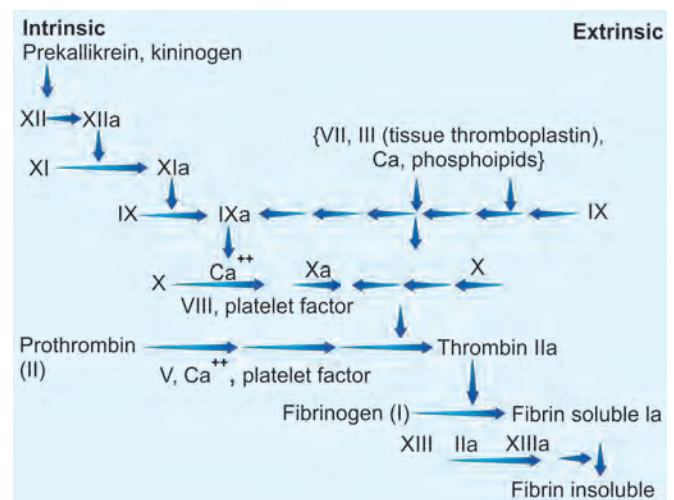
### Treatment of DIC

- ◆ *Treatment of specific cause* as per protocol. Correction of haemodynamic instability by fluid therapy, transfusion of packed cells or whole blood. Dopamine/dobutamine therapy.
- ◆ *Factor replacement—specific therapy* for DIC—FFP, cryoprecipitate, platelet concentrate transfusions are essential. FFP is given at a dose of 15 ml/kg. Cryoprecipitate is used to raise fibrinogen level at a dose to make plasma fibrinogen level 150 mg/dl. Platelet is transfused at a dose of 0.1 unit/kg, when platelet drops below 20,000/or with episodes of bleeding.
- ◆ Heparin use is often controversial. It is used *mainly* in chronic DIC, DIC with purpura, DIC of obstetric cause, cancer induced DIC, DIC due to acute antiphospholipid antibody syndrome.
- ◆ EACA, tranexamic acid can be used but with questionable benefits.

## ■ MECHANISM OF BLOOD COAGULATION (HAEMOSTASIS)

Haemostasis is the spontaneous arrest of bleeding. When an injury occurs *platelet adhesion* occurs to injured vessel/capillary wall which activate the release of ADP (Adenosine diphosphate) which makes more platelet to aggregate (*platelet aggregation*). These activated platelets release thromboxane A<sub>2</sub> which further increases the adhesion and aggregation of platelets. Circulating fibrinogen binds to an activated platelet receptors glycoprotein IIb and IIIa and fibrinogen gets converted into fibrin.

### Coagulation cascade system:



Clotting factors are proteins synthesised by the liver which with a series of cascade reaction activates clotting factors and achieves blood coagulation by a complex mechanism. Factor II, VII, IX and X are vitamin K dependent for their synthesis in liver (carboxylation of glutamic acid). In the process of coagulation each factor gets activated to an enzyme by partial proteolysis, which in turn, activates other needed coagulation factors. Eventually fibrinogen gets converted into soluble fibrin and later into insoluble **fibrin**.

Two types coagulation system are there:

- ◆ *Intrinsic pathway*
- ◆ *Extrinsic pathway*

*In vitro* coagulation occurs by intrinsic coagulation system. Cascade gets activated by vessel wall injury, shear stress of vessel or other factors. It activates the cascade to get final result.

### Coagulation Cascade System

Blood clotting factors	
Factor No.	Common name
I	Fibrinogen
II	Prothrombin
III	Thromboplastin
IV	Ionic calcium
V	Hereditary labile factor, activator (AC) globulin, proaccelerin
VI	Accelerin, supposed to be active form of factor V
VII	Proconvertin; serum prothrombin—conversion accelerator (SPCA)
VIII	Antihemophilic factor (AHF)
IX	Plasma thromboplastin component (PTC; Christmas factor)
X	Stuart-Prower factor
XI	Plasma thromboplastin antecedent (PTA)

Contd...

Contd...

XII	Hageman factor
XIII	Fibrin stabilizing factor, fibrinase
XIV	Prekallikrein
XV	Kallikrein
XVI	Platelet factor

### Hemophilia and Von Willebrand's Disease

They are the two most common inherited bleeding disorders due to deficiency of factor VIII.

Factor VIII has two components; smaller one—factor VIII C is needed for activation of factor X in intrinsic coagulation pathway; its deficiency leads to *classic hemophilia*. It is inherited as an X-linked recessive trait, thus it occurs in males and homozygous females. The larger component of factor VIII called *von Willebrand's factor*, facilitates the adhesion of platelets to subendothelial collagen, hence crucial for hemostasis, its absence leads to *von Willebrand's disease*.

**Classic haemophilia** is called haemophilia A is caused by deficiency of factor *VIII C* with X linked *recessive* trait. It occurs in males or homozygous females. Recurrent haemarthroses is a common presentation. Petechiae and echymoses are absent. Bleeding time is normal but coagulation time is prolonged. Treatment is replacement of factor VIII haemophilic factor. If not known patient may go for a life-threatening bleeding even after dental extraction.

**Von Willebrand's disease** is deficiency of larger component (99%) of the factor VIII-vWF. It is an autosomal *dominant* disease with normal bleeding time and normal platelet count. Common presentations are spontaneous bleeding from mucous membrane, excessive bleeding from wounds and severe menorrhagia. Haemarthroses is not common in von Willebrand's disease. Treatment is replacement of specific factors.

**Haemophilia B** also called as *Christmas disease* is due to factor IX deficiency is inherited as X linked autosomal recessive trait.

# I. Burns

The infusion of large quantities of fluid, mainly a salt solution, as many as 3–4 litres daily, has proved satisfactory. Sometimes a life is saved if not more than one-quarter of the body surface has received a third-degree burn.... I have given blood transfusions to two patients with severe burns, with recovery in one case and postponement of death in the other.

—Gustav Riehl, 1925

## CHAPTER OUTLINE

- ❖ Burns
- ❖ Management of Burns
- ❖ Eschar
- ❖ Contracture in Burn Wound
- ❖ Electrical Burns
- ❖ Inhalation Injury
- ❖ Chemical Burns

## BURNS

### Types of burns

- ❖ Thermal injury
  - Scald—spillage of hot liquids
  - Flame burns
  - Flash burns due to exposure of natural gas, alcohol, combustible liquids
  - Contact burns—contact with hot metals/objects/materials
- ❖ Electrical injury
- ❖ Chemical burns—acid/alkali
- ❖ Cold injury—frost bite
- ❖ Ionising radiation
- ❖ Sun burns

- ◆ Full thickness burns less than 2%.
- ◆ Can be treated on outpatient basis.

#### Moderate:

- ◆ Second degree of 15–25% burns (10–20% in children).
- ◆ Third degree between 2–10% burns.
- ◆ Burns which are not involving eyes, ears, face, hand, feet, perineum.

#### Major (severe):

- ◆ Second degree burns more than 25% in adults, in children more than 20%.
- ◆ All third degree burns of 10% or more.
- ◆ Burns involving eyes, ears, feet, hands, perineum.
- ◆ All inhalation and electrical burns.
- ◆ Burns with fractures or major mechanical trauma.

## Classification of Burns

Depending on the Percentage of Burns (Burn Severity Classification)

Mild (Minor):

- ◆ Partial thickness burns <15% in adult or <10% in children.

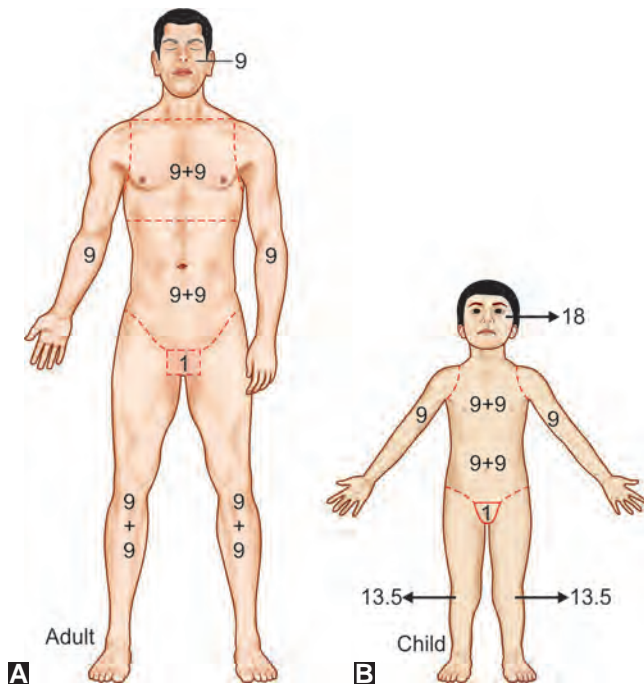
I. Depending on thickness of skin involved

- a. **First degree:** Here the epidermis looks red and painful, no blisters, heals rapidly in 5–7 days by epithelialisation without scarring. It shows *capillary filling*.

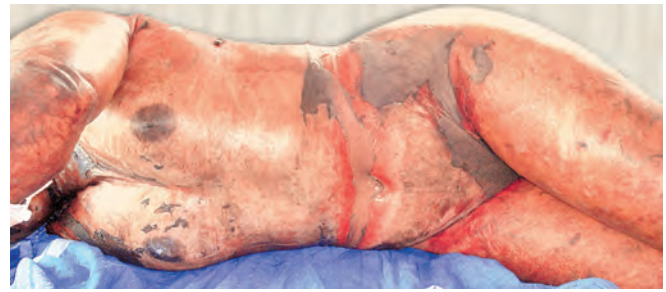### Rule of Nine (Wallace's rule of "9") 1951

	Adults	Children	Infants
Head and neck	9%	18%	20%
Front of chest and abdominal wall	$9 \times 2 = 18\%$	18%	$10 \times 2 = 20\%$
Back of chest and abdominal wall	$9 \times 2 = 18\%$	18%	$10 \times 2 = 20\%$
Lower limb	$18 \times 2 = 36\%$	$13.5 \times 2 = 27\%$	$10 \times 2 = 20\%$
Upper limb	$9 \times 2 = 18\%$	18%	$10 \times 2 = 20\%$
Perineum	01%	01%	
	<b>100%</b>	<b>100%</b>	<b>100%</b>

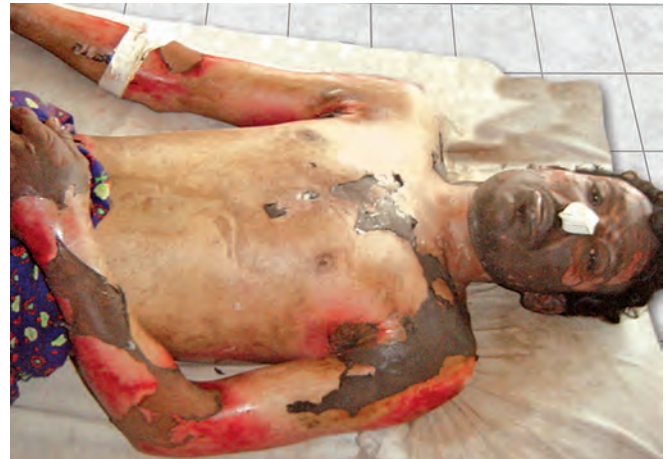**Note:** It is head and lower limb percentage which differ in adults and children.



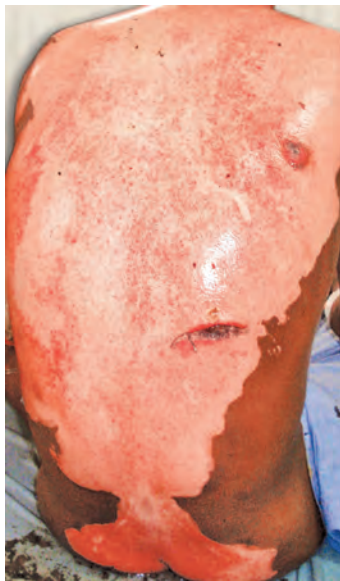**Figs 1.221A and B:** Percentage of burns in (A) Adults; (B) Children



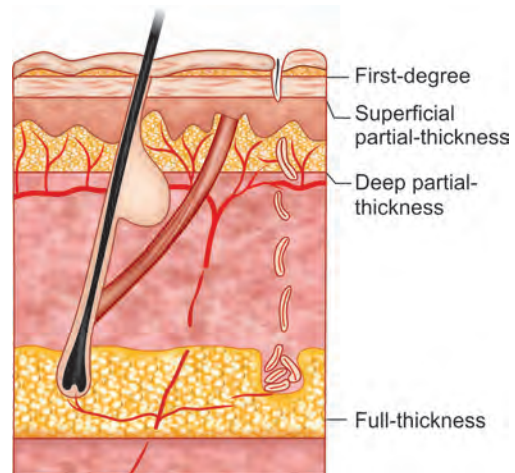
**Fig. 1.224:** Extensive third degree burns with eschar.



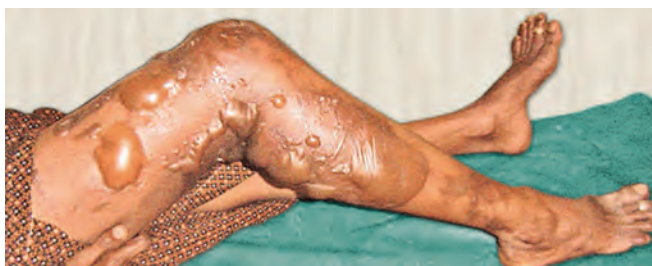**Fig. 1.225:** Extensive burns more than 50%.



**Fig. 1.222:** First and second degree burn.



**Fig. 1.226:** Degrees of burns.



**Fig. 1.223:** Second degree burns with blisters.

- b. **Second degree:** The affected area is mottled, red, painful, with blisters, heals by epithelialisation in 14–21 days.
  - ▶ *Superficial second degree burn* heals, causing pigmentation.
  - ▶ *Deep second degree burn* heals, causing scarring, and pigmentation. Sensation is present but *no blanching*.
- c. **Third degree:** The affected area is charred, *parchment like*, *painless and insensitive*, with thrombosis of superficial vessels. It requires grafting. Charred, denatured, insensitive,

*Success lies not in achieving what you aim at, but in aiming at what you ought to achieve.*

contracted full thickness burn is called as **eschar**. These wound must heal by re-epithelialisation from wound edge.

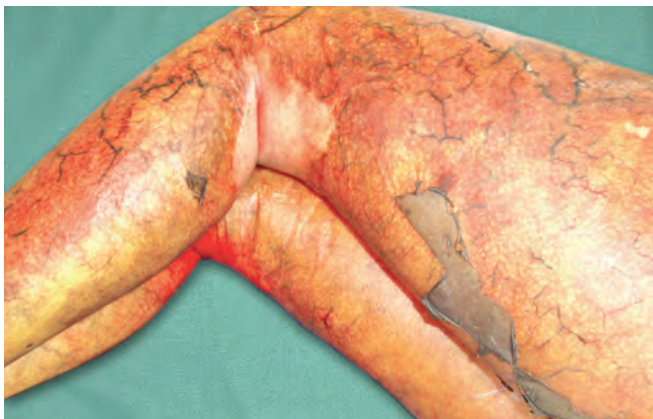
- d. **Fourth degree:** Involves the underlying tissues—muscles, bones.

## II. Depending on thickness of skin involved

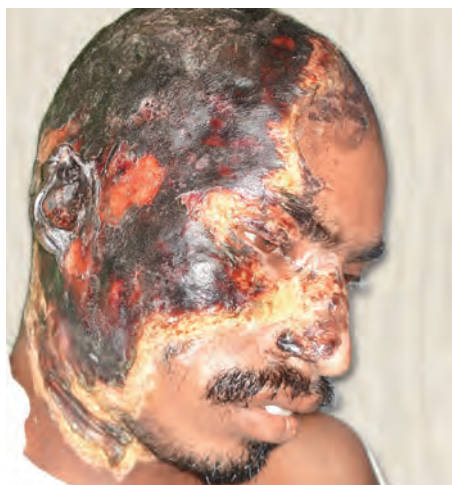- a. **Partial thickness burns:** It is either first or second degree burn which is red and painful, often with blisters.
- b. **Full thickness burns:** It is third degree burns which is charred, insensitive, deep involving all layers of the skin.

## Assessment of Burns

- ◆ Wallace's rule of nine is used for early assessment—refer figure.
  - ◆ Using the Lund and Browder chart is better method for assessing the burns wound. Here each part of the body is individually assessed for involvement of burns.
  - ◆ Patient's *entire hand area* is 1%. Clean piece of paper is cut to the size of hand and through that percentage of burns is assessed. 44°C temperature takes 6 hours to cause deep burns. 65°C takes 45–60 seconds to cause deep full thickness burn.
- Burn is a dynamic wound and so assessment should be repeated at regular intervals.*



**Fig. 1.227:** Third degree burns with charred skin, with thrombosed veins and eschar.



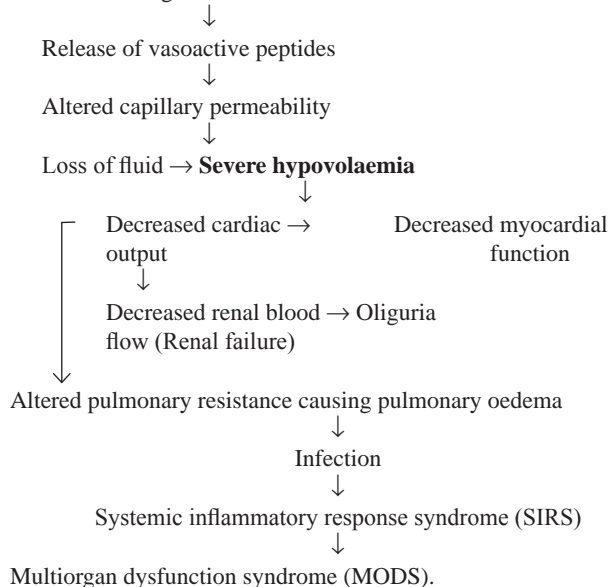
**Fig. 1.228:** Face burns in an adult—severe third degree.

## Clinical Features

- ◆ History of burn.
  - ◆ Pain, burning, anxious status, tachycardia, tachypnoea, fluid loss.
  - ◆ In severe degrees features of shock.
- Tolerable temperature to human skin is 40°C for brief period.

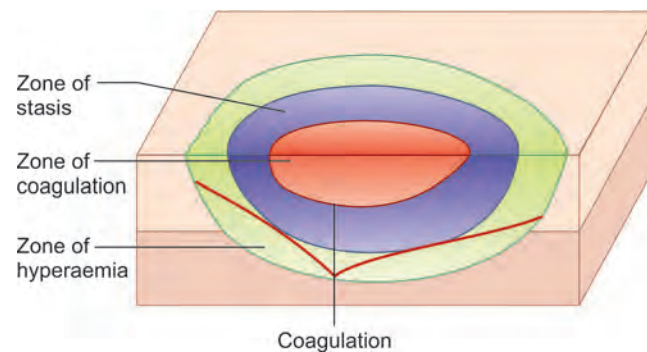
## Pathophysiology

Heat causes coagulation necrosis of skin and subcutaneous tissue



There is increased capillary permeability, decreased plasma oncotic pressure causing loss of protein and fluid from intravascular space. Vasoconstriction occurs due to raised capillary hydrostatic pressure leading into cellular aggregation. Blockage of lymphatics causes poor clearance of fluid and proteins from interstitial spaces. Cell membrane function is impaired causing intracellular fluid accumulation. Activation and release of various complement factors, histamine, and prostaglandins results in myocardial dysfunction, oedema of tissues, reduced immunoglobulin synthesis. Catecholamine levels are raised drastically in patient with burn. There will be lipolysis, proteolysis, increased release of glutamine and alanine from skeletal muscles. Urea production is increased due to more proteolysis.

**Massive oedema** in the body is due to altered pressure gradient because of the injury to basement membrane.



**Fig. 1.229:** Burn zones (Jackson's).

**Cardiac dysfunction** is due to:

- ◆ Hypovolaemia.
- ◆ Release of cardiac depressants.
- ◆ Hormonal causes like catecholamines, vasopressin, angiotensins.

**Renal changes** are due to:

- ◆ Release of ADH from posterior pituitary to cause maximum water reabsorption.
- ◆ Release of aldosterone from adrenals to cause maximum sodium reabsorption.
- ◆ Toxins released from the wound along with sepsis causes acute tubular necrosis.
- ◆ Myoglobin released from muscles (in case of electric injury or often from eschar) is most injurious to kidneys.

**Pulmonary changes** are due to:

- ◆ Altered ventilation-perfusion ratio.
- ◆ Pulmonary oedema due to burn injury, fluid overload, inhalation injury.
- ◆ ARDS.
- ◆ Aspiration.
- ◆ Septicaemia.

#### Assessment of airway injury is important in burns

- ❖ Occurs in burns around face and neck, or trapped in burning room
- ❖ Presents with hoarseness or stridor
- ❖ Inhaled burning gases can cause upper airway burns and laryngeal oedema
- ❖ Smoke inhalation can cause chemical alveolitis, pulmonary oedema, ARDS and respiratory failure
- ❖ Steam inhalation can cause damage to respiratory epithelium and subglottic oedema
- ❖ Carbon monoxide inhalation more than 10% is dangerous as it forms carboxyhaemoglobin (CO has got 240 times more affinity to haemoglobin than oxygen) which blocks oxygen transport completely causing respiratory arrest, hypoxia and metabolic acidosis
- ❖ Chest wall burn causes mechanical block of ventilation— needs escharotomy in chest wall and procedure is painless
- ❖ Airway burn may require early elective intubation or tracheostomy or emergency cricothyroidotomy as a life-saving method

**GIT changes** are due to:

- ◆ *Acute gastric dilatation* which occurs in 2–4 days.
- ◆ Paralytic ileus, Curling's ulcer (due to decreased mucosal defence; not due to increased HCl).
- ◆ Cholestasis and hepatic damage.
- ◆ Acute acalculous cholecystitis, acute pancreatitis can occur.

*Bowel mucosal ischaemia* causes poor motility, reduced food digestion and absorption with increased translocation of bacteria causing peritoneal oedema, septicaemia and abdominal compartment syndrome.

### Metabolic Changes

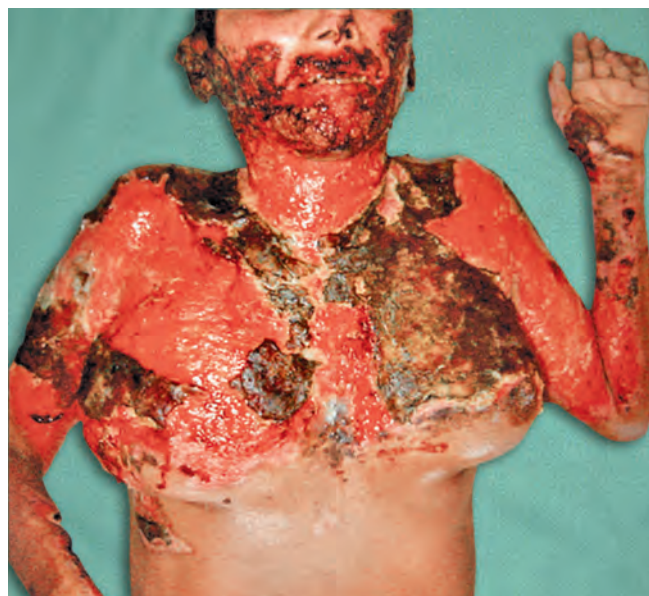- ◆ Hypermetabolic rate (BMR).
- ◆ Negative nitrogen balance.
- ◆ Electrolyte imbalance.
- ◆ Deficiencies of vitamins and essential elements.
- ◆ Metabolic acidosis due to hypoxia and lactic acid.

### Sepsis in Burn Patient

- ◆ Focus may be at the burn site, catheter site, cannula/CVP line site, or respiratory infection.
- ◆ Low immunity, loss of proteins and immunoglobulins, loss of barrier causes sepsis. Opportunistic infection is also common.
- ◆ Associated conditions like diabetes, HIV infection, old age, respiratory diseases worsen the sepsis in burn injury.
- ◆ It may be *local infection commonly* by *Staphylococcus aureus* in early period, *Pseudomonas*, *Candida*, *Aspergillus*, herpes simplex virus in partial thickness nasolabial burns. It may be suppurative thrombophlebitis also.
- ◆ *Systemic infection* like pneumonia, bacteraemia, septicaemia can occur.
- ◆ Burns itself *creates* immunosuppression (*cell-mediated immunity*).
- ◆ Sepsis is identified by fever, lethargy, *leucocytosis*, *thrombocytopenia*.

#### Infections are commonly due to:

- ❖ Streptococci (Beta haemolytic—most common)
- ❖ *Pseudomonas*
- ❖ *Staphylococci*
- ❖ Other gram-negative organisms
- ❖ *Candida albicans*



**Fig. 1.230:** Burns over chest wall with eschar. Note the extent of involvement.

### Effects of Burn Injury

- ◆ Shock due to hypovolaemia.
- ◆ Renal failure.
- ◆ Pulmonary oedema, respiratory infection, adult respiratory distress syndrome (ARDS), respiratory failure.
- ◆ Infection by *Staphylococcus aureus*, beta haemolytic *Streptococcus*, *Pseudomonas*, *Klebsiella* leads to bacteraemia, septi-

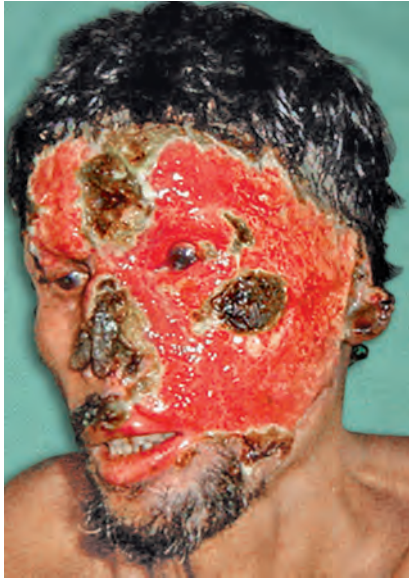
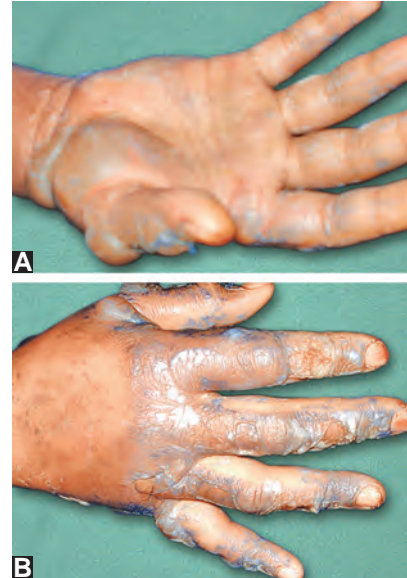
Fig. 1.231: Deep burns face with eyelid involvement.



Figs 1.232A and B: Burns hand both palmar and dorsal aspect.

caemia. Fungal and viral infections of dangerous types can also occur.

- ◆ GIT: Hypovolaemia, ischaemia of mucosa, erosive gastritis—**Curling's ulcer** (seen in burns >35%).
- ◆ Fluid and electrolyte imbalance.
- ◆ Postburn immunosuppression predisposes to severe opportunistic infection.
- ◆ Eschar formation and its problems like defective circulation, ischaemia when it is circumferential.
- ◆ Electrical injuries often cause fractures, major internal organ injury, convulsions.
- ◆ Development of contracture is a late problem. It leads to ectropion, microstomia, disability of different joints, defective hand functions, growth retardation causing shortening.
- ◆ Inhalation burn causes pulmonary oedema, respiratory arrest, ARDS.
- ◆ Chemical injury causes severe GIT disturbances like erosions, perforation, stricture oesophagus (**alkali**), pyloric stenosis (**acid**), mediastinal injury.
- ◆ Other problems commonly seen are DVT, pulmonary embolism, urinary infection, bed-sores, severe malnutrition with catabolic status, respiratory infection.
- ◆ Complications of burns contracture itself like hypertrophic scar, keloid formation.
- ◆ **Toxic shock syndrome:** It is a life-threatening exotoxin mediated disease caused by *Staphylococcus aureus*. It is common in children, presents with rashes, myalgia, diarrhoea, vomiting, and multiorgan failure with high mortality.

#### Causes of death in burns

- ❖ Hypovolaemia (refractory and uncontrolled) and shock
- ❖ Renal failure
- ❖ Pulmonary oedema and ARDS
- ❖ Septicaemia
- ❖ Multiorgan failure
- ❖ Acute airway block in head and neck burns

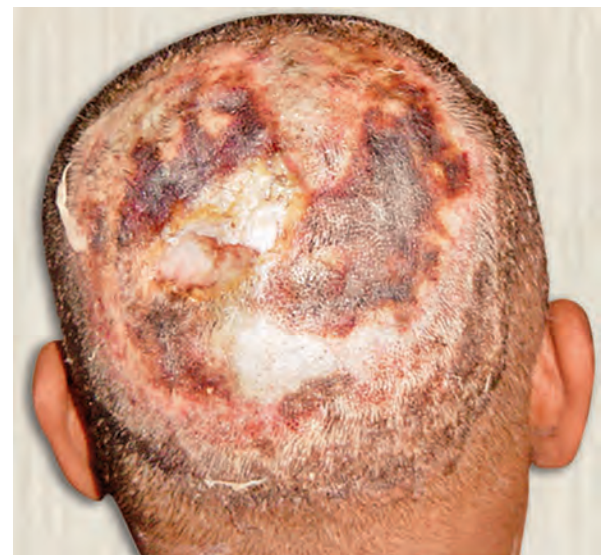

Fig. 1.233: Deep burn in the scalp involving extensively.

## MANAGEMENT OF BURNS

### First Aid

- ◆ Stop the burning process and keep the patient away from the burning area.
- ◆ Cool the area with tap water by continuous irrigation for 20 minutes (not cold water as it can cause hypothermia).

#### Indications for admission in burns

- ❖ Any moderate and severe burns
- ❖ Airway burns of any type
- ❖ Burns in extremes of age
- ❖ All electrical/deep chemical burns

### Initial management

- ❖ Clothing should be removed
- ❖ Cooling of the part by running water for 20 minutes
- ❖ Cleaning the part to remove dust, mud, etc
- ❖ Chemoprophylaxis—tetanus toxoid; antibiotics; local antiseptics
- ❖ Covering with dressings by different methods
- ❖ Comforting with sedation and pain killer

## Definitive Treatment

- ◆ Admit the patient.
- ◆ Maintain airway, breathing, circulation (**ABC**). Emergency endotracheal intubation may be required in early period itself; in such situation *succinylcholine should not be used*.
- ◆ Assess the percentage, degree, and type of burn.
- ◆ Keep the patient in a clean environment.
- ◆ Sedation and proper analgesia.
- ◆ Patient should be in **burns unit** (ideally air-conditioned) with barrier nursing, sterile clothes, bed sheets with all aseptic methods.

## Fluid Resuscitation

Formulas to calculate the fluid replacement:

### a. Parkland regime: Commonly used:

4 ml/% burn/kg body weight/24 hours.

Maximum percentage considered is 50%.

Half the volume is given in first 8 hours, rest given in 16 hours.

### b. Muir and Burclay regime: For colloid after 12–24 hours.

$$\frac{\% \text{ Burns} \times \text{Body weight in kg}}{2} = 1 \text{ Ration}$$

3 Rations given in first 12 hours.

2 Rations in second 12 hours.

1 Ration in third 12 hours.

### c. Galveston regime (pediatric):

5000 ml/m<sup>2</sup> burned + 1500 ml/m<sup>2</sup> total

### d. Modified Brooke formula:

*First 24 hours:*

RL: 4 ml/kg/% burns in 24 hours

(first half in first 8 hours)

Colloid—none.

*Second 24 hours:*

Crystalloids—to maintain urine output

Colloids—0.3 ml to 0.5 ml/kg/burns in 24 hours.

(Albumin in RL solution) (Albumin alone should be given with care if really indicated only).

### e. Evan's formula:

*In first 24 hours:*

Normal saline 1 ml/kg/% burns

Colloids 1 ml/kg/% burns

5% dextrose in water, 2000 ml in adult.

*In second 24 hours:*

Half of the volume used in first 24 hours.

**Fluids used** are Ringer lactate, Hartmann fluid, plasma. *Ringer lactate is the fluid of choice*. Blood is transfused in later period (after 48 hours).

**First 24 hours only crystalloids** should be given (Crystalloids are one which can pass through capillary wall like saline either hypo, iso or hypertonic, dextrose saline, *Ringer lactate*).

*Sodium is assessed* by formula: 0.52 mmol × kg body weight × % body burns, given at a rate of 4.0 to 4.4 ml/kg/hour.

**After 24 hours** up to 30–48 hours, *colloids* should be given to compensate plasma loss (colloids are one which are retained in intravascular compartment). Plasma, haemaccel (gelatin), dextrans, hetastarch are used. Usually at a rate of 0.35–0.5 ml/kg/% burns is used in 24 hours.

- ◆ Urinary catheterization to monitor output; 30–50 ml/hour should be the urine output.
- ◆ Tetanus toxoid.
- ◆ Monitoring the patient: Hourly pulse, BP, PO<sub>2</sub>, PCO<sub>2</sub>, electrolyte analysis, blood urea, nasal oxygen, often intubation is required.
- ◆ IV ranitidine 50 mg 8th hourly.
- ◆ **Ryle's tube insertion initially for aspiration purpose later for feeding** (*Enteral feeding*). For burns >15%.
- ◆ Antibiotics: Penicillins, aminoglycosides, cephalosporins, metronidazole.
- ◆ Culture of the discharge; total white cell count and platelet count at regular intervals are essential to identify the sepsis along with fever, tachycardia and tachypnoea.
- ◆ In burns of oral cavity tracheostomy may be required to maintain the airway.
- ◆ **Total parenteral nutrition (TPN)** is required for faster recovery, using carbohydrates, lipids, vitamins (*through a CVP line*).
- ◆ Tracheostomy/intubation tube may be required in impending respiratory failure or upper airway block.
- ◆ Intensive nursing care.

## Local Management

- ◆ Dressing at regular intervals under general anaesthesia using paraffin gauze, hydrocolloids, plastic films, vaseline impregnated gauze or fenestrated silicone sheet or biological dressings like amniotic membrane or synthetic biobrane.
- ◆ **Open method** with application of silver sulfadiazine without any dressings, used commonly in burns of face, head and neck.
- ◆ **Closed method** is with dressings done to soothen and to protect the wound, to reduce the pain, as an absorbent.
- ◆ **Tangential excision** of burn wound with skin grafting can be done within 48 hours in patients with less than 25% burns. It is usually done in deep dermal burn wherein dead dermis is removed layer by layer until fresh bleeding occurs. Later skin grafting is done. *Advantages* of tangential excision: *It reduces*—the chance of secondary infection, the hospital stay, and formation of hypertrophic scar or contracture, the cost.
- ◆ In burns of head and neck region, exposure treatment is advised.
- ◆ Slough excision is done regularly.



Topical agent	Advantages	Problems
Silver sulfadiazine (1%)	<ul style="list-style-type: none"> <li>Antiseptic (G +ve and G -ve)</li> </ul>	<ul style="list-style-type: none"> <li>Neutropenia, pseudoeschar</li> <li>It diffuses poorly through the eschar</li> </ul>
	<ul style="list-style-type: none"> <li>Soothing, good penetration,</li> <li>Hydration and softening of eschar occurs</li> </ul>	<ul style="list-style-type: none"> <li>Causes hypertrophic granulation and so not used once wound is clean and eschar is separated</li> </ul>
	<ul style="list-style-type: none"> <li>It does not cause pain</li> </ul>	<ul style="list-style-type: none"> <li>Causes wound maceration</li> </ul>
		<ul style="list-style-type: none"> <li>It should be avoided in pregnancy, nursing mother and infants below 2 years of age</li> </ul>
Sulfamylon (5%/11%) (Mafenide acetate)	<ul style="list-style-type: none"> <li>Antipseudomonal, anticlostridial</li> <li>Penetrates very well in to tissues</li> <li>It is water soluble</li> <li>It is good antipseudomonal agent</li> </ul>	<ul style="list-style-type: none"> <li>Very irritant, painful</li> <li>Causes acidosis, by inhibiting the carbonic anhydrase</li> </ul>
Silver nitrate (0.5%)	<ul style="list-style-type: none"> <li>Antiseptic, antipseudomonal.</li> </ul>	<ul style="list-style-type: none"> <li>Stains burnt area</li> </ul>
Povidone iodine (5%)	<ul style="list-style-type: none"> <li>Antiseptic (G +ve, G -ve)</li> </ul>	<ul style="list-style-type: none"> <li>Irritant and painful</li> </ul>
	<ul style="list-style-type: none"> <li>Used on granulation tissue after eschar separation</li> </ul>	<ul style="list-style-type: none"> <li>Not used in partial burns</li> </ul>
	<ul style="list-style-type: none"> <li>Used in perineum and buttocks to prevent maceration</li> </ul>	
Silver sulphadiazine and cerium nitrate	<ul style="list-style-type: none"> <li>Boosts cell-mediated immunity and forms sterile eschar</li> </ul>	

◆ **After cleaning with povidone iodine solution silver sulfadiazine ointment is used.** It is an antiseptic and soothing agent. It causes neutropenia.

Other agents used are *Sulfamylon (Mafenide acetate)* and *Silver nitrate*.

- ▶ *Sulfamylon* is antipseudomonal and anticlostridial agent. It penetrates well into the tissues but it is very irritant. It causes acidosis.
- ▶ *Silver nitrate* causes staining of burnt area.
- ▶ 0.025% sodium hypochlorite (Dakin's solution) is effective against Gram +ve organisms; 0.25% acetic acid is effective against Gram -ve organisms, but both mildly inhibit epithelialisation.

Regular culture and sensitivity for bacteria is required, to see for streptococcal growth which should be less than 1,00,000 ( $10^5$ ) per gram of tissues.

## Wound Coverage

- ◆ Once the area granulates well, in 3 weeks usually, split skin grafting is done (SSG, Thiersch graft).
- ◆ For wider area MESH split skin graft is used.
- ◆ If there is eschar, *escharotomy* is required to prevent compression of vessels.
- ◆ In certain areas like face and ear, full thickness graft (Wolfe graft) or flap is required.
- ◆ **Cultured skin:** Full thickness skin biopsy of patient's skin is done immediately after admission. By specialized culture technology sheets of skin can be manufactured in 3 weeks as cultured epithelial grafts. It can cover skin of almost entire body. It is usually useful in burns of > 80%. Take up of cultured graft is 60–75%. *Limitations are*—time taken to develop cultured graft; more vulnerability for mechanical trauma; costly; time taken to manufacture; scarring.

## Synthetic dressings in burn wound

- ◆ Vaseline impregnated gauze dressing prevents stiffness of eschar.
- ◆ Hydrocolloid dressing (*duoderm*) helps moist environment, proper epithelialisation. It is useful in mixed deep burns. It is changed once in 3 days.

◆ *Opsite* is less expensive, with less pain, creates moist barrier. But it does not have antimicrobial effect and it causes accumulation of exudates.

◆ *Biobrane* is collagen coated silicone sheet which gets adherent to wound acting as barrier without any pain. But it does not have antimicrobial effect and it causes accumulation of exudates. It is used for 2nd degree burns.

◆ *Transcyte* has similar features of biobrane. It contains growth factor derived from cultured fibroblasts which promotes wound healing.

◆ *Integra* contains deeper collagen matrix as dermal substitute; outer silicone sheet as epidermal substitute. Inner collagen matrix acts as dermis whereas outer silicone sheet is removed 2 weeks after dressing and additional autograft should be placed. It provides complete wound cover. Scarring after healing is reduced significantly.

## Biologic dressings for burn wound

It is used to cover the wound temporarily as a barrier and also to have some immunologic function. Eventually graft will slough. Later wound is covered with auto-skin graft. It is used for massive burn injuries more than 50%. Possible problem is transmission of viral diseases.

*Xenograft* is of pig skin. *Allograft* is of cadaver skin (homograft)—it gives all existing normal skin function for temporary period. It may leave a dermal equivalent in the wound later.

## ESCHAR

- ◆ It is charred, denatured, full thickness, deep burns with contracted dermis.
- ◆ It is insensitive, with thrombosed superficial veins.
- ◆ **Circumferential eschar** in the upper limb, lower limb, neck, thorax can cause more oedema which initially causes venous compression and later arterial compression causing ischaemia, gangrene of the distal part. So distal area should be monitored for circulation.
- ◆ If required deep longitudinal full thickness incisions are made in different areas so as to prevent collection of oedema fluid and

also to prevent compression over the vessels. This is called as **escharotomy**. Escharotomy causes large quantity of blood loss and so blood transfusion is needed while doing escharotomy. Incision should be of adequate length and depth during escharotomy. It should be placed in such a way so as to avoid injury to major neurovascular system. Release of muscle compartment is needed often in these patients.

- ◆ Multiple incisions or incisions over the joints may be needed.
- ◆ Early rapid separation of eschar indicates severe sepsis underneath.
- ◆ Eventually eschar should be excised and the area is allowed to granulate and skin grafting should be done.

**Pseudoeschar** is thickened burnt skin due to repeated silver sulphadiazine application.

## CONTRACTURE IN BURN WOUND

Contracture in burns can occur anywhere. It is more common where flexibility and mobility is present like along the joint, eyelids, cheeks, lips, neck, elbow, knee, etc. Contracture can be *intrinsic* by loss of tissue or *extrinsic* by pull during healing phase contraction. Contracture proceeds towards position of comfort until it meets or closely reaches opposite surface. There is clearly wound shortening. Disorganised over formation of compact collagen (3 times normal) causes hypertrophic scar leading further contracture.

*Deficit of neck extension* is graded, normal  $>110^\circ$ ;  $E_1$   $95-110^\circ$ ;  $E_2$  is  $85-95^\circ$ ;  $E_3$  is  $<85^\circ$  with mentosternal synechia.

### Classification of Burns Contracture in the Neck (BM Achauer)

- ❖ Mild (less than 1/3rd)—inability to see ceiling.
- ❖ Moderate (1/3rd to 2/3rd)—flexion is possible but not extension.
- ❖ Severe (more than 2/3rd)—fully contracted in flexed position with pull on lower lip.
- ❖ Extensive—contraction is extensive with mentosternal adhesions.

*Ifeanyichukwu* has classified neck contracture into: *Type 1*—mild anterior with narrow contracting band less than fingerbreadth (1a) or broad band (1b); *type 2*—moderate anterior with narrow band (2a) or broad band (2b); *type 3*—severe anterior mentosternal adhesion with supple neck skin (3a) or without supple skin (3b); *type 4*—posterior with narrow band (4a) or multiple or broad band (4b).

*Reconstruction territories in neck* in burn contracture based on functional benefits are—central above; central below; central above and below; lateral.

## Complications of Burns Contracture

- ◆ Ectropion of eyelid causing keratitis and corneal ulcer.
- ◆ Disfigurement in face.
- ◆ Narrowing of mouth **microstomia**.
- ◆ Contracture in the neck causing restricted neck movements.
- ◆ Disability and nonfunctioning of joints due to contracture.
- ◆ Hypertrophic scar and keloid formation.
- ◆ Repeated breaking of scar and infection, ulcer, cellulitis.
- ◆ Pain and tenderness in the scar contracture.
- ◆ **Marjolin's ulcer:**

It is a very well-differentiated squamous cell carcinoma occurring in a scar ulcer due to repeated breakdown (*unstable scar of long duration*).

- ▶ It is locally malignant.
- ▶ As there are no lymphatics in the scar, so there is no spread to lymph nodes.
- ▶ As there are no nerves in the scar it is painless.
- ▶ It has raised and everted edge with induration.
- ▶ Biopsy confirms the diagnosis.

**Treatment:** Treatment is either *wide excision* or *amputation*. It is *curable*.

Once it spreads out of the scar tissue it behaves like any other squamous cell carcinoma and so can spread to regional lymph nodes.

*Radiotherapy is not given* for Marjolin's ulcer.

## Treatment for Contracture

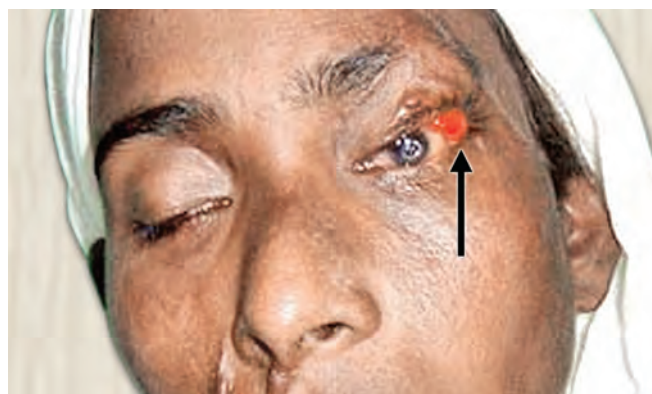- ◆ Release of contracture surgically and use of skin graft or "Z" plasty or different flaps. *Different flaps* used are—transposition flaps, vertical or transverse; laterally based flap; bilobed flap; bipedicle flap; advancement flap; regional flap; random cutaneous flap (*Epaulette flap*, *Charretera flap*); fasciocutaneous/myocutaneous flap; tube flap; expanded skin flap; combined skin graft and flap; microvascular free flap.
- ◆ Proper physiotherapy and rehabilitation is essential.
- ◆ Pressure garments to prevent hypertrophic scars.
- ◆ Management of itching in the scar using aloe vera, antihistamines and moisturizing creams.

## Problems in Managing Burn Contracture

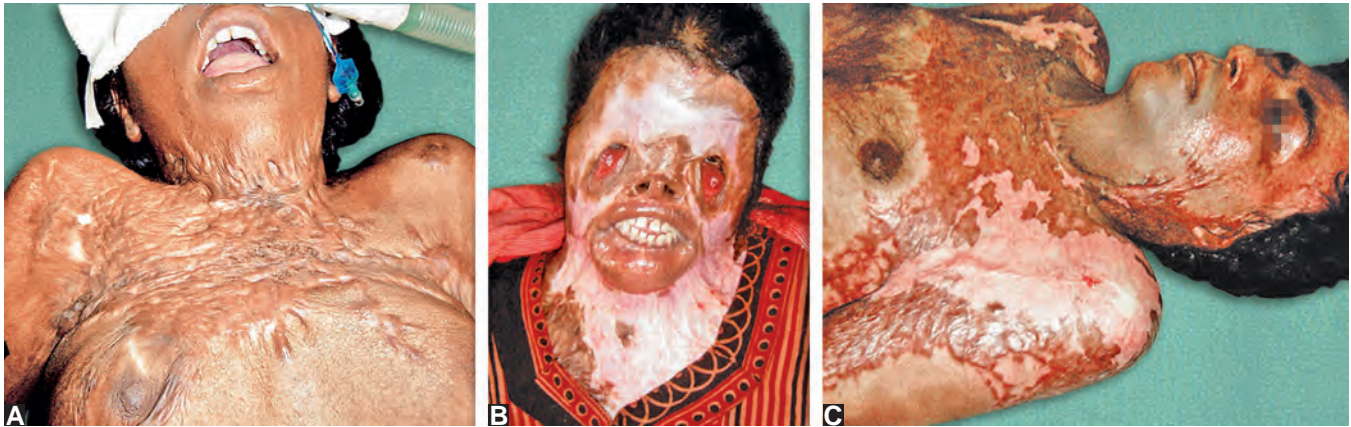- ◆ Giving proper anaesthesia is challenging.
- ◆ Scar excision can cause significant bleeding.
- ◆ Identifying major structures in the area and safeguarding vascular and other structures is often worrisome.
- ◆ Need for repeated surgeries as staged one.
- ◆ Maintaining the position with skeletal traction, fixation, collar, POP cast, etc.
- ◆ Psychological problems and needs counseling.
- ◆ Prolonged hospital stay, cost factors.

### Prevention of development of contracture

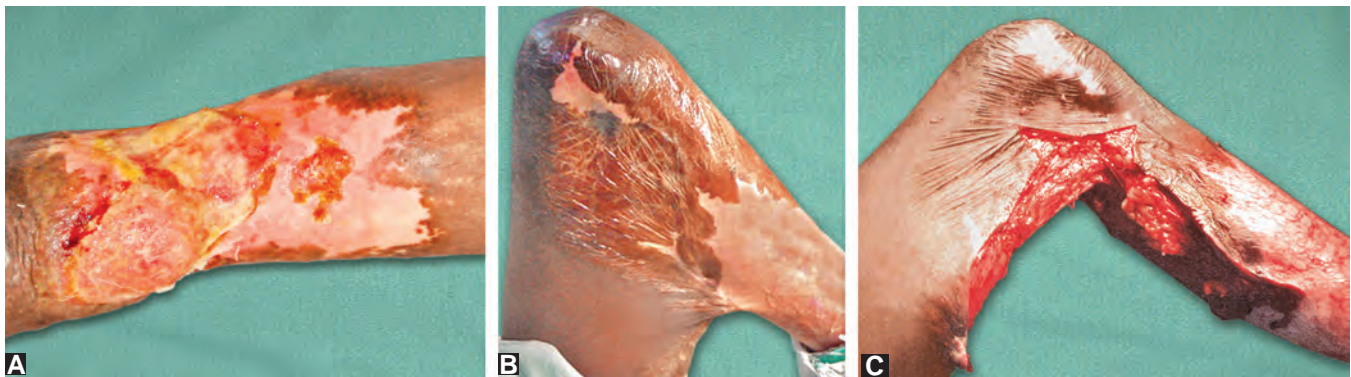
- ❖ Joint exercise in full range during recovery period of burns
- ❖ Pressure garments for a long period
- ❖ Topical silicon sheeting
- ❖ Saline expanders for scars



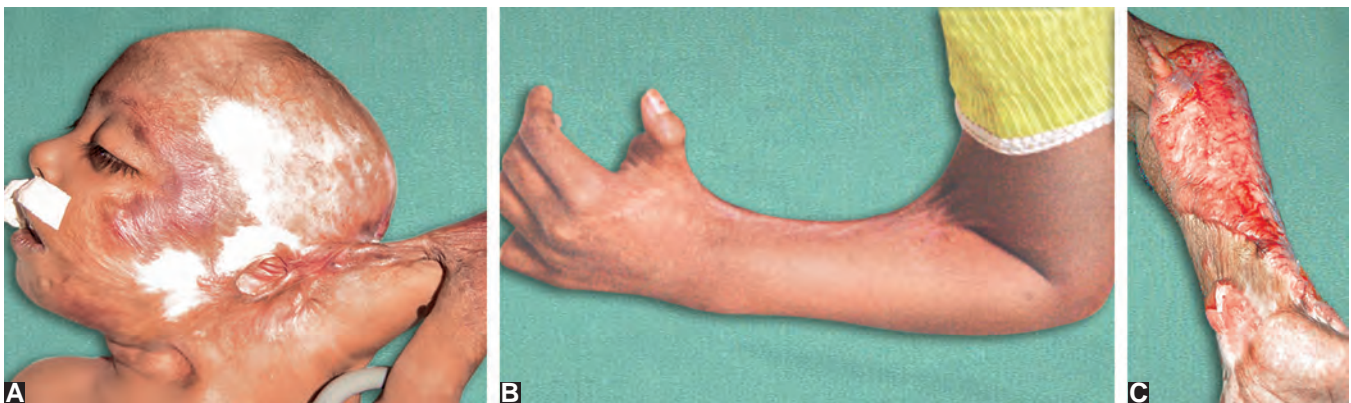
**Fig. 1.234:** Ectropion of upper eyelid due to burns.



Figs 1.235A to C: Contracture at different parts of the body—chest, face and neck.



Figs 1.236A to C: (A) Marjolin's ulcer developed over burns scar; (B) Severe contracture at knee joint causing deformity (C) Same patient with knee contracture undergoing release surgery.

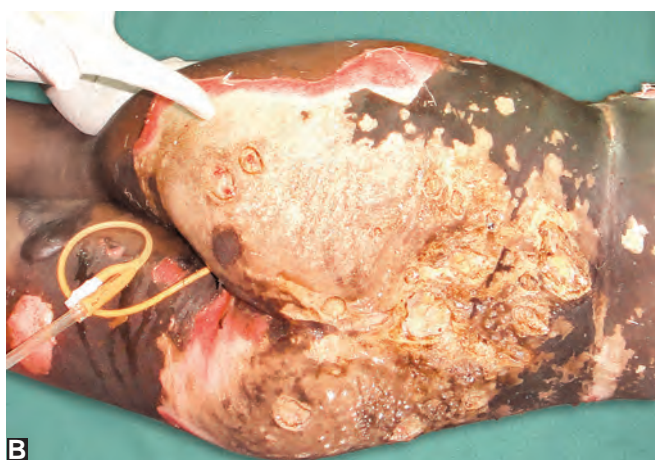
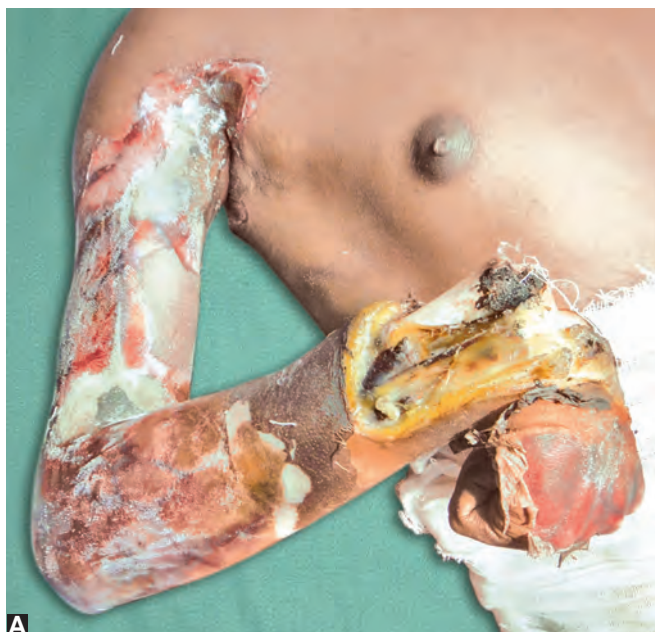

Figs 1.237A to C: (A) Infant had burns in head and neck region causing severe contracture; (B) Elbow contracture due to burns; (C) Keloid in the hand after burn injury.

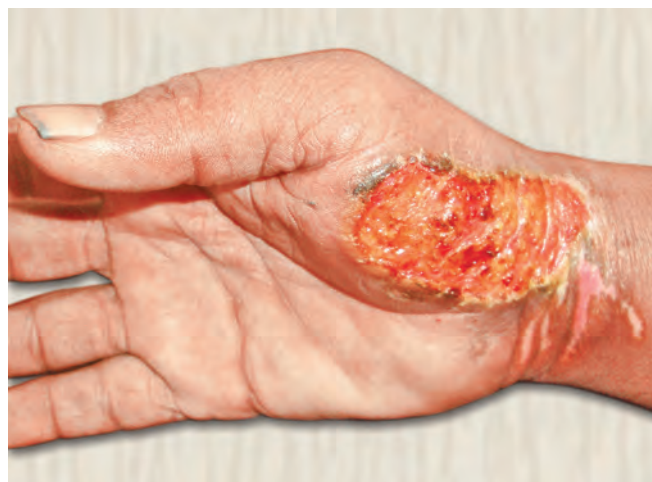## ■ ELECTRICAL BURNS

### Types of Electrical Injury

- ◆ *Low tension injury*: Less than 1000 volts.
- ◆ *High tension injury*: More than 1000 volts—may be due to current itself causing intense damage on the tissues up to 2000°C; flash injury due to electrical arc up to 4000°C; flame injury by catching of fire to the clothing and body; traumatic injury like fractures and internal organ injuries.
- ◆ It is always a deep burn (*always a major burn*).
- ◆ There is a *wound of entry and wound of exit*.
- ◆ Patient may also have major internal organ injuries. GIT, thoracic injuries.
- ◆ Often convulsions can develop.
- ◆ Death may occur due to cardiac arrhythmias (*instant death due to ventricular fibrillation*).
- ◆ *Gas gangrene* is common after electric injury.
- ◆ Release of myoglobin can cause renal tubular damage and *renal failure*.



**Figs 1.238A and B:** High voltage electric burn wound of entry in the hand with extensive destruction. Some patient showing wound of exit in the buttock which is extensive and deep.



**Fig. 1.239:** Wound of entry in an electric burn.

- ◆ Acidosis is common and so often bicarbonate infusion is needed.
- ◆ Patient should *always be admitted* and should be assessed by ECG, cardiac monitor, U/S abdomen, chest X-ray, sometimes even CT scan head, cardiac enzyme analysis.
- ◆ Depending on the injury it is managed accordingly.
- ◆ Fractures and dislocations are common in electrical injuries which is treated accordingly.
- ◆ *Mafenide acetate* is better agent as it penetrates well and it is useful against clostridial infection.
- ◆ *Mannitol* is used to prevent myoglobin induced renal failure.
- ◆ Wound excision, amputation, surgery for internal organ injury, cardiac monitoring are essential part of the surgical management.

## ■ INHALATION INJURY

It occurs after major fire burns.

It is due to:

- ◆ Inhalation of heat.
- ◆ Noxious gases and incomplete products of combustion.
- ◆ At the site of fire, oxygen concentration is less than 2% which can cause death in 45 seconds due to hypoxia.
- ◆ Inhaled carbon monoxide binds with Hb immediately to form carboxyhaemoglobin causing severe anoxia and death.

Electrical burns			
Types	Treatment	Complications	Monitoring and prevention
<p><i>High voltage</i>—can cause ventricular fibrillation, cardiac arrest, death. Extensive organ and surface injuries with fractures.</p> <p><i>Low voltage</i>—deep burn at the site of wound of entry.</p>	<p>Emergency resuscitation</p> <p>Assessment of burn</p> <p>Prevention of renal failure by hydration, dialysis, alkalinisation of urine to clear myoglobin, mannitol therapy, IV sodium bicarbonate.</p> <p>Extensive fasciotomy, debridement.</p> <p>Infection control.</p> <p>Reconstruction.</p>	<ul style="list-style-type: none"> <li>• Neurological like epilepsy, haemiplegia, aphasia, memory loss, headache, transverse myelitis.</li> <li>• Cardiac—arrhythmias.</li> <li>• Vascular injuries—major vessels, bleeding.</li> <li>• Compartment syndromes.</li> <li>• Ischaemia, gangrene of limbs.</li> <li>• Contracture development.</li> <li>• Bronchopneumonia, pleural effusion.</li> <li>• Abdominal—ileus, erosive gastritis, Curling ulcer, injury to liver, pancreas, spleen, GIT, ARF.</li> <li>• Bone and joint injuries.</li> <li>• Cataract can occur in high voltage burn.</li> <li>• Severe potassium deficiency is common.</li> </ul>	<p><b>Monitoring:</b></p> <p>ECG, echocardiography</p> <p>Relevant investigations like X-ray, ultrasound, CT, electrolytes, urine analysis, LFT, renal function tests.</p> <p><b>Prevention:</b></p> <p>Care during electrical work and with electrical system. Unused outlets should be sealed with plastic. Electrical system should be away from water source.</p>

- ◆ CO has got 240 times more affinity for haemoglobin than oxygen. Carboxyhaemoglobin in blood more than 10% is dangerous; more than 60% is life-threatening.
- ◆ Symptoms of carbon monoxide intoxication—headache, disorientation, visual changes, fatigue, vomiting, hallucinations, shock and cardiac arrest.
- ◆ Smoke contains hydrocyanide which causes tissue hypoxia and profound acidosis.
- ◆ Laryngeal oedema and laryngospasm.
- ◆ Bronchial oedema and bronchospasm.
- ◆ Formation of *bronchial cast* is typical which is due to oedema, lymph exudation, separation of ciliated epithelial cells from basement membrane. Inhaled gas causes supraglottic airway burn, laryngeal oedema, loss of respiratory epithelium, ARDS, CO poisoning, mechanical restriction of chest wall movement.

### Later Problems

- ◆ ARDS, pneumonia.
- ◆ Atelectasis, pulmonary embolism.
- ◆ Pulmonary oedema, pneumothorax.

### Clinical Features

- ◆ They have low oxygen saturation.
- ◆ Charring of mouth, oropharynx with facial burns.
- ◆ Carbon sputum.
- ◆ Change in the voice, singed facial and nasal hair.
- ◆ Decreased level of consciousness with stridor or dyspnoea.
- ◆ Acute pulmonary insufficiency with asphyxia, CO poisoning, upper airway obstruction. After 3 to 5 days, ARDS and hypoxia develops. Bronchopneumonia with septicaemia occurs after 5 days.

### Management

- ◆ Replacing the patient from the site earliest.
- ◆ Ventilator support for several weeks.
- ◆ Antibiotics.
- ◆ Bronchoscopy, at regular intervals to remove bronchial cast.
- ◆ Tracheostomy whenever required.
- ◆ Hyperbaric oxygen.
- ◆ IV heparin to reduce bronchial cast. Heparin nebulisation (10,000 units in 3 ml saline 4th hourly) is also useful. N-acetylcysteine nebulisation—20% in 3 ml saline 4th hourly, bronchodilators like albuterol 2nd hourly is very useful. Hypertonic saline inhalation induces the effective coughing to remove casts. Racemic epinephrine is used to reduce mucosal oedema.

#### Note:

Steroids are not beneficial in inhalation burns.

- ◆ Monitoring the patient with arterial blood gas analysis regularly.

### CHEMICAL BURNS

- ◆ In chemical burns, tissue destruction is more and progressive. It is always a deep burn.

- ◆ **Acid burn** occurs in skin, soft tissues and GIT. In GIT, it is common in **stomach** either due to nitric acid or sulphuric acid which may lead to severe gastritis or pyloric stenosis. Other acids are formic acid, hydrofluoric acid. They cause metabolic acidosis, renal failure, ARDS, haemolysis. Acidaemia should be corrected by IV sodium bicarbonate.
- ◆ **Hydrofluoric acid** is commonly used in industrial areas. It is strongest inorganic acid that can produce corrosion and dehydration. It chelates blood calcium causing hypocalcaemia and arrhythmias. It is managed with water irrigation, application of 2.5% calcium gluconate gel at 15 minutes interval, local intradermal and intra-arterial injection of 10% calcium gluconate. Continuous cardiac monitoring, IV calcium gluconate or calcium chloride administration is needed.
- ◆ **Alkali** burns occur in oral cavity and **oesophagus** which leads to multiple oesophageal strictures. Sodium hydroxide, lime, potassium hydroxide and bleach are common alkalis involved. They cause saponification of fat, fluid loss, release of alkali proteinates and hydroxide ions which are toxic.
- ◆ **External chemical burns** are always deep and cause extensive disfigurement with cosmetic problems.
- ◆ **Initial treatment** is dilution with water (**Hydrotherapy**). It is done using 15–20 litres of running tap water.
- ◆ **Neutralisation with antidote should never be done at initial phase** of treatment as it creates exothermic reaction which aggravates the tissue damage. Late neutralisation is done, if required by 0.2% acetic acid in alkali burns; sodium bicarbonate, calcium gluconate 10% gel, topical ziphrin solution in acid burns.
- ◆ Treatment should always be with hospitalisation.
- ◆ Mannitol diuresis, haemodialysis, calcium gluconate IV, pain relief, serum electrolyte management, TPN, ventilator support are systemic management required.
- ◆ Late treatment is reconstruction of the face.
- ◆ Oesophageal dilatation or colonic transposition is done for oesophageal stricture due to alkali burn.
- ◆ Gastrojejunostomy is done for acid induced pyloric stenosis.
- ◆ **Tar burns** are treated additionally with neosprin which contains Tween-80 emulsifier of tar.
- ◆ **Cement** is calcium oxide alkali. Its burn is due to hydroxyl ion which is often deep. Treatment is removal of cloth, irrigation with water, keeping pH below 8. Often it may form eschar.

### Medicolegal and ethical aspects in burns

- ❖ Police should be informed whenever a female, pregnant patient arrives with burns
- ❖ Consent for high-risk should be taken especially in burns >30%
- ❖ Burns should be assessed whether it is accidental or homicidal
- ❖ Relatives should be informed about the duration of stay, problems, repeated surgeries
- ❖ In patients with severe burns who is likely to die, when suspected, dying declaration should be arranged
- ❖ Cost of therapy, long duration of stay and cosmetic problems should be informed to the relatives

# J. Trauma

## CHAPTER OUTLINE

- ❖ Triage
- ❖ Spinal Injury
- ❖ Neck Injuries
- ❖ Bullet Injuries
- ❖ Blast Injuries
- ❖ Penetrating Injuries
- ❖ Abdominal Trauma
- ❖ Blunt Trauma of Abdomen
- ❖ Duodenal Injury
- ❖ Pancreatic Injury
- ❖ Small Bowel Injury
- ❖ Colonic Injury
- ❖ Liver Injury
- ❖ Splenic Injury
- ❖ Renal Injury
- ❖ Urinary Bladder Injury
- ❖ Abdominal Compartment Syndrome
- ❖ Seat-belt Injuries

Trauma is a major public health problem in all countries. It causes death disability and both. 50% die immediately at the time of accident. 25% die in golden hour of trauma, i.e. first 4–6 hours of trauma. 25% may die late during treatment period due to sepsis and complications. Injuries may be penetrating, blunt, blast, chemical, electrical and other injuries.

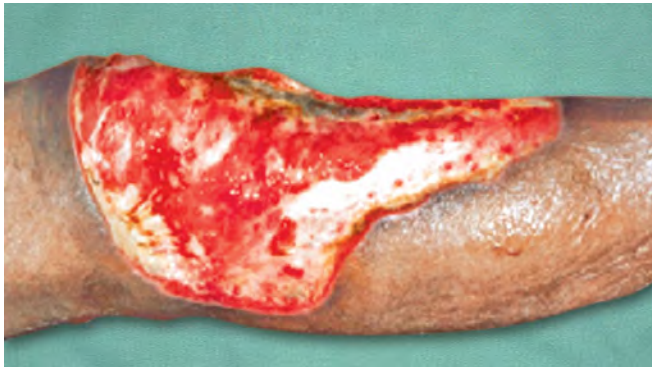

Fig. 1.240: Trauma causing large tissue defect exposing the bone.

## ■ TRIAGE

Triage means “*To sort*” in French.

Triage is a system to attend trauma patients, formulated by *Committee of Trauma of the American College of Surgeons*.

**Advanced trauma life support (ATLS)** is essential for first hour care of an injured patient.

**Pre-hospital trauma life support (PHTLS)** is to prevent deaths while injured patients are transported to the hospital.

## Types of Triage System

- ◆ *Multiple casualties*: Staff and facilities are sufficient but priority is given to life-threatening injuries.
- ◆ *Mass casualties*: Staff and facilities are not sufficient to manage. Here those who are likely to have highest chance of survival are given priority.

### Assessment of four components

- i. Physiologic response
- ii. Anatomical injury
- iii. Biomechanical injury
- iv. Comorbid factors

### Triage algorithm

#### Step One (Assess physiological impact)

Measure vital signs and level of consciousness

- ❖ By Glasgow coma scale
- ❖ Systolic blood pressure
- ❖ Respiratory rate
- ❖ Revised trauma score. It is based on airway, laryngeal injury, spine injury, maxillofacial injury

#### Step Two (Assess anatomical impact)

All penetrating injuries to head, neck, thorax, major burns, fracture bones, pelvic fractures, paralysis

#### Step Three (Assess mechanism)

Automobile accidents, crash or blast injuries, high energy injuries, fall from more than 20 feet. Bullet injury

#### Step Four (Assess history)

- ❖ Patient's age below 5 years or age more than 55 years
- ❖ Cardiac diseases, respiratory and metabolic diseases
- ❖ Pregnancy
- ❖ Patients with bleeding disorders
- ❖ Immunosuppressed individuals

**BASED ON THESE STEPS CONSIDER TO SHIFT THE PATIENT TO TRAUMA CENTER and TRAUMA TEAM SHOULD BE KEPT ALERT.**

*It is important in multiple and mass casualties (fire, blasts, automobile accidents, train accidents).*

## Management

- ◆ Initial evaluation of the patient.
- ◆ Physiologic stabilisation.
- ◆ Control of haemorrhage.
- ◆ Management of thoracic and abdominal injury.
- ◆ Management of cranial injury.

*Action, to be effective, must be directed to clearly conceived ends.*

### I. Primary Management

- ◆ Airway management (blocked by food, vomitus, clot, fallen tongue).
- ◆ Breathing.
- ◆ Circulation.
- ◆ Disability and level of consciousness assessment by Glasgow coma scale.
- ◆ Exposure of the patient from head to toe for final assessment.
- ◆ Fingers and tubes: Finger evaluation, Foley's catheterisation.

### Goals

- ◆ Identify life-threatening conditions.
- ◆ Decide and implement appropriate treatment to the area of trauma.
- ◆ First think to salvage the life, then think to salvage the limb.
- ◆ Rapid assessment, rapid resuscitation, rapid stabilisation.
- ◆ Optimum, complete care.
- ◆ Transport efficiently to higher trauma centre.

#### Categorise the patient

- I: Deceased
- II: Walking wounded
- III: Immobile wounded
- IV: Trapped wounded

#### Tag the patient accordingly

- |                      |                                   |
|----------------------|-----------------------------------|
| <b>Red colour</b>    | : Immediate treatment is required |
| <b>Yellow colour</b> | : Urgent treatment is required    |
| <b>Green colour</b>  | : Delayed treatment is required   |
| <b>Blue colour</b>   | : Expectant treatment is required |
| <b>Black colour</b>  | : Deceased                        |

#### AIRWAY

- Chin lift
- Jaw thrust
- Nasal airway
- Oral airway
- Endotracheal intubation
- Tracheostomy
- (assess airway patency)

#### BREATHING

- 100% oxygen
- Assess bilateral chest raise
- Assess breath sounds
- Use pulse oximetry
- Treat flail chest, pneumothorax
- Intercostal tube drainage

#### CIRCULATION

- Monitor vitals
- Heart sounds
- ECG
- IV fluids blood transfusion
- Treatment of shock
- Control of external bleed
- Use two IV lines—14G/16G

#### DISABILITY EVALUATION

- Neurological examination
- Glasgow coma scale
- Pupillary reaction

#### EXPOSE THE PATIENT

- FULLY** Examine all orifices like P/R,
- Undress the patient P/V, etc.
- Hypothermia assessment
- Assess injuries
- Examine joints, bones, abdomen, other systems
- Look for identification marks

#### FINGERS AND TUBES

- Use required tubes like catheter,
- Ryle's tube

### II. Investigations

- ◆ X-ray spine, chest, pelvis, extremities.
- ◆ CT scan.
- ◆ Blood group and cross-matching.
- ◆ Arterial blood gas analysis.

- ◆ Serum electrolytes.
- ◆ U/S abdomen.

### III. Secondary Survey

Re-evaluate the patient completely again.

### IV. Definitive Care

(All discussed under individual topics.)

### Mechanism of Trauma

- ◆ Blunt trauma—direct or indirect blunt injury can occur. Seat belt reduces the blunt injury in vehicles.
- ◆ Penetrating injury—severity depends on the extent of deeper injury.
- ◆ Blast injury.
- ◆ Crush injury—earthquake, industrial accidents, and train accidents—causes crush syndrome; compartment syndrome.
- ◆ Burn injury.
- ◆ Injury in alcohol patients.

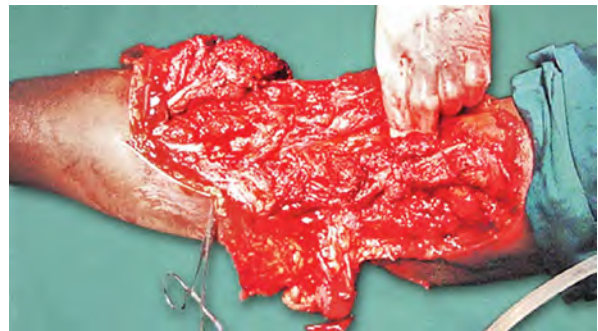


Fig. 1.241: Crush injury leg due to road traffic accident.

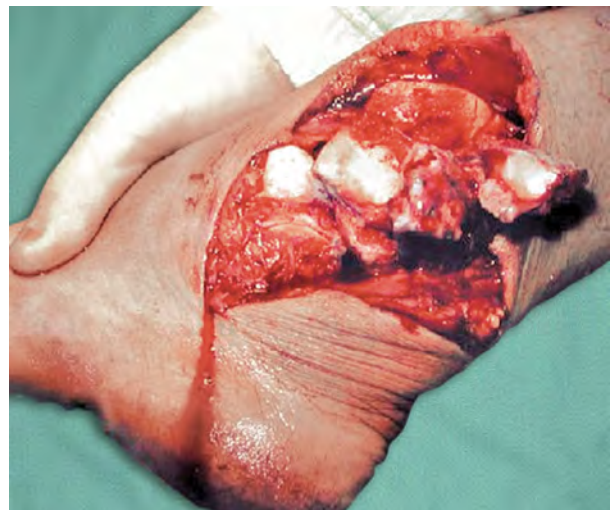


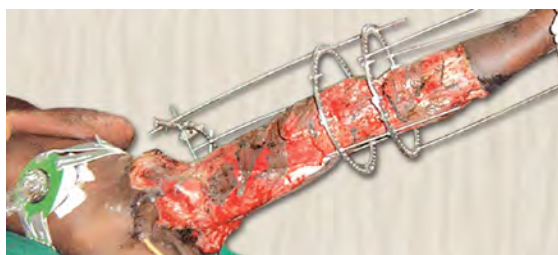Fig. 1.242: Ankle injury with open wound.

### Revised Trauma Score (RTS)

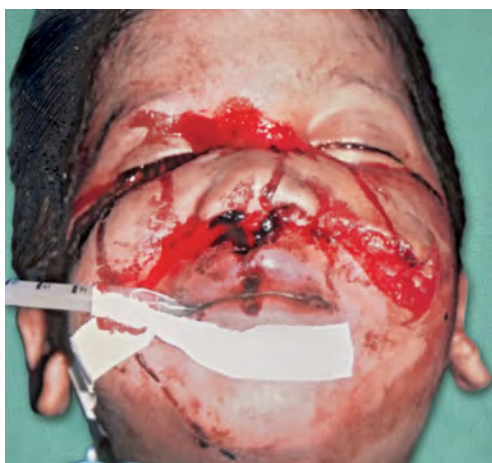It is a reliable physiological scoring system in trauma. Here Glasgow coma scale, systolic blood pressure, respiratory rate are used as parameters.

$RTS = 0.9368 \times GCS + 0.7326 \times \text{systolic BP} + 0.2908 \times \text{Resp rate}$ .  
RTS will come between 0–7.8. Value <4 needs critical care.

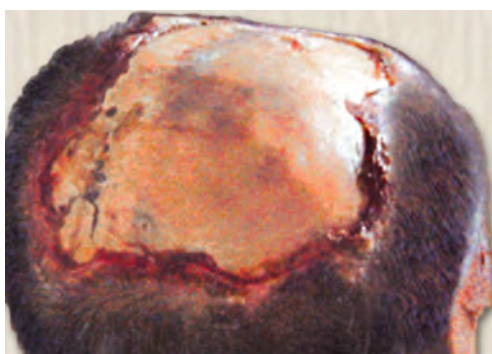
Glasgow coma scale	Blood pressure systolic	Respiratory rate	Value
13–15	>89	10–19	4
9–12	76–89	>29	3
6–8	50–75	6–9	2
4–5	1–49	1–5	1
3	0	0	0



**Fig. 1.243:** Degloving injury involving entire left lower limb, perineum, and left groin. Patient has lost scrotum and both testes. There were no internal injuries and vessels and nerves were intact. Patient underwent wound excision extensively and colostomy was done to promote healing of perineal wound and prevent contamination.



**Fig. 1.244:** Class III dog bite on face in a boy.



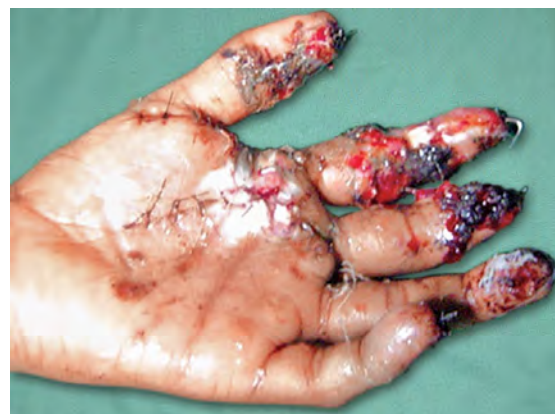**Fig. 1.245:** Degloving of scalp with bone periosteum exposing the skull bone. Outer table was actually dead and required bone removal and graft after healthy granulation tissue was formed.

## CONCEPTS IN TRAUMA MANAGEMENT

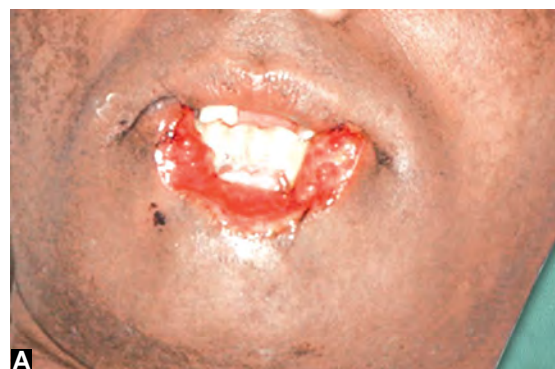- ◆ Concept of ‘golden hour’ to treat the trauma patient is important.
- ◆ Multidisciplinary approach.
- ◆ Planning, setting up, organizing, team work.
- ◆ Assess respiratory system; circulation; bleeding areas—as priority.
- ◆ Assess also whether patient is haemodynamically stable or unstable.
- ◆ Arrange fluids, blood, catheters, ventilator, etc.
- ◆ Further definitive therapy depending on severity and site of injury.

## Damage Control Surgery

- ◆ Resuscitation and early therapy in operation theatre itself.
- ◆ Minimum but essential surgery to control bleeding and prevent contamination.
- ◆ Secondary definitive surgery at a later period to have final control.
- ◆ Damage control surgery is done when there is inability to control bleeding, complex abdominal injuries like of liver or pancreas, major vascular injuries with or without bowel injuries, retrohepatic IVC injury which is not accessible; decline in physiological reserve like temperature, pH, prothrombin time, serum lactate, systolic blood pressure less than 90 mmHg for 60 minutes; if operating time expected is more than one hour, inability to close the wound or whenever reopening the cavity is needed.
- ◆ Principles of damage control surgery apply to injuries of the abdomen, thorax and extremities equally.



**Fig. 1.246:** Hand injury involving all fingers.



**Fig. 1.247A**

*During an injury, unsuspected lesions of the spinal cord may cause the most excruciating abdominal pain.*

**—Theodore Schrire**



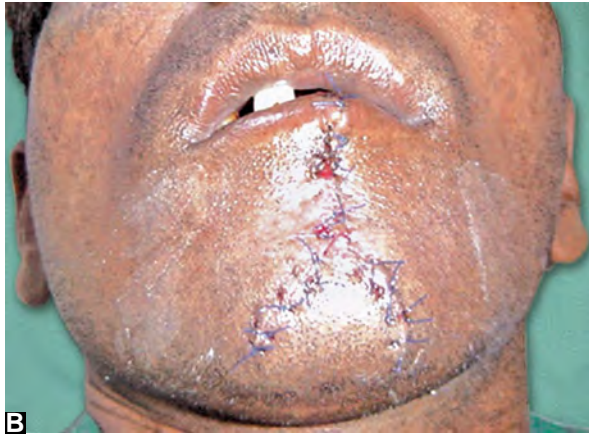

Fig. 1.247B

**Figs 1.247A and B:** A person has bitten this patient during a fight and removed the central part of lower lip. It was repaired primarily by Y repair. **Remember human bites are most dangerous.**

## SPINAL INJURY

- ◆ Assess the type, extent and severity of the injury.
- ◆ Careful first aid and transfer to prevent further damage to the spinal cord.
- ◆ Assess the sensory loss or motor loss properly.
- ◆ Assess fractures clinically, by X-ray, CT scan (for fracture) and MRI (for spinal cord injuries).
- ◆ *Central cord syndrome* is common and is due to hyperflexion or hyperextension of the neck in an injured patient causing ischaemia of spinal column due to interfering of spinal artery blood flow.
- ◆ *Brown-sequard syndrome:* It is due to partial transection of the cord causing ipsilateral motor function loss and contralateral sensory function loss.
- ◆ High dose of steroid is very useful to prevent further damage.
- ◆ Rest, traction to neck.
- ◆ Decompression of spinal canal surgically by removing bone, disc, haematoma is useful.
- ◆ Spinal stabilisation.

## NECK INJURIES

**Neck is divided into zones** for managing neck injuries

- ❖ *Zone I:* From clavicle to cricoid cartilage
- ❖ *Zone II:* From cricoid cartilage to angle of the mandible
- ❖ *Zone III:* Above the angle of the mandible

### Indications for Neck Exploration in Injuries

- ◆ Expanding haematoma.
- ◆ Uncontrolled external haemorrhage.
- ◆ Decreased carotid pulse.
- ◆ Stridor, hoarseness, dysphonia, haemoptysis.
- ◆ Severe dysphagia, odynophagia.
- ◆ Blood in oropharynx.

### Treatment

- ◆ The neck is explored with adequate incision under general anaesthesia.
- ◆ The injured structure like vessels, oesophagus, trachea, muscles are sutured.

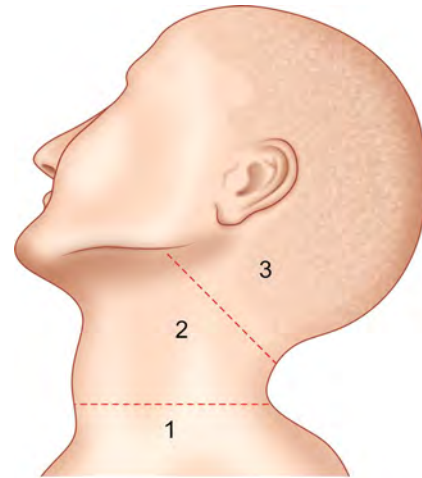


Fig. 1.248: Neck trauma zones.

- ◆ Antibiotics.
  - ◆ Blood transfusion is given as required.
  - ◆ Ryle's tube for 5–7 days.
- Other injuries like head, thorax, abdomen, maxillofacial area are discussed in respective chapters.

## BULLET INJURIES

Bullet injury has *wound of entry* and *wound of exit*. Extent of damage is not related to the external wounds. It is related to the travel of bullet inside and extent of blast or cavitation effect inside caused by the bullet. It causes burn damage.

It can damage vessels, organs like liver, spleen, kidneys, bowel, lungs, heart, cranial structures, soft tissues, bones and joints.




Fig. 1.249: Multiple pellets over elbow region after gunshot.

## Management

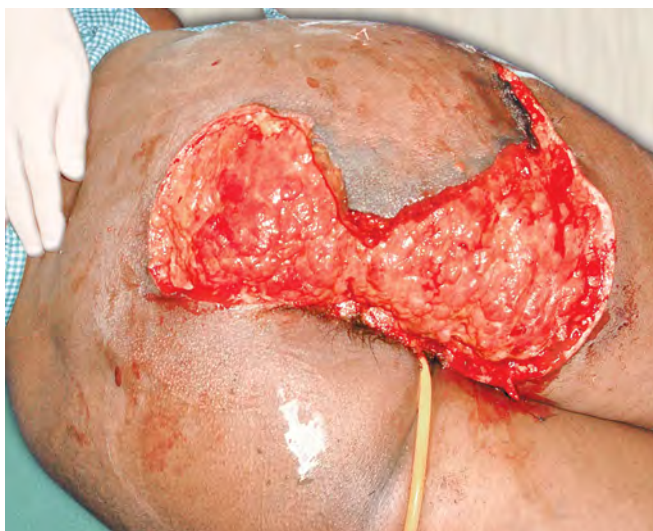- ◆ The wounds are explored properly under general anaesthesia.
- ◆ All dead tissues and dead muscles are excised.
- ◆ Skin is generously and adequately incised.
- ◆ Injured nerves are cleaned and silk marker stitches are placed to identify for later secondary suturing (Nerve should not be sutured primarily in bullet injury).
- ◆ All foreign bodies are removed.
- ◆ Tendon repair should not be done primarily.
- ◆ Wound should not be closed. It should be left open.
- ◆ Adequate blood transfusion and antibiotics coverage should be given.
- ◆ Major artery or vein are sutured. Vein graft can be used. But *synthetic graft should never be used*.
- ◆ Thorough inspection, irrigation and debridement of injured joints is done.
- ◆ Immobilisation is done.
- ◆ Tetanus toxoid, antitetanus globulin (3000 units IM), antigas gangrene serum is given.
- ◆ Second look surgeries at a later period is done once patient has been stabilised.
- ◆ Delayed primary closure in 4–7 days or secondary closure in 14 days is done.
- ◆ Depending on extent of defect, skin grafting or flaps are used.
- ◆ Laparotomy, thoracotomy, craniotomy are done depending on the site of the injury.

## ■ BLAST INJURIES

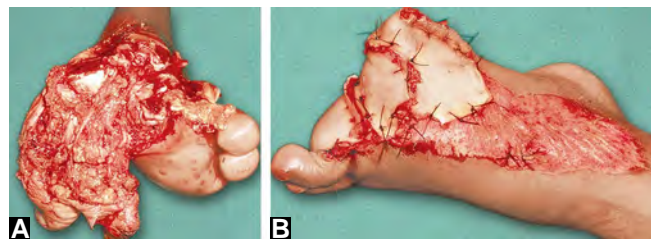
Here extent of damage is much more than bullet injuries.

It creates *complex blast wave* which contains *blast pressure wave* and *mass movement of air*.

This explosion pressure wave is more than 1000 pounds per square inch. This pressure wave has got incident pressure and reflected pressure. Both will cause severe damage.



**Fig. 1.250:** Degloving injury buttock. It needs colostomy to protect the wound from sepsis. Later once skin coverage is done colostomy is closed.



**Figs 1.251A and B:** Crush injury foot with retained skin from plantar aspect was rotated forward (Courtesy: Dr Mayur Rai, Orthopaedician, KMC, Mangaluru).

### Factors causing the damage

- ❖ High pressure wave
- ❖ Mechanical injury
- ❖ Chemical injury
- ❖ Thermal injury
- ❖ Inhalation of toxic gases and smoke

## Organs Affected

- ◆ Ear drums, lungs.
- ◆ GIT, brain.
- ◆ Skeletal system.

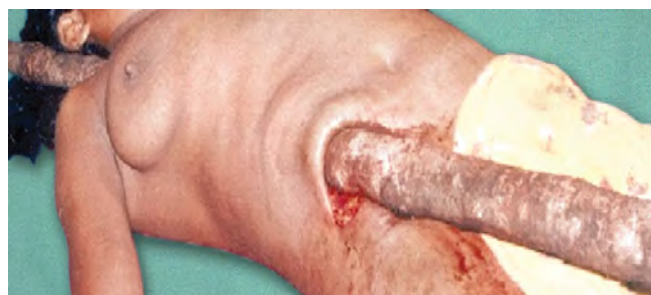Individual becomes *deaf* after blast and so rescue work may be delayed.

## Management

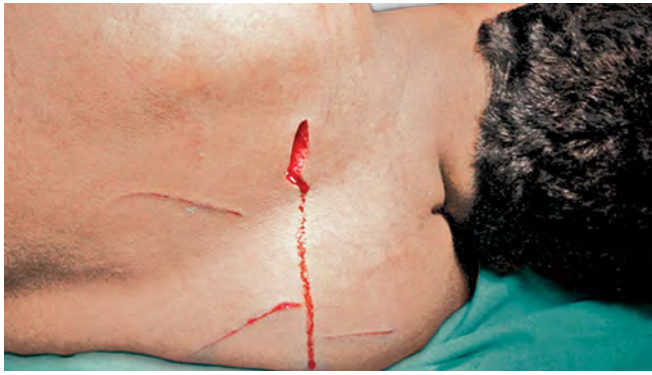- ◆ Critical trauma care.
- ◆ Management of shock and triage primary management.
- ◆ Urgent surgeries like laparotomy, thoracotomy, craniotomy.
- ◆ Massive blood transfusion.
- ◆ Antibiotics.
- ◆ Ventilator support.
- ◆ Management of specific organs like eye, ear.

## ■ PENETRATING INJURIES

- ◆ It can occur in abdomen, thorax, cranial cavity.
- ◆ It causes haemorrhage, damage to internal organs like liver, bowel vessels, lung, pericardium and heart, brain.



**Fig. 1.252:** Penetrating injury. Pole missed all the major vessels. Miraculously the patient survived, after a marathon surgery to tell her tale to her children.



**Fig. 1.253:** Stab wound on the back communicating into the thoracic cavity. Wound was explored and sutured, with an ICT inserted into the thoracic cavity.

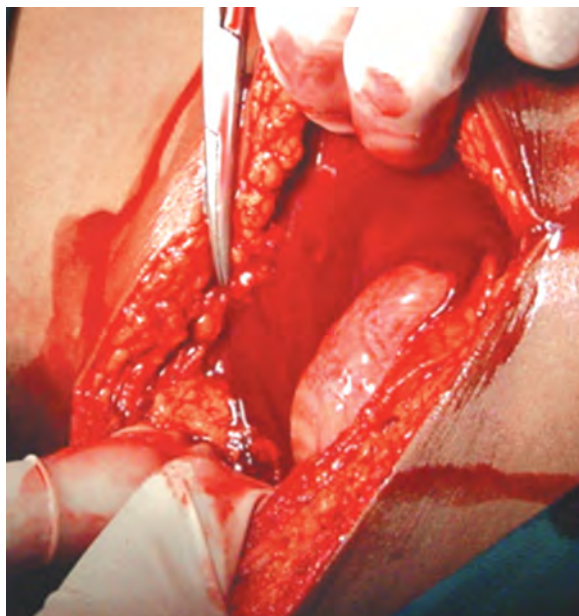
- ◆ It is life-threatening and immediate surgical intervention is the only treatment. Patient requires adequate amount of blood transfusion, antibiotics, shock management.

## ABDOMINAL TRAUMA

It can be:

- ❖ Blunt trauma
- ❖ Stab injury
- ❖ Abdominal wall injury

*Abdominal trauma* is a major surgical emergency which most surgeons face. It is often associated with head injuries, chest, pelvic and bone injuries. Often patient is unconscious causing difficulty in diagnosing the condition. Often more importance is given to other system injuries like of head, thorax and bones whereas abdominal injury is not addressed properly causing life-threatening consequences. When patient is conscious, history related abdominal trauma is useful. Abrasion over the abdominal skin suggests the possibility of internal injury (*London's sign*). Distension, tenderness, rebound tenderness,



**Fig. 1.254:** Traumatic haemoperitoneum.

fullness and dullness in the flank when present one should presume internal injury. Tachycardia, hypotension, shock may be evident when there is significant haemoperitoneum. Injuries may be organ injury like of liver, spleen, kidney, pancreas, etc. or bowel injury or retroperitoneal injury which is often under diagnosed or missed. Major vessel injury like of inferior vena cava, mesenteric vessels can cause real threat to life unless it is identified and managed early. 25% of entire trauma patients need surgical exploration of the abdomen.

Abdominal trauma can be *blunt or stab/penetrating or abdominal wall injuries*. Spleen is the most common organ involved in *blunt trauma*. Often in blunt trauma first part of the jejunum or ileocaecal junction gives way (*blow out effect*) due to traction often causing complete transection of bowel horizontally close to the junction. It is due to force of the mobile part of the bowel over the fixed part. Liver is the most common organ involved in *penetrating injuries*.

Injuries of the abdomen may be *closed injuries, compression injuries and penetrating injuries*. Penetrating injuries may be *low velocity injury* like stab injuries or *high velocity injury* like gunshot injuries. Penetration of blunt weapon causes less deep trauma than sharp weapon (sickle, knife). In sickle injury tip and sharp edge moves in curved pattern and so it is often difficult to predict the depth, track and organs injured.

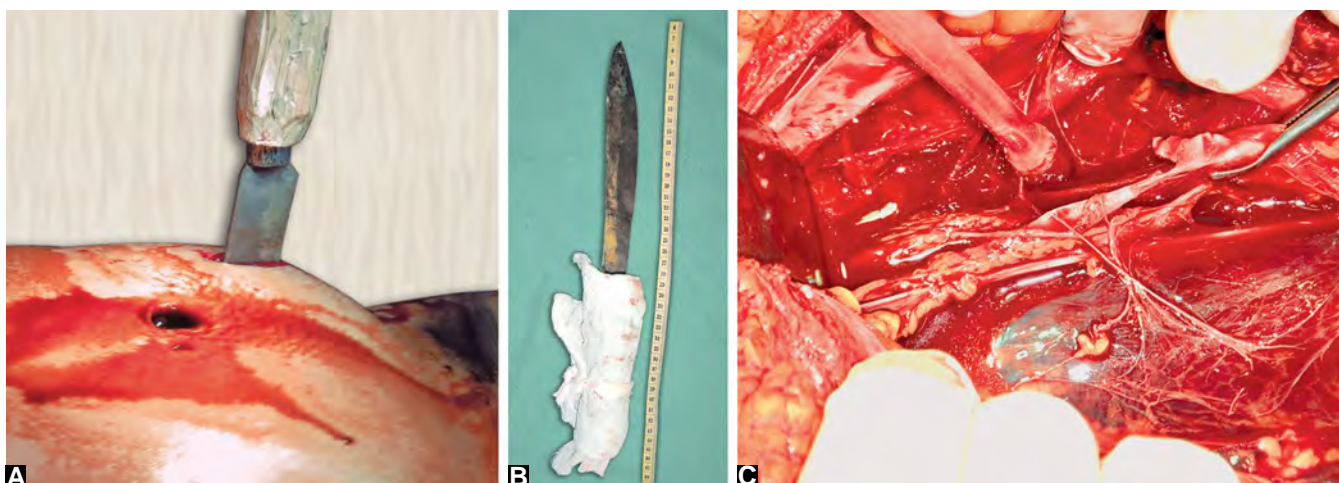
*Routinely followed indications for exploration in abdominal trauma* are—hypotension without any other cause; bleeding through wound; continuous bleeding in nasogastric tube; evisceration of abdominal content through the open wound except in case of protruded omentum without any hypotension and features of peritoneal irritation; air under diaphragm in blunt abdominal injury (not in penetrating injury as external air gets sucked into the peritoneal cavity through the wound).

### Types

- ❖ Liver injury.
- ❖ Spleen injury.
- ❖ Gastric/small bowel/colonic injuries.
- ❖ Duodenal injuries.
- ❖ Pancreatic injuries.
- ❖ Injuries to kidney/bladder/urethra.
- ❖ Mesenteric injury.
- ❖ Vascular injuries.
- ❖ Associated injuries like of diaphragm, lungs.
- ❖ Abdominal compartment syndrome.
- ❖ Gunshot or blast injuries.

### General Clinical Features

- ◆ Features of shock—pallor, tachycardia, hypotension, cold periphery, sweating, oliguria.
- ◆ Abdominal distension.
- ◆ Pain, tenderness, rebound tenderness, guarding and rigidity, dullness in the flank on percussion.
- ◆ Respiratory distress, cyanosis depending on the amount of blood loss.
- ◆ Bruising over the skin of the abdominal wall.
- ◆ Features specific of individual organ injuries.



**Figs 1.255A to C:** Stab injury to LIF by an angry husband to his wife causing left common iliac artery transection injury with aortic partial injury. In spite saphenous vein graft reconstruction patient could not survive (Courtesy: Professor Yogishkumar, MS, KMC, Mangaluru).

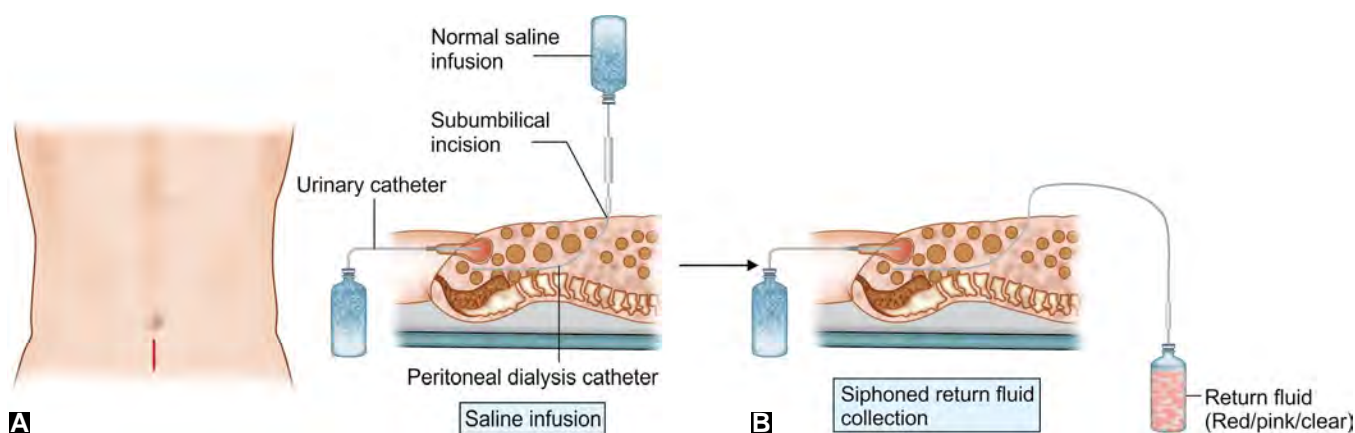
## Investigations

1. Ultrasound abdomen. FAST is *Focused Abdominal Sonar Trauma*: It is rapid, noninvasive, portable bedside method of investigation focusing on pericardium, splenic, hepatic and pelvic areas. Blood more than 100 ml in cavities can be identified. It is not reliable for bowel or penetrating injuries. It often needs to be repeated.
2. **Diagnostic peritoneal lavage (DPL)**: It is done in case of blunt injury abdomen. Through a subumbilical lavage catheter one litre of normal saline/Ringer's lactate is infused

into the peritoneal cavity. Patient is changed to different positions and side-to-side. Fluid content is aspirated from the abdomen for assessment. It has got 98% accuracy rate.

### One of the criterias signifies positive lavage

- ❖ 10 ml or more of gross blood
- ❖ RBC count more than 1,00,000/cumm
- ❖ WBC count more than 500/cumm
- ❖ Amylase level in the fluid more than 175 IU/dl
- ❖ Presence of bile, bacteria, food particles or foreign body



**Figs 1.256 and B:** *Diagnostic peritoneal lavage*—incision and technique. 10 French polyvinyl catheter is used. Urinary bladder is emptied by passing a catheter. After injecting xylocaine local anaesthesia into subumbilical region, 2–3 cm vertical subumbilical midline incision is made. Skin, linea alba is incised. Local anaesthesia is infiltrated into the peritoneum again. Peritoneum is held with two haemostats and a purse string suture is placed using polyglactic acid absorbable suture material. Peritoneum is incised for 3 mm length. Catheter (standard peritoneal dialysis catheter) is introduced into the peritoneal cavity. If blood enters the catheter immediately, it means early laparotomy is needed and carried out without continuing the peritoneal lavage. Otherwise, one litre of normal saline is infused into the peritoneal cavity rapidly in few minutes through the catheter using a drip set with elevation of the fluid bottle/bag. Patient is moved well to mix the fluid in all four quadrants. Now bag is lowered below so that fluid from the peritoneal cavity reenters/siphoned into the bag. Collected fluid is analysed for red cells, leukocytes, etc. DPL may not be useful in bowel injury, retroperitoneal injury, diaphragmatic injury, organ haematoma (subcapsular splenic haematoma). If patient is decided for observation catheter can be left *in situ* for repeat DPL after 6 hours. One has to remember that DPL is not a substitute for clinical assessment and monitoring. In *Lazarus-Nelson* approach Teflon catheter with a guide wire is used.

*Well done is better than well said.*

It is the procedure of choice in physiologically unstable patient with blunt abdominal injury (like with spinal injury, unconscious patient).

#### Contraindications for DPL

- ❖ When laparotomy is definitely indicated
- ❖ Previous laparotomy
- ❖ Pregnancy
- ❖ Obesity

3. CT scan is indicated in assessing retroperitoneum, solid organ injuries. It is noninvasive and highly specific.
4. Diagnostic laparoscopy (DL) is valuable method in stable abdominal trauma patient.

## Treatment

Emergency laparotomy.

#### Indications for laparotomy

- ❖ Frank haemoperitoneum
- ❖ Significant diagnostic peritoneal lavage
- ❖ Haemodynamically unstable patient
- ❖ U/S or CT scan shows significant intra-abdominal injuries

## BLUNT TRAUMA OF ABDOMEN

It is common in accidents. It is often missed or lately diagnosed. Ultrasound/CT abdomen or diagnostic peritoneal lavage (DPL) is useful. In many cases on clinical grounds direct exploratory laparotomy is done. Plain X-ray abdomen may show gas under diaphragm.

Difficulty arises in *deciding about the need for laparotomy* in abdominal trauma in *unconscious* patients. If severity of external injury is out of proportion to the existing severe shock then exploratory laparotomy is indicated in an unconscious patient. It is also often difficult to diagnose bowel injury in such patients. If it is suspected laparotomy should be undertaken in such patients. Associated spinal injury masks the abdominal findings.

Injuries may be of liver, spleen, GIT, pancreas, mesentery, vascular or diaphragm. Associated chest, pelvis, skeletal and head injuries should be remembered.

### Features of Blunt Trauma

- ◆ Features of profound shock, progressive distension of abdomen, pain, tenderness, guarding, rigidity, rebound tenderness, dull flank.
- ◆ Features specific of individual organ injury like obliteration liver dullness in bowel injury.
- ◆ Bruising of skin over the abdomen—*London's sign*.
- ◆ Respiratory distress, cyanosis.
- ◆ Repeated clinical examination is a must in blunt trauma.

## Evaluation

### Ultrasound Abdomen

- ◆ It is very useful, simpler, noninvasive method of evaluating the abdomen. Negative ultrasound means no immediate further intervention is needed and also conservative treatment can be undertaken.

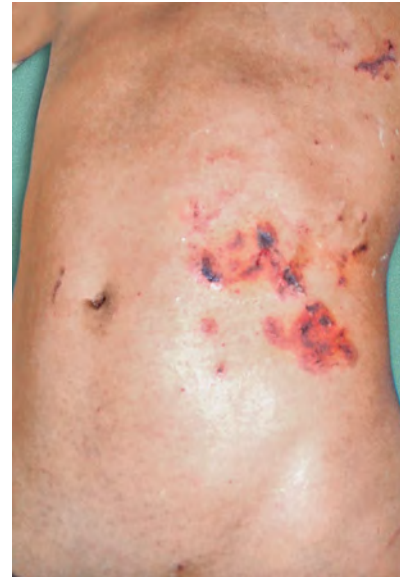


Fig. 1.257: Blunt injury abdomen. Note the bruising over abdominal skin—*London's sign*.

- ◆ *Advantages of ultrasound:* There is no danger of radiation; it can be done bedside; it can be repeated many times; it is cost-effective. Its sensitivity is 90%; specificity is 98%. Focused abdominal sonar (ultrasound) for trauma (*FAST*) is very useful method.
- ◆ *Disadvantages:* It is less useful in obesity, with interposition of gas, when fluid is less than 500 ml; retroperitoneal injuries and bowel injuries.
- ◆ *Focused abdominal sonar trauma (FAST):* It is rapid, noninvasive, portable bedside method of investigation focusing on pericardium, splenic, hepatic and pelvic areas. Blood more than 100 ml in cavities can be identified. It is not reliable for bowel or penetrating injuries. It often needs to be repeated.

### Diagnostic Peritoneal Lavage (DPL) (by Perry)

It is useful in *blunt injury* abdomen. It is not very useful in penetrating injury, bowel injury, retroperitoneal and pelvic injuries.

### CT Scan of Abdomen

It is most commonly used and better investigation for abdominal trauma. It is useful in blunt/penetrating trauma, suspected pancreas, spleen, liver, duodenal, retroperitoneal injuries. Smaller injuries, early haemoperitoneum are better detected. It is noninvasive, highly specific, highly accurate (96%), with low false-positive/low false-negative, noninvasive.

### Other Investigations

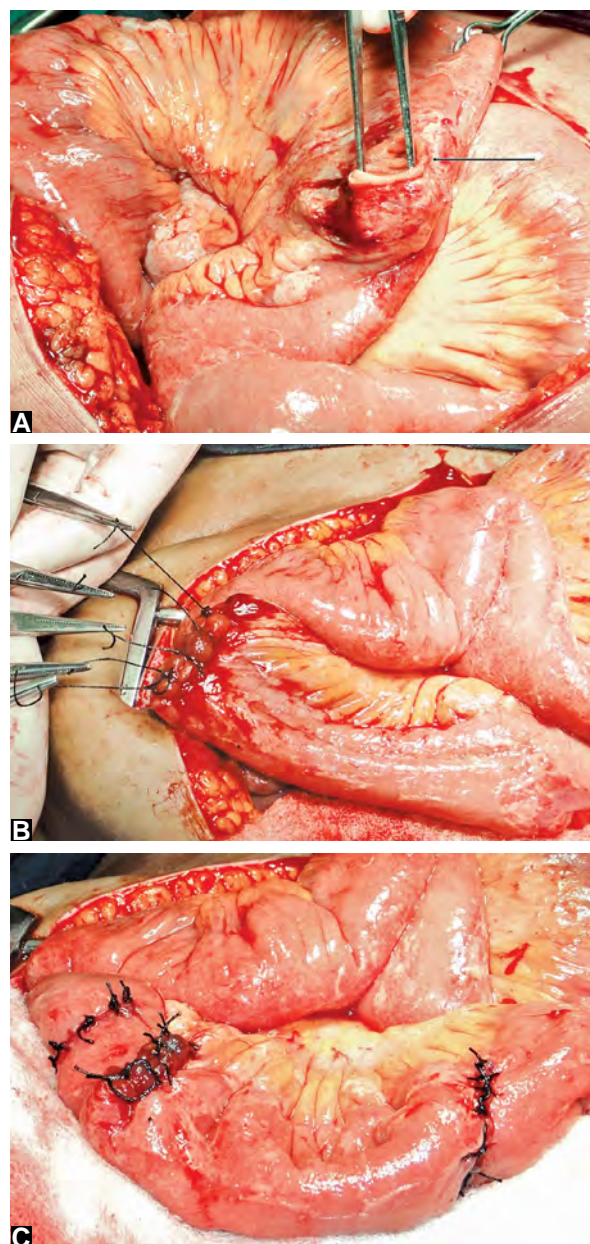
- a. *Abdominal diagnostic paracentesis* (Drapanas and McDonald): Here 18 G short bevel spinal needle is inserted into the peritoneal cavity after injecting local anaesthetic agent into the abdominal wall. With continuous suctioning through syringe, needle is passed at various sites. Positive tap means return of minimum of 0.1 ml of nonclotted blood. False-positive result occasionally can occur due to needle puncture of abdominal wall vessels. Needle should not be inserted close to previous abdominal scar as bowel may be adherent underneath the scar. Change of direction of needle is done by withdrawing the needle tip outer to peritoneum and again

puncturing the peritoneum. Puncture by 18 G needle of nondistended bowel will seal without any leakage. Peritoneal tap should be avoided if bowel is distended. *Bilateral flank tap/four quadrant tap* is also done with similar result. Rectus sheath haematoma and false-negative results are the problems.

- b. *Diagnostic laparoscopy* is very useful. It can be done under local anaesthesia. Haemoperitoneum, solid organ and diaphragmatic injuries are well assessed. But bowel and retroperitoneal injuries are more likely to be missed.
- c. *Arteriography* through Seldinger technique is useful in suspected cases of renal arterial injury (thrombosis/spasm); intimal tears, traumatic aneurysm and aortic occlusion (after seat belt injury) are well diagnosed with arteriography. Often it can be therapeutic also. Pelvic bleed extending into retroperitoneum is not uncommon which can be assessed by arteriography and also the bleeding vessel can be identified. But venous bleed cannot be assessed by this.
- d. *Doppler assessment of major vessels* may be beneficial especially for IVC, aorta, iliac vessels, and portal system; but with haemoperitoneum visualisation window may be poor and vessels can be better identified by contrast CT scan.

## Management Concepts in Abdominal Trauma

- ◆ *Evaluation* of extent of the injury; number of organs injured and severity of injury; haematocrit assessment (haemoglobin drop up to 6 g% is tolerated well with adequate tissue oxygenation. Rapid drop of haemoglobin needs adequate number of blood to be kept ready for transfusion, like 5/10/bottles or more); central line for volume replacement; urinary catheterisation; administration of systemic antibiotics.
- ◆ *Autotransfusion of blood* is very useful as a life-saving procedure in such situation. Blood from the cavity is sucked out into a sterile bottle which contains 150 ml of 3.8% sodium citrate dextrose solution. This blood is strained/filtered through gauze and re-transfused. If there is colonic and small bowel injuries auto transfusion is not possible for fear of sepsis due to contamination.
- ◆ *Upper midline incision* extending down across the left of the umbilicus is the preferred incision. But surgeon should not be hesitant to extend the incision into the thorax or do horizontal T or extend as needed depending on the internal organ injury.
- ◆ *First priority* after opening the abdomen is *immediate control of profuse bleeding using finger compression or mop* or pressure. Later once the field is clean; area is assessed for the extent of injury without releasing the compressed finger on the bleeding site. A vascular clamp or bulldog clamp is helpful in such situation. Once it is applied over the site of bleeding, compressing finger can be removed. Vascular suturing using 4 zero or 6 zero polypropylene/resection of the tissue; reconstruction of the area; persistent pressure mop *in situ* with closure of the abdominal wall with an option of second look surgery in 48 hours are the different options. Individual organs are assessed and graded for injuries and managed accordingly.
- ◆ During laparotomy, entire abdomen should be inspected/palpated carefully for any additional missed injuries. Lesser sac, retroperitoneum, duodenum, pancreas and diaphragm should be checked. Often peritoneum on the margin of the duodenum and right side colon is incised, duodenum and colon is reflected medially to visualise the retroperitoneum. Pelvic structures need special attention. Rectum, urinary bladder injuries are likely to be missed if proper



**Figs 1.258A to C:** Traumatic blunt injury abdomen causing small bowel injury which is sutured using interrupted horizontal silk sutures.

attention is not given. On catheterization, if urine is clear it means urinary system is normal. Portal venous system should be assessed.

- ◆ *Resection or repair* should be decided later once haemostasis is maintained. Whether the injury is to the bowel or organs (liver/spleen/kidney, etc.) resection or repair approach is decided depending on the severity of individual organ injury (based on scale or grade).
- ◆ *Mesenteric tear* may be the cause for haemoperitoneum. Tear may be perpendicular or parallel to the bowel. If it is perpendicular, haemostasis and approximation of the mesentery is sufficient; if it is parallel tear, then blood supply to corresponding bowel may be compromised and resection of that part of the bowel is indicated. Mesenteric haematoma is left alone if small

and nonprogressive. Whether there is any colour changes in the adjacent bowel should be observed. If haematoma is large; if it is progressive; if it causes compromised blood supply to the adjacent bowel, then it should be gently evacuated. Mesenteric leaf is opened using curved scissor; clot is evacuated using gentle finger dissection; bleeder is identified and ligated. If there is compromised bowel function, it should be resected. Bleeding from the major vein like superior mesenteric vein is disastrous as tear may not be localised but may be extensive; and even gentle dissection may cause more tear. It is carefully mobilised; vascular clamps are applied and repaired using 5 zero polypropylene sutures.

- ◆ **Aortic clamping:** Catastrophic bleeding found after opening the abdomen which cannot be controlled and bleeding with profound hypotension are the indications for aortic clamping. Profuse intraperitoneal bleed comes under control temporarily by tamponade effect of tense abdominal wall and it itself temporarily helps the patient. The moment abdomen is opened; tamponade effect is released causing further rapid bleed leading into critical catastrophe. If such event is expected prior to opening the abdomen very quick rapid thoracotomy (*prelaparotomy thoracotomy*) through left 5th intercostal space is done; left lung is deflated and displaced; pleura over the thoracic aorta is incised; aorta is dissected using finger; vascular clamp or soft intestinal occlusion clamp is applied to occlude the thoracic aorta. Later laparotomy is performed to go ahead with management of the bleeding. If profound bleeding is observed after laparotomy necessitating the aortic clamping, it is done by applying the clamp in infradiaphragmatic part of the aorta. Peritoneum is incised on the right of the abdominal oesophagus in infradiaphragmatic area; aorta is dissected using finger high up close to diaphragm to avoid injury to celiac plexus; clamp is applied across (infradiaphragmatic aortic occlusion).
- ◆ *Usually drainage* using tube drains on either side of the abdomen is used even though it is controversial. ICT should be placed if thoracotomy is also undertaken.
- ◆ *Jejunostomy* for enteral nutrition is ideal in all major abdominal injuries. Often gastrostomy is also done along with jejunostomy in case of duodenal and pancreatic injuries.
- ◆ *Management of individual organs* after grading its severity of the injury—duodenum, pancreas, liver, spleen, bowel, kidney, etc. (*Please refer individual chapters for detail—highlights of individual organ injury is given below*).
- ◆ Management as critical care (ICU with intensivist); multiple blood transfusions; management of sepsis, maintenance of respiration, management of electrolyte changes, treatment of renal failure, provision of nutrition, prevention of DVT, management of DIC are very essential part of postoperative treatment.

## DUODENAL INJURY

- ◆ Its severity depends on the type and extent of the injury.
- ◆ It can be haematoma or lacerations.
- ◆ Lacerations can cause duodenal disruption, may be < 50% or >50% or 75% or more.
- ◆ Laceration may extend into the ampulla, distal CBD, pancreas or with duodenal devascularisation.

### Management

- ◆ CT scan is more relevant investigation.
- ◆ Associated other injuries should be managed accordingly.
- ◆ Haematoma without extension is managed conservatively with nasogastric aspiration, antibiotics and IV fluids.

- ◆ Lacerations are sutured surgically with a stenting or often with bypass like gastrojejunostomy.
- ◆ ERCP stenting or CBD bypass is also often required.

### Grading of duodenal injury

Grade I – Haematoma – Laceration	Involving single portion of the duodenum. Partial thickness injury without perforation.
Grade II – Haematoma – Laceration	Involving more than one portion. Disruption less than 50% circumference.
Grade III – Laceration	Disruption of 50–75% of the circumference of 2nd part of the duodenum; disruption 50–100% of the 1st, 3rd or 4th part of the duodenum.
Grade IV – Laceration	Disruption more than 75% of 2nd part of the duodenum and involving the ampulla or distal common bile duct.
Grade V – Laceration – Vascular	Severe disruption of duodenopancreatic complex. Duodenal devascularisation.

### Complications

- ◆ Infection, duodenal leak.
- ◆ Peritonitis, haemorrhage.

## PANCREATIC INJURY

- ◆ It can be in the head or body and tail of the pancreas.
- ◆ It may be associated with injury to duodenum or portal or superior mesenteric veins.
- ◆ It can be contusion or severe lacerations.

### Management

- ◆ High resolution CT scan is diagnostic.
- ◆ Distal pancreatectomy for injuries distally.
- ◆ Conservative treatment is useful with antibiotics, IV fluids.
- ◆ Whipple's operation or total pancreatectomy is done as a last resort.
- ◆ Drainage of the pancreatic bed is simple and often useful method.

### Complications

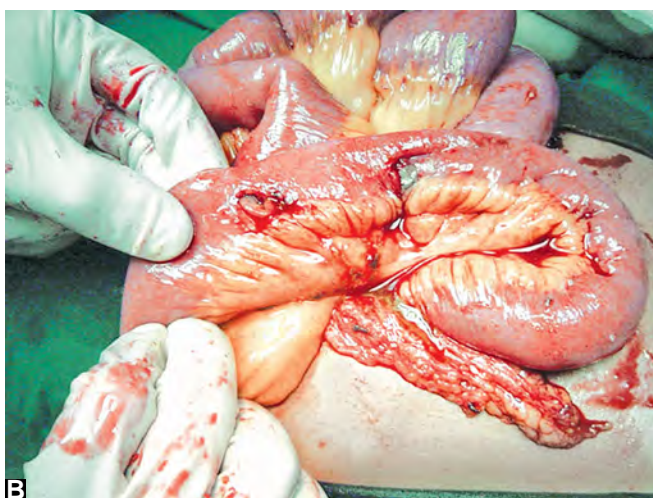
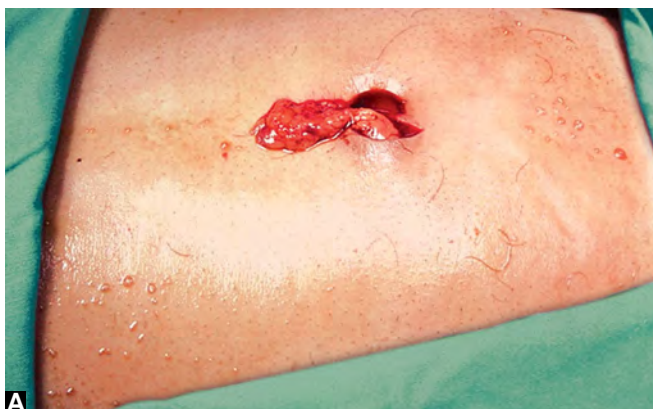- ◆ Pancreatitis, septicæmia.
- ◆ Pancreatic fistula, pancreatic abscess formation.  
Pancreatic injury has got high mortality (>45%).

## SMALL BOWEL INJURY

- ◆ It can be blunt injury or stab injury.
- ◆ Blunt injury causes disruption of either duodenojejunal region or at ileocaecal region.
- ◆ Presentation is like haemoperitoneum or features of peritonitis.
- ◆ *Monks localising zones* in the abdomen signify the location of the small bowel injury.
- ◆ Presence of pattern bruising over the abdominal wall signifies the small bowel injury and its site. It is called as *London's sign*.

### Management

- ◆ Plain X-ray abdomen shows gas under abdomen with ground-glass appearance.



**Figs 1.259A and B:** Assault causing stab injury abdomen. On opening the abdomen, multiple perforations were found in the small bowel and was sutured. Patient recovered well.

- ◆ Ultrasound abdomen is useful.
- ◆ Laparotomy and closure of the perforation if it is small.
- ◆ In presence of extensive bowel injury or multiple injuries, resection and anastomosis is done.
- ◆ Any associated injuries should be dealt with accordingly.

## COLONIC INJURY

- ◆ Left sided injury is treated with proximal colostomy with closure of the wound if it is small, or resection and anastomosis if it is wider area. Closure of colostomy is done at later stages after 3–6 months.
- ◆ Small wound over right-sided colon can be sutured primarily.
- ◆ Ileostomy alone or ileostomy with ileo-transverse anastomosis or right hemicolectomy with ileostomy is indicated in following situations:
  - ▶ Extensive peritoneal contamination.
  - ▶ Colonic vascular injuries.
  - ▶ Haemodynamically unstable patients.
  - ▶ Long-term hypotension after trauma.

## LIVER INJURY

It can be subcapsular haematoma, lacerations, deeper injuries, lacerations with disruption of hepatic lobes or segments or liver injury with vascular injuries like of inferior vena cava or hepatic veins.

Present with features of haemorrhagic shock, distension of the abdomen, tenderness, rebound tenderness, guarding, rigidity.

- ◆ CT is diagnostic tool
- ◆ Liver injury is graded depending on involvement of hepatic veins, portal system, biliary system and duodenum
- ◆ Often high grade liver injury also can be managed nonoperatively
- ◆ *Push* (direct compression); *Pringle* (occluding portal triad at foramen Winslow with fingers temporarily); *plug* by embolisation; *pack* the liver bed; repair of vena cava or portal vein; stenting of biliary tree and hemihepatectomy—are the treatment strategies

## Management

- ◆ Small tear is sutured.
- For larger tears:
  - ▶ Deep sutures.
  - ▶ Packing.
  - ▶ Debridement.
  - ▶ Haemocoagulants.
- ◆ Liver resection is not done (not advisable) usually for injuries.
- ◆ *Pringle manoeuvre*—by compressing the porta near foramen Winslow—to control bleeding (not more than 30 minutes).
- ◆ Blood transfusions.
- ◆ Treatment of associated injuries like of diaphragm, lung, duodenum, colon.
- ◆ Antibiotics.

## Complications of Liver Injury

- ◆ Haemorrhage, septicaemia, bile leak.
- ◆ Liver failure, haemobilia.
- ◆ Subphrenic abscess, CBD stricture.

## SPLENIC INJURY

It can be subcapsular haematoma, laceration or hilar injury.

It can be associated with other organ injuries like left kidney, left lobe of the liver, splenic flexure of the colon or pancreas.

It can cause torrential haemorrhage and shock.

*It is the most common organ injured in blunt injury abdomen.*

## Management

- ◆ Ultrasound abdomen, diagnostic peritoneal lavage are the investigations.
- ◆ Blood transfusions.
- ◆ Splenorrhaphy is done in selected patients so as to save the spleen.
- ◆ Splenectomy.
- ◆ Management of associated injuries.

## Complications of Splenectomy

- ◆ Left lung atelectasis.
- ◆ Overwhelming postsplenectomy infection (OPSI).
- ◆ Pancreatitis and pancreatic fistula.
- ◆ Gastric bleeding.
- ◆ Subphrenic abscess.

*What we need is cup of understanding, barrel of love and an ocean of patience.*



## RENAL INJURY

- ◆ It is commonly managed conservatively.
- ◆ IVU is the investigation of choice in renal injury.
- ◆ Surgery is indicated when there is hilar injury, progressive bleeding, failure of conservative treatment or perinephric abscess formation.

## URINARY BLADDER INJURY

**Intraperitoneal bladder** injury occurs in distended bladder. It is treated always by surgical exploration through transabdominal approach. Bladder tear is sutured with keeping a suprapubic cystostomy using Malecot's catheter.

**Extraperitoneal injury** can be treated conservatively by placing a Foley's catheter for 2–3 weeks.

## ABDOMINAL COMPARTMENT SYNDROME

*Abdominal compartment syndrome* (ACS; Richards and Krons, 1984) is organ dysfunction caused by increased intra-abdominal pressure more than 12 mmHg (intra-abdominal hypertension/IAH); organ dysfunction is usually respiratory, cardiovascular and renal but can be any organ; normal intra-abdominal pressure is being considered as 2–7 mmHg.

*Abdominal perfusion pressure* (APP) is the pressure which maintains adequate abdominal blood flow. It is measured by subtracting the *intra-abdominal pressure* (IAP) from mean arterial pressure (MAP). APP in ACS is usually less than 60 mmHg but should be maintained as more than 60 mmHg.

### Effects

- ◆ **Cardiovascular system:** It is often sudden, rapidly progressive, decreasing the venous return (due to IVC compression) to heart and increasing peripheral resistance, with decreased right atrial pressure and decreased cardiac output.
- ◆ **Respiratory system:** Intrapleural pressure is increased proportionately to the abdominal pressure. Upward displacement of the diaphragm, increased peak inspiratory pressure, hypoxia, hypercapnia, acidosis, respiratory failure, ARDS are other problems. It also causes restrictive lung disease.
- ◆ **Renal system:** Decreased renal blood flow and glomerular filtration causes oliguria, renal failure.
- ◆ **Gastrointestinal system:** Mesenteric venous hypertension; bowel wall oedema and ischaemia.
- ◆ **Central nervous system:** Cerebral oedema and hypoxia, unconsciousness.

### Causes

- ◆ Major abdominal trauma, postoperative haemorrhages, after damage control surgery with abdominal packings, are the common causes; ruptured aortic aneurysm.
- ◆ Closure of the abdomen under tension; forcible reduction of the massive hernia.
- ◆ Bowel wall oedema, mesenteric congestion, acute ascites; profound hypothermia and coagulopathy.
- ◆ Acute gastric dilatation, paralytic ileus, gastroparesis, colonic pseudo-obstruction.

- ◆ Retroperitoneal haemorrhages, pancreatitis.
- ◆ Laparoscopic procedures.
- ◆ Morbid obesity, pregnancy, major burns, continuous ambulatory peritoneal dialysis are precipitating causes.

## Features and Diagnosis

- ◆ Tensely distended abdomen, progressive oliguria, airway obstruction, occult blood loss.
- ◆ *Measurement of urinary bladder pressure:* Transducer and manometer methods are available. Bladder acts as a passive reservoir at volume less than 100 ml (now 25 ml saline is used to measure) and it can transmit IAP without imparting any additional pressure from its bladder musculature. Measurement of bladder pressure reflects the IAP pressure. IAP is measured using a *urinary catheter in the urinary bladder*. Pressure is graded (Burch) as: I—10–15 cm of H<sub>2</sub>O (will not require decompression); II—16–25 cm of H<sub>2</sub>O (needs close monitoring); III—26–35 cm H<sub>2</sub>O (most need decompression); IV—more than 36 cm H<sub>2</sub>O (all need decompression otherwise will die of cardiac arrest in few hours). Beyond grade III immediate decompression is needed. Initial *volume preload is essential* otherwise sudden decompression may cause cardiac arrest in asystole due to reduced preload, sudden influx of high potassium, acid and other metabolic by products into the heart. Grade III and IV becomes a *surgical emergency*.
- ◆ Chest X-ray, ECG monitoring, ICU care, electrolytes, haematocrit and serum creatinine estimation, USG abdomen should be done.
- ◆ *Mortality for ACS is 40%.*

Intra-abdominal pressure grading	Burch grading in cm of water	World Society of the ACS in mm of Hg (Muckart et al., and Malbrain et al.)
I	10–15 cm of H <sub>2</sub> O	12–15 mmHg
II	15–25 cm of H <sub>2</sub> O	16–20
III	25–35 cm of H <sub>2</sub> O	21–25
IV	>35	≥25

Abdominal compartment syndrome (ACS)		
Causes	Features	Management
Multiple trauma and ICU patients—common Postoperative ileus Acute abdomen Acute gastric dilatation Laparoscopic procedures Intestinal obstruction Major burns	Hypoxia, hypercarbia Decreased urine output – anuric renal failure in severe cases Tense abdomen—distended Decreased venous return Refractory hypoxaemia in severe cases Bowel ischaemia Cardiac arrest	Bladder pressure assessment Ryle's tube aspiration Hypotension Resuscitation ICU care Surgical decompression

## Treatment

- ◆ Abdominal decompression is the only ideal treatment for ACS; technique and timings are decided based on the clinical situation.
- ◆ Temperature and coagulation profile should be made as possible as normal prior to decompression.
- ◆ Silastic sheet created *chimneys* sutured to fascia around is often used. Pressure free abdominal closure should be the target. *Bogota bag*, first described by Londoni, chief resident in Bogota, Columbia is cost effective; here irrigation bags are sutured to each other as necessary to get a proper size and is sutured to fascia around using 1 zero nylon suture. Several litres of serosanguineous or ascitic fluid are let out through a plastic stoma bag attached to a closed drainage system. Once patient is haemodynamically stable, definitive closure is performed after 48 hours. Abdominal fascia is closed using nonabsorbable sutures; subcutaneous tissue and skin are closed at a later period. Fluid and electrolyte management, antibiotics, adequate blood or blood product transfusions should be used as needed.
- ◆ *Other methods of closure:* Towel clips, temporary mesh placement; PTFE mesh repair; vacuum assisted closure are all temporary closure methods. Definitive closure methods

– Primary closure of fascia; closure using synthetic mesh if no sepsis in the wound; biological mesh closure; component separation technique; closure using skin graft or flaps.

## SEAT-BELT INJURIES

- ◆ In an individual with seat-belt, during impact, *violent deceleration* of human body occurs. Seat-belt impinges heavily on its point of contact with trunk and viscera continue to move forward. It leads into severe contusion of abdominal contents; *detachment of bowel from its mesentery* due to free forward rapid mobility of the bowel over a relatively fixed mesentery. Solid organ injury occurs only occasionally.
- ◆ *Two point anchorages* causes solid organ injuries like of liver/spleen. *Lap-belt* causes contusion and bowel injury commonly.
- ◆ It is often difficult to identify the injuries due to presence of more obvious other injuries. CT chest and abdomen, diagnostic peritoneal lavage (DPL) are very useful.
- ◆ Petechiae around iliac crest or costal margin are signs wherein one can suspect seat-belt injuries.
- ◆ Distraction fracture of lumbar spine (*chance fracture*) with hyperaesthesia of T12 and L1 level is often associated. 10% of such fractures are associated with intra-abdominal injuries.
- ◆ *Treatment* is immediate laparotomy and proceed—bowel suturing/resection/suturing of the organ injuries/splenorrhaphy/splenectomy.

# K. Hand and Foot

## CHAPTER OUTLINE

- |                                   |                                    |                      |
|-----------------------------------|------------------------------------|----------------------|
| ❖ Hand                            | ❖ Compound Palmar Ganglion         | ❖ Foot               |
| ❖ Hand Infections                 | ❖ Orf                              | ❖ Callosity          |
| ❖ Acute Paronychia                | ❖ Milker's Nodes/Nodules           | ❖ Corn               |
| ❖ Chronic Paronychia              | ❖ Hand Injuries                    | ❖ Plantar Fasciitis  |
| ❖ Apical Subungual Infection      | ❖ Dupuytren's Contracture          | ❖ Ingrowing Toe Nail |
| ❖ Terminal Pulp Space Infection   | ❖ Volkmann's Ischaemic Contracture | ❖ Onychogrophosis    |
| ❖ Infection of Web Spaces         | ❖ Syndactyly                       | ❖ Onychomycosis      |
| ❖ Deep Palmar Space Infection     | ❖ Mallet Finger                    | ❖ Athlete's Foot     |
| ❖ Space of Parona Infection       | ❖ Heberden's Nodes                 | ❖ Hallux Valgus      |
| ❖ Acute Suppurative Tenosynovitis | ❖ Spina Ventosa                    |                      |

## HAND

### Surgical Anatomy of the Hand

#### Flexor Retinaculum

- It extends medially from pisiform and hook of hamate, laterally to scaphoid tubercle and trapezium crest as a strong fibrous band so as to bridge carpus to create a carpal tunnel.
- Ulnar nerve and vessels, palmar cutaneous branches of median and ulnar nerves, palmaris longus muscle are superficial to the carpal tunnel.
- Median nerve, tendons of flexor digitorum superficialis, profundus and pollicis longus, radial and ulnar bursa are deep to flexor retinaculum.

#### Palmar Aponeurosis

It is a thickened, modified deep fascia in the palm with its apex pointing proximally (as continuation of palmaris longus) and base distally which in turn gets divided into four parts. They extend over deep transverse ligament into lumbrical tunnel.

### Blood Supply of the Hand

- Superficial palmar arch is mainly formed by ulnar artery and completed by superficial palmar branch of radial artery. It gives four digital branches to medial three fingers.
- Deep palmar arch is formed by radial artery and is completed by deep branch of ulnar artery. It gives three palmar metacarpal arteries which communicate with superficial palmar arch. It also gives communicating, perforating branches to dorsal metacarpal arteries.

### Muscles of the Hand

- Thenar muscles:** Abductor pollicis brevis, flexor pollicis brevis, opponens pollicis and adductor pollicis.
- Hypothenar muscles:** Palmaris brevis, abductor digiti minimi, flexor digiti minimi and opponens digiti minimi.

- Lumbricals** are four in number—named from lateral to medial.
- Four **palmar interossei**.
- Four **dorsal interossei**.

### Nerve Supply

- Abductor pollicis brevis, flexor pollicis brevis, opponens pollicis and 1st and 2nd lumbricals are supplied by median nerve (5 muscles).
- Rest of the muscles in hand are supplied by ulnar nerve (15 muscles).

### Modified Verdan Zone System in the Hand (Tendon Zones)

#### Zone I

From the fingertip up to the attachment of flexor digitorum superficialis (middle of middle phalanx). It contains tendon of flexor digitorum profundus.

#### Zone II

It begins proximal to metacarpophalangeal joint at distal palmar crease and extends up to the attachment of flexor digitorum superficialis at the middle of the middle phalanx. It is called as "**No-Man's-Land**." Here flexors are tightly enclosed within a fibro-osseous tunnel. It is the **most dangerous zone** in hand injuries (**critical zone**).

#### Zone III

It begins at the distal end of flexor retinaculum (base of the palm) and ends at the transverse crease of the palm. It contains lumbricals attached to flexor digitorum profundus.

#### Zone IV

It begins at the proximal end of the flexor retinaculum and ends at its distal end.

### Zone V

It extends from the proximal end of flexor retinaculum up to distal third of the forearm.

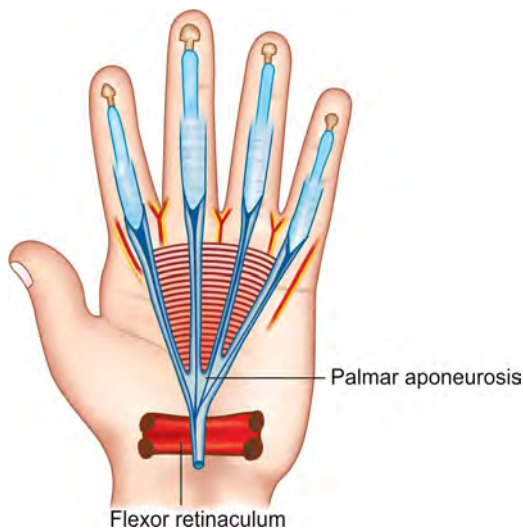


Fig. 1.260: Anatomy of flexor retinaculum and palmar aponeurosis.

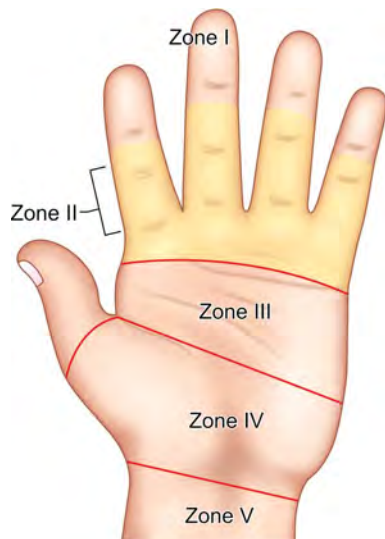


Fig. 1.261: Modified Verdan zone system in the hand.

## HAND INFECTIONS

- ◆ Hand is a compact actively functioning unit. It contains neurovascular bundles, muscles, bones and ligaments.
- ◆ Infection may be due to minor injuries or blood borne.

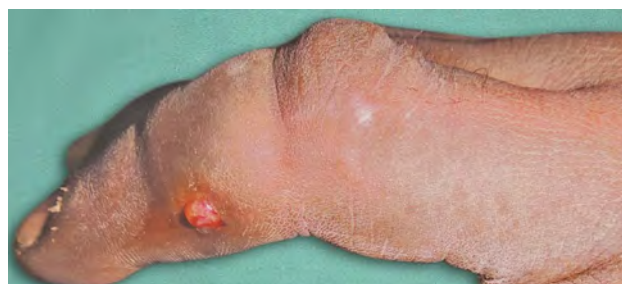

Fig. 1.262: Infection of finger at middle phalanx level. Note the oedema and position of the finger.

### Precipitating causes

- ◆ Diabetes
- ◆ Immunosuppression
- ◆ Trauma
- ◆ HIV infection
- ◆ Steroid therapy
- ◆ Vascular diseases

### Common organisms

- ◆ *Staphylococcus aureus*—most common – 90%
- ◆ *Streptococcus*
- ◆ Gram-negative organisms like *E. coli*, *Klebsiella*, *Pseudomonas*
- ◆ Occasionally fungal infection causing chronic paronychia, Madura hand due to *Nocardia* group of fungi, viral infection like *orf* can occur

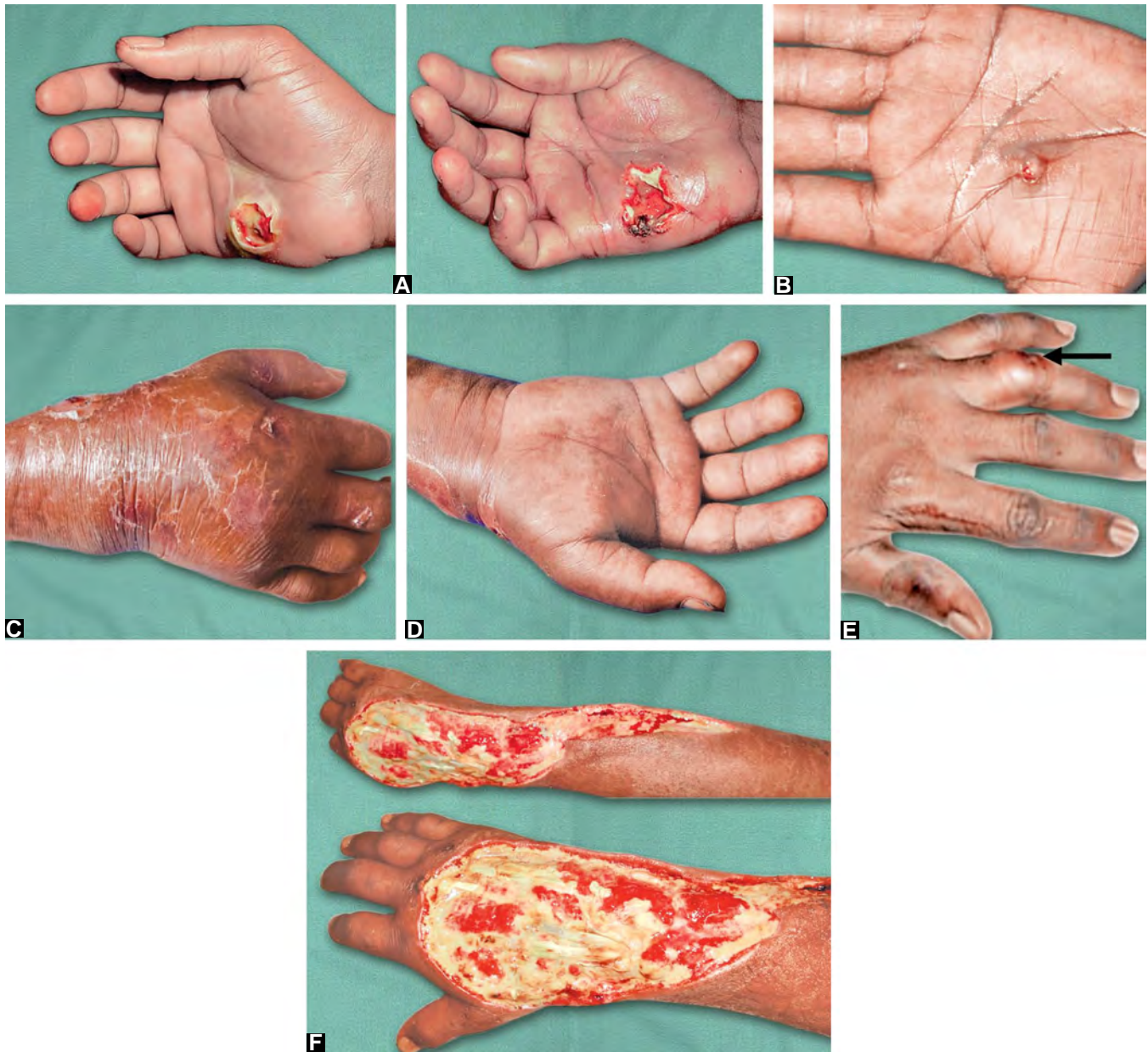## General Features of Hand Infection

- ◆ Infection spreads faster in all areas.
- ◆ Causes oedema over the dorsum of hand due to lax skin and more lymphatic network even though infection per se is more over the volar aspect. It looks like **frog hand**.
- ◆ Restricted movements of fingers and hand. The hand functions like **hook, pinch, grip, grasp** are lost.
- ◆ Severe pain and tenderness, with fever.
- ◆ Tender palpable axillary lymph nodes are often present.

## Different Types of Hand Infections

- ◆ Acute paronychia.
- ◆ Chronic paronychia.
- ◆ Terminal pulp space infection (**felon**).
- ◆ Subungual infection.
- ◆ Web space infection.
- ◆ Mid-palmar space infection.
- ◆ Thenar space infection.
- ◆ Deep palmar abscess.
- ◆ Acute suppurative tenosynovitis.
- ◆ Chronic tenosynovitis of flexor tendon sheath of palm and forearm—compound palmar ganglion.
- ◆ Lymphangitis of the hand.
- ◆ Arthritis of hand joints.
- ◆ Subcuticular abscess

*Hand infection* can be superficial or deep; it can be localised or spreading.



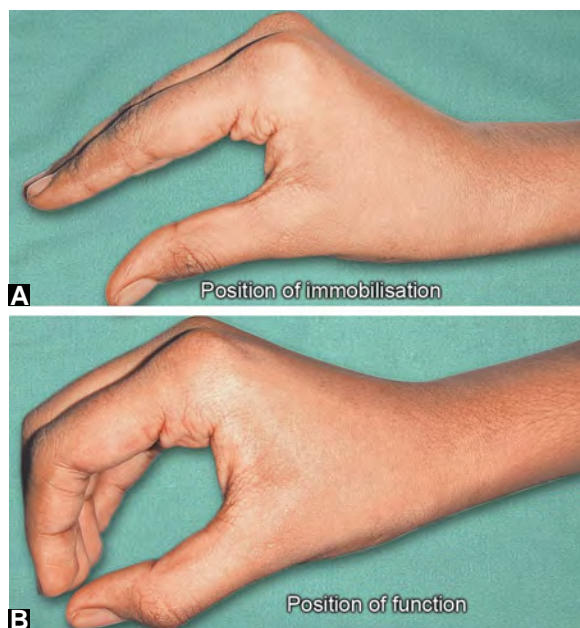
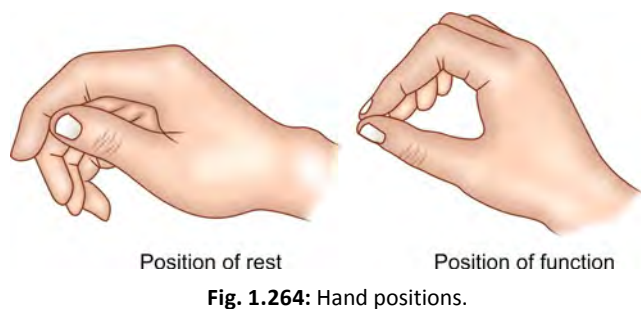
**Figs 1.263A to F:** Different types of hand infections. Note the oedema of hand even on dorsal aspect. Small infective focus can aggravate rapidly and so early proper drainage from deeper plane is important in managing the hand infections. Often it may cause extensive destruction exposing the tendons.

### Investigations

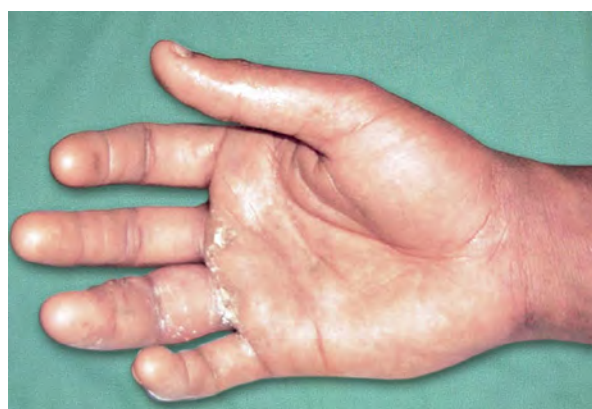- ◆ Pus for culture and sensitivity.
- ◆ Blood sugar.
- ◆ Urine sugar and ketone bodies.
- ◆ X-ray of the part.
- ◆ Arterial Doppler of the hand if needed.

### General Principles of Managing Hand Infections

- ◆ Antibiotic therapy.
- ◆ **Position of rest** with wrist slightly abducted and extended, thumb and index fingers away (glass-holding position). *Position of function* is in which thumb and index fingers are pinching firmly with wrist extension.

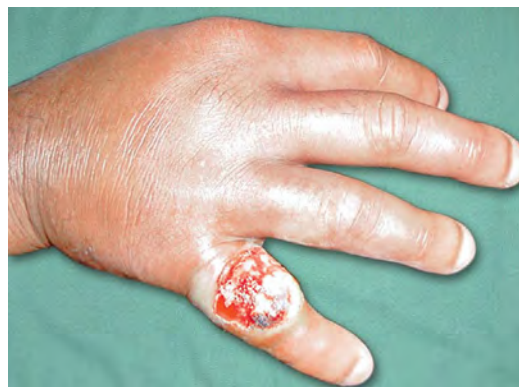

**Figs 1.265A and B:** Hand positions in immobilisation and function.

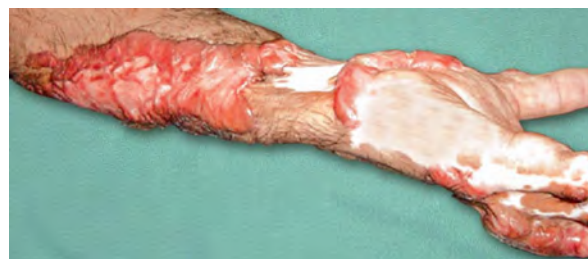

**Fig. 1.266:** Hand infection. Infection of ring finger extending into the palm.

- ◆ *Elevation of hand* reduces the oedema, increases perfusion, promotes healing.
- ◆ Early recognition of localised **pus**. Once localised, **Incision and Drainage** is done ideally under general anaesthesia or regional block (**not local anaesthesia**). Draining incision should not cross the palmar crease. Incision should have



**Fig. 1.267:** Infection of little finger with dorsal oedema.



**Fig. 1.268:** Hypertrophic scar and keloid in hand and forearm after burn contracture.

adequate length and adequate depth (deep to palmar fascia, otherwise evacuation of pus is inadequate). Care should be taken not to injure neurovascular bundles. Pus should be sent for culture and sensitivity. **Slough**, if present should be excised thoroughly. Gauze drain is placed. Regular dressings are done with continuation of antibiotics. Communications into other areas of hand should also be drained.

- ◆ **Bloodless field** (using tourniquet) is better to drain pus from hand.
- ◆ Proper measures must be taken after treatment. Initial rest, elevation of hand and later proper physiotherapy and regular exercise of hand and fingers are encouraged to restore normal function.

#### Complications of hand infections

- ❖ Stiffness of digits and hand (ankylosis)
- ❖ Deformity and disability
- ❖ Bacteraemia and septicaemia
- ❖ Osteomyelitis of bones depending on the location of abscess like metacarpal bones, terminal phalanx
- ❖ Suppurative arthritis of joints
- ❖ Paralysis of median nerve

#### Remember

- ❖ Hand should be flexible and strong; sensitive and pain free and coordinated to show all fine and powerful functions
- ❖ *Pinch* (picking a small object); *power grip* (holding a hammer); *key grip* (holding a key); *chuck grip* (holding a pen); *hook grip* (carrying a bag)—are the functions of hand

*Contd...*

*Early signs of Volkmann's contracture are pain, pallor, puffiness, pulselessness and paralysis.*

—David L Griffiths

Contd...

- ❖ Hand should be properly examined clinically for tendon functions; neurological problems—sensations (sweat test, two point discrimination test); for circulation (Allen's test); joint movements; examination of entire upper limb; opposite hand; axillary lymph nodes and other relevant systemic examinations
- ❖ Nerve conduction studies; electrophysiology; MRI hand; radioisotope bone scan; selective angiograms; X-ray hand are the relevant investigations other than systemic investigations
- ❖ Principles of treatment—elevation to reduce oedema; splintage to prevent contracture; early movements once inflammation subsides; early exploration of wound or surgical drainage of infective area; regional anaesthesia; usage of tourniquet; incisions when done across the flexor creases, should be at 45° angle

## ACUTE PARONYCHIA

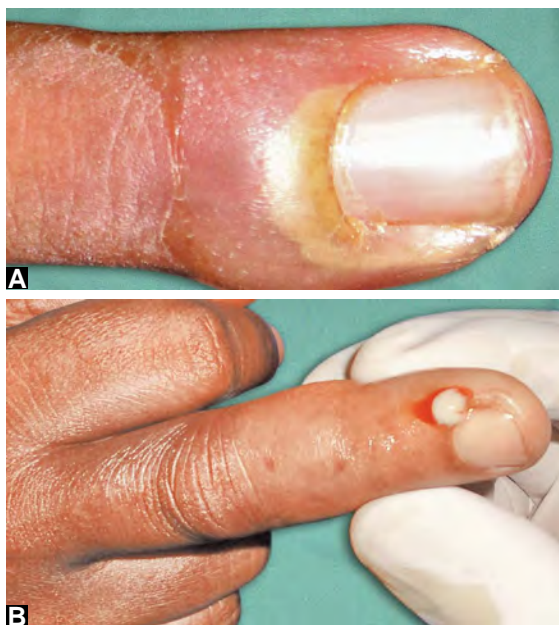
- ◆ It is the *most common* hand infection.
- ◆ It occurs in subcuticular area under the **eponychium**.
- ◆ Minor injury to finger is the common cause.
- ◆ Suppuration occurs very rapidly.
- ◆ It tracks around the skin margin and spreads under the nail causing **hang nail** or **floating nail**.
- ◆ Organisms are *Staphylococcus aureus* and *Streptococcus pyogenes*.
- ◆ Quantity of pus is very less around 0.5 ml but it should be drained to relieve symptoms.

### Clinical Features

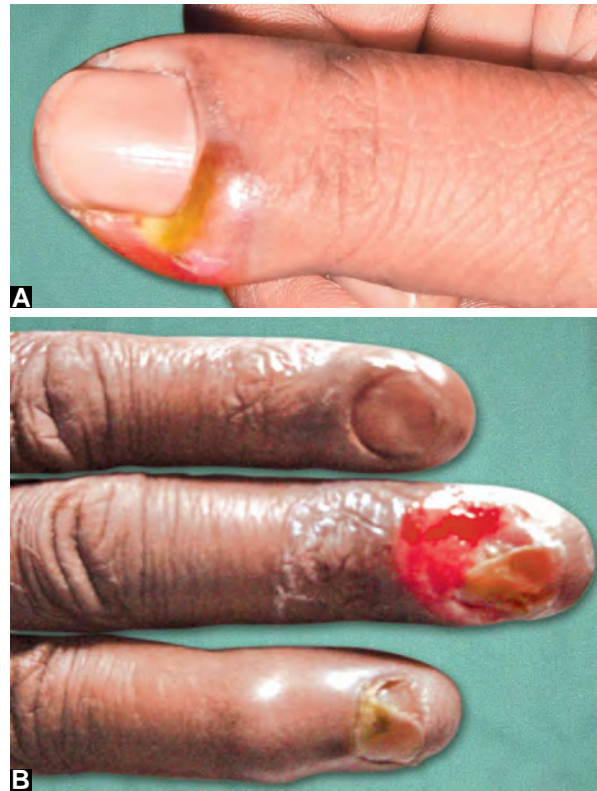
Severe throbbing pain and tenderness (dependent throbbing) with visible pus under the nail root. Nail on touch is very tender (paronychia means “**Run around**”).

### Treatment

- ◆ Pus is sent for culture and sensitivity.
- ◆ Antibiotics like cloxacillin, amoxicillin.



**Figs 1.269A and B:** Pointing pus in acute paronychia. Quantity of pus is very less usually around 0.5 ml.



**Figs 1.270A and B:** Paronychia showing pointing pus in one picture and sloughed area granulating in another picture.

- ◆ Analgesics.
- ◆ The pus is drained by making an incision over the eponychium. Digital block using xylocaine 2% plain (*without adrenaline* as end artery supply to digits can develop arterospasm) is given as anaesthesia.
- ◆ If there is a floating nail, then the nail is dead and it has to be removed.
- ◆ Recovery is fast.

## CHRONIC PARONYCHIA

It is commonly due to fungal infection—due to candida infection commonly.

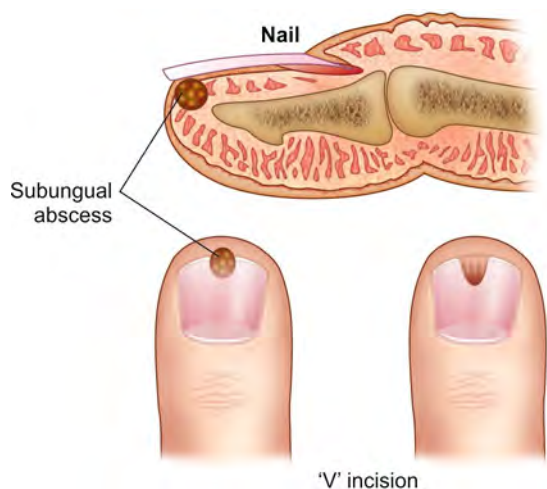
### Features

- ◆ It is common in females.
- ◆ Nail is diseased with ridges and pigmentation.
- ◆ Itching in the nail bed.
- ◆ Recurrent pain, discharge
- ◆ Secondary bacterial infection may supervene.
- ◆ *Investigation:* Culture of scrapings for fungus and other causative agents.
- ◆ *Treatment*
  - ▶ Long-term antifungal therapy—local and systemic.
  - ▶ Antibiotics for secondary infection.
  - ▶ In severe cases removal of nail is required.

## APICAL SUBUNGUAL INFECTION

- ◆ It is infection of the space between subungual epithelium and the periosteum.

- ◆ It occurs after minor trauma or rarely after formation of subungual haematoma.
- ◆ Beneath the free edge of the nail, pus comes to the surface.
- ◆ Excruciating tenderness with small visible pus under the tip (summit) of the nail is the feature.
- ◆ Drainage with 'V' incision over the summit is the treatment along with antibiotics.
- ◆ Osteomyelitis is not common.



**Fig. 1.271:** Apical subungual infection and pus formation. Note the 'V' shaped incision to drain the same.

## ■ TERMINAL PULP SPACE INFECTION (FELON)

- ◆ It is the *second most common hand* infection (25%).
- ◆ Index and thumb are commonly affected.
- ◆ Usually by a minor injury like finger prick.

### Surgical Anatomy

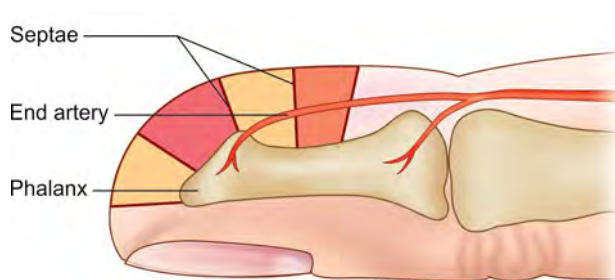
- ◆ Terminal pulp space contains fat and is partitioned by septae which is attached from periosteum of terminal phalanx to skin.
- ◆ Proximally deep fascia is attached to the periosteum distal to the base of terminal phalanx, i.e. distal to the attachment of flexor tendon.
- ◆ So, terminal space is a closed compartment, as the result of which pressure increases when there is infection, compressing terminal artery leading to thrombosis, resulting in osteomyelitis of terminal phalanx.

### Bacteria

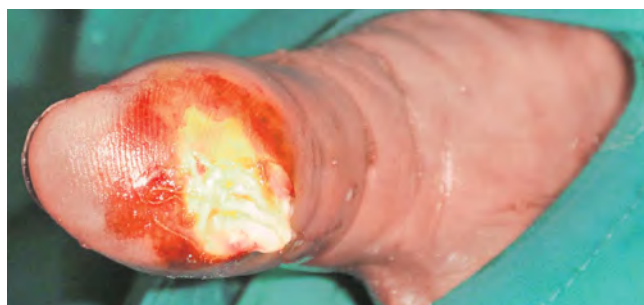- ◆ *Staphylococcus*—most common.
- ◆ *Streptococcus*, Gram-negative organisms.

### Clinical Features

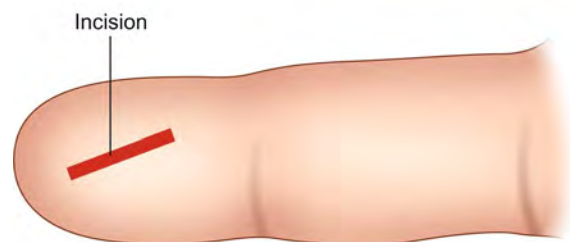
- ◆ Pain, tenderness, swelling in the terminal phalanx.
  - ◆ Fever.
  - ◆ Tender axillary lymph nodes.
- Often suppuration is severe, forming **collar stud abscess** which eventually may burst.



**Fig. 1.272:** Anatomy of the terminal pulp space.



**Fig. 1.273:** Pulp space infection.



**Fig. 1.274:** Incision for pulp space drainage.

### Causes of collar-stud abscess

- ❖ Tuberculous cold abscess
- ❖ Terminal pulp space infection (Felon)
- ❖ Deep palmar space infection

### Investigations

- ◆ X-ray of the part is required often to rule out osteomyelitis of terminal phalanx.
- ◆ Pus for culture and sensitivity.

### Treatment

- ◆ Antibiotics and analgesics.
- ◆ **Drainage** of terminal pulp space by an oblique deep incision.
- ◆ If there is osteomyelitis of the terminal phalanx, it has to be amputated.

*Dupuytren's contracture typically affects the ring finger and years later the little finger becomes implicated. In 30% cases little finger is primarily affected.*

—Peter F Early



## Complications

- ◆ **Osteomyelitis** of the terminal phalanx.
- ◆ **Pyogenic arthritis** of distal interphalangeal joint and tenosynovitis of flexor sheath.
- ◆ **Septicaemia**—in immunosuppressed individuals.

## INFECTION OF WEB SPACES

### Surgical Anatomy

There are three triangular web spaces filled with fat between the dorsal and volar skin. When the space is filled with pus it straddles the deep transverse ligament. Even though pus is volar, it points out dorsally.

Infection of originates from:

- ◆ Abrasion.
- ◆ Infection of proximal volar space of finger.
- ◆ Callosities.
- ◆ Infection of proximal spaces.
- ◆ Trauma.
- ◆ Spread from other palmar spaces and from flexor sheaths through lumbrical canal.

### Bacteria

- ◆ *Staphylococcus*.
- ◆ *Streptococcus*.
- ◆ Gram-negative organisms.

### Clinical Features

- ◆ Fever.
- ◆ Pain and tenderness.
- ◆ Oedema of dorsum of hand.
- ◆ **Maximum tenderness** is on the volar aspect.
- ◆ **'V' sign**—separation of fingers.
- ◆ If untreated, infection may spread into other web spaces and hand spaces.

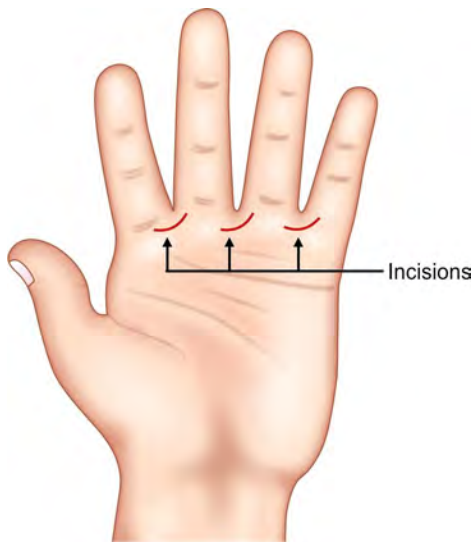


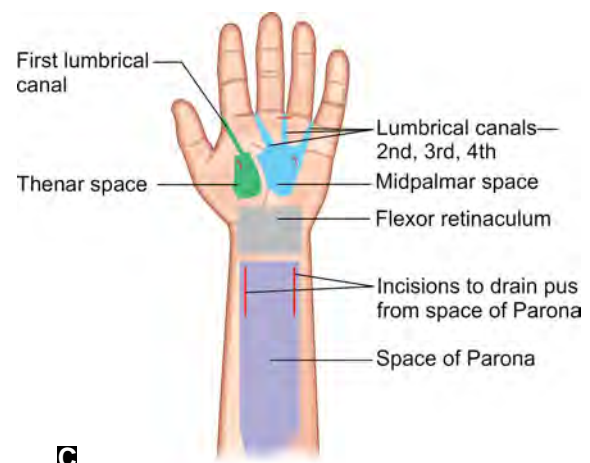
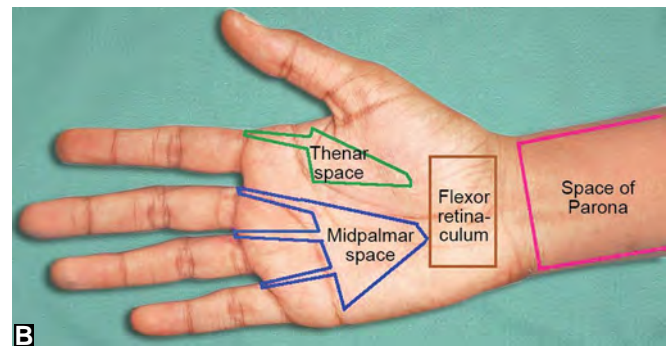
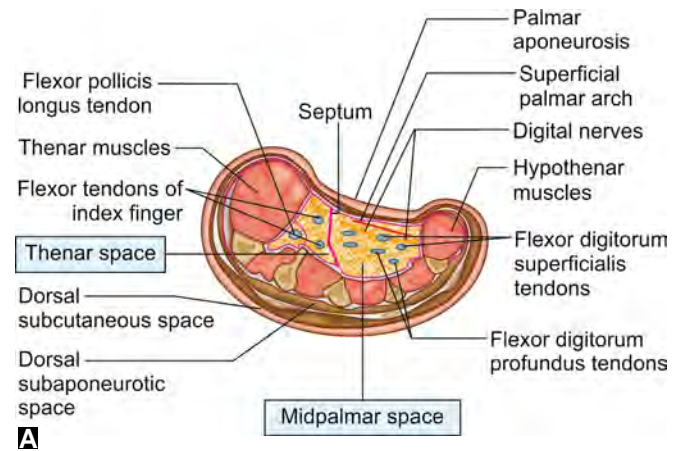
Fig. 1.275: Incision for web space drainage.

## Treatment

- ◆ Elevation of hand.
- ◆ Antibiotics and analgesics.
- ◆ **Drainage** under regional or general anaesthesia. A **horizontal** incision is placed on volar skin of the web and deepened to reach the space by dividing fibres of palmar fascia. Pus is drained and sent for culture and sensitivity. If other web spaces are involved they should be drained through a separate incision. Edges of the wound are cut to leave a *diamond shaped* opening in front. Often counter-incision over dorsal skin of web is needed.

## DEEP PALMAR SPACE INFECTION

### Surgical Anatomy



Figs 1.276A to C: Anatomy of palmar spaces of the hand and forearm. Midpalmar space is on the medial aspect; thenar space is on the lateral aspect. *Space of Parona* is on the lower forearm.

Two deep palmar spaces are present

- ◆ **Midpalmar space.**
- ◆ **Thenar space.**

**Midpalmar space** is bound in front by palmar aponeurosis, behind by medial three metacarpals, laterally by a vertical line from lateral margin of the middle finger. It contains flexor tendons, neurovascular bundles and lumbricals. It is the common site of the infection.

**Thenar space** is located anterior to lateral two metacarpals. Infection here is usually due to extension from midpalmar space.

## Midpalmar Space Infection

### Causes

- ◆ Trauma.
- ◆ Spread from infection of finger spaces and web spaces.
- ◆ Haematogenous spread.
- ◆ Spread from tenosynovitis.

### Clinical Features

- ◆ Pain and tenderness in the palm.
  - ◆ Oedema of dorsum of hand (**frog hand**).
  - ◆ Loss of concavity of palm.
  - ◆ Painful movement of metacarpophalangeal joint (but interphalangeal joint movements are normal and painfree).
  - ◆ Fever.
  - ◆ Palpable tender axillary lymph nodes.
  - ◆ Eventually pus may come out of palmar aponeurosis forming collar stud abscess and later sinus formation.
- X-ray of the part is required.

### Treatment

- ◆ Elevation of the affected limb.
- ◆ Antibiotics and analgesics.

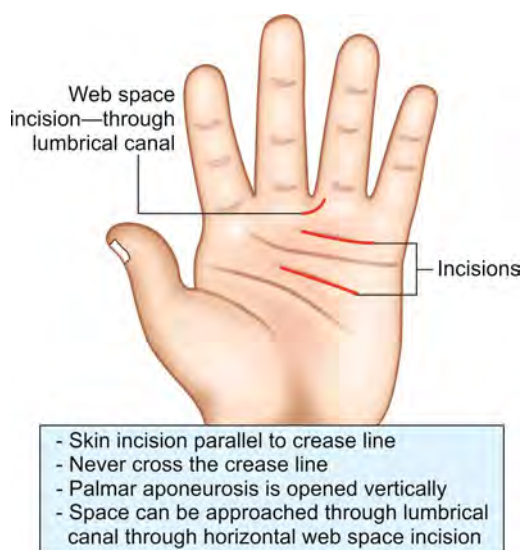


Fig. 1.277: Incisions to drain midpalmar space infection.

- ◆ **Drainage:** It is *drained* under regional/general anaesthesia by placing horizontal/oblique incision parallel to the palmar crease. One should avoid crossing the crease line as much as possible. Palmar aponeurosis is carefully incised vertically to avoid injury of the neurovascular bundles. Alternatively one of the *interdigital web spaces* is incised horizontally; *lumbrical canal* (3rd or 4th) is opened to reach the deep palmar space. Pus is drained and sent for culture and sensitivity. Thorough saline irrigation is very essential. Drain is placed through the wound.

### Complications

- ◆ Osteomyelitis of metacarpals
- ◆ Stiffness of hand
- ◆ Suppurative arthritis
- ◆ Extension of infection into other spaces

## Thenar Space Infection

- ◆ Thenar space (triangular shape) is located anterior to the lateral two metacarpals and fascia over transverse head of adductor pollicis; behind the short muscles of thumb, flexor tendons of index finger and 1st and 2nd lumbricals. Thenar muscles and flexor pollicis longus are lateral to it; fibrous vertical septum from palmar aponeurosis to 3rd metacarpal bone is medial to it. It is on the outer half of the hollow of the palm. Proximally it extends from flexor retinaculum; distally it extends to transverse palmar crease. It communicates to fascial sheath of 1st lumbrical. It is often associated with midpalmar space infection.
- ◆ It is *drained* similarly by placing incision on the lateral aspect of the palm or through the first web space incision is done along the *first lumbrical canal* on the radial side of the index finger. Often incision is made parallel to cleft between index and thumb on the posterior aspect.
- ◆ In some patients, thenar space infection may spread distally to the first web and then dorsally over the first dorsal interosseous muscle, referred to as a *pantaloon abscess*. In such situation an additional counter incision over the dorsal aspect of the hand is needed while draining.

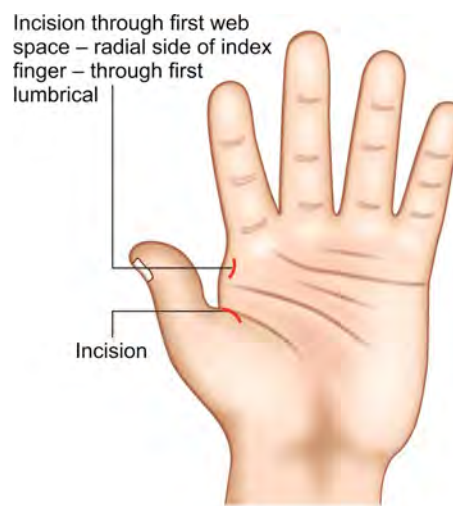


Fig. 1.278: Incision and drainage of thenar space abscess.

*When a hand is seriously inflamed it takes up the position of greatest ease, which is, in fact, the position of rest.*  
— Frederic Wood Jones

## SPACE OF PARONA INFECTION

Forearm space of Parona is a rectangular space situated in the lower part of the forearm above the wrist, in front of pronator quadrates and deep to long flexor tendons. Above it extends up to oblique origin of flexor digitorum superficialis, below up to flexor retinaculum communicating with midpalmar space. Flexor tendon sheath proximally extends into this space. Pus in this space is drained through lateral incisions in the lower part of the forearm.

## ACUTE SUPPURATIVE TENOSYNOVITIS

It is the bacterial infection of flexor tendon sheaths.

### Surgical Anatomy

- ◆ **Radial bursa** is synovial sheath of flexor tendon of thumb which extends to the digit.
- ◆ **Ulnar bursa** is synovial sheaths of medial four flexor tendons of hand which extends into the digit of the fifth (little) finger.

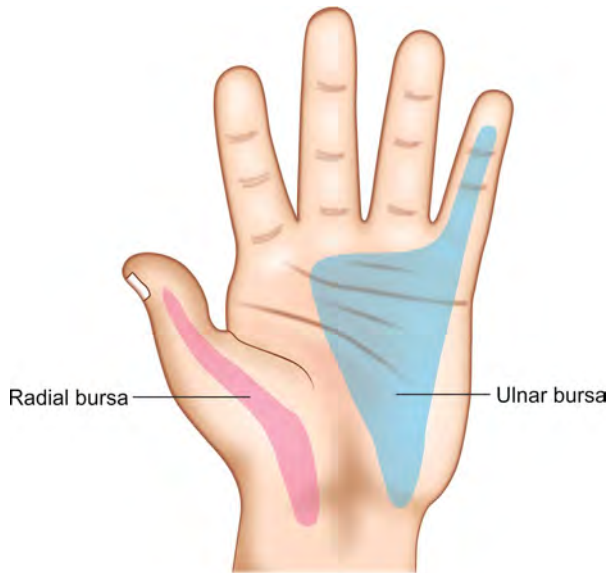


Fig. 1.279: Bursae hand.

- ◆ Extensor tendons are devoid of sheaths.
- ◆ Radial and ulnar bursa communicate with each other in 80% of cases.

#### Common bacteria:

- ◆ *Staphylococcus aureus*, *Streptococcus pyogenes*.

### Clinical Features

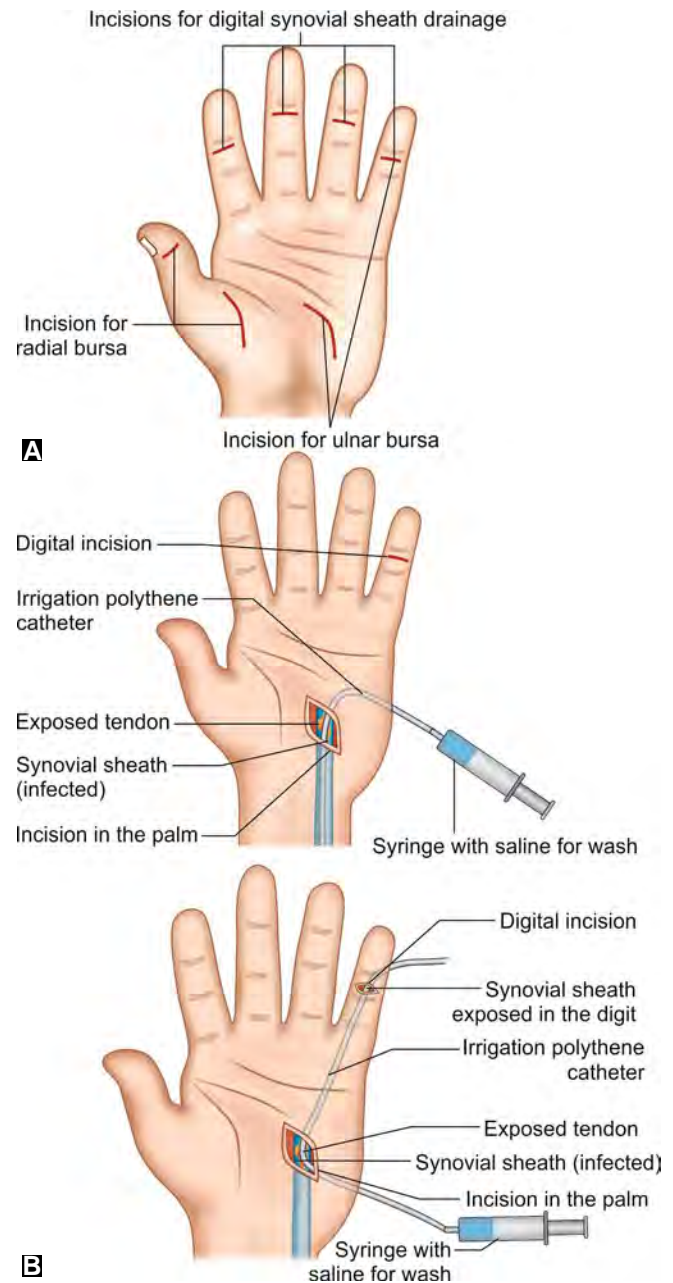
- ◆ Symmetrical swelling of entire finger.
- ◆ Flexion of finger—**Hook sign**.
- ◆ Severe pain on extension.
- ◆ Tenderness over the sheath.
- ◆ Oedema of whole hand, both palm and dorsum (due to lymphatic spread).
- ◆ As ulnar bursa extends into the little finger its infection results in pain and tenderness extending up to little finger but not much to other fingers.

### Kanavel signs

- ◆ Swollen finger held in flexion
- ◆ Exquisite pain on passive extension
- ◆ Tenderness precisely over the tendon sheath
- ◆ *Area of greatest tenderness over the part of ulnar bursa lying between transverse palmar creases*

- ◆ In infection of radial bursa thumb is swollen with pain and tenderness over the sheath of the flexor pollicis longus and there is inextensibility of interphalangeal joint.
- ◆ Swelling just above the flexor retinaculum is common.

### Treatment



Figs 1.280A and B: Suppurative tenosynovitis is drained through incision at proximal part and another at digital sheath. Often by placing fine polythene catheter into the sheath, saline wash is given into the area.

- ◆ Elevation of the affected limb.
- ◆ Antibiotics and analgesics.
- ◆ Position of rest.
- ◆ **Drainage** under general anaesthesia. Incisions are placed over the site of maximum tenderness and flexor sheath should be opened up. Many a times multiple incisions are required.

It is *drained through two incisions*—one over the proximal part of the sheath; other over the distal part of the sheath in the digit—along the crease lines. A fine catheter is passed into the sheath from proximal incision and irrigated with normal saline through this catheter. This catheter is left *in situ* for further regular irrigations, splinting of hand is necessary with boxing glove dressing.

#### Complications

- ❖ Spread of infection proximally into forearm—to *space of Parona*
- ❖ Stiffness of fingers and hand
- ❖ Suppurative arthritis
- ❖ Osteomyelitis
- ❖ Median nerve palsy
- ❖ Bacteraemia and septicaemia

### COMPOUND PALMAR GANGLION

- ◆ It is chronic tenosynovitis of flexor tendon sheaths due to tuberculosis (tuberculous tenosynovitis) or rheumatoid arthritis.
- ◆ It can be unilateral or bilateral.

### Pathology

- ◆ Flexor tendon sheath on either side of the wrist is involved, i.e. both in the volar surface of palm and lower forearm.
- ◆ Swelling contains fluid with typical *melon seed bodies*.
- ◆ Condition is often bilateral in case of rheumatoid arthritis.

### Features

- ◆ Swelling in the palm and lower forearm which is smooth, soft, nontender, fluctuant and also *cross-fluctuant* across flexor retinaculum, nontransilluminating.
- ◆ Wasting of hand and forearm muscles are seen.
- ◆ Matted axillary lymph nodes may be palpable.
- ◆ Primary focus may be present in lungs.
- ◆ *Investigations:*
  - ▶ ESR, chest X-ray.
  - ▶ FNAC of axillary lymph node and swelling itself.

### Treatment

- ◆ Start antituberculous drugs: INH, rifampicin, ethambutol and pyrazinamide for 9 months.
- ◆ Excision of flexor tendon sheath is done along with scraping of caseating material, tubercles, melon seed bodies.
- ◆ Care should be taken not to injure median and ulnar nerves.

### ORF

- ◆ It is a rare, benign, self-limiting exanthematous disease, also known as contagious pustular dermatitis or infectious labial dermatitis or

ecthyma contagiosum or thistle disease or scabby mouth caused by a parapox virus infection. Contracted via direct contact with infected sheep or goats or fomites with orf virus. Human-to-human transmission is not known.

- ◆ It causes a purulent-appearing papule locally and generally without systemic symptoms.
- ◆ Infected locations can include the finger, hand, arm, face and even the penis.
- ◆ It may become progressive and life threatening in immunocompromised host.
- ◆ *Treatment*—1% cidofovir in progressive disease.

### MILKER'S NODES/NODULES (Milkmaid Blisters)

- ◆ It is cutaneous condition caused by Paravaccinia virus; transmitted from udders of infected cows.
- ◆ Disease in humans is nearly identical to Orf.
- ◆ Usually has got self-limiting course, running from 14–72 days, with infrequent systemic symptoms and little or no scarring.

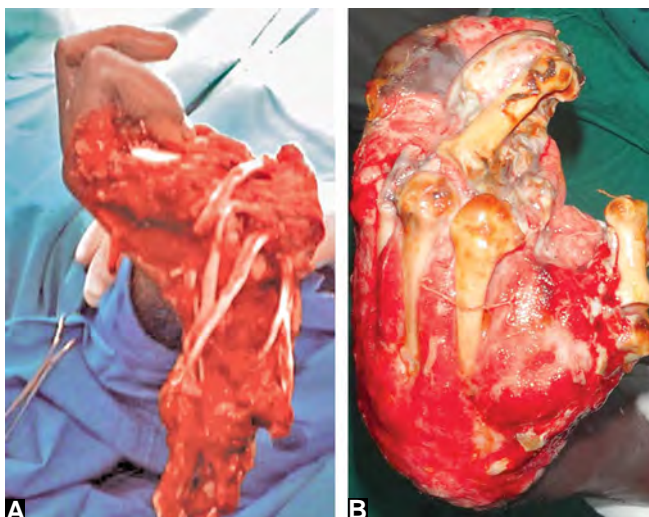
### HAND INJURIES

#### Classification

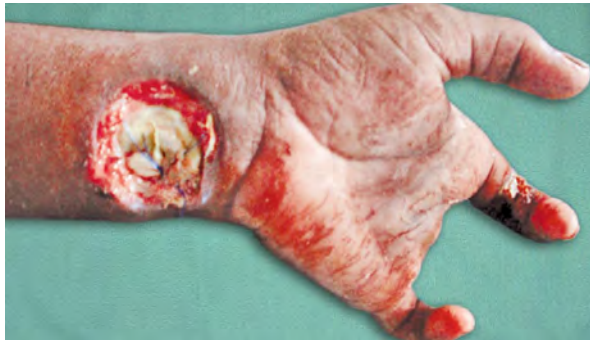- ◆ *Tidy injuries:* They are clean incised wounds and are usually treated by primary suturing but depends on the tissues involved like nerves, tendons and muscles.
- ◆ *Untidy injuries:* They are lacerated wounds. Treated by debridement and later by delayed primary or secondary suturing.
- ◆ *Compartment injuries.*
- ◆ *Degloving injuries*
- ◆ *Indetermined injuries* which could not be assessed.

#### Assessment of Injury

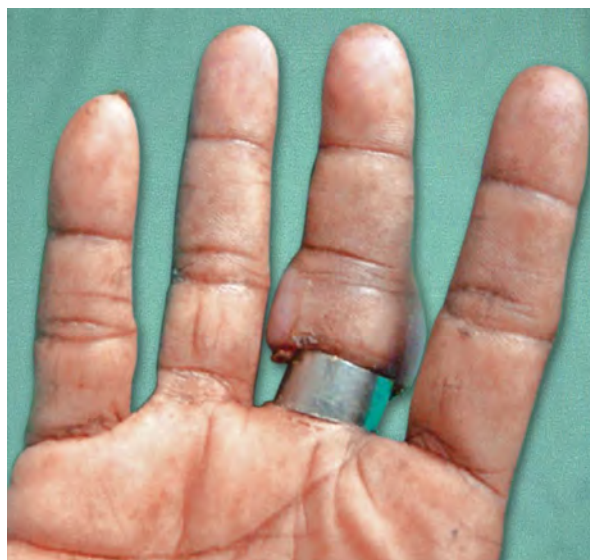It should include: Number, extent, depth, deformity and disability, neurovascular injuries, tendon injuries, muscle injuries bone and joint injuries.



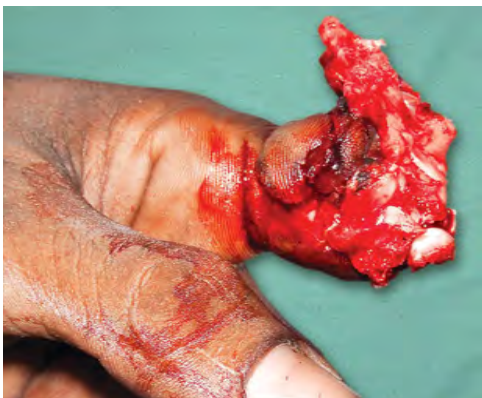**Figs 1.281A and B:** Indeterminate and untidy hand injuries.



**Fig. 1.282:** Hand injury exposing tendons. Note the marker stitch in the tendon. It needs local transposition flap or groin flap to cover. Skin grafting is not possible over tendons.



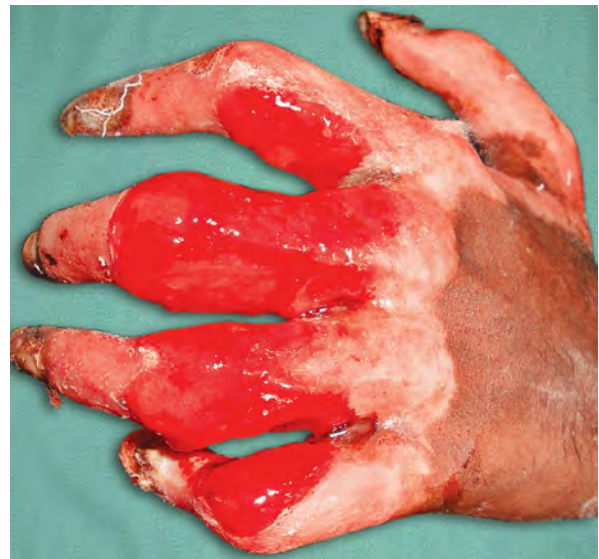**Fig. 1.283:** Stuck finger by a ring. It is removed by applying soap, fat, and wax. String method is winding and unwinding a thread under and across the stuck finger. Sawing is done only when every method fails.



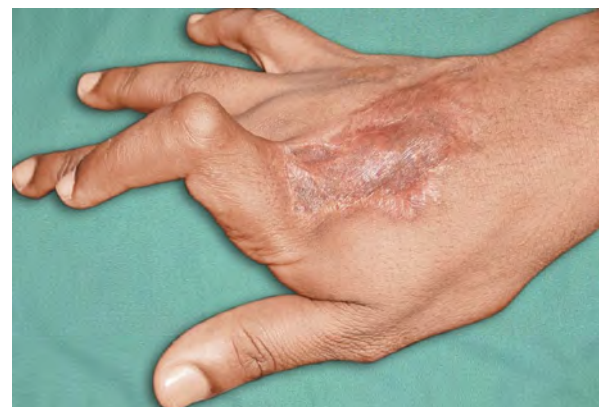**Fig. 1.284:** Avulsion injury of finger causing raw area.

### Principles of Treatment

- ◆ Haemostasis.
- ◆ Use of tourniquet.
- ◆ Wound debridement and cleaning.



**Fig. 1.285:** Hand injury which is healing but with severe deformity of fingers.



**Fig. 1.286:** Typical deformity of finger which needs correction for proper function.

- ◆ Antibiotics and antitetanus treatment (toxoid and antitetanus globulin).
- ◆ Primary suturing if it is a incised wound or delayed primary suturing if there is odema.
- ◆ Skin grafting or flaps for skin loss.
- ◆ Tendon suturing or tendon graft for tendon injuries.
- ◆ Rest and elevation of the affected parts.
- ◆ Management of fractures by splint, wiring.
- ◆ Nerve repair for nerve injuries.
- ◆ Immobilisation up to 21 days.
- ◆ Later physiotherapy with warm, exercise, was bath active movements.
- ◆ Microsurgical restoration of digits. Reimplantation of the digits.
- ◆ Amputation of digits or metacarpals only when inevitable.

*Primary repair of tendons and nerves* are of lesser priority in untidy injuries. Priority is wound debridement/wound excision and early skin cover. Cut ends of nerves and tendons are tagged with coloured stitches for future identification purpose.

In hand	
Do's	Don'ts
Do examine hand carefully	Do not incise every infected digit
Do think of other diagnosis	Do not make puncture incisions or over pads
Do wait for abscess to localise	Do not injure the digital nerves or vessels
Do place adequate length and depth of incisions	Do not place incisions crossing the crease line
Do immobilise, elevate the hand	Do not close human bites or lacerated wounds
Do give antibiotics and proper dressings	Do not forget to send pus for culture and sensitivity

### Complications and morbidity of hand injuries

- ❖ Infection
- ❖ Osteomyelitis
- ❖ Arthritis of joints
- ❖ Stiffness
- ❖ Loss of function due to disability

## DUPUYTREN'S CONTRACTURE

*Individuals pre-disposed to the affection we are describing, observe that it is more difficult to extend the fingers of the affected hand... The first (interphalangeal joint) is flexed at nearly a right angle... the most powerful efforts are insufficient to extend it... Hence, it was natural to conclude, that the commencement of the disease was in the unusual tension of the palmar aponeurosis.*

—Guillaume Dupuytren, 1833

It refers to localised thickening of palmar aponeurosis and later formation of nodules with severe permanent changes in metacarpophalangeal and proximal interphalangeal joints. Terminal interphalangeal joint is *not involved* as palmar aponeurosis does not extend to terminal phalanx. It is common in *males* (10:1).

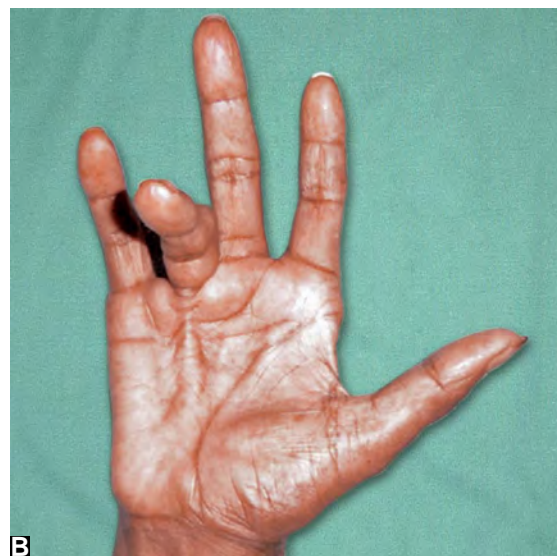
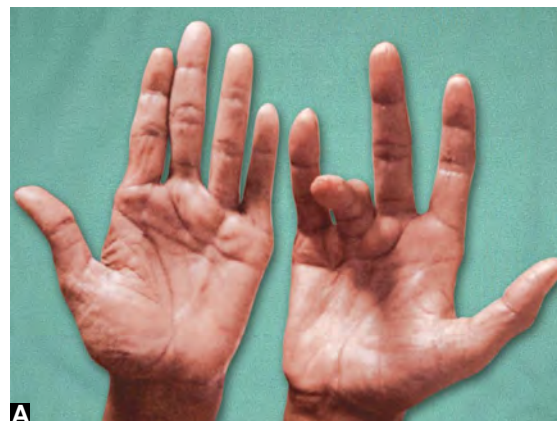- ◆ It starts in ring and little fingers, with flexion of ring and little fingers. Later involving all fingers.
- ◆ There is thickening and nodule formation in the palm with adherent skin.
- ◆ It is often familial and bilateral 45%.
- ◆ Pads (of fat) develop in knuckles and are called as *Garrod's pads* (in proximal IP joints).

### Conditions often associated with

- ❖ Plantar fasciitis 5%—Ledderhose's disease
- ❖ Mediastinal and retroperitoneal fibrosis
- ❖ Peyronie's disease of penis 3%
- ❖ Nodules in the face and ear
- ❖ Pellegrini-Stieda's disease

## Aetiology

- ◆ Repeated minor trauma, use of vibrating tools.
- ◆ Cirrhosis, alcoholism, smoking.
- ◆ Epileptics on treatment with phenytoin sodium.
- ◆ Diabetics, pulmonary tuberculosis, AIDS.
- ◆ Other metabolic conditions.
- ◆ Familial—autosomal dominant.



**Figs 1.287A and B:** Dupuytren's contracture in the hands. Note the involvement of the ring finger. Note the fibrous band on the other hand as early finding.

### Galezia triad

- ❖ Dupuytren's contracture
- ❖ Retroperitoneal fibrosis
- ❖ Peyronie's disease of penis

## Complications

- ◆ Restriction of hand function and so disability.
- ◆ Arthritis of MCP and proximal IP joints.

*"Impossible" is a word found only in the dictionary of fools.*—Napoleon

## Treatment

- ◆ Fasciotomy of palmar aponeurosis and later physiotherapy, Z plasty.
  - ◆ In severe cases fasciectomy partial or complete.
  - ◆ Treatment of the cause.
- Recurrence can occur in 5–50% cases.

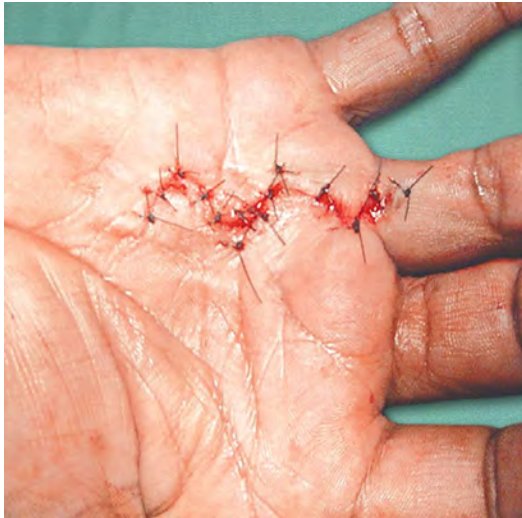

Fig. 1.288: Z plasty done for Dupuytren's contracture.

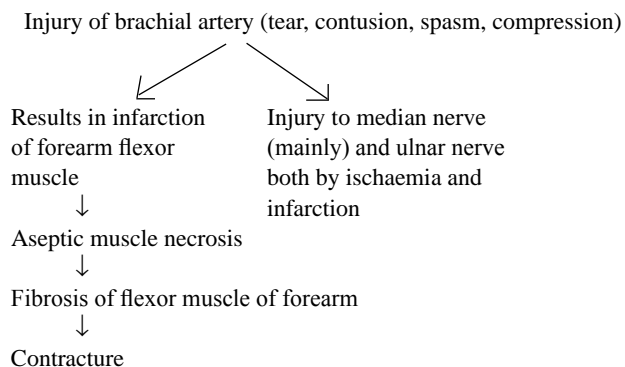
## ■ VOLKMANN'S ISCHAEMIC CONTRACTURE

It is a vascular injury leading to muscular infarction and subsequent contracture.

### Causes

- ◆ Supracondylar fracture of the humerus.
- ◆ IV chemotherapy.
- ◆ Burns.
- ◆ Closed forearm crush injuries.
- ◆ Tight plaster after reduction of fracture.

### Pathogenesis



### Clinical Features

#### Acute phase:

- ◆ Pain (persistent pain in forearm, hand, fingers—ominous symptom).

- ◆ Pallor.
- ◆ Puffiness (due to oedema).
- ◆ Pulseless (absence of radial pulse; but its presence does not rule out the onset of impending contracture).
- ◆ Paresis.

#### Late phase: Deformity

#### Deformity (due to injury to median nerve):

- ◆ Wrist joint extended.
- ◆ Extended metacarpophalangeal joints.
- ◆ Flexed interphalangeal joints.

#### Volkman's sign:

In early stage, the fingers can be extended at the interphalangeal joints, only when the wrist is flexed fully. The fingers tend to flex if any attempt to extend the wrist is made.

## Treatment

#### In acute phase:

- ◆ Removal of plastic cast applied after fracture reduction.
- ◆ Correction of fracture.
- ◆ Exposure of brachial artery and application of 2.5% papaverine sulphate to relieve the spasm if any.
- ◆ Suture of arterial tear if present, often with placement of arterial graft.
- ◆ Lateral incision over the deep fascia of forearm is placed to decompress the oedema.

#### In late phase (once deformity occurs):

- ◆ Physiotherapy
- ◆ Dynamic splints.
- ◆ **Max-Page operation:** Release of flexor muscles (forearm muscles) from their origins from the bone and allowing it slide down until full extension.
- ◆ Excision of fibrous tissue and damaged muscles along with tendon transfer.
- ◆ Arthrodesis.

## ■ SYNDACTYLY

It is *webbing* or *fusion* of fingers.

### Causes

- ◆ Congenital and hereditary—common.
- ◆ Traumatic like burns.

### Types

- ◆ Cutaneous—simple.
- ◆ Fibrous.
- ◆ Bony—complex.
- ◆ It can be unilateral or bilateral.
- ◆ Often all four limbs may be involved with webbing of toes.
- ◆ It may be associated with polydactyly or visceral anomalies.
- ◆ If bony type is suspected, X-ray of the part should be taken.

### Treatment

- ◆ If cutaneous, release of web is done as a staged procedure along with “Z” plasty or skin grafting.
- ◆ If fibrous, release can be done.
- ◆ If bony type, release is difficult because blood supply may be compromised which leads to gangrene of the digit.

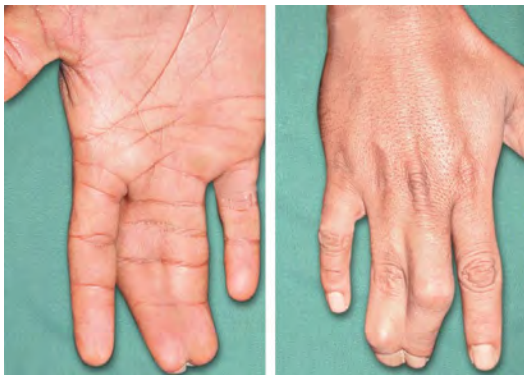

Fig. 1.289: Syndactyly.

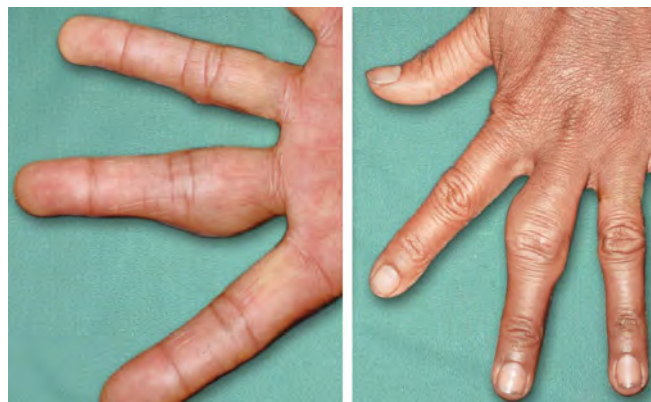


Fig. 1.292: Spina ventosa.

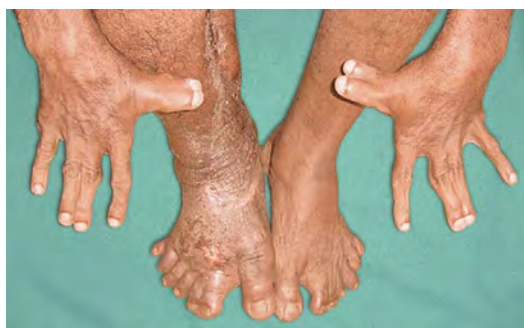

Fig. 1.290: Syndactyly and polydactyly of both hands and both feet.

### ■ MALLET FINGER (Base Ball Finger)

The terminal phalanx can not be extended because of tear at insertion of extensor tendon or avulsion fracture of the base of the terminal phalanx.

### ■ HEBERDEN'S NODES

These are seen in osteoarthritis, occurring behind the distal interphalangeal joints of *index*, middle, little and ring fingers.

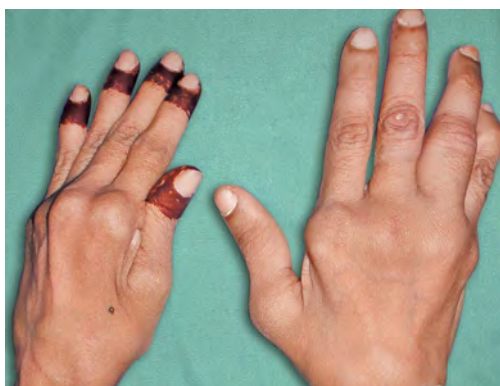

Fig. 1.291: Arthritis of joints of hands.

### ■ SPINA VENTOSA

Refers to phalangeal tuberculosis (*Tuberculous dactylitis*). It is called as spina ventosa because of its appearance as “air- filled balloon”.

### ■ FOOT

Foot contains 7 tarsal bones, 5 metatarsals, 14 phalanges (total 26 bones). Two sesamoid bones of 1st metatarsal bone are common. There are 4 layers of muscles in foot. Ligaments, muscles, joints, maintain the stability of foot complex. Blood supply is by anterior tibial, posterior tibial and peroneal arteries. Nerve supply is by saphenous, sural, posterior tibial, superficial and deep peroneal nerves.

### ■ CALLOSITY

- ◆ It is a hard, thickened skin occurs as a protective measure seen in wider area usually over heel and heads of metatarsals.

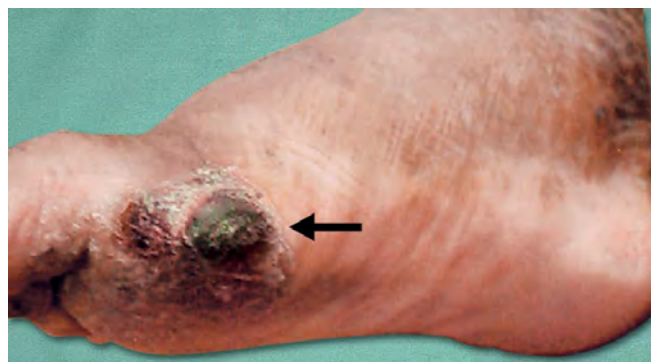

Fig. 1.293: Callosity in the foot.

- ◆ A callosity protrudes outwards from the skin.
- ◆ It is greyish-brown, raised, *protruded outwards*, thickened, hypertrophic skin occurs due to occupation and skeletal structure. It is *painless*. It is *wider* lesion. Paring the top layer exposes the shiny translucent dead skin beneath.
- ◆ It is grayish brown hypertrophic raised thick protective phenomenon which occurs commonly in areas of wear and tear like hands and feet. Top roughened layer when peeled off, shiny, translucent, homogenous dead skin can be exposed beneath.
- ◆ It is painless; it can get rubbed easily to create a sore.
- ◆ As it is a protective phenomenon it is best left alone.



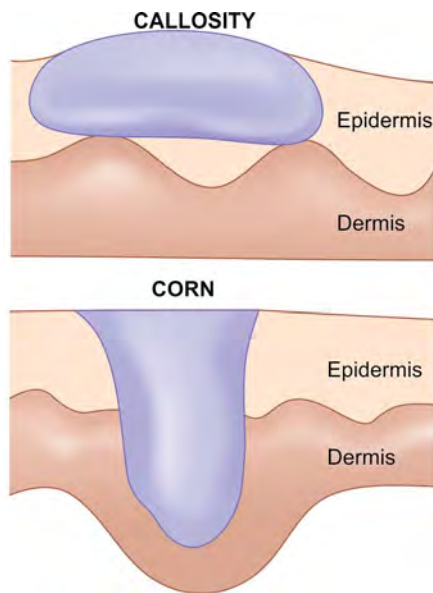


Fig. 1.294: Diagram showing differences between corn and callosity.

## CORN

### Types

- ◆ Hard corn.
- ◆ Soft corn.

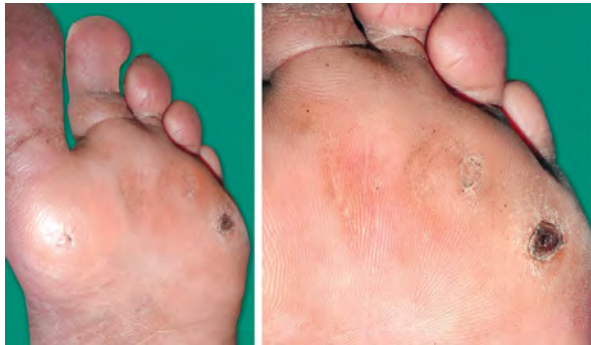

Fig. 1.295: Corn in the plantar aspect of the foot.

### Hard Corn

- ◆ It is localised area of thickening over a bony projections like heads of metatarsals.
- ◆ Histologically it differs from callosity by having severe keratoses with a central core of degenerated cells and cholesterol.
- ◆ It presses over the adjacent nerves causing pain. It can get infected causing severe pain and tenderness with inability to walk.
- ◆ It is *smaller* lesion which is *pushed deep into* the skin forming a *localised palpable painful/tender* nodule with a *central yellow-white core* of dead cornified skin.
- ◆ Corn is common if there is deformity or by wearing tight fitting shoes/foot wears.
- ◆ Corn is narrow, deep and painful/tender.
- ◆ It is common in females.
- ◆ Corn is usually white/gray/yellow coloured, deep seated lesion.

- ◆ Infection, abscess formation and ulceration can occur especially if patient is diabetic.
- ◆ Corn may be associated with bursae causing bursitis.
- ◆ Corn often recurs after excision.

### Treatment

- ◆ Excision.
- ◆ Local application of salicylic acid preparations or mixture of salicylic acid/lactic acid/collodion may be helpful. Skin softening agents are also tried.
- ◆ Eliminating the pressure is very important to prevent recurrence.
- ◆ Avoid excision of corn unnecessarily in diabetic (especially with neuropathy) and in ischaemic foot.

### Soft Corn

It usually occurs between 4th and 5th toes due to friction of bases of adjacent proximal phalanges.

## PLANTAR FASCIITIS (Policeman's Heel)

- ◆ It occurs due to friction or tear of the ossified posterior insertion of the plantar fascia which is common in people who stand or walk for long-time.
- ◆ *Treatment:* Analgesics, rest, steroid injections to the site.

## INGROWING TOE NAIL (Onychocryptosis)

- ◆ It is also called as embedded toe nail.
- ◆ It is due to curling of the side of nail inwards, causing it to form a lateral spike resulting in repeated irritation and infection of overhanging tissues in the nail fold.

### Causes

- ◆ Tight shoes.
- ◆ Improper cutting of nails (very short and convex).

### Clinical Features

- ◆ It is common in *great toe* and is often *bilateral*.
- ◆ Both medial and lateral sides of the toe can be involved.
- ◆ Recurrent attacks of acute and subacute paronychia occurs.
- ◆ Pain, tenderness, swelling of margins of the toe, often along with granulation tissue and foul smelling discharge.

### Treatment

- ◆ Regular dressing and packing.
- ◆ Antibiotics. Discharge is sent for culture and sensitivity.
- ◆ Nails should be cut concavely or straight without leaving lateral spikes towards soft tissues.
- ◆ *Zadik's* or *Fowler's operation*: Skin in lateral margin and root is incised so as to expose the lateral spike and germinal matrix. *Infected tissues with pus and germinal matrix of ingrown part of the nail is excised or often entire nail with its root and germinal matrix is excised.*

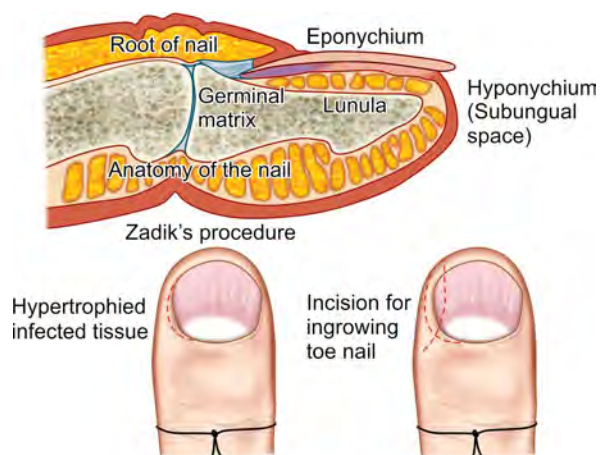
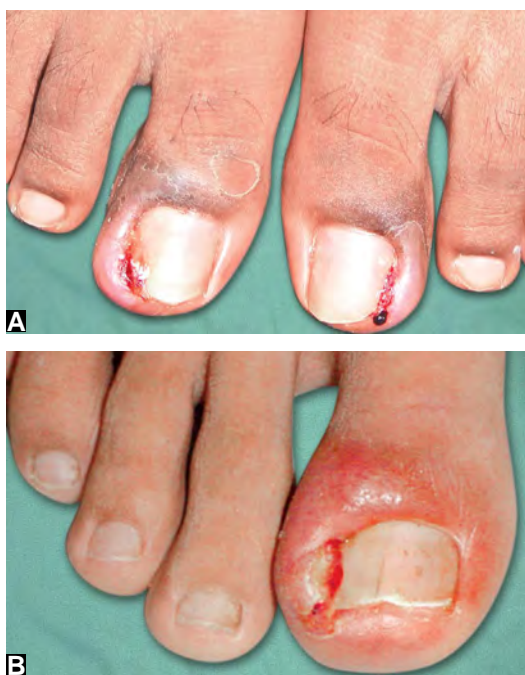

Fig. 1.296: Zadik's or Fowler's operation.



Figs 1.297A and B: Ingrowing toe nail. Note the granuloma caused by repeated infection and inflammation.

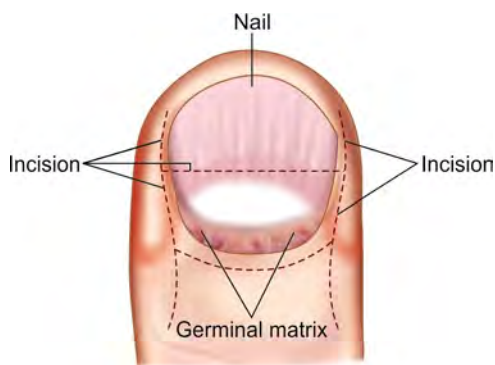


Fig. 1.298: Incision for nail excision. Note the germinal matrix. Removal of nail, entire or partial with adjacent germinal matrix is called as radical nail excision.

## ■ ONYCHOGRYPHOSIS

- ◆ It is curving of nail upwards (*Ram's Horn Nail*).
- ◆ It occurs due to repeated trauma or fungal infection.

## ■ ONYCHOMYCOSIS

It is fungal infection of the nail.

## ■ ATHLETE'S FOOT

- ◆ It is the fungal infection of the skin between the toes—*Tinea pedis*.
- ◆ Fungi enter through cracks; survive due to moisture in between toes.
- ◆ Skin is swollen, red, with sticky fluid, macerated with blisters.
- ◆ Itching, deep cracks, pain and discharge are common.

## Treatment

- ◆ Part should be kept dry. Cotton, clean socks should be worn.
- ◆ Oral antifungals, antihistaminics and topical antifungals are used.
- ◆ Condition is contagious.

## ■ HALLUX VALGUS

- ◆ Here great toe is deviated laterally at first metatarsophalangeal joint. There is outward deviation of great toe with medial deviation of first metatarsal head.
- ◆ It may be due to persistent lateral force or occasionally hereditary.
- ◆ Condition is often *bilateral*.
- ◆ It is common in *females*.
- ◆ Thick walled bursa (*bunion*) over medial aspect of the head of the first metatarsal bone is common.
- ◆ Undue prominence of head of first metatarsal bone is typical often forming an *exostosis* at this point. *Osteoarthritis* of 1st metatarsophalangeal joint can occur.
- ◆ Lateral deviation of proximal phalanx over 2nd toe causing *crowding* of the toes.
- ◆ Initially it is painless; but eventually pain and tenderness develops with infection of bunion and *splaying* of forefoot.
- ◆ X-ray shows deviation with often osteoarthritis of the metatarsophalangeal joint.

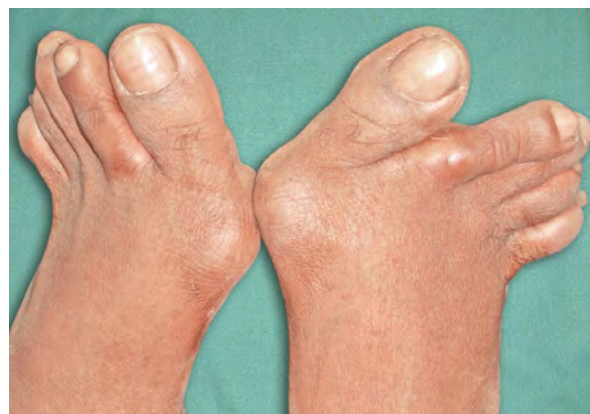
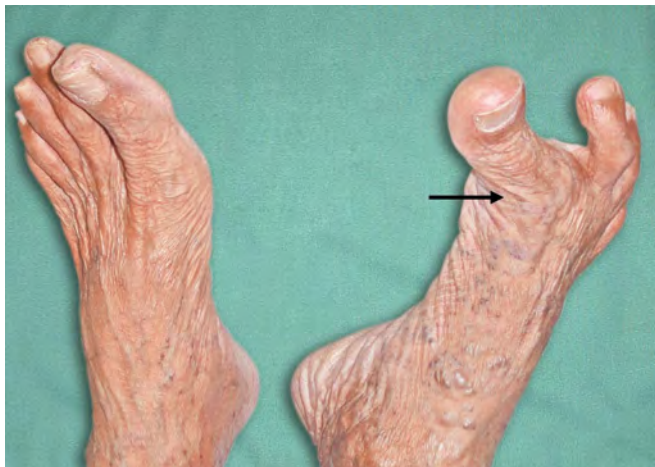
Fig. 1.299: Hallux valgus deformity.



**Fig. 1.300:** Hallux varus deformity. It is opposite of hallux valgus deformity.

## Treatment

**Keller's operation:** Proximal 1/3rd of the proximal phalanx of great toe and medial part of head of 1st metatarsal bone is excised through medial curved incision. Soft tissue interposition is done.

**Mayo's procedure:** Medial part of base of the proximal phalanx of great toe and head of 1st metatarsal bone is excised—opposite of Keller's.

**Simmond's procedure:** Varus osteotomy at the base of 1st metatarsal bone with reinsertion of adductor hallucis tendon is done.

**McBride procedure:** Transfer of adductor hallucis tendon and lateral head of flexor hallucis brevis from proximal phalanx of great toe to the lateral part of head of 1st metatarsal bone.

**Arthrodesis** of metatarsophalangeal joint is done to relieve pain.

Excision of bunion, deformity correction, osteotomy, muscle transfers are also done as a **combined approach**.

# L. Arterial Diseases

## CHAPTER OUTLINE

- ❖ Surgical Anatomy of Thoracic Outlet
- ❖ Arteries of Upper Limb
- ❖ Arteries of Lower Limb
- ❖ Arterial Diseases
- ❖ Intermittent Claudication
- ❖ Rest Pain
- ❖ Limb Ischaemia
- ❖ Pregangrene
- ❖ Gangrene
- ❖ Different Levels of Arterial Obstruction
- ❖ Other Features of Poor Circulation
- ❖ Investigations for Arterial Diseases
- ❖ Diseases of the Arteries
- ❖ Atherosclerosis
- ❖ Thromboangiitis Obliterans
- ❖ Takayasu's Pulseless Arteritis
- ❖ Raynaud's Phenomenon
- ❖ Temporal Arteritis
- ❖ Treatment of Arterial Diseases
- ❖ Subclavian Steal Syndrome
- ❖ Acute Arterial Occlusion
- ❖ Traumatic Acute Arterial Occlusion
- ❖ Embolism
- ❖ Reperfusion Injury
- ❖ Saddle Embolus
- ❖ Embolectomy
- ❖ Air/Gas Embolism
- ❖ Therapeutic Embolisation
- ❖ Caisson's Disease or Decompression Disease
- ❖ Aneurysm
- ❖ Mycotic Aneurysm
- ❖ Abdominal Aneurysm
- ❖ Abdominal Aortic Aneurysm
- ❖ Peripheral Aneurysm
- ❖ Carotid Artery Aneurysm
- ❖ Dissecting Aneurysm
- ❖ Erythromelalgia/Erythralgia
- ❖ Livedo Reticularis
- ❖ Polyarteritis Nodosa
- ❖ Scleroderma/Systemic Sclerosis
- ❖ Acrocyanosis
- ❖ Gangrene
- ❖ Diabetic Foot and Diabetic Gangrene
- ❖ Trophic Ulcer
- ❖ Bedsores
- ❖ Frostbite
- ❖ Ainhum
- ❖ Endovascular Surgeries
- ❖ Upper Limb Ischaemia
- ❖ Arterial Substitutes

### ■ SURGICAL ANATOMY OF THORACIC OUTLET

Thoracic outlet is bounded by manubrium sternum in front, spine posteriorly, and the first rib laterally. At the superior aperture of thorax subclavian vessels, brachial plexus traverse the cervicoaxillary canal to reach the upper limb.

*Cervicoaxillary canal* is divided into proximal *Costoclavicular space* and *distal axilla* (divided by first rib).

Costoclavicular space is bounded superiorly by clavicle, inferiorly by first rib, anteromedially by the costoclavicular ligament, and posterolaterally by scalenus medius muscle along with long thoracic nerve.

Scalenus anticus muscle divides the costoclavicular space into two compartments, the anterior one containing subclavian vein and the posterior one containing subclavian artery and brachial plexus.

This posterior compartment is called as *Scalene triangle* bounded by scalenus anticus anteriorly, scalenus medius posteriorly, and the first rib inferiorly.

Cervical rib narrows this triangle and causes compressive features of the C<sub>8</sub>, T<sub>1</sub> nerve roots and subclavian artery. Anything that narrows costoclavicular space causes *Thoracic outlet syndrome*.

### ■ ARTERIES OF UPPER LIMB

Right subclavian artery begins from brachiocephalic trunk (innominate artery) whereas left subclavian artery arises directly from the

arch of aorta. From underneath the sternoclavicular joint artery arches over the pleura and apex of lung about 2.5 cm above the clavicle and then reaches the lateral border of first rib to continue as axillary artery.

Subclavian artery is divided into three parts by scalenus anterior muscle.

Axillary artery is divided into three parts by pectoralis minor muscle.

At the lower border of teres major muscle it enters the arm and continues as brachial artery.

About 2.5 cm below the crease of the elbow joint, it bifurcates into radial and ulnar arteries which run in the forearm.

Ulnar artery forms the superficial palmar arch which is completed by superficial palmar branch of radial artery.

Radial artery after passing through the anatomical snuff box enters the dorsum of hand and first intermetacarpal space to form deep palmar arch. It is completed by deep palmar branch of ulnar artery and is 1 cm proximal to superficial palmar arch.

### ■ ARTERIES OF LOWER LIMB

Abdominal aorta bifurcates at the level of fourth lumbar vertebra (corresponds to the level of the umbilicus in anterior abdominal wall) into two common iliac arteries.

Common iliac artery is about 5 cm in length passes downward and laterally; and at the level of lumbosacral intervertebral disc, anterior to sacroiliac joint, it divides into external and internal iliac arteries. Internal iliac artery supplies pelvic organs.

External iliac artery continues as common femoral artery at the level of inguinal ligament.

About 5 cm below the inguinal ligament common femoral divides into superficial femoral and deep femoral (Profunda femoris) arteries.

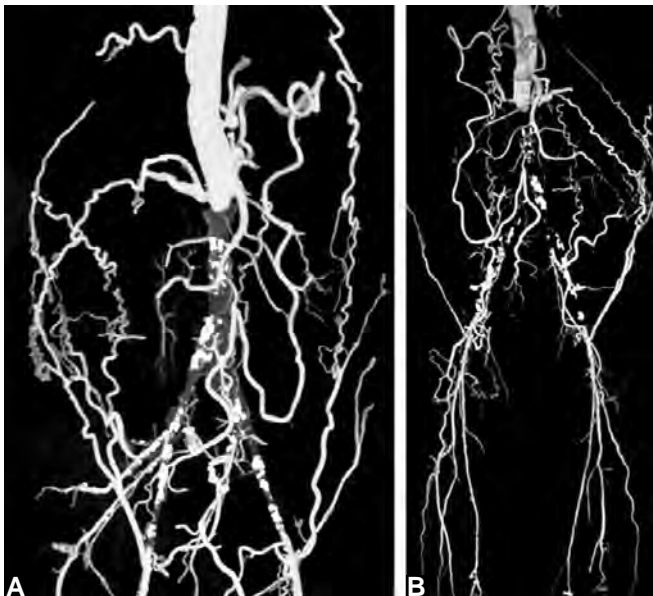
Deep femoral provides collateral circulation around the knee joint and also communicates above with gluteal vessels to maintain collateral circulation around the gluteal region.

Superficial femoral artery at the hiatus in the adductor magnus, continues as popliteal artery up to the inferior angle of the popliteal fossa where it divides into anterior and posterior tibial arteries.

Anterior tibial artery supplies anterior compartment of leg and ankle, continues as dorsalis pedis artery which forms dorsal arterial arch of the foot.

Posterior tibial artery supplies posterior compartment of leg and ends as medial and lateral plantar arteries which forms plantar arterial arch of the foot.

Posterior tibial artery gives peroneal artery which runs close to fibula supplying calf muscles.



**Figs 1.301A and B:** CT angiogram of aortoiliac segment showing aortoiliac block due to atherosclerosis. Collaterals are also well-developed.

## ARTERIAL DISEASES

- ◆ **Stenosis** due to trauma, atherosclerosis, emboli. It may be:
  - ▶ In the brain causing transient ischaemic attacks.
  - ▶ In the limbs causing claudication and rest pain.
  - ▶ In the abdomen causing pain, bloody stool.
  - ▶ In the kidney causing haematuria.
- ◆ **Dilatations are aneurysms.**
- ◆ **Arteritis.**
- ◆ **Small vessel abnormalities.**

## INTERMITTENT CLAUDICATION

Claudio means “*I limp*” a Latin word. It is a crampy pain in the muscle seen in the limbs. Due to arterial occlusion, metabolites like lactic acid and substance P accumulate in the muscle and cause pain.

The site of pain depends on site of arterial occlusion.

- ◆ The most common site is calf muscles.
- ◆ Pain in foot is due to block in lower tibial and plantar vessels.
- ◆ Pain in the calf is due to block in femoropopliteal segment.
- ◆ Pain in the thigh is due to block in the superficial femoral artery.
- ◆ Pain in the buttock is due to block in the common iliac or aortoiliac segment, often associated with impotence and is called as **Leriche’s syndrome**.

Pain commonly develops when the muscles are exercising. Cause for pain is accumulation of substance P and metabolites. During exercise increased perfusion and increased opening of collaterals wash the metabolites.

### Boyd’s classification of claudication

- ❖ Grade I: Patient complains of pain after walking, and distance in which pain develops is called as ‘claudication distance’. If patient continues to walk, due to increased blood flow in muscle and opening of collaterals metabolites causing pain are washed away and pain subsides
- ❖ Grade II: Pain still persists on continuing walk; but can walk with effort
- ❖ Grade III: Patient has to take rest to relieve the pain

### Claudication

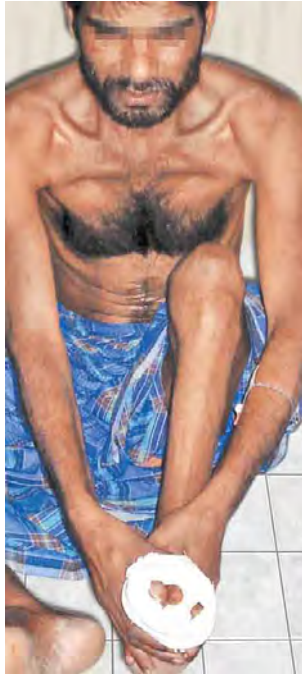- ❖ **Arterial**—typically develops after walking for certain distance and resolves rapidly within 5 minutes once walking is stopped
- ❖ **Neurogenic**—pain develops in standing or walking and disappears immediately after stopping walk; normal feeling pulses without ischaemic changes are present. It is usually due to narrow lumbar canal (spinal canal stenosis)
- ❖ **Venous**—it is rare but definitely occurs. It is observed in chronic pelvic venous obstruction as a mechanical high venous pressure. It is usually due to iliac vein thrombosis. Peripheral pulses are normal

### Note:

- Beta blockers may aggravate claudication.
- Claudication is not that common in upper limb but can occur during writing or any upper limb exercise.

## REST PAIN

- ◆ It is continuous aching in calf or feet and toes or in the region even at rest depending on site of obstruction.
- ◆ It is ‘*cry of dying nerves*’ due to ischaemia of the somatic nerves. It signifies severe decompensated ischaemia. Pain gets aggravated by elevation and is relieved in dependent position of the limb.
- ◆ Pain is more in the distal part like toes and feet. It gets aggravated with movements and pressure.
- ◆ Hyperaesthesia is common association with rest pain.
- ◆ Rest pain is increased in lying down and elevation of foot; it may be reduced on hanging the foot down.
- ◆ Rest pain is worst at night and so patient is sleepless at night.
- ◆ Rest pain is apparently reduced by holding the foot with hand, probably due to suppression of transmission of pain sensation.



**Fig. 1.302:** Rest pain in a patient suffering from TAO. Holding the foot reduces the pain slightly.

#### Features of arterial stenosis/block in limbs

- ❖ Intermittent claudication
- ❖ Rest pain
- ❖ Cold periphery, numbness, paraesthesia
- ❖ Color changes, ulceration, gangrene
- ❖ Altered sensation and decreased function/movements
- ❖ Diminished/absent arterial pulsation
- ❖ Thrill/bruit over the stenosed artery
- ❖ Altered venous filling—normally it is in few seconds; it is delayed in arterial stenosis; it is rapid in AV fistula

## ■ LIMB ISCHAEMIA

### Causes

- ◆ Atherosclerosis.
- ◆ Embolism (acute).
- ◆ Arteriopathies—Buerger's disease, Raynaud's disease, Takayasu's disease.
- ◆ Diabetes.
- ◆ Scleroderma.
- ◆ Physical agents—trauma, tourniquet, radiation injury.

### Classification of Limb Ischaemia

#### Fontaine classification of limb ischaemia

- ❖ Stage 1: No clinical symptoms
- ❖ Stage 2: Intermittent claudication
  - 2a: Well-compensated—can walk > 200 metres
  - 2b: Poorly compensated—walk only < 200 metres
- ❖ Stage 3: Rest pain
- ❖ Stage 4: Gangrene, ischaemic ulcer

#### Rutherford classification

Grade	Clinical feature
0	Asymptomatic
1	Mild claudication
2	Moderate claudication
3	Severe claudication
4	Ischaemic rest pain
5	Minor tissue loss
6	Major tissue loss

#### Limb ischaemia is also classified as:

- ◆ *Functional* ischaemia.
- ◆ *Critical* ischaemia.

### Functional Limb Ischaemia

Here flow of blood is normal when limbs are at rest; but will not be increased during exercise. It presents as claudication. It is defined as, "Muscle discomfort in the limb reproducibly produced by exercise and relieved by rest within 10 minutes."

### Critical Limb Ischaemia

It is persistently recurring ischaemic rest pain for 2 weeks, which requires regular analgesics for > 2 weeks or ulceration or gangrene of the foot or toes with an ankle systolic pressure < 50 mmHg or toe systolic pressure < 30 mmHg. Ankle brachial pressure index (ABPI) will be less than 0.3.

One should check blood pressure in all 4 limbs. ABPI is checked in supine position; systolic blood pressure in upper and lower extremities (two upper and two lower) is checked and higher value of each extremities is taken; ABPI is calculated.

Results—>0.90 is normal; 0.70–0.89 is mild disease; 0.50–0.69 is moderate; <0.50 is severe.

#### Note:

Calcification can alter the ABPI.

## ■ PREGANGRENE

It is the changes in tissue which indicates that blood supply is inadequate to keep the tissues alive and presents with rest pain, colour changes, oedema, *hyperaesthesia* with or without ischaemic ulceration.

## ■ GANGRENE

It is macroscopic death of tissue *in situ* with putrefaction.

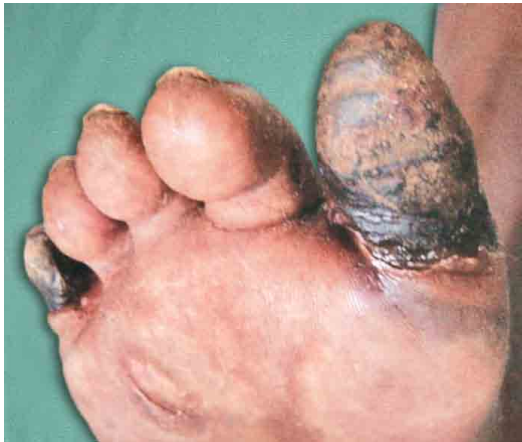### Dry Gangrene

It is dry, desiccated, mummified tissue caused by gradual slowing of bloodstream. There is a *line of demarcation* and is localised.

### Wet Gangrene

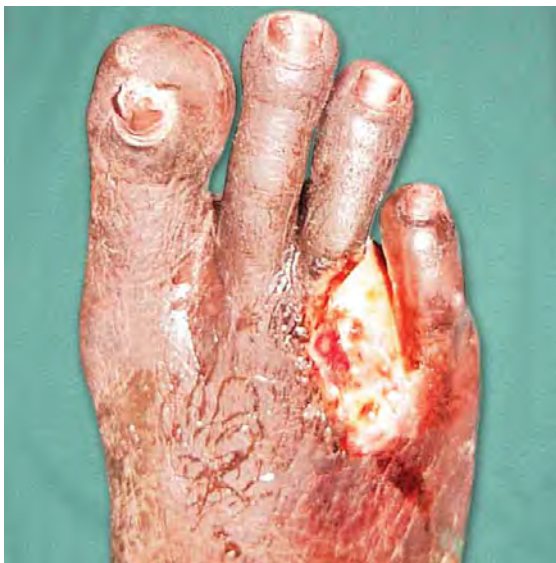It is due to both arterial and venous block along with superadded infection and putrefaction. It spreads proximally and there is *no line of demarcation*. It spreads faster.

Organs in which gangrene can develop—appendix, bowel, gall-bladder, testis, pancreas.

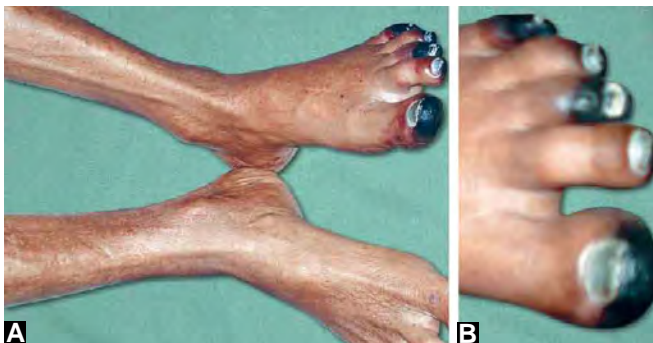

**Fig. 1.303:** Gangrene of great and little toes in a patient with vascular compromise.

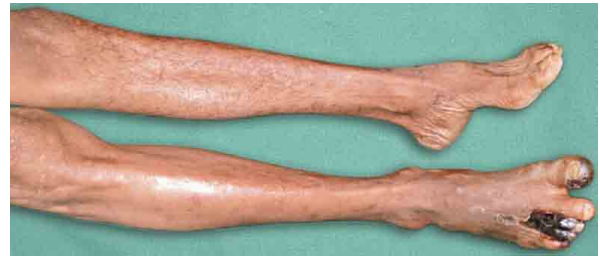
- ❖ **Necrosis:** It is microscopic cell death.
- ❖ **Sequestrum** is dead bone *in situ*.
- ❖ **Slough** is dead soft tissue.



**Fig. 1.304:** Ischaemic ulcer foot in a diabetic patient.



**Figs 1.305A and B:** Gangrene of all toes at their distal phalanges. All ischaemic features are obvious.



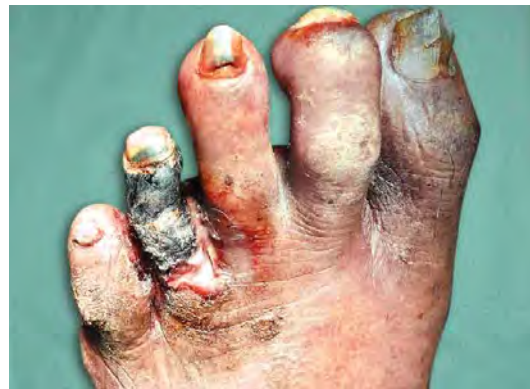**Fig. 1.306:** Ischaemic changes in the right leg. Third and fourth toes are gangrenous with line of demarcation. Great and little toes are partly gangrenous. There are ischaemic features in the right foot and leg like hair loss/skin changes/wasting.

#### Features of ischaemia

- ❖ Marked pallor, purple blue cyanosed appearance
- ❖ Thinning of skin
- ❖ Diminished hair
- ❖ Loss of subcutaneous fat
- ❖ Brittle nails, with transverse ridges
- ❖ Ulceration in digits
- ❖ Wasting of muscles
- ❖ Tenderness and temperature (cold)

#### Line of Demarcation

- ◆ It is a line between viable and dying tissue indicated by a band of hyperaemia. It also indicates that disease is getting localised.
- ◆ *Final separation* between healthy and gangrenous tissue occurs by development of a layer of granulation tissue in between.
- ◆ It is hyperaesthetic due to *exposed nerve endings*.



**Fig. 1.307:** Clear line of demarcation in gangrenous 4th toe.

#### Types of Separation

- ◆ Separation by *aseptic* ulceration is seen in dry gangrene.
- ◆ Separation by *septic* ulceration is seen in infected condition and *wet* gangrene.

#### DIFFERENT LEVELS OF ARTERIAL OBSTRUCTION

- ◆ *Aortoiliac block* causes claudication in both buttocks, thighs, and calves; absence of femoral and distal pulses bruit over aortoiliac region. *Impotence* occurs due to defective perfusion through internal iliac arteries and so into the penis causing erectile dysfunction (*Leriche's syndrome*).

- ◆ *Iliac artery obstruction* causes claudication in thigh and calf; bruit over iliacs with absence of femoral and distal pulses.
- ◆ *Femoropopliteal obstruction* causes claudication in calf with absence of distal pulses but with palpable femoral.
- ◆ *Distal obstruction* shows absence of ankle pulses with palpable femoral and popliteal pulses.
  - ▶ *Paraesthesia* over the skin of the foot is due to shunting of blood from the skin to muscles in deeper plane.
  - ▶ *Sensation* in gangrenous area is absent. But, at the line of demarcation, skin is *hyperaesthetic*.

## OTHER FEATURES OF POOR CIRCULATION

- ◆ The affected part is *cold* with *numbness*, *paraesthesia* and *colour changes*. Observing for *colour change* is important as, if it is not present one may have to think that numbness could be of neurological origin. On elevation the part blanches, on dependency part becomes purple. *Temperature sensation* on the ischaemic limb is lost apart from its coldness.
- ◆ *Ulceration, gangrene, decreased sensation and movements* are the features to be checked.
- ◆ **Delayed capillary filling:** Blanched nails or pulp of fingers, on pressure, will show delay in refilling (to turn pink) after release of pressure.
- ◆ **Delayed venous refilling:** Two fingers are placed over the vein. Finger nearest to heart is moved away so as to empty the vein. Distal finger is released to observe the venous refilling. Delay in filling is called *Harvey's sign*, signifies ischaemia. Venous filling is increased in AV fistulas.
- ◆ **Crossed leg test (*Fuchsig's test*):** Patient is asked to sit with the legs crossed one over the other so that the popliteal fossa of one leg will lie against the knee of other leg. Oscillatory movements of foot can be observed synchronous with the popliteal artery pulsation. This movement is absent with blockage of popliteal artery.
- ◆ **Disappearing pulse syndrome:** Exercise the limb after feeling the pulse. Pulse disappears once patient develops claudication. It is due to vasodilatation and increased vascular space occurring as the result of exercise wherein arterial tension cannot be kept adequately and so pulse will disappear (*unmasking the arterial obstruction*).
- ◆ **Buerger's postural test:** Patient lying down on his back is asked to raise the leg above. In normal individuals, limb (plantar aspect of foot) remains pink even after raising above 90°. Ischaemic limb, when elevated shows marked pallor and empty veins. The angle in which pallor develops is called *Buerger's angle of vascular insufficiency*. If this angle is < 30°, it indicates severe ischaemia.
- ◆ **Systolic bruit** may be heard over stenosed artery like subclavian artery, femoral artery, carotid artery, iliacs, renal artery.
- ◆ **Adson's test (*Scalene manoeuvre*):** In a patient sitting on a stool, the radial pulse is felt. The patient is then asked to take a deep breath (to allow the rib cage to move upwards so as to narrow the cervicoaxillary channel) and turn the face to same side (to contract scalenus anterior muscle so as to narrow the scalene triangle). If the radial pulse disappears or become feeble it signifies cervical rib or scalenus anticus syndrome.
- ◆ **Elevated arm stress test (EAST), or modified Roos test:** With both the arms kept in 90° abduction and external rotation position, patient is asked to make a fist and release repeatedly for 5 minutes. In normal side, patient will continue to do the manoeuvre whereas in diseased (Thoracic outlet syndrome) side patient gets pain and paraesthesia with difficulty in continuing the manoeuvre. Patient drops the arm down to relieve the symptoms.

- ◆ **Costoclavicular compression manoeuvre (*Falconer test*):** Radial pulse becomes absent when patient draws his shoulders backwards and downwards in excessive military position. This is because at this position, subclavian artery is compressed between first rib and clavicle, leading to feeble or absent radial pulse. *Halstead manoeuvre* another similar test.
- ◆ **Hyperabduction manoeuvre (*Wright test*):** When affected arm is hyperabducted, radial pulse becomes absent or feeble due to compression of artery by pectoralis minor tendon.
- ◆ **Allen's test:** It is done to find out the patency of radial and ulnar arteries. Both the arteries are compressed near the wrist and allowed to blanch completely in one minute (In the mean time patient closes and opens the fist several times for further venous outflow). Palm appears pale and white. One of the arteries is released and colour of hand is noted. Normally hand will become pink and flushed in no time; whereas in obstruction, the area will still remain pale. Other artery is also released and looked for changes in hand. Often test has to be repeated to get proper information.
- ◆ Abdomen should be examined for the presence of abdominal *aortic aneurysms*. It presents as pulsatile mass above the umbilicus, vertically placed, smooth, soft, nonmobile, not moving with respiration, resonant on percussion. Expansile pulsation is confirmed by placing the patient in knee-elbow position.
- ◆ Auscultation for *arterial bruit* over femoral artery, abdominal aorta, subclavian and carotid arteries is done.

## Palpation of Blood Vessels

- ◆ *Dorsalis pedis artery* is felt just lateral to the extensor hallucis longus tendon at the proximal end of first web space, felt against the navicular and middle cuneiform bones. It is absent in 10% cases.
- ◆ *Posterior tibial artery* is felt against the calcaneum just behind the medial malleolus midway between it and tendon Achilles.
- ◆ *Anterior tibial artery* is felt anteriorly in the midway between the two malleoli against the lower end of tibia just above the ankle joint, lateral to extensor hallucis longus tendon.
- ◆ *Popliteal artery* is difficult to feel. It is palpated better in prone position with knee flexed about 40–50°, to relax the popliteal fascia. It is felt in the lower part of the fossa over the flat posterior surface of upper end of tibia. In upper end of the fossa, artery is not felt as there is no bony area in intercondylar region.
- ◆ *Femoral artery* in the groin is felt just below the inguinal ligament midway between anterosuperior iliac spine and pubic symphysis. Often hip has to be flexed for about 10–15° to feel it properly.
- ◆ *Radial artery* is felt at the wrist on the lateral aspect against lower end of the front of radius.
- ◆ *Ulnar artery* is felt at the wrist on the medial aspect against lower end of the front of ulna.
- ◆ *Brachial artery* is felt in front of the elbow just medial to biceps brachii tendon.
- ◆ *Axillary artery* is felt in apex of the axilla against shaft of the humerus.
- ◆ *Subclavian artery* is felt against first rib just above the middle of the clavicle.
- ◆ *Facial artery* is felt against body of mandible at the insertion of masseter.
- ◆ *Common carotid artery* is felt medial to sternomastoid muscle at the level of thyroid cartilage against carotid tubercle (*Chassaignac tubercle*) of transverse process of 6th cervical vertebra (in carotid triangle).

Severely diseased distal aorta in atherosclerosis on arteriography is called as "shaggy aorta".



- ◆ *Superficial temporal artery* is felt just in front of the tragus of the ear against zygomatic bone.

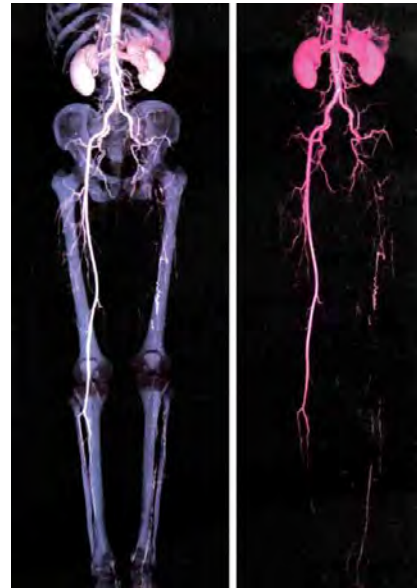## INVESTIGATIONS FOR ARTERIAL DISEASES

- ◆ **Segmental pressure measurements:** Segmental BP is measured at multiple levels (upper and lower thigh, upper calf and ankle); pressure reductions between levels help to localise the occlusion; normally pressures increase as one moves further down the leg (>20 mmHg gradient abnormal); test is inaccurate in calcified artery walls.
- ◆ **Blood tests:** Low Hb delays healing due to poor oxygenation; raised WBC count may be due to infection; raised platelet count may precipitate thrombosis (of arteries and veins both); blood sugar and glycosylated haemoglobin (HbA1C) reflects the diabetic problem; lipid profile; peripheral smear; renal function tests (serum creatinine).
- ◆ **Doppler** to find out the site of block—hand held Doppler can be used (**Doppler:** *Christian Johann Doppler*, Austrian physicist).
  - ▶ **Duplex scan:** It is combination of B mode ultrasound and Doppler study. Difference in transmitted beam of the ultrasound and reflected beam is called as *Doppler shift* which is assessed and converted into audible signals. It is used to study the site, extent, severity of block, and also about collaterals. Audible sound is heard with normal flow, and sound is important. Turbulence is heard when there is stenosed partially blocked artery. Audible sound will be absent if there is complete block. Using Doppler probe blood pressure at various levels can be assessed. Pulse wave tracing along the artery is also important.



**Fig. 1.308:** Hand held Doppler is simpler way to identify and assess the artery.

- ▶ Arterial diameter, blood flow rate, velocity of flowing blood, assessment of stenosed segment is properly done using Doppler.
- ◆ **Angiography:**
  - ▶ *Angiography* is the appropriate investigation for arterial diseases.
  - ▶ **Retrograde transfemoral Seldinger (Sweden) angiography:**
    - It is commonly done angiogram. It is done only when femorals are felt. If femoral pulsation is not felt then angiogram is done either *transbrachially* (*left brachial artery*), or *transaortic*.



**Fig. 1.309:** Angiogram showing vessels in both lower limbs; note the significant block on the left side

### Indications for angiogram

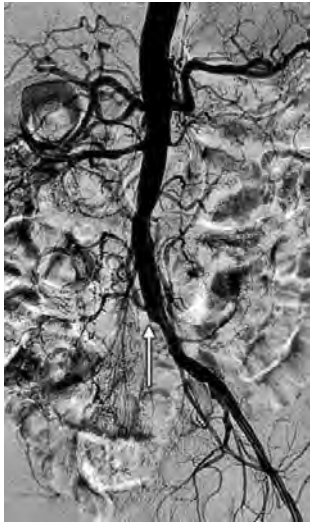
- ❖ TAO
  - ❖ Atherosclerosis
  - ❖ Raynaud's phenomenon
  - ❖ AV fistulas
  - ❖ Haemangiomas
  - ❖ Thoracic outlet syndrome (e.g. cervical rib)
  - ❖ Aneurysms
  - ❖ Neoplastic conditions
- Other angiograms are carotid angiogram, coeliac angiogram, superior mesenteric angiogram, coronary angiogram.

### Seldinger technique (Steps)

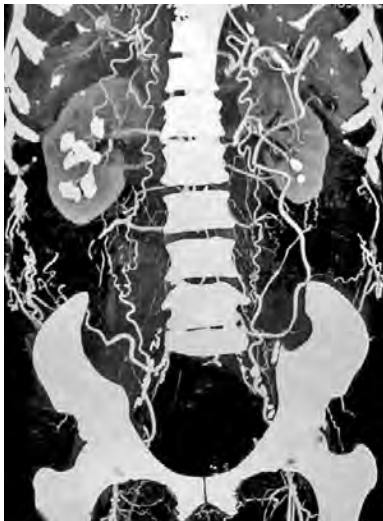- ❖ Arterial cannula is passed into the artery, e.g. femoral artery
  - ❖ Needle is removed and guidewire is passed through the cannula
  - ❖ Cannula is removed
  - ❖ Dilator is passed over the guidewire
  - ❖ Dilator is removed and arterial catheter (5 French sized) is passed over the guidewire
  - ❖ Guidewire is removed
- Femoral artery is used because it can be easily felt and cannulated to pass an arterial catheter.
- Water soluble iodine dye (Sodium diatrizoate) is injected. X-rays are taken to see the block, its extent in the affected limb.
- In TAO *cork screw* appearance is characteristic. *Distal run off* through collaterals is also important.
- If catheter is passed still proximally angiogram of opposite side is possible.
- Seldinger technique can also be used (to study) to do renal angiogram to detect renal artery stenosis, renal carcinomas, renal anomalies (vascular). But a *caution* should be remembered that angiogram in limb may precipitate further rapid thrombus formation, worsening ischaemia and precipitating gangrene.

### Complications of retrograde angiogram

- ❖ Bleeding, hypotension
  - ❖ Dissection of the vessel wall, pseudoaneurysm
  - ❖ Haematoma formation
  - ❖ Embolic blue toe syndrome
  - ❖ Thrombosis, AV fistula
  - ❖ Infection, osmolarity discomfort
  - ❖ Anaphylaxis—4%
- ▶ **Direct aortic angiogram**, practiced earlier, is discouraged at present because of the risk of *aortic dissection* and paraplegia due to blockage/spasm of anterior spinal artery.
- ▶ **Digital subtraction angiography (DSA)**
- Here vessel (artery) is delineated in a better way by eliminating other tissues through computer system. AV fistulas, haemangiomas, lesion in circle of Willis, vascular tumours, other vascular anomalies are well made out.



**Fig. 1.310:** DSA showing total block of right common iliac artery due to thrombosis.

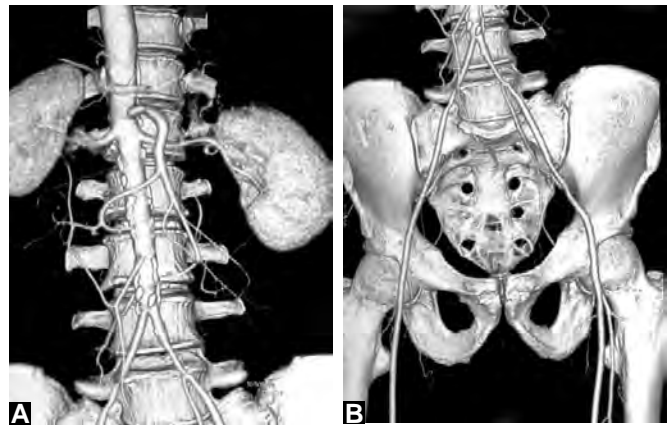


**Fig. 1.311:** CT angiogram showing abdominal aorta, branches and renal vessels.

- Dye is injected either to an artery or vein. Injecting into a vein is technically easier but larger dose of dye is required. Injecting into an artery is technically difficult but small dose of dye is sufficient.
- **Advantages:** Only vascular system is visualised; other systems are eliminated by computer subtraction. Small lesion, its location and details are better observed with greater clarity.
- **Disadvantages:** Cost factor and availability.
- **Complications:** Anaphylaxis, bleeding, thrombosis.

### ◆ CT angiogram/MR angiogram.

- ◆ **Ultrasound abdomen** to see aneurysm/aorta and its anatomical changes/other vessels in the abdomen/other organs.
- ◆ **Treadmill test/ECG/echocardiography** to assess cardiac/coronary status.
- ◆ **Plethysmography:** It measures the blood flow in limbs. Water-filled volume recorder; air-filled volume recorder; mercury in silastic gauze is used after occluding the venous outflow. It is a noninvasive method. Segmental plethysmography using occlusion cuffs of 65 mmHg pressure is placed at thigh, calf and ankle levels and then quantitative measure of pulsation is done.
- ◆ **Ankle-brachial pressure index:** Normally it is 1. If it is less than 0.9, it means ischaemia is present. If it reaches 0.3 or below then it signifies severe ischaemia with gangrene.
- ◆ **Brown's vasomotor index:** Specific nerve of the ischaemic limb is anaesthetised like posterior tibial nerve or ulnar nerve (local anaesthesia or spinal anaesthesia is given to anaesthetise entire limb). If the ischaemic disease is at vasospasm stage (like in TAO), nerve block will relieve the sympathetic vasospasm and skin temperature rises. It is compared to mouth temperature of the patient.



**Figs 1.312A and B:** Aortic and aortoiliac CT angiogram.

It is to assess the degree of vasospasm which is used as a predictor of the efficacy of sympathectomy.

(Rise in skin temperature minus rise in mouth temperature) divided by rise in mouth temperature is called as *Brown's vasomotor index*. If it is more than 3.5, it is due to vasospasm, and can be relieved by sympathectomy. If less than 3.5, sympathectomy is not beneficial.

- ◆ **Transcutaneous oximetry:** By placing polarographic electrodes over the skin over thigh, leg and foot of oxygen tension (tcPO<sub>2</sub>) can be measured which is reflection of underlying tissue perfusion. Normal tcPO<sub>2</sub> in the foot is 50–60 mmHg. Level less than 40 mmHg shows inadequate wound healing. Level below 10 mmHg suggests critical ischaemia with complete failure of wound healing.

#### ◆ Other tests

- ▶ *Xenon 133 isotope method* is used to study muscle blood flow. Xenon 133 after mixing with normal saline is injected IM to study its clearance.
- ▶ Two electromagnetic electrodes are placed in contact with arterial wall in opposite directions which pick up moving blood force to feed into electronic amplifier. But it is invasive as artery has to be dissected to place electrodes.
- ▶ Angioscopy to visualize the vessels directly.

### Treatment Plan for Arterial Diseases

- ◆ Stopping smoking; supervised exercises; regular controlled walk, diet (carbohydrate and lipid free diet); care of limbs.
- ◆ Control of hypertension, diabetes; antilipid drugs like atorvastatin 10 mg or pravastatin 40 mg; low dose aspirin 75 mg; clopidogrel 75 mg; vasodilators; ticlopidine; dipyridamole; cilostazole 100 mg are different drugs used.
- ◆ Percutaneous transluminal balloon angioplasty (PTA) done mainly to iliac arteries, subclavian arteries, renal artery, carotid and occasionally leg arteries and mesenteric or gastrointestinal arteries. PTA with stenting using expandable stents to the arteries is also often done to get a better result.
- ◆ Bypass graft surgeries—aortofemoral; femorofemoral; iliofemoral, etc. Dacron, human umbilical vein (3 mm), saphenous vein; PTFE (Polytetrafluoro ethylene)—are different grafts used.
- ◆ Endarterectomy, atherectomy, thrombectomy, profundaplasty, etc.

### DISEASES OF THE ARTERIES

- ◆ Atherosclerosis.
- ◆ Thromboangiitis obliterans (TAO) (Buerger's disease).
- ◆ Raynaud's disease.
- ◆ Conditions causing Raynaud's phenomenon: Like scleroderma, rheumatoid arthritis, SLE, granulomatosis, vasculitis of other causes.
- ◆ Embolus.
- ◆ Aneurysms.
- ◆ Other causes: Fibromuscular dysplasia, radiation, Takayasu's arteritis.

- ❖ Arterial diseases can be *major arterial (occlusive) diseases* or *peripheral arterial (occlusive) diseases*
- ❖ Major arterial diseases occur in aorta, carotids and iliac arteries
- ❖ Peripheral arterial occlusive diseases occur in limb vessels and distal vessels; commonly lower limbs but can occur in upper limbs also
- ❖ Effects of occlusion depends on anatomy of arteries; collateral circulations, degree and extent of the disease occlusion, demand of the tissues
- ❖ Presentations are being—pain; pallor; pulselessness; poikilothermia (cold periphery); paresis; paraesthesia (due to diversion of blood from skin to muscles); pressure effects.

### ATHEROSCLEROSIS

It is a chronic, complex inflammatory condition of elastic and muscular arteries, involving as systemic and segmental. It begins in childhood as fatty streaks.

#### Risk factors

##### Definitive

- Hypercholesterolaemia, and hyperlipidaemia (cholesterol >200 mg%; high LDL (>100 mg%); low HDL (<35 mg%)
- Cigarette smoking
- Hypertension
- Diabetes mellitus

##### Relative

- Age—elderly
- Common in males
- Hypertriglyceridaemia
- Sedentary life, obesity
- Family history

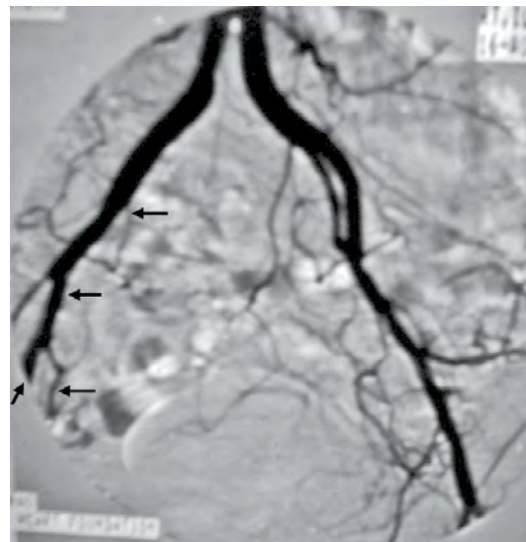


Fig. 1.313: Angiogram showing atherosclerosis.

### Pathogenesis

- ◆ All risk factors cause initial endothelial injury, both mechanical as well as toxic. This reduces significantly *normal atheroprotective features* of endothelium (*barrier function; antiadhesive effect; antiproliferative effect* on smooth muscles of arterial wall). Progressive atheromatous plaque formation, thrombosis, migration and proliferation of vascular smooth muscle cell occur. *Migrated smooth muscle cells* into intima act as neointima and this migration is stimulated by PDGF (*platelet derived growth factor* released by endothelial smooth muscles, platelets); which (this migrated smooth muscle) newly becomes secretory to produce large quantity of matrix of the plaque. Lipid (LDL) gets oxidised to release factors which promote inflammation and coagulation and factors which prevent production of *protective nitric oxide*. Macrophages stabilise the plaque.
- ◆ *Pathology* constitutes of atherosclerotic plaque which contains smooth muscle cells, connective tissue matrix, macrophages and lipid (the feature of atherosclerosis). Ulceration and calcification occurs in these plaques. *Ulcerated plaque* is highly thrombogenic causing thrombosis and further critical block of the vessel leading to tissue ischaemia and infarction distally.

- ◆ Plaques are more at the *dividing junctions* of the artery where stress and shear force of the blood flow is more. Plaques are dynamic in nature with progression and regression phases.
- ◆ Plaque progression has got a unique ability of *adaptation* so that as the plaque progresses, lumen caliber is been tried to be preserved until critical stage occurs. Stenosis more than 40% is said to be *critical*. Beyond this, compensatory mechanism fails causing rapid progression and further stenosis of lumina. Stenosis more than 40% causes *atrophy of tunica media* making arterial wall mechanically unstable leading into dilatation and aneurysm.
- ◆ **Common arteries involved are**—infrarenal part of abdominal aorta, coronary arteries, iliofemoral vessels, carotid bifurcation, popliteal arteries. It is less common in upper limb arteries, common carotid, renal and mesenteric arteries.

### Features and Evaluation

- ◆ It is common after 50 years, but can occur at earlier age group.
- ◆ It occurs in males and females. Family history is common.
- ◆ Smoking, hypertension, diabetes, raised cholesterol are common causes.
- ◆ Veins are not diseased. Arterial wall is thickened on palpation.
- ◆ Thrill and bruit over femoral, renal, carotid arteries may be felt/heard. It suggests localised stenosis with turbulence of blood flow.
- ◆ Features of ischaemia in the affected limb seen. Absence/feeble pulses including main arteries of the limb—femorals. Abdomen should be examined for aortic aneurysm.
- ◆ Transient ischaemic attacks, chest pain, eye problems, mesenteric ischaemia, altered renal function may be associated.
- ◆ Blood sugar, fasting lipid profile, Doppler, angiogram (CT/D SA), US abdomen, ECG, echocardiography are essential investigations. Angiogram shows typical narrowed artery, site, extent, percentage of stenosis, and collaterals.
- ◆ Antiphospholipid antibody (APLA) estimation is done to identify antiphospholipid antibody syndrome (APLS/Hughes' syndrome). It is an autoimmune, hypercoagulable state caused by antiphospholipid antibodies. APLS provokes thrombosis in both arteries and veins as well as causes pregnancy-related complications such as miscarriage, stillbirth, preterm delivery, and severe preeclampsia. It causes lower limb DVT (venous) and arterial thrombosis (causing stroke); it is diagnosed by ELISA test for APLA. It is treated by aspirin and anticoagulant (Warfarin).

#### Complications of atherosclerosis

- ❖ Narrowing of the arteries: Coronary, cerebral, renal, mesenteric, iliofemoral. > 70% narrowing (severe) causes reduced blood flow. Ischaemia, ulcerations, gangrene can occur.
- ❖ Embolism: From atheromatous plaques.
- ❖ Aneurysm formation: Mainly abdominal aorta and also in peripheral arteries.
- ❖ Fatty streaks: Fibrous atheromatous plaque with fibrous, lipid and basal zones → Complicated plaque with calcification, ulceration, narrowing

### Management

- ◆ **Risk factor modification:** Avoid smoking; control of hypertension, diabetes, hypercholesterolaemia; weight reduction by diet, and exercise.
- ◆ **Drugs:** Antiplatelet agents (aspirin 75 mg, clopidogrel 75 mg); cilostazol 50 mg bd; atorvastatin to reduce cholesterol; pentoxifylline.
- ◆ **Percutaneous transluminal angioplasty (PTA)** is very useful for iliac blocks and lower limb blocks.
- ◆ **Surgeries:**
  - ▶ Thrombectomy, endarterectomy, profundaplasty.
  - ▶ Reverse/saphenous vein graft.
  - ▶ By pass grafts—iliofemoral, aortofemoral, iliopopliteal, femorofemoral grafts.
  - ▶ Amputations if limb is gangrenous—toe/below knee, above knee. Forefoot and Syme's amputations are not feasible in vascular conditions.

#### Note:

Lumbar sympathectomy and omentoplasty are not much useful in atherosclerotic limb. Omental vessels as such are often poorly perfused in atherosclerotic patients due to involvement of coeliac trunk.

### Aortoiliac Occlusive Disease

Common site of symptomatic atherosclerotic occlusive arterial disease of lower limb is infrarenal abdominal aorta and iliac arteries. Aortic bifurcation is the most common site of occlusion. Often disease may also extend into infrainguinal level.

### Types of Aortoiliac Occlusive Disease

*Type I:* Disease localised to distal abdominal aorta and common iliac arteries.

*Type II:* Wide spread aortic and iliac disease.

*Type III:* Multiple level diseases along with infrainguinal diseases.

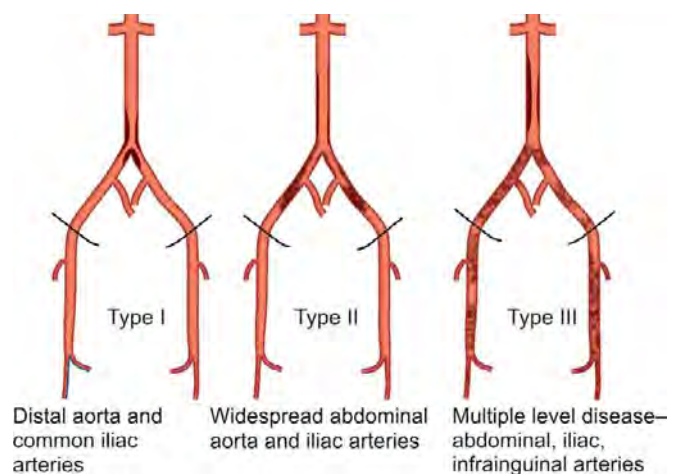


Fig. 1.314: Types of aortoiliac occlusive disease.

## Features

- ◆ Common in 5th and 6th decades. Common in males.
- ◆ Claudication in buttock, Leriche syndrome with impotence, distal ischaemia are the features.
- ◆ Femoral artery pulsations below are absent. Systolic bruit over aorta and iliac arteries may be heard suggesting stenosis.
- ◆ Atheromatous plaque may dislodge and may cause embolus causing acute presentation.
- ◆ Aortic angiogram is diagnostic.

## Management

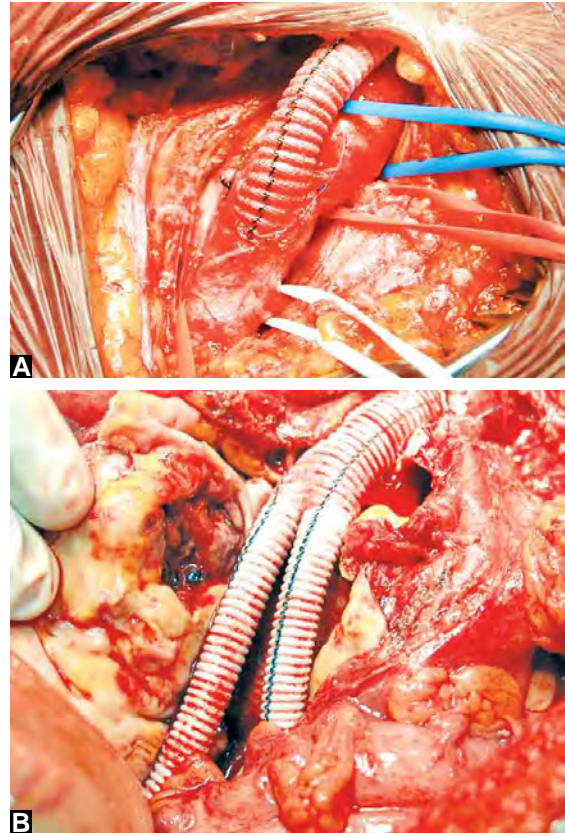
- ◆ Treatment for diabetes, hyperlipidaemia, etc.
- ◆ Surgical treatment is the mainstay.
  - ▶ Direct *anatomical* reconstruction
    - *Aortoiliac endarterectomy* is reborring/disobliteration procedure useful for type I disease. Diseased intima, plaque with thrombus is removed by arteriotomy along the entire length which is closed later using 4 zero/5 zero polypropylene continuous sutures (open endarterectomy). In lengthy disease, after making two small arteriotomies at proximal and distal diseased parts, endarterectomy loop is passed to remove the intima with diseased plaque (*semi-closed endarterectomy*). *Advantages:* It avoids prosthetic graft and its complications. *Problem is*—reocclusion and restenosis.
    - *Aortofemoral bypass graft* is the gold-standard surgical procedure for type I and II disease. Long-term patency rate is 70–80%. Woven Dacron graft is used. *Complications are*—bleeding, thrombosis, embolisation, graft blockage, graft failure, graft infection, graft leak, aortovenacaval/aortoduodenal fistula, mesenteric ischaemia (colonic), impotence.
  - ▶ Indirect *extra-anatomical* bypass
    - It is quicker and technically easier and is suitable to patients who cannot tolerate anatomical bypass. Axillo-bifemoral graft is used, only in such occasional situation.
  - ▶ Nonoperative *catheter based* endovascular procedure
    - If stenosis is less than 5 cm *percutaneous transluminal angioplasty* (PTA) with or without intravascular stents can be done. It is useful for single or multiple short focal stenoses. It is now proved that long-term patency of PTA is equal to surgical intervention.

## Infringuinal Arterial Occlusive Disease

It is either part of type III aortoiliac disease (aortoiliac femoral) or femoropopliteal tibial disease. Superficial femoral artery is most commonly involved. Involvement of long segment of the artery is common. Occasionally, a short stenotic segment may be present.

## Management

- ◆ If the popliteal artery below knee is patent *femoropopliteal bypass* is the ideal procedure used. Otherwise one of the patent branches is used for bypass. *In situ saphenous vein graft* is ideal; reverse saphenous vein graft or synthetic femoropopliteal graft can also be used.
- ◆ *Profundaplasty* may be done to improve the collateral circulation through profunda femoris (deep femoral).



Figs 1.315A and B: Aortofemoral bypass graft.

### Note:

PTA in infringuinal blocks is occasionally useful, only when stenosis is short and well-localised; otherwise it is *not a good* option. Angioplasty with laser drilling is often tried.

## THROMBOANGIITIS OBLITERANS (TAO) Syn. Buerger's Disease

*The disease (occurs) in young adults between the ages of twenty and thirty-five or forty years.... Upon examination we see that one or both feet are markedly blanched, almost cadaveric in appearance, cold to the touch, and that neither the dorsalis pedis nor the posterior tibial artery pulsates.... After months... trophic disturbances make their appearance.... Even before the gangrene, at the ulcerative stage, amputation may become imperative because of the intensity of the pain.*

—Leo Buerger

1908 (Professor of Urology, 1879 to 1943)

- ◆ It is a disease *very commonly* seen in young and middle aged males; seen only in *smokers* and *tobacco users*; *not usually* seen in females due to genetic reasons (but can occur in females very rarely).
- ◆ Almost always starts in lower limb, may start on one side and later on the other side. Upper limb involvement occurs only after lower limb is diseased. Only upper limb involvement can occur (not uncommon) but it is *rare*.
- ◆ It is nonatherosclerotic inflammatory disorder involving medium sized and distal vessels with cell mediated sensitivity to type I and type III collagen.

- ◆ It is common in Jewish people; it is rare even in female smokers.
- ◆ Hormonal influence, familial nature, hypersensitivity to cigarette, altered autonomic functions are probable different causes.
- ◆ Lower socioeconomic group, recurrent minor feet injuries, poor hygiene are other factors.
- ◆ It is segmental, progressive, occlusive, inflammatory disease of small and medium sized vessels with superficial thrombophlebitis often may present as Raynaud's phenomenon with microabscesses, along with neutrophil and giant cell infiltration, with skip lesions.

### Pathogenesis

Smoke contains *carbon monoxide* and *nicotinic acid*  
 ↓ ← Carboxyhaemoglobin  
 Causes initially vasospasm and hyperplasia of intima  
 ↓  
 Thrombosis and so obliteration of vessels occur, commonly medium sized vessels are involved.  
 ↓  
**Panarteritis** is common  
 Usually involvement is *segmental*  
 ↓  
 Eventually artery, vein and nerve are together involved  
 ↓  
 Nerve involvement causes rest pain  
 ↓  
 Patient presents with features of ischaemia in the limb  
 ↓  
 Once blockage occurs, plenty of collaterals open up depending on the site of blockage either around knee joint or around buttock  
 Once collaterals open up, through these collaterals, blood supply is maintained to the ischaemic area  
 ↓  
 It is called as *compensatory peripheral vascular disease*  
 ↓  
 If patient continues to smoke, disease progresses into the collaterals, blocking them eventually, leading to severe ischaemia and is called as *decompensatory peripheral vascular disease*. It is presently called as **critical limb ischaemia**. It causes rest pain, ulceration, gangrene.

#### Note:

- There is vasospasm → intimal hyperplasia → thrombosis → panarteritis → obliteration; tender, cord like veins with *superficial migratory thrombophlebitis* (30%); with nerve involvement due to vasa nervorum block/spasm. Arterial lumen is *blocked* but not thickened like atherosclerosis.
- In 10% disease is bilateral; 10% females may get the disease (but rare); 10% seen in upper limbs.
- Large arteries are not involved by TAO.

#### Smoking index (SI) =

Number of cigarettes smoked per day  
 SI > 300 is a risk factor

Number of years of smoking

#### Pack Years Index (PYI) =

Number of years of smoking  
 PYI > 40 is a risk factor

Number of *packets* of cigarettes per day

#### Shiano's criteria for Buerger's disease

- ◆ Tobacco use. Only in males
- ◆ Disease starts before 45 years
- ◆ Distal extremity involved first without embolic or atherosclerotic features
- ◆ Absence of diabetes mellitus or hyperlipidaemia
- ◆ With or without thrombophlebitis

### Classification of TAO

- Type I: Upper limb TAO—rare.
- Type II: Involving leg/s and feet—crural/infrapopliteal.
- Type III: Femoropopliteal.
- Type IV: Aortoiliofemoral.
- Type V: Generalised.

### Clinical Features

- ◆ Common in male smokers between the 20-40 years of age group. It is a *smoker's disease*.

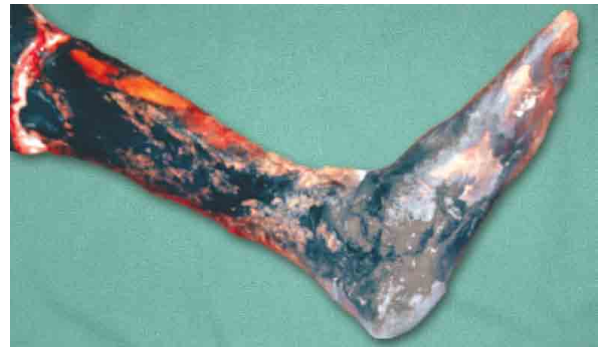

Fig. 1.316: Dry gangrene of leg. Patient needed above knee amputation.

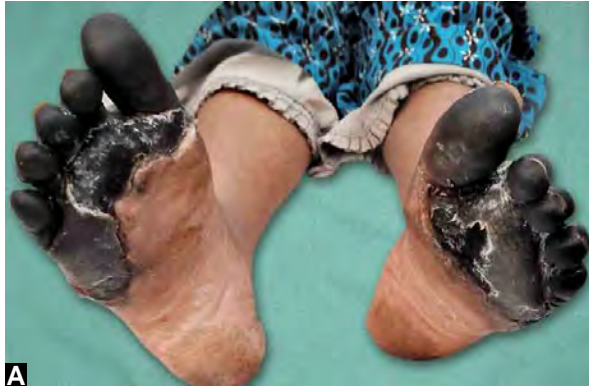- ◆ Intermittent claudication in foot and calf progressing to rest pain, ulceration, gangrene.
- ◆ Recurrent migratory superficial thrombophlebitis.
- ◆ Absence/Feeble pulses distal to proximal; dorsalis pedis, posterior tibial, popliteal, femoral arteries.
- ◆ May present as Raynaud's phenomenon.

### Investigations

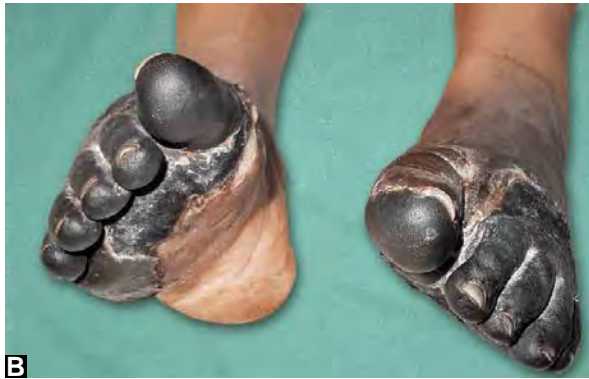- ◆ Hb%. Blood sugar.
- ◆ Arterial Doppler and Duplex scan (Doppler + B mode U/S).
- ◆ **Transfemoral retrograde angiogram** through Seldinger technique:

*Character is like a tree; reputation is like its shadow. The shadow is the one we think of but actually tree is the real thing.*

- ▶ Shows blockage—sites, extent, and severity.
- ▶ *Cork screw* appearance of the vessel due to dilatation of vasa vasorum.
- ▶ Inverted tree/spider leg collaterals.

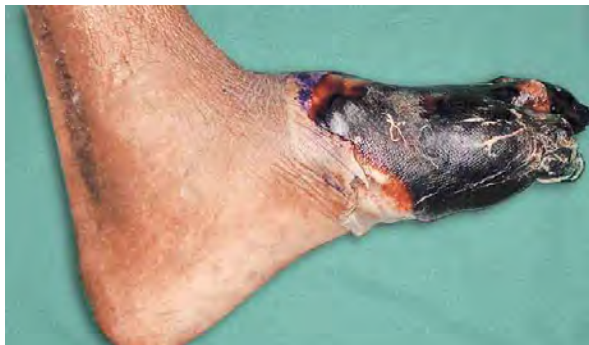

A



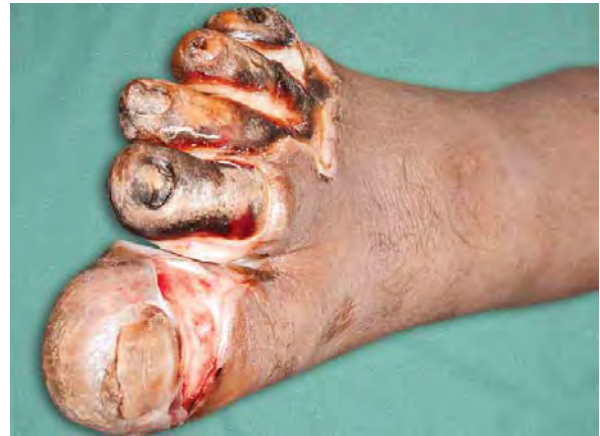B

**Figs 1.317A and B:** Bilateral lower limb TAO causing gangrene of both feet. Patient needs amputation on both sides.

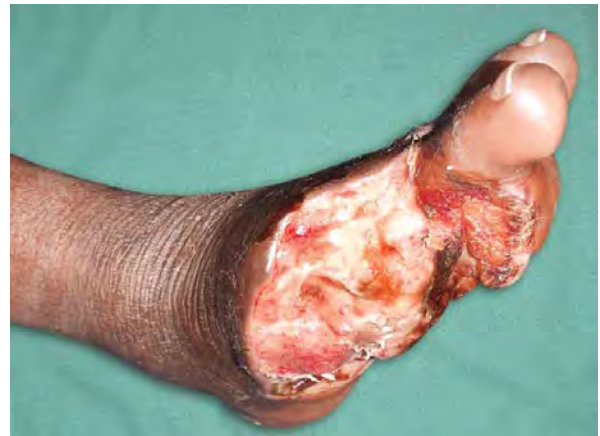

**Fig. 1.318:** Gangrene foot.

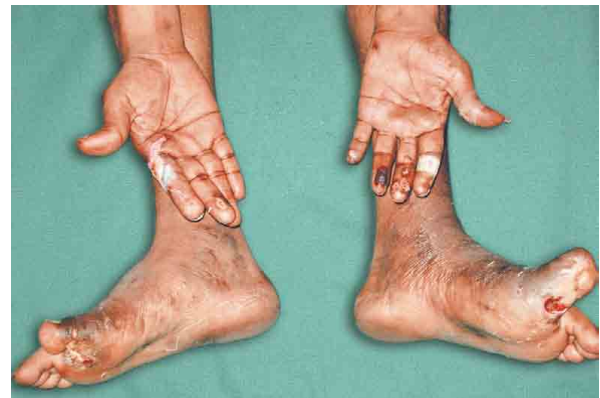- ▶ *Severe vasospasm causing corrugated/rippled artery.*
- ▶ *Distal run off* is amount of dye filling in the main vessel distal to the obstruction through collaterals. If distal run off is good then ischaemia is compensated. If distal run off is poor then ischaemia is decompensated.
- ◆ **Transbrachial angiogram:** If femorals are not felt, then transbrachial angiogram (through left side brachial artery—left subclavian artery—and so to descending aorta) should be done.
- ◆ Ultrasound abdomen to see abdominal aorta for block/aneurysm.
- ◆ Vein, artery, nerve biopsy.



**Fig. 1.319:** Gangrene of all toes in a foot in TAO patient.



**Fig. 1.320:** Ischaemic ulcer foot in a TAO patient.



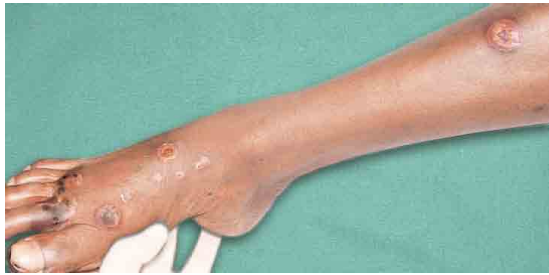**Fig. 1.321:** Ischaemic features in upper and lower limbs (four limbs).

## Treatment

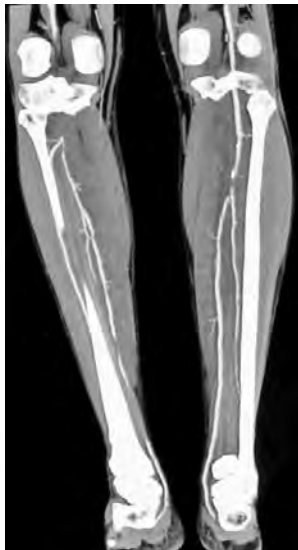Stop smoking. “Opt for either cigarette or limb, but not both.”

## Drugs

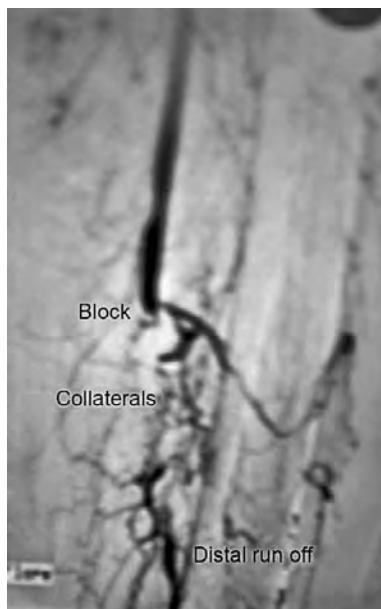
- ◆ Pentoxifylline increases the flexibility of RBC's and helps them reach the microcirculation in a better way so as to increase the oxygenation. Its efficacy is more in *venous ulcer* than arterial diseases (now).



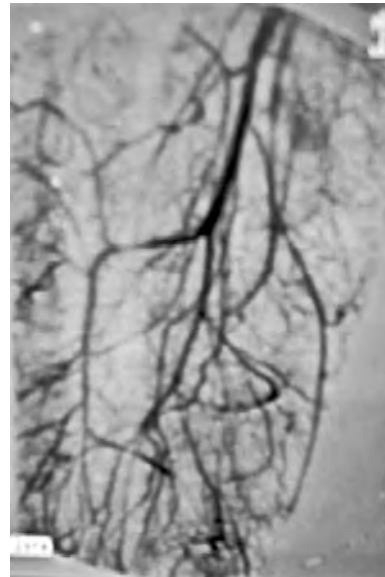**Fig. 1.322:** Skip ischaemic ulcers are common in vascular diseases. It suggests severe ischaemia up to most proximal ulcer level.



**Fig. 1.323:** CT angiogram of lower limb (leg area) showing segmental block.



**Fig. 1.324:** Angiogram showing block in main vessel with opened up collaterals and adequate distal run off.



**Fig. 1.325:** Angiogram showing adequate collaterals.

- ◆ Low dose of aspirin 75 mg once a day—antithrombin activity.
- ◆ Prostacyclins, ticlopidine, praxilene, carnitine.
- ◆ Clopidogrel 75 mg; atorvastatin 10 mg; parvostatin 40 mg; *cilostazole* 100 mg bid—is a phosphodiesterase inhibitor which improves circulation (ideal drug).  
All drugs act *at the collateral level* than on the diseased vessel.
- ◆ Analgesics, often sedatives, antilipid drugs like atorvastatin may be needed. Complamina retard (*xanthine nicotinate*) tablet which was used daily once earlier, is presently not in use. However, graded injection of xanthine nocotinate 3000 mg from day 1 to 9000 mg on day 5 is often practiced to promote ulcer healing, helps to increase claudication distance as a temporary basis. Low molecular dextran may be also used.
- ◆ Naftidofuryl is useful in intermittent claudication; it alters the tissue metabolism.

**Note:**

Vasodilators and anticoagulants are of no use in TAO.

### Care of the Limbs

- ◆ *Buerger's position and exercise*—regular graded exercises up to the point of claudication improves the collateral circulation.  
In *Buerger's position*, head end of bed is raised; foot end of bed is lowered to improve circulation. In *Buerger's exercise* leg is elevated and lowered alternatively, each for 2 minutes for several times at time.
- ◆ *Care of feet (Chiropady)*: Exposure of feet to more cold and warm temperature should be avoided; trauma even minor like nail paring or pressure at pressure points in feet should be avoided. Dryness of feet and legs should be avoided by applying oil to the feet and legs. *Footwear* should be selected carefully. It is better to wear socks with footwear. *Heel raise* by raising the heels of shoes by 2 cm decreases the calf muscle work to improve claudication.

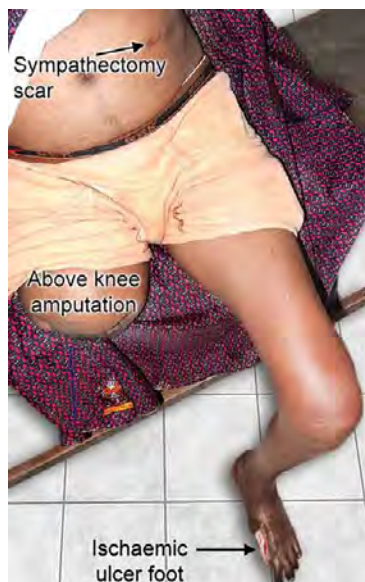

## Chemical Sympathectomy

- ◆ Sympathetic chain is blocked to achieve *vasodilatation* by injecting local anaesthetic agent (xylocaine 1%) paravertebrally beside bodies of L 2, 3 and 4 vertebrae in front of lumbar fascia, to achieve temporary benefit. Long time efficacy can be achieved by using 5 ml phenol in water. It is done under C-Arm guidance. Feet will become *warm immediately* after injection. *Problems* are—possible risk of injecting phenol into IVC/aorta, spinal cord ischaemia.

## Surgery

- ◆ *Omentoplasty* to revascularise the affected limb.
- ◆ *Profundaplasty* is done for blockage in profunda femoris artery so as to open more collaterals across the knee joint (It often makes better perfusion to the knee joint and flap of below-knee amputation).
- ◆ *Lumbar sympathectomy* to increase the cutaneous perfusion so as to promote ulcer healing. But it may divert blood from muscles towards skin causing muscle more ischaemic.



**Fig. 1.326:** Bilateral TAO. Patient has undergone right-sided above knee amputation and left-sided lumbar sympathectomy. Ischemic ulcer on left-sided foot is seen.

- ◆ *Amputations* are done at different levels depending on site, severity and extent of vessel occlusion. Usually either below-knee or above-knee amputations are done.
- ◆ *Ilzarov method* of bone lengthening helps in improving the rest pain and claudication by creating neo-osteogenesis and improving the overall blood supply to the limb.

## Gene Therapy

- ◆ Intramuscular injection of vascular endothelial growth factor (VEGF) which is an endothelial cell mitogen that promotes angiogenesis.

## TAKAYASU'S PULSELESS ARTERITIS (Mikito Takayasu, 1938—Ophthalmologist, Japan)

- ◆ It is progressive, initially symptomless panarteritis involving aortic arch and branches of aorta of unknown etiology, probably immunological.
- ◆ It is common in young females (85%); common in Japan; commonly subclavian artery is involved (85%); involves all layers of arteries of upper limb and neck; often bilateral. It remains unnoticed for long time.

## Features

- ◆ Fever, myalgia, arthralgia, upper limb claudication.
- ◆ Absence pulses in upper limb/limbs, neck; hypertension.
- ◆ Fainting on turning the neck or change in position; atrophy of face.
- ◆ Thrill/bruit along major arteries of upper limb and neck are the features.
- ◆ Optic nerve atrophy without papilloedema.
- ◆ Weakness and paraesthesia of upper limb.
- ◆ Cerebral softening, convulsions, hemiplegia can occur.
- ◆ Occasionally it can be life-threatening. Myocardial infarction; embolism, ischaemia are other *complications*.
- ◆ DSA; MR angiography and Doppler are the *investigations*.

## Treatment

- ◆ To suppress immunity prednisolone 50 mg/day and cyclophosphamide daily is given.
- ◆ Vascular reconstruction.

## RAYNAUD'S PHENOMENON

*Under the influence of a very moderate cold, and even at the height of summer, she (case 1) sees her fingers become ex-sanguine, completely insensible, and of a whitish yellow colour.... One might indeed have suspected that the local asphyxia was connected with a spasmodic state of the vessels,... a functional trouble localised to the arterioles immediately contiguous to the capillaries.*

—Maurice Raynaud, 1862 (French Surgeon)

It is an episodic vasospasm, i.e. arteriolar spasm. It leads to sequence of clinical features called as Raynaud's syndrome.

### Raynaud's syndrome

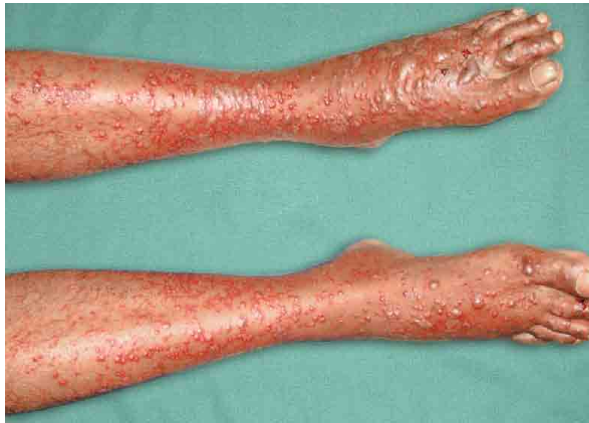Sequence of clinical features due to arteriolar spasm.

- ❖ *Local syncope:* It is due to vasospasm, causing white cold palm and digits along with tingling and numbness
- ❖ *Local asphyxia:* It is due to accumulation of deoxygenated blood as the result of vasospasm causing bluish discolouration of palm and digits with burning sensation (due to accumulated metabolites)
- ❖ *Local recovery:* It is due to relief of spasm in the arteriole, leading to return of blood to the circulation causing flushing and pain in digits and palm (pain is due to increased tissue tension)
- ❖ *Local gangrene:* If spasm persists more than ischaemic time (more than one hour in upper limb), then digits go for ulceration and gangrene. Does not occur regularly but is an occasional phenomenon in the cycle

*Coffman criteria* for Raynaud's syndrome—"episodic attacks of well-demarcated reversible self-limiting colour changes for 1–20 minutes on exposure to cold/emotional stimuli and is symmetrical/bilateral lasting for 2 years".

## Causes for Raynaud's Phenomenon

- ◆ **Raynaud's disease:**
  - ▶ It is seen in females, usually bilateral.
  - ▶ It occurs in upper limb with normal peripheral pulses.
  - ▶ It is due to upper limb (hand) arteriolar spasm as a result of abnormal sensitivity to cold. Patient develops blanching, cyanosis and later flushing as in Raynaud's syndrome. Occasionally, if spasm persists it results in gangrene.
  - ▶ Symptoms can be precipitated and observed by placing hands in cold water.
- ◆ Working with **vibrating tools**: Like pneumatic road drills, chain saws, wood cutting, fishermen travelling in machine boats—*vibration white finger*.



**Fig. 1.327:** Vasculitis can cause arterial insufficiency.

- ◆ **Collagen vascular diseases**: Like scleroderma, rheumatoid diseases causing vasculitis (all autoimmune diseases).
- ◆ **Other causes**: Cervical rib, Buerger's disease, Scalene syndrome.

It is often associated with CREST syndrome (Calcinosis cutis, Raynaud's phenomenon, Esophageal defects, Sclerodactyly, Telangiectasia).

### Types of Raynaud's phenomenon

- ❖ Vasospastic
- ❖ Obliterative

### Raynaud's phenomenon can be:

- ◆ **Primary Raynaud's phenomenon** is an idiopathic vasospastic disorder without underlying identifiable causes. Usually there is no significant pain in primary type. Primary is probably due to increased sensitivity of alpha 2 receptors to nonepinephrine; decreased nitric oxide and endothelin 1 in endothelial cells; increased serotonin and thromboxane. It is common in females and younger age group. Usually it is bilateral involving all digits.

- ◆ **Secondary Raynaud's phenomenon** is vasospasm due to some underlying cause. Significant pain will be present especially during rewarming stage. There are positive autoantibodies; equal in both sexes; occurs at any age group; need not be bilateral.

## Features (of Raynaud's disease)

- ◆ Commonly *bilateral*.
- ◆ Common in young *females*.
- ◆ Raynaud's disease is common in *western white women*.
- ◆ Usually medial *four digits* and palm are involved. Thumb is *spared*.
- ◆ Features of pallor/*blanching* (syncope), *dusky cyanosis* (asphyxia), rubor/painful *red engorgement* (recovery) are the presentation. Occasionally, if vasospasm becomes longer, gangrene or ischaemic ulceration supervenes along the tips of the fingers.
- ◆ Peripheral pulses (radial/ulnar) are *normally* felt. These pulses will be absent in upper limb TAO.
- ◆ Repeated *attacks* are common.

## Investigations

- ◆ Type is identified by angiogram of hand (DSA/MR angiogram), arterial Doppler/Duplex scan.
- ◆ Other investigations required are X-ray of the part, antinuclear antibody (ANA assay) tests specific for different conditions.
- ◆ Assessment of segmental blood pressure gradient from brachial-forearm-wrist-fingers; finger tip thermography; *cold recovery time* (normal is less than 10 minute, but in Raynaud's it is more, often up to 30 minutes); *reactive hyperaemia time* (pneumatic cuff is inflated and kept for 5 minutes and released to observe hyperaemia); nail fold capillary microscopy; Laser Doppler flux to assess microvascular perfusion of finger skin—are *special methods* of evaluations.
- ◆ Other routine investigations for arterial diseases like blood sugar/lipid profile/hypercoagulability status.

## Treatment

- ◆ Treat the cause.
- ◆ Avoid precipitating factors—protect from cold/proper dress/hand warmer electrical or chemical/hand gloves. Avoid smoking even though it is not direct etiological cause (other than upper limb TAO), but it may possibly aggravate the disease. Avoid vibrating tools.
- ◆ Vasodilators/pentoxifylline/low dose aspirin (75–100 mg per/day). Calcium antagonist (nifedipine 20 mg) is useful. Steroids may be useful in case of secondary Raynaud's.
- ◆ ACE inhibitors, nitrates, endothelin inhibitors (bosentan), epoprostenol—prostaglandin a potent vasodilator and antiplatelet drug (continuous intravenous infusion can be given), iloprost—prostacycline analogue, PG E1, misoprostol (oral PG E 1)—are all tried at different stages of the disease.
- ◆ Cervical sympathectomy—is used for nonhealing digital ulceration. Not very beneficial to Raynaud's syndrome.

### Note:

Avoid oral contraceptives, beta blockers and ergot preparations in Raynaud's disease.

## TEMPORAL ARTERITIS

- ◆ There is localised inflammatory giant cell infiltration of arterial wall (*giant cell arteritis*) involving superficial temporal, facial, retinal, upper limb, coronary and vertebral arteries.
- ◆ It is common after 50 years. Common in females (2:1).
- ◆ Claudication of facial muscles, ischaemic severe headache, tender, thrombosed superficial temporal artery and its branches are the features.
- ◆ Retinal ischaemia leading into irreversible blindness is dangerous feature. Involvement of coronary artery may cause myocardial infarction.
- ◆ Temporal artery biopsy is diagnostic—shows giant cell granuloma with CD4+ T lymphocytes.
- ◆ High dose long-term *prednisolone 80 mg/day* is needed. In involvement of retinal artery IV hydrocortisone/*methylprednisolone* may be needed initially.

## TREATMENT OF ARTERIAL DISEASES

### a. Medical

#### General Measures

- ◆ Stop smoking, reduction of weight, exercise.
- ◆ Change in lifestyle, care of feet.
- ◆ Control of diabetes and hypertension.
- ◆ Buerger's position and exercise.

#### Drugs

- ◆ Nifedipine, praxilene, pentoxifylline, low dose aspirin, prostacycline, dipyridamole, ticlopidine.
- ◆ Clopidogrel (75 mg).
- ◆ Cilostazol (type III phosphodiesterase inhibitor) 100 mg BD—inhibits platelet aggregation.
- ◆ Oral anticoagulants are used *only* if there is history of embolism or atrial fibrillation.
- ◆ Prostaglandins, growth factors, vascular endothelial growth factor (VEGF), E<sub>2</sub>Fdecoy (blocks intimal and smooth muscle cell proliferation), mesoglycan (breaks blood clot), testosterone, herbals like garlic (reduces viscosity of blood) are other newer drugs under use and trial.
- ◆ B vitamins and folic acid reduces homocysteine level (which is a risk factor).
- ◆ Inositol, L-carnitine (1500 mg), magnesium 500 mg (not in renal failure or with diarrhea), vitamin E and C are other agents often used to improve walking distance.
- ◆ Heparin is used *only* in acute phase or embolism.

### b. Surgery

- ◆ **Percutaneous transluminal balloon angioplasty (PTA):** Through transfemoral Seldinger approach, initially angiogram is done. Then under guidance (fluoroscopic) stenosed area is approached. First guidewire is introduced through which balloon catheter is passed. Balloon of the angioplasty catheter is inflated at stenosed area *for one minute* and repeated if required. Plaques should rupture. Catheter is withdrawn. It is useful in cases of localised stenosed areas.

#### Note:

- Often *nonexpandable* or *self-expandable* stents are used if stenosed segment is not dilated adequately through balloon—PTA with stenting.
- PTA for carotid artery stenosis is risky and not ideal as there will be possible release of microemboli during dilatation procedure which can precipitate stroke. Specialised balloon catheters with umbrella tip which can trap the microemboli may be used in these places.

#### Types

- ▶ **Conventional:** Here balloon is inflated along the lumen to break the plaque circumferentially.
- ▶ **Subintimal:** Here balloon is inflated after passing subintimal plane to break the plaque.

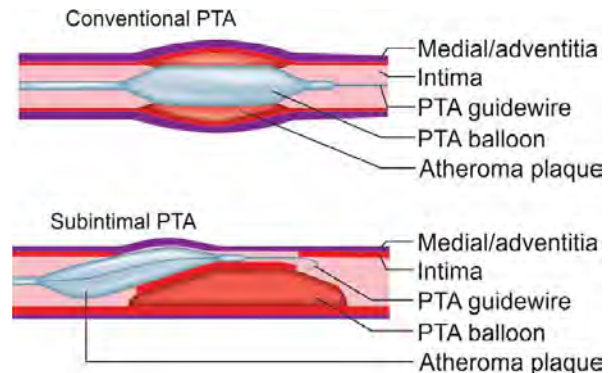


Fig. 1.328: Conventional and subintimal types of PTA.

#### Complications

- ▶ Thrombosis, bleeding, sepsis.
- ▶ Embolism, dissection, retroperitoneal haematoma.
- ▶ Pseudoaneurysm formation.

#### Advantages

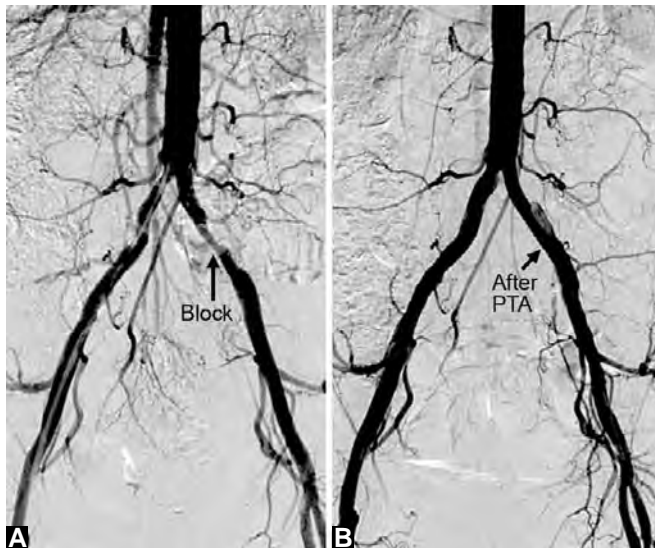
- ▶ It is done under local anaesthesia.
- ▶ Procedure can be repeated if needed.
- ▶ Stent can be placed at a later stage if needed.
- ▶ It is done when stenosis is *less than 5 cm*. In ideal indications its efficacy is equal to surgery.

#### Disadvantages

- ▶ It is less useful for lengthy blocks or stenosis more than 5 cm.

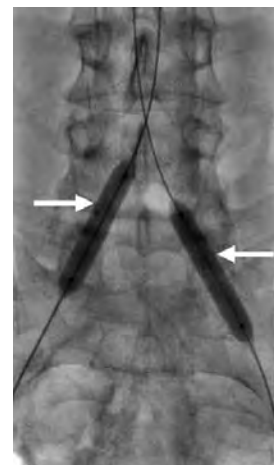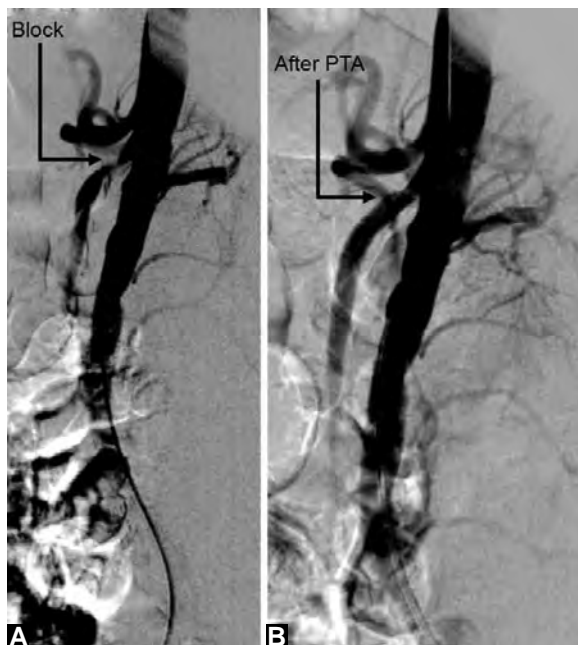


Fig. 1.329: Percutaneous transluminal balloon angioplasty (PTA). Note the inflated balloons on both side iliac arteries.

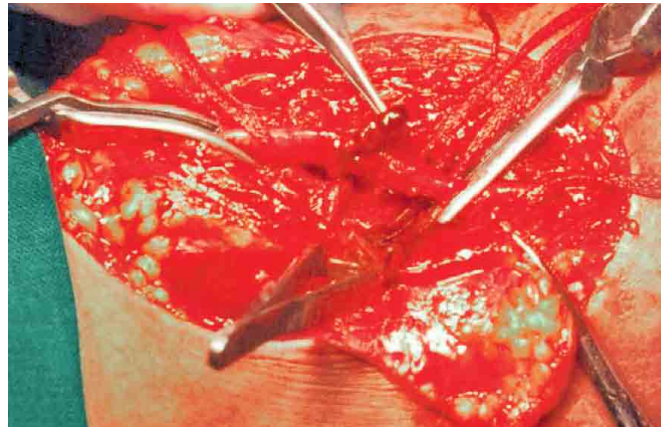


**Figs 1.330A and B:** DSA showing left-sided aortoiliac block and correction after doing PTA.

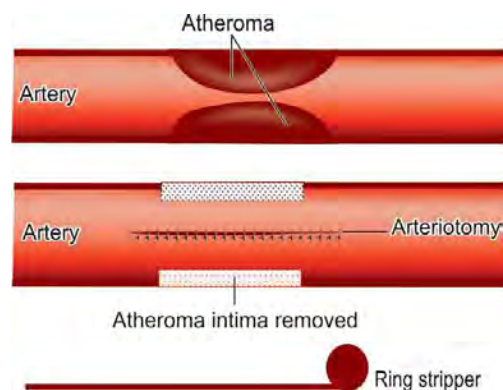
- ▶ It is dangerous to do in stenosis of carotid artery where endarterectomy is ideal.
- ◆ **Atherectomy:**  
It is removal of atheroma either through open surgery or by percutaneous route from the wall of the vessels.
- ◆ **Thrombectomy:**  
It is removal of thrombus through an arteriotomy of larger vessels. Done in aortoiliac, femoropopliteal region.
- ◆ **Endarterectomy:**
  - ▶ It is removal of thrombus along with diseased intima through an arteriotomy. Endothelium of the vessel is removed, hence the name.



**Figs 1.331A and B:** DSA showing superior mesenteric artery stenosis. It is corrected by PTA.



**Fig. 1.332:** Thrombectomy.



**Fig. 1.333:** Endarterectomy technique. Both thrombus and diseased intima are removed through an arteriotomy. Often ring stripper is used to remove the atheromatous plaque.

- ▶ It is done in *carotid*, aortoiliac and occasionally aortofemoral blocks. It is also called as *disobliteration/reboring*. There are three methods—(1) *Open method*—Arteriotomy is done along the entire diseased segment; endarterectomy is done by removing thrombus, diseased intima with plaque along the plane of media. Arteriotomy is closed using 5 zero polypropylene suture and patient is heparinised. (2) *Semiclosed method*—Here two arteriotomies are done on either ends of the level of obstruction; loop endarterectomy stripper is passed from one end to complete the endarterectomy; two arteriotomies are closed. (3) *Wiley's eversion endarterectomy*—Here artery is cut transversely at the junction of diseased and normal nondiseased segment; diseased intima with plaque is circumferentially dissected; artery is everted out to extract the diseased intima like a tube; everted artery is reduced and sutured to normal end of the artery. *Advantages are*—it avoids prosthetic graft and its complications. *Problem is*—reocclusion and restenosis.
- ◆ Placement of *intraluminal stent for localised stenosis*.
- ◆ **Profundaplasty:**
  - ▶ It is done when there is localised block in opening of profunda femoris (deep femoral). Profunda femoris is opened, thrombus if present, is removed. Opening is widened using either venous or synthetic (Dacron or PTFE) grafts. This procedure allows collaterals across the knee joint to open through profunda femoris and so gives good blood supply below-knee level and may prevent patient going in for above-knee amputation.

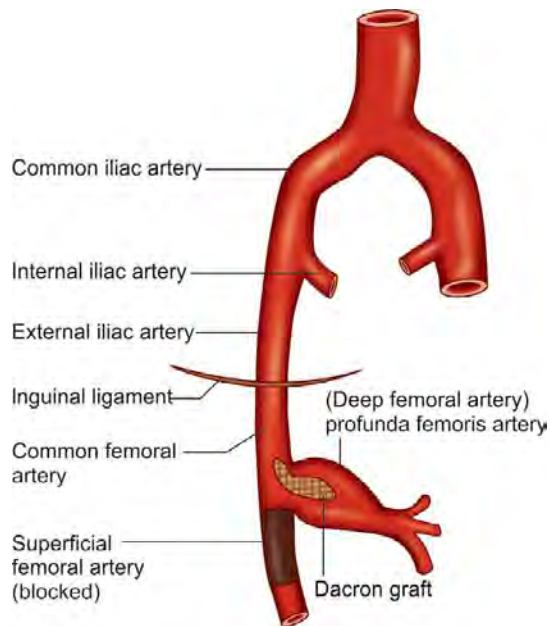


Fig. 1.334: Profundaplasty for deep femoral block.

(May be able to save knee joint with below-knee amputation with better prosthesis.)

- ▶ Lateral angiogram view is needed to identify the orifice of profunda femoris. Disease involves *invariably only at the orifice* without extending distally towards 1st perforator branch. Endarterectomy at the junction and closure with a venous patch widens the opening adequately.

#### ◆ Reverse saphenous vein graft:

In case of femoropopliteal block, saphenous vein is dissected out, reversed and sutured above to the femoral artery and below to popliteal segment so as to bypass the blood through reverse saphenous vein graft. Saphenous vein is reversed to nullify the action of valves so as to allow easy flow of blood.

#### ◆ In situ saphenous vein graft:

It is arterialisation of saphenous vein. Saphenous vein intact in same position is sutured above and below the blocked femoropopliteal region to bypass the blood across. Venous valves are removed through valvulotomy instrument so as to allow the blood to pass. Here nutrient supply of vein is left intact with proximal part of the vein sutured to wider part of the femoral artery, narrow distal part is sutured to narrow part of the artery.

#### ◆ Arterial/venous grafts:

##### Synthetic:

- ❖ Dacron woven graft
- ❖ Dacron knitted graft
- ❖ PTFE—polytetrafluoroethylene graft

##### Natural:

- ❖ Internal mammary artery (ideal one)
  - ❖ Long saphenous vein either reverse or *in situ*
  - ❖ Umbilical vein graft (cryopreserved)—3 mm vein is the minimum diameter required
- Grafts of different length and size are available

#### ◆ Different procedures

- ▶ Aortofemoral bypass graft (end to side)—5% mortality.
- ▶ Ileofofemoral bypass graft.
- ▶ Femorofemoral bypass graft
- ▶ Femoropopliteal graft.
- ▶ Femorodistal graft.
- ▶ Axillofemoral graft.

*Problems with grafts:* Leak, infection, thrombosis, cost factor, availability, reblock.

#### Note:

Angioscope is used to visualise the valves in saphenous vein or to visualise the completion of the by pass grafts like femorodistal graft.

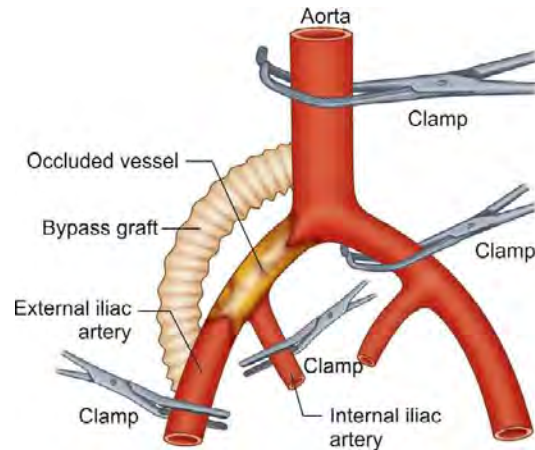


Fig. 1.335: Bypass graft (Aortoiliac).

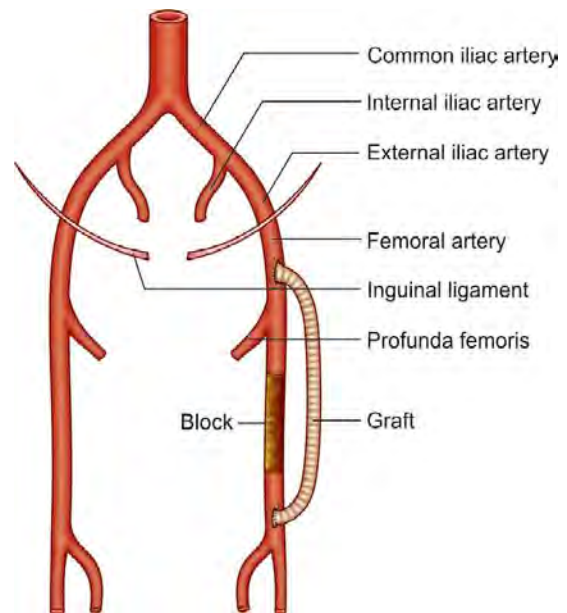


Fig. 1.336: Femoropopliteal bypass graft.

#### ◆ Cervicothoracic preganglionic sympathectomy:

It is removal of 2nd and 3rd thoracic ganglia which contains cells of postganglionic fibres supplying the upper limb. Preganglionic white rami communicantes fibres from 2nd and 3rd sympathetic nerves enter thoracic T1 ganglion and supplies head and neck region through upper part of the stellate ganglion. Preganglionic sympathetic nerve entering the 2nd and 3rd ganglia from below, supplies sympathetic fibres for upper limb through the lower part of the stellate ganglion. In cervical sympathectomy for upper limb ischaemia, lower part of stellate ganglion with Kuntz nerve is divided. For head and neck hyperhidrosis entire stellate ganglion should be removed which leads to development of Horner's syndrome. For hyperhidrosis of axillary area, along with stellate ganglion upper four thoracic ganglia has to be removed.

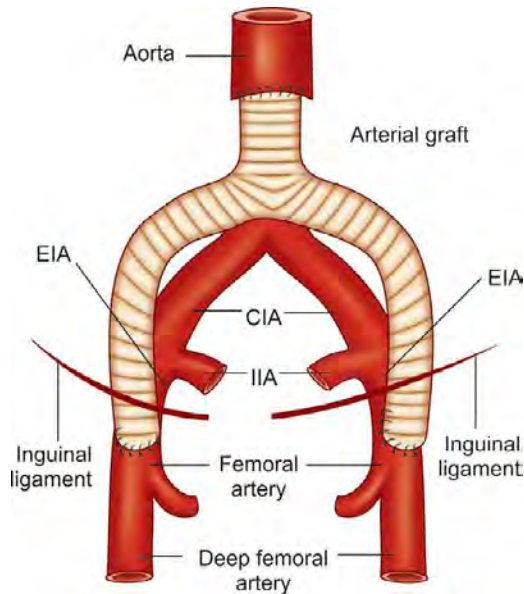


Fig. 1.337: Aortofemoral bypass graft (End to side).

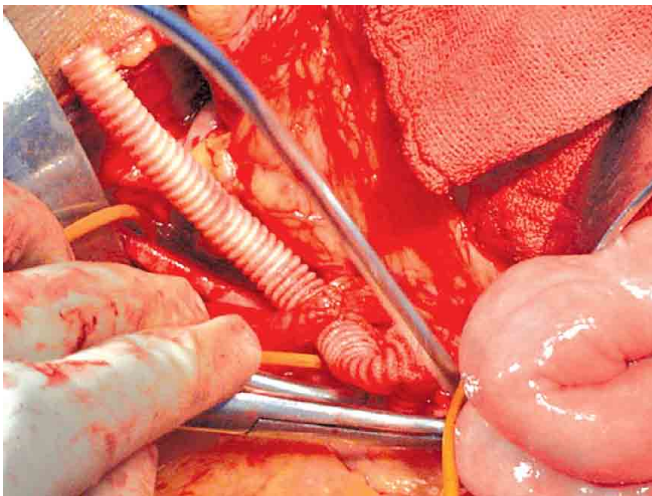


Fig. 1.338: On table picture of aortofemoral arterial graft.

#### Indications

- ❖ Cervical rib with vascular manifestations—useful
- ❖ Raynaud's phenomenon—useful
- ❖ Hyperhidrosis—very useful
- ❖ Upper limb vasospasm due to other causes—useful
- ❖ Acrocyanosis—useful
- ❖ Causalgia—very useful
- ❖ Sudeck's osteodystrophy

#### Approaches

##### ▶ *Supraclavicular approach:*

Through a supraclavicular incision sternomastoid, (omohyoid is retracted or divided) scalenus anterior muscles, are divided. Phrenic nerve is displaced medially; subclavian artery is pushed downwards; thyrocervical trunk is identified and ligated securely, suprapleural membrane is depressed, stellate ganglion is identified in the neck of the first rib. All rami communicantes

from second and third ganglia are divided. Grey ramus from second ganglion to first thoracic nerve called as *Kuntz nerve*, is also divided.

#### Complications

- ❖ Bleeding
- ❖ Injury to subclavian artery and nerves
- ❖ Pneumothorax and haemopneumothorax
- ❖ Horner's syndrome with ptosis, miosis, anhidrosis, enophthalmos
- ❖ Chylous fistula, chylocele
- ❖ Post-sympathetic neuralgia

##### ▶ *Transthoracic/Axillary approach (Hedley Atkins):*

This gives better visibility and easier removal of rami, lower down compared to supraclavicular approach. Patient is placed in lateral position; transverse incision is made just below the hair bearing line; intercostobrachial nerve is preserved. Thorax is opened at 2nd space. Sympathetic chain is identified at the neck of 1st rib.

##### ▶ *Thoracoscopic sympathectomy* is the choice, and popular approach at present.

*Advantages* are better visibility with magnification, less trauma of access (wound), faster recovery, and precise.

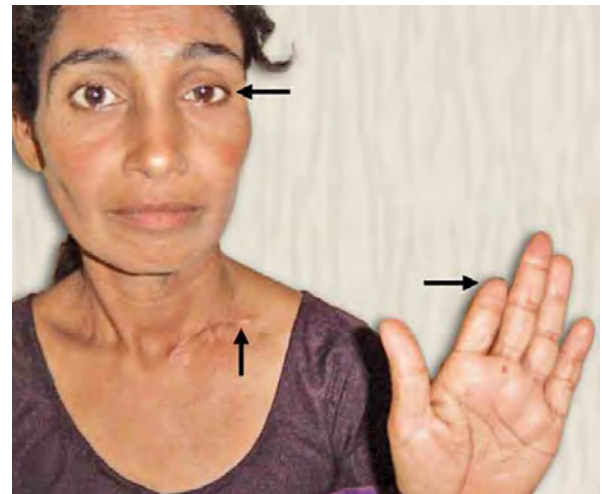

Fig. 1.339: Cervical sympathectomy scar in the neck and patient has developed Horner's syndrome. Healed ulcer over tip of index finger on left side is seen. Patient is asymptomatic after sympathectomy.

##### ◆ *Lumbar sympathectomy:*

#### Indications

- ▶ Peripheral vascular disease like TAO.
- ▶ To promote healing of cutaneous ulcers.
- ▶ To change level of amputation and to make flaps to heal better after amputation.
- ▶ Causalgia of lower limb (it is common in upper limb).
- ▶ Hyperhidrosis of lower limb is rare.

#### Principle

- ▶ It increases the cutaneous blood supply thereby promoting healing of ulcer and skin flaps in amputation. It is a preganglionic sympathectomy. Ganglion L2 and L3 supplies legs below knee level. L1 supplies upper part of thigh and buttock region.

L1 lies under the crus of diaphragm. L4 lies under the common iliac vessels below.

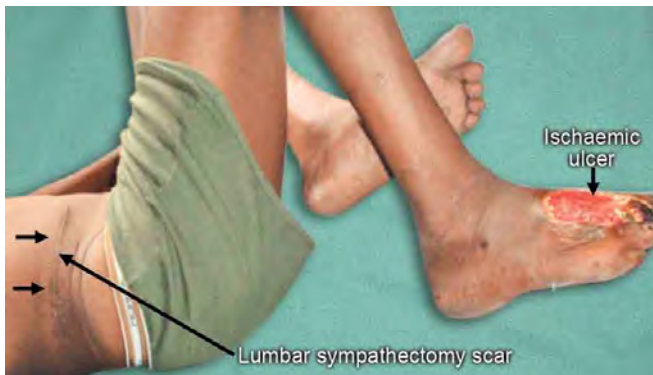- ▶ It increases the blood flow for 2–4 weeks by abolishing constriction of arterioles and precapillary sphincters (basal and reflux). It produces transient small increase in distal perfusion; increases the nutritive perfusion to *promote ulcer healing*; alters the pain perception and pain impulse transmission temporarily.

### Procedure

Under general or spinal anaesthesia, ganglia are approached through a transverse incision in the loin at the level of umbilicus, through extraperitoneal approach, by dividing external oblique, and internal oblique, and splitting transverse abdominis muscles. Inferior vena cava on right side, aorta on left side are identified. Sympathetic chain is identified by its rami, over transverse processes of lumbar spines. L<sub>2</sub>, L<sub>3</sub>, L<sub>4</sub>, L<sub>5</sub> ganglia are removed. L<sub>2</sub> is identified by its size (**Larger**) and more number of rami. L<sub>1</sub> is retained on one side in bilateral cases. If both are removed it will lead to failure of ejaculation and so sterility (*Dry ejaculation*).

### Complications

- ❖ Injury to IVC or aorta
  - ❖ Bleeding lumbar veins
  - ❖ Spinal vessel spasm and so ischaemia of spinal cord and paraplegia, dry ejaculation
  - ❖ Injury to bowel and ureter
  - ❖ Wound infection and abscess formation
  - ❖ Post-sympathetic neuralgia
  - ❖ Paradoxical gangrene of opposite leg and foot
- ▶ Its effects are only temporary (3–4 weeks). Long-term results are doubtful. It can be combined with omentoplasty.
  - ▶ It can also be done along with below-knee amputation to increase the blood supply of skin flap so as to have better healing.
  - ▶ Limb will become warmer immediately after sympathectomy.



**Fig. 1.340:** Lumbar sympathectomy scar with ischaemic ulcer foot showing healing sign.

### Note:

Lumbar sympathetic chain may be mistaken for lymph nodes, fat, tendon of psoas muscle, genitofemoral nerve.

### ◆ Chemical sympathectomy:

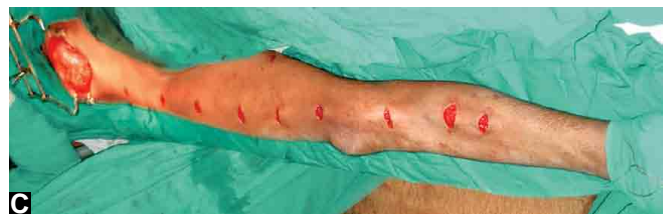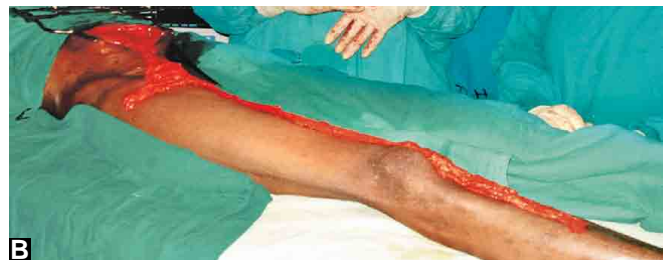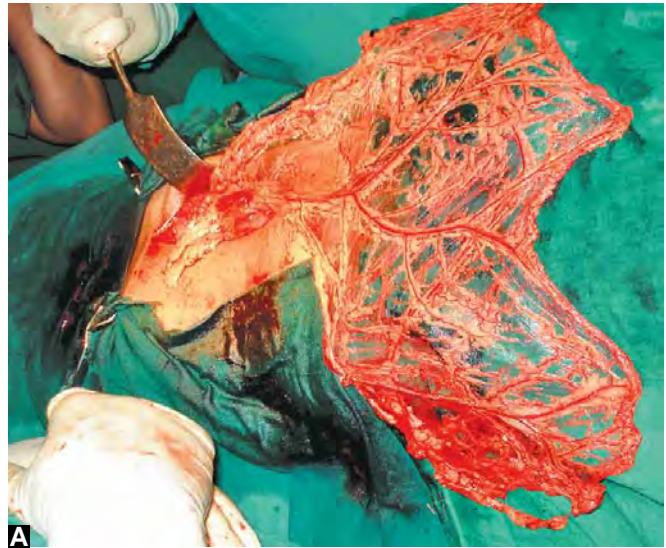
- ▶ It is done in lateral position using a long spinal needle under local anaesthesia. Position is confirmed by injecting dye under fluoroscopy. Later 5 ml of *phenol* in water or absolute alcohol is injected lateral to the vertebral bodies of fourth and second lumbar vertebrae. Care should be taken to see that the needle does not enter IVC or aorta.

- ▶ Procedure is contraindicated in patients with *bleeding disorders* and in patients who are on *anticoagulants*.

### ◆ Omentoplasty:

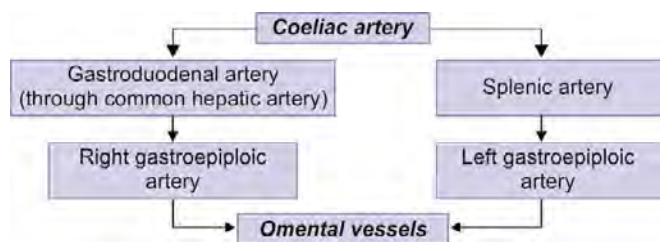
#### Indications

- ❖ Peripheral vascular disease—to improve circulation
- ❖ For lymphoedema, it helps by providing lymphatics and so to drain lymph from the limb
- ❖ It is also tried for revascularisation of pharynx, cranial cavity



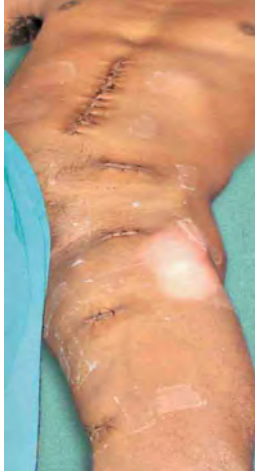**Figs 1.341A to C:** Omentoplasty procedure for revascularisation of the ischaemic limb.

Omentum is supplied by omental vessels



Four layers of omentum has got omental arcades of vessels (*Arc of Burkow*). Omentum is also rich in lymphatics. It has got adhesive property. By retaining one of the pedicles, omentum can be mobil-

ised so as to reach the limb to maintain the circulation. It can also be mobilised up to the ankle. It promotes ulcer healing, reduces the pain and controls the features of ischaemia. It can also be used in upper limb ischaemia. But, if patient continues to smoke, disease spreads to these omental vessels also. Often it can be mobilised to both lower limbs in bilateral diseases.



**Fig. 1.342:** Incisions for omentoplasty in the abdomen (upper midline) and in lower limb.

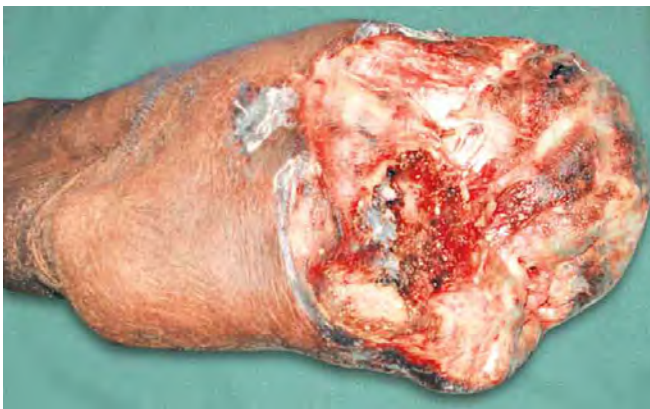#### Complications of omentoplasty:

- ▶ Abdominal sepsis.
- ▶ Incisional hernia, where omental pedicle is tunneled into the limb from the abdomen.
- ▶ Adhesions and intestinal obstruction.

**Procedure:** Under general anaesthesia, abdomen is opened with upper midline incision. Omental vessels are identified. Omentum with its blood supply is carefully mobilised to get an adequate length. Lengthened, mobilised omentum is brought into the subcutaneous plane through abdominal wall, lateral to the lower part of rectus muscle. Later this pedicle is mobilised in the subcutaneous tunnel across the leg, buried in the deep fascia.

#### ◆ Other treatment methods:

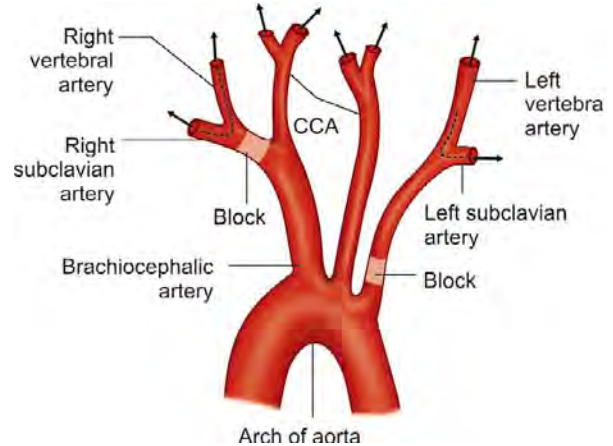
- ▶ *Amputations* are done at different levels depending on extent of gangrene, site of block, amount of collaterals.



**Fig. 1.343:** Below knee amputation stump which is also ischaemic. Patient underwent below knee amputation for gangrene foot. But patient might need above knee amputation.

## ■ SUBCLAVIAN STEAL SYNDROME

Following obstruction of the first part of subclavian artery, vertebral artery provides collateral circulation to the arm by reversing its blood flow. This causes *cerebral ischaemia with syncopal attacks*, visual disturbances, diminished blood pressure in the affected limb.



**Fig. 1.344:** Subclavian steal syndrome.

- ◆ It is more common on left side.
- ◆ Vertebrobasilar symptoms like dizziness, syncope, visual disturbances, vertigo can occur.
- ◆ Pain, heaviness, paraesthesia and fatigue in the arm which is aggravated by exercise.
- ◆ Radial pulses on both sides are asymmetrical.
- ◆ Blood pressure on the diseased side will be 20 mmHg less compared to normal side.
- ◆ *Javid test:* Here compression of carotid artery makes ipsilateral radial pulse feeble.

## Investigations

Duplex scan and angiogram. DSA is useful.

## Treatment

- ◆ Transluminal balloon angioplasty.
- ◆ Endarterectomy or bypass graft.  
(Common carotid—subclavian graft).

## ■ ACUTE ARTERIAL OCCLUSION

It is a condition of acute lack of tissue perfusion due to sudden cessation of circulation. Main axial artery of the limb is blocked presenting within minutes to hour after occlusion.

It is *common* in lower limb, upper limb; but can occur in mesenteric, cerebral, coronary arteries.

## Causes

- ◆ *Embolism* is the most common cause in developing country.
- ◆ *Trauma*.
- ◆ *Thrombosis* of an artery: Normal artery can develop sudden



acute thrombosis in certain special situations with hypercoagulable status like malignancy, leucaemia, antiphospholipid antibody syndrome, protein C/protein S/antithrombin deficiency; polycythaemia rubra vera, thrombocytosis. It is commonly observed in external iliac artery, profunda femoris artery and popliteal artery.

- ◆ *Thrombosis of a bypass graft* is common cause in western countries which occurs at the site of anastomosis.

## Pathophysiology

Distal ischaemia begins immediately after acute obstruction. Most sensitive peripheral nerves are first involved, and then muscles, subcutaneous tissue and skin are affected in order. Irreversible ischaemia occurs in 6 hours. Golden period is 1–6 hours. Ischaemia may get aggravated by—propagation of thrombus below and above the block occluding the orifices of collaterals, fragmentation of embolus, associated thrombosis, acute compartment syndrome.

Acute ischaemia causes endothelial injury of capillaries, arterioles and venules with luminal obliteration. Raised capillary permeability causes fluid leakage into extravascular space forming massive tissue oedema deep to deep fascia which by raising the intracompartmental pressure further reduces the perfusion leading into *acute compartment syndrome*.

## Features

- ◆ *Pain* which is continuous, severe, steady, bursting.
- ◆ *Pallor* of the distal part with extreme cold limb.
- ◆ *Pulselessness*—sudden loss of earlier palpable pulse.
- ◆ *Paraesthesia*—sensory disturbances like tingling, numbness or complete loss of sensation.
- ◆ *Paresis*—damage to motor nerve and muscle leading into paralysis as a late grave feature.
- ◆ *Poikilothermia*—change in the temperature (cold).  
*Pain, paraesthesia, paresis* are due to ischaemia of peripheral nerves which are sensitive to hypoxia.

## ■ TRAUMATIC ACUTE ARTERIAL OCCLUSION

### Causes

- ◆ Thrombus due to trauma.
- ◆ Subintimal haematoma.
- ◆ Acute compartment syndrome.
- ◆ During femoral or brachial arterial catheterisation for either diagnostic or therapeutic procedures.

### Clinical Features

History of trauma, *pain, swelling at the site, pallor, pulselessness, cold limb*.

### Investigation

Duplex scan, angiogram.

### Treatment

- ◆ Wound is explored and tear in the artery is identified. It is sutured using nonabsorbable monofilament material, *polypropylene 6-0*. Often venous or dacron graft is required for interposition.

- ◆ Proper antibiotics and heparin are required to prevent thrombosis of the vessel. Later patient is advised to take oral warfarin for maintenance.
- ◆ **Compartment syndrome** is common in anterior compartment of leg and in front of forearm. Here because of the closed compartment, pressure increases following fracture, haematoma which compresses over the vessel. It leads to blockade of vessel causing acute ischaemia of the limb presenting with severe pain, pallor, pulselessness.
  - ▶ *Treatment: Immediate decompression by longitudinal fasciotomy*, is the treatment of choice, wherein deep fascia is cut adequately to relieve the compression. Otherwise limb may go for severe ischaemia, gangrene and may land in amputation.
- ◆ Associated fractures, haematoma, vessel tear has to be managed accordingly.

## ■ EMBOLISM

(‘Embolus’ means in *Greek*—peg; first this term was used by Virchow in 1854)

It is due to a solid, liquid or gaseous, material which is floating and travelling in the bloodstream, eventually blocking the vessel on its pathway.

- ◆ **Arterial emboli:**

### Sources

- ❖ *Cardiac source* (80%):
  - Due to mural thrombus following mitral stenosis and atrial fibrillation (50%); myocardial infarction (25%); others (5%) like prosthetic valves, endocarditis, intracardiac tumours (atrial myxoma)
- ❖ *Noncardiac* (10%):
  - Aneurysms (5%); atheromatous plaque in proximal artery, paradoxical (1%)
- ❖ *Idiopathic* is 10%
- ❖ Others (4%) like:
  - Cervical rib causing poststenotic dilatation of subclavian artery can cause emboli
- ❖ *Cryptogenic*—an unknown source (5%)—after investigations source is not found

- ◆ **Venous emboli** are due to DVT causing pulmonary embolism.
- ◆ **Venous-arterial paradoxical emboli:** Seen in intra-cardiac shunt (ASD) or intrapulmonary shunts (AV malformations) (*Osler-Weber-Rendau syndrome*).
- ◆ **Fat embolism.**
- ◆ **Air embolism.**

## Effects of Arterial Embolism

- ❖ *Brain:* Blockage at *middle cerebral artery* causes hemiplegia, transient ischaemic attacks (TIA), visual disturbances
- ❖ Blockage at *central retinal artery* causes amaurosis fugax or permanent blindness
- ❖ Blockage at *mesenteric vessels* causes intestinal gangrene
- ❖ Blockage at *renal artery* leads to haematuria, loin pain
- ❖ Blockage at *limb vessels* causes pain, pallor, pulseless, paraesthesia, paresis, ulceration, gangrene
- ❖ Most common site of arterial emboli is *common femoral artery*

## Sites of Lodging of Emboli

The most common site is lower limbs (75%). 10% brain; 10% upper limb; 5% superior mesenteric and renal arteries.

In the lower limb the most common site is at the bifurcation of common femoral artery (40%); popliteal artery (15%); common iliac artery (12%); aortic bifurcation (10%).

## Features of Embolism

- ◆ Earlier history of claudication is absent but history suggestive of disease for source of emboli will be present.
- ◆ Sudden, dramatic, rapid development of pain with numbness.
- ◆ Limb becomes rapidly cold and mottled with blebs.
- ◆ Loss of sensation and movements.
- ◆ Absence of distal pulses but forcible, expansile, prominent proximal pulse. For example—prominent femoral artery pulsation with embolic block at popliteal level.
- ◆ Toxic features.
- ◆ Collapsed veins, cold limb distal to the level of block, oedema and presence of blebs distally.
- ◆ Muscle which is soft normally while palpating will feel doughy initially but later becomes stiff. Once stiffness of muscle is found embolectomy benefit is bleak.

### Differences between embolism and thrombosis

Features	Embolism	Thrombosis
Source	Present	Not present
Pulse	Proximal and contralateral pulses normal	Same and opposite side pulses may be absent
Temperature	Severely cold	Cold or normal
Angiography	Sharp cut off sign	Diffuse tapered disease
Collaterals	Very few—not well-developed	Well-developed

## Investigations for Arterial Embolism

- ◆ Emergency Doppler angiogram, ECG and echocardiography. Angiogram is *gold standard* in all acute limb ischaemia. It differentiates between embolism and thrombosis; status of vessel proximally and distally. Angiography should ideally be done from contralateral limb or through left brachial.

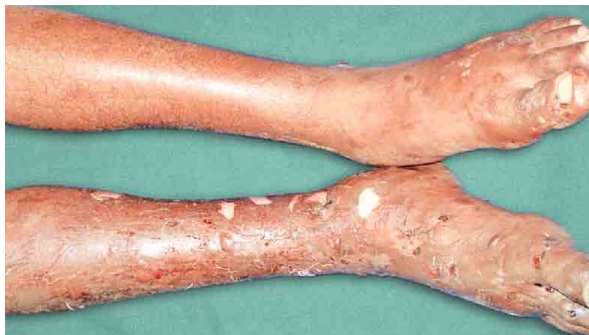

Fig. 1.345: Right leg showing features of acute embolism.

- ◆ Relevant tests for origin of emboli. Prothrombin time, APTT, BT, CT, platelet count should be done.

### Note:

Once embolism occurs irreversible changes occur distally in 6 hours, so ideal period for intervention is within 6 hours.

## Classification of Severity of Acute Limb Ischaemia

*Class I:* Viable—no pain; no neurological deficit; Doppler shows audible signal. Venous flow present.

*Class IIa:* Marginally threatened—no pain; numbness/paraesthesia; no audible Doppler signal. Venous flow present.

*Class IIb:* Immediately threatened—persistent pain; sensory and motor loss; no Doppler signal. Venous flow present.

*Class III:* Irreversible—paralysis and anaesthesia. No venous flow.

Ischaemia up to class IIb with normal venous flow is called as **Early**; ischaemia which is class III, with muscle rigor, marbled skin and without any venous flow is **Late**. This late ischaemia is more likely to land with amputations even though revascularisation can be tried.

## Treatment

### Treatment of Embolism and Thrombosis of Acute Limb Ischaemia

Immediate infusion of 5000–10,000 units of IV heparin and relief of pain are needed first.

### Surgical

- ◆ *Embolectomy (surgical exploration and removal of clot)* is the choice for embolus. It is done either by interventional balloon 5 French (Fogarty, 1963) embolectomy or open method. It is the standard treatment for arterial embolism. It can be repeated several times until adequate bleeding occurs.
- ◆ For acute thrombosis causing acute limb ischaemia, open thrombectomy with or without bypass may be the surgical treatment; but it is not the standard treatment for acute thrombosis (Standard is thrombolysis, Dotter and co, 1974).

### Endovascular therapy

- ◆ Intrarterial thrombolysis using *urokinase*.
- ◆ Percutaneous mechanical thrombectomy—it is done either by suctioning clot via catheter or dissolution of thrombus by pulverisation and aspiration by high speed motors or fluid jets.
- ◆ Ultrasound accelerated thrombolysis using catheter based or transdermal using acoustic cavitation to ablate thrombus.

### Embolectomy

- ▶ It is done as early as possible as an emergency operation.
- ▶ Under fluoroscopic guidance, *Fogarty catheter* (interventional radiology) is passed beyond the embolus and balloon is inflated. Catheter is withdrawn out gently with embolus. Procedure has to be repeated until embolectomy is completed and good back bleeding occurs. Angiogram is repeated to confirm the free flow.
- ▶ Postoperatively initially heparin and later oral anticoagulants are used. Procedure is done under general anaesthesia or local anaesthesia.

*In early painful stage the ischemic foot (gangrene threatened) is nearly always pink, the skin being atrophied as though it were stretched tightly over underlying structure*

—Wilfrid G Oakley

- ▶ *Open arteriotomy and embolectomy* can be done by *direct approach* and later the arteriotomy has to be sutured. Postoperatively anticoagulants and antibiotics are given.

### Intra-arterial thrombolysis using fibrinolytics

After passing arterial catheter, angiogram is done and agents are injected intra-arterially through the arterial catheter.

#### Drugs used are:

- ▶ Streptokinase (Here lysis occurs in 48 hours). Dose is 2.5 lac IV over 30 minutes; or intra-arterially 20,000 units/hour followed by one lac unit in 24 hours.
- ▶ Urokinase. It is commonly used for thrombolysis. It converts plasminogen to plasmin which breaks fibrin clots. Initial bolus of 2,50,000 IU is given followed by an infusion of 4,000 IU/min for 4 hours, later continuous infusion of 2,000 IU/min to complete the lysis. Even though controversial, it is of usual practice to infuse 1000 IU/hour of heparin to prevent new thrombus formation. Check angiography should be done during therapy. Multiholed catheter (5 French) is used for infusion.
- ▶ Tissue plasminogen activator (TPA)—Alteplase, Reteplase—here lysis occurs in 24 hours. TPA is *better and ideal*; but it is costly. It has very less side effects. TPA dose is 50 mg over 2 hours IV.
- ▶ TPA pulse-spray method—here lysis occurs in 6 hours.

#### Contraindications for thrombolysis

- ❖ Recent stroke
- ❖ Recent major surgery or major bleed like of varices
- ❖ Recent eye surgery
- ❖ History suggestive of or confirmed active duodenal/gastric ulcers
- ❖ Pregnancy
- ❖ Uncontrolled hypertension or coagulation disorders

Advantages of thrombolysis	Disadvantages of thrombolysis
• Gentle angiographic clot removal	• Useful only for class I and IIa acute ischaemia
• Survival and limb salvage is equal	• Bleeding at the site and elsewhere is possible
• It is mainly useful for acute thrombus	• 25% rate of failure
• For embolus it is used often as an adjunct along with embolectomy	
• It avoids surgery	

### Anticoagulant Therapy

- ◆ It is to prevent recurrent emboli formation. Immediate infusion of heparin 5,000 units intravenously is helpful to prevent further extension of thrombus. Later oral anticoagulants may be added.

### Complications of Revascularisation in Acutely Ischaemic Limb

- ◆ *Reperfusion injury*
- ◆ *'No reflow' phenomenon*: It is due to severe capillary oedema causing poor peripheral tissue hypoperfusion in spite of major vessel revascularisation.

- ◆ *Acute compartment syndrome* can occur due to massive ischaemic oedema especially of skeletal muscles deep to deep fascia which compress on venules exceeding tissue interstitial pressure causing further compromise in tissue perfusion. Compartment pressure when measured using transducer needles will be more than 40 mmHg or > 30 mmHg for 3 hours or above the mean arterial pressure. Presents with muscle weakness, sensory changes, leg pain which is aggravated by dorsiflexion of toes.
- ◆ Other complications are—sepsis, reblock, bleeding and catheter-related complications.

### REPERFUSION INJURY

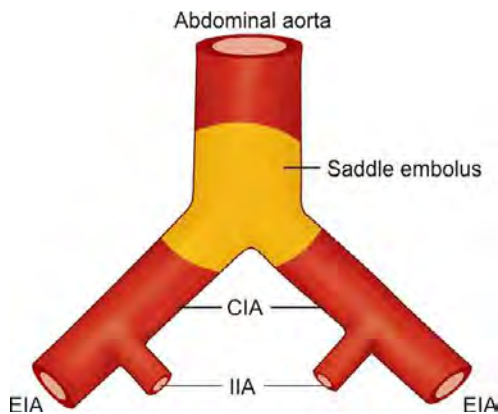
- ◆ It occurs after reestablishment of arterial flow to an ischemic tissue bed which further leads to tissue death causing specifically *peripheral muscle infarction*. It is due to sudden release of oxygen free radicals which blocks the microcirculation, with release of high levels of potassium (hyperkalaemia) and myoglobin (myoglobinaemia and myoglobinuria). Haemodynamically patient becomes unstable with lactic acidosis, intracellular changes, interstitial oedema and cardiac dysfunction. It is often life-threatening.
- ◆ *Haimovici triad* of revascularisation injury (1960)—(1) Muscle infarction; (2) Myoglobinuria; (3) Acute renal failure.
- ◆ Severe ischaemia causes oedema in the muscular compartment with raise in compartment pressure more than the essential capillary perfusion pressure causing *acute compartment syndrome*. It is common in the anterior compartment of the leg. It is basically in the skeletal muscles deep to deep fascia. Compartment pressure when measured using transducer needles will be more than 40 mmHg or > 30 mmHg for 3 hours or above the mean arterial pressure. Muscle weakness, sensory changes, leg pain which is aggravated by dorsiflexion of toes.
- ◆ *'No re-flow' phenomenon* due to tissue oedema causes capillary perfusion block. Even though compartment syndrome and 'no reflow' phenomenon are separate entities they are always seen together along with reperfusion injury.
- ◆ Metabolic acidosis, acute tubular necrosis causing acute renal failure and cardiac arrhythmias may set in and become life-threatening.
- ◆ **Features are**—toxaemia; oliguria; persistent pain and oedema in the leg with muscular tenderness; raised blood urea and serum creatinine with features of acute ischaemia in the limb. Raised creatinine level (renal failure), creatine kinase (muscle lysis) are typical.
- ◆ **Treatment:**
  - ▶ Mannitol to prevent renal failure; fluid therapy.
  - ▶ *Fasciotomy* to reduce raised compartment pressure. All four compartments of lower limb should be decompressed surgically. Long vertical lateral deep fasciotomy incision in the calf behind the fibula along the deep fascia and its fibular attachments is a must. Bleeding is common after fasciotomy as patient is heparinised. Infection of the wound can occur. Later, once the patient is stabilised and oedema subsides with healthy wound, secondary suturing or skin grafting is done. If after fasciotomy, patient survives then it is with eventual development of *Volkmann's ischaemic contracture*.
  - ▶ Antibiotics and supportive therapy.

## ■ SADDLE EMBOLUS

It is an embolus blocking at *bifurcation of aorta*.

### Causes

- ◆ Mural thrombus after myocardial infarction.
- ◆ Mitral stenosis with atrial fibrillation.
- ◆ Aortic aneurysm.



**Fig. 1.346:** Saddle embolus blocking the bifurcation of abdominal aorta. It causes severe, rapid, dramatic symptoms.

The embolus which blocks at aortic bifurcation is usually large.

### Clinical Features

- ◆ Features of sudden, rapidly progressive ischaemia in both lower limbs.

#### Note:

In aortic bifurcation thrombus, there is earlier history of claudication in the buttock often with *Leriche's syndrome*. Symptoms are slow and gradual but not dramatic. Collaterals between aorta and iliac arteries have well-formed and so sudden, rapid development of gangrene will not occur.

- ◆ Gangrene of both lower limbs.
- ◆ Features of associated infection.

### Investigations

- ◆ Arterial Doppler, aortic angiogram.
- ◆ Ultrasound abdomen.

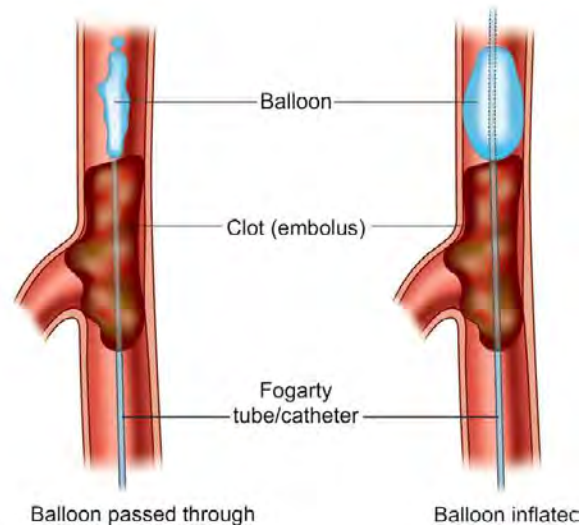
### Treatment

- ◆ Initially, heparin is injected intravenously—10,000 units and later 5,000 units subcutaneously 8th hourly.
- ◆ Embolectomy can be done using Fogarty's catheter.
- ◆ Open arteriotomy and embolectomy can also be tried.
- ◆ Antibiotic prophylaxis is given to prevent infection.

## ■ EMBOLECTOMY

### Indications

- ◆ Acute embolic blockade of artery commonly seen in common femoral, cranial vessels, mesenteric vessels.
- ◆ It should be done within 6 hours as after 6 hours irreversible changes occur—*Golden hour*.
- ◆ It is usually done under local anaesthesia under C arm guidance with anaesthetist monitoring the patient. It can be done under spinal or general anaesthesia.



**Fig. 1.347:** Embolectomy technique.

### Methods

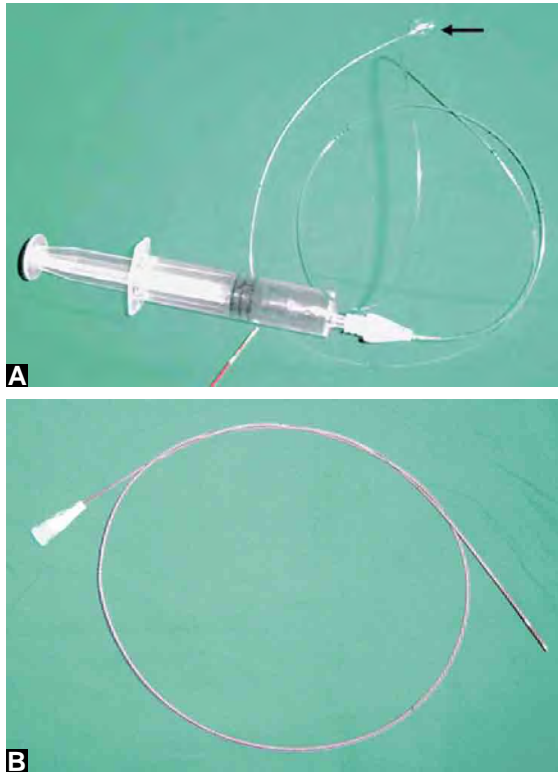
- ◆ *Interventional method* is usually employed using Fogarty's catheter. Good back bleed signifies completeness of embolectomy.
- ◆ *Open arteriotomy method* is done directly over the artery followed by suturing the artery.

#### Note:

- *Intraoperative arteriogram* is a must to confirm the adequacy of blood flow and completion.
- *Intraoperative thrombolysis* as an adjunct to save the limb using urokinase 2,50,000 IU for minutes into distal artery may be beneficial.
- *Prophylactic fasciotomy* is needed in delayed cases to prevent reperfusion injury.
- *Postoperative systemic heparin* and later oral anticoagulant is given.
- *Treatment* for atrial fibrillation, atherosclerotic stenosis and other causes is needed.

### Complications

- ❖ Bleeding
- ❖ Sepsis
- ❖ Thrombosis
- ❖ Narrowing
- ❖ Incomplete removal



**Figs 1.348A and B:** Fogarty's catheter. It is 80 cm in length with 4 to 7 French size. It is used for embolectomy. Note the inflated balloon at the tip.

### After Embolectomy

Patient is placed in ICU care.

Monitoring with—PTT, thromboplastin time.

### ■ FAT EMBOLISM (Ernst Von Bergmann, in 1873)

- ◆ 90% of major trauma especially with fractures develop fat embolism from aggregation of fat globules and chylomicrons derived from bone marrow. Fat globules release fatty acids which act as toxins.
- ◆ It is common in fracture long bones, and multiple fractures. It is observed after intramedullary nailing, liposuction, joint reconstruction, parenteral lipid infusion, cardiopulmonary bypass, and pathological fractures.
- ◆ Only 5–10% will develop *fat embolism syndrome (FES)*. FES shows respiratory distress (ARDS), and skin manifestations. Approximately 20–30% of the population have a patent foramen ovale; fat emboli pass through the pulmonary circulation causing the systemic manifestations of FES, particularly involving the brain and kidneys. As a result of the occluded cerebral vasculature, patients exhibit encephalopathy, localised cerebral edema. FES has got 20% mortality.

### Features

- ◆ *Pulmonary:* Cyanosis, tachypnoea, right heart failure, froth in mouth and nostrils, fat droplets in sputum, eventually respiratory failure.

- ◆ *Cutaneous:* Petechial haemorrhages in the skin.
- ◆ *Cerebral:* Drowsy, restlessness, disoriented, constricted pupils, pyrexia and coma.
- ◆ *Retinal artery emboli* is the earliest sign to appear, causing *striae haemorrhages*, *fluffy exudates* confirmed on fundoscopic examination.
- ◆ *Kidney:* Blockage in renal arterioles results in fat droplets in urine.

### Gurd and Wilson criteria for FES

Major criteria	Minor criteria
<ul style="list-style-type: none"> <li>• Symptoms and radiologic evidence of respiratory insufficiency</li> <li>• Cerebral sequelae unrelated to head injury or other conditions</li> <li>• Petechial rash—over upper body, axillae</li> </ul>	<ul style="list-style-type: none"> <li>• Tachycardia (heart rate &gt;110/min)</li> <li>• Pyrexia (&gt;38.5°C)</li> <li>• Retinal changes or petechiae</li> <li>• Renal dysfunction</li> <li>• Jaundice</li> <li>• Acute drop in hemoglobin level</li> <li>• Sudden thrombocytopenia</li> <li>• Elevated erythrocyte sedimentation rate</li> <li>• Fat microglobulinaemia</li> </ul>

### Differential Diagnosis

- ◆ Pulmonary embolism.
- ◆ Thrombotic thrombocytopenic purpura.

### Investigations

- ◆ Presence of fat lobules in the blood obtained by pulmonary capillary wedging is diagnostic.
- ◆ Haemoglobin estimation, platelet count and total WBC count.
- ◆ Chest X-ray shows snow storm appearance.
- ◆ CT chest is useful; CT head is done to rule out causes of intracranial injuries.
- ◆ Transesophageal echocardiography (TEE) may be of use in evaluating the intraoperative release of marrow contents into the bloodstream during intramedullary reaming and nailing.
- ◆ Bronchoalveolar lavage with staining for fat will show lipid inclusions.

### Treatment

- ◆ Adequate oxygenation with ventilator support (ICU care).
- ◆ Hydration, nutrition, achieving haemodynamic stability, prevention of DVT, avoiding volume overload with proper fluid therapy.
- ◆ Methylprednisolone may be useful; but use of heparin, low molecular dextran and other steroids are controversial even though commonly used.
- ◆ Albumin transfusion may be helpful as it binds with fatty acids to reduce the lung injury.
- ◆ Early fixation of the fractures; placement of IVC filters will prevent the chances of fat embolism or emboli reaching into the lungs.

## AIR/GAS EMBOLISM

### Causes

- ◆ Through venous access like IV cannula, most common cause.
- ◆ During artificial pneumothorax.
- ◆ During surgeries of neck and axilla.
- ◆ Traumatic opening of major veins sucking air inside, causing embolism.
- ◆ During fallopian tube insufflation; laparoscopic surgeries.
- ◆ During illegal abortion.

### Features

It causes respiratory distress, haemoptysis, convulsions, unconsciousness, visual and hearing disturbances, fatigue and numbness, paralysis, haemodynamic instability and coma.

- ❖ Amount of air required causing **venous air/gas embolism** is 15 ml. *To precipitate symptoms in venous embolism 100 ml of air required. 100 ml of air at a rate more than 100 ml/second is fatal.*
- ❖ When the air enters the right atrium, it gets churned up forming foam which enters the right ventricle and blocks the pulmonary artery.
- ❖ **Mill-Wheel murmur (machinery)** heard over the precordium through a stethoscope is diagnostic.
- ❖ During open heart surgery/therapeutic pneumothorax, by accidental pulmonary vein puncture or in atrial septal defect (ASD) air may enter left side of the heart (*paradoxical air embolism*) causing coronary block or cerebral air embolism.
- ❖ **Arterial gas embolism** is more dangerous and often early fatal. *2 ml of gas/air is fatal in cerebral circulation; and 0.5 ml is fatal in coronary arteries.*
- ❖ Through paravertebral veins also air embolism to brain can occur.

### Treatment

- ◆ Patient is placed in *Trendelenburg left lateral decubitus position*. The Trendelenburg position keeps left ventricular air bubble away from the coronary artery ostia (which are near the aortic valve) so that air bubbles do not enter and occlude the coronary arteries. Left lateral decubitus positioning helps to trap air in the non-dependent segment of the right ventricle (where it is more likely to remain instead of progressing into the pulmonary artery and occluding it). The left lateral decubitus position also prevents the air from passing through a potentially patent foramen ovale (present in as many as 30% of adults) and entering the left ventricle, from which it could then embolise to distal arteries.
- ◆ Hyperbaric oxygen is useful in both venous and arterial gas/air embolism as it reduces the ischaemia, reduces the bubble size; in arterial gas embolism it removes the nitrogen from the bubble so that to improve perfusion and oxygenation.
- ◆ By passing a needle, the air has to be aspirated from the right ventricle. Often requires life-saving open thoracotomy to aspirate the excess air causing the block.

## THERAPEUTIC EMBOLISATION

### Indications

- ◆ Haemangiomas.
- ◆ AV fistulas.
- ◆ Malignancies like renal cell carcinoma, hepatoma.
- ◆ Cerebrovascular problems.
- ◆ To arrest haemorrhage from GIT, urinary and respiratory tract.
  - ▶ In bleeding duodenal ulcer or gastric ulcer, embolisation is done to occlude gastroduodenal artery or left gastric artery respectively.
  - ▶ It is also useful in bleeding oesophageal varices, secondaries in liver (mainly due to carcinoids), hepatoma.

#### Materials used for therapeutic embolisation

- |                          |                      |
|--------------------------|----------------------|
| ❖ Blood clot             | Human dura           |
| ❖ Gel foam               | Plastic microspheres |
| ❖ Balloons               | Ethyl alcohol        |
| ❖ Quick setting plastics | Wool                 |
| ❖ Stainless steel coils  |                      |

## CAISSON'S DISEASE OR DECOMPRESSION DISEASE

It occurs due to rapid decompression from high altitude, aircraft, compressed air chambers, deep sea divers causing bubbling of nitrogen which blocks the small vessels.

- ◆ In joints and muscles it causes excruciating pain (*bends*).
- ◆ Spinal cord ischaemia causing neurological deficits.
- ◆ Lungs may be affected causing choking with chest pain, tightness and dry cough.
- ◆ *Treatment*
  - ▶ Oxygen therapy.
  - ▶ Recompression and gradual decompression in special chamber.

## ANEURYSM

*There is no disease more conducive to clinical humility than aneurysm of the aorta.*

—William Osler, Circa 1900

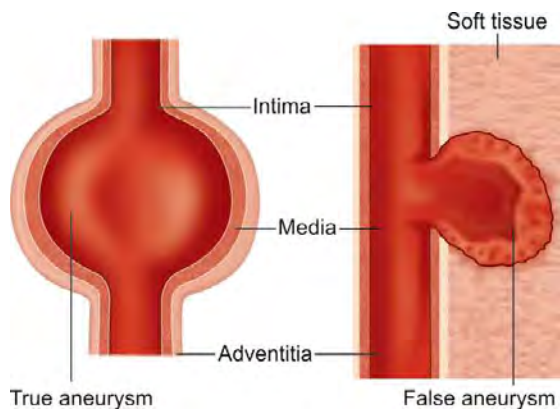
It is an abnormal permanent dilatation of localised segment of arterial system. Diameter will be *50% more* than expected normal diameter of that artery in aneurysm. Atherosclerosis which is the most common (90%) facilitating cause of aneurysm is due to destruction and *loss of stability* of tunica media.

*True* aneurysm contains all three layers of artery.

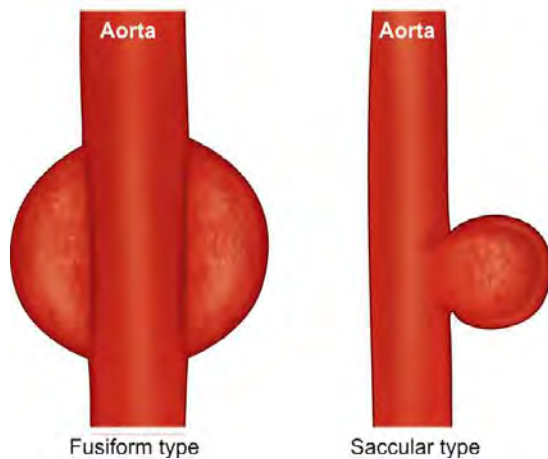
*False* aneurysm contains single layer of fibrous tissue as wall of the sac and it usually occurs after trauma.

#### Types

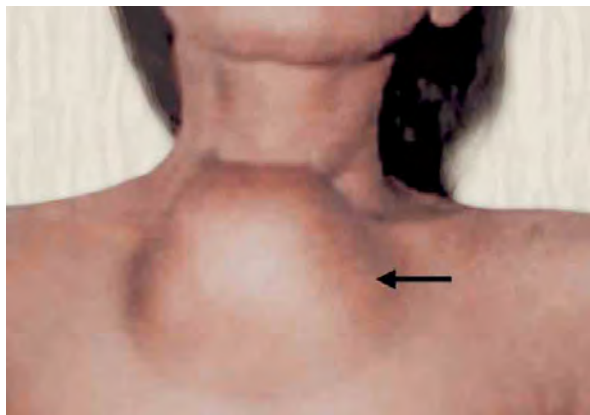
- ❖ *Fusiform*—uniform dilatation of entire circumference of arterial wall
- ❖ *Saccular*—dilatation of part of circumference of the arterial wall
- ❖ *Dissecting*—through a tear in the intima blood dissects between inner and outer part of tunica media of the artery



**Fig. 1.349:** True and false aneurysms. In true type, all layers are intact. In false type all layers breached with haematoma having a false capsule.



**Fig. 1.350:** Fusiform and saccular types of aneurysms.



**Fig. 1.351:** Thoracic aortic aneurysm.

## Causes

### ◆ Acquired:

- ▶ **Degenerative:** Atherosclerosis (most common cause—90%); mucoid degeneration of intima and media (in South African young Negroes).
- ▶ **Traumatic:** Direct; indirect like in post-stenotic dilatation by cervical rib; traumatic AV aneurysmal sac; aneurysm due to irradiation (due to dryness and destruction of vasa vasorum causing weakening).

- ▶ **Infective:** Syphilis; mycotic; tuberculosis (in lung); arteritis; acute sepsis.
- ▶ **Collagen diseases** like Marfan's syndrome, polyarteritis nodosa, Ehler-Danos syndrome.

### ◆ Congenital:

- ▶ Berry aneurysm; cirroid aneurysm; congenital AV fistula.

## Sites

- ◆ Aorta.
- ◆ Femoral.
- ◆ Popliteal.
- ◆ Subclavian.
- ◆ Cerebral, mesenteric, renal, splenic arteries.

The most common is *true, fusiform, atherosclerotic, aortic aneurysms*.

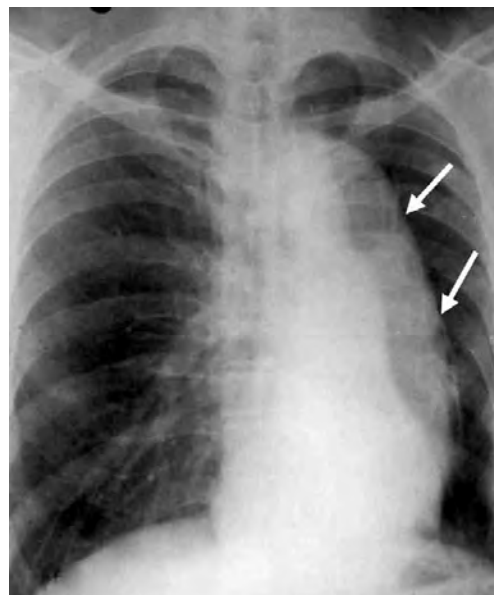
*Berry aneurysms* are multiple aneurysms occurring in circle of Willis.

### Effects and complications of aneurysm

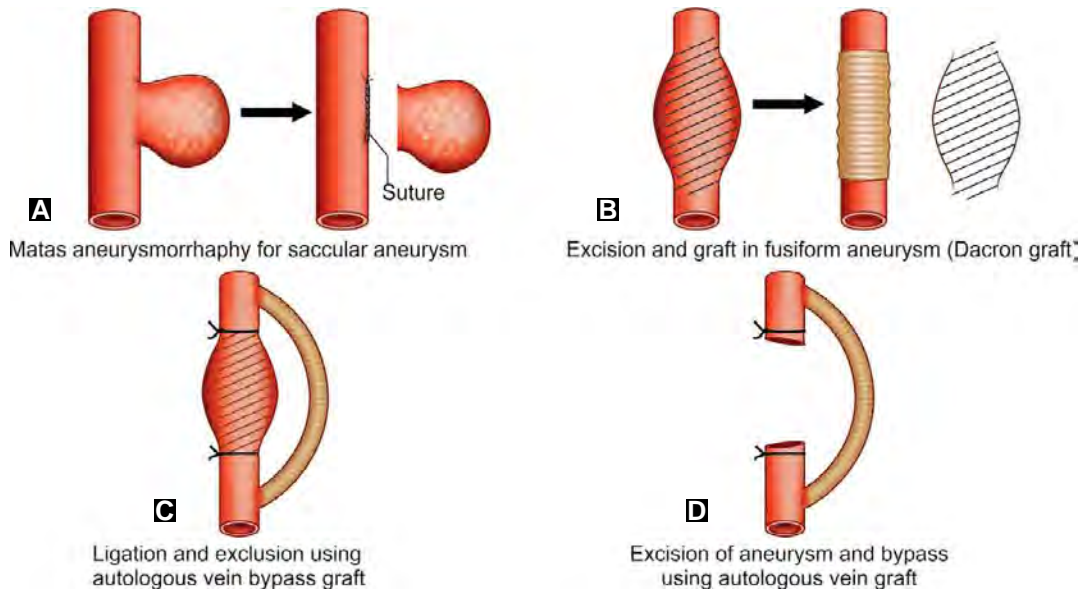
- ❖ Thrombosis and distal ischaemia
- ❖ Release of emboli causing acute arterial occlusion
- ❖ Pressure effects on bone (erosion); skin; veins (oedema); nerves (pain, paraesthesia); stomach (erosion—haematemesis); oesophagus (dysphagia)
- ❖ Rupture
- ❖ Infection of aneurysm

## Clinical Features of Aneurysms

- ◆ Swelling at the site which is *pulsatile (expansile)*, smooth, soft, warm, compressible, with thrill on palpation and bruit on auscultation. Swelling reduces in size when pressed proximally.
- ◆ Distal oedema due to venous compression.
- ◆ Altered sensation due to compression of nerves.
- ◆ Erosion into bones, joints, trachea or oesophagus.
- ◆ Aneurysm with thrombosis can throw an embolus causing gangrene of toes, digits, extending often proximally also.



**Fig. 1.352:** Chest X-ray showing aortic aneurysm.



**Figs 1.353A to D:** Different methods of aneurysm repair. (A) Matas aneurysmorrhaphy for saccular aneurysm; (B) Excision and Dacron grafting; (C) Ligation and exclusion of the aneurysm using autologous vein graft; (D) Excision of aneurysm and bypass using autologous vein graft.

## Differential Diagnosis

- ◆ *Pyogenic abscess*: Abscess has to be always confirmed by aspiration; especially in axilla, popliteal region, groin.
- ◆ *Vascular tumours*.
- ◆ *Pulsating tumours*: Sarcomas, pulsating secondaries.
- ◆ *Pseudocyst* of pancreas mimics aortic aneurysm.
- ◆ AV fistula.

## Investigations

- ◆ Doppler study, duplex scan, angiogram, DSA.
- ◆ Tests relevant for the cause, like blood sugar, lipid profile, echocardiography.

## Treatment

- ◆ *Reconstruction of artery using arterial grafts*.
- ◆ *Arterial endoaneurysmorrhaphy—MATAS*. It is done usually for peripheral saccular aneurysm. Matas aneurysmorrhaphy may be restorative or endo-obliterative or reconstructive.
- ◆ Therapeutic embolisation.
- ◆ Clipping the vessel under guidance (e.g. cranial aneurysms).
- ◆ Older methods which are now not used but popular earlier were—wiring of the aneurysmal sac/wrapping of the aneurysmal sac/ligatures at different levels (ligation just proximal to aneurysmal sac—*Anel's*; ligation proximally proximal to an arterial branch—*Hunter's*; ligation just distal to aneurysmal sac—*Brasdor's*; ligation distally distal to an arterial branch—*Wardrop's*; ligature one proximal and another distal to aneurysmal sac—*Antylus*<sup>7</sup>).

## MYCOTIC ANEURYSM

- ◆ It is a *misnomer*.
- ◆ It is not due to fungus but due to bacterial infection.

- ◆ Common bacteria are gram-positive organisms like *Staphylococcus aureus* (most common) and *Streptococcus*.
- ◆ Common aetiology is bacterial *endocarditis* but could be any infective site.
- ◆ Common vessels involved are aorta, visceral, head and neck and intracranial.
- ◆ Commonly it is saccular, multilobed, with a narrow neck.
- ◆ Patient presents with fever, toxæmia and tender pulsatile mass if it is in the periphery.
- ◆ *Investigations*: Leucocytosis. Positive blood culture, MR or CT angiogram are relevant.

## Treatment

- ◆ Broad-spectrum antibiotics
- ◆ Resection of aneurysm; debridement and drainage of the infected aneurysm with adequate blood transfusions.
- ◆ Extra-anatomic bypass through uninfected tissue planes to avoid contamination of the graft.
- ◆ Long-term antibiotic therapy is necessary.
- ◆ It has got 25% mortality.

### Note:

*Microbial arteritis with aneurysm* is a different entity is due to bacteraemia occurring in an atherosclerotic vessel due to *Salmonella* infection).

## ABDOMINAL ANEURYSM

- ◆ Abdominal aortic aneurysm is the *most common* aortic aneurysm.
- ◆ Splenic artery aneurysm is the *2nd most common* type.
- ◆ Incidence is 2%. It is more common in males.
- ◆ Transverse diameter of aorta in an aneurysm should be 3 cm or more.
- ◆ Common in elderly; common in males (4:1); chance of getting aneurysm in genetically related first degree relatives is 10 times more.



- ◆ Common in smokers (8:1 with nonsmokers); in 55% of patients *Chlamydia pneumoniae* is identified.

**Note:**

Smoking is an important factor.

## ■ ABDOMINAL AORTIC ANEURYSM (AAA)

### Causes

- ◆ *Atherosclerosis* (as degenerative process) is the *most common facilitating* cause (95%)—aortic wall contains smooth muscle cell matrix, elastin, collagen; *elastin* (in tunica media) is the main load bearing part with *collagen* (in adventitia) as safe net in the wall to provide tensile strength preventing aneurysm formation. *Elastin in medial layer* of aorta is *degraded* and reduced significantly in infrarenal aorta in relation to collagen, absence or less vasa vasorum in infrarenal aorta and atherosclerotic instability of the medial wall of aorta cause infrarenal aorta more prone to develop aneurysm. Increased proteolytic activity of aortic medial wall due to increased *matrix metalloproteinases* (MMP) (derived from aortic smooth muscle cells and macrophages) cause elastin and collagen degradation and increase in diameter of aneurysm. *Collagen degradation in adventitia* causes rupture.
- ◆ *Familial* aortic aneurysm (associated with 25% of AAA) is more prevalent in females to reduce male-to-female ratio to 2:1. It is related to decrease in type III collagen,  $\alpha$ 1 antitrypsin and lysyl oxidase. Marfan's, Ehler Danlos syndromes are related genetically.
- ◆ Others: Syphilis, dissection, trauma, collagen diseases, infection, arteritis, cystic medial necrosis, association with *Chlamydia pneumoniae* (55%).

#### ❖ Classification I

- Infrarenal—most common (95%).
- Suprarenal—5%. Isolated suprarenal type is rare; it is usually associated with thoracic and/or infrarenal types.

#### ❖ Classification II

- Asymptomatic.
- Symptomatic.
- Symptomatic ruptured.

### Asymptomatic Type

- ◆ It is found incidentally either on clinical examination or on angiography or on ultrasound.
- ◆ Repair is required if diameter is over 5.5 cm on ultrasound.
- ◆ It is identified during routine abdominal palpation or while assessing or operating for some other abdominal conditions.

### Symptomatic without Rupture (Clinical features/presentations)

- ◆ It presents as *back pain, abdominal pain, mass abdomen* which is smooth, soft, nonmobile, not moving with respiration, vertically placed above the umbilical level, pulsatile both in supine as well as knee-elbow position with same

intensity, resonant on percussion.

- ◆ Common in males (4:1); common in smokers.
- ◆ GIT, urinary, venous symptoms can also occur.
- ◆ Hypertension, diabetes, cardiac problems should be looked for and dealt with.
- ◆ In infrarenal type upper border is clearly felt.
- ◆ Lower limb ischaemia and embolic episodes can occur.
- ◆ Being a retroperitoneal mass *back pain is common*—may be due to retroperitoneal stretching, nerve irritation or vertebral erosion.
- ◆ 5% present as *inflammatory aneurysm* adherent to ureters, left renal vein, inferior vena cava and duodenum. Expanding aneurysm blocks lymphatics causing inflammation and fibrosis; or it may be due to infection and fibrosis of earlier localised ruptured abdominal aortic aneurysm. Such chronically inflamed aneurysm will not rupture further; but it is always symptomatic with fever and severe pain in abdomen and back. It needs surgical repair through retroperitoneal approach.
- ◆ *Aortocaval fistula*, presents as high output cardiac failure with continuous bruit in abdomen and severe lower limb ischaemia (*steal phenomenon*).
- ◆ *Aortoenteric fistula* is due to erosion of aneurysm into 4th part of duodenum presenting as GI bleed, malaena, shock. It is treated by duodenal closure, aortic ligation, aneurysmal exclusion with extra-anatomic bypass graft with gastrojejunostomy. Contamination is the major threat here.
- ◆ Aneurysm in a patient with horseshoe kidney which is anterior to aorta is difficult to manage. Left retroperitoneal approach is needed. EVAR is not possible.

### Investigations

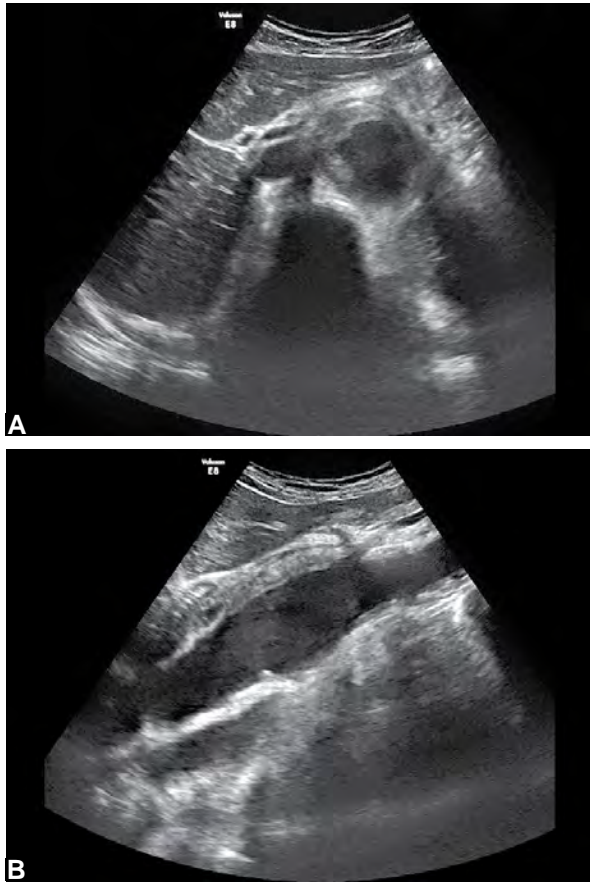
- ◆ Blood urea, serum creatinine.
- ◆ US (*most widely used* noninvasive test; but neck of the aneurysm, dimensions and relation to renal arteries are difficult to assess), aortogram, DSA, CT scan (*most precise*). *US is an effective screening tool*. Screening is done in cardiovascular patients in men (60–85 years), in women (60–85 years); men and women above 50 years with family history; annually in asymptomatic AAA with 4.0–4.5 cm size, with size >4.5 cm once in every 6 months.
- ◆ CT angiogram, MR angiogram.
- ◆ Blood sugar, lipid profile, other relevant investigations like ECG, echocardiography, cardiac and pulmonary assessment.

**Note:**

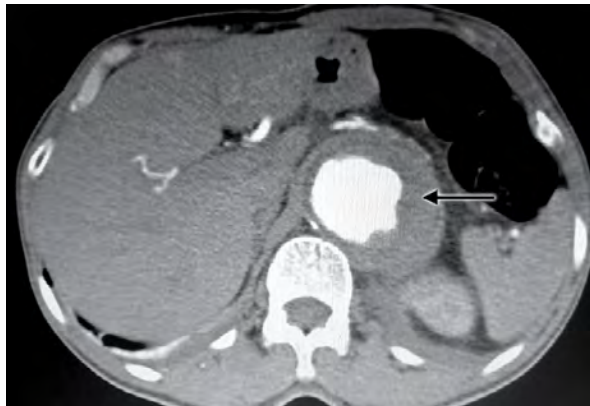X-ray will show eggshell calcification. CT scan is more reliable and precise investigation of choice—gives better information regarding extent on sides/neck, size, dimensions, size and site of the thrombus, calcification, relation of renal arteries, inflammation and fibrosis and adjacent tissues. MRI may be better only in renal failure patients.

#### Complications of abdominal aortic aneurysm

- ❖ Rupture, infection
- ❖ Thrombosis, embolism
- ❖ Distal ischaemia/gangrene
- ❖ Aortocaval fistula formation
- ❖ Aortoenteric fistula
- ❖ Erosion of vertebra
- ❖ Spinal cord ischaemia when thrombosis develops



**Figs 1.354A and B:** USG abdomen showing abdominal aortic aneurysm.



**Fig. 1.355:** Abdominal aortic aneurysm showing widened aortic wall with thrombosis in the periphery in CT angiogram.

## Differential Diagnosis

- ◆ *Retroperitoneal mass, pseudocyst of pancreas, retroperitoneal cyst* mimic abdominal aortic aneurysm especially when it is thrombosed.
- ◆ *Mesenteric ischaemia, acute pancreatitis, perforated duodenal ulcer* may mimic ruptured aneurysm.
- ◆ *Other conditions* causing back pain like disc prolapse, sciatica.

## Treatment

### Conservative/Medical Treatment

- ◆ It is done in *low-risk* abdominal aortic aneurysm (age below 70 years; active physically without cardiac, respiratory, renal impairment and noninflammatory aneurysm); if aneurysm size is  $< 5$  cm; if growth rate is  $< 0.5$  cm/year.
- ◆ It includes risk factor modifications; stopping smoking; control of blood pressure (propranolol), cholesterol; usage of drugs—alpha blockers, elastase inhibitors (NSAID—indomethacin), matrix metalloproteinases (MMP) inhibitor (doxycycline).
- ◆ Periodic size measurement of an aneurysm using ultrasound once in 6 months to find out growth rate is essential during conservative treatment.

### Surgical Treatment

#### ◆ Indications for surgery

- ▶ Asymptomatic aneurysm more than 5.5 cm.
- ▶ Growth rate more than 0.5 cm/year.
- ▶ Painful, tender aneurysm.
- ▶ Thrombosed aneurysm, aneurysm with distal emboli.

*Low-risk* abdominal aortic aneurysm—age below 70 years; active physically without cardiac, respiratory, renal impairment and noninflammatory aneurysm. Here surgical mortality is  $< 3\%$ .

*Intermediate risk*—sedentary; stable coronary disease; mild COPD; creatinine 2–3 mg%; inflammatory/suprarenal aneurysm. Here surgical mortality is 3–7%.

*High-risk*—restricted daily works; significant coronary disease; dyspneic COPD; creatinine  $> 3$  mg%; liver failure status. Here surgical mortality is  $> 10\%$ .

#### ◆ Open surgical repair

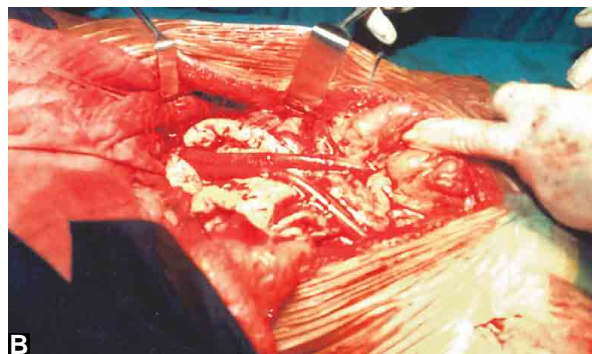
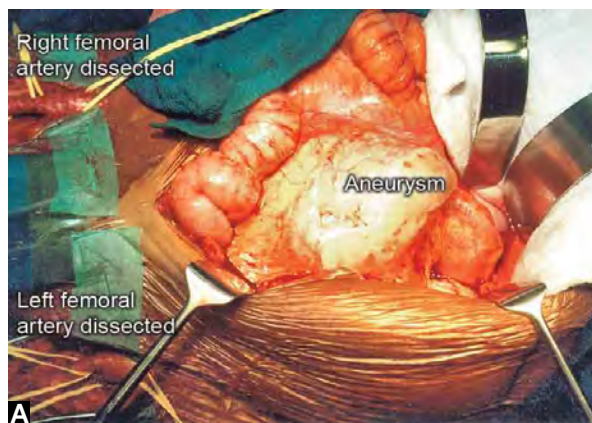
- ▶ It is called as *endo-aneurysmorrhaphy with intraluminal graft placement* (Crawford, 1960). It is done under GA with epidural support. Major challenges during anaesthesia are—blood loss, haemodynamic control, problems during clamping and declamping of aorta, temperature control, renal hypoperfusion, left ventricular strain.
- ▶ Incision is commonly lengthy midline *transperitoneal* or supraumbilical transverse. *Retroperitoneal approach* is used in horseshoe kidney, abdominal wall stoma, inflammatory aneurysm, suprarenal extension, peritoneal dialysis, hostile abdomen. Retroperitoneal approach favors rapid control of proximal aorta but prevents visualisation of abdomen.
- ▶ After laparotomy, duodenum and small bowel are retracted laterally and above; left renal vein which is in front of aorta is dissected and retracted; occasionally it may require to be ligated and it is safer provided left gonadal and left suprarenal veins are intact. Distal arterial clamps are applied first along common or external and internal iliac arteries on both sides. Proximal aortic clamp is applied at infrarenal level. Aorta is opened longitudinally midline towards right to avoid injury to orifice of inferior mesenteric artery. Atheroma, thrombus is removed until adequate back-bleeding occurs. Lumbar vessels are ligated from the luminal side. Knitted Dacron graft after preclotting or woven Dacron graft or ePTFE tube graft is used. Graft is anastomosed above and below using

polypropylene sutures (4 zero). Inferior mesenteric artery can be reimplemented. Clamps are released first below. Colonic and limb perfusion is checked for adequacy. Graft is covered with aneurysmal sac.

- ▶ *Minimal incision aortic surgery (MIAS)* is done in thin individual with midline abdominal incision 12 cm in length with its 9 cm part above the umbilicus. Specialised retractors and vascular clamps are used for this. Advantages are less postoperative pain, ileus and incisional hernia.

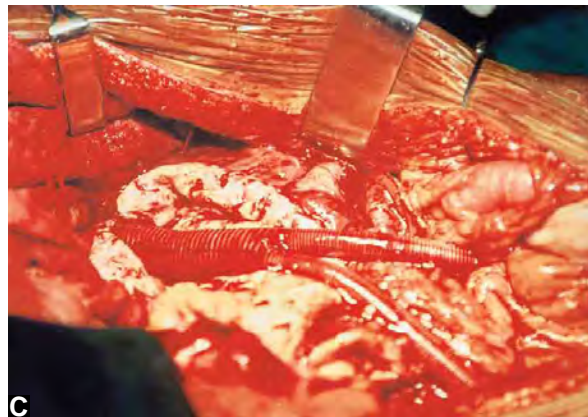#### ◆ Endovascular aneurysm repair (EVAR)

- ▶ In 1991 Juan Parodi and Julio Palmaz first did EVAR. It is less invasive, less morbid with less mortality rate and shorter hospital stay. It is basically aneurysm exclusion method. It is useful in old age and patients who are not fit for surgery. EVAR is basically a prophylactic procedure. EVAR is indicated if aneurysm is less than 5.5 cm in men and less than 5.0 cm in women. It is usually done in patients after 65 years.
- ▶ It is endoluminal stent graft placement into the aneurysmal segment of aorta using interventional radiology with Seldinger's technique approach through femoral artery.
- ▶ Dacron or ePTFE with integral metallic stent for support and firm attachment is used as stent/endovascular prosthesis.
- ▶ One aortic and iliac (of one/same side) stent is commonly used together which is passed through same side common femoral. Other iliac is maintained with a separate stent approached through opposite common femoral.
- ▶ Procedure can cause endoleak, thrombosis, embolism, malposition/displacement of stent, sigmoid ischaemia, renal failure, failure of stent function causing recurrence and infection.



Aorto bifemoral dacron graft (Woven) with right femoral exposed

Figs 1.356A and B



Graft in place in retroperitoneum

Fig. 1.356C

**Figs 1.356A to C:** Abdominal aortic aneurysm with aortofemoral graft placement (Courtesy: Dr Ashok Shetty, MCH, Cardiothoracic Surgeon, Mangaluru).

#### Symptomatic Ruptured Aortic Aneurysm

- ▶ Risk of rupture is 1%, if diameter is within 5.5 cm in size. Risk increases to 20% once the diameter = 7 cm.

It may be *anterior rupture* (20%) into the free peritoneal cavity causing severe shock and *death* very early; or *posterior rupture* (80%) with formation of *retroperitoneal haematoma* of large size causing severe back pain, hypotension, shock, absence of femoral pulses and with a palpable mass in the abdomen.

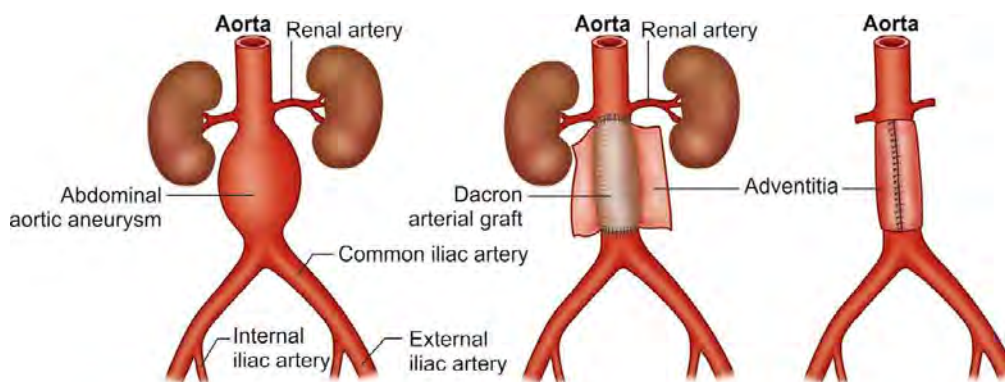
#### ▶ Management of Ruptured Aortic Aneurysm

- Immediate diagnosis by ultrasound.
- Resuscitation.
- Massive blood transfusions (10–15 bottles).
- Emergency surgery is the only life-saving procedure in these cases.

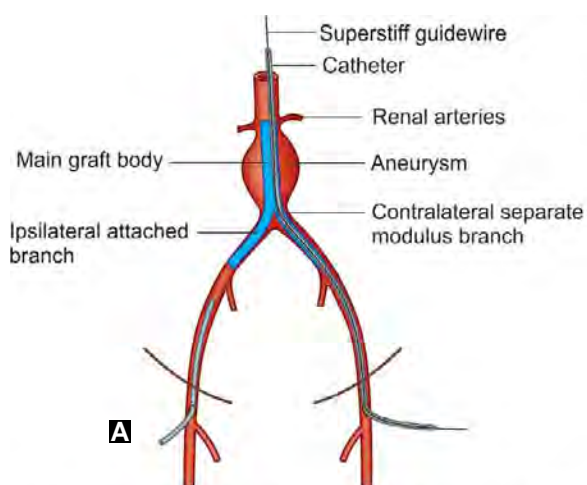
Patient has to be shifted to the operation theatre. Abdomen is opened. *Vascular clamps* or *bull dog clamps* are applied to the aorta above and below the aneurysm. Adventitia is opened and the clot is removed. Aneurysm is excised and the *arterial graft* either *PTFE (Polytetrafluoroethylene)*, *knitted dacron graft*, or *woven dacron graft* is placed. The graft is sutured to the vessel above and below using monofilament, nonabsorbable suture material, polypropylene 5-zero.

#### Complications of surgery

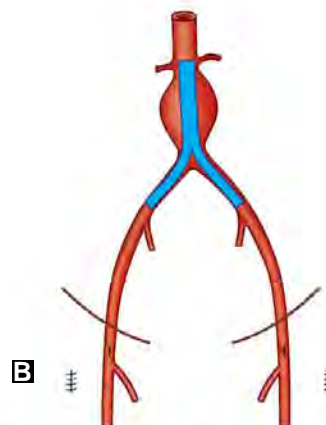
- ❖ *MI* is the most common cardiac complication in perioperative and in first 2 days of postoperative period
- ❖ Haemorrhage and haemodynamic complications
- ❖ Renal failure—is most common noncardiac complication
- ❖ Colonic ischaemia—10% due to poor IMA circulation
- ❖ Sexual dysfunction
- ❖ Aortoduodenal fistula
- ❖ Aortovenacaval fistula
- ❖ Spinal cord ischaemia—paraplegia
- ❖ Paralytic ileus
- ❖ Distal thromboembolism—blue toe syndrome
- ❖ DVT
- ❖ Graft leak, graft thrombosis, graft failure
- ❖ Anastomotic disruption, pseudoaneurysm formation
- ❖ Prosthetic infection/migration



**Fig. 1.357:** Infrarenal aortic aneurysm repair. It is the most common site of aortic aneurysm. Adventitia of aorta is opened; aneurysm is excised; graft is sutured above and below; adventitia is wrapped around.



- Ipsilateral aortic and iliac single unit modulus is passed through same side CFA.
- Opposite side (contralateral side) branch CIA graft is deployed through superstiff guidewire.
- Through opposite CFA.



- Completion of procedure with graft in place. Arteriotomy is closed and skin incision is closed.

**Figs 1.358A and B:** Endovascular aneurysm repair (EVAR). Aortic and one side iliac stent is used as one unit modulus which is passed through same side common femoral artery; opposite side iliac part is inserted as separate modulus through opposite CFA.

### Remember

- ❖ Pulsation of an aneurysm is expansile. Pulsation may be absent if it is thrombosed
- ❖ Abdominal aneurysm of any size which is painful or tender should be operated
- ❖ Abdominal aortic aneurysm of any size causing embolus should be operated
- ❖ Abdominal aortic aneurysm more than 5.5 cm should be operated
- ❖ In ruptured abdominal aortic aneurysm emergency surgery is the only choice operation with rapid resuscitation; immediate opening and repair using graft. Systolic pressure in this patient should be just adequate to maintain the cardiac function but should not be more than 100 mmHg as it will cause more bleeding
- ❖ Anterior rupture is more dangerous than posterior rupture
- ❖ Endoluminal stenting is becoming popular

### PERIPHERAL ANEURYSM

- ◆ *Peripheral aneurysms* are less common compared to aneurysms in the cavity. Such surface aneurysms are easily visible and better amenable for clinical examination. But same time it may be mistaken for abscess and inadvertent wrong attempt of incision and drainage can occur leading to disastrous consequences.
- ◆ Popliteal type is the *most common* one. Peripheral aneurysms occur in *descending order of frequency* in popliteal, femoral, subclavian, axillary and carotid arteries.
- ◆ *Expansile pulsation* which is confirmed using two finger placement with thrill and bruit is typical. Infection, thrombosis make it less pulsatile mimicking an abscess.
- ◆ Erosion into adjacent bone and skin, rupture are known to occur. Distal emboli may lead into digital gangrene.
- ◆ Pressure on the affected artery proximally reduces the size, and eliminates the thrill/bruit; pressure distal to aneurysm increases the prominence of the aneurysm swelling with bounding pulsation.

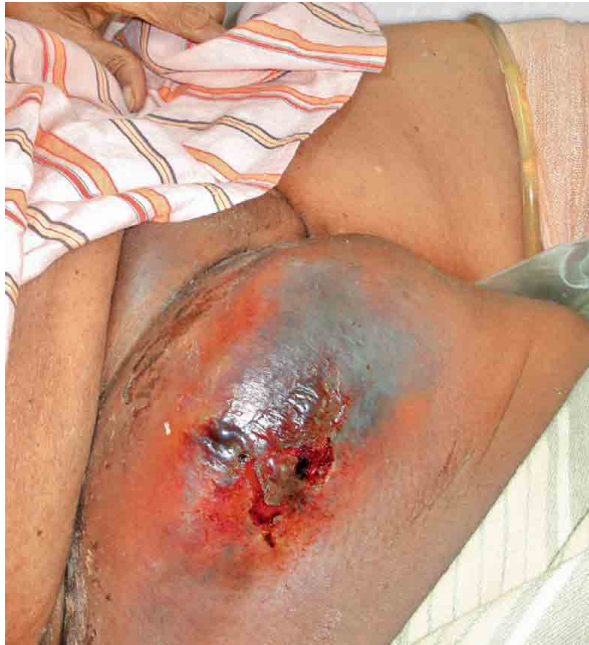- ◆ X-ray, arterial Doppler, angiogram, echocardiogram are needed.
- ◆ *Treatment* is open repair using arterial graft or endovascular stenting.

### Popliteal Aneurysm

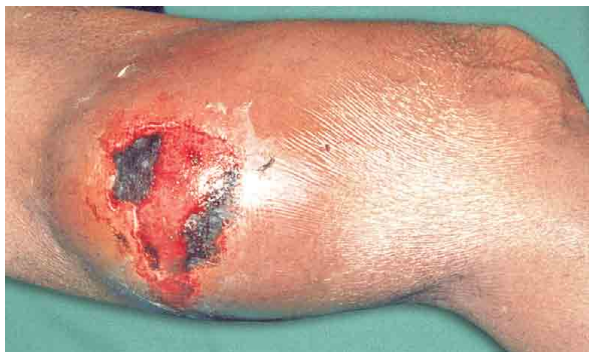- ◆ Is most common (70%).
- ◆ 65% are bilateral.
- ◆ 25% cases are associated with abdominal aortic aneurysm.
- ◆ 75% cause complications in 5 years.

#### Presentations

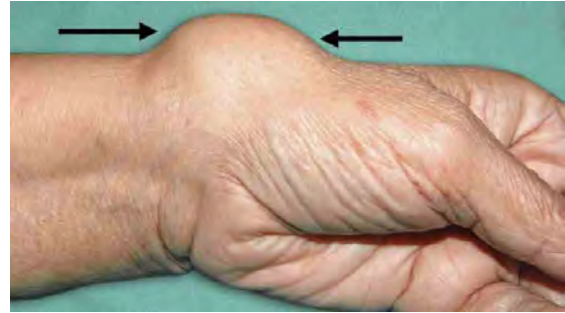- ◆ Swelling in popliteal region which is smooth, soft, pulsatile, well-localised, warm, compressible, often with thrill and bruit. *It may mimic a pyogenic abscess.*
- ◆ Thrombosis and emboli from popliteal aneurysm can cause distal gangrene which may spread proximally and may lead to amputation.
- ◆ Rupture may cause torrential haemorrhage.



**Fig. 1.359:** Femoral artery aneurysm with impending rupture—needs emergency surgical intervention. It is rare type.



**Fig. 1.360:** Popliteal aneurysm about to rupture. It is the most common peripheral aneurysm.



**Fig. 1.361:** Radial artery aneurysm.

#### Investigations

- ▶ Duplex scan, angiogram.
- ▶ CT scan, MRI.

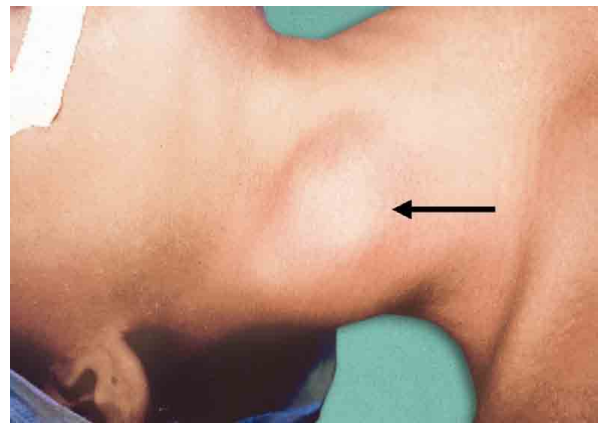
#### Treatment

- ▶ Aneurysmorrhaphy.
- ▶ Repair with arterial graft using PTFE, Dacron.
- ▶ Endoluminal stenting.

### CAROTID ARTERY ANEURYSM (EXTRACRANIAL)

Incidence is less than 4% of peripheral aneurysms.

**Most common site:** Common carotid artery bulb, often extends into the internal carotid artery.



**Fig. 1.362:** Carotid aneurysm.

#### Causes

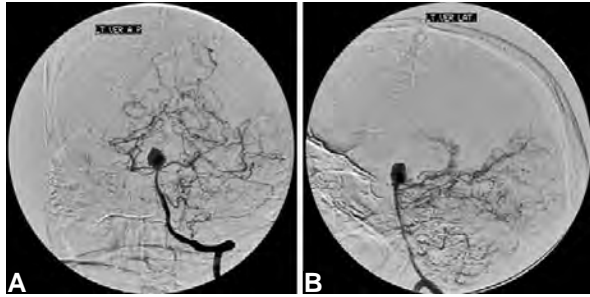- ◆ Atherosclerosis, trauma.
- ◆ Syphilis, Marfan's syndrome.
- ◆ Ehler-Danlos syndrome.
- ◆ Congenital.

#### Clinical Features

- ❖ 10% bilateral.
- ❖ Swelling in the neck at the level of the thyroid cartilage, below the angle of mandible.
- ❖ Pulsatile (expansile pulsation).
- ❖ Smooth, soft, nontender, horizontally mobile.
- ❖ Bruit felt.
- ❖ Neurological features due to embolic episodes (50%).
- ❖ Hoarseness of voice.
- ❖ Horner's syndrome.
- ❖ Dysphagia.
- ❖ Swelling extending into the tonsillar bed.

## Differential Diagnosis

- ◆ Carotid body tumour.
- ◆ Neurofibroma arising from the vagus.
- ◆ Abscess in neck.



**Figs 1.363A and B:** Basilar artery aneurysm—angiogram  
(Courtesy: Dr Muralidhar Pai, MCh, Mangaluru).

## Complications

- ◆ Rupture.
- ◆ Thrombosis.
- ◆ Hemiplegia.

## Investigations

- ◆ Doppler of neck, carotid angiogram.
- ◆ DSA, CT angiogram.

## Treatment

- ◆ Reconstruction of the artery using vascular graft.
- ◆ Ligation of the bulb as a life-saving procedure, but results in hemiplegia.
- ◆ Intravascular stents.

## DISSECTING ANEURYSM

*It is a misnomer. It is not an aneurysm, only an aortic dissection.*

It is the dissection of media of the aorta after splitting through intima creating a channel in the *media* of the vessel wall.

## Causes

- ◆ Hypertension (It is associated in 80% of dissecting aneurysms).
- ◆ Cystic medial necrosis.
- ◆ Marfan's syndrome and collagen diseases.
- ◆ Trauma.
- ◆ Weakening of the elastic layers of the media due to shear forces.

## Features

- ◆ It is always seen in thoracic aorta, common in ascending aorta (70%).
- ◆ It is uncommon in other parts of aorta or other vessels.
- ◆ It can occur in aortic arch or thoracic descending aorta.
- ◆ This dissected aortic channel gets lined by endothelium, often reopens distally into the aorta causing *double-barrelled aorta* which, in fact, prevents complications.

- ◆ It is commonly associated with aortic insufficiency.  
Atherosclerosis is *not a usual cause* for dissecting aneurysm.

### I. Classification (DeBakey's)

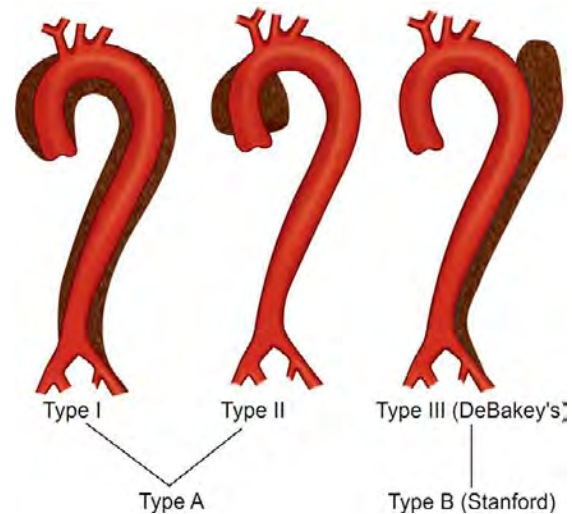
- ❖ *Type I:* Dissection begins in ascending aorta extends into descending thoracic aorta (70%)
- ❖ *Type II:* Dissection originates in ascending aorta and extends only up to the origin of the major vessels. It is safer type with less complications
- ❖ *Type III:* Dissection begins in the descending thoracic aorta beyond the origin of the left subclavian artery

### II. Stanford classification

- ❖ Proximal—includes DeBakey's Type I and II
- ❖ Distal—includes DeBakey's Type III

### III. Dissecting aneurysm can be:

- ❖ Acute
- ❖ Chronic
- ❖ Healed dissecting aneurysm which communicates distally again to aorta as double barrelled aorta



**Fig. 1.364:** Dissecting aneurysm.

### Complications

- ❖ *Acute:* Rupture into the pericardium or pleura—*dangerous* type
- ❖ *Chronic:* Blockage of coronary vessels and major vessels like carotid and subclavian arteries with aortic insufficiency

## Clinical Features

- ◆ Pain in the chest, back which is excruciating.
- ◆ Features of ischaemia due to blockage of different vessels.

### Investigations

- ❖ Chest X-ray shows mediastinal widening
- ❖ Arterial Doppler
- ❖ Angiogram

## Treatment

Antihypertensives.

*Surgery:* Using Dacron graft reconstruction of aorta has to be done with cardiopulmonary bypass.

### Indications for surgery

- ❖ Progressive disease
- ❖ Significant ischaemia
- ❖ Impending rupture
- ❖ Type A aortic dissection

## ERYTHROMELALGIA (ERYTHRALGIA)

- ◆ It is also called as *Mitchell's disease*; an episodic attack precipitated by heat, exertion and stress; common in lower limbs. Primary type is familial and autosomal dominant. Secondary type is seen in gout, erythrocyanosis frigida, polycythaemia, viral infection, mushroom poisoning, drug induced (verapamil, ergots, fluoroquinolones). There is microvascular and neuropathic changes.
- ◆ There is severe burning pain in the limbs with redness and sensation of heat. Warmness in the skin; often excoriation or ulceration, flushing, prominent veins, severe hyperesthesia are the usual features.
- ◆ **Treatment:** Mechanical cooling by elevating the limb (*Note: Should not place the affected limb in cold water* which may flare up the problems); aspirin; pregabalin, gabapentin, IV lignocaine are different drugs used in this condition.

## LIVEDO RETICULARIS

It is a condition with arteriolar spasm along with obstruction of capillaries by tiny blood clots with dilatation of venules, causing lace like purplish discoloration. Persistent, mottled, reddish-blue dermal streaks that do not blanch is typical. It may be idiopathic or related to vasculitis due to autoimmune conditions along with SLE or drug induced. Condition worsens by cold. Treating the cause; PUVA bath; warming the limb; exercise are different therapies.

## POLYARTERITIS NODOSA

- ◆ It is a necrotising inflammatory reaction with commonly microscopic polyarteritis and nodule formation, often of small and medium-sized arteries (not capillaries), causing ischaemia of lower and upper limb.
- ◆ Visceral arterial (mesenteric) involvement (70%) can cause abdominal pain, GI bleed; mucosal ulceration and perforation of small bowel. Massive hepatic infarction, cholecystitis can develop.
- ◆ Renal artery can cause loin pain, haematuria, and renal hypertension.
- ◆ Coronary artery also can get involved causing myocardial infarction.
- ◆ Disease is common at bifurcation of medium/small sized arteries leading to localised aneurysms.
- ◆ It is common in males (3:1); fever, weakness, myalgia, arthralgia are early features.
- ◆ Presents with localised small aneurysms, like multiple 5–10 mm nodules, palpable along the course of the artery.
- ◆ In late stage presents with myocardial infarction, renal failure, sepsis, GI bleed.
- ◆ HBsAg is positive in 40% patients of polyarteritis nodosa.
- ◆ Angiogram of renal, mesenteric, peripheral arteries will show aneurysms at branching points.

- ◆ Biopsy of tender nodule, tender muscle is useful for diagnosis.
- ◆ Treatment is prednisolone 60 mg daily with cytotoxic drugs.
- ◆ Prognosis is poor with rapid death in early years.

## SCLERODERMA/SYSTEMIC SCLEROSIS

- ◆ It is a *progressive* disease causing fibrosis of skin, GI tract, lungs, heart and kidney.
- ◆ It is common in females (4:1) at 4th/5th decade.
- ◆ It is considered as vasculitis even though earlier considered as collagen disease.
- ◆ Pathology consists of cytotoxic endothelial injury causing interstitial oedema, severe fibroblast proliferation causing fibrosis of affected vessels, and dilatation and proliferation of remaining capillaries as telangiectasis.
- ◆ Thin epidermis, thick dermis with more collagen with absence of appendages and rete pegs are typical.
- ◆ Lower 2/3rd oesophagus is sclerosed (50%) with increased collagen in submucosa with atrophied mucosa and muscularis. Dysphagia is common.
- ◆ Diffuse interstitial fibrosis, thickening of alveolar membrane and pulmonary hypertension occurs.
- ◆ Synovial thickening causes arthritis; fibrosis of skeletal muscles; interstitial myocardial fibrosis causes bundle branch block, pericardial effusion.
- ◆ Glomerulosclerosis in kidney is common (50%). Renal failure is common.
- ◆ Fibrosis of thyroid, periodontal membrane can occur. Malabsorption syndrome is common due to small bowel involvement.
- ◆ Involvement of digital arteries present as Raynaud's phenomenon.
- ◆ Calcinosis, Raynaud's, oesophageal hypomotility, sclerodactyly, and telangiectasia are the presentation of CREST syndrome.
- ◆ **Investigations**—anaemia, raised ESR, elevated IgG, presence of antinuclear antibodies and anticentromere antibodies (in CREST)—are different laboratory findings. Skin and peripheral arterial biopsy is confirmative.
- ◆ **Treatment**—is difficult. Drugs like D penicillamine, colchicines, p amino benzoic acid, vitamin E, dimethyl sulfoxide, ranitidine are tried at various levels. Vasodilators, warming and massaging skin, avoiding detergent soaps, oil and hydrophilic ointment application are used. Steroids, oxygen therapy for irreversible pulmonary fibrosis; haemodialysis for renal failure; digitalis and other drugs for cardiac failure are needed later.
- ◆ Death is due to cardiac/pulmonary/renal failure.

## ACROCYNANOSIS (CRURUM PUELLARUM FRIGIDUM)

- ◆ It is persistent, painless cyanosis seen in fingers and often in legs with paraesthesia and chilblains affecting *young females*.
- ◆ It is chronic persistent arteriolar constriction with slow rate of blood flow.
- ◆ Trophic changes and ulcerations are not seen.
- ◆ Cyanosis *which is persisting* may aggravate on exposure to cold.
- ◆ It may be associated with endocrine dysfunction.

## Treatment

- ◆ Vasodilators.
- ◆ Cervical sympathectomy (effective).

Raynaud's phenomenon	Acrocyanosis
• Episodic	• Persistent
• Painful	• Painless
• Acute arteriolar spasm	• Chronic constriction
• Ischaemic changes are common	• Ischaemic changes are not seen

## GANGRENE

*If the tips of (the patient's) fingers are falling off and are black, he will die.*

—(Anonymous), circa 2000 BC

It is macroscopic death of tissue *in situ* (in continuity with adjacent viable tissue) *with putrefaction* (there will be *loss of function* also).

### It can occur in sites like:

- ❖ Limbs
- ❖ Appendix
- ❖ Bowel
- ❖ Testes
- ❖ Gallbladder

## Causes

- ◆ Secondary to arterial occlusion like atherosclerosis, emboli, diabetes, TAO, Raynaud's disease, ergots.
- ◆ Infective: Boil, carbuncle, gas gangrene, Fournier's gangrene, cancrum oris.
- ◆ Traumatic: Direct, indirect.
- ◆ Physical: Burns, scalds, frostbite, chemicals, irradiation, electrical.
- ◆ Venous gangrene.

## Clinical Features

- ◆ *Colour changes*: Pallor, greyish, purple, brownish black due to disintegration of haemoglobin to sulphide.
- ◆ *Absence of pulse*, loss of sensation, loss of function.
- ◆ *Line of demarcation* between viable and dead tissue by a band of hyperaemia and hyperaesthesia along with development of a layer of granulation tissue.

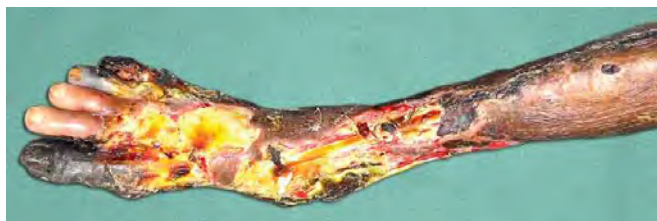

Fig. 1.365: Gangrene foot with ischaemic ulcer.

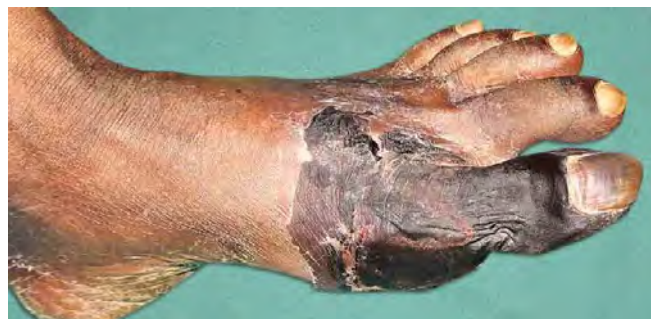
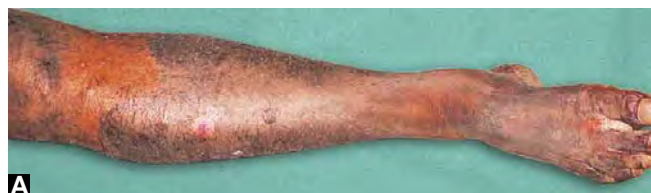
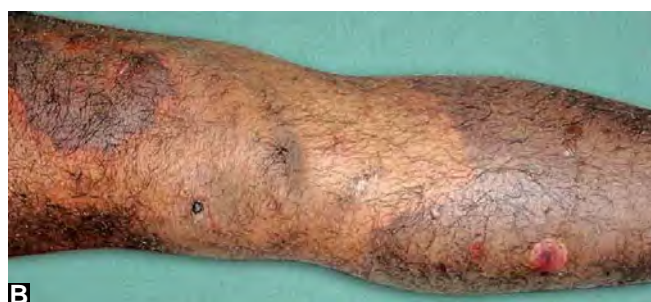Fig. 1.366: Dry gangrene—great toe.



A



B

Figs 1.367A and B: Gangrene of foot and leg. Note the line of demarcation. But skip lesion proximally shown signifies more proximal spread of gangrene which may need above knee amputation.

In *dry gangrene* the separation occurs by aseptic ulceration with minimum infection and the gangrene is dry and mummified.

In *wet gangrene*, separation takes place by septic ulceration. Often demarcation is vague with *skip lesions* more proximally and so landing with higher level of amputations. Even after amputation skin flap may show *die back* process, leading to failure of taking up of flap of amputation and so requiring still higher level of amputation.

- ◆ *Proximal ischaemic features* may be present with rest pain, colour changes, hyperaesthesia—pregangrene.

### Types of gangrene

- ❖ *Dry gangrene* is due to slow, gradual loss of blood supply to the part causing dry, desiccated, wrinkled, mummified part with proper line of demarcation from the viable adjacent tissues
- ❖ *Wet gangrene* is due to infection with putrefaction, causing oedematous, swollen, discoloured part, spreading proximally, with vague line of demarcation from the adjacent viable tissues

## Investigations

- ◆ Hb%, blood sugar.
- ◆ Arterial Doppler, angiogram (Seldinger technique).
- ◆ US abdomen to find out the status of aorta.

*Today well lived makes every yesterday, a dream of happiness and tomorrow, a vision of hope.*



## Differences between dry gangrene and wet gangrene

Dry gangrene	Wet gangrene (Moist)
Clear line of demarcation is seen	Line of demarcation is vague
Dry, shriveled, mummified	Oedematous, putrified, discoloured (H <sub>2</sub> S)
Slow, gradual loss of blood supply	Sudden loss of blood supply
Separation is by aseptic ulceration	Septic ulceration causes separation
Limits to the demarcation	Can extend proximally rapidly
Causes are atherosclerosis, TAO	Emboli, trauma are the causes
Limited amputation is sufficient	Major higher amputation is often needed

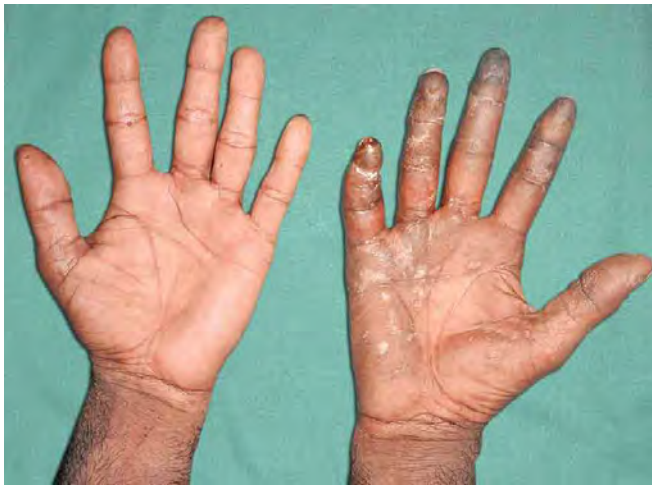

Fig. 1.368: Ischaemic features of right hand; compare to left side which is normal.

## Treatment

### Limb saving methods:

- ◆ Drugs: Antibiotics, vasodilators, pentoxifylline, praxilene, dipyridamole, small dose of aspirin, ticlopidine.
- ◆ Care of feet and toes:
  - ▶ The part has to be kept dry.
  - ▶ Any injury has to be avoided.
  - ▶ Proper footwear is advised (Microcellular rubber footwear, MCR).
  - ▶ Measures for pain relief is taken.
  - ▶ Nutrition supplementation is done.
  - ▶ The limb should not be warmed.
  - ▶ Pressure areas has to be protected.
  - ▶ Localised pus has to be drained.
- ◆ Cause is treated.
- ◆ Diabetes is controlled.
- ◆ Surgeries to improve the limb perfusion: Lumbar sympathectomy, omentoplasty.

Profundaplasty, femoropopliteal thrombectomy or endarterectomy, arterial graft bypass are done according to the need.

### Life-saving procedures:

Amputations may have to be done often.

Level of amputation is decided on skin changes, temperature, line of demarcation, Doppler study.

- ◆ Below-knee amputation is a better option as BK prosthesis

can be fitted better and also the movements of knee joint are retained. There is no need of external support and limp is absent.

- ◆ In *above-knee amputation* range of movements are less, limp is present, and often requires third (stick) support to walk.

Different amputations done are *Ray amputation*, below-knee amputation (*Buerger's amputation*), *Gritti-Stokes transgenial amputation*, above-knee amputation.

Lisfranc's, Chopart's, Symes', Modified Symes' amputations are not commonly used in ischaemic limb as flaps will not survive.

## DIABETIC FOOT AND DIABETIC GANGRENE

Foot is a complex structure with many layers of muscles, ligaments, joints, arches, fat, thick plantar fascia, vascular arches, neurological system which maintains weight-bearing, gravity, normal walk, stability and gait (swing and stance phases).

### Problems in diabetic foot

- ❖ Callosities, ulceration
- ❖ Abscess and cellulitis of foot
- ❖ Osteomyelitis of different bones of foot like metatarsals, cuneiforms, calcaneum
- ❖ Diabetic gangrene
- ❖ Arthritis of the joints

### Meggitt's classification of diabetic foot

- ❖ Grade 0: Foot symptoms like pain, only
- ❖ Grade 1: Superficial ulcers
- ❖ Grade 2: Deep ulcers
- ❖ Grade 3: Ulcer with bone involvement
- ❖ Grade 4: Forefoot gangrene
- ❖ Grade 5: Full foot gangrene

## Pathogenesis of Diabetic Foot/Gangrene

- ◆ High glucose level in tissues is a good culture media for bacteria. So infection is common.
- ◆ *Diabetic microangiopathy* causes blockade of micro-circulation leading to hypoxia.
- ◆ *Diabetic neuropathy*: Due to sensory neuropathy, minor injuries are not noticed and so infection occurs. Due to motor

neuropathy, dysfunction of muscles, arches of foot and joints occurs. And loss of reflexes of foot occurs causing more prone for trauma and abscess. Due to autonomic neuropathy, skin will be dry, causing defective skin barrier and so more prone for infection.

- ◆ *Diabetic atherosclerosis* itself reduces the blood supply and causes gangrene. Thrombosis can be precipitated by infection causing infective gangrene. Blockage occurs at plantar, tibial, and dorsalis pedis vessels.
- ◆ *Increased glycosylated haemoglobin* in blood causes defective oxygen dissociation leading to more hypoxia. At tissue level there will be increased glycosylated tissue proteins, which prevents proper oxygen utilisation and so aggravates hypoxia.

### Clinical Features

- ◆ Pain in the foot.
- ◆ Ulceration.
- ◆ Absence of sensation.
- ◆ Absence of pulsations in the foot (Posterior tibial and dorsalis pedis arteries).
- ◆ Loss of joint movements.
- ◆ Abscess formation.
- ◆ Change in temperature and colour when gangrene sets in.
- ◆ Patient may succumb to *ketoacidosis*, *septicaemia* or *myocardial infarction*.

### Investigations

- ◆ Blood sugar, urine ketone bodies.
- ◆ Blood urea and serum creatinine.
- ◆ X-ray of part to look for osteomyelitis.
- ◆ Pus for culture and sensitivity.
- ◆ Doppler study of lower limb to assess arterial patency.
- ◆ Angiogram to look for proximal blockage.
- ◆ Ultrasound of abdomen to see the status of abdominal aorta.
- ◆ Glycosylated haemoglobin estimation.

### Treatment

- ◆ **Foot can be saved only if there is good blood supply.**
  - ▶ Antibiotics—decided by *pus C/S*.
  - ▶ Regular dressing.
  - ▶ *Drugs*: Vasodilators, pentoxiphylline, dipyridamole, low dose aspirin.
  - ▶ Diabetes is controlled by *insulin only*.
  - ▶ Diet control, control of obesity.
  - ▶ Surgical debridement of wound.
- ▶ Amputations of the gangrenous area. Level of amputation has to be decided by skin changes and temperature changes or Doppler study.
- ▶ Care of feet in diabetic:
  - Any injury has to be avoided.
  - MCR footwears must be used (Microcellular rubber).

- Feet has to be kept clean and dry, especially the toes and clefts.
- Hyperkeratosis has to be avoided.

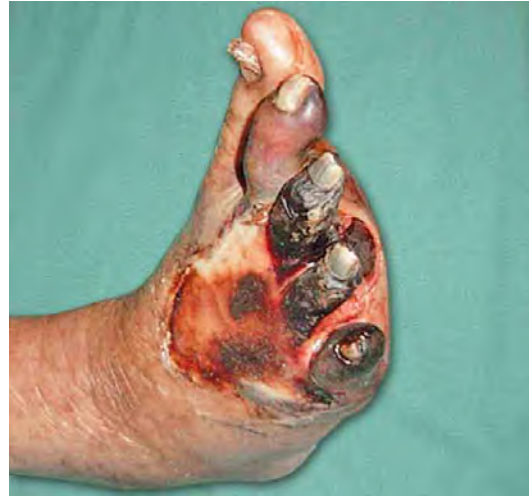

Fig. 1.369: Diabetic foot with ischaemic ulceration and gangrene.

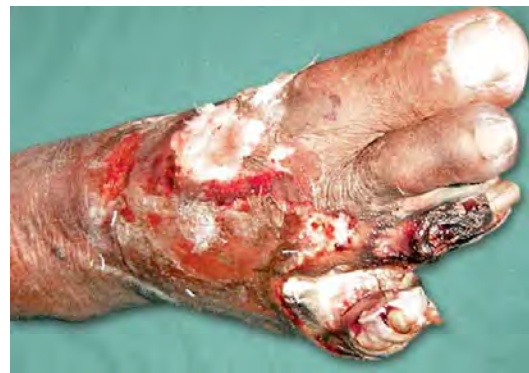

Fig. 1.370: Gangrene of 3rd and 5th toes in a diabetic. Patient already underwent amputation of 4 the toe earlier for gangrene.

### TROPIC ULCER

- ◆ **Aetiology:** Diabetic neuropathy, spinal injury and diseases, other neuropathies.

#### Causes

- ❖ Pressure
- ❖ Anaemia
- ❖ Malnutrition
- ❖ Injury
- ❖ Moisture

- ◆ **Common Sites:** Heel, heads of metatarsals, sacrum, ischium, occipital region. *Bedsore is a trophic ulcer.*
- ◆ **Clinical Features:** They are deep, punched out, nonmobile ulcers, with bone as its base.
- ◆ **Investigations:** X-ray spine, nerve conduction studies, blood sugar, Hb%.
- ◆ **Treatment**

- ▶ Nutrition is improved.
- ▶ Anaemia is treated.
- ▶ Diabetes is controlled.
- ▶ Regular dressing is done.
- ▶ Pressure and injuries has to be avoided.

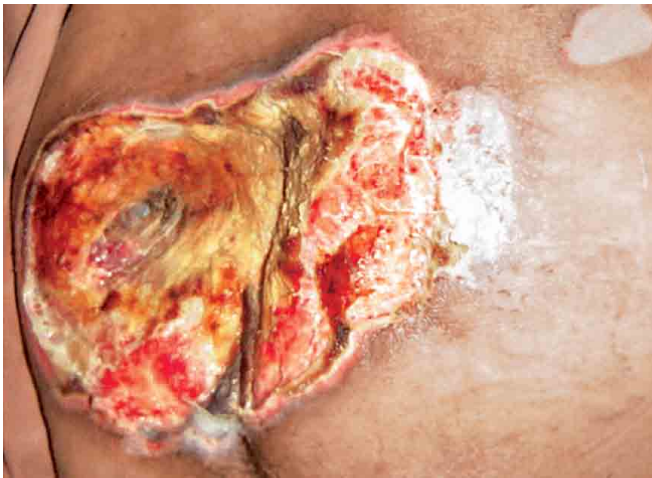### ■ BEDSORES (Decubitus Ulcer) (Pressure Sores)

Bedsore is a *trophic ulcer* with bone as the base.  
It is nonmobile, deep, punched out ulcer.

#### It is common in

Old age Bedridden	Tetanus	Patients with orthopaedic and head injuries
Diabetic Paraplegic	Comatose	

Sites of bedsore are occiput, heel, sacrum, ischium, scapula.  
*Factors:* Malnutrition, pressure, anaemia, sensory loss, moisture.



**Fig. 1.371:** Large bedsore over the sacrum in a bedridden patient. Note the size and slough on the surface.

### Treatment

- ◆ Change of positions is always encouraged.
- ◆ Use of water bed, ripple bed is advised.
- ◆ Moisture has to be avoided.
- ◆ Soaking by urine, sweat, pus, and faeces has to be taken care off.
- ◆ Good nursing, regular dressing, good nutrition are necessary.
- ◆ Antibiotics, blood transfusions are very essential.
- ◆ Excision of dead tissue followed by skin grafting or local rotation flaps may have to be done.
- ◆ Rehabilitation.

### ■ FROSTBITE

- ◆ It is due to exposure to cold wind or high altitude.
- ◆ It is common in old age during cold spells.
- ◆ Damage to vessel wall occurs causing oedema, blistering, gangrene formation.
- ◆ Part is painless and waxy.
- ◆ Cells get frozen at  $-5^{\circ}\text{C}$ . Initially redness and oedema (1st degree); blister formation (2nd degree); skin necrosis (3rd degree); gangrene (4th degree) develops gradually.

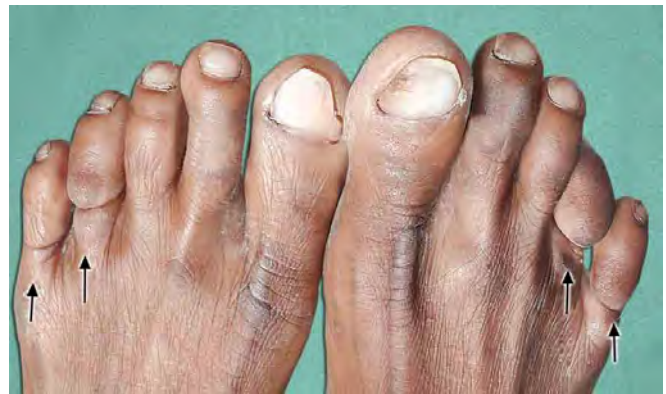### Treatment

- ◆ *Gradual warming is done.* Part should be wrapped with cotton-wool and rested. Warming is gradually done with  $44^{\circ}\text{C}$  in 30 minutes with warm water. Limb elevation is done to reduce oedema. Intra-arterial vasodilators may help.
- ◆ Warm drinks, analgesics, paravertebral injections to sympathetic chain, *hyperbaric oxygen* are effective.
- ◆ If gangrene develops, amputation is needed.

### ■ AINHUM

*Ainhum* also known as ‘dactylolysis spontanea’ is a painful constriction of the base of the fifth toe frequently (occasionally other toes also) followed by bilateral spontaneous auto-amputation a few years later. Grooving  $\rightarrow$  pain  $\rightarrow$  constriction deepens  $\rightarrow$  tendon, nerve and vessel involvement  $\rightarrow$  bone gets cut spontaneously without any bleeding (auto-amputation) in many (2–5) years.

- ◆ Commonly affects males (can also occur in females).
- ◆ Common in blacks, in Negroes.
- ◆ History of running barefoot in childhood is common.
- ◆ *Fifth toe* is commonly affected.
- ◆ A fissure develops at the interphalangeal joint which becomes a fibrous band, that encircles the digit causing necrosis (Gangrene of little toe).
- ◆ Often it can be bilateral.



**Fig. 1.372:** Bilateral Ainhum involving 4th and 5th toes of both feet. Note the constriction ring in the toes.

**Treatment:** It is early ‘Z’ plasty. Amputation is often required later. Most often autoamputation occurs.

#### Note:

Yoruba people of Nigeria named *ainhum*.

### ■ ENDOVASCULAR SURGERIES

It is mainly used in peripheral vessels like femoropopliteal, renal, coronary, cerebral vessels.

### Types

- ◆ *Balloon angioplasty:* It is useful in short segment stenosis in large vessels like renal vessels, iliofemoral, coronary vessels. It is less effective compared to open surgery.
- ◆ *Intravascular stenting:* Balloon expandable and self-expanding stents are used at stenosed area.
- ◆ *Endovascular grafts* (PTFE, DACRON).

- ◆ Endovascular atherectomy.
- ◆ *Angioscopy*: Flexible, small, fiberoptic scopes to visualise vessel wall with sufficient irrigation to avoid opacification by blood.
- ◆ *Intravascular ultrasound*: To evaluate the vessel wall morphology.

#### Indications

- ❖ Aneurysm for stenting and grafting
- ❖ Aortoiliac constrictive disease
- ❖ Renal artery stenosis
- ❖ Carotid occlusive disease
- ❖ AV fistulas
- ❖ Management of pseudoaneurysm

### Complications

- ◆ Thrombosis.
- ◆ Rupture.
- ◆ Sepsis.
- ◆ Fluid overload.
- ◆ Air embolism.

### ■ UPPER LIMB ISCHAEMIA

It is a rare uncommon entity compared to lower limb ischaemia but important because of its difficulty in managing. *Higher-level amputations are rare in upper limb ischaemia.*

Its incidence is rare (5%) due to abundant collateral supply, infrequency of atherosclerosis, decreased metabolic demand and smaller muscle mass.

It mostly affects distal small arteries (90%).

Symptoms are usually delayed.

### Types of Upper Limb Ischaemia

- ◆ Acute.
- ◆ Chronic.

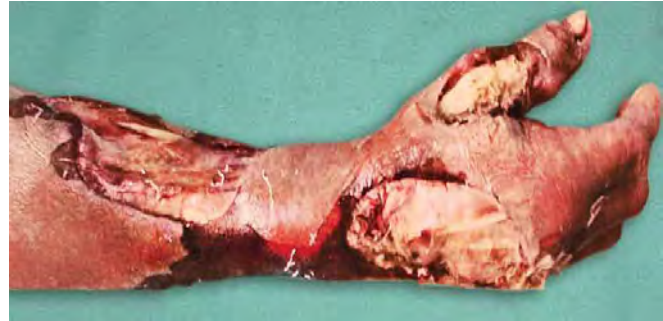#### Acute type

##### Causes:

- ◆ **Embolism—common:** 30% of the peripheral emboli lodge in upper extremity. The most common site is at the bifurcation of brachial artery (40%); next common is at axillary artery (12%). Embolism is due to:
  - ▶ Cardiac origin (70%)—valvular lesions (atrial fibrillation, endocarditis), IHD, paradoxical.
  - ▶ Others—aneurysms, *thoracic outlet syndrome*, plaque.
- ◆ **Trauma—most common:** Brachial artery injury is seen in 30% of civilian trauma with arterial injuries, blunt injuries, fractures and dislocations, penetrating injuries.
- ◆ Iatrogenic.

##### Symptoms of acute ischaemia

- ❖ Pain, pallor, poikilothermia, paraesthesia, paralysis.



**Fig. 1.373:** Upper limb ischaemia with gangrene extending proximally towards elbow joint.

#### Chronic Type

##### Causes:

- ◆ Arteritis—aortoarteritis, Takayasu arteritis, giant cell arteritis, connective tissue disease/vasculitis—scleroderma, SLE, RA, PAN, etc.
- ◆ Atherosclerosis—most common cause in USA.
- ◆ TAO of upper limb.
- ◆ Others—fibromuscular dysplasia; postirradiation—lung, breast; occupational injuries; vibration injury, hypothenar hammer syndrome; hypercoagulable states; APLA, polycythemia, cold agglutinins.

##### Symptoms of chronic ischaemia

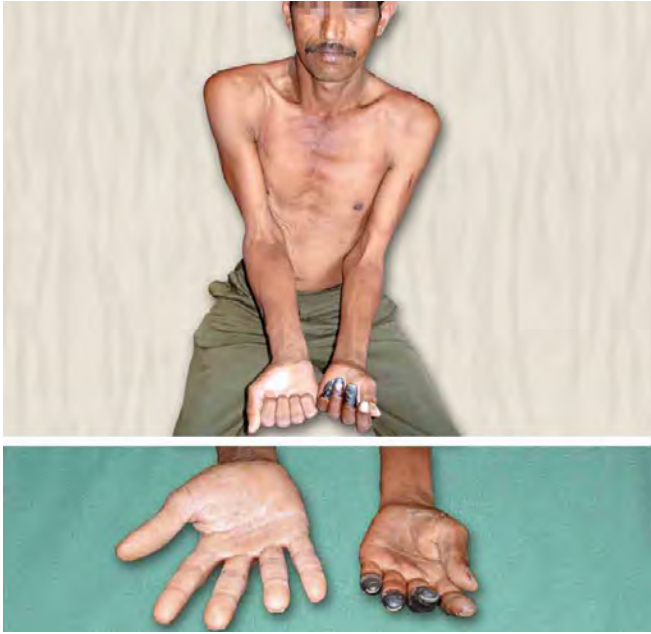- ❖ Upper limb 'Claudication'.
- ❖ Weakness and wasting.
- ❖ Digital ischaemia—ulcer, gangrene in finger tips.
- ❖ Raynaud's phenomenon.

##### Signs of chronic ischaemia

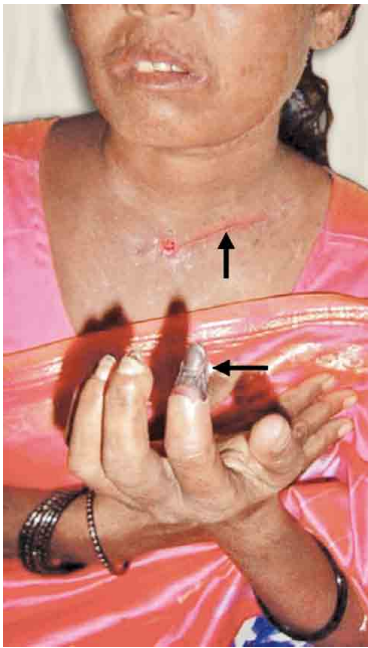- ❖ Wasting of arm, forearm and hand muscles.
- ❖ Ischaemic changes in skin; tapering of finger tips.
- ❖ Drop in systolic pressure >20 mmHg.
- ❖ Proximal thrill or bruit.
- ❖ Mass in the neck, thrill and bruit in the neck in supraclavicular region.
- ❖ Adson test, hyperabduction (Halsted) test, Roos test, Allen's tests are important.

### Raynaud's Phenomenon

- ◆ It is *episodic vasospasm*. It is common in upper limb.
- ◆ *Raynaud's disease*: It is *primary* Raynaud's phenomenon—no cause could be demonstrated (Idiopathic).
- ◆ *Raynaud's syndrome*: It is *secondary* Raynaud's phenomenon—secondary to a demonstrable lesion like SLE, scleroderma, TAO or atherosclerosis.
- ◆ *Symptoms*: Pain, discolouration, sensation of cold and numbness, pronounced on exposure to cold, and under stress.
- ◆ *Signs*: Cyclical colour changes—*Pallor*, *Cyanosis* and *Rubor* with swelling; seen in fingers, toes, nose, ear lobes and lips.
- ◆ *Pathology of Raynaud's phenomenon*: Exaggerated vasomotor response to stress; more common in females; no structural changes in the vessels, except in late stages; recurrent attacks can lead to atrophy of skin, subcutaneous tissue and muscles, ischaemic ulcers and gangrene.



**Fig. 1.374:** Left upper limb ischaemia with gangrene of three fingers and ischaemic changes in hand, forearm and arm.

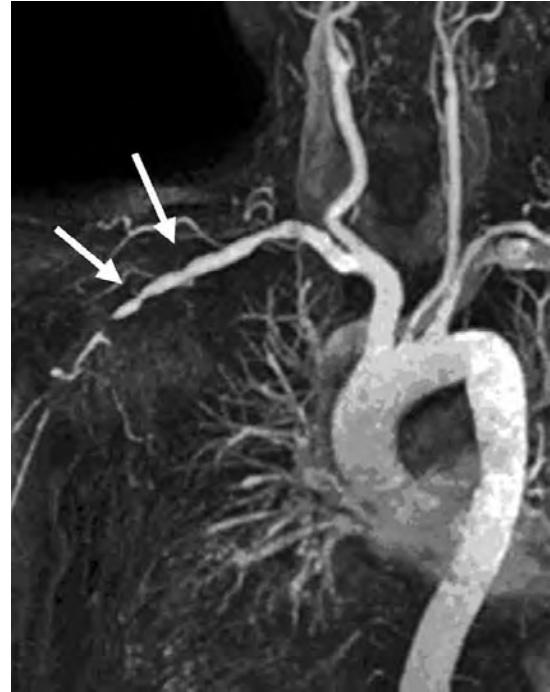

**Fig. 1.375:** Gangrene of left index finger. Patient has undergone cervical sympathectomy.

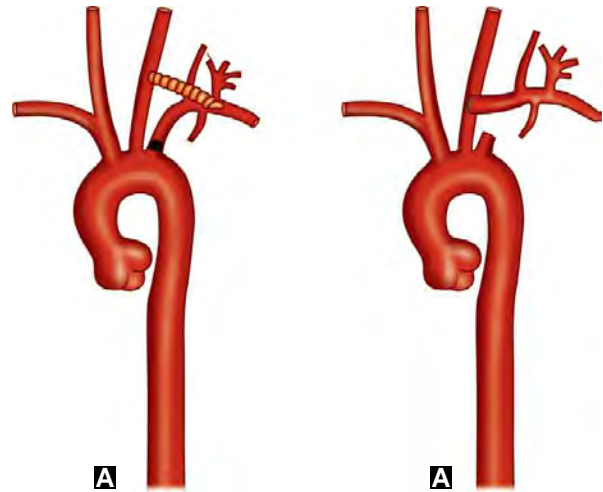
### Investigations in Upper Limb Ischaemia

- ◆ Lab tests for vasculitis, hypercoagulable states, and atherosclerotic risk factors.
- ◆ X-rays—for cervical rib; clavicular and first rib fractures; fractures and dislocations in extremity; pulmonary lesions of connective tissue disorders.
- ◆ Arterial Doppler study.
- ◆ Angiogram (Subclavian angiogram)—CT/MR; conventional.

- ◆ CT scan neck and thorax.
- ◆ Blood sugar, lipid profile, cardiac evaluation.



**Fig. 1.376:** Upper limb angiogram showing blocks in subclavian artery.



**Figs 1.377A and B:** (A) Carotid subclavian bypass; (B) Subclavian carotid transposition.

### Management of Upper Limb Ischaemia

- ◆ Treatment of the cause.

#### Treatment of Embolus

- ◆ Time since the first symptom is very important.
- ◆ Clinical assessment of extent of ischaemia, immediate anticoagulation with heparin, Doppler study and angiogram of the arterial system, evaluation for the source of embolus—are the protocols.
- ◆ Embolectomy

- ▶ *Brachial embolectomy*: Local/regional/general anaesthesia is used. Longitudinal incision in the arm is used for proximal embolus; Lazy S-shaped incision across the elbow is done for embolus extending into the bifurcation and to expose the branches.

### Treatment in Trauma

- ◆ General evaluation and resuscitation.
- ◆ Control of bleeding in open wound: Pressure bandage/manual compression (DO NOT USE TOURNIQUET).
- ◆ Time since the event and clinical assessment of limb perfusion.
- ◆ Stabilisation of fractures and dislocations
- ◆ Doppler study of arterial system, angiogram if required.
- ◆ Arterial repair; bypass graft either venous or synthetic.

### Treatment of Chronic Ischaemia

- ◆ Medical management
  - ▶ Risk modification—diabetes, hypertension, dyslipidemia, smoking, homocystinaemia, exercise training.
  - ▶ Antiplatelets—aspirin/ticlopidine/clopidogrel.
  - ▶ Anticoagulants—heparin/warfarin.
  - ▶ Xanthines/pentoxifylline/cilostazol.

*Cilostazol*—suppresses cAMP phosphodiesterase III rise in cAMP levels with antiplatelet, antithrombotic effects; induces vasodilatation; increases plasma HDL cholesterol; decreases plasma triglycerides.

- ◆ Catheter based interventions
  - ▶ Atherectomy.
  - ▶ Angioplasty ± stenting by conventional or subintimal approach.
  - ▶ Stent grafts.
  - ▶ Cryoplasty.
- ◆ Surgery
  - ▶ Endarterectomy.
  - ▶ Bypass surgery.
  - ▶ Sympathectomy, extraperiosteal resection of the cervical rib.

### Bypass Surgeries in Upper Limb Ischaemia

- ◆ Conventional bypass
  - ▶ Aorto-subclavian/axillary bypass.
  - ▶ Subclavian: Axillary/brachial bypass.
  - ▶ Brachiodistal bypass.
- ◆ Extra-anatomical bypass
  - ▶ **Carotid: Subclavian/Axillary bypass.**
  - ▶ Subclavian: Subclavian bypass.
  - ▶ Axillary: Axillary bypass.
- ◆ Subclavian: Carotid transposition.

### Treatment of Raynaud's Phenomenon

- ◆ Avoiding triggering agents
- ◆ Drugs (vasodilators)—calcium channel blockers, angiotensin II receptor blockers, alpha-1 adrenergic blockers, Sildenafil, prostaglandin E1.
- ◆ Surgery—sympathectomy.

#### Note:

Individual topics about causes of upper limb ischaemia are discussed in different places.

### Upper limb ischaemia

- ❖ Trauma/cervical rib are the common causes
- ❖ Opposite limb, lower limbs should be examined
- ❖ Cardiovascular system should be examined
- ❖ Neck should be examined
- ❖ Wasting/girth should be checked
- ❖ All relevant clinical methods are equally significant
- ❖ Auscultation over neck/axilla/carotids for bruit are important
- ❖ Doppler; angiogram; nerve conduction studies; CT neck and thorax are essential investigations
- ❖ Arterial repair; therapy for cervical rib; scalenotomy; cervical sympathectomy are the different modalities of treatment
- ❖ Digital amputation may be required

### ARTERIAL SUBSTITUTES

Ideal arterial substitute is not yet developed. Ideal arterial substitute should be strong, durable for patient's life, biocompatible, nonthrombogenic, should be resistant for infection, easily available, should have a long-term patency rate, and should have elastic property of normal artery.

#### Features of ideal graft

Strong	Should be leak proof on restoration of blood flow
Durable for patient's life	Should not chemically or physically degenerate
Non-thrombogenic	Should not cause any abnormal reaction to surrounding tissues
Biocompatible	Should not occlude when flexed
Resistant to infection	Should not damage blood contents
Flexible	
Should maintain long-term patency	
Should have elastic property of normal artery	

*Carrel and Guthrie* first did venous autograft into arteries of dogs. They did extensive histological study of viable and nonviable grafts. Lexer in 1907 used saphenous vein for axillary artery repair. Murray started to use intraoperative heparin. Enaz Moniz and dos Santos originated technique of arteriography. Gross and his colleagues in 1948 started to use viable arterial allografts. Later it was found that, as of graft is considered tissue viability is not essential for success of graft uptake.

### Classification of Arterial Substitutes

- ◆ Arterial allograft—not used.
- ◆ Arterial autograft—internal mammary artery (common), internal iliac artery.
- ◆ Arterial xenograft—bovine carotid artery graft—not used.
- ◆ Venous autograft—long saphenous vein (common), small saphenous vein, basilic vein, cephalic vein.
- ◆ Venous allograft—umbilical vein graft.
- ◆ Prosthetic grafts

- ▶ Textile grafts
  - Dacron graft—knitted or woven or crimping or velour types. *Dacron is polyethylene terephthalate.*
  - Teflon graft—knitted or woven crimping or velour types.
- ▶ Non-textile semi-inert polymer graft:
  - ePTFE graft—expanded polytetrafluoroethylene graft.

*Preclotting* the **noncoated knitted** or woven Dacron graft is done to seal the graft and to prevent leak, and to create a smooth lining at graft—blood interface. This step is not necessary for PTFE or newer grafts.

### Complications of Graft

- ◆ *Neointimal fibrous hyperplasia* at suture lines of the graft is due to surgical trauma, PDFG, arterial smooth muscle proliferation.
- ◆ *Graft infection*—incidence is 2%. It is more in lower limb graft than abdominal graft. Perioperative cephalosporin administration reduces the rate of graft infection. If infection occurs graft should be removed and revascularisation is achieved using a saphenous vein graft.
- ◆ *Graft failure* is rare but can occur. It is due to fiber degeneration, manufacturing defect, diffuse dilatation of graft (is due to expansion of the knit in knitted Dacron).
- ◆ *Anastomotic false aneurysm* (3%) occurs just adjacent to suture line towards host artery. It is tearing of the artery adjacent to suture line due to mismatched graft artery compliance, improper suture placement, and arterial degeneration. There will be partial or total separation of the graft from the host with blood collection in a covering of fibrous capsule. Eventually it will rupture/may cause thrombosis and embolism. Treatment is graft—artery reanastomosis with insertion of additional piece of graft.

# M. Vascular Lesions and Hamartoma

## CHAPTER OUTLINE

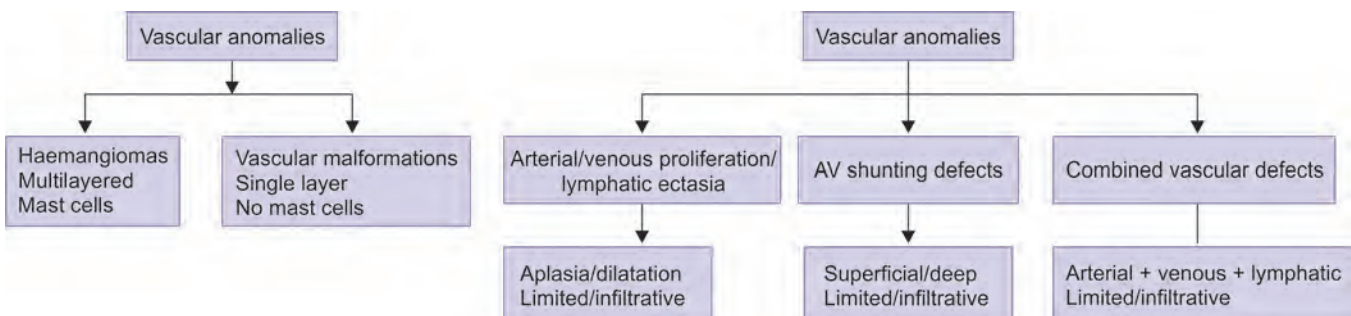
- |                          |                            |                         |
|--------------------------|----------------------------|-------------------------|
| ❖ Vascular Anomalies     | ❖ Cirroid Aneurysm         | ❖ Parry-Romberg Disease |
| ❖ Haemangioma            | ❖ Arteriovenous Fistula    | ❖ Hamartomata           |
| ❖ Vascular Malformations | ❖ Campbell De Morgan Spots |                         |

### VASCULAR ANOMALIES

- It is a *collective term* used for haemangioma and vascular malformations.
- Haemangioma* is a benign tumour containing hyperplastic endothelium with cellular proliferation with increased mast cells. Growth in tissue culture is observed. It is absent at birth, seen by 1 month in 30%. It usually shows biphasic growth phase with slow involution. 95% of cases achieve spontaneous involution. Fast growing type can cause platelet trapping and thrombocytopenia. Associated skeletal changes are not common but can occur. Bone erosion by the lesion can occur. It is common in girls (3:1).
- Vascular malformations* are single layer endothelium lined spaces derived from arterial, capillary, venous or lymphatic system. There is no growth in tissue culture. Rise in mast cells is not seen. 90% cases are seen at birth; only few at later period. It is equal in both sexes (1:1). Quiescent endothelium with vessels showing progressive ectasia is the feature. Intravascular coagulation and mild thrombocytopenia can develop. Skeletal changes and overgrowth are common. Spontaneous involution is not common.
- Disfigurement, tissue destruction, deformity, dysfunction, telangiectasia, skin scarring are common.
- Szilagy classification*—(1) Cavernous haemangioma; (2) Microfistulous AV communications; (3) Macrofistulous communications; (4) Anomalous mature vascular channels.
- Humburg classification*—(1) Predominantly arterial/venous/lymphatic defects with aplasia or obstructive dilatation which is limited or infiltrative; (2) Predominantly AV shunting defects with deep/superficial limited or infiltrating lesions; (3) combined vascular defects—arterial, venous and haemolymphatic which may be limited or infiltrating.
- Diagnosis* is made clinically and by radiological imaging—coloured Doppler, DSA, MRI. *MRI is better* than CT to identify the flow (MR angiogram is ideal). Haemangiomas show intense parenchymal staining; vascular malformations show ecstasic vessels without much parenchyma; AVM shows rapid venous shunting.

### HAEMANGIOMA

- It is the most common tumour in children (in 10% of term deliveries).
- It shows cellular endothelial hyperplasia with increased mast cells.
- Onset is few weeks after birth with biphasic growth showing initial rapid growth with gradual involution over 5–7 years.
- It is benign vascular endothelial tumour, common in girls (3 : 1).
- It is commonly seen in skin and subcutaneous tissue but can occur anywhere in the body like in liver, brain, lungs or other organs.
- It grows rapidly in first year and 70% involutes in 7 years.
- Early proliferative lesion is bright red, irregular; deep lesion is bluish coloured. Involution causes colour fading, softness, shrinkage leaving crepe paper like area.
- Commonly it is central; common in head and neck region (60%).
- Often large haemangiomas may be associated with visceral anomalies. Head and neck haemangioma is associated with ocular and intracranial anomalies; sacral with spinal dysraphism. Multiple cutaneous haemangiomas may be associated with haemangioma of liver causing hepatomegaly, cardiac failure (CCF), anaemia.
- Ulceration, bleeding, airway block and visual disturbances are common complications.
- A definitive even though rare, but important life-threatening complication is platelet trapping and severe thrombocytopenia presenting as ecchymosis, petechiae, intracranial haemorrhage massive GI bleed.



*You may be disappointed if you fail, you are doomed if you don't try.*



- ◆ Raised angiogenic (fibroblastic) growth factor which is secreted in patient's urine is useful lab investigation to differentiate it from vascular malformations.

#### Haemangioma classification (old)

- ❖ **Capillary**
  - Strawberry haemangioma
- ❖ **Cavernous haemangioma**

#### Note:

Salmon patch and port wine stain are actually capillary vascular malformations even though they were earlier classified under capillary haemangioma.

### Capillary Vascular Malformations

- ◆ **Salmon patch (stork bite):**
  - ▶ It is actually capillary vascular malformation also called as naevus simplex; it is very commonly seen in 40% of newborns.
  - ▶ It presents at birth. It commonly occurs in nape of the neck (50%), face, scalp and limbs. It usually involves wide area of skin. It is caused by an area of persistent fetal dermal circulation. With age, it goes for spontaneous regression and disappears completely (usually in one year). Hence masterly inactivity is the treatment.

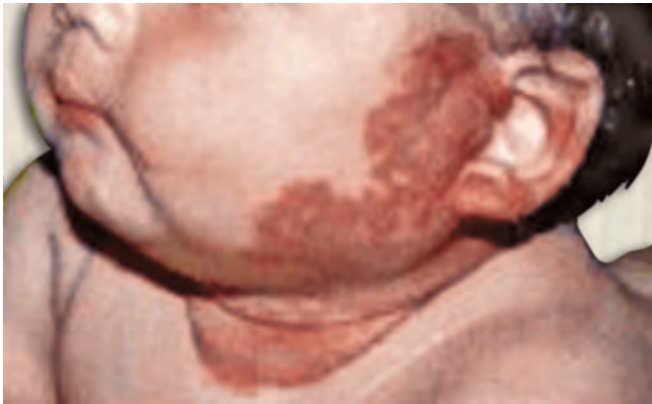


Fig. 1.378: Salmon patch.

- ◆ **Port-wine stain (Naevus flammeus):**
  - ▶ It presents at birth and persists throughout life without any change. Spontaneous regression will not occur. It presents as smooth, flat, reddish blue/intensely purple area; common in head, neck and face; often with maxillary and mandibular dermatomes of 5th cranial nerve. Eventually surface becomes nodular and keratotic.
  - ▶ It persists throughout life. It is less common; seen in 0.3% of all newborns. It is also a capillary vascular malformation.
  - ▶ It is actually a *capillary malformation* even though considered under haemangioma. It results from defect in maturation of sympathetic innervation of skin causing localised vasodilatation of intradermal capillaries.
  - ▶ It is often associated with Sturge-Weber syndrome, Klippel-Trenaunay-Weber syndrome and Proteus syndrome.
  - ▶ It needs treatment—laser (pulsed dye/diode); excision and grafting; cosmetic coverage. Expected result by treatment is not possible many times.

#### Note:

Presently word 'capillary haemangioma' is restricted to strawberry type only; salmon patch and port-wine stain are actually classified under vascular malformations.

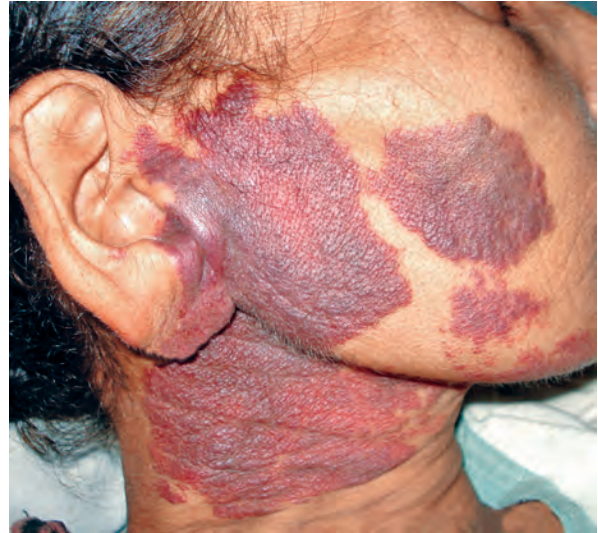

Fig. 1.379: Port-wine stain (Naevus flammeus).

### Capillary Haemangioma

- ◆ **Strawberry haemangioma:**
  - ▶ It may start at birth or child is normal at birth; between one to three weeks it appears as red mark which rapidly increases in size in 3 months to form strawberry/raspberry haemangioma. It contains immature vasoformative tissues. There will be eventually intravascular thrombosis, fibrosis and mast cell infiltration.

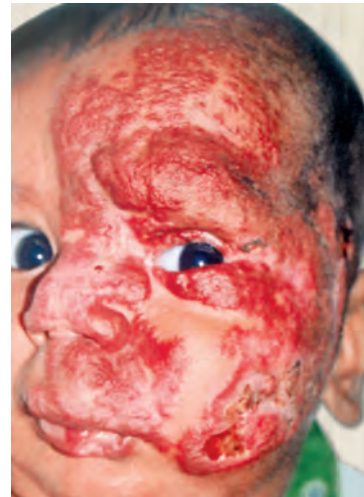

Fig. 1.380: Strawberry haemangioma.

- ▶ It is a *true capillary* haemangioma.
- ▶ It is 20 times more common than port wine stain.
- ▶ It is common in *white girls*. Male to female ratio is 1 : 3.
- ▶ It is common in head and neck region.
- ▶ It is clinically *compressible*, warm with bluish surface.
- ▶ Bleeding can occur after minor trauma and also ulceration.
- ▶ It involves skin, subcutaneous tissues and often muscles also.
- ▶ After one year of age, it slowly begins to disappear, and *completely* in 7–8 years (70% in 7 years).
- ▶ It is the most common haemangioma.

- ❖ Haemangioma in periorbital region obstructs the vision in newborn with amblyopia and if it persists for 7 days causes permanent visual damage. Astigmatism also can occur
- ❖ Haemangioma in nasal area in newborn may obstruct nasal airway seriously (as newborn cannot breathe through mouth—obligatory nasal breathing)
- ❖ Skin ulceration may cause haemorrhage
- ❖ Infection can occur which may lead into sepsis, necrosis or rarely septicaemia
- ❖ Systemic steroid for 3 weeks induces involution
- ❖ Usually there is no role for surgery. Surgery is done only for retained tissue after involution

## Treatment

- ◆ They are treated by *wait and watch policy* commonly—allowed for *spontaneous regression*.
- ◆ Pulsed dye laser (diode laser), surgical excision and reconstruction. *Feeding vessels* may need to be ligated after wide exposure before achieving complete extirpation. Sclerotherapy/cryotherapy/CO<sub>2</sub> snow therapy cause *unpleasant scarring*.
- ◆ *Preoperative embolisation* facilitates surgical excision and reduces the operative blood loss. When once embolisation done, surgery should be done *as early as possible* otherwise recurrence occurs and much more worried formation of enlarged collaterals can occur.
- ◆ Materials used are—foam, plastic spheres, stainless/platinum steel coils, ethanol, polyvinyl alcohol foam of 1000 μ meters size, and rapidly polymerizing acrylic. Problems are tissue necrosis, reaction, normal tissue embolisation. Procedure is done with interventional radiology under *image intensifier guidance*.
- ◆ *Rapidly growing* haemangioma may need systemic/oral and intralesional *steroid* therapy.
- ◆ Antiangiogenic *interferon 2a* may be useful.
- ◆ Life-threatening *platelet trapping* may be controlled by *cyclophosphamide* chemotherapy.
- ◆ Haemangioma with *drug resistant CCF* can be treated with *radiotherapy*.

### Indications for surgery or intervention

- ❖ Uncontrolled growth
- ❖ Functional impairment like vision or hearing
- ❖ Accidental haemorrhage

### Associated syndromes

- ❖ **Klippel-Trenaunay-Weber syndrome:** Naevus flammeus + osteo-hypertrophy of extremities (soft tissue and bone hypertrophy) + varicose veins of lower limbs. If there is an association of arteriovenous fistula (AV fistula), it is called as **Parkes-Weber syndrome**
- ❖ **Kasabach Merritt syndrome:** Capillary haemangioma + DIC (Disseminated intravascular coagulation) with thrombocytopenia
- ❖ **Sturge-Weber syndrome:** Haemangiomas (Naevus flammeus) + hemiplegia and Jacksonian epilepsy (calcified vascular cerebral and meningeal deposits) + glaucoma

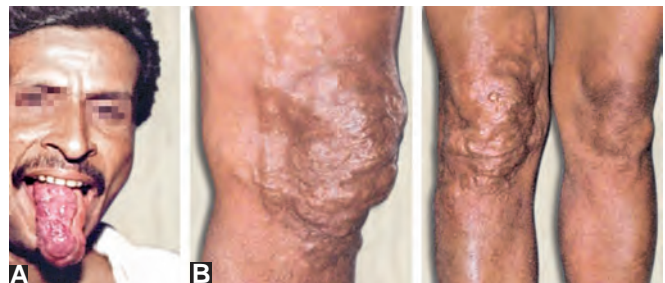Contd...

Contd...

- ❖ **Maffucci syndrome:** Cavernous haemangioma + dyschondroplasia
- ❖ **Proteus syndrome:** Naevus flammeus + regional gigantism with lymphaticovenous malformation (asymmetrical hypertrophy)
- ❖ **Osler-Rendu-Weber syndrome:** Haemangioma of skin and lip with gastrointestinal tract haemangioma (hereditary haemorrhagic telangiectasia), (autosomal dominant)

## Cavernous Haemangioma

- ◆ It is present at birth and consists of a multiple venous channels.
- ◆ Its size increases gradually and may cause problems.
- ◆ It often contains feeding vessels which is of surgical importance.
- ◆ *Sites:* Head, neck, face, limbs, tongue, liver and other internal organs.
- ◆ Large or multiple cavernous haemangiomas can cause *congestive heart failure* (hyperdynamic) due to shunting of large quantity of blood.
- ◆ Cavernous haemangioma with dyschondroplasia is called as Maffucci syndrome.
- ◆ Cavernous haemangioma is often mixed with lymphatic component also (mixed vascular and lymphatic).



Figs 1.381A and B: Cavernous haemangioma in (A) tongue and (B) knee.

## Clinical Features

- ◆ It is smooth, soft, well-localised, warm, fluctuant, compressible, nonpulsatile swelling with bluish surface occurring in skin and subcutaneous tissue (often in mucosa like oral cavity) without any transillumination.
- ◆ *Compressibility and bluish surface* is diagnostic. When swelling is pressed it reduces partially/often completely but when pressure is released it slowly attains its original size and shape. Vascular and lymphatic malformations are compressible.
- ◆ It is usually nontender unless it gets infected or undergoes thrombosis or causes haemorrhage.

## Differential Diagnosis

- ◆ Lymphangioma: It is brilliantly transilluminant unless it is infected or fibrosed.
- ◆ Lipoma, cold abscess, lymph cyst—clinically it is easier to differentiate.

When I was young, I observed that nine out of ten things I did were failures. So I did ten times more work.

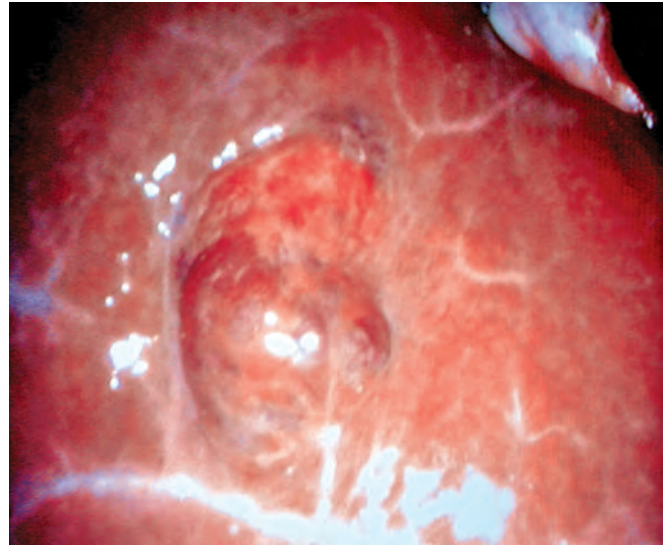
—George Bernard Shaw

## Complications

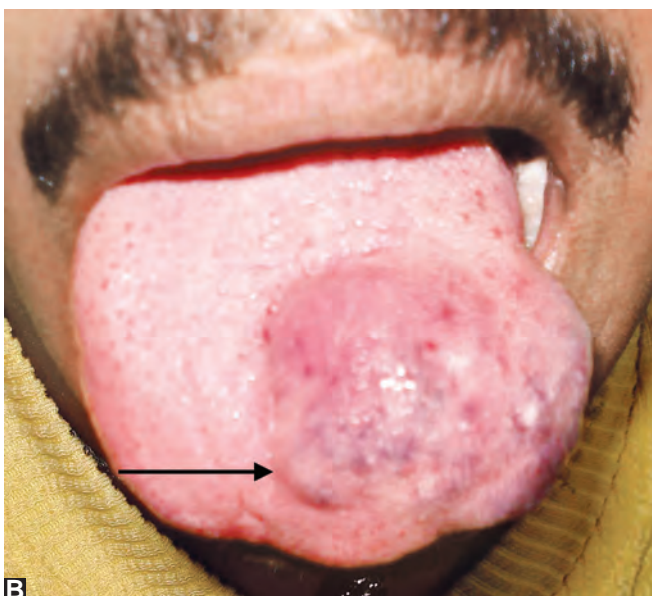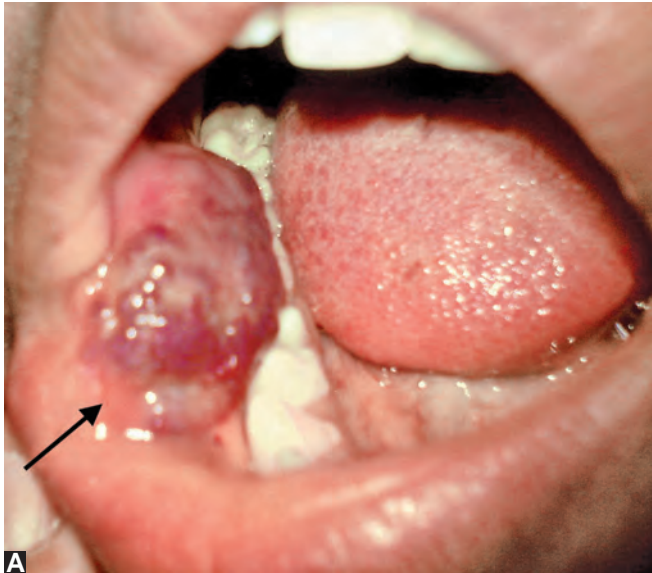- ◆ Haemorrhage.
- ◆ DIC.
- ◆ Thrombosis.
- ◆ Infection, ulceration and septicaemia.
- ◆ Erosion into the adjacent bone.
- ◆ High output cardiac failure.

## Investigations

- ◆ Ultrasound, Doppler.
- ◆ Angiogram to find out feeding vessel.
- ◆ Platelet count.
- ◆ MRI/MR angiogram to see feeding vessels and deeper extension.



**Fig. 1.383:** Laparoscopic view of cavernous haemangioma of liver. It is the most common benign tumour of the liver.



**Figs 1.382A and B:** Cavernous haemangioma in the cheek near angle of the mouth and in the tip of the tongue. Haemangioma tongue is one of the causes of macroglossia.

## Treatment

- ◆ Sclerosant therapy: It is the initial first line of therapy. It causes aseptic thrombosis and fibrosis of the cavernous haemangioma with less vascularity and smaller size. It is directly injected into the lesion. Sodium tetradecyl sulphate/hypertonic saline are used. Often multiple injections are needed to achieve complete required effect. Later excision of the lesion is done.
- ◆ Ligation of feeding artery and often at later stage excision is done once haemangioma shrinks.
- ◆ Therapeutic embolisation.
- ◆ If small and located in accessible area, excision is the initial therapy.
- ◆ Laser ablation—diode pulsed laser is becoming popular because of good control of bleeding. CO<sub>2</sub>/Nd:YAG laser is also equally effective.

## VASCULAR MALFORMATIONS

- ◆ Secondary to defect in development of vascular components, in 8th week of intrauterine period.
- ◆ Single layer endothelium lined spaces derived from arterial, capillary, venous or lymphatic system showing ectasia.
- ◆ There is no growth in tissue culture. Raise in mast cells is not seen.
- ◆ Associated with many syndromes.
- ◆ Can be located in skin or in deeper planes.
- ◆ Present at birth and grows in proportion to child's growth. Pale skin which later darkens over the age or faint blue mass is the presentation.
- ◆ Spontaneous involution is not common.
- ◆ Capillary malformation (CM) type is due to lack of sympathetic control.
- ◆ Venous malformation (VM) type is *most common* vascular malformation which shows hypoplasia, hyperplasia or aplasia of superficial or deeper system. It is seen in subcutaneous plane as faint blue compressible mass with morning pain and stiffness of the area.
- ◆ Lymphatic malformation (LM) type can be microcystic (lymphangioma) or macrocystic (cystic hygroma). It can cause lymphoedema,

soft tissue and bony hypertrophy, asymmetry (face), macrochelia, macroglossia, macrotia, cellulitis.

- ◆ *Low/slow flow* malformations can cause skeletal hypoplasia; *high/fast flow* malformations can cause hypertrophy. AVM is high flow type.
- ◆ Consumption coagulopathy (DIC) can occur.
- ◆ It is equal in both sexes (1:1).
- ◆ Doppler is commonly used investigation; but MRI (*MR angiogram is ideal*) with contrast is ideal to identify and to differentiate low and high flow types.
- ◆ *Treatment*—conservative with compression garments and sclerotherapy. Laser photocoagulation is the choice for superficial malformations; multiple sittings may be needed; complete clearance may not be achieved. Surgical excision can be done. Preoperative embolisation may be needed.

#### *Vin rose patch:*

It is a congenital intradermal pale pink vascular malformation with dilatation of vessels in subpapillary dermal plexus. It may be associated with haemangiomas; AV malformations in limbs; congenital lymphoedema.

### ■ CIRSOID ANEURYSM

- ◆ It is actually *a rare arteriovenous fistula* / malformation of the scalp usually of congenital origin but occasionally can be traumatic. 90% occur in relation to superficial temporal artery but few occur additionally also in relation to occipital arteries. It should be differentiated from the true aneurysm of the superficial temporal artery. *Cirroid means varix*.
- ◆ It is a rare variant of capillary haemangioma occurring in skin, beneath which abnormal artery communicates with the distended veins.
- ◆ Commonly seen in **superficial temporal artery** and its branches.
- ◆ Often the underlying bone gets thinned out due to pressure.
- ◆ Occasionally extends into the cranial cavity.
- ◆ Ulceration is the eventual problem which will lead to uncontrollable haemorrhage.

### Clinical Features

Pulsatile swelling in relation to superficial temporal artery, which is warm, compressible, with arterialisation of adjacent veins and with *bone thinning* (due to erosion). It feels like a '*pulsating bag of worms*'.

### Investigations

- ◆ Doppler study, CT scan.
- ◆ Angiogram, X-ray of the part.

### Treatment

- ◆ Ligation of feeding artery and excision of lesion, often requires preliminary ligation of external carotid artery.
- ◆ Intracranial extension requires formal neurosurgical approach.
- ◆ Endovascular therapy is also useful.

### ■ ARTERIOVENOUS FISTULA (AVF)

It is an abnormal communication between an artery and vein.

### Types

- ◆ Congenital—is arteriovenous malformation.
- ◆ Acquired (Trauma is common cause).

### Congenital Arteriovenous Malformation (Fistula)—AVM (AVF)

During developmental period AV communications occur.

It is high flow type of vascular malformation. It is 30% of all vascular malformation. 90% of AVM contains both arterial and venous components. Shutting of blood with thrill and bruit with hyperdynamic circulation is common.

### Sites

- ◆ Limbs, either part or whole of the limb is involved. It may be localised to toes or fingers.
- ◆ Lungs.
- ◆ Brain—in circle of Willis.
- ◆ Other organs like bowel, liver.

### Clinical Features

*Structural changes* in the limb:

- ◆ Limb is **lengthened** due to increase in blood flow since developmental period.
- ◆ Limb **girth** is also increased.
- ◆ Limb is **warm**.
- ◆ **Continuous thrill and continuous machinery murmur** all over the lesion.
- ◆ **Dilated arterialised varicose veins** are seen due to increased blood flow and also due to valvular incompetence.
- ◆ Often there is **bone erosion** or extension of AVF into the bone as such.

*Physiological changes*

Because of the hyperdynamic circulation, there is **increased cardiac output** and so often **congestive cardiac failure**.

#### Complications

- ❖ Haemorrhage
- ❖ Thrombosis
- ❖ Cardiac failure (CCF)

### Investigations

- ◆ Angiogram—MR angiogram is ideal.
- ◆ Doppler study.
- ◆ X-ray of the part.
- ◆ ECG, echocardiography.

### Treatment

- ◆ *Conservative*—sclerotherapy, compression, avoiding injury.
- ◆ **Indications for intervention**

*When stethoscope is applied aneurysm is either silent or a systolic bruit can be heard, but an arteriovenous fistula emits a continuous murmur throughout the systole and diastole.*

—Charle G Rob

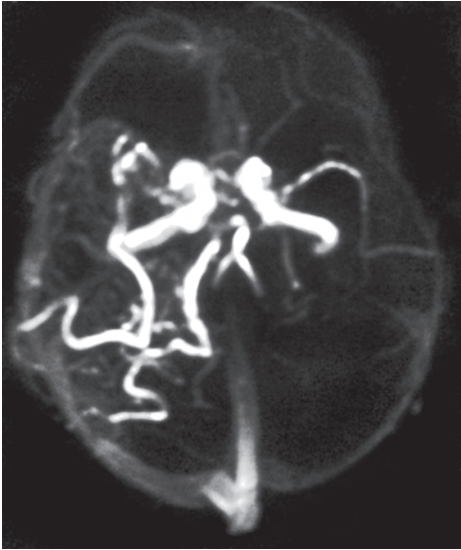

Fig. 1.384: MR angiogram of AV malformation in cranial cavity.

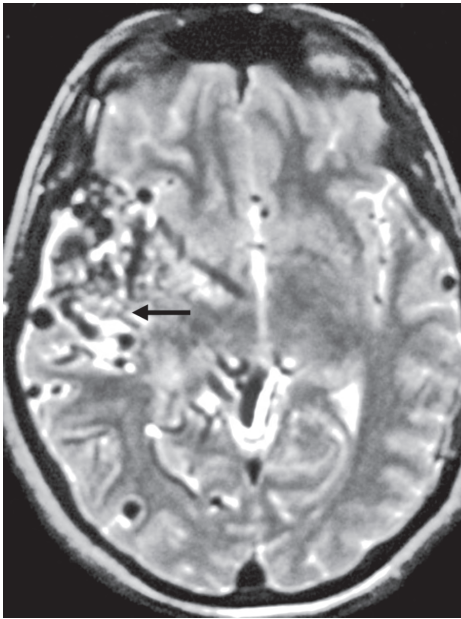
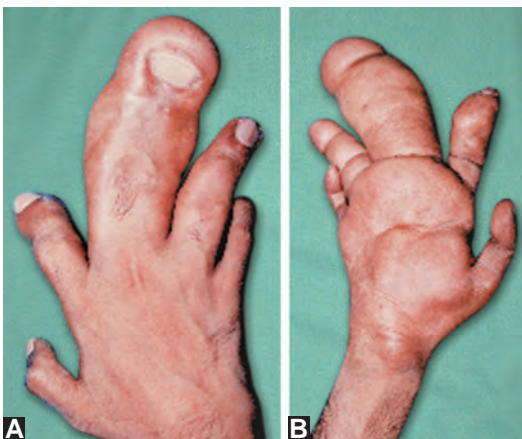
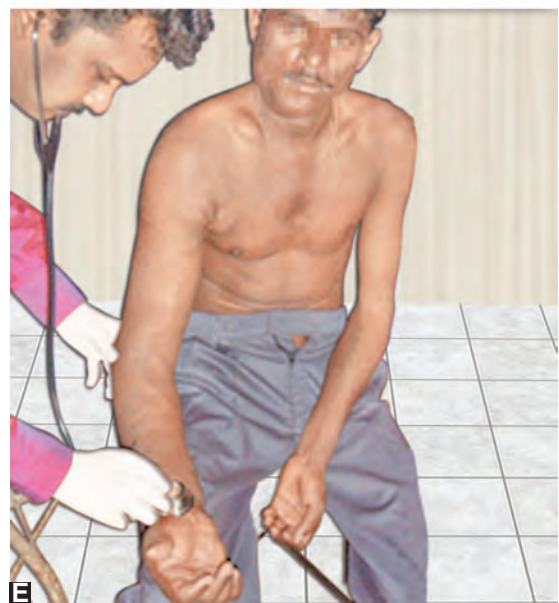
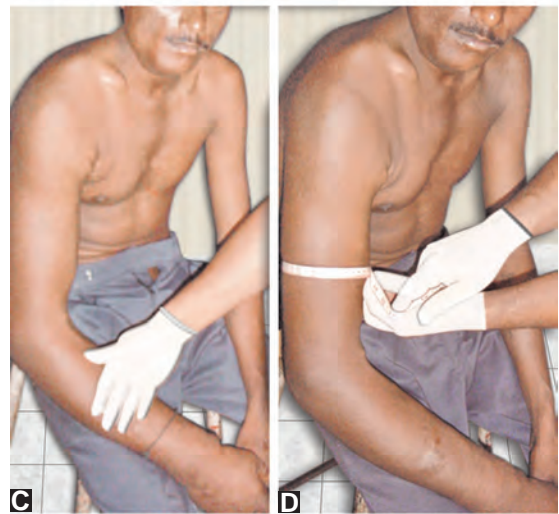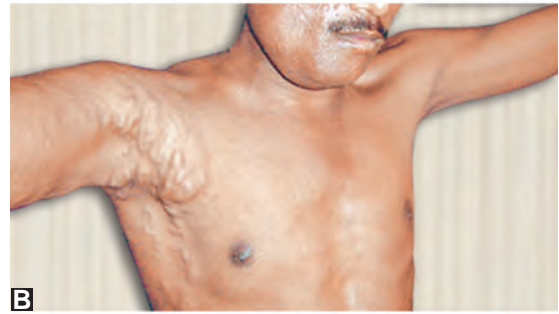Fig. 1.385: MRI picture of AV malformation.



Figs 1.386A and B: Hypertrophic changes due to AV malformation.



Figs 1.387A to E: Congenital arteriovenous malformation involving right upper limb, axillary region and part of right half of neck and face. Note the limb lengthening and widened girth. Limb is warmer. Limb should be measured at each level. Auscultation reveals continuous bruit over the limb. Note the dilated tortuous veins due to hyperdynamic circulation.

- ▶ *Absolute*: Haemorrhage, ischaemia, CCF.
- ▶ *Relative*: Pain, functional disability, cosmesis, limb asymmetry.
- ▶ *Emergency*: Torrential bleeding usually after trauma (example—road traffic accidents).

#### Interventions

- ▶ Surgical ligation of *feeding vessels* and complete excision of the lesion. Often if lesion is extending into deeper planes it is technically difficult; but with *usage of tourniquet*, careful meticulous dissection and ligation of all vessels will lead into successful excision of entire lesion.
- ▶ Therapeutic *embolisation*/preoperative embolisation hasten the proper surgical excision.
- ▶ In *emergency bleeding*, adequate transfusion of blood, tourniquet usage, intraoperative embolisation and then excision of entire lesion is done. Occasionally when extensive AVM is present often involving the entire limb, amputation is the final option left as a life-saving procedure.

### Acquired Arteriovenous Fistula (AVF)

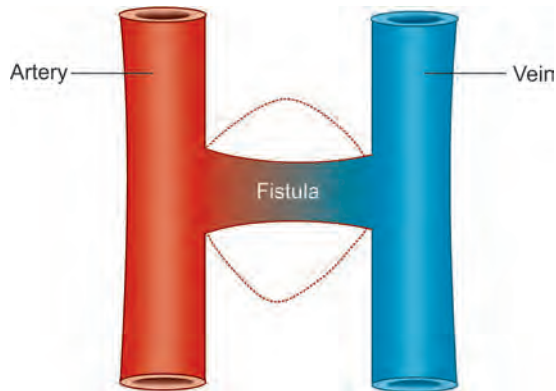


Fig. 1.388: AV fistula.

#### Causes

- ◆ Trauma in (most common cause):
  - ▶ Femoral region.
  - ▶ Popliteal region.
  - ▶ Brachial region.
  - ▶ Wrist.
  - ▶ Aorta—vena caval.
  - ▶ Abdomen.

It may be following road traffic accidents, penetrating wounds, cock-fight injury (common in South India).

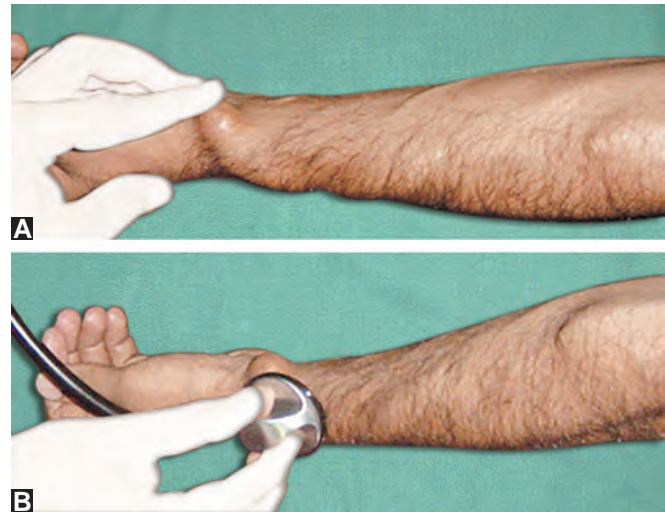
- ◆ After surgical intervention of major vessels.
- ◆ Therapeutic: For renal dialysis, AVF is created (**Cimino fistula**) to achieve arterialisatation of veins and also to have hyperdynamic circulation. It is done to have easy and adequate venous access for long time **haemodialysis**. Common sites are **wrist, brachial, and femoral** region.

#### Pathophysiology

- ◆ *Physiological changes*: Cardiac failure due to hyperdynamic circulation.
- ◆ *Structural changes*:

#### Changes at the Level of Fistula

Blood flows from high pressure artery to low pressure vein causing diversion of most of the blood. Between the artery and vein, at the site of fistula, dilatation develops with formation of fibrous sac called as **aneurysmal sac**. This presents as warm, pulsatile, smooth, soft, compressible swelling at the site with **continuous thrill and continuous machinery murmur**.



Figs 1.389A and B: Acquired arteriovenous fistula in the wrist over radial vessels. It should be palpated for compressibility and thrill. It should be auscultated for bruit.

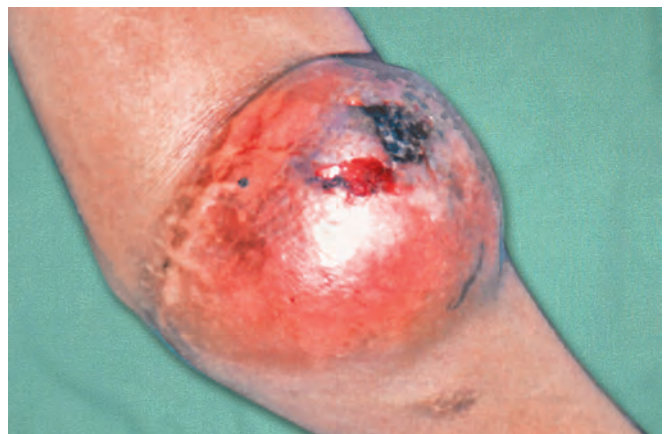

Fig. 1.390: AV fistula created for treating chronic renal failure has formed an aneurysm. It may rupture to cause severe haemorrhage. Thrombosis or sepsis also can occur in this.

### Changes Below the Level of the Fistula

Because of diversion of arterial blood **distal part becomes ischaemic**. Because of high pressure arterialisation of veins and valvular incompetence occurs causing **varicose veins**.

### Changes Proximal to the Fistula

- ◆ **Hyperdynamic circulation** causes cardiac failure. Cardiac failure may be very severe in traumatic AVF (often resistant to drug therapy).
- ◆ If pressure is applied to the artery proximal to the fistula, swelling will reduce in size, thrill and bruit will disappear, pulse rate and pulse pressure becomes normal. This is called as **Nicoladoni's sign** or **Branham's sign**.

### Investigations

- ◆ Doppler, angiogram.
- ◆ ECG, echocardiography.

### Treatment

- ◆ **Excision** of fistula and **reconstruction** of artery and vein with graft.  
Done in early stages—larger vessels. Venous or Dacron graft is used.

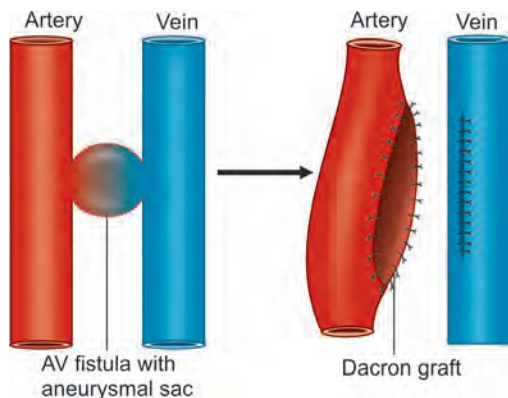
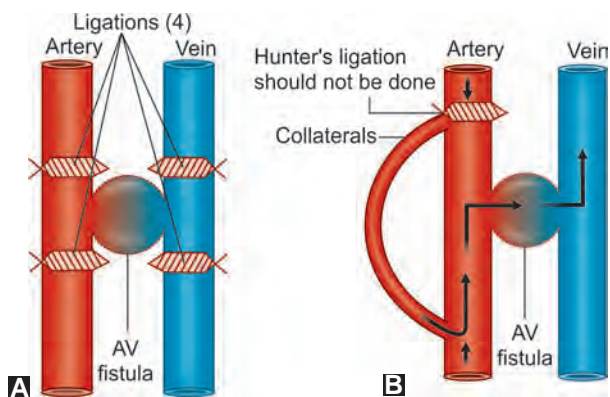


Fig. 1.391: Reconstruction of AV fistula using graft.



Figs 1.392A and B: (A) Quadruple ligation of AV fistula. (B) Hunter's ligation is ligation of artery proximal to AV fistula. It should not be done as it causes diversion of all blood from periphery leading to gangrene of distal part.

- ◆ In emergency situation, **quadruple ligation**, i.e. both artery and vein above and below are ligated without touching the fistula and sac. Patient recovers well from cardiac failure.
- ◆ Therapeutic embolisation may be tried.

**Hunter's ligation should be avoided.** It is used as life-saving measure because it invariably causes limb ischaemia and gangrene even though patient recovers from cardiac failure. It is *ligation of artery* proximally so as to make cardiac function normal. But it invariably steals the blood from the limb leading to gangrene.

### CAMPBELL DE MORGAN SPOTS

- ◆ It is usually smaller (0.2 to 6 mm) in size, circular, elevated and bright red swelling.
- ◆ It is common in trunk. Common in elderly.
- ◆ Also called as *cherry angiomas*.
- ◆ Usually it does not require treatment.
- ◆ When needed, excision or electrodesiccation or laser removal is done.

### PARRY-ROMBERG DISEASE

- ◆ It is hemifacial atrophy of skin, soft tissue and bone.
- ◆ Common in females.
- ◆ It usually begins at twenties.
- ◆ Atrophy of skin, fat, muscle, cartilage and bone causing *coupe de sabre* deformity.
- ◆ It is a self-limiting disease.
- ◆ Aesthetic reconstruction is offered when severe deformity develops.

### HAMARTOMATA

Hamartano means '*I miss*' (Greek). Or 'fault' or 'misfire' or 'error'—(missing the mark in spear throwing).

#### Note:

Presently this terminology is not very much in use.

- ◆ It is a benign lesion with aberrant differentiation producing a mass of disorganised but mature specialised cells or tissue indigenous to the particular site.
- ◆ It is tumour like overgrowth of tissue or tissues proper to that part.
- ◆ It may be single lesion or multiple lesions.
- ◆ Haemangiomas, lymphangiomas, AV malformations, neural malformations are the examples.

#### Problems with hamartomas

- ◆ Pressure symptoms locally
- ◆ Bleeding
- ◆ Infection
- ◆ Gigantism
- ◆ Cosmetic problem

### Treatment

- ◆ Depends on site, type, extent.
- ◆ Cryotherapy, ligation of feeding vessels, sclerotherapy, excision or laser therapy.

# N. Venous Diseases

## CHAPTER OUTLINE

- ❖ Anatomy of Veins of Lower Limb
- ❖ Physiology of Venous Blood Flow in Lower Limb
- ❖ Deep Vein Thrombosis
- ❖ Varicose Veins
- ❖ Venous Ulcer
- ❖ Compression Therapy for Varicose Veins
- ❖ Thrombophlebitis
- ❖ Klippel-Trenaunay Syndrome
- ❖ Anticoagulants
- ❖ Heparin
- ❖ Oral Anticoagulants
- ❖ Direct Thrombin Inhibitors
- ❖ Antiplatelet Drugs
- ❖ Pulmonary Embolism

### ANATOMY OF VEINS OF LOWER LIMB

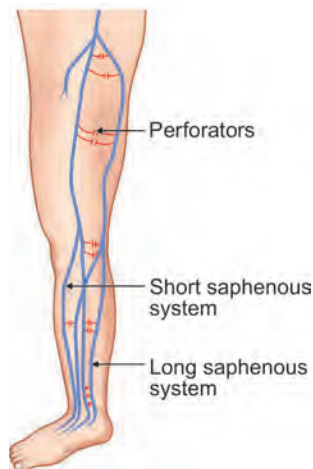


Fig. 1.393: Anatomy of lower limb veins.

### Deep Veins

- ◆ Tibial, popliteal, femoral veins are called as “veins of conduits” which drain blood into iliac veins and then to IVC.
- ◆ *Pumping veins*: They are venous sinuses existing in the calf muscles which pump blood towards major veins. They are better termed as *musculo-venous pumps*. They are also called as *peripheral heart*.

### Superficial Veins

- ◆ *Long (Great) saphenous vein (LSV/GSV)*: It begins from the medial part of the dorsal venous arch of the foot runs in front of the medial malleolus ascends up to the posteromedial aspect of the knee joint, and then ascends upwards in the thigh towards the saphenous opening. Saphenous opening lies 3.75 cm below and lateral to the pubic tubercle. It pierces the cribriform fascia to enter the femoral vein. LSV contains 12–20 valves. It is the longest vein in the body. In the lower part of the leg LSV is closely associated with saphenous nerve which can get damaged during surgeries to LSV varicosity. Tributaries of GSV are— posterior arch vein, anterior vein of the leg, anterolateral vein, posteromedial vein and sometimes accessory saphenous vein.
- ◆ *Short (Small) saphenous vein (SSV)*: Lateral marginal vein of the foot behind the lateral malleolus continues as SSV ascending upwards along the lateral margin of the tendoachilles. It runs along

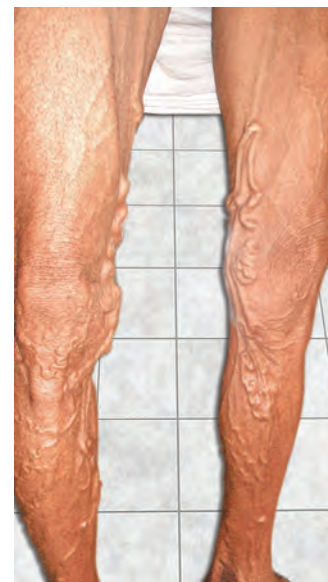

Fig. 1.394: Bilateral varicosity of great saphenous veins.

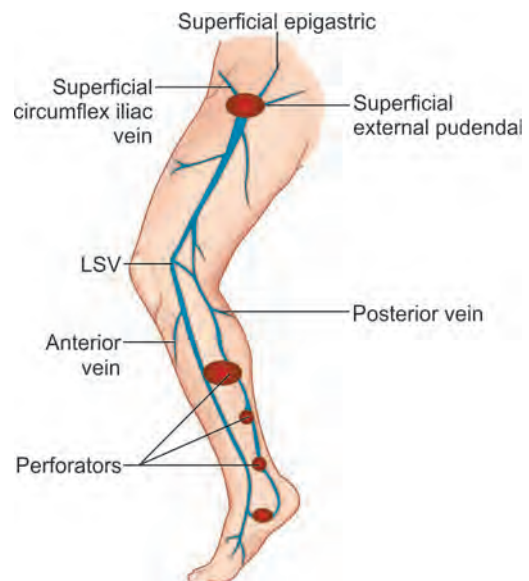
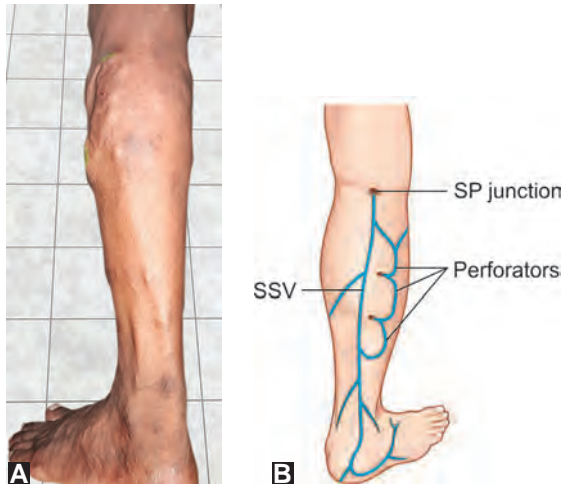


Fig. 1.395: Long saphenous vein, anatomy and its tributaries.





**Figs 1.396A and B:** Short saphenous vein varicosity.

the middle of the back of the leg between two heads of the gastrocnemius into the lower part of the popliteal fossa and ends into the popliteal vein. It has got 6–12 valves. Sural nerve runs closely along the SSV which may get injured during surgery. Saphenopopliteal junction is variable, but usually located at popliteal fossa; it can be above or below the actual site.

- ◆ Posterior arch vein of Leonardo from medial ankle to the LSV below.
- ◆ Anterior arch veins to popliteal veins.

**Note:**

Superficial veins have got multiple valves; blood always drains from superficial veins towards deep veins. Inferior vena cava (IVC) and iliac veins do not have valves. Superficial veins of lower limb drains skin and subcutaneous tissues (10% of blood). Veins can accommodate large quantity of blood hence called as capacitance vessels.

### Perforator Veins

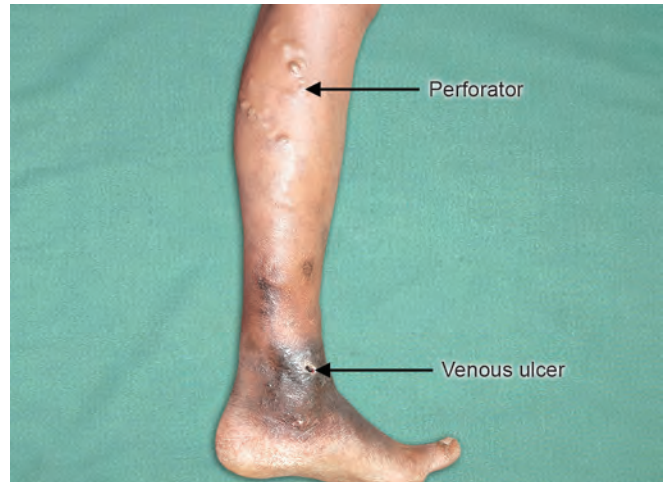They are the veins which connect superficial to deep veins at various levels. They travel from superficial fascia through an opening in the deep fascia before entering the deep veins. The direction of blood flow here is from superficial to deep veins. These perforators are also guarded by valves so that the blood flow is unidirectional, i.e. towards deep veins. Reversal of flow occurs due to incompetence of perforators which will lead to *varicose veins*.

#### Types

- ❖ Ankle perforators (May or Kuster)
- ❖ Lower leg perforators: I, II, III (of Cockett)
- ❖ Gastrocnemius perforators (of Boyd)—below knee
- ❖ Mid-thigh perforators (Dodd)
- ❖ Hunter's perforator in the thigh

### PHYSIOLOGY OF VENOUS BLOOD FLOW IN LOWER LIMB

- ◆ Veins are thin-walled vessels with collapsible walls, that assume an elliptical configuration in collapsed state and circular configuration in the filled state.



**Fig. 1.397:** Long saphenous vein with perforator incompetence with venous ulcer.

- ◆ Venous valves are abundant in the distal lower extremity and the number of valves decreases proximally, with no valves in superior and inferior vena cava.

### Venous Return

- ◆ Arterial pressure across the capillary increases the pumping action of vein.
- ◆ *Calf musculovenous pump:* During contraction phase of walking, pressure in the calf muscles increases to 200–300 mmHg. This pumps the blood towards the heart. During relaxation phase of walking, pressure in the calf falls and so it allows blood to flow from superficial to deep veins through perforators. Normally while walking, pressure in the superficial system at the level of ankle is 20 mmHg.
- ◆ During walking, foot pump mechanism propels blood from plantar veins into the leg.
- ◆ Gravity.

**Note:**

Pressure in *arteriolar end of the capillary* is 32 mmHg; *venular end of capillary* is 12 mmHg.

#### Factors responsible for venous return

- ❖ Negative pressure in thorax
- ❖ Peripheral pump—calf muscles
- ❖ Vis-a-tergo of adjoining muscles
- ❖ Nonrefluxing valves in course of veins

### DEEP VEIN THROMBOSIS

Deep vein thrombosis (DVT) is called as *phlebothrombosis*. It is *semisolid clot* in the vein which has got high tendency to develop pulmonary embolism and sudden death. Common site of beginning of thrombus is soleal veins which later propagate proximally, often getting detached to cause acute massive pulmonary embolism or moderate sized emboli can cause pyramidal/wedge shaped pulmonary infarcts.

## Aetiology: Factors

### Virchow's triad

- ❖ Stasis
- ❖ Hypercoagulability
- ❖ Vein wall injury

## Causes

- ◆ Following childbirth.
- ◆ Trauma—to leg, ankle, thigh, pelvis.
- ◆ Muscular violence.
- ◆ Immobility: Bed ridden patients, individuals on long duration air or bus travel (*Traveller's thrombosis*).
- ◆ Debilitating illness, obesity, immobility, bed rest, pregnancy, puerperium, oral contraceptives, estrogens.
- ◆ Postoperative thrombosis (*Most common cause*): Common after the age of 40 years. Incidence following surgeries is 30%. In 30% of cases both legs are affected. Usually seen after prostate surgery, hip surgery, major abdominal surgeries, gynaecological surgeries, cancer surgeries. Bedridden for more than 3 days in the postoperative period increases the risk of DVT.
- ◆ *Spontaneous thrombosis* is common in visceral neoplasm like carcinoma pancreas or carcinoma stomach. It is often migrating type.
- ◆ Thrombus may start in a venous tributary which eventually may extend into the main vein causing DVT.
- ◆ *Axillary vein thrombosis*
  - ▶ It can occur spontaneously, following compression by cervical rib, by various causes of thoracic inlet syndrome, or arm being in the hyperabduction state for prolonged period (e.g. painting the ceiling), after axillary lymph node block dissection, after radiotherapy to axilla, occasionally as a complication of venous cannulation.
  - ▶ Upper limb DVT is rare compared to lower limb DVT (5% of all DVT). It may be axillary or subclavian vein or both.
  - ▶ But 30% of upper limb DVT can cause pulmonary embolism.
  - ▶ Primary upper limb DVT is *Paget-Schroetter syndrome*, is due to subclavian vein compression that occurs in thoracic outlet syndrome. It may be precipitated by exertion of arms, swimming, exercise, etc.
  - ▶ Idiopathic upper limb DVT is rare. Occult underlying malignancy should be thought of.
  - ▶ Secondary upper limb DVT is due to CVP line, pacemaker thrombocytosis, malignancy, surgeries, radiotherapy, etc.
  - ▶ Unilateral arm, forearm swelling with bluish discoloration, pain, pitting oedema, often with skin blebs are the features.
  - ▶ Investigations are—Duplex scan, MR venography (as clavicle obscures proper duplex evaluation), BT, CT, PT, APTT, platelet count estimation.
  - ▶ *Treatment* is similar, with heparin/LMWH/warfarin, thrombolysis using tissue plasminogen activator, elevation of the arm, using compression stockings.
- ◆ Polycythaemia vera, thrombocytosis.
- ◆ Deficiencies of antithrombin III, protein C, protein S, factor V of Leiden, thrombophilia.

- ◆ Recent myocardial infarction, heart failure, nephrotic syndrome.
- ◆ Thrombosis can occur in individuals who sit with computers for long time—'*ethrombosis*'.

### Sites

- a. *Pelvic veins*—not uncommon; involves internal iliac veins. It is more common in PID (pelvic inflammatory disease) in females. In males prostatic veins may be the site of origin. It is difficult to identify clinically even though rectal or vaginal examination may help.
- b. *Leg veins*—very common in veins of soleus muscle in calf; femoral vein/iliofemoral vein thrombosis can occur along with calf veins or independently without calf vein thrombosis which shows adductor canal tenderness. Ilio-femoral vein thrombosis is common on left side due to its lengthy course/compression by right iliac artery/often due to presence of web at its entry into IVC. Incidence of bilateral leg DVT is 30% which should be differentiated from bilateral pedal oedema due to other causes like hypoproteinaemia, renal failure and cardiac causes.
- c. *Upper limb veins*—not uncommon (Axillary vein thrombosis).

## Phlegmasia Alba Dolens

It is DVT of *femoral vein* (deep femoral vein commonly) causing painful congestion and oedema of leg, with lymphangitis, which further increases the oedema and worsens the situation (*white leg*).

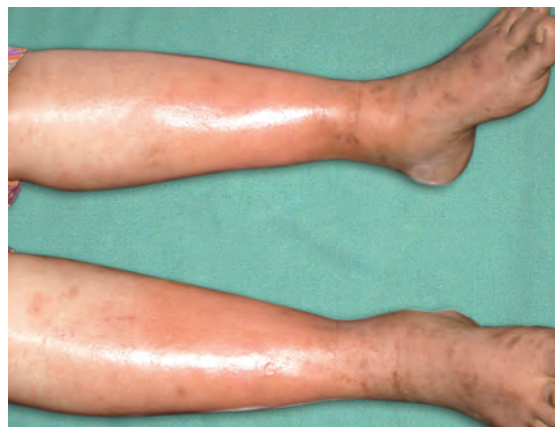

Fig. 1.398: Deep vein thrombosis (DVT) in both legs. 30% cases of DVT are bilateral.

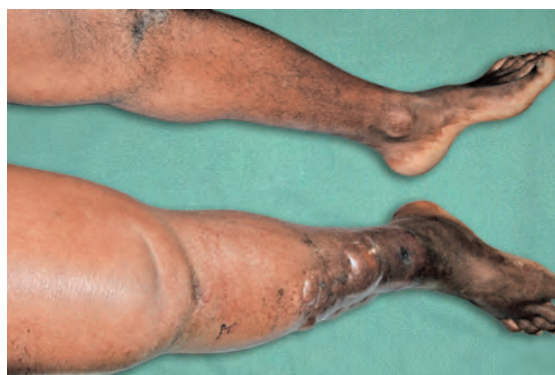

Fig. 1.399: Right leg venous gangrene. Note the discoloration, blebs and oedema.

### Phlegmasia Caerulea Dolens

It is extensive DVT of *iliac and pelvic veins* causing *blue leg* with either venous gangrene or areas of infarction.

#### Features of DVT

- ❖ Commonly it is asymptomatic—60%
- ❖ Fever—most common
- ❖ Tense, tender, warm, pale/bluish, shiny swelling calf
- ❖ Positive Homan's, Mose's or Neuhof's signs
- ❖ Inverted champagne bottle sign
- ❖ Features of pulmonary embolism

### Clinical Features

- ◆ Fever—earliest symptom.
- ◆ Pain and swelling in the calf and thigh (often). Pain is often so severe that the patient finds it difficult to flex (or move) the leg.
- ◆ Leg is tense, tender, warm, pale or bluish with stretched and shiny skin.
- ◆ *Positive Homan's sign*: Passive forceful dorsiflexion of the foot with extended knee will cause tenderness in the calf.
- ◆ *Mose's sign*: Gentle squeezing of lower part of the calf from side-to-side is painful. Gentleness is very important otherwise it may dislodge a thrombus to form an embolus.
- ◆ *Neuhof's sign*: Thickening and deep tenderness elicited while palpating deep in calf muscles.
- ◆ Most often, DVT is *asymptomatic* and presents suddenly with features of *pulmonary embolism* like *chest pain, breathlessness* and *haemoptysis*.
- ◆ After applying tourniquet at saphenofemoral junction, patient is made to walk and without removing the tourniquet, limb is elevated—persisting prominent superficial veins will be observed in DVT—*Linton's test*.

#### Differential diagnosis for DVT

- ❖ Ruptured Baker's cyst
- ❖ Ruptured plantaris tendon
- ❖ Calf muscle haematoma
- ❖ Cellulitis leg
- ❖ Superficial thrombophlebitis

### Investigations

- ◆ *Venous Doppler*.
- ◆ *Duplex scanning*  
It shows noncompressible vein which is wider than normal. On compression over calf muscles, it does not show any augmentation of flow. Normal venous sound at the area of femoral vein which disappears during inspiration is conspicuously absent in DVT.
- ◆ *Venogram*
  - ▶ Contrast material is injected into venous system to get detailed idea of the veins after applying tourniquet into superficial

system. Occlusive and nonocclusive thrombus can be differentiated by this. But as it is invasive one, it is not commonly done at present. MR venogram is under trial at present. Impedance plethysmography is used to measure the rate of venous emptying. Vein occlusion is done using cuff around upper thigh which is confirmed by flat electrical wave pattern. When cuff is released rapid flow of wave is observed in normal; sluggish flow of wave is seen in DVT.

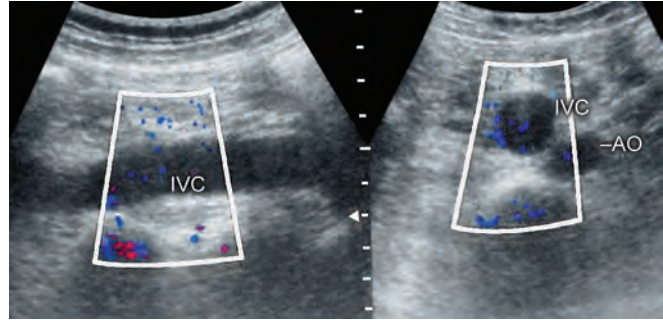


Fig. 1.400: US showing IVC thrombosis.

- ◆ *Radioactive I<sup>125</sup> fibrinogen study*
  - ▶ Sodium iodide 100 mg orally is given to the patient 24 hours before the test to block the thyroid activity. I<sup>125</sup> labelled fibrinogen 100 μ Curies is injected intravenously. First radioactivity of heart is measured by placing the scintillation counter over precordium. Reading obtained by this is adjusted as 100%. After that legs are elevated using adjustable stands and to prevent venous pooling, scintillation counter is placed over the calf. Counting in the leg is done from below upwards at 5 cm intervals. Procedure is done in preoperative period; on 1st, 3rd and 6th postoperative days. A 20% or more raise in percentage value suggests deep vein thrombosis in leg. I<sup>125</sup> labelled fibrinogen is used (earlier I<sup>131</sup> labelled fibrinogen was used) because it has got shorter radioaction; its detectability is done with much lighter and mobile apparatus.
- ◆ *Haemogram with platelet count; D-dimer test/analysis* of fibrin degradation products (FDP) are relevant tests used. D-dimer test is measurement of cross-linked degradation products which interprets the plasmin activity on fibrin. Negative D-dimer test is of more value.
- ◆ *Ventilation*—perfusion scanning with mismatched defects; pulmonary artery CT scan with filling defect; pulmonary angiography are the investigations to confirm the pulmonary embolism.

### Treatment

- ◆ *Rest, elevation of limb, bandaging* the entire limb with crepe bandage.
- ◆ *Anticoagulants*: Heparin/low molecular weight heparin, warfarin, phenindione.
- ◆ *For fixed thrombus*:
  - ▶ Initially high dose of heparin of 25,000 units/day for 7 days is given. Then later patient is advised to continue warfarin for 3–6 months. Dose is controlled by assessing *Activated Partial Thromboplastin Time (APTT)*. Duration of heparin treatment is usually for 7–10 days. *Dose of heparin* is often calculated as— 80 units/kg bolus of heparin followed by 15 units/kg of infusion.
  - ▶ Low molecular weight heparin is preferred to heparin.
  - ▶ Warfarin should be started as early as possible (*same day* of

heparin therapy). Day one and day two—10 mg each day; day three—5 mg. On day three prothrombin time should be done. Warfarin is given for 3–6 months with regular monitoring, depending on the cause, risk group, and severity of DVT. INR should be maintained between 2.0 to 3.0.

- ▶ Oral anticoagulants being teratogenic *cannot be used* during pregnancy. LMWH is the *drug of choice* used during pregnancy and postpartum period.

◆ **For free thrombus:**

**Free thrombus**

- ❖ Fibrinolytics
- ❖ Thrombectomy using Fogarty's catheter
- ❖ In filter

- ▶ **Fibrinolytics:** Streptokinase, 6 lakhs to start with and later one lakh hourly. It is commonly infused directly into the affected vein through a venous catheter. Urokinase or tissue plasminogen activator may also be used to dissolve thrombus (it should not be given when patient is on heparin).

**Fibrinolytics**

- ❖ Tissue plasminogen activator—directly into the thrombus through popliteal/femoral vein
- ❖ Urokinase—1,20,000 to 2,50,000 units/hour; derived from human urine
- ❖ Reptilase—0.5-1 unit/hour
- ❖ Streptokinase—2.5 to 6 lakh to start with later one lakh hourly; derived from streptococci

- ▶ Venous thrombectomy is done using Fogarty venous balloon catheter.
- ▶ Thrombotic emboli is prevented from reaching the heart by filtering it at IVC level using intracaval filters—Kim ray Greenfield filter, suture sieve plication, stapler plication, vena caval ligation, Mobin Uddin umbrella filter.
- ▶ Special thrombectomy device of 7–9 French sheath is passed through the thrombosed segment to have partial mechanical thrombectomy and through that thrombolytics (tissue plasminogen activator) are infused. Thrombus can be removed nowadays through balloon angioplasty tube. Open venotomy and thrombectomy also can be done.

Modified Well's criteria for predicting pulmonary embolism (PE)	Points
Clinical symptoms and signs of DVT	3
Alternative diagnosis less likely PE	3
Heart rate >100	1.5
Immobilization more than 3 days or surgery within last 4 weeks	1.5
Previous DVT or PE	1.5
Haemoptysis	1.0
Malignancy in last 6 months	1.0

Score <4 = PE unlikely; score >4 = suggestive of PE.

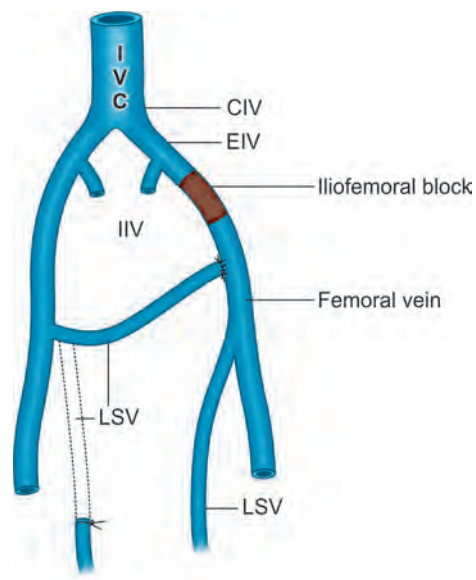


Fig. 1.401: Palma operation for iliofemoral block. Using opposite saphenous vein femoral vein is connected to other femoral vein.

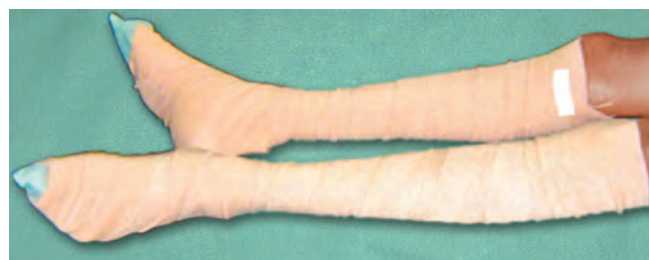

Fig. 1.402: Crepe bandages applied to both legs in bilateral varicose veins and DVT.

- ◆ **Palma operation:** In iliofemoral thrombosis, common femoral vein below the block is communicated to opposite femoral vein through opposite long saphenous vein.
- ◆ **May-Husni operation:** When blockage is in popliteal vein, popliteal vein below the block is anastomosed to long saphenous vein (end-to-end) so as to bypass the blood across the popliteal block.

**Prevention of DVT**

- ❖ Categorise the patient as low/moderate and high-risk. *Low-risk*—young patients undergoing surgery for less than 30 minutes. *Moderate-risk*—patients above 40 years of age undergoing major surgery. *High-risk*—one who had existing cardiac diseases, stroke, previous history of DVT, suffering from malignancy
- ❖ Mechanical methods—elastic compression bandage; elevation; external pneumatic bandage
- ❖ Pharmacological—low molecular weight heparin—once a day
- ◆ Care has to be taken to see for proper positioning of legs with no pressure on the calf muscles.
- ◆ Pressure bandage to the legs has to be applied during major surgeries, laparoscopic surgeries. During postoperative period,

Oral contraceptives increases the risk of DVT by 3–5 times.

elevation, massaging, pressure bandage, early ambulation, maintaining hydration are essential measures.

- ◆ Low dose heparin is given in suspected cases, in major surgeries and continued during postoperative period till the patient is ambulated. 5,000 units is given subcutaneously 2 hours before surgery. Low molecular weight heparin is preferred drug than heparin as it can be used once a day; it does not require monitoring; it does not cause thrombo-cytopenia (like heparin); and there is lesser risk of bleeding.
- ◆ Various measures like graduated static compression, elastic stockings, electrical stimulation of calf muscles, pneumatic compression are used to prevent sluggish flow of blood.
- ◆ Dextran 70, intravenously 500 ml during surgery and another 500 ml postoperatively in 24 hours can also be used to prevent DVT.
- ◆ Smoking increases the viscosity of blood and so should be stopped.
- ◆ Patients on oral contraceptives or oestrogens should stop the drug 6-8 weeks prior to any elective surgery.

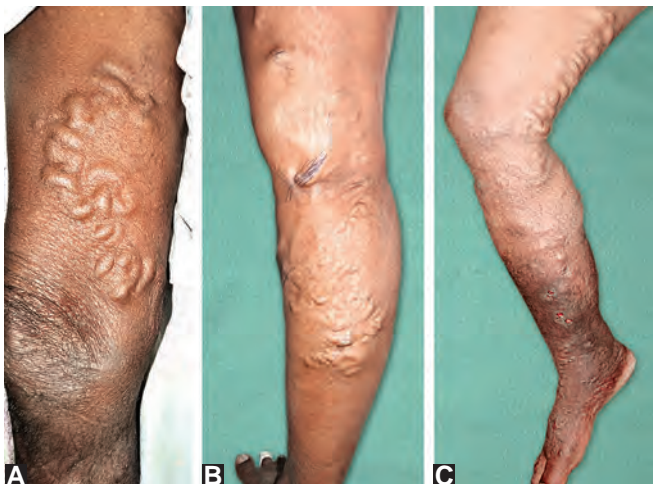#### Effects and sequelae of DVT

- ❖ Pulmonary embolism—15%
- ❖ Infection; venous gangrene
- ❖ Partial recanalisation, chronic venous hypertension around the ankle region causing venous ulcers—*chronic venous insufficiency*—CVI
- ❖ Recurrent DVT—30%
- ❖ Propagation of thrombus proximally—20–30%

## VARICOSE VEINS

They are dilated, tortuous, elongated veins in the leg. There is reversal of blood flow through its faulty valves.

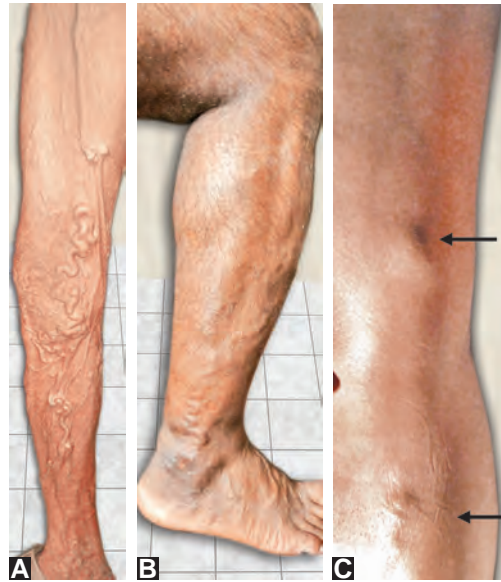- ◆ It is *permanently* elongated, dilated vein/veins with tortuous path causing *pathological* circulation.
- ◆ *Risk factors* being heredity; female sex; occupation that demands prolonged standing; immobility; raised intra-abdominal pressure like in sports, tight clothing, pregnancy, raised progesterone level and altered estrogen-progesterone ratio, chronic constipation, high heels.
- ◆ *Prevalence* of varicose veins is 35%; severe varicose veins is 10%; chronic venous insufficiency (CVI) is 8%; ulcer is 2%.



**Figs 1.403A to C:** Typical varicose vein and with skin changes and venous ulceration.

## Classification I

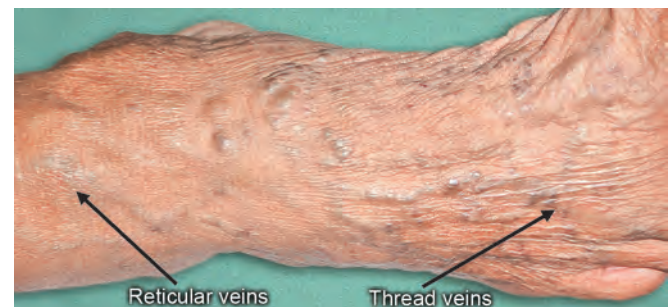- ◆ Long/great saphenous vein varicosity.
- ◆ Short/small saphenous vein varicosity.
- ◆ Varicose veins due to perforator incompetence.



**Figs 1.404A to C:** (A) Great saphenous vein varicosity. (B) Small saphenous vein varicosity. (C) Perforator incompetence (*blow outs*).

## Classification II

- ◆ *Thread veins* (or dermal flares/telangiectasis/spider veins/Hypen veins are 0.5–1 mm in size): Are small varices in the skin usually around ankle which look like dilated, red or purple network of veins (*Venulectasia*). Spider naevi/*venous flares* are common in females.
- ◆ *Reticular varices* (1–3 mm in size): Are slightly larger varices than thread veins located in subcutaneous/subdermal region.
- ◆ *Varicose veins*: They are dilated, tortuous, elongated superficial veins located in the subcutaneous tissue (saphenous compartment) equal or more than 3 mm in diameter measured in standing position.
- ◆ *Combination of any of the above*.



**Fig. 1.405:** Thread veins are up to 1 mm diameter; reticular veins are 1–3 mm in diameter.

#### Note:

- *Atrophic blanche* is localized white atrophic skin surrounded by hyperpigmentation and dilated capillaries.
- *Saphena varix* is a large groin varicosity at SFJ which disappears on lying down and imparts an impulse and thrill on coughing.

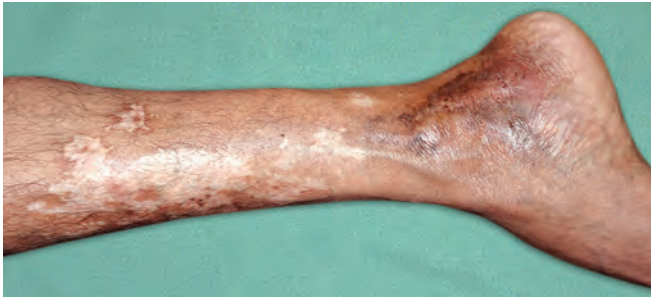


Fig. 1.406: Atrophic blanche.

- Small varicose vein is <4 mm in diameter. Large varicose vein is >4 mm in diameter.
- *Corona phlebectatica* are blue telangiectasias on the medial aspect of the foot below the malleolus around ankle level. More than 5 such lesions are the best independent predictor of the skin changes.

### Classification III

#### CEAP Classification of Lower Limb Varicose Veins (2004)

##### CEAP classification

- C**—Clinical signs (grade 0–6); (A) for asymptomatic or (S) for symptomatic presentation
- E**—Etiological classification: Congenital (Ec), Primary (Ep), Secondary (Es), No venous etiology (En)
- A**—Anatomic distribution: Superficial (As), Deep (Ad) or Perforator (Ap), No venous location identified (An)
- P**—Pathophysiologic dysfunction: Reflux (Pr), Obstructive (Po), Both, or No pathophysiology identified (Pn)

##### Grading of clinical signs (C)

- 0—No visible or palpable signs of venous diseases
- 1—Telangiectases, reticular veins or malleolar flare
- 2—Varicose veins
- 3—Oedema without skin changes
- 4—Skin changes due to venous diseases like pigmentation, eczema or lipodermatosclerosis 4a—pigmentation; 4b—lipodermatosclerosis, atrophie blanche
- 5—Skin changes as above with healed ulceration
- 6—Skin changes as above with active ulceration

##### Anatomical distribution (A)

###### As—superficial system:

- 1—Telangiectases, reticular veins
- 2—Great saphenous vein above the knee—ostial and preterminal
- 3—Great saphenous vein below the knee
- 4—Small saphenous vein
- 5—Nonsaphenous—43%

###### Ad—deep system:

From 6 to 15

###### Ap—perforator system:

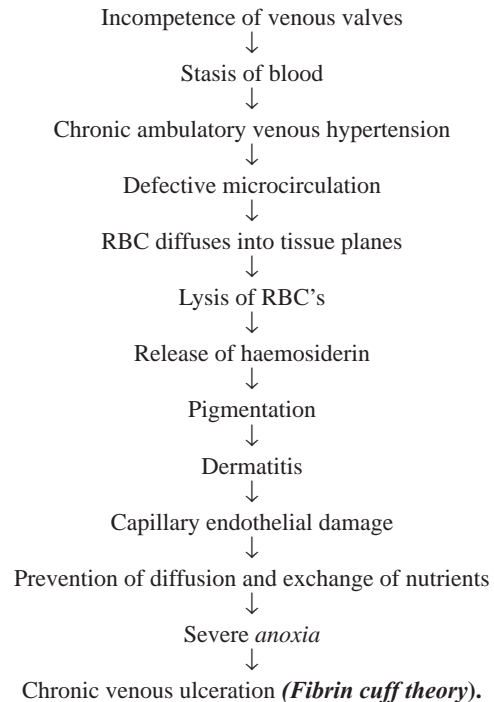
- 17—Perforator vein (PV) of the thigh
- 18—Perforator (PV) of the calf and leg

**An**—no anatomical lesion identified

### Pathogenesis

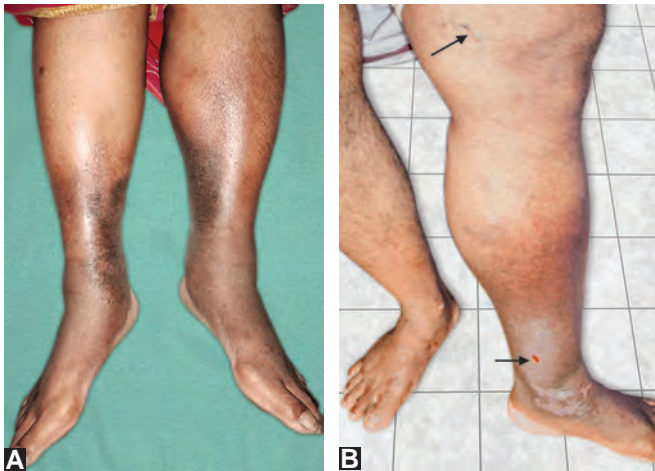#### Two theories

- ❖ Fibrin cuff theory
- ❖ White cell trapping theory



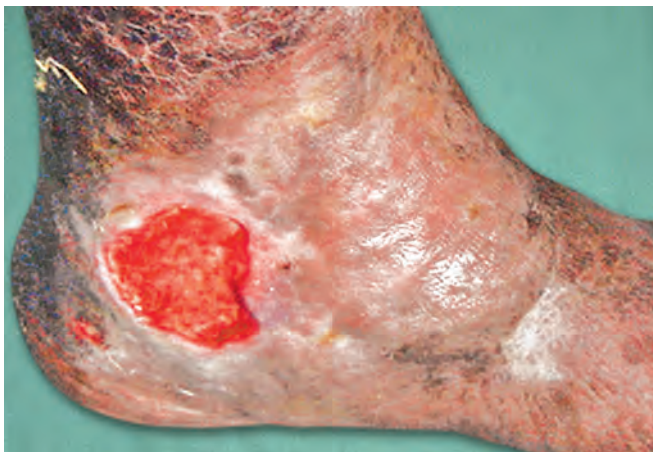- ◆ Inappropriate activation of trapped leucocytes release proteolytic enzymes which cause cell destruction and ulceration—**White cell trapping theory**. Fibrin deposition, tissue death, scarring occurs together, called as *lipodermatosclerosis*.
- ◆ *Secondary valvular failure* → venous reflux → venous wall dilatation → effects. Weakening of the venous endothelial wall and valves occur due to raised venous wall tension by—(1) Shearing stress pressures of blood flow, (2) Increased matrix metalloproteinases (MMPs) activity on endothelium and smooth muscle cells reducing structural integrity of venous wall with decreased elastin content in the media of the vein, (3) Changes in normal venous constriction and relaxation properties, (4) Recurrent inflammation.
- ◆ *Venous system* in the lower limb is maintained by—(1) *Valvular competence*, (2) *Venous patency*, (3) *Calf muscle pump* which is venous channel/plexus within the soleus muscle. Any change in any of these systems can cause venous insufficiency.
- ◆ *Chronic venous insufficiency (CVI)* is a syndrome resulting from continuous chronic venous hypertension/ambulatory venous hypertension [AVP] (>80 mmHg venous pressure at ankle) in the erect posture either on standing or exercise (in normal people venous pressure in superficial system falls during calf contraction). CVI consists of postural discomfort, varicose veins, oedema, pigmentation, induration, dermatitis, lipodermatosclerosis and ulceration. CVI patients may be having superficial vein incompetence (30%) with or without perforator incompetence or deep vein incompetence (30%) or having previous DVT with complete obliteration or partial recanalisation with incompetence called as *post-thrombotic syndrome* (30%).
- ◆ Varicose vein is a condition of *progressive deterioration* even often with interventions.

*Pulsatile varicose veins in lower limb is seen in Klippel-Trenaunay syndrome.*



**Figs 1.407A and B:** Lipodermatosclerosis is pigmentation, thickening, and induration of the skin due to venous diseases.

*Predisposing factors* for varicose veins are—age, sex, race, obesity, height, left > right, occupation, family history, erect posture.



**Fig. 1.408:** Typical site of venous ulcer. Note the pigmentation and chronicity.

#### Sites where varicosities can occur

- ❖ Lower limb
- ❖ Pampiniform plexus of veins
- ❖ Vulva, perineum
- ❖ Sites of portosystemic anastomosis

### Aetiology of Varicose Veins

Varicosities are more common in lower limb because of erect posture and long column of blood has to be supported which can lead to weakness and incompetency of valves. Incidence is 5% of adult population.

- ◆ *Primary varicosities* due to:
  - ▶ Congenital incompetence or absence of valves.
  - ▶ Weakness or wasting of muscles—defective connective tissue and smooth muscle in the venous wall.

- ▶ Stretching of deep fascia.
- ▶ Inheritance (family history) with FOXC2 gene.
- ▶ Klippel-Trenaunay syndrome, avaluia, Parkes-Weber syndrome. Here varices are of atypical distribution.
- ◆ *Secondary varicosities:*
  - ▶ Recurrent thrombophlebitis.
  - ▶ Occupational—standing for long hours (traffic police, guards, sportsman).
  - ▶ Obstruction to venous return like abdominal tumour, retroperitoneal fibrosis, lymphadenopathy, ascites.
  - ▶ Pregnancy (due to progesterone hormone), obesity, chronic constipation.
  - ▶ AV malformations—congenital or acquired.
  - ▶ Iliac vein thrombosis.
  - ▶ Tricuspid valve incompetence.

### Clinical Features

#### Symptoms in varicose veins

- ❖ Dragging pain, postural discomfort
- ❖ Heaviness in the legs
- ❖ Night time cramps—usually late night
- ❖ Oedema feet, itching (feature of CVI)
- ❖ Discolouration/ulceration in the feet/painful walk

#### Causes of pain/cramps in varicose veins/venous diseases

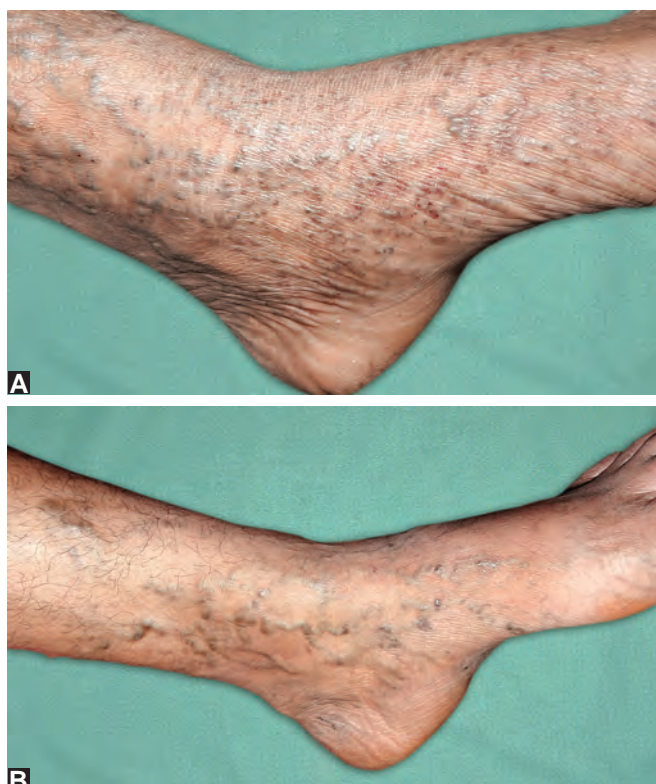
- ❖ Increased venous wall tension—chronic venous hypertension
- ❖ Hypoxia of tunica media of the venous wall due to altered function of vasa vasorum
- ❖ Increased capillary pressure
- ❖ Hyperviscosity of red cells—haemorrhological disorders
- ❖ Platelet hyperaggregation
- ❖ Reduction in capillary permeability causing *capillary functional disorder*
- ❖ Altered cutaneous microcirculation due to leucocyte adhesion and accumulation into the venous wall; release of free radicals cause *microvascular lesional disease*

#### Oedema in venous diseases

- ❖ Can be localised or generalised
- ❖ Localised oedema is due to ankle flare or dilatation of medial marginal vein
- ❖ Cellulitis and lymphangitis association causes oedema
- ❖ Scarring and thickening of dermal and subdermal tissues—*lipodermatosclerosis* (brawny induration)
- ❖ Ankle becomes narrower due to contraction of skin and subcutaneous tissues but calf remains prominent—*champagne bottle appearance*
- ❖ Pale atrophic skin with white patches surrounded by dilated capillaries and pigmentation—*atrophic blanche*

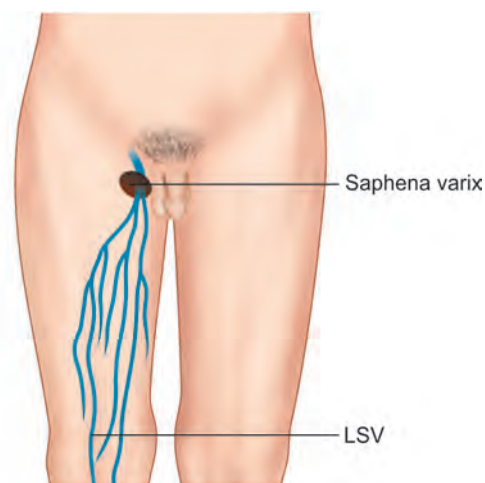
It is more common in females (10 : 1). Often it is familial. *Familial varicose veins* begin in younger age group, seen bilaterally, involves all veins including deep veins.

## Signs

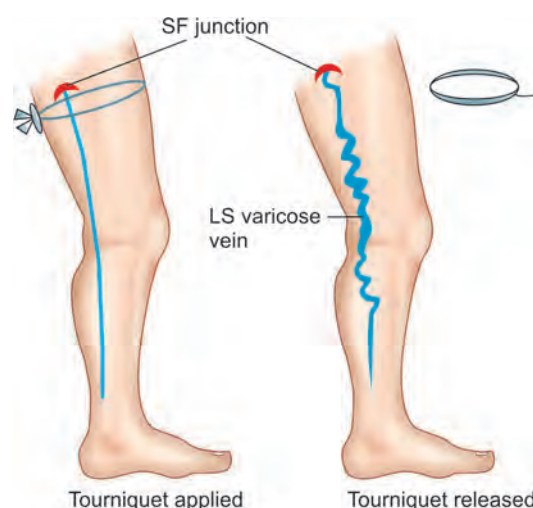


**Figs 1.409A and B:** Thread (<1 mm) and reticular veins (1–3 mm).

- ◆ Visible dilated veins in the leg with pain, distress, nocturnal cramps, feeling of heaviness, pruritus.
- ◆ Pedal oedema, pigmentation, dermatitis, ulceration, tenderness, restricted ankle joint movement.
- ◆ Bleeding, thickening of tibia occurs due to periostitis.
- ◆ Positive cough impulse at the saphenofemoral junction.
- ◆ *Saphena varix*—a large varicosity in the groin, which becomes visible and prominent on coughing.
- ◆ **Brodie-Trendelenburg test:** Vein is emptied by elevating the limb and a tourniquet is tied just below the saphenofemoral junction (or using thumb, saphenofemoral junction is occluded). Patient is asked to stand quickly. When tourniquet or thumb is released, rapid filling from above signifies saphenoemoral incompetence. *This is Trendelenburg test I.*  
In *Trendelenburg test II*, after standing tourniquet is not released. Filling of blood from below upwards rapidly can be observed within 30–60 seconds. It signifies perforator incompetence.
- ◆ **Perthe's test:** The affected lower limb is wrapped with elastic bandage and the patient is asked to walk around and exercise. Development of severe cramp like pain in the calf signifies DVT.
- ◆ **Modified Perthe's test:** Tourniquet is tied just below the saphenofemoral junction without emptying the vein. Patient



**Fig. 1.410:** Site of saphena varix—in the lower part of groin just below the inguinal ligament.



**Fig. 1.411:** Brodie-Trendelenburg test. Note the reversal of blood flow while releasing the tourniquet.

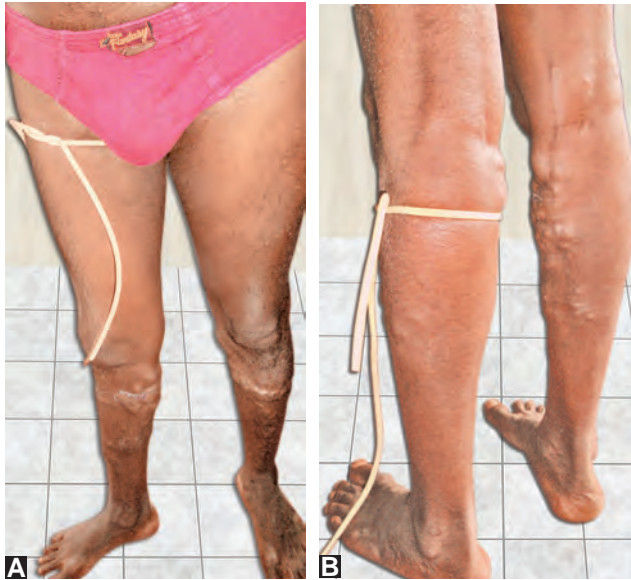is allowed to have a *brisk walk* which precipitates *bursting pain* in the calf and also makes superficial veins more prominent. It signifies DVT.

*DVT is contraindicated for any surgical intervention of superficial varicose veins. It is also contraindicated for sclerosant therapy.*

- ◆ **Three tourniquet test:** To find out the site of incompetent perforator, three tourniquets are tied after emptying the vein.
  - ▶ At saphenofemoral junction.
  - ▶ Above knee level.
  - ▶ Another below knee level.
 Patient is asked to stand and looked for filling of veins and site of filling. Then tourniquets are released from below upwards, again to see for incompetent perforators.
- ◆ **Schwartz test:** In standing position, when lower part of the long saphenous vein in leg is tapped, impulse is felt at the saphenous junction or at the upper end of the visible part

*Venous claudication is acute bursting pain on ambulation due to chronic venous insufficiency.*





**Figs 1.412A and B:** Tourniquet tests for long saphenous vein and short saphenous vein.

of the vein. It signifies continuous column of blood due to valvular incompetence.

- ◆ **Fegan's test:** On standing, the site where the perforators enter the deep fascia bulges and this is marked. Then on lying down, button like depression (crescent like) in the deep fascia is felt at the marked out points which confirms the perforator site.
- ◆ **Pratt's test:** Esmarch bandage is applied to the leg from below upwards followed by a tourniquet at saphenofemoral junction. After that the bandage is released keeping the tourniquet in the same position to see the "blow outs" as perforators.
- ◆ **Morrissey's cough impulse test:** The varicose veins are emptied. The leg is elevated and then the patient is asked to cough. If there is saphenofemoral incompetence, expansile impulse is felt at saphenous opening. It is a venous thrill due to vibration caused by turbulent backflow.
- ◆ **Ian-Aird test:** On standing, proximal segment of long saphenous vein is emptied with two fingers. Pressure from proximal finger is released to see the rapid filling from above which confirms saphenofemoral incompetence.
- ◆ Examination of the abdomen has to be done to look for pelvic tumours, lymph nodes, which may compress over the veins to cause varicosity.

#### Venous disability scoring system

Score 0	Asymptomatic
Score 1	Symptomatic but able to carry out activities without any therapy
Score 2	Symptomatic—can do activities only with compression/limb elevation
Score 3	Symptomatic—unable to do daily activities even with compression or limb elevation

- ◆ **Venous segmental disease score (venous clinical scoring system/VCSS)** is done based on different symptoms/signs/ulcer activity/compression therapy with 10 parameters with each having 3 scores as mild/moderate/severe.

#### Complications of varicose veins

- ❖ **Haemorrhage:** Venous haemorrhage can occur from the ruptured varicose veins or sloughed varicose veins, often torrential, but can be controlled very well by elevation and pressure bandage.
- ❖ **Pigmentation, eczema and dermatitis.**
- ❖ **Periostitis** causing thickening of periosteum. It delays healing of ulcer due to poor perfusion of ulcer bed.
- ❖ **Venous ulcer.**
- ❖ **Marjolin's ulcer**—due to *unstable scar of long duration*—very well-differentiated squamous cell carcinoma.
- ❖ **Lipodermatosclerosis.**
- ❖ **Ankylosis** of the ankle joint is due to fibrosis of soft tissues around ankle joint—fibrous ankylosis.
- ❖ **Talipes equinovarus**, wherein patient walks on the tip of toes like horse.
- ❖ **Deep venous thrombosis** per se due to varicose vein is rare but can occur if there is associated deep vein disease or recurrent thrombophlebitis.
- ❖ **Calcification of the wall** of varicose veins or of sclerosed soft tissue.
- ❖ **Recurrent thrombophlebitis**, clot formation on the superficial system often at perforator level which often get infected causing fever and tenderness over the spot.

#### Investigations

##### ◆ Venous Doppler:

- ▶ With the patient standing, the Doppler probe is placed at saphenofemoral junction and later wherever required. Basically by hearing the changes in sound, venous flow, venous patency, venous reflux can be very well-identified.
- ▶ **Doppler test:** When a *hand held Doppler* (continuous wave 8 MHz flow detector) is kept at SFJ, typical audible, 'whoosh signal' >0.5 sec while performing Valsalva manoeuvre is the sign of reflux at SFJ. It is also used at SPJ and at perforators.



**Fig. 1.413:** Doppler machine to assess venous system and its problems.

**Note:**

All clinical/phlebological tests mentioned above have been superseded by Doppler test. *Doppler test is considered to be a clinical method.*

♦ **Duplex scan:**

- ▶ It is a highly reliable U/S Doppler imaging technique (here high resolution B mode ultrasound imaging and Doppler ultrasound is used) which along with direct visualisation of veins, gives the functional and anatomical information, and also colour map. Examination is done in standing, lying down position and also with Valsalva manoeuvre. *Hand-held Doppler* probe is placed over the site and visualised for any block and reversal of flow. DVT is very well-identified by this method.
- ▶ *Venous haemodynamic mapping/VHM/Cartography* is essential prior to surgery.

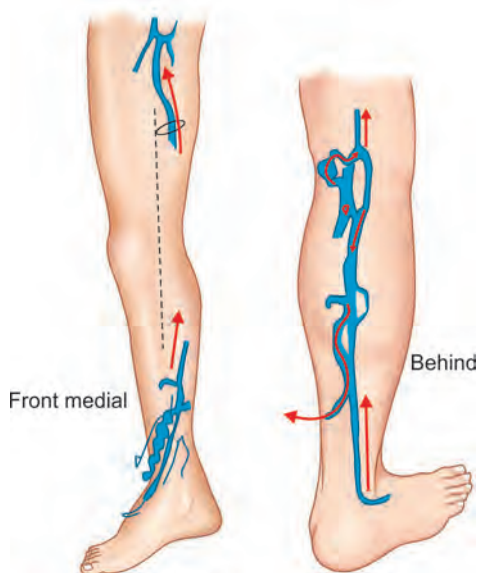
**Note:**

- Proper *venous haemodynamic mapping (VHM)* is essential.
- Saphenous eye (Egyptian eye) at SFJ should be identified in duplex US.
- *Reflux* is defined as retrograde blood flow in reverse direction lasting for more than 0.5 seconds.
- '*Micky mouse sign*' is the duplex scan transverse B mode image showing great saphenous vein (GSV) and femoral vein medially and femoral artery laterally.

#### Venous Doppler in varicose veins

- ❖ To find out DVT—very important
- ❖ To find out saphenofemoral, saphenopopliteal incompetence
- ❖ To find out perforator incompetence
- ❖ Uniphasic signals signify flow in one direction—normal
- ❖ Biphasic flow signifies reversal flow with incompetence

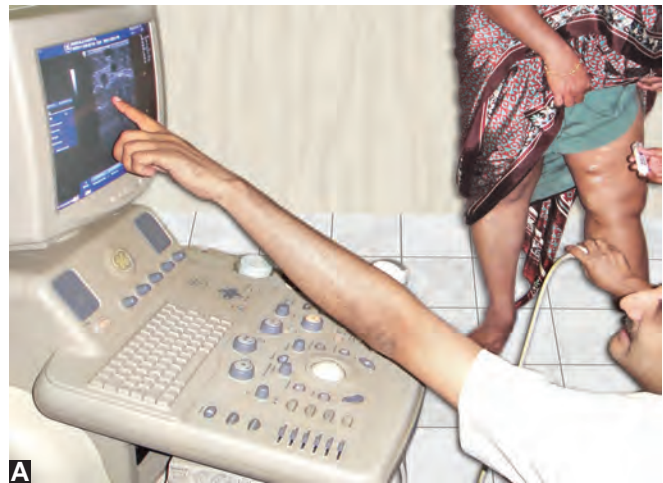- ▶ **Digitally coded free flow (B flow) USG** (Professor Feder Lurie of Hawaii) allows simultaneous visualisation of flowing blood/blood cells and surrounding stationary



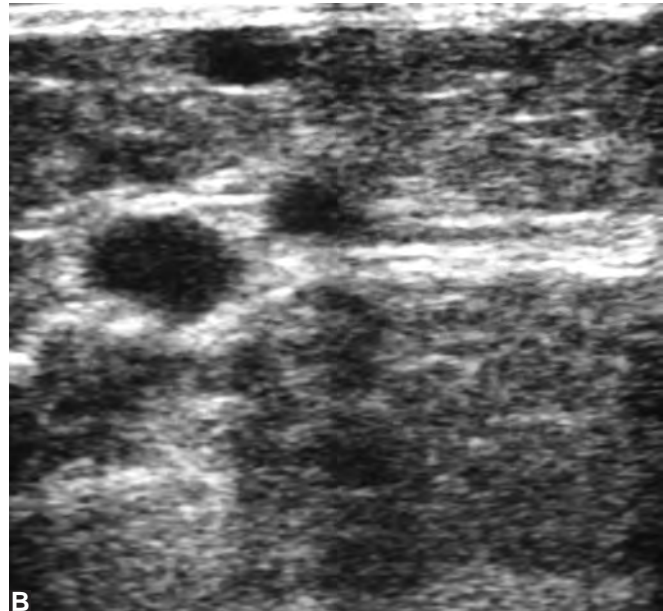
**Fig. 1.414:** Venous haemodynamic mapping (VHM) of the lower limb.

structures to give proper *haemodynamic imaging* with functioning mechanism of venous valves, valve leaflets and flow across leaflets. This may be the *ideal* tool of investigation in future.

- ❖ **Ultrasound abdomen**, peripheral smear, platelet count, other relevant investigations are done depending on the cause of the varicose veins.
- ❖ If venous ulcer is present, then the discharge is collected for culture and sensitivity, biopsy from ulcer edge is taken to rule out Marjolin's ulcer.
- ❖ Plain X-ray of the part is taken to look for periostitis.



**A**



**B**

**Figs 1.415A and B:** Duplex scan for venous diseases of lower limb should also be done in standing position.

♦ **Venography:**

- ▶ *Ascending venography* was very common investigation done before Doppler period. A tourniquet is applied above the malleoli and vein of dorsal venous arch of foot is cannulated. Water soluble dye injected,

*Everybody is in favour of progress. It is the change they don't like.*

flows into the deep veins (because of the applied tourniquet). X-rays are taken below and above knee level. Any block in deep veins, its extent, perforator status can be made out by this.

It is a good reliable investigation for DVT.

If DVT is present, surgery or sclerotherapy are contraindicated.

- ▶ *Descending venogram* is done when ascending venogram is not possible and also to visualise incompetent veins. Here contrast material is injected into the femoral vein through a cannula in standing position. X-ray pictures are taken to visualise deep veins and incompetent veins.

#### Phlebography

- ❖ Ascending phlebography defines obstruction
- ❖ Descending phlebography identifies valvular incompetence
- ❖ Regularly not required to be done

#### ◆ Plethysmography:

- ▶ It is a noninvasive method which measures volume changes in the leg. It gives *functional* information on venous volume changes and *calf muscle pump* insufficiency.
- ▶ *Photoplethysmography*: Using probe transmission of light through the skin, venous filling of the surface venules which reflects the superficial venous pressure is measured. Initially patient performs dorsiflexion at ankle for 10 times to empty the venules and pressure tracing falls in photoplethysmography. Patient takes rest and refilling occurs. In normal people, it occurs through arterial inflow in 20–30 seconds. In venous incompetence filling also occurs by venous reflux and so refilling time is faster than normal.

*Disadvantage*: Site of reflux cannot be localised by this method.

- ▶ *Air plethysmography*: Patient is initially in supine position with veins emptied by elevation of leg. Air filled plastic pressure bladder (inflatable polyurethane cuff filled with air) is placed on calf to detect volume changes. Minimum volume is recorded. Patient is turned to upright position and venous volume is assessed. Maximum venous volume divided by time required to achieve maximum venous volume gives the *venous filling index (VFI)*. VFI is a measure of reflux. *Ejection fraction* is volume change measured prior and after single tiptoe manoeuvre which is a measure of calf pump action. *Residual venous fraction* is an index of overall venous function which is venous volume in the leg after ten tiptoe manoeuvres divided by venous volume prior to manoeuvre. *Increased VFI and diminished ejection fraction in a patient will benefit from surgery.*

#### ◆ Ambulatory venous pressure (AVP):

It is an invasive method. Needle inserted into dorsal vein of foot and is connected to transducer to get its pressure which is equivalent to pressure in the deep veins of the calf. Ten tiptoe manoeuvres are done by the patient. With initial rise in pressure, pressure decreases and eventually stabilises with a balance. Pressure now is called as *ambulatory venous pressure (AVP)*. After stopping exercise, veins are allowed to refill with return of pressure to baseline. Time required for pressure to return to 90% of baseline is called as *venous refilling time (VRT)*. Raise in AVP signifies venous hypertension. Patients with AVP more than 80 mmHg has got 80% chances of venous ulcer formation.

#### ◆ Arm-foot venous pressure:

Foot pressure is not more than 4 mmHg above the arm pressure.

#### ◆ Varicography:

Here nonionic, iso-osmolar, nonthrombogenic contrast is injected directly into the variceal vein to get a detailed anatomical mapping of the varicose veins. It is used in recurrent varicose veins.

#### Differential diagnosis

- ❖ Lymphoedema
- ❖ AV malformation
- ❖ Orthostatic oedema
- ❖ Renal and cardiac disease
- ❖ Hepatic causes
- ❖ Vasculitis
- ❖ Metabolic diseases like gout, myxoedema, and morbid obesity
- ❖ Chronic infections like tuberculosis, syphilis

## Treatment

#### ◆ Conservative treatment:

- ▶ *Elastic crepe bandage application* from below upwards or use of pressure stockings to the limb—pressure gradient of 30–40 mmHg is provided.
- ▶ *Elevation of the limb*—relieves oedema. Two short times, during day and full night, elevation of foot with feet above the level of heart and toes above the level of nose is the method.
- ▶ *Unna boots*—provide nonelastic compression therapy. It comprises a gauze compression dressings that contain zinc oxide, calamine, and glycerine that helps to prevent further skin break down. It is changed once a week.
- ▶ *Pneumatic compression method*—provide dynamic sequential compression.
- ▶ These methods *reduce the AVP*, reduce transcapillary fluid leakage by increasing SC pressure and improve cutaneous microcirculation.

#### ◆ Drugs used for varicose veins:

- ▶ Calcium dobesilate—500 mg BD. Calcium dobesilate improves lymph flow; improves macrophage mediated proteolysis; and reduces oedema.
  - ▶ Diosmin—450 mg BD.
  - ▶ Diosmin 450 mg + Hesperidin 50 mg (DAFLON 500 mg). Mainly used in relieving night cramps but not to improve healing of ulcers.
  - ▶ Toxerutin 500 mg BD, TID. Antierythrocyte aggregation agent which improves capillary dynamics.
  - ▶ Diosmin is micronized purified flavanoid fraction. It protects venous wall and valve, and it is anti-inflammatory, profibrinolytic, anti-oedema, lymphotropic.
  - ▶ Benzopyrones, saponins, plant extracts, Ruscus (venular  $\alpha$  1 adrenergic receptor partial agonist) coumarins are different drugs used.
- Benefits of all these drugs are doubtful.

#### ◆ Injection—sclerotherapy:

- ▶ *Fegan's technique*: By injecting sclerosants into the vein, complete sclerosis of the venous walls can be achieved.

#### Indications

- Uncomplicated perforator incompetence.
- In the management of smaller varices—reticular veins, thread veins (telangiectasis).
- Recurrent varices.
- Isolated varicosities.
- Aged/unfit patients.

### Sclerosants used are:

- ❖ Sodium tetradecyl sulphate 3% (STDS)—commonly used
- ❖ Sodium morrhuate
- ❖ Ethanolamine oleate
- ❖ Polidocanol—3% or 1%

### Mechanisms of action

- ❖ Causes aseptic inflammation
- ❖ Causes perivenous fibrosis leading to block
- ❖ Causes approximation of intima leading to obliteration by endothelial damage
- ❖ Alters intravascular pH/osmolality
- ❖ Changes surface tension of plasma membrane

- A 23 gauge needle is inserted into the vein (3–8 mm sized) and vein is emptied. 0.5–1 ml of sclerosant is injected into the vein and immediately compression is applied on the vein (prevent the entry of blood which may cause thrombosis, which later gets recanalised, further worsening the condition) so as to allow the development of sclerosis and to have proper endothelial apposition.
- Usually injection is started at the ankle region and then proceeded upwards along the length of the veins at different points. Later pressure bandage is applied for six weeks. Often injections may have to be repeated at 2–4 weeks intervals for 2–4 sessions. Technique is called as *macrosclerotherapy*.
- Entrapped blood may require to be evacuated after 14 days which is often essential to prevent recanalisation.

#### ▶ *Foam sclerotherapy by Tessari:*

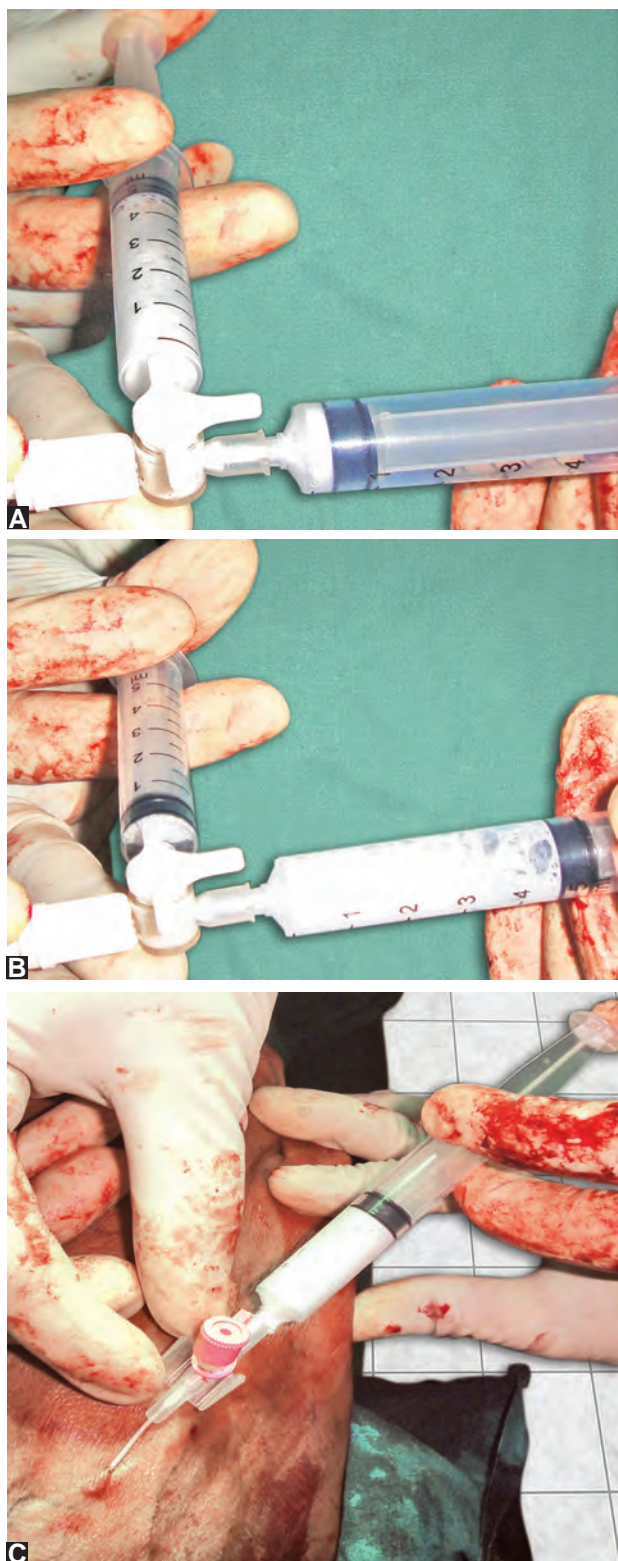
- STDS taken in a syringe is passed rapidly into another syringe which contains air to result in formation of foam. 1 ml of STD is mixed with 4 ml of air to make 5 ml of foam which is injected to vein. Total 6 ml maximum of STDS with 30 ml foam can be used. This foam in much larger quantity is injected into the superficial vein. Air get absorbed between foam and endothelial lining is destroyed. Foam minimises thrombosis by pushing the blood out of the site of the vessel where action is needed. Polidocanol/STDS is used for foam sclerotherapy.
- *Advantages:* Cheap, technically easy, easily available, OPD procedure, can be repeated many times, anaesthesia is not needed, can be used along with other procedures for varicose veins.
- *Complications:* Headache, transient blindness, stroke, air embolism, thrombophlebitis, pain over injected site, pigmentation.
- *Contraindications:* Peripheral arterial disease, DVT.

#### ▶ *Microsclerotherapy:*

Very dilute solution of sclerosing agent like STDS (0.1% of 0.1 ml—dilute) Polidocanol is injected into the thread veins and reticular veins followed by application of compression bandage (30 G needle). Dermal flare will disappear well by this method.

#### ▶ *Transillumination microsclerotherapy (vein—lite):*

It is better imaging of the veins using light generated by halogen bulb with high quality fibre illumination over the skin uniformly and passing 30 gauge needle for microsclerotherapy.



**Figs 1.416A to C:** Technique making foam and injecting into the vein. 4 ml air with 1 ml STD is mixed vigorously using 3 way stopcock and two 5 ml syringes. Created foam is injected into the vein immediately. Total of 6 ml STD (30 ml foam) can be injected.

▶ **Echosclerotherapy:**

Sclerotherapy is done under duplex ultrasound image guidance.

▶ **Catheter directed sclerotherapy:**

It is devised at Miami vein clinic with specific catheter for sclerotherapy. This catheter has got side holes all around the specific length for uniform contact of venous wall with the foam. It also has got a balloon at the tip which after inflation blocks the SFJ thus preventing embolization of foam. It has got three external ports one for balloon inflation; one for bladder valve port; one for injection. This technique is under trial.

#### Contraindications for sclerotherapy

- ❖ Saphenofemoral incompetence
- ❖ Deep venous thrombosis
- ❖ Huge varicosities—may precipitate DVT
- ❖ Peripheral arterial diseases
- ❖ Hypersensitivity/immobility
- ❖ Venous ulcer—relative contraindication

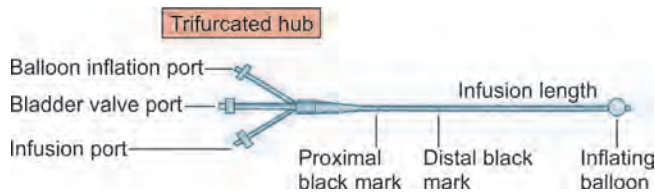


Fig. 1.417: Catheter directed sclerotherapy.

#### Advantages of sclerotherapy

- ▶ It can be done as an outpatient procedure.
- ▶ It does not require anaesthesia.

#### Disadvantages of sclerotherapy

- ▶ Inadvertent subcutaneous injection can cause skin necrosis or abscess formation.
- ▶ Anaphylaxis, vasovagal shock, allergy.
- ▶ Hyperpigmentation.
- ▶ Thrombophlebitis.
- ▶ Deep venous thrombosis can occur.
- ▶ Inadvertent intra-arterial injection—serious complication.
- ▶ Intravenous haematoma.
- ▶ Temporary ocular disturbances.
- ▶ Skin staining, injection ulcers, persistent local pain.

#### Remember about sclerotherapy

- ❖ Current place of sclerotherapy is mainly for recurrent varicosities and thread/telangiectatic veins
- ❖ Sodium tetradecyl sulphate (STDS) is most commonly used sclerosant
- ❖ Hyperpigmentation is common after STDS
- ❖ Anaphylaxis is common after sodium morrhuate
- ❖ Anaphylaxis is least with polidocanol
- ❖ Extravasation (presence of pain/irritation/burning) should be avoided as it will cause skin necrosis
- ❖ Postsclerotherapy walking immediately after injection for 30 minutes with elastic bandage in place prevents/minimises the chances of DVT
- ❖ Compression bandage should be worn for minimum period of 6 weeks
- ❖ Sclerotherapy can be—macrosclerotherapy; microsclerotherapy; echo (ultrasound guided) sclerotherapy; foam sclerotherapy; transilluminated sclerotherapy

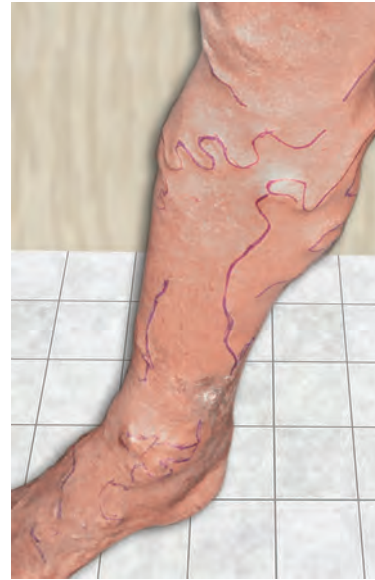


Fig. 1.418: Veins should be marked just prior to surgery using marking ink.

#### Indications for interventional procedures:

- ▶ To relieve **Complaints** which are relevant like pain, discomfort;
- ▶ to reverse **Complications** like skin changes, ulcers, bleeding, superficial thrombophlebitis, lipodermatosclerosis;
- ▶ **Cosmesis; prophylaxis.**

#### ◆ **Surgery:**

##### ▶ **Trendelenburg operation (Crossectomy)**

It is juxtafemoral flush ligation of long saphenous vein (i.e. flush with femoral vein), after ligating named (superficial circumflex, superficial external pudendal, superficial epigastric vein), deep external pudendal vein and unnamed tributaries. All tributaries should be ligated, otherwise recurrence will occur. Double saphenous vein is the most common anomaly occurring near saphenovenous junction.

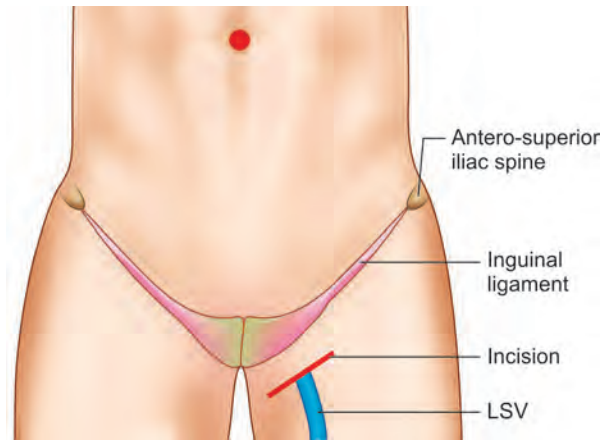
##### ▶ **Stripping of vein**

- Using *Myer's stripper* vein is stripped off. Stripping from below upwards is technically easier. Immediate application of crepe bandage reduces the chance of bleeding and haematoma formation. Stripping avulses the vein as well as obliterates the tributaries. Babcock's stripper and rigid metal pin stripper can also be used.
- **Two methods of stripping** are used: (1) *Extraluminal collision technique* using Myer's stripper (Acorn head stripper, 73 cm long) is practiced since long time; but it damages the adjacent tissue, causes infection, postoperative pain, discomfort and haematoma along the stripped tract with possibility of revascularisation of the tract haematoma. (2) *Invagination technique* is better with less damage to adjacent tissue. *Codman's stripper* is used for invagination technique.
- Stripping of the short saphenous vein is done from ankle below upwards after passing stripper from above downwards. It obliterates the mid calf perforator vein which is the common reason for recurrences.
- **Complications of stripping:** *Saphenous neuralgia* (1–7%)

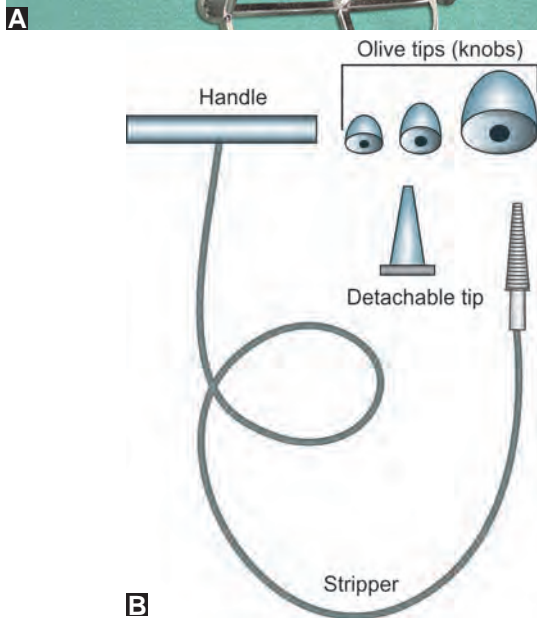
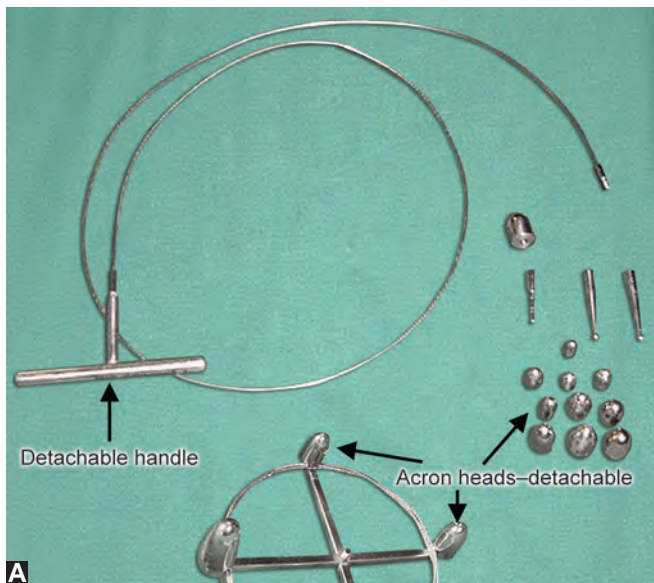
due to saphenous nerve injury/avulsion; numbness and tingling along femoral nerve distribution; haematoma; infection; ulceration; *recurrence of the disease* is common (30%) which is not due to any technical default but due to progression of disease itself by *neo-angiogenesis and re-vascularisation*.

**Note:**

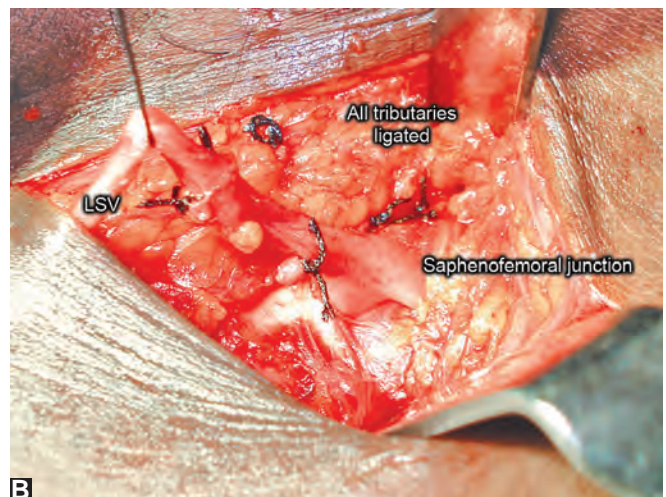
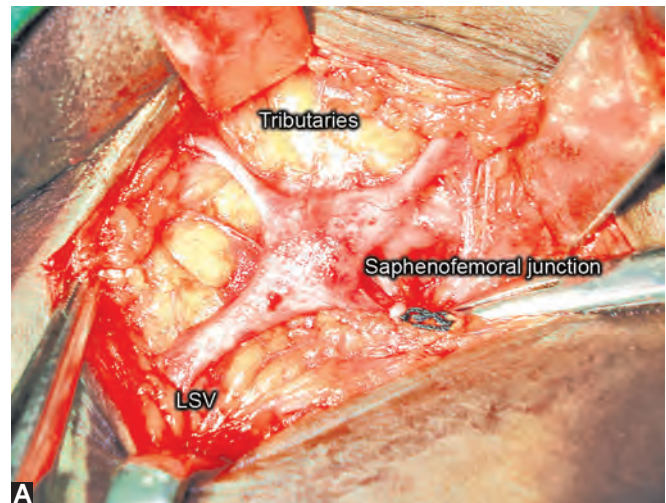
- Stripping of LSV up to knee level reduces the need for re-intervention for recurrent varicose veins; stripping up to the ankle will not benefit additionally but may increase the chance of saphenous nerve injury. So stripping is not at all done in lower part of the leg for LSV.
- Stripping of the vein is more effective than just ligation of the vein at the SFJ/SPJ.
- Stripping of SSV reduces the recurrence but may damage sural nerve.



**Fig. 1.420:** Incision for juxtafemoral flush ligation of long saphenous vein (Trendelenburg operation).



**Figs 1.419A and B:** Photo of Myer's stripper with Olive tips and also diagrammatic look of the same.



**Figs 1.421A and B**

*INR (International Normalised Ratio): Ratio of measured PT to a mean lab control PT corrected for the sensitivity of thromboplastin*

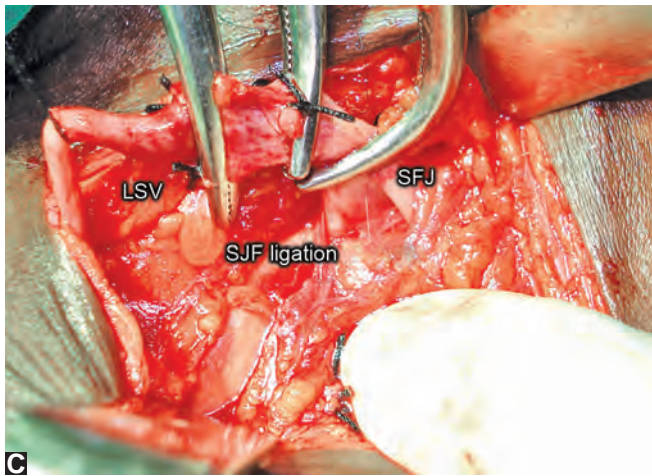


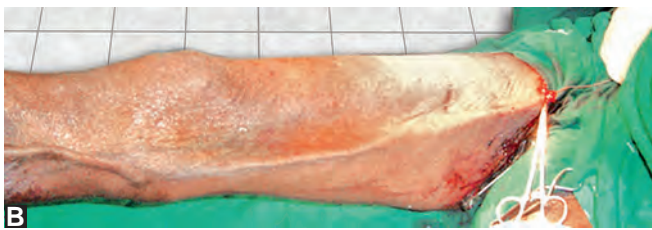
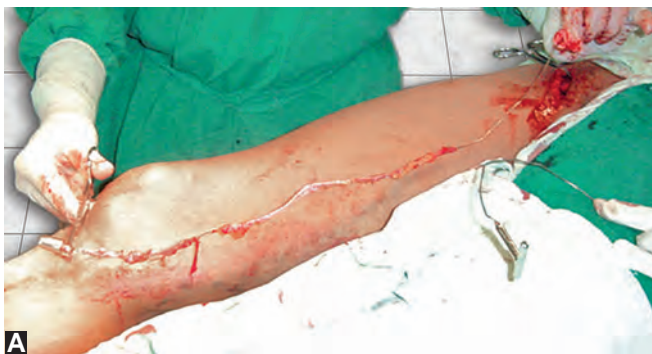Fig. 1.421C

Figs 1.421A to C: Saphenofemoral junction and its ligation. Tributaries are well seen.



Fig. 1.422D

Figs 1.422A to D: Long saphenous vein stripping. Note the stripped vein. Stripping is better than just ligation at the junction.



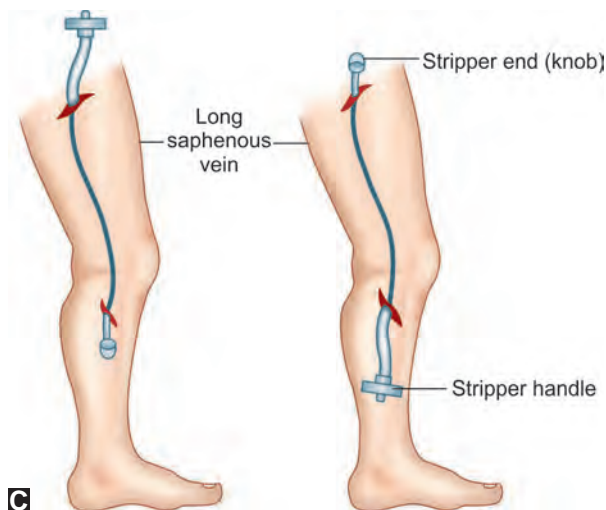
- *'Inverting or invaginating stripping'* using rigid *Oesch pin stripper* is better as postoperative pain and haematoma is less common and also tissue damage. Vein should be very firmly fixed to the end of the stripper and pulled out to cause the inverting of the vein.
- *Stripping of short saphenous vein is more beneficial than just ligation at saphenopopliteal junction.* It is done from above downwards using a rigid stripper to avoid injury to sural nerve.

► **Subfascial ligation of Cockett and Dodd (1938):**

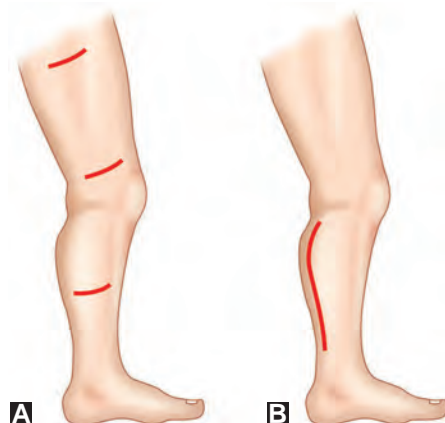
- Perforators are marked out by Fegan's method. Perforators are ligated deep to the deep fascia through incisions in anteromedial side of the leg.

► **Ligation of short saphenous vein at saphenopopliteal junction.** It is done in prone position with horizontal incision. Variations in SP junction are common. But stripping is better.

► **Linton's vertical approach (1938)**—subfascial ligation of perforators.



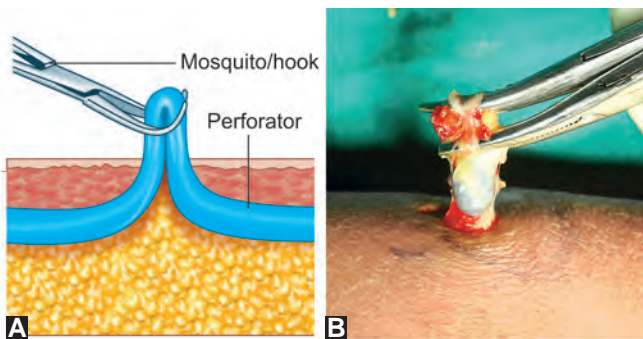
Figs 1.422A to C



Figs 1.423A and B: A. Cockett and Dood subfascial ligation of perforators using multiple small horizontal incisions. B. Linton's vertical approach for subfascial perforator ligation in the leg.

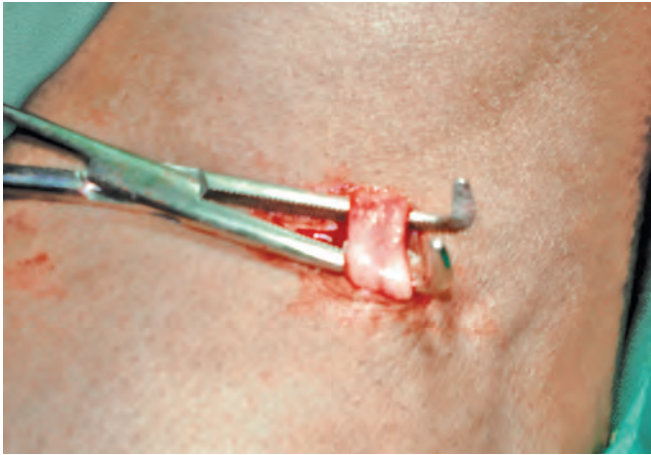

Fig. 1.424: Typical perforator ligation.



Figs 1.425A and B: Avulsion of the perforator using hook or mosquito forceps through a small skin incision—stab avulsion.

- ▶ **Stab avulsion of varicose vein and perforators:** Avulsion is done using mosquito forceps or avulsion hooks—*hook phlebectomy*. It is popular method, also used along with other minimal invasive techniques like EVLA, RFA. Multiple incisions are made and veins are carefully and gently avulsed/teased to clear it. Postoperative compression bandage is a must.

◆ **Minimally invasive methods:**

**a. Subfascial endoscopic perforator ligation surgery (SEPS)**

- A special telescope is introduced deep to deep fascia through a single small vertical incision at proximal leg selecting healthy skin. Potential space between muscle and deep fascia with loose areolar tissue is easy to dissect using endoscope. Technique is done under tourniquet 300 mmHg pressure. Endoscope is advanced down along the medial border of the tibia. Perforators travelling in subfascial plane are identified and fulgurated using bipolar cautery or clips can be applied into the perforators. It is recommended in chronic venous insufficiency (CVI). But its limitation is difficulty in getting ‘lift off’ skin in cases with severe lipodermatosclerosis to identify the perforators.

**b. Radiofrequency ablation (RFA) method (VNUS closure method)** (VNUS medical technologies Inc; Sunnyvale, CA, USA) (by Goldman 2000):

This procedure is done under general or regional anaesthesia.

A RFA catheter is passed into long/ short saphenous vein near saphenofemoral or sapheno-popliteal junction under guidance. 85°C temperature is used for longer period of time to cause endothelial damage, collagen denaturation and venous constriction. 7 French catheter is used and 7 cm segment vein is ablated sequentially. Phlebectomy is done while withdrawing the catheter. Wall of the vein is destroyed through its full thickness. Vein forms a cord, which gets dissolved by macrophages and immune cells.

*CELON RFITT*—Radio Frequency Induced Thermal Therapy (2007) is newer type.

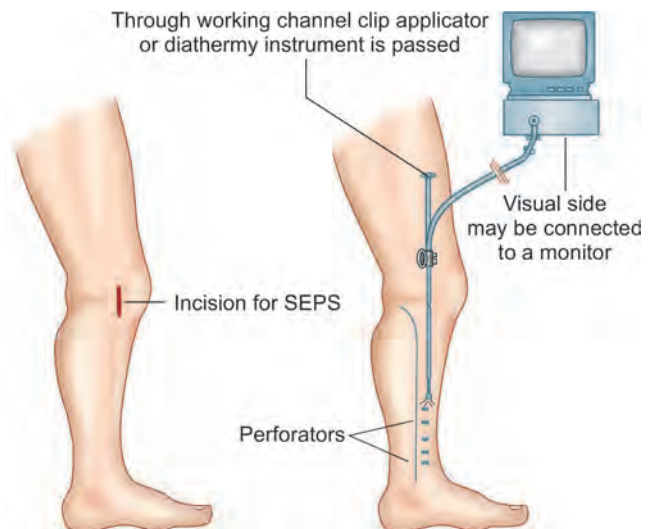


Fig. 1.426: Subfascial endoscopic perforator ligation surgery (SEPS).

**c. Trivex method:**

Under subcutaneous illumination and local anaesthesia, a large quantity of fluid is injected percutaneously to identify the superficial veins under. Tumescence anaesthesia created causes hydrodissection. Trivex resector and illuminator are placed under the skin. Resector gently extracts veins by suction and morcellation. Further stages of tumescence flushes all blood and delivers vasoconstriction solutions. Solution is passed through 18 gauge needle to clear all blood underneath. Method is cosmetically acceptable; removes all sized veins; achieves good pain relief; with minimal complications like bruising, induration which gets resorbed eventually; and can be used when there are venous ulcers.

**d. Endovenous laser ablation (EVLA):**

It is done as an outpatient procedure or as day-care surgery. Patient lies supine with diseased leg flexed, hip externally rotated and knee flexed. With aseptic precaution, under U/S guidance LSV is cannulated guide wire is passed beyond SFJ and 5-French catheter is passed over guide wire and tip is placed 1 cm distal to the junction. 200 ml of 0.1% lignocaine (crystalloid with local anaesthetic) is infiltrated along the length of the LSV. Laser fibre is inserted up to the tip of the catheter and catheter is withdrawn for 2 cm and laser fibre protrudes for 2 cm. Laser fibre is fired step by step using diode laser (810–1470 nm diode laser energy), one mm withdrawal in 2 seconds. Once procedure is over catheter is removed



and pressure bandage is applied for 2 weeks. Heat produced (729–1000°C at tip) by the laser produces steam bubbles with thermal damage of endothelium leading into occlusion of the vein. Laser energy acts on the blood within the vein rather directly through the wall and heats the blood and in turn heats the vein wall. *Drawback of laser therapy* is inability to create flush occlusion allowing tributaries to open up to cause possible recurrence.

*Complications of EVLA:* Pain; ecchymosis, haematoma, skin burns, difficulty in cannulating the unsuitable vein if selected; DVT; sensory disturbances, infection.

**Note:**

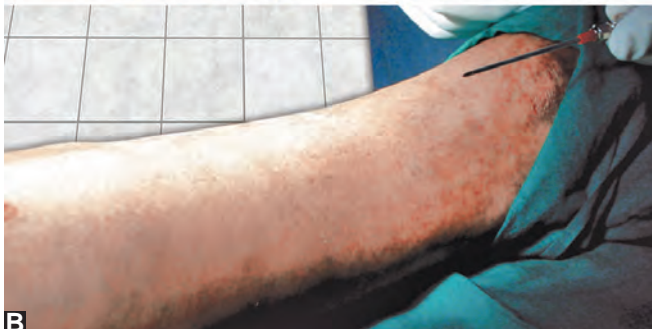EVLA has got 95% efficacy. *Tumescent anaesthesia* is prepared by mixing 500 ml of normal saline, 30 ml of xylocaine 1% with adrenaline, 10–30 ml of 8.4% sodium bicarbonate. It is injected using long needle along the length adjacent to vein to cause tamponade and to prevent heat burn on the surface.

**e. Other methods:**

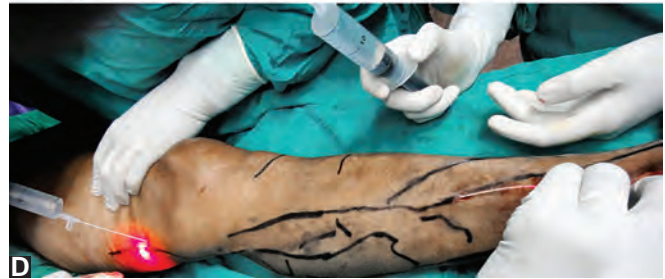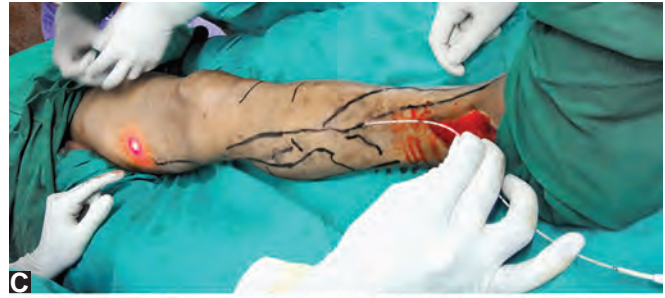- *Transilluminated phlebectomy* is done by passing transilluminating light under the skin and passing a rotating blade through another small incision. Veins are grasped and removed by rotating movements.
- *Ambulatory phlebectomy* is done through tiny small incisions using special phlebectomy instruments.
- *Electrodessication* using weak electric current through a fine needle directly into the spider veins (telangiectasis) is also used.

**Note:**

*Contraindication for surgery is deep vein thrombosis (DVT).*



Figs 1.427A and B



Figs 1.427C and D

Figs 1.427A to D: Endovenous laser ablation (EVLA) for varicose veins.

**Complications (20%) of varicose vein surgeries/ interventions**

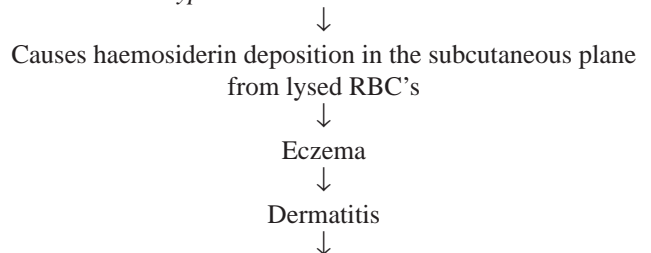
- ❖ Infection – *most common* complication
- ❖ Haematoma formation, bruising, oedema limb
- ❖ Nerve injury is the *most common serious* complication:
  - Saphenous nerve injury in LSV stripping is 1–7%
  - Sural nerve injury in SSV stripping is 20%
  - Common peroneal nerve injury in SSV stripping is 4%
- ❖ Recurrence of varicose veins – 20–30%.
  - Causes are – angiogenesis and revascularisation; improper surgery; reflux in residual axial vein; new reflux; axial vein recanalisation
  - Recurrence is more with SSV disease than LSV; in obese patient
  - Complications are high in surgeries for recurrent varicose veins—40%
- ❖ DVT is rare complication — <0.5%.

■ **VENOUS ULCER (Gravitational Ulcer)**

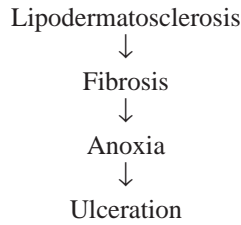
It is the complication of varicose veins or deep vein thrombosis.

**Pathogenesis of Venous Ulcer**

Varicose veins or DVT which are recanalised, eventually causes *chronic venous hypertension* around ankle

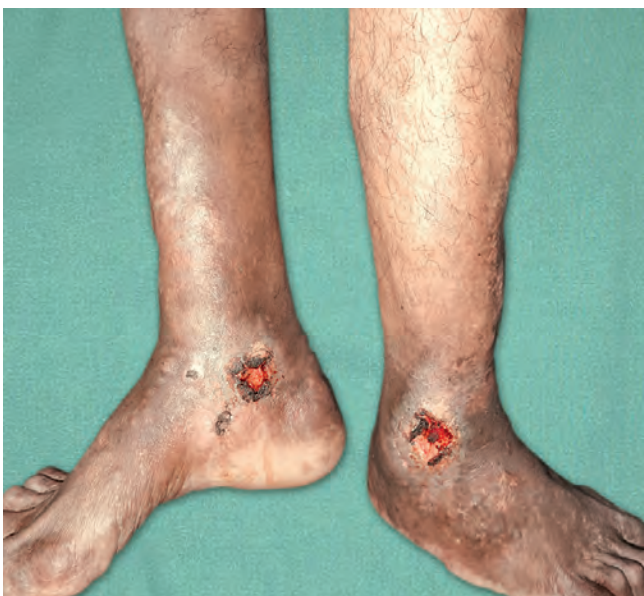

Figs 1.427A and B

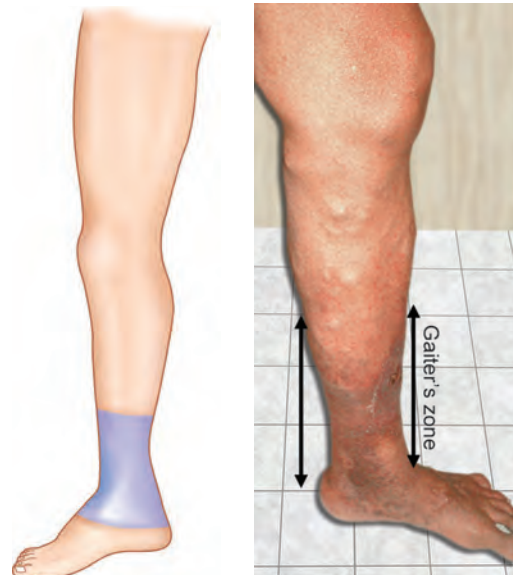

*Ambulatory venous hypertension* is the *prime cause* of venous ulcer formation. Venous hypertension may be *gravitational* which is due to hydrostatic pressure by weight of blood column from the right atrium (*hydrostatic reflux*) which is maximum at foot and ankle **OR** *dynamic* which is due to muscular contraction across the incompetent perforator with a high pressure up to 200 mmHg (*hydrodynamic reflux*). There is a peculiar recycling of blood from deep veins → femoral vein → spillage of blood across incompetent SFJ into LSV/GSV → passage of same blood across perforators into the deep veins to reach femoral vein → again to enter the LSV as spillage. White cell trapping theory and 'fibrin cuff' theory; release of free radicals; increased matrix metalloproteinases (MMPs); abnormal fibroblast activity; inhibition of growth factors; are other causes of venous ulcer formation.

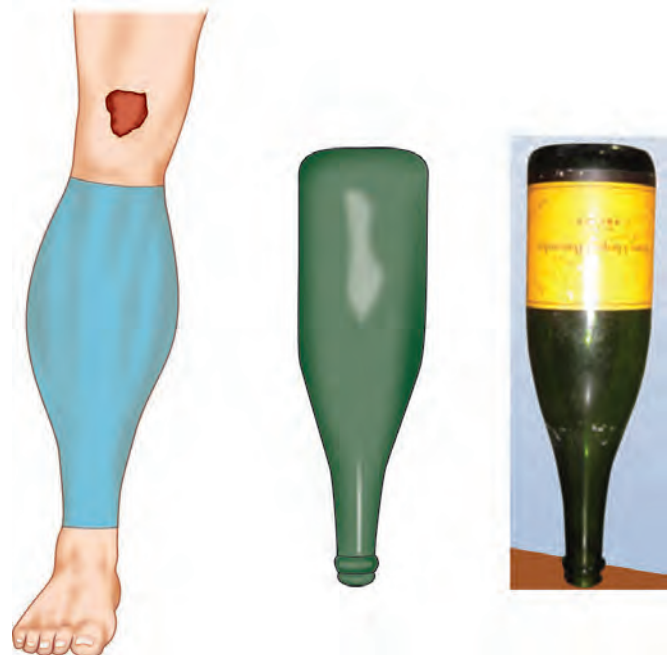- ◆ *Area where venous ulcer commonly develops, is around and above the medial malleoli* because of presence of large number of perforators which transmit pressure changes directly into superficial system. This area is called as *Gaiter's zone*. It can also be on both malleoli.
- ◆ Ulcer is often large, nonhealing, tender, recurrent with secondary infection. Vertical group of inguinal lymph nodes are usually enlarged and tender.
- ◆ Often it leads to scarring, ankylosis, Marjolin's ulcer formation. Slough from the ulcer bed may give way causing venous haemorrhage.
- ◆ *Periostitis is common* which also prevents ulcer from healing.



**Fig. 1.428:** Venous ulcers around both ankles (bilateral).



**Fig. 1.429:** *Gaiter's zone*. It is handbreadth area around malleoli where complications of venous disease occurs. *Word gaiter* (French) is a leather/cloth covering for lower leg and ankle.



**Fig. 1.430:** *Champagne bottle sign/inverted beer bottle sign* is seen in lipodermatosclerosis due to prominent calf with narrow ankle, contracted skin and subcutaneous tissue. Sign is often observed in DVT also.

- ◆ Most of the venous ulcers have surrounding lipodermatosclerosis. *Lipodermatosclerosis is pigmentation, thickening, chronic inflammation and induration of the skin in calf and around ankle.*

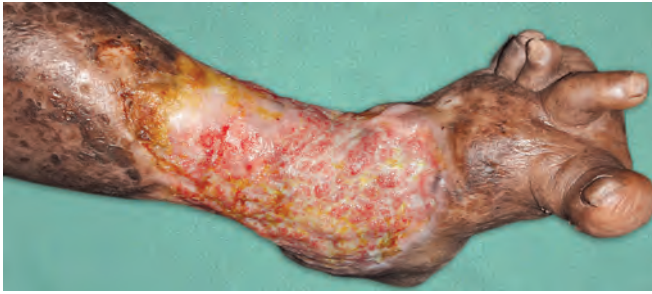

Fig. 1.431: Marjolin's ulcer in a chronic venous ulcer.

- Due to regular walking on toes so as to relieve the pain causes contraction and extra-articular fibrosis of achilles tendon. Proper exercise is the remedy for—*talipes equinovarus*.

**Note:**

70–80% of leg ulcers are venous ulcers.

**Differential diagnosis**

- Ischaemic ulcer, diabetic ulcer.
- Rheumatoid ulcer.
- Traumatic ulcer.
- Neuropathic ulcer.
- Neoplastic ulcer.

**Investigations**

- Discharge from the ulcer for culture and sensitivity.
- X-ray of the area to look for periostitis.
- Biopsy from the ulcer edge to rule out Marjolin's ulcer.
- Investigations to rule out other causes of leg ulcers like arterial; neurological; diabetes; sickle cell disease and other haemolytic diseases.
- Erythrocyte sedimentation rate; C-reactive protein, peripheral smear; red cell counts.
- Doppler—venous and often arterial.

**Treatment**

- Bisgaard method** of treating venous ulcer:
  - Measures to reduce oedema, increase venous drainage, so as to promote ulcer healing.
    - Elevation.
    - Massage of the indurated area and whole calf.
    - Passive and active exercise.
  - Care of ulcer by regular cleaning with povidone iodine, H<sub>2</sub>O<sub>2</sub>.
  - Dressing with EUSOL.
  - Four layer bandage* (45 mmHg pressure) technique to achieve high compression pressure. It is changed once a week.
  - Antibiotics depending on culture and sensitivity of the discharge.
  - Once ulcer bed granulates well, split skin graft (SSG) is placed (*Thiersch Graft*), or pinch graft.

- Specific treatment for varicose veins** should be undertaken—Trendelenburg operation, stripping of veins, perforator ligation.

**Different bandages used are:**

- Charing*—Cross (hospital London) elastic multilayered compression bandage, once a week
- Low compression bandaging
- Graduated elastic compression stockings with a leak proof absorbent dressing beneath
- Unna boots
- Crepe bandage/stockings

- Fifty percent of venous ulcer occurs as a result of recanalisation of DVT, and the leg is commonly called as *postphlebotic limb (leg)*. It presents with all complications of venous diseases like eczema, ulceration, lipodermatosclerosis and venous ulcers. Here surgery for superficial varicose veins are contraindicated. Venous valve repair (*Kistner's valvuloplasty*) or *valve transplantation* or drugs like *Stanazolol*, which reduces the fibrous tissue thereby increasing the oxygenation are beneficial.

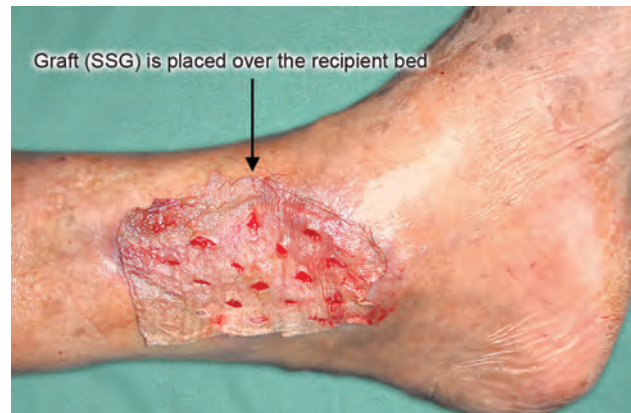

Fig. 1.432: Skin graft is done over a venous ulcer once ulcer has shown healthy granulation tissue.

**Complications of venous ulcers**

- Haemorrhage
- Marjolin's ulcer (in unstable scar of long duration)
- Infection
- Talipes equinovarus
- Periostitis is common over the tibia
- Disability
- Calcification

(**EUSOL** is Edinburgh University solution of lime containing *boric acid, sodium hypochlorite, calcium hydroxide*.)

**Note:**

- Present concept is to treat the ulcer first by compression bandage; regular dressing; skin grafting. Once ulcer has healed definitive procedure for varicose veins is done. Studies show that rapidity of healing of ulcer perse is not dependent on the surgery for varicose veins.
- Recurrence rate of venous ulcer after proper therapy is 30%. Reulcer formation is more in post-phlebotic/ thrombotic limb.

## COMPRESSION THERAPY FOR VARICOSE VEINS

- ◆ Compression reduces the venous wall tension; prevents reflux; controls the venous over-distension.
- ◆ Compression diverts the blood towards deep veins through perforating veins; prevents the outward flow of blood in perforator incompetence; improves the efficacy of calf muscle pump. Compression reduces the oedema and improves the venous and lymphatic drainage; improves venous elasticity; improves the microcirculation and more important is it prevents further damage of the venous wall.
- ◆ Compression may be elastic/inelastic/combination of elastic and inelastic (*Unna boot*)/multilayered (four layered) compression system which can provide sustained high compression for several days—usually up to a week/intermittent pneumatic compression. *Unna boot* is three-layered paste gauze compression dressing containing calamine, zinc oxide, glycerin, sorbitol, gelatin and aluminium silicate which has mainly inelastic inner component with partly elastic outer layer wrap.
- ◆ Recommended pressure in mild varicose veins, pregnancy and postoperative period is 20 mmHg; in symptomatic varicose veins and after sclerotherapy is 30 mmHg; in venous ulcer and post-phlebotic leg it is 40–45 mmHg; in phlebolympoedema (venous oedema with lymphatic oedema which is more dangerous) it is more than 45 mmHg.
- ◆ Skin maceration, excoriation, dryness, infection, ulceration and failure are the complications of compression therapy.



**Fig. 1.433:** Compression stockings should be worn in varicose vein disease even after intervention to reduce the chances of recurrence.

### Remember

- ❖ Compression improves ulcer healing rate
- ❖ Supplementation of phlebotonic drugs in conjunction with compression therapy is accepted
- ❖ Inelastic compression causes more improvement (reduction) in venous filling index (VFI) than elastic compression. But elastic compression is more commonly used because it is better accepted
- ❖ Multilayered bandage system is most effective
- ❖ Ankle-arm pressure index less than 0.6 is contraindication for compression therapy as it may precipitate ischaemic ulcer formation
- ❖ Exercise may improve the muscle—pump action

### Compression garments standard

#### British standard

- ❖ Class I: 14–17 mmHg
- ❖ Class II: 17–24 mmHg
- ❖ Class III: 24–35 mmHg

#### International (European) standard

- ❖ Class I: 20–30 mmHg
- ❖ Class II: 30–40 mmHg
- ❖ Class III: 40–50 mmHg
- ❖ Class IV: 50–60 mmHg

### Compression bandages

- ❖ *Type I:* Light weight conforming stretch bandages. These comprise light weight elastomer with high elasticity but little power. It is used to retain dressings
- ❖ *Type II (short stop):* Light support bandages. Minimal stretch. Exhibit limited elasticity but tends to lock out on minimal extension. In ambulant patient CVI they form an essentially inelastic covering to the leg which will exert pressure during calf systole but not during diastole. They are unsuitable for control of oedema
- ❖ *Type III (Long stop):* These are extensible elastic and powerful to a varying degree

## THROMBOPHLEBITIS

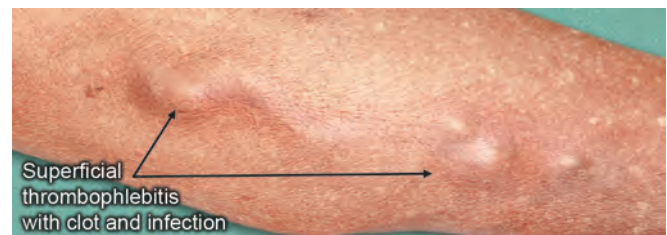It is the inflammation of veins, usually of superficial, veins due to different causes. It is actually *superficial vein thrombosis (SVT)* with inflammation (slight).

### Types

- a. *Acute:* Due to IV cannulation, trauma, minor infections, hypercoagulability.
- b. *Recurrent.*
- c. *Spontaneous:* Polycythaemia vera, polyarteritis, Buerger's disease.
- d. *Thrombophlebitis migrans (Trousseau's sign, 1876):* It is spontaneous migrating thrombophlebitis seen in visceral malignancy like pancreas, stomach.
- e. Mondor's disease.

**It can be**—SVT with varicose veins (V-SVT) or SVT without varicose veins (NV-SVT). It can also be—primary or secondary.

*Duplex ultrasound Doppler* of both limbs is a must.



**Fig. 1.434:** Superficial thrombophlebitis with clot and infection.

## Clinical Features

- ◆ Pain, redness, tenderness, cord like thickening of veins, fever.
- ◆ It can be seen either in upper limb or lower limb.

## Complications

- ◆ Destruction of venous valves resulting in varicose veins.
- ◆ DVT, embolism, infection.

## Treatment

- ◆ Elevation.
- ◆ Anti-inflammatory drugs, antibiotics.
- ◆ Application of crepe bandage—*compression therapy*.
- ◆ *Anticoagulation*—LMWH for SVT >3 cm in length.

## ■ KLIPPEL-TRENAUNAY SYNDROME

It is a nonfamilial mesodermal anomaly with skin naevus, varicose veins, soft tissue and bone hypertrophy. Deep veins are often aplastic. It is usually managed with compression bandages. If patient is undergoing surgery for some other condition, then LMWH should be started. Condition itself occasionally can be treated with EVLA for varicose veins if only deep veins are normal; bone length discrepancy correction of leg is done.

*Parkes-Weber syndrome* is a differential diagnosis. PW syndrome presents with varicose veins, multiple AV fistulas, chronic venous hypertension, high output cardiac failure and ulceration.

## ■ ANTICOAGULANTS

These are the agents used to prevent and treat thrombosis and thromboembolic events.

### ■ HEPARIN (UNFRACTIONATED/UFH)

- ◆ It is a natural anticoagulant, a mucopolysaccharide.
- ◆ It prevents clotting of blood both *in vivo* and *in vitro* by acting on all three stages of coagulation. It *prolongs clotting time* and *activated thromboplastin time* in specific (by 1.5–2.0 times the control).
- ◆ Heparin also causes hyperkalaemia, thrombocytopenia, osteoporosis.
- ◆ Commercial heparin is derived from lung and intestinal mucosa of pigs and cattle.
- ◆ The onset of action is immediate after administration, lasting for 4 hours.
- ◆ It is metabolised in the liver by heparinase.
- ◆ It does not cross placental barrier and is not secreted in breast milk.

## Indications

- ◆ As prophylaxis in major surgeries, postoperative period, puerperium.
- ◆ As therapy in DVT.

## Dose

- ◆ For prophylaxis: 5,000 units/subcutaneously 8th hourly.
- ◆ For therapy: 10,000 units/IV 6th or 8th hourly. Later changed to subcutaneous dose.
- ◆ In severe cases, 5,000 units to 20,000 units is given daily through IV infusion at a rate of 1,000 units per hour. Daily dose should not exceed 25,000 units.

Heparin should not be given intramuscularly and should not be combined with streptokinase or urokinase. Heparin is not given orally. *Heparin administration should always be monitored with APTT.*

## Complications

Allergy, bleeding, thrombocytopenia.

### Note

*Danaparoid* is an antifactor Xa, heparinoid, is an anticoagulant used in patients where heparin is contraindicated.

## LOW MOLECULAR WEIGHT HEPARIN (LMWH)

It is a commercially prepared heparin with a molecular weight of 4,000 to 6,500.

- ◆ Enoxaparin.
- ◆ Dalteparin.
- ◆ Parnaparin.
- ◆ Reviparin.
- ◆ Fraxiparine.

### Advantages

- ❖ Have a longer duration of action—once a day
- ❖ Have a better anticoagulant effect
- ❖ Less interaction with platelets
- ❖ Less antigenic
- ❖ Usage is easier and more acceptable
- ❖ Monitoring is not necessary

### Disadvantages

- ❖ They are expensive.

### Note

Presently, LMWH are becoming very popular.

**Heparin antagonist:** 50 mg of 1% protamine sulphate solution is given slow intravenous. 1 gm reverses 100 units of heparin. It is given only after doing activated thromboplastin time. Overdosing or infusion without indication may itself precipitate bleeding.

## ■ ORAL ANTICOAGULANTS

They are given orally and are slow-acting.

## Types

- ◆ *Coumarin derivatives:* Bishydroxycoumarin (Dicoumarol): First coumarin drug derived from sweet clover. *Warfarin sodium:* Most common oral anticoagulant used.
- ◆ *Indandione derivative:* Phenindione, anisindione.

## Mode of Action of Oral Anticoagulant Therapy

- ◆ By suppressing synthesis of prothrombin, factors VII, IX and X.
- ◆ By inhibiting vitamin K mediated carboxylation of glutamic acid.
- ◆ Oral anticoagulant does not have *in vitro* action.
- ◆ They are slow-acting, and long-acting.
- ◆ Control of oral anticoagulant therapy is by *monitoring prothrombin time*.
- ◆ PT comes to normal only 7 days after cessation of the drug.
- ◆ *They cross placental barrier and are known to cause teratogenicity when given in 1st trimester.*
- ◆ *They are secreted in breast milk.*

### Indications

- ◆ In DVT after cessation of heparin for maintenance therapy.
  - ◆ After valve replacement surgery.
- To achieve adequate anticoagulant effect and to prevent thromboembolic episodes the *INR* has to be maintained within 2–3.

### Side Effects

- ◆ Bleeding—it may require blood transfusion/FFP or vitamin K injection intramuscular or oral to control.
- ◆ Cutaneous gangrene.
- ◆ Fetal haemorrhage and teratogenicity.
- ◆ Alopecia, urticaria, dermatitis.
- ◆ Drug interactions: with NSAIDs, cimetidine, omeprazole, metronidazole, cotrimoxazole, erythromycins, barbiturates, rifampicin, griseofulvin.

### WARFARIN

**WARFARIN** (Wisconsin Alumni Research Foundation + coumARIN derivative) **SODIUM** is the most common drug used. It has got lesser side effects. It has got cumulative action and so given in tapering dose.

Dose is 5 mg, once a day.

It should be discontinued 7 days before any surgery like tooth extraction and prothrombin time should return to normal level. During surgery, if excess bleeding occurs, fresh frozen plasma may be given.

The effects of warfarin sodium is reversed by injection vitamin K; the dose depends on INR and emergency of reversal (takes 24 times to reverse).

**Note**

**In Vitro Anticoagulants:** Oxalates, citrates, EDTA (Ethylene diamine tetra-acetic acid).

#### Thrombolytic agents

- ◆ Streptokinase
- ◆ Urokinase
- ◆ Anistreplase
- ◆ Alteplase

#### Differences between oral anticoagulants and heparin

	Oral anticoagulant	Heparin
	Slow-acting	Immediate
	Long-acting	Short-acting
	Only <i>in vivo</i> action	Both <i>in vitro</i> and <i>in vivo</i> action
Monitored by	Prothrombin time	Partial thromboplastin time
	Crosses the placental barrier	Does not cross the placenta
	Secreted in milk	Not secreted in milk
Administration	Orally	Intravenously/ subcutaneously

#### Contraindications for anticoagulant therapy

- ◆ Ongoing bleeding
- ◆ Recent surgery/invasive procedure
- ◆ Severe trauma
- ◆ Bleeding tendency (clotting factor deficiency)
- ◆ Intracranial haemorrhage
- ◆ Pericarditis/pericardial effusion
- ◆ Patient prone to fall

### DIRECT THROMBIN INHIBITORS

- ◆ Recombinant hirudin and hirudin analogues—derived from leeches, are direct inhibitors of thrombin.
- ◆ Argatroban, dabigatran, etixilate—synthetic direct thrombin inhibitor.
- ◆ **Rivaroxaban**—It is direct factor Xa inhibitor. It is given orally once or twice daily as 15–20 mg dose per day. It is given initially 15 mg twice daily, later 20 mg once daily. It shows rapid bioavailability; shows rapid onset of action; coagulation monitoring is not required. Apixaban and edoxaban are other drugs.

### ANTIPLATELET DRUGS

- ◆ Small dose aspirin—inhibits platelet synthesis of thromboxane A2.
- ◆ Ticlopidine (125 mg BD)—alters platelet membrane, thereby platelet aggregation.
- ◆ Clopidogrel—action similar to ticlopidine.
- ◆ Dextran—decreases platelet aggregation.
- ◆ Abciximab—glycoprotein IIb/IIIa inhibitors, block platelet aggregation, and platelet adhesion to fibrin.
- ◆ Dipyridamole—xanthine oxidase inhibitor.

### PULMONARY EMBOLISM

- ◆ It is commonly due to lower limb DVT (15% of lower limb DVT). It can also occur after pelvic vein DVT or upper limb DVT (30% of upper limb DVT).
- ◆ Chest pain, cough, haemoptysis, dyspnoea are the features.
- ◆ Often site of DVT may be asymptomatic. When symptomatic, fever, pain, tense, tender calf, with positive Homan’s sign may be evident.
- ◆ Massive embolism causes sudden cardiac arrest and death due to pulmonary artery block. Moderate embolism causes *pyramidal wedge-shaped* infarcts in lungs.
- ◆ Duplex scan of limb, CT angiogram of thorax, pulmonary angiogram (gold standard), X-ray chest, ventilation perfusion scan, ECG, echocardiography are useful investigations.
- ◆ **Treatment** is thrombolysis, heparin/LMWH, compression bandage.
- ◆ Occasionally surgical removal of clot from pulmonary artery is done if possible.
- ◆ **IVC filter** placement is essential in recurrent DVT with anti-coagulation, DVT with contraindication for anticoagulation, pulmonary hypertension. *Greenfield IVC filter* is ideal with 95% patency rate. **Complications** are—bleeding, haematoma, migration of filter into pulmonary artery, thrombosis at filter level, IVC perforation.

*Attitudes are more important than facts.*

- ◆ *Retrievable IVC filters* are newer method used to prevent long-term filter complications. It is used in young patients who are at risk of DVT and embolism, for short specified period only like—high-risk trauma with orthopaedic injuries, extensive iliofemoral thrombosis, during thrombolytic therapy. *Recovery filter, Gunthur-Tulip filter, OptEase filters* are used. They are deployed through IJV or femoral vein under angiographic or intravascular US guidance. Recovery and Gunthur-Tulip types are recovered through right IJV. OptEase is recovered from right femoral vein. *Complications* are same as nonretrievable IVC filters. Retrieval failure, retrieval site thrombosis and embolism are specific complications.
- ◆ DVT prophylaxis is a must in all these patients.

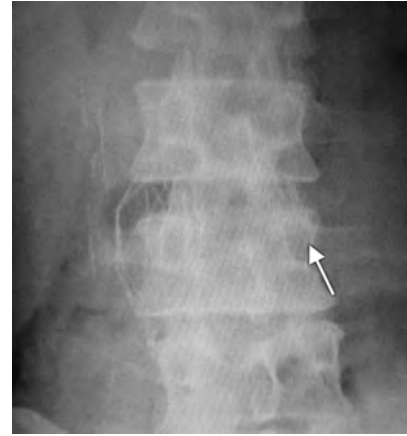

Fig. 1.435: X-ray showing IVC filter in position.

### Venous Thrombo Embolism (VTE)

- ❖ VTE can be provoked (with identifiable causes) or unprovoked (no identifiable causes)
- ❖ Acute dyspnoea, chest pain, haemoptysis, later haemodynamic instability, shock, RV dysfunction are the features. *High, moderate and low risk* groups are identified. *Wells and modified Geneva* criteria are used.
- ❖ *CT angiogram* is diagnostic. D dimer/duplex Doppler US of leg, MRI pelvis, coagulation profile, chest X-ray are other needed investigations
- ❖ *Treatment modalities*—anticoagulants, thrombolysis, percutaneous interventions, surgery
  - **Anticoagulants** (Heparin) are used in pulmonary embolism without haemodynamic instability or without right ventricular dysfunction
  - **Thrombolysis**—*Indications*: Pulmonary embolism with haemodynamic instability with right ventricular dysfunction or instability in spite of heparin therapy or with intracavitary right heart thrombi/*massive embolism*. *Thrombolysis* dissolves the thrombus obstructing the pulmonary artery; prevents the release of neurohumoral factors and serotonin which causes pulmonary arterial hypertension (PAH); reverses right heart failure; dissolves venous thrombus in periphery. *Thrombolysins used* are—*streptokinase* (loading dose is 2,50,000 units IV; continuous infusion of 1,00,000 units/hour for 24 hours), *urokinase* (loading dose 2000 units/lb infused IV in 10 minutes, continuous infusion IV 2000 units/lb/hour for 24 hours), *tissue plasminogen activator (tPA is ideal)*—*alteplase* continuous infusion 100 mg/2 hours, *reteplase* bolus IV 10 units in every 30 minutes, *tenecteplase*, *desmoteplase*. *Contraindications* for thrombolysis—stroke, brain tumour, bleeding disorders, major trauma/surgery, recent GI bleed, pregnancy, endocarditis, advanced liver disease
  - **Percutaneous catheter fragmentation** of clots and thrombolysis using pigtail catheter/clot buster/angio jet
  - **Retrievable IVC filters** are used commonly now. Permanent filters are used only in—high risk group, risk of recurrent embolism, life expectancy less than 6 months
- ❖ **Venous thrombosis/VTE in pregnancy** is more common with 2/1000 pregnancies with 5 times more in postnatal period. It is 90% *left side mainly proximal*. Left calf asymmetry with >2 cm in 1st trimester with features of embolism. Calf and thigh US for leg DVT and MRI for pelvic DVT should be done. Echocardiography should be done to check embolism; chest X-ray with abdominal shield may be needed. LMWH should be given. Warfarin (crosses placenta), rivaroxaban are avoided. TPA crosses the placenta but is used in massive pulmonary embolism with haemodynamic instability as life-saving often along with embolectomy. LMWH is given throughout the pregnancy; stopped peridelivery period; continued postnatal period for 1 month with 75% of earlier dose; later compression stockings and warfarin for 6 months. Compression stockings, hydration, ambulation, left lateral position are preventive measures in pregnancy often along with LMWH if needed/indicated.
- ❖ **ACCP guidelines 2012 for VTE therapy**:
  - *Initial phase* up to 7 days—UFH/LMWH/Fondaparinux/rivaroxaban;
  - *Long-term* up to 3 months—LMWH/rivaroxaban/dabigatran/VKA with INR 2–3 range (optimum 2.5);
  - *Extended* is beyond 3 months—VKA/rivaroxaban/dabigatran/LMWH if needed

# O. Lymphatics

## CHAPTER OUTLINE

- ❖ Surgical Anatomy
- ❖ Lymphangiography
- ❖ Isotope Lymphoscintigraphy
- ❖ Lymphoedema
- ❖ Lymphomas
- ❖ Hodgkin's Lymphoma
- ❖ Non-Hodgkin's Lymphoma
- ❖ Mantle Cell Lymphoma
- ❖ Malt Lymphomas
- ❖ Burkitt's Lymphoma
- ❖ Cutaneous T Cell Lymphoma
- ❖ Chylous Ascites
- ❖ Chylothorax
- ❖ Chyluria
- ❖ Sarcoidosis

### ■ SURGICAL ANATOMY

Primordial lymphatic system begins to develop during 6th week of development adjacent to jugular vein as lymph sacs. Peripheral lymphatic systems develop from these primordial lymph sacs. Lymphatic system has three components. *Terminal lymphatic capillaries*, which have high porosity absorb lymph, macromolecules, cells and microbes from tissues into the system; *lymphatic vessels* which collect and transport lymph; *lymph nodes* which are interposed in the lymphatic pathway filter lymph and maintain immunity of the body. Lymphatic vessels run adjacent to main blood vessels reaching the major lymphatic channels. *Cisterna chyli* is formed in the abdomen, continues as thoracic duct (formed at 9th week of gestation) in the thorax which has got initial main course towards right side of the mediastinum; but later towards left side entering the internal jugular vein at its joining point of the subclavian vein. In the periphery, there is hardly any lymphovenous communications. Lymphovenous communications occur at lymph node level; iliac, subclavian and jugular levels. Lymphatics are absent in epidermis, cornea, CNS, cartilage, tendon and muscle.

*Great lymph ducts* are—the thoracic duct—single; right lymph duct—single; subclavian, bronchomediastinal and jugular trunks on both sides. These ducts contain valves to prevent backflow.

*Cisterna chyli* is formed by joining of right and left lumbar lymphatic trunks and intestinal lymphatic duct. Lumbar trunks are short lymph vessels arising from para-aortic lymph glands. It receives lymph from lower limb, pelvis and pelvic viscera, kidney, adrenal and deep lymphatics of abdominal wall. Left lumbar trunk is behind the aorta. Intestinal lymph duct arises from pre-aortic nodes. It joins the cisterna chyli from front. It receives lymph from stomach, intestines, liver (except most convex surface which drains into right lymph duct), spleen and pancreas. Cisterna chyli is a lymph sac lying in front of the L<sub>1</sub> and L<sub>2</sub> vertebrae between aorta and crus of the diaphragm. From its upper end it continues as thoracic duct. *Thoracic duct* passes through the aortic orifice of the diaphragm, runs medial to azygos vein and right of the aorta in posterior mediastinum. In front it is related to oesophagus, diaphragm and pericardium; behind right intercostal arteries, hemiazygos and accessory hemiazygos vein. At the level of 7th thoracic vertebra, it crosses towards left side behind the oesophagus obliquely reaching left side at 5th thoracic vertebral level. It runs upwards between left margin of oesophagus, medial part of left pleura, and behind left subclavian artery. In the neck, it passes in front of vertebral system (vertebral vessels and sympathetic chain) and behind carotid system (Common carotid artery, internal jugular vein, vagus

nerve), crossing scalenus anterior, phrenic nerve, transverse cervical and suprascapular arteries ending as a single vessel at the junction of internal jugular vein and subclavian vein with a valve. *Tributaries of thoracic duct* are—trunk from lateral intercostal nodes from lower six spaces; efferents from posterior mediastinal nodes, lateral intercostal nodes of upper six spaces, left jugular lymph trunk from head and neck region, left subclavian lymph trunk from left upper limb, left bronchomediastinal trunk from left side of the thorax. Single termination of duct is common (77%); but double/triple/quadruple terminations are known to occur. Occasionally it may end in left subclavian vein, left vertebral vein, right internal jugular vein, right subclavian vein. Thoracic duct is 45 cm in length and 5 mm wide (wider at both ends; narrow in the middle).

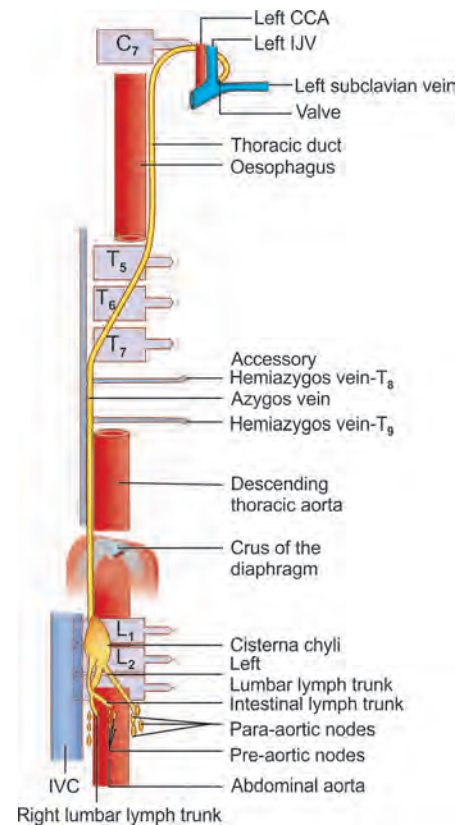
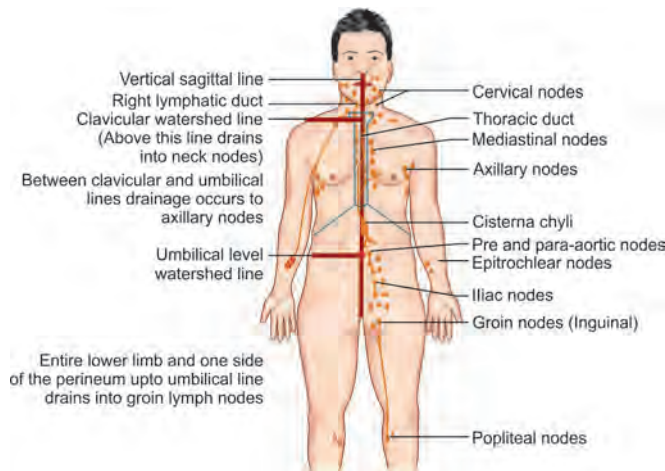


Fig. 1.436: Thoracic duct anatomy; cisterna chyli; tributaries of thoracic duct.

*In very early oedema, during pinching, there is a resistance that is not present on normal site, owing to thickening of dermis and subcutaneous tissue.*  
—Sidney S Rose





**Fig. 1.437: Watershed zones/areas of lymphatic drainage.** Vertical sagittal midline; clavicular horizontal line; umbilical line—are used to divide areas into three zones on each side. Above clavicular line drainage occurs to cervical nodes; between clavicular line and umbilical line drainage occurs into axillary nodes; below umbilical line drainage occurs to inguinal lymph nodes. At the level of (lines) drainage can occur to lymph nodes on either side.

Right lymph duct is 2.5 cm in length, formed by right jugular, right subclavian and right bronchomediastinal trunks; runs on the scalenus anterior joining the junction of right internal jugular vein and subclavian vein.

There are about total 450–600 lymph nodes in the body. Around 200 in the neck; around 100 in the thorax; around 50–60 in the axilla; around 250 in the abdomen and pelvis; around 50 in the groin area.

## Lymphatic Watersheds of Skin

Lymph from the dermis and appendages drain into a plexus in deep fascia which in turn drains into respective lymph nodes. *There are six watershed areas in the body for lymphatic drainage.* One vertical midline divides into right and left. Two horizontal lines on each side divide the area into three zones. First lies above the line of clavicle; second between line of clavicle and line at umbilical level; third below the level of umbilical line. First drains into head and neck lymph nodes; second drains into axillary nodes; third drains into inguinal/groin nodes. Malignancy drains into their respective nodes depending on the location. Lesion on the line can spread to both territory lymph nodes. In skin and appendageal cancers, deep fascia also should be cleared.

## Microanatomy of Lymph Node

Lymph node contains three regions—*cortex; paracortex and medulla.* Cortex contains mainly follicles. It may be rounded lymphocytic aggregations of primary follicles or lymphocytic aggregation with germinal centres of secondary follicles due to antigenic stimulation. It contains B lymphocytes, macrophages, dendritic reticulum cells. Germinal centre is surrounded by small B lymphocytes. Both cortex and medulla are associated with humoral immunity. Proliferation of germinal centres suggests active humoral immunity with antibody production. Central medulla contains mainly lymphatic sinuses, arteries and veins, plasma cell and B lymphocytes. Paracortex is located in a zone between cortex and medulla. It contains T lymphocytes, related to cell mediated immunity. Post-capillary venules with high endothelial cells and lymphocytes in the wall are typical. In cell

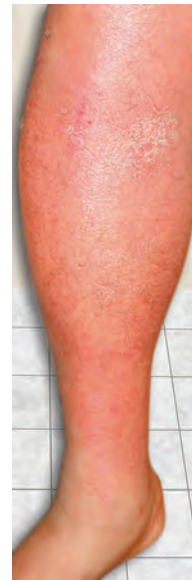mediated immunity, paracortex expansion occurs. Afferent lymph vessels enter the node through the capsule. It enters the marginal sinus, communicates with intranodal sinus, merging as efferent lymph vessels which enter the hilum. Intranodal sinus lining is highly phagocytic containing littoral cells and sinus lining histiocytes. Main artery and veins pass through the hilum to enter the medulla, paracortex and inner part of cortex. Superficial cortex is supplied by direct capsular vessels.

## Function of Lymphatics

Most of the *intravascular proteins are daily filtered through lymphatics* and returned to the circulation again. Macromolecules (albumin, globulin and fibrinogen) and microbes are also filtered at the nodal level as first immune system. From GIT fat is absorbed directly through lymphatics. Lymph shows centripetal flow. Cholesterol, long chain fatty acids, fat soluble vitamins are transferred through lymphatics into cistern chyli directly from GIT bypassing the liver. Transport is mainly due to *intrinsic contractility of the lymphatic vessels* which contain valves for effective forward flow. To a lesser extent other factors like muscle contraction, arterial pressure, thoracic pressure, respiratory movements play role. *8 litres of lymph is produced daily; once it reaches to lymph nodes it is concentrated to 4 litres which enters the venous circulation. Protein concentration in lymph is very high (25 grams/litre).*

### Note:

Lymph drains protein rich fluid; there are no communicating/perforator lymphatics; lymphatics will not regenerate



**Fig. 1.438: Acute lymphangitis leg.** Usually regional lymph nodes are enlarged and tender.

## LYMPHANGIOGRAPHY

### Indications

- ◆ Congenital lymphoedema like aplasia, hypoplasia, hyperplasia.
- ◆ Lymphomas show *reticular* pattern. It is also useful to assess the response to treatment.
- ◆ Secondaries in lymph nodes, especially iliac and para-aortic lymph nodes.

## Technique

Patent blue dye or 1 ml isosulphan blue is injected subcutaneously between toes. Dye is taken up by lymphatics which will be visualised clearly. After making incision, one of the lymphatic vessels is dissected and 30 G needle is passed. Ultra-fluid lipiodol which is an oily contrast medium is injected slowly using pressure pump at a rate of 1 ml in 8 minutes (total quantity is 7 ml). Slowly in 24 hours, it passes through the lymphatics and reaches the iliac and para-aortic lymph nodes. Radiographs taken will help to visualise both lymphatic vessels as well as lymph nodes.

Secondaries in lymph nodes causes filling defects. Lymphomas shows enlarged nodes which have foamy or reticular appearance.

## Disadvantages

- ◆ Technically difficult.
- ◆ Extravasation of dye can occur.
- ◆ Dye may not reach the required area.
- ◆ Time consuming and invasive procedure.

### Lymphangiographic classification of lymphoedema (Browse classification): (Norman Browse)

- ❖ **Congenital hyperplasia (10%):** Congenital; common in males; entire leg is involved; one or both sides; with often family history; progressive; involves increased number of lymphatics and lymph nodes associated with chylous ascites, chylothorax and protein losing enteropathy
- ❖ **Distal obliteration (80%):** Common in females; starts at puberty; calf and ankle are involved; often bilateral; with often family history; slow progression; aplasia/hypoplasia of lymphatics
- ❖ **Proximal obliteration (10%):** Occurs at any age; equal in both sexes; leg and thigh involved; unilateral; rapid progression; proximal aortoiliac nodal block

## ISOTOPE LYMPHOSCINTIGRAPHY

- ◆ Radioactive technetium labelled sulphide colloid particles, or radioiodinated human albumin are injected into the web space using fine needle. These particles are specifically taken up by lymphatics.
- ◆ Using gamma camera, limb and inguinal region is exposed to visualise the lymphatics and inguinal lymph nodes.
- ◆ Radioactivity in inguinal nodes is measured at 30 and 60 minutes. Normal uptake is 0.6–1.6%; if it is <0.3% in 30 minutes it is diagnostic of lymphoedema. If it is >2% it suggests rapid abnormal clearance due to oedema as the result of venous disease.
- ◆ In 3 hours, it reaches the para-aortic lymph nodes, other abdominal lymph nodes and liver.
- ◆ Later thoracic duct also can be visualised. It can be compared to the take up on the other limb.

## Advantages

- ◆ It is more sensitive.
- ◆ Technically easier and faster compared to lymphangiography.
- ◆ Thoracic duct, other lymph nodes and liver can be visualised.
- ◆ It is the test of choice. It is simple and safe.
- ◆ It has 90% sensitivity; 100% specificity.

## LYMPHOEDEMA

It is accumulation of fluid (lymph) in extracellular and extravascular fluid compartment, commonly in subcutaneous tissue. It is primarily due to defective lymphatic drainage.

It is *increased* protein rich interstitial fluid.

## Classification

*Kinmonth* classified lymphoedema as:

- ◆ Primary without any identifiable lymphatic disease.
- ◆ Secondary is acquired due to definitive cause. **Most common form.**

### Primary type

It affects commonly females.

- ❖ It is common in lower limb and left side.

It can be:

- ❖ Familial
- ❖ Syndromic (Turner's / Klinefelter's / Down's / Klippel Trenaunay Weber)

It can be:

- ❖ Lymphoedema — Present at birth— <2 years congenital (10%) — Familial type is called as **Nonne-Milroy's disease**. It is type I familial, autosomal dominant—chromosome 5 related; bilateral upper and lower limbs, genitalia and face may be involved. Incidence is 1:6000 of live births.
- ❖ Lymphoedema — Present at puberty— up to praecox — 2–35 years (80%).  
— Familial type is called as **Letessier-Meige's syndrome**. It is type II familial. It occurs between puberty and middle age.
- ❖ Lymphoedema — Present in adult life—after tarda 35 years

*It can be radiologically (lymphangiography):*

- ❖ Hypoplasia 70%
- ❖ Aplasia 15%
- ❖ Hyperplasia (varicose lymphatics) 15%

## Pathophysiology of Lymphoedema

Decreased lymphatic contractility, lymphatic valvular insufficiency, lymphatic obliteration by infection, tumour or surgery causes all effects and pathology of lymphoedema. This leads to lymphatic hypertension and dilatation causing lymph stasis, accumulation of proteins, glycosamines, growth factors, and bacteria. There is more collagen formation, deposition of proteins, fibroblasts, ground substance causing fibrosis in subcutaneous and outside deep fascia. Muscles are normal *without* any oedema but may get *hypertrophied*.

### Causes of secondary lymphoedema

- ❖ Trauma
- ❖ Surgery—inguinal block or axillary block dissection/post-mastectomy with axillary clearance

*Contd...*

Contd...

- ❖ Filarial lymphoedema due to *Wuchereria bancrofti*—common cause in coastal region
- ❖ Tuberculosis
- ❖ Syphilis
- ❖ Fungal infection
- ❖ Advanced malignancy—hard, fixed lymph nodes in axilla or in inguinal region
- ❖ Postradiotherapy lymphoedema
- ❖ Bacterial infection
- ❖ Rare causes: Rheumatoid arthritis, snake and insect bites, DVT, chronic venous insufficiency

**Note:**

Secondary lymphoedema develops rapidly.

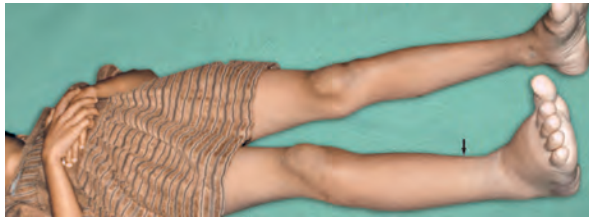


Fig. 1.439: Right side congenital limphoedema in a girl.

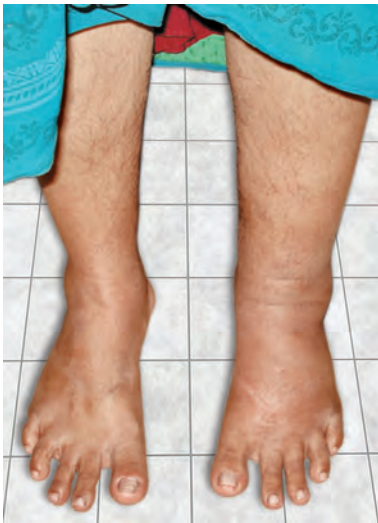

Fig. 1.440: Early lymphoedema left side—pitting type.

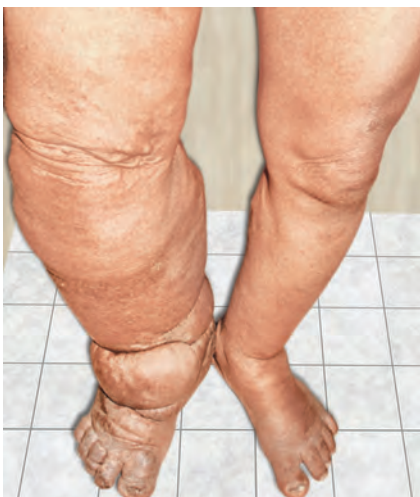

Fig. 1.441: Late lymphoedema—grade 2.

## Filariasis

It is caused by a parasite *Wuchereria (Brazil) Bancrofti (Australia)*. It was also called as Malabar leg in 1709, by Clarke, Cochin. Female adult worm is longer 7–10 cm than male worm (4 cm). *Microfilaria* is colourless, translucent, 300  $\mu$  length and 10  $\mu$  thick. It has head, body and tail. *Microfilaria* circulates in blood. In India, Asian countries and China, they show nocturnal periodicity (from 10 PM to 4 AM). It is related to night biting habits of the vector, *Culex fatigans* mosquito and sleeping habits of the host.

*Man* is the definitive host; animal or reservoir host is not known. *Female mosquito* is intermediate host (in India and China—*Culex fatigans*). Development or multiplication of microfilaria will never occur in human blood. Life span of microfilaria in human blood is 3 months. *Microfilaria* is infective to female mosquito. A density of 15 microfilaria/drop of blood are needed to make it infective.

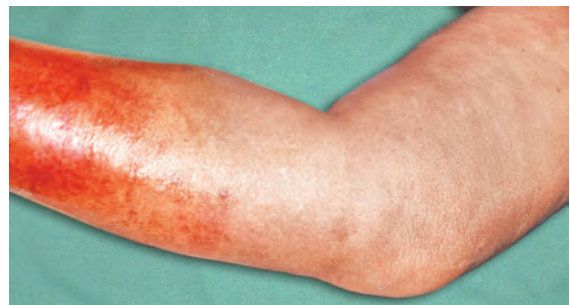
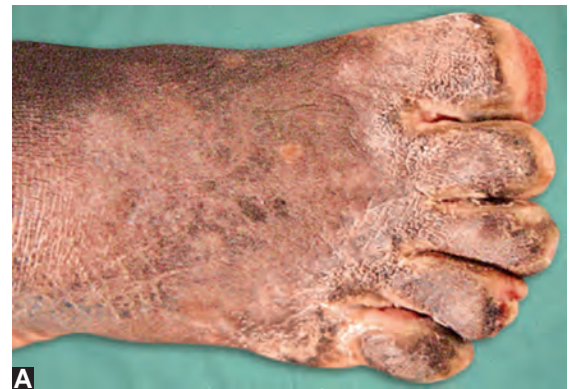
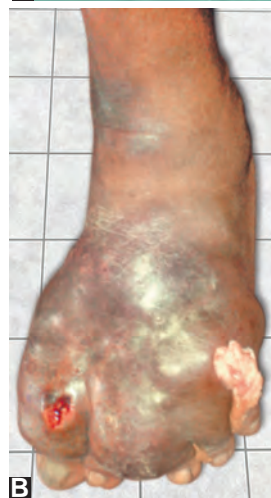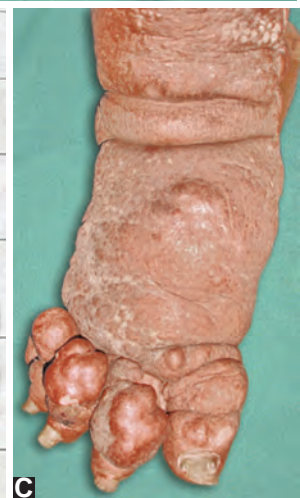Fig. 1.442: Lymphoedema leg extending into the thigh with lymphangitis.



A



B



C

Figs 1.443A to C: Lymphoedema foot in different patients—severe with vesicles/oedema/skin changes/fissures.

## Life Cycle

Microfilaria from carrier human blood → enters the stomach of female *Culex* mosquito when it bites human carrying the parasite in blood → ex-sheathing of microfilaria in stomach of mosquito in 6 hours → penetrate the stomach wall → migrate to thoracic muscles of mosquito in 12 hours → metamorphosis into sausage shaped first stage larva in 48 hours → second stage larva in one week → elongated actively motile *third stage infective larva* in one more week (one microfilaria forms one infective larva; microfilaria never multiplies in mosquito nor in human) → enters the proboscis of mosquito to become infective to human during the mosquito bite; it takes 20 days for microfilaria to develop into infective 3rd stage larva in mosquito [*extrinsic incubation period*] → enters human skin while biting → many larvae get destroyed in human skin by immunity, few enters lymphatics → enters regional lymph nodes in inguinal or axillary or abdominal nodes → develop into adult worm in lymph nodes → mating of female and male worms takes place → gravid female worm releases up to 50,000 microfilariae/day into lymph circulation → thoracic duct → subclavian vein → microfilaria in human circulation → infective to female mosquito. Time from 3rd stage infective larva entering human skin and forming adult worm and later releasing microfilaria into blood is called as *biological incubation period* (12 months); time from 3rd stage infective larva entering human skin to appearance of first clinical feature is called as *clinical incubation period* (16 months).

## Effects of *Wuchereria Bancrofti* Infection

- ◆ *Carrier stage* having circulating microfilaria but *asymptomatic*.
- ◆ *Immune and allergic reactions* by adult worm causing macrophage and lymphocyte infiltration, endothelial hyperplasia, lymphatic vessel wall thickening, lymph stasis, dilatation, further reaction, fibrosis, further blockage, calcification, recurrent streptococcal infection, filarial lymphoedema.
- ◆ *Filarial fever, urticaria, pruritus, epididymo-orchitis* as acute presentation.
- ◆ *Occult filariasis* where microfilaria is not demonstrable in blood but identified in lungs (by biopsy confirmation) causing eosinophilia, bronchospasm, nocturnal cough, fever, wheeze, weight loss, arthritis, thrombophlebitis, tenosynovitis.
- ◆ *Lymphadenitis, lymphangitis*.
- ◆ *Lymphangiomas, lymphorrhagia, lymph scrotum, lymphocele, chyluria, chylous diarrhoea, retroperitoneal lymphangitis, chylous ascites, chylothorax*.
- ◆ *Blood smear—night time (thick and thin), lymph node biopsy, skin test, eosinophilia, serological tests, DEC provocation test (by giving 100 mg DEC) are different investigations.*

### Pathology (commonly in filarial lymphoedema)

Recurrent lymphangitis causes obliteration of lymph vessels  
 ↓  
 Dermal lymphatic backflow  
 ↓  
 Retrograde obliteration (or die back of lymphatics)  
 ↓  
 Oedema, initially pitting but later nonpitting  
 ↓  
 Recurrent cellulitis—thickening of skin  
 ↓

Contd...

Contd...

Accumulation of proteins, growth factor, glycosaminoglycans  
 ↓  
 Activation of collagens and keratinocytes  
 ↓  
 Protein rich lymphoedematous tissue formation  
 ↓  
 Deposition of ground substance, subdermal fibrosis  
 ↓  
 Dermal thickening and dermal proliferation, Fissuring → Cracks—  
 Ulceration—Abscess formation  
 ↓  
 Stout leg with unbearable weight  
 ↓  
 Elephantiasis.

Rarely it causes protein losing diarrhoea, chylous ascites, chylothorax, chyluria, lymphorrhoea. Recurrent lymphadenitis occurs in the region which aggravate the condition.

Disease in the limb is confined to skin and subcutaneous tissue, i.e. often, only superficial lymphatics are involved by the disease, deep lymphatics are not. *Superficial and deep lymphatics are not communicating* with each other (Unlike the veins in the limb where superficial and deep veins are freely communicating with each other).

### Sites of lymphoedema

- ❖ Lower limb—most common
- ❖ Upper limb
- ❖ Scrotum, penis (Ram's horn penis)
- ❖ Breast—requires reduction mammoplasty
- ❖ Labia
- ❖ Eyelid
- ❖ Localised lymphoedema

## Clinical Features

- ◆ Swelling in the foot, extending progressively in the leg—*tree trunk* pattern leg.
- ◆ Loss of normal perimalleolar shape—*tree trunk pattern* leg.
- ◆ *Buffalo hump* in the dorsum of the foot.
- ◆ Squaring of toes.
- ◆ Skin over the dorsum of foot cannot be pinched because of subcutaneous fibrosis—*Stemmer's sign*.
- ◆ Initially pitting oedema occurs, which later becomes nonpitting.

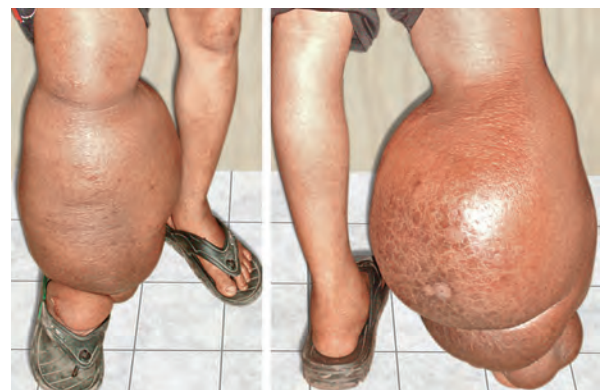
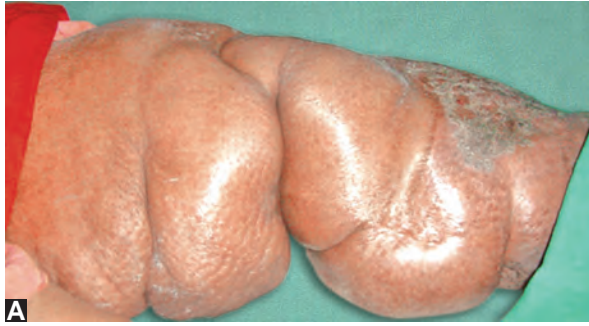
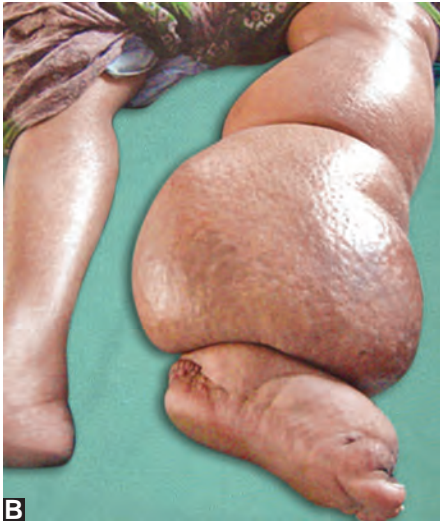Fig. 1.444: Typical elephantiasis leg with late lymphoedema.

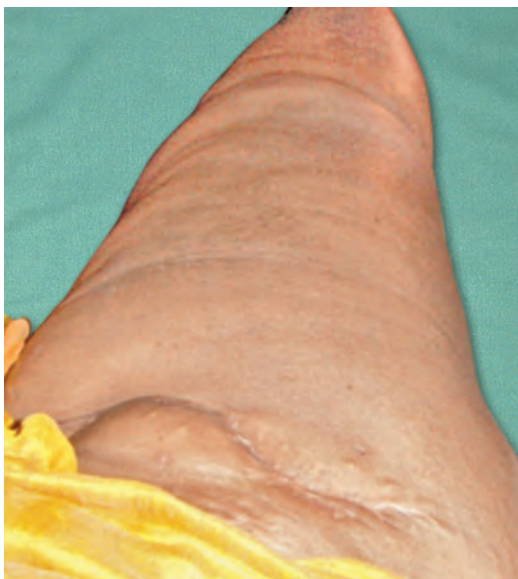

A

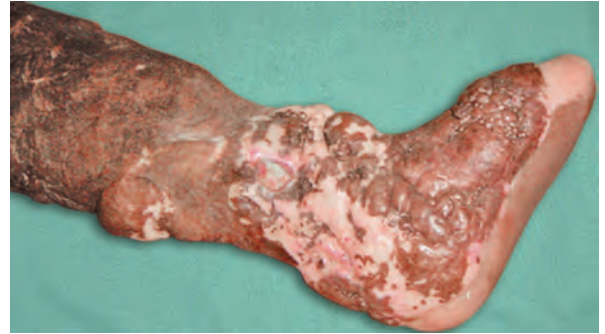

B

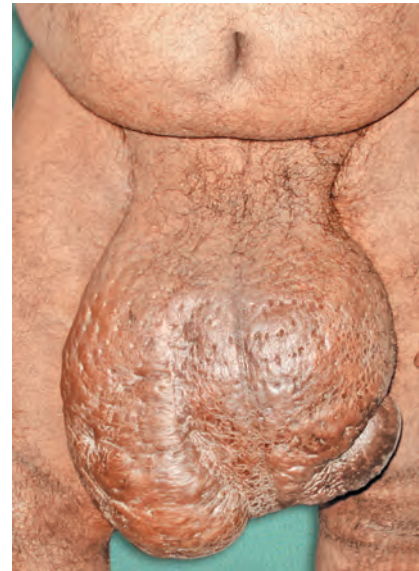**Figs 1.445A and B:** Different lymphoedema pictures. Note the oedema, fissuring, cracks. All these make it more vulnerable for infection.



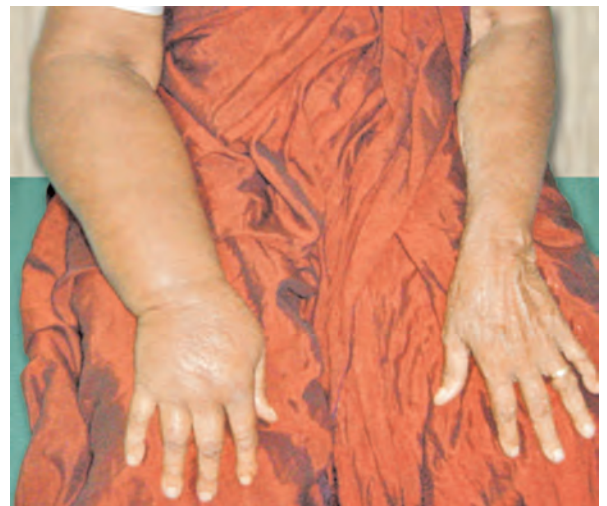**Fig. 1.446:** Lymphoedema of lower limb developed after ilioinguinal block dissection for nodal secondaries from melanoma.



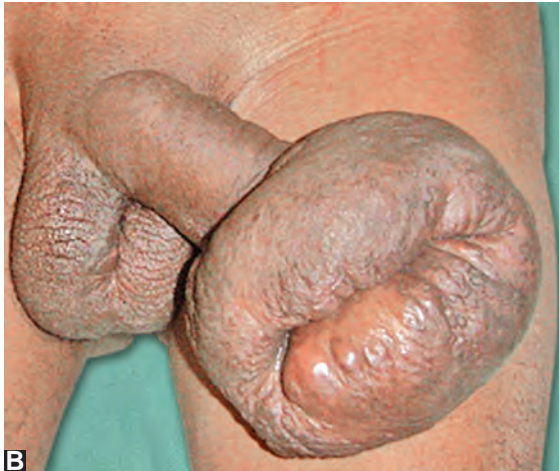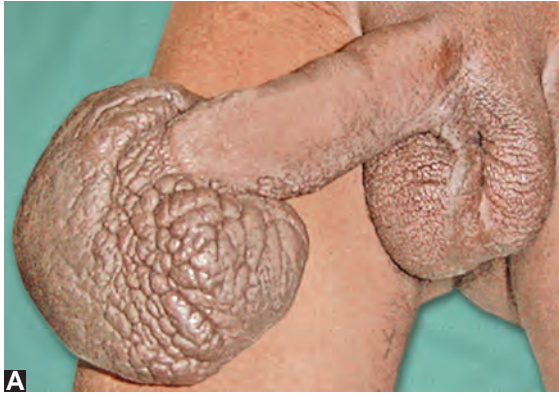**Fig. 1.447:** Recurrent filarial leg with nodules and ulceration.



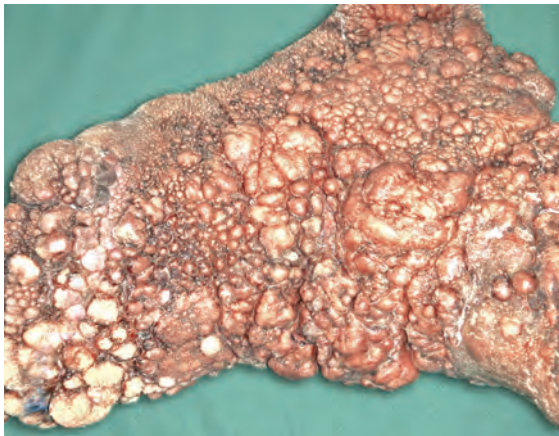
**Fig. 1.448:** Extensive scrotal lymphoedema of filarial origin. Patient underwent scrotal reduction.



**Figs 1.449:** Lymphoedema right forearm. Common causes for upper limb lymphoedema are filarial and post-mastectomy with axillary nodal clearance.



**Figs 1.450A and B:** Lymphoedema of penis. It needs reduction and reconstruction otherwise it may cause urinary problem and sexual dysfunction.



**Fig. 1.451:** Severe lymphoedema foot with vesicles and thickening.

- ◆ Dull ache/severe pain/burning/bursting/cramps; 50% patients will have pain.
- ◆ Debility/immobility/obesity/muscle wasting.
- ◆ Athlete's foot with joint pain and disability.
- ◆ Eczema, fissuring, papillae formation, ulceration, lymph ooze, elephantiasis are other features.
- ◆ Fever, malaise, headache.
- ◆ Recurrent abscess formation.

- ◆ Psychological and social discomfort causing severe morbidity.
- ◆ *Endemic elephantiasis/podoconiosis* is common in Africa; seen in barefoot workers; due to destruction of lymphatics by silica derived from soil containing alkaline volcanic rocks.

#### Brunner's grading of lymphoedema

*Latent*—subclinical: No clinically apparent lymphoedema.

- Grade I Pitting oedema which more or less disappears on elevation of the limb—is due to excess deposition of interstitial fluid
- Grade II Nonpitting oedema occurs which does not reduce on elevation
- Grade III Oedema with irreversible skin changes like fibrosis, papillae, fissuring

#### Lymphoedema can be

- ❖ *Mild* lymphoedema— <20% of excess limb volume.
- ❖ *Moderate* lymphoedema—20—40%.
- ❖ *Severe* lymphoedema— >40%.

### Differential Diagnosis

- ◆ Cardiac causes, hypoproteinaemia, malnutrition, nephrotic syndrome, liver failure.
- ◆ Myxoedema.
- ◆ Trauma.
- ◆ Venous diseases like DVT.
- ◆ Lipodystrophy and lipoidosis (lipoedema). Lipoedema occurs exclusively in females; begins in puberty; bilateral and symmetrical; trunk may be involved; feet are not involved; not pitting; not related to elevation/compression; MRI shows only fat without fluid.
- ◆ Arterial diseases including AV malformations.
- ◆ Gigantism.
- ◆ Drug induced— steroids, estrogens, nifedipine.
- ◆ External compression of veins as caused by abdominal tumours.

#### Investigations

- ❖ For the cause.
- ❖ ESR, peripheral smear.
- ❖ Lymphangiography.
- ❖ Isotope-lymphoscintigraphy.
- ❖ MRI, CT scan to identify the cause.

### Complications

- ◆ Skin thickening, abscess and maggot's formation.
- ◆ Recurrent cellulitis, nonhealing ulcers, septicaemia.
- ◆ Lymphangiosarcoma; *Stewart Treves syndrome* (0.5%, occurs after 10 years), which presents as multiple bluish satellite nodules in the skin of the limb often with ulceration and haemorrhage. Skin/nodule biopsy is confirmative. Chemotherapy, radiotherapy, later even though radical amputation is the treatment, it carries very poor prognosis. This syndrome is usually seen in *upper limb after mastectomy*.
- ◆ Recurrent streptococcal infection.

*Indecisive people are like a blind man looking in a dark room for a black cat that isn't there.*

## Treatment

### Conservative

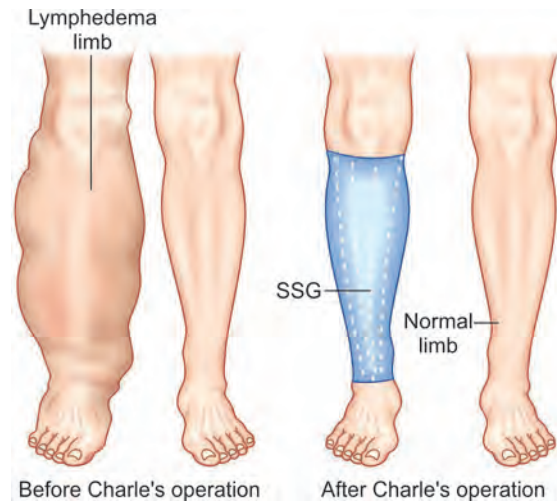
- Elevation of the limb, exercise, weight reduction.
- Static isometric activities like prolonged standing or carrying weights should be avoided; rhythmic isotonic movements like swimming/massaging should be encouraged.
- Diuretics to reduce the oedema is controversial. It more often causes electrolyte imbalance than being beneficial.
- Benzopyrones are protienolytic agents/*lympedim*. They are coumarin (1, 2 benzopyrones) derivatives with no anticoagulant effect but increase the lymphatic peristalsis and pumping mechanism along with proteolysis.
- Daily wearing of below knee stockings.
- Avoid trauma and infection.
- Intermittent pneumatic compression devices (Pressure >50 mmHg); multilayered lymphoedema bandaging (MLLB)—nonelastic type is preferred method; graded stockings.
- Antibiotics—flucloxacillin, erythromycin, long-acting penicillins.
- Topical antifungal 1% clotrimazole and systemic griseofulvin 250–1000 mg.
- Regular washing and keeping the limb clean is very important.
- Diethyl carbamazine citrate (DEC) 100 mg TID for 3 weeks.
- Pain relief—by suitable means.
- Skin care:
  - ▶ Keratolytics like salicylic acid 5%; bland emollient; soft/liquid paraffin.
  - ▶ Avoidance of skin sensitisers like some soaps.
  - ▶ Topical steroids.
  - ▶ Control of allergy.
  - ▶ Control of fungal infection by drugs like fluconazole.
  - ▶ Three per cent benzoic acid ointment to prevent Athlete's foot.
  - ▶ Control of lymphorrhoea.
  - ▶ Prevention/control of skin infections.
- Complex decongestive therapy** is a comprehensive two phase program of elevation, exercise, massaging, and compression wraps. First phase is *intensive therapy* and second phase is *maintenance therapy*.
 

*Compression wraps* may be high stretch wraps or low stretch wraps. Low stretch wraps are better accepted. It should be worn initially for 24 hours. Compression wraps are used in initial intensive phase of therapy. *Graduated elastic compression garments* are used in maintenance phase which provides maximum pressure of 50 mmHg at the distal part with gradual reduction of pressure in proximal portion.
- Manual lymphatic drainage* is a specialised technique to stimulate the contractility of lymph collecting vessels and enhance fluid and protein transport by gentle, light, superficial massaging of the skin so as to open up new lymphatic vessels. Technique is done first on the opposite normal side; then trunk, same side trunk; same side proximal; same side distal and later same side distal to proximal fashion, so as to redirect the lymph towards functioning lymphatic territories.

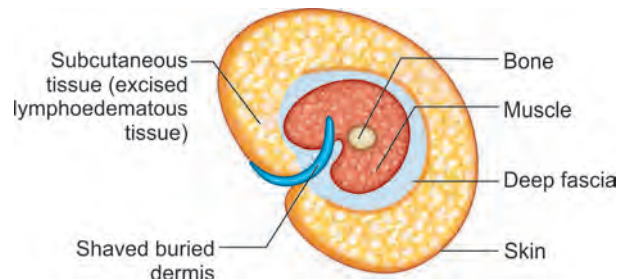
### Surgery

#### Surgeries for lymphoedema has been classified as:

- Excisional*
  - ▶ Charle's operation.
  - ▶ Homan's operation.
- Physiological*
  - ▶ Omentoplasty.
  - ▶ Nodovenous shunt (Neibulowitz).



**Fig. 1.452:** Charle's excisional surgery. Here after excising lymphoedematous tissue, area is covered with skin graft.

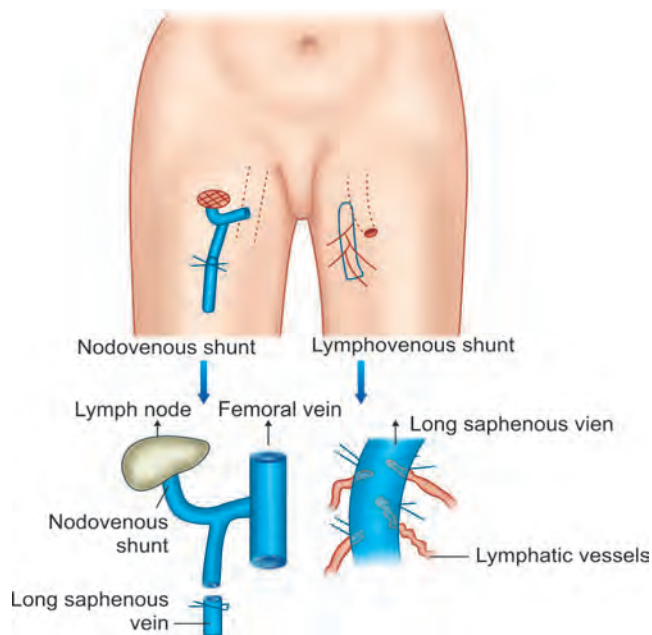


**Fig. 1.453:** Thompson's Swiss-roll operation. Here after removal of lymphoedematous tissue, deep fascia is opened to expose the muscle. Epidermis abraded using skin graft knife. This shaved dermis is buried into the muscle to get communication into the deeper lymphatics.

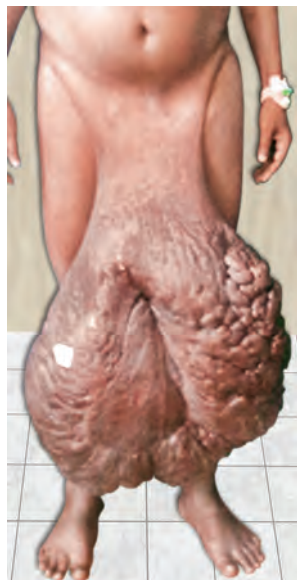- ▶ Lymphovenous shunt (O'Brien's).
- ▶ Ileal mucosal patch.
 

Here either communication between superficial and deep lymphatics are created or new lymphatic channels are mobilised to the site.

*Omentoplasty* (Omental pedicle): As omentum contains plenty of lymphatics, omental transfer with pedicle will facilitate lymph drainage.
- c. *Combined*: Both excision + creation of communication between superficial and deep lymphatics.
  - ▶ Sistrunk operation.
  - ▶ Thompson's operation.
  - ▶ Kondolean's operation.
- d. *Bypass procedure*:
  - ▶ *Handley's* (1908) silk threads/nylon threads/perforated polyethylene tubes placement as burial from ankle to mid-abdominal level, kept for one year. Procedure is only of historical interest.
  - ▶ Skin bridge across the thigh and abdomen (Gillies).
  - ▶ Nodovenous shunt.
  - ▶ Lymphovenous shunt using microscope.
  - ▶ Ileal mucosal patch (Kinmonth). Segment of ileum with pedicle is isolated and opened to expose the mucosa; mucosa is denuded and this mucosa is placed in the thigh as burial to communicate with lymphatics to drain into abdominal lymphatics across ileum.



**Fig. 1.454:** Diagram showing right side groin nodovenous shunt between inguinal lymph node and long saphenous vein. Left side showing lymphovenous shunts between dilated lymphatics and long saphenous vein. At least 4 lymphatics should be anastomosed using 7 zero/11 zero prolene—using operative microscope.



**Fig. 1.455:** Believe it or not! Severe scrotal lymphoedema reaching almost up to feet; after surgical excision it weighed 40 kg; post-operatively patient went home with – 40 kg weight (Courtesy: Professor Shivananda Prabhu, MS, KMC, Mangaluru).

- ▶ Baumeister lymphatic grafting.
- ▶ Autotransplantation of free lymphatic flap from opposite side—done in post-mastectomy lymphoedema (Trevidic and Cormier).

e. *Limb reduction surgeries:*

- ▶ **Sistrunk operation:** Along with excision of lymphoedematous tissue, window cuts in deep fascia is done, so as to allow communication into normal deep lymphatics.

- ▶ **Homan’s operation:** Excision of lymphoedematous tissue is done after raising skin flaps. Later skin flaps are trimmed to required size and sutured primarily. Medial and lateral sides of the limb are done at separate sittings with 6 months interval.
- ▶ **Thompson’s operation:** Lymphoedematous tissue is excised under the skin flaps. Epidermis and part of the dermis of one of the skin flaps is shaved off using Humby’s knife. It is buried under opposite flap, deep to the deep fascia like a *swiss roll* (*Swiss roll operation* or *buried dermal flap operation*). Problems here are formation of epidermal cysts and sinus.
- ▶ **Kondolean’s operation:** Along with excision of lymphoedematous tissue, vertical strips of deep fascia is removed so as to open the deep lymphatics which creates communication between superficial and deep lymphatics.
- ▶ **Macey’s operation:** Here skin and subcutaneous tissue are peeled back with deep fascia and split skin grafting is done over the denuded area. Overlying pad of tissue is sutured back temporarily and after 10 days, it is trimmed away.
- ▶ **Miller’s procedure:** It is excision of subcutaneous tissues under the skin flap with deep fascia in two stages. First stage is done over the medial aspect of the limb; second stage done after two months over lateral aspect of the limb.
- ▶ **Charle’s (1912) operation:** Done in severe lymphoedema with elephantiasis. Along with excision of lymphoedematous tissue, skin grafting is done. It reduces the size and weight of the limb. Patient becomes ambulatory. Wound sepsis, graft failure, dermatitis, hyperkeratosis are the complications.
- ▶ Reduction surgeries are done for lymphoedema of scrotum, penis, labia and eyelid. In severe type, occasionally amputation may be required.

## ■ LYMPHOMAS

They are progressive neoplastic condition of lymphoreticular system arising from stem cells.

Lymphomas are the 3rd most common malignancy among children comprising 15% of paediatric cancers.

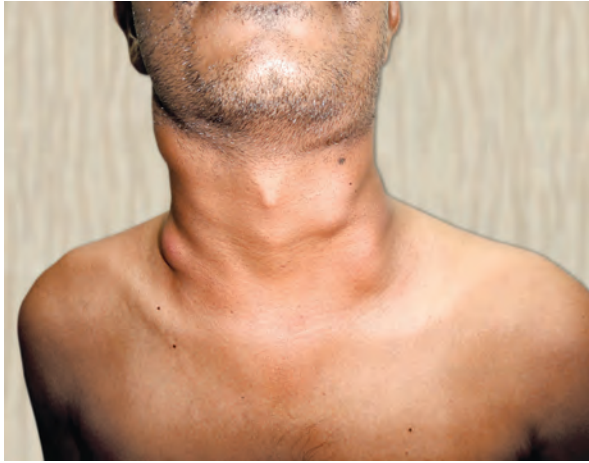### Aetiology

- ◆ Genetic predisposition.
- ◆ Sjogren’s syndrome—30 fold increase of NHL.
- ◆ HIV infection.
- ◆ Wiskott—Aldrich syndrome.
- ◆ Ataxia—telangiectasia.
- ◆ Bloom’s syndrome.
- ◆ Virus aetiology—Epstein-Barr virus.
- ◆ Celiac sprue—intestinal T cell lymphoma.
- ◆ *H. pylori* may be associated with MALT lymphoma.
- ◆ Occupation causes—hair dye workers; herbicide exposure.
- ◆ Ionising radiation.
- ◆ Smoking; alcohol consumption; tobacco usage.
- ◆ Lymphomas are more common in western countries than in Asia.

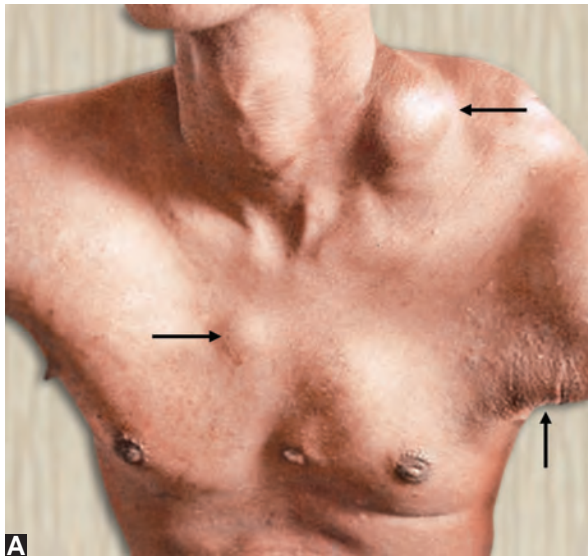
### Types

- ◆ *Hodgkin’s lymphoma (HL).*
- ◆ *Non-Hodgkin’s lymphoma (NHL).*

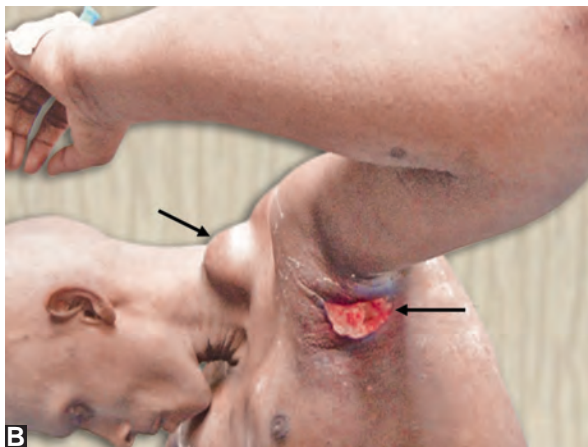




**Fig. 456:** Lymphoma involving neck nodes. Differential diagnosis could be tuberculous lymphadenitis.



**A**



**B**

**Figs 1.457A and B:** Stage IV lymphoma with neck nodes/sternal swelling/axillary nodes which has ulcerated (ulceration is not common in lymphoma).

WHO modified **REAL** classification (**R**evised **E**uropean **A**merican **L**ymphoma) of lymphoma:

- ❖ B-cell neoplasms
    - Precursor B cell neoplasm—ALL, LBL.
    - Peripheral B cell neoplasm—it includes all B cell related non-Hodgkin's lymphomas
  - ❖ T-cell and putative NK cell neoplasms
    - Precursor T cell neoplasms—ALL and LBL T cell related
    - Peripheral T cell and NK cell neoplasm—it includes all T cell related non-Hodgkin's lymphomas
  - ❖ Hodgkin's lymphoma
    - Predominant HL—nodular lymphocyte type
    - Classical HL
      - Nodular sclerosis
      - Lymphocyte rich
      - Mixed cellularity
      - Lymphocyte depletion
  - ❖ Precursor lymphoid neoplasms.
  - ❖ Immunodeficiency-associated lymphoproliferative disorders.
- Note:** ALL is acute lymphoblastic leukaemia. LBL is lymphoblastic lymphoma.

#### Older classifications (Not practiced now)

- ❖ Jackson and Parker (1944): Paragranuloma; granuloma; sarcoma.
- ❖ Lukes and Butler (1966): Lymphocytic and histiocytic nodular; lymphocytic and histiocytic diffuse; nodular sclerosis; mixed cellularity; diffuse fibrosis; reticular.

### HODGKIN'S LYMPHOMA (HL)

*(The lymph glands of the neck) exhibited a firm cartilaginous structure of a light colour and very feeble vascularity, but with no appearance of softening or suppuration. Glands similarly affected accompanied the vessels into the chest, where the bronchial and mediastinal glands were in the same state and greatly enlarged.... The spleen was enlarged to at least four times its natural size... presenting the same structure as the enlarged glands.*

—Thomas Hodgkin, 1832

- ◆ It is the most common type of lymphoma.
- ◆ Infectious mononucleosis, Epstein-Barr virus, HIV infection and genetic monoclonal B cell disorder (90%) may be the aetiologies.
- ◆ Grossly lymph nodes are fleshy, pinkish grey, and rubbery in consistency.
- ◆ Microscopically contains cellular infiltration with lymphocytes, reticulum cells, histiocytes, fibrous tissue and **Reed-Sternberg** cells: (Reed-Sternberg cells are *giant cells with two large mirror image nuclei*). Owl eye, 50 μm sized.

#### Rye's classification

- ❖ Lymphocytic predominance. Has got *good prognosis—rare*
  - ❖ Mixed cellularity—most common, associated with EBV.
  - ❖ Nodular sclerosis—commonest.
  - ❖ Lymphocytic depletion. Has got *poor prognosis—rare*.
- (Reed-Sternberg cells are also seen occasionally in certain other conditions like glandular fever).

## Clinical Features

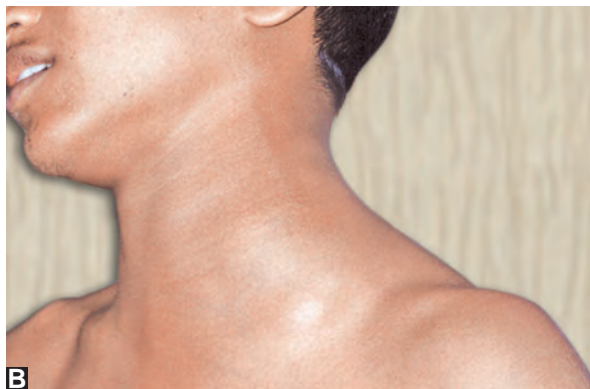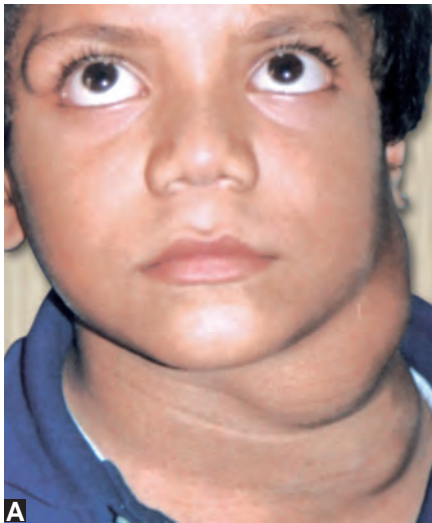- ◆ It is more common in males.
- ◆ It has got bimodal presentation. It is seen in young and adolescents (20–30 years) as well as in elderly (> 50 years).
- ◆ Painless progressive enlargement of lymph nodes. They are smooth, firm, usually discrete (without matting), nontender, typically with *India rubber* consistency.
- ◆ Pain after alcohol consumption even though is very uncommon (3%) with low sensitivity but when present has got high specificity and is pathognomonic of HL. Pain appears within 3 minutes after alcohol intake in the vicinity of the involved node.

## Site

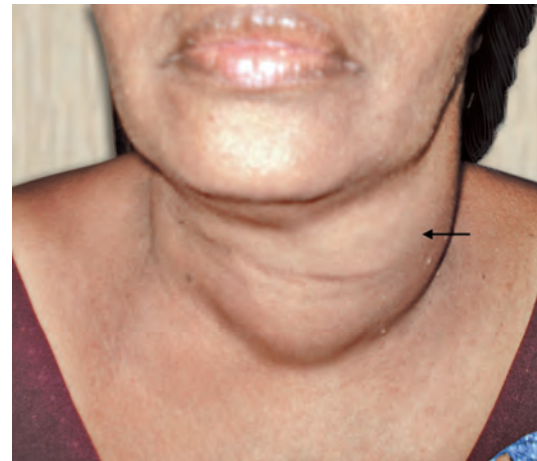- ◆ *Cervical lymph nodes most common*—82% (lower deep cervical group and in posterior triangle).
- ◆ Others include axillary, mediastinal, inguinal, abdominal.
- ◆ Axial lymphatics are commonly involved.

## Specific Features

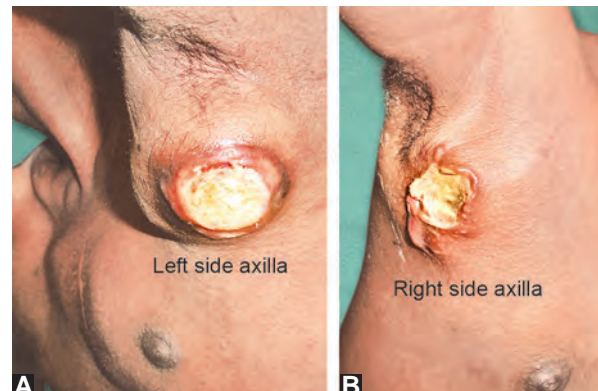
- ◆ Nodular sclerosis is most common type.
- ◆ Consecutive group of lymph nodes are involved.
- ◆ *Splenomegaly* is very common (45%).
- ◆ Hepatomegaly with jaundice (5%)—jaundice is due to haemolysis or due to diffuse liver involvement.
- ◆ *Para-aortic lymph nodes* may be enlarged and often palpable as vertically placed mass at or just left of the midline, which does not move with respiration, does not fall forward, nonmobile, resonant, smooth, firm mass often with transmitted pulsation from aorta (secondaries are hard, nodular usually primary from GI, melanoma, testis). Ascites is not a common feature.
- ◆ Pruritus—25%. It may be the only presenting symptom. It is usually seen in nodular sclerosis type.
- ◆ *Constitutional symptoms like fever, night sweats, weight loss may be present which signifies stage “B”, which has got poor prognosis. Stage “A” is absence of these symptoms which signifies better prognosis.*



**Figs 1.458A and B:** Lymphoma in a boy and in an adolescent with neck nodes. Note the diffuse nature. Nodes are usually *India rubber* consistency.



**Fig. 1.459:** Hodgkin's lymphoma in neck region.



**Figs 1.460A and B:** Fungating lymphoma in both axilla of a patient.

### Stage 'B' symptoms

- ❖ Weight loss, more than 10% in 6 months.
  - ❖ Fever, (earlier called as *Pel Ebstein fever* is *cyclical high fever*, actually is due to brucellosis).
  - ❖ Night sweats.
- ◆ *Mediastinal lymph node* involvement may cause compression features like SVC obstruction. Mediastinal lymphoma is the most common mediastinal malignancy which usually occurs in *anterior* mediastinum. Occasionally presentation may be difficulty in breathing, chest pain, dysphagia and SVC obstruction (*Pemberton's sign may be positive*). It may be asymptomatic also. If ratio between maximum transverse diameter of mediastinal mass to maximum transverse intrathoracic diameter (*MMR*) is more than 0.33 in chest X-ray or more than 0.35 in CT chest, then it carries worst prognosis.
- ◆ *Occasionally bone like vertebrae may get involved.*
  - ◆ Anaemia, pancytopenia, fatigue, bone pain, petechiae with red coloured skin patches, nephrotic syndrome (minimal change disease).

### Ann-Arbor clinical staging

- Stage 1: Confined to one group of lymph node  
 Stage 2: More than one group of lymph nodes on one side of the diaphragm  
 Stage 3: Nodes involved on both sides of the diaphragm  
 Stage 4: Extranodal involvement like liver, bone marrow  
 Suffix 'S'—Spleen involved  
 Suffix 'B'—Presence of constitutional symptoms  
 Suffix 'A'—Absence of constitutional symptoms

#### Note: In modification, following additions are there:

- ❖ Single extralymphoid site is I E
  - ❖ An extralymphoid site with one or more lymph nodes same side of diaphragm is II E
  - ❖ An extralymphoid site with lymph nodes on both sides of diaphragm III E.
  - ❖ An extralymphoid site with spleen and lymph nodes on both sides of diaphragm III SE.
  - ❖ Spleen with lymph nodes on both sides of diaphragm is III S.
- N—Nodes H—Liver S—Spleen L—Lung  
 M—Marrow P—Pleura O—Bone D—Skin  
 Stage III (1) is nodes above renal vein level and  
 Stage III (2) is below it.

#### In Cotswolds revision of Ann Arbor classification:

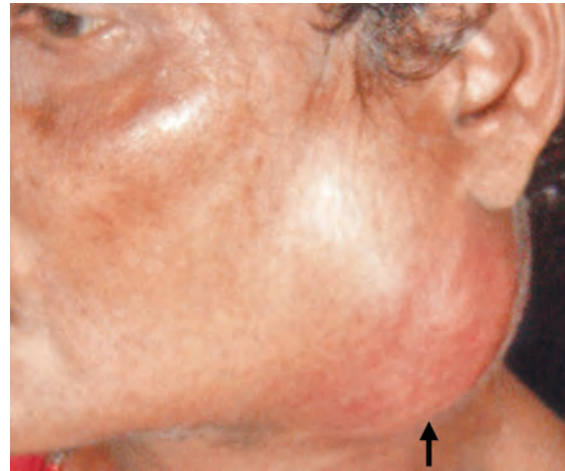*Stage 3:* Involvement of regions or structures on both sides of the diaphragm.

*Stage 4:* Involvement of extranodal sites beyond **E** sites. Here **E** means—involvement of single extranodal site contiguous or proximal to known nodal site.

*X means:* Bulky disease which is defined as >1/3rd widening of mediastinum at T5–T6 or >10 cm maximum dimension of nodal mass.

### Differential diagnosis

- ❖ Tuberculosis
- ❖ NHL
- ❖ HIV
- ❖ Chronic lymphatic leukaemia
- ❖ Nonspecific lymphadenitis
- ❖ Sarcoidosis
- ❖ Secondaries in lymph nodes



**Fig. 1.461:** Secondaries in neck lymph nodes. It is hard, large probably fixed and nonmobile making it advanced and inoperable.

### Investigations

- ◆ **Blood:** Hb%, ESR, peripheral smear, blood urea, serum creatinine. Serum alkaline phosphatase and calcium may be elevated.
- ◆ **FNAC of lymph nodes.** Not very sensitive; but initially done to rule out secondaries or tuberculosis.
- ◆ **Excision biopsy of lymph nodes.** Full lymph node is excised to retain the architecture of the lymph node. It is important to grade the tumour. It is better to have *immunohistochemistry* of tumour tissue. As cell mediated immunity is decreased, CD4/CD 8 ratio will be decreased. CD 15, 30, 45 are very useful.
- ◆ **Chest X-ray**—to look for mediastinal lymph nodes, pleural effusion.
- ◆ **Ultrasound abdomen**—to look for the involvement of liver, spleen, abdominal lymph nodes.
- ◆ **CT scan of mediastinum/chest,** abdomen and pelvis is better, ideal and essential. *CT* is used ideally to stage the disease.
- ◆ **MRI and PET scan** are very useful to identify extranodal tissue involvement. Gallium scan is less useful.
- ◆ **Bone marrow biopsy** or aspiration to stage the disease and to see the response to treatment. Usually iliac crest biopsy is done under local anaesthesia. It gives the staging.
- ◆ **Chamberlain's mediastinoscopy** and biopsy of mediastinal lymph node is done if peripheral nodes are not available for biopsy. *Laparoscopy* and biopsy of different abdominal lymph nodes is also a good option.
- ◆ **Lower limb lymphangiography** to look for the pelvic and retroperitoneal lymph nodes. It shows reticular pattern in node; it can be used to assess the therapeutic response and prognosis. Lymphoscintigraphy is better and acceptable. It is prognostic tool also.
- ◆ **Staging laparotomy:**
  - The abdomen is opened. Splenectomy is done mainly to remove the tumour bulk, as spleen is commonly involved and also to avoid irradiation to splenic area which often causes unpleasant pulmonary fibrosis. Biopsies are taken from both lobes of the liver (needle biopsy) from para-aortic, celiac mesenteric, iliac nodes. In females, ovaries are fixed behind the uterus to prevent radiation oophoritis (*oophoropexy/ovarian translocation*).

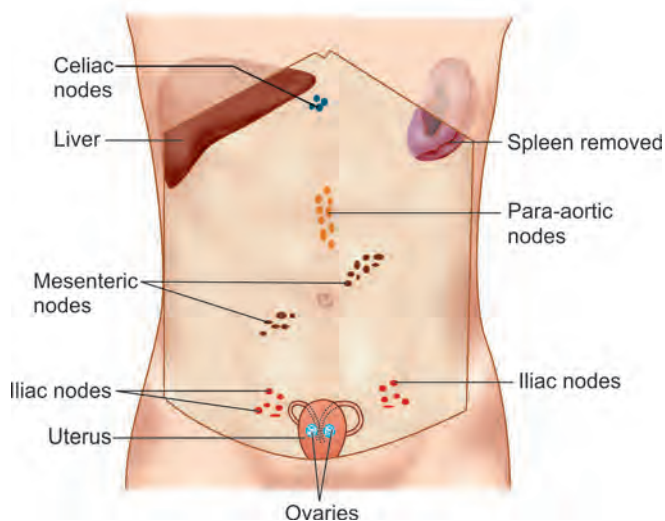
- Staging laparotomy is not routinely done now. It is done only if it benefits the patient to have better plan of treatment or better result.
- It is done in stage I/IIA lymphoma (HL) in selected patients.

**Note:**

Staging laparotomy, splenectomy (requires for immune function), lymphangiogram, IVU are no longer/very rarely done now for HL.

**Problems in HL**

- ❖ Pleural effusion—respiratory discomfort
- ❖ SVC obstruction
- ❖ Spine if involved—not very common but can occur
- ❖ Opportunistic infection—mycobacteria, cytomegalovirus, herpes zoster
- ❖ Bronchopneumonia, septicaemia
- ❖ Immunosuppression and its effects
- ❖ Risk for other malignancies in later life



**Fig. 1.462:** Staging laparotomy for Hodgkin’s lymphoma. Needle and wedge biopsies from liver/nodal biopsies from para-aortic, celiac, mesenteric, iliac nodes/splenectomy/ovarian translocation/ilic crest biopsy are the components of staging laparotomy. This can be very well-achieved through laparoscopy also now. Staging laparotomy is not commonly done now.

**Treatment for HL**

**Treatment strategy for HL**

- ❖ Early favourable stage—extended field radiation only
- ❖ Early unfavourable stage—extended radiation plus chemotherapy
- ❖ Advanced stage—extensive chemotherapy often with local radiation

**Unfavourable signs in early HL**

- ❖ Large mediastinal mass
- ❖ Extranodal disease
- ❖ Elevated ESR
- ❖ Four or more involved regions
- ❖ Presence of B symptoms
- ❖ Anaemia <10 g% low serum albumin level <4 g%
- ❖ Age more than 50
- ❖ Male gender

**Note:**

First five parameters are most important.

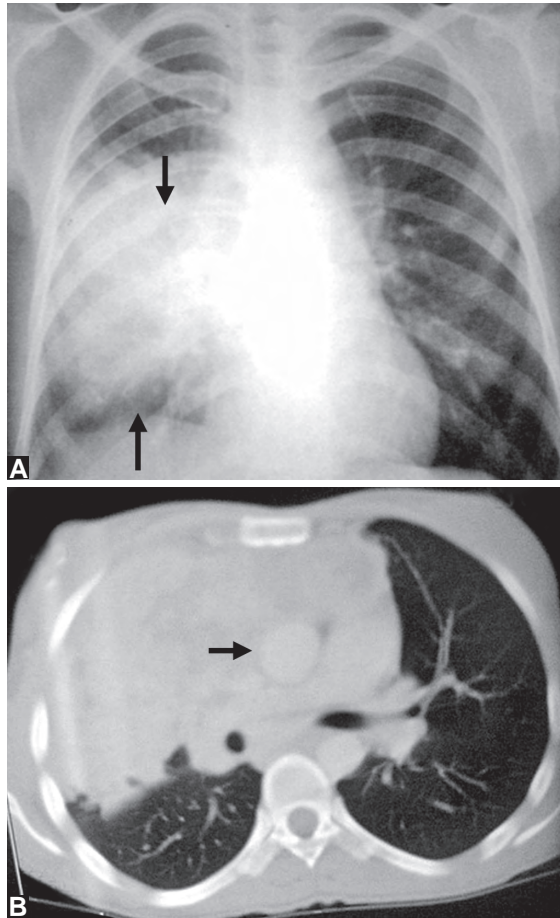
- ◆ Stage I and II:
  - ▶ Mainly **radiotherapy**—external high cobalt RT.
    - Above the diaphragm—“Y” *field therapy*, covering cervical, axillary, mediastinal lymph nodes. It may cause carcinoma of breast.
    - Below the diaphragm, *mantle or inverted “Y” field therapy*, covering para-aortic and iliac nodes. It may cause infertility.
  - ▶ Chemotherapy is also given.
- ◆ Stage III and IV: Mainly **chemotherapy**.

**Treatment for Relapses**

- ◆ Autologous stem cell transplantation.
- ◆ High dose chemotherapy.
- ◆ High dose chemotherapy with autologous stem cell transplantation.
- ◆ MOPP/ABV hybrid regime.
- ◆ Single dose vinorelbine (new vinca alkaloid); gemcitabine; immunotherapy; tumour vaccination; gene therapy.

**Differences between HL and NHL**

	<b>HL (more common)</b>	<b>NHL</b>
Age:	Young and elderly	Middle age and elderly
Pattern of involvement:	Symmetrical and consecutive	Asymmetrical
Cervical lymph node:	Commonly involved	Any group can be involved
Splenomegaly:	Common	Not common
Peripheral lymph node involvement (e.g. epitrochlear nodes)	Not common	Common
Treatment:	Mainly radiotherapy Chemotherapy (MOPP regime)	Mainly chemotherapy
Prognosis:	Better	Poor



**Figs 1.463A and B:** Mediastinal nodes involved in lymphoma as seen in chest X-ray and chest CT scan.

### Prognosis

- ◆ Stage I and II— 80%.
- ◆ Stage III A— 70%.
- ◆ Stage III B and stage IV— <40%.

### Prognostic factors

- ❖ Stage I and II has got better prognosis
- ❖ Lymphocytic predominance has got better prognosis
- ❖ Stage "A" without constitutional symptoms has got better prognosis
- ❖ Anaemia <10 g%; hypoalbuminaemia <4 g%; lymphocyte count <600/mm<sup>3</sup>; WBC count >15,000/mm<sup>3</sup>; age >50 years; involvement of bone and liver are other poor prognostic factors

### NON-HODGKIN'S LYMPHOMA (NHL)

- ◆ It occurs in middle aged and elderly. It is more aggressive than HL.
- ◆ It involves asymmetrical group of lymph nodes.
- ◆ General condition is poor.
- ◆ Inner Waldeyer ring, epitrochlear lymph nodes, peripheral lymph nodes are commonly involved.
- ◆ Spleen is not commonly involved.
- ◆ Hepatomegaly is common.
- ◆ Vertebral involvement is common; paraplegia can occur. (40%).
- ◆ Secondary infection, cachexia and immunosuppression is more common.
- ◆ Inner Waldeyer ring and oropharynx lymphoma (NHL-B cell) may be associated with MALT lymphoma of stomach; so gastroscopy is indicated in these patients.
- ◆ Pyoderma gangrenosum may the presentation.
- ◆ *Small bowel lymphomas* are usually NHL type. *Western type* is annular, ulcerative multiple B cell type, presents as obstruction, bleeding, weight and appetite loss, perforation. *Celiac disease related lymphoma* is usually primary T cell type presents with severe unresponsive diarrhoea, PUO, obstructive features. *Mediterranean lymphoma* of small bowel is seen in North America and Middle East which is associated with alpha chain disease.
- ◆ Sarcoma, carcinomas/secondaries are the differential diagnosis for NHL.

### Chemotherapy for Hodgkin's Lymphoma (HL)

<b>Mopp regime (1960) Not used now</b>	<b>ABVD regime (Standard)</b>	<b>Stanford V regime</b>	<b>BEACOPP regime</b>
<p><b>Mustine</b> (Mechloroethamine)—6 mg/q meter on 1st and 8th day.</p> <p><b>Oncovin</b> (Vinca alkaloids)—1.4 mg/sq meter on 1st and 10th day</p> <p><b>Procarbazine</b>—100 mg orally daily for 10 days</p> <p><b>Prednisolone</b>—45 mg orally daily for 10 days</p>	<p><b>Adriamycin</b>—30 mg/m<sup>2</sup> meter (cardiotoxic)</p> <p><b>Bleomycin</b>—10 mg/m<sup>2</sup> (pulmonary fibrosis)</p> <p><b>Vinblastine</b>— 6 mg/m<sup>2</sup> (bone marrow suppression)</p> <p><b>DTIC/Dacarbazine</b> 350 mg/m<sup>2</sup></p>	<p>Adriamycin (Doxorubicin)</p> <p>Bleomycin</p> <p>Vincristine, vinblastine</p> <p>Mechlorethamine</p> <p>Etoposide</p> <p>Prednisolone</p>	<p><b>Bleomycin</b></p> <p><b>Etoposide</b></p> <p><b>Adriamycin</b> (Doxorubicin)</p> <p><b>Cyclophosphamide</b></p> <p><b>Oncovin</b> - Vincristine</p> <p><b>Procarbazine</b></p> <p><b>Prednisolone</b></p>
<p><b>Note:</b> MOPP is no longer considered effective regime</p>	<p><b>Note:</b> ABVD is becoming more popular, standard and commonly used regime now. It started in Italy, 1970. It is commonly used in US.</p>	<p><b>Note:</b> It involves more intensive schedule with incorporation of radiotherapy. Not well accepted.</p>	<p><b>Note:</b> It is commonly used in Europe; its efficacy is 15% better than ABVD; but it is costly; it needs granulocyte stimulating factor to control adverse effect; secondary leukaemia is slightly higher here</p>

**Note:** Gonadal dysfunction and growth retardation is the long-term adverse effects in childhood HL due to treatment (RT and CT).

Types
<ul style="list-style-type: none"> <li>❖ Nodular (Follicular)</li> <li>❖ Diffuse lymphocytic</li> <li>❖ Undifferentiated</li> <li>❖ Histiocytic type</li> </ul>

Rappaport classification	Working classification
• Nodular	• Low grade
• Diffuse	• Intermediate grade
	• High grade

Pathological classification
<ul style="list-style-type: none"> <li>❖ <i>B cell type</i>—small lymphocytic, follicular, Burkitt’s lymphoma.</li> <li>❖ <i>T cell type</i>—cutaneous, mycosis fungoides, Sezary syndrome, lymphoblastic lymphoma.</li> </ul> <p><b>Note:</b> Many different classifications are there for NHL. Students have to refer pathology book when needed.</p> <ul style="list-style-type: none"> <li>❖ <b>Histochemistry and tumour markers</b> are very sensitive and essential tools other than biopsy; CT chest, abdomen, pelvis; MRI spine, peripheral smear and bone marrow biopsy.</li> <li>❖ <b>Serum LDH</b>, calcium, CD5, CD23 counts are very useful prognostic indicators. Raised LDH carries poor prognosis and also patients require aggressive chemotherapy.</li> </ul>

**Treatment**

Mainly **chemotherapy**

Various regimens available include:

- ◆ **CHOP regime is used**—Cyclophosphamide; Hydroxydaunorubicin; Oncovin; Prednisolone. This is the standard regime commonly used.
  - ▶ *R CHOP regime* is adding Rituximab when lymphoma is B cell type.
  - ▶ *R-CHOEP regime* is when Etoposide is added.
  - ▶ *Side effects are*—haemorrhagic cystitis (Mesna is given); alopecia; nausea and vomiting; neutropenia; severe sepsis.
- ◆ ABVD—Adriamycin, Bleomycin, Vincristine, Dacar-bazine.
- ◆ ABVP—Adriamycin, Bleomycin, Vincristine, Prednisolone.
- ◆ Combinations of above.
- ◆ *Rituximab* may be used with chemotherapy regimes.
- ◆ *Role of radiotherapy* in NHL: When vertebra is involved.
- ◆ Prognosis is poor compared to HL.

**MANTLE CELL LYMPHOMA**

- ◆ It is a type of NHL under B cell subtype comprising 6% of NHL. It is aggressive type of NHL.
- ◆ It is due to CD5 positive antigen-naive pre-germinal center B cell within the mantle zone that surrounds normal germinal center follicles. MCL cells generally over-express cyclin D1.
- ◆ It is an acquired genetic disorder; MCL is neither communicable nor inheritable.
- ◆ *Types are*—*nodular or diffuse* pattern with two main cytologic variants: *typical or blastic (aggressive)*.
- ◆ Common in old people; presenting with lymphadenopathy, fever, weight loss, night sweats, splenomegaly often other visceral organ involvement.
- ◆ *Investigations are* – lymph node biopsy with immunohistochemistry (CD5; CD10; CD23; cyclin D1); CT chest, abdomen, pelvis; bone marrow biopsy; PET scan; cell proliferation index (Ki-67). The Mantle Cell Lymphoma International Prognostic Index (MIPI) was derived to classify as *low, intermediate and high-risk group patients*. Beta-2 microglobulin is another risk factor in MCL used primarily for transplant patients.
- ◆ *Treatment:* Chemotherapy, immune-based therapy, radioimmunotherapy and new biologic agents are used. *R Maxi CHOP alternating with R-HDAC* is used as chemotherapy (see table below). Fludarabine is also can be used additionally. Total body irradiation with stem cell transplantation is also useful. Immunotherapy using rituximab is used in combination; it may be combined with radioactive molecules to have radioimmunotherapy. Targeted therapy using ibrutinib, temsirolimus, bortezomib, also used.
- ◆ *Prognosis:* MCL carries poor prognosis. Mean survival is 3 years.

**MALT LYMPHOMA (MALTOMA)**

- ◆ It is lymphoma arising from mucosa associated lymphoid tissue; it is actually extranodal marginal zone B cell lymphoma of gut mucosa associated lymphoid tissue. It is usually primary GI lymphoma (4% of gastric lymphoma); of non-Hodgkin’s B cell type.
- ◆ Commonest site is stomach. *Helicobacter pylori* infection is the causative agent commonly.
- ◆ It can be low grade or high grade.
  - ▶ Low grade occurs in chronic gastritis patient with *Helicobacter* infection. Diffuse mucosal thickening with ulceration is seen. Anti-helicobacter therapy is very useful in this type.
  - ▶ High grade is aggressive one. It presents with features similar to gastric carcinoma often with smooth, firm gastric mass in epigastric region.

Regime and drugs for NHL				
Drugs	Standard R-CHOP 14 or R-CHOP 21 regime	R-Maxi—CHOP regime	Mode of administration	Number of days
Rituximab	375 mg/m <sup>2</sup>	375 mg/m <sup>2</sup>	Intravenous infusion	Day 1
Cyclophosphamide	750 mg/m <sup>2</sup>	1200 mg/m <sup>2</sup>	Intravenous infusion	Day 1
Hydroxydaunorubicin	50 mg/m <sup>2</sup>	75 mg/m <sup>2</sup>	Intravenous infusion	Day 1
Oncovin	1.4 mg/m <sup>2</sup>	2 mg (max dose)	Intravenous infusion	Day 1
Prednisolone	40 mg/m <sup>2</sup>	100 mg/m <sup>2</sup>	Orally qid	Days 1–5

R – Maxi – CHOP is used in *Mantle cell lymphoma* as 21 days interval regime alternating with R-HDAC (Rituximab with high dose cytarabine). In other NHL excluding aggressive forms, *R-CHOP standard dose is first line therapy*.

*Laugh at obstacles and cry at your success.*

- ◆ *Dawson's criteria for primary GI lymphoma* (NHL)— No palpable superficial lymph nodes; no thoracic lymph nodes in CT scan; normal WBC count and bone marrow; predominant bowel pathology; liver, spleen are normal.
- ◆ Systemic features like fever, night sweats, and weight loss can occur in 50% cases. Bleeding with haematemesis with obstruction is not uncommon. Locoregional lymph nodes (only) may get involved.
- ◆ Endoscopic biopsy is essential to diagnose. Endosonography, bone marrow biopsy, CT scan of chest, abdomen and pelvis is a must to confirm primary GI/gastric lymphoma and to identify or to rule out extragastric lymph node NHL.
- ◆ Ann Arbor staging system is commonly used but is inadequate. *Lugano staging* system is widely accepted one—Early: Single primary lesion or multiple noncontiguous primary lesions confined to GI tract with or without nodal involvement; Advanced: Disseminated extranodal spread or supradiaphragmatic spread.
- ◆ **Treatment: First line treatment**— Primary chemotherapy with anti-*Helicobacter pylori* regime, often with RT is the standard treatment. Palliative gastrectomy in case of bleeding, perforation and obstruction is done. Radical gastrectomy is done in diseases which are confined to stomach only to in selected individuals (limited role).
  - ▶ *Early stage* (Lugano) with +ve *H. pylori*—*H. pylori* eradication therapy is used; Early stage with –ve *H. pylori* or with *H. pylori* therapy failure, local RT is used often with chemotherapy as single or multiple agents.
  - ▶ *Advanced stage* (Lugano) is treated with *H. pylori* regime with immunotherapy (Rituximab with fludarabine) and chemotherapy (oral cyclophosphamide or oral chlorambucil; IV cladribine, bortezomib).

## ■ BURKITT'S LYMPHOMA (Malignant Lymphoma of Africa)

*Thirty-eight cases of a sarcoma involving the jaws of African children are described. This is a syndrome which has not previously been fully recognised. It is by far the most common malignant tumour of childhood seen at Mulago Hospital.*

—Denis Parsons Burkitt, 1958

- ◆ It is common in South Africa and New Guinea.
- ◆ *Epstein-Barr virus* may be the aetiological agent. It is common in children.
- ◆ It is associated with infectious mononucleosis.
- ◆ It is common in malaria endemic area.
- ◆ The tumour is multifocal, rapidly growing, painless.
- ◆ Different groups of lymph nodes can also be affected.

### Microscopy

Primitive lymphoid cells with large clear histiocytes—*starry night (starry sky)* pattern.

### Sites

- ◆ It is common in jaw—either lower or upper.
- ◆ Abdominal presentation and renal involvement is common (75%).
- ◆ Renal involvement often may be bilateral.
- ◆ In females, ovaries are commonly affected.

### Types

- a. Endemic (African)—commonly occurs in jaw.
- b. Nonendemic (sporadic)—commonly occurs in abdomen.
- c. Aggressive lymphoma—occurring in HIV patients.

### Investigation

- ◆ FNAC and biopsy confirms the diagnosis.
- ◆ Jaw X-ray shows osteolytic lesions.
- ◆ Ultrasound abdomen is done to look for involvement of kidneys.
- ◆ Blood urea and serum creatinine estimation is done.

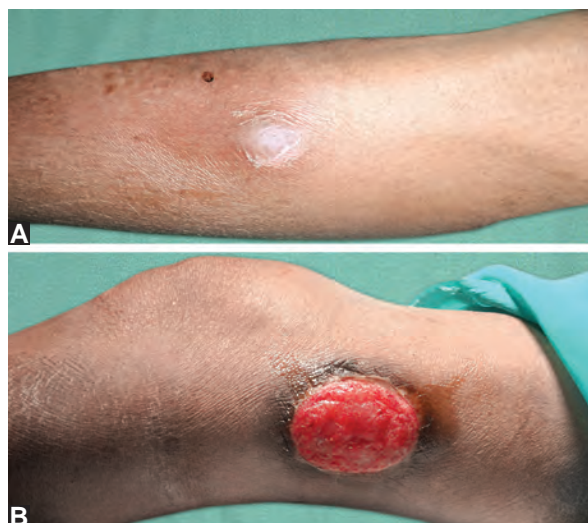
### Treatment

- ◆ Radiotherapy.
- ◆ Chemotherapy: Cyclophosphamide, methotrexate, orthomelphalan.
- ◆ Surgery is usually not indicated unless it is localised or in case of involvement of ovaries.

*Prognosis is good.*

## ■ CUTANEOUS T CELL LYMPHOMA

- ◆ Cutaneous T cell lymphoma comprises mycosis fungoides, Sezary syndrome, reticulum cell sarcoma of skin and other cutaneous lymphocytic dysplasias. Mycosis fungoides is the most common among them.
- ◆ Cutaneous T cell lymphoma can be indolent (commonly mycosis fungoides); aggressive (Sezary syndrome); provisional (granulomatous/panniculitis like T cell lymphoma).
- ◆ Initial macular patch/plaque phase slowly changes into tumour phase with painful, pruritic erythroderma often with visceral spread. Alopecia mucinosa and follicular mucinosis are common in mycosis fungoides. Lymph nodes may get involved. Tumour cells in peripheral smear are also important in deciding therapy and prognosis.
- ◆ Multiple skin biopsies/peripheral smear/node biopsy/immunohistochemistry/pheo or genotyping are important investigations.
- ◆ Prognosis depends on extent of skin involvement (more than 10% body surface area carries poor prognosis)/nodal spread/blood spread.



**Figs 1.464A and B:** Cutaneous T cell lymphoma.

- ◆ *Treatment*: Localised external beam radiotherapy; topical chemotherapy (bexarotene gel/carmustine ointment); phototherapy; total skin electron beam therapy; extracorporeal photochemotherapy. Bexarotene is a type of retinoid.
- ◆ **Sezary syndrome** is a type of cutaneous T cell lymphoma with skin lesions with special Sezary cells having cribriform nucleus. It is often associated with leukaemias. It is treated like any other cutaneous T cell lymphoma.

## ■ CHYLOUS ASCITES

It is collection of lymph in the peritoneal cavity. It is due to obstruction of intestinal lymphatics and subsequent leak.

### Causes

- ◆ *Most common cause* is—*congenital* lymphatic abnormality in children (*megalymphatics* with lymphoedema) and in adults lymph node malignancy, either primary or secondary.
- ◆ Filarial lymphoedema causing obstruction.
- ◆ Malignancy either nodal secondaries or nodal primary causing obstruction.
- ◆ Tuberculosis causing blockage of lymph drainage and rupture and leak into the peritoneal cavity.
- ◆ Post-surgical cause.

### Features

- ◆ Ascites, often massive.
- ◆ Severe malnutrition and protein deficiency.
- ◆ Features specific to the cause.
- ◆ Triglycerides >110 mg/dl in ascitic fluid is diagnostic.
- ◆ Ascitic fluid aspiration is chalky white in colour and it shows chylomicrons. It should be studied for fat globules, proteins, AFB and malignant cells.
- ◆ Laparoscopy and biopsy is necessary when lymphoma/secondaries are suspected.
- ◆ CT scan and CT guided biopsy may be needed.
- ◆ Lymphangiography to find out the site of leak.

### Treatment

- ◆ Control of infection.
- ◆ Antituberculous and antifilarial drugs.
- ◆ Fat free, protein rich diet.
- ◆ Nutritional support—TPN/enteral.
- ◆ Medium chain triglycerides can be given as it directly gets absorbed into the blood rather into the lymphatics.
- ◆ Repeated tapping, peritoneovenous shunts are often required.
- ◆ Surgical ligation of leaking lymphatic duct.

## ■ CHYLOTHORAX

- ◆ It is accumulation of lymph in the pleural cavity.
- ◆ It is *common on right side* because of long course of thoracic duct towards right side.

### Causes

- ◆ Injury due to trauma/surgeries in neck or chest. Surgical trauma is the *most common cause*— may be oesophageal surgeries, pneumonectomy, cervical sympathectomy, neck dissections or aortic surgeries.
- ◆ Tuberculosis, lymphoma or secondaries in the mediastinum.
- ◆ Carcinoma lung or oesophagus.

### Features

- ◆ Chest pain, dyspnoea, pleural effusion.
- ◆ Protein loss and malnutrition
- ◆ Pleural tap will show chalky white fluid rich in chylomicrons. Triglycerides more than 110 mg/dl in the pleural fluid.
- ◆ Chest X-ray, CT chest are needed.

### Treatment

- ◆ ICT placement.
- ◆ Fat free protein rich diet.
- ◆ Antibiotics therapy for the cause.
- ◆ Often pleurodesis using bleomycin, talc, tetracycline or pleural stripping is needed.
- ◆ Thoracic duct ligation is beneficial in traumatic/iatrogenic cases.
- ◆ Through thoracoscopic approach, ligation of the thoracic duct is done if leak persists *beyond one week*. If oral cream is given to the patient 6 hours before surgery, leaking site will be better identified. Thoracic duct is ligated *above and below* the leak either through thoracoscopy or thoracotomy.
- ◆ ICT drainage, oral diet of medium chain triglycerides which is absorbed directly into blood not through lymphatics; with TPN, is the usual earlier way of management.

## ■ CHYLURIA

- ◆ It is passage of milky white chylous urine, which is aggravated after fatty meal.
- ◆ It may be due to obstruction of intestinal lymphatic vessels leading to high lymphatic pressure causing diversion of lymph into renal lymphatics or it often may be due to rupture of intestinal lymphatics into renal pelvis or ureter leading into a lymphourinary fistula.
- ◆ *The most common cause is filarial* (2% of filarial cases): Other causes are tumour, tuberculosis, malaria and ascariasis infestation.
- ◆ Urinary infection, protein loss is common.
- ◆ It mimics bacterial/tuberculous pyuria or phosphaturia.
- ◆ Clot colic due to *lymph clot* in urinary system may be the presentation.
- ◆ Urine study, culture, IVU, lymphangiography, U/S abdomen is needed.
- ◆ *Treatment* is low fat, protein rich diet, antibiotics, DEC, plenty of oral fluid intake, ligation of dilated lymphatics through laparotomy or sclerosing the lymph vessels.
- ◆ Condition causes severe psychological and nutritional problem.

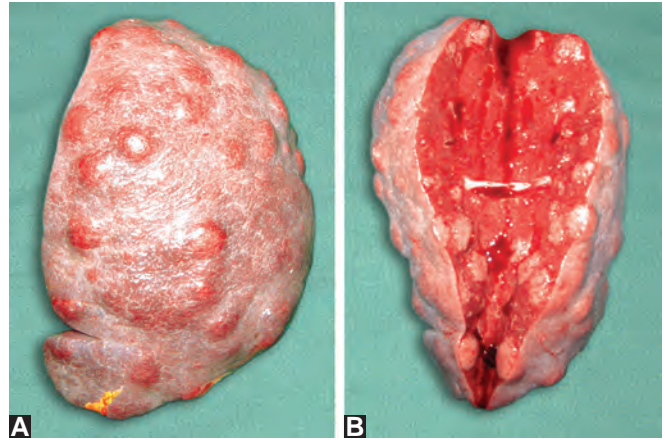


## ■ SARCOIDOSIS

It is a differential diagnosis for lymph node mass. It is basically a granulomatous condition of unknown cause with bilateral hilar lymphadenopathy; with involvement of lungs, liver, spleen, lymph nodes, lacrimal glands, parotid glands, CNS, hypercalciuria, acute onset of erythema nodosum in the skin. Fever and loss of weight are not common. It shows noncaseating epithelioid granuloma with positive Kveim-Siltzbach skin test (80%); high levels of serum angiotensin converting enzyme (SAGE). Investigations needed are—CT chest; mediastinoscopy; nodal biopsy; slit lamp examination of eye; often abnormal immunoglobulins in the circulation. It is treated by corticosteroids with good response. It should be differentiated from other causes of lymphadenopathy especially Hodgkin's lymphoma.

**Note:**

For topics tuberculous lymphadenitis and lymph node secondaries please refer chapter 'Neck'.



**Figs 1.465A and B:** Gross feature of sarcoidosis of spleen  
(Courtesy: Dr Arunkumar, MCh, Gastroenterologist).

## P. Peripheral Nerves

The power of moving in every part of the body by means of the muscles which obey the will, or by means of others the actions of which are involuntary; the various perceptions by the five external senses; and lastly those mental powers named memory, imagination, attention, and judgement, together with the passions of the mind; all these seem to be exercised by the ministry of the nerves; and are impaired, disturbed, or destroyed, in proportion to any injury done to the brain, the spinal marrow, and nerves, not only by their peculiar diseases, of which we know little, but by contusions, wounds, ulcers, and distortions, and by many poisons of the intoxicating kind.

—William Heberden, 1802

### CHAPTER OUTLINE

- |                             |                                |                                 |
|-----------------------------|--------------------------------|---------------------------------|
| ❖ Peripheral Nerve Injuries | ❖ Carpal Tunnel Syndrome       | ❖ Foot Drop                     |
| ❖ Tinel's sign              | ❖ Ulnar Nerve Injury           | ❖ Medial Popliteal Nerve Injury |
| ❖ Brachial Plexus Injuries  | ❖ Claw Hand                    | ❖ Axillary Nerve Injury         |
| ❖ Causalgia                 | ❖ Radial Nerve Injury          | ❖ Long Thoracic Nerve Injury    |
| ❖ Median Nerve Injury       | ❖ Common Peroneal Nerve Injury | ❖ Meralgia Paraesthetica        |

### PERIPHERAL NERVE INJURIES

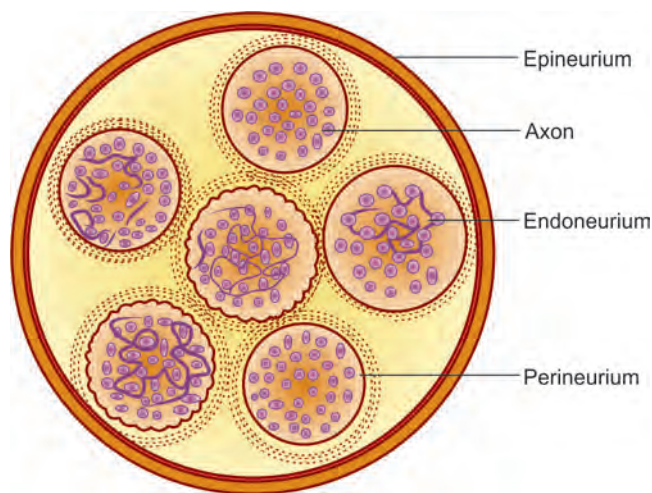


Fig. 1.466: Cross-section of a nerve.

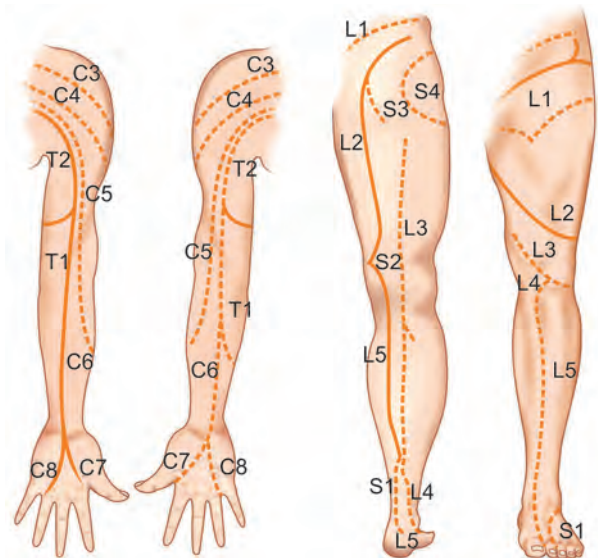


Fig. 1.467: Dermatomes.

### Classification

#### Seddon's Classification

- ◆ **Neuropraxia:** It is temporary physiological paralysis of nerve conduction. Here recovery is complete. There is no reaction of degeneration.
- ◆ **Axonotmesis:** It is division of nerve fibres or axons with intact nerve sheath. There is reaction of degeneration distally with near complete recovery. Patient can present with sensory loss, paralysis of muscles or causalgia.

- ◆ **Neurotmesis:** Here complete division of nerve fibres with sheath occurs. Degeneration occurs proximally up to the first node of Ranvier as well as distal to the injury. Recovery is incomplete even after nerve suturing. There is complete loss of motor and sensory functions with loss of reflexes. If the nerve is mixed type other than pure motor or sensory recovery is still poorer. Injuries may be incised or lacerated or crushed one. Cut end of the nerve forms proximally *neuroma* and distally *glioma*.

Neuromas may be:

- ◆ True neuroma or false neuroma.
- ◆ End neuroma or side neuroma.

#### Sunderland's classification

- I: Conduction block—temporary neuronal block
- II: Axonotmesis but endoneurium is preserved
- III: Axonotmesis with disruption of endoneurium, but perineurium is preserved
- IV: Here disruption of endo and perineurium has occurred but epineurium is intact
- V: Neurotmesis with disruption of endo, peri and epineurium has occurred

### Clinical Features

- ◆ Loss of sensory, motor, autonomous and reflex functions.
- ◆ Secondary changes in the skin and joint.  
Primary nerve suturing is done if it is a clean incised wound.  
Secondary nerve suturing is done after 3 weeks if it is a crushed wound.

### Management

- ◆ Associated injuries like fracture, vessel injury, injuries in other systems should be looked for.
- ◆ Assessment of nerve injury is done by checking sensation, muscle power, reflexes.
- ◆ Nerve conduction studies.
- ◆ Investigations relevant for associated injuries.
- ◆ Exploration of the wound.

Debridement of the area is done. If injury is incised one, then nerve is sutured with 8-0 to 10-0 nonabsorbable interrupted sutures (polypropylene).

### Types of Nerve Suturing

Usually microscope or loup is used for nerve suturing.

- i. *Epineurorrhaphy*: Only epineurium is sutured using interrupted sutures.
- ii. *Epi-perineurorrhaphy*: Initially perineural sheath and then epineurium is sutured.

#### Nerve suturing can be:

- ▶ **Primary repair**: It is done immediately after injury. Nerve ends are minimally trimmed very close using a blade. All fascicles of the nerve are oriented correctly. Two stay sutures are placed to keep the orientation properly. Usually epineural suturing is done using 8-0 polypropylene interrupted sutures. It needs magnification. 6–8 sutures are placed for large peripheral nerve like median or ulnar nerve. For small nerve like digital nerve, only 2–3 sutures are placed.
- ▶ **Secondary repair**: It is done at a later period. It is done in a preexisting scar tissue. Here first nerve ends, both proximal and distal are identified, carefully dissected adequately. Proximal neuroma and distal glioma are trimmed for 1 cm to expose the normal fascicles of the nerve ends. Often guide sutures of silk may be present which were placed earlier during exploration of the trauma. Once nerve ends are clean, it is sutured alike primary suturing with stay sutures, with proper alignment of

fascicles, followed by epineural suturing. Here as epineurium is thicker, suturing is easier.

#### Note

- If nerve is lacerated, then *marker stitches (using silk)* are placed at the cut end site to identify the nerve for suturing at a later period.
- If nerve suturing fails or if could not be done, then tendon transfer is done at a later period after 4–6 months.
- *Incomplete injury* usually does not require any suturing.

#### Easier suturing is achieved by following methods:

- Relaxing incisions.
- Transpositioning of the nerve.
- Shortening of the bone.
- Nerve graft—usually sural nerve is used for nerve graft.
- Positioning of the limb.
- Initially neurolysis (release of the scar tissue adjacent to injury) is done in case of secondary suturing.

#### Prognostic factors in healing of the nerve injury:

- ◆ Higher the lesion worse the prognosis.
- ◆ More the gap between the cut ends worse the prognosis.
- ◆ Associated injuries alter the prognosis.
- ◆ Children do better with nerve injury.
- ◆ Type of the injury also decides the prognosis.  
The rate of growth of nerves after peripheral nerve suturing is 1 mm/day.

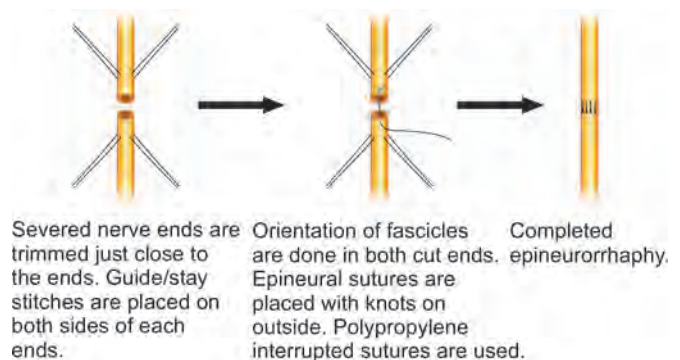


Fig. 1.468: Primary nerve repair.

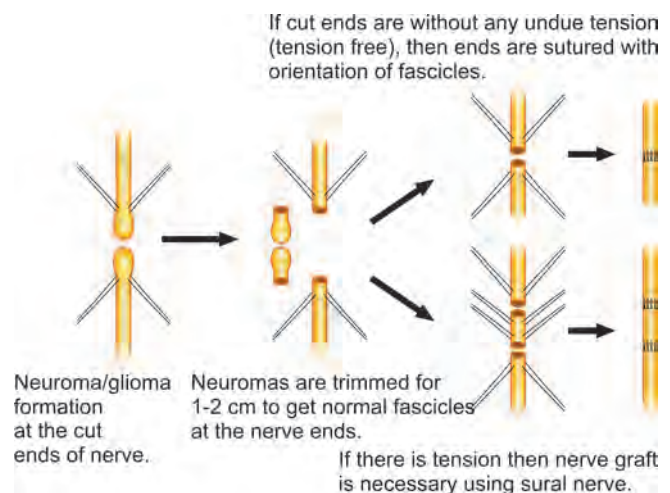


Fig. 1.469: Secondary nerve repair.

## TINEL'S SIGN

It is the clinical sign (prognostic indicator) used to assess the level of regeneration. It is elicited 3 weeks after the nerve injury (Regeneration begins after the completion of nerve degeneration).

Tapping over the course of the nerve is done *from distal to proximal* to elicit a sensation of “pins and needles” or *hyperaesthesia*.

If sensation is felt at the site as well as distally along the distribution of the nerve, that means good recovery can be expected. If sensation is felt only at the site of tapping, then result is equivocal. If no sensation is felt it means no recovery.

### Causes of peripheral nerve lesions

- ❖ Traumatic: Either closed or open injury
- ❖ Inflammatory: Leprosy, herpes zoster, diphtheria
- ❖ Compression neuropathies
- ❖ Lead poisoning
- ❖ Arsenical poisoning
- ❖ Alcoholism
- ❖ Diabetes mellitus
- ❖ Vitamin B<sub>1</sub> deficiency
- ❖ Porphyria
- ❖ Neurofibroma and other neural tumours
- ❖ Idiopathic

## BRACHIAL PLEXUS INJURIES

It can be:

- ◆ Supraclavicular injury                      65%
- ◆ Infraclavicular injury                      25%
- ◆ Combined                                      10%

It can also be:

- ◆ Upper plexus injury.
- ◆ Lower plexus injury.

It can be:

Pre-ganglionic injury	Post-ganglionic injury
Avulsion injury	Usually less severe
More dangerous	Better recovery
Extends into the spinal cord	

## Investigations

- ◆ Nerve conduction studies.
- ◆ CT/MRI.
- ◆ Electromyogram.
- ◆ X-ray cervical spine and part.

## Treatment

- ◆ Conservative, nerve repair.
- ◆ Tendon transfer, physiotherapy.

Osteotomy of coracoid process proximal to the attachment of pectoralis minor, short head of biceps and coracobrachialis is done to improve abduction—*Sever's operation*.

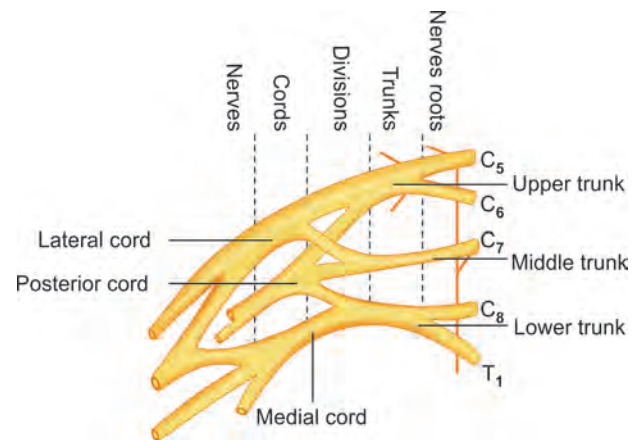


Fig. 1.470: Brachial plexus anatomy.

## CAUSALGIA

It is severe burning pain and hyperaesthesia in the distribution of a peripheral nerve due to *incomplete injury* to the nerve.

## Sites

- ◆ Common in upper limb.
- ◆ Commonly seen in median nerve, also often in brachial plexus injuries. In the lower limb it is seen in sciatic nerve or tibial nerve injuries.

### Features of upper and lower plexus injuries

	Upper plexus injury (Erb-Duchenne paralysis)	Lower plexus injury (Klumpke's paralysis)
1.	It is due to depression of shoulder by trauma	1. Forcible hyperabduction of shoulder causes this injury
2.	After difficult labour in newborn	2. In newborn it result due to difficult breech delivery
3.	Here C <sub>5</sub> and C <sub>6</sub> roots are injured	3. Here C <sub>8</sub> and T <sub>1</sub> are injured
4.	Muscles affected are deltoid, biceps brachioradialis and supinator	4. Intrinsic muscles of the hand are involved
5.	Effects are:	5. Effects are:
	a. Elbow will be extended, pronated and upper limb is internally rotated ( <i>Policeman receiving tip</i> )	a. Combined median and ulnar claw hand
	b. Sensory deficit over the lateral aspect of arm and upper part of the lateral forearm	b. Horner's syndrome
		c. Sensory deficit over the medial aspect of forearm, hand, and medial 1½ finger

## Pathology

Incomplete nerve injury produces abnormal impulse towards sensory nerve ending causing vasomotor instability and pain.

## Features

- ◆ Hyperaesthesia with severe disabling and burning pain.
- ◆ Skin becomes red, shiny and glossy which sweats profusely—*Weir-Mitchell's skin*.
- ◆ Eventually skin becomes atrophic, cyanotic, cold and blotchy.
- ◆ Skin is less sensitive to heat, cold, and pin prick, but hypersensitive to touch and tender to pressure.
- ◆ Nails are rigid, brittle with change in colour.
- ◆ *Investigation*: Nerve conduction studies.
- ◆ *Treatment*:
  - ▶ Anti-inflammatory drugs, steroids, physiotherapy.
  - ▶ IV guanethidine regionally.
  - ▶ If not improved, sympathectomy—cervical for upper limb, lumbar for lower limb.

## MEDIAN NERVE INJURY

- ◆ Median nerve arises from lateral (C<sub>5, 6, 7</sub>) and medial cord (C<sub>8</sub> and T<sub>1</sub>) of the brachial plexus. It is initially lateral to the axillary artery and becomes medial in the lower part of the arm and in the cubital fossa. It passes through the pronator teres, descends in relation to flexor muscles and enters the palm through the carpal tunnel at the wrist.
- ◆ It supplies pronator teres, flexor carpi radialis, palmaris longus and flexor digitorum superficialis. Anterior interosseous branch of the median nerve supplies pronator teres, lateral half of the flexor digitorum profundus, flexor pollicis longus and pronator quadratus.
- ◆ In the wrist, it supplies abductor pollicis brevis, flexor pollicis and opponens pollicis of the thenar eminence and lateral two lumbricals. It gives sensory supply to lateral three and half fingers of the hand.

### Median nerve is affected in:

- ❖ Injuries
  - Supracondylar fracture of the elbow
  - Fracture—dislocation of the elbow
  - Direct cut injuries
- ❖ Leprosy
- ❖ Carpal tunnel syndrome
- ❖ As a part of brachial plexus injury

## Clinical Features of Median Nerve Palsy

*In high median nerve palsy*

- ◆ Wasting of the thenar eminence. Loss of sensation on lateral three and half fingers.
- ◆ Ochsner's clasping test shows pointing index because of the inactivity of lateral two divisions of the profundus.
- ◆ "Ape or Simian thumb deformity" is due to overaction of the adductor pollicis which is supplied by the deep branch of ulnar nerve. As all other thenar muscles are paralysed, thumb comes in the same plane of the metacarpals.

- ◆ "Pen test": In median nerve injury, pen held in front of the hand cannot be touched by thumb as abduction is not possible due to paralysis of the abductor pollicis brevis.

*In low median nerve palsy* profundus is not paralysed and so *pointing index* is not seen.

## Investigations

- ◆ Nerve conduction studies.
- ◆ X-ray of the part in case of fracture.
- ◆ Electromyogram.

## Treatment

- ◆ Nerve suturing or nerve graft.
- ◆ Tendon transfer.
- ◆ Treat the cause like carpal tunnel syndrome.

## CARPAL TUNNEL SYNDROME

- ◆ It is the compression neuropathy of median nerve in the carpus, deep to flexor retinaculum.
- ◆ Flexor retinaculum (transverse carpal ligament) maintains the concavity of wrist and extends laterally from trapezium and scaphoid to pisiform and hook of the hamate medially.

*Carpal tunnel* is formed by carpal bones behind and flexor retinaculum in front. It contains median nerve and long flexor tendons of fingers and thumb. Ulnar nerve lies superficially, not in the carpal tunnel.

Median nerve gets compressed if space of the carpal tunnel gets reduced.

## Causes

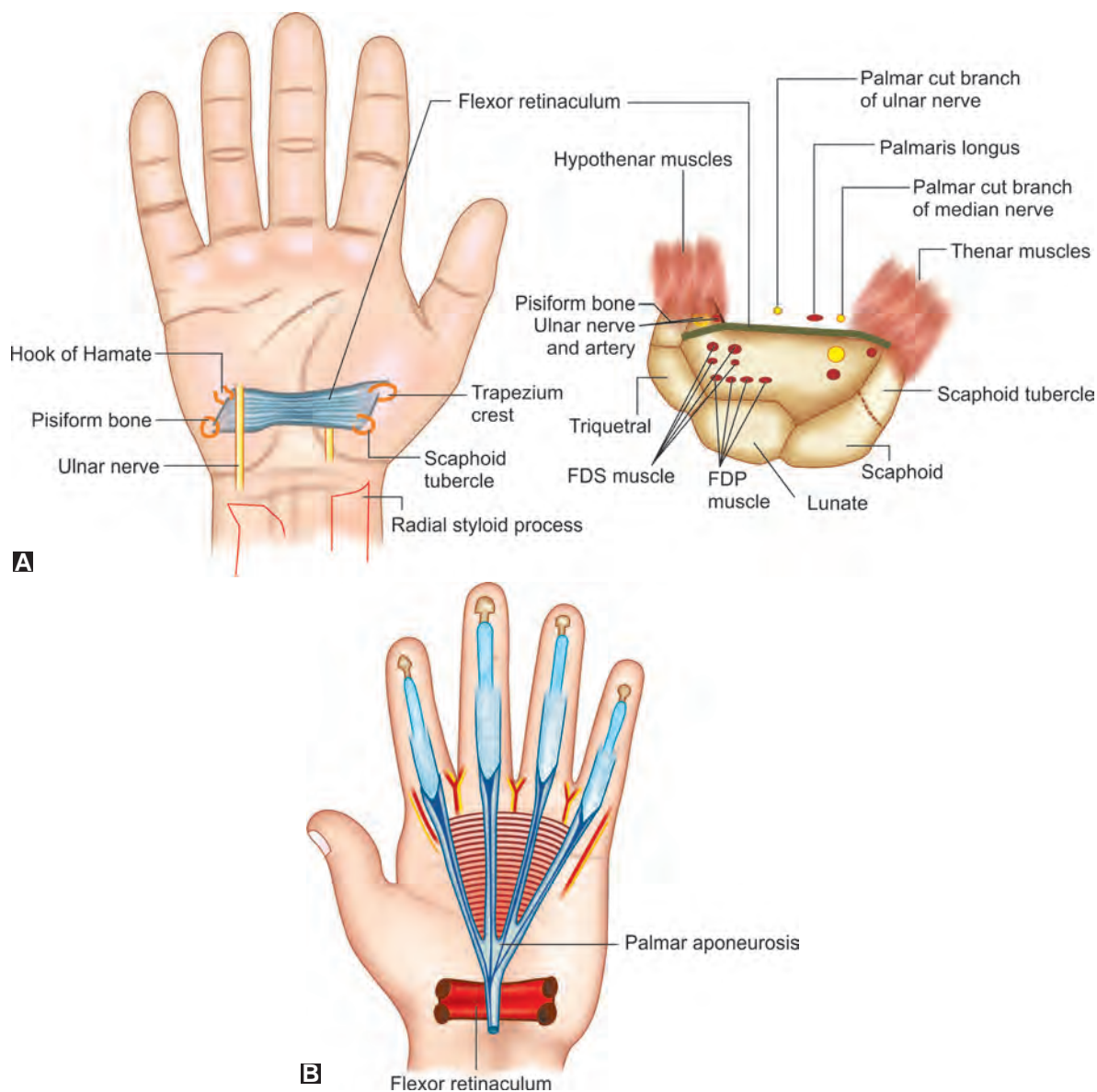
- ◆ Lunate dislocation, malunited Colle's fracture.
- ◆ Radiocarpal arthritis, flexor tendon tenosynovitis.
- ◆ Myxoedema, acromegaly, pregnancy.

## Clinical Features

- ◆ Common in females.
- ◆ Tingling, numbness, paraesthesia and burning sensation in the lateral three and half fingers supplied by median nerve. Burning sensation gets aggravated at night.
- ◆ Ape thumb deformity, wasting of thenar muscles, weakness of opponens pollicis and abductor pollicis brevis, i.e. features of low median nerve palsy.
- ◆ When BP cuff is inflated patient feels the typical pain in the fingers.
- ◆ Tapping the median nerve at the distal end of forearm with the wrist held in extension aggravates the symptoms.
- ◆ Condition is often bilateral.
- ◆ *Phalen's Test (Wrist Flexion Test)*: Flexion of the wrist causes exacerbation of the symptoms within 1 minute and the symptoms will disappear as the wrist is straightened.

## Differential Diagnosis

- ◆ Cervical spondylosis.
- ◆ Cervical rib syndrome.



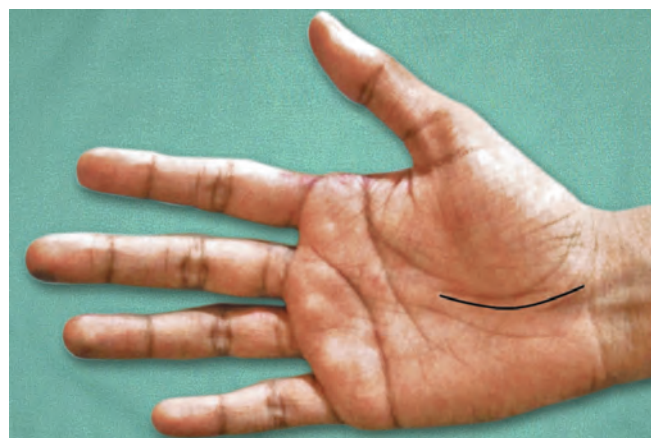
**Figs 1.471A and B:** Anatomy of the carpal tunnel and flexor retinaculum.

## Diagnosis

- ◆ Nerve conduction studies.
- ◆ X-ray/MRI neck.

## Treatment

- ◆ Surgical decompression of median nerve by cutting both superficial and deep part of flexor retinaculum completely, by 'S' shaped incision.
- ◆ Surgery is usually done under *local anaesthesia*. General or brachial block can be used. Tourniquet is commonly used. *Vertical crease incision* is made in the proximal part of the palm with convexity of the incision towards the ulnar side.
- ◆ Skin incision is deepened. Palmar cutaneous branch of the median nerve should be preserved. Incision is deepened to identify the flexor retinaculum. *Entire length, both superficial and deep parts*



**Fig. 1.472:** Incision for carpal tunnel syndrome.

*In lesions of S<sub>1</sub> there is no dropped big toe.—Gosta Norlen*

should be cut properly. It is cut towards ulnar side of the wound. *Only skin* is sutured using interrupted nonabsorbable 3 zero polypropylene or polyethylene sutures.

- ◆ *Complications* are incomplete fasciotomy and recurrence, nerve injury.
- ◆ Using small proximal incision, endoscopy can be passed to visualise and cut the entire flexor retinaculum—*minimal access surgery*.
- ◆ Postoperatively **good physiotherapy** is required.
- ◆ Condition is permanently curable.

## ULNAR NERVE INJURY

- ◆ After arising from the medial cord of the brachial plexus (C<sub>8</sub> and T<sub>1</sub>), it runs on the medial aspect of the axillary artery up to middle of the arm. Then it enters the posterior compartment in relation to triceps muscle. After passing behind the medial epicondyle and through two heads of flexor carpi ulnaris, it runs in front of the flexor digitorum profundus (FDP) in the forearm. It reaches the hand in front of the flexor retinaculum through “*Guyon’s canal*”. Here it divides into superficial and deep branches.
- ◆ Ulnar nerve supplies flexor carpi ulnaris, medial half of flexor digitorum profundus, all muscles of the hypothenar eminence (palmaris brevis, abductor digiti minimi, opponens digiti minimi, flexor digiti minimi), adductor pollicis of the thenar eminence and all interossei of the hand. It also gives sensory supply to medial part of the hand, medial one and half fingers.

### Ulnar nerve is affected in:

- ❖ Supracondylar fracture
- ❖ Injury to the medial epicondyle
- ❖ Tardy ulnar palsy
- ❖ Leprosy
- ❖ Cubitus valgus deformity

## Clinical Features

- ◆ *Claw hand* deformity.
- ◆ Weakness of all the muscles supplied by the ulnar nerve.
- ◆ “*Card test*”: A card is placed between the two fingers of the patient to grasp. As the palmar interossei are weak, patient cannot grasp [palmar interossei are adductors of the fingers (PAD)].
- ◆ Abduction of fingers are checked [dorsal interossei are abductors (DAB)].
- ◆ *Froment’s sign*: A book is placed to grasp between fingers and thumb of the patient. Normally thumb will be straight because of the action of adductor pollicis muscle. As it is paralysed in ulnar palsy, grasp is achieved by the action of flexor pollicis longus and there will be flexed thumb.
- ◆ Loss of sensation over medial one and half fingers and hand.

## Investigations

- ◆ Nerve conduction studies.
- ◆ Electromyogram.

## Treatment

- ◆ Nerve suturing or nerve grafting.
- ◆ Tendon transfer.

*Intrinsic minus deformity*: It is due to loss of intrinsic muscle power, i.e claw hand.

*Intrinsic plus deformity*: It is due to muscle contracture and fibrosis.

*Ulnar paradox*: In ulnar palsy, higher the lesion, lesser the deformity, lower the lesion more the deformity. In higher lesion, FDP is also paralysed. In lower lesion FDP is intact and so FDP causes more flexion (overaction) and so aggravates the claw hand.

## CLAW HAND

- ◆ It is the hyperextension of the metacarpophalangeal joint with flexion of the interphalangeal joints of the hand.
- ◆ Extension of MCP joint is due to unopposed action of extensor digitorum.
- ◆ Flexion of MCP joint and extension of interphalangeal joints are by extensor hood of interossei and lumbricals. So extensor hood is functioning mainly by ulnar nerve and also by median nerve. In ulnar or median nerve palsies, these actions are paralysed and so patient develops claw hand.
- ◆ It is actually *intrinsic minus deformity*.

### Causes

- ❖ Leprosy
- ❖ Trauma
- ❖ Entrapment neuropathies
- ❖ Tardy ulnar palsy
- ❖ Klumpke’s palsy

## Clinical Features

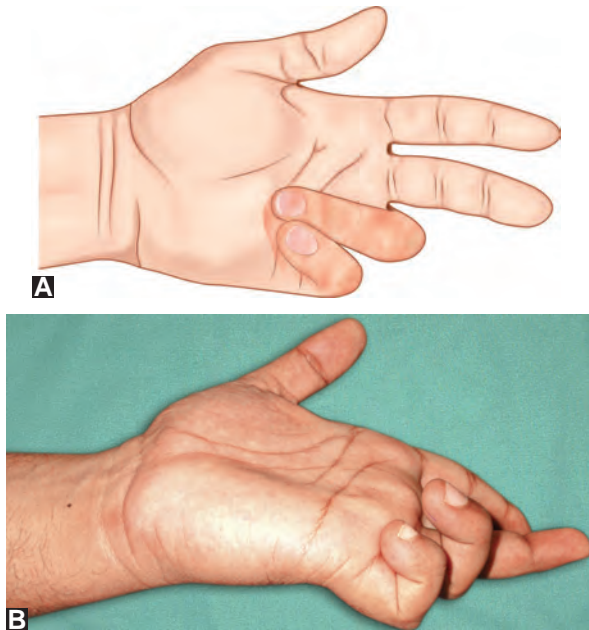
- ◆ Typical claw hand.
- ◆ Loss of sensation along the distribution of the nerve.
- ◆ Inability to grasp card between the fingers.
- ◆ While holding the book between the thumb and fingers, thumb will be flexed in ulnar claw hand (*positive Froment’s test*).

## Types

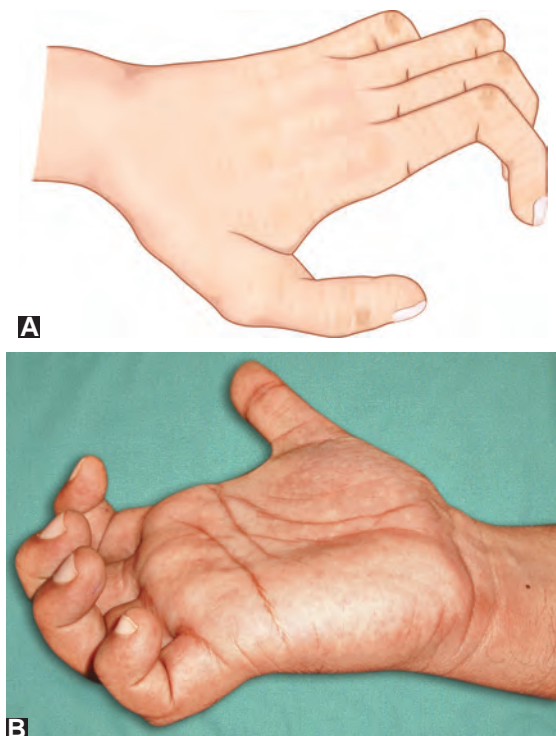
- ◆ *Ulnar claw hand*: Only medial two fingers are involved.
  - ▶ *Low ulnar palsy*: Here lesion is in the wrist (at Guyon’s canal). Here deformity is more because of the overaction of the FDP.
  - ▶ *High ulnar palsy*: Here FDP is also paralysed and overaction is not there. So lesser deformity occurs.
- ◆ *Ulnar paradox*: Higher the lesion lesser the deformity, lower the lesion more the deformity.
- ◆ *Median claw hand*: Only lateral two fingers are involved. It is less common.
- ◆ *Combined median and ulnar claw hand*: Here all four fingers of the hand are involved.

## Investigations

- ◆ Electromyogram.
- ◆ Nerve conduction studies.



**Figs 1.473A and B:** Ulnar claw hand with hyperextension of metacarpophalangeal joints and flexion of proximal and distal interphalangeal joints in medial two fingers due to ulnar nerve palsy.



**Figs 1.474A and B:** Combined claw hand involving all fingers due to both ulnar and median nerve injuries.

## Treatment

- ◆ **Paul Brand's operation:** Extensor carpi radialis longus or brevis (ERCB) is transferred with a graft to the extensor hood through the lumbrical canal. Graft is taken from palmaris longus or plan-taris muscle.

- ◆ **Stye-Bunnell's operation:** Flexor digitorum superficialis of index finger is used (only in ulnar claw hand) to transfer to extensor hood.
- ◆ **Fowler's operation:** Extensor digitorum is used to transfer to extensor hood.
- ◆ **Riordan operation:** Flexor carpi radialis is used for tendon transfer.
- ◆ **Anterior transpositioning** of the ulnar nerve in case of tardy ulnar palsy.

## RADIAL NERVE INJURY

- ◆ Radial nerve is derived from the posterior cord of the brachial plexus (C<sub>5,6,7,8</sub> and T<sub>1</sub>). It descends behind the axillary artery in front of the subscapularis, latissimus dorsi and teres major. It passes through the medial and lateral heads of the triceps muscle, winds round the humerus through the radial groove and enters the forearm in front of the lateral epicondyle in relation to brachioradialis, brachialis and extensor carpi radialis longus muscles.
- ◆ In the arm it supplies triceps, anconeus, brachioradialis, extensor carpi radialis longus and part of brachialis. It gives posterior and lower lateral cutaneous nerves of the arm and posterior cutaneous nerve of the forearm.
- ◆ **Superficial branch** of the radial nerve from the elbow runs in the forearm in relation to supinator and brachioradialis and ends by forming five digital nerves which gives sensory supply to lateral three and half fingers on the dorsal aspect—except skin over the distal phalanges.
- ◆ **Deep branch** also called as posterior interosseous nerve winds round the radius supplying supinator and extensor carpi radialis brevis. It gives three short branches to extensor digitorum, extensor digiti minimi and extensor carpi ulnaris. It also gives two long branches—one to abductor pollicis longus and extensor pollicis brevis; another to extensor pollicis longus and extensor indicis.

### Conditions where radial nerve is affected

#### In the axilla

- ❖ Crutch palsy. It is neuropraxia
- ❖ Fracture upper end of the humerus
- ❖ Bony or soft tissue growth

#### In the radial groove

- ❖ Pressure on the arm from the edge of the operating table
- ❖ **Saturday night palsy**—an individual with excessive alcohol consumption compresses his arm over the chair or by fall. It is neuropraxia
- ❖ Prolonged tourniquet application—**tourniquet palsy**
- ❖ Fracture of the shaft of the humerus
- ❖ **Rarely** intramuscular injection of drugs can cause radial nerve palsy

#### In the elbow

- ❖ Dislocation or fracture neck of the radius

## Clinical Features

- ◆ **Wrist drop** because of inability of extending the wrist.
- ◆ Inability to extend metacarpophalangeal joint, but extensions of the interphalangeal joints are normal.

*To know how to laugh whole heartedly, you have to know how to weep also.*



- ◆ Inability to extend the forearm.
- ◆ Inability to extend the thumb.
- ◆ Flexion of the elbow against resistance with forearm in mid-prone position is difficult because of the weakness of the brachioradialis muscle.
- ◆ Loss of sensation in back of the arm, forearm, hand and lateral three and half fingers.

Posterior interosseous nerve is purely motor and so sensation is intact when it gets injured. *It causes only dropped fingers.*

### Investigations

- ◆ X-ray of the part.
- ◆ Nerve conduction studies.

### Treatment

- ◆ Nerve suturing or nerve graft.
- ◆ Tendon transfer.

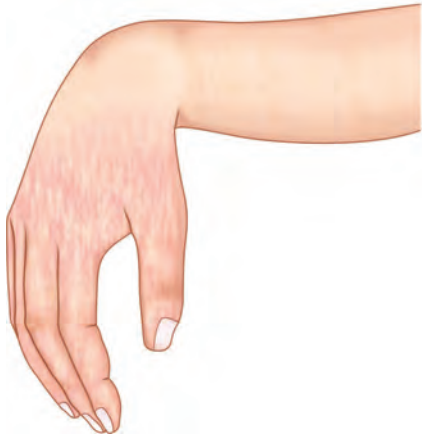

Fig. 1.475: Wrist drop—due to radial nerve palsy.

## COMMON PERONEAL NERVE INJURY

This nerve supplies the extensor and peroneal group of muscles and sensory supply to the skin over the front and lateral aspect of the leg and dorsum of the foot.

### Common peroneal nerve is affected in:

- ❖ Fracture neck of the fibula
- ❖ Leprosy
- ❖ Lead poisoning
- ❖ Iatrogenic

### Clinical Features

- ◆ Foot drop with high stepping gait.
- ◆ Talipes equinovarus deformity.
- ◆ Loss of sensation on the lateral side of the leg and dorsum of the foot.

### Management

- ◆ Treating the foot drop.
- ◆ MCR chappals.

## FOOT DROP

Inability to dorsiflex and evert the foot due to paralysis of the peroneal and extensor group of muscles, as a result of common peroneal nerve injury.

### Causes

- ❖ Fracture neck of the fibula
- ❖ Leprosy
- ❖ Lead poisoning
- ❖ Iatrogenic
- ❖ Direct incised wound

### Clinical Features

- ◆ High stepping gait.
- ◆ Loss of sensation over lateral and dorsum of the foot.

### Treatment

Tendon transfer using tibialis posterior muscle. Tendon of the muscle is detached from its navicular insertion and with a tendon graft (from plantaris) it is transferred to cuboid and cuneiform bones to get dorsiflexion and eversion.

- a. Ober's procedure.
- b. Barr's procedure.

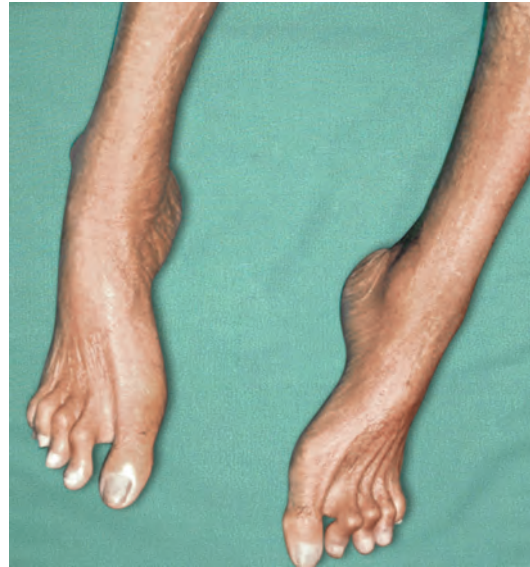

Fig. 1.476: Foot drop with claw toes. It is due to peroneal nerve injury (Lateral popliteal nerve).

## MEDIAL POPLITEAL NERVE INJURY

It supplies the soleus, gastrocnemius, popliteus, plantaris, tibialis posterior, flexor digitorum longus and flexor hallucis longus.

Medial popliteal nerve is rarely involved by any disease process. Trauma can cause medial popliteal nerve palsy.

### Clinical features

- ❖ Inability to plantar flex the foot
- ❖ Claw toes
- ❖ Sensory loss in the sole of the foot

## ■ AXILLARY NERVE INJURY

Axillary nerve supplies the deltoid and teres minor muscle and also sensory supply to the skin over the upper lateral aspect of the arm.

Axillary nerve is affected in:

- ◆ Fracture neck of the humerus.
- ◆ Dislocation of humeral head.
- ◆ Following IM injection into the deltoid.

*Clinically* there will be loss of abduction of the shoulder and anaesthesia of the skin over the lateral part of the arm.

## ■ LONG THORACIC NERVE INJURY

### (Nerve of Bell)

- ◆ It supplies serratus anterior muscle. It arises from C<sub>5, 6, 7</sub> cervical roots.
- ◆ The nerve is injured commonly in malignancy, during breast, axillary or chest wall surgeries.
- ◆ *Clinically*, when outstretched (elbow extended) arm is pushed against the wall, the inferior angle of the scapula will become prominent (*Winging of the scapula*).

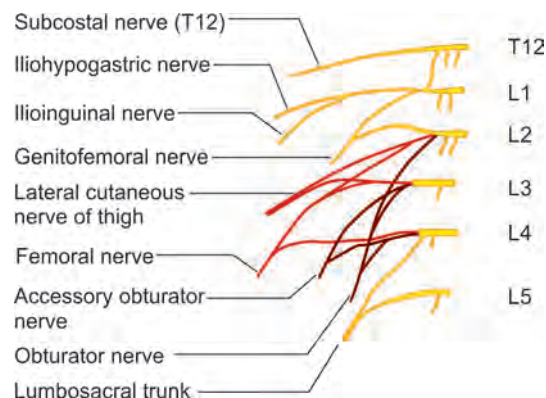
## ■ MERALGIA PRAESTHETICA

(Meralgia – Greek – thigh)

- ◆ It is *entrapment neuropathy* of lateral cutaneous nerve of thigh. Nerve gets *compressed* while passing through the inguinal ligament. It arises from posterior divisions of lumbar plexus (L<sub>2, 3</sub>);

runs over the quadrates lumborum and iliacus muscles; emerges behind the lateral part of the inguinal ligament; divides into anterior and posterior branches, supplying skin over anterolateral part of the thigh and anterior part of the gluteal region.

- ◆ It causes hyperaesthesia, tingling over upper lateral aspect of the thigh along the distribution of the nerve. Symptoms get worsened on standing or walking; it is relieved by sitting.
- ◆ It *mimics* disc prolapse or Hansen's disease or neuropathies.
- ◆ It is *treated* by reassurance; carbamazepine; steroids. Often *release* of inguinal ligament fibres that are compressing the nerve is needed.



**Fig. 1.477:** Lumbar plexus showing origin of lateral cutaneous nerve of thigh.

# Q. Neoplasm

## CHAPTER OUTLINE

- ❖ Definition
- ❖ Dysplasia
- ❖ Carcinoma In Situ
- ❖ Aetiologic Factors
- ❖ Spread of Malignant Tumours
- ❖ Grading of Tumour
- ❖ Staging of the Tumour
- ❖ Paraneoplastic Syndromes
- ❖ Investigations for Neoplasm
- ❖ Management Strategy for Cancers

### DEFINITION

**Willis** defined neoplasm as “*it is an abnormal mass of tissue, the growth of which exceeds and is uncoordinated with that of the normal tissues and persists in the same excessive manner even after cessation of the stimuli.*”

Neoplasia is:

- ❖ Progressive
- ❖ Purposeless
- ❖ Perverted
- ❖ Persistent
- ❖ Pervasive
- ❖ Proliferative mass of tissue.

Sarcoma	Carcinoma
Arising from mesenchymal tissues	Arising from epithelial cells derived from any of the three germ layers
‘Sar’ means flesh (Greek), <i>Oma</i> means tumour	<i>Carc</i> means crab like
Smooth, firm or hard swelling	Hard, proliferative, with everted edge
Warm and vascular with dilated veins over the surface	
Spreads mainly through blood commonly to lungs, e.g. liposarcoma, fibrosarcoma,	Spreads through lymphatics as well as blood, e.g. squamous cell carcinoma, renal cell carcinoma, adenocarcinoma

### Classifications

Benign	Malignant
Well-differentiated	Lack of differentiation
Structures are typical of tissue/cell of origin	Atypical structure with anaplasia
Smooth, slow, progressive rate of growth	Erratic, rapid growth
Normal mitotic figures	Abnormal mitotic activity
Well localised and capsulated	Not localised. Not capsulated
Do not infiltrate surrounding normal tissues	Infiltrate the surrounding tissues
No metastasis	Metastasise through lymphatics or blood
Curable	May not be completely curable
Few benign tumours after a long time may turn into malignancy	
Treatment is simple	Treatment is complex and complicated
No recurrence	Recurrence can occur

- **Neoplasms which are only locally malignant:** No blood spread. No lymph node spread—Marjolin’s ulcer, Rodent ulcer, Verrucous carcinoma, Adamantinoma.
- **Neoplasms which are loco-regionally malignant:** Spread only to regional lymph nodes is observed—Squamous cell carcinoma, Papillary carcinoma thyroid.
- **Neoplasms which are systemic** and spreads through blood and often also to lymph nodes.
- Melanoma, carcinoma breast.

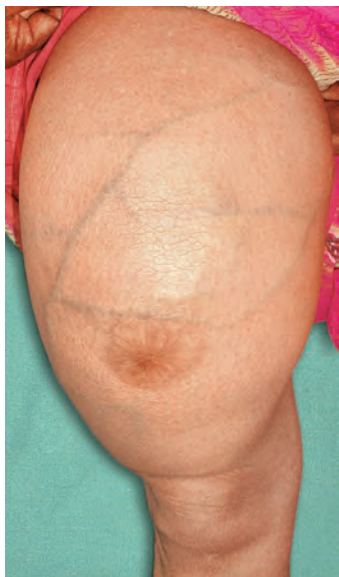
### Components

**Parenchyma:** It contains proliferating neoplastic cells.

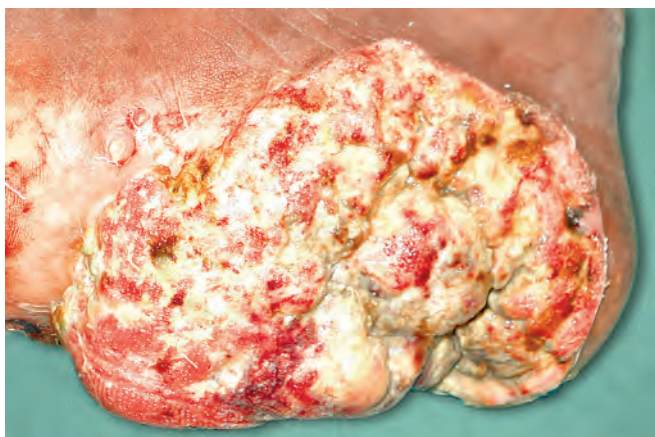**Stroma:** It contains supporting connective tissues and blood vessels.

#### Features of anaplasia

- ❖ Lack of cellular differentiation
- ❖ Pleomorphism—variation in size and shape
- ❖ Hyperchromatism—dark staining nuclei
- ❖ Anisocytosis
- ❖ Anisonucleosis
- ❖ Abnormal mitotic activity



**Fig. 1.478:** Soft tissue sarcoma thigh. Note the dilated vassels on the surface.



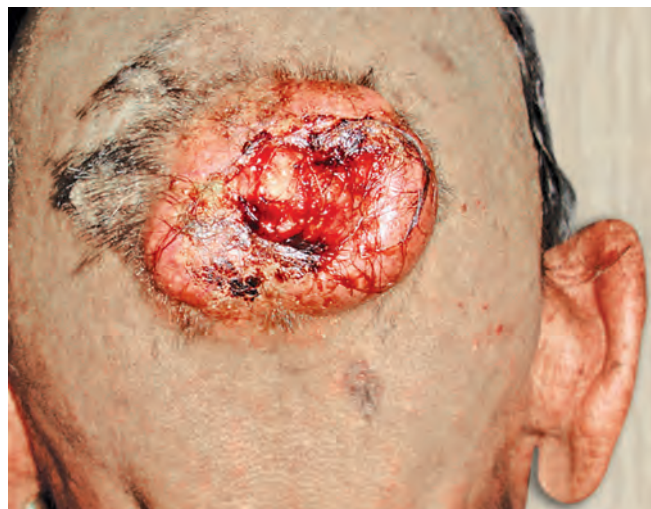**Fig. 1.479:** Carcinoma heel region. Note the everted edge with proliferative cauliflower like look.

#### Features of malignant tissues

- ❖ Altered differentiation, anaplasia
- ❖ Rapid rate of growth
- ❖ Local invasion—locally, lymphatic, vascular and perineural
- ❖ Metastasis
- ❖ Not capsulated
- ❖ Increased vascularity
- ❖ *Microscopic changes*—necrosis, numerous atypical mitotic activities, nuclear changes like pleomorphism/enlargement/hyperchromatism/clumping of chromatin/enlargement and multiplication of nucleoli

#### ■ DYSPLASIA

It means “disordered growth”. There is loss in the uniformity of the cells with pleomorphism and hyperchromatism, as well as loss in their architectural orientation.



**Fig. 1.480:** Squamous cell carcinoma scalp. Note the everted edge. It is ulceroproliferative lesion.

#### ■ CARCINOMA IN SITU

Here dysplasia involves the entire thickness of the epithelium, and is preinvasive. Basement membrane is intact in carcinoma *in situ*.

#### ■ AETIOLOGIC FACTORS

##### Age

##### Heredity

- ❖ Familial: Familial polyposis of colon
- ❖ MEN syndrome
- ❖ Neurofibromatosis
- ❖ von-Hippel-Lindau syndrome
- ❖ Familial breast and ovarian cancers

##### Genetic

- ❖ Xeroderma pigmentosa
- ❖ Ataxia telangiectasia
- ❖ Fanconi anaemia, Bloom syndrome

It is more common in elderly. But it is variable.

**Tumour suppressor gene p53** plays important role in prevention of the cancers. Its function is prevention of replication of damaged DNA. If damaged DNA replicates there is high chances of abnormal mitotic activity and cancer transformation of the tissue. *Loss or reduction of ability/function of p53 suppressor gene* can lead into cancers. Common cancers associated with p53 loss are cancers of breast, colorectum, retina, bone, brain, soft tissues, blood and familial related type.

##### Acquired causes

- ❖ Chronic atrophic gastritis
- ❖ Solar keratosis
- ❖ Leucoplakia of oral cavity
- ❖ Ulcerative colitis

### Chemical carcinogens

- ❖ Alkylating agents
- ❖ Hydrocarbons
- ❖ Smoking—lung, aerodigestive system, bladder cancer
- ❖ Asbestos—lung cancer
- ❖ Alcohol—liver cancer
- ❖ Amides, Azo dyes—bladder cancer
- ❖ Aflatoxin B<sub>1</sub>
- ❖ Arecoline, collagenases and tannins (present in Betel nuts)
- ❖ Nitrosoamines, vinyl chloride, insecticides

### Geographical variation

Japan—Carcinoma stomach  
 China, France—Carcinoma oesophagus  
 HongKong—Nasopharyngeal carcinoma  
 Australia—Melanoma  
 India—Carcinoma oral cavity, gallbladder carcinoma  
 Newzealand—Small bowel tumours

### Radiation carcinogens

- ❖ UV rays, ionising radiation.

### Microbial carcinogens

- ❖ Human papilloma virus—carcinoma cervix
- ❖ Epstein-Barr virus—Burkitt's lymphoma, nasopharyngeal carcinoma
- ❖ Hepatitis 'B' virus—liver cancer
- ❖ Human T cell leukaemia virus Type I
- ❖ *Helicobacter pylori* can cause carcinoma of stomach and is associated with lymphomas [Mucosa Associated with Lymphoid Tissue (MALT)]

## SPREAD OF MALIGNANT TUMOURS

1. **Local spread:** Into adjacent structures like soft tissues, vessels, bone.
2. **Lymphatic spread**
  - ▶ **By permeation:** Here malignant cells proliferate through lymphatic vessels up to lymph node level. For example, in carcinoma breast malignant cells permeate into axillary lymph nodes.
  - ▶ **By embolisation:** Here cells get dislodged from lymphatic vessels and freely travel to spread into further level of lymph nodes. In carcinoma breast by embolisation, spread occurs from axillary lymph node to supraclavicular lymph node.
  - ▶ **Retrograde lymphatic spread** occurs once lymph vessel get blocked by malignant infiltration. In carcinoma breast retrograde spread occurs to opposite breast, opposite axilla, or to mediastinum. In melanoma, through dermal lymphatics and retrograde spread '*in transit nodules*' occur in the skin.
3. **Blood spread**
  - ▶ Occurs through veins, as veins are thin-walled and infiltration is easier (Arteries contain elastic fibres in their wall, which resist malignant infiltration).
  - ▶ Blood spread is commonly to lungs, bone (upper end of femur and humerus, ribs, skull), liver, brain, adrenals and other organs.

- Both by *permeation* (e.g. in renal cell carcinoma permeation through renal vein is common) and by *embolisation* (in other malignancies).
- In carcinoma prostate, due to increased pressure and venous blockade, retrograde venous spread occurs through vertebral venous plexus which causes **osteoblastic secondaries** in pelvic bones and vertebrae.

### 4. Seedling: For example

- ▶ From lower lip cancer to upper lip as **kiss cancer**.

### Kiss cancer

- ❖ Lip
- ❖ Bladder
- ❖ Cervix
- ❖ Vocal cord
- ❖ Vulva

- ▶ Recurrence in the scar after surgery for malignancy, e.g. deposition of malignancy in the scar of SPC from bladder tumour.
- ▶ Seedling in the peritoneal cavity from abdominal malignancy is common causing intractable ascites.

### 5. Transcoelomic spread:

- ▶ Spillage or dislodge of malignant cells occurs from primary site resulting in seedling on other organ, e.g. in carcinoma stomach secondaries in ovary (**Krukenberg tumour**) occurs due to transcoelomic spread. Here cells get deposited on the raw surface of ovary during ovulation (So it occurs in menstruating age group only).

## GRADING OF TUMOUR

- ◆ It signifies aggressiveness of tumour.
- ◆ It is based on differentiation of tumour cells and mitotic activity.

*Broder's grading of squamous cell carcinoma: Based on keratin/epithelial pearls*

Grade I: Well differentiated—>75% epithelial pearls

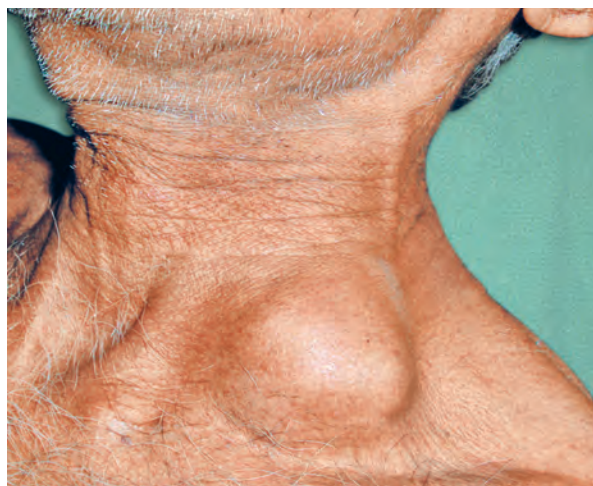Grade II: Moderately differentiated—50–75% epithelial pearls

Grade III: Poorly differentiated—25–50% epithelial pearls

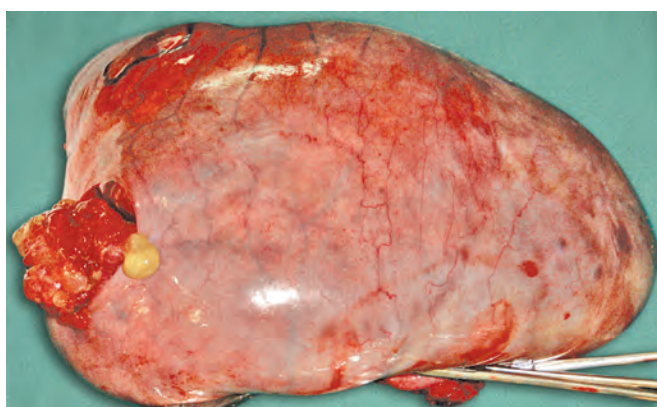Grade IV: <25% epithelial pearls

## Special Features of Malignant Cells

- ◆ Independent and autonomous nature without any control or check.
- ◆ Normal telomeric shortening is altered. Normal cell divides for 40–60 times. Later telomere gets shortened and cell division stops. It is altered in malignancy with infinite cell division.
- ◆ Reduced cellular apoptosis. Normal cell has capacity to die once its function is over. It is normal programmed death of a cell. It is activated by tumour suppressor gene p53. If this gene loses its function, tumour will form.
- ◆ Tumour has got capacity to create and construct blood supply called as *angiogenic* capacity.
- ◆ Malignant cells invade through the basement membrane and spread through blood and lymphatics. It is through secretion of special enzymes, increased interstitial pressure, capacity to have motility, release of collagenases/proteases/integrins.
- ◆ Spread occurs by proliferation and permeation as well as embolisation.



**Fig. 1.481:** Secondaries in neck. FNAC is the investigation to diagnose.



**Fig. 1.482:** Carcinoma ovary specimen. It was malignant teratomas of ovary. Other ovary was normal. So chemotherapy is used as an adjuvant. Patient was 23 years young female.

- ◆ Creation of instability and alteration of existing tissue function (not obeying normal tissue function of that particular site).
- ◆ *Gompertzian growth*—rapid growth of a tumour occurs prior to its clinically detectable stage. Once it becomes clinically detectable which needs thirty generation of cell divisions (1 mm tumour is  $10^9$  cells), its growth slows down later. This late slow growth is due to decreased oxygen to tumour/by competition between host cells and tumour cells and also between tumour cells themselves.
- ◆ Tumour mutation occurs at different generation of divisions stabilising the tumour further.

### ■ STAGING OF THE TUMOUR

It is based on the size of the primary tumour, nodal spread and blood spread. It is called as ‘TNM’ staging. ‘TNM’ staging is more relevant than grading in managing and predicting prognosis.

### ■ PARANEOPLASTIC SYNDROMES

- ◆ Certain symptom complexes which are not specifically explained by the tumour, but are relevant, often problematic and life-threatening are called as paraneoplastic syndromes.
- ◆ *Incidence:* Seen in 10% of patients.

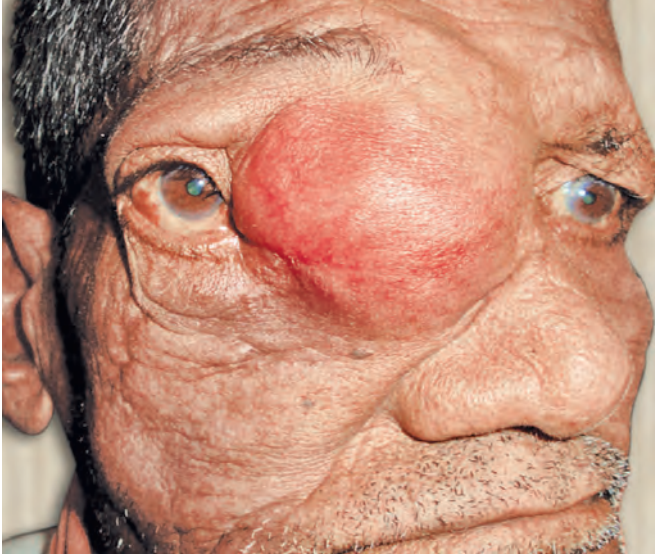### ■ INVESTIGATIONS FOR NEOPLASM

#### I. BIOPSY

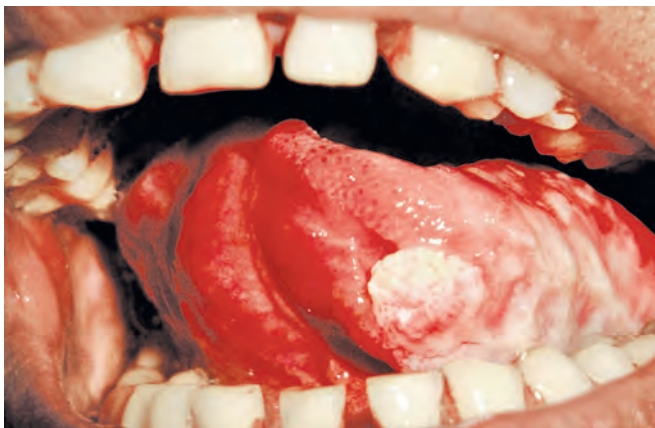
- ‘Bio’ means life or tissue. *Opsis* means vision or microscopy.  
 Biopsy means study of tissues using microscopy.  
 OR *life by vision*  
 OR *vision for life* (to save life).
- ◆ Biopsy is sent in 10% formaldehyde solution. In special occasions like, to assess receptors/to do histochemistry, biopsy is sent in low temperature; in normal saline or in specialised ingredients. Tissues are kept in formalin for 24 hours and then taken for ‘cut up’ by

Paraneoplastic syndromes		
Syndrome	Cause	Type of tumour
Cushing's syndrome ACTH	or ACTH like substance	Small cell carcinoma lung Neural tumour Pancreatic tumour
Syndrome of inappropriate ADH secretion	ADH	Small cell carcinoma lung Brain tumour
Carcinoid syndrome	Serotonin, bradykinin	Bronchial adenoma Gastric and pancreatic carcinoma
Hypoglycaemia	Insulin Insulin like substance	Fibrosarcoma Hepatoma
Hypercalcaemia	PTH related peptide	Renal cell carcinoma Carcinoma breast, SCC lung Ovarian carcinoma, leukaemia
Polycythaemia	Erythropoietin	Renal cell carcinoma, hepatoma Cerebellar haemangioma
Myasthenia	Immunologic	Lung cancer
Acanthosis nigricans	Epidermal growth factor	Lung cancer, uterine cancer, gastric carcinoma
Dermatomyositis	Immunologic	Lung carcinoma, breast carcinoma
Clubbing and hypertrophic Osteoarthropathy of fingers		Ca lung
Migrating thrombophlebitis (Trousseau phenomenon)	Tumour product mucin It activates clotting	Ca pancreas, lung

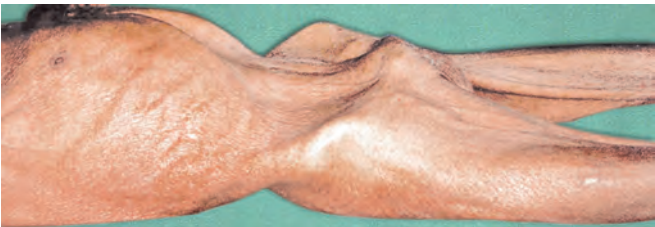*The creation of a thousand forests is in one corn.—Ralph Waldo Emerson*



**Fig. 1.483:** Ethmoidal sinus tumour. Biopsy and CT scan is needed to confirm and assess the extent.



**Fig. 1.484:** Carcinoma tongue is more common in lateral margin. Incision biopsy from the margin is done here.



**Fig. 1.485:** Typical *malignant cachexia* observed in GIT malignancies. It is totally malnourished incapacitated situation.

pathologists. Sections are done after making tissue blocks using microtome up to 5 microns thickness. These sections are placed on a slide for staining with haematoxylin and eosin. This is studied under microscopy by pathologist to give the report. Detailed history, findings, markings of the specimen should be done by the surgeon prior to sending the specimen. Bone specimens are decalcified in hydrochloric acid for 7–21 days before sectioning and staining. So its report will be delayed usually.

- ◆ Inadequate sampling and improper reports may be due to—limited tissue sent; tissues are nonviable; too superficial biopsy done; cautery use on the tissues; crushing effect on the tissues (gentle meticulous biopsy is important without rough handling and without over use of cautery on the required tissues).
- ◆ Specimens are kept for 6 weeks. Blocks are kept for 30 years. Slides are kept for 10 years.
- ◆ Risk of false positivity in malignancy should be remembered. It is probably due to contamination, interchanged specimens, wrong interpretation, ulceration, etc. Re-biopsy/reinterpretation/repeat sectioning may be needed in such situations.
- ◆ Often additional methods like deeper sections; extra blocks; special stains are needed. Special stains are PAS (Periodic Acid Schiff) for glycogen, mucin and fungi; D (diastase) PAS for mucin; Perls Prussian blue for iron in haemochromatosis; reticulin for fibrous tissue; elastin stains for fibrosis; congo red for amyloid; Ziehl-Neelsen for mycobacteria; Grocott for fungi; Giemsa stain for protozoa; Warthin-Starry stain for spirochaetes.

#### Types of biopsies

- ❖ Incision biopsy—*wedge biopsy*
- ❖ Excision biopsy
- ❖ Trucut biopsy
- ❖ Pap smear
- ❖ FNAC
- ❖ Frozen section biopsy
- ❖ Punch biopsy
- ❖ U/S guided biopsy
- ❖ Laparoscopic biopsy
- ❖ CT guided biopsy
- ❖ Thoracoscopic biopsy
- ❖ Endoscopic biopsy (gastroscopic or colonoscopic or through ERCP or through cystoscopy)
- ❖ Proctoscopic biopsy
- ❖ Open biopsy either laparotomy or thoracotomy or craniotomy using Dandy's brain cannula

#### Incision Biopsy

- ◆ It is taken from the edge of the lesion as in ulcer, not from the centre as there is necrosis.
- ◆ Usually *two biopsies* are taken in ulcerative lesion from the edge—edge/wedge biopsy (edge is a line which limits two parts; wedge is an area at two meeting parts like thick to thin, etc).
- ◆ Incision biopsy is contraindicated in a case of melanoma where excision biopsy is preferred.
- ◆ In secondaries in lymph nodes, FNAC is preferred. If it fails to give information, incision biopsy is done.

#### Note:

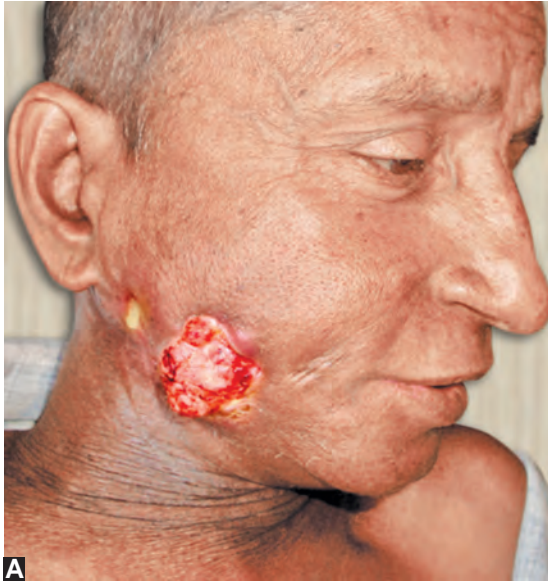Biopsy taken from the centre of the lesion is only in post-radiation ulcer and syphilitic gumma. Because of irradiation there is no blood supply in the margin and tumour proliferates in the centre of the lesion.

#### Excision Biopsy

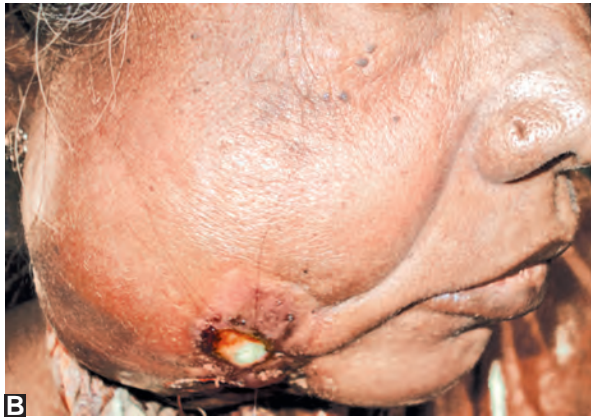In small lesions excision biopsy is done, e.g. lymph node biopsy is done in case of lymphoma.

#### Trucut Biopsy

It is done using a specialised device wherein gun with trucut tip is inserted into the surface tissue/organ and gun is fired to close the

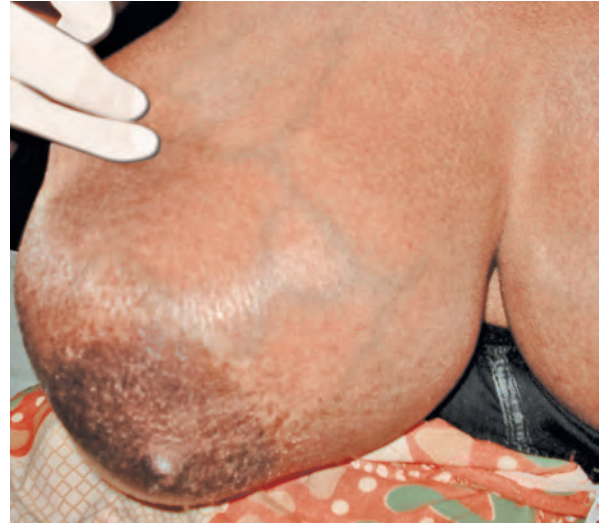

A

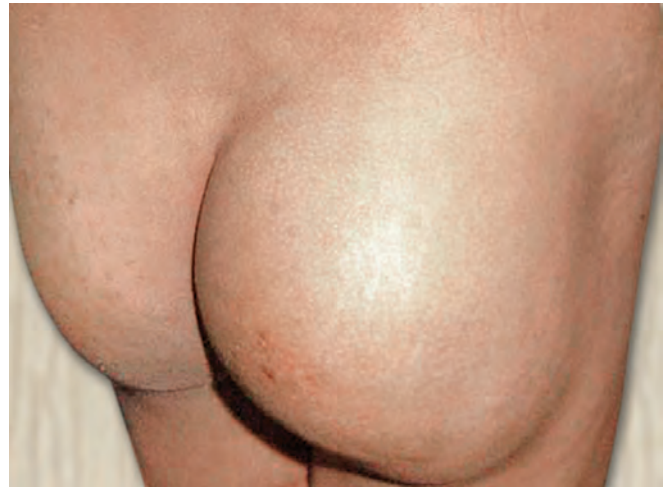

B

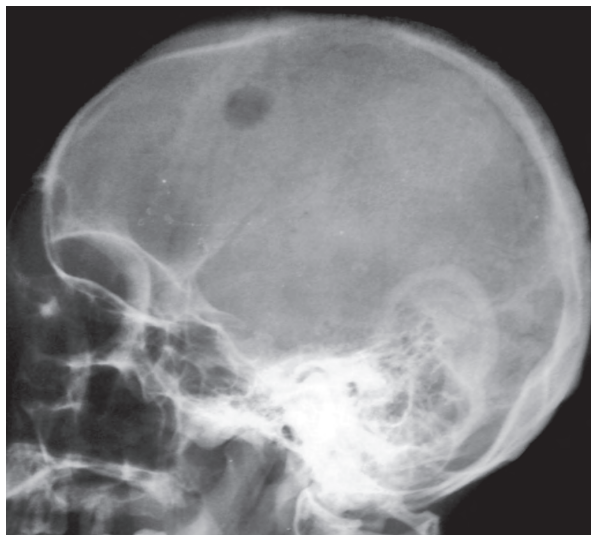
**Figs 1.486A and B:** Carcinoma cheek—advanced. It needs incision biopsy/orthopantomogram X-ray/CT of the part.



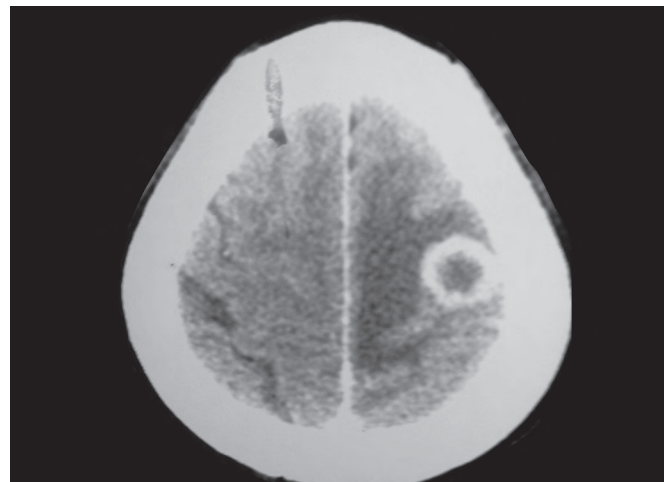
**Fig. 1.488:** Carcinoma breast. Note the dilated veins on the surface. FNAC should be done to confirm the diagnosis.



**Fig. 1.489:** Soft tissue tumour of buttock. It could be sarcoma.



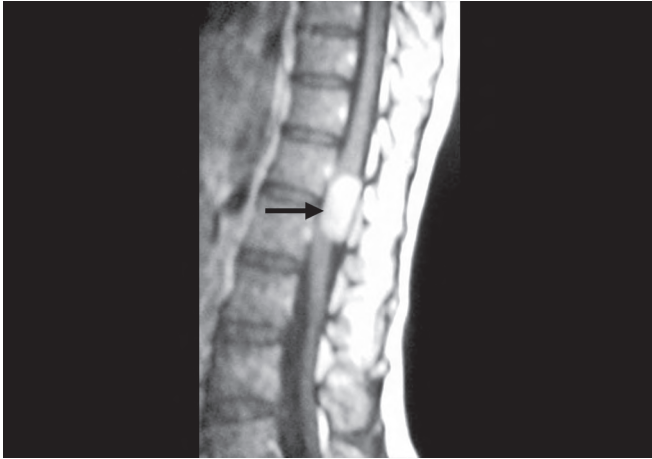
**Fig. 1.487:** Secondaries in skull—solitary.



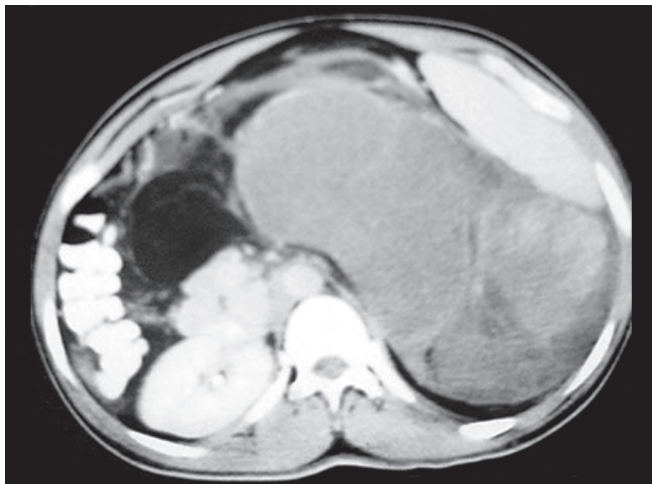
**Fig. 1.490:** CT head showing secondaries in the brain.

*A man carries success or his failure with him; it does not depend on outside conditions.*

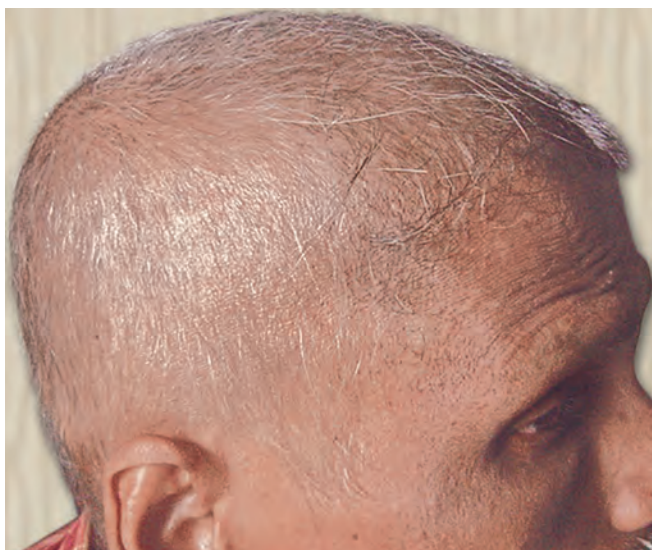



**Fig. 1.491:** Contrast MRI of spinal column showing extradural schwannoma.

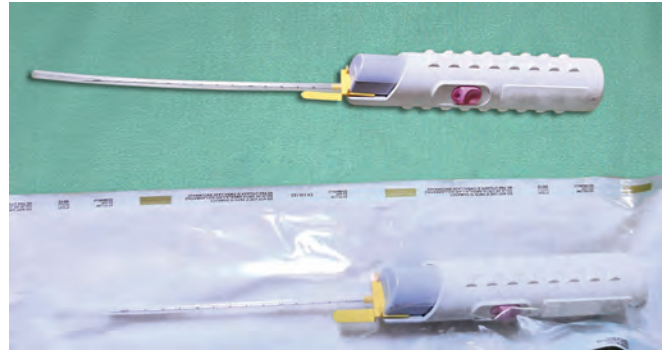


**Fig. 1.492:** CT scan picture of retroperitoneal leiomyosarcoma.



**Fig. 1.493:** Alopecia (hair loss) is common after chemotherapy for cancers.

punching tip of the needle to catch and cut adequate tissue. It is done in prostate, breast and surface tumours. It cannot be done to deeper tissues or tissues which are close to major vessels/structures.



**Fig. 1.494:** Trucut biopsy gun used for trucut biopsy. It gives histological diagnosis; it is also helpful to assess histochemistry.

### FNAC (Fine Needle Aspiration Cytology)

It is cytological study of tumour cells to find out the disease and also to confirm whether it is malignant or not.

**Procedure:** It is done using 23 or 24 gauge needle fixed to specialised syringes which creates negative pressure for aspiration and contents are smeared on the slides. Dry slides as well as slides fixed with 100% methanol are used for study.

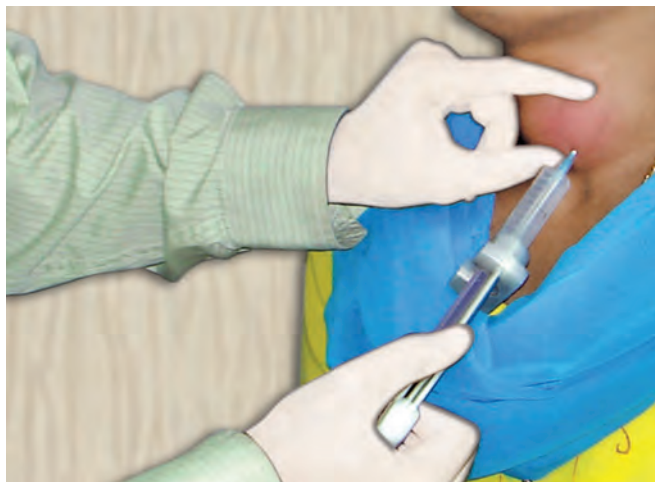- ◆ It is done in parotid, thyroid, lymph node, breast and all other surface lesions.
- ◆ In follicular carcinoma of thyroid it is not very useful, as angioinvasion and capsular invasion which are specific cannot be detected.
- ◆ In lymph nodes it is useful for detecting secondaries and tuberculosis.
- ◆ U/S guided or CT guided FNAC are popular at present—especially when it is done from liver, lungs, kidneys, etc. (from deeper structures/organs).

**It is absolutely contraindicated in testicular tumour.** Because tough tunica albuginea usually prevents tumour spread and once it gets disrupted by FNAC, spread can occur.


Cytological study is done after Papanicolaou stain; Giemsa staining or Romanowsky staining.

#### Note:

- In 1934, Martin and Ellis did **FNAC** using 18 G needle with syringe with local anaesthesia use.
- Kline and Neal in 1973 did syringe needle aspiration using 18 G needle making dry smears.
- In 1982, A John Webb detailed standard FNAC using 21 G needle. Needle is passed obliquely into the lesion; constant suction is applied using **Comeco syringe or braced thumb method**. With suction persisting needle is moved in 4 directions. Suction is gently released and needle is withdrawn. Needle is detached from syringe to draw air which is reattached to withdrawn needle to blow the content over a dry slide.
- In 1987, A Zajdello et al fine needle sampling of the tissue in question **without aspiration**. 25 G needle is used without a syringe. Needle is moved in various directions to detach the cells by sharp end of the needle; by capillary force, cells are conducted into the needle lumen. Air filled syringe is attached to needle to express cells into a glass slide. Trauma to tissue is said to be less; and feel of tissue consistency is better through held needle. It is called as Fine Needle Sampling Without Aspiration / Fine Needle Non-aspirating Cytology (**FNNAC**) / Fine Needle Capillary Sampling (**FNCS**; as capillary action causes conduction of cells into needle).
- US guided/MRI guided/CT guided/Mammographic guided FNAC are available now which are more precise versions of localization of lesions to be aspirated.



**Fig. 1.495:** Fine needle aspiration cytology (FNAC) of thyroid. It is also done in breast, lymph node and other swellings. It is not done for testicular tumour.



**Fig. 1.496:** FNAC vacuum creator with loaded syringe [FNAC gun; Cameco syringe (Sweden) holder]. (Courtesy: Dr Krishna Upadhy, MD, Nandikoor Laboratory, Mangaluru)

- Ether with alcohol in equal proportion is used for wet fixation to stain Papanicolaou or H & E stains. Grace in 1994 used modified ultra Pap stain 3 changes – by rehydration of air dried smears using normal saline to cause RBC haemolysis to restore cell transparency; by using mixture of 4% formaldehyde and 65% ethanol to reduce fixation time from minutes to few seconds; by using Richard Allen Haematoxylin 2 and cyto stain. Total time of staining in this modification is 90 minutes.

### Advantages

- ◆ Very sensitive.
- ◆ Done on OP basis.
- ◆ Least invasive, safer, fast and cheaper.
- ◆ Anaesthesia is not required.
- ◆ Tumour dissemination through the track is not present (except in testicular tumour where it is not done).
- ◆ Presently DNA study of the cell can detect very early malignancy.

### Disadvantages

- ◆ Negative result cannot rule out malignancy.
- ◆ Tissue study is not possible.
- ◆ Further studies not amenable.

### Note:

**FNNAC**—Fine Needle Non-aspirating Cytology is done in some tissues (in some centres). Here needle is passed into the tissue and material collected from the needle (without any aspiration) is studied for cytological analysis.

### Frozen Section Biopsy

Frozen section is done whenever biopsy report is needed at the earliest. It is usually done in a pathology set up existing adjacent to the operation theatre. An unfixed fresh tissue is frozen (using CO<sub>2</sub>) in a metal and sections are made and stained. It is technically difficult; processing and staining is of inferior quality and often it is difficult to give accurate results. But advantage is it is quick and surgeon can decide the further steps of procedure in same sitting like nodal clearance/type of resection to be done, etc.

- ◆ It is done in carcinoma breast or in follicular carcinoma of thyroid when FNAC fails.
- ◆ During surgery after resection of the tumour to look for (on table) the clearance in the margin and depth and also to study the lymph nodes for their positivity.

## II. IMMUNOHISTOCHEMISTRY

It is detection of specific antigen using an antibody. Antibody labelled with a dye, binds to antigen in a section of tissue causing specific colours like brown, and determines its presence and distribution in the tissues. It is safe, specific and quick.

It is used in:

- ◆ *Neoplasia*
  - ▶ To confirm, to find differentiation, to detect metastases; to plan type of therapy.
  - ▶ To categorise leukaemias or lymphomas; either of 'T' cell or of 'B' cell type.
  - ▶ To find out site of origin of metastatic tumours, e.g. by doing prostate specific antigen in prostate cancer or doing thyroglobulin in thyroid carcinomas or clear cells in the lung in metastatic renal cell carcinoma.
  - ▶ Detection of receptors or molecules, e.g. estrogen receptors [ER] in breast cancer. ER positive has got better prognosis. Presence of onco-protein product c—erbB2 in breast cancer signifies poor prognosis.
  - ▶ Gastrointestinal stromal tumour (GIST) can be treated with imatinib if it shows CD 117 expression.
  - ▶ Endocrine tumours are assessed on ki67 proliferative index.
  - ▶ Cytokeratin marker for epithelial tumours like carcinoma; S100 and actin for glandular malignancy; S100 for melanoma; CD31 and CD34 for vascular malignancy; CA 125 for ovarian tumours; PSA for carcinoma prostate; CD3 and CD20 for lymphoma.
- ◆ *Infections*
  - ▶ Detection of specific antibodies to the antigens of certain specific infective agents like Epstein-Barr virus, cytomegalovirus, human herpes virus 8, herpes simplex virus, etc.
- ◆ *To identify abnormal accumulation* of various proteins like  $\alpha$ -1-antitrypsin; deposition of amyloid.
- ◆ *Assessment of immunoglobulins.*
- ◆ *Screening for mutations.*

*The pathological fracture is a transverse one, and although it unites readily, re-fracture is not unusual.*

—Max E Lake

### III. TUMOUR MARKERS

- ◆ Tumour markers are biochemical indicators of presence of a tumour. They are not used for primary pathological diagnosis.
- ◆ They are of prognostic value.
- ◆ Presence of tumour marker signifies recurrence or residual tumour.

### IV. OTHER METHODS

#### Electron Microscopy

- ◆ It is visualisation of tissue in very high magnification of 1000 × 500 000 in difficult deciding cases. But it is time consuming and expensive.

#### In Situ Hybridisation

- ◆ It is determination of presence or absence of a specific gene and its location in a fresh/fixed tissue sections using an oligonucleotide probe, targeting at specific DNA or RNA sequence.

#### Polymerase Chain Reaction (PCR)

DNA is amplified using this special method and detected by technique like electrophoresis. PCR can be done on blood or nontissue samples. It is highly sensitive, fast and safe. Disadvantages are—expensive and risk of DNA contamination.

#### Uses

- ◆ Detection of mutations in congenital conditions like von Hippel-Lindau disease (vHL gene); haemochromatosis (HFE gene); colorectal carcinoma (APC gene).
- ◆ Gene rearrangements in different conditions like lymphoma or other diseases can be detected by PCR (clonality).

- ◆ Assessment of loss of heterozygosity in tumours like oligodendroglioma (1p, 16q).
- ◆ PCR study for infections like tuberculosis.

#### Fluorescent In Situ Hybridization (FISH)

- ◆ It is a type of cytogenetic study (study of chromosomes) that can be done in fixed or fresh tissues. RNA or DNA probes are prepared which are tagged with fluorophores targeted on specific cells or chemicals.
- ◆ It is used in haematological malignancies, genetic evaluation like trisomy 23; oligospermia; cancer study, leukaemias, and in many syndromes.
- ◆ It is used in assessing the remission and prognosis.
- ◆ It is safe and quick.

### MANAGEMENT STRATEGY FOR CANCERS

- ◆ *Diagnosis* is confirmed by biopsy from primary usually.
- ◆ *Evaluations* for staging—metastatic work up.
- ◆ *Approaches for primary*—surgery/radiotherapy/chemotherapy.
- ◆ *Approaches for secondary*.
- ◆ *Palliation* in advanced stage—palliation of *distressing* symptoms.

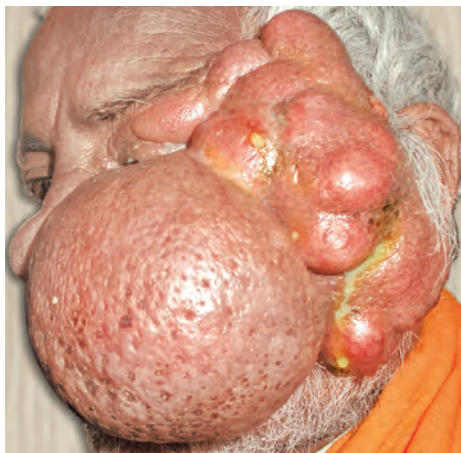#### Treatment of tumours

- ❖ Surgery—wide excision/radical
- ❖ Radiotherapy—curative/palliative
- ❖ Chemotherapy
- ❖ Immunotherapy
- ❖ Gene therapy

Tumour markers	
<b>Category 1</b>	
<i>Hormonal:</i>	
Human chorionic gonadotrophin (HCG)	— Trophoblastic tumour, nonseminomatous testicular tumour
Calcitonin	— Medullary carcinoma of thyroid
Catecholamines and VMA	— Pheochromocytoma
Ectopic hormones	— In tumours of paraneoplastic syndromes
<b>Category 2</b>	
<i>Isoenzymes:</i>	
Prostatic acid phosphatase	— Carcinoma prostate
Neuron specific enolase	— Small cell carcinoma lung, neuroblastoma
<b>Category 3</b>	
<i>Oncofetal antigens:</i>	
Alpha fetoprotein	— Liver cancer, nonseminomatous germ cell tumour
Carcinoembryonic antigen (CEA)	— Carcinoma colon (common). Carcinoma pancreas, lung, stomach and breast
<b>Category 4</b>	
<i>Mucin and other proteins:</i>	
CA—125 (Carbohydrate antigen)	— Ovarian cancer
CA—15-3	— Breast cancer
CA—19-9	— Pancreatic and colon cancer

### Malignancies which are curable

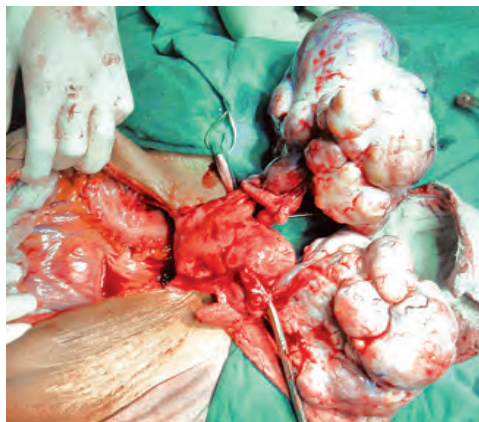
- ❖ Basal cell carcinoma
- ❖ Adamantinoma
- ❖ Verrucous carcinoma
- ❖ Marjolin's ulcer
- ❖ Papillary carcinoma of thyroid
- ❖ Carcinoma colon



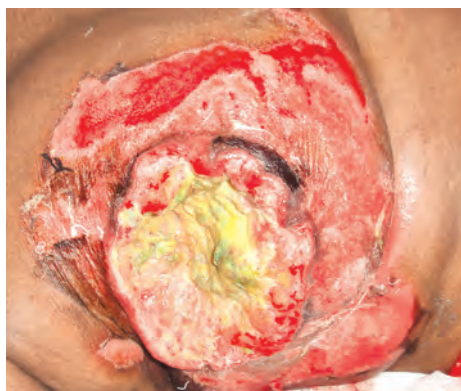**Fig. 1.497:** Advanced aggressive malignancy face may be carcinoma or sarcoma.

### Sarcomas which spread to lymph nodes

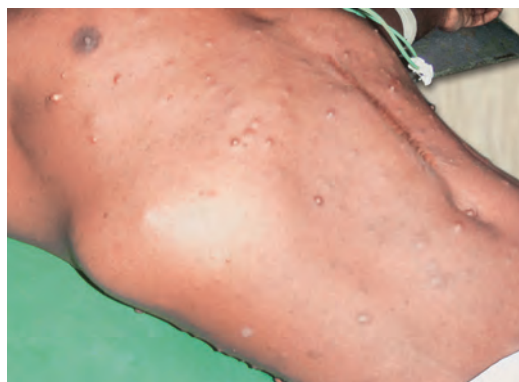- ❖ Synovial sarcoma
- ❖ Ewing's sarcoma
- ❖ Lymphosarcoma
- ❖ Kasposi's sarcoma
- ❖ Rhabdomyosarcoma
- ❖ Angiosarcoma



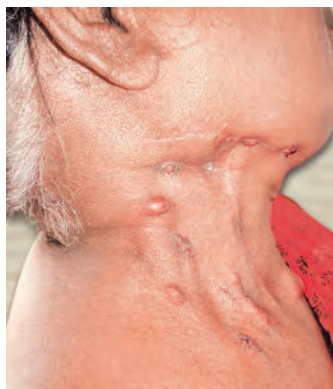**Fig. 1.500:** Secondaries in ovaries—Krukenberg tumour.



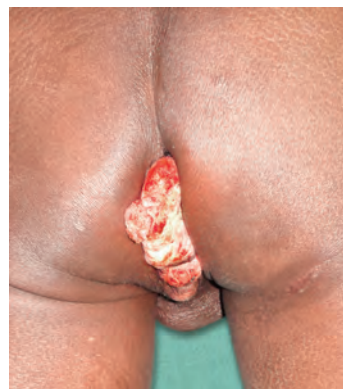**Fig. 1.498:** Advanced fungating carcinoma of breast.



**Fig. 1.501:** Malignant primary nerve sheath tumour (MPNST).



**Fig. 1.499:** Recurrent secondaries in neck after radical neck dissection.



**Fig. 1.502:** Anal canal carcinoma (SCC).

## R. Skin Tumours

### CHAPTER OUTLINE

- ❖ Anatomy
- ❖ Classification of Skin Tumours
- ❖ Skin Adnexal Tumours
- ❖ Dermatofibroma
- ❖ Dermatofibrosarcoma Protuberans
- ❖ Keratoacanthoma
- ❖ Rhinophyma
- ❖ Seborrhoeic Keratosis
- ❖ Squamous Cell Carcinoma
- ❖ Marjolin's Ulcer (1828)
- ❖ Basal Cell Carcinoma
- ❖ Turban Tumour
- ❖ Naevi
- ❖ Melanoma

### ANATOMY

*Skin* is the largest organ in the body with surface area of up to 18,000 sq cms and having 15% of body weight. Its functions are—protective barrier to deeper tissues from infections, chemicals, other agents like heat, solar rays, etc; thermoregulation; fluid, electrolyte, acid and base balance maintenance; perception.

### Epidermis

- ❖ *Epidermis is avascular.*
- ❖ Epidermis is 5% of the total skin. It is thickest (0.5–1 mm) in palm, sole, back and buttocks. It is thinnest in eyelids (0.05–0.09 mm).
- ❖ *Epidermis* has got 5 layers—stratum corneum; granulosum; spinosum; basale and basement membrane. Epidermis contains *keratinocytes* (maintains homeostasis, secretes cytokines); *melanocytes* (secretes melanin); *Langerhans cells* (antigen presenting cells which migrate to regional lymph nodes to reach immune system).

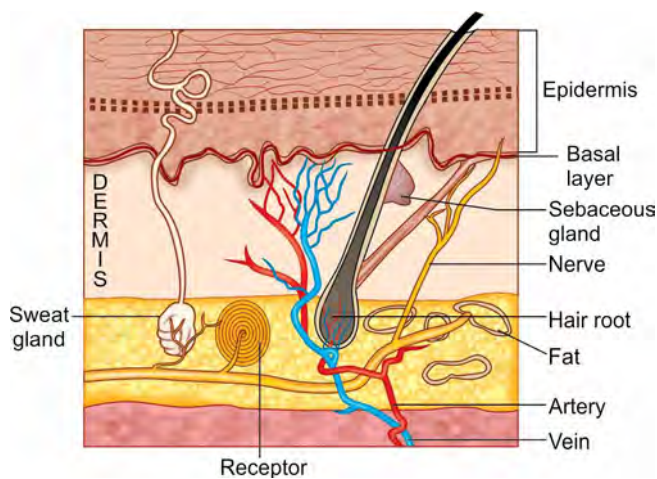


Fig. 1.503: Skin anatomy.

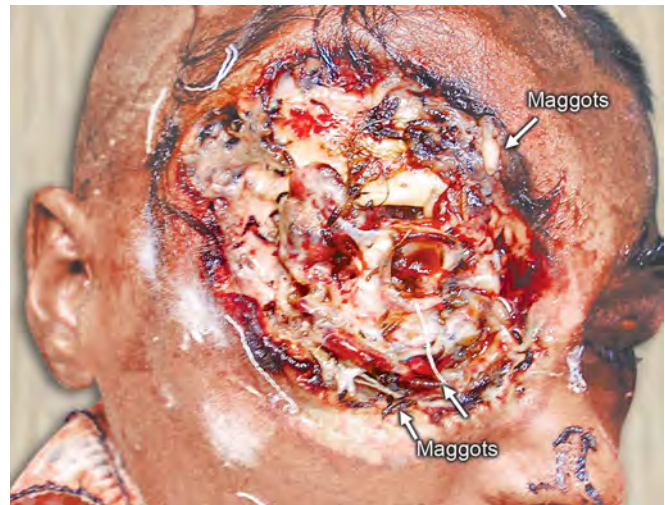

Fig. 1.504: Extensive infective destruction of the eyelids, face exposing bone and deeper structures. Maggots are seen on the surface. It mimics carcinoma but it was of infective origin. *Phagedena* is infective destruction without proliferation. It often mimics malignancy.

- ❖ Stratum corneum—1/3 of epidermis
  - ❖ Stratum granulosum—1–3 layers of cells
  - ❖ Stratum spinosum—3–5 layers of cells
  - ❖ Stratum basale—columnar cells
  - ❖ Stratum lucidum is seen in palms and sole.
- Melanocytes—one melanocyte is seen for every 10 basal cells  
*Langerhans cell*—a clear cell in stratum spinosum.  
 Basement membrane is seen at dermo-epidermoid junction.

### Dermis

- ❖ It contains collagen fibres, elastic fibres, capillaries, venules, arterioles, lymphatics, nerves, erector pilorum muscle, sweat glands (eccrine, apocrine), sebaceous glands. Merkel cells, Meissner and Pacinian corpuscles are receptors in dermis. Dermis constitutes 95% of the skin. Dermis is 15–40 times thicker than epidermis.

- ◆ *Dermis constitutes* papillary and reticular dermis. Dermis contains type I and II collagen. Main *adnexal structures* of the skin are—sweat glands, sebaceous glands, hair follicles with their germinal centres. The apocrine glands are located in axilla and anogenital regions. Sebaceous glands secrete sebum to keep the skin soft and oily. The ducts open at the hair follicles and at the skin surface. Pilosebaceous unit contains hair follicle and sebaceous gland.

## CLASSIFICATION OF SKIN TUMOURS

### Benign

#### Epidermal

- ◆ Seborrhoeic keratosis.
- ◆ Trichilemmal tumour.
- ◆ Sebaceous adenoma.
- ◆ Sebaceous epithelioma.
- ◆ Hydrocystoma, syringoma, spiradenoma.

#### Dermal Tumour

- ◆ Neurofibroma.
- ◆ Dermatofibroma.

### Malignant

- ◆ Squamous cell carcinoma.
- ◆ Basal cell carcinoma.
- ◆ Melanoma.
- ◆ Malignant skin adnexal tumour.
- ◆ Secondaries in the skin. Sister Joseph nodules around umbilicus.

#### Classification of skin tumours

##### Epidermal

- ❖ *Benign*—papilloma, seborrhoeic keratosis
- ❖ *Malignant*—BCC, SCC

##### Melanocytic

- ❖ *Benign*—all types of naevi
- ❖ *Malignant melanoma*

##### Skin adnexal tumour

- ❖ *Benign*—syringoma, hidradenoma, sebaceous adenoma, trichofolliculoma, trichilemmoma
- ❖ *Malignant*—hidradenocarcinoma, sebaceous carcinoma

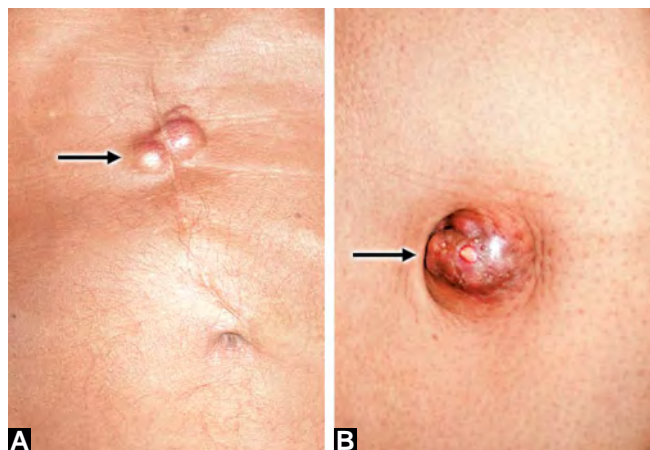
##### Dermal tumours

- ❖ Neurofibroma, dermatofibroma, dermatofibrosarcoma protuberans

- ◆ *Skin cancers (SC) are also classified as melanotic (MSC) or nonmelanotic (NMSC). NMSC are commonest. Patient who had BCC/SCC has higher risk to develop 2nd new skin cancer (35% in 3 years; 50% in 5 years). NMSC can be low risk or high risk groups. Lesion more than 2 cm in trunk and limbs; more than 1 cm in forehead and neck; more than 6 mm in central face; poorly defined margin; recurrent type; moderate or poor differentiation; perineural/vascular invasion; presence of immunosuppression; previous RT— are high risk lesions.*

#### Note:

- Multiple sebaceous adenomas with visceral malignancy are called as *Torre-Muir syndrome*.



**Figs 1.505A and B:** (A) Abdominal wall cutaneous secondaries; primary is from carcinoma stomach; (B) Sister Mary Joseph secondary nodule in umbilicus.

- Secondaries in skin can occur like **Sister Mary Joseph nodules** around the umbilicus. (*Sister Mary Joseph* was Superintendent Nurse in St Mary's hospital, 1856–1939).

## SKIN ADNEXAL TUMOURS

### Classification

- ◆ *Eccrine gland tumours:* Syringoma, hidradenoma, syringocystadenoma.
- ◆ *Hair tumours:* Trichoepithelioma, trichilemmoma.
- ◆ It may be **benign** or **malignant**.

### Features

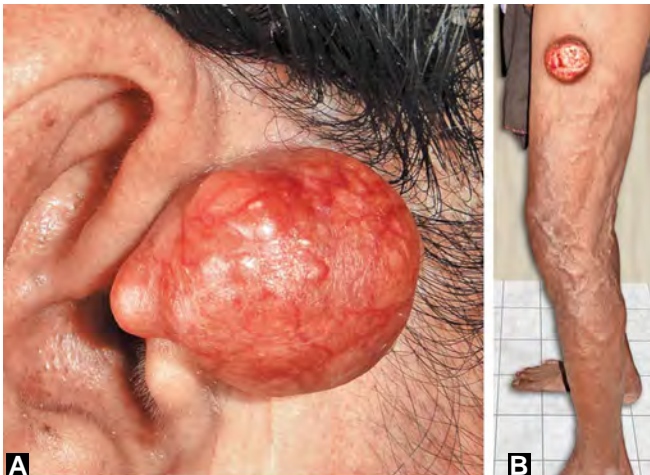
- ◆ They are tumours arising from accessory skin structures like sebaceous glands, sweat glands, hair follicles.
- ◆ It is not uncommon.
- ◆ It presents as protruding well-localised swelling in the skin.
- ◆ *Trichoepithelioma* is usually seen in nasolabial fold; mimics BCC; presents as small cutaneous nodule.
- ◆ *Trichilemmoma* is also called as *naevus sebaceous of Jadassohn*. It is a hamartoma from hair follicle which can turn into BCC in 10% of cases.
- ◆ *Adenoma sebaceum* is seen in tuberous sclerosis as red papules in face which appears below 10 years. It is often called as *Bourneville's disease*.
- ◆ *Calcifying epithelioma of Malherbe/pilomatrixoma* is benign hair matrix cell tumour seen below the age of 10 years, containing basaloid and eosinophilic ghost cells with calcification.
- ◆ *Malignant skin adnexal tumour* forms a nodular, hard, indurated swelling in the skin, often with involvement of regional **lymph nodes** which are hard and nodular.
- ◆ It mimics **squamous cell carcinoma of skin**.

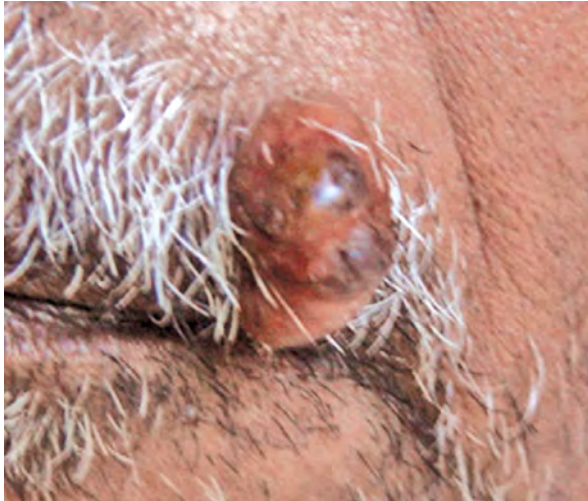

Fig. 1.506: Skin adnexal tumour (benign) in the face.

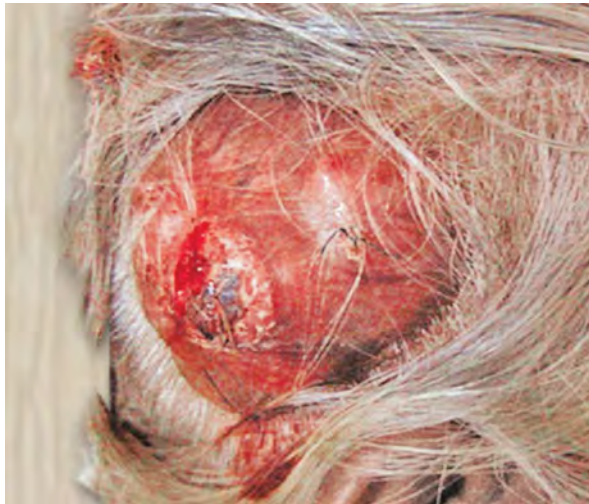

Fig. 1.507: Skin adnexal tumour (malignant) turned out to be of hair follicle origin.



Figs 1.508A and B: Skin adnexal tumour—preauricular region; (B) Skin adnexal tumour. Vascularity is increased and it is malignant.

- ◆ *Differential diagnosis*
    - ▶ Squamous cell carcinoma of skin.
    - ▶ Dermatofibrosarcoma protuberans.
  - ◆ *Diagnosis*
    - ▶ Biopsy—excision or incision type.
    - ▶ FNAC of lymph node.
  - ◆ *Treatment*
    - ▶ Benign tumour—excision.
    - ▶ For malignant tumour—wide excision and regional lymph node block dissection when required.
- Prognosis is good. It is better than squamous cell carcinoma.

**Note:**

- **Merkel cell carcinoma** is aggressive malignant condition arising from neuroendocrine receptor cells of the skin (dermis) which mimics histologically oat cell carcinoma. It is common in white elderly females (4 : 1) may be due to UV rays. Treatment is wide excision with radiotherapy.
- **Adenocarcinoma arising from the apocrine glands** of skin is called as *extramammary Paget's disease* of skin (intraepidermal adenocarcinoma) commonly observed in perianal region.
  - It can occur in genitalia or in axilla (more apocrine glands). In 25% of cases, the condition is associated with an *underlying in situ* or invasive carcinoma. *Presentation* is like red plaque/white/depigmented areas/crusts/scales mimicking dermatitis, eczema, fungal infections. Condition is often associated with GI or urinary malignancies (40%). Biopsy of lesion, CT evaluation for other malignancies, wide local excision and radiotherapy—are the management principles.

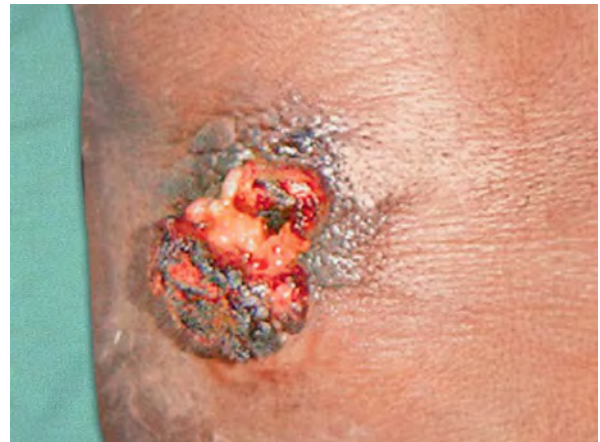

Fig. 1.509: Malignant skin tumour with ulceration of the skin over chest wall. Axillary nodes were enlarged in this patient.

**DERMATOFIBROMA (Sclerosing Angioma or Subepithelial Benign Nodular Fibrosis)**

- ◆ It is a benign tumour arising from skin from dermal dendritic cells.
- ◆ It is formation of firm, single or multiple nodules occurring commonly in extremities (limbs).
- ◆ It can be red, brownish yellow (due to lipid), or bluish black (due to haemosiderin).
  - Histologically, spindle cells are arranged in 'mat like' or 'cart-wheel' pattern.
- ◆ It is also called as *dermal histiocytoma*.
- ◆ *Treatment:* Excision.

### Differential diagnosis

- ❖ Squamous cell carcinoma of skin
- ❖ Melanoma
- ❖ Basal cell carcinoma
- ❖ Skin adnexal tumour

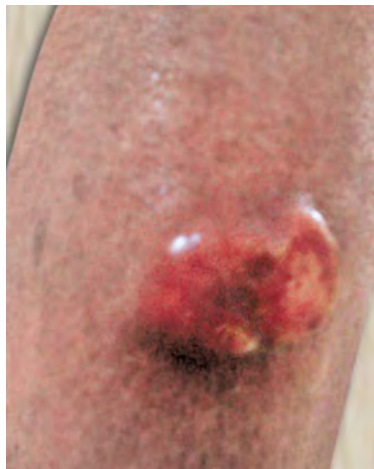

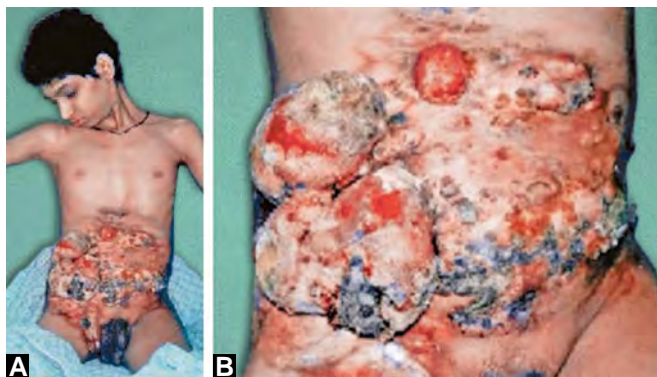
Fig. 1.510: Dermatofibroma in leg.

### DERMATOFIBROSARCOMA PROTUBERANS

- ◆ It is a low grade fibrosarcoma which grows slowly but persistently. It arises from *dermal fibroblasts*.
- ◆ Occurs in head and neck, limbs, abdominal wall and back—Trunk is commonest site (50%).
- ◆ It is not a rare entity, often attains a large size with multiple, nodular, hard, swelling with often involvement of lymph nodes. Malignant spindle cells are seen histologically.
- ◆ Rarely it spreads into lungs through blood.
- ◆ It mimics squamous cell carcinoma of skin and skin adnexal tumour.
- ◆ Positive for CD34 and ring chromosome.
- ◆ With melanin pigmentation it is called as *Bednar's tumour*.

### Diagnosis

- ◆ Biopsy of the lesion.
- ◆ Chest X-ray, CT scan.
- ◆ FNAC of the lymph node.



Figs 1.511A and B: Dermatofibrosarcoma.

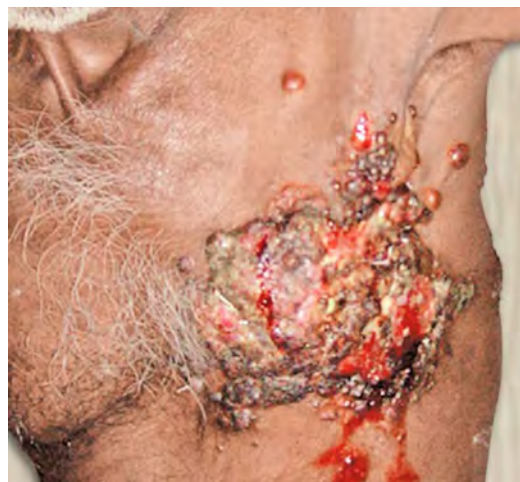

Fig. 1.512: Dermatofibrosarcoma protuberans.

### Treatment

- ◆ Wide excision and follow up.
- ◆ Recurrence is common—50%.
- ◆ Prognosis is good.

### KERATOACANTHOMA (MOLLUSCUM SEBACEUM)

- ◆ It is an overgrowth and subsequent spontaneous regression of *pilosebaceous glands* with proliferation of squamous cells protruding out of the duct which are common in adult males (3:1) and places where more sebaceous glands are found.
- ◆ *Causes*: Human papilloma virus; genetic; immunosuppression; UV rays, trauma are considered.
- ◆ It presents as a rapidly growing, painless, single swelling in the skin with central brown area.
- ◆ It grows usually for 4 weeks and later shows spontaneous regression in 4 months. It is a pseudomalignancy.
- ◆ During regression phase, central area separates from the lesion leaving a deeply seated scar.
- ◆ Eventhough it is usually benign, 6% of cases may be invasive squamous cell carcinoma and often called as keratoacanthoma variant.
- ◆ Commonly keratoacanthoma is solitary, but rarely can be multiple, giant or generalised.

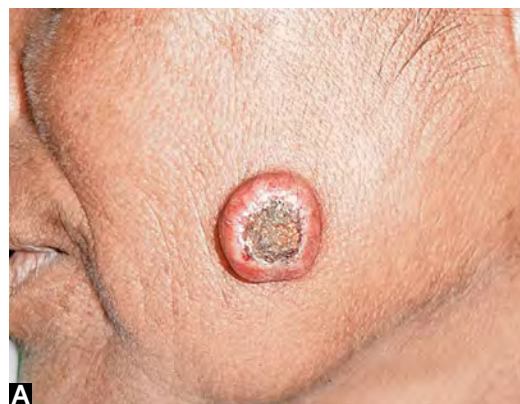

Fig. 1.513A



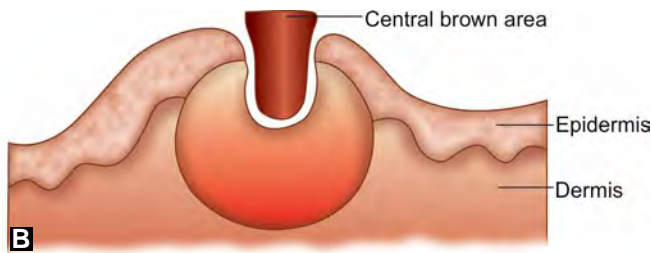


Fig. 1.513B

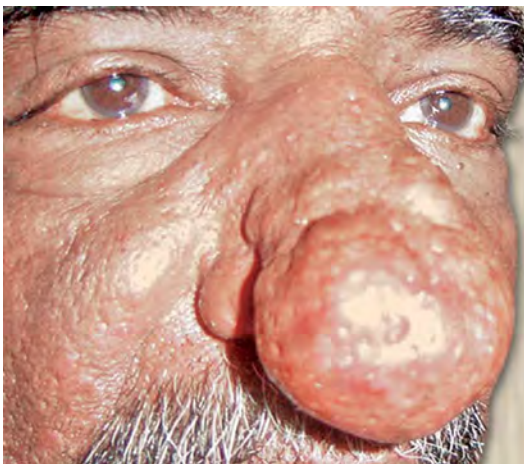**Figs 1.513A and B:** Typical keratoacanthoma with central brownish area. It is self-limiting disease.

### Features

- ◆ Mobile, hard, painless, nontender, lump with a *central brownish volcano* like area. It is common in face. It can be recurrent in lips and fingers.
- ◆ Lymph nodes are not enlarged.
- ◆ *Differential diagnosis:* Squamous cell carcinoma.
- ◆ *Treatment:* Excision. The tissue is sent for histopathological study.

### ■ RHINOPHYMA (Potato Nose) (Bottle Nose)

- ◆ It is a **glandular form of acne rosacea** causing immense thickening of **distal part of skin of nose** with visible openings of sebaceous follicles. Nose is bluish red in colour with dilated capillaries.
- ◆ It is due to hypertrophy and adenomatous changes in sebaceous glands.
- ◆ Male to female ratio is 12:1. Three per cent cases may have occult BCC in it. But rhinophyma itself will not cause BCC.
- ◆ *Treatment:* Excision of excess tissue and reconstruction.



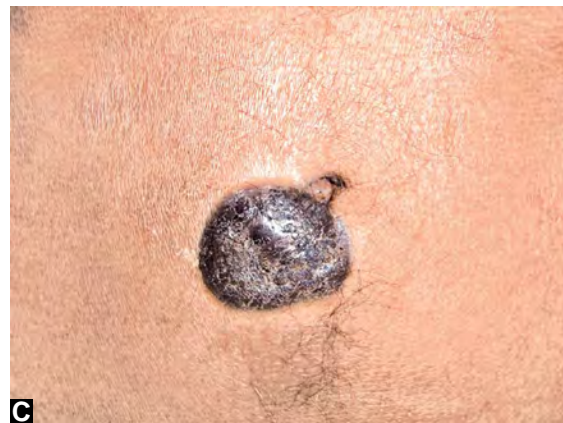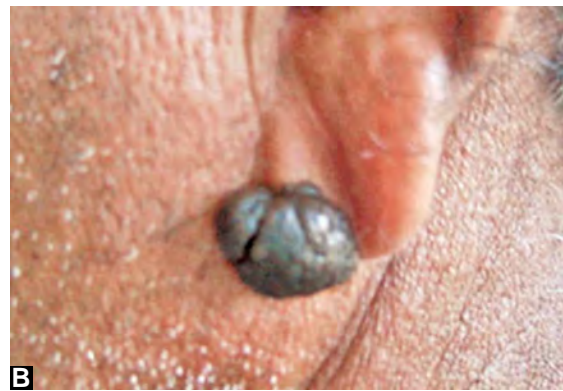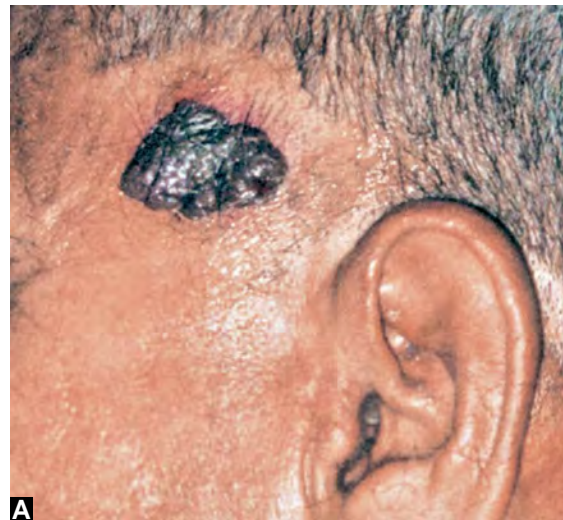Figs 1.514: Rhinophyma. Typical look and site.

### ■ SEBORRHOEIC KERATOSIS (Seborrheic Wart, Basal Cell Papilloma)

It is a benign overgrowth of the basal layer of epidermis with excess of small darkly stained basal cells, which protrudes from the surface of the epidermis to give oily appearance.

### Features

- ◆ It is common in elderly. Common sites are the back, face, neck.
- ◆ It grows slowly with widening in area without altering in thickness.
- ◆ It often gets infected but uncommon to bleed on touch.



Figs 1.515A to C: Seborrheic keratosis in face, ear and in periumbilical region. It is not a premalignant condition.

- ◆ It is pigmented due to melanin and so mimics naevus or melanoma.
- ◆ It is common Caucasians. It is familial—autosomal dominant gene related.
- ◆ Often when it falls off, it leaves a pale pink patch on the skin with visible small surface capillaries.
- ◆ It is not a premalignant condition

#### Note:

- ◆ Solar keratosis is a premalignant condition.
- ◆ It is hard and stiffer than normal skin.
- ◆ Lymph nodes are not involved.
- ◆ It does not occur in palms and soles.
- ◆ It can be picked off from the skin.

- ◆ 'Stuck on' appearance is characteristic.
- ◆ *Differential diagnosis:* Melanoma, pigmented BCC, naevus,
- ◆ *Treatment:*
  - ▶ Excision cures the condition.
  - ▶ Shave excision or curettage can be done.

#### PREMALIGNANT CONDITIONS OF THE SKIN

- ❖ *Bowen's disease* of skin: It is an intradermal precancerous condition. It presents as brownish induration with a well-defined edge. Microscopically it contains large clear cells. Eventually, it will turn into carcinoma (10%). Entire epidermis is disorganised and irregular. It shows parakeratosis, acanthosis, hyperkeratosis. Chronic solar exposure; arsenic; human papilloma virus 16 are the aetiologies. Topical 5 fluorouracil or imiquimod; 4 mm margin surgical excision; MOHS; laser are the therapeutic options. Erythroplasia of Queyrat is Bowen's disease occurring over glans penis
- ❖ *Paget's disease* of nipple
- ❖ Leukoderma
- ❖ *Senile or solar keratosis:* It is multiple, dry, hard, scaly, lesions on the face and back of hands due to exposure to sunlight, occurs after middle age. This is sunray induced hyperkeratosis with irregular, firm, raised or flat patch. Squamous cell carcinoma develops later after 10 years. Lesion in such situation becomes non-healing, indurated with central crust with everted edge; hard enlarged regional lymph nodes may be palpable
- ❖ *Radiodermatitis*, arsenic dermatitis
- ❖ *Chronic scars* develop into Marjolin's ulcer
- ❖ Albinism
- ❖ *Xeroderma pigmentosa* wherein there is defective DNA excision repair mechanism. It turns into malignant melanoma, BCC, SCC
- ❖ *Chronic lupus vulgaris*
- ❖ *Prolonged irritation of skin* by various chemicals like dyes, tar, soot

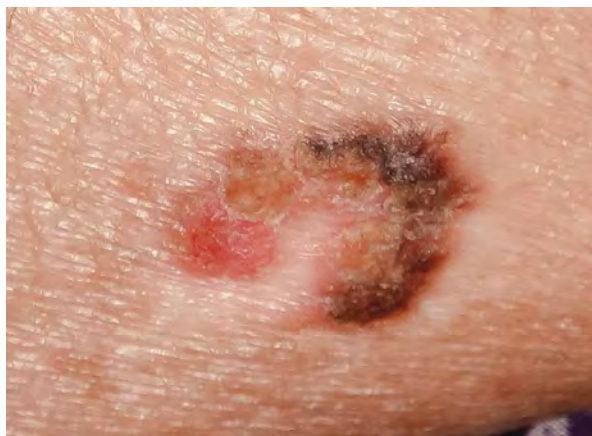

Fig. 1.516: Bowen's disease (John T Bowen, 1912).

#### Skin Cancers are Classified as:

- ❖ Melanotic
- ❖ Non-melanotic
  - BCC
  - SCC
  - Others

#### SQUAMOUS CELL CARCINOMA (Epithelioma)

- ◆ It occurs in premalignant conditions like Bowen's disease, Paget's disease, leukoplakia, chronic scars, chemically induced chronic irritation, radiodermatitis, senile keratosis, e.g. *Kangri cancer in Kashmir*, *Chimney scrotal cancer*, *Kang cancer of Tibetans*.
- ◆ It arises from squamous layer of the skin. Usually it occurs in a pre-existing predisposing lesion; occasionally can develop in *de novo* skin.
- ◆ It can be grossly proliferative/ulcerative/ulceroproliferative/red plaque like. Proliferative type is cauliflower like.
- ◆ It expresses cytokeratins one and ten.
- ◆ It is the 2nd (20%) most common skin cancer.
- ◆ It is common in males.
- ◆ *Exposure to UVB rays* (ultraviolet rays are A, B, C types) causes SCC by direct carcinogenic effects on keratinocytes, unrepaired mutations, decreased immune surveillance response, inhibition of tumour rejection, mutation of p53 suppressor gene (seen in 90% SCC).

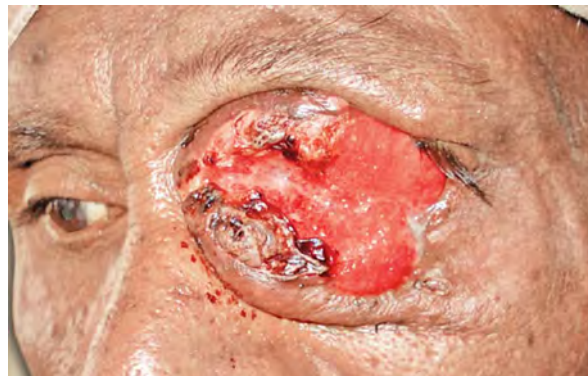

Fig. 1.517: Squamous cell carcinoma eyelid. Note the involvement.

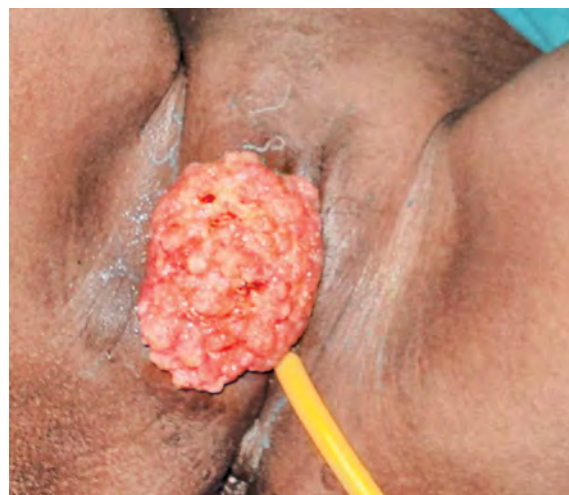

Fig. 1.518: Squamous cell carcinoma on the labia.

### Common Sites are:

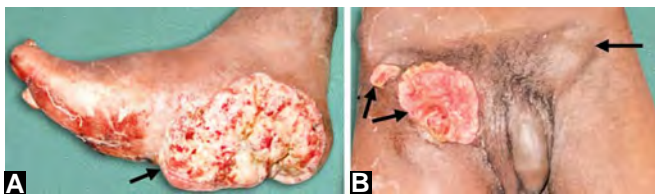
- ◆ Dorsum of hand, limbs, face, and skin of abdominal wall
- ◆ SCC can occur in external genitalia, mucocutaneous junction, oral cavity, respiratory system, oesophagus, gall-bladder, in urinary bladder as metaplasia from transitional cell lining.

#### Aetiology of SCC

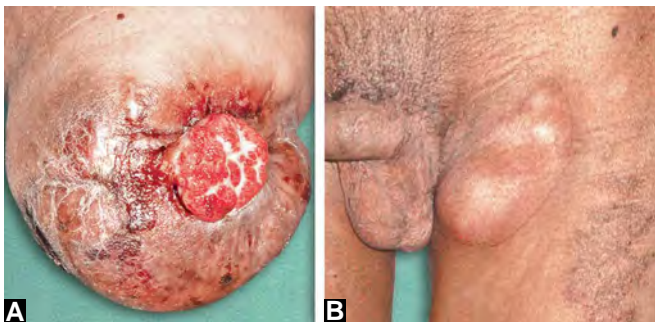
- ❖ Bowen's disease. Exposure to UV B rays
- ❖ Chronic scars and sinuses (burns; osteomyelitis; venous ulcer)
- ❖ Lupus vulgaris
- ❖ Solar keratosis—20% chances of SCC
- ❖ Senile keratosis
- ❖ Xeroderma pigmentosa
- ❖ Tobacco use
- ❖ Viral cause—human papilloma virus (HPV) five and sixteen
- ❖ Chemically induced chronic irritation
- ❖ Radiodermatitis
- ❖ **Kangri cancer**—it is due to constant placing of the hot charcoal pot (kangri) over the abdominal wall to control cold. Seen in Kashmir
- ❖ **Kang cancer** is seen in buttocks and heel of Tibetans due to sleeping over oven bed to control cold
- ❖ **Chimney sweep cancer** is observed in scrotum due to constant irritation by tar
- ❖ **SCC is more common in immunosuppressed individuals**, immunosuppressive drugs like azathioprine, cyclosporine, prednisolone; risk becomes 10% in 10 years of intake of these drugs and 40% in 20 years.

### Clinical Features

- ◆ An ulcerative or ulceroproliferative or proliferative lesion.
- ◆ **Raised and everted edge.**
- ◆ **Indurated** base and edge.
- ◆ Bloody discharge from the lesion.
- ◆ **Regional lymph nodes** are commonly involved, which are hard, nodular, initially mobile but eventually fixed to underlying structures.
- ◆ Usually blood spread does not occur.



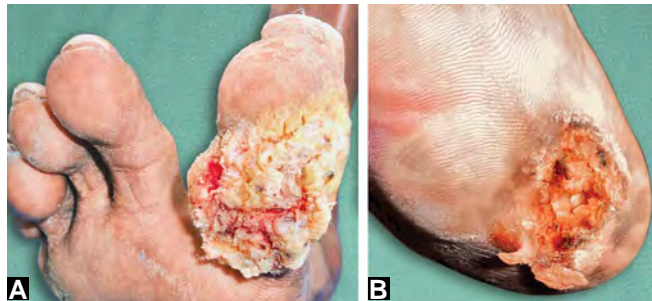
**Figs 1.519A and B:** Squamous cell carcinoma foot—ulceroproliferative lesion with fungating inguinal node secondaries. It is an advanced disease. Opposite inguinal nodes are also significantly enlarged.



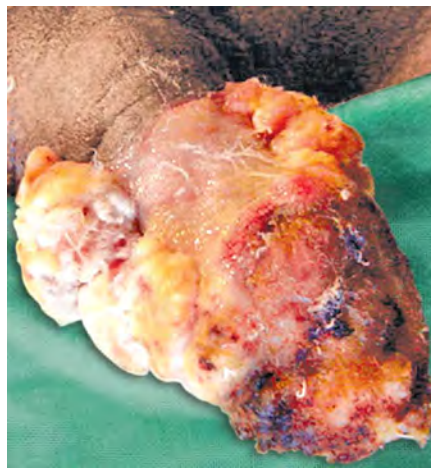**Figs 1.520A and B:** Recurrent SCC in amputated stump. Note the enlarged significant lymph nodes in the groin.

### Variants

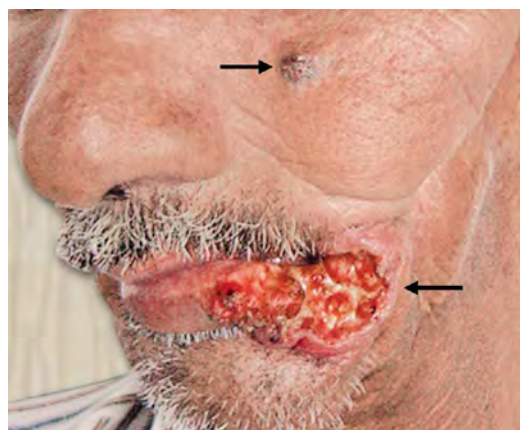- ◆ **Marjolin's ulcer** which occurs in chronic scar is a type of squamous cell carcinoma without lymph node spread.
- ◆ **Verrucous carcinoma** is a squamous cell carcinoma, commonly occurring in mucous membrane or mucocutaneous junction without lymph node spread. It is dry, exophytic, warty, indurated growth. It has good prognosis. It is a curable malignancy.
- ◆ A rare multiple self-healing SCC is observed usually in face as familial autosomal dominant (Ch 9q) disease in Western Scotland—**Ferguson-Smith syndrome**.
- ◆ **SCC often associated with BCC also.**



**Figs 1.521A and B:** Carcinoma cuniculatum—in heel and under great toe which is a low grade verrucous type of SCC.



**Fig. 1.522:** Verrucous carcinoma of penis. It is an exophytic, dry, warty, locally malignant lesion (Squamous cell carcinoma).



**Fig. 1.523:** Squamous cell carcinoma and BCC in face of a patient.

### Histology

- ◆ Malignant whorls of squamous cells with epithelial or **keratin pearls** are characteristic feature.
- ◆ Spindle cells, invasion, deep and peripheral margin clearance.

#### Broder's classification

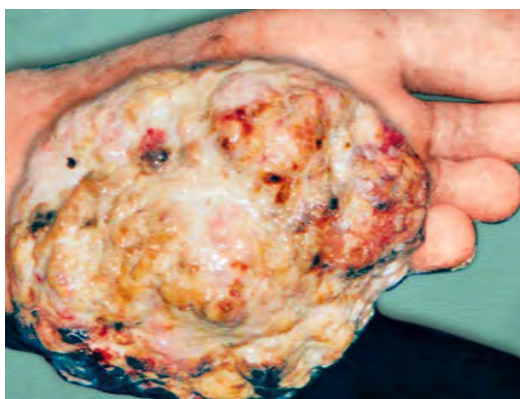- I: Well differentiated: 75% or more keratin pearls
- II: Moderately differentiated: 50–75% keratin pearls
- III: Poorly differentiated: 25–50% keratin pearls
- IV: Undifferentiated/anaplastic: <25% keratin pearls. It is seen in 20% of SCCs.

### Differential Diagnosis

- ◆ BCC.
- ◆ Melanoma.
- ◆ Keratoacanthoma.
- ◆ Skin adnexal tumours.
- ◆ Actinic keratosis.
- ◆ Pyogenic granuloma.

### Investigations

- ◆ Wedge biopsy from the edge.
- ◆ FNAC from lymph node.
- ◆ USG/CT scan to identify nodal disease; MRI to identify local extension is useful.



**Figs 1.524:** Squamous cell carcinoma in the forearm and foot. It is proliferative cauliflower like lesion. *Wedge biopsy* has to be done.

### Treatment

- ◆ **Radiotherapy** using radiation needles, moulds, etc. is given.
- ◆ **Wide excision**, 2 cm clearance followed by skin grafting or flaps.  
(Presently for tumour less than 2 cm, 4 mm clearance and for tumour more than 2 cm, 1 cm clearance is sufficient). Wide excision should show *clearance* both at margin as well as in the depth. If muscle, fascia, cartilage are involved, it should be cleared. Reconstruction is usually done by primary split skin grafting (*SSG/Thiersch*). Delayed skin grafting also can be done once wound granulates well. Often flaps of different types may be needed depending on the site of lesion.
- ◆ **Amputation** with one joint above.
- ◆ For lymph nodes, block dissection of the regional lymph nodes is done.
- ◆ Curative radiotherapy (RT) is also useful in tumours which are not adherent to deeper planes or cartilage as SCC is radiosensitive. It is also useful in recurrent SCC and in patients who are not fit for surgery. A dose of 6000 cGy units over 6 weeks; 200 units/day is used. Recurrence after RT is treated by surgical wide excision.
- ◆ In advanced cases with fixed lymph nodes, **palliative external radiotherapy** is given to palliate pain, fungation and bleeding.
- ◆ **Chemotherapy** is given using methotrexate, vincristine, bleomycin.
- ◆ Field therapy using cryo probe or topical fluorouracil or electrodesiccation.

#### Verrucous carcinoma

- ❖ Dry, exophytic, warty growth
- ❖ No lymph node spread
- ❖ No blood spread
- ❖ Surgery is the treatment—wide excision
- ❖ No radiotherapy
- ❖ Examples:
  - Verrucous carcinoma of genitalia
  - Oral florid verrucous carcinoma
  - Verrucous carcinoma of foot (plantar aspect)—**carcinoma cuniculatum—Ackerman tumour**

#### TNM staging for skin cancer other than melanoma

Tumour	Node	Metastasis
T0 no tumour found	N0—No nodes	M0—No distant spread
T is Tumour <i>in situ</i>	N1—Regional nodes ++	M1—Distant spread ++
T1 Tumour < 2 cm		
T2 Tumour 2-5 cm	G1—Low grade	
T3 Tumour > 5 cm	G2—Moderate grade	
T4 Spread to cartilage, muscle or bone	G3—High grade	

#### Prognostic factors in SCC

- ❖ Tumour size > 2 cm is worse
- ❖ Tumour border—ill-defined border is worse
- ❖ Associated immunosuppression is worse
- ❖ Differentiation—poorly differentiated is worse
- ❖ Perineural involvement has worse prognosis
- ❖ Invasion; depth < 2 mm has got better prognosis; depth more than 16 mm has got worst prognosis
- ❖ Local recurrence rate is 20%. Recurrence period is 5 years, not beyond

### MARJOLIN'S ULCER (1828)

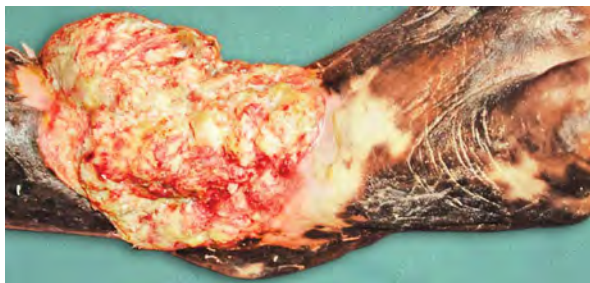
- ◆ It is a well-differentiated squamous cell carcinoma which occurs in chronic scars like burn scar, scar of venous ulcer.
- ◆ As it develops in a scar due to chronic irritation and there are **no lymphatics** in scar tissue, **it will not spread to lymph nodes**.
- ◆ As scar is relatively avascular it grows slowly. As scar does not contain nerves, it is painless.
- ◆ Once it reaches the normal skin it may behave like any other squamous cell carcinoma, i.e. it will spread to lymph nodes. It occurs in *unstable scar of long duration*.

### Clinical Features

- ◆ History of pre-existing venous ulcer or burn scar.
- ◆ Indurated, painless, nontender, ulcer with raised and everted edge.
- ◆ Biopsy from the edge **confirms the diagnosis**.

### Treatment

- ◆ **Wide excision**.
- ◆ In case of large ulcer, **amputation** is required.
- ◆ **Radiotherapy should not be given** as it may turn into poorly differentiated squamous cell carcinoma. It is a curable malignancy.

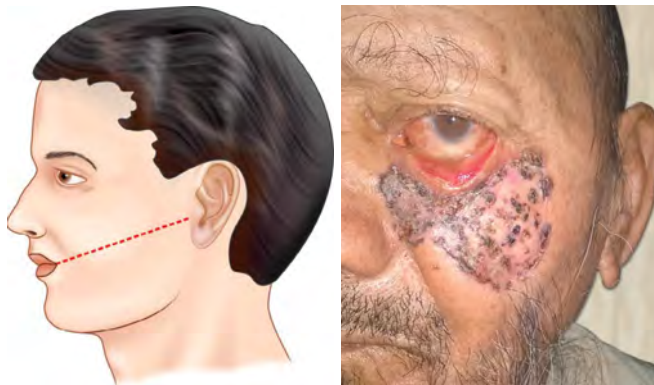

**Fig. 1.525:** Marjolin's ulcer foot in a pre-existing burns scar. It is a well-differentiated squamous cell carcinoma occurring in an unstable scar of long duration.

### BASAL CELL CARCINOMA (Rodent Ulcer)

It is a low grade, locally invasive, carcinoma arising from basal layer of skin (or adnexal basal layer of hair follicle) or mucocutaneous junction. **It does not arise from mucosa.**

- ◆ It is the commonest (70%) malignant skin tumour.
- ◆ It is more common in white-skinned people than blacks.
- ◆ Common in places where exposure to *UV light* is more (*Australia*).
- ◆ Other causes are—arsenics, coal tar, aromatic hydrocarbons, skin tumour syndromes.
- ◆ It is common in males, common in middle-aged and *elderly*.
- ◆ Common site is **face**—above the line drawn between angle of mouth and ear lobule (90%)—*Onghren's line*.
- ◆ It is called as **tear cancer** because it is commonly seen in area where tears roll down.
- ◆ Often it can occur in muco-cutaneous junctions.



**Fig. 1.526:** Note the common site of BCC—in the face above the line drawn between angle of mouth and ear lobule—*Onghren's line*.

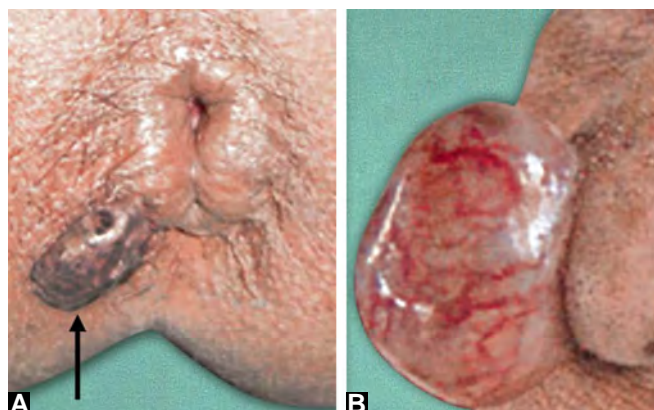
- ◆ *Basal cell naevus syndrome (Gorlin syndrome)* with BCC; medulloblastoma; bifid ribs.
- ◆ **It is only locally malignant**. It does not spread through lymphatics nor through the blood. But it erodes deeply into local tissues including cartilages, bones causing extensive local destruction. Hence the name "**rodent ulcer**".

### Types

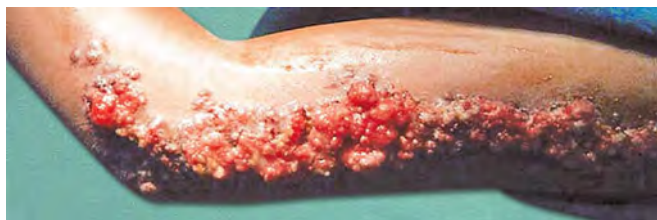1. Nodular—common in face.
2. Cystic/nodulocystic.
3. Ulcerative.
4. Multiple, often associated with syndromes and other malignancies.
5. Pigmented BCC—mimics melanoma.
6. Geographical or field fire or forest fire BCC is wide area involvement with central scabbing and peripheral active proliferating edge.
7. *Basi-squamous*—behaves like squamous cell carcinoma which spread into lymph nodes. BCC which has not been treated for long time can turn into Basisquamous carcinoma.

### Note:

Nodulocystic and noduloulcerative is the commonest form (70–90%).



**Figs 1.527A and B:** (A) BCC in perianal region. It is nodular type. Wide excision is required; (B) Nodular BCC in the nose (Common in face).

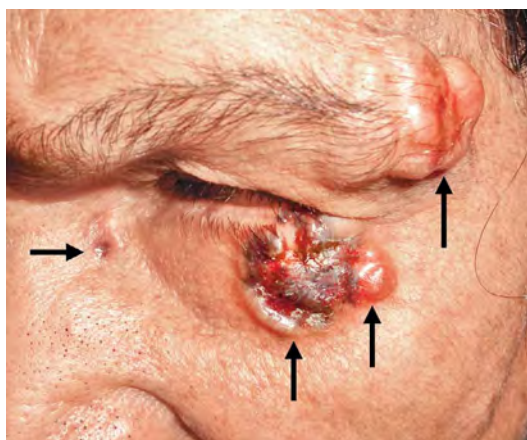


**Fig. 1.528:** *Sebaceous epidermal naevus*. It is common in females, often extensive, begins in childhood. It needs surgical excision and skin grafting. It has got 10% chances of turning into BCC.

### Clinicopathological Types

- Superficial type*—small buds of tumour masses.
- Morpheic type*—dense stroma with basal cells and type IV collagen; spreads rapidly; sclerosing BCC.
- Fibroepithelioma type* of Pinkus shows elongated cords of basalioid cells with mesh work.

It contains outer palisading columnar cells with central polyhedral cells but no *prickle cells* or *keratinisation*.



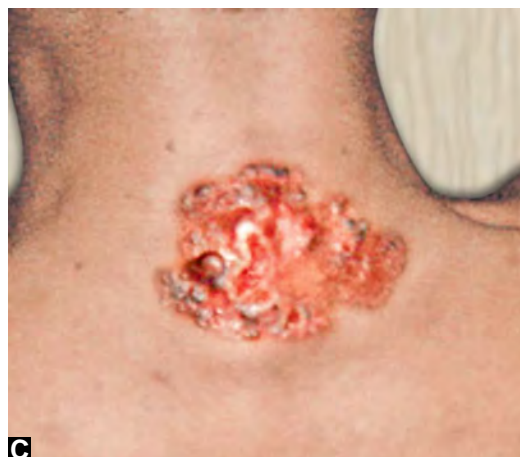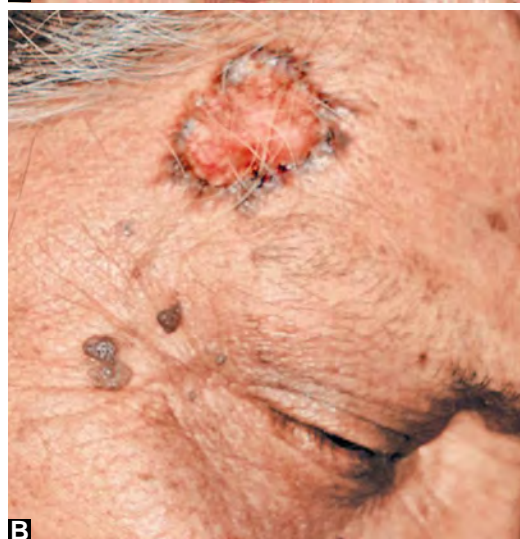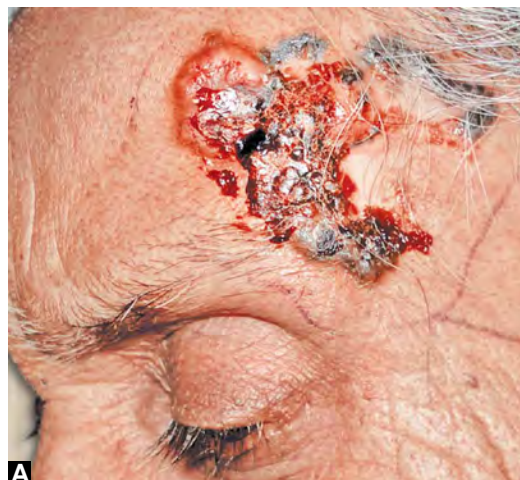**Fig. 1.529:** BCC lesions in different places (multiple).

### Clinical Features

- ◆ Ulcer on the face in a middle-aged man which is nontender, dry, slowly growing, nonmobile, with raised and beaded edge with central scab, often with central depression or umbilication.
- ◆ Site of beading signifies the area of active proliferating cells. In between beaded areas dormant nonactive cells are present.
- ◆ No lymph node or blood spread occurs. Due to large sized tumour cells/tumour cluster, it does not spread through lymphatics.
- ◆ BCC can be *low risk* or *high-risk*.

#### High-risk BCC

- ❖ Size >2 cm
- ❖ Near the eye/nose/ear
- ❖ Ill-defined margins
- ❖ Recurrent tumours
- ❖ Immunosuppressed individuals



**Figs 1.530A to C:** Basal cell carcinoma in different locations. Note the nodularity and ulceration. Note the beaded edge.

### Differential Diagnosis

- Squamous cell carcinoma.
- Melanoma.
- Keratoacanthoma.
- Seborrhoeic keratosis.

*Moles must never be cauterised or curetted.*

## Investigations

Wedge biopsy, X-ray of the part, CT scan.

## Treatment

◆ It is **radiosensitive**. If lesion is away from vital structure (like away from eyes), then curative radiotherapy can be given. **Radiotherapy is not given, once it erodes cartilage or bone.** RT is not given to BCC of ear and close to lacrimal canaliculi.

◆ **Surgery:**

### Indications for surgery

- ❖ Rodent ulcer eroding into cartilage or bone
- ❖ BCC close to the eye
- ❖ Recurrent BCC

- ▶ Wide excision (1 cm clearance) with skin grafting, primary suturing or flap (Z plasty, rhomboid flap, rotation flap) is the procedure of choice.
- ▶ Laser surgery, photodynamic therapy, 5 fluorouracil local application.
- ▶ Cryosurgery.
- ▶ **MOHS** (*Microscopically Oriented Histographic Surgery*) (Federic E Mohs, American Surgeon) is useful to get a clearance margin and in conditions like BCC close to eyes, nose or ear, to preserve more tissues. MOHS is becoming popular in BCC/dermatofibrosarcoma protuberans/melanoma. Procedure is done by dermatological surgeon along with a histotechnician/histologist. Under local anaesthesia, a saucerised excision of the primary tumour is done and quadrants of the specimen are mapped with different colours. Specimen is sectioned by histotechnician from margin and depth, and it is stained using eosin and haematoxylin. It is studied by MOHS surgeon or histologist. Residual tumour from relevant mapped area is excised and procedure is repeated until clear margin and clear depth are achieved. Clearance must be complete and proper in BCC otherwise there will be very high chance of recurrence (70%).

## TURBAN TUMOUR

It is a descriptive term wherein entire scalp looks like a turban because of multiple scalp swellings. It can be due to *multiple cylindroma*; *multiple hidradenomas*; *subcutaneous neurofibromas*; *nodular multiple basal cell carcinoma*.

- ◆ *Multiple cylindroma* is usually considered disease under this term. Cylindroma is a variant of eccrine spiradenoma (skin adnexal tumor). Multiple firm pinkish nodules in the scalp are the presentation in multiple cylindroma. They are rare, often locally malignant, grows slowly over the span of many years to cover entire scalp with reddish lobulated lesion.
- ◆ Hidradenoma is a rare benign sweat gland tumour. Multiple tumours commonly look like a turban in the scalp. They are painless, disfiguring, cosmetically problematic, soft, boggy, non-fluctuant, non-compressible cutaneous swellings; commonly observed in middle age group.
- ◆ Multiple sebaceous cysts over the scalp mimic the same.
- ◆ **Management** is initial biopsy to find out the cause; then wide excision with skin grafting.

## NAEVI

- ◆ It is a *hamartomata* of melanocytes due to excessive stimulation.
- ◆ It may present during birth or appear later in life.

## Types

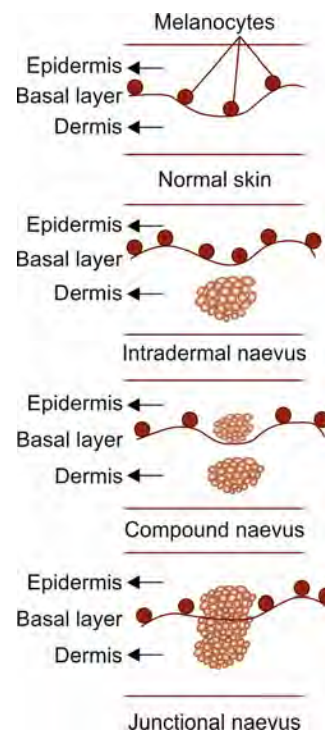


Fig. 1.531: Different types of naevi.

1. **Hairy mole** is a mole with a hair growing on its surface.

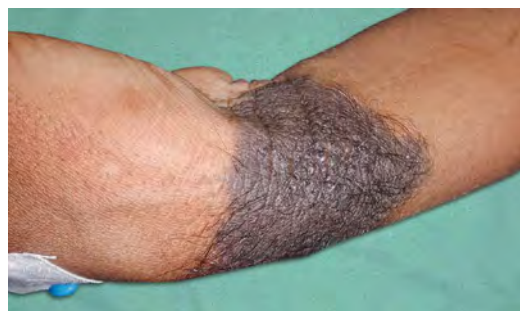

Fig. 1.532: Hairy naevus.

2. **Nonhairy mole.**
3. **Blue naevus.** It is seen in children. It is located deep in the dermis, hence appears blue. It is common in buttock (Mongolian spot), hand, feet.
4. **Junctional naevus.** It lies centred in the junctional layer (basal layer) of the epidermis as clusters. It is immature, unstable and premalignant. Microscopically there is proliferation of melanocytes at the epidermal junction. Features of malignant transformation are—change in the size, colour, bleeding, ulceration, crusting, satellite spots.

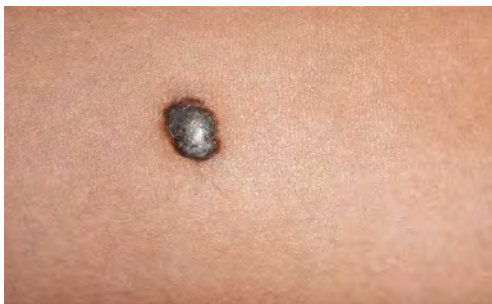

Fig. 1.533: Junctional naevus.

5. **Compound naevus.** It is combination of intradermal and junctional naevus. Intradermal part is inactive but junctional part is potentially malignant.

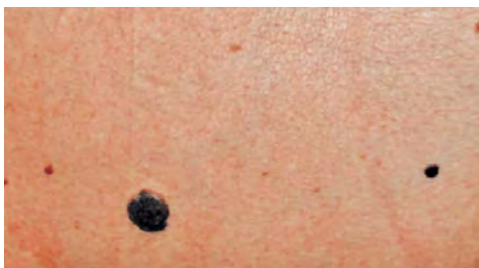

Fig. 1.534: Compound naevus.

6. **Juvenile melanoma (Spitz naevus)** (It is a misnomer). It appears as junctional like mole before puberty. It is seen in children on face. They present as brownish red nodular lesion which needs always excision.
7. **Hutchinson's freckle.** It is seen in elderly with large area of dark pigmentation. In the macular stage it is smooth and brown. In the tumour stage it is dark and irregular. It can turn into melanoma commonly.
8. **Halo naevus:** Halo of depigmentation around the pigmented naevus. This halo is due to antibody response to melanocytes. Halo naevus is often seen along with vitiligo. Similar halo may develop around a malignant melanoma lesion.
9. **Intradermal naevus:** Cluster of dermal melanocytes is seen without junctional component. Common in face.

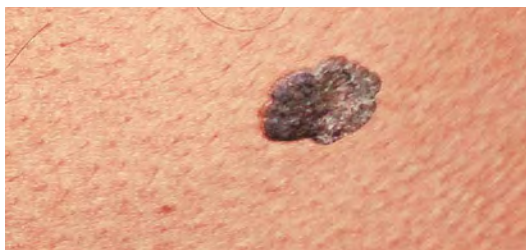


Fig. 1.535: Intradermal naevus.

10. **Spindle cell naevus:** It is dense, black pigmented lesion containing spindle cells and atypical melanocytes at dermo-epidermal junction; seen in females on high with malignant potential.
11. **Naevus spilus:** It is hyperpigmented speckles throughout, also called as *speckled lentiginous naevus*. Malignant potential is rare.

12. **Naevus of Ota** is dermal melanocytic hamartoma seen in distribution area of trigeminal nerve (ophthalmic /maxillary). It is seen in oriental and African race adolescent females (thigh) with a hormonal influence.
13. **Naevus of Ito** is similar lesion occurring in shoulder region.
14. **Dysplastic naevus** is proliferation of atypical melanocytes from epidermal basal layer having variegated irregular look; it is usually >5 mm in size; can be familial; 10% cases may turn into superficial spreading melanoma.
15. **Congenital naevus:** It is present since birth.

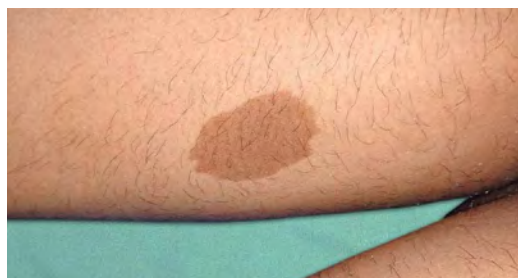

Fig. 1.536: Congenital naevus.

**Note:**

- **Giant naevus** is naevus more than 1% of body surface area or more than 20 cm in size. Giant congenital pigmented naevus (GCPN) often shows dermatomal distribution. Pigment cells spread from epidermis to fat and muscle often. It may turn into melanoma (5% risk). Such melanomas are usually axial; is usually associated with retroperitoneal / intracranial melanosis. Curettage, dermabrasion, laser, excision and SSG are the treatment options.

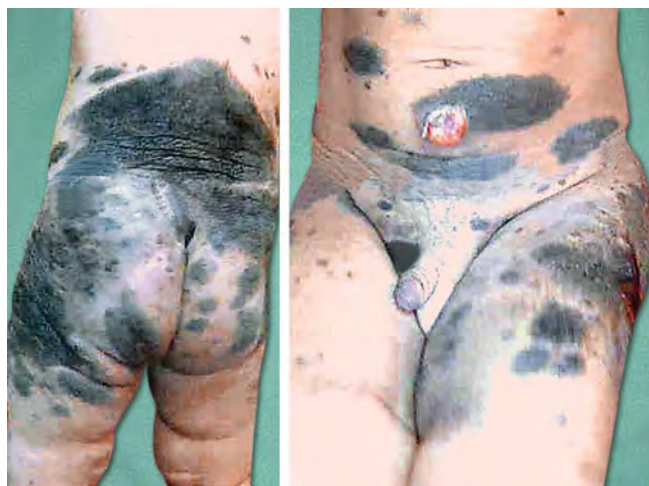

Fig. 1.537: Giant congenital naevus (Courtesy: Dr MuraliKeshav, MD, Pediatrician, KMC Mangaluru).

- **Mongolian spot** is a blue brown/grey pigmented macular area which is seen in sacral region during birth and after initial intense pigmentation regresses fully in 7 years.
- Normal number of melanocytes releasing abnormally higher number of melanin granules is called as *freckle/ephelis*.

**Treatment**

Excision. Always should be sent for histopathology.

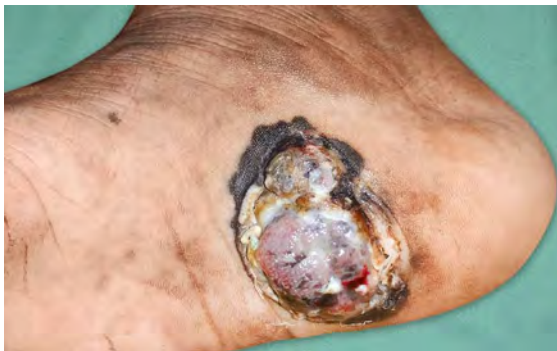


## MELANOMA

- ◆ It is a malignant tumour arising from epidermal melanocyte which is *most aggressive* cutaneous malignant tumour.
- ◆ It is of *neural crest* (ectodermal) origin.
- ◆ It is 20 times more commonly seen in *whites* than blacks.

- ❖ *Melanoblast*: Primitive cell derived from the neural crest.
- ❖ *Melanocyte*: The cell which synthesises melanin is located in the basal layer (melanocyte : basal cell :: 1 : 10).
- ❖ *Melanophores* are pigment melanin carriers through dendrites into the epidermis.
- ❖ *Melanophages* are macrophages having melanin pigment.
- ❖ Melanoblasts and melanocytes contain DOPA oxidase enzyme and synthesise melanin. They show +ve DOPA reaction.
- ❖ Melanophores and melanophages show -ve DOPA reaction.
- ❖ Melanin synthesis is controlled by melanocyte stimulating hormone, ACTH and sex hormones.

DOPA reaction:



**Fig. 1.538:** Large nodular melanoma in the sole.

- ◆ Its incidence is equal in both sexes.
- ◆ Its incidence is increasing over the years.
- ◆ Five per cent of skin cancers are melanomas.
- ◆ It is most common in Queensland, Australia. Auckland, New Zealand.

### Sites

#### Sites of melanoma

- ❖ Head and neck—25%
- ❖ Trunk—25%
- ❖ Lower limb—25%
- ❖ Upper limb—11%
- ❖ Other sites—14%

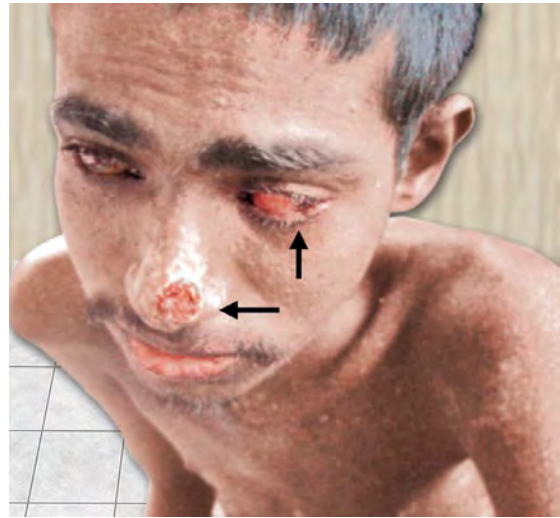- ◆ In females, *leg* is the commonest site.
- ◆ In males, the *front* or *back* of the trunk.
- ◆ In the Bantu tribe, *sole* is the commonest site.

#### Other sites:

Eyes (iris, ciliary body, choroids), mucocutaneous junction (anorectal region, genitalia), head and neck (meninges, oropharynx, nasopharynx, paranasal sinuses).

### Risk Factors

- ◆ Exposure to sunlight (exposure to UV light; more common in white-skinned—20 times).
- ◆ Ethnic factors, socioeconomic status (high society), lifestyle, climate.
- ◆ Albinism.
- ◆ *Xeroderma pigmentosa* – RR is 1000 (By Kaposi in 1874): It is an autosomal recessive (Ch 9q) disease with defect in DNA excision repair mechanism causing formation of aberrant nucleotide causing ultraviolet rays' intolerance, erythema, pigmentation, photophobia, premature skin ageing, multiple malignancies with 60% mortality at the age of 20.



**Fig. 1.539:** Xeroderma pigmentosa with BCC in the nose. Such patients are prone for other skin malignancy like melanoma also. There is defective DNA excision repair.

- ◆ Junctional naevus.
- ◆ Familial dysplastic naevus syndrome.
- ◆ Sporadic dysplastic naevi. 10% risk.
- ◆ Large congenital naevi (larger than 20 cm).
- ◆ Family history of melanoma (10% through chromosomes 1p, 6q, 7 and 9). They often present with multiple primary melanomas; associated with dysplastic naevus.
- ◆ History of earlier skin cancers other than melanoma.
- ◆ Patients who are on immunosuppressive drugs or after renal transplantation or NHL (RR - 30).

#### Malignancies which spread from mother to foetus

- ❖ Melanoma
- ❖ Lymphosarcoma

### Classifications

**Breslow's classification (1970):** Based on thickness of invasion measured by optical micrometer—most important prognostic indicator until nodal spread

- I: Less than 0.75 mm
- II: Between 0.76 to 1.5 mm
- III: 1.51 mm to 4 mm
- IV: More than 4 mm

**Relation of Tumour Thickness to Nodal Spread—Based on AJCC Classification**

Lesion	Tumour thickness	Nodal spread
Thin	<1 mm	<10%
Intermediate	1–4 mm	20–25%
Thick	>4 mm	60%

**Clark’s levels (1969)**

- Level 1: Only in epidermis
- Level 2: Extension into papillary dermis
- Level 3: Filling of papillary dermis completely
- Level 4: Extension into reticular dermis
- Level 5: Extension into subcutaneous tissue

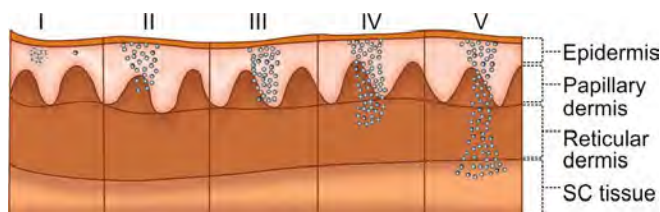


Fig. 1.540: Clark’s level.

**Differential Diagnosis (Other Pigmented Lesions of the Skin)**

- ◆ Seborrhoeic keratosis, dermatofibroma
- ◆ Pigmented BCC, pigmented SCC
- ◆ Naevus, sebaceous epidermal naevus
- ◆ Kaposi’s sarcoma, mycosis fungoides
- ◆ Cutaneous haemangioma
- ◆ Certain skin adnexal tumours
- ◆ Solar keratosis
- ◆ Pyogenic granuloma
- ◆ Cutaneous angiosarcoma

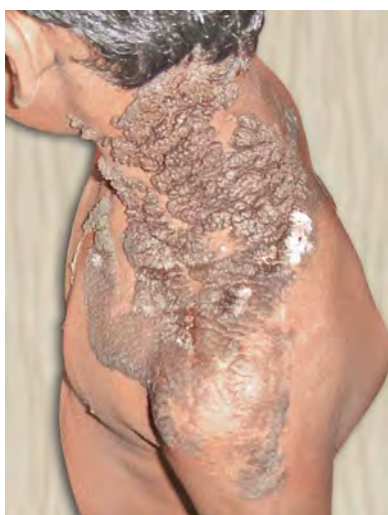

Fig. 1.541: Extensive pigmented lesion of the skin.

**Types**

- ❖ Cutaneous melanoma
- ❖ Extra cutaneous—10% (ocular is common site)
- ❖ Occult (Unknown primary)—2–7%

**Clinical Types**

1. **Superficial spreading:**

- ▶ **Most common.** 70%. Occurs in any part of the body with variegated irregular look. It has more radial growth and better prognosis. It commonly arises from a pre-existing naevus. In men, common in back; in women in leg.

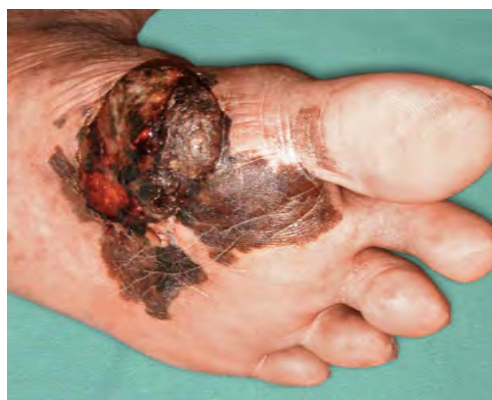

Fig. 1.542: Superficial spreading melanoma (70%).

2. **Nodular melanoma:** 12–25%.

- ▶ **More aggressive.** It is common in younger age group, occurring in any part of the body. It has more vertical growth. Common in mucosa and mucocutaneous junction; uniform; nodular; more vertical growth; nodal spread is common; has got poor prognosis. It usually appears as *de novo*. Common in men; common in trunk, head and neck.

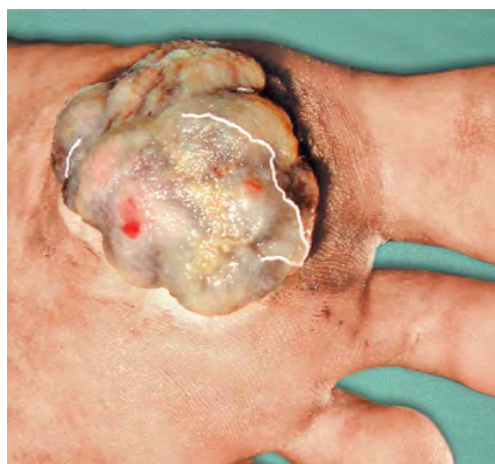

Fig. 1.543: Nodular malignant melanoma.

3. **Lentigo maligna melanoma:**

- ▶ 7–15%. **Less common, least malignant.** Occurs in old age and common in face (**Hutchinson’s melanotic**

**freckle**). It is slow growing, variegated, brown macule/lentigo; common in face/neck/hands; common in elderly women. Lentigo maligna is *in situ* type.

#### 4. **Acral lentiginous melanoma:**

- ▶ 5%. Occurs in palms, soles and subungual region. Common in **Japan**. It has got a **poor prognosis**. It is **least common**. Usually attains large size; nodular type with more vertical growth phase. It is common in Africa and Asia. It is less common in whites. It is often flat, irregular macule. It mimics fungal infection/pyogenic granuloma.

#### 5. **Amelanotic melanoma:**

- ▶ This is the **worst type**. Because of the undifferentiation, tumour cells lose their capacity to synthesise melanin. It presents as rapidly progressive pinkish fleshy tumour. It may mimic soft tissue sarcoma. It needs markers like S100, HMB45 for diagnosis.

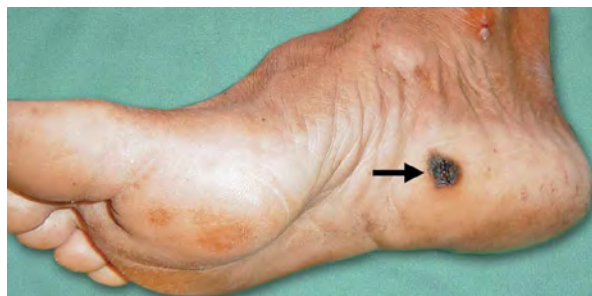6. **Desmoplastic melanoma** has high affinity for perineural invasion; is common in head and neck with higher recurrence rate. It is *amelanotic melanoma with thicker lesion* carrying poor prognosis due to neural invasion.

#### Note:

- Subungual melanoma which was earlier thought of acral lentiginous type is now considered as superficial spreading type. It is involvement of nail fold matrix (not nail plate). Triangular, macular, progressively widening pigmentation of nail fold with nail dystrophy is typical—*Hutchinson's sign*. It should be differentiated from benign racial melanonychia which are dark streaks under the nail. Biopsy of nail matrix should be done here.
- **Ocular melanoma:** It is the commonest malignancy arising in eye. It may arise from retina, iris, ciliary body, choroid. It rarely metastasizes or only at late stage as it is devoid of lymphatics. Ocular melanoma commonly shows its distant spread to liver. Massive hepatomegaly is typical and is often seen many years after the treatment of primary ocular lesion. Condition is treated with enucleation, radiation, photocoagulation.
- **Clark's concept—Two phases of growth:** Initial radial growth phase occurs horizontally, later vertical growth phase occurs with invasion.

### Clinical Features

- ◆ It can start in a pre-existing **naevus** (commonly junctional naevus)—50–60% or as **de novo** in a normal skin—40–50%.
- ◆ Melanoma is **unknown before puberty**.
- ◆ **Induration is not seen in melanoma**.
- ◆ Pigmentation with irregular surface and margin with rapid growth.
- ◆ **Ulceration, bleeding, itching, change in the colour.**



**Fig. 1.544:** Melanoma in the sole. Often such pigmentation may be unnoticed.

#### Note:

**When a mole turns malignant, following changes should be observed (Glasgow criteria):**

- **Major signs:** Change in *size* (diameter more than 6 mm), *shape* and *colour*
- **Other changes:**
  - Inflammation, crusting, bleeding, itching
  - Nodularity, ulceration, halo around a mole
  - Satellite lesions
  - Doppler positive pigmented lesions using hand held Doppler (> 1 mm thick lesion)

#### Five most important features of melanoma

- ❖ **Asymmetry**
- ❖ **Border irregularity**
- ❖ **Colour variation**
- ❖ **Diameter > 6 mm**
- ❖ **Elevation**

### Spread

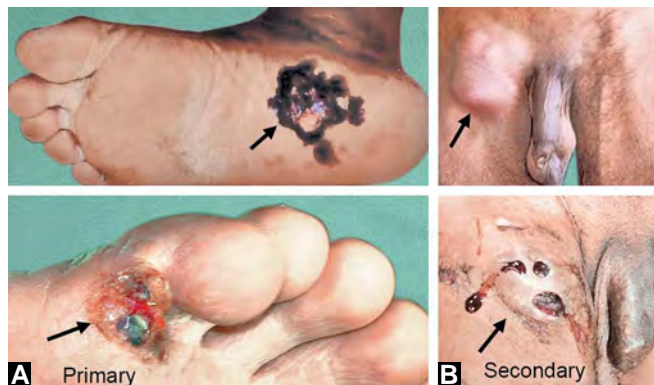
- ◆ **Through lymphatics** it spreads to regional lymph nodes either by permeation or by embolisation.
- ◆ **In-transit nodules or satellite nodules** are seen in the skin between the primary lesion and regional lymph node area, and is due to retrograde spread to dermal lymphatics.
- ◆ **Through blood:** To lungs, liver (huge liver), brain, skin, bones. Secondaries are typically black.

#### Blood spread in melanoma

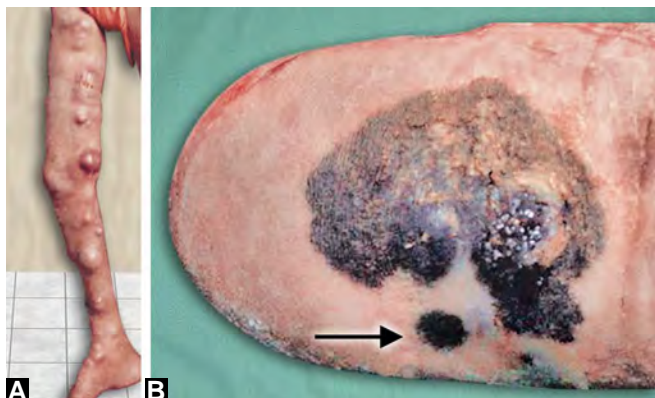
- ❖ **Brain**—convulsions, localising features and raised intracranial pressure
- ❖ **Lung**—cannon ball secondaries, pleural effusion-haemoptysis, chest pain and cough
- ❖ **Liver** (massive liver), ascites
- ❖ **Skin**—cutaneous nodules often pigmented
- ❖ **Bones**—bone pain, pathological fracture. Paraplegia/neurological deficits in spine metastasis

Extensive visceral involvement causes *melanuria*

- ◆ Melanoma **in choroid** has got better prognosis, because as there are no lymphatics, spread is delayed.
- ◆ Sometimes primary is very small and unnoticed (in anus, subungual region). They present with features of secondaries only.



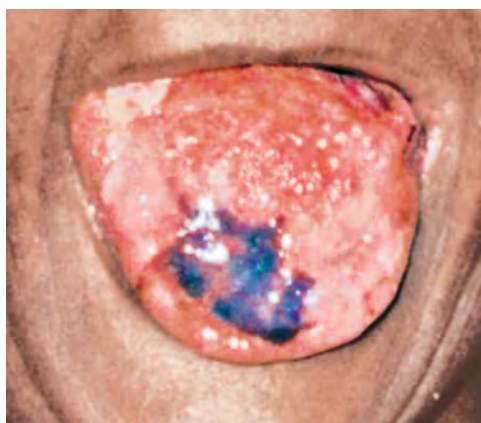
**Figs 1.545A and B:** Primary melanoma with lymph node secondaries in two different individuals. Note the pigmented ulcerated secondaries in one.



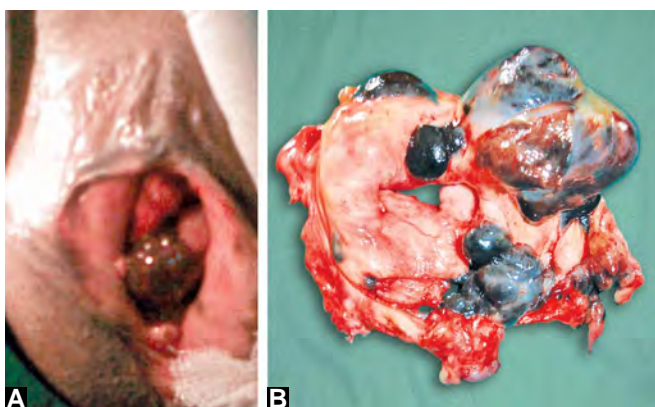
**Figs 1.546A and B:** (A) 'In-transit' nodules in melanoma. They are secondary depositions in dermal lymphatics; (B) *Satellite* nodule in melanoma occurs within 2 cm of primary. Note the primary in the heel and satellite nodule adjacent to it.

**Note:**

- Infiltration into deep fascia by melanoma is rare in initial stages as deep fascia acts as a strong barrier.
- Melanoma can also occur in places other than skin like tongue, mucous membrane or genitalia.



**Fig. 1.547:** Melanoma in tongue.



**Figs 1.548A and B:** Melanoma in vagina—in mucocutaneous junction. On table and excised specimen of melanoma.

**Occult melanomas (primary unknown) are common in**

- Anus
- Scalp
- External auditory canal
- Nail bed
- Genitalia
- Eye
- Adrenal medulla

**Staging of Malignant Melanoma (It is older staging system)**

- IA: Thickness less than 0.75 mm.
- IB: Thickness between 0.76 to 1.5 mm.
- IIA: Thickness between 1.51 to 4.0 mm.
- IIB: Thickness more than 4.0 mm.
- IIIA: Any of the above + nodes less than 3 cm.
- IIIB: Any of the above + nodes more than 3 cm.
- IV: Any of the above + any node + M1 (distant spread).

**Melanoma**

- ❖ 5% of all skin cancers—incidence
- ❖ 20 times more common in whites than blacks
- ❖ Mucosal melanoma has got poor prognosis
- ❖ Can spread from mother to foetus
- ❖ Multiple melanomas are 1% common
- ❖ Melanoma in choroid will not cause lymph node involvement, as it has no lymphatic drainage. But late massive liver secondaries even after 10-20 years is known to occur
- ❖ 10% of melanomas are familial—in whites
- ❖ *Satellite* nodules are secondary skin nodules within 2 cm of primary
- ❖ 'In transit' nodules are secondary skin nodules beyond 2 cm of primary any where up to lymph node region
- ❖ Melanoma may present as secondary (in liver, lungs, bone, brain) with occult primary when primary is situated in anus, genitalia, eye, external auditory canal, adrenal gland, nail bed and scalp—7%
- ❖ Pigmentation is not *mandatory* to diagnose melanoma even though it is commonly present
- ❖ Melanoma also can occur in fishes, dogs and horses

**Investigations**

- ◆ **No incision biopsy.** It can cause early blood spread.
- ◆ **Excision biopsy of primary.** It is done with 2 mm margin with deeper fatty tissue. One should avoid using cautery and avoid crushing the tissues as much as possible. Instead of excision biopsy, punch biopsy is done in case of large primary tumour very close to pinna, eye, nose. Punch biopsy assesses the depth/thickness of the lesion. Punch should be done at the most elevated part of the lesion to get proper depth.
- ◆ **FNAC of lymph node.**
- ◆ **US abdomen** to look for liver secondaries (usually huge hepatomegaly occurs).
- ◆ **Chest X-ray** to look for secondaries in lung ("cannon ball" appearance). HRCT of chest is ideal.

## Newer TNM staging (2010) for melanoma

Tumour	Node
T0 No tumour	N0 No nodes
T is <i>In situ</i> tumour	N1a—one node micrometastasis
T1a <1 mm level II, III no ulceration, mitoses < 1 mm <sup>2</sup>	N1b—one node macrometastasis
T1b <1 mm, level IV with ulceration, mitoses > 1 mm <sup>2</sup>	N2a—2 or 3 nodes micrometastasis
T2a 1–2 mm no ulceration	N2b—2 or 3 nodes macrometastasis
T2b 1–2 mm with ulceration	N2c—no nodes but satellite or in transit lesions
T3a 2–4 mm no ulceration	N3–4 or more nodes; nodes with satellite or in transits
T3b 2–4 mm with ulceration	Stage 0 – T is N0M0
T4a >4 mm no ulceration	Stage IA – T1a N0M0; IB – T1b/T2aN0M0
T4b >4 mm with ulceration	Stage IIA – T2b/T3aN0M0; IIB – T3b/T4aN0M0; IIC – T4bN0M0
M—Metastasis	Stage IIIA – T1-4aN1a/N2aM0; IIIB – T1-4bN1a/N2aM0, T1-4aN1bN2bM0, T1-4a/bN2cM0; IIIC – T1-4bN1b/N2bM0, any TN3M0
M0—no blood spread	Stage IV – Any T, Any N, M0
M1a—Skin, subcutaneous tissue, distant node	
M1b—Lung spread	
M1c—Other viscera or distant spread and increase in LDH	

- ◆ Relevant other methods depending on site and spread, e.g. **CT scan** of head, chest, abdomen, pelvis.
- ◆ Urine for *melanuria* signifies advanced disease.
- ◆ **Sentinel lymph node biopsy (SLNB)**.
- ◆ **Tumour markers**—LDH; Melan – A; S 100; tyrosinase; HMB 45 are the tumour markers used. Human melanoma black 45 (HMB 45) is a monoclonal antibody against specific antigen (Pmel 17) present in melanocytic tumours. HMB 45 has got 92% sensitivity.
- ◆ MRI of the area; PET scan to detect the spread—in selected patients only.

## Tumour markers for melanoma

- ❖ MELAN-A
- ❖ S 100
- ❖ HMB 45 (Human Melanoma Black 45.)
- ❖ LDH

## Treatment

**Surgery is the main treatment.**

**For Primary:**

- a. Handley's **wide local excision (WLE)** is wide excision with clearance of margin as well as depth. Clearance margin used in olden days is 3–5 cm.

Tumour thickness in mm	Wide Local Excision (WLE) margin in cm
<1 mm	1 cm
1–2 mm	2 cm
>2 mm	3 cm

*Present recommendation* is— *in situ* melanoma needs 0.5 cm clearance; melanoma < 1 mm thickness needs 1.0 cm clear-

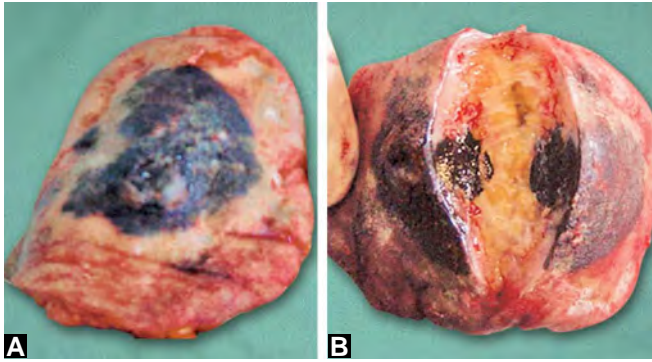
ance; 1–2 mm thickness needs 1–2 (1.5) cm clearance; 2 cm/3 cm clearance is sufficient for >2.0 mm thickness. Procedure can be done under regional or local anaesthesia. Evidence says that more than 2 cm clearance will not show any additional advantage in treating primary tumour.

- Primary closure or SSG or local flaps are used to cover the defect.
- b. If primary area is wide and deep, then amputation with one joint above is done.
- c. In fingers and toes, disarticulation is required.
- d. Melanoma in anal canal may require abdominoperineal resection.
- e. Enucleation in case of melanoma in eye.
- f. *Melanoma in pregnancy* is treated with termination of pregnancy and specific therapy for melanoma. Pregnancy should be postponed for 2 years.

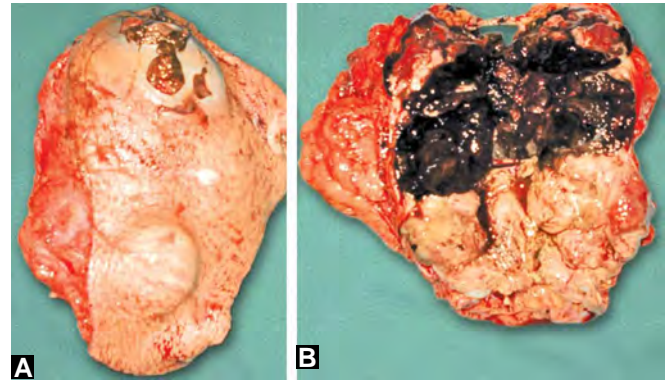
**For lymph node secondaries:**

1. In a clinically palpable lymph node, FNAC of lymph node is done. In case of spread, then regional block dissection, i.e. ilioinguinal or axillary or neck is done. Once FNAC shows positive lymph node 5-year survival rate reduces to 50%.
2. In a fixed lymph node, only chemotherapy is the treatment because it is inoperable.
3. **Lymphatic mapping and sentinel node biopsy** (Dr Donald Morton, 1970): Radioactive colloid is injected around primary site and lymphoscintigraphy is done using hand held gamma camera to visualise the micrometastasis in the nodal field. If there are micrometastasis, then regional block dissection (therapeutic LND) is done.

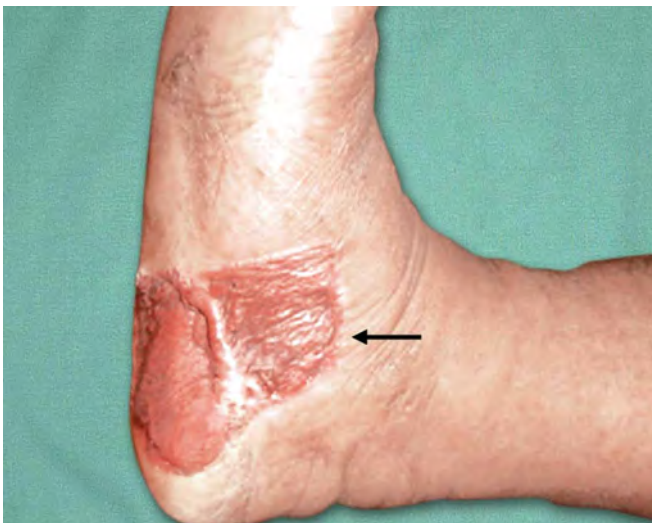SLN (Sentinel lymph node) can be identified in 95% or more of groin and axillary nodes and in 85% cases of head and neck melanomas. Often both blue dye and technetium sulfur colloid is used together to identify the SLN. SLNB is useful for melanoma with thickness more than 1 mm depth. Less than 1 mm thickness is considered as *low-risk* for metastases; between 1–4 mm thickness is considered as *intermediate-risk* for metastases mainly of nodal spread; more than 4 mm thickness will be considered as *high-risk* for both nodal as well as blood spread. SLNB is the investigation of choice for staging in intermediate thickness melanoma.



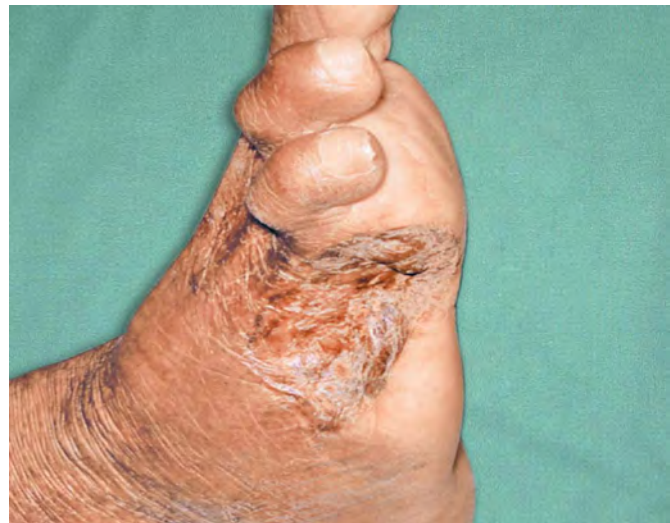**Figs 1.549A and B:** Widely excised melanoma specimen from heel. Cut section of widely excised specimen of melanoma from heel shows the depth of the tumour.



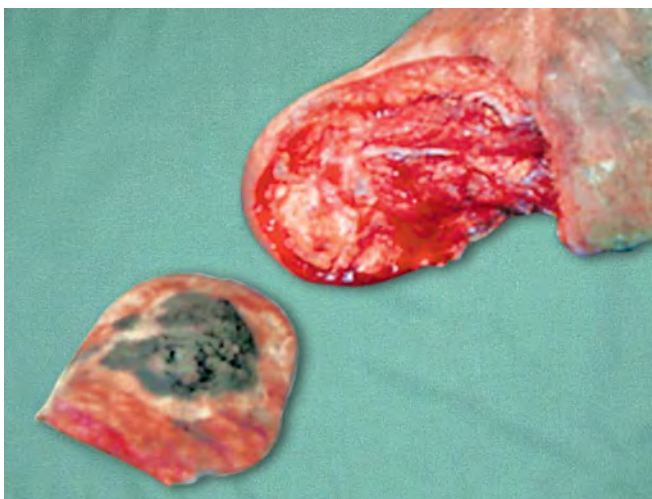
**Figs 1.552A and B:** Melanoma secondaries in groin nodes after block dissection. Black lesions are observed in cut section.



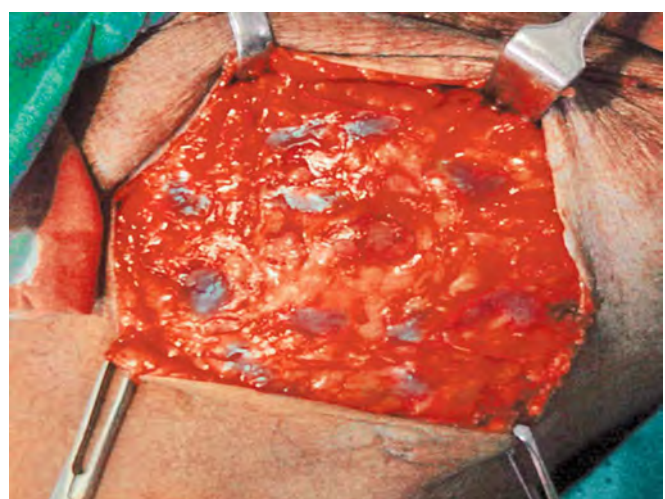
**Fig. 1.550:** Wide excision and skin grafting done for melanoma.



**Fig. 1.553:** Disarticulation of lateral two toes for interdigital melanoma.



**Fig. 1.551:** Wide excision of melanoma from the heel. Note the clearance margin and depth of dissection.



**Figs 1.554:** Secondaries in inguinal lymph nodes from primary melanoma sole-on table finding. Pigmented nodes are observed.

*Creativity begins with thinking different and progress with acting different, thus giving unique results.*

### Technique of SLNB

*Preoperative lymphoscintigraphy* is done on the day of surgery for primary tumour. 0.5 mCi *Technetium 99 sulphur colloid* is injected into the normal dermis within 0.5 cm from the margin of melanoma. Dynamic and static images are taken to identify lymphatic channels, sentinel node (s), interval node (like popliteal node in lower and epitrochlear node in upper limb). After that under general anaesthesia, just before wide local excision (WLE) of the melanoma, 1-5 ml of *isosufan blue dye* is injected into the dermis similarly. By this, senile lymph node is identified in 99% of patients.

*SLN* is defined as a node which indicates a direct lymphatic drainage pathway from primary; it is the most radioactive node in nodal basin; shows radioactive count 10% more than other nodes; takes blue dye adequately; on table this node will be palpably suspicious of tumour. In melanoma nodal basin usually 2 SLNs are identified (as first echelon nodes in nodal basin).

Axillary and inguinal SLNs are easier to identify than head and neck SLNs which are usually located adjacent to spinal accessory nerve. *Entire SLN (s)* should be removed and sent for histology, immunohistochemistry—S-100 and HMB-45.

*Interval lymph nodes* like popliteal or epitrochlear when involved should be cleared surgically.

### Sentinel node biopsy

- Carcinoma breast
- Melanoma
- Carcinoma penis

- Prophylactic regional block dissection which was previously advocated is now controversial. But still used in many centres. Elective lymph node dissection (ELND) is done when tumour thickness is 1–4 mm.
- Management in unknown primary* (2%) presenting as nodal secondaries is by nodal radical dissection at the region with adjuvant chemotherapy. They have better prognosis than with known primary. Patient should be monitored and evaluated to identify the primary site during every follow up. Once primary is identified it is treated accordingly depending on its location.

### For Loco Regional Recurrent Melanoma:

- Local recurrence* is one which recurs within 5 cm radius of the primary tumour in skin or subcutaneous tissues. Risk of local recurrence is 0.2% if primary tumour is less than 0.75 mm; 2% if it is between 0.75–1.5 mm; 6% if it is 1.5–4 mm; 12% if it is more than 4 mm.
    - Isolated limb perfusion* (Creech et al, New Orleans, 1958) using cytotoxic agents like Melphalan (M for M), interleukin 2, tumour necrosis factor (TNF). Concentration used here is 15–25 times more than that is used for systemic therapy. Melphalan dose is 10 mg/l perfusion solution in leg (13 mg/l in arm).
- Melphalan** is injected at high temperature of 41°C with a pump and oxygenator through cannulas in femoral artery and vein with a proximal tourniquet *in situ*. Hyperthermia and oxygenation increase the metabolic activity of tumour cells to make it more vulnerable to melphalan. Procedure controls the local disease well with preserving the functioning limb. *Complications* like DVT, bleeding, sepsis can occur. It is used in local recurrence or 'In-transit' deposits.

It shows 80% response rate with 15% complete response; but only of short period.

- Laser ablation of multiple small cutaneous lesions.
- Isolated limb infusion* (Thompson, 1993): Vascular catheters are passed and placed across femoral artery and vein through opposite femoral vessels or through arm vessels. The limb is warmed; patient is anaesthetised 2 hours later and also heparinised; papaverine is injected into arterial catheter and tourniquet is applied in the thigh/arm. Melphalan 7.5 mg/l, actinomycin D 75 µg/l in 400 ml saline (10 mg and 100 µg/l in 300 ml NS in upper limb) is infused into the isolated limb for 6 minutes which is pumped around the limb repeatedly for 30 minutes with a hypoxia in limb; drugs are washed out using a Hartmann's solution; tourniquet is removed and normal circulation is regained with removal of vascular catheters. Protamine is given to reverse heparin action.

### For Distant Spread

- Brain, lung and liver are the most common sites; skin, bone, GI are less common sites. But melanoma is one of the commonest tumours to spread to *intramural GIT* to present as intussusception.
- Distant spread when found or suspected, CT scan of head, chest, abdomen and pelvis are needed. PET scan and tumour markers are very useful.
  - Chemotherapy and immunotherapy is the main treatment.
  - Isolated lung or liver metastasis can be resected.
  - Radiotherapy is useful for bone and brain secondaries. Stereotactic program using gamma knife is better for brain secondaries.

### Chemotherapy for Melanoma

#### Indications:

- Secondaries in lungs, liver, bones.
- After surgery for melanoma. Usually it is given intravenously.

#### Drugs are:

- DTIC: Diethyl triamine iminocarboxamide.
- Melphalan* (Phenyl alanine mustard) (Melphalan for melanoma).
- Carboplatin, vindesine.
- CVD regime*—is cisplatin, vinblastine and dacarbazine.

### Immunotherapy/Biological Therapy

- It is done using specific tumour antibodies, BCG, levamisole, *Corynebacterium parvum*, alpha interferon, interleukins and tumour vaccines is tried with some success rate up to 40% in advanced melanomas.
- Biochemotherapy* is combination of CVD with interferon  $\alpha$  and interleukin 2.
- Interferon  $\alpha$  is a cytokine which is antiangiogenic and stimulator of natural killer NK cells. Dose is 20 mU/m<sup>2</sup> IV 3 times a week for 4 weeks then maintenance dose of 10 mU/m<sup>2</sup> subcutaneously 3 times a week for one year. Severe myelodepression and fulminant liver necrosis are the toxicity and so often dose is reduced to 3 mU/m<sup>2</sup> three times weekly for 2 years.
- GM2 ganglioside based vaccine (stimulates production of IgM antibodies), Melacine (contains melanoma cell lysates) and cancerVax are three vaccines under trial at present.
- Ipilimumab* is a monoclonal antibody that boosts the body's immune response against melanoma cells.

### Endolymphatic Therapy

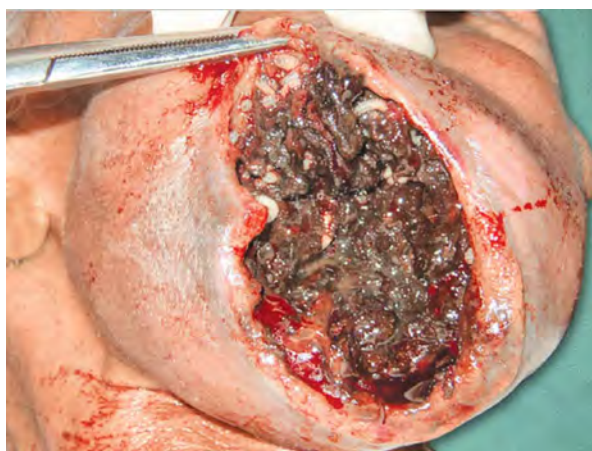
- ◆ It can be done to control disease in the nodes using radioactive  $I_{131}$  or  $P_{32}$  with ultrafluid lipiodol along with lymphangiography.

### Targeted therapy

- ◆ Signal transduction inhibitor therapy—Vemurafenib, dabrafenib, and trametinib are signal transduction inhibitors; oncolytic virus therapy; monoclonal antibody therapy—are different targeted therapies.

### Note:

- There is not much role for radiotherapy.
- Radiotherapy is beneficial only in secondaries in brain and bones.



**Fig. 1.555:** Melanoma involving face extensively with destruction. Note the maggots over the surface of tumour. Melanoma is *most aggressive* cutaneous malignancy.

### Prognosis for Melanoma

- ◆ It is not good since it is a very aggressive tumour.
- ◆ Old age has worse prognosis.
- ◆ Females show better prognosis.
- ◆ Extremity melanoma has better prognosis than head and neck.

Prognostic factors—overall poor	Staging as prognostic factor
• <b>Tumour thickness</b> —very important factor	Stage I: >90% prognosis Stage II: 70%
• Nodal spread—once regional nodes are positive, 85% of patients will have occult distant spread. Number of positive nodes is also important	Stage III: 35% Stage IV: <2%
• Ulceration—poor	
• Angiogenesis, vascular invasion—poor	
• In-transit nodules—poor	
• Vertical growth—poor prognosis	
• Metastatic disease—poor	
• Staging	
• Mitotic activity	

### Follow-up After Therapy in Melanoma

- ◆ In stage I and II disease after treatment, follow-up is done at 6 months interval for 3 years. It is done by clinical examination, LDH assay, USG abdomen and chest X-ray.
- ◆ In stage III disease, PET scan CT of head, chest and abdomen are indicated.



# S. Sarcomas

## CHAPTER OUTLINE

- ❖ Sarcoma
- ❖ Liposarcoma
- ❖ Fibrosarcoma
- ❖ Malignant Fibrous Histiocytoma
- ❖ Leiomyosarcoma
- ❖ Rhabdomyosarcoma
- ❖ Chondrosarcoma
- ❖ Haemangiosarcoma
- ❖ Lymphangiosarcoma
- ❖ Synovial Sarcoma
- ❖ Malignant Peripheral Nerve Sheath Tumour
- ❖ Kaposi's Sarcoma

## SARCOMA

Sarcomas can arise from bone or soft tissue. *Osteosarcoma* is the commonest of all sarcomas. *Soft tissue sarcoma* (STS) which is arising from mesenchyma is the one which will be discussed in this chapter. STS are aggressive tumours which needs multimodality therapeutic approach.

Sarcoma occurs in younger age group compared to carcinoma with fish fleshy gross look with haemorrhage and necrosis. It shows rapid growth, with tendency to show early blood spread. Lymphatic spread is rare even though few sarcomas can spread through lymphatics along with blood spread. Blood spread commonly occurs to lung but liver, skin, brain can also get involved.

*Soft tissue* is the tissue that connect, surround and support the skeletal system which is non-epithelial, extra-skeletal tissue excluding reticuloendothelial system, glial tissue but it also includes peripheral nervous tissue by convention. Embryologically it is mainly from mesoderm but few from neuroectoderm.

STS are named based on their tissue which it resembles. Liposarcoma—fat; fibrosarcoma—fibroblast; malignant fibrous histiocytoma—mesenchyma/histiocytes; leiomyosarcoma—smooth muscle; rhabdomyosarcoma—skeletal muscle; chondrosarcoma—chondroblast; angiosarcoma—blood vessels.

## Features

- ❖ Sarcomas are much lesser in incidence compared to carcinomas.
- ❖ It occurs in younger age group compared to carcinomas.
- ❖ They can arise from bone (osteosarcoma) or from any soft tissues (soft tissue sarcomas) (Mesenchymal tissue).
- ❖ They are much more aggressive compared to carcinomas.
- ❖ They are rapidly growing tumours with fleshy appearance.
- ❖ They are not encapsulated but often are having pseudocapsule.
- ❖ They spread through blood especially to lungs often also to other organs.
- ❖ Lymphatic spread is not common with certain exceptions.
- ❖ Main method of treatment is surgery, i.e. wide excision, amputation.
- ❖ In inoperable cases debulking is the accepted method of treatment.
- ❖ Chemotherapy is the adjuvant therapy.
- ❖ Commonest sarcoma of bone is *osteosarcoma*

### Note:

Commonest malignancy of bone is secondaries.

## Important features of sarcoma

- ❖ More aggressive
- ❖ Rapidly spreading
- ❖ Not very much radiosensitive
- ❖ Blood spread
- ❖ Painless soft tissue mass is the presentation
- ❖ Very vascular

## Soft tissue sarcoma

- ❖ 1% of adult malignancy
- ❖ 15% of paediatric malignancies
- ❖ Incidence:
  - 35% occurs in lower limb (commonest site)
  - 15% upper limb, 15% retroperitoneum
  - 10% trunk, 15% viscera, 10% other areas
- ❖ **Soft tissue sarcoma (STS)** arises from pluripotent mesenchymal stem cell without in situ changes. Transformation from benign lesion to sarcoma is not observed/disproved now except MPNST (Malignant peripheral nerve sheath tumour)
- ❖ Ratio of soft tissue sarcoma to bone sarcoma is 3:1
- ❖ Soft tissue sarcoma is more common in males (4:1)
- ❖ Ratio of benign soft tissue tumour to malignant soft tissue tumour is 100:1. Most of the sarcomas arise as *de novo*. Per se benign will not turn into malignancy, as it is now found that cell of origin to begin with multiples with anisocytosis in soft tissue sarcoma. In olden days it was accepted to consider benign (precursor tumour) turning into malignancy like lipoma turning into liposarcoma which is disproved now. But this argument does not hold good for nerve sheath tumour and probably lymphoedema turning into lymphangiosarcoma (post-mastectomy)
- ❖ 50% of STS occurs in extremities called as extremity STS; 35% lower and 15% upper limb
- ❖ 3% of sarcoma spreads to lymph nodes
- ❖ Soft tissue tumour >5 cm should be biopsied in suspicious of sarcoma

- ❖ Commonest soft tissue sarcoma is *liposarcoma / malignant fibrous histiocytoma* (MFH – 25%) overall; in the extremities both *MFH and liposarcoma*; in the retroperitoneum it is *liposarcoma*.
- ❖ Commonest visceral (GIT) sarcoma is leiomyosarcoma.
- ❖ In genitourinary system leiomyosarcoma is commonest in adults and rhabdomyosarcoma in *paediatric age group*; in uterus leiomyosarcoma; in myocardium angiosarcoma; in hand and foot synovial sarcoma; in skin Kaposi's sarcoma; in head and neck region angiosarcoma.

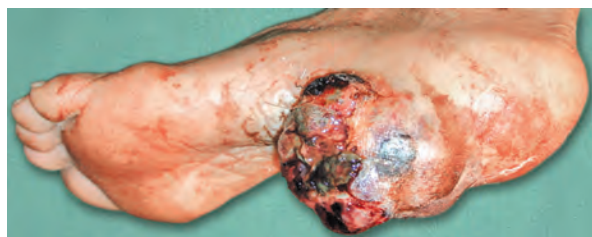

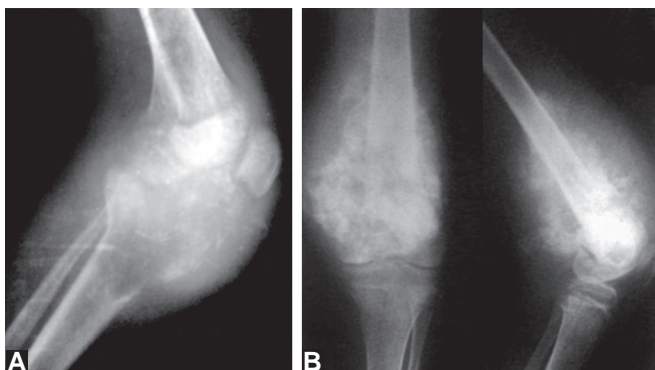
Fig. 1.556: Soft tissue sarcoma foot. Note the vascularity.

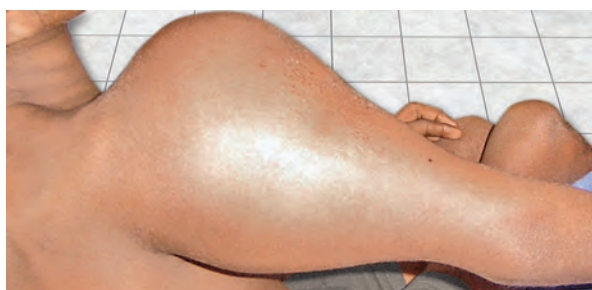

Fig. 1.557: Osteosarcoma of the upper end of humerus in an adolescent boy.

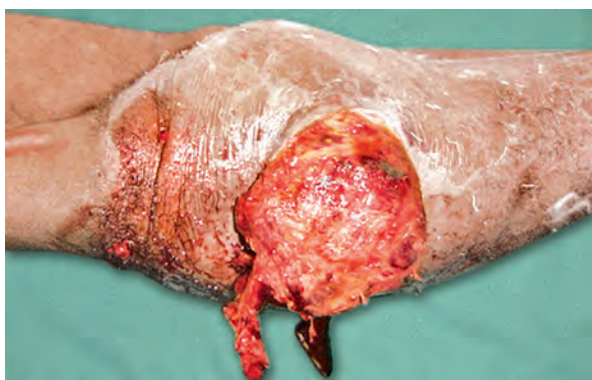

Fig. 1.558: Osteosarcoma upper tibia. Note the size of the tumour and ulceration. It is very vascular.



Figs 1.559A and B: X-ray pictures of osteosarcoma in tibia and femur.

**Note:**

- Many liposarcomas arise at sites devoid of adipose tissue. Most rhabdomyosarcomas arise in locations that lack voluntary muscle.
- 40% of soft tissue sarcomas are more than 10 cm in size at the time of presentation; 30% are 5-10 cm and 30% are less than 5 cm.

## Incidence of STS

### In adults

- ◆ MFH and liposarcoma—35–45%.
- ◆ Rhabdomyosarcoma—10%.
- ◆ Leiomyosarcoma—9–15%.
- ◆ Synovial sarcoma—7%.
- ◆ Malignant peripheral nerve sheath tumour (MPNST)—6%.
- ◆ Fibrosarcoma—5%.

### In children

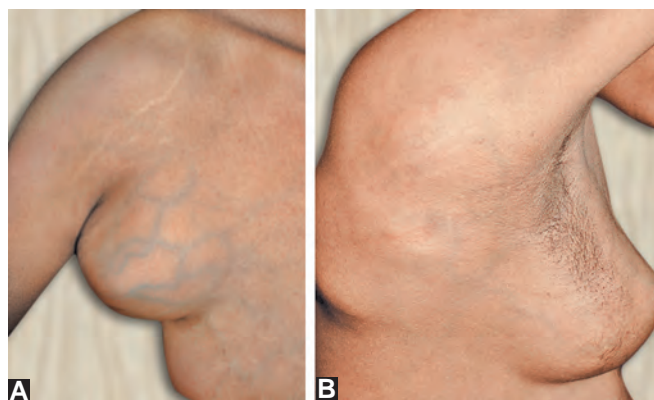
- ◆ Rhabdomyosarcoma, neuroblastoma are common tumours.

### Aetiology

- ❖ **Genetic**
  - von Recklinghausen disease
  - Gardner's syndrome
  - Tuberous sclerosis
  - Basal cell naevus syndrome
  - Li-Fraumeni syndrome
- ❖ **Chemicals**—PVC, tetrachlorodibenzodioxin, arsenic
- ❖ **Viral**—HIV in Kaposi's sarcoma, cytomegalovirus
- ❖ **Ionising radiation**—malignant fibrous histiocytoma (p53)
- ❖ **Lymphangiosarcoma** in post-mastectomy lymphoedema—*Stewart—Treves syndrome*.
- ❖ **Osteogenic sarcoma** in Paget's disease of bone/exposure to radium
- ❖ **Retinoblastoma associated sarcoma**
- ❖ **Gorlin's syndrome**
- ❖ Thorotrast, vinyl chloride, arsenic, pesticides

## Clinical Features of Soft Tissue Sarcoma

- ◆ Painless swelling of short duration with progressive increase in size—*soft tissue mass*. Thirty percent of patients may present as *pain* during first evaluation.
- ◆ *Compression* of adjacent structures
- ◆ *Smooth, firm/hard, warm and vascular*
- ◆ Features of *secondaries in lung*—cough, haemoptysis and chest pain. *Lung* is the commonest site of secondary.
- ◆ *Secondaries in liver* as a principal site especially in visceral STS.
- ◆ There are no reliable findings to distinguish benign from malignant swellings.
- ◆ One has to maintain a high index of suspicion in any soft tissue mass deep-to-deep fascia, any soft tissue mass > 5 cm, any new enlarging or symptomatic soft tissue mass.



Figs 1.560A and B: Soft tissue sarcoma upper chest wall. Note the vascularity and extent.

## Investigations

### Preoperative evaluation of STS is done:

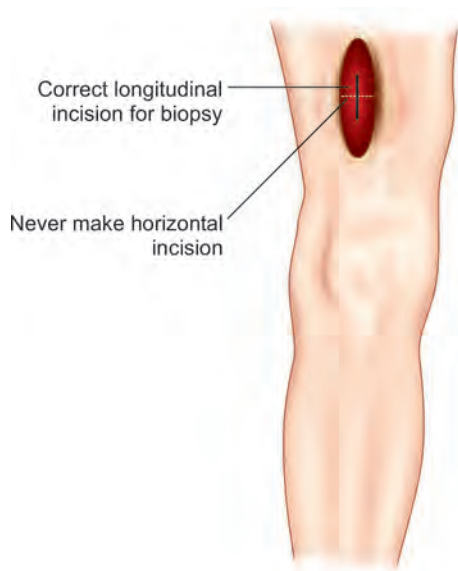
- ❖ To obtain a tissue diagnosis
- ❖ To determine the "exact extent" of the tumour
- ❖ To evaluate metastatic disease
- ❖ Other investigations

### Tissue Diagnosis

- ◆ **Incision biopsy** is the *most reliable method* of diagnosis. It provides adequate tissue sample.

### Incision biopsy for soft tissue sarcoma

- ❖ It is the **ideal tool** to conclude sarcoma histologically
- ❖ Incision should be placed in such a way that it can be included in wide tumor excision at a later period—as biopsy track is always contaminated
- ❖ One should achieve absolute / adequate haemostasis to avoid haematomas as tumours are vascular
- ❖ Proper site of incision biopsy should be decided
- ❖ One should use shortest possible route to tumour while taking incision biopsy; should not violate more than one compartment; should avoid neurovascular bundle. (Injury to vessels and nerves should be avoided)
- ❖ Smallest longitudinal incision is used to provide adequate specimen (Incision should be longitudinal in limbs)
- ❖ Transverse incision is **contraindicated** in the limbs except over the flexures
- ❖ Minimal tissue disturbance and avoiding raising of flaps are crucial (Flaps should not be undermined)
- ❖ It is better to use cold knife
- ❖ One should avoid crushing/distorting the specimen
- ❖ Frozen section/Imprint specimen can be used to avoid sampling error.
- ❖ Drains are *not used* routinely in incision biopsy. If used exit *near/* close to the wound and not away/distant from the incision biopsy wound.
- ❖ Excise the biopsy tract and drain site *enbloc* during the definitive procedure.
- ❖ Immunohistochemistry and cytogenetics are possible



**Fig. 1.561:** Incision for biopsy in STS should be longitudinal so that it can be included in future surgical wide excision. Never place transverse incision for biopsy.

- ◆ *Trucut biopsy/core needle biopsy* is an *acceptable first diagnostic* step as it is technically easier, not costly, with fewer complications. But it is not useful in visceral STS. Again if it is inadequate one should not be hesitant to go for incision biopsy at the earliest. It is done using 14 gauge needle; often US / CT guide is used.
- ◆ Excision biopsy is done *only* if the tumor size is < 3 cm which is cutaneous or subcutaneous wherein wide local re-excision is possible. Otherwise excision biopsy *should be avoided* as it may contaminate the tumour bed and restricts the therapeutic options.

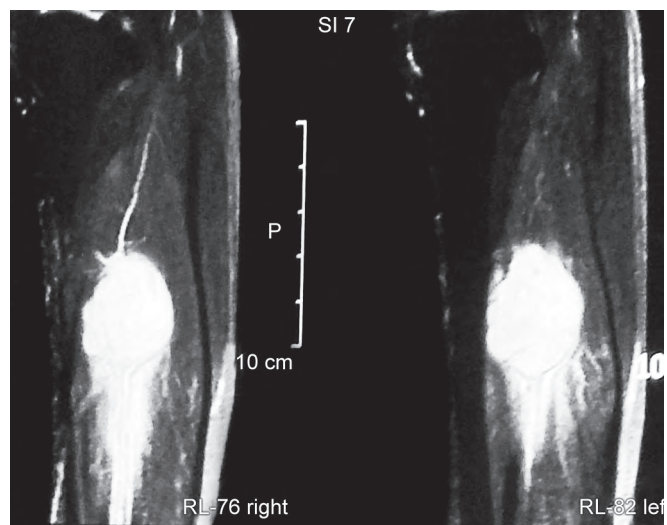
### Note:

FNAC is of less value in STS. It is significant only if it positive. It is useful in local or distant recurrences in documented sarcoma patients, or to evaluate nodal status if enlarged. CT guided FNAC is useful for retroperitoneal/intra-abdominal sarcomas.

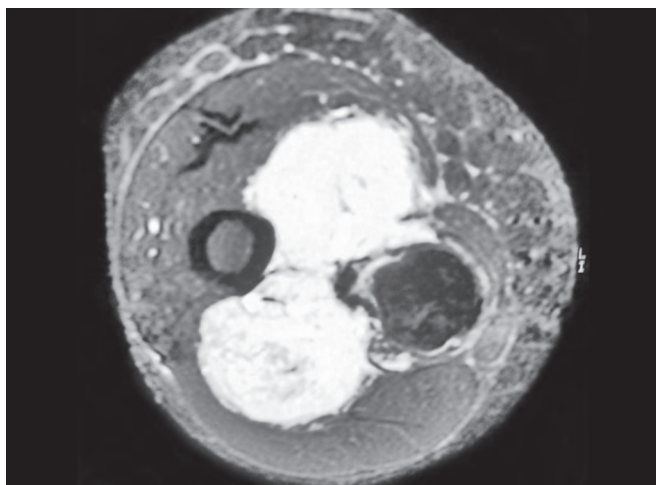
### Assessment of the Extent of Tumour

Imaging in STS provides a 3-dimensional extent of the tumour and helps in accurate planning of surgical procedure. But it does **not** reliably distinguish between a benign and malignant process. It assesses macroscopic and **not** microscopic extent of the disease. Imaging is essential for metastatic work up.

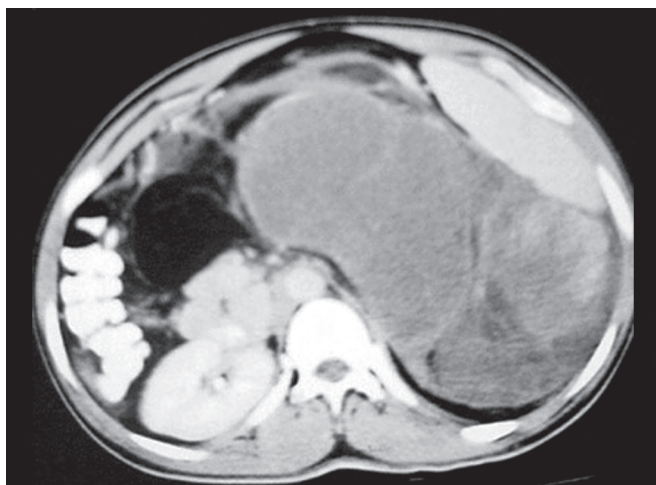
- ◆ **MRI is the investigation of choice** as it determines the vascularity, relation to vessel and fascial planes (extent and invasion). *Advantages of MRI* are—imaging of choice in STS, excellent soft tissue delineation, without radiation, multiplanar imaging possible. Images of skip metastases are possible. *Disadvantages of MRI* are—cost, bone involvement is poorly delineated, claustrophobia, not possible in presence of metal implants and pacemakers.
- ◆ CT scan also can be used to see the extent and invasion but not equivalent to MRI. CT scan helps in identifying presence and extent of the soft tissue mass, status of the adjacent structures, with mandatory contrast enhancement isodense masses, vasculature are better delineated. SPECT—3 dimensional reconstruction feasible. *Advantages of CT* are—easy availability, relatively cost effective, best to demonstrate bony involvement, useful for guided biopsies. *Disadvantages of CT* are—cross-sectional imaging, ionizing radiation, inferior soft tissue detail.
- ◆ *US is less sensitive* investigation. It is useful in extremity lesions to assess vascular system. It is initial/first investigation done in GI leiomyosarcoma/retroperitoneal sarcoma. It is useful for serial studies, guided trucut biopsy.



**Fig. 1.562:** MRI of STS leg.



**Fig. 1.563:** MRI picture of the soft tissue tumour thigh encasing vessels partially and eroding the bone. Patient needed high level, above-knee amputation.



**Fig. 1.564:** CT picture of retroperitoneal leiomyosarcoma.

- ◆ X-ray of part is not necessary; it is only used in initial phases to differentiate STS from bony lesion.
- ◆ *Angiogram* is traditionally used to delineate adjacent vasculature. It is upstaged by CECT/MRA. It is not necessary to do regularly in all cases but when there is a need for accurate assessment of vasculature it is ideal. It is used in intra-arterial chemotherapy for unresectable tumours.
- ◆ CT abdomen is *better* in GI/retroperitoneal sarcomas.

### Evaluation of Metastatic Disease

- ◆ Chest X-ray is done to look for secondaries.
- ◆ *CT chest* is ideal to see early lung secondaries. It is done in all deep seated, high grade and tumour more than 5 cm in size.
- ◆ US abdomen is sufficient to check liver secondaries. But CT abdomen may be better choice. Often CT pelvis is also added.
- ◆ *PET scan or Integrated PET scan* (with CT) is often useful to identify metastatic diseases.

### Other Investigations

- ◆ Radionuclide scintigraphy (Gallium-67).
- ◆ -p-MRS (p-Magnetic Resonance Spectroscopy) and FDG (Fluor-2-Deoxy Glucose) PET are done to assess the metabolic activity of tumour.
- ◆ Immunohistochemistry and *FISH* (fluorescence *in situ* hybridization).
- ◆ Tumour markers.
- ◆ Haematocrit, peripheral smear, ESR, serum alkaline phosphatase, serum creatinine.

### Staging

**Staging of the soft tissue tumour** is done depending on the tumour size, nodal status, metastasis and histological grading of the tumour (**GTNM staging**).

#### TNM staging of soft tissue sarcoma

Grade (G)	Tumour (T)
Gx Cannot be assessed	Tx Cannot be assessed
G1 Well-differentiated	T0 No primary
G2 Moderately differentiated	T1 Size < 5 cm or 5 cm (maximum dimension)
G3 Poorly differentiated	T1a: Superficial
	T1b: Deep tumour
G4—is now not used	T2 Size > 5 cm
G is assessed by <i>differentiation; mitoses; necrosis</i> through scores	T2a: Superficial
	T2b: Deep tumour
<i>Regional lymph nodes (N)</i>	<i>Distant spread (M)</i>
Nx Nodes cannot be assessed	Mx Cannot be assessed
N0 No nodes	M0 No distant spread
N1 Nodes present	M1 Distant spread present

**Note:** Superficial tumour is outside the superficial fascia. Deep tumour is deep to superficial fascia or any tumour invading the superficial fascia.

#### AJCC 2010/UICC staging of STS

*Stage IA*—G1, Gx; T1a, T1b; N0; M0. *Stage IIB*—G1, Gx; T2a, T2b; N0; M0

*Stage IIA*—G2, G3; T1a, T1b; N0; M0. *Stage IIB*—G2; T2a, T2b; N0; M0

*Stage III*—G3, any G; T2a, T2b, any T; N0, N1; M0

*Stage IV*—Any G; Any T; Any N; M1

**Note:** Desmoid tumour, Kaposi's sarcoma and infantile fibrosarcoma are excluded; angiosarcoma, Ewing's sarcoma, dermatosarcoma protuberans are included.

#### Grading of sarcomas

Low	Dermatofibrosarcoma, liposarcoma. Here <15% chances of metastases
High	Synovial, Rhabdomyosarcoma, Angiosarcoma Malignant fibrous histiocytoma, Extrasosseous chondrosarcoma. Here > 50% chances of metastases
Undetermined	Fibrosarcoma, Leiomyosarcoma

**Note:**

- STS is an aggressive, invasive, destructive growth with high recurrence and distant metastases rate. Tumour shows *fish flesh* cut appearance.
- *Basis used for classification of STS*—STS being highly heterogeneous group of tumour is classified based on adult tissue it resembles; i.e. the *type of tissue formed* rather than from the type of origin.
- **Grade** is the single most important factor in staging. It denotes the "biological aggressiveness" of the sarcoma. It predicts the likelihood of metastases.
- Nodal metastases are rare in STS (3%). It has the poor prognosis.
- M1 is – Distant metastases.

**Differential diagnosis for soft tissue sarcoma**

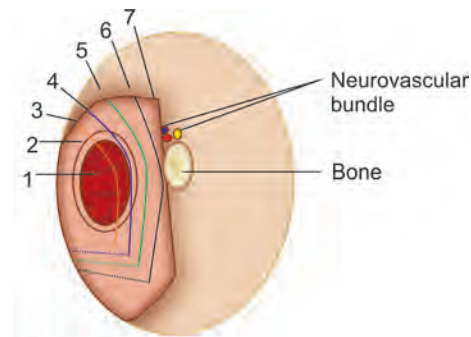
- ❖ Haematoma
- ❖ Abscess
- ❖ Aneurysm
- ❖ Myositis

**Treatment***Principles of Treatment*

- ◆ **Surgery** is the *main treatment* modality. Amputation rate for STS has come down drastically from 50% in 1960 to 5% at present. It is also because of proper **adjuvant radiotherapy** following function/limb sparing complete excision, application of microvascular surgeries. Neoadjuvant chemotherapy, perioperative/postoperative RT also play a major role.
- ◆ In *low grade tumour* without any spread—functional/limb sparing complete wide excision is sufficient without any adjuvant therapy. If microscopic margin is positive for tumour then postoperative External Beam RT (EBRT) is given.
- ◆ In *high grade tumour* <5 cm size, function sparing wide excision with more than 1 cm clearance margin is sufficient. If clearance margin is less than 1 cm or shows microscopic positive margin, then perioperative brachytherapy OR postoperative EBRT is given.
- ◆ In *high grade tumour which is between 5–10 cm* size, function/limb sparing complete wide excision with perioperative brachytherapy OR postoperative EBRT is given.
- ◆ In *high grade tumour more than 10 cm* in size, initially neoadjuvant chemotherapy; then functional/limb sparing complete wide excision with postoperative brachytherapy and EBRT should be given.
- ◆ All limbs should be *conserved* if possible but with curative intent.

**Surgery****Enneking classification of surgical procedures**

- ◆ **Intralesional excision**—done inside pseudocapsule very high recurrence 100%—not used.
- ◆ **Marginal excision**—en bloc resections through the reactive zone—high recurrence rate 70%
- ◆ **Wide excision** means en bloc resection done through normal tissues beyond the reactive zone; it means if the margin is less than 5 cm; tumour is never visualised during surgery; it has local recurrence rate of 30%. Wide margin is classified as adequate if margin is at least beyond 1cm outside the reactive zone or inadequate if margin is within 1 cm.
- ◆ **Radical excision**—if the margin is more than 5 cm outside the reactive zone. It is like compartment excision with very low recurrence rate.



1. Tumour mass.
2. Reactive zone.
3. Intralesional excision.
4. Marginal excision.
5. Wide excision—clearance up to 5 cm.
6. Radical excision—clearance > 5 cm.
7. Compartment excision.

**Fig. 1.565:** Different surgical approaches for STS.**Other procedures**

- ◆ Compartmental excision; function/limb sparing.
- ◆ Vascular resections with vascular reconstruction.
- ◆ Amputation.

**Note:**

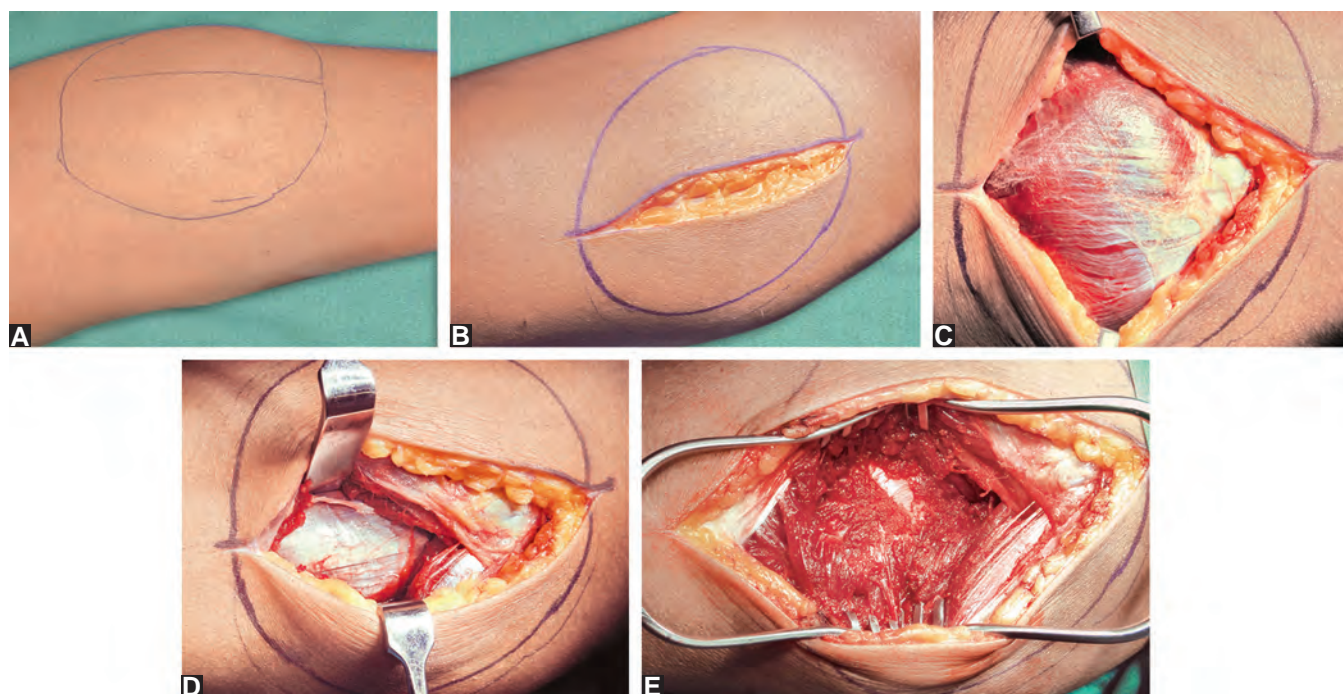
*Limb sparing; function preserving; margin free wide excision—is the new trend.*

A thin barrier is considered to be a 2 cm thickness of normal tissue; a thick barrier is 3 cm thickness; and joint cartilage is said to be equivalent to a 5 cm thickness margin. A surgical margin that is outside a barrier, with normal tissue between the barrier and the reactive zone of the tumour, is considered to be curative.

- ◆ **Wide local excision** with clearance of 2 cm (minimum need is 1 cm) or more with preservation of function is needed. Depth clearance is also important. 3–5 cm clearance even though was practiced in olden days, is not necessary (Figs 1.583A to E).
- ◆ **Compartment resection** is a radical limb saving procedure. Here muscle group of one compartment (anterior, posterior or medial) is resected entirely from its origin to insertion with the tumour. It is done only when tumour is intracompartmental. It is not suitable when tumour is extracompartmental or many compartments are involved or encased to major neurovascular bundle. Basis for compartmental excision is—STS rarely penetrate anatomical barriers unless it is very advanced.
- ◆ Amputation is done in large tumours of upper or lower limbs.
  - ▶ **Radical amputation** is done as disease has not spread systemically which should be confirmed by CT chest, abdomen and pelvis. In metastatic disease there is no need to do amputation as long-term survival is not possible except if primary is fungating and distressing.

**Indications for amputations in soft tissue sarcoma**

- ❖ Major neurovascular encasement
- ❖ Bone involvement
- ❖ Multiple compartment involvement
- ❖ Limb itself is diseased like lymphoedema
- ❖ Recurrence with multicentricity



**Figs 1.566A to E:** Surgical approach to a deep-seated sarcoma in leg—deep to gastrocnemius and soleus.

Tumor site	Level of amputation
Foot	Below knee
Leg	Above knee
Thigh-middle and lower third	Hip disarticulation
Thigh proximal third	Hemipelvectomy
Buttock	Hemipelvectomy
Hand and wrist	Below elbow
Forearm	Above elbow
Distal arm and elbow	Shoulder disarticulation
Axilla and shoulder girdle	Forequarter amputation

- ◆ *Debulking surgery* is useful in large advanced tumours like retroperitoneal sarcomas.

### Radiotherapy

- ◆ *Preoperative radiotherapy* followed by wide excision—neoadjuvant RT.
- ◆ *Postoperative radiotherapy* is commonly used because of less tumour burden and less wound problems. Titanium clips are placed during surgery at high-risk areas to identify the site to concentrate proper RT.
  - ▶ *Brachytherapy* is very effective in local control of the tumour. Initially precise mapping of the area is done in the operation theatre. Loading catheters are placed in surgical field preoperatively. Later these catheters are loaded with iridium 192. Dose is 45 Gy to tumour bed for 6 days.
  - ▶ Permanent radioactive sources can also be placed to the area.
  - ▶ *Postoperative external beam radiotherapy (EBRT)*—it is quiet effective and used in high grade tumour more than 5 cm often with brachytherapy. Dose is 70 Gy-25 fractions.

- ◆ *Palliative external radiotherapy* can be given to prevent bleeding, fungation and to reduce pain in advanced cases. It is also used in secondaries in brain, bone.
- ◆ *Primary radiotherapy* alone (radical) is of less beneficial in soft tissue sarcoma, but now it is used with more favorable results.

### Radiotherapy in soft tissue sarcoma

- ❖ Brachytherapy is given in high grade tumour
- ❖ External beam radiotherapy is used in low grade tumour
- ❖ All tumours more than 5 cm need adjuvant radiotherapy (external beam)
- ❖ Preoperative radiotherapy is also beneficial
- ❖ Deep seated tumour; high grade; size more than 5 cm needs chemoradiation

### Chemotherapy

- ◆ *Chemotherapy drugs*—VAC (*Vincristine, Adriamycin, Cyclophosphamide*) are commonly used. Other drugs *ifosfamide, dacarbazine* are used in combination with above drugs. *Mesna* is used as a protection for haemorrhagic cystitis. Chemotherapy is used when tumour is *more than 5 cm* or high grade.
- ◆ Usually *postoperative chemotherapy* is given. MAID regime is used especially in recurrent STS. Mesna, Adriamycin, Ifosfamide, Dacarbazine drugs (**MAID regime**) are used. Its response rate is 50%. But survival benefit is controversial.
- ◆ *Neoadjuvant chemotherapy* is used to make the primary tumour better operable. It makes eventual surgery better; provides early treatment for micrometastasis; gives idea about the response for chemotherapy. Drugs used are adriamycin and ifosfamide.
- ◆ *Isolated limb perfusion using cytotoxic drugs and tumour necrosis factor* with hyperthermia is also often used.
- ◆ Chemoradiation is a good alternate adjuvant therapy used.

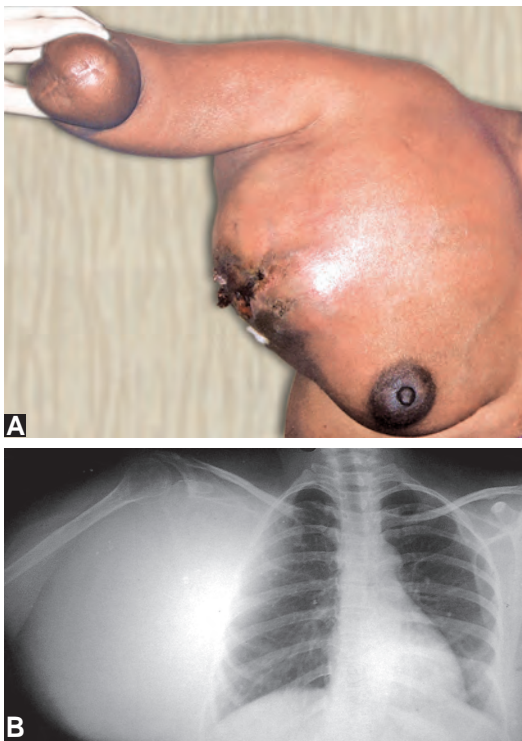
People can be divided into three groups: (1) Those who make things happen, (2) Those who watch things happen, (3) Those who wonder what's happening.

## Distant Spread

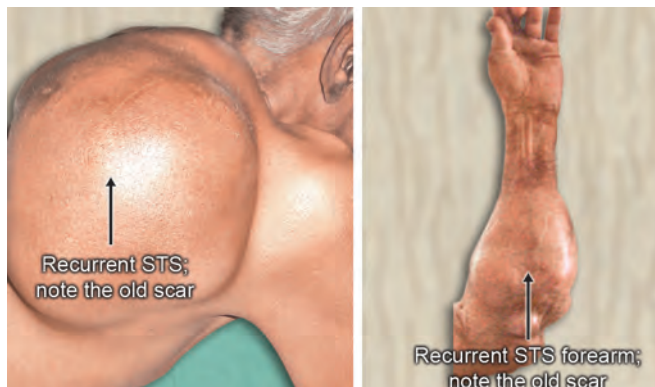- ◆ *Pulmonary metastasis* can be treated with wedge resection, segmentectomy, lobectomy, pneumonectomy. Surgery is done only when primary is well-controlled. Radiotherapy and chemotherapy are also tried. More than three number metastases in lung signify poor prognosis.

### Prognostic factors in STS

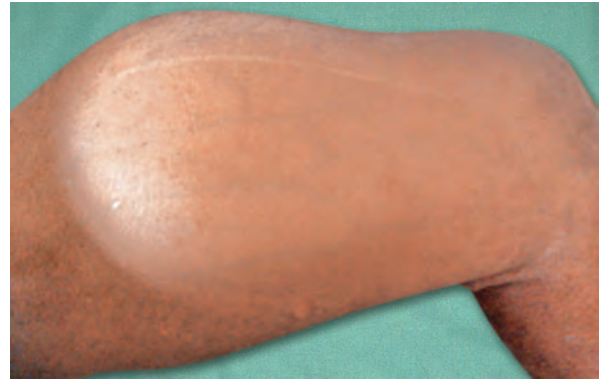- ❖ Size >5 cm—important factor
- ❖ High grade
- ❖ More than one compartment involvement
- ❖ Deep tumours and multicentric
- ❖ Neurovascular invasion
- ❖ Lung secondaries
- ❖ Clearance margin



**Figs 1.567A and B:** Recurrent chest wall tumour, could be secondaries, as patient was earlier amputated for soft tissue tumour hand (forearm amputation). X-ray of the same patient shows large tumour mass.



**Figs 1.568A and B:** Recurrent soft tissue sarcoma over scapular region and forearm in two different patients. Old surgical scar is seen.



**Fig. 1.569:** Recurrent soft tissue tumour thigh. Note the scar of old surgery.

## LIPOSARCOMA

- ◆ It is the **commonest type** of soft tissue sarcoma arising from the fat cells (of primitive mesenchymal cells).
- ◆ Lipoma as a precursor tumour for liposarcoma which was thought earlier is *disproved/not accepted now*.
- ◆ It is 20% of all soft tissue sarcomas.

### Common Sites

1. Thigh—commonest site.
2. Retroperitoneum.
3. Back.
4. Shoulder.

### Types

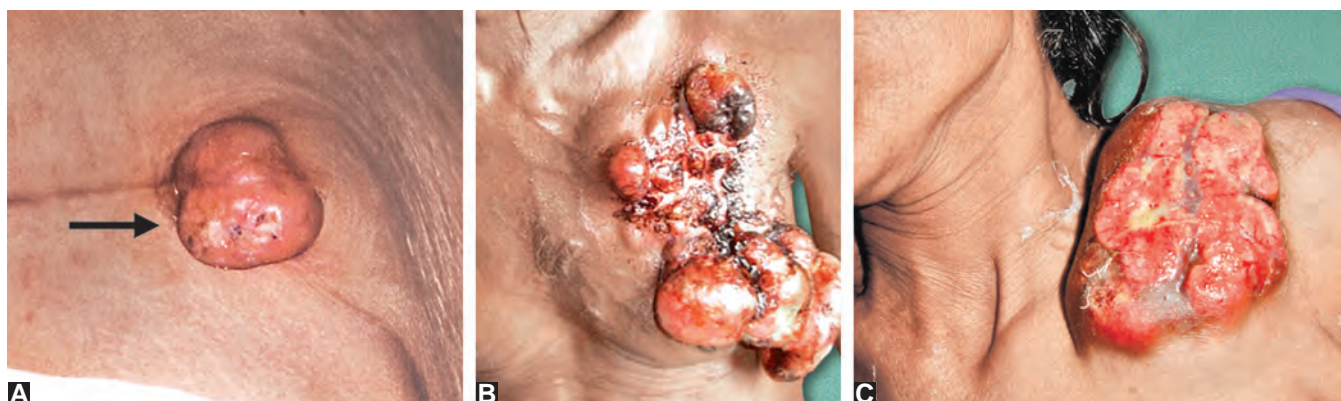
1. *Well-differentiated*—common between 50–70 years age group; common in extremities (75%); metastasis is rare.
2. *Dedifferentiated*—common between 50–70 years age group; common in retroperitoneum (75%); metastasis is high.
3. *Myxoid*—common at 25–45 years age; common in extremities (75%); high rate of metastasis.
4. *Round cell type*—common at 25–45 years age; common in extremities (75%); high rate of metastasis.
5. *Pleomorphic* (5%)—poor prognosis.

### Features

- ◆ *Microscopically*, it contains lipoblasts with ‘signet ring’ malignant cells. It is low grade type:
  - ▶ *Spread is to lungs.*
  - ▶ *Treatment* is wide excision or radiotherapy with surgical debulking in places where complete removal of tumour is not possible like in retroperitoneal liposarcoma.

## FIBROSARCOMA (11%)

- ◆ It can arise from **the bone** or from **soft tissues**.
- ◆ It is common between 30–55 years; common in deep soft tissues of lower extremities with intact overlying skin.
- ◆ It is arising from fibroblasts. Intramuscular and inter-muscular fibrous tissue, fascial envelopes, aponeurosis and tendons are common origin.
- ◆ Commonest site is thigh.
- ◆ Spindle fibroblasts with ‘*herring bone*’ pattern are typical on microscopy.



**Figs 1.570A to C:** (A) Recurrent dermatofibrosarcoma protuberans, (B) Malignant dermatofibrosarcoma left side of the chest wall, (C) Dermatofibrosarcoma.

### Remember About STS

- ❖ Specific and nonspecific genetic alterations with change tumour suppressor genes p53 and RB1 are noted in STS
- ❖ Type is identified based on *tissue formed* or resembled rather than of tissue origin
- ❖ *Liposarcoma* (20%) and *MFH* (18-20%) are the commonest STS
- ❖ Extremity STS spreads principally to *lungs*; visceral STS to *liver*
- ❖ *Low grade* has <15% chance of distant spread; but *high grade* has got >50% chances
- ❖ *Immunohistochemistry* is a must using different markers like CD 31, CD 34, CD 59, CD 99, desmin, vimentin, S 100, cytokeratin etc.
- ❖ *Expansive pathological type* growth shows pseudocapsule, reactive zone (neovascularisation with oedema) and compression zone. *Infiltrative* type shows satellite finger like infiltrations into the pseudocapsule
- ❖ Tumour growth initially contained by fascia, adventitia of vessel, periosteum and nerve sheaths
- ❖ *Incision* or core tissue biopsy is a must; MRI/CT imaging of primary is needed. CT chest is done to see metastases. All high grade STS needs chest CT. MRI of spine may need in selected types like round cell type. CNS CT scan is done in suspected cases, alveolar STS and in angiosarcoma. All visceral STS needs abdominal CT/MRI
- ❖ PET scan is done when targeted biopsy is needed; to predict prognosis; to assess response to chemotherapy. MR spectroscopy may be useful in grading
- ❖ *Limb sparing, function preserve, margin free wide excision* with 2 cm clearance should be done—*present concept*. Limb salvage is the priority
- ❖ Amputation *will not* reduce the chances of regional and distant spread and will not improve disease specific survival
- ❖ Radiotherapy is mainly as postoperative as brachytherapy or EBRT. Intraoperative RT (IORT) is also tried often mainly in visceral/retroperitoneal STS. RT is a must as an adjuvant in high grade/recurrent/ low grade > 5cm/margin positive/margin < 1cm
- ❖ Preoperative RT often used to reduce seedling during surgery; to make pseudocapsule thick and acellular; given 6 weeks prior to planned surgery usually as 50Gy dose
- ❖ *All high grade tumours* are also treated with chemotherapy either single agent or combination (MAID). Preoperative *chemoradiation* is a good additional alternative in stage II and III
- ❖ *Unresectable primary tumour* is treated with RT/chemoradiation/isolated limb chemoinfusion → if resectable surgery → adjuvant RT/chemotherapy
- ❖ *Stage IV STS treatment*—Single organ spread by metastatectomy, management of primary, RT, chemotherapy. Disseminated spread—RT, palliative surgery, chemotherapy
- ❖ *Good prognostic factors are*—Low grade tumor, size <5 cm, superficial tumor. Poor prognostic factors are—High grade, tumor size >5 cm and deep tumor.
- ❖ **Staging in relation to prognosis** (MSKCC/Memorial Sloan Kattering Cancer Centre): *Stage 0*—no poor prognostic factors; *Stage 1*—one poor prognostic factors; *Stage 2*—two poor prognostic factors; *Stage 3*—three poor prognostic factors; *Stage 4*—with metastases

### Types

1. *Well-differentiated*.
2. *Poorly differentiated*.
3. *Dermatofibrosarcoma protuberans*. It is common in trunk. *DFSP* is an intermediate grade fibrohistiocytic tumor with nodular cutaneous mass; common in adult male; common in trunk and proximal extremities having slow growth without deep muscle invasion. Skin is taut, nodular and commonly ulcerated.

4. *Aggressive fibromatoses* are variant of fibrosarcoma which are locally malignant in which desmoid tumour is also included.

### Features

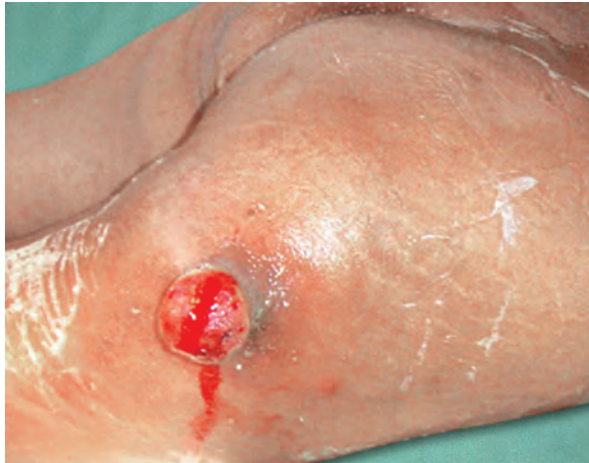- ❖ Fibrosarcoma is slow growing tumour which attains large size.
- ❖ Clinically, it is smooth, hard, warm, localised tumour.
- ❖ It compresses or infiltrates the adjacent structures like neurovascular bundle.

*Small minds are first to condemn great ideas.*



## ■ MALIGNANT FIBROUS HISTIOCYTOMA (MFH)

- ◆ It is group of malignant soft tissue tumours with a fibrohistiocytic appearance.
- ◆ MFH is one of the most common STS in adult (18–20%).
- ◆ 70% occur in skeletal muscles.
- ◆ Lower extremity is the common site.
- ◆ It presents as solitary, multilobular lesion.
- ◆ It spreads along the fascial planes or between muscle fibres which is the probable reason for local recurrence.
- ◆ Myxoid/giant cell/inflammatory/angiomatoid/pleomorphic are the types. It is common in adults and elderly.



**Fig. 1.571:** Large soft tissue tumour over gluteal region with ulceration and vascularity. It was confirmed as malignant fibrous histiocytoma. Patient was successfully operated.

## ■ LEIOMYOSARCOMA

- ◆ It arises from smooth muscle. Cut section shows whorled appearance.
- ◆ It constitutes (10–17%) of STS; common after 60 years.
- ◆ Two third occurs in women.
- ◆ It is undetermined grade—aggressive.
- ◆ It is common in retroperitoneum and viscera, but can occur in limbs and skin. Uterus is also common site.
- ◆ Recurrence is common. It has got poor prognosis.
- ◆ It can occur in the piloerector muscle of skin; inferior vena cava; pulmonary artery.
- ◆ Desmin and actin are the most common immunohistochemical stains.

## ■ RHABDOMYOSARCOMA

- ◆ It arises from striated muscle.
- ◆ It is common in *head and neck*, upper thigh and arm.
- ◆ *It is commonest sarcoma in children.*
- ◆ It can occur in retroperitoneum, pelvis and genitourinary tract.
- ◆ It is common in males.

### Types

1. *Pleomorphic*—most common type of rhabdomyosarcoma. It is common in adult, aggressive with poor prognosis.
2. *Embryonal*—common in infants and children—*is seen in viscera like urinary bladder.*

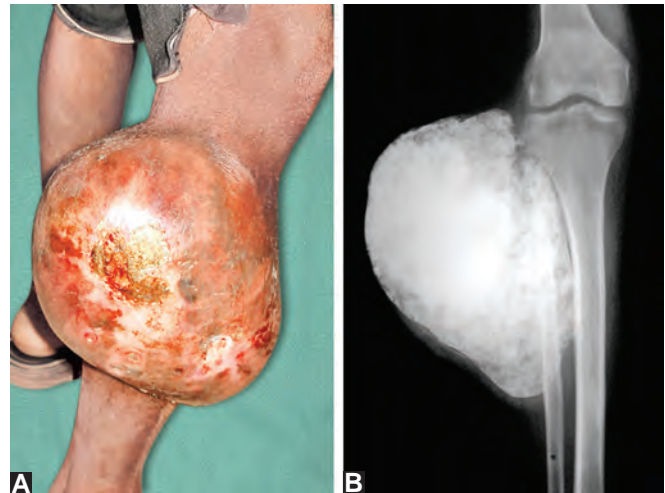
3. *Botryoidal*—slow growing polypoidal—respond well to chemotherapy and radiotherapy.
4. *Alveolar*—chromosomal translocation is common.

### Feature

- ◆ It is more aggressive tumour with poorer prognosis (High grade).
- ◆ It also metastasises to lymph nodes.

## ■ CHONDROSARCOMA

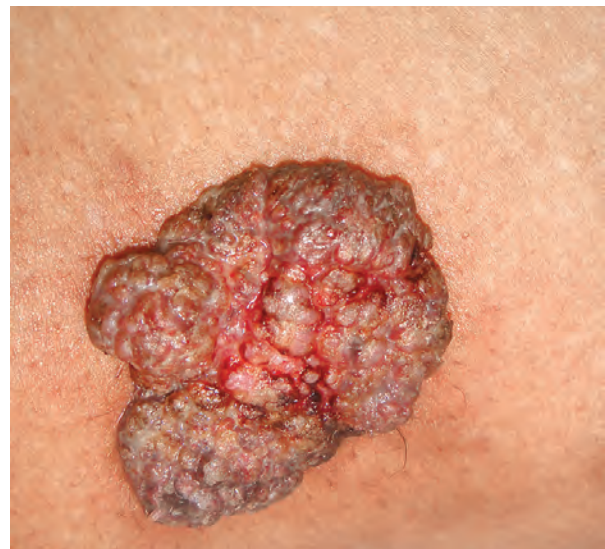- ◆ It arises from chondroblasts.
- ◆ It attains large size with slow growing nature.
- ◆ Common sites are ribs, flat bones.



**Figs 1.572A and B:** Chondrosarcoma leg lateral aspect. X-ray shows calcified tumour. It was successfully removed as limb salvage procedure.

## ■ HAEMANGIOSARCOMA

- ◆ It originates from blood vessel endothelium.



**Fig. 1.573:** Angiosarcoma.

## Types

- ◆ Malignant haemangioendothelioma.
- ◆ Malignant haemangiopericytoma.

## ■ LYMPHANGIOSARCOMA

- ◆ It arises from lymph vessel endothelium.
- ◆ It commonly occurs after radical lymph node dissection *Stewart-Treves syndrome*.

## ■ SYNOVIAL SARCOMA (7%)

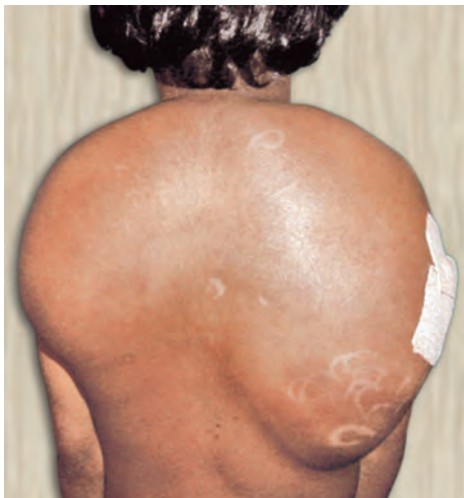

Fig. 1.574: Synovial sarcoma.

- ◆ It is the 4th commonest type. It occurs 15–40 years of age.
- ◆ Origin need not be from synovium.
- ◆ 85–90% occurs in lower limb; head, neck and shoulder are the next common site.
- ◆ It is common in thigh, leg, shoulder, hand and foot.
- ◆ Occasionally it can occur in the abdominal wall and retroperitoneum.
- ◆ It is common in young individuals.
- ◆ It occurs adjacent to joint but uncommon to involve the synovial sheath of the joint.
- ◆ It spreads both through blood as well as through *lymph nodes* (20%).
- ◆ It is very aggressive soft tissue sarcoma (High grade).
- ◆ Calcification with or without ossification is common—10%.
- ◆ Synovial sarcoma may be biphasic or monophasic.
- ◆ It possess specific chromosomal translocation (96–100%) – t(X; 18)(p11.2; q11.2).

## ■ MALIGNANT PERIPHERAL NERVE SHEATH TUMOUR (MPNST) (3%)

- ◆ It arises from peripheral nerves.
- ◆ It shows differentiation along nerve elements.
- ◆ MPNST replaced older terms—malignant schwannoma, neurofibrosarcoma, neurogenic sarcoma, malignant neurilemmoma.
- ◆ 20–50% arises from neurofibromatosis type 1 (latent period 15–20 years). MPNST is an exception to sarcoma will not arise from benign precursor.
- ◆ Common sites are major/proximal nerve trunks.

## ■ KAPOSÍ'S SARCOMA

- ◆ It is malignant blood vessel tumour of multicentric origin arising from vascular smooth muscle or pericytes.
- ◆ It is seen commonly in HIV patients due to immunosuppression.
- ◆ Primary tumour commonly occurs in skin, mucous membrane, lymph nodes or viscera.
- ◆ It is linked with Human Herpes Virus 8 (HHV8) as causative agent.

## Types

1. *European Kaposi's sarcoma*: It is common in old age. It is first described by Kaposi in 1862. It mainly involves skin especially lower extremity. Visceral involvement is rare.
2. *African Kaposi's sarcoma*: It occurs commonly in children and young individual. It involves skin and lymph nodes commonly. It resembles lymphoma.
3. *Transplant associated Kaposi's sarcoma*: It is due to drug-induced immunosuppression. It involves mainly skin and often regresses once immunosuppression is discontinued.
4. *AIDS associated Kaposi's sarcoma*: It occurs in 30–40% of AIDS patients. It is common in homosexuals. It has got wide, disseminated involvement with metastases. It is very aggressive. It is often associated with lymphoma and other malignancies.

### Note:

Kaposi's sarcoma is not found in transfusion related AIDS.

## Clinical Features

- ◆ Multiple reddish-blue nodules in the skin with ulceration over the nodule.
- ◆ Lymph node enlargement.
- ◆ Koebner phenomenon is common in areas of trauma.
- ◆ *Differential diagnosis*:
  - ▶ Lymphomas.
  - ▶ Cutaneous angiomatoses.
  - ▶ Mycobacterial infection of skin.
- ◆ *Investigations*:
  - ▶ Biopsy from the skin lesion.
  - ▶ Tests for HIV infection.
- ◆ *Treatment*:
  - ▶ Irradiation.
  - ▶ Chemotherapy. Drugs used are adriamycin, bleomycin and vinblastine.
  - ▶ Antiretroviral therapy.
  - ▶ Interferons.

### Sarcomas which also spread to lymph nodes

1. Synovial sarcoma
2. Lymphangiosarcoma
3. Rhabdomyosarcoma—alveolar type
4. Ewing's sarcoma
5. Angiosarcoma
6. Epithelioid sarcoma
7. Carcinosarcoma of uterus

# T. Amputations

“Amputation is one of the meanest yet one of the greatest operations in surgery, i.e. mean—when resorted to where better may be done. Great—as the only step to give comfort and prolong life.”

—Sir William Ferguson

## CHAPTER OUTLINE

❖ Amputation

❖ Complications of Amputations

❖ Prosthesis

### ■ AMPUTATION

#### Indications

- ◆ Gangrene due to atherosclerosis, embolism, TAO, diabetes, ergots.
- ◆ Trauma: To save life in crush injuries.
- ◆ Neoplasms: Osteosarcomas, Marjolin’s ulcer, melanomas.
- ◆ Gas gangrene.
- ◆ Severe sepsis.
- ◆ Occasionally severe elephantiasis, madura foot, when all other methods have failed to help.
- ◆ **Dead, dying, devitalised tissues.**
- ◆ Severe deformity congenital or acquired.

#### Types

It can be:

- ◆ *Non-end bearing/side bearing*—Weight is taken up by the joint.
- ◆ *End bearing/cone bearing*—Weight is taken up by the body.

It can be:

- ◆ Weight bearing.
- ◆ Non-weight bearing.

It can be:

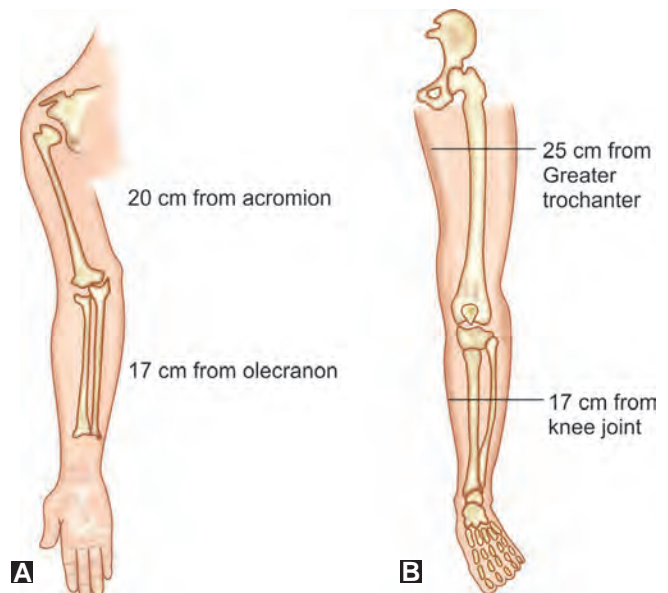
- ◆ *Provisional* amputation with flap—later final formal amputation may be required.
- ◆ *Guillotine* amputation which always requires revision formal amputation.
- ◆ *Formal* amputation—is definitive one.

#### Types of Flaps

- ◆ *Long posterior flap* in below-knee amputation.
- ◆ *Equal flaps* in above-knee amputation.

#### Ideal Stump

- ◆ Should heal adequately by 1st intention.
- ◆ Should have rounded, gentle contour, with adequate muscle padding.
- ◆ Should have sufficient length to bear prosthesis.
  - ▶ For B-K 7.5 (minimum) to 12.5 cm from tibial tuberosity
  - ▶ For above and below elbow 20 cm stump.
  - ▶ For A-K 23 cm from greater trochanter.



Figs 1.575A and B: Different levels of amputation in upper limb and lower limb.

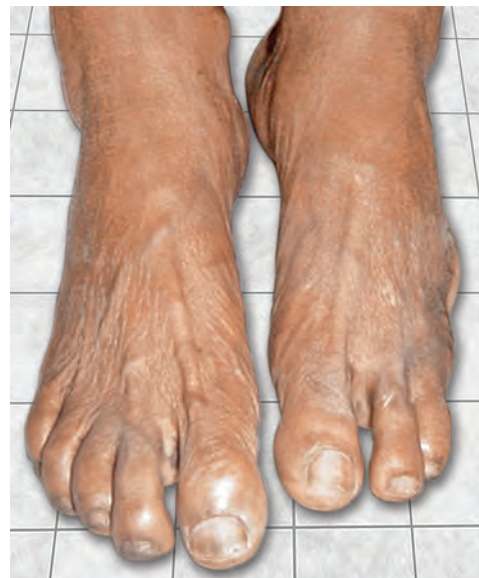

Fig. 1.576: Little toe amputation for gangrene. Wound has healed well.

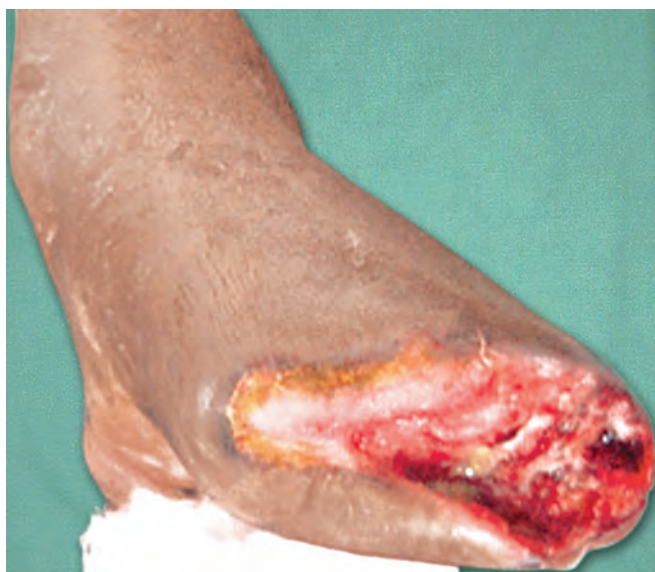

Fig. 1.577: Forefoot amputation.

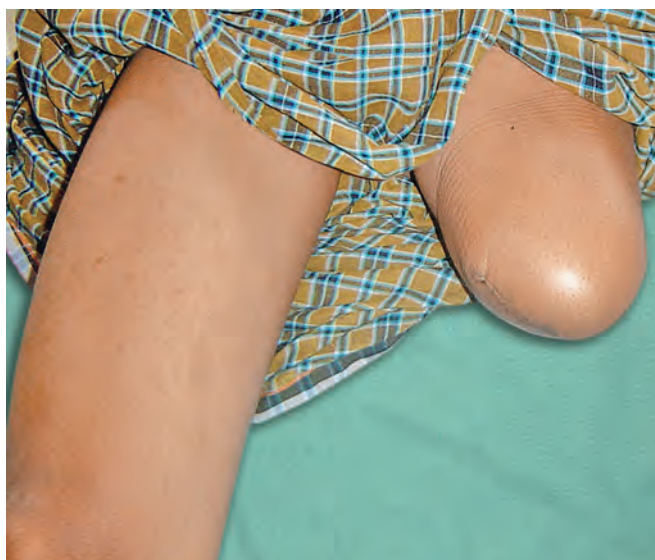

Fig. 1.578: Above-knee amputation done for osteosarcoma of the upper end of the tibia. Here equal flaps are used.

- ◆ Should have thin scar which does not interfere with prosthetic function.
- ◆ Should have adequate adjacent joint movement.
- ◆ Should have adequate blood supply.
- ◆ Scar should be in a place where it is not exposed to pressure.
- ◆ Scar should be freely mobile over underlying tissues. Skin and scar should be freely mobile over the underlying bone. It is achieved only if deep fascia is closed properly. Scar and skin should be free to achieve free movement of the prosthesis. Socket of prosthesis with mobile skin creates a piston to bone to move like a joint.
- ◆ Skin should not be infolded.
- ◆ Redundant soft tissue should not be there.
- ◆ Stump should be free from tenderness and conical.

#### Conical bearing

- ❖ Here healing is by primary intention
- ❖ Bone should not be projecting
- ❖ Myoplastic
- ❖ No neuroma
- ❖ Scar should not be tender
- ❖ Proximal joint should be supple

### Evaluation of the Patients who need Amputation

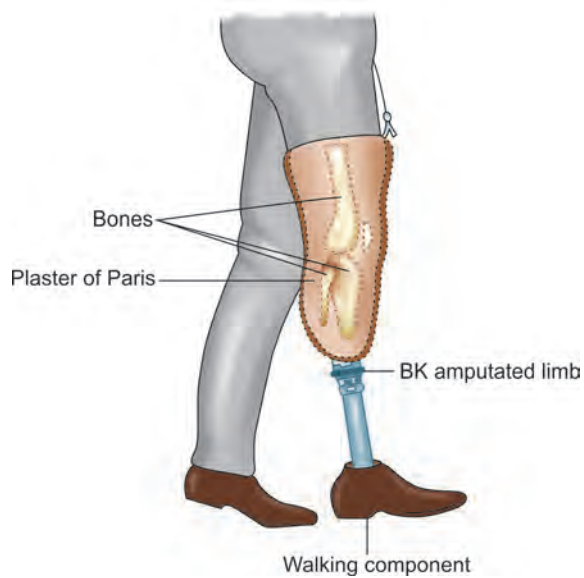- ◆ Haematocrit, control of anaemia by transfusing blood/packed cells.
- ◆ Control of infection using antibiotics.
- ◆ Decision of level of amputation by skin temperature, arterial Doppler.
- ◆ Informed consent should be taken.
- ◆ Plan for prosthesis and rehabilitation by physiotherapist and rehabilitation team.

#### Different incisions for amputation

- ❖ *Circular incision amputation*—skin and muscles are divided circularly at a lower level than that of bone
- ❖ *Elliptical/oval incision amputation*
- ❖ *Racquet incision amputation*—for digital disarticulation
- ❖ *Amputation using flaps*—it may be of equal flap (above-knee amputation) or with long posterior single flap (below-knee amputation). Total length of single flap or combined length of two flaps should be equal to  $1\frac{1}{2}$  times the diameter of the limb at the line of amputation. Flap should be semicircular to get a conical stump, not rectangular

### Principles in Amputation

- ◆ Adequate blood supply of the flap should be maintained.
- ◆ Proper marking of the skin incision is essential.
- ◆ Tourniquet *should not be used* if amputation is done for vascular diseases.
- ◆ Proximal part of the flap contains muscle component but distal part should contain only skin and deep fascia.
- ◆ Flap length should be adequate; not short. It should be ideally semicircular not rectangular to get a conical stump.
- ◆ Nerve should be pulled down and cut using a sharp knife and allowed to retract into the soft tissue otherwise neuromas may develop.
- ◆ In crush injury/entrapment injury/sepsis—guillotine amputation is done. Later skin is pulled down by using skin traction, eventually to have better skin coverage.
- ◆ Bone should be cut with beveling and all sharp margins should be rounded.
- ◆ Postoperatively regular dressings are done. Patient is mobilised using axillary crutches. After 3 months, once scar has matured and stump has become supple, proper prosthesis is fit. *Berlamont* first started immediate postoperative fitting of prosthesis to leg for early mobilisation. *Plaster pylon* is applied to the stump and a prosthetic extension is fit to



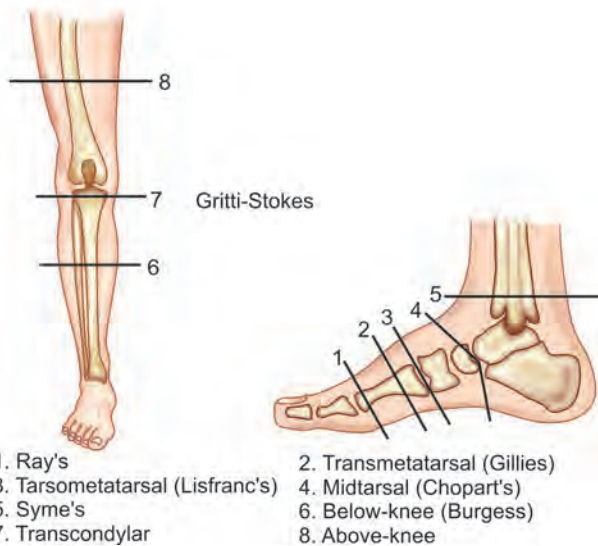**Fig. 1.579:** Pylon is plaster cast with walking component used for immediate mobilisation after below-knee amputation.

facilitate partial weight bearing immediately after surgery. It has got more stump complications and so it has not become popular.

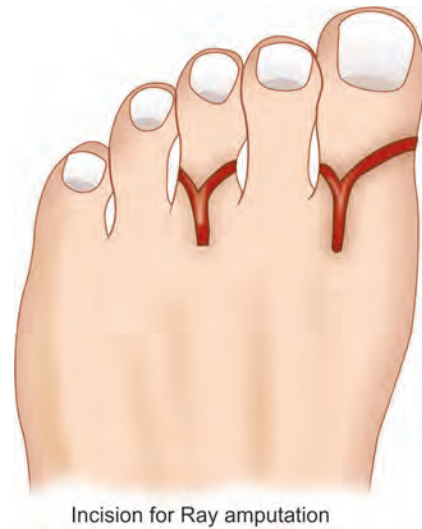- ◆ Stumps can be side bearing (sutures are on the side); end bearing/conical (sutures are on the end) or cylindrical.
- ◆ Postoperatively active exercise should be given to the proximal joint so that prosthesis can be fit to it properly.
- ◆ If there is sepsis especially in gangrene limb, flaps should be left open or loosely sutured otherwise flap necrosis occurs.
- ◆ Proper anatomy of muscles and neurovascular bundle around should be known in all amputations.

**Different Amputations**

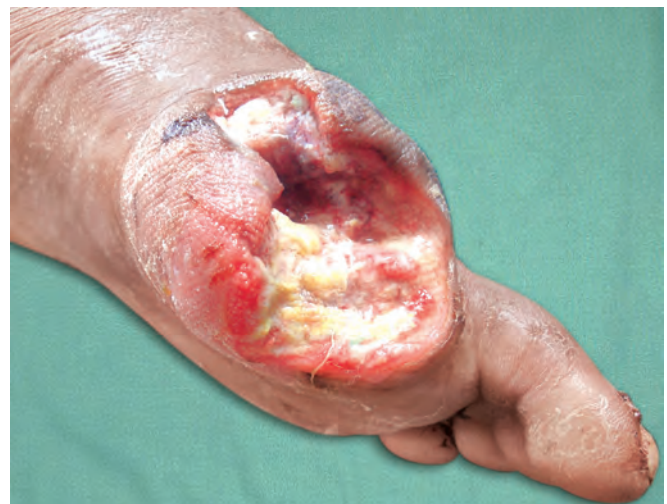◆ *Ray amputation*



**Fig. 1.580:** Different levels of amputation in lower limb.



**Fig. 1.581:** Ray amputation for toes—racquet incision.



**Fig. 1.582:** Ray's amputation done for gangrene of great toe. It is usually not sutured.



**Fig. 1.583:** Forefoot amputation.

Amputation of toe with head of metatarsal or metacarpals.

◆ **Transmetatarsal amputation (Gillies')**

Here amputation is done proximal to the neck of the metatarsals, distal to the base.

◆ **Lisfranc's amputation (Tarsometatarsal amputation)**

Here tarsometatarsal joint is disarticulated with a long volar flap. It needs a surgical boot. But there is inevitable development of equinovarus deformity. So stabilisation of midtarsal and ankle joints is needed. In Hey's modification, 2nd metatarsal is cut at base instead of disarticulation.

◆ **Chopart's amputation (Midtarsal amputation)**

Here talonavicular joint and calcaneo-cuboid joints are disarticulated. Tibialis anterior muscle is sutured to drilled talus bone. A long volar flap is used and immobilised for 6 weeks after surgery.

◆ **Syme's amputation**

- ▶ It is removal of the foot with calcaneum and cutting of tibia and fibula just above the ankle joint with retaining heel flap (dividing both malleoli). Heel flap is supplied by medial and lateral calcaneal vessels (branches of posterior tibial artery). *Elephant boot* is used for the limb after Syme's which is inexpensive. Many patients walk well with Syme's stump without difficulty. It is presently mainly used in trauma (crush injury) and malignancies in distal part of the foot. In vascular diseases, calcaneal vessels may not be adequate to maintain the viability of the flap. While raising the flap, knife should be very close to the calcaneum so as to avoid injury to calcaneal vessels and to maintain the viability of the flap.
- ▶ In *Wagner's method* deep fascia of heel is sutured to drill holes made on the anterior edge of tibia and fibula. *Above-knee cast* is essential.
- ▶ *Advantages are*—it is an end-bearing stump having good proprioception. Patient can walk without prosthesis. Low energy consumption ambulation is possible.
- ▶ *Disadvantages*—posterior displacement of heel pad; poor cosmesis.
- ▶ *Boyd's amputation*—anterior part of the calcaneum is excised (osteotomy) just distal to the peroneal tuberosity and calcaneotibial arthrodesis is created. It is done to prevent posterior migration of heel pad.

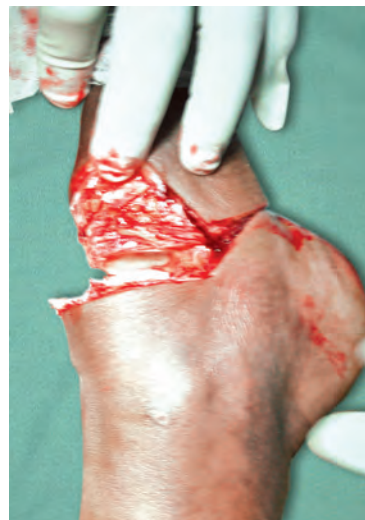

Fig. 1.585: Incision for Syme's amputation.



Fig. 1.586: Elephant boot used after Syme's amputation.

◆ **Modified Syme's amputation**

Here heel flap is elliptical. Tibia and fibula are divided slightly higher. But variation here is the elliptical flap.

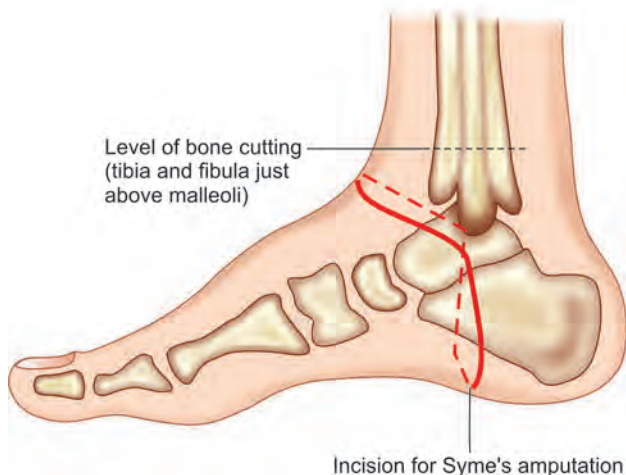


Fig. 1.584: Syme's incision and level of amputation.

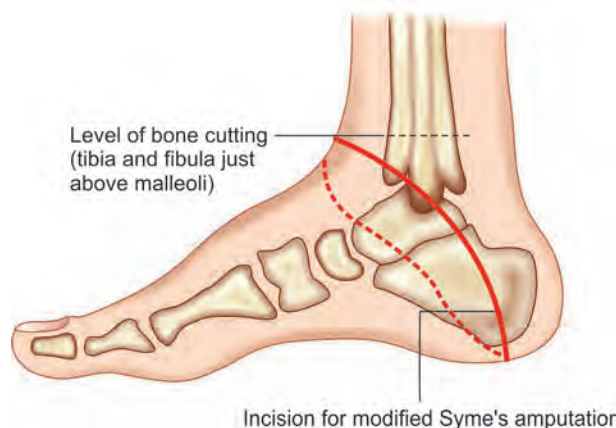
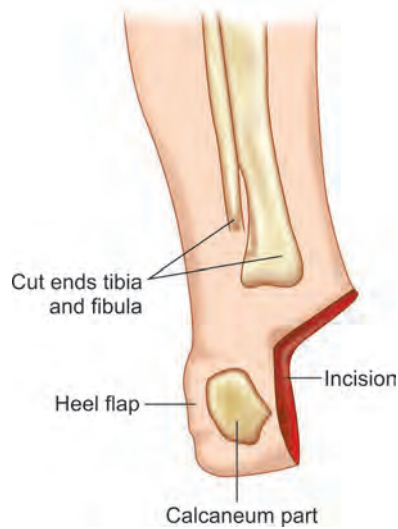

Fig. 1.587: Modified Syme's incision is elliptical one.

◆ **Pirogoff's amputation**

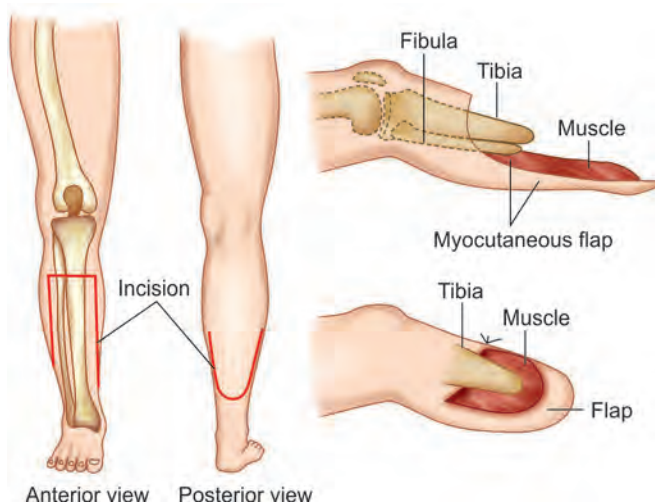
It is like Syme's amputation except posterior part of the calcaneum is retained along with heel flap. It provides longer stump than Syme's amputation.



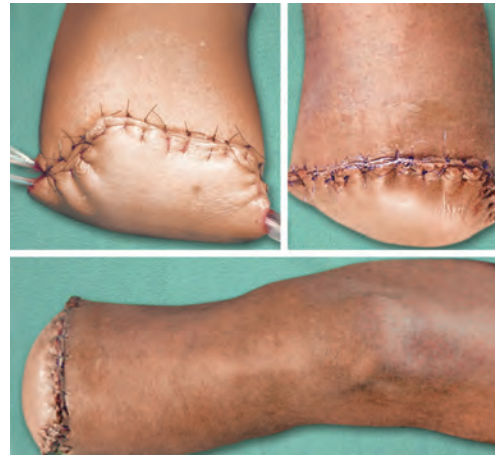**Fig. 1.588:** Pirogoff's amputation.

◆ **Below-knee amputation**

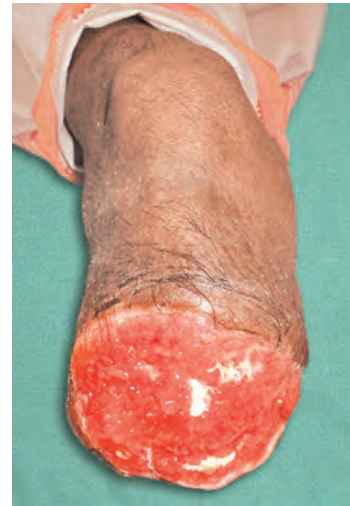Here we use a long-posterior flap with scar placed over anterior aspect is used. Prosthesis placement is better here with greater range of movements without limp and without support. It is also called as *Burgess amputation*. Fibula should be divided first, higher than the proposed site of cut of tibia otherwise its sharp end will press on the skin flap. Tibial stump should be beveled anteriorly. Posterior muscles are sutured across the bone end, to the periosteum in front. In more proximal type of below-knee amputation, fibula often is removed to allow the proper use of flap. Length of the flap should be  $1\frac{1}{2}$  times the circumference of the site (around 12 cm). Stump length is 14–17 cm from knee joint. Minimum length required for prosthesis is 8 cm. If need to extend more proximally, it is better to do above-knee amputation. Modern artificial limbs like *suction socket prosthesis* are used now.



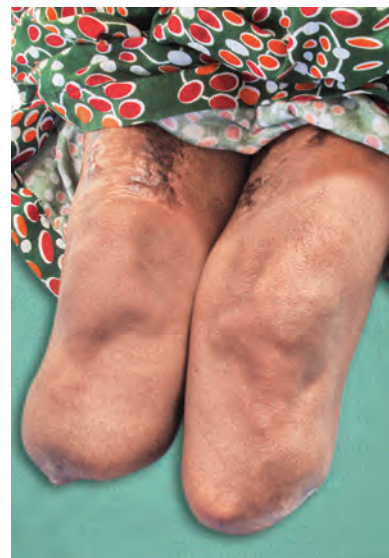**Fig. 1.589:** Below-knee amputation technique—incision, flap and levels of cutting bones.



**Fig. 1.590:** Below-knee amputation—long posterior flap. Note the placing of the drain.



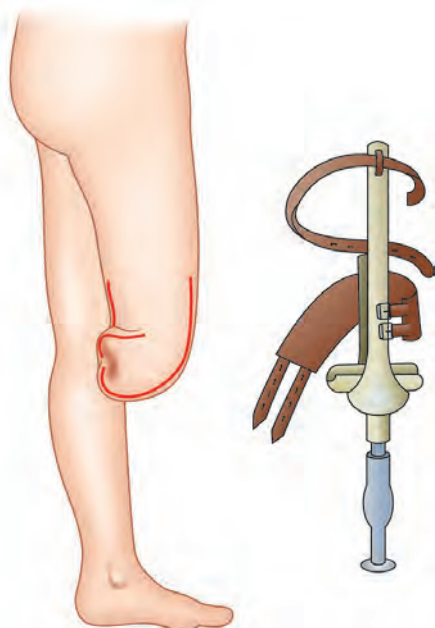
**Fig. 1.591:** Below-knee amputation flap necrosis has occurred which eventually granulated with repeated dressings. Area is ready for skin grafting.



**Fig. 1.592:** Bilateral below-knee amputations done for vascular causes with diabetes.

◆ **'Peg-leg' amputation**

- ▶ It is amputation 5 cm below the knee level – proximal most below-knee amputation. It is *not practiced* nowadays. Here anterior flap is rotated posteriorly like a hood and patient kneels and bears weight which is well-accustomed to pressure. It is done whenever prosthesis cannot be used probably due to economic causes (in developing countries).



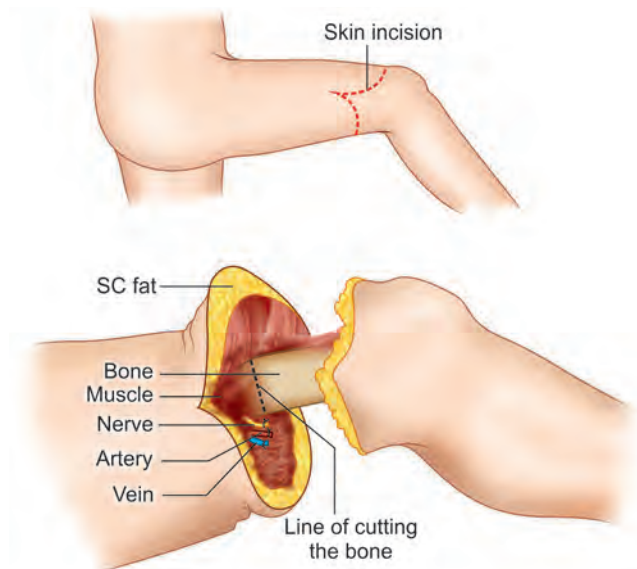
**Fig. 1.593:** 'Peg-leg' amputation is below-knee amputation done close to the knee joint (5 cm stump) with folding flap and metallic support down. It is not used now.

◆ **Transcondylar-Gritti-Stokes amputation** with long posterior flap.

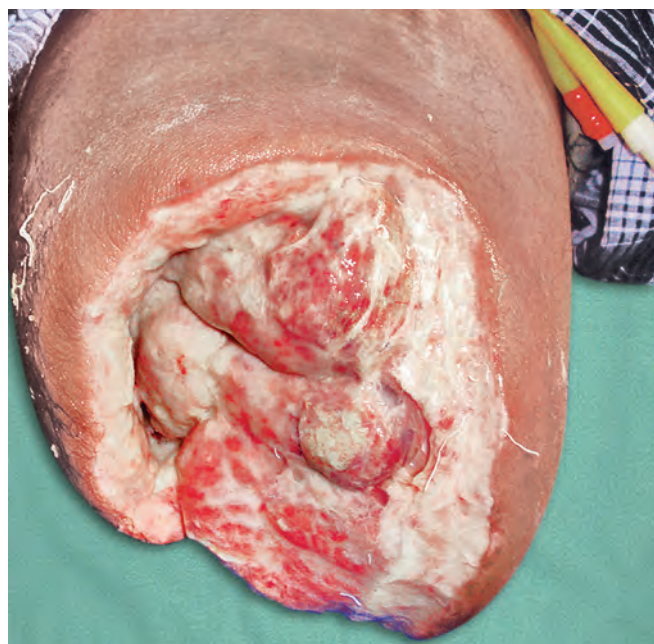- ▶ Femur is divided just above the articular surface and patella is anchored to the divided femur. There is risk of nonunion between patella and femur. This procedure is *no longer performed*.

◆ **Above-knee amputation**

- ▶ Usually equal anterior and posterior flaps are used. Lower third and middle third level amputations are done. Ideally the required length of the femur as stump is 25 cm from the tip of the trochanter. Femur length lesser than 10 cm is not possible and here one needs to do hip disarticulation. In children as growing epiphysis of femur is in lower end, it is essential to preserve as much length of femur as possible. It is done in ischaemia, trauma, sepsis, gangrene which is spreading above. Often patient might earlier have undergone below-knee amputation but now as indicated need above-knee amputation. It is usually contraindicated in children (done only in undue definitive indication) or if stump is less than 7.5 cm.
- ▶ **Advantages** are technically easy, healing chances are better and faster. **Disadvantages** are cosmetically poor, rehabilitation is difficult, and fitting of prosthesis is not proper, patient needs a third support for walk with often a limp.



**Fig. 1.594:** Above-knee amputation, incision and approach.



**Fig. 1.595:** Above-knee amputation wound which is infected in a diabetic patient.

◆ **Hip disarticulation**

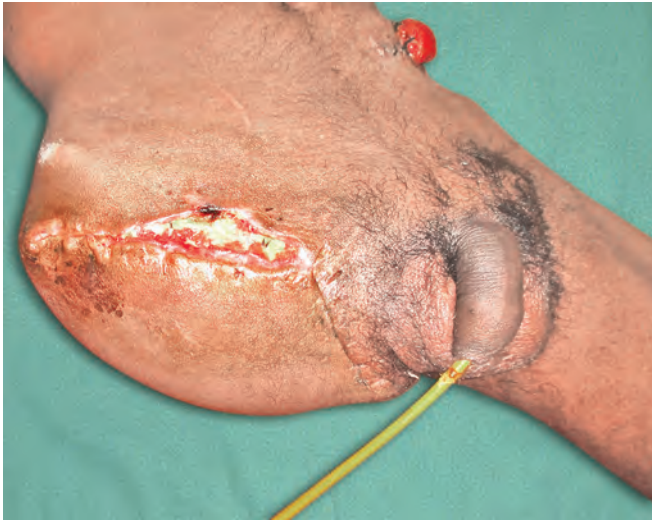It is done whenever it is not possible to save the minimum 10 cm length of the femur. Incision used is either single posterior flap—Solcum's approach (better) or anterior racquet incision—Boyd's approach.

◆ **Hind quarter amputation**

Inter-innominate abdominal amputation (*Sir Gordon Taylor's* amputation): Removal of one side pelvis with innominate bone, pubis, muscles and vessels. Original ligation of common iliac artery is modified to individual ligations of external and internal



iliac vessels. Internal iliac artery is ligated beyond the origin of the superior gluteal artery to keep the large posterior flap viable. *Now hind quarter name is replaced by hemipelvectomy.* It may be *standard hemipelvectomy* with classic gluteal flap; *extended hemipelvectomy* with removal of posterior part of the sacrum; *conservative hemipelvectomy* with retaining part of the pubis, ilium bones on that side. *Internal hemipelvectomy* is new method wherein *hemipelvectomy* is done with preserving the limb.

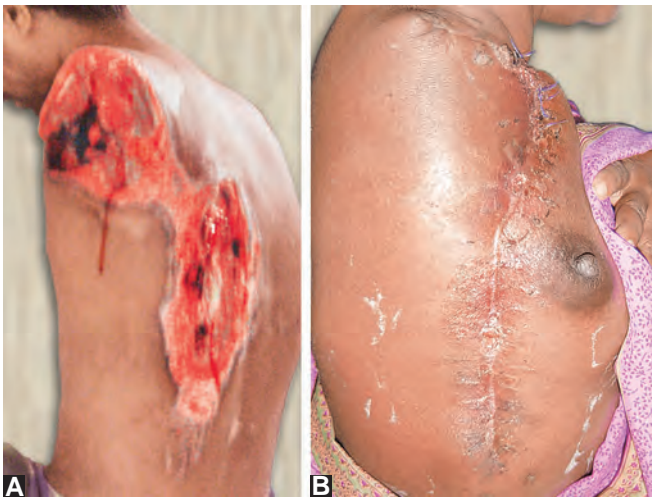

**Fig. 1.596:** Hindquarter amputation done for run over of vehicle over pelvis, right thigh. Patient also underwent colostomy. Patient survived with severe morbidity.

◆ **Krukenberg's amputation**

Done in upper limb following any trauma. Here forearm amputation is done in such a way that it creates a gap between radius and ulna like a claw to have a hold or grip.

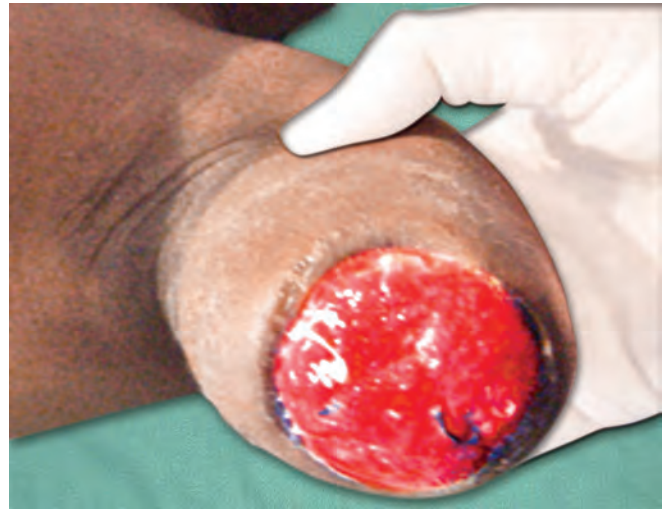◆ **Interscapulothoracic amputation (Forequarter amputation)** (Littlewood's posterior approach or Berger's anterior approach):



**Figs 1.597A and B:** (A) Forequarter amputation done for electric burn which caused extensive damage to upper limb, (B) Forequarter amputation done for sarcoma proximal to shoulder joint.

It is removal of entire upper limb with scapula and lateral 2/3rd of the clavicle and muscles attached to it. It is done in malignancies involving scapula, upper part of humerus and near shoulder joint.

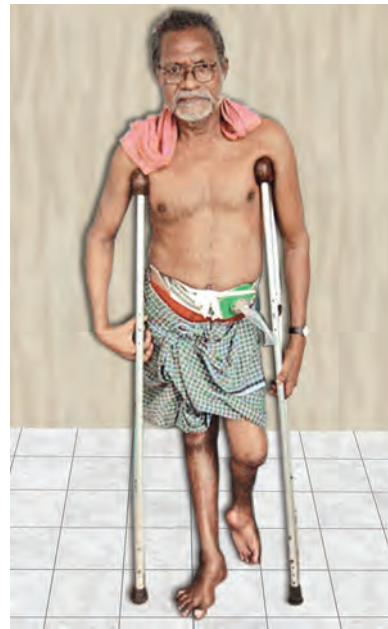- ◆ In emergency conditions like severe sepsis, gas gangrene and machinery entrapment, **Guillotine amputation** is done without suturing. Suturing is done at later period. All tissues are divided at same level.



**Fig. 1.598:** Upper limb Guillotine amputation—above elbow done for trauma induced gas gangrene.

### Postoperative Period

- ◆ Physiotherapy is advised.
- ◆ Regular dressings are done.
- ◆ Crutch is used initially, after 3 months prosthesis is placed.
- ◆ Rehabilitation is important.



**Fig. 1.599:** Patient with axillary crutches.

## ■ COMPLICATIONS OF AMPUTATIONS

### Early

Haemorrhage, haematoma, infection.

## Late

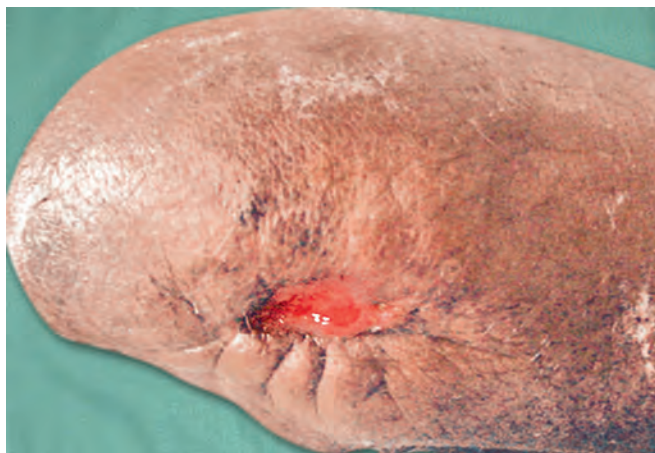
Pain, ulceration of stump, ring sequestrum formation, flap necrosis, painful scar, *Phantom limb*—feeling of amputated part in toto or partially with pain over it.

### Haematoma

It is identified by pain, swelling over the stump underneath the flap. It is aspirated using a wide bore needle. Haematoma may delay healing; may precipitate infection or flap necrosis due to pressure. After aspiration, pressure dressing is needed. If haematoma reforms after 2–3 aspirations, it should be drained by opening the wound on one corner and inserting haemostat into the wound.

### Infection of the Stump

It may cause abscess formation, delay in wound healing, flap necrosis, giving way of the wound. Removing few or all sutures to relieve pressure and draining the pus underneath is needed. Infection may also lead into poor scar, adherent scar which causes difficulty in placing the prosthesis.



**Fig. 1.600:** Above-knee amputation stump having small sinus.

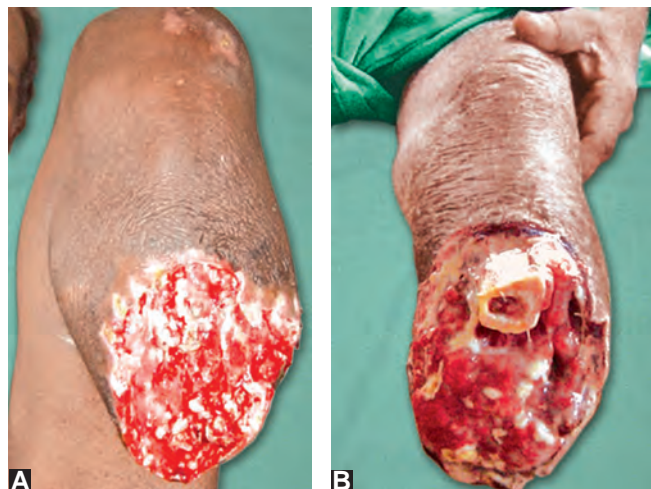
### Flap Necrosis

It is a *common* complication. Main causes for flap necrosis are poor blood supply, infection, haematoma underneath, inadequate length of the flap causing stretching of flap. Small area of necrosis can be excised. Wider area needs laying opening of the wound or revision of the stump or higher level amputation. Anaemia, poor nutrition, nutritional deficiencies, diabetes mellitus, immunosuppression, smoking, old age are other factors causing flap necrosis.

### Stump Neuroma

It can occur due to proliferation of the nerve fibrils beyond the point of nerve division and is usually due to failure of cutting of the nerve more proximal to the level of division of the bone. It

causes pain and tenderness over the stump. It is usually relieved by analgesics, re-assurance and prosthesis. Occasionally, it may require re-exploration of the wound, excision of end neuroma and also cutting nerve more proximally.



**Figs 1.601A and B:** (A) Below-knee amputation stump infected. (B) Tibia is exposed.

### Stump Pain after Amputation

It is a *common problem*. Causes are—infection, poor blood supply, causalgia, stump neuroma, phantom pain/limb, deep vein thrombosis, adherent scar, formation of spurs and osteophytes at amputated bone end. Scar adhesion to bone is prevented by keeping adequate length of deep fascia underneath intact. Spurs and osteophytes are confirmed by X-ray and needs removal using bone nibbler after appropriate skin incision.

### Phantom Limb

It is *typical* awareness of sensation that as if amputated part is still present *partly or in toto*; often such part may be painful or disturbing or hyperaesthetic. Exact cause is not known; but it is probably due to presence of severe pain at the amputated part just prior to amputation making brain area for that part in alert situation causing phantom limb. Reassurance, prosthesis, analgesics help to control the condition. It is said that it can be prevented by proper pain control for 24 hours prior to amputation; but it is often difficult. It is common in upper limb.

### Ulceration over the stump

It is *not uncommon*. It is due to necrosis, infection, lengthy bone stump pressing on the summit of the flap, prosthesis, nutritional deficiencies, diabetes mellitus, ischaemia. Ulcer may be small/large; superficial/deep. Callous chronic ulcer at the end of the stump is called as *Douglas ulcer*. Small ulcer is later treated by regular dressings and suturing. Large ulcer needs flap to cover the defect. *Osteomyelitis of the stump*

should be ruled out in chronic stump ulcer. *Ring sequestrum* may be typical in such situation. Revision amputation is needed for the stump.

### Contracture of the Joint

Contracture of the joint proximal to the amputated stump is *common*. It is mainly due improper positioning after amputation due to pain, poor exercise and occasionally due to inflammation of surrounding soft tissues. Contracture interferes with proper fitting and functioning of the prosthesis and delays rehabilitation. Proper positioning, passive stretching and exercises, strengthening exercises with help to correct it. Rarely needs surgical release of the contracture.

### Other Complications

- ◆ Scar hypertrophy, skin thickening, hyperkeratosis, papilloma, eczema, lymphoedema, boils, bursae over bony point can occur which are treated accordingly.
- ◆ Spur, osteophyte formation, causalgia, jactitation of the stump, stump aneurysm, stump fracture—are other complications.

## PROSTHESIS

*It is the substitution to a part of the body to achieve its optimum function.*

(Orthroses are supplement for limb function.)

### In Lower Limb

- ◆ *Syme's amputation*: Elephant boot, Canadian Syme's prosthesis.
- ◆ *Below-knee amputation*: Patellar-tendon bearing (PTB) prosthesis and solid ankle cushion heel (SACH).
- ◆ *Above-knee amputation*: Suction type prosthesis. It is placed above the stump. It is better and well-tolerated.
- ◆ *Nonsuction type prosthesis*: It is placed at the ends. It requires additional support.
- ◆ *Hind-quarter amputation*: Tilting table prosthesis (TTP) or Canadian prosthesis is used here.
- ◆ *Patellar tendon-bearing prosthesis (PTB prosthesis)*: Here all the weight bearing is done below knee; movement is controlled by his own knee joint. Patellar tendon is the main key weight-bearing area within the socket; stump posteriorly up to the popliteal fossa is also important to provide counter pressure so that patellar tendon is kept in place. Medial and lateral paratibial areas and medial condylar flare also bear significant weight. Head of the fibula, tibial tubercle, cut ends of tibia and fibula are pressure intolerant areas. Socket should have proper relief areas to these intolerant parts.
- ◆ *Computer-assisted designing and computer-assisted manufacturing (CAD – CAM) socket* is an automated processing method

which fulfills all above criteria accurately with modifications. It is more comfortable and is made up of thermoplastic or laminated plastic with closed cell polyethylene foam.

- ◆ Suspension for below knee amputation prosthesis is leather cuff strap above femoral condyles. Exo- or endoskeleton is used. For athletics endoskeleton is preferable.
- ◆ *SACH (Solid Ankle Cushion Heel) foot* is used. It is multiaxial, optimizes gait, and facilitates walking on rough ground. It needs minimal maintenance. It is preferred in old people. Energy storing foot is often used wherein ankle joint is replaced by a plastic spring.

### In Upper Limb

1. Above-elbow prosthesis is a high technology prosthesis. It is sophisticated device with harness, socket, elbow joint unit, control cable, forearm and wrist device.
2. Below-elbow prosthesis.  
Krukenberg's amputation does not require any prosthesis.

### Advantages of Prosthesis

- ◆ Cosmetic.
- ◆ Function of the part relatively can be got.
- ◆ Ambulation in lower limb prosthesis.

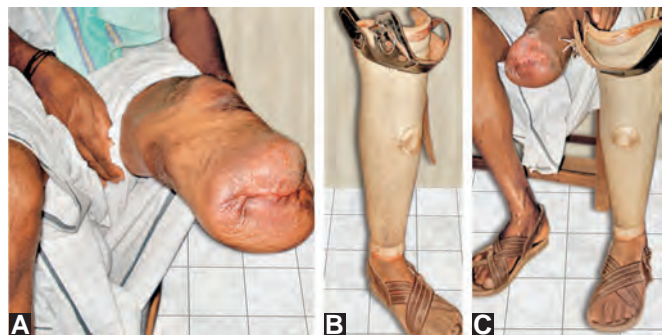### Disadvantages

- ◆ Infection.
- ◆ Pressure ulcers.
- ◆ Joint disability.

### Prosthesis Types

- ◆ Exoskeletal prosthesis.
- ◆ Endoskeletal prosthesis with modular system.

**Internal prostheses** are one used inside. They are placed by open surgery. They are nonreactive, long-durable materials, e.g. hip prosthesis in total hip replacement.



**Figs 1.602A to C:** Below-knee amputee with prosthesis. It gives good range of movements, normal walk and comfort.

# U. Reconstruction

## CHAPTER OUTLINE

- ❖ Graft
- ❖ Skin Grafts
- ❖ Flaps
- ❖ Tendon
- ❖ Tendon Repair
- ❖ Tendon Transfer
- ❖ Tendon Graft

### GRAFT

**Graft:** It is transfer of tissue from one area to other without its blood supply or nerve supply.

**Autograft:** It is tissue transferred from one location to another on the same patient.

**Isograft:** It is tissue transfer between two genetically identical individuals, i.e. between two identical twins.

**Allograft:** It is tissue transfer between two genetically different members, e.g. kidney transplantation (Human to human) (Homograft).

**Xenograft:** It is tissue transfer from a donor of one species to a recipient of another species (Heterograft).

### SKIN GRAFTS

*We bring back, refashion, and restore to wholeness the features which nature gave but chance destroyed, not that they may charm the eye but that they may be an advantage to the living soul, not as a mean artifice but as an alleviation of illness, not as becomes charlatans but as becomes good physicians and followers of the great Hippocrates. For although the original beauty of the face is indeed restored, yet this is only accidental, and the end for which the physician is working is that the features should fulfill their offices according to nature's decree.*

—Gaspere Tagliacozzi, 1597

**Skin Grafting:** It is transfer of skin from one area (donor area) to the required defective area (recipient area). It is an autograft.

### Types

#### 1. PARTIAL THICKNESS GRAFT (Split-thickness skin graft—SSG)

Also called as *Thiersch graft*, is removal of full epidermis + part of the dermis from the donor area.

It may be:

- ◆ *Thin SSG.*
- ◆ *Intermediate SSG*, all depends on the amount of thickness of dermis taken.
- ◆ *Thick SSG.*

### Indications

- ❖ Well-granulated ulcer
- ❖ Clean wound or defect which can not be apposed
- ❖ After surgery to cover and close the defect created. For example:
  - After wide excision in malignancy
  - After mastectomy
  - After wide excision in squamous cell carcinoma
  - Graft can survive over periosteum or paratenon or perichondrium

### Prerequisite

- ❖ Healthy granulation area
- ❖  $\beta$ -haemolytic streptococci load less than  $10^5$  per gram of tissue, otherwise graft failure will occur

### Contraindications

*SSG can not be done over bone, tendon, cartilage, joint.*

### Technique

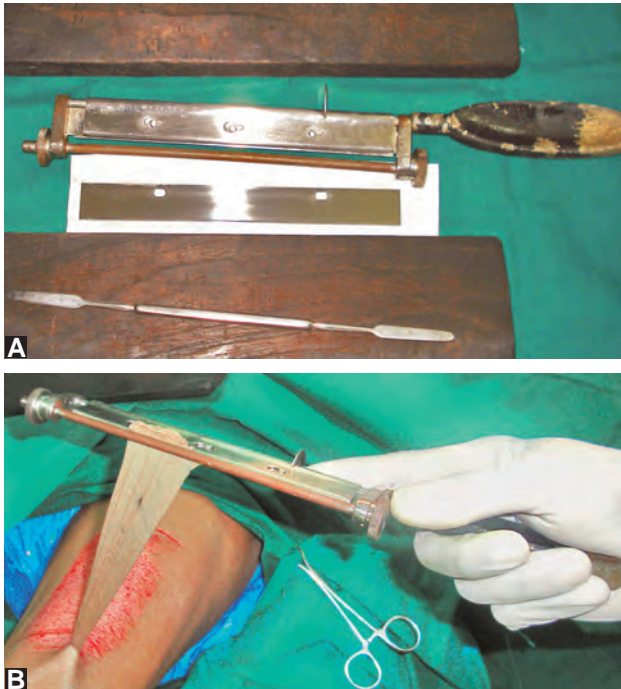
- ◆ **Donor area:** Commonly *thigh*, occasionally arm, leg, forearm.
- ◆ Knife used is *Humby's knife*.
- ◆ Blade is *Eschmann blade*, *Down's blade*.
- ◆ Using Humby's knife graft is taken, punctate bleeding is observed which says that proper graft has been obtained.

### Different instruments used to harvest the skin graft

- ❖ Humby's knife
- ❖ Watson modification of Humby's knife
- ❖ Power dermatome is also used (Brown)
- ❖ Sterilised razor blade can be used with a specialised device to harvest small grafts under local anaesthesia

- ▶ **Donor area** is dressed and dressing is opened *after 10 days*, not earlier.
- ▶ **Recipient area** is scraped well and the graft is placed after making window cuts in the graft to prevent the development of seroma. Graft is fixed and *tie-over* dressing is placed. If graft is placed near the joint, then the part is immobilised to prevent friction which may separate the graft. On *5th day*, dressing is opened and observed for graft take up. *Mercurio chrome* is applied over the recipient margin to promote epithelialisation.

*Happiness is not destination, it is a manner of travelling.*



Figs 1.603A and B: Split skin grafting knife and set; and harvesting.

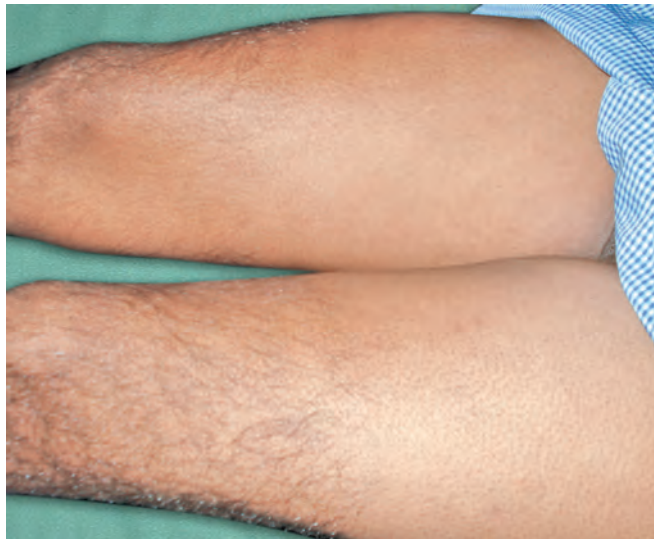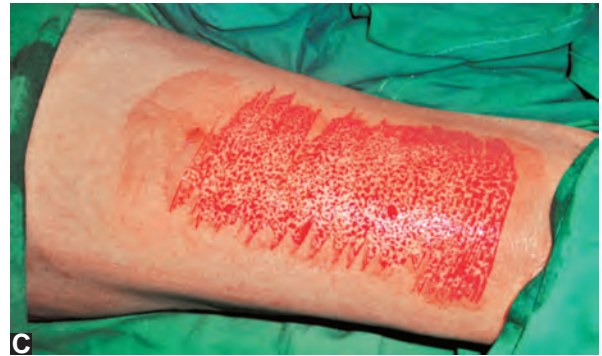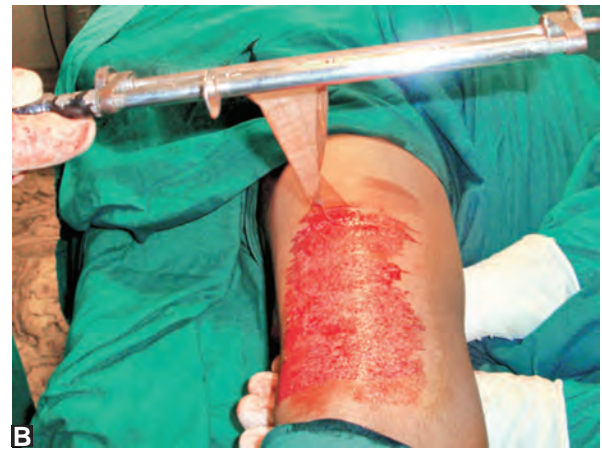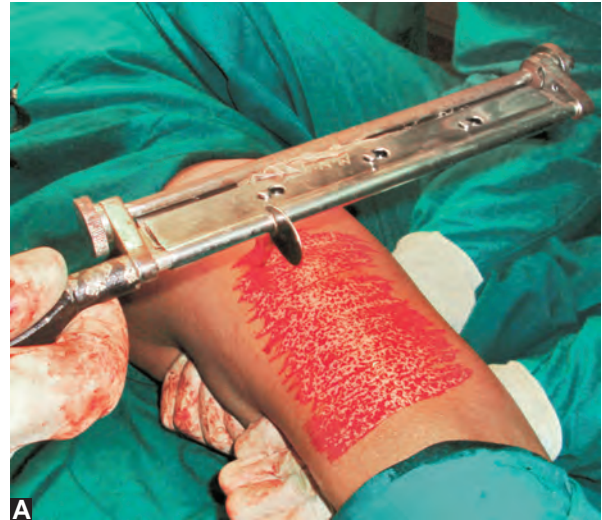


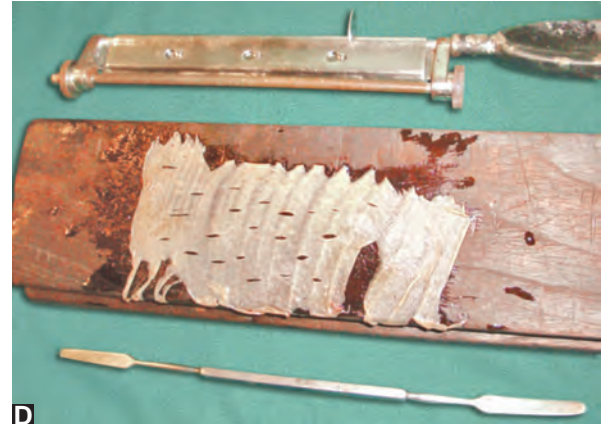
Fig. 1.604: Commonest donor area for split skin grafting is thigh.

### Stages of Graft Intake

1. *Stage of plasmatic imbibition*: Thin, uniform, layer of plasma forms between recipient bed and graft.
2. *Stage of inosculation*: Linking of host and graft which is temporary.
3. *Stage of neovascularisation*: New capillaries proliferate into graft from the recipient bed which attains circulation later.

#### Note:

Graft is stored at low temperature of 4°C for not more than 21 days.



Figs 1.605A to D

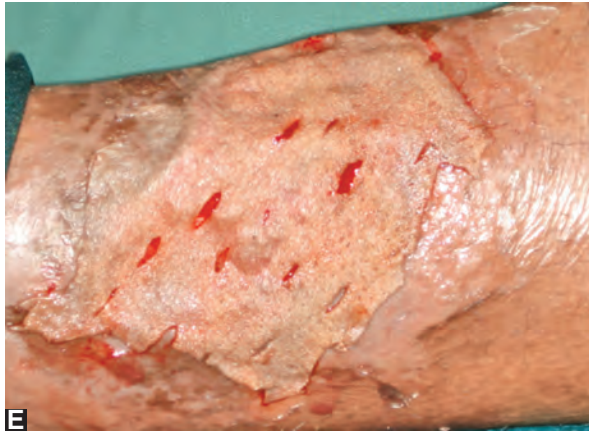
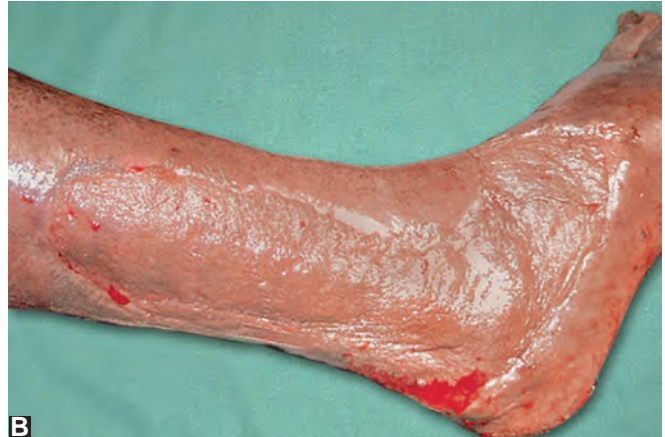
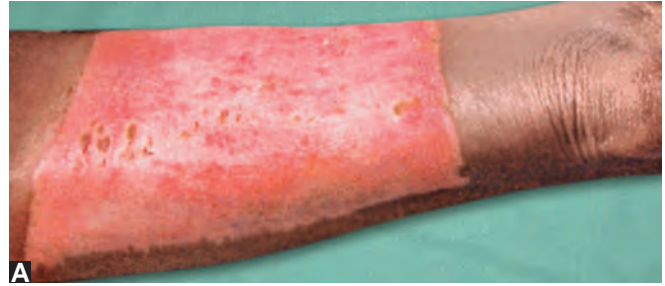Fig. 1.605E

Figs 1.605A to E: Technique of split skin grafting.



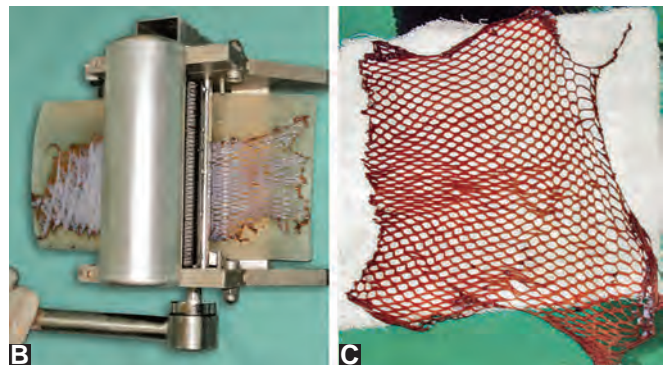
Figs 1.609A and B: Donor area of split skin graft in the thigh and graft placed over raw area in the leg.

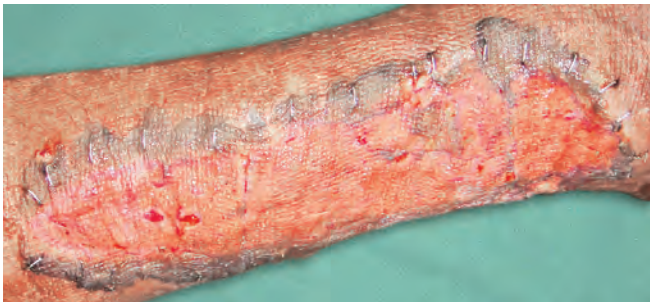

Fig. 1.606: Skin stapler can be used to fix the SSG to the margin of the recipient bed.



Fig. 1.607: Humby's knife with Eschmann blade.



Figs 1.610A to C: Mesher used in split skin grafting to increase its surface area to cover wider area like burns wound. A large defect can be covered by this. It can cause expansion of skin up to six times.

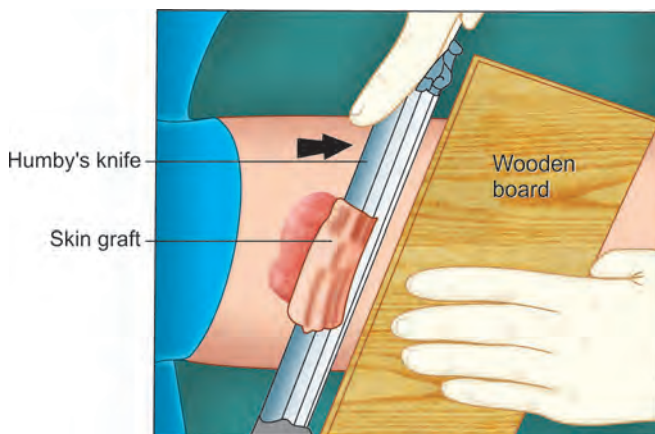


Fig. 1.608: Harvesting a skin graft.

## Disadvantages of SSG

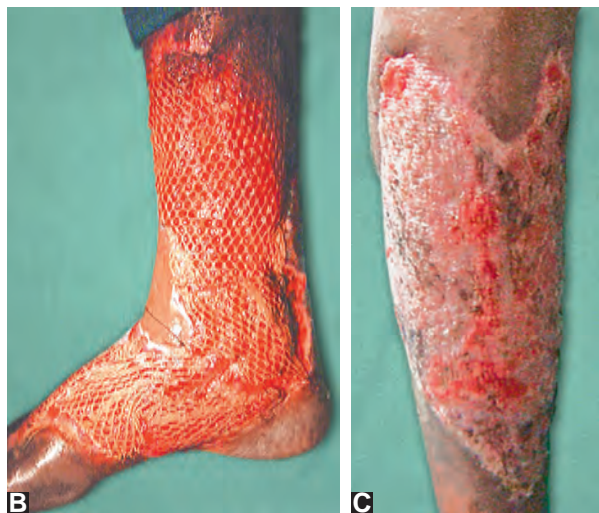- ◆ **Contracture of graft.** Two types:
  - A. *Primary contracture* means SSG contracts significantly once graft is taken from donor area (20–30%). Thicker the graft more the primary contracture.
  - B. *Secondary contracture* occurs after graft has taken up to recipient bed during healing period, due to fibrosis. Thinner the graft more the secondary contracture.
- ◆ *Seroma and haematoma* formation will prevent graft take up.
- ◆ *Infection.*
- ◆ *Loss of hair growth, blunting of sensation.*
- ◆ *Dry, scaling of skin* due to nonfunctioning of sebaceous glands. So after healing, oil (coconut oil) should be applied over the area.
- ◆ *Graft failure.*

## Advantages

- ◆ Technically easier.
- ◆ Wide area of recipient can be covered. To cover large area like burns wound, graft size is increased by passing the graft through a **Mesh** which gives multiple openings to the graft, which can be stretched on the wider area like a net. It can cause expansion up to 6 times.



A



B

C

**Figs 1.611A to C:** Mesh graft placed over donor area and photo of it, once it takes up.

- ◆ Graft take up is better.
- ◆ Donor area heals on its own.

### Note:

Mercurochrome/merbromin once used as a local applicant to the edge of the grafted area (SSG) and small raw areas to promote epithelialisation. It is applied once a day. But it is no longer used now.

## 2. FULL THICKNESS GRAFT (Wolfe Graft)

- ◆ It includes *both epidermis + full dermis.*
- ◆ It is used over the face, eyelid, hands, fingers and over the joints.
- ◆ It is removed using *scalpel blade.* Underlying fat should be cleared off properly. Deeper raw donor area is closed by primary suturing. If large area of graft is taken, then that donor area has to be covered with SSG which is a disadvantage in full thickness graft.

### Common sites of donor area

- ❖ Post-auricular area
- ❖ Supraclavicular area
- ❖ Groin crease area

## Advantages

- ◆ Colour match is good. Especially for face.
- ◆ No contracture (unlike in SSG).
- ◆ Sensation, functions of sebaceous glands, hair follicles are retained better compared to SSG.
- ◆ Functional and cosmetic results are better.

## Disadvantages

- ◆ It can be used only for small areas.
- ◆ Wider donor area has to be covered with SSG to close the defect.

### Other grafts

- ❖ Composite graft which includes skin + fat + other tissues like cartilage
- ❖ Tendon graft
- ❖ Bone graft
- ❖ Nerve graft
- ❖ Venous graft
- ❖ Corneal graft
- ❖ Combined graft (allograft + autograft)
- ❖ *Reverdin graft* (Jacques-Louis Reverdin, Swiss surgeon): It is a pinch graft taken from the skin and seeded in to the needed raw area.

## ■ FLAPS

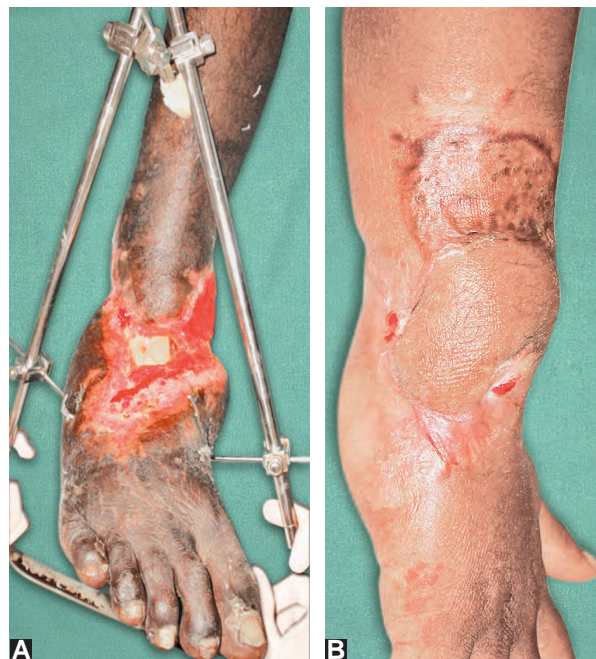It is transfer of donor tissue with its blood supply to the recipient area.

### Parts of Flaps

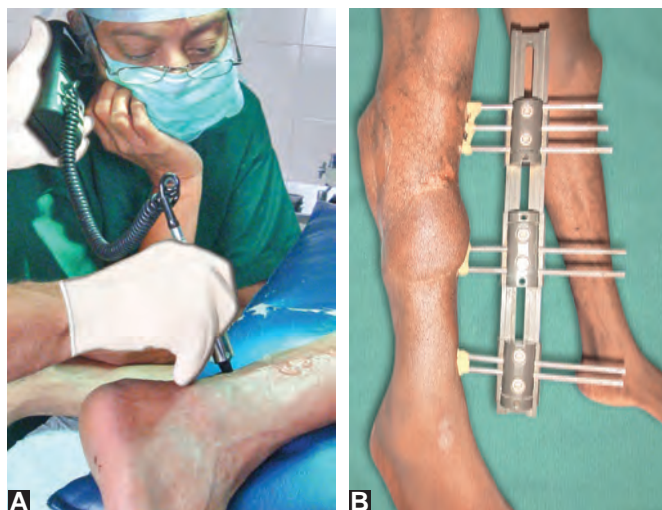
*Base, pedicle, tip of flap.* Vasculature is usually through the pedicle in the centre of the flap. Tip is the place where often flap goes for necrosis.

### Indications

- ❖ To cover the wider, deeper defects
- ❖ To cover over bone, tendon, cartilage
- ❖ If skin graft repeatedly fails



**Figs 1.612A and B:** (A) Traumatic exposure of the bone. Flap is needed to cover this defect. It could be cross leg flap or rotation flap. Skin grafting is not possible in this situation, (B) Flap which has taken up well-placed over the defect on the bone with osteomyelitis.

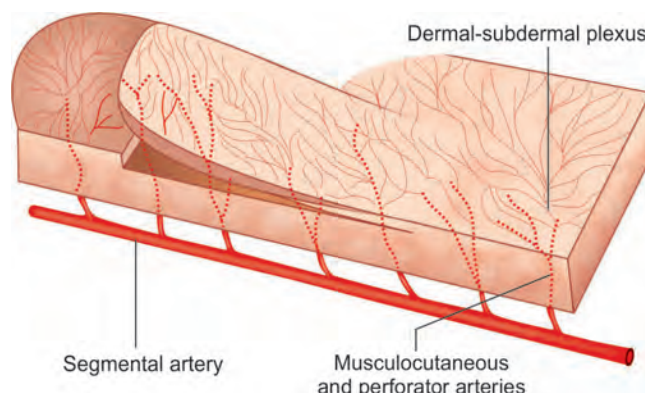


**Figs 1.613A and B:** (A) Hand-held Doppler to hear audible signal of perforator to do rotation flap in the leg, (B) Different methods of immobilisation is needed for flap and SSG. Fixation is often used in limbs.

## Types

1. *Random pattern flaps:* Here vascular basis is subdermal plexus of blood vessels. No known blood vessel is supplying it. Rectangular flap with length to width ratios 1 : 1 or less than 1.5 : 1.

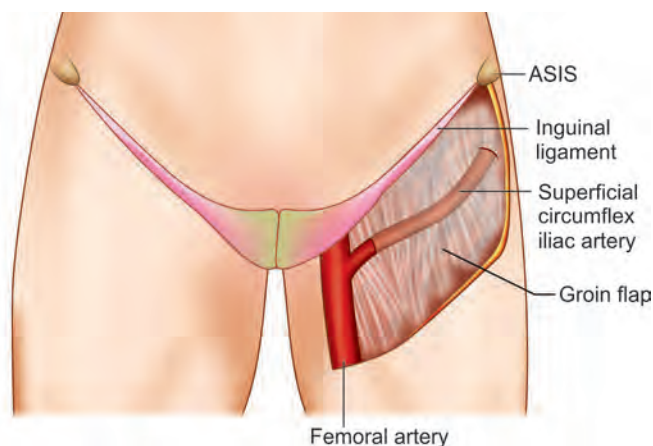
2. *Axial pattern flaps:* Here superficial vascular pedicles pass along their long axes, e.g. forehead flap, deltopectoral flap, groin flap. Anatomically a known blood vessel is supplying it. It is long lengthy flap.



**Fig. 1.614:** Anatomy and blood supply of a skin flap.

## Anatomical types depending on the types of tissue in the flap:

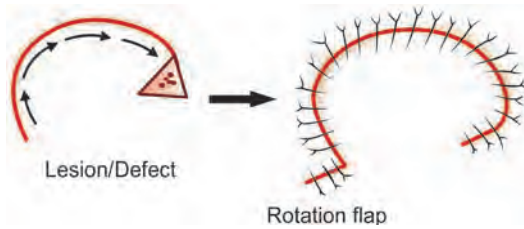
1. *Cutaneous flap:* Forehead flap, deltopectoral flap.
2. *Fasciocutaneous flap:* Radial forearm flap, scapular flap, lateral arm flap, groin flap.



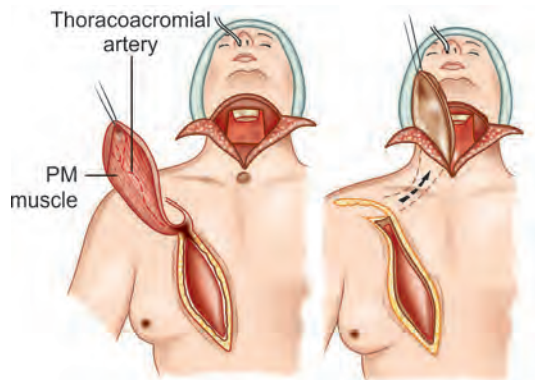
**Fig. 1.615:** Groin flap is based on superficial circumflex iliac artery. It can be used in defects in hand and forearm. It is a cutaneous flap.

3. *Muscle flap:* Gluteus maximus muscle flap, gracilis flap, tensor fascia lata muscle flap.
4. *Myocutaneous flap:* Pectoralis major myocutaneous flap, latissimus dorsi flap—composite flap.
5. *Osteomyocutaneous flaps:* Radius with brachioradialis and skin, rib with intercostal muscles and skin—composite flap.
6. *Local rotation flaps, transposition flaps:* When the flap moves laterally it is called as transposition flap. When the flap rotates laterally towards defect it is called as rotation flap. Transposition flap is squarely designed which moves laterally to close the defect creating a larger area on its original place which has to be covered with split skin graft.

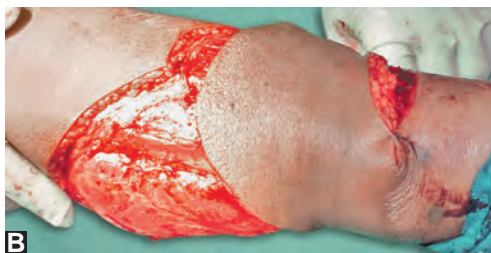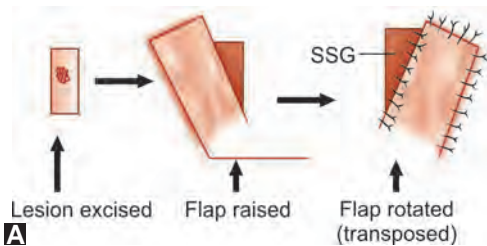




**Fig. 1.616:** Rotation flap. It is commonly used in gluteal region in managing bedsores.

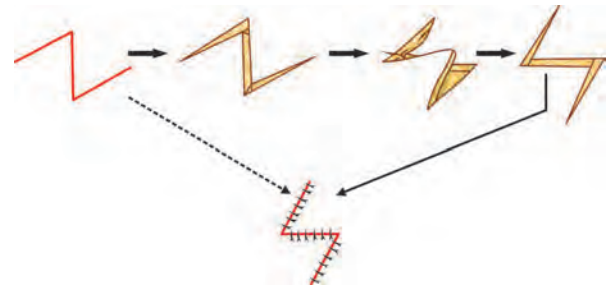


**Fig. 1.617:** Pectoralis major myocutaneous flap.

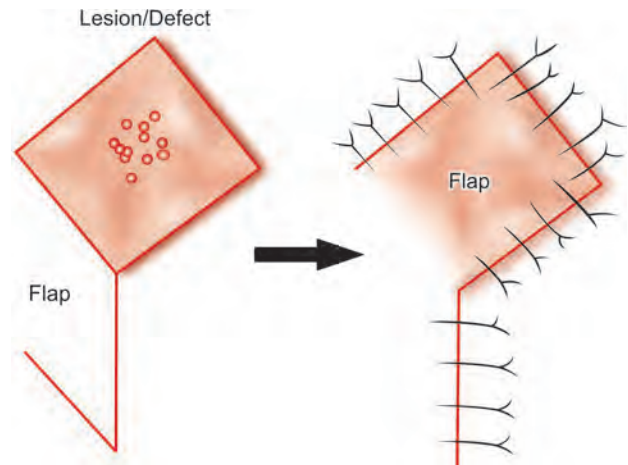


**Figs 1.618A and B:** Transposition flap.

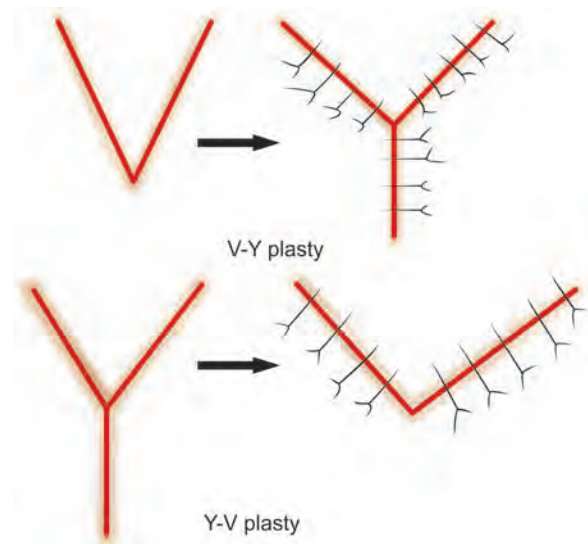
7. *'Z' plasty*: It is a procedure which involves transposition of two interdigitating triangular flaps. There is change in direction as well as gain in length of the common limb of Z. Angle size and length of the limb are the most important factors. It is used in managing contracted scars, facial scars, Dupuytren's contracture and to cover the excised defects like pilonidal sinus (example). There should be transverse skin slack available equal to the length between the axes of Z. It can be single or multiple Z plasty. Complications are flap necrosis near the angle tip, infection, failure.
8. *Free flaps*: Vascular pedicle of the flap, both artery and vein are anastomosed to recipient vessels using operating binocular microscopes.
9. Omental flaps.
10. *Island flap*: Localised flap is swung around a stalk from the donor area to the recipient area often with the pedicle buried underneath the skin bridge in between. Pedicled flap is also an island flap.



**Fig. 1.619:** Technique of 'Z' plasty. It is used in contracture release. Dupuytren's contracture and pilonidal sinus.



**Fig. 1.620:** Rhomboid flap



**Fig. 1.621:** Technique of V-Y plasty and Y-V plasty.

#### Areas where flaps are commonly used

Oral cavity, neck, breast, limbs (leg), buttock, bedsores.

#### Note:

- Flaps mobilised from donor area with its pedicle is placed and sutured to recipient area. Once flap takes up usually in 3–6 weeks, base of the flap is cut and sutured to recipient area.

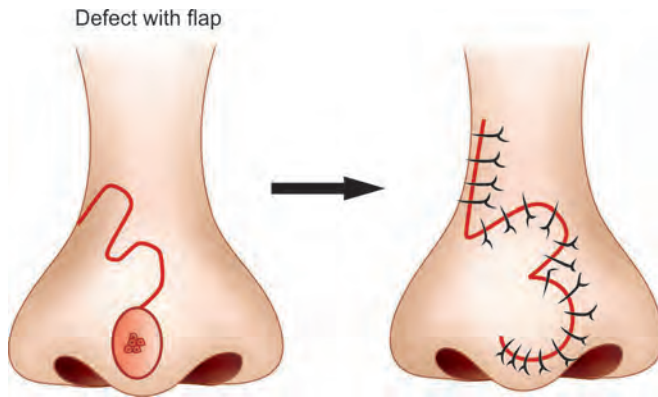


Fig. 1.622: Bilobed flap is used in lesions of the nose commonly.

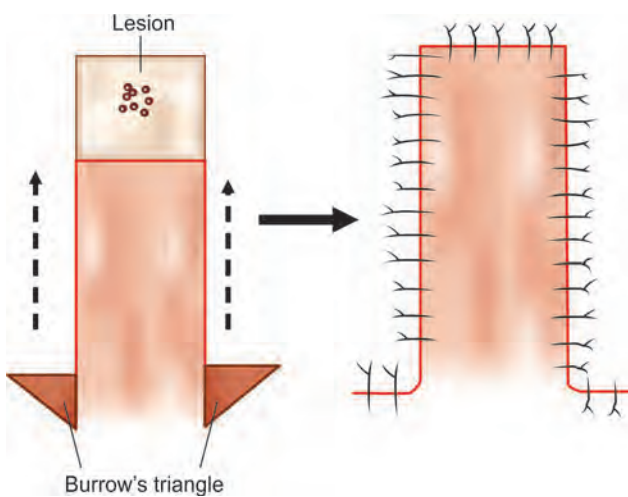


Fig. 1.623: Advancement flaps, used in distal defects.

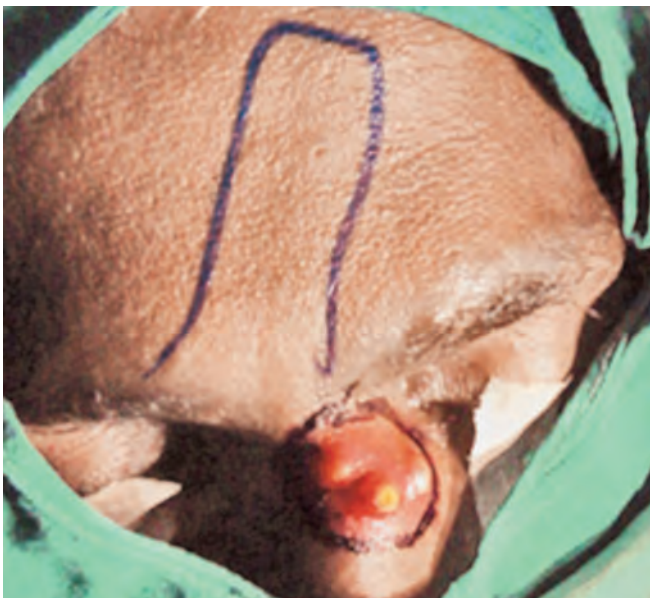

Fig. 1.624: On table marking of glabellar flap to place after excising a lesion in the root of the nose.

- **Saltatory flap** is mobilising the flaps in stages from distant donor area towards recipient area. It requires many staged surgeries and long-term hospitalisation.
- **Waltzing** is a technique wherein flap is moved from donor area and attached adjacent to the recipient defect area. Later in 2nd stage, it is moved towards the defect formally. It reduces the tension on the flap and increases the success rate.

#### Advantages of flaps

- ❖ Good blood supply, good take up
- ❖ Gives bulk, texture, colour to the area
- ❖ Allows required movements in the recipient area. For example, jaw movements after pectoralis major flap after wide excision with hemimandibulectomy for carcinoma cheek
- ❖ Cosmetically better.

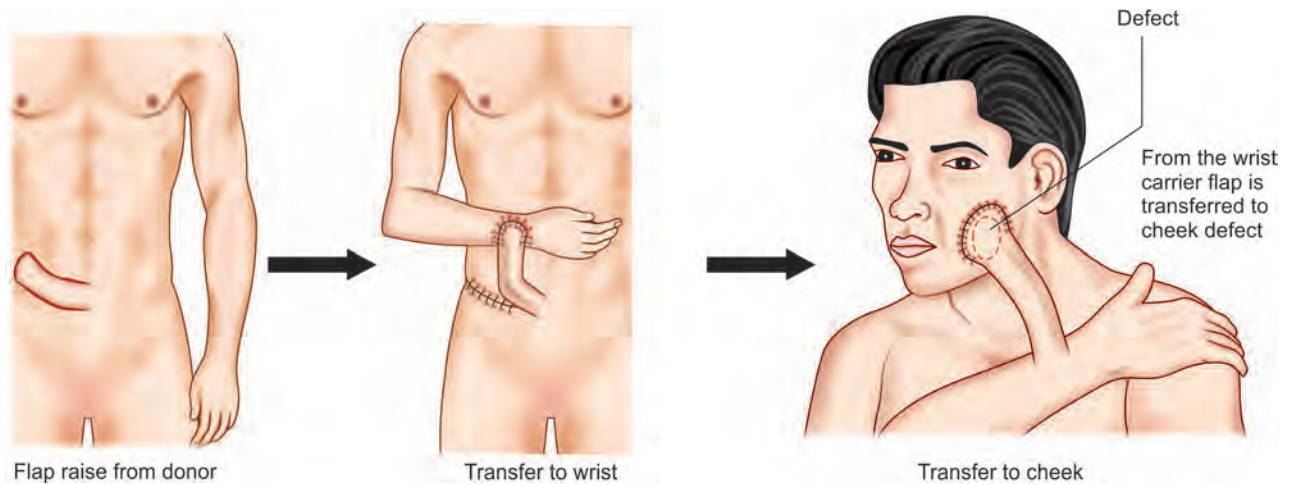
#### Disadvantages of flaps

- ❖ Long-term hospitalisation
  - ❖ Infection
  - ❖ Kinking, rotation and flap necrosis
  - ❖ Staged procedure
- **Positioning of the patient** for long time is important to have a good flap take up which is a real discomfort to the patient.
  - **Delaying of the flap** after mobilisation is done to reorient its blood supply so as to decrease flap necrosis and increase flap survival. Delaying period is 10–14 days. Flap is raised properly as required and resutured to same place so as to allow the formation of reorientation of vasculature near the tip of the flap. This delayed flap is raised again in 10-14 days to place in required area.

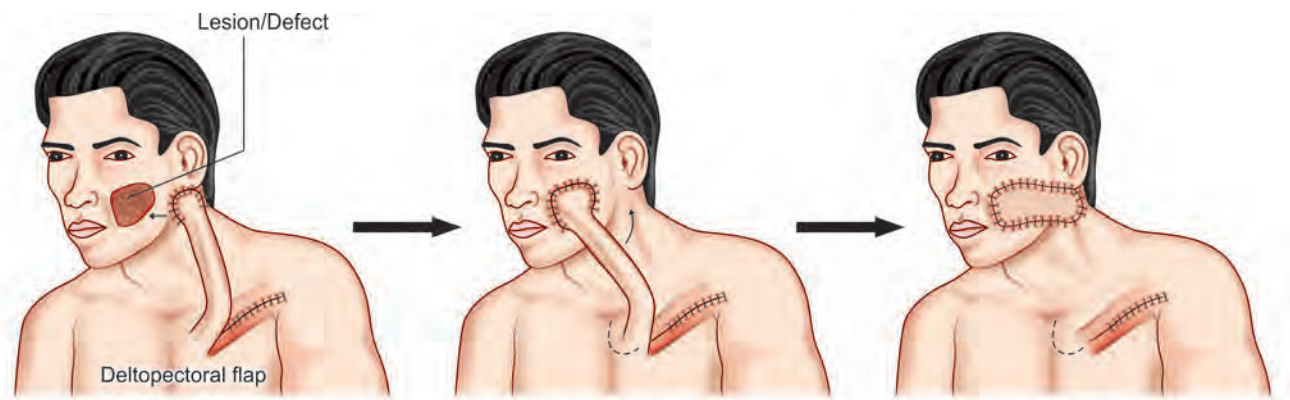### Different Flaps Used are:

#### Forehead Flap

- ◆ It is fasciocutaneous flap from forehead based on *anterior branch of superficial temporal artery*. Superficial temporal artery is terminal smaller branch of external carotid artery. It begins under the parotid behind the neck of mandible, runs vertically upwards, crossing the root of zygoma at preauricular point; 5 cm above the zygoma it divides into anterior and posterior branches. Anterior branch anastomoses with supraorbital and supratrochlear branches of ophthalmic artery. Artery supplies scalp of temple region and side, parotid, ear, facial muscles. Superficial temporal artery gives transverse facial artery which runs from anterior margin of parotid, and middle temporal artery which runs deep to temporalis muscle.
- ◆ It is used for defects in cheek (carcinoma, cancerum oris) and nasal reconstruction.
- ◆ *Standard forehead flap* is taken from forehead above the level of eyebrow starting from the opposite side of the midline with base just above the zygoma. Width of the flap is usually about 3–4 cm. Flap is dissected from the distal end of the marked area going deep up to epicranium, raising the flaps using scissor dissection. Flap is held up using skin hooks. Flap is rotated towards the defect area in the cheek. Inner area of the flap is covered with split skin graft. Donor flap area is covered with another split skin graft. After 3 weeks, base of the flap is disconnected; remaining proximal part of the flap can be replaced into forehead donor area. SSG over donor flap area takes up well. This flap often can be rotated under (deep to) the zygoma also.
- ◆ *A lined forehead flap* can be used. After flap elevation, under surface of the flap is lined by split skin graft prior to rotation. This



**Fig. 1.625:** *Saltatory flap*. Flap raised from the abdomen is reached to the cheek in stages—from abdomen to wrist; from wrist to cheek.



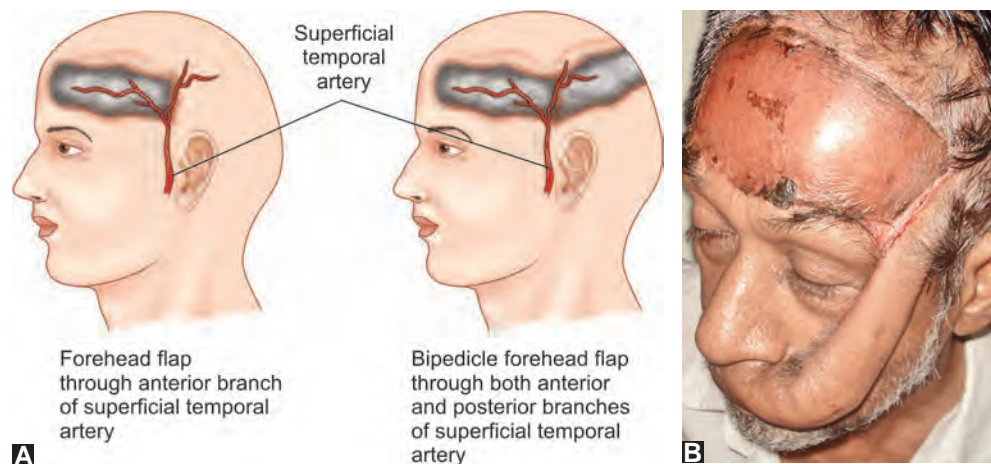
**Fig. 1.626:** Waltzing of flap.

grafted lined flap is resutured into the donor area for 2 weeks until undersurface of graft takes up well; after 2 weeks flap is rotated towards the defect area (cheek).

- ◆ *Delaying of the flap* is often done in forehead flap. Flap after elevation, is replaced into the original position to have optimum vascular reorientation; after 2 weeks it is again rotated towards defect. Delayed flap reduces the flap necrosis chances.

- ◆ Often bipediced forehead flap (*Narayanan's flap*) is used taking both from anterior and posterior branches of the superficial temporal artery. This flap is moved to defect in cheek with anterior branch part staying outside and posterior part will line the mucosal area.

- ◆ A different type—*middle forehead flap* is used for nasal reconstruction.

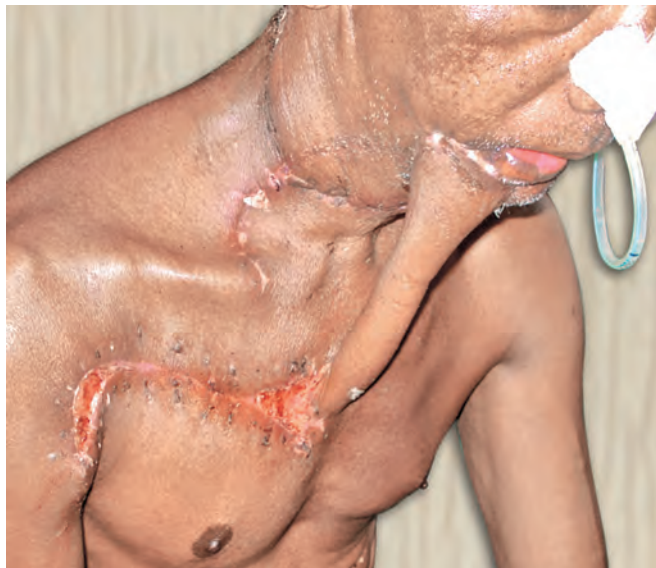

**Figs 1.627A and B:** Forehead flap based on superficial temporal artery. It is fasciocutaneous flap.

- ◆ **Problems**—Poor color match, contraction of flap and donor area is cosmetically nonacceptable.

#### **Deltopectoral cutaneous flap (Bakamjian flap)**

- ◆ It is based on first three perforating branches of the internal mammary artery (mainly 2nd perforator). Flap runs horizontally across the chest wall anteriorly towards shoulder tip from its base over the sternal border. Its upper border is along the line of the clavicle; its lower border is along the line of anterior axillary fold line. Raw area often requires a split skin grafting. It is usually rotated upwards often with waltzing. It is tubed and attached above. Tube is drained to prevent any collection to occur.

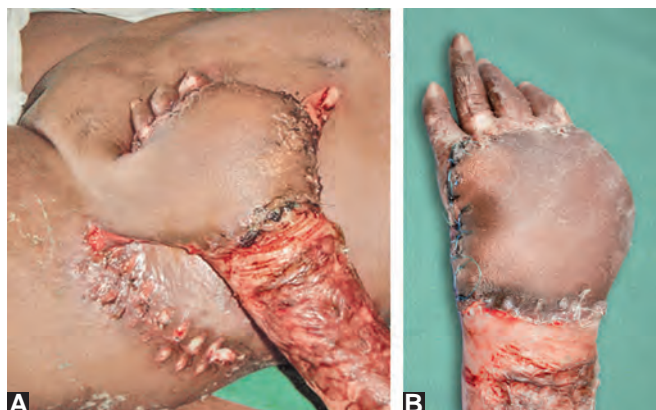


**Fig. 1.628:** Deltopectoral cutaneous flap.

- ◆ Rotation angle is important to prevent any kinking in the pedicle. It is usually used to cover the defects in cheek, chin, mastoid and parotid region. Often flap is delayed to get adequate length.

#### **Groin flap**

- ◆ It is based on superficial circumflex iliac artery which is 2–3 cm below and parallel to the inguinal ligament. Artery originates from femoral artery over medial border of the sartorius and ends at anterior superior iliac spine. 1:1 rectangular flap with deep fascia is used. Secondary defect can usually be closed with sutures. It is used mainly for defects in wrist/forearm where positioning is easier.



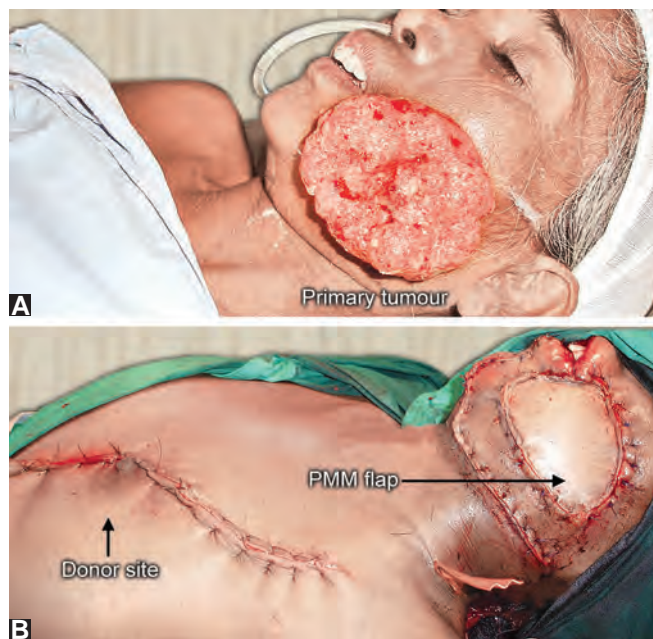
**Fig. 1.629A and B:** Groin flap used for burns defect in the hand.

#### **Latissimus dorsi muscle/myocutaneous flap**

It is based on thoracodorsal artery, a branch of subscapular artery. Skin over the upper and anterior border of latissimus dorsi is used for transfer. It is commonly used to cover the defect after mastectomy. But it does not give the bulk. It is technically easier. It can be used as muscle flap also. It helps as skin cover. Prosthesis is needed to place underneath to provide bulk in post-mastectomy defect.

#### **Pectoralis major myocutaneous flap (PMMF)**

It is based on the pectoral branches of thoracoacromial artery. Usually skin below and medial to nipple over the muscle is used. Muscle pedicle is made as broad as skin. It is used to cover the defect over the cheek/neck/pharynx/intraoral lesions after wide excision with removal of skin over the tumour. Vessel marking is 2 cm medial to coracoid process, obliquely below the clavicle at the junction between middle third and outer third. Skin with muscle is dissected from the deeper structures like ribs, intercostal muscles and pectoralis minor. Flap is raised upwards up to the coracoid. Lateral pectoral vessels if possible are retained, otherwise can be sacrificed. Defect below is usually closed primarily with sutures. Often it needs split skin grafting. Pectoralis major flap can be used along with deltopectoral flap with proper planning.



**Figs 1.630A and B:** Pectoralis major myocutaneous flap used for carcinoma cheek.

#### **Gastrocnemius muscle flap**

It is either medial or lateral and is commonly used to cover the upper part of the tibia and knee joint. It is technically easier and functional deficit occurring at donor area is insignificant. It is rarely used as myocutaneous flap.

#### **Transverse rectus abdominis muscle flap (TRAM flap)**

It is either superior pedicle based on the superior epigastric vessels or inferior pedicle based on the inferior epigastric vessels. Superior pedicle based flap is used to cover postmastectomy area or chest wall defect. To cover post mastectomy area opposite side superior pedicle is used to reduce the arc through which flap has to rotate (but rotating from opposite side is technically difficult). Inferior pedicle flap is used to cover the defects in groin and thigh. Proper

marking of the flap is essential. Skin incision is made like an ellipse. Anterior rectus sheath is cut in the line of incision and is raised upwards carefully of the rectus muscle up to the xiphisternum. Muscle is gently separated of the posterior rectus sheath with care not to injure the epigastric vessels. Once dissection is complete lower part of the muscle is cut in superior pedicle to rotate upwards carefully. In the upper part again anterior rectus sheath is opened to pass the flap towards the defect in subcutaneous plane. TRAM flap gives bulk and contour to the defect. But it is technically difficult. Usually opposite side of the defect is taken as flap as it is easier to rotate from opposite side. Defect in the abdomen usually needs mesh to support and close. It is not possible to do this flap in obese individuals and if patient has undergone laparotomy earlier (with a lengthy scar). Inferior cut end of the inferior epigastric artery in superior pedicle flap can be anastomosed to a vessel in recipient bed to improve the perfusion (*supercharging*). Inferior epigastric artery in inferior pedicle can be additionally perfused using opposite inferior epigastric artery (*recharging*).

#### Radial forearm flap

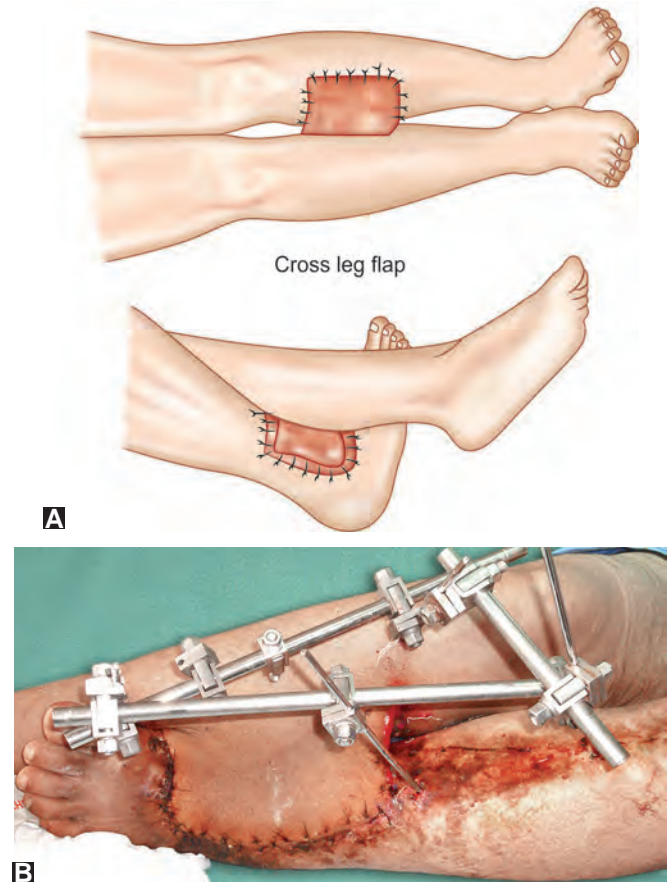
It is perfused from the radial vessels and raised on the flexor aspect of the forearm. Perforating branches of these vessels supply deep fascia and skin over it. Flap can be fasciocutaneous or osteofasciocutaneous/osteomyofasciocutaneous if radial bone is also used as part of the flap. Radial forearm free flap is commonly used for mandible defects. It is technically easier and safer. Flap is raised along with skin, segment of the radius along its intermuscular septum through which vessels pass and brachioradialis as components. Care is taken in dissecting vessels of the bed and not to injure the radial nerve. In free flap artery is sutured to the recipient artery like facial artery using microscope. Other similar flaps are—ulnar forearm flap, scapular flaps, and vascularised fibular transfer.

#### Limberg flap

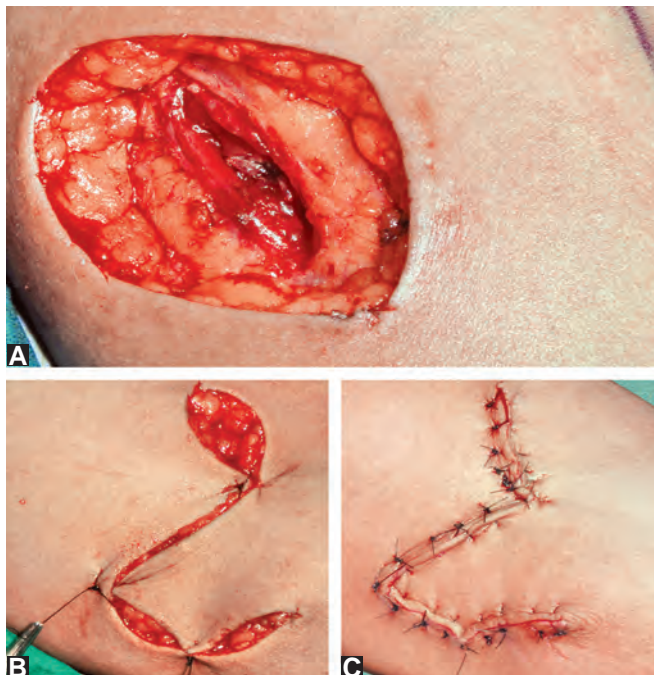
It is a type of rhomboid flap used in pilonidal sinus with base at gluteal skin.

#### Cross leg flap

It is commonly used to cover the defect in the foot/leg from opposite leg.



Figs 1.632A and B: Cross leg flap.



Figs 1.631A to C: Rhomboid flap used to cover the defect after excising a lesion in the arm.

## TENDON

- ◆ Tendon is the continuity of the muscle to have its action at the site especially in hand, foot and digits.
- ◆ It is covered by synovial sheath with a thin layer of fluid in between which allows smooth gliding of the tendon.

Tendon after injury heals by:

1. **Intrinsic healing method** occurs through synovial fluid when tendon is not under stress.
2. **Extrinsic healing method** occurs through proliferation of fibroblasts across epitenon. It occurs when tendon is under stress. It forms a mass of fibrous tissue at the site called as “*tenoma*”. It may interfere with the proper gliding of the tendon.

#### Stages of tendon healing

- ❖ By 21 days, weak healing occurs and contraction of muscle is possible
  - ❖ By 6 weeks, mild traction can be applied to the tendon
  - ❖ By 3 months, moderate stress can be used
  - ❖ By 8 months, full tensile strength is recovered
- ◆ Tendon injuries may be cut wound, lacerations, injury associated with nerve or vessel injury.

## TENDON REPAIR

1. **Primary repair** is done within 24 hours.
2. **Delayed repair** within a week after 24 hours.
3. **Secondary repair** anytime after one week.

### Types of Suturing the Tendon

1. **Kessler method.** Here knot comes in the cut part of the tendon.
2. **Goldner method.** Here knot comes away from the cut ends of the tendon.

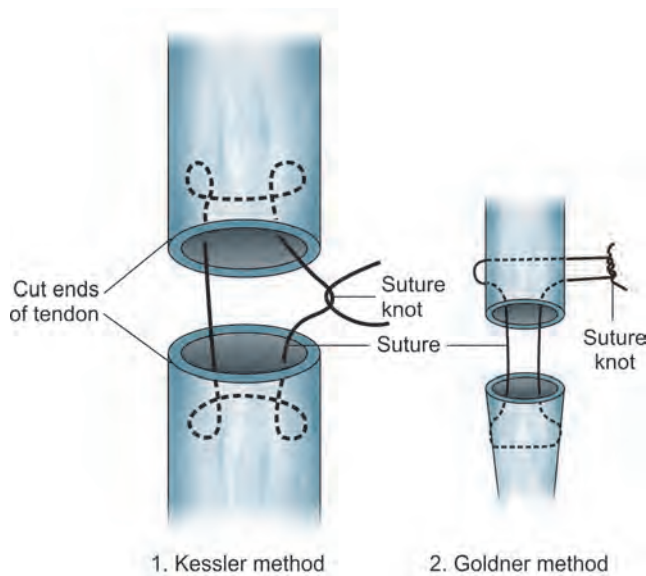


Fig. 1.633: Types of tendon suturing.

### Suture material

Suture material used is monofilament nonabsorbable suture material (polypropylene, 3 or 4 zero).

- ❖ Continuous sutures are used for suturing
- ❖ Epitenon can be later apposed with interrupted sutures
- ❖ Postoperative immobilisation is advised for 3–4 weeks
- ❖ Later passive and active exercise is done with the help of a physiotherapist

**Complications** of tendon suturing are infection, adhesion, stiffness and failure.

## TENDON TRANSFER

- ◆ It is the transfer of one tendon from its existing site to another site where its function is required to have a function required at the newer site.
- ◆ Function of the transferred tendon should be maintained by other tendons.
- ◆ Tendon should be able to acquire the function at the newer site properly.
- ◆ For example, in ulnar claw hand, the tendon of flexor digitorum superficialis (FDS) (of index finger) is transferred to lumbrical canal of the digits to have flexion at MCP joint and extension of proximal IP joint.

## TENDON GRAFT

- ◆ When tendon suturing or transfer is not possible because of inadequate length, tendon of a muscle which is not of much help functionally, is taken as a graft to obtain required length.

### Common grafts used are:

- ❖ Palmaris tendon in forearm
- ❖ Plantaris tendon in leg
- ❖ For example, extensor carpi radialis brevis (ECRB) is lengthened using tendon graft to transfer to lumbrical canals in claw hand

**Problems in tendon graft:** Infection, adhesions, graft failure, stiffness of the part.

# V. Transplantation

## CHAPTER OUTLINE

- ❖ Preoperative Evaluation
- ❖ Organ Procurement
- ❖ Graft Rejection
- ❖ Renal Transplantation
- ❖ Immunosuppressive Agents
- ❖ Liver Transplantation
- ❖ Bone Marrow Transplantation
- ❖ Pancreatic Transplantation
- ❖ Small Bowel Transplantation
- ❖ Dialysis
- ❖ Cimino Fistula

### ■ PREOPERATIVE EVALUATION

- ◆ General evaluation: Pulmonary, cardiac, GIT, renal status and cancer screening.
- ◆ Immunologic evaluation: Serology for hepatitis, HIV, cytomegalovirus.
- ◆ Placing the organ in the same position is called as orthotopic transplantation, e.g. liver.
- ◆ Placing the organ in new position is called as heterotopic transplantation.

### Donor Criteria

- a. *Cadaver donor*
- ▶ Individuals with severe brain injury resulting in brain death.  
Brain death is defined as “complete irreversible cessation of all brain functions”.

#### Criteria for brain death

- ❖ Absence of spontaneous respiration
- ❖ Absence of cranial reflexes
- ❖ Absence of response to stimuli
- ❖ Irreversible causes
- ❖ Absence of cerebral blood flow
- ❖ Isoelectric EEG
- ❖ Sustained apnoea with elevated CO<sub>2</sub>

Other criteria for cadaver donor:

- ◆ Normothermic patient.
  - ◆ No respiratory effort by the patient.
  - ◆ Brain—dead donor.
  - ◆ The heart is still beating.
  - ◆ No depressant drugs intake should be there while evaluating the patient.
  - ◆ Individual should not have any sepsis, cancer (except brain tumour).
  - ◆ Not a HIV or hepatitis individual.
- b. *Living donor*
- ▶ Living unrelated donor.
  - ▶ Living related donor.
  - ▶ Individual should have normal health.

### Requirements

- ◆ ABO typing.
- ◆ Serology tests.
- ◆ Angiogram.
- ◆ Intravenous urography.
- ◆ HLA typing.

### Human Leucocyte Antigens (HLA)

They are cell surface molecules which are highly antigenic. They play main role in graft rejection and hence called as *major histocompatibility complex/antigens* MHC) (Dausset, 1958). *Class I* are located in nucleated cells. *Class II* are located in dendritic cells/macrophages/B cells, etc.

#### Major histocompatibility complex (MHC)

- ❖ MHC is located in chromosome number 6
- ❖ Individual will have two HLA (*Human Leucocyte Antigens*) genes inherited from each parents, which together called as HLA types
- ❖ Class I— HLA is HLA-A, HLA-B and HLA-C. Intracellular antigens
- ❖ Class II—HLA is HLA-DP, HLA-DQ and HLA- DR. Extracellular antigens
- ❖ HLA-DR is most important in kidney transplantation

#### Principles of donor organ retrieval

- ❖ Adequate exposure is needed
- ❖ Control of the vessels above and below the organs to be removed is done
- ❖ Initiation of preservation *in situ*
- ❖ Removal of the organs, and separation
- ❖ Completion of preservation
- ❖ Removal of iliac vessels for vascular reconstruction of pancreas and liver grafts
- ❖ Organ packaging

### ■ ORGAN PROCUREMENT

#### Principles of Organ Procurement

- ◆ Once brain death has been confirmed in cadaver donor, after giving inotropic support drugs (T3 and argipressin) various

organs are surgically removed carefully with preservation of their vessels. After removal, organs are flushed with chilled preservative solution (in specific organ procurement like of kidney, *in situ* perfusion of organs (kidneys) is done by placing double balloon catheter into the abdominal aorta and a balloon catheter into the femoral vein) and placed in sterile bags containing saline and organ preservative solutions which are then immersed in 0–4°C box containing ice. Donor specimens are transported to the site of the recipient centre. *Wisconsin and Euro-Collins solutions* are commonly used.

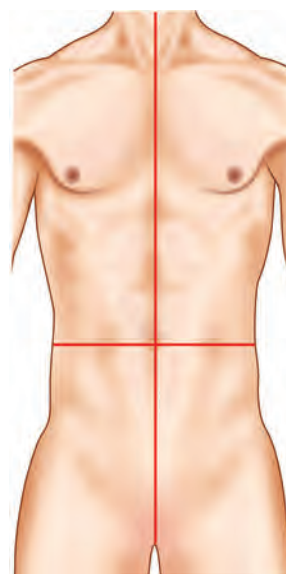
- ◆ *Non-heart beating donors (NHBD)*—here organs are procured from individuals who are just dead on arrival to the hospital or who have died in the hospital in spite of resuscitation. *Category I*—Dead on arrival; *Category II*—Unsuccessful resuscitation; *Category III*—‘Awaiting cardiac arrest’ after support withdrawal; *Category IV*—Cardiac arrest with brain death.
- ◆ *University of Wisconsin solution* contains—potassium lactobionate; sodium phosphate; magnesium sulphate; adenosine; allopurinol; glutathione; raffinose; hydroxyethyl starch; insulin; dexamethasone; potassium; sodium; with 320 mosmol/l osmolality and pH of 7.4.
- ◆ *Living donor’s organs* are used commonly in kidney transplantation from genetically related individuals. It can be used from genetically unrelated donors after proper MHC match. Donor nephrectomy is done through loin incision (commonly from left side). Laparoscopic donor nephrectomy has become popular and safe.

## Technique of Organ Procurement

- ◆ *Positioning the donor on the operating table:* Supine position, with arms abducted on boards and legs laid flat and uncrossed. The neck is extended by placing a sandbag under the shoulders (as during thyroidectomy).
- ◆ Midline sternotomy incision is used extending up to the pubic symphysis with a supraumbilical horizontal part. Abdomen and thorax are exposed properly. Retroperitoneal right sided mobilisation is done (*Cattel-Braasch manoeuvre*). Cannulation of inferior mesenteric vein is done. Aortic cannulation is done. Perfusion of preservative solution is done.
- ◆ *Sequence of the thoracic organ procurement:* First the heart (care must be taken to leave enough supradiaphragmatic IVC for both organs such as the liver and the heart); then the lungs separately or together are procured. Cooling of the abdominal organ has to be continued until the last thoracic organ is procured.
- ◆ *Sequence of abdominal organ procurement:* The small bowel is the most sensitive organ for ischaemia; therefore, it is retrieved first. The second organ to be procured is the pancreas followed by the liver. Liver and the pancreas could also be retrieved *en block* and split on the back table. Finally, the kidneys are the last organs to be procured.
- ◆ The most popular tool kit comprises the iliac vessels, which consists of common, external and internal artery and the vein.

## Organ Packing in Steps (Eurotransplant or National Transplant Organisation)

The first bag is filled with a cold preservative solution. The procured organ must be completely covered by the preservative solution, and the bag must be closed (well tied) without any air. The second bag or a wax-impregnated fibre container is filled with cooled saline or



Incision from manubrium as sternotomy to pubic symphysis with a horizontal part above umbilicus

Fig. 1.634: Incision for organ procurement.

Ringer lactate solution. The first tied bag must be completely covered in one of the solutions and closed (well tied) without air. Third bag dry, without air, well tied and sometimes covered with a sterile drape is also used. Finally the organ is placed in an icebox and well covered with nonsterile melting ice, the box is firmly closed to make the organ ready for transportation.

## GRAFT REJECTION (TRANSPLANT REJECTION)

Host immune system rejects the transplanted organ, recognizing it as foreign body. Immunosuppressive drugs are used to suppress immune response to promote graft take up. In humans, the MHC is called the human leucocyte antigen (HLA) system and is located on the short arm of chromosome 6. The immune response to a transplanted organ consists of both cellular (lymphocyte mediated) and humoral (antibody mediated) mechanisms. The T cells (CD4, CD8 T cells) are central in the rejection of grafts. The rejection reaction consists of the sensitization stage and the effector stage. Initial nonimmunologic ischaemic injury which increases T cell antigen which through MHC initiates macrophage mediated delayed hypersensitivity and also helps B cells to produce antibodies. Cytokines, natural killer cells, apoptosis also play in graft rejection.

## Types of Rejections

1. *Hyperacute rejection:* The transplanted tissue is rejected within minutes to hours because vascularization is rapidly destroyed. Hyperacute rejection is humorally mediated as the recipient has preexisting antibodies against the graft, which can be induced by prior blood transfusions, multiple pregnancies, prior transplantation. The antigen-antibody complexes activate the complement system, causing massive thrombosis in the capillaries, which prevents the vascularization of the graft. The kidney is most susceptible to hyperacute rejection; the liver is relatively resistant.



2. **Acute rejection:** It occurs within 6 months of transplantation.
  - ▶ *Acute cellular rejection* is mediated by recipient lymphocytes against donor antigen.
  - ▶ *Humoral rejection* occurs due to presence of low level donor specific antibodies or preformed antibodies.
3. **Chronic rejection:** Chronic rejection develops months to years after acute rejection episodes have subsided. Chronic rejections are both antibody- and cell-mediated. The use of immunosuppressive drugs and tissue-typing has increased the survival in the first year, but chronic rejection is not prevented in most cases. Chronic rejection appears as fibrosis and scarring in all transplanted organs. In liver transplants, chronic rejection is characterized by the vanishing bile duct syndrome. In kidney recipients, chronic rejection (chronic allograft nephropathy) manifests as fibrosis and glomerulopathy. It is due to previous acute rejection, hypertension, improper immunosuppression, reperfusion injury, long cold ischaemic time, post-transplant infection.

## Treatment

- ◆ **Assessment and monitoring:** It is done by clinical examination; organ-specific assessment (urine output, urine analysis, creatinine estimation, US abdomen, graft kidney biopsy in kidney; liver function tests, liver biopsy); blood parameter estimation.
- ◆ **Immunosuppression:** Cyclosporine, tacrolimus, sirolimus, azathioprine, mycophenolate mofetil, antilymphocytic globulin, basiliximab, daclizumab, steroids, monoclonal antibodies are used at different regimes, combinations and doses. *Complications* are—infection; development of carcinoma, lymphoma; hirsutism, alopecia, hypertension, nephrotoxicity, neurotoxicity.

## IMMUNOSUPPRESSIVE AGENTS

### Induction Therapy

- ◆ It is used *immediately* after transplantation (up to 3 weeks).
- ◆ **Antilymphocytic globulin (ALG)**—human lymphocytes are injected into rabbit/horse to develop antisera—ALG. It acts against T cells. It inhibits cell mediated immunity, allograft rejection, graft versus host reaction. It is used in transplantation of kidney, pancreas, heart, small bowel. Anaphylaxis, anaemia, thrombocytopenia, allergy (*serum sickness*) are the reactions. Rabbit serum is better than horse serum in terms of preventing the graft rejection (acute). Rabbit serum has antibodies against CD2,3,48,11a,18,25; HLADR, HLA class I.
- ◆ **Monoclonal antibody**—OKT3 (1975 by Kohler, Milstein – got Nobel prize) is developed by hybridoma technique, is a monoclonal antibody which acts/blocks at TCR complex (T cell receptor complex CD3) affecting the function of native T cell and cell-mediated immunity. Within 60 minutes of IV injection of OKT3 it blocks T cell function removing the circulating T cells. Problem with OKT3 is its immune reactions. So often it is combined with steroid or indomethacin. It can cause acute *cytokine release syndrome*.
- ◆ **Interleukin 2 receptor (IL2 R) inhibitors**— $\alpha$  chain of IL 2 R is related to activated T cells. Basiliximab (chimeric) and daclizumab (human) are two anti-CD25 monoclonal antibodies which bind with  $\alpha$  chain of IL 2R. These drugs are well tolerated through a peripheral IV line; stops acute rejection; with less risk of infection and malignancy. It does not cause serum sickness or cytokine release

syndrome. But all alone its effects are inadequate and so it should be used only in concomitant with other immunosuppressants.

- ◆ **Rituximab** is an anti-CD20 monoclonal antibody as a depleting agent on B cell. It is used to control humoral mediated rejections. It is used in heart transplantation.
- ◆ **Alemtuzumab**—an anti-CD52 human monoclonal antibody which is expressed in B cell, T cell, monocyte, macrophage. It causes prolonged lymphocyte depletion for 6 months. It is used along with tacrolimus in kidney transplantation. Steroid can be spared while using this. This drug is also used in lymphoma, multiple sclerosis and rheumatoid arthritis.
- ◆ **IVIG** (intravenous immunoglobulin) derived from pooled plasma neutralises the circulating autoantibodies, blocks the T cell cytokines, lymphocyte proliferation and apoptosis.

## Maintenance Therapy

All transplant patients require maintenance therapy for prolonged period. Different drugs are used. Steroid and azathioprine are old drugs commonly used.

### ◆ **Prednisolone:**

- ▶ It inhibits cytokines, binding of IL 2 to receptors, blocks macrophage migration, and inhibits delayed hypersensitivity reaction. But it causes Cushing's syndrome, hypertension, peptic ulcer, cataract, diabetes, osteoporosis, muscle wasting. Often methyprednisolone may be used.

### ◆ **Antiproliferating agents:**

- ▶ They inhibit differentiation and division of lymphocytes by blocking the purine, pyrimidine and folic acid metabolism as a structural analogue.
- ▶ **Azathioprine** is a purine analogue containing 6 mercaptopurine with a labile sulphhydryl chain. Conversion of inosine nucleotide to adenosine and guanosine is blocked. Drug inhibits both humoral and cell-mediated immunity. Toxic effects are—bone marrow suppression, hepatotoxicity.
- ▶ **Mycophenolate mofetil (MMF):** It inhibits inosine monophosphate dehydrogenase of purine metabolism blocking lymphocyte proliferation. Dose is 2 g/day. It is now more commonly used than azathioprine. Diarrhoea and bone marrow suppression are the side effects.
- ▶ **Leflunomide:** It blocks pyrimidine synthesis in lymphocytes by inhibiting dihydroorotate enzyme. This drug is used in rheumatoid arthritis. FK 778 is its analogue which is under trial in renal transplant.

### ◆ **T cell directed immunosuppressants:**

- ▶ **Cyclosporine** (Borel, 1972) is extracted from fungus *Tolypocladium inflatum*. It is selective inhibitor of TCR mediated activation suppressing T cells. It inhibits formation of mature CD4 and CD8 T cells in thymus. It contains 11 amino acids with molecular weight 1202. It is a very good immunosuppressant. But it *does not* cause myelosuppression. It is metabolised in the liver by cytochrome P-450. *Side/toxic effects* are—*nephrotoxicity*, hypertension, hirsutism, gingival hyperplasia, hyperkalaemia, neurotoxicity, tremor, hepatotoxicity, risk if infection (CMV, *Candida*, *Pneumocystis carinii*, secondary infections) and malignancy (lymphoma, skin and CNS). IV dose given initially is 4 mg/kg in 500 ml of saline; later changed to oral therapy as 12 mg/kg daily; after few weeks dose is tapered to 5 mg/kg/day. Regular serum cyclosporine estimation twice weekly with estimation of haematocrit, blood urea and serum creatinine is needed.

- ▶ *Tacrolimus* (FK 506, 1984, Japan) is derived from fungus *Streptomyces tsukubaensis*. It is macrocyclic lactone (MW 822) causes similar effect like cyclosporine. Drug binds with intracellular binding protein immunophilin forming complexes which block the phosphatase activity of calcineurium so that inhibits IL 2 production. It is used in liver transplant, in acute rejection of kidney. Side effects are similar as cyclosporine but will not cause hirsutism and gingival hypertrophy. It causes alopecia and diabetes.
- ▶ *Sirolimus* (rapamycin) is a macrolide antibiotic which inhibits signal transduction from IL2 R to nucleus. It inhibits allograft rejection. It is used along with other immunosuppressants like cyclosporine. It causes anaemia, thrombocytopenia and proteinuria. Nephrotoxicity is less with sirolimus.
- ◆ **Costimulation blockage agent** like *belatacept* which is a fusion protein of extracellular part of CTLA4. It is a good immunosuppressant used monthly or bimonthly.
- ◆ No malignancy other than a primary brain tumour or treated superficial skin cancer.
- ◆ No generalised viral or bacterial infection.
- ◆ Acceptable urinalysis; age between 6 and 50 years.
- ◆ Negative assays for syphilis, hepatitis, HIV, and human T-lymphoproliferative virus.

#### Three types of donors:

1. Living related donors.
2. Living nonrelated donors.
3. Cadaver donors.

Highest chances of success in any transplant (renal) is seen when the donor is the identical twin.

Compatibility should be checked by tissue typing, i.e. ABO blood group system and major histocompatibility complex.

#### Evaluation of living donor:

- ◆ Tissue typing, ABO, MHC typing.
- ◆ Renal function—blood urea, serum creatinine.

## Risks Related to Immunosuppression

They are mainly infection and malignancy. *Individual drug-related toxicity* also can occur.

### Infection

- ◆ Opportunistic infections are common with immunosuppression. Cytomegalovirus (CMV) infection is common causing pneumonia, hepatitis, pancreatitis, GI problems. *Pneumocystis carinii* infection is also common.
- ◆ Trimethoprim, sulfamethoxazole, acyclovir, ganciclovir, valganciclovir, clotrimazole, pneumococcal vaccine, hepatitis B vaccine, pentamidine nebulizer are different drugs used to prevent sepsis.
- ◆ BK virus associated nephropathy is controlled by cidofovir, IV immunoglobulin.

### Malignancy

- ◆ Malignancy potentiality increases by 10 times.
- ◆ Skin cancers and carcinoma cervix are common.
- ◆ Virus-mediated tumours like carcinoma cervix (HPV); hepatoma (Hepatitis B and C); Kaposi's sarcoma (herpes virus 8); lymphoma (EBV) are common. EBV related lymphoma is post-transplant lymphoproliferative disorder (PTLDs). Rituximab, anti-CD20 monoclonal antibody reduces B cells is effective in these patients. Hyper CMS IG is used as prophylaxis in high-risk groups.

## RENAL TRANSPLANTATION

An animal which has undergone a double nephrectomy and grafting of both kidneys from another animal can secrete almost normal urine with his new organs, and live in good health for at least a few weeks.

## The Criteria for an Ideal Deceased Kidney Donor

- ◆ Normal renal function.
- ◆ Without hypertension requiring treatment; without diabetes mellitus.

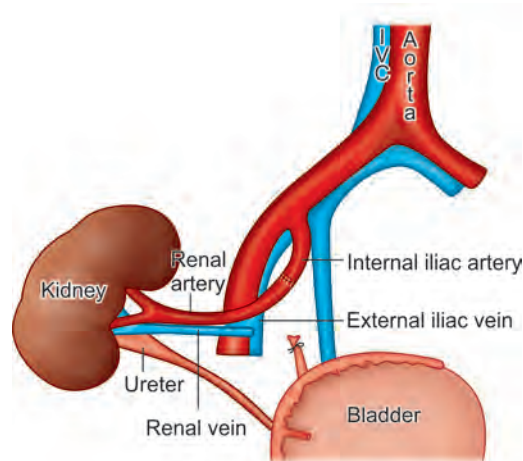


Fig. 1.635: Renal transplantation.

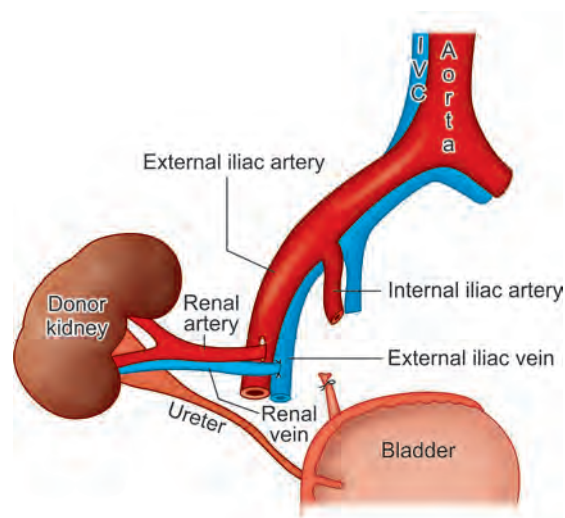


Fig. 1.636: Another method of getting arterial perfusion of the transplanted kidney by suturing (*Carrel stitch*) external iliac artery to renal artery side-to-end.

- ◆ IVP.
- ◆ Selective renal angiogram. Single vessel is better.
- ◆ HIV/hepatitis evaluation.

Usually *left kidney* is taken for *transplantation* because of *long left renal vein*. It is placed in right iliac fossa with ureter connected to the urinary bladder; renal artery to internal iliac artery (end-to-end); renal vein to external iliac vein (end-to-side). Renal artery (end) to external iliac artery (side) through Carrel stitch is also used for arterial continuity.

## Technique

Before the removal of kidney, the donor receives IV mannitol to prevent kidney ischaemia, diuretics and IV heparin. After removal of donor kidney, protamine sulphate is given to the donor. Removed donor kidney is perfused with cold perfusion fluid at 4°C and cold intravascular electrolytes. Solutions used to preserve the donor kidney are *Euro-Collins* solution or *University of Wisconsin (UW)* (both contains inert sugar which prevents swelling of cells). First renal vein, then renal artery and at the end ureter is anastomosed.

Azathioprine, cyclosporine and prednisolone should be started 3 days prior to surgery. Diuretics and mannitol should be continued as required.

*Bilateral nephrectomy* in recipient is required only in:

- ◆ Polycystic kidney disease.
- ◆ Haematuria.
- ◆ Severe hypertension.

*Kidney will stand cold ischaemia for 72 hours.*

### Note:

Overall survival is 90% in one year and 80% in five years.

## Postoperative Management

- ◆ Immunosuppression: By cyclosporine, azathioprine, prednisolone, antithymocytic globulin and antilymphocytic serum.
- ◆ Proper fluid balance has to be taken care of.

## Complications

- ◆ Acute tubular necrosis.
- ◆ Rejection (Rejection is identified by radioisotope study and percutaneous kidney biopsy). Chronic rejection is the common cause of graft failure.
- ◆ Obstruction of the collecting system.
- ◆ Infection.
- ◆ Urine leakage—5%.
- ◆ Secondary haemorrhage.
- ◆ Renal infarction.
- ◆ Hazards of immunosuppression:
  - ▶ Infection by unusual organisms like cytomegalovirus, herpes, *Pneumocystis carinii*, varicella and other bacterial infections, candidial infection.
  - ▶ Changes in the cellular component of blood.
  - ▶ Uncommon malignancies of CNS, skin.
  - ▶ Nephrotoxicity, GIT bleeding and perforation.
  - ▶ Hirsutism, delayed wound healing, cataract formation.

- ▶ Renal artery stenosis—10%.
- ▶ Renal vein thrombosis—5%.
- ▶ Lymphocele.

## LIVER TRANSPLANTATION

*An ideal treatment for several kinds of liver disease would be removal of the diseased organ and orthotopic replacement with a hepatic homograft.*

—TE Starzl, TL Marchioro, KN von Kaulla, et al, 1963

Children respond better for liver transplantation. Tissue typing and cross-matching are not that necessary and do not influence the results.

If the transplantation is done at the same site after doing hepatectomy, it is called as *orthotopic liver transplantation*. If it is placed in a different site it is called as *ectopic* or *heterotopic liver transplantation*. Success rate in liver transplantation is better.

- ◆ *Liver transplantation* is the choice for end stage liver disease. Liver transplant is an accepted and effective treatment. Many tumours can be treated by transplantation. Cirrhosis, hepatitis, sclerosing cholangitis, biliary atresia, tumours are indications.
- ◆ *CTP (Child Turcote Pugh) scoring system* (ascites, encephalopathy, bilirubin, albumin, PT-INR); *Model for end stage liver disease (MELD score)* consists of total bilirubin, INR, creatinine; *Paediatric end stage liver disease scoring (PELD)*; are different scorings used to assess the patients.
- ◆  $MELD\ Score = 0.957 \times \text{Log}_e(\text{creatinine mg/dL}) + 0.378 \times \text{Log}_e(\text{bilirubin mg/dL}) + 1.120 \times \text{Log}_e(\text{INR}) + 0.643$

## Indications

- ◆ Primary biliary atresia, metabolic liver disease.
- ◆ Cirrhosis.
- ◆ Malignant disease of the liver.

## Contraindications for Liver Transplantation

- ◆ Active sepsis, SBP and HIV.
- ◆ Extrahepatic malignancies.
- ◆ Large hepatocellular carcinoma and cholangiocarcinoma.
- ◆ Unfit for surgery—severely advanced cardiopulmonary disease.
- ◆ Active alcohol or substance abuse.
- ◆ Inability to comply with immunosuppression protocols because of psychosocial situations.

## Donor Criteria

They are related to donor liver function, hepatitis screening, history of consumption of alcohol and toxic substances. Marginal donor and expanded donor criteria are in use in places due to very high demand for donor for transplantation. ABO compatibility is important. HLA matching is not necessary unlike in renal transplantation.

## Donor Operation

It is by a midline incision from suprasternal notch to pubic symphysis. Initially dissection is done with a beating heart; but later with a cold preservation into aorta and portal vein and local ice application. UW solution extends cold ischaemic time for 24 hours but usually within 10 hours transplantation is done. IVC segment is removed with hepatic veins. Portal vein is transected. Celiac artery with branches along with hepatic artery is dissected and transected at celiac artery origin. Bile duct is transected.

DDLT (deceased donor liver transplantation) donor	LDLT (living donor liver transplantation) donor
• 50 years or younger	• Young, non-obese, tall
• No hepatobiliary disease	• No infection, malignancy, no fatty liver
• Hemodynamic and respiratory stability (systolic blood pressure >100 mmHg, and central venous pressure >5 cm/H <sub>2</sub> O); an acceptable PaO <sub>2</sub> and haemoglobin level	• Enough liver to donate
• No severe abdominal trauma, systemic infection, or cancer	• Enough residual liver
• Normal kidneys—diuresis greater than 50 ml/h and normal creatinine; and finally, a dopamine requirement less than 10 µg/kg/min	• Suitable anatomy of liver
• Simple technically	• Technically complex procedure
• Recipient complication is low (of bile duct)	• Recipient complication is higher
• Graft quality is average	• Graft quality is good
• Donor's complication—nil	• Donor's complication—25% morbidity; 0.4% mortality

**Note:**

- *Remnant liver*—≥30% of the original liver volume with complete venous drainage is safe for donor survival.

**Recipient Operation**

Bowel preparation, prophylactic antibiotics, administrative immunosuppressive agents are needed before surgery. Bilateral subcostal incision is used with midline upward extension. Falciform ligament, left lateral ligaments, hepatogastric and hepatoduodenal ligaments are divided. Right and left branches of hepatic arteries are ligated. CBD and cystic ducts are divided with ligatures. Portal vein is dissected. Infra and suprahepatic vena cava are exposed. Portal vein and suprahepatic vena cava are clamped. Venovenous bypass between portal and femoral veins and internal jugular vein is created with a flow of blood through it more than 2.5 ml/minute. Warming circuits and ultrafiltration is needed. Suprahepatic vena caval cuff is created at the opening of the right, middle and left hepatic veins. Donor IVC is sutured to recipient IVC first above and then below as end-to-end. Recipient IVC can be preserved entirely and donor IVC is sutured to recipient IVC as end-to-side. Preservative solution is passed. Portal vein is sutured. Reperfusion injury can occur at this stage with hyperkalaemia and acidosis. Arterial reconstruction is done between donor celiac artery to recipient gastroduodenal artery. Bile ducts are sutured as end-to-end with or without T tube. Often choledochojejunostomy is also done.

*Graft should be:*

- 40% of the estimated standard liver volume.
- 0.8 to 1% of the body weight of the recipient is necessary for the recipient recovery.

**Segmental/Lobar/Split/Living Donor Liver Transplantation**

It is newer beginning but becoming preferred one. It is based on segmental anatomy and liver regeneration capacity. Minimum liver mass required is more than 1% of graft to body weight ratio. Right lobe is better. It is basically used in children; but useful in adults also. MELD score in donor should be less than 20 for living donor transplantation. Regeneration occurs very significantly in recipients in first 2 weeks reaching

standard in 1 month. Regeneration is slow in living donor liver in 1 year. Graft to standard liver ratio should be more than 40%. Function of liver in living donor should be optimum. Proper imaging of the donor for entire anatomy including vasculature is important. Individual branches of portal vein, hepatic artery and bile duct are dissected and isolated. Liver is carefully separated from IVC; small branches of hepatic vein are ligated. Main hepatic vein is isolated; liver parenchyma is dissected with finger/Kelly fracture technique. After completion of parenchymal division, vessels are transected; dissected liver is perfused with cold preservative solution. Diseased liver of the recipient is removed completely. Graft is anastomosed in usual manner hepatic vein, portal vein, hepatic artery, bile duct. Living donor transplantation has got higher chances of morbidity, complications compared to cadaveric transplantation.

**Postoperative Management**

- ◆ Antirejection drugs to be given.
- ◆ Liver shows low immunogenicity and high regeneration capacity causing long-term outcome. Initially cyclosporine or tacrolimus with MMF or azathioprine with prednisolone is given. ICU care is needed.
- ◆ Electrolyte and fluid management, sepsis management, prevention of encephalopathy, observation for complications are important.

**Complications and Problems of Liver Transplantation**

- ◆ *Bleeding* on table and postoperatively can occur especially when recipient liver is cirrhotic. FFP, platelet and blood are needed. Re-exploration is needed if bleeding persists postoperatively.
- ◆ *Hepatic artery thrombosis* is the common vascular complication leading into graft failure, CBD necrosis and anastomotic dehiscence.
- ◆ *Immediate graft failure* as primary nonfunctional graft can occur (5% of liver grafts).
- ◆ *Bile leak* due to CBD ischaemia which can be identified by HIDA scan, ERCP, revision anastomosis is needed.
- ◆ *Infection* is common especially enterococci, staphylococci, gram-negative organisms, *Candida*, *Aspergillus*, etc. Antibiotic and antifungal therapy is needed.

*Success is never final and failure is never fatal; its courage that counts.*

- ◆ *Acute rejection* (30%) of T cell mediated is seen within 10 days commonly but can occur up to 6 months. Liver biopsy confirms the rejection. Higher steroid therapy, polyclonal anti-T cell antibodies are used.
- ◆ *Chronic rejection* is seen after 6 months; appears gradually with liver cell dysfunction and hyperbilirubinaemia. Liver biopsy shows very few numbered biliary radicles—*vanishing bile duct syndrome*. It is due to humoral immunity. It is difficult to control; eventually needs retransplantation.
- ◆ *Recurrence* of the earlier disease to the transplanted liver like hepatitis, biliary sclerosis, sclerosing cholangitis. Hepatitis can be controlled by lamivudine (antiviral DNA polymerase for HBV), interferon  $\alpha$ , ribavirin for HCV.
- ◆ *Complications of immunosuppressive drugs* like hypertension, hyperglycaemia, hyperlipidaemia, osteoporosis, malignancy, infection, bone marrow suppression are often difficult to manage.

### Survival

- ◆ 5-year survival is 70% in adults and 80% in children.
- ◆ It depends on age, general condition, earlier disease, associated problems, MELD scoring.
- ◆ The risk of rejection is highest (40%) during the first 3–6 months after transplantation and decreases significantly thereafter.

## BONE MARROW TRANSPLANTATION

### Indications

- ◆ Leucaemias.
- ◆ Aplastic anaemias.
- ◆ Immune deficiencies, etc.

Recipients are initially treated with total body irradiation. As bone marrow is an active immune system, *proper tissue typing* is essential. *Infant bone marrow* is better marrow as a donor. Marrow aspirated from donor's bone is transplanted by *intravenous injection* to the recipient.

Immunosuppression with cyclosporin-A is always needed. It will take few weeks to show the response.

### Problems

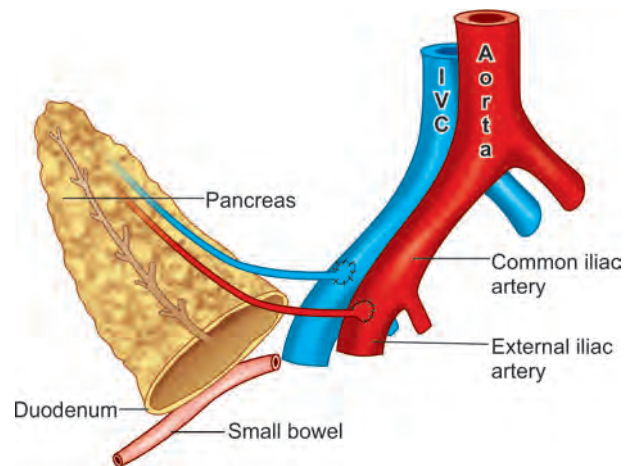
1. Graft rejection.
2. *Graft-versus-host* disease (GVH) is more dangerous.

## PANCREATIC TRANSPLANTATION

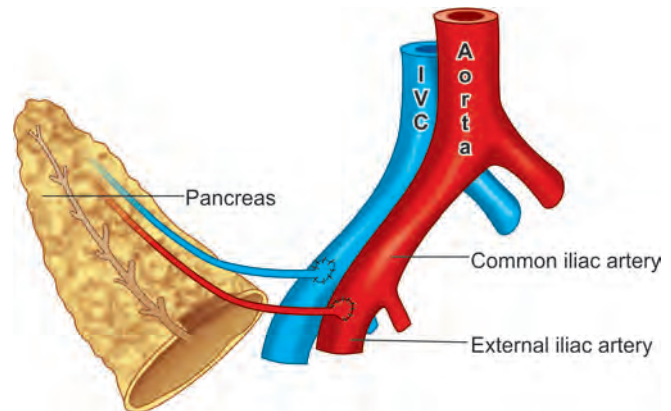
- ◆ It is used in diabetic patients, taken from cadaver donor to replace insulin.
- ◆ It can be combined with kidney transplantation to patients who have diabetes with end stage kidney disease.
- ◆ Donor criteria are individuals without pancreatitis.
- ◆ Entire pancreas with duodenum (Lillehei) or part of the pancreas (body and tail of the pancreas) can be transplanted.
- ◆ It is placed in the *right iliac fossa* with anastomosis done between portal vein and iliac vein, duodenum fixed to bladder.
- ◆ Graft take up is 60–70%.

### Complications

Graft pancreatitis, pancreatic leak, bleeding, urinary infections like cystitis, failure.



**Fig. 1.637:** Pancreatic transplantation with duodenum and small bowel to achieve adequate exocrine function. Exocrine function is achieved immediately; endocrine (insulin) function is achieved after few days.



**Fig. 1.638:** Pancreatic transplantation.

### Isolated Pancreatic Islet Transplantation

Islets of Langerhans are obtained by mechanical disruption of pancreas by injecting collagenase into the pancreatic duct. Tissue disrupted is collected and purified by density gradient centrifugation. These islet cells are injected into the liver through portal vein. Islet cell rejection is prevented by covering them with semipermeable membrane which prevents antibodies reaching islet cells but allowing insulin to get secreted. By this method animal pancreatic islet cells transplantation is also under trial.

## SMALL BOWEL TRANSPLANTATION

- ◆ Indication is short bowel syndrome following massive resection, atresia, necrotising enteritis, Crohn's disease.
- ◆ Bowel anastomosis with a stoma (ileostomy) is usual method.
- ◆ As small bowel is rich in lymphoid tissue, graft versus host reaction is a major problem. So graft take up is poor.
- ◆ It is an immunological challenge even though technically easier.

### Graft rejection

- ❖ **Hyperacute** rejection is due to antibody reaction which occurs within minutes of vascularisation of the graft
- ❖ **Acute** rejection results due to cell-mediated immunity, occurring in a few days to first 3 months of transplant. It responds well to steroids and immunosuppressants
- ❖ **Chronic rejection** occurs in 12 months after transplant, is not very common. It is due to late vasculitis. When it occurs, responds very poorly to steroids or other drugs. It is common type

## DIALYSIS

It is technique for the removal of waste product of metabolism, normalisation of plasma electrolytes and removal of plasma water.

### Types

- ◆ Peritoneal dialysis.
- ◆ Haemodialysis.

#### Peritoneal Dialysis

##### Indications

- ◆ Acute renal failure until renal function recovers.
- ◆ Chronic renal failure until long-term dialysis is instituted.

##### Contraindications

- ◆ Abdominal surgery.
- ◆ Hypercatabolic states.
- ◆ Infection.
- ◆ Pre-existing malignancy.

##### Insertion of catheter

A rigid plastic catheter is inserted through the abdominal wall into the peritoneal cavity using a trocar through a small cut made in the skin under L/A. Catheter is bound to abdomen.

*Dialysis* is done using sterile dialysate solution instilled into and drained out of abdomen.

### Complications

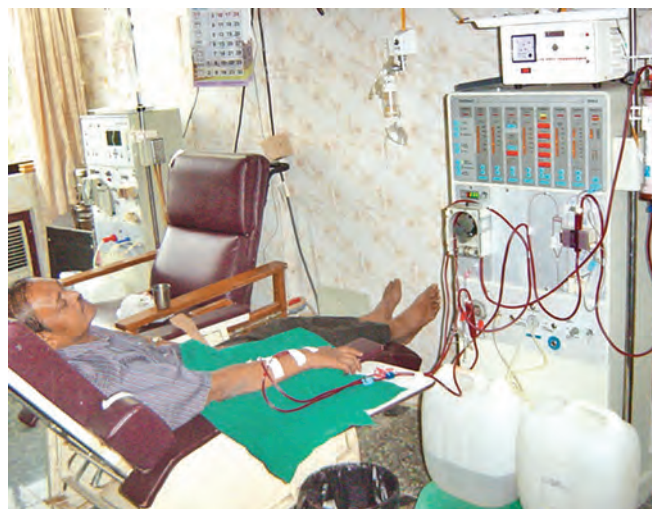- ❖ Leakage
- ❖ Pain—short lasting, mild
- ❖ Peritonitis
- ❖ Membrane failure
- ❖ Hernia

Continuous ambulatory peritoneal dialysis (CAPD) is the preferred method of dialysis in some centre.

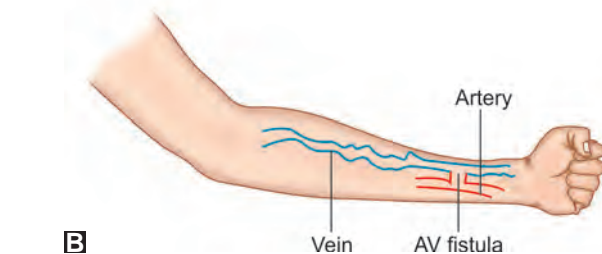
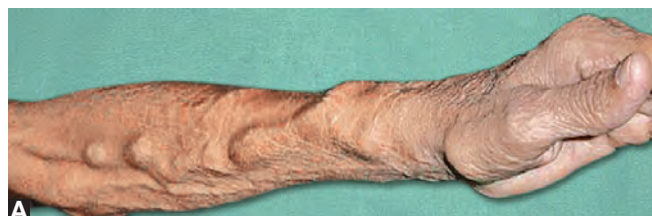#### Haemodialysis

##### Indications

- ◆ Acute renal failure.
- ◆ Chronic renal failure.
- ◆ Acidosis.
- ◆ Electrolyte disturbance.
- ◆ Intoxication.
- ◆ Uraemia (pericarditis and polyneuropathy due to uraemia are absolute indications).



**Fig. 1.639:** Patient with CRF undergoing haemodialysis using a dialysis unit.



**Figs 1.640A and B:** Arteriovenous fistula between radial artery and cephalic vein at wrist is done to attain increased venous engorgement and arterialisation so as to achieve rapid blood flow which is necessary for haemodialysis. Patient with chronic renal failure who requires regular haemodialysis needs this.

Haemodialysis requires access to circulation which is achieved by creating a fistula between the radial artery and the cephalic vein at the wrist (*Cimino fistula*). Here dialysis occurs in a dialysing machine across a semipermeable membrane (usually cellulose membrane).

##### Complications

- ◆ Access site—arterial and venous stenosis, thrombosis, infection.
- ◆ Hypotension.
- ◆ Dyspnoea.
- ◆ Bleeding (due to dysfunctional platelets due to uraemia and due to heparin use).
- ◆ Disequilibrium syndrome.

Even though repeated dialysis (in CRF, at least twice a week is needed) helps, patient needs repeated blood transfusions, which will lead into haemochromatosis/iron overload. Patient should be given erythropoietin injection 3,000 units twice weekly to prevent repeated blood transfusions. But it is expensive. Transplantation is the best answer eventually, in all these individuals.

### ■ CIMINO FISTULA (CIMINO-BRESCIA)

It is an arteriovenous fistula created for *haemodialysis*. Usually at wrist, radial artery is anastomosed to cephalic vein side-to-side and a created

good fistula shows continuous thrill and bruit, with increased venous engorgement along with hyperdynamic circulation. At the ankle, often fistula is created between posterior tibial artery and saphenous vein; in the thigh between femoral artery and long saphenous vein. Distal gangrene is not common.

### Complications

Infection, bleeding, hyperdynamic circulation.

# W. Stings and Bites

## CHAPTER OUTLINE

- ❖ Snake Bite
- ❖ Spider Bite
- ❖ Bee Bite
- ❖ Mammalian Bite

### ■ SNAKE BITE

Snakes belong to *Crotalidae*, *Elapidae* and *Viperidae* family.

Common poisonous snakes are cobra, krait and viper.

Common snakes are cobra, Russell's viper, saw scaled viper, pit viper, krait.

It causes renal failure, pulmonary oedema, cardiac complications and neurological problems.

### Clinical Features

#### Local

- ◆ Burning pain, oedema and erythema.
- ◆ Swelling, echymoses and haemorrhagic bullae.
- ◆ Tissue necrosis, ulceration and gangrene.

#### Systemic

- ◆ Weakness, perioral paraesthesia, muscle twitching.
- ◆ Shock.
- ◆ Pulmonary oedema.
- ◆ Renal failure.
- ◆ Neurological manifestations.
- ◆ Bleeding tendency.

Vipers affect multiple organs and soft tissues. Cobra and coral snakes are neurotoxic.

### Investigations

- ◆ Blood count.
- ◆ Coagulation studies like bleeding time, clotting time and prothrombin time.
- ◆ Blood urea and serum creatinine.
- ◆ Serum electrolytes.
- ◆ Creatine phosphokinase (CPK).
- ◆ Urine analysis for RBCs, albumin, myoglobin.
- ◆ PO<sub>2</sub> and PCO<sub>2</sub> assessment.

### Management

#### First Aid

- ◆ Reassurance.
- ◆ Immobilisation.
- ◆ The site has to be incised and cleaned.
- ◆ Tourniquet to *occlude lymphatics* only but not venous or arterial circulation.
- ◆ The snake has to be identified.

- ◆ The patient must be transferred to proper medical centre as early as possible.
- ◆ The bite wound is identified and assessed.
- ◆ It is thoroughly cleaned with debridement.
- ◆ *Polyvalent antislake venom* (against cobra, krait, vipers) should be given. It should be given earliest within 4–24 hours. Dose is 20–150 ml depending on the type, severity and age of the individual. It is dissolved in normal saline and given as IV infusion in 500 ml saline with 20 drops/minute as flow rate. If the snake has been identified monovalent serum is better and more potent.
- ◆ Tetanus toxoid.
- ◆ IV fluids, blood transfusion and plasma.
- ◆ Antibiotics.
- ◆ Urine output measurement.
- ◆ Monitoring by regular checking of blood urea, serum creatinine and bleeding and clotting time.
- ◆ In cobra bite, there is neuromuscular blockade and paralysis occurs. So *neostigmine* should be given 0.5 mg IV every half hourly and later repeated as required. It is given along with 0.6 mg of atropine.
- ◆ In viper bite DIC is common. So heparin is given as 10,000 to 15,000 units loading dose and later 5,000 units as maintenance dose 8th hourly.
- ◆ Human fibrinogen, whenever required.

### Complications of Snake Bite

- ◆ Cellulitis and gangrene of the part.
- ◆ Deep venous thrombosis (DVT).
- ◆ Pancytopenia.
- ◆ DIC and haemorrhage.
- ◆ Neurological complications.
- ◆ Septicaemia.
- ◆ Renal failure.
- ◆ Marjolin's ulcer.

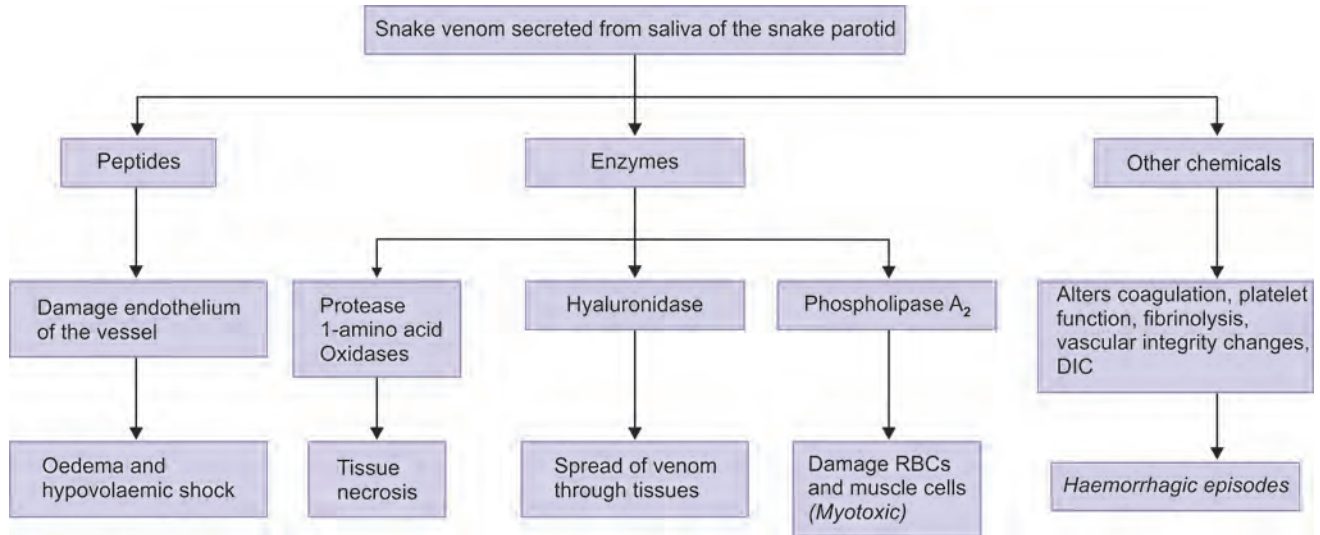
### ■ SPIDER BITE

#### Types

1. *Black Widow Spider Bite*
  - ▶ It causes neurotoxicity.
  - ▶ It causes muscle spasms, pain and abdominal cramp and rigidity.
  - ▶ Hypertension, tachycardia and diaphoresis are the other features.
  - ▶ Its effects last for 2–3 days.
  - ▶ Cleaning the wound, antibiotics, antihistamines, specific anti-venins are the line of treatment.

Awareness of change in important and equally acceptance of it also.





## 2. Brown Spider Bite

- ▶ It releases sphingomyelinase-D which causes necrosis of the skin and haemolysis.
- ▶ Local effects include skin rash, blister formation, necrosis of the skin and extensive ulceration.
- ▶ Systemic effects are anaphylaxis, arthralgia, thrombocytopenia, haemolysis and renal failure.
- ▶ Often it can be life-threatening especially in children and elderly.
- ▶ The effects last for 2–3 weeks.
- ▶ Wound debridement, antibiotics, antihistamines, steroid therapy, antivenins and management of systemic complication.

## ■ BEE BITE

**Honey bee** has got barbed stinger with two lancets. These lancets get attached to human skin to release the venom. Bee dies after bite.

**Wasps:** Yellow jacket wasps are more aggressive.

Bee venom contains dopamine, histamine, neurotoxin and toxic peptides.

## Clinical Features and Management

- ◆ Allergic reactions.
- ◆ Anaphylaxis.

- ◆ Pain in the local region, oedema, pruritus, flushing.
- ◆ Hypotension, laryngeal oedema, bronchospasm.
- ◆ Muscle spasm, convulsions.
- ◆ Renal failure in severe cases.
- ◆ Soda bicarbonate is used to neutralise the bee venom.
- ◆ Antibiotics and antihistamines.

## ■ MAMMALIAN BITE

- ◆ It includes human bites also.
- ◆ Infection rate is more in mammalian bites.
- ◆ Proper wound toileting is very important.
- ◆ Within 12 hours, incised wound is closed primarily.
- ◆ All lacerated wounds and wound which is seen after 12 hours is left open. Wound is closed secondarily.
- ◆ Antibiotics are must in all mammalian bites.
- ◆ Human bite is very dangerous bite.

# X. Pain

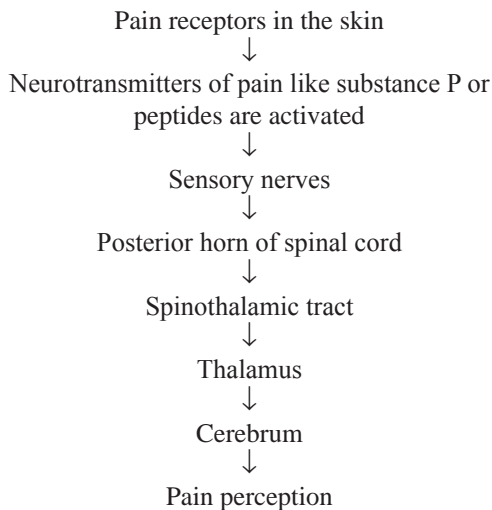
## CHAPTER OUTLINE

### ❖ Gate Control Theory

Pain is a subjective one and is difficult to assess and quantify. Pain perception varies from person-to-person and from time-to-time.

- ❖ It can be physical or mental
- ❖ It can be localised or diffused
- ❖ It can be acute or chronic
- ❖ It can be intermittent or persistent
- ❖ It can be mild or severe

### Pain Pathway



### ■ GATE CONTROL THEORY

Gate control system is located at the junction of first and second neuron. Large diameter 'A' fibre is stimulated by temperature and touch. Fine 'C' fibre is stimulated by pain. If 'A' fibre once gets stimulated, blocks the gate mechanism, then pain from 'C' fibre cannot pass through the gate to reach the brain for perception.

Pain modulators like endorphins and opioid peptides in brain and spinal cord inhibit the release of substance 'P'.

### Causes of Pain

- ◆ Inflammatory causes due to any infection or infestations.
- ◆ Hypoxia due to poor blood supply like in myocardial infarction, peripheral vascular disease.

- ◆ Trauma.
- ◆ Obstruction like intestinal obstruction.
- ◆ Colicky pain like ureteric, biliary, intestinal.
- ◆ Compression over nerve roots like in inter vertebral disc prolapse.
- ◆ Advanced malignancies cause severe distressing pain, which requires proper pain control.
- ◆ Ulcers, perforation, peritonitis, abscess formation are all other causes.

### Clinical Assessment of Pain

- ◆ Its severity, nature, cause should be assessed.
- ◆ Cause should be thoroughly analysed by doing all investigations like haematocrit, sinology, CT scan, culture of the fluid like pus, blood.

Pain is a most common symptom which patient complains to a clinician. Latin word '*poena*' means penalty/punishment. Pain is the one patient feels; tenderness (sign) is one surgeon/clinician elicits.

### Specific Points in History in Relation to Pain to be Asked are:

- ◆ **Original site of pain** is very important. In acute appendicitis original site of pain is in umbilicus; but later it is referred to right iliac fossa. Shift of pain towards other site.
- ◆ **Time and mode of onset of pain**—it is sudden onset and rapidly progressive in acute appendicitis; it is of insidious onset and of long duration with episodic nature in chronic peptic ulcer.
- ◆ **Type/nature of pain**—superficial/deep; dull ache or sharp severe/pricking/bursting/vague aching (continuous mild pain), throbbing, scalding (burning sensation particularly felt during urination in cystitis, pyelonephritis, urethritis), pins and needles pricking sensation in peripheral nerve injury or irritation, shooting pain (seen in intervertebral disc prolapse and sciatica—pain shoots along the course of nerve), stabbing (sudden, severe, sharp, episodic—seen in perforated duodenal ulcer), distension pain (a feeling of restricted or distended like in paralytic ileus or intestinal obstruction), colicky pain is due to muscular contraction in a hollow tube in an attempt to obviate the obstruction by forcing the content out—gripping, episodic pain with vomiting and sweating (seen in intestinal colic, ureteric colic of stone, biliary colic of stone), twisting pain of bowel volvulus/twisted ovarian cyst/torsion testis, constricting pain around the chest by angina, etc.
- ◆ **Severity of the pain:** In acute conditions like peritonitis and abscess pain will be severe compared to chronic one.

Success is dependent upon the glands—sweat glands.

- ◆ **Progression of pain:** It may be persistent and progressive; or initially mild gradually increases, later gradually subsides; fluctuation in intensity whether increases and decreases in intensity at regular intervals; quickly reaches maximum and remains like that.
- ◆ **Duration of Pain**
- ◆ **Periodicity of pain:** Pain appears, persists for few weeks and then disappears for few weeks; again reappear. Such periodicity is often observed in chronic peptic ulcer; trigeminal neuralgia.
- ◆ **Precipitating/aggravating factors:** Abdominal pain may get worsened by taking food like in gastric ulcer. Pain due to appendicitis, ureteric stone aggravates by change of position, walking, jolting. Pain of urinary bladder stone aggravates in standing position. In reflux oesophagitis pain increases while scooping. Pain in pancreatitis increases while lying down. Pain in intervertebral disc prolapse aggravates by lifting the weight.
- ◆ **Relieving factors of pain:** Pain reduce by certain methods and patient uses that method to relieve the pain. Hunger pain of early morning in duodenal ulcer is relieved by taking food. Pain of pancreatitis is relieved in sitting and bending forward. Propped up position relieves pain of reflux oesophagitis. In acute peritonitis, pain reduces temporarily by lying still.
- ◆ **Associated symptoms:** Acute pain may be associated with pallor, sweating and vomiting. Migraine pain with vomiting and visual disturbances; intestinal/ureteric colic with sweating, vomiting and cold periphery; acute pyelonephritis and urinary infections with chills/rigors and fever; ureteric colic with haematuria; biliary colic with jaundice and pale stool are other examples of such association.
- ◆ **Time of occurrence of pain** is often important in diagnosing the condition. In duodenal ulcer, hunger pain occurring in early morning or later evening is typical. Migraine occurs in early morning; frontal sinusitis induced headache occurs a few hours after getting up.
- ◆ **Pain may move from one place to other: Radiation of pain** It is extension of pain from original site to another site with persisting of pain at original site. This radiating pain is of same character of original site. Penetration of duodenal ulcer posteriorly causes pain both in epigastrium and back—is an example. Pain of pancreatitis radiates to back. **Referred pain:** Pain is not felt at the site of the disease but felt at distant site. Diaphragmatic irritation causes referred pain at the tip of shoulder through same segmental supply of diaphragm (phrenic nerve C4, C5) and shoulder (cutaneous supply C4, C5). Hip joint pathology may cause referred pain in knee joint—through articular branches of femoral, obturator and sciatic nerves. Other *examples*—referred ear pain from carcinoma tongue through lingual and auriculotemporal nerve; referred pain in the epigastrium from the heart; referred pain in the abdomen from pleura; referred pain over the testis from the ureter. **Shifting/migration of pain:** Origin of pain is one site; later pain shifts to another site and pain at original site disappears. Pain when begins in viscera, it is felt at the same somatic segmental area in the body; but once parietal layer is involved by inflammation/pathology pain is felt at the anatomical site. Example is pain of acute appendicitis where original visceral pain is at the umbilicus (T9 and T10 segments supply both umbilicus and appendix) shifts later to right iliac fossa when once the parietal peritoneum of that area is inflamed.

#### Types of pain:

- ◆ **Superficial pain:** It is sharp usually localised pain, due to irritation of peripheral nerve endings in superficial tissue by chemical/mechanical/thermal/electrical injury. **Segmental pain:** It occurs

due to irritation of particular nerve trunk/root; located in particular dermatome of the body supplied by the sensory nerve trunk or root.

- ◆ **Deep pain:** It is due to irritation of deeper structures like muscles/tendons/bones/joints/viscera. It is vague and diffuse when compared to superficial pain. It is often referred to common segmental areas of representation. Often spasm of skeletal muscle of same spinal cord segment can occur.
- ◆ **Psychogenic pain:** It may be functional/emotional/hysterical.
- ◆ **Other pain:** like due to thalamic/spinothalamic diseases/*causalgia* (intense burning pain along the distribution of the partially).

**Grading of pain:** It is done using pain scale. It is compared to a 10 cm line numbered 0 to 10. This is called as *visual analogue scale* (VAS). Minimum is 0 means no pain. 10 is the worst excruciating pain. 2 is mild; 4 is discomforting; 6 is distressing; 8 is intense.

#### Reasons to control postoperative pain/acute pain

- ❖ Uncontrolled pain causes tachycardia, hypertension and vasoconstriction
- ❖ Abdominal (upper abdominal mainly) and thoracic wound pain restricts the respiration causing tachypnoea, altered respiration, coughing, chest infection, pneumonia
- ❖ Persisting pain causes restricted movements, deep venous thrombosis and its problems, bed sores
- ❖ Pain delays the recovery and also causes psychological trauma to the patient

#### Management of Pain

- ◆ Correct the cause like removal of renal stone, cholecystectomy for gallstones.
- ◆ Analgesics.
- ◆ Surgical removal of tumour.
- ◆ Injection of phenol or alcohol.
- ◆ Electric stimulation, massaging, infrared therapy, wax bath.
- ◆ Proper physiotherapy.
- ◆ Hormone therapy.
- ◆ Injection to ganglion like in trigeminal neuralgia.
- ◆ Chemotherapy for malignancies.
- ◆ Radiotherapy.
- ◆ Sympathectomy for vascular diseases, causalgia.
- ◆ Cordotomy for severe pain in case of advanced tumours.
- ◆ Mental relaxation.
- ◆ Attending pain clinic.
- ◆ Continuous epidural anaesthesia/analgesia using opioids.
- ◆ **Patient controlled analgesia** (PCA) is injecting opioids through epidural route or intravenous route by patient himself after training him.
- ◆ Intravenous infusions of the analgesia.

Pain may be:

- ❖ Acute pain.
- ❖ Chronic pain due to malignancy.
- ❖ Chronic pain due to benign disease.

#### Drugs for Pain

Drugs can be given orally, intramuscularly, few intravenously, intrathecally, per rectally as suppositories, sublingually.

<b>Acute pain</b>	<b>Drugs/opioids/epidural anaesthesia/drug infusion</b>
Chronic pain due to malignancy	First level—simple analgesics (aspirin, paracetamol, NSAIDs, tricyclic antidepressants) Second level—intermediate opioids codeine, tramadol, dextropropoxyphene
	Third level—strong opioids like oral morphine, intravenous morphine, subcutaneous diamorphine, epidural diamorphine. Analgesic infusion is also useful. Neurolytics are used whenever there is limited life-expectancy. Other methods are—Subcostal phenol injection for rib secondaries/cealic plexus block using alcohol/intrathecal hyperbaric phenol/percutaneous anterolateral cordotomy/pituitary ablation/hormone ablation/palliative radiotherapy/steroids/flecainide therapy
Chronic pain in benign disease	Local anaesthetics/steroid injections/nerve stimulation like acupuncture/nerve decompression/pain due to sympathetic overactivity is corrected by—IV pentolamine (alpha adrenergic block), stellate ganglion block, block using guanethidine, percutaneous chemical lumbar sympathectomy using phenol. Other methods for chronic pain are—paracetamol/NSAIDs/antidepressants/opioids/carbamazepine/ neuroablative surgeries

### Narcotic Analgesics

- ◆ Morphine 10–15 mg. Very useful in intractable pain. It can cause nausea, constipation, and respiratory depression. Its action is neutralised by naloxone.
- ◆ Pethidine 50–100 mg IM.
- ◆ Diamorphine 5–10 mg. It is used only in intractable pain.
- ◆ Pentazocine 30–60 mg.
- ◆ Dihydrocodeine.
- ◆ Codeine phosphate is commonly used after intracranial surgery. It should not be given intravenously as it may precipitate severe hypotension. Codeine also causes constipation.
- ◆ Bupremorphine.

### Non-narcotic Drugs

- ◆ Aspirin.
- ◆ Ibuprofen.

- ◆ Naproxen.
- ◆ All these NSAIDs cause gastric irritation and may risk the gastric bleeding. NSAIDs are nonspecific cyclo-oxygenase inhibitors. So gastric protection and platelet function are lost. Rectal diclofenac as suppository is good analgesic.
- ◆ Paracetamol is effective analgesic and antipyretic agent. It is relatively less common to cause gastric bleeding.

#### Note:

Specific COX2 inhibitors are contraindicated in ischaemic heart disease.

### Other Drugs

- ◆ Anticonvulsants.
- ◆ Antidepressants, anxiolytics.
- ◆ Carbamazepine for neuralgia.

# Chapter 2

## Faciomaxillary Diseases

### CHAPTER OUTLINE

- ❖ Diseases of the Palate
- ❖ Orthopantomogram
- ❖ Cleft Lip and Cleft Palate
- ❖ Maxillofacial Injuries
- ❖ Primary Care (Early Care) in Maxillofacial Injuries
- ❖ Fracture Middle Third Area
- ❖ Zygomatic Complex Fracture
- ❖ Fracture of the Mandible
- ❖ Dislocation of the Mandible
- ❖ Jaw Tumours
- ❖ Epulis
- ❖ Ameloblastoma
- ❖ Dentigerous Cyst
- ❖ Dental Cyst
- ❖ Osteomyelitis of Jaw
- ❖ Alveolar Abscess
- ❖ Fibrous Dysplasia of Bone/Jaw
- ❖ Cherubism

### DISEASES OF THE PALATE

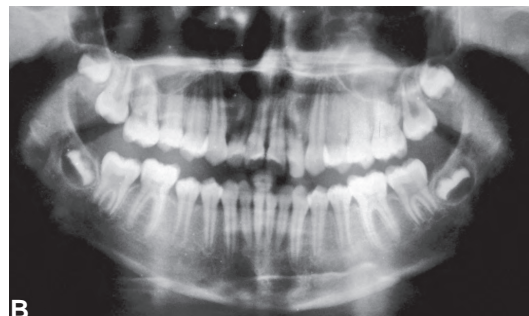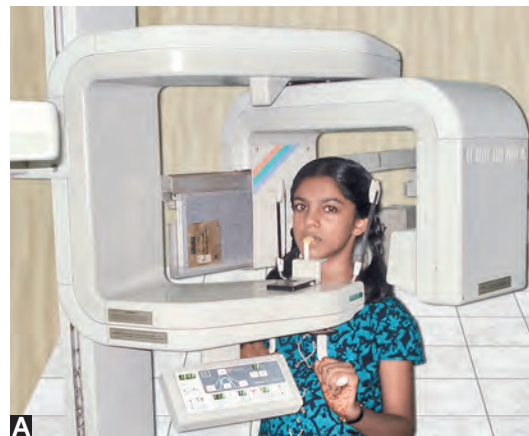- ◆ Cleft palate.
- ◆ *Torus palatinus*—a bony hard swelling in the centre of the hard palate.
- ◆ Nasopalatine cysts.
- ◆ *Epstein's pearls*—at the junction of soft and hard palates, in the midline, in infants due to retained developmental cell rests.
- ◆ Apical cyst or abscess.
- ◆ Minor salivary gland tumour—commonest site is palate.
- ◆ Maxillary tumour extending into the palate.
- ◆ Squamous cell carcinoma of the palate.
- ◆ Gummatous perforation in the middle of the palate seen in congenital syphilis.
- ◆ Perforation of the palate anywhere in carcinoma palate.

### ORTHOPANTOMOGRAM (OPG)

It is a plain X-ray of the mandible which shows the entire mandible in a single plane. It is better than X-ray mandible lateral view as it highlights proper dentition, inner and outer plates of mandible and joints. It is like a rotational tomogram.

### Indications

- ◆ Jaw tumours—Adamantinoma, dental cyst, dentigerous cyst, osteoclastoma.
- ◆ Osteomyelitis of the mandible.



**Figs 2.1A and B:** Orthopantomogram is being taken and also picture showing OPG X-ray.

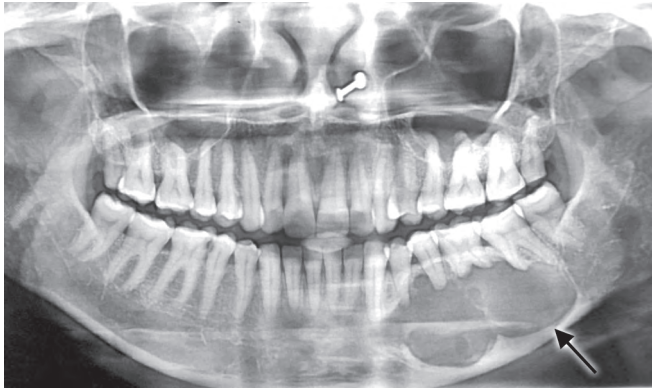


Fig. 2.2: OPG showing jaw tumour probably adamantinoma.

- ◆ Fracture mandible.
- ◆ Carcinoma oral cavity to check *infiltration* into the mandible.

## CLEFT LIP AND CLEFT PALATE

### Development of Face

Face develops from median nasal process, lateral nasal process, maxillary process, mandibular arch, globular arch, olfactory pit and eye. Any change in the development or fusion of these arches leads to formation of different types of cleft lip or cleft palate.

### Aetiology

- ◆ Familial—more common in cleft lip or combined cleft lip and palate (Risk is 1:25 live births).
- ◆ Protein and vitamin deficiency.
- ◆ Rubella infection.
- ◆ Radiation.
- ◆ Chromosomal abnormalities.
- ◆ Maternal epilepsy and drug intake during pregnancy (steroids/epitoin/diazepam).

### Classification

- I. *Cleft lip alone:*
  - Unilateral.
  - Bilateral.
  - Median.
- II. *Cleft of primary palate (in front of incisive foramen) only:*
  - a. Complete—means absence of pre-maxilla.
  - b. Incomplete—means rudimentary pre-maxilla.
    - i. Unilateral.
    - ii. Bilateral.
    - iii. Median.
- III. *Cleft of secondary palate (behind the incisive foramen) only:*
  - a. Complete—nasal septum and vomer are separated from palatine process.
  - b. Incomplete.
  - c. Submucous.
    - It can be - Cleft with soft palate involvement.
    - Cleft without soft palate involvement.
- IV. *Cleft of both primary and secondary palates.*
- V. *Cleft lip and cleft palate together.*

Defect is often associated with other congenital anomalies of cardiac, gastrointestinal, neurological system, *Pierre-Robin syndrome* (most commonly associated syndrome with features of isolated cleft palate, retrognathia, posteriorly displaced tongue), *Klippel-Feil syndrome*, *Stickler's syndrome* (eye, skeletal, muscular, cleft disorder), *Shprintzen's syndrome* (cardiac and cleft disorder), *Down's syndrome*, *Treacher-Collin's syndrome*, *Apert's syndrome* and trisomy.

### Cleft lip

- ❖ *Central*—rare. In upper lip. Between two median nasal processes. (*Hare lip*)
- ❖ *Lateral*—maxillary and median nasal process, *commonest*; can be unilateral or bilateral
- ❖ *Incomplete* cleft lip does not extend into nose
- ❖ *Complete* cleft lip extends into nasal floor
- ❖ *Simple* cleft lip is only cleft in the lip
- ❖ *Compound* cleft lip is cleft lip with cleft of alveolus

### LAHS classification of cleft disorders

- ❖ 'L' for lip, 'A' for alveolus, 'H' for hard palate, 'S' for soft palate
- ❖ *Capital* 'LAHS' for 'complete type'
- ❖ *Small letters* 'lahs' for 'incomplete type'
- ❖ *Asterisks* 'lahs' for microclefts
- ❖ 'LAHSHAL' for bilateral clefts

### Incidence

- ◆ Common in Caucasians.
- ◆ In 75% of cases it is unilateral. Commonly occurs on the left side (60%).
- ◆ In 50% of cases, it is combined cleft lip and palate. Incidence is 1:600 live births. Common in boys.
- ◆ In 15–25% of cases, it is cleft lip alone.
- ◆ In 25–40% of cases it is cleft palate alone. Incidence is 1:1000 live births. More common in girls.

### Problems in Cleft Disorders

- ◆ Difficulty in sucking and swallowing. This is more commonly observed in cleft palate than in cleft lip.

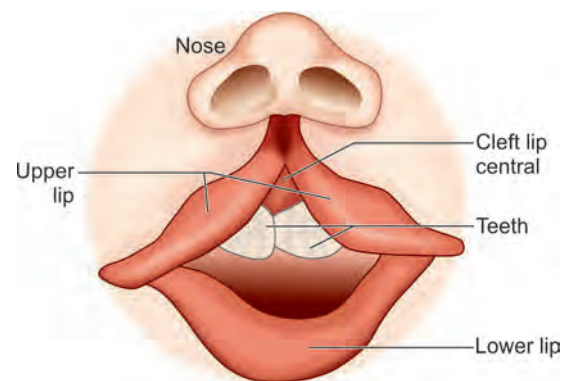
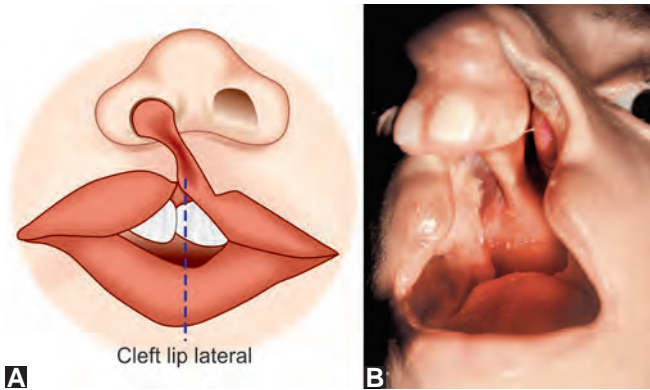


Fig. 2.3: Central cleft lip (Hare lip, Type I cleft lip—It is rare).



**Figs 2.4A and B:** (A) Lateral type of cleft lip (Type II variety—it is commonest). It is due to imperfect fusion of maxillary process and median nasal process. It can be unilateral or bilateral; (B) Wide cleft palate and lip—complete type in a child.

- ◆ Speech is defective especially in cleft palate, mainly to phonate B, D, K, P, T and G.
- ◆ Altered dentition or supernumerary teeth.
- ◆ Recurrent upper respiratory tract infection.
- ◆ Respiratory obstruction (in *Pierre-Robin syndrome*)
- ◆ Chronic otitis media, middle ear problems.
- ◆ Cosmetic problems.
- ◆ Hypoplasia of the maxilla.
- ◆ Problems due to other associated disorders.

### Treatment for Cleft Lip

*Millard criteria* are used to undertake surgery for cleft lip.

#### Millard criteria (Rule of '10')

- ❖ 10 pound in weight
- ❖ 10 weeks old
- ❖ 10 gm % haemoglobin

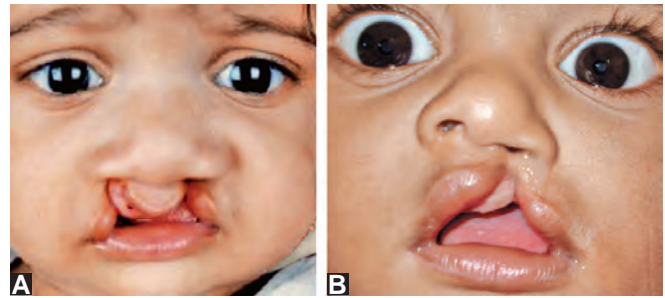- ◆ *Millard cleft lip repair* by rotating the local nasolabial flaps.
- ◆ Management of associated primary or secondary cleft palate deformity.
- ◆ Proper postoperative management like control of infection, training for sucking, swallowing and speech.
- ◆ Tenninson's 'Z' plasty (*Tenninson-Randall triangular flap*).

#### Note:

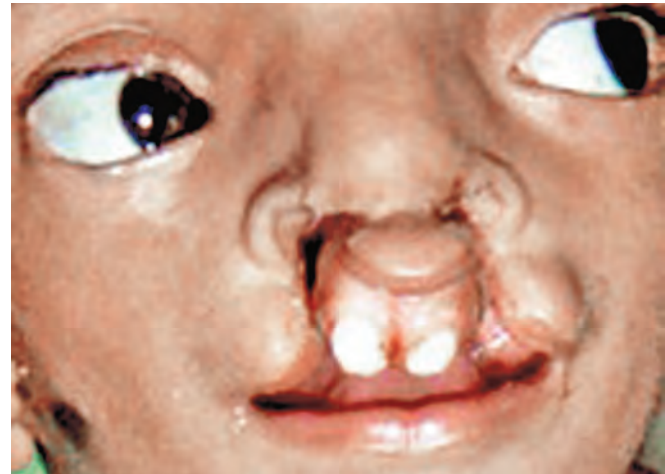*Delaire timing of the cleft surgery* – Unilateral/bilateral cleft lip alone, in one stage operation done in 4–6 months. For cleft palate alone involving only soft palate, in one stage, surgery is done in 6 months. For cleft palate alone but involving both soft and hard palates—soft palate in 6 months; hard palate in 18 months. In combined cleft lip and palate, unilateral or bilateral, in two stages—cleft lip and soft palate in 6 months; hard palate in 18 months.

### Cleft Palate

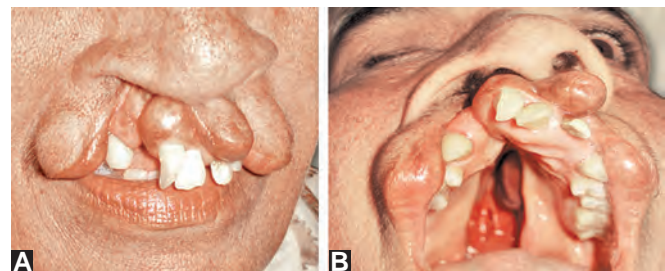- ◆ It is due to failure of fusion of the two palatine processes.
- ◆ Defect in fusion of lines between premaxilla (developed from median nasal process) and palatine processes of maxilla one on each side.
- ◆ When premaxilla and both palatine processes do not fuse, it leads into complete cleft palate (Type I cleft palate).



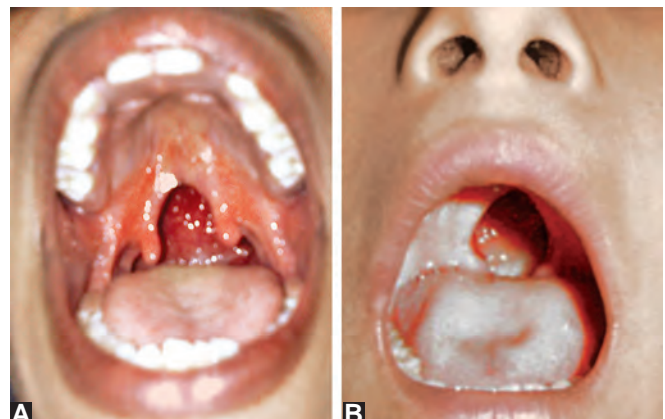
**Figs 2.5A and B:** (A) Bilateral cleft lip; (B) Unilateral cleft lip, lateral type which is commonest.



**Fig. 2.6:** Bilateral cleft lip involving palate.



**Figs 2.7A and B:** Cleft lip and cleft palate in an adult.



**Figs 2.8A and B:** Cleft palate only. Lip is normal. Pre-maxilla is not involved.

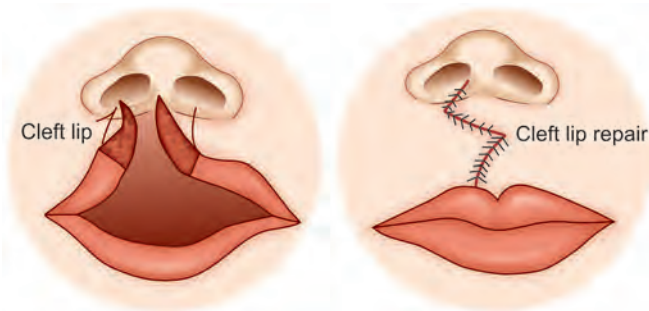
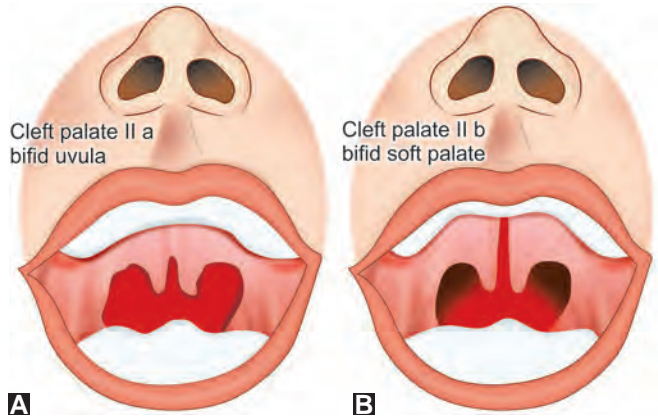


Fig. 2.9: Steps of cleft lip repair.

**Principles of cleft lip repair**

- ❖ "Rule of 10" should be fulfilled
- ❖ Before 6 months, it should be operated
- ❖ Infection should not be present
- ❖ Millard advancement flap is commonly used for unilateral cleft lip repair
- ❖ Bilateral cleft lip repair can be done either in a single or two stages (with 6 months gap between each stage)
- ❖ One stage bilateral cleft lip repair is done using *Veau III method/ Millard's single stage/Black method*
- ❖ Proper markings are made prior to surgery and incision should be over full thickness lip
- ❖ Often 1:2,00,000 adrenaline injection is used to achieve haemostasis
- ❖ Three-layer lip repair should be done (mucosa, muscle and skin)
- ❖ Cupid's bow should be horizontal
- ❖ Continuity of white line should be maintained
- ❖ Vermilion notching should not be there



Figs 2.11A and B: (A) Cleft palate Type II a—bifid uvula; (B) Cleft palate Type II b—bifid soft palate (entire soft palate).

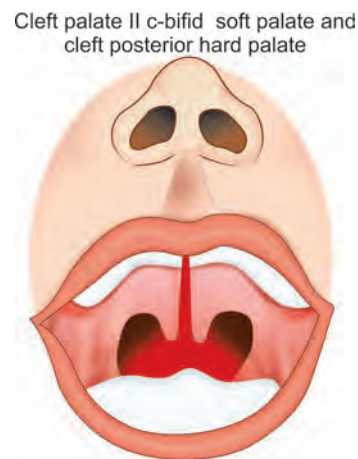
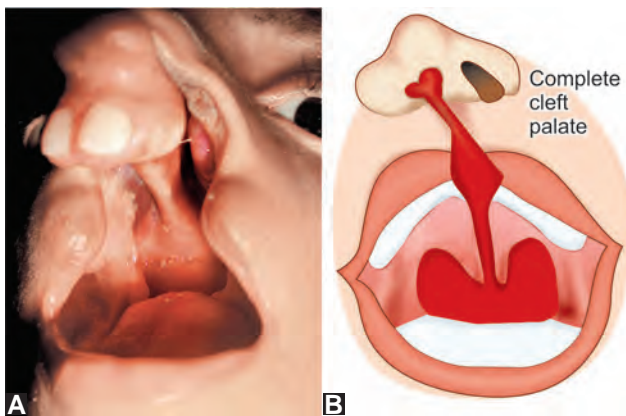


Fig. 2.12: Cleft palate Type II c—bifid soft palate entire length with cleft of posterior hard palate (anterior palate is normal).

- ❖ Chronic otitis media with deafness may occur.
- ❖ Swallowing difficulties to certain extent and speech problems can occur.
- ❖ Cosmetic problems can occur.



Figs 2.10A and B: (A) Cleft palate with cleft lip in a child. Child also is suffering from congenital cardiac defects; (B) Complete cleft palate Type I.

- ❖ Incomplete fusion of these three components can cause incomplete cleft palate beginning from uvula towards posteriorly at various lengths. So it could be Type II a—bifid uvula, Type II b—bifid soft palate (entire length) or Type II c—bifid soft palate and posterior part of hard palate (but anterior part of hard palate is normal).
- ❖ Small maxilla with crowded teeth, absent/poorly developed upper lateral incisors.
- ❖ Bacterial contamination of upper respiratory tract with recurrent infection is common.

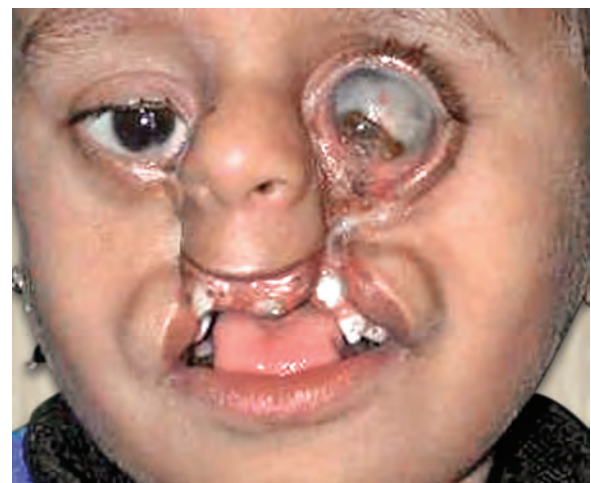

Fig. 2.13: Bilateral congenital craniofacial cleft (Courtesy: Dr Sathish Bhat, Plastic Surgeon, Mangaluru).

Bleeding gums in uraemia are not so spongy as in scurvy: in fact, they may look nearly normal.—Frederic J Wright



## Treatment for Cleft Palate

### Criteria for surgery

- ❖ 10 kg weight
- ❖ 10 months of age (10–18 months)
- ❖ 10 gm % haemoglobin

- ◆ Cleft palate is usually repaired in 12–18 months. Early repair causes retarded maxillary growth (probably due to trauma to growth center and periosteum of the maxilla during surgery if done early). Late repair causes speech defect.
- ◆ Both soft and hard palates are repaired.
- ◆ Abnormal insertion of tensor palati is released. *Mucoperiosteal flaps* are raised in the palate which is sewed together. If maxillary hypoplasia is present, then *osteotomy of the maxilla* is done. With *orthodontic help teeth extraction and alignment* of dentition is done.
- ◆ Regular examination of ear, nose and throat during follow up period.
- ◆ Postoperative speech therapy.
- ◆ Whenever complicated problems are present, staged surgical procedure is done.
- ◆ *Wardill- Kilner push back operation*—by raising mucoperiosteum flaps based on greater palatine vessels.
- ◆ *Secondary management:*
  - ▶ Hearing support is given using hearing aids if defect is present; control of otitis media.
  - ▶ Speech problems occur due to velopharyngeal incompetence; articulation problems also can occur – speech therapy is given. It is corrected by pharyngoplasty, veloplasty, speech devices.
  - ▶ Dental problems like uneruption, unalignments are common. They should be corrected by proper dentist opinion, and reconstructive surgery.
  - ▶ Orthodontic management with alveolar bone graft, maxillary osteotomy—done in 8–11 years of age.
  - ▶ Veloplasty, dental implants, rhinoplasty, orthognathic surgeries, etc.

### Principles of palatoplasty

- ❖ Timing is between 10–18 months
- ❖ Mucoperiosteum flap is raised
- ❖ Palatal defect is closed using 3 layers—nasal, muscle and oral layers
- ❖ Hook of pterygoid hamulus is fractured to relax tensor palata muscle to relieve tension on suture line

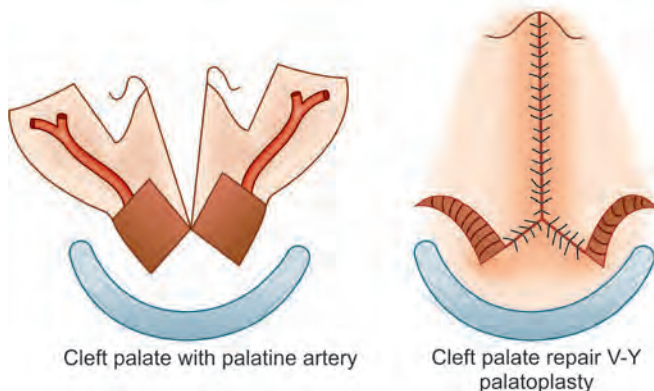


Fig. 2.14: V-Y palatoplasty.

## MAXILLOFACIAL INJURIES

It may be due to road traffic accidents, assaults, bullet injuries or sport injuries.

### Classification

Fracture in maxillofacial region can be grouped as:

- ◆ Fracture lower third that comprises mandible.
- ◆ Fracture middle third that comprises maxilla, zygoma and nose.
- ◆ Fracture upper third of the face involving part of the orbit, frontal bones.

Maxillofacial fracture also can be grouped as:

- ◆ Fractures of the face which do not involve the dental occlusion—fractures of zygoma and nose.
- ◆ Fracture which involves the dental occlusion—fracture mandible and maxilla.

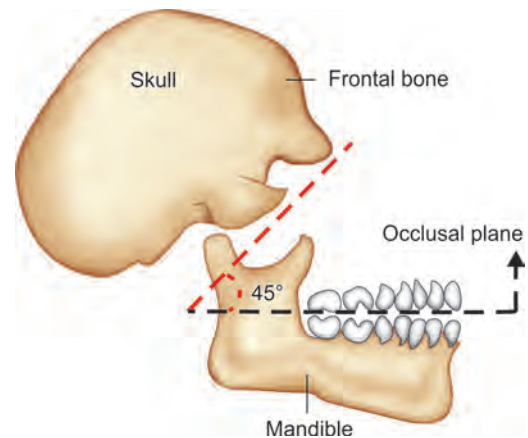


Fig. 2.15: Relation between middle third and cranium in 45° plane.

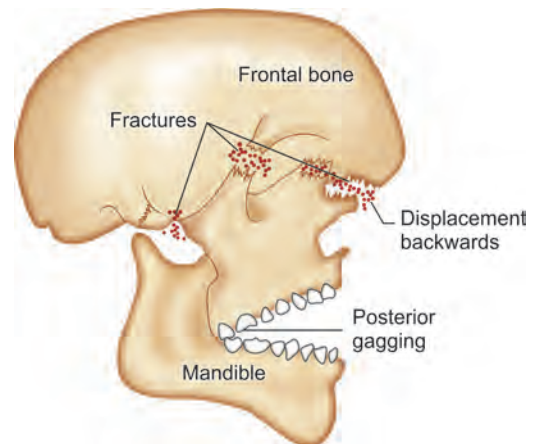


Fig. 2.16: Posterior gagging of occlusion due to backward displacement of fracture segment in middle third fracture.

### Soft Tissue Injuries

- ◆ Lacerations, contusions, cut wounds, etc.
- ◆ Eyelid injuries with black eyes.
- ◆ *Facial nerve injury:* Primary repair is required.
- ◆ *Parotid duct injury:* Here primary anastomosis of the injured duct is done, with a fine polythene cannula is kept as a stent inside the duct which will be removed in 14 days.

- ◆ *Lacrimal apparatus injury*: Here the duct is sutured with a fine nylon thread in the canaliculus which is kept for 3 months.

### Injuries to the Facial Bones

- ◆ *Fracture nose*: Nasal bones are most commonly injured bones in face. Patient presents with pain and swelling in the nose with deviation and displacement. Here reduction of the fractured nasal bones and nasal septum under general anaesthesia is done. Later position is maintained by nasal packs from inside (which is removed in 7 days) and by a nasal plaster from outside (which will be kept for 14 days). Procedure is done using Walsham's and Asch's forceps.
- ◆ Injuries to the *maxilla*.
- ◆ *Zygomatic* bone injuries.
- ◆ *Mandibular* bone fracture and mandibular dislocation.
- ◆ *Orbital bone fracture*: Presents with diplopia, enophthalmos, sensory loss in the area of infraorbital nerve.
- ◆ Infraorbital ecchymosis of the orbit is called *Panda sign*.

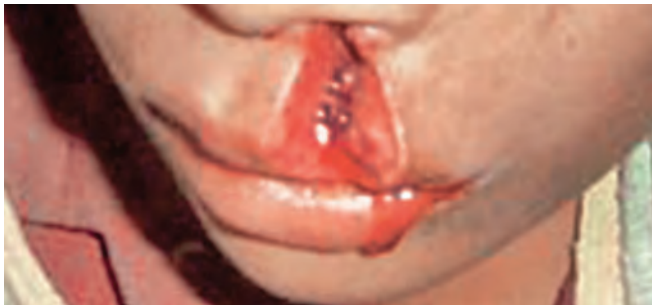

Fig. 2.17: Soft tissue injury face involving upper lip.

### Clinical Features

- ◆ Localised swelling due to haematoma.
- ◆ Facial oedema.
- ◆ Bleeding with open wounds.
- ◆ Asymmetry which is clinically confirmed by observing supraorbital ridges, nasal bridge.
- ◆ Localised tenderness.
- ◆ Step deformity.
- ◆ Trismus.
- ◆ Diplopia.
- ◆ Features of associated injuries like intracranial, abdominal or thoracic injuries.

### Investigations

- ◆ X-ray face.
- ◆ CT scan of head and jaw.

#### General treatment for faciomaxillary injuries

- ❖ Suturing of soft tissues
- ❖ Airway maintenance
- ❖ Control of bleeding
- ❖ Pain relief
- ❖ Control of infection
- ❖ Treating the individual fractures

### PRIMARY CARE (EARLY CARE) IN MAXILLOFACIAL INJURIES

Injury can be isolated as single bone fracture or multiple bone fractures. Real primary care is usually not required except when there is mechanical respiratory block causing airway obstruction.

### Respiratory Obstruction

#### Causes

- ◆ Oronasal airway block can occur by blood clot, vomitus, foreign body, dentures, teeth, saliva, bone pieces, etc.
- ◆ Backward falling of tongue can cause obstruction of the nasopharynx and oropharynx. It is common in bilateral mandibular fracture.
- ◆ Occlusion of the nasopharynx and oropharynx can occur in fracture maxilla with posterior and inferior displacement.
- ◆ Haematoma in floor of the mouth or posterior oral cavity can cause airway block.
- ◆ Oedema of larynx/tongue/posterior third of oral cavity/pharynx.
- ◆ Surgical emphysema.

#### Treatment

- ◆ Cleaning of the oral and nasal cavities to remove obstructing agents like clot, dentures, teeth or bone. Gauze swabbing and suction.
- ◆ Fallen tongue should be placed forward using finger and often temporary alignment of the occlusion may be needed.
- ◆ Maxillary disimpaction is done when needed in fracture maxilla.
- ◆ Positioning of the patient is important. Prone/semiprone position with head towards one side is the safest position. If this is not possible, then patient may be placed in sitting position which also improves the breathing. Placing the patient flat on his back in supine position should be avoided as much as possible.
- ◆ Tracheostomy should be done when needed without delay as it will be life-saving by facilitating the easy airway and breathing.

### Control of Pain

Analgesics like NSAIDs are used to control pain. Morphine and analogues are not used as they may suppress the respiration. They may mask the pain of alarming severe injury in chest, abdomen or other areas, or they may interfere with pupillary reaction and neurological signs in the presence of intracranial injuries.

### Control of Infection

Antibiotics are needed. Tetanus toxoid and often antitetanus globulin (ATG 3000 units IM) are required.

### Haemorrhage in Maxillofacial Injuries

Haemorrhage in maxillofacial injuries is usually not life-threatening. But it should be identified and controlled properly. In association with other internal injury, such haemorrhage may be important to cause the circulatory failure.

*Preauricular ulcer is a late stage of an abscess due to a congenital preauricular sinus. It refuses to heal for infection is maintained from the sinus.*

— Francis AR Stammers

Haemorrhage may be due to:

- ◆ Soft tissue bleeding.
- ◆ Bleeding from inferior alveolar artery, palatine vessels.
- ◆ Nasal bleeding.

## Control of Bleeding

- ◆ Blood transfusion, IV fluids, resuscitation.
- ◆ Nasal packs.
- ◆ Fracture correction.
- ◆ Ligation of the bleeder.
- ◆ Cauterisation.
- ◆ Packing the area.
- ◆ Under running the bleeding field.
- ◆ Embolisation.
- ◆ External carotid artery ligation above the level of the origin of the superior thyroid artery.

Fractures not involving occlusion	Fractures involving occlusion
<b>Central</b>	<b>Dentoalveolar</b>
<ul style="list-style-type: none"> <li>• Fracture nasal bones and/or nasal septum</li> <li>• Fracture of frontal process of maxilla</li> <li>• Fractures of above two extending into ethmoid-nasoethmoid</li> <li>• Fractures above three which extend into frontal bone—fronto-orbito-nasal dislocation</li> </ul>	<b>Subzygomatic</b> <ul style="list-style-type: none"> <li>• Le Fort-I—low level either unilateral or bilateral</li> <li>• Le Fort II—pyramidal either unilateral or bilateral</li> </ul>
<b>Lateral</b>	<b>Suprazygomatic</b>
<ul style="list-style-type: none"> <li>• Fractures involving zygomatic bone, arch and maxilla excluding the dentoalveolar component</li> </ul>	<ul style="list-style-type: none"> <li>• Le Fort III—high level</li> <li>• Craniofacial disjunction—unilateral or bilateral</li> </ul>

### Le Fort classification

(Rene Le Fort—French surgeon classified these fractures by dropping rocks on the face of the cadavers and later dissected the area for study and research and published paper in 1911)

Types	Features
<b>Le Fort I (Guerin's fracture—low level) (floating fracture, horizontal fracture of maxilla)</b> <ul style="list-style-type: none"> <li>• It runs horizontally above the floor of the nasal cavity involving lower third septum, palate, alveolar process of maxilla and lower third of pterygoid plates of maxilla</li> </ul>	<ul style="list-style-type: none"> <li>• Bleeding from nose</li> <li>• Posterior gagging of occlusion</li> <li>• Upper lip swelling</li> <li>• Palatal ecchymosis</li> <li>• Occlusion derangement</li> <li>• Floating maxilla</li> </ul>
<b>Le Fort II (pyramidal fracture)</b>	<ul style="list-style-type: none"> <li>• Oedema of middle third face</li> <li>• Both sides circumorbital and subconjunctival ecchymoses</li> </ul>

Contd...

<ul style="list-style-type: none"> <li>• From the nasal bones at top-most, fracture runs laterally towards lacrimal bones, medial wall of orbit, infraorbital margin, through medial to infraorbital foramen and backwards below the zygomaticomaxillary area through lateral wall of maxillary sinus and pterygoid plates. Zygoma is intact with skull base</li> </ul>	<ul style="list-style-type: none"> <li>• Nasal bleeding/obstruction/deformity</li> <li>• Deformity of face (dish face), diplopia</li> <li>• Retroposition of maxilla with posterior gagging</li> <li>• Limitation of ocular movements, CSF rhinorrhoea</li> <li>• Tenderness and separation of infraorbital margin</li> </ul>
<b>Le Fort III (craniofacial disjunction, high level)</b> <ul style="list-style-type: none"> <li>• Here fracture runs parallel to skull base. It passes through the nasal bone, lacrimal bone, ethmoid bone, optic foramen, inferior orbital fissure, pterygomaxillary fissure and lateral orbital wall with frontozygomatic suture with zygomatic arch</li> </ul>	<ul style="list-style-type: none"> <li>• Lengthening of face</li> <li>• Enophthalmos, ocular level depression</li> <li>• Hooding of eyes, occlusal plane tilting</li> <li>• Entire facial skeleton moves as a single block</li> <li>• Tenderness and separation of suture line</li> <li>• Diplopia</li> <li>• Trismus, teeth mal-alignment</li> </ul> <p><i>Guerin sign:</i> Haematoma at greater palatine foramen</p>

## Associated Injuries

All associated injuries should be assessed properly and individually. On priority basis it should be treated.

- ◆ Soft tissue injuries.
- ◆ Cranial injuries.
- ◆ Orbital injuries.
- ◆ Intra-abdominal/thoracic/pelvic injuries.

## ■ FRACTURE MIDDLE THIRD AREA

It includes:

- ◆ Maxillae, zygomatic bones, palatine bones, nasal bones, lacrimal bones, inferior conchae (one on each side).
- ◆ The vomer, ethmoid and its attached conchae, pterygoid plates of sphenoid.

### Note:

Fracture middle third includes fracture maxilla, zygoma and nasal bones.

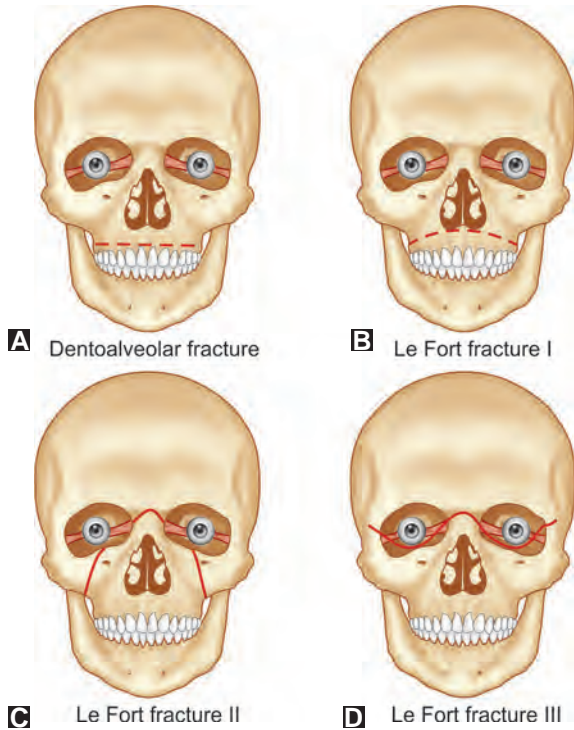
## Clinical Features

- ◆ Oedema face, subconjunctival haemorrhage, ocular ecchymosis.
- ◆ Bleeding from the nose.
- ◆ Diplopia due to trapping of the extra-ocular muscles in the fracture segments.
- ◆ Anaesthesia of the cheek.
- ◆ Trismus and malalignment of teeth.
- ◆ *Guerin's sign:* Haematoma at greater palatine foramen.
- ◆ Always patient should be examined and observed for CSF leak and intracranial injuries.

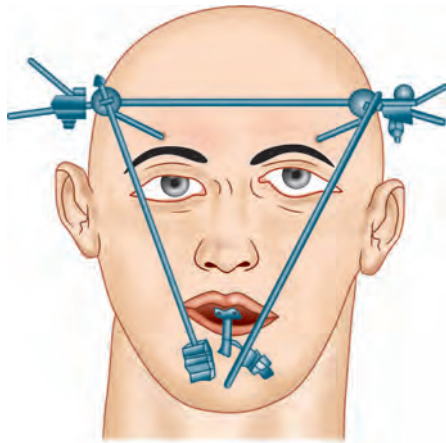
## Investigations

- ◆ CT scan head.
- ◆ X-ray skull.

Contd...



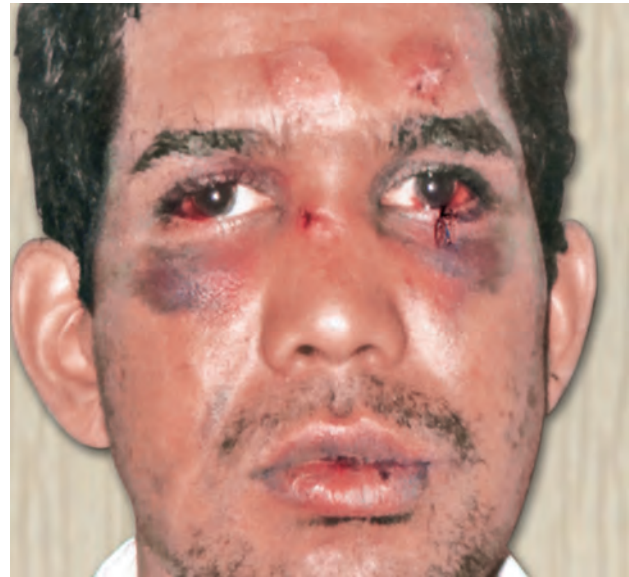**Figs 2.18A to D:** Le Fort classification—different types and also dentoalveolar fracture (Refer table for details).



**Fig. 2.19:** Fixation of the splint to skull. It is often used with gunning splints to fix it to skull.

**Treatment**

- ◆ It should be managed in a center for maxillofacial injuries.
- ◆ Antibiotics.
- ◆ Tracheostomy.
- ◆ Associated zygoma and nasal fractures are reduced first.
- ◆ Direct wire suturing of the zygomaticofrontal region.
- ◆ Fixation of teeth in occlusion using eyelet wires, bars or cap splints.
- ◆ Once reduced, fracture bones are immobilised using extra-oral rods called as *Mount Vernon box frame*.
- ◆ Initially intravenous fluids and blood transfusions are required. Later Ryle’s tube feeding is done.
- ◆ Proper ophthalmic consultation is necessary when there are orbital injuries.



**Fig. 2.20:** Photo showing bilateral maxillary fracture.

**ZYGOMATIC COMPLEX FRACTURE**

**Classification**

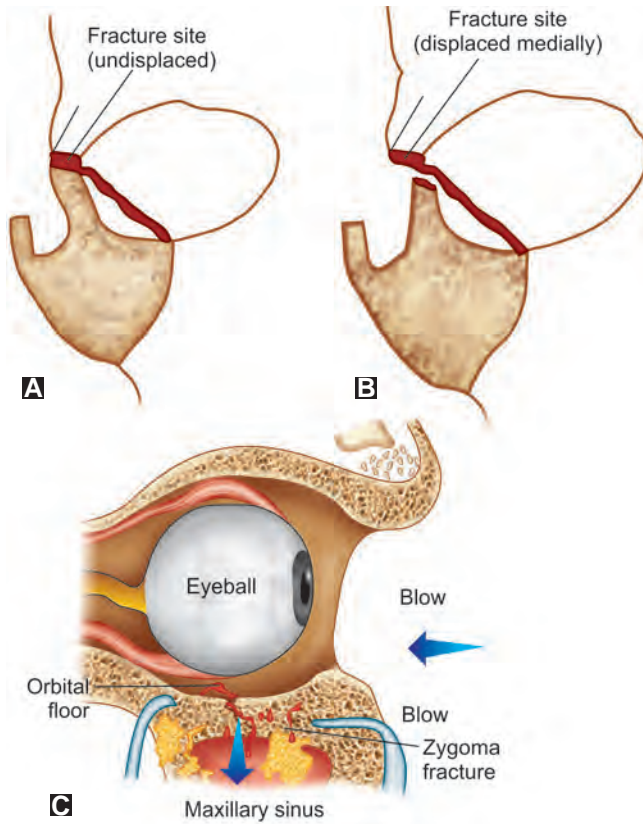
- ◆ *Simple fracture which is stable and undisplaced*— here fracture line passes across the infraorbital foramen downwards over anterior wall of the antrum.
- ◆ *Simple fracture which is displaced medially*. It may be associated with rotation/tilt in vertical axis, either medial tilt or lateral tilt. Infraorbital nerve may get compressed or branches of superior dental nerve may get torn.
- ◆ *Unstable fracture with rotation around horizontal axis with medial tilt or lateral tilt*.
- ◆ *Comminuted fracture* extending into the floor of the orbit.
- ◆ *Fracture of the zygomatic arch* causes a localised depression of the arch which displaces medially and tends to impinge on the coronoid process of the mandible.
- ◆ *‘Blow-out’ fracture* of the orbit is due to direct blunt trauma on the eyeball causing depressed comminuted fracture of the orbital floor with herniation of the orbital fat into the antrum.
- ◆ *Enbloc dislocation of zygomatic bone* medially/inferiorly/posterolaterally.

**Clinical Features**

- ◆ Swelling and bruising in the cheek with subconjunctival haemorrhage.
- ◆ Flattening of the cheek prominence.
- ◆ Step in the margin of the bony orbit at the infraorbital foramen.
- ◆ Sensory loss over the supply of the branches of the superior orbital nerve— teeth on the affected area are anaesthetic on percussion.
- ◆ Sensory loss over the supply of the infraorbital nerve usually

*Ankylosis of mandible joint causes receding of chin giving a characteristic shrew mouse profile.*

—Leon Dufourmentel



**Figs 2.21A to C:** (A and B) Diagrams showing different types of zygomatic fractures, (C) Blow-out fracture.

over infraorbital region, upper lip and alar region of the nose—common.

- ◆ Enophthalmos is due to herniation of the orbital fat across the fracture floor of the orbit into the antrum.
- ◆ Diplopia is due to entrapment of the inferior rectus muscle preventing upward rotation of the eyeball while looking up.
- ◆ Trismus with marked restriction of the lateral movements.
- ◆ Epistaxis, lowering of pupil level.
- ◆ Infraorbital ecchymosis of the orbit is called as *Panda sign*.

### Investigations

- ◆ 30° occipitomental X-ray is used commonly but often obliquity of X-ray may be increased to 60°. In X-ray, findings observed are:
  - ▶ Fracture line near infraorbital foramen, zygomatic arch and lateral wall of the antrum.
  - ▶ Orbital floor line for fracture.
  - ▶ Opacity in the antrum due to blood.
- ◆ CT scan is done to see orbital depression and herniation of orbital fat.

### Treatment

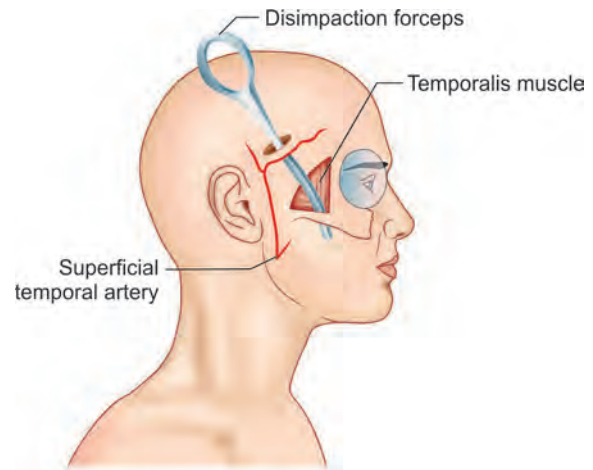
- ◆ Every patient with zygoma fracture need not require surgical correction.
- ◆ Need for surgery is decided based on clinical features.

#### Indications for surgery are:

- ❖ Infraorbital anaesthesia, trismus
- ❖ Diplopia, enophthalmos
- ❖ Flattening of the cheek
- ❖ Undisplaced fracture with infraorbital anaesthesia

### Surgical Approaches

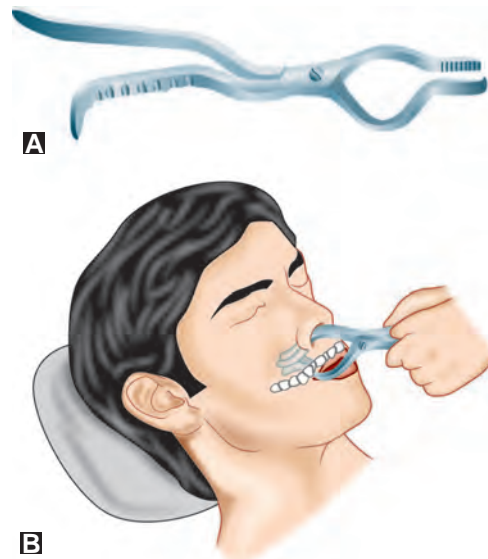
1. Closed reduction of the zygomatic arch through Gillies temporal approach:



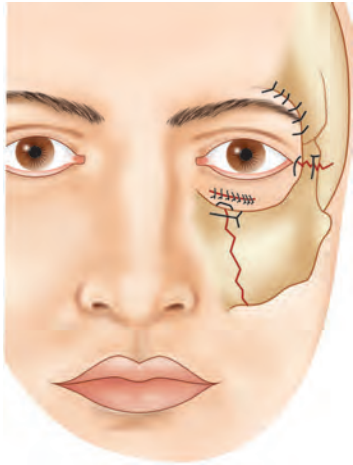
**Fig. 2.22:** Technique showing method of temporal reduction using disimpaction forceps.

An oblique skin incision of 2 cm length temporal is made between the two branches of the superficial temporal artery. Care is taken to avoid injury to artery. Whitish glistening temporal fascia is identified and incised. Zygoma elevator is introduced beneath the zygoma and fracture fragments are manipulated and elevated into proper position. An audible snap is heard when fracture gets reduced into position. Reduced, disimpacted fracture is always stable. Additional corrections in other parts can be done by different leverage actions of the elevator. Orbital rim and zygomatic arch are palpated for completion of correction. Skin wound is closed with sutures.

Elevators used are Bristow's periosteal elevator, Rowe's zygomatic elevator.



**Figs 2.23A and B:** Disimpaction of maxilla using Rowe's disimpaction forceps by downward leverage action.



**Fig. 2.24:** Fracture zygoma showing open reduction and fixation using wires directly. Two types of incisions are shown depending on the site of the fracture.

2. Internal fixation by open reduction and fixation is needed

- ▶ When fracture is unstable or
- ▶ Comminuted or
- ▶ Zygoma fracture with middle third fractures.

By proper incisions, infraorbital and zygomaticofrontal fracture sites are exposed; after open reduction, they are fixed using wires/plates and screws.

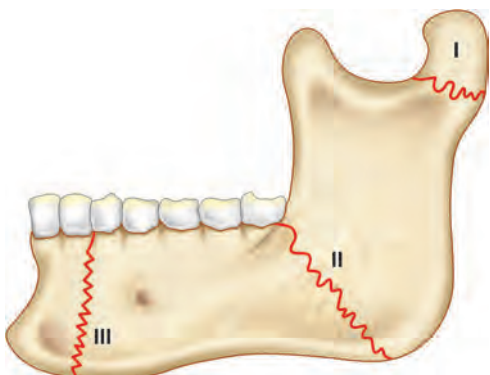
3. Exploration of the orbital floor is necessary whenever there is

- ▶ Comminuted fracture in orbital floor.
- ▶ Orbital fat herniation.
- ▶ Diplopia with entrapment of the inferior rectus muscle.

## ■ FRACTURE OF THE MANDIBLE

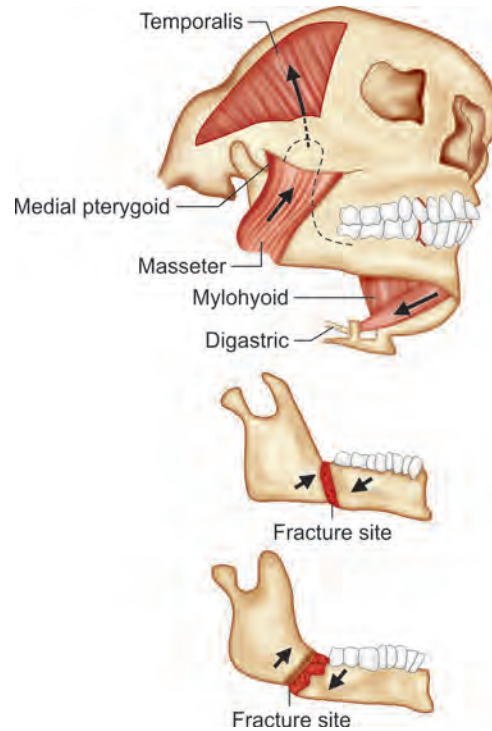
### Types

- I. At the *neck of the condyle* (35%), as it is the weakest point. The condyle is displaced in front and medially often with dislocation. Painful jaw movement is the clinical features. It may be unilateral or bilateral.
- II. At the *angle of the mandible*: If fracture is upwards and inwards, it is impacted and undisplaced. So it is a favourable fracture. If fracture is downwards and outwards, it gets displaced and so it is an unfavourable fracture. It needs open reduction using wires.

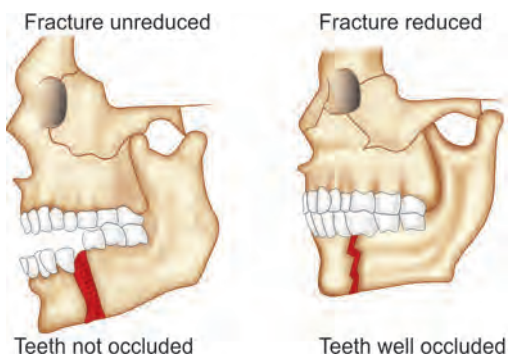


**Fig. 2.25:** Types of mandibular fractures.

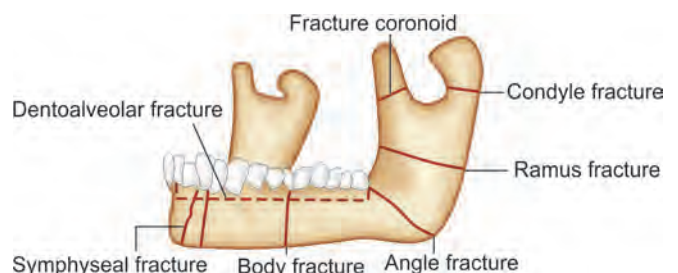
- III. Fracture *near the mental foramen through the canine fossa*. This fracture causes displacement. Such bilateral fractures can cause pull on digastric and geniohyoid muscles precipitating fall of *tongue backwards* which will block the airway.



**Fig. 2.26:** Muscle actions in mandible fracture causing different displacements.



**Fig. 2.27:** Unreduced and reduced fracture mandible.



**Fig. 2.28:** Different sites of fracture mandible.

## Other Classifications

Classification of the fracture mandible	
Depending on the type	Depending on the anatomical site
• Simple	• Dentoalveolar fracture
• Compound	• Condylar fracture
• Comminuted	• Coronoid fracture
• Pathological	• Fracture ramus of the mandible
• Green stick fracture in children	• Fracture angle of the mandible
	• Fracture in the body of the mandible
	• Symphyseal region fracture

*Guardsman fracture* is direct fracture of symphysis and indirect fractures of both the condyles of the mandible. In olden days guards of the queen who are in attention position used to faint and fall forward to get these fractures.

Dentoalveolar fracture	
Features	Management
• Horizontal fracture below the alveolar margin	• Look for other injuries in face
• Dentoalveolar segment will be freely mobile	• X-ray face to see injuries
• Tooth may get split vertically/horizontally	• Dentoalveolar segment reduction and placing jaws in central occlusion position
• Derangement in occlusion and alignment	• Stabilisation using interdental wires or arch bars
• Gingival laceration	• Liquid diet for 3–4 weeks
• Bleeding	
• Infection and late osteomyelitis of mandible	

## Clinical Features

- ◆ Pain and tenderness in the lower jaw with bruising over the surface.
- ◆ Haematoma in the floor of the mouth is called as *Coleman's sign*.
- ◆ Difficulty in opening the mouth, speech and swallowing.
- ◆ Anaesthesia of the lower lip due to compression of inferior dental nerve.
- ◆ Deranged dental occlusion.
- ◆ Step deformity.

## Investigations

- ◆ X-ray of the mandible.
- ◆ Orthopantomogram (OPG), CT head and face.

## Treatment

- ◆ Antibiotics to prevent formation of osteomyelitis of the mandible.
- ◆ Open fixation of the fracture segments using silver wires for 4–6 weeks.
- ◆ Fixation by:
  - ▶ Interdental wiring.
  - ▶ Using arch bars.
  - ▶ Silver alloy or plastic caps.
- ◆ Only fluid diet for 6 weeks.
- ◆ Irrigation wash to the oral cavity to maintain the hygiene.

### Complications of fracture mandible

- ❖ Obstruction of the airway
- ❖ Osteomyelitis of the mandible
- ❖ Trismus
- ❖ Speech disturbances

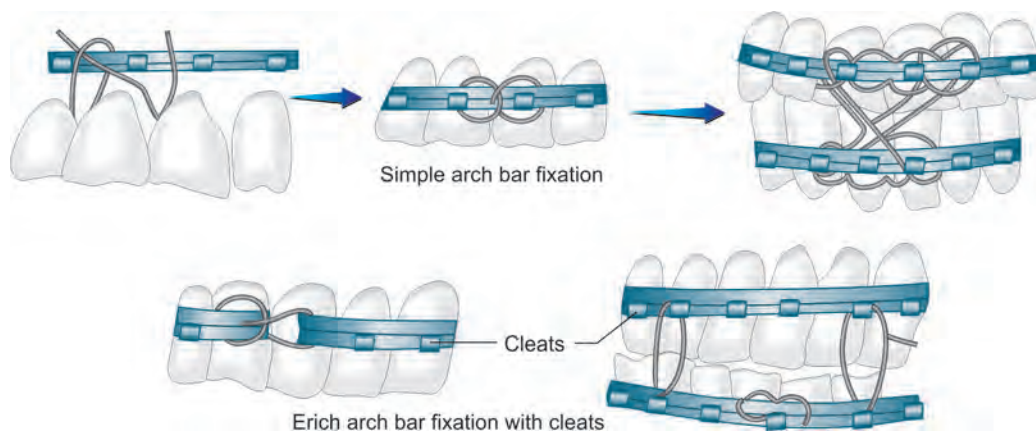


Fig. 2.29: Arch bar wiring. Figure shows both simple and Erich arch bar wiring with cleats to pass wire.

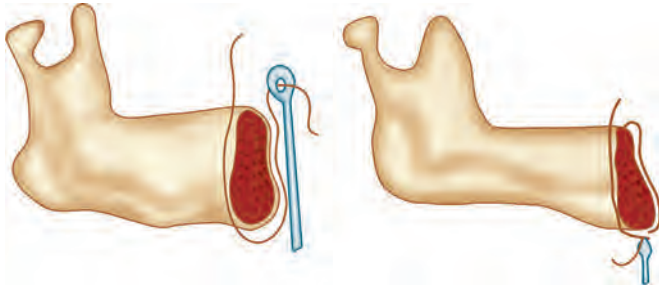


Fig. 2.30: Circummandibular wiring used in gunning splints.

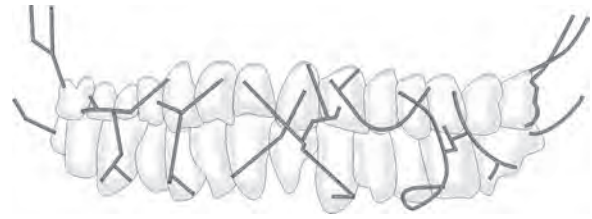


Fig. 2.31: Interdental wiring. It is commonly used and accepted method of wiring.

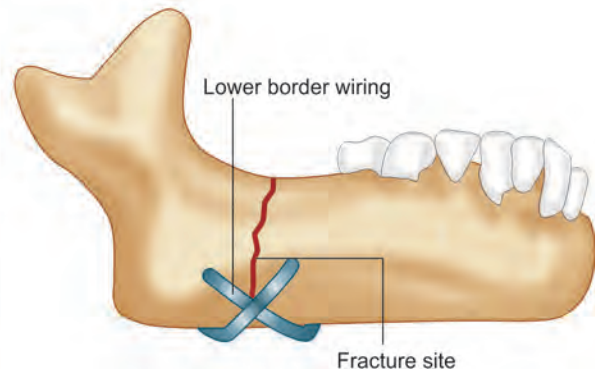
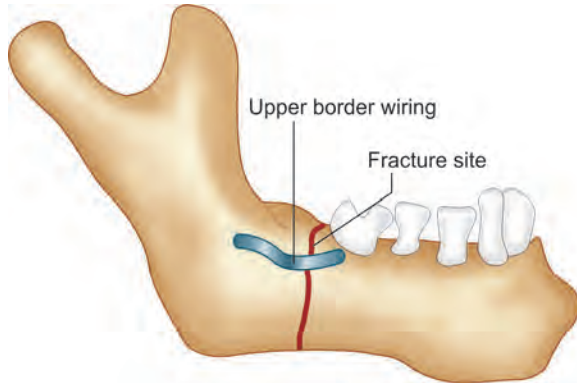


Fig. 2.32: Upper and lower border wiring. It is used to fix the mandibular fractures and is often done together with other fracture fixations in the face.

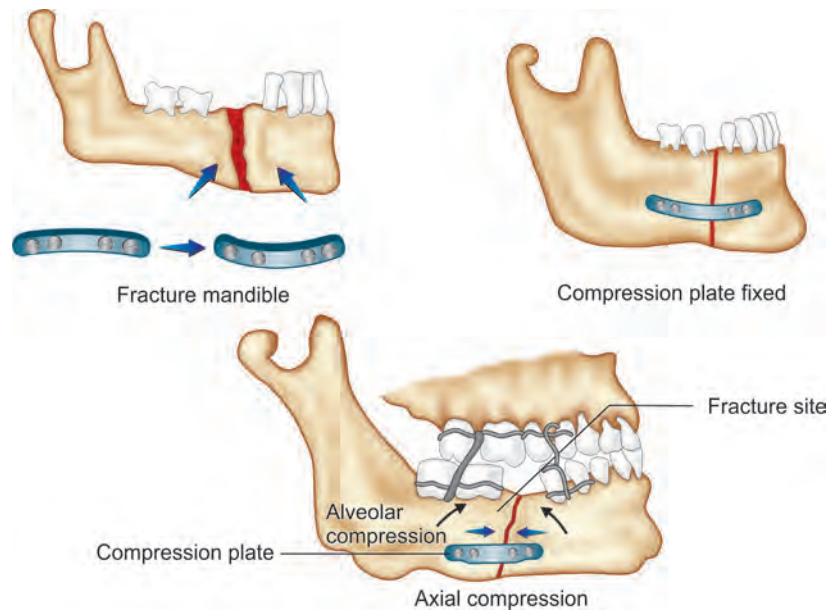


Fig. 2.33: Compression plating of a mandibular fracture. Note the different methods.

## DISLOCATION OF THE MANDIBLE

- ◆ It occurs at *temporomandibular joint*.
- ◆ Unilateral dislocation after trauma is common.
- ◆ Bilateral dislocation occurs during yawning and it is recurrent.
- ◆ **Clinical features** are difficulty in opening the mouth with pain and tenderness over the joint.

## Treatment

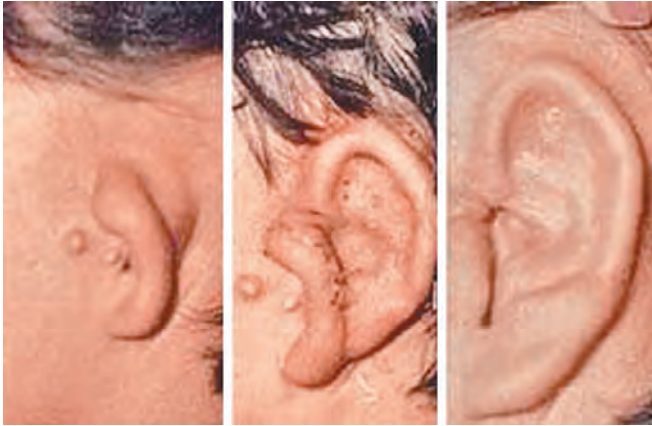- ◆ Reduction of dislocation under general anaesthesia.
- ◆ If there is associated fracture mandible, it should be dealt with accordingly.

*Many receive advice, only wise profit from it.*



### Treacher-Collins syndrome

- ❖ Mandibulofacial dysostosis
- ❖ Hypoplasia of the zygomatic bone and mandible
- ❖ Antimangoloid slant to the palpebral fissure
- ❖ Coloboma of lower eyelid
- ❖ Low ear lobule with deficient middle ears
- ❖ Familial—3rd arch syndrome (Mandibulofacial dysostosis)



**Fig. 2.34:** Microtia which is corrected later  
(Courtesy: Dr Sathish Bhat, Plastic Surgeon, Mangaluru).

## JAW TUMOURS

### Classification

#### I. Swelling arising from the gums (Epulis):

- ▶ Congenital epulis.
- ▶ Fibrous epulis.
- ▶ Pregnancy epulis.
- ▶ Giant cell epulis.
- ▶ Myelomatous epulis.
- ▶ Sarcomatous epulis.
- ▶ Carcinomatous epulis.

#### II. Swelling arising from the dental epithelium (Odontomes):

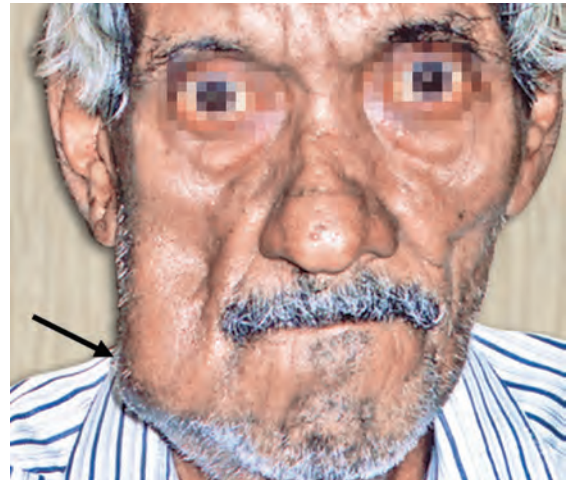- ▶ Ameloblastoma.
- ▶ Compound odontome.
- ▶ Enameloma.
- ▶ Cementoma.
- ▶ Dentinoma.
- ▶ Odontogenic fibroma and myxoma.
- ▶ Radicular odontome.
- ▶ Composite odontome.

#### Cysts arising in relation to dental epithelium:

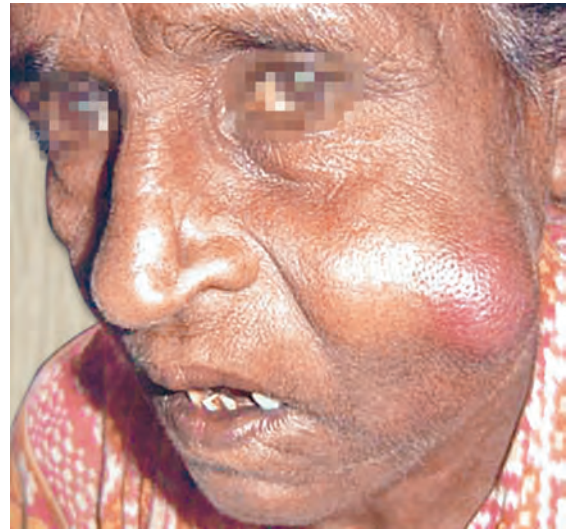- ◆ Dental cyst.
- ◆ Dentigerous cyst.

#### III. Swelling arising from the mandible or maxilla:

- ▶ Osteoma and osteoblastoma.
- ▶ Torus palatinus and mandibularis.
- ▶ Fibrous dysplasia.
- ▶ Osteoclastoma (Common in mandible).
- ▶ Osteosarcoma.



**Fig. 2.35:** Jaw tumour (Right sided).



**Fig. 2.36:** Upper jaw tumour (Left sided).

- ▶ Secondaries.
- ▶ Giant cell reparative granuloma.

#### IV. Surface tumours:

- ▶ Tumours from the surface which extend into the jaw.
- ▶ Ossifying fibroma.
- ▶ Osteofibrosis of maxilla.
- ▶ Ivory osteoma of jaw.
- ▶ Leontiasis ossea (diffuse osteitis).
- ▶ Carcinoma extending into the jaw.

## EPULIS (Greek—means upon gum)

Swelling arising from the mucoperiosteum of gums.

### Congenital Epulis

- ◆ It is a benign condition seen in a *newborn* arising from gum pads.

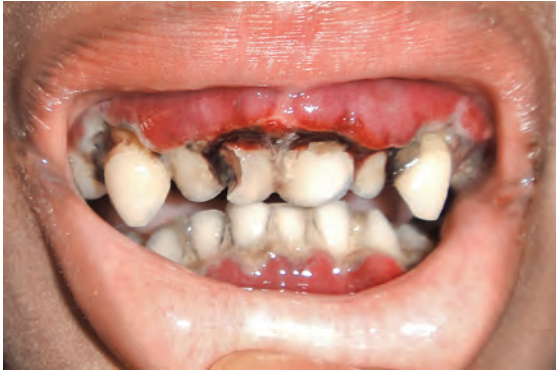

Fig. 2.37: Epulis.

- ◆ It is a variant of granular cell myoblastoma originating from gums.
- ◆ It is more common in *girls*. It is more common in *upper jaw*, common in canine or premolar area.
- ◆ It is not a malignant condition.
- ◆ *Clinical feature*: Well localised swelling from the gum which is firm and bleeds on touch.
- ◆ *Treatment*: Excision.

#### Fibrous Epulis

- ◆ It is a benign condition, can occur in any individual.
- ◆ It is red, firm/hard, sessile/pedunculated.
- ◆ It is the commonest type.
- ◆ It is fibroma arising from periodontal membrane.
- ◆ *Clinical features*: Painless, well localised, hard, non-tender, grey pink swelling in the gum which bleeds on touch.
- ◆ *Differential diagnosis*: Squamous cell carcinoma from the gum.
- ◆ *Investigations*
  - ▶ X-ray jaw.
  - ▶ Orthopantomogram
  - ▶ Biopsy from the lesion.
- ◆ *Treatment*: Excision with extraction of the adjacent tooth. Recurrence can if root is not removed properly.

#### Pregnancy Epulis

- ◆ It occurs in *pregnant women* due to *inflammatory gingivitis*.
- ◆ Usually during 3rd month of pregnancy.
- ◆ *Clinically* it resembles fibrous epulis or pyogenic granuloma.
- ◆ It usually resolves after delivery. Otherwise it should be excised.

#### Myelomatous Epulis

- ◆ It is seen in *leukaemic patients*.
- ◆ *Investigated* for leukaemia by peripheral smear, bone marrow biopsy.
- ◆ *Treatment*: For leukaemia.

#### Granulomatous Epulis

It is a mass of granulation tissue in the gum around a caries tooth. It forms a localised soft/firm/fleshy mass in the gum which bleeds on touch.

#### Giant Cell Epulis

Osteoclastoma causing ulceration and haemorrhage of gum.

#### Carcinomatous Epulis

Squamous cell carcinoma of the alveolus and gum presenting as localised, hard, indurated swelling with ulceration.

#### Fibrosarcomatous Epulis

Fibrosarcoma arising from fibrous tissue of the gum.

#### Epulis

- ❖ Congenital
- ❖ Fibrous—commonest
- ❖ Granulomatous
- ❖ Pregnancy
- ❖ Carcinomatous
- ❖ Myelomatous
- ❖ Fibrosarcomatous

#### Odontogenic tumours

##### Epithelial tumours

- ❖ Ameloblastoma
- ❖ Calcifying odontogenic tumour
- ❖ Odontogenic adenomatoid tumour
- ❖ Composite odontoma, which may be either complex or compound. It is odontogenic hamartoma contains all 4 layers, dentin, enamel, cementum and pulp

##### Mesodermal tumours

- ❖ Odontogenic fibroma, myxoma
- ❖ Cementoma, dentinoma

##### Malignant odontogenic tumours

- ❖ Malignant ameloblastoma
- ❖ Fibrosarcoma

#### AMELOBLASTOMA (Adamantinoma, Eve's Disease, Multilocular Cystic Disease of the Jaw)

- ◆ It arises from the dental epithelium probably from the *enamel/dental lamina*.
- ◆ It occurs commonly in *mandible* or maxilla.
- ◆ Occasionally, it is seen in the base of the skull in relation to Rathke's pouch or in tibia.
- ◆ Histologically, it is a variant of *basal cell carcinoma*.
- ◆ It is a *locally malignant tumour*.
- ◆ It neither spreads through lymph node nor through blood. Hence it is *curable*.

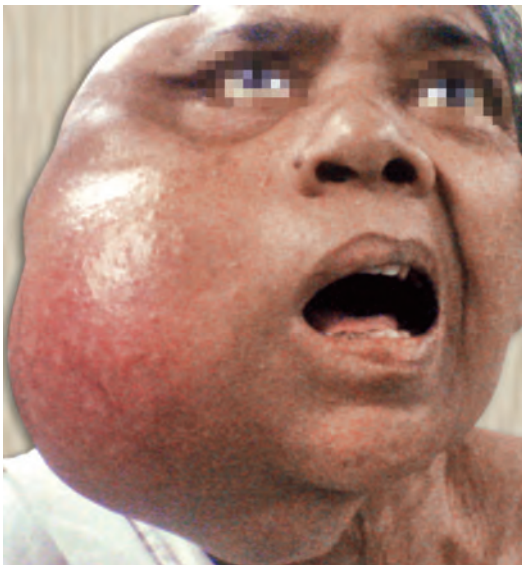- ◆ It is usually unilateral.
- ◆ It can occur in a pre-existing dentigerous cyst.
- ◆ It is usually multilocular cystic spaces but can be unilocular also.
- ◆ Histologically cords of odontogenic epithelium, connective tissue, stellate reticulum like cells with columnar ameloblast like cells.

### Clinical Features

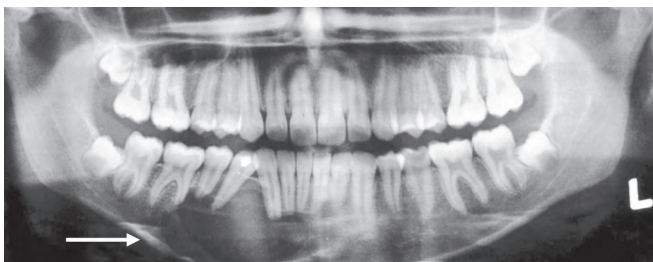
- ◆ Swelling in the jaw usually in the mandible near the angle which attains a large size, extending to vertical ramus—*Eggshell crackling*.
- ◆ It is a gradually progressive, painless swelling which is smooth and hard with intact inner table (enlarges externally).
- ◆ Lymph nodes are not enlarged.
- ◆ *Outer table expansion*.
- ◆ It is common in males, common in 4th to 5th decades.

### Differential Diagnosis

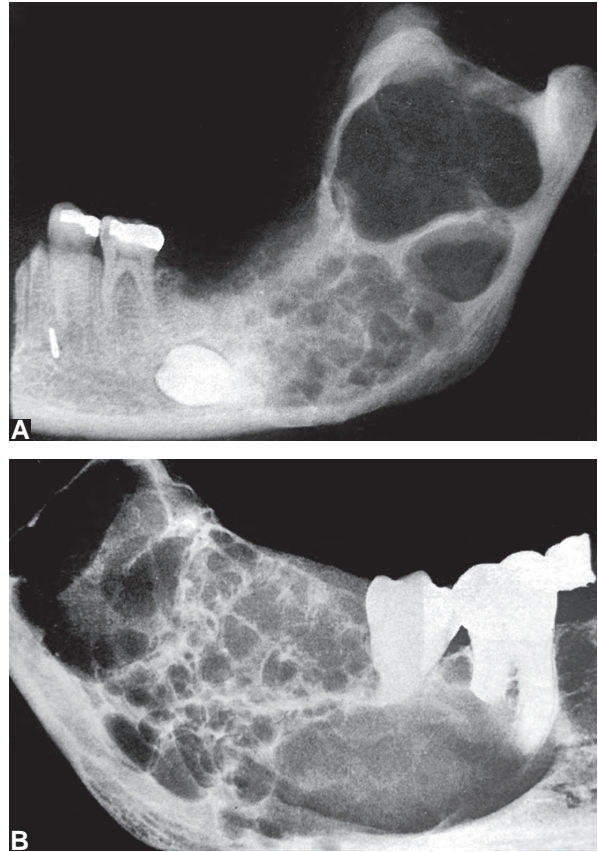
- ◆ Osteoclastoma of the mandible: Here inner table is not intact.
- ◆ Dentigerous cyst.
- ◆ Dental abscess.
- ◆ *Giant cell reparative granuloma (Jaffe's tumour)*: It is a swelling which occurs due to haemorrhage within the



**Fig. 2.38:** Large jaw tumour—could be adamantinoma/osteoclastoma.



**Fig. 2.39:** Orthopantomogram (OPG) X-ray showing unilocular odontogenic tumour in lower jaw.



**Figs 2.40A and B:** X-ray (two different X-rays) showing typical honeycomb/multiloculated features of adamantinoma (Courtesy: Dr Veena Jagadish, MDS).

bone marrow. It contains vascular stroma, collagen and connective tissue cells. It is common in women. It causes painless enlargement of jaw. It can be treated by calcitonin (100 units/0.5 mg subcutaneously daily for 12 months) or surgical curettage.

### Investigations

- ◆ Orthopantomogram (OPG) shows multiloculated lesion—*Honeycomb* appearance.
- ◆ Biopsy from the swelling.
- ◆ CT scan of the region.

### Treatment

- ◆ Segmental resection of the mandible. OR
- ◆ *Hemimandibulectomy with reconstruction of the mandible*.

#### Note:

- Curettage and bone grafting should not be done. It is a curable condition.
- Recurrent adamantinoma can spread through blood into lungs.

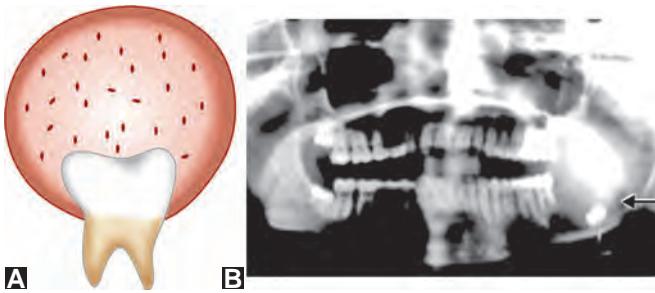
### ■ DENTIGEROUS CYST (Follicular Odontome)

- ◆ It is a unilocular cystic swelling arising in relation to the dental epithelium from an unerupted tooth.
- ◆ Common in lower jaw, but can also occur in upper jaw.

- ◆ It occurs over the crown of unerupted tooth. Commonly seen in relation to premolars or molars.
- ◆ It causes expansion of outer table of the mandible.
- ◆ *Clinical feature:* Painless swelling in the jaw which is smooth and hard.

**Differential diagnosis**

- ❖ Adamantinoma
- ❖ Dental cyst
- ❖ Osteoclastoma

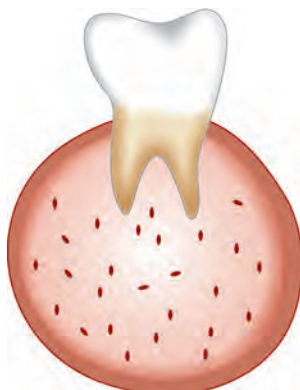

**Figs 2.41A and B:** (A) Dentigerous cyst; (B) Orthopantomogram showing dentigerous cyst.

- ◆ *Complication:* It can turn into *adamantinoma*.
- ◆ *Investigation:* Orthopantomogram. Tooth within the cyst, which is well-defined.
- ◆ *Treatment*
  - ▶ If it is small, excision of the cyst is done.
  - ▶ If it is large, initial marsupialisation and later excision is done.
  - ▶ *Unerupted tooth should be extracted.*

**DENTAL CYST (Radicular Cyst, Periapical Cyst)**

- ◆ It occurs under the root of the chronically infected dead erupted tooth.
- ◆ It is lined by squamous epithelium derived from epithelial debris of *Mallassez*.
- ◆ *Clinical feature:* As a smooth, tender swelling in the jaw in relation to caries tooth which causes expansion of the jaw bone.



**Fig. 2.42:** Dental cyst.

- ◆ *Complication:* It can cause osteomyelitis of the jaw.
- ◆ *Differential diagnosis:* Dentigerous cyst.
- ◆ *Investigation:* Orthopantomogram.
- ◆ *Treatment*
  - ▶ Antibiotics.
  - ▶ Drainage or excision of the cyst with extraction of the infected tooth is done.

**Differences between dental cyst and dentigerous cyst**

	<i>Dental cyst</i>	<i>Dentigerous cyst</i>
a. Site of occurrence	Erupted tooth under the root	Over the crown of an unerupted tooth
b. Infection	Common	Not common
c. Complication	Osteomyelitis	Adamantinoma
d. Treatment	Excision and extraction of tooth	Marsupialisation, excision and then extraction of tooth

**Curable malignancies**

- ❖ Adamantinoma
- ❖ Basal cell carcinoma
- ❖ Verrucous carcinoma
- ❖ Papillary carcinoma thyroid
- ❖ Marjolin's ulcer
- ❖ Carcinoma colon

**OSTEOMYELITIS OF JAW**

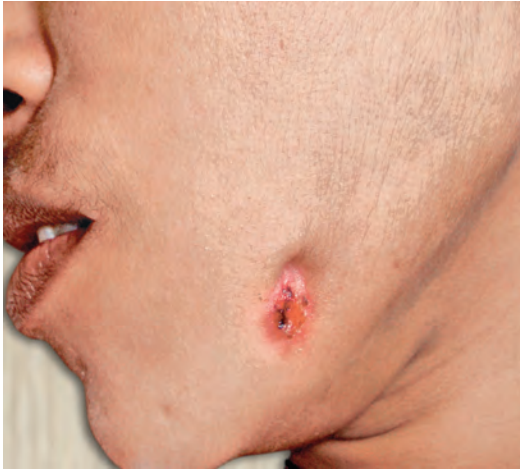It is an inflammatory process in jaw; acute or chronic. It can be in the maxilla or mandible.

**Causes**

- ◆ Alveolar abscess leading into osteomyelitis.
- ◆ Recurrent dental infection.
- ◆ Trauma.
- ◆ After dental extraction; surgeries of the jaw.
- ◆ Postradiotherapy osteomyelitis (osteoradionecrosis).

**Types**

- ◆ *Acute* is common in children; maxilla or mandible may get involved; swelling, redness, fullness are the features; pus may trickle through nostril if it is in maxilla.
- ◆ *Subacute* type is the commonest type; common in adult; apical sepsis, endarteritis, bone necrosis is the pathology; common in mandible; rare in maxilla due to existing network vasculature which prevents endarteritis. Compression over inferior dental nerve causes numbness in chin in area of distribution of mental nerve. Pain, swelling, tenderness, irregularity, bone thickening are typical.
- ◆ *Chronic type* is also common in mandible; apical abscess, alveolar abscess, trauma, radiation, chemicals like phosphorus, tuberculosis, syphilis, actinomycosis are the causes. Pain, bone thickening, irregularity, discharging sinus, sequestrum in the discharge, discomfort are the features. Infection from lower incisor causes median mental sinus. X-ray shows features of osteomyelitis with new bone formation and sequestrum. \



**Fig. 2.43:** Osteomyelitis of the mandible. Discharging sinus is obvious.

### Management

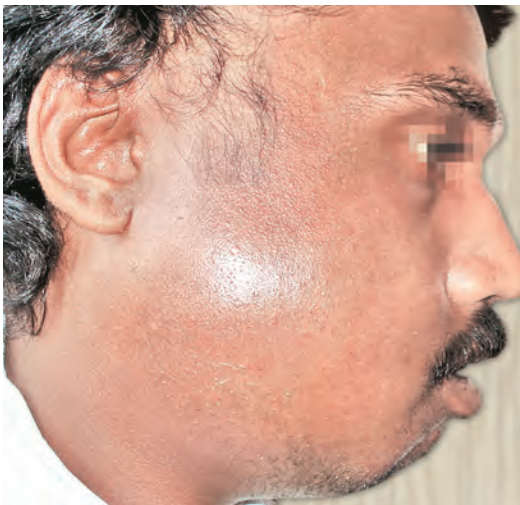- ◆ X-ray jaw; CT scan of jaw; discharge study; ESR are essential investigations. Biopsy from the sinus is needed often.
- ◆ It is often difficult to treat. In acute phase, antibiotic coverage, treatment of cause is done. In chronic type, sequestrectomy, mandibulectomy is needed.

### Actinomycosis of Jaw (Refer Chapter 1D)

Faciocervical is the commonest type; lower jaw is commonly involved; infection begins at carious tooth; indurated gums → nodules → abscess → multiple sinuses → discharging sulphur granules with normal X-ray (*Ray fungus*). *Actinomycosis israelii* is the causative agent. It is treated by penicillins.

### ■ ALVEOLAR ABSCESS (Dental Abscess)

It is due to spread of infection from root of the tooth into the periapical tissue. Initially, it forms periapical abscess which later spreads through the cortical part of the bone into the soft tissues around forming an alveolar abscess.



**Fig. 2.44:** Tooth infection causing large dental abscess. It needs antibiotics, proper drainage and tooth extraction. Patient may develop trismus/retropharyngeal infection/chronic osteomyelitis of the mandible.

Disease begins in the pulp of tooth → pulpitis → spread to root → localized osteitis → abscess formation → spread into soft tissues outside in cheek → initially diffused later localised swelling in the jaw with redness and oedema of gum. Initial dull continuous pain later becomes severe excruciating pain.

**Bacteria:** Staphylococci, streptococci, anaerobic-bacteria and gram-negative organisms.

### Clinical Features

- ◆ Deep, throbbing pain in the jaw and adjacent oral cavity with diffuse swelling over the cheek.
- ◆ Tender soft tissue swelling in the jaw which eventually bursts spontaneously leading to sinus formation.
- ◆ Oedema, pain and tenderness in the floor of the mouth.
- ◆ Trismus and dysphagia.
- ◆ Fever and features of toxæmia.
- ◆ Tender palpable lymph nodes in the neck.

### Investigations

- ◆ X-ray of the mandible or maxilla.
- ◆ Discharging pus for culture study.

### Complications

- ◆ Septicaemia.
- ◆ Spread of infection into other spaces like parapharyngeal spaces; sublingual and submandibular spaces causing Ludwig's angina; oedema of epiglottis and respiratory distress; spread to pterygoid space and along pterygoid muscles through emissary vein → cavernous sinus thrombosis; upper canine tooth abscess → medial corner of eye → angular vein thrombophlebitis → cavernous sinus thrombosis; submasseteric abscess.
- ◆ Lower incisor abscess can cause abscess in the chin and later median mental sinus; chronic osteomyelitis of the jaw with discharging sinuses. Osteomyelitis is common in mandible – *horizontal process near the mentum*, presenting with pain, swelling, discharging sinuses, bone thickening, loose tooth, and trismus. Sequestrum is commonly seen. It is treated by antibiotics, sequestrectomy, mandibulectomy.

*Treatment:* Antibiotics, sequestrectomy, mandibulectomy.

### Treatment

- ◆ Antibiotics.
- ◆ Drainage of the abscess under general anaesthesia.
- ◆ Extraction of the tooth at a later period.
- ◆ Excision of the sinus whenever required.

### ■ FIBROUS DYSPLASIA OF BONE/JAW

- ◆ It is benign self-limiting non-capsulated lesion of bone wherein normal bony architecture is replaced by collagen, fibroblasts, osteoid and calcified tissue. It is often classified as benign tumour with localized developmental arrest, with bone being not differentiated into a mature bone tissue.
- ◆ It is seen in *childhood and adolescents*.

### Types

It may be *polyostotic or monostotic*. Condition can occur in long bones, ribs and jaw bones, either mandible or maxilla. Disease is either metaphyseal or in the shaft, never in epiphysis.

### 1. Monostotic (70%)

- ◆ It is equal in both sexes. It occurs in children and adolescents; stops once growth plate is closed.
- ◆ Femur is the commonest bone involved; tibia, ribs, jaw bones, skull and humerus can get involved.
- ◆ It can present as asymptomatic diffuse hard bony swelling or can be painful due to fracture. Discrepancies of the part with asymmetry are common.
- ◆ Monostotic will not turn into polyostotic type.
- ◆ Monostotic will not turn into sarcoma.

### 2. Polyostotic Fibrous Dysplasia (27%) without Endocrine Dysfunction

- ◆ It begins in earlier age group than monostotic.
- ◆ It is common in femur, skull, tibia, humerus, ribs, fibula, radius, ulna, mandible and vertebrae. Craniofacial bones are involved in more than 50% of patients.
- ◆ It may continue to grow in adulthood (progressive).
- ◆ There is no evidence of hyperparathyroidism. It should be differentiated from primary hyperparathyroidism of bone.
- ◆ Involvement of shoulder and pelvis causes severe deformity.
- ◆ Severe involvement of femur causes 'shepherd crook' deformity.
- ◆ Recurrent spontaneous fractures are common.
- ◆ Polyostotic occasionally turns into sarcoma.

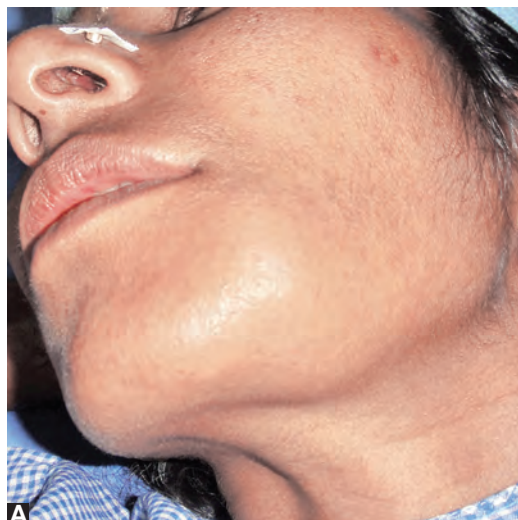### 3. Polyostotic Fibrous Dysplasia with Endocrinopathies (3%)

- ◆ *Polyostotic fibrous dysplasia with skin pigmentation (Café au lait, on same side of the disease in neck, chest, back, shoulder, pelvis, larger) with sexual precocity in females (McCune Albright's syndrome); often with hyperthyroidism, growth hormone secreting pituitary adenoma and primary adrenal hyperplasia is 3% common.*
- ◆ It is due to mutation of guanyl nucleotide binding protein gene (GNAS gene).

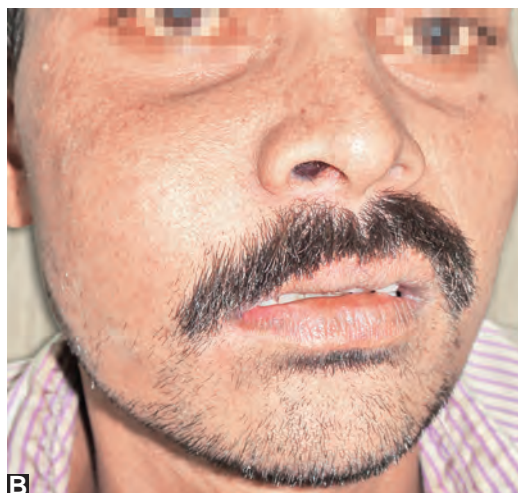- ❖ Fibrous dysplasia is most common in *femur—shepherd crook deformity; metaphyseal*
- ❖ In the jaw, mandible is the common site, vertical ramus, outer table expansion
- ❖ Monostotic is more common
- ❖ Polyostotic is more problematic—discrepancies, pathological fracture, sarcoma changes
- ❖ Monostotic ceases with cessation of growth
- ❖ Surgery should never be done during growing period

### Fibrous Dysplasia of Jaw

- ◆ In the jaw, it can occur in maxilla or mandible; but mandible is more common site.
- ◆ It presents with diffuse swelling of vertical ramus of the mandible or maxilla. Gritty white, hard cartilages with cysts are the pathology. Diffuse hard, painless swelling which causes asymmetry is the usual presentation. It progresses with the growth of the bone.
- ◆ It is commonly monostotic but can be polyostotic. Monostotic ceases once bone develops completely. Polyostotic may continue to grow.
- ◆ Teeth are normal.



Fibrous dysplasia mandible



Fibrous dysplasia maxilla

**Figs 2.45A and B:** Fibrous dysplasia of mandible and maxilla in two different patients. Mandible is common site in jaw. Overall femur is the commonest site.

- ◆ Expansion is towards outer cortex of the mandible.
- ◆ Polyostotic occasionally turns into sarcoma (but not monostotic).

### Complications of Fibrous Dysplasia

- ◆ Deformity and cosmetic problems.
- ◆ Pathological fractures.
- ◆ Sarcomatous transformation in polyostotic type only.

### Differential Diagnosis

- ◆ Osteoclastoma, adamantinoma.
- ◆ Osteitis fibrosa cystica of primary hyperparathyroidism.

### Investigations

- ◆ X-ray is diagnostic showing ground glass/smoke screen appearance.
- ◆ Serum alkaline phosphatase may be slightly elevated.

- ◆ Biopsy may be needed to confirm the condition and to rule out other conditions.
- ◆ Parathormone assay, serum calcium estimation in suspected parathyroid pathology.

### Treatment

It should not be operated during growing period as if intervened there may be chances that it may turn into osteosarcoma. As it is a self-limiting disease it can be left alone once the growth stops or can be corrected by restorative excision to maintain facial contour. Thorough curettage with grafting of cancellous bone may be done. Bisphosphonates are often used to relieve pain.

### ■ CHERUBISM (Cherub—Angelic Being)

It is an autosomal dominant condition that occurs in first year of life.

### Pathology

- ◆ Giant cell granuloma with fibrous tissues in the jaw.
- ◆ It is commonly *bilateral*.
- ◆ Commonly seen in the *angles of the mandible* and also in maxilla.
- ◆ It is familial fibrous dysplasia of jaw commonly involving both halves of the mandible with bulging outwards near the angle of the jaw causing '*winged face*' appearance of angelic babies.

### Clinical Features

- ◆ Diffuse enlargement of maxilla and both sides of the mandible.
- ◆ Bulging of the cheek causes pull of the lower eyelid. Hence, child appears like, as if looking upwards.
- ◆ Interference with the development and eruption of the teeth.

### Treatment

- ◆ It is a self-limiting disease. Often requires dental care and treatment for proper dentition.

#### Pierre-Robin syndrome

- ❖ Congenital condition
- ❖ Cleft palate alone
- ❖ Mandibular hypoplasia
- ❖ Cyanotic episodes
- ❖ Deficiency in transforming growth factor
- ❖ Defective sucking and tongue falling backwards in infants
- ❖ Cryptorchidism

# Chapter 3

## Oral Cavity

### CHAPTER OUTLINE

❖ Ranula	❖ Cheek	❖ Carcinoma of Posterior One-third/ Base of the Tongue
❖ Sublingual Dermoids	❖ Carcinoma Cheek/Buccal Mucosa	❖ Nasopharyngeal Carcinoma
❖ Stomatitis	❖ Lip	❖ Maxillary Tumours
❖ Cancrum Oris	❖ Neoplasm of Lip	❖ Malignant Tumours of Tonsil
❖ Syphilitic Lesions of Oral Cavity	❖ Carcinoma Lip	❖ Carcinoma Hard Palate
❖ Leukoplakia	❖ Tongue	❖ Laryngeal Tumours
❖ Erythroplakia	❖ Tongue Ulcers	❖ Malignant Tumours of Larynx
❖ Oral Submucosal Fibrosis	❖ Benign Tumours of Tongue	❖ Trismus
❖ Premalignant Conditions of Oral Cavity	❖ Tongue Fissure	
❖ Oral and Upper Aerodigestive Cancers	❖ Glossitis	
	❖ Tongue Tie	
	❖ Carcinoma Tongue	

*Oral cavity* includes lips, buccal mucosa, alveolar margins (gingiva), retromolar trigone, hard palate, floor of the mouth, anterior 2/3rd of the tongue (oral/mobile tongue).

### ■ RANULA

(*Rana = Frog*, Ranula looks like belly of frog, hence the name—Latin).

- ❖ Ranula is a *extravasation cyst arising from sublingual gland or mucous glands of Nuhn or glands of Blandin* in the floor of the mouth. Occasionally it can occur in submandibular salivary gland also.
- ❖ Initially there is blockage of the duct (of sublingual gland) causing *retention cyst*, which causes rupture of the acini due to increased pressure leading into *extravasation cyst*.

### Clinical Features

- ❖ Presents as a *bluish smooth, soft, fluctuant, brilliantly transilluminant* swelling in the *lateral aspect* of the floor of the mouth.

- ❖ **Plunging ranula:** Ranula often extends into the submandibular region through the deeper part of the posterior margin of mylohyoid muscle and is called as *plunging ranula*. It is intraoral ranula with cervical extension. It is *cross fluctuant* across mylohyoid. It can arise from both submandibular and sublingual salivary glands as a mucus retention cyst initially, which reaches neck by passing across the mylohyoid muscle presenting as soft, fluctuant, non-tender, dumbbell-shaped swelling in the submandibular region. It is bidigitally palpable. US and/or MRI is diagnostic. It is treated by surgical excision through neck approach along with excision of submandibular and sublingual salivary glands. Small plunging ranula is often excised per orally along with excision of sublingual salivary gland.

### Note:

- Ranula has a delicate fibrous capsule and is lined by a layer of macrophages. It contains clear fluid. It is thin walled.
- It may damage the Wharton's duct.
- It may rupture; it may get infected.
- It may interfere with speech and swallowing occasionally.

*Leukoplakia tongue looks as though it has been covered with white paint that had hardened, dried and cracked.*

—Sir Henry T Butlin



### Clinical features of ranula

- ❖ Occurs in younger age group and both sexes equally.
- ❖ It can be *simple/oral* (confined to floor of the mouth) or *plunging/diving* ranula.
- ❖ Bluish swelling in the floor of the mouth
- ❖ Laterally placed
- ❖ Non-tender, mostly unilateral.
- ❖ Fluctuant and cross fluctuant (plunging ranula)
- ❖ Brilliantly transilluminant

### Differential Diagnosis

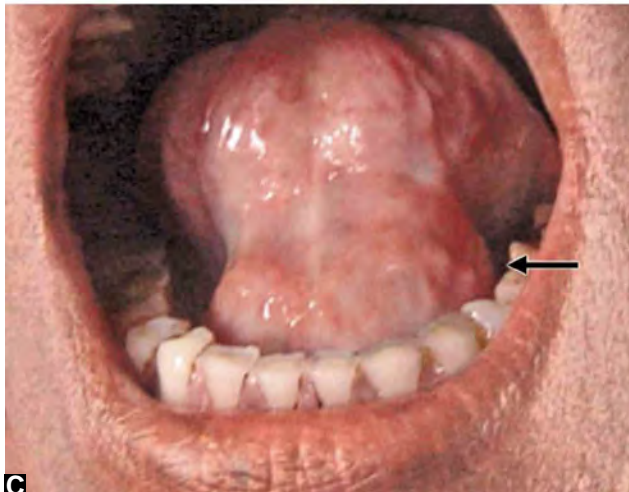
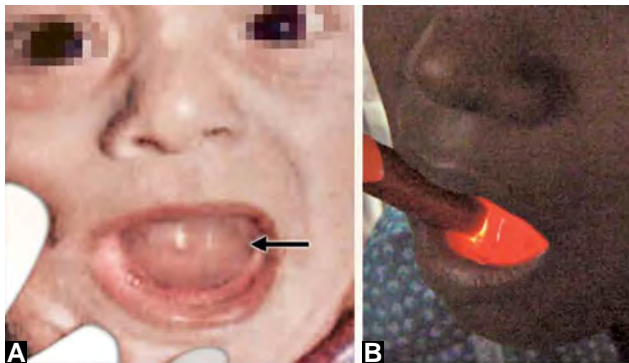
- ◆ Lymph cyst.
- ◆ Sublingual dermoid.

### Investigations

- ◆ US neck or MRI neck and oral cavity is diagnostic.

### Treatment

- ◆ *Marsupialisation* can be done initially, and later once the wall of the ranula is thickened it is excised *completely* (*Marsupial* means pouch where baby is kept, carried and sucked on the mother's belly, like in Kangaroo).
- ◆ If ranula is small it can be excised without marsupialisation.



**Figs 3.1A to C:** Ranula. Note the bluish discoloration, brilliantly transilluminant and the location.

- ◆ Excision of sublingual salivary gland is often needed. In plunging ranula submandibular salivary gland needs to be excised.

#### Note:

- Only marsupialisation has got high recurrence rate up to 50%. Excision of cyst with sublingual gland reduces recurrence rate to < 2%. Transoral excision is sufficient. Care should be taken not to injure lingual nerve.
- Plunging ranula often requires approach from neck for complete excision.

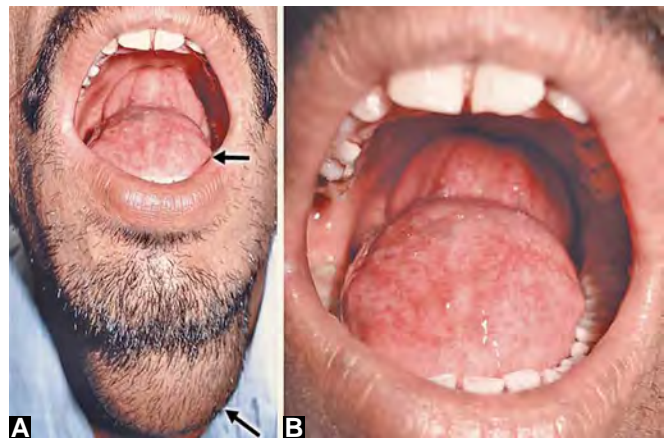
### SUBLINGUAL DERMIDS

- ◆ They are *sequestration dermoids* lined by squamous epithelium containing keratin.
- ◆ It is smooth, soft, fluctuant, non-transilluminant bidigitally palpable swelling.
- ◆ They are *congenital in origin*; commonly occurs as midline swelling; lateral dermoid can occur but rare.
- ◆ Swelling may often attain large size presenting both sublingually, intraorally and midline submentally on external side.
- ◆ Occasionally it can cause trismus, dysphagia, pain, odynophagia.
- ◆ *Differential diagnoses are*—haemangioma, lymphangioma, sublingual dermoid, lipoma and Ludwig's angina.
- ◆ *MRI* is useful investigation.
- ◆ *Excision* is done through intraoral approach usually; large cyst extending under geniohyoid muscle may require external approach.

### Types

#### 1. Median sublingual dermoid:

- ▶ It is derived from epithelial cell rests at the level of fusion of *two mandibular arches*. It may be supramylohyoid or inframylohyoid. It is located between two genial muscles, in relation to mylohyoid muscle. It is a midline swelling which is smooth, soft, cystic, nontender, non-transilluminant.



**Figs 3.2A and B:** Sublingual dermoid. It lies usually in midline. It is not transilluminant. Note the extension into the neck in submental region. Excised specimen is also shown.

- ▶ *Treatment* is excision through oral approach.
- ▶ *Complication* is abscess formation.

## 2. Lateral sublingual dermoid:

- ▶ It develops in relation to submandibular duct, lingual nerve and stylohyoid ligament. It is derived from *first branchial arch*. It forms a swelling in the lateral aspect of the floor of the mouth.
- ▶ *Treatment*: Small one is removed per orally. Larger one, through submandibular incision.

## STOMATITIS

- ◆ It is inflammation of oral mucosa by trauma, radiotherapy, chemicals, nutritional deficiency or infection.
- ◆ *Traumatic stomatitis* may be due to dentures, teeth bite, and brushing of teeth harshly which presents as painful thin covering of furr with increased salivation. Proper mouth wash will cure the condition.
- ◆ *Apthous stomatitis* is seen in malnutrition, debility, steroid usage. Present as multiple hyperaemic painful vesicles later forming deep round painful ulcers. It is treated with mouth wash and if needed by antibiotics. Recurrent apthous stomatitis with ulcers is often familial, more common in women, common in lip, cheek, tongue which are very painful with more salivation. It heals spontaneously. But during active period, it interferes with speech, swallowing distressfully. It is treated by many drugs like levamisole, antibiotics, vitamin B and C, local applications of anaesthetics (xylocaine)/choline salicylate/benzalkonium chloride.
- ◆ *Candida stomatitis* (Monilial thrush) is due to fungal infection, *Candida albicans* which is seen in diabetics, individuals on steroid therapy, long-term antibiotics, patients who are bedridden, on prolonged ICU care, in infants, and debilitated patients. Initially multiple red spots which are painful appear in the tongue and buccal area which later turn into curdy white patches. Often it extends into pharynx and oesophagus causing dysphagia. It is treated with antifungal drugs like clotrimazole or fluconazole. *Rhagades* occur at corners of mouth in congenital syphilis leaving radiating scar and furrow.
- ◆ *Vincent's ulcerative stomatitis* (*Vincent's angina/trench mouth*) is due to infection by Gram -ve anaerobic bacteria *Borrelia vincentii* and *Fusiformis*. It is common in adolescents and young adults below the age of 35 years. Presents with fever, excessive salivation, red swollen gums with painful ulcers covered with yellow slough (*pseudomembrane*) which can be removed like *membrane—ulcerative gingivitis*. From the gums it spreads to cheek, palate, and pharynx. Tongue involvement is uncommon. Tender neck lymph nodes are palpable. *Musty foetor oris* is typical. Edentulous patients will not develop this infection. Infection in tonsillar crypts is called as *Vincent's angina*. It is confirmed by swab culture. It is treated by antibiotics (penicillin group); peeling of membrane, mouth wash, supportive measures, vitamin B and C.
- ◆ *Nutritional stomatitis* is due to—(1) vitamin B deficiency like nicotinic acid (pellagra), riboflavin deficiency. It is common in tongue presenting as red area with atrophy of papillae. (2) Vitamin C deficiency is commonly seen as bleeding gums and loosening of teeth. (3) Iron deficiency anaemia causes superficial glossitis mainly in females.
- ◆ *Angular stomatitis* is superficial lengthy red brown fissures/ulcers in and around the angle of the mouth with cracks. *Candida* and streptococci infections are common. It is often called as *cheilosis/*

*perleche*. It is treated with vitamin B, C, iron and protein supplements with adequate oral hygiene. Perleche is seen in children who suck their finger.

## CANCERUM ORIS (NOMA)

- ◆ 'Noma' means—'to devour' in Greek—'eat greedily' or 'consume destructively'.
- ◆ It is a *gangrenous devastating stomatitis*, beginning in the mucous membrane of the corner of the mouth or cheek, progressing rapidly to involve the entire thickness of the lips or cheek or both, with necrosis and sloughing of the entire tissue; usually observed in poorly nourished children and debilitated adults.
- ◆ It is an infective gangrene, a severe form of Vincent's acute ulcerative gingivitis and stomatitis.
- ◆ Seen in poorly nourished, ill-child due to *Borrelia vincentii* and *Fusiformis* bacteria.
- ◆ It starts in lips later extends to gums, spreads into cheek, bone, soft tissues and skin causing extensive tissue loss with severe toxemia.
- ◆ Extensive necrosis of the mucus membrane of the oral cavity with destruction of deeper soft tissue and often bone.
- ◆ In children it may follow after an attack of measles, gastroenteritis, typhoid, bronchopneumonia. Malnutrition is a predisposing factor.
- ◆ Excessive salivation, fetid odour with destruction, discharge and toxic features.
- ◆ *Borrelia vincentii* can be cultured.
- ◆ X-ray part shows bone destruction.
- ◆ Condition has got high mortality.
- ◆ Secondary infections may also coexist.

### Note:

**Phagedena** is a destructive ulceration with gangrene seen in cancrum oris, chancroid. (Phagedena is destruction without proliferation but malignancy is destruction with proliferation).

## Treatment

- ◆ Systemic antibiotics, high dose penicillins, metronidazole.
- ◆ High protein and vitamin rich diet, through nasogastric tube.
- ◆ Wound irrigation and liberal excision of the dead tissue.
- ◆ Blood transfusion, TPN.
- ◆ Later patient requires flaps to cover the defect.

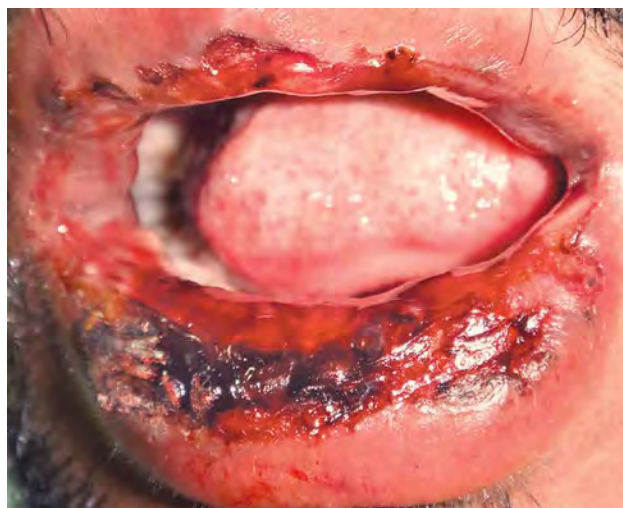

Fig. 3.3: Severe infection of lip.

In the case of malignancy of upper jaw, depression of the angle of the mouth on the affected side is also a typical sign.  
—Charles P Wilson

## SYPHILITIC LESIONS OF ORAL CAVITY

- ◆ *Chancre in lip*: It is highly contagious primary chancre, presents as painless macule later forming painful superficial ulcer. Ulcer eventually heals with a scar. It can be on both upper and lower lip—*primary syphilis*.
- ◆ *Mucous patches* which are greyish white contagious patches seen on lip, cheek and fauces. Mucous patches fuse together to form *linear snail track ulcers* in fauces, pillars—*secondary syphilis*. *Hutchinson's contagious condyloma* in midline tongue can occur.
- ◆ *Gummatous painless ulcer* is seen in anterior 2/3rd of tongue, palate and nasal septum (causes perforation and collapse of nasal bridge).
- ◆ *Syphilitic chronic glossitis* is seen in *tertiary syphilis* which is a precancerous condition.

## LEUKOPLAKIA

- ◆ It is a *white patch* in the mucosa of the oral cavity that cannot be characterised clinically or pathologically to any other disease. It is a premalignant condition.
- ◆ It is hyperkeratotic, *irreversible* patch which is *most common premalignant lesion* of the oral cavity. It is persistent and adherent patch.

### Types

1. *Homogenous*—uniform white patches with less malignant potential; most common type; prevalent in buccal mucosa.
2. *Nodular*—fine nodules on the surface; more malignant potential.
3. *Speckled leukoplakia*—white flecks with fine nodules with an atrophic erythematous base; *much higher potentiality for malignancy*. But it is less common.
  - ▶ Proliferative verrucous leukoplakia is rare but aggressive with 85% malignant potential; is common in elderly women; not associated with tobacco use.

### Features of higher risk potential in leukoplakia

- ❖ Speckled type
- ❖ Nodular type
- ❖ Erosions, ulcerations
- ❖ Hard and indurated type
- ❖ Presence of epithelial dysplasia

### Features

- ◆ White or greyish, well-localized patch which is adherent, firm or hard or indurated. It is often multifocal, bilateral or occurs in many areas like cheek, tongue, gums. Ulcerations are often seen.
- ◆ It is usually painless and non-tender.
- ◆ 80% occur after the age of 40 years.
- ◆ *Hairy leukoplakia* is dense pigmented friable lesion seen commonly in the tongue; it is common in AIDS patients; there are no hairs (misnomer). Surface looks like hairy due to thickening, corrugation by severe hyperkeratosis and acanthosis.

### Common causes

- ❖ Smoking
- ❖ Spirit
- ❖ Sepsis
- ❖ Superficial glossitis
- ❖ Syphilis
- ❖ Spices
- ❖ Sharp tooth
- ❖ Susceptibility, vitamin deficiencies
- ❖ Pan chewing using areca, tobacco, slaked lime
- ❖ Chronic hypertrophic candidiasis (long-standing candida infection)
- ❖ Human papilloma virus, a possible cause.

- ◆ **Incidence of** leukoplakia in those who smoke or chew pan is 20%, whereas incidence in non-smokers is 1%.
- ◆ **Incidence of** its turning into malignancy is 4–10%. It increases with age, duration of the pan chewing, smoking.
- ◆ Buccal mucosa and oral commissures are most common sites. Common in males (3:1).
- ◆ Leukoplakia of long duration; leukoplakia in elderly; leukoplakia in younger females; leukoplakia in floor of the mouth and tongue; leukoplakia with induration, cracks and fissures are more likely to turn into malignancy.
- ◆ **Biopsy** confirms the diagnosis as well as rules out the carcinoma. Tissue study for p53 mutation, inappropriate expression of oncogenes, DNA aneuploidy, reduction in epithelial cadherin adhesive protein (reduction indicates higher malignant potential).
- ◆ **Histology**: *Parakeratosis with widening of rete pegs*.

### Histological staging

- ❖ Acanthosis—elongation of rete pegs—smooth, white, dry patch
- ❖ Parakeratosis
- ❖ Widening of rete pegs
- ❖ Dyskeratosis—keratin cell layer formation deep to epidermis
- ❖ Dysplasia
- ❖ Carcinoma *in situ*

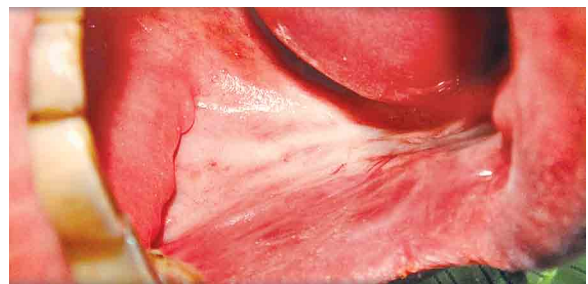


Fig. 3.4: Leukoplakia cheek.

### Treatment

- ◆ Pan chewing and smoking has to be stopped.
- ◆ Excision, if required skin grafting has to be done.
- ◆ Regular follow-up is necessary.
- ◆ Isotretinoin is helpful. Beta-carotene, tocoferol are also used.
- ◆ CO<sub>2</sub> laser excision.

## ERYTHROPLAKIA

- ◆ It is red velvety appearance of the mucosa which cannot characterise any recognised condition.
- ◆ It is 17–20 times more potentially malignant than leukoplakia.
- ◆ Malignant transformation occurs in more than 50% of cases.
- ◆ Histologically *parakeratosis with severe epithelial dysplasia* is the typical feature.
- ◆ Red colour is due to decreased keratin causing shining and prominence of submucosal red vascularised connective tissue.
- ◆ It is equal in both sexes.
- ◆ It is common in lower alveolar mucosa, gingivobuccal sulcus, floor of the mouth, tongue, vestibule and soft palate.
- ◆ It can be homogenous/speckled/granular or erythroplakia interspersed with leukoplakia.
- ◆ Diagnosis is done by biopsy.
- ◆ **Treatment:** Biopsy and surgical excision.

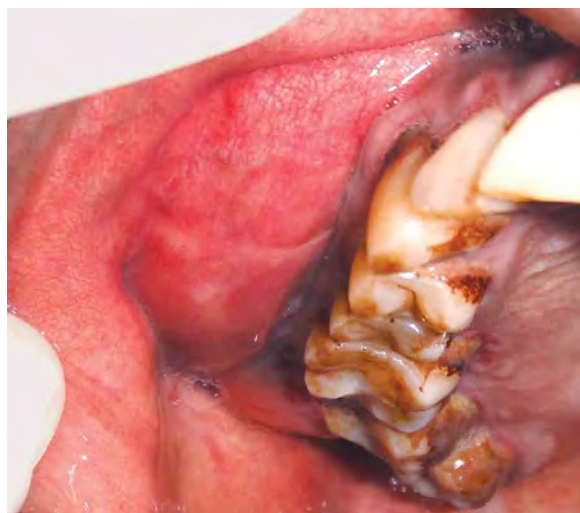

Fig. 3.5: Erythroplakia of cheek.

## ORAL SUBMUCOSAL FIBROSIS

(In 1952, J Schwartz coined the term *atrophica idiopathica mucosa oris* to describe an oral fibrosing disease which he discovered in five Indian women from Kenya. S.G. Joshi subsequently coined the term oral submucous fibrosis in 1953).

- ◆ It is a progressive fibrosis deep to the mucosa of the oral cavity which causes *trismus* and *ankyloglossia*.
- ◆ The mucosa of cheek, gingivae, palate and tongue shows a *mottled/marbled pallor*.
- ◆ It is common among Asians and Indians.
- ◆ **Aetiology:** Hypersensitivity to chilli, betelnut, tobacco and vitamin deficiencies probably alter the collagen metabolism leading to *juxtaepithelial progressive inflammatory fibrosis of the submucosa* epithelial atrophy and dysplasia. *Arecoline* stimulates collagen synthesis; *tannin* stabilizes the collagen fibrils and makes then resistant for collagen degradation by collagenase.
- ◆ 4.5–7.6% of oral submucosal fibrosis turns into malignancy.

## Treatment

- ◆ Precipitating factors should be avoided—spices, chilli, alcohol, tobacco.
- ◆ Maintaining oral hygiene.
- ◆ Local injection of dexamethasone (4 mg) with hyalase (1500 units) biweekly for 10 weeks; vitamin and iron supplements.
- ◆ Chewable hydrocortisone tablets.
- ◆ Submucosal injection of human chorionic gonadotrophin; IFN gamma, colchicine tablets (0.5 mg); lycopene 16 mg a day.
- ◆ Surgical excision of the lesion with coverage of raw area using skin graft or tongue flap.
- ◆ Multiple release incisions with ‘Z’ plasties; tongue flap coverage can be done.
- ◆ Stem cell therapy.

### Submucosal fibrosis

- ❖ Due to:
  - Prolonged local irritation by chillies, tobacco (pan/quid), areca due to arecoline
  - Dietary causes—deficiencies of vitamin A, B complex (riboflavin) and iron
  - Localised collagen disorder
- ❖ **Racial:** It is common among Indians/Asians and people of Indian origin
- ❖ Prevalence in India is 5 per 1000
- ❖ Incidence is 4–7%
- ❖ Common in middle age; equal in both sexes
- ❖ Soreness and burning in mouth which is more during meals; vesicular eruptions; trismus; difficulty in protruding the tongue. Initial red area turns into superficial ulcers which later forms *stiff, fibrotic bands* and scarring
- ❖ Common in soft palate, faucial pillars; buccal mucosa
- ❖ Disease is progressive, even after cessation of causative factor like areca use/smoking
- ❖ It shows epithelial atrophy, hyperplasia, dysplasia and fibrosis

## PREMALIGNANT CONDITIONS OF ORAL CAVITY

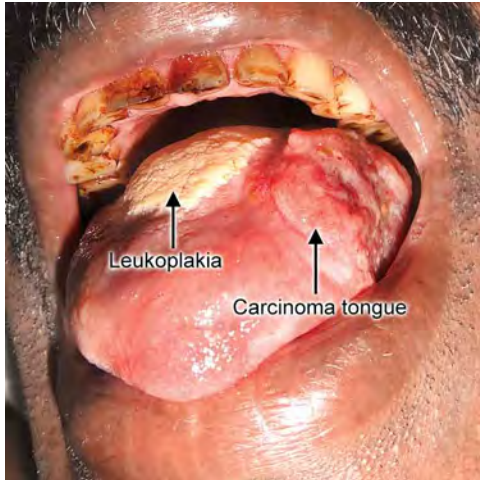
**High risks—lesions with definite risk of malignant change**

- ◆ *Leukoplakia*.
- ◆ *Erythroplakia*.
- ◆ *Chronic hyperplastic candidiasis:* It is common in commissures of the mouth and tongue. Dense plaque of leukoplakia

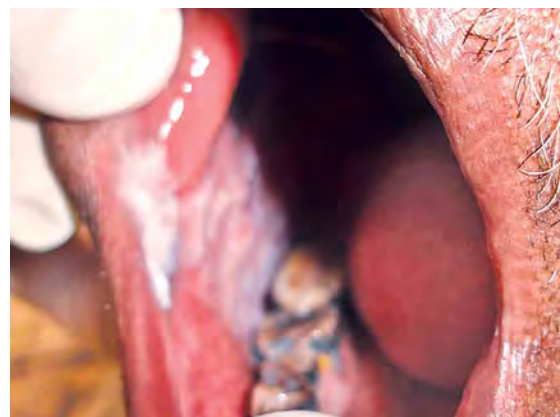

Fig. 3.6: Submucosal fibrosis of right cheek. Note the stiff fibrotic bands and scarring.

is common with curdy white patches due to *Candida albicans* infection. It often may not respond to drugs, surgery or laser. Immunodeficiency is often associated with this. It is treated by topical or systemic antifungal drugs/surgical excision or laser therapy.



**Fig. 3.7:** Extensive leukoplakia on the dorsum of the tongue with carcinoma on the lateral margin. Leukoplakia is high risk premalignant.

**Medium risks—pre-malignant but not associated with higher incidence of carcinoma**

- ◆ Oral submucosal fibrosis.
- ◆ Syphilitic glossitis.
- ◆ *Sideropenic dysphagia* (*Sideropenia* is iron deficiency without anaemia); or Plummer-Vinson syndrome. Sideropenia is common in Scandinavian females. It causes atrophy of epithelium and becomes potentially malignant. Proper iron therapy controls the disease and reduces the risk.

**Equivocal risk lesions**

- ◆ Oral lichen planus.
- ◆ Dyskeratosis congenital—reticular atrophy, nail dystrophy, leukoplakia in oral cavity.
- ◆ Discoid lupus erythematosus.

**Note:**

- Oropharyngeal cancer is the most common cancer—40% in Indian subcontinent. In western countries, it accounts for 4% only.
- *Risk factors*—tobacco and related products; alcohol; areca nut; human papilloma virus; Epstein Barr virus; *Paterson-Kelly syndrome*; nutritional deficiency.
- Patient may develop a second primary (15%) in the oropharynx in different site at same time or within 6 months of the existing primary (*synchronous*—4% prevalence; 20% of second primaries) or after 6 months of first primary (*metachronous*—80% of second primaries). Metachronous second primary is more common than synchronous second primary and it usually occurs in 2 years.

**Premalignant conditions of oral cavity**

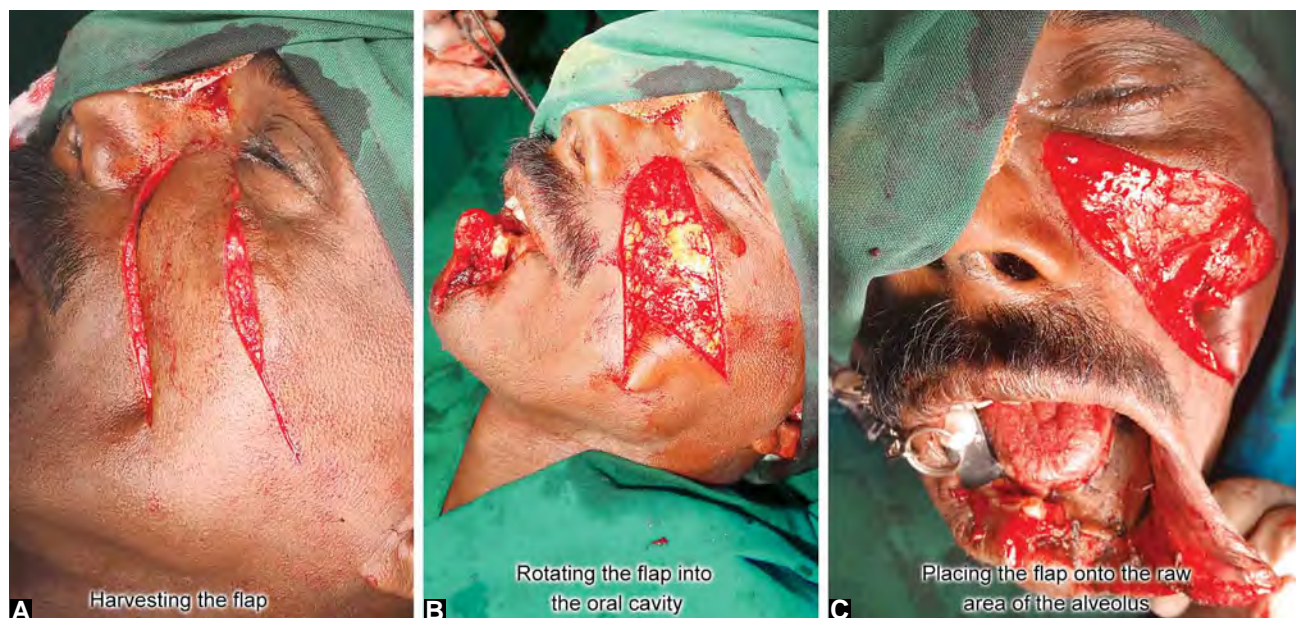- ❖ Leukoplakia
- ❖ Erythroplakia
- ❖ Chronic hyperplastic candidiasis
- ❖ Oral submucosal fibrosis
- ❖ Syphilitic glossitis
- ❖ Sideropenic dysphagia
- ❖ Oral lichen planus
- ❖ Discoid lupus erythematosus
- ❖ Dyskeratosis congenita

**ORAL AND UPPER AERODIGESTIVE CANCERS**

- ◆ It is one of the commonest cancer in Asian countries and India (40%).
- ◆ All 'S' mentioned probably are the causative agents. Smoking, quid of chewing pan are important causes. Tobacco, betel nut, alcohol, human papilloma virus (present in 80% of oral cancers; present in 40% normal individuals), EB virus, vitamin A deficiency, Plummer-Vinson syndrome, bad dental hygiene, denture irritation—are etiologies. Risk is 8 times in tobacco chewers; 10 times with quid users; 30 times with night quid users.

Known risk factors	Possible risk factors
Tobacco, alcohol, betel quid and areca nut	Poor oral and dental health
Human papilloma virus	Poor fitting dentures
Precancerous conditions	Secondary smoking (second hand smoke)
Previous cancer (oral or other)	
Family history of SCC	
Sun exposure	
Diet low in vegetables and fruits	
Weakened immunity	
Graft versus host reaction	
Lichen planus	

- ◆ Alcohol increases the solubility of carcinogens and suppresses the DNA repair.
- ◆ Incidence of oral cancer in India is 28 per 1, 00,000 population. Commonest oral cancer in India is of buccal mucosa (more than 70%).
- ◆ In oral cavity, in West, it is common in tongue (50%), buccal mucosa (25%), floor (15%), gums and others (10%).
- ◆ Leukoplakia (*commonest*), erythroplakia, chronic hyperplastic candidiasis are *precancerous lesions*; submucosal fibrosis, syphilitic glossitis, sideropenic dysphagia are *precancerous conditions*. Oral lichen planus, discoid lupus, dyskeratosis congenita are doubtful associated lesions. Precancerous lesion is one where cancer is more likely to occur; precancerous condition is one where there is increased risk of cancer.
- ◆ Upper aerodigestive cancers include that of oral cavity, larynx and pharynx. Depending on anatomical location they present with different features other than common features—trismus, ear pain, hoarseness of voice, dysphagia, ankyloglossia.
- ◆ Usually they are locoregional disease with high affinity to involve regional lymph nodes. Distant spread is rare except in nasopharyngeal carcinoma. Tongue has highest incidence of nodal spread, then floor of the mouth, lower alveolus, cheek, upper alveolus, palate.
- ◆ *Multiple synchronous* (at same time, 10%) de novo sites and *or metachronous* (at different periods, 15%) multiple sites.
- ◆ Cancers in posterior third of tongue and floor of the mouth is often missed on clinical examination—*coffin corner or sump area*.
- ◆ Primary may be very small to be detected clinically in places like fossa of Rosenmuller, pyriform fossa, nasopharynx, posterior third tongue but present clinically as hard lymph node secondaries in neck called as *secondaries with unknown primary*. Hard secondaries in neck confirmed by FNAC but all investigations including blind biopsies, CT head and neck region and endoscopies could not identify primary lesion creates a situation called as secondaries in neck nodes with an *occult primary* (30%).



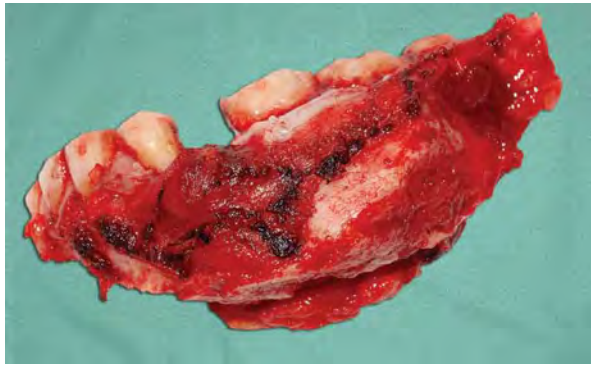
**Figs 3.8A to C:** Nasolabial flap—used to cover the defect in the lower alveolus.

- ◆ *Trismus* (pterygoid muscle involvement), *ear pain* due to auriculotemporal nerve involvement, *eye pain* in nasopharyngeal carcinoma, *dysphagia* due to tongue involvement mainly the posterior third, *hearing loss* due to spread to Eustachian tube can occur.
- ◆ Bronchopneumonia, aspiration are common problems.
- ◆ *Biopsy, endoscopy, CT neck, MRI, chest X-ray* are different investigations needed depending on anatomical location of lesion.
- ◆ *Staging* will help to plan the treatment and predict prognosis.
- ◆ *Surgical wide excision and radiotherapy are main modalities of treatment. Chemotherapy is used as an adjuvant.* Curative treatment in early growth with preservation of functions like swallowing, speech, cosmesis; but with adequate oncological clearance is the principle of surgical approach. Radiotherapy is also used as curative therapy.
- ◆ Palliative chemotherapy, radiotherapy and surgery can be done depending on location of the lesion.
- ◆ Involvement of mandible, neck nodes—number, size and fixity alters the prognosis and treatment schedule.
- ◆ Outcome also depends on the anatomical location of the malignancy. Lip carries better prognosis; tongue has poor prognosis.
- ◆ General principles used in approaching oral cancers are as follows (however it depends on grading and staging of the tumour):
  - ▶ If only primary is present which is mucosal with size less than 2 cm without nodal spread, then wide local excision with supraomohyoid block dissection of same side is done (N0); primary may also be treated with curative brachytherapy or external beam teletherapy. If nodes are histologically positive then radical neck dissection is done.
  - ▶ Larger mucosal primary with similar features are also treated similarly; but post-operative RT or/and chemotherapy is added depending on grading of the tumour.
  - ▶ In all these types of lesions, if there are positive mobile neck nodes which is confirmed by FNAC, then radical neck dissection should be done.
- ▶ If primary lesion extends into adjacent soft tissue with mandibular involvement then mandibular resection (marginal mandibular/segmental/partial/hemi-mandibulectomy) is needed. Part is reconstructed using plates or bone graft taken from iliac crest or opposite 11th rib. 2.4 mm reconstruction plate with PMMF or non-vascularised bone graft (iliac crest cancellous chips) or vascularised bone graft from fibula/iliac crest/scapula are the present recommendations. Skin covering is done by split skin graft inside to mucosa or by appropriate flaps depending on the need and feasibility of donor area (PMMF/DP flap/forehead flap). Neck is addressed similarly. Post-operative EBRT and chemotherapy is needed either concurrent or sequential.
- ▶ If primary is advanced then chemotherapy with EBRT is used. If lesion reduces in size and becomes operable it is then operated accordingly.
- ▶ In fixed primary or secondary, RT with chemotherapy is used for palliation to relieve pain, fungation, sepsis.
- ◆ In advanced stage terminal events may be severe malnutrition, bleeding, sepsis, and bronchopneumonia.
- ◆ Posterior lesions has got poor prognosis than anterior lesions. Lip carries best. Prognosis depends on anatomical location, grading, lymph node status, soft tissue involvement and response of therapy.

### Carcinoma of Gingivobuccal Complex

- ◆ It is cancer (SCC) involving *buccal mucosa and gingiva* etiology of which is keeping tobacco quid in gingivobuccal sulcus.
- ◆ It is often called as *Indian oral cancer* as it is most commonly seen in India.
- ◆ Buccal mucosa extends from upper to lower alveolus; from commissure in front to retromolar region behind.
- ◆ Features, management are same. Marginal mandibulectomy/segmental resection is commonly needed.
- ◆ Adjuvant RT and chemotherapy is useful.

*All surgeries are major; there is no minor surgery.*

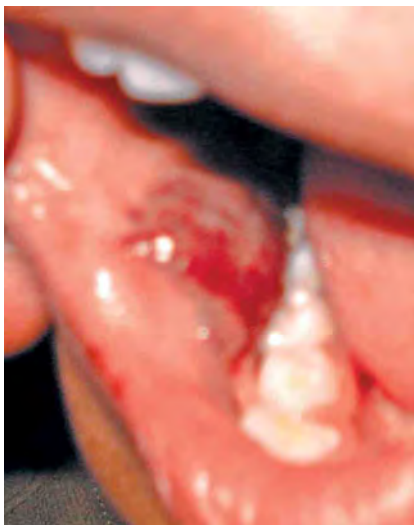

**Fig. 3.9:** Carcinoma alveolus and gingiva—wide excision and marginal mandibulectomy is done.

## CHEEK

### Anatomy of Cheek

- ◆ They are fleshy flaps on either side of the face. The demarcation between the lips and cheek is nasolabial fold.
- ◆ It is composed of skin, superficial fascia with parotid duct, buccinator muscle, submucosa with buccal glands and mucous membrane.
- ◆ **Lymphatics:** Submandibular and preauricular nodes.



**Fig. 3.10:** Haemangioma cheek.

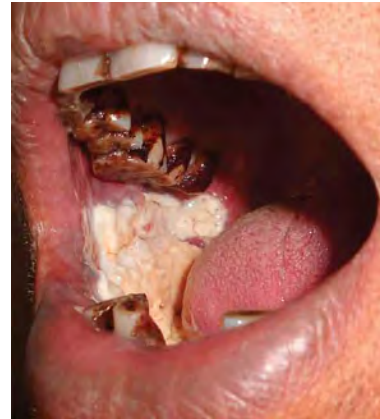### Retromolar Trigone

- ◆ **Retromolar trigone (coffin corner)** is the attached mucosa on the anterior surface of the ascending ramus of the mandible posterior to the last lower molar tooth extending superiorly to the maxillary tuberosity. It is triangular in shape with base is superior behind the 3rd upper molar tooth and apex inferiorly behind the lower 3rd molar tooth.
- ◆ Carcinoma in this area commonly invades the ascending ramus of the mandible and upward spread involves the pterygomandibular space. Tonsillar fossa, soft palate may also get involved. Lymphatics from this area may communicate into pharyngeal lymphatics.

- ◆ SCC in this area can be treated with high voltage radiotherapy or surgery. Lip split incision is required with mandibulotomy. Marginal mandibulectomy is not possible; mandibulectomy with reconstruction is required.

## CARCINOMA CHEEK/BUCCAL MUCOSA

*Squamous cell carcinoma is the most common type of carcinoma of the cheek.*



**Fig. 3.11:** Carcinoma buccal mucosa with extensive necrosis. It is the *most common oral cancer* in India.

- ◆ Occasionally it can be adenocarcinoma arising from the minor salivary glands or mucous glands. Rarely it can also be melanoma.

### Malignancies of the oral cavity

- ❖ Squamous cell carcinoma—commonest
- ❖ Minor salivary gland tumours
- ❖ Melanomas
- ❖ Adenocarcinomas—rare
- ❖ Sarcomas—rare (Sarcomatoid)
- ❖ Basaloid SCC

### Sites of carcinoma in oral cavity in order

#### In India

- ❖ Cheek—commonest
- ❖ Tongue
- ❖ Floor of the mouth
- ❖ Palate
- ❖ Lips

#### In Western countries

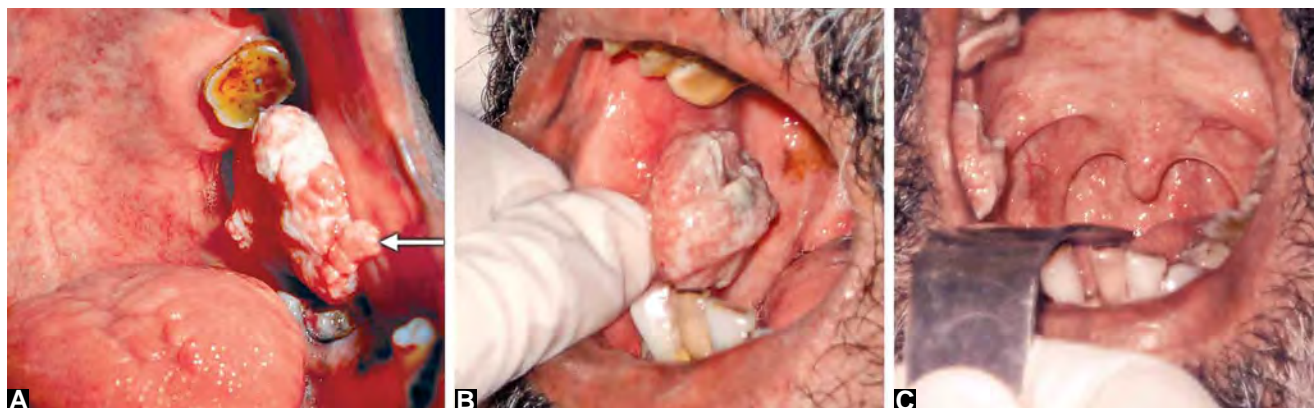- ❖ Tongue
- ❖ Floor of the mouth
- ❖ Lip
- ❖ Cheek

### Precipitating Factors

- ◆ All 'S'—Smoking, spirit, syphilis, sharp tooth, sepsis, spices.
- ◆ Incidence of oral cancer is six times more in smokers than non-smokers.

### Premalignant lesions and conditions

- ❖ Leukoplakia
- ❖ Erythroplakia
- ❖ Chronic hyperplastic candidiasis
- ❖ Oral submucosal fibrosis
- ❖ Sideropenic dysphagia
- ❖ Syphilitic glossitis



**Figs 3.12A to C:** Carcinoma cheek in different patients. Note the usage of tongue depressor for proper visualisation of the lesion.

- ◆ *Betel nut chewing* (*Pan*, with *pan quid* kept in cheek pouch for a long time) is an important causative factor of carcinoma cheek.
- ◆ Betel/areca nut, betel leaf, slaked lime, and tobacco (often with catechu and condiments) wrapped in betel leaf is repeatedly chewed after putting into the mouth; and the *quid* formed is kept for long duration in gingivolabial sulcus; which is said to be highly carcinogenic. Tobacco is the main carcinogenic component, followed by arecoline (stimulate collagen synthesis and fibroblast proliferation) and tannin (stabilizes collagen) alkaloids of areca.

**Types**

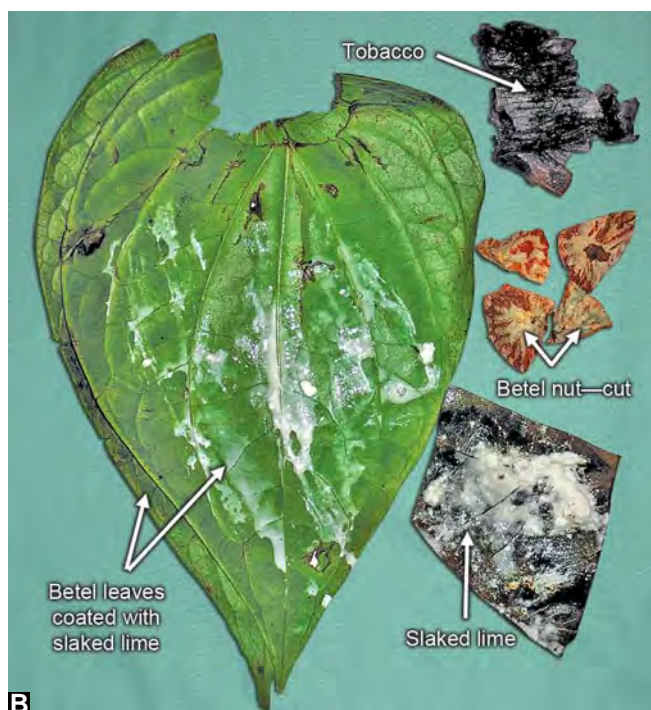
- ❖ Ulcerative
- ❖ Proliferative (exophytic)—commonest
- ❖ Verrucous

**Verrucous Carcinoma**

- ◆ It occurs as a superficial proliferative exophytic lesion with minimal deep invasion, often multiple.
- ◆ Lesion has white, dry, velvety or warty, keratinised surface. It is common in females.

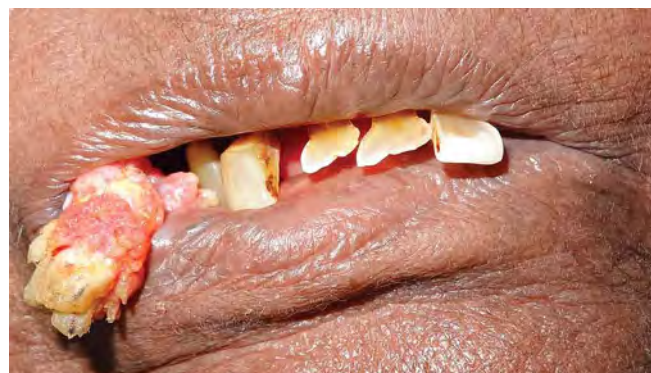

**Fig. 3.13A**



**Fig. 3.13B**

**Figs 3.13A and B:** Betels commonly used to prepare quid which is kept in gingivoalveolar groove. It is common cause for carcinoma oral cavity.



**Fig. 3.14:** Verrucous carcinoma of the cheek extending into the lip.



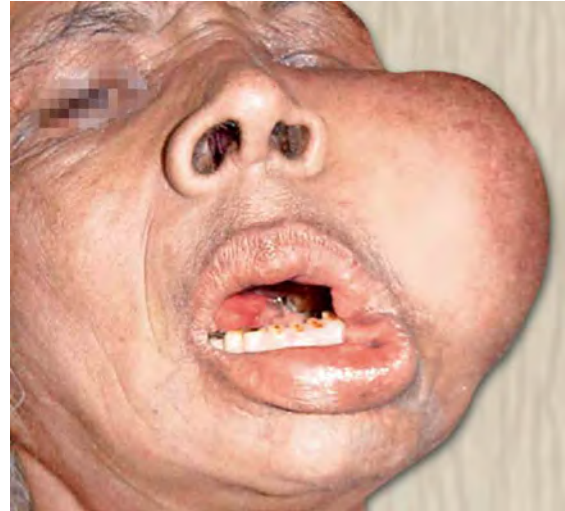- ◆ It is of low grade, very well-differentiated squamous cell carcinoma, which is locally malignant without any lymphatic spread.
- ◆ It is a curable malignancy.
- ◆ After biopsy treatment is *wide excision*. *Radiotherapy* is not given as it may lead to poorly differentiated carcinoma.

### Biological Behaviour of Carcinoma Cheek

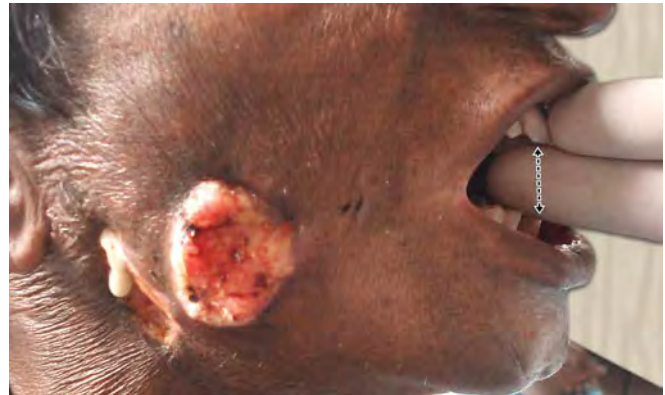- ◆ Carcinoma is common in posterior half of cheek than anterior.
- ◆ It spreads into the deeper plane to involve buccinator, pterygoids; into the retromolar trigone, base of the skull, pharynx.
- ◆ It spreads outwards to involve the skin causing fungation, ulceration, orocutaneous fistula formation.
- ◆ Mandible is commonly involved either by direct extension or through subperiosteal lymphatic plexus which communicates freely with oral lymphatics.
- ◆ Lymph nodes commonly involved are submental, submandibular, deep cervical and often lateral pharyngeal groups. Nodal spread is seen in 50% of cases.
- ◆ Infection of the tumour area and soft tissues around is common, causing fever, foul smelling ulcer, halitosis.
- ◆ Respiratory infection is common in these patients.
- ◆ Once tumour extends into the retromolar region, soft palate and pharynx, dysphagia will occur.
- ◆ Lesion will later spread to involve alveolus.

### Clinical Features

- ◆ *Ulcer (painless to begin with)* in the cheek which gradually increases in size in a patient with history of chewing pan and smoking is the commonest presentation and initially it is painless.
- ◆ *Pain* occurs when it involves the skin, bone or if secondarily infected. Referred pain to the ear signifies involvement of lingual nerve. Lingual and auriculotemporal nerves arise from mandibular division of trigeminal nerve.
- ◆ *Halitosis* which is bad odour breath is common in many oral cancers. It is due to necrosis of tumour, release of *mercaptan*, butyric acid and ammonia.
- ◆ *Involvement of retromolar trigone* indicates that it is an advanced disease, as the lymphatics here communicate freely with the pharyngeal lymphatics.
- ◆ *Everted edge, induration* are the typical features of the ulcer.
- ◆ *Mandible is examined bidigitally*, for thickening, tenderness, irregularity and sites of fracture. Mandible may get involved by direct extension, through mandibular canal, or through periodontal membrane. Loss of central part of mandible due to destruction by tumour will cause pouting of lower lip with drooling of saliva—*Andy Gump* deformity. Mandibular canal is close to occlusive alveolar surface in *elderly and edentulous* patients to cause early mandibular spread in carcinoma.
- ◆ *Trismus and dysphagia* signify involvement of pterygoids or posterior extension.



**Fig. 3.15:** Advanced carcinoma cheek presenting as swelling outside. There is an ulcer inside over the mucosa.

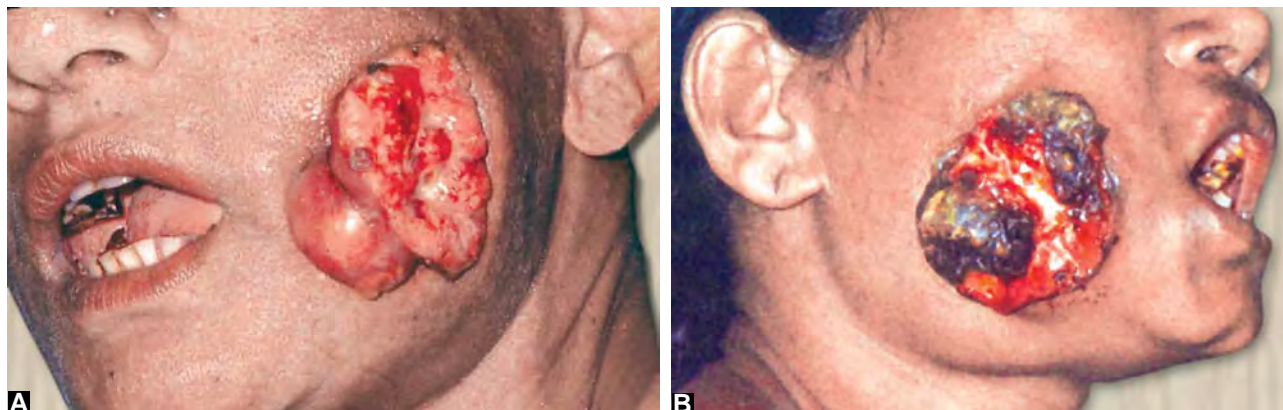


**Fig. 3.16:** Trismus in an advanced carcinoma of cheek.

- ◆ Occasionally it may extend into the *upper alveolus and to the maxilla* causing swelling, pain and tenderness.
- ◆ Once involvement of soft tissue occurs, it may come out through skin as fungating lesion often with *orocutaneous fistulas* with saliva dribbling through fistula.
- ◆ *Submandibular lymph nodes and upper deep cervical lymph nodes are involved* which are hard and nodular; initially mobile and later get fixed to each other and then to deeper structure.
  - ▶ Once lymph nodes get fixed it may infiltrate into hypoglossal nerve (tongue will deviate towards the same side), spinal accessory nerve (defective shrugging of shoulder) and cervical sympathetic chain (*Horner's syndrome*).
  - ▶ *Compression over external carotid artery* leads to absence of superficial temporal artery pulsation. Eventually it causes fungation and bleeding from major vessels—**carotid blow out**.

#### Note:

Node involvement may be due to infection. So often trial antibiotic is given initially.



**Figs 3.17A and B:** Carcinoma cheek fungating outside extensively. Note the pigmentation in one of the pictures.

### Staging (for all oral cancers)

#### TNM Staging

- T<sub>0</sub> No evidence of primary tumour  
 T<sub>is</sub> Carcinoma in situ  
 T<sub>1</sub> Tumour size < 2 cm—greatest dimension  
 T<sub>2</sub> Tumour size 2–4 cm  
 T<sub>3</sub> Tumour > 4 cm  
 T<sub>4</sub> Tumour is of any size involving bone, soft tissues, muscles  
 T<sub>4a</sub> Tumour invading adjacent structures (e.g. through cortical bone, into the deep (extrinsic) muscles of the tongue, maxillary sinus, or skin of the face)  
 T<sub>4b</sub> Tumor invades masticator space, pterygoid plates, or skull base and/or encases internal carotid artery  
 N<sub>x</sub> Nodes cannot be assessed  
 N<sub>0</sub> No lymph node spread  
 N<sub>1</sub> Lymph node size < 3 cm, same side  
 N<sub>2</sub> Lymph node size 3–6 cm and single (N<sub>2a</sub>); multiple lymph nodes 3–6 cm size on same side (N<sub>2b</sub>); bilateral or opposite side nodes up to 6 cm size (N<sub>2c</sub>)  
 N<sub>3</sub> Lymph node spread, more than 6 cm size

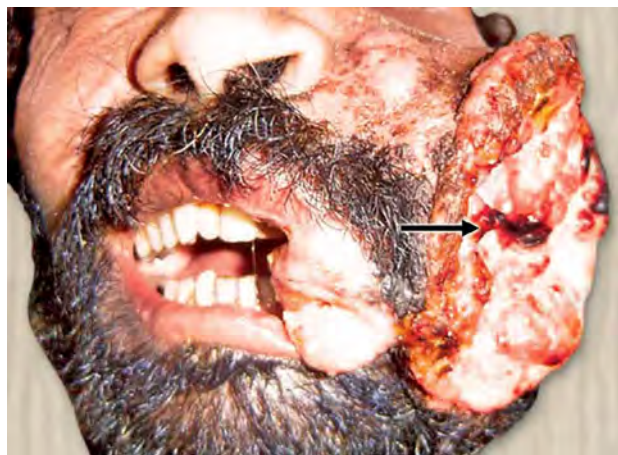#### Stages

Stage I – T1,N0,M0.

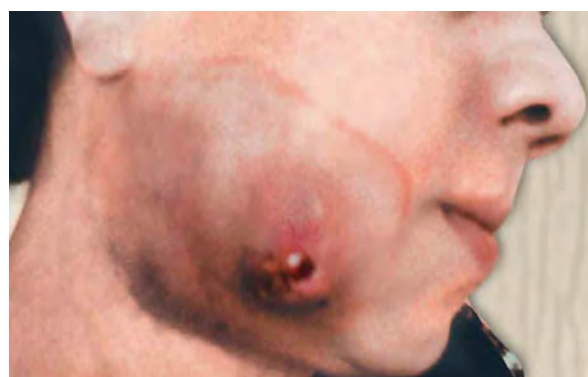Stage II – T2,N0,M0.

Stage III – T3,N0,M0; T1-3,N1,M0.

Stage IV – T4,N0,M0; T1,N2-3,M0; T0,N0,M1.



**Fig. 3.18:** Advanced carcinoma cheek with fungation and orocutaneous fistula.



**Fig. 3.19:** Oral cavity carcinoma with mandibular involvement, with T<sub>4</sub> lesion.

### Features of advanced carcinoma cheek

- ❖ Involvement of retromolar trigone
- ❖ Extension into the base of skull and pharynx
- ❖ Fixed neck lymph nodes
- ❖ Extension to the opposite side

### Problems with oral carcinomas

- ❖ Upper airway obstruction and bronchopneumonia
- ❖ Feeding difficulties and severe malnutrition
- ❖ Immunosuppression
- ❖ Secondary sepsis, uncontrollable bleeding
- ❖ Fixity of secondaries, fungation and disability
- ❖ Psychological trauma
- ❖ When once trismus develops, patient is unable to take adequate food and eventually leads into cancer cachexia. Trismus may develop by tumour infiltration or after RT
- ❖ Orocutaneous fistula causes salivary dribbling which is distressing

### Investigations

1. *Wedge biopsy*, usually taken from two sites. Biopsy has to be taken from the edge as it contains active cells; not from the centre as it is the area of necrosis. *Malignant squamous cells with epithelial pearls (Keratin pearls)* are the histological features.

*Fissuring of tongue due to ariboflavinosis is longitudinal and the bottom of fissure is beefy red.*

—Dimitri Afonsky

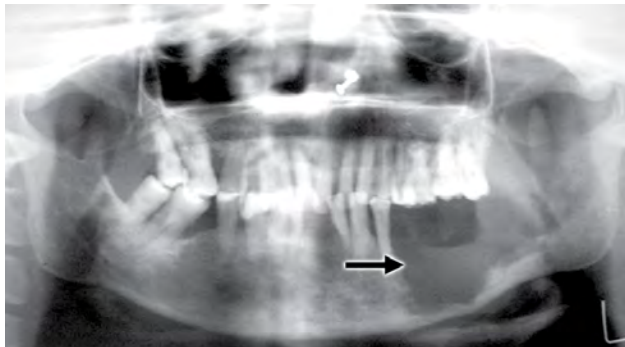
**Broder's histological grading**

- Well-differentiated: > 75% epithelial pearls
- Moderately differentiated: 50–75% epithelial pearls
- Poorly differentiated: 25–50% epithelial pearls
- Very poorly differentiated: < 25% epithelial pearls

**Present grading system**

G X	Grade cannot be assessed
G 1	Well differentiated or low grade
G 2	Moderately well differentiated or intermediate grade
G 3	Poorly differentiated or high grade

- FNAC from lymph nodes.
- CT scan is used to assess the extent of tumour into mandible, pterygoid region, in patient with trismus, with neck lymph nodes, with carotid involvement by lymph nodes.  
MRI is very useful in assessing the soft tissues, base of skull, and perineural spread.
- Orthopantomogram to look for the involvement of mandible—destruction and fracture sites. Symphysis menti and lingual plate are not clearly appreciated. So often OPG may be supported with dental occlusion and intraoral X-rays.
- Opinion and help of dentist is taken for teeth extraction, dental care, for prosthesis preparation especially for palate, alveolus, dentures.



**Fig. 3.20:** Orthopantomogram showing secondaries in mandible.

**Note:**

- Open biopsy should be avoided in case of secondaries in lymph nodes as it may aggravate the spread to further level of lymph nodes.
- Biopsy from the centre is taken only from post-radiotherapy ulcer and ulcerated minor salivary gland tumours.
- Incidence of second primary lesion is 30% mainly at upper aerodigestive tract.

**Treatment**

Treatment may be *curative* or *palliative*.

**Treatment Strategy**

- ❖ **Surgery.** Wide excision, hemimandibulectomy, neck lymph nodes block dissection.
- ❖ **Radiotherapy:** Curative or palliative; external or brachytherapy.
- ❖ **Chemotherapy:** Intra-arterial, IV or orally.

◆ **Early growth without bone involvement:**

- Curative radiotherapy using  $^{137}\text{Caesium}$  needles or  $^{192}\text{Iridium}$  wires, i.e. brachytherapy.

Advantages:

- Surgery is avoided.
- No surgical mutilation.
- Parts are retained.
- As it is a squamous cell carcinoma, primary is radiosensitive—90% cure rate.

- Other option is *wide excision with 1–2 cm clearance*. Often, the approach to the tumour is by raising the cheek flap (outside). After the wide excision, the flap is placed back (*Patterson operation*).

- Present advanced technology in radiotherapy, facilitates the use of external radiotherapy also. The incidence of dreaded complication like *osteoradionecrosis of mandible* has been reduced due to better RT methods.

◆ **Growth with mandible involvement:**

Here along with wide excision of the primary tumour, hemimandibulectomy or segmental resection of the mandible or marginal mandibulectomy (using rotary electric saw) is done.

◆ **Operable growth with mandible involvement and mobile lymph nodes on the same side** (confirmed by FNAC):

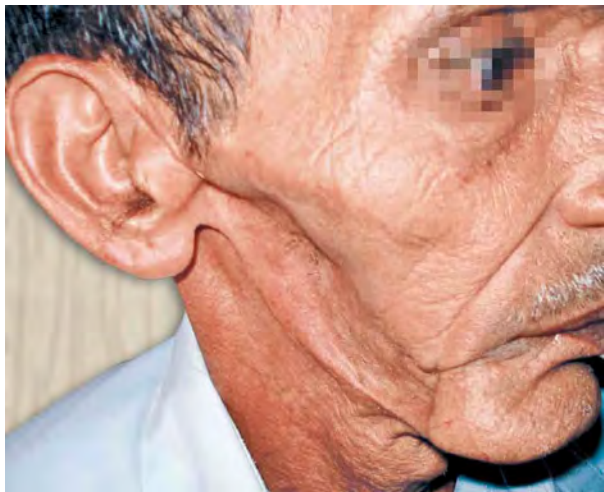Along with wide excision of the primary, hemimandibulectomy and radical neck lymph node dissection is done (like commando operation).

Wide excision of primary lesion, hemimandibulectomy with radical neck node dissection is called as *composite resection*.

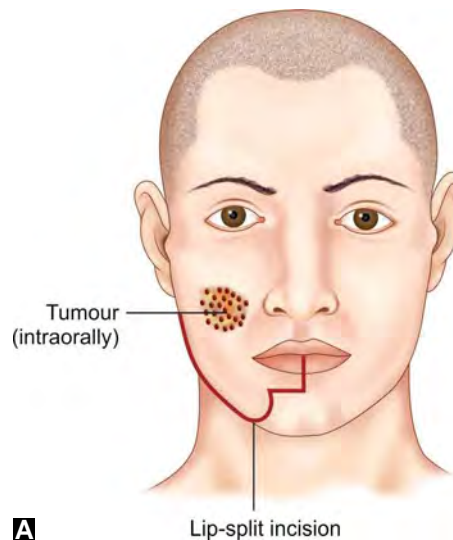
◆ **Operable growth with mandible involvement; mobile lymph nodes on same side and opposite side:**

Along with wide excision of the tumour, hemimandibulectomy, radical neck lymph node dissection on same side and functional block dissection on opposite side are done, retaining the internal jugular vein, sternomastoid, spinal accessory nerve.

Indications for surgery	Advantages	Disadvantages
<ul style="list-style-type: none"> <li>Early tumour</li> <li>Tumour spreading to mandible bone/alveolus</li> <li>Fungation, haemorrhage due to erosion</li> <li>Recurrence of tumour after RT</li> <li>Multiple sites</li> <li>Soft tissue spread</li> <li>Locally advanced but amenable to surgical resection</li> </ul>	<ul style="list-style-type: none"> <li>Pain is controlled</li> <li>Often curative</li> <li>Fungation, ulceration, bleeding is prevented</li> </ul>	<ul style="list-style-type: none"> <li>Mortality (5%)</li> <li>Morbidity, sepsis, flap necrosis, fibrosis</li> <li>Cosmetic problem</li> <li>Loss of anatomy and its function</li> </ul>

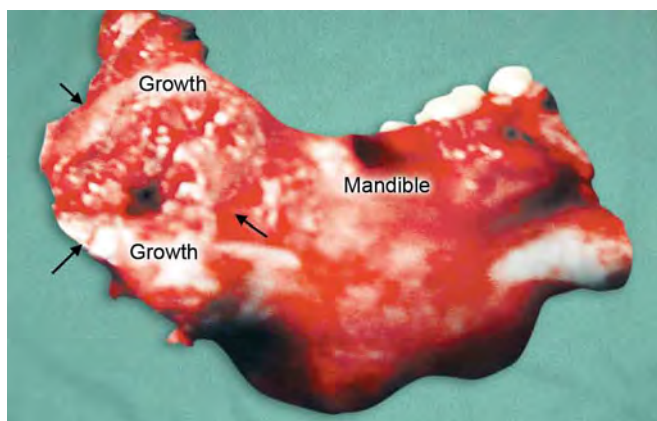


**Fig. 3.21:** Patient who has undergone hemimandibulectomy with primary closure. Note the defect.

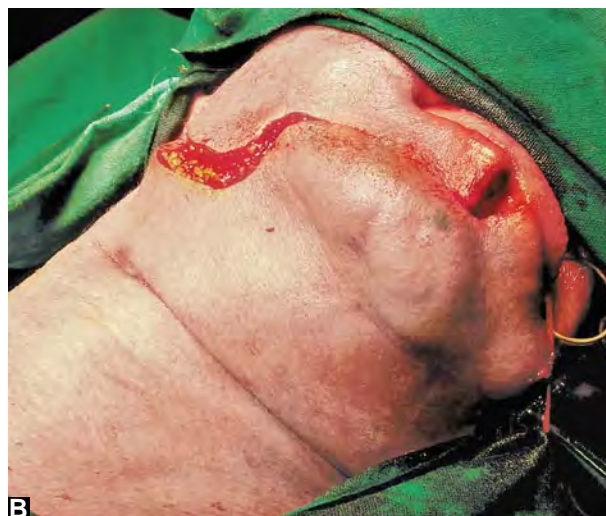

**A**

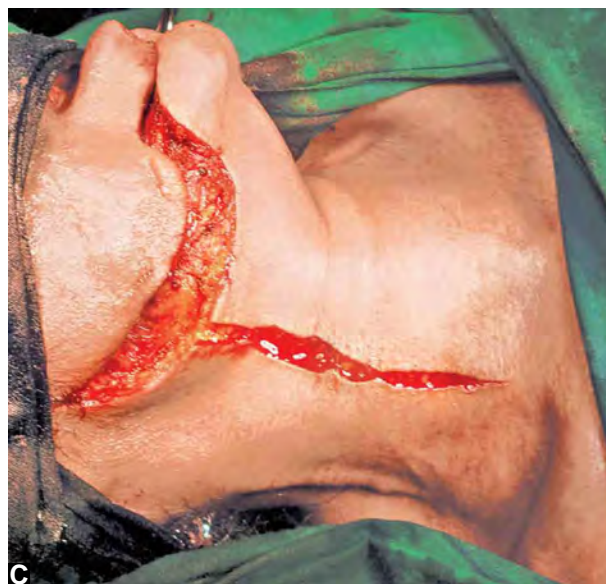Lip-split incision



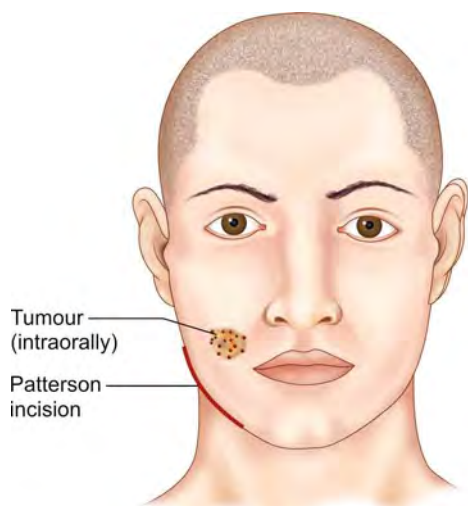
**Fig. 3.22:** Hemimandibulectomy, resected specimen (Courtesy: Dr Jagadish Chandra, MDS).



**B**

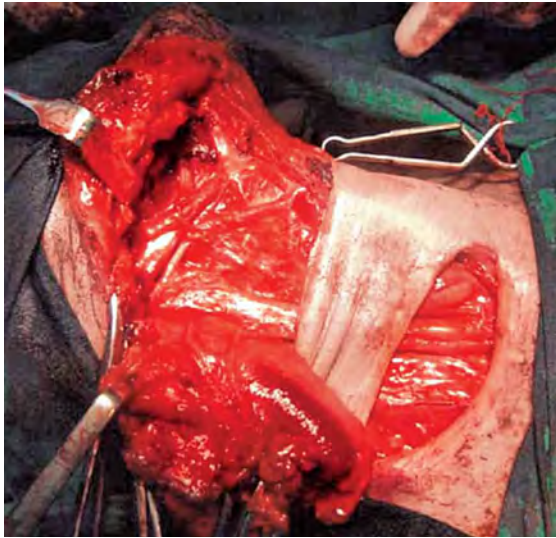


**C**

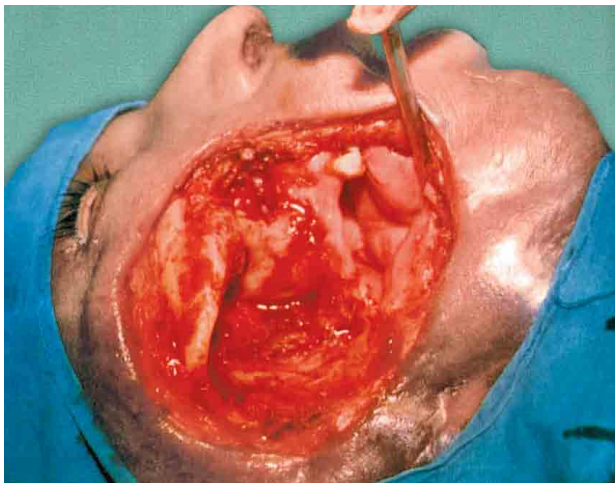


**Fig. 3.23:** *Patterson incision* to approach carcinoma cheek by raising skin flaps from lower part of face adjacent to lower margin of the mandible.

**Figs 3.24A to C:** Lip-split incision approach for carcinoma cheek. It gives adequate exposure of the cheek. Lower extension is for neck block dissection.

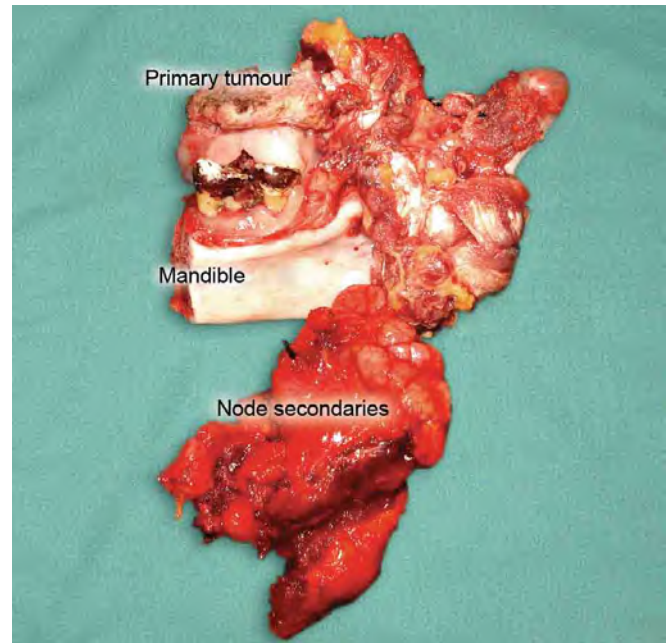


**Fig. 3.25:** Radical neck dissection for secondaries in neck through MacFee incision.

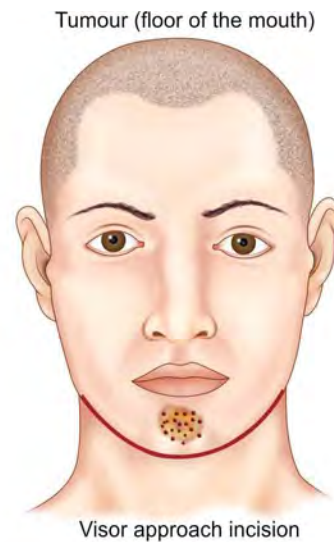


**Fig. 3.26:** Defect in the cheek after wide excision for carcinoma cheek. Defect needs coverage using PMMF with skin graft inside (Courtesy: Professor Kishore Chandra Prasad, ENT Surgeon and Dr Sampath, ENT Surgeon, Mangaluru).

- ◆ **Operable primary tumour with mobile lymph nodes on same side but without mandibular involvement:**  
Wide excision of primary tumour and radical neck lymph node dissection on same side are done. Mandible is not removed.
- ◆ **Fixed primary tumour or advanced neck lymph node secondaries:**  
Only palliative *external radiotherapy* is given to palliate pain, fungation and to prevent anticipated torrential haemorrhage.
- ◆ **Pre-operative radiotherapy is often used in fixed lymph nodes to downstage** the disease so as to make it operable.
- ◆ **Post-operative radiotherapy is given in  $T_3$  and  $T_4$  tumours:**  $N_2$  and  $N_3$  nodal status to reduce the recurrence and to improve the prognosis (in multiple nodes and nodes with extracapsular spread).

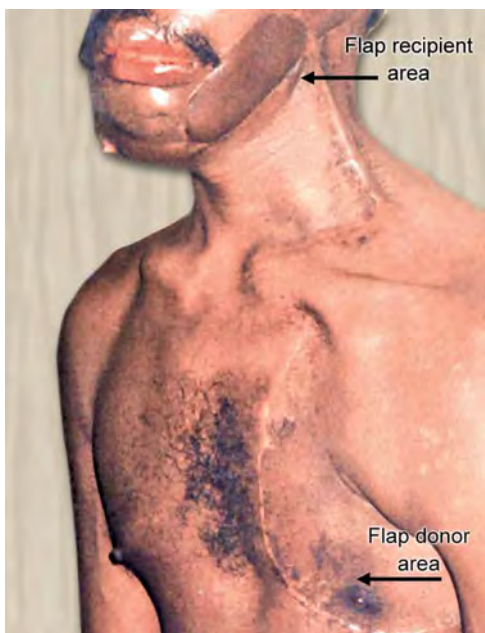


**Fig. 3.27:** Specimen showing primary tumour in cheek with mandible (hemimandibulectomy) and block dissection nodes.



**Fig. 3.28:** Visor approach for oral malignancy. Visor approach for anterior mandible, floor of the mouth and tongue. Here skin over the anterior curved margin of the mandible is incised to approach the floor of the mouth for needed procedure.

- ◆ **Prophylactic block dissection has become popular in  $N_0$  diseases.**  
*Reasons are:*
  - ▶ Even though clinically, lymph nodes are negative, there may be microscopic involvement of lymph nodes (25–65%).
  - ▶ Clinically detectable disease in lymph nodes of the patient signifies extracapsular spread which has got poor prognosis.
  - ▶ Recurrence rate is less after prophylactic block compared to block dissection with clinically positive nodes because



**Fig. 3.29:** Carcinoma cheek operated with radical neck dissection of same side lymph nodes. Reconstruction done using pectoralis major myocutaneous flap.

◆ **Role of chemotherapy:**

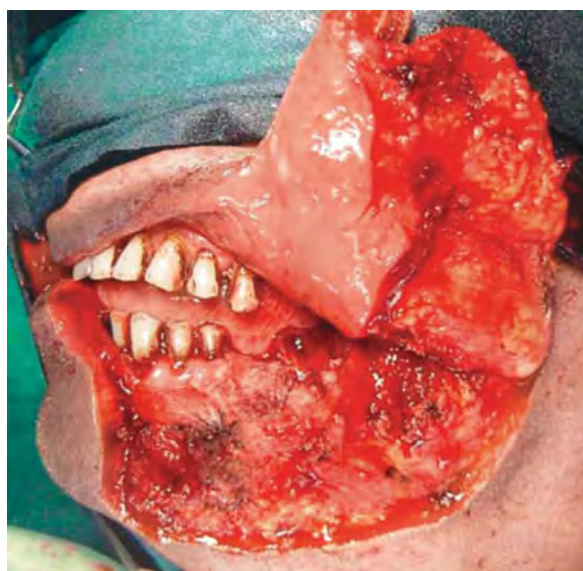Drugs used are methotrexate, cisplatin, vincristine, bleomycin, adriamycin. Often it is given intra-arterially through external carotid artery using arterial pump or by increasing the height of the drip more than 13 feet, so as to attain a pressure more than systolic pressure. Chemotherapy can also be given IV or orally—post-operatively.

- ▶ *Initial chemotherapy* to downstage the tumour followed by surgery and later again end with chemotherapy.
- ▶ *Chemoradiotherapy* is used in unresectable tumours—as consecutive therapies.

**Reconstruction after Surgery**

**Flaps used for reconstruction after oral surgery**

- ❖ Forehead flap based on superficial temporal artery
- ❖ Deltopectoral flap based on 1, 2 and 3 perforating vessels from internal mammary vessels
- ❖ Pectoralis major myocutaneous flap (PMMF) based on thora-coacromial artery
- ❖ Free microvascular flaps may be from radial artery forearm flap
- ❖ For small defects—tongue flap, buccal flap, palatal mucoperiosteal flap



**Fig. 3.30:** Carcinoma cheek, on table wide excision. It requires pectoralis major myocutaneous flap for reconstruction.

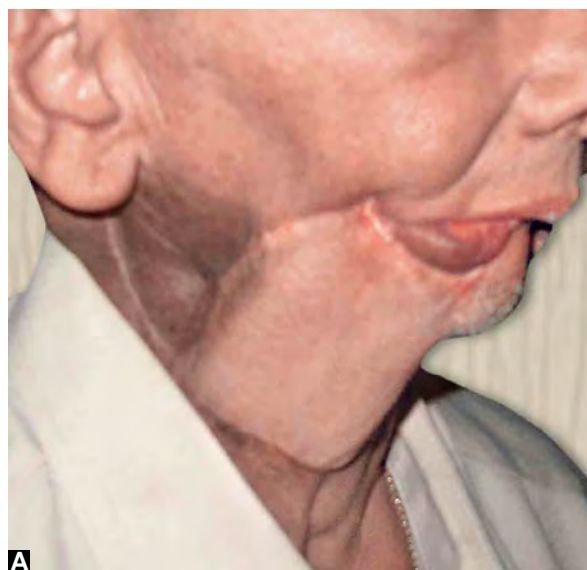there is no extracapsular spread in the former even if there is microscopic spread of tumour in many cases.

- ▶ Block dissection is an acceptable surgery as there is negligible mortality and less morbidity.
- ▶ It is advocated in T3, T4 lesions, carcinoma alveolus or floor of the mouth.

◆ **If growth is extending to upper alveolus:**

Partial maxillectomy or total maxillectomy may be required.

- ◆ Split skin graft.
- ◆ Deltopectoral cutaneous flap.
- ◆ Forehead flap, radial artery forearm flap.
- ◆ Pectoralis major myocutaneous flap.
- ◆ Mandible reconstruction by cortical bone graft or rib, fibula or synthetic material like titanium, stainless steel plate.
- ◆ Free fibular flap; radial forearm flap, anterolateral thigh flap, tongue flap, cheek advancement flaps are becoming popular.

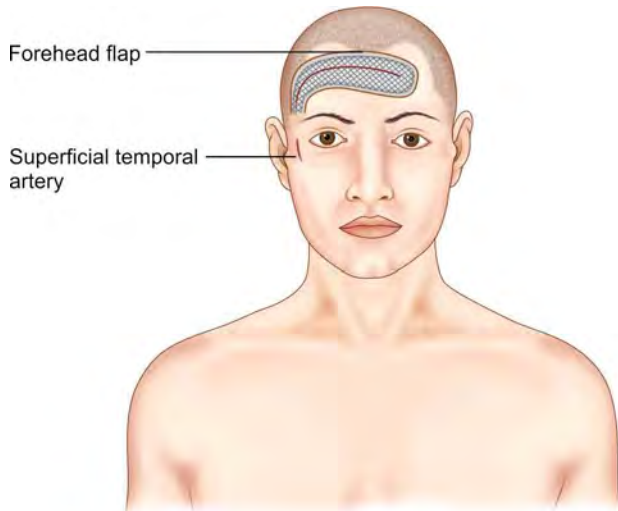


**Fig. 3.31A**

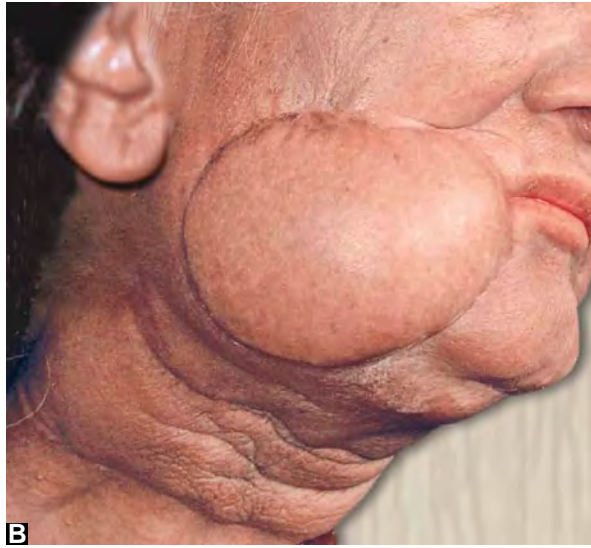

Fig. 3.31B

**Figs 3.31A and B:** Pectoralis major myocutaneous flap to cover the defect in the cheek after wide excision (Courtesy: Professor Kishore Chandra Prasad, ENT Surgeon and Head of the Department and Dr Sampath, ENT Surgeon, KMC, Mangaluru).



**Fig. 3.32:** Forehead flap is used after wide excision of carcinoma cheek. It is based on superficial temporal artery— anterior branch.

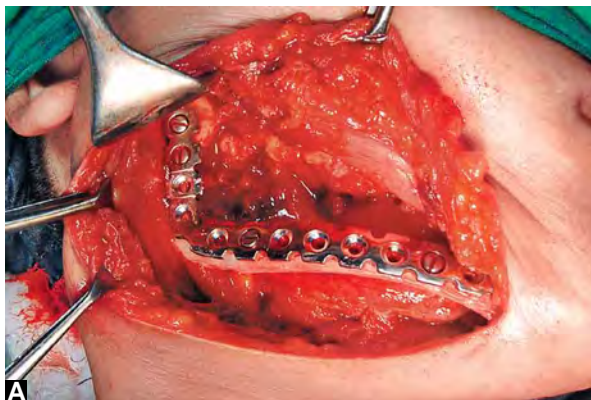
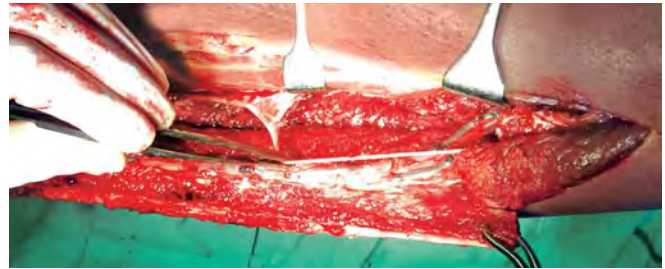


Fig. 3.33A

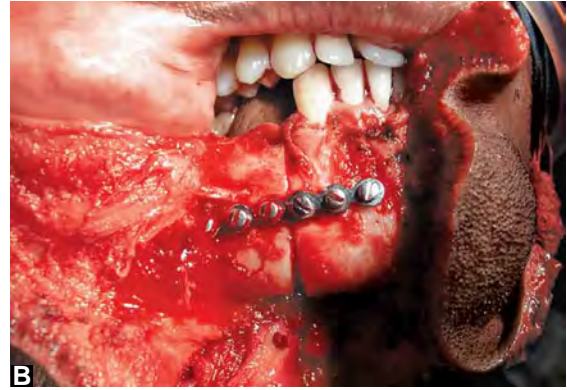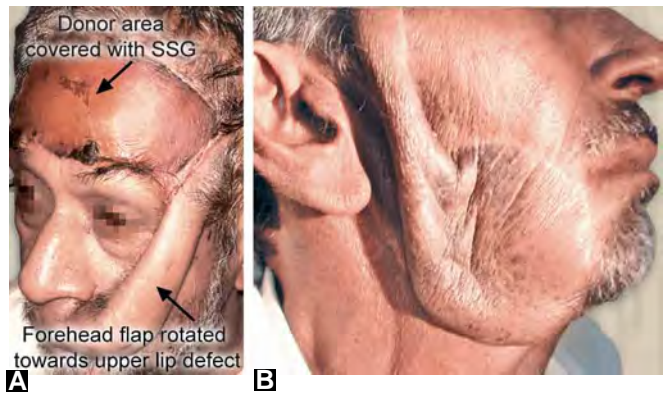


Fig. 3.33B

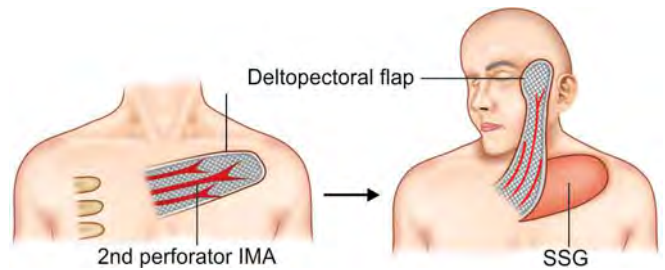
**Figs 3.33A and B:** Reconstruction of the mandible after segmental mandibulectomy using plate and opposite rib fixation (Courtesy: Jagadish Chandra, MDS).



**Fig. 3.34:** Harvesting fibular flap for mandibular reconstruction. (Courtesy: Dr Satish Bhat, MCh, Plastic Surgeon, Mangaluru).



**Figs 3.35A and B:** Forehead flap used to cover the defect after wide excision for carcinoma lip or cheek (Courtesy: Professor Kishore Chandra Prasad, ENT Surgeon and Head of the Department and Dr Sampath, ENT Surgeon, KMC, Mangaluru).



**Fig. 3.36:** Deltopectoral flap used to cover defect after surgical clearance in carcinoma cheek. It is based on 2nd perforator, a branch of internal mammary artery (Bakamjian—1965).

### Approaches to Carcinoma Cheek

- ◆ Transoral/intraoral approach.
- ◆ Lip split incision.
- ◆ Patterson approach.
- ◆ *Visor approach* for anterior mandible, floor of the mouth and tongue. Here skin over the anterior curved margin of the mandible is incised to approach the floor of the mouth for needed procedure. (Visor is French derived word which means mobile lower part of the helmet which covers the chin).

#### Different mandibular resections

- ❖ Marginal mandibulectomy
- ❖ Segmental resection
- ❖ Partial mandibulectomy
- ❖ Hemimandibulectomy
- ❖ Rim resection of mandible
- ❖ Resection of the anterior mandible through visor approach

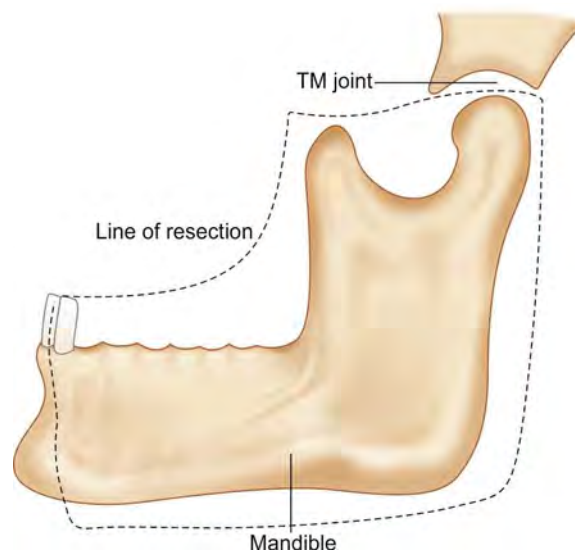


Fig. 3.40: Hemimandibulectomy.

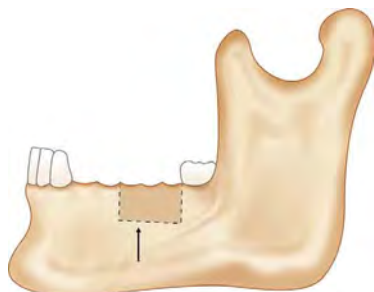


Fig. 3.37: Marginal mandibulectomy.

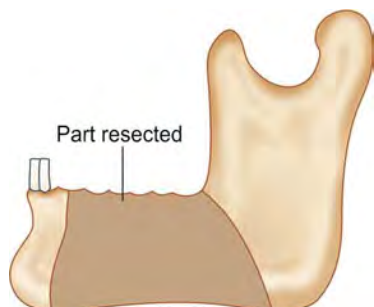


Fig. 3.38: Segmental resection of the mandible (angle of mandible to mental foramen).

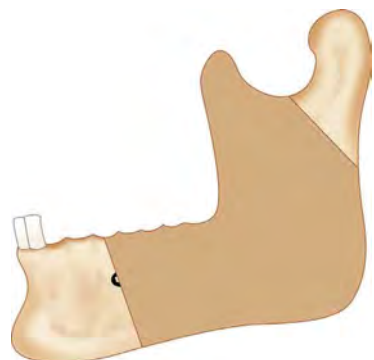


Fig. 3.39: Partial mandibulectomy is removal of mandible one side from mental foramen to line of coronoid process including coronoid process but leaving condylar process.

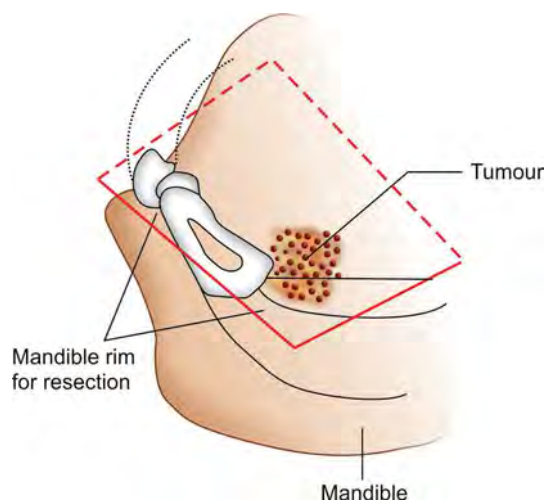


Fig. 3.41: Rim resection of mandible done for carcinoma floor of the mouth.

### Marginal Mandibulectomy

- ◆ It is in continuity wide excision of tumour with gingival and adjacent margin of the mandible.
- ◆ Superior margin is removed using electric saw after proper marking leaving at least 1 cm of inferior margin.
- ◆ It is done in lesion which is close to mandible but not invading. Invasion needs segmental resection. Invasion is invariably through dental root leading into mandibular canal and cancellous bone.
- ◆ Mandibular involvement either clinically or radiologically, previous RT, retromolar lesion (as pterygoid clearance is needed here) are the contraindications.

*In great attempts, it is glorious even to fail.*



### Problems with surgery

- ❖ Mutilation (surgical)
- ❖ Anaesthesia complications
- ❖ Bleeding
- ❖ Infection
- ❖ Flap necrosis
- ❖ Requirement for reconstruction
- ❖ Mortality
- ❖ Morbidity—stiffness; contracture; cosmetic problem; cutaneous anaesthesia; speech and swallowing problems
- ❖ Problems of neck dissection—hypoglossal, accessory, phrenic nerve injuries; thoracic duct injury, carotid blow out; oedema neck and face

### Problems with radiotherapy

- ❖ When mandible is irradiated, chances of the dreaded problem, osteoradionecrosis is high which requires the removal of mandible
- ❖ Loss of taste sensation and dryness, xerostomia
- ❖ Infection, mucositis, dental diseases
- ❖ Skin excoriation, hair loss
- ❖ Trismus may get aggravated
- ❖ Can itself cause dysphagia, laryngeal oedema
- ❖ Hypothyroidism if neck is irradiated
- ❖ Radiation neuritis causing severe pain
- ❖ Carotid artery atherosclerosis
- ❖ Visual impairment
- ❖ Shoulder and neck dysfunction
- ❖ Soft tissue fibrosis

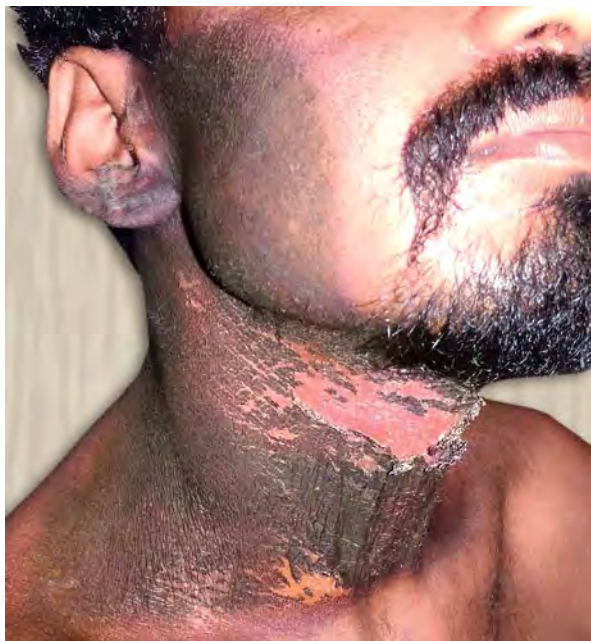

Fig. 3.42: Radiodermatitis after RT to tonsillar growth.

### Problems with chemotherapy

- ❖ Bone marrow suppression
- ❖ Megaloblastic anaemia
- ❖ GIT symptoms
- ❖ Hepatotoxicity and renal toxicity
- ❖ Alopecia
- ❖ Nausea, vomiting and severe stomatitis

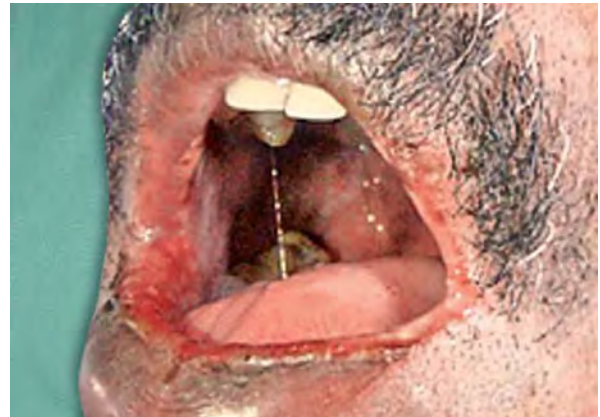

Fig. 3.43: Mucositis in cheek and lip in a patient who is receiving chemotherapy for carcinoma.

### Prognostic factors in oral carcinomas

- ❖ Stage of the disease
  - Stage I and II has got 80% 5 years survival
  - Stage III and IV has got less than 20% 5 years survival rate
- ❖ T3 and T4 lesions has got poor survival rate
- ❖ Carcinoma lip has got best prognosis
- ❖ Carcinoma posterior 1/3rd tongue has got worst prognosis
- ❖ Cheek, floor of the mouth and palate has got intermediate prognosis
- ❖ Perineural invasion and angioinvasion carries poor prognosis
- ❖ Histologically positive nodes decrease the survival rate by 50%
- ❖ Level III and IV, node > 3 cm, bilateral nodes extracapsular nodal spread are poor prognostic factors
- ❖ Grading (differentiation) of the tumour
- ❖ Tumour thickness > 6 mm has got poor prognosis
- ❖ Exophytic tumour is better than infiltrating type

### Recurrent carcinoma cheek

- ❖ 90% recur within 1 1/2 to 2 years of first surgery/therapy.
- ❖ Local recurrence (20%) is more common than regional recurrence (nodal—10%).
- ❖ It is confirmed by biopsy.
- ❖ MRI of the area is very useful to assess spread.
- ❖ Treatment: It is difficult to treat. Wide surgical excision with reconstruction is the initial treatment. Since usually patient had already received RT, repeat RT is contraindicated and chemotherapy with ideal drugs and regimes should be undertaken. Reconstruction is technically difficult in a post- RT field.

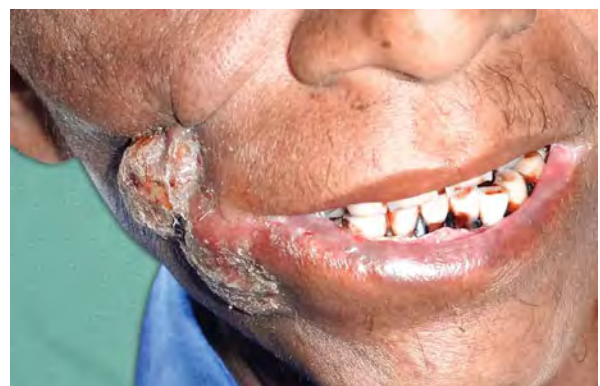
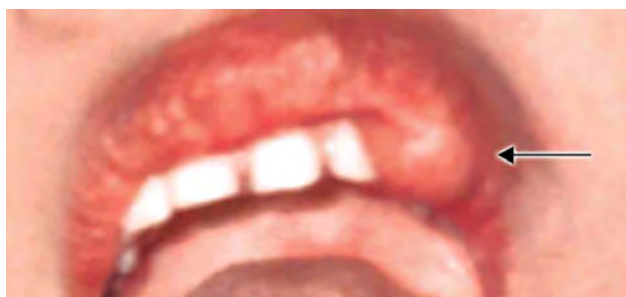
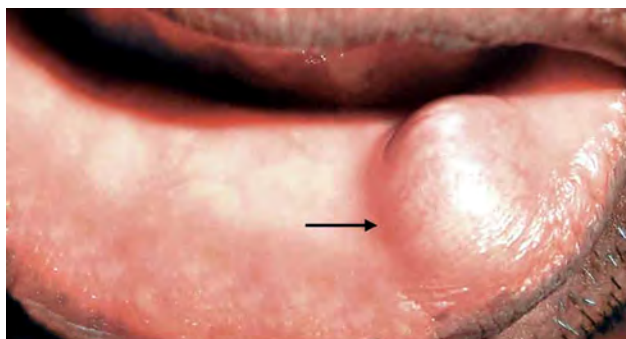Fig. 3.44: Recurrent carcinoma of cheek.

**LIP**

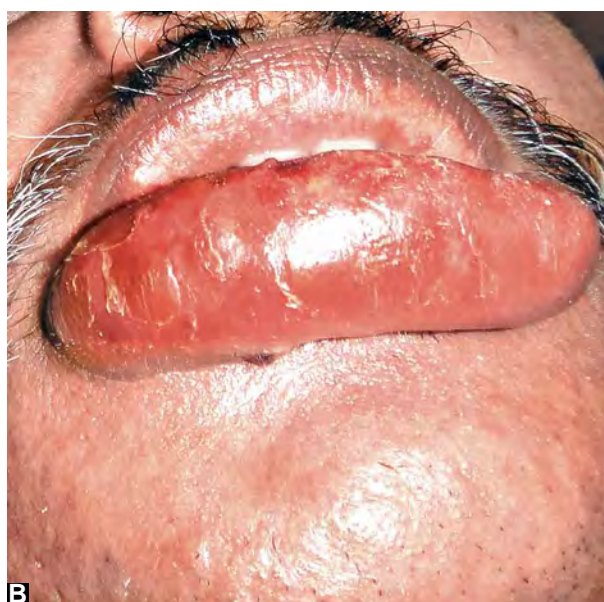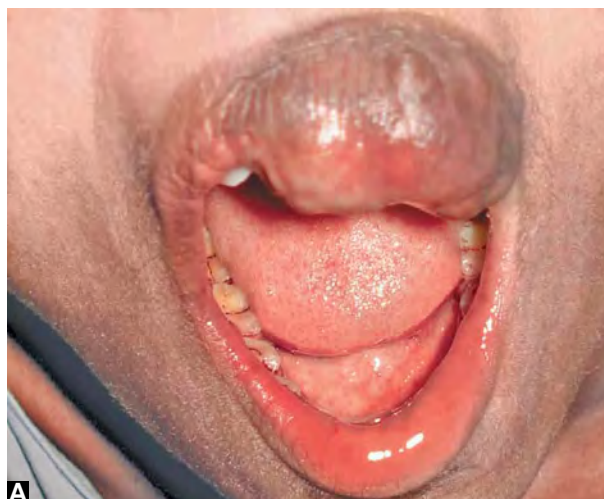- ◆ Lip begins at vermilion border. It has got upper lip, lower lip and oral commissure. SCC is the commonest lip cancer (90%). SCC is common in lower lip; BCC is common in upper lip. Other cancers in lip are spindle cell carcinoma, adenoid squamous carcinoma, malignant melanoma, minor salivary gland tumour.
- ◆ *Mucous cyst* of lip is a common condition. It can occur in upper or lower lip. It is a retention cyst derived from mucous glands of the lip. It presents as bluish, soft, fluctuant often transilluminating well localised swelling. It may resolve on its own. If it does not it should be excised under local anaesthesia. Absorbable suture is used to appose the wound starting from vermilion margin. Usually vertical elliptical incision is used to excise. Sutured wound heals rapidly with very limited scar.
- ◆ *Macrocheilia* is enlargement of lip mass in other than neoplastic conditions. Lymphangioma is the common cause. Haemangioma, inflammatory conditions also can cause macrocheilia.
- ◆ Papilloma, lipoma, pyogenic granuloma, keratoacanthoma, minor salivary tumours are other swellings which can occur in lip.
- ◆ *Cheilitis* often associated with stomatitis is common in vitamin deficiency, malnutrition, sepsis, drug induced, RT induced presents as redness, pain, diffuse swelling. In chronic cases, there will be linear ulcers especially at commissure. *Actinic cheilitis* is a pre-malignant lesion. Cause is treated.
- ◆ *Pigmentation* of lip occurs in Peutz-Jeghers syndrome (brown), Addison's disease (black).
- ◆ *Herpes labialis* is formation ulcers in lip due to herpes simplex virus. Repeated multiple ulcers develop in lip. It is contagious by kissing. So kissing should be avoided including children. Touching repeatedly can transfer the virus to eye causing herpes keratitis.
- ◆ Cleft lip is a common congenital condition.



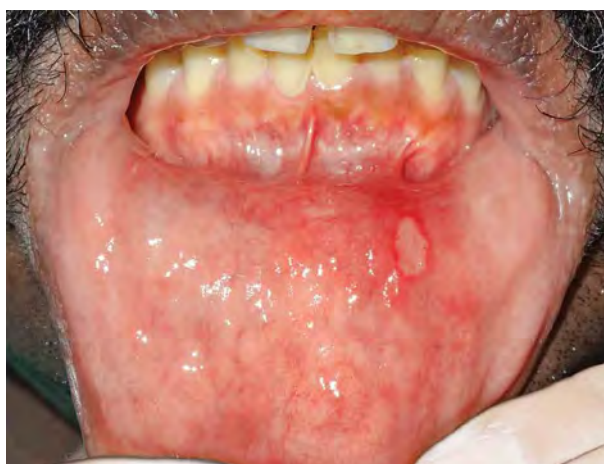**Fig. 3.45:** Mucous cyst upper lip. It requires simple excision. It is a retention cyst.



**Fig. 3.46:** Mucous cyst seen in lower lip. It is bluish, localised, smooth, non-tender, soft, fluctuant swelling, arising as a retention cyst from mucous glands of lip. It needs excision.



**Figs 3.47A and B:** (A) Haemangioma lip causing macrocheilia; (B) Macrocheilia due to inflammatory cause.



**Fig. 3.48:** Aphthous ulcer lower lip. It is painful, self-limiting ulcer. It can occur in tongue, lip, cheek and other parts of the oral mucosa.

## NEOPLASM OF LIP

One may...cure cancers of the lip without applying caustics or any similar thing.... Pass a threaded needle through the cancer so the thread held in the left hand can lift and control the cancer without any of its escaping. One can then cut to good flesh with scissors in the right hand; and so cut that a layer of good flesh of the lip remains to serve as a base and foundation for regeneration of flesh in place of the portion amputated, supposing the cancer has not taken root and spread from top to bottom.

—Ambroise Paré, 1585

Basal cell carcinomas (BCC) are common in upper lip. Minor salivary gland tumours also often occur in upper lip; pleomorphic adenoma is the usual type. Squamous cell carcinoma is the commonest cancer in the lower lip.

## CARCINOMA LIP

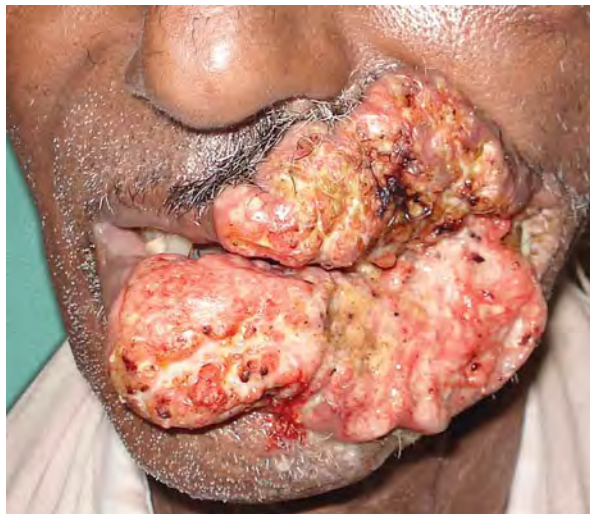
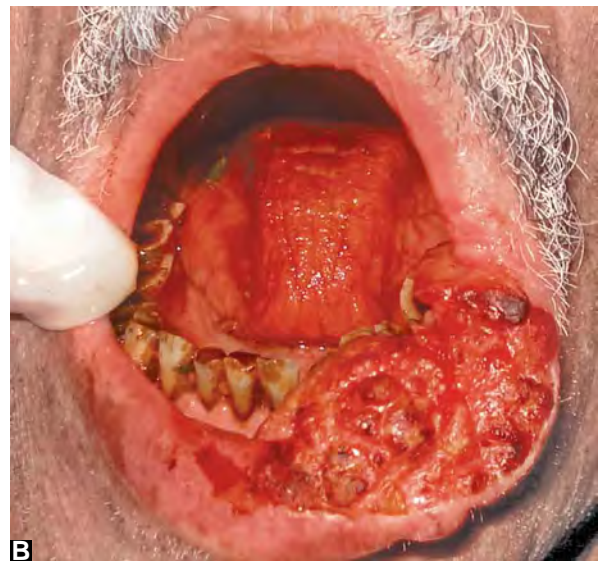
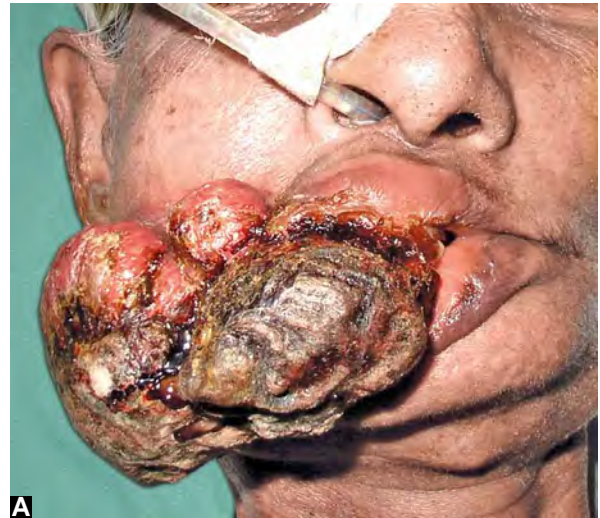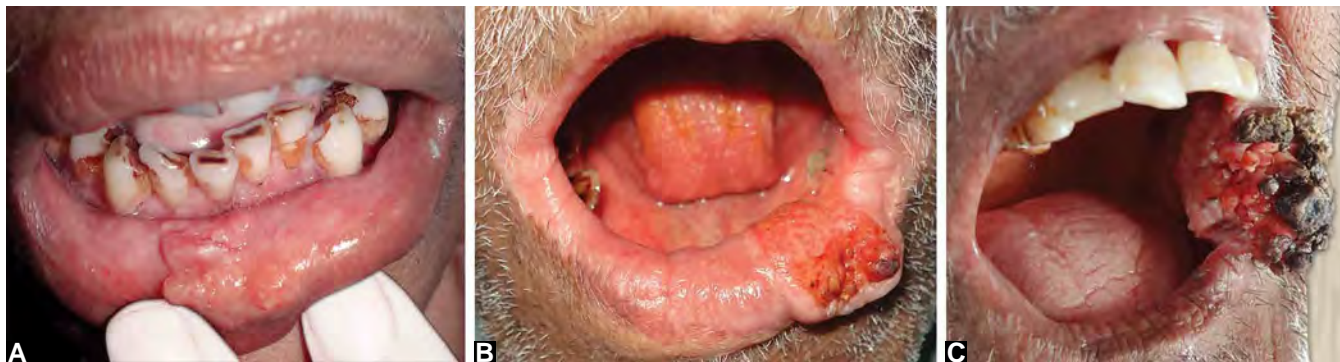Fig. 3.49: Carcinoma lip involving both upper and lower lips.

- ◆ Incidence of carcinoma lip is 15% of head and neck cancers and 1% of all cancers.
- ◆ It may arise from vermilion surface or mucosa part of the lip.
- ◆ It is common after 40 years of age. In younger age group even though it is rare, carries poor outcome.
- ◆ It is more common in whites; rare in blacks. It is common in *Caucasians*.
- ◆ *Khaini*, a mixture of tobacco and lime kept under the lip called as *khaini chewers* are more susceptible for carcinoma lip.
- ◆ All 'S's and irradiation are predisposing factors.
- ◆ *Verrucous carcinoma* can occur in lip. It is well differentiated SCC with exophytic, warty, dry surface. It usually will not invade the deeper tissue and lymph node spread is rare. It carries good prognosis.
- ◆ It is common in men (15:1). Common in *lower lip* (90%); upper lip 5–10%. Upper lip is not exposed to direct actinic radiation.



Figs 3.50A and B: Carcinoma of lip involving extensively.

- ◆ Commonly due to exposure to sunlight (ultraviolet rays). Common in pipe smokers.
- ◆ Initially starts as a red, granular dry lesion which eventually gets ulcerated and forms an ulceroproliferative lesion. Occasionally it occurs at the angle of mouth.
- ◆ It spreads to submental nodes and later to other neck nodes on both sides.
- ◆ Usually it is a *well-differentiated squamous cell carcinoma*.
- ◆ Commissure tumours are 2% of all lip cancers but has higher rate of lymph node spread.
- ◆ Initially it is well localized. A depth of more than 5 mm will spread to lymph nodes mainly submental and submandibular (level I).
- ◆ Painless ulcerative lesion is the most common presentation. Pain develops once necrosis occurs or tumour infiltrates nerve, periosteum of bone underneath.
- ◆ Pigmented SCC can occur. It mimics melanoma.
- ◆ *Anaesthesia of chin* can occur if mental nerve is invaded.
- ◆ Staging is same as other oral cancers.



**Figs 3.51A to C:** Carcinoma lip—different locations in the lower lip. SCC is most common in lower lip; in upper lip BCC is common.

**Clinical features of carcinoma lip**

- ❖ Non-healing progressive ulcer, painless to begin with
- ❖ Everted edge with indurations
- ❖ Growth moves with the lip
- ❖ Submental, submandibular and upper deep neck nodes may get enlarged.
- ❖ Tender firm lymph node may be due to infection; hard initially non-tender node is due to carcinoma spread.
- ❖ In half of the cases lymph nodes are enlarged due to infection or as reactive process
- ❖ Fungation, bleeding, halitosis

**Predisposing Factors**

- ◆ Cheilitis—actinic type
- ◆ Solar keratosis.
- ◆ Papilloma.
- ◆ Leukoplakia.
- ◆ Smoking, U-V rays, pipe smokers, reverse smoking.
- ◆ Tobacco chewing, *Khaini* chewers (tobacco+lime).
- ◆ Agriculturists who are commonly exposed to sunlight get carcinoma lip and is called as *countryman's lip*.

**Differential Diagnosis**

- ◆ Keratoacanthoma.
- ◆ Basal cell carcinoma. BCC occurs only in upper lip.
- ◆ Minor salivary gland tumours.
- ◆ Often carcinoma of lip is an extension from carcinoma of cheek.
- ◆ Pyogenic granuloma in early cases only.
- ◆ Malignant melanoma in case of *pigmented SCC*.

**Diagnosis**

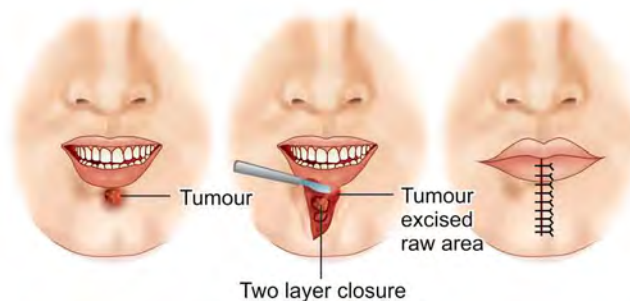
Wedge biopsy, FNAC of lymph nodes, USG/CT neck.

**Treatment**

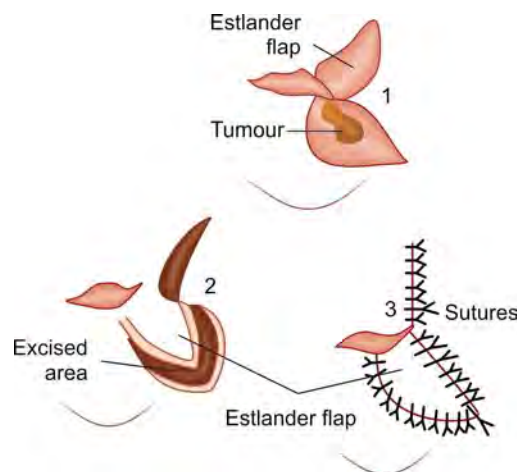
- ◆ If lesion is less than 2 cm, then curative radiotherapy, either brachytherapy or external beam radiotherapy. It gives a good cure.
- ◆ If tumour is more than 2 cm, wide excision is done. Excision of lower lip up to one-third can be sutured primarily, in

layers keeping vermilion border in proper apposition without causing any microstomia.

- ◆ Excision of more than one-third of the lip requires reconstruction using different flaps.



**Fig. 3.52:** Primary repair of lip after wide excision of small tumour. One-third of the lip can be sacrificed. Lip is sutured in layers. First layer, muco-muscular layer with absorbable suture. Second layer is skin with non-absorbable monofilament sutures like polypropylene.



**Fig. 3.53:** Lower lip tumour after excision when primary suturing not possible, then upper lip flap based on upper labial artery can be used—*Abbe-Estlander flap*.

**Methods**

1. *Abbe-Estlander's rotation flap* used for either upper or lower lip lesions (of less than 1/2 of lip) located at the angle based on labial

artery. Here base at a later stage need not be disconnected unlike in Abbe lip.

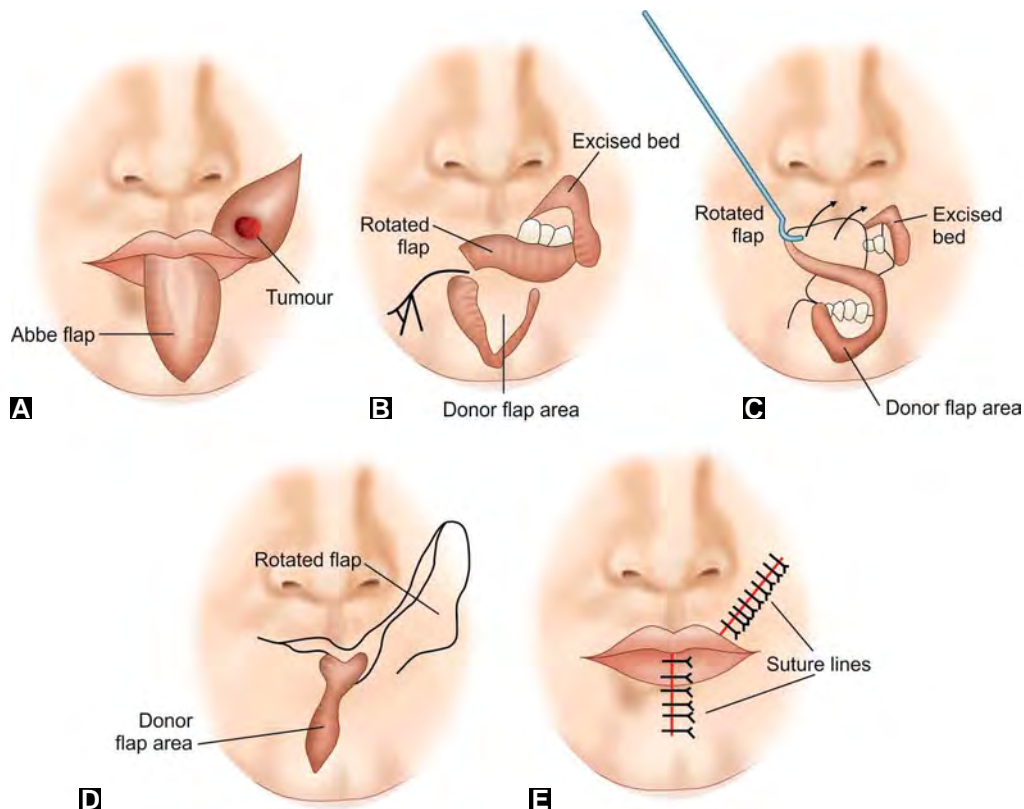
2. *Fries' modified Bernard facial flap*—reconstruction using lateral facial flaps. It is used when defect is more than  $\frac{1}{2}$  of lip and midline.
3. Microvascular flaps.

4. *Nasolabial flap*: It is used when defect is more than  $\frac{1}{2}$  of lip laterally or defect is in the floor of the mouth.

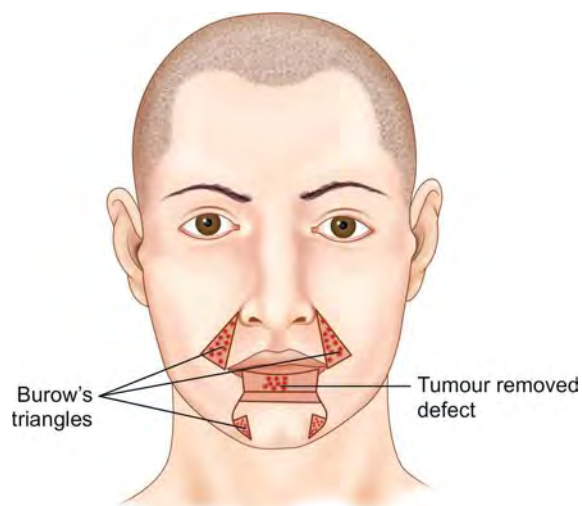
5. Cheek flap.

6. Free radial artery flap.

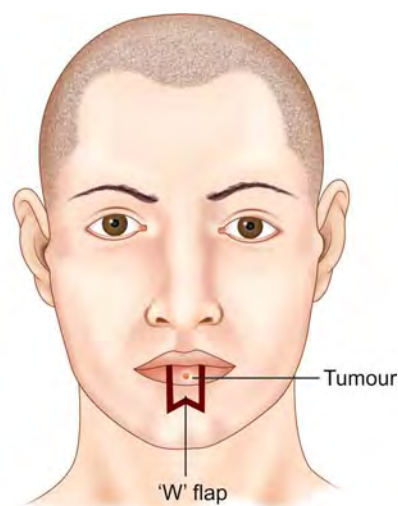
7. *Abbe flap* (switch flap) is used for upper or lower lip lesions at the middle or at the site other than angle based on the labial artery.



**Figs 3.54A to E:** For upper lip tumour when primary repair is not possible, then lower lip flap based on inferior labial artery can be rotated to upper lip—*Abbe flap*.



**Fig. 3.55:** It is used for central lip tumours. Angles of the lower part of the defect and upper part of the angles of the mouth are rotated inwards with Burow's triangles at the site of rotation—*Bernard flap*.



**Fig. 3.56:** It is done for lower lip middle tumour which is less than  $\frac{1}{3}$ rd of the lip—'*W*' flap.

Here at a later 2nd stage base of the flap should be released once flap takes up.

8. *'W' flap plasty*: It is done for lower lip middle tumour which is less than 1/3rd of the lip.
9. *Gillies fan flap*: It is a cheek flap usually bilateral but can be unilateral. Incision is full thickness around commissures extending into nasolabial fold and upper lip upto upper lip vermilion border. Flap which is based on labial vessels is advanced towards the defect. Vermilion is reconstructed with tongue mucosal flap which is divided in 3 weeks.
10. *Karapandzic flap*: It is modified version of the Gillies flap used for lower lip defect with less angulation towards upper lip. Reverse Karapandzic flap is used for upper lip defect.
11. *Johansen 'stepladder'* procedure is used for extensive carcinoma of lower lip.
12. Other regular flaps like forehead flap, deltopectoral flap also can be used.
  - ▶ Lymph nodes are dealt with by radical neck dissection on one side and functional block or supraomohyoid block dissection on other side. For central tumour N<sub>0</sub> disease, bilateral elective (prophylactic) supraomohyoid dissection is done. For

lateral tumour N<sub>0</sub> disease, elective ipsilateral supraomohyoid dissection is done.

- ▶ Post-operative radiotherapy is given if tumour is large or if lymph nodes are involved.
- ▶ When mandible is involved, segmental resection is done.

### Prognosis

- ◆ Prognosis is good, 5 years survival is 70%.
- ◆ Lip has best prognosis.
- ◆ Nerve involvement, fixation, nodal spread, upper lip or commissure lesions, age less than 40 years—are poor prognostic factors.

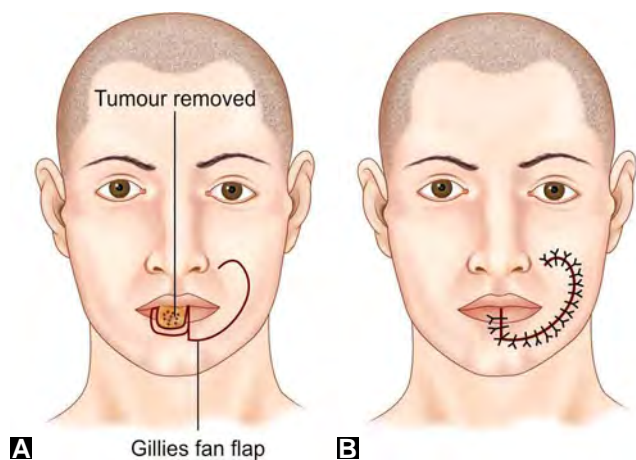
## TONGUE

### Anatomy of Tongue

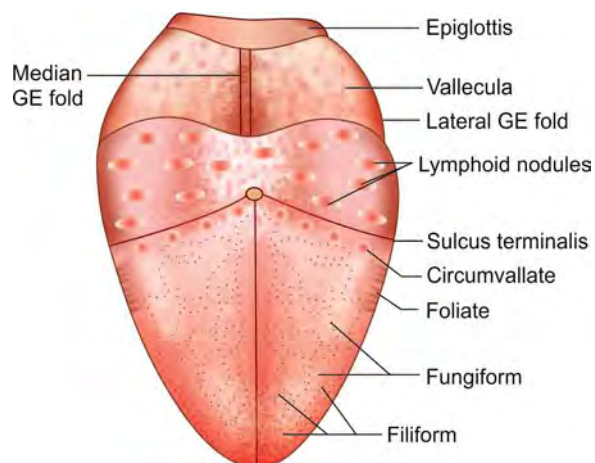
Tongue is a muscular organ located in the floor of the mouth.

#### Parts

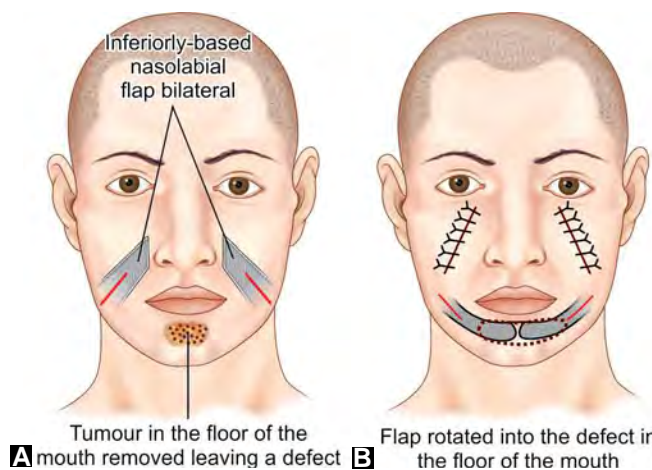
1. *Tip*: Anterior free end lies behind the upper incisor teeth.
2. *Root*: Attached to the mandible above and hyoid bone below.
3. *Body*: Dorsal surface is rough due to papillae; and is divided into anterior 2/3rd (oral part) and posterior 1/3rd (pharyngeal part) by *sulcus terminalis*. Ventral surface is smooth, has a median fold, '*frenulum linguae*' and deep lingual vein on either side.



**Figs 3.57A and B:** Gillies fan flap.



**Fig. 3.59:** Anatomy of the tongue showing parts and papillae.



**Figs 3.58A and B:** Nasolabial flap used in extensive lower lip defect or over the defect after wide excision of a tumour in the floor of the mouth.

### Papillae

1. *Vallate*—large, located in front of sulcus terminalis.
2. *Fungiform*—lies over the tip and margin of the tongue.
3. *Filiform*—lies over the dorsum of tongue, gives the velvety appearance—commonest.
4. *Foliate*—over the margin.

### Muscles of Tongue

- ◆ *Intrinsic muscle*: Superior and inferior longitudinal, transverse and vertical.
- ◆ *Extrinsic muscle*: Genioglossus, hyoglossus, styloglossus, palatoglossus.

Blood supply is from lingual artery, a branch of external carotid artery. Venous drainage by deep lingual vein which drains into fascial vein or internal jugular vein.

### Movements of the tongue

- ❖ Forward protrusion—genioglossus—most commonly affected by carcinoma
- ❖ Backward movement—styloglossus
- ❖ Elevation of tongue—palatoglossus
- ❖ Depression of tongue—hyoglossus

### Lymphatic Drainage of the Tongue

- ◆ Tip of tongue drains into submental lymph nodes.
- ◆ Lateral margin drains to submandibular lymph nodes and into upper deep cervical lymph nodes. Many lymphatic vessels pass as subperiosteal lymphatics of mandible. So carcinoma can involve the bone through this route.
- ◆ Lymphatics in the midline of tongue freely cross communicate with each other and so spread of malignancy can occur to both side neck lymph nodes.
- ◆ Lymphatics from posterior third of tongue drain into pharyngeal group of lymph nodes, as well as to the upper deep cervical lymph nodes. Early spread to the pharyngeal lymph nodes from carcinoma of posterior third of tongue has a poor prognosis.

### Lymphatic vessels are named as

- ❖ Apical vessels
- ❖ Central vessels
- ❖ Marginal vessels
- ❖ Basal vessels

### Development and Nerve Supply of the Tongue

- ◆ *Anterior 2/3rd* develop from first branchial arch through two lingual swellings and one tuberculum impar. It is supplied by lingual nerve for general sensation and by chorda tympani for taste sensation.
- ◆ *Posterior 1/3rd* develops from third arch from cranial half of hypobranchial eminence. It is supplied by glossopharyngeal nerve for both general and taste sensations.
- ◆ *Posterior most part* develops from the fourth arch. It is supplied by vagus nerve (internal laryngeal nerve).
- ◆ *Muscles of the tongue* are derived from occipital myotomes and are supplied by hypoglossal nerve except palatoglossus, which is supplied by cranial part of accessory nerve.

## TONGUE ULCERS

### Differential diagnosis for tongue ulcers

- ❖ Dental ulcers—painful
- ❖ Aphthous ulcers—painful
- ❖ Ulcers in lichen planus—painless
- ❖ Syphilitic ulcers—painless
- ❖ Tuberculous ulcers—painful
- ❖ Malignant ulcers—painless

### Dental Ulcer

It is common on sides of tongue due to sharp tooth, denture, and broken tooth. Usually it is acute painful, self-limiting ulcer. Occasionally repeated trauma form an indolent chronic ulcer which mimic carcinoma; it should be excised to rule out carcinoma and to cure the ulcer.

### Aphthous Ulcer

It can be:

1. *Minor* aphthous ulcer, common in menstruating women as a crop with painful, round, yellow-based ulcer with red margin. It regresses spontaneously in 2 weeks.
2. *Major* aphthous ulcer, large and deep which often becomes chronic and takes more time to subside with a scar. Chlorhexidine gluconate, local application of triamcinolone acetate, choline salicylate gel are different local applicants used to promote healing.
3. *Behcet's syndrome* is genital ulcer, conjunctival ulcer and multiple oral ulcers. *Reiter's syndrome* is urethritis, arthritis, periarteritis nodosa, conjunctivitis, and oral ulcers.
4. Herpetiform aphthous ulcer is not due to herpes simplex. They are small, 1–2 mm diameter ulcers in crops which heal by usual drugs mentioned above.

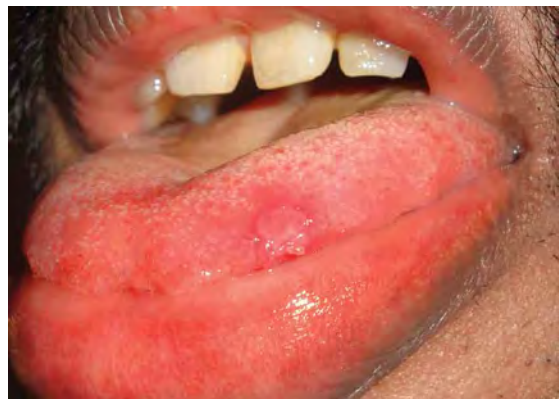

Fig. 3.60: Aphthous ulcer tongue. It is one of the common benign ulcers of the tongue.

### Syphilitic Ulcer

Extragenital chancre often occurs in tongue in *primary syphilis* which is painless with shotty, submental and submandibular lymph nodes. In *secondary syphilis*, multiple shallow snail track ulcers in the margins and undersurface; mucous patches on the tongue and fauces; *Hutchinson's condyloma* wart in midline of tongue can occur. In *tertiary syphilis*, gummatous ulcer occurs in anterior 2/3rd of tongue as a deep punched out painless ulcer as gumma with wash leather slough. Endarteritis is the cause for the punched out look. *Interstitial glossitis* with loss of papillae causes longitudinally fissured bald lobulated tongue in tertiary syphilis. In carcinoma arising from syphilitic ulcer, RT is *questionable* as blood supply is precarious due to endarteritis; RT further compromises it leading to tongue necrosis.

### Tuberculous Ulcer

It is *undermined shallow, often multiple, painful ulcer*. Ulcer can occur in margins, tip or anterior 2/3rd of tongue. Neck nodes may be involved. Associated tuberculous larynx and lung may be present.

### Herpetic Lingual Ulcer

It is involvement of lingual nerve presenting as acute neuralgia with vesicles which form multiple superficial painful ulcers.

### Other Ulcers

Multiple ulcers in smokers due to glossitis (*smoker's ulcer*), ulcers due to vasculitis, eosinophilic granuloma. Post-pertussis ulcer in whooping cough occurs on upper part of frenum linguae and under the tip of tongue.

### Macroglossia (Megaloglossia/Pachyglossia)

It is a disorder in which the tongue is larger than normal. It is commonly painless, diffuse enlargement of the tongue. Macroglossia is usually caused by an increase in the amount (volume) of tissue on the tongue, rather than by a growth, such as a tumour. It is often seen in haemangioma, lymphangioma, muscular macroglossia (in cretins), acromegaly, *Beckwith-Wiedemann syndrome* (hypoglycaemia, abdominal wall defects, Wilms' tumour, macroglossia, adrenal tumour), Down's syndrome, mucopolysaccharidoses, primary amyloidosis, occasionally plexiform neurofibromatosis. Often it causes functional and cosmetic problems.

#### Causes

1. *Lymphangioma*—soft, painless enlarged tongue with ulcers—bilateral; prevents closure of lip and jaw.
2. *Haemangioma*—soft, fluctuant, compressible, bleeding, red/blue lesion
  - i. Both are treated by sclerotherapy (ethanamine oleate)/partial excision
  - ii. Angiogram/MR angiogram is a must in haemangioma
  - iii. Ligation of lingual artery/ECA on both sides may be needed in large lesions

#### Note:

- Varicosities of sublingual veins mimic haemangioma.
- Often causes *unilateral* enlargement of tongue.
- Pressure on alveolus causes spacing of teeth and incisor deformity.

#### Combination of haemangioma and lymphangioma can occur:

1. *Neurofibroma*—partial excision is done
2. *Tongue muscular hypertrophy*: Partial excision is done.

Elongation is corrected by wedge resection of anterior part of extra tongue from midline.

Vertical thickening is rectified by slice cutting of lateral margins without injuring lingual artery and nerve.

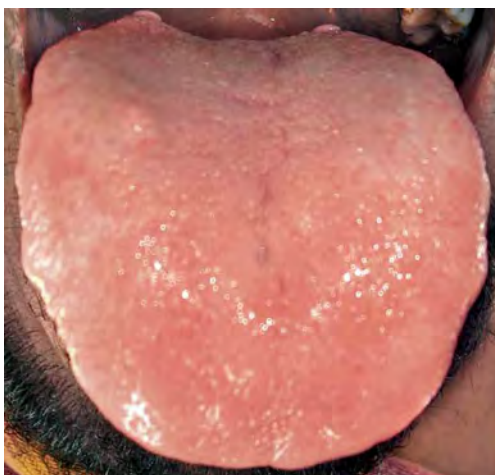

Fig. 3.61: Macroglossia.

## BENIGN TUMOURS OF TONGUE

### Benign tumours of the tongue

- ❖ Papilloma
- ❖ Fibroepithelial polyp
- ❖ Haemangioma and lymphangioma
- ❖ Neurofibroma
- ❖ Lipoma
- ❖ Granular cell myoblastoma

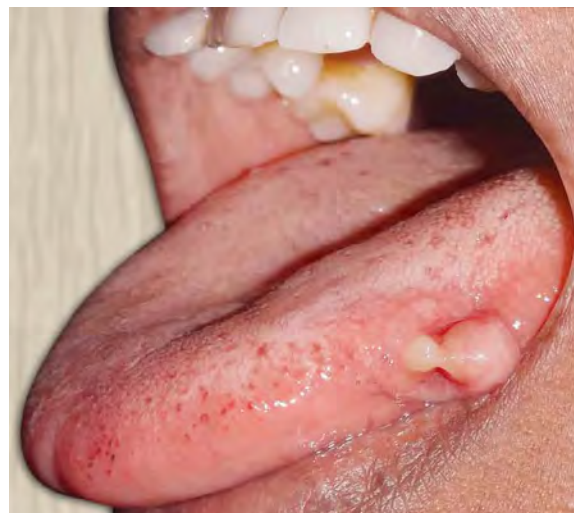

Fig. 3.62: Papilloma of the tongue. It is a premalignant condition. It requires excision biopsy.

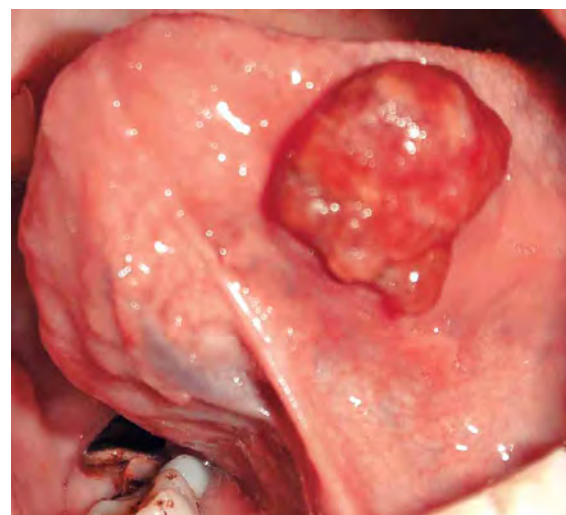


Fig. 3.63: Pyogenic granuloma of tongue under surface.

### Fibroepithelial Polyp

It is due to repeated trauma at one place may be due to teeth (incisor) forming a thickened submucous scar which gets pulled out like a stalked polyp due to sucking and swallowing mechanism. It commonly enters the gap between the lower incisor teeth.

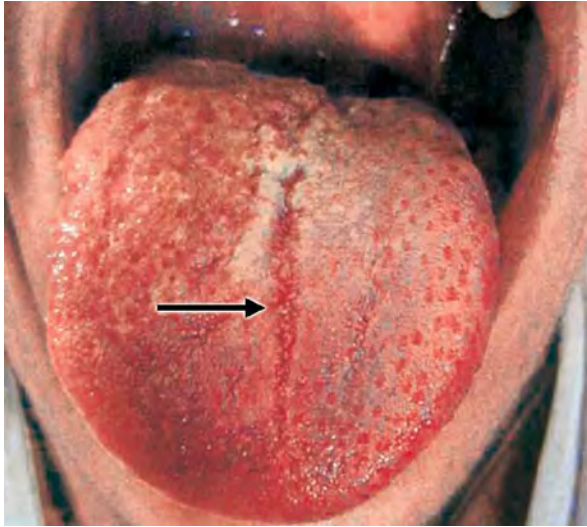
### Granular Cell Myoblastoma

It is a benign non-capsulated firm mobile mass in the tongue showing pseudoepithelial hyperplasia of mucosa of tongue with eosinophilic granular cells in deeper plane. It is often mistakenly diagnosed as carcinoma of tongue. It is treated by excision.

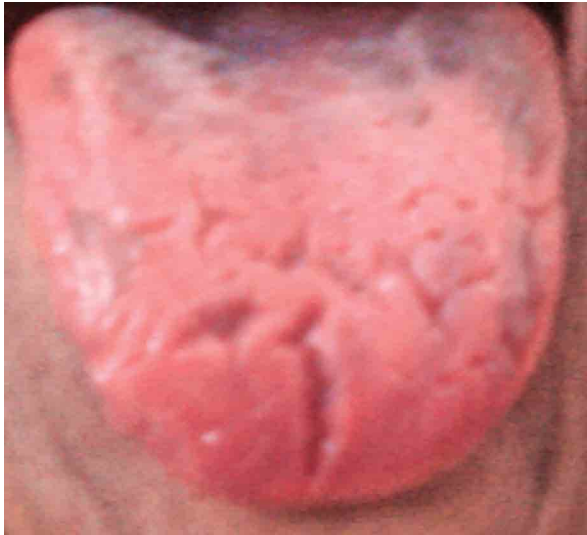### TONGUE FISSURE

- ◆ Congenital fissures are transverse which run laterally from midline with normal papillae in between. *Candida* infection can occur on this.
- ◆ Syphilitic fissures are deep bald and longitudinal.

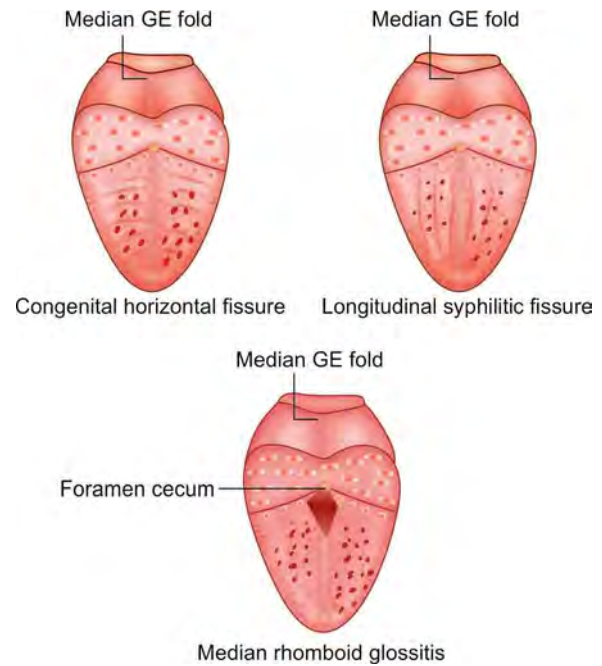




**Fig. 3.64:** Tongue showing fissuring. Fissuring is one of the presentations of carcinoma tongue.



**Fig. 3.65:** Horizontal fissures of tongue.



**Fig. 3.66:** Congenital fissures of tongue are transverse; syphilitic fissures are longitudinal. Median rhomboid glossitis is persistent tuberculum impar.

### Other Glossitis

- ◆ *Hunter's glossitis* is seen in pernicious anaemia.
- ◆ *Hairy tongue* is overgrowth of filiform papillae with black/brown stain on it due to bacteria, fungi, tobacco or drugs. There are no hairs. It is a misnomer. Cessation of causative agent, mechanical scraping, cleaning are the treatment methods.
- ◆ *Agranulocytosis glossitis*.
- ◆ *Non-specific glossitis*.
- ◆ *Pellagra glossitis*, due to deficiency of nicotinamide (B<sub>12</sub>).
- ◆ *Chronic superficial glossitis* in malnutrition, iron and vitamin B deficiencies.

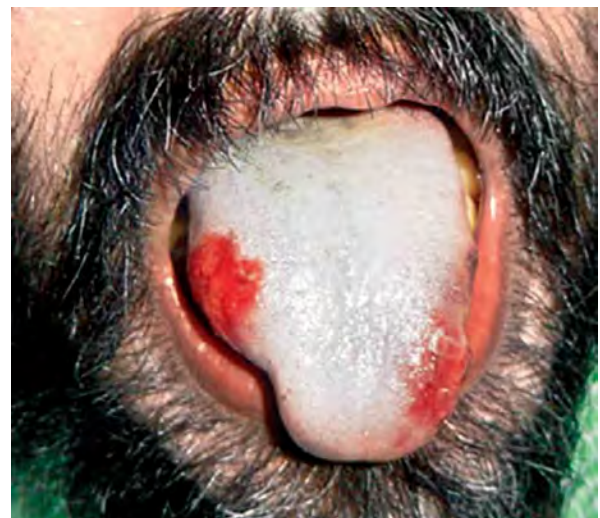## ■ GLOSSITIS

### Median Rhomboid Glossitis

- ◆ It is smooth, lobulated, triangular firm patch anterior to foramen caecum of tongue in midline with deeper colour.
- ◆ *Candida* infection can occur in it.
- ◆ It mimics carcinoma. Biopsy rules out malignancy. Carcinoma is uncommon in midline.

### Glossitis Migrans (Geographic Tongue)

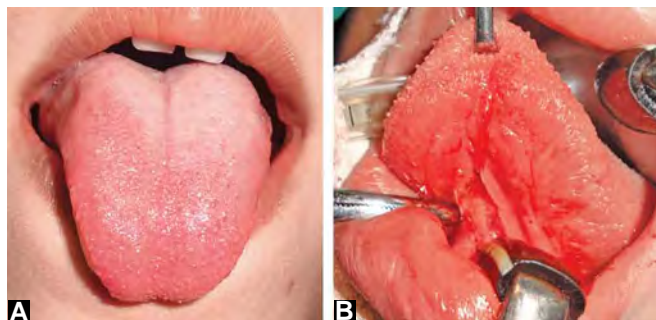
- ◆ It begins as benign small red patches with white furred margin which spread and recede in an irregular way to appear as fresh patches.
- ◆ White margin contains keratinized epithelium and inflammatory cells over filiform papillae.
- ◆ It is often seen in patients with congenital heart diseases and acute gastrointestinal diseases. Etiology is unknown.



**Fig. 3.67:** Severe superficial glossitis.

## TONGUE TIE

- ◆ It is short, thick, fibrous frenum linguae.
- ◆ During protrusion lateral margin and tip of the tongue is everted with dorsal mid part heaping.
- ◆ It causes speech defect, difficulty in cleaning the inner part of lower teeth.
- ◆ It is treated surgically under local anaesthesia (or general in child). Tongue lifted upwards with a stay suture at the tip; fibrous frenum is divided using fine scissor; linear wound is closed longitudinally using fine catgut from the tip of the tongue towards the margin of the floor of the mouth.



Figs 3.68A and B: Tongue tie—on table photo.

## CARCINOMA TONGUE

Incidence is equal in both sexes. Presently its incidence is increasing in females due to increase in number of female smokers.

### Aetiology

- ◆ Leukoplakia.
- ◆ Erythroplakia.
- ◆ All 'S's (as mentioned in leukoplakia).
- ◆ Premalignant conditions mentioned earlier.

### Types

#### Gross

1. Papillary.
2. Ulcerative or ulceroproliferative 60%.
3. Fissure with induration.
4. Lobulated, indurated mass—*frozen tongue*.

#### Histologically

1. Squamous cell carcinoma—commonest.
2. Adenocarcinoma, may arise from minor salivary glands or mucous glands.
3. Melanomas.
4. Transitional cell carcinoma and lymphoepithelioma rarely can occur in posterior 1/3rd of tongue.

#### Sites

1. Lateral margin—commonest—47–50%.
2. Posterior third—20%.

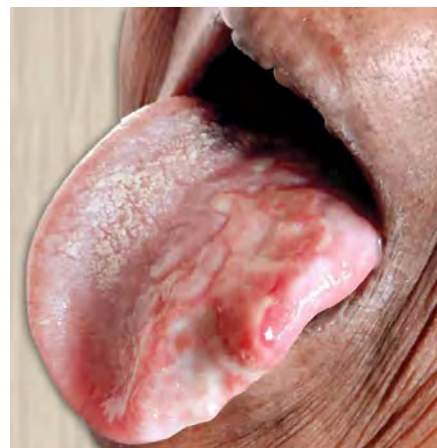


Fig. 3.69: Carcinoma tongue—lateral margin but involving extensively.

3. Dorsum—6.5%.
4. Ventral surface—9%.
5. Tip—10%.

### Clinical Features

- ◆ *Painless ulcer/swelling* in the tongue which later may become painful. *Pain* in the tongue due to infection or ulceration or due to the involvement of lingual nerve (pain is referred to ear). Pain on swallowing, in case of carcinoma of posterior third of tongue.
- ◆ *Excessive salivation*. Saliva is often blood stained.
- ◆ *Dysphagia* either due to fixed tongue or due to the involvement of genioglossus or growth in the posterior third of the tongue.
- ◆ *Visible ulcer* in anterior two-thirds of tongue. Ulcer can bleed on touch; edge, base and surrounding areas are indurated. Often indurated area is much more extensive than the primary tumour (it is also common in carcinoma penis). Edge is everted commonly. Ulcer may cross the midline; may extend into the floor of the mouth/alveolus/mandible. Growth or ulcer in posterior third, is usually not visible.
- ◆ *Ankyloglossia*—involvement of muscles of the tongue.
- ◆ Movements of the tongue especially forward protrusion is commonly affected.
- ◆ *Inability to articulate*.
- ◆ *Foetor* (Halitosis). Due to infection and necrosis in the oral cavity. It is due to release of ammonia, butyric acid and mercaptan by tumour cells.
- ◆ *Change in voice*. Occurs in posterior third tumours. Tumour in posterior third area is more aggressive.
- ◆ Palpable *lymph nodes* in the neck which are hard, nodular and get fixed to underlying tissues in advanced stages.
- ◆ Features of bronchopneumonia—due to aspiration during lying down/sleeping mainly to lower segment of lung.

### Spread of Carcinoma Tongue

#### Local spread:

In case of anterior two-thirds of tongue, the spread occurs to genioglossus muscle, floor of the mouth, opposite side and mandible. In case of posterior third of tongue it spreads locally to tonsil, side of pharynx, soft palate, epiglottis, larynx and cervical spine.

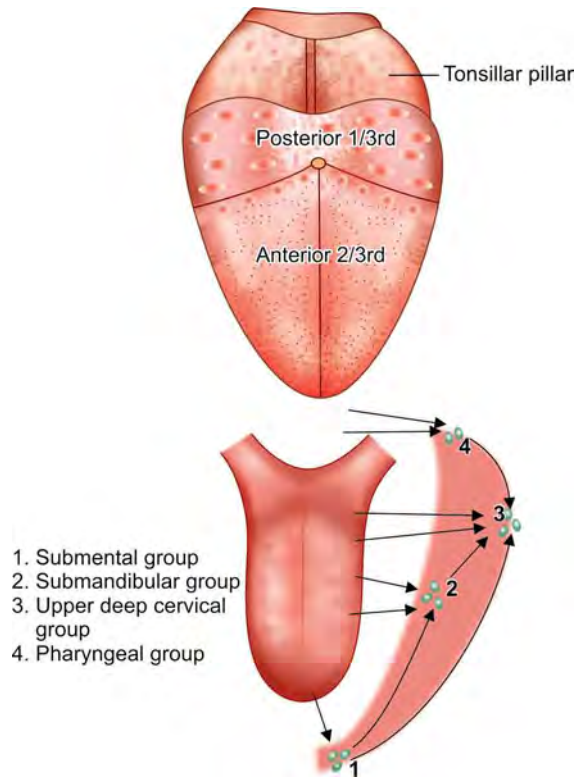


Fig. 3.70: Anatomy and lymphatic drainage of tongue.

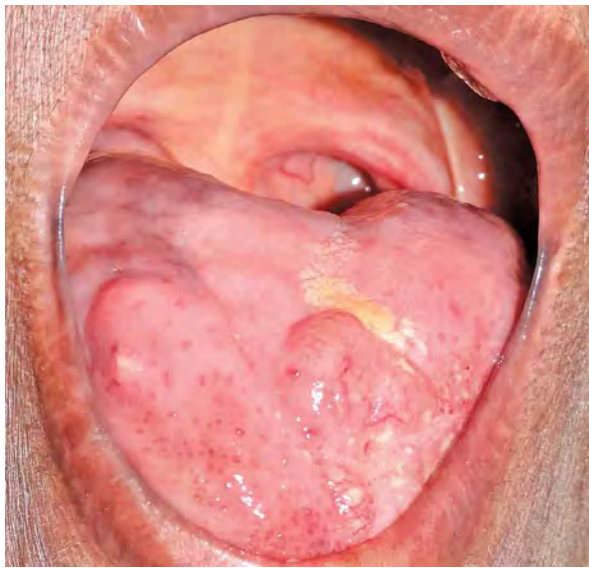

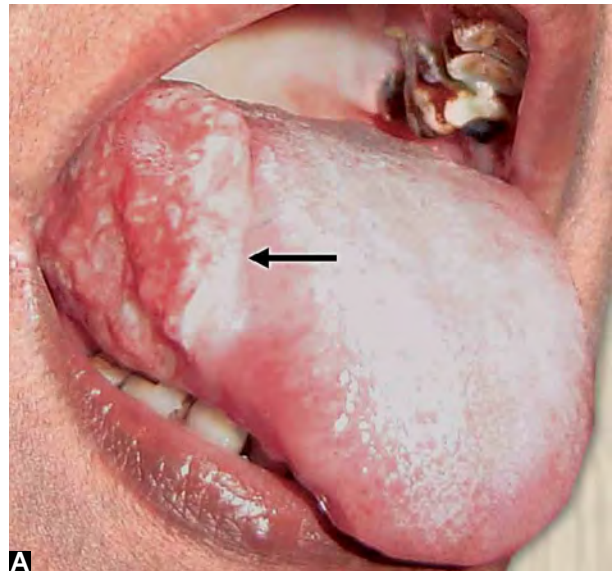
Fig. 3.71: Frozen tongue is feature of carcinoma tongue with ankyloglossia.

*Lymphatic spread:*

From tip of tongue it spreads to submental nodes. From lateral margin it spreads to submandibular lymph nodes and later to deep cervical lymph nodes. Lymphatics in the tongue are freely communicating, and so involvement of bilateral neck lymph nodes is common. From posterior third it spreads to pharyngeal nodes and upper deep cervical lymph nodes.

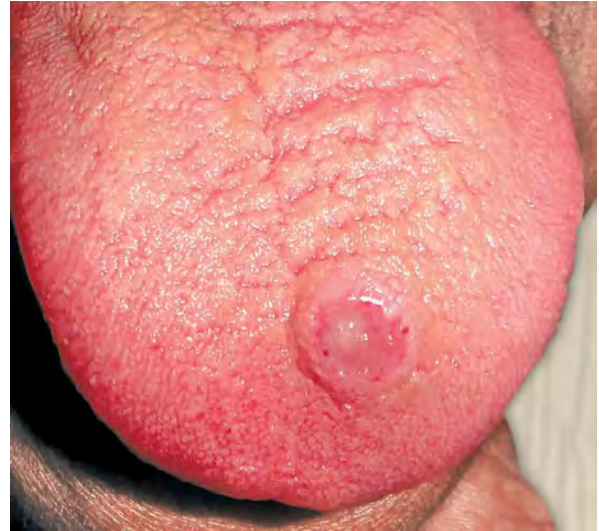
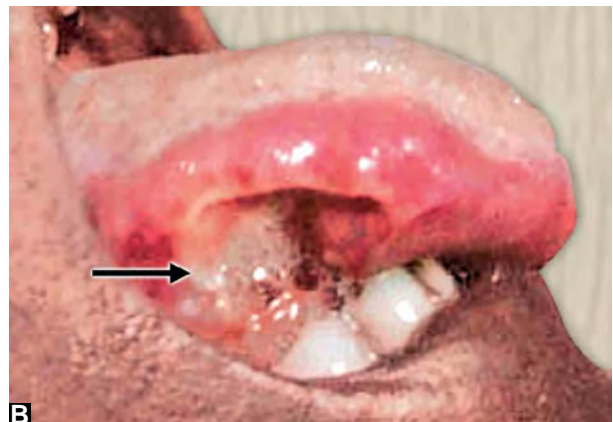
Fig. 3.72: Carcinoma tip of tongue. Well-circumscribed raised edge is seen.



Figs 3.73A and B: Carcinoma tongue lateral margin (commonest site).

**Note:**

- Any tongue lesion more than 4 mm depth has 30% metastasis to lymph nodes.
- Among oral cancers, carcinoma tongue is more aggressive, rapidly growing tumour with high potential for lymph node spread.
- Bilateral neck lymph node spread is common due to crossing of lymph vessels in tongue.
- Clearance of lingual lymph node which is located between tongue and submandibular lymph glands has to be done which may contain micrometastasis.
- Carcinoma tongue has got highest incidence of nodal spread.

**Investigations**

- ◆ *Wedge biopsy.*
- ◆ *FNAC* of lymph nodes.
- ◆ *Indirect and direct laryngoscopy* to see posterior third growth.
- ◆ *CT scan* to see the extension of posterior third growth, or to see the status of lymph node secondaries. *MRI* is also very useful to assess the extent of primary tumour.
- ◆ *Chest X-ray* to see bronchopneumonia.
- ◆ *Orthopantomogram.*

**Note:**

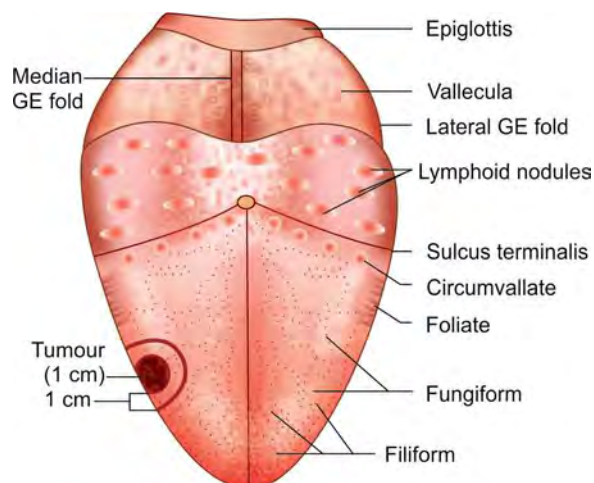
Staging is same as carcinoma cheek.

**Treatment**

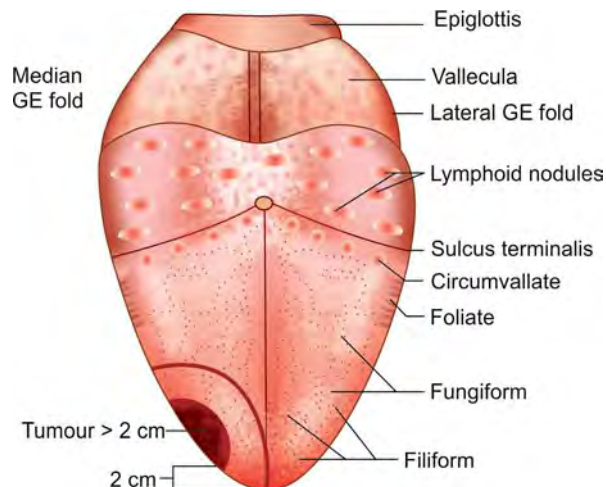
*Surgery, radiotherapy, chemotherapy.*

**Surgery**

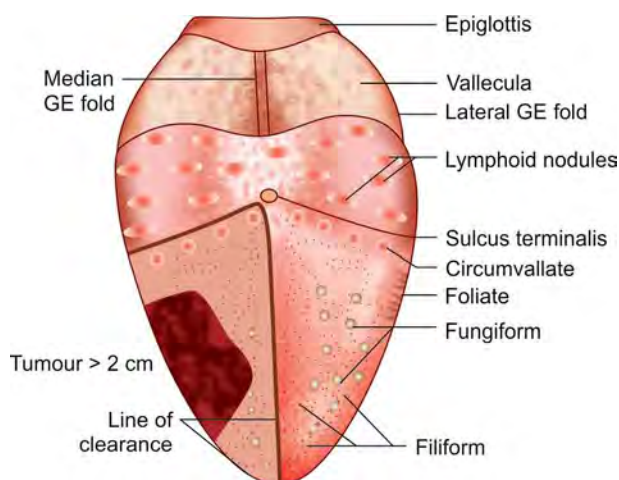
- ◆ *Wide excision* with 1 cm clearance in margin and depth is done in tumour less than 1 cm in size or in carcinoma in situ. Laser ( $\text{CO}_2$ /diode) can be used.
- ◆ Tumour between 1–2 cm in size, *partial glossectomy* is done with 2 cm clearance from the margin with removal of 1/3rd of anterior two-thirds of the tongue.
- ◆ Tumour larger than 2 cm, *hemiglossectomy* is done with removal of anterior 2/3rd of tongue on one side up to sulcus terminalis.
  - ▶ *Raw area* in these procedures can be left alone when area is wide allowing it to granulate and heal by epithelialisation. If area is small like in wide excision it can be closed by primary suturing. Wide raw area can also be covered with PMMF or *quilted split-skin-graft*.
- ◆ Larger primary tumour can be given pre-operative radiotherapy, then later hemiglossectomy is done.
- ◆ Same side palpable, mobile lymph nodes are removed by *radical neck block dissection*.
- ◆ *Bilateral mobile lymph nodes* are dealt with *one side radical block and other side modified radical block dissection with essentially retaining internal jugular vein* (on opposite side) to maintain the cerebral venous blood flow. Other option is doing same side radical neck dissection and on opposite side supraomohyoid block dissection.
- ◆ *Wide excision* is done when growth is in the tip of the tongue.
- ◆ Posterior third growth can be approached by lip split and mandible resection, so as to have *total glossectomy—Kocher's approach*. It is not done commonly as it carries significant morbidity and mortality due to difficulty in speech, swallowing, aspiration, sepsis.
- ◆ When mandible is involved *hemimandibulectomy* is done.



**Fig. 3.74:** Wide excision is done in small lateral margin tumour of 1 cm size with 1 cm clearance.



**Fig. 3.75:** Tumour between 1 and 2 cm size is treated by partial glossectomy with 2 cm clearance.



**Fig. 3.76:** Tumour larger than 2 cm requires hemiglossectomy.

- ◆ The procedure that involves wide excision or hemiglossectomy, hemimandibulectomy and radical neck dissection together is called as *Commando Operation*.
- ◆ Reconstruction of tongue and other area after surgery: By deltopectoral flap, forehead flap, pectoralis major muscle flap, skin grafting.
- ◆ Prophylactic block dissection is becoming popular at present.

#### Post-operative management

- ❖ Control of infection and oedema
- ❖ Regular mouth wash
- ❖ Maintaining the airway
- ❖ Prevention of aspiration
- ❖ Nutrition (through nasogastric tube commonly/TPN often)

#### Radiotherapy

- ◆ In small primary tumour—curative radiotherapy (Brachytherapy using caesium or iridium<sup>192</sup> needles).
- ◆ Large primary tumour—initial radiotherapy is given to reduce the tumour size so that the resection will be better later.
- ◆ Advanced primary as well as secondaries in the neck can be controlled by palliative external radiotherapy.
- ◆ Post-operative radiotherapy is given in large tumours to reduce the chances of relapse.
- ◆ *In case of growths in the posterior third of tongue, radiotherapy is of curative as well as palliative mode.*

#### Complications of radiotherapy

- ❖ Loss of sensation like taste
- ❖ Trismus and ankyloglossia
- ❖ Infection
- ❖ Pharyngeal and laryngeal oedema
- ❖ Dermatitis and skin infection

#### Chemotherapy

- ◆ *Given in post-operative period and also for palliation.*
- ◆ *Price-Hill regimen* is commonly used. Drugs are methotrexate, vincristine, adriamycin, bleomycin and mercaptopurine.
- ◆ It is either given intra-arterially, as regional chemotherapy through external carotid artery using arterial pump or through IV. It can also be given orally.

#### Complications of chemotherapy

- ❖ Megaloblastic anaemia
- ❖ Bone marrow suppression
- ❖ Alopecia
- ❖ Sepsis

- ◆ For melanoma, Melphalan and DTIC are used.
- ◆ Anterior chemotherapy (pre-operative) is becoming popular to downstage the tumour.

#### Terminal events

- ❖ Inhalational bronchopneumonia
- ❖ Haemorrhage from erosion of lingual artery. In posterior third of the tongue, erosion of internal carotid artery can occur
- ❖ Cancer cachexia
- ❖ Asphyxia due to pressure on air passages or due to oedema glottis

#### Prognosis

Five-year survival for females is 50%, for males is 25%.

#### Nodal prognostic factors

- ❖ Positive histology in node reduces the survival
- ❖ Level III and IV has poor prognosis
- ❖ Bilateral/contralateral nodes carry poor prognosis
- ❖ Extracapsular spread/size > 3 cm carry poor survival
- ❖ > 3 in number of nodes involved is poor sign

#### Prognostic Factors

- ◆ Size of the tumour > 4 cm carries poor prognosis.
- ◆ Site of tumour (posterior third has got poor prognosis).
- ◆ Tumour crossing the midline.
- ◆ Lymph nodes status.
- ◆ Differentiation.
- ◆ Bone involvement.

### CARCINOMA OF POSTERIOR ONE-THIRD/BASE OF THE TONGUE

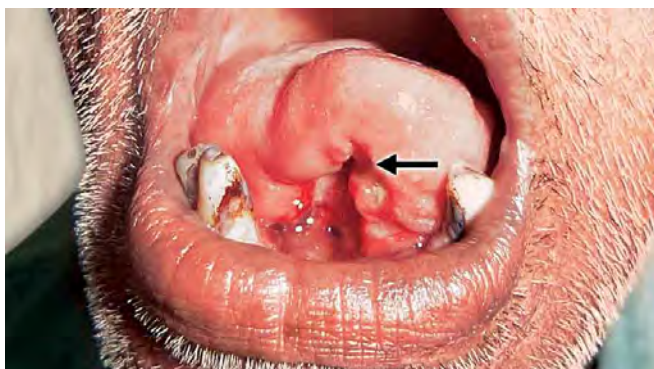
- ◆ Lesion may remain asymptomatic for long time.
- ◆ Clinically may be missed easily.
- ◆ Earlier symptoms are features mimicking sore-throat and throat discomfort.
- ◆ Dysphagia and change in voice (*hot potato voice*) occurs later.
- ◆ Referred pain in the ear, bleeding from mouth, visible mass in posterior third of tongue is late local features.
- ◆ Induration on palpation in posterior third tongue is diagnostic of the carcinoma.
- ◆ As posterior third tongue has got abundant lymphatics which cross communicates on either side, lymph node spread is common (70%). Bilateral nodal spread is common. Massive nodes and involvement of jugulodigastric node are also common.
- ◆ Infiltration into the tongue muscles like genioglossus, epiglottis, pre-epiglottic space, *tonsillar pillars* and hypopharynx are common.
- ◆ Carcinoma posterior third of the tongue is often poorly differentiated and so carries poor prognosis.
- ◆ Blood spread can occur into bones, liver and lungs in posterior third cancers.
- ◆ Palpation *under anaesthesia* gives better idea about the tumour, its spread and also allows the biopsy.
- ◆ Presentation as unknown/occult primary and often with blood spread can occur.
- ◆ CT scan/MRI is always needed to plan the staging and therapy.
- ◆ T<sub>1</sub>, T<sub>2</sub>, N<sub>0</sub> and N<sub>1</sub> diseases are treated by surgical wide excision or often by total glossectomy using midline mandibulotomy incision (mandible split) with neck dissection on both sides (MRND one side). Post-surgery radiotherapy is needed if it is a poorly differentiated type or nodal status is more than N<sub>1</sub>.
- ◆ Advanced lesions need palliative radiotherapy or chemotherapy.
- ◆ T<sub>4</sub> lesions are often treated by total glossectomy with laryngectomy and neck dissection but overall outcome is not good.
- ◆ In many centres *primary curative radiotherapy* is used.
- ◆ Lymphoepithelioma and transitional cell carcinoma can occur in posterior third tongue (rarely).

**Carcinoma alveolus**

- ❖ It is squamous cell carcinoma arising from gums
- ❖ It is common in males
- ❖ It is common in India
- ❖ It is commonly due to tobacco/pan chewing
- ❖ Features and precipitating factors are similar to other oral carcinomas
- ❖ There will be invariable bone involvement by direct extension
- ❖ Nodal spread is also common
- ❖ Wide excision with mandibulectomy and block dissection of neck is the treatment

**Carcinoma floor of the mouth**

- ❖ It is usually aggressive tumour
- ❖ It is rare in India
- ❖ It is 2nd common site of oral carcinoma (SCC) in western countries
- ❖ It invades hyoglossus, mylohyoid, genioglossus and anterior mandible early
- ❖ Bilateral neck nodes are commonly involved
- ❖ Rim resection of mandible with wide excision of tumour with muscles and soft tissues and bilateral neck dissection is necessary
- ❖ Often visor anterior approach with anterior mandible resection followed by proper reconstruction with bone graft and plates is needed
- ❖ Post-operative radiotherapy and later chemotherapy is used to prevent recurrence
- ❖ Prognosis is poor and also has poor cosmetic results



**Fig. 3.77:** Carcinoma of floor of the mouth. It has got poor prognosis.

**NASOPHARYNGEAL CARCINOMA**

- ❖ Nasopharynx lies above the level of the soft palate which divides it from oropharynx below.
- ❖ It is also called as post-nasal space or epipharynx. Eustachian tube opens on its anterolateral wall. Fossa of Rosenmuller is located above and behind the opening of the Eustachian tube as a small depression.
- ❖ Nasopharyngeal carcinoma is common in China and Mongolia. In India it is common in North-East region. It is commonly squamous cell carcinoma (85%). Lymphoma, minor salivary tumours and sarcoma are other malignancies that can occur rarely in nasopharynx.
- ❖ It can be of proliferative, ulcerative, and infiltrative types. Commonest site is fossa of Rosenmuller in lateral wall of pharynx. It is three times common in males.

- ❖ *HO's triangle* in supraclavicular fossa (bounded by medial and lateral ends of clavicle and point where neck meets the shoulder) is the site where metastatic nodes commonly exist in nasopharyngeal carcinoma.
- ❖ In 50% of cases nodal involvement is bilateral. Often cervical lymphadenopathy may be the first presentation.
- ❖ *Clinical features* may be nasal, otogenic, ophthalmoneurogenic (involving most of the cranial nerves with facial pain, squint, diplopia, exophthalmos, and ophthalmoplegia), jugular foramen syndrome (cranial nerves IX, X, XI spread), nodal spread and distant spread to bones, lungs and liver.
- ❖ Unilateral serous otitis media may be the only presentation.

**Clinical Features**

- ❖ *Epistaxis, nasal speech, post-nasal discharge and nasal obstruction.*
- ❖ *Pain* in the ear with unilateral deafness due to compression of Eustachian tube with fluid collection in the middle ear.
- ❖ *Elevation and immobility of soft palate* on the same side.
- ❖ *Pain in the area of distribution of trigeminal nerve* due to direct infiltration of the nerve at foramen lacerum.
- ❖ *Palpable secondaries in upper deep cervical lymph nodes (70%).*

**Trotter's triad**

- ❖ Unilateral deafness
- ❖ Immobile elevated soft palate
- ❖ Pain in the distribution of trigeminal nerve

**Differential Diagnosis**

- ❖ Lymphoma.
- ❖ Lymphoepithelioma.
- ❖ Minor salivary gland tumour.

**Investigations**

- ❖ Biopsy from the primary site.
- ❖ FNAC from the neck lymph nodes.
- ❖ X-ray of the skull to visualise erosions.
- ❖ CT scan skull.

**Histological Type**

Squamous cell carcinoma.

**Treatment**

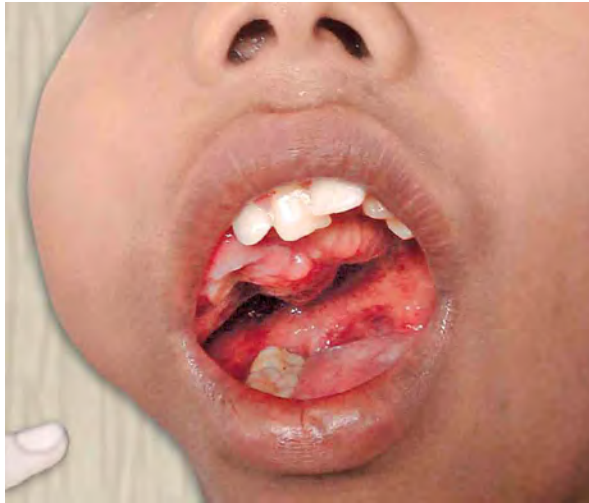- ❖ External irradiation for primary. RT is the main modality of treatment.
- ❖ Radical block dissection of cervical lymph nodes.
- ❖ In N2a, N2b and N2c contralateral neck dissection is needed. Spinal accessory nerve is never preserved while doing block dissection in nasopharyngeal carcinoma.
- ❖ Chemotherapy: Methotrexate, Vincristine.
- ❖ Skull base surgeries are useful.

**MAXILLARY TUMOURS**

They are rare.

- ❖ Maxillary sinus is the commonest site for malignancy of paranasal sinuses. Ethmoids, frontal and sphenoids are next in order.
- ❖ It is common in people working in furniture industries, mustard gas industries, and leather industries. It is common in Bantus in South Africa where snuff with nickel and chromium is commonly used.

*Efforts and energies should be consistent, constructive and compassionate.*



**Fig. 3.78:** Carcinoma maxillary sinus in a boy. Note the extension into the palate.

## Types

- ◆ Squamous cell carcinoma 80%.
- ◆ Adenocarcinoma.
- ◆ Transitional cell carcinoma.
- ◆ Salivary gland tumours.
- ◆ Sarcomas and melanoma.
- ◆ Burkitt's lymphoma.

## Behaviour and Presentation

- ◆ Initially may be symptomless or may present with *epistaxis* or *features of chronic sinusitis*.
- ◆ When it spreads to the floor, loosening of the teeth, necrosis, antro-oral fistula can occur.
- ◆ Extension medially causes nasal block, fungation, nasal discharge, blockage of nasolacrimal duct (*epiphora*).
- ◆ Extension anteriorly causes pain, anaesthesia and swelling in the cheek, ulceration and fungation in the skin of cheek.
- ◆ Extension above into the orbit causes epiphora, diplopia, proptosis.
- ◆ *Posterior spread is most dangerous* as it is not revealed easily. It causes postnasal discharge, pain, trismus, limitation of temporo-mandibular joint movement.
- ◆ Involvement of upper deep cervical lymph nodes in later stage is common.

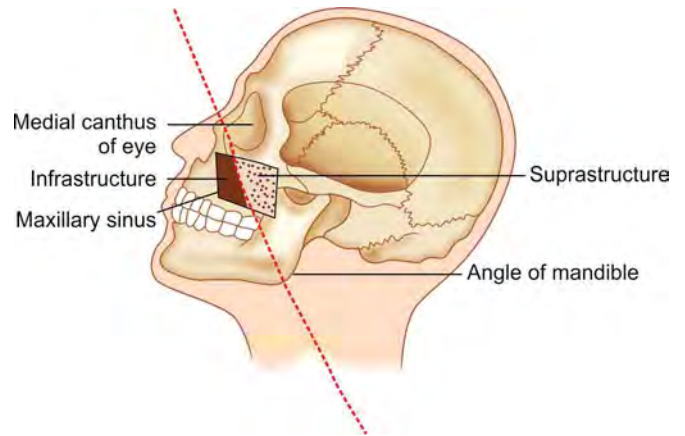
## Differential Diagnosis

Chronic sinusitis.

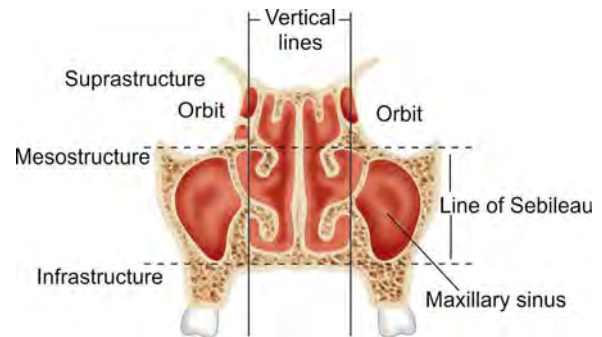
## Classification

### 1. Ohngren's classification

An imaginary plane is drawn extending between medial canthus of eye and the angle of mandible. Growth situated above this plane is called as *suprastructural* which has got poor prognosis. Growth below this plane is called as *infrastructural* and has got better prognosis.



**Fig. 3.79:** An imaginary plane is drawn extending between medial canthus of eye and the angle of mandible and line in this plane is called as *Ohngren's line*.



**Fig. 3.80:** Diagrammatic representation of Lederman's classification.

### 2. Lederman's classification

Two horizontal lines are used, one passes through the floor of the orbit, another passes through the floor of the antra. These lines are called as *line of Sebileau*.

- ◆ *Suprastructure type*: In this type olfactory area of nose, ethmoidal, sphenoid, and frontal sinuses are involved.
- ◆ *Mesostructural type*: This involves maxillary sinus and nasal respiratory part.
- ◆ *Infrastructural type*: This type involves alveolar process.

Lederman's classification is further divided by two vertical lines over medial walls of the orbit to separate ethmoid sinuses and nasal fossa from maxillary sinuses.

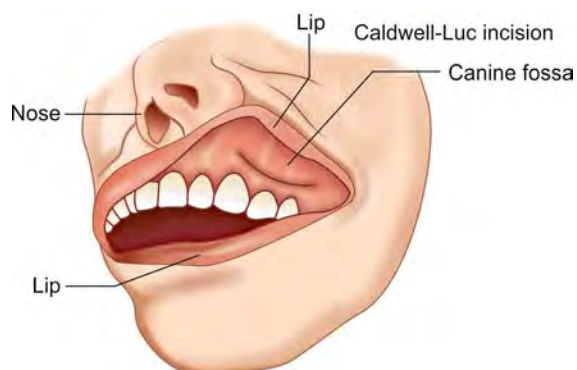
TNM staging	Staging
• $T_1$ Tumour limited to antral mucosa	Stage I $T_1 N_0 M_0$
• $T_2$ Tumour causing bone erosion/ destruction including extension into hard palate or middle meatus of nose.	Stage II $T_2 N_0 M_0$
• $T_3$ Tumour invading bone of posterior wall of maxillary sinus/skin of cheek/ medial wall of orbit/infratemporal fossa/pterygoid plates/ethmoid sinuses.	Stage III $T_3 N_0 M_0$ , $T_1/T_2/T_3 N_1 M_0$
• $T_4$ Tumour invading orbital contents beyond the floor or medial wall including orbital apex/cribriform plate/base of skull/nasopharynx/ sphenoid or ethmoidal sinuses	Stage IV A $T_4 N_0 M_0$ , $T_4 N_1 M_0$
	Stage IV B Any T $N_2 M_0$ , Any T $N_3 M_0$
	Stage IV C Any T Any N $M_1$

**Diagnosis**

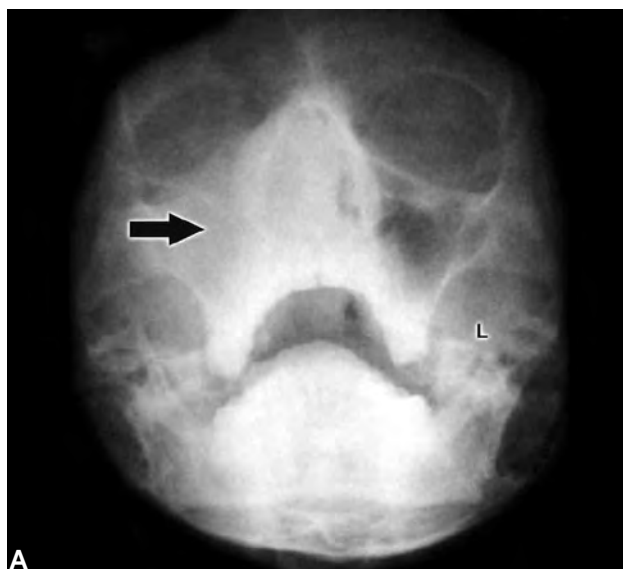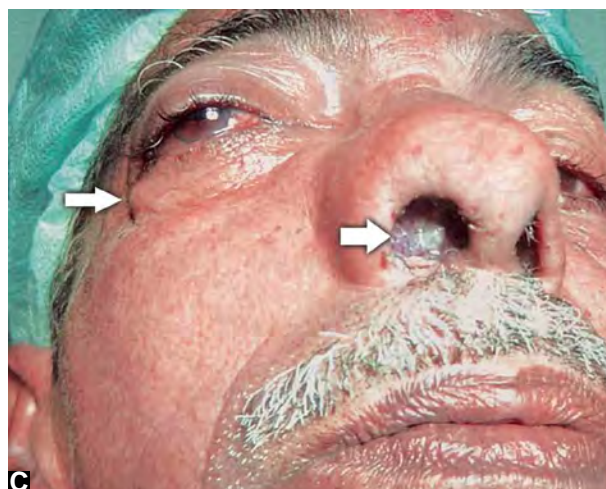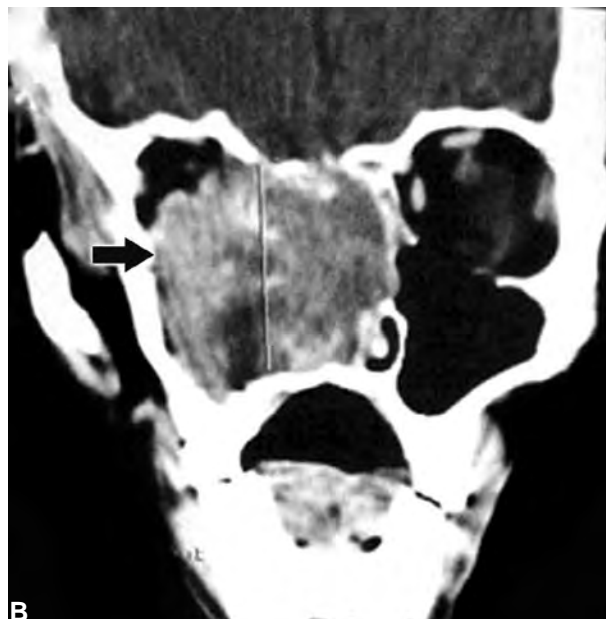- ◆ X-ray of the part—pacity of the involved sinus with destruction of bony walls is seen—*Water's PNS view*.
- ◆ CT scan—ideal method.
- ◆ Sinus endoscopy for detailed examination of sinus and for biopsy.
- ◆ Biopsy is done through nasal/oral or on early stage through Caldwell-Luc operation.

**Treatment**

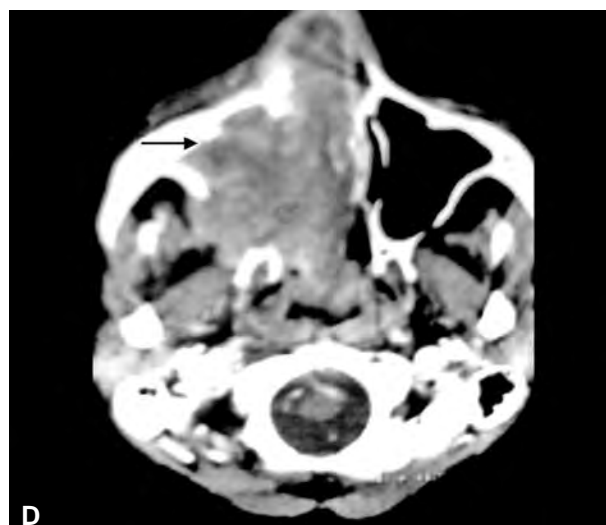
- ◆ Pre-operative megavoltage radiotherapy is given. After six weeks, total maxillectomy is done. Reconstruction of maxilla along with dental reconstruction is required.
- ◆ When lymph nodes are involved radical neck lymph nodes dissection is done.
- ◆ Post-operative radiotherapy and chemotherapy is given as an adjuvant therapy.
- ◆ Overall prognosis is 30–40%.



**Fig. 3.81:** Incision for Caldwell-Luc operation which is used for taking biopsy from maxillary tumour. Incision is not used for definitive therapy for carcinoma maxilla. Incision also used in benign conditions to approach maxillary sinus. Gingivobuccal mucosa is incised and mucoperiosteum is raised. Bone of canine fossa is cut to reach the maxillary antrum.



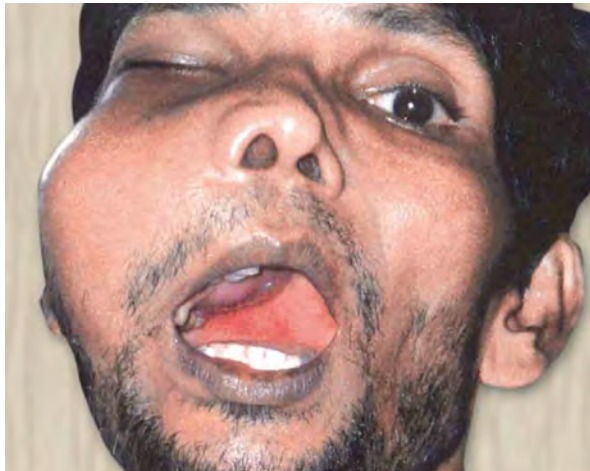**Fig. 3.82A**



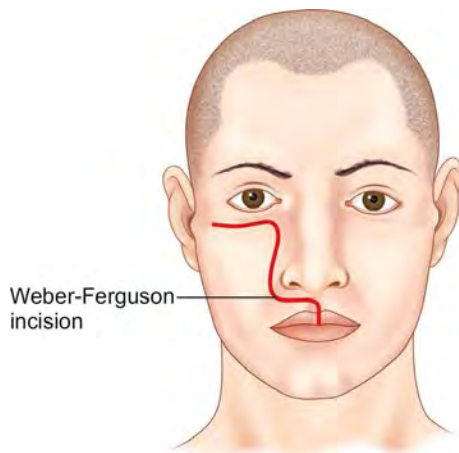
**Figs 3.82B to D**

**Figs 3.82A to D:** Carcinoma maxilla extending into the nose with X-ray and CT pictures. It is a fairly advanced growth.





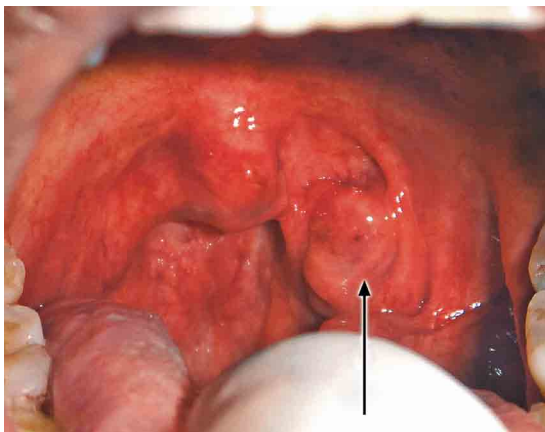
**Fig. 3.83:** Carcinoma maxillary antrum extending outwards on to all walls. An advanced malignancy.



**Fig. 3.84:** Weber-Ferguson's incision used for total maxillectomy.

### MALIGNANT TUMOURS OF TONSIL

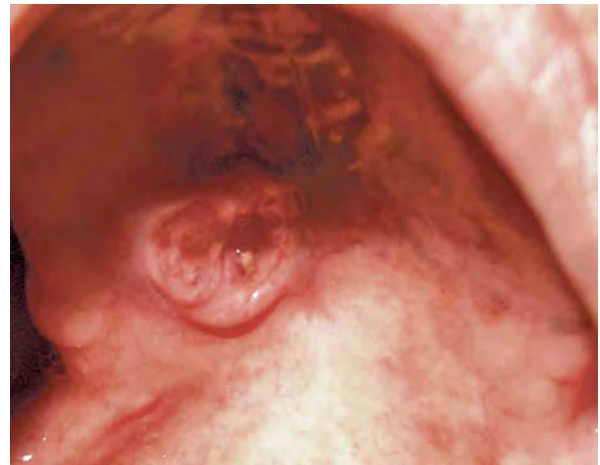
- ◆ **Carcinoma of tonsil:** It is squamous cell carcinoma, similar to carcinoma cheek, but more aggressive with poor prognosis.
- ◆ **Carcinosarcoma** of tonsil.
- ◆ **Lymphoma**—NHL type.



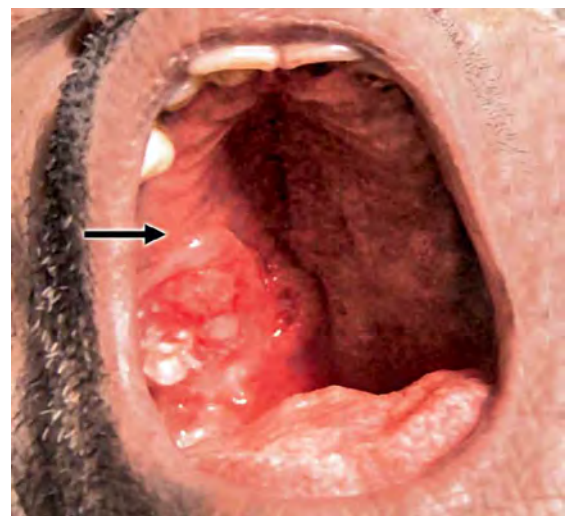
**Fig. 3.85:** Lymphoepithelioma of tonsil.

### CARCINOMA HARD PALATE

- ◆ Minor salivary gland tumours are more common in palate.
- ◆ In males, *in reverse smokers* (*Churat* is rolled tobacco leaf) squamous cell carcinoma is seen in palate due to repeated thermal injury.
- ◆ Malignant tumours may spread to periosteum, bone, maxilla, sinus, or nose.
- ◆ Salivary gland tumours are commonly malignant and are of adenoid cystic type. Other types also can occur. It presents as a single, solid, smooth swelling with ulcer over the summit.
- ◆ Squamous cell carcinoma is ulcerative with raised and everted edge.
- ◆ Upper deep cervical lymph nodes are involved in 25% of patients.
- ◆ Investigations are edge biopsy, FNAC lymph node and CT scan to see extensions.
- ◆ *Treatment* is wide excision with removal of the underlying palatal bone. Often partial or total maxillectomy (*Weber-Ferguson* incision) may be required. Myocutaneous flap with dental prosthesis is essential to reconstruct after surgery. Post-operative radiotherapy and neck block dissection are often required.



**Fig. 3.86:** Minor salivary gland tumour in posterior half of the palate. Note the nodular lesion with ulceration over the summit (*Courtesy:* Professor Kishore Chandra Prasad, ENT Surgeon and Head of the Department and Dr Sampath, ENT Surgeon, KMC, Mangaluru).



**Fig. 3.87:** Carcinoma hard palate extending laterally.

## LARYNGEAL TUMOURS

### Benign

- ◆ *Epithelial* can be papilloma, vocal nodule or vocal polyp. Papilloma is usually single in adult, multiple in children.
- ◆ *Connective tissue tumours* like fibroma, myxoma, angioma.

Indirect laryngoscopy (ILS) or direct laryngoscopy confirms the diagnosis.

Childhood papilloma	Adult papilloma
Multiple, of viral origin (Papova)	Single, of neoplastic origin
Can occur in glottic, supra and infraglottic	Glottic only
Not premalignant	Pre-malignant
Recurrence common	Not common after complete excision
Excision is difficult	Easier removal
Causes more dyspnoea, stridor, cough	Hoarseness only
May require tracheostomy	

#### Note:

Stridor can be inspiratory, expiratory or biphasic.

### Treatment

- ◆ Endoscopic removal. Application of podophyllum
- ◆ Cryosurgery, laser surgery.

## MALIGNANT TUMOURS OF LARYNX

### Aetiology

- ◆ Smoking, tobacco.
- ◆ Alcohol intake.
- ◆ Occupational/industrial exposure to chemicals like mustard gas, asbestos, benzopyrones, petroleum products.
- ◆ Previous radiation.
- ◆ Genetic: Russians develop familial laryngeal cancers.
- ◆ Papillomavirus, keratosis, malnutrition.

### Incidence

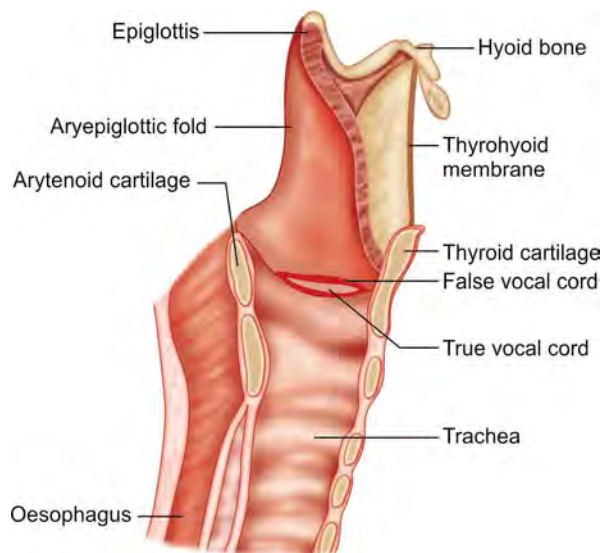
- ◆ Squamous cell carcinoma is commonest (95%).
- ◆ Common in males (10 : 1).
- ◆ Common in 5th/6th decade.

### Types

- ◆ Ulcerative.
- ◆ Proliferative.

### Anatomical Types

- ◆ **Supraglottic (25%):**
  - ▶ It arises from infrahyoid part of epiglottis, ventricles, and arytenoids. It spreads to neck lymph nodes early (40%) due to



**Fig. 3.88:** Anatomy of larynx showing supraglottic, glottic and subglottic regions.

rich lymphatics in this area. Throat pain, dysphagia, palpable neck nodes and referred pain are common features. Hoarseness of voice, loss of weight, respiratory obstruction, and halitosis are late features. Carcinoma in epiglottis causes bilateral nodal spread. Local spread occurs to vallecula, base of tongue and pyriform fossa.

#### ◆ Glottic (65%):

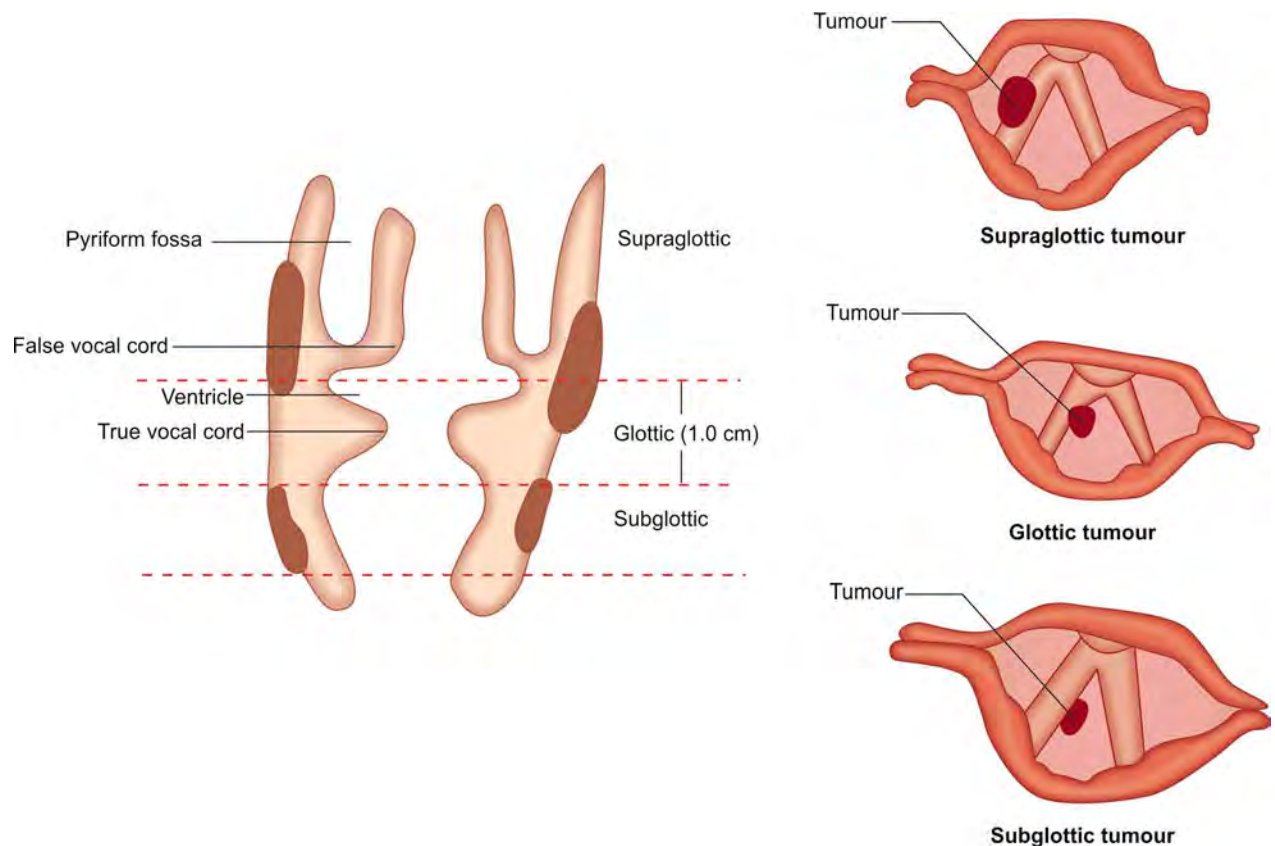
- ▶ It is the commonest type. It begins from upper part or free edge of vocal cords (mid or anterior) often extending 10 mm below. Lymphatic spread is slow (only 4%) as this area has got least lymphatics. Opposite vocal cord can involve as *kiss cancer*. Vocal cord mobility is unaffected in early cases. Vocal cord fixation signifies spread to thyroarytenoid which is a poor prognostic sign. It presents very early due to hoarseness of voice. Eventual cord fixation causes stridor. Locally it spreads anteriorly to anterior commissure, posteriorly to vocal process and arytenoids, above to ventricle and false vocal cords, below to subglottis.

#### ◆ Subglottic (2%)

- ▶ Is less common involving under-surface of true vocal cords and subglottic space. It spreads to deep cervical and paratracheal nodes (20%). Upward spread is rather late and so hoarseness is not an early symptom in this type. It can spread through cricothyroid membrane or thyroid gland.

#### Note:

- In Indian subcontinent supraglottic tumours are more common than glottic. Glottic type is common in Western countries.
- Fixation of cords is due to involvement of thyroarytenoid muscle or cricoarytenoid joint.



**Fig. 3.89:** Laryngeal carcinoma, types. Note the typical sites. Glottic is the commonest site. Next is supraglottic. Subglottic is rare.

Clinical features	Investigations
<ul style="list-style-type: none"> <li>• Hoarseness of voice</li> <li>• Pain and discomfort</li> <li>• Cough, dyspnoea, stridor, dysphagia in late cases</li> <li>• Bloody sputum</li> <li>• Palpable neck nodes, which eventually get fixed</li> </ul>	<ul style="list-style-type: none"> <li>• ILS (Indirect laryngoscopy)</li> <li>• Direct laryngoscopy and biopsy</li> <li>• CT neck—very useful investigation</li> </ul>
<ul style="list-style-type: none"> <li>• Absence of laryngeal crepitus</li> </ul>	<ul style="list-style-type: none"> <li>• Chest X-ray</li> <li>• FNAC of lymph node</li> </ul>
<ul style="list-style-type: none"> <li>• Common in males—10:1</li> </ul>	<ul style="list-style-type: none"> <li>• Microlaryngoscopy in small lesions to identify and to have proper biopsy</li> <li>• Tolidine blue staining to stain early superficial cancers which facilitate the accurate biopsy</li> <li>• Hopkin's endoscopy</li> <li>• Flexible, fibrooptic laryngoscopy</li> </ul>

## Staging

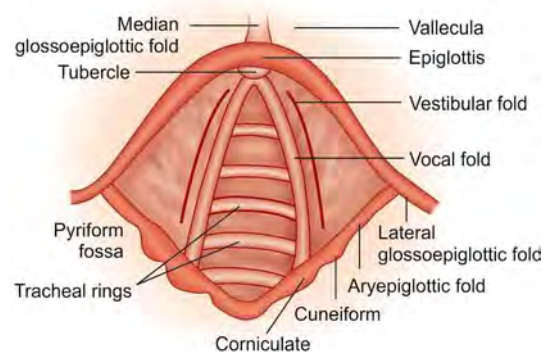
### Tumour

- T1 Tumour confined to one anatomical site in larynx with normal cord mobility.
- T2 Tumour confined to one anatomical region within larynx.

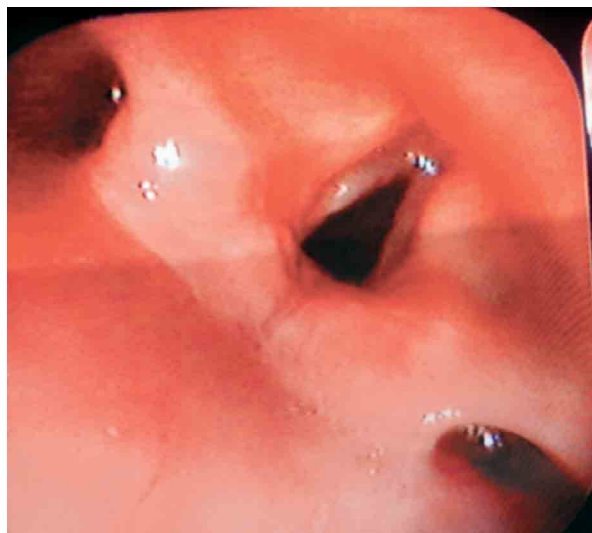- T3 Tumour spreads beyond one anatomical region within larynx with cord fixation.
- T4 Tumour spreads beyond larynx.  
Nodal staging is similar to any other oral carcinomas.

## Treatment

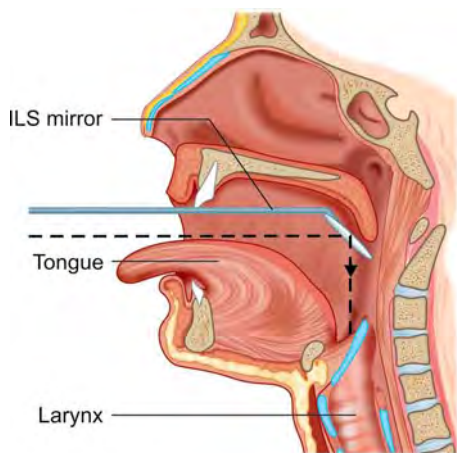
- ◆ *Supraglottic:* Stage I—curative radiotherapy is the choice. In stage II and III total laryngectomy and block dissection of neck nodes.
- ◆ *Glottic:* Radiotherapy is the choice as nodes are commonly not involved. Endoscopic laser surgery or open partial laryngectomy can be done.



**Fig. 3.90:** View of larynx as seen through a laryngoscope.



**Fig. 3.91:** Endoscopic view of vocal cords, pyriform fossa and aryepiglottic fold.

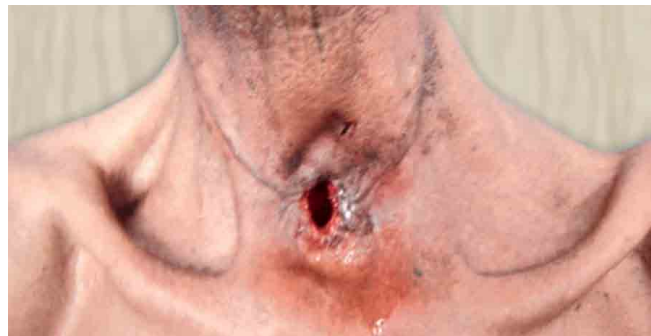

**Fig. 3.92:** Indirect laryngoscopy to visualise larynx and its parts.

- ◆ *Subglottic:* Total laryngectomy is the treatment of choice with nodal block when needed.
- ◆ *In advanced stage IV carcinomas* surgery and radiotherapy both are not possible. Here chemotherapy is given using cyclophosphamide, cis platin and methotrexate.
- ◆ *In advanced resectable tumours,* induction chemotherapy for 3 cycles with methotrexate and cisplatin 100 m/sq metre BSA (at 0, 22, 43 days) and total laryngectomy is under trial. Concurrent chemotherapy and radiotherapy are also under trial in these cases.

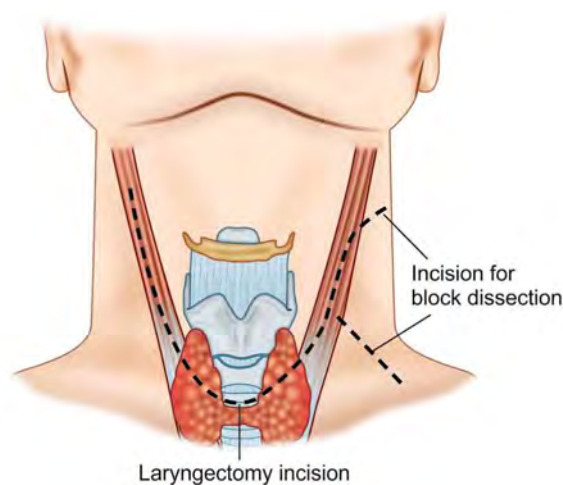
**Role of Radiotherapy in Laryngeal Cancer**

- ◆ In early growth with no impairment in motility curative RT is very useful with 90% cure rate with preservation of voice
- ◆ It is commonly used in superficial exophytic lesions, growth in tip of epiglottis and aryepiglottic folds.
- ◆ In subglottic extension, fixed growths, and in presence of nodes, radiotherapy is less effective.



**Fig. 3.93:** Carcinoma larynx—patients underwent total laryngectomy with permanent tracheostomy.

Conservative laryngeal surgery	
Indications	Advantages
<ul style="list-style-type: none"> <li>• Early growth without fixation especially glottic type</li> </ul>	<ul style="list-style-type: none"> <li>• Permanent tracheostomy is avoided</li> <li>• Voice is retained</li> </ul>
Types	Disadvantages
<ul style="list-style-type: none"> <li>• Cordectomy through laryngofissure—excision of vocal cord after splitting of larynx</li> <li>• Partial frontolateral laryngectomy—excision of vocal cord and anterior commissure</li> <li>• Partial horizontal laryngectomy—excision of supraglottis (epiglottis, aryepiglottic folds, false vocal cords and ventricle)</li> </ul>	<ul style="list-style-type: none"> <li>• Inadequate clearance</li> <li>• Recurrence of the disease</li> </ul>



**Fig. 3.94:** Gluck-Sorensen's laryngectomy incision. Extension lines sideward can be used for adding radical neck dissection.

*Imagination is the beginning of the creation; you imagine what you desire; you will what you imagine; at last you create what you will.*  
**—George Bernard Shaw**

**Total laryngectomy****Indications**

- T<sub>3</sub> lesions with cord fixation
- All T<sub>4</sub> lesions
- Bilateral arytenoids spread
- Thyroid/cricoid spread
- Transglottic cancers involving ventricle with fixation of the cord
- Posterior commissure disease
- Failure of conservative surgery or RT

**Problems**

- Mortality of surgery
- No speech
- Having permanent tracheostomy and its problems

**Technique**

- Entire larynx with hyoid bone, pre-epiglottic space, strap muscles, one or more rings of trachea are removed
- Pharyngeal wall is repaired
- Lower tracheal stump is sutured to the skin as permanent tracheostomy
- Often laryngo-oesophagectomy is done when pharyngeal spread is present. Gastric pull-up is done to maintain GI continuity
- Technique may be combined with neck nodal dissection both sides

**Care after total laryngectomy**

- ❖ Speech therapy by pseudoglottis creation, battery operated artificial larynx or Singer-Blom prosthesis or Panje's prosthesis. Tracheo-oesophageal prosthesis (TOP) is ideal
- ❖ Social and job rehabilitation
- ❖ Care of permanent tracheostomy by avoiding immersion in the water, care during bath, shower use and swimming. Shower covers are available for this purpose
- ❖ Often along with total laryngectomy, total thyroidectomy and removal of parathyroid glands are required. Patient then needs supplementation of thyroxine and calcium for life time

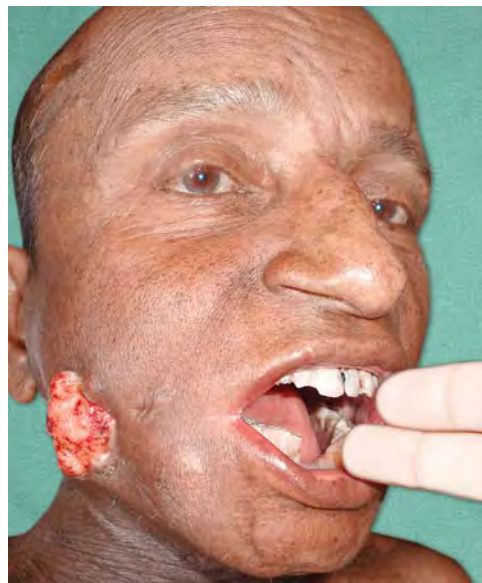**TRISMUS**

- ◆ It is inability to open the mouth adequately.
- ◆ Causes are—submucosal fibrosis, carcinoma buccal and gingivobuccal complex, post-radiotherapy sequelae, infection like tetanus, parotitis, dental or peritonsillar abscess.
- ◆ In carcinoma, invasion of tumour to pterygoids, buccinator, masseter, temporalis causes trismus.

**Khanna and Andrade group classification of trismus (1995)**

- ❖ *Group I*: Earliest stage without limitation of mouth opening with an interincisal distance of greater than 35 mm.
- ❖ *Group II*: Patients with an interincisal distance of 26–35 mm.
- ❖ *Group III*: Moderately advanced cases with an interincisal distance of 15–26 mm. Fibrotic bands are visible at the soft palate, and pterygomandibular raphe and anterior pillars of fauces are present.
- ❖ *Group IVA*: Trismus is severe, with an interincisal distance of less than 15 mm and extensive fibrosis of all the oral mucosa.
- ❖ *Group IVB*: Disease is most advanced, with premalignant and malignant changes throughout the mucosa.

- ◆ It is often clinically assessed by placing fingers perpendicularly between two jaws at incisor level. More than 3 fingerbreadth is considered as normal.
- ◆ *Problems with trismus* are—inability to put fingers or spoon into mouth; difficulty in cleaning the mouth; infection; difficulty in assessing the tumour/pathology clinically. During surgery, intubation is difficult and so tracheostomy may be needed in these patients.
- ◆ *Management*—treating the cause; release of soft tissue in case of fibrosis; draining the abscess and antibiotics for infection.



**Fig. 3.95:** Trismus due to advanced carcinoma cheek. Patient is on chemotherapy so developed alopecia.

# Chapter 4

## Salivary Glands

*(Three weeks after arriving at the anatomy laboratory of Gerhard Blasius in Amsterdam) fortune so favoured me that in the first sheep's head, which I...was dissecting alone in my room, I found a duct which, so far as I knew, had been described by no one before.*

—Niels Stensen, 1661

### CHAPTER OUTLINE

- |                                      |                                              |                                            |
|--------------------------------------|----------------------------------------------|--------------------------------------------|
| ❖ Anatomy                            | ❖ Pleomorphic Adenoma                        | ❖ Submandibular Salivary Gland Tumours     |
| ❖ Saliva                             | ❖ Adenolymphoma                              | ❖ Management of Malignant Salivary Tumours |
| ❖ Sialography                        | ❖ Oncocytoma                                 | ❖ Minor Salivary Gland Tumours             |
| ❖ Salivary Calculus and Sialadenitis | ❖ Basal Cell Adenoma                         | ❖ Parotid Lymphoma                         |
| ❖ Sialosis                           | ❖ Mucoepidermoid Tumour                      | ❖ Parotidectomy                            |
| ❖ Sialectasis                        | ❖ Adenoid Cystic Carcinoma                   | ❖ Frey's Syndrome                          |
| ❖ Recurrent Childhood Parotitis      | ❖ Acinic Cell Tumour                         | ❖ Facial Nerve Injury                      |
| ❖ Parotid Abscess                    | ❖ Malignant Mixed Tumour                     |                                            |
| ❖ Parotid Fistula                    | ❖ Adenocarcinoma of Salivary Glands          |                                            |
| ❖ Sjögren's Syndrome                 | ❖ Squamous Cell Carcinoma of Salivary Glands |                                            |
| ❖ Mikulicz Disease                   |                                              |                                            |
| ❖ Salivary Neoplasms                 |                                              |                                            |

### ■ ANATOMY

#### Parotid Gland (Para—around, otis—ear)

It is the largest of the salivary gland, situated below the acoustic meatus between the ramus of mandible and sternomastoid muscle. The deep cervical fascia splits to form a capsule (parotid capsule) to enclose the gland. The superficial layer is thickened and adherent to the gland.

It is deep to parotid fascia, superficial to masseter. So parotid swelling occupies *below, behind, in front of the ear lobule*, obliterating the normal hollow below the ear lobule. When patient opens the mouth, parotid fascia stretches and swelling may become less pre-eminent but this test is difficult to elicit. When patient clinches his teeth, masseter contracts and parotid becomes more prominent.

#### Parts of the Parotid Gland

- ◆ Superficial part (80%)—lies over the posterior part of the ramus of mandible.
- ◆ Deep part (20%)—lies behind the mandible and medial pterygoid muscle; in relation to mastoid and styloid process.

#### Accessory Parotid

It is prolongation of the gland above the parotid duct (*socia parotidis*).

#### Parotid Duct

Parotid (*Stensen's*) duct is 2-3 mm in diameter, 5 cm in length, emerges from anterior surface of the gland, runs over the surface of the masseter

*Both over-salivation and under-salivation are not advised. Only optimum salivation is accepted and ideal.*

muscle, passes through the buccinator muscle, and opens into the oral mucosa opposite to the crown of upper second molar tooth. It is palpated *bidigitally*, one fingerbreadth below the zygomatic bone with index finger inside and thumb outside, in front of masseter which is felt during clenching of teeth. Transverse facial artery is *above* the parotid duct. Duct is 1 cm below the zygomatic arch.

### Facial Nerve

It emerges from the stylomastoid foramen lying between external auditory meatus and mastoid process. It passes around the neck of the condyle of mandible and becomes superficial, later dividing into *temporofacial and cervicofacial branches* which in turn divides into many branches. Some of these may be interconnected as *pes anserinus* (goose foot). *Branches are* – temporal (auricularis anterior and superior part of frontalis), zygomatic (frontalis and orbicularis oculi), upper buccal and lower buccal (buccinator, orbicularis oris, elevators of the lip) mandibular (lower lip muscles) and cervical (platysma).

While exiting the skull through stylomastoid foramen (it is accompanied by stylomastoid branch of posterior auricular artery which enters the same foramen), it gives posterior auricular nerve and motor nerves to posterior belly of digastric and stylohyoid. Trunk is initially 1 cm from posteromedial surface (*extraglandular*) and *intraglandular* for 1 cm before giving divisions.

Gland is often called as *parotid sandwich* due to transverse of facial nerve.

### Blood Supply

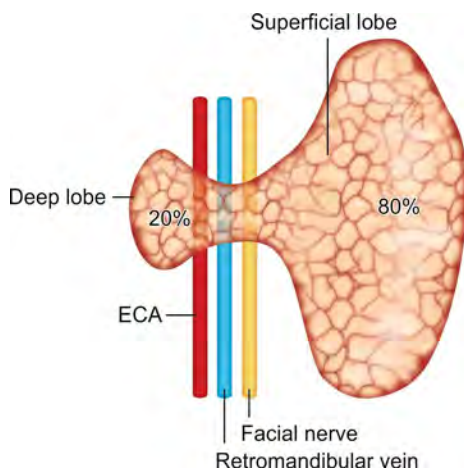
It is from external carotid artery; and venous drainage is by external jugular vein.

### Nerve Supply

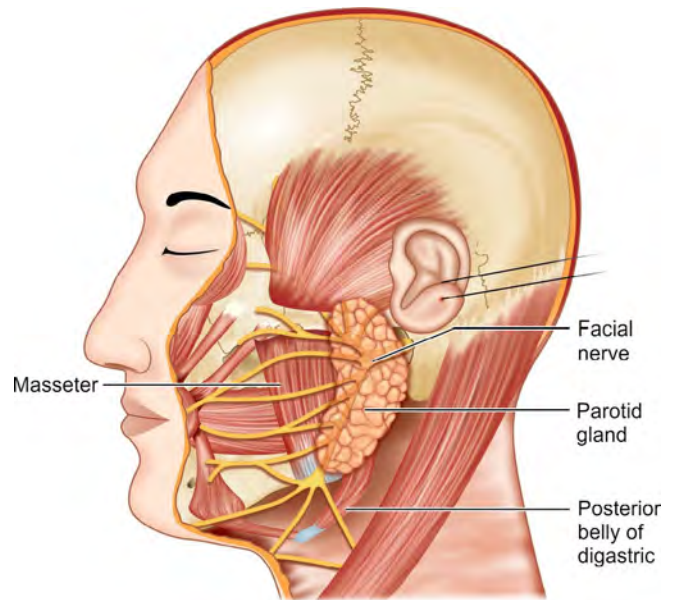
It is from autonomic nervous system, parasympathetic is secretomotor from auriculotemporal nerve, sympathetic is vasomotor from plexus around the external carotid artery.

### Faciovenous Plane of Patey

*Faciovenous plane of Patey* is of surgical importance. Facial nerve is superficial to this plane which contains retromandibular vein and posterior facial vein. External carotid artery dividing into superficial temporal artery and maxillary artery is deeper to venous plane.



**Fig. 4.1:** Superficial lobe (80%) and deep lobe (20%) are separated by external carotid artery, retromandibular vein and facial nerve from deep to superficial.



**Fig. 4.2:** Anatomical relations of the parotid gland.

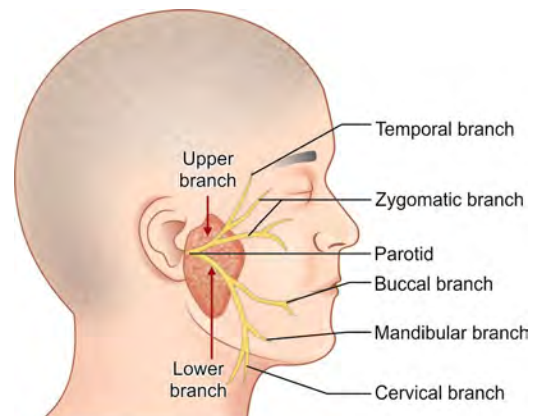
### Lymphatic Drainage of Parotid

It drains into parotid lymph glands which are partly intraglandular and partly extraglandular (preauricular and infra-auricular). Mainly intraglandular nodes are involved which later drains into deep cervical lymph glands. Parotid lymph nodes also drain from temple, side of scalp, lateral part of auricle, external acoustic meatus, upper part of cheek, parts of eyelids and orbit.

#### Structures within the parotid gland from deep to superficial

- ❖ External carotid artery, maxillary artery, superficial temporal artery, posterior auricular artery
- ❖ Retromandibular vein (by maxillary and superficial temporal veins)
- ❖ Facial nerve with its branches

Great auricular nerve (cutaneous sensory around angle and lower part of the ear lobule) and auriculotemporal nerve which is from mandibular division of trigeminal nerve (secretomotor to parotid gland) are other nerves present in relation to parotid gland.



**Fig. 4.3:** Pes anserinus.

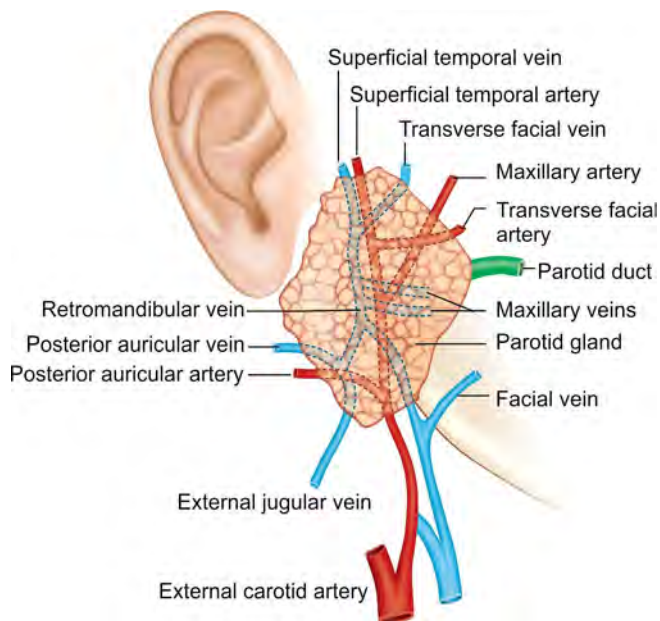


Fig. 4.4: Vascular plane of parotid.

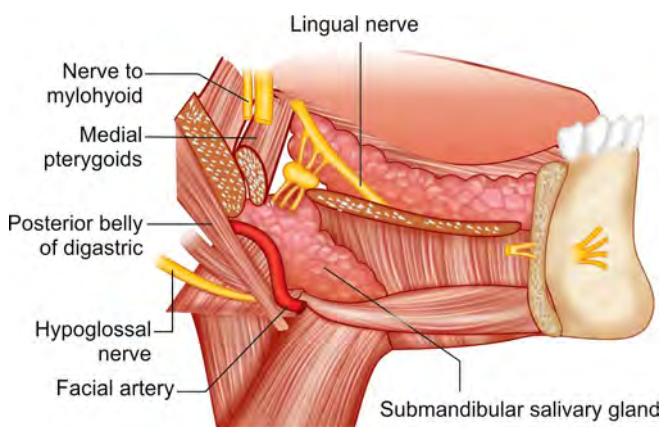


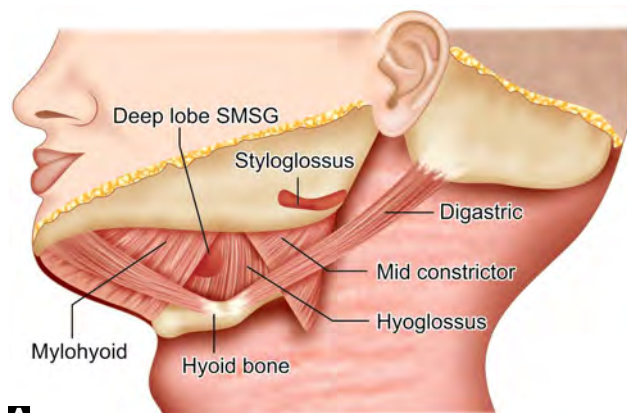
Fig. 4.5: Anatomical relations of the submandibular salivary gland.

## Submandibular Salivary Gland

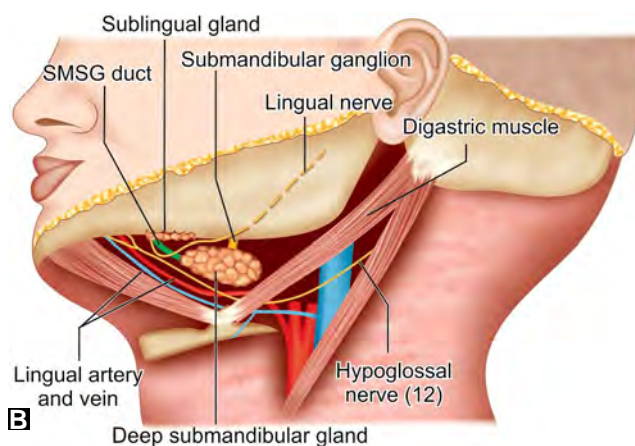
It is a 'J' shaped salivary gland situated in the anterior part of the digastric triangle.

### Parts

- ◆ **Superficial part:** Lies in submandibular triangle, superficial to mylohyoid and hyoglossus muscles, between the two bellies of digastric muscle.
- ◆ **Deep part** is in the floor of the mouth and deep to the mylohyoid.
- ◆ Submandibular (*Wharton's*) duct (5 cm), emerges from the anterior end of the deep part of the gland, enters the floor of the mouth, on the summit of papilla beside the frenulum of the tongue.



A



B

Figs 4.6A and B: Relations of the submandibular salivary gland and its deep lobe.

- ◆ Lingual nerve and submandibular ganglion are attached to upper pole of the gland. Hypoglossal nerve is deep to the gland.
- ◆ Facial artery emerges from under surface of the stylohyoid muscle, enters the gland from posterior and deep surface, reaching its lateral surface crossing the lower border of mandible to enter the face.
- ◆ Venous drainage is to anterior facial vein.
- ◆ **Nerve supply:** Branches from the submandibular ganglion.
- ◆ **Resting salivary flow** usually arises from the submandibular salivary gland. *Sialorrhoea* is increased salivary flow often seen due to drugs, in cerebral palsy, physically handicapped person, children, and psychiatry patients. Intractable sialorrhoea can be corrected by different surgeries to submandibular salivary gland like duct repositioning to excision of the gland.
- ◆ *Xerostomia* is decreased salivary flow. It is seen in post-menopausal women, depression, dehydration, use of antidepressant drugs; anticholinergic drugs, Sjogren's syndrome, radiotherapy to head and neck region.

## Minor Salivary Glands

- ◆ There are around 450 minor salivary glands which are distributed in lips, cheeks, palate and floor of the mouth. Glands also may be present in oropharynx, larynx, trachea and paranasal sinuses. They contribute to 10% of total salivary volume.
- ◆ **Sublingual glands** are minor salivary glands one on each side; located in the anterior aspect of the floor of the mouth in relation to mucosa, mylohyoid muscle, body of the mandible near



mental symphysis. Gland drains directly into mucosa or through a duct which drains into submandibular duct. This duct is called as *Bartholin duct*.

- ◆ Minor salivary glands are not present in gingivae and anterior portion of the hard palate.

### Ectopic Salivary Glands

- ◆ Ectopic salivary gland also called as aberrant salivary gland is nothing but ectopic lobe of the juxtaposed salivary gland. It is commonly seen in relation to submandibular salivary gland.
- ◆ Commonest ectopic salivary tissue is *Stafne bone cyst* (Edward C Stafne, Dental Surgeon, Mayo Clinic). It is invagination of the juxtaposed submandibular salivary gland into the mandible bone on its lingual aspect.
- ◆ X-ray shows radiolucent area due to the cyst below the angle of the mandible, lower to inferior dental vessels and nerve.

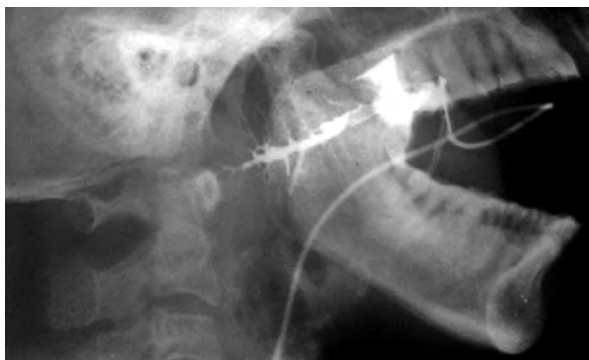### SALIVA

- ◆ 1500 ml of saliva is secreted per day. pH of resting saliva is less, 7.0; active saliva is 8.0.
- ◆ Saliva contains lingual lipase secreted from tongue glands,  $\alpha$  amylase from salivary glands.
- ◆ Saliva contains mucin, glycoproteins, immunoglobulin IgA, lysozyme, lactoferrin which binds iron, proline rich proteins that protect enamel and bind toxic tannins.
- ◆ Parotid saliva is 20% of total secretion of saliva per day and is serous and watery; submandibular is 70% and is mucous and moderately viscous; sublingual is 5% and is mucous and viscous. Minor salivary and other oral glands—5%.
- ◆ Saliva facilitates swallowing, keeps mouth moist, serves as solvent for taste buds, facilitates speech, keeps oral cavity rinsed and clean, antibacterial, and neutralizes gastric acid content in regurgitation to relieve *heartburn*.

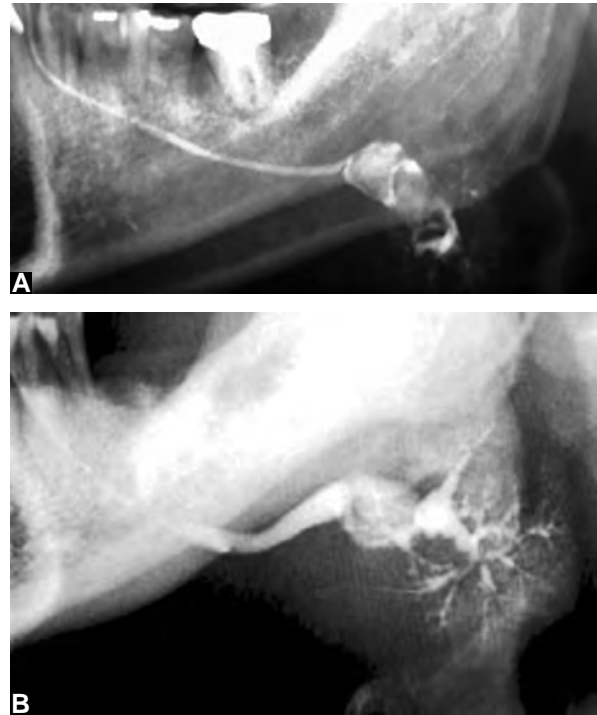
### SIALOGRAPHY

#### Indications

1. Salivary fistulas.
2. Sialectasis.
3. Congenital conditions.
4. Extraglandular masses.
5. Parotid duct stones.



**Fig. 4.7:** Sialogram X-ray done to visualise the ductal pattern in parotid.



**Figs 4.8A and B:** Submandibular gland sialogram pictures (Courtesy: Professor Kishore Chandra Prasad, ENT Surgeon and HOD, KMC, Mangaluru; Dr Sampath, MS ENT, KMC, Mangaluru).

*Dye used is lipiodol or sodium diatrizoate (Hypaque).*

24-gauge cannula is passed into either Stensen's duct or Wharton's duct and one ml of the dye is injected into the duct and X-ray is taken.

#### Findings

- ❖ Narrowing (Stricture)
- ❖ Grape-like cluster appearance (Sialectasis)
- ❖ Dilatations
- ❖ Communications (Fistulas)
- ❖ Mass lesions

#### Precautions

- ◆ *Sialography should never be performed in acute inflammation.*
- ◆ Only one ml of dye should be injected, if more dye is injected it causes *extravasation and chemical sialadenitis*.

### SALIVARY CALCULUS AND SIALADENITIS

- ◆ 80% submandibular.
- ◆ 80% radio-opaque.
- ◆ It is commonly calcium phosphate and calcium carbonate stones.
- ◆ Calculi are more common in submandibular gland, because the gland secretion is viscous, contains more calcium and also, its drainage is nondependent, causing stasis.
- ◆ Secretion from parotid is serous, contains less calcium and so stones are not common.
- ◆ Stone is single in 75% of cases.
- ◆ Incidence of stone in sublingual gland is 1%.

### Salivary calculi

#### Submandibular gland

- ❖ 80% common
- ❖ 80% radio-opaque
- ❖ Seen in plain X-ray (intraoral)
- ❖ Sialogram is not needed

#### Parotid gland

- ❖ 20% incidence (Rare)
- ❖ Radiolucent
- ❖ Not seen in plain X-ray
- ❖ Identified by sialogram

Calculi are common in submandibular salivary gland, because:

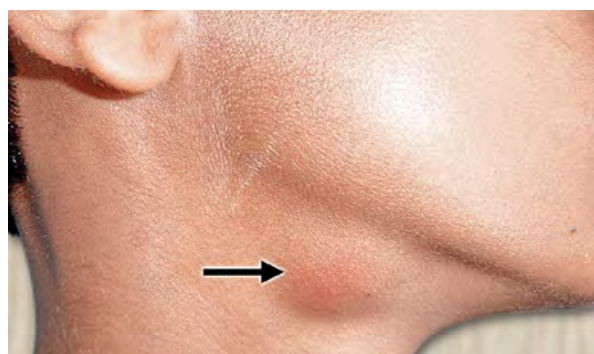- ❖ Viscous nature and mucin content
- ❖ Calcium content
- ❖ Nondependent drainage
- ❖ Stasis
- ❖ Hooking of nerve by submandibular duct

## Presentation

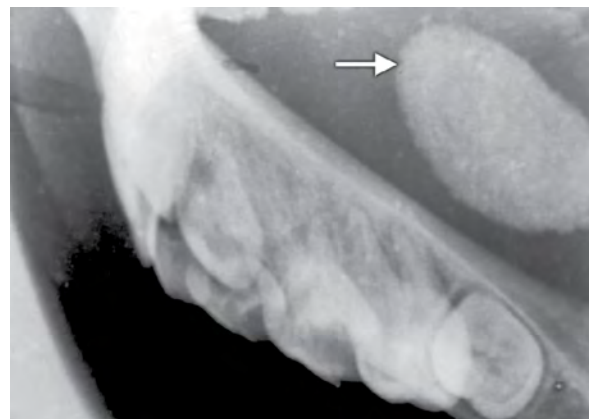### Acute Sialadenitis—Features

- ◆ Pain, swelling, tenderness is seen in submandibular region and floor of the mouth.
- ◆ Dysphagia, trismus, fever.
- ◆ Double chin appearance due to spreading of oedema downwards.
- ◆ Duct is inflamed and swollen.

Causes for submandibular sialadenitis	Types of sialadenitis
<ul style="list-style-type: none"> <li>• Bacterial—more common. It is usually due to obstruction and stasis</li> <li>• Trauma over duct causing oedema/stricture and stasis</li> <li>• Viral—mumps—rare (Paramyxovirus)</li> </ul>	<ul style="list-style-type: none"> <li>• Acute               <ul style="list-style-type: none"> <li>– Bacterial—occurs following submandibular salivary ductal obstruction (Wharton's) or in parotid gland. In parotid, suppuration can occur leading into parotid abscess</li> <li>– Viral—common in parotid</li> </ul> </li> <li>• Chronic—common after partial obstruction of submandibular gland duct or due to stones in submandibular gland or hilum proximal to the level of crossing of the lingual nerve over the duct</li> </ul>



**Fig. 4.9:** Submandibular sialadenitis in a young boy who required excision of gland



**Fig. 4.10:** Stone in the submandibular salivary gland as seen in X-ray (Courtesy: Dr Jagdish, Mangaluru).

### Chronic Sialadenitis—Features

- ◆ Pain is more during mastication due to stimulation (*Salivary colic* which can be induced by meals, lemon juice, etc.). Salivary colic is pain induced by obstruction to the outflow of saliva may be ductal stone. During salivation size of the swelling will decrease again 2 hours after meal/stimulation.
- ◆ Salivary secretion is more during mastication causing increase in gland size.
- ◆ Firm/rubbery tender swelling is palpable bidigitally.
- ◆ When stone is in the duct, it is palpable in the floor of the mouth as a tender swelling with features of inflammation in the duct. Pus exudes through the duct orifice. (Irritation of the lingual nerve, which is in very close proximity to submandibular salivary duct, causes referred pain to tongue—*lingual colic*).
- ◆ In submandibular salivary gland, often the stones are multiple, with chronic inflammation of gland (*sialadenitis*).
- ◆ Often *acute on chronic sialadenitis* can occur.
- ◆ *Kuttner tumour* is chronic sclerosing sialadenitis of submandibular salivary gland.

## Differential Diagnosis

- ◆ Submandibular lymphadenitis.
- ◆ Salivary neoplasm.

## Investigations

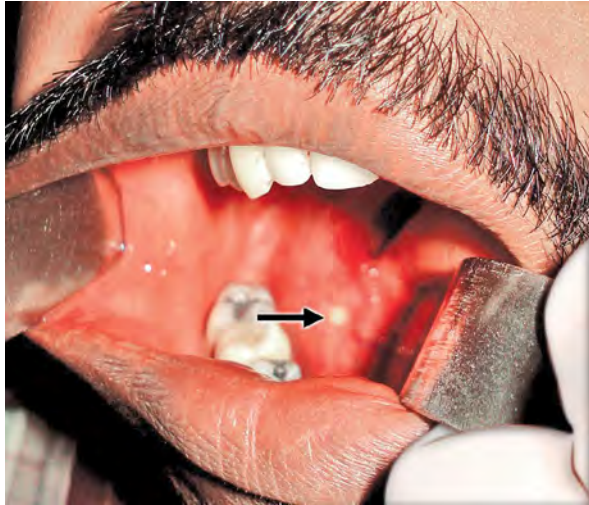
- ◆ Intraoral X-ray (dental occlusion films) to see radio-opaque stones (80%).
- ◆ FNAC of the gland to rule out other pathology.
- ◆ Total count and ESR in acute phase.
- ◆ USG will demonstrate stone *with posterior acoustic shadow*.

### Note:

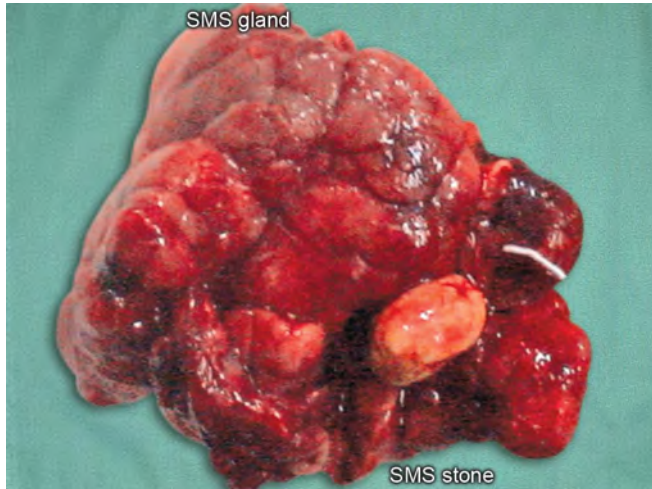
Radiological demonstration of stone/stones is called as *sialolithiasis*.

## Treatment

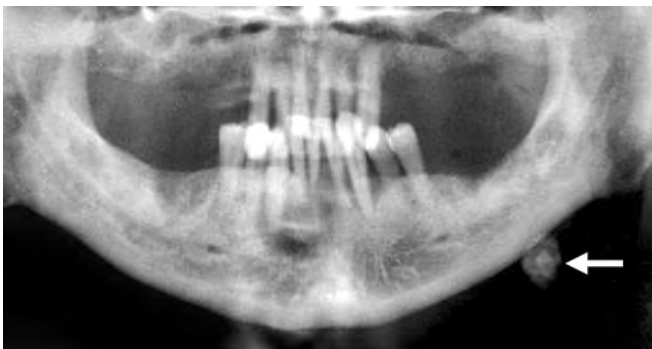- ◆ If the stone is in the duct, removal of the stone is done intraorally, by making an incision in the duct. Incised duct is



**Fig. 4.11:** Stone in the duct of submandibular salivary gland (Wharton's duct).



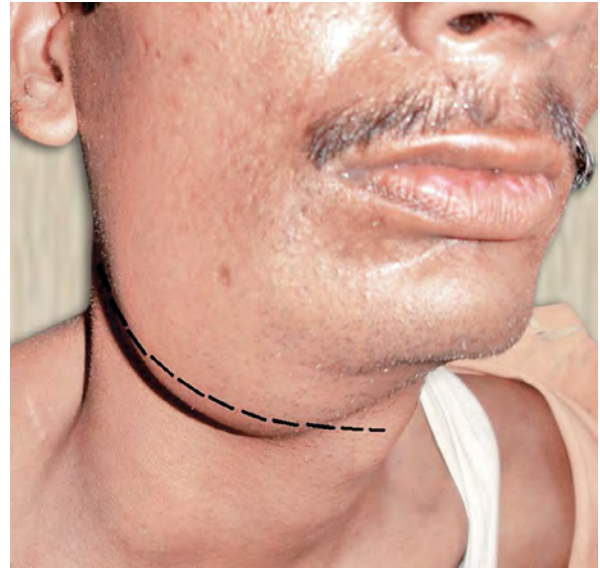**Fig. 4.12:** Excised specimen of submandibular salivary gland with stone in the gland.



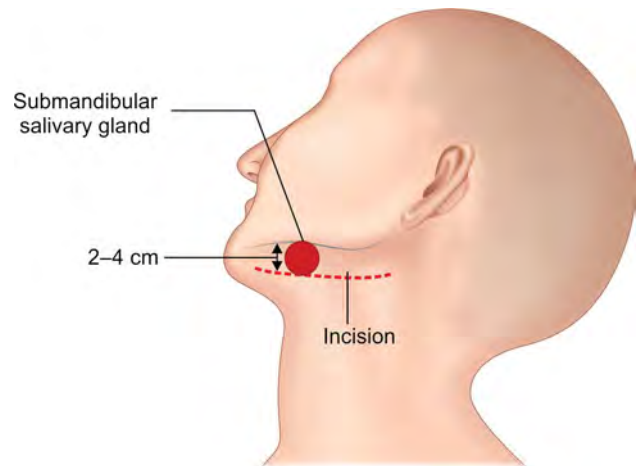
**Fig. 4.13:** X-ray (OPG) showing left sided submandibular salivary stone.

not sutured as it may result in stricture. Laying open allows free drainage of saliva. Procedure is usually done under *local anaesthesia*.

- ◆ If stone is in the gland, *excision of submandibular gland* is done—*sialadenectomy*. It is always done under *general anaesthesia*.



**Fig. 4.14:** Incision for removal of the submandibular salivary gland.



**Fig. 4.15:** Incision for excision of submandibular salivary gland. It should be 2–4 cm below the margin of the mandible to avoid injury to marginal mandibular nerve.

Approach is from submandibular region (outside). An incision is made on the skin in submandibular region, about 5–8 cm length, parallel to and 2–4 cm below the mandible. Incision is deepened through the deep fascia until the gland is visualised without raising the flaps (so as to avoid injury to marginal mandibular nerve, branch of facial nerve). Facial artery is ligated twice. Lingual nerve and hypoglossal nerves are taken care of. Mylohyoid is retracted so as to remove the deep portion of the gland. Drain is placed after removal of the gland.

Antibiotic coverage is a must.

*Facial artery* lies in the groove on the deeper aspect of the gland; often embeds in the gland or runs around the gland with a variable course and so artery has to be ligated twice above anteriorly and below posteriorly.

*Marginal mandibular nerve* is in subplatysmal plane in neck, so incision should be deepened across the deep fascia without raising subplatysmal plane to avoid injury to this nerve.

## Complications of Surgery

- ◆ Haemorrhage.
- ◆ Infection.
- ◆ Injury to marginal mandibular nerve, lingual nerve, hypoglossal nerve.
- ◆ Injury to nerve to mylohyoid causing anaesthesia over submental skin.

### Note:

- Stone in parotid duct can be removed by opening the duct longitudinally.
- Stone in the gland or in collecting duct is treated by parotidectomy.

Indications for submandibular salivary gland excision	Steps in submandibular salivary gland excision
<ul style="list-style-type: none"> <li>• Chronic sialadenitis</li> <li>• Submandibular salivary tumours</li> </ul> <p>Pathway of secretomotor fibres of the submandibular and sublingual salivary glands</p> <p>Superior salivary nucleus ↓ Preganglionic fibres ↓ Facial nerve, Chorda tympani nerve ↓ Lingual nerve ↓ Submandibular ganglion—post-ganglionic fibres ↓ Submandibular and sublingual salivary glands</p>	<ul style="list-style-type: none"> <li>• Anaesthesia—general</li> <li>• Position—neck extension with chin to opposite side</li> <li>• Incision—2–4 cm (3 cm) below and parallel to the margin of the mandible 5–8 cm in length (6 cm)</li> <li>• Mobilisation of the gland—intracapsular in sialadenitis; extracapsular in tumours with ligation of anterior facial vein</li> <li>• Facial artery ligation proximally and distally as artery is in the gland or in the groove posteriorly</li> <li>• Dissection of deeper lobe from mylohyoid muscle</li> <li>• Identification of lingual and hypoglossal nerves</li> <li>• Duct identification and ligation</li> <li>• Wound closure with a suction drain</li> </ul>

### Rule of 2 in submandibular salivary gland

- ❖ 2 parts divided by mylohyoid muscle
- ❖ 2 conditions affect it—tumour and stone
- ❖ 2 superficial nerves—cervical and mandibular branch of facial nerves
- ❖ 2 deep nerves—lingual and hypoglossal nerves
- ❖ Incision—2–4 cm below the mandible
- ❖ Ligate facial artery at 2 places

## SIALOSIS

- ◆ It is enlargement of the salivary gland due to fatty infiltration, as a result of various metabolic causes like diabetes, acromegaly, obesity, liver disease, alcoholism, bulimia, idiopathic, drug induced (sympathomimetics, carbimazole, thiouracil).

- ◆ It is diffuse, bilateral, non-inflammatory, non-neoplastic asymptomatic swelling of the salivary gland mostly of parotids with fatty infiltration and acinar cell hypertrophy.
- ◆ *Clinical features:* Bilateral diffuse enlargement of parotids, which is smooth, firm, non-tender.
- ◆ *Treatment:* The cause is treated.

## SIALECTASIS

- ◆ It is an aseptic dilatation of salivary ductules causing *grape-like* (cluster-like) dilatations.
- ◆ It is a disease of unknown aetiology with destruction of parenchyma of gland accompanied by stenosis and cyst formation in the ductules.
- ◆ It is common in parotids; often bilateral.
- ◆ Presents as a smooth, soft, fluctuant, nontransilluminating swelling which increases in size during mastication. It is tender initially. It lasts for many days with a long symptom-free period of the disease.
- ◆ Sialogram is diagnostic (grape or cluster-like dilatations).
- ◆ Treatment is conservative (nonsurgical).

## RECURRENT CHILDHOOD PAROTITIS

It is a recurrent, rapid enlargement of one or both parotids with fever and malaise in children of age group between 3 and 6 years without any known aetiology. Recurrent episodes with a quiescent period in between are typical. Sialogram shows snowstorm punctate sialectasis. Low dose antibiotics for long period may be required. Occasionally patient may need total conservative parotidectomy especially if it occurs late in adolescent period.

## PAROTID ABSCESS (SUPPURATIVE PAROTITIS)

- ◆ It is a result of an *acute bacterial sialadenitis* of the parotid gland.
- ◆ It is an ascending bacterial parotitis, due to reduced salivary flow, dehydration, starvation, sepsis, after major surgery, radiotherapy for oral malignancies and poor oral hygiene.
- ◆ Parotid fascia is densely thick and tough and so parotid abscess does not show any fluctuation until very late stage.
- ◆ Causative organism are *Staphylococcus aureus* (commonest), *Streptococcus viridans* and often others like gram-negative and anaerobic organisms.

### Causes of acute parotitis (Differential diagnosis of suppurative parotitis)

- ❖ Viral—Mumps, Coxsackie virus A and B, parainfluenza 1 and 3, Echo and lymphocytic choriomeningitis
- ❖ Bacterial—*Staphylococcus aureus*
- ❖ Allergic
- ❖ HIV infection
- ❖ Radiotherapy, postoperative period
- ❖ Specific infections like syphilis
- ❖ Sjogren's syndrome often causes bilateral parotitis

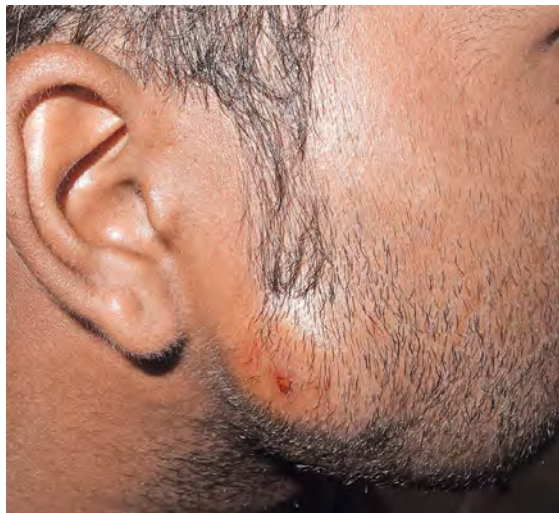

Fig. 4.16: Parotid abscess

### Clinical Features

- ◆ Pyrexia, malaise, pain and trismus.
- ◆ Red, tender, warm, well-localised, firm swelling is seen in the parotid region (brawny induration).
- ◆ Tender lymph nodes are palpable in the neck.
- ◆ Features of bacteraemia are present in severe cases.
- ◆ Pus or cloudy turbid saliva may be expressed from the parotid duct opening.

### Investigations

- ◆ U/S of the parotid region.
- ◆ Pus collected from duct orifice is sent for culture and sensitivity.
- ◆ Needle aspiration from the abscess is done to confirm the formation of pus.

#### Note:

- In suppurative parotitis patient may develop severe laryngeal or pharyngeal oedema and may require steroids, tracheostomy and critical care.
- *Sialogram* is contraindicated in acute phase, as it will cause retrograde infection leading into bacteraemia.

#### Complications of suppurative parotitis and parotid abscess

- ❖ Septicaemia
- ❖ Severe trismus
- ❖ Rupture into the external auditory canal

### Treatment

- ◆ Antibiotics are started depending on culture report.
- ◆ When it is severely tender and localised, incision and drainage is done under G/A.

#### Areas where one should not wait for the abscess to form

- ❖ Parotid
- ❖ Breast
- ❖ Ischio-rectal fossa
- ❖ Thigh

Skin is incised in front of the tragus vertically and then parotid sheath (pyogenic membrane) is opened horizontally. Pus is drained using sinus forceps and sent for C/S. Antibiotics are continued (**Blair's incision**).

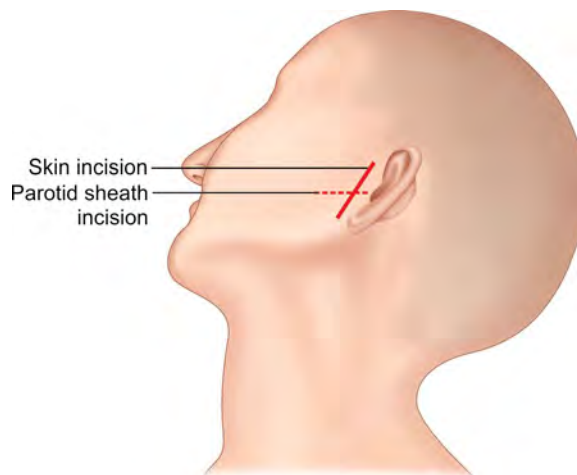


Fig. 4.17: Blair's incision used to drain the parotid abscess.

- ◆ Proper hydration, mouth wash using povidone iodine/potassium permanganate solutions, nutrition. Often patient with parotid infection needs admission and treatment.

### PAROTID FISTULA

- ◆ Parotid fistula may arise from *parotid gland* or *duct* or *ductules*. It may open inside the mouth as internal fistula; or open outside onto the skin as external fistula. Fistula from the duct has profuse discharge. Fistula from the gland often shows only minimal discharge.
- ◆ Incidence of salivary fistula is 0.2–3%.

### Types

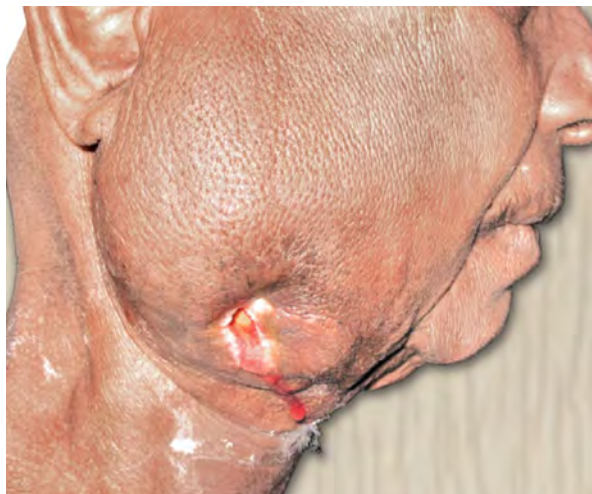1. *Duct fistula* forms after superficial parotidectomy. It is profuse and often persisting. So duct should be ligated using nonabsorbable suture as far as possible, anteriorly to allow normal saliva drainage from deep lobe. If common duct is ligated deep lobe atrophies without causing any fistula.
2. *Gland fistula* occurs from the raw surface after superficial parotidectomy. It is mild and symptom subsides in a month with anticholinergic drugs. Jacobson tympanic neurectomy completely stops the secretion from the fistula in this type.

### Causes

- ◆ After superficial parotidectomy.
- ◆ After drainage of parotid abscess, ruptured abscess.
- ◆ After biopsy.
- ◆ Trauma.
- ◆ Recurrence of malignant tumour.

### Clinical Features

- ◆ Discharging fistula in the parotid region of the face, and discharge is more during eating.
- ◆ Tenderness and induration.
- ◆ Trismus.



**Fig. 4.18:** Parotid fistula with discharging saliva and pus.

## Diagnosis

- ◆ Sialography to find out the origin of the fistula whether from parotid gland or duct or ductules.
- ◆ Fistulogram or CT fistulogram.
- ◆ Discharge study.
- ◆ MRI.

## Treatment

- ◆ *Anticholinergics*—hyoscine bromide (probanthine).
- ◆ *Radiotherapy*.
- ◆ *Often exploration of fistula* is required.
- ◆ *Repair or reinsertion* of the duct into the mucosa.
- ◆ *Newman Seabrock's operation*—a probe is passed into the parotid duct through the opening in the mouth. Another probe is passed through the fistula. Duct and fistula are dissected over the probe. After removal of the fistula track severed duct ends are identified; and ends are trimmed. Probes are removed. A tantalum wire is passed into the duct across the severed ends and duct is sutured over it using 4 zero vicryl. Tantalum stent is removed after 3 weeks.
- ◆ If still persists, auriculotemporal nerve which supplies secretomotor component of parotid is cut.
- ◆ If there is stenosis at the orifice of the Stenson's duct, papillotomy at the orifice may help.
- ◆ Total conservative parotidectomy is done in failed cases.

### Remember about salivary fistula

- ❖ Commonly from the parotid
- ❖ It can be *internal* draining into the mouth or can be *external* draining outside
- ❖ It is *acquired commonly* but rarely can be congenital
- ❖ It can be due to surgery, trauma or due to sepsis
- ❖ Fistula arising from the *gland parenchyma* drains through suture line but usually closes spontaneously. Leakage will be more during meals. Saliva is confirmed by its high amylase content compared to seroma/serous fluid

- ❖ Fistula due to *ductal disruption* leaks profusely and invariably needs surgery to close it
- ❖ Submandibular gland fistula commonly closes spontaneously, rarely if not requires complete removal of the gland
- ❖ Anticholinergics, irradiation, denervation of the gland, duct ligation are done to reduce saliva production
- ❖ Excision of fistula, repair of the duct, diversion of the duct into the mouth are other options
- ❖ In severe intractable cases, removal of the gland/total conservative parotidectomy is needed

## ■ SJÖGREN'S SYNDROME

It is an autoimmune disease causing progressive destruction of salivary and lacrimal glands, leading to *keratoconjunctivitis sicca* (dry eyes), and *xerostomia* (dry mouth).

### Types

1. Primary.
2. Secondary.

#### Primary Sjögren's Syndrome (Primary Glandular Sicca Syndrome)

- ◆ Severe dry mouth.
- ◆ Severe dry eyes.
- ◆ Widespread dysfunction of exocrine glands.
- ◆ Incidence of developing lymphomas is high.
- ◆ There is no association of connective tissue disorders.

#### Primary extra-glandular sicca syndrome

- ❖ Dry mouth, dry eyes
- ❖ Hyperglobulinaemic purpura, vasculitis
- ❖ Raynaud's phenomenon or B cell lymphoma

#### Secondary Sjögren's Syndrome

- ◆ Dry mouth.
- ◆ Dry eyes.
- ◆ With association of connective tissue disorders like:
  - ▶ Primary biliary cirrhosis (near 100%).
  - ▶ SLE (30%).
  - ▶ Rheumatoid arthritis (RA) (15%).
- ◆ Female to male ratio is 10 : 1.

### Clinical Features

- ◆ It is common in middle aged females who present with dry eyes, dry mouth, enlarged parotids and enlarged lacrimal glands.
- ◆ Often they are tender.
- ◆ Superadded infections of the mouth, *Candida albicans* is common.

### Investigations

1. Autoantibody estimation—rheumatoid factor, antinuclear factor, salivary duct antibody.
2. Sialography.
3. Estimation of salivary flow.

*Tumours of ectopic salivary glands are of low grade malignancy (cylindroma) may ultimately metastasize to regional lymph nodes, the viscera and the skeleton.*

—Kenneth Harrison

4. Slit lamp test of eyes.
5. Schirmer test—to detect lack of lacrimal secretion.
6. FNAC of parotids and lacrimal glands.
7. <sup>99</sup>TcTetate scan for gland function.

### Treatment:

*It is conservative.*

- ◆ Artificial tears.
- ◆ Artificial saliva.
- ◆ Frequent drinking of water.
- ◆ Treat the cause.

### MIKULICZ DISEASE

- ◆ It is a clinical variant of Sjögren's syndrome.
- ◆ It is an autoimmune disorder of salivary and lacrimal glands, resulting in infiltration of the glands with round cells.
- ◆ It may be due to or associated with sarcoidosis, Sjögren's syndrome, leukaemia, lymphoma.

#### Triad

- ❖ Symmetrical and progressive enlargement of all salivary glands
- ❖ Narrowing of palpebral fissures due to enlargement of the lacrimal glands
- ❖ Parchment-like dryness of the mouth

### SALIVARY NEOPLASMS

#### Aetiology

- ◆ *Genetic*—loss of alleles of chromosomes in 12q, 8q, 17q. Eskimos are more prone for salivary neoplasm.
- ◆ *Infective*—mumps, Epstein-Barr virus, chronic sialadenitis may be the cause; but not proved emphatically. Recurrent inflammation can cause duct dysplasia and carcinoma.
- ◆ *Radiation*—it is more common in survivors of atomic bomb explosion; mucoepidermoid carcinoma is more in these patients.
- ◆ *Smoking*—adenolymphoma of Warthin's shows 40% risk in smokers.
- ◆ *Sex*—benign tumours and many malignancies are common in females; Warthin's and some malignancies are common in males.
- ◆ *Environment and diet*—Arctic-Eskimos show dietary deficiency of vitamin A and develop salivary tumour. Industrial agents like nickel, cadmium, hair dyes, silica, preservatives may increase the risk of salivary tumours.

#### Classification (WHO)

##### a. *Epithelial* (90%):

###### 1. *Adenomas*

- Pleomorphic adenoma.
- Monomorphic adenomas.
  - » Adenolymphoma (Warthin's tumour).
  - » Oncocytoma (oxyphil adenoma) seen in elderly; seen in parotid gland.
  - » Basal cell adenoma—it is a rare benign tumour.

##### 2. *Carcinomas*

- Mucoepidermoid carcinoma—most common malignancy.
- Acinic cell carcinoma—1%.
- Adenoid cystic carcinoma—very aggressive—10%; common minor salivary glands.
- Adenocarcinoma.
- Squamous cell carcinoma—2%.
- Carcinoma in ex pleomorphic adenoma.
- Undifferentiated carcinoma.

#### Note:

Carcinoma can be:

- *Low grade* (acinic cell; adenoid cystic; low grade mucoepidermoid) or
- *High grade* (adenocarcinoma; squamous cell carcinoma; high grade mucoepidermoid) mesenchymal.

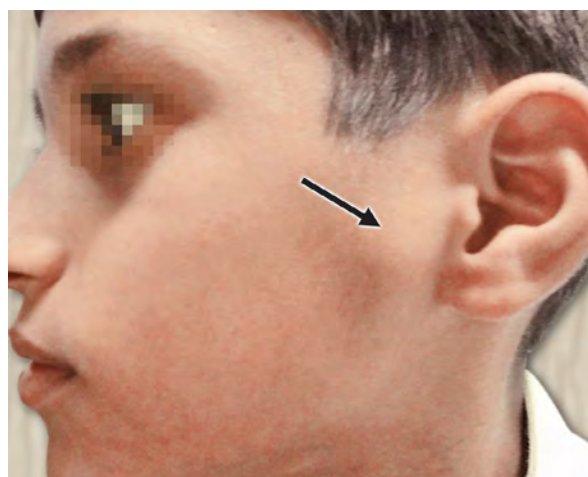


Fig. 4.19: Parotid enlargement in a boy of 11-year-old.

##### b. *Nonepithelial:*

- ◆ Haemangioma—commonly seen in infants, usually in parotids. Spontaneous regression is common. Most common benign salivary gland tumour in paediatric age group.
- ◆ Lymphangioma.
- ◆ Neurofibromas and neurilemmomas.

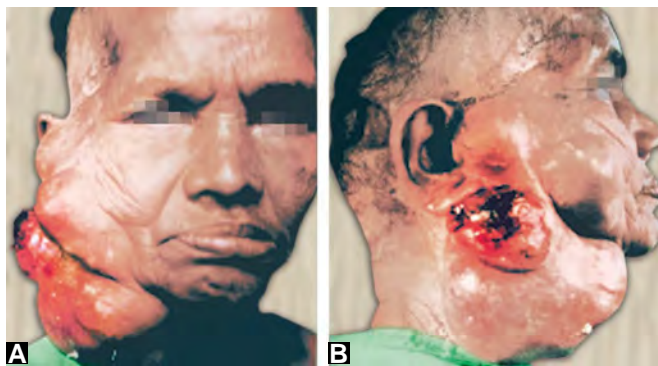##### c. *Malignant lymphomas—NHL type:*

- ◆ Common in parotids.
- ◆ Common with HIV, Sjögren's syndrome (44 times more chances than normal people).

##### d. *Secondary tumours* from head and neck region; bronchus and skin.

##### e. *Lymphoepithelial tumours:*

- ▶ *Benign*—it is 5% of all benign salivary tumours (*Godwin's tumour*). It is common in females; can be bilateral. Benign lymphoepithelial lesion (BLEL) is of unknown etiology characterized by replacement of salivary parenchyma with lymphoid tissue. It may be diffuse/focal/capsulated/unencapsulated. It may be associated with Mikulicz's disease or Sjögren's syndrome.
- ▶ *Malignant*—it is rare tumour occurs in parotid and submandibular glands (ESKIMOMA).



**Figs 4.20A and B:** Neoplasm of parotid gland (Malignant).

### Incidence

- ◆ Eighty per cent salivary neoplasms are in the parotids of which 80% are benign; 80% of these are pleomorphic adenomas; 80% occur in superficial lobe.
- ◆ Fifteen per cent of salivary tumours are in the submandibular salivary gland, of which 50% are benign. 95% of these are pleomorphic adenomas.
- ◆ Ten per cent of salivary neoplasms are in the minor salivary glands—palate, lips, cheeks, and sublingual glands. Of these only 10% are benign.

#### Note:

- Parotid tumours are common but only 20% are malignant.
- Submandibular tumours are uncommon but 50% of them are malignant.
- Minor salivary gland tumours (other than sublingual glands) are rare and 90% of them are malignant.
- Sublingual salivary tumours are very rare but almost all sublingual salivary tumours are malignant.
- Incidence of malignancy in salivary glands is inversely related to size of the gland; in parotid it is 15%; in submandibular it is 50%; in sublingual it is 85%.

### PLEOMORPHIC ADENOMA (Mixed Salivary Tumour)

- ◆ Commonest of the salivary gland tumour in adult.
- ◆ It is 80% common.
- ◆ More common in parotids (80%). 10% in submandibular salivary gland; 0.5% in sublingual salivary gland.
- ◆ It is mesenchymal, myoepithelial and duct reserve cell origin.
- ◆ **Grossly** it contains cartilages, cystic spaces, solid tissues.
- ◆ **Microscopically** it is biphasic in nature with epithelial and stromal components. Benign tumours will usually not show necrosis.

#### Histologically it shows:

- ❖ Epithelial cells
- ❖ Myoepithelial cells
- ❖ Mucoïd material with myxomatous changes
- ❖ Cartilages/pseudocartilages

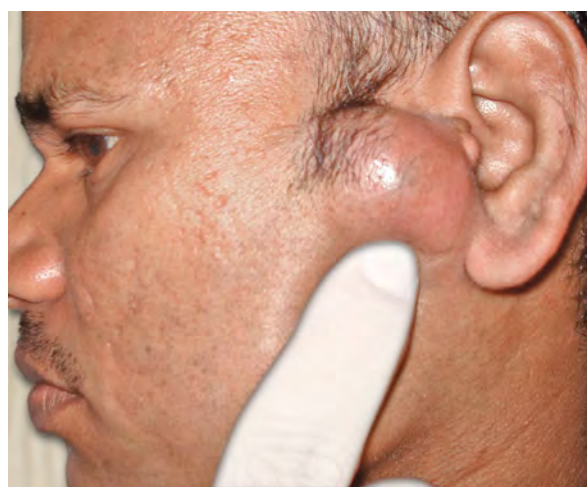- ◆ Even though it is capsulated, tumour may come out as *pseudopods* and may extend beyond the main limit of the tumour tissue.
- ◆ When disease occurs in parotid, commonly it involves superficial lobe or superficial and deep lobe together.
- ◆ But sometimes only deep lobe is involved and then it presents as swelling in the lateral wall of the pharynx, soft palate and posterior pillar of the fauces. There may not be any visible swelling in the preauricular region. It is called as '*dumbbell tumour*'. This tumour is in relation to styloid process, mandible, stylohyoid, styloglossus, stylopharyngeus muscles.

### Clinical Features

#### Clinical features of parotid tumour

- ❖ Swelling, pain, ulceration, dysphagia (if deep lobe is involved)
- ❖ Raised ear lobule
- ❖ Cannot be moved above the zygomatic bone—curtain sign
- ❖ Deviation of uvula and pharyngeal wall towards midline in case of deep lobe tumour
- ❖ Facial nerve, masseter, skin, lymph node and bone involvement eventually occurs in case of malignancy

- ◆ 80% common.
- ◆ Common in females (3:1).
- ◆ Occurs in any age group. But common in 4th and 5th decade
- ◆ Usually unilateral.
- ◆ Present as a single painless, smooth, firm lobulated, mobile swelling in front of the parotid with *positive curtain sign* (As the deep fascia is attached above to the zygomatic bone, it acts as a curtain, not allowing the parotid swelling to move above that level. Any swelling superficial to the deep fascia will move above the zygomatic bone).
- ◆ Obliteration of retromandibular groove is common.



**Fig. 4.21:** Pleomorphic adenoma showing *curtain sign*.



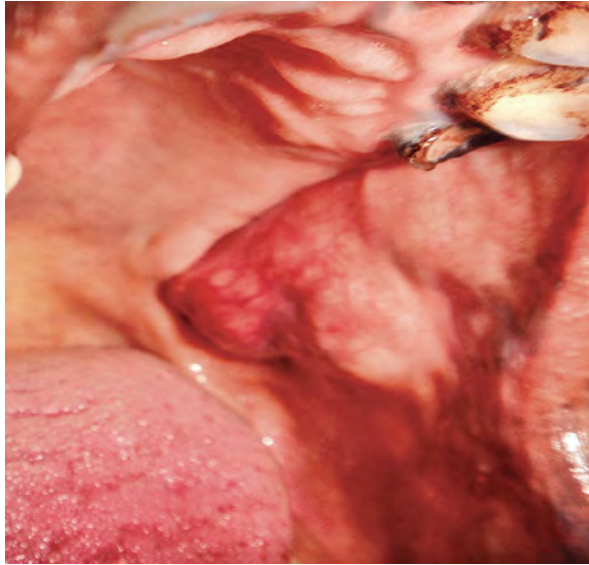

Fig. 4.22: Deep lobe tumour of parotid is examined per orally.

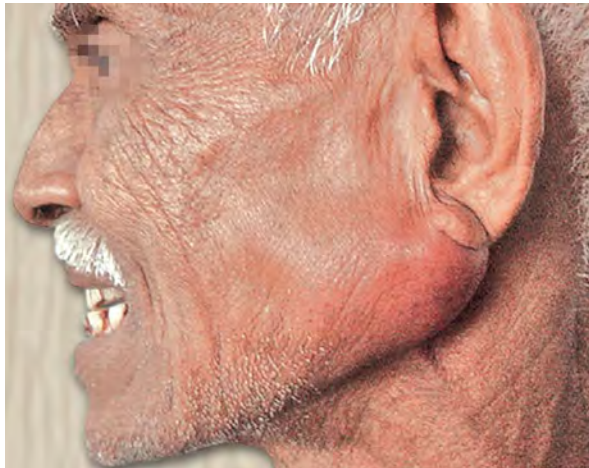

Fig. 4.23: Typical parotid swelling with ear lobe raised. Facial nerve should be tested by clenching the teeth.

- ◆ The ear lobule is lifted.
- ◆ When deep lobe is involved, swelling is commonly located in the lateral wall of pharynx, posterior pillar and over the soft palate—10%. Deep lobe tumour passes through *Patey's stylomandibular tunnel* pushing tonsils, pharynx, soft palate often without any visible swelling or only small swelling when only deep lobe tumour is present; it also presents as dysphagia. Bidigital palpation of parotid is significant in such occasion with one finger inside mouth.
- ◆ Facial nerve is not involved.

**Long-standing pleomorphic adenoma may turn into carcinoma** (carcinoma in ex pleomorphic adenoma). Its features are:

- ❖ Recent increase in size
- ❖ Pain and nodularity
- ❖ Involvement of skin, ulceration
- ❖ Involvement of masseter
- ❖ Involvement of facial nerve—lower facial nerve palsy—(Difficulty in closing eyelid, difficulty in blowing and clenching teeth)
- ❖ Involvement of neck lymph node
- ❖ Restriction of jaw movements

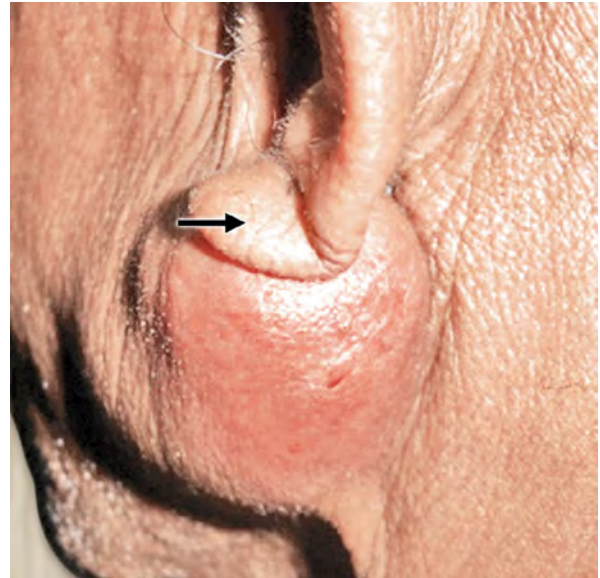


Fig. 4.24: Parotid tumour showing typical raise in earlobe pleomorphic adenoma.

#### Pain in salivary tumours

- ❖ Benign tumours are usually painless
- ❖ Sudden onset of pain denotes malignant transformation
- ❖ Pain is dull boring at primary site or referred to ear through auriculotemporal nerve
- ❖ *Pain is due to:*
  - Capsular distension by tumour
  - Obstruction to free flow of saliva
  - Nerve infiltration
  - Inflammation like in Warthin's
  - Tumour necrosis

#### Complications

- ◆ Recurrence—5–50%.
- ◆ Malignancy.
  - ▶ 3–5% in early tumours.
  - ▶ 10% in long duration (15 or more years) tumours.

#### Investigations

- ◆ FNAC is very important and diagnostic.
- ◆ CT scan to know the status of deep lobe, local extension and spread.
- ◆ MRI is better method.

#### Note:

Incision biopsy of parotid tumour is contraindicated as chances of *seedling and recurrence* are high and also there is a chance of *injuring the facial nerve*, and chance of developing *parotid fistula* while doing the biopsy.

#### Open biopsy is contraindicated in parotid tumours due to:

- ❖ Chance of injury to facial nerve
- ❖ Seedling and high chance of recurrence
- ❖ Chance of parotid fistula formation

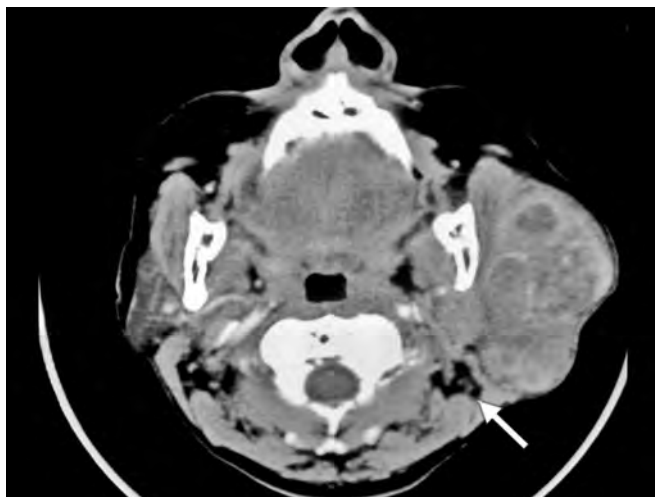


Fig. 4.25: CT picture of pleomorphic adenoma.

## Treatment

- ◆ Surgery—first line treatment.
- ◆ If only superficial lobe is involved, then superficial parotidectomy is done wherein parotid superficial to facial nerve is removed.
- ◆ If both lobes are involved, then total conservative parotidectomy is done by retaining facial nerve.

### Note:

- Enucleation is avoided as it causes high recurrence due to extension of tumour outside as pseudopods across the capsule.
- Incomplete excision, 10% of tumours which are highly cellular are other causes for recurrence.
- RT is given after surgery even though it is benign controversial; a debate.
- Inexplicable metastasis can occur even though it is benign.
- Tumour may implant due to spillage while surgical removal into retained residual parotid (deep lobe in superficial parotidectomy).
- Recurrence after parotidectomy in pleomorphic adenoma is 5%. It is due to spillage, improper technique, inadequate margin, retained pseudopods, multicentricity. Recurrent tumour is multinodular

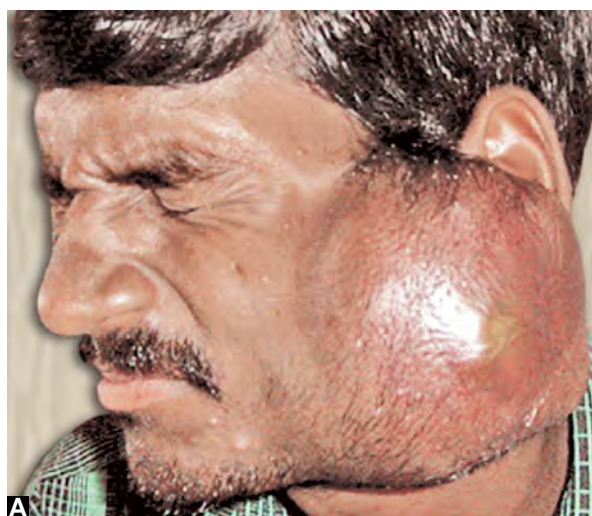

Fig. 4.26A

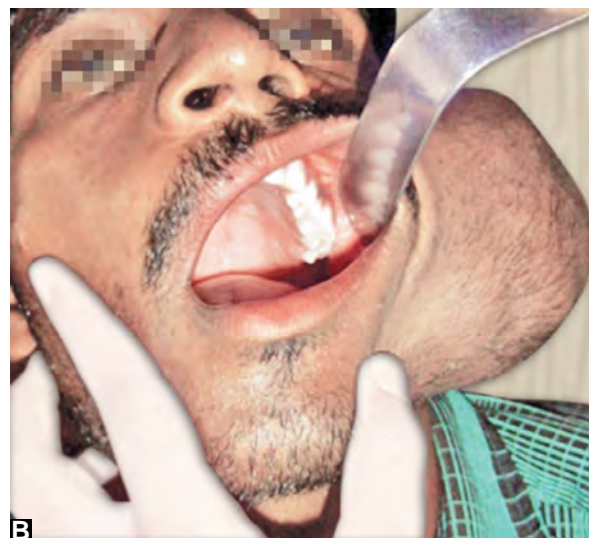

Fig. 4.26B

**Figs 4.26A and B:** Recurrent parotid tumour which has attained large size. Note facial nerve is intact. Duct orifice should be inspected using retractor.

without any capsule. Expression of *MUC1/DF3* in the tumour is marker to predict recurrence.

## ■ ADENOLYMPHOMA (Warthin's Tumour, Papillary Cystadenoma Lymphomatousum)

- ◆ It is a misnomer. It is not malignant, it is not lymphoma.
- ◆ It is a benign tumour that occurs only in parotid, usually in the lower pole.
- ◆ It is said to be due to trapping of jugular lymph sacs in parotid during developmental period.
- ◆ It composed of *double layer of columnar epithelium*, with papillary projections into cystic spaces with lymphoid tissues in the stroma.
- ◆ It usually involves only superficial lobe of parotid gland. It may also be *multicentric*.
- ◆ Smoking (40%/8 times more risk than nonsmokers) and radiation exposure may be the cause.

## Clinical Features

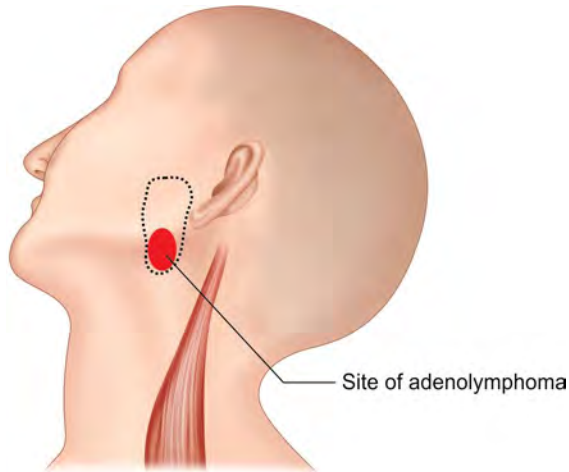
- ◆ It presents as a slow growing, smooth, soft, cystic, fluctuant swelling, in the lower pole, often bilateral and is nontender.
- ◆ It is common in males—4:1. Common in smokers.
- ◆ Common in old people – 60 years.
- ◆ Its incidence is 10%. Common in Whites.
- ◆ It is 2nd most common benign tumour.
- ◆ It is often bilateral—10%.

## Investigations

- ◆ Adenolymphoma produces a “hot spot” in <sup>99</sup>Techetium pertechnetate scan—it is *diagnostic* (Due to high mitochondrial content).

◆ FNAC.

*Adenolymphoma does not turn into malignancy.* But occasionally it can simultaneously be associated with pleomorphic adenoma, carcinoma or lymphoma of parotid.



**Fig. 4.27:** Warthin's tumour. It is seen in parotid gland usually in superficial lobe, in lower pole.



**Fig. 4.28:** Warthin's tumour of parotids. It is common in males; often bilateral; common in elderly.

## Treatment

Superficial parotidectomy.

## ■ ONCOCYTOMA (Oxyphil Adenoma)

- ◆ It is <1% of salivary tumours.
- ◆ Usually benign, originating from *oncocytes* (oxyphilic cells).
- ◆ Radiation and occupational hazards are the causes.
- ◆ Common in parotid; but rarely can occur in submandibular salivary gland.
- ◆ Gross—small, *tan coloured*, well circumscribed encapsulated solid tumour.
- ◆ Microscopy—*large oncocytes* with *swollen granular cytoplasm* due to abundant mitochondria. Tyrosine crystals are present in glandular spaces.
- ◆ Predilection for  $^{99}\text{Tc}$  with hotspots and FNAC are the investigations.

## ■ BASAL CELL ADENOMA

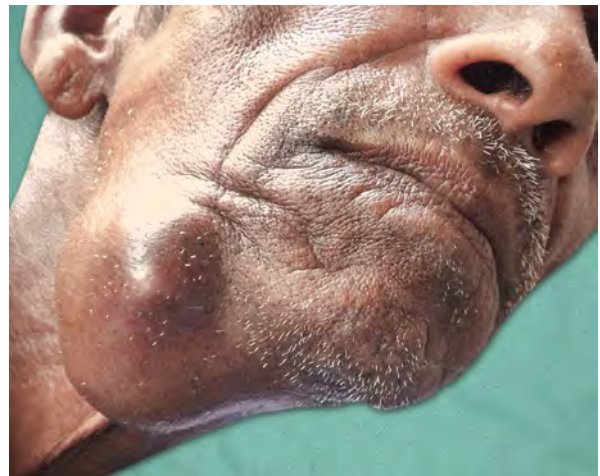- ◆ It is rare, benign, now classified under monomorphic adenoma containing isomorphic basaloid cells with basal layer and basement membrane.
- ◆ It is common in minor salivary glands; in major salivary glands it is multicentric.
- ◆ Grossly it looks like lymph node.
- ◆ *Microscopy*—isomorphic basaloid cells with solid/trabecular/tubular/membranous pattern.
- ◆ *Canalicular adenoma* is its variant with bilayered ribbons of columnar cells separated by vascular stroma.

## ■ MUCOEPIDERMOID TUMOUR

- ◆ It is the commonest malignant tumour in parotid.
- ◆ It is 2nd common malignant tumour in submandibular and sublingual salivary glands.
- ◆ It is commonest malignant tumour of parotid in childhood.
- ◆ Incidence is 9% of salivary tumours; 20% of malignant salivary tumours.
- ◆ It occurs both in major as well as minor salivary glands. Parotid is the commonest site; palate is the commonest minor salivary gland site (In the palate adenoid cystic carcinoma is common).
- ◆ Radiation is the commonest etiological factor.
- ◆ *Gross*—unencapsulated solid tumour with cystic spaces.
- ◆ *Microscopy*—biphasic with *mucin secreting* (+ve for PAS, -ve for diastase) low grade and *epidermoid* with high grade; *clear cell* with intermediate type.
- ◆ It is slowly progressive, often attains a large size and spreads to neck lymph nodes.
- ◆ It contains malignant epidermoid and mucous secreting cells.

## Types

- ◆ Low grade—*mucous cells* mainly—spreads to regional nodes.
- ◆ Intermediate—*clear cell* variety
- ◆ High grade—*epidermoid cells* mainly—spreads to regional nodes and also shows high propensity for distant spread. Facial nerve involvement is late in mucoepidermoid carcinoma of parotid.



**Fig. 4.29:** Mucoepidermoid carcinoma of submandibular salivary gland.

## Clinical Features

- ◆ Swelling in the salivary (parotid or submandibular) region, slowly increasing in size, eventually attaining a large size, which is hard, nodular, often with involvement of skin and lymph nodes.
- ◆ Common in females (3:1); slow growing.
- ◆ Pain, skin and facial nerve involvement are not common unless it is high grade.

## ADENOID CYSTIC CARCINOMA (10% of Salivary Tumours)

- ◆ It is *most common* tumour in submandibular and sublingual salivary glands. 50% of cases occur in minor salivary glands—*palate*.
- ◆ It is also called as *cylidromatous carcinoma*.
- ◆ It is 2nd most common malignant salivary tumour; but it is rare in parotid (2% of parotid tumours, 15% of malignant parotid tumours).
- ◆ It is common in females (3:2). Common in 5th and 6th decades.
- ◆ It is *slow growing but highly malignant* with remarkable capacity for recurrence. But it is classified under *low grade* malignancy.
- ◆ *Microscopy*: Cribriform, tubular, and solid are 3 types. *Cribriform* type shows cells in nests separated by round or oval spaces—‘*Swiss-cheese*’ pattern. Myo and duct epithelial cells with lace like pattern are also seen. It *invades* periosteum and bone medulla early and spreads extensively.
- ◆ It has got high affinity for *perineural spread* (both axially and circumferentially; antegrade and retrograde fashion) along mandibular and maxillary divisions of trigeminal (*common*) nerve and facial nerve. It infiltrates nerve more proximally for long distance. Tumour may reach Gasserian trigeminal ganglion, pterygopalatine ganglion and cavernous sinus.
- ◆ Blood spread can occur to *lungs*, bones and liver. Lung secondaries may remain *dormant for many years* and so is not a contraindication for surgery of primary tumour. Blood spread can occur decades after removal of primary tumour.
- ◆ Radical parotidectomy/wide or radical excision of submandibular and sublingual glands with neck nodal dissection and postoperative RT is the treatment of choice.
- ◆ Positive margin, perineural spread, solid type on microscopy carry poor prognosis. Lung metastasis will not affect the prognosis.
- ◆ Local recurrence is common. 5-year survival is 70%.
- ◆ Regional nodal spread can occur but rare.

## ACINIC CELL TUMOUR

- ◆ It is a rare, slow growing tumour that occurs almost always in parotid and is composed of cells alike serous acini.
- ◆ It is more common in women. It occurs in adult and elderly.
- ◆ It is 3% of salivary tumours; 90% occurs in parotid.
- ◆ Microscopically, it can be microcystic (commonest), papillary, follicular, medullary etc.
- ◆ It can involve facial nerve or neck lymph nodes.
- ◆ Clinically, it is of variable consistency with soft and cystic areas.
- ◆ It is low grade malignant tumour.

## MALIGNANT MIXED TUMOUR (MMT)

- ◆ It is 10% of salivary malignancy in incidence with epithelial and mesenchymal elements.
- ◆ It carries worst prognosis.

## Types

- ◆ *Carcinoma ex pleomorphic adenoma*: It is the commonest type. Previous long standing parotid swelling shows rapid change, fixity, facial nerve spread, neck nodal involvement are typical. Transformation is 2% in tumour of 5 years duration; 10% in 15 years tumour. It is the most aggressive salivary malignancy. Radical parotidectomy is the treatment.
- ◆ *Primary malignant mixed tumour*: It is also called as *carcinosarcoma* which arises as *de novo*. It shows components of both carcinoma and sarcoma with metastatic potential both through lymph nodes and blood.
- ◆ *Metastasizing mixed tumours*: It contains structures typical of benign mixed tumour both at original and at metastases sites.
- ◆ *In situ non-invasive carcinoma* in pleomorphic adenoma: There is no evidence of capsular invasion. Lesion with less than 8 mm invasion in depth shows 100% of 5-year survival; > 8 mm invasion carries 5-year survival < 50%.

## ADENOCARCINOMA OF SALIVARY GLANDS

- ◆ It is 3% of parotid and 10% of submandibular and minor salivary gland tumours.
- ◆ It is equal in both sexes.
- ◆ It is common in children
- ◆ It can be tubular, papillary and undifferentiated.
- ◆ 20% involve facial nerve clinically.
- ◆ Undifferentiated type is aggressive.

## SQUAMOUS CELL CARCINOMA OF SALIVARY GLANDS

- ◆ It is rare in salivary glands.
- ◆ In salivary glands, parotid is the common site.
- ◆ It is almost never seen in minor salivary glands.
- ◆ It is classified as high grade tumour.
- ◆ It is common in men (3:1).
- ◆ It occurs in 6th or 7th decade. It is aggressive nonencapsulated tumour arising from ductal system.
- ◆ It grows rapidly causing pain, facial palsy, skin fixity, ulceration.
- ◆ It spreads commonly to neck nodes.
- ◆ It carries poor prognosis.
- ◆ Radical parotidectomy and RT is the treatment of choice.

## SUBMANDIBULAR SALIVARY GLAND TUMOURS

### Benign tumours:

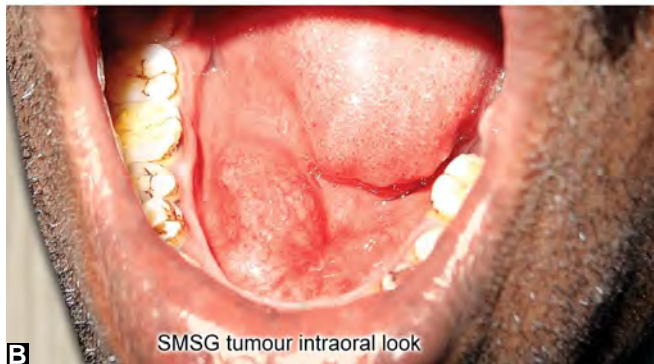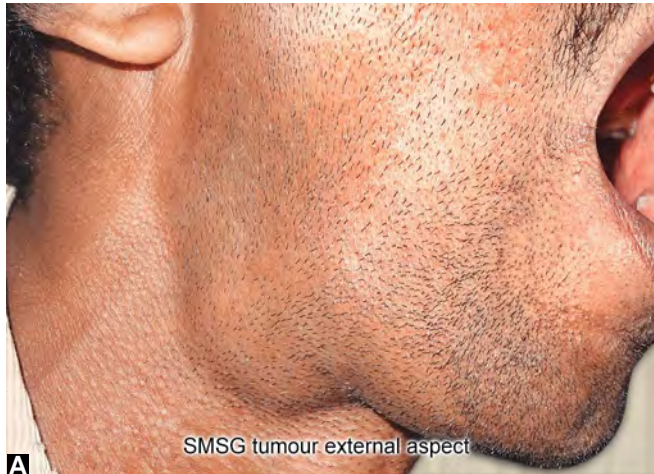- ◆ They are commonly pleomorphic adenomas, are smooth, firm or hard, bidigitally palpable, without involving adjacent muscles or hypoglossal nerve or mandible bone.
- ◆ Diagnosis is by FNAC, Orthopantomogram (OPG) and CT scan.
- ◆ Excision of both superficial and deep lobes of the gland is done.

### Malignant tumours of submandibular salivary gland:

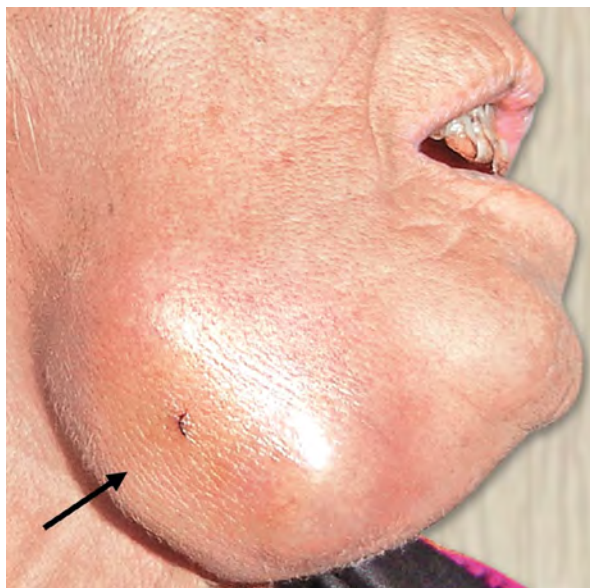- ◆ They are hard, nodular, often get fixed to skin, muscles, hypoglossal nerve and mandible.
- ◆ Diagnosis is by FNAC of primary tumour and of lymph nodes when involved, CT scan and OPG.

◆ **Treatment:**

- ▶ Wide excision, with removal of adjacent muscle, soft tissues and mandible.
- ▶ If lymph nodes are involved, block dissection of neck (Classical neck dissection) is done.



**Figs 4.30A and B:** Submandibular salivary gland tumour both external as well as intraoral look.



**Fig. 4.31:** Submandibular salivary gland tumour which is malignant. Patient underwent wide excision.

### General features of malignant salivary tumours

- ❖ Fixation
- ❖ Resorption of adjacent bone
- ❖ Pain and anaesthesia in the skin and mucosa
- ❖ Muscle paralysis
- ❖ Skin involvement and nodularity
- ❖ Involvement of jaw and masticatory muscle
- ❖ Nerve involvement (facial nerve in parotid or hypoglossal nerve in submandibular salivary gland)
- ❖ Blood spread when occurs, commonly to lungs
- ❖ Mandibular branch of 5th cranial nerve may be involved when tumour tracks along the auriculotemporal nerve to the base of the skull causing severe pain in the distribution area

## MANAGEMENT OF MALIGNANT SALIVARY TUMOURS

### TNM Staging of Malignant Salivary Tumours (AJCC, 7th Edition, 2010, Clinical Staging)

T—Tumour

Tx —Tumour cannot be assessed.

T0 —No evidence of primary tumour.

T1 —Tumour < 2cm without extraparenchymal spread.

T2 —Tumour 2–4 cm, without extraparenchymal extension

T3 —Tumour >4 cm.

—or with extraparenchymal spread.

—but no facial nerve spread.

T4 —Spread to facial nerve, skin, mandible, ear canal

—T<sub>4a</sub>.

—or spread to base of skull, pterygoid plates, encased external carotid artery – T<sub>4b</sub>.

### Staging

Stage I – T1N0M0

Stage II – T2N0M0

Stage III – T3N0/N1M0

Stage IVA – T4aN2N1N0M0

Stage IVB – T4b any NM0; any T N3M0

Stage IVC – Any T any N M1

### Note:

Pathological TNM staging is also present which differs from clinical in many points. Example—T3 is tumor of size 4-6 cm; T4 is size > 6 cm.

### N—Lymph node

Nx — Nodes not assessed.

N0 — Regional nodes not involved.

N1 — Single ipsilateral node < 3 cm.

N2a — Single ipsilateral nodes 3–6 cm.

N2b — Multiple ipsilateral nodes < 6 cm.

N2c — Bilateral or contralateral nodes < 6 cm.

N3 — Single node spread > 6 cm.

### M—Metastases

M0 — No blood spread.

M1 — Blood spread present.

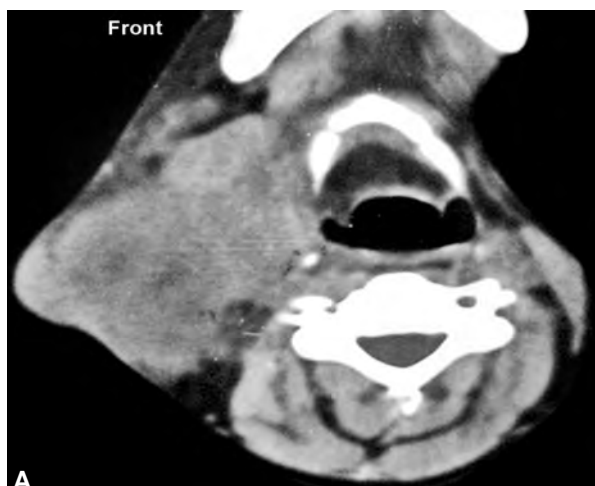
### Specific Investigations

◆ **FNAC.**

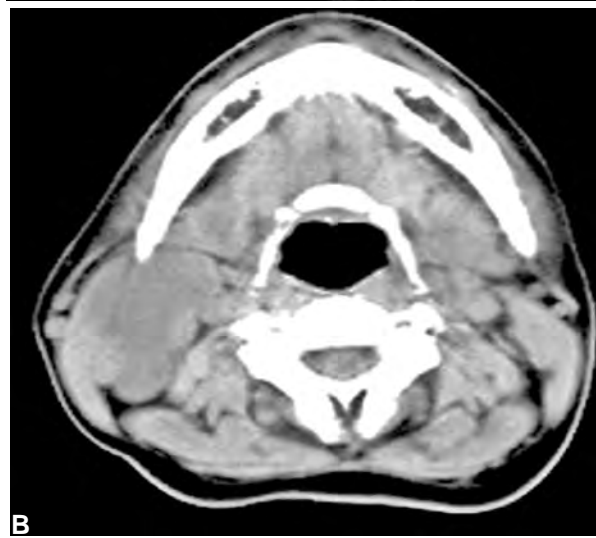
- ▶ FNAC also confirms possibility of (35% of patients) lymphoma/inflammatory masses.

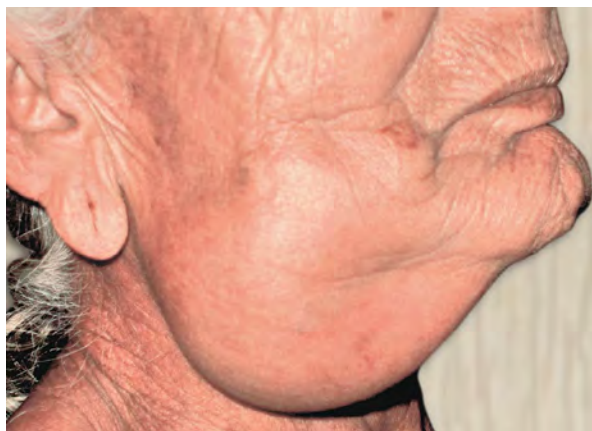

Fig. 4.32: Submandibular salivary gland tumour in old female.



A



B

Figs 4.33A and B: CT scan pictures of salivary tumours.

- ▶ FNAC allows preoperative counselling regarding nature of tumour, likely extent of resection (conservative/radical), management of facial nerve (high grade adenoid cystic), and likelihood of neck dissection (high grade).

- ▶ But FNAC may cause haematoma leading to difficulty in surgical dissection. Sampling problem, difficulty in finding histological type.
- ▶ Conservative approach for benign tumours in high risk surgical candidates may be thought of.
- ◆ CT scan
  - ▶ It is to see the deep lobe of the parotid: the involvement of bone, extension into the base of the skull; relation of tumour to internal carotid artery, styloid process, deep lobe tumour, parapharyngeal space extension. Neck nodes are better assessed. Bony changes in the foramina, erosions and sclerotic margins in fissures or canals, enlarged diameter of canal and fissure are the CT features of perineural spread.
- ◆ MRI
  - ▶ It is very useful to find out perineural spread, bone marrow involvement, skull bones, internal architecture and intracranial extensions, recurrent tumours. Replacement of perineural fat with tumour, contrast (gadolinium) enhancement, increased size of the nerve are features of perineural spread.
- ◆ Other
  - ▶ OPG.
  - ▶ Blood grouping and cross-matching; required amount of blood is kept ready.
  - ▶ FNAC of lymph node.
  - ▶ MRI shows better soft tissue definition than CT scan.

#### Note:

Sialogram is not useful in assessment of tumour.

## Treatment

### In Parotid

#### ◆ Surgery

#### Indications for surgery

- ❖ T1, T2, T3 tumours of low grade—total conservative parotidectomy
- ❖ T4 tumours, high grade tumours, SCC—radical parotidectomy It includes facial nerve sacrifice, may involve resection of skin, mandibular ramus, masseter muscle, infratemporal fossa dissection, subtotal petrosectomy.

Note: In T1 low grade, superficial parotidectomy is often practiced; but not ideal.

- Radical parotidectomy* is done which includes removal of both lobes of parotid, soft tissues, part of the mandible with facial nerve.
  - ▶ It is done in high grade malignant tumours and squamous cell carcinoma.

#### Indications for facial nerve sacrifice

- ❖ Preoperative weakness/paralysis of nerve
- ❖ Intraoperative evidence of gross invasion even in presence of normal preoperative function
- ❖ Tumours transgressing through facial nerve from superficial to deep lobe
- ❖ Nerve stump is checked for frozen section for negative margins, if positive mastoidectomy and nerve dissection in temporal bone is needed

- ▶ Facial nerve is reconstructed using greater auricular nerve, or sural nerve. All branches except buccal branch are repaired using cable graft. Nerve graft is not a contraindication for future RT.

*In time of test, family is best.*

- ▶ Often lateral tarsorrhaphy or temporal sling reconstruction is done.
- b. *Total conservative parotidectomy* is becoming popular in many parotid malignancies.

#### Complications of surgery

- ❖ Haemorrhage
- ❖ Infection, flap necrosis
- ❖ Fistula
- ❖ Frey's syndrome
- ❖ Facial nerve palsy
- ❖ Facial numbness
- ❖ Numbness in ear lobule due to injury to great auricular nerve
- ❖ Sialocele

#### Postoperative radiotherapy

It is quite useful to reduce the chances of relapse. Usually, external radiotherapy is given. It is given in all carcinomas, but more useful in adenoid cystic and squamous cell carcinomas.

#### Indications for radiotherapy

- ❖ T3, T4 tumours
- ❖ High grade tumours
- ❖ Perineural spread
- ❖ Adenoid cystic carcinomas
- ❖ Deep lobe tumour
- ❖ Vascular involvement
- ❖ Close clearance margin
- ❖ Multiple neck nodes involvement
- ❖ Recurrent malignant tumours
- ❖ Recurrent pleomorphic adenoma
- ❖ Spillage after surgery for pleomorphic adenoma
- ❖ Residual/refractory tumours/nerve involvement
- ❖ Inadequate clearance margin

#### Note:

- It is given in 3–6 weeks after surgery. Dose is 50–70 Gy; 1.5–2.0 Gy in 5–8 weeks
- RT is delayed for 6 weeks if nerve grafting is done
- Neuron beam therapy is used

#### Complications

- ❖ Xerostomia
- ❖ Osteoradionecrosis of temporal bone/mandible
- ❖ Skin ulcers, mucositis
- ❖ Fibrosis of optical apparatus, brainstem injury
- ❖ Trismus due to fibrosis of masseter, pterygoids and TM joint
- ❖ Otitis media, localized hair loss

#### Chemotherapy

It is also given. Drugs given here depends on tumour type. Intra-arterial chemotherapy is beneficial. But overall efficacy of chemotherapy is very less compared to RT. 5 FU, cisplatin, doxorubicin, epirubicin, cetuximab are used.

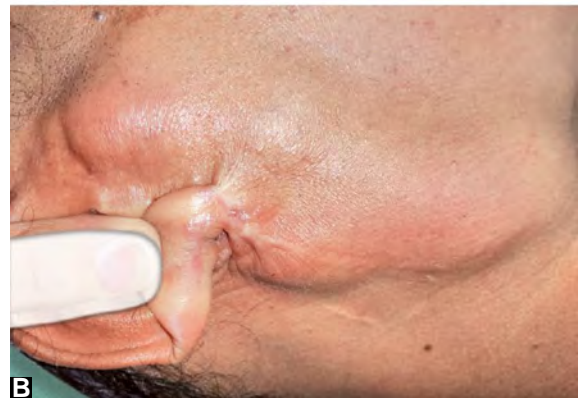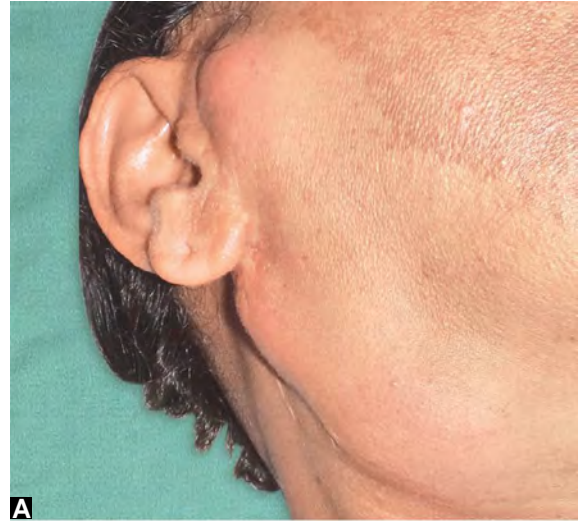#### Preoperative radiotherapy

It is given in large tumours to reduce the size and make it better operable, i.e. to down stage the disease.

- ◆ If lymph nodes are involved, which is confirmed by FNAC, radical neck dissection is done. It is also done in N0 with high-grade tumour or T3/T4 tumours.

#### In Submandibular Salivary Gland

Wide excision is done, with removal of mandible, and soft tissues around—extraglandular excision. If lymph nodes are involved, then block dissection of the neck is done.



**Figs 4.34A and B:** Recurrent parotid tumour right side. Note the scar of previous surgery. It was adenoid cystic carcinoma. Recurrence has occurred after 6 years. Patient underwent radical parotidectomy. Neck nodes were involved in this patient even though it is rare in adenoid cystic carcinoma. Patient needs radiotherapy and chemotherapy.

### MINOR SALIVARY GLAND TUMOURS

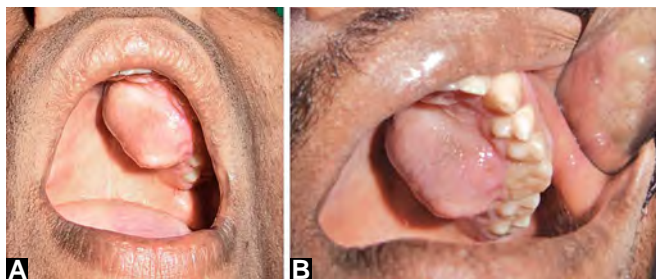
- ◆ It is 10% of salivary tumours.
- ◆ It is common in
  - palate (40%)
  - lip
  - cheek
  - sublingual glands
- ◆ Palate is the commonest site.
- ◆ 10% are benign—commonly pleomorphic adenomas.
- ◆ 90% are malignant—commonly adenoid cystic carcinomas.
- ◆ They present as swelling with ulcer over the summit.
- ◆ If it is malignant, then extension into the palate, maxilla, pterygoids can occur often with involvement of the lymph node.

#### Differential Diagnosis

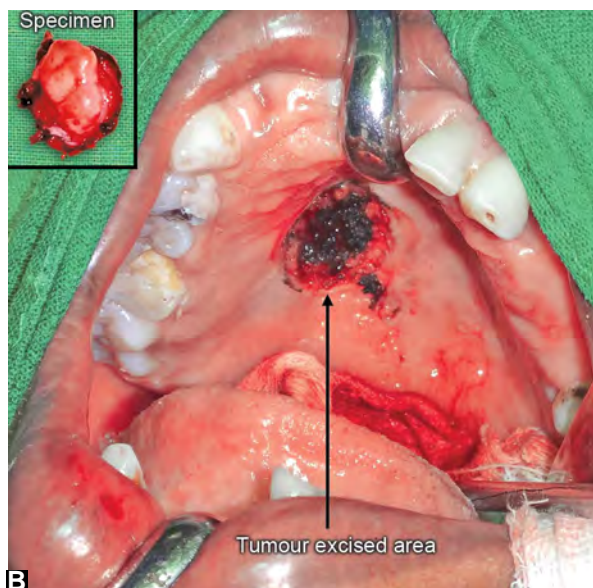
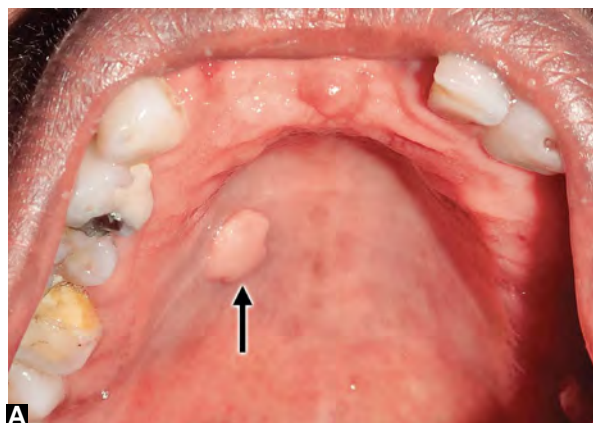
Squamous cell carcinoma of oral cavity.

#### Investigations

1. Incision biopsy.
2. CT scan.
3. X-ray maxilla.
4. FNAC of lymph node.



**Figs 4.35A and B:** Minor salivary gland tumour in the palate. Palate is the common site of minor salivary gland tumour.



**Figs 4.36A and B:** Minor salivary gland tumour of hard palate. It is excised with 1 cm margin; area is allowed to granulate and epithelialise.

### Treatment

- ◆ *Wide excision* often with palatal excision or maxillectomy is done—for malignancy.
- ◆ If the tumour is *less than 1 cm* in size excision biopsy is done with 1 cm clearance margin. If the tumour is *more than 1 cm* in size, initially incision biopsy is done and then wide excision is done. Even in larger defect in hard palate

region, it usually re-epithelialise if once left open to allow it to granulate. If bony palate is infiltrated then that part of palate bone is removed to get a clearance; area is reconstructed by moulds, synthetic materials.

- ◆ Reconstruction by dental plates, skin grafting, or flaps are done.
- ◆ Lymph node block dissection of the neck is done if involved.
- ◆ Excision with primary closure is done for benign tumours.

### Points to be remembered

- ❖ Salivary gland tumours are usually benign in an adult
- ❖ It is rare in children but when it occurs, it is commonly malignant
- ❖ Clinical and FNAC are diagnostic methods
- ❖ Open biopsy is contraindicated
- ❖ Sialogram is not useful in salivary tumours
- ❖ CT scan or MRI are often needed
- ❖ Nerve should be preserved in benign lesions
- ❖ Nerve can be sacrificed to achieve clearance in malignancies

### PAROTID LYMPHOMA

- ◆ Parotid lymphoma can occur from the lymph nodes in the gland or from parotid parenchyma.
- ◆ It can occur in HIV patients; lymphoepithelial diseases and in Sjögren's syndrome.
- ◆ Common in elderly.
- ◆ Disease may be confined to parotid gland or may involve other nodes in neck, mediastinum.
- ◆ When it is confined to parotid total parotidectomy with radiotherapy and later chemotherapy is the treatment.
- ◆ When many other nodes are involved chemotherapy is the choice therapy.

#### Note:

Lymphoma occasionally can occur in other salivary glands also (10% of all salivary lymphomas).

### PAROTIDECTOMY

#### Types

1. *Superficial parotidectomy*: It is the removal of superficial lobe of the parotid (superficial to facial nerve). Done in case of benign diseases of superficial lobe of the parotid.
2. *Total conservative parotidectomy*: It is done in benign diseases of parotid involving either only deep lobe or both superficial and deep lobes. Here both lobes are removed with preservation of facial nerve. Here initially superficial parotidectomy is done and facial nerve and its branches are retracted gently and deep lobe is removed.
3. *Radical parotidectomy*: Both lobes of parotid are removed along with facial nerve, fat, fascia, muscles (masseter, pterygoids and buccinator), lymph nodes. It is done in case of carcinoma parotid. Later facial nerve reconstruction is done using great auricular nerve graft.
  - Conservative surgeries are becoming popular for malignancy but they are not universally accepted.
4. *Suprafacial parotidectomy* is done in lower pole parotid tumours wherein all branches of the facial nerve need not be dissected.



### Steps in parotidectomy

- ❖ Lazy 'S' incision—modified Blair's/Sistrunk's approach and raising the skin flaps
- ❖ Mobilisation of the gland
- ❖ Flap is reflected in front *just up* to anterior margin of the parotid; never beyond. After identification of sternocleidomastoid great auricular nerve is identified and can be sacrificed. Posterior belly of digastric is identified.
- ❖ Location of *stylomastoid branch* of posterior auricular artery is anterior to facial nerve trunk which enters the stylomastoid foramen.
- ❖ Thrust the mosquito haemostat 5 mm in front of facial nerve; *open* the blades for 5 mm; *lift* the blades for 5 mm.
- ❖ One should worry about the nerve but not small bleeding.
- ❖ Identification of facial nerve trunk.
- ❖ Dissection of the gland off the facial nerve using bipolar cautery.
- ❖ Removal of parotid—superficial/both.
- ❖ Distilled water (hypertonic) irrigation to kill spilled tumour cells.
- ❖ Haemostasis and closure with a suction drain.

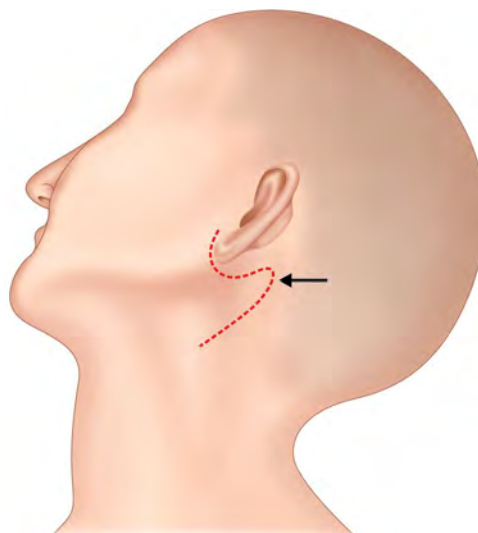


Fig. 4.38: 'S' shaped incision for parotidectomy.

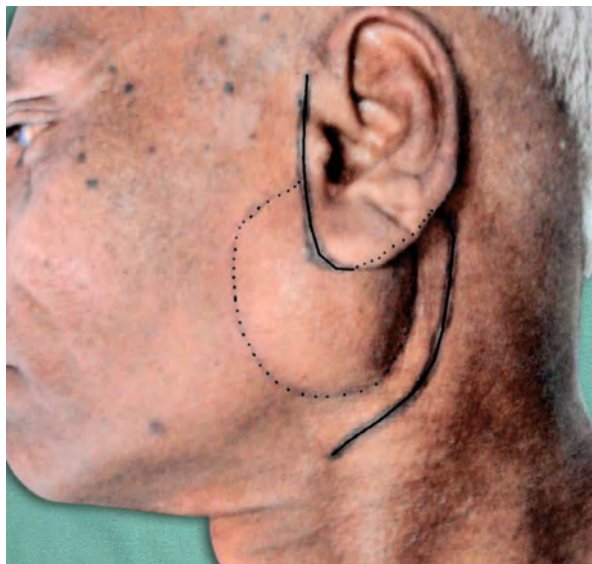

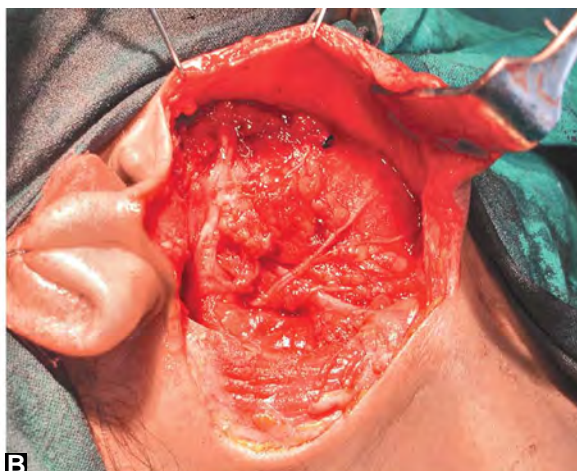
Fig. 4.37: Incision for parotidectomy. Typical lazy 'S'.

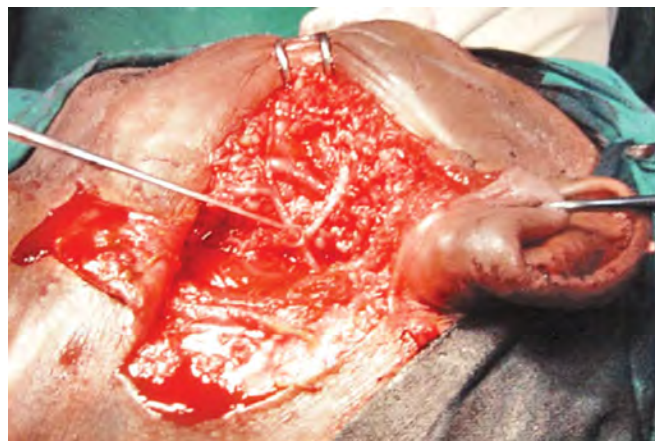
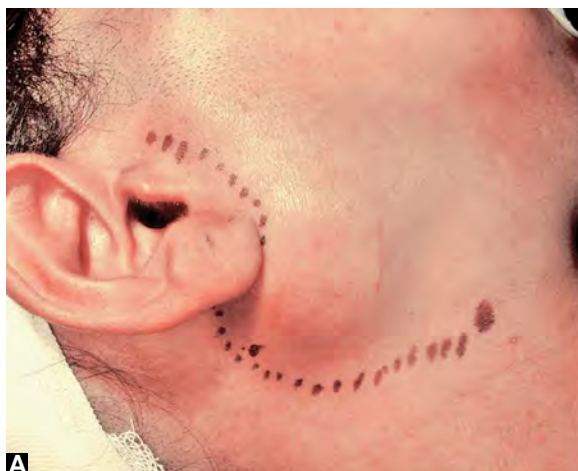
Fig. 4.39: On table exposure of facial nerve branches after superficial parotidectomy for a benign tumour.

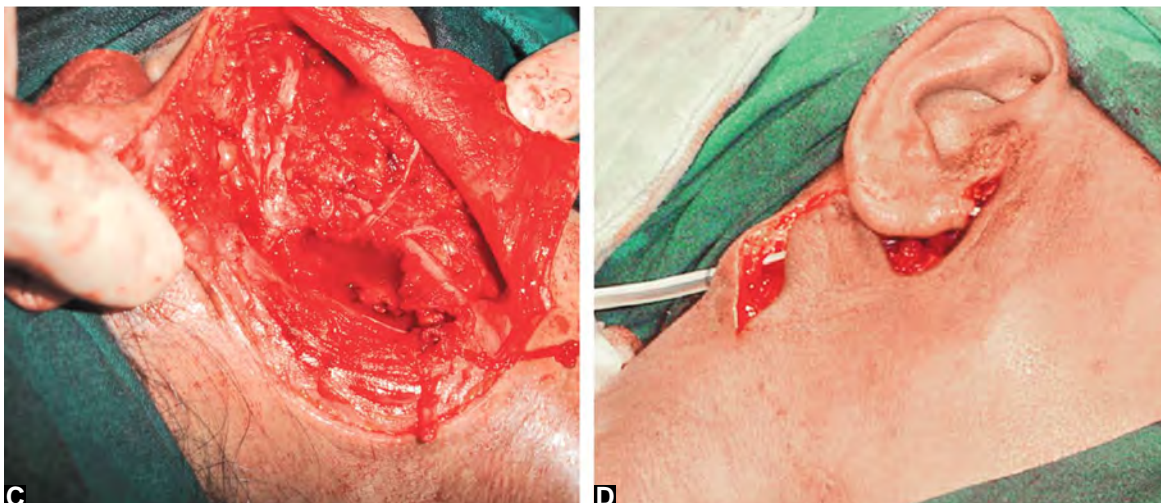


A



B

Figs 4.40A and B



Figs 4.40C and D

**Figs 4.40A to D:** Steps in parotidectomy and demonstration of facial nerve. Note the placement of drain after surgery (Courtesy: Professor Kishore Chandra Prasad, ENT, Mangaluru; Dr Sampath, MS, ENT, Mangaluru).

#### Identification of facial nerve

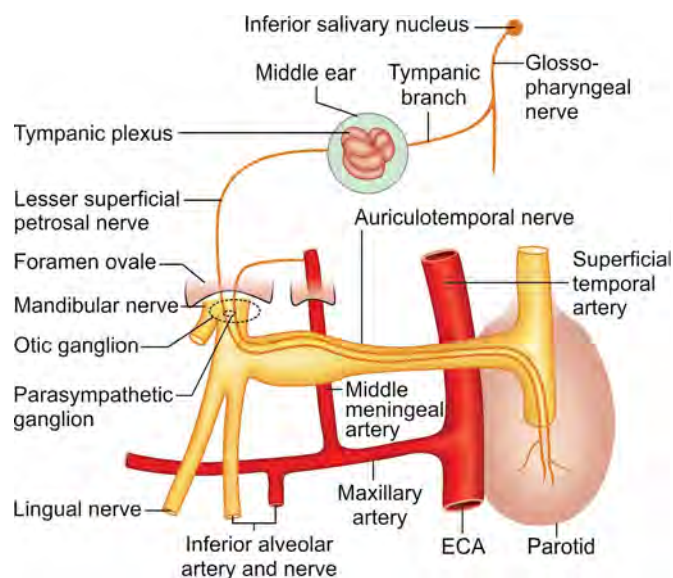
- ❖ Facial nerve is 1 cm deep and below the tip of the inferior portion of the cartilaginous canal—*Conley's point*
- ❖ By nerve stimulator
- ❖ It is inferomedial to tragal point
- ❖ Deep to digastric muscle and tympanic plate
- ❖ Nerve is just lateral to the styloid process
- ❖ Tracing branch from distal to proximal (Hamilton-Bailey technique)

#### Complications of parotidectomy

- ❖ Facial nerve injury
- ❖ Haemorrhage
- ❖ Salivary fistulas
- ❖ Infection—Flap necrosis is common
- ❖ Frey's syndrome
- ❖ Sialocele
- ❖ Numbness over the face and ear—due to injury to great auricular nerve. Female patients find difficult to wear ear rings. Spontaneous recovery may occur in 1½ to 2 years.

### FREY'S SYNDROME (Auriculotemporal Syndrome, Gustatory Sweating); (Lucie Frey—Polish Surgeon—1932)

- ◆ Occurs in 10% of cases.
- ◆ It is due to injury to the auriculotemporal nerve, wherein post-ganglionic parasympathetic fibres from the otic ganglion become united to sympathetic nerves from the superior cervical ganglion (Pseudosynapsis). *There is inappropriate regeneration* of the damaged parasympathetic autonomic nerve fibres to the overlying skin.
- ◆ Auriculotemporal nerve has got two branches. Auricular branch supplies external acoustic meatus, surface of tympanic membrane,



**Fig. 4.41:** Parasympathetic and sympathetic supply of the parotid gland. Otic ganglion located just below the foramen ovale close to mandibular nerve relays the parasympathetic supply from glossopharyngeal nerve through tympanic branch, tympanic plexus in middle ear and then lesser superficial petrosal nerve. Post-ganglionic fibres run in auriculotemporal nerve along with unrelayed sympathetic fibres from middle meningeal plexus.

skin of auricle above external acoustic meatus. Temporal branch supplies hairy skin of the temple. Sweating and hyperaesthesia occurs in this area of skin.

#### Causes

- ◆ Surgeries or accidental injuries to the parotid.
- ◆ Surgeries or accidental injuries to temporomandibular joint.

## Clinical Features

- ◆ Flushing, sweating, erythema, pain and hyperaesthesia in the skin over the face innervated by the auriculotemporal nerve, whenever salivation is stimulated (i.e. during mastication).
- ◆ Condition causes real inconvenience to the patient.
- ◆ Involved skin is painted with iodine and dried. Dry starch applied over this area will become blue due to more sweat in the area in Frey's syndrome—*Minor's Starch iodine test*.

## Treatment

- ◆ Initially conservative and reassurance. Most often they recover without any active treatment in 6 months. Antiperspirants, anticholinergics like scopolamine 3%, glycopyrrolate 1%, methyl sulfate, radiation 50 Gy are used.
- ◆ Occasionally (10%) they require surgical division of the tympanic branch of the glossopharyngeal nerve below the round window of middle ear [i.e. intratympanic parasympathetic (Jacobsen nerve) neurectomy].
- ◆ Dermal/fat graft; avulsion of auriculotemporal nerve; interposition of temporal fascia, fascia lata, sternomastoid muscle, acellular human dermal collagen; alcohol injection—are all tried.

### Note:

Incidence is higher with a flap elevation superficial to platysma. Elevation of thick flap or insertion of fat flap under skin during surgery may reduce the chance of Frey's syndrome.

### Treatment of Frey's syndrome

- ❖ Reassurance
- ❖ Jacobsen neurectomy (tympanic)
- ❖ Injection of botulinum toxin to the affected skin
- ❖ Antiperspirants like aluminium chloride
- ❖ Syndrome can be *prevented* on table by placing muscle (sternomastoid) or fascial (temporalis) flaps or artificial membranes over parotid bed, under the skin

## ■ FACIAL NERVE INJURY (Lower Motor Nerve Lesion, Surgically Related)

### Causes

- ◆ Trauma
- ◆ Surgery—parotidectomy, drainage of parotid abscess
- ◆ Compression of facial nerve—Bell's palsy.
- ◆ Incidence of temporary/transient facial nerve palsy after parotidectomy is 30%. Recovery occurs usually in 12 weeks.
- ◆ It is due to transection of trunk or branches or excessive traction or over use of nerve stimulator.

## Clinical Features

- ◆ Inability to close the eyelid.
- ◆ Difficulty in blowing and clenching.
- ◆ Drooping of the angle of the mouth.
- ◆ Obliteration of nasolabial fold.
- ◆ Loss of forehead wrinkles.
- ◆ Wide palpebral fissure.
- ◆ Epiphora.

## Treatment

- ◆ Nerve grafting using greater auricular nerve, sural nerve, lateral cutaneous nerve of thigh or hypoglossal nerve.

- ◆ Suspension of angle of mouth to zygomatic bone using temporal fascia sling.
- ◆ Lateral tarsorrhaphy—to prevent corneal ulceration.
- ◆ Medial canthus reconstruction—to reduce epiphora.
- ◆ Cross-facial nerve transplantation from opposite side using its insignificant branches.
- ◆ Dynamic neurovascular muscle graft.
- ◆ Upper lid gold weights to protect cornea.

### Surgeries for facial nerve palsy

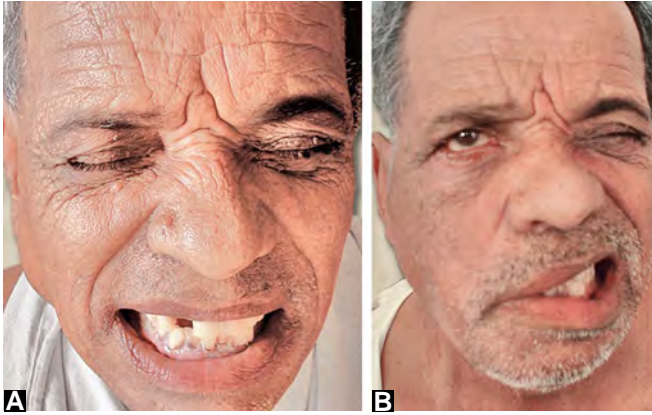- ❖ *Static*
  - Suspension surgeries using temporal fascia
  - Correction of medial canthus
  - Lateral tarsorrhaphy—to prevent exposure keratitis due to widened palpebral fissure
  - Upper lid weights
- ❖ *Dynamic*
  - Muscle transfer—temporal to masseter
  - Free muscle graft. Gracilis muscle neurovascular transfer
  - Cross-facial nerve transplant from opposite facial nerve to injured facial nerve using sural nerve
  - Nerve grafts

### The House-Brackmann score

It is a score used in facial nerve palsy to grade the degree of damage. It is done by measuring the upward movement of the middle portion of the eyebrow top and the outward movement of the angle of the mouth. Each reference point scores 1 point for each 0.25 cm movement, up to a maximum of 1 cm. The scores are then added together, to give a number out of 8. It is a measure of the range of intentional movement of the patient's facial muscles. Even though it is a subjective scale, overall reliability is good and is the most commonly used. Electroneurography is the other method used.

### Remember

- ❖ **Taste sensation** and general sensation (lingual nerve) should be checked. Patient is not allowed to speak but *asked to write* in a paper. Taste material is instilled on the surface of the diseased side first and then normal side. Prior to each instillation patient should wash his mouth with warm water. Usually four substances are used. After 10 seconds patient should identify the substance and write. *Facial nerve serves 3 tastes—salt* (rock salt) on the tip of tongue; sweet using syrup on the tip of the tongue; *sour* using lemon juice on the lateral aspect of the tongue. Bitter taste is mediated by glossopharyngeal nerve and is tested using quinine on posterior third of the tongue.
- ❖ **Secretomotor fibres of parotid:** Secretomotor preganglionic fibres from *inferior salivary nucleus* → glossopharyngeal nerve → tympanic branch → tympanic plexus → lesser superficial petrosal nerve → otic ganglion → post-ganglionic fibres → auriculotemporal nerve, branch of mandibular division of trigeminal nerve → parotid gland.
- ❖ **Secretomotor fibres of submandibular salivary gland:** Preganglionic fibres from *superior salivary nucleus* → facial nerve → chorda tympani nerve → lingual nerve → Langley's submandibular ganglion → postganglionic fibres → sub-mandibular and sublingual salivary glands.
- ❖ Parotid gland is *serous*. Submandibular gland is *mixed* (major is mucous). Sublingual is *mucous*. Minor salivary glands are *mucous* except *von Eber's glands* which empty into the circumvallate papillae and glands in the tongue tip.
- ❖ *70% of total saliva* is from submandibular salivary gland. *25% of saliva* is from parotids. *10% of total salivary volume* is from minor salivary glands.
- ❖ Normal salivary secretion per day is 1500 ml. It is hypotonic fluid with pH 7.0. It contains  $\alpha$ -amylase.



**Figs 4.42A and B:** Features of post-parotidectomy facial nerve palsy.

**Note:**

*Accessory parotid tumour*—Accessory parotid tumour is very rare tumour arising from accessory parotid usually above the parotid duct level in front of the masseter muscle. It can be benign or malignant. Pleomorphic adenoma is common. Tumour behaves like tumour from main parotid gland. Incidence is 1% of all parotid tumours. 30% of them are malignant. It is located in a line at central 1/3rd of the line joining the middle of the tragus to a point between the ala of the nose and vermilion border of upper lip. FNAC confirms the diagnosis. CT scan confirms the anatomical location. Main parotid gland is usually normal. Surgery is the treatment. Standard parotidectomy incision or direct cheek approach can be used. But direct cheek approach can cause higher incidence of buccal and zygomatic branches of facial nerve injuries (40%). Standard parotidectomy approach has got less chance of nerve branch injuries. Lymph node spread in the neck is dealt with radical dissection. Excision cures the benign disease.

*Heerfordt's syndrome* is sarcoidosis of parotid swelling; anterior uveitis; facial palsy and fever.

# Chapter 5

## Neck

### CHAPTER OUTLINE

- ❖ Anatomy of Lymphatics of Head and Neck
- ❖ Thoracic Outlet Syndrome
- ❖ Cervical Rib
- ❖ Branchial Cyst
- ❖ Branchial Fistula
- ❖ Pharyngeal Pouch
- ❖ Laryngocoele
- ❖ Cystic Hygroma
- ❖ Ludwig's Angina
- ❖ Parapharyngeal Abscess
- ❖ Retropharyngeal Abscess
- ❖ Subhyoid Bursitis
- ❖ Carotid Body Tumour
- ❖ Torticollis
- ❖ Sternomastoid Tumour
- ❖ Tuberculous Lymphadenitis
- ❖ Cold Abscess
- ❖ Secondaries in Neck Lymph Nodes
- ❖ Chemotherapy for Head and Neck Cancers

### ■ ANATOMY OF LYMPHATICS OF HEAD AND NECK

#### Waldeyer's Lymphatic Ring (Inner)

It consists of adenoids above, lingual tonsil below and two palatine tonsils and tubal tonsils laterally one on each side.

#### Outer Circular Chain of Nodes (Outer Waldeyer's Ring)

Occipital, postauricular, preauricular, parotid, facial, submandibular, submental, superficial cervical and anterior cervical.

*Facial nodes are:*

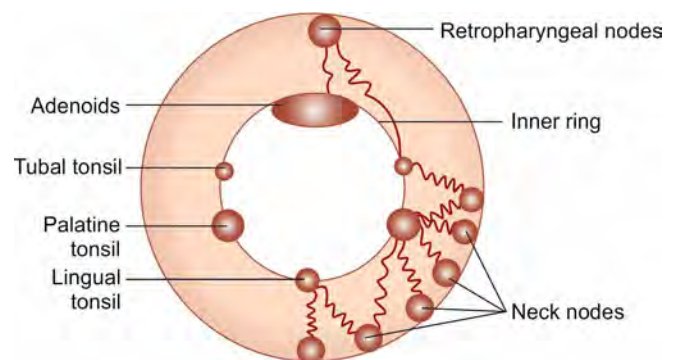
- a. Superficial
  - ▶ Upper—infraorbital.
  - ▶ Middle—buccinator.
  - ▶ Lower—supramandibular.
- b. Deep groups—in relation to pterygoids.

*Submandibular lymph nodes drain*

- ◆ The side of the nose.
- ◆ The cheek.
- ◆ Angle of the mouth.
- ◆ Entire upper lip.
- ◆ Outer part of the lower lip.
- ◆ The gums.
- ◆ Side of the tongue.

*Submental lymph nodes:*

Drain from the central part of the lower lip, floor of the mouth and apex of the tongue.



**Fig. 5.1:** Inner and outer Waldeyer's ring anatomy.

*Superficial cervical nodes:*

They lie on outer surface of the sternomastoid around the external jugular vein. They drain the parotid region and lower part of the ear.

*Deep cervical lymph nodes:*

Upper deep cervical lymph nodes—jugulodigastric nodes  
Below the digastric and in front of IJV.

Lower deep cervical lymph nodes—jugulo-omohyoid nodes—Above the omohyoid and behind the IJV.

They drain the ipsilateral half of head and neck, finally form a jugular lymph trunk from lower deep cervical nodes to join thoracic duct on the left side, and the junction of right subclavian and right jugular vein on right side.

**Rule of 7 in the neck**

- ❖ 7 days—inflammation
- ❖ 7 months—neoplasm
- ❖ 7 years—congenital defect

Note: The Rule of 7 provides a probable diagnosis of the neck mass based on the average duration of the patient's symptoms

**Rule of 80 in the neck**

- ❖ 80% of nonthyroid neck masses are neoplastic
- ❖ 80% of neoplastic neck masses are seen in males
- ❖ 80% of neoplastic neck masses are malignant
- ❖ 80% of malignant neck masses are metastatic
- ❖ 80% of metastatic neck masses are from primary sites above the clavicle

**THORACIC OUTLET SYNDROME (TOS)**

It is syndrome complex due to neurovascular bundle compression in the thoracic outlet.

*Thoracic outlet has got two main spaces:*

- ◆ *Scalene triangle* is bound by scalenus anterior, scalenus medius and first rib. It contains subclavian artery and brachial plexus.
- ◆ *Costoclavicular space* is bound by clavicle, first rib, costoclavicular ligament and scalenus medius. It contains subclavian artery and vein and brachial plexus.

**Causes**

- ◆ Cervical rib.
- ◆ Long C<sub>7</sub> transverse process.
- ◆ Anomalous insertion of scalene muscles.
- ◆ Scalene muscle hypertrophy.
- ◆ Scalene minimus.
- ◆ Abnormal bands and ligaments.
- ◆ Fracture clavicle or first rib.
- ◆ Exostosis.
- ◆ Tumours in the region.
- ◆ Brachial plexus trauma and diseases.

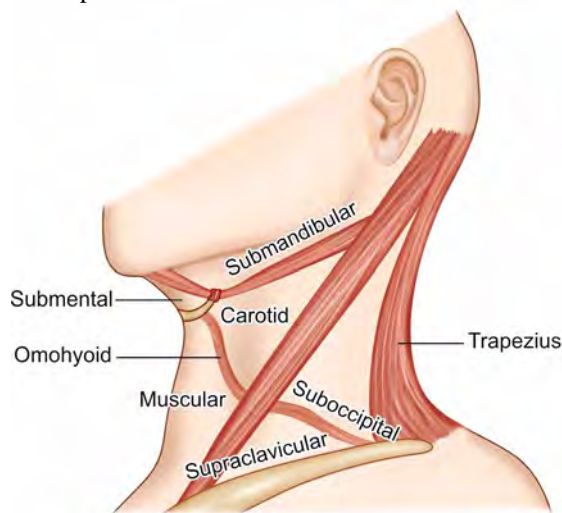


Fig. 5.2: Triangles of the neck.

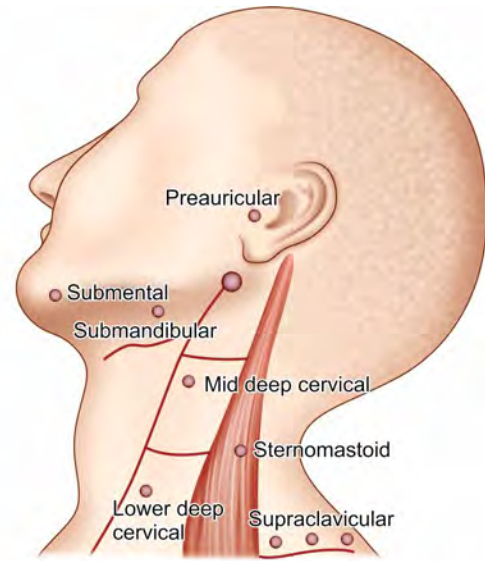
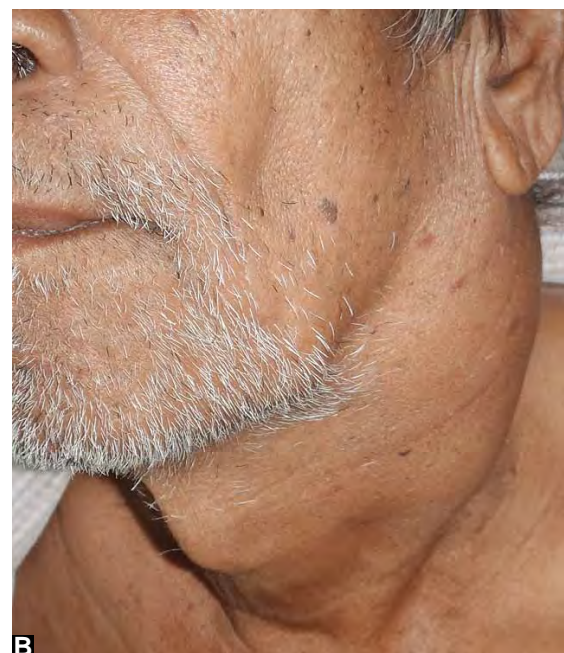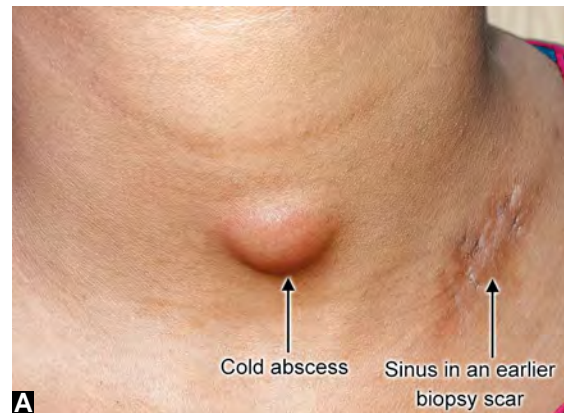


Fig. 5.3: Lymphatic drainage of the neck.



Figs 5.4A and B

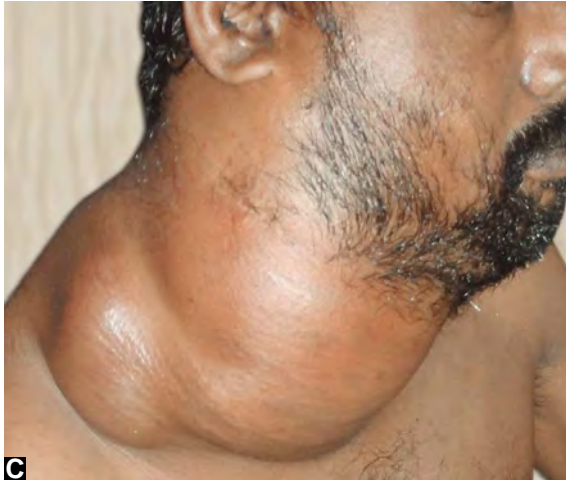

Fig. 5.4C

**Figs 5.4A to C:** Lymph node enlargement due to various causes is the commonest clinical finding in the neck. Nonspecific lymphadenitis, tuberculosis, secondaries and lymphoma are common conditions: (A) Tuberculosis; (B) Secondaries in lymph node; (C) Lymphoma.

#### Differential Diagnosis of TOS

- ❖ Carpal tunnel syndrome
- ❖ Cervical spondylosis
- ❖ Spinal canal tumours
- ❖ Shoulder myositis
- ❖ Angina
- ❖ Raynaud's disease
- ❖ Spinal stenosis
- ❖ Ulnar nerve compression, epicondylitis

### Clinical Features

#### Neurological symptoms

- ◆ Paraesthesia.
- ◆ Pain in shoulder, arm, forearm and fingers.
- ◆ Occipital headache as referred pain from tight scalene muscles.
- ◆ Weakness in forearm, hand.

#### Vascular symptoms

- ◆ Claudication, ischaemic ulcers, gangrene.

#### Signs

- ◆ Scalene muscle tenderness.
- ◆ Pulsatile swelling in supraclavicular region with thrill and bruit (25%).
- ◆ Bony mass above clavicle.
- ◆ Adson's test (+ve).
- ◆ Roos test (+ve).
- ◆ Elevated arm stress test (+ve).
- ◆ Costoclavicular compression manoeuvre. } reveals feeble/absence of radial pulse due to compression of the subclavian artery.
- ◆ Hyperabduction manoeuvre. }
- ◆ Poor capillary refilling.
- ◆ Absence or feeble pulse.

(Please refer Chapter on Arterial Diseases for details of tests).

### Investigations

- ◆ X-ray neck and cervical spine.
- ◆ Doppler.
- ◆ Subclavian angiogram, CT angiogram, CT neck.
- ◆ Nerve conduction studies, electromyography.

### Treatment

- ◆ *Conservative*—if nerve velocity is > 60 m/second
- ◆ *Surgical*—if nerve velocity is < 60 m/second

#### Conservative treatment for TOS

- ❖ Exercises—neck stretching, postural and breathing exercises
- ❖ Drugs—analgesics, muscle relaxants, antidepressants
- ❖ Avoid weight lifting
- ❖ Physiotherapy

#### Surgical treatment of TOS

- ❖ Transaxillary (ROOS)—mainly for first rib excision and also cervical rib
- ❖ Supraclavicular approach for cervical rib and soft tissue excision, scalenotomy, neurolysis, arterial reconstruction
- ❖ Cervical sympathectomy may be needed

## CERVICAL RIB

### Definition

- ◆ It is an extension of costal element (anterior part) of transverse process of C<sub>7</sub> vertebra more than 2.5 cm (normal).
- ◆ Syndrome caused by it is called as *cervical rib syndrome*, *thoracic-inlet syndrome*, *thoracic-outlet syndrome*, *scalene syndrome*.
- ◆ It is 0.46% common; common in females; more frequent on right side.
- ◆ It can be *unilateral or bilateral* (50%) can be *asymptomatic or symptomatic*.

### Types (Refer Fig. 5.5)

1. *Complete bony*: Cervical rib is radio-opaque, anteriorly ends over the first rib or manubrium.
2. *Combined*: Partly bony partly fibrous.
3. *Complete fibrous*: Cannot be demonstrated radiologically.
4. *Partial bony*: With free end expanding as *bony mass*, which is felt in the neck.

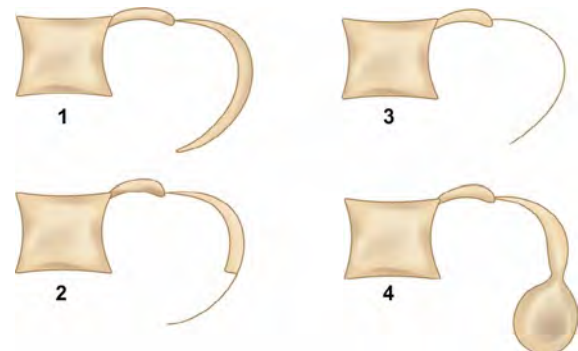


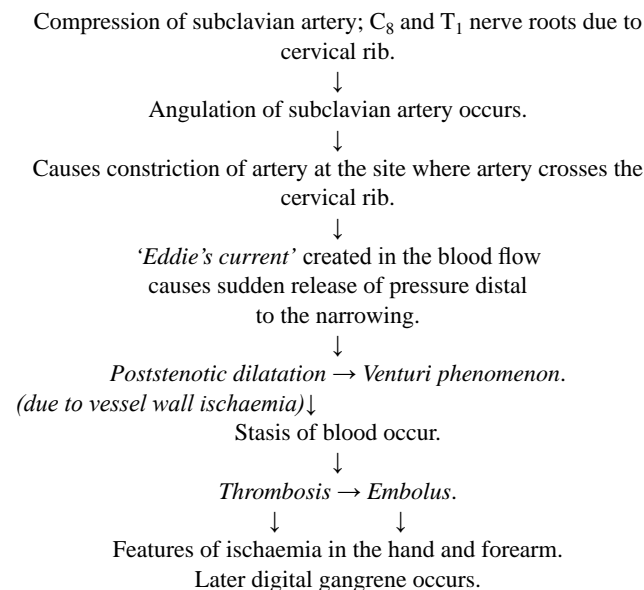
Fig. 5.5: Cervical rib types.

**Note:**

7 types of cervical ribs are identified. Type III is the commonest which is a band extending from C7 vertebra to scalene tubercle of 1st rib elevating the neurovascular bundle upwards causing compression.

**Pathology**

- ◆ Cervical rib narrows the scalene triangle (bounded by scalenus anterior, scalenus medius and first thoracic rib below).



- ◆ Rarely thrombus may extend proximally into the subclavian artery causing vertebrobasilar insufficiency.
- ◆ Compression of C<sub>8</sub> and T<sub>1</sub> causes tingling and numbness along its distribution, i.e. in the little finger, medial side of hand and forearm.
- ◆ **Paget-Schroeter syndrome** is subclavian vein compression by cervical rib. It is rare.

**Clinical Features**

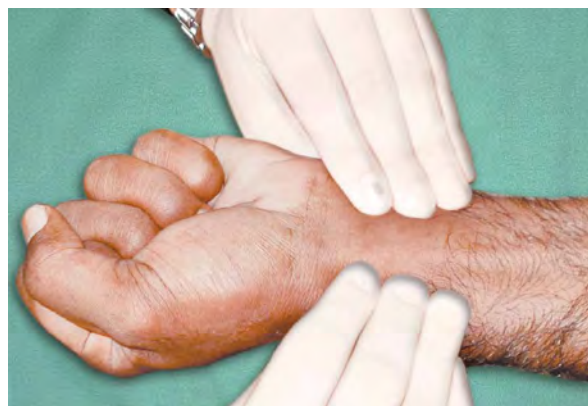Majority of patients are asymptomatic—(80%).

**1. Vascular manifestations:**

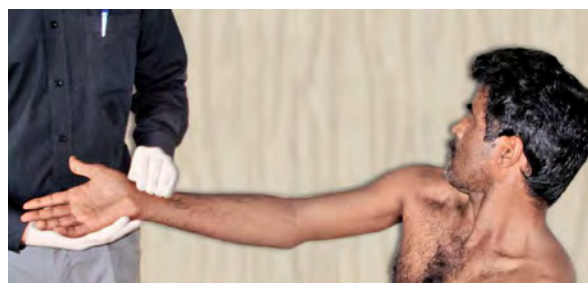- ▶ **Pain** is due to ischaemia in the muscle. It is more during work, exercise, and is relieved by rest.
- ▶ **Upper limb claudication** usually is observed in forearm and arm more obvious after usage of limb. Pain (dull pain) in posterior triangle of neck may be due to presence rib mass. Ischaemic pain in the digits and hand may be present.
- ▶ **Vasomotor changes** with cyanosis, cold fingers, excessive sweating may be observed.
- ▶ **Roos test:** The patient raises his arms to 90° of abduction at shoulder with the arms fully externally rotated and the elbows at 90° of flexion. Their hands are kept in this position for up to 3 minutes. The test is positive if the patient is unable to hold the arms up for 3 minutes, or if the patient feels pain, heaviness or paraesthesia in the shoulder, arm or hand.
- ▶ **Elevated arm stress test (EAST):** Both shoulders (arms) are abducted to 90° with arms fully externally rotated and the elbows braced backwards. Patient will open and close (clench and unclench) the hands rapidly for 5 minutes. Normal individual can do this without any discomfort and pain. Patient with

thoracic outlet syndrome develops pain, fatigue, paraesthesia of forearm with tingling and numbness of fingers which gradually progresses. Patient will not be able to continue the test for 5 minutes. This test can also differentiate thoracic outlet syndrome from cervical disc prolapse disease.

- ▶ **Adson's test:** The hand is raised above after feeling the radial pulse. The patient is asked to take a deep breath and turn the head to the same side. Any change in pulse, i.e. either becoming feeble or absent, is noted.
- ▶ **Modified Adson's test** is same as Adson's, but neck is turned towards the opposite side.
- ▶ **Costoclavicular compression manoeuvre (Falconer test):** While palpating the radial pulse of the patient, he is asked to move his shoulder backwards and downwards (*exaggerated military position*) which may cause absence/feeble radial pulse and a bruit may be heard while auscultating the supraclavicular region—*military attitude test*. This is due to compression of subclavian artery between clavicle and first rib. Similar **Halstead manoeuvre** is done by 45° abduction and extension of arm with downward pushing of the shoulder with neck turned opposite side to cause radial pulse feebly palpable.
- ▶ **Hyperabduction manoeuvre (Wright's test):** While palpating the radial pulse, arm on the diseased side is passively hyperabducted causing feeble or absence of radial pulse. This is due to compression of artery by pectoralis minor tendon (*pectoralis minor syndrome*). An axillary bruit may be heard on auscultation.
- ▶ **Allen's test:** It is used in hand to find out the patency of radial and ulnar arteries. Both radial and ulnar arteries of the patient is felt and pressed firmly at the wrist. Patient clinches his hand

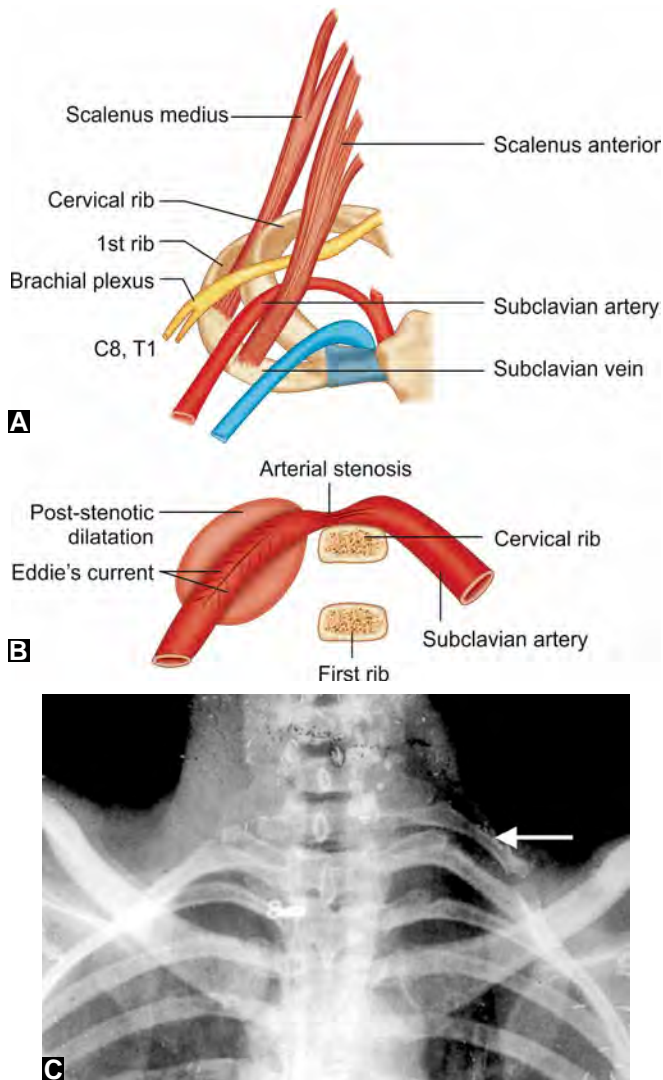


**Fig. 5.6:** Allen's test done upper limb ischaemia to look for perfusion of hand.



**Fig. 5.7:** Adson's test—after palpating radial pulse, elbow with stretched hand is slightly raised; neck is turned to same side; deep breath is taken; feeble or pulse becoming absent may be obvious in positive Adson's.





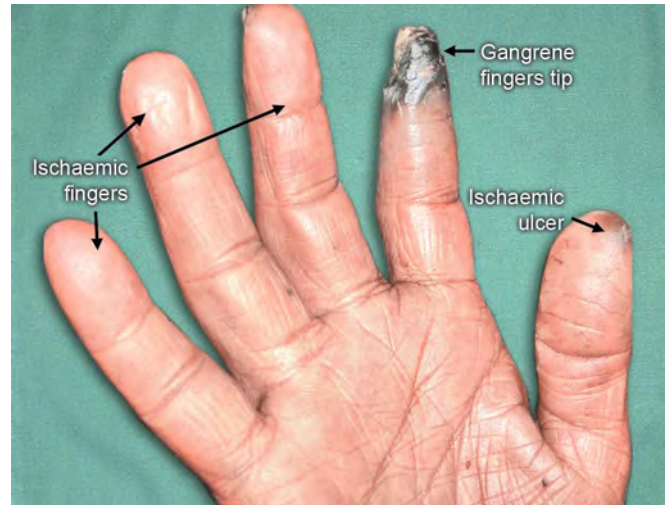**Figs 5.8A to C:** Anatomy of cervical rib and its relation to subclavian artery and vein and brachial plexus. Note the Eddie's current, post-stenotic dilatation due to arterial compression by cervical rib. X-ray shows left-sided complete cervical rib.

firmly (often repeated clenching) and holds it tightly. After 1 minute clinch is released to open the palm of the hand which looks pale. Pressure on radial artery in the wrist is released to see area of distribution of the radial artery. Normally, it becomes flushed with pink color. If there is block in radial artery, the area will remain white. Test is repeated again. This time pressure on the ulnar artery is released to check the patency of ulnar artery. Area will be pale and blanched after releasing in case of ulnar artery block. Otherwise it becomes pink after release in normal individual.

- ▶ **Wasting** of thenar, hypothenar and forearm muscles.
- ▶ Often digital gangrene, ischaemic ulcers in digits, oedema of fingers and hand are observed.
- ▶ Limb is colder and paler than the opposite side.

2. **Neurological features** is due to compression of T<sub>1</sub> and C<sub>8</sub> causing tingling and numbness in the little finger, medial side of hand and forearm.

- ▶ Pain, on the medial side, weakness on the medial side of hand and anaesthesia may be evident.



**Fig. 5.9:** Upper limb ischaemia showing ischaemic ulcers and gangrene of finger tips.

- ▶ *Card test* for interossei muscle weakness, *Froment's sign/test* to detect weakness in adductor pollicis are positive. Wasting may be due to neurological cause also.

### 3. **Features in the neck:**

- ▶ Hard, fixed, bony mass in the supraclavicular region.
- ▶ *Palpable thrill* above the clavicle in the subclavian artery.
- ▶ *Bruit* on auscultation.

#### **Note:**

- Most common presentation is neurological.
- Most problematic presentation is vascular which requires surgery.

#### Differential Diagnosis

- ❖ Cervical spondylosis—to differentiate, X-ray neck—lateral view should be taken
- ❖ Carpal tunnel syndrome
- ❖ Tumours or swellings compressing over the vessel or nerves in the neck
- ❖ Other causes of digital gangrene like atherosclerosis, Raynaud's syndrome, collagen diseases, diabetes mellitus, and embolism
- ❖ Syringomyelia, motor neuron disease
- ❖ Pancoast tumour.

## Investigations

- ◆ Chest X-ray PA view and lateral view including neck—only (radio-opaque) bony rib can be identified.
- ◆ Nerve conduction studies to confirm neurological compression and also to rule out carpal tunnel syndrome or cervical spondylosis.
- ◆ Arterial Doppler of subclavian artery and of the upper limb.
- ◆ Subclavian angiogram, electromyogram.
- ◆ Other relevant investigations like blood sugar, lipid profile, cardiac assessment.
- ◆ CT scan neck and thorax and CT angiogram of subclavian artery are *ideal investigations*. MRI of neck is useful.

## Treatment

#### **Note:**

For conservative treatment refer TOS above.

## Surgical

- ◆ In symptomatic cervical rib without arterial compression (subclavian artery), along with scalenotomy (cutting scalenus anterior muscle), extraperiosteal resection of cervical rib and often resection of first rib is done to increase the thoracoaxillary channel and so as to reduce arterial compression.
- ◆ In symptomatic cervical rib with significant subclavian artery compression along with scalenotomy, extraperiosteal resection of cervical rib, resection of first rib, subclavian artery reconstruction with or without a graft is done.
- ◆ Along with scalenotomy, extraperiosteal resection of cervical rib, resection of first rib, reconstruction of subclavian artery, cervical sympathectomy is also done to improve the circulation to the ischaemic upper limb.
- ◆ Amputation of the gangrenous toe.
- ◆ In pectoralis minor syndrome, pectoralis minor tendon is released from its insertion to coracoid process.

### Approaches

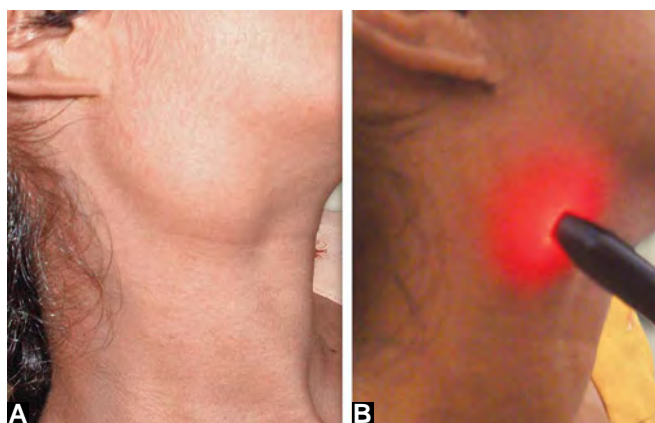
- ❖ Supraclavicular approach—mainly when there is need for vascular reconstruction
- ❖ Transaxillary approach—through axillary crease, rib is approached and removed
- ❖ Thoracotomy approach

## BRANCHIAL CYST

- ◆ It arises from the remnants of second branchial cleft. Normally, 2nd, 3rd, 4th clefts disappear to form a smooth neck. Persistent 2nd cleft is called as *cervical sinus (of His)* which eventually gets sequestered to form *branchial cyst*.
- ◆ *Epithelial infusion* within lymph node may be the other cause as branchial cyst contains lymphoid tissues in their wall.
- ◆ Six branchial arches with five pharyngeal pouches (endoderm lining) inside and five pharyngeal clefts (ectoderm lining) outside are present.

## Features

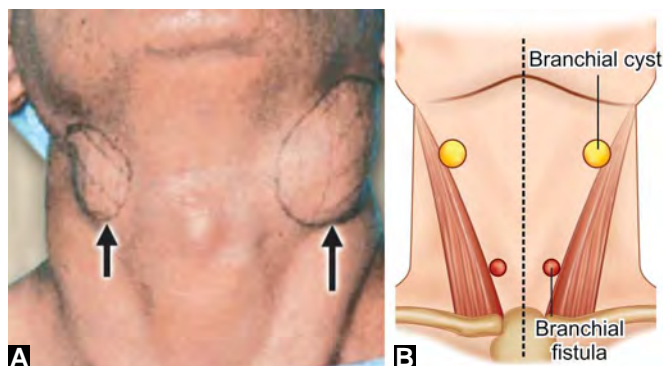
- ◆ Swelling in the neck beneath the anterior border of upper third of the sternomastoid muscle. It is smooth, soft, fluctuant,



**Figs 5.10A and B:** Branchial cyst. It is only occasionally transilluminant.

tuant, often transilluminant with a sensation of ‘*Half-filled double hot water bottle*’.

- ◆ It is equal in both sexes. Even though congenital, it is seen in late adolescents and early 3rd decade.
- ◆ In 3% cases, it is bilateral; it can be familial also.
- ◆ Usually painless unless it is infected.
- ◆ It contains *cholesterol crystals* which is from the lining of mucous membrane which contains sebaceous gland. *Cheesy toothpaste like* material is typical
- ◆ Histologically, it is lined by *squamous epithelium*. Occasionally it contains ciliated columnar epithelium. Cyst wall shows plenty of *lymphoid* tissue.
- ◆ It may get infected to form an abscess.
- ◆ FNAC shows *cholesterol crystals*.
- ◆ MRI allows for finer resolution during preoperative planning.



**Figs 5.11A and B:** (A) Branchial cyst—both sides; (B) Positions of branchial cyst and fistula.

## Complications

- ◆ Recurrent infection.
- ◆ Rupture may cause *acquired branchial fistula* at upper third of sternocleidomastoid muscle.

## Differential Diagnosis

- ◆ Cold abscess, lipoma neck.
- ◆ Lymph cyst.
- ◆ Chronic lymphadenitis.

## Treatment

*Excision* under GA.

Cyst is in relation to carotids, hypoglossal nerve, glossopharyngeal nerve, spinal accessory nerve, posterior belly of digastric and pharyngeal wall. Medially it is close to the posterior pillar of tonsils. During dissection, all these structures should be taken care of.

### Note:

- *Sclerotherapy* with OK-432 (picibanil) has been effective, often done under US guidance.
- In fish, branchial clefts develop into *gills*.

## Complications of Surgery

- ◆ Injury to major structures.
- ◆ Infection.
- ◆ Recurrence/fistula formation due to incomplete removal of the track.

### Cholesterol crystals are seen in:

- ❖ Branchial cyst
- ❖ Dentigerous cyst
- ❖ Hydrocele

## BRANCHIAL FISTULA

- ◆ Branchial fistula is **commonly a congenital lesion**. It is due to *persistent precervical sinus* between 2nd branchial cleft and 5th branchial cleft having opening in the skin at lower 1/3rd of neck on the inner margin of sternocleidomastoid muscle, often ends as a *sinus* just proximal to the posterior pillar of fauces behind tonsil which is also the site of inner opening when presents as *fistula*. Fistula runs between the structures related to 2nd and 3rd branchial arches (2nd arch artery is ECA, nerve is facial; 3rd arch artery is ICA, nerve glossopharyngeal). From external opening at skin below, it runs in subcutaneous plane to pierce deep fascia at level of thyroid cartilage; to travel between ECA and ICA; behind posterior digastric belly and stylohyoid; outer to IJV, stylopharyngeus, hypoglossal and glossopharyngeal nerves; perforates superior constrictor to reach the internal opening.
- ◆ Occasionally **acquired branchial fistula** can occur due to rupture of or after drainage of infected branchial cyst or incomplete excision of the cyst track. This type of fistula is located outside at skin at the level of upper third of sternomastoid muscle.

## Features

- ◆ It is a persistent second branchial cleft with a communication outside to the exterior. It is commonly a congenital fistula. Occasionally, the condition is secondary to incised, infected branchial cyst.
- ◆ Often it is bilateral (30%).
- ◆ *External orifice* of the fistula is situated in the *lower third of the neck* near the anterior border of the sternomastoid muscle.

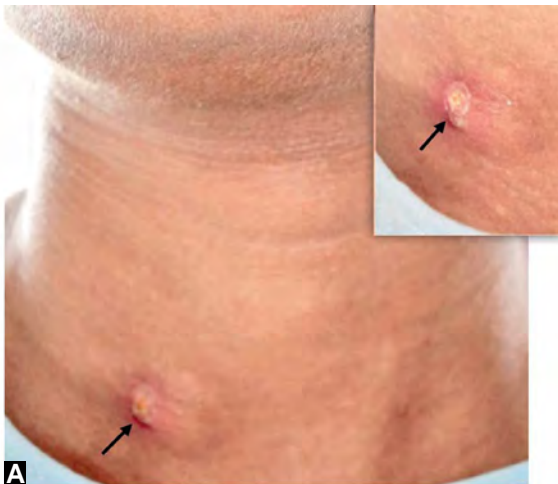

Fig. 5.12A

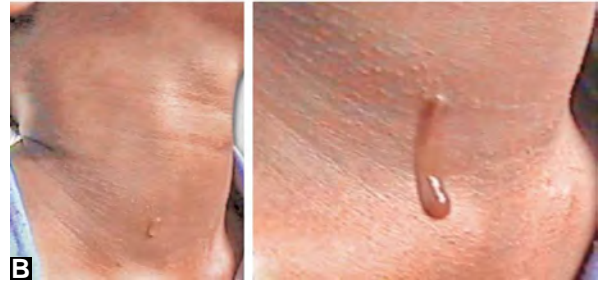

Fig. 5.12B

**Figs 5.12A and B:** Branchial fistula in two different patients. Note the location and discharge (*Courtesy:* Professor Kishore Chandra Prasad, ENT Surgeon and Head of the Department and Dr Sampath, ENT Surgeon, KMC, Mangaluru)

- ◆ *Internal orifice* is located on the anterior aspect of the posterior pillar of the fauces, just behind the tonsils.
- ◆ Sometimes fistula ends internally as blind end.
- ◆ Track is lined by *ciliated columnar epithelium* with patches of lymphoid tissues beneath it, causing recurrent inflammation.
- ◆ It usually presents at birth. It is common in *children* and early adolescent period. Equal in both sexes.
- ◆ *External orifice* is very small with a *dimple* which becomes more prominent on dysphagia with *tuck in appearance*.
- ◆ *Discharge* is mucoid or mucopurulent.
- ◆ *Investigations:* Discharge study, fistulogram, MR/CT fistulogram.

## Treatment

*Always surgery:*

- ◆ Under general anaesthesia, methylene blue is injected into the track. Probe is passed into the fistulous track. Through circumferential/elliptical incision around the fistula opening, entire length of the track is dissected until the internal orifice. Care should be taken to safeguard carotids, jugular vein, hypoglossal nerve, glossopharyngeal nerve and spinal accessory nerve. *Entire track should be excised.*

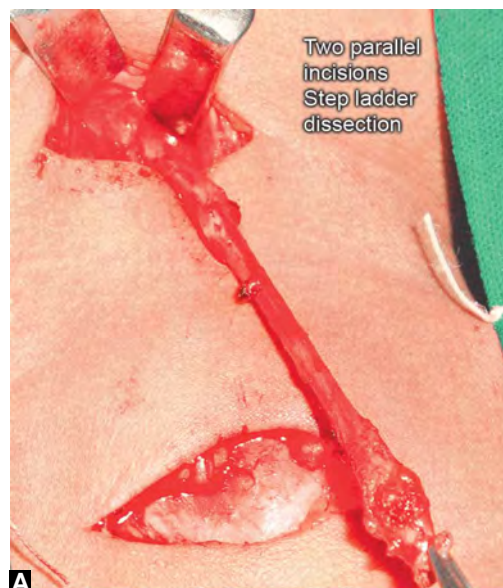

Fig. 5.13A



Fig. 5.13B

**Figs 5.13A and B:** Branchial fistula is usually operated using two transverse parallel incisions with step ladder dissection (Courtesy: Dr Ganesh Pai, MCh)

- ◆ *Step ladder dissection* is done using two parallel incisions one below at lower part another above at upper part of the neck, will make dissection easier and complete.

## PHARYNGEAL POUCH (ZENKER'S)

- ◆ It is a protrusion of mucosa through *Killian's dehiscence*, a weak area of the posterior pharyngeal wall between *thyropharyngeus* (*oblique fibres*) and *cricopharyngeus* (*transverse fibres*) of the *inferior constrictor muscle* of the pharynx.
- ◆ *Thyropharyngeus* is supplied by pharyngeal plexus from cranial accessory nerve. *Cricopharyngeus* is supplied by external laryngeal nerve.
- ◆ Pharyngeal pouch is a pulsion diverticulum. It starts in the midline of posterior pharyngeal wall. Once it expands and reaches the vertebra, it deviates towards left side of the neck because of resistance of vertebra.
- ◆ Imperfect relaxation of the *cricopharyngeus* increases the pressure in the pharynx, mainly during swallowing which leads to protrusion of mucosa through the *Killian's dehiscence* causing pharyngeal pouch.
- ◆ *The protrusion is usually towards left.*

### Stages

- ❖ *Small diverticulum* pointing towards vertebra. It is asymptomatic and incidentally diagnosed by barium meal X-ray. Foreign body sensation in pharynx may be present.
- ❖ *Large, globular diverticulum* with vertical mouth/opening causing regurgitation, violent cough, dysphagia, respiratory infection. Regurgitation is more after meals and while turning the neck.
- ◆ Large pouch which is visible in the neck as a globular swelling often tender, smooth and soft. Swelling is below the level of the thyroid cartilage and behind sternocleidomastoid muscle and can be emptied on pressure. Opening of the pouch is not vertical but horizontal. They present with dysphagia, features of respiratory infection like pneumonia and lung abscess, weight loss and cachexia. Pouch may itself get infected and may form an abscess. Often the pouch may descend downward and enter the superior mediastinum. Gurgling sound in the neck is observed.

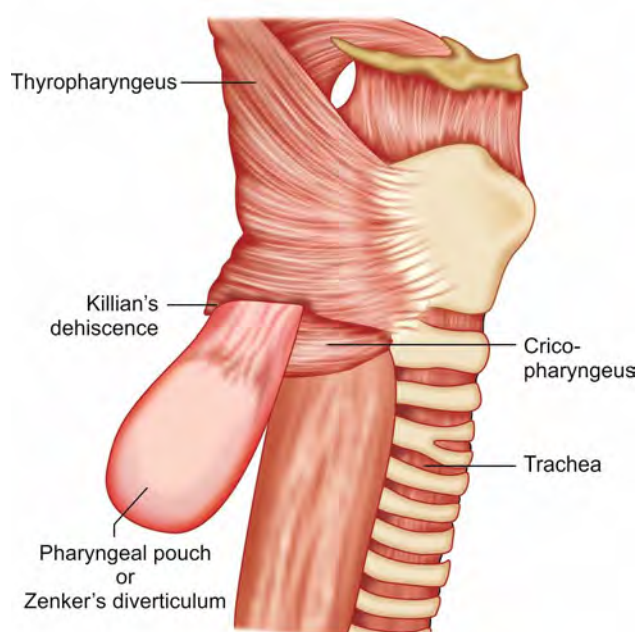


Fig. 5.14: Pharyngeal pouch (Zenker's diverticulum).

### Problems in pharyngeal pouch

- ❖ Progressive dysphagia
- ❖ Respiratory problems like pneumonia, and lung abscess
- ❖ Abscess in the neck due to infection in the pouch
- ❖ Weight loss and cachexia
- ❖ Carcinoma may develop in the pouch rarely

## Differential Diagnosis

- ◆ Branchial cyst.
- ◆ Cold abscess in the neck.
- ◆ Lymph cyst.
- ◆ Haemangioma neck.
- ◆ Other causes of dysphagia like carcinoma, webs and stricture.

## Clinical Features

- ◆ Pain, dysphagia, recurrent respiratory infection, swelling in the neck on the left side which is smooth, soft and tender.
- ◆ Regurgitation during night while turning neck, smooth, soft, tender swelling in the posterior triangle of the left side of the neck; typical gurgling noise while swallowing—are typical features. It is common in males.
- ◆ Swelling is deep to sternocleidomastoid muscle below the level of thyroid cartilage; initially soft and emptying; impulse on coughing may be evident unless opening of the pouch is blocked due to recurrent inflammation.
- ◆ *Halitosis* from decayed food in the pouch is not uncommon. Dyspnoea and change in voice can also occur.

## Investigations

- ◆ *Barium swallow*—lateral view shows pharyngeal pouch.
- ◆ Chest X-ray shows pneumonia.
- ◆ CT neck is very useful.
- ◆ *Indirect laryngoscopy* may show pooling of saliva in pyriform fossa.

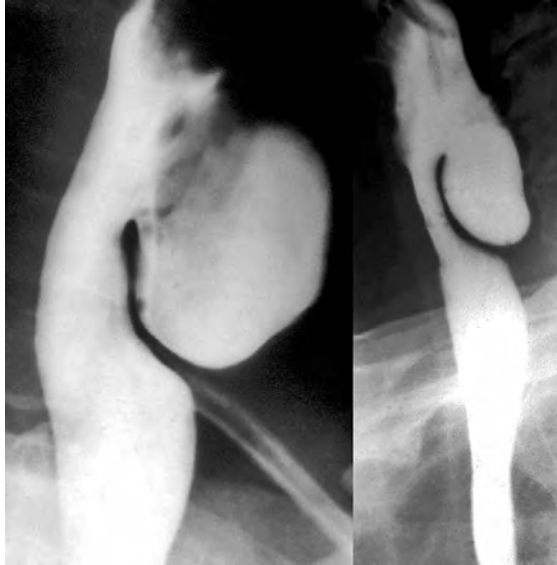

Fig. 5.15: Barium study showing pharyngeal pouch.

### Note:

Oesophagoscopy should be gentle or avoided as scope may enter the friable pharyngeal pouch and can cause perforation and life threatening mediastinitis.

## Treatment

Antibiotics and nutritional support initially.

## Surgery

### Indications for surgery

- ❖ Progressive symptoms; recurrent aspirations; persistent dysphagia.
- ◆ *Diverticulectomy with cricopharyngeal myotomy*: It is done in large lesion. After general anaesthesia, oesophagoscope is passed and pouch is packed with acriflavine gauze. Nasogastric tube is passed under vision through the oesophagus. Oblique or horizontal incision in the neck is made; sternocleidomastoid muscle is cut; diverticula is excised; oesophagopharyngeal wall is closed after doing cricopharyngeal myotomy (Circular muscle fibers are cut at posterior midline without opening the mucosa) is done to relieve the spasm; drain is placed in the neck; nasogastric tube is kept in situ for 7 days.
- ◆ Inversion or diverticulopexy are other procedures.

### Complications of surgery

- ❖ Infection, either mediastinitis or lung infection (Pneumonia or lung abscess)
- ❖ Pharyngeal fistula
- ❖ Abscess in the neck
- ❖ Oesophageal stenosis and recurrence
- ❖ Recurrent laryngeal nerve palsy.

## Endoscopic minimally invasive technique

- ◆ *Dohlman's approach* – Pouch is excised using double lipped endoscopy. Cautery or laser is used. It is quicker procedure with shorter duration of anaesthesia; with faster recovery.
- ◆ *Stapling of the diverticula*.

### Note:

*Friedrich Albert von Zenker* (1851) was a German physician and pathologist. Zenker's pharyngeal pouch; Zenker's muscle degeneration; Zenker's peroneal nerve paralysis.

## LARYNGOCELE

- ◆ It is a unilateral narrow necked, air-containing diverticulum resulting from herniation of laryngeal mucosa.
- ◆ It occurs in professional *trumpet players, glass blowers and in people with chronic cough*.
- ◆ Laryngocele is an abnormal dilatation of the appendage of the laryngeal ventricle of Morgagni forming an airsac lined with pseudostratified ciliated, columnar epithelium (air-filled dilated saccule). Laryngeal ventricle of Morgagni is an elliptical recess between false and true vocal cords. Anterosuperior blind pouch of it is called as appendage of the ventricle which normally communicates with the laryngeal ventricle through a normal stalk.
- ◆ It can be congenital or acquired (common). It may be often associated with laryngeal carcinoma.

## Types

- External:** It is situated in the anterior third of the laryngeal ventricle, between the false cords and thyroid cartilage, herniates through the *thyrohyoid membrane* where it is pierced by superior laryngeal nerve (25%).
- Internal:** Confined within the larynx, presents as a distention of false cords (30%).
- Combined** (45%).

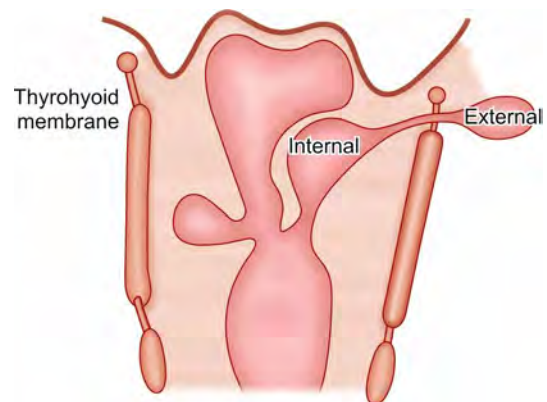
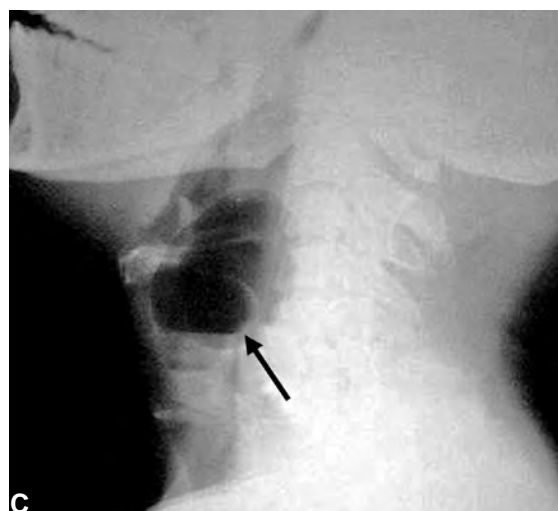
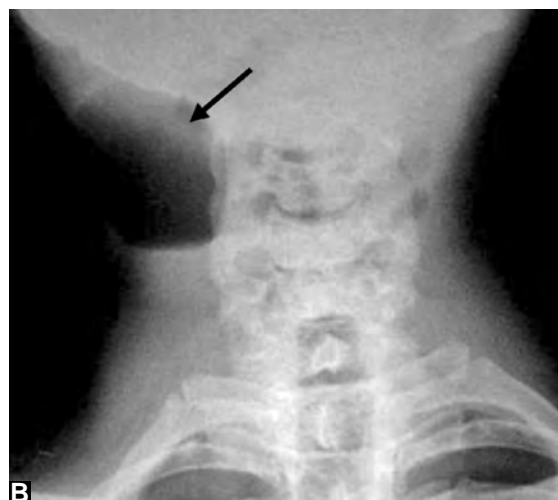
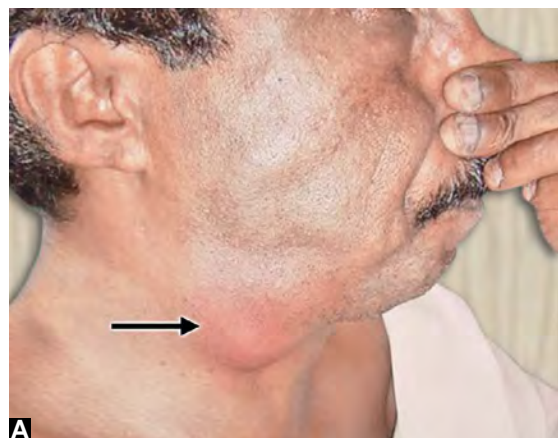
Fig. 5.16: Laryngocele.

## Clinical Features

- ◆ Swelling in the neck in relation to larynx, adjacent to thyrohyoid membrane which is smooth, soft, *resonant* and is more prominent while blowing, coughing and Valsalva manoeuvre.
- ◆ It moves *upwards* during swallowing with *expansile impulse* on coughing.
- ◆ Infection is quite common in the sac of laryngocele, leading to the blockade of opening of the sac causing an abscess.
- ◆ Pus often may be discharged into the pharynx repeatedly.
- ◆ Hoarseness and cough, sudden dyspnoea is often evident.



**Figs 5.17A to C:** Typical laryngocele in the neck which becomes prominent after blowing. X-rays (AP and lateral) show radiolucent air in the neck.

- ◆ If large, causes obstruction to larynx.
- ◆ Sudden compression and asphyxia can occur when it is infected.
- ◆ *Bryce sign*: In combined laryngocele, neck mass when compressed from outside will cause hissing sound of air escaping into the larynx.

## Diagnosis

Clinical features, X-ray neck, laryngoscopy, CT scan.

## Treatment

*External laryngocele*: Excision through neck incision. Neck of the sac should be ligated. Thyrohyoid membrane is repaired using 3 zero nonabsorbable polypropylenes sutures.

*Internal laryngocele*: Marsupialisation, with the help of laryngoscope.

### Complications of surgery for laryngocele

- ❖ Laryngeal oedema causing airway obstruction
- ❖ Subcutaneous emphysema
- ❖ Laryngocutaneous fistula
- ❖ Injury to superior / internal laryngeal nerve
- ❖ Recurrence

## ■ CYSTIC HYGROMA (Cavernous Lymphangioma)

- ◆ It is a cystic swelling due to sequestration of a portion of jugular lymph sac from the lymphatic system, during the developmental period *in utero*.
- ◆ Present at birth and so may cause obstructed labour. Occasionally present in early infancy.
- ◆ Lymphatics fail to communicate to venous system; abnormal budding of lymphatics is seen.
- ◆ Often it is associated with Turner's, Down's, Klinefelter syndromes and trisomy 18 and 13.
- ◆ It is also called as *hydrocoele of the neck*.
- ◆ Cyst will not communicate with normal lymphatics and so existing lymph gets absorbed and cyst will be filled with clear watery mucous derived from endothelial lining of the cyst wall. Cyst even though is subcutaneous; it commonly extends into deeper planes across many anatomical planes and barriers. Cyst is *multilocular*. Often extension may occur across two or more lymphatic regions; example—involve-ment of both neck and axilla.
- ◆ *Lymphangioma circumscripta* (<5 cm), *lymphangioma diffusum* (>5 cm) and *lymphangioma ab agne* (reticulate pattern) are different variants. For detail refer chapter 'Swelling'.

### Sites

1. *Posterior triangle of the neck*—75%—most common site. Eventually may extend upwards in the neck
2. Axilla—20%
3. Cheek
4. Tongue—lymphangiogenetic macroglossia
5. Groin
6. Mediastinum
7. Often multiple sites

## Pathology

- ◆ It contains aggregation of cysts looking like *soap bubbles*. Cysts have *mosaic appearance* with larger cysts near the surface and

*One-third of congenital torticollis is due to sternomastoid tumour and two-third due to abnormal position in utero which recovers spontaneously in a few weeks.*

— Kenneth F Hulbert

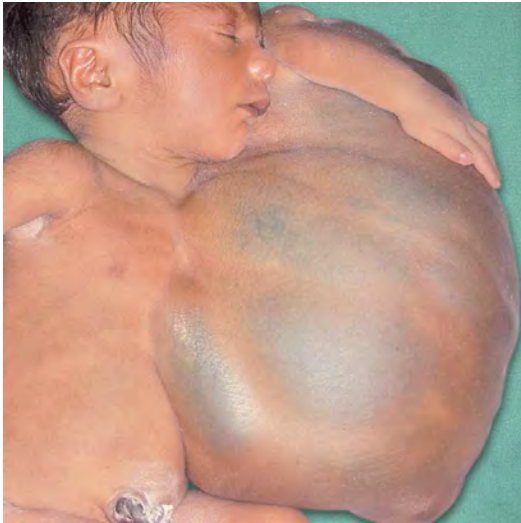

Fig. 5.18: Cystic hygroma in newborn baby.

smaller cysts in the deeper planes. Each cyst contains clear lymph with endothelial lining. Fluid *does not* coagulate.

### Clinical Features

- ◆ Swelling is *present at birth* in the *posterior triangle of neck* causing obstructed labour.
- ◆ Swelling is smooth, soft, fluctuant (cystic), *partially compressible*, *brilliantly transilluminant*. It is *not reducible* completely.
- ◆ During crying swelling often increases in size.
- ◆ *Disfigurement* of face of the child which is more worrying factor for the parents.

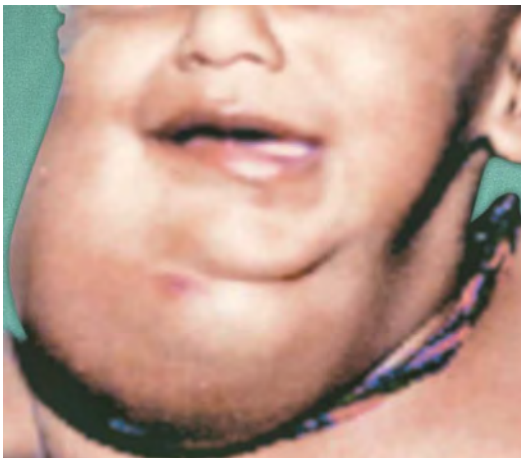

Fig. 5.19: Cystic hygroma.

- ◆ Swelling may rapidly increase in size causing *respiratory obstruction*—dangerous sign.
- ◆ It may get infected forming an *abscess* which is a tender, warm, soft swelling. It may cause septicaemia which may be life threatening.
- ◆ Rupture with lymph ooze can occur.

### Treatment

- ◆ Aspiration of the contents. Later once the sac or capsule gets thickened by fibrous tissue, it is excised.
- ◆ Care should be taken to have meticulous dissection across all planes including deeper muscular one to *clear entire cyst wall*; otherwise recurrence will occur.

- ◆ When it causes respiratory obstruction, *aspiration* and *tracheostomy* is done.
- ◆ Under proper antibiotics coverage, drainage of abscess is done. Later sac is excised.
- ◆ Preoperative injection of sclerosants (OK-432, PICIBANIL recently used) and later once fibrosis develops excision of entire aggregation of cysts. In olden days injecting boiling water into the cyst as a sclerosant used to be popular. OK-432 is an inactive strain of group A *Streptococcus pyogenes*. Pure ethanol, interferon  $\alpha$  2a, doxycycline are other sclerosants often used.

### Complications

- ❖ Respiratory distress
- ❖ Infection → Abscess → Septicaemia
- ❖ Surgery itself may cause torrential haemorrhage
- ❖ Chylous fistula, chylothorax
- ❖ Recurrence of cyst – 15%

### LUDWIG'S ANGINA

- ◆ It is an inflammatory oedema of submandibular region and floor of the mouth, commonly due to streptococcal infection.
- ◆ It causes diffuse swelling and brawny oedema of the submandibular region. It is common in severely ill and in advanced malignancy, causing *trismus*, *laryngeal oedema*. Extension of infection into *parapharyngeal space* may lead to dreaded *internal jugular vein thrombosis*.
- ◆ As the infection is deep to the deep fascia in a closed fascial plane, it spreads very fast causing dangerous complications.

### Precipitating factors

- ❖ Caries teeth
- ❖ Oral or other malignancy
- ❖ Submandibular salivary infection/calculi
- ❖ Chemotherapy
- ❖ Chronic diseases like diabetes mellitus
- ❖ Cachexia of any cause

### Special features

- ❖ Brawny oedema/diffuse swelling of submandibular and submental region
- ❖ Intraoral oedema in floor of the mouth
- ❖ Putrid halitosis
- ❖ Severe toxicity
- ❖ Dyspnoea, dysphagia
- ❖ May cause laryngeal oedema, septicaemia, extension of sepsis into other spaces in the neck

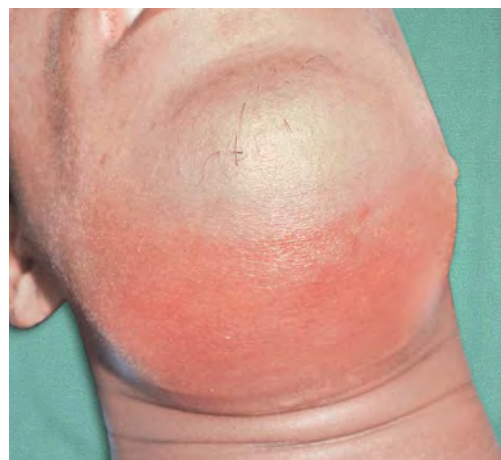

Fig. 5.20: Typical Ludwig's angina.

### Clinical Features

- ◆ Fever, toxicity, diffuse swelling, dysphagia, dyspnoea, trismus.
- ◆ Intraoral oedema is common.
- ◆ Brawny swelling in submandibular region.
- ◆ Putrid halitosis, drooling of saliva, earache.

### Treatment

- ◆ Antibiotics, IV fluids.
- ◆ *Decompression of the submandibular region is done, by making a deep incision extending into the deep fascia and also cutting both the mylohyoid muscles.* Either it is left open and *delayed suturing is done* (better option) or it is loosely sutured.

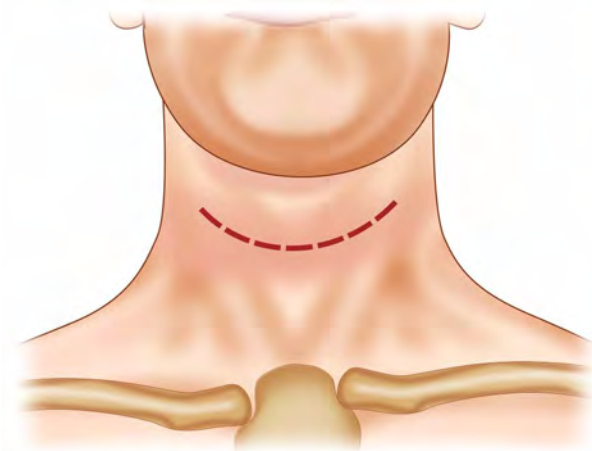


Fig. 5.21: Incision for draining Ludwig's angina.

#### Complications

- ❖ Laryngeal oedema and respiratory distress, may require tracheostomy
- ❖ Septicaemia
- ❖ Extension of infection into parapharyngeal space

### PARAPHARYNGEAL ABSCESS

- ◆ It is *infection of pharyngomaxillary space.*
- ◆ This is a cone-shaped space; base is formed by the base of skull; apex is formed by the greater cornu of hyoid bone; medial wall by the superior constrictor; lateral wall is formed by the lateral pterygoid, angle of mandible and below by submandibular salivary gland.
- ◆ Usually, infection arises from the tonsils, after tonsillectomy and from the submandibular space.

### Clinical Features

- ◆ It causes diffuse swelling in the upper neck, trismus, fever, toxicity.
- ◆ Swelling lies behind the posterior pillar with oedema of soft palate.

### Complications

- ◆ Thrombosis of internal jugular vein.

- ◆ Erosion into the internal carotid artery causing torrential bleeding.
- ◆ Septicaemia.

### Treatment

- ◆ Under G/A, drainage is done by making incision (deep incision) between angle of the mandible and hyoid bone. Early drainage is needed.
- ◆ Antibiotics are given.
- ◆ Causative pathology should be addressed.

## RETROPHARYNGEAL ABSCESS

### Surgical Anatomy

The wall of the pharynx has got 5 layers. Mucosa, submucosa, pharyngobasilar fascia, muscular layer (contains 3 constrictors and stylo, salpingo, palatopharyngeus muscles) and buccopharyngeal fascia covers outer part of constrictors and extends over buccinator. Buccopharyngeal fascia is adherent to prevertebral fascia posteriorly in the midline. Retropharyngeal lymph nodes are located between buccopharyngeal fascia and prevertebral fascia in paramedian (eccentric) position (not midline).

### Types

- ◆ Acute.
- ◆ Chronic.

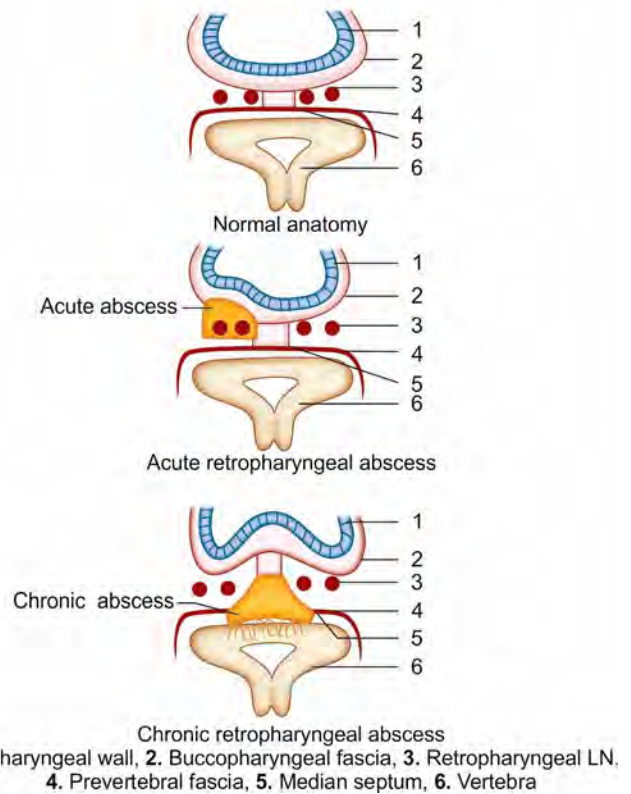


Fig. 5.22: Note acute and chronic retropharyngeal abscess. Normal anatomy is also shown. Acute is eccentric and is due to suppuration of retropharyngeal lymph nodes. Chronic is central, midline and is due to tuberculosis of the cervical vertebra.

*It is better to aim at good things and miss it, than to aim at a bad thing and hit it.*



### Acute Retropharyngeal Abscess

- ◆ It is infection and suppuration of retropharyngeal lymph nodes due to staphylococci or streptococci organisms.
- ◆ Commonly from tonsils or pharynx.
- ◆ Common in infants and children.

### Clinical Features

- ◆ It presents as *lateral (paramedian, eccentric) smooth, tender swelling* in the pharynx with dysphagia, dyspnoea, cough, toxic features and neck rigidity.
- ◆ Diagnosis is obvious on proper clinical examination.

### Treatment

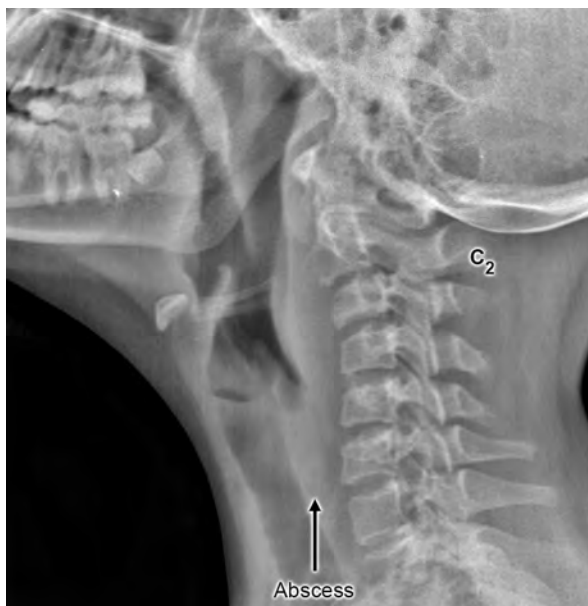- ◆ Antibiotics intravenously.
- ◆ Drainage is done usually *through per oral incision* under careful general anaesthesia. Only occasionally drainage may be done through a neck incision. Pus should be sent for culture.

### Chronic Retropharyngeal Abscess

- ◆ It is invariably due to tuberculosis of cervical spine.
- ◆ Abscess is in the *midline behind the prevertebral fascia*.
- ◆ There is destruction of the body of the vertebra due to tuberculosis.

### Clinical Features

- ◆ It is *midline swelling in the posterior pharyngeal wall*, which is smooth and nontender.
- ◆ Features of tuberculosis of cervical spine will be observed.
- ◆ Often abscess may point in the neck in relation to sternomastoid.
- ◆ Neurological manifestations may occur in severe disease.



**Fig. 5.23:** X-ray neck showing retropharyngeal abscess with tuberculosis lesion involving the C<sub>2</sub> cervical spine (Courtesy: Dr Navin Chandra Shetty, MD, Radiologist, Professor and Head, Department of Radiodiagnosis, KMC, Mangaluru).

### Investigations

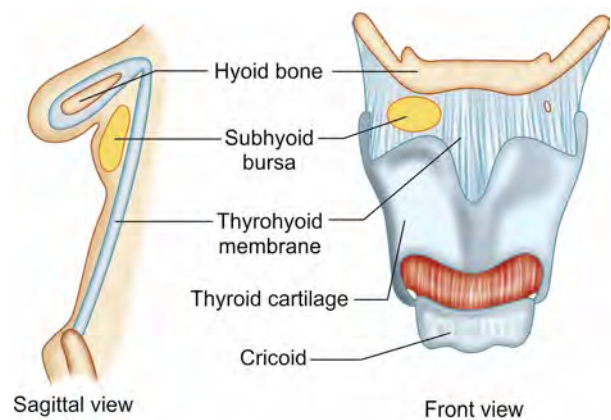
X-ray spine, chest X-ray, ESR, MRI of cervical spine are essential investigations.

### Treatment

- ◆ Antitubercular drugs.
- ◆ Drainage of the abscess should be done *through neck approach (never intraoral approach)*.
- ◆ Decompression of the vertebra and stabilisation is also often required.

### SUBHYOID BURSTITIS (Retrohyoid Bursa/Boyer's Bursa)

- ◆ Subhyoid bursa is space between posterior surface of the body of hyoid bone and thyrohyoid membrane. It lessens friction between these two structures during swallowing.
- ◆ Due to constant friction inflammatory fluid collects in the bursa leading to bursitis, which presents like a *horizontally placed midline swelling* between lower part of the hyoid bone and thyrohyoid membrane.



**Fig. 5.24:** Sagittal and front view showing location and relation of subhyoid bursa.

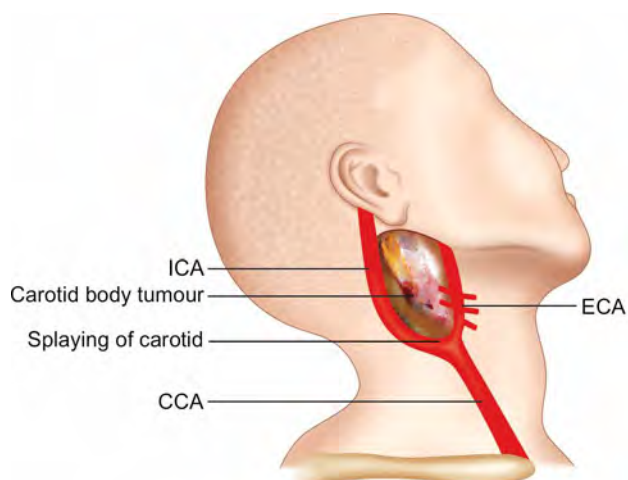
### Features

- ◆ Smooth, soft, cystic, fluctuant, nontransilluminating swelling which moves upwards with deglutition but *not while protruding the tongue out*.
- ◆ It should be differentiated from thyroglossal cyst and prelaryngeal lymph nodes.
- ◆ It contains turbid fluid often may get infected to make the swelling tender or to form an abscess.
- ◆ *Treatment:* Excision under general anaesthesia.

### CAROTID BODY TUMOUR (Potato Tumour, Chemodectoma, Nonchromaffin Paraganglioma)

- ◆ It arises from the carotid body, which is located at the bifurcation of the common carotid artery.
- ◆ Carotid is derived from neural crest which is essential for adaptation in fluctuation in the O<sub>2</sub>, CO<sub>2</sub> and pH.

- ◆ Carotid body tumour can be *sporadic* (75%); *familial* (20%, common in young, can be multiple); or *hyperplastic* (5%) which is associated with the chronic hypoxia seen in high altitude (5,000 feet from sea level), COPD, cyanotic heart disease.
- ◆ The tumour is situated in the adventitia of the artery.
- ◆ They are benign or locally malignant tumours (10%), but in 20% cases spread can occur to the regional lymph nodes and lungs.
- ◆ Blood supply to the tumour is from ascending pharyngeal artery and *external carotid artery*. Tumour does not secrete epinephrine or any endocrine substances. Blood supply comes through *Meyer's ligament* on the posteromedial wall of the carotid at bifurcation.
- ◆ Pathologically, it is well-encapsulated, hard creamy yellowish tumour with dense fibrous tissue. Carotid body tumour cells are not hormonally active.
- ◆ *Histologically* cells are arranged in a classical pseudoalveolar pattern known as cell ball – *Zellballen*. It contains type I chief cells with catecholamine granules and type II sustentacular cells without granules.



**Fig. 5.25:** Carotid body tumour—note the site and location. *Splaying* of the carotid is common.

### Carotid body

- ❖ Normal carotid body is 3–5 mm sized, 15 mg weight, flat brownish nodule in the adventitious of common carotid artery
- ❖ It consists of chief cells (contains catecholamine granules) and supportive cells
- ❖ Its nerve supply is from *Hering nerve*, a branch Glossopharyngeal nerve
- ❖ These chemoreceptors are sensitive to changes in pH and temperature in the body especially in hypoxia, help in autoregulation of respiration and circulation
- ❖ Carotid body hyperplasia can occur in people residing in high altitudes who are exposed to chronic hypoxia
- ❖ Other chemoreceptors in the body are—aortic bodies in the arch of aorta; glomus jugular in the bulb of the internal jugular vein; glomus intravagale in relation to ganglion nodosum of the vagus nerve and others like pulmonary (near pulmonary artery) and myocardial (near coronary artery origin) receptors

### Clinical Features (0.5%—Incidence)

- ◆ Usually unilateral; 5% bilateral.
- ◆ More common in middle age. Common in females.

- ◆ Swelling (75%) in the carotid region of the neck which is smooth, firm, pulsatile (*transmitted pulsation*—due to pulsatile carotid vessel overlying its surface) and moves only side to side but not in vertical direction (*Fontaine sign*).
- ◆ It can often compress over oesophagus and larynx.
- ◆ Headache, neck pain (35%), dysphagia, and syncope are other presentations.
- ◆ 10% may present with *cranial nerve palsy* (hypoglossal, glosso-pharyngeal, recurrent laryngeal or spinal accessory) or sympathetic chain; so present as pain, tongue deviation towards same side while protruding, dysphagia, unilateral vocal cord palsy, hoarseness of voice, drooping shoulder and Horner's syndrome.
- ◆ Features of transient ischaemic attacks due to compression over the carotids, "*carotid body syncope*."
- ◆ Thrill may be felt and bruit may be heard.
- ◆ It is located at the level of hyoid bone deep to anterior edge of the sternomastoid muscle in anterior triangle, vertically placed, round, firm 'potato' like swelling.
- ◆ Often tumour may extend into the cranial cavity along the internal carotid artery as *dumbbell tumour*.

### Sites where dumbbell tumours are seen

- ❖ Parotid tumour
- ❖ Spinal cord tumour
- ❖ Carotid body tumour

### Shamblin classification of carotid body tumor

- ❖ Type I: Localised, easily resectable (26%)
- ❖ Type II: Adherent, partially surrounding the carotids (46%)
- ❖ Type III: Adherent, encased carotids completely (27%)

### Investigations

- ◆ Doppler.
  - ◆ Angiogram to see the '*tumour blush*'—DSA. Widening/splaying of the carotid artery with tumour blush in an angiogram is called *Lyre sign*.
  - ◆ CT scan, MRI, *MR angiography*.
  - ◆ *MIBG scan* in useful in multiple familial and functioning tumours (they are smaller in size); in nonfunctioning tumours pentetretotide scan using radiolabeled somatostatin analogue is used.
- No FNAC, No trucut biopsy, No partial excision.*

### Differential Diagnosis

- ◆ Carotid artery aneurysm.
- ◆ Soft tissue tumour (Sarcoma).
- ◆ Lymph node enlargement.
- ◆ *Neurofibroma of the vagus nerve* presents as swelling in the carotid triangle in the region of thyroid as vertically placed, oval, hard swelling. On palpation of the swelling, patient often develops bradycardia and dry cough. It does not move with deglutition and has only transverse mobility. As the tumour lies behind the carotid it can stretch the carotid in front causing transmitted pulsation.

### Treatment

- ◆ If it is small, then it can be excised easily as the tumour is situated in the adventitia.

- ◆ When it is large, as commonly observed, *complete excision has to be done followed by placing a vascular graft.*
- ◆ During resection a *temporary shunt* (diversion of blood) is placed between common carotid below and internal carotid above to safeguard cerebral perfusion; external carotid artery is ligated. Venous or prosthetic graft is placed between common carotid and internal carotid arteries.
- ◆ Carotid body tumour is not *radiosensitive* (controversial).

### Complications of the Surgery

- ◆ Bleeding.
- ◆ Blockage of common carotid artery, leading to contralateral side hemiplegia (3%). This can be prevented by *stenting the common carotid artery* towards internal carotid artery and is done *during surgical excision* of the tumour.
- ◆ Cranial nerve injury X and XI (40%). Injury to vagus causes hoarseness of voice; injury to superior laryngeal nerve alters the pitch of voice.

#### Cystic swellings in the neck

- ❖ Cold abscess
- ❖ Cystic hygroma
- ❖ Branchial cyst
- ❖ Thyroglossal cyst
- ❖ Laryngocoele
- ❖ Pharyngeal pouch
- ❖ Subhyoid bursa

### TORTICOLLIS (Wry Neck)

It is turning of the neck to one side with chin pointing towards opposite side.

#### Causes

- ◆ Sternomastoid tumour.
- ◆ Trauma—spinal injury, disc prolapse, spondylosis.
- ◆ Inflammatory: Lymphadenitis either tuberculous or suppurative; tuberculosis of cervical spine.
- ◆ Spasmodic—due to spasm of sternomastoid muscle of same side or spasm of posterior cervical muscles of opposite side.
- ◆ Reflex.
- ◆ Rheumatic—after exposure to cold/draught.
- ◆ Burns—causing contracture.
- ◆ Ocular causes.
- ◆ Compensatory due to scoliosis.

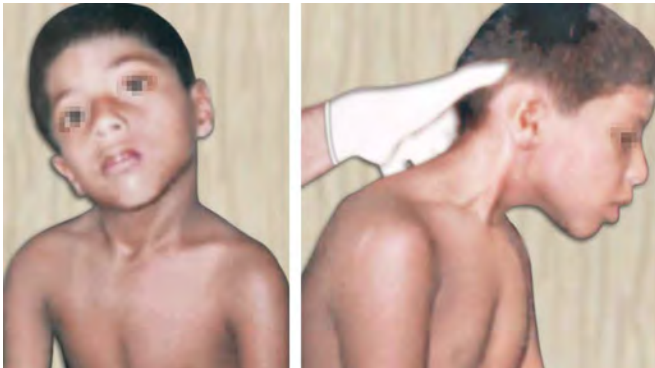

Fig. 5.26: Boy having right-sided torticollis.

#### Features

- ◆ Restricted neck movements.
- ◆ Chin pointing towards opposite side.
- ◆ Squint.
- ◆ Features relevant of the causes.
- ◆ *Treatment:* The cause is treated.

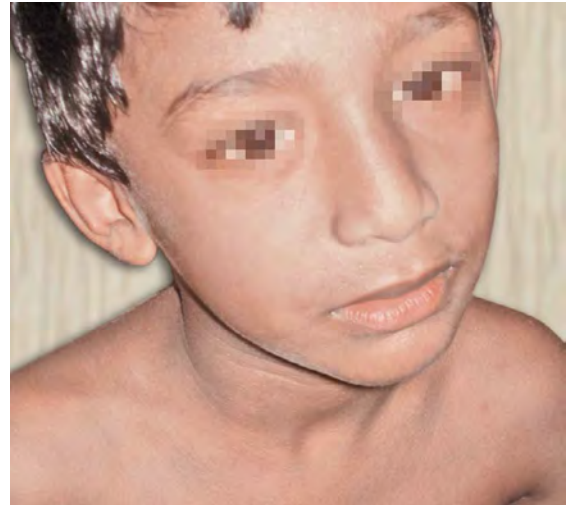

Fig. 5.27: Torticollis (right-sided) with chin towards opposite side.

### STERNOMASTOID TUMOUR

It is due to birth injury to the sternomastoid muscle. It is a *misnomer*. It is not a tumour.

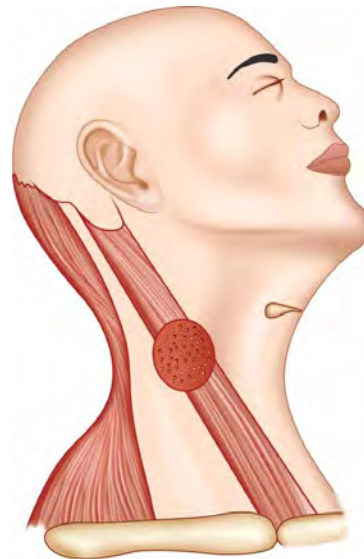


Fig. 5.28: Sternomastoid tumour—typical location.

#### Pathogenesis

- ◆ During child birth, injury to the sternomastoid muscle causes *haematoma* in the muscle which gets organised to form sternomastoid tumour.
- ◆ Common in breech delivery.

## Features

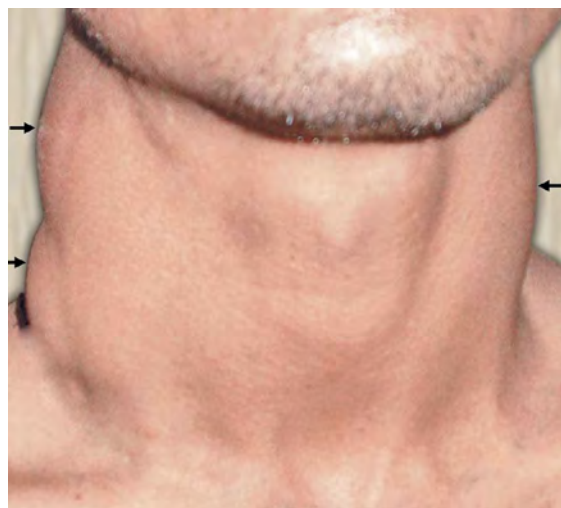
- ◆ It is seen in infants of 3–4 weeks age.
- ◆ Swelling of about 2 cm size, in the sternomastoid muscle which is smooth, hard, nontender and adherent to the muscle—in the middle part.
- ◆ Chin pointing towards opposite side. Head towards same side (*Scoliosis capitis*).
- ◆ In later age groups it causes *hemifacial atrophy* due to less blood supply as a result of compression of the external carotid artery by sternomastoid tumour and due to kinking by position of neck. Distance between the outer canthus of eye to angle of mouth is reduced, with less arched eyebrow, flat or less filled cheek and flat nose compared to opposite side.
- ◆ Compensatory cervical scoliosis.
- ◆ Compensatory squint.
- ◆ *Differential diagnosis*: Other causes for torticollis.

## Treatment

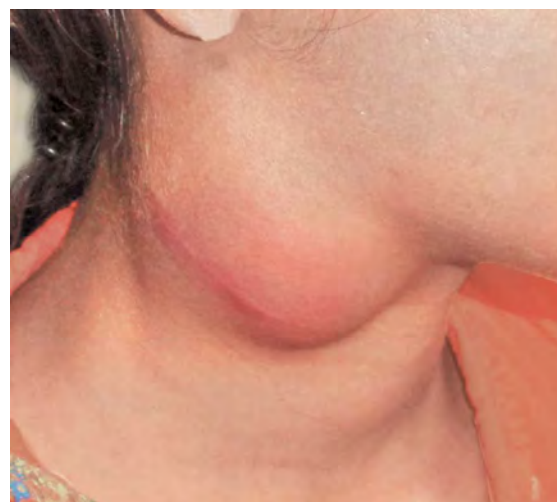
- ◆ Division of the lower end of the sternomastoid muscle or excision of the muscle. Both sternal and clavicular heads of sternocleidomastoid muscle should be divided under general anaesthesia using horizontal incision. One should not injure IJV, carotid, vagus, spinal accessory nerve. Additional all fibrous bands are also cut. Usually over correction is done. Physiotherapy exercise and torticollis harness is used for 6–12 months.
- ◆ Exercise and active stimulation of muscles in early cases.

### Differential diagnosis for neck lymph node enlargement

• Tuberculous lymphadenitis	• Secondaries in lymph nodes
• HIV infection	• Lymphomas
• Chronic lymphatic leukaemia	• Nonspecific lymphadenitis
• Infectious mononucleosis	• Sarcoidosis
• Actinomycosis	• Brucellosis
• Toxoplasmosis	



**Fig. 5.29:** Lymphoma neck involving both sides. Lymphomas are smooth, nontender, firm/India rubber consistency.



**Fig. 5.30:** Swelling in the neck well-localised. Note the scar of previous biopsy/excision. It could be lymph node enlargement due to lymphoma or tuberculosis.

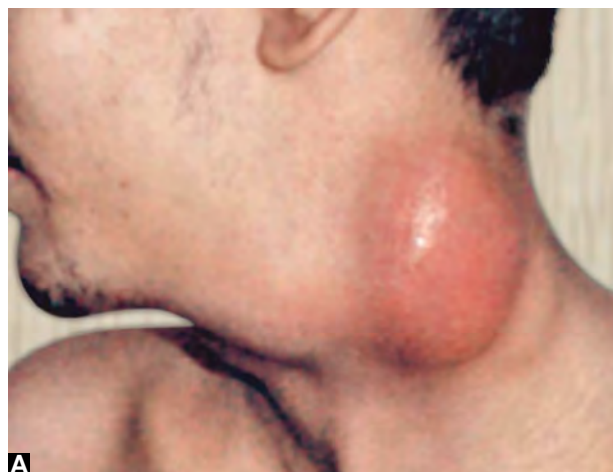## TUBERCULOUS LYMPHADENITIS

### Causative organism:

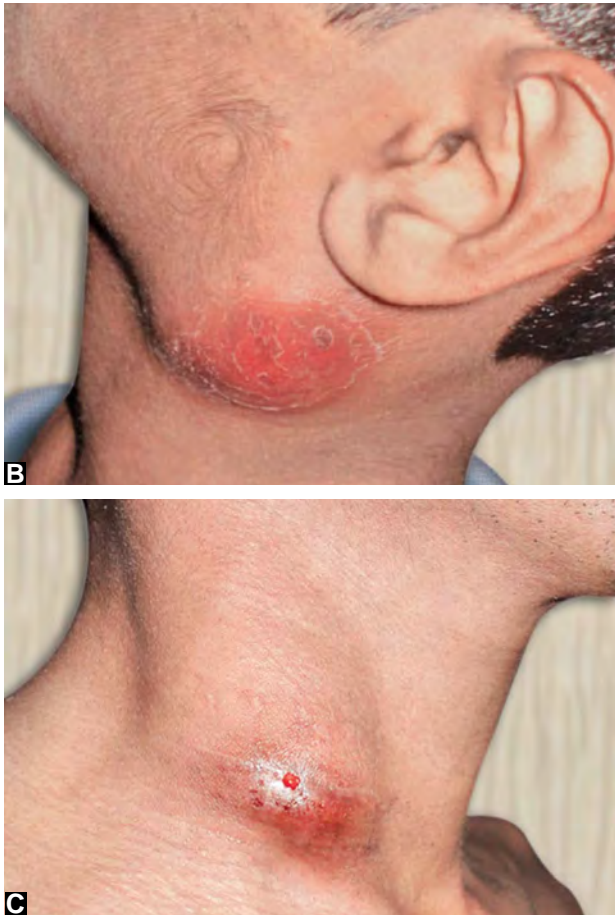*Mycobacterium tuberculosis* (not *M. bovis*).

### Site

- ◆ Common in neck lymph nodes.
- ◆ Common in *upper deep cervical (jugulodigastric—54%) lymph nodes*.
- ◆ Next common is posterior triangle lymph nodes (22%).
- ◆ Disease can also occur in other lymph nodes like, axillary lymph nodes, para-aortic lymph nodes, mesenteric lymph nodes, inguinal lymph nodes.
- ◆ Disease may be associated with HIV infection, lymphomas.



**Fig. 5.31A**

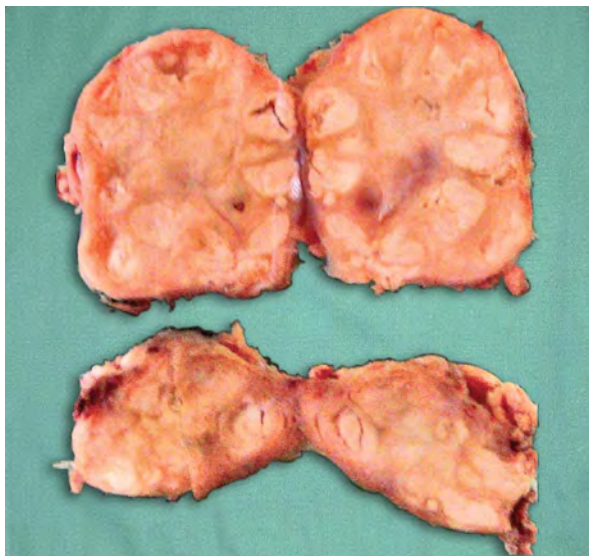


Figs 5.31B and C

**Figs 5.31A to C:** Cold abscess due to caseating tuberculous lymphadenitis in neck. Collar stud abscess in the neck. Tuberculous sinus formation after drainage.

### Mode of Infection

- Usually through the *tonsils*, occasionally through blood from lungs. *Tonsillar* infection shows multiple tubercles on



**Fig. 5.32:** Tuberculous lymphadenitis—cut section of the specimen. Note the yellowish caseating material with periadenitis (matting). Caseating type is more common than hyperplastic type.

its surface; from here infection spreads into jugulodigastric nodes (anterior triangle nodes) then to other nodes. Infection reach lymph node first into subcapsular space/sinus then to lymph node cortex which contains plenty of lymph follicles. Matting is due to periadenitis involving subcapsular sinus/space of lymph node. In children infection to neck node can come from either tonsils or adenoids or both. When it occurs from *adenoids*, lymph nodes in posterior triangle are involved through retropharyngeal lymphatics.

- It may be associated with pulmonary tuberculosis or renal tuberculosis. Through blood infection reaches medullary cords of lymph node and so medulla of lymph node.
- Rarely spread can occur from tuberculous lesion of the apex of lung through suprapleural Sibson's fascia/membrane to supraclavicular nodes.

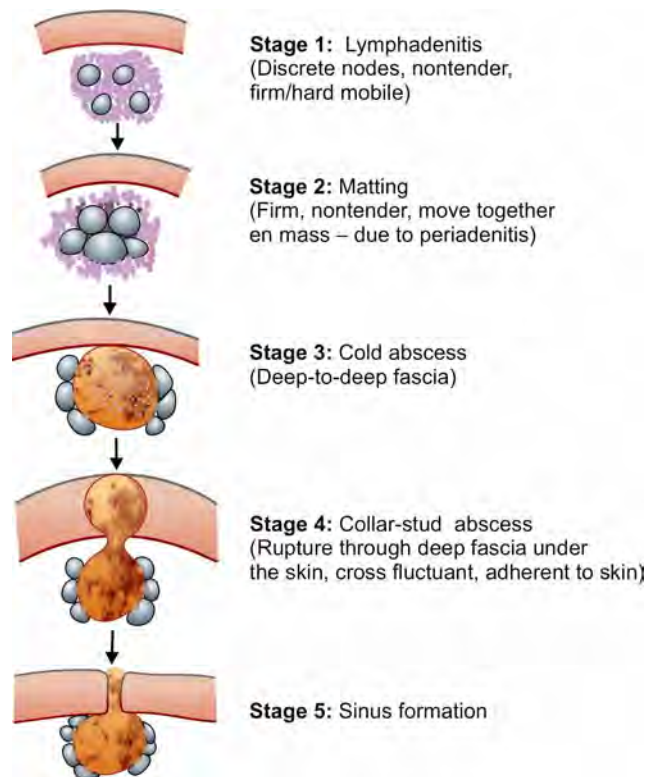
### Stages of tuberculous lymphadenitis

- Stage of infection, and lymphadenitis
- Stage of periadenitis with matting
- Stage of caseating necrosis and cold abscess formation
- Stage of formation of collar stud abscess
- Stage of formation of sinus which discharges yellowish caseating material

- Often fibrosis and calcification can occur with or without treatment.

### Gross Pathology

- Firm, matted, lymph node, with cut section showing yellowish caseating material.



**Fig. 5.33:** Stages of tuberculous lymphadenitis (*Hogarth's Rake*).

Types	
1. Hyperplastic	2. Caseating
a. 20% common	a. 80% common
b. Discrete, firm or hard	b. Matted due to periadenitis
c. Occurs in the cortex of lymph node	c. Involves medulla with periadenitis
d. Host immunity is good	d. Body resistance is not adequate
e. Drugs act better	e. Drugs do not reach in proper concentration and may not be effective
f. Drug resistance is uncommon	f. Drug resistance is common
g. No cold abscess or sinus formation	g. Cold abscess or sinus are common
h. Blood spread	h. Spread from tonsils

## Microscopic Features

- ◆ *Epithelioid cells* with caseating material are seen along with Langhans type of giant cells.

### Clinical types

- ❖ *Acute type*: Seen in infants and early childhood below 5 years
- ❖ *Hyperplastic type*: Lymphoid hyperplasia is typical; it is seen in patients with good resistance; hard discrete mobile lymph nodes; 15–20% common
- ❖ *Caseating type*: 75–80% common; matted nodes often with cold abscess; poor body resistance; seen in young adults
- ❖ *Atrophic type*: Rare type; seen in elderly; small lymph nodes but caseating type with atrophied nodes

## Clinical Features

- ◆ Swelling in the neck which is firm, matted.
- ◆ Cold abscess is soft, smooth, nontender, fluctuant, without involvement of the skin. It is not warm.
- ◆ As a result of increased pressure, cold abscess ruptures out of the deep fascia to form *collar stud abscess* which is adherent to the overlying skin.
- ◆ Once collar stud abscess bursts open, discharging sinus is formed. It can be multiple, wide open mouth, often undermined, nonmobile with bluish color around the edge. It is usually not indurated.
- ◆ *Tonsils may be studded with tubercles* and so clinically should always be examined.
- ◆ Associated pulmonary tuberculosis should also be looked for. In 20% cases of tuberculous lymphadenitis, there may be associated pulmonary tuberculosis or it may be a primary focus.
- ◆ Cervical spine is examined for tuberculosis.
- ◆ Axillary nodes, when involved, is due to retrograde lymphatic spread from neck nodes or blood spread.
- ◆ Inguinal lymph nodes are involved occasionally through blood.
- ◆ Bluish hyperpigmented involved overlying skin is called as *scrofuloderma*.
- ◆ Tuberculous pus with *caseating cheesy creamy* material is *infective* as it contains multiplying organisms.
- ◆ Atypical mycobacterial tuberculosis can occur occasionally. Such disease may be *resistant* to drug therapy.
- ◆ *Sinus may persist due to*—fibrosis, calcification, secondary infection, inadequate reach of drug to maintain optimum concentration in caseation.

## Differential Diagnosis

1. Nonspecific lymphadenitis.
2. Lymphomas, and chronic lymphatic leukaemia.
3. Secondaries in the neck.
4. Branchial cyst mimics cold abscess.
5. Lymph cyst mimics cold abscess.
6. HIV with lymph node involvement.
7. When there is discharging sinus—actinomycosis.

### Cold abscess

- ❖ Deep-to-deep fascia
- ❖ No evidence of signs of inflammation
- ❖ Not warm, nontender, smooth, soft and fluctuant, non-transilluminating
- ❖ Not adherent to skin (skin is free); no redness
- ❖ Contains cheesy caseating material
- ❖ It is seen in caseating tuberculous lymphadenitis due to caseation necrosis
- ❖ It may form collar stud abscess and later sinus
- ❖ FNAC, AFB, culture are useful investigations
- ❖ Differential diagnosis are branchial cyst, lymph cyst
- ❖ Treated by
  - Antituberculous drugs
  - 'Zig-zag' aspiration by wide bore needle in nondependent area to prevent sinus formation
  - Drainage using nondependent incision; later closure of the wound without placing a drain

## Investigations

- ◆ Haematocrit, ESR, peripheral smear.
- ◆ FNAC of lymph node and smear for AFB and culture. FNAC is very useful but not as superior as open node biopsy. False negative, false positive results and altering the node architecture, and so eventual need of open biopsy are the problems. *Epithelioid cells* (modified histiocytes/macrophages) are diagnostic. *Langhans giant cells*, lymphocytes, plasma cells are other features.
- ◆ *Open biopsy* when FNAC is inconclusive. Open biopsy is more *reliable* for tuberculosis (and also in lymphoma; but it is contraindicated in node secondaries); entire node ideally two nodes if possible has to be taken intact; one in formalin for pathology, other in normal saline for microbiology (AFB).

*It takes 5 years to learn when to operate, and 20 years to learn when not to.*

- ◆ HIV test (ELISA and western blot).
- ◆ *Löwenstein–Jensen media* is used for culture which takes 6 weeks to give result; *so selenite media* is often used which shows growth in 5 days.
- ◆ *Mantoux test* may be useful; but not very reliable.
- ◆ Chest X-ray to look for pulmonary tuberculosis.
- ◆ Polymerase chain reaction (PCR) is very useful method.

## Treatment

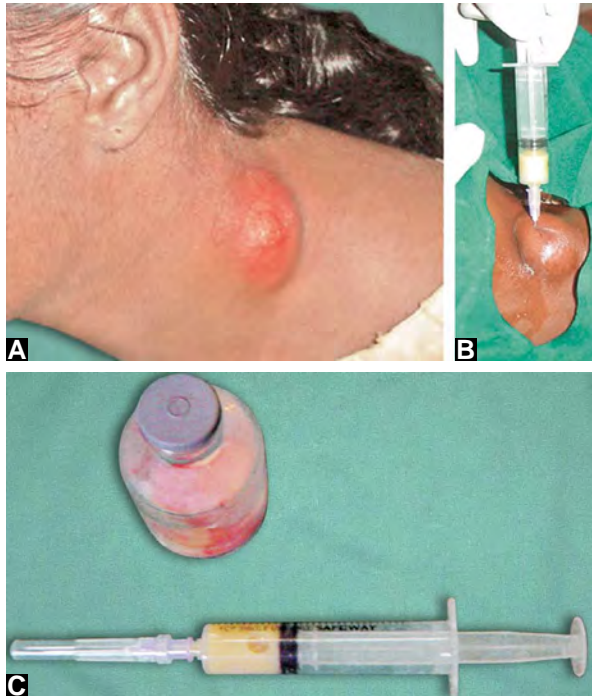
- ◆ Drugs

Antitubercular drugs has to be started:

- ◆ Rifampicin 450 mg OD on empty stomach. It is bactericidal. It discolours urine red. It is also hepatotoxic.
- ◆ INH: 300 mg OD. It is bactericidal. It causes intolerance of GIT, Neuritis, Hepatitis (INH).
- ◆ Ethambutol 800 mg OD. It is bacteriostatic. It causes GIT intolerance, retrobulbar neuritis (green colour blindness).
- ◆ Pyrazinamide 1500 mg OD (or 750 mg BD). It is bactericidal. It is hepatotoxic, also causes hyperuricaemia and increases psychosis. Duration of treatment is usually 6–9 months.

- ◆ *Aspiration*

When there is cold abscess, initially it is aspirated. [Wide bore needle is introduced into the cold abscess in a nondependent site along a “Z” track (in zig-zag pathway) so as to prevent sinus formation].



**Figs 5.34A to C:** Typical cold abscess in the neck in which pus is aspirated. Pus should be sent for cytology (for epithelioid cells), staining (Ziehl-Neelsen—AFB) and culture.

- ◆ *Incision and drainage*

If it recurs, then it should be drained. Drainage is done through a nondependent incision. After draining the caseating material, wound is closed without placing a drain.

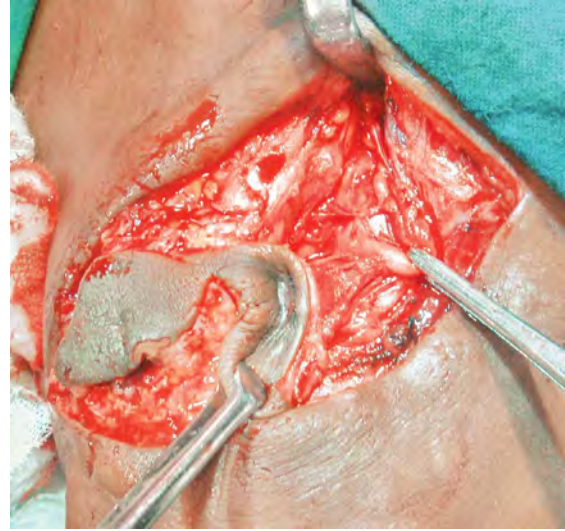
- ◆ *Surgical removal*

Surgical removal of tubercular lymph nodes are indicated, when

1. There is no local response to drugs or
2. When sinus persists.

It is done by raising skin flaps and removing all caseating material and lymph nodes. Care is taken not to injure major structures.

- ◆ *Excision of the sinus track* is often essential when sinus develops.



**Fig. 5.35:** Tuberculous sinus excision with excision of diseased lymph nodes.

## ■ COLD ABSCESS

Cold abscess is common in neck. It can also occur in groin, intercostal space, loin or any site where tuberculous caseating material with cheesy content can get collected and localised.

### Sites of Origin

Cold abscess may originate from tuberculosis of spine (thoracic or cervical spines), lymph node, internal organs, bone, etc.

### In the Neck

- ◆ *Tuberculous lymphadenitis* is common cause. Here cold abscess is commonly seen in *anterior triangle*.
- ◆ *Tuberculosis of cervical spine* is also an important cause. Commonly here cold abscess occurs in *posterior triangle*. Caseating material from the cervical spine collects *in front of* the vertebra behind the prevertebral fascia which eventually ruptures either anteriorly or posteriorly.
  - ▶ *Anterior rupture* allows passage of caseating material *below* and behind the prevertebral fascia reaching superior mediastinum; *laterally* behind the prevertebral fascia and carotid sheath to form cold abscess in posterior triangle; in midline upper part, protruding *forwards* from behind the prevertebral fascia in *midline* presenting as chronic retropharyngeal abscess; in midline lower part protrudes into oesophagus; caseation runs along the axillary sheath and neurovascular plane to reach axilla and arm to cause cold abscess in axilla and arm/cubital fossa.
  - ▶ *Posterior rupture* occurs towards spinal canal facilitating the passage of caseation along the cervical nerves towards posterior triangle and brachial plexus and so axilla and arm.

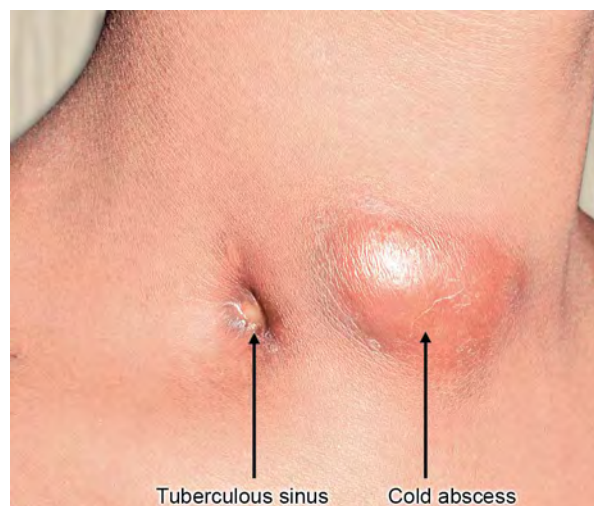


Fig. 5.36: Tuberculous cold abscess and sinus in the neck.

## Features

- ◆ It is common in young but can occur in any age group. Equal incidence in both sexes.
- ◆ Swelling in the neck, which is smooth, nontender, soft, fluctuant, nontransilluminating, with restricted mobility but is not adherent to skin.
- ◆ Neck pain, neck rigidity, restricted movements of cervical spine in case of cervical spine tuberculosis. With every change of position and often when patient is seated he supports his head with his hands and forearm—*Rust's sign* (Jan N Rust, Surgeon, Poland).
- ◆ Evening fever, loss of weight and appetite, anaemia.
- ◆ Features of systemic disease, if present like of pulmonary tuberculosis—cough, haemoptysis.
- ◆ Matted lymph nodes adjacent to cold abscess may be palpable.
- ◆ Oral cavity, tonsils, chest should be examined.
- ◆ Raised ESR, positive Mantoux test, anaemia, lymphocytosis, chest X-ray may show pulmonary tuberculosis, aspiration of cold abscess (FNAC) to see microscopically *epithelioid cells*. Acid-fast bacilli may be identified from the aspirated fluid using Ziehl-Neelsen stain.
- ◆ X-ray neck in case of cervical spine tuberculosis to identify reduced joint space, vertebral destruction, soft tissue shadow.
- ◆ MRI of cervical spine, US/CT scan neck are needed to confirm the anatomical location, number of lesions.

## Sequelae of Cold Abscess

- ◆ Secondary infection of the cold abscess making it tender.
- ◆ Formation of collar stud abscess, once pressure increases inside the cold abscess which will give way through the deep fascia to reach the subcutaneous plane to get adherent to skin.
- ◆ Sinus formation.
- ◆ Spread of disease to multiple lymph nodes and other organs.

## Differential Diagnosis

- ◆ Branchial cyst and other cystic swellings in neck.
- ◆ Secondaries in neck lymph nodes.
- ◆ Secondaries in cervical spine.

## Treatment

- ◆ Antituberculous drugs.
- ◆ Nondependent aspiration or drainage of the cold abscess.
- ◆ Excision of the diseased neck nodes.
- ◆ Immobilization of cervical spine by plaster jacket/collar for 4 months. Cervical spine fusion by open surgical method, if diseased spine is unstable.

## SECONDARIES IN NECK LYMPH NODES

### Levels in Neck Nodes (Memorial Sloan—Kettering Cancer Centre Levelling of Neck Nodes)

Level I—Submental (Ia) and submandibular (Ib) lymph nodes.

Level II—Lymph nodes in upper deep cervical region. (It extends from base of skull to hyoid bone and from lateral margin of sternohyoid to posterior margin of sternomastoid muscle). Level IIa is below and in front of the line of the spinal accessory nerve in the upper part; IIb is above and posterior.

Level III—Lymph nodes in middle cervical region (from hyoid bone to omohyoid muscle or cricothyroid membrane).

Level IV—Lymph nodes in lower cervical region (from omohyoid muscle/cricothyroid membrane to clavicle).

Level V—Lymph nodes in posterior triangle including supraclavicular region from posterior border of sternocleidomastoid muscle to anterior border of trapezius muscle. Level Va is above the line of spinal accessory nerve in the lower part; Vb is below.

Level VI—Lymph nodes in the midline neck—pretracheal and prelaryngeal from hyoid bone above to suprasternal notch below, medial border of carotid sheath on either side.

Level VII—Lymph nodes in the mediastinum. inferior to suprasternal notch to innominate artery below.

#### Note:

- Level II and V are now subdivided into Level IIa/Level IIb and Level Va/Level Vb; depending whether these nodes are above the level (Level IIb/Level Va) of the spinal accessory nerve or below (Level IIa/Level Vb).
- *Level I node* from oral cavity, lip, salivary gland, skin; *level II node* from oral cavity, oropharynx, nasopharynx, salivary gland; *level III node* from oral cavity, oropharynx, hypopharynx, larynx, thyroid; *level IV node* from oropharynx, hypopharynx, larynx, thyroid, cervical oesophagus; *level V node* from nasopharynx, scalp, GIT, breast, lungs.

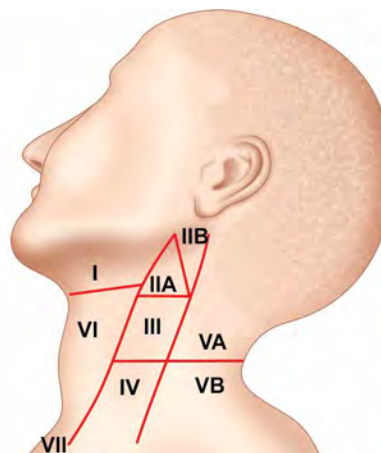


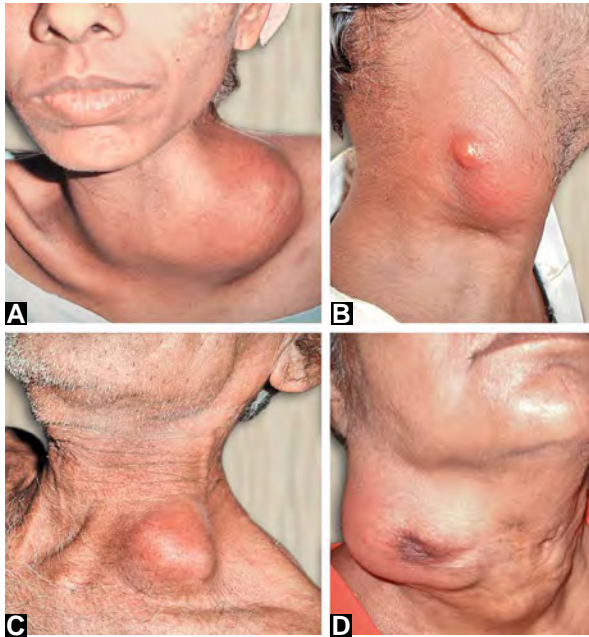Fig. 5.37: Levels of neck nodes.



### Common sites of primary

- ❖ Oral cavity, tongue, tonsils
- ❖ Salivary glands
- ❖ Pharynx—nasopharynx
- ❖ Larynx
- ❖ Oesophagus
- ❖ Lungs
- ❖ GIT
- ❖ Thyroid

- ◆ It is commonly from squamous cell carcinoma, but can also be from adenocarcinoma or melanoma.
- ◆ Squamous cell carcinoma is mainly from oral cavity, pharynx.



**Figs 5.38A to D:** Typical secondaries in the neck. Note the different levels involved in different patients. Note the skin involvement and sinus formation in few photos.

- ◆ Adenocarcinoma is usually from GIT, commonly involving left supraclavicular lymph nodes.
- ◆ Breast, lungs, abdominal viscera are other areas where primary may cause secondaries in neck which should be examined when suspected.

#### Note:

- 20% of metastatic squamous cell carcinoma is from aerodigestive tract.
- Source of primary from head and neck region usually have frequency like this—nasopharynx, tonsil, base of tongue, thyroid, larynx, floor of the mouth, cheek, palate, pyriform fossa. Non-head and neck source of primary are bronchus, oesophagus, breast, stomach.
- Histologically it is SCC (80%) or non-SCC. In non-SCC it may be poorly differentiated carcinoma (10-15%), adenocarcinoma (5-10%) or others like melanoma, poorly differentiated neoplasm (5%).
- In poorly differentiated neoplasm immunohistochemistry/immunoperoxidase staining, electron microscopy and chromosome analysis are needed to rule out lymphoma, neuroendocrine tumours, undifferentiated sarcomas.
- 3 years after treatment of one primary, if recurrence occur it is called as *new primary* in aerodigestive tract.
- Lower lip, tongue, soft palate and supraglottis can cause bilateral secondaries in neck.

- Soft palate, retromolar region, nasopharynx, hypopharynx posterior and lateral oropharynx can involve retropharyngeal nodes.
- Nasopharyngeal carcinoma spreads to level II-V, retro and parapharyngeal nodes.
- 15% of secondaries are from *infraclavicular primaries*—lung, pancreas, oesophagus, stomach, breast, ovaries, testis, prostate.
- Nodal spread below the lower border of cricoid (level IV and V; Lower) carries poor prognosis compared to nodes above cricoid (Upper).

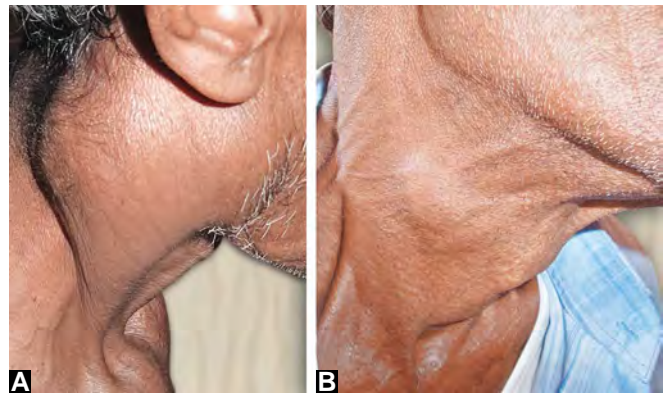
### Branchiogenic Carcinoma

It is a primary squamous cell carcinoma which is uncommon, arising from remnants of branchial cleft or arch. It is a differential diagnosis for secondaries in neck. It is common in men. It is common near the area of carotid bifurcation. Histologically it contains malignant squamous cells with lymphoid tissues around. It spreads to lymph nodes and can infiltrate into adjacent soft tissues.

*Treatment:* Wide excision.

### Features of Secondaries in Neck

- ◆ Common in adult/elderly male (Male to female ratio is 4:1), presents as painless rapidly increasing localised swelling in the neck.
- ◆ Nodular surface and hard in consistency, often fixed when it is advanced. Fungation, ulceration, haemorrhage can occur in advanced disease.
- ◆ Secondaries from *papillary carcinoma of thyroid* can be soft, cystic with brownish black fluid.



**Figs. 5.39A and B:** (A) Typical secondaries in the neck—well localized, hard swelling which is fixed to the sternocleidomastoid muscle; (B) Secondaries in the neck nodes from laryngeal carcinoma.

- ◆ Secondaries can infiltrate into carotids, sternomastoid, posterior vertebral muscles, spinal accessory nerve (shrugging of shoulder is affected), hypoglossal nerve (tongue will deviate towards the same side), cervical sympathetic chain (*Horner's syndrome*).
- ◆ Secondaries spread into adjacent soft tissues and also to the skin causing fungation and ulceration. Often because of tumour necrosis, softer area develops in the hard node. Skin fold prominence due to infiltration of the platysma is typical.
- ◆ In advanced cases tumour may infiltrate into the major vessels like carotids, or branches of external carotid artery causing torrential haemorrhage.
- ◆ Dysphagia, dyspnoea, haemoptysis, hoarseness of voice, ear pain, deafness are other features depending on the primary site.

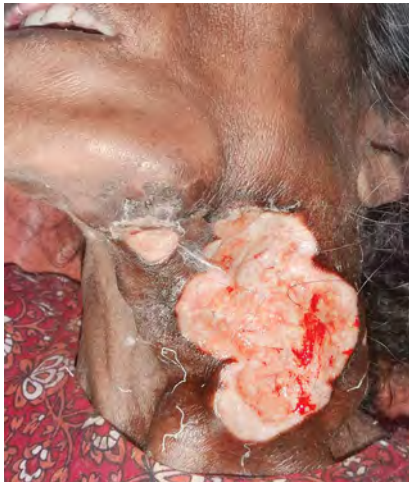
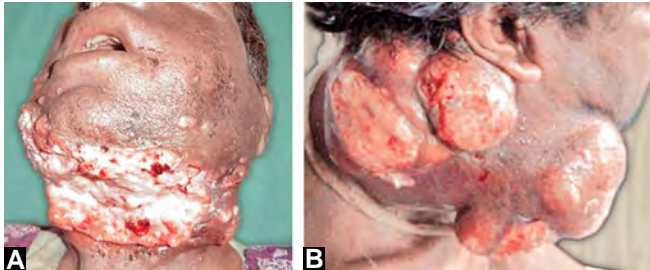
Fig. 5.40: Fungating secondaries in the neck—terminal illness.

- ❖ *Hoarseness*—carcinoma larynx, thyroid
- ❖ *Dysphagia*—carcinoma posterior 1/3rd of the tongue, pharynx, oesophagus
- ❖ *Haemoptysis, cough, dyspnoea*—carcinoma lung
- ❖ *Ear pain, deafness*—nasopharyngeal carcinoma
- ❖ *Spinal accessory nerve*—shrugging of shoulder is difficult
- ❖ *Hypoglossal nerve*—tongue deviates to same side with wasting
- ❖ *Sympathetic chain*—Horner's syndrome with miosis, anhidrosis, upper eyelid droop (pseudoptosis), enophthalmos, loss of spinociliary reflex



Figs 5.41A and B: Advanced secondary carcinoma neck with ulceration and fungation.

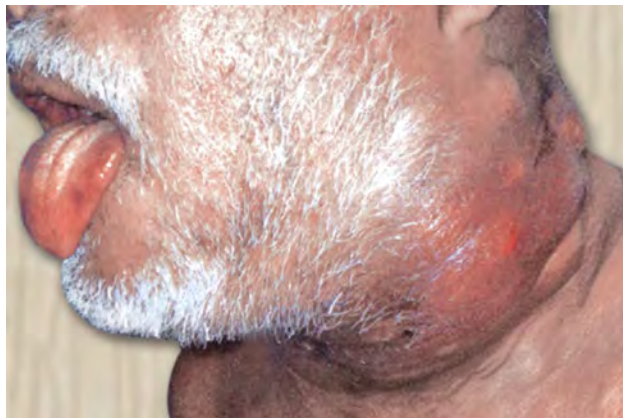

Fig. 5.42: Secondaries in neck with nodules and ulceration. Note the deviation of tongue towards same side due to hypoglossal nerve involvement.

## Types of Secondaries in the Neck

### 1. Secondaries in the Neck with Known Primary

- ❖ Here secondaries are present and primary has been identified clinically in the oral cavity, pharynx, larynx, thyroid or other areas.
- ❖ Biopsy from the primary and FNAC from the secondaries are done.
- ❖ Primary is treated accordingly either by curative radiotherapy or by surgery (wide excision).
- ❖ Secondaries, when mobile are treated by radical lymph node block dissection in the neck.

### 2. Secondaries in the Neck with Clinically Unidentified Primary

- ❖ Hard neck lymph nodes are the secondaries, but primary has not been identified clinically.
- ❖ FNAC of the neck node is done and secondaries is confirmed. Then search for the primary is done by various investigations.

They are:

- a. Panendoscopy
  - ▶ Nasopharyngoscopy.
  - ▶ Direct laryngoscopy.
  - ▶ Oesophagoscopy.
  - ▶ Bronchoscopy—if needed only.
- b. *Blind biopsies* are taken from fossa of Rosenmüller, lateral wall of pharynx, pyriform fossa, tonsillar bed, base of tongue, subglottic region (larynx). It is called as *surveillance biopsy* and is done to reveal unknown primary in 15% of cases of secondaries in neck. If this surveillance biopsy is negative, then *ipsilateral tonsillectomy* may be needed. *Presently bilateral tonsillectomy is recommended.*
- c. FNAC of thyroid and suspected areas.
- d. CT scan.

Once the biopsy confirms the primary, it is treated either by surgery or by *curative radiotherapy*.

Secondaries in the neck is treated by *radical neck dissection*.

### 3. Secondaries in the Neck with an Occult Primary

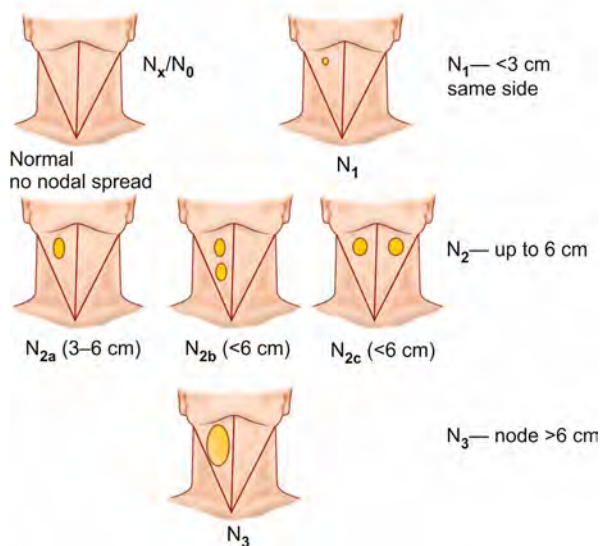
It is biopsy (FNAC) proven cancer of the neck node, which even after a complete clinical and radiological workup (that includes physical examination, CT scan, oesophagoscopy, laryngoscopy, bronchoscopy and multiple surveillance biopsies) reveals or yields no primary demonstrable lesion.

#### Occult primary sites which can cause secondaries in neck

- ❖ Fossa of Rosenmüller
- ❖ Lateral wall of pharynx
- ❖ Posterior third of the tongue
- ❖ Thyroid
- ❖ Paranasal sinuses
- ❖ Bronchus
- ❖ Oesophagus

Histologically secondaries in neck with occult primary may be of squamous cell carcinoma or of nonsquamous cell carcinoma, i.e. adenocarcinoma/poorly differentiated tumours (lymphoma/sarcoma/melanoma). In upper and midcervical region 80% are due to squamous cell carcinomas. In lower cervical and supraclavicular region 40% can be adenocarcinomas. Common sites of primary here (for adenocarcinoma) are thyroid, breast, gastrointestinal tract, salivary glands, lungs, prostate and kidney.

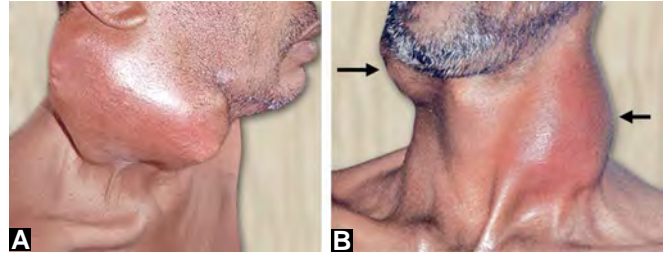
- ◆ Here secondaries in the neck lymph nodes are confirmed by FNAC, but primary has not been revealed clinically and by any available investigations.
- ◆ When all the investigations mentioned above are done, do not show any evidence of primary, only then it is called as *occult primary*.
- ◆ Primary tumor is not identified at the time when definitive therapy has started.
- ◆ 70% of occult nodes occur in jugulodigastric group.
- ◆ Differential diagnosis for secondary with occult primary is lymphoma and *primary branchiogenic carcinoma*.
- ◆ Reasons for primary lesion being occult—too small a primary to detect; possibility of immunological spontaneous regression of primary and inability of the present diagnostic tools to detect the primary.
- ◆ FNAC is the tool to confirm the occult secondary. If FNAC is inconclusive, only then open biopsy (incision/excision) is done to confirm. Open biopsy helps in high suspects of lymphomas or poorly differentiated carcinomas. It facilitates tissue study, immunohistochemistry, and special stains. Many studies prove that risk of seeding, survival and prognosis will not alter by open biopsy. But at present it is proposed only when FNAC fails or special methods are mandatory to type the disease. After open biopsy, frozen section confirmation and immediate neck dissection has to be done.
- ◆ Immunoperoxidase staining can be done in FNAC specimen or formalin fixed paraffin tissue using monoclonal or polyclonal antibodies. Immunoperoxidase is the most commonly used tool. It is mainly useful in lymphomas/neuroendocrine tumours. Electron microscopy is superior to immunohistochemistry as ultrastructure details can be assessed. But it is costly. Chromosomal analysis for tumour specific genes is used in B, T and germ cell lymphomas.
- ◆ Initially the secondaries in the neck are treated by *radical neck dissection*, then *regular follow-up* is done (at three monthly intervals) until the primary reveals.
- ◆ Once primary is revealed it is *confirmed by biopsy* and treated accordingly, either by *curative radiotherapy* or by *wide excision* depending on location of revealed primary.
- ◆ This type is usually less aggressive and has got better prognosis.



**Fig. 5.43:** Diagrammatic representation of neck lymph node staging in secondaries.

#### Nodal staging in secondaries

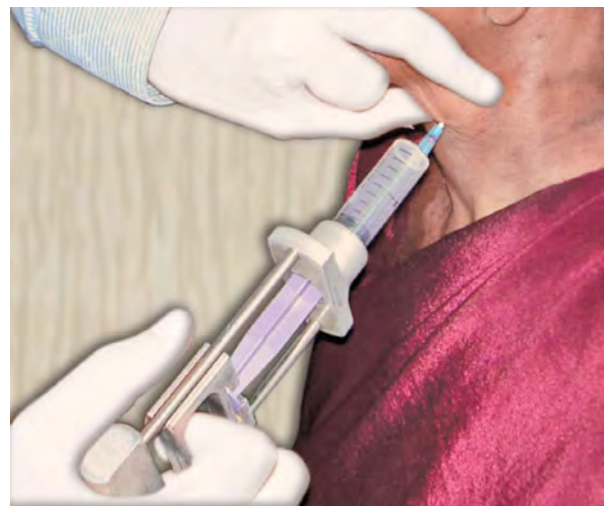- $N_x$ —nodes cannot be assessed
- $N_0$ —no nodal metastasis
- $N_1$ —single node same side <3 cm in greatest dimension
- $N_{2a}$ —single node same side 3–6 cm
- $N_{2b}$ —multiple nodes same side <6 cm
- $N_{2c}$ —bilateral/contralateral nodes <6 cm
- $N_3$ —node >6 cm



**Figs 5.44A and B:** (A) Large secondaries in neck with nodularity, with involvement of platysma below. (B) Bilateral secondaries are observed. **Skin fold prominence is obvious.**

#### Investigations for Secondaries in Neck

- ◆ *FNAC of secondary:* Open incision biopsy is not advised here. It destroys the fascial barriers and causes the spread of tumour faster and earlier into next level nodes or other soft tissues. Eventual neck dissection technically becomes difficult. Recurrence rate in neck will be higher after open biopsy. If FNAC of node and all investigations for primary become negative, then open biopsy of node following confirmation with frozen section and immediate neck dissection is undertaken. In such situation if neck dissection is delayed after open biopsy confirmation, chances of cure will be reduced.



**Fig. 5.45:** FNAC of neck lymph node. It is very useful method in secondaries in neck node and tuberculosis. Its use is equivocal in lymphoma where open biopsy of the node is preferred method. (Courtesy: Dr Krishna Upadhy, Pathologist, Nandikoor Laboratory, Mangaluru).

- ◆ *Biopsy from primary:* Incision biopsy is the choice here.
- ◆ Blind biopsies from suspected areas.
- ◆ Nasopharyngoscopy, laryngoscopy, bronchoscopy, oesophagoscopy—*panendoscopy* with examination under anaesthesia.
- ◆ CT scan is to see the base of skull, paranasal sinuses, nasopharynx, extension of primary tumour/secondary deposits; CT scan of chest and abdomen.
- ◆ Chest X-ray to visualise primary or secondaries in case of melanomas or mediastinal nodes.
- ◆ MRI scan or PET scan in conjunction with CT scan or MRI. MRI identifies soft tissue extension/changes; guided primary biopsy is possible; extension into bone is identified.
- ◆ CT chest and abdomen in case of infraclavicular primaries or to assess nodes.

#### Note:

- Testing for human papilloma virus (HPV) and Epstein-Barr virus (EBV) is useful in primary carcinoma of tonsil or base of the tongue.

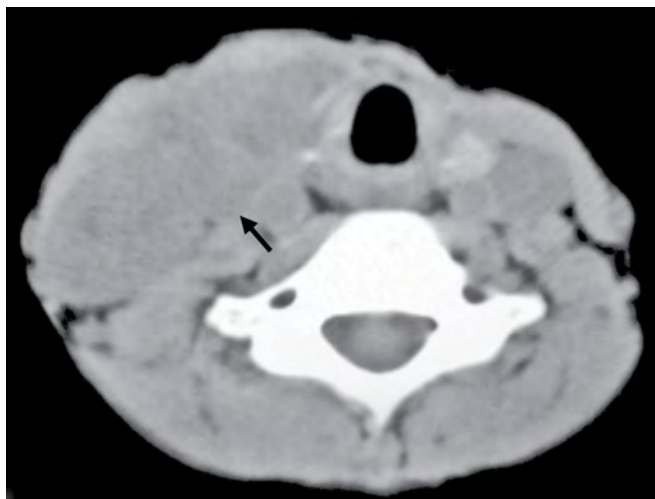
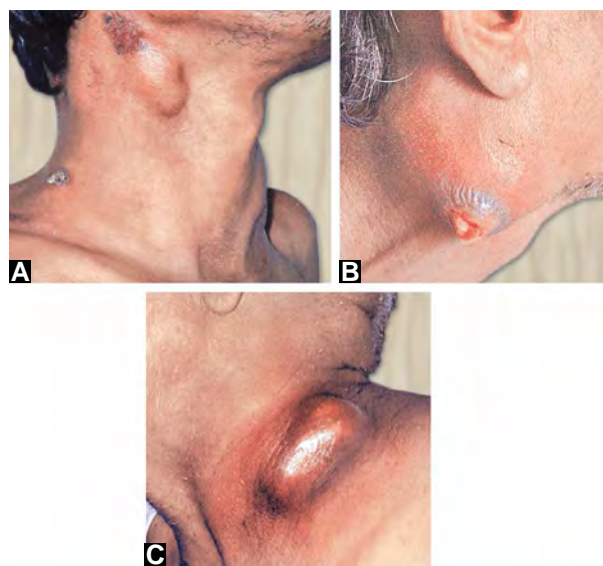


Fig. 5.46: CT neck showing secondaries.

- Open incision biopsy is avoided in secondaries in neck nodes; done only if FNAC fails or in suspected lymphoma or poorly differentiated carcinoma.
- Neck secondaries adenocarcinoma is common in lower neck, where primary is located below the clavicle—breast, lungs or digestive tract. Adenocarcinoma in nodes of upper neck may be from salivary glands, thyroid or parathyroids.
- *Triple endoscopy* includes nasopharyngoscopy; direct laryngoscopy; oesophagoscopy.

#### Differential diagnosis

- ❖ Lymphomas
- ❖ Tuberculous lymphadenitis
- ❖ Nonspecific lymphadenitis
- ❖ HIV
- ❖ Chronic lymphatic leukaemia



Figs 5.47A to C: (A) Secondaries in neck but no skin involvement; (B and C) Secondaries with skin involvement is obvious.

#### In secondaries neck with occult primary

- ❖ FNAC of node/open biopsy to confirm
- ❖ Proper clinical methods to identify the location of primary
- ❖ CECT is the investigation of choice to look for primary
- ❖ Other methods are—MRI, triple endoscopy, examination under anaesthesia, blind biopsies from fossa of Rosenmuller, pyriform fossa, base of tongue, subglottic area and tonsils, FNAC of thyroid, ipsilateral/*bilateral* tonsillectomy if surveillance biopsy and other methods are negative
- ❖ Once occult primary is confirmed and if node is less than 3 cm in size, it is treated as N<sub>1</sub> disease with RND/MRND
- ❖ Postoperative RT is essential if disease is N<sub>2a</sub>; N<sub>2b</sub> (more than 2 nodes are positive); if 2 or more levels are involved; if extracapsular spread is present
- ❖ In fixed lymph node/nodes, initially radiotherapy is given followed by surgery (RND), if nodes become mobile and later adjuvant chemotherapy
- ❖ In N<sub>2c</sub> bilateral neck dissection (one side IJV preservation) with bilateral RT is given
- ❖ N<sub>3</sub> stage has got poor prognosis. RND and RT with later chemotherapy are used. In fixed nodes, RT and then chemotherapy is used
- ❖ Proper follow-up at regular intervals is essential with all diagnostic tools to identify the possible site of primary which may get revealed during follow-up period

#### Treatment

<b>N1</b>	MRND/RND and RT, if capsular invasion
<b>N2a</b>	Mobile node RND then RT Fixed node RT to downstage then RND
<b>N2b</b>	RT then RND
<b>N2c</b>	Bilateral RND then bilateral RT
<b>N3</b>	Fixed—first RT then RND, if it becomes mobile (downstage) followed by chemotherapy Mobile—RND then RT, followed by chemotherapy

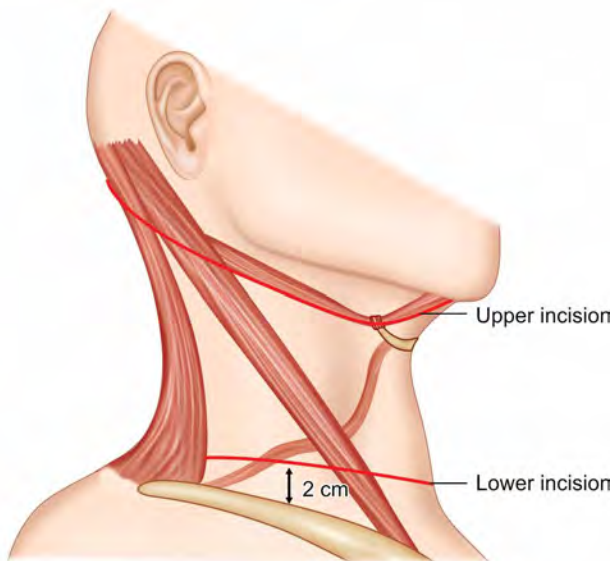
Note: Chemoradiation (Chemo—RT) is also a good option either before or after RND. IMRT (Intensity Modulated RT) is better.

*Listen to the faintest sound; for opportunities knock only once.*

- ◆ Primary is treated depending on the site, either by *wide excision (surgery)* or by *curative radiotherapy*. Then the secondaries are treated.
- ◆ Secondaries when *mobile*, are treated by *radical neck dissection*.
- ◆ When *fixed* it is *inoperable*. *Palliative external radiotherapy* is given to palliate pain and to prevent the anticipated bleeding.
- ◆ Sometimes *initially*, *external radiotherapy* is given to *downstage* the disease so that it becomes operable and later classical block dissection can be done.
- ◆ *Postoperative RT* is given after neck dissection when—more than two lymph nodes are positive for metastases; nodes show metastases at two or more levels; extracapsular spread in lymph node. Suspected occult primary is included/covered in the RT field. RT is also given to contralateral neck nodes in nasopharyngeal carcinoma. Level II lymph node *alone* from an occult is more likely to be from nasopharyngeal carcinoma and RT is preferred in such situation covering nasopharyngeal area; later RND is done.

## Types of Block Dissection

### 1. Classic Radical Neck Dissection



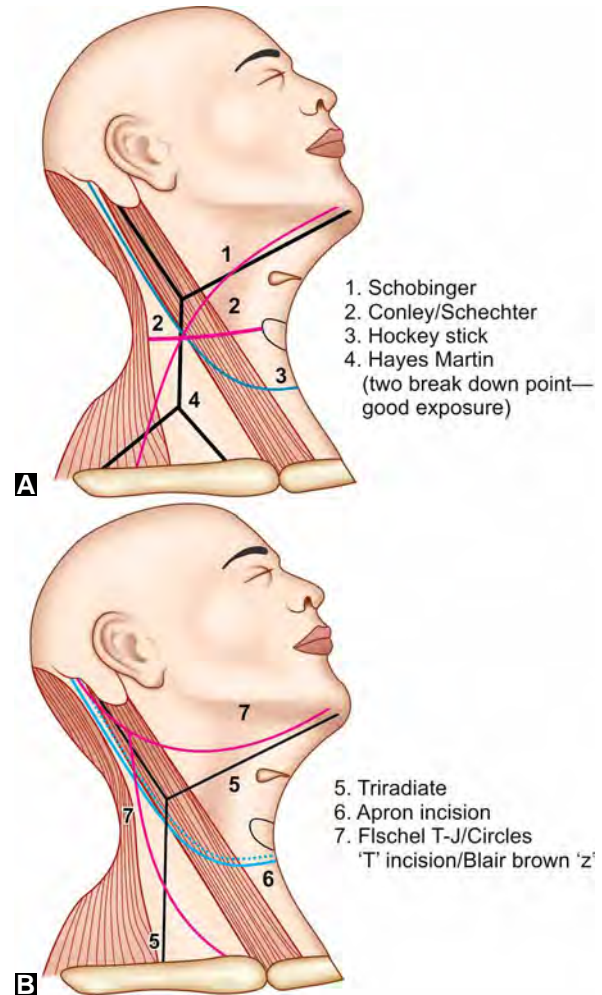
**Fig. 5.48:** MacFee incision for radical neck dissection. Upper incision is from mastoid process along the line of digastric to hyoid bone point, then upwards to chin. Lower incision is parallel to clavicle 2 cm above from anterior margin of trapezius to midline.

It is resection of lymph nodes (level I to V), fat, fascia, sternomastoid muscle, omohyoid muscle, internal jugular vein, external jugular vein, accessory nerve, sub-mandibular salivary gland, lower part of parotid, prevertebral fascia—“*en-block*” (*Criles' operation*).

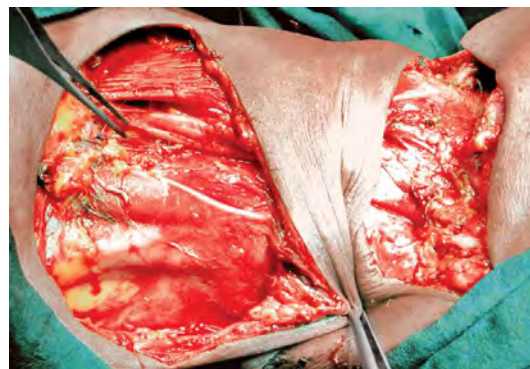
Incision that is commonly made are *Fischel T* or *modified Criles'* or *Mac Fee* incisions which are two parallel incisions, one at submandibular region, another at supraclavicular region. Blood supply of the flap remains intact and so healing will be better without flap necrosis.

### 2. Conservative Functional Block Dissection (After BOCCA Surgeon): (Modified Radical Neck Dissection—MRND)

It is done only in selected cases where tumour is very well-differentiated and less aggressive like in papillary carcinoma of thyroid with

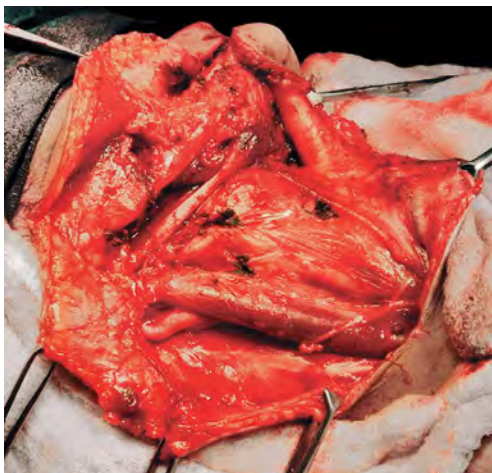

**Figs 5.49A and B:** Incisions/different approaches for radical (RND/MRND) neck dissections. There are many incisions mentioned. Few of them are shown in diagram.



**Fig. 5.50:** Radical neck dissection, on table.

lymph node secondaries. Structures preserved here are sternomastoid muscle, internal jugular vein and spinal accessory nerve.



**Fig. 5.51:** Radical neck dissection on table photo. Note the internal jugular vein, digastric muscle, strap muscles, lower margin of the mandible.

- ◆ Only spinal accessory nerve is preserved—MRND type I (most important). N-Preserved.
- ◆ Accessory nerve and sternocleidomastoid are preserved—MRND type II. NM-Preserved.
- ◆ Accessory nerve, sternomastoid and internal jugular veins are preserved—MRND type III. NMV-Preserved. It is called as *functional neck dissection*.

### 3. Supraomohyoid Block

Removal of only fat, fascia, lymph nodes, muscles, submandibular salivary gland, with dissection above the omohyoid muscle is done. Done only in selected individuals with well-differentiated tumour and involvement of few submandibular lymph nodes (*Levels I, II, III are removed*). Done in N0 lesions.

Here ideally (*done in N0 cases*) after dissection, frozen section biopsy should be done; if nodes are positive, MRND/RND should be done depending on grading of the primary.

### 4. Bilateral Neck Dissection

Here internal jugular vein is preserved on one side. *Always the side where the vein is preserved, is operated first* (If both the jugulars are ligated, cerebral congestion occurs leading to cerebral oedema which is dangerous. Jugular veins are ligated as an inevitable procedure during surgery, the patient is kept in propped-up position; antibiotics, diuretics, steroids, mannitol infusion are given, repeated CSF taps are done to control the cerebral oedema).

*Ligating one IJV increases the ICP by 3 fold; both IJV ligations increase ICP by 5 fold.* ICP gradually falls over 8–10 days. For this reason pressure dressing should be *avoided* over the wound of neck dissection after surgery.

### 5. Commando Operation (Combined Mandibular Dissection and Neck Dissection)

It is *en-block removal*, which includes wide excision of primary tumour with hemimandibulectomy and neck block dissection, *Examples:* It is done usually in carcinoma of tongue or floor of the mouth; it is a *composite resection* of primary tumour, mandible and radical neck dissection (RND).

### 6. Lateral Neck Dissection (Anterolateral/Jugular/ALND)

It is done in laryngeal and pharyngeal primaries with clinically negative nodes. Levels II, III, IV are removed bilaterally.

### 7. Anterior (Central) Dissection

Level VI (pre, paratracheal) nodes are removed.

### 8. Posterolateral Dissection

Levels II, III, IV, V are removed for cutaneous malignancies, with suboccipital nodes.

### 9. Extended Radical Dissection

Removal of one or more additional groups of lymphatics or removal of nonlymphatic structures with RND is called as extended RND.

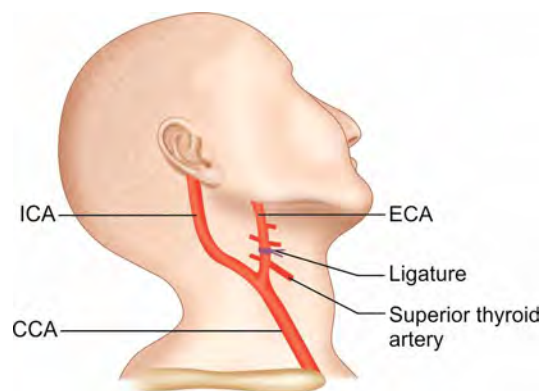
Additional nodes in the mediastinum are cleared (level VII). Nodes like level VI or parapharyngeal, retropharyngeal, external carotid artery, hypoglossal nerve, vagus nerve, parotid gland, mastoid tip—are addressed.

#### Complications of block dissection

- ❖ Haemorrhage
- ❖ Infection
- ❖ Lymph ooze
- ❖ Carotid blow out
- ❖ Seroma and flap necrosis
- ❖ Frozen shoulder is common
- ❖ Rarely pneumothorax and chylous fistula
- ❖ Drooping of shoulder due to paralysis of trapezius in radical neck dissection

#### Note:

- To control haemorrhage in head and neck cancers and during head and neck surgeries (like radical parotidectomy, commando operation, maxillectomy) often ligation of external carotid artery is required. **Ligation should be done distal to the origin of the superior thyroid artery.** It should never be ligated below the origin of the superior thyroid artery as this will lead to formation eddy current and thrombus at the carotid bifurcation and intracranial embolism. Ligation of ECA to control bleeding is usually done in continuity.
- Middle of the neck, laterally over CCA is the poorly vascularised area of skin which can lead into skin necrosis. So vertical incision or three point junctions at this point should be avoided. Horizontal incisions are better in neck.
- Carotid artery should be protected by *muscle flap* or *free dermal graft*. *Levator scapulae* muscle flap is commonly used.



**Fig. 5.52:** Ligation of external carotid artery should be done when needed distal to the origin of the superior thyroid artery.

Type of neck dissection	Nodes removed	Structures preserved
<b>Comprehensive:</b>		
Radical neck dissection (RND):	Level I-V	None
MRND type I	Level I-V	Spinal accessory nerve
MRND type II	Level I-V	Spinal accessory nerve; sternomastoid muscle
MRND type III	Level I-V	Spinal accessory nerve; sternomastoid muscle; IJV
<b>Selective node dissection:</b>		
Supraomohyoid neck dissection (N <sub>0</sub> )	Level I-III	Spinal accessory nerve; sternomastoid muscle; IJV
Extended supraomohyoid dissection (N <sub>0</sub> )	Level I-IV	Spinal accessory nerve; sternomastoid muscle; IJV
Anterolateral neck dissection (N <sub>0</sub> )	Level II-IV	Spinal accessory nerve; sternomastoid muscle; IJV
Posterolateral neck dissection (N <sub>0</sub> )	Level II-V with suboccipital, retroauricular nodes	Spinal accessory nerve; sternomastoid muscle; IJV
Anterior/central dissection	Level VI	Spinal accessory nerve; sternomastoid muscle; IJV

Carotid blow out is most dangerous complication. It is due to sepsis, wound breakdown, stripping of arterial adventitia, necrosis and drying of the artery. Ligation of the carotid is done to save the life of the patient but procedure itself has got 20% mortality and 50% morbidity (hemiplegia).

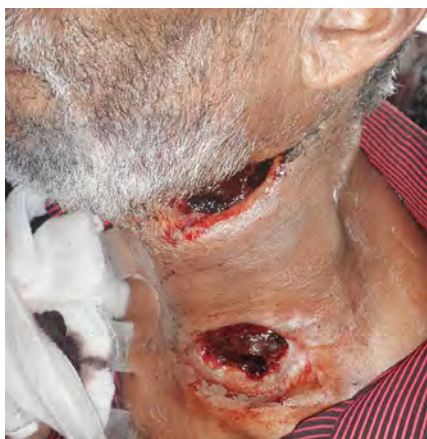

Fig. 5. 53: Impending carotid blow out after radical neck dissection.

## CHEMOTHERAPY FOR HEAD AND NECK CANCERS

It may be used alone or as multimodality therapy.

### Types

- ◆ **Adjuvant chemotherapy:** Chemotherapy is used before, during or after main therapeutic modality (surgery or radiotherapy). When

used before it is called as anterior/*induction* chemotherapy. It reduces the burden, downstages the tumour, reduces the chance of micrometastasis that may occur during surgery. When used with radiotherapy (concurrent) it is used as radiosensitiser. When used after surgery/radiotherapy it is called as *posterior* chemotherapy.

- ◆ **Palliative chemotherapy:** It is used in advanced/recurrent/metastatic cancers to relieve symptoms like pain/dysphagia/dyspnoea or to prevent chances of bleeding or fungation. It may be single drug therapy like methotrexate/bleomycin/cisplatin/5-fluorouracil or multidrug combination chemotherapy. Combination chemotherapy is more beneficial which increases efficacy.
  - ◆ Methotrexate—40 mg/m<sup>2</sup> IV weekly. It causes mucositis, bone marrow suppression with liver and kidney toxicity. Hydration and alkalinisation of urine before and after therapy is beneficial to reduce toxicity.
  - ◆ 5-Fluorouracil—10–15 mg/m<sup>2</sup> IV daily for 5 days. Complications are bone marrow suppression and gastrointestinal symptoms.
  - ◆ Bleomycin—10–20 mg/m<sup>2</sup> IV weekly. Pneumonitis and *pulmonary fibrosis* are the complications.
  - ◆ Vincristine—1–2 mg/m<sup>2</sup> IV monthly. *Neurotoxicity* (sensory and motor neuropathy), constipation and alopecia are the side effects.
  - ◆ Cisplatin—80–120 mg/m<sup>2</sup> IV infusion once in 3 weeks. Complications are neurotoxicity, bone marrow suppression, renal toxicity, ototoxicity. Adequate hydration and mannitol diuresis may be needed.
  - ◆ Cyclophosphamide—60–120 mg/m<sup>2</sup> IV for 5 days at regular 3 weeks cycles. Alopecia, bone marrow suppression and *cystitis* (haemorrhagic) are the toxicities (ABC). Barbiturates should be avoided during therapy.
  - ◆ Adriamycin—60–90 mg/m<sup>2</sup> IV. It is *cardiotoxic* and hence cardiac monitoring is needed while infusion.
  - ◆ Paclitaxel and carboplatin as empiric chemotherapy are used in neck secondaries with occult primary.

### Mode of Administration

- ◆ It can be given by *intra-arterial route*, through *external carotid artery* (Never through internal carotid as it will cause cerebral damage). Site of arterial catheter should be confirmed by Doppler or angiogram. Drug is usually administered through an arterial pump. Other method is to increase the height of the drip stand to get a pressure above the level of the systolic pressure of the patient (i.e. more than 13 ft).
  - ◆ Drugs can also be given intravenously or orally (methotrexate).
- General toxicity of chemotherapeutic agents:** Mucositis, alopecia, stomatitis, nausea and vomiting, diarrhoea, bone marrow suppression.

Often transfusions of blood/FFP/platelet are needed before or after chemotherapy depending on parameters.

### Monitoring the Patient on Chemotherapy

- ◆ Clinical assessment—pulse, blood pressure, alopecia, urine output, jaundice, skin changes like rashes, fever, pallor.
- ◆ Biochemical parameters—total count, platelet count, blood urea and serum creatinine, liver function tests.
- ◆ Specific relevant tests—chest X-ray, endoscopy, CT scan, tumour marker if specific in some types of carcinomas.

#### Note:

For carotid artery aneurysm—refer Chapter on Arterial Diseases.

# Chapter 6

## Thyroid

*(The thyroid gland) has no very evident mechanical or local office to fulfill.... Yet we may one day be able to show that a particular material principle is slowly formed, and partially kept in reserve; and that this principle (serves) important subsequent functions in the course of the circulation.... Something analogous to a reservoir function obtains in this part.*

—Thomas Wilkinson King, 1836

### CHAPTER OUTLINE

❖ Development	❖ Retrosternal Goitre	❖ Hashimoto's Thyroiditis
❖ Anatomy	❖ Thyrotoxicosis and Hyperthyroidism	❖ De-Quervain's Subacute Granulomatous Thyroiditis
❖ Physiology	❖ Radioactive Iodine	❖ Riedel's Thyroiditis
❖ Congenital Anomalies	❖ Thyroid Neoplasms	❖ Thyroid Incidentaloma
❖ Thyroid Function Tests	❖ Differentiated Thyroid Carcinoma	❖ Thyroidectomy
❖ FNAC of Thyroid	❖ Papillary Carcinoma of Thyroid	❖ Emil Theodor Kocher
❖ Classification of Goitre	❖ Follicular Carcinoma of Thyroid	❖ Kocher's Test
❖ Diffuse Hyperplastic Goitre	❖ Anaplastic Carcinoma of Thyroid	❖ Hypothyroidism
❖ Multinodular Goitre	❖ Medullary Carcinoma of Thyroid	❖ Recurrent Laryngeal Nerve Palsy
❖ Discrete Thyroid Nodule	❖ Malignant Lymphoma	
❖ Solitary Thyroid Nodule		

### DEVELOPMENT

The thyroid gland develops from a median down growth of a column of cells from the pharyngeal floor between the first and second pharyngeal pouches (subsequently marked by the foramen caecum of the tongue).

The canalised column becomes the *thyroglossal duct* which is displaced forward by the developing hyoid bone and then below the hyoid, lies slightly to one side, more commonly to the left. The duct bifurcates to form the thyroid lobes and a portion of the duct forms the pyramidal lobe.

### ANATOMY

It is located in the anterior triangle of the neck. It weighs about 20 grams. Gland lies against C5 to T1 vertebra.

### Parts

- ❖ *Right and left lateral lobes* located in a space (thyroid fossa) between trachea and oesophagus medially and carotid sheath laterally. Each lobe is  $5 \times 3 \times 1.5$  cm in size, extends from the middle of thyroid cartilage to 6th tracheal ring. Right lobe is larger than left. Gland is larger in females compared to males.
- ❖ *Isthmus* is the connecting part between two lateral lobes in midline extending from 2nd to 4th tracheal rings.
- ❖ *Pyramidal lobe* is upward extension as fibrous strands or muscular strands from the junction of the isthmus and left lateral lobe. It is seen in 30% of individuals.
- ❖ Gland is invested by *pretracheal fascia*.
- ❖ *Berry's ligament* is a strong condensed vascular connective tissue between the lateral lobe and cricoid cartilage on each side.

*Success is the ability to go from one failure to another with no loss of enthusiasm.*



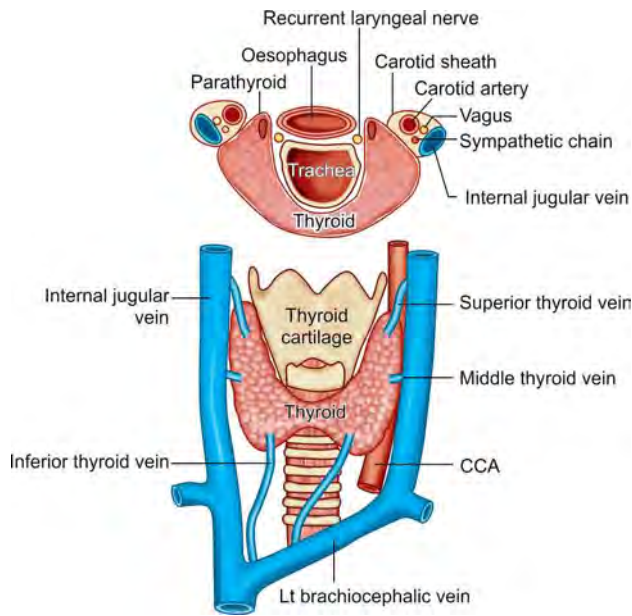


Fig. 6.1: Relations of the thyroid.

## Blood Supply

- ◆ *Superior thyroid artery* is first anterior branch of external carotid artery enters the gland near superior pole as a larger anterior superficial branch and a smaller posterior branch.
- ◆ *Inferior thyroid artery*, a branch of thyrocervical trunk of subclavian artery passes behind the carotid sheath running medially reaching the posterolateral aspect of the gland.
- ◆ *Thyroidea ima artery*, a branch of aorta or brachiocephalic artery enters the isthmus or lower pole of one of the lateral lobes (3%).
- ◆ Tracheal and oesophageal branches serve blood supply to retained thyroid gland after thyroidectomy.

## Venous Drainage

- ◆ *Superior thyroid vein*. It accompanies the superior thyroid artery to join IJV or common facial vein.
- ◆ *Middle thyroid vein* is short and stout; drains into the internal jugular vein. It is first to be ligated in thyroidectomy.
- ◆ *Inferior thyroid veins* are many in number. They join the left brachiocephalic vein.
- ◆ Kocher's 4th thyroid vein is found in between middle and inferior thyroid veins which join the IJV.

## Lymphatic Drainage

- ◆ **Primary:**
  - ▶ *Prelaryngeal or cricothyroid node* also called as *Delphian node* is a node (single node) located anterior to cricothyroid membrane between cricothyroid muscles and is the most important node among level VI nodes. Delphian node receives afferent lymphatics from larynx and from upper anterior parts of the both lobes of the thyroid gland and its isthmus. It has got two efferent lymphatics; one towards paratracheal and lower jugular, other towards pretracheal (sub-Delphian), mediastinal and supraclavicular lymph nodes. R. Randall from Harvard coined the term Delphian (formerly purpose of this node was uncertain. Delphi is a place in Greece where Pythia, snake

women after inhaling sulphurous fumes uttered meaningless jargon, the purpose of which was unclear; it also means that spread to this node predicts the outcome of laryngeal and thyroid cancers in the same way prophecy of Apollo at temple of Delphi foretold the future in the ancient Greece).

- ▶ *Paratracheal* (located at lateral wall of the trachea and tracheo-oesophageal groove) and *pretracheal* (*sub-Delphian nodes* are in front of trachea and isthmus) receive afferents from remaining thyroid and from Delphian node. Its efferents reach lower jugular and mediastinal nodes.
- ▶ *Perithyroidal nodes* are nodes along the superior and inferior thyroid veins which drain into pretracheal, paratracheal nodes.
- ▶ *Mediastinal nodes* up to the level of innominate (brachiocephalic) vessels get the afferent from pretracheal and paratracheal nodes. *Central nodal compartment* includes all nodes from trachea to carotids; nodes from hyoid bone above to innominate artery below with pretracheal nodes. It is level VI and mediastinal nodes above the level of innominate artery.

- ❖ Ascending medial lymph vessels from the upper border of isthmus drain to prelaryngeal nodes which are located in the cricothyroid membrane.
- ❖ Ascending lateral vessels from the upper pole of the gland along the superior thyroid artery drain into deep cervical nodes.
- ❖ Descending medial vessels begin at lower part of the isthmus to reach pretracheal lymph nodes.
- ❖ Descending lateral vessels run from the deep surface of the thyroid to recurrent laryngeal chain nodes.

## Secondary:

- ▶ Deep cervical nodes.
- ▶ Supraclavicular nodes.
- ▶ Occipital nodes.

## Important Relations of Thyroid Gland

- ◆ *Recurrent laryngeal nerve* lies in the tracheo-oesophageal groove, in relation to Berry's ligament.
- ◆ *Superior laryngeal nerve* which gives a branch, external laryngeal nerve supplies cricothyroid muscle. It accompanies superior thyroid artery.
- ◆ *Parathyroid glands*—four in number, two on each side embedded in thyroid.

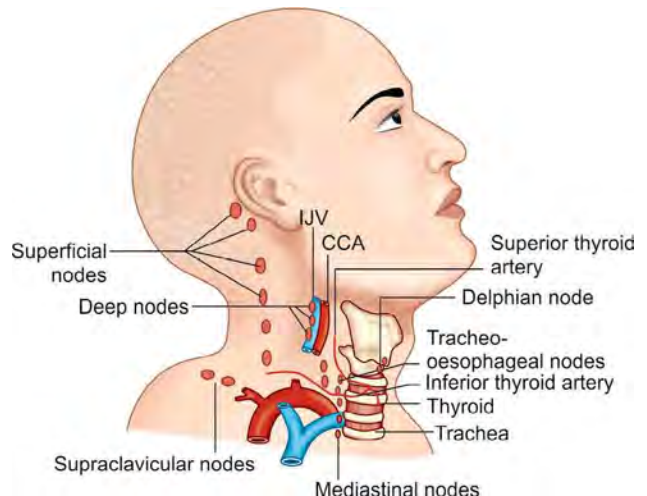


Fig. 6.2: Lymphatic drainage of thyroid.

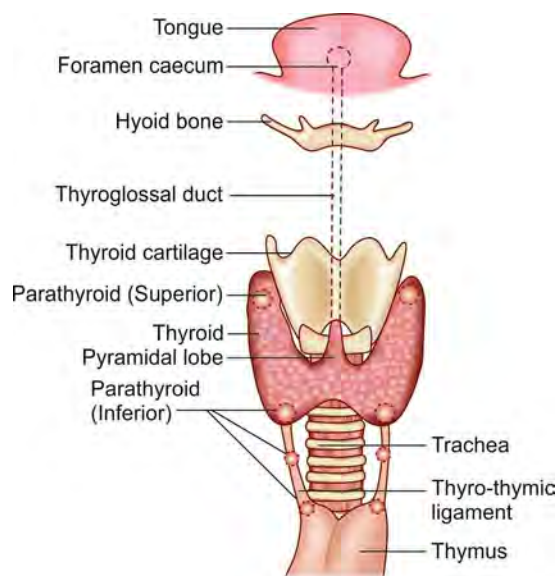


Fig. 6.3: Anatomy of thyroglossal duct showing its pathway.

## PHYSIOLOGY

Thyroid gland has two secretory cells:

1. *Follicular cells*—secretes thyroid hormones (Thyroxine ( $T_4$ ), Tri-iodothyronine ( $T_3$ )).
2. *Parafollicular cells* ('C' cells)—secretes calcitonin.

## I<sub>2</sub> Metabolism

Ninety per cent of body iodide uptake is in the thyroid gland, whose uptake into the follicular cells is regulated by TSH and follicular iodide content.

## Thyroid Hormone Synthesis

Iodothyronines (MIT, DIT) are formed in follicular cells by the coupling of inorganic iodide with tyrosine. These are biologically inert molecules.  $T_4$  (Thyroxine) is formed by coupling of 2 DIT molecules and  $T_3$  (Tri-iodothyronine) is formed by coupling of 1 MIT and 1 DIT molecules. Both are bound to thyroglobin which is the primary component of colloid matrix.

The hypothalamus-pituitary-thyroid axis regulates thyroid hormone production and releases in a classic feedback system. TRH is a regulatory hormone from hypothalamus and TSH is a regulatory hormone from anterior pituitary.

## CONGENITAL ANOMALIES

*Athyreosis* is total absence of lateral lobes and isthmus with hypothyroidism.

## Ectopic Thyroid

Ectopic thyroid refers to the presence of thyroid tissue in locations other than the normal anterior neck region. It is the most frequent form of thyroid agenesis. It lies along the course of the thyroglossal tract as entire gland or as residual thyroid tissue.

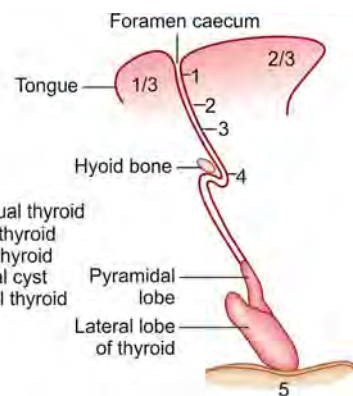


Fig. 6.4: Ectopic sites of thyroid.

Ectopic thyroid tissue may lie anywhere along the line of descent. Whole of the thyroid gland or residual thyroid lies in an abnormal position either in the posterior part of the tongue, or in the upper part of the neck in midline, or intrathoracic region. Carcinoma develops more commonly in ectopic thyroid tissue than normal thyroid. Radioisotope scan, CT scan for intrathoracic thyroid will confirm the diagnosis.

## Lingual Thyroid

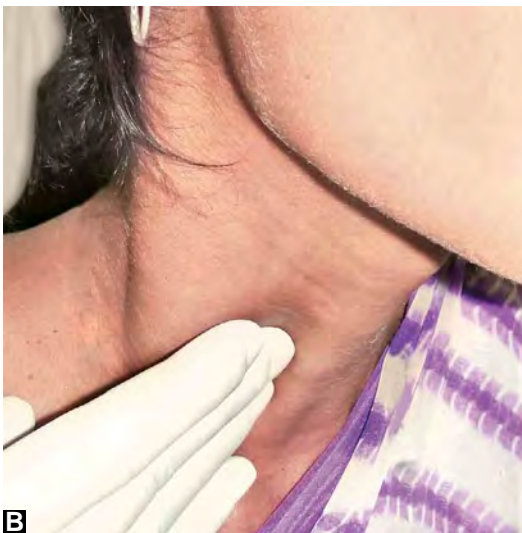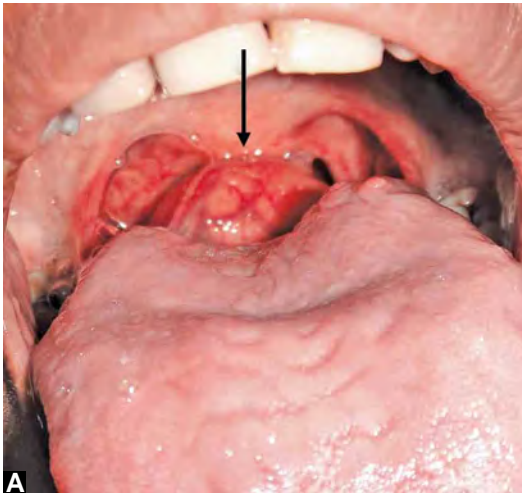
- ◆ It is a thyroid swelling in the posterior third of tongue, at the foramen caecum, presenting as rounded swelling (pink round strawberry like mass). It may be the only existing thyroid tissue which may cause:
  - a. Dysphagia, pain, speech impairment, stomatolalia (speech with clogged nostrils), foreign body sensation, cough, snoring, sleep apnoea.
  - b. Respiratory obstruction, haemorrhage.
  - c. 70% present as hypothyroidism, 10% as cretin.
  - d. Common in females (3:1).
  - e. Symptoms coincide with puberty, pregnancy.
- ◆ Bare tracheal rings in midline with absence of normal thyroid tissue may often be evident.
- ◆ Incidence is 1:100,000.
- ◆ Any diseases which can occur in normal thyroid can also occur in lingual thyroid, i.e. nodularity, toxicity, malignancy (If turns malignant, *follicular carcinoma* is more common, papillary carcinoma is very rare).

### Differential diagnosis for lingual thyroid

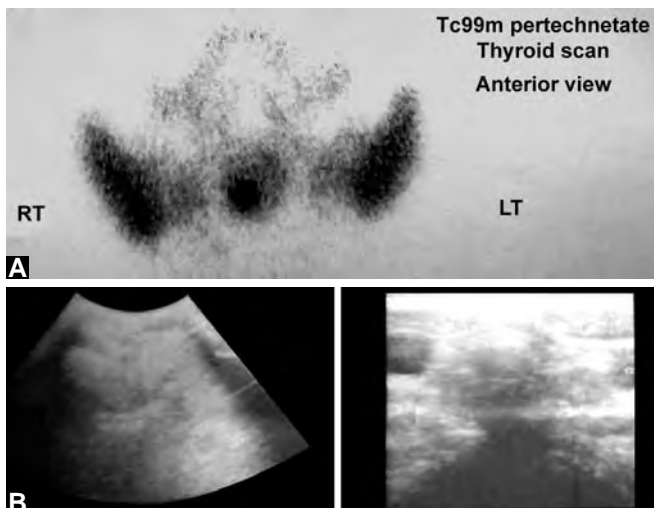
- ❖ Carcinoma of posterior third of tongue
- ❖ Angiofibroma, haemangioma, lipoma, papilloma
- ❖ Sarcoma, minor salivary gland tumour
- ❖ Hypertrophied lingual tonsil

### Diagnosis

- ◆ *Radioisotope study* shows the uptake of iodine by the lingual thyroid and also shows the status of the thyroid in normal fossa.
- ◆ Ultrasound neck has to be done to see the absence of thyroid in normal location.
- ◆ MRI is very useful in lingual thyroid.



**Figs 6.5A and B:** Lingual thyroid visible on the posterior 1/3rd of the tongue. Neck should be palpated for the presence or absence of normal thyroid.



**Figs 6.6A and B:** Technetium-99 radioisotope scan in lingual thyroid. USG of neck is done to assess lingual thyroid and normal thyroid region.

- ◆ Endoscopy guided FNAC/tissue biopsy is done to confirm or lingual thyroid is suspected to be pathological.
- ◆ Thyroid function tests should be done. Commonly, it is hypothyroid but rarely can be toxic.

#### Treatment

- ◆ L-thyroxine is given daily orally.
- ◆ *Surgical excision* is indicated in a large lingual thyroid with obstructive features, bleeding, ulceration, cystic degeneration or malignant transformation. Usually it is done through *transoral approach*. Energy sources like harmonic device or laser is very useful in avoiding troublesome bleeding and safe extirpation. Mucosa is sutured after excision using polyglatin. Occasionally mandibulotomy and tongue splitting/transhyoid/suprahyoid or lateral pharyngotomy incision as *external approach* may be needed when there is malignancy or very large mass.
- ◆ Radioisotope therapy for ablation is also often used.

#### Thyroglossal Cyst

- ◆ Thyroglossal cyst is a swelling occurring in the neck in any part along the line of thyroglossal tract.
- ◆ It is due to failure of the thyroglossal duct/tract to obliterate completely; there will be persistent duct at certain part forming cystic swelling containing mucus fluid.

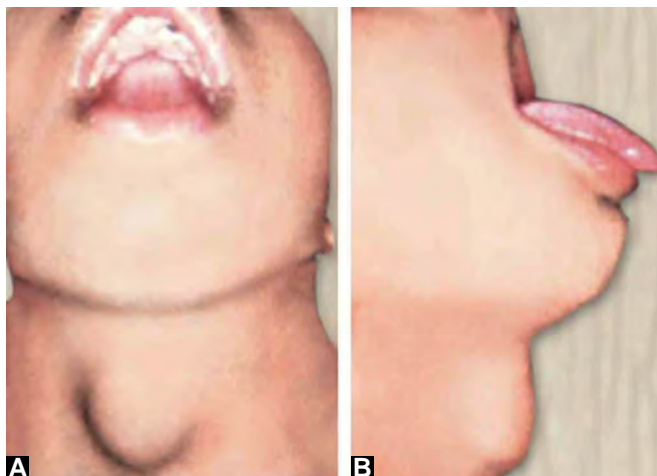
##### Possible sites for thyroglossal cyst

- a. Beneath the foramen caecum
- b. In the floor of mouth
- c. Suprahyoid
- d. Subhyoid—commonest site
- e. On the thyroid cartilage—2nd common site

- ◆ It is usually *congenital* wherein there will be degeneration of a part of the tract causing cystic swelling. Normal thyroid may be present in the normal location (fossa). Sometimes, thyroid may not be present in the normal site but may be present in the wall of the thyroglossal cyst.
- ◆ It is a tubulodermoid type of cyst.
- ◆ It is lined by pseudostratified, ciliated columnar epithelium.

#### Clinical Features

- ◆ Swelling in the midline, towards the left.
- ◆ Moves with deglutition as well as with the protrusion of tongue. Patient is asked to open the mouth and keep the lower jaw still. Examiner holds the cyst between the thumb and forefinger. When the patient is asked to protrude the tongue, a “*tugging sensation*” can be felt.
- ◆ Swelling is smooth, soft, fluctuant (cystic), nontender, mobile, often transilluminant.
- ◆ Thyroid fossa is empty, if there is no thyroid in normal location.
- ◆ Thyroglossal cyst can get infected and may form an abscess. Cyst wall contains lymphatic tissue and so infection is common.
- ◆ Malignancy can develop in thyroglossal cyst (papillary carcinoma)—1%. Cyst will be harder, fixed, with palpable neck nodes. More often it is difficult to suspect and will



Figs 6.7A and B: Thyroglossal cyst.

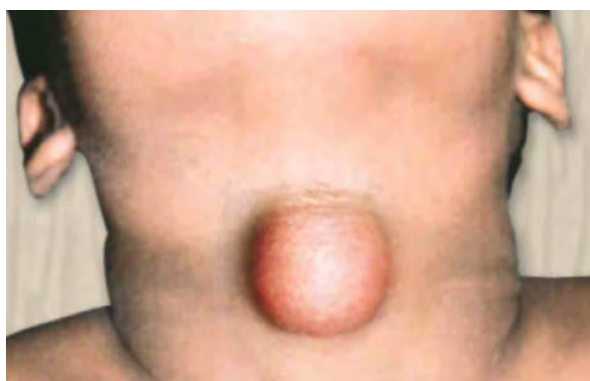


Fig. 6.8: Thyroglossal cyst in a boy. It is a midline swelling with a 'TUG' feeling while protruding the tongue out.

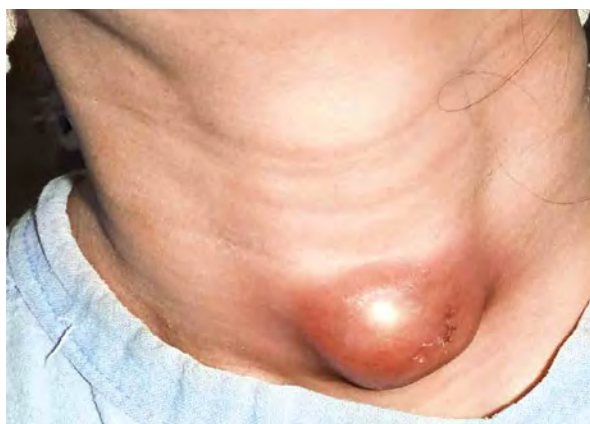

Fig. 6.9: Infected thyroglossal cyst.

be confirmed by histology after excision. If biopsy report is papillary carcinoma, then completion thyroidectomy is indicated if the remaining part is nodular thyroid or shows cold nodule or there are enlarged neck nodes, or with history of neck irradiation. If neck nodes are present, node dissection, and radioactive iodine therapy with suppressive dose of L thyroxine 0.3 mg OD is needed.

- ◆ Incidence is equal in both sexes.

### Investigations

- a. Radioisotope study.
- b. Ultrasound neck; T3, T4, TSH estimation.
- c. FNAC from the cyst.

### Differential diagnosis for thyroglossal cyst

- ❖ Subhyoid bursa
- ❖ Pretracheal lymph node
- ❖ Dermoid cyst
- ❖ Solitary nodule of thyroid—isthmus
- ❖ Submental lymph node
- ❖ Collar stud abscess

### Treatment

#### a. Sistrunk operation:

Excision of cyst and also full tract upto the foramen caecum is done along with removal of central part of the hyoid bone, as the tract passes through it.

#### Technique

Through transverse neck incision placed over the cyst, skin flap is raised above along with platysma. Care should be taken not to open the cyst. Cyst with surrounding tissues is dissected up to the hyoid bone. Sternohyoid and thyrohyoid muscles are divided. Central part of the hyoid bone of 1 cm width is resected along with intact track within it. Geniohyoid and mylohyoid muscles are divided off from the hyoid. Track with adjacent tissues is dissected above upto the foramen caecum. Adjacent tissues also should be removed because of possibility of multiple tracks which otherwise lead to recurrence or fistula formation. Often anaesthetist is asked to apply digital pressure over the base of tongue near foramen caecum to facilitate the dissection and to confirm the reach up to the foramen caecum. Track is ligated at foramen caecum and removed. Recurrence rate by removal of only track without central hyoid is 25%. Removal of track with central hyoid of 1 cm width reduces the recurrence rate to 5%. Complications are recurrence, thyroglossal fistula formation, haemorrhage/haematoma formation and infection. Low lying cyst often requires two parallel incisions to remove entire track up to foramen caecum.

- b. If there is no normal thyroid gland after the surgery, maintenance dose of L-thyroxine 0.1 mg OD is given life long.

#### Note:

If tract is not completely excised, it will result in thyroglossal fistula.

### Thyroglossal Fistula

- ◆ It is not a congenital condition. It is acquired.
- ◆ It either follows infection of thyroglossal cyst which bursts open or after inadequate removal of the cyst.
- ◆ It is lined by columnar epithelium, discharges mucous and is a seat of recurrent inflammation. "Hood sign" is characteristic. Opening of fistula is indrawn and been overlaid by a fold of skin as 'hood'.
- ◆ Peculiar crescentic appearance is called as *semilunar* sign.
- ◆ It secretes mucus discharge.
- ◆ Site of the fistula is just below the hyoid bone commonly; in infants it may be much lower.
- ◆ **Investigations:** Radioisotope study and fistulogram.
- ◆ **Treatment:** Sistrunk operation.

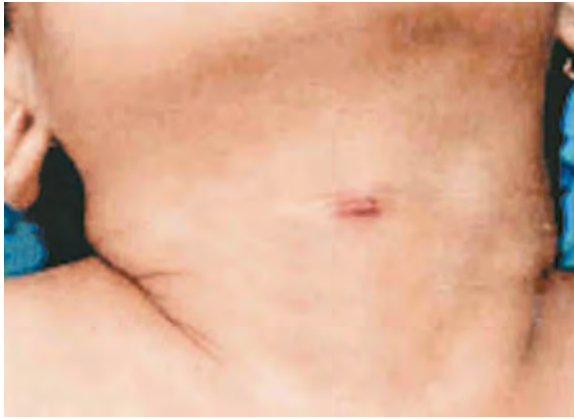

Fig. 6.10: Thyroglossal fistula.

**Note:**

One more sistrunk operation is done in case of lymphoedema.

### Lateral Aberrant Thyroid

- ◆ It is at present considered as a misnomer.
- ◆ It is the metastasis into cervical lymph node from a papillary carcinoma of thyroid.
- ◆ FNAC has to be done and treated as papillary carcinoma of thyroid.

### Agensis

- ◆ Total agensis of one thyroid lobe may occur. This is rare but can be clinically important. It leads to confusion in diagnosis, especially in the toxic gland, where it could be diagnosed as a secreting nodule.

### Dyshormonogenesis

- ◆ It is an autosomal recessive condition wherein there is either deficiency of thyroid enzymes (either peroxidase or dehalogenase) or inability to concentrate or to bind or to retain iodine.
- ◆ It may be familial and patient presents with large diffuse vascular goitre involving both lobes.
- ◆ They respond very well to L-thyroxine and may not require surgery at any time.
- ◆ Condition may be associated with congenital deafness which is being called as *Pendred's syndrome*. CT scan of temporal bone shows abnormal bony labyrinth. Condition shows thyroid peroxidase deficiency.

### THYROID FUNCTION TESTS

1.  $T_3$  (Serum tri-iodothyronine): 1.2–3.1 nmol/litre. 80% of  $T_3$  is from deiodination of  $T_4$  at periphery in liver, muscle, kidney and pituitary.  $T_3$  is 4 times more potent with half life of 24 hours.
2.  $T_4$  (Serum thyroxine): 55–150 nmol/litre. It reflects the output of the gland (Edward Calvin Kendall 1915).
3. TSH 0–5 IU/ml of plasma. TSH is secreted from anterior pituitary; its secretion is inversely related to circulating thyroid hormones. TSH secretion is regulated by TRH from hypothalamus.
4. *PBI* (Protein-bound iodide)—8  $\mu\text{g}/100\text{ ml}$ .
5. *Free*  $T_3$  is 0.3% (3–9 nmol/litre). It is the best single test in assessing hyperthyroidism.
6. *Free*  $T_4$  is 0.03% (8–26 nmol/L).

7. *RA I<sup>123</sup>* scan can show either cold nodule, hot nodule, or warm nodule.
8. *TRH stimulation test* for hypothalamic—pituitary axis: Intravenous TRH (200  $\mu\text{g}$ ) shows rise in serum TSH level in 20 minutes (from basal 1  $\mu\text{ unit/ml}$  to 10  $\mu\text{ unit/mL}$ ) and reaches to normal in 2 hours. Patients with pituitary insufficiency develop a subnormal response; patient with hypothyroidism will show enhanced TSH response; in hyperthyroidism there will be no response. This test is useful in doubtful hyperthyroidism, hypothyroidism,  $T_3$  thyrotoxicosis, ophthalmic Graves' disease.
9. Serum creatinine is increased in hyperthyroidism; decreased in hypothyroidism.
10. Serum cholesterol is increased in hypothyroidism and decreased in hyperthyroidism.
11. BMR is increased in hyperthyroidism.
12. *Thyroid autoantibodies* are also useful to evaluate the function (LATS). TSH receptor antibodies (TSH RAb) has got long-acting potential and are reasons for all primary thyrotoxicosis.
13. *Werner's  $T_3$  suppression test*: Initial isotope uptake study is done. 40  $\mu\text{g}$  of  $T_3$  is given to the patient orally 8th hourly for 5 days. Uptake study is repeated. In normal uptake suppression up to 80% is noted. In toxic goitre suppression is 10–20%. It is used in patients with antithyroid drugs for primary thyrotoxicosis to assess the remission status.
14. *Thyroglobulin estimation*: Normal value is 0.5–50  $\mu\text{g/L}$ . It is used during follow-up period especially in follicular carcinoma of thyroid. But if thyroglobulin antibodies are raised in patient, then it is of no use. Thyroglobulin is produced only by the thyroid tissue. After total thyroidectomy, its level drastically reduces. It is the ideal follow-up marker in well-differentiated thyroid carcinoma after thyroidectomy. Sudden raise in its serum level can occur in thyroiditis, primary or secondary toxic goiter.

### FNAC OF THYROID

- ◆ It is the investigation of choice in most of the thyroid diseases to conclude pathological diagnosis.
- ◆ It is useful in papillary/medullary (amyloid)/anaplastic carcinomas, lymphomas, colloid nodule, thyroiditis.
- ◆ 23G needle is used. Suspicious solitary/multiple nodules/dominant nodules should be aspirated.
- ◆ *Karolinska hospital* (Lowhagen) at Sweden pioneered this method.
- ◆ Minimum six aspirations should be done. An adequate FNAC smear should have six aspirations with six groups of cells with each group containing 20 cells. USG-guided aspiration is better.
- ◆ Diagnostic accuracy of FNAC is 95%; sensitivity 85%; specificity 94%.
- ◆ Aspiration is *graded* as: Thy 1—Nondiagnostic; Thy 2—Nonneoplastic; Thy 3—Follicular; Thy 4—Suspicious of malignancy; Thy 5—malignancy.
- ◆ In a cyst of thyroid FNAC may be less reliable; if cyst recurs after 3 aspirations, surgery is needed.
- ◆ Malignancy rate in a simple cyst is 5%; in a complex cyst, it is 75%.
- ◆ FNAC is *not reliable* at present in follicular carcinoma of thyroid as capsular and vascular invasions cannot be found. But by newer technique it is possible to identify the differences—Benign is polyploidy, malignant is aneuploidy; benign are monoclonal, malignant are polyclonal; MR spectroscopy and thyroimmunoperoxidase estimation are useful to differentiate.
- ◆ FNNAC (fine needle nonaspiration cytology)—is said to be more reliable.

### USG in thyroid

- ❖ To identify nodules, number, size, vascularity, echogenicity
- ❖ To do USG-guided FNAC
- ❖ To identify neck lymph nodes
- ❖ To find out solid or cystic nature
- ❖ Benign lesion is *hyperechoic*, often cystic with well-defined margin; shows peripheral *egg shell calcification* with sonolucent rim (halo) around nodule
- ❖ Malignant lesion is *hypoechoic* with poorly defined margin, with high vascularity, with microcalcification without any halo around

## CLASSIFICATION OF GOITRE

**Goitre** is enlargement of thyroid gland. ('goiter'-Latin-guttur-throat)

### 1. Simple nontoxic

#### a. Diffuse hyperplastic:

- Physiological
  - Puberty.
  - Pregnancy.
- Primary iodine deficiency (Endemic; dietary iodine intake less than 100 µg/day).
- Secondary iodine deficiency:
  - Goitrogens of Brassica family, e.g. cabbage, soya bean. Common in hill stations.
  - Excess dietary fluoride.
  - Drugs: PAS, lithium, phenylbutazone, thiocyanates, potassium perchlorate, antithyroid drugs, radioactive iodine.
  - Dysmorphogenetic goitre.

#### b. Colloid goitre.

#### c. Nodular goitre (Multinodular).

#### d. Solitary nontoxic nodule.

#### e. Recurrent nontoxic nodule.

#### f. Wolff-Chaikoff effect (1948):

Intake of large quantity of iodides inhibits the further release of thyroid hormones (inhibits organification) by autoregulatory mechanism; but later may cause escape phenomenon.

#### g. Hokkaido goiter:

Hokkaido is northern island in Japan where iodine rich seaweeds are the main diet intake of which causes goitre in these individuals.

### 2. Toxic

#### a. Diffuse (Primary)—Graves' disease.

#### b. Multinodular (Secondary)—Plummer's disease.

#### c. Toxic nodule (solitary) (Tertiary).

#### d. Recurrent toxicosis.

### 3. Neoplastic

#### a. Benign—adenomas: follicular, Hurthle cell.

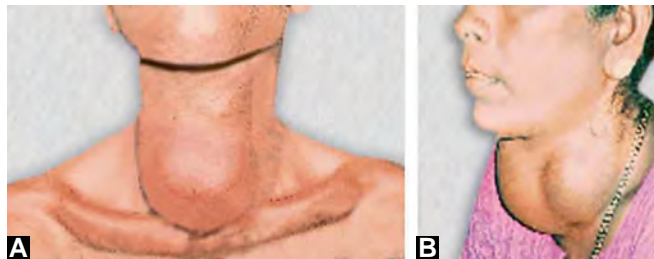
#### b. Malignant:

- Carcinomas: Papillary, follicular, medullary, anaplastic.
- Lymphomas.

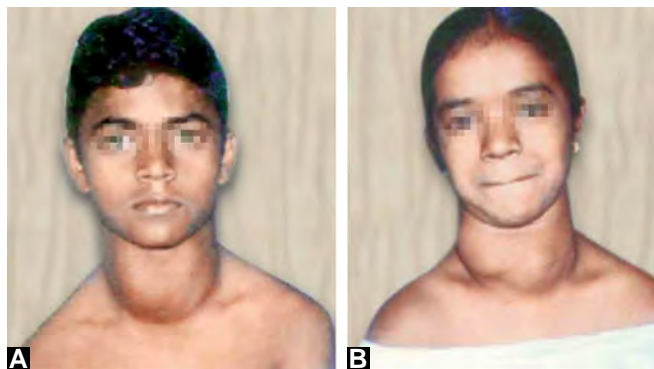### 4. Thyroiditis

#### a. Hashimoto's autoimmune thyroiditis.

- b. de-Quervain's autoimmune thyroiditis.
  - c. Riedel's thyroiditis.
5. Rare causes: Bacterial (suppurative), amyloid.



**Figs 6.11A and B:** Note the goitres in (A) male and (B) female patient.



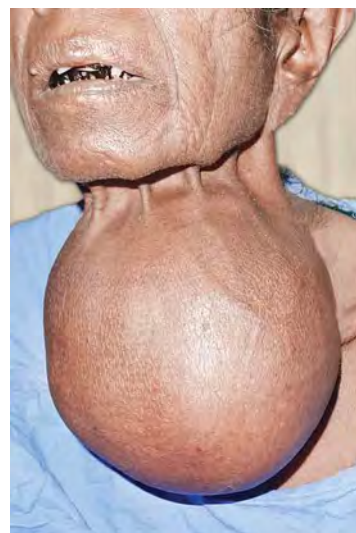**Figs 6.12A and B:** Familial goitre. Goitres in brother and sister.

### WHO grading of goitre

Grade 0: No visible or no palpable goitre.

Grade 1: Palpable thyroid/goitre but not visible in normal positioned neck.

Grade 2: Goitre which is visible in normal positioned neck.



**Fig. 6.13:** Large goitre—could be colloid type.

*In the case of retrosternal goitre, hemoptysis unmixed with sputum is due to rupture of an engorged tracheal vein.*  
—Peter Burgess

### In a case of thyroid disease, following things should be made very clear

- ❖ Functional status—hyperthyroid/euthyroid/ hypothyroid
- ❖ Compression on trachea/recurrent nerve
- ❖ Neck lymph nodal status
- ❖ Tracheal deviation
- ❖ Carotid infiltration
- ❖ Retrosternal extension
- ❖ Systemic features like toxicity or malignant spread to different organs like bone/liver/lungs

## DIFFUSE HYPERPLASTIC GOITRE

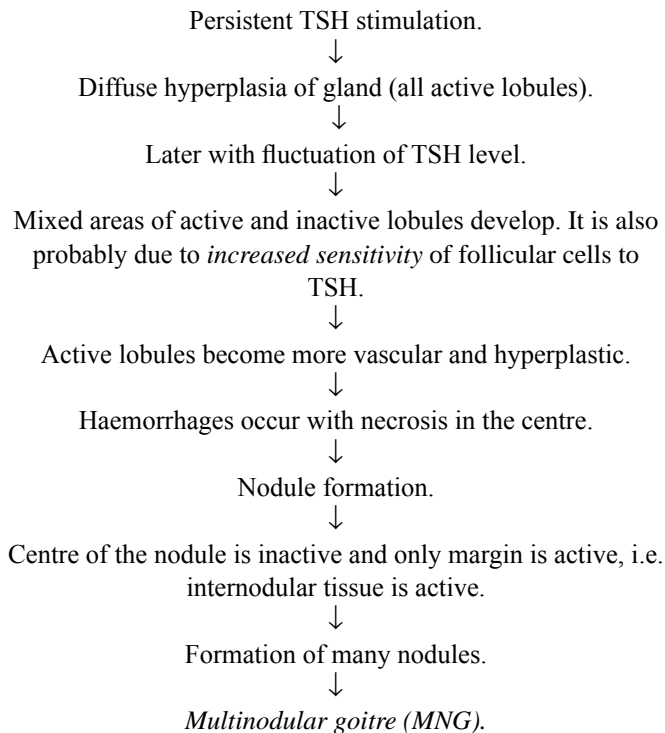
Initial persistent increase in TSH level causes diffuse active lobules. In late stages of diffuse hyperplasia, TSH stimulation decreases and many follicles become inactive, get filled with colloid and it is called as *colloid goitre*.

As *diffuse hyperplastic goitre* is a reversible stage, *L-thyroxine* is beneficial.

## MULTINODULAR GOITRE (MNG)

- ◆ MNG is discordant growth with functionally and structurally altered thyroid follicles presenting as multiple nodules in thyroid.
- ◆ It may be due to mainly *fluctuation in TSH level*; other causes may be iodine deficiency, goitrogens, hereditary, dysmorphogenesis.

## Pathogenesis



Other factors involved are growth-stimulating immunoglobulins and growth prone cell clones.

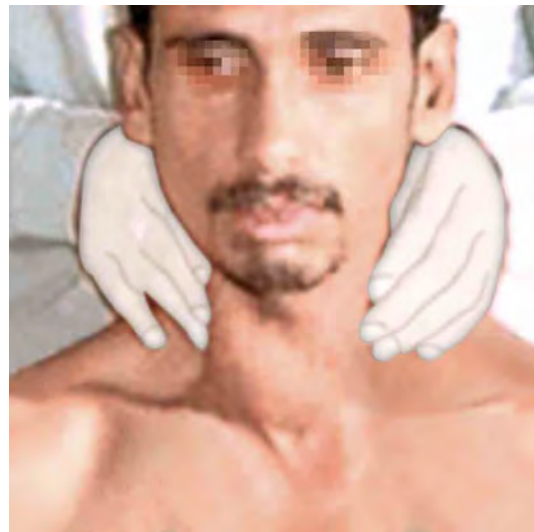## Stages of multinodular goitre formation

- ❖ Stage of hyperplasia and hypertrophy
- ❖ Stage of fluctuation in TSH
- ❖ Stage of formation of nodules (inactive); (inter-nodular tissues are active)

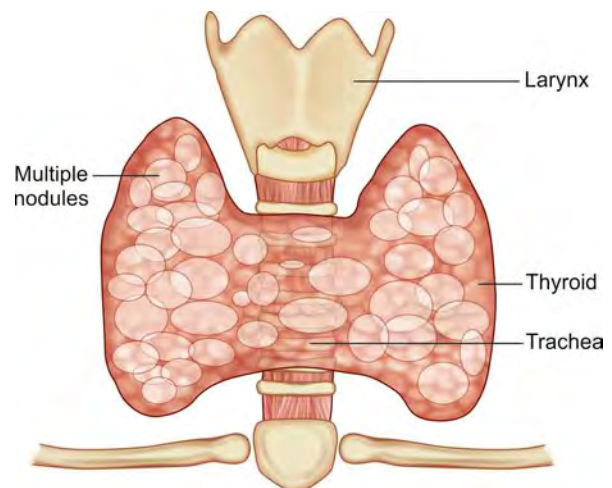
*Colloid goitre* is a goitre due to long-standing iodine deficiency with localised accumulation of significant colloid in the gland.

## Clinical Features

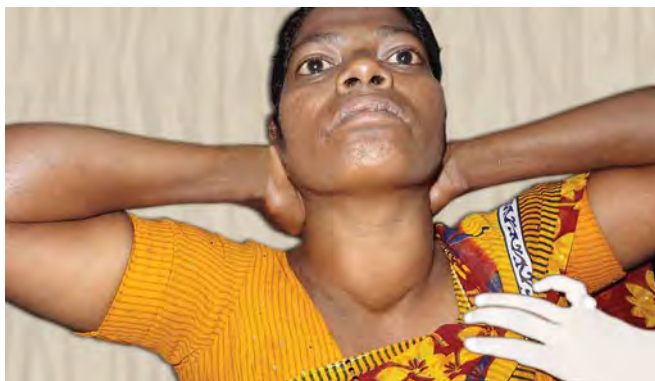- ◆ More common in middle aged females (10:1).
- ◆ It is a slowly progressive disease with many years of history.
- ◆ Multiple nodules of different sizes are formed in both lobes, also in isthmus, which is firm, nodular, nontender, moves with deglutition.
- ◆ Recent increase in size signifies malignant transformation or haemorrhage.



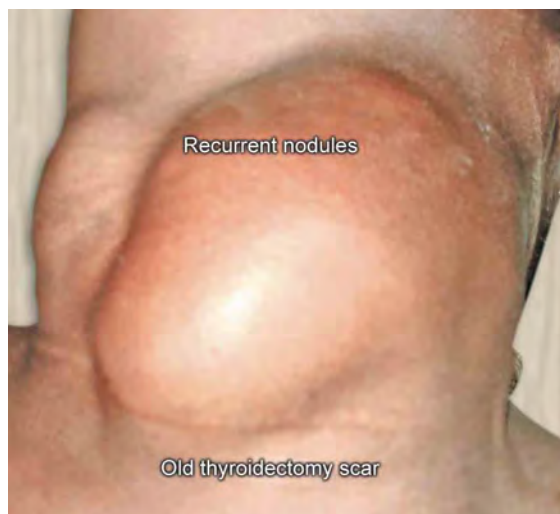
**Fig. 6.14:** Examination of the thyroid gland from behind for any nodules. Thyroid enlargement in male is rare. Nodule in a male could be malignant.



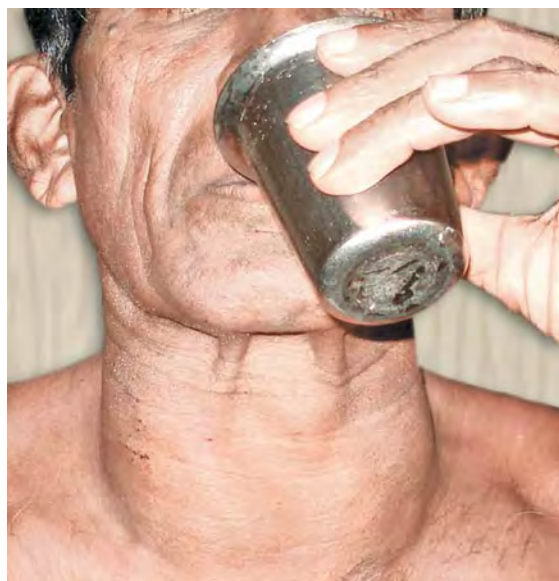**Fig. 6.15:** Multinodular goitre.



**Fig. 6.16:** Pizzillo's method to make the thyroid more prominent while examining.



**Fig. 6.17:** Recurrent nodule thyroid. Note scar of previous surgery.



**Fig. 6.18:** Thyroid swelling moves on deglutition because of attachment of pretracheal fascia through Berry's ligament to cricoid cartilage and to constrictor muscles.

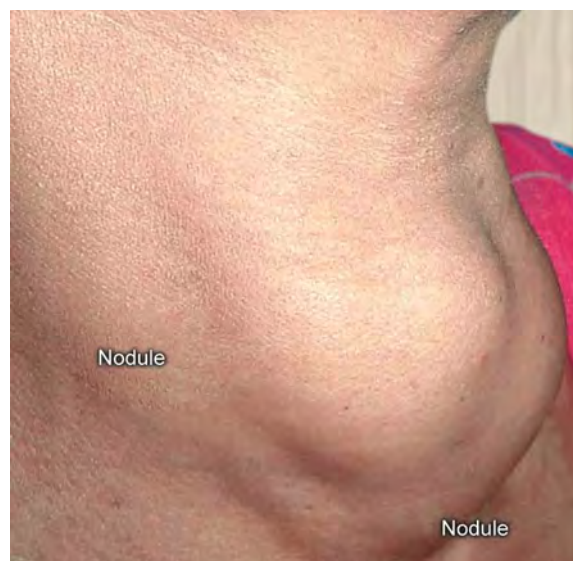
- ◆ Positive Kocher's test is due to compression over trachea (tracheomalacia/scabbard trachea) in a long-standing MNG.
- ◆ Nodule when calcified becomes harder; necrosis softens the nodule.

**Note:**

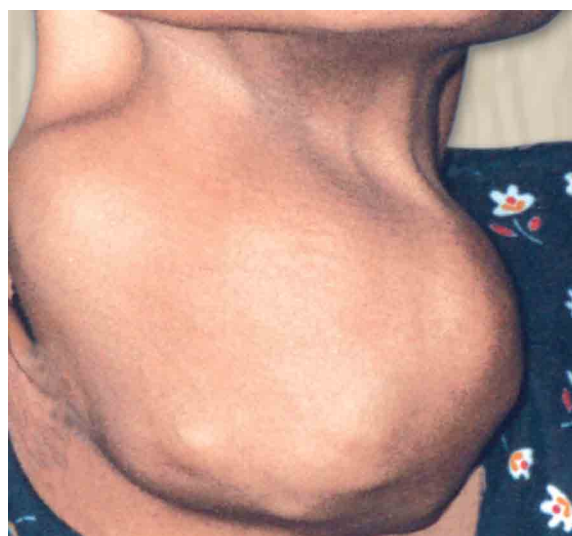
Thyropharyngeus and cricopharyngeus parts of inferior constrictor muscle are attached to thyroid and cricoid cartilages respectively; during swallowing these muscles will contract to move thyroid and cricoid cartilages upwards. Thyroid is attached to larynx (cricoid) through condensed pretracheal fascia, *Berry's ligament*. So thyroid moves upwards with deglutition.

**Complications of MNG**

- ❖ Secondary thyrotoxicosis (30%)
- ❖ Follicular carcinoma of thyroid (10%)
- ❖ Haemorrhage in a nodule
- ❖ Tracheal obstruction, calcification
- ❖ Cosmetic problem



**Fig. 6.19:** Multinodular goitre. Note the nodules marked.



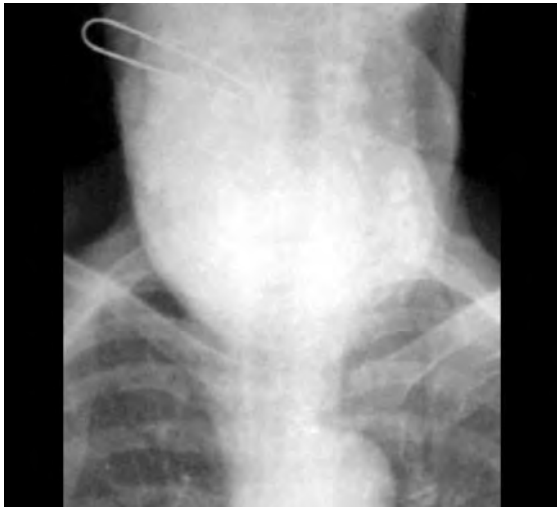
**Fig. 6.20:** Large multinodular goitre.

*Some people speak from experience; others, from experience, don't speak.*



## Investigations

- ◆  $T_3$ ,  $T_4$ , TSH, free  $T_4$ , US neck, FNAC. FNAC is done from most *dominant* and *suspicious* nodule. FNAC from more than one nodule is better; US-guided FNAC is more reliable. High resolution US identifies impalpable nodules, number, nature of nodule, vascularity of nodule. Nodule less than 0.3 cm is identifiable in US.
- ◆ X-ray neck shows ring or rim calcification; also reveals the position (displacement) and compression of trachea.
- ◆ *Indirect laryngoscopy* to see vocal cords prior to surgery (This is mainly for documentation and legal purpose as even in individual with normal voice, one of the vocal cords may have been paralyzed by viral infection like mumps, probably during childhood and have compensated)—occult *recurrent laryngeal nerve* (RLN) palsy.



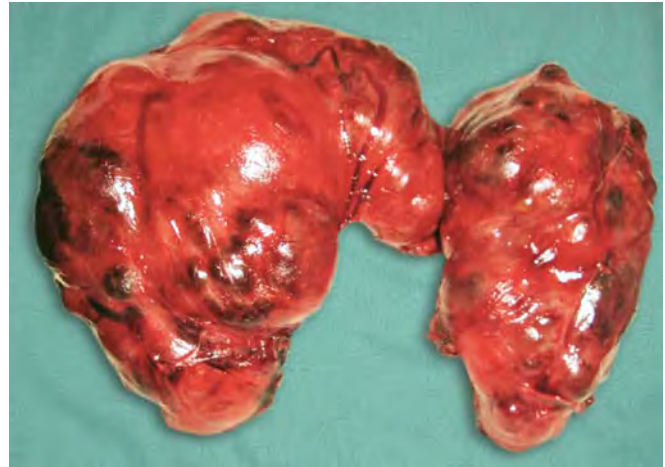**Fig. 6.21:** X-ray neck showing calcification in thyroid. *Fine* calcification is seen in papillary carcinoma. *Coarse* calcification is seen in multinodular goitre.

- ◆ *Radioisotope iodine scan*—in selected patients when indicated only.
- ◆ Routine blood investigations, serum calcium.
- ◆ CT scan/MRI are routinely not indicated. It is done in retrosternal extension.

## Treatment

*Usually surgery is preferred.* Reason for doing surgery in nodular goitre is—it is an irreversible stage and chances of complications like development of toxicity, haemorrhage and follicular carcinoma are high and also for cosmetic reason.

- ◆ When entire gland is diseased *total thyroidectomy* is a better option.
- ◆ *Subtotal thyroidectomy* is done depending on the amount of gland involved, amount of normal gland existing and location of nodules—commonly done procedure in multinodular goitre. Eight grams of thyroid tissue is retained in each lateral lobe.
- ◆ Often partial thyroidectomy or *Hartley Dunhill operation* (isthmus + one entire lateral lobe and opposite side subtotal or partial) is also done depending on the amount of diseased gland and normal tissues behind. Partial thyroidectomy is not well approved now.



**Fig. 6.22:** Multinodular goitre surgical specimen—total thyroidectomy was done.

- ◆ Postoperative L thyroxine is often given to prevent any fluctuation in TSH level which may cause recurrent nodule formation.
- ◆ *Prevention of multinodular goitre* is possible by supplementing with L-thyroxine (0.1–0.2 mg) when patient develops goitre in puberty. Formation of nodular goitre can be prevented by correcting iodine deficiency by using iodine-rich diet like eggs/seafood/milk or iodized salts and also avoiding goitrogenic drugs and diet.
- ◆ Suppressive dose of L-thyroxine alone may be used occasionally in small nodules with limited results. TSH level should be suppressed consistently below 0.5 mIU/L. Problems are need of periodic monitoring with TSH estimation; hormone insensitive part of thyroid tissue continue to grow; indefinite period of treatment; high recurrence after stopping L-thyroxine. So it is not ideally accepted therapy. It is found that TSH suppression is of no use in treating residual/recurrent MNG.

### Note:

Adequate thyroidectomy is essential, either total or subtotal, complete removal of diseased thyroid without retaining is considered, in view of chances of high recurrence in 10 or more years due to incomplete removal. Re-surgery for recurrent MNG is difficult due to loss of anatomical plane and fibrosis; hence total thyroidectomy is often advised.

## DISCRETE THYROID NODULE

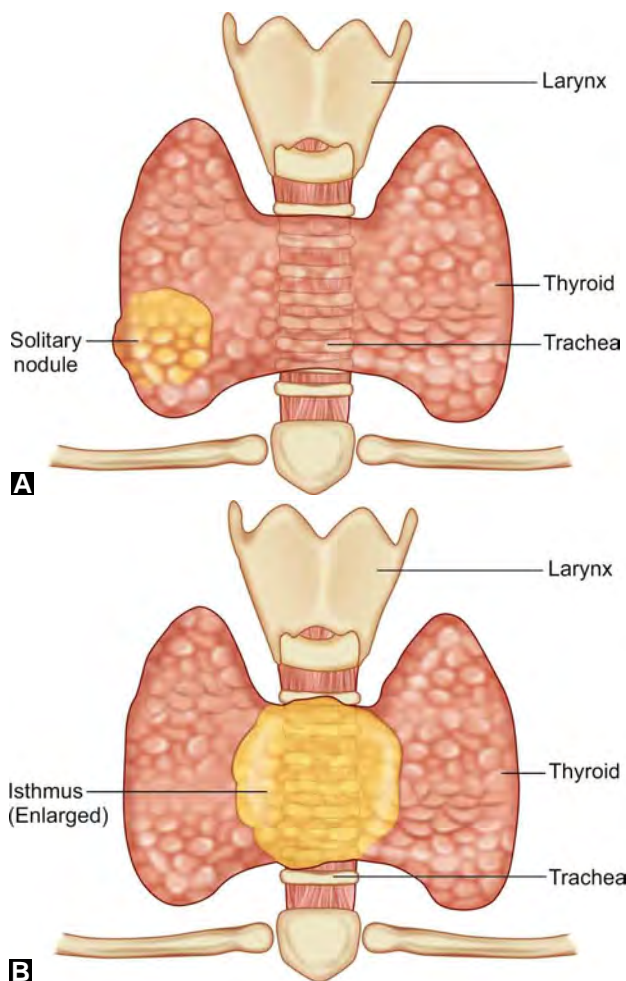
- ◆ *Discrete thyroid nodule* (4% of adult population) is a clearly palpable nodule in thyroid. It can be *solitary (isolated) nodule* (70%) if clinically only a nodule is felt without palpable remaining gland OR it can be *dominant nodule* (30%) if clinically a nodule is felt in a palpable remaining one or both lateral thyroid lobes.
- ◆ A *discrete thyroid nodule* is common in females. Discrete nodule may be solid or cystic. USG, CT, MRI may confirm the diagnosis.
- ◆ 15% solitary/isolated nodule may be malignant; 40% may be follicular adenoma. Other causes are thyroid cyst, thyroiditis or colloid degeneration.
- ◆ Incidence of malignancy in *dominant nodule* is 50% less than that of solitary nodule.
- ◆ Risk factors for malignancy in *discrete thyroid nodule* are—(1) *solitary* is 2 times more risk than dominant; (2) *male* is 4 times more than female (in solitary—48% to 12% in solid, 24% to 6% in cystic; in dominant 24% to 6% in solid, 12% to 6% in cystic); (3) *solid nodule* is 2 times more risk than cystic—Rule of 12.

## SOLITARY THYROID NODULE

It is a single palpable nodule in thyroid on *clinical examination*, in an otherwise normal gland. *Rest of the gland is impalpable*. *Current definition* – A discrete lesion/nodule within the thyroid gland that is *palpably and or radiologically* distinct from surrounding thyroid parenchyma (in an otherwise normal gland). The importance of thyroid nodule rests with the need to exclude thyroid malignancy which occurs in 5–15% cases.

### Causes

- ◆ Thyroid adenomas  
*Almost all thyroid adenomas are follicular*. Follicular adenoma can be – *Colloid* (do not have potential for microinvasion; commonest type); *Fetal* (microfollicular – has potential for microinvasion); *Embryonal* (atypical – has potential for microinvasion); *Hurthle cell/oxophil or oncocytic* (has potential for microinvasion); *hyalinising trabecular* adenoma.
- ◆ Carcinomas – papillary (commonest carcinoma), follicular, medullary (non-familial or familial or with MEN syndrome), anaplastic.



**Figs 6.23A and B:** Solitary nodule thyroid in one lateral lobe and isthmus.

- ◆ Thyroid cysts.
- ◆ Thyroiditis presenting as solitary nodule (localized form).

### Note:

- Papillary adenoma earlier called, was actually papillary carcinoma; papillary adenoma is very rare or probably non existing.
- Earlier definition was only clinically palpable nodule which also included only palpable nodule in an underlying multinodular goitre (other nodules are not palpable clinically) accounted for 50%; now radiological finding is added to definition. Hence MNG cause is not considered.

### Solitary nodule is also classified as

- ❖ Benign–70%
- ❖ Malignant–5%
- ❖ Indeterminate–10%-suspicious and follicular neoplasm
- ❖ Nondiagnostic–15%

### Types

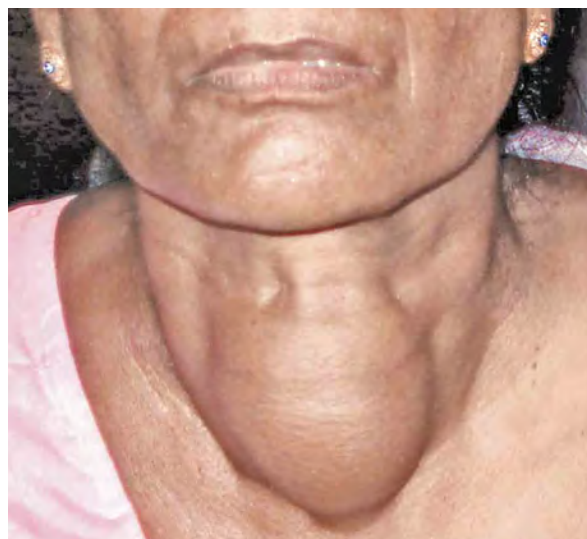1. Toxic solitary nodule—3–5% of solitary nodules of thyroid
2. Nontoxic solitary nodule.

Based on radioisotope study:

- ▶ *Hot*: Means autonomous toxic nodule. Normal surrounding thyroid tissue is inactive and so will not take up isotope. Nodule is overactive. It is 5% common of which only 5% can be malignant.
- ▶ *Warm*: Normally functioning nodule. Nodule and surrounding normal thyroid will take up the isotope (active). It is 10% common of which 10% can be malignant.
- ▶ *Cold*: Nonfunctioning nodule; may be malignant (need not be always). Nodule will not take up isotope (underactive). It is 80% common of which 20% are malignant.

### Features

- ◆ Single nodule palpable in one or other lobes of the thyroid which is usually smooth and firm.



**Fig. 6.24:** Solitary nodule thyroid involving isthmus.

*A genius is someone who shoots at a target which no one else sees and hits it.*

- ◆ Lahey's test does not show any other nodules in posterior part of the gland.
- ◆ *Hot or warm* in  $^{99m}\text{Tc}$  scan but *cold* in  $I^{123}$  scan (*discordant nodule*) commonly they are malignant.
- ◆ Thyroid nodule in children and elderly can be malignant.
- ◆ Rapid enlargement of thyroid nodule can be malignant.
- ◆ Tracheal deviation towards opposite side is common—confirmed by *trail sign*, three-finger test, auscultation and X-ray neck.
- ◆ 30% of solitary nodules are cystic.
- ◆ 20% of cold nodules are malignant. Cold nodule may be due to malignancy, thyroiditis, thyroid cyst or haemorrhage, benign adenoma.
- ◆ Commonest site of a nodule is at the junction of isthmus with one of the lateral lobes.
- ◆ Solitary thyroid nodule is the *most common* thyroid surgical disease.

#### Possible features of suspected malignancy in solitary nodule thyroid

- ❖ Any nodule can be malignant whether it is hard/ firm/cystic/ small/large/asymptomatic
- ❖ Rapid onset/rapid recent increase in size
- ❖ Hoarseness of voice/dysphagia/stridor/dyspnoea
- ❖ Fixity of the nodule
- ❖ Palpable significant neck nodes
- ❖ Nodule in a male patient
- ❖ Nodule in a child (50% are malignant)
- ❖ Nodule in extremes of age group

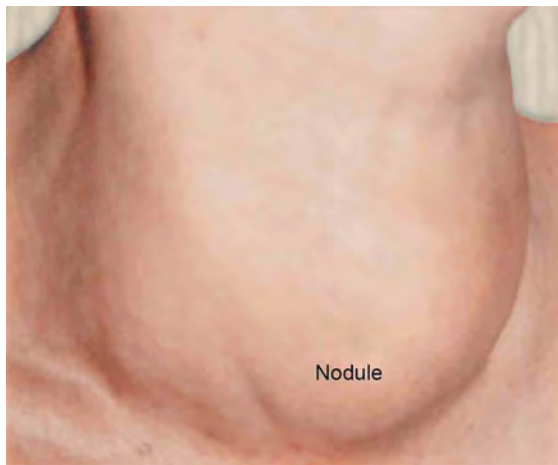
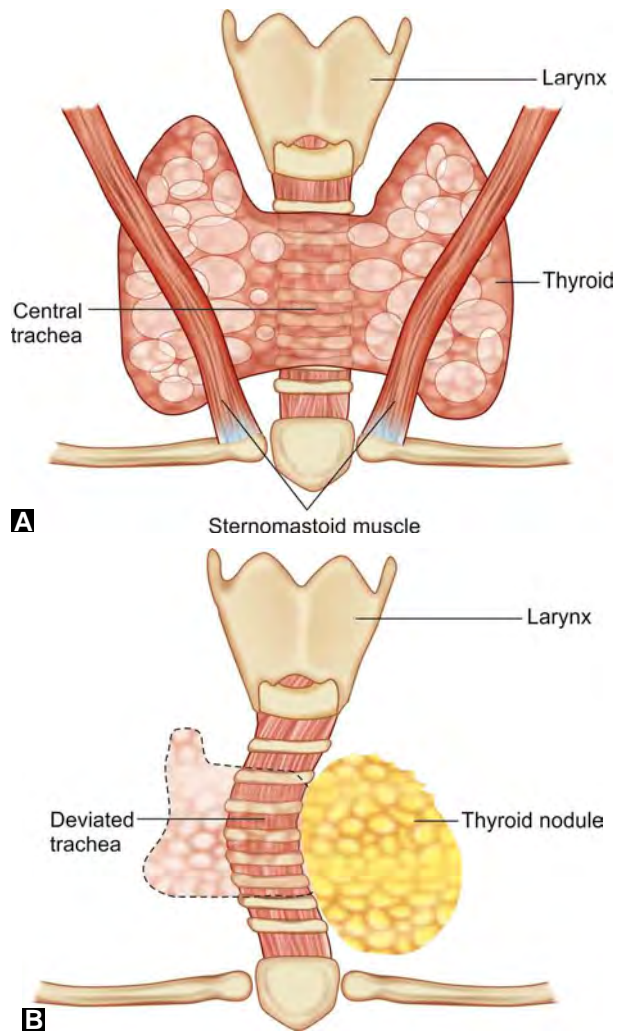


Fig. 6.25: Solitary nodule thyroid.

### Investigations

- ◆ *Ultrasound neck (very useful)*. It shows size, number, echogenicity, solid or cystic, vascularity, presence of significant lymph node (irregular, thick walled, without halo, more/chaotic vascularity, absence of hilus, microcalcification, cystic / necrotic changes).
- ◆ *FNAC* shows benign (70%); indeterminate (10% - it can be suspicious or follicular neoplasm); malignant (5%); nondiagnostic (15%; reaspiration should be done in 4 weeks). US-guided FNAC is the investigation of choice due to its safety and accuracy.

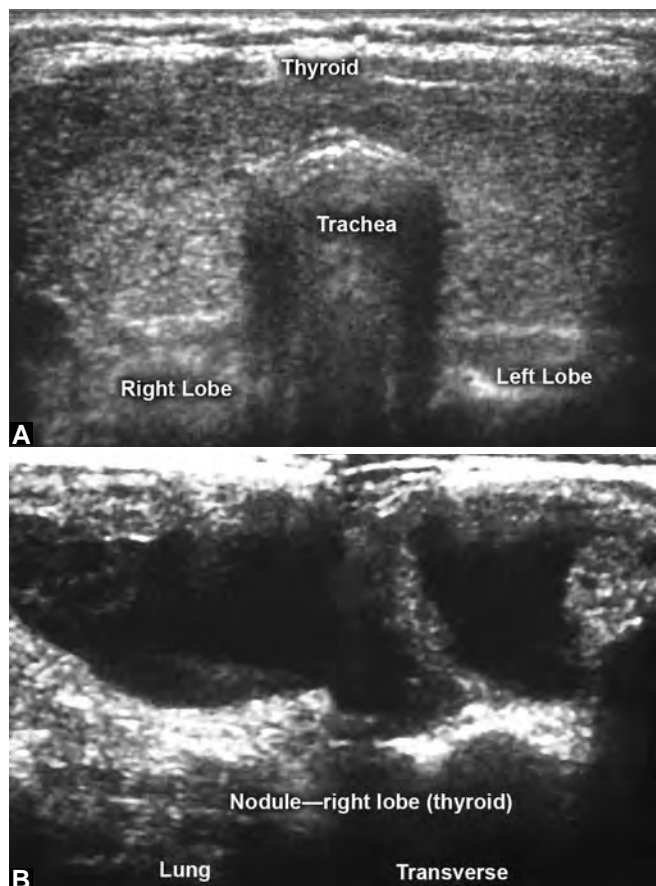


**Figs 6.26A and B:** Trachea should be clinically examined to find out whether it is central or deviated. In goitre involving both lobes, it is central. One lateral lobe enlargement usually causes deviation of trachea towards opposite side. Tracheal compression should be checked by *Kocher's test*. It confirms the *scabbard trachea*.

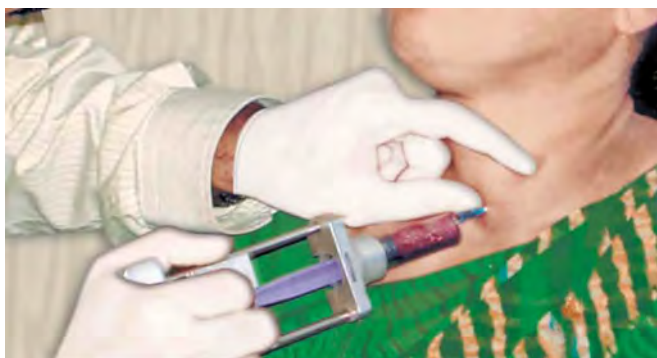- ◆  $T_3$ ,  $T_4$ , *TSH*.
- ◆ *Radioisotope study* ( $I^{123}/I^{131}/^{99m}\text{Tc}$ ).
- ◆ *Power Doppler* is done to know the vascularity of the gland. Vascularity is described in **resistive index (RI)** (Harley De Nicola 2005). Normal RI is 0.65–0.7; if RI is more than 0.7 it indicates malignancy in that nodule. Malignant nodule shows anarchical angiogenesis. Flow patterns are: Type 0 – no flow; Type 1: only peripheral flow; Type 2: peripheral with small central flow; Type 3: peripheral with extensive central flow; Type 4: only central flow.
- ◆ Serum calcitonin estimation if FNAC confirms medullary carcinoma.
- ◆ CT scan or MRI neck is not done routinely, but only in selected cases. Large swelling/to see vascularity/retrosternal extension are the indications.
- ◆ X-ray neck to see tracheal deviation.

#### Note:

True incidence of solitary nodule will come down to 50% from its original clinical diagnosis after investigations and surgical exploration.



**Figs 6.27A and B:** Ultrasound pictures of thyroid. It is often used to see nodules, content—solid/fluid, size and extent.

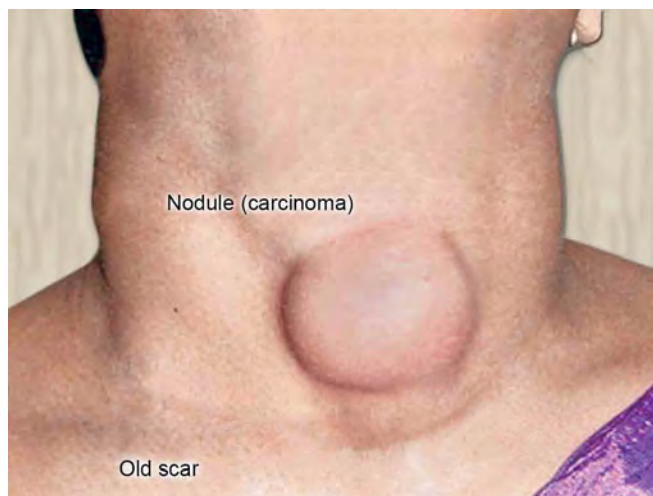


**Fig. 6.28:** FNAC of thyroid (Courtesy: Dr Krishna Upadhy, Pathologist, Nandikoor Laboratory, Mangaluru).

## Treatment

### Indications for surgery in solitary nodule thyroid

- ❖ Malignant nodule
- ❖ Follicular neoplasm
- ❖ Toxic nodule in young
- ❖ Nodules with obstruction
- ❖ Recurrent cystic nodule
- ❖ Complex cyst (both solid and cystic components)
- ❖ Cosmetic reason



**Fig. 6.29:** Patient earlier operated for nodular goitre. Note recurrent nodule and scar of previous surgery.

## Benign Nodule

- ❖ Nontoxic benign nodule is treated with observation without any therapy. There is no role of any hormone therapy (L thyroxine). Annual clinical examination and ultrasound neck is needed during essential follow up—any nodule of 20% increase in size or more than 2 mm increase in diameter warrants a repeat FNAC and hemithyroidectomy (removal of entire one lateral lobe and entire isthmus) may be considered. Compressive symptoms and cosmesis are the indications for surgery – hemithyroidectomy.
- ❖ Solitary toxic nodule needs initial antithyroid drugs and then radioactive iodine therapy (5 m curie); occasionally surgery is done – hemithyroidectomy.
- ❖ Colloid nodule can be observed or hemithyroidectomy is done for cosmesis or just in pain or increase in size; thyroxine therapy even though is commonly used, its benefit is not proved.
- ❖ Risk of malignancy in follicular lesion of undetermined significance (FLUS) is 10%. Total thyroidectomy is indicated here.

## Malignant Nodule

- ❖ If FNAC comes as papillary carcinoma of thyroid, then *total* or near total thyroidectomy is done. If tumour is more than 2 cm, with extracapsular spread then radioactive iodine therapy is needed. Later suppressive dose of L thyroxine (0.2 to 0.3 mg daily) is given orally in morning time on empty stomach.
- ❖ If FNAC report says follicular adenoma, then hemithyroidectomy is done. If histology report says follicular carcinoma (capsular and vascular invasion), then completion total thyroidectomy is done. *Completion thyroidectomy* is done usually within 7 days or after 3 weeks. If frozen section biopsy proves carcinoma, then total thyroidectomy is done.
- ❖ If there is a nodule in the isthmus, isthmectomy is done with excision of part of adjacent lateral lobes.
- ❖ If FNAC report says medullary carcinoma of thyroid, then total thyroidectomy with bilateral neck nodal dissection including central compartment is done.

### Indeterminate Nodule

- ◆ If FNAC shows follicular neoplasm, then hemithyroidectomy, paraffin section confirmation for capsular and vascular invasion; completion thyroidectomy in 7–14 days; later radioactive iodine therapy is used.
- ◆ If FNAC shows suspicious variety, then repeat FNAC is done. If it is also suspicious then hemithyroidectomy is done; frozen section biopsy is done to confirm if it is papillary carcinoma; if so, total thyroidectomy with ipsilateral central node neck dissection is carried out. (Frozen section is not suitable for follicular neoplasm).

### Nondiagnostic Nodule

Cyst that recurs and repeat FNAC also becomes nondiagnostic then hemithyroidectomy and proceed is the better option especially if nodule is more than 4 cm in size and or in high-risk group. Repeat FNAC becomes diagnostic in 50% of initial nondiagnostic.

#### Thyroid cyst

- ❖ It is thyroid swelling which is cystic in nature eliciting positive fluctuation
- ❖ But tensely cystic swelling can be hard (*thyroid paradox*—with cellular tumour of thyroid can be soft also)
- ❖ Common cause is colloid degeneration—50%. There will be absence of epithelial lining
- ❖ Involution in follicular adenomas present like a cyst; 15% of such cysts may be malignant
- ❖ 30% of solitary nodules are cystic
- ❖ 15% cystic swellings in thyroid are malignant
- ❖ Cyst formation is common in papillary carcinoma of thyroid
- ❖ A cyst if contains both solid and cystic areas, is called as complex cyst which is more likely to be malignant
- ❖ FNAC may cause regression of simple cyst. Even after three repeated aspirations if recurrence occurs, surgery is needed
- ❖ Surgery is indicated in complex cyst and if cyst is more than 4 cm in size

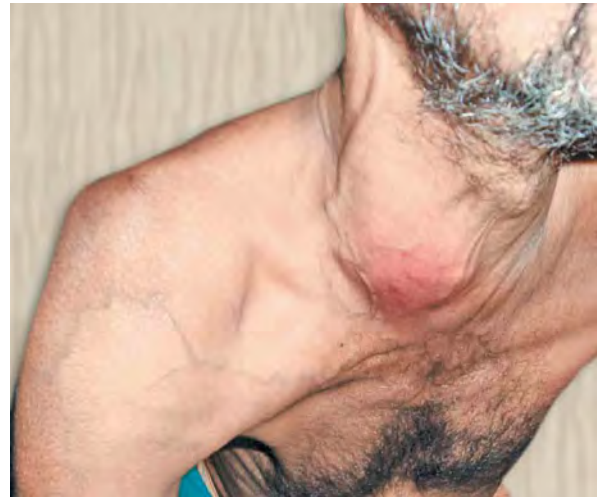## RETROSTERNAL GOITRE

*Retrosternal goitre* is defined as having >50% goitre below the suprasternal notch, i.e. below the plane of thoracic inlet. Major intrathoracic extension requiring mediastinal dissection, extension into the anterior mediastinum more than 2 cm in depth or mass reaching the level of 4th thoracic vertebra are other factors considered.

- ◆ *Primary* is rare—1%. Primary retrosternal goitre arises from ectopic thyroid tissue from mediastinum. It gets its blood supply from mediastinum itself, not from the neck. And also it is not related to the existing thyroid in the neck.
- ◆ *Secondary* is common. It is extension from the enlarged thyroid from the neck. Usually arises from the lower pole of a nodular goitre. Commonly seen in short neck or obese individuals. Due to negative intrathoracic pressure, nodule gets drawn into the superior mediastinum.

### Types

1. *Substernal type*: Part of the nodule is palpable in the lower neck.
2. *Plunging goitre*: An intrathoracic goitre is occasionally forced into the neck by increased intrathoracic pressure.
3. *Intrathoracic goitre* itself. Neck is normal.



**Fig. 6.30:** Superior vena cava obstruction due to thyroid extending into the retrosternal area. Note the dilated veins over neck, chest wall and arm.

### Features

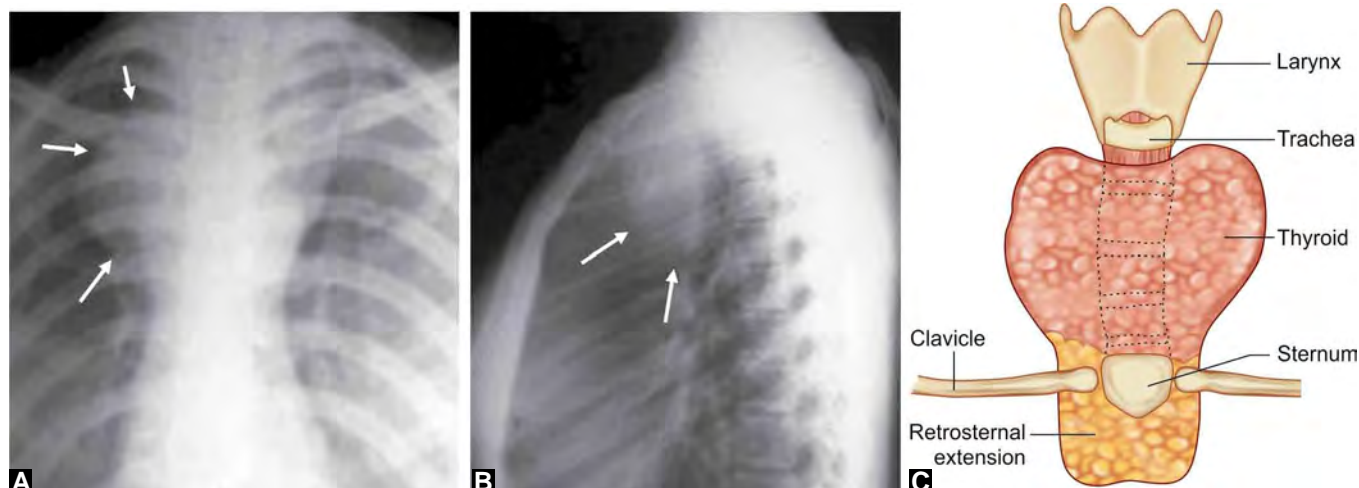
- ◆ Dyspnoea at night during lying down or neck extended.
- ◆ Cough and *stridor* (stridor is harsh sound on inspiration).
- ◆ Dysphagia.
- ◆ Engorgement of neck veins and superficial veins on the chest wall.
- ◆ Lower border is not seen on inspection and not felt on palpation.
- ◆ *Pemberton's sign* is positive. The patient is asked to raise the arm above the shoulder level. Dilated veins are seen over neck and upper part of chest wall. Stridor and rarely dysphagia may occur. (When patient raises the arm above the shoulder level, retrosternal goitre compresses over the easily compressible structures like SVC and trachea causing dilated veins and dyspnoea respectively).
- ◆ Dull note over the sternum on percussion.
- ◆ Retrosternal goitre can be either nodular, toxic or malignant.
- ◆ Rarely recurrent nerve palsy can occur.
- ◆ Retrosternal goitre has got similar chance of turning into malignancy alike cervical goitre; but identifying by US or FNAC is difficult.
- ◆ *Differential diagnosis*: Mediastinal tumours.

### Investigations

- ◆ Radioactive iodine study is diagnostic ( $I_{123}$  or technetium).
- ◆ CT/MRI is very useful investigation.
- ◆  $T_3$ ,  $T_4$ , TSH estimation.
- ◆ Chest X-ray will show soft tissue shadow; barium swallow X-ray will show oesophageal indentation.
- ◆ Lung function tests are useful.

### Treatment

- ◆ Surgical removal of retrosternal thyroid is done. Commonly, it can be removed through an incision in neck (as blood supply of retrosternal goitre is from neck), but in case of large retrosternal extension or in malignant type median sternotomy is required (rarely). Even asymptomatic retrosternal goitre needs surgery; total thyroidectomy with careful extirpation of the retrosternal extension through cervical incision is the choice.



**Figs 6.31A to C:** (A and B) X-rays (PA view and lateral view) showing retrosternal goitre. (C) Diagrammatic representation of the retrosternal goitre.

#### Note:

- Radioiodine therapy is not accepted in retrosternal goitre.
- Stridor due to compression of tracheobronchial tree by retrosternal goitre is very dangerous because it is often not possible to clear the airway either by intubation or by tracheostomy.
- Surgical removal should be complete because recurrent retrosternal goitre is very difficult to re-operate.

#### Breathing difficulties in thyroid swelling

- ❖ Retrosternal goitre—positive Pemberton's sign
- ❖ Multinodular goitre of long duration—positive Kocher's test—compressive stridor
- ❖ Secondary toxic goitre—congestive cardiac failure
- ❖ Carcinoma infiltrating the trachea—stridor on rest—without compression with fingers

## THYROTOXICOSIS AND HYPERTHYROIDISM

I have lately seen three cases of violent and long-continued palpitations in females, in each of which the sample peculiarity presented itself—viz., enlargement of the thyroid gland.... A lady, aged twenty, became affected with some symptoms which were supposed to be hysterical.... It was now observed that the eyes assumed a singular appearance, for the eyeballs were apparently enlarged, so that when she slept, or tried to shut her eyes, the lids were incapable of closing.

—Robert James Graves, 1835 (Irish physician)

*Thyrotoxicosis is symptom complex due to raised levels of thyroid hormones.*

*Thyrotoxicosis* refers to biochemical and physiological manifestations of excessive thyroid hormones. *Hyperthyroidism* is the term used for overproduction of the hormones by thyroid gland. In hyperthyroidism pathology is in thyroid gland itself. Hyperthyroidism is one of the causes of *thyrotoxicosis*. *Thyrotoxicosis* can also occur due to other causes other than hyperthyroidism.

*Other causes of thyrotoxicosis* without hyperthyroidism are—ectopic functioning thyroid, struma ovarii, functioning metastatic follicular carcinoma, trophoblastic tumours, thyrotoxicosis factitia.

### Types

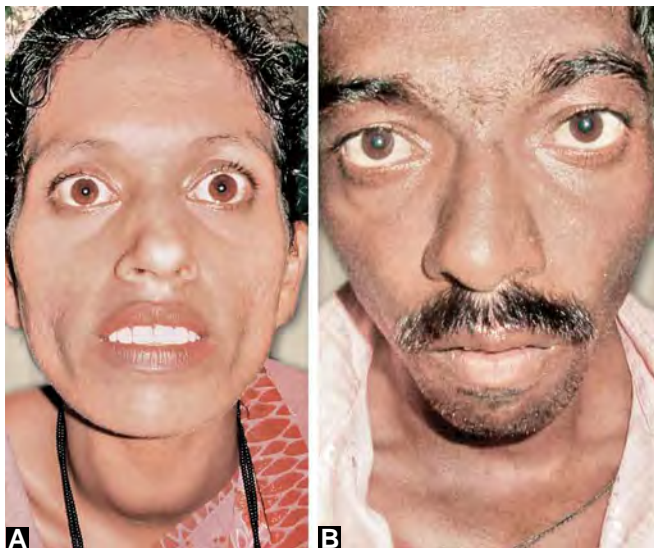1. Diffuse toxic goitre—(Graves' disease, *Basedow's disease*. Primary thyrotoxicosis)—60%.
2. Toxic multinodular goitre (Secondary thyrotoxicosis) (*Plummer disease*)—20%.
3. Toxic nodule (*Goetsch's disease*)—5%.
4. Thyrotoxicosis due to rarer causes:
  - a. *Thyrotoxicosis factitia*—drug induced. Due to intake of L-thyroxine more than normal.
  - b. *Jod Basedow thyrotoxicosis*—because of large doses of iodides given to a hyperplastic endemic goitre.
  - c. *Autoimmune thyroiditis or de Quervain's thyroiditis*.
  - d. *Neonatal thyrotoxicosis*. It subsides in 3–4 weeks as TsAb titres fall in the baby's serum.
  - e. Struma ovarii.
  - f. Drugs like amiodarone—an antiarrhythmic agent. Amiodarone is rich in iodine having structural similarity to T<sub>4</sub> causing thyrotoxicosis.
  - g. Very rarely, well-differentiated carcinoma can cause thyrotoxicosis—*metastatic type*.
  - h. Patients with hydatidiform mole or choriocarcinoma with high levels of β HCG which can stimulate TSH receptor and can cause thyrotoxicosis.

### Graves Disease

*Graves disease* is an autoimmune disease with increased levels of specific antibodies in the blood (TSH receptor antibodies). It is often associated with vitiligo. It is often familial. Thyroid stimulating immunoglobulins (TSI)/thyroid stimulating anti-

bodies (Ts Ab) and long-acting thyroid stimulator (LATS) cause pathological changes in the thyroid. Histologically, there is acinar cell hypertrophy and hyperplasia with absence of normal colloid in the tall columnar epithelium (normal is flat epithelium with colloid). As cells are empty, they look vacuolated. Tissues are highly vascular. Exophthalmos producing substance (EPS) causes Graves ophthalmopathy.

- ◆ Diffuse goitre, thyrotoxicosis and autoimmune manifestations like infiltrative ophthalmopathy, dermatopathy, myopathy are essential components of Graves disease.
- ◆ Thyroid stimulating immunoglobulins (TSIs) are produced against thyroid antigen in Graves disease which is directed to TSH receptor acting as TSH receptor antibody. *This TSHR Ab is observed only in Graves disease.*
- ◆ Puberty, pregnancy, emotion and infection are the precipitating factors for primary thyrotoxicosis.
- ◆ Familial/genetic cause is also attributed in Graves disease (50%); both identical twins can develop Graves disease.
- ◆ There is *hyperplasia and hypertrophy* of entire thyroid due to prolonged continuous action by binding of abnormal thyroid stimulating antibodies to TSH receptor sites.



**Figs 6.32A and B:** Graves disease in a female and male patient. Note the exophthalmos with clearly visible lower sclera.

### Toxic Adenoma

- ◆ It is benign functioning monoclonal thyroid tumour, usually more than 3 cm in size.
- ◆ It usually presents as *functioning (toxic) solitary nodule* of thyroid.
- ◆ It is autonomous functioning tumour; not TSH responding.
- ◆ Toxic adenoma secretes large quantity of thyroid hormones suppressing the function of the remaining normal thyroid tissue.
- ◆ There are no eye signs and other features of Graves disease.
- ◆ It commonly shows higher  $T_3$  levels than  $T_4$ .
- ◆ TSH receptor or G protein genes show somatic mutation.
- ◆ US neck,  $T_3$ ,  $T_4$ , TSH and radioisotope scan (shows *hot nodule*)—are the relevant investigations.

### Treatment

- ◆ Initial control of toxicity with antithyroid drugs; later hemithyroidectomy is done after 6 weeks. Once thyroidectomy is done, suppressed remaining normal thyroid tissue starts functioning to secrete normal level of thyroid hormones.
- ◆ Radioactive iodine therapy can be used which selectively concentrates and ablates the thyroid adenoma; later remaining normal thyroid starts functioning.

#### Note:

- Radioactive iodine therapy after initial control of toxicity using antithyroid drugs, has become the standard mode of treatment after the age of 10 years. But RAI therapy should not be used in pregnancy, lactation as it crosses placental barrier and secretes in milk causing newborn or infant hypothyroid.

### $T_3$ Toxicosis

- ◆ Here  $T_3$  alone is raised; TSH is decreased;  $T_4$  is normal.
- ◆ Free  $T_3$  estimation is important.

### Subclinical Hyperthyroidism

- ◆ *Subclinical hyperthyroidism* is defined as a state of decreased TSH level but not undetectable with  $T_3$ ,  $T_4$ , free  $T_3$  and free  $T_4$  are within the normal range without any clinical symptoms.
- ◆ Its incidence is 1% of hyperthyroidism.
- ◆ It is one of the causes of infertility in females (both subclinical hyper or hypothyroidism can cause infertility).
- ◆ It may present as cardiomyopathy or arrhythmias.
- ◆ Hormone assay, radioisotope scan and US neck, ECG are used for evaluation.

### Struma Ovarii

- ◆ Ovarian teratoma with thyroid differentiation will secrete  $T_3$  and  $T_4$  and suppress TSH.
- ◆ Function of normal thyroid in neck is suppressed.
- ◆ Radioisotope scan shows uptake in pelvis with no or less uptake in neck.

#### Note:

The River *Struma* arises in Bulgaria and flows into Aegean Sea. Endemic goitre exists in area along its banks; '*Struma*' means goitre.

### Hashitoxicosis

- ◆ It is due to autoimmune Hashimoto's thyroiditis.
- ◆ Mild toxic features develop during initial stage of hyperplasia.
- ◆ Already formed thyroid hormones are released by inflamed gland causing toxicity. It eventually leads into euthyroid and later hypothyroidism in Hashimoto's disease.

### Thyrotoxicosis Factitia

Intake of L thyroxine *without indications* to lose weight or overdose intake causes toxicity.

### Postpartum Hyperthyroidism

It is exacerbation of previously confirmed or undiagnosed hyperthyroidism during pregnancy or after delivery due to increased autoimmune factors.

It is associated with HLA DR3 and HLA DR5.

### Neonatal Thyrotoxicosis

It is seen in infants born to mother with Graves disease due to crossing of the thyroid stimulating antibody (TSH RAb) across placental barrier. Infant will be toxic for 3–4 weeks which subsides gradually.

### Trophoblastic Thyrotoxicosis

HCG secreted from vesicular mole, choriocarcinoma or metastatic embryonal carcinoma in females, acts like TSAAb causing toxicity.

### Jod Basedow Thyrotoxicosis

Patient with hyperplastic endemic goitre takes large doses of iodide, which will be taken up by hyperplastic gland in large quantity causing temporary hyperthyroidism called as *Jod Basedow thyrotoxicosis*. It differs from Basedow disease which is the other name for Graves disease ('*Jod*'—in German means iodine).

### Apathetic Hyperthyroidism

- ◆ It lacks all usual clinical features of toxicity.
- ◆ It is commonly observed in old people.
- ◆ Thyroid gland is not enlarged.
- ◆ Patient presents with behavioral problems; often considered as psychiatry patient with decreased appetite.
- ◆ Such lethargic individual also often shows features of recent angina and atrial fibrillation.
- ◆ Unless serum T<sub>3</sub>, T<sub>4</sub> and TSH are done, diagnosis is masked.

### Subacute Thyroiditis (Toxic Phase)

Other common cause of thyrotoxicosis is subacute thyroiditis (15–20% of cases), a destructive release of preformed thyroid hormone. Radioactive iodine scan does not show any radioactive iodine uptake in the

thyrotoxic phase of the disease. Thyroid hormone levels can be highly elevated. Low ESR, low T<sub>3</sub> T<sub>4</sub> ratio are other features.

## Clinical Features of Thyrotoxicosis

- ❖ It is eight times more common in females
- ❖ Occurs in any age group
- ❖ Primary type is seen commonly in younger age group
- ❖ Secondary type is common in older age group
- ❖ Graves disease often presents without any obvious thyroid swelling in the neck. Whenever there is unexplained behavioural problem, insomnia, myopathy, unexplained diarrhoea or loss of weight, tachycardia, Graves disease should be suspected and evaluated
- ❖ The degree of thyrotoxicosis is determined by estimation of thyroid hormone levels; the severity of clinical manifestations may not correlate with the degree of thyroid hormone elevation.

### A. Symptoms of Hyperthyroidism/Toxicosis

#### Gastrointestinal system

- ◆ Weight loss in spite of increased appetite.
- ◆ Diarrhoea (due to increased activity at ganglionic level).

#### Cardiovascular system

- ◆ Palpitations.
- ◆ Shortness of breath at rest or on minimal exertion.
- ◆ Angina.
- ◆ Irregularity in heart rate.
- ◆ Cardiac failure in the elderly (CCF).

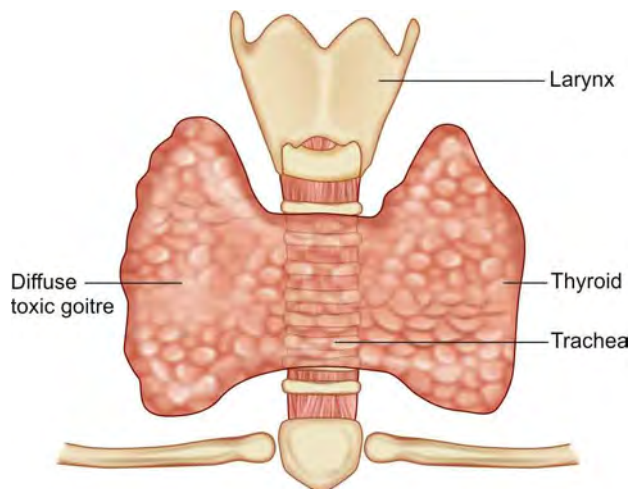
#### Neuromuscular system

- ◆ Undue fatigue and muscle weakness.
- ◆ Tremor.

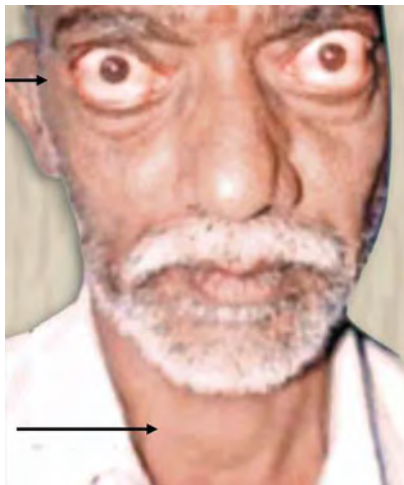### Differentiating points between primary and secondary hyperthyroidism

Primary thyrotoxicosis	Secondary thyrotoxicosis
1. Symptoms appear first, then thyroid swelling	1. Thyroid swelling appears first
2. Goitre is diffuse, smooth, firm or soft, both lobes are involved with thrill and bruit	2. Swelling is large nodular, obvious
3. Features are much more severe compared to that of secondary toxicosis of short duration	3. Symptoms appear after long time, which is less severe and slowly progressive compared to primary toxicosis
4. Eye signs and exophthalmos are common	4. Eye signs are not common
5. As it is an autoimmune disease, there may be hepatosplenomegaly	5. Cardiac features are more common
6. It occurs in younger age group	6. It occurs in adult and elderly individual
7. Entire gland is overactive	7. Internodular tissues are overactive
8. There is no preexisting goitre	8. Occurs in a long-standing pre-existing multinodular goiter
Histologically, there is hyperplasia of acini, lined by columnar epithelium, often containing vacuolated colloid scalloping with pseudopapillary formation	

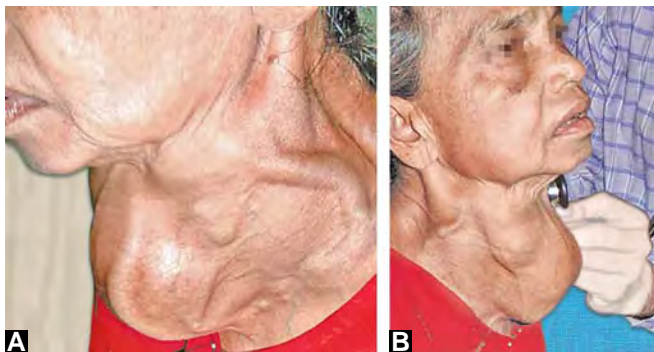



**Fig. 6.33:** Diffuse toxic goitre (primary) involves both lobes with hyperfunctioning acini.



**Fig. 6.34:** Primary thyrotoxicosis. Note the exophthalmos.



**Figs 6.35A and B:** Note the dilated veins in an enlarged vascular thyroid gland. Auscultation is important to hear a bruit.

### Skeletal system

- ◆ Increase in linear growth in children.

### Genitourinary system

- ◆ Oligo- or amenorrhoea.
- ◆ Occasional urinary frequency.

### Integument

- ◆ Hair loss, gynaecomastia.
- ◆ Pruritus.
- ◆ Palmar erythema.

### Psychiatry

- ◆ Irritability.
- ◆ Nervousness.
- ◆ Insomnia.

### Sympathetic overactivity

- ◆ It causes dyspnoea, palpitation, tiredness, heat intolerance, sweating, nervousness, increased appetite and decrease in weight.
- ◆ Because of the *increased catabolism* they have increased appetite, decreased weight and so also increased creatinine level which signifies *myopathy* (due to more muscle catabolism).

*Fine tremor* is due to diffuse irritability of grey matter.

### B. Signs of Hyperthyroidism/Toxicosis

#### 1. Eye Signs in Toxic Goitre

Eye signs are common in primary thyrotoxicosis. Lid lag, lid spasm can occur in secondary thyrotoxicosis also.

1. **Lid retraction:** Here upper eyelid is higher than normal; lower eyelid is in normal position. It is due to *sympathetic overactivity* causing spasm of involuntary smooth muscle part of the levator palpebrae superioris (*Muller's muscle*). It is a *sign* of thyrotoxicosis, *not a sign* of exophthalmos.
2. **von Graefe's sign** (Lid Lag's sign): It is inability of the upper eyelid to keep pace with the eyeball when it looks downwards to follow the examiner's finger.
3. **Dalrymple's sign:** Upper eyelid retraction, so visibility of upper sclera.
4. **Stellwag's sign:** Absence of normal blinking—so *staring look*. First sign to appear. It is due to widening of palpebral fissure due to lid retraction and also due to contraction of voluntary part of levator palpebrae superioris muscle.
5. **Joffroy's sign:** Absence of wrinkling on forehead when patient looks up (frowns) with head is bent down/flexed position.
6. **Moebius sign:** It is lack of convergence of eyeball. Defective convergence is due to lymphocytic infiltration of inferior oblique and rectus muscles in case of primary thyrotoxicosis. There will be diplopia. It may be an early sign of eventual ophthalmoplegia.
7. **Naffziger's sign:** With patient in sitting position and neck fully extended, protruded eyeball can be visualized when observed from behind.
8. **Jellinek's sign:** Increased pigmentation of eyelid margins.
9. **Enroth sign:** Oedema of eyelids and conjunctiva.
10. **Rosenbach's sign:** Tremor of closed eyelids.
11. **Gifford's sign:** Difficulty in everting upper eyelid in primary toxic thyroid. Differentiates from exophthalmos of other causes.
12. **Loewi's sign:** Dilatation of pupil with weak adrenaline solution.
13. **Knie's sign:** Unequal pupillary dilatation.
14. **Cowen's sign:** Jerky pupillary contraction to consensual light.
15. **Kocher's sign:** When clinician places his hands on patient's eyes and lifts it higher, patient's upper lid springs up more quickly than eyebrows.

### Order of appearance of signs

- ❖ Stellwag's sign—mild; first sign to appear
- ❖ von Graefe's sign—mild
- ❖ Joffroy's sign—moderate
- ❖ Moebius sign—severe

### EXOPHTHALMOS

- ◆ It is proptosis of the eye, caused by infiltration of the retrobulbar tissues with fluid and round cells, with *lid spasm* of upper eyelid (Lid spasm is spasm of levator palpebrae superioris muscle which is partly innervated by sympathetic fibres).
- ◆ Sclera can be seen clearly below the limbus of the eye.
- ◆ Proptosis can be measured by *exophthalmometer*.
- ◆ Exophthalmos is often self-limiting, but not always. Sleeping in propped up position and lateral tarsorrhaphy will help to protect the eye.
- ◆ Exophthalmos even though is usually bilateral it can be unilateral or frequently unequal in both eyes.

### Severe Exophthalmos

- ◆ Eyelid oedema, chemosis, conjunctival injection.
- ◆ Diplopia, ophthalmoplegia (complete weakness of all extraocular muscles and so no movements possible).
- ◆ Corneal ulceration.
- ◆ Papilloedema soon develops.
- ◆ Finally it may also cause loss of vision.

It is called as **malignant exophthalmos** (It is misnomer even though it is not malignant nor related to any malignancy).

**Treatment is emergency**, i.e. large doses of systemic steroids (Prednisolone) are given along with *orbital decompression*, systemic antibiotics, steroid drops, antibiotic drops.

- ◆ **Remember:**
  - ▶ *Antithyroid drugs may worsen exophthalmos and the patient should be observed once antithyroid drugs are started as steroid supplementation may be required.*
  - ▶ Ophthalmopathy may worsen by thyroidectomy or radioiodine therapy also.

### Wayne's diagnostic indices (clinical) of thyrotoxicosis

	Symptoms	Present	Absent
1.	Dyspnoea on effort	+1	
2.	Palpitation	+2	
3.	Tiredness	+2	
4.	Preference to heat		-5
5.	Preference to cold (Heat intolerance)	+5	
6.	Excessive sweating	+3	
7.	Nervousness	+2	
8.	Appetite increased	+3	
9.	Weight decreased	+3	
	Signs	Present	Absent
1.	Bruit over thyroid	+2	
2.	Exophthalmos	+2	
3.	Lid retraction	+2	
4.	Lid lag	+1	
5.	Hyperkinetic movements	+4	-2
6.	Fine finger tremors	+1	
7.	Hands hot	+2	-2
	Moist	+1	-1
8.	Atrial fibrillation	+4	-3
9.	Pulse rate 80/minute	0	
	80–90/minute	+3	
	More than 90/minute	+3	
10.	Palpable thyroid		
	<11 points—nontoxic goitre	11–19 equivocal	>19 points—toxic

*One person with passion is greater than ninety-nine who have only an interest.*

### Treatment of severe exophthalmos

- ❖ Steroids intravenously
- ❖ IV antibiotics
- ❖ Guanethidine, steroid, antibiotic drops
- ❖ Lateral tarsorrhaphy
- ❖ Orbital decompression by surgical removal of lateral wall or roof of orbit
- ❖ Diuretics
- ❖ Dark spectacles, protective eye patches
- ❖ Eyelid surgeries, extraocular muscle surgeries
- ❖ Local radiation therapy to orbital space
- ❖ 1% methylcellulose eye drops to prevent corneal ulceration
- ❖ Sleeping with head end elevation
- ❖ **Lid retraction** is higher upper eyelid with normal lower eyelid with visible sclera adjacent to upper eyelid
- ❖ **Lid lag** is inability of the upper eyelid to keep pace with the eyeball when it looks downwards to follow the examiner's finger
- ❖ **Exophthalmos** is visible sclera *first below* (lower part) the lower edge of the iris and later eventually upper part of sclera will be visible. It is due to pushing of the eyeball forwards due to fat, oedema fluid, cells like macrophages in retrobulbar space

### Important signs to be remembered

- ❖ *Visible lower sclera—sign of exophthalmos*
- ❖ Naffziger's sign
- ❖ von Graefe's sign—upper lid lag—contraction/overactivity of the involuntary part of the levator palpebrae superioris muscle—Muller's muscle
- ❖ Joffroy's sign
- ❖ Moebius sign—*most important—early sign of ophthalmoplegia*

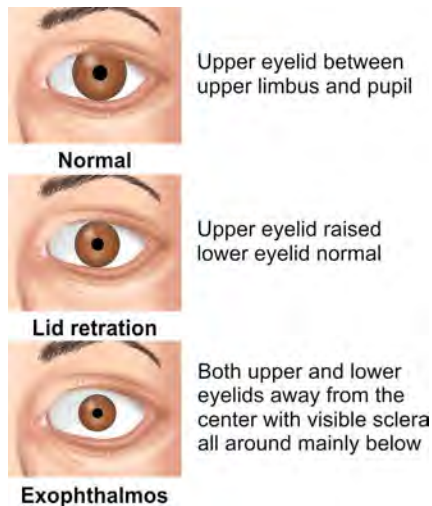


Fig. 6.36: Diagram showing normal relation of eyelid and pupil in lid retraction and exophthalmos.

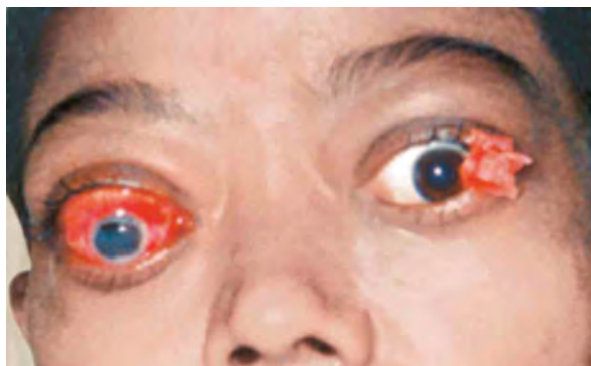

Fig. 6.37: Malignant exophthalmos.

### Thyroid ophthalmopathy in Graves disease-Werner's abridged classification of ocular changes with van Dyke's modification

Class-grade	Definition
0	No signs and symptoms
1	Eye signs only—refer table below for eye signs
2	Soft tissue involvement
3	Proptosis more than 22 mm
4	Extraocular muscle involvement
5	Corneal involvement-ulceration
6	Loss of sight/vision due to optic nerve and corneal involvement

#### Eye signs only

- ❖ Resistance to retro-displacement of eye
- ❖ Oedema of conjunctiva and caruncle
- ❖ Lacrimal gland enlargement
- ❖ Injection of conjunctiva
- ❖ Oedema and fullness of lids

### Grading of exophthalmos

- ❖ **Mild:** Widening of palpebral fissure due to lid retraction
- ❖ **Moderate:** Orbital deposition of fat causing bulging with positive Joffroy's sign
- ❖ **Severe:** Congestion with intraorbital oedema, raised intraocular pressure, diplopia and ophthalmoplegia
- ❖ **Progressive:** In spite of proper treatment progression of eye signs is seen with chemosis, corneal ulceration and ophthalmoplegia

### Causes of exophthalmos

#### Endocrinal

- Thyrotoxicosis—common
- Cushing's syndrome, acromegaly—rare

#### Congenital deformities of skull

- Craniostenosis, oxycephaly, hypertelorism

#### Primary tumours

- Periorbital meningioma
- Optic nerve glioma
- Orbital haemangioma
- Lymphoma

#### Osteoma

- Pseudotumour—granuloma

#### Secondary tumours

- Antral carcinoma, neuroblastoma

#### Inflammatory

- Orbital cellulitis, frontal sinusitis

#### Vascular causes

- Cavernous sinus thrombosis/A-V fistula
- Ophthalmic artery aneurysm

#### Other eye causes

- Severe myopia
- Severe glaucoma—buphthalmos

**Causes of pulsating exophthalmos**

Carotid-cavernous sinus A-V fistula  
Cavernous sinus thrombosis  
Orbital vascular neoplasm  
Orbital haemangioma  
Ophthalmic artery aneurysm

**2. Cardiac Manifestations**

- ◆ Tachycardia is common.  
As per **Crile's grading**  
*Sleeping pulse rate is usually checked for three consecutive nights and average is taken as the value.*

**Pulse rate**

- ❖ Grade I: < 90/min
- ❖ Grade II: 90-110/min
- ❖ Grade III: >110/min

- ◆ Ectopic.
- ◆ Pulsus paradoxus.
- ◆ Wide pulse pressure.
- ◆ Multiple extrasystoles.
- ◆ Paroxysmal atrial tachycardia.
- ◆ Paroxysmal atrial fibrillation.
- ◆ Persistent atrial fibrillation (not responsive to digoxin).

**3. Myopathy**

- ◆ Weakness of proximal muscles occurs, i.e. the front thigh muscles, arm muscles.
- ◆ Weakness is more when muscle contracts isometrically either while getting down steps, or lifting a full bucket.
- ◆ Often when it is severe it resembles myasthenia gravis. Once hyperthyroidism is controlled, recovery occurs.

**4. Pretibial Myxoedema**

It is a misnomer. *Pretibial myxoedema* is often a feature of primary thyrotoxicosis:

- ◆ Is usually bilateral, symmetrical, shiny, red thickened dry skin with coarse hair in the feet and ankles.
- ◆ In severe cases skin of entire leg below the knee with involvement of foot and ankle can occur.
- ◆ It is due to deposition of myxomatous tissues (mucin-like deposits) in skin and subcutaneous plane. Glycosaminoglycans (hyaluronic acid) deposition occurs.
- ◆ It might or might not regress completely after treatment for toxicity.
- ◆ It is associated with exophthalmos with high levels of thyroid stimulating antibodies.
- ◆ Skin becomes cyanotic when cold. Skin changes in toxicosis are called as *thyroid dermopathy*. They include—pretibial myxoedema, pruritus, palmar erythema, hair thinning, Dupuytren's contracture (fascial).

**5. Thyroid Acropachy**

*Thyroid acropachy* is clubbing of fingers and toes in primary thyrotoxicosis. Hypertrophic pulmonary osteoarthropathy can develop.

**6. Others**

- ◆ *Thrill is felt* in the upper pole of the thyroid and also bruit on auscultation. It is because in upper pole, superior thyroid artery enters the gland superficially and so thrill and bruit can easily be felt. In lower pole inferior thyroid artery enters the gland from deeper plane and so thrill cannot be felt.
- ◆ Hepatosplenomegaly.

**TOXIC NODULE**

- ◆ Is a solitary overactive nodule.
- ◆ There is an autonomous hypertrophy and hyperplasia of a part of the gland where there is a nodule. [It is not due to thyroid stimulating antibody (Ts Ab)].
- ◆ Here high levels of circulating thyroid hormones suppress TSH secretion and so, normal thyroid tissue surrounding the nodule is itself suppressed and inactive.
- ◆ Once patient becomes euthyroid by drugs, surgery (hemithyroidectomy) or radioactive iodine therapy  $I^{131}$  in a therapeutic dose of 5 m curie is given orally.
- ◆ Because normal gland is inactive, radioactive iodine affects only the autonomous nodule, allowing the normal gland to remain intact which later gets activated and functions normally.
- ◆ Drugs are used initially, only for a temporary period to make the patient euthyroid.

**Investigations for Thyrotoxicosis**

- ◆ *Thyroid function tests*  
Serum  $T_3$  and  $T_4$  levels are very high. TSH is very low or undetectable. Sometimes, only  $T_3$  level is increased and is called as  *$T_3$  toxicosis*. Here in  $T_3$  toxicosis, *free  $T_3$  estimation is important*. Free  $T_3$ , free  $T_4$  estimation is done as total  $T_3$  and total  $T_4$  levels will vary depending on the amount of thyroid binding globulin (TBG). TBG will be raised in pregnancy, cirrhosis, hyperestrogenism. It decreases in conditions with high androgen level, hypoproteinaemia, acromegaly. Free  $T_3$  and free  $T_4$  are measured using radioimmunoassay. Normal free  $T_3$  is 3.0–9.0 pmol/L; free  $T_4$  is 8–26 nmol/L.

Type of disease	$T_4$	$T_3$	TSH
Conventional hyperthyroidism	Increased	Increased	Undetectable
$T_3$ hyperthyroidism	→	Increased	Undetectable
Subclinical hyperthyroidism	→	→	Undetectable

### ◆ Radioisotope study

- ▶ **Radioisotope study by  $I^{131}$**  (Diagnostic dose -5 microcurie is used) shows more uptake, i.e. *hot nodules* or hot areas. This is very useful in autonomous solitary toxic nodule.
- ▶  $I^{131}$  causes more irradiation and its half-life is 8 days. So *intravenous  $^{99m}Tc$*  is used for diagnostic purpose.  $^{99m}Tc$  has become isotope of choice for diagnosis as it is cheap, less radiation, scanning is done 20 minutes after IV injection of  $^{99m}Tc$  (half-life is 6 hours). Drawback of technetium is that it concentrates in carcinoma, so forms hot nodule (means hot nodule need not be benign in Tc scanning). Warm nodule in Tc scan may appear as cold nodule in RAI scan and so is called as *discordant nodule* which suggests malignancy. If radioactive iodine is used for diagnosis, then  $I^{123}$  is better as it has got short half-life (13 hours).
- ▶ Autonomous toxic nodule is absolute indication for radioisotope scan in toxic thyroid showing *hot nodule*. Graves disease shows *diffuse overactivity (uniform)*; hypofunctioning cold nodule in Graves disease could be malignant. In secondary thyrotoxicosis internodular tissues are overactive (*heterogeneous activity*). Non-hyperthyroid toxicosis shows increased uptake in non-thyroid areas of toxicity like struma ovarii in pelvis.
- ◆ TRH estimation.
- ◆ ECG—to look for cardiac involvement; if required opinion from cardiologists is taken and cardiac problems are managed.
- ◆ Total count and neutrophil count are very essential base-line investigations before starting antithyroid drugs (as it may cause agranulocytosis).
- ◆ Thyroid antibodies estimation—antithyroglobulin antibody, TSH receptor antibody, antithyroid peroxidase (anti-TPO) antibody.

## Treatment for Thyrotoxicosis

### Medical

- ❖ Relief of symptoms:
  - Beta blockers-propranolol, nadolol, metoprolol - Control cardiovascular and hyperadrenergic manifestations. Bronchial Asthma, heart Block, Cardiac failure are contraindications.
  - Calcium channel blockers (e.g. verapamil and diltiazem) can be used
  - Oral rehydration
- ❖ **Antithyroid pharmacotherapy.** It prevents the–
  - Release of hormones: Lugol's iodine (potassium iodide and iodine) 10 drops – 3 times day
  - Production of thyroxine : **Methimazole** – long-acting, 20–40 mg OD; more potent; but not used in pregnancy; Tapazole 5 or 10 mg tablets. **Carbimazole** 20 mg three times a day up to 120 mg. **Propyl thiouracil** (PTU) 100 mg three times a day, used in pregnancy; 50 mg tablets
  - Action of thyroxine on end organs: Propranolol – 40 mg tid up to 120–160 mg; PTU
  - Production of antibodies: Steroids, methimazole, carbimazole; Levels of TSH R Ab fall and permanent cure may occur in 50% of patients in Grave's

### Radioactive iodine therapy Thyroidectomy

## 1. ANTITHYROID DRUGS

### Indications for antithyroid drugs:

- ❖ Toxicity in pregnant women—Propylthiouracil is preferred
- ❖ Toxicity in children and young adults
- ❖ Before thyroidectomy, to make the patient euthyroid
- ❖ Soon after starting radioactive  $I^{131}$  therapy for 6 to 12 weeks (Effects of radiotherapy start only in 6 to 12 weeks)

### a. Carbimazole:

- ▶ Is the commonest drug used.
- ▶ Dose is 5–10 mg, exactly 8th hourly (as T1/2 of carbimazole is 8 hours). Each tablet is 5 mg.
- ▶ Usually given for 12–18 months.
- ▶ Peak plasma level should be maintained in optimum concentration to have a proper benefit.
- ▶ Often tri-iodothyronine 20 microgram 4 times daily or Thyroxine 0.1 mg daily are given in combination with antithyroid drugs, to prevent iatrogenic thyroid insufficiency or to prevent the increase in size of goitre.
- ▶ It acts by blocking thyroid hormone synthesis. Carbimazole also suppresses the autoimmune process in thyroid in Grave's disease.
- ▶ Carbimazole causes fever, rashes, arthralgia, myalgia, neuritis, lymph node enlargement, liver cell dysfunction, psychosis, agranulocytosis.

### b. Methimazole:

- ▶ Methimazole is more potent and longer-acting than propylthiouracil
- ▶ Once a day dose; 20 – 40 mg.
- ▶ Methimazole is not used in 1st trimester pregnancy as it may cause cloacal and scalp abnormalities.

### c. Propyl thiouracil:

- ▶ It acts by blocking thyroid hormone synthesis as well as by blocking peripheral conversion of  $T_4$  to  $T_3$ .
- ▶ It also decreases the thyroid autoantibody levels.
- ▶ It can be given for hyperthyroidism in children and in pregnancy, lactation.
- ▶ Dose is 200 mg 8th hourly.
- ▶ Propylthiouracil is reserved for use in thyroid storm, first trimester of pregnancy, and methimazole allergy or intolerance.
- ▶ PTU causes dose unrelated hepatotoxicity; agranulocytosis; antineutrophilic cytoplasmic antibody in 20% of patients after long-term usage.

### Note:

- Dose of antithyroid drug are titrated every 4 weeks until thyroid functions (TSH and FT4) normalize.
- Toxic multinodular goiter and toxic adenoma will not go into remission.
- Reduction of thyroid hormones occurs in 2–8 weeks
- In Graves, once patient is rendered euthyroid options include use of ATD for 12–18 weeks or definitive treatment with RAI or surgery.
- After cessation of therapy, close follow up for 3–6 months is required to detect relapse.
- 40% experience recurrence in 1 year in Grave's; in such situation RAI or surgery has to be considered.
- Antithyroid drugs are continued during and after surgery, for 7–10 days. It has to be given after starting radioactive iodine therapy for 6 weeks to 12 weeks.
- Response to treatment and possibility of relapse in primary thyrotoxicosis can be assessed by studying HLA status and TsAb level.

**d. Propranolol:**

- ◆ It is a beta blocker, which is used as an antithyroid drug.
- ◆ Dose is 40 mg tid.
- ◆ It reduces the cardiac problems and also blocks the peripheral conversion of  $T_4$  to  $T_3$ , as it is the  $T_3$  which is the principle active agent in periphery.
- ◆ Contraindications are bronchial asthma, heart block, cardiac failure.
- ◆ Long-acting nadolol 160 mg OD can also be used.

**e. Lugol's iodine (5% iodine + 10% potassium iodide):**

It decreases the vascularity of the gland and makes it more firm and easier to handle during surgery. Dose is 10–30 drops/day (minims) for 10 days prior to surgery. Potassium iodide tablets 60 mg tid also can be given instead of Lugol's iodine. But its use at present is disqualified.

(One minim = one drop. One ml = 16 drops).

**Note:**

- Lugol's iodine prevents the release of hormone from the gland – **thyroid constipation**. After 2 weeks, effect of Lugol's iodine is lost causing thyroid escape from iodine control.

**f. Block and replacement therapy:**

It is giving high dose of carbimazole to inhibit  $T_3$  and  $T_4$  production completely with a maintenance dose of 0.1 mg of L thyroxine. It reduces the iatrogenic thyroid insufficiency.

**g. High dose of glucocorticoids.**

It impair peripheral conversion of  $T_4$  to  $T_3$  and also lowers serum TSH level; hence can be used in severe resistant/refractory cases.

**Advantages of Antithyroid Drugs**

- ◆ Avoids surgery and its complications.
- ◆ Avoids radioiodine therapy.
- ◆ Clinical improvement occurs in 2 weeks. Biochemical improvement occurs in 6 weeks.
  - ▶ *Remission is confirmed by TsAb assessment, which will be low.*
  - ▶ Permanent remission rate is very less in adults and is 20% in children.

**Disadvantages**

- ◆ Prolonged course of treatment for 18 months, and in spite of this, cannot predict the remission or relapse. Relapse rate is 40%. Large gland/severe disease/abnormal TSH receptor antibodies (TSH-RAbs) are likely to lead into high recurrence.
- ◆ Size of swelling may not regress.
- ◆ It may lead to *agranulocytosis and thrombocytopenia*, liver damage, hair loss (except propranolol). Sore throat is the earliest presentation of agranulocytosis. If it is so, drug is stopped, total count is done. If it is less, agranulocytosis is confirmed. High doses of injection benzyl penicillin 10–20 lac, 6th hourly, IV is started to prevent infection. If required, blood transfusion is done. Patient usually recovers by this. To control toxicity, Tab. Propranolol 40 mg tid is started. Rarely they need bone marrow transplantation.

**Complications of antithyroid drugs**

- ❖ Allergic reactions
- ❖ Agranulocytosis
- ❖ Severe hepatitis more often with PTU
- ❖ Polyarthrititis
- ❖ Lupus vasculitis

**Note:**

- They are dose-related in methimazole but not so in PTU.
- Patients with agranulocytosis usually present with fever and pharyngitis.
- After the drug is stopped, granulocyte counts usually start to rise within several days but may not normalize for 10–14 days.
- Granulocyte colony-stimulating factor (G-CSF) appears to accelerate recovery in patients with a bone marrow aspiration showing a granulocyte-to-erythrocyte ratio of 1:2 or greater than 0.5.

**Other Drugs Which are Effective (But not Commonly Used)**

- ◆ Potassium perchlorate inhibits iodide transport.
- ◆ Iopanoic acid 1 gram/day is used in severe unresponsive cases. It inhibits peripheral conversion of  $T_4$  to  $T_3$ .
- ◆ Lithium carbonate 300 mg 6th hourly.
- ◆ Guanethidine 40 mg orally 6th hourly.
- ◆ Reserpine 5 mg IM.
- ◆ Dexamethasone 2 mg orally 6th hourly. It inhibits peripheral conversion of  $T_4$  to  $T_3$ . It is used in thyroid storm.
- ◆ 2 mg IV propranolol in thyroid storm.
- ◆ Cholestyramine - Decreases reabsorption of thyroid hormones from the enterohepatic circulation; used orally at the rate of 4g four times daily, in combination with methimazole or PTU.

**2. SURGERY****Indications**

- ❖ Failure of drug treatment in primary thyrotoxicosis in young patients
- ❖ Autonomous toxic nodule
- ❖ Nodular toxic goitre
- ❖ When malignancy cannot be ruled out
- ❖ Graves disease in children, Graves with nodules
- ❖ Need for antithyroid drugs for more than 2 years
- ❖ Large goitre, substernal/intrathoracic goitre
- ❖ Pressure symptoms, Graves ophthalmopathy
- ❖ Amiodarone-induced thyrotoxicosis.

- ◆ It is now observed that *total thyroidectomy* may be a better option in Graves disease to achieve lowest relapse rate and successful stabilisation of thyroid ophthalmopathy as it clears the antigenic focus in thyroid completely.
- ◆ Surgery done is *subtotal thyroidectomy*—Both lobes with isthmus are removed and a tissue equivalent to pulp of finger is retained at lower pole of the gland on both sides (5–8 grams).

*Dissatisfaction and discouragement are not caused by the absence of things but the absence of vision.*

- ◆ In autonomous nodule, *hemithyroidectomy* is done. Here entire lateral lobe with whole of isthmus is removed.

### Advantages

- ◆ Rapid and high cure rate.
- ◆ Problems of radioiodine therapy are avoided.
- ◆ Surgery provides tissue for biopsy, removes the occult malignant foci.
- ◆ Surgery is better option for ophthalmopathy due to thyrotoxicosis.
- ◆ It is the option for women planning for child.
- ◆ Coexisting parathyroid carcinoma can be removed.
- ◆ For intrathoracic retrosternal toxic thyroid, surgery is the choice. Antithyroid drugs and also radioactive iodine may increase the goitre size.

Patient should be made euthyroid before doing surgery. (It should be confirmed by repeated estimation of serum T<sub>3</sub>, T<sub>4</sub> and TSH levels).

### Disadvantages

- ◆ Recurrent thyrotoxicosis (5%).
- ◆ Thyroid insufficiency (20–45%). It is revealed in 6 months to 2 years and is confirmed by estimating T<sub>3</sub>, T<sub>4</sub> and TSH levels. Hypothyroidism is better than recurrent thyrotoxicosis. It is treated by tab. L-thyroxine 0.1 mg daily (OD) for life-long—usually given in morning.
- ◆ Complications of thyroid surgery itself.

## 3. RADIOIODINE THERAPY

### Indications

- ❖ Primary thyrotoxicosis
- ❖ In autonomous toxic nodule
- ❖ In recurrent thyrotoxicosis

- ◆ Radioiodine destroys the cells and causes the complete ablation of thyroid gland.
- ◆ *Usual dose is 5 to 10 millicurie, or 160 microcurie/gm of thyroid.*
- ◆ Patient is made euthyroid using antithyroid drugs; drug is discontinued for 5 days; I<sup>131</sup> 300–600 MBq is given orally; antithyroid drugs are started after 7 days and are continued for 8 weeks. In 30% of patients, additional 2 or 3 doses may be required.
- ◆ It takes 3 months to get full response and so until then, the patient has to take antithyroid drugs. Often additional one or two doses of radioiodine are required to have complete ablation. Eventually they go for hypothyroidism and so require maintenance dose of L-thyroxine 0.1 mg daily.
- ◆ To give therapeutic dose, patient should be admitted and isolated for 7 days (Half-life) to prevent irradiation. It is given orally soon after getting from the manufacturer without much delay to have optimal efficacy.

### Radioactive iodine therapy (RAIT)

- ❖ Preferred therapy for hyperthyroidism as it avoids surgery, prolonged drug therapy with >90% cure rate; but proper follow up is needed and facilities should be available (not much centers are having)
- ❖ Administered orally as a single dose in capsule or liquid form <sup>131</sup>I (Sodium iodide-131)
- ❖ Causes fibrosis and destruction of the thyroid over weeks to many months causing hypothyroidism
- ❖ It is effective, safe, and does not require hospitalization
- ❖ Given orally as a single dose in a capsule or liquid form - I<sup>131</sup> is given (6 to 8 millicuries)
- ❖ Very few adverse effects as no other tissue absorbs RAI
- ❖ But the effect is less rapid than drugs or thyroidectomy
- ❖ Goal is to make the patient hypothyroid
- ❖ Not recommended with patients of severe ophthalmopathy
- ❖ Not advisable in chronic smokers
- ❖ Pregnancy, breastfeeding, and recent lactation are contraindications
- ❖ A gland-specific dosage based on the estimated weight of the gland and the 24-hour uptake is used. The dose of I<sup>131</sup> administered is 75–200 μCi/g of estimated thyroid tissue divided by the percent of <sup>123</sup>I uptake in 24 hours
- ❖ No evidence indicates that radioactive iodine therapy for hyperthyroidism causes the development of thyroid carcinoma or results in increased mortality for any other form of cancer, including leukemia
- ❖ Radioactive iodine should be avoided in children younger than 5 years. In children 5 to 10 years old, <sup>131</sup>I therapy is acceptable if the calculated activity of administered <sup>131</sup>I is less than 10 mCi. In children older than 10 years of age, radioactive iodine therapy is acceptable if the activity is greater than 150 μCi/g of thyroid tissue
- ❖ Radioactive iodine should never be administered to pregnant women, because it can cross the placenta and ablate the fetus's thyroid, resulting in hypothyroidism

- ❖ Risk of hyperparathyroidism may be there after RAI therapy
- ❖ Similarly, breastfeeding is a contraindication, as the radioisotope is secreted in breast milk. Women will continue to receive increased radiation to the breast from radioactive iodine for few months after ceasing lactation
- ❖ It is standard practice to check for pregnancy before starting radioactive iodine therapy and to recommend to the patient not become pregnant for at least 6–12 months after the treatment. No excess fetal malformations or increased miscarriage rates have been found in women previously treated with radioactive iodine for hyperthyroidism.

### TOXIC THYROID IN PREGNANCY

- ◆ *Radioiodine therapy is absolutely contraindicated* in pregnancy (High-risk to foetus).
- ◆ Antithyroid drugs can be administered carefully.
- ◆ But, the problem here is that both TSH and antithyroid drugs cross the placental barrier and baby born may be hypothyroid and goitrous.
- ◆ Propylthiouracil is preferred in pregnancy.
- ◆ Subtotal/total thyroidectomy can be done in second trimester.

### TOXIC THYROID IN CHILDREN

- ◆ Radioiodine therapy is *absolutely contraindicated* in children.
- ◆ Recurrence rate is also very high after surgery.
- ◆ So proposed treatment is initially antithyroid drugs are given until adolescent period and then subtotal thyroidectomy is done.

### THYROCARDIAC

Severe cardiac damage (partly or wholly) resulting from hyperthyroidism, usually secondary type, requires proper opinion from cardiologists and treatment with propranolol. Subtotal thyroidectomy is the treatment.

### IN A PATIENT WITH THYROTOXICOSIS, WITH RECENT ONSET OF PROPTOSIS

- ◆ Early thyroidectomy has to be avoided, because early surgery may precipitate malignant exophthalmos. Here the patient has to be treated initially with antithyroid drugs and if required with steroids, until the proptosis has remained static for six months. Then subtotal thyroidectomy is done.
- ◆ Since half-life of L-thyroxine is 7 days, propranolol and antithyroid drugs have to be continued for 7 days after thyroidectomy.
- ◆ **T<sub>3</sub> Thyrotoxicosis** should be suspected if the clinical picture is suggestive of toxicosis, but routine tests for thyroid function are within normal range.

## RADIOACTIVE IODINE

It is used both as a diagnostic as well as a therapeutic agent.

1. **I<sup>131</sup>**—is used for radioactive iodine therapy ( $\beta$ -rays are used).
2. **I<sup>123</sup>**—is used for diagnostic studies ( $\gamma$ -rays are used).

For diagnostic purpose I<sup>123</sup> is given orally in empty stomach on previous day (*dose*—5 micro curie; *T<sub>1/2</sub>* (half-life) of I<sup>123</sup> is 13 hours and so it is suitable for diagnostic purpose). Patient should not take L-thyroxine for 6 weeks prior to radioisotope study.

#### Note:

- If the patient is on T<sub>3</sub> (60  $\mu$ g/day) medication, the drug is stopped 10 days before radioisotope scan.
  - Injection TRH, if given, radioisotope scan can be done in 24 hours.
  - ◆ Thyroid treats this I<sup>123</sup> similar to inorganic I<sup>127</sup>. This I<sup>123</sup> enters the thyroid from the circulation and gets incorporated into T<sub>3</sub>, T<sub>4</sub> and later released into circulation as protein bound iodide (PBI). *Normal value of PBI is 8  $\mu$ gm%.*
  - ◆ Using *Gieger Muller's gamma ray counter*, scanning of thyroid gland is done to visualize the gland.
  - ◆ *Hot* area suggests more uptake,
  - ◆ *Warm* area suggests normal uptake,
  - ◆ *Cold* area suggests no uptake.
- I<sup>123</sup> radioisotope can be safely used in children and pregnancy for diagnostic purpose only (5 microcurie) as the dose is low.

#### Indications for diagnostic radioactive iodine study

- ❖ Doubtful toxicity
- ❖ Ectopic thyroid
- ❖ Autonomous toxic nodule
- ❖ After total thyroidectomy, to look for secondaries in follicular carcinoma thyroid
- ❖ Retrosternal thyroid

#### Note:

- Presently I<sup>131</sup> is also becoming popular as a diagnostic tool. For treating malignancy  $\beta$ -rays are more used than  $\gamma$ -rays.
- Technetium 99 scan is used for diagnostic purpose at present as it is effective and faster (in 20 minutes). IV administration is used.
- Radioisotope study is done to look for secondaries by doing whole body scanning (total body scintigraphy). For diagnostic radioactive study Technetium 99 pertechnetate can also be used.

### Therapeutic Uses

1. In primary thyrotoxicosis.
2. In autonomous toxic nodule, it is useful as remaining gland still will function adequately after radiotherapy (As during radiotherapy radioisotope will not be taken up by this retained normal gland as it is suppressed in the presence of toxic nodule which will function later adequately).
3. In follicular carcinoma of thyroid, after total thyroidectomy, if there are secondaries elsewhere in the body, as in bones or lungs, then radioiodine therapy is given. I<sup>131</sup> is given as its half-life is 8 days. Patient should be isolated for this period and careful disposal of urine has to be done during this period. It is given orally in a dose of 5 millicuries (160 microcurie/g of thyroid).

### Problems in Radioactive Iodine Therapy

- ◆ *Permanent thyroid failure* with hypothyroidism.
- ◆ *Effects will be seen only* after 3 months.
- ◆ *Ophthalmopathy and dermatopathy* will be worsened.
- ◆ It may induce *hyperparathyroidism*.

#### Dose of radioactive iodine

Diagnostic	Therapeutic
• For thyroid—5-50 microcurie	• Residual thyroid ablation—50 mCi
• For whole body iodine scan 5-10 millicurie in 72 hours	• Bone secondaries from FCT—100-120 mCi
	• Lung secondaries from FCT—180 mCi

### Contraindications for Radioactive Iodine Therapy

- ◆ Pregnancy/females desiring to have pregnancy within 1 year/ lactating mothers.
- ◆ Children, lactating women.

#### Radioactive isotopes used in thyroid

Isotopes	Route of administration	Half-life	Type of rays
I <sup>123</sup>	Oral	13 hr	$\gamma$ rays
I <sup>125</sup>	Oral	60 days	$\gamma$ rays
I <sup>131</sup>	Oral	8 days	$\beta$ , $\gamma$ rays
I <sup>132</sup>	Oral	2.3 hr	
Tc 99 scan*	IV	6 hr	

\* Used mainly for malignancy in thyroid itself. It is sensitive, convenient, low radiation exposure, inexpensive, with good images but nonspecific and not used for therapy. Lithium is also used as isotope for diagnosis in thyroid diseases. Technetium is better to identify nonfunctioning secondaries.

*Don't spend a dollars' worth of time for ten cents worth of results.*



**Note**

- ❖ High dose of retinoic acid will make  $I^{131}$  to concentrate in tumour cells (70 mg/daily for 2 weeks)
- ❖ Fertility should be avoided for 1 year after  $I^{131}$  therapy
- ❖ Avoid contrast CT in thyroid diseases as much as possible because  $I^{131}$  study in later period will be difficult
- ❖ MRI is ideal when radioiodine therapy is needed

**THYROID NEOPLASMS****A. Benign**

Follicular adenoma can be – *Colloid* (do not have potential for microinvasion; commonest type); *Fetal* (microfollicular – has potential for microinvasion); *Embryonal* (atypical – has potential for microinvasion); *Hurthle cell/oxyphil* or *oncocytic* (has potential for microinvasion); *hyalinising trabecular* adenoma.

**Note:**

- All adenomas are invariably follicular.
- Colloid adenoma is the commonest.
- The existence of papillary adenoma is doubtful; it is invariably a low-grade papillary carcinoma.

**B. Malignant (Dunhill classification).****a. Differentiated—80%**

1. Papillary carcinoma (60%).
2. Follicular carcinoma (17%).
3. Papillofollicular carcinoma behaves like papillary carcinoma of thyroid.
4. Hurthle cell carcinoma behaves like follicular carcinoma.

**b. Undifferentiated—20%**

Anaplastic carcinoma (13%)

**c. Medullary carcinoma (6%)****d. Malignant lymphoma (4%)****e. Secondaries in thyroid (rare)—from colon, kidney, melanoma, breast.****Incidence and Spread**

- ◆ Annual incidence of thyroid cancers is 3.7 per 1,00,000 population. It is common in females (3:1).
- ◆ Papillary carcinoma mainly spreads through lymphatics; follicular through blood; anaplastic through lymphatics and blood.

**Aetiology of Thyroid Malignancy**

- ◆ Radiation either external or radioiodine can cause papillary carcinoma thyroid. There is increased incidence of thyroid carcinoma among children following exposure to ionising radiation after the *Chernobyl nuclear disaster* in Ukraine in 1986; in children in Marshall island after atomic bomb testing.

Earlier irradiation was practised to head and neck region to treat benign conditions like tonsillitis, adenoids, thymus enlargement, acne vulgaris, haemangiomas during first two decades of life. As a consequence papillary carcinoma of thyroid became common in these individuals. Radiotherapy received in adolescent period for Hodgkin's lymphoma may predispose to papillary carcinoma.

- ◆ Pre-existing multinodular goitre. It turns into follicular carcinoma of thyroid.

- ◆ Medullary carcinoma thyroid is often familial.
- ◆ Hashimoto's thyroiditis may predispose to NHL/papillary carcinoma of thyroid.
- ◆ Familial.
- ◆ Elevated TSH is observed in papillary carcinoma of thyroid.
- ◆ Genetic—*Cowden syndrome* is differentiated thyroid carcinoma, carcinoma breast, multiple hamartomas. It is due to germ cell mutation of *PTEN tumour suppressor gene*. Oncogenes—C myc, C erb, C fos, Ras are associated thyroid neoplasms.

**DIFFERENTIATED THYROID CARCINOMA (DTC)**

- ◆ DTC is a spectrum of disease derived from follicular cells. Both papillary and follicular carcinomas are grouped under this. 90% of thyroid malignancies are differentiated one. Papillary (PTC), follicular (FTC) and Hurthle cell carcinomas are DTCs. Insular variety is poorly DTC having intermediate position between DTC and anaplastic; it can cause bone and lung spread; it is common in younger age group; p53 and p21 are negative; with 40% 10-year survival.
- ◆ AGES (Mayo Clinic, Hay); AMES (Lahey clinic); MACIS; *Sloan Kettering* scoring – are different scoring systems used for DTCs. Sloan Kettering scoring includes low, intermediate and high-risk groups. First three scoring systems have low- and high-risk groups.
- ◆ Papillary spreads through nodes; follicular through blood. FCT causes pulsatile vascular secondaries.
- ◆ Incidence of thyrotoxicosis in DTCs is 2%.
- ◆ Galectin – 3, RET/PTC rearrangements, CD44, leukocyte common antigen (LCA), cytokeratin are the probable tumour markers under evaluation. For indeterminate, FNAC molecular markers are used to identify RAS and BRAF mutations.
- ◆ *TNM staging for DTCs are –*
  - ▶ *Tumour* - T0 – no evidence of primary tumour; T1 - < 2 cm – (T1a < 1 cm; t1b 1–2 cm). T2- 2–4 cm. T3 - > 4 cm limited to thyroid or only minimally extrathyroid extension (to sternothyroid or soft tissue). T4a – invasion to subcutaneous tissue, larynx, trachea, oesophagus and recurrent laryngeal nerve; T4b – invasion to prevertebral fascia, carotid encasement or involvement of mediastinal vessels.
  - ▶ *Regional nodes* (central/lateral neck compartment/superior mediastinal) – Nx – regional nodes cannot be assessed. N0 – no nodes. N1a – spread to level VI (pre/paratracheal, prelaryngeal). N1b – neck nodal spread same or opposite or both sides or superior mediastinal nodes.
  - ▶ *Metastases* – Mx – metastases cannot be assessed. M0 – no distant spread. M1 – distant spread present.
  - ▶ *Note:* Age is included in staging which is an important factor.

**Postoperative AJCC staging for DTCs for predicting risk of death****Age less than 45 years**

Stage I – Ant T, any N, M0; Stage II – any T, any N, M1.

**Age after 45 years**

Stage I – T1, N0, M0; Stage II – T2, N0, M0;

Stage III – T3, N0, M0 or T1, N1a, N0; T2, N1a, M0; T3, N1a, M0

Stage IVA – T4a, N0, M0; T4a, N1a, M0; T1, N1b, M0; T2, N1b, M0;

T3, N1b, M0; T4a, N1b, M0

Stage IVB – T4b, any N; M0

Stage IVC – Any T, any N, M1.

### American thyroid association for predicting the risk of recurrence

#### Low risk—90% of patients

- ❖ T1–2 N0 M0 and absence of aggressive histology or vascular invasion
- ❖ Microscopic tumour clearance
- ❖ No spread to node/blood
- ❖ No capsular/vascular invasion
- ❖ Extrathyroid I<sup>131</sup> uptake is not found
- ❖ 25-year mortality is 2%

#### Intermediate risk

- ❖ T3 or tumour with aggressive histology or vascular invasion
- ❖ Microscopic perithyroid invasion
- ❖ Vascular invasion

#### High-risk

- ❖ T4 or any T, N1 or M1
- ❖ Incomplete tumour removal
- ❖ Macroscopic invasion
- ❖ Distant spread
- ❖ Extrathyroid bed I<sup>131</sup> uptake present
- ❖ 25 years mortality is 46%

### European Consensus Report defined three risk categories for DTC

#### Very low risk

Unifocal T1 (<1 cm) N0 M0, no extension beyond the thyroid capsule and favorable histology (classical or follicular variant of papillary and minimal invasive follicular carcinoma)

#### Low risk

T1 (>1 cm) or T2 N0 M0 or multifocal T1 N0 M0

#### High risk

Any T3 and T4 or any T, N1, or any M1

## Investigations

- ◆ *US neck* is essential investigation. It shows the nature, size, margin, echogenicity, vascularity, nodal status, invasion through thyroid capsule. Lymph node may show loss of hilus, round shape, hypoechogenicity, cystic changes and calcification, with increased peripheral vascularity.
- ◆ *FNAC of the nodule* (US-guided is ideal); it is very useful in PTC; but not much useful in FCT. FNAC of the lymph node is useful; thyroglobulin estimation of the lymph node aspirate is very useful.
- ◆ *Functional status* should be checked – T3, T4, TSH. TSH may be raised in PTC.
- ◆ *MRI of neck if needed* only; CT is not done as iodine contrast is not used; if needed, should be done as non-contrast CT.

## Treatment

- ◆ *Total thyroidectomy* with either prophylactic (in T3 and T4 of T staging) or therapeutic (when involved sonologically or FNAC or frozen section [of node] wise) central cervical (compartment) node dissection (CCND). Prelaryngeal, pre and paratracheal, nodes above the level of innominate vein and up to carotids and hyoid bone are removed often may be with thymus (compartment). CCND provides accurate staging; treats micrometastases (90% in

PTC in central nodes) which may be often the cause for recurrence or persistence of disease; central nodes being primary nodes are commonly involved. It also provides accurate RAI dosing; lowers the postoperative serum thyroglobulin level which facilitates the accurate TG monitoring during follow up. Reoperation of CCND is technically difficult after total thyroidectomy as a separate sitting. But there is no oncological survival benefit and increased chances of postoperative hypoparathyroidism and recurrent laryngeal nerve injury. Lateral cervical node dissection (LCND. Nodes -IIA, III, IV and VB) is done only when it shows the evidence of involvement (by FNAC or US); there is no role for prophylactic LCND.

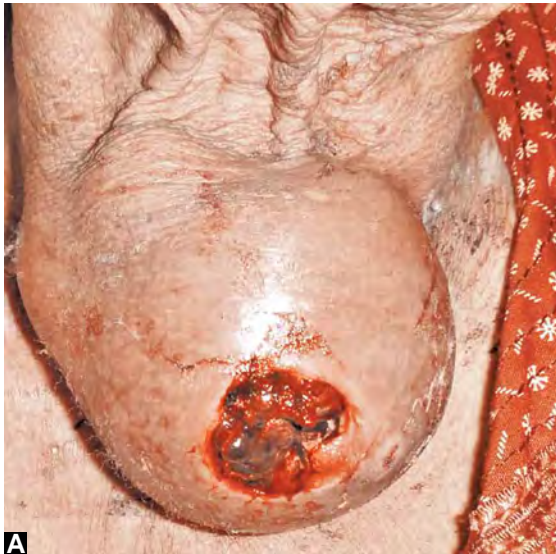
- ◆ *Only hemithyroidectomy is done* if tumour is <1 cm; node negative; unifocal and intrathyroidal disease.
- ◆ *Radioactive iodine therapy (RAIT)* – RAIT reduces the recurrence; ablates the possible small residual thyroid tissue in thyroid bed; treats the potential possible micrometastases sites in remnant thyroid or lymph nodes or at distant sites. So it facilitates the proper thyroglobulin surveillance during follow up. RAIT is indicated in tumor >1 cm, extracapsular thyroid invasion or locoregional extension, high-risk group, unfavorable histological subtype (follicular, diffuse sclerosing, or tall cell-variant papillary cancer), multifocal disease; BRAF positive tumor in the specimen. Criteria for RAI are - TSH should be >30 mU/ml. L-Thyroxine replacement is stopped 3–4 weeks before radioiodine treatment; OR - in time being switch over to T3 80 µg/day and RAI in 7 days; OR - When L-thyroxine withdrawal is not advisable, TSH stimulation was achieved using Recombinant Human Thyrotropin (rhTSH) (0.9 mg IM one dose – 2 consecutive days; after 24 hours RAI given). Dose of I<sup>131</sup> – usually – 3700 MBq (100 mCi); for metastases, it is 200 mCi.
- ◆ *Suppression hormone therapy* using high dose L thyroxine – dose is to make TSH level <0.1 mu/L; orally - morning 30 minutes before food. Problems with TSH suppression are – Subclinical thyrotoxicosis; cardiac irregularities; osteoporosis.
- ◆ *Medical therapy*: Mainly for advanced DTC; Targeted therapy using – Sorafenib (Nov, 2013 FDA approval); Vandetanib; cabozatinib (FDA approved).
- ◆ *Metastatic disease*: Total thyroidectomy; RAIT; external RT for bone, brain and lung metastases; targeted medical therapy; surgical excision of the isolated bone secondaries like clavicle or sternum.

## Prognosis

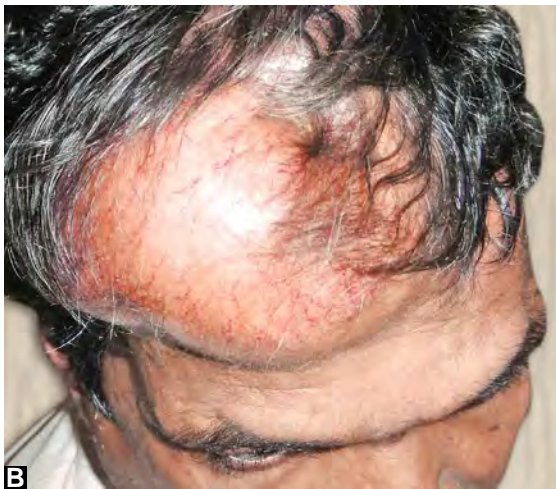- ◆ They usually carry good prognosis.
- ◆ Tall/columnar cell, trabecular, scirrhous, solid types of papillary carcinoma; oxyphilic, insular types of FCT carry poor prognosis.

## Follow-up

- ◆ Serum thyroglobulin measurement - ≤0.2 ng/mL (IRMA assay) after TSH suppression; Tg antibody level (TgAb) estimation. Serum thyroglobulin estimation is done along with TgAb.
- ◆ RAI whole body scan (WBS). It is done 3 months after RAIT; then once in 12 months.
- ◆ TSH estimation is done once in 6 months.
- ◆ USG neck/USG-guided FNAC/MRI neck.
- ◆ USG-guided FNAC of lymph node and Tg measurement in FNAC fluid washout (FNAC-Tg).
- ◆ When there is negative I<sup>131</sup> scan with elevated TG during follow up, PET scan is indicated.



A



B

**Figs 6.38A and B:** (A) Fungating follicular carcinoma thyroid in a female. (B) Pulsatile vascular skull secondaries from FCT in a male patient.

#### Differential diagnosis for carcinoma thyroid

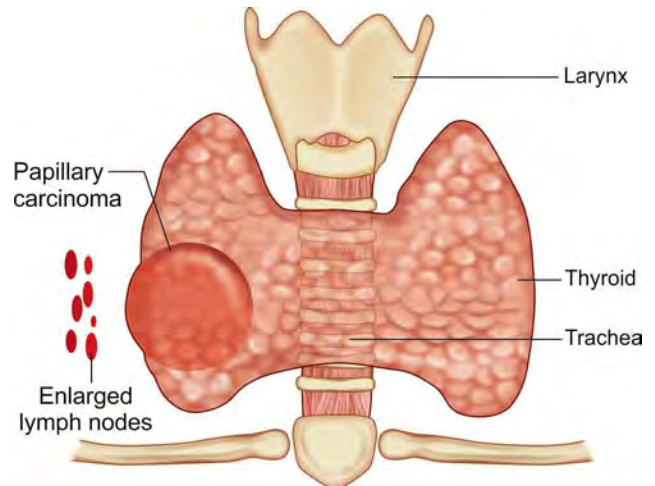
- ❖ Multinodular goitre
- ❖ Solitary nodule of other causes
- ❖ Riedel's thyroiditis

### PAPILLARY CARCINOMA OF THYROID (PCT)

- ◆ It is 70–80% common.
- ◆ Common in females and younger age group.

#### Aetiology (see page 478)

- ◆ Radiation either external or radioactive iodine therapy. TSH levels in the blood of these patients are high and so it is called as *hormone dependent tumour*.



**Fig. 6.39:** Papillary carcinoma of thyroid with nodal infiltration—diagrammatic representation.

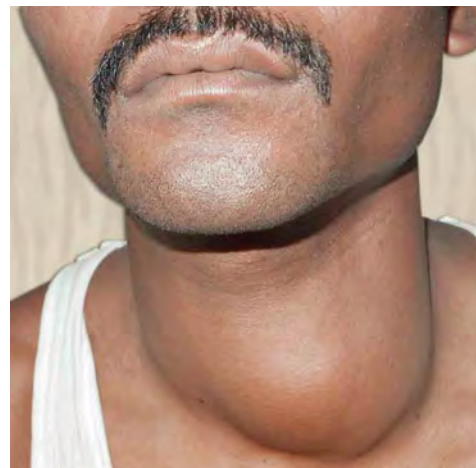### Woolner Classification

#### Types

- i. Occult primary (< 1.5 cm).
- ii. Intrathyroidal.
- iii. Extrathyroidal.

#### Note:

- *Micropapillary carcinoma* is a tumour, clinically not detectable or less than 1 cm.
- *Encapsulated variant of papillary carcinoma*, like adenoma shows capsule with local invasion, commonly nodal spread; it often mimics hyperplastic nodule; but this type carries good prognosis.
- *Diffuse sclerosing variant* is seen in children which is very aggressive type with lymphocytic infiltration; it shows near 100% nodal spread; it carries poor prognosis.
- *Encapsulated papillary variant* and follicular carcinoma may be found together as *papillofollicular (Lindsay tumour)*; it behaves like papillary carcinoma with good prognosis.



**Fig. 6.40:** Papillary carcinoma thyroid (PCT) in male patient. Male patient is high-risk patient. But PCT and all thyroid carcinomas are more common in females.

## Gross

It can be soft, firm, hard, cystic. It can be solitary or multinodular. It contains brownish black fluid.

## Microscopy

- ◆ It shows cystic spaces, papillary projections with *psammoma* bodies (50% cases), malignant cells with ‘*Orphan Annie eye*’ nuclei (intranuclear cytoplasmic inclusions), nuclear groove, nuclear pseudoinclusions.
- ◆ *Orphan Annie eye nuclei* are identified in histology (paraffin section of formalin tissue). It is not seen in FNAC. Orphan Annie is strip cartoon character with empty circled eyes.
- ◆ Tall cell type of papillary carcinoma (10% of papillary carcinomas) is very aggressive type seen in elderly, 30% show capsular and vascular invasion, with 25–30% 5-year survival rate.
- ◆ Columnar type is seen only in males with near 100% mortality in 5 years.

## Spread

- ◆ It is a slowly progressive and less aggressive tumour.
- ◆ It is commonly multicentric.
- ◆ It spreads within the gland through intrathyroidal lymphatics to other lobe, comes out of the capsule and spreads to cervical lymph nodes.
- ◆ Usually there is no blood spread. Extrathyroidal disease— invasion into thyroid capsule can cause blood-borne secondaries occasionally.

## Clinical Features

- ◆ Soft or hard or firm, solid or cystic, solitary or multinodular thyroid swelling.
- ◆ Compression features are uncommon in papillary carcinoma thyroid.
- ◆ Often discrete lymph nodes in the neck (40%) are palpable.
- ◆ May present with secondaries in neck lymph nodes with occult primary.

## Diagnosis

- ◆ *FNAC* of thyroid nodule and lymph node.
- ◆ Radioisotope scan shows cold nodule.
- ◆ TSH level in the blood is higher.
- ◆ Plain X-ray neck shows fine calcification whereas nodular goitre shows coarse—ring/rim calcification.
- ◆ US neck to identify non-palpable nodes in neck and also lymph node.
- ◆ MRI may be useful.

## Treatment

- ◆ *Total or near total thyroidectomy*, with central node compartment dissection (level VI).

- ◆ *Suppressive dose* of L-thyroxine 0.3 mg OD life long. TSH level should be < 0.1 m U/L.
- ◆ Lateral cervical/neck node dissection (LCND) levels IIA, III, IV and VB) or MRND (with preservation of sternocleidomastoid, IJV, spinal accessory nerve) is done depending on involvement of one side or both (if node positive on imaging or FNAC only as therapeutic).
- ◆ Radioactive iodine therapy (RAIT) if tumour is multicentric, >1 cm size, presence of nodes, extrathyroidal spread, high-risk group.
- ◆ ‘*Berry picking*’ (picking up the enlarged lymph nodes) earlier practiced is not done now.

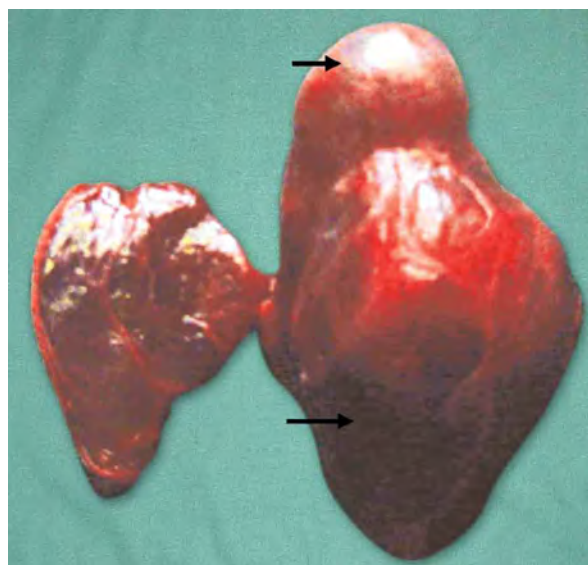


Fig. 6.41: Papillary carcinoma thyroid, operated specimen.

### Note:

- If tumour is < 1.0 cm, solitary, low grade, probably unicentric, hemithyroidectomy is done with proper follow up at regular intervals.
- Suppressive dose of L-thyroxine can cause osteoporosis and so often needs calcium and Vitamin D supplementation.

## Prognosis

Prognosis is good and it is one of the curable malignancies.

### AMES scoring

- A : Age. Age less than 40 years has got better prognosis
- M : Distant metastasis
- E : Extent of the primary tumour
- S : Size of the tumour. Size less than 4 cm has got better prognosis

### AGES scoring

- A : Age less than 40 years has got better prognosis
- G : Pathologic grade of the tumour
- E : Extent of the primary tumour
- S : Size of the primary tumour. Size less than 4 cm has got better prognosis

**Note:**

- Lymph node status does not alter the prognosis of papillary carcinoma of thyroid.
- MACIS scoring system is metastases, age, and completeness of excision, invasion, and size.
- All scoring systems categorise the patients as *high risk* for death—40% in 20 years; low risk for death—1% in 20 years. 80% of patients are in low risk for death. Low death risk is achieved by complete clearance of macroscopic tumour without any possible retaining of the disease during first surgery.
- *Follow-up:* Regular estimation of TSH levels, helps to monitor recurrence.
- **Thyroid paradox:** Cellular tumours are soft, and cystic tumours are firm or hard (tensely cystic). It is observed in papillary carcinoma of thyroid.

**Psammoma bodies are seen in:**

- ❖ Papillary carcinoma thyroid
- ❖ Meningioma
- ❖ Serous cystadenoma of ovary

**Berry's in thyroid**

- ❖ Berry ligament
- ❖ Berry sign
- ❖ Berry picking

**Role of ultrasound (US) in thyroid diseases**

- ❖ To detect number, size, nature of the nodules (cystic/solid/complex) (complex means cystic and solid together—more suspicious of carcinoma). Size up to 2 mm can be detected
- ❖ US guided FNAC is very useful
- ❖ US at regular intervals is advisable to observe a small nodule in thyroid
- ❖ To detect recurrent nodule
- ❖ To find out the invasion/spread/vascularity/status of carotid artery and internal jugular vein
- ❖ To find out enlarged lymph nodes in neck

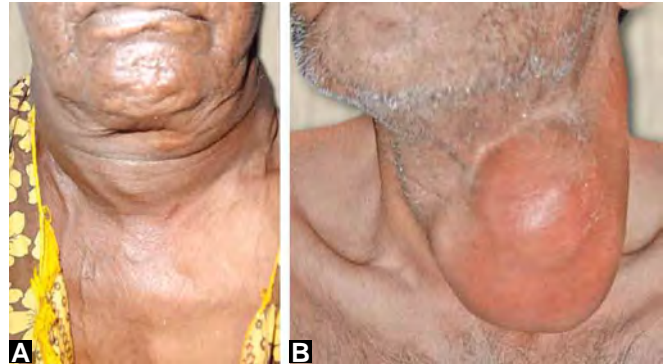**Role of FNAC in thyroid swelling**

- ❖ Highly sensitive in papillary carcinoma of thyroid and also its nodal spread
- ❖ Useful to differentiate between benign and malignant
- ❖ Should be done in all thyroid diseases especially when there is a nodule or multiple nodules
- ❖ Useful in lymphoma/anaplastic carcinoma/medullary carcinoma thyroid/Hashimoto's thyroiditis
- ❖ It is not very useful in follicular carcinoma as it is difficult to differentiate it from follicular adenoma as the main feature in follicular carcinoma is capsular invasion/vascular invasion which are not made out in FNAC

**FOLLICULAR CARCINOMA OF THYROID (FCT)**

- ◆ It is 10–15% common.
- ◆ It is common in females.

- ◆ It can occur either *de novo* or in a pre-existing multinodular goitre.
- ◆ Thyroglobulin immunostaining is positive.



**Figs 6.42A and B:** (A) Advanced carcinoma of thyroid with compression features with dilated veins; (B) Follicular carcinoma of thyroid in a male patient. It involved mainly left lobe but it is extensive and spreading to soft tissues adjacent to it.

**Types**

- Noninvasive—blood spread not common.
- Invasive—blood spread common.

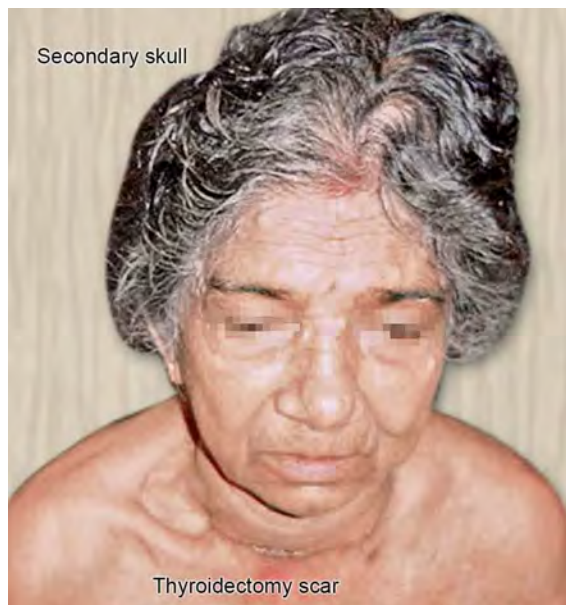
*Typical features:* Capsular invasion and angioinvasion.

**Spread**

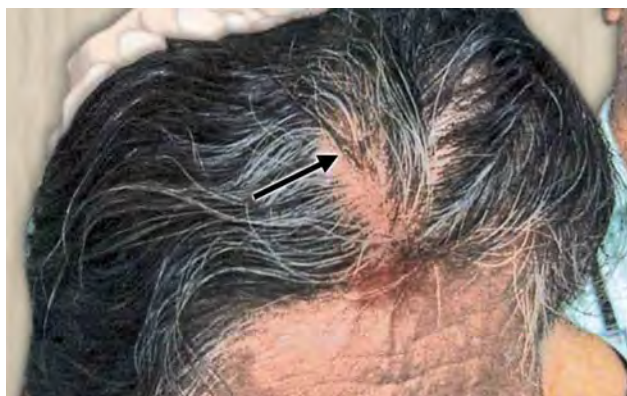- ◆ It is a more aggressive tumour.
- ◆ It spreads mainly through blood into the bones, lungs, liver.
- ◆ Bone secondaries are typically vascular, warm, pulsatile, localised, commonly in *skull*, long bones, ribs.
- ◆ It can also spread to lymph nodes in the neck occasionally (10%).

**Clinical Features**

- ◆ Swelling in the neck, firm or hard and nodular.
- ◆ Tracheal compression/*infiltration* and stridor.
- ◆ Dyspnoea, haemoptysis, chest pain when there are lung secondaries.
- ◆ Recurrent laryngeal nerve involvement causes hoarseness of voice, +ve '*Berry's sign*' signifies advanced malignancy (infiltration into the carotid sheath and so absence of carotid pulsation).
- ◆ Well localised, nonmobile, *soft, fluctuant* (because of colloid content) and *pulsatile* (as both inner and outer tables of skull bone are disrupted allowing brain pulsation to transmit secondaries in the skull. Secondaries can also occur in long bones also).



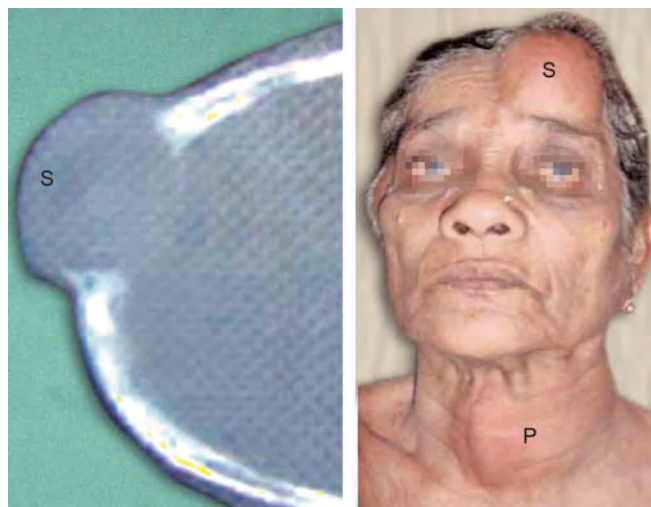**Fig. 6.43:** Secondaries in the skull in a patient who underwent thyroidectomy earlier for follicular carcinoma thyroid.



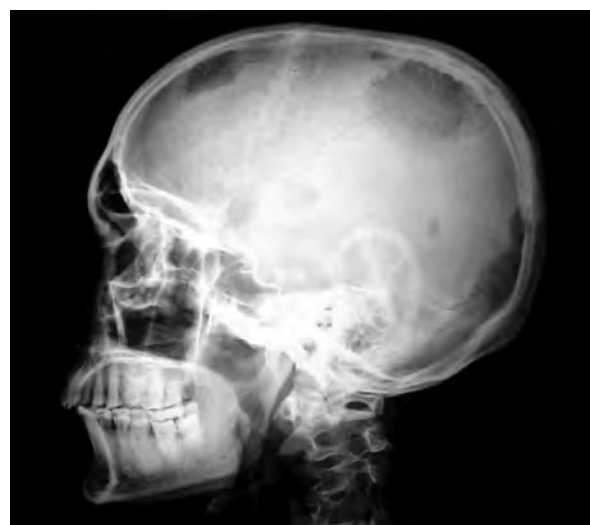**Fig. 6.44:** Secondaries in the skull from thyroid primary. Note well-localised, warm, pulsatile, vascular tumour with underlying bone erosion. It is common in flat bone like skull/ribs/sternum/scapula. Most common in frontoparietal part of skull.

### Investigations

- ◆ Most often FNAC is inconclusive, because capsular and angioinvasion, which are the main features in follicular carcinoma, cannot be detected by FNAC.
- ◆ Frozen section biopsy was said to be useful earlier; but it is questionable now. In 15% cases frozen section biopsy may be inconclusive or facility for frozen section biopsy may not be available in many places, then initial hemithyroidectomy is done.
- ◆ Ultrasound abdomen, chest X-ray, X-ray bones are the other investigations required, CT head, body scan.
- ◆ *Trucut biopsy* gives tissue diagnosis, but danger of haemorrhage and injury to vital structures like trachea, recurrent laryngeal nerve, vessels are likely. It may be useful in



**Fig. 6.45:** CT skull showing secondaries from follicular carcinoma thyroid.



**Fig. 6.46:** X-ray skull showing secondaries with lytic lesions from follicular carcinoma of thyroid as primary.

lymphoma and anaplastic carcinoma; but it is *not very well accepted*.

### Treatment

- ◆ *Total thyroidectomy is done* along with central node compartment dissection (level VI).
- ◆ Lateral cervical/neck node dissection (LCND) levels IIA, III, IV and VB) or MRND (with preservation of sternocleidomastoid, IJV, spinal accessory nerve) is done depending on involvement of one side or both (if node positive on imaging or FNAC only as therapeutic).
- ◆ Postoperative radioactive iodine ( $I^{131}$ ) therapy with a dose of 100 mCi (3700 MBq). Patient should be kept in isolation; excreta disposal and vomitus, blood, saliva should be in separate leak proof thrash bags.

- ◆ Maintenance dose of L-thyroxine 0.1 mg OD or T<sub>3</sub> 80 µg/day is given lifelong. Immediate thyroxin supplementation is often not started following surgery to keep TSH level raised so that all extrathyroidal tissues that take up iodine will also take up radioiodine to achieve optimum radioablation. TSH level should be more than 30 mIU/L for this.
- ◆ *On table frozen section biopsy* is useful in negative FNAC but doubtful cases. Definitive procedure is undertaken once frozen section report comes on table. But in frozen section biopsy itself, 15% of follicular carcinoma report may be inconclusive or negative which causes difficulty in taking decision. In such occasion, hemithyroidectomy is done and once histology report of follicular carcinoma is obtained completion thyroidectomy is done usually immediately within a week. If biopsy report is delayed, then completion thyroidectomy is done after 6–12 weeks.

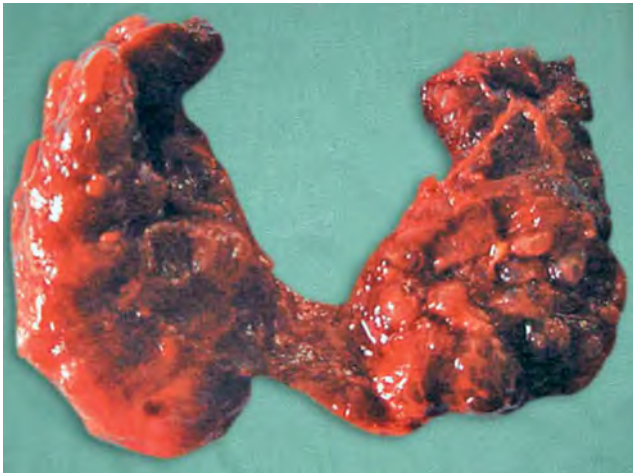


Fig. 6.47: Total thyroidectomy specimen—done for carcinoma thyroid.

### Follow-up

- ◆ It is by radioisotope I<sup>123</sup> scan done at regular intervals (6 months to one year) to look for secondaries.
- ◆ **Thyroglobulin estimation** is a good follow-up method to decide for radioisotope study. Normal value (0.5–50 µg/L). TG >50 µg/L is abnormal. It should be done once in 3–6 months. Its raise signifies recurrent/metastatic disease. Serum thyroglobulin level estimation is of no value in preoperative assessment. After thyroidectomy thyroglobulin secretion is stopped, hence its level should not be traceable after total thyroidectomy.
- ◆ Ultrasound neck or MRI neck to identify early relapse. MRI neck is better.

### Further Treatment

- ◆ If secondaries are detected *therapeutic dose* Ra I<sup>131</sup> is given orally. L-thyroxine has to be stopped 6 weeks prior to RT, then required dose of Ra I<sup>131</sup> is given (50–150 m curie).
- ◆ Radio remnant ablation (RRA)
  - ▶ Initially thyroid radioisotope scan is done. If patient is on 300 µg suppressive dose of L-thyroxine, it should

be stopped for 3–6 weeks so as to achieve serum TSH level above 30 M IU/l or two intramuscular injections of 0.9 mg of recombinant human TSH is given.

- ▶ If iodine isotope scan detects remnant disease, then 30–100 mCi of radio-ablation dose of I<sup>131</sup> is given orally. RR will destroy occult microscopic disease. Post-ablation isotope scanning is done in 8 days. Later in intermediate and high risk patients, follow up body scan is done once in 6 months. Serum thyroglobulin estimation is done for 6–12 months, later once in 6 months; neck US at 6, 12 months and annually for 5 years. Raise in thyroglobulin level indicates for further whole body isotope scan. To detect metastases radioisotope I<sup>131</sup> 100–200 mCi is given and 250–300 mCi is given for bone.
- ▶ *Prior to radioactive iodine therapy following precautions* should be taken—low iodine diet for 10 days; isolation when dose is more than 30 mCi; increase intake of oral fluid to maintain high urine output to avoid radioiodine induced bladder injury; sucking of lemon to avoid sialadenitis; laxatives; reduced sperm count for 6–8 months; pregnancy should be avoided for 6–12 months.
- ◆ Secondaries in bone are treated by *external radiotherapy*. Internal fixation should be done whenever there is pathological fracture.
- ◆ There is *no role* of chemotherapy for follicular carcinoma thyroid.

### Hurthle Cell Carcinoma

**Hurthle cell carcinoma** is a variant of follicular carcinoma of thyroid which contains *abundant oxyphil cells*. It spreads more commonly to regional lymph nodes than follicular carcinoma of thyroid.

#### Note

- ❖ Hurthle cell carcinoma does not take up I<sup>131</sup>
- ❖ It secretes thyroglobulin
- ❖ It has got poorer prognosis than follicular cell carcinoma
- ❖ 30% multicentric
- ❖ <sup>99m</sup>Tc sestamibi scan is very useful for Hurthle cell carcinoma
- ❖ Regional nodes are more commonly involved than follicular carcinoma
- ❖ 20% show distant spread
- ❖ Abundant oxyphil cells (*Askanazy*) are specific
- ❖ Total thyroidectomy, MRND and TSH suppression is the treatment

### Central Node Compartment Neck Dissection

It is removal of paratracheal, tracheo-oesophageal, pretracheal and prelaryngeal nodes along with thymus and thyroid enbloc *extending* from hyoid bone above, brachiocephalic vein below, carotids on both sides.

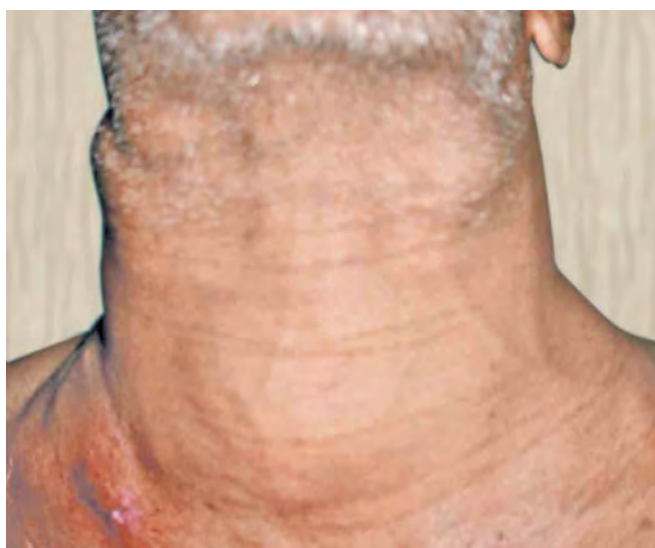### Completion Thyroidectomy

- ◆ It is done after hemithyroidectomy if histology confirms as differentiated thyroid cancer, either papillary or follicular.
- ◆ *It is indicated in*—high-risk patients, age more than 45 years, family history, size more than 1 cm, opposite side thyroid nodule, nodal or distant spread, multifocal disease, extrathyroidal spread, capsular and vascular invasion.
- ◆ *Reasons for completion of total thyroidectomy* are:
  - ▶ In differentiated thyroid cancer (for follicular carcinoma of thyroid) radioiodine I<sup>131</sup> is the treatment for blood spread secondaries. It is only possible if entire thyroid gland is removed to make radioiodine to concentrate on tumour tissue to achieve needed efficacy.

- ▶ In many indications papillary carcinoma of thyroid also needs radioablation like extrathyroid spread, size more than 4 cm, etc.
- ▶ During follow up, in DTCs/FCT thyroglobulin as tumour marker estimation at regular intervals (6 months; to suspect tumour bed recurrence/metastases) can be done if thyroid tissue is removed entirely.
- ▶ Papillary carcinoma of thyroid are multicentric with intrathyroid spread and so completion thyroidectomy is better.
- ◆ *Timing of completion thyroidectomy* is within 7 days of first surgery or after 6–12 weeks to allow the settling of inflammatory response (dissection and to get surgical planes is difficult during this period).

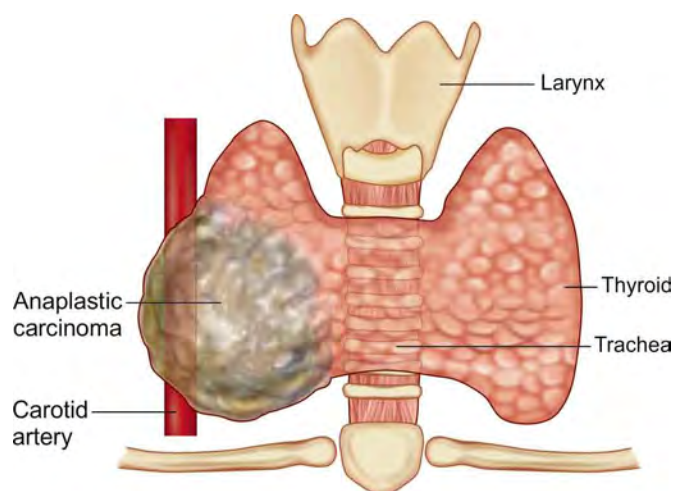
## ANAPLASTIC CARCINOMA OF THYROID

- ◆ It is an *undifferentiated* very aggressive carcinoma (1%) occurs commonly in elderly females.
- ◆ It is a very aggressive tumour of short duration, presents with a swelling in thyroid region which is rapidly progressive causing:
  - i. Stridor and hoarseness of voice due to tracheal obstruction.
  - ii. Dysphagia.
  - iii. Fixity to the skin.

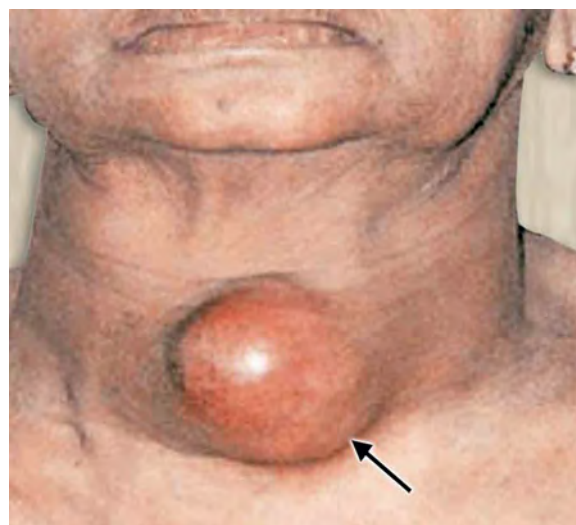


**Fig. 6.48:** Carcinoma of thyroid gland. It is anaplastic carcinoma. It carries poor prognosis.

- iv. *Positive Berry's sign*—involvement of carotid sheath leads to absence of carotid pulsation.
- ◆ Swelling is hard, with involvement of isthmus and lateral lobes.
- ◆ FNAC is diagnostic.
- ◆ All anaplastic carcinomas are T4. T4a is intrathyroidal anaplastic carcinoma – surgically resectable. T4b is extrathyroidal anaplastic carcinoma – surgically unresectable.
- ◆ It shows p53 and p21 positive; causes multiorgan spread.
- ◆ Tracheostomy and isthmectomy has got a role to relieve respiratory obstruction temporarily.
- ◆ Treatment is *external radiotherapy*, as usually thyroidectomy is not possible.



**Fig. 6.49:** Anaplastic carcinoma of thyroid with infiltration through the capsule. It commonly encases the carotid artery causing Berry's sign positive.



**Fig. 6.50:** Anaplastic carcinoma of thyroid.

- ◆ Adriamycin as chemotherapy.
- ◆ However prognosis is poor. Lifespan is counted in few weeks to months only. 5-year survival is less than 15%.

### Follow-up in differentiated thyroid carcinoma

- ❖ Proper clinical examination in the neck for residual/nodal disease and for distant spread
- ❖ Whole body radioisotope scan after one week of surgery to see residual tumour in the neck or metastases
- ❖ Estimation of thyroglobulin at regular intervals is very important—once in 6 months
- ❖ Follow up whole body radioisotope scan at 3–6 months intervals. Thyroxine should be stopped for 6 weeks. But it is commonly done if thyroglobulin level in the blood is significantly high



### Stage grouping for papillary or follicular thyroid carcinoma (differentiated thyroid cancer)

#### Patients younger than 45 years:

**Stage I:** The tumour can be any size and may or may not have spread to nearby lymph nodes. It has not spread to distant sites.

**Stage II:** The tumour can be any size and may or may not have spread to nearby lymph nodes. It has spread to distant sites.

#### Patients 45 years and older:

**Stage I:** The tumour is less than 2 cm across; no lymph nodes/distant spread.

**Stage II:** The tumour is 2 to 4 cm across; no lymph nodes/distant spread.

**Stage III:** The tumour is larger than 4 cm or slightly outside the thyroid; no lymph nodes/distant spread. OR The tumour is any size and has spread to lymph nodes around the thyroid in the neck (cervical nodes) but not to distant sites.

**Stage IVA:** The tumour is of any size and has grown beyond the thyroid gland to invade nearby tissues of the neck. Cervical nodes  $\pm$  but no distant spread. OR The tumour is any size and may have grown outside of the thyroid gland. It has spread to lymph nodes in the side of the neck (lateral cervical nodes) or upper chest (upper mediastinal nodes) but not to distant sites.

**Stage IVB:** The tumour is of any size and has grown either back to the spine or into nearby large blood vessels. Nearby lymph nodes  $\pm$  but no distant spread.

**Stage IVC:** The tumour is of any size and may or may not have grown outside the thyroid. It may or may not have spread to nearby lymph nodes. It has spread to distant sites.

### Stage grouping for medullary thyroid carcinoma

It is same as of differentiated thyroid cancer older than 45 years.

### Stage grouping for anaplastic/undifferentiated thyroid carcinoma

All anaplastic thyroid cancers are considered *stage IV*

**Stage IVA:** Tumour is still within the thyroid and may be *resectable* (removable by surgery). Nearby lymph nodes  $\pm$  but no distant spread.

**Stage IVB:** Tumour has grown outside of the thyroid and is *not resectable*. Nearby lymph nodes  $\pm$  but no distant spread.

**Stage IVC:** The tumour is any size and may or may not have grown outside of the thyroid. Nearby lymph nodes  $\pm$  but distant spread *always present*.

### Features of thyroid carcinoma

Any thyroid can be malignant of any size, of any texture—solid/cystic, of any number—single/multiple, in any age group.

### Features of infiltration

- ❖ Infiltration of strap muscles often with sternomastoid muscle
- ❖ Infiltration of laryngotracheal complex causing stridor and often haemoptysis
- ❖ Infiltration of recurrent laryngeal nerve causes hoarseness of voice
- ❖ Infiltration of oesophagus causes dysphagia/odynophagia (painful swallowing)
- ❖ Infiltration into carotid sheath causing absence of carotid pulsation—*Berry's sign*
- ❖ Infiltration of cervical sympathetic chain causing Horner's syndrome
- ❖ Rarely infiltration into cranial nerves or brachial plexus can occur

### Features of lymph nodal spread

- ❖ Discrete neck node involvement can occur commonly in papillary carcinoma of thyroid, often in medullary carcinoma and occasionally in follicular carcinoma. Lymph node is often cystic (20%) and contains brownish—black material in papillary carcinoma
- ❖ Central neck (level VI) and mediastinal nodes often gets involved in thyroid malignancy. Primary nodes may be involved but clinically may not be palpable. Superior mediastinal nodes (level VII) can cause compression of SVC, recurrent laryngeal nerve with often dullness on percussion over the sternum. These nodes can get involved without palpable neck nodes
- ❖ In the neck commonly palpable nodes are levels—II, III, IV and occasionally level V. Secondary nodes—clinically palpable
- ❖ Only palpable neck node may be the presentation without clinically palpable thyroid—occult secondary with primary (papillary) thyroid carcinoma. FNAC of the node concludes the diagnosis
- ❖ Central node dissection is the common practice while doing total thyroidectomy in carcinoma thyroid especially in medullary carcinoma of thyroid

### Features of blood spread

- ❖ Follicular carcinoma commonly spreads through blood to bone, lungs, and liver. Bone secondary is typical. It is well-localised, smooth, soft/hard, warm, non mobile, vascular and pulsatile. It is common in the skull bone—frontal/parietal bone. It can occur in other bones also
- ❖ Lung secondaries present with chest pain, dyspnoea and haemoptysis
- ❖ Liver secondaries cause hepatomegaly and jaundice
- ❖ Blood spread also can occur in medullary carcinoma of thyroid

### Degroot's staging of carcinoma thyroid\*

Stage 1: Malignancy is intrathyroidal

Stage 2: Malignancy is intrathyroidal with mobile lymph nodes

Stage 3: Malignancy is intrathyroidal with fixed lymph nodes

Stage 4: Distant metastasis

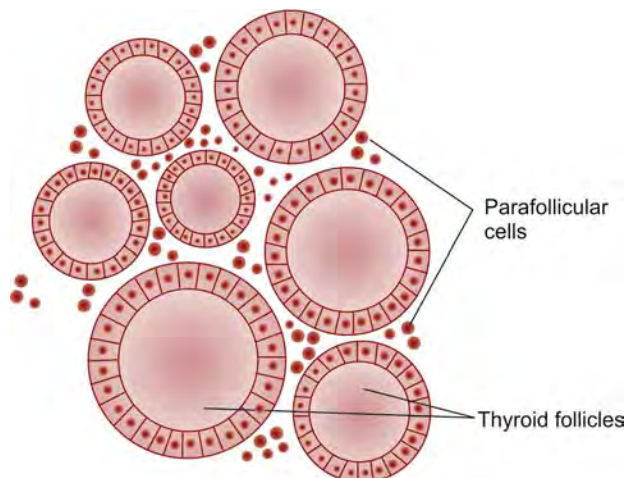
\*This staging is applicable to all thyroid malignancy but mainly used in follicular carcinoma of thyroid

## MEDULLARY CARCINOMA OF THYROID (MCT)

- ❖ It is uncommon (5%) type of thyroid malignancy.
- ❖ It arises from the *parafollicular 'C' cells* which is derived from the ultimobranchial body (neural crest). C cells are more in upper pole of the thyroid gland or at junction of upper 1/3<sup>rd</sup> and lower 2/3<sup>rd</sup>.
- ❖ It contains characteristic '*amyloid stroma*' wherein malignant cells are dispersed. Immunohistochemistry reveals calcitonin in amyloid.
- ❖ In these patients blood levels of *calcitonin* both basal as well as that following calcium or pentagastrin stimulation is high, a very useful tumour marker.
- ❖ Tumour also secretes 5-HT (serotonin), prostaglandin, ACTH and vasoactive intestinal polypeptide (VIP).
- ❖ It spreads mainly to lymph nodes (60%).
- ❖ It may be associated with MEN II syndrome and pheochromocytoma with hypertension. MCT associated with MEN

type II B with pheochromocytoma (Sipple's disease) is most aggressive.

- ◆ There may be mucosal neuromas in lips, oral cavity, tongue, eyelids with marfanoid features.
- ◆ MCT is not TSH dependent and does not take up radioactive iodine.



**Fig. 6.51:** Note the parafollicular cells. Cell of origin of medullary carcinoma thyroid.

## Clinical Features

- ◆ Thyroid swelling often with enlargement of neck lymph node.
- ◆ Diarrhoea, flushing (30%).
- ◆ Hypertension, pheochromocytomas and mucosal neuromas when associated with MEN II syndrome.
- ◆ Sporadic and familial types occur in adulthood whereas cases associated with MEN syndrome II occur in younger age groups.
- ◆ Paraneoplastic syndrome like Cushing's and carcinoids.

### Note:

- Consider MCT in thyroid swelling with significant diarrhoea and hypertension.
- 50% of MCT spread to neck nodes.
- 15% have distant spread to liver, lung and bone.

## Types

1. *Sporadic*. Usually solitary—70%. It is unifocal; occurs in 5th / 6th decade; more in females; common in posterior part of thyroid, so compression is common.
2. *MCT with MEN II syndrome*. It is more aggressive, bilateral, multifocal/multicentric, affects younger age group. MCT with MEN type IIb is most aggressive, often involves infants and children, with marfanoid features.
3. *Familial MCT (20%)*. Commonly multicentric, autosomal dominant in chromosome no. 10. Familial non-MEN MCT is least malignant, occurs in 4th and 5th decades, shows extra and intracellular cysteine codon.

### Note

- ◆ *Hereditary type (20%)* occurs in younger age; multifocal; bilateral. It is autosomal dominant.
- ◆ It can be - *Familial MCT* in isolation (only MCT but familial without MEN syndrome); or *part of MEN syndrome II A* or II B.
- ◆ *Association with MEN IIA* is the commonest type among hereditary MTC (75%). MTC is present in 95% cases of MEN IIA; multifocal and bilateral; 50% will have pheochromocytoma which is bilateral, multifocal and associated with adrenal medullary hyperplasia; 35% will have hyperparathyroidism.
- ◆ *MEN IIB* - 100% develop MTC here. Seen in infancy; very aggressive. 50% develop pheochromocytoma. Hyperparathyroidism is not seen. Diffuse ganglioneuromas of lips, tongue, eyelids, GI tract; marfanoid face; megacolon; skeletal abnormalities with thick peripheral nerves. Infants die at young age.
- ◆ *C-cell hyperplasia*—is defined as more than 6 C cells per follicle or more than 50 per low power field; its significance is in hereditary MCT but not in non-hereditary.

## Investigations

- ◆ *USG neck* – mass; nodal status. US abdomen to rule out pheochromocytoma.
- ◆ *FNAC* – amyloid stroma with dispersed malignant cells and C-cell hyperplasia; calcitonin level of FNAC washout; cytology with IHC is very useful.
- ◆ *Serum calcitonin level* – In normal individual it is <10 pg/ml or undetectable. If its unstimulated level is >100 pg/ml then it is suggestive of MCT. Increase in stimulated calcitonin level is accurate after injection of calcium 2 mg/kg or pentagastrin 0.5 ug/kg.
- ◆ Serum CEA level will be raised in >50% of MTC patients. CEA >30 mg/ml indicates incurability by surgery; CEA >100 mg/ml suggests extensive nodal spread; raising CEA with stable calcitonin indicates dedifferentiation and poor prognosis.
- ◆ CT neck, chest, abdomen should be needed for metastatic work up. CT abdomen is also done for pheochromocytoma.
- ◆ Urinary metanephrine, VMA, (24 hours) should be done in suspected pheochromocytoma.
- ◆ Serum, calcium and parathormone (PTH) estimation for hyperparathyroidism.
- ◆ 111-Indium octreotide scanning is useful in detecting MCT (70% sensitivity). It is also useful in postoperative follow up to find out residual or metastatic disease.
- ◆ Genetic testing for ret mutations.

## Treatment

*Surgery is the main therapeutic modality.*

- ◆ Total thyroidectomy with bilateral central node dissection and ipsilateral lateral neck dissection if primary tumour is > 1 cm or central nodes are positive. Positivity of central nodes is 81%.
- ◆ Opposite lateral neck node dissection is done if US neck shows opposite nodes or extensive ipsilateral neck nodes when present or bilateral primary tumours (multifocal/ bilateral).

- ◆ Thyroxine replacement/maintenance therapy 100ug morning before food daily, is needed.
- ◆ No role of suppressive hormone therapy or radioactive iodine therapy.
- ◆ External beam radiotherapy for residual tumour disease.
- ◆ Somatostatin/octreotide for diarrhoea.
- ◆ Adriamycin is the drug used as chemotherapy with limited results.
- ◆ If there is associated pheochromocytoma, it should be treated surgically by adrenalectomy first and later only total thyroidectomy is done.
- ◆ *All family members of the patient should be evaluated for serum calcitonin and if it is high they should undergo prophylactic total thyroidectomy* (Can also be assessed by genetic evaluation). If there is positive RET proto-oncogene in MCT with MEN II A and familial MCT types, prophylactic total thyroidectomy is done at the age of **5 years**. In positive RET proto-oncogene in MCT with MEN II B, prophylactic total thyroidectomy is done at the age of **one year**.
- ◆ MCT with associated parathyroid hyperplasia (30%) in MEN IIA, total thyroidectomy with central nodal dissection with total parathyroidectomy and autotransplantation of half of gland in sternomastoid or nondominant forearm brachioradialis muscle is done.

#### Other therapies

- ◆ External RT; Somatostatin analogues; Imatinib mesylate tyrosine kinase inhibitor; Chemotherapy—less success—adriamycin, capacetabine, 5 FU, irinotecan; newer targeted therapies.

#### Prognosis

- ◆ Sporadic MCT and MCT with MEN syndrome II are aggressive.
- ◆ Familial MCT not associated with MEN II syndrome has got better prognosis.
- ◆ Presence of nodal disease carries poor prognosis.
- ◆ Survival is overall good -10 years – 85%; depends on type, familial nature, association for MEN syndrome; status at the time of presentation – size, nodal status, distant spread.
- ◆ Incidence of recurrence is 50% in MCT.

#### Follow-up

- ◆ Serum calcitonin and CEA level.
- ◆ Imaging as needed – USG/CT neck and mediastinum.
- ◆ Recurrence in the neck should be treated with resurgery – exploration and disease clearance. External beam RT may be useful also.
- ◆ PET scan; MIBG scan are also useful.
- ◆ Follow-up for late onset pheochromocytoma or hyperparathyroidism should regularly be assessed annually.

#### Calcitonin

- ◆ It is a polypeptide of 32 amino acids. It is derived from ultimobranchial body. It is secreted from C cells of thyroid (parafollicular cells).
- ◆ It lowers the plasma calcium and phosphorus levels. It blocks the PTH-induced bone resorption. Calcium from the circulation is shunted into the bone. It increases the excretion of calcium, phosphorus, sodium and potassium. It rapidly lowers the serum calcium.
- ◆ Normally, it is less than 0.08 ng/L (undetectable).

- ◆ It is increased in medullary carcinoma of thyroid. It is very good tumour marker for MCT. It confirms the relapse/metastases/residual disease. Increased levels in family members confirm the genetic relation and such relatives should undergo prophylactic total thyroidectomy.
- ◆ Calcitonin level will further increase after injection of calcium 2 mg/kg or pentagastrin 0.5 µg/kg.
- ◆ In disease-free individual, after therapy for MCT calcitonin level decreases.
- ◆ Calcitonin as a therapeutic agent is used in hypercalcemia, Paget's disease, bone pain of neoplastic diseases, menopausal osteoporosis. Calcitonin (pork), 4 units/kg is given SC or IM three times a week.
- ◆ Salmon calcitonin SC/IM/nasal spray—50–400 units can be given three times a week or daily depending on need.

#### MALIGNANT LYMPHOMA

- ◆ It is NHL type. Occurs in a pre-existing Hashimoto's thyroiditis (Not proved well).
- ◆ FNAC is useful to diagnose the condition (Often trucut biopsy).
- ◆ Chemotherapy and radiotherapy is the main treatment.
- ◆ Rarely total thyroidectomy is done to enhance the results.

#### HASHIMOTO'S THYROIDITIS (Struma Lymphomatosa)

- ◆ Also called as diffuse non-goitrous thyroiditis.
- ◆ It is an autoimmune thyroiditis—common in women (15 times more common).
- ◆ There is hyperplasia initially, then fibrosis, eventually infiltration with plasma cells and lymphocytic cells.
- ◆ *Askanazy cells* are typical (like Hurthle cells).
- ◆ The river Struma arises in Bulgaria and flows into Aegean Sea. Struma means goitre. Banks of this river are endemic area for goitre.

#### Features

- ◆ Painful, diffuse, enlargement of usually both lobes of thyroid which is firm, rubbery, tender and smooth (occasionally one lobe is involved).
- ◆ Initially they present with toxic features, but later, they manifest with features of hypothyroidism.
  - Hyperplasia → Hyperthyroid—*Hashitoxicosis*  
→ Euthyroid.
  - Fibrosis → Hypothyroid.
- ◆ There may be hepatosplenomegaly,
- ◆ It is often associated with other autoimmune diseases.
- ◆ In 85% cases significant rise in the thyroid antibodies (microsomal, thyroglobulin, or colloid antibodies) is observed.
- ◆ Common in perimenopausal females.
- ◆ It can predispose to papillary carcinoma of thyroid.
- ◆ Often condition may be associated with or may predispose to *malignant lymphoma*. It is, at present, not well-proved.

#### Investigations

FNAC, T<sub>3</sub>, T<sub>4</sub>, TSH. Thyroid antibodies assay. Usually ESR is very high (over 90 mm/hour).

## Treatment

- ◆ L-thyroxine therapy.
- ◆ Steroid therapy often is helpful.
- ◆ If goitre is large and causing discomfort, then subtotal thyroidectomy is done.

## ■ DE-QUERVAIN'S SUBACUTE GRANULOMATOUS THYROIDITIS

It is due to viral aetiology either mumps or coxsackie viruses causing inflammatory response with infiltration of lymphocytes, neutrophils, multinucleated giant cells.

### Features

- ◆ Painful diffuse, swelling in thyroid which is tender
- ◆ Commonly seen in females.
- ◆ Initially there is transient hyperthyroidism with high T<sub>3</sub> and T<sub>4</sub> but poor radioiodine uptake.
- ◆ FNAC is useful.
- ◆ It is usually a self-limiting disease.
- ◆ Prednisolone 20 mg for 7 days helps.

## ■ RIEDEL'S THYROIDITIS (0.5% Common)

- ◆ A very rare benign entity wherein thyroid tissue is replaced by fibrous tissue which interestingly infiltrates the capsule into surrounding muscles, paratracheal tissues, carotid sheath.
- ◆ ('Woody Thyroiditis', 'Ligneous Thyroiditis').
- ◆ It is often associated with retroperitoneal and mediastinal fibrosis and sclerosing cholangitis.
- ◆ There is both intrathyroidal as well as extrathyroidal fibrosis.
- ◆ It also encroaches parathyroids and recurrent laryngeal nerves.
- ◆ It may be unilateral or bilateral.

### Features

- ◆ Swelling with *irregular* surface, *stony hard* consistency, stridor, with positive *Berry's* sign (absence/*impalpable* carotid pulsation); small goitre; common in males.
- ◆ *Differential diagnosis*: Anaplastic carcinoma of thyroid.
- ◆ *Investigations*:
  - ▶ T<sub>3</sub>, T<sub>4</sub> may be low due to hypothyroidism.
  - ▶ Radioisotope scan will not show any uptake.
  - ▶ FNAC to rule out carcinoma.

## Treatment

Isthmectomy is done to relieve compression on the airway. They require L-thyroxine replacement later, as hypothyroidism is common.

- ◆ High dose of steroid often used.
- ◆ Thyroidectomy is not necessary.

### Causes of dyspnoea/stridor in thyroid diseases

- ❖ Carcinoma thyroid infiltrating recurrent laryngeal nerve/trachea
- ❖ Large, long-standing goitre causing tracheomalacia
- ❖ Retrosternal goitre
- ❖ Congestive cardiac failure in thyrotoxicosis

### Recent rapid increase in thyroid swelling is due to:

- ❖ Previous MNG undergoing malignant transformation
- ❖ Haemorrhage into a nodule
- ❖ Anaplastic carcinoma of thyroid

### Remember

- ❖ *Goitre* is enlargement of the thyroid gland
- ❖ *Solitary nodule* is single palpable nodule on clinical or sonological examination without palpable rest of the gland
- ❖ *Dominant nodule* is single nodule with palpable enlargement of the remaining thyroid gland
- ❖ *Thyroid swelling* is confirmed by its *movement with deglutition* due to attachment of enclosed pretracheal fascia to inferior constrictor muscle which is attached to trachea and cricoid cartilage and so moves with deglutition
- ❖ *Berry's ligament* is condensed vascularised pretracheal fascia postero-supero-medially. It is important as it is close to recurrent laryngeal nerve
- ❖ Any thyroid swelling *can be malignant* unless proved otherwise
- ❖ Ultrasound neck, FNAC, estimation of T<sub>3</sub>, T<sub>4</sub>, TSH are essential investigations
- ❖ CT scan neck is needed in large goitre and fixed or malignant thyroid
- ❖ Radioisotope study I<sup>123</sup> is done only in selected cases like borderline toxicity, ectopic thyroid, retrosternal goitre and after thyroidectomy in follicular carcinoma thyroid to see secondaries during follow-up period
- ❖ Normal thyroid gland is usually not palpable
- ❖ A rare entity called as *black thyroid* shows lipofuscin deposition in thyroid in a patient who is on longstanding tetracycline therapy which may interfere with thyroid function

### Occasions wherein thyroid swelling may not move upwards with deglutition

- ❖ Anaplastic carcinoma thyroid—often
- ❖ Carcinoma thyroid with extensive local infiltration into soft tissues, trachea/larynx and posterior muscles
- ❖ Intrathoracic retrosternal extension with infiltration/impaction
- ❖ Riedel's thyroiditis with encasement of trachea
- ❖ Massive thyroid wherein upward movement is difficult to observe and appreciate

### Narrowing of trachea is seen in:

- ❖ Scabbard trachea in longstanding MNG
- ❖ Retrosternal goitre
- ❖ Carcinoma of thyroid
- ❖ Riedel's thyroiditis

## ■ THYROID INCIDENTALOMA

*Thyroid incidentaloma* is defined as an unsuspected, asymptomatic thyroid lesion that is discovered on an imaging study or during an operation unrelated to the thyroid gland. Thyroid incidentalomas are most commonly detected on ultrasound, followed in frequency by CT scan and MRI, carotid duplex scanning and PET scan. The incidence of carcinoma in incidentaloma is not insignificant. As these imaging methods are done for some other purpose as "non-thyroid" imaging modality, a thorough specific sonographic evaluation of the thyroid gland should be performed in all thyroid incidentalomas. A sonographically confirmed thyroid nodule should be managed like any other clinically identified thyroid nodule/disease.

## ■ THYROIDECTOMY

### Types

1. *Hemithyroidectomy*: Along with removal of one lobe, entire isthmus is removed. It is done in benign diseases of only one lobe. It is also done in follicular neoplasm involving only one lobe. Solitary toxic or nontoxic nodule, thyroid cyst are other indications.
2. *Subtotal thyroidectomy* commonly done in toxic thyroid either primary or secondary and also often for nontoxic multinodular goitre. Here about 8 grams, or a tissue, size of pulp of finger is retained on lower pole, on both sides and rest of the thyroid gland is removed. It is also done in MNG.
3. *Partial thyroidectomy* (By Thomas) is removal of the gland in front of trachea after mobilisation. It is done in nontoxic multinodular goitre. Its role is controversial.
4. *Near total thyroidectomy*: Here both lobes except the lower pole (*one* or other sides) which is very close to recurrent laryngeal nerve and parathyroid is removed (To retain blood supply to parathyroids). It is done in case of papillary carcinoma of thyroid. Here less than 2 grams of thyroid tissue is left behind near its lower pole *on one side usually opposite side of the diseased*, occasionally on both sides.
5. *Total thyroidectomy*: Entire gland is removed. It is done in case of follicular carcinoma of thyroid, medullary carcinoma of thyroid.
6. *Hartley Dunhill operation* is removal of one entire lateral lobe with isthmus and partial/subtotal removal of opposite lateral lobe. It is done in non-toxic multinodular goitre. 4 grams of tissue is left behind only on one side.

### Preoperative preparation

- ❖ Blood grouping and cross matching. Keep the required blood ready
- ❖ Indirect laryngoscopy. Patient is asked to tell 'E' to check the abduction of vocal cord
- ❖ *Videostroboscopy* – it is special method to visualize the vocal cord vibration. 70 degree rigid strobolaryngoscope is used with mounted microphone. Flexible laryngostroboscope also can be used. Patient in sitting position, videostroboscope is passed to visualize vocal cords and patient is asked to tell eeee to examine vocal cord vibration as a slow motion.
- ❖ Serum calcium estimation
- ❖ T<sub>3</sub>, T<sub>4</sub>, TSH
- ❖ Thyroid antibodies
- ❖ ECG and cardiac fitness especially in toxic goitre
- ❖ Lugol's iodine 10 days prior to surgery to make gland firm and less vascular.

### Procedure

- ◆ *Position*:
  - ▶ Under general anaesthesia patient is put in supine position with neck hyperextended by placing a sand bag under shoulder—with table tilt of 15 degree head up to reduce venous congestion (*Rose position*).
- ◆ *Incision*:
  - ▶ Horizontal crease incision is done, two-finger breadth above the sternal notch, from one sternomastoid to the other (Kocher's thyroid incision) (Posterior margin of sternomastoid).
- ◆ *Procedure*:
  - ▶ Skin and platysma are incised (Subplatysmal plane)—upper flap raised up to thyroid cartilage, lower flap up to sternoclavicular joint. Deep fascia is opened vertically in the midline.

- ▶ *Strap muscles* are retracted; in large goitre they are often divided in upper part to retain their nerve supply *ansa cervicalis*. Often anterior jugular veins need to be ligated using 3 zero vicryl.
- ▶ *Pretracheal fascia* is opened vertically to expose thyroid gland. Short stout middle thyroid vein which enters the IJV is ligated immediately (first vessel to ligate; it is vein without accompanying artery) using vicryl or silk and divided. Avulsion of this vein from its junction to IJV will cause bleeding. Gland is mobilised medially using peanut dissection and bipolar cautery.
- ▶ *Superior pedicle* is dissected; artery and vein are individually ligated and divided. In olden days mass ligation close to gland at superior pole was the practice. Chances of injuring external laryngeal nerve and AV fistula may happen in mass ligation. It is also always better to identify external laryngeal nerve entering the cricothyroid. Dissection is done in an avascular plane between cricothyroid and gland.
- ▶ *Parathyroids* both superior and inferior are identified. They are 6 × 4 × 2 mm in size weighing 50 mg with yellowish brown/orange brown colour. Superior (parathyroid IV) and inferior (parathyroid III) glands are identified and dissected. Both

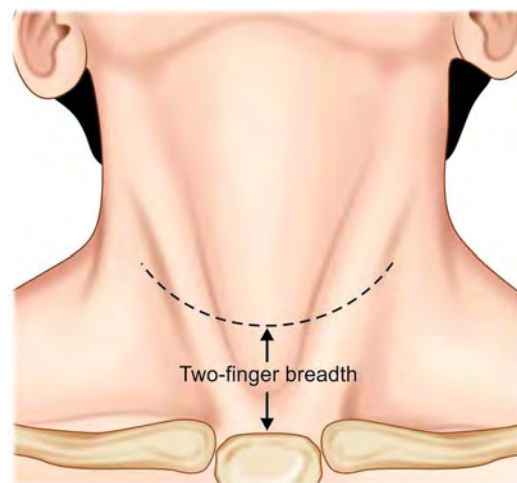


Fig. 6.52: Note the incision for thyroid surgery.

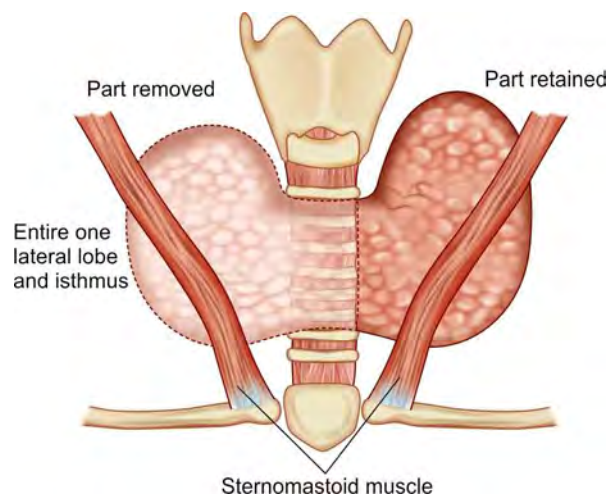
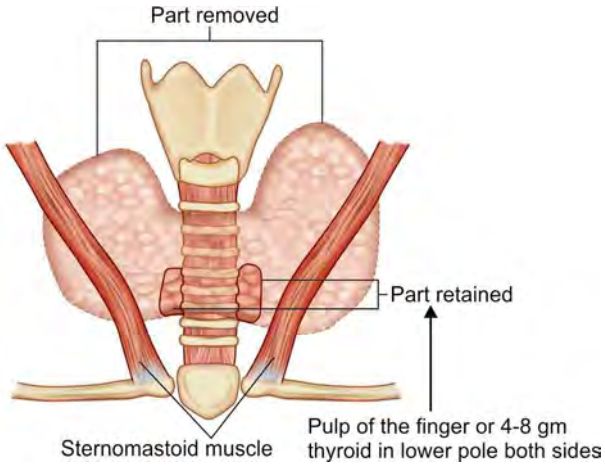
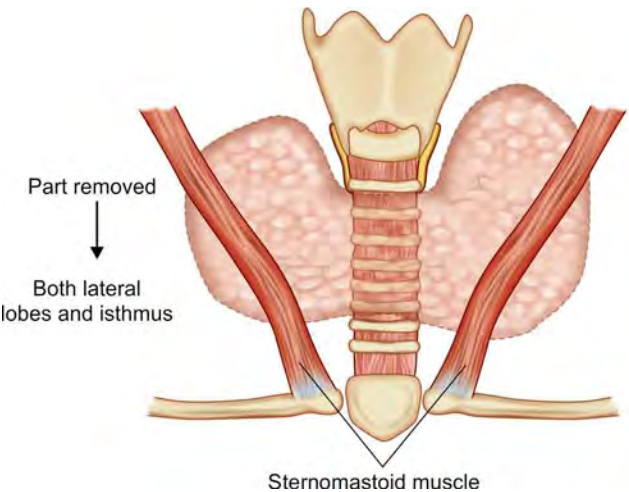


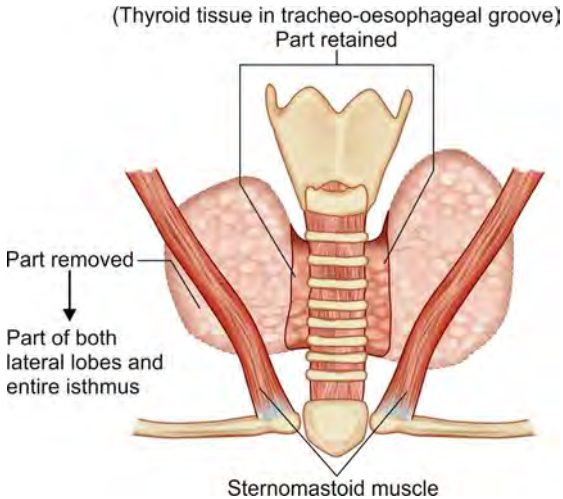
Fig. 6.53: *Hemithyroidectomy*: Entire one lateral lobe and entire isthmus are removed retaining entire opposite lateral lobe. It is done in solitary nodule/toxic or nontoxic adenoma in one lobe.



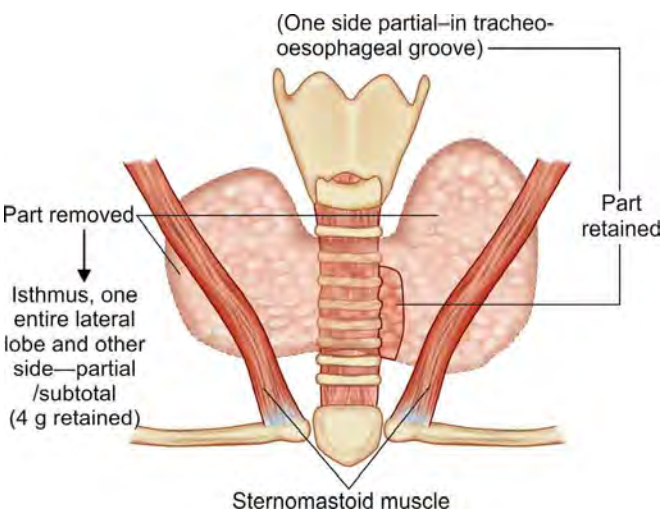
**Fig. 6.54: Subtotal thyroidectomy**—it is done in toxic/nontoxic multinodular goitre. Most of the gland except lower pole (4-8 gram) on both sides is removed.



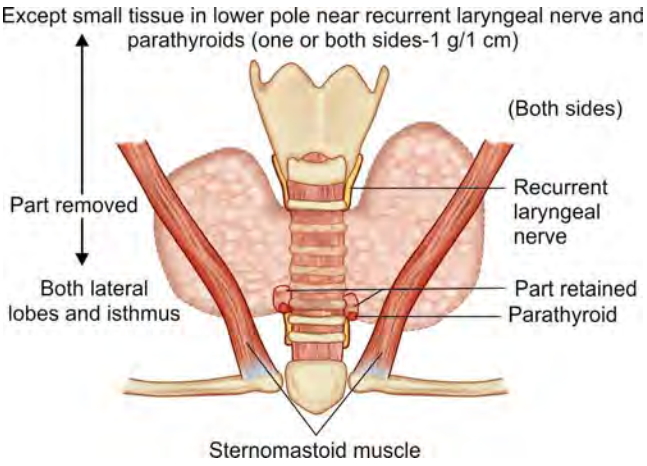
**Fig. 6.57: Total thyroidectomy** is done for follicular carcinoma and medullary carcinoma of thyroid.



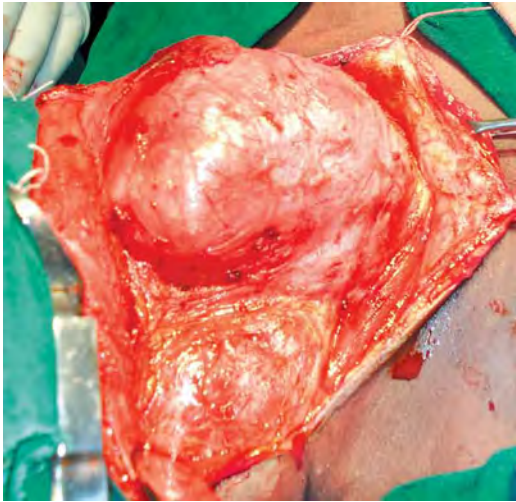**Fig. 6.55: Partial thyroidectomy**—it is done in nontoxic nodular goitre if there is adequate normal gland posteriorly. Tissue in the tracheo-oesophageal groove is retained. Isthmus and gland with nodules in front is removed. It is not commonly done now.



**Fig. 6.58: Hartley Dunhill procedure:** Here one entire lateral lobe, isthmus, and most part of the opposite lateral lobe except small quantity of tissue in the lower pole/tracheo-oesophageal groove—subtotal/partial/one gram is retained.

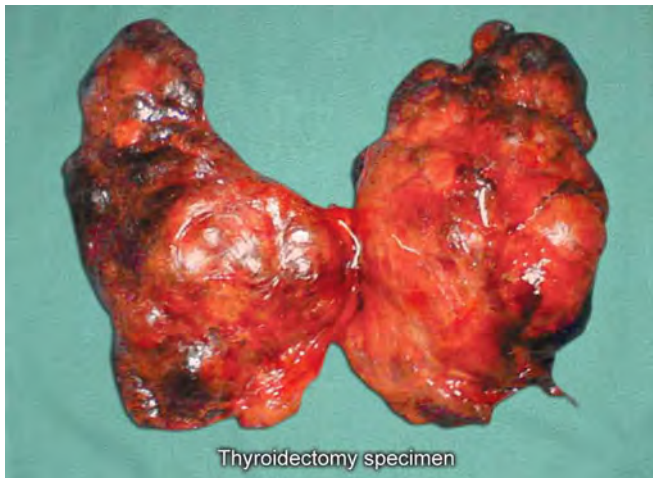

**Fig. 6.56: Near total thyroidectomy** is done in papillary carcinoma of thyroid. Here most of the gland except small tissue of 1 g on lower aspect of one side usually is retained to safeguard recurrent laryngeal nerve and parathyroid gland.

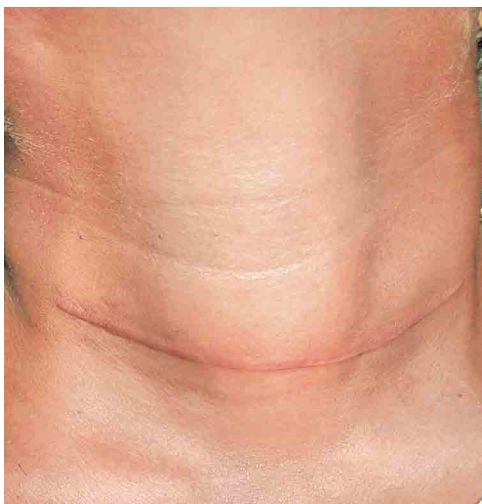


**Fig. 6.59:** Skin flaps raised in thyroidectomy. Thyroid covered with pretracheal fascia is seen.

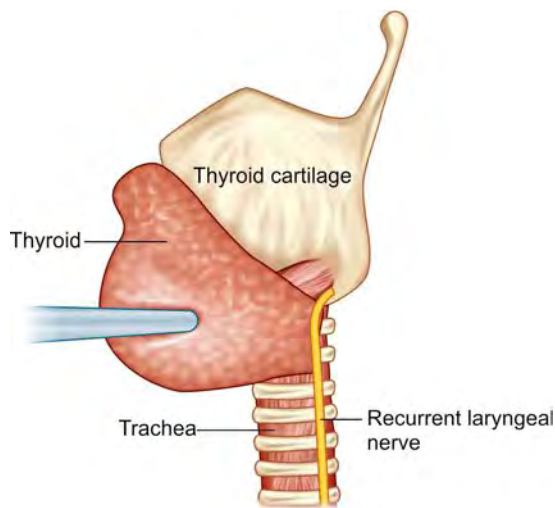
*Do not waste one moment in regret, for to think feelingly of mistakes of the past is to re-infect yourself.*



**Fig. 6.60:** Total thyroidectomy specimen done for follicular carcinoma of thyroid.



**Fig. 6.61:** Typical thyroidectomy postoperative scar.



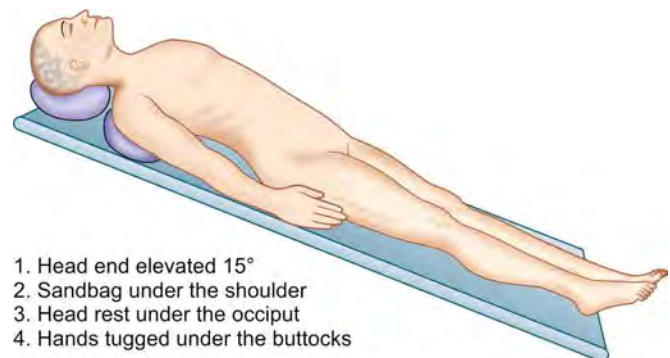
**Fig. 6.62:** Note the relation of recurrent laryngeal nerve.

glands receive their blood supply from inferior thyroid artery and through an anastomotic branch. Superior parathyroid is *above and behind* the junction of RLN and inferior thyroid artery; inferior parathyroid is *below and in front* of this junction.

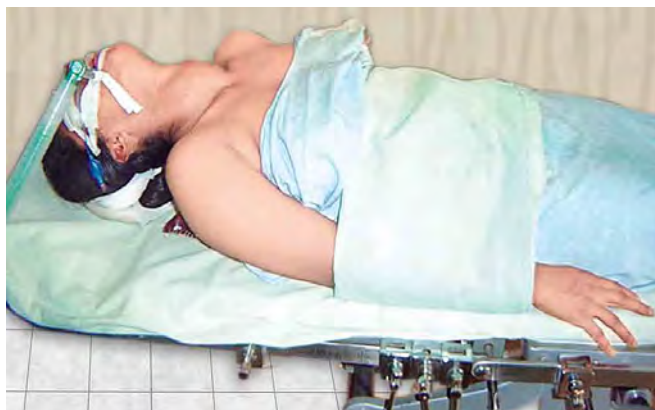- ▶ *Recurrent laryngeal nerve* should be identified with careful dissection through its entire course. *Riddle's triangle* is between inferior thyroid artery above, carotid artery laterally trachea medially. From this area nerve runs upwards to enter the larynx at greater cornu of thyroid cartilage. Many branches of nerve and the variations should be remembered while dissecting here. One should not use monopolar cautery here; only bipolar cautery should be used carefully. Nerve usually crosses the inferior thyroid artery from deeper aspect; but variations are common. Posterior extension of lateral thyroid lobes close to Berry's ligament is called as *Zuckerkindl tubercle* which is seen in 40% of cases. Nerve runs upwards in a fissure between Zuckerkindl tubercle and trachea or main thyroid gland. *Nonrecurrent laryngeal nerve* (0.5%) is occasionally seen in right side due to failure of development of 4th aortic arch; it directly arises from vagus enters the larynx at the level of inferior horn of thyroid cartilage. Recurrent laryngeal nerve is in close contact with *suspensory ligament of Berry*.
- ▶ *Inferior thyroid artery* which is a branch of thyrocervical trunk ascends upwards reaching gland at its lower pole after turning towards midline behind the carotid artery. Here ligation is done at capsular level by identifying every small branch entering the gland (*capsular ligation of inferior thyroid artery*). This retains the blood supply of parathyroids which is very important. In olden days, ligation of inferior thyroid artery was done away from the gland often in continuation using absorbable suture material, is now no longer in practice.
- ▶ Mobilized gland is removed. *Critical points of recurrent laryngeal nerve injury* are—at the entry of inferior thyroid artery and crossing the nerve, at suspensory ligament of Berry, at lower pole of the gland.

**Thyroid steal:** In thyrotoxicosis, patient is taken to operation theatre daily for few days before doing surgery, so as to reduce the anxiety of the patient.

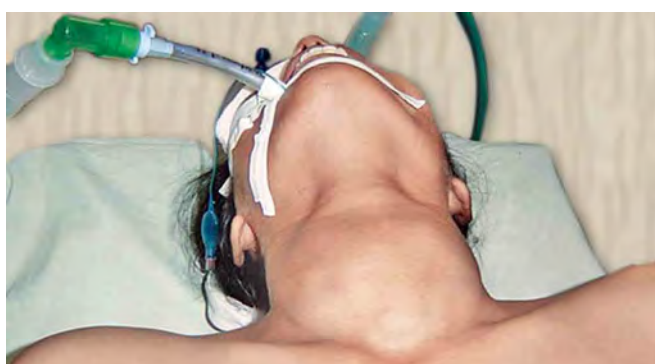**MIVAI—Minimally Invasive Video-Assisted Thyroidectomy** is becoming popular for small nodules and gland without thyroiditis. But it is costly.



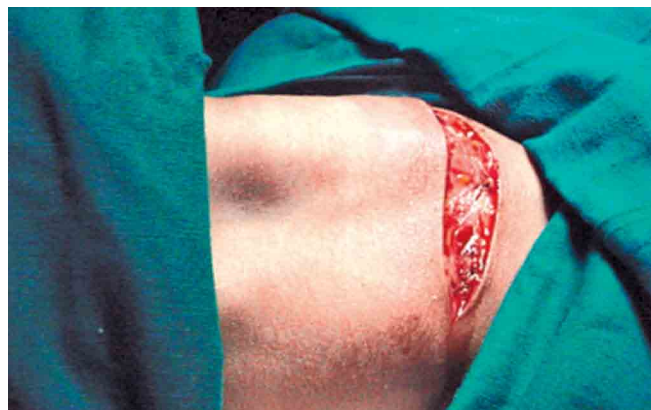**Fig. 6.63:** Position of the patient for thyroid surgery. Head end elevated, sand bag under the shoulder.



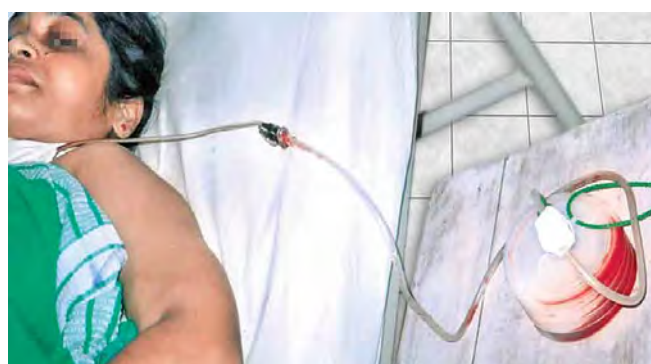**Fig. 6.64:** Patient under anaesthesia with proper position for thyroidectomy surgery.



**Fig. 6.65:** Position of neck in thyroid surgery.



**Fig. 6.66:** Kocher's thyroid incision for thyroidectomy.



**Fig. 6.67:** Suction drain kept after thyroidectomy.

## Complications of Thyroidectomy

### 1. Haemorrhage:

May be due to slipping of ligatures either of superior thyroid artery or other pedicles or small veins. It causes tachycardia, hypotension, breathlessness and compression over the trachea may cause severe stridor, respiratory obstruction due to tension haematoma under strap muscles. As a first aid, immediate release of sutures including that of deep fascia has to be done and pressure over the trachea is released. Then patient is shifted to operation theatre and under general anaesthesia exploration is done and bleeders are ligated. Blood transfusion may be required.

### 2. Respiratory obstruction:

It may be due to haematoma (if it is so, the haematoma has to be evacuated), or due to laryngeal oedema, or due to tracheomalacia or bilateral RLN palsy (*emergency endotracheal intubation* is done along with steroid injections). Often emergency tracheostomy may be required as a life-saving procedure.

*Laryngeal oedema* is the commonest cause may be due to haematoma with tension along with intubation injury and surgical trauma. In such situation even though haematoma should be evacuated immediately to avoid further compression, airway obstruction will not be relieved due to laryngeal oedema and so endotracheal intubation is also needed immediately; in difficult situation if it is impossible to intubate, a needle

tracheostomy using 12-gauge needle (2.3 mm diameter) is done temporarily.

### 3. Recurrent laryngeal nerve palsy:

It can be transient or permanent. Transient is 3% common. They usually recover in 3 weeks to 3 months. Often they require steroid supplement and speech therapy. Permanent paralysis is rare. It presents with hoarseness of voice, aphonia, aspiration, ineffective cough. Unilateral injury can be well compensated. It is advisable to do routine postoperative ILS on 5th postoperative day. Later ILS is done in 4 weeks and 12 weeks.

### 4. Hypoparathyroidism:

It is rare 0.5% common. Mostly it is temporary due to vascular spasm of parathyroid glands, occurs in 2nd-5th postoperative day. Present with weakness, +ve Chvostek's sign, carpopedal spasm, convulsions. Serum calcium estimation is done and then 10 ml of 10% calcium gluconate is given IV 8th hourly. Later supplemented by oral calcium carbonate 500 mg 8th hourly. After 3–6 weeks, patient is admitted, drug is stopped and serum calcium level is repeated.

#### **Note:**

Earliest symptom of hypocalcaemia is muscle weakness.

### 5. Thyroid crisis/thyroid storm/thyrotoxic crisis

It is a *rare but severe* life-threatening complication of hyperthyroidism with acute hypermetabolic state induced by release of excessive thyroid hormones. Crisis can be due to surgical or medical causes.



Complications of thyroidectomy		
<b>Metabolic</b>	<b>Nerve injuries</b>	<b>Other complications</b>
<b>Hypoparathyroidism</b> <ul style="list-style-type: none"> <li>• Temporary hypoparathyroidism</li> <li>• Temporary hypocalcaemia without hypoparathyroidism (hungry bone syndrome)</li> <li>• Permanent hypoparathyroidism</li> <li>• Spurious hypoparathyroidism (total calcium is less but ionized calcium is normal)</li> </ul> <b>Thyroid crisis</b> <b>Hypothyroidism/thyroid failure/myxoedema</b>	<ul style="list-style-type: none"> <li>• External laryngeal nerve injury – pitch of the voice is lost</li> <li>• Recurrent laryngeal nerve injury</li> </ul> <b>Vascular complications</b> <ul style="list-style-type: none"> <li>• Haemorrhage – primary and reactionary</li> <li>• Haematoma formation</li> <li>• Compromised tracheo-oesophageal blood supply</li> </ul>	<ul style="list-style-type: none"> <li>• Respiratory obstruction</li> <li>• Skin flap necrosis – rare</li> <li>• Infection</li> <li>• Discharge and sinus formation</li> <li>• Wound granuloma</li> <li>• Keloid formation</li> </ul>
<b>Intraoperative</b>	<b>Immediate postoperative</b>	<b>Late postoperative</b>
<ul style="list-style-type: none"> <li>• Haemorrhage</li> <li>• Nerve injuries</li> </ul>	<ul style="list-style-type: none"> <li>• Haematoma</li> <li>• Laryngeal oedema</li> <li>• Respiratory obstruction – stridor</li> <li>• Hypoparathyroidism</li> <li>• RLN injury and its problems</li> </ul>	<ul style="list-style-type: none"> <li>• Hypothyroidism</li> <li>• Recurrent nodule</li> <li>• Recurrent toxicity</li> <li>• Wound infection</li> <li>• Granuloma/keloid</li> </ul>

### Causes

- ◆ It occurs in a thyrotoxic patient inadequately prepared for thyroidectomy or thyrotoxic patient presents with crisis following an unrelated operation or stress.
- ◆ Other causes are – infection, trauma, pre-eclampsia, diabetic ketoacidosis, emergency surgery, stress, drugs like anticholinergics or antiadrenergic or NSAIDs or chemotherapy, diabetes mellitus.

### Features

- ◆ They present 12–24 hours after surgery; but on table also, it can occur occasionally.
- ◆ Hyperpyrexia ( $> 41^{\circ}\text{C}$ ), severe dehydration, circulatory collapse, hypotension, palpitations, tachycardia, tachypnoea, hyperventilation, cardiac arrhythmias, cardiac failure.
- ◆ GI symptoms like vomiting, diarrhoea, jaundice.
- ◆ Restlessness, irritability, delirium, tremor, convulsions and coma can occur.
- ◆ *Bailey's symptom complex* of thyroid storm are – insomnia, anorexia, diarrhoea, vomiting, sweating, emotional instability, fever, tachycardia, aggravated toxic features, multiorgan dysfunction.

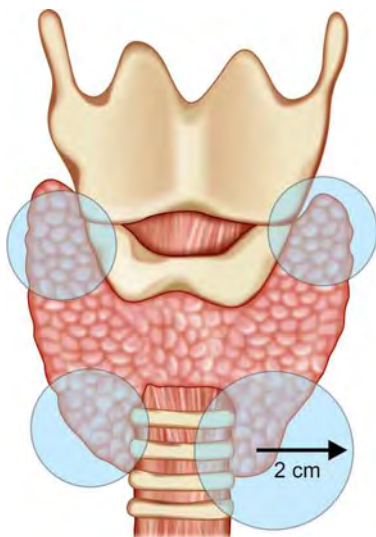


Fig. 6.68: Note the location of parathyroid glands.

- ◆ *Burch-Wartofsky score* (1993) is used to identify or predict the thyroid storm using different parameters – score of below 25 excludes storm; score 25–45 suggests impending storm; more than 45 means thyroid storm.
- ◆ Death may ensure suddenly.
- ◆ Differentia diagnoses are—malignant hyperpyrexia, septic shock, anxious status, cardiac disorders.
- ◆ Investigations – Raised T3, T4, suppressed TSH, raised serum calcium, ECG and echocardiography shows changes, raised total count, altered liver function tests, arterial blood gas (ABG) shows changes; altered electrolytes.

### Treatment

- ◆ *Supportive measures* – rehydration by proper fluid therapy, tepid sponging, cooling blankets, antipyretics like paracetamol IV infusion, glucocorticoids (Hydrocortisone 500 mg IV or dexamethasone injections), IV dextrose infusion as there is more metabolic demand, correction of electrolytes, treating cardiac arrhythmias, ICU care with ventilator support. Central line, CVP monitor, nasogastric tube, urinary catheter should be placed.
- ◆ *Antiadrenergic drugs* – Propranolol 80 mg orally or through nasogastric tube 6<sup>th</sup> hourly, or IV propranolol 1 mg IV in 10 minutes followed by 2 mg in 10 minutes as per need. When propranolol is contraindicated in asthma, heart block and failure, cardioselective beta blockers like atenolol, metoprolol can be used; esmolol IV loading dose as 500 ug/m/kg followed by 100 ug/kg minute infusion is also effective. Reserpine 500 ug/kg loading dose, then 5 ug/kg/minute; heart rate should be  $< 100/\text{minute}$ .
- ◆ *Thionamides* – propylthiouracil (PTU) 200 mg 4<sup>th</sup> hourly or methimazole 20 mg 4<sup>th</sup> hourly or carbimazole is used. Hepatotoxicity of PTU should be remembered.
- ◆ *Iodide compounds* – Lugol's iodide or potassium iodide is given one hour after intake of thionamides. 10–15 drops of Lugol's iodine 8<sup>th</sup> hourly is used or SSKI (saturated solution of potassium iodide) 5 drops 6<sup>th</sup> hourly is useful. Injection sodium iodide 1 gram IV is also used.
- ◆ *Glucocorticoids* – reduce the peripheral conversion of T4 to T3 and controls the shock. Hydrocortisone 5 mg/kg 6<sup>th</sup> hourly or dexamethasone 0.2 mg/kg/day are used.
- ◆ *Bile acid suppressants* to prevent reabsorption thyroid hormone from the gut – cholestyramine 4 grams 6<sup>th</sup> hourly. Iodinated radiocontrast dyes like iopanoic acid is also beneficial. Lithium carbonate 300 mg 6<sup>th</sup> hourly is also useful.

- ◆ Digitoxin, *cardiac monitoring* are crucial.
- ◆ *Treating* specific causes like diabetes, sepsis are important. Antibiotics, fluid and electrolyte management and monitoring is a must.
- ◆ *Other measures*—Haemodialysis, plasmapheresis, exchange transfusion, charcoal plasma perfusion are other methods used to control the storm.
- 6. *Injury to external laryngeal nerve*  
It causes weakness of cricothyroid muscle leading to alteration in pitch of voice, voice fatigue, breathy voice, frequent throat clearing. ILS reveals short hyperaemic vocal cords, lower level affected vocal cord, oblique glottis chink due to rotation of the posterior commissure to the paralyzed one.
- 7. *Hypothyroidism*.  
Revealed clinically after 6 months.
- 8. Wound infection, stitch granuloma formation.
- 9. Keloid formation.
- 10. *Recurrent thyrotoxicosis* is 5% common. It is due to retaining of more thyroid tissue during thyroidectomy for toxic thyroid. It is difficult to manage. It is treated with *antithyroid drugs, radioiodine therapy* or re-excision surgically which is technically demanding (so often avoided).

#### Remember in thyroidectomy

- ❖ Middle thyroid vein is present only in 30% of cases
- ❖ Bipolar cautery or harmonic scalpel (harmonic wave) are better to control bleeding and to prevent injury to RLN
- ❖ RLN should be identified in both sides. Variations should be remembered
- ❖ Parathyroids should be retained and also their blood supply
- ❖ Parathyroid autotransplantation may be needed if their blood supply is compromised
- ❖ Rapid influx of serum calcium into bones in immediate postoperative period may cause severe hypocalcaemia—*hungry bone syndrome* which is initially corrected by IV calcium gluconate—10 ml of 10%. It is more commonly observed in patients with beta blockers. It is due to sudden drop in PTH level after surgery
- ❖ Tension haematoma under strap muscles is very dangerous and should be relieved by removing sutures from the skin and strap muscles
- ❖ Permanent hypoparathyroidism is rare (0.5–1%) whereas temporary hypoparathyroidism and hypocalcaemia is common (25%) which is corrected well with calcium for certain period of 3–6 months.
- ❖ External laryngeal nerve injury is more common than of RLN. There is loss of tension of vocal cords causing reduced power and range in voice (pitch)
- ❖ Thyroid insufficiency develops in 25–45% cases. It is confirmed by doing serum T<sub>3</sub>, T<sub>4</sub> and TSH after 6 months

#### EMIL THEODOR KOCHER

*We have arrived at the point where we generally recommend the radical operation for goitre as the surest and simplest method of treatment.... Surgeons have simply assumed that the thyroid gland has no function whatever.... Patients with total excision... all show more or less severe disturbances in their general condition... We cannot fail to recognise (the) relation to idiocy and cretinism... We see no objection for the time being, to the use of the name cachexia strumipriva.*

—Emil Theodor Kocher, 1883

He is the first surgeon to get Nobel prize. He did extensive work on thyroid surgeries and designed present technique of thyroid surgeries.

He was from Switzerland. He was the founder of:

- ◆ Kocher's vein.
- ◆ Kocher's forceps (has got tooth in the tip).
- ◆ Kocherisation (Duodenal mobilisation).
- ◆ Kocher's incision (Right subcostal for cholecystectomy).
- ◆ Kocher's thyroid incision.
- ◆ Kocher's test.
- ◆ Kocher's method for reduction of shoulder dislocation.

He died in 1917. *He is the father of thyroid surgery.*

Other surgeons who got Nobel prizes are—Alexis Carrell, for his work on vascular anastomosis; Christian Bernard, for heart transplantation, Charles Huggins, urologist, for management of carcinoma prostate.

#### KOCHER'S TEST

In case of a huge or long-standing thyroid enlargement, both lateral lobes of thyroid are pushed posteromedially with fingers. The test is positive, if it produces **stridor**. This signifies weakened tracheal (rings) cartilage because of constant pressure by the thyroid gland. But then trachea is kept patent by the thyroid itself. Once the gland is removed there is no support to trachea and so it collapses causing stridor (*scabard trachea*). Such patient *requires temporary tracheostomy for 2–3 weeks*. By then trachea regains its strength back.

#### HYPOTHYROIDISM

##### Causes

After thyroidectomy, common cause

- ❖ Agenesis or dysgenesis
- ❖ Enzyme deficiency
- ❖ Iodine deficiency
- ❖ Hashimoto's thyroiditis
- ❖ Antithyroid drugs
- ❖ Radioiodine
- ❖ *Drugs:* Lithium, amiodarone

*Primary*—is due to thyroid diseases or removal of thyroid.

*Secondary*—is due to hypopituitarism.

*Tertiary*—is due to hypothalamic diseases.

#### Cretinism

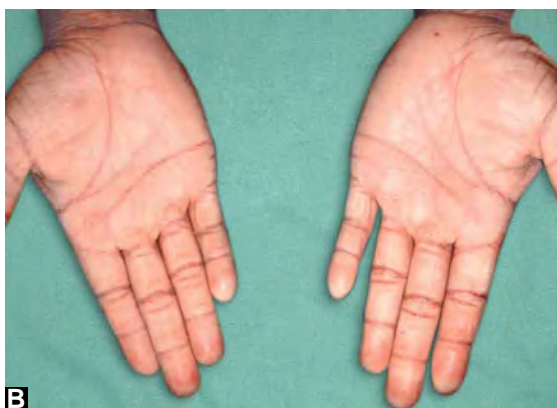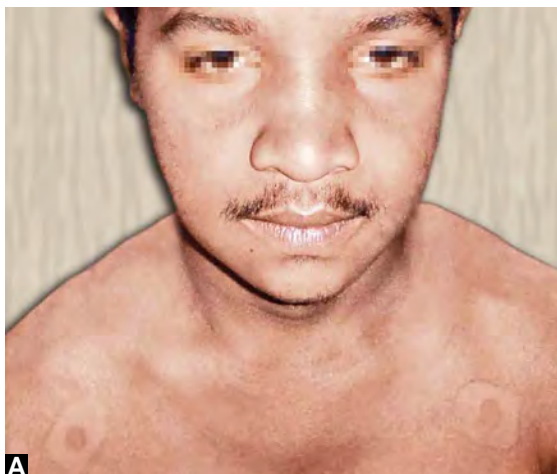- ◆ It is foetal/infantile hypothyroidism due to inadequate thyroid hormone production during fetal and neonatal period. It may be due to agenesis, inborn error of thyroid metabolism, dysmorphogenesis or dietary deficiency (endemic).
- ◆ Typical hoarse cry, macroglossia, umbilical hernia, thickened skin are the features.
- ◆ TSH will be raised; T<sub>3</sub> and T<sub>4</sub> will be low.
- ◆ Incidence is 1:4000 live births.
- ◆ It is treated with L thyroxine once a day morning orally.

#### Clinical Features

- ◆ *General:* Tiredness, weight gain, cold intolerance, goitre, hyperlipidaemia.

*The same beam of light can illuminate two objects and produce two different effects.*

- ◆ **Cardiovascular:** Bradycardia, angina, cardiac failure, pericardial effusion.
- ◆ **Haematological:** Anaemia.
- ◆ **Dermatological:** Dry skin, vitiligo, alopecia, erythema.
- ◆ **Reproductive:** Infertility, menorrhagia, galactorrhoea.
- ◆ **Gastrointestinal:** Constipation, ileus.
- ◆ **Developmental:** Growth and mental retardation, delayed puberty.
- ◆ **Other features:** Carpal tunnel syndrome, myalgia, hoarseness, deafness, ataxia, depression, psychosis (Myxoedema madness).



Figs 6.69A and B: Typical myxoedema patient.

Myxoedema coma		
Characteristic features	Precipitated by	Treatment
Hypothermia	Cold	Drug of choice—T <sub>3</sub> , (Levothyronine) 10 µg given IV 6th hourly
Hypotension	Infection trauma	Levothyroxine—300 µg IV/1000 µg orally (large dose)
Hyponatraemia		Glucocorticoids
Hypoventilation		Antibiotics
Hypoglycaemia		Slow warming
Bradycardia		Electrolyte management
Skin is deadly cold like of a toddler		
Coma		

Note: Myxoedema is severe thyroid failure.

## Investigations

- ◆ T<sub>3</sub>, T<sub>4</sub> estimation.
- ◆ TSH level estimation which is higher.

## Treatment

- ◆ Replacement with L-thyroxine 100 to 150 µg/day. In old patients with ischaemic heart disease initial therapy is with 25–50 µg/day and then gradually increased up to the required dose.
- ◆ Initial rapid response can be achieved by giving L iodothyronine 20 µg tid.

## ■ RECURRENT LARYNGEAL NERVE PALSY

### Anatomy and Relations of Nerves with Thyroid Gland

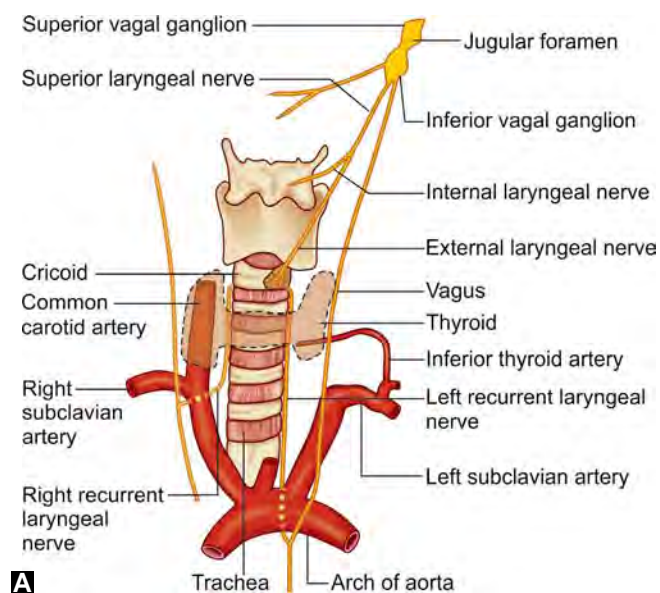
- ◆ **External laryngeal nerve** is a branch of superior laryngeal nerve. Vagus gives superior laryngeal nerve branch at inferior ganglion of vagus which is at the level of greater cornu of hyoid bone, which in turn, divides into internal laryngeal and external laryngeal nerves. Internal laryngeal nerve pierces the thyrohyoid membrane and gives sensory supply to larynx above the vocal cord and hypopharynx. External laryngeal nerve runs close to superior thyroid vessels to supply cricothyroid muscle which is tensor of vocal cord. It may get injured while ligating superior pedicle causing defective pitch of the voice. So upper pedicle of thyroid should be ligated close to gland.
- ◆ **Recurrent laryngeal nerve** is a branch of vagus which hooks around ligamentum arteriosum with arch of aorta on the left and right subclavian artery on the right side. It runs in the tracheo-oesophageal groove near the posteromedial surface close to thyroid gland. Nerve lies in between branches of inferior thyroid artery. So inferior thyroid artery should be ligated away from the gland. Anomalies of the nerve should be remembered. In 5% of cases nerve passes through the gland. Nerve may be much more away from the gland. Nerve may be closely adherent to gland posteriorly. Nerve may lie within the ligament of Berry (25%). Non-recurrent laryngeal nerve may be present in 1 in 1,000 cases with a horizontal course. RLN supplies all muscles (abductors, adductors) of the larynx except cricothyroid and also gives sensory supply of larynx below the vocal cords.

### Muscles of the Larynx

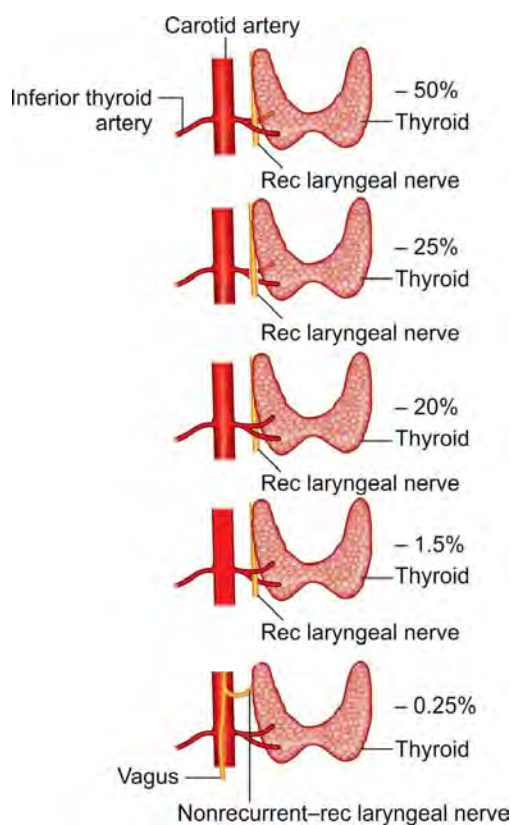
- ◆ **Cricothyroid:** It is the only muscle which is located on the external aspect of the larynx. It is supplied by external laryngeal nerve. It is tensor and mild adductor of the vocal cord.
- ◆ **Abductors of the vocal cord—Posterior cricoarytenoids.**
- ◆ **Adductors of the vocal cord—Lateral cricoarytenoids, transverse arytenoid, thyroarytenoids and cricothyroids.**
- ◆ **Relaxant of vocal cords—Thyroarytenoids and vocalis.**
- ◆ **Muscles which close the laryngeal inlet—oblique arytenoids and aryepiglottic.**
- ◆ **Muscles which open the laryngeal inlet—thyroepiglotticus.**

### Positions of Vocal Cord

Median; paramedian (1.5 mm); normal; cadaveric/neutral (3.5 mm); gentle abduction (7 mm); completely abducted (9.5 mm).

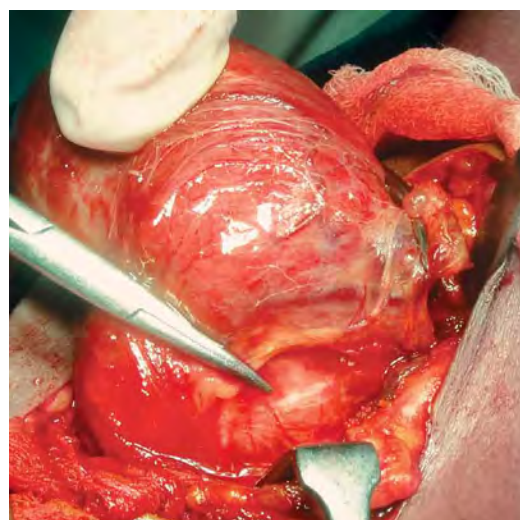


A



B

**Figs 6.70A and B:** Anatomy of superior and recurrent laryngeal nerve. Superior laryngeal nerve divides into internal and external laryngeal nerves. Right recurrent winds round subclavian artery and left winds around arch of aorta.



**Fig. 6.71:** On table identification of recurrent laryngeal nerve is a must during thyroidectomy.

#### Assessment of voice change

- ❖ Pitch of the voice—whether raised/lowered or pitch locked
- ❖ Breath support during speaking is adequate or not
- ❖ Ability to alter the rapidity of speech—slow/fast/ medium
- ❖ Altered laryngeal and neck muscle tension
- ❖ *Indirect laryngoscopy*—with tongue pulled out using gauze, warmed ILS is placed into the oral cavity to see vocal cords. Patient is asked to say 'e' to see the vocal cord movements

#### Types

1. Unilateral recurrent laryngeal nerve palsy.
2. Bilateral recurrent laryngeal nerve palsy.
3. Unilateral, combined recurrent laryngeal and superior laryngeal nerve palsy.
4. Bilateral, combined recurrent laryngeal and superior laryngeal nerve palsy.

#### 1. Unilateral Recurrent Laryngeal Nerve Palsy

All intrinsic muscles of the larynx except cricothyroid are paralysed. Vocal cord becomes median or paramedian position.

Reasons are:

- a. Only retained cricothyroid is a weak adductor of vocal cord causing median or paramedian position of vocal cords (*Wagner-Grossman hypothesis*).
- b. Abductor fibres which are phylogenetically newer (to posterior cricoarytenoid) of the recurrent laryngeal nerve is more susceptible and paralysed than adductor fibres (*Semon's law*).

### Causes for unilateral recurrent laryngeal nerve paralysis

- ❖ Infiltration from carcinoma thyroid
- ❖ Infiltration from carcinoma oesophagus
- ❖ Infiltration from carcinoma bronchus (left-sided)
- ❖ Mediastinal tumours (left-sided)
- ❖ Aortic aneurysms
- ❖ Trauma
- ❖ Idiopathic
- ❖ Thyroidectomy
- ❖ Neck or mediastinal lymph node mass

### Clinical features

- ◆ Asymptomatic in 33% cases.
- ◆ Some change in voice, which gradually becomes normal with speech therapy.
- ◆ Aspiration never occurs.
- ◆ Airway obstruction never occurs.

### Treatment

No specific treatment is required.

But steroid should be started. Prednisolone 20 mg tid for 10 days orally after food is given with gradual tapering in another 10 days.

### 2. Bilateral Recurrent Laryngeal Nerve Palsy

Both side intrinsic muscles are paralysed. So both vocal cords lie in median or paramedian position due to unopposed actions of the both side cricothyroid.

### Clinical features

- ◆ Change in voice.
- ◆ Severe dyspnoea and stridor (more during exertion) leading to airway block and respiratory arrest.

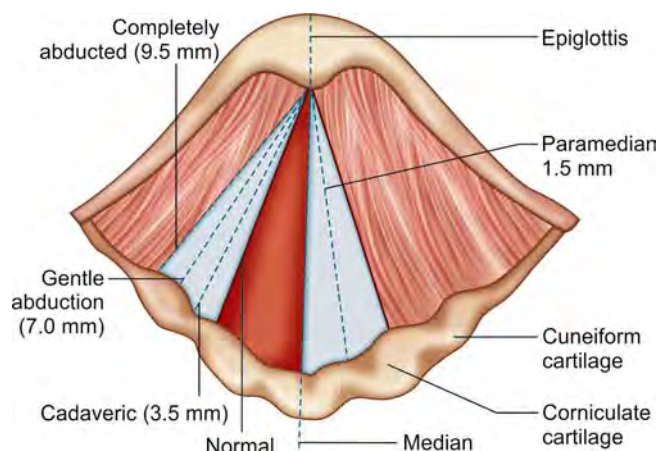


Fig. 6.72: Vocal cord in recurrent laryngeal nerve palsies.

### Treatment

- ◆ Emergency tracheostomy.

- ◆ Lateralisation of the cord by:
  - ▶ Arytenoidectomy by open surgery or through an endoscope.
  - ▶ Vocal cord lateralisation through endoscope.
- ◆ Excision of vocal cord through an endoscope or laser cordectomy.
- ◆ Implantation of sternohyoid.
- ◆ Thyroplasty.

### 3. Unilateral, Combined Recurrent Laryngeal Nerve and Superior Laryngeal Nerve Palsy

All the muscles on one side are paralysed. Vocal cord is in cadaveric position, 3.5 mm from the midline.

### Clinical features

- ◆ Hoarseness of voice.
- ◆ Aspiration through ineffective glottis.
- ◆ Ineffective cough.

### Treatment

- ◆ Speech therapy (Commonly healthy opposite cord moves to opposite side of the midline so as to compensate for the paralysis of the opposite side).
- ◆ Injection of Teflon to the paralysed cord.
- ◆ Muscle or cartilage implant to the paralysed cord.
- ◆ Arthrodesis of cricoarytenoid joint.

### 4. Bilateral, Combined Recurrent Laryngeal Nerve and Superior Laryngeal Nerve Palsy

### Causes

- ◆ All (total) paralysis of intrinsic muscles of larynx
- ◆ Total laryngeal anaesthesia

### Clinical features

- ◆ Aphonia (no voice).
- ◆ Aspiration due to severe glottis incompetence and laryngeal anaesthesia.
- ◆ Absence of cough.
- ◆ Retention of secretions in the chest.
- ◆ Respiratory arrest.

### Treatment

- ◆ Emergency tracheostomy.
- ◆ Fixing epiglottis over the arytenoids to prevent aspiration.
- ◆ Plication of vocal cords to prevent aspiration.
- ◆ Total laryngectomy.

❖ Unilateral recurrent laryngeal nerve palsy	- Not dangerous
❖ Bilateral recurrent laryngeal nerve palsy	- Most dangerous
❖ Unilateral combined palsy	- Not dangerous
❖ Bilateral combined palsy	- Dangerous

# Chapter 7

## Parathyroids and Adrenals

*About three years ago I found on the thyroid gland...a small organ, hardly as big as a hemp seed, which was enclosed in the same connective tissue capsule as the thyroid, but could be distinguished therefrom by a lighter color. A superficial examination revealed an organ of a totally different structure from that of the thyroid, and with a very rich vascularity.... (I) suggest the use of the name Glandulae parathyreoideae; a name in which the characteristic of being bye-glands to the thyroid is expressed.*

—Ivar Victor Sandström, 1879

### CHAPTER OUTLINE

- |                       |                            |                                                 |
|-----------------------|----------------------------|-------------------------------------------------|
| ❖ Anatomy             | ❖ Hypoparathyroidism       | ❖ Conn's Syndrome                               |
| ❖ Calcium             | ❖ Tetany                   | ❖ Virilising Syndrome or Adrenogenital Syndrome |
| ❖ Hyperparathyroidism | ❖ Adrenals                 | ❖ Neuroblastoma                                 |
| ❖ Parathyroidectomy   | ❖ Adrenal Cortical Tumours | ❖ Pheochromocytoma                              |
| ❖ Men Syndrome        | ❖ Adrenocortical Carcinoma |                                                 |
| ❖ Apudomas            | ❖ Cushing's Syndrome       |                                                 |

### ANATOMY

- ◆ Parathyroids are endocrine glands situated behind the thyroid gland. They are four in number two on each side.
- ◆ Two upper glands are constant in position. Superior is *behind* recurrent laryngeal nerve. They develop from 4th pharyngeal pouch hence called as parathyroid IV.
- ◆ Two lower glands are variable in position. They develop from endoderm of 3rd pharyngeal pouch hence called as parathyroid III. It is usually *in front* of the recurrent laryngeal nerve, lower part.
- ◆ Inferior parathyroids are larger than superior; adenoma is common in inferior parathyroids. Inferior parathyroid and thymus develop from 3rd pharyngeal arch.
- ◆ Each gland weighs 40–50 mg. It is brownish (*khaki* coloured) firm gland, which sinks in the fluid unlike fat which floats. It is usually adjacent to the anastomosis between superior and inferior thyroid arteries posteriorly.
- ◆ Glands (chief cells) secrete parathormone (PTH) which controls the calcium metabolism.
- ◆ Variations are common in inferior parathyroids. It can be located in thyrothymic ligament, superior pole of thyroid, tracheo-oesophageal groove, behind oesophagus, carotid sheath. There may be more than two glands on one side called as supernumerary gland (2.5–22%).

- ◆ Both superior and inferior glands receive their blood supply from inferior thyroid artery and its anastomotic branch. Blood supply is through *an end arterial* branch.
- ◆ Gland contains *chief and oxyphil* (water clear) cells.

### Parathormone—PTH

- ❖ PTH is a peptide of 84 amino acids.
- ❖ PTH secretion is not dependent on pituitary gland.
- ❖ It converts vitamin D into 1, 25-dihydrocholecalciferol in the kidney, an active principle.
- ❖ Increases absorption of the calcium from the gut
- ❖ Mobilizes calcium from the bone
- ❖ Increases the calcium reabsorption from the renal tubules
- ❖ Half life of PTH is 4 minutes.

### CALCIUM

Total calcium in plasma in ionised and nonionised (unbound and bound) form is 8.5–10.2 mg/dl (2.2–2.5 mmol/L). 55% is bound; 45% is unbound ionised free active part (4.5–5.0 mg/dl). Commonest protein part of bound calcium is albumin (80%); remaining is beta globulin, non-protein molecules. Ionised calcium is inversely related to pH of blood; raise in pH by 1 will reduce the ionized calcium by

*Today well lived makes every yesterday, a dream of happiness and tomorrow, a vision of hope.*

0.36 mmol/L. Levels of calcium is controlled by PTH, calcitonin and vitamin D acting on bone, kidney and GIT. PTH (84 amino acids) is secreted by chief cells whenever serum calcium level falls. PTH stimulates osteoclasts for bone resorption; kidney to promote calcium reabsorption and production of 1,25-dihydroxy vitamin D; GIT to promote absorption of calcium and phosphorous. Vitamin D hydroxylation at carbon 25 occurs in liver, and later at carbon 1 occurs in kidney. It is important for blood coagulation, neuromuscular activity, cellular activity, bone integrity.

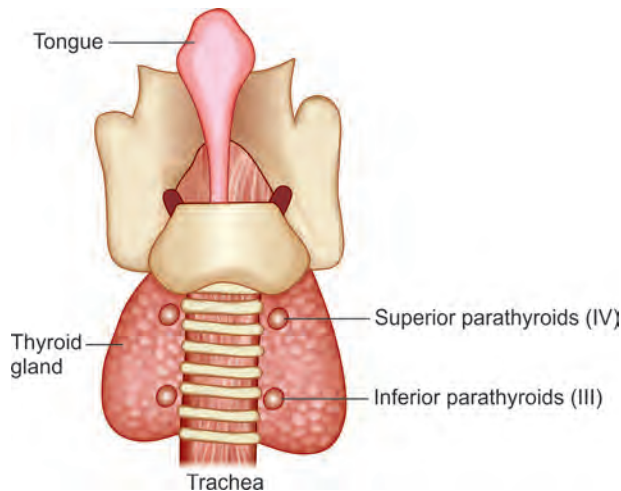


Fig. 7.1: Anatomical location of parathyroids.

## ■ HYPERPARATHYROIDISM (HPT)

### Types

1. Primary.
2. Secondary.
3. Tertiary.

**Primary** is unstimulated inappropriate high PTH secretion due to hyperplasia or adenoma causing hypercalcaemia.

#### Primary hyperparathyroidism

- ❖ Adenoma (75–90%)
- ❖ Hyperplasia (20–24%)
- ❖ Carcinoma, rare (1%)

**Secondary** is due to chronic renal failure or due to malabsorption, vitamin D deficiency rickets, i.e. due to chronic hypocalcaemia. There is always parathyroid hyperplasia. CRF causes hyperphosphataemia and reduced conversion of 25 DHCC to 1, 25 DHCC. So absorption of calcium from GIT is reduced causing chronic hypocalcaemia which stimulates PTH secretion and parathyroid hyperplasia.

In secondary hyperparathyroidism, cause is not in the parathyroids but away from that; all four glands get affected here. Serum calcium is normal or low; metastatic calcification is common; vertebral body shows ‘Rugger Jersey pattern’ (simulates transverse band of rugby jersey).

**Tertiary** is due to autonomous reactive hyperplasia of parathyroids often seen like after renal transplantation.

**Carcinoma of parathyroid** is rare—1%. It is aggressive. It presents as nodule, palpable neck lymph nodes along with HPT. It is invasive to soft tissues, thyroid, perineural spaces. Often blood spread can occur. It needs wide tumour excision, hemithyroidectomy, neck node dissection and later radiotherapy to neck and mediastinum. With therapy 5-year survival rate is 85%.

### Primary Hyperparathyroidism

Primary HPT is 3rd most common endocrine disease after diabetes and thyroid disease. Increased PTH causes hypercalcaemia.

Adenoma is common in *inferior parathyroid*; adenoma is the *most common cause*. Hyperplasia, carcinomas are less common causes.

*Exact etiology* is unknown; familial or genetic causes are common; MEN I syndrome is often associated. Therapeutic ionizing radiation (like RAIT) can cause hyperparathyroidism. Lithium can cause parathyroid hyperplasia and HPT but without causing bone or renal problems.

### Clinical Features

- ◆ *Clinical vignette of hyperparathyroidism: “Bones, stones, abdominal grains and psychiatric moans”*. As palpable neck swelling is uncommon, disease is suspected by various clinical features and so to confirm by biochemical evaluation (PTH assay).
- ◆ It is common in middle-aged women (3:1).
- ◆ Incidence is 1:1000 patients.
- ◆ Presentation may be asymptomatic >50% cases—(*Asymptomatic hypercalcaemia*).
- ◆ **Bones:** Raised PTH causes increased osteoclastic activity leading into *extensive decalcification of the bone* resulting into bone pain, subperiosteal erosions on the radial aspect of the middle phalanges and clavicle. There will be osteitis fibrosa cystica (**von Recklinghausen disease of hyperparathyroidism/brown tumour of hyperparathyroidism—15% cases of PTH**) which shows single or multiple cysts or *pseudotumours* in the jaw, skull or phalanges. There will be osteopenia, osteoporosis and pathological bone fractures. Acquired trachyonychia (racquet nails) suggests bone resorption. Lamina dura of tooth is the first bone to show changes. Brown tumour is seen in long bones.
- ◆ **Stones:** In the kidney due to hypercalcaemia, renal stones (25%) develop which are usually multiple. 3% of all renal patient stones is due to primary PTH. Recurrent stones are commonly observed in PTH. Calculi are usually calcium phosphate or oxalate types. Metastatic calcification of the renal parenchyma can occur resulting in nephrocalcinosis resulting into renal failure. Calcification occurs in the renal vessels leading into *renal hypertension*.
- ◆ **Abdominal groans:** Hypercalcaemia stimulates gastrin release which causes peptic ulceration. Hypercalcaemia can precipitate acute pancreatitis. Gallstone disease is increased due to hypercalcaemia; calcium bilirubinate type is the one usually observed.

- ◆ *Psychic moans*: Behavioural and neurotic problems with depression, anxiety; present as nonspecific symptoms.
- ◆ *Other features*: They are prone for skin necrosis, corneal ulceration, band keratopathy (identified through slit-lamp examination), pseudogout, myalgia, joint pain, back ache, polyuria, polydipsia, constipation, glycosuria and hypertension. Proximal myopathy and muscle wasting can occur.
- ◆ MEN syndrome (I and IIA) can co exist. Primary HPT is the *earliest and commonest manifestation* of MEN I syndrome and develops in more than 80% of these patients.
- ◆ *Calcinosis of PTH* can present as renal stones, gallstones. *Metastatic calcifications* occur in kidney (nephrocalcinosis), chondrocalcinosis, calcifications in skin, vessels, cardiac valves and soft tissues.
- ◆ *On examination of the neck, it is not common to reveal a palpable swelling of parathyroid enlargement.*

- ❖ Primary HPT is commonly sporadic than familial
- ❖ Histological difference between adenoma and hyperplasia is difficult to assess
- ❖ On table gross look is preferred method
- ❖ Adenoma is usually single. Multiple adenomas occur in elderly (5%)
- ❖ Hyperplasia involves all four parathyroids
- ❖ Parathyroid cyst may be developmental/secondary to degeneration of nodule or adenoma. Cyst aspiration shows clear fluid with high PTH level in the content fluid
- ❖ Preoperative IV methylene blue 5 mg/kg in 500 ml dextrose saline which stains parathyroids is used often to localise glands
- ❖ 50 percentage of one gland is sufficient to maintain function
- ❖ Persistent HPT is one in which HPT persists immediately even after initial surgery
- ❖ Recurrent HPT (initially after first surgery HPT is corrected but recurs 12 months after surgery) is due parathyromatosis, development of new adenoma, and hyperplasia of transplanted parathyroid. *Parathyromatosis* is due to rupture and spillage of parathyroid tissue in neck, mediastinum forming functioning nodules
- ❖ Re-exploration and removal in persistent/recurrent HPT needs on table PTH assay. On table PTH level drop more than 50% of preoperative value indicates the success of surgical removal
- ❖ CT, MRI, PET scan and selective angiography are usually done only for recurrent diseases

## Acute Hyperparathyroidism (Crisis)

### Causes

- ◆ Sudden increase in PTH level due to rupture of parathyroid cyst or bleeding in the parathyroid tumour.
- ◆ Severe dehydration precipitates crisis.
- ◆ Secondaries in bone (primary may be from breast).

Acute hyperparathyroidism is rare but dangerous presentation (crisis) wherein patient presents with abdominal pain, vomiting, dehydration, oliguria, muscular weakness and death.

Serum  $\text{Ca}^{++}$  is very high  $> 12 \text{ mg\%}$  ( $3.5 \text{ mmol/L}$ ).

### Treatment of Crisis

- ◆ Forced diuresis using 3–5 litres of saline with frusemide.
- ◆ Rehydration using normal saline 300 ml/hour.

- ◆ Steroids, inhibits effects of vitamin D. Dose is 400 mg/day IV for 5 days.
- ◆ Clodronate  $\text{Na}^+$ , Pamidronate (90 mg IV slowly in 4 hours, is a biphosphonate inhibits mobilization of the calcium from the bone). Zoledronic acid 4 mg IV initially and later 8 mg is also used.
- ◆ Drugs to reduce  $\text{Ca}^{++}$  level, i.e. *mithramycin, calcitonin, prednisolone, biphosphonates*. Mithramycin rapidly controls the hypercalcaemia of malignant disease but temporarily. *Cinacalcet* is calcium receptor agonist which reduces the serum calcium level. Gallium nitrate inhibits osteoclast resorption of calcium at a dose of 200  $\text{mg/m}^2/\text{day}$  for 5 days.
- ◆ Condition has high mortality rate. Patient develops hyperchloraemic metabolic acidosis.

## Investigations for HPT

- ◆ *High serum calcium level* more than 10  $\text{mg\%}$ . Serum albumin level also should be assessed to identify accurate ionic calcium level.

Parameters	Primary HPT	Secondary HPT
Parathormone	High	High
Calcium	High	Normal
Phosphate	Decreased	Increased

- ◆ *Increased serum PTH level* is specific and diagnostic— $> 0.5$ . Assay of '*Intact PTH*' is more relevant; Intact PTH is biologically active PTH molecules. "*whole*" or "*biointact*" *parathyroid hormone assays* using two different antibodies against two different segments of parathyroid hormone is still more specific.
- ◆ Serum phosphate level will be decreased in primary HPT; but in secondary HPT serum phosphate level is increased.
- ◆ Bone density assessment.
- ◆ Vitamin D estimation.
- ◆ Increased urinary calcium level  $> 250 \text{ mg}/24 \text{ hours}$ .
- ◆ Raised serum alkaline phosphatase level.
- ◆ *X-ray skull shows salt and pepper appearance*; X-ray phalanges (subperiosteal bone resorption and tufting of distal phalanges) and jaw are also specific showing osteitis fibrosa cystica; X-ray spine may show Ruggier jersey spine.

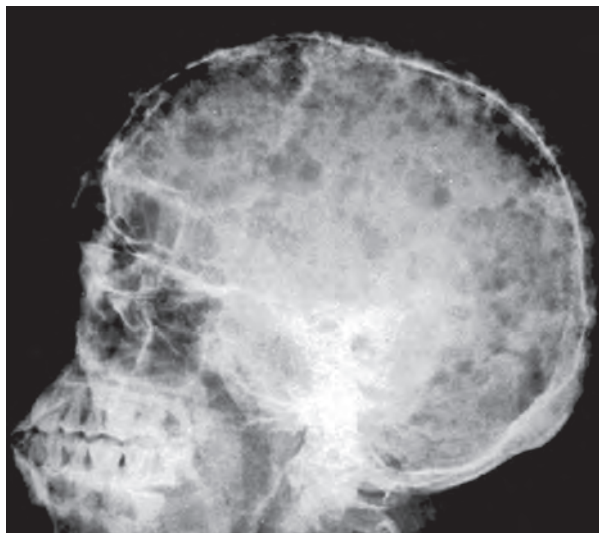
### X-ray features in hyperparathyroidism

- ❖ Pepper lesions in the skull
- ❖ Sub-periosteal erosion of radial side of middle phalanx
- ❖ Calcification in bones

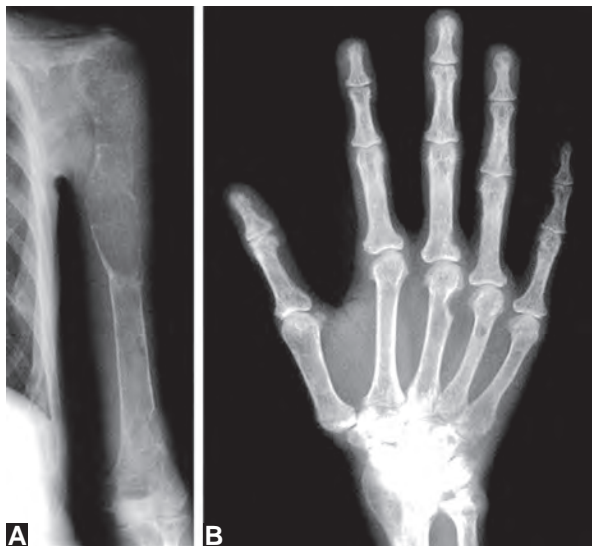
- ◆ Ultrasound abdomen to find out problems in kidney, pancreas.
- ◆ Ultrasound neck and CT/MRI scan neck and mediastinum.
- ◆ Selective venous sampling for PTH is also very useful.
- ◆ Thallium-Technetium scan shows *hot spots* which is diagnostic of parathyroid adenoma.
- ◆ *Technetium-99m labelled Sestamibi isotope* scan is better and sensitive (80%) than Thallium-Tc scan. As it is very

*Any adrenal tumour more than 50 gm is usually malignant.*





**Fig. 7.2:** Plain X-ray skull. Note the characteristic salt-pepper appearance of the skull bone.



**Figs 7.3A and B:** X-ray of humerus bone and hand bones showing bone features—**brown tumour**—osteitis fibrosa cystica.

expensive, it is used in parathyroid re-exploration. It is often combined with *single photon emission computerised tomography* (SPECT).

- ◆ Urinary cAMP level increases in 90% cases.
- ◆ Angiography, venous sampling, USG-guided biopsy are other methods.

### Differential Diagnosis

- ◆ Secondaries in the bone—due to secretion of PTH related polypeptide by tumour. Actual PTH is suppressed.
- ◆ Multiple myeloma.
- ◆ Vitamin D intoxication.
- ◆ Sarcoidosis.

- ◆ Functioning carcinoma.
- ◆ *Familial hypocalcaemic hypercalcaemia* is an autosomal dominant disease with mild raise in serum calcium and PTH levels secondary to mutation in the cell membrane calcium receptor. Urinary calcium excretion is low. It does not require parathyroidectomy. Calcium creatinine clearance ratio is less than 0.01 in this condition whereas it is  $> 0.02$  in primary HPT.

### Treatment

#### Indications for parathyroidectomy

- ❖ Severe symptoms
- ❖ Young age group
- ❖ Markedly reduced bone density
- ❖ Serum calcium more than 11 mg%
- ❖ Urinary calculi
- ❖ Neuromuscular presentations
- ❖ Urinary calcium more than 400 mg /24 hours

- ◆ Surgical removal of the glands and implantation of fragments of the gland in forearm muscle mass (brachioradialis) or neck (sternomastoid). Marker stitch is placed at the transplantation site. 1/3rd of one gland or 100 mg of parathyroid gland is autotransplanted—subtotal parathyroidectomy.
- ◆ If it is carcinoma, additional hemithyroidectomy with post-operative radiotherapy is required.
- ◆ Adenoma when occurs in one gland with normal other glands, removal of that gland with adenoma may be sufficient.
- ◆ When all four glands are diseased, transcervical thymectomy is also added along with total parathyroidectomy to reduce persistent and recurrent disease.
- ◆ In familial and MEN syndromes, total parathyroidectomy is better.
- ◆ If it is mediastinal parathyroid adenoma, after proper localisation thoracoscopic removal may be sufficient.
- ◆ *Nonsurgical care* like good hydration, regular exercise, avoiding immobilisation, daily calcium and vitamin D intake is done in patients who have recovered from acute crisis. Estrogens reduce the calcium level and maintain bone density. Raloxifene, a selective estrogen receptor modulator is also reduces the serum calcium level. Bisphosphonates mainly alendronate improves the bone mineral density (BMD) in primary HPT but without altering the levels of PTH or calcium. *Cinacalcet*, a calcimimetic drug activate calcium receptor and reduces the levels of PTH and calcium but not increasing the BMD. Calcitonin, mithramycin are other drugs used. *Mithramycin is used once a week but is hepatotoxic and causes thrombocytopenia.* But medical treatment for primary HPT is *less effective and not popular.*

### Problems in parathyroidectomy

- ❖ Permanent hypoparathyroidism
- ❖ Persistent hyperparathyroidism—5%
- ❖ Recurrent hyperparathyroidism—hypercalcaemia recurs 12 months after first parathyroid surgery
- ❖ Recurrent laryngeal nerve injury—1%
- ❖ Often needs additional thyroidectomy
- ❖ Variations in positions of the gland especially lower—may be in mediastinum
- ❖ Sudden drop in calcium level after surgery due to increased absorption of calcium by bones—*hungry bone syndrome*

## PARATHYROIDECTOMY

### Indications in Primary HPT

- ◆ *Symptomatic HPT*
- ◆ *Asymptomatic HPT* with—Criteria (2002) for surgical intervention are:
  - ▶ Raise in serum calcium level more than 1 mg/dl of upper limit of the normal calcium range;
  - ▶ 24 hour urinary calcium if more than 400 mg; creatinine clearance when reduced more than 30%;
  - ▶ Bone density greater than 2.5 standard deviations below peak bone mass in lumbar spine/hip/lower end of radius;
  - ▶ Age below 50 years;
  - ▶ When medical therapy is not possible.

### Indications in Secondary HPT

Here indication for removal of all four glands with auto-transplantation of parathyroid is only in severe cases or with renal osteodystrophy.

### Preoperative Preparation

Vocal cords should be assessed by preoperative indirect laryngoscopy.

High calcium levels preoperatively may require treatment with hydration; diuresis; steroids (prednisolone 20 mg TID for 5 days before surgery); 100 mmol phosphate infusion in 6 hours; 200 units calcitonin subcutaneous injection for 5 days twice daily before surgery; diphosphanate—etidronate disodium 7.5 mg/kg daily as slow IV infusion for 3 days; mithramycin 25 µg/kg as single dose.

### Anaesthesia and Position

General anaesthesia is used with neck hyperextension by placing rolled sheet under the shoulder blades. Head is placed on the head ring; head end of the table is raised to semi-erect position (*Semi-Fowler position*).

### Incision and Dissection

It is same as for thyroidectomy. Flaps are raised in similar way. Strap muscles are separated after opening the deep fascia in the midline. Thyroid gland is mobilised to identify the parathyroid adenoma. Parathyroid having adenoma is mobilised which is close to recurrent laryngeal nerve. End artery of the parathyroid is identified and ligated. Adenoma is separated from adjacent thyroid tissue using gauze dissection. Either on table venous sampling for PTH assay is done or venous sample from cubital vein is done for PTH assay.

Parathyroid may be confirmed by frozen section biopsy or on table aspiration of parathyroid tissue which is analysed for PTH assay which will be more than 1500 pg/ml (confirms that removed tissue is parathyroid).

Total parathyroidectomy is done for parathyroid hyperplasia by removing all four glands and one-third of one gland is autotransplanted into the forearm muscle (brachioradialis) or sternocleidomastoid muscle with marker stitch. Gland to be transplanted is sliced into 1 mm pieces and around 18 pieces are embedded in decided muscle with a marker stitch or clip. If in postoperative period patient still presents with features of primary HPT; transplanted area is re-explored and further reduction in parathyroid tissue is done.

Wound is closed with proper haemostasis.

### Complications

- ◆ Haemorrhage, recurrent laryngeal nerve palsy, hypocalcaemia and *hungry bone syndrome* are known to occur.
- ◆ *Persistent HPT* (serum calcium does not normalise immediately after surgery leading to total failure) or *Recurrent HPT* (serum calcium after surgery becomes normal but in 6-12 months, it again increases) may be a problem.
- ◆ Hypoparathyroidism with severe hypocalcaemia is a problem when all glands are removed (3½) with bilateral neck exploration. 10 ampoules of calcium gluconate is diluted with one liter of normal saline and given as continuous infusion at a rate of 30 ml/hour—initial method of management. Hypomagnesaemia should also be corrected.
- ◆ Migration or inability to identify the transplanted parathyroid is often a problem in autotransplantation of parathyroid.
- ◆ **Hungry bone syndrome**
  - ▶ It occurs usually in patients with preoperative hyperthyroidism. They have increased bone breakdown in their hyperthyroid state. When a patient's thyroid hormone level drops acutely after surgery, stimulus to break down bone is removed. The bones are now "hungry" for calcium, remove calcium from the plasma rapidly.
  - ▶ It usually occurs after parathyroidectomy; thyroidectomy for toxic thyroid; prostate cancer patients on estrogen therapy. Sudden cessation of existing increased bone breakdown makes bones to absorb calcium, magnesium and phosphorus rapidly. Calcium levels in blood prior to operation cannot predict hungry bone syndrome.
  - ▶ Hypocalcaemia, hypophosphataemia, hypomagnesaemia and hyperkalaemia are four typical features in these patients. Estimation and correction of all these four factors is essential. ECG changes can occur. Hyperkalaemia should be treated judiciously. Magnesium infusion is needed. There is an unusually high need for calcium, with a low calcium excretion in the urine.
  - ▶ Bone-specific alkaline phosphatase (ALP) continues to rise in the first few weeks indicating increased bone reconstruction.
  - ▶ Supplementation of vitamin D and elemental calcium is needed during discharge for 6 months.
  - ▶ Postoperatively they need calcitriol (gradually increased to 16 mg in 1 month, then gradually reduced) with 2 gm calcium supplement.
  - ▶ Monitoring is done by evaluating serum calcium, albumin, magnesium, phosphorus and bone specific alkaline phosphatase.
- ◆ Injury to recurrent laryngeal nerve, oesophagus can occur.

*The fact which Addison has published seem to lead to the conclusion that these little organ are essential to life.*

—Charles Edward Brown-Sequard

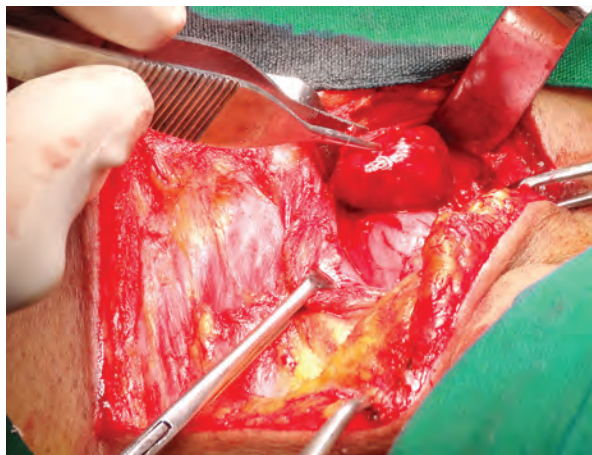
## Effects of Surgery

- ◆ Among neuromuscular symptoms of primary HPT, proximal muscle weakness responds better than respiratory muscle weakness by parathyroidectomy.
- ◆ Among psychiatric illnesses, depression and spatial learning and processing improve well by surgery.
- ◆ Bone mineral density in hip and lumbar spine becomes better.
- ◆ Nephrocalcinosis is improved by surgery; but hypertension and renal excretion will not improve much.
- ◆ Half life of PTH is 4 minutes. On table serial PTH assays are done at several intervals—before dissection of the gland, during dissection and after dissection. 50% reduction in PTH level from baseline in post-removal sample is a 96% predictor of complete removal.
- ◆ Operative failure rate is 1.5 to 6%. Intraoperative PTH assay improves the success rate very much (76–94%). Cure rate is defined as normocalcaemia in 6 months postoperative period.
- ◆ Radio-guided parathyroidectomy using intravenous injection of 20 mCi of <sup>99m</sup>Tc sestamibi 2 hours before surgery is not routinely practiced but may be useful for removal of adenoma appropriately. Hand-held quantitative gamma counter is used intraoperatively on the neck over all parathyroid tissues.

## Surgical Approaches

### Classic Approach (Traditional Approach)

It is under general anaesthesia exploring bilateral neck to remove parathyroid tissue which is confirmed by frozen section biopsy. It shows 95% cure rate with 2% complication rate.



**Fig. 7.4:** On table look of parathyroid adenoma of inferior parathyroid gland (left sided).

### Minimally Invasive Parathyroidectomy (MIP)

It is done in case of *single adenoma* of parathyroid under regional cervical block anaesthesia usually in ambulatory set up. It is actually unilateral parathyroidectomy with removal of adenoma and involved entire that particular one parathyroid gland using limited neck exploration (small incision of 2–4 cm). Procedure is not useful in multiple adenomas or hyperplasia. Preoperative localisation with sestamibi combined with SPECT is a must. Intraoperative PTH assay is a must to confirm drop in PTH level to required level. Cervical block is given by infiltrating the xylocaine (1%) with adrenaline along posterior and deep to sternocleidomastoid muscle and also along the neck incision. Direct field block along the

anterior border of the sternocleidomastoid and over the incision is also used. Post-operative serum calcium and PTH level should be assessed until 7th day.

### Median Sternotomy (3%) Extension

Median sternotomy is often needed when parathyroid is in anterior mediastinum along with thymus. Often parathyroids may be 5, 6 or 7 in numbers instead of four.

### Video-assisted Parathyroidectomy (Paolo Miccoli)

It is done in *localised single adenoma* using multiple ports on one side with intermittent CO<sub>2</sub> insufflation and suction irrigation. 1.5 cm incision 1 cm above the sternal notch helps in tactile assessment and dissection. Strap muscles are retracted laterally and thyroid is retracted medially. Conversion rate is 11%; RLN palsy is 2%.

### Endoscopic Parathyroidectomy

Entire parathyroidectomy is done using laparoscopy. It is first used (1994) for a mediastinal parathyroid adenoma. In 1996, it was used for neck parathyroid hyperplasia by Gagner for removing 3½ glands. Now technique is *limited to single adenoma* to remove tumour and gland. Low pressure insufflations with 5 mm four trocars are used. Placement of trocars is dependent on the need of the operating surgeon. Many place trocars on one side only; but few prefer to place working trocars on opposite side.

### Remedial Parathyroidectomy

It is done for persistent HPT (serum calcium is not normalised immediately after surgery leading to total failure) or recurrent HPT (serum calcium after surgery becomes normal but in 6–12 months, it again increases). It is done through lateral approach (*Feind*) between anterior margin of sternocleidomastoid and strap muscles so that scar tissues are avoided from initial dissection. On table localisation methods, on table PTH assay are needed. Medial sternotomy often may be needed to explore the mediastinum for complete removal of the gland. Parathyroids in such situations may be embedded in the tissue of thyroid or thymus. So removal of these glands also may be a need in such situations.

### Subtotal Parathyroidectomy

It is indicated in hyperplasia or secondary HPT wherein 3½ glands are removed, retaining ½ of one gland.

### Total Parathyroidectomy with Parathyroid Autotransplantation

It is done alternatively in hyperplasia wherein all four glands are removed; ½ or ⅓ of one gland is transplanted into sternocleidomastoid or brachioradialis muscle with a marker. Disease control will not occur, if more part of the gland is transplanted. It is removing all four glands and ½ or ⅓ of one gland is autotransplanted into the forearm muscle (brachioradialis) or sternocleidomastoid muscle with marker stitch. Transplanting gland is sliced into 1 mm pieces and around 18 pieces are embedded in decided muscle with a marker stitch or clip. If postoperatively patient still presents with features of primary HPT; transplanted area is re-explored and further reduction in parathyroid tissue is done. Migration or inability to identify the transplanted parathyroid is often a problem in autotransplantation of parathyroid.

## ■ MEN SYNDROME (MEA SYNDROME)

- ◆ Commonly inherited as an *autosomal dominant*.
- ◆ Cells involved has got common features of *APUD cells* (*APUDomas*).

### Note:

- **APUD**—Amine Precursor Uptake Decarboxylation.
- **MEN**—Multiple Endocrine Neoplasia; **MEA**—Multiple Endocrine Adenomatosis.

## Types

- ◆ **Type—I:** Parathyroid hyperplasia or adenomas; pituitary tumour; pancreatic tumour [Endocrine—Insulinoma, gastrinoma, glucagonoma, vipoma]. It is also called as *Werner's syndrome*. Here the defect is in chromosome 11.
- ◆ **Type—II:** Also called as *Sipple's disease*.
  1. IIa includes medullary carcinoma of thyroid + pheochromocytoma + parathyroid hyperplasia (50%). Here the defect is in chromosome 10.
  2. IIb includes medullary carcinoma of thyroid + pheochromocytoma mucosal neuromas in lips and eyelids with bumpy-lumpy lesions, with marfanoid face, mega-colon.

**Evaluation and management of MEN syndrome:** Family history; biochemical screening with parathormone, serum calcium, prolactin, growth hormone, blood sugar, insulin, proinsulin, pancreatic polypeptide, glucagons, gastrin levels, calcitonin, urinary catecholamines estimation; genetic screening from isolated DNA from peripheral blood white cells for ret proto oncogene. Specific surgical treatment of conditions is needed.

## ■ APUDOMAS

*APUD* (Amine Precursor Uptake Decarboxylation) *cells* are cells having specific cytochemical characteristics. *They are:*

- ▶ High amine content.
- ▶ Capacity of amine precursor uptake.
- ▶ Property of decarboxylation of these precursors to form amines.
- ◆ Initially it is thought that APUD cells are derived from *neural crest cells* (Pearse) but now found to be from endoderm. Cells share *similarities* in structure, properties, histological, histochemical, immunocytochemical and electron microscopic appearance. *Neuron specific enolase* enzyme is specific for these cells.
- ◆ These cells have got capacity to *synthesize peptides* which has got different modes of action. They are:
  1. *Endocrine action* where peptides get secreted into circulation to have distant target actions.
  2. *Paracrine action* where peptides get secreted locally to have action at local sites.
  3. *Neurocrine action* where peptides act as neurotransmitter at neuronal synapses.
  4. *Neuroendocrine action* where peptides stimulate release of peptide product of the neuron into the circulation.

- ◆ Tumours arising from these cells are grouped as *Apudomas*. Many of parathyroid tumours, pancreatic tumours are under this group. Their presentations are commonly due to increased secretions of these neuroendocrine hormones. Commonly *presentation* is like syndromes. Insulinoma, glucagonoma, gastrinoma, VIPoma are different examples. Tumours are *entopic type*, if they secrete hormones normal to the tissue like insulinoma/glucagonoma. They are *ectopic type* if they produce hormones which are not normal to the tissue of origin like gastrinoma/VIPoma.
- ◆ APUDOMAS are commonly associated with *MEN syndrome* (commonly type I). Radioimmunoassay, MRI abdomen, CT neck are *useful investigations*.
- ◆ **Treatment** is of individual diagnosed components of the condition.

## ■ HYPOPARATHYROIDISM

- ◆ *Hypoparathyroidism* is defined as a PTH level < 10 pg/ml; normal values range between 10 and 65 pg/ml; was considered permanent when it lasted for more than 6 months.
- ◆ *Permanent hypoparathyroidism* would be defined as requirement of therapeutic vitamin D and/or calcium replacement at 6 months or fasting albumin-corrected serum calcium below 8.0 mg/dl.

## Types

<i>Temporary</i>	More common (2–50%) average 10%	Usually lasts for 2 months maximum up to 6 months. Decrease in calcium; increase in phosphorous
<i>Permanent</i>	Less common (0.4–13%) average 1%	Permanent— continues beyond 6 months. Decrease in calcium; increase in phosphorous
<i>Hungry bone syndrome</i>	Common (5–13%)	Severe, rapid begins in immediate postoperative period. Decrease in calcium; decrease in phosphorous

- ◆ Inadequate production of PTH leads to hypocalcemia. Hypoparathyroidism and the resulting hypocalcemia may be permanent or transient. The rate of permanent hypoparathyroidism is 0.4–13%.
- ◆ *Causes* are—direct trauma to the parathyroid glands, devascularization of the glands, or removal of the glands during surgery like-thyroidectomy and parathyroidectomy.
- ◆ The rate of *temporary hypocalcemia* is reportedly 2–50%. The cause of transient hypocalcemia after surgery is due to temporary hypoparathyroidism caused by reversible ischaemia to the parathyroid glands, hypothermia to the glands, or release of endothelin-1. Endothelin-1 is an acute-phase reactant which suppresses PTH production. Other hypothesis is—calcitonin release and hungry-bone syndrome. Calcitonin is produced by the thyroid C cells which inhibits bone breakdown while stimulating renal excretion of calcium (opposite of PTH).

- ◆ An effective method of evaluation of parathyroid function is to assess ionized calcium (or total calcium and albumin) levels in the perioperative period. A normal postoperative PTH level can accurately predict normocalcemia after thyroid surgery. Immediate postoperative PTH level if  $<1.5$  pmol/L and morning serum calcium  $<2.0$  mmol/L, then patient is at risk of hypocalcemia.

### Features of Hypoparathyroidism

- ◆ Circumoral tingling, numbness, paraesthesia.
- ◆ Carpopedal spasm, laryngeal stridor.
- ◆ Respiratory muscle spasm, suffocation.
- ◆ Convulsions, blurred vision due to intraocular muscle spasm.
- ◆ Cataract formation as late feature.

### Treatment

- ◆ Patients who have *symptomatic hypocalcemia* in the early postoperative period or whose calcium levels continue to fall rapidly need treatment. In symptomatic patients, intravenous calcium gluconate 10 ml 10% solution (1 gm) is administered over 10 minutes. A calcium infusion is started at a rate of 1–2 mg/kg/hr if symptoms do not resolve. Rate of infusion is decided by repeated analysis of serum calcium and clinical features.
- ◆ One to two grams of elemental oral calcium should be given each day. Calcium carbonate 1250 mg provides 500 mg of elemental calcium; the patient should take 2500–5000 mg/day.
- ◆ The patient needs vitamin D supplementation with calcitriol 0.25–1 mcg/day. The calcium supplementation should be divided 4–5 times per day rather than in a single dose to maximize absorption by the GI tract.
- ◆ Intravenous/intramuscular magnesium 0.5 gm/4 mEq/kg body weight for 5 days; later magnesium gluconate tablets 500 mg orally.
- ◆ In 2 months, trial weaning of oral calcium can be made to identify whether the hypoparathyroidism is temporary. Need for calcium supplementation longer than 6 months, indicates *permanent* hypoparathyroidism.

### Prevention of Hypoparathyroidism

- ◆ Proper preoperative parathyroid localisation.
- ◆ Maintaining blood supply of parathyroids.
- ◆ Capsular ligation of the thyroid vessels at lower pole to retain parathyroid end arteries.
- ◆ Parathyroid autotransplantation, if all 4 parathyroids are removed.

### Spurious Hypocalcemia

- ◆ It is decrease in total calcium, albumin and haematocrit in the first two postoperative days following any surgery including non-thyroid. Surgical stress releases ADH causing water retention and haemodilution. Albumin bound total calcium is decreased. Free ionized calcium is normal unlike in true hypocalcaemia.

### TETANY

Decreased level of calcium in blood causing its effects.

### Causes

- ◆ After thyroidectomy (It is decreased level of parathormone in the blood causing hypocalcaemia). It is usually temporary, lasts for 4–6 weeks. It is the commonest cause of hypoparathyroidism.
- ◆ Other causes of hypoparathyroidism are neck dissection, haemochromatosis, Wilson's disease, DiGeorge's syndrome.
- ◆ Severe vomiting, hyperventilation associated with respiratory alkalosis.
- ◆ Metabolic alkalosis.
- ◆ Rickets, osteomalacia.
- ◆ Chronic renal failure.
- ◆ Acute pancreatitis.

*Decreased PTH* causes decrease in calcium level in the blood leading to:

- ◆ *Circumoral paraesthesia*, paraesthesia of neck, fingers and toes.
- ◆ Twitching and weakness of tongue muscles, muscles of forearm, hand, foot and digits—*carpopedal spasm*. Fingers are extended except at the MCP joints and thumb is strongly adducted (obstetrician's/accoucheur's hand); there is extension of feet to develop carpopedal spasm.
- ◆ *Chvostek's sign*—Tapping above the angle of the jaw to stimulate branches of facial nerve causes the twitching of the angle of mouth and eyelids.
- ◆ Applying the sphygmomanometer to the arm and inflating the pressure more than systolic pressure (200 mm of Hg) of the patient for 3 minutes can demonstrate carpal spasm (*Trousseau's sign*).
- ◆ *Stridor* and difficulty in breathing due to paralysis of respiratory muscles.
- ◆ Generalised weakness and twitching all over the body in severe cases mimicking *convulsions*.
- ◆ Prolonged QT interval and QRS complex in ECG.

### Management

- ◆ Serum calcium estimation is done. It will be less than 7 mg%.
- ◆ IV calcium gluconate 10% 10 ml 6th–8th hourly is given.
- ◆ Later oral calcium (1 gram three times daily) with vitamin D supplementation (1–3 µg daily).
- ◆ Follow up at regular intervals by doing serum calcium level.
- ◆ Magnesium sulphate supportive therapy is also often needed—10 ml 10% magnesium sulphate intravenously.

#### DiGeorge's syndrome

- ❖ Absence parathyroids
- ❖ Thymic aplasia with immunodeficiency
- ❖ Cardiac defects

## ADRENALS

*The facts which Addison has published seem to lead to the conclusion that these little organs are essential to life.*

—Charles Edouard Brown-Séquard, 1856

Adrenal cortex contains three layers:

1. Zona glomerulosa secretes mineralocorticoids.
2. Zona fasciculata secretes glucocorticoids.
3. Zona reticularis secretes sex hormones.
  - ▶ Cortex—85%; mesoderm; produces and secretes aldosterone, cortisol, DHEA.
  - ▶ Medulla—15%; neuroectoderm; produces and secretes norepinephrine, epinephrine.

### Note:

- Adrenal gland is essential for life.
- It is the only gland which is fully developed at birth.
- Each gland weighs about 5 g.

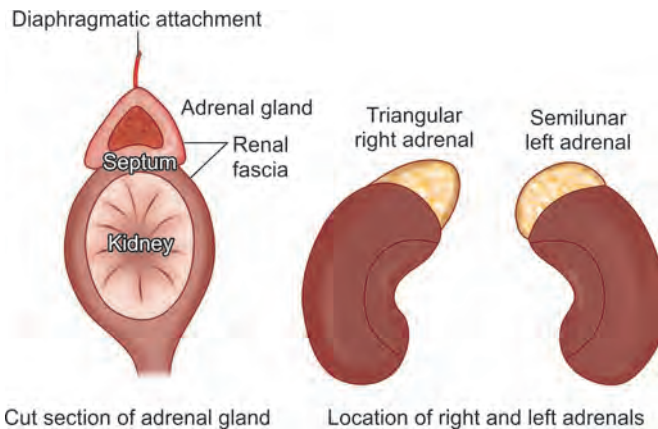


Fig. 7.5: Anatomy of adrenal gland.

## ADRENAL CORTICAL TUMOURS

- ◆ Are usually adenomas.
- ◆ Any tumour measuring 6 cm or more are likely to be malignant, or have high risk of turning into malignancy. So requires surgical resection.
- ◆ *Adenocarcinoma* is the commonest adrenal cortical malignancy (1%). It is very aggressive tumour.
- ◆ Cortical tumours may be functioning or nonfunctioning.
- ◆ Functioning tumours secrete mineralocorticoids, glucocorticoids or sex hormones or combinations of these.
- ◆ **Investigations:**
  - ▶ Ultrasound abdomen.
  - ▶ CT scan, hormone evaluation.
- ◆ **Treatment:**
  - ▶ *Adrenalectomy*.

## Incidentalomas (3–5%)

- ◆ Incidentalomas are adrenal tumours incidentally identified either through U/S; CT scan; MRI; or any other methods done for other reasons.
- ◆ Whether incidentaloma is hormonally active; whether it is potentially malignant has to be assessed.

- ◆ When incidentalomas are identified a proper biochemical work up for hormones is essential. Overnight dexamethasone suppression test; 24-hour urinary cortisol excretion assay; 24-hour urinary excretion of catecholamines; serum potassium, renin and aldosterone analysis are done in these patients. MRI in suspected malignancy is better.
- ◆ If secondaries are suspected adrenal mass biopsy is done. Otherwise it should not be done. Non-functioning adenomas (commonest—78%), Cushing's adenoma, adrenocortical carcinoma, pheochromocytoma, secondaries, Conn's adenoma are different causes of adrenal incidentalomas. Adenoma with Cushing's syndrome is better than adenoma with Conn's syndrome. Tumour with adrenogenital syndrome is commonly malignant.
- ◆ Non-functioning adrenal tumour more than 4 cm should be operated. Smaller tumours that increase in size over specified period should be removed. All functioning tumours should be operated.
- ◆ Non-functioning tumour less than 4 cm should be followed up at regular intervals by hormone tests and CT/MRI.

## ADRENOCORTICAL CARCINOMA

- ◆ It is a rare malignancy with 1 case in 1000000 population. It is common in females with bimodal presentation.
- ◆ **Features are**—tumour size; necrosis; haemorrhage; capsular invasion; vascular invasion. Immunohistochemistry is specific.
- ◆ **Presentations are**—abdominal pain; back pain; Cushing's syndrome (60%); hyperaldosteronism; virilisation.
- ◆ It is *least common* malignant endocrine tumour.
- ◆ One of the *most malignant* endocrine tumour after anaplastic carcinoma of the thyroid.
- ◆ Can be functioning or nonfunctioning tumour.
- ◆ Larger tumours (>6 cm), >100 g weight are more likely to be malignant.
- ◆ Cytologic criteria alone are not diagnostic but should find capsular infiltration and vascular invasion.
- ◆ Often presents with no symptoms or only vague symptoms.
- ◆ May present with mass effect and compression of adjacent structures.
- ◆ Increased secretion of one or more steroid hormones can occur.
- ◆ **Diagnosis is by** hormone evaluation, CT/MRI; MR angiography to identify IVC tumour thrombus.
- ◆ Secondaries occur commonly in lungs. So HRCT of lungs is usually done.
- ◆ **McFalane staging:** Stage I—tumour <5 cm; Stage II—tumour >5 cm; Stage III—tumour with local invasion; Stage IV—distant spread. In stage I and II, 5 year survival is 25%; in stage III and IV, 5-year survival is 5%.
- ◆ **Treatment** is en block adrenalectomy; adjacent organs like kidney, spleen may be removed if needed; removal of tumour thrombus from vena cava if present; chemotherapy using mitotane—Op-DDD (choice) with cis platin, etoposide and doxorubicin. Adjuvant radiotherapy may be used to prevent recurrence (*little role*).
  - ▶ *Recurrence* is treated by debulking and chemotherapy.
  - ▶ Laparoscopic adrenalectomy is not advisable in adrenocortical carcinoma.
- ◆ **Prognostic factors**—tumour size > 12 cm; high mitotic activity > 6 mitoses/ high power field; intratumour haemorrhage.

### Secondaries in adrenal gland

- ❖ Common entity
- ❖ Commonly from breast, lungs, kidney, melanoma
- ❖ 1/3rd of above primaries show secondaries in adrenal gland
- ❖ Commonly bilateral
- ❖ In unilateral secondaries, adrenalectomy can be done
- ❖ Bilateral secondaries are treated by chemotherapy depending on type of primary

### Approches for adrenals (surgical)

- ❖ Posterior lumbotomy
- ❖ Anterior transabdominal
- ❖ Abdominothoracic
- ❖ Laparoscopic
- ❖ Retroperitoneoscopic

## CUSHING'S SYNDROME

- ◆ Results from lengthy and inappropriate exposure to excessive glucocorticoids; iatrogenic administration of steroids (commonest cause); endogenous Cushing can also occur.
- ◆ More common in women.

### Corticotropin (ACTH) Dependent—80%

- ◆ ACTH secreting pituitary adenoma.
- ◆ Ectopic ACTH secreting tumour.

### Corticotrophin Independent—20%

- ◆ Adenoma.
- ◆ Carcinoma.
- ◆ Macronodular adrenal hyperplasia.
- ◆ Primary pigmented nodular adrenal disease.

### Features

- ◆ Centripetal obesity; redistribution of fat centrally.
- ◆ Moonface; fullness of supraclavicular pad of fat.
- ◆ Buffalo hump; proximal muscle wasting.
- ◆ "Lemon on toothstick appearance".
- ◆ Skin changes.

### Diagnosis

- ◆ Loss of normal diurnal or circadian rhythm of serum cortisol. Values more than 4 fold the upper limit of normal is diagnostic.
- ◆ 24 hour urinary free cortisol is elevated > 90% of Cushing's syndrome.
- ◆ *Low dose dexamethasone suppression test*: Dexamethasone is a potent glucocorticoid that suppresses adrenal production of corticosteroids in normal persons but not in persons with Cushing's syndrome. 1 mg of dexamethasone is injected; normal—<1.8 mcg/dl; in Cushings—high >10 mcg/dl.
- ◆ *Late night salivary cortisol*—Cortisol concentration in saliva correlates with free plasma cortisol; it is independent of salivary flow rate; it shows high sensitivity and specificity.

- ◆ Negative urinary free cortisol and Low dose dexamethasone suppression test rules out Cushing's syndrome.
- ◆ *Measurement of corticotropin (ACTH)*: If low—corticotropin independent Cushing's syndrome; if high—corticotropin dependent Cushing's disease.
- ◆ *Localising methods/imaging*: **Adrenal**—CT scan/MRI abdomen; Iodocholesterol scan. **Pituitary**—MRI pituitary. It can be incidentaloma in pituitary. Inferior petrosal sinus sampling of blood for ACTH shows central to peripheral ratio of ACTH >3.

## Treatment

### Medical

Metapyrone; ketaconazole; aminoglutethamide; mitotane.

### Surgical

#### For pituitary disease

- ◆ Trans-sphenoidal microsurgery.
- ◆ Pituitary irradiation—conventional fractionated therapy; Stereotactic radiosurgery.
- ◆ Bilateral adrenalectomy.

#### For adrenal disease

- ◆ Unilateral adrenalectomy in adenoma, carcinoma.
- ◆ Bilateral adrenalectomy in macronodular adrenal hyperplasia and primary pigmented nodular adrenal disease.

## CONN'S SYNDROME (Jerome Conn, 1954)

It is primary hyperaldosteronism with excessive secretion of aldosterone from the adrenal gland associated with suppression of plasma renin activity.

Aldosterone secretion is related to angiotensin I and II and plasma rennin with angiotensin converting enzyme.

### Causes

- ◆ Aldosterone producing adrenocortical adenoma (Aldosteronoma)—65%;
- ◆ Idiopathic hyperaldosteronism—30%.

### Features

- ◆ *Hypertension; hypokalaemia.*
- ◆ Hypernatremia or normal sodium; metabolic alkalosis
- ◆ In primary hyperaldosteronism—hypertension of early onset which is difficult to control and is with hypokalaemia.

### Diagnosis

- ◆ *Hypokalemia*; increase in urinary potassium excretion.
- ◆ *Elevated plasma aldosterone concentration (PAC); suppressed plasma renin activity (PRA)*; PAC: PRA > 30; it is confirmed by suppression test by oral or IV salt loading.
- ◆ *Localising tests*—CECT abdomen; Selective adrenal venous sampling—*Gold standard* to differentiate between unilateral versus bilateral aldosterone hypersecretion.

## Treatment

- ◆ Adenoma—unilateral adrenalectomy.
- ◆ Idiopathic hyperaldosteronism—medical treatment with spirinolactone.

## VIRILISING SYNDROME OR ADRENOGENITAL SYNDROME

- ◆ Virilising tumours/syndromes. Such tumours are excised.
  - ▶ *In female*: Virilism, ambiguous external genitalia, clitoral enlargement.
  - ▶ *In male*: Precocious puberty, premature fusion of epiphysis, short stature.
- ◆ Congenital adrenal hyperplasia (adrenogenital syndrome) is—enzyme 21 hydroxylase deficiency; autosomal recessive. It is treated by—replacement of deficient steroids. Adrenal hyperplasia does not require surgical intervention but the genital manifestations of excess androgen production, particularly in women, may require specialised surgery.

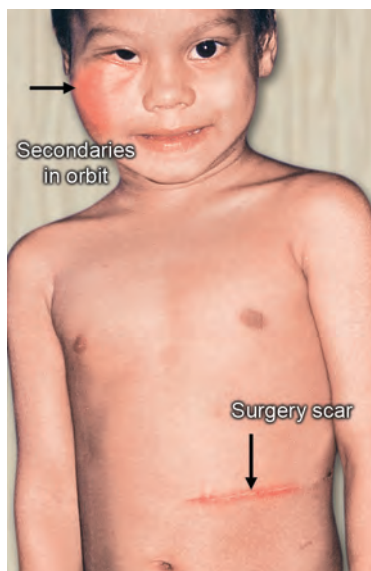## NEUROBLASTOMA

- ◆ *Commonest childhood abdominal tumour.*
- ◆ It is a tumour of adrenal medulla.
- ◆ An aggressive malignant tumour in childhood usually below the age of 5 years.
- ◆ Incidence is equal in both sexes.
- ◆ A reddish-grey tumour gets invaded early into kidney, pancreas and adjacent tissues. It can also cause distant spread to liver, bones (skull), orbit.

It can occur anywhere in sympathetic chain but common in adrenal gland (40%).

## Types

1. *Pepper type* is right side adrenal neuroblastoma with liver secondaries. Common in infants.



**Fig. 7.6:** Left-sided adrenal neuroblastoma with secondaries in orbit. Note scar of left-sided adrenalectomy.

2. *Hutchinson's type* is left side adrenal neuroblastoma with secondaries in orbit and skull. Common in late childhood. Secondaries in the skull mimics spicular osteogenic sarcomas.

## Risk Groups

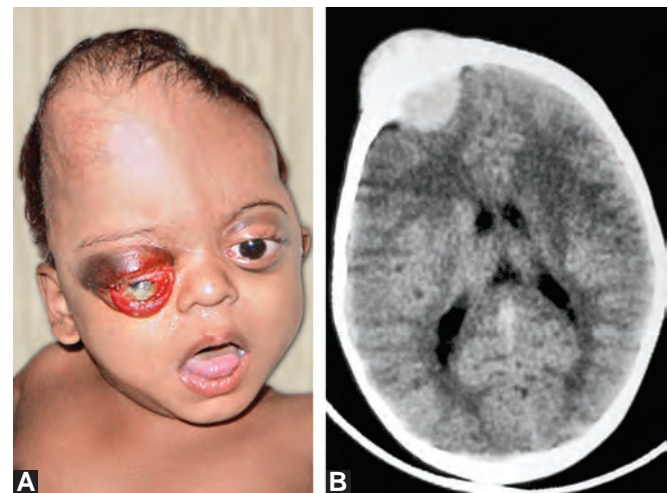
- ◆ Low risk groups—Stage I disease; Stage II disease with single N myc value; Stage II with favourable Shimada histology.
- ◆ Intermediate risk groups—Stage III without N myc amplification; Stage III with favourable Shimada's histology.
- ◆ High-risk groups—all patients with N myc amplification; stage IV neuroblastoma.

## Pathology

- ◆ *Gross*—tumour with vascularity, necrosis, haemorrhage and often calcifications.
- ◆ *Histologically* it contains uniform round cells with hyperchromatic speckled nucleus with *Homer-Wright rosettes* with central fibrillar core. PAS stain is negative and NSE stain is positive. Often histochemistry is needed to differentiate from other tumours.
- ◆ *Shimada's histological classification*:
  - ▶ *Stroma rich tumour*: Presence of Schwannian spindle cell stroma.
  - ▶ *Stroma poor tumour*: Absence of Schwannian spindle cell stroma.

## Clinical Features

- ◆ Child presents as a huge mass per abdomen, in the loin which is non-mobile. Not moving with respiration. Knobby (nodular) surface, crosses the midline.
- ◆ *Dancing eye syndrome* and *opsomyoclonus*.
- ◆ *Raccoon's eye sign* is infraorbital ecchymosis due to secondaries in retroorbital region.



**Figs 7.7A and B:** Typical secondaries in skull and orbit with primary in adrenal gland. Such patients carry poor prognosis. *Raccoon's eye sign* is infraorbital ecchymosis due to secondaries in retro-orbital region. *Dancing eye syndrome* and *opsomyoclonus* are other eye features. CT picture of the same patient shows obvious secondaries.

*There is no service than doing something for someone who will never find it out!*



- ◆ Hypertension, fever, weight loss, anaemia, flushing (due to catecholamine release) and sweating.
- ◆ Diarrhoea, hypokalaemia due to release of Vasoactive Intestinal Polypeptide (VIP). Other hormones like ACTH are also released.

#### Staging of neuroblastoma

- ❖ *Stage I*: Localised tumour with gross complete excision. Same side representative nodes are negative on microscopy
- ❖ *Stage II A*: Localised tumour with incomplete gross excision. Same side representative nodes are negative on microscopy
- ❖ *Stage II B*: Localised tumour with or without complete gross excision. Same side nonadherent representative nodes are positive but contralateral nodes are (may be enlarged) negative on microscopy
- ❖ *Stage III*: Unresectable unilateral tumour infiltrating across midline/localised tumour with opposite side node spread/bilateral nodal spread/midline tumour with bilateral infiltration
- ❖ *Stage IV*: Any primary tumour with spread to distant nodes, bone, bone marrow, liver, skin and other organs
- ❖ *Stage IV S*: Localised primary tumour (stage I, IIA, IIB) with spread to skin, liver or bone marrow—limited to infants younger than one year

### Differential Diagnosis

*Wilm's tumour*, which is mobile, with smooth surface, moves with respiration, does not cross the midline.

### Diagnosis

- ◆ Ultrasound, CT to assess the mass and secondaries in liver. MRI is better than CT.
- ◆ Plain X-ray abdomen shows stippled calcification.
- ◆ Urinary VMA and Homovanillic acid (HVA) estimation in 90% cases.
- ◆ MIBG scan.
- ◆ Bone marrow biopsy may be positive in 60% cases. Iliac bone both sides under GA.
- ◆ PET scan is done if MIBG is not beneficial.

### Treatment

- ◆ Adrenalectomy (Complete surgical excision).
- ◆ In inoperable cases, debulking is beneficial.
- ◆ Postsurgical radiotherapy and folic acid supplements are useful.
- ◆ Chemotherapy is useful adjuvant. Drugs used are carboplatin, doxorubicin, cyclophosphamide and etoposide.
- ◆ Rarely spontaneous regression of tumour is known to occur.
- ◆ Low risk groups are treated by surgery. Intermediate risk groups are treated by surgery and multidrug chemotherapy. High risk groups are treated by high dose multidrug chemotherapy and later surgery.
- ◆ Other treatment modalities—retinoids (fenretinide), immunotherapy (G<sub>D2</sub>), radionuclide targeted therapy, angiogenesis/tyrosine kinase/aurora kinase inhibitors are on trial. Bone marrow or stem cell transplantation are newer methods used.

### Prognosis

- ◆ It depends on staging of the neuroblastoma—1, 2A, 2B, 3, 4, 4S.
- ◆ Low risk has got 3 years survival—90%; intermediate risk—70% and high risk group has got 30%.

- ◆ Factors are—age of the child; stage of the disease; Shimada's histology; N myc amplification status (more means high risk); DNA ploidy; neurotrophin receptor Trk A (increased favourable); neurotrophin receptor Trk B (increased unfavourable).

## PHAEOCHROMOCYTOMA

- ◆ It is a tumour arising from chromaffin cells, commonly from the adrenal medulla but occasionally can arise from extraadrenal chromaffin tissues (*Organ of Zuckerkandl*). The *organ of Zuckerkandl* (Emil Zuckerkandl, Professor of Anatomy, Vienna, 1901) comprises a mass of chromaffin cells derived from neural crest located along the aorta beginning above cranial to the superior mesenteric artery or renal arteries and extending below to the level of the aortic bifurcation; highest concentration is seen at the origin of inferior mesenteric artery.
- ◆ It is catecholamine secreting tumours that arise from chromaffin cells of sympathetic origin derived from neural crest representing a potentially curable form of hypertension.
- ◆ *Incidence* is 0.005–0.1% of general population; 0.1–0.2% of adult hypertensive population.
- ◆ It is a soft, brownish grey pink tumour, mainly *secretes noradrenaline* or other catecholamines.
- ◆ It may also secrete calcitonin, ACTH, VIP (vasoactive intestinal polypeptide), PTH-related polypeptide.
- ◆ Prevalence of phaeochromocytoma is 0.05%. In patients with hypertension it is up to 0.6%. 4% of incidentalomas are phaeochromocytoma.
- ◆ Often it is difficult to differentiate between benign and malignant types. Necrosis, haemorrhage, high Ki-67 positive cells, size of the tumour, increased phaeochromocytoma of adrenal gland scale score (PASS), capsular invasion and vascular invasion, nuclear DNA ploidy and increased neuron specific enolase (NSE) level are possible features of malignant phaeochromocytoma.
- ◆ Currently mutations in at least six distinct genes predispose to phaeochromocytomas—RET, NF1, VHL, SDHB, SDHC, SDHD.
- ◆ Extra-adrenal pheochromocytoma—10% common; occurs in organ of *Zuckerkandl*, urinary bladder, paravertebral or para-aortic area, thorax, neck. It secretes norepinephrine rather than epinephrine because they lack the enzyme PNMT.
- ◆ Commonly benign (90%).

#### Tumour is:

- ❖ 10% malignant
- ❖ 10% extra-adrenal
- ❖ 10% bilateral
- ❖ 10% familial
- ❖ 10% childhood
- ❖ 10% multiple
- ❖ 10% not associated with hypertension
- ❖ 10% calcified

### Clinical Features

- ◆ Clinical manifestations are due to increased secretion of epinephrine and norepinephrine.

- ◆ Commonest presentation is severe *headache*.
- ◆ Palpitation, dyspnoea, weakness, pallor, blurred vision and other symptoms of sympathetic overactivity.
- ◆ They may present as persistent or paroxysmal hypertension (90%).
- ◆ As an abdominal mass which is nonmobile, smooth, does not move with respiration, crossing the midline, palpation may cause fluctuation in BP.
- ◆ It may precipitate hypertensive encephalopathy, cardiac arrhythmias or cerebral haemorrhage.
- ◆ Panic attacks and sudden death are known to occur.
- ◆ It may be associated with *MEN-IIa* or *MEN-IIb* syndromes which includes medullary carcinoma of thyroid and mucosal neuromas.
- ◆ It may be associated with familial multiple neurofibromatosis with cafe au lait spots in the skin (*von Recklinghausen's disease*). Or with *von Hippel-Lindau syndrome* (cystic lesion of pancreas, non-functioning islet cell tumour, pheochromocytoma), RCC, CNS and retinal haemangioblastoma.
- ◆ *Familial paraganglioma syndrome* may be an association with carotid body and extra-adrenal paraganglioma.

#### Differential diagnosis

- ❖ Hyperthyroidism
- ❖ Anxiety status
- ❖ Cardiac conditions
- ❖ Carcinoids (functioning)

### Investigations

- ◆ *VMA excretion* in urine in 24 hours will be >7 mg/24 hr in pheochromocytoma.
- ◆ U/S abdomen, IVU, CT scan.
- ◆ MRI is preferred to CT as contrast used for CT scan can precipitate paroxysms.
- ◆ Measurement of *plasma-free metanephrines* is the recommended *test of choice* for excluding or confirming diagnosis of pheochromocytoma.
- ◆ *Urinary normetadrenaline* or other catecholamines estimation.
- ◆ Arteriography.
- ◆ Iodine labelled metaiodo-benzylguanidine (*I, MIBG*). MIBG is useful to find out extra-adrenal involvement—SPECT scan is very useful.  $I^{131}$  MIBG scan is safe, noninvasive with 100% sensitivity and 95% specificity.
- ◆ Measurement of plasma free metanephrine and normetanephrine has the *highest sensitivity and specificity* and appears to be the *best initial test* for screening patients with pheochromocytoma.

### Treatment

#### Adrenalectomy

- ◆ Before surgery, BP is controlled initially by  $\alpha$ -blocking agent, phenoxybenzamine or doxazosin; then by  $\beta$ -blocking agent,

propranolol. Then during surgery, sodium nitroprusside IV infusion is used.

- ◆ *Adequate fluid therapy* to have volume expansion is essential.
- ◆ Careful anaesthetic management with a good postoperative care is very essential. In case of bilateral presentation, opposite side can be operated in later period.
- ◆ Intraoperative hypovolemia and postoperative hypotension is a demanding situation for anaesthetist to manage.
- ◆ Handling of adrenal tumour on table must be careful and gentle.
- ◆ Adrenal vein should be ligated first. CVP, arterial lines should be present for monitoring.
- ◆ Rupture and spillage of tumour should be prevented.

#### Note:

- *Laparoscopic adrenalectomy is becoming popular*. It is choice of approach for benign functioning or non-functioning adrenal tumours that are less than 6 cm in size. It is contraindicated in malignant tumours and tumour more than 6 cm.
- *Recent trends are*—cortical sparing adrenalectomy; thoracoscopic transdiaphragmatic approach; Robotic-assisted laparoscopic adrenalectomy.
- Specimen should be sent for *bichromate staining which stains the specimen brown*.
- *Metyrosine* is indicated in pheochromocytoma who are awaiting for surgery or when surgery is contraindicated or in refractory to phenoxybenzamine therapy. Metyrosine inhibits tyrosine hydroxylase thus reducing the catecholamine biosynthesis.

#### Remember

- ❖ Pheochromocytoma is rarely malignant in MEN II
- ❖ Pheochromocytoma under 40 years of age suspect MEN 2A, VHL
- ❖ Beta-blocker is given only after patient is fully alpha blocked with phenoxybenzamine (20–60 mg/day) or doxazosin
- ❖ Alpha-blocker is given 4 weeks prior to surgery to control hypertension and beta-blocker is given one week before surgery to control tachycardia and arrhythmias
- ❖ Tumours, those secrete dopamine exclusively has got high malignant chances
- ❖ 5-year survival for malignant pheochromocytoma is 50%. It needs additional chemotherapy using vincristine, dacarbazine and cyclophosphamide.
- ❖ Pheochromocytoma in pregnancy has got 50% maternal mortality
- ❖ Vaginal delivery is contraindicated in pregnancy with pheochromocytoma
- ❖ Adrenal vein should be ligated first
- ❖ Avoid breach in the capsule of tumour during surgery
- ❖ Careful handling and haemodynamic monitoring is a must
- ❖ Sodium nitroprusside may be required on table to control the hypertension—10  $\mu$ g/kg/minute

*Malignant pheochromocytoma* is 10% common. It is more common in extra-adrenal site. It commonly spreads to lymph nodes, bone and liver. Adrenalectomy in early tumour and debulking in advanced cases with  $\alpha$ -blockers, mitotane and  $I^{131}$ MIBG therapy and combination chemotherapy are the therapeutic choices. Overall prognosis is not good with 5-year survival being <50%.

*One only gets to the top rung of the ladder by steadily climbing up one at a time.*

# Chapter 8

## Breast

### CHAPTER OUTLINE

- ❖ Anatomy
- ❖ Mastitis
- ❖ TNM Staging of Carcinoma Breast
- ❖ Mammography
- ❖ Antibiooma
- ❖ Management of Early Carcinoma Breast
- ❖ Aberration of Normal Development and Involution (ANDI) of the Breast
- ❖ Duct Ectasia
- ❖ Advanced Carcinoma Breast
- ❖ Fibroadenoma
- ❖ Mondor's Disease
- ❖ Prognostic Factors in Carcinoma Breast
- ❖ Fibrocystadenosis
- ❖ Tuberculosis of the Breast
- ❖ Prophylactic Mastectomy
- ❖ Sclerosing Adenosis
- ❖ Breast Cysts
- ❖ Carcinoma of Male Breast
- ❖ Phylloides Tumour
- ❖ Galactorrhoea
- ❖ Breast Reconstruction
- ❖ Mastalgia
- ❖ Gynaecomastia
- ❖ Breast Implants
- ❖ Traumatic Fat Necrosis
- ❖ Duct Papilloma
- ❖ Nipple Retraction
- ❖ Galactocele
- ❖ Zuska-Atkins Disease
- ❖ Mammary Fistula of Atkins
- ❖ Carcinoma Breast

### ANATOMY

Breast is a modified sweat gland derived from ectoderm, as branching epithelial cords which form lactiferous ducts. About 15–20 lobes develop during puberty, each of which drains into a single lactiferous duct. True secretory alveoli develop during pregnancy and lactation under the influence of oestrogen, progesterone and prolactin.

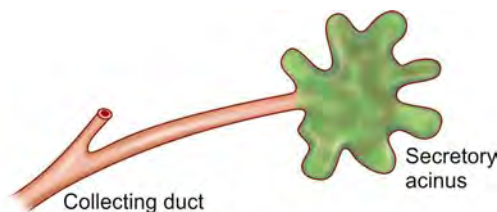


Fig. 8.1: Secretory apparatus of the breast.

### Secretory Apparatus of Breast

The breast is composed of acini which make up lobules, aggregation of which form the lobes of the gland. The lobes are arranged in a

radiating fashion like the spoke of a wheel and converge on the nipple, each lobe is drained by a lactiferous duct.

Different portions of the duct system are associated with different diseases.

1. Larger ducts are sites of *duct papilloma* and *duct ectasia*.
2. The distal smaller ducts are the sites of *fibroadenoma* during development of the breast; and *cyst formation* and *sclerosing adenosis* during the involution period.

- ❖ *Estrogen*—ductal proliferation
- ❖ *Progesterone*—glandular proliferation
- ❖ *Prolactin*—milk secretion

### Topography

*Vertically*—it extends from the second to the sixth rib in the mid-clavicular line and lies over pectoralis major, serratus anterior and external oblique muscles.

*Horizontally*—from the side of sternum to the mid-axillary line.

2/3rd of the breast rests upon pectoralis major.

1/3rd rest upon serratus anterior.

At its lower medial quadrant the gland rests on the external oblique aponeurosis, which separates it from the rectus abdominis.

Breast lies in superficial fascia. Deep to breast, structures related are—retromammary space containing loose areolar tissue, pectoral deep fascia, muscles (pectoralis major, serratus anterior, external oblique), chest wall.

*Retromammary bursa/space* is located between deep layer of superficial fascia and pectoral (deep) fascia allowing free mobility of breast.

*Nipple* is located at the level of 4th intercostal space just below the centre/summit of the breast. It contains circular and longitudinal muscles to make nipple stiff or flat. It is pierced by 15–20 lactiferous ducts. Each duct independently opens into the nipple. It has rich sensory nerve endings. It also contains modified sweat and sebaceous glands. Nipple is supplied by 4th intercostal nerve.

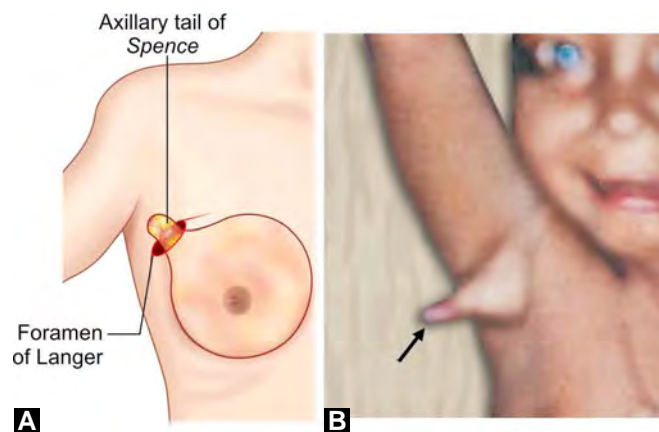
*Areola* is circular pigmented area around the nipple. It is rich in modified sebaceous glands which enlarge during pregnancy and lactation as *Montgomery tubercles*. They secrete oily lubricant to nipple and areola. Areola and nipple do not contain hair and fat beneath.

*Breast parenchyma* contains 15–20 lobes. Each lobe contains alveoli, lactiferous sinus and lactiferous duct (2–4 mm in diameter). Alveolus is lined by cuboidal (in rest) and columnar (in lactation) epithelium; smaller duct is by single layer of columnar epithelium; larger ducts by many layered columnar; lactiferous duct is by stratified squamous epithelium. *Myoepithelial cells* lie between epithelium and basement membrane from alveoli to duct.

### Axillary Tail of Spence

This is a prolongation from the outer part of the gland which passes up to the level of the 3rd rib in the axilla through a defect in the deep fascia (*Foramen of Langer*) where it is in direct contact with the main lymph node of the breasts (anterior axillary nodes).

This process of the breast gets into axilla through an opening in the deep fascia, known as *foramen of Langer*. When it enlarges it is often mistaken for a lipoma. Axillary tail of *Spence* is deep to deep fascia.

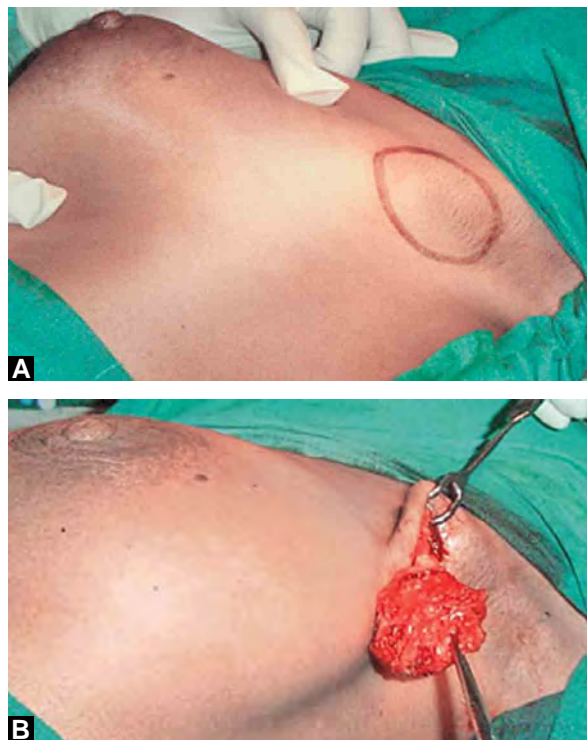


**Figs 8.2A and B:** (A) Axillary tail of *Spence*; (B) Hypertrophy of the axillary tail.

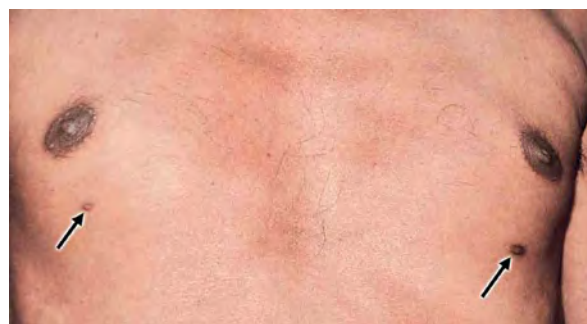### Ligament of Cooper

The breast is anchored to the overlying skin and to the underlying pectoral fascia by bands of connective tissue called *ligament of Cooper*:

1. In cancer, the malignant cells may invade these ligaments and consequent contraction of these strands may cause dimpling of the skin or attachment of the growth to the skin, which in turn cannot be pinched off from the lump.
2. If the cancer grows along the ligament of Cooper binding the breast to the pectoral fascia, the breast gets fixed to the pectoralis major. It then cannot be moved along the long axis of the muscle.



**Figs 8.3A and B:** Axillary tail of *Spence*—exact location and excision of hypertrophied axillary tail.



**Fig. 8.4:** Accessory nipple is not an uncommon condition. Often it can be bilateral.

### Polands syndrome

- ❖ Absence of breast—Amazia
- ❖ Absence of sternal portion of pectoralis major
- ❖ Common in males

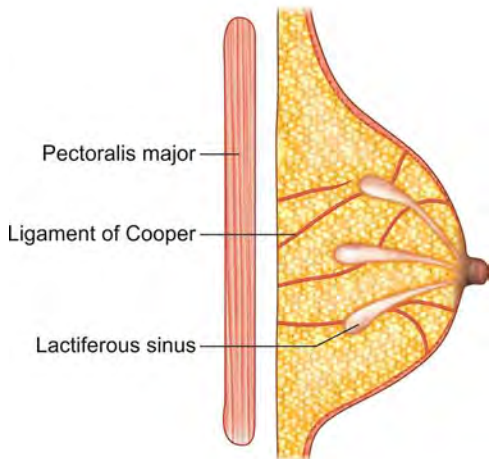


Fig. 8.5: Anatomy of the breast.

#### Note:

- *Amazia* is very rare entity with congenital absence of breast.
- *Polymazia* is accessory breasts along milk line like in axilla (most common site), groin, thigh and buttock.
- *Athelia* is absence of nipple; accessory nipples are called as *polythelia* or supernumerary nipples.
- *Micromastia* is small sized breast due to less hormonal stimulation due to ovarian deficiency.

### Blood Supply to the Breast

- ◆ The lateral thoracic artery, from the 2nd part of the axillary artery—30%.
- ◆ The perforating cutaneous branches of internal mammary artery to the 2nd, 3rd and 4th intercostal spaces—60%.
- ◆ The lateral branch of the 2nd, 3rd and 4th intercostal arteries.
- ◆ Pectoral branches of acromiothoracic artery.
- ◆ Superior thoracic artery.

### Venous Drainage

- ◆ The superficial veins from the breast characterised by their proximity to the skin drain to the axillary, internal mammary, and intercostal vessels.
- ◆ Phlebitis of one of these superficial veins feel like a cord immediately beneath the skin—'*Mondor's disease*'.
- ◆ Through posterior intercostal veins, venous drainage communicates with paravertebral venous plexus (*Batson's venous plexus*). So secondaries in vertebrae, is common in carcinoma of breast.

### Nerves-related (During MRM)

- ◆ Long thoracic nerve—*Bell* supplies serratus anterior.
- ◆ Thoracodorsal nerve supplies latissimus dorsi.
- ◆ Medial pectoral nerve (from medial cord of brachial plexus) which lies *lateral*, runs and winds from lateral margin of pectoralis minor.
- ◆ Lateral pectoral nerve arises from lateral cord passes through the

pectori either middle or medial part.

- ◆ Intercostobrachial nerve is communicating nerve between lateral cutaneous branch of 2nd intercostal nerve and medial cutaneous nerve of arm; denervation of this nerve causes sensory loss of skin over upper medial and inner aspect of the arm, apex and lateral axilla.

**Nerve supply of breast** is by anterior and lateral cutaneous branches of 4th to 6th intercostal nerves.

**Milk secretion** is brought by prolactin hormone from anterior pituitary—not by nerves.

### Lymphatic Drainage of the Breast

Commonly into the axillary lymph nodes (25–35 nodes)—75%.

1. Anterior group (pectoral, external mammary)—along lateral thoracic vessels. Main drainage node.
2. Central group—next common node. It is the node most easily properly clinically palpable in axilla.
3. Posterior group (subscapular)—rare to involve in carcinoma.
4. Lateral group—along axillary vein; rare to involve in carcinoma.
5. Interpectoral node (*Rotter's node*)—signifies the retrograde spread of tumour. It lies between pectoralis major and minor.
6. Apical. They are 4–6 nodes, also called as subclavicular or *Halsted nodes*. It lies most superior and deep to pectoralis minor medial to axillary vessels.

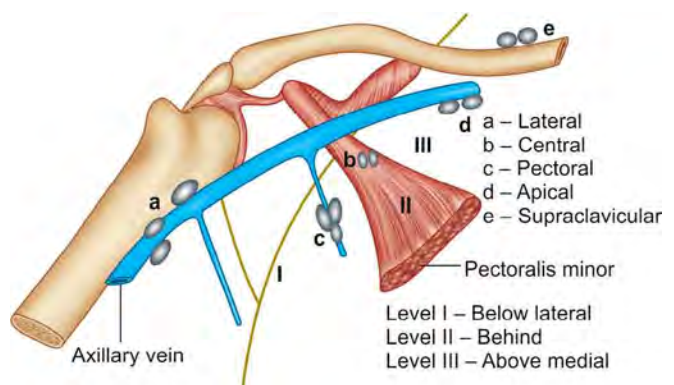


Fig. 8.6: Surgical levels of lymph nodes in the axilla draining the breast.

- ▶ Later they drain into supraclavicular lymph nodes.
- ▶ 25% drains mainly from medial half of the breast into 2nd, 3rd and 4th intercostal space internal mammary lymph nodes. *Internal mammary nodes* are located in retrosternal intercostal spaces 1–2 cm lateral to the sternal margin (usually in 2nd, 3rd, and 4th spaces in parasternal area—3–4 internal mammary nodes); it is vertically placed parallel to internal mammary vessels in relation to endothoracic fascia; its efferent ends in subclavicular nodes.
- ▶ Drainage into contralateral axilla and opposite lymph nodes also occur.
- ▶ The concept of Sappey's subareolar drainage of lymph centripetally is not well accepted now.
- ▶ *Axillary reverse mapping (ARM)*: Here blue dye is injected into upper part of inner aspect of the arm to achieve a mapping of axillary lymphatic drainage.
- ▶ Sentinel node concept is well accepted in carcinoma breast management.
- ▶ Posterior and lateral groups are rarely involved in carcinoma breast and is by retrograde spread.

### Levels of the axillary nodes (Berg's levels)

- ❖ **Level I:** Below and lateral to the pectoralis minor muscle— anterior, lateral, posterior
- ❖ **Level II:** Behind the pectoralis minor muscle—central, inter-pectoral
- ❖ **Level III:** Above and medial to pectoralis minor muscle— apical or infraclavicular

### Note in carcinoma breast

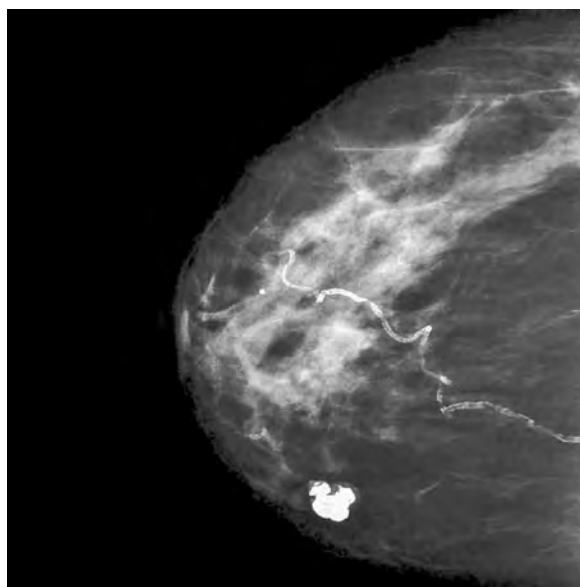
- ❖ Spread restricted to level I nodes carries better prognosis
- ❖ Spread to level II has poor prognosis
- ❖ Spread to level III indicates worst prognosis

## MAMMOGRAPHY

It is a plain X-ray of soft tissue of breast using low voltage and high amperage X-rays. Two films are taken.

1. *Craniocaudal* from above downward.
2. *Mediolateral* from side to side.

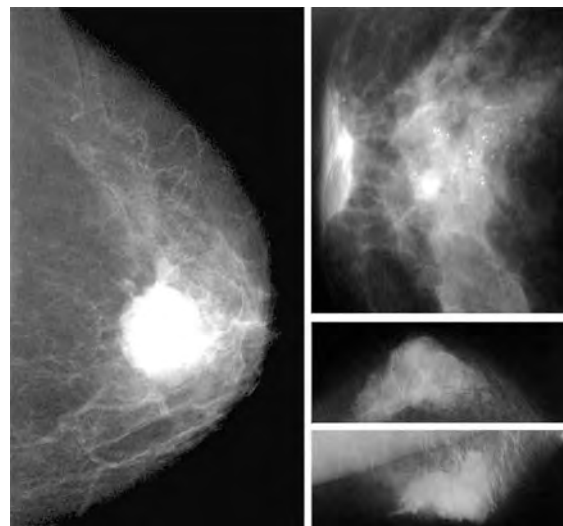
Dose of radiation is 0.1 Gy, a low dose. So it is a safe and effective procedure.



**Fig. 8.7:** Mammography showing calcified lactiferous duct with a benign lesion.

### Findings

- ◆ *Microcalcifications* signify malignancy. They are < 0.5 mm, pleomorphic/heterogenous, grouped, fine, linear and branching.
- ◆ *Soft tissue shadow* may be smooth, round/oval and regular in benign conditions or irregular in carcinomas. Lobulated mass is also suggestive of carcinoma.
- ◆ *Size and location* of mass lesion.
- ◆ *Spiculations, duct distortion*—features of malignancy.
- ◆ Margin may be circumscribed (benign lesion), microlobulated, obscure, ill-defined, spiculated or stellate.



**Fig. 8.8:** Different mammography pictures, craniocaudal and mediolateral films showing mass lesion, microcalcification (Courtesy: Dr Ganesh, MDRD, Mangalore).

### Breast imaging reporting and data system (BIRADS)

Grade	Feature
0	Need further imaging
1	Negative
2	Benign—repeat mammography 1 year
3	Probably benign—mammography after 6 months
4	Suspicious of carcinoma—biopsy
5	Highly suggestive of carcinoma—biopsy
6	Known carcinoma

### Indications

- ◆ *Screening mammography:* For screening purpose it is done after 40 years. Early screening is indicated when there is family history of carcinoma breast or histological risk factor. Mammography before 35 years of age is usually not done unless there is a suspicious lump or a strong family history. Screening is done in asymptomatic female where even cancer is suspected.
- ◆ *Diagnostic mammography* is done in a patient to evaluate the existing symptoms/features of breast disease like breast lump, nipple discharge; or in patient who had breast conservative surgery earlier.
- ◆ In obese patients.
- ◆ Whenever conservative breast surgeries are planned.
- ◆ To find out spread or *de novo* tumour in the opposite breast.
- ◆ Mammography guided biopsy can be done.
- ◆ Evaluation and follow-up in benign breast disease with malignant potential.
- ◆ Follow-up mammography after conservative breast surgery (of operated side and opposite side) when needed.
- ◆ Mastalgias.

### Note:

- 5% of breast cancers are missed in total mammographic screening.

- Breast imaging reporting and data system (BIRADS) have got its own categories, assessment (0–6) and recommendations.
- Digital mammography is computerised electronic image of the breast with enhanced magnified pictures.
- 3 D mammography (breast tomosynthesis) is newer one and may be beneficial in identifying early lesions and in reducing the false positive results.
- Digital spot-view mammography allows faster and more accurate stereotactic biopsy.
- The condition when lump is clinically not palpable but mammogram shows identifiable carcinoma is ideal for breast conservative surgery like quadrantectomy/QUART therapy.
- Mammography should be done one week after menstruation; not just before menstruation.

**Xeromammography** is same as above, but here a photoconductor is used to produce a final image on a Selenium paper rather than on X-ray film.

**Advantages:** Edge enhancement effect, therefore, useful in dense breasts.

**Disadvantage:** Exposure to high radiation dose and selenium plates are needed.

## ■ ABERRATION OF NORMAL DEVELOPMENT AND INVOLUTION (ANDI) OF THE BREAST

ANDI includes variety of benign breast disorders occurring at different periods of reproductive periods in females—early, matured and involution phase of reproductive age group. It was first coined at Cardiff breast clinic in 1987 by LE Hughes. All conditions under ANDI should be carefully clinically examined and often mammography and FNAC/core cut biopsy should be done to rule out malignancy. ANDI includes different aberrations and diseases.

It is based on change in *normal three phases* of physiology of breast—(1) Lobular development; (2) Cyclical hormonal modifications; (3) Involution.

*In early reproductive age group (15–25 years):*

- ◆ Normal lobule formation may cause aberration as *fibroadenoma*. If it is more than 5 cm it is called as *giant fibroadenoma* as a *diseased status*. It is AND of a lobule.
- ◆ Normal stroma may develop juvenile hypertrophy as aberration and multiple fibroadenoma as *diseased status*.

*In mature reproductive age group (25–40 years):*

- ◆ Normal cyclical hormonal effects on glands and stroma get exaggerated by aberration causing generalised enlargement. Its *diseased status* is cyclical mastalgia with nodularity also called as *fibrocystadenosis*.

*Involution age group (40–55 years):*

- ◆ *Lobular involution* with microcysts, fibrosis, adenosis, apocrine metaplasia and eventual aberrations as macrocysts and cystic disease of breast. Macrocyst is an aberration of normal involution (ANI). Sclerosing adenosis is also a type of aberration.
- ◆ *Ductal involution* may cause ductal dilatation and nipple discharge as aberration. Later disease status develops with periductal mastitis, bacterial infection, nonlactational breast abscess and mammary duct fistula. Periductal fibrosis may cause partial nipple retraction.
- ◆ *Epithelial changes* leads into epithelial hyperplasia and atypia.

## ■ FIBROADENOMA

- ◆ It is a benign encapsulated tumour occurring commonly in young females of 15–25 years age group—older definition.
- ◆ Presently, it is considered as *hyperplasia of a single lobule of the breast (classified under ANDI)*.
- ◆ It is the most common benign tumour of the breast below 30 years of age in females.
- ◆ It is aberration in normal development (AND) of a lobule.
- ◆ It shows similar hormonal activities of normal breast like lactation, perimenopausal involution.
- ◆ Incidence is 15% of palpable breast lumps. It is common in blacks and Negroes.
- ◆ It is bilateral in 20% of cases. 20% are multiple.
- ◆ *Juvenile fibroadenoma* occurs in adolescent girls, rarely (variant). Even though it shows rapid growth with stromal and epithelial hyperplasia, it does not show any alteration in stromal epithelial balance or cellular atypia or periductal cellular concentration. It may clinically mimic phyllodes tumour. But it does not turn into phyllodes tumour or carcinoma.
- ◆ *Complex fibroadenoma (Dupon et al)* is a condition (variant) having typical fibroadenoma with fibrocystic changes like apocrine metaplasia, cyst formation, sclerosing adenosis. 15% of proven fibroadenomas are complex. It occurs in older age group. *Occasionally* it may turn into malignancy unlike usual fibroadenomas. *Core biopsy* is needed to confirm the condition.
- ◆ 30% of fibroadenomas may disappear or reduce in size in 2–4 years.
- ◆ 10–15% will increase in size progressively. It does not occur after menopause unless women are on hormones.
- ◆ Fibroadenoma *does not* turn into malignancy.

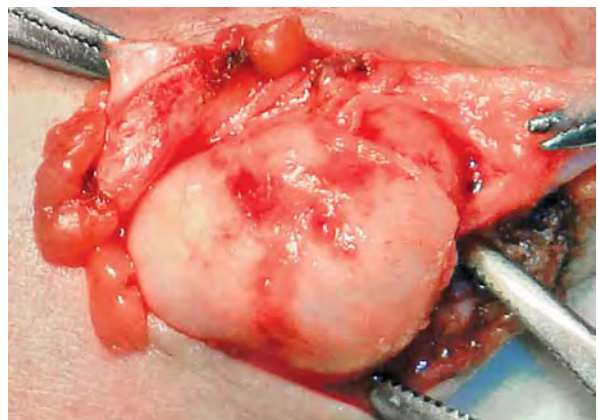
## Types

*Gross:*

1. Soft—common after 30 years; more cellular; often bilateral.
2. Hard—common below 30 years; more fibrous.
3. Giant (> 5 cm in size)—common in Africa.

*Microscopy:*

1. Intracanalicular—large and soft—mainly cellular. Stroma with distorted duct.



**Fig. 8.9:** Fibroadenoma, on table look—well-capsulated neoplasm. It is part of ANDI.

2. Pericanalicular—small and hard—mainly fibrous. Stroma with normal duct.

### Clinical Features

- ◆ It presents as a painless swelling in one of the quadrants, which is *smooth, firm, nontender, well-localised and moves freely* within the breast tissue (mouse in the breast).
- ◆ Axillary lymph nodes are not enlarged.

### Investigations

- ◆ Mammography (well-localised smooth regular shadow). It may show popcorn calcification on mammography.
- ◆ FNAC.
- ◆ Ultrasound (to confirm solid nature).

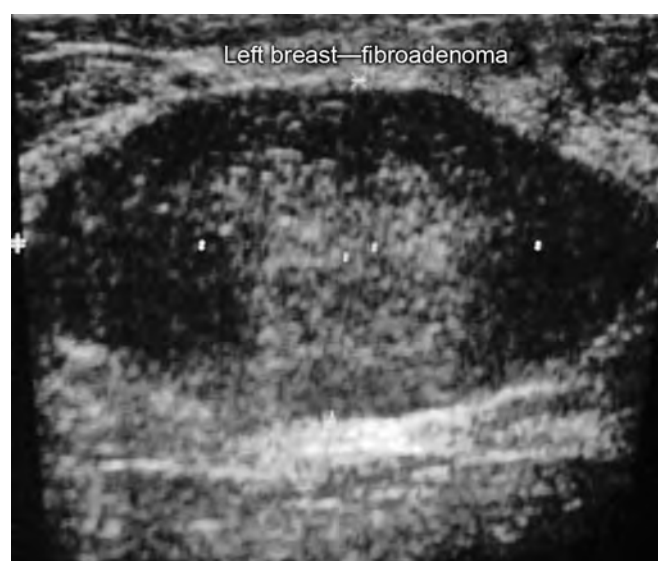

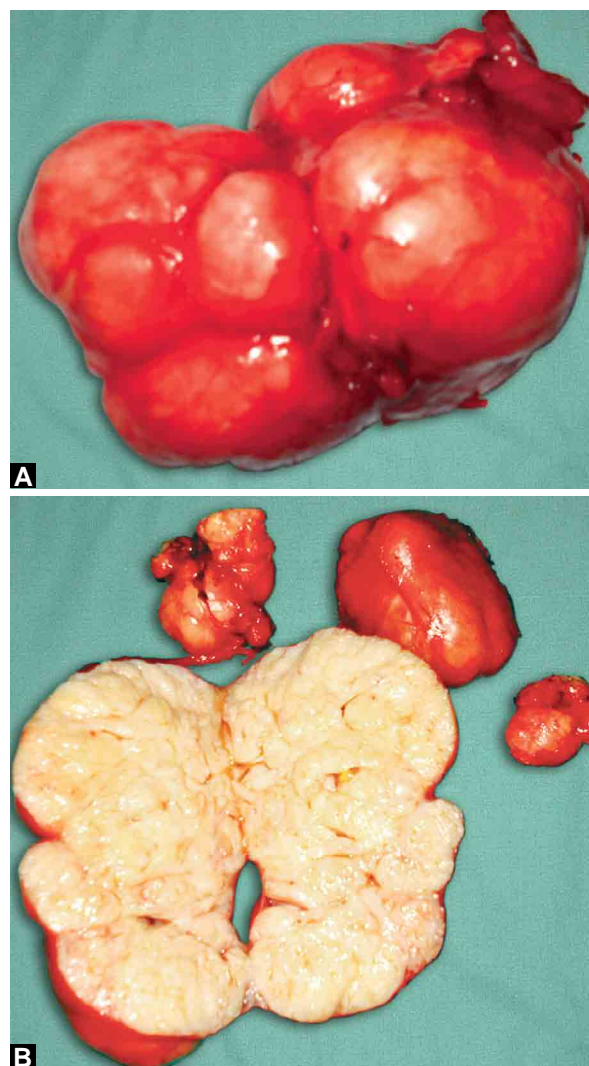
Fig. 8.10: US picture showing fibroadenoma left breast.

### Treatment

Excision through a circumareolar incision (*Webster's*) or submammary incision (*Gaillard Thomas incision*) is done under general anaesthesia.

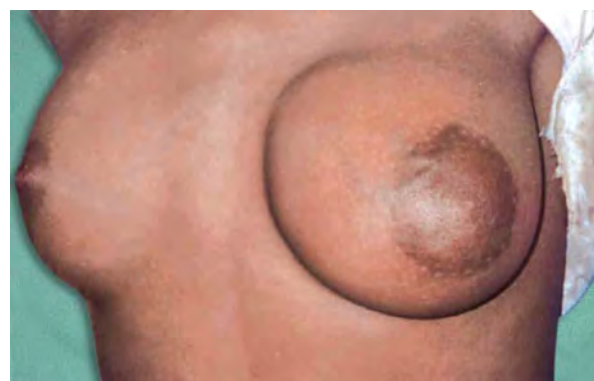

Fig. 8.11: Large fibroadenoma left breast in a 14-year-old female.



Figs 8.12A and B: Multiple fibroadenomas.

Fibroadenoma which is small (<3 cm)/single/age <30 years can be left alone with regular follow-up with USG at 6 monthly interval. But anxiousness of patient and parents find difficult for this conservative approach.

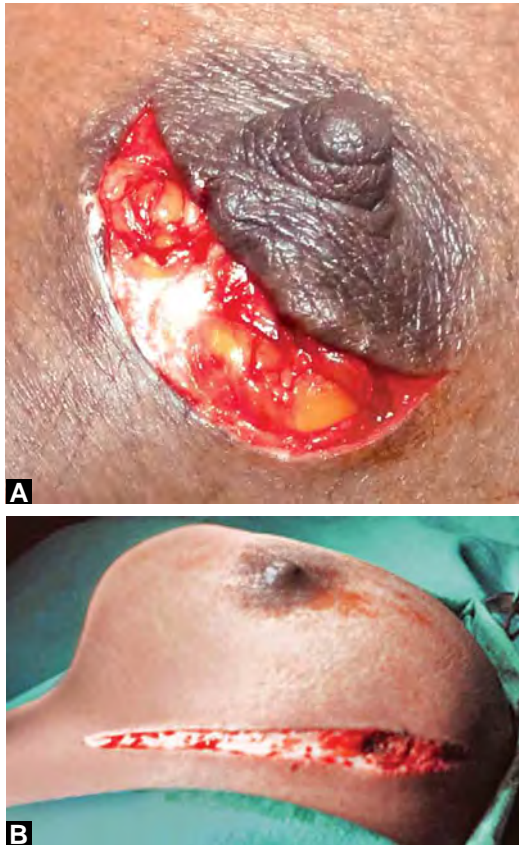
#### Indications for surgery are:

- ◆ Size >3 cm.
- ◆ Multiple.
- ◆ Giant type.
- ◆ Recurrence.
- ◆ Cosmesis.
- ◆ Complex type.

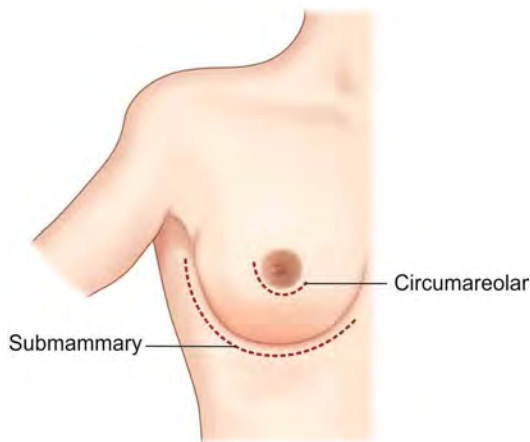
#### Points to be remembered

- ❖ Size of giant duodenal ulcer is >2 cm
- ❖ Size of giant gastric ulcer is >3 cm
- ❖ Size of giant fibroadenoma is >5 cm
- ❖ Diameter of transverse colon in toxic megacolon is >6 cm
- ❖ Size of giant naevus is >20 cm





**Figs 8.13A and B:** Subareolar and submammary incision to excise benign lesions of the breast.



**Fig. 8.14:** Diagram showing circumareolar and submammary (Gaillard Thomas) incisions.

### FIBROCYSTADENOSIS (FIBROCYSTIC DISEASE OF THE BREAST/MAMMARY DYSPLASIA/CYCLICAL MASTALGIA WITH NODULARITY)

- ◆ It is due to Aberration of Normal Development and Involution (*ANDI*) of breast causing changes in the breast.
- ◆ It is presently called as *cyclical mastalgia with nodularity*.

#### Microscopic changes

- ❖ Stromal fibrosis
- ❖ Microcyst formation
- ❖ Glandular proliferation (Adenosis)
- ❖ Hyperplasia (Epitheliosis)—in ducts and acini
- ❖ Papillomatosis—within the ducts, often with apocrine metaplasia

- ◆ It is an estrogen dependent condition. One of the cysts may get enlarged to become a clinically palpable, well-localised swelling—*bluedome cyst of Bloodgood*. It is fluctuant, transilluminant, nontender, often tensely cystic swelling (macrocyt) with thin bluish capsule. It should be aspirated initially. Surgical excision is done if it persists or recurs even after two aspirations; if it is blood stained; if there is residual lump after aspiration.
- ◆ When diffuse small, multiple cysts are the main component, it is called as *Schimmelbusch's disease*.
- ◆ *It is the most common breast disease.*
- ◆ It is common in upper and outer quadrant.
- ◆ It is an exaggerated response of breast stroma and epithelium to hormones and growth factors.
- ◆ It is rare in nulliparous/ovulating/OCP taking women.

#### Classification

- ◆ *Nonproliferative—moderate hyperplasia of ductal luminal cells—no life time risk for cancer.*
- ◆ *Proliferative without atypia (severe hyperplasia).*
- ◆ *Proliferative with atypia (Atypical ductal/lobular hyperplasia)—is risk factor for breast cancer—often mimics in situ carcinoma. RR is 4.5.*

*Usual hyperplasia* is presence of 3 or more layers of proliferating epithelial cells without atypia above the basement membrane in a lobular or ductal unit. It can be mild, moderate or florid. It is seen in 20% of biopsies. Risk of developing cancer is 1.5 times. Observation of such patient is the advice.

*Atypical ductal hyperplasia (ADH)* is defined as a lesion that has got some but not all features of DCIS; a lesion that has all features of DCIS but less than 2 mm in size; lesion with all features of DCIS but involving less than 2 duct spaces. Its incidence is 30% of all mammographies and 5% of benign breast disease biopsies. Risk of developing cancer is 5 times the normal women of that age.

*Atypical lobular hyperplasia (ALH)* is LCIS with half of the acini of lobular unit is involved. Developing invasive carcinoma in 10 years is 20%.

#### Stages

- I—Stromal proliferation or hyperplasia.
- II—Adenosis (increased glands).
- III—Cyst formation.

### Pathophysiology of fibrocystadenosis

- ❖ Oestrogen predominance over progesterone is considered causative
- ❖ Serum levels of oestrogen  $\geq$
- ❖ Luteal phase is shortened
- ❖ Progesterone level decreased to 1/3rd normal
- ❖ Corpus luteum deficiency/anovulation in 70%
- ❖ Patients with premenstrual tension syndrome more likely to develop fibrocystadenosis
- ❖ Prolactin levels are increased in 1/3rd of women with fibrocystadenosis. It is probably due to oestrogen dominance on pituitary
- ❖ Thyroid in suboptimal levels sensitize mammary epithelium to prolactin stimulation
- ❖ Methylxanthiones derived from increased intake of coffee, tea, cold drinks, chocolate is associated with development of fibrocystadenosis
- ❖ Oestrogens stimulate proliferation of connective and epithelial tissues
- ❖ Fibrocystadenosis entails simultaneous progressive and regressive change

### Clinical Features

- ◆ Presentation is during menstruating age group as a *bilateral, painful, diffuse, granular, tender, swelling* which is better felt with palpating fingers (poorly felt with palm).
- ◆ Common in upper outer quadrant.
- ◆ Pain and tenderness are more just prior to menstruation (*cyclical mastalgia*).
- ◆ It subsides during pregnancy, lactation and after menopause.
- ◆ Discharge from the nipple when present will be serous or occasionally greenish.
- ◆ Occasionally shotty enlargement of axillary lymph nodes can occur (20%).
- ◆ Not fixed to skin, muscle or chest wall.

### Investigations

- ◆ FNAC (Epitheliosis, when florid is undoubtedly pre-malignant).
- ◆ Ultrasound.
- ◆ Mammography.

### Treatment

- I. *Conservative line of management* is preferred.
  1. *Reassurance*, avoid caffeine, chocolate, salt.
  2. *Medical (Drugs)*
    - Goal:
      - To stop progression.
      - To relieve pain.
      - To reverse changes.
      - To soften breast tissue.
    - Indicated when:
      - Fibroadenosis is not increasing in size.
      - No nipple discharge especially blood.
      - No psychological effect.

### Drugs are:

- ▶ *Oil of evening primrose* used in moderate pain—*drug of choice*. It contains gamolenic acid which reverses saturated to unsaturated fatty acids. 1000–3000 mg/day for 4–6 months—but costly. It also contains 7% of linolenic acid and 72% of linoleic acid.
- ▶ Gamolenic acid—120 mg/day.
- ▶ Danazol—interferes with FSH and LH (gonadotrophin releasing hormone inhibitor); *most effective drug*; but *second drug of choice*; used in severe cases; 200 mg/day; very effective but causes acne, hirsutism, weight gain and amenorrhoea. It is teratogenic and so cannot be used if patient is planning for pregnancy.
- ▶ Bromocriptine—lowers prolactin—2.5 mg/day for 3 months.
- ▶ Tamoxifen—10 mg BD is an antiestrogenic drug.
- ▶ LHRH agonist (Goserelin) is *reserved for refractory cases*. It shows 96–99% success. But it causes reversible postmenopausal symptoms.
- ▶ Vitamin E and B<sub>6</sub> are tried.
- ▶ NSAIDs—oral and topical.
- ▶ Diuretics even though used by many—*not effective*.

### II. Surgery:

- ◆ Subcutaneous mastectomy with prosthesis placement—only in severe, persistent disease.
- ◆ Excision of the cyst or localised excision of the diseased tissue.

### Indications for surgery

- ❖ Intractable pain
- ❖ Florid epitheliosis—on FNAC
- ❖ Bloodgood cyst
- ❖ Persistent bloody discharge
- ❖ Psychological reason

### Note:

- *Subcutaneous mastectomy* is removal of entire breast with retaining skin over the breast, areola and nipple. It is done through a submammary Gaillard Thomas incision. Adequate skin flap containing subcutaneous fat is raised which maintains the blood supply of the flap and prevents flap necrosis. After haemostasis drain is placed. Breast implant can be placed in subcutaneous/submuscular plane either immediately or as delayed reconstruction. Indications for subcutaneous mastectomy are—fibrocystadenosis with epitheliosis, sclerosing adenosis, persistent nodules, gynaecomastia and DCIS.
- *Macrocysts* (>1 cm) is an advanced form of fibrocystic disease; occurs in women in their forties and pericyclic fibrosis develops later making cyst harder.

### SCLEROSING ADENOSIS

- ◆ It is a benign proliferative condition of terminal duct lobular units with increased number of acini.
- ◆ It occurs in 30–50 years of age group.
- ◆ It may be diffuse or focal.
- ◆ Multiple, small, firm, nodules with fibrous tissue and tiny cysts are common pathology.
- ◆ Recurring pain alike cyclical mastalgia and often breast mass (20% cases) is the presentation.

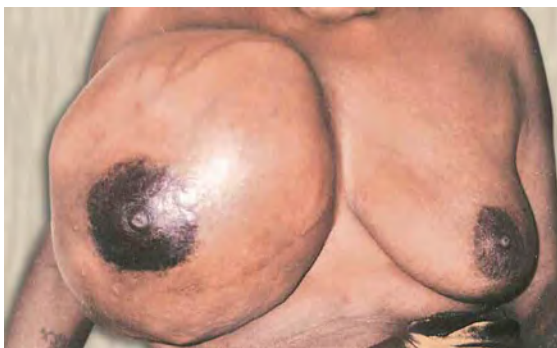*Gratitude, joy, love, passion, excitement, enthusiasm, hope, goal, satisfaction, humility, contentment – are different needs of happy life but difficult to acquire.*

- ◆ Tender breast often with palpable tender firm mass may be felt with granular surface.
- ◆ It contains proliferative terminal ductules and acini with proliferation of stroma often with deposition of calcium. Number of acini per terminal duct is increased more than double the number of normal lobule. There is lobular enlargement, fibrous stromal proliferation and distortion.
- ◆ *Complex type* is with papilloma and epithelial hyperplasia often with fibroadenoma. Radial scar is a variant of this.
- ◆ Condition mimics carcinoma clinically, radiologically and histologically.
- ◆ It is at present included in ANDI.
- ◆ Sclerosing adenosis can co-exists with both or either invasive and *in situ* carcinoma breast.
- ◆ Mammography may show distortion, asymmetrical density, amorphous calcifications mimicking carcinoma breast.
- ◆ MRI is better investigation with guided trucut or stereotactic or vacuum assisted biopsy.
- ◆ It is considered as an independent risk factor for developing breast cancer with 1.5–2 higher risk. But it is not a precancerous condition.
- ◆ *Treatment:* Like ANDI. Regular follow is needed.

### ■ PHYLLOIDES TUMOUR (CYSTOSARCOMA PHYLLOIDES/SEROCYSTIC DISEASE OF BRODIE)

- ◆ They are not simply giant fibroadenoma.
- ◆ They show a wide spectrum of activity, varying from almost a benign condition (85%) to a locally aggressive and sometimes metastatic tumour (15%).
- ◆ Depending on mitotic index and degree of pleomorphism they are graded as low grade to high grade tumours.
- ◆ When malignant (sarcoma) spreads to lungs or bone.
- ◆ Phylloides tumour is the most commonly occurring nonepithelial neoplasm of the breast, although it represents only about 1% of tumors in the breast. It can also often be fibroepithelial.
- ◆ They can be benign, borderline or malignant.

*Gross:* Large capsulated area with cystic spaces and cut surface shows soft, brownish, cystic areas.



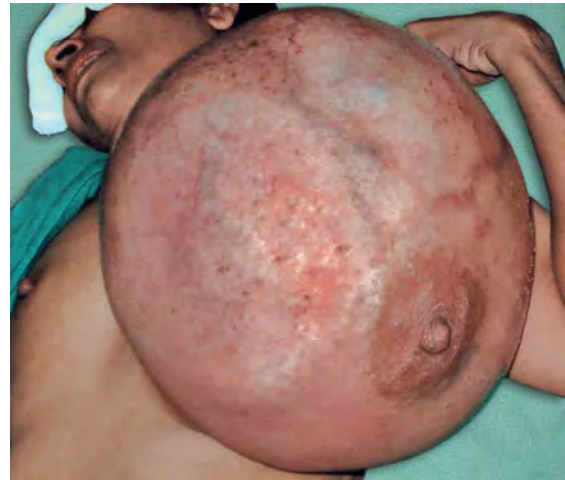**Fig. 8.15:** Cystosarcoma phylloides of right breast. Note the dilated veins. Tumour occupies the entire breast.

#### Microscopy:

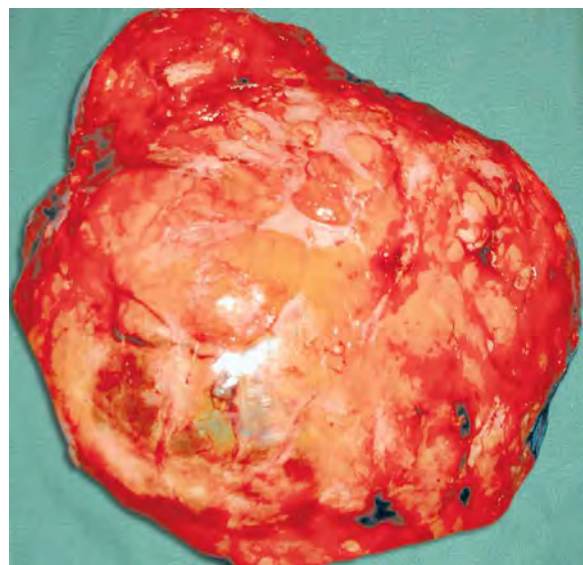
- ◆ It contains cystic spaces with leaf like projections, hence the name (*Phylloides*—Greek—leaf-like).
- ◆ Cells show hypercellularity and pleomorphism.
- ◆ It may be a variant of intracanalicular fibroadenoma of breast (*Giant type*).

#### Clinical Features

- ◆ They occur in premenopausal women (30–50 years).
- ◆ It is usually unilateral, grows rapidly to attain a large size with *bosselated* surface.
- ◆ Swelling is *smooth, nontender, soft, fluctuant with necrosis of skin* over the summit due to pressure.

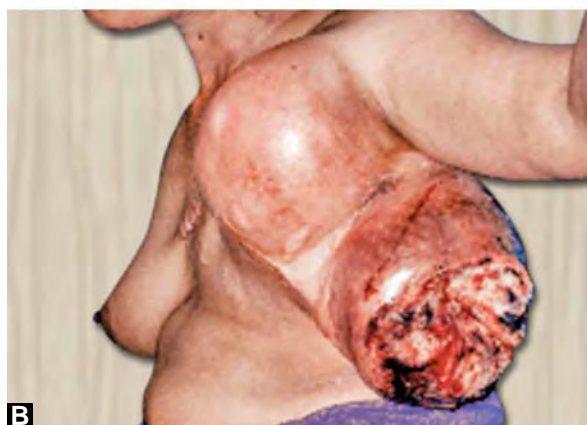
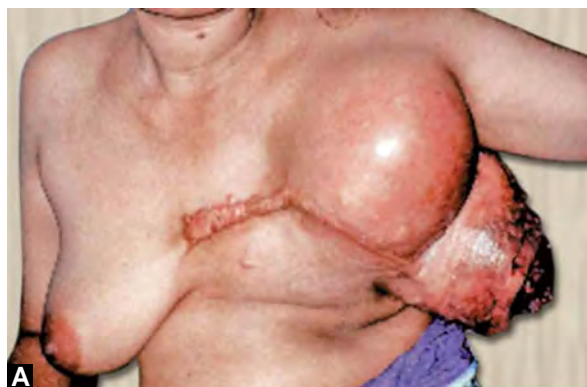
**Fig. 8.16:** Phylloides tumour of left breast (Cystosarcoma phylloides of left breast).



**Fig. 8.17:** Operated specimen of cystosarcoma phylloides.

- ◆ Skin over the breast is stretched, red and with dilated veins over it. Tumour is warmer, not fixed to skin or deeper muscles or chest wall. Nipple retraction is absent. Lymph nodes are usually not involved. These are the *differentiating features* from carcinoma.
- ◆ Tumour grows rapidly; undergoes necrosis at various places; causes cystic areas.
- ◆ Recurrence is common.



**Figs 8.18A and B:** Recurrent cystosarcoma phylloides.

## Investigations

- ◆ Ultrasound.
- ◆ FNAC, core biopsy
- ◆ Mammography.
- ◆ Chest X-ray CT chest in malignancy to see secondaries.

## Treatment

- ◆ Excision or subcutaneous mastectomy is done.
- ◆ If malignant (sarcoma), total mastectomy is indicated.

## ■ MASTALGIA (“Pain in the Breast”)

- ◆ 45% of women report breast pain, 21% severe.
- ◆ An entity that is ubiquitous; has an unknown aetiology, and a poorly understood.
- ◆ Mastitis, carcinoma presenting with only mastalgia (8%).
- ◆ Patients who are on HRT, caffeine, tobacco, large pendulous breasts, etc.

## Types

- ◆ Cyclical—65%.
- ◆ Noncyclical—30%.
- ◆ Chest wall pain—5%.

## Cyclical

- ◆ Pain related to menstrual cycles.
- ◆ Usually seen in ANDI like fibrocystadenosis.
- ◆ Present in women of menstruating age group.
- ◆ Pain is more during menstruation.
- ◆ It is bilateral, diffuse with “heavy feeling”.

### Treatment:

- ◆ Evening primrose oil 325 mg BD.
- ◆ Gamolenic acid 120 mg BD.
- ◆ Danazol (100–200 mg BD)—antigonadotrophin agent.
- ◆ Bromocriptine (2.5 mg BD)—prolactin inhibitor.
- ◆ Tamoxifen (20 mg daily).
- ◆ GnRH analogue 3.6 mg injection depot-monthly.
- ◆ Testosterone undecanoate 40 mg BD.
- ◆ Vitamin B<sub>6</sub>, B<sub>12</sub>.
- ◆ Analgesics.

## Noncyclical

- ◆ Other causes of breast pain are periductal mastitis, malignancy, cervical root pain, musculoskeletal pain, previous surgery, Tietze’s syndrome, idiopathic, Mondor’s syndrome.
- ◆ It is unilateral, chronic, burning or dragging in nature, occurs both in pre- and postmenopausal age group.
- ◆ 5% of breast cancers present as pain during first presentation.

### Treatment:

- ◆ Cause has to be identified.
- ◆ Malignancy has to be ruled out.
- ◆ Avoid coffee and stress.
- ◆ Proper support to breasts.

### Tietze’s syndrome:

Costochondritis of second costal cartilage, commonly seen in females, mimics mastalgia.

## ■ TRAUMATIC FAT NECROSIS

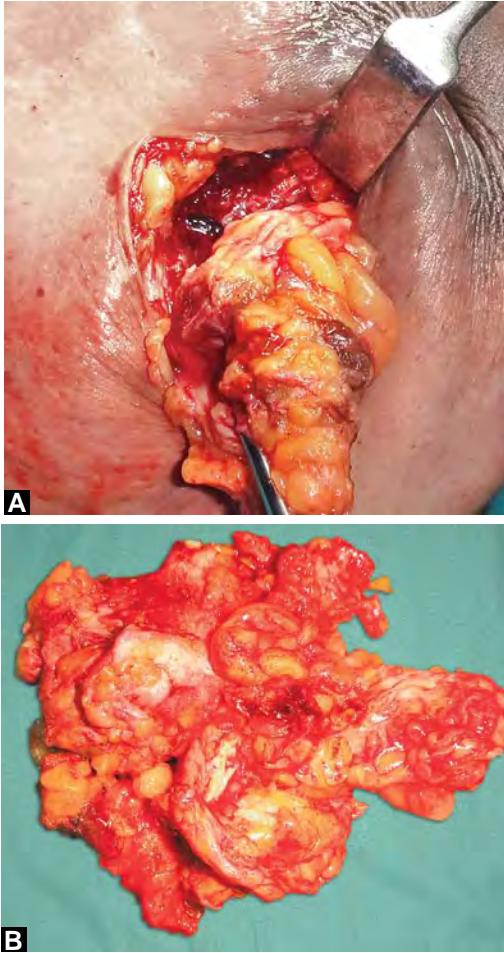
It may be due to either direct or indirect trauma (trauma may not be noticed many times).

## Pathogenesis

Capillary ooze causes triglyceride in the fat to dissociate into fatty acids. It combines with calcium from the blood resulting in *saponification* which causes inflammatory reaction and later presents as a nonprogressive swelling in the breast.

## Features

- ◆ Painless swelling in the breast which is *smooth, hard, nontender and adherent* to breast tissue.
- ◆ It is nonprogressive, nonregressive.
- ◆ *Investigations:*
  - ▶ FNAC shows chalky fluid with fat globules.
  - ▶ Mammography to rule out malignancy.
- ◆ *Differential diagnosis:* Carcinoma breast.
- ◆ *Treatment:* Excision.



**Figs 8.19A and B:** Traumatic fat necrosis.

### ■ GALACTOCELE

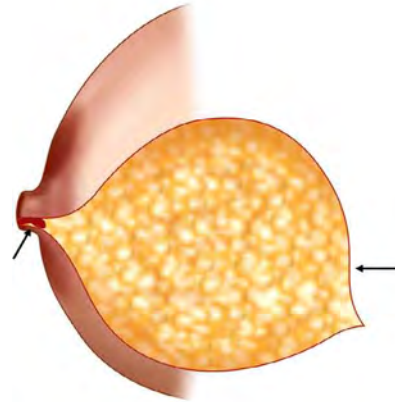
- ◆ Seen in lactating women.
- ◆ Occurs during cessation of lactation. Often up to 10 months after lactation.
- ◆ It is due to the blockage of lactiferous duct resulting in enormous dilatation of lactiferous sinus.
- ◆ It contains milk and epithelial debris within.
- ◆ It is a retention cyst in subareolar region attaining large size.

### Clinical Features

- ◆ Lump in the lower quadrant of the breast which is usually *unilateral, large, soft, fluctuant, with smooth surface*.
- ◆ It is usually nontender.
- ◆ It may get *precipitated, inspissated* or get *calcified*. When it is calcified it mimics carcinoma breast. If it gets infected it will form an abscess.
- ◆ When it is cystic other cystic swelling in the breast should be ruled out.

### Investigations

- ◆ Ultrasound.
- ◆ FNAC. Aspiration shows thick, creamy, greenish/brown fluid.



**Fig. 8.20:** Galactocele.

### Treatment

- ◆ Aspiration of the content.
- ◆ Excision (submammary incision).
- ◆ Abscess when formed should be drained under general anaesthesia under cover of antibiotics.

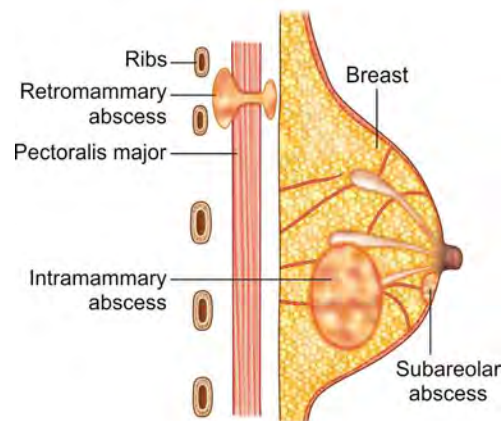
### ■ MASTITIS

#### Types

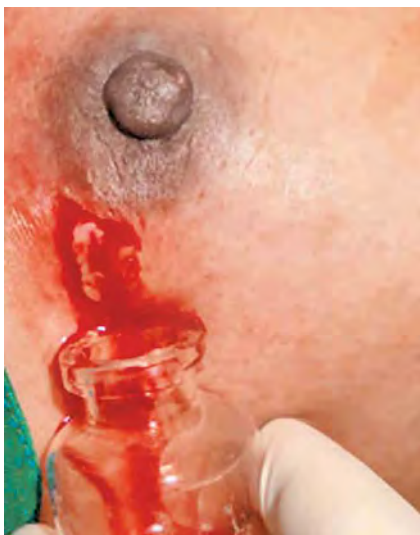1. Subareolar.
2. Intramammary.
3. Retromammary (submammary).

#### Subareolar Mastitis

- ◆ It is the infection under the areola due to cracks in the nipple or areola. It results from an infected gland of Montgomery or a furuncle of the areola. There is blockage of the ducts of these glands.
- ◆ Often it is associated with duct ectasia—causing formation of abscess, sinus and fistula.
- ◆ It is common in nonlactating women.
- ◆ *Risk factors are* – diabetes, smoking, nipple cracks.



**Fig. 8.21:** Diagram showing subareolar, intramammary and retromammary abscess.



**Fig. 8.22:** Subareolar abscess.

#### Clinical features

- ◆ Red, inflamed, edematous areola with a tender swelling underneath.
- ◆ Nipple retraction may develop.

#### Differential diagnosis

Paget's disease of the nipple.

#### Treatment

- ◆ Under cover of antibiotics pus is drained by making a subareolar incision.

#### Intramammary Mastitis (Breast Abscess)

##### a. Lactational abscess of the breast:

Commonly seen in lactating women. Usually up to 6 months of lactation period. It occurs in 3% of breastfeeding mothers.

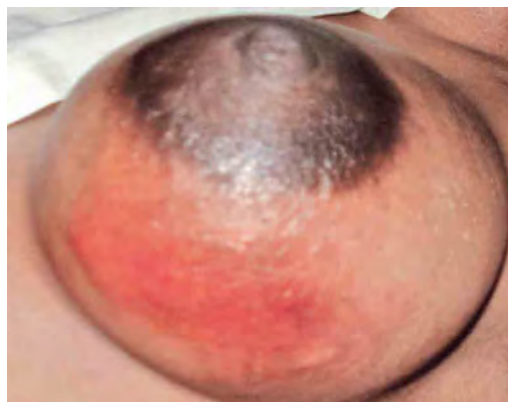#### Precipitating factors

- ❖ Cracked nipple
- ❖ Retracted nipple
- ❖ Improper cleaning of the nipple
- ❖ Inadequate milk sucking by baby or milk expression causing stasis
- ❖ Infection from the mouth of the baby
- ❖ Haematoma getting infected

#### Mode of infection:

Bacteria (*Staph. aureus*—most common) enters the breast during sucking through the cracked nipple. Occasionally, it can be from haematogenous spread. *Staphylococcus epidermidis*, streptococci, anaerobic bacteria also can cause acute mastitis. Gram-negative and other bacterial infections can supervene later.

*Staphylococcus aureus* causes clotting of milk in the blocked duct and multiply. Duct initially gets blocked by epithelial debris or by retracted nipple. Initially it begins in one quadrant but later involves entire breast.



**Fig. 8.23:** Typical breast abscess with features of acute inflammation.

#### Clinical features:

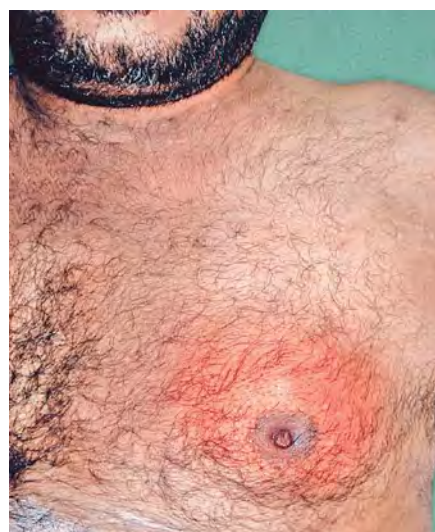- ◆ Continuous throbbing pain in the breast and high grade fever.
- ◆ Diffuse redness, tenderness, warmth and *brawny induration* in the breast.
- ◆ Purulent discharge from the nipple.
- ◆ Entire breast may get involved eventually.
- ◆ Occasionally tender fluctuant swelling (10%) may be felt; ulceration and discharge can occur at a later period. Tender axillary lymph nodes may be palpable.
- ◆ It is difficult to differentiate initial *stage of mastitis* (stage of cellulitis) from *stage of breast abscess* formation. When it is treated with antibiotics without incision and drainage eventually it may get organised to form a nontender, hard breast lump with sterile pus inside—*stage of antibioma* formation.

#### Differential diagnosis:

Inflammatory carcinoma of breast.

#### Investigations

- ◆ Blood total and differential count.



**Fig. 8.24:** Breast abscess in a male patient. Breast abscess even though is uncommon in males, it can occur in puberty and middle age.

*When arms are raised fully above the head, visible signs of breast carcinoma frequently becomes more apparent.*  
—Hugh Auchincloss

- ◆ US breast to identify an abscess, its location, size, loculi. US guided aspiration can be done; pus should be sent for culture and sensitivity.

*Treatment:*

- ◆ Antibiotics—cephalosporins, flucloxacillin and amoxicillin.
- ◆ *Repeated US guided aspirations* (using 18 gauge needle with saline lavage) can be tried which avoids surgery and scar—ideal and standard now.
- ◆ Drainage under general anaesthesia, a *counter incision* may be needed.

It is not advisable to wait till the formation of abscess.

Often takes very long time to heal after surgery causing distress to patient and surgeon as well.

**Indications for drainage in mastitis/breast abscess**

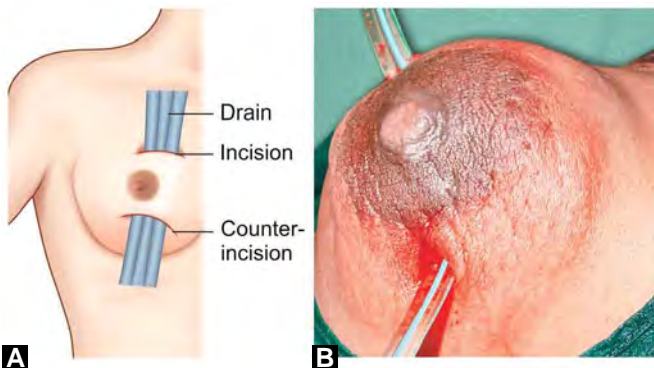
- ❖ Mastitis not resolving with antibiotics in 48 hours
  - ❖ Persistent fever and progression of mastitis
  - ❖ Brawny induration
- Do not wait for abscess to form (fluctuation to develop)

*Complications:*

- ◆ Antibiooma formation.
- ◆ Sinus formation, skin necrosis, milk fistula formation.
- ◆ Recurrent infection, bacteraemia, septicaemia.

**Note:**

- Proper antibiotics are needed.
- Support to breast is done to relieve pain.
- Milk from affected breast should be removed either manually or using breast pump.
- Occasionally milk suppression may be needed if milk fistula or recurrent abscess develops. It is achieved by giving bromocriptine (2.5 mg BD for 2 weeks) or stilbestrol.



**Figs 8.25A and B:** (A) Incision and counter-incision for breast abscess; (B) Drain should be placed after incision and drainage in such abscesses. Often gauze drain can be used.

**b. Nonlactational abscess of the breast:**

- ▶ It commonly occurs in duct ectasia and periareolar infections. Common organisms are *bacteroides*, *anaerobic streptococci*, enterococci and Gram-negative organisms. It is *commonly recurrent* with tender swelling under the areola.
- ▶ It is common in diabetes mellitus and immunosuppression.

*Treatment:*

- ◆ Antibiotics.
- ◆ Repeated aspirations.
- ◆ Drainage and later cone excision of the duct is done.

**Retromammary Mastitis**

- ◆ It is due to tuberculosis of the intercostal lymph nodes or ribs beneath or suppuration of the intercostal lymph nodes.
- ◆ Breast is normal.

**Causes**

- ❖ Tuberculosis of intercostal lymph nodes
- ❖ Tuberculosis of ribs beneath
- ❖ Suppuration of intercostal lymph nodes
- ❖ Empyema necessitatis
- ❖ Infected haematoma

*Investigations:*

- ◆ Chest X-ray, FNAC, ESR.
- ◆ Peripheral smear.
- ◆ US of breast and chest wall.
- ◆ Often CT scan chest may be needed.

*Treatment:*

- ◆ Cause has to be treated.
- ◆ Drainage through submammary/retromammary incision.

**Note:**

- Mastitis of infancy (*Witch's milk*) is due to maternal hormone in infant blood. It usually subsides but may cause suppuration.
- Mastitis of infancy affects both sexes equally.
- Mastitis of puberty is common in boys, is invariably unilateral with tender, swollen and inflamed breast.
- Mastitis of mumps is usually unilateral and can occur in both sexes.
- Bacterial mastitis is seen in adult women, commonly lactating and is due to staphylococci infection.
- Subareolar mastitis is due to infection of gland of Montgomery or due to areolar furuncle.

**ANTIBIOMA**

If intramammary mastitis is not drained but only treated by antibiotics, pus localises and becomes sterile (flaques) with a thick fibrous tissue cover and it is called as antibioma.

**Features**

- ◆ Previous history of mastitis treated with antibiotics.
- ◆ Swelling which is painless, smooth, nontender, hard, fixed to breast tissue without involving the pectorals and chest wall.
- ◆ *Differential diagnosis:* Carcinoma breast (Scirrhus carcinoma breast).
- ◆ *Investigations:* FNAC; mammography; US breast.
- ◆ *Treatment:* Excision (Submammary incision). Later antibiotics are given. It should be sent for histology.

## ■ DUCT ECTASIA

- ◆ It is dilatation of lactiferous ducts due to muscular relaxation (myoepithelial relaxation) of duct wall with *periductal mastitis*.
- ◆ It is also called '*plasma cell mastitis*' as periductal inflammation contains plasma cells.
- ◆ Commonly many ducts are involved.
- ◆ Hormonally induced myoepithelial relaxation with poor ductal absorption of secretions and desquamated cells causing obstruction are the probable other causes and features.

### Features

- ◆ Greenish discharge or *creamy/paste* like from the nipple.
- ◆ Indurated mass under the areola which is often *tender*.
- ◆ Retraction of nipple which occurs at later stage of the disease. *Slit like retraction of nipple* due to fibrosis occurs.
- ◆ Eventually it forms an *abscess* and *fistula*.
- ◆ Often they are bilateral and multifocal.
- ◆ *More common* in smokers—in relation to arterial pathology.
- ◆ Common in multiple pregnancies, *perimenopausal age*, hyperprolactin status.
- ◆ May present as mastalgia.
- ◆ Axillary nodes may be palpable as nonspecific.
- ◆ Secondary bacterial infection (anaerobic) is common.
- ◆ *Differential diagnosis*: Carcinoma breast.
- ◆ *Investigations*:
  - ▶ Discharge study, FNAC.
  - ▶ Mammography.

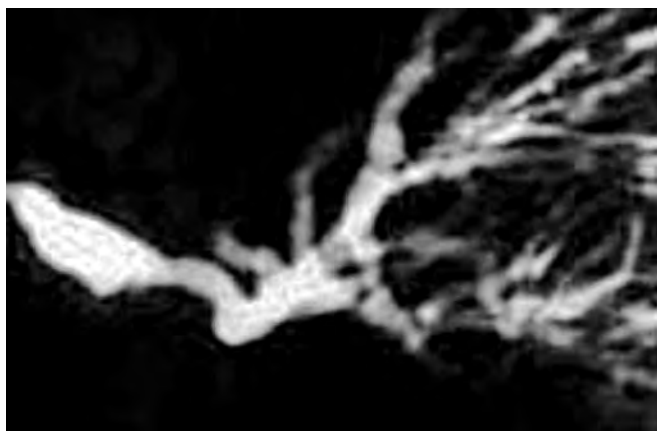


Fig. 8.26: Duct ectasia—ductography.

### Treatment

- ◆ It is important to stop smoking.
- ◆ Cone excision of involved major ducts (*Adair-Hadfield operation*).
- ◆ Antibiotics.
- ◆ *Melhem Novel modified* breast ductal system excision.

## ■ MONDOR'S DISEASE (Henri Mondor—Paris, 1939)

- ◆ Mondor's disease is *spontaneous* thrombophlebitis of the superficial veins of the breast and anterior chest wall.
- ◆ Cause is not known. History suggestive of injury or infection is not observed.
- ◆ Presents as a thrombosed subcutaneous cord (2–3 mm sized) which is attached to the skin.
- ◆ On raising the arm above, a narrow, shallow subcutaneous groove appears alongside the cord like thrombosed vein.
- ◆ The thoracoepigastric vein, the lateral thoracic vein, and the superior epigastric vein—are involved. The upper, inner portions of the breast are never involved.
- ◆ Trauma, infection, surgery may be the cause but clearly not proved and so controversial.
- ◆ Rarely penile Mondor's disease and Mondor's in the arm are observed.
- ◆ It is often a self-limiting disease without any recurrence, complication or deformity.
- ◆ It often mimics the lymphatic permeation of carcinoma breast.
- ◆ Restriction of arm movements, brassiere support and anti-inflammatory drugs may be needed. Occasionally refractory cases need surgical excision of involved segment of vein.

## ■ TUBERCULOSIS OF THE BREAST

- ◆ It is relatively rare. Even though it is rare, often seen in India (4% of benign breast diseases). It may be due to high resistance offered by mammary gland tissue to the survival and multiplication of the tubercle bacillus, a resistance similar to that offered by spleen and skeletal muscle.
- ◆ Usually associated with active pulmonary tuberculosis.
- ◆ Infection reaches through blood or retrograde lymphatic spread from lymph nodes of axilla.
- ◆ Common in lactation.
- ◆ Nipple and areola are *not commonly* involved.
- ◆ *Lump*—irregular ill-defined; Peaud' orange; discharge, sinus, matted axillary nodes often with sinus are the features.
- ◆ Presents as a swelling in the breast with cold abscess, sinuses and a typical bluish appearance of surrounding skin with matted lymph nodes in the ipsilateral axilla.

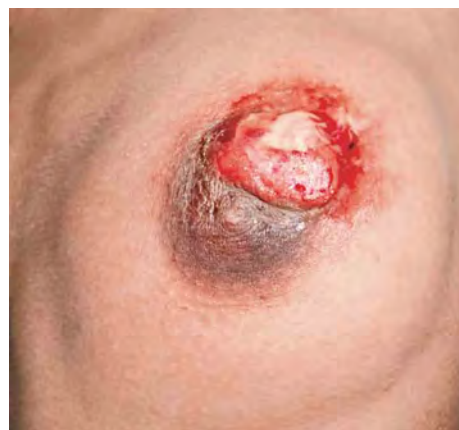

Fig. 8.27: Tuberculosis of breast showing undermined lesion.

Transillumination in a case of duct papilloma may reveal an opacity in the line of the duct due to pent-up blood.  
—William J Moore



- ◆ *Differential Diagnosis:* Carcinoma breast.
- ◆ *Investigations:*
  - ▶ FNAC.
  - ▶ Frozen section biopsy is useful to differentiate from carcinoma.
  - ▶ Excision biopsy.

### Treatment

- ◆ Antituberculous drugs—INH, rifampicin, ethambutol, pyrazinamide.
- ◆ Drainage of cold abscess.

#### Note:

- Mastectomy is not done.

### BREAST CYSTS

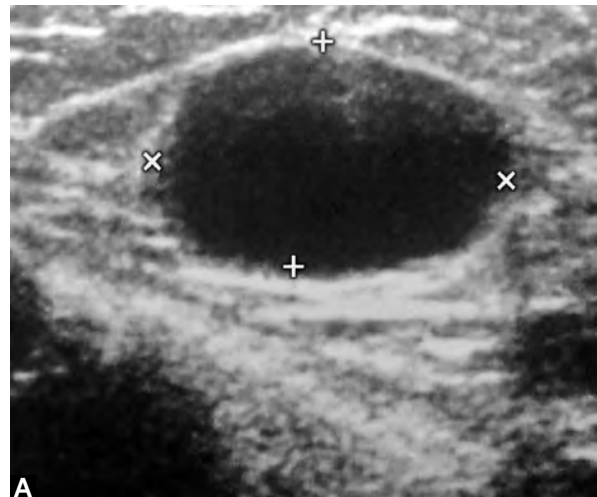
- ◆ They are cavities lined by epithelium in the breast containing fluid. It arises from destruction and dilatation of breast lobule and terminal ductules. It is due to nonintegrated stromal and epithelial involution.
- ◆ Cyst may be microscopic or macroscopic. It contains straw coloured or green or opaque fluid.
- ◆ Incidence is very high (1 in 14 females). It is common after the age of 35 years up to menopause. It is uncommon after menopause. Hormone replacement can cause cyst formation in old women.
- ◆ Cyst size varies with menstruation due to influence of ovarian hormones.
- ◆ Cysts can be multiple (50%). Often bilateral.
- ◆ Cysts can be recurrent (50%).
- ◆ Risk of breast cancer in breast cyst is very less (0.1%). But incidental associated carcinoma may be present in 3% of breast cysts.
- ◆ *Clinically*—smooth, soft, fluctuant often transilluminating well-localised swelling may be felt.
- ◆ *Differential diagnoses* are—*Bloodgood cyst*, haematoma, cystic necrosis in a carcinoma, Brodie's disease, galactocele, lymph cyst, hydatid cyst.
- ◆ *Investigations*—US of breast; FNAC. Mammography to rule out associated carcinoma.

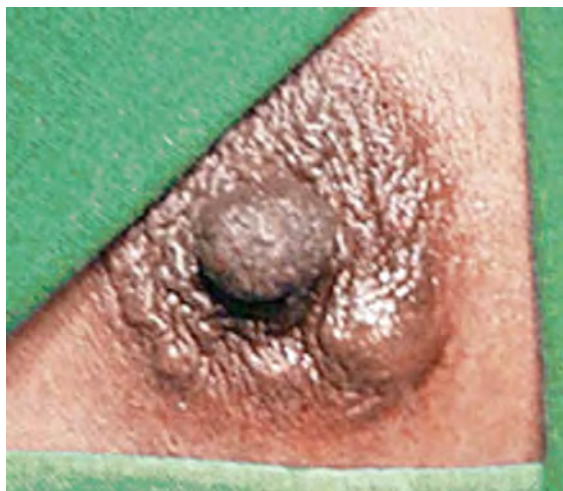
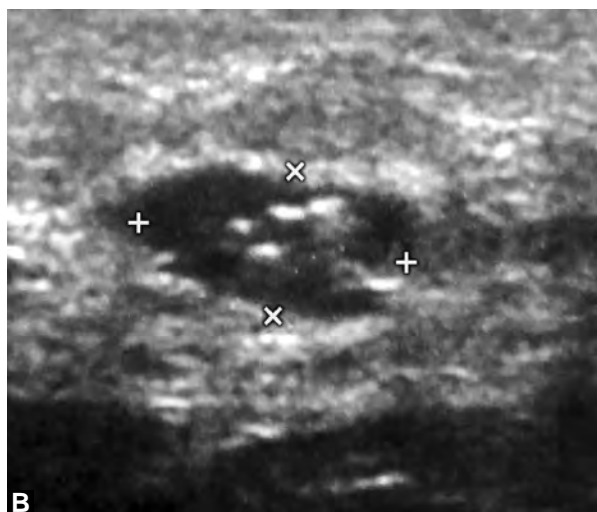
Fig. 8.28: Retention cyst in areola.

### Treatment

- ◆ Aspiration for *two* times.
- ◆ Surgical excision is done if cyst *recurs* after two aspirations or if there is *bloody* discharge or *residual mass* if felt after aspiration.



Figs 8.29A and B: Ultrasound look of breast cysts—simple and complex type.

#### Note:

- Fluctuation in the cyst is checked by examiner standing behind the patient.
- Mammogram should be done if patient is more than 35 years.
- 21 Gauge needle is used for aspiration.
- Fluid is sent for analysis (cytology); evidence says that if fluid is clear no need to send for cytology but in practice it is commonly sent and safer to send also.
- All fluid which is altered should be sent for cytology.
- After aspiration one should examine for the residual lump. FNAC of this residual lump should be done.
- Cyst when recurs (30%) reaspiration should be done.
- Patient should be examined for refilling of the cyst in 6 weeks.

#### Other cystic swellings of the breast

- ❖ Bloodgood cyst
- ❖ Breast abscess
- ❖ Hydatid cyst
- ❖ Galactocele
- ❖ Serocystic disease of Brodie
- ❖ Cystic necrosis in carcinoma breast
- ❖ Lymph cyst
- ❖ Haematoma in breast

## ■ GALACTORRHOEA

- ◆ It is secretion of milk not related to pregnancy or lactation.
- ◆ It is always bilateral.

### Primary galactorrhoea is due to:

- ◆ Stress and other factors. It is physiological in puberty or menopause. Reassurance is the treatment.

### Secondary galactorrhoea is due to:

- ◆ Dopamine receptor blocking agents like haloperidol, methyl dopa, chlorpromazine, metoclopramide or by hyperprolactinaemia due to pituitary tumours. It enhances the prolactin activity.
- ◆ Hypothyroidism.
- ◆ Drugs like oral contraceptives, atenolol, clonidine, ranitidine.
- ◆ Ectopic prolactin secreting tumours usually from lungs (bronchogenic carcinoma).
- ◆ Chronic renal failure.

## Management

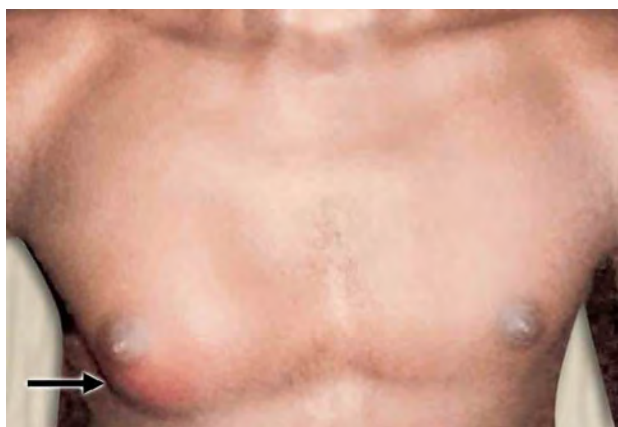
- ◆ Estimation of serum prolactin, T3, T4, TSH, CT/MRI head.
- ◆ Bromocriptine therapy.
- ◆ Treatment of cause. Causative drug should be stopped and different drugs should be used for the needed condition.

### Note:

**Witch's milk** is secretion of milk in both male and female infants due to maternal hormonal effects in foetus. It lasts up to three weeks after child birth.

## ■ GYNAECOMASTIA (Greek—Women Breast)

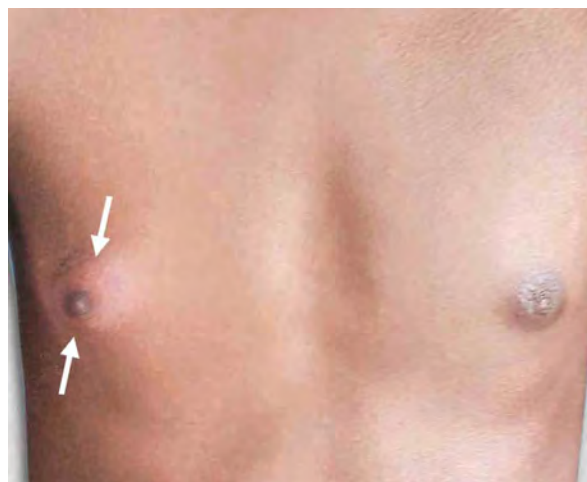
- ◆ It is hypertrophy of male breast more than usual due to increase in ductal (epithelial) and connective tissue (stromal) elements often attaining features of female breast.
- ◆ It can be unilateral or bilateral. Bilateral can be symmetrical or asymmetrical.



**Fig. 8.30:** Gynaecomastia—right side breast (diffuse type). Compare with opposite side to note the difference in size.

- ◆ It is nonphysiological *stimulatory* oestrogen excess or *inhibitory* androgen deficiency. There is nonphysiological hypertrophy of male breast attaining the size of female breast with increase in connective and ductal tissues.

- ◆ It can be *diffuse*—involving all quadrants or small *well localised* hard subareolar nodule.



**Fig. 8.31:** Right-sided gynaecomastia (well-localised—puffy nipple).

## Aetiology

- ◆ *Oestrogen excess*—increased estradiol secretion due to testicular tumour (*Leydig cell*) or nontesticular tumours from adrenal cortex, lung, liver; hyperthyroidism (increases conversion of androgen to estrogen), liver diseases, oestrogen therapy for prostate cancer.
- ◆ *Androgen deficiency*—aging, *Klinefelter's/Kallmann syndromes*, eunuch, ACTH deficiency.
- ◆ *Secondary testicular failure*—cryptorchidism, orchitis, trauma, CRF, etc.
- ◆ *Drugs (25%)*:
  - ▶ Increases estrogen activity (digitalis, anabolic steroid)/estrogen synthesis (reserpine, theophylline, frusemide).
  - ▶ Inhibition of testosterone synthesis—cimetidine, phenytoin, spironolactone.

## Features

Initially there will be *florid proliferative stage* of ductal epithelium with oedematous stroma without acini (1 year); later there will be *quiescent stage* with ductal dilatation and stromal fibrosis.

- ◆ Always one should examine genitalia and liver.
- ◆ It is physically *embarrassing*; psychologically *devastating*.

### Types

- ◆ *Neonatal* gynaecomastia is due to action of placental estrogen
- ◆ *Pubertal (25%)* in young boys is due to excess estrogen level in relation to testosterone. It is usually unilateral. Here breast tissue will be more than 2 cm in diameter in nonobese young male
- ◆ *Senescent* in old is due to fall circulating testosterone causing relative hyperestrogenism

*In the presence of troubles some people grow wings; others buy crutches.*

- ❖ *Prepubertal*—may also be seen in girl child

*It can be:*

- ❖ Puffy nipples
- ❖ Pure glandular
- ❖ Adolescent hereditary
- ❖ Adult—most common
- ❖ Androgenic

*Simon's classification of gynaecomastia:*

- Group 1—Minor visible type without skin redundancy
- Group 2 A—Moderate without skin redundancy
- Group 2 B—Moderate with minor skin redundancy
- Group 3—Gross pendulous breast

## Differential Diagnosis

- ❖ Pseudogynaecomastia—adipose tissue deposition as a part of obesity; needs liposuction.
- ❖ Pectoral muscle hypertrophy.
- ❖ Lipoma, dermoid, haematoma.

## Presentations

- ❖ Diffuse enlargement of breast occupying all quadrants.
- ❖ Often well-localised, small, firm or hard nodule under the areola which is often painful and tender.

### Causes

- ❖ Idiopathic—25%
- ❖ Teratoma testis—3%
- ❖ Ectopic hormonal production in bronchial carcinoma
- ❖ Anorchism, after castration
- ❖ Adrenal and pituitary disease
- ❖ Leprosy, because of bilateral testicular atrophy
- ❖ Drugs (25%): Stilbestrol, digitalis, cimetidine, spironolactone, INH, phenothiazides
- ❖ Liver diseases and liver failure—10%
- ❖ Klinefelter's syndrome (XXY Trisomy), Kallman syndrome
- ❖ Primary or secondary hypogonadism
- ❖ Hyperthyroidism
- ❖ Renal diseases, dialysis induced (1%)

## Investigations

Relevant to the cause, e.g. liver function tests, DNA study, hormone assay, FNAC, USG breast.

## Treatment

- ❖ Well-localised type which is symptomatic or patient is psychologically worried is treated by surgical excision using circumareolar incision.
- ❖ Large diffuse gynaecomastia needs *Gaillard Thomas* submammary incision for excision.
- ❖ *Reduction mammoplasty*; nipple reduction surgeries.
- ❖ *Drugs*—tamoxifen, clomiphene, androgens (dihydrotestosterone), danazol, testolactone as aromatase inhibitor—but less useful. Drugs are given only for 6 months. Gynaecomastia more than 2 years duration is less likely to show benefit from drugs.

- ❖ Breast irradiation to prevent gynaecomastia in prostatic cancer patients who are on oestrogen therapy.
- ❖ Causative drugs should be stopped.
- ❖ Testicular tumours, hyperthyroidism should be treated if they are the causes.
- ❖ Testosterone can be given if hypogonadism is the cause.
- ❖ Endoscopic assisted subcutaneous mastectomy is done and under trial mainly for cosmetic purpose.

### Note:

- Rarely gynaecomastia may turn into malignancy. Gynaecomastia is a differential diagnosis for male breast cancer.
- 80% of Klinefelter's syndrome shows gynaecomastia; it has got very high-risk (20 times) of developing carcinoma.

## DUCT PAPILLOMA

- ❖ It is the most common cause of bloody discharge from nipple
- ❖ It is usually single, from a single lactiferous duct
- ❖ It blocks the duct causing ductal dilatation

- ❖ They are epithelium lined true polyps of breast lactiferous ducts.
- ❖ Usually, it is <1 cm in size often with a small lump under areola. But can attain large size.
- ❖ Vascular stalk is present usually.
- ❖ Rarely a cystic soft swelling may be present underneath which is probably due to obstruction of the duct by papilloma.
- ❖ Papilloma may often project out like a pedunculated mass.

## Types

- ❖ Subareolar—common.
- ❖ Peripheral—occasional.
- ❖ Solitary—common.
- ❖ Multiple.
- ❖ Unilateral—common.
- ❖ Bilateral.

## Clinical Features

- ❖ Papilliferous swelling (projection), usually seen near the nipple orifice.
- ❖ Blood stained discharge from the nipple is common.
- ❖ But serous or serosanguinous discharge can also occur.
- ❖ Single papilloma is not premalignant.
- ❖ But multiple papillomas in many ducts can be premalignant.
- ❖ Peripheral papilloma should be differentiated from invasive papillary carcinoma.

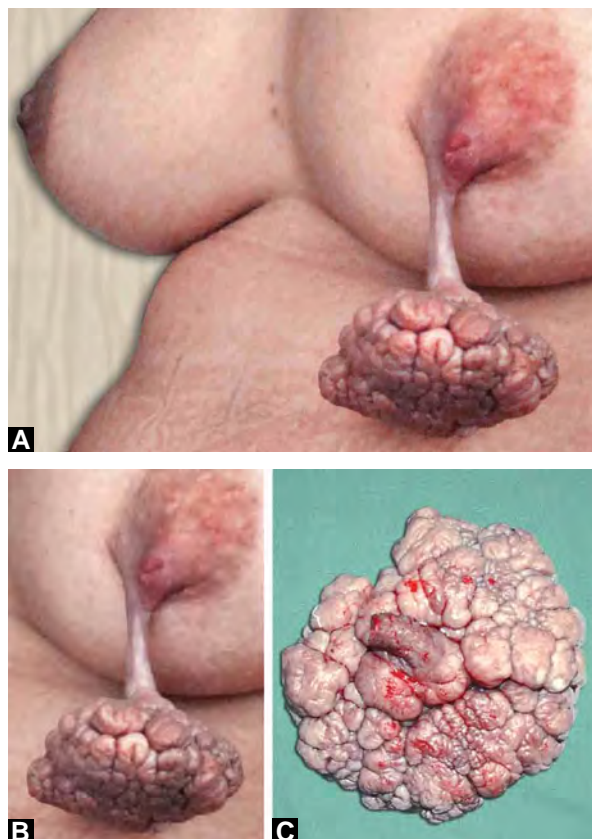
## Investigations

- ❖ Discharge study (FNAC).
- ❖ Injection of contrast into the duct (Ductogram).
- ❖ Mammography may show dense lesion under the areola.

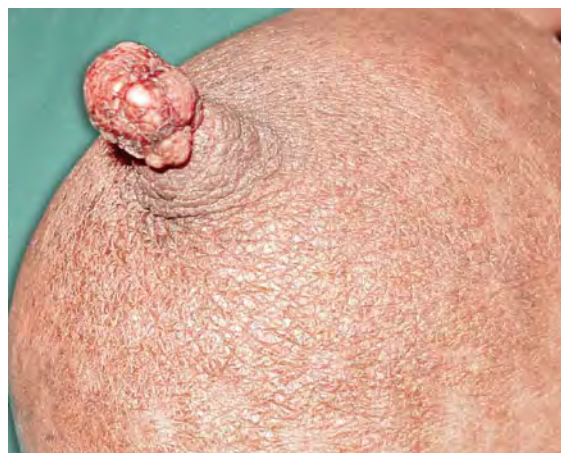## Treatment

**Microdochectomy:** Probed lactiferous duct is opened, and the papilloma is excised using *tennis racquet* incision.

Probing of lactiferous duct is done up to 5 cm deep and excised with part of the areolar skin.



**Figs 8.32A to C:** Papilloma breast which is large. Usually it is small intraductal.



**Fig. 8.33:** Breast papilloma. It usually arises from single duct. It projects near the nipple orifice.

**Note:**

- Intraductal papillary carcinoma arises usually not from a pre-existing duct papilloma but as *de novo*.
- *Papillomatosis* is hyperplasia of the duct lining, filling the duct like a polyp without a pedicle/stalk (not a true polyp); it is not duct papilloma but part of fibrocystadenosis.
- Axillary nodes are not involved.

### ZUSKA-ATKINS DISEASE

- ◆ A condition considered mainly by pathologists. Squamous metaplasia causes plugging and obstruction of the ducts; subsequent inflammatory reaction and infection.
- ◆ Nipple retraction, recurrent episodes of infection and presence of painful nodules under the areola in a nonlactating woman is seen.
- ◆ The presence of a sinus draining milky discharge in the areola is characteristic.
- ◆ *Seen in smokers*—men or women. Vitamin A deficiency is also the cause.
- ◆ It can mimic carcinoma.
- ◆ *Treatment* is antibiotics and surgical excision like for duct ectasia.

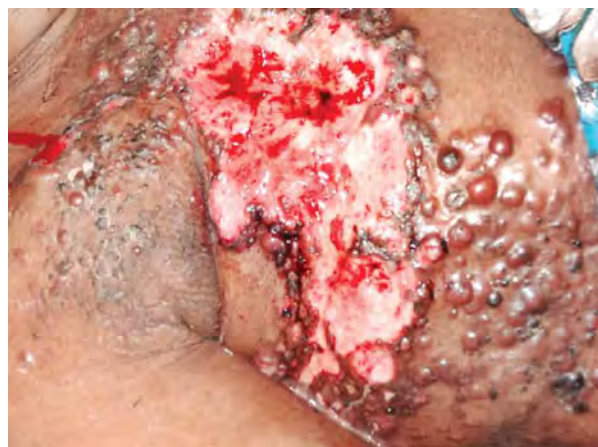### MAMMARY FISTULA OF ATKINS

- ◆ It is a fistula of lactiferous duct which opens on to the areola.
- ◆ It causes recurrent abscess that points on to the areola which discharges and continues to discharge for a week.
- ◆ It is a differential diagnosis for carcinoma breast.
- ◆ *Treatment:*
  - ▶ Antibiotics.
  - ▶ Excision of fistula along with lactiferous duct.

### CARCINOMA BREAST

*When cancer occurs in the breast of women under forty, it is more rapid in its progress than when the patient is older, and also more extensive; remote sympathy likewise takes place more readily in them than in the old, so that the operation succeeds better in the latter on this account.*

—John Hunter, 1728–1793



**Fig. 8.34:** Carcinoma breast involving extensively with nodules, destruction, ulceration and cancer en cuirasse with oedema arm.

### Aetiology

- ◆ Carcinoma breast is more common in developed, Western countries.
- ◆ In African-American women, it is more aggressive. It is less common in Japan, Taiwan.

- ◆ It is second most common carcinoma in females. Incidence is 19–34%. Median age is 47 years.
- ◆ Carcinoma in one breast increases the risk of developing carcinoma on opposite breast by 3–4 times. Incidence of bilateral carcinoma is 2%.
- ◆ It is more common after middle age, but can occur at any age group, after 20 years.
- ◆ It can be familial in 2–5% cases. Vast majority of cases are sporadic without family history.
- ◆ Mutation of tumour suppressor genes *BRCA1/BRCA2* is thought to be involved with high-risk of breast carcinoma. (BRCA means BReast CArcinoma). *BRCA1* mutation is having more risk (35–45%) than *BRCA2* mutation. It is located in long arm of chromosome 17, whereas *BRCA2* is located in long arm of chromosome 13. *BRCA1* more commonly shows *ER negative* status, high grade, aneuploid with raised S fraction than *BRCA2* which shows *ER positive* status. *BRCA1* is associated with increased risk in males. Lifelong risk of breast cancer in *BRCA1* and *BRCA2* mutations is 50–70%. Both are associated with high-risk for ovarian cancer.
- ◆ Occasionally mutation of *BRCA3* and p53 suppressor gene is also involved.
- ◆ *Li-Fraumeni's syndrome* (LFS) is autosomal dominant condition with breast cancer inheritance (90%) along with sarcoma, leukemia, brain tumours, adrenocortical tumours.
- ◆ Diet low with phytoestrogens and high alcohol intake have high-risk of breast cancer. Vitamin C reduces the risk.
- ◆ It is more common in nulliparous woman.
- ◆ Attaining early menarche and late menopause have high-risk of breast malignancy.
- ◆ Early child-bearing and breastfeeding reduces the chances of malignancy. Early 1st child birth reduces the risk; late first child birth after 35 years increases the risk.
- ◆ It is more common in obese individuals.
- ◆ Breast cancer relative risk is qualified as relative risk (RR). If RR is 2.0 means, risk is twice the normal population. If RR is 0.5 means, risk is 50% less than normal population.
- ◆ Risk is 3–5 times more if 1st degree relative is having breast cancer. Risk is more if 1st degree relative is younger or premenopausal or having bilateral breast cancers.
- ◆ In males, occasionally gynaecomastia turns into carcinoma—not proved.
- ◆ Benign breast diseases with atypia, hyperplasia and epitheliosis has got higher risk in a patient with family history. RR in nonproliferative fibrocystic disease is 1.0; proliferative without atypia is 1.5; proliferative with atypia is 4.0 (with family history 6.5, premenopausal 6.0).
- ◆ *Cowden's syndrome*—it is an autosomal dominant condition, with cutaneous facial lesion (100%), bilateral breast lesion (50%), GI polyps, brain, thyroid tumours.
- ◆ It is often associated with ataxia telangiectasia.
- ◆ Previous *therapeutic* radiation (*thoracic*) may predispose carcinoma breast especially when RT is given at younger age mainly for Hodgkin's lymphoma.

- ◆ Radial scar may predispose the carcinoma. It is a *complex sclerotic* condition of breast with microcyst, epithelial hyperplasia, adenosis, central sclerosis with lesions less than 1 cm in size. It mimics carcinoma clinically and mammographically.
- ◆ It is more common in individuals who are on oral contraceptive pills (not proved) and hormone replacement therapy (HRT) for more than 5 years.
- ◆ Presently carcinoma breast is considered as a systemic disease. **Halsted concept** of spread is *sequential spread*. Breast—axillary lymph node—systemic spread. **Fischer concept** is early to begin with itself, there is distant blood spread because of *micrometastasis* without nodal disease. Only tumour lesser than 1 cm size can be sequential. **Helman spectrum concept** is new one where disease spreads loco-regionally as well as systemically which makes it to aim at both locoregional disease control as well as systemic disease control.
- ◆ Prior diagnosis of uterine/ovarian/colonic cancers.

#### Incidences in carcinoma breast

- ❖ 30% of all female cancers
- ❖ 20% of cancer related deaths in females
- ❖ 2–4% bilateral
- ❖ 2–5% hereditary
- ❖ Lump in the breast—most common presentation (75%)
- ❖ 10% presents with pain
- ❖ 35–45% with mutation of *BRCA1* gene
- ❖ 70% blood spread occurs to bones
- ❖ Incidence in India is one in 100 women.

#### Modified Gail risk assessment model

- ❖ Age, age at menarche, age at 1st live child birth, race
- ❖ Number of 1st degree female relatives having breast cancer
- ❖ Number of previous breast biopsies
- ❖ Proliferative lesion with atypia

These risk factors are translated into risk scores by specified calculations.

But model does not include genetic factor

## Pathology

- ◆ Breast carcinoma arising from lactiferous ducts is called as **ductal carcinoma**.
- ◆ Breast carcinoma arising from lobules is called as **lobular carcinoma**. It is 10% common.

#### Risk factors for breast carcinoma

- ❖ Breast carcinoma in 1st degree relative
- ❖ Breast carcinoma in contralateral breast
- ❖ *BRCA1/BRCA2* gene mutation
- ❖ Obesity and alcohol intake
- ❖ Nulliparity
- ❖ Early menarche and late menopause

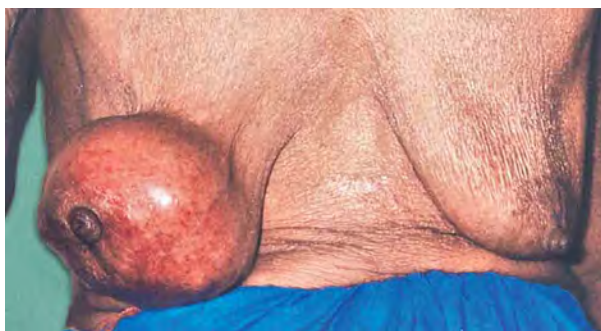- ◆ **In situ carcinoma** is preinvasive carcinoma which has not breached the epithelial basement membrane.

Risk factors classification		
Slight to moderate risk	Moderate to high-risk	Very high-risk
• Florid hyperplasia	• Age > 60 years	• Therapeutic radiation
• Solid duct papilloma	• ADH/ALH/ LCIS	• Family history of breast cancer in two 1st degree relatives
• Obesity, alcohol, HRT	• History of DCIS	• Family history of breast and ovarian cancer
• Nulliparity	• Cancer on one side breast	• <i>BRCA1</i> and <i>BRCA2</i> mutation carrier or 1st degree relative with mutation
• Early menarche, late menopause		

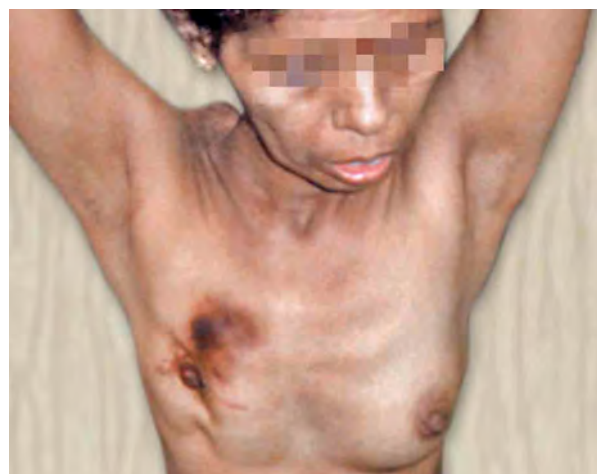It may be:

- ▶ *Ductal in situ carcinoma (Ductal Carcinoma In Situ, DCIS)* or
- ▶ *Lobular in situ carcinoma (Lobular Carcinoma In Situ, LCIS)*.

◆ **Invasive carcinoma** can occur eventually.



**Fig. 8.35:** Carcinoma right breast in an elderly—an atrophic scirrhous carcinoma.



**Fig. 8.36:** Examination with both arms raised above the shoulder.

## Classifications

- I. Ductal carcinoma.
  - Lobular carcinoma.
- II. (a) *In situ carcinoma (Noninvasive)*
  - DCIS (Ductal carcinoma *in situ*).
  - LCIS (Lobular carcinoma *in situ*).

(b) Invasive.

- Invasive ductal carcinoma—most common type. Adenocarcinoma with *no special type* (80%) is more common. 60% of this will show micro- or macroscopic spread to axillary nodes. Invasive type can be special type or no special type (*NST*) [not otherwise specified/*NOS*]. *Special type (ST)* is 20% common; tubular, mucinous, cribriform, medullary, etc. and they carry good prognosis. *No special type (NST)* carry poor prognosis.

- ▶ Invasive lobular carcinoma. It is commonly multifocal and often bilateral.

III. Unilateral.

Bilateral—2–5% common.

IV. Unifocal.

Multifocal—tumour tissues within the same quadrant at multiple foci.

Multicentric—tumour tissues within the same breast but in different quadrant.

### Foote Stewart original classification of invasive breast cancer

- ❖ Paget's disease of nipple
- ❖ Invasive ductal carcinoma (adenocarcinoma with productive fibrosis [scirrhous/simplex/no special type]—80%; medullary—4%; colloid—2%; papillary—2%; tubular and invasive cribriform—2%)
- ❖ Invasive lobular carcinoma—10%
- ❖ Rare other types—adenoid cystic, squamous cell, apocrine type

### Classification of primary breast cancer

#### Noninvasive epithelial

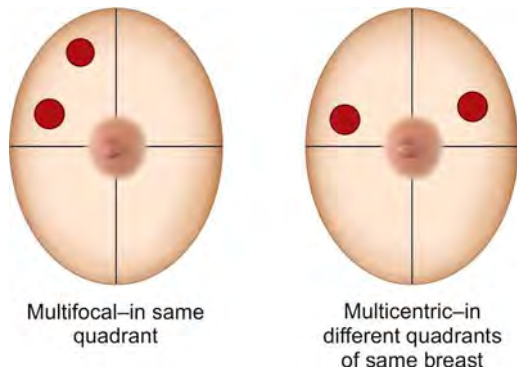
- ❖ LCIS
- ❖ DCIS (intraductal)—papillary, solid, cribriform, comedo

#### Invasive epithelial

- ❖ Invasive lobular—10%
- ❖ Invasive ductal
  - Invasive ductal with NST (no special type)/NOS (not otherwise specified)—70%
  - Tubular—2%
  - Colloid—2%
  - Medullary—5%
  - Medullary variant—basal like
  - Invasive cribriform—2%
  - Invasive papillary—1%
  - Adenoid cystic—1%
  - Metaplastic—1%

#### Mixed connective tissue and epithelial

- ❖ Phyllodes, angiosarcoma, carcinosarcoma



**Fig. 8.37:** *Multifocal* is occurrence of 2nd *in situ* breast cancer within the same breast quadrant as the primary *in situ* cancer: *multicentricity* is occurrence of 2nd *in situ* breast cancer outside (other) the breast quadrant as the primary *in situ* cancer in the same breast.

### DCIS (Ductal Carcinoma *In Situ*)

- ◆ It is intraductal carcinoma (proliferation of malignant mammary ductal epithelial cells) without any invasion into the basement membrane.
- ◆ It is 5–20% common.
- ◆ It can be:
  - ▶ Solid—*high grade*.
  - ▶ Comedo with necrosis is *high grade* with increased chances of microinvasion.
  - ▶ Cribriform—*low grade*.
  - ▶ Papillary—*low grade*.
  - ▶ Micropapillary.
- ◆ It is associated with high expression of C-erb2 gene (80%).
- ◆ It can be high grade DCIS or low grade DCIS.
- ◆ It can be comedo DCIS (more malignant and more likely to be invasive later) or noncomedo DCIS (less malignant).
- ◆ In 20% of cases synchronous invasive carcinoma in duct is seen.
- ◆ Untreated DCIS becomes invasive in > 50% cases (5 fold).
- ◆ 5% of *male* breast cancers are DCIS.
- ◆ Minor ductal epithelial proliferation is the typical histology.
- ◆ Invasive ductal cancer forms in the same breast and same quadrant of DCIS unlike LCIS. DCIS is an *anatomical precursor* of invasive DC.
- ◆ Presence of > 25% of DCIS component is present in the *main invasive tumour* or if DCIS is present elsewhere in the surrounding breast tissue, it is called as *extensive in situ component*.
- ◆ Nipple discharge and often small swelling are main presentations.
- ◆ US assisted FNAC and mammography are the needed investigations.
- ◆ Risk of lymph node spread in DCIS is less than 4%. So axillary dissection is not necessary.
- ◆ *Sentinel Lymph Node Biopsy* and proceed is the preferred method.

### Van Nuy's prognostic index for DCIS

Score	1	2	3
Size in mm	<15 mm	15–40 mm	>40 mm
Clearance in mm	>10 mm	1–10 mm	<1 mm
Grade and necrosis	not high grade	not high grade	high grade
	No necrosis	Necrosis present	Necrosis present
Total score is 9			
Score 3–4 conservative breast surgery (wide local excision)			
Score 5–7 conservative surgery + Radiotherapy			
Score 8–9 total mastectomy			

**Nottingham Prognostic Index (NPI):** (0.2 × Tumour size in cm) + Lymph node stage + Tumour grade

NPI score—<3.4 Good prognosis with 80% survival (15 years)

NPI score—3.4–5.4 Moderate prognosis with 40% survival

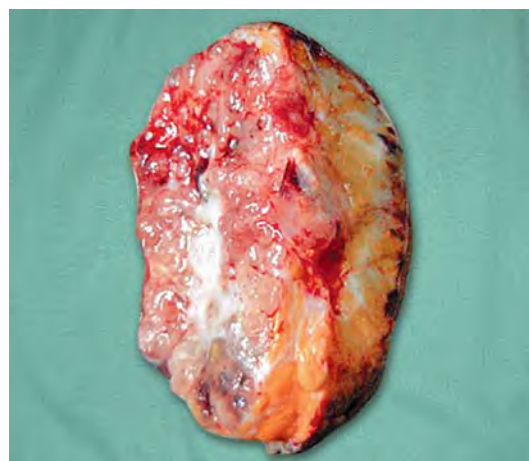NPI score—>5.4 Poor prognosis with 15% survival

### Management of DCIS

- ❖ FNAC confirms the disease but will not differentiate from DCIS and invasive carcinoma
- ❖ Mammography, US breast, MRI breast
- ❖ Routine metastatic work up
- ❖ *Breast conservative surgery with RT* to breast and axillary dissection after SLNB (if +ve)
- ❖ *Hormone therapy* (tamoxifen) prevents both local recurrence and development of new primary breast carcinoma
- ❖ *Total mastectomy* is done in DCIS when—positive margin after wide local excision; two or more primary tumour; when radiation to breast is not possible (collagen diseases); tumour/breast size ratio is not appropriate for conservative surgery and DCIS in pregnancy. *Skin sparing mastectomy (SSM)* may be ideal in such occasions with immediate TRAM/LD flap.

### Types of Carcinoma Breast

1. **Scirrhus carcinoma:** It is 60% common. It is hard, whitish, or whitish yellow, noncapsulated, irregular, with *cartilagi-*



**Fig. 8.38:** Specimen of carcinoma breast. Cut section showing tumour tissue of scirrhus type (most common type).

nous consistency. It contains malignant cells with fibrous stroma.

2. **Medullary carcinoma (5%):** Also called as ‘encephaloid type’ because of its brain like consistency. It contains malignant cells with dispersed lymphocytes.

▶ *Medullary variant with some features of pure form* shows uniformly high grade aggressive tumour cells with negative ER, PR, HER<sub>2</sub> NEU cell surface receptors (triple negative). They express molecular markers of basal/myoepithelial cells and so now termed as *basal-like breast cancers*.

3. **Inflammatory carcinoma/Lactating carcinoma/Mastitis carcinomatosa:**

- ▶ Most aggressive type of carcinoma breast.
- ▶ It is 2% common.
- ▶ It is common in lactating women or pregnancy.
- ▶ It mimics acute mastitis because of its short duration, pain, warmth and tenderness.
- ▶ Clinically, it is a rapidly progressive tumour of short duration, diffuse, painful, warm often involving whole of breast tissue with occurrence of *peau d’orange*, often extending to the skin of chest wall also.
- ▶ More than 1/3rd of skin over the breast is involved; diffuse lymphoedema is due to tumour emboli within *dermal lymphatics*. Underlying localised palpable mass need not be evident clinically. It should be differentiated from other LACB with skin involvement where underlying palpable mass is well evident.
- ▶ Mammography *may not* show any finding except skin thickening. Inflammatory carcinoma of breast is a *clinical diagnosis*.
- ▶ *Ductal or lobular* invasive type with cancer cells in dermal lymphatics is the histology.
- ▶ It rapidly metastasises to chest wall, bone and lungs.
- ▶ It is always stage **IIIB carcinoma (T<sub>4d</sub>)**. FNAC confirms the diagnosis—it contains undifferentiated cells. Punch biopsy is ideal and better which shows undifferentiated cells.
- ▶ Total count is normal.

#### Treatment

- ▶ External radiotherapy and chemotherapy.
- ▶ Salvage surgery whenever possible.
- ▶ It has got *worst prognosis*.

#### Differential diagnosis

- ▶ Acute mastitis—total count is increased here.

4. **Colloid carcinoma:** It produces abundant mucin, both intra- and extracellularly carrying better prognosis.

5. **Paget’s disease of the nipple**

*I believe it has not yet been published that certain chronic affections of the skin of the nipple and areola are very often succeeded by the formation of scirrhus cancer in the mammary gland.... In the majority (the affection) had the appearance of a florid, intensely red, raw surface...like the surface of very acute diffuse eczema.*

—James Paget, 1874

- ▶ It is superficial manifestation of an intraductal carcinoma. The malignancy spreads within the duct up to the skin of the nipple and down into the substance of the breast. It mimics eczema of nipple and areola.

- ▶ In Paget’s disease, there is a hard nodule just underneath the areola, which later ulcerates and causes destruction of nipple. Histologically, it contains large, ovoid, clear *Paget’s cells* with malignant features. *Paget’s hyperchromatic cells* are located in rete pegs of epidermis containing intracellular *mucopolysaccharides* as clear *halo* in cytosol.

Differences between Paget’s disease and eczema of nipple	
Paget’s disease	Eczema
1. Unilateral	1. Bilateral
2. Edges are distinct	2. Edges are indistinct
3. Itching absent	3. Itching present
4. Seen in menopausal women	4. Occurs during the time of lactation
5. Vesicles absent	5. Vesicles present
6. Nipple is usually destroyed	6. Nipple is usually intact
7. Underlying lump is usually present	7. No underlying lump present

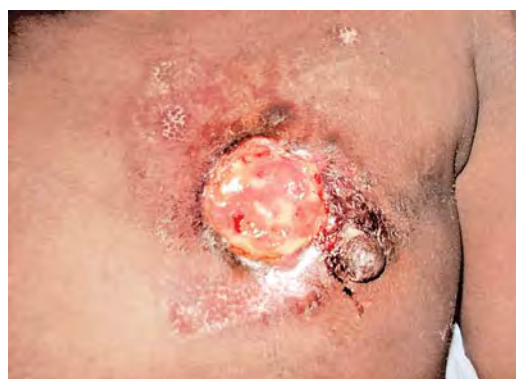

Fig. 8.39: Paget’s disease of the breast.

- ▶ It is 2% common. 90% is invasive ductal carcinoma. 70% shows mass underneath nipple and areola.
  - ▶ Breast conservation surgery (BCS) is difficult here; hence, MRM is needed.
6. **Tubular, papillary, cribriform** are other types of duct carcinomas.
7. **Atrophic scirrhous carcinoma:**
- ▶ Seen in elderly females. It is a slow growing tumour which has got better prognosis.
  - ▶ FNAC is diagnostic.
  - ▶ Mastectomy or curative brachytherapy (using breast moulds) is the treatment of choice.
  - ▶ It is curable.
8. **Lobular carcinoma in situ:**
- ▶ It originates in terminal duct lobular unit *only of female breast* showing its distension and distortion.
  - ▶ It is 12 times more common in *white females*. Predominantly *perimenopausal*.
  - ▶ It is 3–5% common. High chance to predispose to invasive cancer. 35% of LCIS may develop invasive lobular carcinoma either in same or contralateral breast; 65% may develop invasive ductal cancer (same side/opposite side/both sides). LCIS is a *marker/predictor* of increased risk of invasive breast cancer; not an anatomical precursor unlike DCIS. It is now *advocated as a risk factor* for developing breast cancer.



- ▶ It is multifocal, bilateral (50%).
- ▶ It is an incidental pathological entity. *Classical type* carries better prognosis; *pleomorphic type* does not so; occasionally *mixed ductal and lobular in situ* may be seen.
- ▶ Clinically it does not form a lump.
- ▶ Need not be detected by mammography, as it does not provoke calcification.
- ▶ 50% cancers can develop in the contralateral breast.
- ▶ Immunohistochemistry using e-cadherin antibody shows positive reaction in lobular carcinoma.
- ▶ It has poor prognosis due to bilateral, multifocal nature and difficulty in identifying it.
- ▶ Tamoxifen (risk reduction in premenopausal) or raloxifen (postmenopausal) often with bilateral total mastectomy is the treatment.

9. **Disease of Reclus:** It is a rare intracystic papilliferous carcinoma of breast presenting as a cystic swelling with bloody discharge from the nipple.

### Grading of the Tumour

- ◆ It is based on nuclear pleomorphism; tubule formation; mitotic rate.
- ◆ It can be—well-differentiated (grade 1); moderately differentiated (grade 2) and poorly differentiated (grade 3).

Tumour doubling occurs in 6 months with reaching 1 cm in size in 30 doublings. Breast cancer more than 1 cm has its own blood supply and so high chances of systemic spread and so systemic therapy is a must.

### Elston-Ellis Modified Bloom-Richardson Grading System

- ❖ **Nuclear pleomorphism:** Score 1—relatively small uniform nuclei; score 2—intermediate pleomorphic nucleoli; score 3—relatively large prominent nucleoli
- ❖ **Mitotic count:** Score 1—< 10% mitoses in 10 HPF; score 2—10-20% mitoses; score 3—>20% mitoses
- ❖ **Tubule formation:** Score 1—>75% cells in tubule forms; score 2—10-75% cells in tubule forms; score 3—< 10% cells in tubule forms

Grade	Score
Favourable	1
Unfavourable	Up to 3
Grade I	3-5
Grade II	6-7
Grade III	8-9

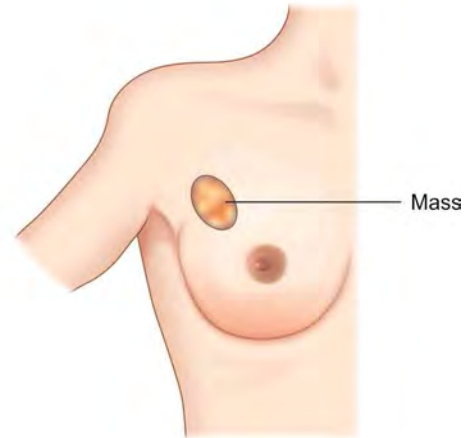
- ❖ Well differentiated low grade—grade 3, 4, 5
- ❖ Moderately differentiated intermediate grade—grade 6, 7
- ❖ Poorly differentiated high grade—8, 9

#### Presentation of carcinoma breast

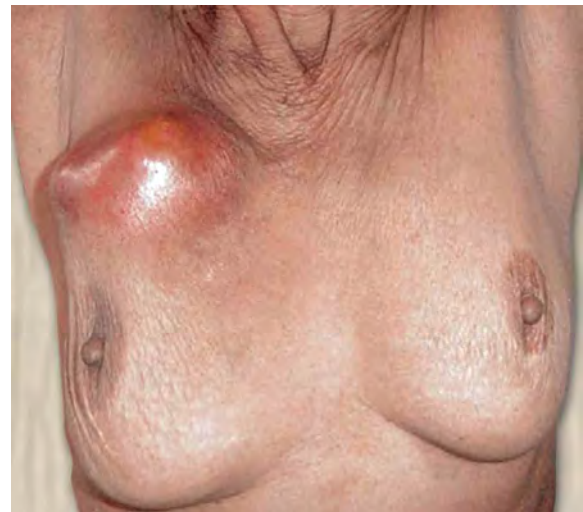- ❖ Lump in the breast which is hard, painless (most common). At least tumour should become 1 cm to clinically palpable
- ❖ Nipple discharge is the second common presentation
- ❖ Ulceration and fungation
- ❖ Axillary lymph node enlargement; supraclavicular lymph node enlargement
- ❖ Chest pain and haemoptysis
- ❖ Bone pain, tenderness, and pathological fracture
- ❖ Pleural effusion, ascites
- ❖ Liver secondaries, secondary ovarian tumour
- ❖ Pain in the lump in 10% cases

### Biological Behaviour and Clinical Features of Carcinoma Breast

Most common site is *upper outer quadrant* (60%) because *breast tissue is more in this quadrant*.



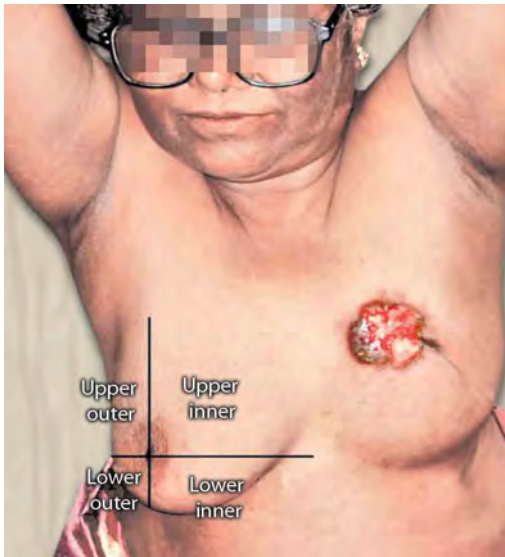
**Fig. 8.40:** Mass in the upper outer quadrant—is the most common site of the carcinoma breast.



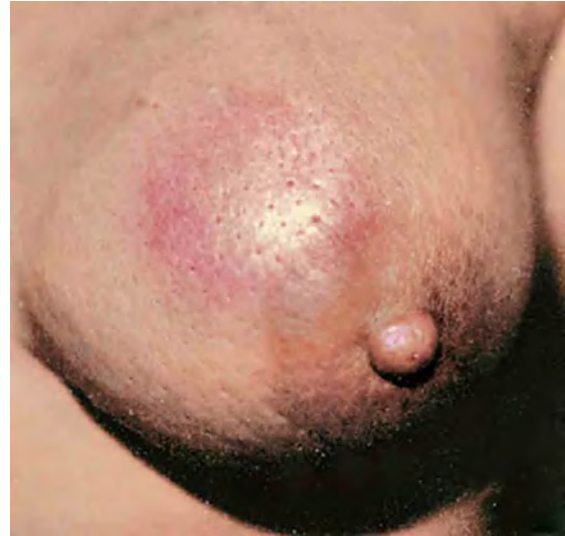**Fig. 8.41:** Carcinoma breast over the most common site—upper outer quadrant—more visible on raising the arm.

### Cutaneous Manifestations of Carcinoma Breast

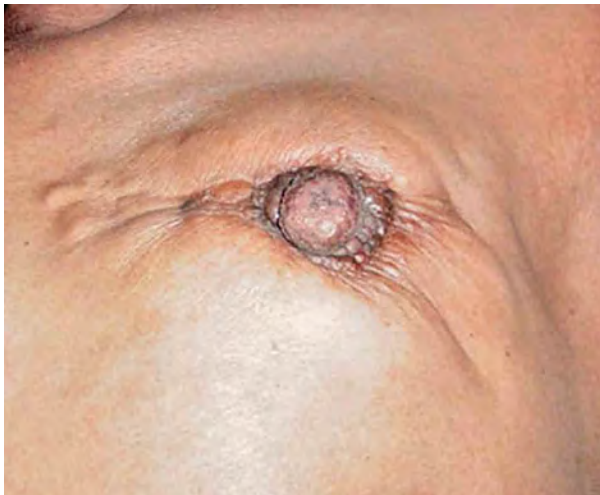- ◆ *Peau d'orange:* Due to obstruction of dermal lymphatics, openings of the sebaceous glands and hair follicles get buried in the oedema giving rise to orange peel appearance.
- ◆ *Dimpling of skin* due to infiltration of ligament of Cooper.
- ◆ *Retraction of nipple* due to infiltration of lactiferous duct.
- ◆ *Ulceration, discharge* from the nipple and areola.
- ◆ Skin ulceration and fungation.
- ◆ *Cancer-en-cuirasse:* Skin over the chest wall and breast is studded with cancer nodules appearing like an armour coat.
- ◆ *Tethering to skin.*



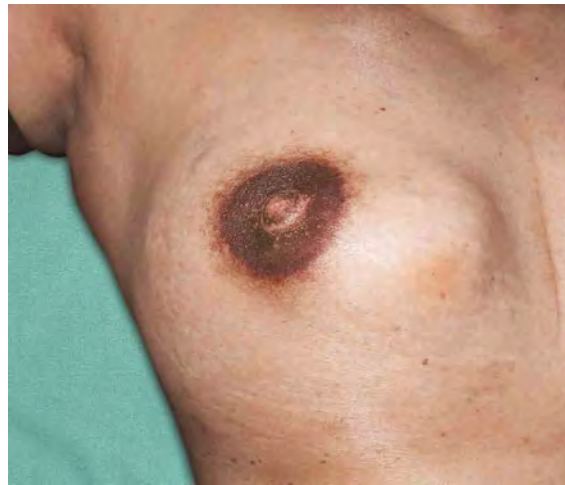**Fig. 8.42:** Quadrants of breast. Carcinoma is more common in upper outer quadrant as more breast tissue is located in this quadrant.



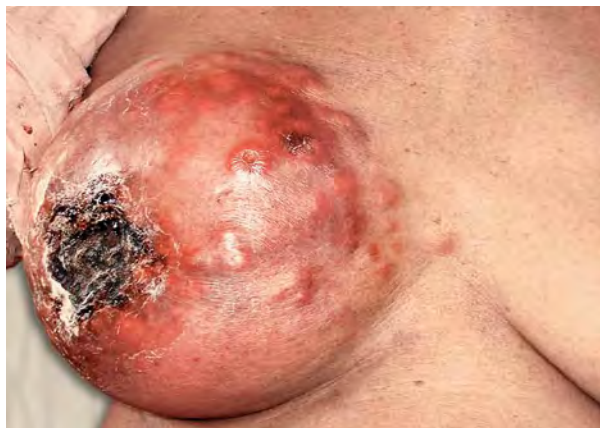**Fig. 8.45:** *Peau d'orange* appearance of skin.



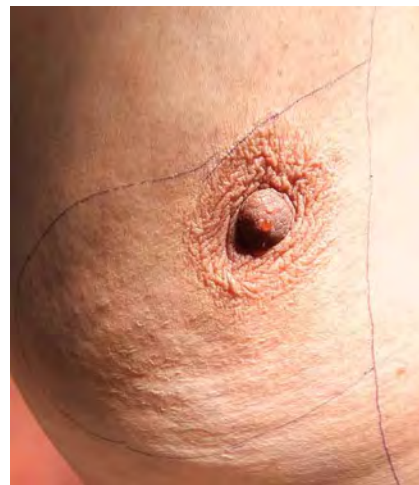
**Fig. 8.43:** Carcinoma breast with extensive skin involvement.



**Fig. 8.46:** Lump (painless) in the breast is the commonest presentation; here lump is in inner quadrant.

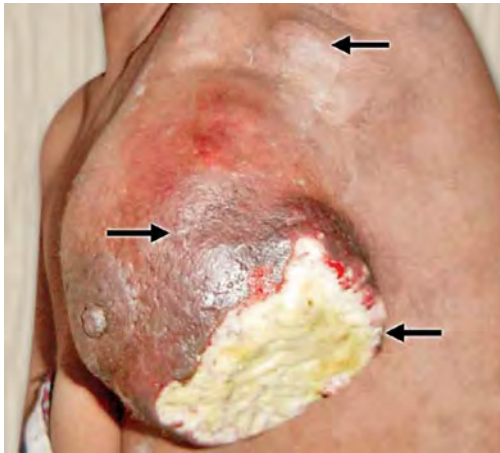

**Fig. 8.44:** *Cancer-en-cuirasse* with malignant nodules in the chest wall and skin.



**Fig. 8.47:** Bloody discharge from the nipple in carcinoma of breast.

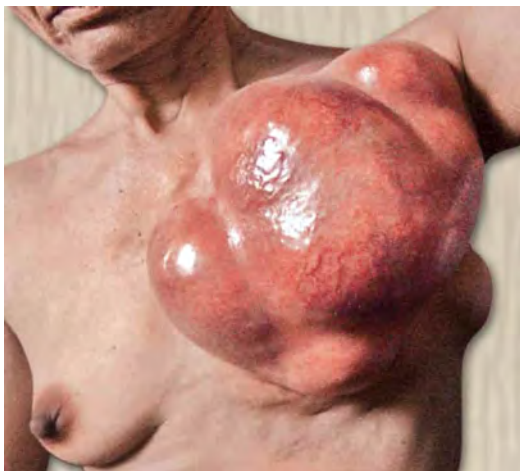*Have a heart that never hardens and a temper that never tires and a touch that never hurts.*



**Fig. 8.48:** Ulcerated carcinoma breast with peau d'orange. Note the lymph node enlargement.

### Spread into the Deeper Plane

- ◆ Into pectoralis major muscle (is confirmed by observing the restricted mobility of the swelling while contracting the PM muscle).
- ◆ Into latissimus dorsi muscle (extending the shoulder against resistance).
- ◆ Into serratus anterior (by pushing the wall with hands without flexing the elbow).
- ◆ Into the chest wall (breast will not fall forward when leaning forward, and while raising the arm above the shoulder, breast will not move upwards as it is fixed to the chest wall).



**Fig. 8.49:** Advanced carcinoma left breast involving entire breast with nodularity.

### Lymphatic Spread

- ◆ It occurs through:
  - ▶ Subareolar Sappey's lymphatic plexus (presently its significance is discounted).
  - ▶ Cutaneous lymphatics.
  - ▶ Intramammary lymphatics.
- ◆ Lymphatic drainage of the breast is predominantly through axillary (75%) and internal mammary lymph nodes.

### Axillary group of nodes are:

1. *Anterior* along lateral thoracic vessels (Pectoral).
2. *Central* embedded in fat in the centre of the axilla.
3. *Posterior* along subscapular vessels.
4. *Lateral* along axillary vein.
5. *Apical* lies above pectoralis minor tendon in continuity with the lateral nodes and receive efferents from all the groups. Spread to these lymph nodes occur by *lymphatic permeation*.

Groups 1st and 2nd are commonly involved.

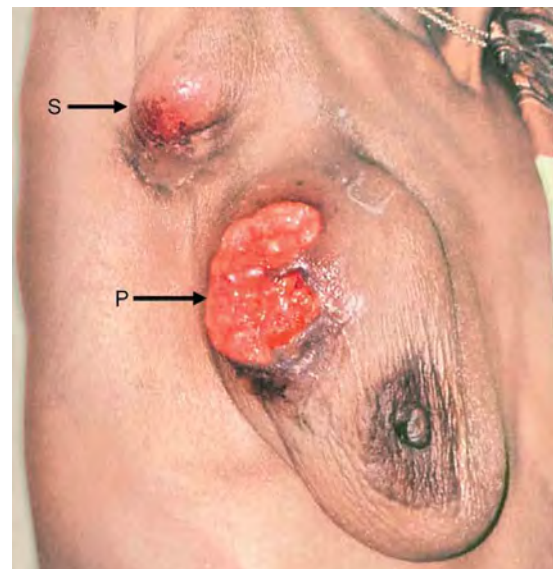
Groups 3rd and 4th are rarely involved.

Finally Group 5th is involved.

Spread restricted to level I nodes carries better prognosis.

Spread to level II has poor prognosis.

Spread to level III indicates worst prognosis.

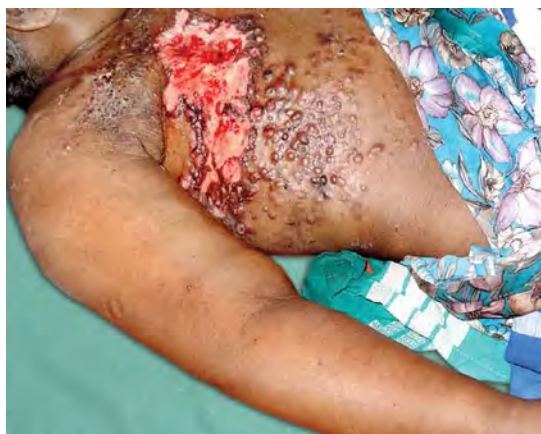

**Fig. 8.50:** Carcinoma right breast with ulceration in the primary (P) with axillary lymph node secondaries (S).

- ◆ *Interpectoral*, lies between pectoralis major and minor muscle (**Rotter's nodes**). Presently involvement of these lymph nodes are considered due to retrograde spread. These lymph nodes are cleared during *Patey's mastectomy*.
- ◆ From axillary lymph nodes spread occurs to supraclavicular lymph nodes by *lymphatic embolisation*.
- ◆ Through dermal lymphatics, it may spread to opposite breast or to opposite axillary lymph nodes.
- ◆ Spread may occur into internal mammary lymph nodes of same side and then to mediastinal lymph nodes.
- ◆ Contralateral internal mammary lymph nodes can also get involved by retrograde spread.
- ◆ *Fixed enlarged axillary nodes* can cause lymphoedema due to lymphatic block; venous thrombosis and venous oedema due to venous block; and severe excruciating pain along the distribution of the median and ulnar nerves (rare in radial nerve) with often significant sensory and motor deficits due to tumour infiltration of the cords of brachial plexus (*medial cord* often lateral cord).

Once axillary lymph nodes get fixed, it can result in **lymphoedema of the upper limb**. It develops gradually.

Compression of nodes on axillary vein can cause sudden onset of **venous oedema of upper limb** (Venous edema develops faster, and is more proximal with bluish discoloration of the skin of the upper limb. It may lead to venous gangrene and so the compression has to be relieved early by radiotherapy).

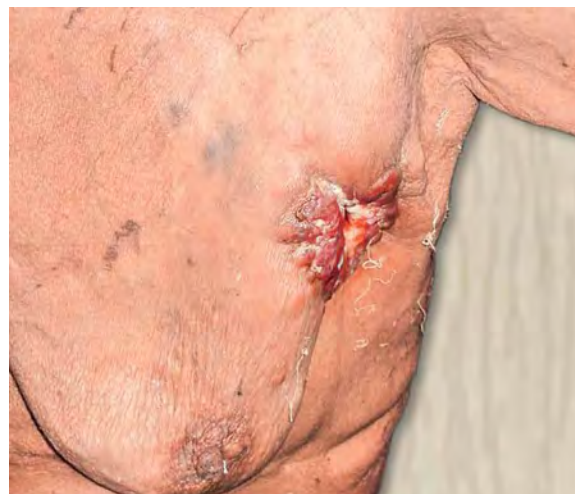

**Fig. 8.51:** Carcinoma breast right sided causing extensive oedema (lymphoedema) in right upper limb.

<b>Causes of lymphatic block in carcinoma breast</b>	<b>Treatment of lymphoedema of arm</b>
<ul style="list-style-type: none"> <li>• Involvement and fixation of the axillary nodes level I, II and III</li> </ul>	<ul style="list-style-type: none"> <li>• Elevation of limb</li> <li>• Elastic stockings</li> <li>• Pneumatic compression</li> </ul>
<ul style="list-style-type: none"> <li>• After levels I, II and III dissection</li> </ul>	<ul style="list-style-type: none"> <li>• Drugs like diuretics and benzopyrones</li> </ul>
<ul style="list-style-type: none"> <li>• After radiotherapy to axilla</li> </ul>	
<ul style="list-style-type: none"> <li>• Inoperable fixed nodes in axilla</li> </ul>	
<ul style="list-style-type: none"> <li>• Recurrent axillary disease</li> </ul>	
<ul style="list-style-type: none"> <li>• May be associated with <i>cancer-en-cuirasse</i></li> </ul>	
<ul style="list-style-type: none"> <li>• Secondary infection</li> </ul>	

<b>Effects of lymphatic obstruction</b>
<ul style="list-style-type: none"> <li>• Peau d'orange</li> </ul>
<ul style="list-style-type: none"> <li>• Brawny oedema of arm—indurated, painful, non-pitting—occurs in fixed nodes in axilla</li> </ul>
<ul style="list-style-type: none"> <li>• Elephantiasis chirurgens—after radical mastectomy or radiotherapy to axilla</li> </ul>
<ul style="list-style-type: none"> <li>• <i>Cancer-en-cuirasse</i>—seen in locally advanced carcinoma of breast. Skin of chest wall is studded with hard fixed nodules like armour coat (of soldiers)</li> </ul>
<ul style="list-style-type: none"> <li>• Lymphangiosarcoma after radical mastectomy or MRM (Stewart-Treves's)</li> </ul>

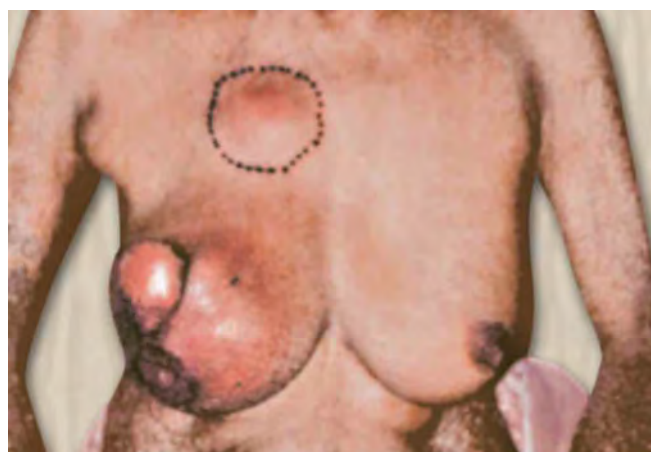Breast is in subcutaneous plane, but its extension, *axillary tail of Spence* passes through an opening in the deep fascia (*foramen of Langer*). Often it is difficult to differentiate between lymph node in pectoral region and tumour invasion of axillary tail. Mobility will be independent if it is a lymph node, but if it is an axillary tail tumour, it is along with the primary tumour in the breast.



**Fig. 8.52:** Carcinoma breast involving axillary tail of Spence.

#### Haematogenous Spread

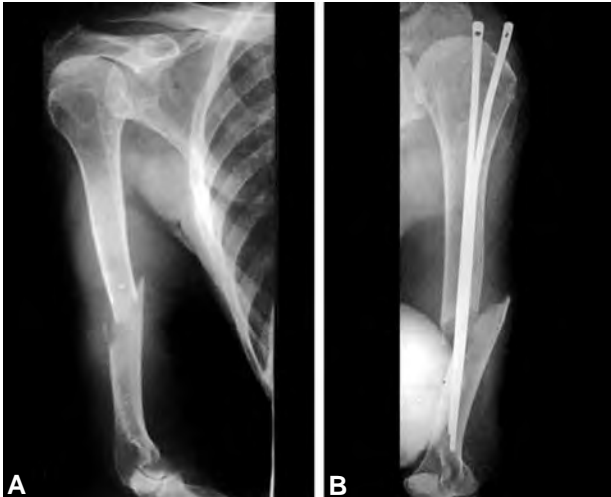- ◆ **Bone (most common) (70%)**
  - ▶ Lumbar vertebrae, femur, ends of long bones, thoracic vertebrae, ribs, skull, in order.
  - ▶ They are *osteolytic* lesion often with pathological fracture.
  - ▶ Presents with painful, tender, hard, nonmobile swelling, with disability.
  - ▶ *70% of secondaries in bone in a women is due to carcinoma breast.*
  - ▶ Spine secondaries can cause paraplegia.



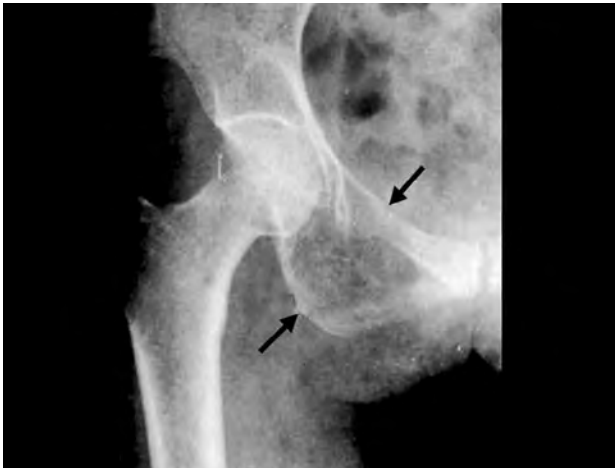**Fig. 8.53:** Carcinoma breast with rib secondaries.

**Mammary fistula presents as a recurrent abscess that points and discharges on to the areola and continues to discharge for weeks at a time.**

—Sir Headly Atkins



**Figs 8.54A and B:** (A) Pathological fracture of the humerus due to metastatic secondaries from the carcinoma breast. (B) Intramedullary nailing as a treatment for pathological fracture.



**Fig. 8.55:** Osteolytic secondaries involving ischium and pubic bones.

#### Features of bone secondaries

- ❖ Pain
  - ❖ Swelling
  - ❖ Pathological fractures
- ◆ **Liver**—either through blood, occasionally through transcoelomic spread.
  - ◆ **Lung**—causes malignant pleural effusion and ‘cannon ball’ secondaries.
  - ◆ **Brain**—causes increased intracranial pressure, coning.
  - ◆ **Adrenals and ovaries.**

#### Common sites of distant spread in carcinoma breast

- ❖ Bones—70% (lumbar vertebrae, pelvic bones, long bones)
- ❖ Lungs and pleura—20–30%
- ❖ Soft tissues—5–15%
- ❖ Liver—10–12%
- ❖ Brain—2–5%
- ❖ Adrenals—2–5%

#### Transcoelomic Spread

Through mediastinal lymph nodes, it may spread into peritoneal cavity causing secondaries in liver, peritoneum, ovary (*Krukenberg secondaries*—occurs in menstruating age groups. During ovulation, cells get attached over the ovarian capsule).

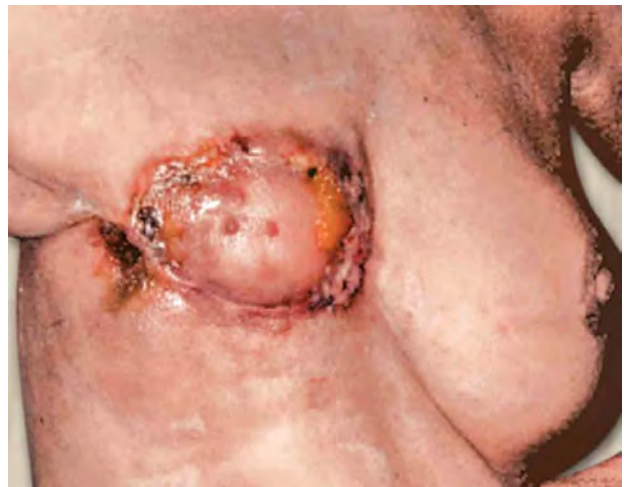#### Note:

Present concept of Krukenberg tumour is haematogenous and lymphatic modes of spread. Older concept of transcoelomic spread is no longer well-accepted.

#### Recurrent Carcinoma of Breast

- ◆ It is recurrence of breast cancer after initial curative therapy; recurrence can occur in months or years after initial therapy; it may occur in the same original site (*local recurrence*) or elsewhere in the body at distant site (*distant recurrence*).
- ◆ In local recurrence, lump or ulceration or nodules which are hard and fixed can appear at the local site; if patient has undergone breast conservative surgery then nipple discharge, destruction of nipple areolar complex may develop.
- ◆ Recurrence can also occur at axillary or neck (supraclavicular) nodes as palpable, hard often fixed and fungating mass.
- ◆ Distant recurrences are of features of metastatic disease in the bone, lungs, liver or brain.
- ◆ *Factors* which are of poor prognostic one are risk factors for recurrence—tumour size/spread/stage, histologic/nuclear grade, receptor status.
- ◆ It is *evaluated* by trucut biopsy from local area, FNAC of the nodes, CT chest, MRI brain, isotope bone scan and PET scan.

*Treatment* differs in individual patients depends on the type and site of recurrence—wide local excision, nodal clearance, RT, chemotherapy, hormone therapy, immunotherapy. Recurrence carcinoma carries poor prognosis.



**Fig. 8.56:** Recurrent carcinoma breast.

#### Note:

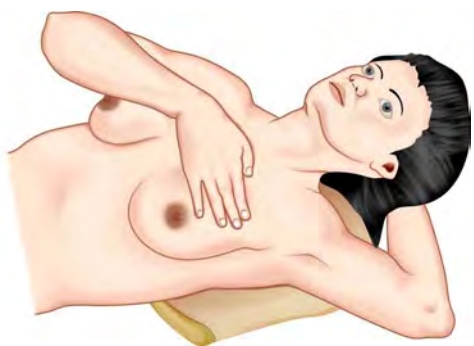*Dominant breast mass* is three-dimensional, distinct from surrounding tissue of same breast, asymmetric in relation to other breast.

## Breast Self-examination (BSE)

*Breast self-examination* plays a major role in early detection and intervention of breast carcinoma. This underlines the importance of advocating *self-examination of the breast*.

Ideally done once a month just after the menstruation, as during this time breasts are less engorged. In postmenopausal age group it is done at monthly regular intervals.

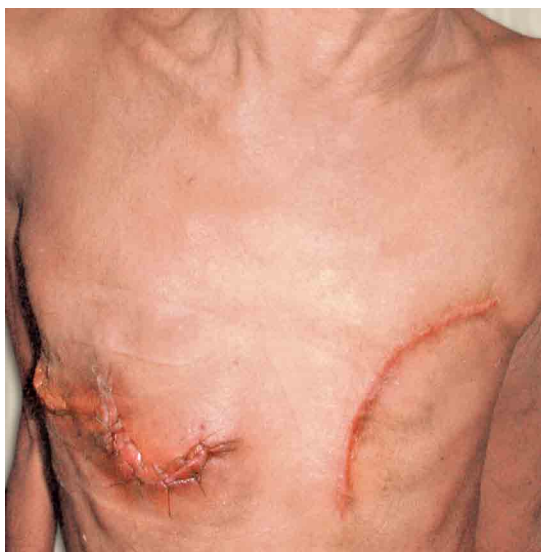- ❖ Examine both breasts
- ❖ Remind the patient that 90% of breast lumps are not cancer.
- ❖ Better way is in lying down position with arm raised with a mattress support behind
- ❖ Palpation should be using the fingers over all quadrants of the breast
- ❖ If any doubtful swelling is palpable, consult the surgeon
- ❖ American Cancer Society recommends monthly BSE after 20 years of age
- ❖ Nursing mother should perform BSE just after feeding the baby



**Fig. 8.57:** Self-examination of breast is done in lying down position.

## Bilateral Breast Cancer

- ❖ It is separate primary breast cancer on the opposite side in a patient who is having or treated for ipsilateral breast cancer.
- ❖ It can be synchronous or metachronous.



**Fig. 8.58:** Bilateral breast cancer operated.

- ❖ There is 5 fold increase in 2nd breast cancer on opposite side in a female, who has had breast cancer on ipsilateral side.
- ❖ LCIS, multifocal breast cancer, family history are other risk factors.
- ❖ *Choudary Millis criteria* that help to differentiate primary contralateral breast cancer from metastatic—*in situ* change, different histological pattern, different differentiation shown in opposite breast, clinically or by evaluation ipsilateral tumour has not shown any features of spread.
- ❖ It is investigated like any breast cancer, staged accordingly and treated.
- ❖ If tumour on the opposite side is metastatic then it will show separate histology and differentiation with mammography showing less infiltrative, diffuse, without microcalcifications but with oedema. If it is metastatic, it is stage IV disease.

## TNM STAGING OF CARCINOMA BREAST (AJCC 7th EDITION, 2010)

### Primary Tumour (T)

Tx Primary tumour cannot be assessed (already treated elsewhere without documentation).

T0 – No evidence of primary.

Tis – Carcinoma *in situ*.

Tis (DCIS) Ductal carcinoma *in situ*.

Tis (LSCIS) Lobular carcinoma *in situ*.

Tis (Paget's) – Paget's disease of the nipple not associated with invasive carcinoma or with DCIS/LCIS in the parenchyma

T1 – Tumour less than 2 cm (20 mm)

T1 mi – Microinvasion 1 mm or less in greatest dimension

T1a – 1 – 5 mm

T1b – 5 – 10 mm

T1c – 10 – 20 mm

T2 – 20 – 50 mm in greatest dimension

T3 – >50 mm in greatest dimension

T4 – Any size with direct extension to the chest wall or skin or both.

T4a – Tumour of any size extending into the chest wall, not including only pectoralis muscle invasion/adhesion (chest wall means ribs, intercostal muscles and serratus anterior but not pectoral muscles).

T4b – Ulceration or ipsilateral satellite nodules and/or oedema including peau d'orange of the skin which do not meet the criteria for inflammatory carcinoma.

T4c – T4a and T4b.

T4d – Inflammatory carcinoma.

### Regional Lymph Nodes (N)

Nx – Regional nodes cannot be assessed

N0 – No regional nodes involved

N1 – Metastases to mobile ipsilateral level 1 and 2 axillary nodes

N2 –

N2a – Metastases in ipsilateral level 1 and 2 axillary nodes which are fixed to one another (matted) or other structures

N2b – Metastases only in clinically detected ipsilateral internal mammary nodes and in the absence of clinically evident level 1 and 2 axillary nodes

**N3 —**

N3a – Metastases to ipsilateral infraclavicular lymph nodes (level III axillary) with or without level 1 and 2 axillary lymph node involvement.

N3b – Metastases to ipsilateral internal mammary lymph nodes with clinically evident level 1 and 2 axillary lymph nodes involvement.

N3c – Metastases to ipsilateral supraclavicular lymph nodes with or without axillary or internal mammary lymph node involvement.

**Note:**

**Clinically detected** is defined as detected by imaging studies (excluding lymphoscintigraphy) or by clinical examination and having characteristic highly suspicious for malignancy or a presumed pathologic micro-metastases based on the fine needle aspiration biopsy with cytologic examination. Confirmation of clinically detected metastatic disease by fine needle aspiration without excision biopsy is designated with f suffix.

**Distant Metastases (M)**

M0—No clinical or radiological evidence of distant metastases  
cM0(i+)—No clinical or radiological evidence of distant spread metastases but deposits of molecularly or microscopically detected tumour cells in circulating blood, bone marrow or other non-regional nodal tissue that are no larger than 0.2 mm in a patient without symptoms or signs of metastases.

M1—Distant detectable metastases as determined by classic clinical and radiographic means and/or histologically proven larger than 0.2 mm.

**Note:**

- Mx is removed in 7th edition of TNM staging.
- **c:** stage given by clinical examination of a patient.
- **p:** stage given by pathologic examination of a surgical specimen.
- **y:** stage assessed after chemotherapy and/or radiation therapy; in other words, the individual had neoadjuvant therapy.
- **r:** stage for a recurrent tumor in an individual that had some period of time free from the disease.

**Stage Groups**

Stage	TNM status
0	Tis N0 M0
IA	T1/T1 mi N0 M0
IB	T0 N1 mi M0 T1/T1 mi N1 mi M0
IIA	T0 N1 M0 T1 N1 M0 T2 N0 M0
IIB	T2 N1 M0 T3 N0 M0
IIIA	T0 N2 M0 T1 N2 M0 T2 N2 M0 T3 N1 M0 T3 N2 M0
IIIB	T4 N0 M0 T4 N1 M0 T4 N2 M0
IIIC	Any T N3 M0
IV	Any T any N M1

**Note:**

- T1 includes T1mi
- T0 and T1 with nodal micrometastases are excluded from stage IIA and is classified as stage IB.
- If patient presents with M1 prior to neoadjuvant systemic therapy, the stage is considered as stage IV and will remain stage IV regardless of response to neoadjuvant therapy.

**Molecular subtypes of carcinoma breast**

- ❖ **Basal-like (15–25%):** ER–ve, PR–ve and HER2–ve; also called *triple negative breast cancer* (TNBC). Most BRCA1 breast cancers are basal-like TNBC. They are high grade, aggressive with poor prognosis. Common in black and young individuals; high incidence of lung and brain secondaries.
- ❖ **Luminal A (50%):** ER+ HER2 –ve and low grade. They are slow growing and occur in postmenopausal women. They respond well hormone therapy.
- ❖ **Luminal B (15–20%):** ER+ PR+ve Her2 +ve (triple positive) but often high grade. They respond to chemotherapy.
- ❖ **Her2 rich (10%):** ER –ve. Poorly differentiated, aggressive with higher incidence of brain secondaries. Treated with chemotherapy and trastuzumab. Lapatinib is used if brain metastases are present as trastuzumab will not cross the blood-brain barrier.
- ❖ **Normal breast like (5%):** ER +ve, Her2 –ve.
- ❖ **Luminal ER–/AR+:** recently identified androgen responsive subtype which may respond to antihormonal treatment with bicalutamide.
- ❖ **ERBB2/HER2+:** has amplified HER2/neu.
- ❖ **Claudin-low:** a more recently described class; often triple-negative, but distinct in that there is low expression of cell-cell junction proteins including E-cadherin and frequently there is infiltration with lymphocytes.

**DNA microarrays (gene) analysis**

- ❖ Oncotype Dx – 21 gene assay (16 cancer related and 5 normal genes)
- ❖ Mammaprint – 70 genes are analysed

**Note:**

Manchester staging and Columbia classification are obsolete (not used now). Readers can refer 4th edition if needed. *Manchester staging* is—1. Mobile tumour in the breast; no deeper fixation; skin if involved lesser the size of the tumour; lymph node spread is absent. 2. Same as stage 1 with mobile discrete axillary nodes. 3. Fixed to pectoralis major or skin involvement more the tumour size or fixed/adherent node. 4. Tumour fixed to chest wall/involvement same or opposite supraclavicular nodes, opposite axillary nodes, opposite breast, cancer en cuirasse, distant blood spread.

**Differential diagnosis for carcinoma breast**

- ❖ Fibroadenosis
- ❖ Traumatic fat necrosis
- ❖ Tuberculosis of breast
- ❖ Bloodgood cyst
- ❖ Filariasis breast
- ❖ Mastitis
- ❖ Antibioma
- ❖ Galactocele
- ❖ Mondor's disease
- ❖ Cystosarcoma phyllodes

## Investigations in Carcinoma Breast

### ◆ Mammography.

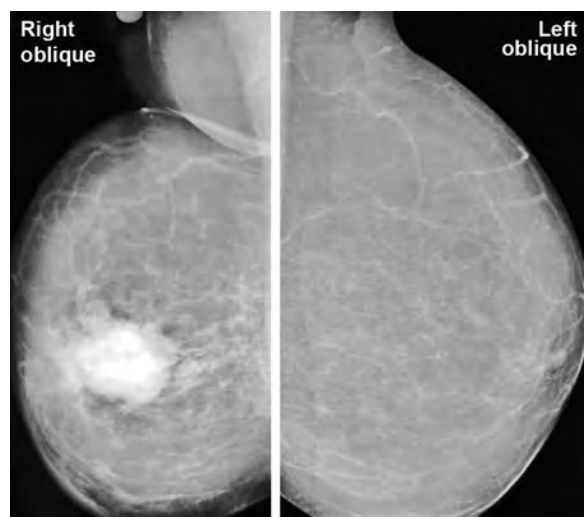


Fig. 8.59: Mammography in carcinoma breast.

#### Findings

- ❖ Size and location of mass lesion
  - ❖ Microcalcifications signify malignancy
  - ❖ Soft tissue shadow is irregular
  - ❖ Spiculations
- ◆ Bilateral mammography is done to identify multicentricity, to have guideline for assessing eventual chemotherapy or RT in LABC.
  - ◆ Stereotactic mammography guided biopsy is very useful.
  - ◆ LCIS may be missed in mammography.
  - ◆ Fifty per cent of breast cancers can be seen on mammography before they are palpable.
  - ◆ It is noninvasive with less radiation exposure.
  - ◆ Five per cent false-positive rate in mammography; hence, biopsy is a must.
  - ◆ Mammogram is used during follow-up period after conservative breast surgery and of opposite side.
  - ◆ Ideally specimen mammography is a must after conservative breast surgery to assess the completion; and after core biopsy to confirm the sample tissue.
  - ◆ **Ultrasound of breast:**
    - ▶ To find out whether the lesion is solid or cystic.

#### Ultrasound of breast

- ❖ To look for whether the lesion is solid or cystic, margin of the lesion, internal echoes, retro-tumour acoustic shadowing, compressibility, dimensions.
- ❖ *Irregular margin, irregular internal echoes, irregular posterior shadowing, noncompressibility, ratio between anteroposterior to width (lateral/horizontal) dimensions more than 1 are the features of carcinoma.* Doppler will show high frequency signals with continuous flow. It is hypoechoic with more vertical taller growth.

- ❖ Benign lesions are smooth, rounded with well-defined margins with weak internal echoes and compressibility. It can be elliptical, hyperechoic/hypoechoic smooth lesion.
- ❖ Cyst is anechoic, oval/round, well circumscribed lesion.
- ❖ Disadvantage is lesions less than 1 cm may not be identified.
- ❖ FNAC can be done under US guidance.
- ❖ It is cheaper, easily available and there is no risk of radiation.
- ❖ It is preferred method of screening in young females where mammography is not done and in pregnancy and early lactation.
- ❖ US of axilla also can be done to assess axilla and to do guided FNAC of node.

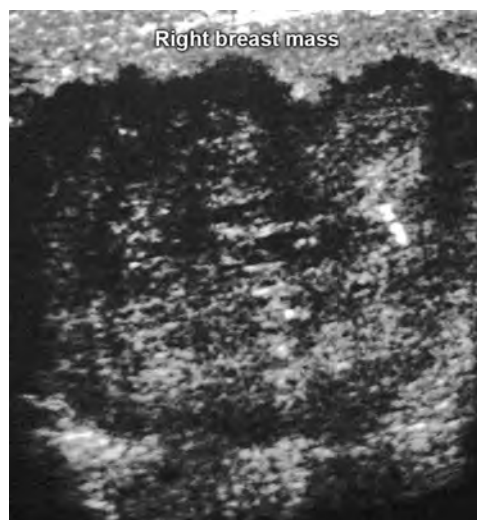

Fig. 8.60: Ultrasound picture of right breast showing breast mass.

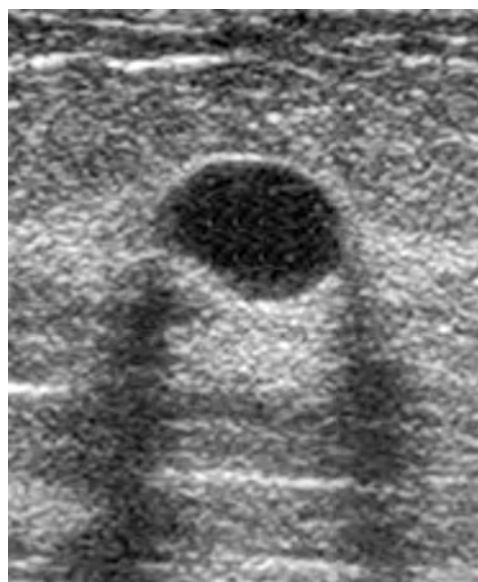

Fig. 8.61: Ultrasound breast is basic noninvasive simple investigation to assess breast lump.

- ◆ **FNAC** (Martin and Ellis 1930): It is very useful in diagnosing the carcinoma breast. US guided FNAC is also used. But negative results are difficult to interpret because it may

*If you don't know where you're going, you may miss it when you get there.*



be due to sampling errors and so requires further diagnostic methods. FNAC of opposite breast, lymph nodes, opposite axillary lymph nodes are also often required.

It is done with 23 gauge needle using FNAC aspiration special syringe (aspiration gun). With the lump held firmly, the needle is passed into the lump and with negative pressure continuous aspiration is done until adequate material comes through the needle (suction pressure of 40 cm of H<sub>2</sub>O is created into the syringe). Needle with syringe is removed without negative pressure. Material is collected on a slide; a smear is made using 100% alcohol. Cytology is studied after staining it under microscopy.

- ◆ Minimum six aspirations are done.
- ◆ Giemsa, Papanicolaou, hematoxylin and eosin stains are used.
- ◆ Repeat FNAC can be done for further 2 times.
- ◆ But it gives only cytological diagnosis. Receptor study cannot be done.
- ◆ It is difficult to differentiate between *in situ* and invasive breast cancer by FNAC.

### Advantages

FNAC is least painful, can be done on OP basis, reliable and cheaper. Malignant deposits will not occur along FNAC track (only contraindication for FNAC is testicular tumour).

### Note:

**FNNAC** is Fine Needle Non-Aspirating Cytology.

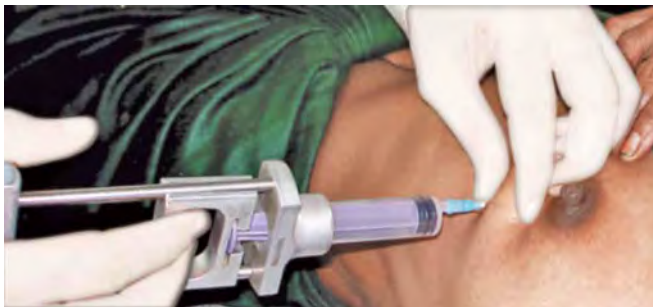

Fig. 8.62: FNAC of breast lump.

Reliability of FNAC and mammography		
	FNAC	Mammography
Sensitivity (true positivity)	90–98%	90%
Specificity (without false-positive)	98–100%	90%
False-negative	2–10%	10%
False-positive	Near	10%

### FNAC scoring

- C<sub>0</sub> : No epithelial cells
- C<sub>1</sub> : Scanty epithelial cells, benign
- C<sub>2</sub> : Benign cells
- C<sub>3</sub> : Atypical cells
- C<sub>4</sub> : Suspicious cells
- C<sub>5</sub> : Malignant cells

### ◆ Corecut/Trucut biopsy:

- ▶ It is done under local anaesthesia. It gives clear histological evidence and also confirms DCIS (FNAC cannot confirm DCIS). This allows proper neoadjuvant/primary chemotherapy, receptor status of the tumour. Wide bore needle biopsy with vacuum is also used.
- ▶ 14–18 gauge spring loaded needle is used. Multiple punctures are needed. US guided biopsy is also done.
- ▶ Large core biopsy is done using 6–14 gauge needle; single puncture is sufficient; large single sample of tissue is obtained.
- ▶ Vacuum-assisted core biopsy is also done.
- ▶ Stereotactic mammographic/MRI/US guided core biopsy are also used in small/impalpable lesions. Stereotactic core biopsy is done in prone position with compressed breast. Under local anaesthesia, 3 mm incision is made and 11 gauge core needle is passed under digital mammographic guidance. Multiple core biopsies are taken using vacuum. A clip may be placed under guidance at the site of the lesion as marker. Mammography of core biopsy specimen is done to confirm the sample tissue. If stereotactic biopsy is inconclusive then a wire localised surgical excision should be done.
- ▶ *Core needle biopsy is the method of choice.*

### Image guided biopsies

It is done when lump is not clearly palpable.

- ❖ US guided core needle biopsy.
- ❖ Stereotactic mammographic core needle biopsy.
- ❖ Mammography guided wire localisation using needle sheath over the tumour and through an incision under local anaesthesia hook is reached and biopsy is done. It is used if core needle biopsy fails in localising nonpalpable lesion.
- ❖ MRI guided core needle biopsy.

- ◆ **Frozen section biopsy:** If FNAC fails even after two trials or in cases of negative FNAC, then on table frozen section biopsy is done for diagnosis. Frozen section biopsy also has got drawbacks. It has got 20% false-negative results. So its use at present is under debate even though it is practiced in few oncocenters. It is *not ideal method*.

### ◆ Excision biopsy:

- ▶ It is done only when FNAC is inconclusive and a facility for frozen section is not available. Incision should be planned in such a way that it will be included in eventual mastectomy.

### ◆ Edge biopsy:

- ▶ Done only when there is ulceration and fungation. Diathermy should be avoided in incision biopsy as it may distort the histology of tumour and study of hormone receptor status may not be possible.

### ◆ Oestrogen receptor study:

- ▶ They are oestrogen sensitive receptors, which are cytosolic, glycoprotein present in the breast and tumour tissue. It is an important indicator of prognosis of carcinoma breast.
- ▶ Tissue for receptor study is sent at low temperature in

ice flasks. It is assessed by quantitative analysis (Frozen  $-70^{\circ}$ ).

- ▶ If value is more than 10 units (f/mols) per n gram of tissue it is called as *ER +ve status*. ER positivity is common in postmenopausal women (60%) compared to premenopausal women (30%). If value is less than 10 units per gram of tissue it is called as *ER -ve status*.

In ER +ve status

- Prognosis is good.
- Hormone therapy including tamoxifen is more beneficial.
- Response to treatment is better.

In ER -ve status

- Prognosis is poor.
- Hormone therapy is not very beneficial (but used) as compared to ER +ve patients.
- Response to treatment is not good.

- ◆ **Progesterone receptor (PR status)** study or *Her 2 Neu receptor status* or *cErb B2* (growth factor receptor study) are other studies done at present to plan the therapy and assess the prognosis.

- ▶ *Her 2/Neu receptor* (Human epidermal growth factor receptor 2 Neu oncogene [Neuropilin 2]) is a tyrosine kinase receptor and is associated with ER negative, high grade, tumours. It carries poor prognosis. Over expression of Her 2/Neu shows good response to adriamycin.

- ◆ **Study of discharge** from the nipple.

- ▶ Nipple discharge is usually unilateral in carcinoma breast. *Ductal lavage* may be useful in some patients. Microcatheter of 1 cm length is introduced gently into the ductal opening. 10 ml saline is infused through the catheter. Fluid is withdrawn into the syringe and cytological analysis is done.

- ◆ **Sentinel lymph node biopsy (SLNB):**

- ▶ The first axillary node draining the breast (by direct drainage) is designated as the *sentinel lymph node (SLN)*. SLN is first node involved by tumour cells and presence or absence of its histological involvement, when assessed will give a predictive idea about the further spread of tumour to other nodes. The incidence of involvement of other nodes without SLN is less than 3% and so if SLNB is negative nodal dissection can be avoided but regular follow-up is needed. SLNB is done in all cases of early breast cancers, T1 and T2 *without clinically palpable node*.
- ▶ It is not done in clinically palpable axillary node as there is already distortion of lymphatic flow due to tumour. It is also not done in multifocal and multicentric tumours, as there is involvement of many lymphatic trunks from different places of breast, and chances of false-negative is high.
- ▶ Sentinel node is localised by preoperative (within 12 hours prior) or perioperative injection of patent blue

(Isosulfan vital blue dye 2.5–7.5 ml) or 99m TC radioisotope labelled albumin (one mCi on previous day)/sulphur colloid (6 hours before) near the tumour (peritumour area) or into subdermal plexus around the nipple. Marker will pass through the sentinel node which can be visually detected as blue staining or with a hand held gamma camera; and is biopsied with a small incision made directly over it. Frozen section biopsy or touch imprint cytology is done for presence of malignant cells. If there is no involvement of sentinel node by tumour then further axillary dissection is not required as *skip lesions* (skipping sentinel node) occur only in less than 3% cases.

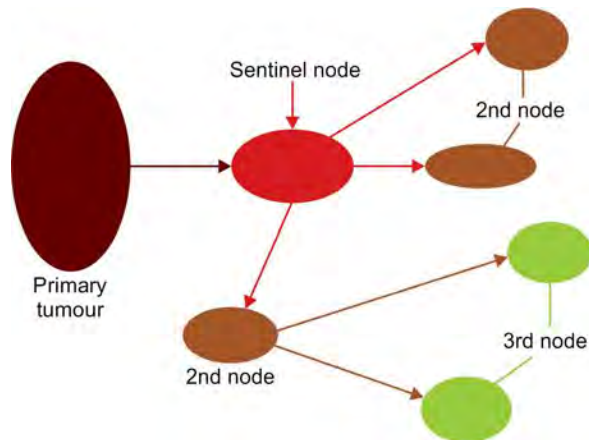
- ▶ Detection rate of sentinel node for blue dye and radioisotope is 90% and 98%, respectively. Subdermal/subareolar injection of radioisotope *has got better* sentinel node localisation than peritumour injection. But better imaging is obtained by peritumour injection and so *peritumour injection is usually* practiced. Radioisotope tracer injection done in the early morning of the day of surgery into peritumour area and perioperative injection of patent blue dye in subareolar region—as a *combined method* is often used in many centres. After injection of patent blue, breast is massaged continuously to enhance the uptake. *Incision* is made after 5–7 minutes between pectoralis major and latissimus dorsi to identify blue stained lymphatics which are traced to 2–3 blue lymph nodes. Hand-held radio-probe is used to identify the sentinel node which is later excised. Often 2–3 nodes are removed.
- ▶ *Paraffin section histology is better* than frozen section to identify positive sentinel lymph node. If report comes negative immunohistochemistry test is done to confirm that lymph node is negative for tumour. Sentinel lymph node biopsy *should be done before* wide local excision of the primary tumour.
- ▶ Wide local excision of the primary tumour is done after SLNB in the same sitting.
- ▶ SLNB is *less invasive* than axillary dissection. It is ideal in early invasive carcinoma. Positive SLNB is again classified as macrometastasis (> 2 mm) or micrometastasis (< 2 mm).
- ▶ SLNB is *contraindicated* in patients who are allergic to vital blue dye or radio-colloid, in pregnancy and in inflammatory carcinoma of breast.
- ▶ *Complications* of SLNB are rare. They are—blue tattooing of skin which gradually fades; blue—green urine and stool for short period; allergic reactions; anaphylaxis (0.1%); seroma formation. Blue dye binds to oxyhaemoglobin and so artificially registers in oximeter as hypoxaemia.

**Note:**

Facility for SLNB is not available in many centres.

**SLNB is done in:**

- ❖ Carcinoma breast
- ❖ Carcinoma penis
- ❖ Malignant melanoma



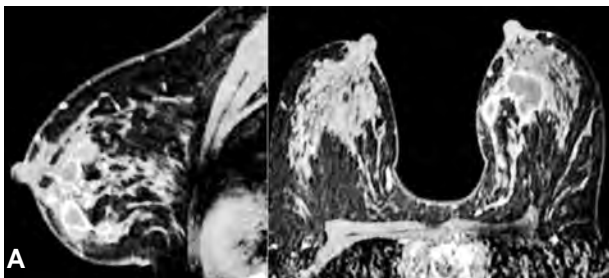
**Fig. 8.63:** Sentinel lymph node biopsy (SLNB) of breast. Note: Spread by skipping the sentinel node is less than 3%.

◆ **Axillary sampling:**

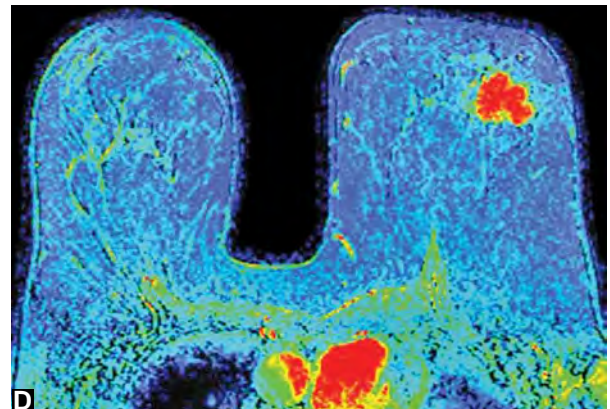
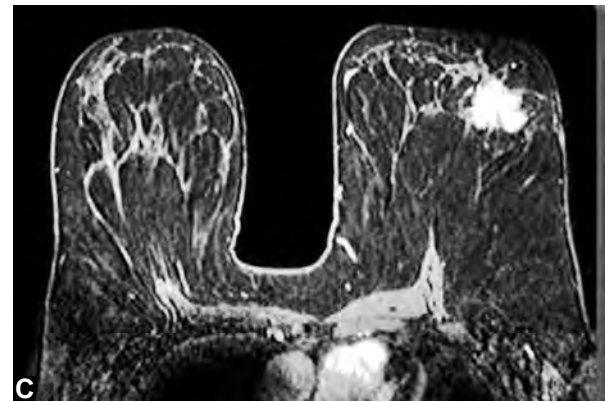
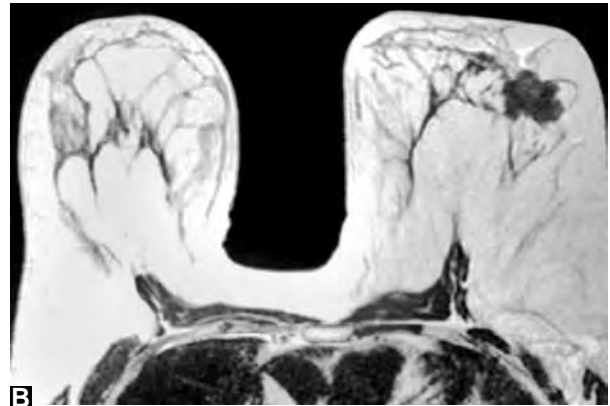
- ▶ It is often done with an adequate axillary incision. 10–15 nodes are removed for sampling. It is not commonly practiced now (Minimum 10 nodes should be removed—level I nodes).

◆ **MRI of breast:**

- ▶ To differentiate scar from recurrence.
- ▶ To image breasts of women with implants.
- ▶ To evaluate the management of axilla and recurrent disease.
- ▶ It is useful in screening females with high-risk group and *young women* and in pregnancy.
- ▶ T1 and T2 weighed images are taken.
- ▶ Irregular mass with spiculations, changes in skin and nipple, lymphoedema are the findings in carcinoma breast.
- ▶ Lesion indeterminate by US/mammography is assessed by MRI.
- ▶ Ionising radiation is not there with MRI.
- ▶ It is the method *choice of imaging* breasts in pregnancy.
- ▶ It is better in dense breasts.
- ▶ Patient lies in *prone position* with breasts placed over breast coils; both precontrast and postcontrast (*gadolinium*) MRI are taken.



**Fig. 8.64A**



**Figs 8.64B to D**

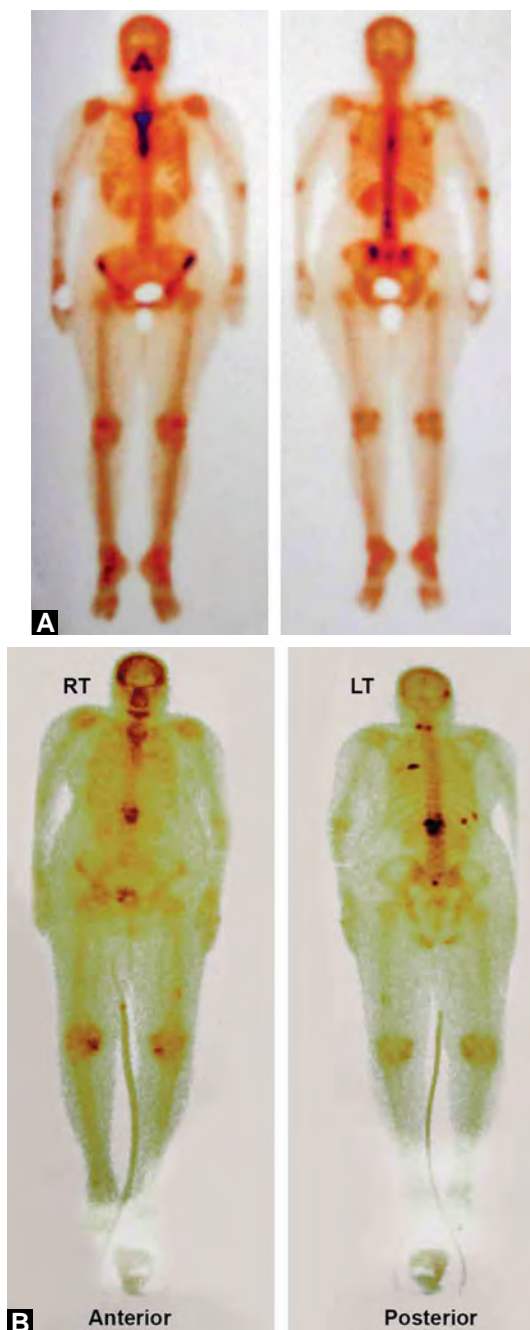
**Figs 8.64A to D:** MRI of breast is ideal method to assess or identify recurrence after BCS or after breast implants. (A) T1 weighted with contrast; (B) T1 weighted; (C) T1 weighted with contrast and fat suppressed; (D) MRI perfusion image (Courtesy: Dr Raghavendra Bhat, MD, Radiologist, Balmatta Scan and Research Centre, Mangaluru).

- ▶ *Disadvantages are*—it is costly; nonavailability; not sensitive for premalignant lesions. It cannot be done in patients who are having incompatible metal prosthesis in the body. It is not accurate if done within 9 months of the radiotherapy for carcinoma breast.

◆ **Tumour markers:** CA 15/3 (normal value < 40 U/ml of serum) are used mainly during follow-up period. CEA, CA 15-3, CA 27-29 may be useful.

◆ **MRI spine/pelvis** show osteolytic secondaries in the bone like vertebra and pelvic bones.

◆ **Radioisotope bone scan** to look for secondaries in bone in



Figs 8.65A and B: Isotope bone scan is a must in LABC/T3 disease.

advanced cases. It is not done routinely in early carcinoma of breast.

#### Indications for whole body bone scan in carcinoma breast

- ❖ T3, T4 advanced disease
- ❖ Advanced nodal disease
- ❖ Bone pain, bone swelling, pathological fracture
- ❖ Chest/liver secondaries

#### ◆ PET scan:

- ▶ It may be an effective single scan for bone, soft tissue or

visceral metastases in patients with symptoms or signs of metastatic disease.

- ◆ **CT scan of chest, abdomen and brain** whenever needed.
  - ▶ CT is said to be more useful to detect secondaries in these regions.
- ◆ **Chest X-ray:**
  - ▶ To look for pleural effusion, cannon ball secondaries in lungs, mediastinal lymph nodes, secondaries in rib.
- ◆ **Ultrasound abdomen:**
  - ▶ To look for liver secondaries, ascites, 'Krukenberg' tumour.
- ◆ **X-ray spine** shows osteolytic secondaries.
- ◆ **Ductography:**
  - ▶ It is contrast study of ducts of breast in case of unilateral nipple discharge. Fine cannula is passed under vision carefully through the duct opening into the duct and 0.2 ml of dilute water-soluble contrast media is injected into the duct. Craniocaudal and mediolateral X-ray films are taken. Contrast irregular filling defect may be observed.
- ◆ **Breast ductal endoscopy:**
  - ▶ It is useful in direct visualisation of the tumour in DCIS and invasive ductal carcinomas. But it is technically difficult and demanding.
- ◆ **Thermography:**
  - ▶ It is not very sensitive test (50%). Malignant tumours are hypervascular and so transmitted temperature is detected through different thermographic methods.
- ◆ **Blood count, complete liver function tests** are needed.

#### Triple assessment includes:

- ❖ Clinical assessment-history (age) and examination.
- ❖ Radiological imaging US/MRI/ mammography (after 40 years).
- ❖ Cytological or histological analysis FNAC/core biopsy- pathology.

#### Newer investigation modalities for carcinoma breast

- ❖ Stereotactic core biopsy using computer mammography
- ❖ Vacuum-assisted biopsy using 11-gauge biopsy probe (becoming popular)
- ❖ Needle localised biopsy under mammographic guidance
- ❖  $^{125}\text{I}$  – seed localisation biopsy

## Treatment

#### Treatment of carcinoma breast

It is usually through a combined approach

- ❖ Surgery
- ❖ Radiotherapy
- ❖ Hormone therapy
- ❖ Chemotherapy

#### A. Surgeries for Carcinoma Breast

##### ◆ Total (simple) mastectomy:

- ▶ Along with the tumour, entire breast, areola, nipple, skin over the breast, including axillary tail are removed. There is no axillary dissection. Often the patient is subjected to radiotherapy later (External) to axilla. *Pectoral fascia*

*The place to improve this world is first in one's own heart, head and hands.*

is removed along with breast specimen; breast tissue superficial to axillary fascia is removed.

◆ **Total mastectomy with axillary clearance:**

- ▶ Commonly used procedure. Total mastectomy is done along with removal of axillary fat, fascia and lymph nodes. *Level I and II axillary nodes* are removed along with total/simple mastectomy.

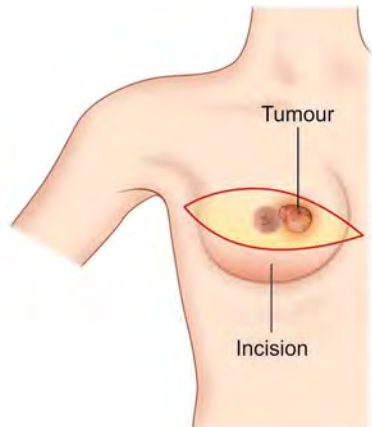


Fig. 8.66: Horizontal incision for total mastectomy.

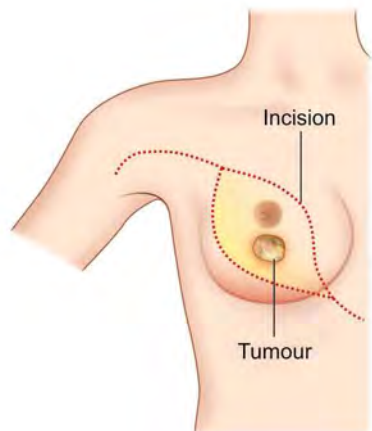
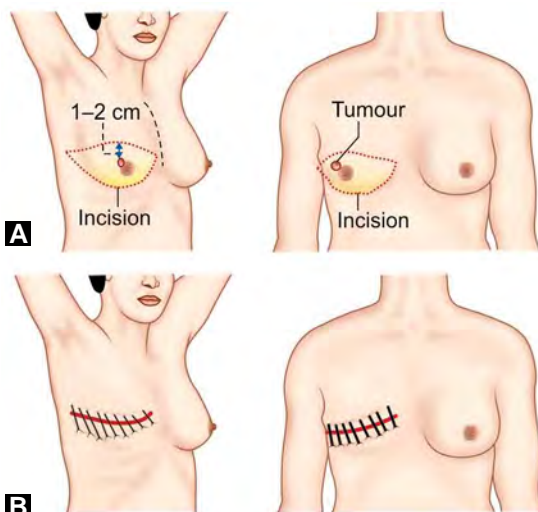


Fig. 8.67: Oblique incision extending into the anterior axillary fold for radical mastectomy.



Figs 8.68A and B: Stewart incision for mastectomy.

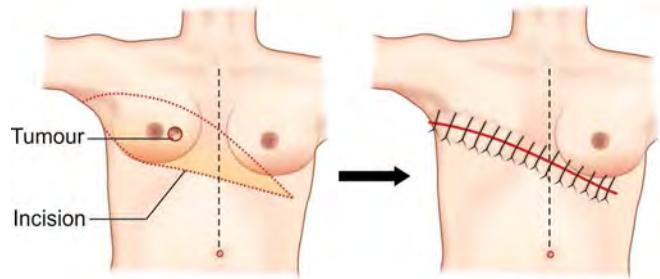


Fig. 8.69: Gray incision for mastectomy in carcinoma breast which extends to opposite side.

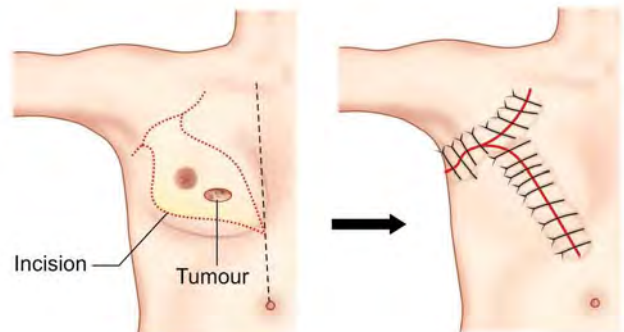


Fig. 8.70: Greenough incision for mastectomy.

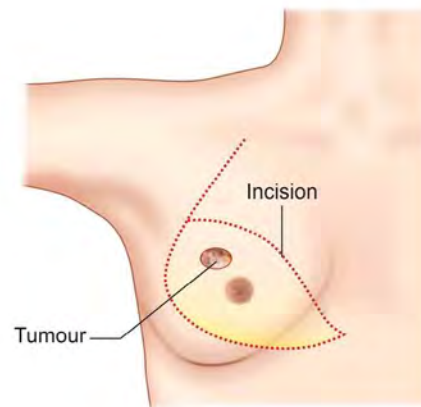


Fig. 8.71: Kocher's incision for mastectomy.

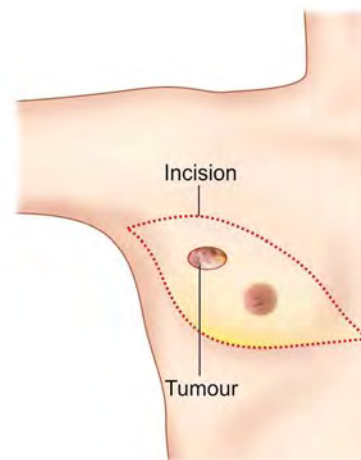


Fig. 8.72: Orr incision for mastectomy.

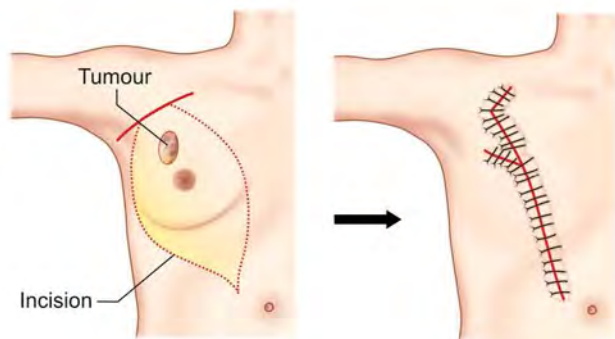


Fig. 8.73: Rodman incision for mastectomy.

◆ **Modified radical mastectomy [MRM]:**

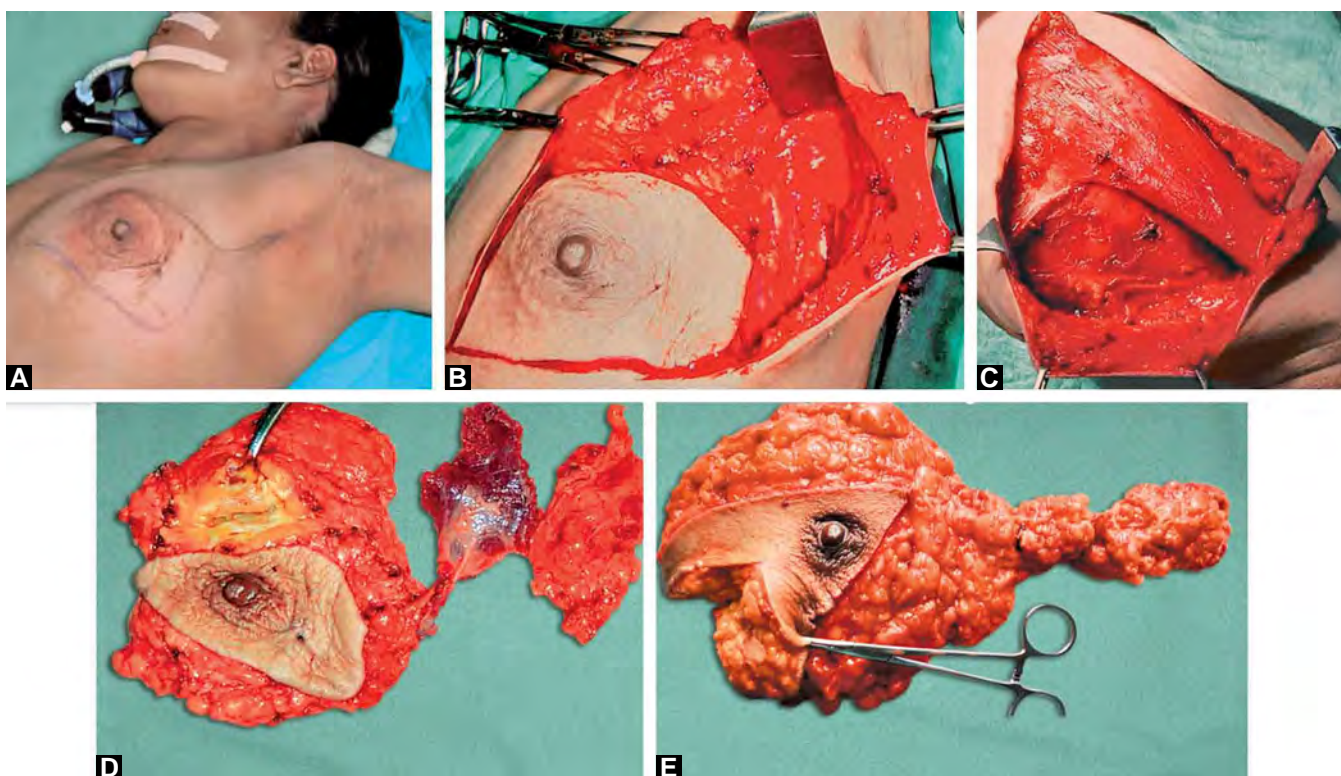
- ▶ **Patey's operation:** It is total mastectomy along with clearance of all levels of axillary nodes and removal of pectoralis minor muscle. It is enblock dissection of breast and axilla. An elliptical incision is made from medial aspect of the second and third intercostal space enclosing the nipple, areola and tumour extending laterally into the axilla along the anterior axillary fold. Upper and lower skin flaps are raised. Breast with tumour is raised from the medial aspect of the pectoralis major muscle. Dissection is proceeded laterally with ligating pectoral vessels. Once dissection reaches axilla, lateral border of pectoralis major muscle is cleared with level I nodes. Pectoralis minor is divided from

coracoid process to clear level II nodes. Medial and lateral pectoral nerves should be preserved (otherwise atrophy of pectoral muscle occurs). Later from the apex of axilla level III nodes are cleared. Nerve to serratus anterior, nerve to latissimus dorsi, intercostobrachial nerve, axillary vein, cephalic vein and pectoralis major muscle are preserved. Wound is closed with a suction drain.

- ▶ **Scanlon's operation:** It is a modified Patey's operation wherein instead of removing pectoralis minor, it is incised to approach the affected level III lymph nodes.
- ▶ **Auchincloss modified radical mastectomy:** Here pectoralis minor muscle is left intact and level III lymph nodes are not removed—commonly done now.

**Mastectomy specimen should be carefully inspected and sent to pathology department**

- ◆ Specimen is sent in formalin for histology.
- ◆ It is sent in saline in low temperature for ER/PR/Her 2 neu status study (histochemistry).
- ◆ Specimen mammography is often done.
- ◆ Tumour grading, tumour clearance, nodal involvement—its number and capsular breach are assessed histopathologically.
- ◆ **Halsted Radical Mastectomy\* (Complete Halsted) (RM):**  
Structures removed are:
  - ▶ Tumour.
  - ▶ Entire breast, nipple, areola, skin over the tumour with margin.
  - ▶ Pectoralis major and minor muscles.
  - ▶ Fat, fascia, lymph nodes of axilla.
  - ▶ Few digitations of serratus anterior.



Figs 8.74A to E: Different steps of Patey's mastectomy with incision, flap raise, dissection in breast and axilla and specimen after surgery.

**Structures retained are (ABC)**

- ❖ Axillary vein
- ❖ Bells nerve (nerve to serratus anterior)
- ❖ Cephalic vein

Complications are lymphoedema and eventual lymphangiosarcoma (after 3 to many years later) of the limb.

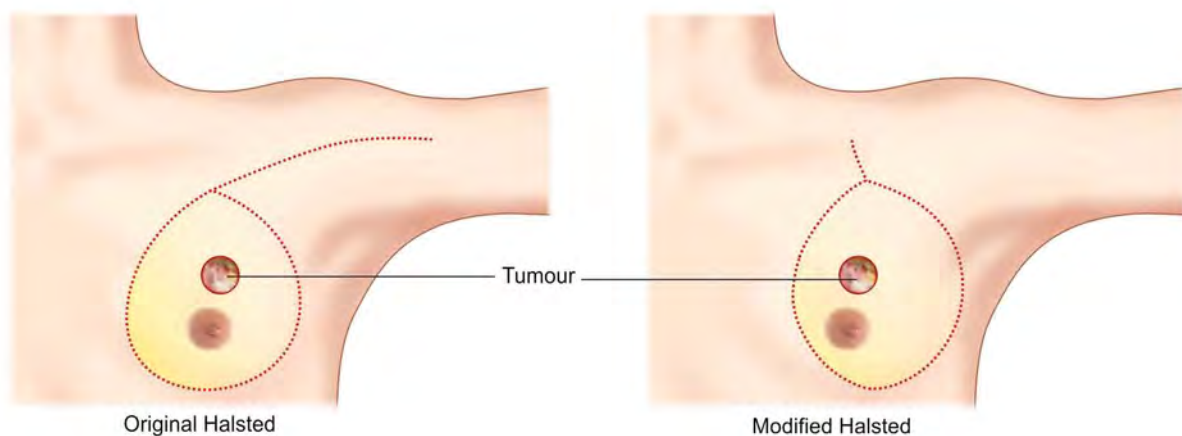
**Note:**

Hangensen and Stout (1943) criteria were used in identifying the clinically inoperable cases (for Halstead's RM) in olden days: Extensive oedema of skin over the breast and/or arm; satellite nodules; supraclavicular or internal mammary nodes; inflammatory carcinoma of breast; distant spread.

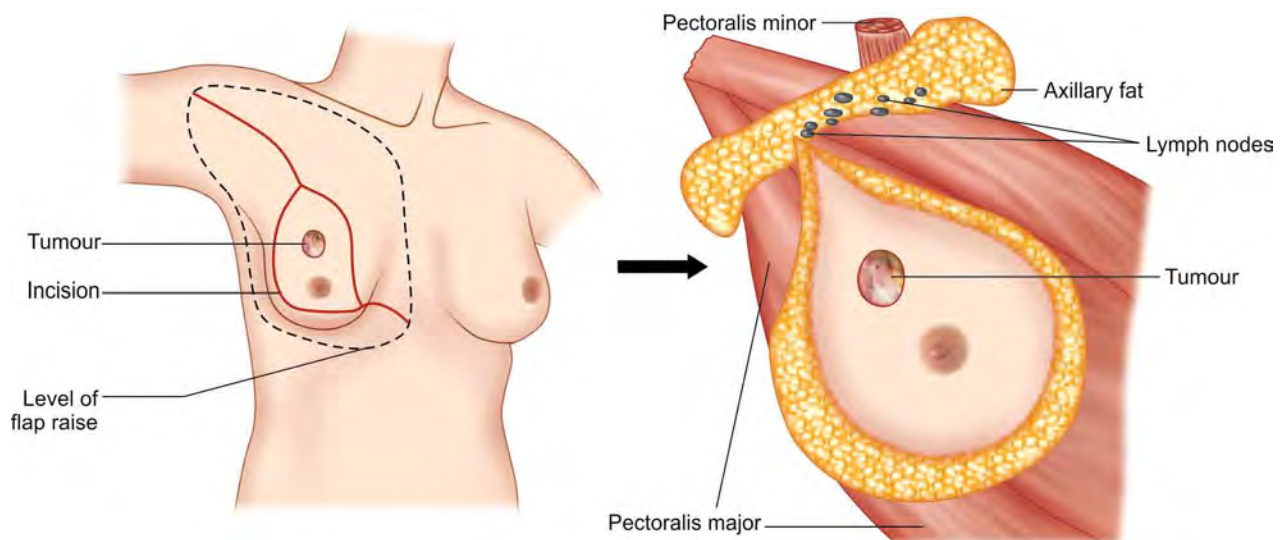
William Stewart Halsted (1852–1922) pioneered in radical mastectomy, surgeries for inguinal hernia, invented the use of surgical gloves, mosquito haemostat forceps, mattress suture, use of cocaine and anaesthetic agent, developed resident program in surgery. He did cholecystostomy to his mother using kitchen knife as emergency. He gave his own blood to his delivering sister (who became critical) to save her life and it is one of the earliest blood transfusions.

◆ **Conservative breast surgeries:**

- a. **Wide local excision:** It is removal of unicentric tumour with 1 cm clearance margin. Incision is made directly over the tumour. Skin flaps should not be raised. Normal breast tissue of 1 cm clearance with excision of tumour is done. Pectoral fascia is usually not opened in wide local excision unlike in total mastectomy. The specimen is marked after placing in orientation grid and mammography of the specimen is done followed by frozen section biopsy to look for clearance. At least 1 mm clearance is needed for adequacy. Margins where clearance is less than 1 mm need re-excision at that particular margin. If margins show no clearance then patient requires probably total mastectomy. So prior consent for mastectomy should be taken. Drain is not placed; deeper cavity is usually not closed/obliterated as small seroma gets absorbed without any problem. Skin is closed cosmetically. It is often called as *lumpectomy* or *partial mastectomy*; but better term is *wide local excision*. It is ideal



**Fig. 8.75:** Note the original Halsted and modified Halsted incision.



**Fig. 8.76:** Complete Halsted operation—radical mastectomy with removal of fat, lymph nodes, pectoralis major, pectoralis minor, entire breast with tumour and skin over the breast, nipple and areola.

breast conservative surgery. Along with this, axillary dissection through separate incision and RT to breast and chest wall area is given.

**b. Quadrantectomy:** It is removal of entire segment/quadrant with ductal system with 2–3 cm normal breast tissue clearance. It is not advocated now as it is proved that there is no outcome benefit between wide local excision and quadrantectomy. Quadrantectomy is done as a part of *QUART therapy* (by Umberto Veronesi from Milan, Italy) along with axillary dissection (level I and II) through separate incision and RT to breast area.

◆ **Toilet mastectomy:**

▶ In locally advanced tumour, tumour with breast tissue and whatever possible is removed to prevent further fungation. But its use and significance is under question. It is often done after giving chemotherapy.

◆ **Extended radical mastectomies:**

▶ It includes radical mastectomy + removal of internal mammary lymph nodes of same side with or without opposite side. **It is not done at present.**

◆ **Skin sparing mastectomy** (SSM/Key hole mastectomy) is becoming popular with different approaches.

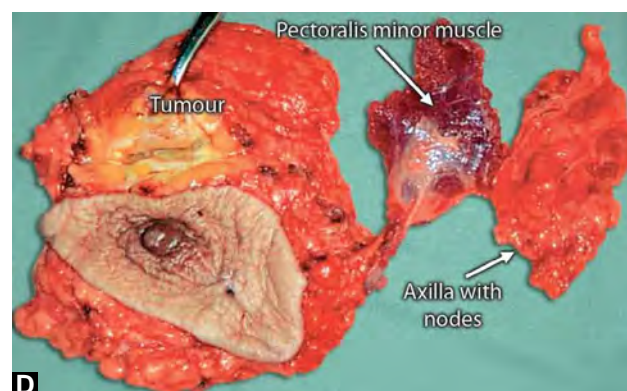
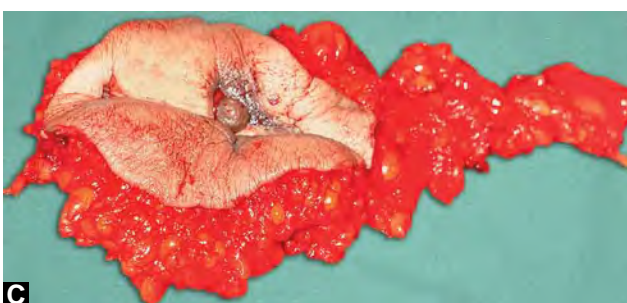
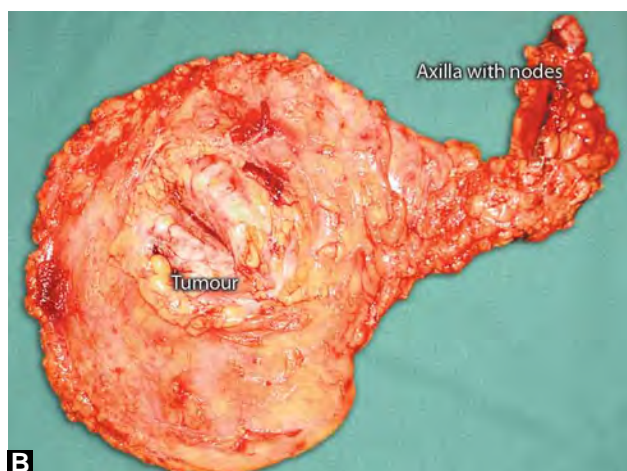
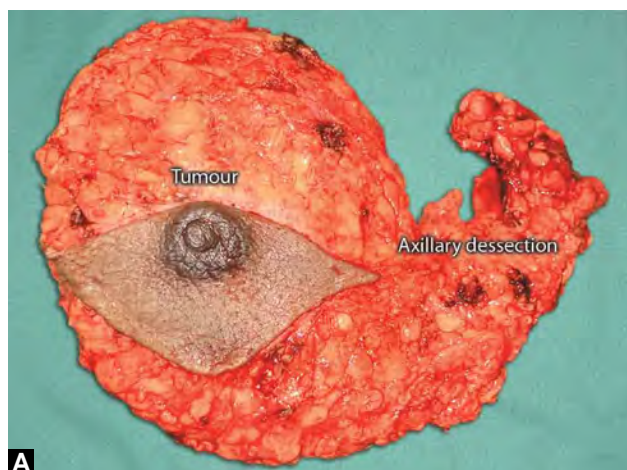
◆ **Lumpectomy/partial mastectomy is better called as wide local excision** which includes removal of tumour with gross rim (1 cm) of normal breast tissue.

▶ Small (< 0.5 cm), unicentric, low grade tumour of breast may be treated with lumpectomy with RT. But it is technically difficult to assess such indications. Stereotactic wire localisation, lumpectomy with clearance, specimen mammography and proper follow-up are the needed principles in such situations. One should achieve negative margin of 1 mm on frozen section and with post-excision mammography of retained breast to confirm adequacy of excision. Presently term ‘lumpectomy’ is *rarely* used to such procedure which basically is wide excision with 1 cm clearance. Patient always needs postoperative adjuvant RT and chemotherapy if poor prognostic factors are present.

#### Complications of MRM/mastectomy

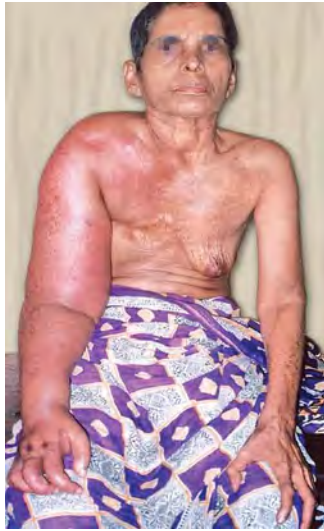- ❖ Injury/thrombosis of axillary vein
- ❖ Seroma—50–70%
- ❖ Shoulder dysfunction 10%
- ❖ Pain (30%) and numbness (70%)
- ❖ Flap necrosis/infection
- ❖ Lymphoedema (15%) and its problems
- ❖ Axillary hyperaesthesia (0.5–1%)
- ❖ Winged scapula
- ❖ Occasionally if on table injury occurs to axillary vein, it should be repaired by vascular suturing using 5 zero polypropylene
- ❖ Numbness over the medial upper part of the arm can occur due to intercostobrachial nerve injury
- ❖ Pectoral muscles atrophy if medial and lateral pectoral nerves are injured
- ❖ Weakening of internal rotation and abduction of shoulder occurs due to injury to thoracodorsal nerve

**Lymphangiosarcoma (Stewart-Treves syndrome)** of upper limb can develop in patients who have developed lymphoedema after mastectomy with axillary clearance. Usually, it occurs 3–5 years after development of lymphoedema. Such patient may require fore-quarter amputation. It has got poor prognosis. It presents as multiple subcutaneous nodules.



**Figs 8.77A to D:** (A to C) Mastectomy specimen with dissected axillary nodes. (D) Organ specimens removed during Patey's operation. Note the pectoralis minor, axillary area and tumour with breast tissue.





**Fig. 8.78:** Postmastectomy lymphoedema. Note the mastectomy scar.

### B. Radiotherapy in Carcinoma Breast

#### Indications:

- ◆ Patient who undergo conservative breast surgery, breast is irradiated after surgery.
- ◆ After total mastectomy, external irradiation is given to axilla.
- ◆ Patients with higher risk of local relapse after surgery:
  - a. Invasive carcinoma.
  - b. Extensive *in situ* carcinoma.
  - c. Patients under 35 years.
  - d. With multifocal disease.
- ◆ In bone secondaries, to palliate pain and swelling. If there is pathological fracture in the bone, internal fixation has to be done along with external irradiation.
- ◆ Inflammatory carcinoma of breast.
- ◆ In atrophic scirrhous carcinoma of breast, as a curative radiotherapy.
- ◆ As preoperative radiotherapy, to reduce the tumour size and downstage the tumour, so that the operability is better.
- ◆ More than 4 positive lymph nodes in the axilla, pectoral fascia involvement, positive surgical margins, extranodal spread or in patients with axillary status not known/not assessed.

**External radiotherapy** is given over the breast area, axilla (in selected patients like if axillary dissection is not done or more than 4 positive axillary nodes), internal mammary and supraclavicular area

- ❖ Total dosage 5000 cGY units
- ❖ 200-cGY units daily 5 days a week for 6 weeks

### C. Hormone Therapy in Carcinoma Breast

#### Principles:

- ◆ It is used in ER/PR positive patients in all age groups (earlier it is used in perimenopausal age groups).
- ◆ It is relatively safe, easy to administer.
- ◆ It gives prophylaxis against carcinoma of opposite breast.
- ◆ It is useful in metastatic breast carcinoma.
- ◆ Hormone therapy (tamoxifen) is useful in breast cancer in elderly (positive ER) after wide local excision or occasionally as tamoxifen alone.
- ◆ It is now not used in ER negative patients.
- ◆ Menopausal status; nodal status; chemotherapy used are not factors to defer the use of hormone therapy.
- ◆ Hormone therapy reduces the recurrence rate and so probably improves the life span and quality of life.

#### Includes:

- ◆ Oestrogen receptor antagonists—*tamoxifen*.
- ◆ Ovarian ablation by surgery (Bilateral oophorectomy) or by radiation.
- ◆ LHRH agonists (Medical oophorectomy).
- ◆ Oral aromatase inhibitors for postmenopausal women.
- ◆ Adrenalectomy or pituitary ablation.
- ◆ Progesterone receptor antagonist.
- ◆ Androgens—Inj testosterone propionate 100 mg IM three times a week.
- ◆ Aminoglutethimide—blocks the synthesis of steroids by inhibiting conversion of cholesterol to pregnenolone—*medical adrenalectomy*.
- ◆ Progestogens, e.g. medroxyprogesterone acetate.

#### Tamoxifen

- ◆ It is an antioestrogen. It blocks cytosolic oestrogen receptors.
- ◆ Dose is 10 mg BID or 20 mg OD for 5 years.
- ◆ Half life of tamoxifen is 7 days; it takes 4 weeks to show its benefits. It reduces the cholesterol and also cardiovascular morbidity.

#### Adverse effects:

- ◆ *Tamoxifen flare*—flushing, tachycardia, sweating, genital itching, vaginal atrophy and dryness (premenopausal), vaginal discharge (postmenopausal), fluid retention, weight gain.
- ◆ Occasionally it causes bone pain which should be differentiated from pain due to bone metastasis. It is due to loss of bone density in premenopausal women.
- ◆ It increases the incidence of endometrial cancer.
- ◆ DVT (3%), pulmonary embolism, CVA, TIA, cataract, fractures.

#### Radiotherapy in carcinoma breast

To chest wall	To axilla:	
• T3 tumour >5 cm	• 4 or more nodes positive	• RT is a must after conservation of breast
• Residual disease-LABC	• Extranodal spread	• Local with or without to axilla
• Positive margin/close surgical margin of <2 cm	• Axillary status not known/not assessed	• Tangential fields 50 Gy/25 fractions/5 weeks
• After conservative surgery		• Another 10 Gy to tumour bed
• Higher risk group		• Internal mammary and supraclavicular area may be included in radiation field
• Inflammatory carcinoma		

Drugs used in hormone therapy			
Drug	Mechanism of action	Dose	Adverse effects
Tamoxifen	Antioestrogen	20 mg	Nausea, weight gain, hot flushes, vaginal bleeding, bone pain, amenorrhoea
Medroxyprogesterone	Progestogen	400 mg	Nausea, flushing, vaginal bleeding
Aminoglutethimide	Aromatase inhibitor	250 mg QID	Rash, dizziness, lethargy, Cushing facies
Arimidex	Aromatase inhibitors	1 mg	Lethargy, GI upset
Letrozole	Aromatase inhibitor	2.5 mg OD	Vaginal dryness, hot flushes, vaginal bleeding, cardiovascular problem
Zoladex (Goserelin)	LHRH agonist	3.6 mg monthly	Amenorrhoea, nausea. It is expensive
Diethylstilbestrol	Oestrogen	15 mg daily	Fluid retention, vomiting, thrombosis, hypercalcaemia
Fluoxymestron	Androgen	30 mg daily	Masculinization, nausea

It is more beneficial in ER +ve patient; perimenopausal patient with node +ve; postmenopausal patient. Presently *Tamoxifen and Oophorectomy* are the commonly used methods.

Side effects and endometrial cancer are less in selective drugs like raloxifene.

#### Advantages:

- ◆ It reduces the recurrence rate by 25%.
- ◆ It improves the prognosis.
- ◆ It is used presently in all age group, ER +ve patients.
- ◆ Preservation of bone density in postmenopausal women. But it causes bone loss in premenopausal women.
- ◆ Cheap, easily available, less toxic effects, very effective.
- ◆ It is equally effective in carcinoma male breast.
- ◆ It is presently also **under trial** for certain benign diseases of breast (*ANDI, cyclical mastalgia*).

#### Selective oestrogen antagonists

- ◆ Do not cause endometrial hyperplasia or endometrial carcinoma.
- ◆ Drugs include droloxifen, toremifen, raloxifene.

#### Tamoxifen used in:

- ❖ Carcinoma breast
- ❖ Benign diseases of the breast like fibroadenosis
- ❖ Infertility in males
- ❖ Desmoid tumour
- ❖ Risk reduction therapy in high-risk females in premenopausal age.

#### Letrozole

- ◆ It is a nonsteroidal competitive inhibitor of the enzyme 'aromatase'. This enzyme converts adrenal androgens to oestrogen (aromatization). So it is an aromatase inhibitor.
- ◆ Other aromatase inhibitors are *anastrozole and exemestane* (in postmenopausal). It is expensive but more effective than tamoxifen. It is also used in recurrent disease.
- ◆ Letrozole is used as an adjuvant endocrine therapy in postmenopausal women with hormone sensitive breast cancer (In premenopausal women this will cause rise in gonadotrophins and ovarian aromatase is not well suppressed). It can also

be used in metastatic and recurrent cases. It slows down and stops the growth of oestrogen sensitive breast tumours. It reduces oestrogen level by 98%. Its half life is 45 hours. It decreases the bone density.

- ◆ Dosage of letrozole is 2.5 mg once daily.
- ◆ It is given for 5 years or for 2 years following 3 years of tamoxifen.
- ◆ Side effects of letrozole are vaginal dryness, night sweats, hot flushes, vaginal bleeding, cardiovascular problems and osteoporosis.

#### Transtuzumab (Herceptin)

- ◆ It is a monoclonal antibody that blocks HER-2/Neu receptors thereby preventing growth of cancer cells. It is a new drug. It is presently marketed as herceptin. It is c-ErbB2 (growth factor receptor) inhibitor. It is a newer biological agent. Her 2/Neu receptor is tyrosine kinase receptor.
- ◆ It has very little effect on HER-2/Neu negative cancers.
- ◆ It is useful only in HER-2/Neu positive cancers. It is currently approved by FDA for use only in metastatic disease. It is given as intravenous infusion.
- ◆ Studies have shown substantiate improvement in disease free and overall survival rate.
- ◆ *Pertuzumab* is another similar agent. But both do not cross the blood-brain barrier.
- ◆ Dose is 4 mg/kg as loading; 2 mg/kg as maintenance for 1 year.
- ◆ It has got cardiac side effects.

#### Note

- ❖ *Tamoxifen* interferes with oestrogen receptors
- ❖ *Letrozole* interferes with oestrogen production
- ❖ *Transtuzumab* (Herceptin) interferes with HER-2 Neu receptors
- ❖ *Bevacizumab*—vascular growth factor receptor inhibitor—newer agent
- ❖ *Lapatinib*—is dual HER 2 neu and EGF receptor inhibitor; it crosses the blood-brain barrier.

\*Not commonly done at present. If at all, it is done in early stage I carcinoma breast.

*What lies within us is more important than what lies before or behind us.*

### Lapatinib

- ◆ Lapatinib ditosylate is dual tyrosine kinase inhibitor which interrupts with HER 2 neu and EGFR by inhibiting autophosphorylation.
- ◆ It is oral drug used in breast carcinoma with over expression of HER 2 neu (HER 2 neu positive). It is used in post-menopausal metastatic tumour with over expression of the HER 2 neu.
- ◆ It is often combined with capecitabine. It is used in diseases which has progressed after using anthracyclines, taxanes and trastuzumab.
- ◆ Dose—lapatinib at a dose of 1250 mg daily and capecitabine at a dose of 2000 mg per square meter of body-surface area daily on days 1 through 14 of a 21-day cycle).
- ◆ Lapatinib has got better cardiac safety compared to trastuzumab. Lapatinib crosses the blood-brain barrier.

#### Hormone therapy for carcinoma breast

##### In premenopausal women

- ❖ Tamoxifen—antioestrogen
- ❖ Ovarian ablation by surgery/by Goserelin/by radiation
- ❖ Progestogens—medroxyprogesterone 400 mg
- ❖ Androgens—fluoxymestrone

##### In postmenopausal women

- ❖ Tamoxifen
- ❖ Aromatase inhibitor like letrozole 2.5 mg OD
- ❖ Progestogens
- ❖ Androgens
- ❖ Medical adrenalectomy using aminoglutethimide (Mitotane)—as major source of oestrogen after menopause is adrenal gland. Cortisone supplement is also needed to prevent feedback rise of ACTH which may block the effect of aminoglutethimide.

#### Surgical endocrine ablations

- ❖ Bilateral oophorectomy (Beatson—1896) in premenopausal age
- ❖ Bilateral adrenalectomy
- ❖ Pituitary ablation

#### Note:

*Present changing concept*—is letrozole and tamoxifen are continued even after five years (probably life long) to reduce the chance of late recurrence.

### D. Chemotherapy in Carcinoma Breast

- ◆ *Adjuvant chemotherapy* refers to administration of cytotoxic drugs to women after breast cancer surgery in the hope of eliminating clinically undetectable distant spread. Reduced recurrence rate and improved survival rate is observed in all women with *invasive* breast cancer. Chemotherapy is usually not indicated in DCIS.
- ◆ *Neoadjuvant chemotherapy* refers to administration of cytotoxic drugs in a large operable tumour to reduce the loco-regional tumour burden to make it better amenable for surgical resection, usually after 3 doses. It downstages the disease; may achieve breast conservative surgery in *selected patients* (only); early systemic control is achieved.
- ◆ *Palliative chemotherapy* is used in advanced and metastatic carcinoma breast.

#### Indications:

- ◆ All node positive patients.
- ◆ Primary tumour more than 1 cm in size.
- ◆ Presence of poor prognostic signs of any tumour—vascular and lymphatic invasion; high nuclear and histologic grade; Her 2/Neu overexpression; negative hormone receptor status.
- ◆ In advanced carcinoma breast as a palliative procedure.
- ◆ In postoperative period after simple mastectomy in stage III carcinoma breast with fixed axillary nodes.
- ◆ In inflammatory carcinoma of breast.
- ◆ In stage IV carcinoma breast with secondaries in bone, lungs, liver.
- ◆ In premenopausal age group with poorly differentiated tumours.

#### Different regimes

*Toxic effects are:* Alopecia, bone marrow suppression, cystitis, megaloblastic anaemia, GIT disturbances, nephritis.

- ◆ Other anthracyclines like epirubicin should be used often for better result.
- ◆ **Taxanes:** They are newer chemotherapeutic drugs which act by G2/M phase of cell cycle. It is commonly used in metastatic carcinoma of breast. Drugs are **paclitaxel and docetaxel**. Taxanes have no cross-resistance with anthracyclines and so can be used sequentially or concurrently with anthracyclines.
- ◆ Gemcitabine is also used often in selected cases for better results.

#### Chemotherapy drugs

- ❖ *1st line drugs*—anthracyclines
- ❖ *2nd line drugs*—taxanes
- ❖ *3rd line*—gemcitabine, others

#### Note:

- Neoadjuvant (primary) chemotherapy is useful in large operable primary tumour to make it amenable for conservative breast surgeries. Postoperative radiotherapy and chemotherapy is a must in this situation.
- High dose chemotherapy with stem cell rescue is not found to be beneficial by trials in patients with heavy large nodal spread.
- Hormone therapy is given after completion of chemotherapy for additive effect. Concurrent therapy of both (together) is not used at present. It is sequential—chemotherapy then hormone therapy. Chemotherapy gives quicker and better response initially and so it is used early and later only hormone therapy is continued.
- Adriamycin shows better response with Her-2 Neu overexpression patients.
- Paclitaxel may be combined with trastuzumab in Her-2 Neu (Human epidermal growth receptor 2) over expression patients.
- Chemotherapy and radiotherapy can be given concurrently or as sandwich therapy.
- Presently one day dose of all drugs of the regimen used as a *standard* at 3 weekly cycles for 6 cycles for stage III—CAF regime. For metastatic paclitaxel single day dose cycles or etoposide and cisplatin 3 days cycle—6 cycles.
- CAF regime is better than CMF. AC regime (Adriamycin and cyclophosphamide) with taxanes or AC regime 4 cycles followed by taxanes 4 cycles are also used.

CAF	CEF	CMF	TAC/AC	Others
Cyclophosphamide	Cyclophosphamide	Cyclophosphamide	Taxane (Docetaxel/ Paclitaxel)	For Her – 2 Neu positive –
Adriamycin (Doxorubicin)	Epirubicin	Methotrexate	Adriamycin	AC followed by paclitaxel + Trastuzumab
5 Fluorouracil	5 Fluorouracil	5 Fluorouracil	Cyclophosphamide	Docetaxel + trastuzumab with CEF

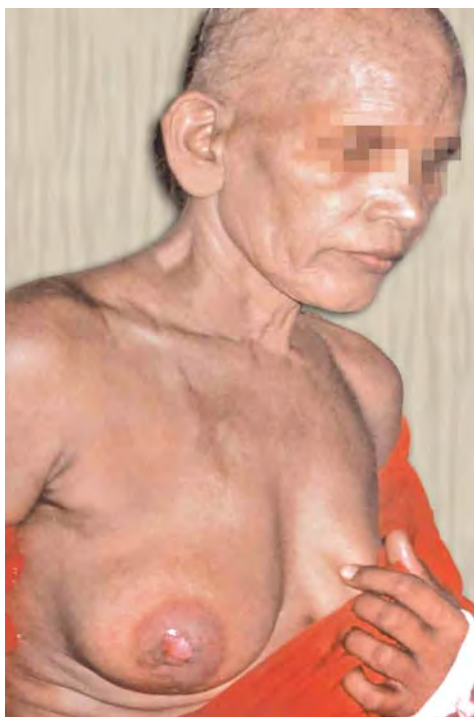

Fig. 8.79: Patient with carcinoma breast on chemotherapy having alopecia.

**Complications of chemotherapy**—bone marrow suppression, alopecia, GI side effects, cardiac toxicity. Monitoring with haematocrit, blood urea, serum creatinine, LFT are

needed. Cytoprotective agents like GMCF (granulocyte macrophage colony stimulating factor), GCSF (granulocyte colony stimulating factor) are given to reduce severity and duration of neutropenia. It is given in 24 hours as 30 million units.

### MANAGEMENT OF EARLY CARCINOMA BREAST

- ◆ Early breast cancer is the one diagnosed by mammography or stage I and IIA carcinoma breast.
- ◆ Usually chest X-ray, blood count and liver functions are sufficient to screen the early breast cancer patients.

#### Aims of treatment

- ❖ To achieve possible 'cure'.
- ❖ Control of local disease in breast and axilla.
- ❖ Breast conservation, i.e. breast form and function.
- ❖ Prevention of distant metastasis.
- ❖ To prevent local recurrence.

### Modalities of Treatment

- ◆ **Breast conservative surgery (BCS)**—ideally done as *wide local excision* with axillary dissection with RT to breast and chest wall. Quadrantectomy as a part of QUART therapy may be used only in selected patients. RT is given to the entire breast with 4500 cGy dose.

Breast conservative surgery	
Indications	Contraindications
• Lump <4 cm	• Tumour >4 cm
• Clinically negative axillary nodes	• Positive axillary nodes >N1
• Mammographically detected lesion	• Tumour margin is not free of tumour after breast conservative surgery needs MRM
• Well-differentiated tumour with low S phase	• Poorly differentiated tumour
• Adequate sized breast to allow proper RT to breast	• Multicentric tumour
• Breast of adequate size and volume	• Earlier breast irradiation
• Feasibility of axillary dissection and radiotherapy to intact breast	• Tumour/breast size ratio is more (central tumour)
	• Tumour beneath the nipple
	• Extensive intraductal carcinoma

*He who reigns within himself and rules his passions, desires and fears is more than a king.*

**Note:**

Initial neoadjuvant chemotherapy in an operable breast carcinoma may make it a candidate for BCS instead of total mastectomy in 15–20% of patients. Initial placement of metallic marker clips over primary tumour under image guidance is essential to identify the exact location of the tumour for eventual BCS.

- ◆ *Patey's or Auchincloss operation* or simple mastectomy with axillary clearance.
- ◆ Postoperative radiotherapy in high-risk patients.
- ◆ Hormone therapy, i.e. tamoxifen 10 mg BID or 20 mg OD.
- ◆ Sentinel node biopsy when required.
- ◆ Regular follow-up often with radioisotope bone scan and CEA tumour marker.

In early breast cancer, breast conservative surgery like *wide local excision/quadrantectomy*, axillary dissection (level I and II) and postoperative radiotherapy (to the breast) is used which prevents the disfigurement and psychological trauma of mastectomy to the patient. Tumour is removed with a rim of normal tissue. Wide excision and QUART therapy are different procedures. *Wide local excision* is ideal and better where clearance margin is 1 cm. In *quadrantectomy* entire segment with ductal system with 2–3 cm clearance margin is achieved. But it is not advocated now as there is no benefit in outcome (survival/recurrence rate) by quadrantectomy over wide local excision.

### Indications for Total Mastectomy in Early Breast Cancer

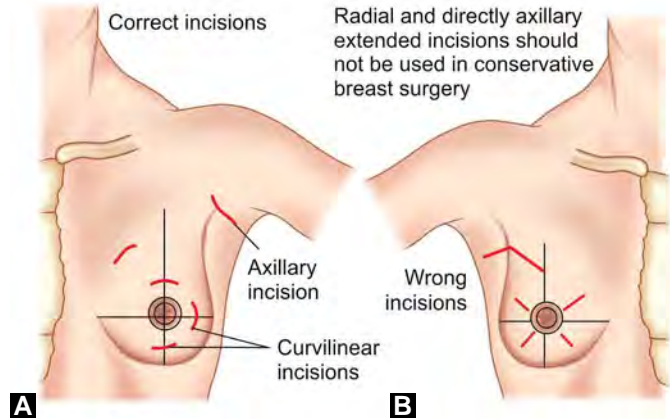
- ◆ When tumour is more than 4 cm.
- ◆ Multicentric tumour.
- ◆ Poorly differentiated tumour—high grade.
- ◆ Tumour margin is not clear of tumour after breast conservative surgery.

#### Adjuvant therapy after surgery in early breast cancer

- ❖ Radiotherapy
- ❖ Chemotherapy—CMF, CAF regime commonly used. Taxanes are also used
- ❖ Endocrine manipulation:
  - ◆ Ablation
  - ◆ Tamoxifen (receptor antagonist)—20 mg/day for 5 years
  - ◆ Aromatase inhibitors—blocks oestrogen production. Letrozole 2.5 mg OD
  - ◆ LHRH agonists—Goserelin 3.6 mg/28 day's cycle for 2 years

### Principles of Conservative Breast Surgery (Refer Table Above)

- ◆ Curvilinear nonradial incisions (radial incisions should not be placed, because if there is a need to convert into total mastectomy, then incision plan may be difficult).
- ◆ Separate incision for axillary dissection.
- ◆ Undermining of the skin flap must be avoided.
- ◆ Confirm tumour clearance by frozen section. It may be often difficult and so tumour is cut and only margin which is close and doubtful is advocated for frozen section.
- ◆ Radiotherapy is a must to breast and chest wall region (locally).



**Figs 8.80A and B:** Curvilinear incision should be placed in conservative breast surgeries. Never place wrong radial incisions because if conversion to total mastectomy is needed then placement of incision will be difficult. In conservative breast surgery for axillary dissection separate incision in the axilla should be placed.

### QUART Therapy

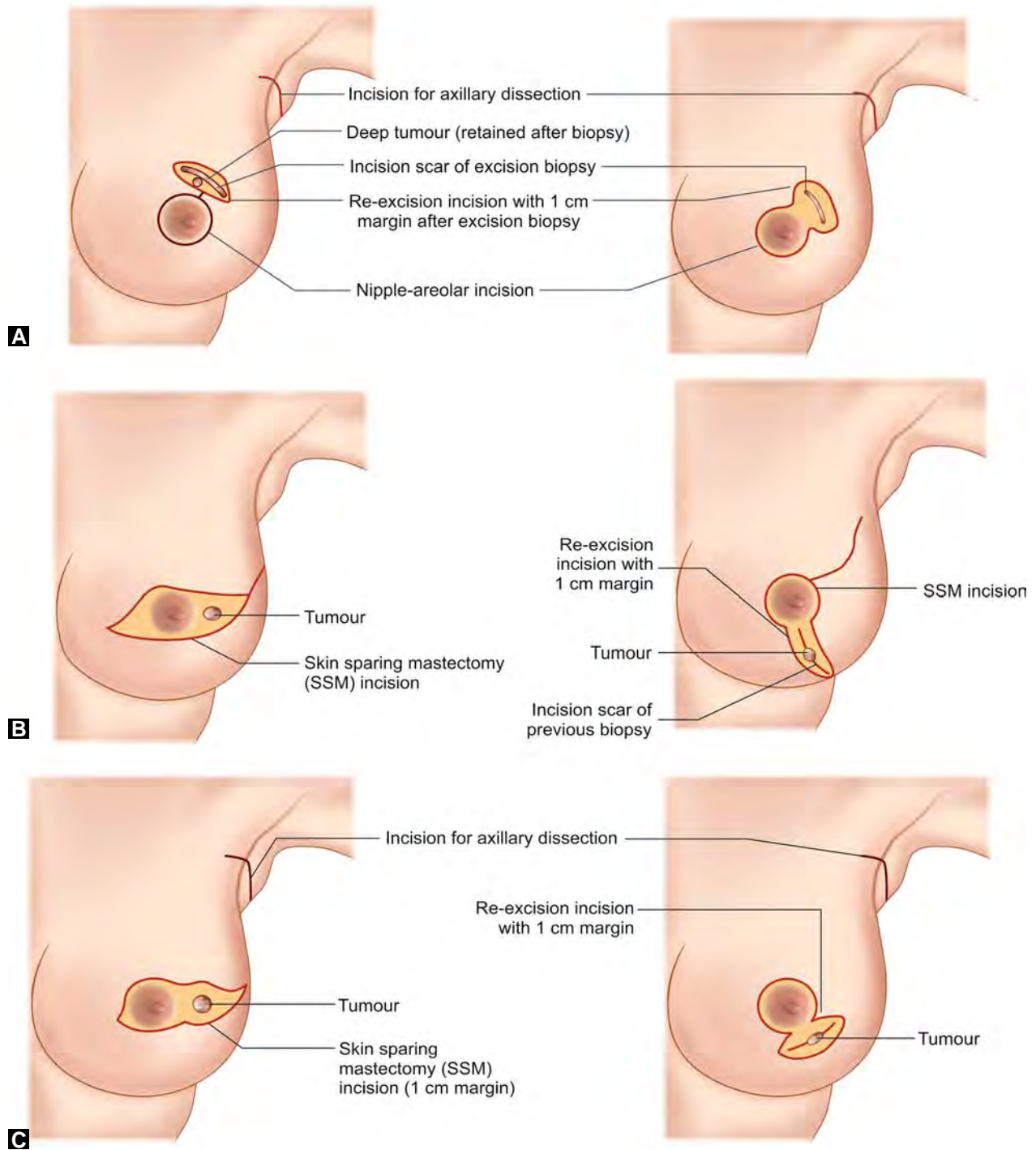
It is *quadrantectomy, axillary dissection* of level I and II nodes with separate axillary incision and *postoperative radiotherapy* to breast (5000 cGy) and axilla (1000 cGy). First, it was started by *Umberto Veronesi* from Milan. Now Quart therapy is only occasionally used.

### Skin Sparing Mastectomy (SSM)

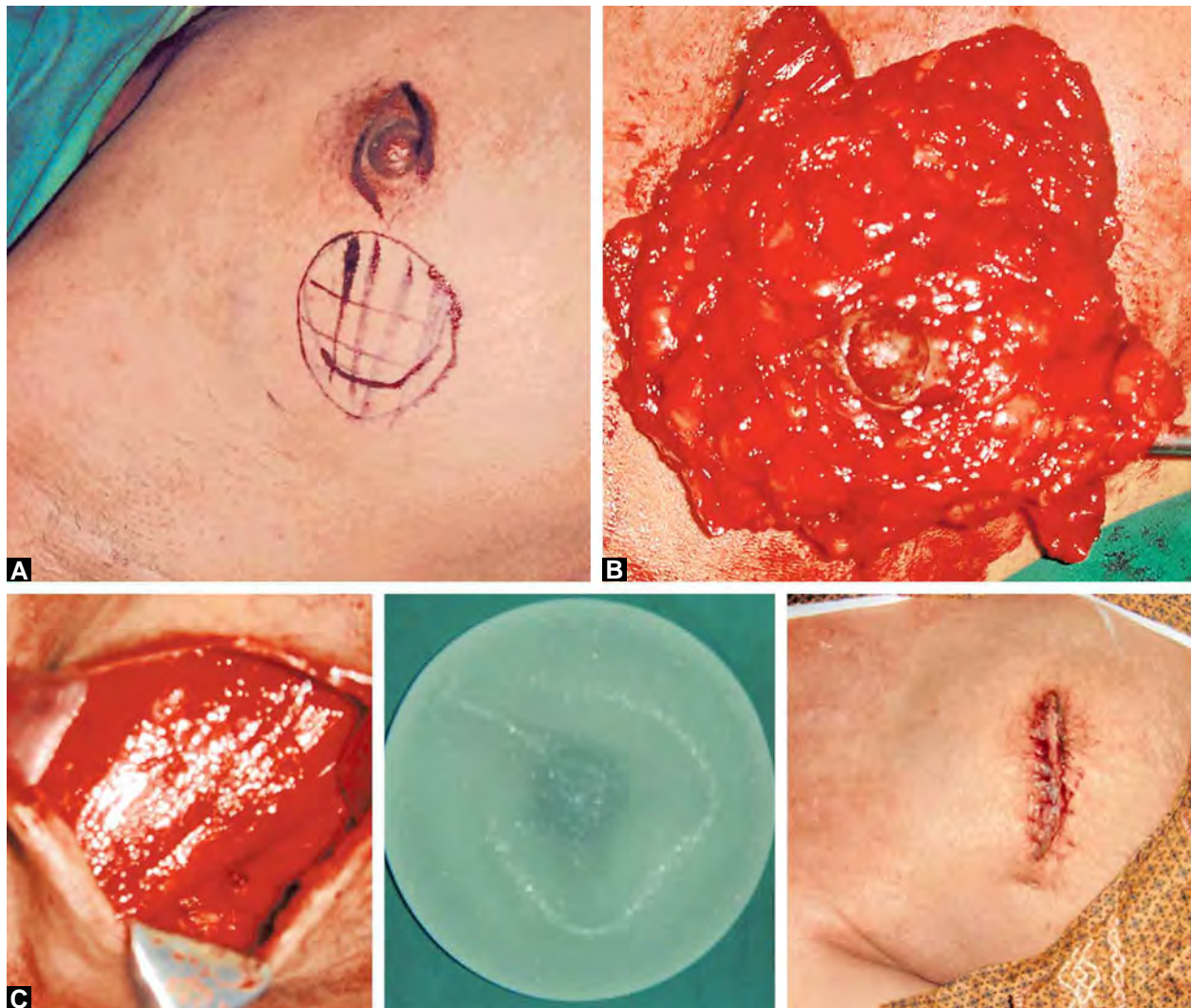
- ◆ It is like a key-hole surgery of breast.
- ◆ Skin sparing/limited skin excision (5–10%) will not alter/affect the recurrence rate.
- ◆ *Indications are*—central tumour/multicentric/extensive intraductal/T1/not feasible for conservation.
- ◆ Excision of nipple-areola complex with very limited skin removal.
- ◆ Marginal skin excision over the tumour/biopsy site.
- ◆ Total glandular mastectomy.
- ◆ Axillary dissection using either same (extension of SSM incision) or separate incision in the axilla.

### Management of Axillary Nodes when Clinically Not Palpable

- ◆ *Sentinel lymph node biopsy (SLNB)* is done. If node is positive for tumour then axillary dissection is done. But facility for SLNB is not available in most of the centres and so axillary dissection is done as a routine. Usually level I and II nodes—below the axillary vein are dissected.
- ◆ *Axillary sampling* is done by separate curved incision between the outer border of pectoralis major and latissimus dorsi 6 cm below the apex of axilla. About 10–15 nodes (level I) are sampled. Aim is to remove *largest nodes* in axilla which are likely to be involved. At least 4 lymph nodes should be removed. All 4 nodes should be sent *separately* for histology. First level I nodes are removed; if they are not palpable then only level II or III are sampled. Axillary sampling is said to detect *skip metastasis* in level II and III. It is not commonly advocated now.



**Figs 8.81A to C:** Skin sparing mastectomy for carcinoma breast—different approaches. Skin sparing mastectomy (SSM) does not affect the recurrence rate.



**Figs 8.82A to C:** Skin sparing mastectomy incision with prosthesis implant for placement.

### Principles of axillary dissection/axillary clearance

It is removal of different levels of axillary nodes; with fat and axillary fascia

<b>Why axillary dissection is done?</b>	<b>Which levels?</b>	<b>Technical principles</b>
<ul style="list-style-type: none"> <li>• For staging</li> </ul>	<ul style="list-style-type: none"> <li>• Level I—60%</li> </ul>	<ul style="list-style-type: none"> <li>• Any incision but caudal hair-line incision is preferred</li> </ul>
<ul style="list-style-type: none"> <li>• To assess the prognosis—number of nodes/size of the node</li> </ul>	<ul style="list-style-type: none"> <li>• Level I, II—20–25%</li> <li>• Level I, II, III—15–20%</li> </ul>	<ul style="list-style-type: none"> <li>• Nerve to serratus anterior/thoracodorsal nerve should be safeguarded</li> </ul>
<ul style="list-style-type: none"> <li>• As a treatment—regional control of the disease</li> </ul>		<ul style="list-style-type: none"> <li>• Medial and lateral pectoral nerves should be retained when the dissection is done with the mastectomy</li> </ul>
<ul style="list-style-type: none"> <li>• To plan adjuvant therapy irradiation/chemo/hormone</li> </ul>	<ul style="list-style-type: none"> <li>• Level I and II dissection</li> <li>• Low axillary dissection less chances of lymphoedema</li> </ul>	<ul style="list-style-type: none"> <li>• Drain should be kept to the area</li> <li>• After surgery specimen should be properly dissected for all lymph nodes, labelled and sent for histological study. Usual number of nodes in axilla are 20–32. So minimum of 10 nodes should be dissected, identified and sent for study. Nodes can be easily identified if fat dissolving agents are used over them.</li> </ul>

### Principles of Axillary Dissection/ Axillary Clearance

- ◆ **Indications:** Axillary dissection is done when there is clinical involvement of nodes; when FNAC of lymph node or sentinel node biopsy proved malignancy; when in a large tumour where reconstruction is needed so that 2nd eventual axillary surgery is difficult at a later period.
- ◆ It is **removal** of fat, fascia, nodes in the axilla. Usually level I and II nodes are removed. Nodes below the axillary vein are only

removed. Level III dissection increases the chances of lymphoedema. Risk of lymphoedema further rises if RT is given later along with level III dissection.

- ◆ Dissection is done through an individual crease transverse incision in the axilla, when it is advocated with breast conservative surgery.
- ◆ When it is advocated along with total mastectomy it is done like modified radical mastectomy—*Auchincloss* is commonly used.
- ◆ In *skin sparing mastectomy* also axillary dissection is done using an extension of SSM incision or by separate axillary incision.

## ■ ADVANCED CARCINOMA BREAST

Refers to:

- ◆ Locally inoperable (adherent to chest wall) tumour.
- ◆ Inflammatory carcinoma of breast.
- ◆ Fixed axillary lymph nodes, or supraclavicular lymph nodes, or opposite axillary nodes.
- ◆ Bilateral carcinoma breast.
- ◆ Metastatic carcinoma of breast, i.e. spread to bones, liver, lungs, brain.

### Locally Advanced Carcinoma of Breast (LACB)

- ◆ It means locally advanced tumour with muscle/chest wall involvement, extensive skin involvement or fixed axillary nodes. It will be T3, T4a, T4b, T4c or T4d or N2 LACB is stage II B and III disease.
- ◆ It is investigated by FNAC of tumour/core needle biopsy/incision biopsy/mammography of opposite breast, chest CT, CT abdomen or whole body bone scan. Biopsy is needed to assess *receptor status (ER/PR/HER2Neu)*.
- ◆ *Bilateral mammography* is done to assess tumour size and multicentricity which is needed to check the chemotherapy response at a later period. FNAC of axillary node is required. If bone scan is positive it becomes metastatic carcinoma of breast not LACB. Only when 60% of bone is demineralised in metastatic bone disease, plain X-ray bone will detect the lesion. Even though X-ray may be normal in stage III disease, in 30% of these patients bone scan will be positive making the disease stage IV metastatic.

#### Treatment of LACB

- ◆ Neoadjuvant chemotherapy, mastectomy either total or modified radical mastectomy (MRM—usually after 3 cycles of initial chemotherapy), further chemotherapy, radiotherapy [local breast field and axilla (concurrent)], hormone therapy (as sequential—trastuzumab for HER2 Neu positive/tamoxifen/letrozole) is becoming more popular. Evaluation with bone scan and HRCT chest is a must to rule out metastatic type. Survival rate will be increased to 50% by these modalities. *Targeted therapy like* trastuzumab in HER2 Neu positive patient with neoadjuvant chemotherapy can be safely administered prior to mastectomy.
- ◆ *This anterior (neoadjuvant) chemotherapy* helps in downstaging the diseases by cytoreduction; controls the microme-

tastases first which will be present mostly in LACB; it allows the chemosensitivity; also provides systemic chemotherapy.

- ◆ Remaining chemotherapy should be started within 6 weeks of surgery. If BCS is done RT should be given first then chemotherapy. After completion of chemotherapy hormone therapy is started.
- ◆ LACB with entirely fixed fungating masses, chemotherapy, palliative total mastectomy (often with skin graft to cover the defect), hormone therapy using tamoxifen or letrozole or trastuzumab. Axillary dissection is not necessary in this type.
- ◆ Only chemotherapy and radiotherapy (to breast and axilla) is also advocated in few; later with hormone therapy.
- ◆ Treatment for LACB is targeted at present as curative; but it is achieved only in 50% of patients. So in 50% of patients therapy becomes palliative.
- ◆ During treatment period for LACB, disease may become metastatic (systemic) and so evaluation at regular intervals with CT chest, bone scan, MRI spine, liver function tests, CT abdomen is needed.
- ◆ Breast conservative surgery (BCS) has got limited role as it will effect on the survival rate (even though many proponents practice, this may not be ideal).
- ◆ 5-year survival is 50% with proper therapy and 10-year survival is 25% or less.

#### Present strategy of treatment for LACB

- ❖ *Initial neoadjuvant* (anterior) chemotherapy is given to downstage and achieve cytoreduction, to target possible micrometastases first, to assess chemosensitivity. *FEC, CMF, CAF* regimes are used.
- ❖ *Response to chemotherapy* is assessed by *complete responders* without palpable tumour; *partial responders* with >50% decrease in tumour size; *nonresponders* with <50% decrease in tumour size; *progressive disease* with >25% increase in size.
- ❖ Patients with nonresponders and progressive disease are treated by RT to breast, chest wall, axilla and supraclavicular region; taxanes; hormone therapy; surgery if operable.
- ❖ *Responders* are later treated with total mastectomy/MRM, occasionally BCS. After surgery remaining 3 or 4 cycles of chemotherapy are completed. Later hormone therapy should be given for 5 years (tamoxifen 20 mg OD). ER +ve (>10 fmol/mg) patients show 75% positivity.
- ❖ Stage IIIA patients are *classified* as operable and inoperable.

### Inflammatory Carcinoma of Breast

- ◆ *Inflammatory carcinoma* is T4d LACB (Stage IIIB). It is a clinical diagnosis. It is also called as mastitis carcinomatosis or lactating carcinoma of breast. It is 2% common.
- ◆ It is observed in younger age group usually in pregnancy or lactating period. There will be extensive skin involvement with pain. It often mimics mastitis of lactation.
- ◆ FNAC or incision biopsy concludes diagnosis. It can be ductal or lobular. It is initially treated by chemotherapy or radiotherapy and later if tumour reduces in size total mastectomy with axillary clearance can be done. But most often it is inoperable. After surgery, chemotherapy and tamoxifen



is given. 5-year survival for inflammatory carcinoma of breast is 25–30%.

### Metastatic Carcinoma of Breast

It is blood spread into different places like bone, lungs and pleura, liver, soft tissues, brain and adrenals. It is evaluated by FNAC/incision biopsy, chest CT, LFT, US abdomen, CT abdomen, whole body bone scanning, CT brain, tissue study for ER/PR/HER-2 Neu receptor status. It is *stage IV* disease.

- ◆ *Bone* is the most common site of metastasis. Spread to vertebra is through posterior intercostal vein and *Batson's venous plexus (valveless)*. Vertebrae, ribs, upper end of humerus and femur are common bones involved.
- ◆ *Lungs and pleural* spread causes 'cannon ball' secondaries, effusion, consolidation, chest wall secondaries.
- ◆ *Liver* secondaries may develop either by haematogenous or through lymphatics across diaphragm from lower inner quadrant of breast.
- ◆ *Brain* secondaries present with headache, vomiting, convulsions, localising features.
- ◆ Soft tissue secondaries has got *better prognosis*; visceral secondaries has got worst prognosis.
- ◆ Response to treatment decreases with number of organs involved with secondaries.
- ◆ Receptor negative secondaries are more aggressive.
- ◆ Median survival time for metastatic breast cancer is 24 months.

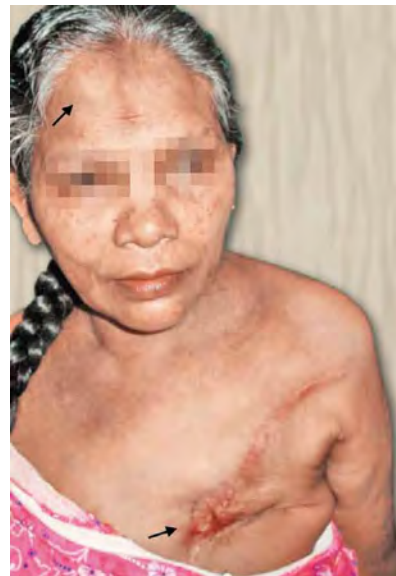#### Treatment concept in metastatic carcinoma of breast

- ❖ To improve quality of life.
- ❖ To relieve pain of secondaries like bone, lungs.
- ❖ To relieve neurological problems like convulsions, space occupying cranial problems.
- ❖ Other symptomatic relief.

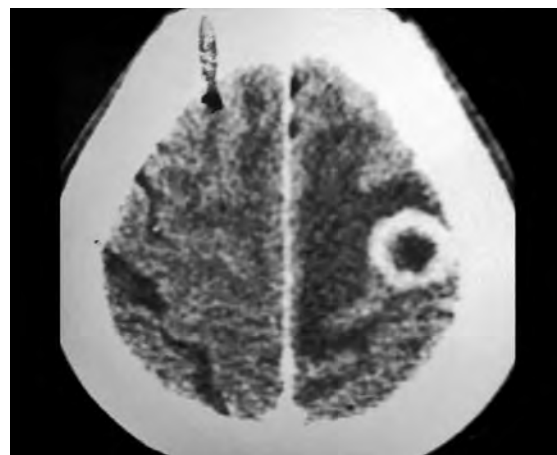
#### Treatment strategy in metastatic carcinoma of breast

- ◆ *Chemotherapy*—CMF, CAF, Taxanes in combination. Chemotherapy in metastatic breast cancer is useful (indicated/commonly used) in rapidly spreading visceral and skin secondaries, lymphangitis or when predicted disease free survival is less than 2 years; if response is negative for first line hormone therapy; in receptor negative status.
  - ▶ High dose of chemotherapy using cyclophosphamide, cisplatin, carmustine, melphalan is tried in view to get high response rate of 55–70% along with bone marrow transplant. But toxic effects are often life-threatening. Its advantages are now doubtful when compared to toxic effects.
  - ▶ Haemopoietic growth factor is also used along with chemotherapy to enhance the cell kill with less bone marrow toxicity. It may also allow multiple high dose chemotherapy to increase the response rate.
- ◆ *Radiotherapy* is used in bone metastasis, brain secondaries, to prevent paraplegia in spine involvement, and advanced axillary nodes. It is also used in painful bone secondaries, chest wall secondaries.

- ◆ *Hormone therapy* has got important role. Tamoxifen, oophorectomy, adrenalectomy, androgens, progestogens, aminoglutethimide are used. It is useful in slow growing soft tissue or bone secondaries; or predicted disease-free survival is more than 2 years or age more than 35 years.
- ◆ Blockage of over expression of epidermal growth factor (EGF)/transforming growth factor alpha (TGF-alpha) which are related to ErbB1/ErbB2 receptors in relation to aggressive carcinoma factor is tried.



**Fig. 8.83:** Carcinoma of breast operated earlier with skull secondaries. It is metastatic carcinoma of breast. Skull secondaries are not common. Common site of bone secondaries are lumbar vertebrae, pelvis, upper part of femur, ribs, etc.



**Fig. 8.84:** Secondaries in brain—primary is from breast.

- ◆ Palliative surgeries done are total/toilet mastectomy, fixation of bones in case of pathological fractures, spinal cord decompression to prevent paraplegia, lung resection in case of localised secondaries, bilateral oophorectomy.
- ◆ Trastuzumab (herceptin) is monoclonal antibody used in cancers with good results. It blocks the Her-2/Neu and ErbB2 receptors. Bevacizumab and lapatinab are other newer biological agents of different actions.

- ◆ Metabolic complications like *hypercalcaemia* may be life-threatening emergency in metastatic breast cancer. It is treated with hydration, steroids, biphosphonates (pamidronate, clodronate) 90 mg intravenously once a month. It also reduces the demineralisation of bone, fracture, pain and paraplegia.

#### Bone secondaries in carcinoma breast

- ❖ Most common site of blood spread (70%)
- ❖ Lumbar vertebrae, femur, pelvis
- ❖ Pathological fracture can occur
- ❖ Spinal compression and paraplegia
- ❖ Radiotherapy, internal fixation, spinal decompression is required
- ❖ Biphosphonates 1600 mg/day

#### Malignant pleural effusion as secondaries from carcinoma breast

- ❖ It signifies terminal event
- ❖ It has got poor prognosis
- ❖ Respiratory distress and failure is the main feature
- ❖ HRCT is ideal diagnostic tool
- ❖ Treated by
  - ◆ Intercostal tube drainage
  - ◆ Pleurodesis using talc/tetracycline (1.5 gm)/bleomycin (60 units)
  - ◆ Chemotherapy

#### Causes of death in carcinoma breast

- ❖ Secondaries in lung—haemoptysis, respiratory failure
- ❖ Spine involvement—quadriplegia
- ❖ Secondaries in brain
- ❖ Cancer cachexia

### Treatment Strategy for Carcinoma Breast

<b>Stage 0—DCIS</b>	Less than 4 cm – wide local excision; RT to breast; hormone therapy (Tamoxifen 20 mg OD for 5 years). More than 4 cm – total mastectomy with SLNB (if +ve axillary dissection); hormone therapy
<b>Stage 0—LCIS</b>	Screening mammogram yearly/ MRI breast/ observation; Tamoxifen or raloxifene (in premenopausal age)/bilateral mastectomy. <i>LCIS is high-risk category</i> to develop invasive carcinoma both invasive ductal or lobular
<b>Stage I and II (Early)</b>	Breast conservative surgery (BCS) + RT + if SLNB +ve axillary dissection. If tumour > 1 cm, +ve axillary nodes, high nuclear grade, vascular/lymphatic invasion, ER/Pr –ve with over expression HER2 Neu, then adjuvant chemotherapy.
<b>Stage III</b>	Neoadjuvant chemotherapy + MRM + RT + CT + Hormone therapy.
<b>Stage IV</b>	Hormone therapy (Trastuzumab/Lapatinib) with chemotherapy using taxanes or capecitabine + palliative mastectomy (toilet mastectomy if needed when fungation is present)

### PROGNOSTIC FACTORS IN CARCINOMA BREAST

Stage	5 years survival
I	90%
II	70%
III	40%
IV	20%

- ◆ **Spread to axillary nodes** is the most important prognostic indicator.
- ◆ **Age:** Younger the age worse the prognosis.
- ◆ **Sex:** Carcinoma male breast has got worse prognosis compared to female breast. Because of early spread in carcinoma male breast.

#### Lymph node—as a prognostic factor

- ❖ Number of nodes: >2 carries poor prognosis
- ❖ Location of nodes
- ❖ Capsular invasion
- ❖ Extranodal status
- ❖ Size of the node: >2.5 cm has poor prognosis
- ❖ More than 4 nodes/level III (apical nodes) involvement has got worst prognosis (5-year survival is 30%) and also decides for radiotherapy to axilla.

- ◆ **Stage I and II** has got better prognosis.
- ◆ **Atrophic scirrhous** has got best prognosis.
- ◆ **Medullary carcinoma** has got better prognosis than scirrhous carcinoma because of lymphocytic infiltration.
- ◆ **Invasive carcinoma** has got worse prognosis.
- ◆ **Inflammatory carcinoma** breast has worst prognosis.
- ◆ **ER +ve** tumours has got better prognosis.
- ◆ **Differentiation** also decides prognosis.
- ◆ **Presence of elastic fibres** in histology has got better prognosis.
- ◆ Tumour proliferation stages, growth factor and oncogene factors.
- ◆ Tubular, colloid, papillary types has got better prognosis.
- ◆ **Tumour grade**, growth factor and oncogene factors. ErbB2—Her-2/Neu positive has got poor prognosis. ErbB1 with overexpression of epidermal growth factor (EGF), TGF alpha and cathepsin D has got poor prognosis.
- ◆ **DNA flow aneuploid** status has got poor prognosis. Low S phase fraction (< 5%) has got good prognosis.
- ◆ **Size of the tumour**—tumour size less than 1 cm has got better prognosis.
- ◆ **p53 tumour suppressor gene** (guardian gene) shows bad prognosis.

#### Prognostic factors are classified as:

- ◆ **Host factors:** Age; sex; menopausal status; family history; previous breast cancer; immunosuppression; nutrition.
- ◆ **Tumour factors:** Tumour size; nuclear grade; staging; receptor status; DNA nature; spread, etc.

*When you get angry, you lose more than your temper.*

Breast cancer group	Features	Prognosis—5-year survival
Very low-risk primary	DCIS; tubular	>90%
Low-risk primary	Node negative; favourable microscopy	70–90%
High-risk primary	Node positive; unfavourable microscopy	<70%
Locally advanced	Inflammatory Ca/large primary (T4)	<30%
Metastatic	Blood spread	Poor

## PROPHYLACTIC MASTECTOMY

It is removal of *entire breast including axillary tail of Spence* prophylactically as risk reduction procedure in high-risk patients with indications. It reduces the developing of invasive cancer by 90% in high-risk group and also decreases the chances of death due to the disease. Axillary dissection is not done.

Modified Gail model and evaluation of mutation carriers are used to assess the risk group for risk reduction surgeries.

### Indications

- ◆ DCIS (noninvasive).
- ◆ LCIS.
- ◆ Florid changes in fibrocystadenosis.
- ◆ Suspicious lesion in mammogram.
- ◆ Strong family history with 1st degree relatives having carcinoma breast.
- ◆ *BRCA1* and *BRCA2* mutation carriers.

### Risk Reduction Surgeries

- ◆ Total mastectomy.
- ◆ Subcutaneous mastectomy.
- ◆ Skin sparing mastectomy.

*Mastectomy is done bilaterally in LCIS and in strong family history.* In suspicious unilateral lesion only unilateral mastectomy may be done.

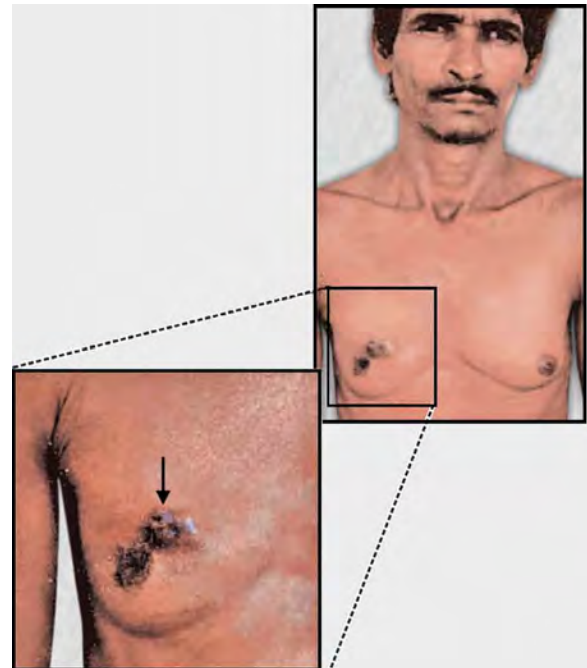
#### Note:

Other risk reduction methods are—life style modifications, avoiding alcohol and HRT, *tamoxifen*.

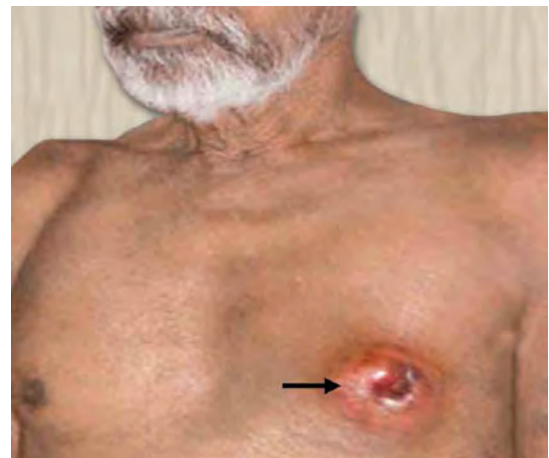## CARCINOMA OF MALE BREAST

- ◆ It is less than 1% of cases of breast cancers. Mean age is 65 years.
- ◆ Commonly associated with *BRCA2* gene mutation.
- ◆ Other *risk factors* are—radiation, excess oestrogen, cirrhosis, Klinefelter's syndrome, liver schistosomiasis, family history, testicular disease, infertility, obesity.
- ◆ Commonly it is *infiltrating duct carcinoma* (90%), DCIS (10%). Lobular carcinoma is *not seen* in male breasts.
- ◆ Unilateral hard breast lump often eccentric with nipple retraction and discharge, skin dimpling and axillary lymphadenopathy are the clinical features.
- ◆ Differential diagnosis—gynaecomastia, breast abscess, sarcoma, secondaries.
- ◆ Presentation, spread, behaviour are same as carcinoma of female breast. Investigations and treatment are same as carcinoma female breast.
- ◆ MRM (as pectoralis major is involved early) with RT to breast area and axilla is the treatment.
- ◆ *Tamoxifen* is very useful in carcinoma male breast.
- ◆ Carcinoma male breast has poorer prognosis when compared to carcinoma breast in females.

- ◆ 80% cases are ER positive. 75% PR +ve; 35% overexpress HER 2/Neu.
- ◆ LHRH agonists are also often used. It works at hypothalamo-pituitary axis level via tachyphylaxis. It produces reversible “*chemical castration*”. Goserelin 3.6 mg/28 days for 2 years is the current recommendation.
- ◆ Bilateral orchidectomy which was earlier used is no longer commonly advocated. Orchidectomy may be only useful in metastatic male breast cancer.



**Fig. 8.85:** Carcinoma male breast in a pre-existing gynaecomastia. Note the gynaecomastia on opposite side.



**Fig. 8.86:** Carcinoma male breast showing mass under the areola, puckering and nipple retraction.

### Carcinoma breast in pregnancy

- ❖ Incidence is 3%
- ❖ *Breastfeeding* should be avoided during chemotherapy. Lactation should be suppressed by giving bromocriptine 2.5 mg OD for 5 days
- ❖ *Hormone treatment* during pregnancy is potentially teratogenic
- ❖ During pregnancy breast shows increased vascularity, density, water content and cellularity. So US and mammogram may show false-positive results. Chest X-ray can be done with abdominal shield
- ❖ Alkaline phosphatase is elevated during pregnancy and so it is also not significant
- ❖ Bone isotope scan cannot be done during pregnancy
- ❖ *MRI* is the investigation of choice for primary in breast and also for metastatic work-up
- ❖ Treatment is modified radical mastectomy (MRM)
- ❖ Chemotherapy can be given in 2nd trimester with care
- ❖ Radiotherapy has no role
- ❖ As commonly ER negative, hormone therapy is not used
- ❖ When distressing secondaries are present termination of pregnancy may be required
- ❖ *Women with breast cancer can become pregnant 2 years after the completion of therapy, as recurrence is more common in 2 years.*

### Management in carcinoma breast during pregnancy

1st trimester	2nd trimester	3rd trimester
MRM	MRM	MRM
If axillary node is +ve then pregnancy is terminated; chemotherapy is given	Chemotherapy carefully	After delivery, chemotherapy with suppression of lactation

### Follow-up after Therapy for Carcinoma Breast

- ◆ Clinical examination in detail at regular intervals.
- ◆ Yearly/two yearly mammography of treated and contralateral breast is a must.
- ◆ Bone scan/CT chest, abdomen/tumour marker are done only if there is clinical suspicion of spread/metastases. It is not a regular routine follow-up method at present.

## BREAST RECONSTRUCTION

- ◆ **Immediate reconstruction.**
  - ▶ In early stages of malignancies as well as in selected more advanced stages where the response to neoadjuvant chemotherapy has been good. Not advised in locally advanced disease.
  - ▶ *Advantages of immediate reconstruction* are—maximum amount of breast skin is preserved for reconstruction. It will not affect the long-term survival or recurrence rate.
- ◆ **Delayed reconstruction** (3–9 months after surgery).

### Indications

- ◆ Locally advanced disease.
- ◆ Radiation needed in postoperative period.
- ◆ Patient unfit for prolonged surgical procedure.

### Advantages

- ◆ Allows for post-operative radiation without prosthesis exposure.
- ◆ Avoids fibrosis and fat necrosis where TRAM flap is used.

### Factors deciding the reconstruction

- ❖ Amount of skin retained
- ❖ Stage of the carcinoma
- ❖ Earlier radiotherapy
- ❖ Type of flap used

## Methods of Reconstruction

- ◆ Oncoplastic techniques.
- ◆ Insertion of breast implants or expanders. They are best for small breasts. Healthy nonirradiated overlying skin is the requirement.
- ◆ Flap with implant or expanders.
- ◆ Flap reconstruction:
  - ▶ Pedicled flap—TRAM flap.
  - ▶ Free flap—free TRAM flap into internal mammary artery.
  - ▶ Muscle preserving perforator abdominal flap.

## Types

- ◆ Silicon gel implant under pectoralis major muscle.
- ◆ Expandible saline prosthesis with prior tissue expansion.
- ◆ If there is less skin or after radiotherapy latissimus dorsi musculocutaneous flap (*LD flap*) or contralateral transversus abdominis muscle flap (*TRAM flap*) is used.

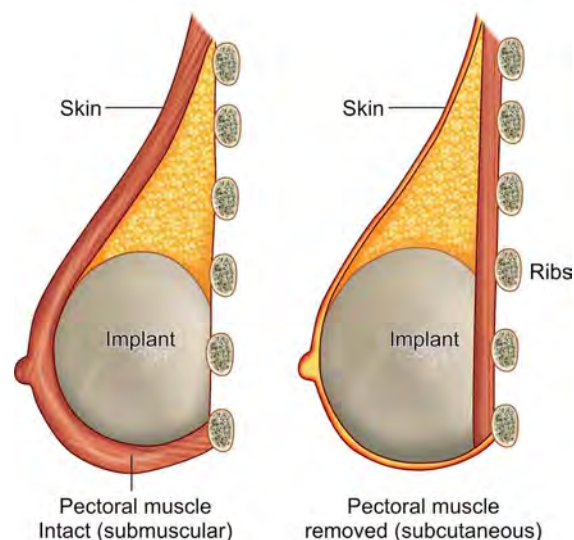


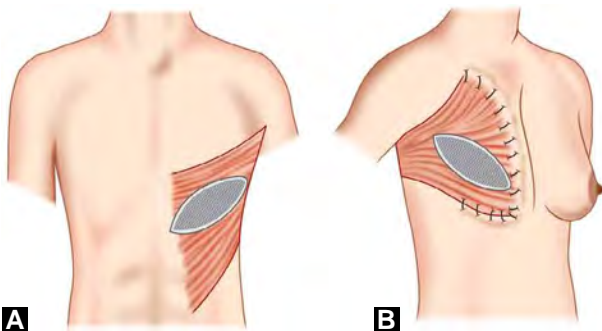
Fig. 8.87: Breast implant.

<b>LD flap</b>	<b>TRAM flap</b>
Myocutaneous flap based on subscapular artery	Transverse rectus abdominis myocutaneous flap based on superior epigastric artery. ipsilateral or contralateral TRAM flap is used
Easy to perform	It gives the bulk needed for reconstruction and so implant is not needed
Reliable flap, well vascularised	Donor site morbidity and fat necrosis can occur
Can be placed over prosthesis	Free TRAM flap into internal mammary/thoracodorsal axis can be done
Low complication rate	Limitations to position, shape and rotate; often needs mesh placement in the abdomen wound to prevent development of incisional hernia
But causes unsightly donor area on the back	

- ◆ Superior gluteal flap based on superior gluteal vessels.
  - ◆ *Ruben's flap* using soft tissue pad overlying the iliac crest based on deep circumflex iliac vessels.
- External breast prosthesis which fits within the bra is a simpler cosmetic method.

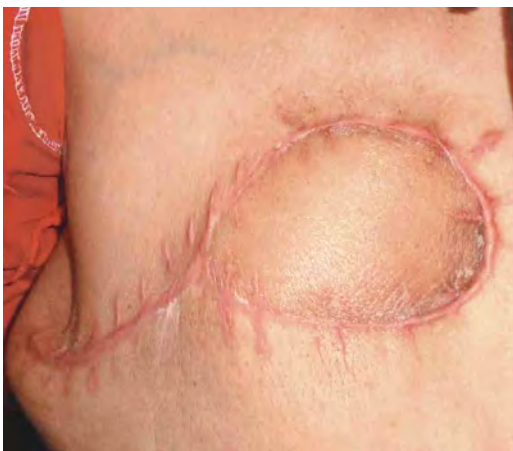

Fig. 8.88: LD flap.



Figs 8.89A and B: LD flap (A) Donor area; (B) Recipient area.

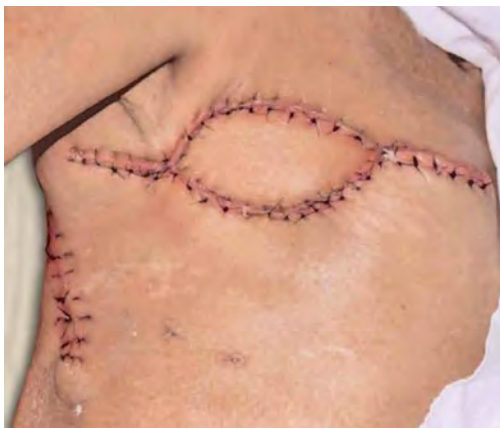

Fig. 8.90: Latissimus dorsi flap (LD flap) placed after mastectomy. It is based on thoracodorsal artery.

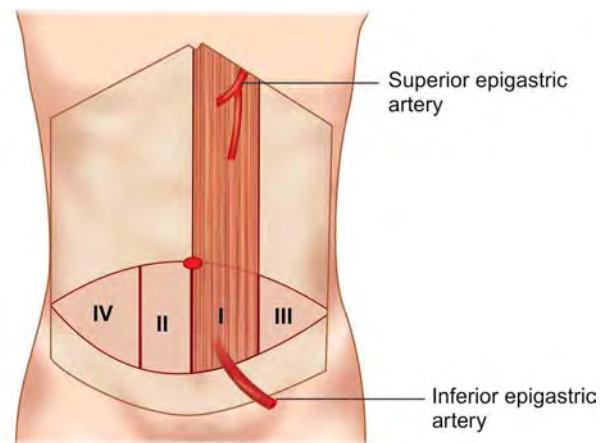
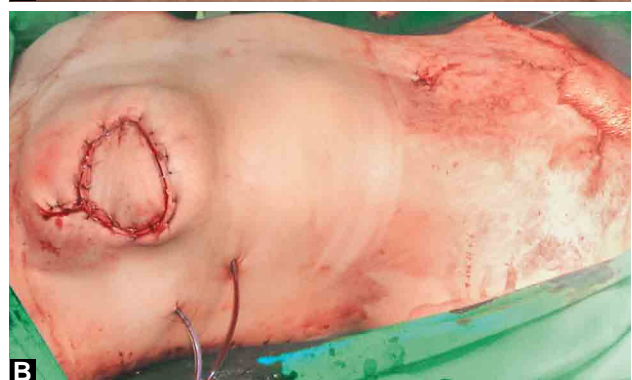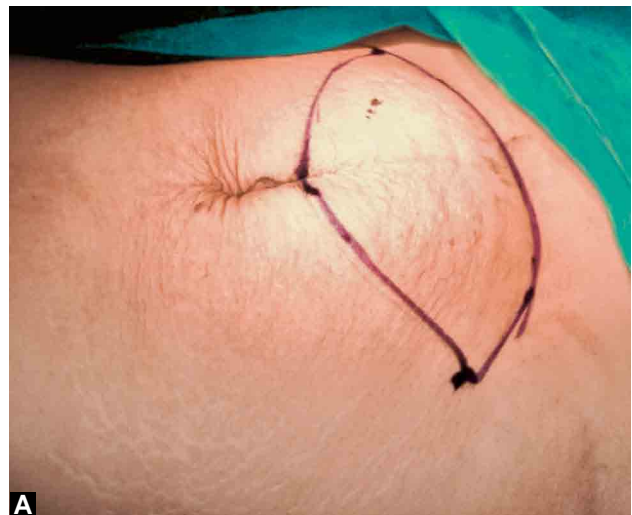

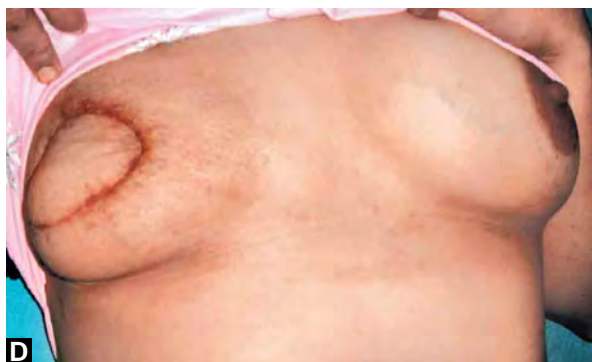
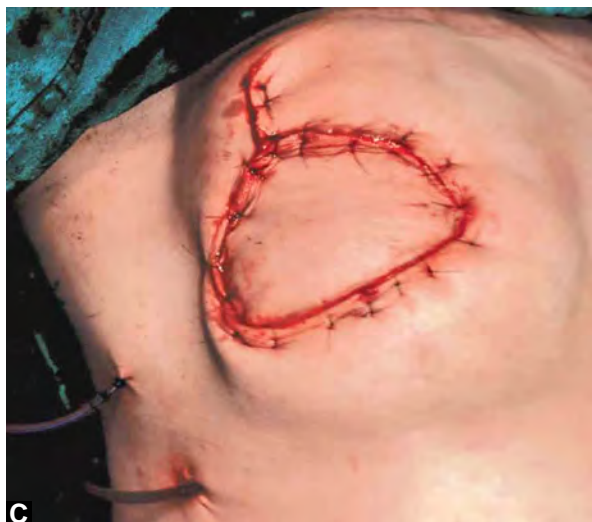Fig. 8.91: Transverse rectus abdominis myocutaneous flap (TRAM). Note the blood supply of the flap.



Figs 8.92A and B



Figs 8.92C and D

Figs 8.92A to D: Different operative steps in TRAM flap.

#### Note:

- Breast reconstruction is done in young patients with early stage disease.
- Skin sparing mastectomy with removal of nipple areola complex may be better for reconstruction.
- Symmetry is the most important factor in breast reconstruction.

#### Nipple is created using:

- ◆ Local breast flaps 3 months after breast reconstruction.
- ◆ Nipple sharing from contralateral nipple using composite graft.
- ◆ *Skate flap*: Local flap with de-epithelialised donor site around the periphery over which a full thickness graft is applied.
- ◆ Nipple prosthesis can be fitted.

**Areola pigmentation is created using** (it is done 3 weeks after nipple creation):

- ◆ Full thickness skin graft from non-hairy skin lateral to labia majora, as the pigmentation of this graft matches that of the areola.
- ◆ From contralateral areola if reduction mammoplasty is done on that side.

- ◆ Tattooing—colour tends to fade with time and may need to be repeated.
- ◆ SSG from retroauricular area or from thigh.

## BREAST IMPLANTS

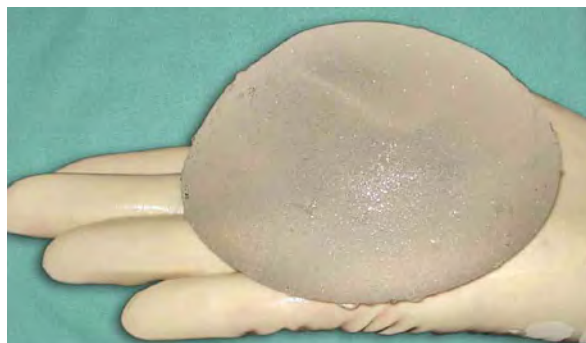

Fig. 8.93: Typical breast implant and its placement. It can be placed in subcutaneous or submuscular plane.

- ◆ Technically simple.
- ◆ Achieve symmetry easily.
- ◆ Implant in *submuscular plane* is better whenever muscle is not removed during surgery.
- ◆ If muscle is removed as in radical mastectomy, then *subcutaneous implant* is placed.
- ◆ Silicon gel implants are used.

### Complications of breast implants

- ❖ Pain, exposure of implant and rupture
- ❖ Displacement, extrusion
- ❖ Infection
- ❖ Capsular contraction

### Causes of massive enlargement of breast

- ❖ Benign hypertrophy—usually bilateral
- ❖ Giant fibroadenoma
- ❖ Serocystic disease of Brodie
- ❖ Sarcoma
- ❖ Colloid carcinoma
- ❖ Filariasis of breast

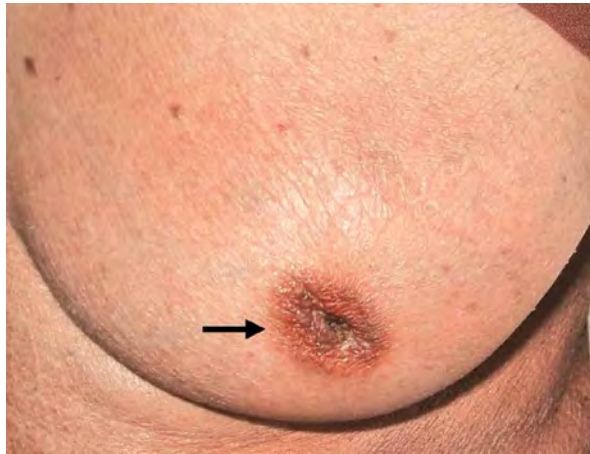### Changes that can occur in nipple

- ❖ Destruction
- ❖ Depression—retraction
- ❖ Discolouration
- ❖ Displacement
- ❖ Deviation
- ❖ Discharge
- ❖ Duplication

### Causes of hard swellings in the breast

- ❖ Carcinoma breast
- ❖ Antibioma breast
- ❖ Traumatic fat necrosis
- ❖ Calcified haematoma
- ❖ Fibroadenoma—hard variety

## NIPPLE RETRACTION



**Fig. 8.94:** Typical nipple retraction in carcinoma breast. It is circumferential retraction in carcinoma and partial slit like in duct ectasia.

- ◆ 25% of retractions are bilateral.
- ◆ Congenital nipple retraction is simple nipple inversion. It causes problems in breastfeeding, recurrent infection, collection of secretions.
- ◆ Slit like retraction is due to duct ectasia and periductal mastitis.
- ◆ Circumferential retraction is usually due to carcinoma.
- ◆ Any nipple retraction of recent onset should be evaluated.

### Note:

- *Nipple inversion* is congenital, developmental one; it is seen in 25% of females; can be bilateral; does not interfere with infant feeding; can predispose periductal mastitis. Surgical correction is not usually required and is technically difficult. Suction device is often tried mechanically.
- *Nipple retraction* occurs in a nipple which was normal earlier and is now pathologically retracted. Duct ectasia, carcinoma, previous surgeries may be the cause.

Nipple discharge			
Classifications	Significant nipple discharge	Types of nipple discharge	Discharge which suspects' carcinoma
<p><i>It can be:</i></p> <ul style="list-style-type: none"> <li>• Physiologic               <ul style="list-style-type: none"> <li>– Bilateral, involves multiple ducts.</li> <li>– Usually not bloody.</li> <li>– Nonspontaneous</li> </ul> </li> </ul>	<ul style="list-style-type: none"> <li>• Spontaneous.</li> <li>• Persistent.</li> <li>• Nonlactating patient.               <ul style="list-style-type: none"> <li>– Incidence of carcinoma in nonlactating nipple discharge is 4%.</li> </ul> </li> </ul>	<p><b>Blood:</b></p> <ul style="list-style-type: none"> <li>• Papilloma/malignancy.</li> </ul> <p><b>Purulent</b></p> <ul style="list-style-type: none"> <li>• Infection, usually related to lactation; often in malignancy.</li> </ul>	<ul style="list-style-type: none"> <li>• Spontaneous discharge.</li> <li>• Age <math>\geq</math> 40.</li> <li>• Unilateral discharge.</li> <li>• Bloody or guaiac-positive discharge.</li> <li>• Palpable lump/mass.</li> </ul>
<ul style="list-style-type: none"> <li>• Pathologic               <ul style="list-style-type: none"> <li>– Unilateral.</li> <li>– Spontaneous.</li> </ul> </li> <li>– Can be often bloody.</li> <li>– Most common cause intraductal papilloma.</li> </ul> <p><i>It can be:</i></p> <ul style="list-style-type: none"> <li>• Spontaneous.</li> <li>• Nonspontaneous.</li> </ul> <p><i>It can be due to:</i></p> <ul style="list-style-type: none"> <li>• Benign cause—88%.</li> <li>• Malignant cause—12%.</li> </ul>	<p><b>Causes of nipple discharge</b></p> <ul style="list-style-type: none"> <li>• Physiological is—during lactation and pregnancy.</li> <li>• Galactorrhoea is milk secretion not related to pregnancy either primary or secondary.</li> <li>• Fibrocystic disease of breast—serous or greenish discharge.</li> <li>• Duct papilloma—bloody discharge.</li> <li>• Duct ectasia—thick, creamy discharge.</li> <li>• Carcinoma—bloody discharge.</li> <li>• Idiopathic—here cause of discharge is not identified in spite of all investigations. Patient can be reassured with regular follow-up. It may be improper reabsorption of the normal ductal secretions (Normally, all ductal secretions which occur continuously are reabsorbed completely).</li> </ul>	<p><b>Milky:</b></p> <ul style="list-style-type: none"> <li>• After childbearing up to one year; hypothyroidism, prolactinomas, galactorrhoea.</li> </ul> <p>• Medications: Oral contraceptives, tricyclic antidepressants, dopamine agonists.</p> <ul style="list-style-type: none"> <li>• In milk fistula; rarely in galactocele.</li> </ul> <p><b>Grey, brown, green, sticky:</b></p> <ul style="list-style-type: none"> <li>• Duct ectasia. Common in 5th decade, with nipple tenderness and pain.</li> </ul> <p><b>Creamy discharge:</b></p> <ul style="list-style-type: none"> <li>• Duct ectasia.</li> </ul> <p><b>Serous:</b></p> <ul style="list-style-type: none"> <li>• Fibrocystic disease (most common; but can be serous/greenish/greenish black), ectasia.</li> </ul> <p><b>Serosanguinous:</b></p> <ul style="list-style-type: none"> <li>• Carcinoma, infection.</li> </ul> <p><b>Greenish:</b></p> <ul style="list-style-type: none"> <li>• Fibrocystadenosis (commonly), duct ectasia.</li> </ul> <p><b>Black:</b></p> <ul style="list-style-type: none"> <li>• Duct papilloma/carcinoma.</li> </ul>	<p><b>Management:</b></p> <ul style="list-style-type: none"> <li>• Discharge study for cytology, culture.</li> <li>• Mammography, US of breast and axilla, FNAC/core biopsy.</li> <li>• Ductography is specific for duct ectasia.</li> <li>• Treat the identified cause accordingly.</li> </ul>

# Chapter 9

## Peritoneum

*Among the inflammations of the abdominal region, I have given a place in our Nosology to the Peritonitis, comprehending under that title, not only the inflammations affecting the peritoneum lining the cavity of the abdomen, but also those affecting the extensions of this membrane in the omentum and mesentery.*

—William Gullen, 1792

### CHAPTER OUTLINE

❖ Anatomy	❖ Other Forms of Peritonitis	❖ Mesenteric Malignancy
❖ Physiology	❖ Pelvic Abscess	❖ Mesenteric Trauma
❖ Acute Peritonitis	❖ Subphrenic Spaces and	❖ Peritoneal Malignancy
❖ Spontaneous Bacterial Peritonitis	Subphrenic Abscess	❖ Omental Cyst
❖ Sclerosing Peritonitis	❖ Mesenteric Cysts	❖ Omental Torsion
❖ Biliary Peritonitis	❖ Mesenteric Panniculitis	❖ Omental Tumour
❖ Post-operative Peritonitis	❖ Acute Mesenteric Lymphadenitis	

### ■ ANATOMY

#### Peritoneum

It is a serous membrane lining the abdominal cavity. It is composed of outer fibrous tissue layer (which gives strength) and inner mesothelial cell layer (secretes fluid giving lubricating function to the peritoneum).

#### Parts of Peritoneum

1. *Parietal peritoneum*: It lines the inner surface of the abdominal wall, under surface of diaphragm and pelvic wall. It is loosely attached to the overlying walls and can be easily stripped off. It is innervated by the somatic nerves, so pain sensitive. Anterior peritoneum is most sensitive when compared to pelvic peritoneum.
2. *Visceral peritoneum*: It lines the outer surface of the abdominal viscera, firmly adherent, cannot be stripped off. It is innervated by autonomic nervous system; hence not pain sensitive.

#### Peritoneal Cavity

It is the potential space between the parietal and visceral peritoneum. Normally it contains 100 ml of clear, straw coloured fluid secreted by the mesothelial cells. Its quantity and quality varies in pathological conditions. It has got lubricating function, allowing frictionless movements of adjacent peritoneal surfaces.

**Spaces in peritoneal cavity:** Peritoneal cavity being largest cavity in the body is divided into *different spaces* by ligaments and mesenteries. Eleven ligaments are—coronary, gastrohepatic, hepatoduodenal, falciform, phrenicocolic, splenorenal, gastrosplenic, duodenocolic, gastrocolic; mesenteries are—transverse mesocolon and bowel mesentery. Intra-abdominal spaces are nine in number; they are—right and left subphrenic, subhepatic, lesser sac, supramesenteric, inframesenteric, right and left paracolic gutters, and pelvic. Peritoneal cavity is surgically divided basically into *supracolic and infracolic* compartments.

### ■ PHYSIOLOGY

Surface area of peritoneum is 2 m<sup>2</sup> equal to surface area of skin. It has property of bidirectional transfer of substances. It can absorb from or transfer to peritoneal cavity, fluid and electrolytes. This property is used in peritoneal dialysis. The mesothelial cells facilitate rapid healing following any injury, which takes place very fast in matter of hours. Adhesions occur due to delayed or incomplete peritoneal healing.

**Diaphragmatic defense:** Movement of peritoneal fluid and lymph in the peritoneal cavity depends on the diaphragmatic movement and phases of respiration. During expiration altered intrathoracic and intra-abdominal pressure makes all fluid, bacteria and particles to move/circulate upwards towards diaphragm; during inspiration,

*Do what you have, with what you have, where you are—Theodore Roosevelt*



it facilitates the entry of these contents into lymph to clear it. There are fine intercellular pores in the peritoneum called as *diaphragmatic stomatas* covering the inferior surface of the diaphragm which leads into diaphragmatic lymphatics and so to regional lymph nodes and thoracic duct. During expiration intra-abdominal pressure is reduced and peritoneal fluid through capillary action travels upwards towards diaphragm. Peritoneal macrophages promote leukocyte migration into the peritoneal cavity. Peritoneal mast cells release vasoactive products causing vasodilatation on peritoneal surface and release of complements and immunoglobulins into the peritoneal cavity. Complements cause bacterial opsonisation and phagocytosis. Release of fibrin causes adhesions and localisation of infection to one place preventing generalised peritonitis; this often leads into localised abscess formation.

## ■ ACUTE PERITONITIS

### Definition

*Peritonitis* is defined as inflammation of the parietal and serosal layer of the peritoneum either due to chemical like acid (gastric) or bile or due to bacterial infection. Peritoneal cavity is sterile normally. Commonly it is *secondary peritonitis* which is due to bowel (hollow viscus) perforation. It can be *primary peritonitis* (1% of all peritonitis) without any secondary causes (*without any documented source of infection*) like bowel perforation or pelvic infection; it is commonly seen in young girls where infection occurs through Fallopian tubes or in males through respiratory tract or otitis media; it is also common in patient with cirrhosis and ascites as Spontaneous Bacterial Peritonitis (SBP). *Tertiary peritonitis* is seen in post-operative patients (after laparotomy) due to leak or bowel necrosis and seen on 7th or later day after laparotomy with an incidence of 2%.

Peritonitis can be *generalised or localised*; generalised type if not treated surgically carries near 100% mortality. Localised type commonly forms abscess like pelvic, subphrenic, paracolic, interloop and so on.

*Peritonitis can be chemical or bacterial or initially chemical induced but later becoming bacterial.* Chemical peritonitis is caused by acid, bile, blood, barium or other substances.

#### Types

- ❖ Primary
- ❖ Secondary
- ❖ Tertiary

### PRIMARY PERITONITIS

- ❖ It is commonly due to pneumococci, and can occasionally be due to streptococci, haemophilus, *Gonococcus* (rare now) and other gram-negative (*Escherichia coli*) organisms. It is common in young girls between 3 and 9 years of age group and also in women.
- ❖ Here there is no documented source of infection. Infection usually spreads from lower genitals through fallopian tubes, from upper respiratory tract infection or from middle ear in males.
- ❖ Primary peritonitis is also common in cirrhotic patients with ascites, as spontaneous bacterial peritonitis (SBP) and is due to translocation of gut bacteria or through mesenteric lymphatics or occasionally as blood spread. 30% of

patients with ascites in cirrhosis will develop SBP. 90% of SBP is monomicrobial infection due to *E. coli* (40%), *Klebsiella*, *Pseudomonas*, proteus (Gram-negative organisms); *Streptococcus pneumoniae* (15%) and *Staphylococcus* and anaerobic microorganisms (5%).

- ❖ Primary peritonitis can occur in children with nephrotic syndrome or systemic lupus erythematosus.
- ❖ Ascitic fluid protein content when becomes less than 1 g/dl increases the risk of primary peritonitis (SBP). Ascitic fluid WBC count if more than 250 cells/mm<sup>3</sup> with more than 50% cells are polymorphonuclear cells (PMN) suggestive of primary peritonitis (SBP).
- ❖ It is uncommon after 10 years of age. It is common in malnourished child and child with nephritis. Child is toxic, severely ill and develops septicaemia very early.
- ❖ It is also seen in ascites, patient with indwelling catheter for peritoneal dialysis, patients with peritoneovenous shunt.
- ❖ It can also be due to Chlamydial, fungal or mycobacterial infection.
- ❖ TC is very high >30,000/mm<sup>3</sup>.

### Treatment

- ❖ Diagnostic tapping, tube peritoneal drainage and laparoscopic drainage and wash are useful methods.
- ❖ Laparotomy and peritoneal toilet.
- ❖ Broad spectrum antibiotics including combination of aminoglycosides, cephalosporins and metronidazole.
- ❖ Local instillation of antibiotics, into the peritoneal cavity to achieve quick and effective results.

Mortality is high.

### SECONDARY PERITONITIS

It is secondary to any bowel or other visceral pathology, e.g. perforation, appendicitis. *Escherichia coli* (70%) is the most common organism involved. Other bacteria are— aerobic and anaerobic streptococci, *Clostridium welchii*, bacteroides, staphylococci, *Klebsiella*, *Salmonella typhi*.

*Duodenal perforation and burst appendicitis* are the commonest causes of secondary peritonitis.

### TERTIARY PERITONITIS

- ❖ It occurs after any abdominal surgeries, which is usually severe and the patient may go in for SIRS or MODS early.
- ❖ Tertiary peritonitis is defined as persistent or recurrent intra-abdominal infection after an adequate treatment for primary or secondary peritonitis—usually after 48 hours.
- ❖ It is common in immunosuppressed individual with ineffective peritoneal host defenses against microbes. Infection due to *E. faecalis*, *E. faecium*, *S. epidermidis*, *P. aeruginosa*, *C. albicans* are common in such patients. Virulence and resistance to drugs are other factors.
- ❖ It is difficult to diagnose clinically causing delay in therapy. CT abdomen, total and platelet count, LFT, monitoring of renal functions, hourly urine output assessment, chest X-ray are *required investigations*.

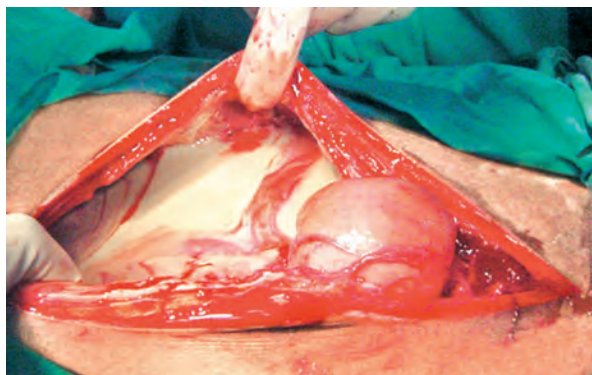
- ◆ *Treatment* is aggressive antibiotic therapy, antifungal therapy, TPN, maintaining of haemodynamic stability, exploration of abdomen, thorough wash, colostomy/ileostomy or exteriorisation of bowel segment. FFP, packed cells, platelet transfusions may be required. Ventilator, ICU care is often needed.
  - ◆ Often these bacteria like enterococci, *Candida*, *Staphylococcus epidermidis*, *Enterobacter*, *pseudomonas* shows multidrug resistant and so finding difficulty in managing such patients.
  - ◆ *Mortality rate* is >50%. Problems are—DIC, septicaemia, uraemia (haemodialysis may be needed), haemorrhage, pneumonia, ARDS.
- ◆ Dialysis.
  - ◆ Foreign body.
  - ◆ Appendicitis, cholecystitis, diverticulitis.
  - ◆ Intestinal obstruction with strangulation.
  - ◆ Via fallopian tubes.
  - ◆ Through blood spread—in septicaemia.
  - ◆ Transmural spread.
  - ◆ Following uterine perforation/injury during abortion or termination of pregnancy.

### Bacteria Causing Peritonitis

- a. *Bacteria from GIT*—*E. coli*, aerobic streptococci, *Streptococcus faecalis*, *Staphylococcus*, anaerobic streptococci, anaerobes (bacteroides), *Klebsiella*, *Cl. welchii*.
- b. *Bacteria not from GIT*—*Gonococcus*, *Pneumococcus*, are from fallopian tubes, commonly occurs in young females. *Chlamydia*,  $\beta$ -haemolytic streptococci, *Mycobacterium* are few other bacteria which can cause peritonitis.

1. <i>Primary</i>	Monomicrobial, extraperitoneal source, blood spread
2. <i>Secondary</i>	Most common, polymicrobial, intra-peritoneal source
3. <i>Tertiary peritonitis</i>	Due to superadded infection following treatment of secondary/primary

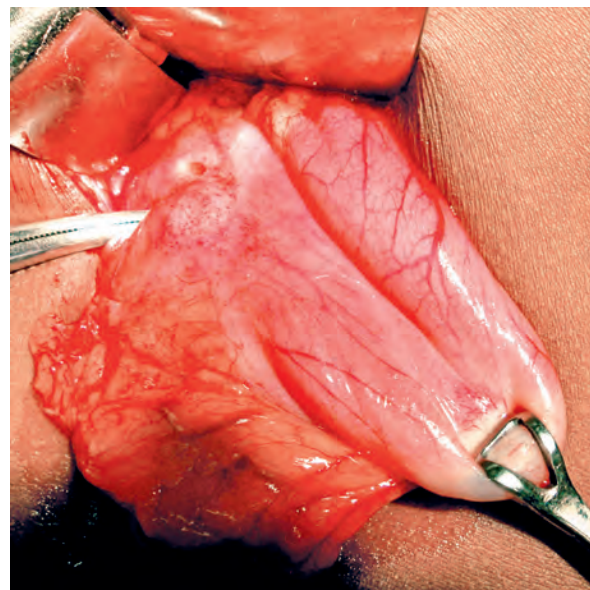Most common bacteria during the phase of peritonitis is *E. coli* and during abscess formation is *B. fragilis*. *Mortality for diffuse peritonitis is 10%*.



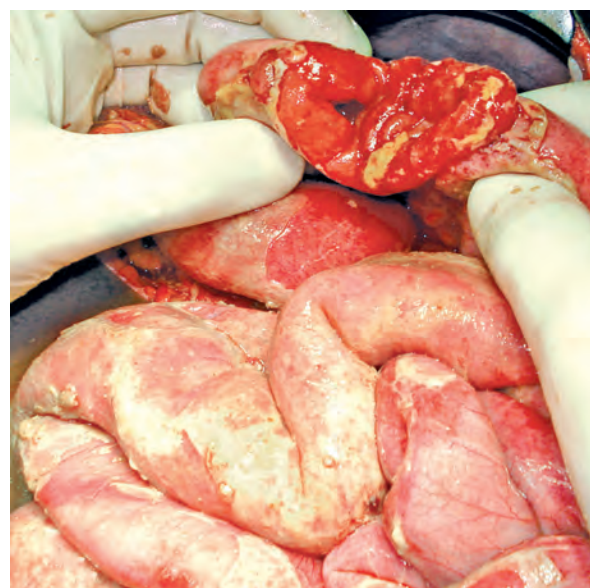**Fig. 9.1:** On table finding in a case of peritonitis, where the peritoneal cavity is filled with pus.

### Mode of Infection

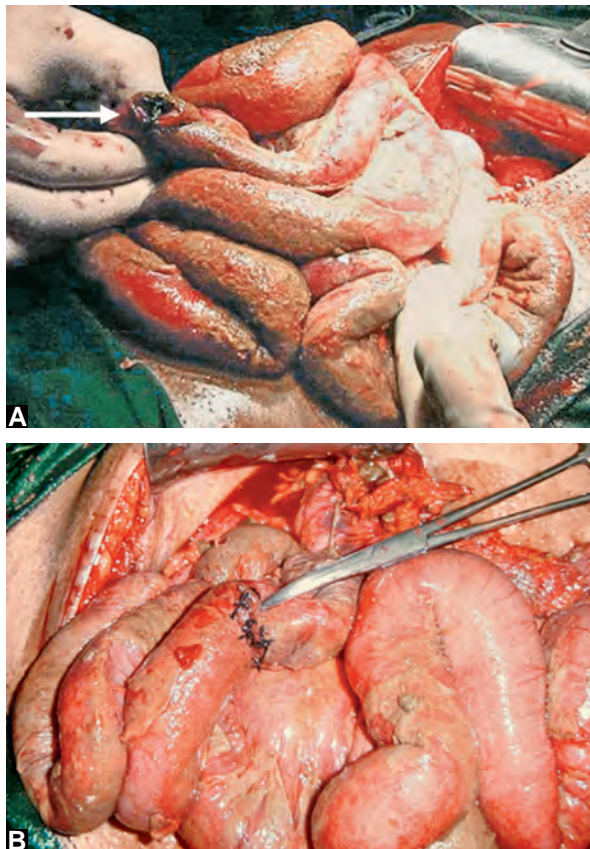
- ◆ Perforation of the GIT—duodenal/gastric/enteric/colonic ulcers; Meckel's diverticulitis perforation.
- ◆ Penetrating or blunt trauma.
- ◆ Surgery.
- ◆ Drains.



**Fig. 9.2:** Duodenal ulcer perforation causing peritonitis.



**Fig. 9.3:** Jejunal perforation due to trauma. Trauma is the common cause for jejunal perforation. It is commonly blunt abdominal injury due to shearing force (traction injury) causing jejunal tear near duodenojejunal junction.



**Figs 9.4A and B:** Ileal perforation with severe peritonitis. Note the closure done horizontally. It could be typhoid perforation.

#### Factors affecting the spread of the infection in peritonitis

- ❖ Rapidity by which the pus is gushed into the peritoneal cavity, e.g. burst appendix, perforations
- ❖ Amount of peristalsis (more the peristalsis more the spread)
- ❖ Virulence of the organism, bacterial load and nature
- ❖ Localising action of the omentum (in children localisation is poor as omentum is small)
- ❖ Immunosuppression—HIV, steroids
- ❖ Anatomical nature of the peritoneal cavity
- ❖ Age, associated diseases like malignancy, malnutrition, anaemia

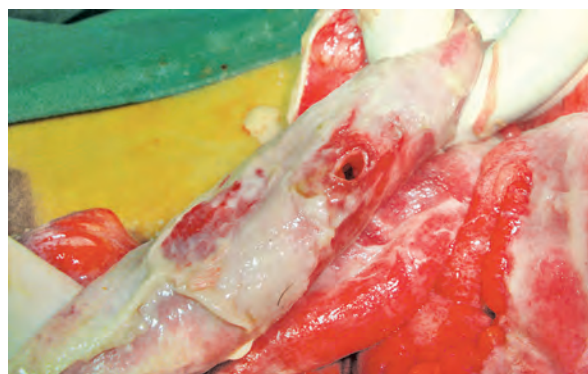#### Pathogenesis

- ◆ Lot of fluid is secreted into the peritoneal cavity which is infected, containing bacteria and toxins causing shock, toxæmia and its subsequent effects. Fibrinogen forms fibrin which tries to localise the infection. Bowel gets adhered to each other with fluid collecting between the loops. Thick flakes are formed adhering to the surface of the bowel. Peritoneum is thick, oedematous, becomes velvety and reddish with loss of its glistening appearance. Omentum is thickened, adherent. Often site of perforation may be identified by the location of the end of the omentum. Dilated bowel loops with site of obstruction/gangrene may be found. Pus, often with pockets may be present in subphrenic, paracolic and pelvic spaces.
- ◆ Peritoneal contents are initially sterile but eventually become infected in certain situations, as in acute pancreatitis, in haemoperitoneum, and in ruptured urinary bladder. It is due to transmural migration of bacteria.

- ◆ In perforated duodenal or gastric ulcers, contents in the peritoneal cavity are initially sterile but later get infected to form bacterial peritonitis.
- ◆ Bacterial load ( $2 \times 10^8$  CFU/ml) and virulence overwhelm the host defense. It interfere with the phagocytosis, neutrophil activity leading into bacterial multiplication and toxæmia and pus formation.
- ◆ *Localised peritonitis*—initially localisation of peritonitis occurs based on the anatomical factors like supracolic/infracolic compartments; greater omentum; paracolic gutters; dilated small bowel, etc. Pathological factors are thickened peritoneum, fibrin deposition, omental adhesions, reduced bowel peristalsis. Localised peritonitis may resolve by proper therapy. It may form abscess—pelvic/subphrenic. If it progresses it may form generalised peritonitis.
- ◆ *Diffuse peritonitis* sets in due to poor localisation, rapid peritoneal contamination, violent peristalsis, virulent organisms, immunodeficiency status, and small omentum in children (not properly developed in children). Diffuse peritonitis may occasionally get localised to form abscess. Mortality in diffuse peritonitis is 10%.

#### Clinical Features

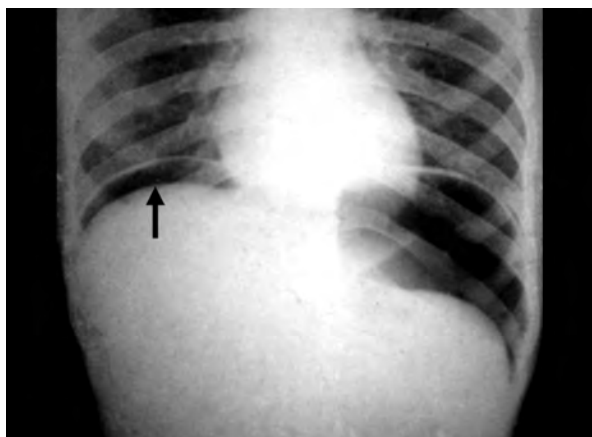
- ◆ Sudden onset of pain which is *severe*.
- ◆ Fever, vomiting.
- ◆ Tenderness—initially localised later becomes diffused.
- ◆ Rebound tenderness—*Blumberg sign*.
- ◆ Guarding and rigidity, dull flanks on percussion.
- ◆ Tachycardia, tachypnoea.
- ◆ Tenderness on P/R examination.
- ◆ Distension with silent abdomen.
- ◆ Eventually leading to Hippocrates facies, septicæmic shock and loss of consciousness.
- ◆ Bowel sounds are absent due to paralytic ileus.
- ◆ Fever may be absent in severe peritonitis due to loss of pyrogenic reaction. Total count also may be very low in severe peritonitis.
- ◆ *APACHE II* (Acute Physiology And Chronic Health Evaluation [using 12 physiological variables]) and *Mannheim peritonitis index* (8 parameters) scoring systems are used to assess the severity and predicting the outcome in peritonitis.



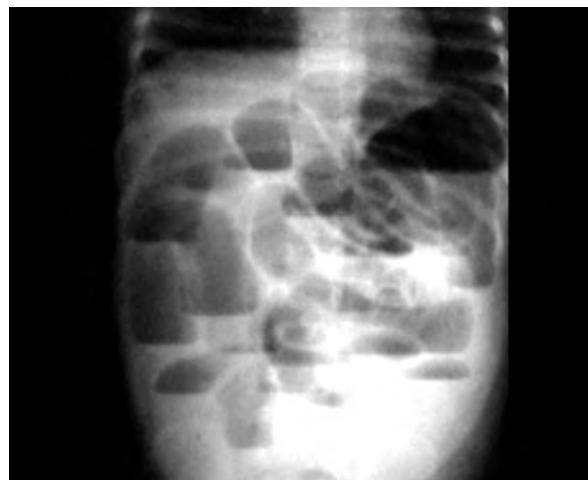**Fig. 9.5:** Small bowel perforation with peritonitis with thick plaques on the bowel surface.

## Investigations

- ◆ *Chest X-Ray in standing position with abdomen (erect)* will show *ground glass appearance* of the abdomen with *gas under diaphragm* suggesting hollow viscous perforation. *Left lateral decubitus X-Ray* is very useful in very critical patient where patient cannot be made to stand in erect posture. It should be differentiated from the rare *Chilaiditi syndrome* wherein interposition of bowel in front and above the liver looks radiologically like gas under diaphragm.
- ◆ Total count is increased.
- ◆ U/S abdomen—shows fluid in the abdominal cavity. Also clinches the other causes like haemoperitoneum, pancreatitis.
- ◆ Electrolyte study, blood culture
- ◆ Blood urea and serum creatinine.
- ◆ Serum amylase if *four times the normal value*, it is significant. LFT also should be done. Platelet count, bleeding time, clotting time, prothrombin time are to be assessed in severe peritonitis.
- ◆ Four quadrant abdominal tap—reveals pus or infected fluid. In suspected pancreatitis fluid should be analysed for amylase level (which will be high). Often US guided aspiration is better and more accurate. Fluid collected should be sent for culture.
- ◆ *Diagnostic peritoneal lavage (DPL)* is useful. DPL with more than 500 WBCs/ml suggests peritonitis; fluid should be assessed for pH, sugar, protein, LDH, cell count, Gram stain, culture. Fluid is analysed for amylase or bilirubin or creatinine in suspected cases of pancreatitis or biliary leak/peritonitis or urinary leak. pH (<7.0) and glucose (<50 mg/dl) of aspirated fluid will be low in bacterial peritonitis but will show raised protein and LDH (greater than serum LDH).
- ◆ *Diagnostic laparoscopy. It can also be used as therapeutic for duodenal ulcer perforation or primary peritonitis to give peritoneal wash.*
- ◆ CT scan is useful to confirm the cause or to rule out conditions like pancreatitis. CT scan detects bowel ischaemia, gangrene, perforation, internal hernias and quantity of pus/fluid in the peritoneal cavity.
- ◆ MRI is reliable in identifying intra-abdominal abscess.



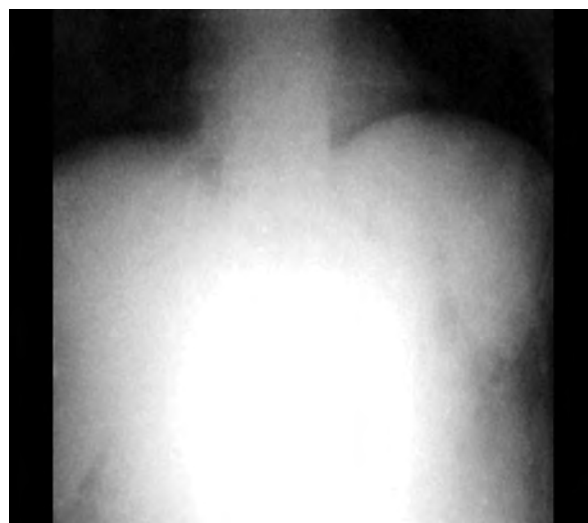**Fig. 9.6:** Plain X-ray abdomen showing gas under diaphragm. Perforation is the most common cause of peritonitis.



**Fig. 9.7:** Multiple air fluid levels in plain X-ray abdomen—feature of intestinal obstruction.

## Differential Diagnosis

- ◆ *Pancreatitis:* In pancreatitis back pain is common. But it is often difficult to differentiate clinically from acute peritonitis. Serum amylase is increased. CT abdomen may help in differentiating from peritonitis.



**Fig. 9.8:** Plain X-ray abdomen showing ground glass appearance—a feature of peritonitis.

- ◆ *Intestinal obstruction:* There will be distension, vomiting and pain. Plain X-ray shows dilated bowel loops. CT scan confirms intestinal obstruction and its cause.
- ◆ *Ruptured ectopic pregnancy:* Urine pregnancy test will be positive. History of amenorrhoea is significant. Palor, tachycardia, lower abdominal pain and distension are common presentations. US abdomen and pelvis confirms the diagnosis.
- ◆ *Acute pyelonephritis:* Often clinically acute pyelonephritis mimics acute peritonitis. Guarding, tenderness, rigidity

may be present in pyelonephritis also. Urinary symptoms, tender renal angle, urine microscopy revealing pus cells, US abdomen may confirm the diagnosis.

- ◆ *Acute mesenteric ischaemia*: Bloody diarrhoea, colicky pain, tender abdomen, toxicity are the features of mesenteric ischaemia. CT abdomen and angiogram are useful investigations.
- ◆ *Diabetic acute abdomen*: Patient with diabetes mellitus may present as acute abdomen. Free fluid in the flank may not be present. Patient may be ketotic also.

## Treatment

### Principles of therapy in peritonitis

- ❖ To control source of infection—perforation
- ❖ To eliminate bacteria and sepsis
- ❖ To maintain vital organ function—cardiac, pulmonary, renal
- ❖ Nutrition and metabolic support

### Modalities of therapy

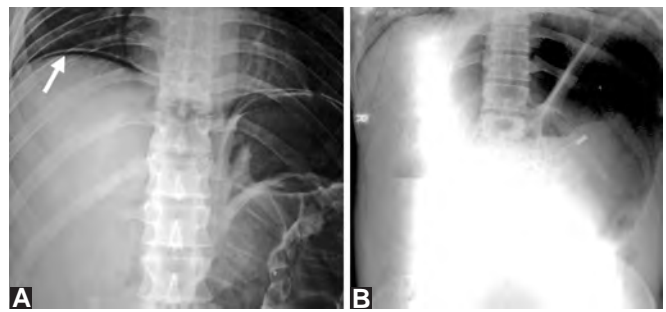
- ❖ *Systemic antibiotic therapy*—3rd generation cephalosporins or quinolones or piperacillin and tazobactam or meropenem, imipenem; single or combination therapy
  - ❖ *Resuscitation* with haemodynamic, pulmonary, renal supports with ICU care
  - ❖ *Fluid therapy*, parenteral or enteral nutrition if needed blood or blood products transfusions
  - ❖ *Electrolyte management*; nasogastric tube aspiration, urinary catheter placement
  - ❖ *Surgical drainage*—main essential modality of treatment; laparotomy, laparoscopy (controversial)—closure of perforation, resection of gangrene area, diversions like ileostomy or colostomy; peritoneal lavage (warm normal saline)
  - ❖ *Percutaneous USG or CT guided drainage* by placing pigtail/Foley's/abdominal drainage tube catheters in selected patients who are unstable severely ill or subacute or localised sepsis
  - ❖ *Proper post-operative care*—ICU care, ventilator, prevention of complications like respiratory infection, renal failure, reinfection, DVT; monitoring by regularly checking electrolytes, platelet count, blood count, liver and renal function tests; checking oxygen saturation, heart rate, blood pressure, urine output (hourly); if needed repeating USG or chest X-Ray
- ◆ Intravenous fluids for resuscitation are essential. It improves the tissue perfusion, corrects the hypotension and also improves the urine output. Normal saline, Ringer's lactate are usually used. Usual requirement is 2 ml/kg/hour.
  - ◆ Nasogastric tube aspiration—to decompress bowel; to reduce toxic fluid; to prevent aspiration.
  - ◆ Total parenteral nutrition, CVP line to perfuse and to monitor.
  - ◆ Blood transfusion, FFP, platelet transfusions if indicated.
  - ◆ Catheterisation with maintenance of adequate urine output (30 ml/hour) (0.5 ml/hour/kg).
  - ◆ Antibiotics—ampicillin, gentamicin, metronidazole, ceftazidime, cefoperazone, cefotaxime, tazobactam, piperacillin, meropenem, linezolid, etc.
  - ◆ Analgesics to relieve pain by drugs, epidural analgesia.
  - ◆ Sitting propped up position, early mobilisation, exercise,

respiratory physiotherapy, prevention of DVT using heparin/low molecular heparin are essential.

- ◆ Surgical correction of underlying cause.
- ◆ Use of dopamine, steroids, and management of shock.
- ◆ Often ICU and ventilator support is required during post-operative period.
- ◆ Monitoring the patient using PO<sub>2</sub>, PCO<sub>2</sub>, electrolytes, and pulse oximeter.

### Laparotomy and proceed

- ▶ On laparotomy, the cause for peritonitis is identified and corrected.
- ◆ In bowel perforation—perforation closure.
- ◆ In intestinal obstruction—resection and anastomosis.



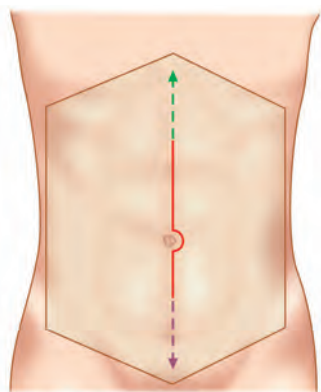
**Figs 9.9A and B:** X-ray showing gas under diaphragm due to perforation. Ground glass appearance of peritonitis is seen in another X-ray.

- ◆ In appendicitis—appendicectomy.
  - ▶ Proper peritoneal toilet (wash with 10 litres of saline) is given. A drain is placed (tube).
  - ▶ Pus should be sent for culture and sensitivity.
  - ▶ Tension sutures are placed when required to prevent burst abdomen. Its benefit is questioned even though it is commonly used.

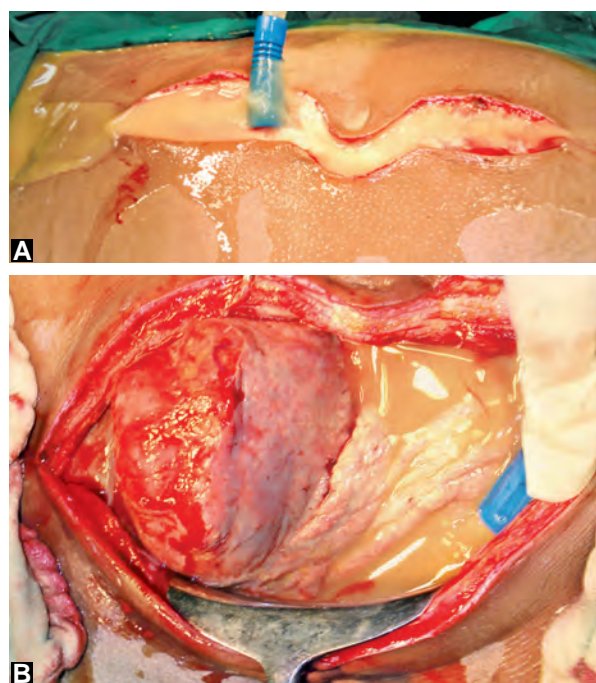
**Laparostomy**—It may be *open or closed method*. In *open method*, (Ettapan's lavage) abdominal wall/fascia and peritoneum are not sutured but kept open. It will reduce the chances of abdominal compartment syndrome and also allows easier and faster drainage of the infected fluid from the peritoneal cavity. But disadvantages are it causes lot of fluid loss and electrolyte imbalance and open area itself may allow infection to get into the peritoneal cavity. In *closed method*, abdominal fascial wound is closed using a zip. It facilitates the regular washing of the peritoneal cavity with normal saline without contaminating the cavity from outside and reduces the unnecessary fluid loss. But it may cause abdominal compartment syndrome.

### Technique of emergency laparotomy

Abdomen is opened with midline incision (with wide exposure), often extending both above and below the umbilicus, with incision inclined towards the left side at umbilicus. Once peritoneum is opened gushing pus is removed using suction. Pus is collected for culture. Abdominal cavity is inspected thoroughly for site of origin of sepsis—appendicitis/perforation/gangrene, etc. Definitive procedure is done depending on the cause. Proper wash is given using warm normal saline (10 litres). Drain should be placed. Wound is closed with tension sutures using nonabsorbable monofilament sutures (zero or one number).



**Fig. 9.10:** Vertical midline incision is used for emergency laparotomy in peritonitis. Lengthy incision with wide exposure of the peritoneal cavity is advisable.

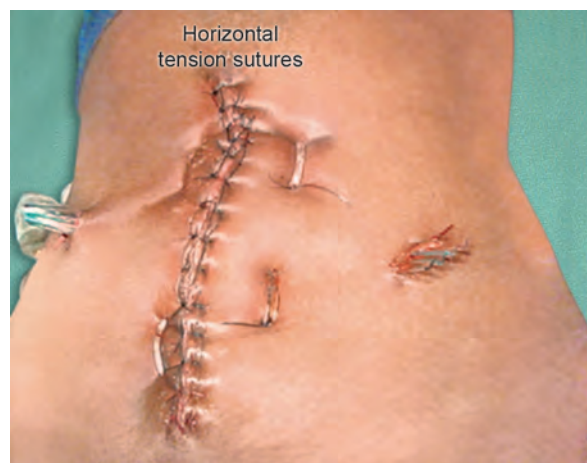

**Figs 9.11A and B:** Severe peritonitis showing pus in the peritoneal cavity.

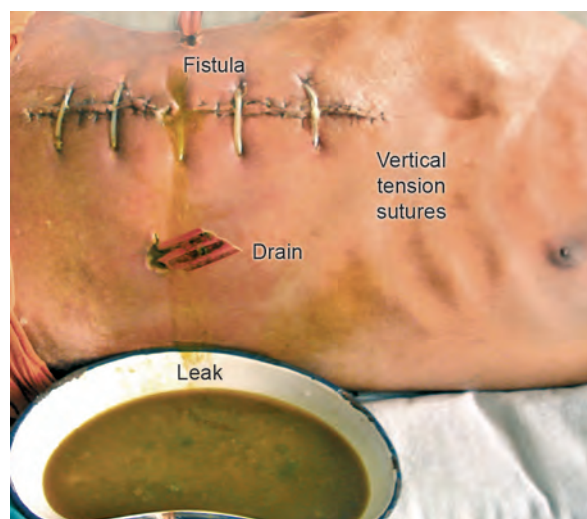
### Postoperative management

- ◆ Proper critical care (ICU) postoperatively.
- ◆ Ventilatory support; monitoring with urine output, temperature, breathing, pulse rate, blood pressure, arterial blood gas analysis, total count estimation (both very high and very low counts signify severe sepsis/septicaemia), neutrophil count estimation, platelet count, prothrombin time analysis, blood urea and serum creatinine, liver function tests (altered liver function signifies septicaemia). These investigations need to be repeated as and when required.
- ◆ Proper fluid and electrolyte management.
- ◆ Total parenteral nutrition (TPN).
- ◆ Prevention of deep vein thrombosis by leg exercises, low molecular weight heparin.

- ◆ Prevention/identification of ARDS and its management.
- ◆ Prevention of bedsore.



**Fig. 9.12:** Abdomen is closed with tension sutures in case of peritonitis using monofilament non-absorbable sutures to prevent post-operative burst abdomen. Drain also should be placed into the peritoneal cavity.



**Fig. 9.13:** Post-operative patient with tension sutures with fistula and leak. Patient has undergone resection and anastomosis for gangrene bowel.

### Note:

- If primary pathology is effectively treated surgically then primary fascial close of the abdomen can be done.
- If primary source is difficult to treat then open method and re-exploration is needed. It facilitates the re-exploration, avoids abdominal compartment syndrome. In open method, abdominal wound is covered temporarily using absorbable or nonabsorbable mesh or vacuum-assisted devices (VAC), Wittman patch with artificial burrs.
- *Re-exploration* is needed in multiple perforations, critical patients; here initial surgery is as damage control surgery but later definitive procedure is done. Diversion like ileostomy or colostomy should be considered whenever needed.
- Laparoscopic approach—It is used as initial tool of diagnosis at early stage. Early duodenal perforations, appendicectomy in burst peritonitis, diverticulitis perforation laparoscopy is found beneficial.
- Drain tubes are commonly placed after laparotomy in acute peritonitis even though its use is controversial.

- Multiple catheters can be placed into the abdominal cavity before closure of the abdominal wound to facilitate *continuous post-operative lavage*. Lavage is done using 3–4 litres of normal saline with heparin solution as 3 hours cycles for 3 days. It reduces the post-operative abscess formation and mortality rate.

### Terminal Features in Peritonitis

- a. *Hippocratic facies*—bright, hollow eyes; pale, pinched face; cold perspiration in eyebrows; dry, fissured tongue; blue lips. Patient will be in severe shock. It signifies terminal status with high mortality rate. It is a typical facial sign of *severe end stage peritonitis*.

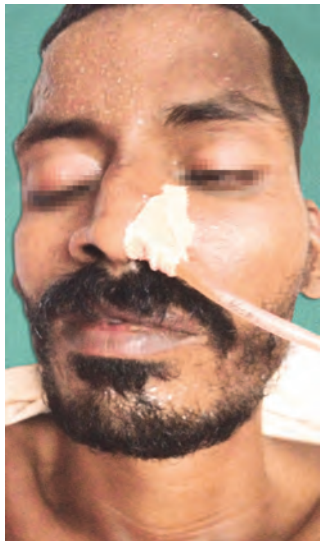

Fig. 9.14: *Hippocratic facies* in severe end stage peritonitis.

- b. Septic shock (cold stage).  
c. Systemic inflammatory response syndrome (SIRS).  
d. Multiorgan dysfunction syndrome (MODS).

#### Complications and sequelae of peritonitis and after surgery

##### Systemic

- ❖ Septicaemia, ARDS, renal failure, DIC, SIRS, MODS—life-threatening
- ❖ Respiratory infection, bronchopneumonia, pleural effusion/empyema
- ❖ Electrolyte imbalance, metabolic problems, DVT

##### Abdominal

- ❖ Burst abdomen (abdominal wound dehiscence), biliary/gastric/enteric/pancreatic/faecal fistula formation
- ❖ Formation of pelvic/subphrenic/intra-abdominal abscesses/portal pyaemia
- ❖ Surgical site infection, poor wound healing
- ❖ Tertiary peritonitis
- ❖ Abdominal compartment syndrome (ACS)
- ❖ Paralytic ileus, adhesive obstruction
- ❖ Incisional hernia

## SPONTANEOUS BACTERIAL PERITONITIS

Spontaneous bacterial peritonitis (SBP) is defined as bacterial infection of ascitic fluid in the absence of an intra-abdominal surgically treatable source of infection.

It is seen in:

- ◆ Infants and children commonly.
- ◆ In nephritic syndrome.
- ◆ In adults, with cirrhosis, most common cause. In cirrhotic patients, there is low Fc  $\gamma$  receptor on macrophage surface causing poor phagocytosis; opsonic action of peritoneal surface cells in presence of ascites is low causing poor control of bacterial load.
- ◆ In patients who has undergone splenectomy.
- ◆ Patients with ascites due to any cause.
- ◆ Malnutrition and malignancy.

### Causative Organisms

- ◆ Gram-negative bacilli (70%)—*E.coli*, *Klebsiella*.
- ◆ Gram-positive cocci (20%)—pneumococci, streptococci and enterococci.
- ◆ Anaerobes (10%).
- ◆ In girls it is commonly through fallopian tubes. In males it is always bloodborne from respiratory tract infection or otitis media.

### Features

- ◆ Features of peritonitis but initially with dull aching pain.
- ◆ Features of shock.
- ◆ Common in girls.
- ◆ High fever with neutrophilia is characteristic.
- ◆ Profuse diarrhoea is common.
- ◆ Features relevant of cause.
- ◆ Total count, LFT, U/S is useful tool.
- ◆ SBP is rare in ascites with high protein content like in peritoneal carcinomatosis. More than 250 neutrophils/cu mm<sup>3</sup> of ascitic fluid are diagnostic.

#### Note:

Scoring of the severity of the peritonitis is done based on age, sex, duration, cause, origin, content, general condition, haematocrit, electrolytes, O<sub>2</sub> saturation, blood urea, serum creatinine.

1. Mannheim peritonitis index.
2. Acute physiology and chronic health evaluation score (APACHE score).

### Management

- ◆ Usually conservative with proper higher generation antibiotics. But condition has got high mortality.
- ◆ Tapping of the purulent fluid from the peritoneal cavity is done only with atypical needed cases.
- ◆ Laparoscopy is useful method.
- ◆ Often peritoneal purulent fluid tube drainage may be beneficial.
- ◆ Laparotomy and peritoneal wash is done occasionally if secondary peritonitis and toxicity develops.
- ◆ Plasma albumin is helpful in SBP with cirrhosis to reduce hepatorenal syndrome and to decrease mortality.

#### Note:

- Exudate in pneumococcal peritonitis is odourless, turbid and sticky.
- Exudate in streptococcal peritonitis, is odourless, thin, blood stained with flecks of fibrin. Greenish watery diarrhoea is common. It is common in infants and children. Upper respiratory tract infections, tonsillitis, pharyngitis are the causes. It is treated with penicillins, amoxicillins, cephalosporins.
- *Staphylococcus aureus* peritonitis is common in those who use intra-vaginal tampons causing toxic shock syndrome and DIC.

## ■ SCLEROSING PERITONITIS

It is usually Practolol ( $\beta$  blocker) induced peritonitis. It is fibrinous peritonitis causing thickening of bowel and other contents of abdomen. It leads to intestinal obstruction and malnutrition.

## ■ BILIARY PERITONITIS

### Causes

- ◆ Trauma.
- ◆ Post-operative leak after surgery for gallbladder, CBD, duodenum, ERCP, pyloroplasty, post-gastrectomy duodenal stump leak/blow out, leak from choledochojejunal anastomosis.
- ◆ Perforation of gallbladder or CBD.
- ◆ Gangrenous cholecystitis and rupture.
- ◆ Idiopathic.
- ◆ Leakage from accessory bile duct after surgery; leakage from displaced T tube or displaced percutaneous stent.

### Clinical Features

- ◆ Features of peritonitis—abdominal distension, guarding and rigidity.
- ◆ *Jaundice*: It may be due to CBD injury, liver biliary ductile injury, sectorial duct injury, cystic duct leak or by absorption of bile from free peritoneal cavity.
- ◆ Toxicity.
- ◆ Features of shock.

### Investigations

- ◆ X-ray abdomen.
- ◆ Diagnostic peritoneal lavage.

### Treatment

- ◆ Laparotomy, wash, drainage.
- ◆ Cause to be treated. US guided percutaneous drainage; ERCP stenting; duodenal stump exploration, wash and drainage or jejunal serosal patch over it; ligation of cystic or accessory duct; choledocho/hepaticojejunostomy, etc. depending on cause.
- ◆ It has got high mortality.
- ◆ It may get localise and form abscess or may lead into biliary fistula.

## ■ POST-OPERATIVE PERITONITIS

- ◆ It is the development of peritonitis in post-operative period, either due to anastomotic leak, or biliary leak; and there is collection of pus in the peritoneal cavity including interloop areas.
- ◆ It is often difficult to differentiate it from post-operative urinary infection, respiratory infection like broncho-pneumonia, cardiac causes in old people, and infection in other areas like intravenous cannula site (thrombophlebitis). Symptoms may mask if patient is on steroid therapy.
- ◆ In all abdominal surgeries patient initially develops paralytic ileus which lasts for 3–5 days. If it persists or progresses one should suspect post-operative peritonitis. Other suspicious features are—persisting toxaemia in spite of antibiotics, oliguria, pyrexia, altered liver functions, altered total WBC count (very high as well as very low and neutrophil count is more specific) and increasing leak from drain site either fecal/intestinal/biliary, increase in abdominal distension, pain and tenderness. Leak may be due to sepsis, hypotension in pre/per and post-operative period, hypoxia,

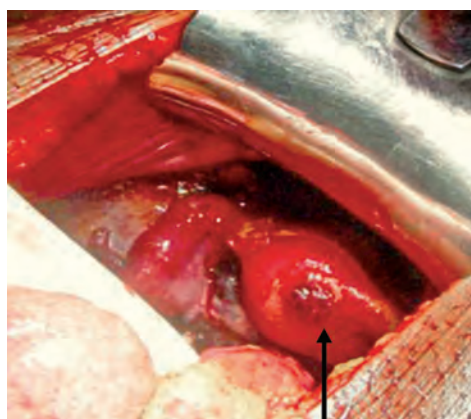
blood loss, ischaemia of bowel and friability of bowel wall, and specific causes like tuberculosis, malignancy or Crohn's disease. Often multiple areas of the bowel become necrotic which eventually causes leak. Leak from multiple sites is difficult to manage and has got poor prognosis.

### Management

- ◆ Immediate US or CT abdomen to find out the abdominal cause, total count, assessment of urinary parameters like blood urea and serum creatinine, liver function tests.
- ◆ Immediate exploration is the only way to save the life of the patient. Proper exploration with wide exposure of the abdomen, is done to identify the cause for infection is done. Resuturing of the anastomotic site can be done but chances of re-leak are more likely. It can be done, if leak site is small and less friable. Otherwise either ileostomy or colostomy is the better choice. Often continuous tube irrigation and drainage is needed to clear the infective material. Laparostomy using zip technique is also beneficial. Multiple cavities with multiple abscesses are often found which should be drained and irrigated adequately with normal saline. Extensive bowel necrosis is the finding often observed which needs massive bowel resection that leads to short bowel syndrome which is difficult to manage on long-term basis. Higher antibiotics like piperacillin, meropenem are required. Ventilator support, total parenteral nutrition (TPN) haemodialysis support and critical care management is required. Postoperative peritonitis has got high mortality and morbidity.

## ■ OTHER FORMS OF PERITONITIS

1. Meconium peritonitis.
2. Chronic bacterial peritonitis—tuberculous.
3. Chronic nonbacterial peritonitis—granulomatous peritonitis due to talc or starch (from surgical gloves)—starch peritonitis.
4. Gonococcal peritonitis with perihepatitis—*Curtis-Fitz-Hugh syndrome*.
5. **Familial periodic peritonitis (Familial mediterranean fever)**: A rare entity gets recurrent pain abdomen often after appendectomy. It is familial, common in Arabs, Americans and Jewish populations. It is common in children; common in females; associated with MEFV gene mutation. Specific gene produces a protein—pyrin from neutrophils in these patients. Peritoneum adjacent to spleen and gallbladder are inflamed. But these two organs are normal. It is common in children and common in girls/females. Pain is usually in upper quadrant, left side. There is localised peritoneal inflammation. It is treated conservatively using colchicines.



**Fig. 9.15:** Perforation in the fundus of the uterus due to attempted abortion. It caused severe peritonitis.



6. **Parturition/abortion peritonitis:** It occurs after delivery and abortion conducted without asepsis and instrumentation, incomplete instrumental abortion, uterine perforation with or without bowel injury. It causes pelvic peritonitis commonly, generalised peritonitis often. It is due to anaerobic bacteria, anaerobic streptococci, and gram-negative bacteria like *Escherichia coli*. It is often rapidly progressive causing septic shock. It needs emergency surgery. Complications are ARDS, intestinal obstruction, faecal fistula and intraperitoneal abscess formation.

## ■ PELVIC ABSCESS

- ◆ It is the most common intraperitoneal abscess (50–60%).
- ◆ It is the collection of pus in rectovesical or rectouterine pouch (pouch of Douglas).

### Causes

- ◆ Appendicitis.
- ◆ Pelvic infections.
- ◆ Sequelae of diffuse peritonitis.
- ◆ Post-operative and other abdominal causes.

**Bacteria:** *Bacteroides fragilis*, *E. coli*, anaerobic streptococci.

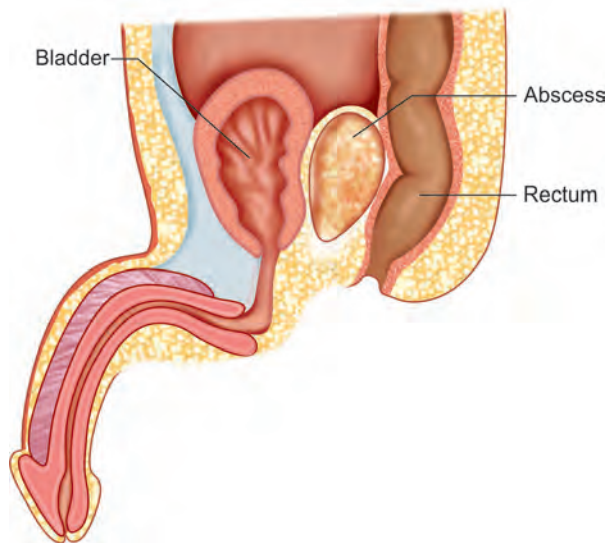


Fig. 9.16: Pelvic abscess.

### Clinical Features

- ◆ Diarrhoea.
- ◆ Mucus discharge per rectum.
- ◆ High temperature with chills and rigors.
- ◆ Lower abdominal pain and distension.
- ◆ Frequency and burning micturition.
- ◆ P/R shows a soft, boggy, and tender swelling in the anterior wall of the rectum.

### Investigations

- ◆ TC is raised.
- ◆ Ultrasound is diagnostic—shows pus in rectovesical or pouch of Douglas.
- ◆ CT scan to find out the size and extent.

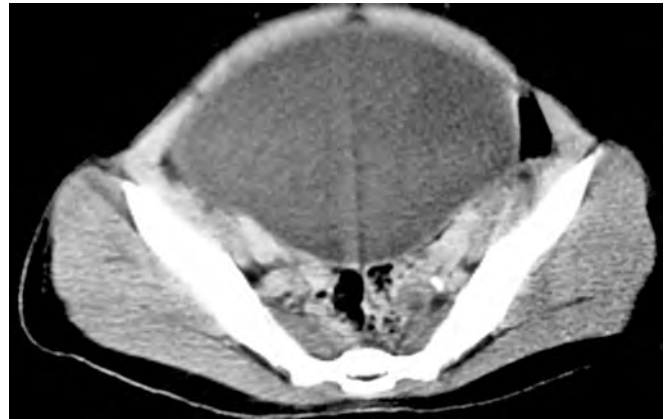
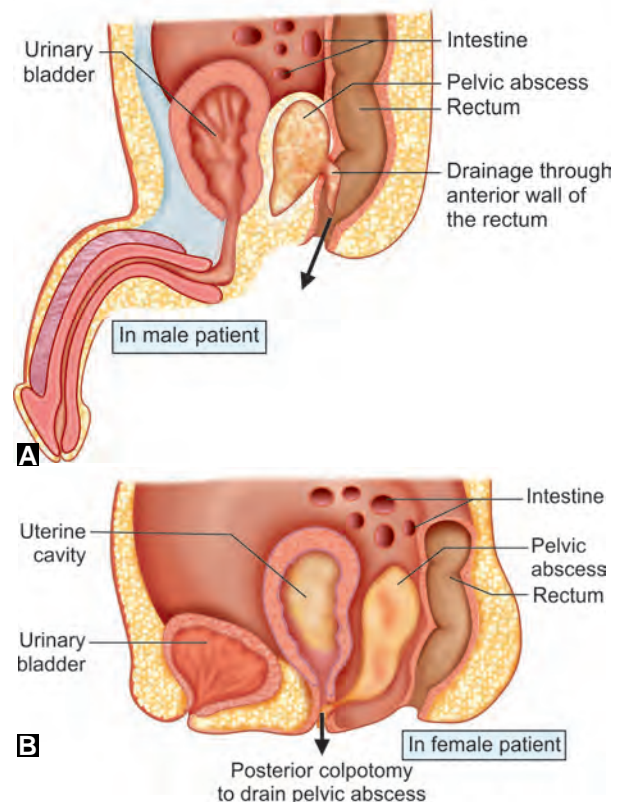


Fig. 9.17: CT pelvis showing pelvic abscess.

### Treatment

- ◆ After starting antibiotics, under G/A, abscess is drained **per rectally**, through the boggy area. Catheter is passed to the bladder before draining the pus.



**Figs 9.18A and B:** In male, pelvic abscess is drained through an incision over the anterior aspect of the rectum. In female, it is drained through posterior colpotomy.

- ◆ In females, *posterior colpotomy* is done to drain the pus.
- ◆ Occasionally spontaneous rupture of the abscess into the rectum occurs leading to natural regression.
- ◆ When abscess is very large, when it is progressing into the general peritoneal cavity or when in doubt, laparotomy through lower abdomen incision is done to drain the pus.

and to correct the cause. Often in such cases, drainage tube can be placed through the abdomen under U/S guidance.

- ◆ CT or US guided insertion of drainage tube into the abscess cavity per rectally or per vaginally or percutaneously.
- ◆ But most often laparotomy is not necessary.

## ■ SUBPHRENIC SPACES AND SUBPHRENIC ABSCESS

### Surgical Anatomy (By Boyd)

There are four intraperitoneal and three extra-peritoneal spaces.

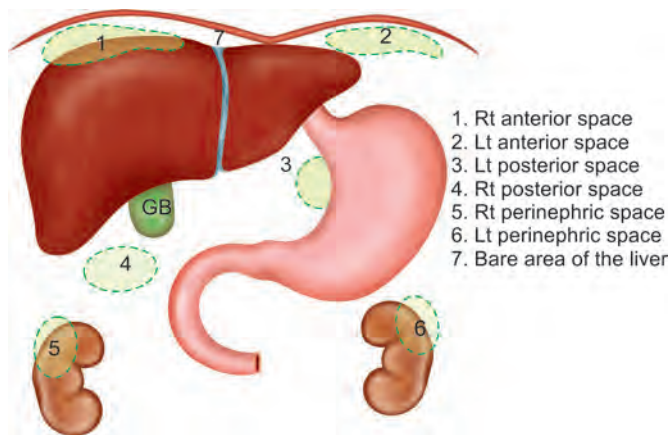


Fig. 9.19: Subphrenic spaces.

### Intraperitoneal Spaces

**Right anterior intra-peritoneal space (Right subphrenic space):** It is bounded by right lobe of the liver and diaphragm, posteriorly by anterior layer of coronary and right triangular ligament, and to the left by falciform ligament.

*Causes:* Abscess here occurs due to cholecystitis, perforated duodenal ulcer, post-operative, appendicitis, duodenal cap blow out.

**Right posterior intra-peritoneal space (Right subhepatic space):** (*Rutherford Morison's kidney pouch*) is bounded in front by the liver and gallbladder, above by the liver, behind by the right kidney and diaphragm, below by the transverse colon and hepatic flexure, to the left by foramen of Winslow and duodenum. It is large and deepest space of all. *It is the most common site of subphrenic abscess.*

*Causes:* Appendicitis, cholecystitis, post-operative, perforated duodenal ulcer, intestinal obstruction.

**Left anterior intra-peritoneal space (Left subphrenic space):** It is bounded above by the diaphragm, behind by left lobe of liver and left triangular ligament, gastrohepatic ligament and anterior surface of the stomach, to the right is the falciform ligament.

*Causes* for abscess here are surgeries of the stomach, tail of the pancreas, spleen, colon (splenic flexure), diverticulitis.

**Left posterior intra-peritoneal space:** It is bounded by stomach, pancreas, greater omentum, liver, transverse colon (Lesser sac).

Most common *cause* here is pseudocyst of pancreas. Rarely perforated gastric ulcer.

### Extraperitoneal Spaces

**Right extra-peritoneal space** is right perinephric space and **left extra-peritoneal space** is left perinephric space.

*Causes:* Abscess here are due to tuberculosis, trauma, haematoma.

**Midline extraperitoneal** is *bare area* of the liver. Pus collects here commonly due to ruptured amoebic liver abscess and pyogenic abscess of the liver.

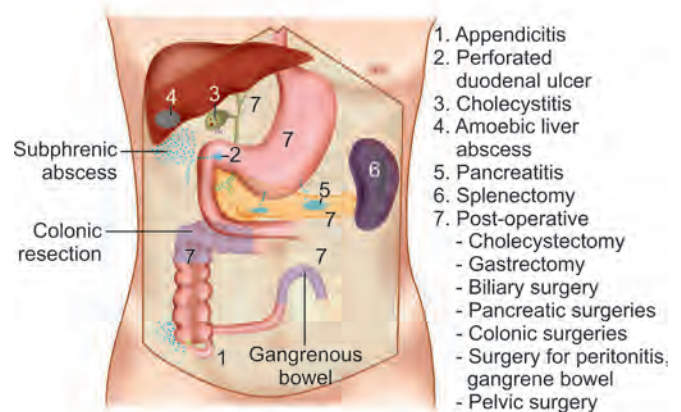


Fig. 9.20: Common causes of subphrenic abscess both right and left. Subphrenic abscess is common on right side.

### Pathology of Subphrenic Abscess

- ◆ During expiration, intra-abdominal pressure (especially in subphrenic area) is reduced and so this with capillary action and upward movement of the diaphragm make the peritoneal fluid to move upwards towards the diaphragm. This is the reason why there is higher incidence of subphrenic abscess and *subphrenic abscess is the second most common type of intra-abdominal abscess*, first one being the pelvic abscess.
- ◆ Subphrenic abscess is more common on the right side than on left (left anterior) because infective conditions are more common on the right side (like appendicitis/perforation/liver abscess/cholecystitis); and right paracolic gutter is wide and deep without any barrier (unlike left side paracolic gutter which is narrow and limited above by colophrenic ligament). Left posterior space is lesser sac in which infected fluid commonly collects following pancreatitis. Right subphrenic abscess causes elevation of the diaphragm. Pus collects in front or posterior aspect of the liver (right anterior or right posterior spaces) or often in both. Pus may be in a single cavity or may be multiloculated. Occasionally pus may get thickened to form a thick fibrous wall around leading into a chronic stage which causes generalised ill health. Pus gets well localised with a thick pyogenic membrane pushing pleura away and above and peritoneum away and below making subphrenic abscess essentially *extraserosal*. Because of the congestion/hyperaemia of the pleura and elevation of the diaphragm, there will be *sympathetic pleural effusion* on the side of the abscess. In severe acute subphrenic abscess, empyema thorax can also occur.
- ◆ If infective organism is gas forming one, abscess will contain pus with gas. So it is resonant above the liver dullness; dull above it

due to collapsed lung/atelectasis; then again resonant on topmost due to normal lung (From below upwards—dull liver—resonant gas in abscess cavity—dull collapsed lung—resonant normal lung topmost). But it is rare presently.

- ◆ *Post-operative surgeries*—mainly of gastric/biliary/colonic and emergency surgeries (peritonitis) are *becoming most common cause* of the subphrenic abscess.

#### Bacteria causing

- ❖ *E. coli*
- ❖ *Klebsiella*
- ❖ Streptococci
- ❖ Anaerobic organisms

### Clinical Features

*Barnard's aphorism* (Harold Barnard):

*"Pus somewhere, pus nowhere else, pus under diaphragm"*.

History relevant of the specific causes; history of any previous surgery:

- ◆ Fever with chills and rigors.
- ◆ Pain in right hypochondrium, epigastrium or lower thorax.
- ◆ Tenderness in right hypochondrium.
- ◆ Sympathetic right sided pleural effusion due to congestion and hyperaemia of the diaphragm.
- ◆ Collapse of the lung/basal atelectasis—right side may be evident. Tachypnoea and respiratory distress can be observed.
- ◆ Pain in the right shoulder due to irritation of phrenic nerve.
- ◆ Hiccough, tachycardia.
- ◆ **Hoover's sign**: Scoliosis towards same side in subphrenic abscess.
- ◆ Wasting and anorexia is common.
- ◆ Occasionally tender mass in the right hypochondrium may be palpable.
- ◆ Tenderness over 11th intercostal space may be evident in right subhepatic space abscess.

#### Differential diagnosis

- ❖ Amoebic liver abscess
- ❖ Pylephlebitis
- ❖ Empyema
- ❖ Pulmonary collapse

#### Note:

*Waltman-Walters syndrome*: It is postcholecystectomy fluid collection in subphrenic space causing compression over IVC. It mimics coronary thrombosis.

### Investigations

- ◆ Plain X-ray chest and abdomen shows soft tissue shadow, pleural effusion, tenting of diaphragm, collapse of the lung. Fluoroscopy shows elevated right diaphragm with reduced right sided diaphragmatic movement.
- ◆ U/S abdomen confirms the diagnosis.
- ◆ TC is high. There is raise in 'C' reactive protein.
- ◆ CT scan is very useful (*most accurate*) to find out the extent and relation. CT shows 'rind' sharp outer margin; septations; size, shape, extent, diaphragmatic position, pleural changes, displaced bowel and other organs and communications.
- ◆ Gallium 67 or iridium 111 isotope imaging.

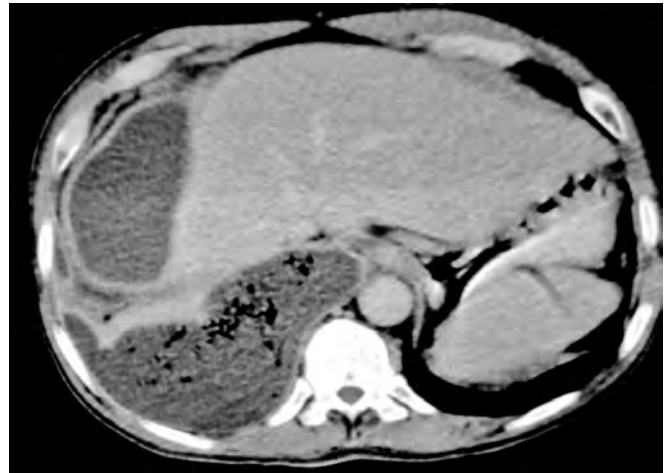

Fig. 9.21: CT scan of abdomen showing subphrenic abscess.

### Treatment

- ◆ **Antibiotics**: Ampicillin, metronidazole, gentamicin, cephalosporins.
- ◆ **Percutaneous drainage**: Initially ultrasound guided aspiration is useful. Here, under ultrasound or CT guidance, a catheter is placed and pus is drained. Catheters used are pigtail catheter, 16 French trocar catheter or sump catheter. 90% of subphrenic abscess are drained percutaneously.

#### Catheters used for drainage are:

- ❖ Malecot's catheter/wide Foley's catheter when open drainage is done
- ❖ Pigtail catheter
- ❖ Catheter placement through trocar under guidance (16 French trocar catheter)
- ❖ Sump catheter (double lumen tube which allows irrigation as well as suction drainage)

*Note: Catheter is removed when pus drainage from the tube is <10 ml/day, normal total count, improvement in symptoms, U/S shows clearance of abscess cavity.*

#### Note:

Aspiration alone is not done in subphrenic abscess.

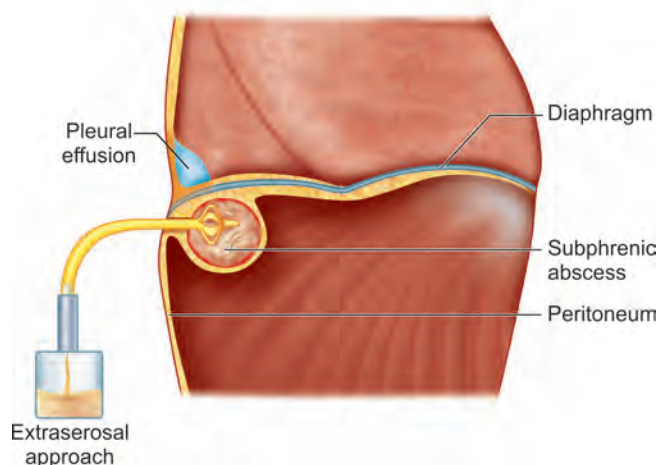
- ◆ **Open drainage is indicated** (Required in 10–20% of cases) in:

- ❖ When symptoms persist
- ❖ When abscess increases in size
- ❖ When there is thick pus or multiloculated pus or multiple abscesses
- ❖ Failure of/contraindications for catheter drainage
- ❖ Multiple abscesses
- ❖ Presence of foreign body/necrosis/haematoma/obstruction/fistula

- ▶ Under G/A through anterior or posterior subcostal incision, abscess is approached extraperitoneally and extrapleurally (extraserosally), so as to prevent serosal contamination. Pyogenic membrane is opened, pus is collected for culture sensitivity. Pus is drained by breaking all loculi. Malecot's catheter is placed *in situ*.
- ▶ Both *anterior and posterior extraperitoneal approaches* are used. Posterior approach allows dependent drainage; anterior

approach (Clairmont approach for left side) is technically easier and allows proper assess.

- ▶ *Transperitoneal approach* is needed whenever definitive procedure has to be undertaken like managing the existing fistula, treating the cause, removal of foreign body, multiple abscesses, active intra-abdominal pathology, etc.
- ◆ Antibiotics are continued. Malecot's catheter is removed once pus stops draining, usually after 14 days, which can also be confirmed by U/S abdomen or by X-ray with injection of dye.
- ◆ Good nutritional supplement, respiratory physiotherapy are additional support required.



**Fig. 9.22:** Subphrenic abscess open drainage. Incision must be extraserosal. Malecot's tube is placed in the abscess cavity.

#### Complications

- ❖ Empyema.
- ❖ Respiratory arrest.
- ❖ Septicaemia.
- ❖ Sinus formation.
- ❖ Recurrence.
- ❖ Peritonitis.

## MESENTERIC CYSTS

### Causes

1. Chylolymphatic.
2. Enterogenous.
3. Cysts of urogenital remnant.
4. Teratomatous dermoid cysts.
5. Other causes:
  - ▶ Traumatic haematoma and cyst formation.
  - ▶ Tuberculous cold abscess of mesentery.
  - ▶ Hydatid cyst of mesentery.

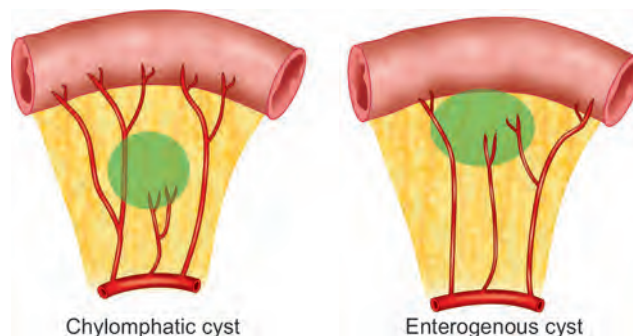
*Chylolymphatic cysts* are the most common one.

- ◆ It arises from congenitally misplaced lymphatic system. It does not have efferent communication into lymphatic system.
- ◆ Common in ileum, is a thin walled cyst with flat endothelium occasionally containing lymph or chyle, which is either milky or cream coloured.

- ◆ It is solitary and commonly unilocular, with loop of the bowel in front.
- ◆ It has got independent blood supply, i.e. not from the adjacent bowel loop. So enucleation can be done without resecting bowel.
- ◆ They are often called as *non-neoplastic mesothelial cysts* as it is lined by mesothelium. It is common in small bowel mesentery (60%); but can occur in colonic mesentery (40%). It occasionally may contain chyle even though serous fluid is the common content. It is common in females.
- ◆ Cyst is *enucleated* surgically (*standard therapy*); aspiration should not be done; in a large cyst internal drainage of cyst into the peritoneal cavity is advocated by few. Cyst wall should be sent for histology to rule out neoplastic condition.

### Enterogenous type

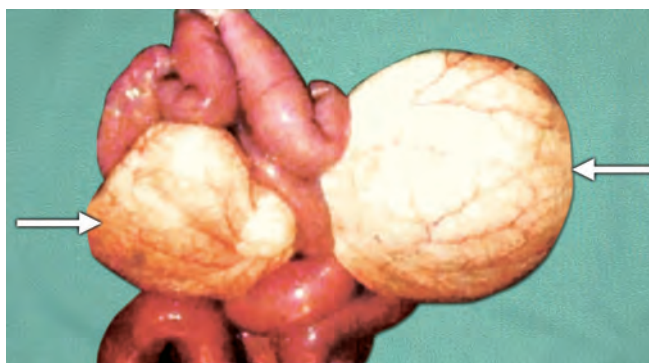
- ◆ It arises as a diverticulum or duplication from the adjacent bowel.
- ◆ Hence it is a thick walled cyst (contains all layers of the bowel) and receives its blood supply from the adjacent bowel (not independent). So resection of the adjacent bowel along with the cyst is essential. Enucleation is contraindicated.



**Fig. 9.23:** Mesenteric cyst.

### Clinical Features

- ◆ It presents as a painless abdominal swelling in umbilical region, smooth, fluctuant, not moving with respiration.



**Fig. 9.24:** Mesenteric cyst.

- ◆ It is common in 2nd decade, often in childhood.
- ◆ It is freely mobile, mobile in the direction perpendicular to the line of mesentery.

- ◆ There is a band of resonance in front of the cyst.
- ◆ Presentation as complications.

#### Tillaux's triad

- ❖ Soft, smooth swelling in the umbilical region
- ❖ Freely mobile in a direction perpendicular to mesentery
- ❖ Zone of resonance all around

#### Complications of mesenteric cysts

- ❖ *Torsion of cyst* can lead to volvulus of the adjacent bowel
- ❖ *Rupture of the cyst*
- ❖ *Haemorrhage* into the cyst
- ❖ *Infection*—patient presents with acute painful swelling in umbilical region

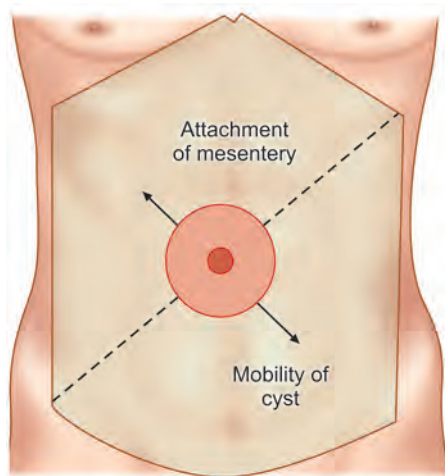


Fig. 9.25: Mobility of mesenteric cyst.

### Investigations

- ◆ U/S abdomen.
- ◆ Barium meal X-ray.
- ◆ Plain X-ray abdomen.
- ◆ CT scan of the abdomen is diagnostic.

### Differential Diagnosis

- ◆ Hydronephrosis.
- ◆ Omental cysts.
- ◆ Tuberculosis.
- ◆ Ovarian cyst.

### Treatment

- ◆ In chylolymphatic cyst—*enucleation*.
- ◆ In enterogenous type, removal of the cyst with resection of adjacent bowel is done, because blood supply is from adjacent bowel.

### MESENTERIC PANNICULITIS

- ◆ It is an inflammatory disease of mesentery with mesenteric *fat necrosis, acute/chronic inflammation and fibrosis*.
- ◆ Enormous thickening of the mesentery near its root with multiple

discrete nodules are typical. Venous and lymphatic obstruction of mesentery develops, causing bowel oedema, congestion and ischaemia.

- ◆ It commonly involves small bowel mesentery; but can involve colonic mesentery also. Spontaneous resolution is known to occur.
- ◆ It is common in middle aged men. Recurrent abdominal pain, features of obstruction, distension of abdomen, tender resonant mass abdomen are the features.
- ◆ ESR and CRP is elevated. CT is useful with features like—pseudocapsule with well delineated fat margin; normal adipose tissue surrounding the mesenteric vessels—*fat ring sign*; no vascular deviation; intra-abdominal mass displacing bowel without infiltration. Laparoscopic biopsy of mesentery is conclusive.
- ◆ *Differential diagnoses* are—peritoneal carcinomatosis, carcinoid tumour, mesenteric or retroperitoneal sarcoma, mesenteric tuberculosis and intestinal obstruction.
- ◆ *Treatment*: Usually conservative using corticosteroids and immunosuppressive drugs. Laparotomy is done only when diagnosis is in doubt or intestinal obstruction is suspected.

### ACUTE MESENTERIC LYMPHADENITIS

- ◆ It is nonspecific acute inflammation of the mesenteric lymph nodes (*Nurse's syndrome*) usually due to *Yersinia enterocolitica* infection; often in 30% of cases respiratory infection will be present. Occasionally virus, parasite, fungal infections may also be the cause. Other regional lymph nodes (axilla, groin, neck) are also often involved and enlarged.
- ◆ Mesenteric nodes in ileocaecal region are inflamed, enlarged often clinically palpable in right iliac fossa. Lymph nodes are red but not attached to mesenteric leaves or peritoneum. Appendix is normal.
- ◆ It is self-limiting recurrent disease.
- ◆ It is common in children and young females.
- ◆ Pain in right iliac fossa, slight fever, vomiting, abdominal colicky, but normal bowel habits; tender nodes may be palpable in RIF.
- ◆ Leucocytosis is common but regresses rapidly. US abdomen will be normal.
- ◆ Condition often mimics acute appendicitis.
- ◆ *Treatment*: Bed rest, re-assurance, analgesics, follow-up. Laparoscopy and appendicectomy is often needed to diagnose and to prevent missed appendicitis.

### MESENTERIC MALIGNANCY

The most common mesenteric malignancy is *secondaries*. GI adenocarcinoma is the most common site of origin. Carcinoid also can cause mesenteric metastasis. Mesentery is involved by either direct spread or through lymphatics or transperitoneal route. Distortion, fixation, desmoplastic reaction with intestinal obstruction are the features.

### Mesenteric Desmoid Tumour

- ◆ It is the most common primary tumour of mesentery.
- ◆ It is common in familial adenomatous polyposis and Gardner's syndrome.
- ◆ FAP shows 75% intra-abdominal desmoid with 75% of them in mesentery.
- ◆ Mesenteric desmoid is aggressive tumour causing infiltration of adjacent structures.
- ◆ *Complications* are—intestinal obstruction, bowel necrosis and perforation, hydronephrosis, aortic erosion and bleeding.
- ◆ 10-year survival rate is 65%. But recurrence rate is also high—75%.

- ◆ **Investigations:** CT abdomen, laparoscopy and biopsy, colonoscopy in case of FAP, to look for other features of Gardner's syndrome.
- ◆ **Treatment:** Even though surgery is the treatment, in view of high recurrence rate and inability to clear tumour surgically, drug therapy is becoming popular many times. Drugs used are—sulindac; antiestrogen drugs, imatinib mesylate orally (inhibits tyrosine kinase receptor for PDGF and c-kit).

### Mesenteric Lymphoma

It is also *not uncommon* as mesenteric fold contains plenty of lymph nodes. It is commonly NHL type. Other regional lymph nodes like of para-aortic, axillary, neck region may be enlarged. Liver and spine may be involved. CT abdomen, peripheral smear, laparoscopy and node biopsy, CT chest, bone marrow biopsy are investigations done. Treatment is usually chemotherapy.

### MESENTERIC TRAUMA

Mesenteric injury is commonly seen in blunt abdominal trauma; traction injury or seatbelt injury causes mesenteric tear. Penetrating injury can also cause mesenteric injury.

### Presentations

Features of haemoperitoneum—shock, pallor, abdominal distension and pain, guarding and rigidity.

### Types

1. **Transverse tear** in mesentery causes not only more bleeding but also causes adjacent bowel ischaemia. So laparotomy and resection of bowel is needed.

2. **Longitudinal tear** can be sutured using interrupted absorbable sutures (vicryl) after haemostasis.

### Investigations

- ◆ Ultrasound abdomen; diagnostic peritoneal lavage.
- ◆ CT abdomen.
- ◆ Always evaluate for associated injuries—fractures, thoracic and head injuries.
- ◆ Haematocrit, electrolyte estimation, blood grouping.

### Treatment

Emergency laparotomy and resection of bowel or suturing of the mesentery.

### PERITONEAL MALIGNANCY

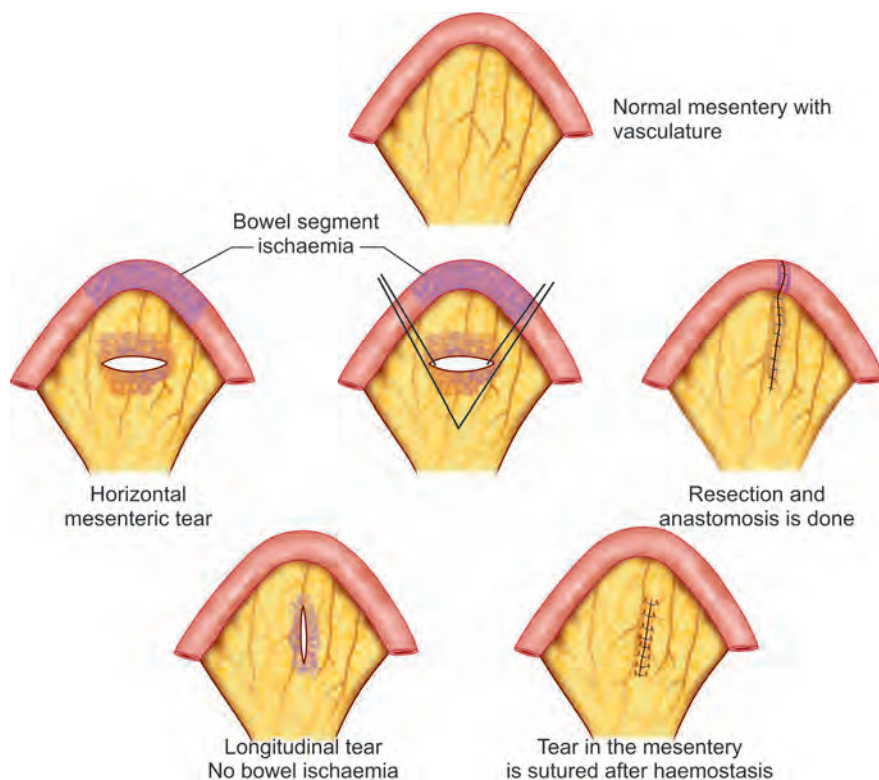
The most common peritoneal malignancy is *secondaries*. Primaries causing peritoneal secondaries are—*GIT*: stomach, colon, pancreas, small bowel, liver, lower oesophagus; *Genitourinary*: ovarian tumour commonly; *Extra-abdominal*: Breast.

Peritoneal carcinomatosis is diffuse metastatic deposits all over parietal and visceral peritoneum.

### Primary Peritoneal Malignancy

The most common is malignant mesothelioma; sarcomas are rare type.

**Malignant mesothelioma:** It is very aggressive primary type with survival rate of 6–12 months. Presentation is abdominal



**Fig. 9.26:** Mesenteric tears due to trauma can be transverse or longitudinal; transverse tear needs bowel resection; longitudinal tear needs just suturing.

pain, ascites, weight loss, and cachexia. Omentum is involved with malignant nodules presenting like a nodular abdominal mass. Peritoneal cavity is studded with nodular deposits. Entire peritoneal cavity is involved often involving the organs like liver or their surfaces. It is often difficult to differentiate it from peritoneal carcinomatosis. However, extra-abdominal spreads to lungs and bone is uncommon in malignant mesothelioma. CT abdomen, ascitic fluid analysis are the diagnostic methods. Chemotherapy, intraperitoneal hyperthermic perfusion of mitomycin C, intraperitoneal chemotherapy of cisplatin, surgical peritonectomy—are treatment options.

### Pseudomyxoma Peritonei

- ◆ It is a rare malignant condition that develops due to ruptured malignant ovarian cyst or adenocarcinoma of appendix. Peritoneum is coated with mucus secreting tumour tenacious gel like mucus with cystic masses. It is common in old aged females.
- ◆ Vague abdominal pain with distension and dullness which is not shifting are typical findings. CT scan shows bowel displacement with fluid content in the peritoneal cavity.
- ◆ *Treatment:* If origin is known then it is treated accordingly. In patients operated by appendectomy, removal of all mucus gel with right hemicolectomy with omentectomy is done. If ovarian tumour is the cause then panhystrectomy with omentectomy is done. In cases with unknown cause, after laparotomy, panhystrectomy, right hemicolectomy, omentectomy are done. Intraperitoneal chemotherapeutic agents like 5 FU, mitomycin C, oxaliplatin; intraperitoneal instillation of mucolytic agents like dextran, urokinase after surgery is beneficial.
- ◆ It shows better prognosis compared to mesothelioma and carcinomatosis.

#### Peritoneal carcinomatosis (carcinoma peritonei)

- ❖ Entire peritoneal cavity is studded with carcinomatous nodules—both parietal and visceral peritoneum
- ❖ Haemorrhagic ascites, interloop bowel adhesions, hard studded nodules in the omentum are common. Intestinal obstruction can occur
- ❖ It may be primary peritoneal carcinomatosis (mesothelial) or secondary from GIT, ovary, breast, pancreas
- ❖ Liver secondaries are often present
- ❖ It mimics peritoneal tuberculosis, acute pancreatitis, and multiple lymphomatous nodules, multiple peritoneal hydatids
- ❖ As malignant ascitic fluid contains high immunoglobulin, peritonitis is not common
- ❖ Instillation of radioactive gold and chemotherapy are the treatment
- ❖ It has got poor prognosis

### OMENTAL CYST

- ◆ It arises from obstruction of omental lymphatics either congenital or acquired.
- ◆ It is unilocular or multilocular cyst lined by endothelium.
- ◆ It is common in children.
- ◆ When it attains large it presents as mass in central or lower abdomen which is smooth well localised mobile often moves with respiration.
- ◆ It can cause torsion, rupture and infection. Extrinsic compression of bowel can occur.
- ◆ US/CT shows cyst with internal septations.
- ◆ Differential diagnoses are—mesenteric cyst, retroperitoneal cyst and desmoid tumour.
- ◆ Treatment is laparotomy and cyst excision which can also be done laparoscopically.

### OMENTAL TORSION

- ◆ Torsion of greater omentum is twist of omentum along its longitudinal axis; it usually occurs on right side of omentum.
- ◆ Primary torsion is torsion occurring without any existing cause.
- ◆ Secondary torsion is occurring due to some cause like omentocele in a hernial sac or tumour or adhesion.
- ◆ Torsion is more common in men (2:1) in 5th decade.
- ◆ Sudden severe abdominal pain, mainly right sided often mimicking acute appendicitis, cholecystitis, ureteric stone or twisted ovarian cyst.
- ◆ Often signs of peritonitis may be present.
- ◆ CT abdomen is diagnostic. Total count will be raised.
- ◆ Treatment is laparotomy and omentectomy which can also be done laparoscopically.

### OMENTAL TUMOUR

- ◆ Metastatic omental deposits are common; usually from GIT cancers.
- ◆ Primary neoplasm of omentum is rare. It may be soft tissue tumour arising from fat of omentum.

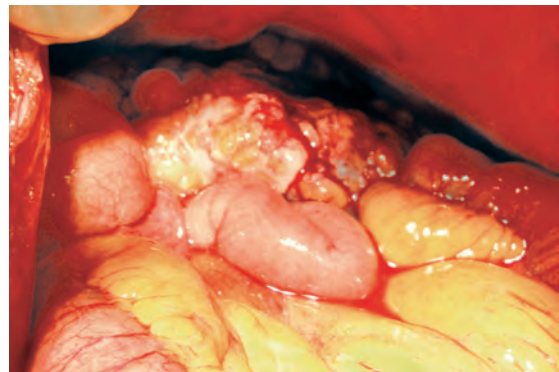

Fig. 9.27: Omental secondaries.

# Chapter 10

## Abdominal Tuberculosis

*In man the balance between immunity and susceptibility to tuberculosis is delicately adjusted: There is a small factor of safety.*

—Milton Rosenau, 1927

### CHAPTER OUTLINE

- ❖ Abdominal Tuberculosis
- ❖ Ileocaecal Tuberculosis
- ❖ Ileal Tuberculosis
- ❖ Peritoneal Tuberculosis
- ❖ Tuberculous Mesenteric Lymphadenitis
- ❖ Ano-recto-sigmoidal Tuberculosis
- ❖ Tuberculosis of the Omentum

### ■ ABDOMINAL TUBERCULOSIS

It is common in India and developing countries.

It is the 6th most common type of extrapulmonary tuberculosis. Its incidence is high in HIV infected patients.

#### Types

##### 1. Intestinal

Ileocaecal region

- ▶ Ulcerative—60%.
- ▶ Hyperplastic.
- ▶ Ulcero-hyperplastic.

Ileal region, 40% commonly:

- ▶ Stricture type.

##### 2. Peritoneal tuberculosis

- a. Acute.
- b. Chronic.
  - i. Ascitic type.
  - ii. Encysted (loculated) type.
  - iii. Plastic (fibrous/adhesive) type.
  - iv. Purulent type.

##### 3. Tuberculosis of mesentery and its lymph nodes.

##### 4. Ano-recto-sigmoidal—present as fistula, fissure, abscess, mass.

##### 5. Involvement of liver, spleen and other organs as a part of miliary tuberculosis.

##### 6. Tuberculosis of the omentum.

##### 7. Rare types: Oesophageal (0.2% of abdominal tuberculosis)/gastroduodenal (1% of abdominal tuberculosis)/retroperitoneal

Site spectrum	Ileocaecal and terminal ileum—most common site
<ul style="list-style-type: none"> <li>• Luminal GI tuberculosis—55–60%</li> </ul>	Jejunum and colon—less common
<ul style="list-style-type: none"> <li>• Abdominal solid organ tuberculosis—liver, spleen, pancreas—1%</li> </ul>	Stomach, duodenum, oesophagus—rare
<ul style="list-style-type: none"> <li>• Peritoneal tuberculosis—<i>adhesive</i> (cocoon/doughy/rolled up omentum)/<i>ascitic</i> (wet)—loculated. It could be acute or chronic—40%.</li> </ul>	<b>Pathology:</b> <ul style="list-style-type: none"> <li>• In malnourished poor resistance patients—ulcerative and or stricture types</li> </ul>
<ul style="list-style-type: none"> <li>• Abdominal lymph node tuberculosis—mesenteric/periportal/para-aortic/retroperitoneal. It could be caseating/hyperplastic/calcified—5%</li> </ul>	<ul style="list-style-type: none"> <li>• In well nourished with good resistance—hyperplastic and nodular types</li> <li>• Combination types—ulcerostricture type; ulcero-hyperplastic type</li> </ul>

*Phthisis is an ulcer of the lung that consumes the whole body.*—Bernard de Gordan, 1495



Different clinical presentations of abdominal tuberculosis	
<p><i>Clinical presentation may be:</i></p> <ul style="list-style-type: none"> <li>• Acute</li> <li>• Acute on chronic</li> <li>• Chronic</li> </ul>	<p><i>Types:</i></p> <ul style="list-style-type: none"> <li>• <i>Ulcerative</i>—diarrhoea and malabsorption</li> <li>• <i>Stricture</i>—subacute or acute intestinal obstruction</li> <li>• <i>Hyperplastic</i>—mass abdomen (RIF) and obstruction</li> <li>• <i>Ascites</i>—generalised distension of abdomen</li> <li>• <i>Peritoneal</i>—abdominal cocoon; vague abdominal pain, parietal peritoneal thickening as doughy abdomen; mass abdomen</li> <li>• <i>Mesenteric</i>—tabes mesenterica, obstruction, mass</li> <li>• Associated tuberculosis of other organs is seen in 30% of cases</li> </ul>
<p><i>Constitutional symptoms:</i></p> <ul style="list-style-type: none"> <li>• Low-grade fever, malaise, night sweats, anaemia, weight loss</li> <li>• Observed in 30% of patients</li> </ul>	
<p>Abdominal tuberculosis is 6th most common form of tuberculosis</p>	
<p>It may be associated with HIV/lymphoma/carcinoma</p>	
<p><i>Atypical presentations:</i></p> <ul style="list-style-type: none"> <li>• Lower GI bleed, fistula-in-ano, PID like pain, gastric disease symptoms, dysphagia, GI fistulae, perforation</li> </ul>	<p><i>Tuberculosis of pancreas:</i></p> <ul style="list-style-type: none"> <li>• Like or part of miliary tuberculosis</li> <li>• Common in immunocompromised</li> <li>• Usually presents as acute or chronic pancreatitis</li> <li>• Pancreatic mass or abscess may develop</li> <li>• Can mimic malignancy</li> </ul>
<p><i>Tuberculosis of liver:</i></p> <ul style="list-style-type: none"> <li>• Miliary type</li> <li>• Granuloma/tuberculoma</li> <li>• Like liver abscess/intra-hepatic calcification</li> <li>• Obstructive jaundice</li> <li>• PUO/altered LFT</li> </ul>	<p><i>Tuberculosis of spleen:</i></p> <ul style="list-style-type: none"> <li>• Disseminated or miliary form</li> <li>• Can present as PUO with hepatosplenomegaly</li> <li>• Can occur as multiple abscess</li> </ul>

tuberculosis. Because of hydrochloric acid (acid media) gastric tuberculosis is rare.

#### Note:

- Chronic peritoneal tuberculosis may be associated with pleural effusion and pericardial effusion.
- Tuberculosis is not common in stomach, duodenum and jejunum.
- *Diffuse tuberculous colitis* is less commonly seen (4%), mimics ulcerative colitis in every respect even in colonoscopy. Patient recovers well with antituberculous drugs.
- *Intestinal tuberculosis* is called as **Koenig's syndrome** (1892).

### Modes of Spread of Abdominal Tuberculosis

- ◆ By ingestion
  - ▶ Ingestion of food contaminated with tubercle bacilli causing *primary intestinal tuberculosis*.
  - ▶ Ingestion of sputum containing tuberculous bacteria from primary pulmonary focus causing *secondary intestinal tuberculosis*.
- ◆ Haematogenous spread from tuberculosis of lungs.
- ◆ From neck lymph nodes (tuberculous cervical lymphadenitis—5–10%) through lymphatics.
- ◆ From Fallopian tubes by retrograde spread to involve peritoneum (10%).

### ILEOCAECAL TUBERCULOSIS

Most common site of abdominal tuberculosis due to presence of Peyer's patches; and stasis of luminal contents favoured by ileocaecal valve.

#### Causative organism

- Mycobacterium tuberculosis*
- ❖ Acid fast 20% H<sub>2</sub>SO<sub>4</sub>
  - ❖ Alcohol fast
  - ❖ Gram neutral

#### Histology

- ❖ Epithelioid cells diagnostic
- ❖ Langhans giant cells
- ❖ Features of granuloma
- ❖ Caseating necrosis

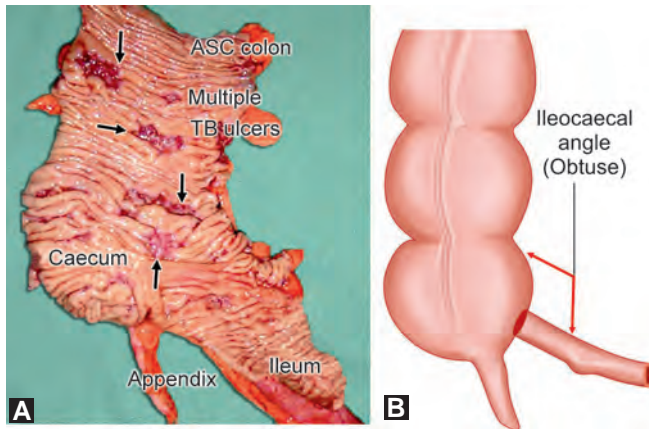
- ◆ *It is presently due to Mycobacterium tuberculosis*, earlier used to be due to *Mycobacterium bovis*. Mode of infection may be direct or blood spread, usually from lungs.
- ◆ Atypical mycobacteria can spread directly.
- ◆ *Mycobacterium avium* spreads through lymphatics.

#### Ileocaecal region is common site due to:

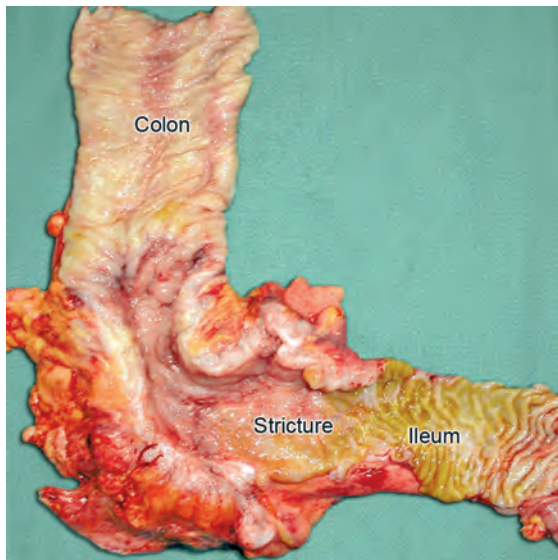- ❖ Stasis
- ❖ Abundant Peyer's patches—organisms get trapped in Peyer's patches
- ❖ Bacteria contact time with mucosa is more
- ❖ M cells in Peyer's patches phagocytose bacilli and transfer to host cells
- ❖ Liquid content in the region
- ❖ Increased rate of fluid and electrolyte absorption
- ❖ Minimal digestive activity

### Types

- ◆ *Ulcerative*—most common 60%. *Circumferential transverse often multiple 'girdle' ulcers*—with skip lesions. It is common in old, malnourished people. Long-standing ulcers cause fibrosis and later stricture formation. Stricture (*Napkin ring stricture*) is common in ileal part. Often related intestinal nodes are also involved with caseation, abscess (cold) formation. Bowel adhesions are common. Patient mainly presents with diarrhoea, blood in stool, loss of appetite and reduced weight.



**Figs 10.1A and B:** Ileocaecal tuberculosis. (A) Note the multiple transverse ulcerated ulcers. (B) Obtuse ileocaecal angle—ileocaecal tuberculosis.



**Fig. 10.2:** Note the ileocaecal tuberculosis with stricture.

- ◆ **Hyperplastic:** Fibroblast reaction in submucosa and subserosa causing thickening of bowel wall and lymph node enlargement, leading to nodular mass (tumour-like) formation. It is 10% common, less virulent, with adequate host resistance, seen in young well nourished individuals. It is common in caecal part. It causes extensive chronic inflammation, fibrosis, bowel adhesions, nodal enlargement, often presents with mass in the right iliac fossa. Caseation necrosis is not common. When present as a mass, it can cause subacute intestinal obstruction. It is commonly primary intestinal tuberculosis. There is no primary focus in the lungs.
- ◆ **Ulcerohyperplastic—30%.**

**Clinical Features**

- ◆ Abdominal pain is the most common symptom (90%). It is dull in mesenteric type; colicky in intestinal type.
- ◆ Common in 25–50 years age group. Equal in both sexes.
- ◆ Anaemia, loss of weight and appetite (80%).
- ◆ Diarrhoea—10–20%.
- ◆ Fever—50–70%.
- ◆ **Mass in right iliac fossa, (35%)** which is hard, nodular, nonmobile, nontender with impaired resonance, which may mimic carcinoma caecum. Subacute obstruction can occur.
- ◆ Ileocaecal tuberculosis can be associated with adenocarcinoma of caecum, or large bowel lymphoma or HIV.
- ◆ Often ileocaecal TB can cause intestinal obstruction (20%).

Differential diagnosis	
❖	Carcinoma caecum
❖	Ameboma
❖	Appendicular mass
❖	Ectopic kidney
❖	Retroperitoneal tumour
❖	Lymph node mass
❖	Psoas abscess
❖	Crohn's disease

Differences between ulcerative and hyperplastic types of ileocaecal tuberculosis		
	<b>Ulcerative type (60%)</b>	<b>Hyperplastic type (10%)</b>
1.	Secondary to pulmonary tuberculosis	1. Primary GIT tuberculosis, could be due to bovine bacilli
2.	Virulent organism	2. Less virulent organism
3.	Poor body resistance, old people	3. Good body resistance, young individual
4.	Multiple transverse ulcers commonly in the ileum, often in the caecum	4. Chronic granulomatous lesion in the ileocaecal region
5.	Clinically presents with diarrhoea, bleeding P/R, loss of appetite and reduced weight	5. Presents as a mass in right iliac fossa
6.	Complications: Stricture, intestinal obstruction	6. Complication: Subacute intestinal obstruction
7.	Chest X-ray shows primary lesion	7. No primary lesion in chest X-ray
8.	Barium study shows ileal strictures with hypermotility	8. Barium study—pulled-up caecum, obtuse ileocaecal angle

*Whilst meagre Phthisis gives a silent bow, her strokes are sure, but her advances slow. No loud alarms, nor fierce assaults are shown. She starves the fortress first, then takes the town.*  
**—Samuel Garth**

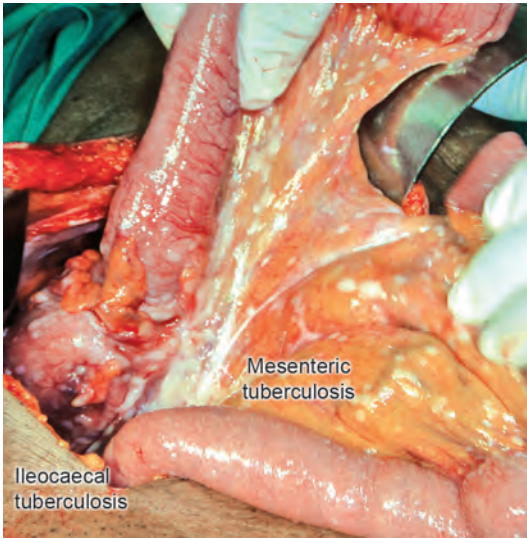

Fig. 10.3: Ileocaecal and mesenteric tuberculosis.

### Investigations

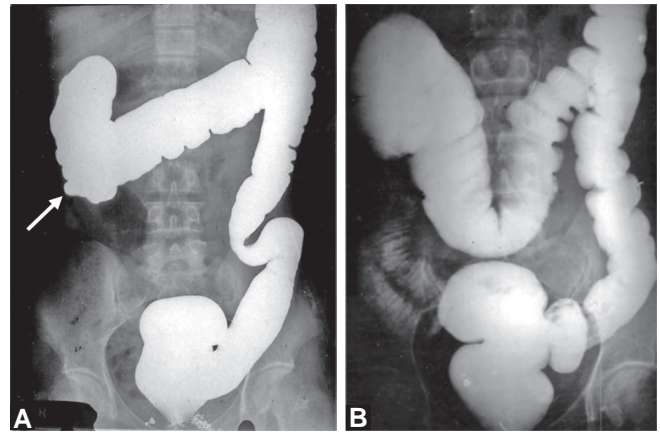
- ◆ Chest X-ray to find out primary focus.
- ◆ Mantoux test, ELISA (90%), SAFA (soluble antigen fluorescent antibody—80%), serum IgG.
- ◆ ESR is raised.
- ◆ U/S abdomen to see ascites, caecal thickening, nodal status and other organs.
- ◆ Plain X-ray abdomen, if presentation is of intestinal obstruction. It often shows calcification. It shows calcified lesion in the bowel; in the lymph node; in the liver (calcified granuloma). Perforation when it occurs (rare) shows gas under diaphragm.
- ◆ Colonoscopy is of value to rule out carcinoma. It is *easiest and most direct method* in establishing the diagnosis. Colonoscopy shows mucosal nodules or ulcers; caecal and ileal strictures; deformed ileocaecal valve; mucosal oedema and pseudopolyps and occasionally diffuse colitis. Biopsy can be taken to confirm the diagnosis. Tissue culture or tissue PCR can be done.

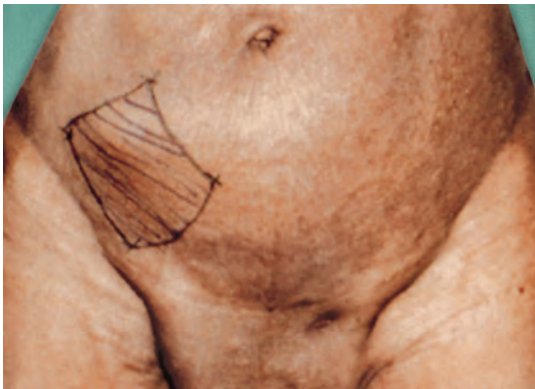

Fig. 10.4: Ileocaecal tuberculosis or tuberculous mesenteric lymphadenitis can present as mass in the right iliac fossa which is usually nontender, nonmobile, hard/firm resonant/impaired resonant.

### Barium study X-ray (Enteroclysis followed by barium enema or barium meal follow through X-ray) (efficacy—75%)

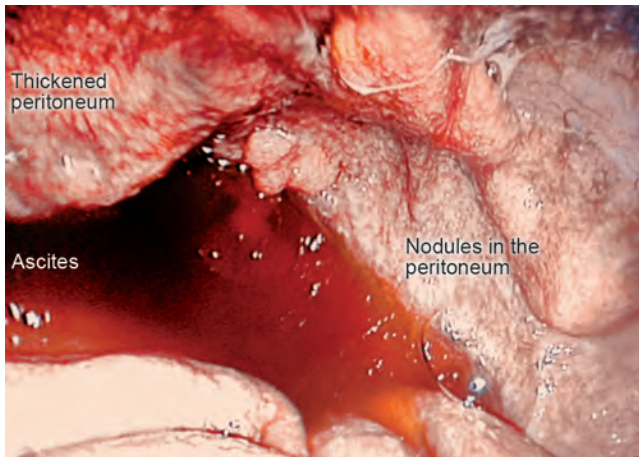
- ❖ Pulled up caecum, conical caecum, pulled down hepatic flexure
- ❖ Obtuse ileocaecal angle
- ❖ Hurrying of barium due to rapid flow and lack of barium in inflamed segment (*Steirlin sign*)
- ❖ Narrow ileum with thickened ileocaecal valve (*Fleischner sign*) (*Inverted umbrella sign*)
- ❖ Calcifications
- ❖ Incompetent ileocaecal valve, ileocaecal spasm
- ❖ Ulcers and strictures in the terminal ileum and caecum—*Napkin lesions*
- ❖ Earliest signs are—increased transit time; hypersegmentation (chicken intestine); flocculation of barium
- ❖ Other signs are—persistent narrow stream (string sign); multiple strictures with enormous dilatation of proximal ileum (mega ileum); straightening of ileocaecal junction with 'goose neck' deformity



Figs 10.5A and B: Pulled-up caecum, obtuse ileocaecal angle—ileocaecal tuberculosis in barium study X-ray.

- ◆ Capsule endoscopy is also useful to see small intestinal (tuberculous) pathology in difficult cases.
- ◆ FNAC of palpable mass.
- ◆ Laparoscopy is very useful method of investigation. Transabdominal peritoneoscopy is visualisation of the peritoneal cavity using endoscope through a small incision in the abdomen. It aids in visualisation, to collect ascitic fluid for analysis and to take biopsy. Biopsy can be taken from omentum, peritoneum, nodes and suspected areas. Ascitic fluid can be collected for analysis.
- ◆ Abdominal CT scan is better and more reliable.
- ◆ PCR assay of endoscopically biopsied tissue or of ascitic fluid. DNA—PCR can detect 1–2 organism or 8 fg of mycobacterial DNA. Positive PCR signifies infection but need not be active disease.
- ◆ Stool culture for AFB—not useful. Presence of tuberculous bacteria in stool does not signify disease.
- ◆ Blind percutaneous needle peritoneal biopsy using *Cope's/Abraham's needle* is also practiced.
- ◆ Ascitic tap fluid analysis.
- ◆ Anticord factor antibody to differentiate it from Crohn's disease.

- ◆ Biochemical assay—proteins, ADA (Adenosine deaminase activity) and interleukins. ADA is specific and sensitive marker with 95–98% sensitivity and specificity. Its value more than 33 IU/litre in ascitic fluid and more than 42 IU/litre in serum is significant. Gamma interleukin is two times more expensive than ADA.



**Fig. 10.6:** Laparoscopic view of abdominal tuberculosis showing peritoneal nodules and thickening, ascitic fluid, bowel surface tubercles. Fluid for analysis, peritoneal, omental biopsy can be taken.

#### Note:

- Serum ADA > 54 U/l; ascitic ADA > 33 U/l; ascitic fluid: serum ADA > 0.985.
- **Bactec MGIT broth culture:** It is *Mycobacterium* growth indicator tube culture system containing Middlebrook Broth with silicon base; fluorescent technology is used.

Method used to isolate tuberculous bacteria	AFB/ml specimen	Time taken for reporting	Sensitivity	Specificity
Ziehl-Neelsen stain microscopy	5,000–10,000/ml	1–2 hours	75%	85%
Lowenstein-Jenson solid media culture	100/ml	4–8 weeks	80%	90%
Bactec MGIT broth culture	10/ml	2–6 weeks	94%	92%
COBAS Taqman PCR	Less than 10/ml	24–48 hours	97%	99%

#### Ascitic fluid in abdominal tuberculosis

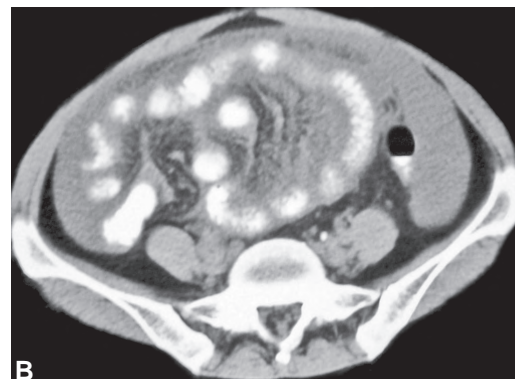
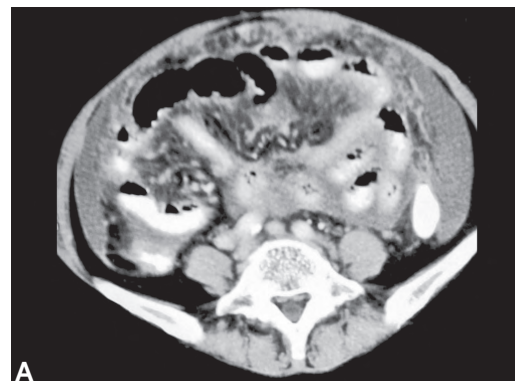
- ❖ Exudate with protein level >2.5 g/dl
- ❖ Serum-ascitic fluid albumin gradient is <1.1
- ❖ Lymphocyte predominant cells with count as high as 4000/mm<sup>3</sup> >250/cumm
- ❖ AFB in ascitic fluid is seen only <3% cases
- ❖ ADA (Adenosine deaminase activity) in ascitic fluid (95% specificity and 98% sensitivity)
- ❖ Specific gravity >1.016
- ❖ Glucose <30 mg
- ❖ Decreased pH
- ❖ LDH more than 90 units/litre

#### Ultrasound features observed in abdominal tuberculosis

- ❖ Thickened bowel wall, mesentery, omentum, peritoneum
- ❖ Loculated ascites with fine septae
- ❖ Interloop ascites with alternate echogenic and echofree areas—Club-sandwich appearance
- ❖ Bowel loop radiates from its mesenteric root—*stellate sign*
- ❖ Mesenteric thickness *more than 15 mm*
- ❖ Hepatosplenomegaly
- ❖ Lymph nodal enlargement matted
- ❖ Pulled up caecum presenting with a mass in subhepatic region and also sonologically visible—“pseudokidney sign”
- ❖ Concentric uniform mural thickening

#### CT scan in abdominal tuberculosis

- ❖ It is very useful and reliable investigation
- ❖ It is done with oral contrast—CT enteroclysis
- ❖ Findings are:
  - Thickened bowel wall, thickened peritoneum
  - Ileocaecal valve thickening
  - Enlarged/necrosed/matted mesenteric nodes often with cold abscess
  - Adhesions
  - Mesenteric thickening and nodules
  - Nodules in the peritoneum/solid organs like liver
  - Adhesions in the bowel/stricture/dilatations of the bowel/features of obstruction
  - Loculated ascites
- ❖ CT guided FNAC/biopsy/aspiration of fluid can be done



**Figs 10.7A and B:** CT scan of abdomen showing features of abdominal tuberculosis.

### Complications of abdominal tuberculosis

- ❖ Obstruction—20%
- ❖ Malabsorption, blind loop syndrome
- ❖ Dissemination of tuberculosis to other areas of abdomen as well as extra-abdominal sites
- ❖ Faecal fistula
- ❖ Cold abscess formation
- ❖ Haemorrhage, perforation (rare)

#### Note:

- Perforation is **rare** in GIT tuberculosis **but can occur**.

## Treatment

### Drugs

- ◆ INH; rifampicin; pyrazinamide; ethambutol—*first line drugs*. In drug resistance cases second line drugs are needed. WHO recommends 6–9 months course. Commonly patient presents with complications and late presentations are also common in many. So, more often treatment for one year may be required in these patients. Recurrent abdominal tuberculosis has got high mortality and difficult to manage.
- ◆ As they are malnourished supportive therapy in the form of TPN, blood transfusion in preoperative as well as postoperative period is required. Often steroid is used to prevent adhesions along with antituberculous drugs.

### Surgery

#### Indications for surgery

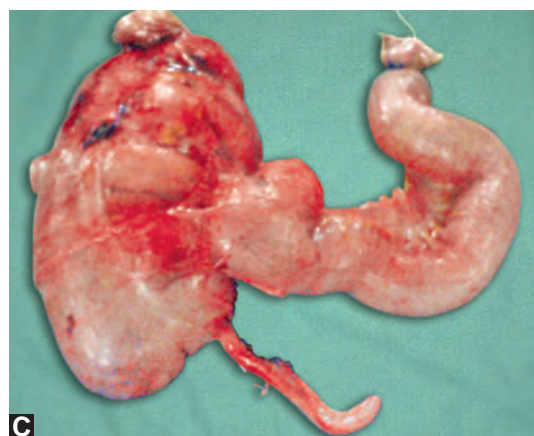
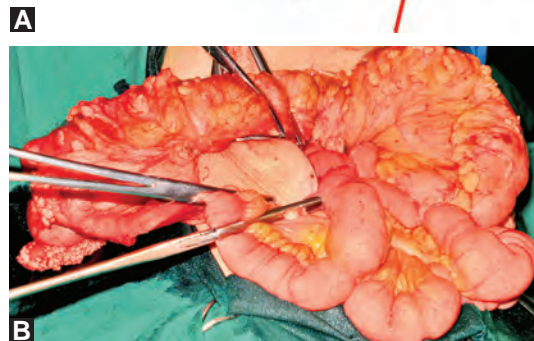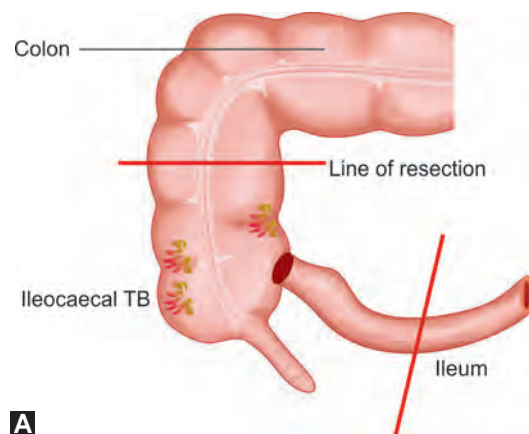
- ◆ Intestinal obstruction.
- ◆ Severe haemorrhage.
- ◆ Acute abdominal presentation like perforation.
- ◆ Intra-abdominal abscess formation or fistula formation.
- ◆ Uncertain diagnosis.

#### Surgeries are:

- ◆ *Limited ileocaecal resection* (with 5 cm margin) is the surgical therapy of choice for ileocaecal tuberculosis. This may be done in initial period depending on the obstructive and other presentations. Often during therapeutic period, healing with fibrosis causes stricture and obstruction in 3–6 weeks after drug therapy. Patient during this time needs limited ileocaecal resection.
- ◆ In single ileal stricture—*stricturoplasty* may be done. But if bowel wall is oedematous and friable then resection would be the ideal choice.
- ◆ In multiple strictures *resection of ileum and anastomosis* is done (ideal). Multiple strictures with long segment gaps between each can be treated by *multiple stricturoplasty*. But viability of the sutured area should be ensured. Resection is better option for stricture within 10 cm of ileocaecal valve.
- ◆ In perforation of ileal bowel, resection and anastomosis is done. Biopsy from perforation site and closure can be done in early perforations but chances of leak and fecal fistula formation is high (due to closure of perforation over a diseased bowel) and so resection is better option. In severely

contaminated peritoneum, resection and exteriorisation is done. Bowel continuity is maintained after proper antituberculous chemotherapy and proper nutritional improvement.

- ◆ During therapy, if patient develops ileocaecal obstruction, ileotransverse colon anastomosis (bypass) can be done. But this is not a good procedure, as it causes blind loop and tuberculous focus is retained. Now this bypass is used only in patient presenting with acute intestinal obstruction with poor general condition and in high-risk group patients as a life-saving procedure. A definitive second stage right hemicolectomy is needed in these patients at a later period.
- ◆ Adhesive obstruction may be released through laparoscopic adhesiolysis. It is often technically difficult to release dense adhesions even by open method.



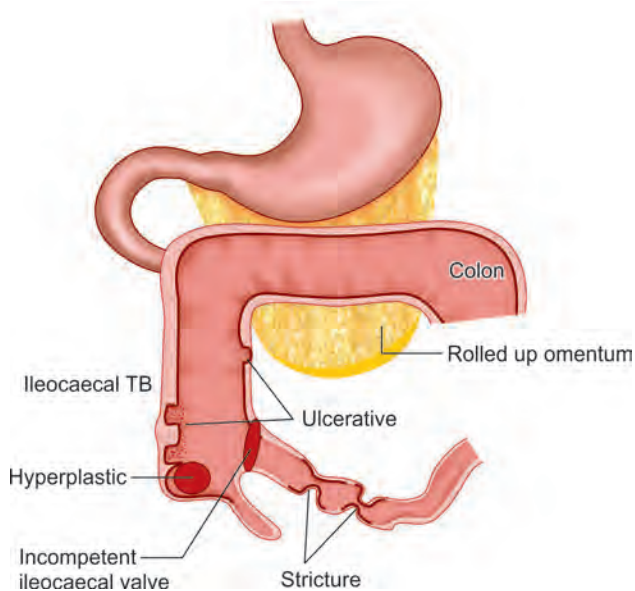
**Figs 10.8A to C:** ileocaecal limited resection with 5 cm bowel margin is the treatment of choice for ileocaecal tuberculosis.

- ◆ Drainage of intra-abdominal abscess, perianal abscess and treatment for tuberculous fistula-in-ano is done when necessary.

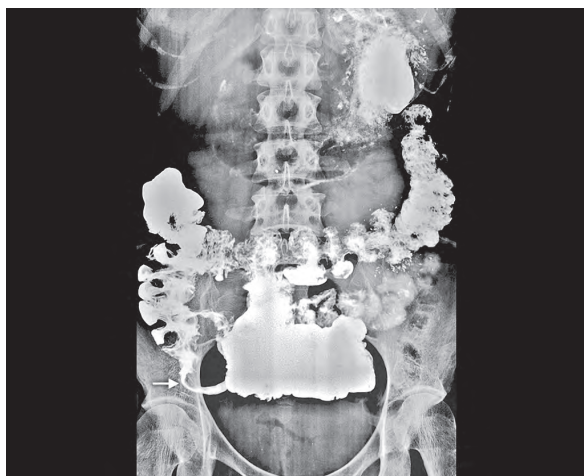
## ILEAL TUBERCULOSIS

- ◆ It is usually *stricture* type.
- ◆ It may be multiple.
- ◆ It presents usually with intestinal obstruction.
- ◆ Bowel adhesion, localisation, fibrosis, secondary infections are quiet common.
- ◆ Perforation (5%) though rare culminates in peritonitis.
- ◆ Plain X-ray shows multiple air fluid levels.
- ◆ Treatment is *resection and anastomosis and to continue anti-TB drugs*.

Often *stricturoplasty* is beneficial.



**Fig. 10.9:** Ileocaecal tuberculosis with rolled up omentum. Note the sites and tubercles in ileocaecal valve, which will be incompetent due to fibrosis.



**Fig. 10.10:** Barium enema X-ray showing stricture in ileocaecal region due to ileocaecal tuberculosis.

## PERITONEAL TUBERCULOSIS

- ❖ *Peritoneal tuberculosis is not uncommon*; many patients present with peritoneal tuberculosis. There will be thickening and fibrosis of the peritoneal wall which is studded with multiple tubercles. It can be 'wet' type or 'dry' type. *Wet type* is common (95%) with formation of different types of ascites. *Dry type* (5%) shows typical fibrosis and adhesions. It may be post primary as activation of long-standing latent focus. It can be from blood spread or can develop from diseased mesenteric lymph nodes or Fallopian tubes.
- ❖ *Presentations are*—Distension of abdomen, recurrent subacute intestinal obstruction, pain abdomen, recurrent fever, loss of weight and appetite. Different types are—abdominal cocoon, ascitic, loculated, plastic, acute and purulent.
- ❖ *Evaluation*—Chest X-ray, USG abdomen, CT abdomen, ascitic fluid analysis, peritoneal biopsy or diagnostic laparoscopy. Serum ascitic fluid gradient is less than 1.1 g/dl; ascitic fluid/blood glucose ratio is less than 0.96; cells mainly of lymphocytes will be more than 1000/ul. Achieving positive AFB staining in ascitic fluid is only 3%; fluid culture will show *Mycobacterium tuberculosis* in 20% cases; centrifuged ascitic fluid once cultured will show 80% positivity for AFB. Ascitic fluid ADA raises (33 units/litre is very sensitive) due to stimulation of T cells by tubercular antigen. It is compared to serum ADA level. Serum ADA >54 units/litre and ascitic fluid to serum ADA ratio > 0.985 is considered as tuberculosis. It is low or normal in HIV; it is high in malignancy. Interferon raises in ascitic fluid along with ADA.
- ❖ *Treatment*—Antitubercular drug therapy is the main modality. Surgery is only indicated if there is complete or recurrent intestinal obstruction, perforation or multiple strictures. Stricturoplasty, localised resections are done. Sepsis, abscess formation, fistula formation, surgical site infection are the complications of surgery.

## Pathology in Peritoneal Tuberculosis

- ◆ Enormous thickening of the parietal peritoneum with multiple tiny yellowish tubercles.
- ◆ Dense adhesions in peritoneum and omentum with content inside as small bowel looking like *abdominal cocoon*. It may precipitate intestinal obstruction.
- ◆ Multiple dense adhesions between bowel loops and between bowel and peritoneum and omentum.
- ◆ Thickening of bowel wall with adhesions.

## Types

### 1. Acute Type—Mimics Acute Abdomen

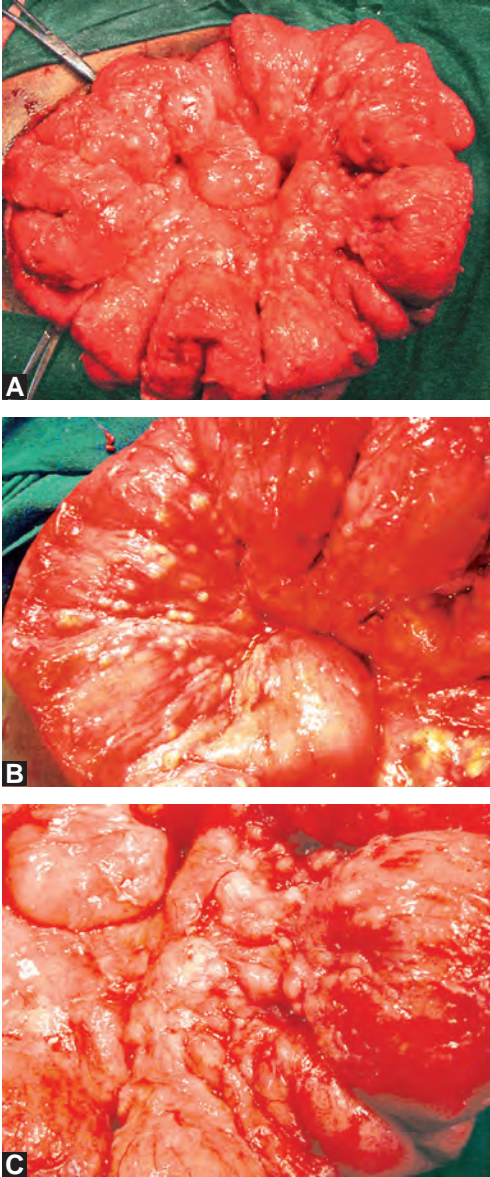
Exploratory laparotomy reveals straw-coloured fluid with tubercles in the peritoneum, greater omentum and bowel wall. It is an on-table diagnosis. Fluid is evacuated and collected for AFB study and culture. Omental biopsy is taken. Abdomen is closed (without a drain) with tension sutures to prevent burst abdomen. ATD is started.

### Acute peritoneal tuberculosis

- ❖ Rare
- ❖ On-table diagnosis
- ❖ Features of peritonitis
- ❖ Due to perforation or rupture of mesenteric tuberculous lymph nodes

## 2. Chronic Tuberculous Peritonitis

- ◆ Present as abdominal pain, fever, ascites, loss of weight and appetite, abdominal mass, **doughy abdomen (10%)**.
- ◆ Peritoneum is thickened with multiple tubercles. Omentum is thick, **fibrosed, rolled up**.
- ◆ Infection is usually from mesenteric lymph nodes, ileocaecal tuberculosis, from Fallopian tubes rarely blood born (from lungs).
- ◆ *Laparoscopy is very useful in this type to diagnose.*



**Figs 10.11A to C:** On-table findings in intestinal tuberculosis, of extensive involvement with multiple tiny tubercles, thickening, adhesions and involvement of mesenteric lymph nodes.

### Ascitic form

- ◆ **Ascitic form** shows enormous distension of abdomen with dilated veins.
- ◆ It presents with congenital hydrocele in male with patent processus vaginalis, umbilical hernia, rolled up omentum, shifting dullness, fluid thrill, and mass abdomen.

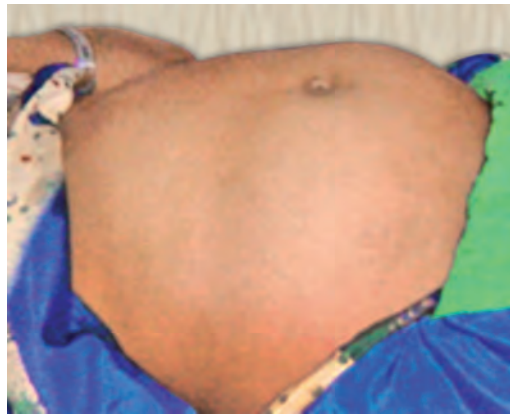- ◆ **Ascitic tap** reveals straw coloured fluid from which AFB can be isolated. Fluid is pale yellow, clear, rich in lymphocytes, with high-specific gravity.
- ◆ Chest X-ray, Mantoux test are other required investigations.
- ◆ ATDs for one year is required. Repeat tapping may be required initially as part of the treatment.

### Note:


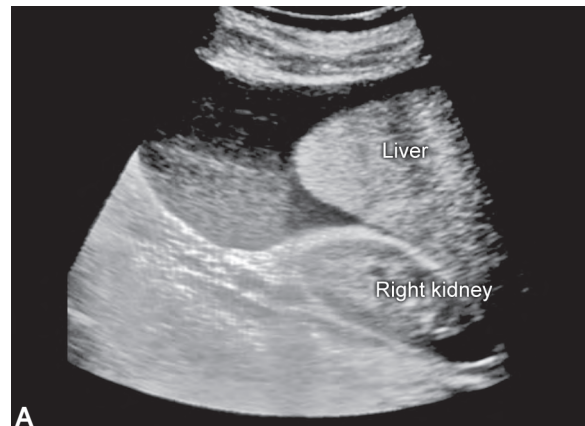
Ascites may be *free or loculated; clear or complex; debris or septae; 'sliced bread' appearance.*

### Encysted (Loculated) ascites

- ◆ Ascites gets loculated because of the fibrinous deposition.
- ◆ Dullness, which is not shifting, is the typical feature.
- ◆ They may present as intra-abdominal mass, which may mimic ovarian cyst, retroperitoneal cyst or mesenteric cyst.
- ◆ Treatment is U/S guided aspiration along with ATDs.



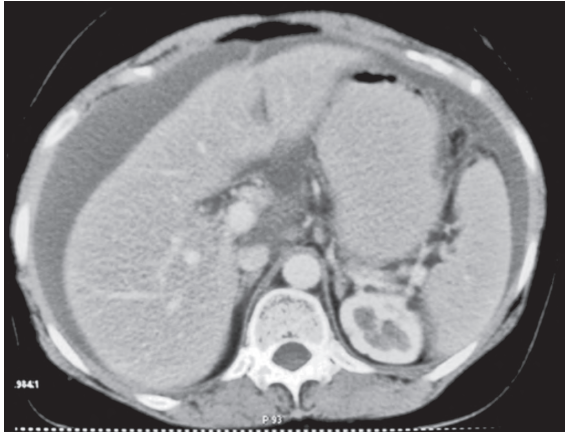
**Fig. 10.12:** Abdominal distension with ascites due to abdominal tuberculosis.



**Figs 10.13A and B:** US picture showing ascites. Straw coloured ascitic fluid tapping done under US guidance.

### Plastic type

- ◆ Here there are widespread adhesions between the coils of the intestine (ileum commonly), abdominal wall, omentum, with distension of the small bowel, leading to blind loop, ileus, intestinal obstruction (subacute, acute), thickened parietal peritoneum.

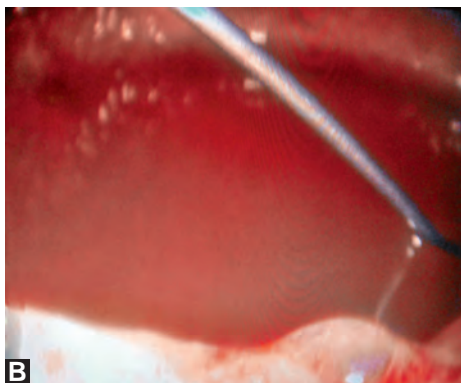
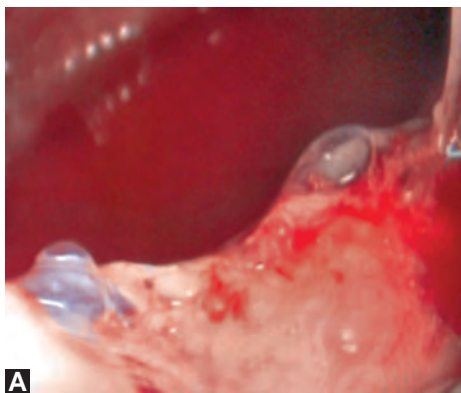


**Fig. 10.14:** CT scan abdomen showing ascites due to tuberculosis.

- ◆ They get recurrent colicky abdominal pain, diarrhoea, wasting, and loss of weight, mass abdomen, and *doughy abdomen*.
- ◆ *Differential diagnosis:* Peritoneal carcinomatosis. Open/laparoscopic peritoneal biopsy is very useful tool to diagnose.
- ◆ They respond well for drug treatment. Surgery is indicated if obstruction occurs.

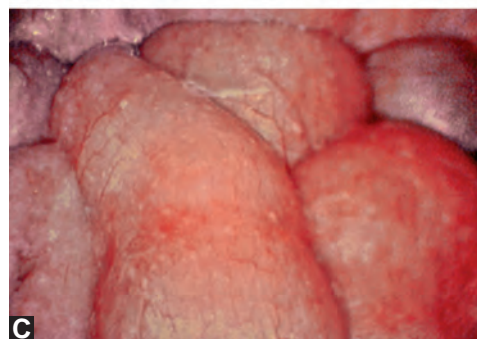
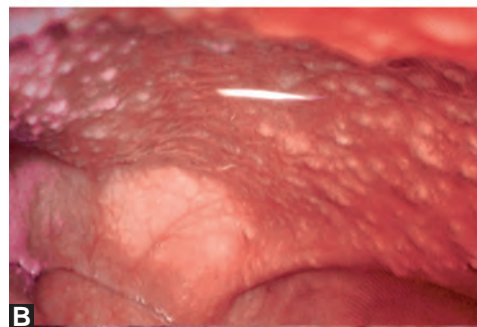
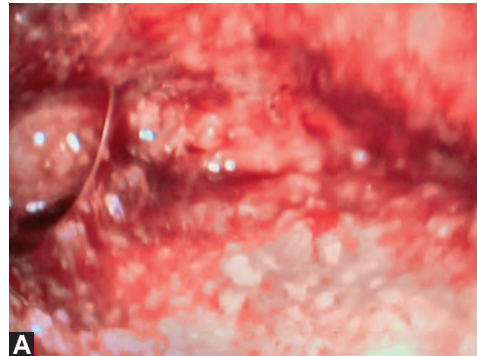
#### **Purulent form**

- ◆ It is invariably due to tuberculous salpingitis, presenting as a mass in the lower abdomen containing pus, omentum, fallopian tubes, small and large bowel.

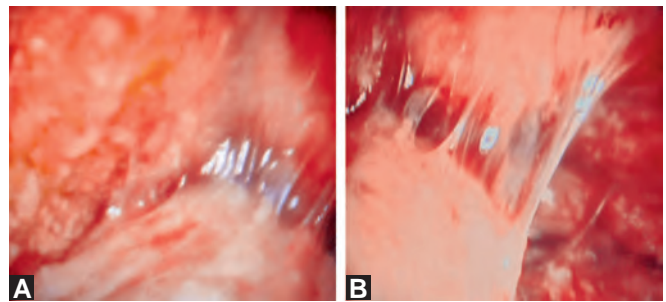


**Figs 10.15A and B:** Laparoscopic picture of loculated ascites due to abdominal tuberculosis. Fluid is getting aspirated using a needle under laparoscopic vision.

- ◆ Cold abscess gets adherent to the abdominal wall, umbilicus and may form an umbilical fistula.
- ◆ Patient commonly has got genitourinary tuberculosis.
- ◆ U/S, discharge study, X-ray abdomen and other investigations are useful.
- ◆ *Treatment:* ATDs are started exploration of umbilicus, exploration of fistula and bowel bypass is done.
- ◆ Prognosis is poor in this type.



**Figs 10.16A to C:** Laparoscopy showing plastic type of abdominal tuberculosis and multiple tubercles over parietal and visceral surface of the peritoneum.



**Figs 10.17A and B:** Laparoscopy showing adhesions between bowel and abdominal wall due to tuberculosis.



<b>Ascitic form</b>	<b>Loculated form</b>
Insidious onset Fatigue, weight loss, fever, anorexia	Loculated abdominal swelling Ascites which is not shifting
Abdominal pain usually absent	Diagnosis—US guided aspiration
Abdominal distension usually without pedal oedema	Antituberculous drugs
<i>Rolled up omentum</i> is common association as mass	
<b>Fibrous form</b>	<b>Purulent form</b>
Widespread adhesion of bowel loops	Due to tuberculous sal-pingitis
Adhesions, matting and dilatation	Presenting as lower abdo- minal mass
Act as blind loop— malabsorption	Umbilical fistula, abdominal wall abscess can occur
Abdominal pain, loss of weight, <i>doughy abdomen</i> due to thickened parietal peritoneum, diarrhoea, often mass abdomen—are usual features	Cold abscess adherent to abdominal wall

## TUBERCULOUS MESENTERIC LYMPHADENITIS

- ◆ Infection is usually through the Peyer's patches of the intestine (i.e. through oral cavity). Usually several lymph nodes are involved often causing massive lymph node enlargement. Commonly right-sided lymph nodes are involved, but left sided nodes can also get involved.
- ◆ It presents with general symptoms (fever, malaise, weight loss).
- ◆ Pain in umbilical region and right iliac fossa, mass in right iliac fossa, which is matted, nonmobile.
- ◆ It may present with features of *acute appendicitis*.
- ◆ Often coils of intestine get adherent to the caseated mesenteric lymph nodes leading to intestinal obstruction.
- ◆ Most often caseating material may collect between the layers of the mesentery, forming a cold abscess, mimicking a mesenteric cyst (*Pseudomesenteric cyst*).
- ◆ *Massive enlargement of mesenteric lymph nodes due to tuberculosis is called as **tabes mesenterica**.*
- ◆ Mesenteric tuberculous adenitis is more common in children. Present with anaemia, fever, loss of appetite and reduced weight, failure to thrive, palpable mass in right iliac fossa which is firm and nodular.

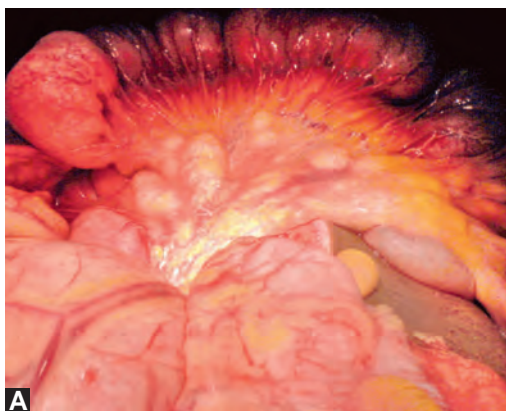
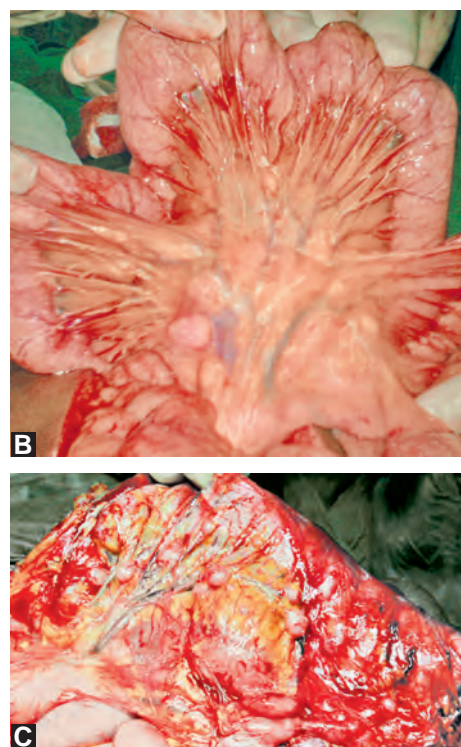
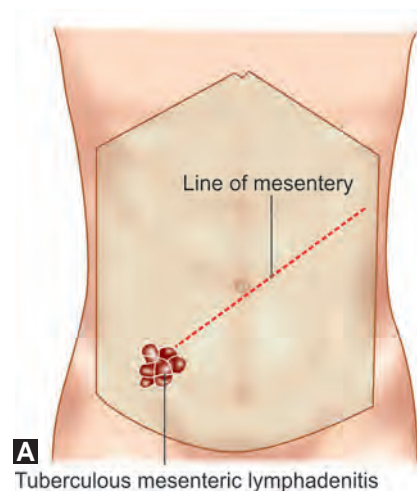


Fig. 10.18A

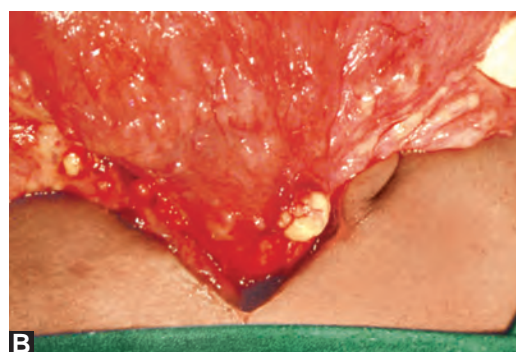

Figs 10.18B and C

Figs 10.18A to C: Mesenteric tuberculous lymphadenitis on table findings.



A  
Tuberculous mesenteric lymphadenitis



Figs 10.19A and B: Note the location of mesenteric tuberculous lymphadenitis in the right iliac fossa. But it can occur anywhere in the line of mesentery. On-table caseating tuberculous lymphadenitis is also shown.

### Presentations of mesenteric tuberculous lymphadenitis

- ❖ Mesenteric tuberculous adenitis—acute/chronic in right iliac fossa—mass
- ❖ Pseudomesenteric cyst
- ❖ Cold abscess within the mesentery
- ❖ Tabes mesenterica

## Differential Diagnosis

- ◆ Carcinoma caecum.
  - ◆ Lymphoma.
  - ◆ Retroperitoneal tumour.
  - ◆ Nonspecific lymphadenitis.
- (Acute nonspecific mesenteric lymphadenitis is called as **nurses' syndrome**).

## Investigations

- ◆ X-ray abdomen shows calcification.
  - ◆ U/S may confirm the diagnosis.
  - ◆ Mantoux test may be positive.
  - ◆ *Diagnostic laparoscopy*—is very useful in TB lymphadenitis. Mesenteric cold abscess can be drained safely through laparoscopy.
- Treatment:* ATDs; Laparoscopy and proceed. Prognosis is good.

## ANO-RECTO-SIGMOIDAL TUBERCULOSIS

- ◆ It mimics carcinoma rectum.
- ◆ It presents as tenesmus, diarrhoea, and discharge from the fistula and occasionally as mass per abdomen. Rectal tuberculosis occurs usually within 10 cm of anal verge.
- ◆ Fistulas are *painful and characteristically not indurated*. Tuberculous fistulas are commonly multiple.
- ◆ Tuberculous anal ulcers when occur are shallow, bluish, with undermined edges.
- ◆ Sigmoidoscopy, U/S, discharge study, fistulectomy and biopsy confirms the diagnosis.
- ◆ Treatment is ATDs, fistulectomy, often *sigmoid resection*.

## TUBERCULOSIS OF THE OMENTUM

- ◆ It usually occurs as a part of the other types of abdominal tuberculosis.
- ◆ *Rolled up omentum* with thickening is characteristic.
- ◆ Often cold abscess can develop *per se* in the omentum.
- ◆ If it is so, it can be dealt with laparoscopy safely under the cover of ATDs.

In all abdominal tuberculosis, drug treatment is for one year.

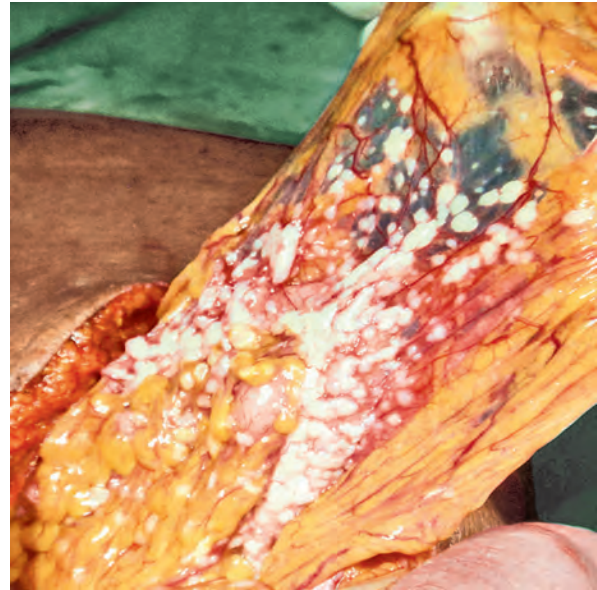
In adrenal tuberculosis and severe adhesions, steroids may be beneficial.

### Indications for steroids in tuberculosis

- ❖ Miliary tuberculosis
- ❖ Tuberculous meningitis
- ❖ Adrenal tuberculosis
- ❖ Tuberculous pericarditis
- ❖ Pleural and endobronchial tuberculosis
- ❖ In abdominal tuberculosis to prevent adhesions
- ❖ Tuberculosis of the mediastinal lymph nodes (Rapidly progressive)
- ❖ Genitourinary tuberculosis
- ❖ Ocular tuberculosis

## Remember

- ◆ AFB staining of fixed tissue in abdominal tuberculosis is possible only in 5% cases. *Ziehl-Neelsen* staining is done. (Carbol fuchsin—steam heat for 7 minutes—water wash—decolorisation with 20% H<sub>2</sub>SO<sub>4</sub>—95% ethanol wash—counterstain with Loeffler's methylene blue/1% picric acid/0.2% malachite green. Tuberculous bacilli are bright red rods seen under oil immersion lens).



**Fig. 10.20:** Omental tuberculosis showing tubercles.

- ◆ Culture takes 8 weeks to get the result. 35% of abdominal tuberculosis shows positive in culture. *Lowenstein Jensen media* is used. Guinea pig inoculation is also useful method.
- ◆ *WHO now recommends* antituberculous drugs for 6 months. Uncomplicated cases—4 drugs for 2 months and 2 drugs for 4 months. Complicated cases—4 drugs for 2 months and 2 drugs for 7 months. But many patients need one year treatment. Because of complications and difficulty in managing recurrent cases of abdominal tuberculosis one year therapy is commonly used in developing countries.
- ◆ *First line drugs* are—isoniazid—5 mg/kg; rifampicin—10 mg/kg; ethambutol—15 mg/kg; pyrazinamide—25 mg/kg.
- ◆ *Second line drugs* are—amikacin; kanamycin; PAS (Para-amino sulphuric acid); ciprofloxacin; ofloxacin; clarithromycin; azithromycin; rifabutin.
- ◆ Follow-up and prognosis is monitored by—regular weight check to see for gain; improvement in appetite; reduction of abdominal pain and distension; absence of fever; normal bowel habits; normal haemoglobin; ESR becoming normal; and US abdomen shows improvement in sonological features.
- ◆ Patients who are not responding in 6 weeks should be reassessed again for—drug resistance; associated other diseases like malignancy (carcinomas or lymphoma), Crohn's disease, eosinophilic enteritis.
- ◆ During therapy, patient who is responding for drug therapy can also go for intestinal obstruction due to fibrosis during healing stage. It needs surgical intervention.
- ◆ Repeated surgery in abdominal tuberculosis is difficult and dangerous as chances of developing faecal fistula, further adhesions are more likely.

# Chapter 11

## Liver

*The liver...that great maroon snail.... No wave of emotion sweeps it. Neither music nor mathematics gives it pause in its appointed tasks.*

—Richard Selzer, 1976

### CHAPTER OUTLINE

- ❖ Surgical Anatomy of Liver
- ❖ Liver Function Tests
- ❖ Alpha-Fetoprotein
- ❖ Liver Biopsy
- ❖ Liver Injury
- ❖ Infections of Liver
  - Amoebic Liver Abscess
  - Pyogenic Liver Abscess
  - Portal Pyaemia
  - Hydatid Cyst of Liver
  - Actinomycosis of Liver
- ❖ Liver Tumours
  - Benign Tumours of the Liver
  - Primary Malignant Tumours of the Liver
  - Hepatocellular Carcinoma
  - Secondaries in the Liver
- ❖ Liver Cysts
  - Congenital Liver Cysts
  - Neoplastic Liver Cysts
  - Traumatic Liver Cyst
- ❖ Portal Hypertension
- ❖ Oesophageal Varices
- ❖ Emergency Management in Severe Haemorrhage
- ❖ Portal Hypertensive Gastropathy
- ❖ Ascites
- ❖ Ascites in Portal Hypertension
- ❖ Budd-Chiari's Syndrome
- ❖ Hepatic Failure
- ❖ Hepatic Encephalopathy
- ❖ Hepatorenal Syndrome
- ❖ Hepatic Resection
- ❖ Portal Biliopathy

### ■ SURGICAL ANATOMY OF LIVER

Liver has four lobes—*right lobe, left lobe, quadrate lobe* and *caudate lobe*.

Supporting structures are *right triangular ligament, left triangular ligament* and *falciform ligament*.

### Blood Supply

It is a unique organ with dual blood supply. Hepatic blood flow is around 1500 ml/minute of which *portal vein* contributes 80% and *hepatic artery* 20%.

Hepatic artery commonly originates from coeliac axis. There are many variations of hepatic artery, both in its origin and its pathway

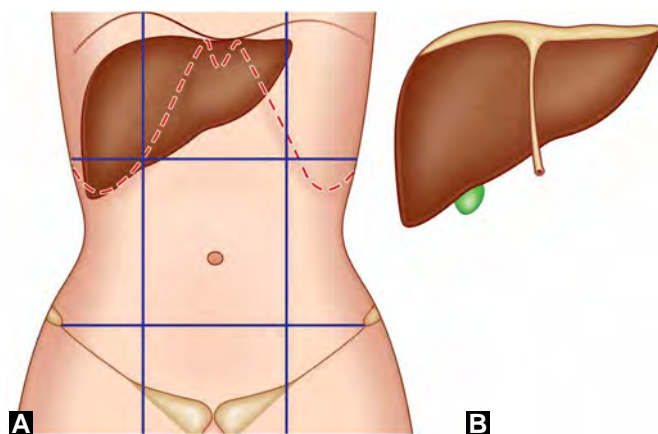
and is considered surgically important. Hepatic artery ligation is one of the surgical palliation for advanced hepatocellular carcinoma and secondaries in liver as tumour tissue is supplied exclusively by hepatic artery but normal tissue is also supplied by portal vein.

Superior mesenteric vein and splenic vein join dorsal to the neck of pancreas to form portal vein.

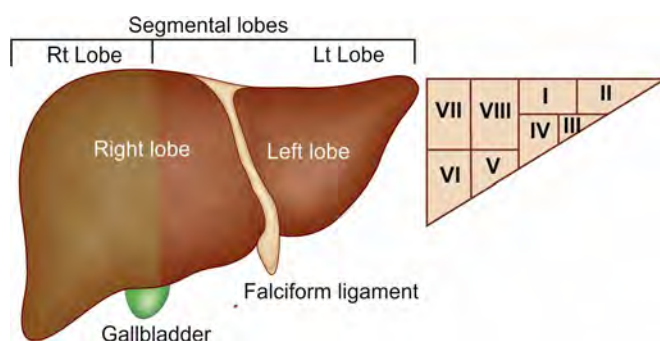
Hepatic artery, portal vein and bile duct are located in the free edge of the lesser omentum until it enters the liver.

*Venous drainage* is usually through the three major hepatic veins, right, left, and middle which drain into the IVC. Often inferior hepatic vein may be present.

The liver parenchyma is entirely covered by a thin capsule called '*Glissons capsule*' and by visceral peritoneum in all but the posterior surface of liver termed 'bare area'.



**Figs 11.1A and B:** Anatomical location of liver and its lobes.



**Fig. 11.2:** Segmental anatomy of the liver.

### Segmental Anatomy of Liver

- ◆ Liver is divided into functional right and left lobes by a line passing from the left of the gallbladder fossa to the left of IVC—*Cantlie's line* creating *Couinaud's* segments. There are *eight segments*:
  - ▶ Segments I, II, III, and IV are of left lobe.
  - ▶ Segments V, VI, VII, VIII are of right lobe.
  - ▶ Segment I is the caudate lobe of the liver and has independent supply of portal and hepatic veins. This hepatic vein directly joins IVC.
- ◆ Right lobe is having right hepatic artery, right branch of portal vein, and right hepatic duct.
- ◆ Left lobe is having left hepatic artery, left portal vein, left branch of bile duct.
- ◆ *Bismuth's classification* is similar but separation of the sectors is by hepatic veins.
- ◆ *Functional unit* is called as *hepatic lobule* and it contains *central hepatic vein* and *portal triad* (*hepatic arteriole, portal venule, bile ductule*).

### Lymphatic Drainage of the Liver

- ◆ *Superficial vessels* drain in four directions; from ligaments into the thoracic duct; porta hepatis to the hepatic nodes then to celiac nodes; from rest of the right lobe to the celiac nodes; posterior part of the left lobe drains to paracardial nodes near oesophageal hiatus; rest of the left lobe to celiac nodes.
- ◆ *Deep lymphatic vessels* form ascending and descending trunks; ascending trunk drains to nodes adjacent to IVC; descending trunk drains into hepatic nodes and to celiac nodes.

### Functions of the liver

- ❖ Removal of gut endotoxins and foreign antigens—liver acts as the first filter
- ❖ Drug and hormone metabolism
- ❖ Formation of bilirubin and its metabolism
- ❖ Formation of urea from protein catabolism
- ❖ Glucose metabolism, glycolysis, and gluconeogenesis
- ❖ Clotting factors synthesis
- ❖ pH balance and correction of lactic acidosis
- ❖ Maintaining body temperature
- ❖ Storage of vitamin B12, vitamin A, Cu, Fe

### LIVER FUNCTION TESTS (LFT)

1. Serum bilirubin which includes both direct and indirect. Test is known as *van den Bergh's test*.
2. Serum albumin, globulin and A : G ratio; serum albumin is the indicator of chronic liver disease.
3. Prothrombin time: Normal value is *12–16 seconds*. Difference between control and test more than 4 seconds or test being more than 1½ times the control is significant. When it is altered it is corrected by injecting vitamin K, 10 mg IM for 5 days or by fresh frozen plasma (FFP)—*For cell synthesis*.
4. Alkaline phosphatase—*Secretory function*.
5. Aspartate amino transaminase *5–40 IU/litre* (AST, SGOT)—*signifies inflammation*.
6. Alanine transaminase *5–40 IU/litre* (ALT, SGPT), liver specific.
7. 5 nucleotidase.
8. Gamma glutamyl transpeptidase (GGT) *10–48 IU/L*.
9. Immunological tests: Antimitochondrial or antinuclear antibodies.
10. AFP.
11. Specific tests: (a) For haemochromatosis: Serum iron, total iron binding capacity, serum ferritin. (b) Wilson's disease: Serum copper, urinary copper, serum ceruloplasmin.
12. Fluorodeoxyglucose-positron emission tomography (FDG-PET): It is to find out the uptake of labelled glucose which varies in different diseases of liver, i.e. benign, malignant and inflammatory.
13. Technetium-99m labelled radioisotope scan shows the uptake and excretion of bile.
14. A sulphur colloid liver scan shows specifically Kupffer cell activity. Sulphur colloid will not show uptake in adenoma and haemangioma as Kupffer cells are absent in these lesions.
15. Urine for bile salts (*Hay's test*), for bile pigments (*Fouchet's test*) and for urobilinogen (*Ehrlich's aldehyde test*).

Hepatocyte function	AST, ALT
Synthetic function and metabolism	PT-INR, factor V, VII, albumin, bilirubin
Biliary canalicular function	ALP, 5' nucleotide, gamma glutamyl transferase, bilirubin

### Other investigations for liver diseases

- ❖ US abdomen
- ❖ Angiography
- ❖ CT Scan
- ❖ PTC
- ❖ ERCP
- ❖ MRI
- ❖ Laparoscopy and laparoscopic US
- ❖ Liver biopsy

*I prefer to learn and to teach anatomy, not from books but from dissections; not from the positions of philosophers but from the fabric of nature.*

—William Harvey

## ALPHA FETOPROTEIN (AFP)

- It is normal component of the plasma protein of the fetus secreted by yolk sac and embryonal hepatocytes (fetal liver), which usually reduces after birth and persists as a low value level. Gene is located in the q arm of chromosome 4- 4q25. It binds to copper, nickel, fatty acids and bilirubin.
- It is a *glycoprotein* containing a carbohydrate moiety with 591 amino acids. AFP in fetus protects fetus from maternal estradiol. Normal value is up to 10 ng/ml. Immediately after birth it will be higher but in a year it reaches to normal value.
- It is an important tumour marker for HCC more often to HCC with cirrhosis (100–1000 ng/ml) where it increases enormously. In HCC, it is also prognostic indicator to identify relapse or residual disease. HCC less than 4 cm may show only raise up to 200 ng/ml. 20% of HCCs and variants like fibrolamellar type may have normal AFP. Serum lens culinaris agglutinin reactive fraction of AFP, an isoform of AFP (AFP-L3) is also used as tumour maker for HCC.
- It also increases in benign conditions also to certain extent but never more than 100 ng/ml.
- It also increases in nonseminomatous testicular tumours, hepatoblastoma, and some ovarian tumours (yolk sac tumour).
- Serum value in adults, serum and amniotic fluid value in pregnant women are assessed.
- It is useful in diagnosing the omphalocele, ataxia telangiectasia, neural tube defects.
- AFPep is a peptide derived from AFP which shows anticancer features.

## LIVER BIOPSY

### Prerequisites:

- Prothrombin time should be normal before doing liver biopsy, otherwise severe bleeding can occur.
- Normal value of prothrombin time is 12–16 seconds (It is compared to control and difference should be less than 4 sec between test and control). It is corrected by giving injection vitamin K 10 mg IM, for 5 days. After that if repeat PT is still high then fresh frozen plasma (FFP) is required to correct it.

### Indications

- Cirrhosis, chronic hepatitis, haemochromatosis, Wilson's disease, metabolic diseases, and neonatal conditions.
- Only advanced hepatocellular carcinoma (HCC), in selected liver secondaries where primary is not detected.

### Complications

- Haemorrhage
- Bile leak and biliary peritonitis
- Infection

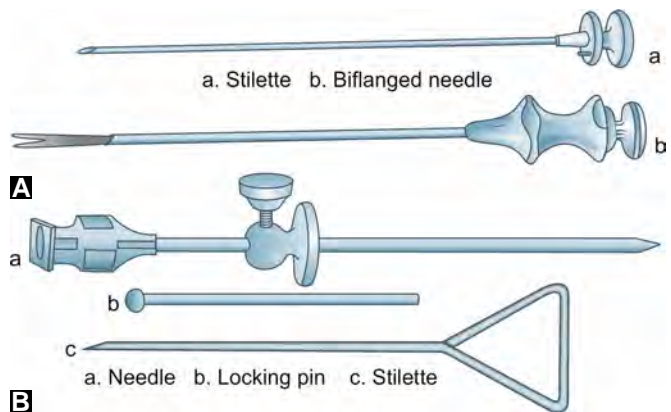
### Contraindications

- Hydatid disease, where it will precipitate anaphylaxis
- Haemangioma, bleeding disorders
- Ascites

### Procedure

- Needle used here is either *Vim-Silvermann needle* or *Menghini needle* (better option).

- Needle is usually punctured through right midaxillary line in 9th intercostal space or under US guidance into any place as required.
- Presently, guided liver biopsy is commonly recommended and popular, i.e. US guided, CT scan guided, laparoscopy guided.



**Figs 11.3A and B:** Liver biopsy needles. A. Vim-Silvermann, B. Menghini.

## LIVER INJURY

### Causes

It can be due to blunt injury, stab, and gun shot injury.

About 5% of all trauma admissions will have liver injury; liver is the most common organ injured in blunt abdominal trauma.

### Types

It can be contusion, laceration, avulsion, extension into thorax and biliary tree may be associated with other organ injuries (spleen, kidney, duodenum, bowel, IVC) and with fracture ribs.

### Liver injury can be:

- Penetrating:** It often requires surgical intervention. After laparotomy with rooftop incision, laceration is assessed, clots and blood in the peritoneal cavity is removed. Using *Pringle manoeuvre* bleeding is temporarily controlled. Often suprahepatic IVC and infrahepatic IVC control may be required. Liver wound is sutured using specialized needle with vicryl using *co-opting sutures*. Gelfoam or Surgicel is placed over it. Other injuries like of diaphragm, biliary system, bowel should be looked for. Adequate amount of blood, FFP should be kept for transfusions. Postoperative assessment of BT, CT, PT, platelet count, observation for sepsis is needed. Ideal antibiotic coverage using 3rd generation cephalosporins or higher are needed.
- Blunt trauma:** It is assessed by CT scan. It is usually treated conservatively. Indications for surgical intervention are—progressive deterioration and bleeding, grade 5 liver injury on CT scan, associated bowel injury. Commonly used procedure after laparotomy is keeping packs between liver and diaphragm which is removed in 48–72 hours. Occasionally venovenous bypass, hepatic resection may be required.

### Clinical Features

- Features of shock due to severe torrential bleeding (pallor, hypotension, tachycardia, and sweating).

- ◆ Distension of abdomen with dull flank, guarding, tenderness and rigidity.
- ◆ Oliguria.
- ◆ Tachypnoea, respiratory distress and often cyanosis.
- ◆ Rupture of right lobe is more common than left lobe leading to *haemoperitoneum*.
- ◆ Occasionally can cause localized haematoma which may form an abscess.
- ◆ Bile leak from the injured site can lead to *biliary peritonitis*.

## Investigations

- ◆ Chest X-ray to look for rib fractures.
- ◆ US abdomen, FAST (Focused assessment with sonography for trauma) CT scan of chest and abdomen (CT is ideal).
- ◆ Diagnostic peritoneal lavage. 10 ml gross blood on initial aspiration, > 1,00,000 cu mm RBCs, > 500 WBCs, and presence of enteric contents suggest positive DPL. Diagnostic peritoneal aspiration only can also be done.
- ◆ Hb%, PCV, blood grouping and crossmatching. Adequate amount of blood (5-10-15 bottles of blood) must be kept ready for transfusion, i.e. requires massive transfusion.
- ◆ Arterial blood gas analysis.
- ◆ *Coagulation profile*.
- ◆ *Thromboelastography (TEG)* is dynamic form of assessing the coagulation status on table.
- ◆ Arteriography to visualise the bleeding branch/vessel in the liver and embolisation can be tried.

## Treatment

### General measures

- ◆ IV fluids, blood transfusion (massive), FFP.
- ◆ Have both central venous access, and peripheral venous access.
- ◆ Bladder catheterisation has to be done to measure the urine output.
- ◆ *Factor VII*—proconvertin (SPCA—0.6 mg/ml up to 4.8 mg); very effective, makes INR normal; but very expensive.

### Initial conservative nonoperative management

- ◆ It is done in—nonprogressive liver injuries in patients who are haemodynamically stable, low grade (I-III) liver injury, need of less than 2 units of transfusion, without peritoneal signs, normal mental status.
- ◆ However, CT abdomen (absence of extravasation of contrast during arterial phase can be treated nonoperatively) and repeat CT or regular ultrasound follow-up is a must.
- ◆ Replacement of lost blood; prevention of sepsis; regular monitoring by haematocrit, liver function tests, prothrombin time are needed.
- ◆ *Angiographic embolisation* increases the success rate of nonoperative therapy.
- ◆ Intensive care unit (ICU) management for 2–5 days; repeat CT scan after 5 days; bedrest to be continued; patient can have normal activity only after 3 months.

### CT grading of liver injury 1994

Grade and type	Injury
I – Haematoma – Laceration	Subcapsular haematoma less than 10% surface area. Capsular laceration less than 1 cm in depth.
II – Haematoma – Laceration	Subcapsular haematoma 10–50%; intraparenchymal less than 10 cm diameter. Capsular laceration 1–3 cm in depth; less than 10 cm length.
III – Haematoma – Laceration	Subcapsular haematoma more than 50%; intraparenchymal more than 10 cm diameter—expanding. Capsular laceration >3 cm in depth.
IV – Laceration	Parenchymal disruption 25–75% hepatic lobe; 1–3 Couinaud segments.
V – Laceration – Vascular	Parenchymal disruption more than 75% or more than 3 Couinaud segments. Major hepatic veins or retrohepatic venacaval injuries.
VI – Vascular	Hepatic avulsion.

- ◆ When at any time patient's condition worsens, he should be taken up for laparotomy.
- ◆ *Success rate* of nonoperative treatment is 85% in grade I-III injuries; 40% in grade IV-VI injuries. It is the associated injuries which decides the success.
- ◆ *Intervention radiology* methods like *angioembolisation* through hepatic artery are used especially when there is pseudoaneurysm. But life-threatening hepatic necrosis and gallbladder necrosis can occur. Gallbladder necrosis warrants cholecystectomy.

### Specific treatment

- ◆ *Push (direct compression)*; *plug* (plugging the deep track injuries using silicone tube or SB tube); *Pringle's manoeuvre*; *pack* (liver wound is directly packed with mop).

### Damage control surgery initially

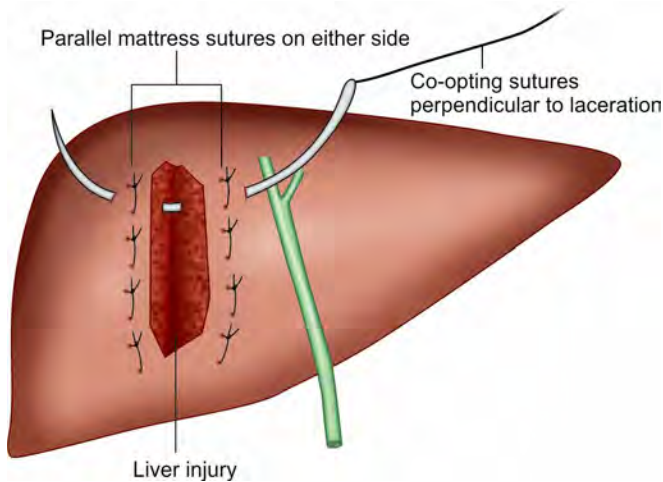
**Phase I** – Laparotomy control of bleeding by various methods, closure with pack.

**Phase II** – Resuscitation, managing metabolic insult (hypothermia with temperature <34°C, coagulopathy with PT INR more than 50% above normal, and acidosis with pH <7.2).

**Phase III** – Re-exploration and definitive procedures—resection or debridement and suturing, reconstruction of major vessels, etc.

- ◆ Laparotomy is done through a large *bucket handle* abdominal incision or thoracoabdominal incision, and extent of liver injury and also other associated injuries are looked for.
- ◆ Small liver tear is sutured with *vicryl* or *PDS* mattress sutures with placing of gel foam to control bleeding.
- ◆ To control bleeding on table, from hepatic artery and portal vein, both are temporarily occluded using fingers, compressing at foramen of *Winslow-Pringle manoeuvre*. Often bull-dog clamp or vascular clamps can be used.

*Regeneration of liver after resection is complete in 4-6 months. 80% of liver can be resected without compromising its function.*



**Fig. 11.4:** Co-opting sutures are placed perpendicular to already placed parallel mattress sutures.

**In deep severe injuries, following methods are used:**

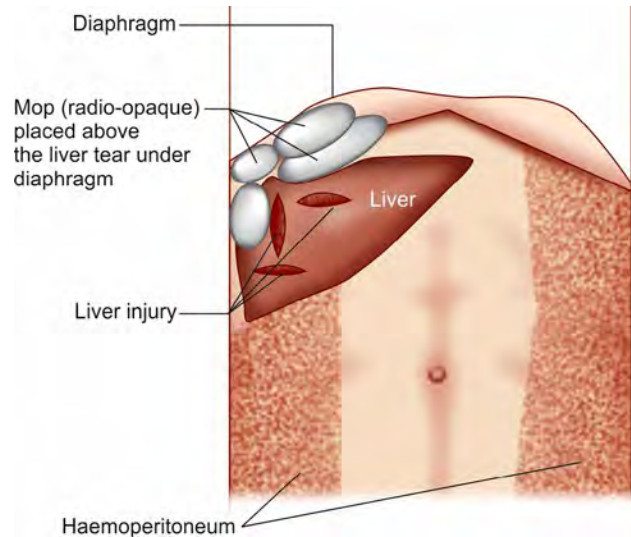
- ❖ Hepatic artery ligation, not usual.
  - ❖ Segmental resection.
  - ❖ Hemihepatectomy, not commonly used.
  - ❖ Packing the liver temporarily with mops and closing the abdomen.
- ◆ Ligation of bleeding vessel individually on the cut surface is needed and is called as *tractotomy*. Biliary ductules are also ligated. As vessels are supported by *fibrous adventitia* ligation suture holds well on these vessels even though liver parenchyma is soft and friable.
  - ◆ Liver can be wrapped with absorbable mesh (*mesh hepatorrhaphy*) to achieve haemostasis.
  - ◆ Cholecystectomy and placement of 'T' tube in CBD.
  - ◆ In associated IVC injuries, it is very difficult to manage (has high mortality). A *veno-venous bypass* between femoral vein and SVC is done and then repair of IVC is carried out.
  - ◆ ICT placement to thorax and repair of diaphragmatic injury.
  - ◆ Management of other organ injuries accordingly.
  - ◆ *Kous Netzoff aluminium needle* is used to suture liver tear.
  - ◆ Postoperatively patient requires ventilator support, blood transfusion, electrolyte management, antibiotics like third generation cephalosporins, ceftazidime, cefoperazone.
  - ◆ FFP, cryoprecipitate are also required.

**Management of liver trauma**

- ❖ Control of haemorrhage—packing; tractotomy; mesh hepatorrhaphy; debridement of devitalized tissue; segmentectomy, vein repair with veno-venous bypass; transfusions.
- ❖ Management of metabolic disturbances—prevention of acidosis, DIC, FFP; platelets.
- ❖ Monitoring—repeat US; repeat CT; urine output; LFT; prothrombin time; platelet count; haematocrit.
- ❖ Prevention of sepsis—proper debridement; irrigation of liver wound with warm normal saline; antibiotics.
- ❖ Identification and management of complications of liver injury

**Porta hepatic injury**

- ◆ It is life-threatening even though rare. Penetrating trauma commonly cause this injury.
- ◆ It is commonly associated with organ injuries. Isolated porta injury is rare. It is difficult to manage with mortality 50–80%.



**Fig. 11.5:** By placing 3–5 mops between injured liver and diaphragm tamponade can be achieved to control bleeding from the liver. After 48–72 hours abdomen is re-explored electively for further intervention. By then, often bleeding will be controlled and further management becomes easier. Sepsis should be taken care of by higher generation antibiotics.

- ◆ Portal vein is sutured after veno-venous bypass.
- ◆ Common bile duct injury involving less than half the circumference can be sutured over a T tube. Injury more than 50% or transection needs choledochojejunostomy.

**Complications and sequelae of liver injury**

- ❖ Shock and haemorrhage
- ❖ Liver abscess or septicaemia—7%
- ❖ Bile leak, biliary peritonitis, biliary fistulas—10%
- ❖ Disseminated intravascular coagulation
- ❖ Hepatic artery aneurysm, arteriovenous and arterio-biliary fistulas—haemobilia
- ❖ Intra-hepatic haematoma
- ❖ Intra-abdominal abscess—subphrenic, pelvic
- ❖ Complications of massive blood transfusion
- ❖ Electrolyte imbalance
- ❖ Respiratory complications
- ❖ Liver failure
- ❖ **Late sequelae** of liver trauma is *CBD stricture* causing obstructive jaundice. It can be managed by endoscopic stenting or by open Roux-en-Y hepaticojejunostomy
- ❖ Mortality is 10%; morbidity is 30%. Associated injuries increase the mortality from isolated liver injury of 3–20%.

**INFECTIONS OF LIVER**

**AMOEBIC LIVER ABSCESS**

- ◆ It is common in India and other tropical countries and it is caused by a parasite *Entamoeba histolytica*.
- ◆ It is more common in *alcoholics and cirrhotic* patients.
- ◆ It is the commonest extraintestinal presentation (8–10%) of amoebiasis. It is often called as *tropical abscess*.
- ◆ Infection commonly occurs from the caecum after an attack of amoebic typhilitis (inflammation of the caecum) through the superior mesenteric vein and portal vein. Infection from sigmoid (rectosigmoid) colon spreads through the inferior mesenteric vein and portal

vein to liver. Right lobe is commonly involved over posterosuperior surface (because of streamline effect and larger size of the right lobe). Trophozoites destroy the hepatocytes by releasing *histiolysin*, a cytolytic agent. It causes amoebic hepatitis with multiple micro-abscesses formation. It leads into liquefaction necrosis, thrombosis of blood vessels, release and, breaking of red cells. It causes formation of 'Anchovy sauce' pus which is chocolate brown coloured and odourless (Anchovy sauce is sauce prepared from a type of fish). Pus may be green coloured if mixed with bile. Secondary infection is common (30%).

- ◆ In Western countries pyogenic abscess is much more common. Amoebic abscess is much more common than pyogenic abscess in endemic areas like Indian sub-continent, and Africa.
- ◆ Amoebic abscess is usually sterile unless infected. Trophozoites are found in the wall of the abscess not in the content.

#### Note:

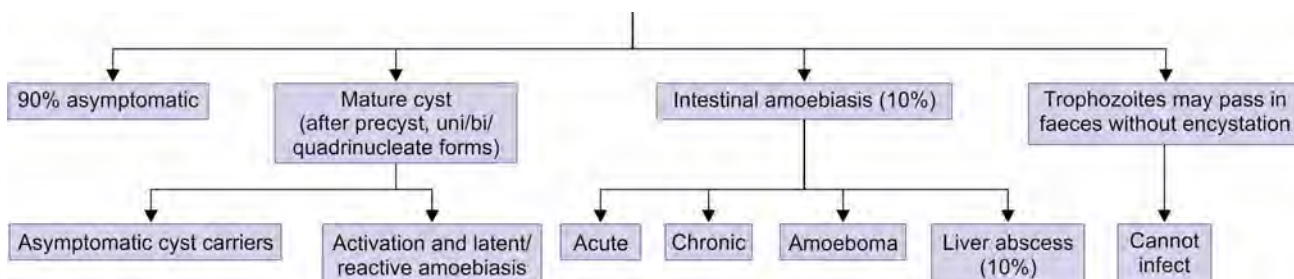
- 10% of amoebic infection causes intestinal amoebiasis commonly in caecum; 10% intestinal amoebiasis leads into amoebic liver abscess.
- Malnutrition, patients on steroid therapy, immunosuppression, cirrhosis and alcoholism increases the infection rate and also rate of amoebic liver abscess.
- Amoebic liver abscess is not common in females especially in menstruating age group.
- Anchovy sauce pus is odourless unless infected secondarily.
- Size is the independent important *risk factor* for rupture.

### Pathology

- ◆ Initially from infected rectosigmoid or ileocaecal region, amoebic trophozoites reach the liver through portal veins causing amoebic hepatitis, may be in the form of micro-abscesses all over the liver. This might resolve on its own or with anti-amoebic drugs, but often leads to a localised *amoebic liver abscess*.
- ◆ In 80% of cases it is *single large abscess*, in 20% it is multiple, may involve both lobes. Problems and difficulties in treating, in addition to poor prognosis are more common in *multiple abscesses*.
- ◆ Amoebic liver abscess is more common in *right posterior-superior* region (80%) because of streamline effect, i.e. the portal vein is in direct continuation with the right branch. It can be *multiloculated* also. 10–15% cases *solitary left lobe abscess* occurs; 5–10% cases both lobes are involved.
- ◆ Pus is *chocolate coloured*, classically called as **anchovy sauce**, contains dead liver cells, RBCs, necrotic material. Pus may be green due to bile admixture. (*But no WBCs*).

### Life Cycle of *Entamoeba histolytica*

Mature cyst in faeces → contaminate food/water → ingestion of cyst → pass through stomach undamaged → in alkaline medium, cyst wall lysis occurs by trypsin → excystation → release of quadrinucleate amoebae—metacyst trophozoites formed → Habitat in crypts of caecum commonly, often in sigmoid colon *as to form trophozoites*.



*Amoebic liver abscess may be present as bulge in the right lower intercostal spaces and may exhibit pitting edema.*

—Ajit K Basu

- ◆ Often secondary infection by *E. coli*, staph, strepto may occur (30%) and so may present with features of pyogenic liver abscess. Because of perihepatitis, liver is fixed to diaphragm or abdominal wall, hyperaemia in the diaphragm causes sympathetic *pleural effusion on right side*.

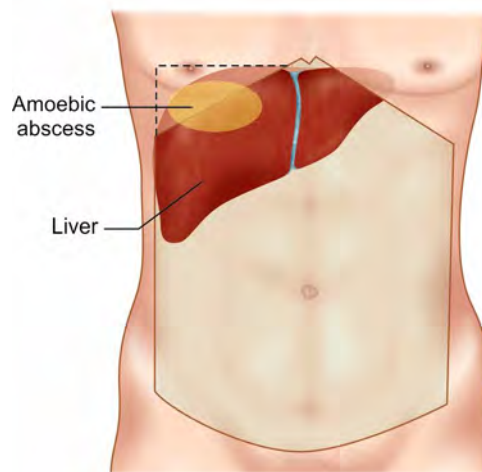


Fig. 11.6: Commonest location of amoebic liver abscess—right posterosuperior part of the liver.

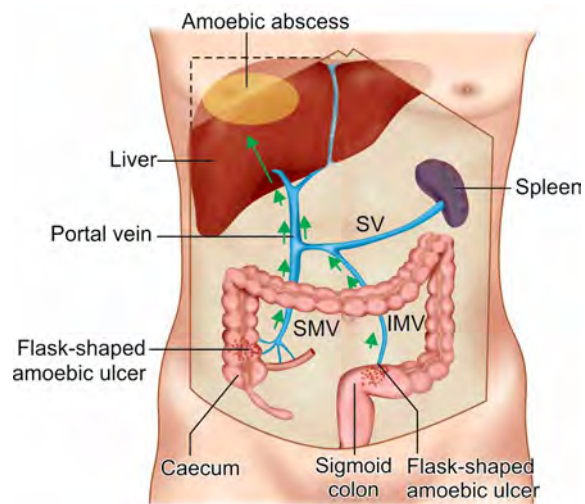


Fig. 11.7: Spread of trophozoites occurs from ileocaecal region and sigmoid through mesenteric vessels.



- ◆ Commonly amoebic abscess presents as an *acute entity*, but it can also be present as *chronic type* where it is covered by a capsule, that remains dormant for a long period.
- ◆ Sometimes it can get calcified also.

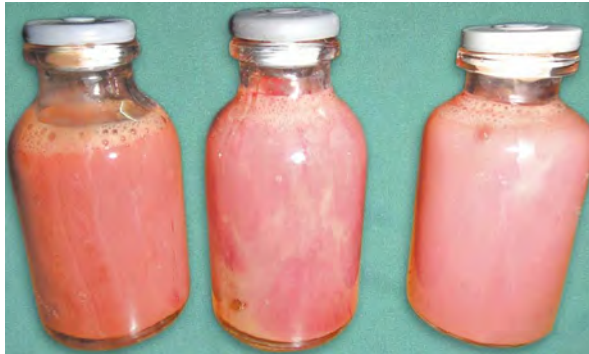

Fig. 11.8: Anchovy sauce pus seen in amoebic liver abscess.

#### Course and sequelae of amoebic liver abscess

- ❖ It can *rupture into lungs* leading to expectoration of chocolate-coloured sputum resulting in natural regression of abscess—commonest site of rupture. It can rupture into the pleura causing empyema; pleuropulmonary rupture complication is 75%.
- ❖ It can rupture into the peritoneum causing *peritonitis* which requires emergency laparotomy—10%.
- ❖ Rupture into bronchus can cause bronchopleural fistula leading into coughing out of Anchovy sauce pus.
- ❖ Rupture into bare-area of liver causing *retroperitoneal abscess*. Rupture into subphrenic space is 15%.
- ❖ Rupture into the intestines, or to the skin (*Amoebiasis cutis*).
- ❖ Most dangerous complication is rupture into pericardial cavity (2%) (*cardiac tamponade*) which has very high mortality (30%) requiring emergency thoracotomy and pericardial decompression. It is typically seen in left lobe abscess.
- ❖ *Septicaemia and liver failure* can occur in a patient with amoebic liver abscess with *cirrhosis*.
- ❖ *Hepatic encephalopathy/failure* can develop in multiple abscesses, abscess in cirrhotic, when there is occlusion of right hepatic vein or portal vein radicles or in pylephlebitis.
- ❖ ALA can cause compression on hepatic veins or IVC causing *Budd-Chiari syndrome*.

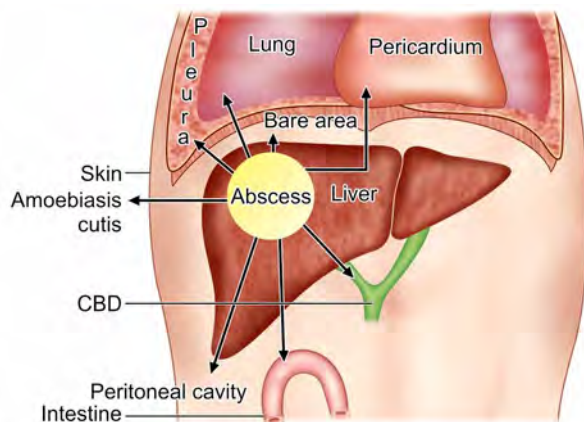


Fig. 11.9: Complications of amoebic liver abscess.

#### Clinical Features

- ◆ It is common in males (10:1), may be after an attack of amoebic dysentery or many months after the attack or history of dysentery may not be there at all.
- ◆ They present with fever, loss of weight, chills and rigors, non-productive cough, shoulder pain.
- ◆ Pain in the right hypochondrium—30%.
- ◆ Soft, tender, smooth, liver with increased liver span—70%.
- ◆ **Intercostal tenderness** is elicited which is a useful clinical sign.
- ◆ Right sided pleural effusion may be evident.
- ◆ Mild jaundice is not uncommon especially in cirrhotics and multiple abscesses which may signify poor prognosis—30%.
- ◆ Tenderness, rigidity and skin oedema in right hypochondrium may be present in acute cases.
- ◆ In chronic amoebic liver abscess, smooth, firm/hard, nontender liver may be palpable.

#### Amoebic liver abscess may be:

- ❖ *Acute*—present with high fever, chills, rigors, tender, soft palpable liver, with intercostal tenderness.
- ❖ *Chronic*—present with firm/hard, smooth, nontender palpable liver without acute features.

#### Features may be of:

- ❖ *Systemic*—present with fever, chills and rigors, loss of appetite, reduced weight, and jaundice.
- ❖ *Abdominal*—present with pain and tenderness, localised guarding and rigidity, mass in right upper abdomen (tender, soft liver), ascites, splenomegaly, abdominal wall oedema.
- ❖ *Thoracic*—present with dry cough, chest pain in right lower part, right shoulder pain, pleural effusion, and intercostal tenderness.
- ❖ *Features of complications*—rupture/infection/septicaemia/liver failure.

#### Differential diagnosis

##### For acute type

- ❖ Acute cholecystitis
- ❖ Acute presentation of hepatocellular carcinoma (HCC) due to haemorrhage or necrosis
- ❖ Subphrenic abscess
- ❖ Pyogenic liver abscess

**Chronic amoebic liver abscess mimics hepatoma in every respect**

#### Investigations

- ◆ Total count may be increased. Low Hb% in 50% cases.
- ◆ Liver function tests may show altered bilirubin and albumin level.
- ◆ Prothrombin time may be widened and if it is so injection vitamin K 10 mg IM or IV for 5 days should be given. Even with this if P.T. remains widened then fresh frozen plasma (FFP) is needed to rectify the P.T.
- ◆ Serum alkaline phosphatase, SGPT, SGOT levels are altered.
- ◆ US abdomen shows altered echogenicity (anechogenic, hypoechoic), size, location, number of abscess, nature of the liver—90% sensitivity.
- ◆ Chest X-ray findings:

- ❖ Raised fixed diaphragm (tenting)
- ❖ Pleural effusion
- ❖ Soft tissue shadow

- ◆ CT scan-contrast study. CT scan shows raised diaphragm; abscess cavity (low density area)—its size, location, number; presence of effusion; changes in the lung—95% sensitivity.

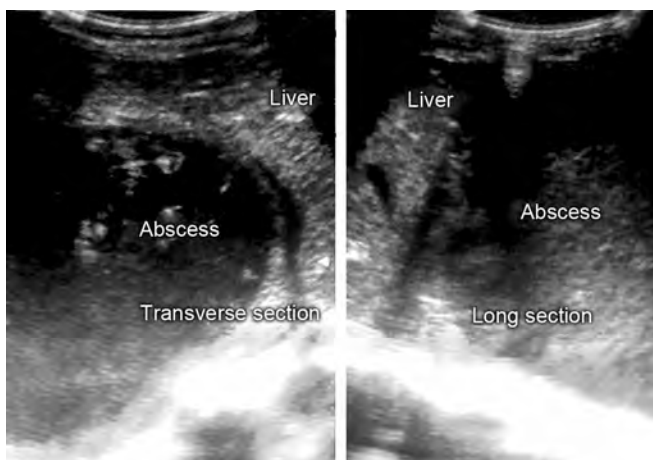
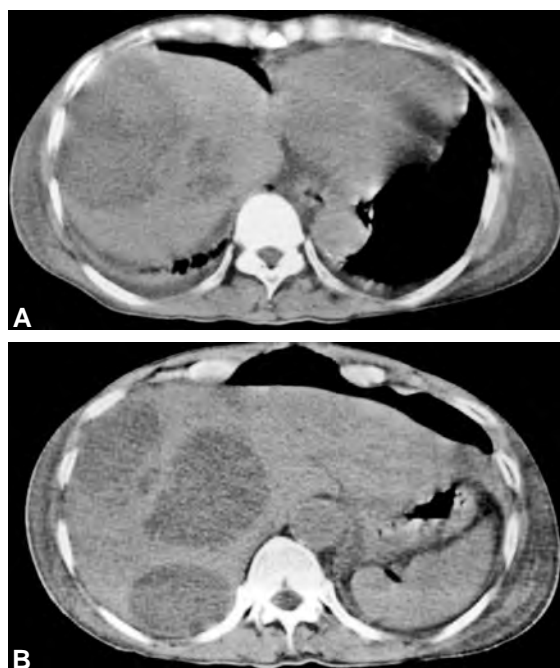

Fig. 11.10: Ultrasound picture of amoebic liver abscess. US guided aspiration is very useful.



Figs 11.11A and B: CT scan pictures showing single, large and multiple liver abscesses.

- ◆ Sigmoidoscopy/colonoscopy are used to identify the active ulcers. Scrapings of the ulcer show trophozoites.
- ◆ *Technetium 99 nuclear image liver scanning* is helpful in differentiating amoebic from pyogenic abscess as amoebic abscess do not contain WBCs. Amoebic abscess shows cold lesion with a hot rim or halo whereas pyogenic abscess is entirely hot.
- ◆ Indirect haemagglutination test [IHA] (95% positive rate), ELISA and gel diffusion precipitative test are reliable serological tests. Serological tests are reliable in non-endemic areas than endemic areas. Counter immunoelectrophoresis is more useful in active disease. *IHA is most sensitive test* but it remains positive for long time after eradication of infection. Detection of serum antibodies

to serum rich *E. histolytica* protein (SREHP) and galactose specific adhesion (170-KD unit), and detection of serum *E. histolytica* Gal. GalNAc lectin are highly specific; but they costly and not available.

## Treatment

### Drugs

- ◆ Tablet metronidazole 800 mg tid or injection metronidazole 500 mg IV tid for 10–14 days (40 mg/kg/day).
- ◆ Tinidazole 600 mg BD dose for 5 days.
- ◆ IV or oral antibiotics are essential to control secondary infection (cefotaxime, ciprofloxacin, amoxicillin) (Small abscesses < 3 cm respond to drugs).
- ◆ *Other drugs:*
  1. Injection dihydroemetine 1.5 mg/kg/day IM for 5 days should be given under cardiac monitoring.
  2. Chloroquine 250 mg BD given for 10–14 days.

### Drugs used for amoebic infection

- ❖ Metronidazole, Tinidazole, Secnidazole, Ornidazole
- ❖ Dihydroemetine injection
- ❖ Chloroquine, tetracycline
- ❖ Diloxanate furoate, iodoquinol, paromomycin—as *cyst eradicators*

### Note:

Metronidazole is not given in 1st trimester of pregnancy.

### Aspiration

- ◆ *Indications:* In case of large abscess (> 10 cm), infected abscess, failure of drug therapy, large left lobe abscess, seronegative abscess, abscess in pregnancy where drug therapy cannot be used.
- ◆ *Ultrasound guided wide bore needle aspiration* is done; last part of the aspirant fluid is sent for trophozoite study; fluid CS should also be done; PT INR should be made normal by using injection vitamin K IV or FFP transfusion (three units).
- ◆ Previously without US, aspiration used to be done by passing needle in right 6th intercostal space in midaxillary line.

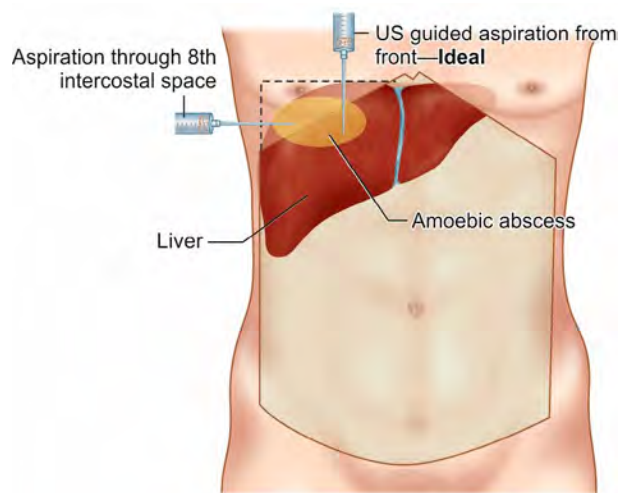
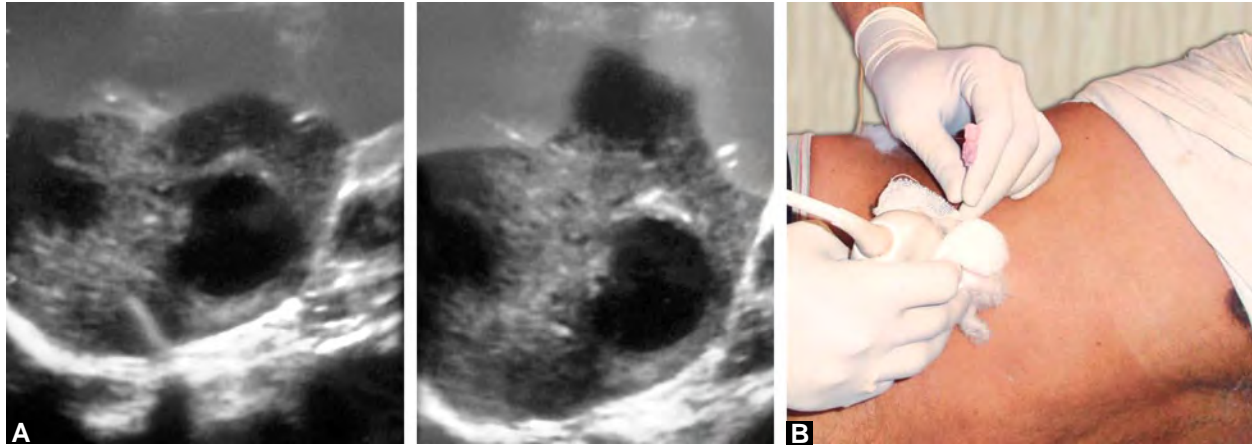


Fig. 11.12: Aspiration of the amoebic liver abscess under US guidance or through right 8th intercostal space in midclavicular line.



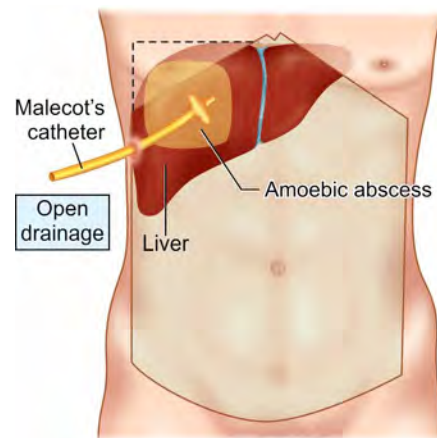
**Figs 11.13A and B:** Amoebic liver abscess US picture. US guided aspiration is being done.

### Percutaneous Drainage

- ◆ Under US guidance pigtail catheter is placed into the abscess cavity percutaneously to drain the pus. It may fail if there is thick pus, multiloculated abscess, and multiple abscesses. Procedure may cause bleeding and infection.

#### Note:

- Aspirated fluid is sent for C/S, cytology and for study of trophozoites (last part of the aspirated fluid should be sent for this).
- 12-French catheter is used for *percutaneous drainage* and should be kept for 7–20 days; removed once drainage is minimal and USG confirms that cavity shows adequate collapse. Percutaneous drainage is the *mainstay* of therapy with antiamebic drugs.
- *Percutaneous drainage* is also successfully advocated in pulmonary/pericardial/peritoneal complications even though open surgical approach is the mainstay of treatment.
- ◆ Presently *open surgical drainage* is used only when percutaneous drainage fails or in presence of complications.



**Fig. 11.14:** Drainage of amoebic liver abscess transperitoneally and placing Malecot's/pigtail catheter into the abscess cavity.

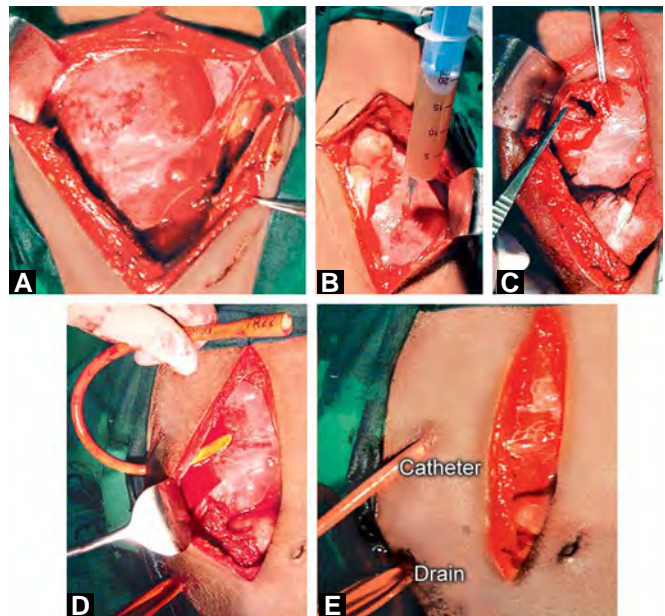
### Surgery

#### Indications for surgery

- ❖ Even after repeated aspirations or percutaneous drainage if abscess cavity fills again
- ❖ Thick pus
- ❖ Multiloculated abscess
- ❖ Left lobe abscess, because of danger of rupture into pericardial cavity
- ❖ Ruptured abscess
- ❖ Caudate lobe abscess
- ❖ Multiple abscesses

#### Procedure

- ◆ Through transperitoneal approach, abscess area is opened, pus is evacuated. Malecot's catheter is placed and brought out through a separate stab incision. The catheter is kept *in situ* until drainage stops completely. Complete drainage of pus will be confirmed by repeat US. During discharge, advice is given to avoid alcohol, Chloroquine 250 mg BD for 10 days and Diloxanide furate 500 mg tid is given for 10–14 days.



**Figs 11.15A to E:** Operative findings of amoebic liver abscess. Note the exposed abscess in the liver, its aspiration and drainage. Placement of Malecot's catheter in the abscess cavity and drain placed into the peritoneal cavity is also seen.

- ◆ *Complications of surgery*—anaesthetic problems; bleeding; liver failure (in cirrhotic patients); intraperitoneal abscess formation; bile leak—bile peritonitis and fistula.
- ◆ Laparoscopic approach is also tried successfully in draining the liver abscess.

### Follow-up

At regular intervals is important. Measures taken are proper counselling to avoid alcohol; repeat LFT; repeat ultrasound to confirm the complete resolution of the abscess cavity.

### Prognosis

- ◆ *Mortality* in amoebic liver abscess is 4%. It rises with rupture especially pericardial (30%).
- ◆ *Poor prognostic factors* are—Rupture, serum bilirubin >3.5 mg%, serum albumin <2.0 g/dl, liver failure, cirrhosis, multiple abscesses, volume of abscess > 500 ml, anaemia, diabetes.

## PYOGENIC LIVER ABSCESS

### Aetiology

1. *Biliary sepsis* 35%; commonest route.
  - a. Empyema gallbladder.
  - b. Cholangitis.
  - c. After biliary tract surgery.
  - d. Instrumentation.
  - e. Stone disease, Caroli's disease, biliary ascariasis, biliary enteric anastomosis.
2. *Portal vein sepsis* 20%.
  - a. Appendicitis 2%.
  - b. Diverticulitis.
  - c. Inflammatory bowel disease, pancreatitis, perforation, PID, colorectal carcinoma.
  - d. Omphalitis in newborn.
3. *Distant infections (through hepatic artery* 15%):
  - a. Pneumonia.
  - b. Upper UTI.
  - c. Endocarditis, osteomyelitis, bacteraemia.
4. *Super added infections* 5%:
  - a. Amoebic liver abscess.
  - b. Hydatid cyst.
5. *Cryptogenic liver abscess* 20%—No identified primary infection.
6. *Trauma* becoming common cause—4–10%
7. *Direct extension*:—5%.
 

From suppurative cholecystitis, subphrenic abscess, perforation, perinephric abscess.

#### Causative bacteria

- ❖ *E. coli*—commonest
- ❖ *Klebsiella*
- ❖ *Proteus*
- ❖ *Pseudomonas*
- ❖ Clostridia
- ❖ Enterococci, streptococci viridians in polymicrobial infection

### Pathology

- ◆ Due to laminar blood flow right lobe (75%) is commonly involved; left lobe (20%), caudate lobe (5%) are also often involved.
- ◆ Usually solitary—60%; occasionally it can be bilobar and multiple.
- ◆ Cavity contains pus with virulent organisms. Usually abscess is acute. In cryptogenic type chronic presentation is known to occur.
- ◆ Ascites and splenomegaly is not common.
- ◆ It is more common in diabetics.
- ◆ Male to female ratio is 1:1. It is more common in old people after 55 years of age.
- ◆ *Blood culture* commonly shows positive for bacteria.

### Clinical Features

- ◆ Pain in the right hypochondrium—60%.
- ◆ High fever, with rigors—90%.
- ◆ Weight loss.
- ◆ Jaundice—occasionally—20%.
- ◆ Intercostal tenderness.
- ◆ Tender, soft liver—60%.
- ◆ Features of toxicity.
- ◆ Constitutional symptoms like malaise, lethargy, vomiting.

### Diagnosis

- ◆ Ultrasound abdomen, CT scan. Sensitivity is 90% for USG; 97% for contrast CT scan.
- ◆ LFT, total count.
- ◆ Ultrasound guided aspiration of pus after controlling PT.
- ◆ Chest X-ray shows elevated diaphragm often with right sided pleural effusion.
- ◆ Blood culture is very relevant.

### Differential Diagnosis

- ◆ Amoebic liver abscess, hydatid cyst, subphrenic abscess.

### Treatment

- ◆ Systemic antibiotics—combination of third generation cephalosporins and metronidazole.
- ◆ *Ultrasound guided aspiration/pigtail catheter—Percutaneous drainage* is the treatment of choice at present. Drainage tube/catheter are placed under US/CT guidance into the liver abscess. Pus should be sent for culture and sensitivity. Follow-up USG, LFT, assessment of quantity of daily drainage—should be done to assess the response. 75% of pyogenic abscess is drained percutaneously. *Percutaneous aspiration* without drainage tube placement is also used; but repeated guided aspirations are required; otherwise success rate is similar to drainage.
- ◆ Occasionally, open drainage is required. *Open drainage* is indicated in recurrent abscess, failure of percutaneous drainage, large abscess of size more than 5 cm. Open drainage is becoming *less common* at present; but in selected patients it may be a life-saving essential therapeutic modality.
- ◆ Treating the primary causes is very essential.

### Complications

- ◆ Septicaemia, liver failure.
- ◆ Rarely rupture and peritonitis can occur.

- ◆ *Klebsiella* hepatic abscess can cause dangerous endogenous endophthalmitis commonly in diabetic patients impairing vision.

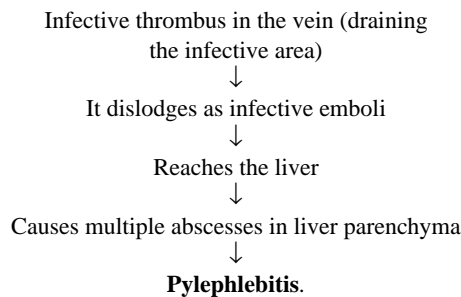
## PORTAL PYAEMIA (PYLEPHLEBITIS)

It usually follows after severe infection of areas drained by portal vein.

### Causes

- ◆ Appendicitis.
- ◆ Diverticulitis.
- ◆ Any severe abdominal sepsis.

Presently it is becoming *rare* because of availability of good effective antibiotics.



*E. coli* is the most common organism. Often staphylococci, anaerobes, or combined infections may be involved.

### Note:

Gas and thrombus in portal vein is diagnostic of portal pyaemia.

### Clinical features

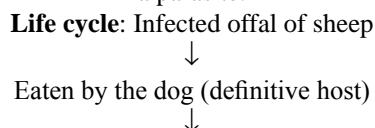
- ❖ High fever with rigors
- ❖ Toxicity
- ❖ Drowsiness, jaundice
- ❖ Tender soft liver
- ❖ Ascites
- ❖ Blood culture is a useful investigation

### Treatment

- ◆ **Antibiotics:** Combination of third generation cephalosporin + aminoglycoside, ceftriaxone sodium, cefoperazone, ceftazidime, amikacin, tobramycin, metronidazole.
- ◆ IV fluids, blood transfusion, FFP.
- ◆ Ventilator support.
- ◆ Mortality is very high and usually patients die of hepatic failure, septicaemia, MODS.
- ◆ It is better to prevent portal pyaemia by prior good antibiotics in suspected cases.
- ◆ Treatment of primary cause is very important.

## HYDATID CYST OF LIVER

Word meaning is 'dew drop' (Latin). In Greek it means 'watery vesicle'. Echinococcus means 'hedge hog berry' in Greek. Caused by *Echinococcus granulosus* (EG), dog tape worm, a parasite.



EG released, develops in the dog's intestine into a parasite of 1 cm long with a head and three segments, last of which contains about 500 ova.

Ova expelled from the dog's intestine to grass and vegetables

Eggs are ingested by sheep, cattle or human beings (*intermediate host*)

Through portal vein—liver—larva form

**Hydatid cysts** (70% in liver).

It takes few years to evolve into a complete hydatid cyst.

Most commonly involved segment is segment VII—27%. Commonly right lobe—66%; both lobes in 16% and only left lobe is involved in 17%.

### Pathology

It has got 3 layers

1. *Adventitia (pseudocyst)* is an inseparable fibrous tissue due to reaction of the liver to the parasite.
2. *Laminated membrane (ectocyst)*, formed of the parasite itself is whitish, elastic, containing hydatid fluid, which can be peeled off readily from the adventitia.

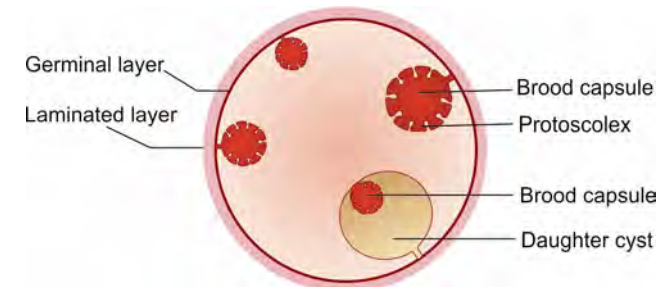
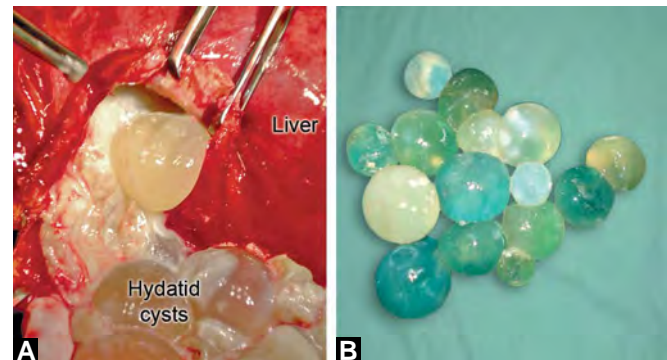


Fig. 11.16: Anatomy of hydatid cyst.

3. *Germinal epithelium* is the only living part, lining the cyst (*endocyst*).

This layer secretes *hydatid fluid*, *brood capsules with scolices* (heads of future worms).



Figs 11.17A and B: Hydatid cyst of the liver—typical look.

### Features of hydatid fluid

- ❖ Clear
- ❖ High specific gravity (1.005–1.009)
- ❖ Shows hooklets and scolices

Once brood capsules disintegrate, it grows into daughter cysts.

#### Note:

- Liver is commonly involved (65%); lungs (25%); muscles (5%); bones (3%); rarely kidneys, brain, spleen.
- Pressure in the cyst is very high 70 mm of H<sub>2</sub>O; so leak and anaphylaxis becomes rapid when punctured.
- Separated laminated membrane fall in the cyst causing “*water lily sign*” which is more often observed in lung hydatid but can be seen in liver also.
- ERCP is done in presence of hydatid debris in CBD, biliary cyst communication lasting more than 3 weeks, presence of jaundice.
- PAIR becoming popular; risk of anaphylaxis should be taken care off.
- Radical surgery is not commonly advocated; but pericystectomy is very effective therapy.
- Liver resection is occasionally required.
- Laparoscopic approach gained acceptance for hydatid cyst of the liver.

### Course of the Disease

- ◆ The parasite may die and cyst eventually may get *calcified*.
- ◆ Commonly cyst *enlarges* and is palpable per abdomen.
- ◆ It may cause complications like *jaundice* due to pressure over biliary tree.
- ◆ *Rupture into the peritoneal cavity* causes anaphylactic reaction which may cause life-threatening shock, requiring proper management with steroids.
- ◆ *Rupture into biliary channels is commonest (60%)*. Rupture into bowel, pleural cavity can occur.
- ◆ *Secondary infection* causing suppuration and septicaemia.
- ◆ *Secondary cysts* in the lung, spleen, mesentery, retroperitoneum and other organs can occur.
- ◆ *Hepatic dysfunction*.
- ◆ *Disseminated abdominal hydatidosis* can occur after silent rupture.

### Clinical Features

- ◆ Asymptomatic palpable liver with *classical thrill (hydatid thrill)* elicited by *three-finger test*.
- ◆ Jaundice and pain.
- ◆ Features of anaphylaxis.
- ◆ Discomfort in right upper quadrant area; dyspepsia; hydatid cachexia in children; weight loss; fatigue; vomiting.
- ◆ Occasionally splenomegaly, pleural effusion, cholangitis, allergic asthma, fever.
- ◆ *Camellotte sign*: Following intrabiliary rupture, gas enters into cyst causing partial collapse of the cyst wall.

### Differential diagnosis

- ❖ Hepatoma
- ❖ Amoebic liver abscess
- ❖ Cystic disease of the liver

### Complications of hydatid

- ❖ Anaphylaxis
- ❖ Rupture
- ❖ Obstructive jaundice— ERCP sphincterotomy may be needed
- ❖ Infection
- ❖ Calcification
- ❖ Liver failure

### Investigations

- ◆ Ultrasound is diagnostic. It reveals rosettes of daughter cysts, double contoured membrane of the cyst due to detachment of the cyst membranes, and calcification of cyst wall. Intraoperative ultrasound (IOUS) is very useful tool.

### Hassen Gharbi's ultrasound based classification of liver hydatid cysts (1981)

- Type 1 – Pure fluid collection
- Type 2 – Fluid collection with split wall
- Type 3 – Fluid collection with septa
- Type 4 – Heterogeneous appearance
- Type 5 – Reflecting thick walls

- ◆ X-ray often shows calcification.
- ◆ CT scan abdomen is more accurate in identifying cyst characteristics—*cart wheel* like—multivesicular rosette like.

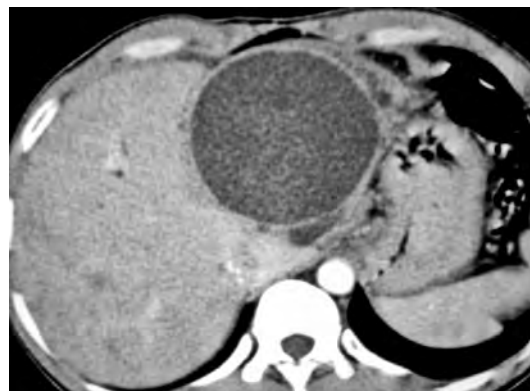


Fig. 11.18: CT scan of hydatid disease of the liver.

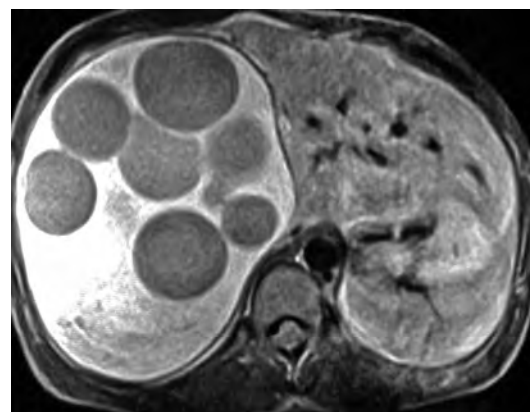


Fig. 11.19: MRI picture of multiple hydatid cyst of liver—MRI is very useful investigation in hydatid cyst of liver.

- ◆ **Primary serological tests**—ELISA; indirect haemagglutination test; latex agglutination test; immunofluorescence antibody test; immunoelectrophoresis. 80–95% sensitivity for liver hydatid.
- ◆ **Secondary laboratory tests**—Detection of precipitation line—arc 5 in immunoelectrophoresis is *most specific and virtually diagnostic* of hydatid disease; immunoblotting; polymerase chain reaction (PCR). More specific, very useful in extrahepatic hydatid disease and calcified non-fertile liver hydatid.
- ◆ Liver function tests—altered in 20% cases.
- ◆ Casoni's test (intradermal test—75% sensitive); complement fixation test—historical interest.
- ◆ MRI when there is jaundice to visualise biliary tree and its relation to hydatid cyst; to find out cystobiliary communication; biliary hydatids in bile duct and hepatic ducts. ERCP can also be done to find out the communications. Other method to find out the cystobiliary communications is intraoperative cholangiogram.
- ◆ ERCP to find out biliary communications but not as useful as MRI. *MRI is superior to CT also.*

*Aspiration of the cyst should not be done due to risk of anaphylaxis but presently PAIR (Puncture-Aspiration-Injection-Reaspiration) is done effectively.*

#### WHO classification of liver hydatid cyst

- Type – CL – Active; unilocular; no cyst wall; early stage; not fertile
- Type – CE 1 – Active; cyst wall present; hydatid sand present; fertile
- Type – CE 2 – Active; multivesicular rosette like cyst wall; fertile
- Type – CE 3 – Transitional; detaching laminated membrane; *water-lily* sign; beginning of degeneration
- Type – CE 4 – Inactive; degenerative contents; no daughter cysts; not fertile
- Type – CE 5 – Inactive; thick calcified wall; not fertile

## Treatment

### Drugs

#### Indications for drug therapy

- ❖ 10 days prior to intervention and to continue it for 1 month (albendazole) to 3 months (mebendazole) after the intervention
- ❖ Inoperable cysts
- ❖ Multiple or multiorgan cysts
- ❖ Recurrent hydatids
- ❖ Surgically unfit patients
- ❖ Cysts in lungs

#### Contraindications

- ❖ Large cysts
- ❖ Honeycomb cysts (with septae)
- ❖ Infected cysts
- ❖ Calcified cysts
- ❖ Pregnancy.

- ◆ **Drugs used are:**
  - ▶ Albendazole 4-week cycles with 2 weeks drug free interval. It is ovicidal/larvicidal/vermicidal. Commonly used. 3 such cycles are used; dose is 400 mg twice daily/10 mg/kg/day.

Albendazole may alter LFT, cause fever, alopecia, leucopenia; it is contraindicated in pregnancy. *Drug therapy is less effective in hydatids of bone, brain and eye.*

- ▶ Praziquantel—60 mg/kg along with albendazole for 2 weeks.
- ▶ Mebendazole—600 mg daily for 4 weeks.

## PAIR – (Puncture – Aspiration – Injection – Reaspiration) – Percutaneously Done [1980]

### Technique of PAIR

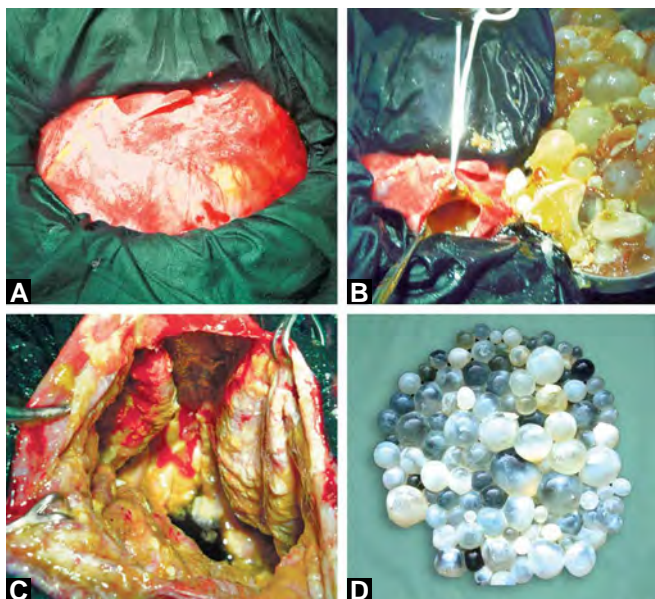
- ◆ Done under US/CT guidance.
- ◆ Under local anaesthesia cyst is punctured using a cholangiography 22 gauge needle through thickest route/part of cyst wall.
- ◆ Cyst is entered through non-dependent wall and 50% of fluid is aspirated. All multiple/daughter cysts are aspirated. Radiopaque dye is injected to see if any communications are present. Scolicidal agents—15–20% hypertonic saline is injected into the cyst. After 20 minutes reaspiration is done. A sclerosant—alcohol is injected. If cyst is 6 cm or more, a drainage catheter is placed for 24 hours for complete drainage and later alcohol sclerosant is injected.
- ◆ Double—puncture aspiration and injection (D-PAI) or modified PAIR/PEVAC (Percutaneous EV Acuation of Cyst) are other procedures done.
- ◆ PAIR has gained wide acceptance as it is safe, less invasive, and easier to do, with low morbidity and mortality. Complications and results are same as open surgery.

Indications for PAIR	Results and problems of PAIR
• Inoperable patients	• Complication rate—10–40%
• Patients who refuse surgery	• Mortality rate—0.9–2.5%
• CL, CE 1, CE 2 and CE 3 types/Gharbi type 1 and 2	• Fever—35%—disappears in 72 hours
• Relapse cysts	• Anaphylaxis—0.1–0.2%— Same as open surgery—but drugs should be kept ready for anaphylaxis
• Infected cysts	• Infection—10% well controlled by antibiotics
• In pregnant women; children less than 3 years	
• Cysts more than 5 cm in different liver segments	• Local recurrences—4% Repeat PAIR can be done
<b>Contraindications for PAIR</b>	
• Inaccessible cysts	
• Cysts with multiple septae—honeycomb cysts	
• Hyperechogenic cysts	
• Communicating cysts to bile duct	
• Calcified cysts	
• Cysts in the lung	

## Surgery

- ◆ Surgery is still the choice and *gold standard* therapy for hydatid disease. The abdomen is opened, and the peritoneal cavity is packed with mops [black or coloured mops are used to identify white scolices clearly so as to pick up all and prevent any spillage]. Fluid

from the cyst is aspirated and scolical agents [cetrimide, chlorhexidine, alcohol, hypertonic saline (15–20%), 10% povidone iodine or H<sub>2</sub>O<sub>2</sub>] are injected into the cyst cavity (formalin should not be used). Hypertonic saline should be left within the cavity for 15–20 minutes to have effective scolical effect.



**Figs 11.20A to D:** On table finding of hydatid cyst of liver. Black mops are used to identify and isolate scolices. Note the cavity containing bile suggestive of biliary communication.

- ◆ Detection of *cystobiliary communications* is very crucial as it may cause caustic sclerosing cholangitis when scolical agent like formalin is used. Communicating openings may be single or multiple. Cyst more than 10 cm is likely to have cystobiliary communications. Often clinical features of communications may not be present. Preoperatively there may be recurrent cholangitis; dilated bile duct. Factors important are—its size; number; site; involvement of hepatic/bile ducts; liver dysfunction. Finding of bile stained cyst on table during aspiration is highly suggestive of communication. White mops soaked with hypertonic saline are kept in the cyst cavity and gallbladder is gently squeezed to see for the bile staining of the mop in the cavity which confirms communication.
- ◆ *Laparoscopic pericystectomy* is becoming more popular. Contraindications are deeply situated cyst, densely adherent cyst, and inaccessible cysts; more than 3 cysts; calcified cysts and cysts in other organs. Main problem with laparoscopic pericystectomy is spillage and difficulty in preventing it.
- ◆ Liver resection—only occasionally segmental or hemihepatectomy is done.

#### Scolical agents

- ❖ Cetrimide—can cause acidosis
  - ❖ Alcohol 80%—can cause cholangitis
  - ❖ Hypertonic saline—hypernatraemia
  - ❖ Sodium hypochlorite—hypernatraemia
  - ❖ Hydrogen peroxide
- In cases with biliary communication only hypertonic saline (15–20%) is used (not other agents)

*Procedures used to correct the cystobiliary communications and to obliterate the cavity are:*

- ◆ Suturing of the communication—simple suture using vicryl/PDS suture with T tube drain of bile duct.
- ◆ Pericystectomy (*Pericystectomy* is done by peeling off the cyst wall and abdomen is closed with or without a drain); marsupialization.
- ◆ Tube drainage of the cavity; *capitonnage*—spiral suturing of the bottom of the cavity upward from base of cavity to the edge of the cyst wall; *introflection*—inverting the rim of the cyst edge without apposition; *omentoplasty*.
- ◆ Internal drainage procedures like choledochojejunostomy; transduodenal sphincteroplasty; Roux-en Y cysto/intracystic hepaticojejunostomy; Roux-en-Y hepatico-jejunostomy.
- ◆ In cystobiliary communication (fistula), cystobiliary disconnection is achieved anatomically between cyst and fistula and a multiperforated transparenchymal drain is placed into the fistula through the cyst and another multiperforated drain is placed into the cyst cavity. A ‘T’ tube drain is placed into the bile duct (*perdomo procedure*) to achieve complete external drainage with facilitation of closure of the communication.
- ◆ Bipolar drainage—a drain is placed to cyst cavity and a T tube is placed into common bile duct.
- ◆ Reconstructive procedure like *pericysto-jejunostomy*; bile duct repair.
- ◆ ERCP sphincterotomy.

#### Malignant hydatid disease

- ❖ It is a misnomer as it is a benign condition
- ❖ It is caused by *Echinococcus multilocularis (Alveolaris)*. It presents with multiple small cysts in both lobes of the liver, all over
- ❖ It is difficult to treat, and mimics clinically and prognosis-wise to malignancy, hence the name
- ❖ They die of liver failure

### ACTINOMYCOSIS OF LIVER

- ◆ *Actinomyces israelii* reaches the liver—via portal vein from caecum (60%) or via hepatic artery from distant focus—from faciocervical region—30%.
- ◆ Disease progresses gradually and slowly to destroy the liver tissue causing multiple actinomycotic abscesses which produce a typical ‘*honeycomb liver*.’
- ◆ *Complications*
  - ▶ Secondary infection.
  - ▶ Liver failure.
- ◆ *Investigations*
  - ▶ Liver function tests.
  - ▶ Ultrasound guided aspiration and staining of pus shows ‘*sun-rays*’ appearance.
- ◆ *Treatment:* Penicillins for 3–6 months.

### LIVER TUMOURS

#### BENIGN TUMOURS OF THE LIVER

##### Benign tumours of the liver

- ❖ It is two times common than malignant liver tumour
- ❖ It is seen in 20% of population
- ❖ Haemangioma is the most common benign tumour
- ❖ CT and MRI are the essential investigations

*Contd...*

*Venous hum, which is heard louder on inspiration in epigastrium, in portal hypertension is called as Kenawy's sign*

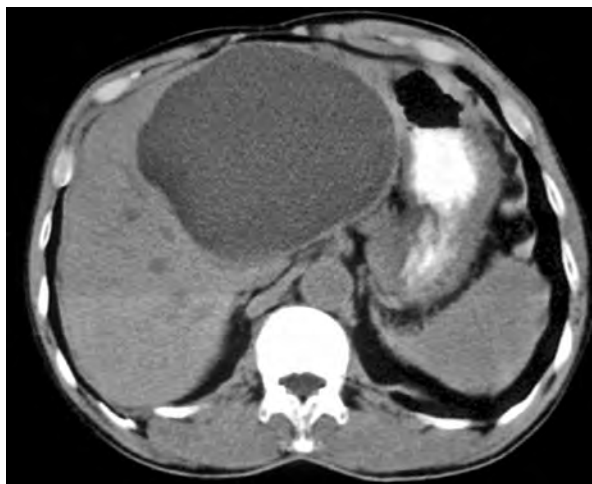

Contd...

- ❖ MRI shows 95% accuracy
- ❖ Diagnostic accuracy of liver biopsy is low—40%
- ❖ Hepatic adenoma is potentially malignant
- ❖ FNH and haemangiomas are not premalignant
- ❖ Primary (HCC) tumour or secondaries are differential diagnosis; AFP and CEA are helpful to differentiate

### 1. Haemangiomas

- ◆ They are the *commonest benign* tumour of the liver.
- ◆ It is usually solitary but can be multicentric.
- ◆ *Compressibility of tumour is diagnostic.*
- ◆ It is common in females (3:1) in 5th decade.
- ◆ Commonly they are asymptomatic (85%).
- ◆ They can occur in right and left lobes.
- ◆ *Calcification* is seen in 10% cases.



**Fig. 11.21:** Solitary benign cyst of the liver. It is a rare entity. Polycystic liver also can occur. Polycystic liver is associated with polycystic kidney disease. Condition is a rare differential diagnosis for hydatid cyst, hepatoma, and solitary secondary.

- ◆ It is congenital in origin and enlarges by ectasia.
- ◆ Involution of a large haemangioma can occur forming a dense fibrosis which mimics metastasis.
- ◆ It may compress over gastroduodenum to cause abdominal pain and vomiting. Acute thrombosis with sudden onset of pain and fever may mimic liver abscess; but symptoms subside gradually in 3–4 weeks.
- ◆ Spontaneous rupture is very rare.
- ◆ *Differential diagnoses* – HCC, vascular solitary secondaries, hepatic adenoma, liver abscess.
- ◆ In children it is 10–15% of liver tumours. They are multifocal, often involves other organs also. Large one can cause AV shunting leading to CCF. Large childhood hepatic haemangiomas have got 70% mortality due to rupture, DIC, thrombocytopenia. It is confirmed by MRI. It is treated by embolisation, radiotherapy and often resection.
- ◆ Cavernous haemangioma, consumption coagulopathy, thrombocytopenia is called as *Kasabach-Merritt syndrome*.

- ◆ LFT, AFP and CEA are normal.

### Complications

- ❖ Bleeding rupture
- ❖ Thrombosis
- ❖ DIC
- ❖ Infection

- ◆ Complication usually occurs if haemangioma is *more than 8 cm* in size.
- ◆ ***Needle aspiration and biopsy are contraindicated.***
- ◆ US and CT scan are confirmative.
- ◆ Angiogram may be needed if surgical intervention is planned.
- ◆ MRI is 100% sensitive and shows 97% accuracy.
- ◆ Giant haemangioma is of size > 5 cm.

*Treatment:*

- ◆ Prior radiotherapy is given to reduce the size and then hemihepatectomy is done.
- ◆ Surgery is done when size is large, symptomatic, impending rupture or any other complications. Enucleation or anatomical resection with inflow control is needed.

**Note:**

It has got very little or no malignant potential.

### 2. Hepatic adenomas

- ◆ They are common in females (10:1). They present as a solitary nodular lesions in the liver.
- ◆ It is said to be due to use of oral contraceptive pills (OCPs).
- ◆ It is uncommon in males, but can occur with androgen use.
- ◆ It is relatively rare compared to FNH and haemangioma.
- ◆ It is commonly solitary; but 20% of cases can be multiple; situation where > 10 adenomas are present is termed as *adenomatosis*. Multiple adenomas are not related to OCP intake and not more common in females. Multiple type may occur in glycogen storage disease type I.
- ◆ Upper abdominal pain (65%) is the commonest presentation.
- ◆ AFP is normal but rises if there is malignant transformation.
- ◆ They might turn into malignancy, hence resection is advised.
- ◆ US, CT scan are diagnostic but angiography is needed prior to resection, as it is vascular.
- ◆ MRI is ideal tool.
- ◆ Haemorrhage is more common.
- ◆ Hepatic adenoma cells are larger, contain glycogen and lipids. They are devoid of bile ducts whereas FNH contains bile duct components.
- ◆ Surgical resection is the needed treatment. Limited resection is needed. It is better to do resection prior to pregnancy. In adenomatosis either hemihepatectomy or transplantation may be required.
- ◆ OCP should be stopped.

### Indications for surgical resection

- ❖ Rupture of adenomas—50%
- ❖ If there is possibility of turning into malignancy (large adenomas)

**Note:**

Kupffer cells are not present in hepatic adenomas.

### 3. Focal nodular hyperplasia (FNH)

- ◆ It is a benign condition of unknown aetiology, seen in females showing focal overgrowth of functioning liver tissue with fibrous stroma support.

- ◆ It is hyperplasia of liver containing all components of liver in disorganized pattern.
- ◆ It is 8 times more common in females.
- ◆ It contains hepatic cells as well as Kupffer cells which is characteristic.
- ◆ It is 2nd most common benign tumour.
- ◆ Usually it presents as solitary nodule.
- ◆ A sulphur colloid liver scan is diagnostic, shows 'hot spot' with a spoke wheel pattern—85%.
- ◆ It is a harmless condition.
- ◆ CT scan shows central scar with stellate distribution of the blood vessels, Kupffer cell activity, without calcifications with homogeneous mass lesion in arterial phase enhancement.
- ◆ Telangiectatic FNH and hyperplastic with adenomatous FNH are non-classic forms of FNH, which are 20% common and more common in men.
- ◆ It is totally benign tumour; but often difficult to differentiate from *fibrolamellar type of HCC*. AFP is normal.
- ◆ It also should be differentiated from HCC, hepatic adenoma, nodular regenerative hyperplasia of liver (NRH).
- ◆ Vague pain abdomen may be the presentation.
- ◆ Rupture, bleeding are very rare.
- ◆ Histologically it can be typical (*with central scar*) or atypical (*without central scar*)—15%.
- ◆ Usually it does not require any treatment. OCP should be stopped.

**Note:**

*Von Meyenburg's complexes* are benign liver malformations that originate from embryonic bile ducts that fail to involute with cystic dilatation. It mimics metastatic liver disease. MRI is essential to diagnose.

### PRIMARY MALIGNANT TUMOURS OF THE LIVER

1. Hepatocellular carcinoma/Hepatoma/HCC (80%).
2. Cholangiocarcinoma (20%).
3. Hepatoblastoma in infants and children.

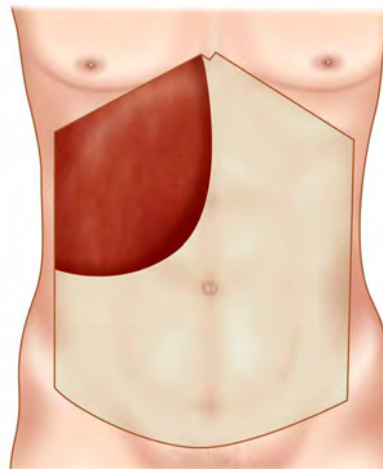
*Hepatoblastoma* occurs within 2 years of life. It is most common primary malignant tumour of liver in children. It is common in male child. It is derived from fetal or embryonic hepatocytes. Serum AFP is *elevated* in 90% of cases. CT scan shows vascular mass with speckled calcification. It is highly sensitive to chemotherapy (vincristine, doxorubicin, 5FU). If it is resectable, it is the initial choice of therapy. Liver transplantation is also beneficial.

### HEPATOCELLULAR CARCINOMA (HCC/HEPATOMA)

- ◆ HCC is a primary malignant tumour of the liver with hepatocellular differentiation.
- ◆ Its incidence is increasing; becoming 4th most common malignancy worldwide. HCC is the commonest primary liver malignancy (90%). But in the liver, secondaries is the most common malignancy (20 times more common than primary).
- ◆ It is common in cirrhotics and hepatitis B and hepatitis C virus infection.
- ◆ It is common in Japan, Mozambique, South East Asia,

tropical Africa, Taiwan. In Mozambique it is often seen in younger age group—below 30 years.

- ◆ Male to female ratio is 4:1.
- ◆ It is usually unicentric but occasionally can be multicentric.
- ◆ Right lobe is commonly involved.



**Fig. 11.22:** Hepatocellular carcinoma (HCC/hepatoma) is usually solitary, common in right lobe, attains large size.

### Aetiology

- ◆ Aflatoxin B<sub>1</sub>, a product of fungus *aspergillus*. It is powerful carcinogen.
- ◆ Hepatitis B and hepatitis C virus infection. It is more common in individuals who have chronic positive status for HBs Ag and chronic carriers. Vertical transmission of virus at birth raises HCC rate. In Europe, Japan, USA, HCV infection is more common cause. It is not necessary to develop cirrhosis to cause HCC. It is the infection which is the cause.
- ◆ Alcoholic cirrhosis. It is co-carcinogen.
- ◆ *Clonorchis sinensis* infestation.
- ◆ Smoking.
- ◆ Haemochromatosis,  $\alpha 1$  antitrypsin deficiency.
- ◆ Hepatic adenoma—potentially malignant.
- ◆ Environment related chemicals like DDT, nitrite and nitrate-related food products; trichloroethylene (dry cleaning solvents), biphenyls, carbon tetrachloride, herbicides, solvents like dioxane.
- ◆ Tannins, griseofulvin, bush tea (pyrrolizidine), rice toxins.
- ◆ Anabolic steroids, polyvinyl chloride.

### Pathology

#### Gross

It is highly vascular with indistinct margin. Often it is well demarcated by fibrous tissue. Haemorrhage and necrosis are common.

- ◆ *Hanging type of tumour*—tumour attached to normal liver by a small vascular stalk—always very well resectable.

- ◆ *Pushing type of tumour*—large, well demarcated, displaces normal vasculature—resectable.
- ◆ *Infiltrative type of tumour*—indistinct, infiltrative—often difficult to resect.

#### Other macroscopic classifications of HCC

- ❖ Unifocal
  - Expanding with sharp demarcation – portal vein invasion is high
  - Pedunculated – type 1 is intrahepatic; type 2 is extrahepatic
  - Spreading type – without a clear demarcation (Engel's type)
- ❖ *Multifocal* – synchronous
- ❖ *Indeterminate* – different features in different parts of the liver
- ❖ *Diffuse*

#### Okuda classification – (Okuda staging is different)

- ❖ Multifocal
- ❖ Indeterminate
- ❖ Spreading
- ❖ Expanding

#### NCCN classification

- ❖ Nodular
- ❖ Massive
- ❖ Diffuse

#### Note:

- Small HCC nodule is less than 2 cm in size.
- PV extension as tumour thrombosis indicates inoperability and cause portal hypertension.
- Infiltration into hepatic veins is not common but when it occurs, tumour thrombus extends rapidly into IVC and right atrium.
- Invasion into biliary system causes haemobilia and obstructive jaundice.
- Lymphatic spread occurs to hilar nodes, celiac nodes, pericardial nodes, paracaval nodes.
- Local infiltration into diaphragm and adjacent organs can occur.
- Blood spread occurs to lungs, bones, meninges, kidney and adrenals.
- Dysplastic nodules and hepatic adenomas are premalignant conditions.
- Histologically it can be well/moderate or poorly differentiated tumour.
- **Variants of HCC are** – *fibrolamellar* (good prognosis); mixed hepatocellular cholangiocellular (poor); clear cell variant (better); giant cell variant; (bad) *sarcomatoid variant* (carcinosarcoma).

### Fibrolamellar Variant of HCC (FL HCC)

- ◆ FL HCC occurs in *younger* age group.
- ◆ Incidence is *equal* in both sexes—5% common.
- ◆ It does not show any elevated levels of serum AFP.
- ◆ *Tumour marker for FL HCC type is increase in serum vitamin B<sub>12</sub> binding protein and increase in neurotensin levels.*
- ◆ It is not related to viral hepatitis or cirrhosis.
- ◆ Left lobe is commonly involved.
- ◆ It involves lymph nodes more commonly than HCC.
- ◆ CT scan shows characteristic central scarring.
- ◆ Fibrous stromas with thin hyaline bands are typical. Sheets of well-differentiated hepatocytes are seen which are sandwiched between collagen and fibroblasts.
- ◆ It is fairly resectable (50–75%) with better prognosis than HCC.

#### Okuda staging system (1984) for HCC

Parameter		Points	Stage
Tumour size	<50 %	0	Stage one—0 points
	>50 %	1	Stage two—1–2 points
Ascites	Absent	0	Stage three—3–4 points
	Present	1	
Serum	<3 mg %	0	
Albumin	>3 mg %	1	
Serum	<3 mg %	0	
Bilirubin	>3 mg %	1	

#### Staging of HCC (AJCC)

T<sub>0</sub> – No tumour

T<sub>1</sub> – Solitary tumour without vascular invasion

T<sub>2</sub> – Solitary tumour with vascular invasion/multiple tumours equal or less than 5 cm

T<sub>3</sub> – Multiple tumours, more than 5 cm (T3a)/tumour invading major branch of portal or hepatic veins (T3b)

T<sub>4</sub> – Tumour with direct invasion of adjacent organs other than gallbladder or to visceral peritoneum

N<sub>0</sub> – No regional nodes are involved

N<sub>1</sub> – Regional nodes are involved

M<sub>0</sub> – No distant spread

M<sub>1</sub> – Distant spread is present

#### Cancer of liver Italian group scoring (CLIP scoring)

Parameters	Values	Scores
Child Pugh's stage	A	0
	B	1
	C	2
Tumour morphology—Gross	Uninodular less than 50% of extension	0
	Multinodular less than 50% of extension	1
	Massive—extension more than 50% of liver	2
AFP ng/dl	Less than 400	0
	More than 400	1
Portal vein thrombosis	No	0
	Yes	1
Total scores 0–6		
Early disease with potential long-term survival 0–3		
Advanced stage 4–6		

*Chinese university prognostic index (CUPI) scoring system* uses TNM staging, symptoms, ascites, bilirubin, alkaline phosphatase, AFP. It is used mainly for HBV induced HCC.

### Clinical Features

- ◆ Painless mass in right hypochondriac region with loss of appetite and weight. Liver is hard, smooth/irregular and often massively enlarged. Cirrhotic liver may be nodular.
- ◆ Acute presentation is not uncommon, when the tumour undergoes necrosis and haemorrhage. Both types of presentations mimic amoebic liver abscess (Haemoperitoneum is also known).

- ◆ Jaundice when present is commonly due to hepatic dysfunction, but occasionally due to compression of bile ducts.
- ◆ Ascites (40%) often it is massive, splenomegaly and features of portal hypertension may be present.
- ◆ Hepatic thrill and bruit—25%.
- ◆ Fever (10–20%) may be present due to tumour necrosis.
- ◆ Dull aching pain in right upper quadrant is common.
- ◆ Features of chronic liver disease—jaundice, dilated veins, palmar erythema, gynaecomastia, testicular atrophy, etc.
- ◆ Liver failure sets in once tumour replaces the functioning liver parenchyma or portal vein gets occluded by tumour thrombus.
- ◆ Gastrointestinal bleeding may be the presentation in 10% of cases due to portal hypertension or portal vein invasion by tumour.
- ◆ Occasionally may present with paraneoplastic syndromes. 1%; hypercalcaemia, hypoglycaemia, hyperlipidaemia, hyperthyroidism, erythrocytosis, sexual changes like gynaecomastia, precocious puberty, testicular atrophy and porphyria cutanea tarda.

### Presentations

**Asymptomatic** – incidentally identified

**Symptomatic** – abdominal pain (capsule stretching, tumour necrosis), weight and appetite loss, jaundice, mass abdomen

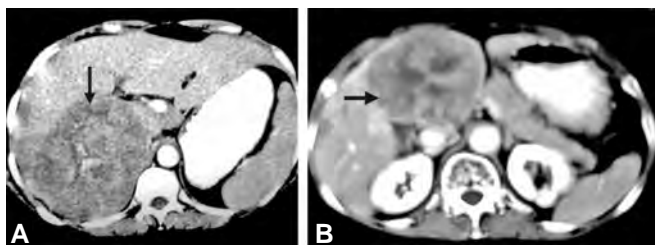
**Symptoms due to complications** – Bleeding HCC can cause life threatening spontaneous *haemoperitoneum* after an attempt of biopsy; *jaundice* (in 10% of HCC) due to obstruction by tumour of main intrahepatic ducts or CHD at porta hepatis or by tumour infiltration of biliary system or by haemobilia or due to underlying cirrhosis; oesophageal varices causing haematemesis with portal hypertension

**Symptomatic due to metastasis** – from pulmonary metastases, bone metastases (10%)

**Paraneoplastic syndrome** (1%)

### Spread of Tumour

- ◆ **Lymphatic spread:** It can spread to other part of liver through lymphatics within the liver, to the lymph nodes in the porta hepatis and other abdominal lymph nodes later. Often spread occurs directly to cisterna chyli.
- ◆ **Blood spread:** To lungs, bones and adrenals often can occur.
- ◆ **Direct infiltration:** To diaphragm and neighbouring structures.



**Figs 11.23A and B:** CT pictures of hepatoma. In right lobe and left lobe.

### Differential diagnoses for HCC

- ❖ Secondaries in liver
- ❖ Liver abscess – amoebic
- ❖ Polycystic liver disease, hydatid cyst
- ❖ Benign tumours of liver
- ❖ Cholangiocarcinoma
- ❖ Hepatosteatoses

### Investigations

- ◆ **Ultrasound abdomen**—very useful method. It shows hyperechoic mass; mosaic pattern with thin halo and lateral shadows. Extent, tumour thrombi extension can be made out.
- ◆ **CT scan abdomen (CECT)** more reliable and ideal (hypodense, mosaic, vascular lesion with irregular margin).
  - ▶ reveals the size, location and extent, vascularity, portal vein invasion, nodal status, portal vein thrombosis.
  - ▶ helps to assess operability.
- ◆ **Tumour markers**— $\alpha$  fetoprotein (AFP). AFP will be raised more than 100 IU; as high as 1000 IU is possible in HCC. PIVKA II is des  $\gamma$  carboxy prothrombin protein induced by vitamin K abnormality/antagonists 2. It is increased in 80% of HCC patients. AFP is usually more than 400 IU in 70% of HCC patients. AFP-L3 (serum lens culinaris agglutinin reactive fraction of AFP, DCP (des  $\gamma$  carboxy prothrombin) and *glypican-3* are other tumour markers used. AFP begins to rise once vascular invasion by the tumour starts, hence it becomes insensitive in detecting early tumour.
- ◆ **Celiac angiography/CT angiography**—it shows the vascularity of the tumour, tumour blush, arterial pattern of the liver and tumour; venous phase can show portal vein invasion or thrombosis and invasion/spread to IVC. Angiogram is essential while planning for hepatic resection.
- ◆ **Liver function tests** like serum bilirubin, albumin, enzymes (alkaline phosphatase, transaminase, 5' nucleotidase) including prothrombin time.

### Note:

- Preoperative liver biopsy is *not recommended* now. Biopsy is relatively contraindicated in any candidate for resection, as there is a significant risk of haemorrhage and peritoneal implantation of tumour cells. In case of potentially resectable tumour one should proceed to surgical exploration without tumour biopsy. Biopsy is done only in inoperable advanced cases wherein palliative therapies are undertaken to establish the diagnosis as in a typical images with normal AFP.
- Liver biopsy is done after controlling prothrombin time if it is elevated (by Inj vitamin K IM or IV 10 mg for 5 days; FFP transfusion). US/CT guided core liver biopsy is useful in non-surgical therapies and mandatory before clinical trials. It is better than FNAC as it reveals tissue architecture. Problems with the core liver biopsy are spillage of tumour and bleeding (due to hypervascularity, associated thrombocytopenia and reduced liver dependent clotting factors like prothrombin). Such problems may be minimal in FNAC. Patients with high suspicious of HCC by clinical and imaging methods and who are appropriate for surgery may be taken up for surgery without a preoperative biopsy. In case of portal vein infiltration by tumour a portal vein biopsy may be done to exclude the patient for surgery or transplantation.
- ◆ Contrast MRI/CT scan 1–2 weeks following intrahepatic infusion of lipiodol (ethiodized oil emulsion 5–15 ml) with contrast agent through hepatic artery is very useful. Such *Lipiodol enhanced*

*Adversity is better teacher than prosperity—James Thurber.*  
*If aim is ended most be ended in this life—Rabindranath Tagore*

CT/MRI even though is ideal and gold standard, but not practiced commonly; during selective angiogram lipiodol is injected into the hepatic artery which is taken up by the tumour, follow-up CT can be done to assess tumour in 2–4 weeks.

- ◆ MRI—T<sub>2</sub> weighted studies are useful for small HCC. MR angiography is also done to see tumour thrombus in portal vein, hepatic vein and IVC.
- ◆ Ascitic tap when ascites is present for cytology.
- ◆ Laparoscopic evaluation and laparoscopic US is useful for proper assessment of the tumour.
- ◆ Investigations in relation to hepatitis B and hepatitis C virus infections.
- ◆ Metastatic work up—HRCT of chest is essential.
- ◆ FDG – PET scan and bone scans are useful in detecting the early metastatic diseases.
- ◆ Surveillance screening for high-risk group like cirrhosis is done using USG once in 6 months and AFP.

## Treatment

### Definitive Treatment

- ◆ When limited to one lobe, *hemihepatectomy* is done (Removal of 70% liver is compatible with life). Laparoscopic resection is becoming popular. It is done only to Child's grade A and favourable Child's B group patients. It is the treatment of choice for operable HCC in non-cirrhotic patients. There is no regenerative capacity in cirrhotic patients with poor coagulation status, portal hypertension, varices, and ascites.
- ◆ In cirrhotic patients with HCC, *total hepatectomy* with *orthotopic liver transplantation* is required. Now it is found that even resection candidates will do better by transplantation than resection. But waiting period for transplantation is long. To bridge this waiting period for transplantation radiofrequency ablation, transarterial embolisation, ethanol/acetic acid injections are used.

#### Indications for transplantation in HCC

- ❖ Patient who is not a candidate for resection
- ❖ Tumour less or equal to 5 cm
- ❖ Tumour less than 3 in number
- ❖ Tumour without portal/hepatic vein invasion
- ❖ Tumour without extra hepatic spread

#### Note:

- 30% of liver tissue or at least two segments should be retained in liver resection when underlying liver is normal; hepatic reserve is assessed by indocyanine green clearance test and CT or MR volumetry.
- MELD (Model for End Stage Liver Disease) score is used for resectability using creatinine, bilirubin, PT- INR.
- *Milan's criteria* are tumour less than 5 cm or number less than 3 with each less than 3 cm.
- *University of California Sanfrancisco criteria* – single tumour < 5cm; < 3 tumours but total diameter less than 8 cm and largest one should be less than 4.5 cm.
- Involvement of extrahepatic tissues or nodes or portal vein tumour thrombus formation, distant spread are contraindications for liver resection.
- Liver mass which is confirmed by CT/MRI and serum AFP is >500 ng/dl is almost diagnostic and resection treatment can be started without tissue diagnosis.

### Adjuvant Therapy

- ◆ Systemic chemotherapy using intravenous adriamycin (doxorubicin), cisplatin, carboplatin, mitomycin C, 5 fluorouracil.
- ◆ Octreotide is used along with other chemotherapeutic agents. It decreases the size of the tumour.

- ◆ Neoadjuvant (preoperative) chemotherapy also practiced to increase the operability/resectability of the tumour.
- ◆ Newer treatments are tried using tamoxifen, interferons, EGFR antibody, interleukins, I<sup>131</sup> lipiodol, Yttrium<sup>90</sup> microspheres, etc.

### Palliative Treatment

- ◆ *Radiofrequency ablation (RFA)*: It is thermal ablation of the tumour by passing 18G needle into the middle of the tumour and passing electric current of 500 kHz. This creates frictional heat causing sphere of necrosis. Maximum zone of necrosis which can be created is 7 cm for a 5 cm tumour. This causes adequate cyto-destruction of the tumour. Tumour close to vessels and biliary tree, tumour more than 3–5 cm and multicentric tumours are difficult to manage by radiofrequency ablation. One course ablation takes around 20 minutes. It can be done percutaneously under US or CT guidance or through laparoscopy. Percutaneously it can be done on outpatient basis. It can be repeated several times. Tumour less than 3 cm, tumour deep in parenchyma, tumour away from hilum is ideal for radioablation.
- ◆ *Percutaneous ethanol or acetic acid injection*: (*Rule of 3* is used here—indicated in HCC not >3 cm and not >3 nodules). Ethanol injection is minimally invasive, can be injected using fine needle, and is cheaper. Local recurrence is lower with acetic acid injection than ethanol. But radiofrequency ablation has got better result than ethanol/acetic acid injection. RFA is costly and not available in many centers.
- ◆ *Trans-arterial chemotherapy (TAC)* using Adriamycin/cisplatin/mitomycin through gastroduodenal artery. It is often given along with lipiodol to make drugs to stay longer time in the liver tissue so that better results are achieved. This regional chemotherapy is much more successful in HCC.
- ◆ *Trans-arterial embolisation (TAE)* using gelfoam, microspheres, gelatin sponge, or chemoembolisation (TACE). TACE is combined TAE with chemotherapy using lipiodol, doxorubicin, mitomycin and cisplatin. TACE can be conventional or Drug eluted beads (particles) TACE [DEB-TACE].
- ◆ *Microwave or cryoablations* similar to RFA.
- ◆ As it is considered that tumour tissue exclusively gets its blood supply from hepatic artery, *ligation of hepatic artery* can be a good palliation (to achieve tumour necrosis) for HCC. Normal tissue will still have its blood supply from portal vein.
- ◆ Transarterial I<sup>131</sup> lipiodol, Yttrium 90 microspheres.
- ◆ *Targeted Iodine 131 with lipiodol injection* into hepatic artery is used as *targeted RT* as *adjuvant therapy* after liver resection. It is also makes disappearance of the portal vein thrombosis in HCC and used as *neoadjuvant therapy* prior to liver resection.

#### Neoadjuvant therapy in HCC

Large primary tumour—downstaging/*downsizing* may make resection possible

- ❖ Transarterial chemoembolisation (TACE)
- ❖ Chemotherapy and radiotherapy
- ❖ Hepatic artery infusion of chemotherapy (HAI)
- ❖ Radioimmunotherapy
- ❖ Fractionated radiotherapy
- ❖ Transarterial <sup>90</sup>Y microspheres (TARE- Transarterial radioembolisation)

### Treatment strategies for HCC

- ❖ Surgical resection, only 20% have resectable liver
- ❖ Liver transplantation
- ❖ Radiofrequency ablation
- ❖ Percutaneous ethanol/acetic acid injection
- ❖ Transarterial embolisation/chemoembolisation
- ❖ Microwave/cryoablation
- ❖ Transarterial radiotherapy
- ❖ Transarterial Yttrium<sup>90</sup> microspheres/<sup>131</sup>I lipiodol
- ❖ Hepatic artery ligation
- ❖ Adjuvant systemic chemotherapy
- ❖ Immunotherapy/hormone therapy/growth factors

### Hepatoma/hepatocellular carcinoma/HCC

- ❖ Common aetiologies are aflatoxins, hepatitis B and hepatitis C virus infection, alcoholic cirrhosis, haemochromatosis, smoking, hepatic adenoma, clonorchis sinensis, polyvinyl chloride
- ❖ Unicentric and right lobe involvement is more common
- ❖ Fibrolamellar variant is common in left lobe, not related to hepatitis or cirrhosis without AFP level raise. There are increased serum vitamin B<sub>12</sub> binding capacity and neurotensin levels
- ❖ Invasion to portal veins is common and it has got negative prognosis with lesser chances of resection or transplantation. It may cause portal vein thrombosis and so splenomegaly
- ❖ It can be multifocal/indeterminate/spreading/expanding—*Okuda classification*
- ❖ Presents as large, smooth, hard liver mass—later jaundice, fever, pain and tenderness, ascites and bruit over mass
- ❖ Spreads by lymphatics, blood and direct extension
- ❖ Mimics amoebic liver abscess, secondaries, hydatid cyst, polycystic liver disease
- ❖ LFT, CT scan, raised AFP, liver biopsy are the investigations
- ❖ *Liver mass, confirmed by CT/MRI and serum AFP > 500 ng/dl is almost diagnostic* and treatment can be started without tissue diagnosis
- ❖ Liver biopsy is done (FNAC) only in patients with nondiagnostic level of AFP and not a candidate for curative surgery but only for palliation
- ❖ Hemihepatectomy is the treatment in early operable growth
- ❖ Liver transplantation is the good surgical option
- ❖ Hepatic artery ligation/intra-arterial chemotherapy/chemoembolisation/percutaneous ethanol or acetic acid injection/radiofrequency ablation/chemotherapy using adriamycin, carboplatin, gemcitabine—are palliative procedures

## SECONDARIES IN THE LIVER

It is the *commonest malignant tumour* in liver. The incidence of primary : secondary : : 1 : 20.

### Secondaries are common malignant tumours

- ❖ In bone
- ❖ In liver
- ❖ In brain

## Causes

**Abdominal:** Carcinoma in stomach, colon, pancreas, small bowel, kidney, abdominal oesophagus, rectum, and carcinoids.

### Extra-abdominal:

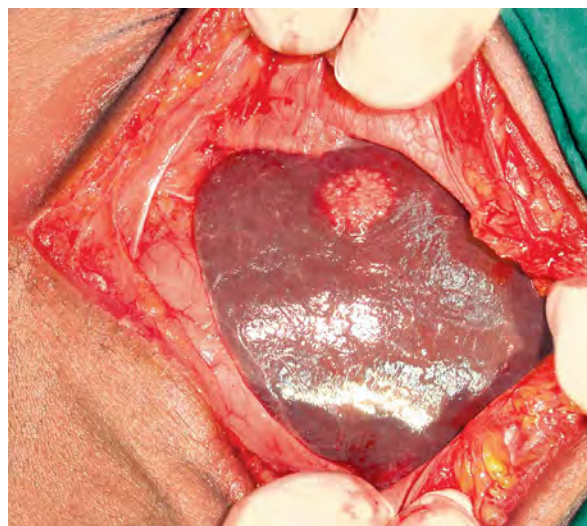- ◆ Melanoma.
- ◆ Carcinoma breast, lung, thoracic oesophagus, bladder, prostate.
- ◆ Testicular and adrenal tumours.
- ◆ Follicular carcinoma thyroid (FCT).

*Commonly secondaries in liver are multiple, multiple in one lobe or in both lobes. It can be solitary (rare).*

## Classification

### Colorectal

- ◆ Colorectal carcinoma has got special interest in relation to its secondaries in liver. It carries good prognosis.
- ◆ Secondaries can be *synchronous or metachronous*.
- ◆ Resection of secondaries in liver often gives good outcome.
- ◆ PET scan is done to identify occult extrahepatic metastases. CEA is reliable indicator of spread or recurrence.
- ◆ Resection, chemotherapy, intra-arterial chemotherapy are therapeutic modalities.
- ◆ *Contraindications for liver resection* are—extrahepatic spread, nodal involvement along with primary, short disease free interval less than 1 year, four or more secondary deposits, bilobar spread, CEA more than 200 ng/dl, secondary more than 5 cm in size, involved histologic margin.
- ◆ Colorectal liver secondaries show good prognosis when secondary are solitary, and with absence of all poor prognostic indicators.
- ◆ 5 FU with irinotecan or oxaliplatin, bevacizumab (anti-vascular endothelial antibodies) are also useful.



**Fig. 11.24:** Secondaries in liver—solitary type from colonic primary.

### Neuroendocrine

Gastrinoma, glucagonoma, somatostatinoma, nonfunctioning neuroendocrine tumours can cause liver secondaries.

- ◆ These tumours are slow growing.
- ◆ Main symptoms are often due to secreting peptides causing different clinical syndromes.

- ◆ Hormonal assay, CT abdomen, CT angiogram are needed.
- ◆ Hormone controlling therapies, chemotherapy and cytoreduction using liver resection gives good 5-year survival up to 75% in these patients.

### Non-colorectal and Non-neuroendocrine

- ◆ These are aggressive primary tumour causing liver secondaries like from stomach, pancreas, small bowel, oesophagus, gallbladder, melanoma, urinary bladder and prostate.
- ◆ They carry poor prognosis.
- ◆ Treatment is chemotherapy. Early primary like—in stomach with isolated liver secondaries without extrahepatic spread can be benefited with liver resection.
- ◆ But overall prognosis is guarded.

### Other Classifications

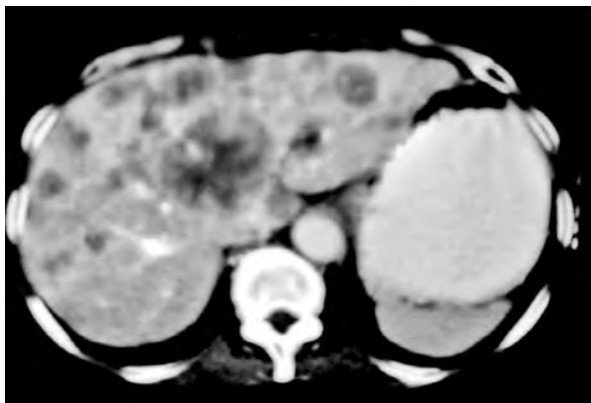
- ◆ *Precocious*: Secondaries are presented/identified before primary is suspected—carcinoid, colorectal cancer.
- ◆ *Synchronous*: Both primary and secondaries are identified at the same time—carcinoma stomach.
- ◆ *Metachronous*: Secondaries develop much later may be long time after the treatment for primary—melanoma, breast carcinoma.

### Route of Spread

- Direct spread*: Stomach, colon, gallbladder, bile ducts.
- Hepatic artery*: Melanoma.
- Portal vein*: Carcinoid tumours, other GIT malignancies.
- Lymphatic spread*: Breast, lung.

### Clinical Features

- ◆ They are multiple, hard, nodular, with nodule showing umbilication due to *central necrosis*.
- ◆ Patient may have jaundice depending on the extent of liver involvement.
- ◆ Loss of appetite and weight.
- ◆ Ascites.
- ◆ Pain in liver secondaries is due to stretching of liver capsule/ tumour necrosis. Often pain may be of primary tumour.
- ◆ Rectovesical secondaries—'*Blumer shelf*'.
- ◆ Supraclavicular lymph node enlargement—*Virchow's node* (*Troisier's sign*).



**Fig. 11.25:** Secondaries in liver. Note the multiple lesions (nodules) in both lobes of the liver.

- ◆ Clinical features of primary tumour, e.g. stomach, colon—
  - ▶ Stomach: Vomiting; visible gastric peristalsis; palpable stomach mass.
  - ▶ Colon: Constipation/diarrhoea; palpable mass; features of obstruction.
  - ▶ Pancreas: Jaundice; steatorrhoea; itching; palpable gallbladder.
  - ▶ History of earlier surgery: Like mastectomy/wide excision of the melanoma.
  - ▶ Testis: Fullness; hard mass; loss of testicular sensation.

#### Clinical features of secondaries in the liver

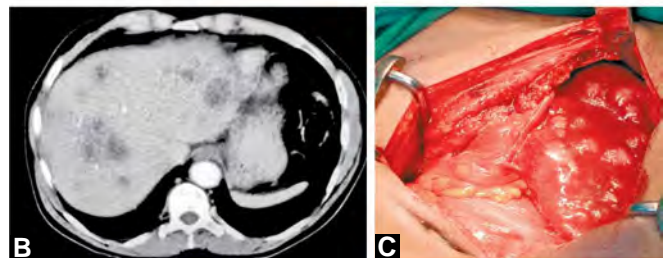
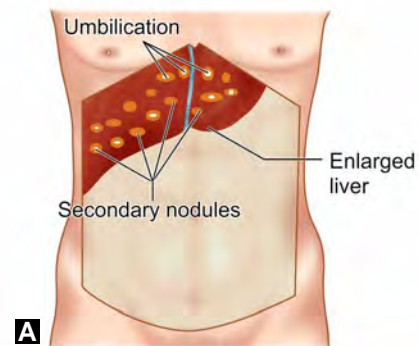
- ❖ Poor general condition
- ❖ Palpable liver which is hard, multinodular with umbilication
- ❖ Clinical features of primary
- ❖ Ascites ±
- ❖ Jaundice ±

### Differential Diagnosis

- ◆ Multicentric hepatoma.
- ◆ Macronodular cirrhosis.
- ◆ Polycystic liver disease, hydatid cyst of liver.

### Investigations

- ◆ Primary is identified by—gastroscopy, colonoscopy, contrast X-rays, CT scan.



**Figs 11.26A to C:** Secondaries in liver are multiple and often with umbilication. CT picture shows multiple secondaries with ascites. On table photo of multiple liver secondaries with umbilication.

- ◆ Liver biopsy is done, only if primary is not identified by any of these methods.
- ◆ Liver function tests.
- ◆ Ultrasound abdomen—multiple hypo- or hyperechoic lesions; site of possible primary; nodal status; ascites.

- ◆ Tumour marker: CEA.
- ◆ MRI/CT scan whenever resection is indicated.
- ◆ Laparoscopy often with laparoscopic US is very useful to detect small secondaries.

## Treatment

- ◆ Chemotherapy is the treatment of choice.
- ◆ *Surgery has a definitive role if primary is from the colon, kidney.*
- ◆ If the primary growth is in the colon, then a palliative hemicolectomy is done. Along with that if a solitary secondary in the liver is present, it can be resected. If secondaries are in single lobe, hemihepatectomy is done.

*Criteria for selection for liver resection in secondaries in liver, when primary is in colon are:*

- ❖ Stage of the primary
  - ❖ Type of primary resection
  - ❖ Size of the largest liver secondary
  - ❖ Number of secondaries
  - ❖ Segments involved
  - ❖ Associated liver disease like cirrhosis
- ◆ Palliative procedures for other primaries like—for carcinoma stomach—palliative partial gastrectomy/anterior gastrojejunostomy; for carcinoma pancreas—triple anastomosis/ERCP stenting.
  - ◆ Depending on the site of primary, drugs vary.
    - ▶ For carcinoma stomach, mitomycin and 5FU are given.
    - ▶ For carcinoma colon, 5-FU, oxaloplatinum/VEGF or EGFR antibodies used with folinic acid.
  - ◆ Hepatic artery ligation or therapeutic embolization with clot/gel foam can be tried to relieve pain.
  - ◆ Intra-arterial chemotherapy is tried with little success.

*Methods other than resection available to ablate the tumour locally in secondaries in liver*

- ❖ Microwave therapy
- ❖ Radiofrequency ablation
- ❖ Laser hyperthermia
- ❖ Ultrasound or electrolyte therapy

*Overall outcome is poor in liver secondaries.*

*They die of malignant cachexia, infection, liver failure.*

### Causes of massive enlargement of liver

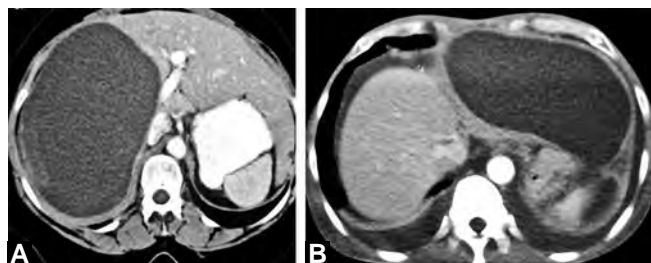
- ❖ Hepatoma
- ❖ Secondaries in liver when primary is from melanoma, carcinoid tumour
- ❖ Syphilitic enlargement of liver (hepar lobatum)

## LIVER CYSTS

### CONGENITAL LIVER CYSTS

#### Simple Liver Cyst

- ◆ It is 3% common. It is common in males (2:1).
- ◆ Solitary simple cyst is congenital; developing from abnormal intrahepatic bile duct *in utero*.
- ◆ 1/4th of simple cysts are symptomatic only at 4th or 5th decade.
- ◆ It is thin bluish walled cyst in one or other lobe containing clear fluid. Simple cyst will never communicate with biliary system. If communication is found, it should be cystadenoma.



**Figs 11.27A and B:** Simple liver cysts—CT pictures in two different patients.

- ◆ 50% present with abdominal pain. Hepatomegaly is common. Jaundice can be present.
- ◆ *Differential diagnoses* are—hydatid cyst, cystic neoplasms and solitary secondary with tumour necrosis.
- ◆ US shows anechoic lesion with smooth margin.
- ◆ CT scan shows nonenhancing thin lesion. MRI shows hypointense T<sub>1</sub> image and hyperintense T<sub>2</sub> image.
- ◆ Aspiration confirms the diagnosis. Aspiration will not cure the cyst as it recurs 100%.
- ◆ *Treatment* is—aspiration with sclerosant therapy where the recurrence rate is 20%. Deroofing with partial excision of cyst wall, by laparoscopic or open method has recurrence rate of 10%. Complete excision has very less recurrence rate but surgical mortality of 2% is present.

### Polycystic Liver Disease

- ◆ It is autosomal dominant condition associated with polycystic kidney disease in 40% of cases.
- ◆ It arises from biliary epithelium but does not communicate with biliary system.
- ◆ Usually they are asymptomatic.
- ◆ Hepatomegaly, pain abdomen, jaundice and portal hypertension are the presentations.
- ◆ Haemorrhage, biliary obstruction, Budd-Chiari syndrome, rarely malignant transformation—are the *complications*.
- ◆ Liver function is well preserved and so liver failure will not occur.
- ◆ US, CT, MRI are investigations done.
- ◆ *Treatment:* Percutaneous aspiration with sclerosant injection, deroofing of all cysts, resection, liver transplantation.

### NEOPLASTIC LIVER CYSTS

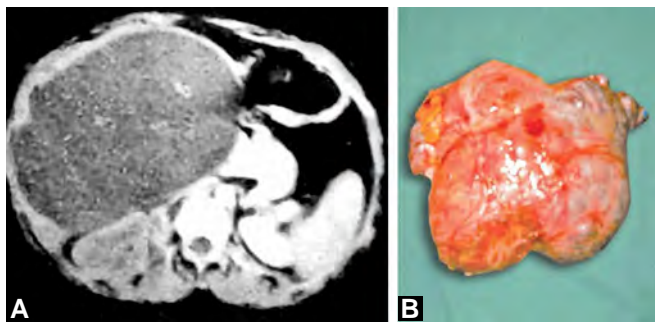
- ◆ They are *acquired* cysts.
- ◆ They are common in *females*.



- ◆ They attain large size; multiloculated with papillary projections.
- ◆ 10% of neoplastic cysts are malignant.
- ◆ Cystadenoma is benign containing *mu*cinous or *bilious* fluid.
- ◆ Cystadenocarcinoma contains *haemorrhagic* fluid.
- ◆ AFP, CEA are normal; CA 19/9 is elevated.

## Hepatobiliary (Hepatic) Cystadenoma

- ◆ Incidence is 5% of biliary intrahepatic cysts.
- ◆ 50% are in right lobe; 30% are in left lobe; 15% bilateral.
- ◆ Cystadenoma *without mesenchymal stroma* is equal in both sexes and occurs in 5th decade. It is not associated with cystadenocarcinoma.
- ◆ Cystadenoma *with mesenchymal stroma* is common in *young females* and is often associated with cystadenocarcinoma.
- ◆ It is septated, multiloculated, whereas if cavity contains debris it suggests malignancy. It is surrounded by a smooth and thick fibrous capsule. It contains internal septations and intraluminal papillary projections and lined by cuboidal or columnar biliary epithelium.



**Figs 11.28A and B:** Hepatic cystadenoma of right lobe of liver—CT picture and on table look (Courtesy: Dr Ashfaque Mohammed, DNB, KMC, Mangaluru).

- ◆ It originates from—congenital aberrant bile duct/embryonic foregut cells/peribiliary endocrine cells.
- ◆ MRI is diagnostic. US/CT scan is also useful.
- ◆ ERCP is done to identify communication with biliary system; usually to proximal left hepatic duct.
- ◆ *Treatment*—enucleation of entire cyst with surrounding rim of normal liver tissue. Hepatic resection is also an option.
- ◆ *Note:* Aspiration/deroofting, partial excision, sclerotherapy *should not be done*.

## Hepatic Cystadenocarcinoma

- ◆ It presents as large palpable smooth liver with abdominal pain.
- ◆ It carries better prognosis than HCC or cholangiocarcinoma.

*It can be:*

- ▶ Cystadenocarcinoma arising from pre-existing cystadenoma with mesenchymal stroma, which occurs only in young females, carries good prognosis.
- ▶ Cystadenocarcinoma without mesenchymal stroma not associated with cystadenoma, which is common in males and is more malignant.
- ▶ Cystadenocarcinoma without mesenchymal stroma occurring in women.
- ◆ Resection is the treatment. It carries good prognosis.

## TRAUMATIC LIVER CYST

- ◆ It is an *acquired* cyst of liver after liver injury in a blunt abdominal trauma. Biliary duct which is injured will cause bile leak into the

existing intrahepatic haematoma causing mixture of bile and blood. Cyst is pseudocyst in liver without an epithelial lining.

- ◆ It may resolve spontaneously or may cause abdominal pain, jaundice. It may present months or years later.
- ◆ CT scan, old history of liver trauma may be helpful. MRI is diagnostic.
- ◆ *Treatment* is conservative. Often deroofting or cyst excision with ligation of biliary ductule may be needed but technically demanding.

### Differential diagnosis of space occupying lesions in the liver

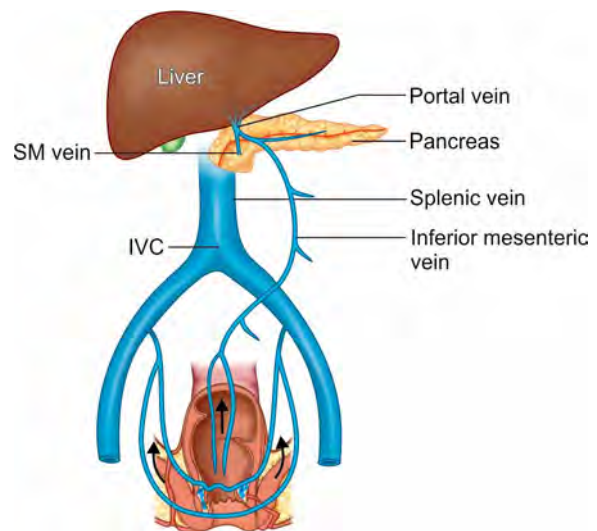
- ❖ Hepatoma
- ❖ Amoebic liver abscess
- ❖ Secondaries in the liver
- ❖ Cysts of the liver
- ❖ Haemangioma

## PORTAL HYPERTENSION

(Gilbert and Villaret first coined the term portal hypertension in 1906)

### Definition

It is *sustained elevation of the portal venous pressure more than 10 mm of Hg*. Normal portal venous pressure is 5–10 mmHg. It is also defined as *elevation of the hepatic venous pressure gradient (HVPG) > 5 mmHg*. HVPG is the difference between the wedged hepatic venous pressure (WHVP) and free hepatic venous pressure (FHPV). When HVPG is more than 10 mmHg, porta systemic shunting develops; when it becomes more than 12 mmHg, risk for variceal bleeding increases; often it will be as high as 20 mmHg in bleeding oesophageal varices.



**Fig. 11.29:** Anatomy of the portal system.

### Causes

There is increased portal resistance and altered portal blood flow. Increased resistance may be presinusoidal, sinusoidal, postsinusoidal.

- ◆ Presinusoidal
  - ▶ Extrahepatic – Portal/splenic vein thrombosis.

- ▶ Intrahepatic – Schistosomiasis, sarcoidosis, congenital hepatic fibrosis, primary biliary cirrhosis.
- ◆ *Sinusoidal* – Cirrhosis, haemochromatosis, Wilson’s disease, non-alcoholic steatohepatitis (NASH).
- ◆ *Postsinusoidal* – Budd-Chiari syndrome, constrictive pericarditis, veno-occlusive disease.

#### Note

- Left sided portal hypertension (*sinistral*) can be caused by isolated splenic vein thrombosis, which is often caused by adjacent pancreatitis.
- A rise in portal pressure stimulates portosystemic circulation.
- Portal vein carries 75% of blood flow to liver with all nutrients to maintain its integrity and gives 50% oxygen supply to liver. 25% hepatic arterial blood flow gives remaining 50% of oxygen supply to liver.
- Portal hypertension causes compensatory portosystemic venous collateral formation, altered intrahepatic circulation and increased splanchnic blood flow. High pressure portal blood is diverted via coronary (left gastric vein), short gastric and oesophageal veins into azygos venous system.
- There is *dysregulation* of compensatory increased hepatic arterial flow response in relation to decreased portal vein flow.
- 30% of varices patients will bleed; 30% of them will die of bleed; 30% of patients with cirrhosis will develop portal hypertension; 30% of them have variceal bleed in 2 years; 70% of patients who had bleeding once, will rebleed later.
- Variceal bleed accounts for 7% of upper GI bleed.
- In western country, more than 90% cases cirrhosis is the cause. In India, extrahepatic portal vein obstruction (33%) and extrahepatic periportal fibrosis (33%) is becoming more common. As liver is normal in these two conditions, patients get better cure rate by shunt surgery.
- Small varix is <5 mm in size; large one is >5 mm.

#### Sites of Portosystemic Collateralisation

1. *Lower end of oesophagus*, between left gastric and short gastric veins with azygos vein resulting in *oesophageal varices*—commonest.

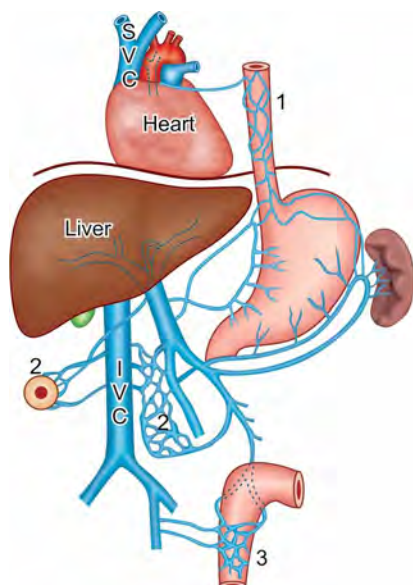


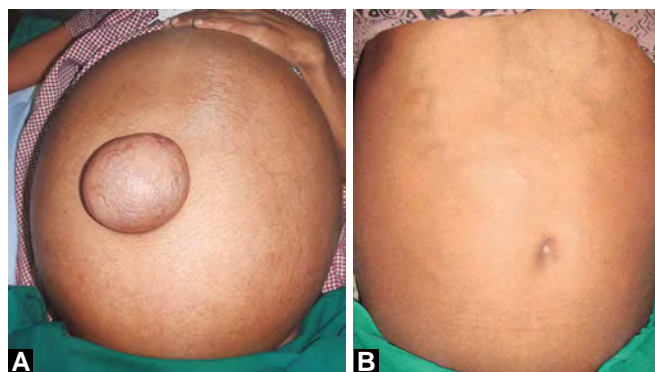
Fig. 11.30: Portosystemic collaterals.

2. *Umbilicus*, between paraumbilical vein and anterior abdominal vein resulting in *caput medusae*.
3. *Lower end of rectum*, between superior haemorrhoidal vein and inferior, middle haemorrhoidal vein resulting in *piles*.
4. *Retroperitoneum (vein of Retzius)*.
5. *Bare area of the liver*.

#### Presentations

- ❖ *Triad of portal hypertension*
  - Oesophageal varices.
  - Splenomegaly.
  - Ascites.
- ❖ Jaundice.
- ❖ Features of encephalopathy.
- ❖ Recurrent infection.
- ❖ Coagulopathy.
- ❖ Hepatorenal syndrome.

- ◆ *General*—weakness, tiredness, anorexia, weight loss, abdominal pain, jaundice, oedema, pruritus, spontaneous bleeding and bruises, impotence, muscle cramps, palor, cyanosis, hypotension.
- ◆ *Features of variceal bleeding*—anaemia, haematemesis, melaena, shock. Bleeding may be from gastric/oesophageal varices or portal gastropathy.
- ◆ *Features of encephalopathy*—memory loss, altered behaviour and mental status, asterixis (flapping tremor/liver flap), unconsciousness, foetor hepaticus.
- ◆ *Features of liver cell failure*—gynaecomastia, palmar erythema, leuconychia, testicular atrophy, spider angioma, parotid enlargement, cyanosis, and tachypnoea.
- ◆ *Features of porta systemic shunting*—see above; venous hum.
- ◆ *Ascites and generalised anasarca* with oedema scrotum and abdominal wall and limbs. Ascites is a sign of hepatic decompensation.
- ◆ Decreased urine output features of renal failure—*hepatorenal syndrome*.
- ◆ *Splenomegaly* causing hypersplenism; *hypersplenism* occurs in 30% of cases with features of leucopaenia (WBC <4,000/cumm), thrombocytopenia (platelet <1,00,000).



Figs 11.31A and B: (A) Ascites with umbilical hernia; (B) Caput medusae in liver disorder

Venous hum in epigastrium observed in portal HT is called as Kenawy’s sign.

Causes of portal hypertension		
Prehepatic	Hepatic (80%)	Posthepatic
Portal vein or splenic vein thrombosis	Portal pyaemia	Budd-Chiari syndrome
Hypercoagulable status	Alcoholic cirrhosis	Constrictive pericarditis
Periportal inflammation	Idiopathic portal hypertension	Congestive cardiac failure
Trauma	Primary biliary cirrhosis	Veno-occlusive disease
Extrinsic compression from pancreas, stomach	Schistosomiasis	
Neonatal umbilicus sepsis	Hepatitis	
	Nodular regenerative hyperplasia	
	Wilson's disease	
	Haemochromatosis	
	Congenital hepatic fibrosis	

Note: Commonest prehepatic cause of portal hypertension is portal vein thrombosis.

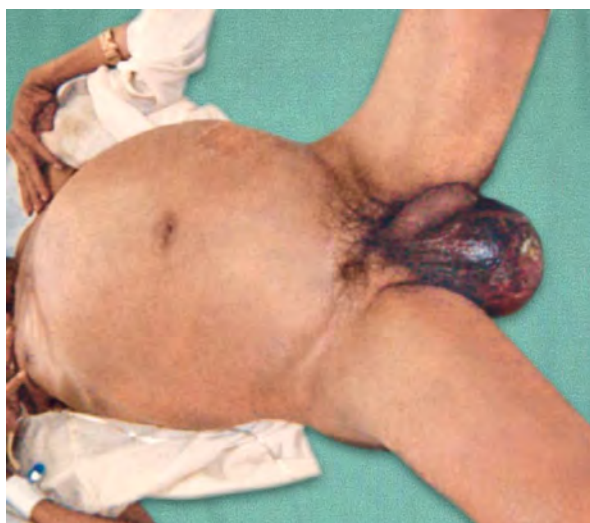

Fig. 11.32: Patient with portal hypertension showing massive ascites with oedema of limb and scrotum—end-stage liver disease.

*Symptomatic hypersplenism* manifests with low Hb% in the absence of GI bleed, platelet count  $<50,000$ , WBC count  $<2,000/\text{cumm}$  with recurrent infection and spontaneous petechiae.

- ◆ **Others**—Features of spontaneous bacterial peritonitis (SBP); rectal haemorrhoids, paraumbilical hernia.

**Note:**

- **Cruveilhier-Baumgarten syndrome** is loud venous hum heard at umbilicus in case of portal hypertension through congenital patent umbilical vein to portal vein.

### Investigations

- ◆ **Blood**—Hb%—anaemia is due to bleeding, hypersplenism, nutritional, bone marrow suppression. Pancytopenia shows leucopenia, thrombocytopenia. Counts may be serially repeated during monitoring period. Blood grouping should be done as often patient needs packed cell or FFP transfusions.
- ◆ **Liver function tests**—usually altered with raised bilirubin. Prothrombin time (INR), activated partial thromboplastin

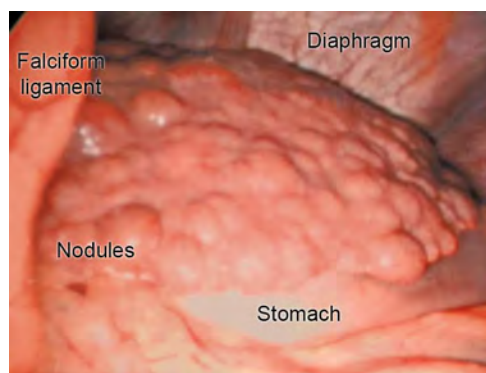
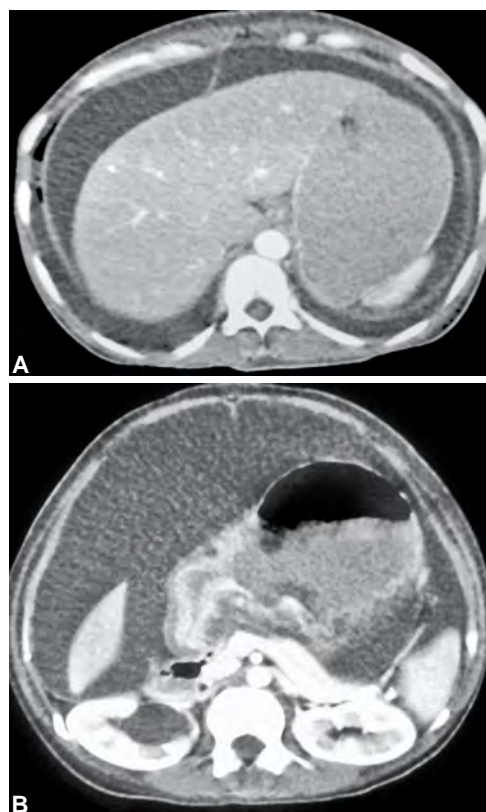


Fig. 11.33: Laparoscopic view of cirrhosis with nodules on the surface.



Figs 11.34A and B: CT scan pictures showing ascites, splenomegaly.

time (APTT) and other *coagulation profile* should be done as coagulopathy is not uncommon.

- ◆ *AFP and other relevant markers* may be useful. Serum iron,  $\alpha$ 1-antitrypsin, ceruloplasmin, autoantibodies, evaluation for hepatitis, B, C, D are important.
- ◆ *Renal function tests*—blood urea, serum creatinine, serum potassium.
- ◆ *Ultrasound abdomen*—easier, simple initial screening method to identify, liver status, portal vein, ascites, splenomegaly. Doppler imaging will help to assess the vascular pattern, blood flow, size of the vein, thrombosis in the portal system.
- ◆ *Contrast CT and MRI* are very useful to see nodules, collaterals, portal vein status/thrombosis, splenomegaly. *CT angiogram (SMA and celiac artery)* is very useful.
- ◆ *MR venogram* is very sensitive non-invasive method to study extrahepatic portal vein thrombosis. MR angiography/venography better delineates the portal and hepatic venous anatomy; it is very useful in Budd-Chiari syndrome.
- ◆ *Hepatic venous pressure gradient (HVPG)*—It is the **gold standard** to diagnose portal hypertension. Through transjugular or transfemoral (vein) route, balloon tip catheter passed under guidance into the hepatic vein via IVC; IVC pressure is assessed; free hepatic venous pressure (FHVP) is measured with catheter in the hepatic vein; catheter is further negotiated into the vein and balloon is inflated to wedge and pressure is measured. This wedge hepatic vein pressure (WHVP) is actually sinusoidal pressure and is equivalent to portal vein pressure. *WHVP minus FHVP is HVPG*. It is less than 5 mmHg; if more than 5 mmHg suggests portal hypertension; 5–10 mmHg suggests subclinical type; >10 mmHg suggests significance shunting and varices; >12 mmHg suggests high risk for bleed. Often it may raise as high as 30 mmHg.
- ◆ *Oesophagogastrosocopy*—to identify varices oesophageal and gastric or portal gastropathy; bleeding varices (spurt or ooze). Grading of the varices can be done. Other causes of bleed like gastric or duodenal ulcers or erosions will be ruled out. Risk of bleeding increases with widened PT INR, thrombocytopenia, HVPG more than 12 mmHg, portal vein diameter >13 mm; presence of ‘*cherry red spots*’ or ‘*white nipple sign*’ (platelet fibrin plug on the summit of the varix), *suggests rebleed*. Endosonography is also useful.
- ◆ Liver biopsy to identify the aetiology once coagulation profile is corrected using FFP and vitamin K injection.
- ◆ *Ascitic tap* is useful; fluid is evaluated for cells, proteins. *Serum ascitic albumin gradient (SAAG – serum albumin minus ascitic fluid albumin)* if more than 1.1 suggests high gradient means portal hypertension.
  - ▶ *Transient elastography ultrasound based*—is non-invasive method to detect clinically significant portal hypertension.
  - ▶ *MELD scoring system* (Model for End Stage Liver Disease by Dr Patrick Kamath) is done using PT INR, creatinine and bilirubin. *Child-Turcotte-Pugh scoring system* also should be assessed.
  - ▶ *Splenoportography* earlier was a common investigation is now not used. It is done to assess splenic/portal pressure and size of portal and splenic vein or presence of thrombus

or communications and collaterals. After correcting the PT INR and platelet levels, with antibiotic prophylaxis and monitor use, fine lumbar puncture needle is passed into the spleen under guidance through left 9th intercostal space in midaxillary line to reach the pulp of the spleen. Needle is connected to manometer to measure pressure. Water-soluble iodine dye is injected under C arm guidance to get splenoportogram films to assess the portal system. Complications are – bleeding, infection, left shoulder pain.

## Management of Portal Hypertension

- a. *General measures:*
  - ▶ Anaemia to be corrected.
  - ▶ Nutrition supplementation.
  - ▶ Inj. vitamin K—10 mg IM for 5 days.
  - ▶ Blood and blood product transfusions as required.
- b. *Specific measures:*
  - ▶ *Treatment of oesophageal varices.*
  - ▶ *Prevention of hepatic encephalopathy.*
  - ▶ *Treatment of ascites.*
  - ▶ *Measures to reduce portal pressure:*
    - Surgeries—Portosystemic shunt.
      - Nonselective.
      - Selective.
    - TIPSS.
    - Drugs to reduce the portal pressure like propranolol, nadolol, isosorbide-5-mononitrate.
  - ▶ *Liver transplantation.*

## OESOPHAGEAL VARICES

- ◆ May be asymptomatic.
- ◆ May present with *haematemesis* or *melaena* or as *recurrent bleeding*. Varices begin to bleed when portal pressure exceeds 12 mmHg.
- ◆ When present with severe haematemesis, patient shows features of *shock*.
- ◆ Mortality in bleeding varices is 25–30%.
- ◆ Factors related to variceal bleed are—portal venous pressure; gastro-oesophageal reflux causing ulceration; variceal size; variceal wall tension.

## Types of Varices

1. *Oesophageal* which is in the lower 1/3rd of the oesophagus, usually 3 or more in number, graded as I, II, III, IV (based on gastroscopic findings) (80%).
2. *Gastric* which is fundal or in upper part of the stomach (20%).

### Gastric varices

#### Classification

- A. Extension of oesophageal varices
  - I. Into lesser curve
  - II. Into fundus
- B. Isolated gastric varices
  - I. In fundus common
  - II. In other parts—stomach, duodenum—rare

*Gastric varices* are treated by endoscopic *N butyl cyanoacrylate glueing, sclerotherapy*. Banding is usually not done.

*Glyceryl trinitrate* should be given along with *vasopressin* to prevent coronary vasospasm.

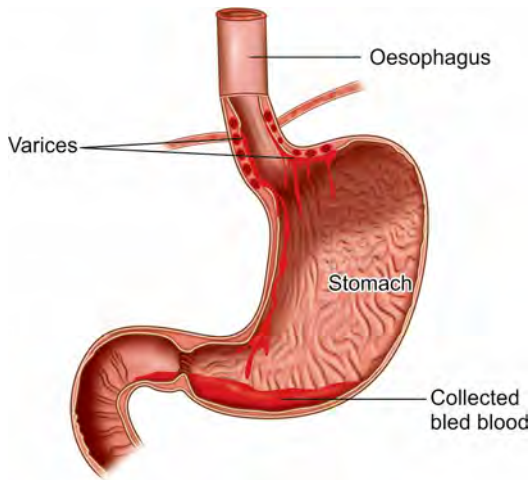


Fig. 11.35: Picture showing variceal bleed.

#### Differential diagnosis for oesophageal varices (Other causes for haematemesis)

Bleeding peptic ulcer	Carcinoma stomach
Mallory-Weiss syndrome	Acute erosive gastritis
Bleeding disorders	Dieulafoy's syndrome
Gastric polyps	Gastric leiomyoma
Gastric lymphoma	

### Investigations

- ◆ Hb%, liver function tests, packed cell volume, blood grouping and crossmatching, prothrombin time, platelet count, blood urea, serum creatinine.
- ◆ Endoscopy—*Grading of varices:*

- I. Minimal varices without luminal prolapse, visible on Valsalva, nontortuous
- II. Moderate varices, with luminal prolapse and with minimal obscuring of O-G junction—occupy <25% of lumen, tortuous, nonprotruding
- III. Large varices, with luminal prolapse and with moderate obscuring of O-G junction—occupy 25–50% of lumen, protruding but normal mucosa in between
- IV. Very large varices, with luminal prolapse and with complete obscuring of O-G junction—obliterate lumen and no normal mucosa in between

#### Note

- *Signs of impending/predicting ruptures* should be looked for during endoscopy – cherry red spots, red wale marks, blue varices, varices upon varices, erosions and ulcerations. Risk is more with larger varices (30%) than small one (15%).
- “Cherry red spots” may be sign of impending rupture.
- ◆ *Endoscopic sclerotherapy or variceal band ligation* should be tried in acute bleed also, while doing initial endoscopy to confirm the variceal bleed. If facility for sclerotherapy is not available or sclerotherapy/banding fails or not

possible due to massive bleed, then balloon tamponade should be used.

- ◆ Occasionally patient may be having varices, but bleeding (upper GI bleed) is due to other causes like duodenal or gastric ulcer.
- ◆ Once acute bleed stops patient is investigated further by USG abdomen, liver biopsy, and CT superior mesenteric or celiac angiography, MR angiogram.

### Treatment of Oesophageal Varices

- ◆ Treatment of varices prior to bleed (no history of earlier variceal bleed)—*primary prophylaxis.*
  - ▶ Drugs—propranolol (reduces the portal pressure by 20% with pulse rate below 55/minute or 25% of resting pulse); nadolol (long acting, less lipophilic, not metabolised by liver); isosorbide mononitrate. Drugs reduce bleeding by 40%.
  - ▶ Endotherapy – endoscopic variceal banding/ligation (EVB/EVL) or endoscopic variceal sclerotherapy (EVS). *EVB is the standard practice now.*

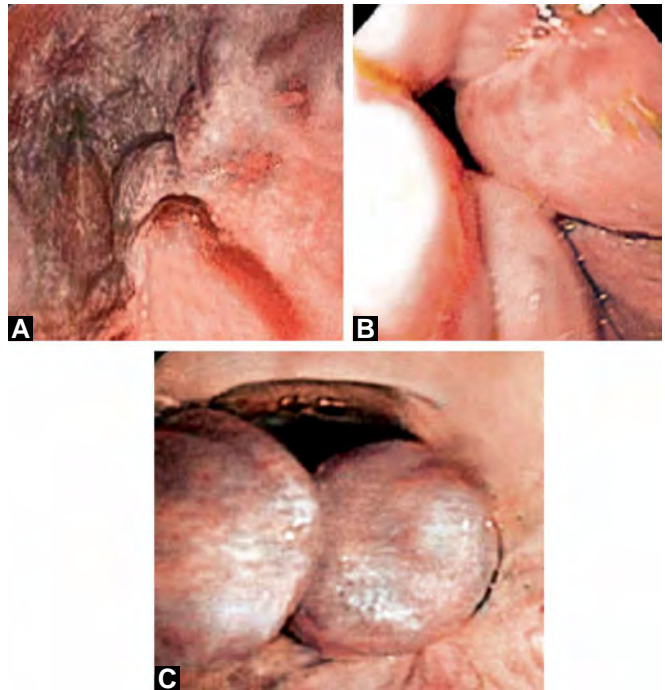
#### Note:

No prophylactic shunt surgeries.

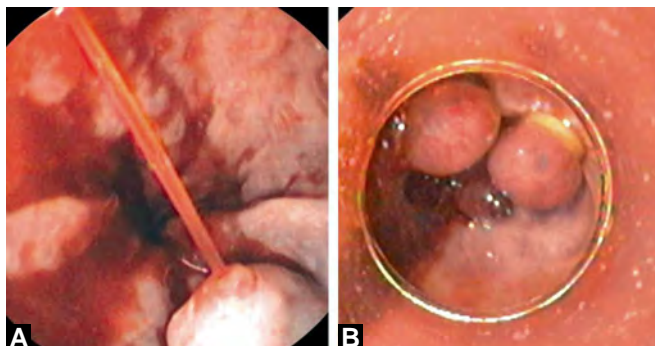
- ◆ Treatment of varices after one or more episodes of bleeding—*secondary prophylaxis.*
  - ▶ Endotherapy—*Endoscopic variceal banding (EVB) is ideal and preferred.* HVPG reduces within 48 hours.
  - ▶ Shunt surgeries.
  - ▶ Drugs like propranolol. Drugs may prevent rebleed by 40%.

*Treatment of varices is considered under two headings:*

- ◆ Emergency management of bleeding varices.
- ◆ Definitive management of varices.



Figs 11.36A to C: Different grades of oesophageal varices—endoscopic views.



**Figs 11.37A and B:** Active spurting variceal vessel. Endoscopic variceal banding is gold standard for oesophageal varices. It is not very useful for gastric varix.

## EMERGENCY MANAGEMENT IN SEVERE HAEMORRHAGE

### Control of acute bleed

- ❖ Initial important measures
  - Volume and electrolyte corrections; volume replacement using crystalloids with central line (CVP line placement with CVP maintained at 5 cm of water, sudden overload should be avoided which may precipitate pulmonary oedema/ascites/hyponatraemia)
  - Blood (massive transfusion of 5,10, 15 bottles) and blood products (FFP, platelets) replacement endotracheal intubation, ventilator, critical care/ICU management
  - Antibiotics, nutrition (TPN)/Vitamin K injection
  - Catheterisation and hourly urine output monitoring
  - Prevention of encephalopathy
  - Rest/sedation only if needed with care
- ❖ Pharmacotherapy—*octreotide is the choice*
- ❖ Endoscopic banding/sclerotherapy
- ❖ Balloon tamponade
- ❖ TIPSS
- ❖ Devascularisation surgical procedures

## Pharmacotherapy (Drugs)

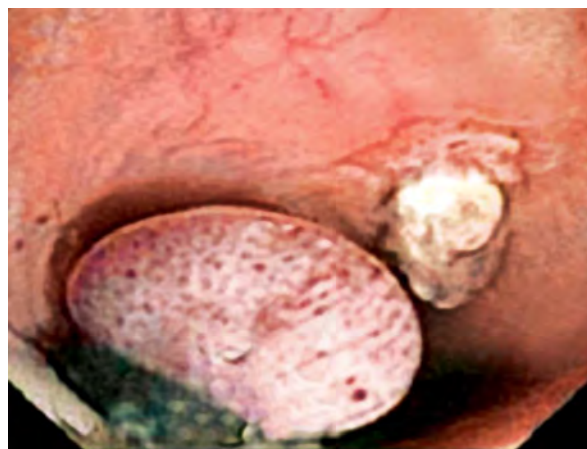- ◆ *Inj. Vasopressin* 0.4 units/min for 24 hours is commonly used. 20 units in 100 ml 5% dextrose IV in 20 minutes also can be given. Vasopressin infusion is combined with glyceryl trinitrate tablets sublingually (to reduce cardiac side effects and increase the efficacy). Vasopressin is contraindicated in ischaemic heart disease as it causes coronary vasoconstriction. Nitroglycerine prevents the coronary vasoconstriction and also reduces the portal pressure. Vasopressin can cause fluid retention and hyponatraemia.
  - ▶ Vasopressin *constricts* the splanchnic vessels thus *lowers the portal pressure* controlling the variceal bleed. It controls acute bleed in 80% of cases; it is often used along with balloon tamponade to increase bleeding control to 95%. Complications are—MI, arrhythmias, intestinal ischaemia, hyponatraemia and reduction in hepatic, renal blood flow.

- ◆ *Glypressin* (terlipressin), *desmopressin*. Glypressin 2 mg IV bolus 5th hourly is better than vasopressin. It has got longer half-life with fewer side effects.
- ◆ *Somatostatin*—half-life 2 minutes. Somatostatin does not cause systemic vasoconstriction like vasopressin but reduces the splanchnic and hepatic blood flow. It is given as continuous IV infusion 250 µg/hour after an initial bolus of 250 µg.
- ◆ *Octreotide*—It is the synthetic analogue of somatostatin with half-life of 2 hours. It is the agent of choice in acute bleed. It decreases portal pressure and azygos blood flow; stops variceal bleed in 80% of the cases; efficacy is similar to endoscopic sclerotherapy and better than vasopressin; reduces bleeding after endoscopic therapy; causes mild hyperglycaemia and abdominal cramping; dose is 100–200 µg IV Bolus—followed by infusion 50 µg/hour for 5 days. *Vapreotide* is another newer long-acting somatostatin analogue.
- ◆ *Propranolol* decreases the portal pressure. It is used at later period as prophylaxis to prevent bleeding. Nadolol is also used which has got a longer half-life.
- ◆ Metoclopramide (20 mg IV, it causes lower oesophageal sphincter constriction); isosorbide 5 mononitrate which is not metabolised in liver can be safely used in patients in liver failure.
- ◆ Acid inhibiting drugs (ranitidine IV, pantoprazole IV); and antifibrinolytics (tranexamic acid) are also used.

## Endoscopic Therapy

Endotherapy—banding/sclerotherapy/glueing is used to control acute bleed as well as to prevent further bleeding. Pharmacotherapy is often combined with endotherapy.

1. *Endoscopic variceal banding (EVB)*
  - ▶ It is done for oesophageal varices. Banding/band ligation has become *gold standard and ideal* for oesophageal varices.
  - ▶ Multishoot banding device is used.
  - ▶ It is not commonly done for gastric varix as banding is difficult in retroflexed position.
  - ▶ Banded varices thrombose and slough off leaving small discrete ulcers.
  - ▶ It controls the bleeding in 90% cases. It is technically easier; chances of rebleeding are less; complications like perforation or stricture are less.



**Fig. 11.38:** Endoscopic view of variceal banding. Endoscopic variceal banding (EVB) is done for oesophageal varices. Not commonly used for gastric varices.

- ▶ Earlier single band application device was used. It should be passed through an oesophageal overtube as it requires repeated endoscopy for shooting many bands. Multishoot banding device/applicator carries 5/6/8/10 bands. It does not require repeated removal and insertion of endoscope and so overtube can be avoided.

### 2. Endoscopic variceal sclerotherapy (EVS)

- ▶ Endoscopic sclerotherapy is also commonly used. It is technically easier, and cheaper.
- ▶ Both intravariceal and paravariceal or only intravariceal injections are given.
- ▶ In large varix lower part and upper part of the varix is sclerosed. Around 6 ml of sclerosant to lower part and 2–3 ml to upper part is injected. In small varix, injection is sufficient to only lower part.
- ▶ In combined para and intravariceal injection, first paravariceal injection is done into submucosal plane followed by intravariceal injection.
- ▶ Sclerosants used are—*Fatty acid derivatives*: ethanalamine oleate (5%); sodium morrhuate (2–5%); *Synthetic*: sodium tetradecyl sulphate; polidocanol (3%). Polidocanol is hydroxyl polyethoxy dodecan (HPD/aethoxysklerol 1–3%)
- ▶ Varices should not be injected blindly.
- ▶ In acute bleed it is better to insert an endotracheal tube to the patient and give 45° elevation to the head end of the table.
- ▶ Sclerotherapy causes intimal injury, submucosal vessel thrombosis, ulceration, submucosal fibrosis. 5–6 sclerotherapies are needed to create total obliteration. If after sclerotherapy aspiration fluid is clear, then it is called as successful sclerotherapy. Success rate is 80%. Sclerotherapy during bleeding is called as acute sclerotherapy; at bleed free intervals, it is called as chronic.

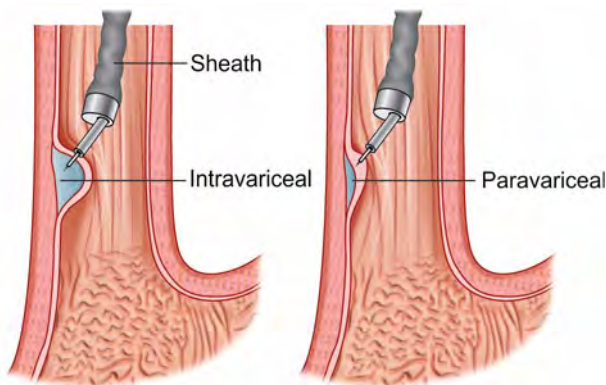


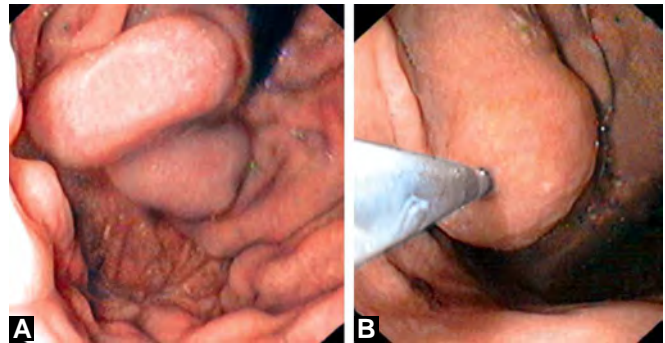
Fig. 11.39: Types of sclerotherapy.

- ▶ **Complications**
  - Fever, retrosternal pain, massive bleed, perforation, mediastinitis, stricture oesophagus.
  - Atelectasis, pleural effusion, ARDS are known to occur.
- ▶ Sclerotherapy is done weekly for 6–8 sessions until varices are obliterated. Later follow up endoscopy is done once in 3 months for 6 months; and once in 6 months for 2 years; then yearly for life time.
- ▶ Sclerotherapy causes 70–80% control of bleeding but rate of re-bleed is higher than banding.

### 3. Endoscopic gluing using tissue adhesives

- ▶ It is commonly used for gastric varices.

- ▶ Butyl cyanoacrylate is used. It hardens in 20 minutes. If properly injected into the varix it controls the bleeding immediately with 90% success rate.
- ▶ Risk of equipment damage is high if it spills into the working channel and blocks it. Lipiodol is used along with cyanoacrylate to delay premature hardening. Silicone oil is applied to the tip of the instrument to prevent the damage.
- ▶ Needle tip is correctly placed into the gastric varix and 0.5–1 ml of adhesive is injected. Instrument should be removed immediately.



Figs 11.40A and B: Typical tortuous gastric varix and cyanoacrylate glue injection to the same.

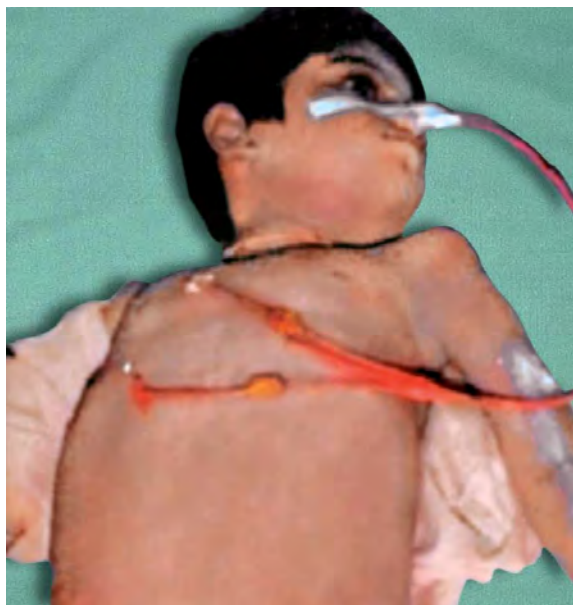### 4. Endoscopic thrombin/dilute adrenaline injection into the varices.

## Balloon Tamponade

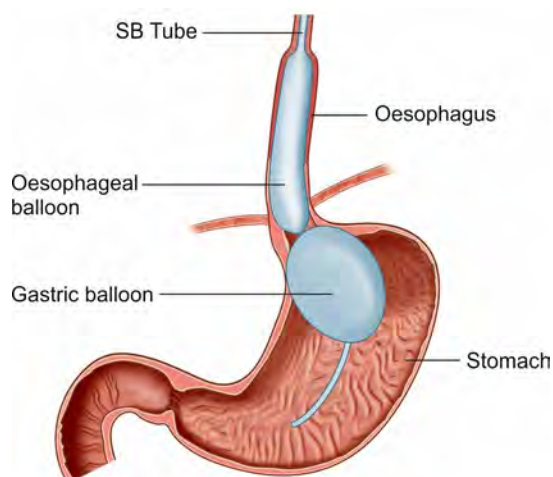
- ◆ *Four lumen Minnesota tube/Sengstaken-Blakemore tube/Linton's tube/modified 4 lumen Pitcher tube* are used for the procedure. If bleeding does not stop by banding/sclerotherapy/gluing, balloon tamponade should be tried. Most of the time bleeding comes under control by balloon tamponade.
- ◆ Initially gastric balloon is inflated with 300–400 ml of air, later the oesophageal balloon is inflated with air at 30–40 mmHg pressure. This should be deflated for a short period in 12–24 hours so as to prevent necrosis of oesophageal mucosa. Inflation of gastric balloon is most important. Oesophageal balloon inflation is done if needed only.
- ◆ X-ray should be taken to confirm the position of balloons.
- ◆ Usually within 24–72 hours bleeding comes under control and in mean time resuscitative measures has to be undertaken. Success rate is very good but only temporary. It should be followed by definitive procedures like banding/sclerotherapy. Otherwise re-bleed rate is 60%. Balloon tamponade is only a rescue procedure and emergency bridging method for more definitive procedures.

## TIPSS (Transjugular Intrahepatic Portosystemic Shunt/Stenting)

It is used if all other earlier methods mentioned have failed, in less than 10% of acute bleed patients. It commonly controls the uncontrolled acute bleeding and prevents further bleed and also acts as a bridge for future transplantation.



**Fig. 11.41:** Child with Sengstaken-Blakemore (SB) tube for haematemesis showing three channels.



**Fig. 11.42:** Sengstaken-Blakemore tube showing how it controls the bleeding varices. Oesophageal balloon is inflated with 40 mmHg pressure of air, gastric balloon with 400 ml of air.

## Surgeries for Acute Bleeding Varices

- ◆ *Open oesophageal stapler transection and oesophago-gastric anastomosis* (Jhonston).
- ◆ *Borema-Crile operation*: The oesophagus is opened. Oesophageal varices are under-run using vicryl.
- ◆ *Sugiura-Futagawa operation*: Oesophagogastric transection and devascularization, vagotomy, pyloroplasty and splenectomy.
- ◆ *Milnes-Walker thoracic oesophageal transection*.
- ◆ *Tanner's abdominal oesophagogastric resection*.
- ◆ *Hassab operation*.

*Shunt surgeries are not commonly used to control bleeding in acute stage.*

### Note:

Once a bleed, there will be always a re-bleed without treatment and re-bleed is much more severe than earlier bleed. Time gap between each re-bleed shortens.

## Other Measures

- ◆ *Liver biopsy* to confirm the cause for the portal hypertension (after controlling PT).
- ◆ *Correction of clotting mechanisms* by vitamin K, blood, plasma or platelet concentrate.

### Control of encephalopathy

- ❖ Purgatives
- ❖ Protein free diet
- ❖ Lactulose syrup 30 ml tid
- ❖ Lactitol
- ❖ Neomycin orally—1.5g 6th hourly
- ❖ Parenteral nutrition

## Definitive Management of Varices

- ◆ **Sclerotherapy**
- ◆ **Shunt surgery**

Prophylactic shunt surgery should not be done.

Shunt surgeries should not be done if the varices have not bled before.

### Indications

*Child's Grades A and B.*

(Child's grading is used for selecting patients for surgery and predicting prognosis.)

*Surgery is contraindicated in Child C.*

#### 1. Non-selective shunts:

- ▶ *Porta-caval shunt* (end-side, side-to-side).
- ▶ *Mesentericocaval shunt* with or without graft.
- ▶ *Mesenterico-renal shunt*.
- ▶ *Proximal splenorenal shunt—Linton's shunt*.

Non-selective shunts control and prevent further bleeding as well as reduce the ascites. But since it diverts the blood from liver there is high incidence of encephalopathy.

### Note:

- End to side porta caval shunt is called as ECK fistula.

#### 2. Selective shunts:

- a. *Distal splenorenal shunt—Warren's shunt*. End of splenic vein is shunted to the side of the left renal vein. Splenic vein should be more than 10 mm in size (diameter). It selectively decompresses the portal bed near oesophago-gastric area (so that it prevents bleeding). Liver is also perfused adequately and so possibility of encephalopathy is less.
- b. *Inokuchi shunt* is a selective shunt between IVC and left gastric vein (using a graft).

#### 3. Partial shunts:

*Sarfesh's small diameter* of 8 mm H graft interposition portacaval shunt is often used.



### Sclerotherapy

Sclerosants used	Method of injection	Problems with sclerotherapy
Ethanolamine oleate (5%)	Both intravariceally (6 ml) as well as para variceally (2–3 ml) to create thrombosis as well as fibrosis	Oesophageal ulceration
Sodium tetradecyl sulphate (1–3%)		Oesophageal perforation
Sodium morrhuate 2–5%		Worsening of bleeding
Polidocanol 3%	Repeated sessions in 2–3 weeks	Aspiration pneumonitis
Absolute alcohol	Total 15 ml in one session	Difficult to inject gastric varices
		Chest pain and dysphagia are common

### Child's grading of the severity of liver disease (Child-Turcotte-Pugh scoring system)

Clinical and biochemical measurement	Points scored		
	1	2	3
Bilirubin (mg/dl)	<2.0	2.0–3.0	>3.0
Albumin (gm/dl)	>3.5	3.0–3.5	<3.0
Ascites	None	Controlled	Uncontrolled
Mental status	Normal	Disoriented	Coma
Nutrition	Very good	Good	Poor
<b>Total Score</b>	<b>&lt;6 Child's 'A' disease</b>	<b>7–9 Child's 'B' disease</b>	<b>10–15 Child's 'C' disease</b>
<i>(Pugh's modification)</i>			
Prothrombin time seconds prolonged	Increase up to 3	Between 3–6	>6

#### ◆ Splenectomy

Left sided portal hypertension also called as *segmental portal hypertension* (sinistral portal hypertension) is due to splenic vein thrombosis (If partial channels are present within it, it is called as *splenic vein cavernoma*). Here liver is normal and *splenectomy* alone will correct the condition.

#### ◆ TIPSS (Transjugular Intrahepatic Portosystemic Stenting/ Shunt)

- ▶ Size of stent must be 10 mm. It is a non-surgical, interventional radiological method wherein a stent is placed in the liver between hepatic venule and portal venule through a guidewire following dilatation.
- ▶ It is a simple and easier method to reduce portal pressure.
- ▶ It can cause hepatic encephalopathy, bleeding, bile leak and infection.
- ▶ It is contraindicated in encephalopathy, tumours and liver cysts.
- ▶ It is quite useful as a temporary measure to reduce portal bed pressure, before doing orthotopic liver transplantation in cirrhotic patients.

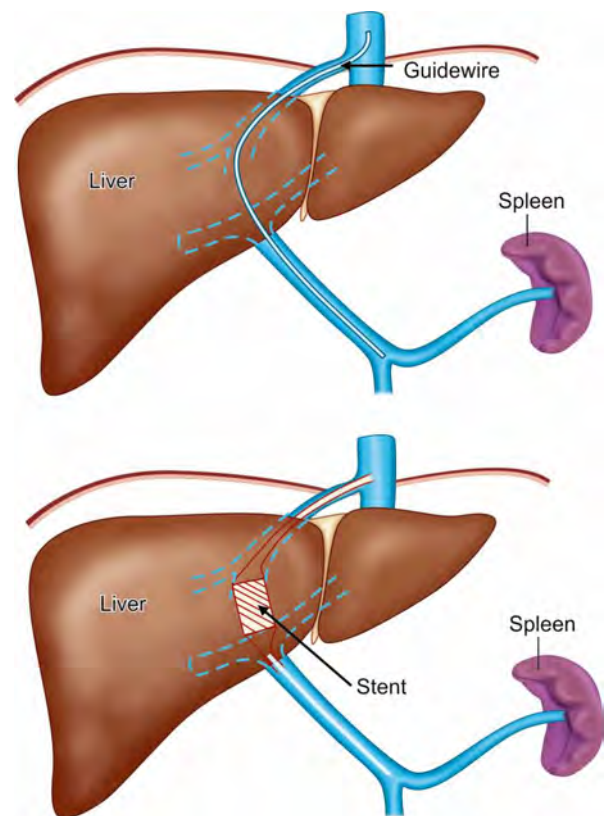


Fig. 11.43: TIPSS.

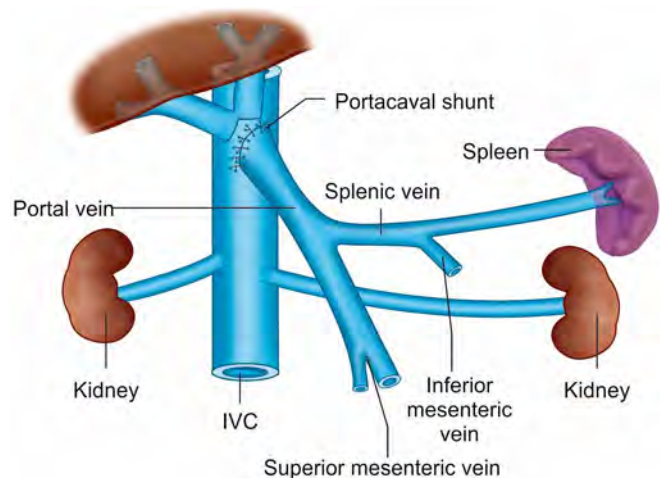
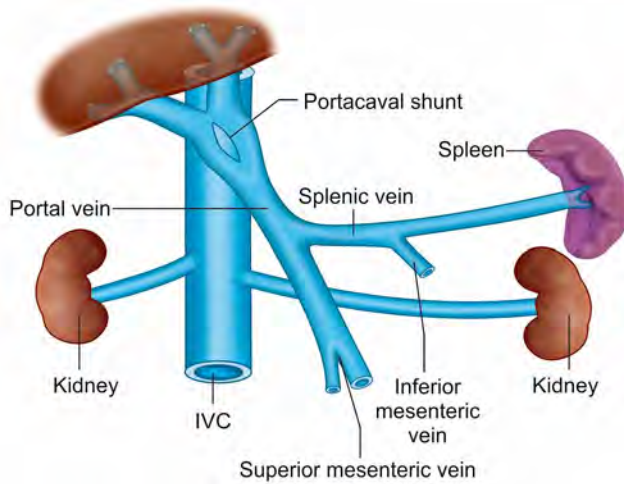
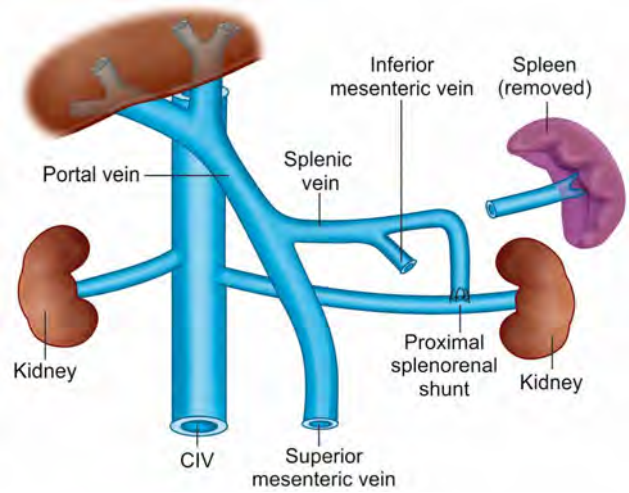


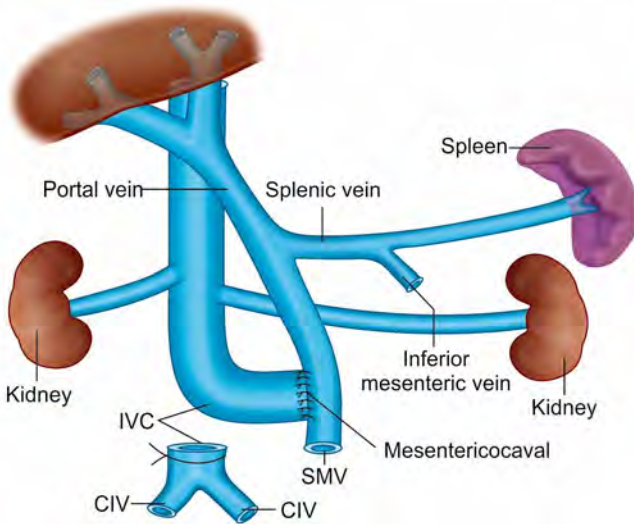
Fig. 11.44: End-to-side portocaval shunt (Eck fistula).



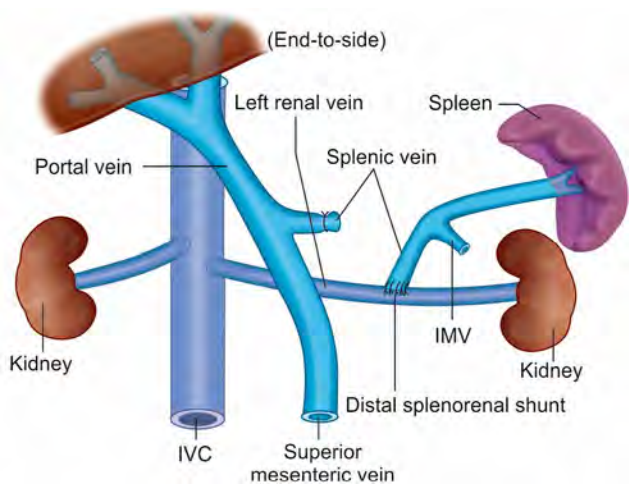
**Fig. 11.45:** Side-to-side portocaval shunt.



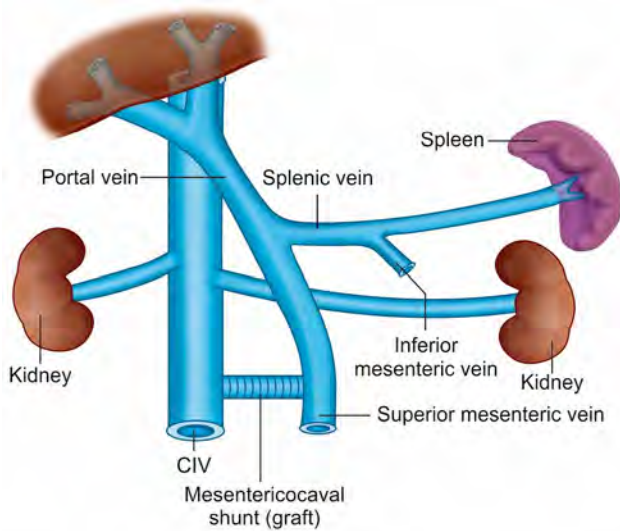
**Fig. 11.48:** Proximal splenorenal shunt (Linton's)



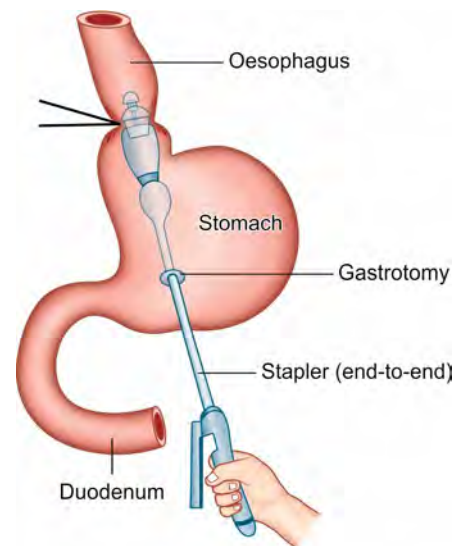
**Fig. 11.46:** Side-to-side mesentericocaval shunt.



**Fig. 11.49:** Distal splenorenal shunt (Warren's, DSRS)—selective.



**Fig. 11.47:** Side-to-side mesentericocaval shunt using a graft.



**Fig. 11.50:** Oesophageal open stapler transection.

*During infancy until about the end of the third year the normal liver extends one to two finger breadth below the costal margin. During inspiration at this period of life, the extreme edge of normal spleen is also palpable.*

### Problems with TIPSS

- ❖ Post-stent encephalopathy—40%
- ❖ Stenosis (50%) and recurrent varices
- ❖ Bleeding
- ❖ Bile leak
- ❖ Sepsis

### Surgeries for portal hypertension

- ❖ Devascularisation surgeries
- ❖ Decompression surgeries
- ❖ Orthotopic liver transplant (OLT)

### Surgeries for oesophageal varices and portal hypertension

#### Non-selective shunts

- ❖ End-to-side portacaval shunt (ECK fistula)
- ❖ Side-to-side portacaval shunt
- ❖ Mesentericocaval shunt
- ❖ Mesentericocaval shunt with graft
- ❖ Proximal splenorenal shunt—Linton's shunt
- ❖ TIPSS

#### Selective shunts

- ❖ Distal splenorenal shunt—Warren's shunt
- ❖ Inokuchi shunt between left gastric vein and IVC through a graft

#### Porta azygos disconnection

- ❖ Oesophageal stapler transection of Johnston
- ❖ Boerema-Crile operation—thoracic approach
- ❖ Milnes-Walker thoracic oesophageal transection
- ❖ Tanner's abdominal oesophagogastric transection
- ❖ Hassab operation. Devascularisation and splenectomy.
- ❖ Sugiura-Futagawa operation—vagotomy, pyloroplasty, devascularisation, splenectomy
- ❖ Splenectomy

#### Liver transplant

#### ◆ Liver transplant (orthotopic)

Liver transplant is becoming popular for cirrhosis with varices. It is ideal, final and best. But donor availability and cost is the problem. If patient is for orthotopic liver transplantation (OLT),

open shunt surgeries should not be done as liver hilum should be kept virgin for effective transplantation. TIPSS can be done as a bridge in such patients.

### PORTAL HYPERTENSIVE GASTROPATHY

- ◆ Portal hypertension causes vascular dilatation and ectasia in the stomach which appears pink, speckled, with red mosaic pattern in the gastric mucosa. It occasionally causes upper GI bleed (5% of total; 20% of portal hypertension bleed). Endoscopy is diagnostic.
- ◆ Mucosal changes are diffuse and so not amenable for endotherapy.
- ◆ Portal gastropathy is more common in cirrhotic patients.
- ◆ Commonly presents with chronic bleed causing anaemia; but acute bleed with haematemesis and melaena also can occur.
- ◆ Treatment is mainly to reduce the portal pressure using propranolol.

### ASCITES

It is pathological collection of fluid in the peritoneal cavity.

In Western countries cirrhosis is the commonest cause (80%) of ascites. Ascites is the most common complication of cirrhosis. It is a poor prognostic factor. Portal hypertension, renin angiotensin aldosterone pathway causing renal sodium retention, increased hydrostatic pressure in hepatic sinusoids and splanchnic vessels cause ascites. In metastatic malignancy ascites develops due to liver secondaries, peritoneal carcinomatosis which secretes protein rich fluid and lymph. Leakage of pancreatic juice, bile, lymph also causes specific ascites.

### Types

- ◆ Mild — Up to 150 ml amount required to demonstrate radiologically
- ◆ Moderate — 1500–2000 ml causes clinical dullness in flanks.
- ◆ Severe — > 2000 ml.

### Classification

- ◆ *Transudate* (Protein < 2.5 g/dl).
  - ▶ CCF—Commonest (SAAG >1.1).
  - ▶ Hypoproteinaemia.
  - ▶ Anaemia.
  - ▶ Beri-beri.
  - ▶ Nephrotic syndrome.
  - ▶ Portal hypertension.
  - ▶ Polyserositis.

### Management of oesophageal varices

Emergency management in acute bleed	Definitive management
1. Pharmacotherapy	1. Sclerotherapy, banding, glueing
2. Banding	2. Nonselective shunts: Portacaval
3. Sclerotherapy	Mesentericocaval
4. Balloon tamponade	Mesentericorenal
5. Oesophagogastric transection	3. Selective shunts: Distal-splenorenal shunt
6. Borema-Crile operation	Inokuchi shunt
7. Sugiura-Futagawa operation	4. Splenectomy
	5. TIPSS
	6. Liver transplant

- ◆ *Exudate* (Protein >2.5 g/dl) (SAAG <1.1).
  - ▶ Peritoneal diseases.
    - Tuberculosis.
    - Bacterial, fungal and parasitic infection.
    - Neoplasm.
  - ▶ Collagen disorder.
  - ▶ Eosinophilic gastroenteritis.
  - ▶ Granulomatous peritonitis.

## Clinical Features

### Symptoms

- ◆ Gradual distention of abdomen
- ◆ Severe cases of ascites may lead to respiratory embarrassment.
- ◆ Specific features related to the cause may be evident.
- ◆ Risk of spontaneous bacterial peritonitis.

### Signs

#### Mild:

- ◆ *Puddle sign*—Tapping around the umbilicus in knee-elbow position elicits dullness.

#### Moderate:

- ◆ Positive shifting dullness in the abdomen.

#### Severe:

- ◆ Positive fluid thrill.
- ◆ *Tanyol sign*: Umbilicus is shifted upward in pelvic mass (ovarian cyst) downwards in ascites.
- ◆ Hamilton ruler test is also used to differentiate ascites from ovarian cyst. This *Blaxland (Athelstan Blaxland) ruler test* shows pulsation in ovarian cyst not in ascites. A flat ruler is placed on the abdomen just above the anterior superior iliac spines and pressed firmly backwards. If the swelling is due to ovarian cyst, transmitted aortic pulsation can be felt across the ruler.
- ◆ *Smiling horizontal umbilicus*.

## Investigations

- ◆ Ultrasound abdomen.
- ◆ *Ascitic tap*—always should be done after emptying the bladder by placing the needle below the umbilicus lateral to the rectus muscle. It may be *Diagnostic* or *Therapeutic tap*. Fluid is sent for analysis.
  - ▶ Ascitic fluid having cells less than 1000/mm<sup>3</sup> is clear; from 1000–5000/mm<sup>3</sup> is unclear; more than 5000/mm<sup>3</sup> is turbid/cloudy.

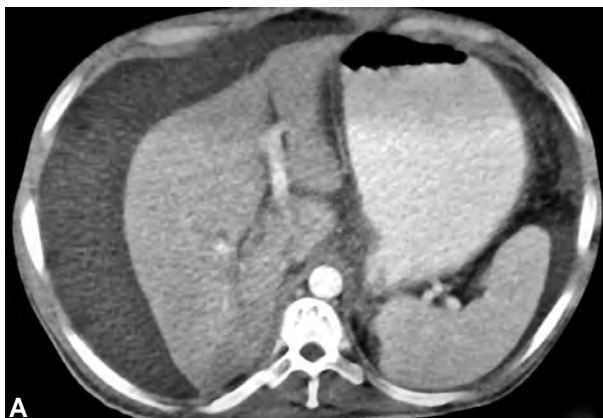

Fig. 11.51A

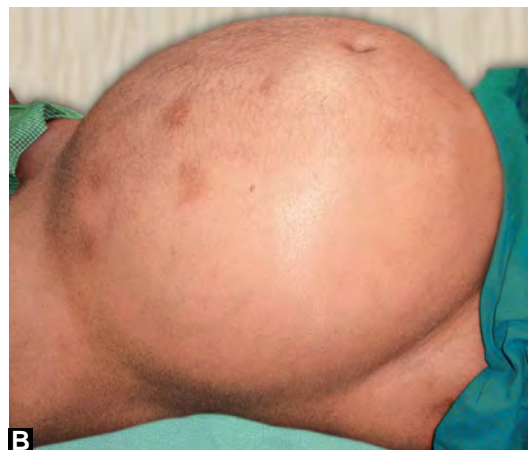

Fig. 11.51B

Figs 11.51A and B: Ascites on CT scan and gross clinical look of severe ascites.

- ▶ Non-traumatic blood in the ascitic fluid does not clot. Traumatic (trauma during tapping) blood will clot.
- ▶ Lipid in the ascitic fluid is seen in chylous ascites.
- ▶ In cirrhotic patients, ascitic fluid without SBP contains less than 500 cells/mm<sup>3</sup> with 50% of them are neutrophils. If ascitic fluid contains more than 250 neutrophils/mm<sup>3</sup> it suggests acute inflammation.
- ▶ **Serum ascites albumin gradient (SAAG)** is calculated by subtracting ascitic fluid albumin level from serum albumin level. If SAAG more than 1.1, it is called as high gradient which suggests portal hypertension. If SAAG is less than 1.1, it is called as low gradient which suggests absence of portal hypertension. SAAG is 98% accurate.
  - *High gradient SAAG* is seen in—cirrhosis, alcoholic, cardiac ascites, multiple liver secondaries, fulminant liver failure, Budd-Chiari syndrome, portal vein thrombosis.
  - *Low gradient SAAG* is seen in—peritoneal secondaries, peritoneal tuberculosis, pancreatic ascites, biliary ascites, nephrotic syndrome, lymph leak, connective tissue diseases causing ascites.

## Treatment

- ◆ The cause is treated.
- ◆ Therapeutic tap—It should be slow and gradual or staged tapping. Up to 5 litres can be tapped in 90 minutes.
- ◆ Ascitic shunt surgeries.
- ◆ Spironolactone, salt restriction.
- ◆ Salt (sodium) restriction in diet is important. It is assessed by measuring 24-hour urinary sodium excretion. If it is more than 78 mmol/day patient will loose weight with salt restricted dite.
- ◆ Spironolactone 100 mg/day and furosemide 40 mg/day promotes natriuresis and reduces the ascites. It is very useful after paracentesis to prevent re-accumulation of fluid.
- ◆ TIPSS.
- ◆ Liver transplantation.

### Complications of ascites

- ❖ Respiratory embarrassment
- ❖ Umbilical hernia with erosion, ulceration and leak
- ❖ Spontaneous bacterial peritonitis

## ASCITES IN PORTAL HYPERTENSION

### Causes

- ◆ Hypoproteinaemia.
- ◆ Increased hydrostatic pressure.
- ◆ Decreased colloidal osmotic pressure.
- ◆ Lymphatic blockage.
- ◆ Altered aldosterone mechanism.

### Treatment of ascites in portal hypertension

- ❖ Medical—spironolactone, salt restriction
- ❖ Abdominal paracentesis
- ❖ TIPS as a bridge to liver transplant
- ❖ Liver transplantation

### Abdominal fluid

- ❖ *Straw coloured fluid*
  - Cirrhosis
  - Tuberculosis
  - Hypoproteinaemia
  - Nephrotic syndrome
  - Budd-Chiari syndrome (Hepatic vein thrombosis)
  - Constrictive pericarditis
  - Chronic pancreatitis
  - Ovarian tumour (Meig's syndrome)
  - Malignancy
- ❖ *Haemorrhagic fluid*
  - Traumatic tap
  - Tumour
  - Acute haemorrhagic pancreatitis
  - Bleeding disorder
- ❖ *Chylous fluid*
  - Parasitic infestation—filariasis
  - Tuberculosis
  - Malignancy of thoracic duct
  - Trauma to thoracic duct
  - Thrombosis of subclavian vein
- ❖ *Purulent fluid*
  - Abdominal infections
  - Penetrating wounds or infections
  - Pyaemia and septicaemia
  - Rupture/perforation of an organ

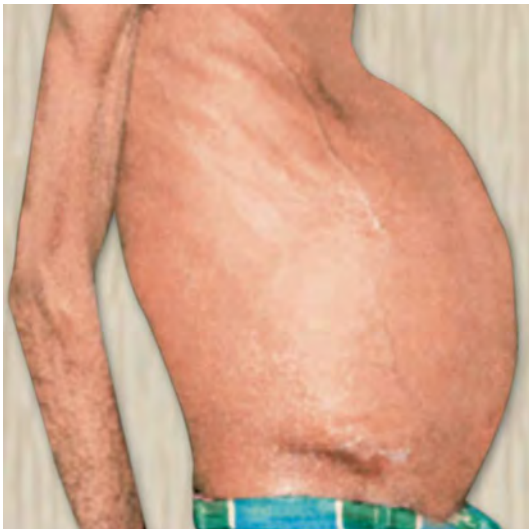

Fig. 11.52: Ascites. Observe the dilated abdominal veins.

### Investigations

Liver function tests, US, CT scan, MRI, gastroscopy.

### Treatment

- ◆ Correction of serum proteins, salt restriction.
- ◆ *Ascitic tap*—Site of tap is below the umbilicus, lateral to the rectus muscle. Bladder should be empty before tapping. Slow gradual tapping is important, otherwise patient goes in for fluid and electrolyte imbalance. Up to 5 litres can be tapped at a time.
- ◆ *Spironolactone* 25 mg orally BD and other diuretics are often used.
- ◆ *Le Veen shunt* is a one way valve *peritoneo-venous shunt* done in order to drain ascitic fluid from peritoneal cavity to internal jugular vein.
- ◆ *Denver shunt* is similar to Le Veen type with additional facility of having a chamber to evacuate the debris by digital pressure.
- ◆ *Liver transplantation* may be beneficial for ascites in liver diseases.
- ◆ The cause is treated.
- ◆ TIPSS.

### Ascitic shunts are not used when there is

- ❖ Hepatorenal syndrome
- ❖ Bacterial peritonitis

### Complications of Ascitic Shunt Procedure

- ◆ Bleeding, infection.
- ◆ Displacement, blockage.
- ◆ Thrombosis of the vein, volume overload.

## BUDD-CHIARI'S SYNDROME

It is a *syndrome or group of disorders* caused by occlusion of major hepatic veins or IVC or both at or near the level of the hepatic vein ostia.

Usually three major hepatic veins are involved by thrombosis or block. It is common in *females*.

### Causes

1. Spontaneous thrombosis of hepatic veins (due to myeloproliferative diseases (50% commonly seen in adults and IVC webs commonly seen in children).
2. Neoplastic encroachment of hepatic veins.
3. Polycythaemia.
4. Contraceptive pills.
5. A membranous web in suprahepatic portion of IVC—a curable type of Budd-Chiari syndrome.
6. Plant extracts of *Senecio* and *Crotalaria* used in herbal tea in Jamaica causes acute Budd-Chiari syndrome.
7. Protein C, S or antithrombin III deficiency, Behcet's disease.

} Majority of cases

### Clinical Features

1. *In acute form*: Nausea, vomiting, severe pain in right hypochondrium, rapid enlargement of liver, hypotension and often death.
2. *In less sudden onset type*: Rapid development of ascites, hepatic insufficiency, oedema feet, features of IVC obstruction, hepatic coma can occur.

3. *Chronic type*: Present with hepatic cirrhosis, ascites, oesophageal varices, infection, which gradually leads to hepatic failure.
4. Jaundice, ascites and hepatomegaly is common.

*Fulminant type* is rare but has high mortality

## Investigations

- ◆ Transcutaneous Doppler will show hepatic vein thrombosis and collaterals across retrohepatic IVC.
- ◆ CT shows caudate lobe (segment I) hypertrophy with non-homogenous contrast enhancement.

## Treatment

- ◆ Anticoagulation, or *thrombolysis (TPA)* is the standard therapy.
- ◆ In membrane obstructing IVC, it can be cut by transatrial meatotomy, i.e. under guidance a catheter is passed, via right atrium to IVC and the web is cut. It is curable.
- ◆ In other types of portacaval or mesocaval shunts are tried but results are equivocal.
- ◆ Mesoatrial shunt between right atrium and SMV using Gortex graft.
- ◆ TIPSS/IVC stenting/liver transplantation is also useful.

**Aim:** Decompress liver and restore liver function; depends on type and extent of block and degree of liver damage—reversible/irreversible.

## HEPATIC FAILURE

### Aetiology

- ◆ Cirrhosis.
- ◆ Congenital diseases.
- ◆ Terminal liver diseases.
- ◆ Drug induced.
- ◆ Fulminant hepatitis.

### Precipitating Causes

- ◆ Infection.
- ◆ GIT bleeding.
- ◆ Surgery.
- ◆ General anaesthesia.
- ◆ Drugs—narcotics, analgesics.
- ◆ Old age.
- ◆ Electrolyte abnormality—hypokalaemia.

### Clinical Features

- ◆ Weakness and jaundice.
- ◆ Cyanosis.
- ◆ Fever, foetor hepaticus.
- ◆ Features of hyperdynamic circulation: Bounding pulse, flushed extremities, fresh crops of spider naevi, palmar erythemas.
- ◆ Loss of axillary and pubic hairs.
- ◆ In male, gynaecomastia and testicular atrophy.

### Fulminant Hepatic Failure

It occurs as a result of massive liver cell death due to:

1. Acute viral hepatitis.
2. Drugs like carbon tetrachloride, halothane, cytotoxic drugs.

### Presentation

- ❖ Sudden onset of the disease
- ❖ Personality changes
- ❖ Delirium
- ❖ Altered behaviour
- ❖ Oliguria and kidney failure

## Treatment

- ◆ Correction of precipitating factors, e.g. GIT bleed, infection, hypokalaemia.
- ◆ High carbohydrate diet.
- ◆ IV fluids or nasogastric feeding.
- ◆ Diuretics and morphine is avoided as it may precipitate coma.
- ◆ Correction of hypoglycaemia and electrolytes.
- ◆ Management of renal failure by haemodialysis.
- ◆ Correction of clotting factors.
- ◆ Temporary hepatic support like:
  - ▶ Exchange blood transfusion
  - ▶ Cross circulation between donor and patient
  - ▶ Extracorporeal perfusion of patient's blood through pigs liver.
  - ▶ Perfusion through columns of activated charcoal.

## HEPATIC ENCEPHALOPATHY

It is a chronic neuropsychiatric disorder wherein blood bypasses the liver, as a result of which, detoxification of *toxic products* do not occur, which, in turn enters the brain to cause toxicity.

### Toxic Products

1. Ammonia.
2. Aminobutyric acid.
3. Mercaptan.
4. Methionine.
5. Short chain fatty acids.

Collaterals developed in chronic liver disease like cirrhosis or after shunt surgeries, allow the blood with toxic products to enter the brain causing toxic effects (As toxic products of bacterial degradation, and nitrogenous material from the bowel is normally metabolized in the liver, these toxic products bypass the liver through collaterals to enter the cerebral circulation).

*Encephalopathy is precipitated by:*

- ◆ Large protein meal.
- ◆ GIT bleed.
- ◆ Hypokalaemia.
- ◆ Drug-induced diuresis.
- ◆ Uraemia.
- ◆ Narcotics.
- ◆ Infection.
- ◆ Dehydration.
- ◆ Constipation.

### Clinical Features

- ◆ Disorientation, *flapping tremor*.
- ◆ Cogwheel rigidity of limbs, ankle clonus.
- ◆ Slurred speech, intellectual deterioration.
- ◆ Personality changes.

**Grading of hepatic encephalopathy**

- ❖ Decreased skills—Subclinical
- ❖ Confusion—Grade 1
- ❖ Drowsiness—Grade 2
- ❖ Somnolence, hyperreflexia—Grade 3
- ❖ Coma—Grade 4

**Treatment**

To reduce the entry of nitrogenous products and toxic products from the gut into the circulation.

- ◆ Restriction of dietary protein.
- ◆ Removal of blood from bowel by purgation or enemas.
- ◆ Antibiotics administration.
  - Oral neomycin to reduce bacterial load inside the bowel lumen. 1 gm 4–6 hours or metronidazole 250 mg every 8 hours.
- ◆ Oral lactulose 30–50 ml 4 times a day.
- ◆ Sedatives like benzodiazepines and opioids are avoided.
- ◆ Correction of vitamin and electrolyte deficiencies.
- ◆ Lactulose enema: 300 ml of lactulose in 700 ml of water can be given.

**HEPATORENAL SYNDROME**

- ◆ It is development of acute renal failure due to severe hepatic or biliary disease with jaundice.
- ◆ Patient develops oliguria, azotaemia and hyponatraemia.

**Causes**

- ◆ Bile salt sludging in the tubules.
- ◆ Absorption of toxins.
- ◆ Increased ADH release.
- ◆ Hypoperfusion and renal ischaemia.
- ◆ It may be precipitated by surgery, stress.

**Treatment**

- ◆ Mannitol infusion.
- ◆ Diuretics.
- ◆ The cause is treated.
- ◆ Dialysis.
- ◆ Liver transplantation.

**HEPATIC RESECTION****Anatomy and Types of Resections**

- ◆ Right hepatic artery divides into anterior and posterior segmental arteries. Left hepatic artery divides into medial and lateral segmental arteries.
- ◆ Portal vein divides at porta hepatis as right and left branches and these branches enter the respective lobes of the liver.
- ◆ Hepatic veins originate as central vein of the liver which is formed by liver sinusoids. Middle hepatic vein is located in main lobar fissure. Left hepatic vein is in left segmental fissure—upper portion; right hepatic vein is in right segmental fissure. Inferior part of middle and

anterior segments are drained by middle hepatic vein. In 60% of cases middle and left hepatic veins join to form single trunk to enter IVC.

- ◆ Main portal fissure divides liver into two lobes by Cantlie's line from anteroinferior part of gallbladder fossa to left of the IVC with 75° angle with horizontal plane. It divides into right/left paramedian sectors/segments.
- ◆ Liver is divided into 8 segments (Couinaud segments). Right lobe is formed by segments V, VI, VII, VIII from front to behind. Left lobe formed by segments II, III and IV. Segment I (Spigel lobe) is caudate lobe which has got independent blood supply.
- ◆ Resection along the main portal fissure (Cantlie's line) and removal on right side is *right hemihepatectomy* and removal on left side is *left hemihepatectomy*.
- ◆ Resection on right of the ligamentum teres is called as *right trisegmentectomy* (older—right lobectomy); and left of the ligamentum teres is called as *left lateral segmentectomy*- segment II and III (older left lobectomy).
- ◆ Removal of single segment is called as *unisegmentectomy*.
- ◆ *Plurisegmentectomy* is removal of two or more segments. Segments IV and V are removed in carcinoma of gallbladder.
- ◆ Removal of small portion of liver either within the segment or traversing segments is called as *wedge resection* of the liver.

**Technical Principles**

Inflow (portal vein, hepatic artery, bile duct) control; outflow (hepatic veins) control; parenchymal transection; preservation of adequate sized liver remnant with intact inflow, biliary drainage and venous outflow; mobilisation of left and right triangular ligament; ligation of branches of portal vein and hepatic artery and resection of hepatic duct branch of the side; ligation of hepatic vein at a later period; proper haemostasis and ligation of individual biliary ductules. Retrohepatic caval dissection includes—dissection of right adrenal vein, inferior hepatic veins and IVC ligament.

**Types of Hepatectomy Techniques**

- ◆ Preliminary vascular section (Lortat-Jacob).
- ◆ Primary parenchymal transection (Ton That Tung in 1965).
- ◆ Selective clamping.
- ◆ Total vascular exclusion.
- ◆ Pedicular clamping (Pringles).
- ◆ Suprahilar clamping (Glissonian approach).
- ◆ Intrahepatic portal control.

**Procedure**

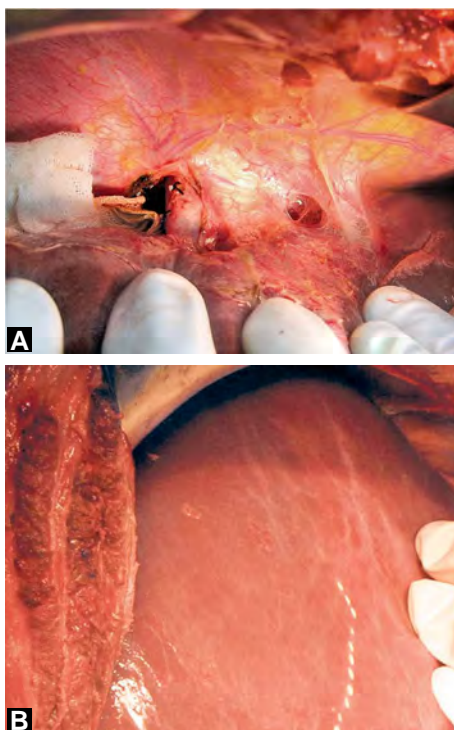
- ◆ Proper preoperative preparation is essential. LFT, prothrombin time is done. Adequate blood, FFP, along with central line is kept ready.
- ◆ Subcostal or thoracoabdominal incision is needed.
- ◆ Proper mobilisation, identification and dissection of portal areas is essential; dissection of hepatic veins, usage of vascular clamp secured ligation of branches of portal vessels and major hepatic veins are essential steps.
- ◆ Liver is dissected by finger dissection, back of scalpel, Cavitron ultrasonic surgical aspirator (CUSA), laser ligation of biliary radicles and vascular branches individually using non-absorbable sutures are other methods.

**Nomenclature for liver resection**

Segments	Brisbane - 2000	Couinaud - 1957	Goldsmith and Woodburne—1957
V-VIII	Right hemihepatectomy	Right hepatectomy	Right hepatic lobectomy
IV-VIII	Right trisectionectomy	Right lobectomy	Extended right hepatic lobectomy
II-IV	Left hemihepatectomy	Left hepatectomy	Left hepatic lobectomy
II, III	Left lateral sectionectomy	Left lobectomy	Left lateral segmentectomy
II, III, IV, V, VIII	Left trisegmentectomy	Extended left hepatectomy	Extended left lobectomy

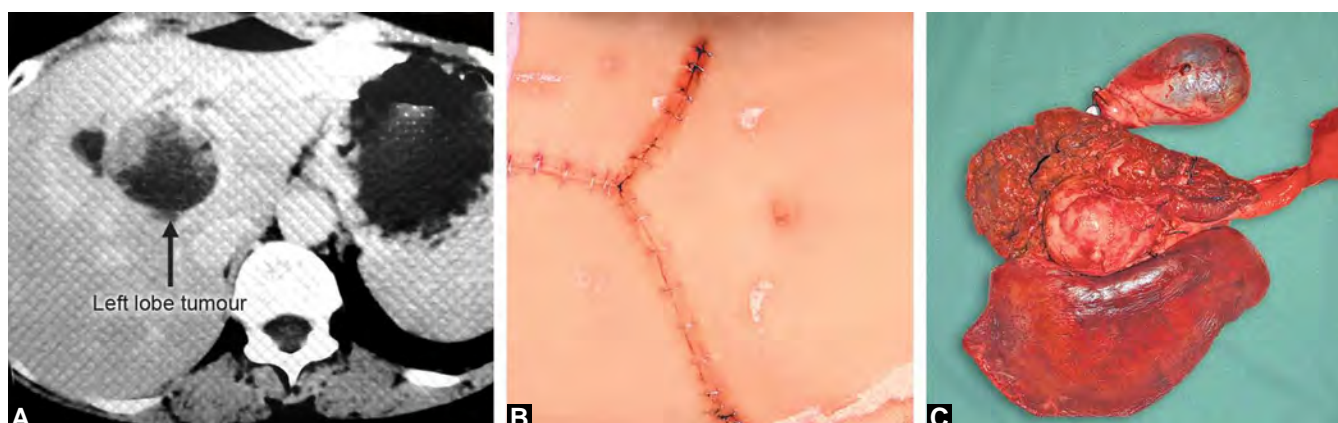
Indications	Contraindications
<ul style="list-style-type: none"> <li>Primary/Secondary malignancy from gallbladder or colorectum or carcinoids</li> </ul>	<ul style="list-style-type: none"> <li>Acute hepatitis—viral/alcoholic</li> </ul>
<ul style="list-style-type: none"> <li>Benign tumours of liver</li> </ul>	<ul style="list-style-type: none"> <li>Severe chronic hepatitis</li> </ul>
<ul style="list-style-type: none"> <li>Parasitic/non-parasitic cysts—hydatid cysts/simple liver cysts</li> </ul>	<ul style="list-style-type: none"> <li>Poor liver reserve</li> </ul>
<ul style="list-style-type: none"> <li>Refractory abscess/Caroli disease/RPC</li> </ul>	<ul style="list-style-type: none"> <li>Severe portal hypertension</li> </ul>
<ul style="list-style-type: none"> <li>LDLT</li> </ul>	<ul style="list-style-type: none"> <li>Severe coagulopathy</li> </ul>
<ul style="list-style-type: none"> <li>Klatskin's tumour</li> </ul>	<ul style="list-style-type: none"> <li>Severe thrombocytopenia—platelet count less than 30,000/-</li> </ul>
<ul style="list-style-type: none"> <li>Trauma to liver</li> </ul>	

- ◆ Control of bleeding is done by on table Pringle manoeuvre, gel foam, cautery, laser and vessel ligation.
- ◆ Proper antibiotic coverage is needed to prevent sepsis.
- ◆ Postoperative ICU care is needed.



**Figs 11.53A and B:** Liver resection. Suprahepatic outflow control and parenchymal marking is shown (Courtesy: Dr Ravishankar, MCh, Gastroenterologist and Liver Transplantation Surgeon, Bengaluru).

Techniques of parenchyma dissection	Intraoperative ultrasound is done to:
<ul style="list-style-type: none"> <li>Kelly clamp and bipolar forceps</li> </ul>	<ul style="list-style-type: none"> <li>Identifying tumour</li> </ul>
<ul style="list-style-type: none"> <li>Water jet dissection</li> </ul>	<ul style="list-style-type: none"> <li>Recognising the anatomy</li> </ul>
<ul style="list-style-type: none"> <li>Ultrasonic dissection</li> </ul>	<ul style="list-style-type: none"> <li>Unexpected contralateral tumour</li> </ul>
<ul style="list-style-type: none"> <li>Ultrasound cutting</li> </ul>	<ul style="list-style-type: none"> <li>Intrahepatic selective vascular control using a balloon catheter</li> </ul>
<ul style="list-style-type: none"> <li>Dissecting sealer</li> </ul>	<ul style="list-style-type: none"> <li>Guided biopsy</li> </ul>
<b>How much to cut:</b>	
<ul style="list-style-type: none"> <li>Remnant liver—<math>\geq 30\%</math> of the original liver volume with complete venous drainage is safe</li> </ul>	
<b>After completion of resection</b>	<b>Complications</b>
<ul style="list-style-type: none"> <li>Check for bile leak by injecting dye through cystic duct</li> </ul>	<ul style="list-style-type: none"> <li>Bleeding, infection, septicaemia</li> </ul>
<ul style="list-style-type: none"> <li>Check for absolute haemostasis.</li> </ul>	<ul style="list-style-type: none"> <li>Subphrenic abscess formation</li> </ul>
<ul style="list-style-type: none"> <li>Cholangiogram to confirm contralateral biliary patency</li> </ul>	<ul style="list-style-type: none"> <li>Bile leak, haemobilia</li> </ul>
<ul style="list-style-type: none"> <li>Fix the left lobe</li> </ul>	<ul style="list-style-type: none"> <li>Liver failure</li> </ul>
	<ul style="list-style-type: none"> <li>Pleural effusion, empyema</li> </ul>



**Figs 11.54A to C:** Liver resection of left lobe tumour. CT picture, incision scar and specimen are also shown.



## ■ PORTAL BILIOPATHY

- ◆ In patients with portal hypertension, particularly with extrahepatic portal vein obstruction, *portal biliopathy* producing biliary ductal and gallbladder wall abnormalities are common. Portal cavernoma formation, *choledochal varices* and ischemic injury of the bile duct have been implicated as causes of these morphological alterations.
- ◆ Gallbladder varices, bile duct varices are typical. Often it may cause torrential haemorrhage *per se* or on table if patient is undergoing choledocholithotomy.
- ◆ While a majority of the patients are asymptomatic, some present with a raised alkaline phosphatase level, abdominal pain, fever and cholangitis.
- ◆ Choledocholithiasis may develop as a complication and manifest as obstructive jaundice with or without cholangitis.
- ◆ Endoscopic sphincterotomy and stone extraction can effectively treat cholangitis when jaundice is associated with common bile duct stones.
- ◆ Definitive decompressive shunt surgery is sometimes required when biliary obstruction is recurrent and progressive.
- ◆ Portal biliopathy is a specific entity which may cause severe technical difficulties especially bleeding during ERCP sphincterotomy or open biliary surgeries.

# Chapter 12

## Gallbladder

*If the passages which convey the bile to the intestine be obstructed from inflammation or scirrhus, the bladder gets over-distended, and the bile regurgitates; it, therefore, becomes mixed with the blood, and the blood, passing over the whole system, carries the bile to every part of the body, which acquires the appearance of bile. But the hardened faeces are white and clayey, as not being tinged with bile, because the bowels are deprived of this secretion.*

—Aretaeus the Cappadocian

### CHAPTER OUTLINE

- ❖ Surgical Anatomy
- ❖ Oral Cholecystogram
- ❖ IV Cholangiogram
- ❖ Endoscopic Retrograde Cholangiopancreatography
- ❖ Percutaneous Transhepatic Cholangiography
- ❖ Magnetic Resonance Cholangiopancreatography
- ❖ Radioisotope Scan Study
- ❖ Peroperative Cholangiogram
- ❖ Postoperative T-tube Cholangiogram
- ❖ Congenital Anomalies of Gallbladder
- ❖ Choledochal Cysts
- ❖ Caroli's Disease
- ❖ Biliary Atresia
- ❖ Gallstones
- ❖ Acute Cholecystitis
- ❖ Acute Acalculous Cholecystitis
- ❖ Mirizzi Syndrome
- ❖ Empyema Gallbladder
- ❖ Mucocele of the Gallbladder
- ❖ Chronic Cholecystitis
- ❖ Murphy's Sign
- ❖ Gallstone Ileus
- ❖ Cholecystoses
- ❖ Dissolution Therapy for Gallstones
- ❖ Choledocholithiasis
- ❖ Sump Syndrome
- ❖ Courvoisier's Law
- ❖ Surgical Jaundice
- ❖ CBD Strictures
- ❖ Sclerosing Cholangitis
- ❖ Gallbladder Polyp
- ❖ Benign Biliary Papilloma
- ❖ Carcinoma Gallbladder
- ❖ Cholangiocarcinoma
- ❖ Klatskin Tumour
- ❖ Biliary Fistulas
- ❖ Hemobilia
- ❖ White Bile
- ❖ Cholecystectomy
- ❖ Laparoscopic Cholecystectomy
- ❖ Single Incision Laparoscopic Surgery (SILS) in Cholecystectomy
- ❖ Bile Duct Injuries
- ❖ Post-cholecystectomy Syndrome
- ❖ Biliary Dyskinesia

### ■ SURGICAL ANATOMY

#### Gallbladder

It is a pear-shaped (size is 5–12 cm) reservoir, located in a fossa on the inferior surface of the liver.

#### Parts

- ◆ Fundus, body, infundibulum and neck. *Hartmann's pouch* is pathological one located in the infundibular region created by gallstones.

*Your mind will give back exactly, what you put into it.*

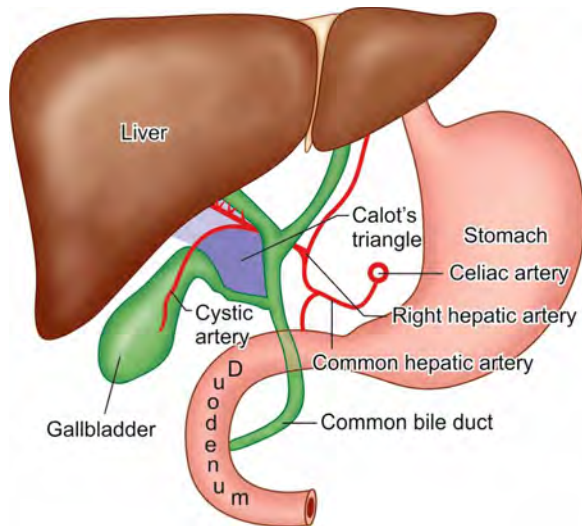


Fig. 12.1: Anatomy of gallbladder.

- ◆ Gallbladder drains through cystic duct into common hepatic duct to form common bile duct.
- ◆ It is supplied by cystic artery, a branch of right hepatic artery.
- ◆ *Calot's triangle* (Cystohepatic/Cystobiliary—JR Calot, France, 1891) is formed by common hepatic duct to the left, cystic duct below, and inferior surface of liver/cystic artery above. Cystic artery originating from right hepatic artery passes behind the common hepatic duct, enters the Calot's triangle to reach the gallbladder. It contains lymph node of 'Lund' (*Fred Bates Lund*)—*Mascagni's node*.
- ◆ Often cystic artery, hepatic artery, cystic duct have anomalous positions and anomalous origins. Both gallbladder neck and cystic duct contain mucosal fold called *valves of Heister*.

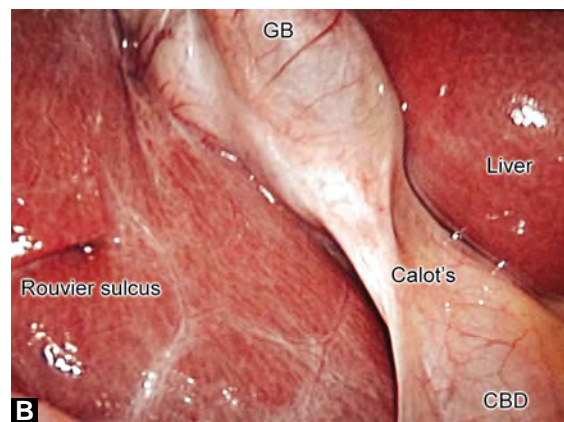
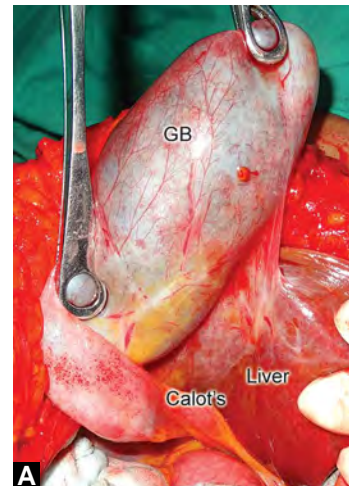
### Extrahepatic Biliary Tree

- ◆ The left hepatic duct is formed by the ducts draining II, III, IV segments of the liver. The right hepatic duct is formed by the ducts draining V, VI, VII, VIII segments of the liver. Both join to form the *common hepatic duct*, which joins with the cystic duct to form the *common bile duct*.
- ◆ Common bile duct is normally 10–12 cm in length and 6–8 mm in diameter. It joins the major pancreatic duct in the wall of the 2nd part of duodenum to form the *ampulla of Vater*. Intra-duodenal part of common bile duct (CBD) is surrounded by smooth muscle fibres called as *sphincter of Oddi*.

**Blood supply:** From gastroduodenal, retroduodenal, postero-superior pancreaticoduodenal arteries.

### Bile

- ◆ Daily up to 1000 ml of bile is secreted from the liver which contains water (98%), bile salts, bile pigments, fatty acids, lecithin, cholesterol, and electrolytes (sodium, potassium, chloride, bicarbonate, calcium, magnesium) with a pH more than 7.0.
- ◆ Main function of gallbladder is to concentrate and store the bile. Capacity of gallbladder is 40–50 ml.
- ◆ Bile salts form micelle which makes cholesterol soluble. Bile salts (i.e. salts of cholic and chenodeoxycholic acids) with formed deoxycholic acid (in the bowel) enters the enterohepatic circulation to get resecreted in the bile.



Figs 12.2A and B: Calot's triangle in (A): Open cholecystectomy method. (B) Laparoscopic method. Note the Rouvier sulcus in laparoscopic view which is an important landmark during dissection.

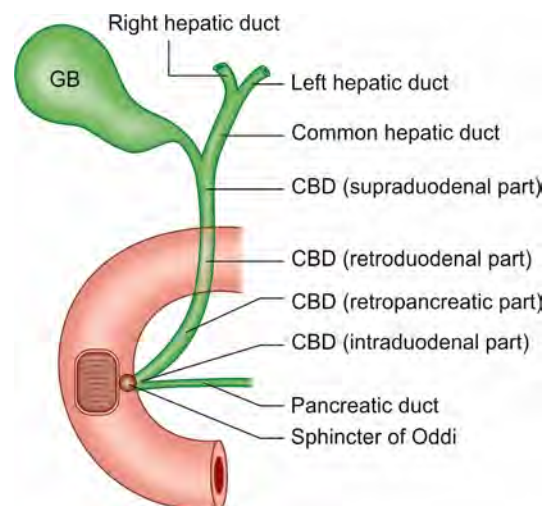
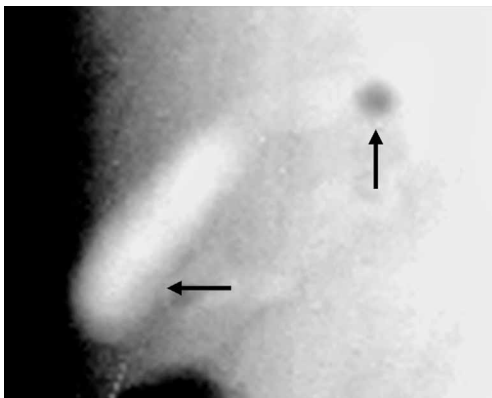


Fig. 12.3: CBD parts.

- ◆ Bilirubin conjugated in the liver is secreted into the bile, which in the bowel is converted into urobilinogen by bacteria. Urobilinogen gets absorbed in the bowel, enters the liver for resecretion again and part of it is excreted in the urine. Absence of urobilinogen in the urine signifies obstructive jaundice.
- ◆ In the absence of gallstones or any other disease, bile is sterile. Symptomatic gallstone disease shows positive culture for bacteria, commonest being *E. coli* and *Klebsiella*.

## ORAL CHOLECYSTOGRAM (OCG; GRAHAM-COLE TEST)

- ◆ This test is done to study function of the gallbladder.
- ◆ Patient is advised to have fat-free diet for 3 days. Previous night 6 tablets of *iopanoic acid* (Telepaque) is given orally. On the day of OCG, plain X-ray abdomen in erect posture is taken to visualise the gallbladder.



**Fig. 12.4:** Oral cholecystogram with smooth filling defect (Cystic duct stone).

- ◆ Later, fatty meal is given and one more X-ray is taken to see the change in the size of the gallbladder (which should be less in size compared to the earlier film, as the gallbladder contracts on stimulation with fat-rich meal if it is functioning normally). Smooth filling defect signifies non-opaque stone.

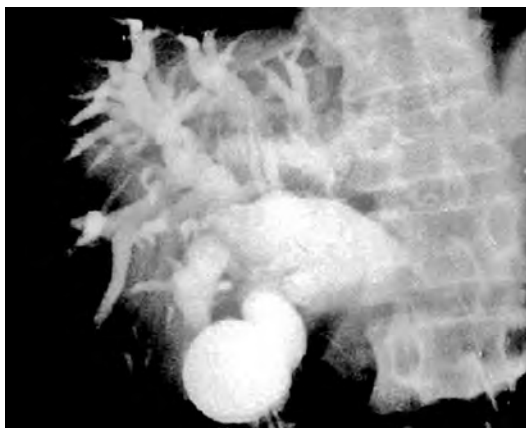
### Note:

- One tablet of Iopanoic acid is 500 mg.

### Contraindications

- ❖ Patients with serum bilirubin >3 mg%
- ❖ Acute cholecystitis
- ❖ Vomiting

## IV CHOLANGIOGRAM



**Fig. 12.5:** Cholecystocholangiogram. Note the dilated CBD, complete block in lower CBD, dilated biliary radicles.

- ◆ It is to visualise bile ducts and biliary tree, by injecting IV *Meglumine ioglycamate* (Biligram) and taking X-ray abdomen.
- ◆ It can be combined with OCG.
- ◆ Problems with this method are poor visualisation, drug reaction. It is not very useful if serum bilirubin is >3 mg%.

## ENDOSCOPIC RETROGRADE CHOLANGIO-PANCREATOGRAPHY (ERCP)

Through a side viewing gastroduodenoscope, sphincter of Oddi is cannulated, and dye is injected. Biliary and pancreatic trees are visualised. It is done under C-arm guidance and sedation like midazolam or propofol anaesthesia. Patient is placed in prone position with the head turned towards right. After passing gastroduodenoscope, sphincter is identified and cannulated. Under visualisation 3 ml of water-soluble iodine contrast is injected into the bile duct and pancreatic duct. When cannula goes upwards beside vertebra, it signifies that it is in bile duct; and if cannula goes across the vertebra, it is in pancreatic duct.

### Indications

- ◆ Malignancy—irregular filling defect.
- ◆ Chronic pancreatitis—‘chain-of-lakes’ appearance.
- ◆ Congenital anomalies.
- ◆ Stones.
- ◆ Stricture of biliary tree.
- ◆ Choledochal cyst.
- ◆ For sampling of biliary and pancreatic juices for analysis and cytology.
- ◆ Brush biopsy from tumour site.

### Therapeutic uses

- ❖ Extraction of stone from biliary duct
- ❖ Nasobiliary drainage
- ❖ Stenting of tumour in the CBD or in the pancreas
- ❖ Dilatation of the biliary stricture
- ❖ Endoscopic papillotomy

### Complications

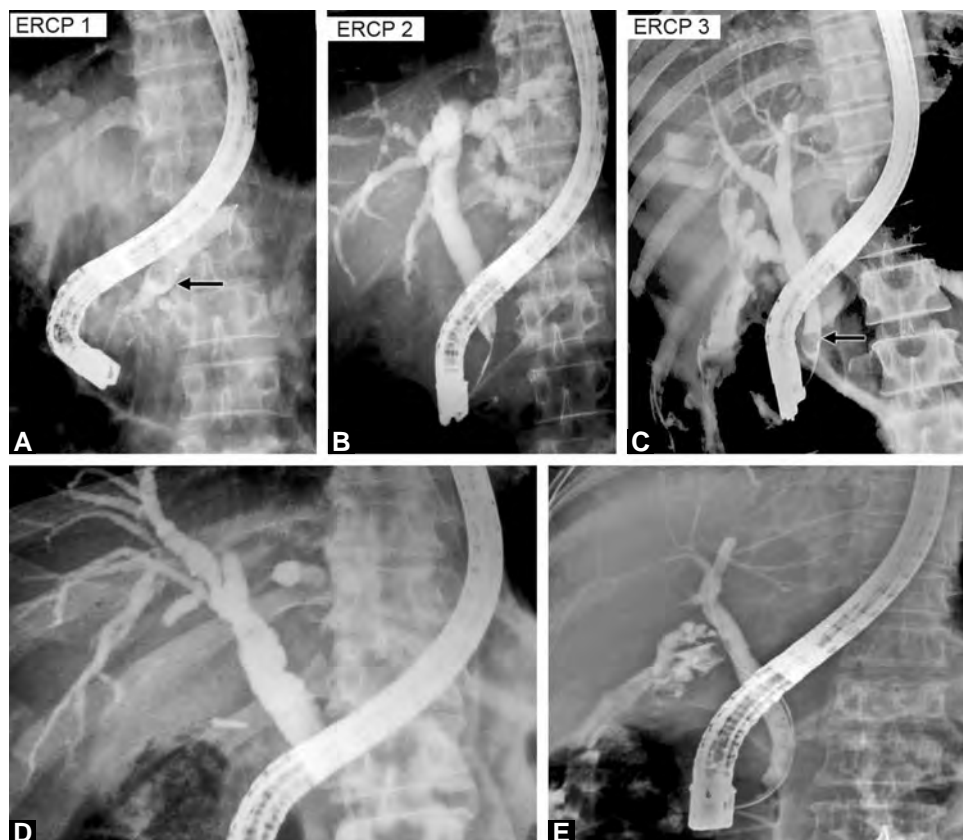- ◆ Pancreatitis.
- ◆ Duodenal injury, perforation.
- ◆ Cholangitis.
- ◆ Bleeding from pancreaticoduodenal artery.
- ◆ Sphincter stenosis.

### Relative Contraindications

- ◆ Acute pancreatitis.
- ◆ Previous gastrectomy.

*There is little if any restriction to respiratory movements of the abdominal wall in pleuropneumonia.*

—C Allan Birch



**Figs 12.6A to E:** ERCP being done. Note the gastroduodenoscope with injection of dye. (A) Shows filling defect in the CBD. (B) Shows dilatation of biliary radicles. (C) Shows radiolucent stone (smooth filling defect) in distal CBD which can be removed through ERCP. Antibiotics should be given to prevent cholangitis.

## ■ PERCUTANEOUS TRANSHEPATIC CHOLANGIOGRAPHY (PTC)

- ◆ It is done in case of severe obstructive jaundice under the cover of antibiotics and after control of any bleeding tendency—by giving injection vitamin K or FFP transfusion.

### Indications

- ❖ Failure of ERCP
  - ❖ High biliary strictures
  - ❖ Klatskin tumour
  - ❖ High blocks when external external catheter drainage is needed
  - ❖ Stenting in high tumours
- ◆ With the help of fluoroscopy (C-arm)/US/CT guided, *Chiba* or *Okuda needle* which is long, flexible, thin, blunt, without a bevelled end (15 cm long and 0.7 mm in diameter) is passed into the liver through right 8th intercostal space in midaxillary line. Once needle is in the dilated biliary radicle, bile is aspirated (sent for culture, cytology, analysis) and then water-soluble iodine dye is injected into the same so as to visualise the dilated biliary radicles, also the site and extent of the obstruction, i.e. tumour, stricture.
  - ◆ Procedure can be used for therapeutic stenting across the biliary tree through the obstruction either in the hepatic ducts or in the CBD into the duodenum.

- ◆ It is used whenever ERCP fails, in high strictures (in CHD), in Klatskin tumour, in catheter drainage (external) in high blocks, in stenting high tumours.

### Prerequisites for PTC

- ◆ Should have normal prothrombin time (or should be made normal by injection of vitamin K or FFP).
- ◆ Should be a last and final inevitable method for evaluation or therapy.
- ◆ Blood for transfusion in case of bleed, consent for intervention in need, antibiotic prophylaxis—are a must prior to PTC.

#### Note:

- Chiba is a University in Japan. Okuda is the name of the person.
- **PTBD** is percutaneous transhepatic biliary drainage. It can be *external* or *internal*. It is done through PTC.

### Complications

- ❖ Bleeding
- ❖ Biliary leak and biliary peritonitis
- ❖ Septicaemia

## ■ MAGNETIC RESONANCE CHOLANGIO-PANCREATOGRAPHY (MRCP)

- ◆ It is a non-contrast non-invasive imaging method, better than ERCP as diagnostic tool in biliary and pancreatic diseases.

## RADIOISOTOPE SCAN STUDY

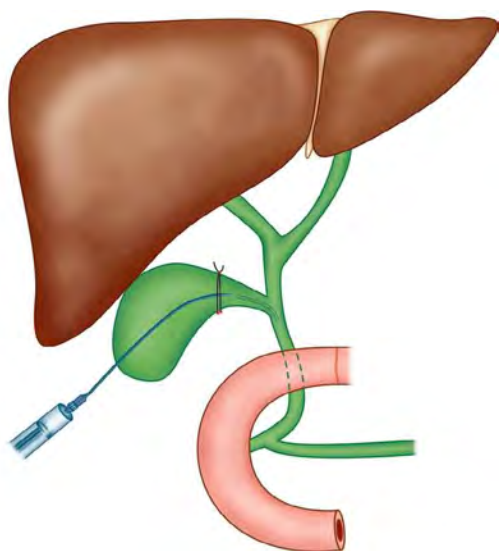
- ◆  $I^{131}$  Rose Bengal and  $Tc^{99}$  labelled iminodiacetic acid (HIDA, PIPIDA) are very useful in diagnosing acute cholecystitis and other biliary disorders, like biliary atresia.

### Note:

- HIDA is Hippuran Iminodiacetic Acid.
- Technetium 99 m IDA scan using bilirubin analogue like choletec or hepatolite is done currently. It is a dynamic scintiscan that assesses function of the gallbladder and cystic duct patency.

## PEROPERATIVE CHOLANGIOGRAM

- ◆ It is done during CBD exploration for stricture, residual CBD stones, atresia, choledochal cyst, cholangitis.
- ◆ Fine polythene catheter is passed into the CBD through cystic duct and dye is injected. Under C-arm image-intensifier, any block or stricture can be identified and completion of the procedure can be confirmed.
- ◆ **Complications,**
  - ▶ Infection.
  - ▶ Bile leak.



**Fig. 12.7:** Peroperative cholangiogram. Fine catheter is passed through cystic duct into the CBD. Care should be taken to avoid air getting into the CBD (it will mimic stone). Dye is injected under C-arm guidance.

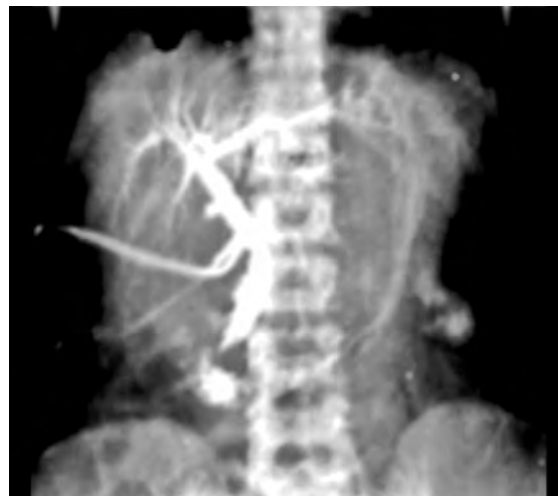- ◆ **Precaution:** Air should not be present in the syringe, as it may mimic stones.

## POSTOPERATIVE T-TUBE CHOLANGIOGRAM

After choledochotomy, *Kehr's T-tube* is placed in CBD for 14 days and then water-soluble dye is injected into the tube and X-ray is taken. Complete free flow of dye into the duodenum indicates that there is no blockage. T-tube can then be removed safely. Block indicates residual CBD stones.

### Residual CBD stones are removed by:

- ❖ Dormia basket
- ❖ Fogarty's catheter
- ❖ Choledochoscope
- ❖ ERCP

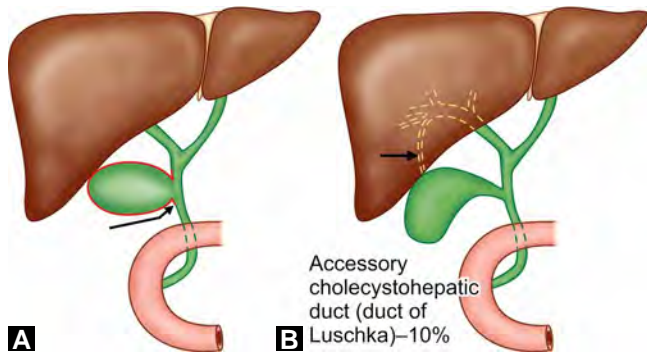


**Fig. 12.8:** T-tube cholangiogram.

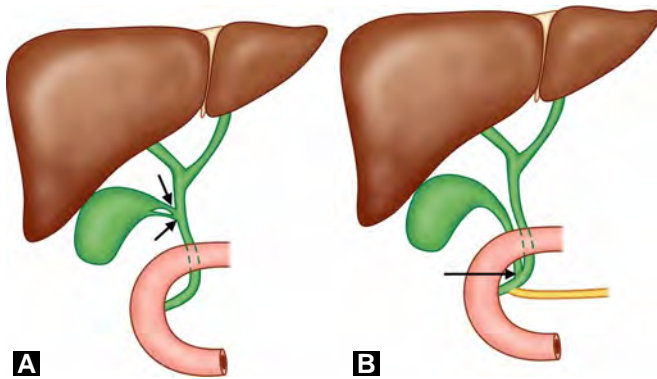
## CONGENITAL ANOMALIES OF GALLBLADDER

- ❖ *Absence of gallbladder*—rare
- ❖ *Phrygian cap*—cap-like projection and bend over the fundus of the gallbladder (*Phrygia* is an ancient Asian country—Mongolia) (Liberte cap of French revolution). It is identified in cholecystogram. It is 6% common
- ❖ *Double/triple gallbladder*—additional one may be intrahepatic. Cystic ducts may join to form a common cystic duct which joins the CBD or cystic duct of each gallbladder may join separately into the CBD
- ❖ *Mobile/floating/mesenteric gallbladder*—gallbladder has a long mesentery attached. It may cause torsion. It can cause recurrent abdominal pain. Its removal is easier through laparoscopic or open method
- ❖ *Long cystic duct* with low insertion of the cystic duct into CBD near the ampulla. This is important in all pancreatic/biliary/laparoscopic biliary surgeries
- ❖ *Absence of cystic duct* with gallbladder directly entering the CBD through a wide opening near infundibulum
- ❖ *Accessory cholecystohepatic duct (duct of Luschka)* may be present (10%) which, if not identified and ligated during cholecystectomy, will cause biliary fistula/ peritonitis due to continuous leak
- ❖ *Cystic artery may originate anteriorly* (15%) from right hepatic artery/from common hepatic artery
- ❖ Very tortuous common or right hepatic artery in front of the origin of the cystic duct is called as *Moynihan's caterpillar hump*. It is important cause of bleeding in cholecystectomy
- ❖ There may be *double cystic duct* or cystic duct may insert high into the common hepatic duct or right hepatic duct

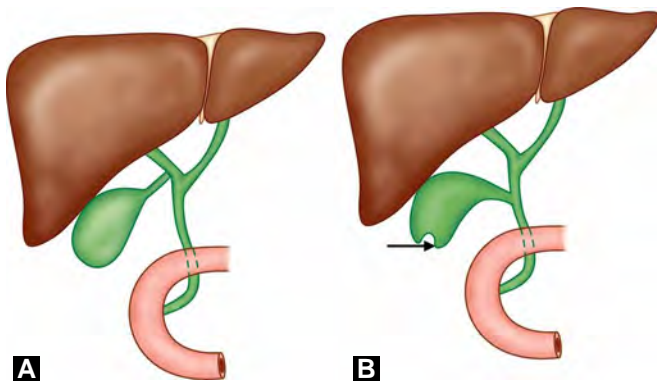
*If vomiting or distinct nausea precedes pain, the case is not one of appendicitis.— John B Murphy*



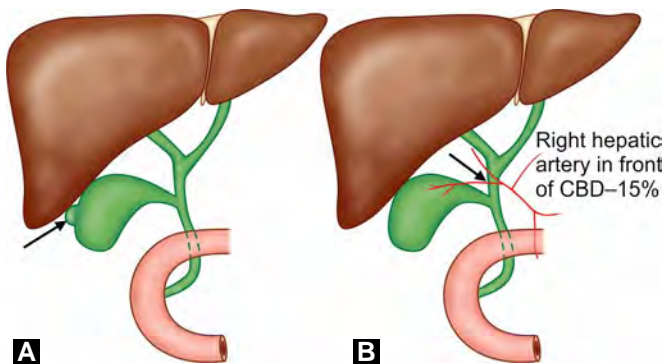
**Figs 12.9A and B:** (A) Cystic duct is absent with wide communication into CBD. There is higher chance of CBD injury here; (B) Accessory cholecystohepatic duct (*Duct of Luschka*—10%). It may cause bile leak postoperatively if it is not ligated during cholecystectomy.



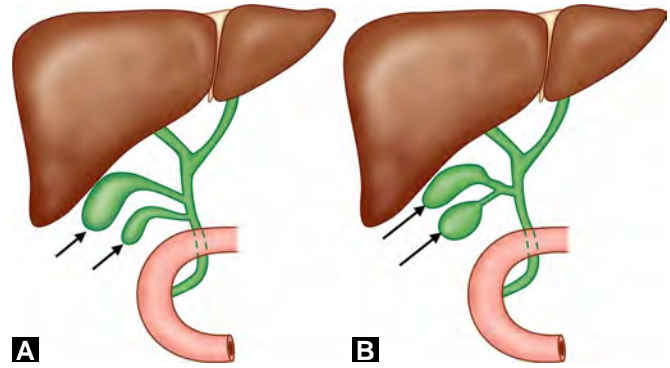
**Figs 12.10A and B:** (A) Double cystic ducts from the gallbladder joining the CBD; (B) Long cystic duct joining the CBD very low.



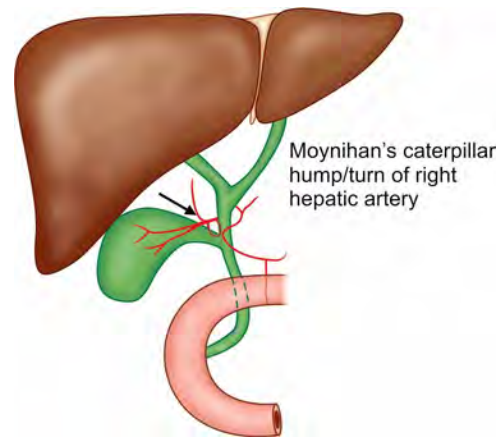
**Figs 12.11A and B:** (A) Cystic duct joining the right hepatic duct—a variation; (B) *Phrygian (cap) gallbladder*.



**Figs 12.12A and B:** (A) Gallbladder diverticulum; (B) Cystic artery originates from right hepatic artery which is anterior to common bile duct.



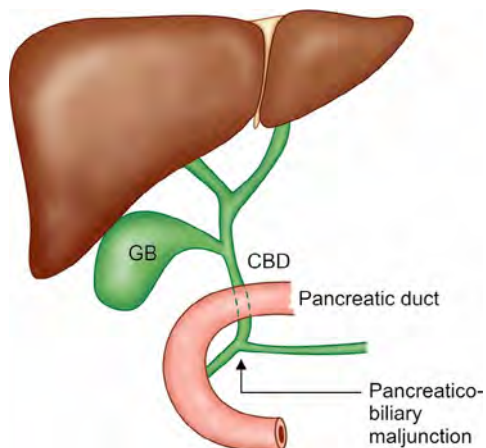
**Figs 12.13A and B:** Double gallbladder. One may be intrahepatic. It may have separate cystic ducts joining CBD or two cystic ducts join to form single duct to join the CBD.



**Fig. 12.14:** *Moynihan's caterpillar turn/hump* is bend of right hepatic artery in front of/close to cystic duct. It may get injured during cholecystectomy causing torrential haemorrhage.

## ■ CHOLEDOCHAL CYSTS

- ◆ It is defined as isolated/focal or combined/diffuse congenital dilatation of extra or intrahepatic biliary tree.
- ◆ It is congenital cyst with partial or complete weakness of the CBD biliary wall.
- ◆ It may be single/multiple or extrahepatic or intrahepatic.
- ◆ It is more common in Asia. It is common in Japan. Its incidence is 1 in 1000 hospital admissions.
- ◆ It is often associated with pancreaticobiliary maljunction. There is long common channel more than 2 cm. It causes reflux of pancreatic juice into the bile duct, enzymatic destruction of the bile duct wall, ductal wall weakening and dilatation—*Babbitt theory*.
- ◆ During embryogenesis, there is abnormal early canalisation of bile duct with distal obstruction causing increased proximal pressure, weakening and ductal dilatation.
- ◆ Reduced postganglionic autonomic neurons in the distal portion of the cyst causing its poor function distally.
- ◆ Chronic inflammation, sparse mucin glands and metaplasia are the histological features. Histologically, it is either glandular with normal cuboidal epithelium with cavities in the mucosa. Or fibrotic type with fibrous cyst wall with thickened bile duct.



**Fig. 12.15:** Pancreaticobiliary maljunction. Here pancreatic duct joins CBD more proximally than normal causing reflux of pancreatic enzymes into the CBD. It leads into weakening, dilatation and choledochal cyst.

### Types of Choledochal Cysts (Todani Modification of Alonso-Lej Classification)

- ◆ Type I: Dilatation of extrahepatic biliary tree (60%).
  - ▶ Type Ia—cystic.
  - ▶ Type Ib—focal segmental (saccular).
  - ▶ Type Ic—fusiform.
- ◆ Type II: Diverticulum of extrahepatic biliary tree (5%).
- ◆ Type III: Choledochocele—cystic dilatation of intraduodenal part of CBD (5%).
- ◆ Type IV: Dilatation of extra- and intrahepatic or multiple parts of extrahepatic biliary tree (30%).
  - ▶ Type IVa: Dilatation of extrahepatic and intrahepatic biliary tree. It is 2nd most common.
  - ▶ Type IVb: Dilatation of multiple sections of the extrahepatic bile duct.
- ◆ Type V: Dilatation of the only intrahepatic biliary tree (*Caroli's disease*).

### Presentations

- ◆ Common in females 4:1. Common in Japan.
- ◆ Present in infants, children and even in adults.
- ◆ Obstructive jaundice (80%), pain in right hypochondrium, cholangitis.
- ◆ Mass per abdomen—mass is to the right and above the umbilicus, smooth, soft, not moving with respiration, not mobile and resonant (30%).
- ◆ Failure to thrive.

#### Triad of choledochal cyst (seen in 10% of cases)

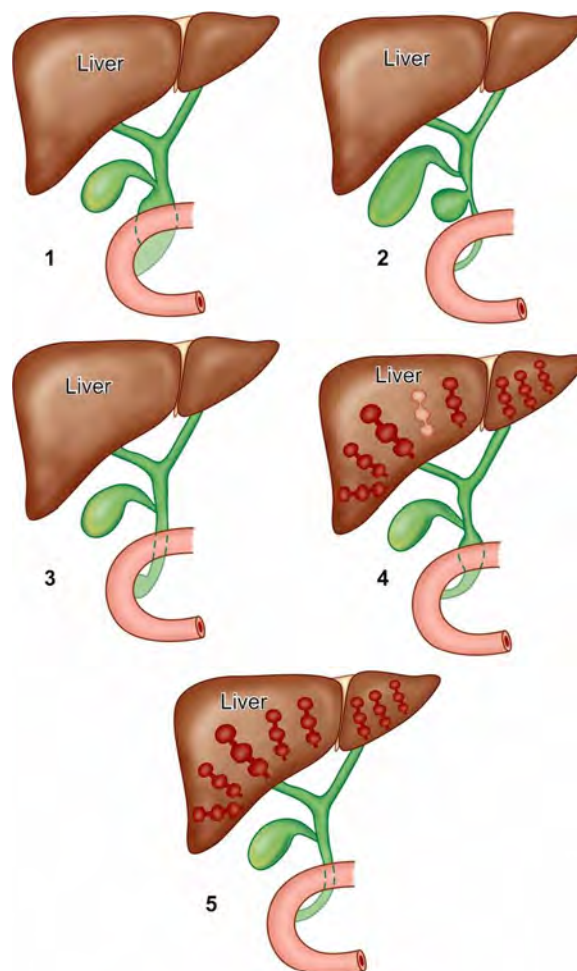
- ❖ Right upper quadrant pain
- ❖ Jaundice
- ❖ Palpable abdominal mass

#### Swellings which appear and disappear

- ❖ Hydronephrosis
- ❖ Intussusception
- ❖ Pseudopancreatic cyst
- ❖ Choledochal cyst

### Complications

- ◆ Pancreatitis, mainly in type III.
- ◆ Suppurative cholangitis.
- ◆ Gallstone and CBD stone formation.
- ◆ Biliary cirrhosis—secondary; portal hypertension.
- ◆ Rupture of cyst and peritonitis.
- ◆ Cholangiocarcinoma in CBD (30% of cases). Incidence of malignancy increases with age and is more common in type I and V. Reflux, stasis, superinfection, pancreaticobiliary maljunction are the causes for malignant transformation. Malignancy can develop even in residual cyst or at anastomotic site.
- ◆ Malignancy is common in posterior wall.



**Fig. 12.16:** Different types of choledochal cysts—(1) Fusiform type, (2) Saccular type, (3) Choledochocele, (4) Fusiform + Intrahepatic type, (5) Intrahepatic type.

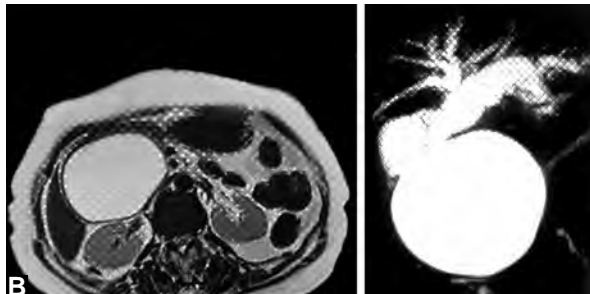
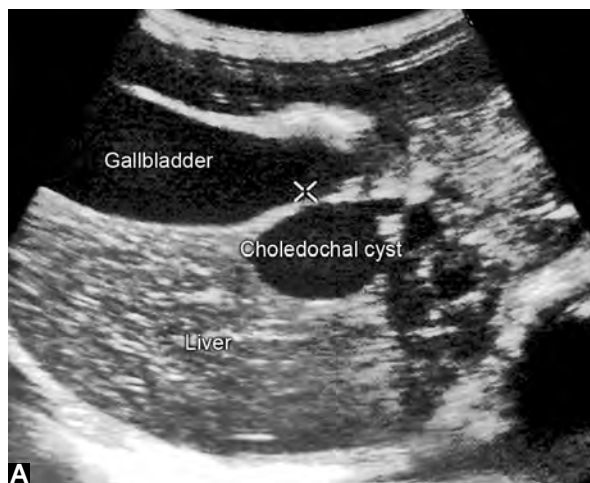

## Diagnosis

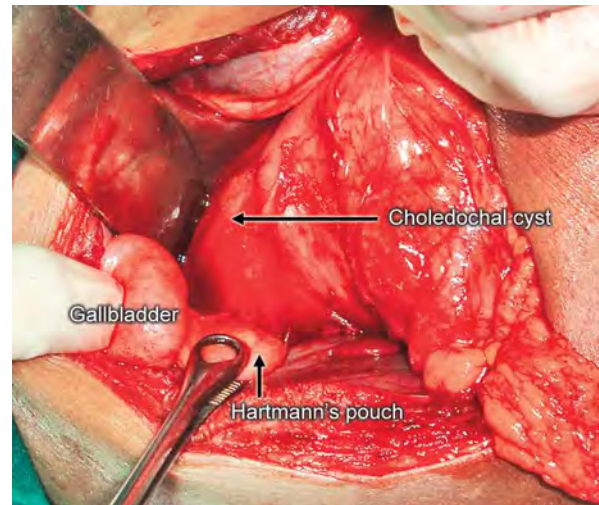
- ◆ US abdomen—unilocular cyst mainly in infants.
- ◆ CT scan—mainly to see intrahepatic biliary system.
- ◆ Hepatobiliary nuclide scanning.
- ◆ ERCP, Cholangiography—to see ductal anatomy.
- ◆ MRCP—to see status of pancreatic and biliary system and pancreaticobiliary maljunction—*ideal*.
- ◆ Liver function tests.
- ◆ PTC to see intrahepatic biliary tree.

## Treatment

- ◆ *Resection of extrahepatic biliary tree* with removal of choledochal cyst along with cholecystectomy and Roux-en-Y hepaticojejunostomy is the ideal treatment for choledochal cyst especially types I, II and IVb.
- ◆ In type I—excision of cyst with its mucosa and reconstruction by Roux-en-Y hepaticojejunostomy.
- ◆ In type II—excision of the diverticulum and suturing of the CBD wall, can be done.
- ◆ In type III—endoscopic sphincterotomy is done. Excision is also often needed.
- ◆ Intrahepatic dilatation is difficult to treat. If it is localised, hepatectomy is sufficient, but if it is diffuse, liver transplantation may be required.
- ◆ In type IV, if cyst is adherent to portal vein posteriorly, that part of the cyst wall over the portal vein is left behind. But mucosa of the part should be removed (*Lily's operation*).



**Figs 12.17A and B:** CT picture of choledochal cyst (Courtesy: Dr Yogish Kumar, MS, Professor, KMC, Mangaluru).



**Fig. 12.18:** Choledochal cyst on table look.

- ◆ Cholecystectomy is a must in all these types. Incidence of gallbladder carcinoma is also high in these patients.
- ◆ If cyst has already turned into malignancy—adenocarcinoma, then radical surgery and chemotherapy is given.
- ◆ *Liver transplantation* is the choice in type IV and V cases.

## CAROLI'S DISEASE

- ◆ It is congenital, nonfamilial, multiple, irregular, dilatations of the intrahepatic ducts with stenotic segments in between. It is associated with *congenital hepatic fibrosis* and *medullary sponge kidney*.
- ◆ It can also be included under type V choledochal cyst.

### Investigations

- ❖ CT scan
- ❖ ERCP
- ❖ LFT
- ❖ MRCP

## Complications

- ◆ Recurrent cholangitis.
- ◆ Stones in biliary tree.
- ◆ Portal hypertension.
- ◆ Cholangiocarcinoma (7%).

## Treatment

1. Liver transplantation.
2. Hepatectomy.

## BILIARY ATRESIA

- ◆ It may be either due to viral infection or defective embryogenesis resulting in fibrosis of extra- and intrahepatic biliary tree.
- ◆ Incidence is 1 in 10,000.
- ◆ It is obstructive cholangiopathy with inflammation, destruction and obliteration predominantly involving the extrahe-

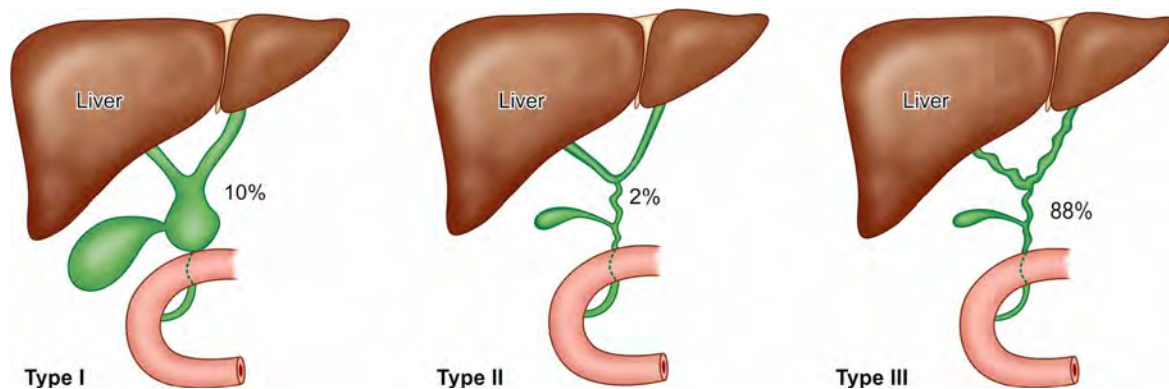


Fig. 12.19: Types of biliary atresia.

patric biliary tree. There is bile duct proliferation, cellular and canalicular bile stasis, bile plugs in portal tract bile system, periportal inflammation and fibrosis.

#### Aetiology of biliary atresia

- ❖ Infections—cytomegalovirus, reovirus, rotavirus and human papilloma virus
- ❖ Immune and autoimmune diseases
- ❖ Abnormal development of the biliary system
- ❖ Toxins
- ❖ Vascular defects of the hepatic artery

#### Classification

- ◆ *Correctable*—10%.
- ◆ *Noncorrectable*—90%.

#### Biliary atresia

- ❖ Type I: Atretic CBD—10%
- ❖ Type II: Atretic CBD and common hepatic duct
- ❖ Type III: Atretic CBD, common hepatic duct and right and left hepatic ducts—88%

Biliary atresia can be:

- ◆ *Perinatal acquired* (70%), not associated with congenital anomalies.
- ◆ *Fetal/embryonic* (30%) is associated with congenital anomalies.

It may be associated with other congenital anomalies (20%) of the GIT—(malrotation, annular pancreas duodenal atresia) and congenital heart diseases, polysplenia, situs inversus, absent vena cava, preduodenal portal vein.

#### Clinical Features

- ◆ Progressive jaundice in a newborn.
- ◆ Steatorrhoea (Pale stool is common).
- ◆ Hepatomegaly.
- ◆ Splenomegaly with portal hypertension.
- ◆ Osteomalacia.
- ◆ Biliary rickets.
- ◆ Severe pruritus.
- ◆ Clubbing, skin xanthomas.

#### Differential Diagnosis

- ◆ Neonatal hepatitis.
- ◆ Choledochal cyst.
- ◆ Cholestatic jaundice.
- ◆ Sclerosing cholangitis.
- ◆ Metabolic diseases.
- ◆ Storage disorders.
- ◆ Alagille syndrome—hypoplastic biliary ducts.

#### Diagnosis

- ◆ Liver function test—conjugated hyperbilirubinaemia.
- ◆ US abdomen shows triangular cord, tubular echogenicity extending above the bifurcation of the portal vein which is more than 4 mm thick—diagnostic.
- ◆ MRCP—100% accuracy.
- ◆ Radioisotope study (HIDA or PIPIDA scan).
- ◆ On table cholangiogram.
- ◆ Liver biopsy (Percutaneous)—is usually first test obtained.
- ◆ Rose Bengal I<sup>131</sup> study, if shows <10% secretion it is biliary atresia. If secretion is >10%, it is more likely to be hepatitis.

#### Treatment

- ◆ *In correctable cases*: Roux-en-Y jejunal anastomosis.
- ◆ In noncorrectable cases, hepaticportojejunosotomy (*Kasai's operation*).
- ◆ Liver transplantation is becoming more popular in biliary atresia—ideal.
- ◆ Presently *Kasai (1974) porto-enterostomy* is done (in 8 weeks) as a preliminary procedure followed by liver transplantation eventually.
- ◆ After opening the abdomen, gallbladder is cannulated and on table cholangiogram is done to confirm atretic segment. Liver biopsy should also be done at the same time. If biliary patency is found, procedure is abandoned. In atretic biliary tree, gallbladder is dissected off the liver and by applying traction to it, fibrotic atretic biliary tree is felt and dissected upto intrahepatic segment (up to the segmental branches of portal vein). Portal plate is anastomosed to Roux-en-Y part of the small

*Porcelain gallbladder is radiopaque gallbladder, due to calcification of the gallbladder wall following chronic cholecystitis which has got high malignant potential.*

bowel. Postoperatively, antibiotics, intravenous corticosteroids initially, later orally (for 6–12 weeks), ursodeoxycholic acid (for 1 year), nutrition, medium chain and essential fatty acids, essential elements supplementation is given. Success of procedure depends on age of the patient; presence of cholangitis; ductule size (more than 200  $\mu\text{m}$  is better); bridging fibrosis; type of atresia; bilirubin level. Eventually cholangitis, portal hypertension, variceal bleeding will develop.

## GALLSTONES

*Thus with stone obstruction of the common duct, dilatation of the gallbladder is rarely observed; the organ has already undergone contraction; with obstruction from other causes, dilatation is to be expected.*

—Ludwig Courvoisier, 1890



Fig. 12.20: Multiple gallstones removed along with gallbladder.

### Types

1. *Cholesterol stones* (Cholesterol solitaire—radiating crystalline appearance) are 6% common, often solitary.
2. *Mixed stones* are 90% common. It contains cholesterol, calcium salts of phosphate carbonate, palmitate, proteins, and are multiple faceted.
3. *Pigment stones* are small, black or greenish black, multiple. Often they can be sludge like.

Common in “*Fat, Fertile, Forty, Flatulent, Female*”.

Common in western countries and in north India.

### Pathogenesis

#### I. Metabolic:

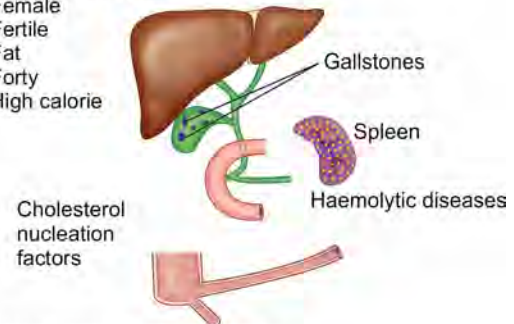
- ▶ Cholesterol is synthesised in liver. Its solubility is determined by relative concentration of cholesterol, bile salts and lecithin. Altered levels of cholesterol, lecithin, and bile salts in bile reduces the micelle concentration in the bile leading to precipitation of insoluble cholesterol, hence, the stone formation (*Lithogenic bile*).
- ▶ Normal ratio of bile salt and lecithin to cholesterol is 25:1. Ratio below 13:1 leads to precipitation of cholesterol. Insoluble cholesterol is within the soluble micelle which is formed by lecithin and bile salts. If cholesterol component

#### Altered GB function

- Stasis
- Poor emptying
- Poor absorption
- Infection

#### Supersaturated bile

- Female
- Fertile
- Fat
- Forty
- High calorie



#### Altered enterohepatic circulation

- Ileal resection
- Ileal diseases
- Altered bowel transit time
- Altered bowel flora
- Cholestyramine
- Deoxycholate

Fig. 12.21: Diagram showing different causes of gallstone formation.



Fig. 12.22: Pigment stones showing faceted look.

increases, bile gets supersaturated and inadequate micelle makes insoluble cholesterol to undergo crystallisation and cholesterol monohydrate stone formation (*Admiron's triangular hypothesis*).

- ▶ Some cholesterol remains as bilayered lipid vesicles which are soluble. A specific heat labile glycoprotein in bile induces cholesterol monohydrate crystal formation in the vesicle and causes their aggregation. It is called as *nucleation*.
- ▶ Eventual precipitation and stone formation occurs by infection/infestation; pancreatic fluid reflux into CBD causing conversion of toxic lecithin to lysolecithin which is also toxic (causes supersaturated bile); bile stasis or altered enterohepatic circulation.
- ▶ Any condition which either increases the cholesterol secretion in the bile or reduces the bile salt concentration causes cholesterol stone formation. Old age; OCP; obesity; clofibrate may increase cholesterol secretion. Oestrogen, ileal resection and cholestyramine reduce the bile salt concentration.

- ▶ Chenodeoxycholic acid and ursodeoxycholic acid prevent cholesterol stone formation by maintaining bile acid pool; reducing cholesterol synthesis and secretion; converting supersaturated bile into normal bile.

#### Factors altering the cholesterol to bile salt ratio

- ❖ Obesity, Mutation (MDR3, CYP7, A1)
- ❖ Drugs
  - Oral contraceptive pills, octreotide
  - Clofibrate
  - Cholestyramine
- ❖ Ileal disease
- ❖ Ileal resection
- ❖ Altered enterohepatic circulation

#### II. Infections and Infestations:

- ▶ Bacteria like *E. coli*, *Salmonella*
- ▶ Parasites like *Clonorchis sinensis* and *Ascaris lumbricoides* are often associated.
- ▶ *Moynihan's aphorism*: "A gallstone is a tomb stone erected to the memory of the organism within it."

#### III. Bile stasis:

- ▶ Occurs due to estrogen therapy, pregnancy, vagotomy and in patients who are on long-term intravenous fluids or TPN.

#### IV. Increased bilirubin production

- ▶ Due to any of the causes of haemolysis as in hereditary spherocytosis, sickle cell anaemia, thalassaemia, malaria, cirrhosis. Here pigment stones are common.

#### Saint's triad

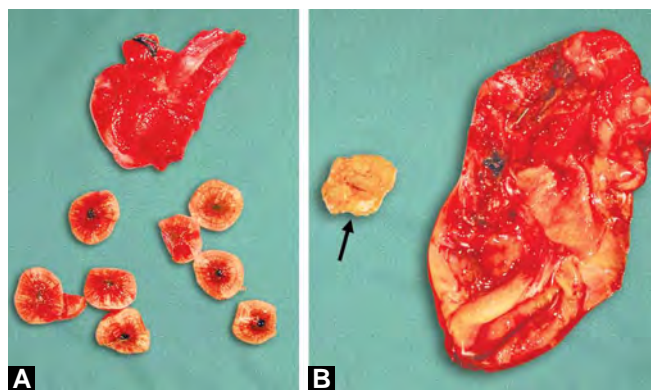
- ❖ Gallstones
  - ❖ Diverticulosis of the colon
  - ❖ Hiatus hernia
- ◆ Rarely centre of the stone contains radiolucent gas which is either triradiate (*Mercedes Benz sign*) or biradiate (*Seagull sign*).
  - ◆ Sometimes gallbladder may be filled by 'toothpaste like' material which is a mixture of calcium carbonate and phosphate, which on plain X-ray looks like an opacified gallbladder, so called as *Limy gallbladder*.
  - ◆ Only 10% of gallstones are radio-opaque, 90% are radiolucent.



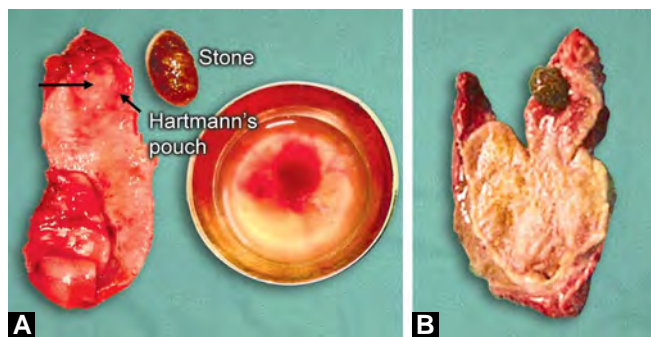
Fig. 12.23: Multiple gallstones collected during cholecystectomy.

#### Note:

- Black pigment stones are common in gallbladder. It is usually calcium bilirubinate, calcium phosphate and bicarbonate stone with a matrix. It is common in haemolytic disorders. They are usually multiple, small black and hard in consistency. Mucin A and mucin C5 secreted by biliary glands may be the aetiology. Cholesterol component here is less than 30%. It is often seen in cirrhosis. They almost always form in gallbladder. They are common in Asia and Japan.
- Brown pigment stones are formed in biliary tree as primary biliary stones. It is commonly due to infection like *Escherichia coli* and bacteroides (98%) with bacterial nidus at the centre (often *Ascaris lumbricoides* or *Clonorchis sinensis* infestation or foreign body or stents). They secrete  $\beta$  glucuronidase to cause hydrolysis of soluble conjugated bilirubin to insoluble calcium bilirubinate. It also contains calcium palmitate, calcium stearate and cholesterol. They are brownish yellow, soft and mushy.



Figs 12.24A and B: (A) Gallstones removed, on cutting showing central nidus; (B) Thickened gallbladder due to chronic cholecystitis with single cholesterol stone.



Figs 12.25A and B: Gallbladder with stone removed from Hartmann's pouch.

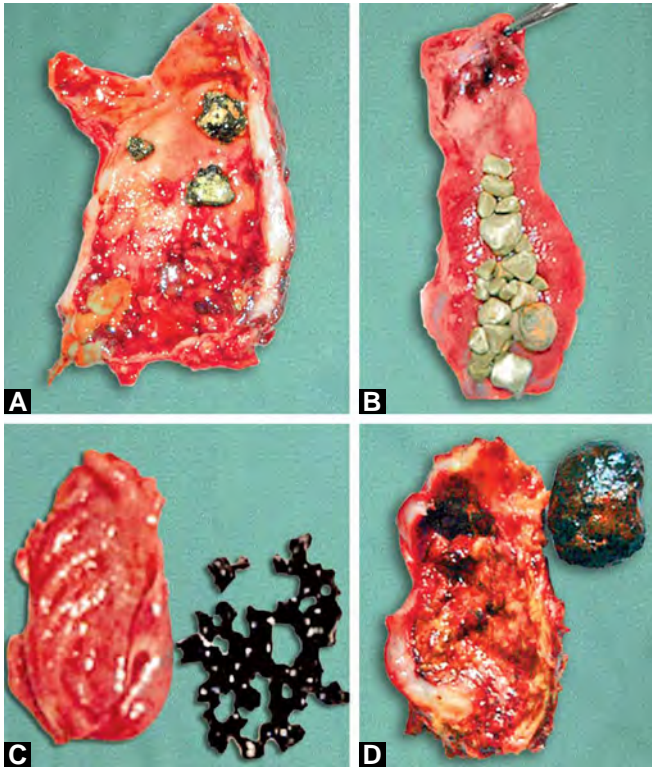
#### Effects of the Gallstones

##### a. In the gallbladder

- Silent asymptomatic stones occur in 10% of males and 20% of females.
- Biliary colic with periodicity*, severe within hours after meal (commonest presentation). Biliary colic is spasmodic pain often severe, in right upper quadrant and epigastrium radiating to chest, upper back and shoulder. It is self-limiting, recurs unpredictably, often precipitated by a fatty/heavy meal. Fever and increased WBC count may be observed.
- Acute cholecystitis.
- Chronic cholecystitis.

*It frequently happens that gallstones are found in the gallbladder after death. Where there was not the least suspicion of existence during life.*

— Mathew Baillie

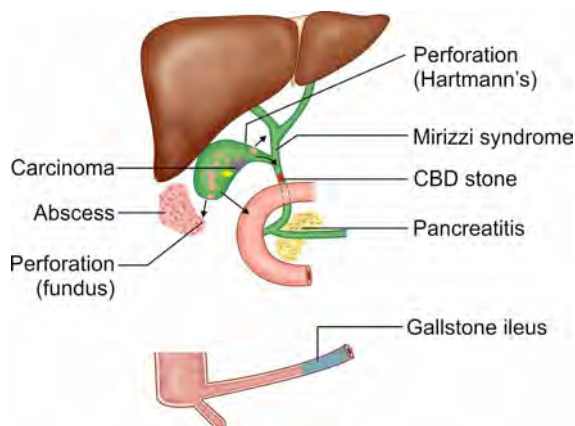


**Figs 12.26A to D:** Different types of gallstones. Note the faceted stones; black stones; brown stones; green stones. Thickening of gallbladder is seen. Hartmann's pouch is obvious in one of the photos (with cholesteroses).

- v. Empyema gallbladder.
- vi. Perforation causing biliary peritonitis or pericholecystic abscess.
- vii. Mucocele of gallbladder.
- viii. Limey gallbladder.
- ix. Carcinoma gallbladder.

#### b. In the CBD

- x. Secondary CBD stones (occurs in 10% of gallstones).
- xi. Cholangitis.
- xii. Pancreatitis.
- xiii. *Mirizzi syndrome* (compression of CHD/CBD by stone from cystic duct or cholecysto-choledochal fistula).



**Fig. 12.27:** Diagram showing complications of gallstones.

#### c. In the intestine

- xiv. Cholecystoduodenal fistula causing *gallstone ileus* and so intestinal obstruction.

### Flatulent Dyspepsia

- ◆ It is discomfort in the abdomen, belching, heartburn, fat intolerance, sensation of fullness in the abdomen usually observed in *fatty, fertile, flatulent female*.

### Gallstone Colic

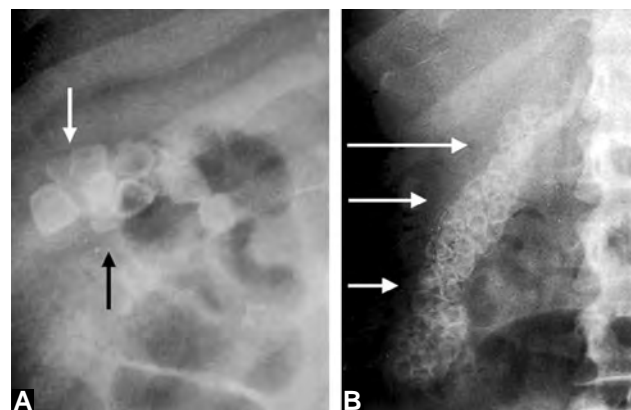
- ◆ It is sudden, severe colicky abdominal pain in right upper quadrant which radiates to back and shoulder. This pain is due to sudden spasm of gallbladder wall when gallstone moves towards the neck of the gallbladder or cystic duct and gets impacted. Tachycardia and restlessness are common. Right hypochondrium is tender.
- ◆ It is precipitated by supine position while sleeping at night. It lasts for few hours and is episodic. It may precipitate acute cholecystitis or empyema gallbladder.
- ◆ There is reflex pylorospasm causing vomiting.

#### Silent gallstone

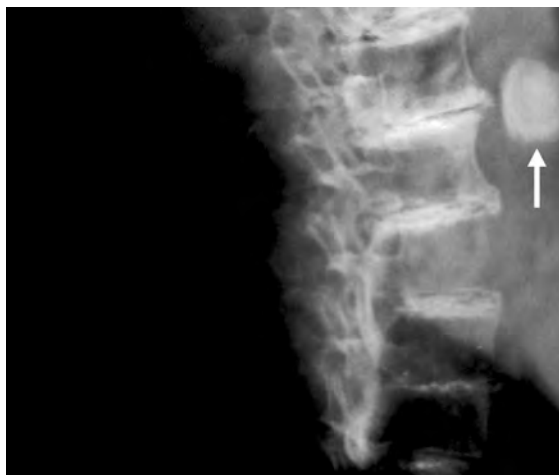- ❖ *Asymptomatic stone in the gallbladder*
- ❖ Usually it is cholesterol stone, often single
- ❖ It is accidentally discovered by U/S
- ❖ It need not be treated unless:
  - Patient is diabetic/immunosuppressed
  - High chances of developing gallbladder carcinoma
  - Stone more than 2.5 cm/multiple stones
  - If gallbladder wall is thickened
  - If there is high risk for carcinoma GB

### Management of Gallstones

- ◆ Ultrasound abdomen (gallstones are seen with posterior acoustic shadowing); plain X-ray abdomen; LFT; total WBC count.
- ◆ CT scan abdomen to rule out presence of CBC stones
- ◆ Laparoscopic cholecystectomy ideal.
- ◆ Open cholecystectomy is done through right subcostal Kocher's incision. Open approach is used if patient is not fit for laparoscopic surgery (anaesthesia); in suspected CBD stones; Mirizzi syndrome, suspected carcinoma gallbladder.

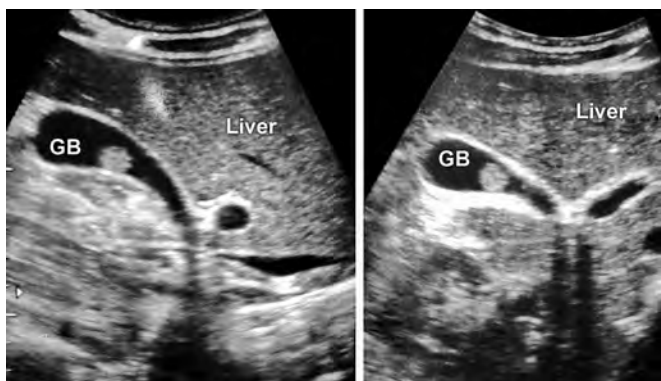


**12.28A and B:** Multiple gallstones in a plain X-ray. Only 10% gallstones are radio-opaque. Often they are faceted because of compactness and equal pressure exerted by each stone. Centre of the gallstone is often found radiolucent and is called as *Mercedes Benz sign/Seagull sign*.



**Fig. 12.29:** Lateral X-ray of spine showing radio-opaque shadow in front of the vertebrae—could be radio-opaque gallstone. Note also the fused intervertebral disc spaces.

- ❖ During laparoscopic cholecystectomy, if there is on table difficulty in dissection at Calot's triangle, then conversion into open approach may be required.
- ❖ Dissolution therapy for asymptomatic cholesterol stones using ursodeoxycholic acid can be tried. It is not very successful.



**Fig. 12.30:** Ultrasound gallbladder showing echogenic lesion. US should be done with change of position to find out movement of the lesion with posterior acoustic shadow to say it as gallstone. Otherwise it will be gallbladder polyp or sludge ball.

#### Differential diagnosis of radio-opaque shadow in X-ray

- ❖ Kidney stone
- ❖ Gallstone
- ❖ Calcified 12th rib tip
- ❖ Phlebolith
- ❖ Pancreatic stone
- ❖ Radio-opaque foreign body
- ❖ Faecolith
- ❖ Calcified lymph node
- ❖ Calcified renal tuberculosis
- ❖ Renal cell carcinoma—calcifications
- ❖ Adrenal tumour—calcification
- ❖ Teratomatous dermoid
- ❖ Calcification of atheroma in aorta
- ❖ Calcified lesion in liver—amoebic liver abscess/calcified hydatid cyst

## ACUTE CHOLECYSTITIS

- ❖ Commonly, it occurs in a patient with pre-existing chronic cholecystitis but often also can occur as a first presentation.
- ❖ Usual cause is impacted gallstone in the Hartmann's pouch, obstructing cystic duct.

#### Causative bacteria are:

- ❖ *E. coli*—most common
- ❖ *Klebsiella*, *Pseudomonas*, *Proteus*
- ❖ *Strep. faecalis*
- ❖ *Salmonella*
- ❖ *Clostridium welchii*

## Classification

1. Acute calculous cholecystitis.
2. Acute acalculous cholecystitis (10%).

## Mode of Infection

- ❖ Haematogenous through hepatic artery—cystic artery.
- ❖ Portal vein.
- ❖ Through bile after filtering in the liver via portal circulation.

## Pathogenesis of Acute Cholecystitis

- ❖ Stone causes obstruction at Hartmann's pouch or in cystic duct. Obstruction causes stasis, oedema of the wall, bacterial infection, acute cholecystitis and its effects.
- ❖ Impacted stone also causes mucosal erosion allowing bile salts to act over the submucosal tissues as bile is toxic to these tissues. It leads into necrosis, further infection and often perforation of the gallbladder usually at Hartmann's pouch.

## Pathology of Acute Cholecystitis

- ❖ Gallbladder will be distended with oedematous friable wall. Wall contains dilated vessels.
- ❖ Areas of necrosis and patchy gangrene may occur in severe cases.
- ❖ Mucosa shows ulceration and necrosis.
- ❖ Lumen contains infected fluid/infected bile or frank pus.
- ❖ Histology shows features of acute inflammation with neutrophils, oedema, and areas of necrosis and cell death.

## Complications of Acute Cholecystitis

*Acute cholecystitis* can lead to:

- ❖ *Perforation*—5–10% which usually occurs in the fundus or in the neck (Hartmann's). It can cause cholecystoduodenal, cholecystointestinal or cholecystobiliary fistula, Mirrizi's syndrome.
- ❖ *Peritonitis*.
- ❖ Pericholecystitic abscess.
- ❖ Cholangitis and septicaemia.
- ❖ Empyema gallbladder, gangrenous gallbladder.

### Emphysematous cholecystitis

- ❖ Seen in elderly male patients
- ❖ Common in diabetic and immunosuppressed individuals
- ❖ *Clostridium welchii*, Coliform, streptococci are common organisms.
- ❖ USG and CT scan are diagnostic.
- ❖ Gas is seen in the gallbladder
- ❖ Results in life-threatening septicaemia
- ❖ It causes severe fulminant cholecystitis
- ❖ Gangrene, perforation and peritonitis are common
- ❖ Emergency cholecystectomy is needed
- ❖ Absence of stones—observed in more than 50% of cases.

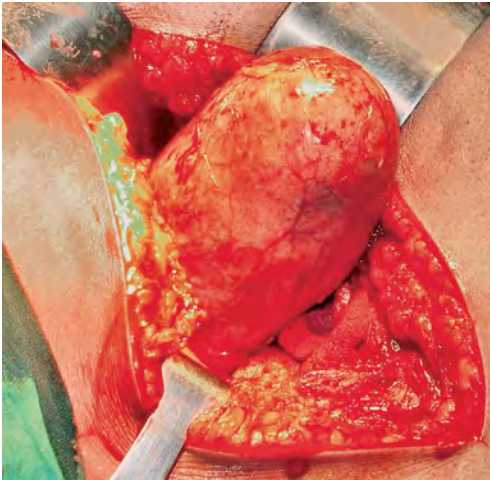


Fig. 12.31: On table look of gallbladder with acute cholecystitis.

### Clinical Features

- ◆ Sudden onset of pain in the right hypochondrium, with tenderness, guarding, and rigidity.
- ◆ Palpable, tender, smooth, soft gallbladder.
- ◆ Area of hyperaesthesia between 9th and 11th ribs posteriorly on the right side (*Boas's sign*).
- ◆ Jaundice may be present.
- ◆ Fever, nausea, palpable tender mass in GB region (25%).
- ◆ Tachycardia and toxic features.
- ◆ Murphy's sign may be positive (*mid-inspiratory arrest*).

### Investigations

- ◆ Ultrasound abdomen—very useful, reveals presence or absence of gallstones; and thickening of gallbladder wall. Sonographic Murphy's sign may be positive.
- ◆ Plain X-ray abdomen—10% of gallstones are radio-opaque; also rules out other causes of acute pain abdomen. Gas is seen in emphysematous GB.
- ◆ Total count shows neutrophilia.
- ◆ HIDA/PIPIDA radioisotope study—very useful. Non-visualisation of gallbladder is diagnostic.
- ◆ LFT is important. Increased serum bilirubin often signifies cholangitis or stone in the CBD.
- ◆ Plain X-ray abdomen is not very relevant but is often important to rule out duodenal ulcer perforation, peritonitis. Only 10% of gallstones are radio-opaque. In emphysema-

tous cholecystitis gas shadow may be seen in the region of gallbladder. Porcelain gallbladder may be seen as opacified area in gallbladder region.

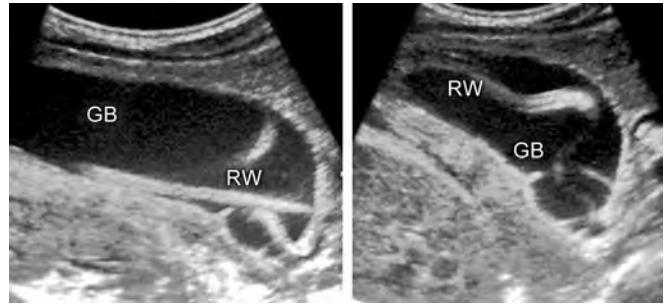


Fig. 12.32: Ultrasound showing roundworm in gallbladder.

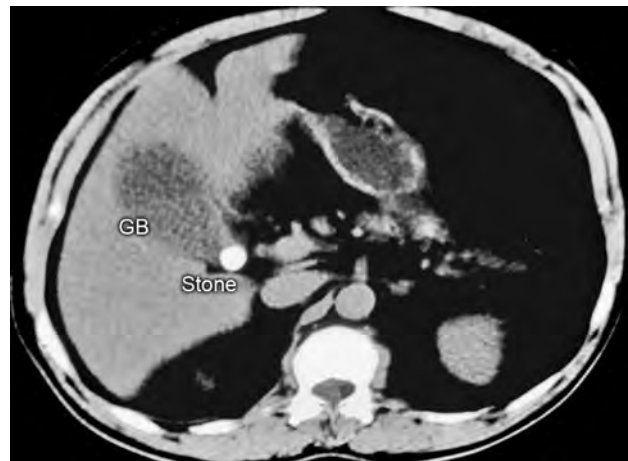

Fig. 12.33: CT scan showing stone in the neck of the gallbladder.

- ◆ CT scan is useful in identifying the perforation, impacted stone, gallbladder wall thickness and oedema.

### Differential diagnosis

- ❖ Duodenal ulcer perforation
- ❖ Acute pancreatitis
- ❖ Acute appendicitis
- ❖ Acute pyelonephritis
- ❖ Lobar pneumonia, myocardial infarction
- ❖ Ruptured ectopic pregnancy

### Treatment

- ◆ Advised hospitalisation.
- ◆ Initially (*nonoperative*) *conservative treatment* (95%):
  - ▶ Nasogastric aspiration.
  - ▶ IV fluids.
  - ▶ Analgesics and antispasmodics.
  - ▶ Broad spectrum antibiotics (cefoperazone, ceftazidime, ceftriaxone, cefotaxime + amikacin, tobramycin + metronidazole {antimicrobial}).
  - ▶ Observation.
  - ▶ Follow-up U/S scan.
- ◆ *Later after 3–6 weeks, elective interval cholecystectomy*, either by open method through right subcostal (Kocher's) incision or through laparoscopy is done.

Cholecystostomy is done immediately if patient is having:

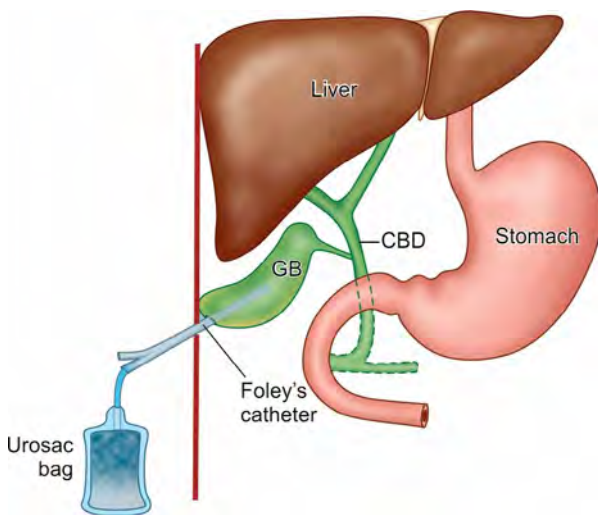
1. Empyema gallbladder.
2. Persisting symptoms.
3. Progressing symptoms.

Here the gallbladder is opened and all stones and pus are removed. Either a Foley's or Malecot's catheter is placed in the gallbladder and is exteriorised. *US-guided percutaneous cholecystostomy* also can be used.

After 3 weeks, elective cholecystectomy is done.

#### Indications for cholecystostomy or emergency cholecystectomy (5%)

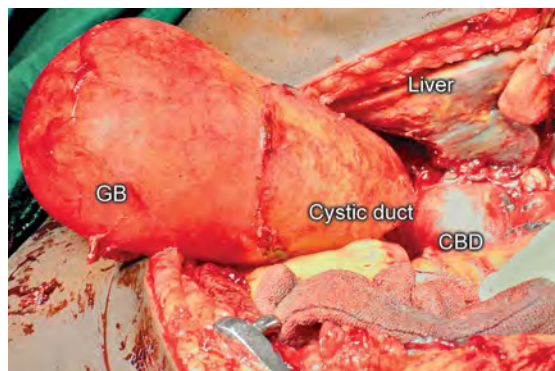
- ❖ Empyema GB
- ❖ Persisting symptoms/failure of medication
- ❖ Emphysematous cholecystitis
- ❖ Perforation/peritonitis
- ❖ Elderly



**Fig. 12.34:** A Foley's or Malecot's catheter is placed in severely ill-patient with acute cholecystitis to drain pus initially, and later elective cholecystectomy is done. Procedure is done in elderly, severely ill, empyema GB, emphysematous GB, perforation of GB (cholecystostomy).

#### Note:

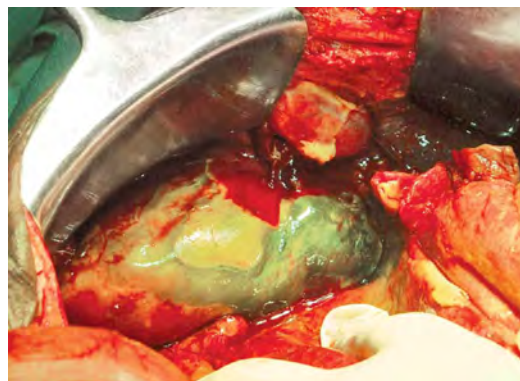- Cholecystostomy is better option than *emergency cholecystectomy* as chances of injuring adjacent structures are higher in emergency cholecystectomy. Other option is *partial/subtotal cholecystectomy* with removal of part of GB distal to the Calot's triangle.
- There is a *changing trend* now towards *early cholecystectomy* in acute cholecystitis. Laparoscopic cholecystectomy can be done in 48–72 hours in these patients. But conversion chances are high—5–6 times more than usual. Complications also may be higher due to difficulty in dissecting the Calot's triangle. It can be done in good set up with surgeons having adequate experience.
- When patient's condition is deteriorating, and acute cholecystitis is progressing, suspicious about forming empyema or necrosis and perforation; surgery should be done by abandoning conservative treatment. Usually open surgery, either cholecystectomy (may be partial) or cholecystostomy is done.



**Fig. 12.35:** On table photo of distended gallbladder. Note the Calot's triangle, liver and CBD.

#### ACUTE ACALCULOUS CHOLECYSTITIS (5%)

- ◆ It is not an uncommon entity, but can be commonly missed.
- ◆ It is common in patients who have undergone major surgeries, trauma, burns, or any other stress or in cases of *cholecystoses*.



**Fig. 12.36:** Acalculous cholecystitis. Note the necrotic gallbladder wall.

- ◆ Common in ICU patients—in critically-ill patients. It is due to bile stasis and ischaemia. Common in AIDs, elderly males, diabetics, patients who have undergone major non biliary surgery, patients who are on TPN, atherosclerotics.
- ◆ Exact cause is not known. Gallbladder distension, release of activation factor VII may be the causes.
- ◆ Pathology is oedema and necrosis of the gallbladder wall with features of acute inflammation.
- ◆ Presentation is usually acute. *Gangrene, perforation, empyema are very common (70%)*.
- ◆ *Investigations:* Isotope study (HIDA), U/S abdomen.
- ◆ *Treatment:* Cholecystectomy. Percutaneous US-guided/CT-guided or open cholecystostomy initially, later cholecystectomy is the treatment of choice.

#### MIRIZZI SYNDROME (Physician from Argentina, 1948)

- ◆ In Mirizzi syndrome, gallstone impacts in the gallbladder wall and compresses it causing pressure necrosis which further gets adherent

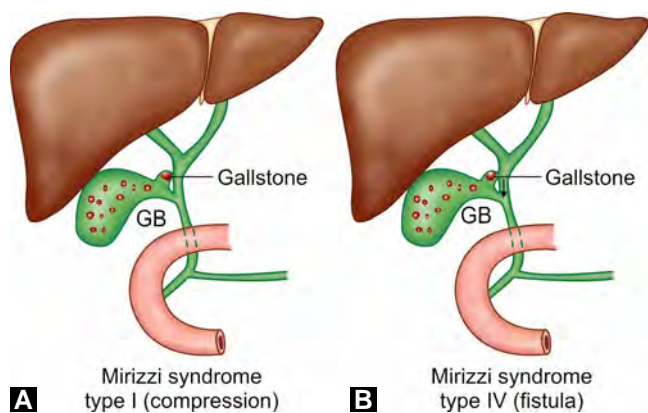


to CHD/CBD wall. It eventually causes compression and later occasionally leads into cholecystocholedochal fistula. It occurs either from Hartmann's pouch into CHD/CBD (common) or from fundus of gallbladder into the CBD.

- ◆ *Presentations are*—fever, abdominal pain, obstructive jaundice, upper abdominal tenderness on right side. Soft, enlarged liver may be palpable.
- ◆ *Investigations* – USG, CT scan, ERCP/MRCP to delineate duct anatomy, dilatation of intrahepatic biliary system with block at CHD is found.

Mirizzi's types	Features (Csendes classification)
Type I – 10%	Extrinsic compression of the CBD/CHD by a large impacted stone in Hartmann's pouch; IA is presence of cystic duct; IB is obliterated cystic duct
Type II – 40%	The stone has eroded the CBD/CHD less than 1/3rd circumference of the CBD/CHD forming a fistula
Type III – 45%	Involving up to 2/3rd of the circumference of CBD/CHD
Type IV – 5%	Cholecystocholedochal fistula (>2/3rd) with destruction of the CBD/CHD – needs hepaticojejunostomy

- ◆ Mirizzi syndrome is suspected on CT scan, but usually identified on table. It needs cholecystectomy; on table cholangiogram; and exploration of CBD. It often needs Roux-en Y hepaticojejunostomy.
- ◆ Partial cholecystectomy with primary closure of CHD/CBD is done with a T-tube insertion through a separate choledochotomy in type 2.
- ◆ Partial cholecystectomy with closure of gallbladder flaps is done with T-tube insertion through a separate choledochotomy in type 3.
- ◆ Partial cholecystectomy with duodenal/jejunal anastomosis is done in type 4 in few centres.
- ◆ Open approach is ideal for Mirizzi even though laparoscopic approach is done in few centres.



**Figs 12.37A and B:** Mirizzi syndrome type I and IV.

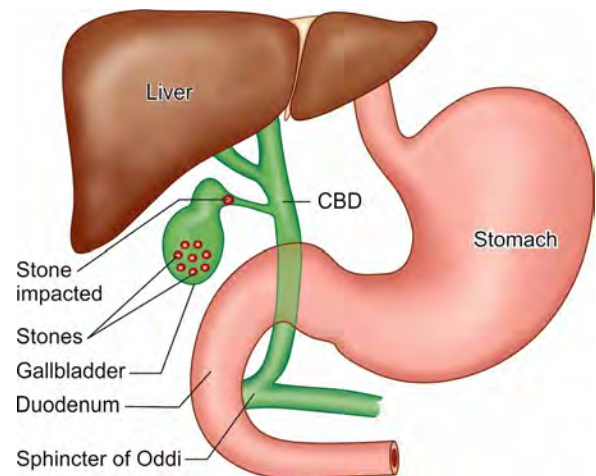
## EMPYEMA GALLBLADDER

- ◆ It is a type of acute cholecystitis wherein the gallbladder is filled with pus. In 30% cases pus may be sterile.
- ◆ It also can occur in a pre-existing mucocele of the gallbladder where it gets infected.

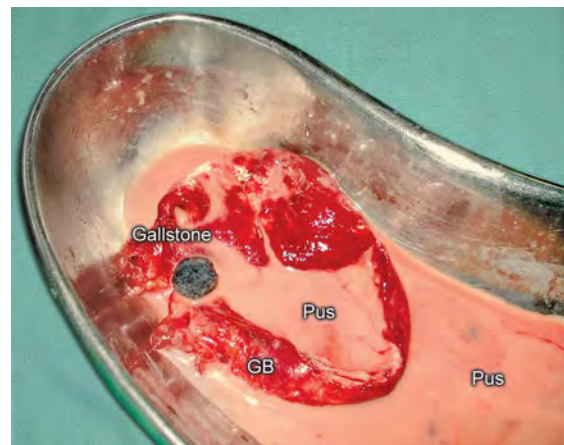
- ◆ It is commonly observed in impacted stone, diabetic individual, immunosuppressed people like HIV, long-time steroid therapy.
- ◆ It can perforate; can form abscess or can cause peritonitis—biliary and bacterial.
- ◆ Condition has got high mortality.

## Features

- ◆ Fever, toxicity.
- ◆ Pain and tenderness in right hypochondrium.
- ◆ Tender, smooth, globular, gallbladder is palpable in right hypochondrium to the right of the right rectus muscle.



**Fig. 12.38:** Gallstone obstructing the neck of the gallbladder in Hartmann's pouch, may lead into empyema or mucocele of the GB.



**Fig. 12.39:** Empyema gallbladder. Note the pus and stone.

- ◆ *Complications*
  - ▶ Septicaemia.
  - ▶ Rupture and peritonitis.
- ◆ *Investigations*
  - ▶ Ultrasound abdomen.
  - ▶ Total count is raised.
  - ▶ Radioisotope scan.
  - ▶ Haematocrit, LFT, PT-INR.

## Treatment

- ◆ Antibiotics: Cefotaxime, quinolones, ceftriaxone.
- ◆ Cholecystectomy—an emergency procedure.
- ◆ Often initially cholecystostomy is done, with either Foley's or Malecot's catheter kept *in situ*.  
Later after 3–6 weeks, cholecystectomy is done. Laparoscopic cholecystectomy can be tried.

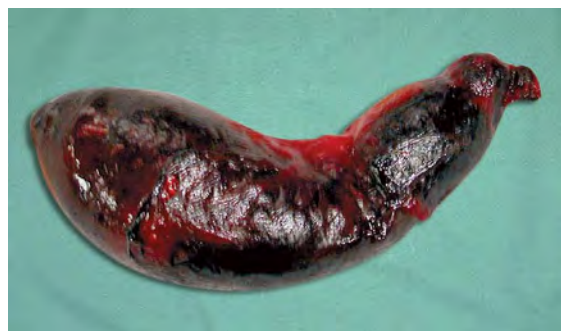

Fig. 12.40: Gangrenous gallbladder.

## MUCOCELE OF THE GALLBLADDER

- ◆ It is due to obstruction of the cystic duct by a stone in the neck (Hartmann's pouch) of the gallbladder, without any infection or inflammation in the gallbladder. This causes absorption of all bile and secretion of mucous into the gallbladder allowing gallbladder to distend causing *mucocele* of the gallbladder (*Hydrops* of the gallbladder).
- ◆ Rarely cholangiocarcinoma occluding cystic duct may cause mucocele of gallbladder.
- ◆ Content is usually sterile.

## Features

- ◆ Painless swelling in the right hypochondrium.
- ◆ Nontender, smooth, soft, globular, palpable gallbladder (content is sterile).
- ◆ Features of dyspepsia.

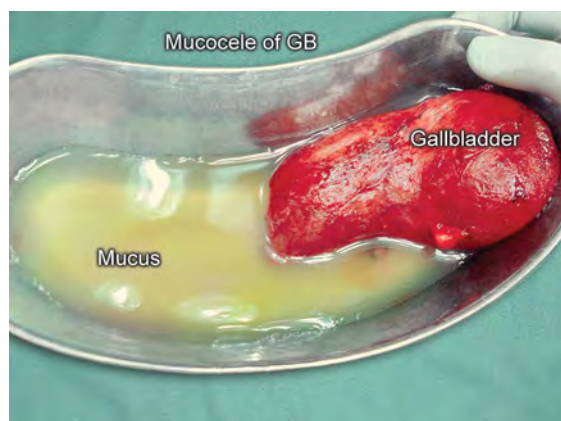


Fig. 12.41: Mucocele of gallbladder.

- ◆ *Complications*
  - ▶ If infected, can cause empyema gallbladder.
  - ▶ Rupture can cause pseudomyxoma peritonei (but rare).
- ◆ *Investigations*
  - ▶ US abdomen.
  - ▶ Liver function tests.
- ◆ *Treatment:* Cholecystectomy, either laparoscopic or open method.

## CHRONIC CHOLECYSTITIS

It is chronically inflamed, thickened gallbladder, which is nonfunctioning and nondistending.

## Causes

- ◆ Gallstones.
- ◆ Cholecystoses.
- ◆ Chronic acalculous cholecystitis.

## Organisms

- ◆ *Klebsiella*.
- ◆ *Streptococci*.
- ◆ *Salmonella*.

## Pathology

- ◆ Gallbladder is shrunken, contracted, small, non-functioning and fibrotic with thickened gallbladder wall. Mucosa proliferates into the lumen creating deep clefts in the wall projecting into the muscular wall of the gallbladder being lined by epithelium. It is called as *Rokitansky-Ashchoff's sinuses*.
- ◆ Muscular wall is atrophied and is often replaced by fibrous tissue.
- ◆ Histologically, it shows dense chronic inflammation with fibrous tissue.

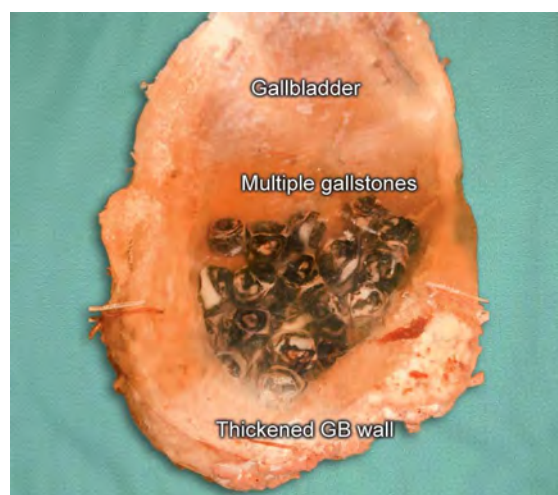

Fig. 12.42: Specimen of gallbladder showing thickened gallbladder wall with multiple gallstones. Facing of stones is due to equal pressure.

## Clinical Features

- ◆ Pain in right hypochondrium, may be colicky, or persistent.
- ◆ Positive *Murphy's sign*, wherein sitting position during deep inspiration, while palpating in right hypochondrium, patient winces with pain at the summit of the inspiration. Same sign elicited in lying down position is called as *Moynihan's sign*. It may also be elicited in acute—on chronic cholecystitis.
- ◆ Flatulent dyspepsia.
- ◆ Intolerance to fatty meals.
- ◆ Biliary dyspepsia.

## Complications

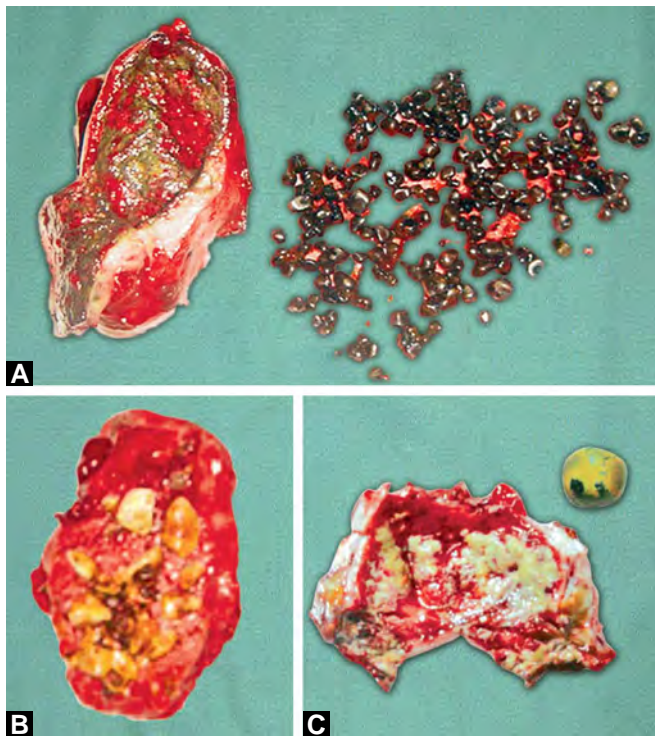
- ◆ CBD stone.
- ◆ Cholangitis.
- ◆ Pancreatitis.
- ◆ Mirizzi's syndrome.

## Differential Diagnosis

- ◆ Peptic ulcer.
- ◆ Pancreatitis.
- ◆ Hiatus hernia.

## Investigations

- ◆ Ultrasound abdomen may show stone with posterior acoustic shadowing. Gallbladder wall will be thickened.
- ◆ Isotope study may help to confirm the infection.
- ◆ LFT.
- ◆ Total count may be raised if there is an acute recurrent infection.



**Figs 12.43A to C:** (A and B) Thickened GB due to chronic cholecystitis with multiple stones; (C) Thick GB with single large stone.

## Treatment

Cholecystectomy (Laparoscopic or open method).

### MURPHY'S SIGN

- ◆ It is a sign of cholecystitis—acute or acute on chronic cholecystitis.
- ◆ *John Benjamin Murphy* (1857–1916) American surgeon, identified significance of his sign. His name is associated with many things—signs like *Murphy's punch*, *Murphy's triad*, *Murphy's sign test* for metacarpals and *Murphy's sign* for gallbladder and instruments like *Murphy's intestinal anastomosis buttons*, *Murphy-Lane bone skid* and *Murphy drip*.
- ◆ *Murphy's sign* of gallbladder was described in 1903 as hypersensitivity elicited by deep palpation in the subcostal area when a patient with presumed gallbladder disease takes a deep breath. This sign is also called *Naunyn's Sign* after the name of *Bernard Naunyn* (1839–1925, Berne) who described a similar sign 13 years before *Murphy*.
- ◆ Patient in upright/sitting position, the right hand of the examiner curls up under the right costal margin (or extended fingers with moderate pressure) of the patient at the tip of the ninth rib and patient is requested to take a deep breath. If the gallbladder is inflamed, the patient will experience pain (winces with pain) and catch the breath as the gallbladder descends and contacts the palpating hand. Patients with cholecystitis often experience distress with this maneuver and may have a sudden cessation of inspiration when the inflamed gallbladder reaches the examining fingers. This is termed *inspiratory arrest* and has been described as a “shutting off” of the inspiration.
- ◆ *Moynihan's modification of eliciting Murphy's sign:* The left hand of the examiner is placed on the patient's lowermost right anterior rib cage; index finger is resting on the most inferior rib. The extended and abducted left thumb is placed in right subcostal region without pressing deep; the patient is requested to take a deep breath. When the inflamed gallbladder presses/touches against the thumb the patient will experience pain or tenderness enough to halt the inspiration. *Moynihan's sign* is elicited in lying down supine position.
- ◆ The presence of *Murphy's sign* is both sensitive (97%) and highly predictive (93%). Negative *Murphy's sign* is less sensitive (35%). *Bree RL* found that this sign as unreliable in separating acute from chronic cholecystitis. Often in acute cholecystitis there is as such severe tenderness, guarding and rigidity in right hypochondrium and so test cannot be elicited. So it is the sign used for cholecystitis without any specific identification as acute or chronic.
- ◆ *Sonographic Murphy's sign* is eliciting same sign using sonographic transducer. It is more sensitive and more accurate.

### GALLSTONE ILEUS

It is a type of acute intestinal obstruction, often seen in elderly and is due to blockage by a bolus or mass of gallstones which commonly enter the intestine through cholecystoduodenal fistula (75%) or rarely through cholecystointestinal or gastric fistulas.

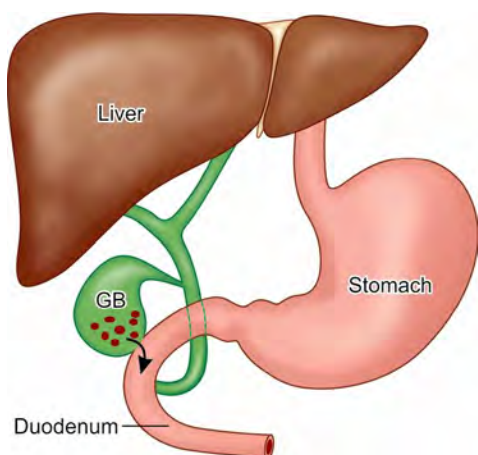
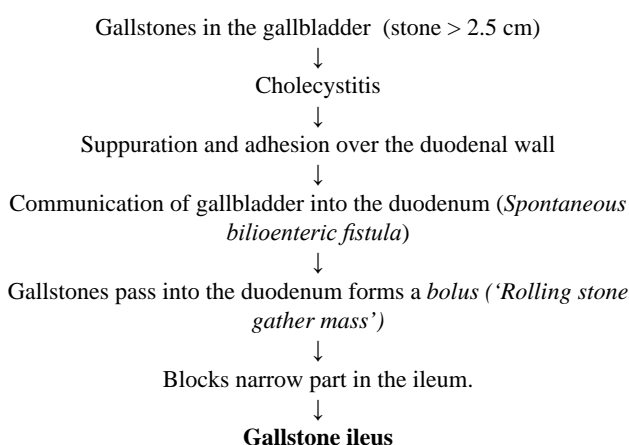


Fig. 12.44: Gallstone ileus.



## Clinical Features

- ◆ Pain abdomen and features of intestinal obstruction.
- ◆ Stones may perforate the ileum to cause peritonitis.
- ◆ It is 1% of all intestinal obstruction overall; 25% of obstruction in elderly.
- ◆ Recurrent episodic obstruction due to moving stone bolus is typical—*tumbling obstruction*.

## Investigations

- ◆ Plain X-ray abdomen in erect posture shows *air in the biliary tract* (branching gas pattern, pneumobilia) and multiple air fluid levels.
- ◆ U/S abdomen.
- ◆ CT is diagnostic.

## Treatment

- ◆ Laparotomy, enterotomy, removal of gallstones and closure of enterotomy is done. Enterotomy is done not at the site of obstruction but more proximal to the site of obstruction and stones are milked towards the enterotomy site. If bowel is found ischaemic at the impacted area, resection and anastomosis is done.
- ◆ Laparotomy and crushing of stones with fingers to relieve the obstruction is only occasionally useful.
- ◆ Cholecystectomy, correction of fistula with T-tube drainage can be done in same sitting if patient's general condition is good. Other-

wise it is done after 12 weeks. If cholecystectomy and definitive corrective surgery is not done, recurrent gallstone ileus is likely to occur.

### Causes for gas in the biliary tree

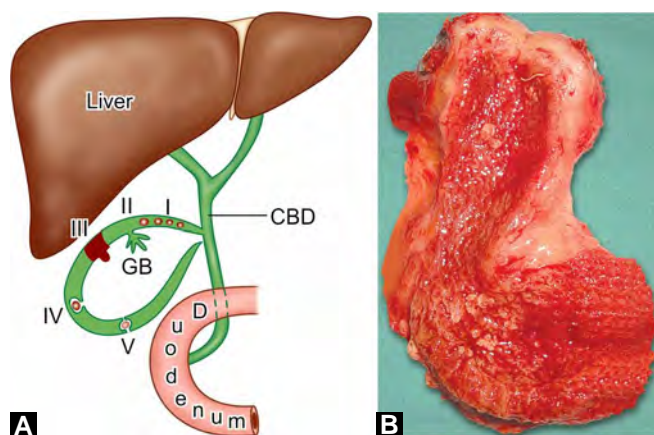
- ❖ Cholecystoduodenal fistula
- ❖ Choledochoduodenostomy
- ❖ Choledochojejunostomy
- ❖ Transduodenal sphincteroplasty
- ❖ Emphysematous cholecystitis

## Bouveret's syndrome

- ◆ A rare entity with cholecystoduodenal fistula causing gallstones from gallbladder to pass into the duodenum leading to *duodenal obstruction*.

## CHOLECYSTOSES

- ◆ Cholecystoses are chronic inflammatory conditions of gallbladder with cholesterol deposits.
- ◆ It is due to defective transport of the absorbed cholesterol which accumulates in mucosa. There is also increased absorption of cholesterol by gallbladder epithelium.
- ◆ Cholecystoses gallbladder is more prone for infection.
- ◆ It may precipitate stone formation.
- ◆ It is a premalignant condition.



**Figs 12.45A and B:** (A) Types of cholecystoses. (I) Cholesterosis, (II) Cholesterol polyposis, (III) Cholecystitis glandularis proliferans, (IV) Diverticulosis of gallbladder, (V) Fistula; (B) Cholesterosis of gallbladder. It is a premalignant condition.

## Types

- I. Aggregations of cholesterol crystals in the mucosa or submucosa—*cholesterosis* (*Strawberry gallbladder*). Lipoid contents are present in large foamy cells which has phagocytosed cholesterol. Here cystic duct is normal. Disease occurs only in gallbladder. It is a premalignant condition.
- II. Cholesterol laden polypoid projections in the mucosa—*cholesterol polyposis* (Gallbladder polyp).
- III. Granulomatous thickening and hyperplasia of the gallbladder—*cholecystitis glandularis proliferans*.

- IV. Diverticula formation in the wall of the gallbladder—*diverticulosis of gallbladder*.
- V. Gallbladder wall fistula.

## Clinical Features

- ◆ Features of acalculous cholecystitis like dyspepsia, positive Murphy's sign.

## Investigations

- ◆ US abdomen.
- ◆ OCG.
- ◆ Isotope study.

## Treatment

Cholecystectomy—always should be done whether it is symptomatic or not as it is potentially malignant.

## DISSOLUTION THERAPY FOR GALLSTONES

### Indications

- ◆ Functioning gallbladder with cholesterol stone.
- ◆ Single stone less than 1.5 cm.
- ◆ Radiolucent stone.
- ◆ Old age.
- ◆ Patients who are not fit for surgery.

### Contraindications

- ❖ Nonfunctioning gallbladder
- ❖ Stone more than 1.5 cm
- ❖ Radio-opaque stone
- ❖ Multiple stones

## Drugs Used

- ◆ Chenodeoxycholic acid (for 2 years).
- ◆ Ursodeoxycholic acid (15 mg/kg/day).

They inhibit absorption of cholesterol from the gut and synthesis of cholesterol in the liver. They inhibit HMG CoA—a rate limiting step in cholesterol synthesis. Ursodeoxycholic acid also inhibits absorption of cholesterol in GIT.

### Other methods used

- ❖ Citrate
- ❖ Monoterpenes
- ❖ Percutaneous infusion of methyl-tertiary butyl ether (MTBE) into the gallbladder using a catheter
- ❖ Extracorporeal shock wave lithotripsy (ESWL)—not popular

## Problems with Dissolution Therapy

- ◆ Drugs should be given for a long time.
  - ◆ Results are not good.
  - ◆ Expensive.
  - ◆ Causes side effects like diarrhoea, pruritus.
  - ◆ Hepatic dysfunction.
- Overall results are not good by dissolution therapy.*

## CHOLEDOCHOLITHIASIS

It is stones in the CBD and biliary tree.

### Classification

- i. Primary—Rare—brown pigment stones.
- ii. Secondary—Common—black pigment stones/cholesterol stones. It is seen in 15% of gallstone disease; 75% are cholesterol stones, 15% are pigment stones.

### Primary stones

They are formed in CBD and biliary tree itself, and are multiple, often sludge like, commonly pigment or mixed type, extends into hepatic ducts (Brown pigment stones).

### Causes:

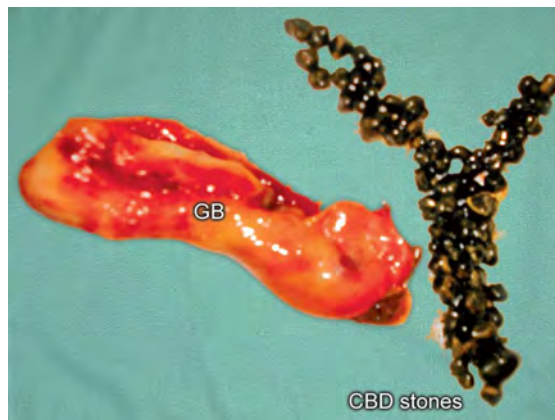- ◆ Defective pathophysiology of biliary tree causing stasis, biliary dyskinesia, benign biliary stricture, sclerosing cholangitis, biliary dilatation, choledochal cyst.
- ◆ Congenital conditions like Caroli's disease, choledochal cyst.
- ◆ Infections and infestations like clonorchiasis, ascariasis.
- ◆ Others: Low-protein diet, malnutrition, obesity, females, old age.

### Note:

Stasis and bactibilia are the main causes of primary CBD biliary tree stones.

### Secondary biliary stones

- ◆ They are from gallbladder (gallstones) pass through cystic duct to CBD. Here CBD and biliary tree are otherwise normal.
- ◆ *Secondary stones are better and easier to manage than primary stones.*
- ◆ Commonly gallstones get impacted in supraduodenal portion of CBD.



**Fig. 12.46:** Multiple stones removed from common bile duct and hepatic ducts. They cause cholangitis. After stone removal, patient needs choledochoduodenostomy/sphincteroplasty/choledochojejunostomy.

### Note:

- Black pigment stones are common in—haemolytic diseases, cirrhosis, ileal resection, fasting for long time, TPN for long time (home TPN).
- Intrahepatic stones are common—biliary sepsis, biliary stasis, parasitic infection, malnutrition.
- Retained stones mean—if stones are found in CBD within 2 years of cholecystectomy.
- Recurrent stones mean—if stones are found in CBD 2 years after cholecystectomy.
- 5% of CBD stones can be asymptomatic

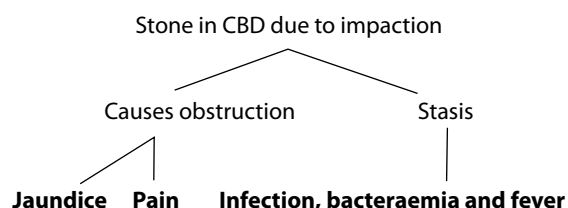
## Clinical Features

- ◆ Incidental CBD stones along with jaundice/without jaundice.
- ◆ Pain: It may be biliary colic; nonspecific abdominal pain; pain of ascending cholangitis, pain of pancreatitis.
- ◆ Jaundice—most common clinical manifestation.
- ◆ Fever with chills and rigors.

### Charcot's triad of ascending cholangitis

- ❖ Intermittent pain (may be colicky)
- ❖ Intermittent fever
- ❖ Intermittent jaundice

Stone moves proximally and floats, obstruction is relieved and symptoms subside (**Intermittent features**).



- ◆ **Reynold's pentad** of acute obstructive cholangitis (suppurative cholangitis—5%).

### Sometimes obstruction persists causing

- ❖ Persistent pain
- ❖ Persistent fever
- ❖ Persistent jaundice
- ❖ Shock (toxicity) and
- ❖ Altered mental status

Here biliary tree contains pus.

- ◆ Pain and tenderness in epigastrium and right hypochondrium.
- ◆ Steatorrhoea and darkening of urine.
- ◆ Pruritus.

## Complications

- ◆ Liver dysfunction and biliary cirrhosis.
- ◆ White bile formation and liver failure.
- ◆ Suppurative cholangitis.
- ◆ Liver abscess.
- ◆ Septicaemia.
- ◆ Pancreatitis if CBD stone is near sphincter of Oddi blocking drainage of bile and pancreatic duct.

### Differential diagnosis

Obstructive jaundice due to other causes:

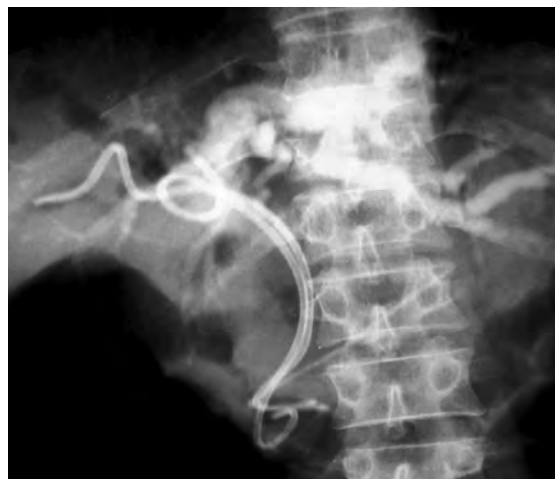- ❖ Carcinoma of head of pancreas
- ❖ Carcinoma of periampullary region
- ❖ Carcinoma of biliary tree
- ❖ Biliary stricture
- ❖ Viral hepatitis

## Investigations

- ◆ US abdomen may show gallstones, dilated CBD >8 mm which suggests biliary obstruction. Sensitivity for CBD stones is only 65%.
- ◆ *CT scan is the most sensitive* investigation for CBD stones; it shows stones, location, ductal stricture or block, ductal dilatation, intrahepatic biliary changes and stones. Helical CT cholangiography is also useful but bilirubin level should be normal which is the limitation.
- ◆ *MRCP* is noninvasive investigation which delineates biliary tree anatomy and pathology clearly; but it is not therapeutic.
- ◆ *Blood*: Total count may be raised; LFT deranged with raised bilirubin (direct) and alkaline phosphatase. PT INR and platelet count should be done. Serum amylase and lipase should be done to rule out associated pancreatitis.
- ◆ EUS (endosonography) is useful and accurate but it is invasive.
- ◆ *ERCP* identifies pathology, site of block, stones, etc. (95% sensitivity). It is therapeutic also for extraction of biliary stones and stenting.
- ◆ PTC is done only when indicated like in those with previous gastrectomy, failed ERCP. PTC is not routinely needed. PTC can be therapeutic also in extracting the stones and stenting.

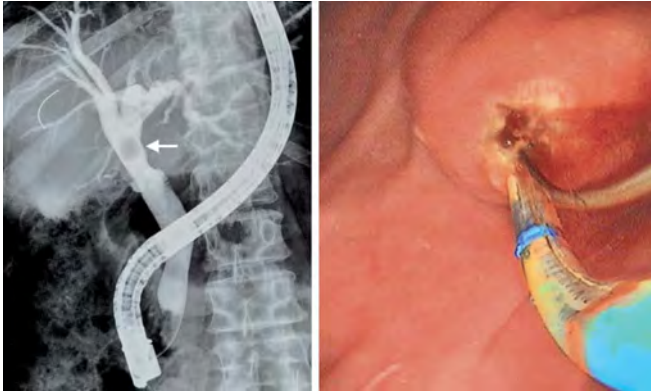
## Treatment

- ◆ Injection Vit. K 10 mg IM once a day for 5 days or FFP infusion to correct the prothrombin time.
- ◆ IV antibiotics (cefoperazone, cefotaxime).
- ◆ *Correction of dehydration*.
- ◆ IV mannitol daily 200 ml BD to prevent *hepatorenal syndrome*.
- ◆ **ERCP—Therapeutic**, i.e. endoscopic papillotomy (sphincterotomy) and stone extraction through Dormia basket or balloon catheter; or fragmenting the stone and extraction; or removal through baby endoscope. CBD stent is placed *in situ*.



**Fig. 12.47:** Plain X-ray showing stents in CBD and pancreatic ducts. It was placed in a patient who presented with recurrent pancreatitis with block/stricture in both terminal CBD and pancreatic duct. Later patient underwent choledochojunostomy and pancreaticojejunostomy.

**Typhoid Mary:** *Salmonella typhi* infection with chronic cholecystitis acting as a carrier. Mary was a cook who spread typhoid to many people.



**Fig. 12.48:** ERCP showing CBD stones. Endoscopic view of stenting is also seen.

#### Complications of sphincterotomy

- ❖ Bleeding
- ❖ Sepsis
- ❖ Perforation
- ❖ Pancreatitis

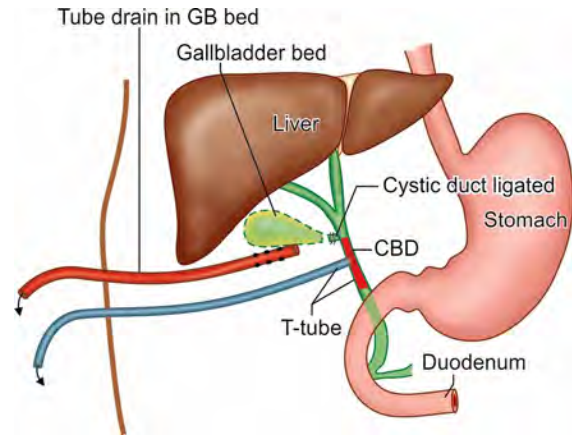
Once CBD stones are extracted through ERCP, laparoscopic cholecystectomy is done.

- ◆ In open cholecystectomy
  - ▶ After the removal of gallbladder, on table cholangiogram is done through cystic duct using water-soluble iodine dye to see any stones in CBD. Using stay sutures choledochotomy is done (opened longitudinally) to remove stones in CBD.
  - ▶ *False results/failure of intraoperative cholangiogram (IOC)* is possible if air is trapped, if there is contrast leakage, if quick flow of contrast into the duodenum, if there is spasm of sphincter of Oddi.

#### Indications for choledochotomy

(After open cholecystectomy)

- ❖ U/S shows stone in CBD
  - ❖ Palpable stone in CBD
  - ❖ CBD diameter >8–10 mm
  - ❖ Recent history of jaundice, and with raised serum alkaline phosphatase level
  - ❖ On table cholangiogram shows stone (done using C-arm image machine)
  - ❖ Failure of stone extraction by ERCP prior to cholecystectomy.
  - ❖ When in doubt
- ▶ After choledochotomy, stones are removed using Des Jardin's choledocholithotomy forceps. Bakes CBD dilator is used to confirm the CBD patency.
  - ▶ T-tube (Kehr's) is then placed in the CBD and kept for 14 days.
  - ▶ After 14 days a postoperative T-tube cholangiogram is done to see for free flow of dye into the duodenum, so that T-tube can be removed.
  - ▶ If T-tube cholangiogram shows persistent stone, it can be extracted after 6 weeks, through a basket (Dormia) or catheter (Fogarty) through the track or through a



**Fig. 12.49:** Diagram showing placement of T-tube in CBD after choledocholithotomy. Note the separate drain placed in the cholecystectomy bed to drain fluid, blood, bile.

choledochoscope. Retained stones can also be removed through ERCP.

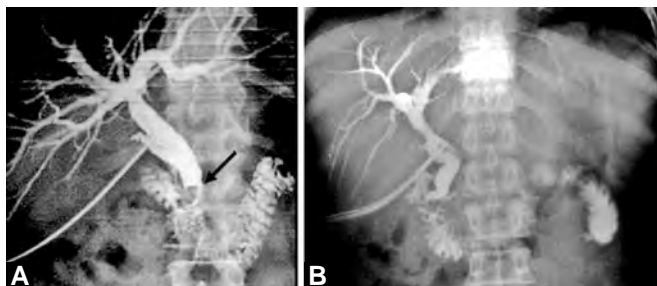
- ◆ After open cholecystectomy, on table ERCP can be tried if there are indications for CBD intervention case of secondary CBD stone/s and if ERCP was not done prior to cholecystectomy. If secondary stone is retrieved by this method, open exploration of CBD can be avoided.
- ◆ *Intraoperative ultrasound (IOUS)* or *intraoperative choledochoscope* is very useful to confirm that all stones are removed.
- ◆ Laparoscopic CBD exploration is becoming popular with availability of expertise and high technology imaging and instruments.

#### Methods to confirm the removal of T-tube

- ❖ Clamp the T-tube, after 10–14 days and observe 48 hours for development of pain, jaundice and fever
- ❖ Confirm free flow of dye in T-tube cholangiogram

#### Management of retained CBD stones

- ❖ Small stones may *spontaneously* pass down.
- ❖ Heparinised saline or bile acid *flushing* through the T-tube. (Wash 250 ml of normal saline with 25,000 IV heparin for 5 days)
- ❖ Burhenne technique (Canada)—after 6 weeks once T-tube track gets matured, track if needed, is dilated using graduated dilators. Either using Dormia basket or Fogarty catheter or choledochoscope, stone is removed through T-tube track under fluoroscopic guidance (C-arm)
- ❖ *ERCP* and stone removal in 3 weeks
- ❖ *Reoperation* if everything fails, either transduodenal sphincteroplasty or choledochojejunostomy
- ❖ ESWL with endoscopic sphincterotomy/extraction/lavage/stenting
- ❖ Through percutaneous transhepatic route, cholangioscope is passed and CBD is visualised, stone is identified and removed using Dormia basket or Fogarty catheter
- ❖ Laparoscopic choledocholithotomy
- ❖ Open choledocholithotomy often with choledochojejunostomy



**Figs 12.50A and B:** (A) T-tube cholangiogram showing retained stone in the CBD (Courtesy: Dr Navin Chandra Shetty, HOD, Department of Radiodiagnosis, KMC, Mangaluru); (B) T-tube cholangiogram showing dye in the duodenum and visualisation of normal biliary tree without any obstruction.

### Treatment of Primary CBD Stones

- ❖ *Difficult and is associated with more complications.*

Preferred procedures:

- ❖ *Transduodenal sphincteroplasty (open method), or*
- ❖ *Open choledochoduodenostomy, side-to-side, or*
- ❖ *Open choledochojejunostomy—Roux-en-Y method.*
  - ▶ These procedures attain complete drainage of bile.
  - ▶ Postoperatively they may often require long-term antibiotics.

#### Indications for choledochoduodenostomy/choledochojejunostomy:

- ❖ Multiple CBD calculi with distal narrowing (Funnel syndrome).
- ❖ Papillary stenosis.
- ❖ Impacted calculi.
- ❖ Biliary sludge—symptomatic.
- ❖ Residual stones.
- ❖ Sphincter of Oddi dysfunction/stenosis.
- ❖ Primary CBD stones.
- ❖ Previous choledochotomy.
- ❖ Marked CBD dilatation.

*Prerequisite for choledochoduodenostomy:*

- ❖ CBD should be more than 1.4 cm and stoma should be 2 cm.

*Advantages of choledochoduodenostomy are:*

- ❖ Bile leak is minimal/not there.
- ❖ Beneficial as a permanent remedy in multiple stones/sludge/stenosis/strictures/intrahepatic stones.

*Problem with choledochoduodenostomy:*

- ❖ Sump syndrome.

#### Note:

Roux-en-Y choledochojejunostomy is equally good as choledochoduodenostomy.

#### Remember

- ❖ Gallstones are commonly radiolucent (90%).
- ❖ Multiple stones are usually faceted because of exertion of equal pressure in a compact gallbladder.
- ❖ Plain X-ray shows radio-opaque lesion to the right side of the vertebra below rib cage. It should be differentiated from kidney stones. In lateral view X-ray, gallstone will be in front of the vertebra whereas kidney stone overlaps the vertebra. Often gallstone has got central radiolucent area—*seagull sign/Mercedes Benz sign.*

*Contd...*

*Contd...*

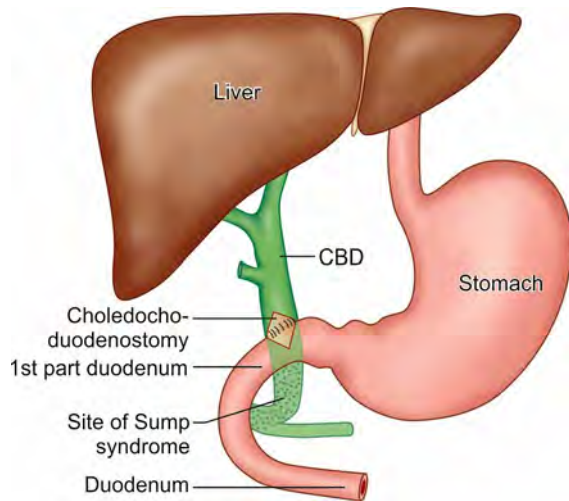
- ❖ *Silent/asymptomatic gallstone* is one which is identified on routine investigation where there are no specific relevant symptoms related to gallstones. Chances of developing symptoms in a silent gallstone is 5% in 5 years and 20% in 15 years.
- ❖ Presently ultrasound is ideal investigation for gallstones.
- ❖ To see gallbladder function or confirm cholecystitis radioisotope HIDA/PIPIDA scan is ideal.
- ❖ Cholecystitis can cause jaundice due to cholangitis. But other causes of jaundice should be ruled out—CBD stones/Mirizzi syndrome.
- ❖ *Limey gallbladder* is gallbladder filled with toothpaste like mixture of calcium carbonate and calcium phosphate. Plain X-ray shows dense radio-opaque gallbladder shadow (*opacified gallbladder*).
- ❖ *Porcelain gallbladder* is one where gallbladder wall is calcified because of chronic cholecystitis. It is potentially malignant. It should be removed either by open or laparoscopic method.
- ❖ Cholesterol stone occurs when there is alteration in levels of cholesterol, lecithin and bile salts. This altered bile has got more cholesterol than adequate micelle and is called as *lithogenic bile*. Here bile is in supramicellar zone. Cholesterol stone is radiolucent but causes acoustic shadow in U/S
- ❖ Mixed stones are most common—90%.
- ❖ '*Gallstone is a tomb stone erected to the memory of the organism within it*'—Moynihan's aphorism.
- ❖ *Saint's triad:* Gallstones—colonic diverticulosis—hiatus hernia.
- ❖ *Complications of gallstones:* Acute cholecystitis, chronic cholecystitis, empyema gallbladder, mucocele of gallbladder, perforation and peritonitis, secondary CBD stones, cholangitis, pancreatitis, Mirizzi syndrome, gallstone ileus, pericholecystic abscess and carcinoma of gallbladder.
- ❖ Black pigment stones are more common in gallbladder; brown pigment stones are common in CBD.
- ❖ Cholesterol stones are common in Western countries; pigment/mixed stones are common in Asian countries.
- ❖ *Acute acalculous cholecystitis* is 5% common. It occurs after stress, major surgeries or in cholecystoses.
- ❖ *Xanthogranulomatous cholecystitis* is a rare pathological condition. Gallbladder is thickened with chronic inflammation. It is yellow xanthogranulomatous in nature. It often extends to adjacent organs. It is due to reaction to penetrated bile.
- ❖ *Residual/retained bile duct stones* are one which is present in CBD within 2 years of initial surgery—cholecystectomy. They are usually missed secondary bile duct stones.
- ❖ *Recurrent bile duct stones* are one which is present 2 years after the initial surgery—cholecystectomy and CBD exploration. They are primary biliary stones.
- ❖ *Salmonella cholecystitis* (Typhoid Mary—a cook in New York transmitted typhoid through her infected faeces and urine) causes typhoid gallbladder. It can cause acute or chronic cholecystitis. *Salmonella* itself may predispose stone formation. Patient may be silent typhoid carrier.

### SUMP SYNDROME

It is commonly observed after choledochoduodenostomy rarely after choledochojejunostomy. CBD distal to the choledochoduodenostomy acts as a reservoir with stasis of food particles, bile, stones and sludge. Often it causes cholangitis and narrowing of the stoma of choledochoduodenostomy. Conversion to end-to-end Roux-en-Y choledochojejunostomy is required.

*Commitment is what transforms a promise into reality.*

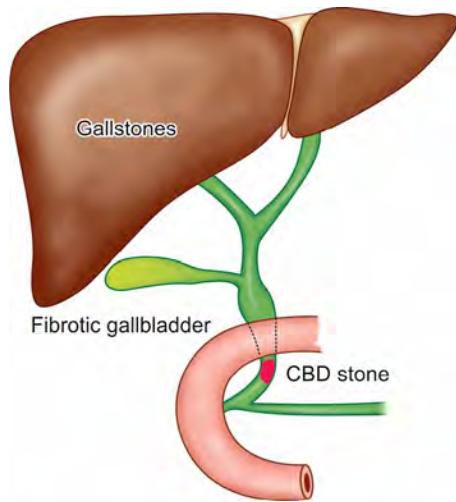




**Fig. 12.51:** Technique of cholecystoduodenostomy for CBD stones. Note the site of possible occurrence of *Sump syndrome*.

### ■ COURVOISIER'S LAW (SIGN)

- ◆ 'In a patient with jaundice if there is palpable gallbladder, it is not due to stones'.



**Fig. 12.52:** Courvoisier's law—"In a patient with jaundice if there is palpable gallbladder it is not due to stones". In stone disease gallbladder is contracted and fibrotic and so nondistensible.

- ◆ In obstruction due to CBD stone, gallbladder does not distend because it is chronically inflamed, thickened, fibrotic, contracted and nondistensible.
- ◆ In malignancy, like carcinoma of head of the pancreas or periampullary carcinoma, gallbladder will be distended and palpable to the right of rectus muscle in the right hypochondrium, as non-tender, globular, smooth, soft, dull mass which moves with respiration and with horizontal mobility.

#### Rule may not be useful in

- ❖ Absence of gallbladder
- ❖ Intrahepatic gallbladder
- ❖ Previous cholecystectomy

*Exceptions to the rule are:*

- ◆ Double impacted stone—one in CBD and one in cystic duct, with mucocele of gallbladder.
- ◆ Large stone in Hartmann's pouch.
- ◆ Empyema gallbladder with CBD stone.

### ■ SURGICAL JAUNDICE (Obstructive Jaundice)

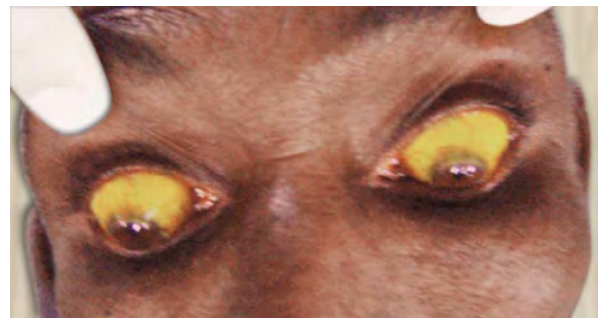
#### Definition

It is the jaundice that develops due to biliary obstruction, partial or complete or intermittent. It causes conjugated hyperbilirubinaemia. Normal serum bilirubin level is 0.2–0.8 mg%. Scleral icterus is visible when serum bilirubin level exceeds 2.5 mg%.

#### Pathophysiology in Obstructive Jaundice

##### Bilirubin metabolism and enterohepatic circulation

- ❖ Aged red cells get lysed in the reticuloendothelial cells and breakdown into haem and globin. Haem is divided into globin and bilirubin. Bilirubin is combined with albumin and transported to liver.
- ❖ In the liver bilirubin get separated from albumin and conjugated to bilirubin glucuronide by glucuronyl transferase. This conjugated bilirubin glucuronide is water soluble and can be excreted in kidney (So in obstructive and hepatic jaundice bile pigment – bilirubin is seen in the urine).
- ❖ This conjugated bilirubin is excreted through biliary canaliculi reaching intestine. In the intestine, it is converted into stercobilinogen and urobilinogen by intestinal bacteria. 70% of this is absorbed in the colon and brought back to liver as enterohepatic circulation. Unabsorbed stercobilinogen colours faeces brown. Circulating urobilinogen is taken up by kidneys for excretion.
- ❖ If direct bilirubin in the serum is more than 0.4 mg%, then bilirubin is seen in urine. Normal urinary urobilinogen is 100–200 mg/day. It is absent in obstructive jaundice. Normal faecal stercobilinogen is 300 mg/day. It is also absent in obstructive jaundice.
- ❖ In obstructive jaundice urine contains bilirubin and bile salts but urobilinogen is absent; stool is devoid of stercobilinogen.



**Fig. 12.53:** Sclera of the patient with obstructive jaundice is greenish yellow in colour.

- ◆ *Obstructive jaundice, often called as surgical jaundice occurs due to intrahepatic or extrahepatic biliary outflow obstruction.* It leads into cholestasis which means conjugated hyperbilirubinaemia; probably due to impaired bile flow and impaired bile formation. Bile acid secretion into the gut is impaired causing defective absorption of fat and fat-soluble vitamins like vitamin K; this, in turn causes poor synthesis of prothrombin and conversion of

prothrombin to thrombin causing widened PT and PT INR. Factors II, VII, IX, and X are vitamin K-dependent clotting factors. PT indicates the extrinsic pathway of coagulation; whereas partial thromboplastin time represents the intrinsic pathway. Bile acid stasis causes hepatocytes injury. Fat malabsorption causes steatorrhoea and also deficiencies of vitamins A (visual problem, thick skin), D (osteomalacia), E (peripheral neuropathy, cerebellar ataxia, posterior column dysfunction), K (bleeding tendencies). Cholestyramine and colestipol, used to treat pruritus, bind to bile salts and can exacerbate these vitamin deficiencies. Persistent cholestasis may be associated with deposits of cholesterol in the skin (cutaneous xanthomatosis), occasionally in bones and peripheral nerves.

- ◆ **Bilirubinostasis** (bile plugs) cause hepatocytes degeneration, small duct and ductular obstruction, pericholangitis, oedema, bile leak, liver infarction and biliary cirrhosis.
- ◆ **Obstruction may be due to** benign conditions like biliary tree stones (*most common cause*) or strictures or sclerosing cholangitis; or due to malignant conditions like carcinoma of pancreas or cholangiocarcinoma. **Extrahepatic obstruction** may be *luminal* (stones, infestations [ascariasis, clonorchis sinensis and schistosomiasis]) or *mucosal/wall* (growth, stricture [post-inflammatory, postsurgical or post-RT], primary sclerosing cholangitis) or *external compression* (pancreatitis, pancreatic tumour, compression by nodal mass).
- ◆ **Intrahepatic cholestasis** generally occurs at the level of the hepatocyte or biliary canalicular membrane. Causes include hepatocellular disease (e.g. viral hepatitis, drug-induced hepatitis/cholestasis (thiazides, chlorpromazine), biliary cirrhosis. In hepatocellular disease, interference in the 3 major steps of bilirubin metabolism—uptake, conjugation and excretion usually occur. **Excretion is the rate-limiting step** and is usually impaired to the greatest extent. As a result, conjugated bilirubin predominates in the serum.
- ◆ **The lack of bilirubin in the intestinal tract** is responsible for the pale stools in biliary obstruction. The cause of itching (pruritus) associated with biliary obstruction is not clear; may be related to the accumulation of bile acids in the skin; or may be related to the release of endogenous opioids.
- ◆ **Severe biliary obstruction** causes cell damage usually in 1 month and, if unrelieved, may lead to secondary biliary cirrhosis. Acute cholangitis is another complication associated with obstruction of the biliary tract and is the most commonly seen in stricture, most often at the level of the CBD. Bile here is usually sterile. Bile flow obstruction → stasis → colonization and multiplication of bacteria → concomitant increased intraductal pressure → reflux of biliary contents → bacteremia, septicaemia → septic shock. If recurrence of biliary colic after cholecystectomy occurs, one should think of possible choledocholithiasis.

## Effects of Obstructive Jaundice

- ◆ **In liver:** Enlarged green bile stained liver (*hydrohepatosis*) shows dilated intrahepatic biliary radicles. Once intraductal CBD pressure increases bile secretion from liver is reduced causing formation of ‘white bile’ in CBD. Biliary cirrhosis may develop later.
- ◆ **In the biliary tree:** Recurrent inflammation—cholangitis—fibrosis can occur.
- ◆ **In bowel:** Absence of bile from bowel impairs digestion, reduces fat absorption making faeces bulky and fatty.

Vitamin K absorption is reduced causing fall in prothrombin level raising PT-INR.

- ◆ **Retention of bile salts and bile pigments** in blood and body fluids occurs.
- ◆ **Altered coagulation profile; hepatorenal syndrome and renal failure; sepsis.**

## Classification of Causes of Obstructive Jaundice

1. **Congenital:** Biliary atresia, choledochal cyst.
2. **Inflammatory:** Ascending cholangitis, sclerosing cholangitis.
3. **Obstructive:** CBD stones, biliary stricture, parasitic infestation.
4. **Neoplastic:** Carcinoma of head or periampullary region of pancreas, cholangiocarcinomas, Klatskin tumour.
5. **Extrinsic compression** of CBD by lymph nodes or tumours.

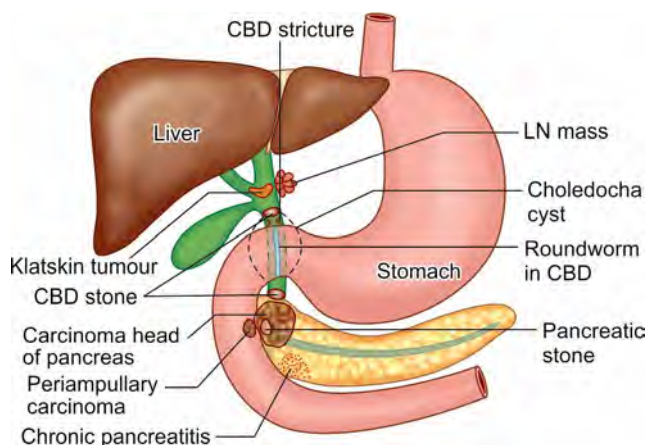


Fig. 12.54: Different causes of obstructive jaundice (surgical jaundice).

### Benjamin's (1983) classification of biliary obstruction

#### Type 1: Complete obstruction

- ❖ Tumours—pancreatic, cholangiocarcinoma
- ❖ CBD ligation—iatrogenic
- ❖ Primary/secondary liver tumours

#### Type 2: Intermittent obstruction

- ❖ Choledocholithiasis
- ❖ Periampullary tumour
- ❖ Choledochal cyst
- ❖ Bile duct papilloma
- ❖ Hemobilia
- ❖ Duodenal diverticula

#### Type 3: Chronic complete obstruction

- ❖ Bile duct stricture
- ❖ Congenital
- ❖ Traumatic
- ❖ Post-radiotherapy
- ❖ Chronic pancreatitis
- ❖ Cystic fibrosis

#### Type 4: Segmental obstruction

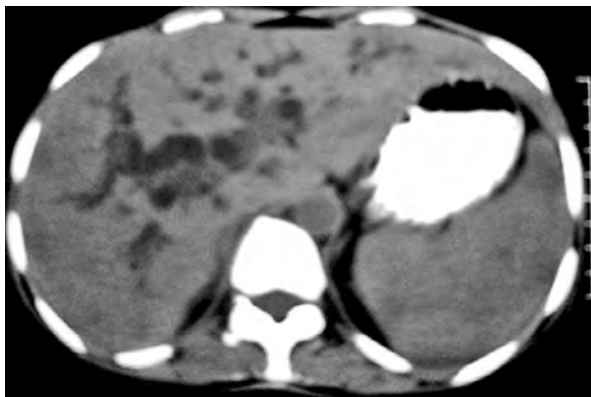
- ❖ Traumatic
- ❖ Sclerosing cholangitis
- ❖ Cholangiocarcinoma, intrahepatic biliary stones (hepatolithiasis)

### Clinical features

- ❖ Severe jaundice.
- ❖ Pruritus, more on the back and forearms.
- ❖ Fever, may or may not be present.
- ❖ Loss of weight.
- ❖ Loss of appetite.
- ❖ Pain in right hypochondrium, *palpable gallbladder*, hydrohepatic palpable, smooth, soft, non-tender liver are other features.
- ❖ Courvoisier's law may suggest inflammatory/neoplastic cause.
- ❖ Charcot's triad/Reynold's pentad as presentation in cholangitis.
- ❖ Steatorrhea (more fatty stool) due to improper absorption of fat soluble vitamins.

### Investigations for Obstructive Jaundice

- ◆ Serum bilirubin. Normal value is less than 1.0 mg%. Both direct and indirect bilirubin are assessed. Direct is increased in obstructive jaundice, i.e. conjugated hyperbilirubinaemia. van den Bergh's test is done.
- ◆ Serum albumin, globulin and A:G ratio. Normal S. albumin is more than 3.5 gm%.
- ◆ Prothrombin time. Normal value is 12–16 seconds. It is significant if it is more than 4 from the control or more than one and half times the control. It is corrected by injection vitamin K, 10 mg IM OD for 5 days or by FFP—5–10 units.
- ◆ Serum alkaline phosphatase, SGPT, SGOT, 5' nucleotidase.
- ◆ Total count may be raised with neutrophilia in inflammatory conditions. *Serum alkaline phosphatase (ALP) and  $\gamma$  glutamyl transpeptidase (GCT)* are relevant enzymes in biliary obstruction; especially ALP/GCT ratio is more relevant in differentiating between obstructive jaundice and hepatitis.
- ◆ Ultrasound abdomen.
- ◆ ERCP to visualise the site of obstruction, brush biopsy, bile sample for analysis.
- ◆ PTC to decompress, assess proximal dilated obstructed biliary system if ERCP fails; dine polythene catheter can be kept *in situ* to have biliary drainage; PTC—stenting across the obstruction can be done under image (C-arm) guidance.
- ◆ MRCP—Noninvasive diagnostic tool. It shows 96% sensitivity; 99% specificity.
- ◆ CT scan in case of tumours to assess operability.



**Fig. 12.55:** CT scan showing hydrohepatosis due to obstruction below, in a patient with obstructive jaundice.

- ◆ *Tumour markers:* CA 19/9 is useful for carcinoma pancreas (more than 70 units/L) with 70% sensitivity and 90%

specificity. But it may also increase in other causes of biliary obstruction and cystadenoma.

- ◆ *Endoscopic US (EUS):* It is done through endoscope. It is more accurate in assessing pancreatic mass, staging of the disease, to identify involvement of portal venous system, CBD stones. It is also useful in EUS-guided FNAC, celiac axis neurolysis, EUS-guided immunotherapy.
- ◆ *Intraductal US (IDUS):* It is very useful in assessing tumour stage, tumour margin in bile duct cancer. It is also used in assessing pancreatic duct to differentiate pancreatic cancer and chronic pancreatitis.
- ◆ *CT/MR angiogram or venogram* to assess vascularity and portal venous system in malignancy.
- ◆ Urine tests: Fouchet's test for bile pigments, Hay's test for bile salts and test for urobilinogen in urine.

**Fouchet's test:** 10 ml of urine + 5 ml of BaCl<sub>2</sub> + pinch of MgSO<sub>4</sub> causes formation of BaSO<sub>4</sub> which is filtered over a filter paper and few drops of Fouchet's reagent is added. Green or blue colour signifies presence of bile pigments in the urine.

**Hay's test for bile salt:** Sprinkle sulphur to 2 ml of urine. In presence of bile salts sulphur sinks to the bottom.

**Ehrlich's test:** 5 ml of freshly voided urine + 1 ml of Ehrlich reagent (p-dimethyl amino benzaldehyde) and wait for 5 minutes. Formation of red colour signifies presence of urobilinogen in urine. Normally it is present in traces; in obstructive jaundice, it is absent; and in haemolytic jaundice, it is in excess.

### Preoperative preparation of patient with obstructive jaundice

- ❖ Proper diagnosis and assessment
- ❖ Injection vitamin K IM 10 mg for 5 days
- ❖ Fresh Frozen plasma—often requires 6 bottles or more
- ❖ *Adequate hydration* is most important 5/10% dextrose
- ❖ Blood transfusion in case of anaemia
- ❖ Oral neomycin, lactulose
- ❖ Mannitol 100–200 ml BD IV to prevent hepatorenal syndrome
- ❖ Repeated monitoring by doing prothrombin time, electrolytes
- ❖ Antibiotics like third generation cephalosporins.
- ❖ Calcium supplements as calcium chloride IV
- ❖ *Preoperative decompression* is indicated if bilirubin is > 12 mg%, sepsis, hepatorenal syndrome, severe malnutrition or cardiopulmonary disease.
- ❖ Correction of coagulopathy, prevention of renal failure, infection, hepatic encephalopathy and electrolyte imbalance (correction of hypoglycaemia and dilutional hyponatraemia due to water retention; avoiding isotonic saline infusion).

### Treatment of Obstructive Jaundice

- ◆ CBD stones—ERCP stone removal, choledocholithotomy, transduodenal sphincteroplasty, choledochojejunostomy or choledochoduodenostomy.
- ◆ Carcinoma periampullary or head of pancreas—Whipple's operation or triple bypass or ERCP stenting.
- ◆ Biliary stricture—Stenting, choledochojejunostomy, Roux-en-Y hepaticojejunostomy.

- ◆ Klatskin tumour—Radical resection or palliative stenting.
- ◆ Biliary atresia—Kasai's operation or liver transplantation.
- ◆ Choledochal cyst—Excision, hepaticojejunostomy, mucosal resection.
- ◆ *Management of pruritus*: Pruritus may be due to retention of bile salts which activates the release of histamine in skin, central mechanism or by release of endogenous opioids. It is often difficult to treat. Once cause is treated and obstruction is relieved, pruritus will regress. Drugs and therapies used are—cholestyramine (ion exchange resin binds bile salts in intestine inhibiting their absorption), rifampin, ondansetron, gabapentin, sertraline, ursodeoxycholic acid, antioxidants, phototherapy, plasmapheresis.

### Postoperative Management

- ◆ Monitoring with prothrombin time, bilirubin, albumin, creatinine, electrolyte estimation.
- ◆ FFP or blood transfusion.
- ◆ Antibiotics.
- ◆ Observation for septicemia, haemorrhage, pneumonia, pleural effusion, bile leak.
- ◆ Care of T-tube and drains.
- ◆ T-tube cholangiogram in 10–14 days.
- ◆ TPN, CVP line, nasogastric tube, urinary catheter.

### ■ CBD STRICTURES (BILIARY STRICTURES)

#### Causes

1. *Postoperative (80% common)*
  - ▶ After cholecystectomy [open or laparoscopic, more common following laparoscopic (0.8%) than open method (0.35%)].
  - ▶ Biliary surgery.
  - ▶ Gastrectomy.
  - ▶ Liver surgery.
  - ▶ Duodenal and pancreatic surgery.

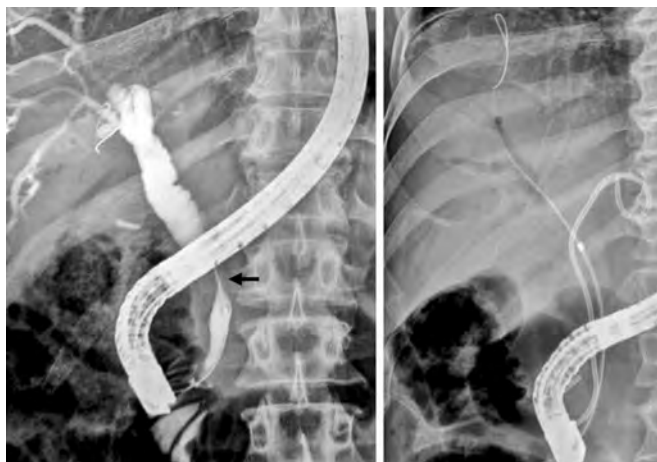

Fig. 12.56: ERCP picture showing stricture and passing stent into CBD.

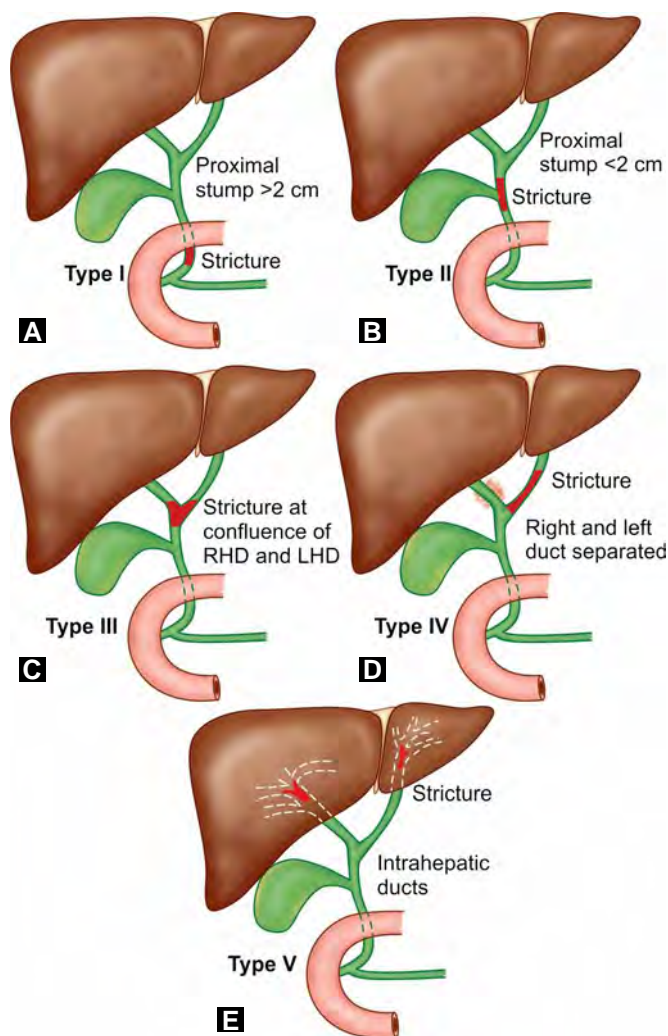
2. *Inflammatory*: Stricture following recurrent attacks of cholangitis due to:
  - ▶ CBD stones.
  - ▶ Parasites—*Ascaris lumbricoides*, *Clonorchis sinensis*.
  - ▶ Primary sclerosing cholangitis.
3. *Malignant*: Due to cholangiocarcinoma.
4. *Traumatic*.

#### Bismuth classification of biliary stricture

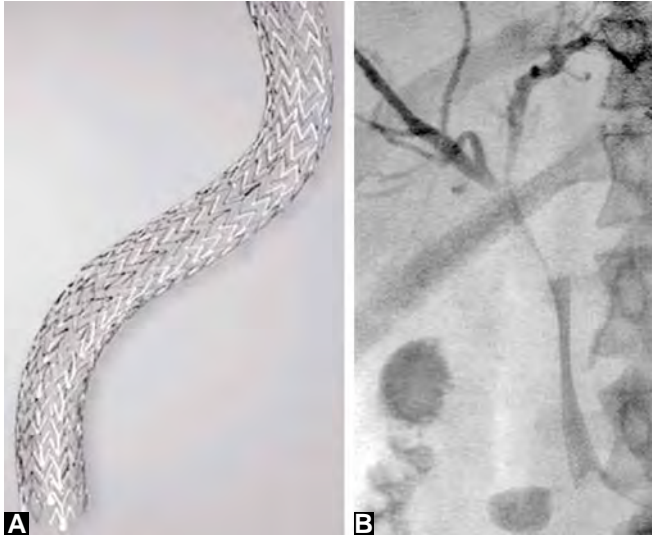
- I. Low CBD stricture with stump (proximal to stricture) > 2 cm
- II. Middle CBD stricture with proximal stump < 2 cm
- III. Hilar. Confluence of right and left hepatic ducts is intact
- IV. Separated right and left hepatic ducts
- V. Stricture involving intrahepatic ducts

#### Clinical Features

- ◆ Obstructive jaundice.
- ◆ Pain abdomen.
- ◆ Features of ascending cholangitis.
- ◆ Profuse persistent bile leak.



Figs 12.57A to E: Bismuth classification of stricture CBD.



Figs 12.58A and B: CBD stent and imaging after placement.

#### Causes of postoperative stricture

- ❖ Too much traction to the GB during 'Fundus first' cholecystectomy'
- ❖ Blind application of artery forceps in Calot's to control bleeding
- ❖ Anomalies of biliary tree
- ❖ Inflammatory adhesions at Calot's triangle
- ❖ Injury during other surgery like gastrectomy

#### Note:

*Hogarth Pringle's manoeuvre* is ideal to control bleeding on table by applying pressure using thumb and fingers over the Foramen Winslow.

### Investigations

- ◆ Ultrasound abdomen.
- ◆ Liver function tests.
- ◆ ERCP.
- ◆ On table cholangiography.
- ◆ MRCP.

### Treatment

- ◆ ERCP stenting.
- ◆ Choledochoduodenostomy or jejunostomy.
- ◆ Roux-en-Y hepaticojejunostomy—ideal.

### SCLEROSING CHOLANGITIS

- ◆ It is fibrous thickening of the CBD and biliary ductular wall, associated with multiple strictures with dilatation in between the strictures. Both extra- and intrahepatic ducts are involved.
- ◆ They have increased risk of developing cholangiocarcinoma.

### Types

1. *Primary sclerosing cholangitis* is one wherein no cause is found and is associated with ulcerative colitis, Sjögren's syndrome, Crohn's disease, Graves disease. It eventually leads to biliary cirrhosis. *Primary sclerosing cholangitis* (PSC) is an idiopathic, progressive, chronic, cholestatic pathology with diffuse inflammation, sclerosis,

and obliteration of intra- and extrahepatic biliary systems. There will be multiple areas of strictures and dilatations (1%/year). It has high risk for cholangiocarcinoma. It could be an autoimmune disease. It is common in HLA/B8/DR3 halotype.

2. *Secondary sclerosing cholangitis* is due to stones, trauma, congenital lesions. AIDS, chemotherapy (5FU), transplantation, collagen diseases, sarcoidosis, histiocytosis.

### Features

- ◆ Common in young men (70%).
- ◆ Intermittent jaundice.
- ◆ Abnormal liver functions.
- ◆ Weight loss, pain, fever, pruritus.
- ◆ Features of ulcerative colitis in case of PSC (70%).
- ◆ PSC may be associated with retroperitoneal fibrosis, mediastinal fibrosis, Riedel's thyroiditis, orbital pseudo-tumour.
- ◆ *Hepatic duct confluence* is most severely strictured segment in PSC.

### Investigation

- ◆ ERCP shows *beaded appearance* of biliary tree.
- ◆ LFT is altered.
- ◆ Liver biopsy is needed to identify the severity of hepatic fibrosis.

### Treatment

- ◆ Stenting.
- ◆ T-tube drainage.
- ◆ Large dose steroids.
- ◆ Immunosuppression therapy—methotrexate, azathioprine, tacrolimus, cyclosporine.
- ◆ Ursodeoxycholic acid is beneficial.
- ◆ Liver transplantation.
- ◆ *Median survival in PSC* after diagnosis is 10 years.

### GALLBLADDER POLYP

- ◆ Its incidence is 5% in routine US abdomen; 10% in cholecystectomy tissue specimen.
- ◆ It is usually less than 10 mm in size, pedunculated appearance.
- ◆ Sessile polyps are often more than 10 mm in size.
- ◆ 30% are multiple.
- ◆ Gallbladder polyp more than 10 mm in size, associated with gallstones, age above 60 years, symptomatic, sessile polyp and multiple polyps—are indications for surgical intervention.
- ◆ CT scan should be done if malignancy is suspected on US.
- ◆ It is treated by laparoscopic cholecystectomy. Histology is a must to confirm benign nature and to rule out carcinoma.

### BENIGN BILIARY PAPILLOMA

- ◆ It is the most common benign biliary tumour.
- ◆ 50% occurs close to ampulla presenting as obstructive jaundice.
- ◆ Benign adenoma (soft), benign inflammatory pseudotumour and cholangiocarcinoma—are differential diagnosis.
- ◆ ERCP, CT scan, EUS, LFT—are the investigations.
- ◆ Treatment—papillotomy, wide local excision.

## ■ CARCINOMA GALLBLADDER

- ◆ It is more common in *India (Patna)* and Asian countries. It is also common in Chile.
- ◆ It is common in *females* and elderly. Male:Female = 1:3.

### Aetiologies for Carcinoma of Gallbladder

- ◆ 3% of gallstones with cholecystitis will develop carcinoma of gallbladder.
- ◆ 90% of carcinoma of gallbladder is associated with gallstones. Risk of developing carcinoma in gallstone disease is 7–10 times more than general population. Relative risk is less if stone size is less than 2 cm; if stone size is 2–3 cm in size, it is 2.5; it is 10 or more if stone size is more than 3 cm.
- ◆ Choledochal cyst, anomalous pancreaticobiliary duct junction (20%), cholesteroses of gallbladder, gallbladder polyp more than 1 cm in size or more than 3 in number or adenomatous polyp, PSC.
- ◆ Chronic typhoid carriers, carcinogens, inflammatory bowel disease, hepatitis B and hepatitis C virus infection.
- ◆ Porcelain gallbladder is more prone for malignant transformation (25%) and 90% of them are inoperable tumours.
- ◆ Nitrosamines.
- ◆ Polypoid lesions (GB polyp), xanthogranulomatous cholecystitis.

### Gross Types of Carcinoma Gallbladder

- ◆ Polypoid/papillary—better prognosis.
- ◆ Scirrhus/nodular.
- ◆ Proliferative/infiltrative.

### Microscopy

- ◆ Commonly it is adenocarcinoma (90%); occasionally squamous cell carcinoma, adenosquamous or carcinoid tumour can occur.
- ◆ 25% show only localised disease; 35% have lymph node spread; 40% have distant spread at the time of first diagnosis.
- ◆ It is very *aggressive* tumour.

### Spread of Carcinoma Gallbladder

- ◆ Direct spread to liver (segment IV and V), bile duct, duodenum, colon and kidney.
- ◆ Lymphatic—lymph node of Lund, periportal nodes, peri-pancreatic and periduodenal nodes.
- ◆ Blood spread—to liver, lungs and bones.
- ◆ Perineural spread is also known to occur.

#### Staging of carcinoma gallbladder

*Nevin's staging:*

Stage I – Intramural

Stage II – Spread to muscularis propria

Stage III – Spread to serosa

Stage IV – Spread to cystic lymph node of Lund

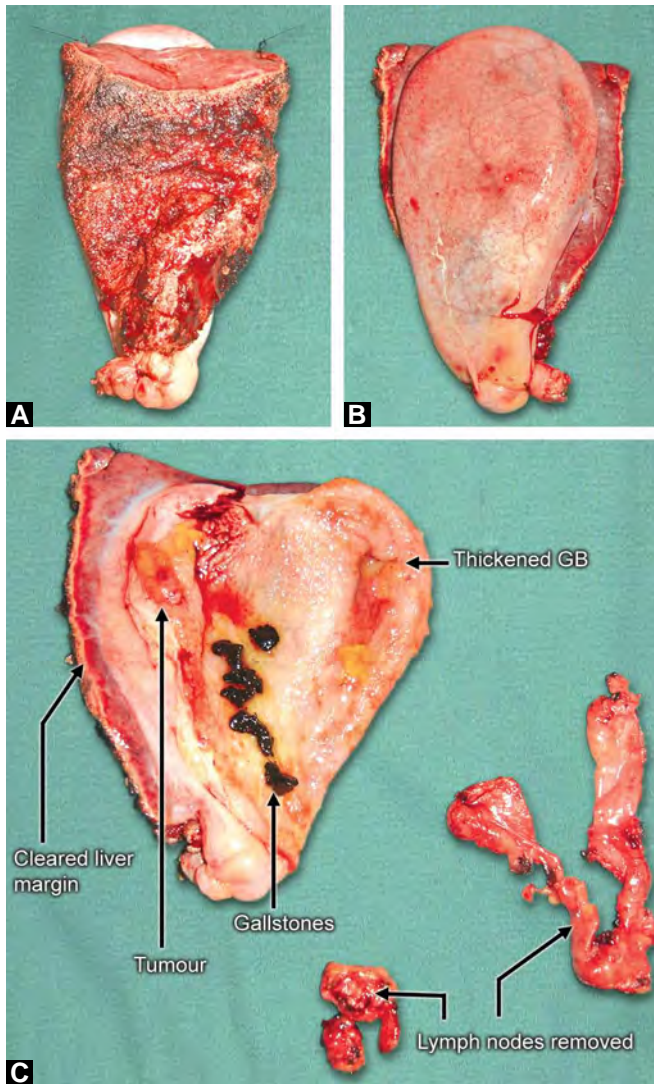
Stage V – Direct spread to adjacent organs/metastases

#### TNM staging for gallbladder cancer (AJCC)

Tumour (T)	Metastases (M)
TX Primary tumor cannot be assessed	M0 – No distant spread. M1 Distant spread.
T0 No evidence of primary tumor	
Tis Carcinoma in situ	
T1 Tumor invades lamina propria or muscular layer	
T1a Tumor invades lamina propria	
T1b Tumor invades muscular layer	
T2 Tumor invades perimuscular connective tissue; no extension beyond serosa or into liver	
T3 Tumor perforates the serosa (visceral peritoneum) and/or directly invades the liver and/or one other adjacent organ or structure, such as the stomach, duodenum, colon, pancreas, omentum, or extrahepatic bile ducts	
T4 Tumor invades main portal vein or hepatic artery or invades at least two extrahepatic organs or structures	
Nodes (N)	Staging
Nx Regional lymph nodes cannot be assessed	Stage 0- Tis, N0, M0
N0 Regional lymph node metastasis	Stage I – T1,N0,M0
N1 Metastases to nodes along the cystic duct, common bile duct, hepatic artery, and/or portal vein	Stage II – T2, N0, M0
N2 Metastases to periaortic, pericaval, superior mesenteric artery, and/or celiac artery lymph nodes	Stage III A – T3, N0, M0
	Stage III B – T1 to T3, N1,M0
	Stage VI A – T4, N0 or N1, M0
	Stage IV B – Any T, N2, M0;
	Any T, any N, M1
	Note: Stage I is Localised;
	Stages II to IV B are unresectable.

### Features of Carcinoma of Gallbladder

- ◆ Pain in right hypochondrium, mass in right upper abdomen which is hard and nontender.
- ◆ Jaundice is common.
- ◆ Significant weight loss in short duration, anorexia
- ◆ Acute presentation of cholecystitis.
- ◆ Palpable nodular liver secondaries, ascites.
- ◆ It is common in places where there is more prevalence of gallstone disease—Patna, Bihar
- ◆ It is common in females.
- ◆ Incidentally confirmed as carcinoma gallbladder histologically after cholecystectomy for chronic cholecystitis.
- ◆ *Three clinical presentations* – 1. Clinically obvious type with pain, obstructive jaundice, mass. 2. Early GB cancer mimics GB stone disease. 3. Atypical as unusual features.



**Figs 12.59A to C:** Specimen of gallbladder after extended cholecystectomy. Note the liver margin cleared of carcinoma, stone in the gallbladder and lymph nodes cleared.

### Investigations

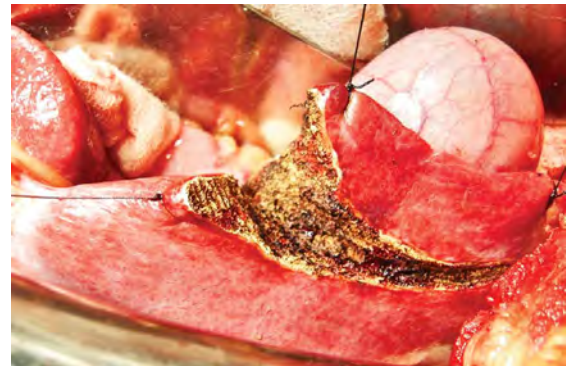- ◆ Ultrasound abdomen.
- ◆ CT abdomen to see operability.
- ◆ US-guided FNAC.
- ◆ Liver function tests.
- ◆ MRCP.
- ◆ Laparoscopy.
- ◆ CA 19-9 is elevated in 80% of cases.

### Treatment

- ◆ Cholecystectomy with resection of liver segments IV and V—*extended cholecystectomy with perihepatic nodal clearance*. At least 2 cm margin in the liver from the gallbladder bed should be cleared. All pericholedochal lymph nodes should be removed. Frozen section biopsy from cystic duct stump should be done to identify for the existence of microscopic tumour. If present, CBD resection and hepaticojeju-

nostomy is done. *Open approach* rather than laparoscopic is ideal for carcinoma gallbladder.

- ◆ Hemihepatectomy with cholecystectomy with nodal clearance.
- ◆ During laparoscopic cholecystectomy, any suspicious of GB cancer, procedure should be converted into open cholecystectomy.

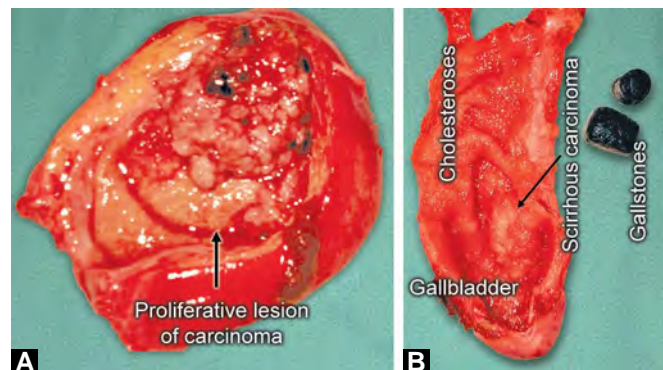


**Fig. 12.60:** Extended cholecystectomy technique.

- ◆ If patient has undergone laparoscopic cholecystectomy and histology confirmed carcinoma, then staging should be done. All port areas should be re-excised to prevent *port site recurrence*. Often extended resection of segment IV and lymph nodes may be needed. Spillage of bile during laparoscopic cholecystectomy is common (30% in non-malignant GB, 50% in carcinoma GB).
- ◆ Chemotherapy either systemic or intra-arterial, and adjuvant radiotherapy but with poor success rate.

### Prognosis

- ◆ Overall prognosis for carcinoma gallbladder is poor due to early spread and aggressive nature of the tumour.
- ◆ 5-year survival is only 5%. Muscle invasion, nodal and distant spread carry poor prognosis. In stage T<sub>1</sub> simple and extended cholecystectomy will not make difference in prognosis. In T<sub>2</sub>, stage extended cholecystectomy is very much beneficial which gives 60% 5-year survival rate. T<sub>3</sub> and T<sub>4</sub> carry poor prognosis.



**Figs 12.61A and B:** (A) Gallbladder showing proliferative carcinomatous lesion; (B) Gallbladder showing scirrhous carcinoma with pre-existing gallstones and cholesteroses.

## ■ CHOLANGIOCARCINOMA (Bile Duct Carcinoma)

- ◆ It is associated with sclerosing cholangitis, clonorchiasis infestation, Caroli's disease or choledochal cyst.
- ◆ It is an aggressive adenocarcinoma which presents as obstructive jaundice.
- ◆ It commonly occurs at the hepatic duct confluence.

### Risk Factors for Cholangiocarcinoma

- ◆ Primary sclerosing cholangitis (PSC): Here commonly it is extrahepatic, usually at the confluence.
- ◆ Choledochal cyst.
- ◆ Hepatolithiasis.
- ◆ Hepatitis B and C are risk factors for intrahepatic cholangiocarcinoma.
- ◆ Lynch syndrome II.
- ◆ Multiple biliary papillomatosis.
- ◆ Previous biliary enteric anastomosis.
- ◆ Clonorchis sinensis infestation.
- ◆ Thorotrast, nitrosamines, dioxin.

### Classification I

- ◆ Intrahepatic—10%.
- ◆ Perihilar—65%.
- ◆ Distal—25%.

### Classification II—Pathological

*Sclerosing (80%); nodular; papillary.*

### Classification III

- ◆ *Upper third*—from porta to cystic duct – 50%.
- ◆ *Middle third*—from cystic duct to upper margin of first part of the duodenum—25%.
- ◆ *Lower third*—from upper margin of first part of duodenum to ampulla—20%.
- ◆ *Diffuse*—5%.

#### Classification of perihilar cholangiocarcinoma (Bismuth)

- ❖ Type I : Below the confluence of RHD and LHD
- ❖ Type II : Reaching the confluence of RHD and LHD
- ❖ Type III : Involving CHD and RHD/LHD
- ❖ Type IV : Involving confluence and both RHD and LHD or multicentric tumour

### Features

- ◆ Main presentation is painless obstructive jaundice of short duration.
- ◆ Palpable liver either smooth and soft (hydrohepatic) or hard nodular (secondaries).
- ◆ Weight loss and anorexia is typical and significant.

### Investigations

- ◆ ERCP and choledochoscope.
- ◆ Liver function tests.
- ◆ PTC.

- ◆ Ultrasound abdomen, CT scan.
- ◆ MR scan—Best investigation. MRCP to *see duct*; MRI to *see nodes*; MR angiogram to *see vascularity*.

Assessment should be done to check the operability of tumour by—assessing the spread in bilateral hepatic duct up to secondary radicles, both hepatic arterial spread, portal vein encasement, hepatic lobe atrophy, distant spread.

#### American Joint Cancer Committee/Union for International Cancer Control 7th edition, TNM staging for perihilar cholangiocarcinoma

Primary tumor (T)	Regional lymph nodes (N)
Tx Primary tumor cannot be assessed	NX Regional lymph nodes cannot be assessed
T0 No evidence of primary tumor	N0 No regional lymph node metastases
Tis Carcinoma in situ	N1 Regional lymph node metastases present (including nodes along the cystic duct, common bile duct, hepatic artery, and portal vein)
T1 Tumor confined to the bile duct, with extension up to the muscle layer or fibrous tissue	N2 Metastases to periaortic, pericaval, superior mesenteric artery, and/or celiac artery lymph nodes
T2A Tumor invades beyond the wall of the bile duct to surrounding adipose tissue	
T2B Tumor invades adjacent hepatic parenchyma	
T3 Tumor invades unilateral branches of the portal vein or hepatic artery	
T4 Tumor invades main portal vein or its branches bilaterally; or the common hepatic artery; or the second-order biliary radical bilaterally; or unilateral second order biliary radicals with contralateral portal vein or hepatic artery involvement	
<b>Note:</b> TNM staging defers for intrahepatic, perihilar and distal cholangiocarcinoma.	
	<b>Distant metastases (M)</b>
	M0 No distant metastases
	M1 Distant metastases present
	<b>Staging</b>
	Stage 0 Tis N0 M0
	Stage I T1 N0 M0
	Stage II T2A-B N0 M0
	Stage IIIA T3 N0 M0
	Stage IIIB T1-3 N1 M0
	Stage IVA T4 N0-1 M0
	Stage IVB Any T N2 M0
	Any T Any N M1

### Treatment

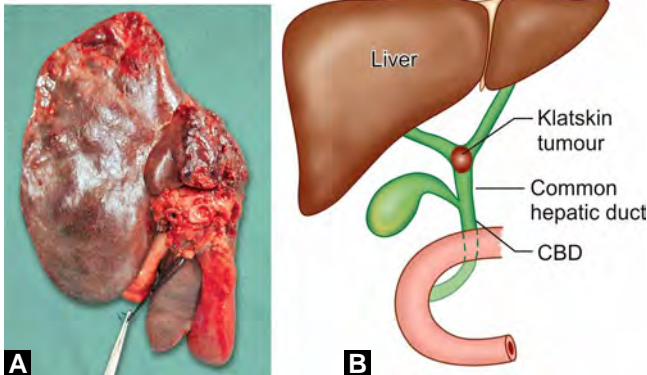
- ◆ When operable, portal region clearance with hemihepatectomy can be done. *Intrahepatic type* is treated with hemihepatectomy. *Perihilar* is treated with hemihepatectomy or extensive bile duct resection, nodal clearance, caudate lobe removal, cholecystectomy. Distal tumour is treated with Whipple's pancreaticoduodenectomy.
- ◆ Most often it is inoperable. Stenting can be done to relieve jaundice, through PTC or ERCP or on table.
- ◆ Chemotherapy—5 FU; Gemcitabine, cis platin.
- ◆ Chemotherapy, with external beam radiotherapy (ERBT).

## ■ KLATSKIN TUMOUR

- ◆ It is cholangiocarcinoma at the confluence of the hepatic ducts and common hepatic duct above the level of the cystic duct (20% of cholangiocarcinomas).
- ◆ *Klatskin tumour is classified as 4 types*—I: Just at or below the confluence; II: At the confluence; III: at the confluence extending along the RHD; IV: at the confluence extending along the LHD.



- ◆ It causes obstructive jaundice with hydrohepatosis without enlargement of gallbladder.
- ◆ Management is like cholangiocarcinoma.
  - ▶ Hilar resection with hepaticojejunostomy.
  - ▶ Segment III left hepaticojejunostomy—Blumgart's.
  - ▶ Longmire's left hepaticojejunostomy after left liver lobe resection.
  - ▶ Cattell's hepaticojejunostomy.
  - ▶ Smith's mucosal graft hepaticojejunostomy.
  - ▶ Palliative PTC with stenting/ERCP stenting, intraoperative stenting. Metal stents show long period of patency (12 months) than polyethylene stents (4 months).



**Figs 12.62A and B:** (A) Resected specimen of Klatskin tumour (Courtesy: Dr Arunkumar, MCh); (B) Klatskin tumour.

### Cholangiocarcinoma

- ❖ It is an uncommon tumour of elderly. 1 in 100,000 is the incidence
- ❖ Primary sclerosing cholangitis is the commonest association. 20-fold increased risk
- ❖ Choledochal cyst, Caroli's disease, pyogenic cholangiohepatitis, Clonorchis sinensis, opisthorchis viverrini infestation, hepatolithiasis, hepatitis C, Lynch syndrome II, bile duct adenoma and papillomatosis are other causes
- ❖ Chemical carcinogens like thorium, nitrosamines, diosmin also can cause
- ❖ Intrahepatic cholangiocarcinoma is 10%
- ❖ 60% cases are proximal to cystic duct CBD junction
- ❖ Features are jaundice, pain, hepatomegaly, cachexia, early satiety and weight loss
- ❖ It is adenocarcinoma type
- ❖ Lymph node spread is common
- ❖ Resection along with liver/resection along with pancreas are surgical options
- ❖ But surgical resection is possible only in 5% of cases
- ❖ Stenting/bypass are palliative options
- ❖ Doxorubicin, cis platin and  $I_{131}$  anti-CEA antibodies are adjuvant therapies
- ❖ Condition has got 90% mortality in one year

## BILIARY FISTULAS

### Types

- a. *External:* Usually occurs as a complication of surgery following:
  - ▶ Gastrectomy.
  - ▶ Cholecystectomy open or laparoscopic.
  - ▶ CBD surgery.
  - ▶ Pancreatic surgery.

- b. *Internal:*

- ▶ Cholecystoduodenal fistula causing gallstone ileus.
- ▶ Cholecystoenteric fistula.
- ▶ Cholecystocholedochal fistula.

*External biliary fistulas are difficult to manage, often dangerous, but many a times resolve spontaneously.*

### Investigations

- ◆ Fistulogram.
- ◆ ERCP.
- ◆ Electrolyte estimation.
- ◆ Liver function tests.

### Treatment

- ◆ Total parenteral nutrition (TPN).
- ◆ Antibiotics.
- ◆ Blood transfusion.
- ◆ Electrolyte management.
- ◆ Care of the fistula wound with regular dressing, using zinc oxide cream has to be done to protect the skin.
- ◆ Later continuity of biliary system has to be restored by open surgery or through ERCP and stenting.

## HEMOBILIA

- ◆ It is bleeding commonly from the liver or occasionally from the gallbladder into the biliary tract.
- ◆ There is abnormal communication between a blood vessel and a bile duct or any part of the biliary tree.

### Causes

- ◆ Accidental trauma, *iatrogenic* trauma (50%). In accidents hemobilia is more commonly caused by blunt trauma than by penetrating one.
- ◆ Percutaneous diagnostic and therapeutic procedures.
- ◆ Vascular diseases of the hepatic artery—10%.
- ◆ Malignant liver diseases > common (5%) than benign.
- ◆ Portal hypertension.
- ◆ Parasitic liver diseases like hydatid disease.
- ◆ Gallstones rarely erode into hepatic artery causing life-threatening hemobilia.
- ◆ Blood and necrotic material drains into the biliary tree causing gastrointestinal bleeding. As bile interferes with coagulation a fatal haemorrhage can occur.
- ◆ Arterial hemobilia is more common. Portal venous hemobilia is rare. *Hepatic artery aneurysm* is common cause.
- ◆ Early rapid presentation can occur; but delayed, after weeks/months/years, presentations are known to occur which is often difficult to suspect and diagnose.
- ◆ These recurrent clots can cause pancreatitis, cholangitis, anaemia, cholecystitis.

### Clinical Features

- ◆ Pain which is colicky in nature.
- ◆ Obstructive jaundice.
- ◆ Haematemesis and melaena.

### Triad of Sandblom/Quincke's in hemobilia

- ❖ Jaundice—60%
- ❖ Pain—70%
- ❖ Upper GI bleed with melaena (90%), haematemesis (60%)

All three features of triad are seen only in 20% of cases.

### Investigations

- ◆ LFT.
- ◆ US abdomen.
- ◆ **Selective arteriography**—test of choice in detecting bleeding site in 90% of cases. *CT angiogram* is useful.
- ◆ Upper GI scopy—useful only in 10% of cases.

**Note:** ERCP is usually not indicated.

### Treatment

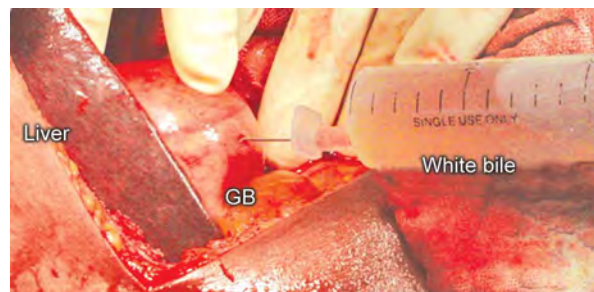
- ◆ *Aim: To stop bleeding and to relieve biliary obstruction.*
- ◆ Antibiotics.
- ◆ Blood transfusions.
- ◆ Selective arterial embolisation. Transarterial embolisation (TAE) shows 90% success rate. It is the *choice therapy* with least morbidity. *Coils and glue* are used.
- ◆ Surgical intervention is *only rarely indicated* in failed TAE. Laparotomy, ligation of bleeding vessel or hepatic artery, excision of aneurysm, hepatic resection—are the procedures done. *Hemobilia is often a fatal condition.*

#### **Note:**

*Bilhemia:* It is different very rare entity wherein bile flows into the hepatic or portal venous system due to raise in intrabiliary pressure more than that of portal or hepatic venous pressure. It may be due to trauma, iatrogenic or gallstone eroding into the venous system. Large quantity of bile enters the venous system and later to lung becoming fatal. If flow is low which is common, subsides spontaneously. ERCP is diagnostic. Treatment is stenting. Septicaemia and mortality is common.

### WHITE BILE

- ◆ It is double misnomer.
- ◆ It is *neither white nor bile*. It is opalescent.
- ◆ It is *mucous secreted by the lining of biliary tree*.
- ◆ It signifies severe obstruction due to stone (impacted in the CBD), or carcinoma head of pancreas or periampullary region.
- ◆ It is on table finding during surgery.
- ◆ It means liver is unable to secrete bile due to raised intraductal pressure, and so can anticipate hepatic failure.
- ◆ Indicates a poor prognosis.



**Fig. 12.63:** Demonstration of white bile on table. It is not white but opalescent. It is not bile but it is mucus.

### CHOLECYSTECTOMY

It is the surgical removal of gallbladder.

#### Prophylactic cholecystectomy is done in

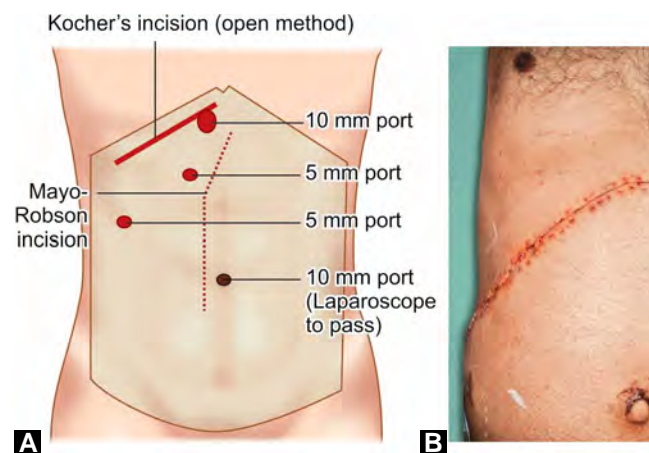
- ❖ Diabetic patients
- ❖ Congenital haemolytic anaemia
- ❖ Patients who has underwent bariatric surgery

### Indications

- ◆ Gallstones—symptomatic.
- ◆ Cholecystitis—acute, chronic.
- ◆ Acalculous cholecystitis.
- ◆ Empyema gallbladder.
- ◆ Mucocele gallbladder.

### Approach

- ◆ *Open*
  - ▶ Right subcostal incision (Kocher's).
  - ▶ Right paramedian.
  - ▶ Horizontal incision.
  - ▶ Mayo-Robson incision.
- ◆ *Laparoscopic approach.*



**Figs 12.64A and B:** (A) Incisions for open cholecystectomy and laparoscopic cholecystectomy; (B) Kocher's incision used for open cholecystectomy.

### OPEN APPROACH CHOLECYSTECTOMY

#### Technique

After opening the abdomen, colon is pushed downwards and stomach medially.

*Duct—first method:* Here *Calot's triangle* is dissected. Cystic artery is identified and ligated. Cystic duct is ligated close to the gallbladder. Gallbladder is separated from gallbladder fossa and removed. Haemostasis is maintained.

*Fundus—first method:* It is done in difficult gallbladder due to dense adhesions. Fundus is separated from the liver bed. Dissection is carried

*Love all, trust a few, do wrong to none—William Shakespeare*

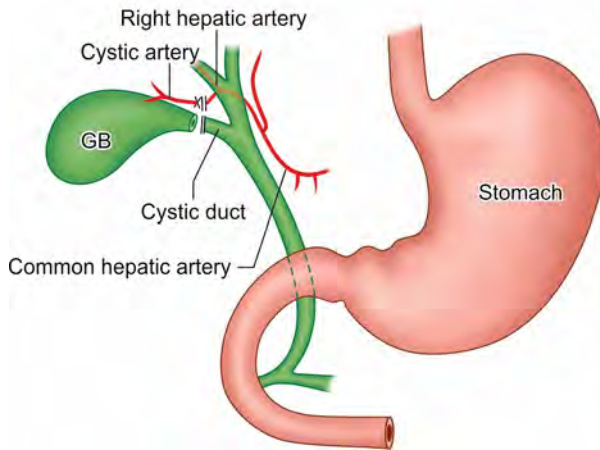
*It is the quality of our work that will please god and not the quantity—Mohandas Gandhi*

proximally until cystic duct and cystic artery are identified, which are then ligated.

Drain is placed, which is removed after 72 hours.  
On table cholangiogram is a must after cholecystectomy.

### Complications of Cholecystectomy

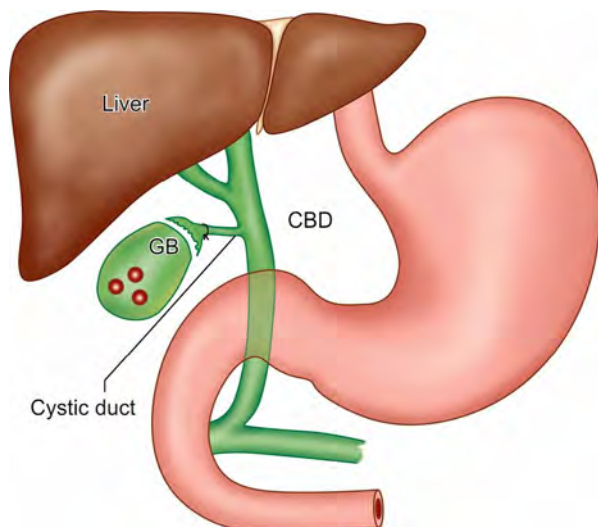
- ◆ Complications can occur either in open method or in laparoscopic method.
- ◆ Open method is done through either right paramedian incision or Kocher's incision (right subcostal).



**Fig. 12.65:** Ligation of cystic duct and cystic artery while doing cholecystectomy.

*Complications which can occur in both:*

- ❖ Infection and subphrenic abscess
- ❖ Bleeding from cystic artery, and from liver bed
- ❖ Injury to CBD or hepatic duct
- ❖ Bile leak and biliary fistula formation
- ❖ Biliary stricture formation
- ❖ Injuries to colon, duodenum, mesentery



**Fig. 12.66:** Diagram showing the partial cholecystectomy wherein GB is removed at Hartmann's pouch, distal to Calot's triangle. It is done when there is dense adhesions, with difficult surgical plane.

### LAPAROSCOPIC CHOLECYSTECTOMY

It is the most popular method to remove gallbladder. It is the gold standard treatment for gallstone.

#### Position

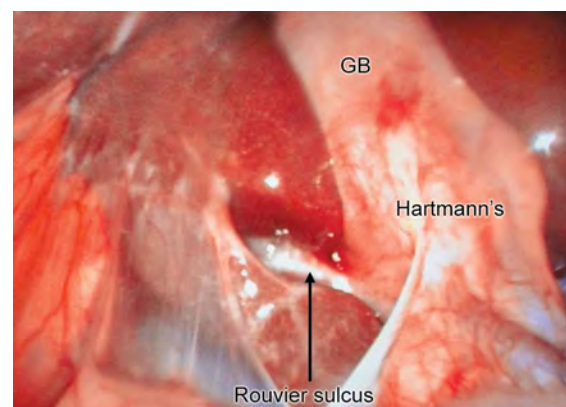
- ◆ Supine, head end up and right side up.
- ◆ *Anaesthesia*—general.

#### Ports

- ◆ 10 mm port in umbilicus to pass 10 mm telescope.
- ◆ 10 mm port in midline epigastrium as working channel.
- ◆ Two 5 mm ports at midclavicular and anterior axillary line in subcostal region.

#### Procedure

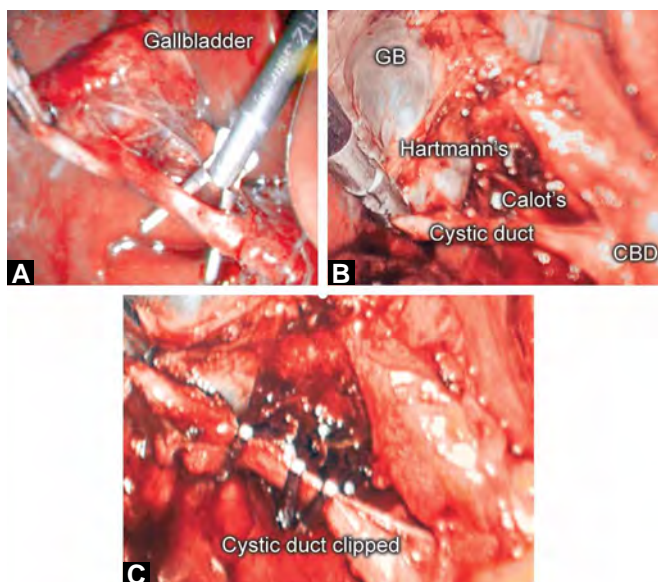
After creation of pneumoperitoneum with 12–14 mm pressure, 10 mm umbilical port is inserted. Telescope is passed. Under vision remaining ports are passed. With lateral 5 mm port, gallbladder grasper forceps is passed and fundus of gallbladder is held and pushed up towards the diaphragm. With middle 5 mm port grasper is passed to hold Hartmann's pouch. With 10 mm port dissector is passed using reducer. Calot's triangle is dissected. Cystic duct is identified. Adhesions are released. First posterior dissection is completed. Cystic artery is above and deep to cystic duct. Cystic duct is clipped or ligated. Cystic artery is also clipped. Gallbladder is dissected off the liver bed using cautery (hook/spatula)/harmonic scalpel. Gallbladder is removed through 10 mm working port with reducer or using a sterile bag. Any bleeding points are coagulated. If needed, saline wash is given to the bed. If infected, if gallbladder is opened, if there are adhesions, if there is oozing from gallbladder bed, a tube drain is placed through lateral 5 mm port. All ports are removed. Umbilical port is sutured in layers. Other ports are sutured. Patient is asked to take oral food in 24 hours and can be discharged in 24–48 hours.



**Fig. 12.67:** Rouvier sulcus on the undersurface of liver is a guideline during laparoscopic cholecystectomy wherein dissection in Calot's should be always kept in front of it to avoid CBD/hepatic duct injury.

#### Problems

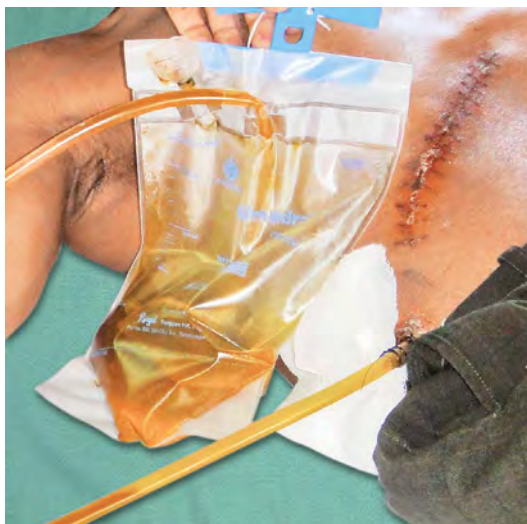- ◆ Difficult Calot's triangle.
- ◆ Dense adhesions.
- ◆ Bleeding.
- ◆ Anomalies of cystic duct, cystic artery.



**Figs 12.68A to C:** Photos of laparoscopic cholecystectomy showing cystic duct, gallbladder, Calot's triangle and clipped cystic duct.

## Complications

- ◆ Bile duct injury—0.8%.
- ◆ Bleeding.
- ◆ Bile leak.
- ◆ Infection, cholangitis, septicaemia.
- ◆ Subphrenic abscess formation.
- ◆ Injury to colon, duodenum, mesentery.



**Fig. 12.69:** Post-cholecystectomy bile leak with fistula. It is common and problematic complication after cholecystectomy.

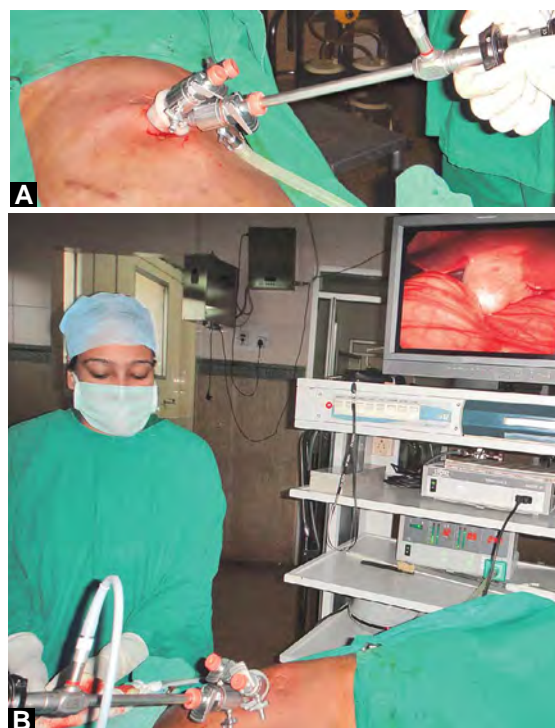
## SINGLE INCISION LAPAROSCOPIC SURGERY (SILS) IN CHOLECYSTECTOMY

*SILS* is an advanced minimally invasive surgical procedure wherein surgeon operates exclusively through a single umbilical entry port. It is also called as single port access surgery (SPA), one port umbilical

surgery (OPUS), and single port incision less conventional equipment-utilising surgery (SPICES), natural orifice transumbilical surgery (NOTUS).

It needs general anaesthesia, specialised umbilical large trocars which accommodates working instruments along with flexible laparoscope, rotatable instruments, articulating handles, harmonic scalpel.

Here through a large 2.5 cm umbilical vertical incision dissection is done by open method to reach peritoneal cavity. Specialised port in which one can pass 10 mm telescope and two 5 mm instruments for work is used. Instruments are angled and flexible to meet the ergonomic principles to certain extent. Dissection of gallbladder is done in similar fashion like four-port technique. Specimen is easily retrieved through umbilical port as it is wide enough. If difficulty arises any time, one can add additional ports as required.



**Figs 12.70A and B:** Single incision laparoscopic surgery (SILS) for cholecystectomy.

## Advantages

- ◆ There is no visible scar like a traditional multiport.
- ◆ Faster recovery time, early return to work.
- ◆ Cosmetically better.

## Disadvantages

- ◆ Expensive trocars and instruments—cost factor.
- ◆ Skilled work, learning curve.
- ◆ Dissection against normal surgical ergonomics.

## Complications

- ◆ Umbilical wound pain, infection.
- ◆ Umbilical hernia.
- ◆ Because of limited visibility time consuming.

- ◆ During learning curve complications of cholecystectomy and conversion rate may be more.

**Note:**

*Waltman-Walter syndrome:* It is compression of IVC due to collection of fluid in subphrenic space during post-cholecystectomy period. It mimics coronary thrombosis.

## BILE DUCT INJURIES

### Causes

- ◆ Cholecystectomy—open or laparoscopic.
- ◆ Trauma.
- ◆ Instrumentation—ERCP, baby endoscope, choledochoscope.
- ◆ Other surgeries—pancreatic, duodenal, gastric.
- ◆ Anomalous biliary system increases the risk of injury.

### Classifications

#### Strasberg classification

- ❖ Class A: Bile leak from the cystic duct or an accessory duct showing continuity with the common bile duct
- ❖ Class B: Section/injury of an accessory duct/sectorial ducts aberrant right hepatic duct with no continuity with the common bile duct with occlusion
- ❖ Class C: Leak/open drainage from a sectorial duct/aberrant right hepatic duct with no continuity with the common bile duct
- ❖ Class D: Partial section/lateral injury of an extrahepatic duct bile duct with no complete loss of continuity with the rest of the bile duct system
- ❖ Class E: Complete section/circumferential injury of the bile duct with subtypes according to the length of the stump at various levels
  - E1- Stricture/injury at more than 2 cm distal to bifurcation.
  - E2 – Stricture/injury less than 2 cm distal to bifurcation.
  - E3 – Stricture/injury at bifurcation
  - E4 – Stricture/injury involving right and left hepatic ducts
  - E5 – Complete obstruction of entire bile duct

*Note:* Only right and left partial injuries are not included in this classification

#### Stewart-Way classification

This classification involves four strata based on the mechanism and anatomy of injury.

- ❖ Class I: It refers to the incomplete section of bile duct with no loss of tissue. It has a prevalence rate of 8%
- ❖ Class II: It is a lateral injury of the common hepatic duct that leads to stenosis or bile leak. It is the consequence of thermal damage and clamping the duct with surgical staples. It has a prevalence of 2% with a concomitant hepatic artery injury in 20% of cases. T-tube related injuries are included within this class
- ❖ Class III: It is the most common (60%) represents the complete section of the common hepatic duct. It is subdivided into type IIIa, remnant common hepatic duct; type IIIb, section at the confluence; type IIIc, loss of confluence; and type IIId, injuries higher than confluence with section of secondary bile ducts. Associated injury of right hepatic artery occurs in 25% of cases
- ❖ Class IV: It is right (65%) and accessory right (25%) hepatic duct injuries with associated injury of the right hepatic artery (60%). Occasionally it includes the common hepatic duct injury at the confluence (5%) besides the accessory right hepatic duct lesion (prevalence of 10%)

#### Hannover classification (2007)

It classifies injuries in relationship to the confluence and also includes vascular injuries.

- ❖ Type A: It refers to cystic and/or gallbladder bed leaks
- ❖ Type B is a complete or incomplete stenosis caused by a surgical staple
- ❖ Type C represents lateral tangential injuries
- ❖ Type D refers to complete section of the common bile duct emphasizing their distance to the confluence as well as the concomitant injuries of hepatic artery and portal vein
- ❖ Type E is late bile duct stenosis at different lengths to the confluence

*Note:* Bismuth classification (for open surgery/pre-laparoscopic era) is discussed under biliary stricture earlier.

### Presentations

- ◆ Fever, pain, features of bile stasis like cholangitis, jaundice.
- ◆ 10% of laparoscopic bile duct injuries are identified on table; 30% with bile leak; 25% with obstructive jaundice; 30% with cholangitis. Patients with bile leak present early; with formed biliary stricture presents with jaundice and cholangitis months or years later.

### Complications

- ◆ Biliary fistula with electrolyte imbalance.
- ◆ Biliary peritonitis, septicemia.
- ◆ Subphrenic abscess formation.
- ◆ *Biloma* formation.
- ◆ Severe malnutrition, deficiencies.
- ◆ Late—biliary cirrhosis, portal hypertension.

### Investigations

- ◆ LFT, coagulation profile.
- ◆ US abdomen, fistulogram.
- ◆ Dynamic CT scan will delineate the anatomy of injury.
- ◆ ERCP is useful if injury is only partial where stenting can also be done.
- ◆ PTC is the *investigation* of choice to identify site, nature, extent of stricture. It also facilitates drainage and stenting.
- ◆ Hepatobiliary scintigraphy may be useful.
- ◆ MRCP may be useful to identify ductal anatomy.
- ◆ CT arteriography is useful to identify associated hepatic artery or portal vein injury which is 20% in association with CBD injury.

### Management

- ◆ General: antibiotics, nutrition, TPN.
- ◆ Conservative: Small partial injury to CBD may resolve spontaneously or with the help of ERCP, sphincterotomy and stenting is done.
- ◆ *Management of biliary duct injury on table* (during *laparoscopic cholecystectomy*/open): Conversion into open surgery with a lengthy subcostal/bucket handle incision. Intraoperative cholangiogram should be done. Partial injury of CBD less than 30% of circumference is treated with primary repair with a T-tube in place. Extensive injury more than 30% of the circumference or cautery injury or complete CBD transection should be treated with Roux-en-Y choledochojejunostomy. Isolated hepatic duct injury less than

3 mm in size should be ligated. More than 3 mm in size should be reimplanted or Roux-en-Y hepaticojejunostomy should be done. If facility for surgical repair is available, patient should be sent to a higher centre after placing a drain with abdomen closure.

- ◆ **Management of bile duct injury identified at a later period:** In such a situation it is better to wait for 6 weeks for the inflammation to subside which facilitates easier identification of proximal CBD. After proper assessment of injury, Roux-en-Y choledochojejunostomy or Roux-en-Y hepaticojejunostomy is done.
- ◆ **Hepp-Couinaud approach:** Here hilar plate is meticulously dissected; left hepatic duct is anastomosed to Roux jejunal loop to create hepaticojejunostomy often with creation of proximal 'access loop' for future endoscopic approach. Complications are—recurrent cholangitis, bile leak from stoma, hemobilia, stenosis of biliary enteric anastomotic site (10%, occurs often after many years).

### POST-CHOLECYSTECTOMY SYNDROME (15%)

- ◆ Recurrent, new or persistent symptoms after cholecystectomy in patients who have no demonstrable abnormality is called as post-cholecystectomy syndrome.
- ◆ It may be due to loss of reserving function of the gallbladder or continuous bile flow into the duodenum may be causing oesophagitis/gastritis or diarrhoea and colicky pain. 20% causes are other than due to hepatopancreatic biliary problems.
- ◆ However importance lies in ruling out the other causes of the symptoms like peptic ulcer, hiatus hernia, pancreatic diseases, residual CBD stone, cystic duct remnant, papillary stenosis.
- ◆ True post-cholecystectomy syndrome is treated with proper counseling, psychiatric evaluation and drug therapy. It should be evaluated thoroughly.

#### Causes of post-cholecystectomy syndrome

Gallbladder	Residual or reformed gallbladder Stump stones in cystic duct Neuroma in the stump Slipped stones into the peritoneum Clips applied to cystic duct
Biliary tree	Residual stone in CBD Biliary dyskinesia Stricture Dilatation without obstruction Fistula Cholangitis Malignancy
Liver	Fatty liver, hepatitis, cirrhosis Sclerosing cholangitis
Pancreas	Pancreatitis, stones Carcinoma pancreas Sphincter of Oddi dyskinesia

Contd...

Contd...

GIT	Oesophagitis / hiatus hernia/ achalasia cardia Duodenal diverticula IBS, constipation, incisional hernia Mesenteric ischaemia
Cardiac	Coronary heart disease
Others	Adrenal tumour Thyrotoxicosis Intercostal neuralgia Arthritis Psychiatric diseases

### BILIARY DYSKINESIA

Biliary dyskinesia is *motility disorder* of either gallbladder or sphincter of Oddi. Patient presents with features of biliary colic without any evidence of gallstone disease.

It can be:

#### Gallbladder dyskinesia:

- ▶ Here CT scan, gastroscopy, ERCP are normal. CCK is injected intravenously after filling gallbladder with radionuclide labeled Tc99m, gallbladder ejection fraction is assessed after 20 minutes. If it is less than 35%, then it is called as gallbladder dyskinesia.
- ▶ It is treated with laparoscopic cholecystectomy.
- ◆ **Sphincter of Oddi dysfunction:**
  - ▶ It is also known as *biliary sphincter dyskinesia or pancreatic sphincter dyskinesia*. It is benign acalculous obstruction to bile and/or pancreatic flow across sphincter of Oddi causing cholestasis, pancreatitis and pain.
  - ▶ It may be due to trauma, congenital anomalies.
  - ▶ In occurs in 1% of cholecystectomy patients. Condition is common in females.
  - ▶ Normally CCK relaxes sphincter by decreasing its pressure. After IV injection of CCK, if CBD diameter becomes more than 12 mm or if there is increase in CBD diameter in response to CCK on US evaluation it suggests dysfunction of sphincter of Oddi. If basal sphincter pressure, on study, increases more than 40 mmHg it also suggests the same.
  - ▶ **Milwaukee's classification:** **Type I:** Any one of the following features—unexplained biliary pain for more than 6 months after cholecystectomy, ERCP showing CBD >12 mm, delayed bile drainage >45 minutes, altered liver enzymes. **Type II:** Unexplained biliary pain for more than 6 months after cholecystectomy + with any one of the other criteria. **Type III:** Only unexplained biliary pain for more than 6 months after cholecystectomy, without any of other criteria.
  - ▶ ERCP/MRCP/sphincter of Oddi manometry, IV cholangiography are the *investigations*.
  - ▶ **Treatment:** Endoscopic sphincterotomy, botulinum toxin injection into the sphincter, nifedipine, transcutaneous electric nerve stimulation to raise serum vasoactive intestinal peptide (VIP) level which decreases the sphincter pressure.

# Chapter 13

## Spleen

### CHAPTER OUTLINE

- |                             |                                       |                                          |
|-----------------------------|---------------------------------------|------------------------------------------|
| ❖ Surgical Anatomy          | ❖ Thassaemia                          | ❖ Overwhelming Postsplenectomy Infection |
| ❖ Functions of the Spleen   | ❖ Sickle Cell Disease                 | ❖ Splenic Artery Aneurysm                |
| ❖ Splenunculi               | ❖ Idiopathic Thrombocytopenic Purpura | ❖ Splenic Abscess                        |
| ❖ Splenic Injury            | ❖ Thrombotic Thrombocytopenic Purpura | ❖ Hypersplenism                          |
| ❖ Splenomegaly              | ❖ Splenectomy                         | ❖ Splenic Cyst                           |
| ❖ Hereditary Spherocytosis  |                                       | ❖ Atraumatic Rupture of Spleen           |
| ❖ Immune Haemolytic Anaemia |                                       |                                          |

### ■ SURGICAL ANATOMY

- ◆ It is a wedge-shaped organ lying mainly in left hypochondrium, along the long axis of 10th rib.
- ◆ Hilum of spleen transmits splenic vessels and nerves. The visceral surface is related to stomach, splenic flexure of colon, kidney.
- ◆ Spleen in English means “*ill temper*”. Galen called it as *organ of mystery*.

### Ligaments of Spleen

Spleen is suspended by two ligaments (*a*) *lienorenal ligament*, (*b*) *gastrosplenic ligament*.

- ◆ Lienorenal ligament transmits blood vessels to spleen. The tail of pancreas lies in this ligament, which can be damaged during splenectomy.
- ◆ The gastrosplenic ligament contains short gastric vessels which supply the left half of greater curvature of stomach.
- ◆ Phrenicocolic ligament comes in contact with lower pole of spleen, which may be damaged during mobilization of splenic flexure of colon.

### Blood Supply

*Splenic artery* is the branch of coeliac artery but may arise from aorta or superior mesenteric artery, blood flow is 300 ml/mt. *Splenic vein* joins the superior mesenteric vein at right angle behind the neck of pancreas to form the portal vein.

Splenic parenchyma contains *white pulp* and *red pulp*. *White pulp* lies in centre surrounding the central artery, which is a branch of trabecular artery. It is made up of lymphatic nodules with germinal centres and periarterial lymphatic sheaths with a network containing

lymphocytes and macrophages. White pulp is surrounded by marginal zone which contains end arteries from central and peripheral peniciliary arteries. Marginal zone contains marginal sinus which filters the materials from the white pulp. Immunoglobulins secreted by white pulp enter marginal zone and into main bloodstream.

*Red pulp* is located outer to marginal zone. Red pulp contains cords and sinuses. Central artery gives reticular branches which open into these sinuses and cords wherein particles are phagocytosed. Commonly central artery eventually ends in these cords and sinuses. Few end branches of the central artery directly enters the pulp vein. Cords and sinuses eventually drain into pulp vein. Blood circulating through these cords and sinuses are called as ‘*open*’ circulation (90%). Blood passing through white pulp but not entering these cords and sinuses are called as ‘*closed*’ circulation (10%).

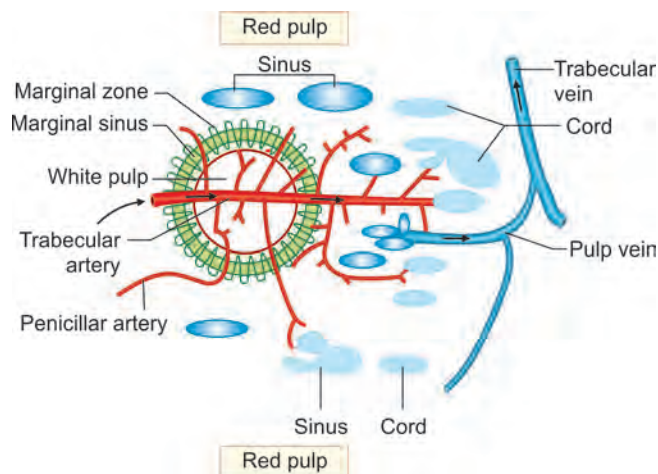
Spleen is palpated under left costal margin during inspiration. It has to enlarge 2–3 times its normal size to become palpable.

### ■ FUNCTIONS OF THE SPLEEN

*Spleen has got two groups of functions:*

#### 1. Cellular function.

- ◆ Removal of non-deformable intracellular substances from deformable cells is called as “*pitting*”. *Heinz bodies/Howell-Jolly bodies, Pappenheimer siderotic bodies* are removed by this method from RBCs. Post-splenectomy patients will show these bodies in the RBCs in peripheral smear. In splenunculi, these bodies will be absent even after splenectomy.
- ◆ Removal of aged/abnormal red cells is done by a process of “*culling*”. RBCs which loose osmotic balance and membrane integrity is called as non-deformable and they are removed by this method.



**Fig. 13.1:** Architecture of spleen showing red pulp (peripheral); white pulp (central); open and closed circulation; marginal zone and sinuses and trabecular artery and vein.

- ◆ Half-life of platelets is 10 days. In splenomegaly 80% of platelets may be sequestered in spleen causing thrombocytopenia. Normally spleen is reservoir for platelets. 1/3rd of total platelet mass is present in spleen. In pathological status like immune diseases phagocytosis of platelets in spleen is accelerated by many folds.
- ◆ Splenomegaly and hypersplenism can cause neutropenia. Neutrophil half-life is 6 hours.
- ◆ Bacterial clearance also occurs in spleen by phagocytosis. After splenectomy, patients are more prone for OPSI.

2. *Immunologic functions* like synthesis of antibody IgM; formation of lymphocytes; production of tuftsin, opsonins, properdin and interferons.

#### Functions of spleen

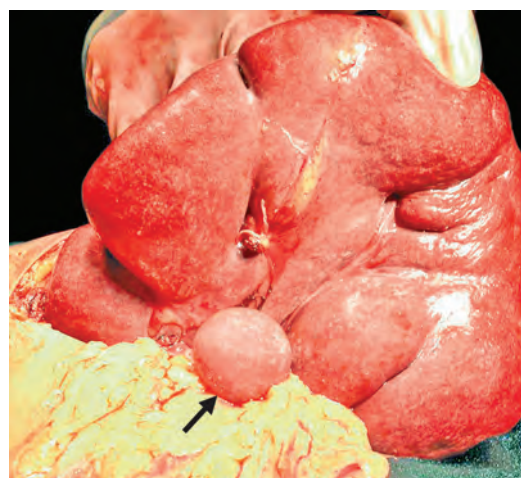- ❖ Response to antigenic challenge—by secreting antibodies like IgM, tuftsin, opsonins, properdin, interferons. These agents make bacteria and other organisms more vulnerable to phagocytosis. All bacteria including the capsulated types, virus and fungi are destroyed efficiently.
- ❖ Destruction or correction of abnormal cells like old RBCs, target cells, siderocytes, spherocytes or removal of inclusion bodies or parasites from the RBCs by culling and pitting.
- ❖ Phagocytosis of foreign substances.
- ❖ As platelet reservoir.
- ❖ *Erythrocyte production*: In fetal life, it is an important site of RBC production till 5th month of gestation. In adults erythropoiesis in spleen occurs only if marrow production is inadequate, e.g. in myelofibrosis.
- ❖ Iron reutilisation.

#### SPLENUNCULI (30%)

- ◆ These are single or multiple **accessory spleens**.

#### Sites

- ❖ Hilum of spleen (50%)
- ❖ Near splenic vessels
- ❖ Tail of the pancreas (30%)
- ❖ Splenic ligaments—gastrosplenic/splenorenal
- ❖ Mesocolon
- ❖ Greater omentum



**Fig. 13.2:** On table photo of splenunculi with splenomegaly. Splenunculi should be removed otherwise disease will recur.

- ◆ After splenectomy, they undergo hyperplasia and lead to recurrence of the disorder for which spleen was removed.
- ◆ Blood peripheral smear, in these patients with splenunculi *will not show* Howell-Jolly bodies. Pappenheimer siderotic bodies.
- ◆ Accessory spleen can also be occasionally present adjacent to left ovary or adjacent to left testis.
- ◆ All accessory spleens should be removed along with splenectomy while doing for ITP or haemolytic disorders.

#### SPLENIC INJURY (RUPTURE SPLEEN)

The spleen can rupture as—**Trauma** to a *normal spleen* OR to a *diseased spleen*; **Atraumatic** rupture of a diseased spleen [*pathologic (occult) rupture*] and **Spontaneous** rupture of a normal spleen [*spontaneous (idiopathic) rupture*].

#### Causes

- ◆ Splenic injury occurs commonly following road traffic accidents, other blunt injury or penetrating/stab injuries.
- ◆ Most often associated with fracture of left lower ribs, haemothorax, injury of liver (left lobe commonly, occasionally both lobes), bowel, tail of pancreas, left kidney.
- ◆ Injury is more common and severe in *enlarged spleen*, i.e. in malaria, tropical splenomegaly, infectious mononucleosis.
- ◆ Spontaneous rupture of spleen can occur in malaria and infectious mononucleosis.
- ◆ *Larang* was used to kill by the murderers in far east where malaria was endemic leading to splenomegaly, which ruptured more easily.
- ◆ Spleen is the most common solid organ injured in blunt abdominal trauma.

#### Types of Injury

1. *Splenic subcapsular haematoma*: After initial injury patient remains asymptomatic for a short period. But this haematoma ruptures later, may be after few days causing torrential haemorrhage.

*Success isn't owned, it's leased and the rent is due every day. Success is not a destination, it's a journey*



2. *Clean incised wound over the surface*: This can be treated by splenorrhaphy.
3. *Lacerated wound*.
4. *Splenic hilar injury* causes torrential haemorrhage, may even cause death. So immediate surgical intervention and splenectomy is done.
5. Splenic injury associated with other injuries (left kidney, left colon, small bowel, pancreas, diaphragm, left lung).

#### Associated injuries

- ❖ Left lobe liver injury
- ❖ Tail of pancreas injury
- ❖ Left kidney, left colonic injury
- ❖ Small bowel injury
- ❖ Diaphragm and left lung injury
- ❖ Fracture lower ribs—left sided (30%)
- ❖ Left sided haemothorax

### Presentation

Hilar injury presents with rapid development of *shock and deteriorates fast*. Even death can occur sometimes. Here *emergency surgery and splenectomy is mandatory*.

- ◆ In other types, features of shock (pallor, tachycardia, restlessness, hypotension), pain, tenderness and abdominal rigidity in left upper quadrant is seen.
- ◆ Later there will be abdominal distension due to haemoperitoneum.
- ◆ Dullness in the left flank which does not shift, as the collected blood gets clotted. *Dullness without shifting—Ballance's sign*.

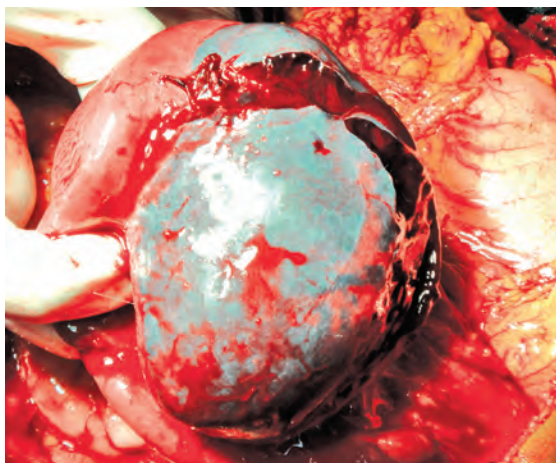
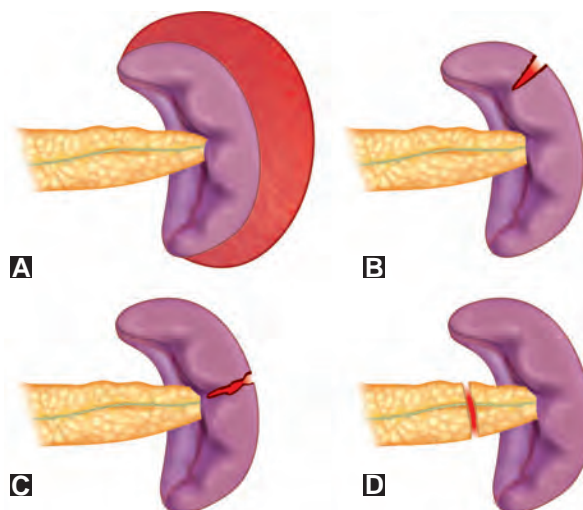


Fig. 13.3: Large subcapsular splenic haematoma.

- ◆ Clot collected under the left side of the diaphragm irritates it and the phrenic nerve causing *referred pain in the left shoulder—Kehr's sign*. There may be left sided haemothorax with fracture of ribs.

**Delayed presentation** is also possible due to formation of subcapsular haematoma which later gives way. Initially gets temporarily localized by greater omentum, later giving way leading to torrential bleeding. Blood clot temporarily seals off the bleeding which later gets dislodged causing severe bleeding. This time period in between is called '*latent period of Bandet*'.

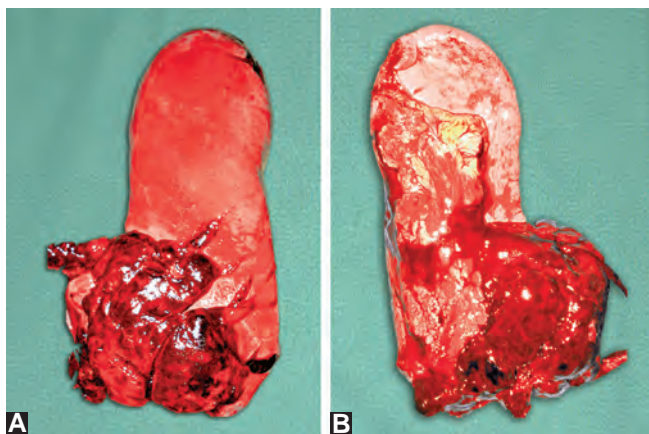


Figs 13.4A to D: Types of splenic injury. (A) Subcapsular haematoma; (B) Incised wound; (C) Lacerated wound; (D) Hilar injury.

- ◆ Pseudoaneurysm and traumatic splenic arteriovenous fistula formation can also occasionally cause delayed life-threatening haemorrhage.
- ◆ Features of other abdominal organ injuries may be present.

#### Signs in splenic rupture

- ❖ *Kehr's sign*—pain in left shoulder 15 minutes after foot end elevation
- ❖ *Ballance's sign*—left sided abdominal dullness which will not shift
- ❖ *Saegesser's tender point* between left sternomastoid and scalenus medius
- ❖ Latent period of Bandet—refer above



Figs 13.5A and B: Splenic injury with splenic haematoma.

#### Note:

**Splenis:** Autotransplantation of fragments of splenic tissue may occur within the peritoneal cavity following rupture of spleen.

### Investigations

- ◆ U/S abdomen is the investigation of choice, as it is quicker, cheaper and non-invasive.
- ◆ Hb%, PCV, blood grouping and cross matching.
- ◆ *Adequate amount of blood must be kept ready for transfusion.*
- ◆ CT scan will show type of splenic injury and its class.

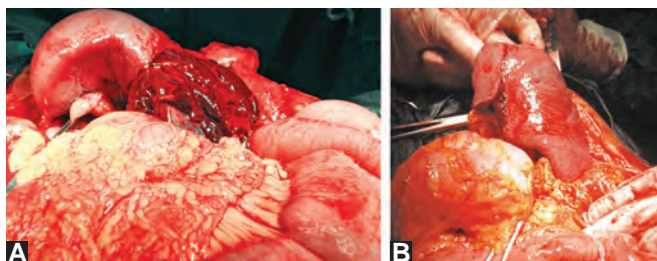
**Plain X-ray abdomen. Findings are:**

- ❖ Obliteration of splenic outline
- ❖ Obliteration of psoas shadow (most important feature)
- ❖ Indentation of fundic gas shadow
- ❖ Fracture of lower ribs
- ❖ Elevation of left side of diaphragm
- ❖ Free fluid in the abdomen between coils of intestine

◆ **Diagnostic peritoneal lavage (DPL):** By subumbilical incision the peritoneal lavage catheter is introduced into the peritoneal cavity. One litre of crystalloid (normal saline) is introduced into the cavity. Patient is turned to both left and right side and fluid is collected back. It is sent for cytology, culture, microscopy and biochemical analysis.

It is significant when the aspirated fluid contains:

- ▶ Gross blood of 10 ml.
- ▶  $>100000/\text{mm}^3$  of RBC.
- ▶  $>500/\text{mm}^3$  of WBC.
- ▶ Bile, bacteria or food fibres.
- ▶ Amylase  $>175$  units/dl.



**Figs 13.6A and B:** Lacerated injury over the spleen. Patient underwent splenectomy.

- ◆ Angiogram, for diagnosis and often for angiographic embolisation to reduce the bleeding and to manage splenic injury non-operatively is also becoming routine in many centres.

**Complications of Splenic Rupture/Trauma**

- ◆ Blood loss.
- ◆ DIC.
- ◆ Sepsis.
- ◆ Splenic artery pseudoaneurysm.
- ◆ Splenic arteriovenous fistula.
- ◆ Problems of associated injuries like of pancreas.

**Splenic organ injury scale (1994)**

Grade I	Non-expanding subcapsular haematoma $<10\%$ surface area. Non-bleeding capsular laceration with $<1$ cm depth
Grade II	Non-expanding subcapsular haematoma $10\text{--}50\%$ surface area. Non-expanding intraparenchymal haematoma $<5$ cm in diameter Laceration—capsular tear $1\text{--}3$ cm in depth which does not involve trabecular vessel

Contd...

Grade III	Expanding subcapsular or $>50\%$ surface area or ruptured bleeding subcapsular haematoma / intraparenchymal haematoma. Intraparenchymal haematoma $>5$ cm or parenchymal laceration $>3$ cm depth involving trabecular vessels
Grade IV	Laceration involving segmental or hilar vessels with $>25\%$ devascularization
Grade V	Shattered or avulsed spleen; hilar devascularization with entire spleen separation

**Treatment****Initial Management**

- ◆ Central venous line for perfusion and monitoring.
- ◆ Transfusion of blood as needed, resuscitation using crystalloids like Ringer's lactate.
- ◆ Antibiotics coverage.
- ◆ Urinary catheterisation.
- ◆ Nasogastric tube aspiration.

**Surgical Management****Emergency splenectomy**

- ◆ It is done through midline/left subcostal incision. Thoracoabdominal extension of incision may be needed for rapid control of bleeding for injury to a large tropical spleen with severe bleeding. Other associated injuries should be looked for and dealt with (injury to left lobe liver/pancreas/intestine/colon).

**Partial splenectomy (upper/lower)**

- ◆ It can be done by retaining either of the upper or lower polar branches of the splenic artery.

**Splenorrhaphy**

- ◆ In especially clean incised wound, spleen can be salvaged by suturing the wound carefully with placement of gel foam, topical thrombin, absorbable mesh wrap over the wound. Suture repair, oxidised cellulose, debridement of lacerated spleen—are other methods used. Temporary occlusion of splenic artery is often needed during splenorrhaphy. 10% of splenic injuries undergo splenorrhaphy. Its application is getting reduced due to non-operative approach in such patients
- ◆ But in class IV or V injuries splenorrhaphy is not possible.

**Advantages of splenorrhaphy**

- ❖ It avoids OPSI
- ❖ It avoids dead space and so prevents potential space for subphrenic abscess
- ❖ Cellular components of blood are better maintained

**Note:**

**Salutary effect:** In traumatic rupture of spleen, spleen is cut into pieces of  $0.5$  cm and placed in omental pockets.

**Non-operative Management**

- ◆ When facilities are available, splenic injury can be managed conservatively by non-operative management.

Contd...

*A smile is the shortest distance between two people.*

- ◆ Clinically close observation, serial haematocrit evaluation, serial CT abdomen/U/S abdomen at regular intervals to assess the progress or regress of the bleeding spleen has to be done.
- ◆ Absolute bed rest, sedation, antibiotic coverage and proper monitoring are needed.
- ◆ It is often supported by angiographic embolisation to improve the splenic salvage rate. But it may cause pain, splenic abscess or infarction.
- ◆ *Indications for non-operative treatment*
  - ▶ Only splenic injury—no other associated injuries.
  - ▶ Grade I, II and III injuries.

**Note:**

- If patient shows features of haemodynamic instability—blood pressure below 90 mmHg, pulse rate above 120/minute, if patient does not show any positive response after 2 litre of crystalloid solution infusion, and 2 units of blood transfusion then non-operative management should be abandoned.
- Non-operative approach prevents possibility of OPSI, thrombocytosis causing possible *DVT*.
- 80% of children (due to more elastin in spleen and complete coverage with ribs in childhood) and 50% of adult with splenic injury are treated by non-operative method.
- Failure rate in nonoperative management up to grade II is 15–20% which is gradually reducing to 5% in many centres. It is more in patients with age more than 55 years.
- Delayed splenic rupture and formation of splenic pseudoaneurysm are problems in non-operative approach.
- Normal activity of the patient can be resumed only after 3 weeks following non-operative treatment in grade I and II injuries; after 8 weeks in grade III or beyond usually with a confirmation by CT scan.

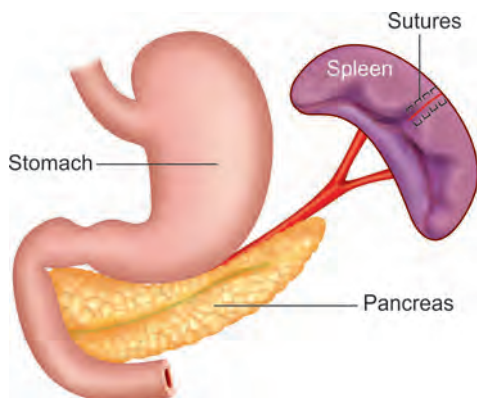


Fig. 13.7: Splenorrhaphy is done in incised wound.

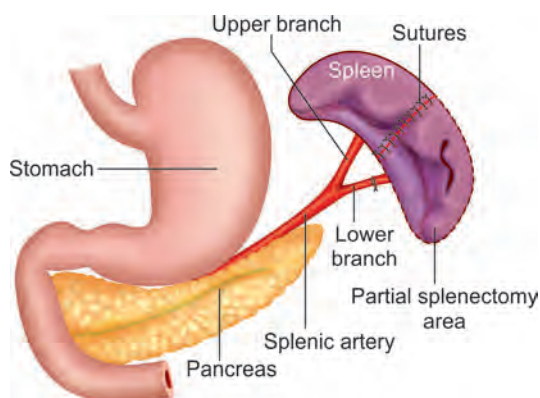


Fig. 13.8: Partial splenectomy is done when one of the branches of the splenic artery is ligated and other part is retained.

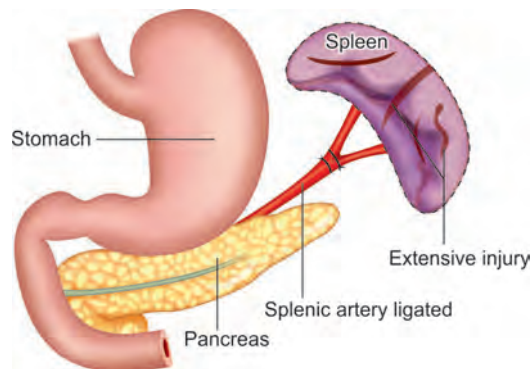


Fig. 13.9: Splenectomy is done in large wounds, lacerations, hilar injuries.

### Complications of splenectomy

- ❖ Haemorrhage and shock
- ❖ Haematemesis
- ❖ Pancreatitis
- ❖ Pancreatic fistula
- ❖ Gastric dilatation
- ❖ Left sided pleural effusion
- ❖ Left sided colonic injury
- ❖ Severe sepsis
- ❖ Changes in cellular component of blood
- ❖ DIC

## SPLENOMEGALY

### Causes

1. *Infective*: Tuberculosis, splenic abscess, infectious mononucleosis, malaria, typhoid, kala azar.
2. *Blood diseases*: Chronic myeloid leukaemia, myelofibrosis, polycythaemia, hereditary spherocytosis, haemolytic anaemia, idiopathic thrombocytopenic purpura (ITP).
3. *Metabolic*: Gaucher's disease, amyloidosis, porphyrias,
4. *Portal hypertension*.
5. *Collagen diseases*.
6. *Malignancy*: Hodgkin's lymphoma, splenic sarcomas.

### Masses which mimic enlarged spleen

- ❖ Kidney mass (Left sided)
- ❖ Retroperitoneal mass
- ❖ Left colonic mass
- ❖ Left adrenal mass

### Clinical features of enlarged spleen

- ❖ Mass in the left hypochondrium
- ❖ Notch is felt
- ❖ Moves with respiration
- ❖ Dull to percuss
- ❖ Directed towards right iliac fossa
- ❖ *Hook sign*: Inability to hook under left costal margin
- ❖ Cannot insinuate finger under left costal margin

## HEREDITARY SPHEROCYTOSIS

It is an autosomal dominant disease effecting males and females equally.

### Pathology

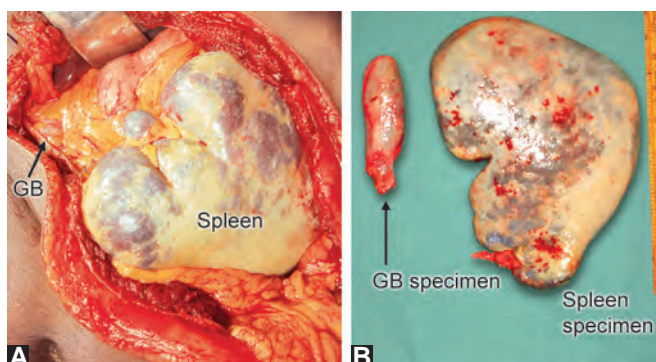
- ◆ Here there is an increase in red cell wall permeability to sodium. So sodium leaks into the red cells and it becomes spherical and more fragile. This leads to greater loss of membrane phospholipid resulting in weakening of the membrane with increase in energy and oxygen requirement. So these RBCs are destroyed in spleen causing haemolytic anaemia, haemolytic jaundice, unconjugated hyperbilirubi-naemia, pigmented gallstones, cholangitis.
- ◆ Defect in components of red cell membrane like *spectrin* (mainly), ankyrin, band 3, or protein 4–2 causes weakness of red cell wall. This promotes the influx of sodium into the cell.
- ◆ Condition is common in North America.

### Clinical Features

- ◆ Pallor, jaundice, recurrent fever, pain abdomen, splenomegaly, hepatomegaly, chronic leg ulcer. Gallstones are seen in 60% of cases.
- ◆ Spontaneous remission is uncommon.
- ◆ Patients are more prone for several infections.
- ◆ *Acute haemolytic crisis* precipitated by infection and stress; with features of acute pain abdomen, fever, vomiting and anaemia. It often mimics other acute abdominal conditions.

### Investigations

- ◆ *Fragility test*: Here increased fragility of the erythrocytes is the typical feature. Haemolysis occurs in 0.6% or in even stronger solutions.



**Figs 13.10A and B:** Hereditary spherocytosis—on table and after surgery showing gallbladder and spleen specimens.

- ◆ LFT-↑ serum bilirubin.
- ◆ Reticulocyte count is increased significantly (25% increased).
- ◆ Faecal urobilinogen is increased.
- ◆ Labelled radioactive chromium shows faster red cell destruction.
- ◆ U/S abdomen is done to look for gallstones, spleen, liver, CBD.
- ◆ Peripheral smear shows spherocytes, haematocrit.
- ◆ Direct Coomb's test—negative.
- ◆ Radioactive chromium 51 labelled patients' red cells shows rate of sequestration of red cells in spleen.

### Problems with hereditary spherocytosis

- ❖ Haemolytic anaemia
- ❖ Haemolytic jaundice
- ❖ Pigmented CBD stones
- ❖ Cholangitis with Charcot's triad
- ❖ Gallstones (30%)
- ❖ Chronic leg ulcers

### Treatment

- ◆ Blood transfusion to improve the Hb status. Later splenectomy is done—Optimum age for splenectomy is 7 years.
- ◆ Accessory spleen should be removed.
- ◆ Splenectomy prevents early RBC destruction thereby controlling anaemia, jaundice and also prevents further formation of leg ulcers.
- ◆ Pneumococcal vaccine should be given to all these patients before elective splenectomy—3 weeks prior to surgery; 3 weeks after surgery and later once in 5–6 years.
- ◆ If there are gallstones, cholecystectomy is done.
- ◆ Both splenectomy and cholecystectomy can be done through *laparoscopy*.
- ◆ Splenectomy for hereditary spherocytosis is not done before the age of 6 years.

#### Note:

- *Hereditary elliptocytosis* is an autosomal dominant condition where 90% of RBCs are elliptical. Mostly they are asymptomatic, if symptomatic splenectomy cures the condition.

## IMMUNE HAEMOLYTIC ANAEMIA

Here IgG or IgM antibodies bind to erythrocyte antigens causing red cell destruction through complement and RE systems.

It can be:

- ◆ *Alloimmune haemolytic anaemia*: It occurs after exposure to allogenic erythrocytes during transfusion, pregnancy or transplantation.
- ◆ *Drug-induced immune haemolytic anaemia*: It is drug-induced antibody reaction for drugs like  $\alpha$  methyl dopa, penicillins or 2nd generation cephalosporins. It occurs via new antigen formation with positive Coomb's test. Cessation of causative drug and steroid therapy will cure the disease.
- ◆ *Autoimmune haemolytic anaemia (AIHA)*: Here there is development of IgG and IgM antibodies that bind to RBCs which are identified by Fc receptors of macrophages and RE cells causing phagocytosis and destruction of red cells.

Two types of antibodies are:

1. *Common warm antibodies*: They react at 98.6°F. Often it is associated with CLL. In classical type, platelets are normal. Evan's syndrome is combination of AIHA and ITP. Coomb's test is positive (95% cases). Clinical features are of any haemolytic anaemias like palor, jaundice, splenomegaly (50%), and gallstones (25%). Long-term prednisolone is the treatment of choice. Failure to respond after long-term treatment is an indication for splenectomy. 80% of patients benefit with splenectomy.

2. *Less common cold antibodies (Cold agglutinin syndrome)*: It is treated by avoiding exposure to cold; folic acid; chlorambucil; cyclophosphamide and plasmapheresis. Splenectomy is not beneficial in this condition.

### THALASSAEMIA (Mediterranean Anaemia/Cooley's Anaemia/Erythroblastic Target Cell Anaemia)

- ◆ It can be  $\alpha$ ,  $\beta$  and  $\gamma$  thalassaemia depending on defect in the synthesis of particular peptide.
- ◆ *Beta thalassaemia* is commonest. There is decrease in Hb-A and persistence of Hb-F. Homozygous, thalassaemia major is commonest type. Heterozygous, thalassaemia minor also can occur.
- ◆ Intracellular *Heinz bodies* are typical.
- ◆ Chronic anaemia, jaundice and splenomegaly are the features. Major type presents in first year of life with retarded growth, frontal bossing and prominent malar bones. Leg ulcers, recurrent infections, splenic infarction, pleural effusion, crisis, gallstones (25%) are other features.
- ◆ *Complications* are haemosiderosis, diabetes mellitus, pancreatitis, cirrhosis of liver, intractable sepsis and aplastic crisis.
- ◆ Haemoglobin electrophoresis, peripheral smear, LFT, bone marrow study and U/S abdomen are the investigations required.
- ◆ Regular blood transfusions, splenectomy are the treatment options.

### SICKLE CELL DISEASE

- ◆ It is hereditary haemolytic anaemia seen commonly in blacks wherein HbA is replaced by HbS leading to formation of *crescent shaped* red cells which is deformed and more prone for trapping in spleen and destruction. Under low oxygen tension, HbS undergoes crystallisation causing elongated and deformed red cells. It increases the blood viscosity and causes stasis in circulation. Splenic micro-infarcts are common causing initial splenomegaly and later autosplenectomy and calcification.
- ◆ Because of autosplenectomy patient is more prone for infection by pneumococcus and other organisms due to reduced production of antibodies.
- ◆ Patients are commonly asymptomatic.
- ◆ It is common in Africa. Patients in India have high HbF which protects them from developing symptoms.
- ◆ Anaemia, pain abdomen, leg ulcers are the usual features.
- ◆ Cerebral, pulmonary and mesenteric infarctions can occur which may be often life threatening.
- ◆ Peripheral smear and electrophoresis are diagnostic. U/S abdomen is needed to see spleen and for gallstones.
- ◆ *Treatment* is sodium cyanate (prevents sickling of HbS); hydration; partial exchange transfusion, antibiotics, symptomatic therapy by folic acid. Splenectomy has only limited role in initial sequestration stage.

### IDIOPATHIC (IMMUNE) THROMBOCYTOPAENIC PURPURA (ITP)

- ◆ It is development of *antiplatelet antibodies*, (IgG) which damage patient's own platelets. These platelets get sequestered earlier and faster in the spleen than normal causing thrombocytopenia. Spleen is the source of antiplatelet antibody production and destruction of formed platelet—antiplatelet antibody complex (by macrophage phagocytosis).

- ◆ Low platelet count, a normal bone marrow and absence of other causes of thrombocytopenia are the features. Bone marrow megakaryocytes are normal or increased but there is relative marrow failure in terms of compensatory platelet production for more destruction.
- ◆ In adult it is common in females (70%) who are young below the age of 40 years (70%). Chronic type is common in adults.
- ◆ In children it is equal in both sexes. Acute is common in children. Spontaneous remission (80%) is common. In girls it may become chronic continuing to adolescent period.
- ◆ Platelet count above 50,000/mm<sup>3</sup> usually will not cause spontaneous bleeding and undue bleeding is not common with invasive procedures. So specific therapy is not indicated. Regular platelet count estimation is needed.
- ◆ Regular careful observation is done clinically and haematologically for count between 30,000–50,000/mm<sup>3</sup> if there is no bleeding. If any spontaneous bleeding occurs or any invasive procedure is needed then platelet count should be corrected with steroids, platelet transfusion. With steroid/prednisolone therapy count becomes more than 50,000/mm<sup>3</sup> in 1–3 weeks.

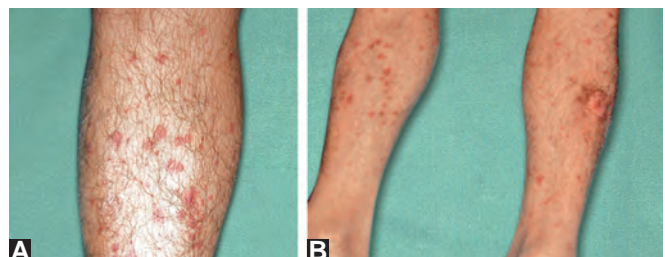
### Types

1. *Acute ITP*:
  - ▶ Initiated after viral infection.
  - ▶ Common in children (90%).
  - ▶ Spontaneous remission is common.
2. *Chronic ITP*:
  - ▶ Common in adults (90%).
  - ▶ Gradual, may be present for years.

#### Clinical features

- ❖ Common in young women (3:1 ratio)
- ❖ Purpuric patches in skin and mucous membrane (most common presenting sign)
- ❖ Epistaxis
- ❖ Menorrhagia
- ❖ Haematuria, haemarthrosis (rare)
- ❖ GIT bleeding
- ❖ Intracranial haemorrhage—2%; dangerous
- ❖ Tourniquet test is *positive (Hess test)*

- ◆ Purpuric and petechial patches are common in buttocks and limbs as these areas are more dependant having more vascular pressure. These patches and petechiae are mild or moderate.
- ◆ Splenomegaly is present in 25% of cases.
- ◆ After applying sphygmomanometer cuff and inflation (just below systolic pressure for 10 minutes), cubital fossa is observed for petechial haemorrhagic spots. More than 20 petechial spots in 3 cm circled area are significant—*Hess test*.



Figs 13.11A and B: Purpura spots in legs in case of ITP.

## Differential Diagnosis

- ◆ Other causes for purpura—pregnancy, pre-eclampsia, drugs like heparin, quinidine, sulphonamides, HIV, rubella, infectious mononucleosis, myelodysplasia, congenital thrombocytopenia, thrombotic thrombocytopenic purpura, uraemia.
- ◆ Increased capillary fragility.
- ◆ Bone marrow suppression due to aplastic anaemia.
- ◆ Chemotherapy.
- ◆ DIC.
- ◆ Autoimmune diseases, SLE.

## Investigations

- ◆ Bleeding time is increased by several times.
- ◆ Clotting and prothrombin time are normal.
- ◆ Platelet count is decreased.
- ◆ Bone marrow biopsy reveals increased megakaryocytes.
- ◆ Usually anaemia and neutropaenia is not observed.
- ◆ U/S shows splenomegaly only in 25% cases.

### Note:

Positive Hess test is formation of >20 purpuric patches in an area of 3 cm diameter.

## Treatment

### Drugs

- ◆ In children, spontaneous regression occurs in 75% of cases after one attack.
- ◆ Short courses of *steroids* or *azathioprine* hastens the recovery.
- ◆ In adults, treatment is indicated when platelet count is < 30000/mm<sup>3</sup>.
- ◆ Glucocorticoid—1 mg/kg is given. Response to treatment is seen within a week. Prednisolone 10 mg/day for 6 weeks is given. Response to steroid (prednisolone—1 mg/kg body weight) therapy showing complete remission is 25%.

### Indications for admission

- ❖ Platelet count less than 30,000/mm<sup>3</sup>
- ❖ Platelet count less than 50,000/mm<sup>3</sup> showing bleeding episodes/mucosal bleed
- ❖ Risk factors association like existing peptic ulcer, hypertension.
- ❖ Life-threatening haemorrhage

### Indications for splenectomy

- ❖ Relapsed severe cases after treatment with steroids—for 6 weeks
- ❖ Girls attaining menarche
- ❖ ITP persisting even after 6–9 months refractory to treatment
- ❖ In 2nd trimester pregnancy, with platelet count <10000/mm<sup>3</sup> and severe bleeding problems
- ❖ Recurrence after stopping/tapering steroids
- ❖ Profound GI bleed and intracranial bleed
- ❖ ITP with persistent platelet count below 10,000/mm<sup>3</sup> for 6 weeks whether bleeding present or not, ITP with only transient response to drugs for 3 months with platelet count less than 30,000/mm<sup>3</sup>

- ◆ Danazol 200 mg TID decreases IgG receptor on phagocytes causing lesser degradation of platelets.

- ◆ Vincristine 2 mg per week for 6 weeks.
- ◆ IV immunoglobulin 0.4–1.0 g/kg × 5 days (action like danazol). It is very useful in acute bleed, in preparing the patient for surgery, in conducting delivery in pregnancy with ITP. Dose should be given for at least two days before taking up for surgery. It is also used in preparing ITP patient for therapeutic splenectomy.
- ◆ Anti-RhD antibodies.

### Note:

- Splenectomy is not indicated in non-bleeding ITP for 6 months with platelet count above 50,000/cu mm<sup>3</sup>.
- Response rate is 80%; it is usually achieved in first 10 days of splenectomy.
- Relapse of ITP after splenectomy is 10%. It is probably due to hepatic sequestration of platelets in such patients or presence of accessory spleens (10% of such cases). Such patients are difficult to treat. They need prednisolone, azathioprine (single agent—needs 4 months to achieve initial response in such patients), cyclophosphamide (single drug).
- Presence of accessory spleen is confirmed by blood smear and radionuclide imaging but exact anatomical number and location of accessory spleen is often difficult to identify preoperatively. Thorough exploration for possible all sites of splenunculi should be done to achieve good success rate.
- 15% of HIV patients develop ITP; splenectomy response is good in these patients; splenectomy does not progress HIV status.

### Surgery

- ◆ *During surgery and in emergency*, fresh blood transfusions or platelet transfusions are required. Sometimes anti-platelet immune response is temporarily blocked by IgG transfusion so to allow the platelet count to rise at the time of surgery or in cases of severe bleeding or in pregnancy.
- ◆ Accessory spleen should be identified and removed.
- ◆ In 7 days platelet count raises to more than 100000/cu mm.
- ◆ Laparoscopic approach is ideal in elective splenectomy for ITP.

### Treatment for ITP

- ❖ Methylprednisolone IV for 3–5 days only
- ❖ Oral prednisolone tablets—drug of choice for 6–12 weeks
- ❖ IV immunoglobulin 0.4–1.0 g/kg/day for 5 days only. It competes with antibodies
- ❖ Vincristine 2 mg/week for 6 weeks
- ❖ Danazol 200 mg tid
- ❖ Anti-RhD antibodies
- ❖ Azathioprine
- ❖ Splenectomy
- ❖ FFP, platelet concentrate, fresh blood transfusions.

## THROMBOTIC THROMBOCYTOPAENIC PURPURA (TTP)

It is an idiopathic disease associated with bone marrow transplantation, drugs like penicillin, mitomycin, cyclosporine.

*Main features are (pentad):*

1. Microangiopathy haemolytic anaemia.
2. Thrombocytopenia.
3. Fever.
4. Neurological disturbances.
5. Renal dysfunction.

*Autosplenectomy can occur in sickle cell anaemia.*

### Features and management

- ◆ Here only arterioles and capillaries of microcirculation are involved. Venules are not involved. Platelet microthrombi, endothelial proliferation are the pathological features.
- ◆ Anaemia, platelet trapping in the spleen and thrombocytopenia are typical.
- ◆ Altered mental status, neurological deficits and renal failure are common.
- ◆ Plasmapheresis improves the survival which is the main treatment.
- ◆ Laparoscopic splenectomy is done only to reserved patients.

**Felty's syndrome** is chronic rheumatoid arthritis, mild leukopenia and splenomegaly.

## SPLENECTOMY

### Indications for Splenectomy

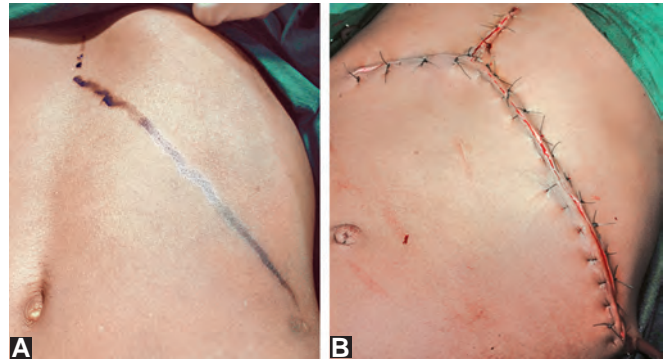
1. Trauma.
2. Hereditary spherocytosis and other haemolytic anaemias.
3. Idiopathic thrombocytopenic purpura (ITP).
4. In radical gastrectomy—removed “*en bloc*” with stomach.
5. Portal hypertension with variceal bleeding.
6. Staging laparotomy in case of Hodgkin's lymphoma.
7. Tuberculosis of spleen.
8. Others:
  - ▶ Gaucher's disease.
  - ▶ Chronic myeloid leukaemia.
  - ▶ Felty's syndrome.
  - ▶ Carcinoma of tail of the pancreas during distal pancreatectomy.
  - ▶ Schistosomiasis.
  - ▶ Splenic artery aneurysm.
  - ▶ Splenic infarction.
  - ▶ Cystic disease of spleen.
  - ▶ Splenic tumours.

#### Indications for splenectomy

Benefit is maximum/very good	Benefit is equivocal	Benefit may be there/low
<ul style="list-style-type: none"> <li>• Splenic injury</li> <li>• Hereditary spherocytosis</li> <li>• ITP</li> <li>• Splenic cysts</li> <li>• Splenic tumours</li> <li>• Hypersplenism</li> <li>• Segmental left sided portal hypertension</li> </ul>	<ul style="list-style-type: none"> <li>• AIHA (autoimmune haemolytic anaemia)</li> <li>• Tropical splenomegaly</li> <li>• Felty's syndrome</li> </ul>	<ul style="list-style-type: none"> <li>• Thalassemia</li> <li>• CML</li> <li>• Gaucher's disease</li> <li>• Hodgkin's lymphoma for staging laparotomy</li> <li>• Sickle cell anaemia</li> </ul>

### Procedure

- ◆ Incision—left paramedian or left subcostal or in case of large adherent spleen left thoracoabdominal approach.
- ◆ Lienorenal ligament and short gastric vessels are ligated. Splenic vessels are ligated at the hilum of spleen. Spleen is removed. Abdomen is closed after placing a drain *in situ*. Presently, drain is indicated only if there is injury to tail of pancreas during splenectomy.

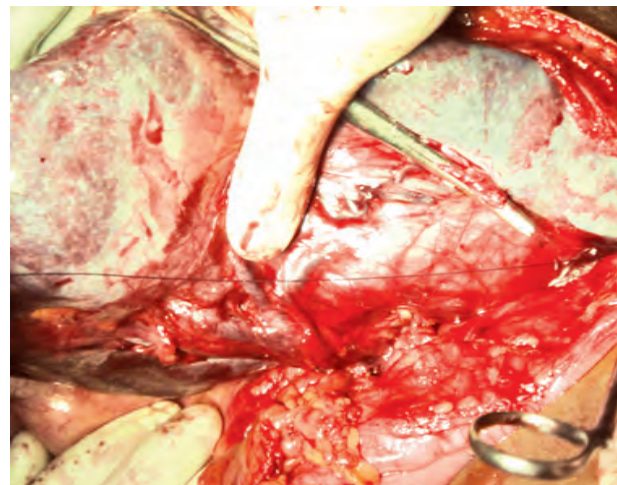


**Figs 13.12A and B:** Incision for open splenectomy—left subcostal. Often in a massive spleen or adherent spleen incision need to be extended to opposite side and towards xiphisternum.

- ◆ Presently laparoscopic splenectomy is becoming popular.
- ◆ Preoperative splenic artery embolisation is beneficial in massive spleen.

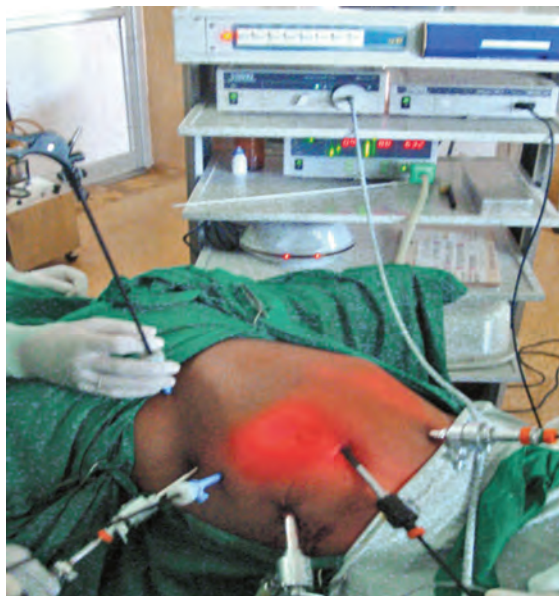### Complications of Splenectomy

- ◆ *Haemorrhage*—mainly from short gastric vessels. Re-exploration and control of bleeding is needed.
- ◆ *Gastric dilatation*.



**Fig. 13.13:** Splenic vessels should be ligated individually securely with double ligatures in large spleen during splenectomy.

- ◆ *Haematemesis* due to mucosal congestion following ligation of short gastric vessels.
- ◆ *Left sided pleural effusion and left basal atelectasis* (left lobe atelectasis is the commonest complication) (30%).
- ◆ *Left subphrenic abscess*.
- ◆ *Pancreatitis* following damage to tail of the pancreas and pancreatic fistula (3%).
- ◆ *Haematologic changes:* Rise in WBC and platelet count, rise in abnormal RBCs and RBC bodies.
- ◆ *Gastric fistulas*.
- ◆ *Left sided colonic injury*.
- ◆ *Infection*—Post-splenectomy septicæmia, OPSI—most dangerous.
- ◆ *Portal vein thrombosis* can occur.
- ◆ *DVT as a late sequelae* after splenectomy is often dangerous. Risk is 4 times more than in non-splenectomised people and so also pulmonary embolism. It is better to put them on long-term small dose of *aspirin* to reduce the incidence of thromboembolism.



**Fig. 13.14:** Laparoscopic splenectomy is also a good alternative in many splenectomies when splenomegaly is not massive. It is not useful in massive spleens and trauma.

## OVERWHELMING POST-SPLENECTOMY INFECTION (OPSI)

- ◆ As there is reduced IgM, tuftsin, properdin and other antibodies, phagocytosis of encapsulated bacteria is defective. So the postsplenectomised patient is more prone for *Pneumococcal septicaemia* (commonest), *N. meningitidis*, *H. influenzae*, *Babesia microti* infections. Risk is more in patients on chemotherapy, radiotherapy and haemolytic diseases.
- ◆ Incidence is 4%.
- ◆ Common in first two years after splenectomy. But it can occur any time. Risk persists for lifetime.

### Clinical Features

- ◆ Prodromal phase—fever, chills, sore throat.
- ◆ Hypotension, shock.
- ◆ DIC.
- ◆ Respiratory distress, coma, death.

Mortality for fully developed OPSI—50–70%.

### Prevention

- ◆ *Pneumococcal vaccine* should be given to all splenectomised patients. Polyvalent pneumo-vac is given 2–3 weeks prior to surgery and soon after recovery from surgery and it is repeated once in 5 years (Given to patients older than 2 years).
- ◆ Other vaccines advised are meningococcal vaccine (only to those who travel with high-risk), *H. influenzae* 'B' vaccine (to all whatever the age, once in 10 years).
- ◆ In malaria endemic areas, antimalarial prophylaxis is given for patients after splenectomy.

### Treatment of OPSI

- ❖ Antibiotics like Cefoperazone, Ceftazidime, Amikacin
- ❖ Ventilatory support—ICU care
- ❖ Blood transfusion
- ❖ Immunoglobulin transfusion
- ❖ Nutrition (TPN) and maintaining of urine output

### Note:

- OPSI is more common when splenectomy is done for malignancy or haematological diseases or done in young individuals.
- Usage of prophylactic penicillin (benzathine) is controversial in adult even though it is beneficial in children up to 16 years.
- OPSI can occur at any time after splenectomy. Drugs like erythromycin, amoxicillin are also used as prophylactic agents.
- Mortality in fully developed OPSI (hypotension, DIC, MODS) is 60%—very high.
- Patients who survived after OPSI with therapy may develop residual problems like – gangrene of limbs, deafness, meningitis, mastoid osteomyelitis, heart valve destruction.
- 7% of OPSI cases have *S. pneumoniae* sepsis. Others are—*N. meningitidis*, *H. influenzae*, *Capnocytophaga canimorsus* after dog bite.
- PPV 23 is the commonest vaccine used. Revaccination is done once in 5 years; decline in pneumococcal antibody level may be the criteria for revaccination.
- Preservation of 25% of spleen is sufficient to protect against pneumococcal infection. So partial splenectomy is definitely helpful.
- Splenic autotransplantation into the omental pouch is under trial at present to reduce the chance of OPSI.
- Vaccine is best avoided during pregnancy.

### Prevention of OPSI

- ❖ Life long prophylaxis using benzathine penicillin 12–24 lac units—controversial in adults
- ❖ Pneumococcal vaccine given 2–3 weeks prior to splenectomy—70% protection
- ❖ *H. influenzae* B type vaccine
- ❖ Meningococcal vaccine is given only to high-risk groups, as its effects are short term. So it is not routinely given

Note: Protection by vaccine is not completely guaranteed

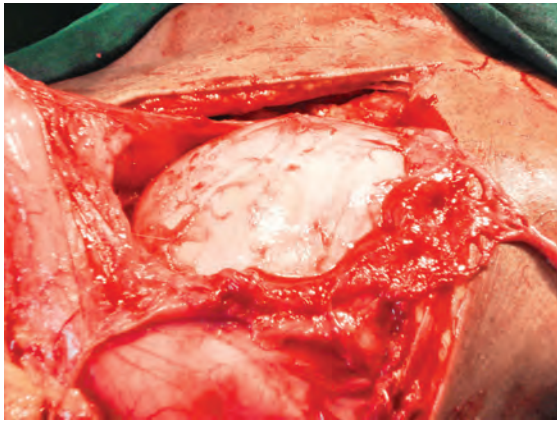
## SPLENIC ARTERY ANEURYSM

- ◆ Most common intra-abdominal site for aneurysm after abdominal aorta.
- ◆ Most common in women, due to atherosclerosis.
- ◆ Congenital splenic artery aneurysm can occur.
- ◆ Splenic artery pseudoaneurysm (10%) can occur after an attack of acute pancreatitis which may cause life-threatening rupture.
- ◆ Rupture of splenic artery may be intraperitoneal or into the stomach, colon and intestine. Calcified aneurysm rarely ruptures.
- ◆ Plain X-ray shows calcified lesion in 70% of cases.
- ◆ Contrast CT, angiogram are needed.

### Indication for surgery:

- ❖ >2 cm diameter.
- ❖ Symptomatic aneurysm.
- ❖ Anticipating pregnancy.
- ❖ Aneurysm identified during pregnancy should be operated before 3rd trimester.



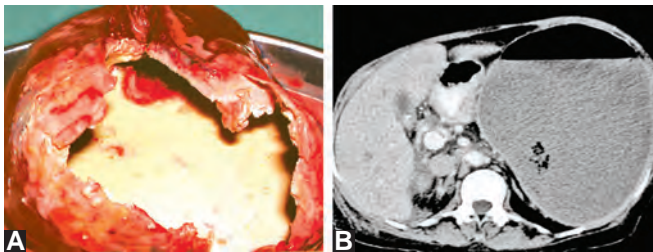


**Fig. 13.15:** Splenic artery aneurysm. It is the commonest site of aneurysm in the abdomen after aorta.

### Treatment

- ◆ Splenectomy with ligation of artery proximal to aneurysm.
- ◆ Splenic artery embolisation under radiological guidance is also beneficial.

### ■ SPLENIC ABSCESS



**Figs 13.16A and B:** (A) Splenic abscess due to tuberculosis, (B) CT scan showing abscess in the spleen.

- ◆ It is uncommon but potentially fatal.
- ◆ Incidence is 0.7%.
- ◆ **Precipitating factors:**
  - ▶ Endocarditis is commonest focus.
  - ▶ AIDS.
  - ▶ Polycythaemia.
  - ▶ Malignancy.
  - ▶ Sickle cell disease.
  - ▶ Splenic vein thrombosis.
  - ▶ Trauma.
  - ▶ Drug abuse.
  - ▶ Typhoid, osteomyelitis, puerperal sepsis, pancreatitis, otitis media.

#### Organisms responsible

*Staphylococcus*, *Streptococcus*, *Enterobacter*, *E. coli*, *Proteus*, *Klebsiella*, *Candida albicans*, *Mycobacterium tuberculosis* in developing countries.

#### Clinical features

- ❖ Fever
- ❖ Pain in left hypochondrium
- ❖ Pain in left side of chest
- ❖ Left sided pleural effusion
- ❖ Spleen when palpable is tender
- ❖ Single or multiple abscesses
- ❖ Need not move with respiration

### Investigation

Ultrasound, ESR, chest X-ray, CT scan, blood culture.

### Treatment

- ◆ High dose antibiotics has to be started.
- ◆ ATT in case of tuberculosis.
- ◆ Ultrasound/CT scan guided aspiration of abscess is done.
- ◆ Splenectomy.

#### Note:

- Splenic abscess can rupture causing peritonitis and left subphrenic abscess.
- Splenic abscess has 80% mortality in immunocompromised patients and 20% in an otherwise normal individual.
- 2/3rd of splenic abscesses in adults are single and 1/3rd are multiple; in children 1/3rd are single, 2/3rd are multiple.
- Solitary abscess responds well for guided aspirations; whereas multiple abscesses need splenectomy.

### ■ HYPERSPLENISM

- ◆ It is overactivity of spleen causing pancytopenia with more of hypercellular bone marrow.
- ◆ It is splenomegaly with defect in any peripheral cell line with anaemia (Hb% < 8 gm, normocytic, normochromic); total WBC count <  $3.5 \times 10^9/L$ ; platelet count <  $150 \times 10^9/L$ .

### Causes

- ◆ Primary hypersplenism.
- ◆ Portal hypertension.
- ◆ Malaria, kala-azar.
- ◆ Schistosomiasis.
- ◆ Tuberculosis.
- ◆ Myeloproliferative disorders.

### Features

- ◆ Symptomatic hypersplenism is the one with transfusion-dependant anaemia/recurrent infections/spontaneous bleeding episodes like epistaxis, bleeding gum, menorrhagia.
- ◆ Splenomegaly in portal hypertension is not just related to portal pressure or variceal grade; it is congestive hyperplastic.
- ◆ Peripheral blood smear; complete blood count, bone marrow aspiration, US abdomen, LFT, investigations relevant to condition are done.

### Treatment

- ◆ Treat the cause.
- ◆ Hypersplenism often requires splenectomy.
- ◆ Splenectomy with proximal splenorenal shunt in portal hypertension.
- ◆ Total splenic artery embolization.
- ◆ Splenectomy with splenic autotransplantation may be beneficial.

### ■ SPLENIC CYST

Splenic cysts can be –

#### 1. True primary cyst (20%).

It can be—

- ▶ *Non-parasitic* [simple congenital cysts, epidermoid cysts (75% of non-parasitic cysts)]. It is common in 3rd decade,

usually lined by squamous epithelium. Even though they are truly benign without malignant potential, they often show +ve for Ca 19/9 and CEA. Usually they are asymptomatic, but may present with splenic mass with pain, chest pain and left shoulder pain usually when cyst attains more than 8 cm in size. Occasionally sepsis, rupture and bleeding in a cyst can occur.

**Note:**

- ❖ Commonest primary splenic neoplasm is haemangioma
  - ❖ *Littoral cell angioma* is rare splenic tumour
  - ❖ Lymphangioma, inflammatory pseudotumours are rare splenic tumours
  - ❖ Hodgkin's lymphoma commonly involves spleen
  - ❖ Secondaries in spleen are rare. Occasionally spread can occur from lungs, stomach, pancreas, breast, melanoma
  - ❖ Primary malignant splenic tumours are exceedingly rare. Angiosarcoma is the most common primary tumour
  - ❖ *Wandering spleen* is due to failure to form suspensory ligaments of spleen so that the spleen is *not* fixed in position. It is due to failure of dorsal mesogastrium to fuse with the posterior abdominal wall. It shows long splenic pedicle. It is prone for torsion and recurrent ischaemia. It is common in females. CT scan is diagnostic. If there is no ischaemia, *splenopexy* is done; if there is ischaemia which is confirmed by absence of perfusion in CT scan, splenectomy is done
- ▶ *Parasitic* (hydatid)—one should look for associated liver hydatids. CT abdomen confirms the diagnosis. It is treated with splenectomy; care should be taken not to spill or rupture during surgery.
2. **Pseudocyst/secondary cysts** (80%): They are due to old trauma, malaria, tuberculosis, infectious mononucleosis, old parenchymal haematoma and syphilis. They are not epithelial lined; they are smooth, unilocular, thick walled. Initially treatment is guided percutaneous drainage or partial splenectomy. Splenectomy is done when entire spleen is involved with pseudocyst.

## ■ ATRAUMATIC RUPTURE OF SPLEEN

It is rupture of spleen causing hemorrhagic shock which is not due to any trauma. So its rupture may mimic GI perforations or myocardial infarction, pulmonary embolism, etc.

*Atraumatic rupture may be:*

**Pathological (occult) rupture** wherein trauma occurs in a diseased spleen like *infectious mononucleosis* (commonest cause in Western country), leukaemia, lymphoma, anticoagulation/thrombolysis therapy, pregnancy, congenital malposition of the spleen, polyarteritis nodosa, bacterial, viral, protozoal [malaria (acute rapid enlargement of *vivax malaria*)/kala-azar] infection, haematologic causes, metabolic causes (amyloidosis/ Gaucher's disease), uraemia, primary splenic diseases, infective endocarditis, acute pancreatitis.

**Spontaneous (idiopathic) rupture**—It is atraumatic rupture of a normal spleen (gross and histologically). *Orloff and Peskin criteria* (1958) are used for diagnosis. It may be due to reflex spasm of splenic vein or weak points in artery or ruptured point which is the only point pathological that is destroyed during rupture or due to unduly mobile spleen.

### Orloff and Peskin criteria of spontaneous rupture of spleen

1. On thorough questioning, either prior to operation or in retrospect after operation, there should be no history of trauma or of unusual effort which conceivably could injure the spleen.
2. There should be no evidence of disease in organs other than the spleen that is known to affect the spleen adversely and, thereby, could cause it to rupture.
3. There should be no perisplenic adhesions or scarring of the spleen which suggests that it had been traumatised or had ruptured previously.
4. Other than the findings of haemorrhage and rupture, the spleen should be normal on both gross and histological examination.

*Expect the best; prepare for the worst; capitalize on what comes. If you correct your mind, the rest of your life will fall into place.*

# Chapter 14

## Pancreas

### CHAPTER OUTLINE

- |                                                |                                |                                         |
|------------------------------------------------|--------------------------------|-----------------------------------------|
| ❖ Anatomy                                      | ❖ Pancreatic Tumours           | ❖ Ectopic (Accessory) Pancreatic Tissue |
| ❖ Serum Amylase                                | ❖ Exocrine Pancreatic Tumours  | ❖ Pancreatic Divisum                    |
| ❖ Serum Lipase                                 | ❖ Carcinoma Pancreas           | ❖ Pancreatic Calculus                   |
| ❖ Magnetic Resonance Cholangio-pancreatography | ❖ Endocrine Pancreatic Tumours | ❖ Pancreatic Ascites                    |
| ❖ Pancreatitis                                 | ❖ Insulinomas                  | ❖ Pancreatic Fistulae                   |
| ❖ Acute Pancreatitis                           | ❖ Gastrinomas                  | ❖ Pancreatic Necrosis                   |
| ❖ Complications of Acute Pancreatitis          | ❖ Glucagonomas                 | ❖ Pancreatic Trauma                     |
| ❖ Pseudocyst of Pancreas                       | ❖ Zollinger–Ellison Syndrome   | ❖ Cystic Lesions of Pancreas            |
| ❖ Chronic Pancreatitis                         | ❖ Cystic Fibrosis              | ❖ Pancreatic Exocrine Insufficiency     |
|                                                | ❖ Annular Pancreas             |                                         |

Pancreas is also called as *abdominal tiger*. Pancreas means all flesh (*Pan means all, kreas means flesh*).

### ANATOMY

Pancreas is an elongated retroperitoneal organ; 15–20 cm in length; lies against L<sub>1</sub>–L<sub>2</sub> vertebra. It lies posterior to stomach, separated by lesser sac.

### Parts

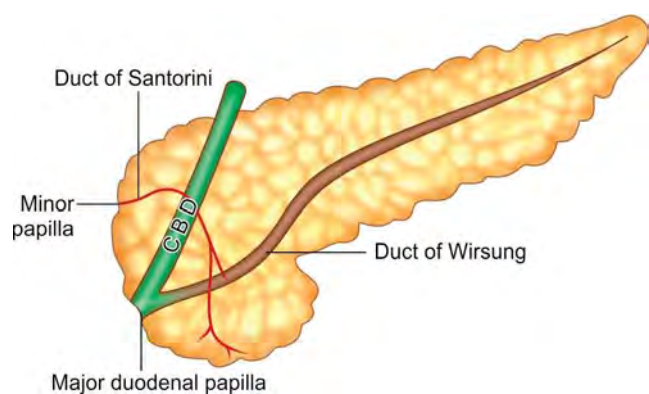
It is divided into head, neck, body, and tail.

- ◆ The head lies in the concavity of duodenum and tail reaches the hilum of the spleen.
- ◆ The posterior surface of the neck of pancreas is related to terminal part of superior mesenteric vein and beginning of portal vein.

### Ducts of Pancreas

1. **Main duct of pancreas (Duct of Wirsung):** It begins in the tail of pancreas and runs on the posterior surface of the body and head of pancreas, receives numerous tributaries at right angle along its length (*Herring bone pattern*).
2. **Accessory pancreatic duct (Duct of Santorini):** It begins in the lower part of the head and opens into the duodenum at minor duodenal papilla (6–8 cm from the pylorus).

It joins the bile duct in the wall of the second part of duodenum to form hepatopancreatic ampulla (*of Vater*) and opens on the summit of major duodenal papilla (8–10 cm from pylorus).



**Fig. 14.1:** Ducts of pancreas.

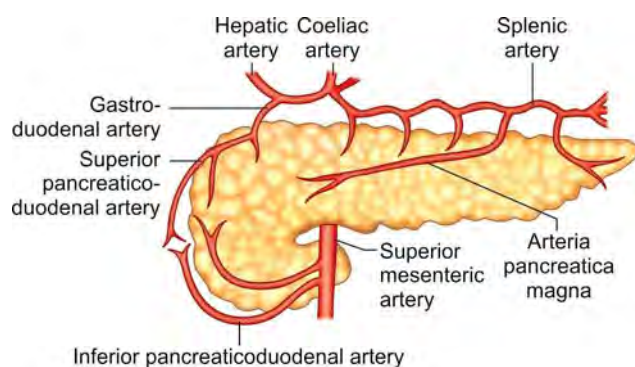


Fig. 14.2: Arterial supply of pancreas.

## Blood Supply of Pancreas

### Arterial

1. Pancreatic branches of splenic artery.
2. Superior pancreaticoduodenal artery.
3. Inferior pancreaticoduodenal artery.

Venous drainage is into portal vein.

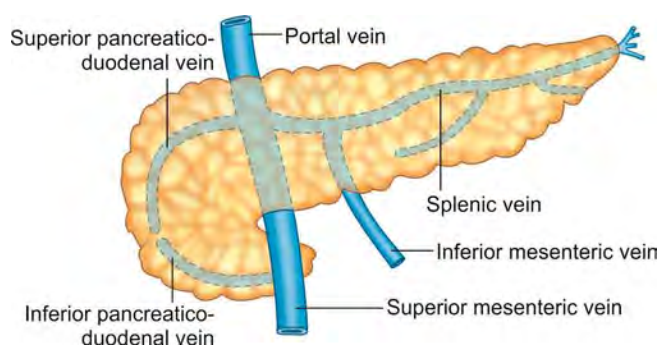


Fig. 14.3: Venous drainage of pancreas.

## Nerve Supply

Parasympathetic supply is from vagus and sympathetic innervation is from splanchnic nerves.

## Functions

- ◆ *Exocrine* part secretes pancreatic juice which helps in digestion of proteins, carbohydrates and fats.
- ◆ *Endocrine* part constitutes islets of pancreas which is distributed more numerous in tail of pancreas.
  - β cells of islets secrete insulin.
  - α cells secrete glucagon.

*Normal pancreatic juice* is colourless bicarbonate rich fluid containing around 15 g of protein in total, 2.5 litres secretion/day. It alkalises duodenal content and helps digestion. Inactive proenzymes secreted into the duodenum from pancreatic juice are activated by trypsin in duodenum. Amylase and lipase can also be secreted in active forms. Basal secretion of these enzymes is low at rest; rapidly increases by hormonal and neural stimulation. It is controlled by secretin (cAMP) and cholecystikinin (phospholipase C, calcium). Protein part of the juice is secreted by *acinar cells*. *Duct cells* secrete fluid and electrolytes. Pancreatic secretion is very low in resting phase.

During eating, cephalic phase stimulates 10% of pancreatic secretion through peripherally mediated acetylcholine; gastric phase stimulates further 15% of pancreatic secretion through gastrin release and vagal stimulation; finally in main intestinal phase, 75% of the pancreatic juice is secreted by release of secretin due to duodenal acidification, and by release of bile and cholecystikinin following the entry of fat and proteins in duodenum.

## SERUM AMYLASE

*Amylase* is an enzyme that hydrolyses the starch, glycogen and polysaccharides into simple sugar. It is mainly secreted by pancreas and salivary glands as α amylase. One secreted by pancreas is called as amylase *isoenzyme* – P; one by salivary glands (parotid) is amylase *isoenzyme* – S.

Normal value of serum amylase is 200–250 Somogyi units (40–140 IU/L). Normal value of urinary amylase is 24–400 IU/L. Its half-life is 2–4 hours.

It increases more than 1000 units in acute pancreatitis; raising titer is more useful. But amylase estimation is not specific. P isoenzyme estimation is more relevant. It is estimated with urinary amylase and serum lipase to have a better sensitivity. Amylase level will be very high in peritoneal fluid in acute pancreatitis or pancreatic ascites, in fluid obtained from pseudocyst.

2 hours fasting serum is used for estimation; 24 hours urine is used for urine amylase estimation and adequate hydration is a must while estimating urine amylase.

Serum amylase is said to be elevated if level is more than *three times of upper limit of the normal*.

Amylase – creatinine clearance ratio (ACR) is more relevant. It is estimated by urinary amylase X serum creatinine divided by serum amylase X urinary creatinine X (multiplied by) 100. More than 5% suggests acute pancreatitis; but it also increases in diabetic ketoacidosis, renal diseases. ACR less than 1% indicates macroamylasaemia.

### Raise in amylase level is common in -

- ❖ Acute pancreatitis, pseudocyst of pancreas, pancreatic trauma, after ERCP

### Amylase is also often increased in other conditions like –

- ❖ Salivary gland diseases like parotitis
- ❖ Mesenteric ischaemia
- ❖ Ruptured aortic aneurysm
- ❖ Intestinal obstruction
- ❖ Ectopic gestation, salpingitis
- ❖ Duodenal ulcer perforation
- ❖ Ectopic amylase production in cancers of breast, lungs, ovary, multiple myeloma
- ❖ Renal failure

### Amylase may be low in –

- ❖ Cystic fibrosis
- ❖ Liver damage
- ❖ Pancreatic cancer
- ❖ Pregnancy with toxemia

### Amylase may not raise in -

- ❖ Chronic pancreatitis due to significant destruction and loss of acinar cells

*It is what a man thinks of himself that really determines his fate.*

- ◆ Magnitude of amylase elevation is not related to severity of the pancreatitis. It increases once symptoms appear for 12–24 hours then decreases in 6 days. Persistent elevation suggests complications like pseudocyst, ascites and abscess formation.
- ◆ 10% cases of severe pancreatitis with necrosis show normal serum amylase level. This is due to necrosis of most of the acinar cells retaining hardly any functioning cells at time.
- ◆ Rise in pancreatic amylase will be very high in comparison with nonpancreatic causes of rise where it is than 2–3 times the normal.
- ◆ Raised urinary amylase level persists for longer period than serum amylase level.
- ◆ Amylase enters the lymphatics and circulation from the basal part of acinar cells and also, weakened intercellular adhesions in pancreatitis allow amylase to seep into the space to enter circulation.
- ◆ Circulating amylase inhibitors often when present, mask the true amylase level in pancreatitis.
- ◆ Occasionally amylase binds with large abnormal circulating albumin like protein which cannot be cleared normally causing false raise in serum amylase level (false positive) even though there is absence of pancreatitis. This *macroamylasaemia* is 0.5% common.

## SERUM LIPASE

- ◆ Lipase is secreted by pancreas, liver, intestines and other organs also. It hydrolyses triglycerides into fatty acids and glycerol. Normal value is 0–50 units/L but it depends on method and laboratory.
- ◆ Lipase is increased in acute and chronic pancreatitis, pseudocyst, cystic fibrosis, pancreatic cancer, bowel ischaemia, renal failure, liver diseases, alcoholism, after ERCP.
- ◆ Its half-life is 10 hours much more than amylase and so remains longer than amylase in the serum. It is mainly used in acute pancreatitis. Lipase or amylase level estimation has no role in identifying the etiology of acute pancreatitis.

## MAGNETIC RESONANCE CHOLANGIO-PANCREATOGRAPHY (MRCP)

It is a non-invasive diagnostic method using magnetic field and energy as resonance.

T<sub>1</sub>-weighted images are used for pancreas.

T<sub>2</sub>-weighted images are used for biliary tree.

Both images are used to see invasion and adjacent structures.

### Advantages

- ◆ It is non-invasive.
- ◆ It gives equal or better imaging than ERCP.
- ◆ Pancreatic divisum or annular pancreas are identified easily by MRCP.
- ◆ Ductal dilatation in chronic pancreatitis and visualization of duct beyond stricture is possible.
- ◆ Islet tumours are better visualised and diagnosed by MRCP.

### Disadvantages

- ◆ Availability.
- ◆ It is only diagnostic. Not therapeutic (ERCP is both diagnostic as well as therapeutic).
- ◆ Costly.

## PANCREATITIS

*We learn that pain was an early symptom in nearly one-half of the cases; that it was usually severe, and might be intense, and was to be found in the abdomen or lower chest....The appearances found after death are conspicuously the haemorrhage within and near the pancreas....It is evident that all treatment, at the onset, can be nothing but palliative.*

—Reginald Heber Fitz, 1889

*Pancreatitis* is inflammation of the pancreas acute, chronic or relapsing which may lead into complications. It is one of the most devastating conditions in the abdomen.

## Classification

### I. Marseilles' classification

1. Acute pancreatitis.
2. Acute relapsing pancreatitis.
3. Chronic relapsing pancreatitis.
4. Chronic pancreatitis.

Acute means acute inflammatory changes which are reversible.

Chronic means chronic continuous inflammatory changes which are morphologically irreversible.

### II. Trapnell's aetiological classification

#### Major causes

- ❖ Biliary tract disease 50%—stones—common cause
- ❖ Alcoholism 25%

#### Other causes

- ❖ Trauma
- ❖ After biliary, gastric, splenic surgery, ERCP
- ❖ Hyperparathyroidism
- ❖ Hypercalcaemia, hyperlipidaemia
- ❖ Diabetes
- ❖ Porphyria
- ❖ Drugs: Steroids(?), INH, diuretics (thiazides), septran, azathioprine, 5-amino salicylic acid, estrogens, tetracycline, valproic acid, petamidine – 5%
- ❖ Viral infections (mumps, coxsackie)
- ❖ Autoimmune diseases
- ❖ Vascular diseases
- ❖ Idiopathic
- ❖ Scorpion venom—Common in Trinidad
- ❖ Biliary ascariasis, Clonorchis sinensis
- ❖ *Mycoplasma pneumoniae*
- ❖ Infectious mononucleosis
- ❖ Pancreatic divisum

## ACUTE PANCREATITIS

*Acute pancreatitis* is an acute inflammation of the prior normal gland parenchyma which is usually reversible (but acute attack can occur in a pre-existing chronic pancreatitis) with raised pancreatic enzyme levels in blood and urine. It may be first attack or relapsing attacks with an apparently normal gland in between.

**Biliary tract disease** is the **commonest** cause of acute pancreatitis.

*Early phase* lasts for 2 weeks with *oedematous pancreatitis* or *sterile necrosis* which carry less mortality; death here occurs by multiorgan failure.

In *late phase* after 2–3 weeks pancreatic abscess or infective necrosis can occur. Pancreatic abscess has got 40% mortality which needs drainage. *Infective necrosis* usually develops after 3 weeks and carries 100% mortality without surgical drainage (necrosectomy).

### Pathogenesis

- ◆ *Present concept* is the biliary stone induced *pancreatic ductal obstruction* and ductal hypertension as etiological factor (*Pancreatic duct obstruction* occurs due to biliary tract stones (*commonest*), duodenal ulcer, duodenal Crohn's, periampullary diverticulum/tumour, trauma, pancreatic duct stricture, pancreatic divisum, ascariasis, *Clonorchis sinensis*).
- ◆ OR *alcohol* causes direct toxicity, hypersecretion of gastric and pancreatic juices, reflux, plugging of pancreatic proteins, injury by release of free radicals like superoxide and hydroxyl, spasm of Oddi and stimulates trypsinogen.

All these *aetiological factors*

↓  
Either cause spasm of sphincter of Oddi and lead into the parenchyma (*common channel theory*), OR causes increased secretion of pancreatic enzymes

↓  
*Trypsinogen* gets activated forming trypsin which activates other enzymes.

↓  
*Proelastase to elastase.*

↓  
Causes capillary rupture.

↓  
Sequestered fluid, saponified fat, blood, toxins all together forms a **chicken broth fluid**.

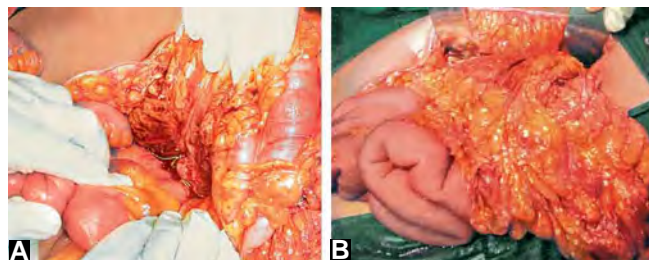
↓  
Lecithinase, amylase and factors like lysolecithinase, prostaglandins, bradykinins, kallikrein, myocardial depressant factor, free radicals, cytokines, tumour necrosis factor, and platelet activation factor are also released to have local and systemic effects.

↓  
Infection occurs causing bacteraemia, septicaemia.

↓  
Large volume of fluid sequestration occurs causing *hypovolemic shock*.

↓  
*Prolipase to lipase.*

↓  
Metabolises triglycerides to glycerol + fatty acids and fatty acids combine with calcium forming saponified fat.

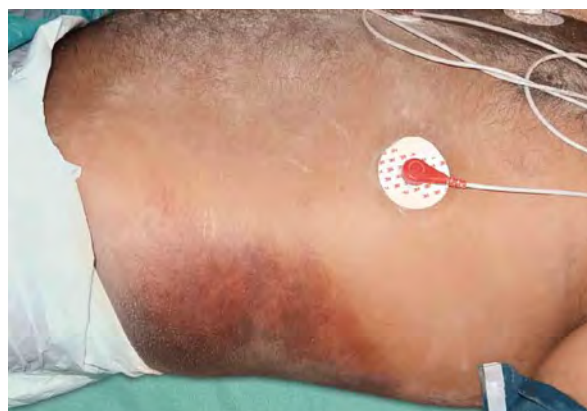

**Figs 14.4A and B:** Features of acute pancreatitis with necrosis in the omentum and over pancreas; with haemorrhage.

- ◆ Toxins released may lead to *acute tubular necrosis* and so *acute renal failure*.
- ◆ Left sided diaphragm gets elevated and *left sided pleural effusion* occurs.
- ◆ Lecithinase reduces the surfactant in the alveoli of lung, and infection leads to pulmonary insufficiency, *ARDS* and *respiratory failure*.
- ◆ Because calcium is utilised for saponification, *hypocalcaemia* sets in.
- ◆ Diffuse oozing in pancreatic bed occurs which utilizes platelets and causes *disseminated intravascular coagulation (DIC)*.
- ◆ In severe cases, extensive necrosis with haemorrhage occurs causing *acute haemorrhagic necrotising pancreatitis (Fulminant pancreatitis)*, which has got a high mortality.
- ◆ Here enzymes seep across the retroperitoneum causing haemorrhagic spots and ecchymosis in the flanks (**Grey-Turner's sign**), or through falciform ligament causing discolouration around the umbilicus (**Cullen's sign**), umbilical black eye or below the inguinal ligament (**Fox sign**).
- ◆ SIRS and later MODS set in.
- ◆ *Sequence of events:*

Acute oedematous → → → → Severe acute pancreatitis  
 → Acute sterile necrosis  
 → Acute infected necrosis  
 ↓ ↓ ↓  
 Resolution/recovery/ complications (rare)  
 Less mortality  
 Local or systemic complications with high mortality.  
 (pseudocyst/abscess/ARDS/ MODS/haemorrhage, etc.)

- ◆ **Moynihan** described acute pancreatitis as "*The most terrible of all the calamities that occur in connection with abdominal viscera*".



**Fig. 14.5:** Grey-Turner's sign in a patient with acute pancreatitis.

*Surgery is a painful procedure to relieve the pain.*

### Effects of alcohol on pancreas

- ❖ Hypertriglyceridaemia, fatty acids and ethyl ester metabolites → pancreatic injury
- ❖ Formation of pancreatic juice which contains high enzymes but low enzyme inhibitors → enzyme activation within pancreas; precipitation of proteins, intraductal plug formation, ductal hypertension and obstruction → pancreatic injury
- ❖ Formation of O<sub>2</sub> free radicals inside the pancreas → pancreatic injury
- ❖ Direct pancreatic acinar injury
- ❖ Sphincter of Oddi spasm by alcohol leading into ductal obstruction
- ❖ Repeated subclinical acute pancreatitis causes fibrosis and chronic pancreatitis

#### Note:

- **Hereditary pancreatitis:** In normal individuals small amount of spontaneous trypsinogen activation into trypsin occurs in pancreas which is further prevented and protected by trypsin inhibitors. In hereditary pancreatitis genetic mutation causes defective trypsin inhibitors and trypsin becomes resistant to trypsin inhibitors leading into high concentration of intrapancreatic active trypsin which activates all other enzymes leading into pancreatitis. Here even though acute pancreatitis can occur; this is commonly subclinical leading into chronic pancreatitis.
- **Autoimmune pancreatitis:** It can be associated with primary sclerosing cholangitis, Sjögren's syndrome, biliary cirrhosis. *Lymphoplasmacytic autoimmune pancreatitis* is a condition which causes high levels of circulating IgG<sub>4</sub>, pancreatitis, bile and pancreatic ductal strictures (*double duct sign* like mimicking the pancreatic cancer), pancreatic head mass.
- ERCP, major surgeries activate pancreatic enzymes causing acute pancreatitis.
- Hypercalcaemia, hyperlipidaemia type I, IV, V can cause pancreatitis. It is due to activation of digestive enzymes, blockage of pancreatic microcirculation causing pancreatic ischaemia.
- **Idiopathic pancreatitis (20%):** Even though it is due to some unidentified cause, it is probably due to gallbladder *sludge* or microcrystals which often can be very well controlled or further prevented by cholecystectomy and sphincterotomy. It also can be due to malfunction of sphincter of Oddi which is treated by sphincterotomy and pancreatic septotomy. Some genetic cause is also postulated.
- **Colocalisation hypothesis:** Trypsinogen within the cytoplasmic vacuoles of acinar cell gets colocalised into the lysosomal hydrolases, commonly cathepsin B to activate into trypsin which in turn activates other intracytoplasmic digestive enzymes leading into intrapancreatic inflammation and pancreatitis.
- **Infection** occurs by *bacterial translocation across gut* due to altered mucosal barrier.

### Revision of the Atlanta Classification and Definitions by International Consensus 2012

#### Definition

2 of 3 three criteria –

1. Characteristic abdominal pain.
2. Elevation of the pancreatic enzymes > 3 times of upper normal limit.
3. Characteristic finding in CECT.

#### Types

1. Acute interstitial oedematous pancreatitis; it is common with mortality only less than 1%

Contd...

2. Acute necrotizing pancreatitis (10%)—it may be sterile necrosis or infected necrosis (occurs after first week). Sterile necrosis has got < 10% mortality whereas infected necrosis has got more than 40% mortality. CT guided aspiration, Gram's staining and then necrosectomy is the need

#### Organ Failure

- ❖ Cardiovascular, renal, respiratory (commonest organ failure in severe AP is respiratory)
- ❖ Modified Marshall scoring system is used. A score of 2 or more suggests. It is based on PaO<sub>2</sub>/FiO<sub>2</sub> (respiratory); serum creatinine (renal); systolic blood pressure and blood pH (cardiovascular).
- ❖ Transient is <48 hours; persistent is >48 hours

#### Systemic Complications

- ❖ Exacerbations of pre-existing comorbid conditions

#### Local Complications—Based on CECT findings

- ❖ **Acute pancreatic fluid collection (APFC)**—Peripancreatic fluid collection with interstitial pancreatitis, no necrosis, no wall formation, occurs within 4 weeks
- ❖ **Encapsulated fluid collection** with a well-defined inflammatory wall with minimal or no necrosis, occurs more than 4 weeks after the onset of interstitial pancreatitis
- ❖ **Acute necrotic collection (ANC)**—Collection containing variable amounts of both fluid and necrosis associated with necrotizing pancreatitis
- ❖ **Walled of necrosis (WON)**—Mature, encapsulated collection of pancreatic and or peripancreatic necrosis with a well-defined walled of necrosis

#### Severity grading of acute pancreatitis (AP)

1. **Mild AP**—No organ failure, no local or systemic complications
2. **Moderately severe AP**—Organ failure that resolves in 48 hours (transient organ failure) and or local/systemic complications without persistent organ failure
3. **Severe AP**—Persistent organ failure (> 48 hours), can be single or multiple organ failure

#### Phases of acute pancreatitis

1. **Early phase** usually lasts for first week commonly with initial systemic response to AP
2. **Late phase** has got a protracted course of many weeks to months with local complications and organ failure

#### Systemic inflammatory response syndrome (SIRS)

Core body temperature <36°C or >38°C; heart rate >90/minute; respiratory rate >20/minute or PaCO<sub>2</sub> <32 mmHg; WBC count <4,000 cells/mm<sup>3</sup> or >12000/mm<sup>3</sup>. If SIRS is present >48 hours the patient is likely to have severe pancreatitis

### Determinant-based classification

#### Based on:

1. **Local determinant** is peripancreatic or pancreatic necrosis which is non-viable tissue located in pancreas alone or in peripancreatic tissue alone or both. It can be solid or semisolid and without a radiologically defined wall; should be detected as areas of non-enhancement on CECT.
2. **Systemic determinants** as organ failure—cardiovascular, respiratory, renal; is assessed based on SOFA scoring as transient or persistent.

Type	(Peri) pancreatic necrosis		Organ failure
Mild AP	Absent	And	Absent
Moderate AP	Sterile	And/Or	Transient (<48 hours)
Severe AP	Infected	Or	Persistent (>48 hours)
Critical AP	Infected	And	Persistent

Contd...

## Organisms Involved

Infection is commonly polymicrobial (60%). It may be from gallbladder, colon or small bowel via transmural migration or by haematogenous spread. Infection rate in one week is 24% and in 3 weeks it is 70%.

- ◆ *E. coli* (35%).
- ◆ *Klebsiella* (25%).
- ◆ *Enterococcus* (25%).
- ◆ Others—staphylococci, *Pseudomonas*, *Proteus*, *Enterobacter*, *Anaerobes*, *Candida* (10%).

## Clinical Features

*Clinical features may be mild, severe or fulminant.*

- ◆ Sudden onset of upper abdominal pain which is referred to back. Pain is severe, agonizing and refractory. Pain may be relieved or reduced by leaning forward.
- ◆ Vomiting and high fever, tachypnoea with cyanosis.
- ◆ Tenderness, rebound tenderness, guarding, rigidity and abdominal distension, severe illness.
- ◆ Often mild jaundice (due to cholangitis). Jaundice may also be due to bile duct disease/obstruction or cholestasis.
- ◆ Features of shock and dehydration.
- ◆ Oliguria, hypoxia and acidosis.
- ◆ Grey-Turner's sign, Cullen's sign, Fox sign.
- ◆ Haematemesis/melaena due to duodenal necrosis, gastric erosions, decreased coagulability/DIC.
- ◆ Hiccough when present is refractory.
- ◆ Ascites may be present. Paralytic ileus is common.
- ◆ Pleural effusion (20%), pulmonary oedema, consolidation, features of rapid onset ARDS is often observed.
- ◆ Neurological derangements due to toxæmia, fat embolism, hypoxia, respiratory distress can occur. It may be mild psychosis to coma.
- ◆ Occasionally haematemesis or melaena can occur.

## Fluid, Metabolic, Haematologic and Biochemical Changes

- ◆ *Hypovolemia* due to diffuse capillary leak and vomiting causing raised haematocrit, blood urea, serum creatinine levels.
- ◆ *Hypoalbuminaemia* which is more revealed after fluid correction.
- ◆ *Hypocalcaemia* is either due to decreased albumin level or specific loss of ionized calcium. Hypocalcaemia due to reduced ionised calcium carries poor prognosis. Response of calcium reserve in bone to PTH is also reduced.
- ◆ Total count is raised with *neutrophilia*. *Thrombocytopaenia*, raised FDP, decreased fibrinogen, prolonged partial thromboplastin time and PT—are common. DIC can develop later.
- ◆ *Hypochloraemic metabolic alkalosis* is common due to repeated vomiting.
- ◆ Reduced insulin secretion, increased glucagon and catecholamine secretion causes *hyperglycaemia*, more so in diabetic patients.
- ◆ *Hyperbilirubinaemia* may be due to biliary stone/obstruction or cholangitis or non-obstructive cholectasis.

- ◆ *Hypertriglyceridaemia* is common especially in hyperlipidaemic patients.
- ◆ *Methemalbuminemia*, when it occurs in acute pancreatitis indicates poor prognosis.

### Differential diagnosis

- ◆ Perforated duodenal ulcer
- ◆ Cholecystitis
- ◆ Mesenteric ischaemia
- ◆ Ruptured aortic aneurysm
- ◆ Ectopic pregnancy
- ◆ Salpingitis
- ◆ Intestinal obstruction
- ◆ Diabetic ketoacidosis

## Investigations

- ◆ *Serum amylase* is very high (>1000 Somogyi units) or shows rising titre.
- ◆ *Amylase creatinine clearance* ratio is increased. It is urine amylase/serum amylase X serum creatinine/urinary creatinine X 100. Normal value is 1–4%. More than 6% signifies acute pancreatitis.
- ◆ *Serum lipase* more specific than amylase. Serum lipase level after rise persists for longer period than amylase. Pancreas is the only source unlike amylase, hence more specific.

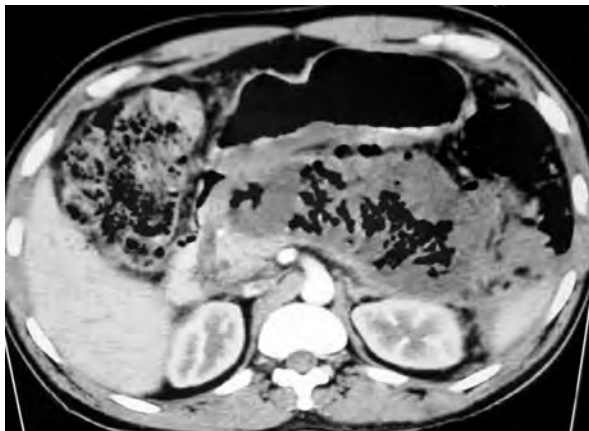
CTSI Balthazar, 1990 (Emil J Balthazar)		CTSI Mortelet et al. 2004	
Grade and appearance	Score	Grade and appearance	Score
<b>CT Grade—</b>		<b>CT Grade—</b>	
A – Normal pancreas	0	A – Normal pancreas	0
B – Oedematous pancreatitis	1	B – Intrinsic pancreatic abnormalities with or without inflammatory changes in peripancreatic fat	2
C – B+ mild extrapancreatic changes	2		4
D – Severe extrapancreatic changes with one fluid collection	3	C – Pancreatic/peripancreatic fluid collection or peripancreatic fat necrosis	4
E – Extensive/multiple extrapancreatic collections or gas bubbles in or adjacent to pancreas	4		2
<b>Necrosis score</b>		<b>Necrosis score</b>	
None		None	
< 1/3rd		< 30%	
More than 1/3rd less than 1/2	4	>30%	
More than half	6	One or more extrapancreatic complications	
<b>CT SI (CT severity index) – CT grade + necrosis score</b>			
0–3= mild; 4–6= moderate; 7–10= severe			



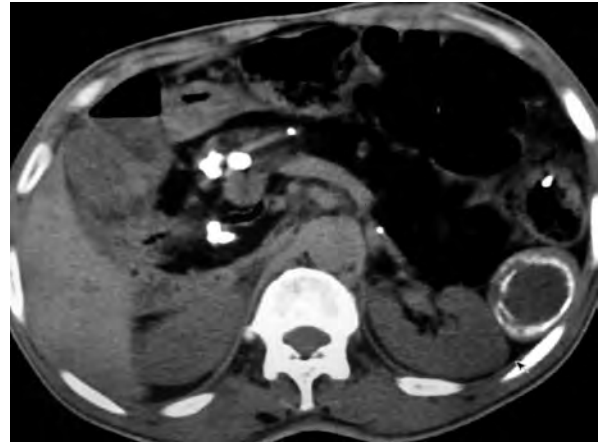
- ◆ *Serum lactescence* (related to triglyceride metabolism)—Most specific in hereditary hyperlipidaemia or alcohol pancreatitis.
- ◆ Serum trypsin is the most accurate indicator but it is not commonly used.
- ◆ Trypsinogen activation polypeptide (TAP) assay in serum and urine reveals the severity of the acute pancreatitis. CRP (>150 mg/L) is also useful. Phospholipase A2, LDH levels are also often assessed.
- ◆ *Liver function tests*: Serum bilirubin, albumin, prothrombin time, alkaline phosphatase.
- ◆ Blood urea, serum creatinine.
- ◆ Blood glucose (hyperglycaemia is seen).
- ◆ Serum calcium level (hypocalcaemia occurs).
- ◆ Arterial PO<sub>2</sub> and PCO<sub>2</sub> level to assess pulmonary insufficiency (or ARDS).
- ◆ Urinary lipase estimation.
- ◆ Total count, haematocrit, platelet count, coagulation profile.
- ◆ Peritoneal tap fluid shows *high amylase* and protein level (very useful method). Lipase level in ascitic fluid is also useful.
- ◆ Plain X-ray shows
  - ▶ 'Sentinel loop' of dilated proximal small bowel.
  - ▶ Distension of transverse colon with collapse of descending colon (*colon cut off sign*).
  - ▶ Air-fluid level in the duodenum.
  - ▶ Renal halo sign.
  - ▶ Obliteration of psoas shadow.
  - ▶ Localized ground glass appearance.
- ◆ US abdomen.
- ◆ *Spiral CT (CECT—contrast enhanced CT)* is better—gold standard. It is done after 72 hours. To look for oedema, altered fat and fascial planes, fluid collections, necrosis (non-enhancement area > 30% or 3 cm), bowel distension, mesenteric oedema and haemorrhage. CT-guided aspiration (fluid should be sent for Gram's stain and bacterial culture); pigtail catheter insertion can also be done. If fluid culture shows bacterial growth with CT showing necrosis, it means it is infected necrosis and needs early pancreatic necrosectomy. CT-guided aspiration and Gram's staining may need to be repeated.

*CECT gives diagnosis of AP; assesses the severity; detects local complications. But CECT should be done ideally after first week not in initial period unless diagnosis is in doubt or associated pathology is suspected. Non-enhancement finding is typical of pancreatic necrosis (WON).*

- ◆ MRI, MRCP—should be done at a later date.
- ◆ ERCP is usually not done in acute phase.
- ◆ Chest X-ray for effusion and ARDS.
- ◆ EUS—to see necrosis, calcifications and to assess CBD.



**Fig. 14.6:** CT picture showing features of acute pancreatitis.



**Fig. 14.7:** CECT showing pancreatitis with stones in the duct.

## Treatment

### Treatment of acute pancreatitis

- ❖ Conservative, 70–90%
- ❖ Surgical treatment when indicated, 10–30%
- ❖ Management of complications like acute pseudocyst, abscess, fistula, haemorrhage; systemic complications like ARDS, renal failure, MODS

## Conservative Treatment

### AIM

#### Assessment of haemodynamic status and early resuscitation

- ❖ *Aggressive early hydration* in first 24 hours using 400 ml/hour crystalloids (**Ringer lactate**, normal saline) to achieve rapid repletion of the severe volume depletion
- ❖ *Risk assessment stratification*
- ❖ Patient with organ failure or SIRS should have *ICU care* in anticipation of ventilator and organ support (haemodialysis)
- ❖ Prevention or treatment of *abdominal compartment syndrome (ACS)* which carries high mortality; ACS is intra-abdominal pressure (IAP) more than 12 mmHg. It can occur during fluid therapy also; it requires often decompression by percutaneous catheter insertion or laparotomy
- ❖ *Infection control, electrolyte management*

#### Risk assessment stratification

- ❖ *Patient features*—Age >55 years; obesity (BMI >30); altered mental status; comorbid conditions
- ❖ *SIRS*
- ❖ *Laboratory findings*—BUN >20 mg/dl with rising BUN; altered haematocrit; elevated creatinine; CRP > 210/L initially
- ❖ *Radiological features* (X-ray initially; CECT later)—pleural effusion, ARDS, multiple or extrapancreatic fluid collections
- ❖ *Scoring system*—APACHE II, Ranson's, Glasgow, Modified Marshall, etc.

- ◆ *Rehydration* is essential (250–400 ml/hour) as there is lot of fluid sequestration and 3rd space fluid loss. It is done by using ringer lactate, normal saline, dextrose saline, plasma and fresh blood transfusion/packed cells.
- ◆ *Pain relief* by pethidine and other analgesics. Morphine is not used as it causes spasm of sphincter of Oddi.
- ◆ *In severe haemorrhagic episodes*, fresh frozen plasma and platelet concentrate may be required in anticipation of DIC and haemorrhage.

- ◆ *Nasogastric aspiration*, urinary catheterisation to maintain and monitor urine output 50 ml hourly. *Nasojejunal tube* placement for feeding is very useful.
- ◆ *Antibiotics* like third generation cephalosporins, imipenem, meropenem, cefuroxime are used even though its role is not clear but it is commonly used to reduce the anticipated sepsis.

#### Indications for antibiotics

- ❖ In severe infected necrosis with/without proved culture.
- ❖ Prophylactic antibiotic therapy, in severe pancreatitis.
- ❖ In biliary pancreatitis with biliary stones and cholangitis.
- ❖ Clinically disease is rapidly progressing with deterioration.

No role of antibiotics in early pancreatitis.  
Imipenem, cilastatin, cefuroxime are used.

- ◆ Calcium gluconate 10 ml 10% IV 8th hourly is given as patient will be hypocalcaemic.
- ◆ *CVP line is essential to monitor*, for rapid fluid therapy and for Total Parenteral Nutrition (TPN) using carbohydrate, amino acids, vitamins, essential elements.
- ◆ IV ranitidine 50 mg 6th hourly or IV omeprazole 40 mg BD or IV pantoprazole 80 mg BD to prevent stress ulcers and erosive bleeding.
- ◆ *Proper electrolyte management* with monitoring is needed.
- ◆ It is always better to manage the patient in an *intensive care* set up so that when needed endotracheal intubation, ventilatory support, tracheostomy can be done as an emergency basis.

#### Mainly conservative treatment

- 1) (P)** : Pain relief [pethidine, meperidine (no morphine)]  
Protease inhibitors (aprotinin, antsnake venom, EACA etc.), Plasma
- 2) (A)** : Antibiotics (ceftazidime, cefoperazone, cefotaxime) imipenem  
Anticholinergics (to reduce sphincter pressure)
- 3) (N)** : Nasogastric aspiration, Nasal O<sub>2</sub>  
Nutritional support (TPN)
- 4) (C)** : Calcium gluconate 10 ml 10% 8th hourly  
Calcitonin  
CVP line
- 5) (R)** : Rehydration by IV fluids, plasma, blood  
Ranitidine IV 50 mg 8th hourly  
Respiratory support (ventilator)  
Resuscitation when required
- 6) (E)** : Endotracheal intubation  
Electrolyte management
- 7) (A)** : Antacids
- 8) (S)** : Swan-Ganz catheter for CVP and TPN  
Somatostatin and its analogue (*Octreotide*)

- ◆ In case of *renal failure haemodialysis* is required.
- ◆ Somatostatin/octreotide is often used to reduce pancreatic secretion.
- ◆ Anticholinergics, protease inhibitors and calcitonin are other agents used. Their efficacy is not sure.
- ◆ Steroid injection in initial phase of shock is beneficial. It is also useful in respiratory distress and ARDS.

- ◆ Nebulisation, bronchodilators are also tried.
- ◆ *Nasojejunal tube placement and feeding* should be started as early as possible once ileus subsides so that it reduces the infection rate by transmucosal migration of bacteria and it also improves nutritional status. During recovery period nasogastric feeding or jejunostomy feeding can be undertaken.
- ◆ Repeated calcium estimation, US examination to see the response is useful.
- ◆ Dopamine or low molecular weight dextran (to improve renal perfusion), somatostatin/octreotide (to reduce pancreatic secretion) are also often used.
- ◆ *Management of complications* like acute lung injury, atelectasis, renal failure, GI bleeding, metabolic encephalopathy, electrolyte deficiency as and when needed by repeated observation and evaluation.

#### Other measures:

Continuous monitoring, observation, maintaining good urine output 30 ml/hr. The required investigations are repeated to find out the response to treatment like serum calcium, total count, blood urea, creatinine, PaO<sub>2</sub>, haematocrit, ECG.

#### Uses of octreotide

- ❖ Pancreatic surgeries
- ❖ Variceal bleeding
- ❖ Endocrine pancreatic tumours
- ❖ GI fistulas, pancreatic fistulas
- ❖ Dumping syndrome
- ❖ Carcinoid tumour, acromegaly
- ❖ Acute pancreatitis

#### Dose:

50 µg as loading dose IV  
50 µg 1 hour in 5% dextrose as maintenance dose.

#### Surgery

##### Indications for Surgical Intervention (10% cases)

1. If condition of patient deteriorates in spite of good conservative treatment.
2. If there is pancreatic infected necrosis.
3. In severe necrotising pancreatitis as a trial to save the life of the patient which has got very high mortality.

##### Surgical management of acute pancreatitis

Surgery removes intra- and extra-pancreatic necrotic materials, pancreatic fluid, and toxins. It permits preservation of viable pancreatic tissue. *Open surgery is the gold standard for infected pancreatic necrosis.*

- ◆ After opening the abdomen, all necrotic tissue, pus, infected fluid and toxins are removed. 10–12 litres of normal saline wash is given. Drainage tubes are placed liberally. Abdomen is closed in layers—*Conventional closed method* (necrosectomy, wide debridement, adequate drainage, cholecystectomy, closure). Re-laparotomy is done only on demand later.

*Each case has its lesson—a lesson that may be, but is not always, learnt for clinical wisdom is not the equivalent of experience.*

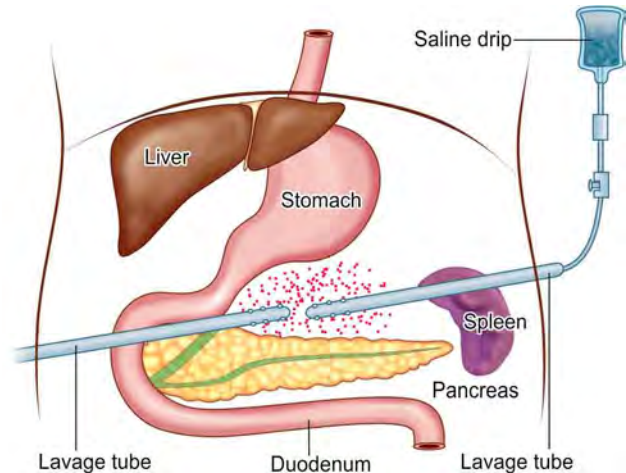
— William Osler

- ◆ Laparotomy–necrosectomy–wide debridement–wash–wide packing. Wound is left open. Repeated wash and packings are done until healthy granulation develops – *open method*.
- ◆ Laparotomy–necrosectomy and closure with drain and re-laparotomy later—*semi-open method*.
- ◆ *Zip technique* can be used to give repeated wash to remove toxins and necrotic tissues until healthy granulation tissue develops in the pancreatic bed—*Bradley's repeated laparotomies and wash*.
- ◆ *Continuous closed peritoneal lavage* of the pancreatic bed and lesser sac is done with 10–12 litres of normal saline or hyperosmolar, potassium free dialysate fluid 2 litres/hour using multiple tubes to remove toxic material in the peritoneal cavity/retroperitoneal area until return fluid becomes clear—*Beger's lavage*. Procedure is done after initial surgical debridement.
- ◆ Extra peritoneal lavage through bilateral flank incisions is also used. But being a blind procedure it is technically difficult and one may not be sure about the adequacy of the procedure.
- ◆ Under laparoscopic visualisation, necrosectomy, wash and drainage can be done. But often it is difficult to create pneumoperitoneum in acutely ill patient. But it is increasingly becoming popular.
- ◆ A jejunostomy is often done along with these procedures to have early enteral nutrition.
- ◆ *Endoscopic necrosectomy* is often done in some centres. *Early endoscopic intervention* (within 48 hours) with ERCP, biliary stone removal and stenting in biliary pancreatitis is done and favored in many centres.
- ◆ *Further management* is important to prevent recurrence. Gallstones should be dealt by laparoscopic cholecystectomy in 2 weeks after acute attack during same admission period. Endoscopic sphincterotomy (ERCP) and often stenting may be needed if there are CBD stones.

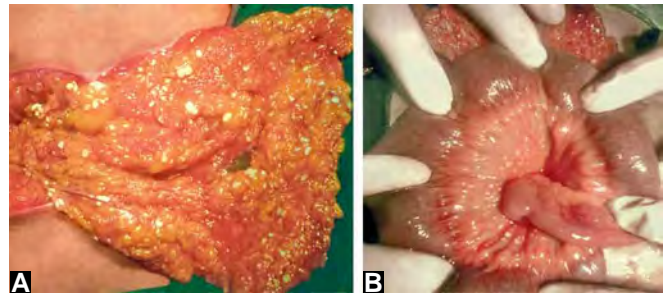
**Note:**

- GI fistula either enteric or pancreatic and incisional hernia are the late complications of these surgeries.
- Localized collection of purulent material without significant necrotic material (considered as pancreatic abscess) is an extremely uncommon entity and so term '*pancreatic abscess*' is not used now as per revised Atlanta classification 2012. Earlier it was thought to be 5%

common; after an attack of severe acute pancreatitis or infection in pseudocyst; said to be seen in alcoholics; with a mortality of 25%. CECT confirmation, CT-guided aspiration and culture, CT-guided catheter drainage or open drainage is needed. Septicaemia, bleeding due to erosion and sloughing of vessel wall can occur.



**Fig. 14.8:** Beger's lavage to pancreatic bed. Tubes are placed post-operatively. Continuous saline irrigation through the tube is done until irrigation fluid becomes clear.



**Figs 14.9A and B:** On table photos of acute pancreatitis. Note the typical saponification in the omentum and mesentery.

<b>Ranson's prognostic criteria in gallstone pancreatitis score &gt;3 suggests severe AP</b>	<b>Ranson's prognostic criteria in Non-gallstone pancreatitis</b>	<b>Glasgow–Imrie prognostic criteria</b>	<b>Acute Physiology and Chronic Health Evaluation (APACHE II) score &gt;8 points predicts 11 to 18% mortality</b>
On admission: <ul style="list-style-type: none"> <li>• Age &gt;70 years</li> <li>• TC &gt;18,000/cu mm</li> <li>• Blood sugar &gt;220 mg%</li> <li>• LDH &gt;400 IU/L</li> <li>• AST &gt;250 IU/100 ml</li> </ul>	On admission: <ul style="list-style-type: none"> <li>• Age &gt;55 years</li> <li>• TC &gt;16,000/cu mm</li> <li>• Blood sugar &gt;200 mg%</li> <li>• LDH &gt;350 IU/L</li> <li>• AST &gt;250 IU/100 ml</li> </ul>	On admission: <ul style="list-style-type: none"> <li>• Age &gt;55 years</li> <li>• TC &gt;15,000/cu mm</li> <li>• PaO<sub>2</sub> &lt;60 mmHg</li> <li>• Blood urea &gt;16 mmol/L (No response to IV fluids)</li> <li>• Blood sugar &gt;200 mg% (no H/O diabetes)</li> </ul>	<ul style="list-style-type: none"> <li>• Equation includes the following factors: age, rectal temperature, mean arterial pressure, heart rate, PaO<sub>2</sub>, arterial pH, serum potassium, serum sodium, serum creatinine, haematocrit, white blood cell count, Glasgow coma scale score.</li> </ul>
Within 48 hours: <ul style="list-style-type: none"> <li>• Haematocrit drop &gt;10%</li> <li>• BUN rise &gt;2 mg%</li> <li>• Serum calcium &lt;8 mg%</li> <li>• Base deficit &gt;5 mEq/L</li> <li>• Fluid sequestration &gt;4 L</li> </ul>	Within 48 hours: <ul style="list-style-type: none"> <li>• Haematocrit drop &gt;10%</li> <li>• BUN rise &gt;5 mg%</li> <li>• PaO<sub>2</sub> &lt; 60 mmHg</li> <li>• Serum calcium &lt;8 mg%</li> <li>• Base deficit &gt;4 mEq/L</li> <li>• Fluid sequestration &gt;6 L</li> </ul>	Within 48 hours: <ul style="list-style-type: none"> <li>• Serum calcium &lt;2 mmol/L</li> <li>• Serum albumin &lt;3.2 g/dl</li> <li>• LDH &gt; 600 U/L</li> <li>• AST/ALT &gt;200 U/L</li> </ul>	APACHE II modified (1996) LFT is added in biliary pancreatitis APACHE – O (Toh 1996) Obesity is added

**Note:**

- Decrease serum calcium level is *worst prognostic indicator* of pancreatitis.
- These scoring systems differ for non-gallstone pancreatitis and gallstone pancreatitis.
- Other scoring systems which are often used are APACHE II (Acute Physiology And Chronic Health Evaluation II) and SAP (simplified acute physiology) scoring systems. Twelve variables are used to assess in APACHE II scoring.
- *C-Reactive Protein (CRP)* > 210 mg/L in first 4 days and >120 mg/L in one week; phospholipase A2 assay; pancreas related protein; interleukin-6; polymorphonuclear elastase > 120 µg/L; serum ribonuclease assay—are other parameters used to assess the severity.

**COMPLICATIONS OF ACUTE PANCREATITIS**

- ❖ Shock—Hypovolemic and septic
- ❖ Respiratory failure and ARDS—Common in 7 days
- ❖ Septicaemia—Common after 7 days
- ❖ Hypocalcaemia
- ❖ Disseminated intravascular coagulation (DIC)
- ❖ Acute renal failure
- ❖ Pancreatic pleural effusion (left sided 20%)
- ❖ Pancreatic pseudoaneurysm
- ❖ Pancreatic ascites
- ❖ Colonic stricture
- ❖ Pseudocyst of pancreas
- ❖ Chronic pancreatitis
- ❖ Splenic vein thrombosis
- ❖ Abdominal compartment syndrome (ACS)
- ❖ Pancreatic endocrine (15%) and exocrine (20%) insufficiency as late sequelae can occur.

◆ *Acute fluid collection*

- ▶ It is collection of fluid in or near the pancreas during an attack of acute pancreatitis with an ill-defined or lacking fibrin wall or granulation tissue.
- ▶ It is 40% common; it usually occurs at peripancreatic area, occasionally intrapancreatic.
- ▶ More than 50% of acute fluid collection regress spontaneously, remaining may form pseudocyst of pancreatic necrosis.
- ▶ CT-guided aspiration at one puncture site is often necessary to confirm that it has not infected.

◆ *Acute pseudocyst*

- ▶ It is collection of fluid with pancreatic juice in or near the pancreas localised by thin fibrin wall or granulation tissue.
- ▶ Occurs in 2 weeks, usually resolves spontaneously.
- ▶ Fluid can be removed percutaneously under guidance or through an endoscope.

◆ *Pancreatic pseudocyst*

- ▶ It is collection of fluid in a false cavity which commonly contains brownish pancreatic enzyme rich fluid, *lined by granulation tissue but not true epithelium* with an organised thick fibrous covering.
- ▶ It is commonly located in peripancreatic region, in lesser sac. It can be often intrapancreatic or in other places in the peritoneal cavity. It can be multiple also.

- ▶ It usually forms 4 weeks after an attack of pancreatitis—a *chronic entity*.
- ▶ It is usually sterile but can get infected.
- ▶ Pseudocyst may rupture to form pancreatic ascites.
- ▶ It may cause pancreaticopleural fistula when once it erodes into left side pleural cavity or it may erode into splenic vessels causing life-threatening haemorrhage.

◆ *Pancreatic necrosis infected. (Walled of necrosis/WON)*

- ▶ It is focal/diffuse area of non-viable pancreatic parenchyma with peripancreatic fat necrosis.
- ▶ It is initially sterile but eventually gets infected.
- ▶ It contains *paste/putty* like material.
- ▶ It may form pseudocyst, abscess or may be replaced by fibrous tissue during healing.
- ▶ It can be sterile or infected necrosis.
- ▶ It is confirmed by CT-scan and CT-guided aspiration usually at one site; collected fluid should be sent for culture.
- ▶ *Infection of necrotic area* usually occurs within 4 weeks. It is ideally *conventionally* treated with laparotomy, debridement is done by removing all necrotic tissue with adequate drainage for remaining viable exocrine function. Often repeat laparotomies are done once in 3 days until all necrotic materials are cleared and jejunostomy is done in final approach.
- ▶ Laparotomy and debridement done once with continuous lavage; antibiotics with percutaneous drainage/only surgical drainage without debridement/debridement using minimally invasive methods—are *unconventional* approaches.
- ▶ It may slough off the pancreatic/splenic vessel wall to cause torrential haemorrhage. *Walled of necrosis (WON)* may be single or multiple (60%). It is commonly in head/body or tail. But often entire gland may be involved (25%).
- ▶ *Walled of necrosis (WON)* may rupture into viscera or extend into other part of the abdomen. Features of sepsis, tender palpable mass in the epigastrium with leukocytosis are observed.

◆ *Respiratory complications*

- ▶ They are often severe and life-threatening. It is due to distension of abdomen, diaphragmatic elevation, pleural effusion, reduced surfactant (lecithin) activity in alveoli due to lecithinase, severe pain, pleural effusion (left), intravascular coagulation in lungs and ARDS. *Arterial blood gas analysis* should be done. Often it needs ventilator support.

◆ *Pancreatic pseudoaneurysm*

- ▶ It is due to enzymatic digestion (elastase) of the wall and weakening and aneurysmal dilatation of the splenic (50%) or gastroduodenal vessels (15%) or inferior and superior pancreaticoduodenal arteries (10%).
- ▶ It may rupture and cause life-threatening haemorrhage or may rupture into stomach or duodenum to cause massive upper GI bleed or may rupture into pancreatic duct causing *haemosuccus pancreatitis*.
- ▶ It is diagnosed by CT angiogram.
- ▶ It is treated by critical care, blood transfusion, emergency angiographic embolisation or by open surgery and ligation of the involved vessel. It carries high mortality.

◆ *Pancreatic fistula*

- ▶ It can occur due to ductal wall disruption and necrosis or after surgical intervention for acute pancreatitis (necrosectomy).

*In case of chronic pancreatitis jaundice supervenes in only fifteen percent of cases, but diabetes is present on thirty percent.*

— Richard B Cattell

- ▶ It may be internal into bowel or external to skin.
  - ▶ Fistula may be low (< 200 ml) or high (> 200 ml) out put.
  - ▶ It can be straight or curved.
  - ▶ It is confirmed by biochemical analysis, ERCP, CT fistulogram.
  - ▶ If fistula persists for 6 months then sphincterotomy, resection of fistula with pancreatic resection, pancreaticojejunostomy is done.
- ◆ *Emphysematous pancreatitis*
- ▶ It is gas in pancreatic parenchyma, a dangerous type and can be diagnosed by CT scan.

#### Criteria to find out systemic failure in acute pancreatitis

- ❖ *Cardiac*: Hypotension; pulse > 130/minute; arrhythmias, ECG changes.
- ❖ *Pulmonary*: PaO<sub>2</sub> > 60 mm Hg; ARDS.
- ❖ *Renal*: Urine output < 40 ml/hour; increase in blood urea and serum creatinine.
- ❖ *Metabolic*: Falling serum calcium; magnesium and albumin.
- ❖ *Haematologic*: Fall in haematocrit; DIC.
- ❖ *Gastrointestinal*: Severe ileus; sequestration of fluid.
- ❖ *Neurologic*: Irritability; confusion; localising features.

## PSEUDOCYST OF PANCREAS

- ◆ It is localized collection of sequestered pancreatic fluid, usually 3 weeks after an attack of acute pancreatitis.
- ◆ It can occur after trauma and recurrent chronic pancreatitis.
- ◆ Collection usually occurs in the lesser sac in relation to stomach, but can occur in relation with duodenum, jejunum, colon, splenic hilum.
- ◆ About 50% of acute pancreatitis leads to pseudocyst formation, but among that 20–40% will resolve spontaneously.

#### Sites of pseudocyst

- ❖ Lesser sac—commonest, i.e. between colon and stomach
- In relation to:
- ❖ Duodenum
  - ❖ Jejunum
  - ❖ Colon
  - ❖ Splenic hilum

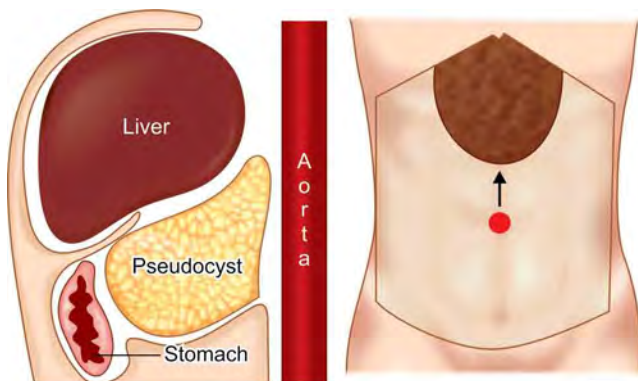


Fig. 14.10: Pseudocyst of pancreas.

- ◆ Initially cyst wall is thin (*unformed*), but later it gets fibrosed and thickened (*formed*) (matured).

- ◆ It is lined by fibrin layer but no endothelium, hence called as pseudocyst.
- ◆ It contains typically brownish fluid with sludge like necrotic material. It can get infected to form *infected pseudocyst* or *pancreatic abscess*.
- ◆ Amylase level in the cyst fluid is very high (>5000 units/ml).

## Types

Depending on whether it communicates with pancreatic duct or not it is classified as:

1. *Communicating pseudocyst*.
2. *Noncommunicating pseudocyst*.

It can be

- ◆ *Acute pseudocyst*.
- ◆ *Chronic pseudocyst*.

#### D'Egidio classification of pseudocyst

- ❖ *Type I*: After an attack of acute pancreatitis. Normal duct anatomy; no fistula/communication.
- ❖ *Type II*: After an attack of acute on chronic pancreatitis. Abnormal duct anatomy without stricture; 50% chances of fistula.
- ❖ *Type III*: After an attack of chronic pancreatitis, abnormal anatomy with stricture; always communicating. It appears like retention cyst.

#### Sarle's classification

- ❖ Necrotic pseudocyst in acute pancreatitis.
- ❖ Retention cyst in chronic pancreatitis.
- ❖ Intrapaneatic retention due to pancreatic duct dilatation.
- ❖ Extrapaneatic retention cyst due to rupture into peripaneatic tissues.

#### Nealon and Walsler classification

- I – Normal duct; no duct communication into pseudocyst.
- II – Normal duct with communication.
- III – Normal duct with stricture without communication.
- IV – Normal duct with stricture with communication.
- V – Normal duct with abrupt duct termination.
- VI – Chronic pancreatitis without duct cyst communication.
- VII – Chronic pancreatitis with duct cyst communication.

#### Note:

- It is not a true cyst as there is no epithelial lining.
- 75% of cystic lesions of pancreas are pseudocysts; Others are—cystadenomas, IPMNs, cystic necrosis of adenocarcinoma, congenital polycystic disease.

## Clinical Features

- ◆ A swelling in the epigastric region which is hemispherical, smooth, soft, not moving with respiration, not mobile, upper margin is diffuse but lower margin well defined, resonant or impaired resonant on percussion, with transmitted pulsation confirmed by knee-elbow position.
- ◆ If it is infected, it will be tender mass and patient will be toxic with fever and chills.
- ◆ Because stomach is stretched towards the abdominal wall, Ryle's tube passed will be felt per abdominally (*Baid test*).

## Differential Diagnosis

- ◆ Aortic aneurysm.
- ◆ Retroperitoneal cyst or tumour.
- ◆ Cystadenocarcinoma of pancreas.
- ◆ Cyst of the liver.
- ◆ Mesenteric cyst.
- ◆ Hydatid cyst.

## Investigations

- ◆ *US abdomen (commonly done procedure)*, US reveals the size and thickness of the pseudocyst. Size less than 6 cm indicates that one can wait for spontaneous resolution. Endosonography (EUS) is very useful.
- ◆ *CT scan is ideal and study of choice*. It is two times more sensitive than US. It demonstrates size, shape, number, wall thickness, contents, pancreatic duct size, and extent of necrosis in pancreas, calcification and atrophy in chronic pancreatitis, regional vessels, pseudoaneurysm, splenic/portal vein thrombosis.
- ◆ MRCP delineates the ductal anatomy and its abnormality.
- ◆ ERCP is done to find out the communication.
- ◆ Barium meal (lateral view) shows widened vertebrogastric angle with displaced stomach (Not usually done now).
- ◆ LFT, serum amylase platelete count, PT INR.
- ◆ *EUS-guided aspiration* and analysis of fluid for amylase and CEA. Amylase will be high with normal CEA in pseudocyst; amylase will be normal/low with high CEA >400 ng/ml in mucinous neoplasm.

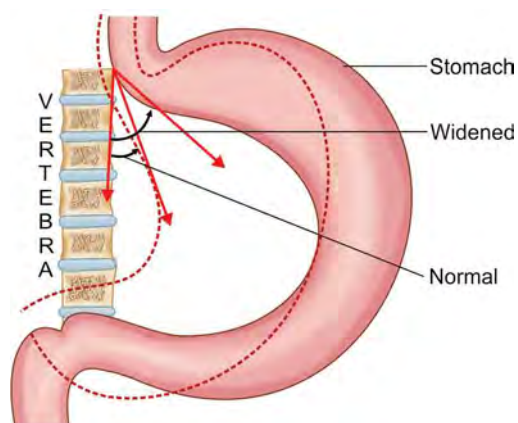


Fig. 14.11: Vertebrogastric angle.

## Treatment

1. **Conservative**—Observation, follow-up using repeat USG at regular intervals. 50% of pseudocysts show spontaneous resolution.
2. **Interventional**—Needs ERCP to delineate ductal anatomy, pancreatic duct stones, mainly communication into the pseudocyst. It is Guided—Endoscopic/EUS/US-guided drainage
  - ▶ *Transpapillary*—Through side viewing endoscopy, pancreatic sphincterotomy is done; guidewire is passed into the pancreatic

duct; stones if present are removed from the duct; 5 French pancreatic stent is placed which is removed in 6–8 weeks. Confirmation of resolution of pseudocyst is done by follow-up CT. This procedure is suitable only in communicating pseudocyst; it is safer and effective.

- ▶ *Transmural endoscopic or EUS-guided stent placement* to the pseudocyst; guided needle aspiration is done initially on the visible bulge; then endoscopic stent is placed to allow internal drainage; stent is removed after 8 weeks endoscopically. Recurrence rate is high; necrosectomy is not possible.
- ▶ *Percutaneous drainage under USG guidance*—It is technically easier; catheter drainage is done after placing the catheter under guidance in large pseudocyst; high recurrence, infection, displacement and blockage of catheter are common.
- ▶ *Simple US-guided aspiration* has got high recurrence and failure rate; so it is not practiced routinely.

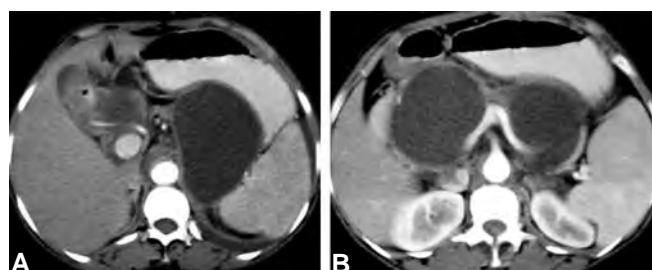
3. **Surgical drainage**— It is either *open or laparoscopic* method.

### Indications for surgery/intervention

- ❖ Size more than 6 cm
- ❖ Formed pseudocyst
- ❖ Infected pseudocyst
- ❖ Cyst persisting after 6 weeks/progressive cyst
- ❖ Multiple cysts/cyst due to trauma
- ❖ Communicating cysts/cyst with severe pain
- ❖ Thick-walled pseudocyst

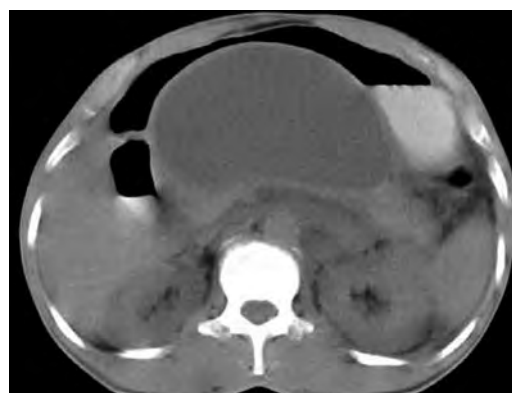

Fig. 14.12: CT scan showing typical pseudocyst of pancreas.

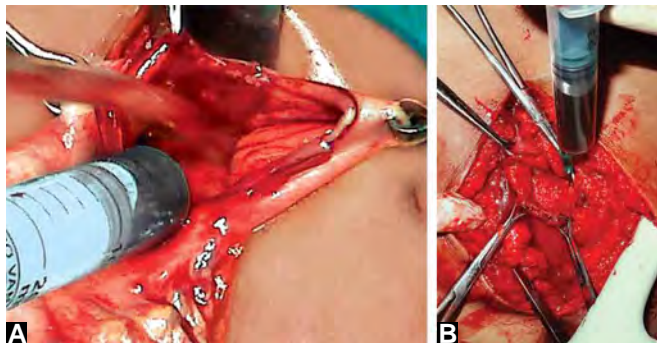


Figs 14.13A and B: CT scan showing pseudocyst of pancreas both single and multiple. Note the cyst cavity and the thick cyst wall. Patient needs drainage procedure either cystogastrostomy or cystojejunostomy.

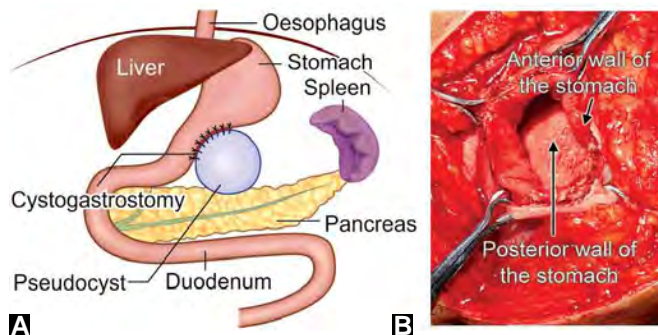
*Doing the surgery may be easier, but it is managing the patient which counts finally.*

## Surgery

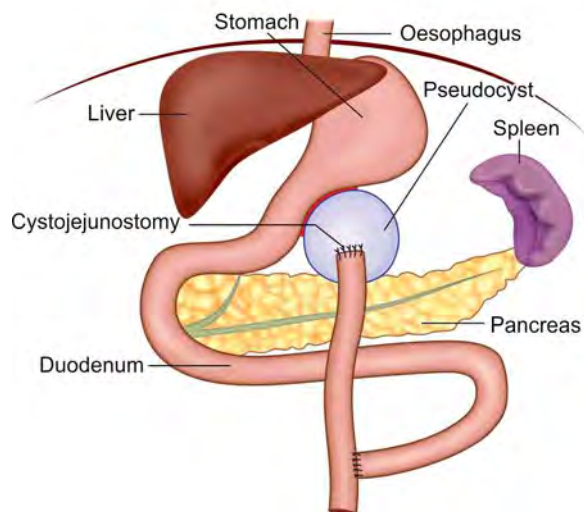
- ◆ **Cystogastrostomy:** At laparotomy, anterior wall and posterior wall of the stomach is opened. *Brownish fluid* is aspirated. The thick capsule of pseudocyst is opened. All fluid with necrotic material are sucked. Fluid should be sent for cytology, culture and sensitivity and amylase estimation. Cyst wall always should be biopsied. Cyst cavity should be washed with normal saline after breaking septae. Pseudocapsule is anastomosed to posterior wall of the stomach—*Jurasz operation*.



**Figs 14.14A and B:** Pseudocyst of pancreas aspiration of table. Note the brownish-black colour of the fluid aspirated.



**Figs 14.15A and B:** (A) Cystogastrostomy for pseudocyst of the pancreas; (B) Cystogastrostomy procedure. Anterior layer of the stomach is opened to visualize the bulge in the posterior wall. Aspiration of it shows brownish black coloured fluid, typical of pseudocyst of the pancreas.



**Fig. 14.16:** Roux-en-Y cystojejunostomy for pseudocyst of the pancreas.

## Other procedures

- ◆ Cystoduodenostomy.
- ◆ Cystojejunostomy is done in large cyst, recurrent cyst.
- ◆ If infected, cystogastrostomy with external drainage is done using Malecot's catheter (*Smith operation*).
- ◆ Laparoscopic cystogastrostomy is becoming popular, effective and less invasive.
- ◆ Along with cystojejunostomy, pancreaticojejunostomy should be done if there is ductal stricture and dilatation and communication with pseudocyst.
- ◆ Distal pancreatectomy with pseudocyst removal if cyst is in distal part.

## Complications of pseudocyst

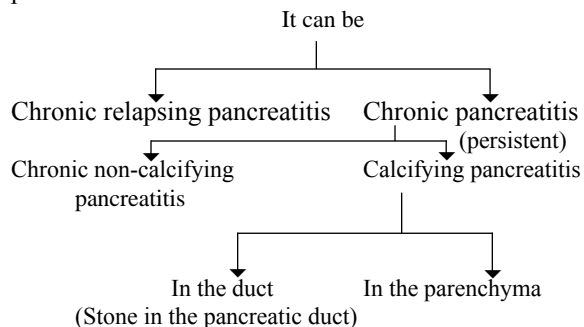
- ❖ Rupture—3%—into bowel or peritoneum
- ❖ Infection, commonest—20%, abscess
- ❖ Bleeding from the splenic vessels—7%
- ❖ Cholangitis
- ❖ Duodenal obstruction
- ❖ Portal/splenic vein thrombosis and segmental portal hypertension
- ❖ Cholestasis due to CBD block

## Note:

- Roux-en-Y cystojejunostomy is better with lesser recurrence rate than cystogastrostomy.
- *Pseudopseudopancreatic cyst:* It is a mass in epigastric region due to pancreatitis formed by bowel, omentum which clinically mimics a pseudocyst of pancreas. But fluid collection is absent.
- Small cyst can be drained through endoscopy. But debridement is not possible. Bleeding and cyst leakage are other problems.
- CT-guided percutaneous catheter placement is done in critically ill patients, infected pseudocyst, unfit patients, cyst in pelvis/mediastinum. Improper drainage, recurrence and fistula formation are the problems.
- External drainage is done when cyst is infected, haemorrhagic or ruptured. Problem with external drainage is formation of fistula (20%).
- Therapy is decided based on thickness of the wall of pseudocyst; location of pseudocyst; contents of pseudocyst and ductal status.
- Pseudocysts following trauma and chronic pancreatitis have got lesser chances of spontaneous resolution.
- Pseudocyst following biliary pancreatitis has got 4 times more mortality than that of alcoholic pancreatitis.
- Spontaneous resolution rate is 40% for pseudocyst less than 6 weeks; 8% for 6–12 weeks; less than 1% for cyst more than 12 weeks.
- Presence of significant debris is a contraindication for endoscopic or image-guided drainage.

## CHRONIC PANCREATITIS

- ◆ It is persistent progressive irreversible damage of the pancreas due to chronic inflammation.



- ◆ Chronic pancreatitis is more common in males, common in Kerala (induced by diet, rich in Tapioca).

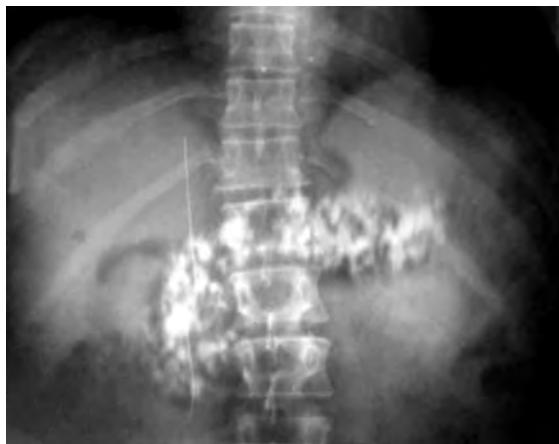

Fig. 14.17: Calcifications in the parenchyma of the pancreas.

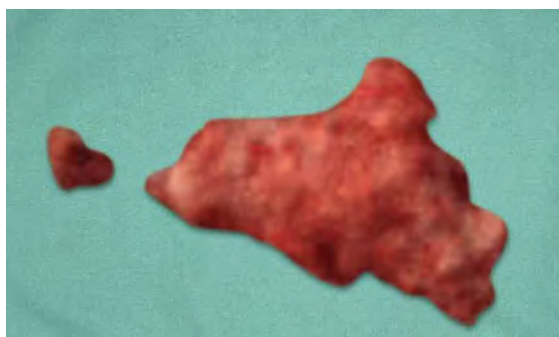

Fig. 14.18: Pancreatic ductal stone removed—specimen. Patient underwent pancreaticojejunostomy.

#### Aetiology

- ❖ Alcohol—80% main cause
- ❖ Stones in biliary tree—rare cause
- ❖ Malnutrition, diet
- ❖ Hyperparathyroidism
- ❖ Hereditary (familial hereditary pancreatitis)—Autosomal dominant
- ❖ Idiopathic—20%—as mutation
- ❖ Trauma
- ❖ Congenital anomaly (Pancreatic divisum)
- ❖ Cystic fibrosis
- ❖ Autoimmune pancreatitis
- ❖ Hyperlipidaemia

#### TIGAR-O Risk Factor Classification 2001

- T** – Toxic - alcohol/tobacco/dietary/drug.  
Metabolic-hypercalcaemia/lipidemia/lipoprotein lipase deficiency.
- I** – Idiopathic—early/late onset/tropical –30%
- G** – Genetic mutations—CFTR/SPINK 1.
- A** – Autoimmune primary/with Sjögren/Crohn's disease.
- R** – Recurrent and severe acute/ischemic.
- O** – Obstructive—pancreas divisum/annular pancreas/stenotic papilla/duodenal obstruction/trauma/pancreatic ductal stones/cholechocele.

- ❖ Alcohol reduces pancreatic blood flow, alters cell viability, releases the free radicals, creates pancreatic ischaemia, and activates the pancreatic stellate cells which produce abundant extracellular matrix and collagen.
- ❖ Genetic predisposition may be the cause of idiopathic pancreatitis. Mutation in pancreatic secretory trypsin inhibitor causes activation of trypsin causing pancreatitis.
- ❖ Hereditary pancreatitis is an autosomal disorder with mutation in trypsinogen gene in chromosome 7. It causes recurrent painful episodes of acute pancreatitis in childhood, leading to chronic pancreatitis and pancreatic cancer in adulthood.

### Theories and Concepts in Pathogenesis of Chronic Pancreatitis

- ❖ *Oxidative stress hypothesis*—Reactive by-products of hepatic mixed function oxidase activity damage the pancreas through chronic reflux of bile into the pancreatic duct.
- ❖ *The toxic-metabolic theory*—Alcohol is directly toxic to the acinar cell where it brings changes in intracellular metabolism causing pancreatic lipid accumulation, fatty degeneration, cellular necrosis, and eventual widespread fibrosis.
- ❖ *Stone and duct obstruction theory*—Alcohol increases the lithogenicity of pancreatic juice, leading to stone formation. Chronic contact of stones with duct epithelial cells produces ulceration, scarring, atrophy, fibrosis and chronic obstruction of the acini.
- ❖ *The necrosis-fibrosis theory*—Acute and chronic pancreatitis represents a spectrum of disease. Inflammation from acute pancreatitis leads to scarring, extrinsic compression of the pancreatic ductules, obstruction, stasis, atrophy and stone formation.
- ❖ *The genetic defect* of hereditary pancreatitis produces recurrent acute pancreatitis in early childhood, leading to chronic pancreatitis in early adulthood.
- ❖ *Cellular mechanisms* of pancreatic fibrogenesis is due to pancreatic stellate cells which are stimulated and activated by alcohol, oxidative stress, cytokines of acute pancreatitis; activated stellate cells migrate to the periacinar areas to deposit collagen and fibronectin. Transforming growth factor beta 1 is an important mediator of pancreatic fibrosis.
- ❖ *The sentinel acute pancreatitis event (SAPE) hypothesis*—An episode of acute pancreatitis, the sentinel event, sets the stage for the attraction of collagen-secreting stellate cells.
- ❖ *Heavy, prolonged alcohol use* is the most common cause of chronic pancreatitis. Alcohol-related chronic pancreatitis is associated with more severe pain, more extensive calcification and ductal changes, and more rapid progression to endocrine and exocrine insufficiency. Often recurrent episodes of acute pancreatitis for several years are seen in these patients. Some cofactors amplify the effect of alcohol in these patients. Prevalence of some genetic mutations linked with pancreatitis like cystic fibrosis transmembrane regulator (*CFTR*), serine protease inhibitor Kazal type-1 (*SPINK1*) has been noted in alcoholic pancreatitis. A high-fat diet and smoking affect pancreatic bicarbonate and water secretion adversely, inducing oxidative stress and increases the rate of pancreatic calcification.
- ❖ *Tropical pancreatitis* is endemic in some regions of India (Kerala), Africa, and South America. Episodic abdominal pain begins in childhood and is followed by rapid progression to endocrine and exocrine insufficiency with pancreatic calculi in non-alcoholic

*Carcinoma pancreas should be suspected when an elderly person develops diabetes and in spite of adequate treatment, continues to loose weight.*  
— Robert D Lawrence



individuals. Dietary toxins (cyanogens in the cassava plant, tapioca) and micronutrients like zinc, copper, and selenium, vitamin A deficiencies, genetic factors, ductal abnormalities are the probable causes of tropical pancreatitis. *Linnamarin* and its methyl derivative, in acid pH of stomach releases hydrocyanic acid which is cytotoxic in presence of rhodanase releases thiocyanates causing depletion of methionine, damaging pancreas → pancreatitis. Gross look is small, firm fibrotic/adipose type.

- ◆ *Early-onset* idiopathic chronic pancreatitis manifests with severe abdominal pain in childhood, with relatively few structural and functional changes. *Late-onset* idiopathic chronic pancreatitis manifests in middle and late adulthood, often with minimal pain and pronounced exocrine insufficiency.

## Pathology

- ◆ It shows atrophy of acini, hyperplasia of duct epithelium, interlobular fibrosis, calcifications, ductal dilatation, with strictures in the duct, focal necrosis.
- ◆ There is loss of exocrine function initially and endocrine functions eventually.
- ◆ Ductular metaplasia and acinar atrophy along with fibrosis and cyst formation develops.

### Pathology of chronic pancreatitis

- ❖ Focal necrosis
- ❖ Segmental or diffuse fibrosis
- ❖ Parenchymal calcification or ductal stones
- ❖ Stricture and/or dilatation of the duct

## Spectrum of Chronic Pancreatitis

- ◆ *Early*—pancreatic oedema—chronic inflammation—normal secretory function.
- ◆ *Moderate*—early fibrosis; only few acinar cells—exocrine dysfunction.
- ◆ *Late*—fibrosis—loss of secretory function—diabetes mellitus.
- ◆ *Complications* develop secondary to healing and fibrosis; deposition of inspissated proteinaceous material in the duct; over expression of CTGF and TGF-β1 that stimulate extracellular matrix.

### Pain hypothesis include:

- ❖ Acute and chronic inflammation of the pancreas.
- ❖ Increased pressure within the pancreatic ductal system and parenchyma, ductal dilatation, stasis.
- ❖ Ischaemia of the parenchyma secondary to increased interstitial pressure.
- ❖ Over expression of a particular protein in pancreatic nerve fibres.
- ❖ Pancreatic nerve growth factor released by degenerating acinar cells and its high affinity receptor that promotes nerve growth and repair.
- ❖ Pain may be due to perineural sheath destruction by toxins, ischaemia and also due to tissue acidosis.

## Classification of Chronic Pancreatitis

### I: Based on main duct dilated or not:

- ◆ Large duct disease—main pancreatic duct is dilated.
- ◆ Small duct disease—main pancreatic duct, is normal or smaller in size.

### II: Staging/classification of chronic pancreatitis (Stages A, B, C)

A new classification of chronic pancreatitis, based on combination of clinical signs, morphology and function, is presented (2009 Büchler et al).

#### Specific definition of chronic pancreatitis stage A

##### ◆ Stage A chronic pancreatitis

It is the early stage of chronic pancreatitis where complications have not yet appeared and the clinical exocrine and endocrine function is preserved. Subclinical signs (impaired glucose tolerance, reduced exocrine function but without steatorrhoea) might already be apparent.

Stage A is accepted under the following conditions: Pain of any type and degree and/or attacks of acute pancreatitis, no complications, no steatorrhoea, and no insulin-dependant diabetes mellitus.

#### Specific definition of chronic pancreatitis stage B

##### ◆ Stage B chronic pancreatitis

It is the intermediate stage where chronic pancreatitis has led to complications but clinical exocrine and endocrine function is still preserved. The type of complication is specified (e.g. stage B, bile duct). Stage B is accepted under the following conditions: Patients with complications but without steatorrhoea or diabetes mellitus.

#### Specific definition of chronic pancreatitis stage C

##### ◆ Stage C chronic pancreatitis

Stage C is the end stage of chronic pancreatitis, where pancreatic fibrosis has led to loss of clinical exocrine and/or endocrine pancreatic function (steatorrhoea and/or diabetes mellitus). Complications of chronic pancreatitis might or might not be present. The type of exocrine and/or endocrine pancreatic function loss is specified (e.g. stage C, steatorrhoea).

Stage C can be sub-classified into three categories:

- C1: Patients with endocrine function impairment.
- C2: Patients with exocrine function impairment.
- C3: Patients with exocrine/endocrine function impairment and/or complications—as they are defined.

Stage C is accepted under the following conditions—Patients with clinical manifestation of end-stage functional impairment with or without complications.

## Clinical Features

### ◆ Pain in epigastric region (80%)

- ▶ It is persistent and severe, which radiates to back.
- ▶ This pain is due to irritation of retropancreatic nerves, or due to ductal dilatation and stasis, or due to chronic inflammation itself.
- ▶ *Two patterns of pain* have been described (Ammann and Muellhaupt). *Type A* pain is short relapsing episodes lasting days to weeks, with pain-free intervals. *Type B* pain is prolonged, severe, unrelenting pain.
- ▶ Pain exacerbations *need not be always* associated with rise in amylase and lipase levels.
- ▶ There is often a gradual diminish in pain over years due to “*pancreatic burnout*” by extensive calcifications, exocrine and endocrine insufficiency.



**Fig. 14.19:** Patient will occupy leaning forward position to relieve severe pain of pancreatitis.

- ◆ **Exocrine dysfunction:** Diarrhoea, asthenia, loss of weight and appetite, steatorrhoea (signifies severe pancreatic insufficiency) (90%), malabsorption.
- ◆ **Endocrine dysfunction:** Diabetes mellitus. Pancreatic diabetes may often be *typically brittle* because of concomitant glucagon deficiency and *requires insulin*.
- ◆ **Mild jaundice** is due to narrowing of retropancreatic bile duct and cholangitis.
- ◆ **Mass per abdomen**, just above the umbilicus, tender, nodular, hard, felt on deep palpation, not moving with respiration, not mobile, resonant on percussion.

#### Triad of chronic pancreatitis

- ❖ Pancreatic calcification
- ❖ Steatorrhoea
- ❖ Diabetes mellitus

Triad is found in *less than one-third* of patients with CP

**Mallet-Guys sign:** In right knee-chest position, if left hypochondrium is palpated tenderness can be evoked in case of chronic-relapsing pancreatitis. In this position, bowel loops are being shifted to right so as to have a direct palpation of pancreas.

#### Note:

- *Chronic pancreatitis can lead to carcinoma pancreas.*

#### Clinical presentations

- ❖ **Stage A:** 85%, recurrent/acute episodic pain with weight loss.
- ❖ **Stage B:** Severe prolonged progressive pain with impaired pancreatic function with cholestasis, pseudocyst, sinistral portal hypertension.
- ❖ **Stage C:** Severe exocrine/endocrine deficiency, less severe pain, complications like pseudocyst and obstruction.

#### Differential Diagnosis

- ◆ Carcinoma of head of the pancreas.
- ◆ Retroperitoneal tumour.

#### Complications of chronic pancreatitis

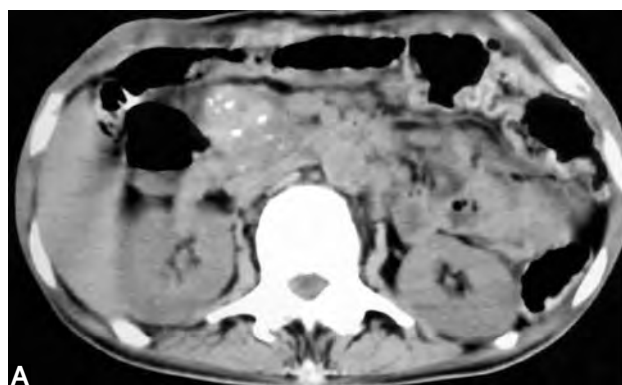
- ❖ Pseudocyst of pancreas
- ❖ Pancreatic ascites
- ❖ CBD stricture due to oedema or inflammation
- ❖ Duodenal stenosis
- ❖ Portal thrombosis—segmental portal hypertension
- ❖ Peptic ulcer
- ❖ Carcinoma pancreas
- ❖ Pancreatic pleural effusion, pancreatic ascites
- ❖ Pancreatic fistula
- ❖ Splenic vein thrombosis
- ❖ Pancreatic enteric fistula

#### Investigations

- ❖ Serum amylase—not very useful
- ❖ Blood sugar
- ❖ Liver function tests and prothrombin time
- ❖ US abdomen to see duct dilatation, stones, parenchyma, liver status, CBD (normally, diameter of pancreatic duct is < 3 mm)
- ❖ Endosonography
- ❖ CT scan—CT-guided FNAC
- ❖ ERCP—*Chain of lake appearance*. Duct is dilated
- ❖ MRCP
- ❖ Plain X-ray shows calcification in 65% of patients
- ❖ Pancreatic secretory juice analysis
- ❖ *Pancreolauryl test*—pancreatic esterase cleaves fluorescein dilaurate after oral intake. Fluorescein is absorbed and quantified in urine after 2 days.
- ❖ Oral glucose tolerance test
- ❖ Faecal chymotrypsin and elastase analysis
- ❖ Bentiromide test

#### Investigations presently used are:

- ◆ **CT scan abdomen:** It is 95% reliable; to see pseudocyst, calcification, ductal stones, duct stricture and dilatation, vasculature, fibrosis, surrounding structures, CBD status. It shows 90% sensitivity; 95% specificity.



**Fig. 14.20A**

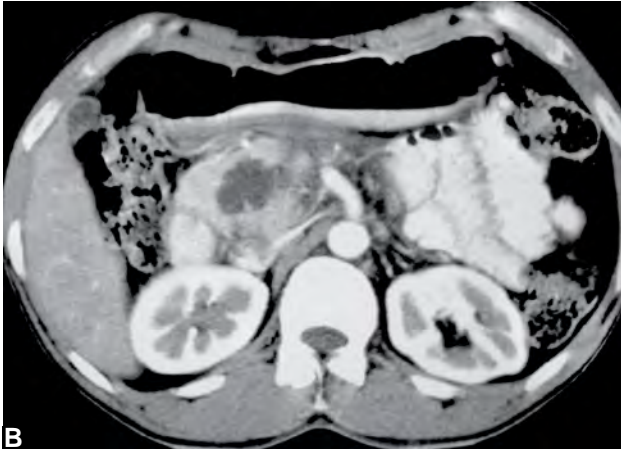

Fig. 14.20B

**Figs 14.20A and B:** CT scan abdomen showing features of chronic pancreatitis—calcification, ductal changes, and cyst formation.

- ◆ *ERCP* is useful in chronic pancreatitis to see dilatations, strictures and altered ductal anatomy. It is mainly to assess *structural pathology* of the pancreas.

#### Cambridge grading of CP on ERCP

Grade	Main pancreatic duct	Side branches
I: Normal	Normal	Normal
II: Equivocal	Normal	<3 Abnormal
III: Mild	Normal	>3 Abnormal
IV: Moderate	Abnormal	>3 Abnormal
V: Severe	Abnormal with at least one of the following:	>3 Abnormal
	• Large cavity (>10 mm)	
	• Obstruction	
	• Filling defects	
	• Severe dilatation or irregularity	

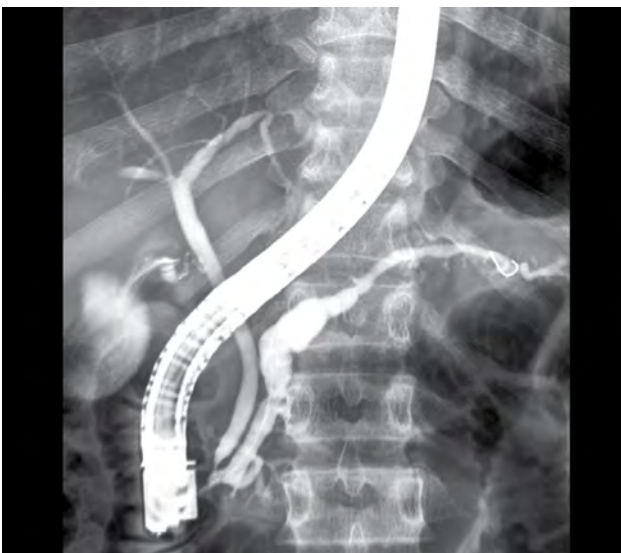


Fig. 14.21: ERCP showing pancreatic duct.

- ◆ *MRCP* is non-invasive method to see ductal anatomy.
- ◆ *Endosonography (EUS)* to see possible malignant site and to take FNAC. Site, duct status, stricture, stones, parenchyma, pseudocyst, CBD status, nodes are identified in EUS. Positive five parameters suggest chronic pancreatitis. It also helps in assessing operability.

#### EUS criteria in chronic pancreatitis—parenchymal

- Gland atrophy
- Hyperechoic foci
- Hyperechoic stranding
- Cysts, lobularity

#### EUS criteria in chronic pancreatitis—ductal

- Narrowing, dilation, irregularity
- Calculi
- Side branch dilation
- Hyperechoic walls

#### Rosemont EUS criteria

##### Major:

- A—Hyperechoic foci with shadowing and calculi in main pancreatic duct (PD)
- B—Lobularity with honeycombing

##### Minor:

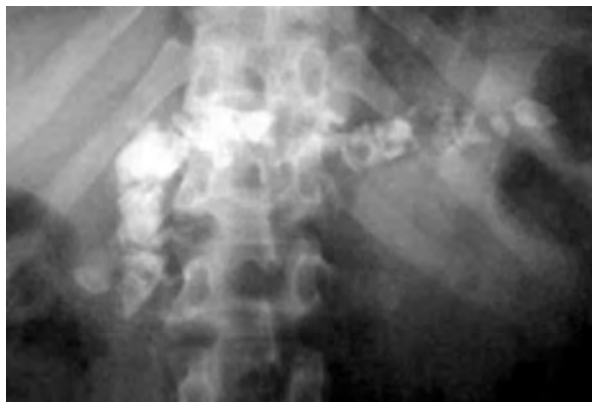- Cysts
- Dilated ducts  $\geq 3.5$  mm
- Irregular PD contour
- Dilated side branches  $\geq 1$  mm
- Hyperechoic duct wall, strands
- Non-shadowing hyperechoic foci
- Lobularity with non-contiguous lobules

- ◆ *Secretin cholecystokinin test* is the gold standard for assessing pancreatic function. After overnight fasting, double lumen tube is placed into the duodenum at the level of ligament of Treitz under C ARM guidance. Gastric and duodenal juices are aspirated. Continuous IV secretin 1 u/kg/hour and CCK are infused in 90 minutes. Sampling of duodenal juice is done in every 10 minutes for one hour for analysis of *volume*,  $HCO_3$ , amylase, lipase and proteases. It is to assess *functional deficiency*. In chronic pancreatitis volume is normal— $>2$  ml/kg but less bicarbonate content— $<80$  mEq/L. In malignancy volume is reduced due to obstruction— $<2$  ml/kg; bicarbonate level is normal— $>80$  mEq/L; enzyme levels are normal.
- ◆ *Pancreolauryl test*: After overnight fasting, blood sample is taken. IV secretin is injected 1 u/kg in 3 minutes. Test meal containing bread, butter, tea and fluorescein dilaurate is given to eat. IV metoclopramide 10 mg is injected. Blood samples are taken at 2, 2½, 3 and 4 hours to assess serum fluorescein concentration. It is also quantified in urine after 2 days.
- ◆ *LFT, prothrombin time* is needed to manage the patient.
- ◆ Serum trypsinogen  $<20$  ng/ml and fecal elastase  $<200$  mcg/g stool—severe exocrine insufficiency.
- ◆ Plain X-ray abdomen may show ductal calculi or parenchymal calcifications.

## Treatment

### Aim of treatment

- ❖ Control of pain
- ❖ Improvement in maldigestion and nutrition
- ❖ Management of complications



**Fig. 14.22:** Multiple stones in pancreatic duct with ductal dilatation. It needs removal of stones with pancreaticojejunostomy.

### Conservative

- ◆ Avoid alcohol.
- ◆ Low fat, high protein, high carbohydrate diet; small and more frequent meals.
- ◆ Pancreatic enzyme supplements, vitamins and minerals, medium chain fatty acids.
- ◆ For pain—analgesics, splanchnic nerve or coeliac plexus block. *Pancreatic enzyme replacement therapy (PERT)* is used to relieve pain based on—negative feedback mechanism of pain; protease content responsible for pain relief (dose: >50,000 units). It may be beneficial only in females with idiopathic pancreatitis, small duct disease and pancreas divisum. Other drugs used are—antioxidants, amitriptyline, fluoxetine, octreotide. Novel pain therapies like NGF, antinociceptive agents, mast cell directed therapies are also used.
- ◆ Control of diabetes by oral hypoglycaemics or insulin.
- ◆ Somatostatin and its analogues. Its role is not clear.
- ◆ Repeated ascitic taps for pancreatic ascites.
- ◆ *Steatorrhea* can be controlled by proton pump inhibitors with 1,50,000 units of oral lipase with low fat diet. PPI inhibits acid in stomach to prevent lipase getting inactivated in stomach.

### Endoscopic Therapy in Chronic Pancreatitis

- ◆ It is used as it has got low morbidity.
- ◆ Main *indications* are—pain relief, ductal stones, main duct stricture, pseudocyst drainage, pancreatic ascites, effusion and fistula.
- ◆ It is quite useful for main pancreatic duct obstruction and pseudocyst. It is less useful for biliary stricture.
- ◆ *Procedures* are—pancreatic duct sphincterotomy, main ductal stone extraction using Dormia basket, main ductal stenting in strictures, stricture dilatation, ESWL of main duct stones, minor papillary sphincterotomy.
- ◆ *Pseudocyst* can be treated by *transmural stenting* across gastric wall if there is visible bulge, distance of cyst wall is less than 1 cm, no major vessel at puncture site. *Transpapillary stenting* is done if pseudocyst is communicating, if cyst is less than 6 cm, if there is no visible bulge in the stomach.
- ◆ *Complications* are—pancreatitis, stent displacement/occlusion, perforation, bleeding, sepsis, restenosis.
- ◆ *Advantages* of endotherapy are—less invasive, can be repeated, less severe complications, can be used as bridge therapy prior to surgery.
- ◆ *Disadvantages* are—long-term benefits are less (50%). Definitive treatment is delayed. It is not useful in small duct disease; main duct dilatation decides the success rate.

### Surgery

#### Indications for surgery

- ◆ Persisting pain—main indication
- ◆ Severe malabsorption
- ◆ Suspicion of malignant transformation
- ◆ Multiple relapses
- ◆ Complications like pseudocyst, segmental portal hypertension
- ◆ Biliary obstruction (*Wadsworth syndrome*)
- ◆ Pseudocyst
- ◆ Pancreatic ductal dilatation > 7 mm
- ◆ Pancreatic ascites/fistula
- ◆ Pancreatic ductal stenosis

#### Objectives of Surgery

- ◆ Pain relief when endotherapy has failed.
- ◆ Management of complications.
- ◆ Procedure selected is one which shows less morbidity and mortality.
- ◆ Quality of life (QOL) should be preserved.

#### Problems and Limitations of Surgery

- ◆ Disease is irreversible parenchymal and ductal damage and so surgery cannot cure or reverse completely.
- ◆ Disease progression cannot be prevented or arrested by surgery.
- ◆ Risk of development of cancer continues.
- ◆ Complications of surgery are a drawback.

#### Benefits of Surgery in Relation to Pain Relief and Obstruction

- ◆ Relieves intraductal, interstitial, intracellular hypertension—through drainage procedures.
- ◆ Entrapped nerves are released and reduction in pancreatic enzyme reduces nerve irritation—resectional methods.
- ◆ *Pacemaker*—head of pancreas is removed in head coring procedure (Frey's) to relieve pain. It is less morbid and acceptable method.
- ◆ Resection is better than drainage procedure.

#### Principles of Surgery

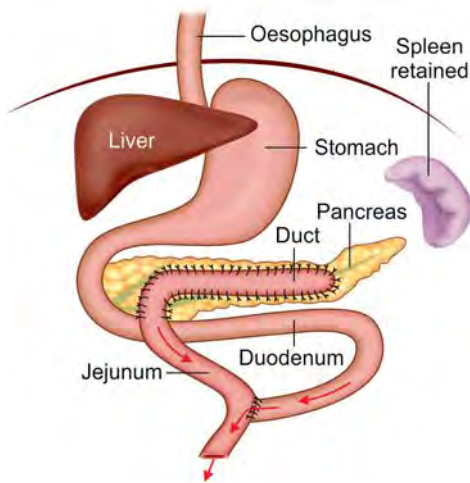
- ◆ *Pancreatic duct decompression (drainage)* reduces the pain and retains the existing exocrine and endocrine functions. But chances of malignant transformation are still high. In significant number of patients recurrence of symptoms (50% recurrence of pain in 5 years) and progression of the disease pathology occurs and it does not give a complete cure. Normal diameter of pancreatic duct 4 mm in head; 3 mm in body; 2 mm in tail of the pancreas. *Pancreatic duct diameter more than 7 mm is an indication for surgery (pancreaticojejunostomy).*
- ◆ *Pancreatic resection* (total pancreatectomy) is the actually ideal technique which relieves pain, removes entire diseased tissue. But technical difficulty; high surgical mortality (21%); and severe exocrine and endocrine deficiency (brittle diabetes) are the drawbacks. Head

of pancreas is considered as pacemaker of the pancreatitis disease and so pancreaticoduodenectomy (*Whipple's*) is the other option to give adequate relief. It is preferred in patients who are having relatively normal body and tail of the pancreas. Occasionally when disease is limited to tail and body then *distal pancreatectomy* with or without splenectomy often with distal pancreatico-jejunostomy may be done. But it is not beneficial if disease is extensive and diffuse. Resection is the main method of treatment if ductal dilatation is not adequate.

- ◆ A combined resection and drainage procedures are also done. Head is decored at various levels and decompressed duct is anastomosed to jejunum.

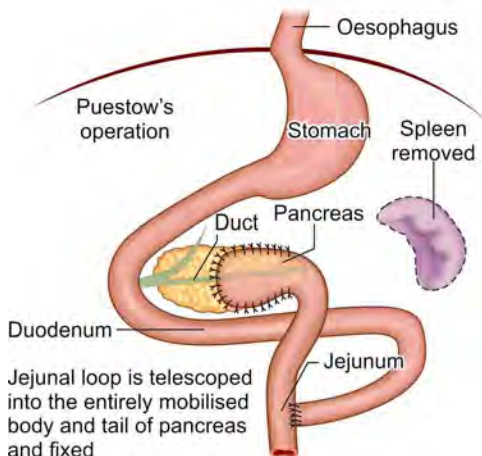
### Surgeries

- ◆ *Partington-Rochelle operation*: Here longitudinal pancreaticojejunostomy is done using almost entire laid open pancreatic duct. Spleen is retained in this procedure. This is now commonly done procedure.



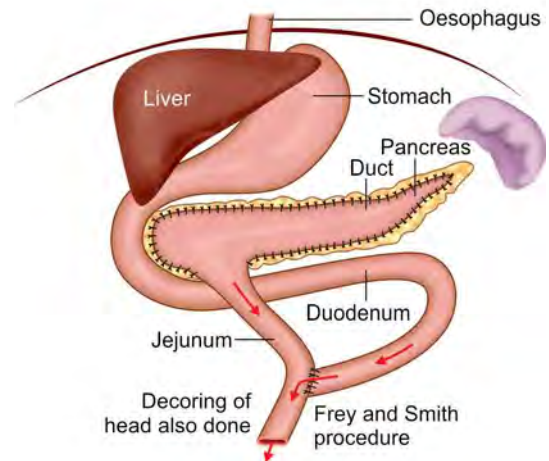
**Fig. 14.23:** *Partington-Rochelle operation*. Here spleen is retained and longitudinal pancreaticojejunostomy is done to the opened duct from front.

- ◆ *Puestow's operation* [*Puestow-Gilesby* (1958)]—As the duct is dilated more than 8 mm, duct can easily be opened longitudinally. After removing all stones from the duct, it is anastomosed to the jejunum as *Roux-en-Y anastomosis*. In Puestow's operation spleen is removed.

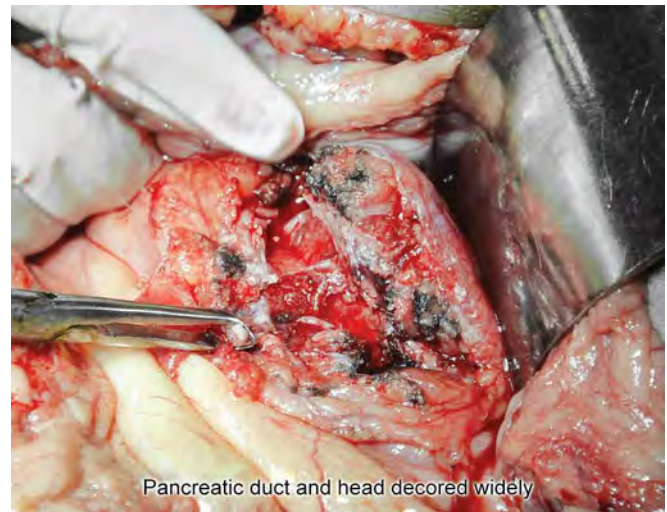

**Fig. 14.24:** *Puestow's pancreaticojejunostomy*. Here spleen is removed. Entire length of dilated duct is opened. Distal pancreas is mobilised up to superior mesenteric vessels. Pancreas with opened duct is telescoped into the Roux loop of jejunum and anastomosed.

- ◆ *Longitudinal pancreaticojejunostomy* after excision of peripancreatic duct tissue—here superficial part of the head of pancreas is removed to achieve improved drainage—*Frey procedure*. It is done when ductal dilatation is not adequate; head is more than 4 cm thick. Head coring is done with retaining 5 mm thick tissue in front of veins, close to duodenum. It shows 75% pain relief in 3 years.

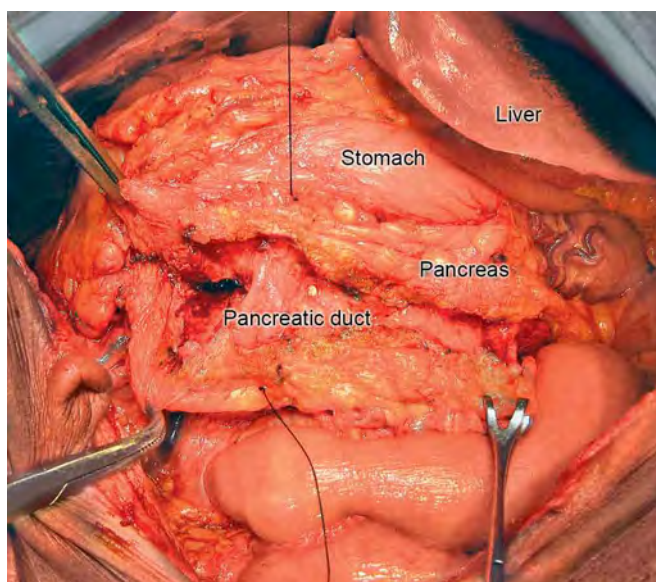


**Fig. 14.25:** *Frey's procedure*. Here head of pancreas is decored and opened duct with decored head is anastomosed to Roux loop of jejunum.

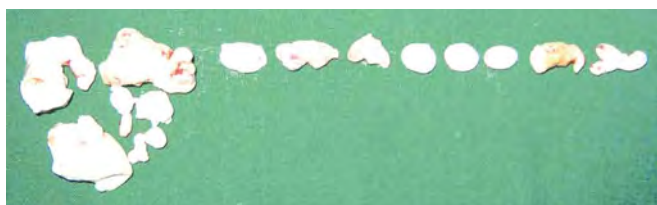


**Fig. 14.26:** Decoring of the head with duct part to resect all diseased tissue; it shows good result. But it is technically demanding; bleeds often profusely.

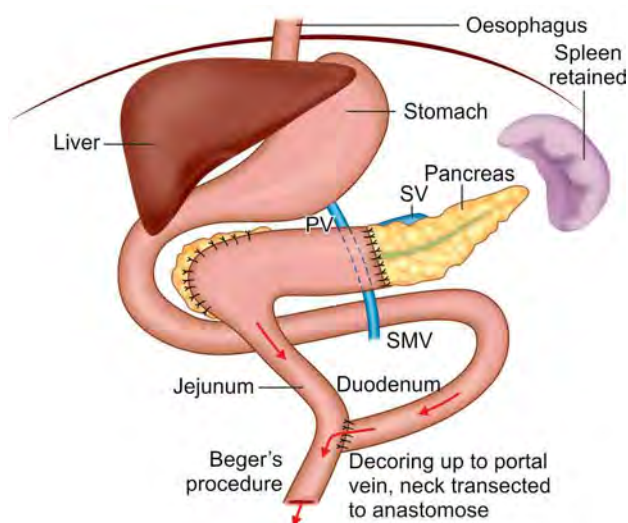
- ◆ Duodenal preserving resection of head of pancreas in front of portal vein with jejunal loop anastomosis to transected neck of pancreas—*Beger procedure*. Here extensive resection of head (than Frey's) is done.
- ◆ *Total pancreatectomy* is indicated when entire gland is diseased. It relieves the pain and also prevents the diseased pancreas from turning into malignancy. Patient has to take insulin and oral pancreatic enzymes permanently (*brittle diabetes*).
- ◆ The cause is treated like cholecystectomy for gallstones.
- ◆ Therapeutic ERCP is useful in removal of stones in dilated duct.
- ◆ If disease mainly involves head of the pancreas, then pancreaticoduodenectomy can be done—*Whipple's procedure*.



**Fig. 14.27:** Dilated pancreatic duct is laid open; multiple stones are removed and duct is ready for longitudinal pancreaticojejunostomy (LPJ).



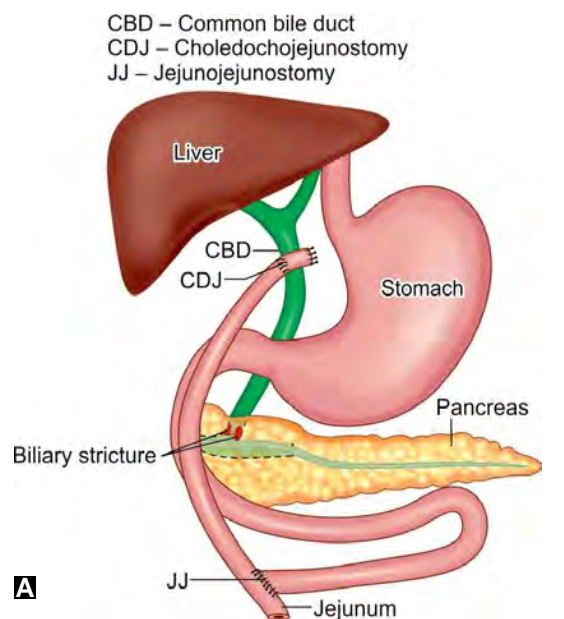
**Fig. 14.28:** Pancreatic duct stones—removed during pancreaticojejunostomy.



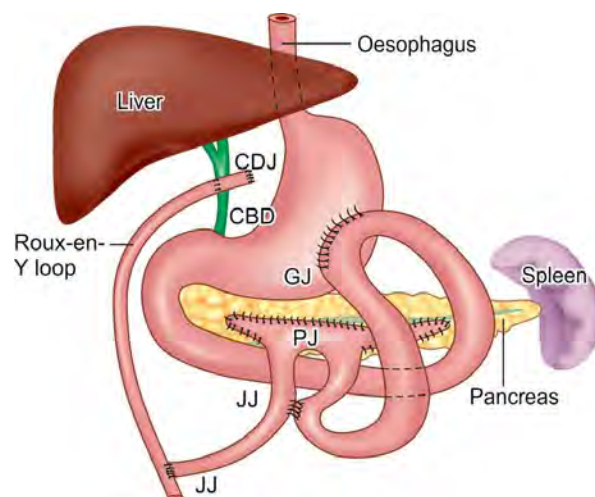
**Fig. 14.29:** *Beger's procedure.* Here head is decored up to the visible portal vein. Neck is transected. Distal end of the pancreas with retained part is anastomosed to Roux loop of jejunum.

- ◆ 95% subtotal pancreatectomy.
- ◆ Distal pancreatectomy—Spleen, body and tail of the pancreas are removed—*Child's operation.*

- ◆ Resection of tail of pancreas with retrograde pancreatico-jejunostomy—*Duval procedure.*



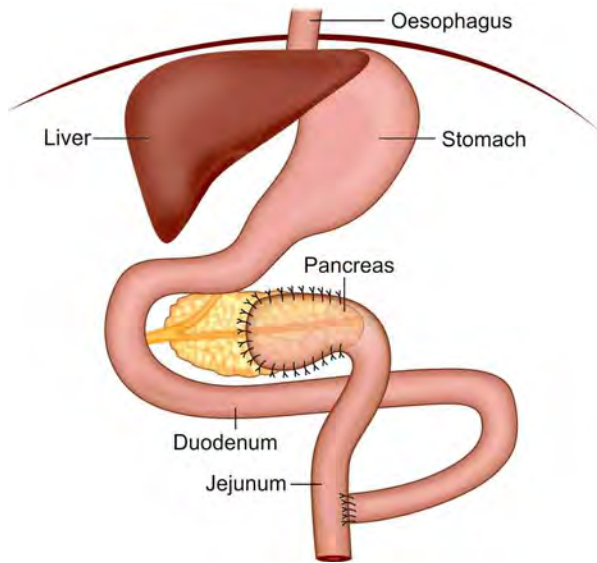
**A**



**B**

**Figs 14.30A and B:** *Choledochojejunostomy.* It is Roux-en-Y anastomosis. It is done whenever there is complication of biliary stricture after pancreatitis. Often triple anastomosis may be required—pancreaticojejunostomy, choledochojejunostomy and gastrojejunostomy. It is done whenever there is duodenal obstruction, biliary block and pancreatic duct dilatation (drainage procedure).

- ◆ When duodenal, biliary and pancreatic obstruction is present—choledochojejunal, pancreaticojejunal and gastrojejunal anastomosis may be needed—*triple anastomosis.* Only biliary stricture which cannot be managed by ERCP needs choledochojejunostomy.



**Fig. 14.31:** Retrograde pancreicojejunostomy after resection of the tail of the pancreas (Duval).

#### Complications of surgery:

- ◆ Pancreatic leak/fistula (10%); infection; bleeding; recurrence; brittle diabetes.
- ◆ *Pain relief* in chronic pancreatitis is achieved by drugs; decompression/drainage surgeries, resection surgeries, epidural analgesia, coeliac ganglion block, operative chemical splanchnicectomy, extra/intra-peritoneal right and left splanchnicectomy, transhiatal bilateral splanchnicectomy, thoracoscopic splanchnicectomy.

#### Post-operative care

- ❖ Nutrition—TPN/jejunostomy feed
- ❖ Fluid and electrolyte management
- ❖ Prevention/control of sepsis
- ❖ Proper monitoring
- ❖ Octreotide on table and postoperatively—regular intervals or slow infusion—5 days

#### Surgery for chronic pancreatitis

##### Drainage

- Technically easier
- Less mortality <2–5%
- Adequate pain relief
- Recurrence of pain in 5 years—50%
- Diseased tissue is left behind
- Disease progression
- Fear of existing occult carcinoma (17%) or later onset

##### Resection

- Technically demanding
- Mortality 8–21%—very high
- Used when carcinoma is suspected or localised disease
- Head is the pacemaker of the disease
- Whipple's is preferred
- Total pancreatectomy causes high mortality, brittle diabetes; though ideal it is not done commonly

## PANCREATIC TUMOURS

### Classification

#### A. Exocrine tumours

*Benign:* Benign cystadenoma. It is rare.

*Malignant:*

1. Adenocarcinoma in ampulla or periampullary region or head of pancreas. Periampullary carcinoma may arise from any of the component—duodenal mucosa or CBD or pancreatic duct component or all. Occasionally squamous cell carcinoma, or combination of adeno squamous can occur.
2. Cystadenocarcinoma of pancreas occurs commonly in body and tail of the pancreas, which usually attains a large size (5%).

#### B. Endocrine tumours

- |                                                         |                                                              |
|---------------------------------------------------------|--------------------------------------------------------------|
| 1. Insulinoma ( $\beta$ cells)                          | Whipple's triad                                              |
| 2. Gastrinoma (G cells)                                 | Peptic ulcer.                                                |
| 3. Glucagonoma ( $\alpha$ cells)                        | Diabetes, necrolytic migratory erythema.                     |
| 4. Vipoma—Pancreatic cholera (Verner-Morrison syndrome) | Watery diarrhoea, hypokalaemia achlorhydria. (WDHA syndrome) |
| 5. Somatostatinoma. (S cells) $\delta$ cells            | Diabetes, steatorrhea, gallstones.                           |

#### C. Lymphomas

## EXOCRINE PANCREATIC TUMOURS

### Exocrine Pancreatic Tumours can be Solid (75%) or Cystic

#### Solid neoplasms

- ◆ *Infiltrating ductal adenocarcinoma* (85%) is common in head (yellowish white mass), neck and ampulla. There is evidence of ductal/glandular differentiation; with intense non-neoplastic desmoplastic stromal reaction; haphazard infiltrative growth pattern; growth along the nerve roots; and lymphovascular invasion. Initial early non-invasive epithelial proliferation is called as *pancreatic intraepithelial neoplasia* (PanIN). Immunohistochemistry shows CA 19-9; mucins (MUC1, 3, 4, 5); CEA; cytokeratins 9, 19. 5 years survival is < 5%. After surgery it may be 20%. *Signet ring, colloid, anaplastic types are variants.*
- ◆ *Acinar cell carcinoma* shows sheets of acinar structures with often metastatic fat necrosis, eosinophilia, polyarthralgia. Presence of zymogen granules; antibodies against trypsin/chymotrypsin and lipase are typical.
- ◆ *Pancreatoblastoma* are malignant tumour seen commonly in children.

#### Cystic neoplasms

- ◆ They mimic closely pseudocyst of pancreas.
- ◆ Cystic fluid analysis will commonly differentiate the problem. Pseudocyst is the fluid of low viscosity, with low levels of CEA, and tumour markers like CA 15/3, CA 72/4 but high levels of amylase with inflammatory cells on cytology. In cystic neoplasms fluid shows high viscosity, high CEA (mucinous) but low amylase and tumour markers with tumour cells on cytology.
- ◆ They are 1% of all pancreatic tumours; 10% of all cystic lesions of pancreas.
- ◆ They can be *mucinous* (commonest) or *serous cystadenoma*; *mucinous ductal ectasia of pancreas* (common in elderly males, common in head, can turn into malignancy); *papillary cystic tumours, tera-*

*tomas*, etc. (Note: cystic islet tumours also cystic neoplasm but are endocrinal nonfunctioning with 30% malignant potential).

#### Types of cystic neoplasms

##### ◆ Mucinous cystic neoplasms:

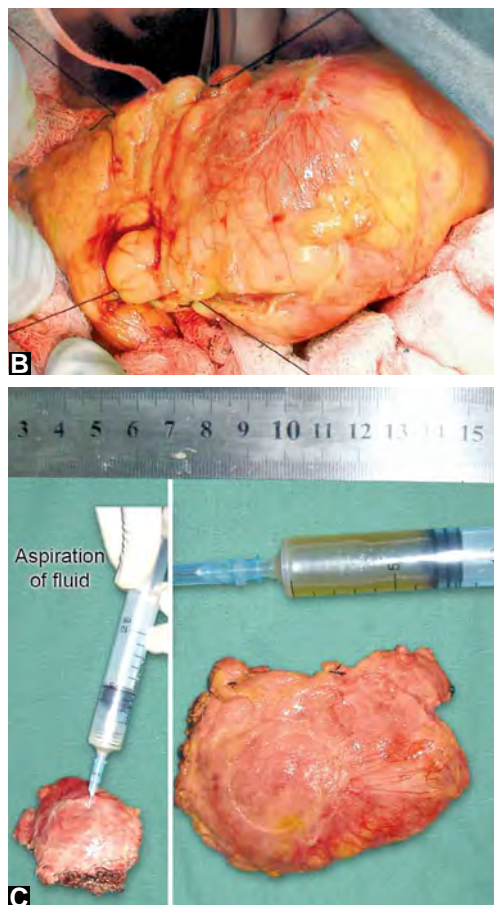
- ▶ They are more common.
- ▶ They are common in females (90%) and often seen in early age group.
- ▶ They are common in *tail and body*. They do not communicate with main pancreatic duct.
- ▶ It can be unilocular or multilocular. Mucous secreting columnar epithelium (mucin rich goblet cells) with dense ovarian like stroma is typical histology. It is not associated with extrapancreatic neoplasm.
- ▶ It can be mucinous cystadenoma; borderline; *in situ*; mucinous cystadenocarcinoma. Mucinous cystadenoma can turn into malignancy. Increased mitosis, atypia, tumour markers like CA 15/3, CA 72/4 will be positive with over expression of EGFR.
- ▶ Mucinous tumours may show high levels of CEA but low levels of amylase.
- ▶ Presentations may be mass abdomen (75%, large epigastric mass, non-mobile, not moving with respiration), abdominal pain, back pain, weight loss.
- ▶ *Investigations*—CT scan; EUS; EUS-guided aspiration for cytology, fluid analysis for CEA (↑), amylase (↓), angiography shows hypervascularity.
- ▶ *Treatment*: Depends on location of tumour either Whipple's operation; distal pancreatectomy; median pancreatectomy.
- ▶ Survival rate for mucinous cystadenocarcinoma is 50%.

##### ◆ Serous cystic neoplasms

- ▶ They are almost always benign and are common in females (2:1).
- ▶ It can be *microcystic adenomas* (90%) or *oligocystic adenomas* (10%).
- ▶ Extrapancreatic neoplasm can be associated (20%) with it.
- ▶ It is more common in *von Hippel-Lindau syndrome*.
- ▶ Abdominal pain, backache, features of pancreatitis (5%), jaundice (10%) and palpable mass in epigastrium (65%) are the presentations.
- ▶ It is common in *head of pancreas*, usually solitary cells which contain only glycogen but *no mucin*.
- ▶ Microcysts of 3–6 mm size within the cyst is common; cyst is lined by cuboidal epithelium.

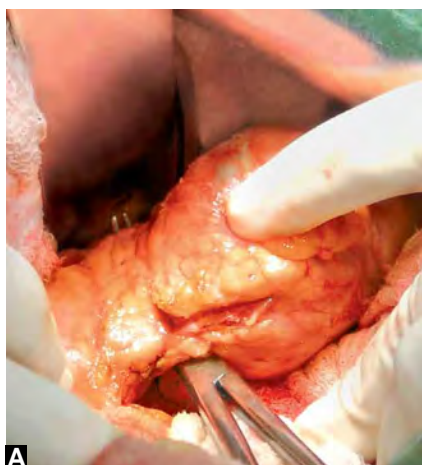

Fig. 14.32A



Figs 14.32B and C

**Figs 14.32A to C:** Mucinous cystadenoma of pancreas. Only cystadenoma is removed and specimen was aspirated for fluid content (Courtesy: Dr Arunkumar, MCh).

- ▶ CT scan shows central calcification with enhancing septae. EUS is very useful investigation.
- ▶ *Treatment*: Central or distal pancreatectomy.

#### Intraductal papillary mucinous neoplasms (IPMN) (Ohashi 1982):

- ◆ It is '*intraductal papillary mucinous* neoplasm with tall, columnar, mucin containing epithelium with or without papillary projections, involving main pancreatic duct and or the branch ducts'.
- ◆ It is common in 7th decade; equal in both sexes.
- ◆ It can be **main duct IPMN** with duct (75% proximal part) dilatation  $\geq 1$  cm containing mucous bulges through ampulla; **branch—duct IPMN** involving side branches of the non-dilated main duct but communicating to main duct mainly involving uncinate process, often head, neck and body, seen as multifocal disease. **Combined IPMN** involving both main duct and branch ducts is also possible.
- ◆ IPMN can be benign; borderline; malignant *histologically*. 70% main duct IPMN and 25% of branch duct IPMN is associated with *malignancy*. *Invasive type* is more common with main duct IPMN. Adenoma—carcinoma sequence is commonly observed.
- ◆ IPMN is also classified as—PAN IN 1 with absence of dysplasia; PAN IN 2 with moderate dysplasia; PAN IN 3 with carcinoma *in situ*.
- ◆ Main duct IPMN presents *with* abdominal pain, features of pancreatitis, steatorrhoea where as branch duct IPMN can be asymptomatic. Jaundice, recent onset/worsening diabetes occur once it is *malignant*.



- ◆ ERCP shows *triad of Ohashi*—a bulging ampulla of Vater, mucin secretion and dilated main pancreatic duct. Dynamic MR is very useful. Endosonography and helical CT are useful. EUS aspiration is also useful.
- ◆ IPMN should be identified first from other cystic diseases of the pancreas; then type should be assessed; later invasiveness should be evaluated.
- ◆ Features of malignant IPMN are—presence of jaundice/steatorrhoea/worsening diabetes/cyst > 3 cm; thick wall cyst; nodules/papillary lesions; main duct > 1 cm; raised CEA (120 ng/ml) in pancreatic juice/cyst fluid.
- ◆ **Treatment:** Main duct IPMN should be resected always. Branch duct IPMN < 3 cm without nodules can be observed carefully. Middle pancreatectomy is done when needed in branch duct IPMN. Multifocal disease needs total pancreatectomy or extended resections to achieve clearance. Nodal spread in malignant IPMN is 45%. Long-term survival is good for noninvasive type.

## CARCINOMA PANCREAS

- ◆ Carcinoma pancreas is higher in men.
- ◆ It is common in African American males.
- ◆ 80% of pancreatic cancers are metastatic at the time of first diagnosis.
- ◆ It is common in Jewish heritage and native Hawaiians.
- ◆ Its incidence is 9 new cases per 100000 people. Mean age is 60–65 years.

### Aetiology

- ◆ Smoking.
- ◆ High energy diet rich in fat.
- ◆ Chronic pancreatitis.
- ◆ Familial pancreatitis.
- ◆ Diabetes mellitus.
- ◆ Carcinogens like benzidine.
- ◆ Hemochromatosis with pancreatic calcification.
- ◆ Cirrhosis, obesity.
- ◆ Occupational exposure to carcinogens like DDT, benzidine.
- ◆ Previous cholecystectomy.
- ◆ 85% show mutant *K ras gene on codon 12*; 60% show mutation of p53 gene in chromosome 17; over expression of EGFR.
- ◆ *Peutz-Jegher syndrome, HNPCC (Hereditary Non-polyposis Colonic Cancer—Lynch II type), ataxia telangiectasia, hereditary breast and ovarian cancers, hereditary atypical multiple mole melanoma syndrome, familial adenomatous polyposis (FAP).*

#### Sites

- ◆ Head and neck region
  - ◆ Ampullary and periampullary region
  - ◆ Body and tail—30%
- } 70%

### Periampullary Carcinoma

It is tumour arising at or near the ampulla.

It could be:

- ◆ Adenocarcinoma from head of pancreas close to the ampulla—50%.
- ◆ Tumour from ampulla of Vater—30%.

- ◆ Distal bile duct carcinoma—10%.
- ◆ Duodenal carcinoma adjacent to ampulla—10%.

### Pathology

#### Gross

- ◆ Grayish white scirrhous nodular gritty tumour in the head is the usual gross look. More than 3 cm sized tumour shows nodal and distant spread commonly. Induration, areas of haemorrhage and necrosis are common.
- ◆ Pancreatic duct may be dilated due to obstruction.
- ◆ Carcinoma head of pancreas present earlier than carcinoma body and tail of pancreas.

#### Microscopy

- ◆ It shows malignant cells with variable degree of differentiation, high mitotic index, severe *desmoplastic reaction* with fibrosis, a *halo* around the tumour due to obstruction of the adjacent ducts caused by the tumour leading into chronic pancreatitis in close proximity.
- ◆ Along with vascular and lymphatic invasion tumour has got high propensity for *perineural spread* and so to neural plexus causing back pain.
- ◆ Colloid (mucinous noncystic), signet cell, squamous, adenosquamous, anaplastic, sarcomatoid are variants of duct cell carcinoma.

### Spread

#### Local Spread

- ◆ To adjacent structures like duodenum, portal vein, superior mesenteric vein, retroperitoneum.
- ◆ Spread is more likely in carcinoma head of pancreas than in periampullary carcinoma.
- ◆ Spread is common once carcinoma head of pancreas becomes more than 3 cm in size.
- ◆ Perineural spread is common.

#### Nodal Spread

- ◆ Usually to perihepatic nodes around the duodenum and CBD, subpyloric, celiac nodes.
- ◆ Hard dark greenish nodes are typical. Often nodal enlargement may be due to just reactive hyperplasia.

#### Distant Spread

- ◆ To liver commonly as multiple secondaries in both lobes.
- ◆ Occasionally to lungs, adrenals, brain, bone, etc.

### Clinical Features

#### Presentations

- Ampullary tumours mainly present with *jaundice and weight loss*.
- Carcinoma of head and neck region present with *weight loss and jaundice*.
- Cystadenocarcinoma* of pancreas present with pain, weight loss and mass.

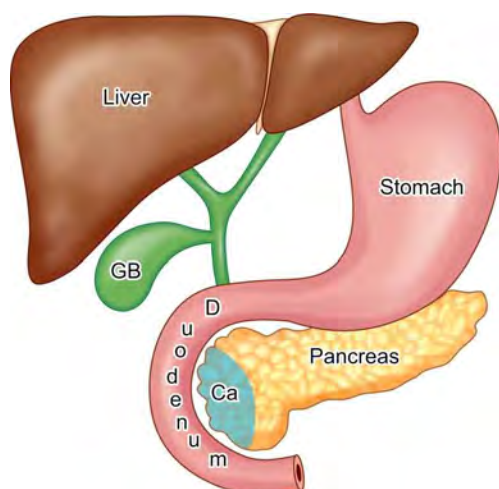


Fig. 14.33: Carcinoma head of the pancreas.

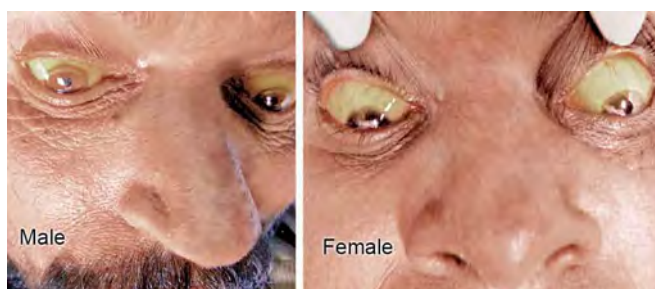


Fig. 14.34: Obstructive jaundice due to periampullary carcinoma in male and female patients.

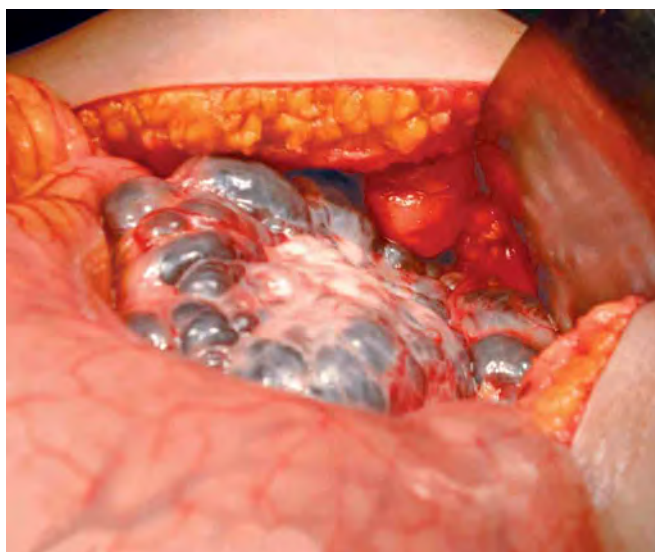


Fig. 14.35: On table finding of cystadenocarcinoma of pancreas.

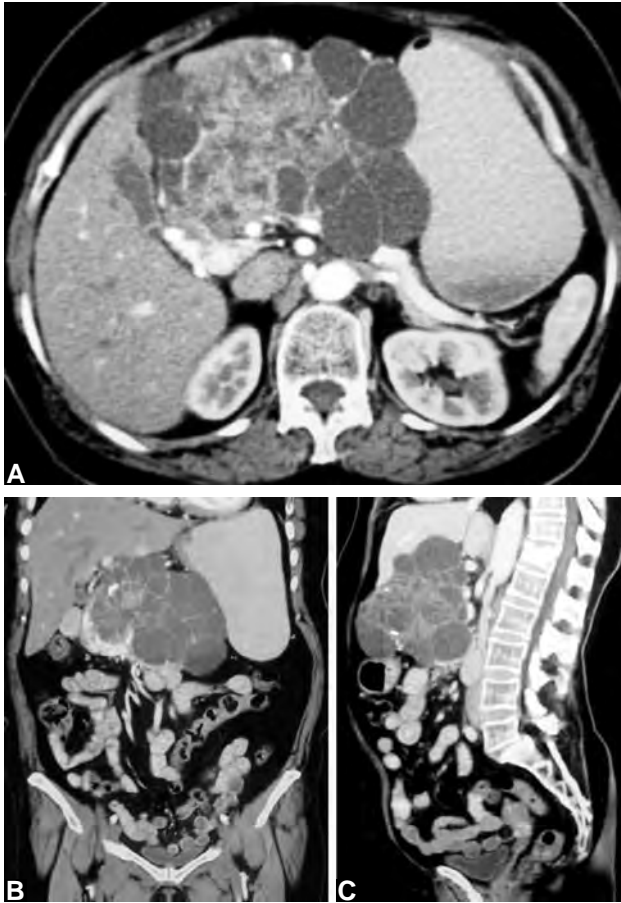### Features

- ♦ *Jaundice is of obstructive nature* which is of short duration, severe, progressive, associated with pruritus (due to deposi-

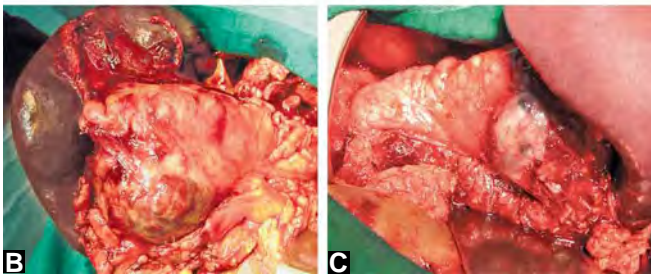
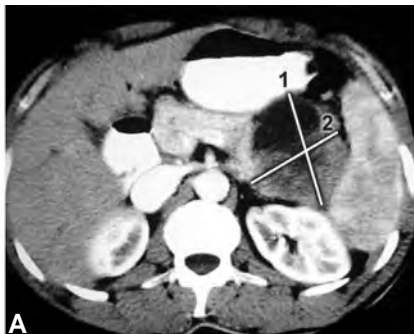- tion of bile salts in the skin which releases histamine). Painless jaundice is seen in ampullary malignancies.
- ♦ In periampullary carcinoma sometimes necrosis of tumour occurs, as a result of which jaundice may reduce temporarily thus being *intermittent*.
- ♦ Pain in the right hypochondrium, epigastrium, or left hypochondrium depending on location of the tumour.
- ♦ Back pain, when present, is due to involvement of retropancreatic nerves, or pancreatic duct obstruction or stasis, disruption of nerve sheath by tumour. Pain is more at night, after food and on recumbency; it is relieved by leaning forward.
- ♦ Diarrhoea, steatorrhoea, acholic stools, tea coloured urine.
- ♦ Silvery stool (due to mixing of undigested fat with metabolised blood derived from the ooze of periampullary growth).
- ♦ Loss of appetite and weight.
- ♦ Scratch marks on the back.
- ♦ *Migratory superficial thrombophlebitis—Trousseau's sign* (10%) is due to release of platelet aggregating factors from the tumour or its necrotic material (Trousseau himself died of carcinoma pancreas, also had migrating thrombophlebitis).
- ♦ Ascites.
- ♦ Left supraclavicular palpable lymph node.
- ♦ Secondaries in rectovesical pouch (Blumer's shelf).
- ♦ Gallbladder may be palpable which is nontender, soft, globular, smooth, moving with respiration, mobile horizontally, dull on percussion (30% in carcinoma head of pancreas; 50% in periampullary carcinoma). *Courvoisier law* favours gallbladder enlargement.
- ♦ Liver is enlarged, smooth, firm, non-tender, due to dilated bile filled biliary radicles—*Hydrohepatosis*. Liver can show multiple hard nodules due to secondaries (70%).
- ♦ Cystadenocarcinoma of pancreas can present with mass in epigastric region, which is non-mobile, not moving with respiration, smooth, soft, non-tender.
- ♦ Splenic vein thrombosis with splenomegaly (10%) can occur.

### Cystadenocarcinoma of the pancreas

- ❖ Common in body and tail of the pancreas
- ❖ Epigastric pain which is radiating to back is common
- ❖ Mass in epigastrium which is non-mobile, smooth, soft/hard but not moving with respiration. It is resonant, does not fall forward
- ❖ Jaundice is not observed
- ❖ May mimic pseudocyst of pancreas or retroperitoneal tumours
- ❖ 1% of pancreatic malignant tumours
- ❖ Papillary cystadenocarcinoma is common
- ❖ Mucinous cystic tumours show high levels of CEA
- ❖ CT scan is diagnostic
- ❖ Distal pancreatectomy is the procedure of choice. In large tumours total pancreatectomy is required
- ❖ It has got better prognosis



**Figs 14.36A to C:** CT scan pictures of cystadenocarcinoma of pancreas.



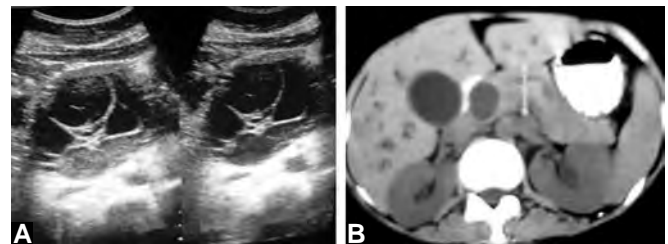
**Figs 14.37A to C:** Mucinous cystadenocarcinoma of distal body and tail of pancreas—CT picture and on table look. Distal pancreatectomy was done (Courtesy: Dr Arunkumar, MCh).

### Differential diagnosis

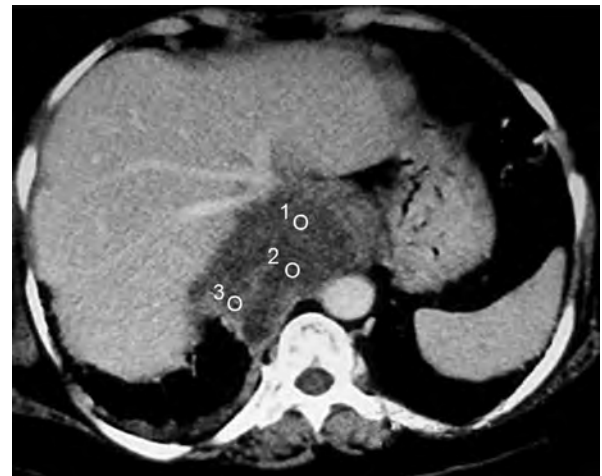- ❖ Retroperitoneal mass/tumour/lymph nodes
- ❖ Advanced adherent carcinoma of stomach
- ❖ Advanced carcinoma of transverse colon
- ❖ CBD stone
- ❖ Bile duct stricture
- ❖ Lymph node compressing CBD
- ❖ Cholangiocarcinoma of CBD
- ❖ Chronic pancreatitis

### Investigations

- ◆ *Liver function tests:* Serum bilirubin, direct component (conjugated) is increased (van den Bergh's test). Serum albumin is decreased with altered A : G ratio. Prothrombin time is widened. Serum alkaline phosphatase is increased.
- ◆ US abdomen to see gallbladder, liver, growth, CBD size (normal diameter is < 10 mm), lymph node status, portal vein, ascites.



**Figs 14.38A and B:** (A) Ultrasound showing mass lesion in the pancreas, (B) CT picture of carcinoma pancreas showing dilated CBD due to obstruction.



**Fig. 14.39:** CT scan abdomen showing features of carcinoma of pancreas.

- ◆ *Spiral CT scan (ideal)* shows portal vein infiltration, retroperitoneal lymph nodes, size of the tumour.
- ◆ *Endoscopy* is helpful in periampullary carcinoma to visualize and take biopsy. ERCP though not routinely done in operable cases as

## Differences between presenting features of carcinoma of head of pancreas and periampullary carcinoma of pancreas

	<b>Carcinoma of head of pancreas</b>	<b>Periampullary carcinoma</b>
1. Pain and weight loss	Early features	Late features
2. Jaundice	Persistent and progressive	Intermittent
3. Occult blood in stool	Absent	Present; stools are silvery
4. Endoscopic examination	Growth not visible	Growth visible
5. Prognosis	Not good	Good

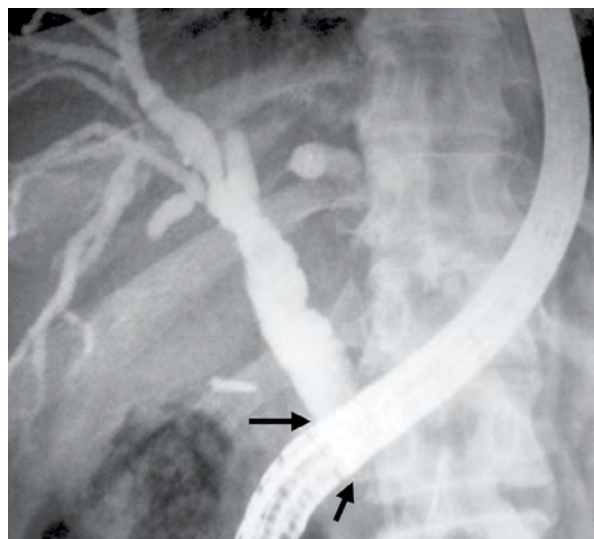


Fig. 14.40: ERCP showing growth in the distal CBD.

it may contaminate the biliary tree leading into difficult dissection and post-operative sepsis, often useful in taking brush biopsy and pancreatic fluid cytology; severe cholangitis associated with malignancy even though rare but is life-threatening and needs decompression by ERCP stenting as an emergency procedure. In inoperable cases, ERCP stenting is done (with biopsy for tissue diagnosis) to relieve biliary obstruction.

- ◆ Barium meal shows widened duodenal “C” loop—*pad sign*. *Reverse 3 sign* is seen in carcinoma—periampullary region.
- ◆ CA 19-9 (carbohydrate antigen) is a useful tumour marker. More than 37 units/ml is significant with 85% sensitivity and specificity. CA 494 is useful to differentiate it from chronic pancreatitis. CEA is also often done in suspected cystadenocarcinoma.
- ◆ *Coeliac* and superior mesenteric angiogram can be done to reveal tumour circulation and invasion.
- ◆ Gastroduodenoscopy reveals ampullary tumour and biopsy can also be taken.
- ◆ *Endosonography* is useful to see the invasion and size, to stage and to do EUS-guided FNAC.
- ◆ Urine for bile salts (*Hay’s test*), bile pigments (*Fouchet’s test*), urobilinogen.
- ◆ *Role of biopsy*:
  - ▶ Trucut biopsy and other biopsies are not advisable as it may cause bleeding, infection, leak and negative biopsy will not rule out malignancy. Biopsy is not done in potentially resectable tumour; it is probably useful in inoperable cases

to start palliative therapy (chemotherapy). Transduodenal/transgastric or EUS-guided trucut biopsy may be useful in such situation.

- ◆ Laparoscopy to assess. Laparoscopy and laparoscopic US is useful for staging and to identify peritoneal deposits which prevents unnecessary laparotomy. Palliative laparoscopic bypass like cholechojejunostomy can also be done.
- ◆ CT angiogram to see the vascularity. It also provides idea about resectability of the tumour in 70% cases.
- ◆ *PTC is useful* if ERCP fails to detect and assess the site of lesion proximally; to decompress the obstructed biliary system through a fine catheter left *in situ* or to place an endobiliary prosthesis across the obstruction.

## Resection status

- R0 – No residual tumour found after resection
- R1 – Microscopic residual tumour after resection
- R2 – Macroscopic residual tumour after resection

<b>TNM staging of carcinoma pancreas</b>	<b>Staging</b>
<b>Tumour—T</b>	0 – Tis N0 M0
Tx – Primary cannot be assessed	IA – T1 N0 M0
T0 – No evidence of tumour	IB – T2 N0 M0
Tis – Carcinoma in situ	IIA – T3 No Mo
T1 – Growth limited to pancreas < 2 cm	IIB – T1,2,3 N1 M0
T2 – Growth limited to pancreas > 2 cm	III – T4 Any N M0
T3 – Extension to duodenum or bile duct	IV – Any T Any N M1
T4 – Extension to portal vein, SMV, SMA, stomach, spleen, colon, celiac axis	
<b>Nodes—N</b>	
Nx – Regional nodes cannot be assessed	
N1 – No nodal spread	
N2 – Nodal spread present	
<b>Metastases—M</b>	
Mx – Distant spread cannot be assessed	
M0 – No distant spread	
M1 – Distant spread present	

To overcome rigidity of abdomen in refractory cases, with the base of the left hand pressing upon the lower part of the sternum, thoracic respiration is impeded and the abdominal muscles relax. —Neville J Nicholson

ERCP signs	Important investigations
<ul style="list-style-type: none"> <li>• Abrupt block of pancreatic duct with irregular stricture</li> <li>• Pancreatic duct encasement</li> <li>• <i>Double duct sign</i>—cut off of both pancreatic and bile duct</li> <li>• Parenchymal filling</li> <li>• Scrambled egg appearance</li> </ul>	<ul style="list-style-type: none"> <li>• Spiral CT/3D CT is ideal—to detect operability, portal vein invasion, size, extent, pancreatic and biliary tree and nodal status</li> <li>• ERCP to take biopsy/brush cytology, stenting, to see the luminal extent of the tumour</li> <li>• MRCP is non-invasive—entire biliary tree is visualised properly</li> <li>• Endosonography (EUS)—to assess size of primary properly; to take endosonographic FNAC</li> <li>• PTC often with PBD if ERCP fails</li> </ul>
Barium meal X-ray	Investigations to stage the disease
<ul style="list-style-type: none"> <li>• Is rarely done in periampullary carcinoma</li> <li>• <i>Rose thorn</i> appearance in hypotonic duodenography</li> <li>• <i>Reverse 3 sign</i> in periampullary carcinoma</li> <li>• <i>Pad sign</i>—widened C loop of duodenum in carcinoma head of pancreas</li> <li>• Features of Gastric outlet obstruction</li> </ul>	<ul style="list-style-type: none"> <li>• 3D/spiral CT scan</li> <li>• EUS</li> <li>• Laparoscopy</li> <li>• ERCP</li> </ul>

### Pre-operative Preparation in Carcinoma Pancreas

- ◆ *Adequate hydration* is important in prevention of dehydration post-operatively. Dehydration is common in obstructive jaundice.
- ◆ *Glycogen reserve in liver* will be inadequate which should be replenished by giving pre-operative glucose orally or intravenously.
- ◆ *Patient is prone to develop hepatorenal syndrome* post-operatively, leading into renal failure due to sludging of the bile salts, due to toxins and sepsis; and so mannitol should be given intravenously for 3 days prior to surgery to flush the kidney (200 ml IV twice a day).
- ◆ *Injection vitamin K* 10 mg IM for 5 days.
- ◆ *ERCP stenting is done only* if serum bilirubin is >30 mg%, severe cholangitis or severe albumin deficit or in inoperable cases to relieve obstruction. Routine ERCP is not advisable as it may contaminate biliary system. Percutaneous transbiliary drainage (PTBD) or cholecystostomy are other options. Whipple's operation or resections are done 3 weeks later.
- ◆ Antibiotics one day prior to surgery—cephalosporins/aminoglycosides.
- ◆ Often TPN may be required preoperatively which is also continued postoperatively.
- ◆ Pulmonary function study and respiratory physiotherapy to have adequate post-operative pulmonary function.

#### Note:

- In obstructive jaundice, serum bilirubin level will not go beyond 40 mg%. At this point raised intrabiliary pressure (Normal is 12–22 cm of H<sub>2</sub>O) to 25 cm of H<sub>2</sub>O, blocks the formation of bilirubin and secretion of cholesterol and bile acids completely. Maximum production of bilirubin per day possible is 250 mg%. Normal maximum excretion of bilirubin by kidney per day is 210 mg%. So maximum possible raise of serum bilirubin is 40 mg% in obstructive jaundice.
- Cholangitis in malignant obstruction is rare; but when it occurs it is rather severe form.
- Pre-operative albumin therapy is usually *not done*.

### Treatment

Only 10–15% of pancreatic carcinomas (head) are operable. 40–50% are locally advanced. Another 40–50% will have distant spread to liver or lungs.

#### Criteria for resection

- ❖ Tumour size less than 3 cm
- ❖ Periampullary tumours
- ❖ Growth not adherent to portal system

### In operable cases:

- ◆ *Whipple's operation* is done by removing tumour with head and neck of pancreas, C loop of duodenum, 40% distal stomach, 10 cm proximal jejunum, lower end of the common bile duct, gallbladder, peripancreatic, pericholedochal, paraduodenal and perihepatic nodes. Continuity is maintained by choledochojejunostomy, pancreaticojejunostomy and gastrojejunostomy. Few advocate pancreaticogastrostomy into posterior wall of the stomach. Mortality in Whipple's operation is 2–8%. Original Whipple's operation (1935) was two staged procedure—initial bypass and a second stage resection with closure of pancreatic stump. In 1941, Trimble performed one stage pancreaticojejunostomy. *Complications* are delayed gastric emptying (19%); pancreatic fistula (14%); infection (intra-abdominal abscess, wound infection, cholangitis, pancreatitis, pneumonia); bile leak. Mortality is 3%.
- ◆ *Traverso-Longmire pylorus preserving pancreatico-duodenectomy* (1978): Here duodenum is cut 2 cm distal to the pylorus and continuity is maintained by anastomosing with jejunum.
- ◆ *Fortner's regional pancreatectomy* (extended Whipple's) includes resection like Whipple's along with removal of segment of superior mesenteric vein and clearance of all regional nodes; and portal vein continuity is maintained by a synthetic vascular graft. Even though technically it gives adequate clearance, results are only equivocal.

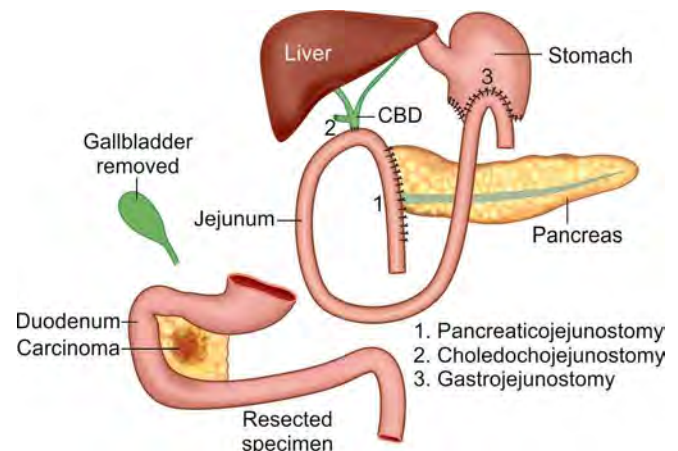
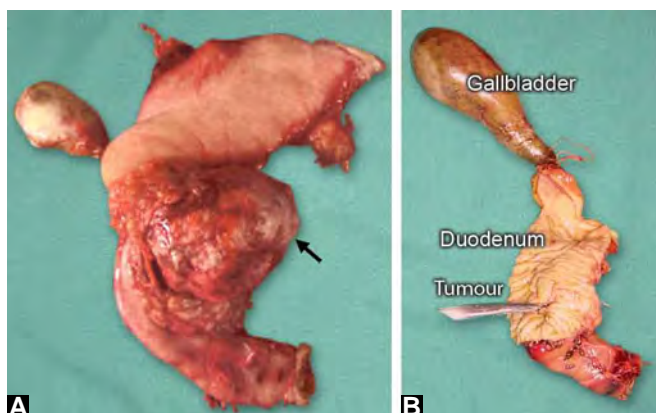
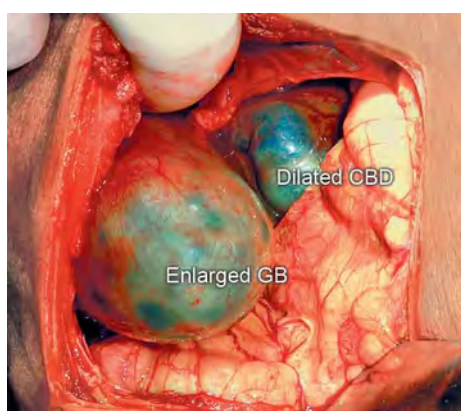


Fig. 14.41: Whipple's operation.

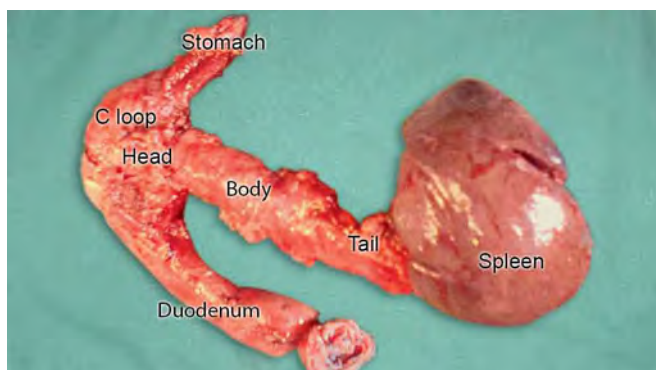

**Figs 14.42A and B:** (A) Specimen of pancreaticoduodenectomy with tumour in the head of pancreas; (B) Resected specimen (after Whipple's operation) of periampullary carcinoma of pancreas.



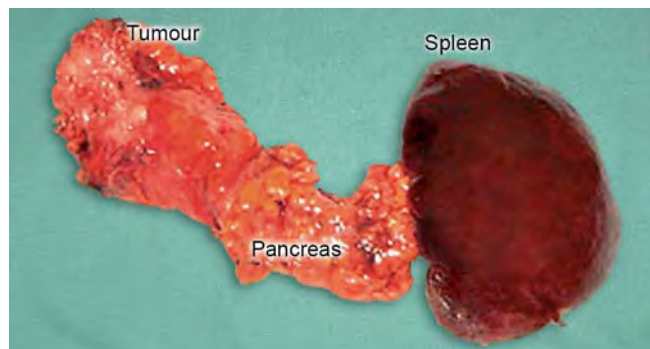**Fig. 14.43:** On table finding in periampullary tumour showing dilated gallbladder and CBD.

- ◆ *Total pancreatectomy is presently said to be better.* It is done along with nodal clearance. Reasons are—possibility of multicentric nature of the disease, higher chance of recurrence after Whipple's operation, malignant cells may be present in pancreatic duct, morbidity by pancreatic fistula or pancreatitis after Whipple's operation is not seen here. Mortality in total pancreatectomy is higher 10–20%. Severe, resistant brittle diabetes mellitus may be seen after total pancreatectomy.



**Fig. 14.44:** Specimen of total pancreatectomy with C loop, head, body and tail of pancreas with spleen. Total pancreatectomy is done in refractory severe chronic pancreatitis and carcinoma pancreas.

- ◆ *Distal pancreatectomy or central pancreatectomy or total pancreatectomy for cystadenocarcinoma of pancreas depending on the extent and size of the tumour.*

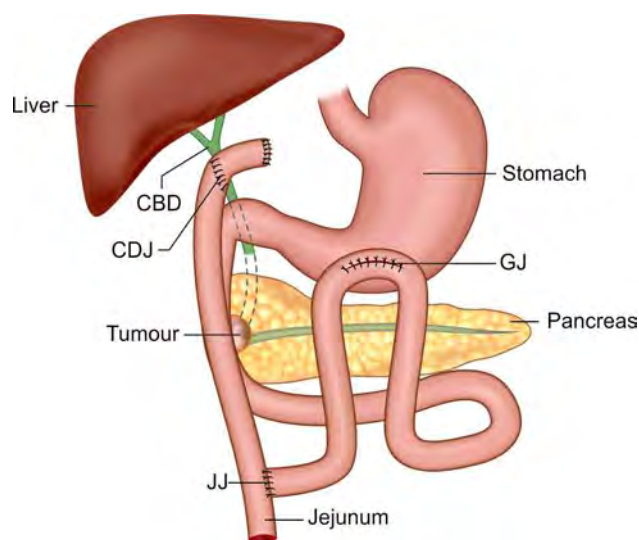


**Fig. 14.45:** Photo showing specimen of distal pancreatectomy.

### In inoperable cases:

Here mainly to *palliate* obstructive jaundice, duodenal obstruction and pain.

- ◆ *Roux-en-Y choledochojejunostomy is ideal palliative procedure* along with gastrojejunostomy after doing cholecystectomy. Choledochojejunostomy is better than cholecystojejunostomy as CCJ may get blocked either by tumour infiltration or by bile sludge or by inflammation. 30% of periampullary carcinoma/carcinoma of head of pancreas eventually develop gastric (duodenal) outlet obstruction and so gastrojejunostomy is undertaken.
- ◆ *ERCP and stenting is done to drain bile.* Problems here are recurrent cholangitis, stent blockage and displacement, requirement of repeated stenting procedure. Duodenal stenting for duodenal obstruction is tried.
- ◆ Chemotherapy; neoadjuvant chemotherapy.
- ◆ Steatorrhea is treated by enzymes. Control of diabetes is important.



**Fig. 14.46:** Choledochojejunostomy (CDJ) with gastrojejunostomy (GJ) and jejunojunction (JJ). It is a Roux-en-Y anastomosis. CDJ should be 70 cm from the JJ.

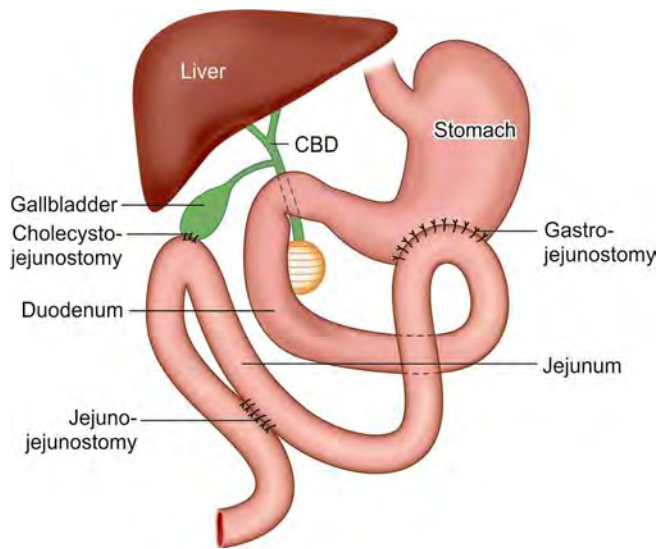


Fig. 14.47: Cholecystojejunostomy—is not a preferred method.

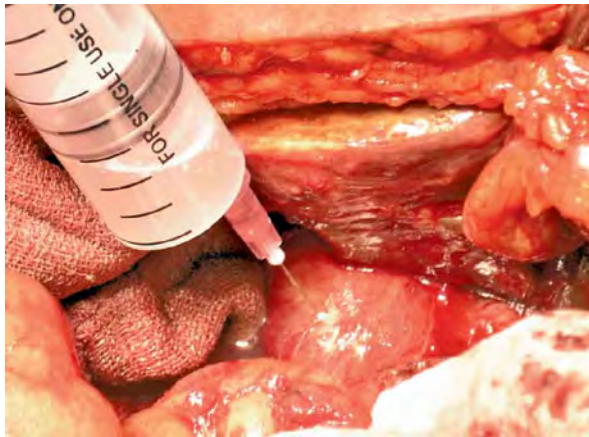

Fig. 14.48: White bile. It is neither white nor bile. It is opalescent; and is mucous. It suggests complete obstruction. It is usually observed in carcinoma pancreas. It is peroperative finding.

### Adjuvant Therapy

- ◆ Adjuvant chemotherapy using gemcitabine—better but costly; dose is 1000 mg/m<sup>2</sup> surface area; 5-fluorouracil; mitomycin; vincristine, cisplatin, docetaxel, oxaliplatin are used along with gemcitabine.
- ◆ Radioactive iodine seeds I<sup>125</sup> to the field are on trial. External radiotherapy 4000 cGy units to relieve pain and to reduce the tumour size.
- ◆ *Immunotherapy*—specific type to increase the effectiveness of chemotherapy and to improve the cure rate (allogeneic tumour cell vaccine).

### Neoadjuvant Chemoradiotherapy

Only 20% of pancreatic carcinomas are amenable for surgical resection. Even in these patients in spite of resection, overall outcome is poor. So neoadjuvant chemoradiotherapy is becoming popular [(50 Gy dose of *radiotherapy* for 5–6 weeks (25–30 fractions) with *infusion chemotherapy*, then *surgical resection*)] and under trial to improve the resecta-

bility and survival. It increases the R0 resection status and reduces the node positive rate. There is less chance of tumour hypoxia (which is more after surgery) by which increases the susceptibility of tumour to chemoradiotherapy; less chance of mucosal anastomotic toxicity. It reduces the tumour burden at surgery; decreases the local or regional recurrence; decreases the chances of pancreatic fistula. *But* there is no survival benefit.

### Post-operative Management in Carcinoma Pancreas

- ◆ Maintenance of proper fluid and electrolyte balance.
- ◆ Observation for bleeding and its control by transfusion of blood, fresh frozen plasma (FFP), and prevention of DIC at initial period.
- ◆ Injection vitamin K 10 mg IM for 5 days.
- ◆ Respiratory care—ideally post-operative ICU care is better. Often ventilator is needed for 24 hours.
- ◆ Maintaining adequate urine output—mannitol should be continued.
- ◆ Injection octreotide infusion for 5 days to suppress pancreatic secretion so as to prevent leak.
- ◆ Antibiotics, nasogastric aspiration.
- ◆ Continuous monitoring the patient with pulse/blood pressure/oxygen saturation/hourly urine output/inspection of drain site/abdomen distension/by doing HB%, LFT, serum creatinine, bilirubin, arterial blood gas analysis if needed, platelet count, prothrombin time.

### Pain Control in Carcinoma Pancreas

- ◆ CT-guided 50% of 20 ml ethanol injection into coeliac ganglion.
- ◆ Epidural anaesthesia.
- ◆ Opioids administration.
- ◆ Transthoracic splanchnicectomy—greater splanchnic nerve.
- ◆ Palliative radiotherapy—4000 cGy units.

#### Prognostic factors in carcinoma pancreas—poor prognosis

- ❖ Mean survival rate 6–9 months
- ❖ Growth more than 3 cm
- ❖ Nodal involvement
- ❖ Resection status—R0/R1/R2
- ❖ Portal vein infiltration
- ❖ Liver/lung secondaries
- ❖ Ascites/Trousseau's sign/left supraclavicular lymph nodal spread
- ❖ *White bile* on table carries poor prognosis
- ❖ Associated problems like pancreatitis, diabetes mellitus
- ❖ Liver dysfunction

### ENDOCRINE PANCREATIC TUMOURS

- ◆ Most common is insulinoma. Others are gastrinoma, glucagonoma, vipoma, pancreatic polypeptidoma.
- ◆ They belong to group of tumours called “APUDOMAS”.
- ◆ Endocrine tumours are associated with MEN syndrome (Type I Werner's syndrome).
- ◆ They are associated with:
  - ▶ Parathyroid adenoma.
  - ▶ Pituitary adenoma.
  - ▶ Peptic ulcer.
- ◆ They are usually multiple, small, 35–50% are malignant and presents with features of endocrine lesion. Commonly occurs in body and tail (except gastrinomas).

- ◆ Requires special method to identify.
- ◆ MRI, angiogram, hormone assay are the diagnostic methods required.
- ◆ Normal islet cells are < 2% of pancreatic mass. They contain  $\alpha$ ,  $\beta$ ,  $\delta$ , G, D2 and PP cells (pancreatic polypeptide).
- ◆ Incidence is 5 per 100000 per year.
- ◆ 20% are non-functional.
- ◆ Insulinomas are commonly benign; glucagonomas are almost always malignant.

## INSULINOMAS

- ◆ Insulinomas are *commonest endocrine pancreatic tumour* (60%) arising from B cells ( $\beta$  cells) of pancreas.
- ◆ They are commonly solitary but 10% can be multicentric and secrete insulin in excess causing profound hypoglycaemic features.
- ◆ Equal in both sexes.
- ◆ 90% of insulinomas are <2 cm in size.
- ◆ 15% are malignant. 85% are benign.

## Clinical Features

- ◆ Abdominal discomfort, trembling, sweating, hunger, dizziness, diplopia, hallucinations. Later epilepsy and unconsciousness. They are usually over weight.
- ◆ Weight gain is common due to overeating.
- ◆ Permanent neurological deficits can occur with behavioural changes.

### Whipple's triad

- ❖ An attack of hypoglycaemia in fasting state
- ❖ Blood sugar below 45 mg% during the attack
- ❖ Symptoms relieved by glucose

## Diagnosis

- ◆ Insulin radioimmunoassay. An insulin level >7  $\mu$ U/ml; insulin/glucose ratio >0.3 signifies insulinoma. Proinsulin level more than 24% of total insulin signifies insulinoma. Proinsulin level more than 40% of total insulin signifies malignant insulinoma. C peptide level >1.2  $\mu$ g/ml with glucose level <40 mg% suggests insulinoma.
- ◆ MRI to localize the tumour.
- ◆ Angiogram (coeliac).
- ◆ Endosonography.
- ◆ On table US.
- ◆ Blood sugar estimation.
- ◆ Insulin provocation test using calcium gluconate or tolbutamide.

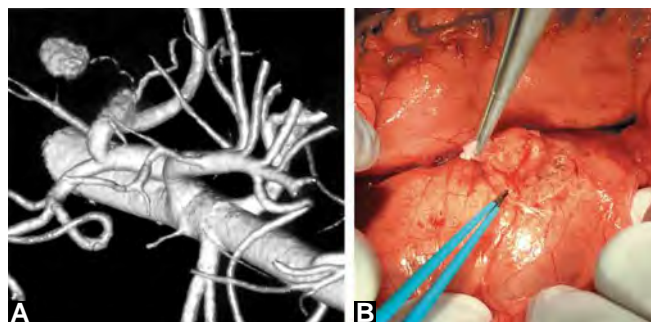
### Radioimmunoassay in insulinoma

- ❖ Increase in insulin levels of plasma
- ❖ Increased ratio of proinsulin to insulin >20%
- ❖ Increased circulating C-peptide
- ❖ Plasma insulin to glucose ratio >0.3 is diagnostic

## Differential Diagnosis

- ◆ Nesidioblastosis.
- ◆ Non-insulinoma pancreatogenous hypoglycaemia.

## Treatment



**Figs 14.49A and B:** Insulinoma imaging picture and on table look (Courtesy: Dr Arunkumar, MCh).

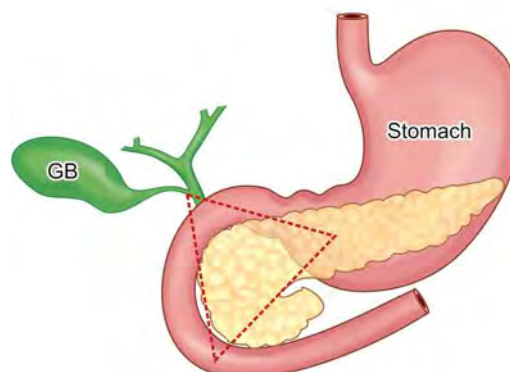
### Treatment of insulinoma

- ❖ Enucleation commonly, often distal pancreatectomy
- ❖ Diazoxide, beta blockers, phenytoin, verapamil, steroids, growth hormone to control hypoglycaemia
- ❖ Octreotide decreases the insulin secretion
- ❖ Calcium channel blockers
- ❖ Streptozotocin whenever secondaries are present in liver or elsewhere

- ◆ Enucleation of all tumours.
- ◆ Often distal pancreatectomy is required (spleen; tail and body of the pancreas are removed) 90% are curable.

## GASTRINOMAS

- ◆ They arise from non-beta cells (G cells) of the pancreas, which secretes high levels of gastrin.
- ◆ It is *2nd most common endocrine pancreatic tumour*.
- ◆ It is the commonest endocrine pancreatic tumour seen in MEN I syndrome. In MEN II syndrome lesion is often seen in duodenum (30%).
- ◆ It is common in males.
- ◆ Common in gastrinoma triangle (*Passaros triangle*).



**Fig. 14.50:** Passaros triangle.

*If you tell the truth you do not have to remember anything—Mark Twain.*



**Three points forming Passaros triangle**

1. Junction between the head and neck of the pancreas
2. Junction of cystic duct with CBD
3. Junction between the 2nd and 3rd parts of the duodenum

- ◆ Half of them are multiple and malignant (50%).
- ◆ It causes severe, multiple peptic ulcers in the stomach, duodenum and jejunum.
- ◆ It is due to hypergastrinaemia causing high levels of acid secretion.
- ◆ Other features are diarrhoea, steatorrhoea, hypokalaemia.
- ◆ It causes ZES type II.
- ◆ When malignant commonly present with secondaries in liver (80%)/lymph nodes/lungs or bones.

**Salient features of ulcers in gastrinomas**

- ❖ Multiple ulcer
- ❖ Resistant ulcer/refractory ulcer
- ❖ Jejunal ulcer
- ❖ Recurrent ulcer
- ❖ Ulcer which is more prone for bleeding and perforation

**Investigations**

- ◆ Gastrin assay (normal level <200 pg/ml).
- ◆ Gastroscopy.
- ◆ US, Endosonography.
- ◆ MRI (more sensitive) or CT scan to detect the site of the tumour.
- ◆ Angiogram.
- ◆ Increased gastrin level by calcium (injection IV) provocation test.
- ◆ Pentagastrin test (both shows very high basal and peak levels).
- ◆ Secretin provocation test.
- ◆ Somatostatin receptor scintigraphy (SRS) with radiolabeled octreotide is used to locate the site of tumour.

**Note:**

Normal level of gastrin is 100–150 pg/ml. It is more than 200 pg/ml in gastrinoma patients. It usually reaches upto or greater than 1000 pg/ml in gastrinoma. Other causes of hypergastrinaemia like G cell hyperplasia, incomplete antrectomy, low gastric acid level, achlorhydria, pernicious anaemia, acid controlling drugs like H<sub>2</sub> receptor block or proton pump inhibitors and atrophic gastritis should be ruled out. Basal acid output in gastrinoma is > 15 mEq/hour which is specific of gastrinoma (ZES II). Gastric pH more than 3 rules out gastrinoma. *Secretin stimulation test* by injecting 2 units/kg secretin IV and assessing blood samples before and every 5 minutes after injection of secretin for 30 minutes will show rise in gastrin level more than 50% of baseline.

**Treatment**

- 60% are curable.
- ◆ Enucleation of tumours.
  - ◆ Distal pancreatectomy.
  - ◆ Pancreaticoduodenectomy.
  - ◆ Subtotal pancreatectomy.
  - ◆ Often total gastrectomy may be required.

**Remember**

- ❖ Gastrinomas are often associated with MEN syndrome and are multiple
- ❖ Sporadic gastrinomas are often solitary and then are malignant
- ❖ Gastrinoma often secretes ACTH
- ❖ Most common malignant endocrine pancreatic tumour is gastrinoma
- ❖ Gastrinoma causes ulcer of unusual nature (refractory/resistant); unusual recurrence (repeated and multiple); unusual number (multiple); unusual sites (2nd/3rd part duodenum/jejunum); unusual age (young and aged)

**Triad of somatostatinoma**

- ❖ Diabetes mellitus
- ❖ Steatorrhoea
- ❖ Cholecystolithiasis

**GLUCAGONOMAS**

- ◆ Arise from  $\alpha$  cells of pancreas.
- ◆ Common in body and tail of pancreas.
- ◆ It is common in females.
- ◆ It attains large size of 5–10 cm.
- ◆ It is commonly sporadic. 17% associated with MEN type II syndrome.
- ◆ It is commonly malignant (80%). 80% spreads to liver.

**Clinical Features**

- ◆ Necrolytic migratory erythema (65%).
- ◆ Diabetes (90%).
- ◆ Diarrhoea and weight loss.
- ◆ Stomatitis.
- ◆ Anaemia and features of amino acid deficiency.
- ◆ Vulvovaginitis is common.

**Investigations**

- ❖ MRI, CT scan.
- ❖ Endosonography.
- ❖ Angiogram.
- ❖ Increased serum glucagon level. Fasting glucagon level more than 50 p mol/litre is diagnostic.

**Treatment**

- ◆ Correction of anaemia, protein and amino acid deficiency by enteral/parenteral nutrition.
- ◆ Intravenous amino acid infusion to control necrolytic dermatitis.
- ◆ Prevention of DVT.
- ◆ Distal pancreatectomy.
- ◆ Occasionally Whipple's/total pancreatectomy is needed.
- ◆ Enucleation is rarely sufficient for glucagonoma.
- ◆ Dacarbazine is specifically effective in glucagonoma.

**Vipoma**

- ❖ Arising from D2 cells of pancreas
- ❖ Watery diarrhoea, hypokalaemia, achlorhydria (WDHA syndrome)
- ❖ Also called as *pancreatic cholera or Verner- Morrison syndrome, weak—tea syndrome*
- ❖ Usually malignant
- ❖ Secretes vasointestinal polypeptide >150 pg/ml
- ❖ Common in body and tail—solitary
- ❖ Distal pancreatectomy is the treatment of choice
- ❖ Prednisolone controls the diarrhoea
- ❖ Octreotide is useful

## ZOLLINGER-ELLISON SYNDROME

*Type I:* “G” cell hyperplasia with hypergastrinaemia and chronic peptic ulceration.

*Treatment* is partial gastrectomy with removal of “G” cell area.

*TYPE II:* Gastrinomas (see above).

### Note:

- Somatostatinoma arises from  $\delta$  cells of pancreas. It is exceedingly rare. Usually larger than 2 cm and single. It is common in head of pancreas and duodenum. Its association with MEN II syndrome is rare. It is often associated with neurofibromatosis type I and phaeochromocytoma. Presentations are steatorrhea; diabetes mellitus; gallstones; hypochlorhydria and occasional jaundice. Tumour is commonly malignant and commonly present with nodal and liver spread. Elevated fasting somatostatin level is diagnostic. Treatment is pancreaticoduodenectomy.
- 20% of pancreatic endocrine tumours are nonfunctional. Nonfunctional means these tumours do not produce hormones or produced hormones will not produce any symptoms.
- Pancreatic polypeptide tumour (PP tumour) is classified under the non-functioning endocrine tumour as it does not cause any symptoms even though there is high pancreatic polypeptide. It is commonly malignant, often with spread. PPoma occurs predominantly in head of pancreas. Pancreaticoduodenectomy is the treatment.

## CYSTIC FIBROSIS

It is inherited as an autosomal recessive disease. It causes—

1. *Severe exocrine dysfunction*—due to blockage of pancreatic ducts as a result of precipitation of pancreatic enzymes leading to duct ectasia.
2. *Chronic pulmonary disease* due to blockage of bronchi and bronchioles.
3. *Elevated sodium and chloride*—in the sweat more than 90 mmol/L.
4. It is common in Caucasians. It is inherited as mutation in cystic fibrosis transmembrane conductance regulator gene in chromosome 7.

## Presentations

- ◆ Chronic pulmonary disease with emphysema, bronchiectasis.
- ◆ Steatorrhea.
- ◆ Meconium ileus with intestinal obstruction.
- ◆ Salty sweat (while kissing the baby).
- ◆ Poor growth due to malabsorption.
- ◆ Cirrhosis of liver due to bile plugging.
- ◆ Pancreatitis is common.
- ◆ Sialadenitis, choroiditis can occur.
- ◆ Absence of vas deferens in men.

## Diagnosis

- ◆ DNA study.
- ◆ Vomitus when put on an exposed X-ray film will not digest the gelatin in half an hour (wherein in normal individual vomitus contains trypsin which will digest the gelatin of X-ray film and turns white).
- ◆ US abdomen.
- ◆ Sweat test for sodium and chloride.
- ◆ Pulmonary function tests.

## Treatment

- ◆ Low fat and salt rich diet.
- ◆ Correction of malabsorption.
- ◆ Pancreatic enzyme supplements.
- ◆ Antibiotics.
- ◆ Respiratory physiotherapy.
- ◆ If meconium ileus is present, it might require surgery, i.e. Bishop-Koop operation.

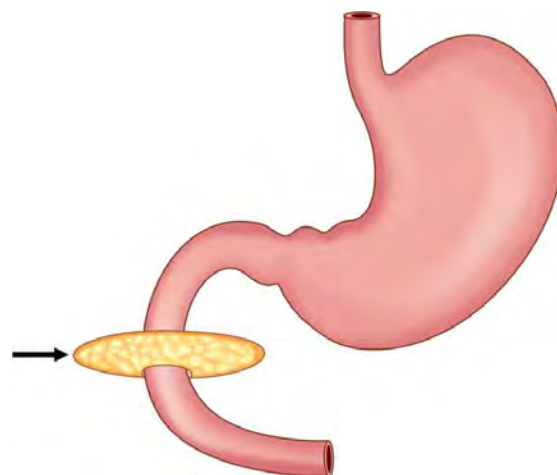
**Prognosis** is poor.

### Problems in cystic fibrosis

- ❖ Meconium ileus
- ❖ Recurrent respiratory infection and complications
- ❖ Sodium deficit
- ❖ Severe malnutrition
- ❖ Sialadenitis, choroiditis
- ❖ Cirrhosis of liver
- ❖ Usually die in childhood or early age group

## ANNULAR PANCREAS

It is due to failure of complete rotation of ventral bud of pancreas, so that ring of pancreatic tissue encircles the 2nd part of the duodenum causing obstruction. It contains a duct that joins the main pancreatic duct.



**Fig. 14.51:** Annular pancreas.

## Clinical Features

- ◆ Distension of upper abdomen.
- ◆ Bilious vomiting.
- ◆ Visible gastric peristalsis.
- ◆ It is often associated with the Down's syndrome, and other congenital gut abnormalities.

## Types

- ◆ *Neonatal type*—produces symptoms of intestinal obstruction.
- ◆ *Adult type*—presents after the age of 20. Presents with features of duodenal ulcer and bilious vomiting.

### Differential Diagnosis

- ❖ Duodenal atresia.
- ❖ Wilkie's syndrome.

### Investigations

- ❖ Plain X-ray abdomen shows double-bubble appearance.
- ❖ ERCP and Radioisotope study.
- ❖ Barium meal shows obstruction at 2nd part of duodenum.

## Treatment

- ◆ *Duodenoduodenostomy—Ideal.*
- ◆ Duodenojejunostomy.
- ◆ **Do not resect the ring.** Attempt at resection will lead to pancreatic fistula.
- ◆ G-J is not done.

## ECTOPIC (ACCESSORY) PANCREATIC TISSUE

### Sites

- ❖ Stomach wall.
- ❖ Small intestine.
- ❖ Meckel's diverticulum.
- ❖ Greater omentum.
- ❖ Splenic hilum.

- ▶ In the bowel, it may be in the submucous or intramuscular plane. It may precipitate intussusception.
- ▶ About 30–33% contain islet of Langerhan cells. Often endocrine pancreatic tumour can arise from ectopic pancreas.
- ▶ It may cause upper GI bleed.

## PANCREATIC DIVISUM

- ◆ During development ventral pancreatic bud with distal bile duct is towards right and dorsal pancreatic bud is towards left side. Ventral pancreatic bud forms uncinete process and inferior part of the head of the pancreas. Dorsal bud forms body and tail of the pancreas. Ventral bud rotates clockwise towards left from behind the duodenum to join dorsal bud to form pancreas. Ventral pancreatic bud duct forms main pancreatic duct of *Wirsung*; dorsal bud duct forms accessory pancreatic duct of *Santorini*.
- ◆ *Pancreatic divisum* is failure of fusion of ventral and dorsal pancreatic ducts. So that dorsal pancreas drains through duct of Santorini (proximal minor papilla); ventral one drains through duct of Wirsung into *major papilla of Vater*.
- ◆ Its incidence is 10%.
- ◆ Here major pancreatic secretion drains through minor papilla causing partial obstruction precipitating pancreatitis.

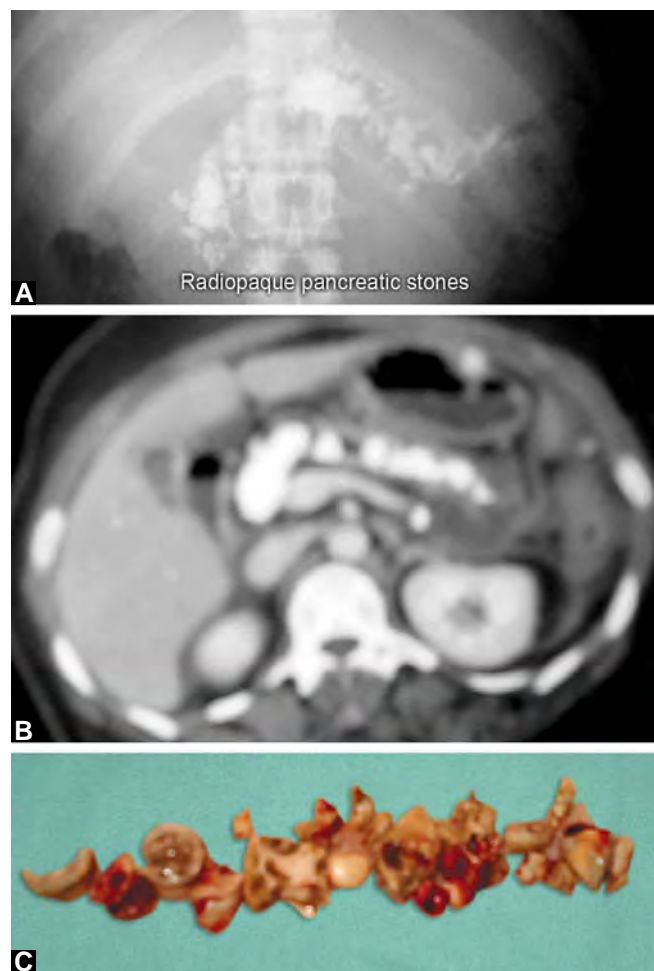
## PANCREATIC CALCULUS

### Causes

- ◆ Chronic pancreatitis commonly due to dietary factors, familial, hyperparathyroidism.
- ◆ Commonly they are multiple and associated with or due to chronic pancreatitis.

### Pathogenesis

Stricture of pancreatic duct and stasis of pancreatic secretion.



**Figs 14.52A to C:** (A) X-ray showing multiple pancreatic ductal stones; (B and C) CT scan picture showing pancreatic ductal stones. Stones that are removed from the same patient are also shown. Patient underwent longitudinal pancreaticojejunostomy.

### Types

#### a. Calculi in the duct:

- ▶ Here parenchyma is still functioning and less severely affected.
- ▶ Duct is dilated significantly (more than 3 mm) with multiple large stones in the duct along with multiple strictures.
- ▶ Duct is having dilatation alternating with strictures—*chain of lake appearance*.

- Plain X-ray abdomen shows stones placed horizontally at L<sub>1</sub>-L<sub>2</sub> level.
- US, ERCP, MRCP are other useful investigations.
- Blood sugar should be checked.

#### Treatment

The duct is opened longitudinally and after removing all stones, side-to-side pancreaticojejunostomy is done.

#### b. Calculi in the Parenchyma

- ▶ Here multiple calcifications occur in the pancreatic parenchyma with pre-existing chronic pancreatitis. Gland is fibrosed and severely affected with less functioning capacity.
- ▶ Plain X-ray, US, ERCP, MRCP are the diagnostic methods.

#### Treatment

- ▶ Total pancreatectomy.
- ▶ It is more likely to turn into carcinoma pancreas.

## PANCREATIC ASCITES

- ◆ It can occur in chronic pancreatitis or as a complication of acute pancreatitis or in ruptured pseudocyst of pancreas or after pancreatic trauma (10%, in children trauma is the cause).
- ◆ It may be associated with pleural effusion which can be both sided but commonly on left side. Often pleural effusion and ascites may be massive. It is due to *internal pancreatic fistula*.
- ◆ Incidence is 1%. If not treated mortality is 30%.
- ◆ It is due to leakage from disrupted pancreatic duct or ruptured pseudocyst. Anterior disruption causes pancreatic ascites. Posterior disruption causes fluid to travel along oesophageal and aortic hiatus resulting in pleural effusion.
- ◆ Pancreatic ascites and fistula are common in pancreatitis due to alcohol intake. It is less common in pancreatitis due to biliary tract disease.
- ◆ US, very high amylase and protein levels in ascites fluid, ERCP to identify leak, CT scan are the essential investigations.
- ◆ Repeated ascitic tap; pleural tap; TPN; somatostatin or octreotide to reduce pancreatic secretion are tried as conservative therapy for 3 weeks. 50% respond to this therapy.
- ◆ If there is no improvement beyond 3 weeks, ERCP stenting of pancreatic duct is done initially. Then resection (better option) or drainage (jejunal loop Roux-en-Y anastomosis directly over disrupted duct) surgery is done. Pancreatic pleural effusion disappears once abdominal cause or ascites is corrected.

## PANCREATIC FISTULAE

### Types

External and internal fistulae.

#### External Fistulae

#### Types

- Low output fistulae <200 ml.
- High output fistulae >200 ml.  
(Note: For other GI fistulae it is 500 ml)

**Present ISGPF (International study group of pancreatic fistula) grading system is** – Grade 0,A,B,C using various parameters like amylase level of fluid, clinical features, imaging etc.

#### Causes

- ◆ Whipple's operation.
- ◆ Pancreaticojejunostomy.
- ◆ Splenectomy.
- ◆ Colonic surgeries.
- ◆ Trauma.
- ◆ After external drainage of the infected pseudocyst of pancreas.
- ◆ After percutaneous drainage of the pseudocyst.

#### Clinical features

- ❖ Patient is in a catabolic state
- ❖ Skin excoriation
- ❖ Electrolyte imbalance
- ❖ Malnutrition
- ❖ Sepsis.

#### Investigations

- ❖ CT scan
- ❖ ERCP
- ❖ Fistulogram
- ❖ Amylase estimation of the discharge.

#### Treatment

##### Conservative treatment:

- ◆ Total parenteral nutrition.
- ◆ Zinc oxide cream for skin excoriation.
- ◆ Correction of electrolyte imbalance.
- ◆ Antibiotics.
- ◆ Octreotide.

##### Surgery:

- ◆ Roux-en-Y anastomosis.
- ◆ Resection of fistula with pancreas.
- ◆ Endoscopic stenting of the pancreatic duct.

#### Internal Fistulae

- ◆ Communicating pseudocyst.
- ◆ Pancreatic ascites.
- ◆ Pancreatic pleural effusion.
- ◆ Pancreatic-enteric fistulae.

#### Complications of pancreatic fistulae

- ❖ Septicaemia
- ❖ Malnutrition
- ❖ Bleeding due to erosion of vessels
- ❖ Electrolyte imbalance
- ❖ Severe skin excoriation

## ■ PANCREATIC NECROSIS

It is diffuse or focal area of non-viable parenchyma of pancreas, occurs during an attack of severe pancreatitis that is associated with peripancreatic fat necrosis. It occurs in 20% of acute pancreatitis.

### Types

- ◆ Sterile necrosis is 60% of total pancreatic necrosis. Mortality here is 10%.
- ◆ Infected necrosis is 40% of total necrosis. Mortality here is 30–40%, very high. Risk of infection is 25% in one week of acute attack; 35% at the end of 2nd week; and 70% at the end of 3rd week.
- ◆ Necrosis extends to retroperitoneal fat, mesentery, retrocolic and perinephric areas.

### Pathogenesis

- ◆ Premature activation of proteolytic enzymes.
- ◆ Intrapancreatic vessel thrombosis.
- ◆ Pancreatic microcirculation failure.
- ◆ Release of inflammatory mediators.

#### Mode of infection

- ❖ Haematogenous
- ❖ Reflux through ampulla
- ❖ Mucosal translocation of bacteria
- ❖ From the biliary tree
- ❖ Lymphatic route
- ❖ Transperitoneal spread.

#### Bacteria

- ❖ 65% are polymicrobial.
- ❖ *E. coli* is commonest.
- ❖ Others are—*Proteus*, *Pseudomonas*, *Klebsiella*, staphylococci, *Streptococcus faecalis*, enterococci, anaerobes, *Clostridium welchii*.

### Diagnosis

- ◆ Clinical features.
- ◆ CT scan abdomen and CT-guided FNA for Gram's staining and culture.
- ◆ CRP value—> 120 mg/litre; interleukin level; elastase level; urinary TAP assessment.

### Treatment

- ◆ Antibiotics—imipenem, cefuroxime, ofloxacin, meropenem.
- ◆ Percutaneous drainage.
- ◆ Laparotomy, necrosectomy, debridement, saline wash, closure with tube irrigations/lavage.

### Complications

- ◆ Septicaemia, ARDS, renal failure, MODS.
- ◆ Pancreatic fistula after surgery.

- ◆ Intra-abdominal abscess.
- ◆ Abdominal dehiscence, incisional hernia after surgery.

## ■ PANCREATIC TRAUMA

- ◆ It is rare because of its anatomical location—retroperitoneum.
- ◆ Its injury is usually associated with injuries to liver/duodenum/spleen/portal system/biliary system/ kidney.
- ◆ Deep force in epigastrium may cause crushing of body of pancreas against vertebra—closed injury.
- ◆ Penetrating injury may cause direct sharp injury of pancreas.

### Types

- ◆ Parenchymal contusion/laceration without duct disruption.
- ◆ Parenchymal injury with duct disruption.
- ◆ Complete transection of pancreas.
- ◆ Massive destruction of pancreatic head.

#### Classification

##### *Pancreatic injury*

*Class I* Capsular damage; minor parenchymal injury

*Class II* Transection of duct in body or tail—partial or complete

*Class III* Major duct injury in pancreatic head or intrapancreatic CBD injury

##### *Duodenal injury*

*Class I* Contusion, haematoma, partial thickness injury

*Class II* Full thickness duodenal injury

*Class III* Full thickness duodenal injury with

1. More than 75% circumference injury

2. Extrapancreatic CBD injury

##### *Combined pancreatico duodenal injury*

*Type I* Class I injury to both organs/class I injury of one organ with class II injury to other

*Type II* Class II injuries of both organs

*Type III* Class III injury to one organ with less severe injury to other

*Type IV* Class III injury to both organs

#### Grading of pancreatic injury

Grade I – Minor contusion/laceration without duct injury

Grade II – Major contusion/laceration without duct injury

Grade III – Distal transection or injury with duct involvement

Grade IV – Proximal transection or injury with involving ampulla

Grade V – Massive disruption of pancreatic head

### Features

- ◆ Pain in epigastrium.
- ◆ Features of associated injuries.
- ◆ Features of shock.
- ◆ Rise in serum amylase level is common.

### Investigations

- ◆ CT scan is diagnostic.
- ◆ ERCP to confirm duct disruption.
- ◆ Assessment of blood loss and other injuries.

## Treatment

- ◆ Commonly conservative with fluid management; blood transfusions; antibiotics; pain relief.
- ◆ Surgery is needed when there is:
  - ▶ Major ductal disruption.
  - ▶ Vascular injury.
  - ▶ Extensive injury to head.
  - ▶ Other organ injury.

## Surgeries are

- ◆ Proper exploration and haemostasis.
- ◆ In neck transection, distal pancreatectomy with splenectomy.
- ◆ In injury to head, haemostasis and external drainage is done.
- ◆ Pancreaticoduodenectomy is done if there is major injury.
- ◆ Choledochojejunostomy is done if there is CBD injury.
- ◆ Different pancreatic drainage procedures are done to prevent sepsis and fistula.
- ◆ Portal system injury carries poor prognosis. It needs repair or intervening graft placement to control and maintain the continuity.

## Prognosis

- ◆ Depends on type and class of injury and other associated injuries.

### Complications

- ❖ Haemorrhage
- ❖ Septicaemia
- ❖ Pancreatitis—acute/recurrent
- ❖ Pseudocyst formation
- ❖ Pancreatic fistula
- ❖ Pancreatic abscess
- ❖ Pancreatic duct stricture at the site of duct injury as a delayed complication.

## ■ CYSTIC LESIONS OF PANCREAS

### Types

1. True pancreatic cysts:
  - ▶ Congenital.
  - ▶ Not premalignant.
  - ▶ Asymptomatic.
  - ▶ May be associated with cystic diseases of liver, kidney.
  - ▶ Multiple true pancreatic cysts (polycystic disease of pancreas) are common than solitary true cyst. They are lined with cuboidal epithelium and are associated with *von Hippel-Lindau disease* in 50% of patients. They do not require any treatment.
2. Pseudocyst of pancreas.
3. Cystic tumours of pancreas.
  - a. Serous cystadenoma.
  - b. Mucinous cystadenoma.
  - c. Cystadenocarcinoma.
  - d. Angioma.
  - e. Cystic teratomas.
4. Hydatid cyst of the pancreas.

## ■ PANCREATIC EXOCRINE INSUFFICIENCY (EXOCRINE PANCREATIC DISEASE)

### Causes

Chronic pancreatitis, cystic fibrosis, pancreatic resections (total or partial), pancreatic duct obstruction by haemochromatosis or  $\alpha 1$  anti-trypsin deficiency, short gut syndrome, gastric resection, Shwachman Diamond syndrome (congenital entity with pancreatic exocrine insufficiency, cytopenias, skeletal abnormalities).

### Features

- ◆ Maldigestion of fat and proteins causing steatorrhoea and weight loss.
- ◆ Metabolic bone disease, impaired night vision, fat soluble vitamin deficiencies can occur.
- ◆ Vitamin B<sub>12</sub> deficiency can occur as decreased intestinal pH prevents transfer of vitamin B<sub>12</sub> to intrinsic factor from R factor; it shows positive dual label Schilling test.

### Evaluation

#### Direct methods:

It is done by directly collecting the fluid from duodenum using double lumen collecting tubes, one is duodenum to collect pancreatic fluid and other being in stomach to aspirate gastric content so that to avoid it mixing with pancreatic fluid.

- ◆ *Lundh test* (Goran Lundh)—Liquid test meal containing protein, fat and carbohydrate (300 ml) is given orally; duodenal fluid is collected for 2 hours; assessed for enzymes. Normally trypsin level is  $> 8$  mEq/L. It is very low in pancreatic insufficiency. Test is *obsolete* now.
- ◆ *Secretin test*—Initial test dose of secretin is given 0.2 ug; then full dose of 0.2 ug/kg as a bolus IV dose is given; duodenal fluid is continuously collected with segregations as 15 minutes as 4 groups; in pancreatic insufficiency HCO<sub>3</sub> level will be  $< 80$  mEq/L in all four groups; total HCO<sub>3</sub> output and volume also analysed.
- ◆ *Secretin—CCK test* is more reliable and accurate than secretin test alone. Both hormones are administered as bolus injection continuously either simultaneously or sequentially; similar assessments are done. Normally duodenal fluid contains more than 80 mEq/L of HCO<sub>3</sub> and HCO<sub>3</sub> greater than 15 mEq/30 minutes.

#### Indirect methods:

These methods are measure of effects of pancreatic insufficiency.

- ◆ *Serum trypsinogen* and trypsin level estimation; trypsinogen level less than 20 ng/ml suggest advanced pancreatic exocrine insufficiency.
- ◆ *Faecal fat estimation* after collecting 72 hours faecal fat and estimation is done for daily fecal fat using Sudan stain. In a person ingesting 100 gm of fat/day, if faecal excretion of fat is more than 7 gm/day, it signifies pancreatic insufficiency. It is the most sensitive and specific test. (Presence of neutral fat suggests pancreatic disease whereas split fat suggests small bowel disease).

- ◆ *Pancreolauryl test*—Fluorescein dilaurate is ingested along with breakfast which is a substrate for pancreatic enzyme cholesterol esterase; depending on the activity of the cholesterol esterase this substrate is cleaved to release proportionate fluorescein; released fluorescein rapidly absorbed from the gut and excreted in the urine. Serum fluorescein and 24-hour urine fluorescein assay gives the quantitative estimation of the pancreatic exocrine function. It is accurate and acceptable test for pancreatic exocrine insufficiency.
- ◆ *Triolin breath test*—Triolin labelled  $^{13}\text{C}$  or  $^{14}\text{C}$  is administered as test meal; it is hydrolyzed in the gut lumen depending on

the quantity of pancreatic lipase activity; hydrolysed products are absorbed, metabolised and released through pulmonary endothelium as  $^{13}\text{CO}_2/^{14}\text{CO}_2$  which is measured using mass spectrometry or infrared. It is mainly used to quantify steatorrhea.

### **Treatment of Pancreatic Exocrine Insufficiency**

Low fat diet; pancreatic enteric coated tablets during meals, treatment of cause.

# Chapter 15

## Retroperitoneal Space

### CHAPTER OUTLINE

- ❖ Anatomy of Retroperitoneum
- ❖ Retroperitoneal Swellings
- ❖ Psoas Abscess
- ❖ Retroperitoneal Fibrosis
- ❖ Retroperitoneal Tumours

### ANATOMY OF RETROPERITONEUM

This is the space between the peritoneal cavity and posterior abdominal wall. It is bounded anteriorly by posterior parietal peritoneum; posteriorly by vertebral column, psoas muscles, quadratus lumborum muscle and tendinous portion of transversus abdominis muscles; superiorly by diaphragm; inferiorly by pelvic levator muscles (by Ackerman). It is real potential space.

#### Diseases of retroperitoneal spaces

- ❖ Retroperitoneal fibrosis
- ❖ Retroperitoneal cysts
- ❖ Retroperitoneal tumours
- ❖ Retroperitoneal lymphomas
- ❖ Retroperitoneal vascular diseases, e.g. aneurysms
- ❖ Retroperitoneal trauma and haematoma
- ❖ Retroperitoneal infection, e.g. psoas abscess, pyogenic abscess

*Diseases of the specific retroperitoneal organs, e.g. adrenals, kidney.*

### RETROPERITONEAL FIBROSIS

- ◆ *Idiopathic type (70%) is called as Ormond's disease* which is associated with mediastinal fibrosis, Dupuytren's contracture, plantar fasciitis, Peyronie's disease, Riedel's thyroiditis, sclerosing cholangitis, mesenteric panniculitis, pseudotumour of the orbit and other fibromatosis. It is nonspecific inflammation of fibrofatty tissue in the retroperitoneum.
- ◆ Patient presents with severe and persistent *back pain*.
- ◆ Diffuse fibrosis in retroperitoneum can compress both ureters leading to bilateral hydronephrosis and renal failure.
- ◆ Extravasation of urine, ascending lymphangitis, and autoimmune cause are the aetiologies.

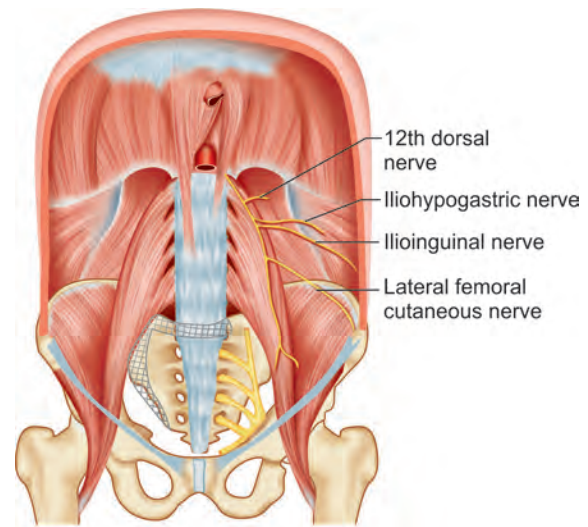


Fig. 15.1: Anatomy of retroperitoneal space.

- ◆ In 30% cases it is bilateral. Hypertension, lower limb oedema (lymphatic or venous block), feeble lower limb arterial pulses are common.
- ◆ It is like woody fibrous tissue which narrows ureters, vessels and nerves. Ureteric obstruction commonly in lower 1/3rd causing dysuria, frequency, oliguria, renal failure. Venous and lymphatic oedema of limbs can occur.
- ◆ It may be localised or generalised. Generalised type (15%) may extend into duodenum, CBD and pancreas. It is not encapsulated but margin is well-demarcated.
- ◆ It can also cause vascular compression, both venous and arterial.
- ◆ Disease is progressive one.

*The lesser the indication, the greater the complication.*



## Investigation

- ◆ Ultrasound
- ◆ IVU—diagnostic:

### Triad

- ❖ Deviation of middle 1/3rd of ureter medially
- ❖ Hydroureteronephrosis
- ❖ Extrinsic ureteral compression

- ◆ Blood urea and serum creatinine, raised ESR and CRP.
- ◆ CT scan.

## Treatment

- ◆ *Drug therapy:* Methylprednisolone, azathioprine, penicillamine, tamoxifen.
- ◆ Cystoscopic stenting of the ureters to prevent renal failure.
- ◆ *Symptomatic treatment:* If stenting fails, bilateral nephrostomy is done.
- ◆ Ureterolysis.
- ◆ Lateral repositioning of ureters.
- ◆ Omental wrap after ureterolysis.
- ◆ Vascular bypass graft for vascular encasement.

### Other causes for retroperitoneal fibrosis (30%)

- ❖ Methysergide and beta-blocker drugs
- ❖ Urine leak and collection in the space
- ❖ Haematoma, blood collection
- ❖ Advanced malignancy, radiation.
- ❖ Ergot's alkaloids, dopamine agonists
- ❖ Retroperitoneal surgeries, haemorrhage
- ❖ Trauma, infection

## RETROPERITONEAL SWELLINGS

### Types of retroperitoneal (RP) tumours (0.3–3%)

*Benign—20% of RP tumours*

- ❖ Retroperitoneal lipoma
- ❖ Retroperitoneal neurofibroma, neurilemmoma
- ❖ Retroperitoneal leiomyoma
- ❖ Extra-adrenal chromaffinomas
- ❖ Paraganglioma
- ❖ Mucinous cystadenoma
- ❖ Haemangiopericytoma

*Malignant—80% of RP tumours*

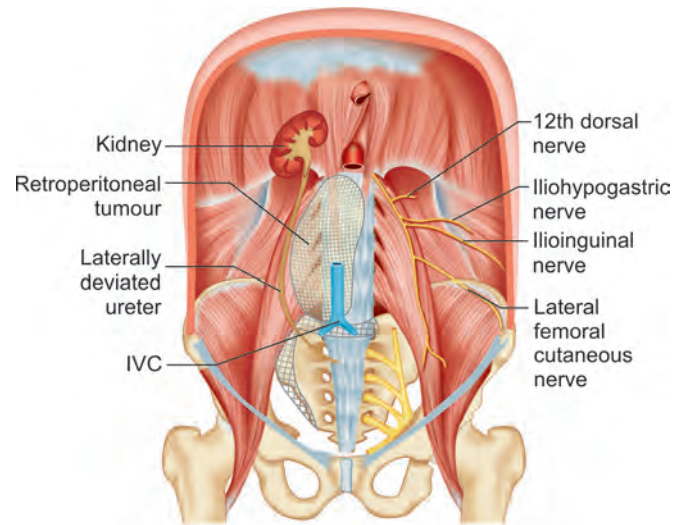
- ❖ Retroperitoneal liposarcoma, leiomyosarcoma—50%
- ❖ Retroperitoneal lymphoma (commonly NHL)
- ❖ Malignant tumours from specific organs
- ❖ Germ cell tumours, chordomas
- ❖ RPLN secondaries with hard nodules

### Note:

- Tumours of retroperitoneal organs like kidneys, ureters, pancreas, and adrenals are conventionally *not included* in retroperitoneal tumours.
- *Paragangliomas* are of neural crest origin that arises from paraganglionic tissues distributed along the major vasculatures (abdominal aorta in abdomen) or sympathetic chain, may be functioning or nonfunctioning. 20% secrete catecholamines. They may be multiple.

Only 0.5% of cases present with hypertension. It can be familial, often associated with von Hippel-Lindau disease and RET proto-oncogene. It may arise from *type I cells* as chromogranin A positive—NSE positive; or *type II cells* as S 100 positive with good prognosis.

- *Costello syndrome* is mental retardation, benign papilloma; develop embryonal rhabdomyosarcoma.
- *Retroperitoneal cysts* are—cysts arising from Wolffian remnants or urogenital tract; RP mesenteric cyst; teratomatous dermoid cysts; RP lymphatic cyst; parasitic cysts.



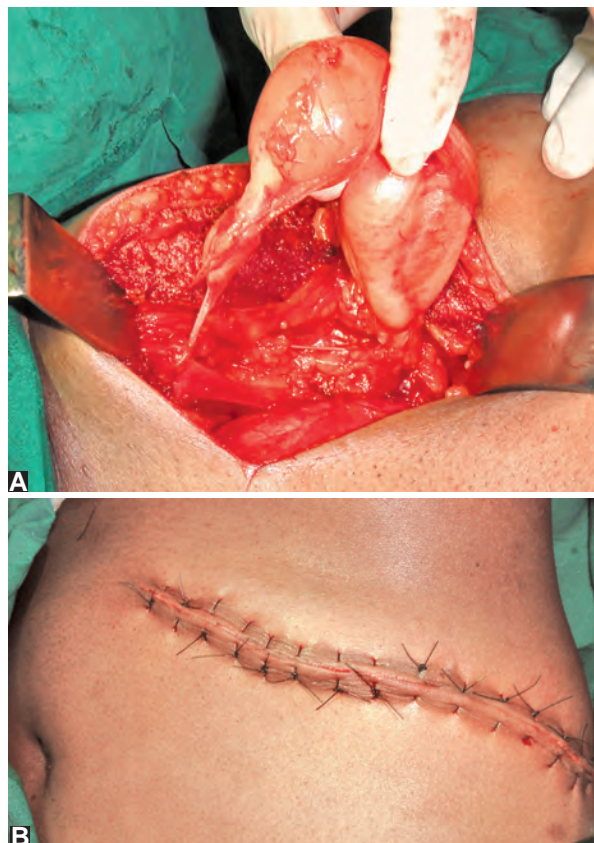
**Fig. 15.2:** Retroperitoneal tumour can attain very large size often. It causes deviation of ureter laterally often may invade the ureter (In retroperitoneal fibrosis ureter is deviated medially). It may invade or encase the IVC also causing IVC obstruction with features of bilateral oedema feet, dilated lateral abdominal wall vein with upward direction flow of blood.

## Features of the Retroperitoneal Mass

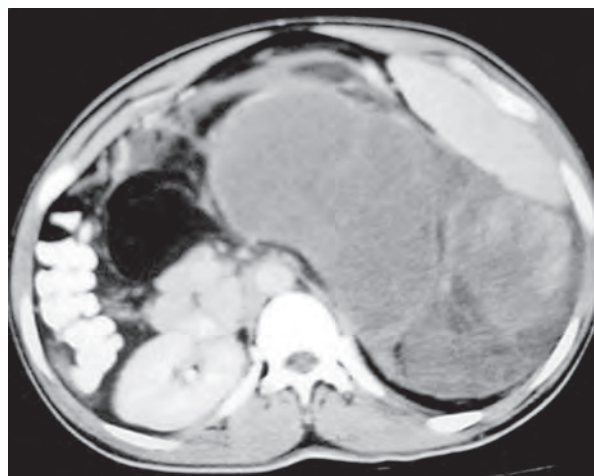
- ◆ It is usually large.
- ◆ Not moving with respiration.
- ◆ Nonmobile.
- ◆ Does not fall forward (confirmed by knee-elbow position).
- ◆ Deeply placed.
- ◆ Resonant on percussion (because of the bowel in front).
  - ▶ In retroperitoneal cyst and sarcoma the swelling is smooth.
  - ▶ In lymphoma it is smooth and firm.
  - ▶ In aneurysm it is pulsatile (expansile pulsation) which will persist even in knee-elbow position.
  - ▶ Confirmation is by U/S, CT scan, MRI.
  - ▶ Most common retroperitoneal benign tumour is lipoma.
  - ▶ Sarcoma (*commonest is liposarcoma 40%*) which attains a very large size, goes for myxomatous degeneration very early and is aggressive.

## RETROPERITONEAL TUMOURS

- ◆ Retroperitoneal tumour can be *benign or malignant* (refer table above); *solid or cystic*. Solid tumours are commonly malignant (85%); cystic tumours are usually benign.



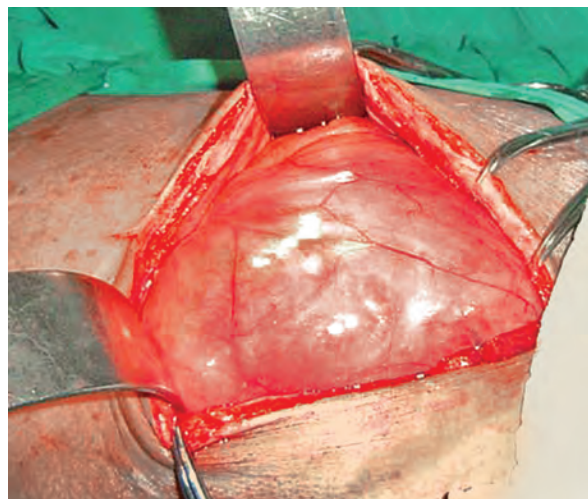
**Figs 15.3A and B:** Retroperitoneal tumour—benign lipoma was excised with a loin retroperitoneal approach.



**Fig. 15.4:** Retroperitoneal leiomyosarcoma, CT picture.

- ◆ Malignant retroperitoneal tumour may be *mesodermal* (75%), *neuroectodermal* (24%) or *embryonic remnant* (1%) in origin. Rarely it can be urologic or metastatic also. Sarcoma is the most common malignancy; *in adult*—liposarcoma is the *most common* retroperitoneal sarcoma (50%); leiomyosarcoma is 30%; malignant nerve sheath tumour (5%); fibrosarcoma (5%); malignant fibrous histiocytoma (MFH—10%) can also occur. 20% show neurological deficit; 40% show distant blood spread. *In children* rhabdo-

mysarcoma is the most common one. 15% of all sarcomas are of retroperitoneal.



**Fig. 15.5:** Retroperitoneal tumour, on table finding. It was large and inoperable.

### Aetiology

- ◆ Retroperitoneal tumors may be associated with radiation; exposures to chemicals like vinyl chloride/thorium dioxide, familial Gardner's syndrome, familial retinoblastoma or familial neurofibromatosis, Li Fraumeni syndrome, germline mutations of p53 in chromosome 17.

### Features

- ◆ Tumor arises from fat, areolar tissue, vessels, nerves, skeletal and smooth muscle, fascia, lymph node and lymphatic systems and tissues of embryologic origin. Sarcomas can be commonly solid, cystic or mixed. Usually tumour develops a pseudocapsule. Liposarcoma often originates from (>30%) perinephric fat.
- ◆ *Liposarcoma* can be well-differentiated (60%) or undifferentiated (dedifferentiated). It spreads along the fascial planes *enveloping* the organs. Infiltration of organs occurs only at late stage. It shows whorl-like pattern in histology with myofibroblastic or osteoblastic differentiation. Insulin like production by tumour or rapid utilisation of glucose by active tumour causes intermittent *hypoglycaemia (paraneoplastic)*.
- ◆ Spread of retroperitoneal sarcoma mainly occurs through blood to lungs and often to liver. Nodal spread occurs rarely (5%).
- ◆ Malignant tumours of the retroperitoneum are 4 times common than benign one.
- ◆ Retroperitoneum is the 2nd most common site of malignant mesenchymal tumour first site is being lower extremities.

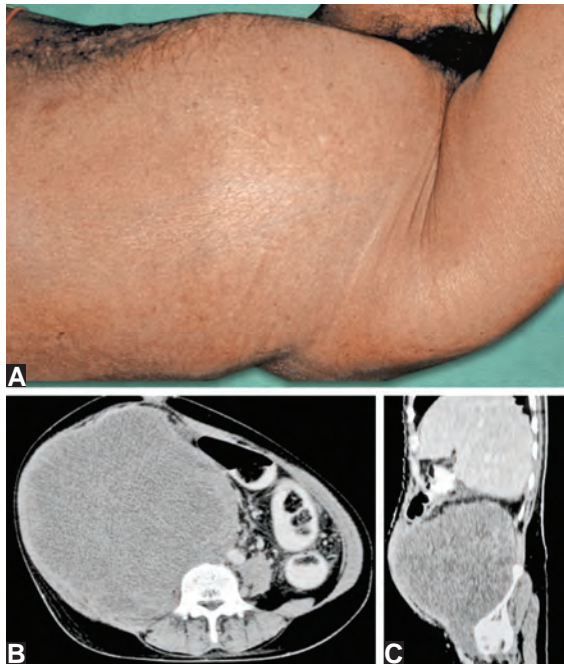
### Presentations

- ◆ Most patients have initial asymptomatic course with eventual presentation as *mass abdomen* (90%). Pelvic mass (20%), vague abdominal pain and discomfort (70%), anorexia, fatigue, vomiting,

*Time neither subtracts nor divides, but adds to such a pace it seems like multiplication.*

weight loss, fullness in abdomen, back pain due to compression over lumbar and pelvic nerves, leg pain, recurrent episodes of fever—are other features.

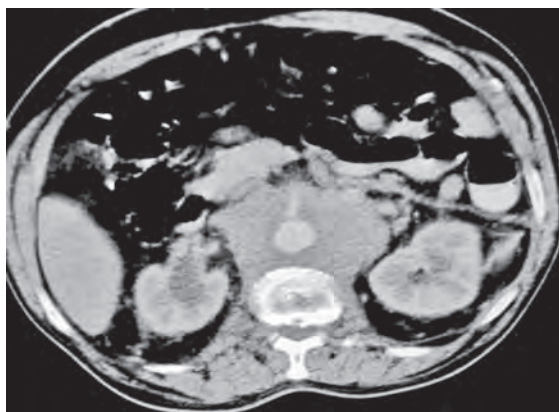
- ◆ *Other* presentations are—GI bleeding; intestinal/urinary obstruction (10%); neurological manifestations (20%) by compression or invasion of neurological systems by tumor; iliac vein or IVC compression can cause lower limb varicosities, varicocele, and dilated abdominal veins with venous flow from below upwards, and oedema.



**Figs 15.6A to C:** Retroperitoneal tumour presenting as large mass abdomen with all features. CT pictures of the same patient.

## Investigations

- ◆ CT abdomen—helical contrast CT (commonly used) and pelvis and *CT chest* (to see metastases) are essential investigations.
- ◆ *CT-guided core biopsy*; laparoscopic biopsy are needed. FNAC has got limited role.



**Fig. 15.7:** Retroperitoneal tumour showing encasement of major vessels. It becomes inoperable. Ureter, duodenum, intestines, kidney are other structures which may get infiltrated by tumour.

- ◆ *MRI* is better than CT with near 100% accuracy. It identifies extent, desmoplastic reaction. Liposarcoma shows decreased signal in T1 and increased signal in T2. MFH shows heterogeneous signals.
- ◆ Retroperitoneoscopy may be ideal to take biopsy.
- ◆ IVU shows laterally deviated ureter. Plain X-ray may show soft tissue shadow, obliterated psoas shadow, and often calcification.
- ◆ AFP, HCG and other tumour markers are done often. LFT, blood urea and serum creatinine is done.
- ◆ Histochemistry is essential in many suspicious types.

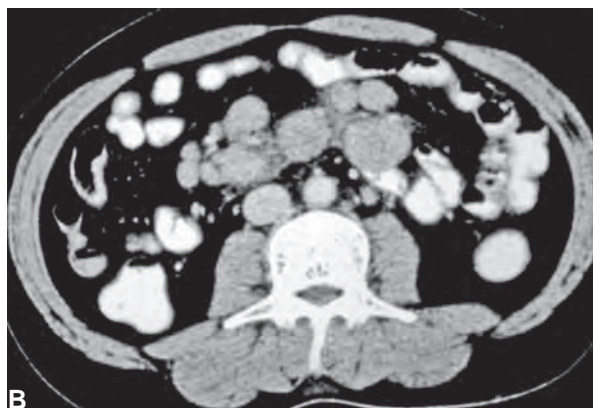
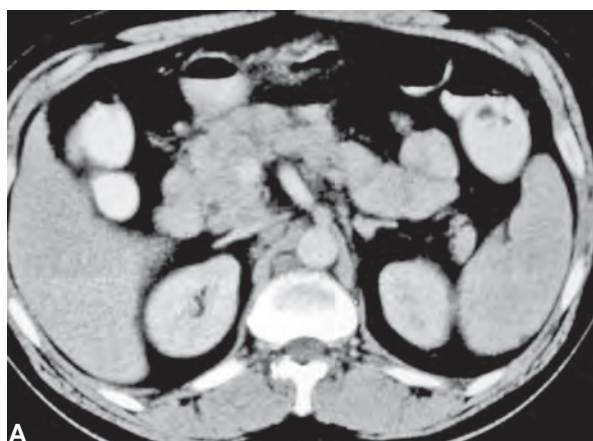<b>TNM staging (AJCC 6th edition)</b>	<b>AJCC (6th edition) grading</b>
<b>Tumour (T):</b> Tx: Cannot be assessed T0: No tumour T1: 5 cm or less T2: > 5cm	Low grade High grade
<b>Nodal (N):</b> N <sub>x</sub> : Nodes cannot be assessed N <sub>0</sub> : No nodes N <sub>1</sub> : Nodes present	<b>Staging (AJCC 6th edition):</b> I: T <sub>1</sub> /T <sub>2</sub> ; N <sub>0</sub> ; M <sub>0</sub> ; low grade II: T <sub>1</sub> ; N <sub>0</sub> ; M <sub>0</sub> ; high grade III: T <sub>2</sub> ; N <sub>0</sub> ; M <sub>0</sub> ; high grade IV: Any T; N <sub>1</sub> ; M <sub>1</sub>
<b>Metastasis (M):</b> M <sub>x</sub> : Distant spread cannot be assessed M <sub>0</sub> : No metastases M <sub>1</sub> : Distant spread present	<b>Note:</b> Nodal spread carries poor prognosis; it is equal to M <sub>1</sub> when outcome is considered

## Treatment

- ◆ *Surgery is the main modality* of therapy with wide excision—*complete enblock excision* (possible only in 30% of cases) is the ideal. Limited resection; debulking (controversial) are other options. Often it needs extensive surgical dissection; resection of adjacent bowel. Wide exposure is the key for successful surgery (lengthy midline/thoracoabdominal). Limiting factors are encasement of major vessels; invasion of ureters; extension into duodenum or pancreas; extensive involvement of mesentery and spread. Proper bowel preparation, colostomy, urinary diversion, adequate blood to replace the lost blood, *hypotensive* general anaesthesia are the *requirements* during surgery. Posterior dissection along the IVC, aorta and near spinal canal are the difficult areas of dissection. *Complications* are—injury to major structures, bleeding, sepsis, and leak.
- ◆ Postoperative chemotherapy and radiotherapy is used as adjuvant method.
- ◆ *Radiotherapy* may be external beam RT (5000 cGy); or IORT (intraoperative RT during surgical resection) which reduces local recurrence and radiation enteritis. Problems with RT are radiation injury to kidney, bowel, liver and spinal cord. Preoperative intensity modulated RT (IMRT) is tried.
- ◆ Recurrent disease needs re-exploration but often difficult to do complete clearance.
- ◆ Mesna, *Adriamycin* (*main drug*), ifosfamide and dacarbazine (MAID) are the chemotherapeutic agents used.
- ◆ Germ cell tumour, lymphoma (NHL) are treated accordingly.

## Prognosis

- ◆ *Prognosis* depends on:
  - ▶ Tumour grade—low or high;
  - ▶ Resectability;
  - ▶ Invasion into organs, veins, nerves;
  - ▶ Size of tumour < 5 cm or > 5 cm or > 10 cm;
  - ▶ Deep location;
  - ▶ Nonliposarcoma in histology—poor prognosis;
  - ▶ Recurrent disease;
  - ▶ Distant spread.
  - ▶ Tumour grade and completeness of resection without distant spread are important prognostic factors.
  - ▶ RP tumours has got overall 40% recurrence rate. Overall survival is 1½ to 2 years.
  - ▶ 5-year survival for well-differentiated tumour is 75%; < 40% for undifferentiated tumours.



**Figs 15.8A and B:** Retroperitoneal lymph node mass. It could be tuberculosis/lymphoma/secondaries/autoimmune lymph node enlargement.

### Features of retroperitoneal sarcomas

- ❖ Mass per abdomen
- ❖ Pain in the back and compressive features
- ❖ GIT obstruction especially by leiomyosarcoma
- ❖ Compression over the ureter causing hydronephrosis
- ❖ Compression over the major veins causing varicose veins
- ❖ Arterial compression features are not common
- ❖ Liver and lung secondaries can occur
- ❖ CT-guided biopsy is ideal method of investigations

### Retroperitoneal sarcoma (RPS)

- ❖ Accounts for 15% of all sarcomas
- ❖ Common *presentations* are—nontender palpable RP mass (90%); weight loss, pain and discomfort; neurologic (20%); urinary (10%); weight loss (20%); bowel obstruction; paraneoplastic syndrome (hypoglycaemia)
- ❖ 70% present with tumour more than 10 cm; 20% present with metastases
- ❖ Liposarcoma is the *most common* RP sarcoma; it can be well-differentiated, dedifferentiated, myxoid, round cell, pleomorphic
- ❖ *Histological grading* is important prognostic factor—*high grade* carries median survival of 2–3 years; *low grade* has got survival of 10 years
- ❖ CT scan, *CT-guided core biopsy* through posterior approach, MRI (extremely accurate)—are the investigations needed. CT chest and abdomen, isotope renal scintigraphy or IVU to check the function of opposite kidney has to be done which may required to be removed
- ❖ A preoperative biopsy is *not usually* indicated in patients with resectable RPS; but is needed when preoperative therapy alters or lymphoma/germ cell tumours are suspected
- ❖ Open biopsy is also *not* done in a resectable tumour as it is potentially dangerous, can cause peritoneal contamination. It is done only if CT core biopsy is inconclusive
- ❖ FNAC in RPS is *not useful*
- ❖ PET scan do not have usual role in screening, diagnosis and staging. It *can be used* to quantify tumour activity; to assess the response of neoadjuvant chemotherapy and response of newer therapies targeted at specific molecular level to arrest the tumour growth
- ❖ **Dutch/memorial Sloan-Kettering cancer centre classification system of RPS (post-surgical)** is commonly used:
  - Stage I – Low grade, complete resection, no metastases
  - Stage II – High grade, complete resection, no metastases
  - Stage III – Any grade, incomplete resection, no metastases
  - Stage IV – Any grade, any resection, distant metastases
- ❖ **Surgery is the choice of therapy**—monobloc complete surgical resection with dissection outside the pseudocapsule with adequate negative margin is possible only in 50% of cases
- ❖ Often associated visceral organ resection (in 50% cases) is needed—kidney and adrenals (45% cases), colon (25%), small bowel, pancreas (15%), spleen (10%). Need for removal of kidney arises when there is encasement of renal hilar vessels and fascia of Gerota, but not invasion of kidney
- ❖ **Adjuvant RT to retroperitoneum** is used to prevent local recurrence. It can be—preoperative, intraoperative (IORT), postoperative. It can be external beam (EBRT) or brachytherapy. *Advantages of preoperative RT* are—well-demarcated gross tumour; radiosensitive viscera is displaced away by tumour itself without adhesions; absence of potential contamination of abdomen cavity; better oxygenated tumour bed. *IORT is given* as a single large dose (20 Gy) of RT to the retroperitoneum on table after displacing sensitive viscera away. *Intensity modulated RT (IMRT)* gives 45 Gy RT to planned gross tumour with 1.5 cm margin with intergraded booster doses of 65 Gy at 2.5 Gy per fraction to the margins at high-risk; IMRT has minimal local toxicity like damage to kidney, bowel (stricture), spinal cord. *Postoperative RT* has more disadvantages and toxicity but *allows* patient selection in terms of risk of local recurrence
- ❖ **Chemotherapy (CT)**—no role of neoadjuvant CT. *Adjuvant CT* may be useful in synovial and myxoid types of liposarcoma. Palliative CT is used in unresectable and metastatic RPS—*MAID and AIM* regimes are used
- ❖ **Specific targeted therapy on tumourogenesis**—antiangiogenic agent, tyrosine kinase inhibitors, and mammalian target of rapamycin inhibitors (MTOR) are used. Trabectedin—synovial sarcoma, myxoid sarcoma, leiomyosarcoma
- ❖ **Prognostic factors**—*tumour grade and completion of surgical resection* are the best prognostic factors (not tumour size)
- ❖ **Local recurrence** is common in 50% of cases. It is usually seen in high-grade liposarcoma. Leiomyosarcoma, malignant peripheral nerve sheath tumours show distant spread commonly along with local recurrence

*A man carries success or his failure with him; it does not depend on outside conditions.*

### Treatment of retroperitoneal tumours

- ❖ *Wide local excision.* Often requires removal of adjacent structures like colon, kidney, and spleen
- ❖ *Debulking operation* as a palliative
- ❖ *Enucleation* through pseudocapsule. It has got high recurrence rate—not done; may be useful in advanced cases
- ❖ *Radiotherapy* either brachytherapy or external beam radiotherapy or intraoperative RT
- ❖ *Chemotherapy* using adriamycin
- ❖ Retroperitoneal NHL is treated by *chemotherapy*

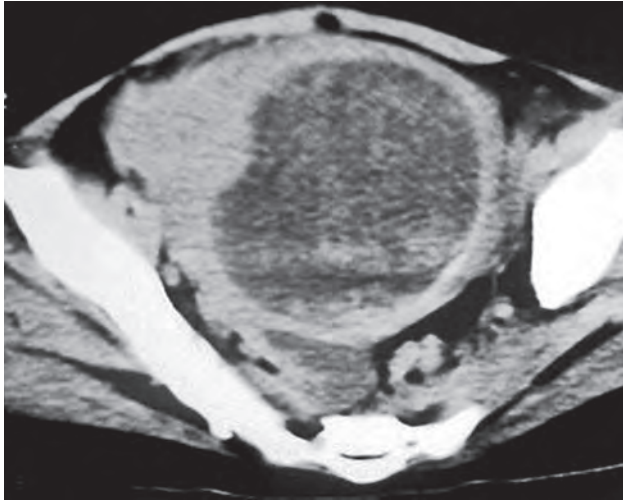


Fig. 15.9: Large pelvic retroperitoneal tumour.

### PSOAS ABSCESS

- ◆ Abscess in the psoas region in the iliac fossa, is commonly due to tuberculosis of spine (T 10) and lymph nodes, retroperitoneal structures, lower intercostal region.
- ◆ It can also be a pyogenic abscess.

### Clinical Features

- ◆ Back pain, fever, spinal tenderness, paraspinal spasm and restricted spine movement.
- ◆ Swelling in iliac fossa which is smooth, nontender, nonmobile, not moving with respiration.
- ◆ When it extends across the groin and below the inguinal ligament, it is **cross fluctuant** across the inguinal ligament.
- ◆ Patient has typical *psoas muscle spasm* in which patient is able to flex his hip but finds it difficult to extend.

### Swellings which are cross fluctuant

- ❖ Psoas abscess
- ❖ Ranula
- ❖ Compound palmar ganglion
- ❖ Bilocular hydrocele

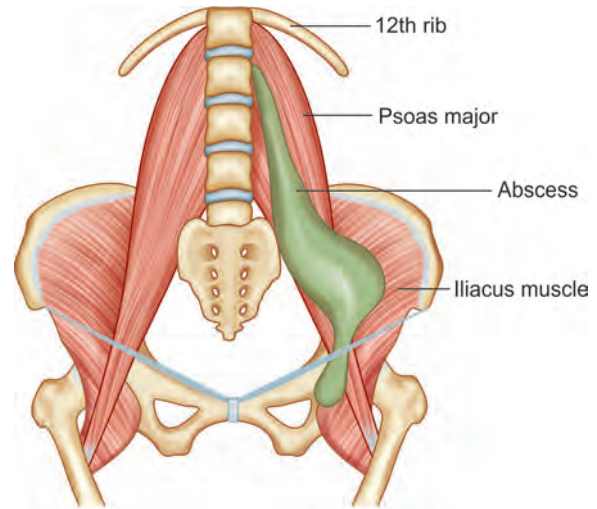


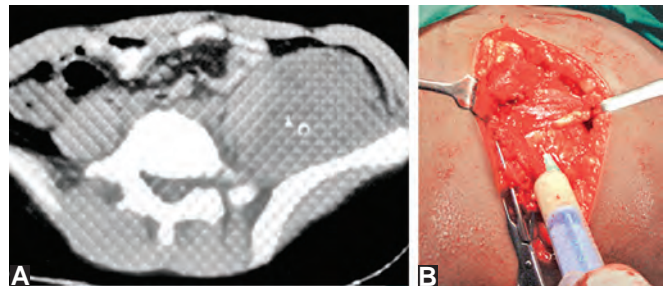
Fig. 15.10: Psoas abscess.

### Differential Diagnosis

- a. Iliac artery aneurysm.
- b. Ovarian cyst in females.
- c. Soft tissue tumours and cysts in the iliac region.
- d. Hernia.

### Investigations

- ◆ X-ray spine and chest, CT scan.
- ◆ Mantoux test, ESR, peripheral smear.
- ◆ Ultrasound abdomen.



Figs 15.11A and B: (A) CT picture of large psoas abscess; (B) On table finding of psoas abscess.

### Treatment

- ◆ Antituberculous drugs are started—INH, ethambutol, rifampicin, pyrazinamide.
- ◆ Under G/A through lateral loin incision, the psoas region is reached extraperitoneally. The pus is drained and collected for culture and sensitivity, AFB, culture. The wound is closed. All caseating material and diseased parts of vertebra should be removed.

- ◆ Only lateral approach is advised. In thoracic region—*anterolateral decompression with costotransversectomy with bone grafting* is the treatment.

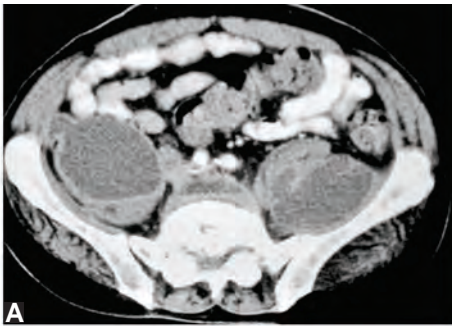
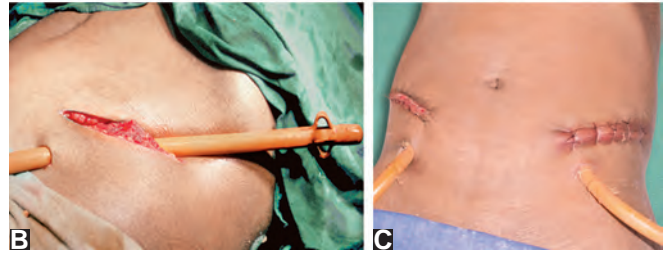


Fig. 15.12A



Figs 15.12B and C

**Figs 15.12A to C:** Bilateral large psoas abscess—CT picture. Drainage and placement of Malecot catheters for the same. Note the location of incisions. It is obliquely placed incision above the lateral aspect of groin with extraperitoneal approach.

**Note:**

*Posterior approach, i.e. laminectomy—**not advised.***

# Chapter 16

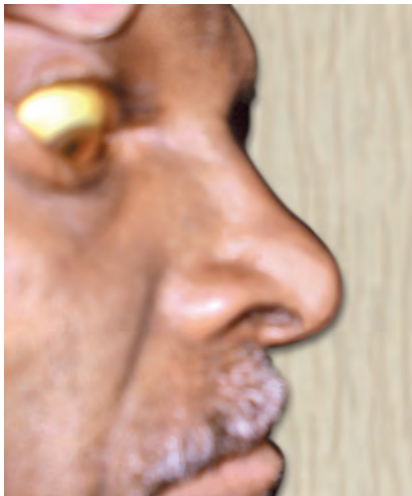## Differential Diagnosis of Mass Abdomen

### CHAPTER OUTLINE

- ❖ Mass in the Right Hypochondrium
- ❖ Mass in the Epigastrium
- ❖ Mass in the Left Hypochondrium
- ❖ Mass in the Lumbar Region
- ❖ Mass in the Umbilical Region
- ❖ Mass in the Right Iliac Fossa
- ❖ Mass in the Left Iliac Fossa
- ❖ Mass in the Hypogastrum
- ❖ Distal Rectal Examination for Prostate and Other Conditions

In a patient presenting with mass abdomen, generally following clinical features should be assessed carefully.

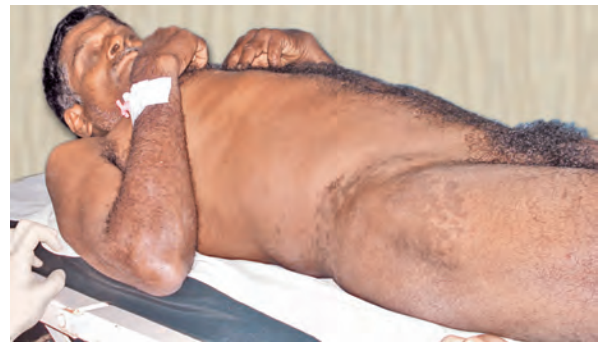- ◆ *Pain*: Site, nature, aggravating or relieving factors, duration of pain, referred pain.
- ◆ *Vomiting*: Type, content, haematemesis, relation to food, frequency.
- ◆ *Jaundice*: It is an important factor in relation to liver, gallbladder or pancreatic masses.



**Fig. 16.1:** Obstructive jaundice in a patient with carcinoma head of pancreas. Note the sclera for discolouration. Severe itching is common in these patients.

- ◆ *Bowel habits*: Constipation, diarrhoea, bloody diarrhoea, furious diarrhoea, tenesmus.
- ◆ Decreased *appetite* and *weight*.
- ◆ *Inspection of the mass*: Anatomical location, margin, surface, movement with respiration.

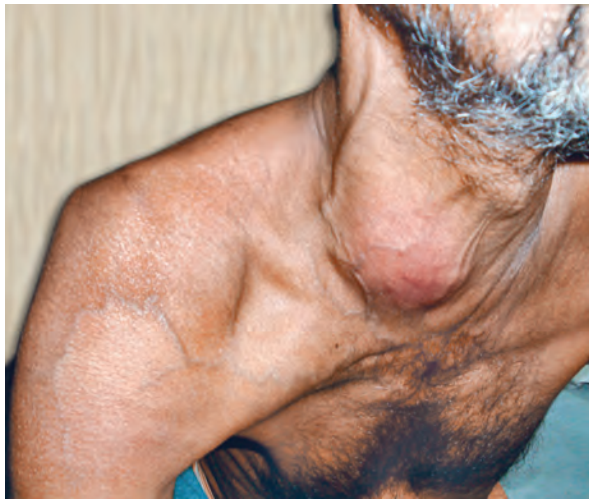
- ◆ *Palpation of the mass*: Site, extent, surface, tenderness, consistency, movement with respiration, mobility, borders, plane of the swelling (by leg raising test), presence of other masses.



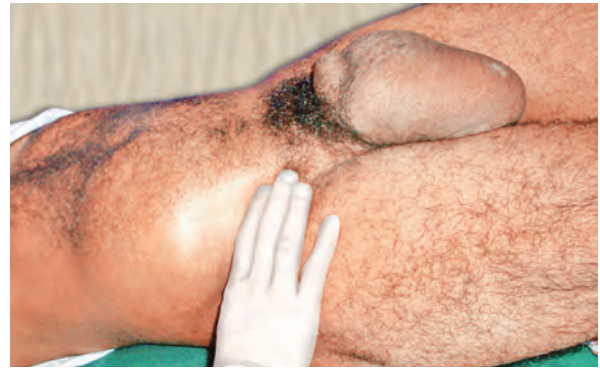**Fig. 16.2:** Abdomen should be inspected by exposing from nipple level to knee level. Inspection is done from foot end and from right side.

- ◆ *Often mass needs to be examined for change of position*—in sitting, in standing, in side position, after a brisk walk, in knee elbow position for retroperitoneal mass and *for puddle sign* (but difficult to keep patient in this position).
- ◆ *Percussion* is an important aspect of examination in case of an abdominal mass. Percussion over the mass is important to predict the anatomical location of the mass. If mass is dull, then it is in the anterior abdominal wall or in front of the bowel intra-abdominally like liver, spleen, gallbladder. If the mass is with a impaired resonant note, then the mass is arising from the bowel like stomach, colon, small bowel. If the mass is resonant on percussion, then the mass is probably in the retroperitoneal region. Other than this, liver dullness, free fluid in the abdomen should be elicited during percussion.

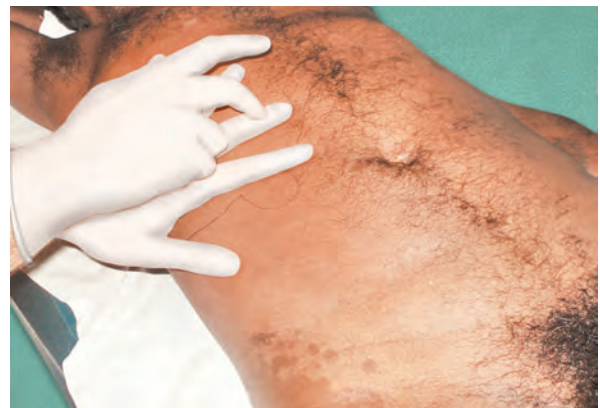- ◆ *Per rectal examination:* It is done to look for any secondaries in rectovesical pouch, primary tumour or relation of lower abdomen masses (pelvic masses).
- ◆ *Pervaginal examination* is done to assess pelvic masses.



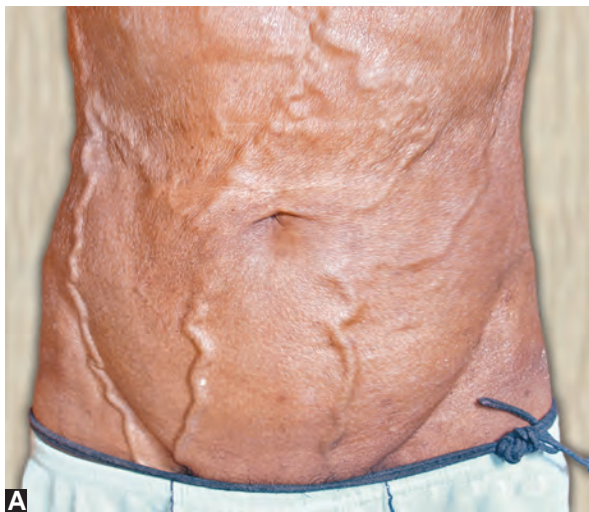**Fig. 16.3:** Superior vena caval obstruction causing dilated veins in the neck, chest wall and shoulder. Note the neck swelling extending into the mediastinum.



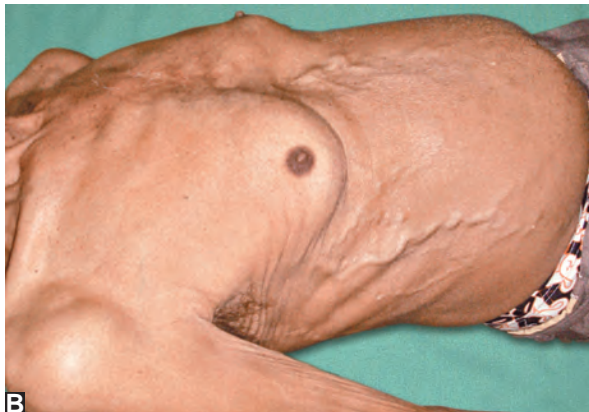**Fig. 16.5:** Abdomen mass should be palpated clinically properly.



**Fig. 16.6:** Percussion over the mass is absolute need to find out the plane of the mass. Anterior masses are dull on percussion; posterior masses are resonant and mass from bowel has impaired resonance.

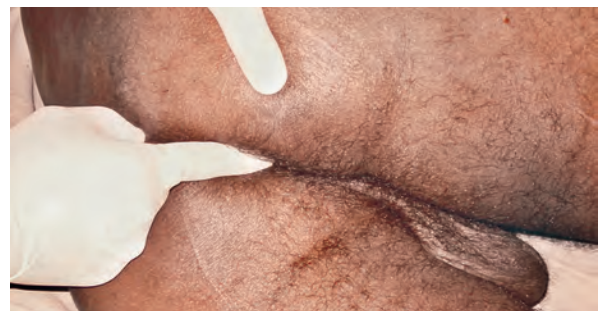

**A**

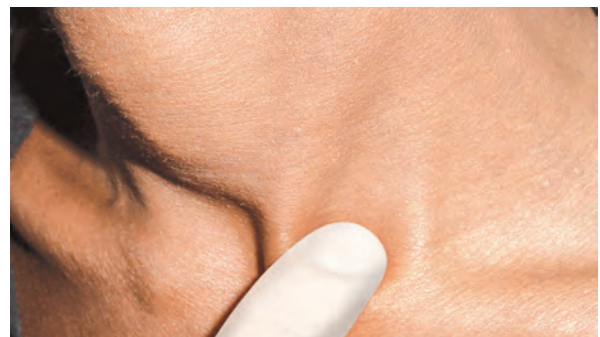

**B**

**Figs 16.4A and B:** Inferior vena caval obstruction causing dilated veins over the lateral aspect of the flank with flow of blood upwards.

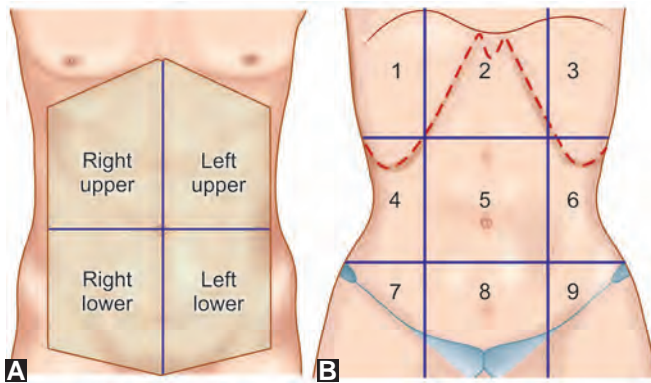


**Fig. 16.7:** Digital examination of rectum is a must in patients with mass abdomen to look for secondaries, possible primary and often to assess the mass itself.



**Fig. 16.8:** Neck should be examined for left supraclavicular lymph node enlargement in all abdominal masses.





**Figs 16.9A and B:** (A) Different quadrants in the abdomen. They are four in number formed by two lines—one is vertical midline through the umbilicus; another is horizontal line passing through the umbilicus. Quadrants are—right upper, right lower, left upper and left lower, (B) Regions in the abdomen.

### Regions in the abdomen

1. Right hypochondrium
2. Epigastric region
3. Left hypochondrium
4. Right lumbar region
5. Umbilical region
6. Left lumbar region
7. Right iliac fossa
8. Hypogastrum
9. Left iliac fossa

Abdomen is divided into nine regions by four lines.

1. Upper horizontal or *transpyloric line* is mid-way between the umbilicus and xiphisternum.
2. Lower horizontal line is *transtubercular line* at the level of two tubercles on the iliac crest.
3. Right vertical line is the line through the midpoint of right antero-superior iliac spine and pubic symphysis.
4. Left vertical line is the line through the midpoint of left antero-superior iliac spine and pubic symphysis.

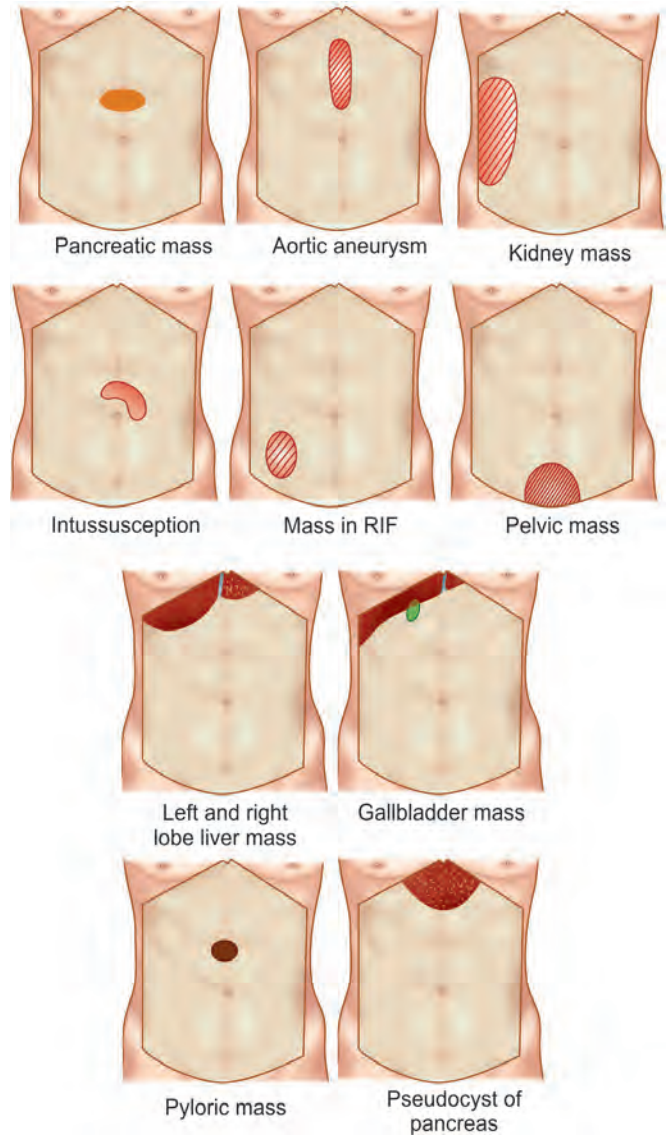
## MASS IN THE RIGHT HYPOCHONDIUM

### Liver Palpable as Mass in Right Hypochondrium

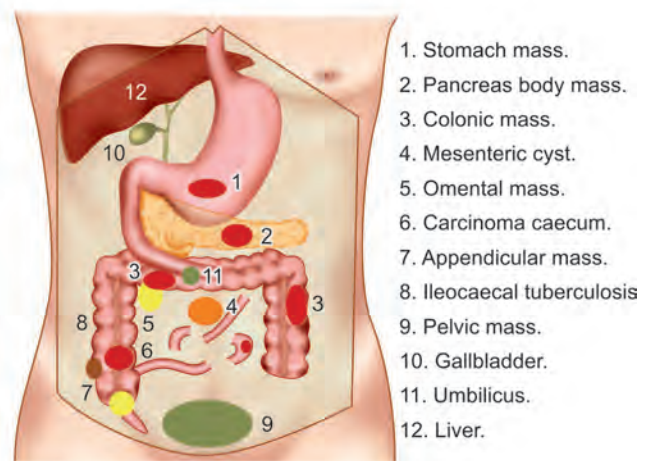
- ◆ It is horizontally placed.
- ◆ It usually moves with respiration.
- ◆ Upper border is not felt.
- ◆ It is dull on percussion (This dullness continues over liver dullness above).
- ◆ Fingers can not be insinuated under right costal margin.

Conditions where liver gets enlarged:

1. *Soft, smooth, nontender liver:*
  - ▶ *Hydrohepatosis:* It is due to obstruction of CBD causing dilatation of intrahepatic biliary radicles.
  - ▶ Congestive cardiac failure.
  - ▶ *Hydatid cyst of the liver:* Here mass is well-localised in the liver with typical hydatid thrill. *Three finger test:* Three fingers are placed over the mass widely. When central finger is tapped fluid movement is elicited in lateral two fingers.



**Fig. 16.10:** Mass abdomen.



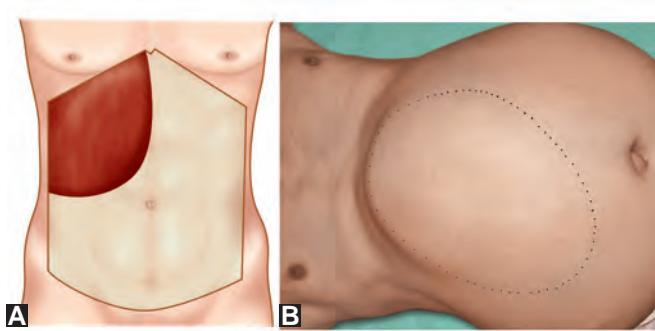
**Fig. 16.11:** Different causes of mass abdomen.

2. *Soft, smooth, tender liver:*

- ▶ *Amoebic liver abscess:* Here liver often gets adherent to the anterior abdominal wall and will not move with respiration. Intercostal tenderness, right-sided pleural effusion are common.

3. *Hard, smooth liver:*

- ▶ *Hepatoma (HCC):* Here a large, single, hard nodule is palpable in the liver. But occasionally there can be multiple nodules when it is multicentric. Rapidly growing tumour can be soft also. Hepatoma often can also be tender due to tumour necrosis or stretching of the liver capsule. Vascular bruit may be heard over the liver during auscultation. It mimics amoebic liver abscess in every respect.
- ▶ Solitary secondary in liver.



**Figs 16.12A and B:** (A) Hepatocellular carcinoma/hepatoma. It is common in right lobe, unilocular, attains large size; (B) Large upper abdomen mass—could be liver mass, pancreatic mass, retroperitoneal mass.

4. *Hard, multinodular liver:*

- ▶ Multiple secondaries in liver: Here hard nodules show umbilication which is due to central necrosis.
- ▶ Macronodular cirrhotic liver.

### Palpable Gallbladder in Right Hypochondrium

- ◆ It is smooth and soft (except in carcinoma gallbladder).
- ◆ It is mobile horizontally (side-to-side).
- ◆ It moves with respiration.
- ◆ It is located right of the right rectus muscle, below the right costal margin or below the lower margin of the palpable liver.
- ◆ It is dull on percussion.

*Conditions where gallbladder is palpable:*

1. *Soft, nontender gallbladder:*

- ▶ Mucocele of the gallbladder.
- ▶ Enlarged gallbladder in obstructive jaundice due to carcinoma head of the pancreas or periampullary carcinoma or growth in the CBD.

2. *Hard gallbladder:*

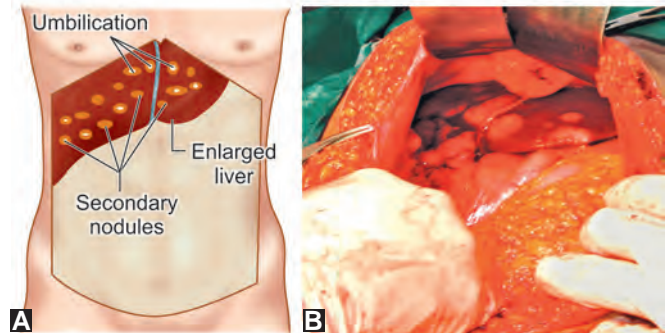
- ▶ Carcinoma gallbladder.

3. *Tender gallbladder—empyema GB.*

### Other Masses in the Right Hypochondrium

- ◆ *Pericholecystic inflammatory mass:* It is tender, smooth, firm or soft, nonmobile, intra-abdominal mass often with guarding.

- ◆ *Kidney mass arising from upper pole of the kidney:* It may be due to renal cell carcinoma or hydronephrosis.



**Figs 16.13A and B:** Multiple secondaries in liver with umbilication. It is due to central necrosis. Secondaries are the most common malignant tumour of the liver. It could be from GIT or extra-gastrointestinal sites like from breast, lungs, melanoma, thyroid, prostate, kidneys, etc. Patient with liver secondaries has got poor general condition. It should be differentiated from multicentric hepatoma. It is usually treated by palliative chemotherapy. Solitary secondary from carcinoma colon can be removed by segmentectomy.

## MASS IN THE EPIGASTRIUM

### Palpable Left Lobe of the Liver

- ◆ It is in the epigastric region.
- ◆ Its upper border cannot be felt.
- ◆ It moves with respiration.
- ◆ It extends towards left hypochondrium.
- ◆ It is dull on percussion.

#### Conditions where left lobe of the liver is palpable

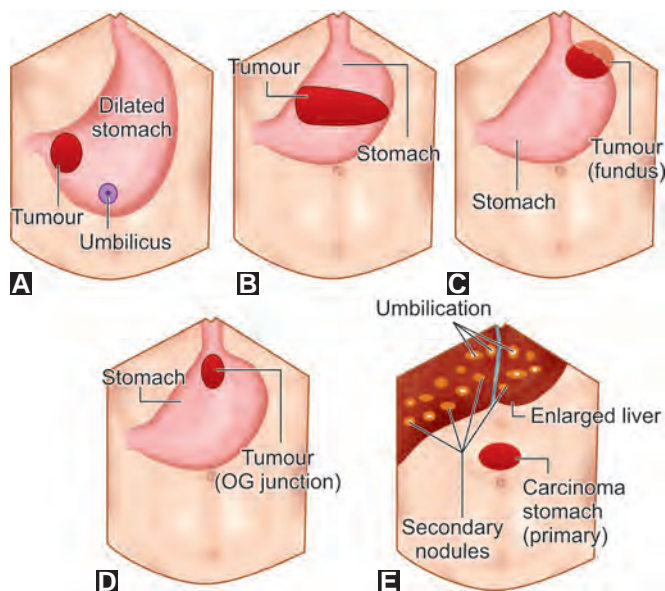
- ❖ Hepatoma
- ❖ Amoebic liver abscess in left lobe
- ❖ Left lobe secondaries
- ❖ Hydatid cyst of the left lobe

### Features of Stomach Mass

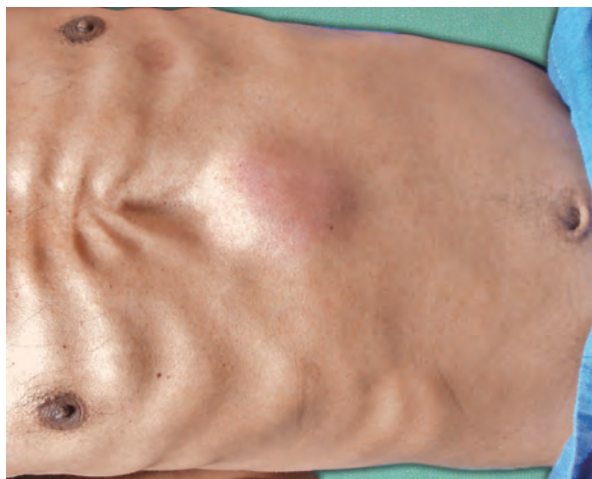
- ◆ It is located in the epigastric region.
- ◆ It moves with respiration. It is intra-abdominal.
- ◆ It is resonant or impaired resonant on percussion.
- ◆ Mass may be better felt on standing or on walking.
- ◆ Mass is often mobile, unless it gets adherent posteriorly.
- ◆ In pylorus mass, all margins are well felt which is mobile with features of gastric outlet obstruction.
- ◆ Mass from the body of the stomach is horizontally placed without any features of obstruction.
- ◆ Mass from the upper part of the stomach near the OG junction causes dysphagia.
- ◆ Mass from the fundus of the stomach is in the upper part of the epigastric region towards left side.
- ◆ Carcinoma stomach is nodular and hard. It is the most common cause for stomach mass.
- ◆ Leiomyoma of stomach is smooth and firm.

*As beds and couches vary in height, the examiner to palpate the abdomen, if need be, must sit on a suitable chair or even kneel upon the floor, no matter how undignified this may appear.*

— Charles P



**Figs 16.14A to E:** Carcinoma pylorus causes gastric outlet obstruction with palpable mass above the umbilicus. Carcinoma body of stomach mainly presents as loss of appetite and decreased weight with horizontally placed stomach mass. Carcinoma from fundus of the stomach presents as mass abdomen with loss of appetite and weight. Carcinoma oesophagogastric (OG) junction presents as dysphagia. Carcinoma stomach is one of the common causes of secondaries in liver.

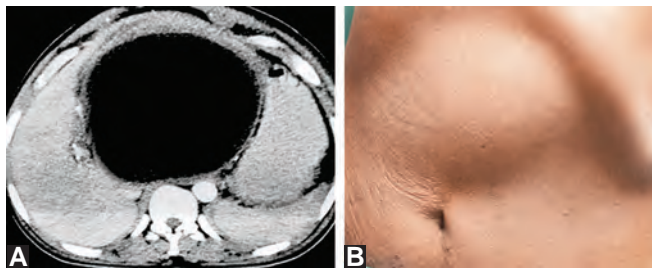


**Fig. 16.15:** Epigastric mass arising from carcinoma stomach.

### Pseudocyst of the Pancreas

- ◆ Mass in the epigastric region. It is smooth, soft. It can be tender if it is infected.
- ◆ It does not move with respiration.
- ◆ It is not mobile.
- ◆ It has got transmitted pulsation. It is confirmed by placing the patient in knee-elbow position.
- ◆ Lower border is well felt. Upper border is not clear.
- ◆ It is resonant on percussion.

- ◆ *Baid test:* As the stomach is pushed in front, Ryle's tube when passed, can be felt per abdomen on palpation.



**Figs 16.16A and B:** (A) Pseudocyst of pancreas—CT scan picture; (B) Pseudocyst of pancreas presenting as epigastric mass.

### Cystadenocarcinoma of the Pancreas

Mass is smooth, firm, does not move with respiration, nonmobile, resonant on percussion. Patient complains of back pain.

### Colonic Mass

- ◆ It is due to carcinoma of transverse colon.
- ◆ It is mobile, horizontally placed, nodular, hard mass which does not move with respiration. Caecum will be dilated and palpable.
- ◆ It is resonant or impaired resonant on percussion.
- ◆ Patient will be having bowel symptoms, loss of appetite and decreased weight.

### Para-aortic Lymph Node Mass

- ◆ Mass in the epigastric region which is deeply placed, nonmobile, not moving with respiration.
- ◆ It is vertically placed, above the level of the umbilicus and resonant on percussion.
- ◆ Causes for enlargement are: *Secondaries, lymphomas or tuberculosis.*

### Aortic Aneurysm

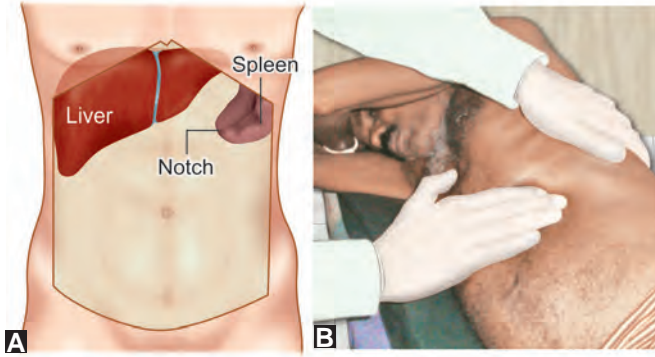
It is smooth, soft, pulsatile (expansile pulsation which is confirmed by placing the patient in knee-elbow position).

It is vertically placed above the level of the umbilicus, nonmobile, not moving with respiration and resonant on percussion.

## MASS IN THE LEFT HYPOCHONDIUM

### Enlarged Spleen

- ◆ Spleen has to enlarge three times to be palpable clinically.
- ◆ It enlarges towards the right iliac fossa from left costal margin.
- ◆ It moves with respiration, mobile, obliquely placed, smooth, soft or firm, with a notch on the anterior edge which is directed downwards and inwards.
- ◆ Fingers cannot be insinuated over the upper border.
- ◆ "*Hook sign*" is positive, i.e. one cannot insinuate the fingers under the left costal margin.
- ◆ It is dull on percussion.



**Figs 16.17A and B:** (A) Hepatosplenomegaly is the common condition (clinical entity). It is due to macronodular cirrhosis with portal hypertension, lymphoma, autoimmune diseases, congestive cardiac failure, hepatoma with portal hypertension, haemolytic diseases, etc. There may be ascites, supraclavicular palpable lymph node and pleural effusion (right-sided); (B) Method of palpating spleen.

### Left-sided Colonic Mass

- ◆ It is mobile, nodular, resonant.
- ◆ It does not move with respiration.
- ◆ It is commonly due to carcinoma colon.

### Left Renal Mass from Upper Pole of any Cause

It has got features of renal mass.

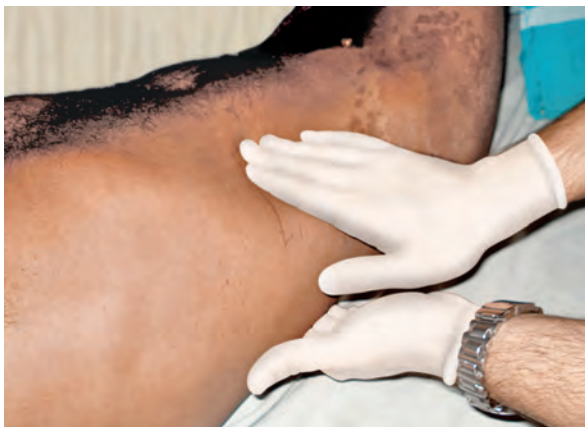### Left-sided Adrenal Mass

- ◆ It does not move with respiration. It is not mobile.
- ◆ It is deeply placed mass. Often it crosses the midline.
- ◆ It is resonant on percussion. It mimics kidney mass.

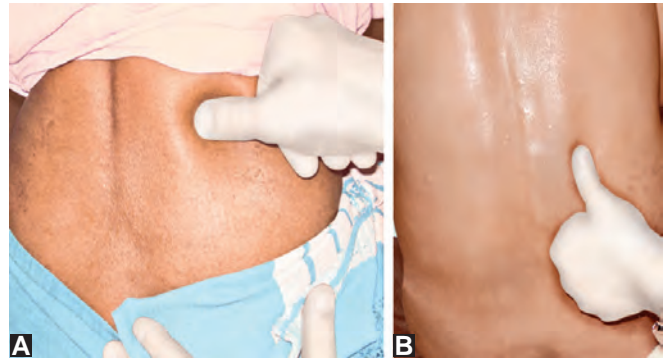
### Mass Arising from the Tail of the Pancreas

Clinical features are same as other pancreatic masses. Causes are pseudocyst in tail of the pancreas and cystadenomas.

## MASS IN THE LUMBAR REGION



**Fig. 16.18:** Kidney should be palpated bimanually with two hands. Ballotability also should be checked.



**Figs 16.19A and B:** Renal (Kidney) punch. Renal angle should be palpated for tenderness. Renal angle is junction of 12th rib and erector spinae. *On percussion it is normally resonant* as it is occupied by colon. It is replaced by kidney in kidney enlargement. Renal angle should be inspected, palpated and percussed in sitting position from behind.

### Palpable Kidney Mass

- ◆ There is fullness in the loin which is better observed in sitting position.
- ◆ Mass moves with respiration. It is vertically placed.
- ◆ It is bimanually palpable. It is ballotable.
- ◆ Renal angle is dull on percussion (normally it is resonant due to colon).
- ◆ There is a band of resonance in front due to reflected colon.
- ◆ It does not cross the midline.

### Conditions Where Kidney Gets Enlarged

#### Hydronephrosis:

- ◆ It is smooth, soft, lobulated, nontender mass, nonmobile.

#### Pyonephrosis:

- ◆ History of throbbing pain in the loin, pyuria and fever with chills.
- ◆ It is smooth, soft and tender kidney mass, nonmobile.

#### Polycystic kidney:

- ◆ History of loin pain and haematuria.
- ◆ Hypertension, anaemia and features of renal failure.
- ◆ Usually bilateral. But one side can present early than on the other side.
- ◆ Lobulated smooth surface.

#### Renal cell carcinoma:

- ◆ History of mass in the loin, haematuria, fever and dull pain.
- ◆ Mass is nodular and hard.
- ◆ It does not cross the midline.
- ◆ Initially mobile; eventually it infiltrates gets fixed and becomes nonmobile.

### Mass from the Ascending Colon on Right Side or Descending Colon on Left Side

- ◆ History of altered bowel habits with decreased appetite and weight.
- ◆ Mass is nodular, hard which does not move with respiration and is not ballotable.
- ◆ It is resonant or there is impaired resonance on percussion.
- ◆ Renal angle is resonant.
- ◆ Proximal dilated bowel may be palpable.

## Adrenal Mass

- ◆ It is nodular and hard.
- ◆ It does not move with respiration.
- ◆ It is not mobile and often crosses the midline.
- ◆ It is felt on deep palpation.
- ◆ It is resonant in front.
- ◆ It is not ballotable.

## Retroperitoneal Tumours

- ◆ They are not mobile, resonant and do not fall forward in knee-elbow position.
- ◆ They are deeply placed mass which are usually smooth and hard.
- ◆ They may be retroperitoneal sarcomas or teratomas or lymph node mass.

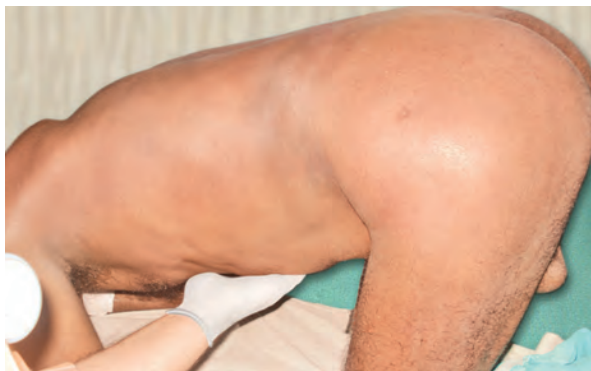

Fig. 16.20: Palpation of mass in knee-elbow position. Mobility and falling forward should be confirmed in knee-elbow position.

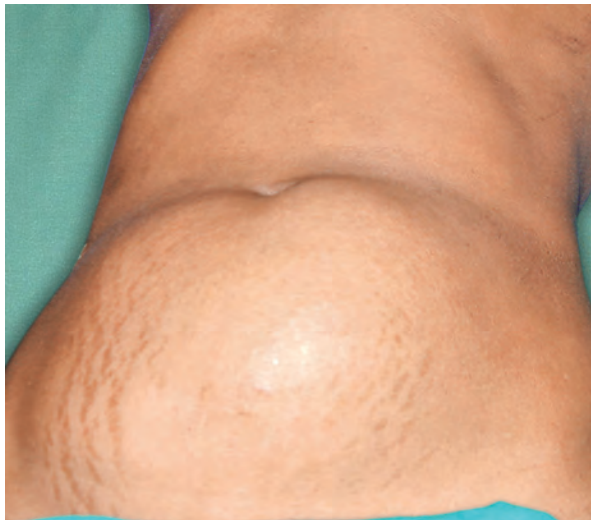


Fig. 16.21: Retroperitoneal tumour.

## Retroperitoneal Cysts

They are *smooth and soft* with the same features as retroperitoneal tumours.

### Cystic lesions in the abdomen

- ❖ Mucocele/empyema of gallbladder
- ❖ Pseudocyst of pancreas
- ❖ Hydatid cyst of liver
- ❖ Congenital nonparasitic cyst of liver
- ❖ Hydronephrosis
- ❖ Mesenteric cyst
- ❖ Ovarian cyst
- ❖ Omental cyst
- ❖ Aneurysm
- ❖ Retroperitoneal cyst
- ❖ Cystadenocarcinoma of ovary
- ❖ Loculated ascites

## MASS IN THE UMBILICAL REGION

### Usual masses are:

- ❖ Mesenteric cyst
- ❖ Omental cyst
- ❖ Ovarian cyst (pedunculated)
- ❖ Small bowel tumours
- ❖ Extension of masses from other region
- ❖ Transverse colon mass
- ❖ Mass in the body of pancreas
- ❖ Mesentery mass
- ❖ Lymph node mass—secondaries (primary from GIT, testis, ovary, melanoma)/lymphoma/tuberculosis
- ❖ Retroperitoneal tumour

## Mesenteric Cyst

- ◆ **Tillaux triad:**
  1. Soft intra-abdominal umbilical mass.
  2. Mobile in the direction perpendicular to the attachment of the mesentery.
  3. Resonant mass.
- ◆ May precipitate intestinal obstruction, volvulus.

## Omental Cyst

- ◆ It is smooth, soft and nontender.
- ◆ It moves with respiration. It is mobile in all directions.
- ◆ It is dull on percussion.

## Small Bowel Swellings

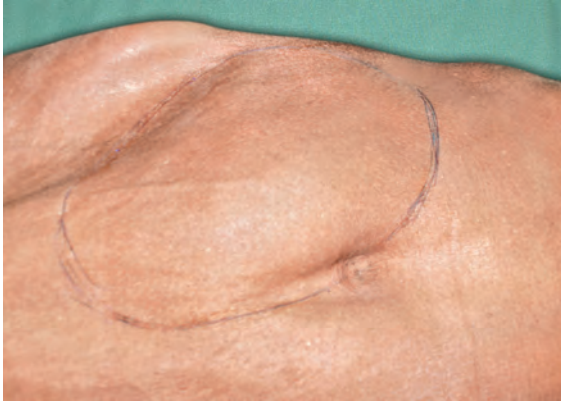- ◆ Small bowel lymphomas.
- ◆ Small bowel carcinomas.
- ◆ Intussusception.

## Intussusception

- ◆ Mass in umbilical region usually towards left and above the umbilicus.
- ◆ Occasionally towards right side.
- ◆ Mass is intra-abdominal which is *sausage shaped*, with concavity towards umbilicus, well-defined, smooth, firm and mobile.
- ◆ *Mass does not move with respiration.*
- ◆ Mass contracts under palpating fingers.

- ◆ Often mass disappears and reappears.
- ◆ Mass is resonant or there is impaired resonance on percussion.
- ◆ “Red currant jelly” stool with features of intestinal obstruction may be present.

## MASS IN THE RIGHT ILIAC FOSSA



**Fig. 16.22:** Mass in right iliac fossa. All possible differential diagnosis should be considered and clinically analysed. Common masses are appendicular mass; carcinoma caecum; ileocaecal tuberculosis; lymph node mass; amoeboma.

- ❖ Appendicular mass or abscess
- ❖ Carcinoma caecum
- ❖ Ileocaecal tuberculosis
- ❖ Amoeboma
- ❖ Psoas abscess
- ❖ Lymph node mass either mesenteric or external Iliac lymph nodes
- ❖ Bony swellings
- ❖ Ectopic kidney
- ❖ Undescended testis (Abdominal)
- ❖ Actinomycosis
- ❖ Crohn's disease
- ❖ Iliac artery aneurysm
- ❖ Ovarian swelling-ovarian cyst
- ❖ Tubo-ovarian mass
- ❖ Uterine mass like pedunculated fibroid

### Appendicular Mass

- ◆ It is *smooth, firm, tender mass* in the right iliac fossa.
- ◆ It is not mobile. It does not move with respiration.
- ◆ It is *resonant on percussion*. It is well-localised mass with distinct borders.

### Appendicular Abscess

It is *smooth, soft, tender and dull mass* in the right iliac fossa with indistinct borders.

### Carcinoma Caecum

- ◆ It is nodular, hard, mass in the right iliac fossa.
- ◆ It does not move with respiration.
- ◆ It is mobile but mobility may be restricted once it gets adherent to psoas muscle.
- ◆ Mass is resonant or there is impaired resonance on percussion.
- ◆ Often features of intestinal obstruction may be present.

### Ileocaecal Tuberculosis

- ◆ Mass in the right iliac fossa which is smooth, hard, resonant and nontender.
- ◆ It does not move with respiration and has restricted mobility.
- ◆ Caecum may be *pulled up* to lumbar region due to fibrosis.

### Amoeboma

- ◆ History of dysentery with pain in the right iliac fossa.
- ◆ Smooth, hard, well-defined mass in the right iliac fossa which is nonmobile.
- ◆ It may or may not be tender.

### Psoas Abscess

- ◆ It is localised, smooth, soft, nonmobile mass in the right iliac fossa.
- ◆ *Psoas spasm* (flexion of the hip joint) is typical.
- ◆ Spine may show *gibbus, tenderness, paraspinal spasm*. Spinal movements will be restricted.

## MASS IN THE LEFT ILIAC FOSSA

- ❖ Carcinoma sigmoid or descending colon
- ❖ Bony masses
- ❖ Ovarian/uterine masses
- ❖ Psoas abscess
- ❖ Ectopic kidney
- ❖ Lymph node mass
- ❖ Undescended testis

## MASS IN THE HYPOGASTRIUM

### Bladder Mass

- ◆ It is in the midline. It is dull on percussion. Lower border is not felt.
- ◆ It can be mobile in horizontal direction. Mass reduces in size after emptying the bladder. It can be felt on per-rectal examination.
- ◆ It is either carcinoma bladder (common) or leiomyoma or sarcoma bladder.

### Uterine Mass

- ◆ It is midline mass which is smooth, hard.
- ◆ Lower border is not felt which extends into the pelvis.
- ◆ It is felt on pervaginal examination.

### Ovarian Mass

Pelvic soft tissue mass.

*In all lower abdomen masses P/R and/or P/V is a must.*

*In all regions **parietal masses** can occur:*

- ◆ Benign and malignant soft tissue tumours.
- ◆ Common, is lipoma.
- ◆ Fatty hernia of linea alba.
- ◆ Desmoid tumour.
- ◆ Parietal wall abscess.

*Blaxland ruler test (Athelstan J Blaxland):* A flat ruler placed on the lower abdomen just above the anterosuperior iliac spines and pressed firmly backwards. In ovarian cyst, aortic pulsation is transmitted to fingers through ruler; it is not so in ascites.

### Carnett's test

The patient, in lying down position, is asked to lift both legs off the bed with knee extended. This puts the abdominal muscles into contraction. Intra-abdominal mass becomes less prominent, parietal mass persists as same, but becomes less mobile.

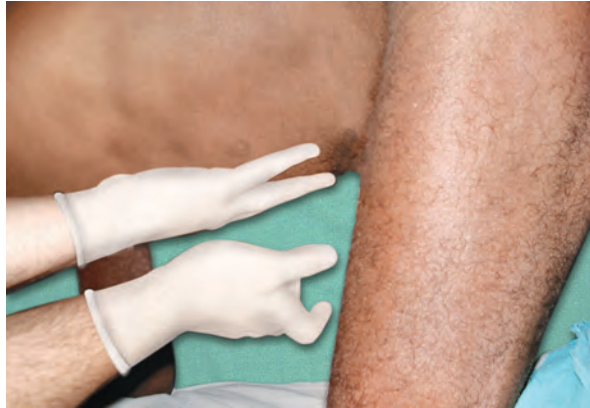

Fig. 16.23: Looking for minimal ascites in knee-elbow position—Puddle sign.

### Investigations for Mass Abdomen

- ◆ Haematocrit, liver function tests, renal function tests, stool/urine examination.
- ◆ Ultrasound abdomen.
- ◆ Endoscopies-gastroscopy-colonoscopy-ERCP-MRCP.
- ◆ Barium studies-Barium meal-Barium enema-Barium meal follow through.
- ◆ CT scan-MRI.
- ◆ Endosonography.
- ◆ Ascitic tap.
- ◆ Diagnostic laparoscopy.
- ◆ Ultrasound-guided/CT-guided biopsy.
- ◆ IVU/RGP/Cystoscopy/Isotope renogram.
- ◆ Exploratory laparotomy.

### Note

- ❖ Hard mass in the abdomen is commonly malignant
- ❖ Firm mass may be tuberculous, lymphoma or many benign conditions
- ❖ Soft masses are hydronephrosis, pseudocyst, mesenteric cyst, omental cyst, and loculated ascites
- ❖ In tuberculosis abdomen may be doughy due to thickened parietal peritoneum or omentum
- ❖ It is difficult to elicit fluctuation in the mass abdomen as mass cannot be fixed properly
- ❖ Plane of the swelling should be checked by leg raising/head raising test/Valsalva manoeuvre/knee elbow test
- ❖ Bimanual palpation, ballotability, renal angle inspection, palpation and percussion should be done in case of renal mass
- ❖ Intrinsic mobility should be checked. Different mobilities/movements are—gallbladder shows side to side; stomach lateral; ovarian mass—all over; mesenteric cyst—right angle to line of mesentery; transverse colon mass—vertical; small bowel mass all over; appendicular mass/pancreatic mass/nodal mass

Contd...

Contd...

(para-aortic)/retroperitoneal mass do not show any mobility; cystadenocarcinoma of pancreas may show false mobility (*tree top mobility*)

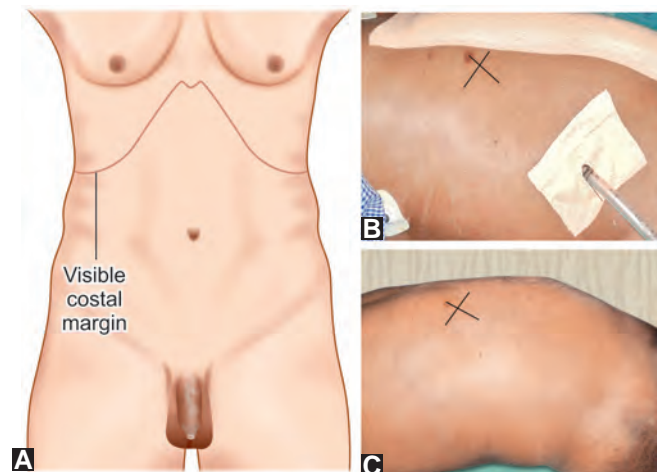
- ❖ Percussion is very important method of examination to find out the anatomical plane of the mass. Mass in front of the bowel like liver/spleen/gallbladder/parietal mass are dull on percussion. Mass from the bowel is resonant on percussion like from stomach, small bowel and colon. Retroperitoneal masses like cyst, sarcoma, nodal mass, aneurysm, pancreatic mass are resonant on percussion
- ❖ Succussion splash and auscultopercussion tests are done for gastric outlet obstruction in pyloric stenosis
- ❖ Digital examination of rectum (PR) and left supraclavicular examination for nodes is a must. PR is done to see Blumer shelf secondaries in rectovesical pouch. Pervaginal examination should be done in pelvic mass in females
- ❖ Bladder should be emptied while examining pelvic mass
- ❖ Bimanual examination is done often under general anaesthesia in case of pelvic mass
- ❖ Auscultation for bruit depends on condition and location of mass—over epigastrium, over liver
- ❖ Other relevant systemic examination is a must in examination of mass abdomen—respiratory system, skeletal and neurological systems

### Mass that appears and disappears

- ❖ Pseudocyst of pancreas (communicating)
- ❖ Hydronephrosis (intermittent)
- ❖ Choledochal cyst
- ❖ Intussusception

### Srinivasan Costal Sign

*Srinivasan costal sign* is an inspeitory finding to assess the acute distended abdomen secondary to surgical or post-operative status or medical causes under treatment. The bilateral costal margin is visualised tangentially on the either side of the abdomen in supine position to appreciate this costal sign.



Figs 16.24A to C: Srinivasan costal sign: This sign can be appreciated under inspection, the costal margin which is not visible or poorly visible in case of distended abdomen. Once the acute abdomen or distended abdomen secondary to medical cause start settling, the costal margins become visible and prominent, this holds good even in case of fatty protuberant abdomen.

“Prominence of costal margins will be lost in distended abdomen. During therapy, once distension reduces, prominence of costal margins will be visible (during recovery)”.

### Acknowledgements

With kind permission, from Professor Narayanaswamy Srinivasan, MS, FRCS, who was earlier worked as HOD, General Surgery, Bangalore Medical College; Director of Sanjay Gandhi Accident Hospital and Research Institute, Byrasandra, Bengaluru; Dean and Director of Bangalore Medical College and Research Institute, Bengaluru; Joint Director of Medical Education, Government of Karnataka, India.

## DIGITAL RECTAL EXAMINATION FOR PROSTATE AND OTHER CONDITIONS

(By kind permission from Professor Laxman Prabhu, MS, MCh, Urologist, Kasturba Medical College, Mangaluru)

*Rectum is the Dictum*

—Anonymous

The prostate by virtue of its placement just anterior to the rectum easily tends itself to digital examination. This makes Digital rectal examination (DRE) of the prostate not only easy but an effective method of clinical assessment of prostatic diseases. The prefix ‘digital’ to rectal examination of the prostate became a necessity with the advent of transrectal ultrasound of the prostate (Watanabe et al 1968, 1974) when the two methods of examining the prostate, namely *digital* (clinician’s forefinger) and *sonological per rectum* were established as reliable clinical tools.

### DRE is employed in the following situations specifically with respect to affections of the prostate

1. Grading of benign prostatic enlargements.
2. Local staging of prostatic cancer and in the performance of digitally guided biopsy.
3. In the evaluation of inflammatory disorders of the prostate.
4. To assess the integrity of prostatic-membranous urethra in suspected urethral injuries.
5. In the evaluation of ejaculatory dysfunctions.

### Note:

- Few generalizations in DRE are essential. The need for a rectal examination is explained to the patient and his consent is taken. The patient is always requested to empty the bladder. During this, urinary samples of initial stream and midstream are collected for culture in sterile wide-mouthed receptacles. Abdominal examination to rule out a distended bladder should always precede examination of the prostate. Findings on DRE of the prostate are unreliable in the presence of a full bladder. Posterior surface of the distended bladder can be erroneously labeled as a large prostate. Uroflowmetry can be performed during voiding to empty the bladder whenever appropriate or if such facility is accessible.
- It is absolutely essential to ensure privacy. Chaperoning (as insisted while examining a female patient) is not necessary but a caretaker may be allowed to stand next to the patient, especially when the patient is very old and dependent on assistance; presence of a female nurse is better.

- DRE can be uncomfortable in those patients who are apprehensive and this may persuade the inexperienced clinician to conclude that the patient has a tender prostate.
- It is recommended that DRE is done only after collecting blood for prostatic specific antigen (PSA) assay as digital manipulation can falsely raise the PSA value (<4 ng/ml is taken as normal), though elevation caused by rectal examination is negligible.
- In those with co-existing painful rectal conditions like fissure-in-ano, digital examination is avoided or done with utmost gentleness using local anesthetic jelly for lubrication of the examining digit. In patients with prostatic abscess and neutropenia, digital examination can precipitate bacteremia.

## The Technique of Rectal Examination

The following positions can be used to perform DRE: (1) *Left lateral position* where patient lies on the left side with knees and hips flexed. (2) *Dorsal position* where the patient is supine with knees flexed, hips abducted and the feet squarely on the couch. This position easily orients the clinician as to the two sides of lobes of the prostate facilitating diagrammatic recording. (3) *The lithotomy position* is used whenever a prostatic biopsy is performed. (4) *Other positions like right lateral, knee elbow and Picker position* (patient leaning forward onto to a stool/examination table to facilitate the proper feel of seminal vesicle while DRE) are rarely used.

### Note:

- Standard works on clinical methods from the western countries recommend knee-elbow/chest position as the most suitable for DRE of the prostate. The other position used for DRE in the west is one where the patient is standing and bent over the examination table. However, these two positions are seldom used in India and many countries.
- DRE begins by separating the buttocks and inspecting the perianal region. The gloved examining digit is lubricated well with lignocaine jelly or white petroleum jelly and introduced into the rectum with gentleness, pulp of the digit first. Only one phalanx is inserted initially and the clinician awaits relaxation of the anus. The anal tone is gauged during this, which mirrors the tone of the urinary sphincters.

*The finger is then advanced slowly into the rectal lumen and the entire prostate is palpated carefully noting the following:*

- ◆ The normal landmarks namely the median sulcus and the lateral sulci (preserved or obliterated).
- ◆ The surface of the gland (smooth, granular, nodular or irregular).
- ◆ The consistency of the gland. The normal consistency is likened to that of a contracted thenar eminence with the thumb opposed to the little finger.
- ◆ The size (*Grading by Roger Barne’s method*).
- ◆ Presence or absence of tenderness.
- ◆ Rectal mucosa (free or adherent).
- ◆ Mobility of the gland.
- ◆ Elicit the Bulbo-cavernosus reflex (S2-4).
- ◆ When an indwelling catheter is present, note whether the same can be felt through the substance of the prostate. Its presence can also be exploited to elicit the BC reflex.
- ◆ Inspection of the external urinary meatus after DRE for any discharge (suggestive of inflammatory pathology).



### Normal DRE

- ❖ The clinician should possess a clear conception of what is normal on DRE with respect to prostate and structures about it. The normal prostate feels firm and elastic and this feel is unmistakable as the structures around the prostate have a contrasting consistency.
- ❖ The two lateral lobes separated by the median furrow, also known as median sulcus, are about the size equaling the distal segment of the thumb. When the examining digit is run along the median sulcus above downwards, it encounters a soft area just distal to the apex of the prostate and this corresponds to the membranous urethra.
- ❖ An indwelled catheter can be felt here. On either sides of this point lie the bulbourethral glands of Cowper.
- ❖ Upon sliding the finger upwards in the median sulcus, one can reach the upper margin of the gland, on either sides of which are located the seminal vesicles. Normal seminal vesicles are not palpable. The lymphatics lie between the vesicle and the lateral lobe on each side.

## DRE in Benign Enlargement of the Prostate

The prostate feels typically elastic in benign enlargements implying the gland yields to the pressure exerted by the examining digit only to recoil. When fibrous elements predominate, it feels firm. When the lateral lobes enlarge, they cause convex bulges into the rectal lumen which is invariably apparent to the examining finger. The enlargement of lateral lobes could be asymmetric. It is difficult to make out a purely median lobe enlargement. A median lobe can be felt against a bougie, introduced just before DRE. Rarely, a large median lobe can be felt bimanually in a thin subject. The rectal mucosa can be moved over a benign enlargement, exception being a massive enlargement stretching the anterior rectal wall. The surface of a benign enlargement is usually smooth. A benign prostate retains its mobility which is checked by gently pushing the gland forwards and upwards. A bougie or cystoscope sheath can be used to depress the prostatic urethra to demonstrate this mobility.

It is common practice among urologists to grade prostatic size by DRE.

**The various grades (Normal, Grades 1 to 4) have been published in the endoscopy volume of Encyclopedia Urologica (Roger W Barnes, 1959):**

*Normal:* Encroaches 0–1 cm into the rectal lumen

*Grade 1:* Encroaches 1–2 cm into the rectal lumen

*Grade 2:* Encroaches 2–3 cm into the rectal lumen

*Grade 3:* Encroaches 3–4 cm into the rectal lumen

*Grade 4:* Encroaches more than 4 cm into the rectal lumen

**Note:** The above grading system takes into account only that part of the gland which is bulging into the rectal lumen and hence does not give an accurate estimate of prostatic volume. However, studies have suggested that DRE provides a fairly accurate estimate of the gland size when the prostate measures 50 cm<sup>3</sup> or less.

**The clinical method of grading is as follows:** The examining finger is run over the gland from one side to the other and above downwards to determine the summit of the bulge. The finger is then slide towards the lateral sulcus, mentally counting the number of pulp breadths. Breadth of the digital pulp is roughly taken as one centimeter. Total number of pulp breadths gives the measurement of the encroachment into the rectal lumen, which is recorded as a particular grade.

## DRE in Prostate Cancer

Most cancers of the prostate commence *per primam* in the peripheral zone (McNeal's Zones) of the prostate which is directly accessible to the examining finger. However small and early cancers (Jewett-Whitmore A or T1 of TNM staging) remain impalpable for a long time. Digital rectal examination therefore can pick up only higher stages of the disease (Jewett-Whitmore B and C or T2 and T3 of TNM staging). Stage T2 cancers are felt as indurated or hard areas within the confines of the gland, involving it to varying extent (half of one lobe—T2a; more than half of one lobe—T2b and both the lobes—T2c). Contour abnormalities (asymmetry, loss of median sulcus and irregularity) suggest extraprostatic spread (T3a). The areas of hardness may tail into one or both the seminal vesicles (T3b). The rectal mucosa may be tethered in most areas as the cancer spreads. The mobility of the gland is also lost in higher stages of the disease. When the disease involves the lateral pelvic wall (T4), the situation is called 'frozen pelvis' implying there is total loss of normalcy (vide supra-normal DRE)

In the past, clinicians have used a bougie or a Cystoscope as an aid to clinical methods to evaluate prostatic cancer. A bougie or a cystoscope passed into the bladder is gripped by the prostate as though by a rigid ring and a finger in the rectum feels the instrument with great difficulty where it passes through the gland (**Gerachty's sign**).

Benign enlargements can exist *pari passu* with cancers. It is therefore prudent look for discrete induration within a firm enlargement. Only 50% of abnormal DRE's suggestive of a tumor turn out to be cancers. The fact that an abnormal DRE in the presence of a 'normal' PSA (<4.0 ng/ml) carries a 30% chance of harboring cancer underscores its relevance in clinical practice. Long-standing inflammation and prostatic calculi alter consistency of the gland mimicking a malignant process. Rarely, the prostatic calculi give an impression of 'beads in a bag' and this called **Erichsen's sign**.

*Prostatic biopsy* can be done transrectally with digital guidance. The digit can actually lead the biopsy needle into suspicious areas to enhance the yield of sampling. Systematic multiple biopsies (Four quadrant, sextant, octant, 5 region) can also be done using the digital guidance, although biopsy with transrectal ultrasound guidance has replaced digitally guided biopsies.

## DRE in Inflammatory Disorders of the Prostate

In acute prostatitis, the gland is swollen, tense and exquisitely tender. A great deal of gentleness is desirable during DRE of such a patient. Areas of softening coupled with tenderness are suggestive of an abscess. In chronic prostatitis, the enlargement is minimal with nodularity and exhibits little or no tenderness. In cases of long-standing urethral strictures, the prostate is often flattened and is barely perceptible to the finger. The flattening is a result of high voiding pressures in the prostatic urethra in such patients. Seminal vesicles may be implicated in tubercular afflictions of the prostate, although there are no specific signs which are pathognomonic of this infection. Here, the seminal vesicles are hard and irregular, often described as 'craggy' (characterized by rugged, sharp or coarse features).

It is prudent to complete segmented urine cultures (VB1, 2, 3) in all cases of inflammatory disorders as it helps to localize bacteria to specific parts of the lower urinary tract by sampling different segments of the urinary stream. Further, *expressed prostatic secretions (EPS)* after DRE and prostatic massage will greatly assist in disclosing the presence of inflammation in the prostate.

*VB1 (Voided bladder 1)*: First 10 ml of urine voided. Positive culture indicates urethritis or prostatitis

*VB2 (Voided bladder 2)*: Mid stream urine. Positive culture indicates cystitis

*VB3 (Voided bladder 3)*: First 10 ml of urine voided after prostatic massage. Positive culture indicates prostatitis.

*EPS*: Positive culture indicates prostatitis. Negative culture with increased leukocyte per high power field (>10) indicates inflammatory chronic pelvic pain syndrome.

### DRE in High Riding Prostate

In prostatic-membranous disruptions due to trauma, the prostate is pushed upwards by the expanding pelvic hematoma. This is said to give rise to a sign called 'high riding prostate' or 'pie in the sky'. A large pelvic hematoma can make it impossible to feel the prostate and therefore this is an unreliable sign (Elliot and Barrett, 1997). Blood staining of the finger stall should alert the clinician of a possibility of rectal injury.

### DRE in Bulbocavernosus Reflex (BCR)

With the finger still in the rectum, this reflex is elicited by either squeezing the glans or gently tugging an indwelled catheter. Contraction of the anus around the finger represents a positive BCR, suggestive of integrity of spinal segments S2-4. Negative BCR should prompt a detailed neurological evaluation, especially in a patient with retention of urine deemed to be due to benign prostatic enlargement.

### DRE in Ejaculatory Disorders

Low volume semen may be associated with a flat-atrophied prostate. Turgid and distended seminal vesicles suggest ejaculatory duct obstruction. Prostatic massage with a cystoscope positioned at the verumontanum may prompt an efflux of whitish secretion confirming patency of ejaculatory ducts.

#### Note:

**Therapeutic artifacts**—Therapeutic interventions like long-term ingestion of 5 alpha-reductase inhibitors (Finasteride and Dutasteride); transurethral resection of the prostate; radiation to the prostate and repeated needle biopsies as in active surveillance for prostatic cancer induce changes that may bring about abnormalities of contour and consistency. This should be borne in mind while interpreting findings of DRE.

### DRE in other Surgical Conditions

- ◆ In identifying rectovesical secondaries (*Blumer shelf*) as hard, nodular mass on the anterior aspect of the rectum and above the prostate; here mucosa will be free.
- ◆ *Rectal cancers* are clinically palpable in 90% of cases; elderly patient coming with history suggestive of piles could be due to a growth above in the rectum.
- ◆ *Pelvic masses* can be assessed by DRE often with bimanual palpation with other hand per abdomen in the hypogastrium; usually done under general anaesthesia; bladder tumour also often can be assessed by this. Bladder should be empty ideally here.
- ◆ *Thrombosed piles* is clinically palpable by DRE.
- ◆ *Sphincter tone* can be assessed.
- ◆ In *acute abdominal conditions* like peritonitis, intestinal obstruction, empty rectum and tenderness may be felt.
- ◆ *Pelvic abscess* is felt by DRE as tender, smooth, soft, boggy swelling on the anterior aspect of the rectum. Pelvic abscess can be drained per rectally in males.
- ◆ *Prior to proctoscopy or sigmoidoscopy or colonoscopy DRE is a must.*

# Chapter 17

## Abdominal Wall and Umbilicus

*Why do they meet this most unfortunate and lamentable fate? Have these vessels committed some great crime, that you, O Nature, a just and provident mother to all other parts of the body, have become a step-mother to these alone, so that they deserve to be visited with an affliction so dire, a punishment so severe as wasting and death? Did not the vein continuously supply blood to the fetus? Did not the arteries give life to it? Were they not the means of bestowing increase and nutrition upon the fetus?*

—Girolamo Fabrizio (Fabricius ab Aquapendente), 1649

### CHAPTER OUTLINE

- |                                       |                          |                                                                          |
|---------------------------------------|--------------------------|--------------------------------------------------------------------------|
| ❖ Diseases of the Umbilicus           | ❖ Umbilical Fistula      | ❖ Rectus Sheath Haematoma                                                |
| ❖ Omphalitis                          | ❖ Patent Urachus         | ❖ Abdominal Wall Abscess                                                 |
| ❖ Umbilical Granuloma                 | ❖ Burst Abdomen          | ❖ Meleney's Progressive Synergistic Bacterial Gangrene of Abdominal Wall |
| ❖ Anomalies of Vitellointestinal Duct | ❖ Abdominal Wall Tumours | ❖ Diverication of Recti                                                  |
| ❖ Umbilical Sinus                     | ❖ Desmoid Tumour         |                                                                          |
| ❖ Umbilical Adenoma                   | ❖ Exomphalos             |                                                                          |
|                                       | ❖ Gastroschisis          |                                                                          |

### DISEASES OF THE UMBILICUS

#### 1. Inflammations:

- ▶ Omphalitis.
- ▶ Umbilical granuloma.
- ▶ Pilonidal sinus.

#### 2. Fistulas:

- a. *Faecal*
  - Patent vitellointestinal duct.
  - Neoplastic ulceration.
  - Tuberculosis of peritoneum.
- b. *Urinary*—Patent urachus.

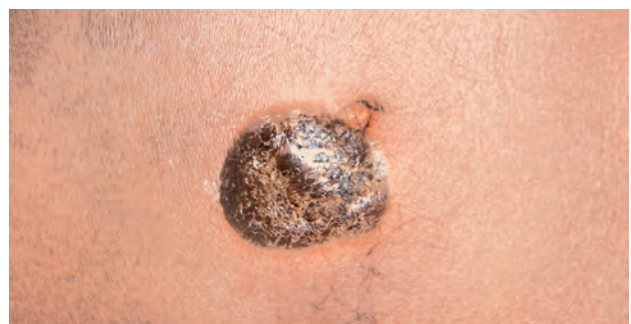#### 3. Neoplasms:

- a. *Benign*
  - Adenoma (Raspberry tumour).
  - Endometrioma.
- b. *Malignant*
  - Primary (rare).

- Secondary carcinoma—Sister Joseph's nodule through lymphatics of the round ligament, primary being in the stomach, colon, ovary, uterus, breast (often blood spread).

#### 4. Umbilical hernias.

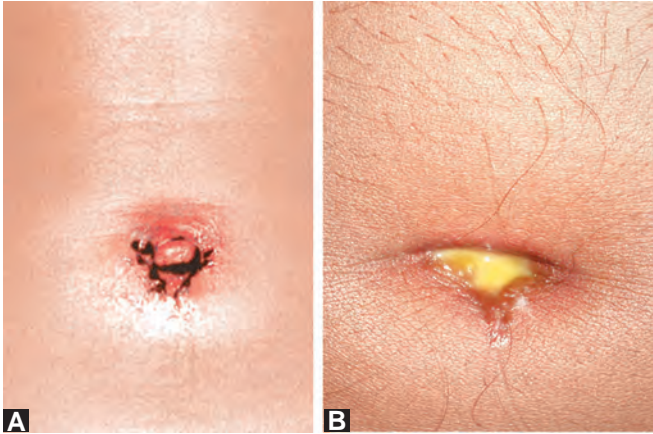
#### 5. Umbilical calculus (Umbolith).



**Fig. 17.1:** Periumbilical pigmented lesion—could be melanoma.

## OMPHALITIS

- ◆ It is infection and inflammation of umbilicus. It is usually seen in newborn babies.
- ◆ Umbilical cord which is severed during birth contains bacteria like staphylococci (50%), streptococci, *E. coli*, *Clostridium tetani* (occasionally). Proper aseptic technique (by staff nurses and doctors) and cleaning of umbilical cord with chlorhexidine solution will reduce the umbilical infection.



**Figs 17.2A and B:** (A) Omphalitis (Umbilical infection); (B) Umbilical sepsis with profuse discharge.

## Causes

- ◆ Ligation of the umbilical cord without aseptic precautions.
- ◆ Poor asepsis and umbilical hygiene during delivery and after birth.

## Bacteria

- ◆ Staphylococci, streptococci.
- ◆ Gram-negative organisms.
- ◆ *Clostridium tetani* causing neonatal tetanus.

## Features

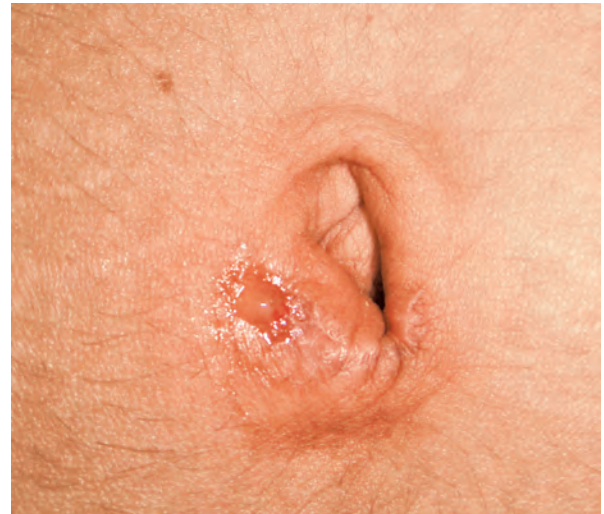- ◆ Infection may spread along the hypogastric vessels into the abdominal wall causing abdominal wall abscess.
- ◆ Infection may spread into the peritoneum causing peritonitis.
- ◆ In severe cases, septicaemia can occur.
- ◆ Umbilical granuloma can occur once infection gets localised.
- ◆ Purulent discharge with red, swollen umbilicus.
- ◆ *Investigations*
  - ▶ Culture study of discharge.
  - ▶ USG abdomen.

## Treatment

- ◆ Antibiotics.
- ◆ Drainage of the abscess.
- ◆ Aseptic precautions while ligating the cord will prevent the chances of umbilical sepsis.
- ◆ Excessive granulation tissue must be removed surgically or by cautery (commonly) using trichloroacetic acid or silver nitrate or copper sulphate in small quantity.

## Complications

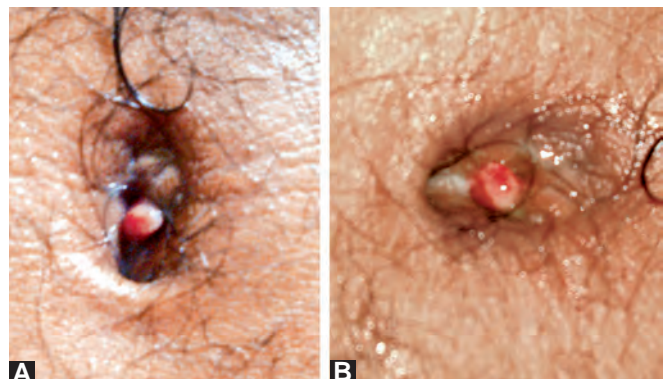
- ❖ Abdominal wall abscess
- ❖ Extensive abdominal wall ulceration and skin and subcutaneous gangrene formation
- ❖ Septicaemia via umbilical vein
- ❖ Peritonitis carries poor prognosis
- ❖ Umbilical granuloma, umbilical hernia
- ❖ Neonatal tetanus
- ❖ Portal vein thrombosis and portal hypertension
- ❖ Neonatal jaundice due to cholangitis—6 weeks after childbirth due to spread of infection into liver across umbilical vein



**Fig. 17.3:** Umbilical infection causing abdominal wall abscess.

## UMBILICAL GRANULOMA

- ◆ It is due to chronic infection of the umbilical cicatrix, causing the granulation tissue to pout, leading to the formation of umbilical granuloma.
- ◆ It occurs in any age group, but common in infants and children. Presents as umbilical discharge with tender, red, swelling protruding from the umbilicus which bleeds on touch.
- ◆ It has to be differentiated from the anomalies of vitello-intestinal duct. It also mimics umbilical adenoma.



**Figs 17.4A and B:** Umbilical granuloma due to sepsis.

*Umbilical black eye is Cullen's sign in acute pancreatitis and ruptured ectopic pregnancy.*

### Treatment

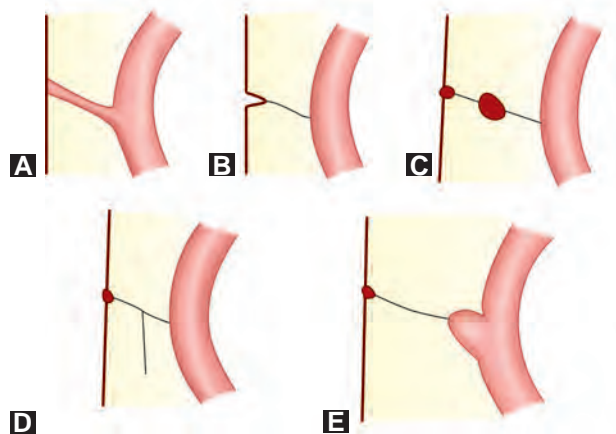
- ◆ Antibiotics, application of silver nitrate and dry dressings.
- ◆ Occasionally might require excision of granuloma or umbillectomy (rarely).

## ANOMALIES OF VITELLOINTESTINAL DUCT

During development of fetus, midgut communicates with yolk sac through vitellointestinal or omphalomesenteric duct. This duct slowly narrows during the development of abdominal wall to lie within the cord, later this communication obliterates to free intestine from yolk sac. Any defect in obliteration causes different anomalies.

### Anomalies are:

1. May remain completely patent, forming a *intestinal fistula*.
2. Only a small portion near the umbilicus may remain patent forming discharging *umbilical sinus*. Often the mucosa of this retained portion (epithelial lining) protrudes or everts to form *umbilical adenoma*.
3. Duct is closed on either side, but the intervening portion may remain as an *intra-abdominal cyst*.
4. Vitellointestinal duct which is obliterated can retain as a *band* which may be a seat for intestinal obstruction, volvulus, internal herniation.
5. Intestinal end may remain patent forming Meckel's diverticulum, which may be attached to umbilicus with a fibrous band. *Meckel's diverticulum* itself can cause diverticulitis, obstruction.



**Figs 17.5A to E:** Anomalies of vitellointestinal duct. (A) Intestinal fistula; (B) Umbilical sinus; (C) Intra-abdominal cyst; (D) Band; (E) Meckel's diverticulum with band.

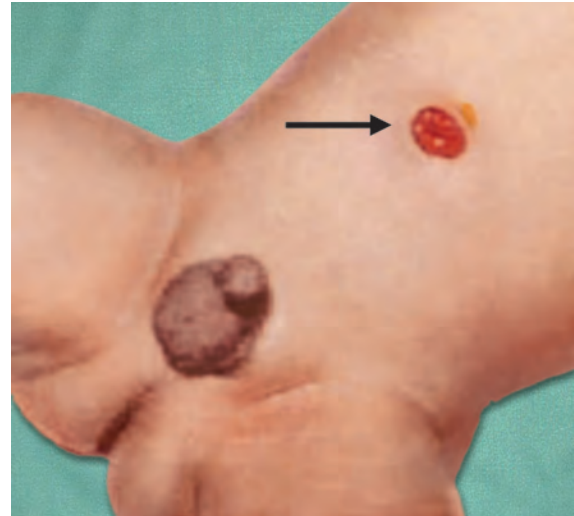
### Anomalies of vitellointestinal duct

- ❖ Intestinal fistula
- ❖ Umbilical sinus
- ❖ Umbilical adenoma
- ❖ Intra-abdominal cyst
- ❖ Meckel's diverticulum
- ❖ Intra-abdominal band

### Investigations

- ◆ Fistulogram.
- ◆ Ultrasound abdomen.

- ◆ Radioisotope study.
- ◆ If obstruction is present, plain X-ray abdomen in erect posture is useful to visualise the multiple air-fluid levels.



**Fig. 17.6:** Patent vitellointestinal duct.

### Treatment

Excision of vitellointestinal duct is done, along with resection of bowel segment containing Meckel's diverticulum.

## UMBILICAL SINUS

### Causes

- ◆ Persistent vitellointestinal tract partially towards umbilical side.
- ◆ Persistent urachus.
- ◆ Tuberculosis.
- ◆ Umbilical infection.
- ◆ *Umbolith*—desquamated epithelium of umbilicus gets collected and inspissated in the umbilical recess causing black/brown coloured stone (umbilical stone). It causes recurrent umbilical infection and sinus.
- ◆ Pilonidal sinus of the umbilicus.
- ◆ Malignancy in the urachus.
- ◆ *Clinical features*
  - ▶ Pain, swelling, discharge and tenderness in the umbilicus.
  - ▶ Features of the specific causes.

### Investigations

- ◆ Study of the discharge culture and sensitivity, cytology for malignant cells, AFB study.
- ◆ Sinusogram.
- ◆ Ultrasound abdomen, CT abdomen.
- ◆ Chest X-ray, ESR.

### Treatment

- ◆ Treat the cause.
- ◆ Antibiotics.
- ◆ Antitubercular drugs in case of tuberculosis.
- ◆ Umbilectomy.

## ■ UMBILICAL ADENOMA (Raspberry Tumour)

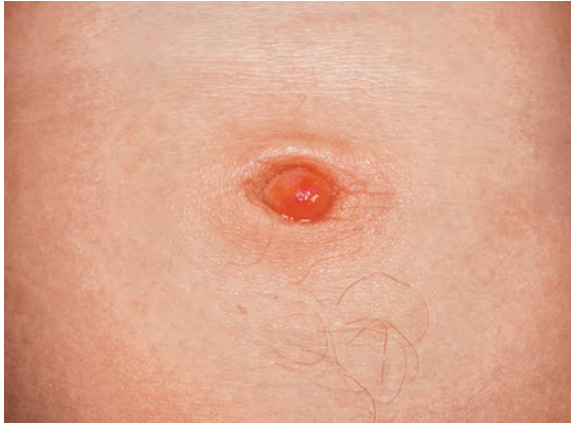

Fig. 17.7: Umbilical adenoma (Raspberry tumour).

- ◆ It is commonly seen in infants. It is due to partially obliterated vitellointestinal duct towards umbilical end, causing prolapse of the mucosa giving rise to umbilical adenoma also called as Raspberry tumour.
- ◆ It protrudes out as a red swelling, which is moist with mucus and tends to bleed on touch. It often gets infected, discharging pus through the umbilicus.
- ◆ Histologically, it consists of columnar epithelium rich in goblet cells.
- ◆ *Differential diagnosis:* Umbilical granuloma.

### Treatment

- ◆ If the tumour is pedunculated, a firm ligature is tied round it, so that tumour will fall off in few days. If it reappears, umbilectomy is done.
- ◆ Sometimes there may be a patent vitellointestinal duct or a Meckel's diverticulum, which may require resection along with the bowel segment.

#### Note:

Umbilical adenoma does not disappear after silver nitrate application.

## ■ UMBILICAL FISTULA

- ◆ *Causes*
  - ▶ Patent vitellointestinal duct.
  - ▶ Patent urachus.
  - ▶ Postsurgical.
  - ▶ Tuberculosis.
- ◆ *Clinical features*
  - ▶ Faecal discharge or urinary discharge, mucoid discharge.
  - ▶ Recurrent infection.
  - ▶ Pain, tenderness and excoriation in and around the umbilicus.
- ◆ *Investigations*
  - ▶ Fistulogram, CT fistulogram.
  - ▶ Discharge study. CS, AFB and cytology.
  - ▶ Ultrasound abdomen.

#### ◆ Treatment

- ▶ Fistulectomy, along with resection of bowel segment, patent vitellointestinal tract, and anastomosis of the bowel.
- ▶ Fistulectomy and excision of vitelline duct up to the antimesenteric surface of the ileum. Opening in the ileum is closed transversely using vicryl or silk sutures.

## ■ PATENT URACHUS

Allantoic duct/stalk which is remnant of cranial part of ventral urogenital sinus forms urachus. It gets fibrosed and forms median umbilical ligament.

### When urachus is patent it can form:

- ◆ *Patent urachus (Urachal fistula)* between umbilicus and dome of the urinary bladder (It is persistent median umbilical ligament).
- ◆ *Urachal sinus* if only umbilical side of the urachus is patent.
- ◆ *Urachal cyst* if only middle portion of the urachus is patent with lining and fluid content.
- ◆ *Urachal diverticulum* when bladder side of the urachus is patent.

### Features

- ◆ Persistent discharge from the umbilicus often stained with urine, if it is fistula.
- ◆ Recurrent infection and bleeding.
- ◆ Pain in the umbilicus and below.
- ◆ Recurrent urinary infection.

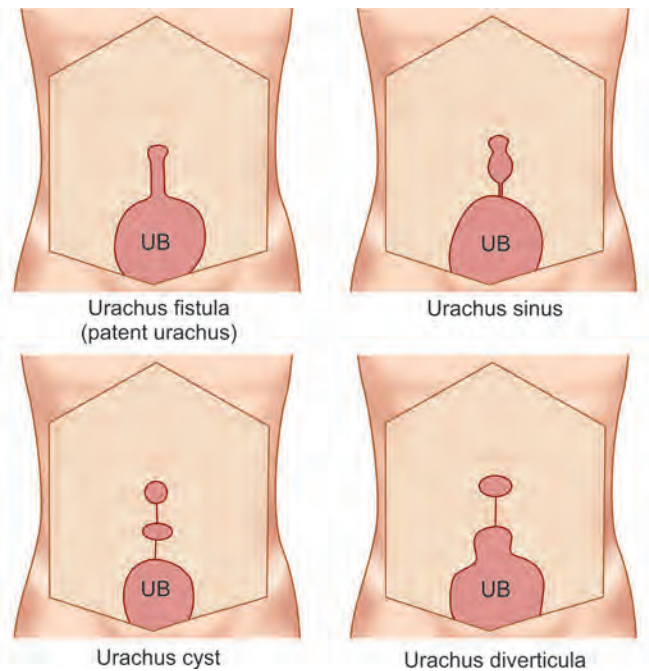


Fig. 17.8: Different types of urachal anomalies.

*Tanyol's sign:* Umbilicus is equidistant from xiphoid process and symphysis pubis. It is displaced downwards in ascites and upwards in pelvic masses.

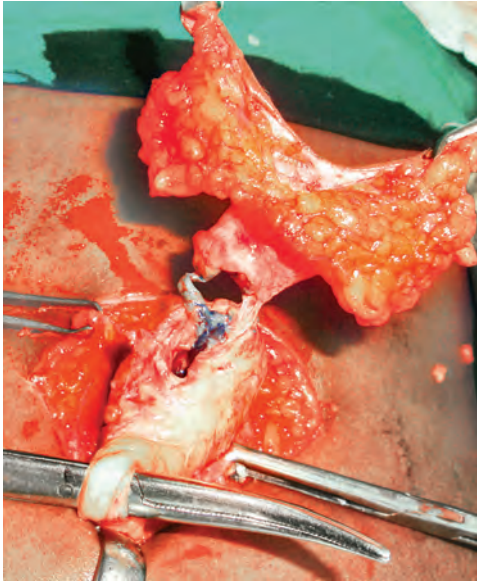


Fig. 17.9: Tuberculosis of urachus which is excised.

### Investigations

- ◆ Fistulogram to see the extent.
- ◆ US abdomen.
- ◆ Discharge analysis and culture.
- ◆ Urine analysis.

### Treatment

- ◆ Surgical excision of the tract.
- ◆ Often umbilical excision may be required.

#### Note:

Malignancy (adenocarcinoma) or tuberculosis can occur in patent urachus.

### ■ BURST ABDOMEN (Abdominal Wound Dehiscence) (ACUTE WOUND FAILURE)

- ◆ It is disruption of a laparotomy wound, occurring usually between 5th and 8th postoperative day.
- ◆ Usually sutures opposing the deep layers, i.e. peritoneum and rectus sheath tear through, causing burst abdomen—*Acute wound failure*. It is a *mechanical wound failure* due to various factors causing separation of the closed abdominal wound often with evisceration of the contents.
- ◆ There is postoperative separation of the abdominal musculoaponeurotic layers.
- ◆ It is 2% common. Common in males. Mortality is more than 30%.
- ◆ Other than technical errors, deep wound infection causes localised separation of the wound which in addition to raised intra-abdominal pressure leads to wound dehiscence.
- ◆ *Vertical incision* is more prone for dehiscence than transverse as vertical incision cuts across the aponeurosis and when abdominal wall contracts, it creates laterally directed tension on vertical closure. Mass closure is better than layer-by-layer closure.

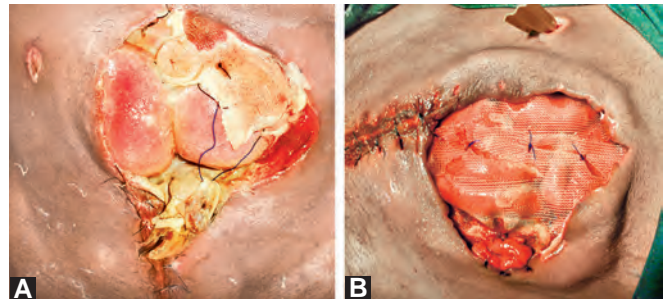
- ◆ *Suturing of the peritoneum* is not vital in wound failure; it is the fascial closure which decides the strength.
- ◆ *Nonabsorbable monofilament suture material* is used for the closure even though evidence says that there is no difference between synthetic absorbable like polyglactic acid and nonabsorbable monofilament suture. Nonabsorbable suture causes prolonged wound pain but is preferred in risk category patients.
- ◆ *Suture bite interval should be 1 cm but not more; suture length and wound length ratio should be 4 : 1 or more but not less.*

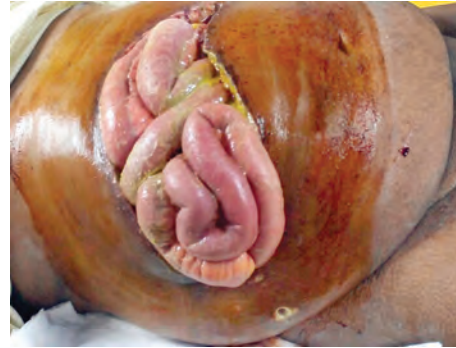

Fig. 17.10: Abdominal wound dehiscence in a transverse incision with evisceration of bowel; it is rare to have dehiscence of transverse incision.

### Clinical Features (2%)

- ◆ A sudden feeling of giving way from the wound—on 5th to 8th postoperative day often precipitated by bouts of severe cough.



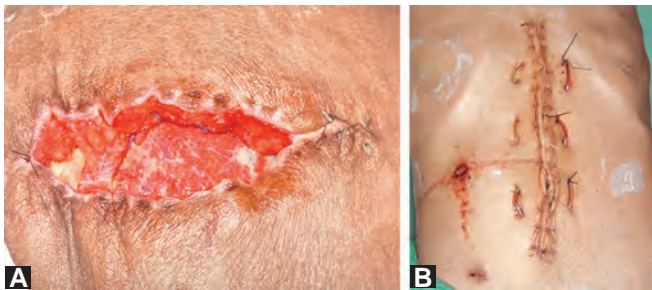
Figs 17.11A and B: Burst abdomen wound exposing intestines outside. It is covered with a mesh later.

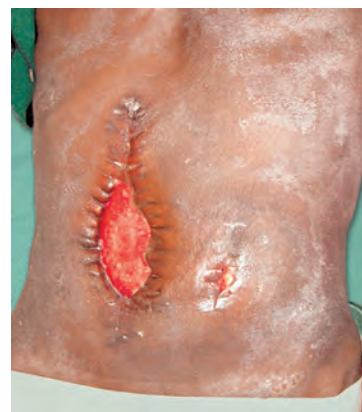

Fig. 17.12: Ulcer over the postoperative wound.

### Factors related to burst abdomen

- ❖ Choice of suture materials used
  - ❖ Method of closure; Tension free suturing is most important.
  - ❖ Upper midline and vertical wounds are more likely to disrupt than transverse
  - ❖ Surgical wounds of peritonitis, acute abdomen, major surgeries like pancreatic, hepatic, gastric, surgeries for malignancies have a high incidence of disruption
  - ❖ Severe cough, vomiting and distension in postoperative period
  - ❖ Poor general condition of the patient—anaemia, jaundice, hypo-proteinaemia, obesity, uraemia and diabetes mellitus, old age, steroids, radiation, malignancy, chemotherapy.
  - ❖ Ascites, previous laparotomies, duration of surgery > 150 minutes are other risk factors.
- ◆ *Pinkish serosanguineous discharge* (salmon-coloured large quantity of fluid) from the wound.
  - ◆ Often omentum or coils of intestine are forced out of the wound.
  - ◆ *Clinically burst abdomen can be diagnosed without fail.*
  - ◆ Probing of the wound using gloved finger appreciates dehiscence of musculoaponeurotic layer.



**Figs 17.13A and B:** Incisional hernia which was repaired earlier has gaped exposing the mesh; (B) Horizontal tension sutures.

### Treatment

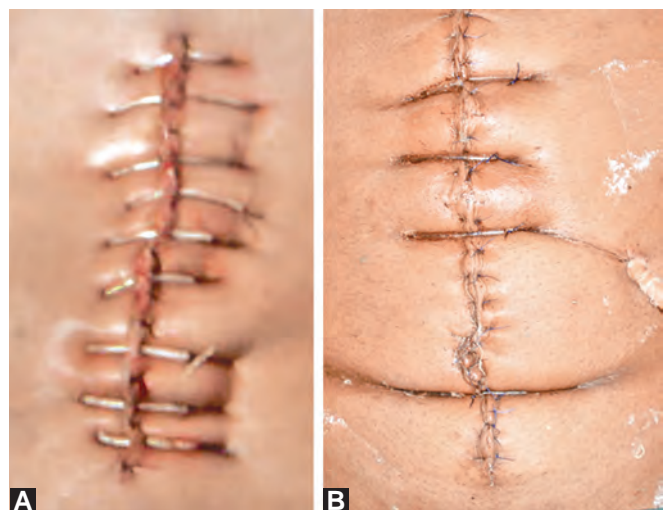
- ◆ Nasogastric aspiration, IV fluids.
- ◆ *Emergency surgery*, i.e. under anaesthesia, wound is opened up properly.
  - ▶ Coils of intestines are replaced into the abdominal cavity. Thorough wash is given. Wound is closed by *all layer sutures*, passing a nonabsorbable suture material through the red rubber or plastic collar—*tension sutures* (which is kept for 14 days).
  - ▶ **Modified Smead-Jones closure** mainly used to prevent burst abdomen—it is interrupted specialised suture used in the closure of abdomen as single layer excluding the skin. Linea alba is held with Allis' forceps. Number one polyethylene or PDS suture material is used. First bite on one side taken 3 cm away (width) from the margin from outside to inside; it is then passed through the corresponding opposite edge with 3 cm width from inside to outside; later again one small loop of 5 mm width from the edges of each side of the wound from first bite site to second bite site is taken; suture is knotted on the free edge of the first bite side. Full thickness bite holds the suture and maintains the tension in the wound. Smaller loop keeps the linea alba in apposed place. Large curved Ferguson needle

is better to place these sutures. Each suture is placed at 2 cm interval. This is the type of suturing used at present in acute abdominal conditions instead of the retention sutures. Here also it is better to place all sutures under proper vision and knotting is done at the end. At least four knots should be placed. Excessive tension should be avoided. In upper abdomen peritoneum need not be included in the bite; but in lower abdomen as linea alba is indistinct, peritoneum is included in this.

- ▶ Subcutaneous drain with loose skin sutures are preferred. In severe infection, skin wound is left open and closed as secondary suturing after 14 days.
- ▶ Problem with immediate closure with forced attempt may cause abdominal compartment syndrome.
- ◆ Antibiotics and IV fluids are continued.
- ◆ Wound usually heals well without much second dehiscence. Late problem, may be development of incisional hernia.
- ◆ Biological dressings, wound vacuum systems are newer modalities used.

### Newer present methods of managing the burst abdomen

- ◆ If the fascial edges are necrotic, *proper debridement* of the wound edges is done. One should not attempt forcible wound closure as it will increase intra-abdominal pressure further and re-dehiscence occurs (When fascia is strong and intact primary closure can be done). Wound and contents are covered with *absorbable mesh* or *biological prosthesis* like decellularised porcine submucosa and dermis or human cadaveric dermis. They prevent bowel desiccation, bacterial infection.
- ◆ *Wound vacuum system* using—open cell foam, semioclusive drape over the foam and suction apparatus. It provides immediate coverage, minimises heat loss, by negative pressure it clears interstitial fluid, reduces the bowel oedema and contamination, increases wound blood flow and promotes wound healing. Once wound granulates wound is closed with primary closure or with skin graft or flaps depending on the size of the wound.
- ◆ Component separation technique may allow primary fascial closure.



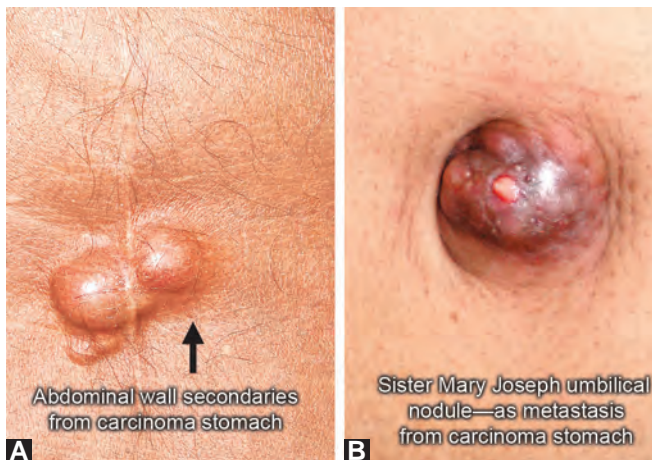
**Figs 17.14A and B:** Vertical tension sutures.



### Management of burst abdomen

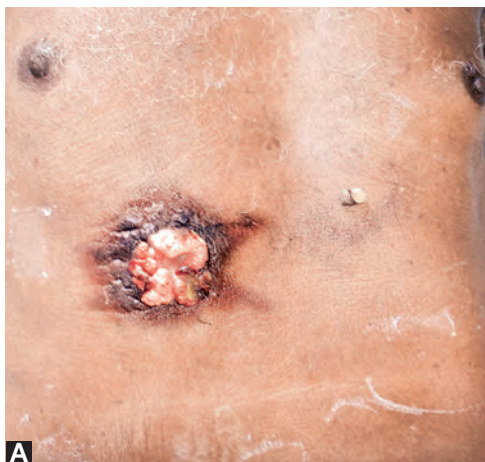- ❖ Primary deep fascial closure—deep tension/retention sutures
- ❖ Delayed closure with initial mesh wrap or pack/oppsite or Bogota bag
- ❖ Topical negative (vacuum) pressure closure
- ❖ Delayed skin closure or skin graft over the dehiscence wound once it granulates well.
- ❖ Component separation technique with primary fascial closure
- ❖ Placing drain in subcutaneous plane
- ❖ Suitable antibiotic therapy; fluid management
- ❖ Prevention of abdominal compartment syndrome, haematoma or intra-abdominal abscess formation or sepsis
- ❖ Blood or blood product transfusion; nutrition supplementation

## ABDOMINAL WALL TUMOURS

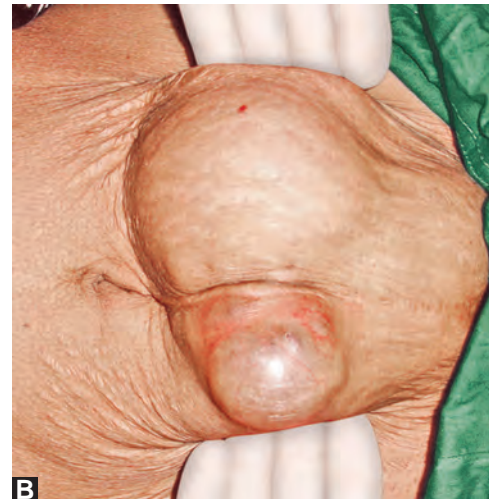


**Figs 17.15A and B:** (A) Abdominal wall secondaries from carcinoma stomach; (B) Sister Mary Joseph (Nee Julia Dempsey, Mayo Clinic USA) metastatic umbilical nodule from carcinoma stomach.

- ◆ They are not uncommon but often present late as they are usually asymptomatic.
- ◆ Common tumours are lipoma, fibroma, neurofibroma, and fibromatosis.
- ◆ Malignant tumours occasionally when occurs, are either from skin or soft tissues. They may be desmoid tumour, soft tissue sarcoma like fibrosarcoma, dermatofibrosarcoma, liposarcoma, umbilical secondaries (*Sister Joseph Mary tumour*).



**Fig. 17.16A**



**Fig. 17.16B**

**Figs 17.16A and B:** Abdominal wall proliferative ulcer (A) and large tumour, may be fibromatosis of abdominal wall also (B).

- ◆ Presents usually as painless progressive swelling. Often ulceration can occur. Attaining large size is also known. It is dull to percuss. On contracting the abdominal wall muscles, swelling becomes prominent and less mobile.
- ◆ Differential diagnoses are—abdominal wall abscess, haematoma, intra-abdominal tumours (adherent to abdominal wall).
- ◆ US abdomen, CT abdomen is diagnostic. Biopsy is essential.
- ◆ *Treatment* is wide excision with adequate clearance with removal of adjacent skin and musculoaponeurotic layer. Defect is covered with a *large mesh*.

## DESMOID TUMOUR

(‘*Desmo*’ Means Band/Tendon in Greek)

- ◆ It is a tumour arising from the musculoaponeurotic layer of abdomen, *below* the level of the umbilicus.
- ◆ It is unencapsulated, hard, fibroma, presently classified under **aggressive fibromatosis**.
- ◆ 80% of cases occur in women, commonly after deliveries. It is common over old abdominal operation scars (lower abdomen), may be due to old haematomas. Oral contraceptive (OCP) use is more commonly associated with desmoid.
- ◆ It is often associated with the familial polyposis colon (FAP), osteomas, odontomes epidermal cysts—**Gardner’s syndrome**. Desmoid tumour is 1000 times more common in FAP.
- ◆ It is a slow growing tumour involving muscle and soft tissue of the abdominal wall, locally spreading, often undergoes myxomatous changes.
- ◆ Unlike fibromas, it never turns into sarcoma.
- ◆ It is often classified as *superficial and deep*. It is also classified as *abdominal* (common in females); *extra-abdominal* (common in males, common in back, head, scars, chest wall, neck); and *peripheral*.

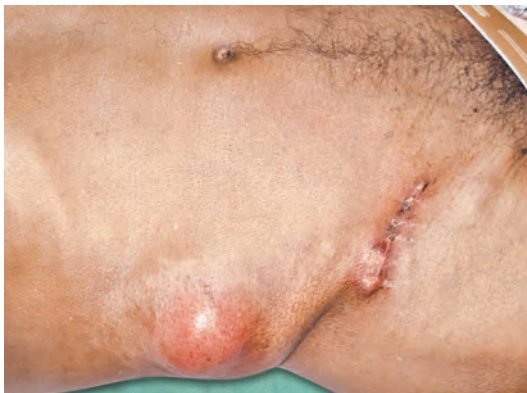**Histologically** it contains multinucleated plasmoidal giant cells.

**Gardner's syndrome**

- ❖ Familial polyposis colon
- ❖ Osteomas
- ❖ Odontomes
- ❖ Epidermal cyst—20%

**Management**

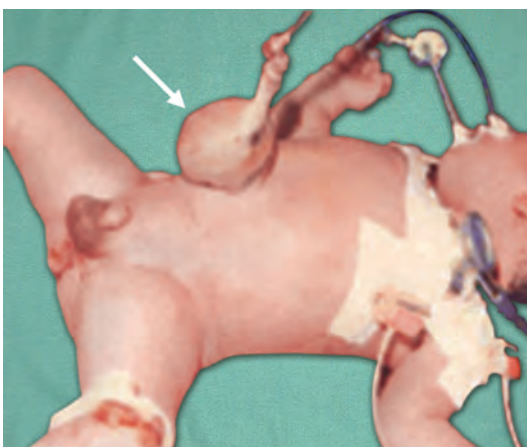
- ◆ The possible association of Gardner's syndrome is looked for and Barium enema, X-ray, U/S abdomen are done. *MRI is useful.* Biopsy is done to confirm the diagnosis.
- ◆ *Wide excision* of the tumour with a margin of 2.5 cm is done along with *placement of a mesh* to the abdominal defect.
- ◆ It is moderately radiosensitive.
- ◆ Drugs like sulindac and tamoxifen are also used.
- ◆ Chemotherapeutic agents like doxorubicin, actinomycin D, dacarbazine, carboplatin are used but with significant toxicity.
- ◆ Recurrence rate is high—20–40%.



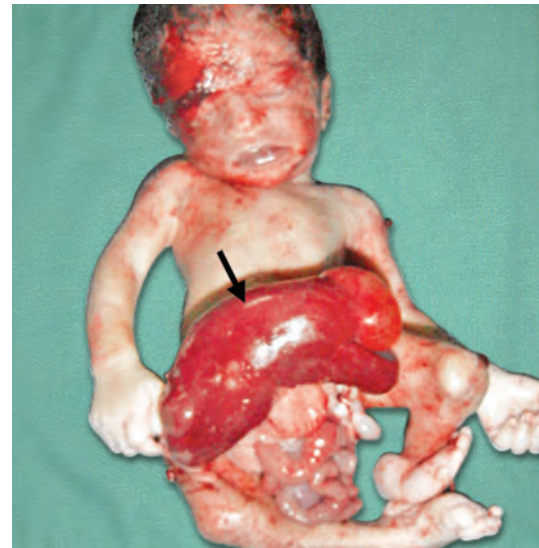**Fig. 17.17:** Recurrent abdominal wall tumour. It may be fibromatosis or recurrent dermatofibroma.

**EXOMPHALOS (Omphalocele)**

- ◆ It is the failure of all or a part of the gut to return to the coelomic cavity during early foetal life, as coelomic cavity has not developed properly.



**Fig. 17.18:** Exomphalos.



**Fig. 17.19:** Exomphalos major. Note the liver, small and large bowel.

- ◆ Sac covering the content is very thin, consists of three layers—outer amniotic membrane, middle Wharton's jelly and inner peritoneal layer. Sac may get ruptured during birth.
- ◆ *Omphalocele is often associated with congenital anomalies of cardiac and genitourinary system—70%.*
- ◆ Vitellointestinal anomaly, diaphragmatic hernia, malrotation can co-exist, exomphalos, macroglossia, gigantism (EMG) can co-exist in 2/3 of such babies—is called as *Beckwith-Weidemann syndrome*.
- ◆ Chromosomal trisomies—13, 15, 18 and 21, bladder extrophy, imperforate anus, sacral vertebral anomaly, meningomyelocele.
- ◆ Abdominal wall defect can be confirmed *in utero* by US. Amniocentesis and chromosomal analysis can be done. This will allow deciding the possible need for termination of pregnancy, or management plan immediately after delivery.
- ◆ Abdominal wall muscle is normally developed but peritoneal layer is hypoplastic.

**Types**

Two types:

**Differences between exomphalos minor and exomphalos major**

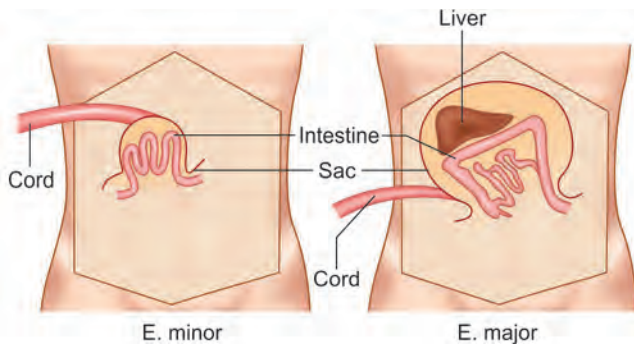
<i>Exomphalos minor</i>	<i>Exomphalos major</i>
Small sac	Large sac
Defect < 5 cm	Defect > 5 cm
Content is small bowel only	Liver, small and large bowel
Primary closure is possible	Primary closure is not possible
Good prognosis	Poor prognosis

**Exomphalos minor:**

- ◆ Here the sac is small and *umbilical cord is attached to the summit*, with small bowel as the content. Treatment for E. minor is relatively easier. The sac has to be twisted so as to reduce the content to the peritoneal cavity through the umbilical defect and the abdomen is strapped. Later the defect is closed (Defect is < 5 cm).

**Exomphalos major:**

- ◆ A large defect (> 5 cm) is present with contents lying completely outside. *Umbilical cord is attached to the inferior aspect of the sac.* Contents being small bowel, large bowel and liver.
- ◆ Often the sac ruptures during delivery, which in turn leads to severe infection and high mortality. Here immediate surgery (within hours) is the only hope to save the child.



**Fig. 17.20:** Diagram showing differences between exomphalos minor and exomphalos major.

- ◆ As there is hardly any properly developed abdominal cavity, it is not possible to reduce the contents to the peritoneal cavity. So initially, relaxing incisions are placed over the lateral abdominal wall and also the subcutaneous layer has to be undermined so as to accommodate, whatever possible contents in the cavity. The contents are not to be forced into the cavity, which in turn may cause intestinal obstruction, respiratory distress, venous engorgement.
- ◆ Often a sterile polythene bag (*Silastic silo*) can be wrapped over the content carefully. Gradual twisting of the bag over the summit at regular intervals over two to three weeks will stimulate the peritoneal cavity to increase in capacity and eventually the contents get reduced. Later the defect is closed properly.
- ◆ Antibiotics, IV fluids, nutritional support are required during this period.
- ◆ *Mortality is higher* in spite of all these—due to sepsis, dehydration, hypothermia and respiratory failure.
- ◆ Late ventral hernia should be corrected at later period.

#### Management of exomphalos

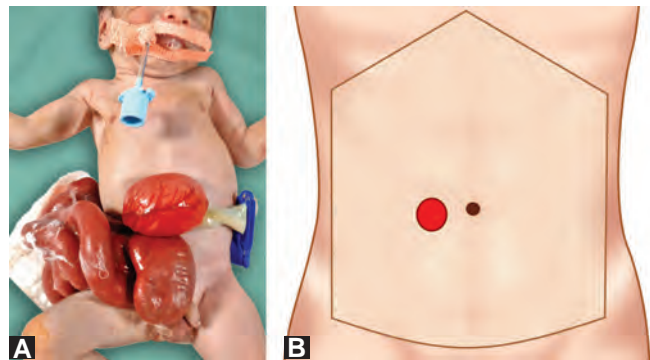
- ❖ Vitamin K injection, TPN
- ❖ Sepsis control with antibiotics
- ❖ Evaluation for other anomalies
- ❖ In E. major when sac is intact application of 0.5% mercurochrome with 65% alcohol to promote granulation tissue formation
- ❖ Prevention of aspiration
- ❖ Prevention of hypothermia
- ❖ Wrapping the content with sterile bag/wrapper
- ❖ Correction of dehydration
- ❖ Definitive surgical procedures like release incisions and closure

### GASTROSCHISIS (Belly Cleft)

- ◆ It is a defect of the anterior abdominal wall just lateral to the umbilicus. It is common in premature babies.
- ◆ It is associated with defect in the involution of 2nd umbilical vein. It is common in mothers *younger than 20 years*, those who take,

aspirin, ibuprofen, pseudoephedrine during 1st trimester and who regularly smoke and take alcohol.

- ◆ Umbilicus is normal. The defect is almost always to the right of an intact umbilical cord. Evisceration of the bowel occurs through the defect during intrauterine life. There is no peritoneal sac and the irritating effect of amniotic fluid causes chemical peritonitis with formation of a thick, oedematous membrane.
- ◆ *Nonrotation and intestinal atresia are common associations (15%).* Cardiac anomaly is not common as in omphalocele.
- ◆ After delivery, these infants are more prone for fluid loss, hypothermia, hypovolaemia, sepsis, metabolic acidosis.
- ◆ Necrotising enterocolitis is also common in such infants (20%). They are also more prone for paralytic ileus.



**Figs 17.21A and B:** Gastroschisis.

### Treatment

#### General:

- ❖ Fluid management
- ❖ TPN
- ❖ Antibiotics
- ❖ R-T aspiration
- ❖ Calorie supplement.

#### Specific:

- ◆ Later under GA, intestines are pushed into the abdomen through the defect and defect is closed with interrupted nonabsorbable sutures. Often when bowel is not accommodating in the abdominal cavity, bowel is initially placed in sterile silastic silo bag. In later period, it is pushed into the abdomen gradually. Often a part of the bowel may not be viable, then resection and anastomosis has to be done.
- ◆ With proper surgery, nutrition, resuscitation, survival rate is 90% which is better than omphalocele.
- ◆ *Prolonged postoperative ileus* is the common problem in these patients.

Exomphalos	Gastroschisis
1. Defect through umbilicus	1. Defect lateral to umbilicus
2. Covered by sac which has three layers	2. No peritoneal sac
3. Associated with anomalies	3. Not associated (except malrotation)

### RECTUS SHEATH HAEMATOMA

- ◆ Rectus abdominis muscle is supplied by superior and inferior epigastric arteries. Injury to one of these vessels will cause bleeding and haematoma in rectus sheath.

- ◆ Commonly it is due to bleeding from inferior epigastric artery in the lower abdomen.

#### Causes

- ❖ Trauma
- ❖ Surgery
- ❖ Spontaneous haematoma, typhoid fever
- ❖ Blood dyscrasias, haemophilia, anticoagulant therapy
- ❖ Severe straining and exercises
- ❖ Tetanus and other convulsions
- ❖ Patients on anticoagulants
- ❖ Puerperium.

#### Features

- ◆ Common in females.
- ◆ Sudden onset of swelling in lower abdomen, which is tender, warm, firm on one side of the abdomen. Swelling does not cross the midline.
- ◆ Bluish discoloration over the swelling.
- ◆ US and aspiration confirms the diagnosis.
- ◆ Should be differentiated from other masses and parietal hernias.
- ◆ Coagulation profile is a must.
- ◆ CT scan abdomen is often needed.

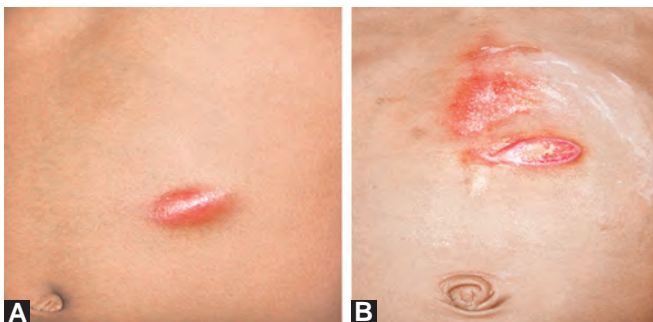
#### Treatment

- ◆ Usually conservative with analgesics and antibiotics.
- ◆ Angiographic *embolisation* of inferior epigastric artery.
- ◆ Occasionally requires drainage of haematoma and ligation of inferior epigastric artery.

### ABDOMINAL WALL ABSCESS

#### Causes

- ❖ Infected haematoma
- ❖ Umbilical sepsis spreading into the abdominal layers causing the abscess
- ❖ Blood spread from distant focus.



**Figs 17.22A and B:** (A) Abdominal wall abscess in a child; (B) Abdominal wall infection with a wound.

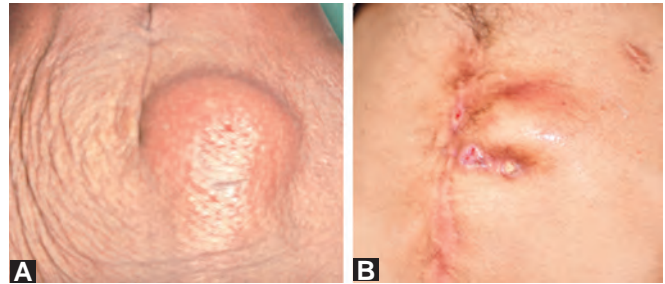
#### Features

- ◆ Tender, soft/firm swelling which is well-localised, adherent to skin and abdominal muscles underneath and not mobile.

- ◆ Aspiration will show pus.
- ◆ Should be ruled out from intra-abdominal mass, cold abscess, parietal hernia.
- ◆ Ultrasound and needle aspiration is confirmative.

#### Treatment

It is antibiotics and drainage under general anaesthesia.



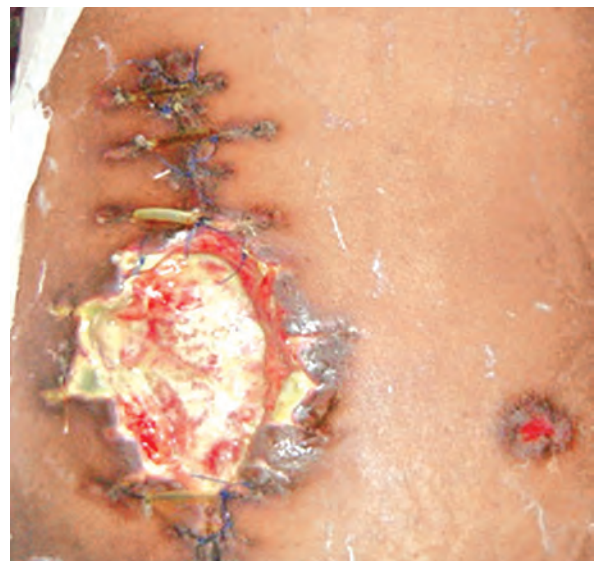**Figs 17.23A and B:** (A) Abdominal wall abscess; (B) Postoperative abdominal wall abscess.

### MELENEY'S PROGRESSIVE SYNERGISTIC BACTERIAL GANGRENE OF ABDOMINAL WALL

- ◆ It is due to infection by microaerophilic streptococci, staphylococci and other anaerobes of the postoperative abdominal or thoracic wounds.
- ◆ It is common in HIV, diabetic and immunosuppressed people.
- ◆ Sudden pain, redness, blackening and gangrene of the skin of the abdomen with abdominal wall necrosis.
- ◆ Toxicity, septicæmia, renal failure can occur.

#### Treatment

- ◆ Antibiotics like penicillins and metronidazole.
- ◆ Excision of necrotic and gangrenous tissue until it bleeds.

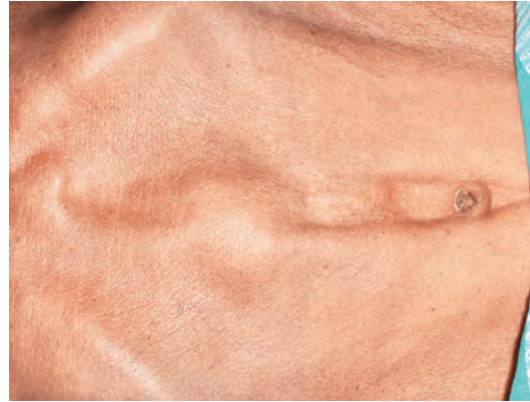

**Fig. 17.24:** Severe abdominal wall sepsis in a postoperative patient.

- ◆ Blood transfusion, nutrition supplement.
- ◆ Maintaining adequate urine output.
- ◆ Management of toxaemia, hyperbaric oxygen and critical care.
- ◆ Skin grafting and coverage, when it granulates well.

### ■ DIVARICATION OF RECTI (DIASTASIS RECTI)

- ◆ It is thinning of linea alba in midline in epigastrium.
- ◆ Abdominal wall protrudes in midline with prominent divaricated edges of both recti.
- ◆ Transversalis fascia remains intact and hence hernia will not be present; so impulse on coughing will be absent.
- ◆ Diastasis will become prominent on lifting the head from the bed.
- ◆ It does not require any treatment.



**Fig. 17.25:** Divarication of the recti with visible mass in epigastrium.

# Chapter 18

## Hernia

### CHAPTER OUTLINE

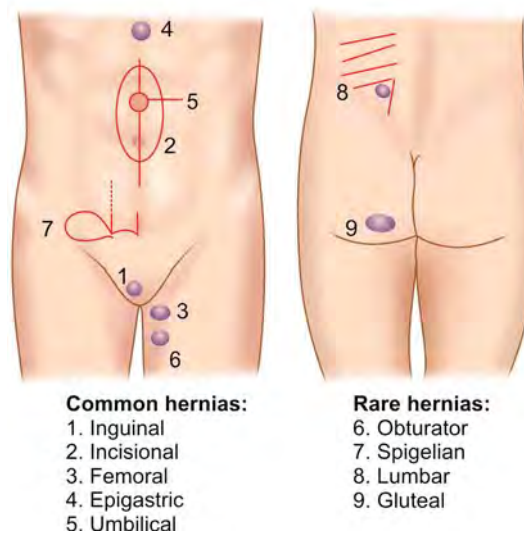
- ❖ Introduction
- ❖ Aetiology
- ❖ Parts of Hernia
- ❖ Classification of Hernia
- ❖ Inguinal Hernia
  - Surgical Anatomy of Inguinal Canal
  - Classification of Inguinal Hernia
  - Indirect (Oblique) Inguinal Hernia
  - Direct Inguinal Hernia
- Recurrent Hernia
- Hernioplasty
- Malgaigne Bulging
- Incarcerated Hernia
- ❖ Strangulated Hernia
- ❖ Sliding Hernia
- ❖ Pantaloon Hernia
- ❖ Femoral Hernia
- ❖ Ventral Hernia
- ❖ Incisional Hernia
- ❖ Umbilical Hernia
- ❖ Paraumbilical Hernia
- ❖ Epigastric Hernia
- ❖ Spigelian Hernia
- ❖ Obturator Hernia
- ❖ Richter's Hernia
- ❖ Lumbar Hernia
- ❖ Phantom Hernia
- ❖ Sciatic Hernia
- ❖ Complications of Hernia Surgery
- ❖ Parastomal Hernia

### INTRODUCTION

Hernia means—'To bud' or 'to protrude', 'offshoot' (Greek) 'rupture' (Latin).

- ◆ A hernia is defined as an area of weakness or disruption of the fibromuscular tissues of the body wall. Often hernia is also defined as an actual anatomical weakness or defect. 75–85% of abdominal wall hernias are groin hernias. 15% of males and 5% of females will develop groin hernia. Presently all hernias in groin are grouped as groin hernias. But in this chapter discussion of the indirect/direct/femoral hernias are given, in detail as it is still practiced and followed in most of the centres and still it is important when surgical technical aspects are considered.
- ◆ Hernia is defined as an abnormal protrusion of a viscous or a part of a viscous through an opening, artificial or natural with a sac, covering it.
- ◆ Inguinal hernia is the most common hernia (73%) because the muscular anatomy in the inguinal region is weak and also due to the presence of natural weakness like deep ring and cord structures. Indirect is more common than direct.
- ◆ Femoral is 7%; umbilical is 8.5%; others are 1.5% (Excluding incisional hernia).
- ◆ In general, incisional hernia is next to inguinal hernia in occurrence—15%.

- ◆ Groin hernia is 25 times more common in men than women. Indirect inguinal hernia is commonest hernia in men and women. Femoral hernias are more common in females (10:1); umbilical and incisional hernias are also common in females (2:1).



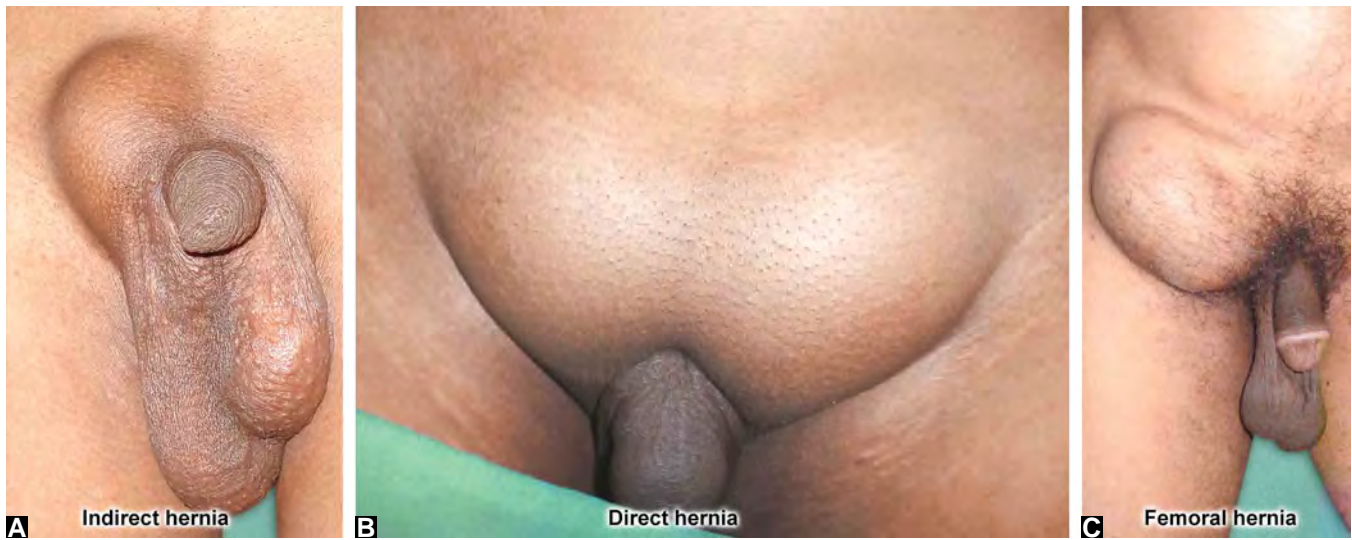**Common hernias:**  
1. Inguinal  
2. Incisional  
3. Femoral  
4. Epigastric  
5. Umbilical

**Rare hernias:**  
6. Obturator  
7. Spigelian  
8. Lumbar  
9. Gluteal

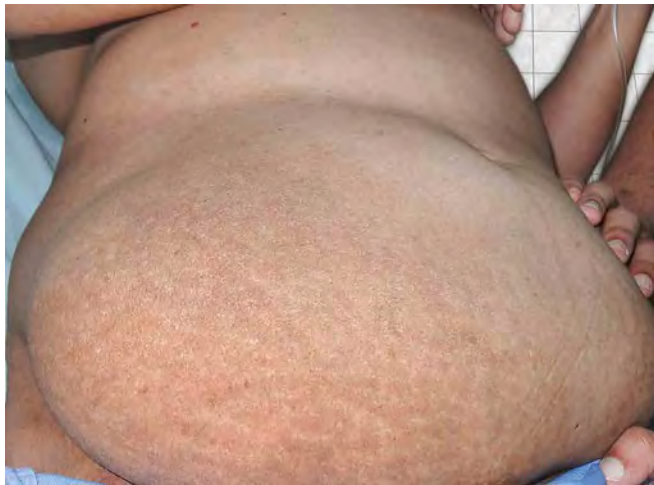**Fig. 18.1:** Common and rare sites of hernias.

*In order to achieve a radical cure of inguinal hernia it is absolutely essential to restore those conditions in the area of hernial orifice which exist under normal circumstances.*

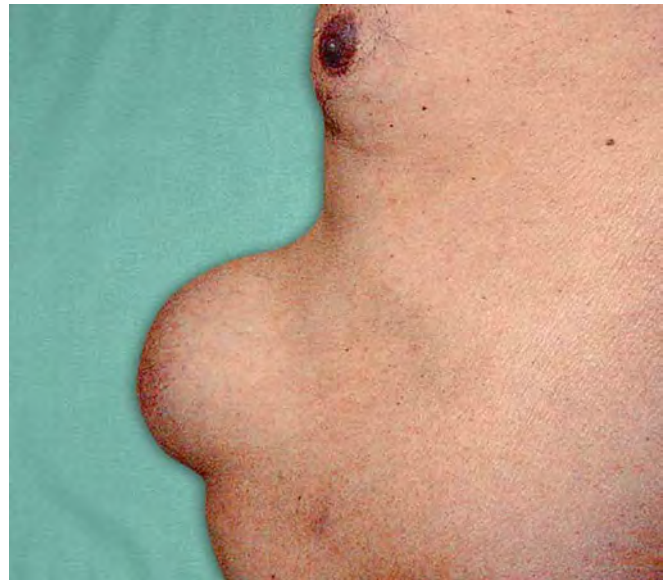
—Edoardo Bassini



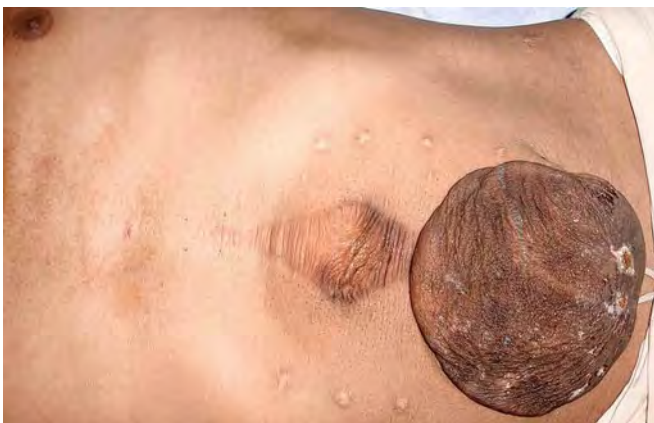**Figs 18.2A to C:** Note the clinical look of indirect inguinal (commonest), direct inguinal and femoral hernias.



**Fig. 18.3:** Large ventral hernia in the lower abdomen.



**Fig. 18.5:** Epigastric hernia.

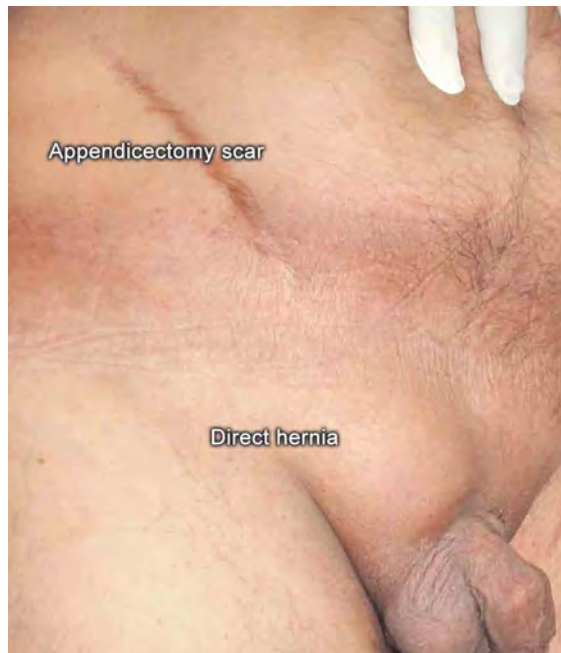

**Fig. 18.4:** Incisional hernia; common in lower abdomen.

## ■ AETIOLOGY

- ◆ Straining.
- ◆ Lifting of heavy weight.
- ◆ Chronic cough (tuberculosis, chronic bronchitis, bronchial asthma, emphysema).
- ◆ Chronic constipation (habitual, rectal stricture).
- ◆ Urinary causes
  - ▶ Old age—BPH, carcinoma prostate.
  - ▶ Young age—stricture urethra.
  - ▶ Very young age—phimosis, meatal stenosis.
- ◆ Obesity.

- ◆ Pregnancy and pelvic anatomy (especially in femoral hernia in females).
- ◆ Smoking.
- ◆ Ascites.
- ◆ Appendectomy through McBurney's incision may injure the ilioinguinal nerve causing right sided *direct* inguinal hernia.



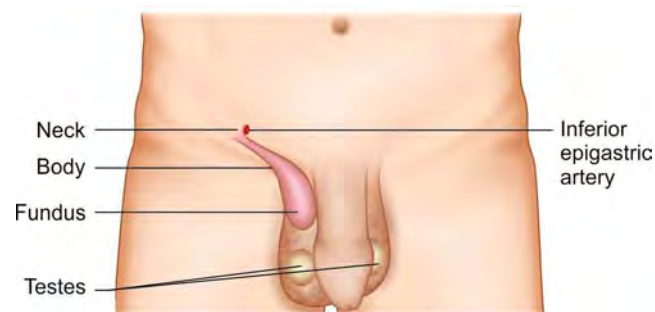
**Fig. 18.6:** Old appendectomy scar with direct inguinal hernia. It is due to injury to ilioinguinal nerve during appendectomy.

- ◆ An indirect inguinal hernia occurs in a congenital, preformed sac, i.e. the remains of processus vaginalis. Chances of presence of bilateral preformed sac is 60%.
- ◆ Familial collagen disorder—*Prune Belly syndrome*.
- ◆ Acquired herniation is also probably due to collagen deficiency called as *metastatic emphysema of Read*.

### ■ PARTS OF HERNIA

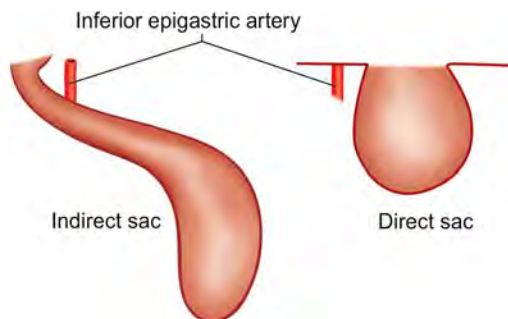
Hernia comprises of:

- ◆ *Covering*.
- ◆ *Sac*.
- ◆ *Content*.



**Fig. 18.7:** Parts of hernia. Note the fundus, body and neck of the hernia.

**Sac** is a diverticulum of peritoneum with mouth, neck, body and fundus. Neck is *narrow in indirect sac but wide in direct sac*. Body of the sac is thin in infants, children and in indirect sac, but is thick in direct and long-standing hernia.



**Fig. 18.8:** Diagram showing the differences between indirect and direct sacs.

- ▶ Hernia without neck: Those hernias with larger mouth lack neck, e.g. direct hernia, incisional hernia.
- ▶ Hernia without sac: Epigastric hernia—it is protrusion of extraperitoneal pad of fat.

**Coverings** of the sac are the layers of the abdominal wall through which the sac passes.

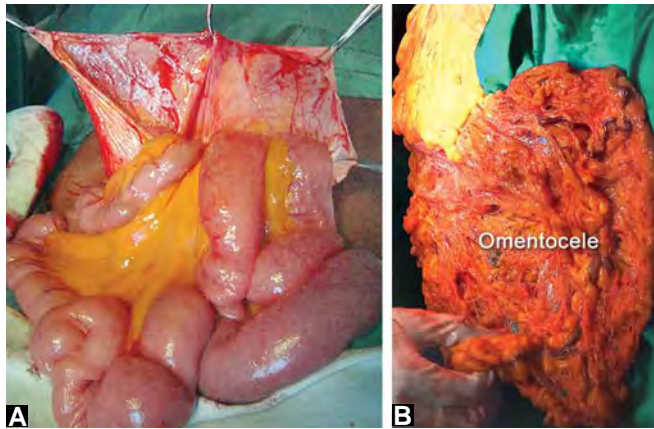
#### **Contents of Sac**

- ▶ Omentum—*Omentocele* (Epiplocele). Difficult to reduce the sac later, initially it can be reduced easily.
- ▶ Intestine—*Enterocoele*—commonly small bowel, but sometimes even large bowel.
- ▶ Difficult to reduce the sac initially.
- ▶ *Richter's hernia*: A portion of circumference of bowel is the content.
- ▶ Urinary bladder may be the content or part of the posterior wall of the sac—*cystocoele*.
- ▶ Ovary, often with fallopian tube.
- ▶ Meckel's diverticulum—*Littre's hernia*.
- ▶ Appendix in inguinal hernial sac which is often incarcerated—*Amyand's hernia*.
- ▶ *Fluid*: Fluid is secreted from congested bowel or omentum. It may be an infected fluid or ascitic fluid or blood from the strangulated sac.

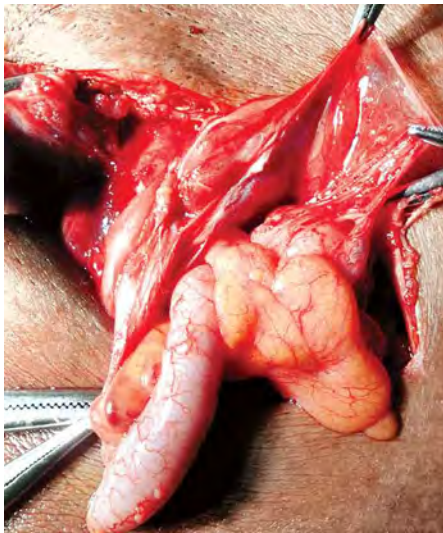
#### **Note:**

- **The Groin** even though anatomically not a well-defined area, it includes inguinal and femoral regions; both are separated by medial part of the inguinal ligament. Clinically when hip is completely flexed inguinal and femoral regions touch each other and that area is recognised as groin. Sebaceous cyst, lipoma, neurofibroma are swellings arising from integuments; inguinal and femoral hernias; lymphadenopathy; saphena varix and aneurysms are vascular swellings; ectopic testis, lipoma or hydrocele of the cord, hydrocele of the canal of Nuck (in females) are swellings related to inguinal canal; psoas abscess which is deeper—are groin swellings. Common groin swellings are inguinal and femoral hernias, inguinal lymphadenopathy and saphena varix. *Groin pain* may be due to hernia, funiculitis, varicocele, lymph node diseases or post surgery pain.

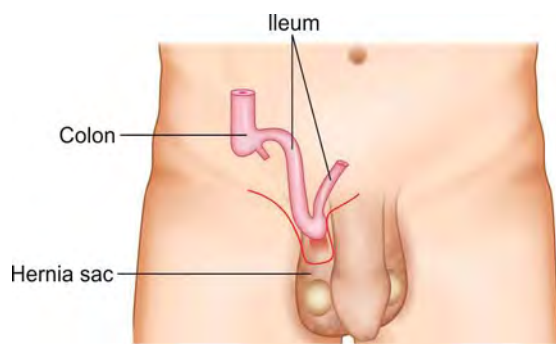




**Figs 18.9A and B:** Hernial sac containing small bowel (*enterocele*) and omentum (*omentalocele*) in two different patients.



**Fig. 18.10:** *Amyand hernia*—is appendix in inguinal hernial sac.



**Fig. 18.11:** *Littre's hernia* with Meckel's diverticulum as content.

- **Herniography (by Gullmo):** Injection of contrast into the peritoneal cavity and taking films in supine and prone positions to diagnose small protrusions of peritoneal sac is called as herniography. It was earlier also used for diagnosing undescended testis.
- **Gilmore's groin or hockey groin or Athletic pubalgia or hockey/sports hernia, or groin disruption** is a condition of the pubic joint in athletes; presents with chronic groin pain and a dilated superficial inguinal ring. Football and ice hockey players are most frequently affected. Present with pain during movements of sports, particularly hip extension, twisting and turning

which radiates to the adductor region and even the testicles. Symptoms can often be reproduced by performing sit-ups or crunches or with the patient in "frog position", in which the patient is supine with knees bent and heels together. It is probably due to torn external oblique aponeurosis or conjoint tendon or transversalis fascia or internal oblique muscle or entrapment of ilioinguinal nerve. MRI may be useful. Sleeping in a prone position with the hip on the affected side flexed and externally rotated can be a cure in some individuals. Many eventually require a definitive treatment consisting of surgical repair followed by a structured rehabilitation.

## ■ CLASSIFICATION OF HERNIA

### Classification I (Clinical)

#### 1. *Reducible Hernia*

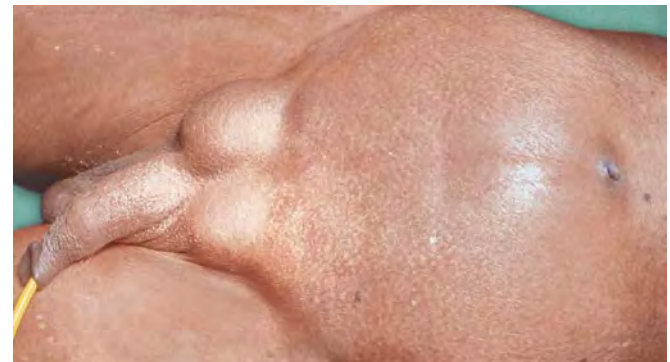Hernia gets reduced on its own or by the patient or by the surgeon. Intestine reduces with gurgling and it is difficult to reduce the first portion. Omentum is doughy, and it is difficult to reduce the last portion. Expansile impulse on coughing present.

#### 2. *Irreducible Hernia*

Here contents cannot be returned to the abdomen due to narrow neck, adhesions, overcrowding. Irreducibility predisposes to strangulation.

#### 3. *Obstructed Hernia*

It is an irreducible hernia with obstruction, but blood supply to the bowel is not interfered. It eventually leads to strangulation.



**Fig. 18.12:** Inguinal hernia presenting with features of intestinal obstruction.

#### **Note:**

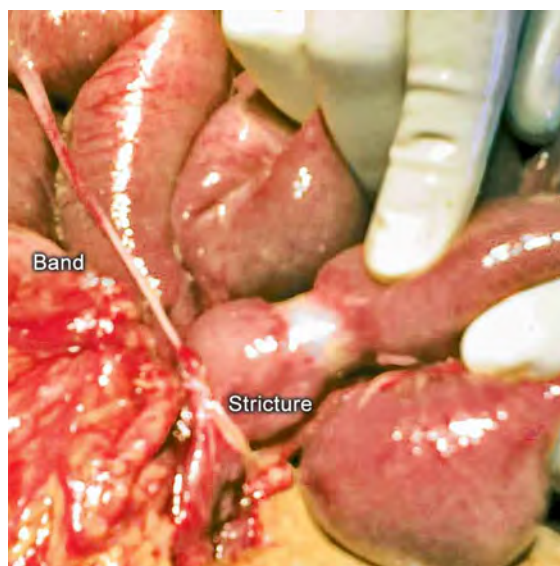
- **Garrey's stricture:** Constriction that occurs due to ischaemic narrowing of small bowel which has reduced from an obstructed hernia.

#### 4. *Inflamed Hernia*

It is due to inflammation of the contents of the sac, e.g. appendicitis, salpingitis. Here hernia is tender but not tense; overlying skin is red and oedematous.

#### 5. *Strangulated Hernia*

- ◆ It is an irreducible hernia with obstruction to blood flow. The swelling is tense, tender, with no impulse on coughing and with features of intestinal obstruction.



**Fig. 18.13:** Garrey's stricture on table. Due to ischaemia, a stricture is formed in the bowel at the constriction ring after reduction.

- ◆ Features of intestinal obstruction may be absent in case of omentocele, Richter's hernia, Littre's hernia.
- ◆ Strangulation is the most serious complication of hernia; most common strangulated hernia is indirect inguinal hernia. Highest rate of strangulation is seen in femoral hernia (ratio of strangulated femoral hernia to total number of femoral hernia).

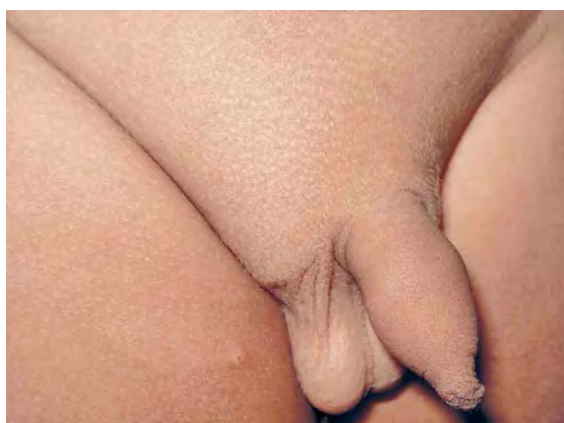## Classification II

### Congenital—Common

It occurs in a preformed sac/defect. Clinically may present at a later period due to any of the precipitating causes like in indirect inguinal hernia.

### Acquired

It is secondary to any causes which raise the intra-abdominal pressure leading into weakening of the area like in direct inguinal hernia.



**Fig. 18.14:** Inguinal hernia on right side in a child. It needs only herniotomy.

## Classification III: According to the Contents

- ❖ Omentocele—omentum.
- ❖ Enterocele—intestine.
- ❖ Cystocele—urinary bladder.
- ❖ Littre's hernia—Meckel's diverticulum.  
*Note:* Littre described Meckel's diverticulum in a hernial sac 81 years before Meckel was born.
- ❖ Maydl's hernia.
- ❖ Sliding hernia.
- ❖ Richter's hernia—part of the bowel wall.

## Classification IV: Based on Sites

- ❖ Inguinal hernia—occurring in inguinal canal.
- ❖ Femoral hernia—occurring in femoral canal.
- ❖ Obturator hernia.
- ❖ Diaphragmatic hernia.
- ❖ Lumbar hernia.
- ❖ Spigelian hernia.
- ❖ Umbilical hernia.
- ❖ Epigastric hernia.

## ■ INGUINAL HERNIA

### SURGICAL ANATOMY OF INGUINAL CANAL

**Superficial inguinal ring** is a triangular opening in the external oblique aponeurosis and is 1.25 cm above the pubic tubercle. The ring is bounded by a superomedial and inferolateral crus. Normally, the ring does not or just admit the tip of little finger.

**Deep inguinal ring** is a U-shaped condensation of the transversalis fascia, lies 1.25 cm above the inguinal ligament midway between the symphysis pubis and the anterosuperior iliac spine.

**Inguinal (Poupart's) ligament:** It is formed by the lower border of the external oblique aponeurosis which is thickened and folded backwards on itself, extending from anterosuperior iliac spine to pubic tubercle.

**Inguinal canal:** It is an oblique passage in lower part of abdominal wall, 4 cm long, situated above the medial ½ of inguinal ligament, extending from deep inguinal ring to superficial inguinal ring.

In infants both superficial and deep rings are *superimposed* without any obliquity of the inguinal canal.

Inguinal canal in female is called as '**canal of Nuck**'.

#### Contents of inguinal canal

- ❖ Spermatic cord in males
- ❖ Round ligament in females
- ❖ Ilioinguinal nerve

#### Contents of spermatic cord

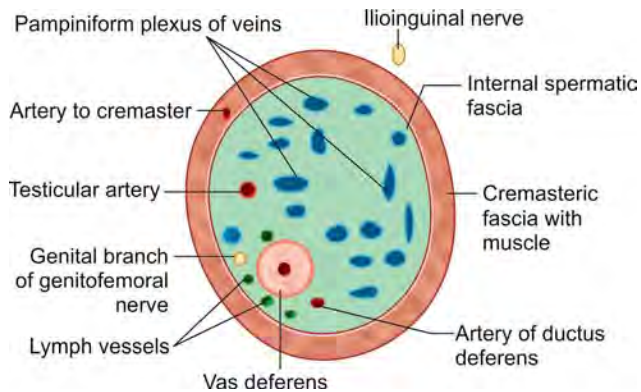
- ❖ Vas deferens
- ❖ Artery to vas
- ❖ Testicular and cremasteric artery
- ❖ Genital branch of genitofemoral nerve
- ❖ Pampiniform plexus of veins
- ❖ Remains of processus vaginalis
- ❖ Sympathetic plexus around the artery to vas

*When spermatic cord is rolled transversely beneath the gentle pressure of index finger. Thickening of the cord denotes presence of a hernia.*

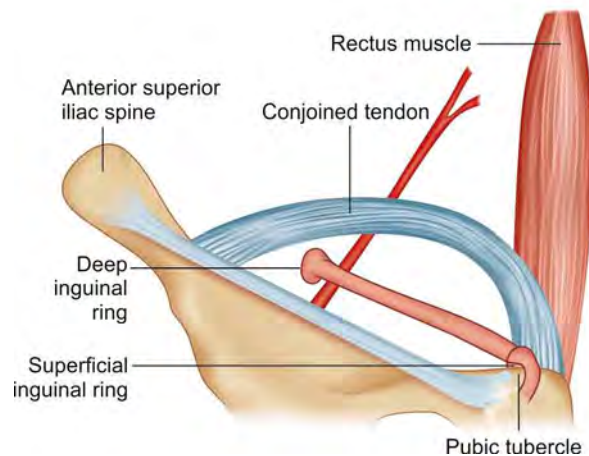
— William E Ladd

## Coverings of Spermatic Cord

- ◆ Internal spermatic fascia from fascia transversalis.
- ◆ Cremasteric fascia.
- ◆ External spermatic fascia from external oblique aponeurosis is seen below the external ring in the scrotum.



**Fig. 18.15:** Structures related to cord in the inguinal canal.



**Fig. 18.16:** Surgical anatomy of inguinal canal.

## Boundaries

*In front:* External oblique aponeurosis and conjoined muscle laterally.

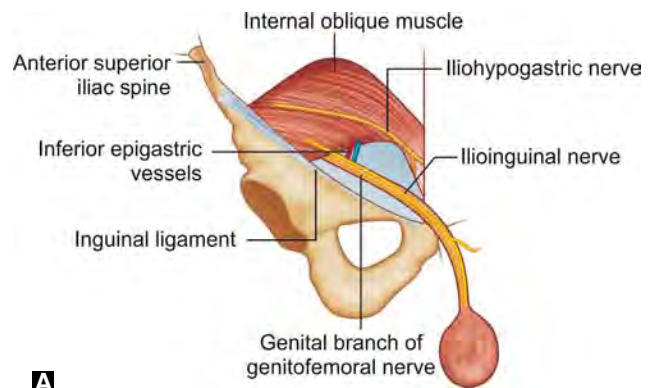
*Behind:* Inferior epigastric artery, fascia transversalis and conjoined tendon medially.

*Above:* Conjoined muscle (Arched fibres of internal oblique).

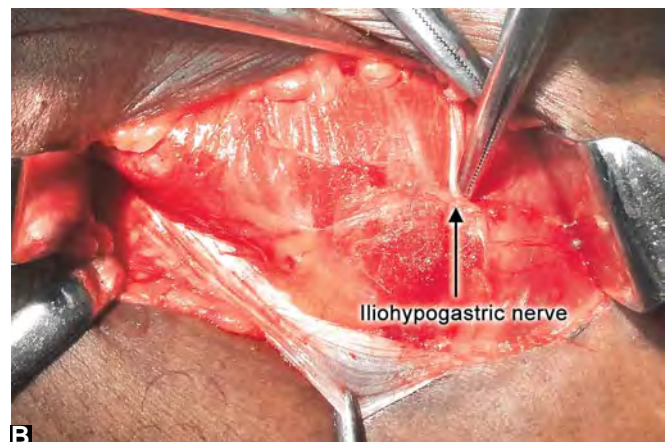
*Below:* Inguinal ligament.

### Defence mechanism of inguinal canal

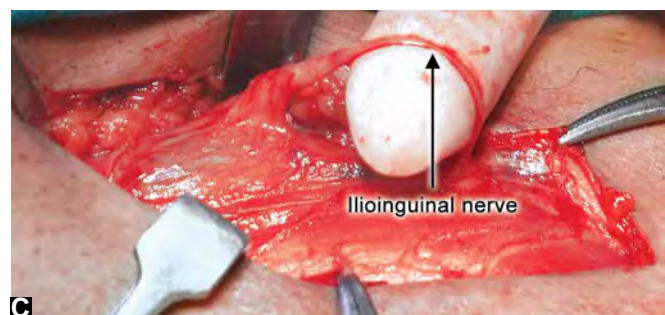
- ❖ Obliquity of inguinal canal
- ❖ Arching of conjoint tendon
- ❖ 'Shutter mechanism' of internal oblique
- ❖ 'Ball valve mechanism' due to contraction of cremaster muscle which plugs to superficial ring
- ❖ When external oblique muscle contracts, intercrural fibres of superficial ring appose causing 'slit valve mechanism'
- ❖ Hormones



**A**



**B**



**C**

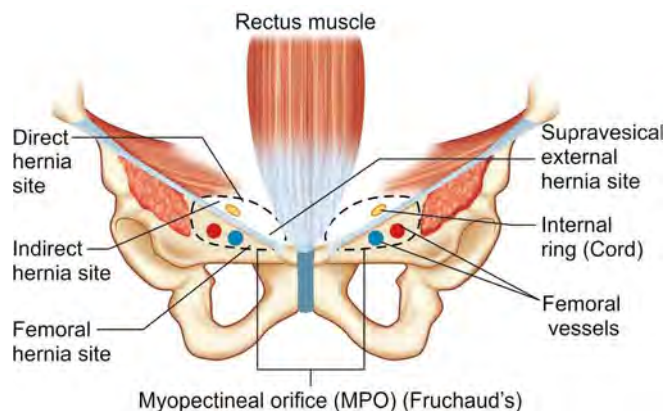
**Figs 18.17A to C:** Nerves in inguinal canal: *Iliohypogastric nerve* ( $T_{12}$ ,  $L_1$ ) runs between transversus abdominis and internal oblique divides into lateral and anterior branches; anterior branch pierces internal oblique 2 cm medial to anterosuperior iliac spine and later pierces the external oblique 3 cm above the superficial inguinal ring to supply abdominal skin above the pubis. *Ilioinguinal nerve* ( $L_1$ ) pierces the transversus abdominis near anterosuperior iliac spine, pierces the internal oblique just above the internal ring, and enters the inguinal canal within cremasteric fascia outside the cord supplies medial thigh, base of penis and proximal scrotum. *Genital branch of genitofemoral nerve* ( $L_1$ ,  $L_2$ ) enters the cord through internal ring supplying the cremaster and scrotum.

### Fruchaud's myopectineal orifice

It is an osseo-myo-aponeurotic tunnel. *It is through this tunnel all groin hernias occur.*

It is bounded:

- ❖ Medially by lateral border of rectus sheath.
- ❖ Above by the arched fibres of internal oblique and transversus abdominis muscle.
- ❖ Laterally by the iliopsoas muscle.
- ❖ Below by the pectin pubis and fascia covering it.



**Fig. 18.18:** Fruchaud's myopectineal orifice is bound—by lateral border of rectus, iliopsoas, conjoint tendon, pectin pubis.

## CLASSIFICATION OF INGUINAL HERNIA (EARLIER)

### Classification I

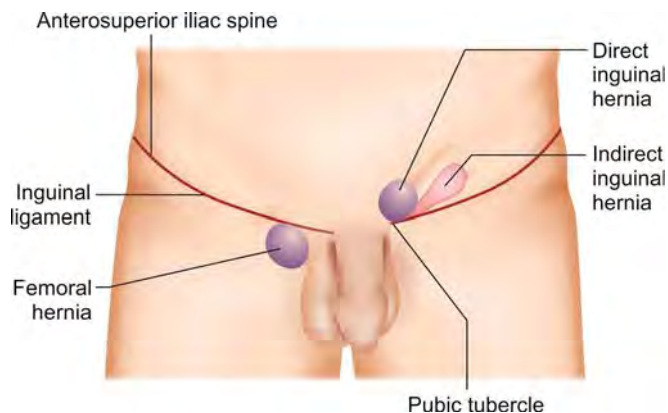
*Anatomical Classification (in Inguinal Hernia)*

#### Indirect hernia

It comes out through internal ring along with the cord. It is lateral to the inferior epigastric artery.

#### Direct hernia

It occurs through the posterior wall of the inguinal canal through 'Hesselbach's triangle' (bounded medially by lateral border of rectus muscle, laterally by inferior epigastric artery, below by inguinal ligament). Sac is medial to the inferior epigastric artery.



**Fig. 18.19:** Location of direct and indirect inguinal hernia and femoral hernia.

## Classification II

*According to the Extent*

- ◆ **Incomplete:**
  - ▶ **Bubonocoele:** Here sac is confined to the inguinal canal.
  - ▶ **Funicular:** Here sac crosses the superficial inguinal ring, but does not reach the bottom of the scrotum.
- ◆ **Complete:** Here sac descends to the bottom of the scrotum. Saddle-bag or pantaloon hernial sac has got both medial and lateral component.

**Note:**

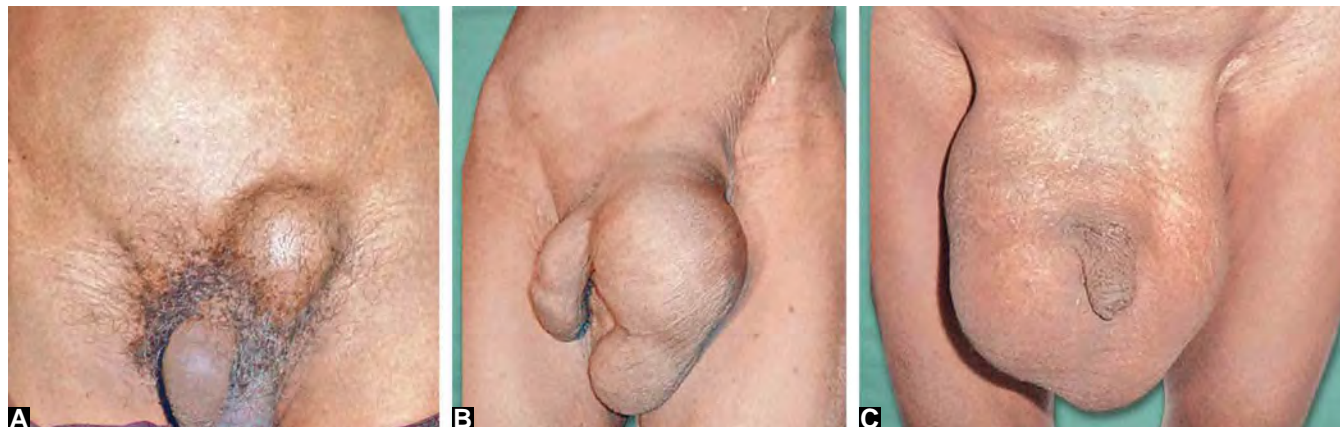
Inguinal hernia is above and medial to the pubic tubercle. Femoral hernia is below and lateral to pubic tubercle.

### Newer classification of hernia

#### I. Gilbert Classification

**Type I:** Hernia has got snug internal ring through which a peritoneal sac passes out as indirect sac.

**Type II:** Hernia has a moderately enlarged internal ring which admits one finger but lesser than two finger breadth. Once reduced it protrude during coughing or straining.



**Figs 18.20A to C:** (A) Bubonocoele; (B) Irreducible left side inguinal hernia. It is above the upper part of the testis (funicular). Taxis is the method used to reduce it; (C) Bilateral complete inguinal hernia. Here hernia descends up to the bottom of the scrotum.

**Type III:** Hernia has got large internal ring with defect more than two finger breadth. Hernia descends into the scrotum or with sliding hernia. Once reduced it immediately protrudes out without any straining.

**Type IV:** It is direct hernia with large full blow out of the posterior wall of the inguinal canal. The internal ring is intact.

**Type V:** It is a direct hernia protruding out through punched out hole/defect in the transversalis fascia. The internal ring is intact.

**Type VI:** Pantaloon/double hernia.

**Type VII:** Femoral hernia.

**Type VI and VII are Robbin's modifications.**

## II. NYHUS Classification

**Type I:** Indirect hernia with normal deep ring.

**Type II:** Indirect hernia with dilated deep ring.

**Type III:** Posterior wall defect.

- Direct.
- Pantaloon hernia.
- Femoral hernia.

**Type IV:** Recurrent hernia.

## III. BENDAVID Classification [Type, Staging, Diameter (TSD) Classification]

**Type I:** Anterolateral defect (indirect).

**Type II:** Anteromedial (direct).

**Type III:** Posteromedial (femoral).

**Type IV:** Posterior prevascular hernia.

**Type V:** Anteroposterior defect: Inguino-femoral hernia.

## IV. Classification—Casten's Staging

Stage 1: An indirect hernia with a normal internal ring.

Stage 2: An indirect hernia with enlarged internal ring.

Stage 3: All direct or femoral hernias.

## V. Halverson and McVay Classification

Class 1: Small indirect hernia.

Class 2: Medium indirect sac.

Class 3: Large indirect hernia or direct hernia.

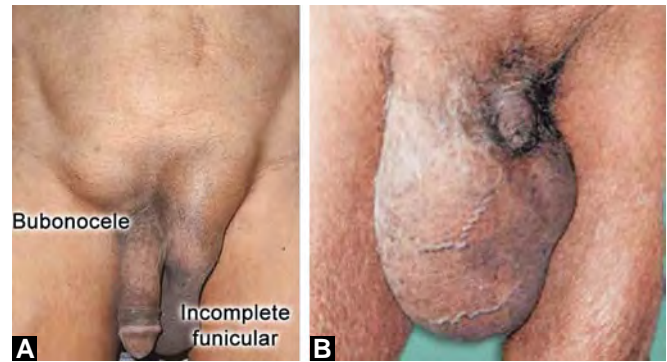
Class 4: Femoral hernia.

## VI. Ponka's Classification

- Indirect inguinal hernia:
  - Uncomplicated indirect hernia.
  - Sliding indirect hernia.
- Direct hernia:
  - Small defect on the medial aspect of the Hesselbach's triangle.
  - Diverticular hernia in the posterior wall with an otherwise intact inguinal floor.
  - A large diffuse direct inguinal hernia of the entire floor of Hesselbach's triangle.

## INDIRECT (OBLIQUE) INGUINAL HERNIA

- This is the most common type of hernia (65%).
- It is more common in younger age group as compared to direct inguinal hernia which is more common in elderly.
- It is more common on right side in 1st decade but in 2nd decade, the incidence is equal on both sides.
- Hernia is bilateral in 30% of cases.
- Sac is thin in indirect type. Neck is narrow and lies lateral to inferior epigastric vessels.



**Figs 18.21A and B:** (A) Indirect inguinal hernia. Right sided bubonocoele and left sided funicular; (B) Complete indirect hernia.

### Coverings of indirect hernia (from inside out)

- ❖ Extraperitoneal tissue
- ❖ Internal spermatic fascia
- ❖ Cremasteric fascia
- ❖ External spermatic fascia
- ❖ Skin

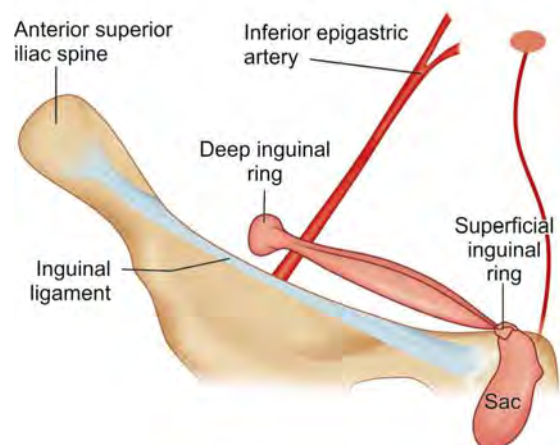
### Precipitating causes for inguinal hernia

- ❖ Smoking
- ❖ Obesity
- ❖ Respiratory causes like bronchial asthma, tuberculosis, bronchitis
- ❖ Ascites
- ❖ Previous surgery like appendectomy which can cause direct inguinal hernia
- ❖ Chronic constipation due to anorectal strictures. Rectal stricture may be due to chronic proctitis (amoebic), tuberculosis of anorectum, previous anorectal surgery, rectal carcinoma or stricture due to lymphogranuloma venereum
- ❖ Urinary problems like benign prostatic hyperplasia (BPH), urethral stricture
- ❖ Straining
- ❖ Multiple pregnancies

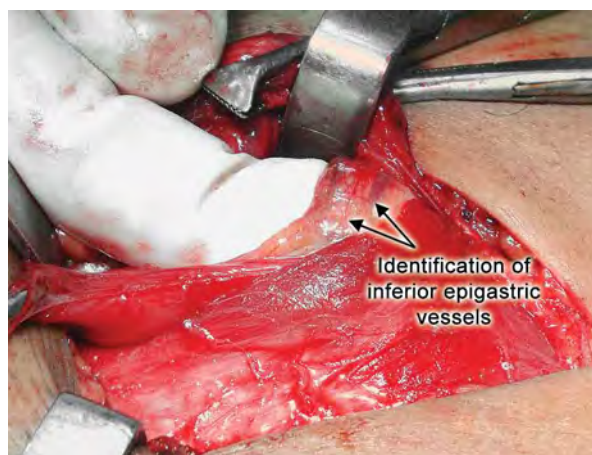## Types

Three types

- Bubonocoele:** Where the hernia is limited to inguinal canal.
- Funicular:** Processus vaginalis is closed just above the epididymis. Contents of the sac can be felt separately from testis, which lies below the hernia.



**Fig. 18.22:** Surgical anatomy of indirect hernia.



**Fig. 18.23:** Inferior epigastric artery (IEA) on table look during open inguinal hernia repair.

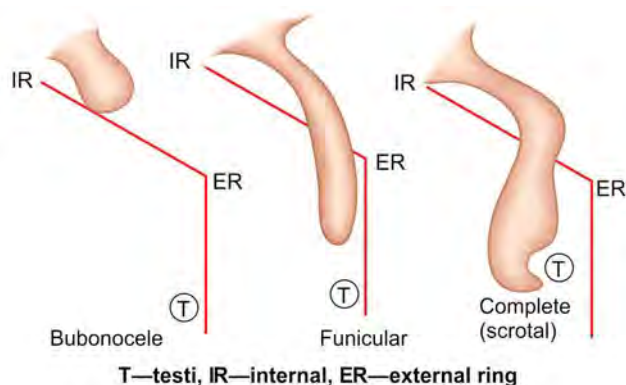
3. **Complete (Scrotal):** Testis appears to lie within the lower part of hernia. It can occur in any age group. It occurs in a congenital preformed sac (processus vaginalis). More commonly contents descend into the pre-existing sac, only when there are precipitating causes which force the content down.

**Expansile impulse on coughing**

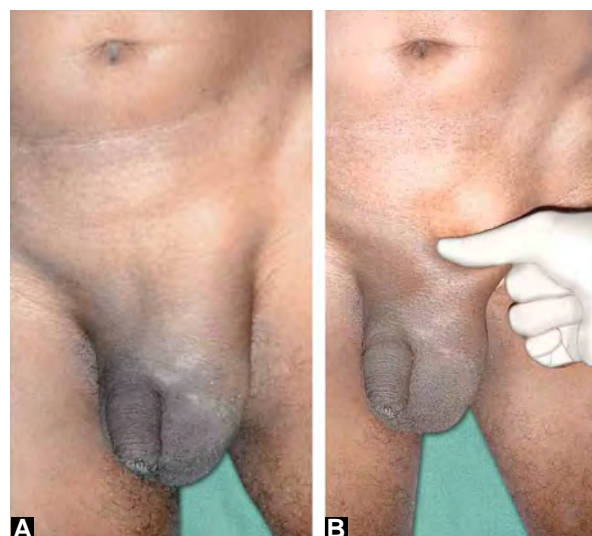
- ❖ Hernia
- ❖ Laryngocele
- ❖ Meningocele
- ❖ Empyema necessitans
- ❖ Swellings with intracavitary communications like thorax, cranium, and abdomen like dermoid

**Clinical Features**

- ◆ Prevalence of inguinal hernia is 25% in males; 2% in females.
- ◆ It is more common in males (20 : 1 :: Male : Female).
- ◆ Patient presents with dragging pain and swelling in the groin which is better seen while coughing and standing; and felt together with an expansile impulse (momentary increase or occurrence of the swelling during the act of coughing).
- ◆ In *complete* type, the content descends down to the scrotum completely. On palpation, one cannot get above the swelling.



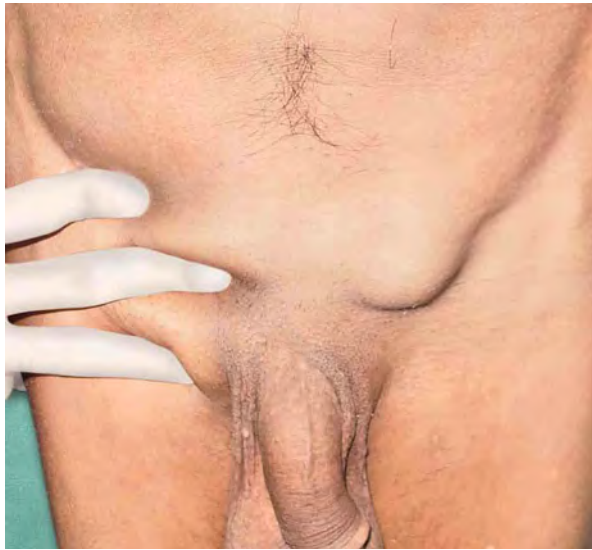**Fig. 18.24:** Types of indirect inguinal hernia.



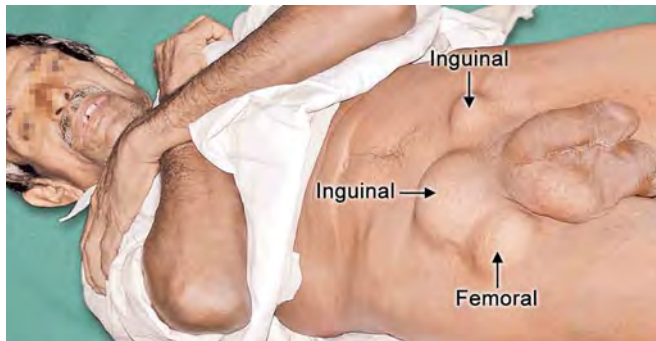
**Figs 18.25A and B:** Left side indirect inguinal hernia (inguinoscrotal swelling); one cannot get above the swelling on palpation.

- ◆ Contents are either small bowel, large bowel, omentum or combination of all these. In females, sometimes ovary and tubes may be the content. In infants, swelling appears when the child cries and is often translucent.
- ◆ It is usually reducible, but can go for irreducibility, inflammation, obstruction, strangulation.
- ◆ **Internal ring occlusion test:** Internal ring is located half inch above the mid-inguinal point (center point between anterosuperior iliac spine and pubic symphysis). After reducing the contents, in lying down position, internal ring is occluded using the thumb. Patient is asked to cough. If a swelling appears medial to the thumb, then it is a direct hernia. If swelling does not appear and on releasing the thumb swelling appears during coughing, then it is an indirect hernia confirmed in standing position.
- ◆ **Ring invagination test:** After reduction of hernia, the little finger/index finger of the examiner is invaginated from the bottom of the scrotum, gradually pushed up and rotated to enter the superficial inguinal ring. The impulse on coughing is felt at the tip of the invaginated finger. This test is done only in males.
- ◆ **Zieman's test:** The examiner places his index finger on the deep inguinal ring and middle finger on the superficial inguinal ring, ring finger over saphenous opening. The patient is asked to cough or to hold the nose and blow. If the impulse is felt on the index finger, it is indirect hernia.
- ◆ **Head or leg rising test** is done to look for abdominal wall muscle tone and Malgaigne bulgings. *Valsalva manoeuvre* is also used to check the tone of abdominal wall muscles.
- ◆ Abdominal, respiratory, urological examination is done to look for any precipitating factors like chronic bronchitis, ascites, stricture urethra, BPH.
- ◆ **Per rectal** examination is a must.
- ◆ **Inguinal hernia in females:** Increased thickness of labium majus on palpation, when compared to contralateral side.
- ◆ **Silk glove sign:** Index finger is invaginated across scrotum towards the external ring. When patient coughs, inguinal hernia is felt as a slit like sensation.

*Hydrocele of canal of Nuck is the most common differential diagnosis for inguinal hernia in females.*

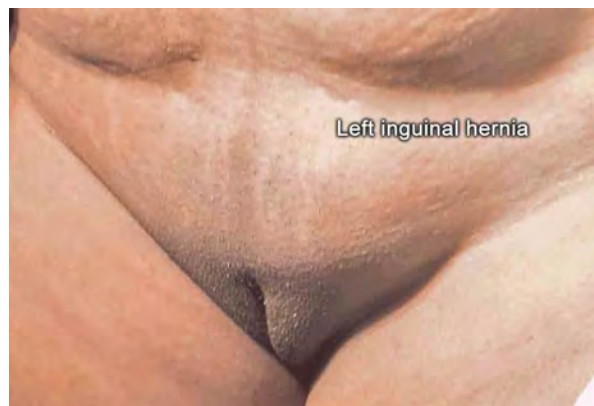

**Fig. 18.26:** Ziemann's test. Index finger on deep ring; middle finger on superficial ring and ring finger over saphenous opening—are placed after reducing the content. Patient is asked to cough and impulse is felt in finger corresponding to the existing hernia.



**Fig. 18.27:** Head or leg rising or Valsalva manoeuvre is important to elicit abdominal muscle tone. Note the bilateral inguinal (direct) and right sided femoral hernias; femoral hernia is rare in males.

- ◆ Palpation of bulbar urethra for stricture (thickening/crescent like feel/button like depression).



**Fig. 18.28:** Left side inguinal hernia in a female. In female, commonest hernia is inguinal hernia; but also femoral hernia is common in females.

#### Use five fingers of the hand to complete all tests for hernia

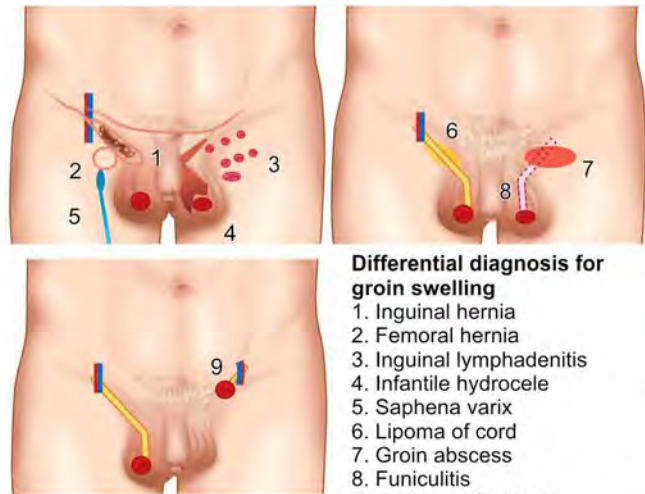
- ❖ Thumb—for deep ring occlusion test
- ❖ Index, middle and ring fingers for Ziemann's test
- ❖ Little finger for superficial ring invagination test

#### Rules of hernia examination

- ❖ Never forget to examine opposite side
- ❖ Never forget to do *per rectal* examination
- ❖ Never forget to examine urethra
- ❖ Never forget to check abdominal muscle tone

#### Differential diagnosis

- ❖ Hydrocele—infantile/encysted/large vaginal/bilocular
- ❖ Undescended testis
- ❖ Femoral hernia
- ❖ Lipoma of the cord
- ❖ Hydrocele of the canal of nuck (in females)
- ❖ Inguinal lymph node enlargement
- ❖ Groin abscess



#### Differential diagnosis for groin swelling

1. Inguinal hernia
2. Femoral hernia
3. Inguinal lymphadenitis
4. Infantile hydrocele
5. Saphena varix
6. Lipoma of cord
7. Groin abscess
8. Funiculitis
9. Undescended testis

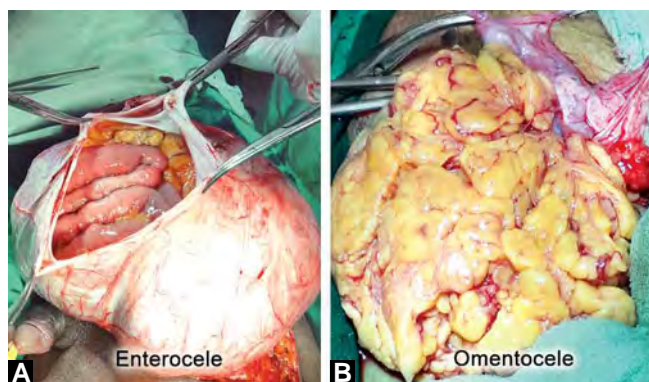
**Fig. 18.29:** Differential diagnosis for groin swellings.

Indirect inguinal hernia	Direct inguinal hernia
Can occur in any age from childhood to adult	Common in elderly
Occurs in a pre-existing sac	Always acquired
Protrusion through the deep ring; herniation occurs later	Herniation through posterior wall of the inguinal canal
Pyriform/oval in shape; descends obliquely and downwards	Globular/round in shape; descends directly forward bulge
Can become complete by descending down into the scrotum	Descent down into the scrotum is rare

Contd...

Contd...

Sac is anterolateral to the cord	Sac is posterior to the cord
Ring occlusion test does not show any impulse after occluding the deep ring	Test shows impulse even after occluding the deep ring
Invagination test shows impulse on the tip of the little finger	Impulse is felt over the pulp of the little finger
Zieman's test shows impulse on the index finger	Test shows impulse on the middle finger
Commonly unilateral but can be bilateral	Commonly bilateral
Obstruction/strangulation are common	Rare but can occur
Sac should be opened during surgery	Sac is not necessarily opened unless obstruction is present



**Figs 18.32A and B:** Typical enterocele and omentocele.

### Investigations

- ◆ Chest X-ray to rule out chronic bronchitis.
- ◆ Ultrasound abdomen to find out BPH, ascites.
- ◆ Tests relevant to other precipitating causes.

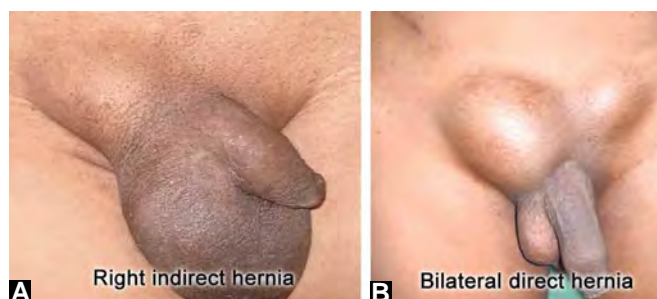### Treatment

*This method reconstructs the inguinal canal as it is physiologically, with two rings, one abdominal, the other subcutaneous; and with two walls, one posterior and the other anterior, between which the spermatic cord passes obliquely.*

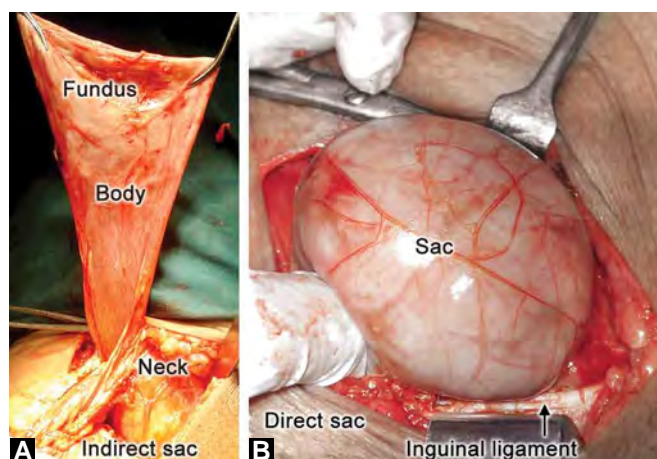
—Edoardo Bassini, 1887

- ◆ Treatment for inguinal hernia is **always surgery**. However, asymptomatic direct hernia patients can wait without opting for any surgical intervention. *Precipitating causes should be treated or controlled first* like treating asthma, tuberculosis, bronchitis, chronic cough, stopping smoking, treating enlarged prostate by TURP (transurethral resection of prostate), etc. TURP and hernioplasty can be combined together.

**Note:** *Wearing truss should be discouraged.* Usually, elective surgery is done; but if it is irreducible or obstructed/or strangulated immediate surgery is the need; especially strangulated hernia which should be operated as an emergency at the earliest.

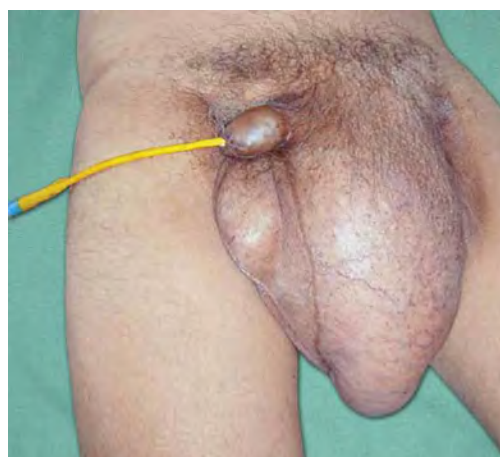

**Figs 18.30A and B:** Indirect and direct inguinal hernias.



**Figs 18.31A and B:** Indirect and direct sacs of inguinal hernia.

In enterocele	In omentocele (epiplocele)
First part is difficult to reduce but last part is easier. There will be gurgling sound on reduction	First part is easier to reduce but last part is difficult. Has a doughy feeling
Resonant on percussion	Dull on percussion
Peristalsis is seen	No peristalsis seen
Bowel sounds may be heard	Bowel sounds not heard

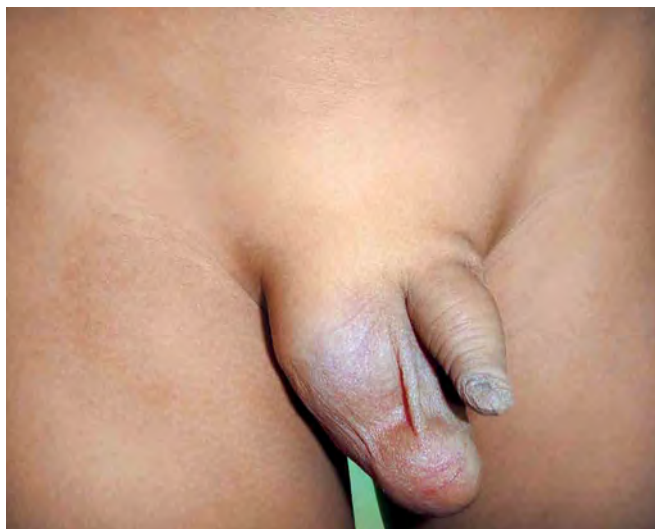


**Fig. 18.33:** Large hernia with BPH (benign prostatic hyperplasia) with Foley's catheter in place as patient presented with retention of urine. He underwent transurethral resection of prostate (TURP) first and later hernioplasty was done.

*Usually saphena varix feels softer than a femoral hernia.*— Robert Milnes Walker



- ◆ **Lichtenstein open tension free onlay hernia mesh** (Prolene mesh) repair (**hernioplasty**) is the standard treatment (most commonly done) through inguinal (anterior) approach. Hernial sac should be ligated and excised in indirect sac (herniotomy) prior to mesh placement (hernioplasty). Strengthening of the posterior wall is important in all inguinal hernia repairs whether direct or indirect (Either tissue repair or prosthetic repair is used).
- ◆ Bassini's tissue repair (even though lasted for a century; *Bassini is father of hernia surgery*) is not commonly used now except in strangulated hernia where mesh is contraindicated. Shouldice tissue repair shows less recurrence, but it is technically demanding. New no mesh tension free tissue repair invented by Professor Mohan Desarda from Pune, India as "**Desarda no mesh tissue repair**" is becoming popular with less recurrence and least postoperative chronic pain.
- ◆ In Western countries, most of the open inguinal hernia surgeries are done under local anaesthesia as day care procedure. In developing countries spinal anaesthesia is commonly used. In infants and children and in adult for TEP (Totally Extraperitoneal Preperitoneal mesh repair) and TAPP (Trans Abdominal Pre Peritoneal mesh repair) general anaesthesia is preferred and ideal.
- ◆ In infants and children whether inguinal hernia or hydrocele, herniotomy is done through inguinal approach (Michaelis Plank operation); neither tissue repair nor mesh repair is needed (only herniotomy ideally open; can be through laparoscopy).

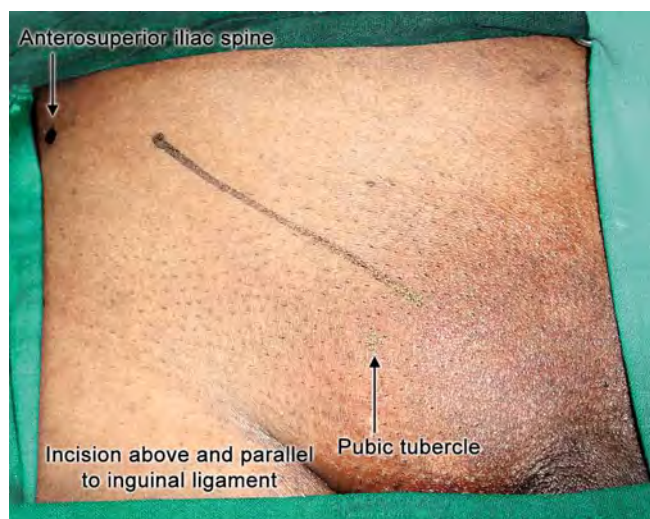


**Fig. 18.34:** Inguinal hernia in a child; here just herniotomy is required. Repair is not done.

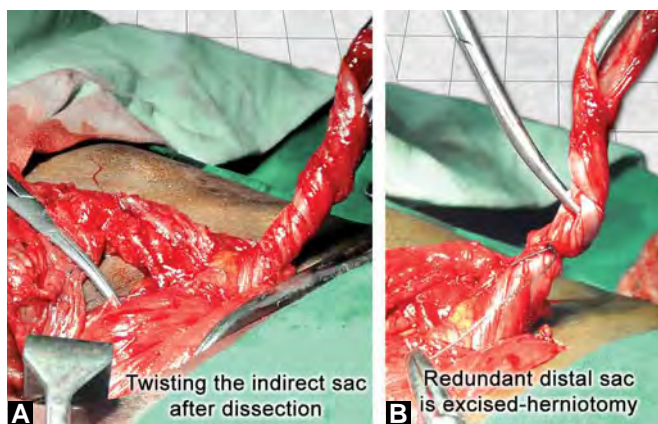
## Herniotomy

**Anaesthesia:** Spinal or general anaesthesia or **local anaesthesia**. Urinary catheterisation is better done in large hernia, direct hernia, sliding hernia and old people.

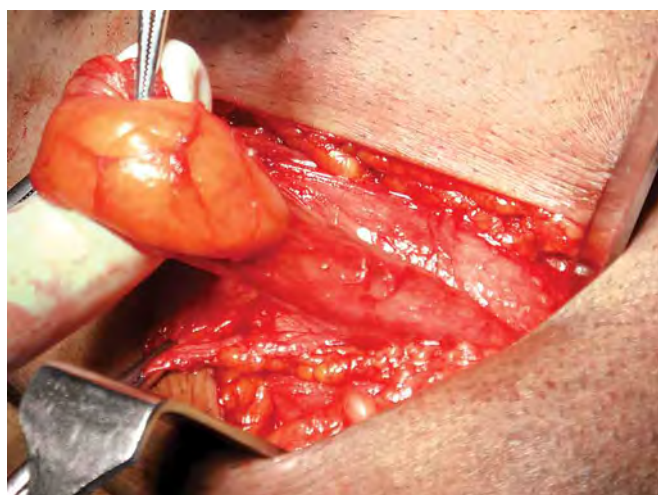**Procedure:** After cleaning and draping, skin is incised 1.25 cm above and parallel to the medial two-thirds of inguinal ligament. Two layers of superficial fascia (outer Camper's fascia and inner Scarpa's fascia) are incised. Superficial pudendal and superficial epigastric vessels are ligated with catgut or cauterised. Self-retaining mastoid or similar retractor is placed to retract the skin edges. External oblique aponeurosis is incised along its long axis parallel to the line of skin incision. Incision is extended on either ends of the incision; medially it is extended to cut the margins of the superficial ring. Upper leaf is reflected above and held with haemostat; using peanut dissection upper leaf is raised adequately to visualise conjoined tendon and lateral rectus sheath. *Iliohypogastric nerve* is identified above and medially which after piercing the internal oblique enters the external oblique. Lower leaf is reflected downwards to visualise and expose the inguinal ligament. Entire inguinal ligament is dissected medially and exposed with its shelving edge and iliopubic tract. *Ilioinguinal nerve* is safeguarded which is located in the inguinal canal outside the cord. Cremasteric muscle (box) with its fascia is opened longitudinally as medial and lateral flaps. *Genital branch of genitofemoral nerve* passes through the cord structures. Care should be taken not to injure it. Cremasterectomy is not done, even though it clearly exposes cord and posterior inguinal wall, it causes hanging testis without support (*clapper in bell*). If there is a *lipoma of the cord* it should be excised. Cord structures are dissected. Sac lying anterior and lateral to cord is identified and is pearly white in color. Dissection is usually started from the fundus and extended towards the neck which is identified by the extra-peritoneal fat. The neck is narrow and is lateral to inferior epigastric artery. *High dissection beyond the deep ring* is done. Sac is opened at the fundus. Finger is passed to release any adhesions. Sac is twisted so has to prevent the content from coming back. It is transected using absorbable suture material (chromic catgut 2-0 or **vicryl**) and is excised (redundant sac) distally. In complete hernia, distal scrotal part of the hernial sac can be left *in situ* as left open/lay open) without suture ligating the distal end (*Wantz procedure*). *Direct sac* is usually not opened unless it shows adhesions or obstruction. Direct sac *should be inverted* using vicryl or PDS by taking purse string suture around.



**Fig. 18.35:** Incision for inguinal hernia surgery (open surgery through anterior approach).



**Figs 18.36A and B:** Herniotomy—is usually done in indirect sac of inguinal hernia. After twisting to prevent contents getting in, transfixation is done using vicryl; redundant sac is excised.



**Fig. 18.37:** Lipoma of the cord should be excised during herniotomy.

### Hernia Repair

#### Repair may be

- ❖ *Pure tissue repair:* Desarda, Shouldice, MacVay (Still very useful repairs) and modified Bassini (not used now)
- ❖ *Prosthetic repair:* Lichtenstein, Rives, Gilbert, Stoppa, TEP, TAPP

#### Approach for repair may be

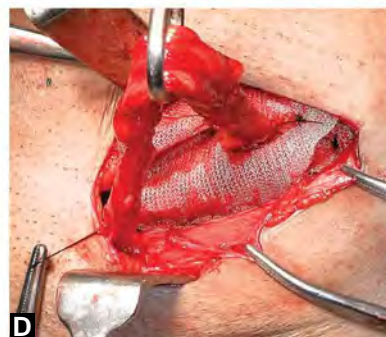
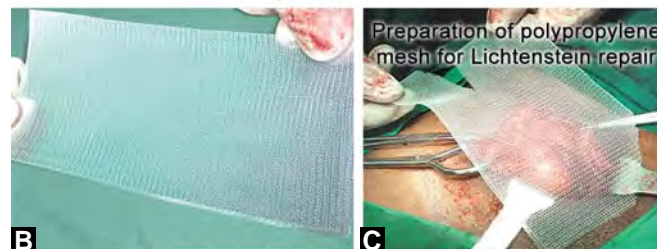
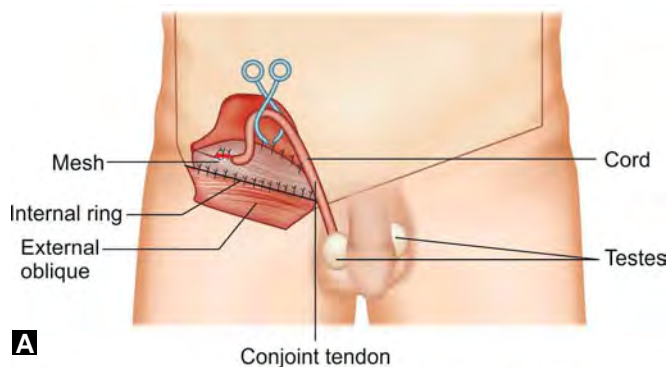
*Anterior (inguinal) approach repair:* Bassini's, Desarda, Shouldice, MacVay, darning, Andrew's, Wilkinson's, Cooper's, Lichtenstein mesh repair, PHS repair, Rives preperitoneal mesh repair  
*Posterior approach repair:* Through suprainguinal preperitoneal approach—Nyhus repair (tissue or mesh), Kugel's, Stoppas, TEP, TAPP

It means repair or strengthening of the posterior wall of the inguinal canal. Strengthening can be done by tissue or

prosthetic repair. Strengthening by tissue repair has got various approaches where transversalis fascia or tendinous fascio-aponeurotic upper part is approximated to iliopubic tract or Cooper's ligament or shelved edge of the inguinal ligament. Upper leaf taken for repair should be tendinous fascio-aponeurotic layer not fleshy red muscle. Non-absorbable monofilament sutures like polypropylene should be used ideally. Prosthetic repair is done by placing mesh or prosthesis by onlay/inlay/sublay/sublay intraperitoneal method. *Polypropylene mesh is commonly used* with different modifications. Tissue prosthesis like tensor fascia lata or temporal fascia is not used now. But an innovative technique as advocated by Mohan Desarda, live aponeurotic tissue is used as prosthesis in his "*Desarda no mesh tissue repair*" is said to very effective tissue prosthesis repair.

#### Lichtenstein hernioplasty

After herniotomy 15 × 8 cm or suitable sized mesh is selected. Mesh is placed deep to the cord structures; below it is sutured to the inguinal ligament using continuous non-absorbable polypropylene sutures; medially it should overlap 2–2.5 cm over the pubic tubercle. Suture should be ended laterally at the level of internal ring. Mesh on its lateral part is slit onto two tails; 2/3rd upper leaf and 1/3rd lower leaf; slit is done up to the internal ring and cord with ilioinguinal nerve is passed in between the tails; upper leaf is overlapped onto



**Figs 18.38A to D:** Lichtenstein mesh repair—polypropylene is used; often mesh is trimmed.

*In exomphalos, the protruding abdominal contents being covered only by a diaphanous membrane, through which viscera are exposed to view, as if exhibited in a show case.*

— William E Ladd

the lower leaf in front below and is sutured to inguinal ligament at the level of internal ring. Laterally both leaflets are spread up to anterior superior iliac spine for 6 cm. Above and medially mesh is fixed to conjoint tendon using interrupted non-absorbable sutures. Care should be taken to avoid taking bites from the iliohypogastric nerve. Cord is placed on the mesh and external oblique is sutured using same suture material or delayed absorbable suture. Subcutaneous and skin is closed. Recurrence rate has reduced significantly by prosthetic mesh repair. But incidence of mesh *inguinodynia* has increased due to entrapment of ilioinguinal or iliohypogastric nerves in the mesh.

Even though it is a commonly done procedure at present for inguinal hernia, in adolescents whether it should be used or not is a debate. In children, it is not used. It is not done in strangulated hernia or in presence of sepsis where only tissue repair is done. (*Different mesh procedures are discussed at a later part of this chapter*).

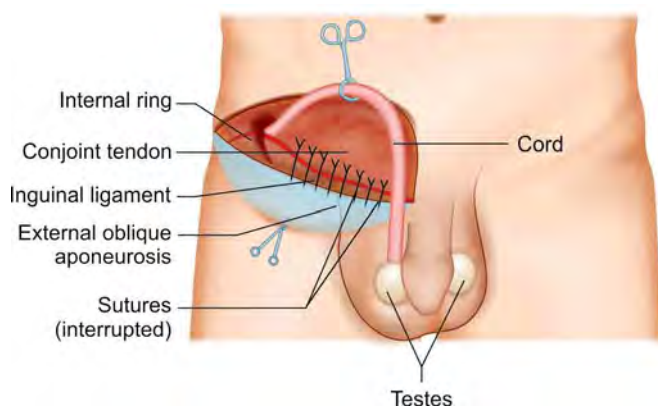
#### Note:

#### Other methods of mesh repair are:

- Nyhus pre-peritoneal mesh repair (sublay).
- Gilbert mesh repair (patch and plug). Gilbert's PHS (Prolene Hernia System) repair (onlay and sublay).
- Stoppa's (Rene S Stoppa) giant prosthesis reinforcement of visceral sac (GPRVS- sublay).
- Kugel (Rober D Kugel) groin hernia mesh repair (sublay).

#### Tissue repairs are:

- *Modified Bassini's Herniorrhaphy*: Conjoined tendon and inguinal ligament are approximated using interrupted non-absorbable monofilament sutures (polypropylene); medial most stitch is taken from the periosteum of pubic tubercle (*called as key or Bassini's stitch*); external oblique is closed and other layers are closed. Bassini originally used silk suture for the repair (1887). He also used triple layer of upper leaf which contains transversalis fascia, transversus abdominis and internal oblique muscles in his repair. Care should be taken not to injure iliac vessels (mainly vein) while taking bite from inguinal ligament. It is often practiced to take bites in inguinal ligament at different levels to prevent tearing of the fibres of inguinal ligament. Laterally repair is done beyond the line of internal ring. Few advocate horizontal mattress sutures starting from conjoined tendon to inguinal ligament and from inguinal ligament to conjoined tendon.

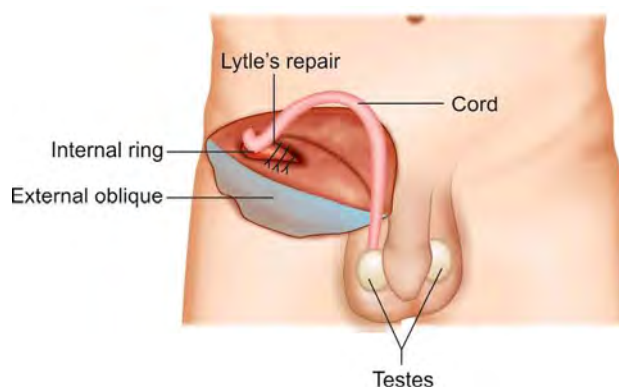


**Fig. 18.39:** Modified Bassini's repair: It is approximation of inguinal ligament to conjoined tendon using interrupted non-absorbable sutures.

- *Desarda no mesh tension free tissue repair* (Professor Mohan Desarda, Pune, India): It is live external oblique tissue flap reconstruction of the posterior wall of the inguinal canal. He proposed that strength

of the inguinal canal depends on the aponeurotic extensions from the transverse abdominis aponeurotic arch normally which is physiologically dynamic and strong and his repair supports this effectively with least complications and recurrence.

- *Shouldice repair*: Even though transversalis fascia is thin, it is a tough layer and so double-breasting of this fascia using continuous sutures (with non-absorbable material) strengthens the posterior wall of the inguinal wall. It is a multilayered repair. Continuous sutures provide *even distribution of tension* throughout the repair. It was originated at *Shouldice hernia clinic in Toronto* by Shouldice (EE Shouldice 1930) where it was usually done under local anaesthesia. Often cremasteric resection is done in Shouldice in order to have proper revelation of the posterior inguinal wall. Cremasteric vessels (located at lateral part of the cord along with genital branch of genitofemoral nerve) need ligation during cremasterectomy (it causes *hanging testis/clapper in bell*). After doing herniotomy as in any other inguinal hernia, transversalis fascia is incised along the line of the wound from deep ring to pubic tubercle. Upper medial flap is elevated without elevating lower lateral flap. *First suture line*—Lower lateral flap of fascia is sutured to posterior deep part of the elevated upper flap using continuous sutures from pubic tubercle to internal ring which is tied at deep ring without cutting/ending. *Second suture line*—Using same suture which is not cut, free margin of upper flap is sutured to the shelving edge of the inguinal ligament from deep ring towards pubic tubercle. It causes double-breasting of the transversalis fascia. Knot is placed at the end over the pubic tubercle. First and second line sutures are done using a single suture material. *Third suture line*—The conjoined tendon and anterior to the shelving part of the inguinal ligament is sutured from internal ring to pubic tubercle continuously and tied without cutting. *Fourth suture line*—Same uncut suture is again sutured back continuously between conjoined tendon and anterior fibres of the inguinal ligament to reach internal ring. External oblique aponeurosis is sutured in two layers (5th and 6th suture lines; double-breasting) in front of the cord in original Shouldice repair. Hence, this original Shouldice repair is 6-layered procedure. Suture material used here is 34 gauge fine steel wire (in original Shouldice repair) or polypropylene or polyethylene. Recurrence rate in Shouldice repair is 1%. *Berliner modified Shouldice repair*—It involves double-breasting of the transversalis fascia like in Shouldice repair and single layer closure of the external oblique aponeurosis without any additional two-layered repair of conjoined tendon to inguinal ligament.
- *Lytle's repair* (William James Lytle): Often internal ring is narrowed by placing interrupted sutures over the medial side of the ring to the transversalis fascia using either silk or polypropylene (to narrow the ring and push the cord laterally).



**Fig. 18.40:** Lytle's repair is narrowing of the widened internal ring.

- *Halsted (USA)—Tanner (London) slide operation*: To reduce the tension in the repair area, relaxing incision is placed over the lower rectus sheath so that conjoined tendon is allowed to slide downward.

- *Abrahamson nylon darning*: Continuous intervening network of non-absorbable sutures are placed between conjoint tendon and inguinal ligament to give good support to posterior wall inguinal wall.
- *Koontz's operation* (Koontz AR, New York, 1963): In old people after taking consent, orchidectomy is done along with removal of full cord, testis and total closure of posterior inguinal wall by repair so as to reduce the recurrence.

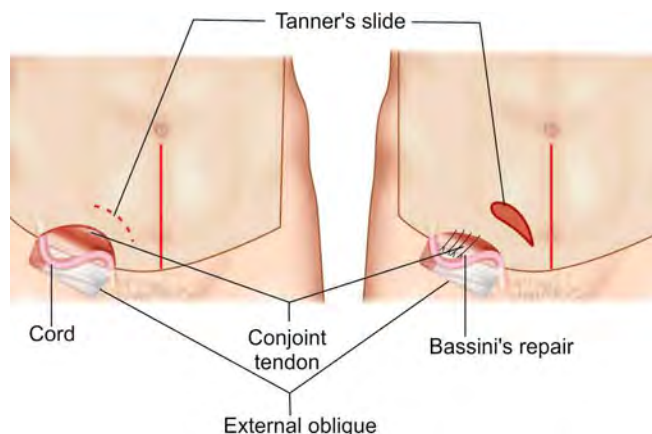


Fig. 18.41: Tanner slide operation.

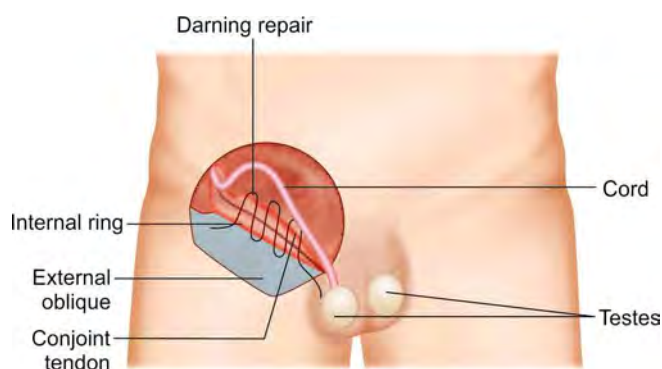


Fig. 18.42: Darning in inguinal hernia—Abrahamson's nylon darning.

- *Removal of cord at inguinal region* (Hamilton Bailey): Cord is removed from the inguinal canal by ligating both at external and internal ring. But testis is retained [for psychological reason] and closure of inguinal canal by repair is done.
- *McVay operation, 1940* (Cooper's ligament repair): It is repair by placing interrupted sutures between edge of the transversus abdominis to Cooper's ligament starting from pubic tubercle medially towards femoral sheath and later continued as suture repair between transversus abdominis and iliopubic tract laterally up to the entrance of cord. It is a pure tissue repair. It requires relaxing vertical / curvilinear oblique incision at the lateral border of the anterior rectus sheath from pubic tubercle to a point superiorly for 4 cm. It covers all three groin defects (Myopectineal orifice)—indirect, direct and femoral.
- *Nyhus (original) iliopubic repair*: Through suprainguinal approach, a transverse incision is made two fingerbreadths above the pubic symphysis to expose the rectus sheath. Left index finger is passed into the external ring; level of internal ring is confirmed. Anterior rectus sheath is incised horizontally above the level of the deep ring; lateral part of lower end of the rectus is retracted. Posterior rectus sheath is opened. External oblique, internal oblique and transversus abdominis muscles are cut along the length of the inci-

sion. Transversalis fascia is cut to reach the preperitoneal space. If it is direct sac, it is dissected without opening and isolated. Sac is inverted using absorbable purse string suture. If it is indirect sac, it is dissected proximally high up, opened and ligated. Transaponeurotic arch (transverse abdominis muscle and transversalis fascia) is sutured below to Cooper's ligament and iliopubic tract. Nyhus mesh repair is done similarly through this approach by placing mesh and suturing to Cooper's ligament.

- *Andrew's operation*: It is overlapping of the external oblique aponeurosis.
- *Condon procedure*: It is anterior iliopubic tract repair by suturing the transversus abdominis to iliopubic tract from pubic tubercle to deep ring; then extending lateral to the cord. In direct sac relaxing incision is made on the lower rectus before tying all placed sutures.
- *Wilkinson method*: Transversus abdominis and internal oblique are sutured to inguinal ligament with continuous monofilament sutures—1st layer; lower free edge of the external oblique is passed above, behind the cord and is sutured to internal oblique surface—2nd layer; upper free edge of the external oblique is brought down in front of the cord and is sutured to lower visible surface of the external oblique—3rd layer. It has less recurrence rate.

**Complications of tissue repair are:**

- ◆ Haemorrhage, haematoma, seroma, haematocele.
- ◆ Infection, osteitis pubis.
- ◆ Post-herniorrhaphy hydrocele, lymphocele.
- ◆ Hyperaesthesia over the medial side of inguinal canal due to injury to iliohypogastric nerve—neuralgia (15%).
- ◆ Recurrence—10–15% in modified Bassini; 1–5% only in other types.
- ◆ Injury to urinary bladder, bowel, ileus.
- ◆ Testicular atrophy due to thrombosis of pampiniform plexus of veins, penile oedema—rare.

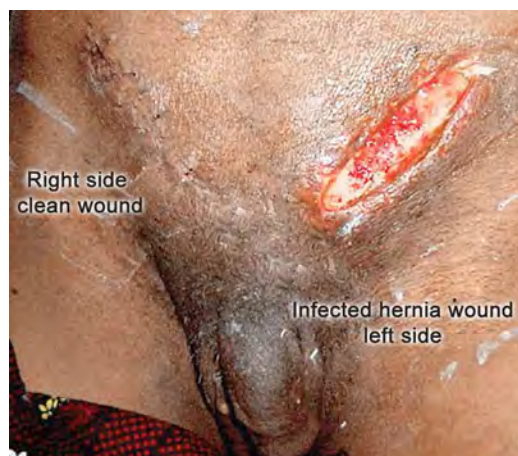

Fig. 18.43: Left sided inguinal hernia repair wound is infected; right side is clean.

**Technique of local anaesthesia**

Around 50 ml of xylocaine 0.5% is used. Plain xylocaine 0.5% or xylocaine 0.5% with adrenaline can be used. Plain xylocaine— dose is 2 mg/kg body weight. Xylocaine with adrenaline—is 7 mg/kg body weight.

Two methods are used:

1. *Nerve block method (Point block)*: 10 ml of xylocaine is infiltrated 2 cm above and medial to anterior superior iliac spine to block

Contd...

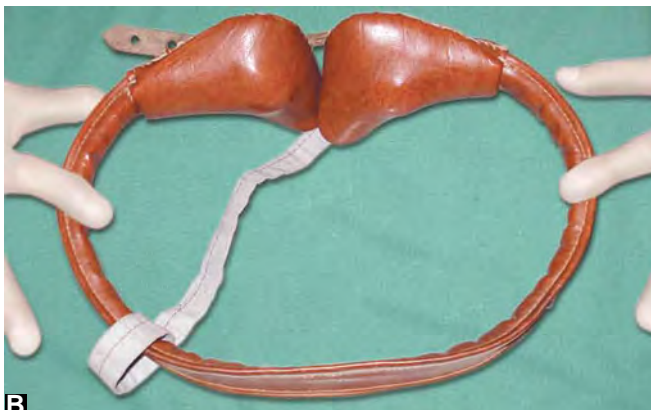
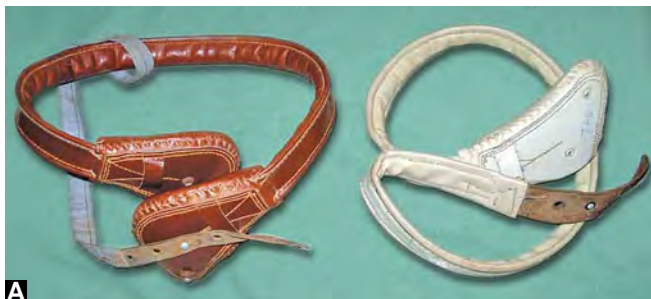Contd...

the iliohypogastric nerve. Midinguinal point is infiltrated with 10 ml xylocaine. Pubic tubercle place is infiltrated with 10 ml xylocaine. 10 ml of xylocaine is infiltrated just below the inguinal ligament lateral to femoral artery to block the genital branch of genitofemoral artery. Line of skin incision is infiltrated with 10 ml of xylocaine. Later neck of the hernial sac is infiltrated with 10 ml of xylocaine.

2. **Field block method (Shouldice method):** Skin of around 4 cm wide area is infiltrated including the subcutaneous plane as first layer from anterior superior iliac spine to pubic symphysis. Skin, subcutaneous and two layers of superficial fascia (Camper and Scarpa's) are incised. Area deep to external oblique aponeurosis is infiltrated with 10 ml of xylocaine. External oblique aponeurosis is incised. Exposed inguinal canal and hernial sac is infiltrated with 10 ml of xylocaine to continue with the dissection.

### Conservative treatment

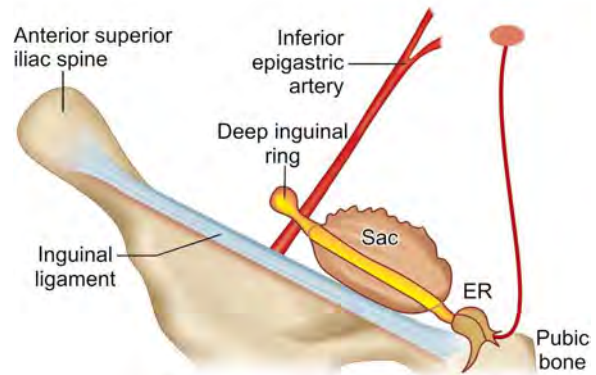
- ❖ **Taxis:** Patient is placed in supine position with hip and knee flexed and hip internally rotated. Contents are pushed with one hand directing with other hand
- ❖ **Use of Truss:** Rat-tailed sprung truss is used. Measurement is taken from the tip of greater trochanter to third piece of sacrum circumferentially
  - Complications are discomfort, ulceration, strangulation, inflammation, testicular atrophy, ilioinguinal neuritis, femoral neuritis
  - It may be used in elderly people, who are not fit for anaesthesia and surgery
  - Conservative treatment should be avoided in hernia as much as possible
  - Truss is absolutely contraindicated in femoral and sliding hernia
  - Truss increases the surgical bleeding, postoperative oedema, testicular pain



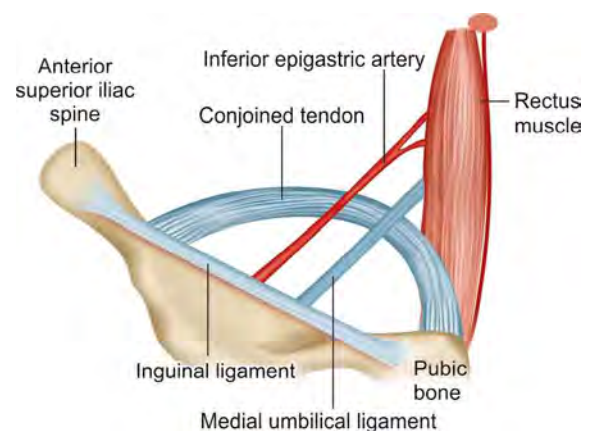
**Figs 18.44A and B:** *Hernia truss*. It is used only when patient is not fit for surgery. It may precipitate strangulation. Before placing truss, contents of the hernia should be reduced completely.

### DIRECT INGUINAL HERNIA

- ◆ 10–15% of the hernias are direct.
- ◆ 50% of direct hernias occur bilateral.
- ◆ 35% of inguinal hernias are direct.
- ◆ It is uncommon in females and children.
- ◆ It is always acquired, due to weakening of posterior wall of inguinal canal.
- ◆ Hernia is medial to the inferior epigastric artery with wide neck. Sac is thick and often the medial wall or content may be bladder.
- ◆ Direct hernia occurs through *Hesselbach's triangle* which is bounded by inferior epigastric artery laterally, lateral border of rectus medially, inguinal ligament below. It is divided into medial and lateral halves by obliterated umbilical artery (medial umbilical ligament). So, direct hernia is classified as *medial or lateral depending on which part of the Hesselbach's triangle, it is arising from*.



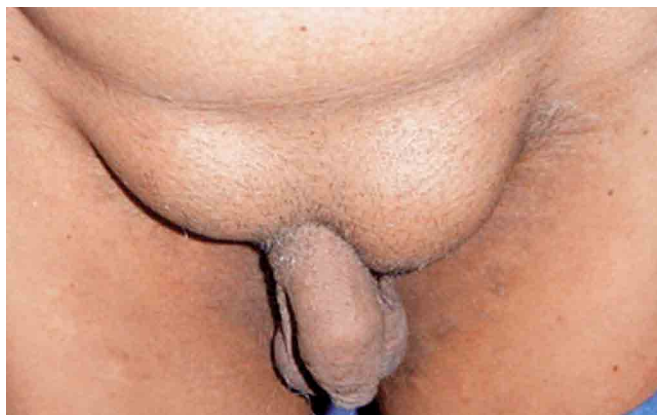**Fig. 18.45:** Surgical anatomy of direct inguinal hernia.



**Fig. 18.46:** Surgical anatomy of Hesselbach's triangle.

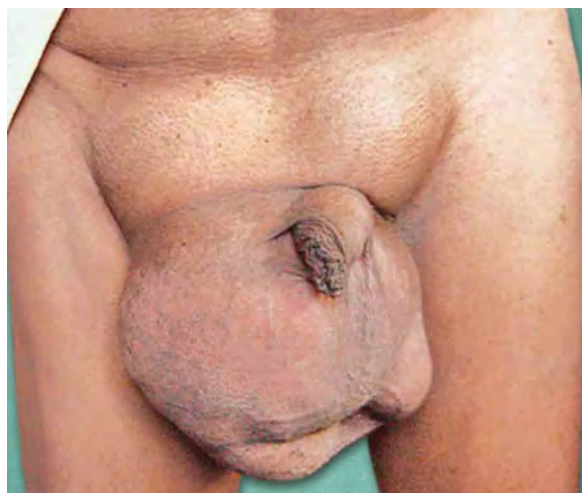### Predisposing factors

- ❖ Chronic cough, smoking
- ❖ Straining
- ❖ Constipation
- ❖ Heavy work
- ❖ Previous appendicectomy



**Fig. 18.47:** Bilateral direct hernia. Note the medial location of the direct hernias.

- ◆ **Malgaigne bulgings** are often seen in these patients on examination, more often than in indirect hernia. They are protrusion of abdominal wall muscle during leg raising test as weak, soft, supple, swellings which signifies poor abdominal muscle tone. It is common in old age, obesity; it indicates that *hernia requires mesh repair*.
- ◆ Direct hernia rarely descends into the scrotum and strangulation is not as common as in indirect hernia. But in long-standing cases, it can descend down to the scrotum and strangulation can occur.



**Fig. 18.48:** Large bilateral direct hernia. Occasionally direct hernia descends down and becomes complete and then may cause obstruction. Descent is not as common as indirect hernia.

## Treatment

### Surgery:

- ◆ Usually direct sac is not opened.
- ◆ Care should be taken at the medial aspect due to the presence of bladder (*bladder should be emptied before surgery*).

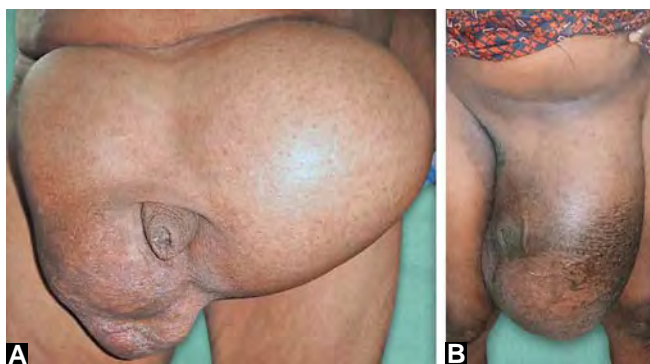
- ◆ Ideally *hernioplasty (mesh repair)* is done. In case of bilateral hernia, mesh repair can be done on both sides together. Laparoscopic approach (TEP) or suprapubic approach may be better in bilateral cases.

### Funicular direct hernia (prevesical hernia)

- ❖ It is also called as *Ogilvie's hernia*.
- ❖ It is a type of direct hernia which is prone for strangulation.
- ❖ It is a narrow necked hernia with prevesical fat and a portion of bladder, and or intestine that herniates through a small defect in the medial part of the conjoined tendon just above the pubic tubercle.
- ❖ It occurs in elderly males.

### Giant inguinal hernia

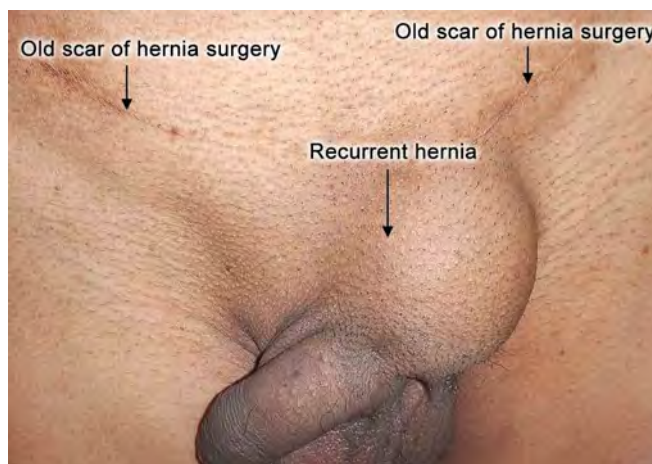
Hernia reaches below the mid-level of thigh when patient stands.



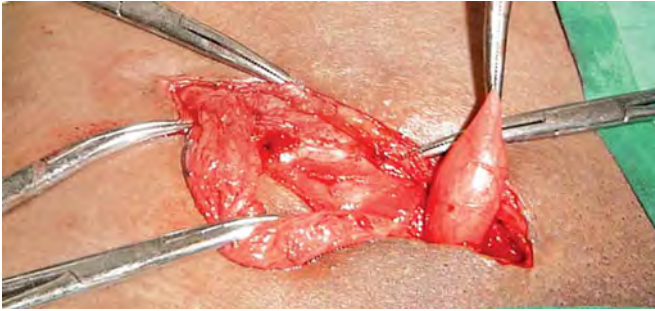
**Figs 18.49A and B:** Giant indirect and direct inguinal hernias. (Courtesy: Prof Ramlingam, KIMS, Narkatpally, Telangana, India).

## RECURRENT HERNIA (Inguinal)

- ◆ Incidence is 10%.
- ◆ If recurrence is within 3 years it is called as *early*; if after 3 years it is *late*.



**Fig. 18.50:** Recurrent inguinal hernia—left sided. Note the scar earlier surgery.



**Fig. 18.51:** Recurrent inguinal hernia is 10% common. It is commonly medial recurrence. It is treated by mesh repair.

#### Predisposing factors

##### Preoperative

- ❖ Smoking
- ❖ Chronic cough
- ❖ Constipation
- ❖ Old age
- ❖ Anaemia
- ❖ Hypoproteinaemia
- ❖ Straining
- ❖ Increased intra-abdominal pressure of any cause (BPH, carcinoma prostate, stricture urethra)
- ❖ Ascites

##### Operative

- ❖ Tension in the sutures
- ❖ Weak anterior abdominal wall

##### Postoperative

- ❖ Infection (50%)
- ❖ Haematoma formation during earlier surgery
- ❖ Retained sac in pantaloon hernia
- ❖ Straining

### Recurrence Rate

- ❖ Bassini's repair—10%.
- ❖ Shouldice repair—1%.
- ❖ Hernioplasty—1 to 3%.
- ❖ Other methods—1 to 5%.

*True or false recurrences are the types of recurrence.* If hernia occurs in inguinal region after inguinal hernia repair it is called as *true recurrence*. If other groin hernia occurs after inguinal hernia repair like femoral hernia or obturator or other rare types, it is called as *false recurrence*. But presently hernia is classified grossly as groin hernias and so all recurrences are true recurrences.

### Clinical Features

- ❖ Same as for inguinal hernia. Defect is usually narrow and so more likely to go in for strangulation.
- ❖ It can be *medial recurrence* or *lateral recurrence* depending on the location of the sac. Medial recurrence is common as tension in suture line is greatest near the pubic tubercle.

### Treatment

- ❖ After thorough investigations, the cause of recurrence has to be treated and later *hernioplasty* is done.
- ❖ *Laparoscopic (TEP/TAPP) approach* is better for recurrent hernia. In open repair, preperitoneal mesh repair is ideal. In elderly people, *Koontz orchidectomy* or cord excision at inguinal canal may be added after proper prior consent.

### Rerecurrent Hernia

1% common.

### Causes

Infection, earlier mesh extrusion, failure of treating the precipitating causes.

### Treatment

- ❖ The cause is treated and *mesh repair is done*.
- ❖ GPRVS (Giant prosthesis reinforcement of the visceral sac) or TEP through laparoscopy is ideal.

### HERNIOPLASTY

It is strengthening of posterior inguinal wall in case of indirect hernia or in any large hernia with weak abdominal wall using a supportive material. This allows and supports good fibroblast proliferation which in turn strengthens the weak posterior wall of inguinal canal or abdominal wall.

#### Material used

- ❖ *Synthetic:* Prolene mesh (white in colour) Dacron mesh, Morlex mesh, Mersilene sheath.
  - ❖ *Biological:* Tensor fascia lata, temporal fascia and skin. (presently biological materials are not well-accepted as infection is common and its efficacy is not proved).
- Prolene mesh* is commonly used at present. Non-absorbable interspersed absorbed mesh (Vipro/Ultrapro) are also used nowadays.

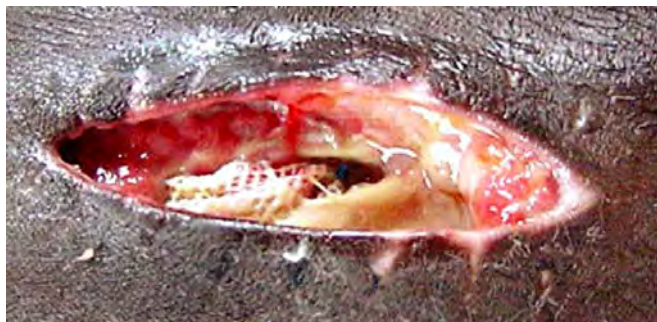
### Indications

- ❖ Direct hernia.
- ❖ Recurrent hernia.
- ❖ Re-recurrent hernia.
- ❖ Incisional hernia.
- ❖ Old age.
- ❖ Hernia with weak abdominal muscle tone.
- ❖ Sliding hernia.

### Complications

- ❖ Infection.
- ❖ Mesh extrusion.
- ❖ Foreign body reaction.
- ❖ Mesh *inguinodynia* causing hyperaesthesia and pain along the distribution of ilioinguinal or iliohypogastric nerves.

- ◆ Mesh erosion into bladder, bowel or vessels can occur occasionally (rare).



**Fig. 18.52:** Infected mesh after open hernioplasty; it needs removal of the mesh.

## Principle

- ◆ Size of the mesh should be bigger than the size of the defect.
- ◆ Mesh should be fixed above and below to the conjoint tendon and inguinal ligament or abdominal wall using interrupted, non-absorbable sutures.
- ◆ Absolute haemostasis and control (prevention) of infection is important.

### Types of mesh repair

- ❖ Onlay repair
- ❖ Lichtenstein mesh repair—a type of onlay
- ❖ Inlay repair—mesh placed at myopectineal level—*bridging repair*
- ❖ Underlay repair—mesh placed at deeper plane usually in preperitoneal space
- ❖ Gilbert patch and plug repair/Gilbert's PHS repair (onlay + sublay)
- ❖ Nyhus preperitoneal mesh repair
- ❖ Kugel groin hernia mesh repair
- ❖ Modified Rives preperitoneal mesh repair through inguinal approach
- ❖ Stoppa GPRVS repair
- ❖ TEP mesh repair
- ❖ TAPP mesh repair

*Hernioplasty* is becoming the prime treatment for inguinal hernia.

#### Note:

- *Onlay mesh* repair by placing mesh in front. It is sutured above to conjoint tendon and below to inguinal ligament using monofilament non absorbable suture material.
- **Lichtenstein tension free onlay mesh repair** (1993) where the cord is encircled with mesh which is often done under local anaesthesia. Sutured of mesh is done similar to onlay mesh repair. It has got less recurrence rate.
- *Nyhus preperitoneal mesh repair*: It is done through *suprainguinal*-horizontal incision above the pubic symphysis and internal ring. Preperitoneum is approached through lateral border of the lower part of rectus muscle by making an opening in the posterior rectus sheath. Mesh is placed in the preperitoneal space deep to the cord, conjoint tendon, and transversalis fascia. Below, it is folded deep to

the iliopectineal ligament of Cooper and sutured to it using two or three interrupted non-absorbable sutures. It is sutured to transverse abdominis above and transversalis fascia from deep.

- *Modified Rives preperitoneal mesh repair (Read-Rives)* is preperitoneal mesh repair through *transinguinal approach*. Direct sac, is inverted with sutures. For indirect sac, a high ligation is done. Here mesh is placed in preperitoneal space, folded and sutured below to iliopectineal ligament, above to the transverse abdominis in deeper plane. Often transversalis fascia opened earlier is sutured back using nonabsorbable suture material in front of the placed mesh.
- *Stoppa's giant prosthesis reinforcement of visceral sac (GPRVS)*: It is done in large hernias, hernias in elderly, bilateral hernias, recurrent and re-recurrent hernias, hernia with very lax abdomen, and hernia with collagen diseases like Marfan's syndrome. Horizontal length (size) of the mesh is 2 cm less than distance between two anterosuperior iliac spines and vertical length (size) is distance between the umbilicus and pubic symphysis. Large mesh is placed between peritoneum and lateral, inferior, anterior abdominal wall which stretches in the lower abdomen and pelvis. It is done through lower midline or Pfannenstiel incision. Usually, such large mesh is placed without any anchorage.
- *Gilbert mesh repair (patch and plug)*: After herniotomy, internal ring is plugged by cone-shaped (umbrella plug) piece of prolene mesh. Later onlay/inlay mesh repair of posterior wall of the inguinal canal is done.
- *Gilbert's PHS (Prolene Hernia System) repair (onlay and sublay—sandwich technique)*: It is an open transinguinal approach to place a specially devised mesh in both preperitoneal as inlay and in front as onlay mesh repair. This mesh has got a rounded deeper part which is placed in preperitoneal space and a modified quadrangular part which is placed as onlay. Both parts are connected through a connecting stiff rounded part in between which steadies the mesh in place preventing its displacement.
- *Kugel (Rober D Kugel) groin hernia mesh repair (sublay)*: It is done through *posterior preperitoneal* approach with tension free less invasive sutureless repair. Kugel patch contains two overlapping layers of knitted polypropylene mesh which are attached to each other ultrasonically. Near the outer edge of the mesh it has got a polyester spring which stiffens the mesh to unfold. 1 cm of mesh extends outer to the spring which also has radial slits to have easy maneuverability. Anterior layer of the mesh has got single transverse slit to facilitate the insertion. Multiple 3 mm holes through both layers of the mesh are present that allow tissue contact in better way to prevent mesh displacement. Small V shaped triangular cuts on the anterior layer adjacent to these multiple holes act as sutureless anchors. Incision is above the deep ring and lateral to inferior epigastric vessels. Skin, subcutaneous tissue, external oblique aponeurosis is cut; internal oblique and transversus abdominis muscles are split to reach deeper space. Transversalis fascia split vertically to avoid injury to inferior epigastric vessels which are retracted medially. Preperitoneal space is created; indirect sac is dissected off the deep ring from above; proximal part being ligated using absorbable 3 zero vicryl. Direct sac is dissected off the defect without opening; its pseudosac which is modified transversalis fascia is dissected off entirely from the peritoneum behind. Kugel's mesh patch is placed properly without allowing any tissue bands folding it. Transversalis fascia is sutured with one absorbable suture. Transversus abdominis and internal oblique muscles are not sutured. External oblique aponeurosis is sutured.
- ◆ *Transabdominal preperitoneal laparoscopic mesh repair (TAPP repair)*: It is mainly used in irreducible and large hernias.

**Spigelian line:** Runs along the lateral border of rectus sheath and extends from the pubic tubercle to the tip of the 9th costal cartilage.

**Spigelian fascia:** Is the fascia between the aponeurosis of external and internal oblique, transversus abdominis and recuts sheath.



- ◆ *Totally extraperitoneal laparoscopic mesh repair (TEP)*—becoming popular.

### Transabdominal Preperitoneal Mesh Repair (TAPP) Using Laparoscope

This is used in large indirect hernia or irreducible inguinal hernia. 10 mm umbilical port is used for laparoscope. 5 mm ports are placed one on each side on pararectal point at the or above the level of umbilicus so as to achieve adequate triangulation. Contents of the hernia are reduced. Hernial sac is dissected in preperitoneal plane after making horizontal incision at the upper part of the sac opening. Vas, gonadal vessels, pubic bone, inferior epigastric vessels are identified. Once sac is dissected and excised, a prolene/vipro/ultrapro mesh of  $15 \times 10$  cm sized or smaller is placed in preperitoneal space. It is fixed to pubic bone using tacks. Peritoneum is closed with continuous prolene sutures.




Fig. 18.53: Gibert's PHS mesh.

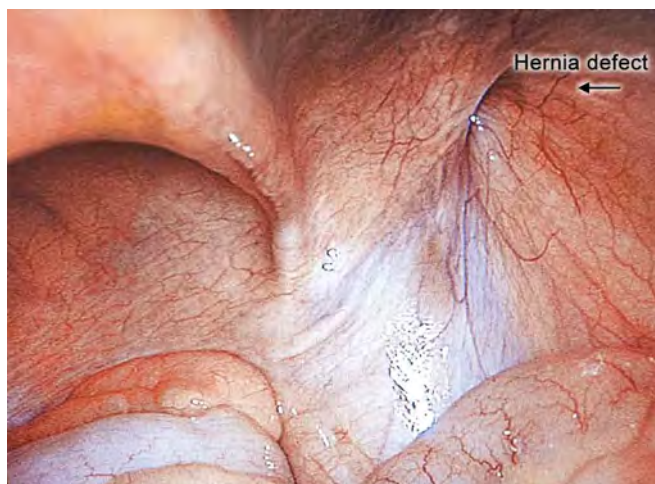

Fig. 18.54: View of indirect hernia laparoscopically during TAPP.

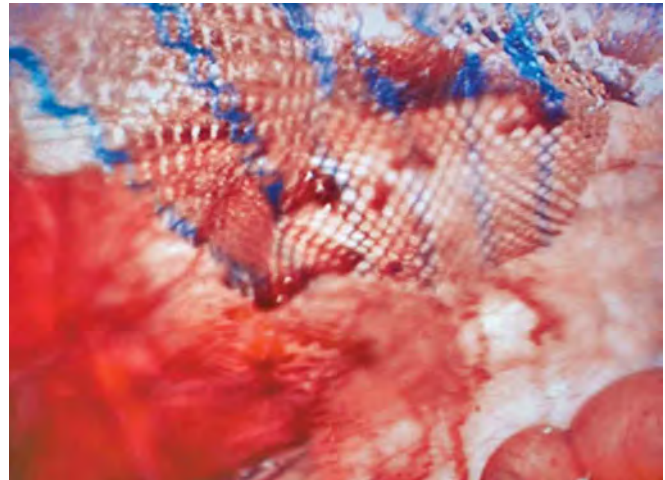


Fig. 18.55: Mesh placement in TAPP procedure.

### Totally Extraperitoneal Repair (TEP Repair) Using Laparoscope

- ◆ This technique is gaining more popularity than TAPP. Through subumbilical incision (10 mm) extraperitoneal space is reached. After CO<sub>2</sub> insufflation, another 5 mm port is inserted 4 cm below the first port in the midline. Third 5 mm port is inserted in the same line 4 cm below or in the right iliac fossa. Dissection is carried out downwards carefully, then medially up to the pubic tubercle, iliopectineal ligament, laterally to iliac vessels, and inferior epigastric vessels. Once adequate space is dissected,  $15 \times 15$  cm mesh is placed and spread. Care should be taken not to have any folding in the mesh. Mesh may be sutured to iliopectineal ligament. Displacement of mesh is not common. Other side also can be done together.

#### Anatomical considerations

- ❖ Preperitoneal space is a potential space in front of the peritoneum, behind the transversalis fascia and anterior rectus muscle. Below in front of the urinary bladder, it is called as *space of Retzius* (medially), laterally it is called as *space of Bogros*. Median umbilical fold is formed by urachus in the midline. Medial umbilical ligament is formed by obliterated umbilical arteries, lateral umbilical fold by inferior epigastric vessels. Three fossae are lying in relation to these folds—supravesical and medial fossae are medial to lateral umbilical fold which are sites of direct hernia whereas lateral fossa is lateral to lateral umbilical fold and is site of indirect hernia.
- ❖ In 1956 *Fruchaud* described his *myopectineal orifice* bounded medially by the lateral border of rectus abdominis, laterally by iliopsoas, superiorly by conjoint tendon and inferiorly by pectin pubis. This area is the site of groin hernia which should be covered by mesh of adequate size to strengthen the defect and to prevent the recurrence. Iliopubic tract is analogue of the inguinal ligament, extends from Cooper's ligament to anterosuperior iliac spine which divides endoscopic view of preperitoneal space into *superior compartment* (contains inferior epigastric artery, Hesselbach's triangle, cord structures and is site of inguinal hernia) and *inferior compartment* (contains femoral canal, iliac vessels, iliopsoas muscle, genitofemoral nerve, lateral femoral cutaneous nerve). External iliac vessels lie in a triangle formed by gonadal vessels laterally, vas deferens medially and peritoneal reflection inferiorly (*triangle of doom*).

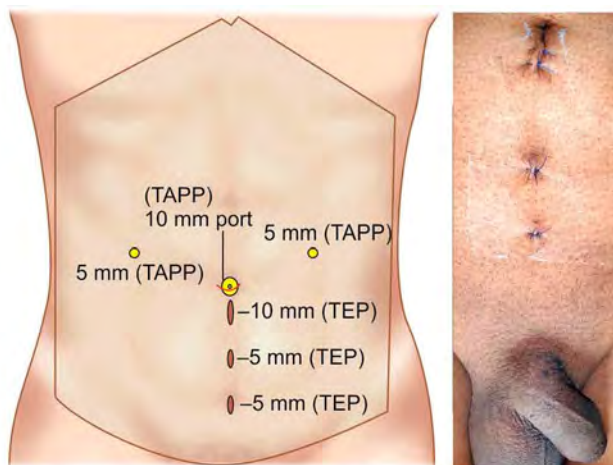


Fig. 18.56: Ports used for TEP and TAPP.

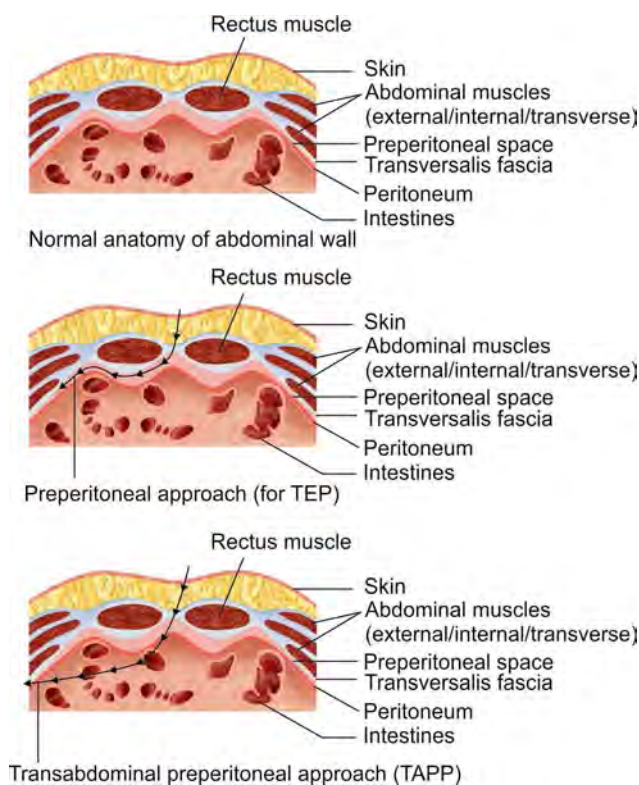


Fig. 18.57: Diagrammatic representations of TEP and TAPP.

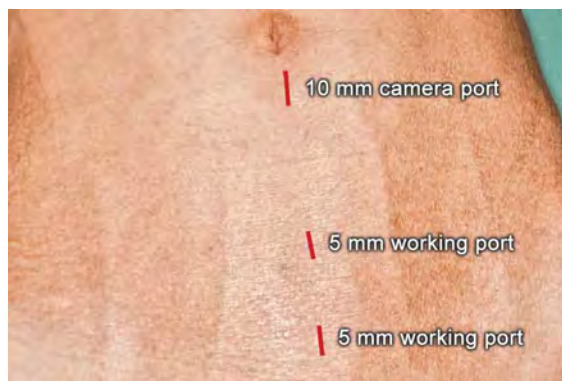

Fig. 18.58: Port incisions in TEP.

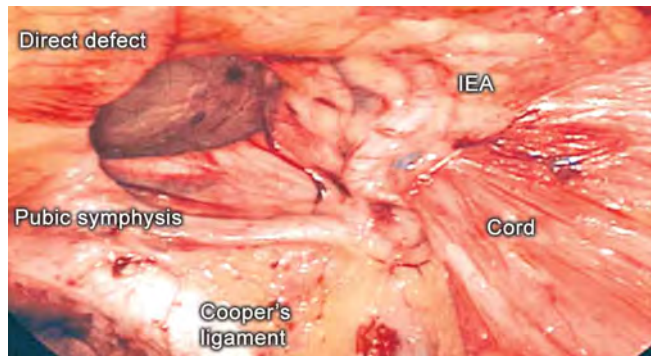


Fig. 18.59: TEP after dissection prior to placement of mesh. Direct defect, inferior epigastric artery, pubic symphysis and Cooper's ligament are clearly seen.

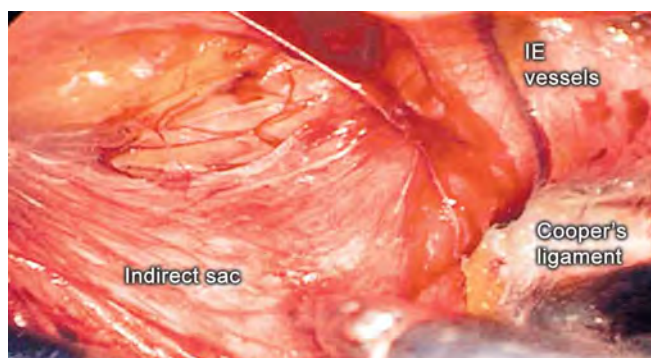


Fig. 18.60: TEP after dissection showing indirect sac, inferior epigastric vessels, Cooper's ligament.

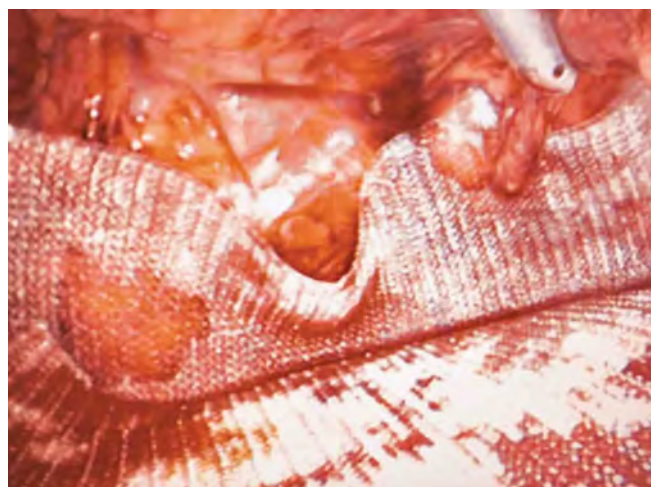


Fig. 18.61: TEP mesh placement in preperitoneal space.

- ◆ Aberrant obturator artery is an occasional branch of inferior epigastric artery replacing its pubic branch travels across Cooper's ligament, which during fixation of mesh can cause torrential haemorrhage—*circle of death*. *Triangle of pain* is formed by gonadal vessels medially, iliopubic tract laterally and peritoneal reflection below. Genitofemoral nerve and lateral cutaneous nerve of thigh traverse this triangle. Injury to these nerves either by dissection or by tacks cause postoperative pain. Tacks/staplers should not be placed in this triangle.

*Smile is the curve which puts everything straight.*

Indications for TEP	Contraindications for TEP
<ul style="list-style-type: none"> <li>• Recurrent hernia</li> <li>• Bilateral hernia</li> <li>• Indirect/direct/femoral hernia</li> </ul>	<ul style="list-style-type: none"> <li>• Obstructed/strangulated inguinal hernias</li> <li>• Ascites</li> <li>• Bleeding disorders</li> </ul>

Landmarks to be identified in TEP	Principles in TEP
<ul style="list-style-type: none"> <li>• Pubic bone midline</li> <li>• Inferior epigastric artery</li> <li>• Cooper's ligament</li> <li>• Iliopubic tract</li> <li>• Cord and vas deferens</li> <li>• Psoas muscle and nerves in relation</li> </ul>	<ul style="list-style-type: none"> <li>• Head-down supine position</li> <li>• Surgeon standing on opposite side of hernia</li> <li>• Camera person placed on opposite side of hernia</li> <li>• Monitor at foot end</li> <li>• Catheterise/empty the bladder properly prior to TEP</li> <li>• Adequate wide space creation</li> <li>• Careful dissection of cord and sac</li> <li>• Ligate indirect sac</li> <li>• Mesh should not be fixed laterally</li> <li>• Size of mesh is 15 × 15 cm</li> <li>• Two point fixation—one at pubic bone other at Cooper's ligament by tacks/staplers</li> </ul>

#### Difficulties and complications in TEP repair

- ❖ Difficulty in dissecting indirect sac. Cord/vas injury
- ❖ Inadvertent opening of the sac/peritoneum and creation of pneumoperitoneum.
- ❖ Injuries to major structures like iliac vessels—0.5–1.0%
- ❖ Displacement of mesh or erosion into structures like urinary bladder—rarely may occur
- ❖ Nerve injury
- ❖ Formation of seroma/haematoma
- ❖ Infection
- ❖ Recurrence

#### Advantages of TEP repair

- ❖ Approach is totally extraperitoneal
- ❖ Small incision
- ❖ Proper placement of mesh in right space that is preperitoneal space
- ❖ Peritoneal cavity is intact and not opened

## INCARCERATED HERNIA

- ◆ Here the lumen of the portion of colon occupying a hernial sac is blocked with *faeces*. Here scybalous content of the bowel should be capable of being indented with the finger, like putty.
- ◆ In incarcerated hernia, sac and contents are densely adherent to each other (contents are fixed to sac). It is always irreducible; often obstructed but may not be strangulated.

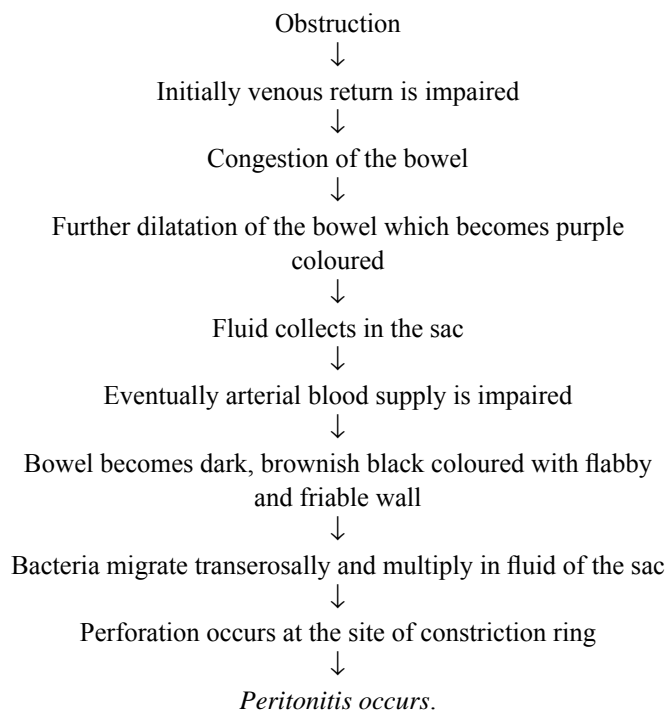
## STRANGULATED HERNIA

### Pathology

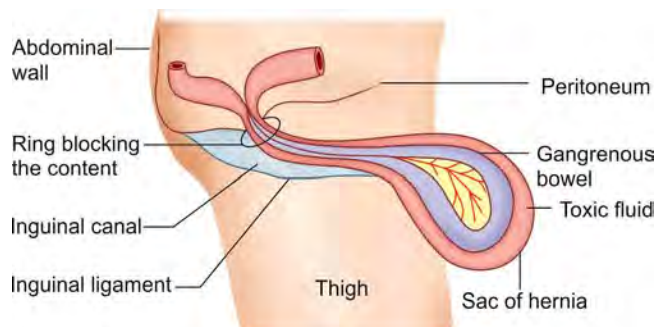
It occurs when blood supply of the contents of hernia is seriously impaired leading to formation of gangrene.

#### Common bacteria in strangulated hernia

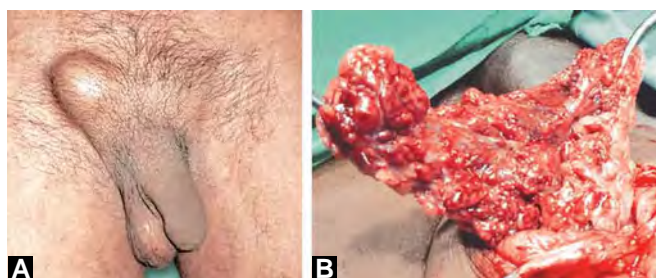
- ❖ *E. coli*
- ❖ Anaerobic streptococci
- ❖ Anaerobic bacteria
- ❖ *Klebsiella*



- ◆ Strangulation commonly occurs in the *small bowel* and also in large bowel. Occasionally strangulated omentocele also can occur without any intestinal obstruction.
- ◆ Strangulation can occur in inguinal, femoral, obturator, umbilical or any hernias.
- ◆ Indirect inguinal hernia is more prone for strangulation than direct inguinal hernia. It is due to narrow neck, adhesions, narrow external ring in children.
- ◆ Part of circumference of the bowel when strangulated, is called as **Richter's hernia** wherein the patient presents with diarrhoea, toxicity mimicking *gastroenteritis*. Richter's hernia is more common with femoral, obturator hernias.



**Fig. 18.62:** Picture showing strangulated hernia with toxic fluid and site of constriction.

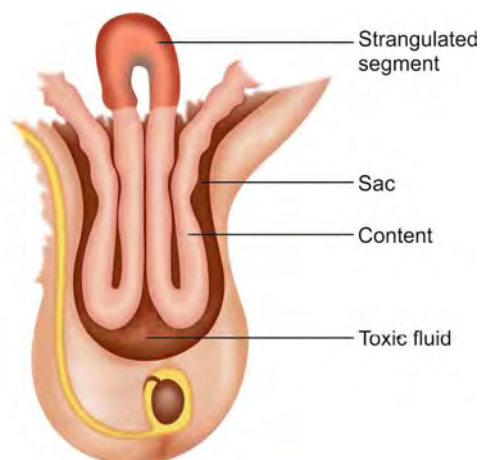


**Figs 18.63A and B:** (A) Strangulated inguinal hernia will be tender and irreducible without impulse on coughing; (B) Hernia with gangrenous omentum. Note the colour of the gangrenous omentum.

#### Causes of strangulation

- ❖ Narrow neck
- ❖ Adhesions
- ❖ Irreducibility
- ❖ Long-time, large hernia with adhesions

**Maydl's hernia (Hernia-in-W):** Here a loop of bowel in the form of 'W' lies in the hernial sac and the centre portion of the 'W' loop is strangulated and lies within the abdominal cavity. Thus local tenderness over the hernia is not marked and hernia gets reduced with the strangulated loop in the centre of the 'W'. Strangulation in this case is often missed during surgery and may lead to peritonitis due to retained gangrenous loop.



**Fig. 18.64:** Maydl's hernia (Hernia-in-W).

#### Clinical Features of Strangulated Hernia

- ❖ Sudden severe pain, initially over a pre-existing hernia which later becomes generalised over the abdomen.
- ❖ Persistent vomiting, constipation and distension of the abdomen.
- ❖ *Hernia is tense, severely tender, irreducible and without any expansile impulse on coughing. Rebound tenderness is diagnostic.*
- ❖ Features of toxicity and dehydration.
- ❖ Electrolyte imbalance.
- ❖ Abdominal distension with guarding and rigidity.
- ❖ Oliguria.

- ❖ 3% in incidence.

#### Features of strangulated hernia

- ❖ Tense, tender, irreducible
- ❖ No impulse on coughing
- ❖ Shock, toxicity
- ❖ Features of obstruction when there is enterocele
- ❖ Abdominal distension, vomiting
- ❖ Rebound tenderness

#### Strangulation during infancy

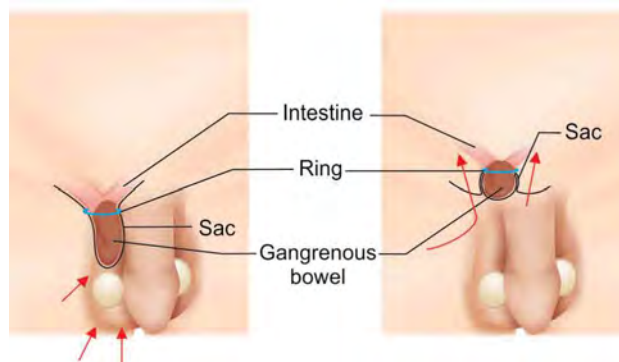
- ❖ Incidence is 4%. Female to male ratio is 5:1
- ❖ In female infants, the content may be ovary with or without fallopian tube

#### Taxis

- ❖ Often in irreducible hernia, *reduction* of hernia is *tried* by elevation, sedation and *taxis* (i.e. with flexion and medial rotation of the hip, reduction of hernia is tried).
- ❖ *In obstructed hernia, taxis may be dangerous* as during taxis, contusion and rupture of the intestinal wall can occur. Reduction-en-masse may mask the gangrenous bowel existing in the sac. Inner gangrenous loop of Maydl's hernia may be missed. Rupture of the sac extraperitoneally is also a possibility.
- ❖ *Taxis has no role in femoral hernia and strangulated hernia.* If tried, contusion, reduction-en-masse and rupture of the sac can occur.

#### Taxis

- ❖ Used in irreducible or partially reducible hernia
- ❖ *Trial reduction by flexing and medially rotating the hip*
- ❖ It is dangerous in:
  - Obstructed hernia
  - Maydl's hernia
 (As rupture can occur leading to peritonitis)
- ❖ No role in femoral and strangulated hernia



**Fig. 18.65:** In an obstructed hernia, if reduction is forced it may get reduced with the sac and ring with the obstructed/strangulated bowel—*Reduction-en-masse*.

- ❖ *In strangulated omentum* features of obstruction are not present (i.e. vomiting, constipation). Omentum becomes congested, oedematous and black in colour which secretes toxic fluid with secondary bacterial infection. But here, initially the sepsis is slower than that of strangulated intestinal obstruction.

*The most important thing that you wear is the expression on your face.*

- ◆ Eventually the infection spreads causing diffuse peritonitis. Downward spread of infection can cause scrotal abscess.

## Investigations

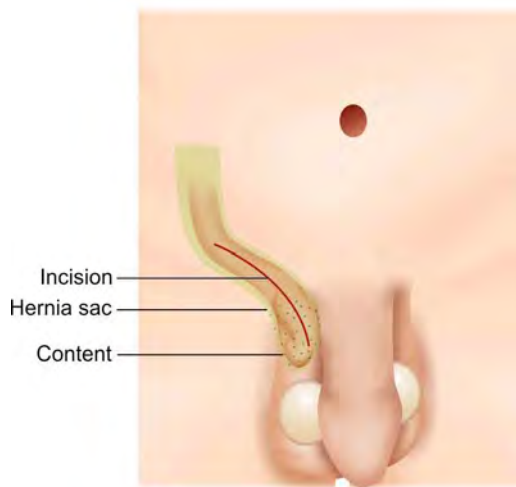
- ◆ Plain X-ray abdomen in erect posture shows multiple air-fluid levels.
- ◆ Serum electrolytes.
- ◆ Blood urea and serum creatinine.
- ◆ Total count is increased.
- ◆ U/S abdomen.

### Strangulation without obstruction

- ❖ Richter's hernia
- ❖ Omentocele

## Treatment of Strangulated Hernia

- ◆ The patient is admitted.
- ◆ Ryle's tube aspiration.
- ◆ Intravenous fluids to correct dehydration and electrolyte imbalance.
- ◆ Antibiotics.
- ◆ Catheterisation to maintain adequate urine output.
- ◆ *Emergency surgery:*



**Fig. 18.66:** Incision for strangulated hernia is obliquely placed extending to the scrotum.

Groin incision is made with incision extending into the most prominent area of the swelling.

↓  
Sac is exposed.

↓  
Constriction ring and superficial ring is released (cut).

↓  
Sac is opened carefully *without allowing the spillage of fluid*  
(Usually spillage occurs extraperitoneally)

↓  
Fluid is sucked with a suction apparatus.

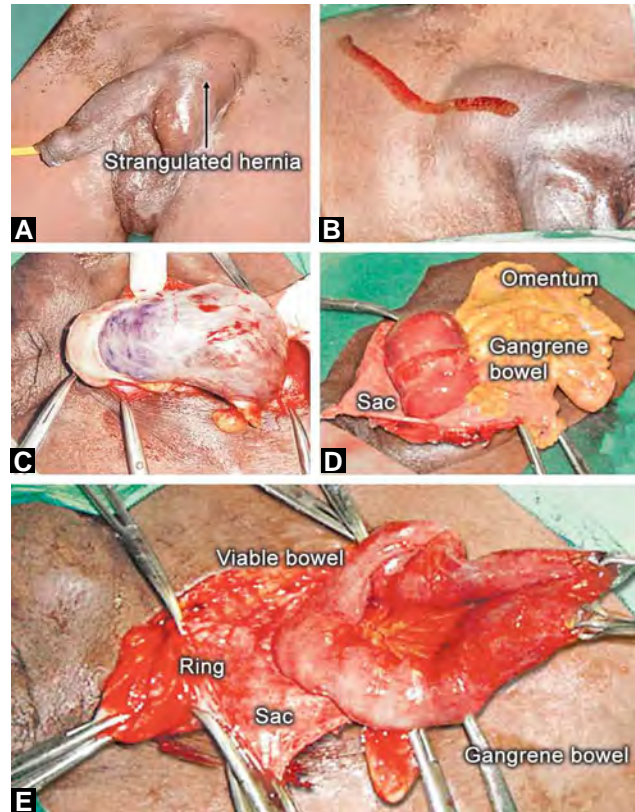
↓  
The bowel is held with fingers so as to prevent it from getting reduced.

↓

The viability of the bowel is checked by *colour, peristalsis, pulsation, bleeding.*

↓

When gangrenous, resection and anastomosis is done and drain is placed.



**Figs 18.67A to E:** Strangulated hernia—left side. It is tense, tender, without any impulse on coughing. Note the incision, discoloured sac, content (gangrenous bowel) and proximal viable bowel.

*Bassini's repair* is done by placing interrupted non-absorbable sutures. Antibiotics, IV fluids are continued. Drain is removed in 4–5 days. Once the bowel movement begins, oral diet is started (in 5 days).

### Note:

*During surgery for strangulated hernia mesh is usually not used, only repair is done. Biological mesh can be used.*

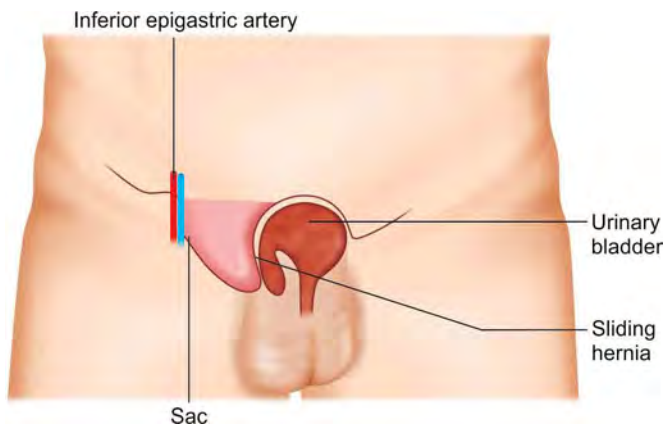
## Postoperative Problems

Infection, leak with fistula, septicaemia.

### ■ SLIDING HERNIA (HERNIA-EN-GLISSADE)

- ◆ Here posterior wall of the sac is not only formed by the parietal peritoneum, but also by sigmoid colon with its mesentery on left side; caecum on right side and often with portion of the bladder (Both sides) (1:2000).
- ◆ Rarely small bowel sliding hernia or sacless sliding hernia can occur (1:8000).
- ◆ Content of the sac is usually small bowel or omentum.
- ◆ *Sliding hernia occurs exclusively in males. Mainly on the left side (85%).*
- ◆ It commonly occurs in *indirect sac* even though femoral and direct sliding hernias are known to occur.
- ◆ Bilaterality is extremely rare.

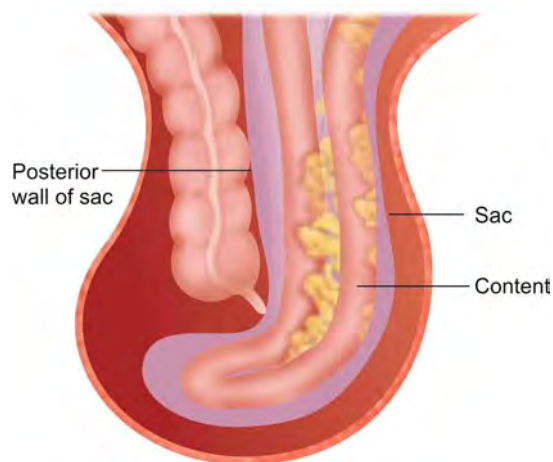
- ◆ It is seen commonly in adults and elderly.
- ◆ Huge hernia can occur which extends into the scrotum and do not get reduced totally.



**Fig. 18.68:** Sliding hernia with urinary bladder as posterior wall of the sac.

### Clinical Features (2%)

Large globular swelling in the inguinal region descending into the scrotum, often irreducible.



**Fig. 18.69:** Sliding hernia (Hernia-en-Glissade).

Small bowel as the content of sliding hernia can lead to strangulation.

### Treatment

#### Always Surgery

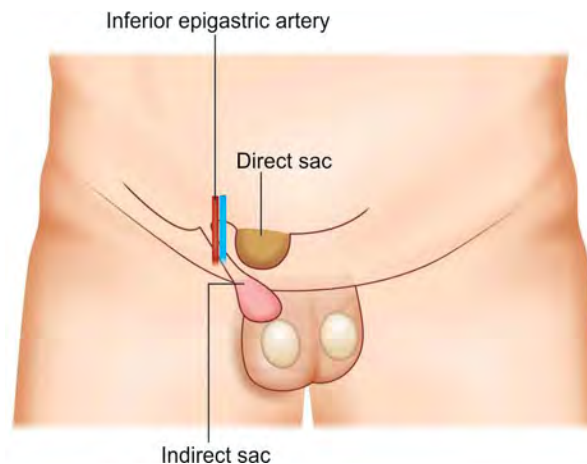
- ◆ *Posterior wall of the sac should not be separated from large bowel or bladder.* If tried, injury may result to these organs leading to faecal or urinary fistulas.
- ◆ Partially excised sac is pushed into the peritoneal cavity with posterior wall and repair is done usually using *prolene mesh* (Hernioplasty).
- ◆ In *LaRoque repair* deep ring is incised above and below; reefing of the sigmoid colon mesentery is done which forms the posterior wall of the inguinal canal so that entire sigmoid is replaced into

the peritoneal cavity. Posterior wall of the sac should not be separated from large bowel or bladder. If tried it may lead into faecal or urinary fistulas. Often sac can be excised partially; this partially excised sac can be pushed into peritoneal cavity. Right sided sliding hernia will have caecum and appendix in its posterior wall; caecum should not be separated from posterior wall of the sac which may otherwise create faecal fistula. Appendix should not be removed as it may precipitate sepsis. Appendices epiploicae from sigmoid colon should not be removed as there are chances that they may contain small colonic diverticula which may get opened to contaminate the field. Bladder will be present on medial side of the sac and sac should not be separated; if bladder injury occurs it should be sutured in two layers with vicryl. Inside out purse string suture on the opened sac is applied and the sac with its posterior wall is pushed into the abdominal cavity. Urinary catheterisation is a must.

- ◆ Truss *should not be used* in sliding hernia.

### PANTALOON HERNIA (DOUBLE HERNIA, SADDLE HERNIA, ROMBERG HERNIA)

- ◆ Here both direct and indirect inguinal sacs are present and clinically present as *direct hernia*.
- ◆ During surgery, indirect sac may be missed and so leads to *recurrent hernia* through retained (or unidentified) indirect sac.
- ◆ Here both medial and lateral sacs *straddle* the inferior epigastric artery.
- ◆ It is one of the causes for recurrent hernia.



**Fig. 18.70:** Saddle/Pantaloona hernia. It is on either side of the inferior epigastric artery having both direct and indirect sacs.

### Infantile hernia

- ◆ Clinically difficult to diagnose.
- ◆ Often it is diagnosed on table.
- ◆ Processus vaginalis is closed at internal ring and hernial sac either invaginates processus vaginalis as "inverted umbrella" or comes behind processus vaginalis.

### FEMORAL HERNIA

#### Surgical Anatomy of Femoral Canal

It is the medial, most compartment of the femoral sheath, which extends from femoral ring above to saphenous opening below. It contains fat,

*It takes 26 muscles to smile, and 62 muscles to frown.*

lymphatics, lymph node of Cloquet. It is 1.25 cm long and 1.25 cm wide at the base. Below it is closed by cribriform fascia.

Femoral ring is bounded anteriorly by inguinal ligament; posteriorly by iliopectineal ligament of Cooper, pubic bone and fascia covering the pectineus muscle; medially by concave, sharp lacunar (Gimbernat's) ligament; laterally by a thin septum separating from femoral vein.

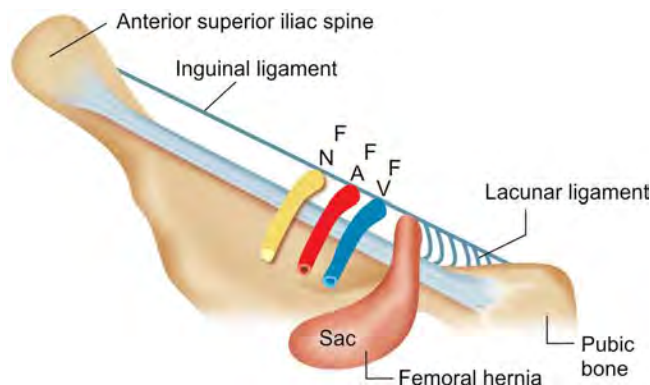


Fig. 18.71: Surgical anatomy of femoral hernia.

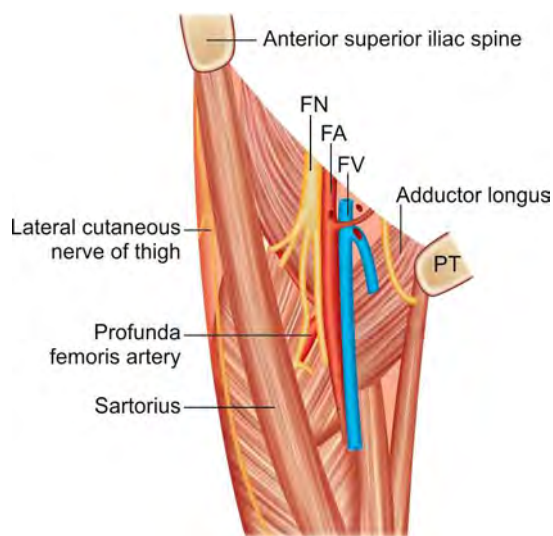


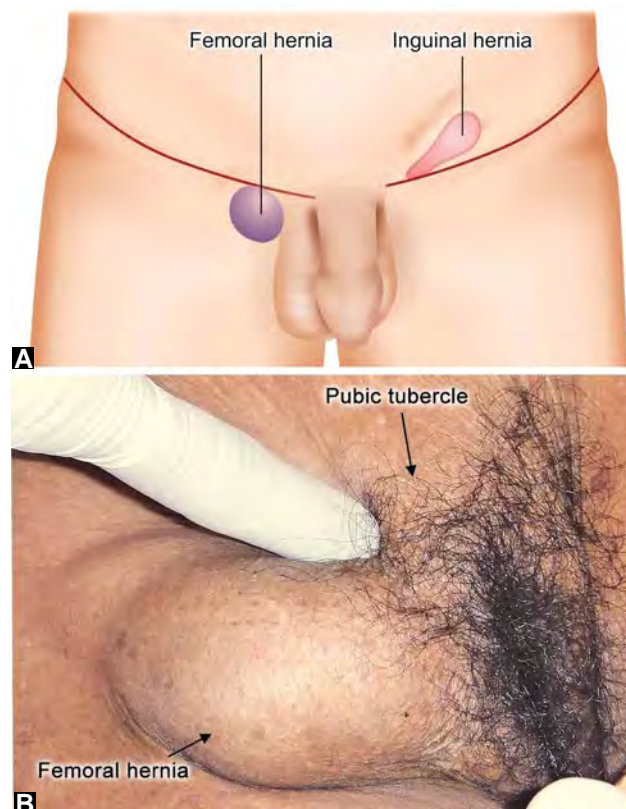
Fig. 18.72: Femoral triangle.

### Aetiology

- ◆ Wide femoral canal.
- ◆ Multiple pregnancies.

### Pathology in Femoral Hernia

Through femoral canal, hernial sac descends down vertically up to saphenous opening and then escapes out into the loose areolar tissue to expand out like a *retort*. Because of its irregular pathway and narrow neck, it is more prone for obstruction and strangulation. During surgery, precaution should be taken about the femoral vein and pubic branch of obturator artery (or accessory obturator artery) which often may get injured leading to torrential haemorrhage.



Figs 18.73A and B: Hernia; inguinal hernia is above and medial to tubercle, and femoral hernia is below and lateral.

### Clinical Features

- ◆ Common in females (2:1 ratio), common in multipara.
- ◆ Rare before puberty. 20% occurs bilateral, however, more common on right side.
- ◆ Presents as a swelling in the groin *below and lateral* to the pubic tubercle (Inguinal hernia is *above and medial* to the pubic tubercle).
- ◆ Swelling, impulse on coughing, reducibility, gurgling sound during reduction, dragging pain, are the usual features.
- ◆ When obstruction and strangulation occurs which is more common, presents with features of intestinal obstruction—painful, tender, inflamed, irreducible swelling without any impulse. They also present with abdominal distension, vomiting and features of toxicity.
- ◆ Often femoral hernia can be associated with inguinal hernia also.
- ◆ 40% of femoral hernias present as emergency hernia with obstruction/strangulation.

#### Note:

- **Gaur's sign:** In femoral hernia, distension of superficial epigastric and/or circumflex iliac veins occurs due to the pressure by the hernial sac.

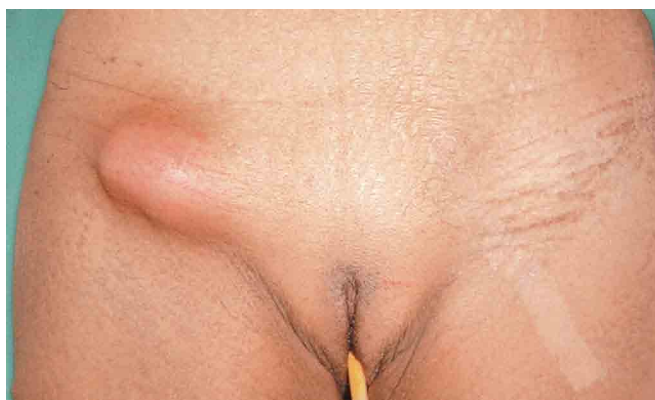#### Differential diagnosis

- ❖ Inguinal hernia
- ❖ An enlarged Cloquet lymph node of any cause
- ❖ Psoas abscess—psoas spasm with flexed hip but difficulty in extension

- ❖ Lipoma
- ❖ Femoral aneurysm
- ❖ Distended psoas bursa (Disappears on hip flexion)
- ❖ *Saphena varix*—it is enlarged terminal portion of long saphenous vein. It is soft, disappears on lying down, fluid thrill, impulse on coughing and venous hum on auscultation are present. There is associated varicose veins on leg
- ❖ Haematoma in the region

- *Hydrocele* of femoral hernia occurs when adherent omentum which is the content secretes fluid into the sac.
- *Herniation* through a gap in the lacunar ligament (medial) is always strangulated and is called as *Laugier's femoral hernia (L for L)*.
- In congenital dislocation of hip, femoral hernia occurs *behind* the femoral vessels—*Narath's femoral hernia*.
- If sac lies under the pectineal fascia, is called as *Cloquet's hernia*.
- Strangulation and Richter's hernia are common in femoral hernia.
- Often on medial side, a portion of bladder forms the wall of the femoral hernial sac—*sliding—femoral hernia*.

- ❖ Femoral hernia—occurs medial to femoral vein
- ❖ *Narath's hernia*—occurs behind femoral artery, in congenital dislocation of hip
- ❖ *Hesselbach's hernia*—occurs lateral to femoral artery
- ❖ *Serofini's hernia*—occurs behind femoral vessels
- ❖ *Laugier's hernia*—through lacunar ligament
- ❖ *Teale's hernia*—in front femoral vessels
- ❖ *Callison-Cloquet hernia*—through pectineal fascia
- ❖ *Cooper's hernia*—femoral hernia with two sacs
- ❖ *The de Garengot's hernia*—incarcerated (acute appendicitis) appendix in femoral hernial sac



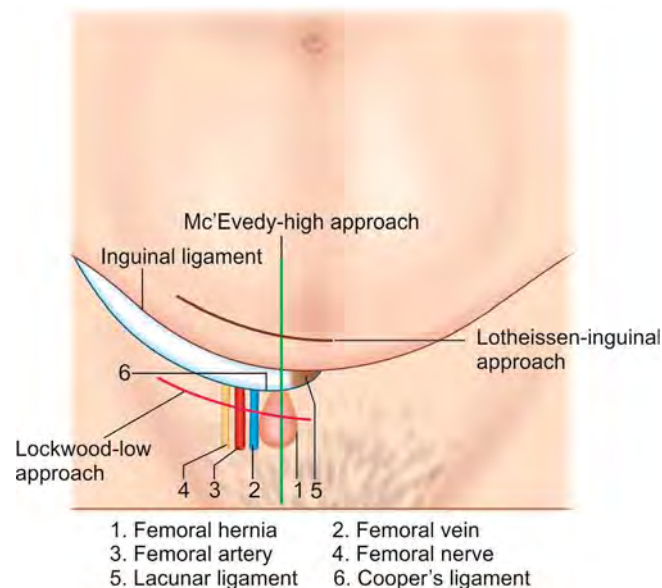
**Fig. 18.74:** Femoral hernia on right side. Note the location below the inguinal ligament. Femoral hernia is common on right side. It is common in females.

## Treatment

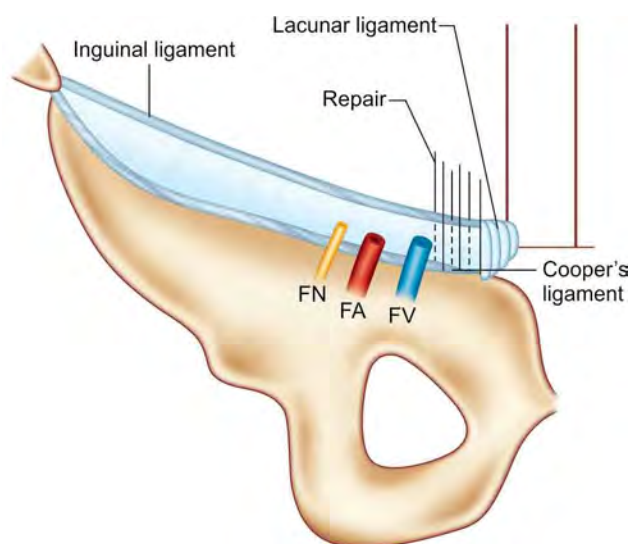
### Approaches

1. **Lockwood-low operation:** Here sac is approached below the inguinal ligament through groin crease incision (or over the swelling) so that fundus of sac is dissected by direct vision and repair is done from below.  
*Here inguinal ligament is sutured to Cooper's ligament.* standard and ideal (Cooper's ligament repair).

2. **Mc'Evedy-high operation:** A incision is made over the femoral canal extending vertically above the inguinal ligament. Sac is dissected from below, neck from above and repair is done from above. It gives a very good exposure of both neck, fundus of sac and repair is also easier. It is done in strangulated femoral hernia.
3. **Lotheissen's operation:** It is through inguinal canal approach (like for inguinal hernia). Transversalis fascia is opened and neck of the sac is identified in the femoral ring. Sac is dissected from above, neck is ligated and repair is done.

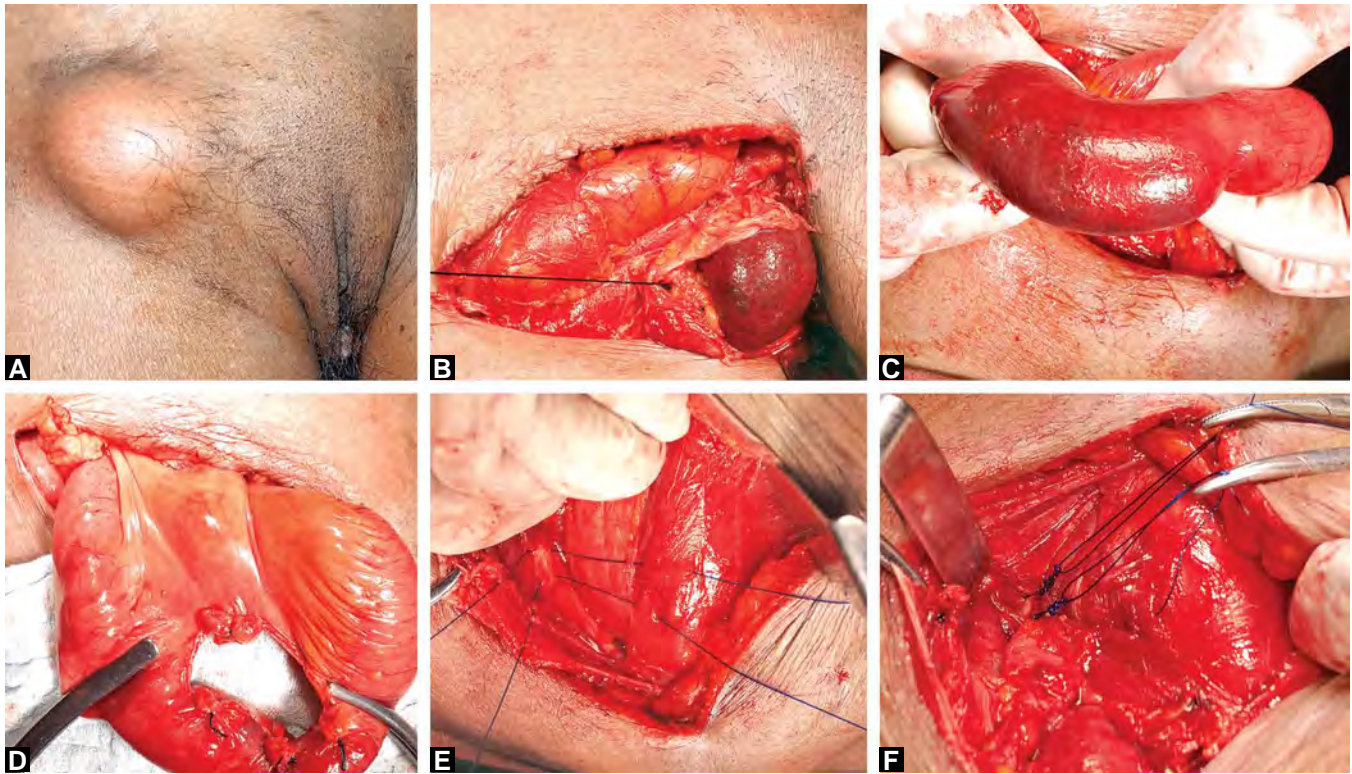


**Fig. 18.75:** Different surgical approaches for femoral hernia.



**Fig. 18.76:** Femoral hernia repair. Inguinal ligament is approximated to Cooper's (Iliopectineal line) ligament. In Lotheissen's repair conjoint tendon is sutured to iliopectineal line.





**Figs 18.77A to F:** Strangulated femoral hernia. *Note:* clinical look, Richter's gangrenous bowel, resection and Lotheissen's repair.

**Lotheissen's repair:** After herniotomy, *conjoined tendon* is sutured to *iliopectineal line* (ligament) by interrupted sutures (2 or 3), using nonabsorbable monofilament sutures. Care should be taken to avoid injury to femoral vein, pubic branch of obturator artery, bladder. It is not as strong as Cooper's ligament repair.

**Complications:** Bleeding haematoma, abscess formation.

4. **AK Henry's approach:** Repair of bilateral femoral hernia through lower abdominal incision.
5. Polypropylene mesh can be buttressed over the femoral canal to close the defect.
6. Laparoscopic mesh repair—TEP/TAPP.

#### Causes

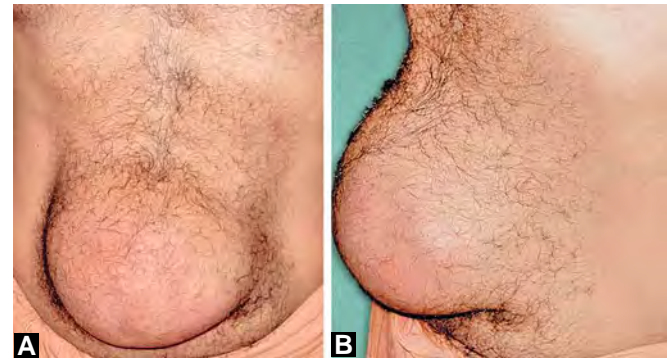- ◆ Congenital defect.
- ◆ Obesity.
- ◆ Smoking.
- ◆ Chronic cough.

## VENTRAL HERNIA

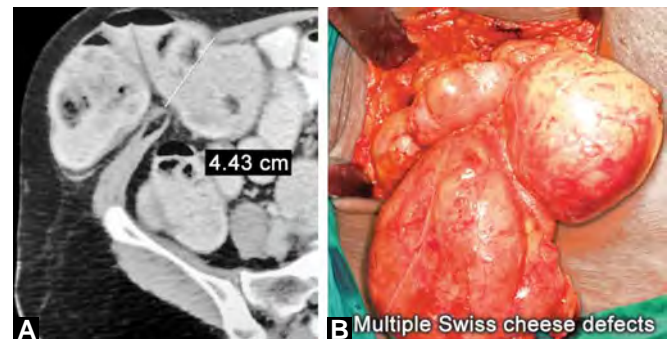
Any protrusion through abdominal wall with the exception of hernia through the inguinofemoral region is defined as *ventral hernia*. Incisional hernia (80%) and primary defects in abdominal fascia which can cause umbilical hernia, epigastric hernia, paraumbilical hernia or Spigelian hernia are grouped under ventral hernia.

#### Ventral hernia can be:

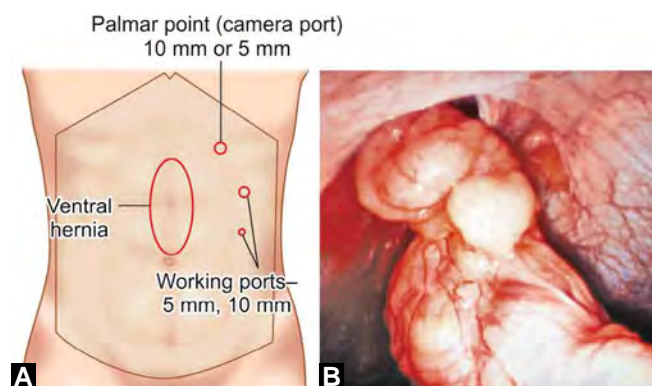
- ❖ Reducible.
- ❖ Irreducible.
- ❖ Obstructed.
- ❖ Strangulated.
- ❖ Single.
- ❖ Multiple small defects (*Swiss cheese hernia*).



**Figs 18.78A and B:** Large ventral hernias. It needs proper mesh repair.



**Figs 18.79A and B:** (A) CT scan showing ventral hernia which is irreducible; (B) Ventral hernias with Swiss cheese multiple defects.



**Figs 18.80A and B:** (A) Port placement for laparoscopic ventral hernia repair. Left subcostal point is *Palmar point*; (B) Laparoscopic view of ventral hernia with omentum as irreducible content. Content is released and duval or four-layered mesh is fixed with tackers or sutures.

#### Preoperative preparation

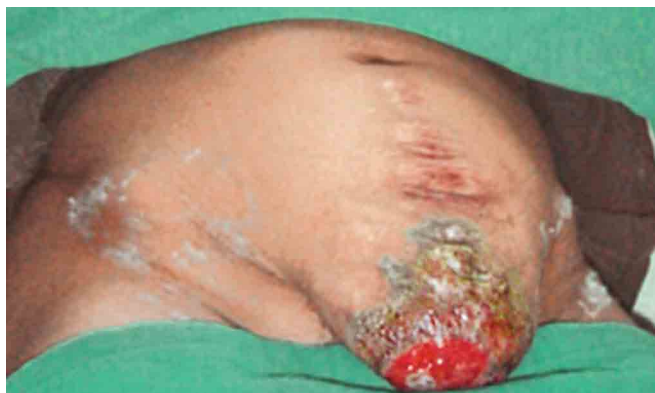- ◆ Proper skin hygiene.
- ◆ Respiratory care.
- ◆ Control of obesity.
- ◆ Antibiotics.

#### Management

- ◆ Relevant investigations
- ◆ Open mesh repair—inlay; onlay; sublay—retrorectus; underlay.
- ◆ Laparoscopic mesh placement—underlay (directly in front of the contents) using dual mesh or four layered mesh.

## INCISIONAL HERNIA

- ◆ It is herniation through a weak abdominal scar (scar of previous surgery).
- ◆ It is common in old age and obese individuals.
- ◆ It occurs in 10% of abdominal surgeries; 70% occurs in first 5 years; 30% occurs in 5–10 years.



**Fig. 18.81:** Incisional hernia adherent to skin. Note the ulceration over the summit. Patient underwent resection and anastomosis with removal of the ulcerated skin with mesh placement.

## Additional History to be Collected in Incisional Hernia

- ◆ Details of surgery that patient has undergone earlier. Duration after how long incisional hernia has occurred is important.
- ◆ History of wound infection, wound dehiscence, whether surgery done was an emergency or elective, and tension sutures placed or not.
- ◆ History of pain, irreducibility and details of precipitating factors to be asked.
- ◆ Other precipitating factors are similar to inguinal hernia like smoking, urinary/respiratory/abdominal symptoms.

## Predisposing Factors

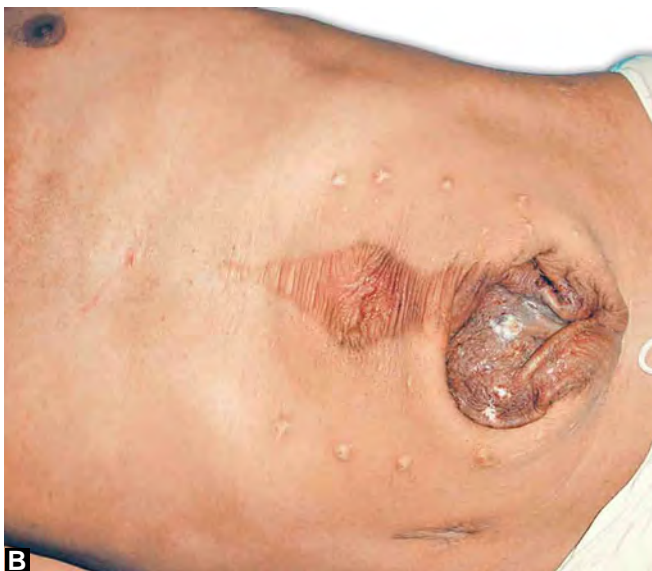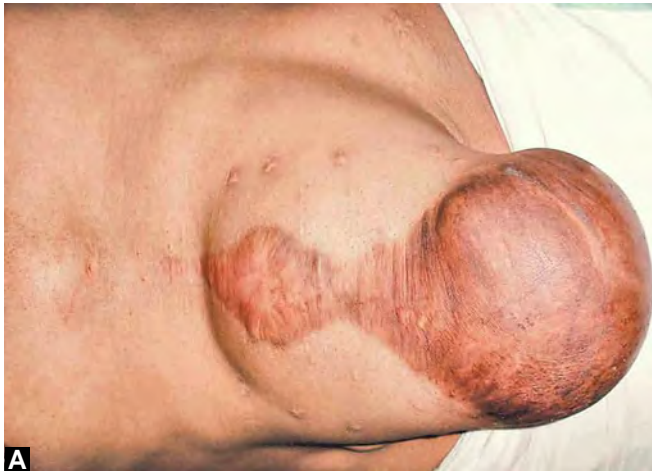- ◆ Vertical scar, midline scar, lower abdominal scar—may injure the nerves of the abdominal muscles.
- ◆ Scar of major surgeries (biliary, pancreatic).
- ◆ Scar of emergency surgeries (peritonitis, acute abdomen).
- ◆ Faulty technique of closure.
- ◆ Poor nutritional status of the patient.
- ◆ Presence of cough, tuberculosis, jaundice, anaemia, hypoproteinaemia.
- ◆ Malignancy, immunosuppression.
- ◆ Smoking in postoperative period.
- ◆ Causes which increases the intra-abdominal pressure (BPH, straining, stricture urethra or rectum, ascites).

### Factors responsible for development of incisional hernia

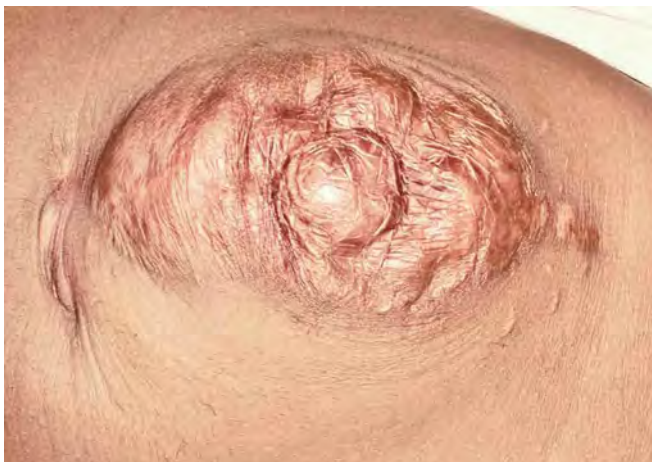- ❖ Vertical incision has got higher chances of incisional hernia than horizontal incision
- ❖ Layered closure of the abdomen has got higher chance than single layer
- ❖ Continuous closure has got higher chances than interrupted closure
- ❖ Using absorbable suture material has got higher chances of hernia than nonabsorbable sutures
- ❖ Emergency surgical wound has higher chances than elective surgical wound
- ❖ Laparotomy for peritonitis, acute abdomen, and trauma can commonly cause incisional hernia
- ❖ Drainage through the main laparotomy wound may precipitate formation of incisional hernia
- ❖ Chronic cough, smoking, obstructive uropathy, constipation can precipitate incisional hernia
- ❖ Diabetes, old age, malnutrition, malignancy, anaemia, hypoproteinaemia, jaundice, ascites, liver disease, uraemia, steroid therapy, immunosuppressive diseases are other precipitating factors

## Features

- ◆ Swelling in the scar region.
- ◆ Pain.
- ◆ Impulse on coughing.
- ◆ Gurgling sound.
- ◆ Often bowel peristalsis may be visible under the skin.
- ◆ Eventually features of irreducibility, obstruction, strangulation is seen.



**Figs 18.82A and B:** Incisional hernia in a patient during straining and during relaxing.



**Fig. 18.83:** Incisional hernia which is irreducible with visible bowel beneath.

**Defect is felt and assessed** during head rising, by placing fingers over the scar horizontally  
Size of the defect is very important

- ◆ Hernia is common in lower abdomen.
- ◆ It may be *small or large; huge or massive (diffuse)*.
- ◆ Scar, its extent and location, whether healed primarily or secondarily, skin over the scar and swelling is noted. Details of the swelling with expansile impulse on coughing and examination both in lying down and standing are done.
- ◆ Gap cannot be assessed in an irreducible hernia.

#### Type of defects in incisional hernia

- ❖ Small defect <2 cm
- ❖ Large and wide defect >2 cm
- ❖ Very large defect
- ❖ Massive/diffuse
- ❖ Multiple defects—*Swiss cheese pattern*

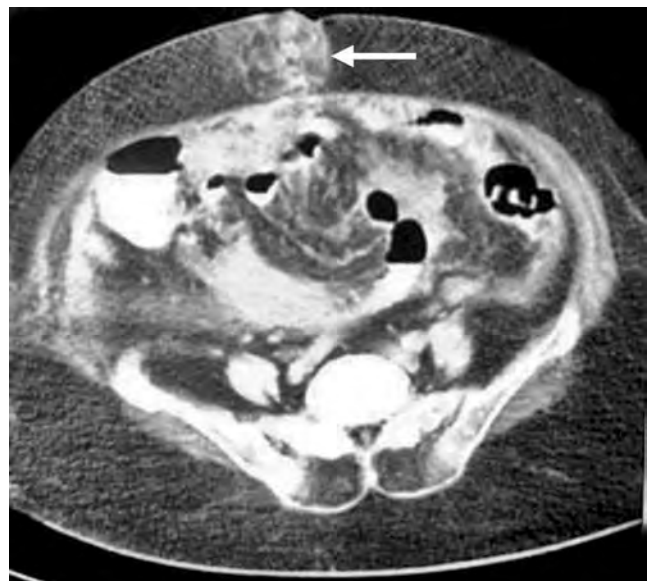#### Note:

- Size of the defect is important to decide the type of surgical closure in incisional hernia.
- Midline hernia expels the content more outwards due to contraction of rectus muscles on both sides.
- ◆ Investigations: Always the precipitating factors must be looked for:
  - ▶ Chest X-ray.
  - ▶ US abdomen.
  - ▶ Tests relevant for causes.

**Complications of incisional hernia:** Irreducibility, obstruction, strangulation, incarceration

### Preoperative Preparations for Incisional Hernia Surgery

- ◆ Reduction in weight and control of obesity.
- ◆ Nutrition, control of anaemia.
- ◆ Treatment for diabetes, hypertension, cardiac diseases, respiratory problems.
- ◆ Treating the precipitating causes.
- ◆ Chest X-ray, U/ S abdomen to be done.

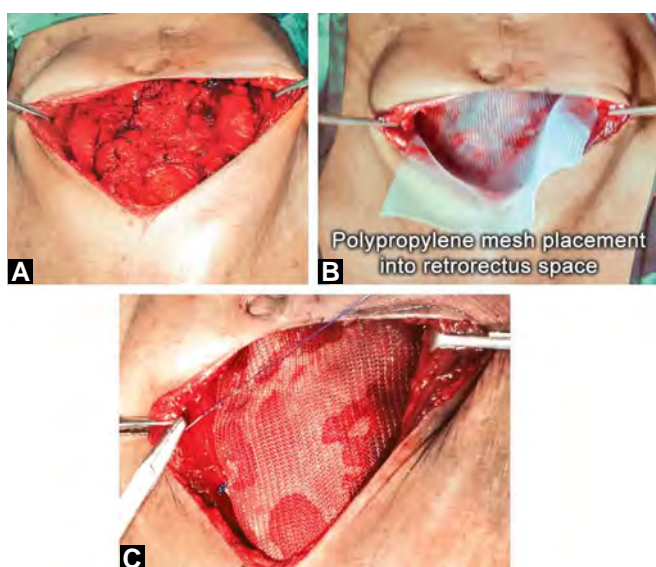


**Fig. 18.84:** CT scan abdomen showing incisional hernia.

- ◆ Massive incisional hernia after reduction might cause IVC compression, paralytic ileus and diaphragmatic elevation with respiratory embarrassment (*abdominal compartment syndrome*). It is prevented by prior increasing the capacity of peritoneal cavity by creating pneumoperitoneum using CO<sub>2</sub> so as to increase the peritoneal pressure by 12–15 cm of H<sub>2</sub>O, daily for 3–6 weeks. Later definitive surgery is done.

### Treatment Strategy for Incisional Hernia

- ◆ **Mesh repair of the incisional hernia** defect is always better and ideal with less chances of recurrence—retrorectus or sublay is ideal (mesh onlay is not accepted).
  - ▶ Adequate sized mesh is placed either outer to peritoneum (*sublay*), or occasionally combined sublay and onlay mesh placement, both deep and outer to musculoaponeurotic layer. *Onlay/overlay mesh* is placement of mesh outer to the abdominal musculoaponeurotic layer which is not advisable in ventral / incisional hernias.
  - ▶ *Rive's Stoppa's mesh placement* for incisional hernia is placing mesh between posterior rectus sheath and rectus muscle—**retrorectus mesh placement** is easier for dissection and mesh placement.
  - ▶ Commonly polypropylene mesh is used. Other materials used are Dacron, polytetrafluoroethylene (PTFE) mesh, polyglycolic mesh (vicryl mesh) or combined polypropylene and polyglycolic acid mesh (vipro mesh). Drain (suction drain) must be placed after surgery.
  - ▶ Mesh repair is ideal approach for incisional hernia. Prevention of infection/haemostasis and drainage are important.
- ◆ **Laparoscopic mesh repair is done for incisional hernia** by placing a mesh under the defect laparoscopically in intraperitoneal plane. The only problem of this underlay

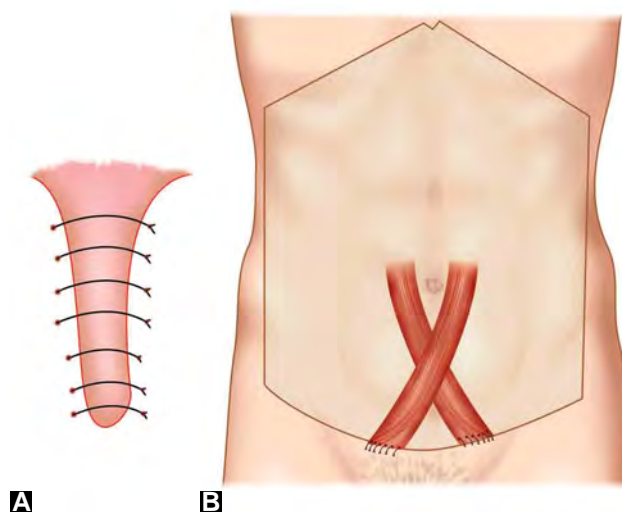


**Figs 18.85A to C:** On table incisional hernia defect also showing mesh placement in retrorectus plane.

placement is chances of adhesion and GI fistula formation, but still it is found to be safer. Laparoscopic preperitoneal mesh placement is also done for smaller defects. Now dual mesh (PTFE) or four layered mesh are available. Here mesh is placed under the peritoneum deep to the defect after reducing the contents. Mesh is fixed with sutures and tacks. In four-layered mesh, deepest 1st layer is absorbable cellulose which allows new peritoneum to creep underneath. 2nd layer is PDS/PTFE mesh 3rd layer is polypropylene mesh and the last 4th layer is again PDS/PTFE mesh. It is ideal but costly.

#### Note:

- **Cattell's operation:** When the defect is less than 3 cm, and if the patient is having adequate abdominal muscle tone, *layer by layer anatomical repair* is done using monofilament nonabsorbable suture material like polypropylene/polyethylene, ideally with interrupted sutures. Sac should be dissected, ligated and excised prior to repair. Peritoneum and posterior rectus sheath is apposed as first layer and anterior rectus sheath as second layer.
- **Double breasting of the rectus sheath** using interrupted nonabsorbable sutures using monofilament suture material. It is overlapping the rectus sheath in two layers with two rows of sutures.
- **Keel operation** is done in large defect. Scar is excised and is dissected beyond the margin of the defect. Sac is never opened unless there is obstruction of the content. Sac is inverted using continuous/interrupted inverting non-absorbable sutures, layer by layer until the defect margins are apposed together which is then again sutured with interrupted sutures. Keel is inverted beam of the ship.
- **Nuttall's operation** is done for lower midline incisional hernia. Recti attachments are detached from the pubic bones and are crossed over to fix to opposite pubic bones so as to create a firm abdominal wall support by crossed recti muscles.



**Figs 18.86A and B:** (A) Keel operation, and (B) Nuttall's operation.

### Different Types of Mesh Repair for Incisional Hernia

- ◆ *Outer to peritoneum is ideal method (sublay):* Large sized mesh is placed in preperitoneum. It need not be fixed as abdominal pressure keeps it in position (according to Pascal's law).

- ◆ *Under the peritoneum, directly over the content (underlay):* Now it is accepted but there are chances of adhesions/fistula formation. It is used in laparoscopic repair. Dual mesh/four-layered mesh is used.
- ◆ *Overlay* mesh placed outer to musculoaponeurotic layer. Here mesh is placed under subcutaneous tissue; it carries high recurrence rate (30%). So it is *not recommended*.
- ◆ *Combined inlay and overlay* with two layers of mesh.
- ◆ *Rive's Stoppa's method* of placing mesh between posterior rectus sheath and rectus muscle widely. Dissection is done at least 10 cm beyond the defect under rectus muscle in front of the posterior rectus sheath; mesh should cover 5 cm beyond the defect all around. Recurrence rate with this is less than 10%.
- ◆ *Components separation technique* is better method in large defects. Here skin and subcutaneous fat are dissected of the anterior rectus sheath → external oblique is incised 2 cm lateral to rectus abdominis → external oblique is separated from internal oblique until posterior axillary line → additional relaxing incisions are made over rectus sheath, internal oblique, transverse abdominis → it is repeated on opposite side → 20 cm mobilisation is achieved → also reinforced with a large mesh. Component separation technique causes often lateral bulges on both sides. If it is done without mesh support recurrence rate is high. Advantage is defect up to 20 cm can be easily brought together. Technique is also called as *Autogenous repair by vascularised innervated muscle flaps* (Ramirez, 1990).
- ◆ *Bridging at myoaponeurotic level outer to peritoneum (inlay):* Adequate sized mesh is placed in the defect level bridging the gap to cover preperitoneum. It is better by principle but still shows high recurrence.

#### Surgeries for incisional hernia

- ❖ Mesh repair—commonly done and ideal
- ❖ Component separation technique
- ❖ Layer by layer closure—Cattell's operation
- ❖ Double breasting of the rectus sheath
- ❖ Keel operation—not commonly used now
- ❖ Nuttall's operation—not commonly used now

### Postoperative Care

- ◆ Antibiotics.
- ◆ Analgesics.
- ◆ Nasogastric aspiration.
- ◆ Abdominal binder for support.
- ◆ Prevention of paralytic ileus.
- ◆ Control of obesity and other precipitating factors.
- ◆ Stop smoking and treat other associated causes.
- ◆ Early ambulation.
- ◆ Fluid management, catheterisation.
- ◆ Drain should be kept until drainage becomes minimal.
- ◆ Abdominal binder is used to support abdominal wall during recovery period.

#### Complications of incisional hernia surgery are:

- ❖ Wound infection, seroma formation
- ❖ Paralytic ileus, abdominal compartment syndrome in large hernias
- ❖ Wound sinus, enterocutaneous fistula
- ❖ Infection of the mesh, recurrence

### Additional Problems in Large Incisional Hernia

- ◆ While reducing the bulky contents like bowel and omentum, inadequate intra-abdominal capacity leads to increased intra-abdominal pressure causing IVC compression, mesenteric oedema followed by stasis of splanchnic bed, paralytic ileus, diaphragmatic elevation and respiratory distress (*abdominal compartment syndrome*), urinary and bowel disturbances. Abdominal capacity can be raised by creating regular pneumoperitoneum over the period of 3–6 weeks.
- ◆ Lordosis and back pain may be presenting feature.
- ◆ Sac and contents may get adherent to the thin skin over the summit of the hernia leading to skin ulceration and occasionally fistula formation.
- ◆ Often might need resection of the adherent bowel segment.
- ◆ Large mesh placement is required.

#### Note:

- *It is now universally accepted that prosthetic repair is gold standard for all incisional hernia.* Prostheses used are polypropylene mesh, e PTFE, Dacron, dual intraperitoneal mesh, biologic grafts.
- Nonprosthetic repair has got only historical value as recurrence rate is very high (as high as 55%).

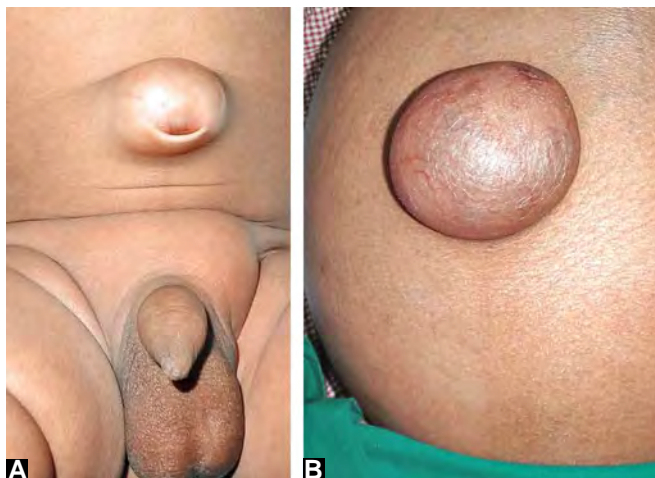
## ■ UMBILICAL HERNIA

### Anatomy of Umbilical Region

Umbilical ring is a complex structure which is related to linea alba, falciform ligament, obliterated urachus (median umbilical ligament) and umbilical fascia (*Richet's fascia*). It is located at the level of L<sub>4</sub> and L<sub>5</sub> vertebral disc. It is at lower position in infants. It is water shed area for venous and lymphatic drainage—above umbilicus it drains to axillary vein or lymphatics; below to inguinal area. Umbilical skin is supplied by T<sub>10</sub> spinal cord. It is the meeting point of four folds of embryonic plate and three systems—GI (vitellointestinal), urinary (urachus), and vascular (umbilical vessels). Umbilical hernia develops due to either absence of umbilical fascia or incomplete closure of umbilical defect. Weakest part in the umbilical cicatrix is upper part where hernia begins.

### Features

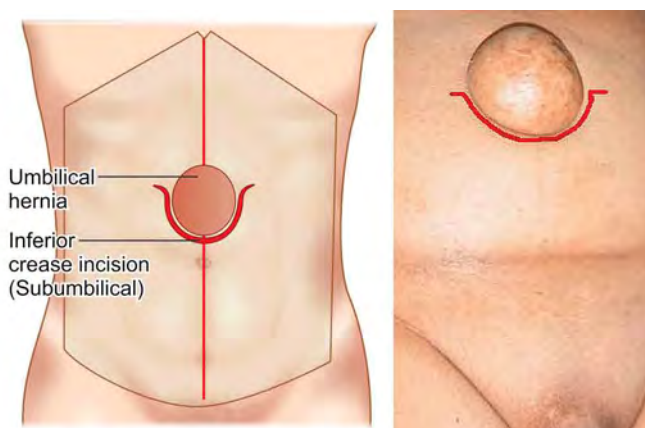
- ◆ Umbilical hernia can be **congenital** in newborn and infants (common in males) or **acquired** in adults (common in females). Congenital umbilical hernia is *common* in Africa or in African origin people (8 times). Acquired is like any ventral hernia.
- ◆ It is herniation through a weak umbilical scar (cicatrix).
- ◆ It is common in infants and children, occurs commonly due to neonatal sepsis.
- ◆ Male : female :: 2:1.
- ◆ It is seen in 20% of newborn infants.
- ◆ Umbilical hernia is common in Down's syndrome, *Beckwith-Weidman syndrome*, *ascites*.
- ◆ Presents with a swelling in the umbilical region within first few months after birth, the size increases during crying. It is hemispherical in shape.
- ◆ Defect can be felt with finger during crying.
- ◆ Occasionally it can go for irreducibility and obstruction which presents with pain, distension, vomiting.



**Figs 18.87A and B:** Umbilical hernia in a male child and adult. Often it can attain a large size.

## Treatment

Initially conservative. In 93 to 95% of cases, it disappears spontaneously in few months after birth (masterly inactivity). It can be hastened by adhesive strapping across the abdomen.



**Fig. 18.88:** Incision for umbilical hernia repair (infraumbilical)—inferior crease incision.

## Surgery

### Indications for surgery

- ❖ If persists even after the age of two years.
- ❖ If the defect is more than 2 cm in size.
- ❖ Acquired/adult umbilical hernia.

### Different surgeries are:

#### Primary closure of the defect:

An infraumbilical incision is made encircling its lower half. Sac is dissected circumferentially and is released off from the umbilicus and subcutaneous tissue. Sac is opened; contents are reduced; excess part is excised up to the umbilical ring. Defect is closed with interrupted nonabsorbable polypropylene sutures.

#### Mayo's operation:

Here horizontally opened rectus sheath is approximated as double-breasting with upper flap overlapping lower flap in front. It is rarely done today.

#### Sublay mesh repair:

In a large umbilical hernia (>3 cm size defect) with a degenerated skin on its surface it is often difficult to retain the umbilicus. When umbilicus is tried to be saved, infraumbilical incision should extend laterally about 2 cm on each side at 3 and 9 o'clock positions. Sac is dissected similarly. Sac is excised after excision of redundant sac. Presently it is standard to use polypropylene mesh as sublay or in retrorectus position and then rectus sheath is closed.

#### Umbilectomy:


Unhealthy thin skin over the large umbilical hernia is a real problem. It is better to do umbilectomy in these patients (excision of umbilical cicatrix). It is done only in adult with large umbilical hernia with thinning of umbilical skin. Prior consent and eventual creation of umbilicus is needed.

#### Open dual PTFE and polypropylene mesh placement:

Umbilical hernia is dissected similarly through subumbilical incision. Redundant sac is excised. Peritoneum is not closed. A special composite mesh containing wider PTFE on the inner side with little smaller polypropylene mesh on the outer aspect is used. It has also got two additional straps of the mesh attached to the outer part of the main composite mesh which are used to hold and later to fix into the defect anteriorly. This has got excellent results with low recurrence rate.

#### Laparoscopic umbilical hernia repair:

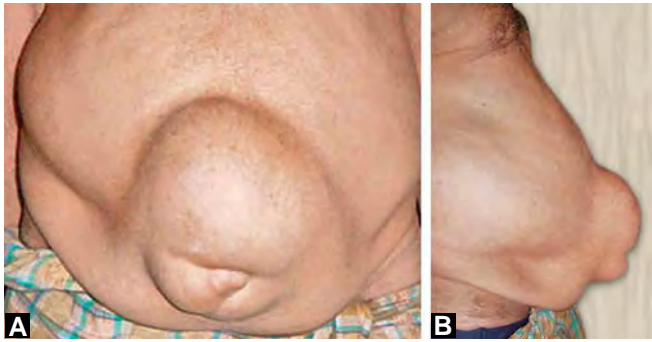
It is similar like any ventral hernia repair through laparoscopy which is done under general anaesthesia. It is useful only in large umbilical hernia.



**Fig. 18.89:** Umbilical hernia dual mesh to place both intraperitoneally and retrorectus plane with straps to fix.

## ■ PARAUMBILICAL HERNIA (Supra- and Infraumbilical Hernia)

- ❖ It occurs commonly in adults. It is a protrusion or herniation through linea alba, just above or below the umbilicus.
- ❖ It enlarges ovally, often attains a large size and sags downwards.
- ❖ Neck of the sac is relatively narrow. Contents are usually omentum, small bowel, sometimes large bowel.
- ❖ It has got tendency to go for adhesion, irreducibility and obstruction.



**Figs 18.90A and B:** Large ventral hernia front and side views. It needs preperitoneal mesh repair.

#### Predisposing factors

- ❖ Obesity
- ❖ Multiple pregnancies
- ❖ Flabby abdominal wall

### Clinical Features

- ◆ Common in females (5:1 ratio).
- ◆ It presents as a swelling which has smooth surface, distinct edges, soft, resonant with dragging pain and impulse on coughing. Large hernias can present with intestinal colic due to subacute intestinal obstruction. Eventually strangulation can occur.

### Treatment

#### Is always surgery

- ◆ Dissection of hernial sac and placement of mesh in retro-rectus plane and under the umbilicus is the ideal treatment.
- ◆ Often *umbilectomy* is required and also *mesh placement is beneficial* (when defect is > 4 cm in size).
- ◆ If there is strangulation, resection of bowel segment and anastomosis is done followed by repair of the hernia.
- ◆ **Mayo's operation:** Through a transverse elliptical incision, sac is identified and dissected. Herniotomy is done. *Double breasting of the defect* in the rectus is done by interrupted nonabsorbable sutures.
- ◆ Additional lipectomy (panniculectomy) may be done in case of pendulous abdomen.

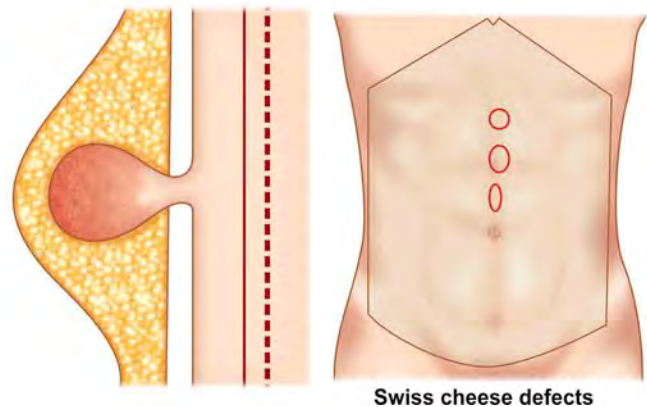
#### Mayo's operation

- ❖ It is done for umbilical and paraumbilical hernia
- ❖ Once lower flap or umbilicus is raised above, sac is identified, dissected and opened
- ❖ After reducing the contents sac is transfixed using vicryl
- ❖ Rectus sheath is repaired with double breasting using non-absorbable sutures between superior and inferior fascial margins as 'vest on pant' imbrications
- ❖ Skin flap is closed with a drain. Infection, recurrences (30%) are known complications
- ❖ It is not commonly used now

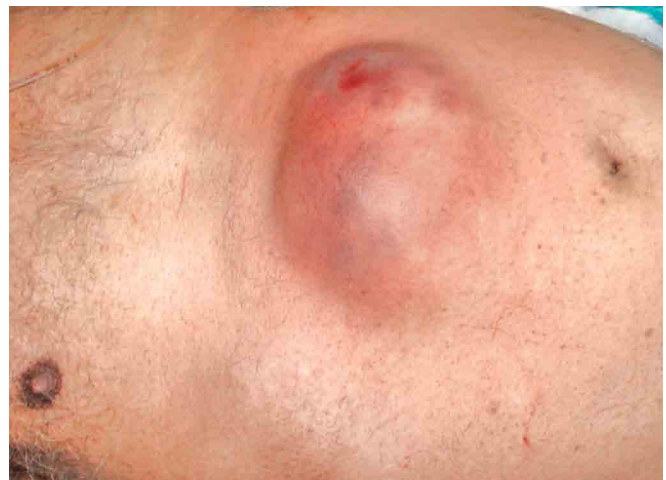- ◆ Postoperative weight reduction, use of abdominal binder is required for these patients.

### EPIGASTRIC HERNIA (Fatty Hernia of Linea Alba)

- ◆ It is 10% common; common in males.
- ◆ 20% of epigastric hernias are multiple—*Swiss cheese like*.
- ◆ It occurs usually through a defect in the decussation of the fibres of linea alba, any where between xiphoid process and umbilicus.
- ◆ Extraperitoneal fat protrudes through the defect as fatty hernia of the linea alba presenting like a swelling in the upper midline with an impulse on coughing.
- ◆ *It is sacless hernia*. Later protrusion enlarges and drags a pouch of peritoneum, presenting as a *true epigastric hernia*.
- ◆ If the defect is less than 1.5 cm, lateral margin of the defect is formed by only anterior and posterior lamina of the rectus sheath; if the defect is > 1.5 cm, then lateral margin is also formed by rectus muscle.
- ◆ Content of true epigastric hernia is usually omentum, sometimes it may be small bowel.
- ◆ Common in muscular men; manual labourers.



**Fig. 18.91:** Epigastric hernia. Often multiple *Swiss cheese defects* are seen.



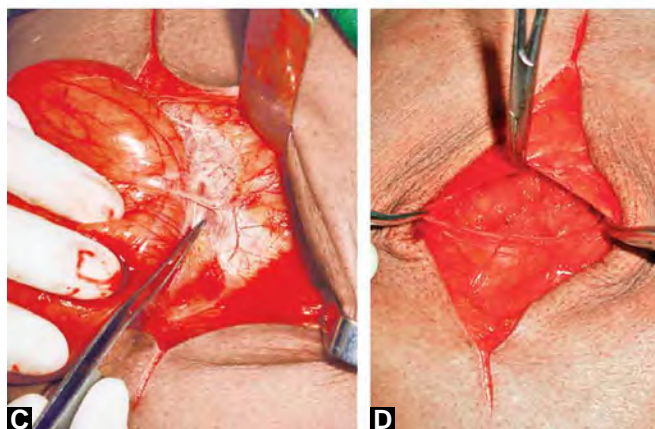
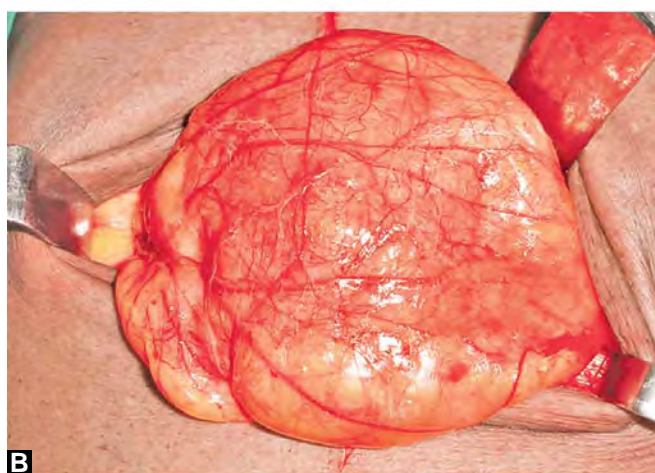
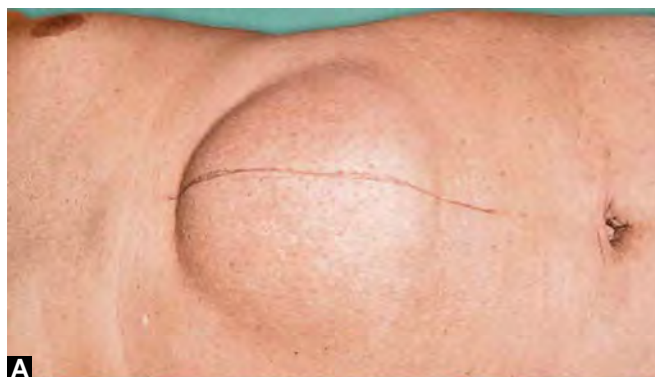**Fig. 18.92:** Epigastric hernia showing features of strangulation.

### Clinical features

- ❖ Often asymptomatic.
- ❖ Swelling in the epigastric region which is tender.
- ❖ Pain in epigastric region. It is often associated with peptic ulcer and so pain may be due to peptic ulcer. So gastroscopy is done to rule out acid peptic disease.
- ❖ Impulse on coughing; defect in the epigastric region are also found.
- ❖ Irreducibility, obstruction, strangulation as seen in any other hernia can also occur in epigastric hernia.

### Treatment

- ❖ Through a vertical incision, sac is dealt with. Defect is closed with nonabsorbable interrupted sutures.



**Figs 18.93A to D:** Epigastric hernia—incision, sac and defect.

- ❖ Large defect is supported with preperitoneal mesh.
- ❖ Complete reconstruction of linea alba is needed from xiphisternum to umbilicus especially in *Swiss cheese* type using different methods like—interrupted primary closure using polypropylene sutures; *modified shoelace technique* is used after removing strip of medial margins of the linea alba; double breasting of the linea alba.

### Interparietal hernias/interstitial hernias

- ❖ Herniation through parietal peritoneum into various layers of the abdominal wall
- ❖ Common in Down's syndrome, Prune Belly syndrome
- ❖ Often it can attain large size
- ❖ May mimic abdominal wall lipoma; haematoma
- ❖ As neck of the sac is often narrow, can present with irreducibility or obstruction
- ❖ Commonly it is deep to external oblique aponeurosis
- ❖ *Types:*
  - Preperitoneal—between peritoneum and transversus abdominis muscle—20%
  - Interparietal/intermuscular—between external oblique and internal oblique; most common—60%. It is commonly associated with inguinal hernia
  - Extraparietal (inguinosuperficial)—herniates through external oblique aponeurosis into subcutaneous plane—20%
- ❖ U/S; X-ray abdomen; often CT confirms the diagnosis
- ❖ Through a transverse incision, surgical ligation of sac, repair or mesh placement is the treatment

### SPIGELIAN HERNIA

- ❖ It is a type of interparietal hernia occurring at the level of arcuate line through spigelian point. Hernial sac lies either deep to the internal oblique or between external and internal oblique muscles.
- ❖ It is lateral ventral hernia through *Spigelian fascia* at any point along its line. *Semilunar line of Spigel* is a line from pubic tubercle to tip of 9th costal cartilage. It marks the lateral margin of the rectus sheath. Semicircular arcuate line (fold) of Douglas is lower end of posterior lamina of rectus sheath below the umbilicus and above the pubis. Spigelian fascia is area between lateral border of the rectus muscle and external and internal oblique and transversus abdominis muscle.
- ❖ Spigelian hernia can occur above (10%) or below (90%) the umbilicus. Below the umbilicus it occurs at the junction of linea semilunaris and linea semicircularis (wider and weaker point). In Spigelian hernia, defect is formed by internal oblique and transversus abdominis muscle. External oblique is outer to the hernial sac.

### Features

- ❖ Presents as a soft, reducible mass lateral to the rectus muscle and below the umbilicus, with impulse on coughing. Strangulation is common in spigelian hernia.
- ❖ Presence of precipitating factors like obesity, chronic cough, old age, multiple pregnancies.
- ❖ Common in females after 50 years of age.
- ❖ *Investigation:* Ultrasound abdomen.



### Differential diagnosis

- ❖ Abdominal wall lipoma.
- ❖ Soft tissue sarcoma.
- ❖ Abdominal wall haematoma.

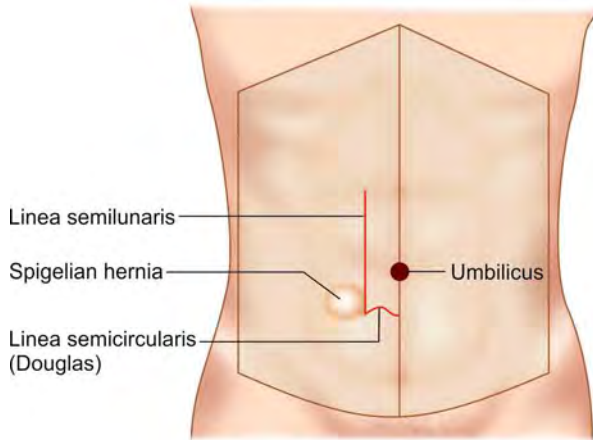
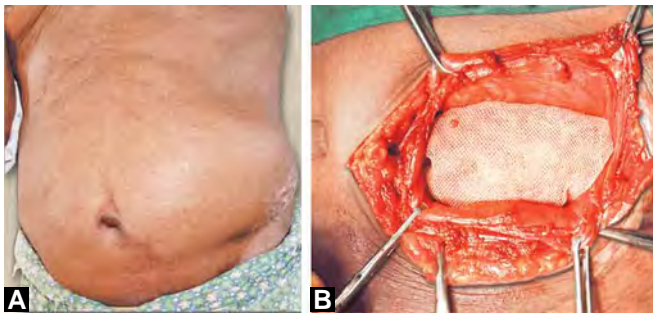


Fig. 18.94: Spigelian hernia.

### Treatment

- ◆ Through a lengthy transverse incision herniotomy and later closure of the defect layer by layer using nonabsorbable interrupted sutures.
- ◆ But *ideally* mesh is required to cover the defect properly.
- ◆ Laparoscopic dual mesh placement is also useful.



Figs 18.95A and B: Spigelian hernia. On table finding and placement of mesh in same patient.

### OBTURATOR HERNIA

- ◆ It is hernia occurring through obturator canal between superior ramus of pubis and obturator membrane. It is a rare entity, seen in elderly females (6:1 ratio female to male).

### Clinical Features

- ◆ Usually presents with features of intestinal obstruction (85%) and more often confirmed only on laparotomy.
- ◆ Rarely seen as a swelling in Scarpa's triangle (20%) deep to the pectineus muscle, with limb in flexed and abducted position. Movement of limb is painful.

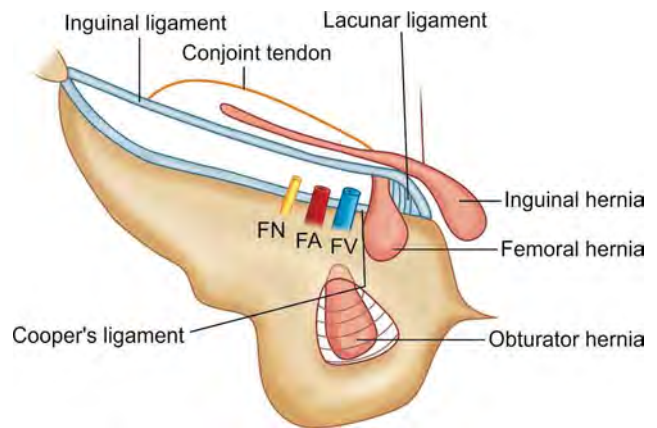


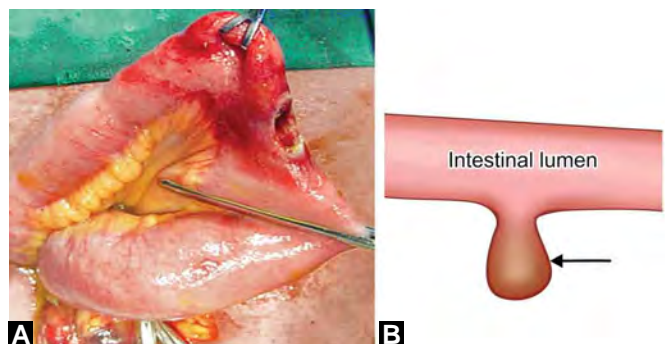
Fig. 18.96: Obturator hernia through obturator canal in obturator foramen. Note also the locations of inguinal and femoral hernias.

- ◆ Referred pain in knee joint through geniculate branch of obturator nerve signifies not only obturator hernia but also strangulation—*Howship-Romberg sign* (50%).
- ◆ On per vaginal examination, tender swelling is felt over the obturator foramen.
- ◆ Here strangulation is usually of Richter's type.

### Treatment

- ◆ Laparotomy is done and the sac is identified. It is dissected and ligated. If strangulation is present (common), resection and anastomosis is done. Broad ligament is stitched over the opening to prevent recurrence.
- ◆ Mesh placement is the ideal way of repairing the obturator defect.
- ◆ In *nonobstructive* type, if diagnosed clinically and by CT scan imaging, either TEP (laparoscopic) or lower abdominal midline extraperitoneal approach may be the method to manage the obturator hernia.
- ◆ In strangulated hernia, rarely additional exposure in thigh often may be required to reduce the content through a vertical medial pectineus muscle split incision.

### RICHTER'S HERNIA



Figs 18.97A and B: (A) Strangulated femoral hernia, Richter's type with perforation. Patient underwent resection and anastomosis; (B) Richter's hernia.

It is a hernia in which the sac contains only a portion of the circumference of the intestine (small bowel). It is usually *seen in femoral and obturator hernia*.

### Clinical Features

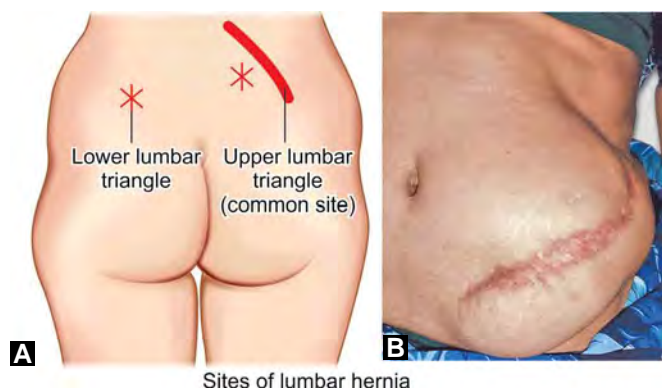
- ◆ It *mimics gastroenteritis* with pain abdomen, diarrhoea, toxicity, vomiting.
- ◆ There are no features of intestinal obstruction.
- ◆ Constipation does not occur in Richter’s hernia.
- ◆ Gangrene (strangulation) of a part of bowel occurs, eventually leading to peritonitis.

### Treatment

- ◆ Resection and anastomosis is done.
- ◆ The type of hernia is treated.
- ◆ Mortality increases with delay in surgical intervention.

### LUMBAR HERNIA

- ◆ It is herniation either through superior or inferior lumbar triangle.
- ◆ Superior lumbar triangle (*Grynfelt’s/Lesgaft’s triangle*) is bounded by sacrospinalis, 12th rib and posterior border of internal oblique.
- ◆ Inferior lumbar triangle is bounded by latissimus dorsi, external oblique and iliac crest (*triangle of Petit*).
- ◆ Lumbar hernia is more common through superior lumbar triangle.
- ◆ It can be:
  - ▶ **Primary.**
  - ▶ **Secondary**, which is due to previous renal surgery, more common.



**Figs 18.98A and B:** (A) Lumbar triangles; (B) Lumbar incisional hernia—large. Previous lumbar incision scar is visible.

#### Differential diagnosis

- ❖ Lipoma.
- ❖ Cold abscess.
- ❖ Lumbar phantom hernia.

### Treatment

Repair using fascial flaps or mesh.

### PHANTOM HERNIA

- ◆ It is a muscular bulge as a result of local muscular paralysis due to interference with nerve supply of the affected muscles, like poliomyelitis. It is common in lumbar region. It is often seen in lower abdomen.

*Phantom hernia* is muscular bulge due muscle paralysis in lumbar region  
*Phantom limb* is feeling of pain in amputated toe or limb  
*Phantom tumour* is tumour like lesion in lung like interlobar pleural effusion

### SCIATIC HERNIA

- ◆ It is a rare hernia.
- ◆ It is the protrusion of the peritoneal sac through the greater or lesser sciatic foramen.

#### Types

Classified based on their relationship to the piriformis muscle and ischial spine.

1. Suprapiriformis.
2. Infrapiriformis.
3. Subpiriformis.

Sac lies deep to gluteus maximus. Large hernias protrude below the buttock crease.

*Diagnosis:* Usually on laparotomy for intestinal obstruction.

*Treatment:* Defect is covered by fascia mobilised from pyri-formis muscle after reducing the sac contents.

### COMPLICATIONS OF HERNIA SURGERY

Proper idea of complications of hernia surgery are important as often complications may become more problematic than hernia itself. 20 years back where tissue repair was popular recurrence was the most worried complication. Now since recurrence rates have come down due to standard usage of mesh, mesh related complications have become more common than recurrence. Inguinodynia, mesh extrusion, mesh infection, mesh erosion are the worried problems.

• Complications of open hernia surgery	• Early
• Complications of TEP/TAPP	• Delayed
• Complications of other hernia surgery—ventral/femoral	• Late
	• Life-threatening

## Inguinodynia

- ◆ It is chronic inguinal pain seen in post-hernia surgery patients (30%)—whether tissue or mesh repair.
- ◆ *Causes are*—traction, cautery, transection, entrapment. Even though it can occur in both tissue and mesh repair, it is more observed in mesh repair especially in onlay mesh repair. It is due to entrapment of nerve in the suture or in the mesh itself or nerve gets adherent to the mesh during fibrosis (perineural fibrosis) (*Mesh inguinodynia*).

Complications of open hernia surgery	Complications of TEP/TAPP surgery
<ul style="list-style-type: none"> <li>• Infection</li> <li>• Groin pain; osteitis pubis</li> <li>• Ischaemic orchitis—due thrombosis of pampiniform venous plexus (0.5%)</li> <li>• Injury to vas</li> <li>• Injury to viscera</li> <li>• Recurrence</li> <li>• Hydrocele formation</li> <li>• Seroma, haematoma</li> <li>• <i>Inguinodynia</i>—neural</li> <li>• <i>Dysejaculation</i>—painful, burning sensation just before/during/after ejaculation due to cremaster dysfunction or vas stricture (0.25%)</li> </ul>	<ul style="list-style-type: none"> <li>• SC emphysema</li> <li>• Pneumothorax, hypercarbia</li> <li>• Vascular</li> <li>• Neural</li> <li>• Visceral</li> <li>• Infection, ileus</li> <li>• Conversion</li> <li>• Recurrence</li> </ul>

Immediate	Late/delayed
<ul style="list-style-type: none"> <li>• Vascular—injury to iliac vessels/IE vessels</li> <li>• Visceral injury—bowel/bladder</li> <li>• Vas injury</li> <li>• Anaesthetic complications</li> </ul>	<ul style="list-style-type: none"> <li>• Seroma/haematoma</li> <li>• Neural complications</li> <li>• Intestinal obstruction</li> <li>• Bowel adhesion/fistula</li> <li>• Testicular atrophy</li> <li>• Mesh related complications</li> <li>• Recurrence</li> </ul>

- ◆ It may be transient or persistent.
- ◆ Nerves involved are—iliohypogastric, ilioinguinal, genital branch of genitofemoral nerve, paravasal nerves.
- ◆ *Features are*—distressing pain in the groin which often radiates to thigh, scrotum and loin. Arch and twist mobility of pelvis reproduce the pain. Bupivacaine injection relieves the pain. Imaging/nerve conduction studies are of no use.
- ◆ Open method has higher (32–38%) incidence of inguinodynia than TAPP/TEP. In open hernia surgery inguinodynia has replaced recurrence as a primary complication. It is distressing discomfort to both patient and surgeon. Incidence is less in posterior or laparoscopic approach.

- ◆ It is treated with analgesics/nerve block (Injection of steroid, local anaesthetic agents, phenol, and alcohol)/transcutaneous stimulation/cryotherapy/radiofrequency therapy/neurectomy.
- ◆ Neurectomy is done via groin or suprainguinal or laparoscopic or laparotomy approach. Commonly groin approach is used. Ilioinguinal, iliohypogastric and genitofemoral nerves are carefully dissected. Nerve which is causing the problem is transected at a point where it comes out of the internal oblique muscle and proximal end should be ligated, otherwise end neuroma may form to cause recurrence of the pain. This ligated stump is buried in the internal oblique muscle. Just neurolysis may be sufficient but chances of re-adhesion are higher with recurrence of symptoms. In difficult cases nerve may be transected through laparotomy/laparoscopy approach.

## PARASTOMAL HERNIA

- ◆ It is herniation of intestine on the side of bowel stoma—ileostomy/colostomy/other stomas.
- ◆ Incidence is 8%.
- ◆ *Classification (Devlin's)*: (1) Subcutaneous—intestine herniates along the side of stoma to reach subcutaneous plane—most common. (2) Interstitial—along the side of stoma intestine herniates into intermuscular plane. (3) Intrastomal—bowel herniates between emerging and everted parts of the stoma. (4) Perstomal—herniation occurs between the layers of the prolapsed stoma.
- ◆ *Features*: Pain, features of obstruction, stomal malfunction, swelling which is tender, toxicity.
- ◆ *Diagnosis*: X-ray; CT abdomen.
- ◆ *Treatment*: Surgery is indicated in recurrent obstruction, narrow neck, strangulation, interference with stoma.
  - ▶ Stoma is dissected, hernia content is reduced and defect is repaired. But it shows high recurrence.
  - ▶ Subcutaneous mesh repair as onlay placement after reduction of hernia.
  - ▶ Extraperitoneal mesh repair around the stoma.
  - ▶ Intraperitoneal mesh repair deep to peritoneum surrounding the stoma and defect.

### Different types of hernia

1. Gibbon's hernia—It is hernia with hydrocoele
2. Berger's hernia—Hernia in pouch of Douglas
3. Romberg hernia—Saddle hernia
4. Obturator hernia—Hernia through obturator foramen (canal)
5. Grynfelt's hernia—Upper lumbar triangle hernia
6. Petit's hernia—Lower lumbar triangle hernia
7. Femoral hernia—Hernia medial to femoral vein
8. Cloquet's hernia—Hernia through pectineal fascia
9. Narath's hernia—Behind femoral artery, in congenital dislocation of hip
10. Hesselbach's hernia—Lateral to femoral artery
11. Serofini's hernia—Behind femoral vessels
12. Laugier's hernia—Through lacunar ligament

Contd...

*Contd...*

13. Teale's hernia—In front of femoral vessels
14. Richter's hernia—Part of circumference of bowel wall is gangrenous
15. Littre's hernia—Hernia with Meckel's diverticulum as the content
16. Sliding hernia—Posterior wall of the sac is formed by colon or bladder
17. Maydl's hernia—'W' hernia
18. Phantom hernia—Localised muscle bulge following muscular paralysis
19. Spigelian hernia—Hernia through spigelian fascia

*Contd...*

*Contd...*

20. Mery's hernia—Perineal hernia
21. Sciatic hernia—Hernia through greater or lesser sciatic foramen
22. Amyand hernia—Appendix in inguinal hernial sac
22. Amyand hernia—Appendix in inguinal hernial sac
23. Beclard's hernia—Femoral hernia through the saphenous opening
24. Barth's hernia—Hernia between abdominal wall and persistent vitellointestinal duct
25. Holthouse's hernia—Inguinal hernia that has turned outwards into the groin
26. De Garengeot's hernia is incarcerated appendix in femoral hernia

# Chapter 19

## Oesophagus

### CHAPTER OUTLINE

- ❖ Anatomy
- ❖ Lower Oesophageal Sphincter
- ❖ Dysphagia
- ❖ Contrast Study of Oesophagus
- ❖ Oesophagoscopy
- ❖ Oesophageal Endosonography
- ❖ Third Space Endoscopy
- ❖ Gastro-oesophageal Reflux Disease
- ❖ Hiatus Hernia
- ❖ Rolling Hernia
- ❖ Reflux Oesophagitis
- ❖ Barrett's Oesophagus
- ❖ Barrett's Ulcer
- ❖ Oesophageal Motility Disorders
- ❖ Achalasia Cardia
- ❖ Plummer-Vinson Syndrome
- ❖ Corrosive Stricture of Oesophagus
- ❖ Schatzki's Rings
- ❖ Boerhaave's Syndrome
- ❖ Mallory-Weiss Syndrome
- ❖ Tracheo-oesophageal Fistula
- ❖ Oesophageal Diverticulum
- ❖ Carcinoma Oesophagus
- ❖ Benign Tumours of the Oesophagus
- ❖ Oesophageal Perforation

### ANATOMY

Oesophagus is a hollow muscular tube which begins at the lower edge of the cricoid cartilage (C<sub>6</sub> vertebra) and ends at oesophagogastric junction (T<sub>12</sub> vertebra). It is 25 cm in length. Upper end is closed by cricopharyngeus muscle which is 18 cm from upper incisors. Lower end is 40 cm from the upper incisors (upper jaw is fixed and so is used as the landmark to measure, but not the lower jaw which is mobile).

It lies anterior to vertebral column and posterior to the trachea. It lacks serosal layer but is surrounded by a layer of loose fibroareolar adventitia.

#### Anatomical specialities

- ❖ Lacks serosa (other structure without serosa is rectum).
- ❖ Contains 2 different types of muscles (striated and smooth at proximal 1/3 and distal 2/3 respectively)
- ❖ Contains 2 different types of epithelium.
- ❖ Segmental blood supply.
- ❖ Only part of GIT which shows *very thinly scattered* Meissner's plexus.
- ❖ Longitudinal arrangement of veins and lymphatics.

It is lined by squamous epithelium throughout the length except the last 3 cm (OG junction) which is lined by columnar epithelium. Submucosa of the oesophagus is thick and strongest part.

### Parts

1. **Cervical oesophagus:** It extends from cricopharyngeus which is the horizontal part of inferior constrictor muscle. Upper oblique part is called as thyropharyngeus. Gap between the two is called as *Killian's dehiscence* which is a *site of occurrence of pharyngeal pouch*. Cervical oesophagus is related to trachea and recurrent laryngeal nerve.
2. **Thoracic oesophagus:** Lies initially towards the right side. In lower third, it deviates towards the left and continues as abdominal oesophagus. It is related to azygos vein, thoracic duct (which crosses the oesophagus posteriorly from right to left), aorta, pleura and pericardium.
3. **Abdominal oesophagus** is 2.5 cm long and grooves behind the left lobe of the liver.

#### Three areas of anatomic narrowing

- ❖ Cervical constriction—occurs at the level of cricopharyngeal sphincter—*narrowest point of GIT*—15 cm from upper incisor—site of F/B impaction
- ❖ Bronchoaortic constriction—located at the level of T<sub>4</sub>—25 cm from upper incisor—site of endoscopic perforation
- ❖ Diaphragmatic constriction—occurs where oesophagus traverses the diaphragm (Level of T<sub>10</sub>)—40 cm from upper incisor

**Arterial supply of oesophagus**

By inferior thyroid artery, oesophageal branches of the aorta, gastric arteries and inferior phrenic arteries.

**Venous drainage of oesophagus**

By inferior thyroid vein, brachiocephalic vein, hemiazygos vein, azygos vein, coronary vein, splenic vein and inferior phrenic vein. Veins are longitudinal and they lie in submucosal plane in lower third and in muscular plane above.

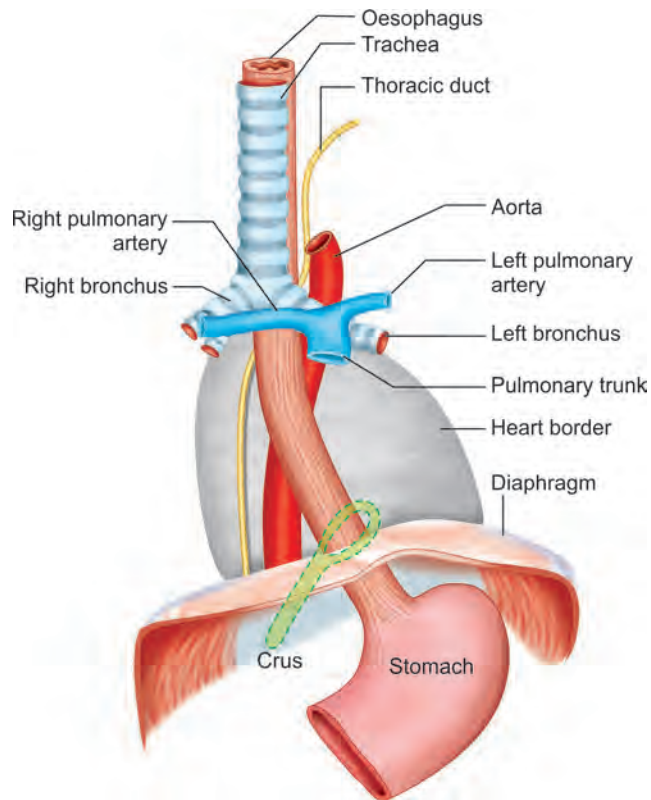


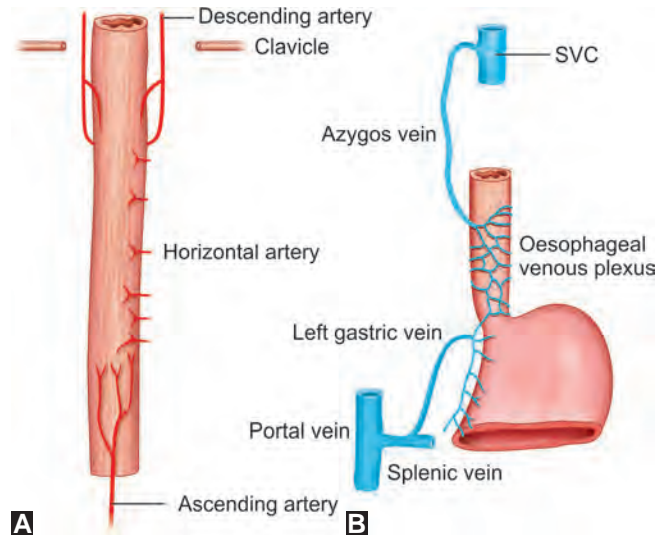
Fig. 19.1: Anatomical relations of the oesophagus.

**Lymphatic drainage**

Lymphatic arrangement in oesophagus is longitudinal and so spread of carcinoma to distant lymph nodes occurs early. Longitudinal lymphatics are 6 times more than transverse one. There are *more lymph vessels* in submucosa than blood vessels.

Lymph nodes are:

- ◆ *Paraoesophageal groups* located in the wall of the oesophagus and are cervical, thoracic, paraoesophageal and paracardial nodes.
- ◆ *Perioesophageal groups* located immediately adjacent to oesophageal wall. They are deep cervical, scalene, paratracheal, mediastinal, diaphragmatic, gastric and coeliac lymph nodes.
- ◆ *Lateral oesophageal groups* receive lymph from para and perioesophageal lymph nodes.
- ◆ Upper oesophagus drains into supraclavicular nodes.
- ◆ Thoracic oesophagus drains into paraoesophageal and tracheobronchial nodes in thorax.
- ◆ Abdominal oesophagus drains into coeliac nodes.



Figs 19.2A and B: (A) Arterial supply and (B) Venous drainage of oesophagus.

- ◆ However, due to longitudinal arrangement of lymphatic plexus in the wall of oesophagus, any group of (neck/thorax/coeliac) lymph nodes can get involved in diseases at any level.

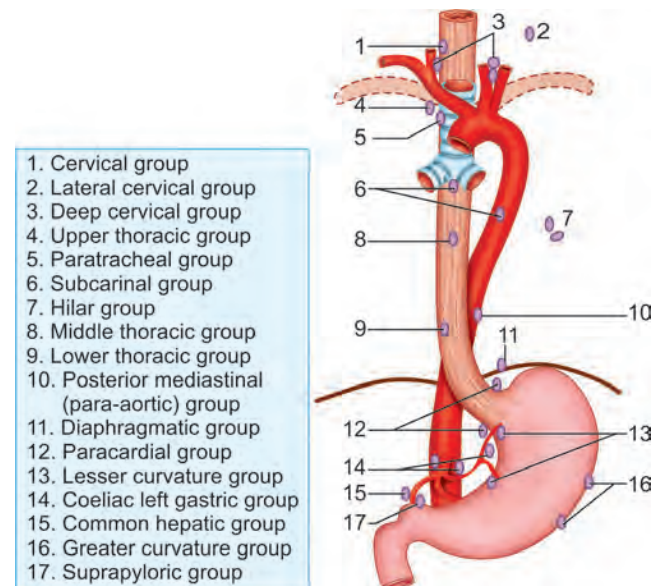


Fig. 19.3: Lymphatic drainage of the oesophagus.

**Nerve Supply**

- ◆ Oesophagus is innervated by vagus.
- ◆ It has got both sympathetic and parasympathetic innervation.
- ◆ It has got mainly *Auerbach's plexus* between longitudinal and circular muscle layers.

**Leugart's pouch** is prolapse of the wall of the oesophagus like a diverticulum over a band (*Leugart's band*) between the left bronchus and adjacent vertebra.

## Physiology

Three types of contractions in the oesophagus:

1. *Primary*: Progressive, triggered by swallowing.
2. *Secondary*: Progressive, generated by distension or irritation.
3. *Tertiary*: Nonprogressive.

*Presbyoesophagus* is less efficient oesophageal peristalsis.

### Note:

- *Laimer's triangle* is formed with base above formed by cricopharyngeus and on either side divergent longitudinal oesophageal muscles. Laimer's triangle is in the posterior part of the oesophagus midline.
- *Collar of Helvetius* is the site where oesophageal circular muscle fiber becomes oblique muscle of the stomach.

## LOWER OESOPHAGEAL SPHINCTER (LOS)

- ◆ It is a high physiological pressure zone located in the lower end of the oesophagus in terminal 4 cm, with a resting pressure of 10–25 mmHg.
- ◆ LOS prevents reflux of gastric and duodenal contents.
- ◆ It is influenced by food, gastric distension, gastric pathology, smoking, GI hormones, alcohol.
- ◆ Normally there is a *transient relaxation period* wherein reflux (*physiological*) occurs but then immediately gets cleared by oesophageal clearance mechanism.
- ◆ *So pathological reflux or GORD* can occur due to decreased LOS tone, altered relaxation time, reduced oesophageal clearance mechanism, or other altered mechanical factors.
- ◆ *Oesophageal clearance mechanism* is due to primary oesophageal peristalsis which carries saliva with high bicarbonate content which neutralizes and clears the transient physiological reflux. Manometry with special microtransducers are used to measure the LOS pressure.

## DYSPHAGIA

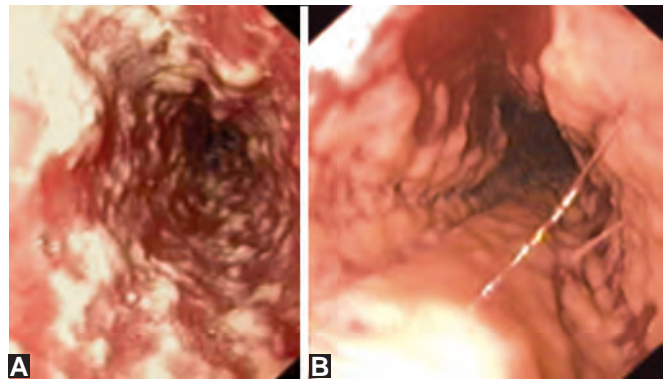
- ◆ *Dysphagia* is difficulty in swallowing. Painful swallowing is *odynophagia*.
- ◆ It can be *acute*—due to foreign body impaction or acute infection or *chronic* due to causes like stricture or carcinoma, etc.
- ◆ Associated hoarseness of voice may be present in advanced pharyngeal or post-cricoid carcinomas. At late stage laryngeal carcinoma also can cause dysphagia along with hoarseness of voice.

- ◆ Dysphagia can be *oropharyngeal* or *oesophageal* depending on the cause.
- ◆ Dysphagia may be due to pathology in *voluntary/pharyngeal phase* of the swallowing wherein patient also develops cough while swallowing. Dysphagia due to problem in *oesophageal involuntary phase* of swallowing is specified by food getting stuck in the pathway. But site of “*food getting stuck*” feeling is not relevant.
- ◆ Dysphagia can be *progressive or intermittent*.

## Causes of Dysphagia

### Common causes:

- ◆ Gastro-oesophageal reflux diseases (GORD/GERD/Hiatus hernia).
- ◆ *Carcinoma oesophagus*: Here dysphagia is of short duration and progressive. 2/3 of the lumen should be blocked by tumour to develop dysphagia.
- ◆ *Foreign body in oesophagus*: It may be coin/bone piece/ denture. It is common in children. It causes acute dysphagia. It may be often life-threatening.
- ◆ Carcinoma of pharynx or posterior 1/3rd of the tongue.
- ◆ *Corrosive strictures*: It is usually alkali stricture. Squamous mucosa is resistant to acid effect to certain extent.
- ◆ *Oesophageal candidial infection*: It is becoming common due to immunosuppression in association with HIV infection; steroid therapy; cancer chemotherapy; post-transplant period, etc. Presentation is dysphagia and odynophagia. Oral candidiasis (thrush) is obvious. Endoscopy shows whitish curd-like plaques in the oesophageal mucosa which cannot be moved (whereas food particles can be moved). Barium swallow shows mucosal ulceration and irregular areas. Biopsy confirms the diagnosis. Treatment is oral antifungal as well as topical antifungal therapy.



**Figs 19.4A and B:** Endoscopic view of oesophageal candidiasis infection. Note the whitish curd-like plaques.

### Causes of dysphagia

#### Extraluminal causes

- Mediastinal nodes—secondaries/lymphoma/tuberculosis
- Aortic aneurysm
- Rolling hiatus hernia
- Thyroid enlargement—malignant
- Dysphagia lusoria
- Congenital anomalies
- Mediastinitis/mass

#### Causes in the wall of oesophagus or other area

- Carcinoma oesophagus
- Corrosive/tuberculous/inflammatory/congenital stricture oesophagus
- GERD
- Achalasia cardia
- Plummer-Vinson syndrome
- Oesophageal diverticulum
- Carcinoma posterior 1/3rd of tongue/pharynx
- Diffuse oesophageal spasm
- Congenital anomalies
- Retropharyngeal abscess/peritonsillar abscess (Quinsy)/acute tonsillitis/pharyngitis

#### Causes in the lumen

- Foreign body in the oesophagus—coin/dentures/fish or meat bone
- Other causes*
- Cranial causes (neurological):
- Bulbar palsy/infarction/hemiplegia
  - Vertebrobasilar insufficiency

- ◆ Plummer-Vinson syndrome.
- ◆ Mediastinal swellings—primary tumours/nodal mass either lymphoma or secondaries or tuberculosis.

#### Rare causes:

- ◆ *Diffuse oesophageal spasm*: They are incoordinated contractions of oesophagus causing chest pain or dysphagia. It is common in distal 2/3rd of the oesophagus. Hypertrophy of circular muscle fibres with very high persistent pressure of 400–500 mmHg is specific. Treatment is calcium channel blockers, vasodilators, endoscopic dilatation and extended oesophageal surgical myotomy up to the aortic arch (very useful especially for dysphagia; not much for chest pain).
- ◆ Oesophageal diverticula, Chaga's disease.
- ◆ *Dysphagia lusoria* (*Lusoria means in Latin "sport of nature"*): It is a congenital vascular anomaly of aortic root. *Aortic arch anomalies* are—double arch (40%), right arch and left ligamentum arteriosum (25%), anomalous innominate or common carotid artery or aberrant right subclavian artery (10%). It is due to disappearance of proximal right 4th aortic arch instead of distal portion. All patients having this anomaly (*dysphagia lusoria*) have got an *aberrant right subclavian artery* in a transposed position arising from descending aorta that courses posterior to oesophagus. Often there will be a complete *vascular ring* around trachea and oesophagus. It is categorised based on their specific subclavian anomaly—depends on presence of aneurysm, occlusive disease and compression. Commonly they are asymptomatic. Presentations may be dysphagia, chest pain, stridor, wheeze, recurrent respiratory infection (usually presents after the age of 40).  
*Investigations*: CT chest, MRI, chest X-ray, barium swallow (T4 level diagonal impression) and endoscopy (shows pulsating extraluminal compressive mass).  
Treatment is reconstruction or ligation of aberrant right subclavian artery by sternotomy/by neck approach.
- ◆ *Thyroid swelling*: It is uncommon to develop dysphagia in a thyroid swelling. There will be always dyspnoea when dysphagia develops. Large malignant thyroid or anaplastic thyroid can cause dysphagia with dyspnoea or stridor.
- ◆ *Boerhaave's syndrome*: It is vertical full thickness tear of lower oesophagus due to vomiting with closed glottis. It is often life-threatening and emergency.
- ◆ Neurological causes like stroke, bulbar palsy, motor neuron disease, Parkinson's disease, etc.
- ◆ Congenital anomalies of oesophagus.
- ◆ *Drug-induced dysphagia*: Drugs like KCl, quinine, NSAID can cause dysphagia.
- ◆ Mediastinal fibrosis.

## Evaluation of a Patient with Dysphagia

- ◆ Proper history.
- ◆ Haematocrit.
- ◆ Chest X-ray often shows mediastinal mass lesion/foreign body.
- ◆ *Oesophagoscopy*: Once lesion is detected, it is treated accordingly. Biopsy from lesions, endotherapy if needed should be carried out (like F/B removal; stricture dilatation; sclerotherapy).
- ◆ Barium swallow may show irregular filling defect or extrinsic compression.
- ◆ CT scan chest is very useful method to identify the anatomical location of the cause (nodes/tumour/aorta/cardiac cause/congenital).

Extent, spread, nodal status, size and operability of tumour also well-assessed.

- ◆ Oesophageal manometry in achalasia cardia/GERD.
- ◆ 24 hours pH monitoring is ideal and most accurate for GERD. Small pH probe (transnasal catheter) is passed into the distal oesophagus 5 cm proximal to upper margin of LOS under manometry guidance. Probe is connected to a digital recorder worn by the patient for 24 hours. Record is analysed using a computer. A pH less than 4 for more than 4% of total 24 hours period (more than near to one hour in toto in 24 hours) is pathological reflux. It is often assessed by scoring system. Radio-telemetry pH probes are used now without any nasal tube. It is passed and placed on the oesophageal wall using endoscope.
- ◆ Endosonography is very useful in many conditions causing dysphagia. It can assess site, layers of the oesophagus, nodes, spread, etc. properly. Different layers are seen as alternating hyperechoic and hypoechoic bands.
- ◆ Ultrasound abdomen to see abdominal nodes/liver/ascites.
- ◆ MRI study.

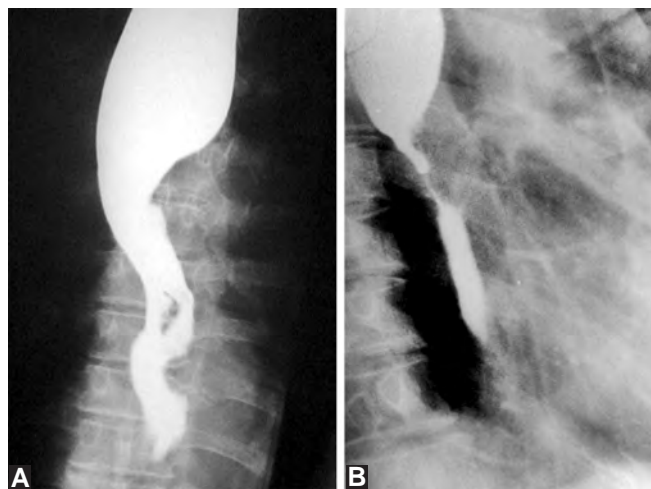## Treatment for Dysphagia

Depends on cause—modified Heller's myotomy; oesophageal resection; dilatation; F/B removal, etc.

## ■ CONTRAST STUDY OF OESOPHAGUS

### Types

1. Barium swallow using barium sulphate (thick paste).
2. Using water-soluble contrast like 'Gastrografin'.



**Figs 19.5A and B:** Barium swallow X-rays showing narrowing and irregularity in carcinoma oesophagus.

### Indications

1. *Barium swallow*
  - ▶ Dysphagia due to motility disorder like achalasia cardia, diffuse oesophageal spasm.
  - ▶ Dysphagia due to mechanical causes like carcinoma, benign strictures and neoplasms, external compression.
  - ▶ Pharyngeal pouch and other diverticula.
  - ▶ GORD.

*Instrumentation is the most common cause of oesophageal rupture.*



## 2. Water-soluble contrast radiograph

- ▶ In suspected oesophageal perforation.
- ▶ Leaking oesophageal anastomosis.

## Important Findings in Barium Swallow

- ◆ Achalasia cardia—'Bird beak' appearance, as the oesophagus is grossly dilated above an apparent narrowing at the cardia. In long-standing cases—'sigmoid oesophagus'.
- ◆ Diffuse oesophageal spasm—'Corkscrew' appearance.
- ◆ GORD—shows reflux when done in Trendelenburg's position.
- ◆ Oesophageal carcinoma—irregular stenosing lesion with shouldering ('Rat tail' is a fluoroscopic finding).
- ◆ Pharyngeal pouch—demonstration of the pouch.
- ◆ External compression—indentation of barium column by superior or posterior mediastinal mass, enlarged left atria as in mitral stenosis.

## OESOPHAGOSCOPY

### Indications

#### Diagnostic

- ❖ To identify the lesion and to take biopsy in carcinoma oesophagus.
- ❖ For diagnosing other oesophageal conditions.

#### Therapeutic

- ❖ To remove foreign body
- ❖ To dilate stricture
- ❖ To place endostents for inoperable carcinoma oesophagus
- ❖ To inject sclerosants for varices

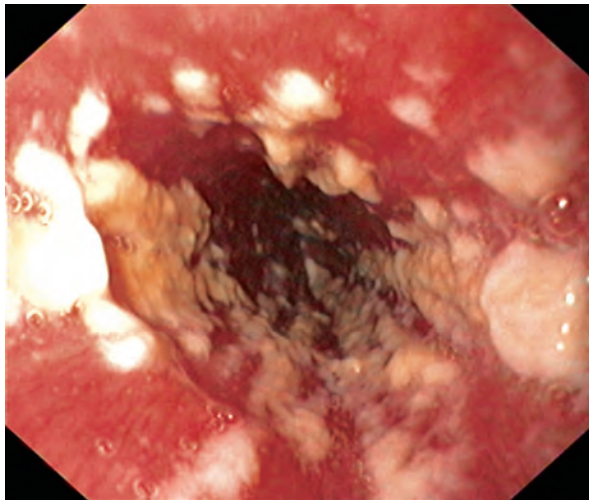


Fig. 19.6: Oesophageal candidiasis—note the multiple curd-like lesions.

## Types

### 1. Rigid oesophagoscope (Negus type)

- ▶ It is done under general anaesthesia. Head is extended and head end of the table is tilted upwards, scope is passed behind the epiglottis and cricoid through the cricopharyngeal opening. This is the most difficult part in oesophagoscopy. After that, negotiating through the oesophagus is easier. The lesion is identified and biopsy is taken if required.

- ▶ *Complications* are perforation (most common site of perforation is at the level of cricopharyngeus), bleeding.

### 2. Fiberoptic flexible oesophagoscope

- ▶ It can be done under local anaesthesia. Reflux and hiatus are well identified. Stomach also can be visualised. Easy to pass and perforation is unlikely.
- ▶ But tissue taken for biopsy is smaller and removal of foreign body is also difficult.

## OESOPHAGEAL ENDOSONOGRAPHY

- ◆ It is useful method of finding and assessing involvement or pathology of different layers of oesophagus especially in carcinoma oesophagus. It shows all layers clearly and distinctly and so invasion can be better made out and operability can be decided.
- ◆ **Endoscopic oesophageal staining** using labelled iodine is used to identify early carcinoma in oesophagus. Normal mucosal cells contain glycogen which takes up iodine and so stains brown, whereas carcinoma cells will not take up iodine and so mucosa appears pale (not stained).

## THIRD SPACE ENDOSCOPY

- ◆ It is newer method wherein submucosal or intramural space which is called as 3rd space (first being luminal space and 2nd peritoneal space) is approached for various therapeutic and diagnostic purposes. It is also designated as SuMO (SubMucosal Operation).
- ◆ Currently, it is used in upper gastrointestinal area like oesophagus and stomach. Procedures done are – POEM (Per oral endoscopic myotomy) for achalasia cardia, submucosal tunneling tumour biopsy, submucosal tunneling pyloromyotomy for gastroparesis after vagotomy (G-POEM), submucosal tunneling tumour excision (STER). It is said to be safer, effective and less invasive; procedure is fast developing.

## GASTRO-OESOPHAGEAL REFLUX DISEASE (GORD/GERD)

- ◆ It is a pathological reflux from the stomach into the lower oesophagus.
- ◆ It accounts for 75% of oesophageal pathology (most common).
- ◆ Symptoms may be due to peptic oesophagitis, LOS dysfunction, aspiration due to reflux, due to late effects like stricture and obstruction.
- ◆ It is due to varied *anatomical and physiological factors*.

## Anatomical Factors

- ◆ Obesity.
- ◆ Altered length of intra-abdominal oesophagus. Level of acid exposure is inversely related to length of the intra-abdominal oesophagus. More the length more the need of intra-abdominal pressure to cause the reflux and so less the reflux with more length.
- ◆ Alteration of phreno-oesophageal ligament.
- ◆ Altered obliquity of O-G junction (alteration in angle of 'His').
- ◆ Reduced pinching action (*Pinch-Cock effect*) of right crus of diaphragm.
- ◆ Alteration in normal mucosal rosette at O-G junction.
- ◆ Alteration in *sling mechanism* of gastric musculature.

## Physiological Factors

- ◆ Reduced LOS pressure. Normal resting LOS pressure is 10–25 mmHg. During swallowing, pressure drops to 1–3 mmHg for few seconds (10 seconds). Resting pressure is increased by gastrin, cholinergic, adrenergic, prokinetic drugs; decreased by secretin, cholecystokinin, glucagon, calcium channel blockers, deriphylline, coffee, fatty meal.
- ◆ Altered transient relaxation period in LOS.
- ◆ *Reduced oesophageal clearance* mechanism. Change in oesophageal clearance is due to *altered oesophageal body pump* (primary peristalsis with 30–80 mmHg amplitude propagative downwards waves; secondary by food bolus), *altered salivary bicarbonate* neutralizing mechanism of reflux acid, *altered mucosal defense* mechanism (mucous and surface active phospholipid).
- ◆ *Delayed gastric emptying* due to diabetes, neuromuscular block, gastroparesis, medications.
- ◆ *Increased gastric distension* and gastric acid hypersecretion.

### Note:

GERD is not associated with *H. pylori* infection.

## Other Factors

- ◆ Alcohol, smoking, stress, lifestyle.
- ◆ It is seen in infants and children and also in pregnant women.

## Pathogenesis

GERD begins from *distended fundus* due to variety of causes and other anatomical and physiological factors, repetitively unfolding the sphincter to the gastric juice leading to all problems. There is reduced and low LES resistance causing loss of barrier to reflux. It is probably due to gastric distension, delayed gastric emptying, and raised intragastric or intra-abdominal pressure. Gastric distension may be due to overeating or aerophagia. Fundic distension → stretching of fundus → LOS squamous epithelium exposed to acid gastric juice → oesophagitis → increased stimulus to swallow saliva to neutralise oesophagitis → further fundal distension → cycle repeats → sphincter is taken into stretched fundus → effects like erosion, ulceration, fibrosis, mucosal metaplasia.

### Types

#### Classification I

- ◆ *Symptomatic uncomplicated GORD* (NERD—*Nonerosive Reflux Disease*)
- ◆ *Symptomatic, complicated GORD*

#### Classification II

- ◆ *Primary*: Incompetent LOS
- ◆ *Secondary*: Due to surgery/disease

#### Classification III

- ◆ *GORD with sliding hernia*
- ◆ *GORD without sliding hernia*

#### Classification IV

- ◆ *Acute* – After alcohol intake, stress, burns.
- ◆ *Chronic* – Hiatus hernia, postoesophageal surgery.

## Clinical Features

- ◆ Fatty dyspepsia.
- ◆ Chest pain and heart-burn (**pyrosis**)—80%—main symptom. Pain is more in lying down position and at night. It may mimic cardiac pain/angina. It often begins in the epigastrium and becomes substernal.
- ◆ Odynophagia (painful swallowing).
- ◆ Appearance of symptoms within seconds of ingestion of food is typical.
- ◆ Regurgitation—50%. It is return of oesophageal content.
- ◆ Laryngeal symptoms—*hoarseness of voice*.
- ◆ Dysphagia will occur once complications begin.
- ◆ Symptoms are more with change of position.
- ◆ Chronic cough, shortness of breath and hoarseness—Nocturnal reflux—reflux is return of gastric content.
- ◆ Haematemesis.
- ◆ Post-prandial fullness, choking, wheezing, recurrent pneumonia are other features.

### Triad

- ❖ Heart burn
- ❖ Epigastric pain with dysphagia
- ❖ Regurgitation

## Typical Symptoms

Heart burn, regurgitation, dysphagia mainly; odynophagia, haematemesis often.

## Atypical Symptoms

Cough, hoarseness, wheezing, sore throat, noncardiac chest pain and palatal/dental erosions. It will eventually lead into recurrent pneumonia and pulmonary fibrosis. If pH of the cervical oesophagus is below 4, for less than 1% of time, then respiratory symptoms are due to GERD.

### De Meester's scoring system

Grade	Features
	<b>Heart burn</b>
0	None
1	Minimal—occasional episodes
2	Moderate—medical therapy visits
3	Severe—interferes daily activities
	<b>Regurgitation</b>
0	None
1	Minimal—occasional episodes
2	Moderate—on position and straining
3	Severe—features of aspiration
	<b>Dysphagia</b>
0	None
1	Minimal—occasional episodes
2	Needs fluid to clear
3	Causes food impaction

*Reflux is precipitated by flexion of the trunk—Boot lacing sign.*

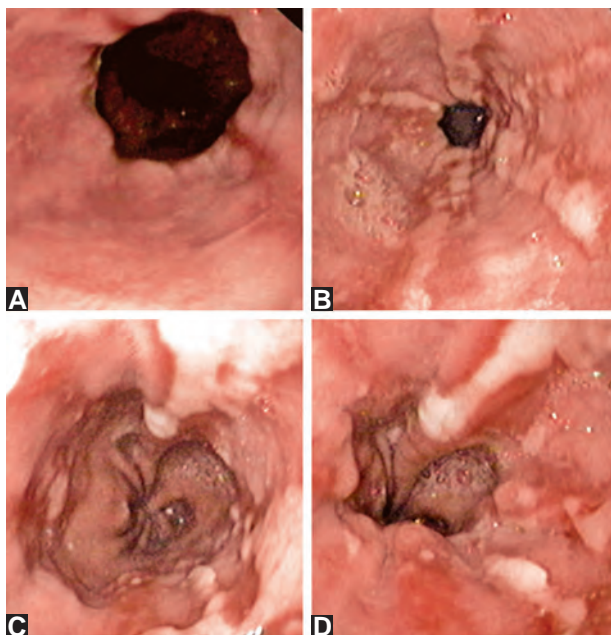
## Complications

- ◆ Reflux oesophagitis.
- ◆ Sliding hiatus hernia.
- ◆ Stricture lower-end oesophagus.
- ◆ Oesophageal shortening.
- ◆ Barrett's oesophagus.
- ◆ Carcinoma (adeno) oesophagus (10% of GERD).

Oesophageal	Extraoesophageal
<ul style="list-style-type: none"> <li>• Oesophagitis</li> <li>• Stricture</li> <li>• Barrett's oesophagus</li> <li>• Oesophageal shortening</li> <li>• Carcinoma (adeno)</li> </ul>	<ul style="list-style-type: none"> <li>• Laryngitis</li> <li>• Recurrent pneumonia</li> <li>• Progressive pulmonary fibrosis</li> </ul>

## Investigations

- ◆ Barium study in head down position.
- ◆ Endoscopy to exclude other disease and to assess any mucosal injury—red inflamed mucosa often with ulceration. Sliding hernia can be identified through endoscopy. When patient retches, gastric mucosa will enter the OG junction and ascends upwards to variable distance.
- ◆ Mucosal biopsy to confirm metaplastic transformation.
- ◆ Oesophageal manometry to assess the function of LES. Length and pressure of LOS is important. Transient relaxation period which is increased is most important.
- ◆ 24 hours oesophageal pH monitoring—*gold standard*. PPI should be stopped for 3 weeks prior to pH monitoring.



**Figs 19.7A to D:** Gastro-oesophageal reflux disease (GORD) endoscopic views.

- ◆ **Bernstein test:** Instillation of 1:10 HCl into stomach of patient with reflux will reproduce the symptoms; and pH in the lower end of the oesophagus decreases. Later pain disappears with saline infusion.
- ◆ Dual probe pH monitoring (one in distal oesophagus and one in proximal oesophagus/trachea) is used to confirm the respiratory complications of GORD.

- ◆ *DeMeester scoring system* is used to assess the severity of the GORD.
- ◆ <sup>99</sup>Tc sulphur colloid mixed with saline scan to study OG reflux and <sup>99</sup>Tc HIDA scan to study and detect duodeno-gastric reflux are used.

### Differential diagnosis

- ❖ Achalasia cardia
- ❖ Carcinoma oesophagus
- ❖ Peptic ulcer
- ❖ Gallstones
- ❖ Pancreatic diseases
- ❖ Gastritis
- ❖ Cardiac angina

## Treatment of Uncomplicated GORD

### A. General measure—Lifestyle changes

- ▶ Control of obesity.
- ▶ Stop smoking and alcohol.
- ▶ Avoid tea, coffee and chocolate.
- ▶ Propped up position.
- ▶ Small frequent meals.

### B. Drugs

- ▶ **H<sub>2</sub> antagonists; antacids.**
- ▶ **Proton pump inhibitors (PPIs)—very effective**
  - Omeprazole 20 mg—BD for 3–6 months.
  - Lansoprazole 30 mg.
  - Pantoprazole 40 mg.
  - Esomeprazole 20 mg.
  - Rabeprazole 20 mg, Ilaprazole 10 mg.
- ▶ **Prokinetic drugs**
  - Metoclopramide, Domperidone 30 mg.
  - Cisapride, Mosapride.
  - Itopride 50 mg—does not cause cardiac arrhythmias.
- **Defoaming** semethicone, alginic acid along with antacids.
- **Anticholinergic drugs**—pirenzipine.
- **Mucosal protector drugs**—sucralfate, colloid bismuth.

### C. Endoluminal therapies for GORD

- ▶ Endoluminal *suturing* (Wilson-Cook)
- ▶ *Plexiglass microspheres* (PMMA). Microsphere suspended in gelatin is injected through endoscopic needle. Gelatin gets absorbed and spheres cause a tissue bulking.
- ▶ *Gatekeeper reflux* repair system. Endoscopic delivery of preformed radiopaque hydrogel into submucosa.
- ▶ *Stretta catheter*. Flexible, soft, 6 mm sized, 65 cm length tube with balloon/basket and 5.5 mm NITI electrode, irrigation and suction
- ▶ *Enteryx* injection technique (estrinyl vinyl alcohol)
- ▶ *Endocinch* technique
- ▶ Endoscopic full thickness *plication*.

### D. Surgery

- ▶ *Indications for surgical treatment*
  - Failure of drug treatment
  - Sliding hernia
  - Barrett's ulcer
  - Severe pain
  - Presence of complications like bleeding/stricture/shortening, respiratory problems

### Surgeries

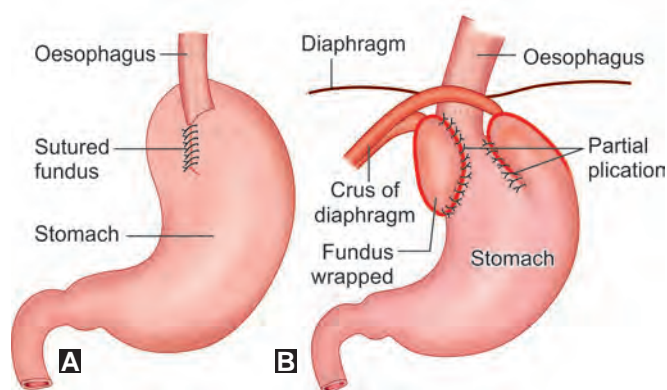
**Antireflux surgery** is the only effective long-term beneficial therapy ideally available and considered now. *Laparoscopic fundoplication* (most popular), Collis-Nissen vertical gastropasty and fundoplication, resection of OG junction when metaplasia is present, Belsey Mark 4 operation (technically difficult) are the procedures used now.

#### Principles of antireflux surgeries

- ❖ Operation should restore the LES pressure twice the resting gastric pressure
- ❖ The adequate length of the intra-abdominal oesophagus should be maintained
- ❖ Apposition of diaphragmatic crurae, reduction of hiatus hernia when present
- ❖ Repaired OG junction should relax during swallowing adequately
- ❖ Tension free fundoplication should be done

### Fundoplication

- ◆ **Nissen's posterior total fundoplication:** Here after narrowing the crus of diaphragm, mobilised *posterior part of the fundus* of the stomach is wrapped totally 360° around the area of OG junction.



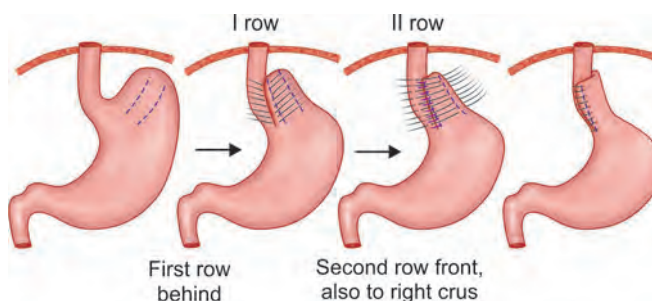
**Figs 19.8A and B:** (A) Nissen's fundoplication; (B) Toupet's partial fundoplication.

- ▶ *Rudolph Nissen* (1959) first did total fundoplication.
- ▶ Opening the peritoneum over the oesophagus to mobilise the lower end of oesophagus.
- ▶ Dissection of the diaphragmatic crura of the oesophagus.
- ▶ Mobilisation of entire fundus by ligating short gastric vessels.
- ▶ Vagi are preserved.
- ▶ In Nissen's, 60 French bougie wrap is ideal; after complete mobilisation, only *posterior part of the fundus* is wrapped around

after crural repair (otherwise fundoplication may displace into thorax causing paraoesophageal hernia); intra-abdominal length of 2 cm oesophagus is created (not more); fundus of the stomach is known to relax in concert with oesophageal sphincter so only fundus should be used to buttress the sphincter; wrapping should be done only around sphincter oesophagus not around body of stomach; fundoplication should be kept in abdomen without under tension and without displacing into thorax. Nonabsorbable polypropylene sutures are used.

- ▶ Crural repair is done using interrupted polypropylene sutures.
- ▶ Fundoplication should prevent sphincter shortening/ unfolding during gastric distension, should preserve normal swallowing ability, allow proper belching and allow vomiting whenever needed.
- ▶ Bougie; on table and postoperative manometry to assess the pressure of new LOS; on table and postoperative gastroscopy—are commonly used in fundoplication.
- ▶ Mortality of procedure is very less; other parts of the abdomen can be assessed and addressed like gallstones.
- ▶ *Complications* are—*gas bloat syndrome* (inability to belch); dysphagia; inability to vomit; slippage, proximal migration; paraoesophageal hernia, splenic injury. Floppy Nissen's fundoplication reduces the incidence of gas bloat syndrome.
- ▶ *Laparoscopic Nissen's fundoplication* is ideal and equally successful.
- ▶ *Transthoracic approach* is used for Nissen's fundoplication in patients who had hiatus hernia repair earlier; who has short oesophagus; in patients who is having sliding hiatal hernia that does not reduce below the diaphragm, associated pulmonary disease, in obese, in patients who are having narrow subcostal angle or barrel-shaped chest.

- ◆ **Toupet's partial 180° posterior fundoplication:** It is similar to Nissen's posterior fundoplication; it controls reflux alike Nissen's but gas bloat is very less. It is commonly done procedure now. Short gastric vessels are divided completely or partially.
- ◆ **Rosetti Hell anterior fundoplication:** Here *anterior part of fundus* of stomach is used. Superomedial part of the fundus is brought around oesophagus to suture into anterior part of fundus. Here *short gastric vessels are not ligated* and much less fundus need to be mobilised.
- ◆ **Dor anterior fundoplication:** Here right margin of the fundus is sutured to left margin of the oesophagus; front part of fundus is sutured to right margin of the oesophagus; 2nd row is also sutured to right crus.



**Fig. 19.9:** *Dor anterior fundoplication.* Right margin of the fundus is sutured to left margin of the oesophagus. Front aspect of the fundus is sutured to right margin of the oesophagus. Second row is also sutured to right crus.

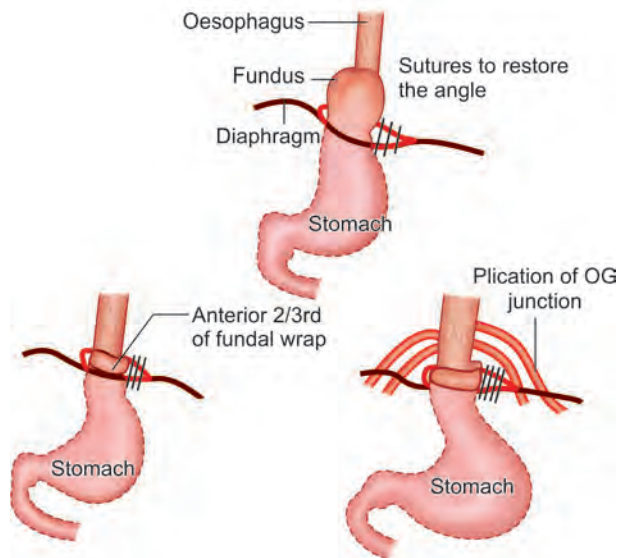
- ◆ *Watson's anterolateral fundoplication*: 5 cm intraabdominal oesophagus is created with blunt transhiatal dissection. 120° anterolateral fundoplication augments the LOS function during stomach distension. Bougie insertion, division of short gastric vessels are not needed here.
- ◆ *Lind both anterior and posterior fundoplication* of 300° with 60° anteriorly uncovered area is not routinely practiced now.
- ◆ *Partial fundoplication with mesh wrap* around is also used. But complications of mesh like erosion, stricture and adhesions are problems.

### Funduplications

- ❖ *Nissen's*—total 360° posterior fundoplication
- ❖ *Toupet's*—partial 180° posterior fundal/posterolateral
- ❖ *Rosetti Hell*—total anterior fundal
- ❖ *Dor*—anterior partial
- ❖ *Watson's*—anterolateral 120° partial
- ❖ *Lind*—posterior and anterior

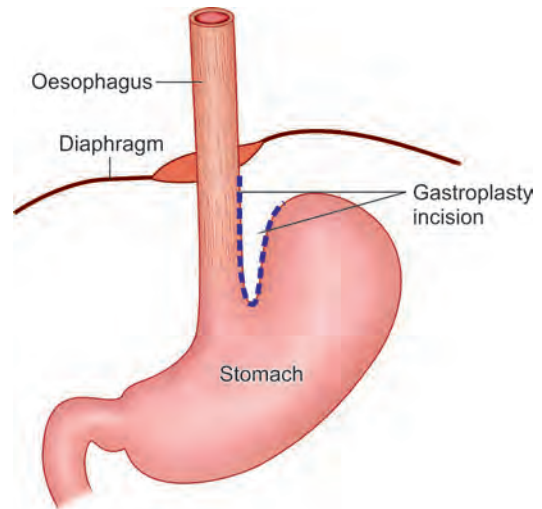
### Note: Other Procedures

- *Belsey Mark IV operation* (1967): It is plication of oesophagus to the diaphragm through many interrupted mattress sutures so as to push the oesophagus downwards to make it intra-abdominal with adequate length. It is done through left transthoracic approach. 240° fundoplication, creation of intra-abdominal oesophagus, crural sling repair are the techniques. It corrects GERD and also maintains normal eructation and physiological reflux. But long hospital stay and respiratory complications are distressing problems.



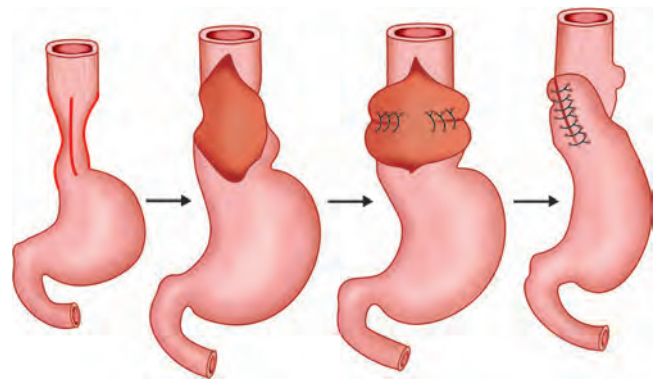
**Fig. 19.10:** *Belsey mark 4 operation* for sliding hiatus hernia. It is done through thoracic approach. Here angle of oesophagus is restored with sutures and partial anterior fundal wrap is done. Then oesophagus is pushed down by oesophago-diaphragmatic plication sutures.

- *Hill's operation*: Intra-abdominal fixation of OG junction (cardia) into median arcuate ligament to augment the effect of LOS, to enable the effective oesophageal peristalsis. Procedure is done by transabdominal approach which is assessed by intraoperative manometry. But it is technically difficult, may damage celiac plexus.
- *Placement of Angelchik prosthesis*: Annular silicone gel filled angelchik prosthesis with a tape on either end. After insertion around OG junction ends are tied around.
- *Collis' vertical gastroplasty* is done using fundus of stomach. A vertical cut along the line of oesophagus is made on the fundus which is sutured to create extra length of oesophagus and new lesser curvature. It is done whenever oesophagus cannot be mobilised due to oesophageal shortening by a stricture developed as a complication of GORD. Partial fundoplication is added to this usually.



**Fig. 19.11:** Vertical gastroplasty is done to lengthen the intra-abdominal oesophagus.

- *Thal's patch procedure*: It is done for localised nondilatable stricture oesophagus. Stricture is incised full thickness longitudinally. Mobilised fundus of stomach is placed and sutured as a serosal patch technique over the defect.



**Fig. 19.12:** *Thal's patch* done for oesophageal stricture due to reflux oesophagitis.

- *Narbona's ligamentum teres cardiopexy* (commonly done in Spain): Ligamentum teres is mobilised from falciform ligament with its blood supply from left lobe of liver; it is detached from umbilicus and brought around the mobilised lower oesophagus with traction until LOS pressure becomes 15–20 mmHg with manometry; flap end is sutured left of OG junction and anterior wall of stomach. It is more physiological and division of short gastric vessels is not required.
- *Boerema operation*: It is fixing OG junction in front into anterior abdominal wall. It is not practiced now.
- *Oesophagogastrectomy* is required whenever there is *failure of antireflux procedure/metaplasia* is present / *nondilatable stricture* is present. Lower end of oesophagus and proximal stomach is resected with oesophagogastric anastomosis is done through thoracoabdominal approach.
- *Transhiatal oesophagectomy* with anastomosis between cervical oesophagus and stomach in the neck is an alternate procedure which can be used in severe extensive disease and stricture.
- *Allison's procedure*: It is transthoracic repair of GE junction to replace the GE junction in its normal intra-abdominal location is one of the earliest procedures done with symptomatic relief but 80% recurrence rate; hence it is *not done*.
- Stricture oesophagus due to GERD which is dilatable can be treated by *regular oesophageal dilatation* and long-term PPI therapy.

### Complications of Surgery

- ◆ Oesophageal/gastric perforation.
- ◆ Haemorrhage.
- ◆ Pneumothorax/pyothorax.
- ◆ Vagus nerve injury.
- ◆ Cardiac arrhythmias.
- ◆ Sepsis – mediastinitis or septicaemia.
- ◆ Disruption/failure of fundoplication.
- ◆ Gas bloat syndrome.

### HIATUS HERNIA

It is the most common type of diaphragmatic hernia.

#### Types of hiatus hernia—classification

- ❖ *Type I* hiatus hernia: It is the cephalad displacement of the gastro-oesophageal junction through the hiatus into the mediastinum. It is usually small, asymptomatic and reducible. It is commonest type
- ❖ *Type II* hiatus hernia: It is superior migration of the fundus of the stomach along side the GE junction and oesophagus into the mediastinum with GE junction in normal intra-abdominal location. It is rolling hernia
- ❖ *Type III* hiatus hernia: It is combination of type I and type II
- ❖ *Type IV* hiatus hernia: It is the hernia containing other abdominal viscera as content like transverse colon and omentum

### Types

- ◆ Sliding hernia (85%).
- ◆ Rolling hernia (10–12%).
- ◆ Combined.

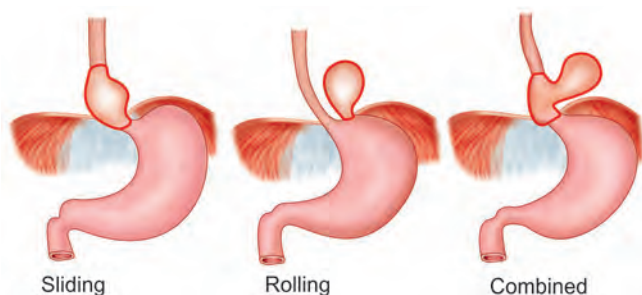
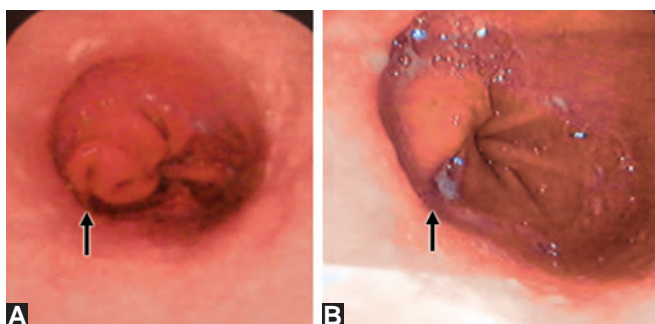


Fig. 19.13: Different types of hiatus hernia.



Figs 19.14A and B: Endoscopic view of oesophageal hiatus hernia.

*Sliding hernia* is commonly associated with GORD (should be discussed like GORD).

Here the cardia migrates back and forth between the posterior mediastinum and peritoneal cavity.

#### Saint's triad

- ❖ Hiatus hernia
- ❖ Diverticulosis
- ❖ Gallstones

#### Grading of hiatus hernia

Grade	Type
I-H0	Normal
II-H1	Sliding
III-H2	Rolling
IV-H3	Mixed
V-H4	Massive herniation

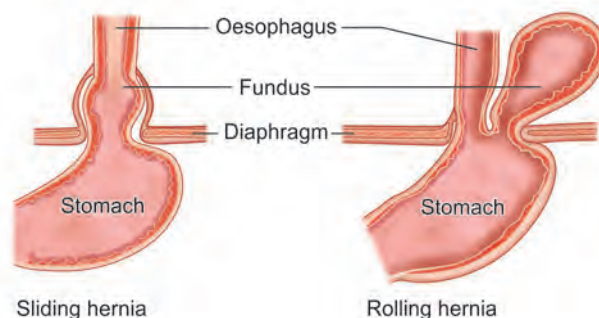


Fig. 19.15: Types of hiatus hernia.

### ROLLING HERNIA (PARAOESOPHAGEAL HERNIA)

It is herniation of stomach fundus or rarely other abdominal contents colon/spleen through a hiatus, usually towards left side.

### Clinical Features

- ◆ Common in elderly.
- ◆ Abdominal pain and chest pain.
- ◆ Hiccough, early satiety.
- ◆ Regurgitation, postprandial bloating.
- ◆ Cardiac abnormality (arrhythmia).
- ◆ Dysphagia dyspnoea.
- ◆ 40% presents as acute features with perforation/gangrene/bleeding.

#### Complications

- ❖ Gangrene of stomach.
- ❖ Perforation into the mediastinum.
- ❖ Perforation into the peritoneum.
- ❖ Gastric volvulus.
- ❖ Ischaemic longitudinal ulcer in the herniated stomach in rolling hernia is called as *Cameron ulcer*.

## Investigations

- ◆ Plain X-ray—lateral and PA erect view showing retrocardiac air-fluid level.
- ◆ Barium meal study very useful.
- ◆ ECG.
- ◆ 3D CT scan is useful.

## Treatment

- ◆ Treatment is always *surgical*.
  - ▶ Excision of sac and repair of the defect.
  - ▶ If it is gangrenous, gastrectomy is required.
  - ▶ Either abdominal or thoracic or laparoscopic approach can be used in treating rolling hernia surgically.
  - ▶ Mesh reinforcement to hiatus to close the defect may be needed.

## REFLUX OESOPHAGITIS

### Types

1. **Acute:** Following *burns, trauma, infection, peptic ulcer*.
2. **Chronic:** Reflux of acid in sliding hernia, after gastric surgery.  
Reflux is quite common in pregnancy.  
Site is always in lower oesophagus.

### Pathology

There is bleeding granulation tissue in lower oesophageal mucosa with spasm of longitudinal muscle which pulls the adjacent gastric area upwards into the oesophagus causing sliding hernia.

#### Grading

1. Mucosal erythema
2. Mucosal erythema + superficial ulceration
3. Mucosal erythema + superficial ulceration + submucosal fibrosis
4. Mucosal erythema + extensive ulceration + paramural fibrosis

#### Savary-Miller classification of reflux oesophagitis—grading

1. Single or isolated erosive lesion(s), oval or linear but affecting only one longitudinal folds
2. Multiple erosive lesions, noncircumferential affecting more than one longitudinal fold with or without confluence
3. Circumferential erosive lesions
4. Chronic lesion: Ulcers, strictures and or short oesophagus alone or in association with grade 1–3 lesions
5. Columnar epithelium in continuity with the Z-line, non-circular, star shaped or circumferential, alone or in association with grade 1–4 lesions

#### Los Angeles classification of reflux oesophagitis—grading

- A. One or more mucosal break *no longer than 5 mm* that does not extend between the tops of two mucosal folds
- B. One or more mucosal break *more than 5 mm* long that does not extend between the tops of two mucosal folds
- C. One or more mucosal break that continues between the tops of two or more mucosal folds but which involves *less than 75%* of the circumference
- D. One or more mucosal break, which involves *at least 75%* of the oesophageal circumference

## Clinical Features

- ◆ It is a part of GORD.
- ◆ Pain and burning sensation in retrosternal area often referred to shoulder, neck, arm.
- ◆ Heart burn is common.
- ◆ Dysphagia.
- ◆ Anaemia.

## Diagnosis

- ◆ Barium meal X-ray.
- ◆ Gastroscopy and biopsy.  
**Barrett's ulcer** is an ulcer with gastric (columnar) metaplasia in lower oesophagus.

## Treatment

- ◆ *Antacids*
- ◆ *H<sub>2</sub> blockers:* Ranitidine, famotidine.
- ◆ **Proton pump inhibitors**—*Main method and more effective.*
  - ▶ Omeprazole 20 mg BD one hour before food (Morning) for 6 months
  - ▶ Lansoprazole 30 mg
  - ▶ Pantoprazole 40 mg
  - ▶ Esomeprazole 20 mg
  - ▶ Rabeprazole 20 mg (can be given with food).
- ◆ **Prokinetic drugs** like metochlopramide, domperidone, cisapride, mosapride.
- ◆ *Treating GORD and associated causes.* By fundoplication and other surgeries.
- ◆ *Resection in severe cases.*

### Note:

Erythromycin is a prokinetic drug (motilin agonist), which acts by binding with motilin receptor on GI smooth muscle cells.

## BARRETT'S OESOPHAGUS (Norman Barrett, British, 1950)

- ◆ It is the metaplastic changes in the mucosa of the oesophagus as the result of GORD.
- ◆ Squamous epithelium of lower end of the oesophagus is replaced by diseased columnar epithelium (columnar metaplasia).
- ◆ There is macroscopic visible length of columnar mucosa with microscopic features of intestinal metaplasia.
- ◆ It affects lower oesophagus commonly often middle oesophagus also.
- ◆ *There is proximally displaced squamocolumnar junction on endoscopy with acid—mucin containing goblet cells that is specialized intestinal metaplasia.* There is presence of *columnar epithelium lined oesophagus* (CELO) with intestinal metaplasia on histology.

### Types (Based on Length)

- a. If the length of metaplasia is more than 3 cm, it is called as *long segment Barrett's oesophagus*—classic Barrett type.
- b. If the length is less than 3 cm, it is called as *short segment Barrett's oesophagus*.

## Histological Types

- Gastric type*: Contains chief and parietal cells.
- Intestinal type*: Contains goblet cells.
- Junctional type*: Contains mucous glands alike of gastric cardia.

*Cardia metaplasia* is metaplasia at OG junction without any macroscopic change in gastroscopy.

This diseased columnar epithelium is more prone for malignant transformation, i.e. when there is intestinal metaplasia, risk of malignant transformation increases (**40 times more than general population**). More the amount of dysplasia, more is the risk of malignant transformation. *Dysplasia may be indefinite; low grade or high grade.*

## Clinical Features

- ◆ Features of GORD.
- ◆ Haematemesis.
- ◆ Common in *men*; common in whites.

### Complications of Barrett's oesophagus

- ❖ Ulcerations and stricture
- ❖ Dysphagia
- ❖ Bleeding
- ❖ Perforation
- ❖ Adenocarcinoma of O-G junction (25 times more common)

## Management

- ◆ Regular endoscopic biopsy and surveillance for low-grade dysplasia.
- ◆ Ablation of Barrett's oesophagus by laser.
- ◆ Photodynamic therapy—through endoscopy.
- ◆ Argon beam coagulation.
- ◆ Proton pump inhibitors—high dose for 3–6 months.
- ◆ Antireflux treatment by surgery.
- ◆ Resection—*Always better choice*—for high-grade dysplasia. *Transhiatal oesophagectomy* is preferred.
- ◆ Endoscopic mucosal resection.

### BARRETT'S ULCER

It is an ulcer in columnar epithelium lined Barrett's oesophagus at or just above the squamocolumnar junction.

It is more prone for:

- ◆ *Bleeding.*
  - ◆ *Perforation.*
  - ◆ *Adenocarcinoma of oesophagus—very high > 40 times.*
- Treatment for Barrett's ulcer is endoscopic biopsy and resection.

### OESOPHAGEAL MOTILITY DISORDERS

#### Primary

- ◆ *Achalasia*, vigorous achalasia.
- ◆ *Diffuse and segmental oesophageal spasm*: It is 5 times less common than achalasia, mainly primary spasm of the oesophageal body, predominantly presenting only as chest pain and less severe

dysphagia. There is hypertrophy of oesophageal wall muscle with degeneration of vagal fibers; Simultaneous multiphasic waveforms of high amplitude and long duration with 20 or more simultaneous waveforms out of 10 wet swallows is diagnostic. Often it can be segmental or involve distal 2/3rd of oesophagus. LES resting pressure is normal with normal deglutition relaxation time. Barium swallow shows *corkscrew* pattern. Treated with nitrates, calcium channel blockers, bougie dilatation, long oesophageal myotomy either video assisted or thoracotomy approach.

- ◆ *Nutcracker oesophagus (supersqueeze oesophagus)*: Common hypermotility disorder with high amplitude peristalsis, equal in both sexes. Severe chest pain (noncardiac), dysphagia without regurgitation, odynophagia are the features. Waves of hypertensive amplitude pressure >180 mmHg often can become very high >400 mmHg; long duration contraction waves >6 seconds with normal LES pressure and LES relaxation. It is treated with nifedipine, nitrates, antispasmodics, occasionally long myotomy.
- ◆ *Hypertensive LES*: LES pressure is above normal (>26 mm Hg). LES relaxation, amplitude pressure, contraction waves, oesophageal body peristalsis are normal. Botulinum, balloon dilatation, modified Heller's myotomy are the treatment.
- ◆ *Ineffective oesophageal motility disorders*: It is irreversible contraction abnormality of distal oesophagus in association with GORD. It is often due to secondary inflammation of oesophageal body following more exposure to gastric contents and poor oesophageal acid clearance. Reflux, dysphagia, heartburn, chest pain, are the features. Manometry shows—sum of total number of low amplitude contractions of less than 30 mmHg and nontransmitted contractions exceeds 30% of wet swallows.
- ◆ *Nonspecific oesophageal motility disorders*: It shows slow transit incomplete emptying, with normal or hypertensive LES pressure, LES shows incomplete relaxation, decreased amplitude pressure <35 mmHg, >20% nontransmitted, prolonged waves of >6 secs with abnormal peristalsis. Dysphagia, chest pain reflux and regurgitations are the features.

#### Secondary

- ◆ *Neurological*—stroke, bulbar palsy, motor neuron disease, multiple sclerosis, Parkinson's disease, poliomyelitis.
- ◆ *Muscular*—myasthenia gravis, muscular dystrophy, dermatomyositis.
- ◆ *Autoimmune* disorders—systemic sclerosis, polymyositis, SLE, CREST syndrome, scleroderma.
- ◆ Eosinophilic allergic oesophagitis, alcoholic neuropathy.
- ◆ Endocrine and metastatic diseases.

### ACHALASIA CARDIA (Cardiospasm)

*The symptom—complex in cardiospasm (the term by which oesophageal achalasia was formerly known) is as a rule almost pathognomonic. It may be divided into the three stages—first, cardiospasm without food regurgitation; second, cardiospasm with immediate food regurgitation; third, cardiospasm with dilated oesophagus, the retention of food in the dilated portion and its regurgitation at irregular intervals after taking.*

— Henry Stanley Plummer, 1908

It is failure of relaxation of cardia (oesophago-gastric junction) due to disorganised oesophageal peristalsis, as a result of failure

*Never forget that only dead fish swims with the stream.*



of integration of parasympathetic impulses causing *functional obstruction* (*Achalasia* means failure to relax—Greek). It is first identified by Thomas Willis in 1672.

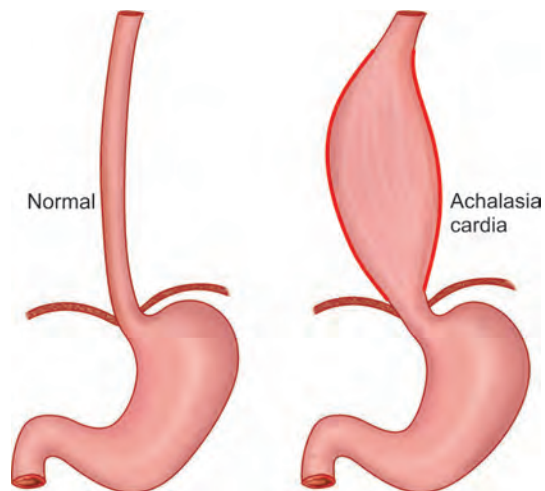


Fig. 19.16: Diagrammatic representation of achalasia cardia.

## Aetiology

- ◆ There is absence or less numbered ganglions in myenteric plexus.
  - ▶ Stress.
  - ▶ Vit B<sub>1</sub> deficiency.
  - ▶ Chaga's disease. It is caused by *Trypanosoma cruzi*, which is common in South America called as sleeping sickness.
  - ▶ Diffuse oesophageal spasm (*Corkscrew oesophagus*).
  - ▶ Most commonly it is *idiopathic*. There is *degeneration of Auerbach's myenteric plexus* along the entire length of oesophagus more so in LOS.
- ◆ There is pencil-shaped narrowing of cardia (O-G junction) with enormous dilatation of proximal oesophagus, which contains foul smelling fluid and is more prone for aspiration pneumonia.
- ◆ Achalasia cardia is a *precancerous* condition—seven times chances of getting *squamous cell carcinoma* (8%, after 15 years).

## Pathology

- ◆ Thickening of circular muscle fibres in distal oesophagus.
- ◆ Myenteric inflammation; depletion of ganglion cells; neural fibrosis, reduced nitric oxide and VIP (mediators of LES relaxation).
- ◆ Absence of peristalsis; raised LES pressure; failure of relaxation with functional obstruction of OG junction.
- ◆ Dilatation of proximal oesophagus with atony.

## Clinical Features

- ◆ Common in females between 20 and 40 years age group.
- ◆ Incidence is 6 per 1, 00,000 population.
- ◆ Chest pain occurs in early stage.

- ◆ Achalasia with diffuse oesophageal spasm is called as '*vigorous achalasia*'.
- ◆ Presents with progressive dysphagia, which is more for liquid than to solid food.
- ◆ Regurgitation and recurrent pneumonia are common (60%).
- ◆ Walking while eating, chin thrusting, neck and shoulder extension, Valsalva manoeuvre facilitates emptying of food from the oesophagus.
- ◆ Heartburn (50%) is common. Chest pain during meal is common.
- ◆ Malnutrition and general ill health.
- ◆ Lung abscess formation.
- ◆ Odynophagia and weight loss.

### Triad

- ❖ Dysphagia
- ❖ Regurgitation
- ❖ Weight loss

### Staging/Grading

- I: Proximal dilatation <4 cm
- II: Dilatation between 4–6 cm
- III: Dilatation >6 cm
- IV: Sigmoid dilatation

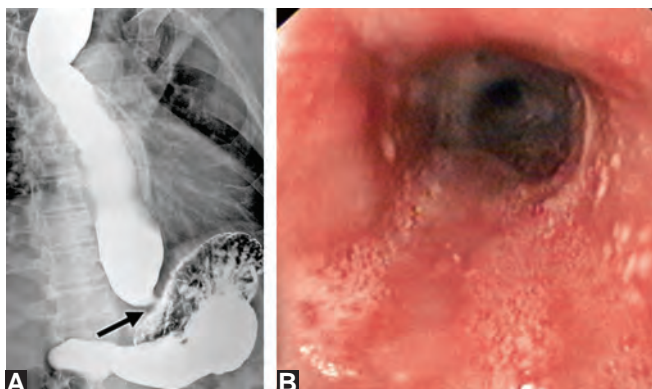
### Note:

Clinical scoring of achalasia cardia are:

- 0 No weight loss or dysphagia or retrosternal pain or regurgitation.
- 1. Weight loss < 5 kg; occasional dysphagia, retrosternal pain, regurgitation.
- 2. Weight loss 5–10 kg; daily dysphagia, retrosternal pain, regurgitation.
- 3. Weight loss >10 kg; dysphagia and regurgitation during each meal; retrosternal pain several times a day.

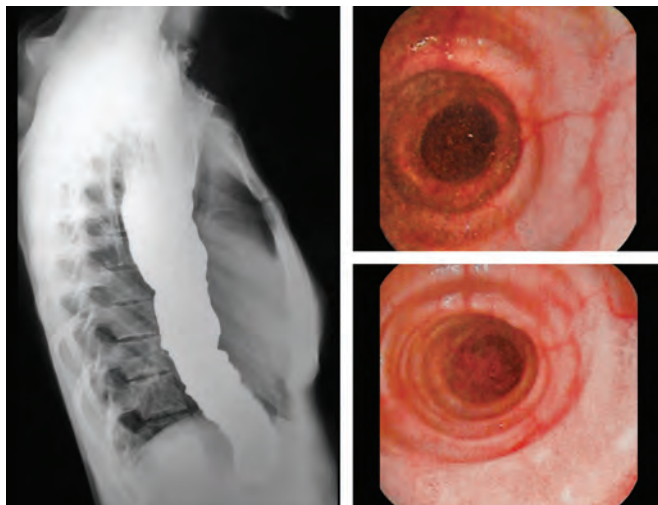
## Investigations

- ◆ *Barium swallow is diagnostic*—shows.



Figs 19.17A and B: (A) Barium swallow X-ray showing features of achalasia cardia; (B) Endoscopic view of achalasia.

- ❖ Pencil-like smooth narrowing of lower oesophagus—*Bird beak appearance*
- ❖ Dilatation of proximal oesophagus—*cucumber oesophagus*
- ❖ Absence of fundic gas bubble
- ❖ Sigmoid oesophagus or megaesophagus



**Fig. 19.18:** Sigmoid oesophagus in achalasia cardia—Barium X-ray and endoscopic view.

- ◆ *Chest X-ray* shows patches of pneumonia. *Double mediastinal strip* of dilated oesophagus is typical with air fluid level in posterior mediastinum on lateral view.
- ◆ *Oesophageal manometry* shows unrelaxed lower oesophageal sphincter with high resting pressure—very useful and gold standard. It shows failure of LES to relax completely during swallowing and complete absence of peristalsis. LES pressure is >35 mmHg. Baseline oesophageal pressure will be high without progressive oesophageal peristalsis with low amplitude muscular tone. Intraoesophageal pressure in relation to intragastric pressure is elevated.
- ◆ *Oesophagoscopy* is done to confirm the diagnosis and to rule out carcinoma oesophagus. It shows totally closed LES (*rosette like*) with atonic, dilated proximal oesophagus. Biopsy of mucosa at LES should be done.

## Differential Diagnosis

- ◆ Carcinoma oesophagus.
- ◆ Stricture oesophagus.
- ◆ Scleroderma.

## Treatment

### Treatment for achalasia cardia

#### Surgery:

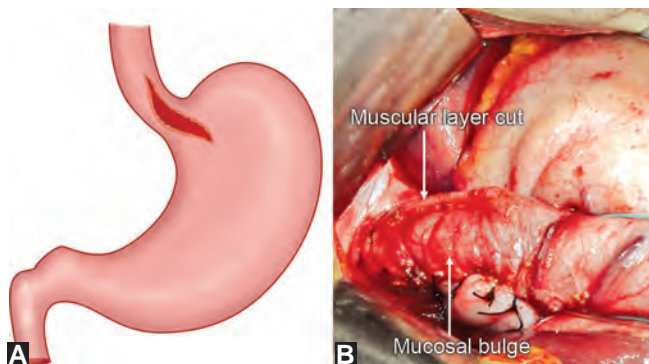
- ❖ Modified Heller's cardiomyotomy with Toupet's / Dor's fundoplication
  - Open abdominal/thoracic (rare) approach
  - Laparoscopic approach—ideal
  - Robotic-assisted laparoscopic approach

Contd...

- ❖ Resection of OG junction/transhiatal total oesophagectomy in severe cases—megaesophagus/metaplasia
- POEM (Per Oral Endoscopic Myotomy)*
- Forcible dilatation:*
- ❖ Plummer's pneumotic dilatation
  - ❖ Negus hydrostatic balloon dilatation
- Drugs:*
- ❖ Botulinum toxin
  - ❖ Nitroglycerin, nifedipine

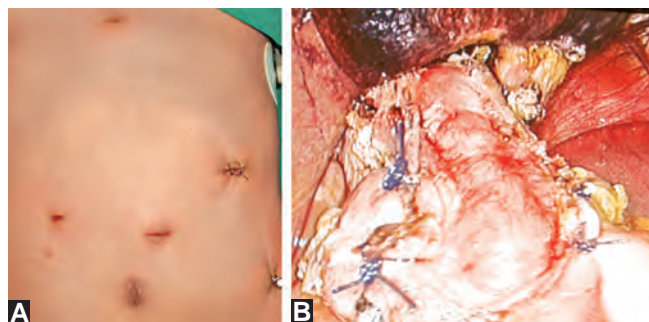
## Surgery

- ◆ *Modified Heller's operation* (Heller—German, 1913): Oesophagocardiomyotomy. Success rate is 85%.



**Figs 19.19A and B:** (A) Heller's cardiomyotomy for achalasia cardia. Only circular muscle layer is cut longitudinally in OG junction until mucosa protrudes out without perforating the mucosa; (B) Heller's cardiomyotomy—on table look with partial fundoplication (*Courtesy:* Dr Yogishkumar, Professor of Surgery, KMC, Mangaluru).

- ▶ Either through thoracic or through abdominal approach, thickened circular muscle fibres are cut longitudinally for about 8–10 cm, 2 cm proximal to the thickened muscle to 1 cm distal to OG junction. Care should be taken not to open the mucosa (anterior myotomy is done now. Original Heller's is both anterior and posterior myotomies).
- ▶ *Nissen's or Toupet's fundoplication* is done along with the above procedure to prevent reflux.
- ▶ Resection is done when failure of myotomy occurs or when megaesophagus or metaplasia is present. *Transhiatal total oesophagectomy* with gastric pull up and oesophagogastric anastomosis in the neck is a good option in such patients.



**Figs 19.20A and B:** Laparoscopic port positions and view of Heller's cardiomyotomy for achalasia cardia (*Courtesy:* Dr Roshan, MS DNB, Laparoscopic Surgeon, City Hospital, Mangaluru).

Contd...

- ▶ *Laparoscopic/thoracoscopic* cardiomyotomy—ideal.
- ▶ *Robotic-assisted laparoscopic cardiomyotomy* improves the dexterity and three-dimensional vision.

### POEM (Per Oral Endoscopic Myotomy)

Here using endoscope, methylene blue diluted saline is injected into the submucosa of the oesophagus 15 cm proximal to OG junction; mucosal incision of 2 cm is made proximally to enter submucosal space; adequate tunnel in the space is created; small bleeders are controlled by specialized cautery device; LES myotomy is done using special electric endoknife. Mucosa is closed using clips. It is a novel seemingly effective technique.

### Forcible Dilatation

- ◆ It stretches spasmodic segment. Gradual repeated dilations are required. Dilatation up to 54 French bougie can be done. Two types of dilations are used—*pneumatic* and *hydrostatic*.
  - ▶ *Plummer's pneumatic dilatation* is done using balloons of 30–40 mm diameters. It is inserted over a guidewire. Risk of perforation (5%), need for repeated dilations are the problems.
  - ▶ *Negus hydrostatic dilatation* is done to dilate O-G junction. It is not very well-accepted method as chances of perforation is high. Success rate is 65%. 30 mm diameter balloon is inflated for 3 minutes.

### Drugs

- Endoscopic injection of botulinum toxin to sphincter—high recurrence rate.
- Calcium channel blocker, nitroglycerin sublingually.

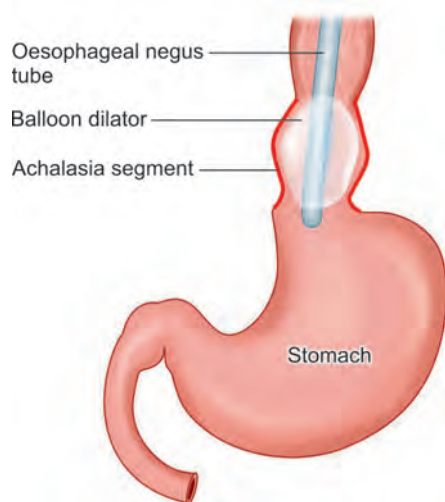


Fig. 19.21: Negus hydrostatic dilator used for achalasia cardia. It has got only 65% success rate.

### Note:

- *Pseudoachalasia* shows features like of achalasia cardia with dysphagia and weight loss, seen in an elderly due to carcinoma. Amylnitrate inhalation causes sphincter relaxation in Achalasia cardia but not in pseudoachalasia.

- *Botulinum toxin* is neurotoxic protein derived from *Clostridium botulinum* is highly toxic poisonous substance. Very small dose is used for therapeutic purpose. Seven types of toxins are found. A (A1 /A2 /A3) type is used for therapy. It blocks the cholinergic nerve ends reducing the cholinergic acetylcholine release causing flaccid paralysis of muscles. It is used in cosmetic facial line, strabismus, focal dystonia, tremor, tics, muscle spasms, achalasia, smooth muscle hyperactivity, Frey syndrome, and hyperhidrosis.

## ■ PLUMMER-VINSON SYNDROME (Paterson-Kelly Syndrome)

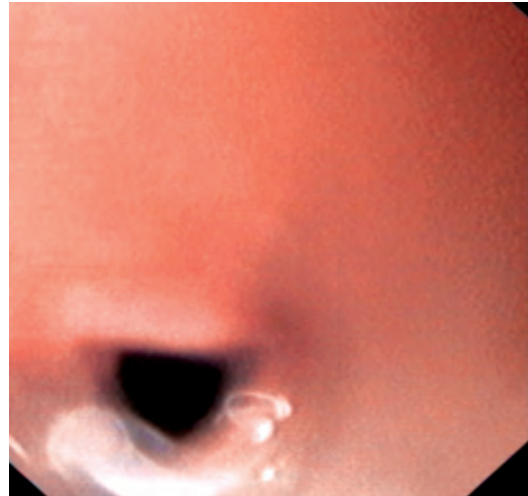


Fig. 19.22: Oesophageal web, endoscopic view.

- ◆ Here *oesophageal webs* are seen in uppermost portion of the oesophagus with spasm of circular muscle fibres.
- ◆ Common in patients with long-standing *iron deficiency anaemia*.
- ◆ Common in females.
- ◆ *Superficial glossitis, cheilitis, koilonychia* commonly seen.
- ◆ Splenomegaly may be present.
- ◆ In oesophageal webs, mucosa is hyperkeratotic, friable, desquamated.
- ◆ It is a *pre-malignant condition* and presents with severe dysphagia.
- ◆ Oesophagoscopy and biopsy is required to rule out malignancy.

### Treatment

- ◆ Oral iron—ferrous sulphate 300 mg TDS with vitamins.
- ◆ Blood transfusion is given when there is severe anaemia (Transfusion of packed cells).
- ◆ IV or IM iron therapy.
- ◆ Once anaemia comes under control, webs will clear and patient can swallow.
- ◆ *Follow-up endoscopy is a must.*
- ◆ Dilatation of web may be required.

## ■ CORROSIVE STRICTURE OF OESOPHAGUS

### Features of oesophageal corrosive lesion

- ❖ *Acute/immediate*
  - Severe pain, shock, laryngeal oedema
  - Mediastinitis, septicaemia, haemorrhage, perforation
- ❖ *Late/chronic*
  - Dysphagia
  - Stricture—50%

Contd...

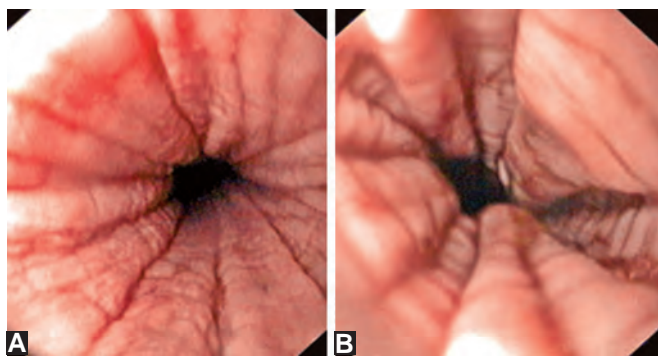
Contd...

- Severe malnutrition
- Recurrent respiratory infection
- Oesophageal shortening
- Malignant changes
- Tracheo-oesophageal fistula formation

*Corrosive strictures can be multiple. Damage is more in lower 1/3rd of oesophagus*

- ◆ Corrosives are commonest cause of oesophageal stricture.
- ◆ Mainly due to ingestion of alkali (*Lye stricture*—Lye is strong alkali sodium hydroxide) sodium hydroxide, occasionally due to acid (sulphuric acid, nitric acid). Acid commonly damages the stomach.
- ◆ It causes extensive inflammation of the mucosa with perioesophagitis which, if not treated, leads to multiple strictures in oesophagus.
- ◆ Sometimes it causes severe life-threatening necrotising lesion which requires immediate surgical intervention.
- ◆ Acute phase lasts for 3 weeks.
- ◆ Damage is more in lower 1/3rd of oesophagus.
- ◆ Alkali is odourless and tasteless and so large volume is ingested. Alkali causes liquefaction, saponification and thrombosis of vessels and later leading to fibrosis and stricture. Acid causes intense pylorospasm, antral pooling of acid, coagulation necrosis and eschar formation.
- ◆ Severity depends on type of agent, its concentration and volume.

Phases of tissue injury in corrosive ingestion	Degrees of burns after corrosive oesophageal and gastric burns
Phase 1: Acute necrosis—1–4 days	1st degree: Mucosal hyperaemia and oedema
Phase 2: Ulceration—granulation—4–12 days	2nd degree: Small bleeding, exudates, ulcers, pseudomembrane
Phase 3: Cicatrisation and scarring—3 weeks to 6 months	3rd degree: Mucosal slough, deep ulcers, massive bleed, complete obstruction, charring, perforation



**Figs 19.23A and B:** Endoscopic view of corrosive injury. Endoscopy should be done very gently in corrosive injury.

## Treatment

- ◆ *Acute phase management:*
  - ▶ *Neutralisation* with vinegar or citrus food if it is alkali ingestion (If pH of the solution is less than 11.5, then damage is less); it is with antacids, milk, egg whites if it is acid ingestion. Early endoscopy is needed to assess the severity and extent.
  - ▶ Emetics and  $\text{NaHCO}_3$  are *avoided* as they may precipitate perforation.
  - ▶ *In 1st degree burns:* 48 hours observation; oral feeds are started once patient swallows saliva painlessly. Regular follow-up endoscopy at 1st, 2nd and 8th months. Stricture, if formed, can be identified by this time.
  - ▶ *2nd and 3rd degree burns:* They are treated with fluid therapy, antibiotics, nutrition, resuscitation, PPIs, aerosolised steroids, fiberoptic-guided airway intubation if needed/tracheostomy; endoscopic oesophageal stenting, feeding jejunostomy, laparoscopy for evaluation. Unstable patients have high mortality. Laparotomy is done in such patients. If oesophagus and stomach shows full thickness necrosis, resection of these parts is done and end cervical oesophagostomy with jejunostomy is done. When in doubt, re-exploration for second look is done after 36–48 hours to assess the stomach.
- ◆ Careful early gentle repeated endoscopy is mandatory.
- ◆ Though advocated often for 2–3 weeks, use of steroids is controversial and under debate.
- ◆ Antibiotics if there are chances of aspiration or perforation.
- ◆ *Regular oesophageal dilatation* is done for stricture. Stricture is dilated endoscopically using guidewire. Dilators are solid type with gradual increase in diameters. Often radiologic C-arm guidance is needed to pass the guidewire into the stomach. Dilatation should be done up to minimum *16 mm diameter*. Pneumatic or balloon dilatation is also practiced. Gum elastic dilators, mercury weighted dilators, Eder-Puestow dilators, Savary-Gilliard dilators, balloon dilators are other dilators used. Earlier, blind dilatation using oesophageal bougies of increased diameters was the practice, which is followed even now in many places, but chances of perforation is more.
- ◆ Oesophageal resection in corrosive strictures is technically difficult and may be hazardous. Oesophageal bypass is better and easier, and following later by regular endoscopic surveillance for malignant transformation (5%). Colon is used as replacing conduit as stomach itself may be diseased in corrosive pathology.
- ◆ In multiple strictures oesophageal resection and colonic transposition may be advocated if risk of malignancy is considered.

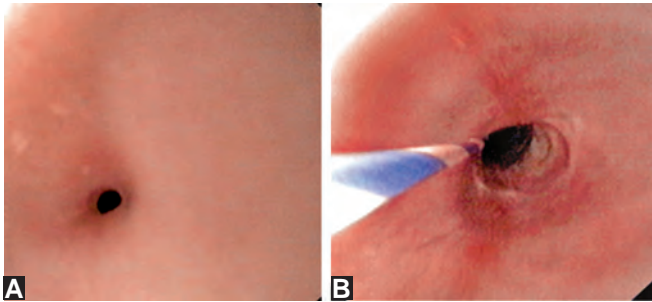
### Note:

*Malignancy can develop in corrosive strictures—5%. It is 1000-fold greater than general population.*

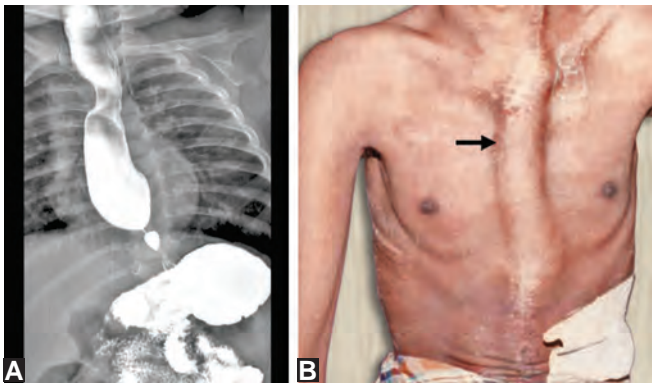
### Causes of stricture oesophagus

- ❖ Peptic stricture (oesophagitis induced)
- ❖ Corrosives—most common cause
- ❖ Foreign body
- ❖ Postsurgical, radiotherapy
- ❖ Congenital
- ❖ Infection like tuberculosis
- ❖ Drugs like tetracycline, vitamin C

*Happiness comes more from loving than being loved. Happiness is not a destination; it is a method of life and is a way of travel.*



**Figs 19.24A and B:** (A) Endoscopic view of oesophageal stricture; (B) Oesophageal dilatation is being done endoscopically.

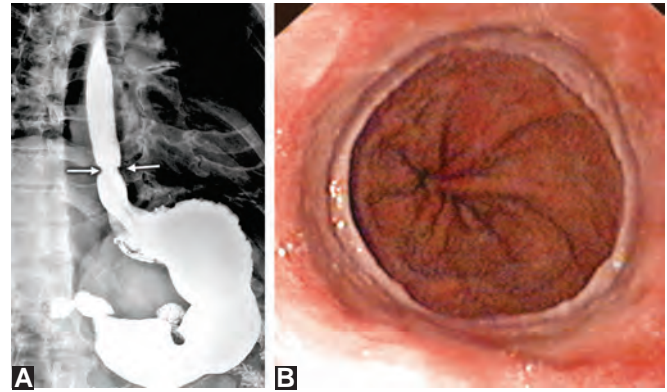


**Figs 19.25A and B:** (A) Barium swallow showing stricture at lower oesophagus. It may be due to oesophagitis, congenital, tuberculosis, malignancy, drug induced, etc; (B) Patient underwent total oesophagectomy with colonic transposition. Colon placed in subcutaneous plane.

## ■ SCHATZKI'S RINGS

They are semicircular protrusion of lower oesophageal mucosa located at or just above the oesophagogastric junction (squamo-columnar junction). Its undersurface is lined by columnar gastric epithelium.

- ◆ They involve only the mucosa and submucosa of the oesophagus, not the muscle.
- ◆ They present with dysphagia and reflux.
- ◆ *Episodic aphagia* can occur causing food bolus or meat bone to get impacted which requires emergency rigid oesophagoscopy to remove the food. 5 ml of 2.5% oral papain every 30 minutes to digest food protein along with 50 mg meperidine IV to dislodge the impacted food bolus can be tried initially.



**Figs 19.26A and B:** (A) Barium swallow X-ray showing Schatzki ring, also shows features of hiatus hernia; (B) Schatzki's ring—endoscopic view.

## Treatment

- ◆ Intermittent oesophageal bougienage.
- ◆ Antireflux drugs.

### Note:

Ring *should not* be excised.

## ■ BOERHAAVE'S SYNDROME

It is a tear in the lower third of the oesophagus which occurs when a person vomits *against a closed glottis*, causing leak into the mediastinum, pleural cavity and peritoneum (Refer Table).

## Site

2–10 cm of posterolateral part of lower oesophagus.

## Investigations

- ◆ Chest X-ray—shows pneumomediastinum (*'V' sign of Naclerio*).
- ◆ MRI/CT chest.
- ◆ Total count.

## Treatment

- ◆ Nil by mouth.
- ◆ Antibiotics, IV fluids, TPN.
- ◆ Feeding by jejunostomy.
- ◆ Most often surgery with resection may be required (thoracotomy and repair)—left thoracotomy is better.
- ◆ *When severe mediastinitis occurs, condition has high mortality.*

### Features of Boerhaave's syndrome

Presentations	Differential diagnosis	Complications
Sudden onset of symptoms	Myocardial infarction	Mediastinitis
Severe chest pain	Pancreatitis	Septicaemia
Pain abdomen		Peritonitis
Subcutaneous emphysema		Emphysema
Shock		
'Crunching effect in the chest' is called as <i>Hamman's sign</i> .		
<i>Mackler's triad</i> : (1) vomiting, (2) chest pain, (3) subcutaneous emphysema.		

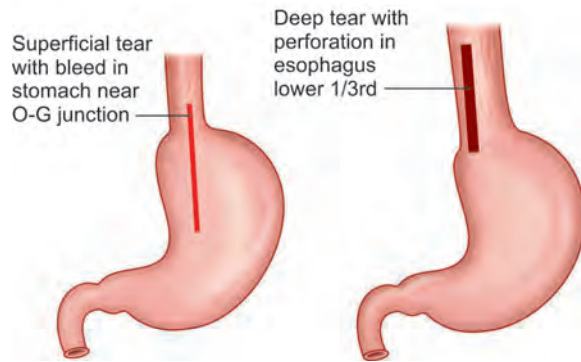


Fig. 19.27: Diagrams showing Mallory-Weiss syndrome and Boerhaave's syndrome.

### MALLORY-WEISS SYNDROME

- It is seen in adults with severe prolonged vomiting, causing longitudinal tear in the mucosa of stomach at and just below the cardia, leading to severe haematemesis.
- Violent vomiting often may be due to migraine or vertigo or following a bout of alcohol.
- Presents with severe vomiting and later haematemesis, with features of shock.
- It is common in 1 o'clock position.
- Only 10% of cases involve lower oesophageal mucosa.

### Investigations

- Gastroscopy, Hb%, PCV, blood grouping.
- During gastroscopy, if stomach is not inflated properly, 50% cases may be missed.

#### Differential diagnosis

- Bleeding peptic ulcer
- Oesophageal varices
- Erosive gastritis
- Carcinoma stomach

### Treatment

- Conservative, as it is only a mucosal tear.
- Blood transfusion.
- IV fluids.
- Sedation.
- Haemostatic agents like vasopressin.
- Endoscopic injection therapy is used if required.
- Surgery is rarely required.

### TRACHEO-OESOPHAGEAL FISTULA (OESOPHAGEAL ATRESIA)

#### Types (Refer Figure 19.28)

- In 85% cases, it is a blind upper end with lower end communicating with trachea.
- It may be associated with VACTER anomalies.
- It is a spectrum of anomalies which shares a defect of the oesophageal continuity with or without a fistula to the trachea or bronchi.

V	—	Vertebral defects
A	—	Anal atresia
C	—	Cardiac defect (PDA/VSD)
TE	—	Tracheo-oesophageal fistula
R	—	Radial hypoplasia and renal agenesis

### Clinical Features

- Incidence is 1 in 4,500 births; common in males (3:1).
- TOF should be recognised within 24 hours of birth.
- Newborn baby regurgitates all feeds and there is continuous pouring of saliva from the mouth which is a diagnostic feature.
- Cough and cyanosis.
- It is commonly associated with maternal hydramnios (50%).

### Investigations

- Obstruction is revealed while passing nasogastric tube.
- Contrast study will reveal fistula and obstruction (Dionosil 1 ml).

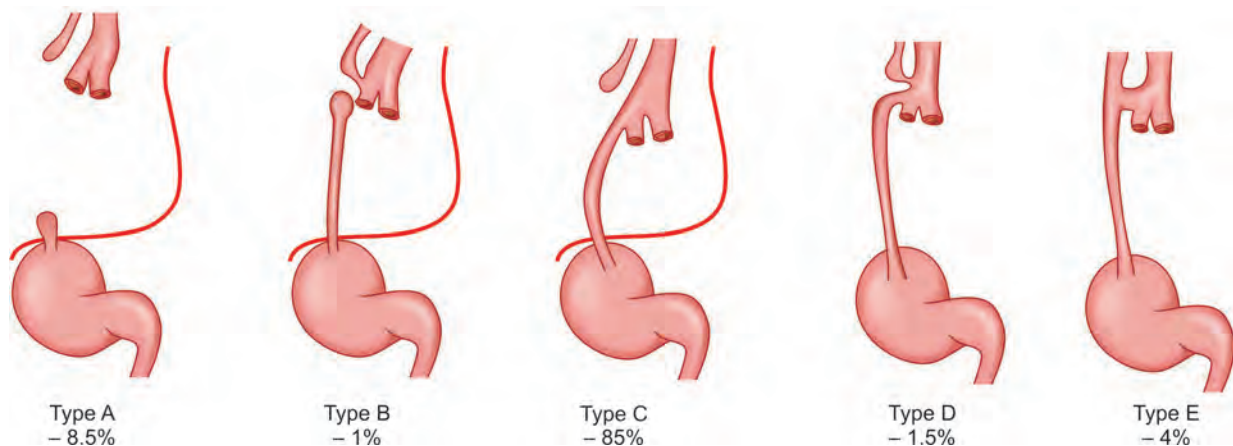


Fig. 19.28: Gross classification of TOF – Type A: Atresia without fistula – 8.5%. Type B: Atresia with proximal TOF – 1%. Type C: Atresia with distal TOF – 85% (commonest). Type D: Atresia with both proximal and distal TOF – 1.5%. Type E: No atresia but 'H' type TOF – 4%.

- ◆ Other anomalies are looked for.
- ◆ Chest X-ray.
- ◆ Echocardiography.

## Treatment

### Surgery

- ◆ Child requires feeding gastrostomy commonly.
- ◆ Often the procedure is staged one.
- ◆ Through right-sided thoracotomy (opposite to the side of aortic arch), fistula is identified and resected. Lower segment is anastomosed to the blind upper segment. Occasionally if the length is inadequate or the atretic segment is long one, then colonic or gastric transposition is required.

### Complications of surgery

- ❖ Pneumonia
- ❖ Leak from the anastomotic site
- ❖ Reflux
- ❖ Dysphagia

## OESOPHAGEAL DIVERTICULUM

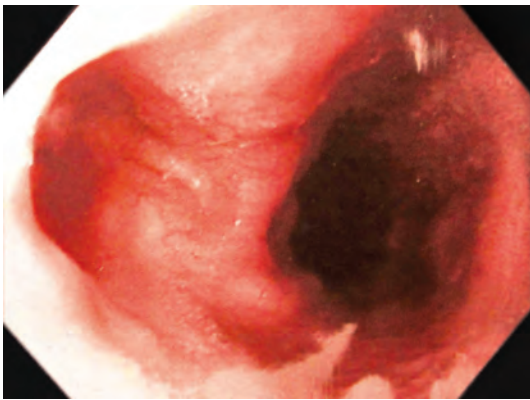


Fig. 19.29: Endoscopic view of oesophageal diverticulum

## Types

### 1. Pulsion diverticulum:

Pulsion diverticula are *false type* containing *mucosa and submucosa* only; is due to high abnormal intraluminal oesophageal pressure developed due to various motility disorders.

- a. Pharyngeal pouch through Zenker's or Killian's dehiscence (*Refer chapter Neck*).
- b. *Epiphrenic pulsion* diverticulum occurs in lower oesophagus, usually towards right side, due to obstruction in the distal oesophagus or due to incoordinated LOS relaxation.
  - Site is within 10 cm of OG junction. It is *false type*.
  - It is associated with *nonspecific oesophageal motility* disorders and often with achalasia and diffuse oesophageal spasm. Ehler Danlos syndrome and trauma are the other causes.
  - It is common on *right* side with wide mouth.
  - *Features* are of motility disorders like dysphagia, regurgitation, cough, weight loss, chest pain.
  - Barium study, CT chest are *diagnostic*; endoscopic evaluation with EUS, manometry is a must.

- *Treatment*: Diverticulopexy/diverticulectomy (excision) + oesophageal myotomy (Heller's) + repair of associated hiatus hernia/antireflux procedure.

### 2. Traction diverticulum:

Occurs in mid-oesophagus or in parabranchial region, is due to mediastinal granulomatous disease like tuberculosis.

- ▶ Traction diverticulum is a *true type* containing all layers in its wall and is due to traction by the healing fibrosing mediastinal lymph nodes.
- ▶ It is seen commonly towards right side. It has got wide mouth and it rests on the spine.
- ▶ *Presentation* is dysphagia, chest pain and regurgitation.
- ▶ CT scan (chest), barium study, manometry, endoscopy to assess mucosa with EUS, blood test for tuberculosis (ESR, peripheral smear) are the *investigations*.
- ▶ *Treatment*: Treating the *cause* like tuberculosis, histoplasmosis. Diverticulum less than 2 cm is observed; progressive symptoms, size >2 cm needs surgery. *Surgeries* are—diverticulopexy, long oesophageal myotomy.

## CARCINOMA OESOPHAGUS

- ◆ Carcinoma oesophagus is common in China, South Africa and Asian countries.
- ◆ It is 6th most common cancer in the world.
- ◆ It is less than 1% of all cancers. It is 7% of all GI malignancies.
- ◆ It is less common in America and European countries.
- ◆ In India, it is common in Karnataka and Orissa.
- ◆ When patient presents with dysphagia, often it is fairly advanced and inoperable and only palliation is the possibility. But then surgery is the treatment of choice in early growths.

## Aetiology

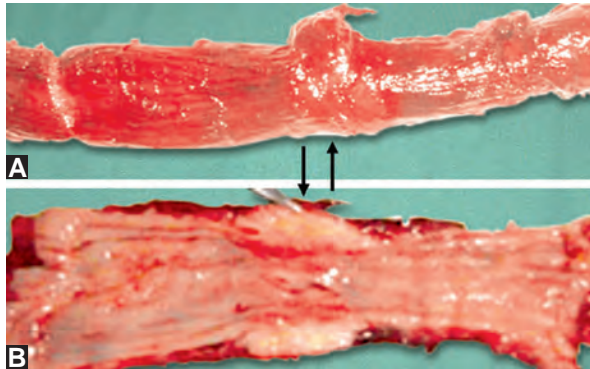
Diet, deficiencies (vit. A, C, riboflavin)	5% common
Mycotoxin	Common after 45 years
Alcohol and tobacco	Common in men
Fungal contamination of food	Common in <i>China</i> – <i>Henan</i> province
Human papilloma virus (HPV 16,18)	In India, common in Orissa and Karnataka
Geotrichum candidum fungi in China	
Achalasia cardia	30%
Oesophageal webs	25%
Barrett's oesophagus	
Plummer-Vinson's syndrome	15%
Corrosive strictures	30%
Tylosis* (Hovels-Evans syndrome)	
Nitrosamines	
*Tylosis is an inherited disease with thickening of skin of palm and sole	

### Tylosis

- ❖ Autosomal dominant condition seen from childhood
- ❖ Soles and palms are involved called as palmoplantar keratoderma
- ❖ Waxy, yellow lesions, which do not itch
- ❖ 60% of members of families develop carcinoma oesophagus after the age of 60
- ❖ Systemic retinoids are the drugs used for tylosis

## Pathology

- ◆ Common in:
  - ▶ Middle third—50%.
  - ▶ Lower third—33%.
  - ▶ Upper third—17%.
- ◆ Lower 3 cm of oesophagus is lined by columnar epithelium, and so adenocarcinoma is common here. Barrett's columnar metaplasia which occurs in lower third of oesophagus is also more prone for adenocarcinoma.
- ◆ Squamous cell carcinoma is commonest type in India and Asian countries.



**Figs 19.30A and B:** Carcinoma oesophagus middle third—pathology specimen, gross and cut section.

### Note:

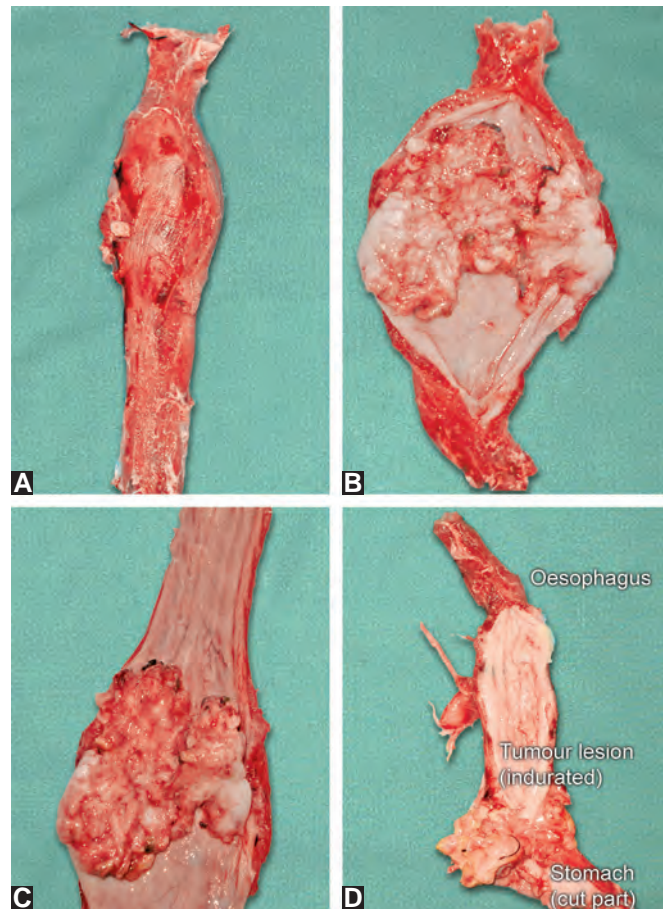
- In India 90% are squamous cell carcinomas.
- In western countries, adenocarcinoma is becoming more common. Adenocarcinoma arises from submucosal oesophageal glands/heterotrophic columnar epithelium/Barrett's oesophagus.
- *H. pylori* infection is associated with *reduced risk* of oesophageal adenocarcinoma (inversely related).

### Gross types

- ❖ Annular (15%)
- ❖ Ulcerative (20%)
- ❖ Fungating—cauliflower like (60%)
- ❖ Polypoid
- ❖ Varicoid—diffuse submucosal type

## Spread

- ◆ *Direct*
  - ▶ Lack of serosal layer in oesophagus favours local extension. In upper third it spreads through muscular layer and gets adherent to left main bronchus, trachea, and left recurrent laryngeal nerve (causes hoarseness), aorta or its branches (causes fatal haemorrhage, but rare).
  - ▶ It may perforate and cause mediastinitis.
  - ▶ It may get adherent to pleura also.
  - ▶ *Broncho-oesophageal, tracheo-oesophageal, oesophago-aortic fistulas* can occur in advanced cases; it may cause torrential haemorrhage, pulmonary infection. Barium study, contrast dynamic CT, bronchoscopy will help in identifying fistulas. Surgery and radiotherapy are not possible in such situation. It is the terminal stage of the disease. *Endoscopic stenting* is the better palliation method.



**Figs 19.31A to D:** Gross outer look and cut-section of proliferative and indurated lesions of carcinoma oesophagus.

### ◆ *Lymphatic spread*

- ▶ It spreads both by lymphatic permeation and lymphatic embolisation.
- ▶ It can cause satellite nodules elsewhere in the oesophagus, away from the main tumour.
- ▶ Above in the neck, it spreads to supraclavicular lymph nodes.
- ▶ In thorax, it spreads to paraoesophageal, tracheobronchial lymph nodes to subdiaphragmatic lymph nodes.
- ▶ In abdomen, it spreads to coeliac lymph nodes.

### ◆ *Blood spread occurs* to liver, lungs, brain and bones.

## Clinical Features

- ◆ *Recent onset of dysphagia* is the commonest feature. *For the dysphagia to develop, two-third of the lumen should be occluded.*
- ◆ Regurgitation.
- ◆ Anorexia and loss of weight (severe), cachexia.
- ◆ Pain—substernal or in the abdomen.
- ◆ Liver secondaries, ascites.
- ◆ Bronchopneumonia, melaena.
- ◆ Features of broncho-oesophageal fistula in carcinoma of upper third oesophagus (30%).
- ◆ Left supraclavicular lymph nodes may be palpable.

*All things must change to something new and strange.*



- ◆ Hoarseness of voice due to involvement of recurrent laryngeal nerve.
- ◆ Hiccough, due to phrenic nerve involvement.
- ◆ Back pain—due to nodal spread (paraoesophageal/*coeliac* nodes).
- ◆ Male to female ratio is 3:1. In adenocarcinoma, it is 15:1.

**TNM staging and histologic grading for carcinoma oesophagus and esophagogastric junction (AJCC 7th edition)**

**T status – Tumour**

T0 No primary tumour  
 Tis High-grade dysplasia  
 T1 Invasion into the lamina propria, muscularis mucosae (T1a) or submucosa (T1b)  
 T2 Invasion into muscularis propria  
 T3 Invasion paraoesophageal (adventitia) tissues without adjacent structure spread  
 T4a Invades resectable adjacent structures (pleura, pericardium, diaphragm)  
 T4b Invades unresectable adjacent structures (aorta, vertebral body, trachea)

**N status – Nodes**

N0 No regional lymph node metastases  
 N1 1 to 2 positive regional lymph nodes  
 N2 3 to 6 positive regional lymph nodes  
 N3 7 or more positive regional lymph nodes

**M status – Metastasis**

M0 No distant metastases  
 M1 Distant metastases

**Histologic grade**

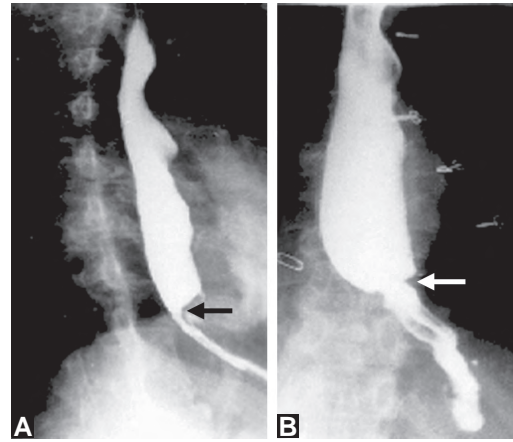
G1 Well differentiated  
 G2 Moderately differentiated  
 G3 Poorly differentiated  
 G4 Undifferentiated

**Stage groups**

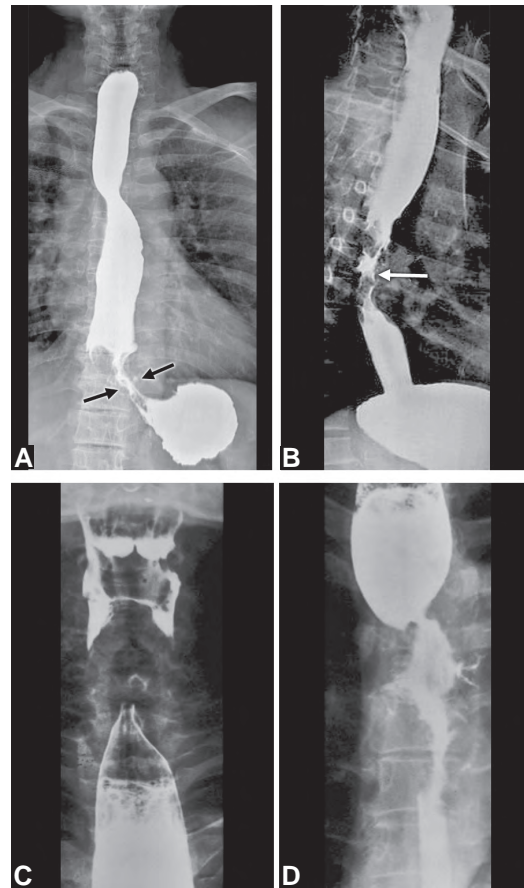
Stage	Adenocarcinoma	SCC	Location
0	TisN0M0G1	TisN0M0G1	Any
IA	T1N0M0G1-2	T1N0M0G1	Any
IB	T1N0M0G3 T2N0M0G1-2	T1N0M0G2-3 T2-3N0M0G1	Any Lower
IIA	T2N0M0G3	T2-3N0M0G1 T2-3N0M0G2-3	Upper, middle Lower
IIB	T3N0M0Gany T1-2N1M0Gany	T2-3N0M0G2-3 T1-2N1M0Gany	Upper, middle Any
IIIA	T1-2N2M0Gany T3N1M0Gany T4aN0M0Gany	T1-2N2M0any T3N1M0Gany T4aN0M0Gany	Any Any Any
IIIB	T3N2M0Gany	T3N2M0Gany	Any
IIIC	T4aN1-2M0Gany T4bNanyM0Gany TanyN3M0Gany	T4aN1-2M0Gany T4bNanyM0Gany TanyN3M0Gany	Any Any Any
IV	TanyNanyM1Gany	TanyNanyM1Gany	Any

**Investigations**

- ◆ *Barium swallow*: Shouldering sign and irregular filling defect. *Rat tail lesion on fluoroscopy* is typical.
- ◆ *Oesophagoscopy*—to see the lesion, extent and type.

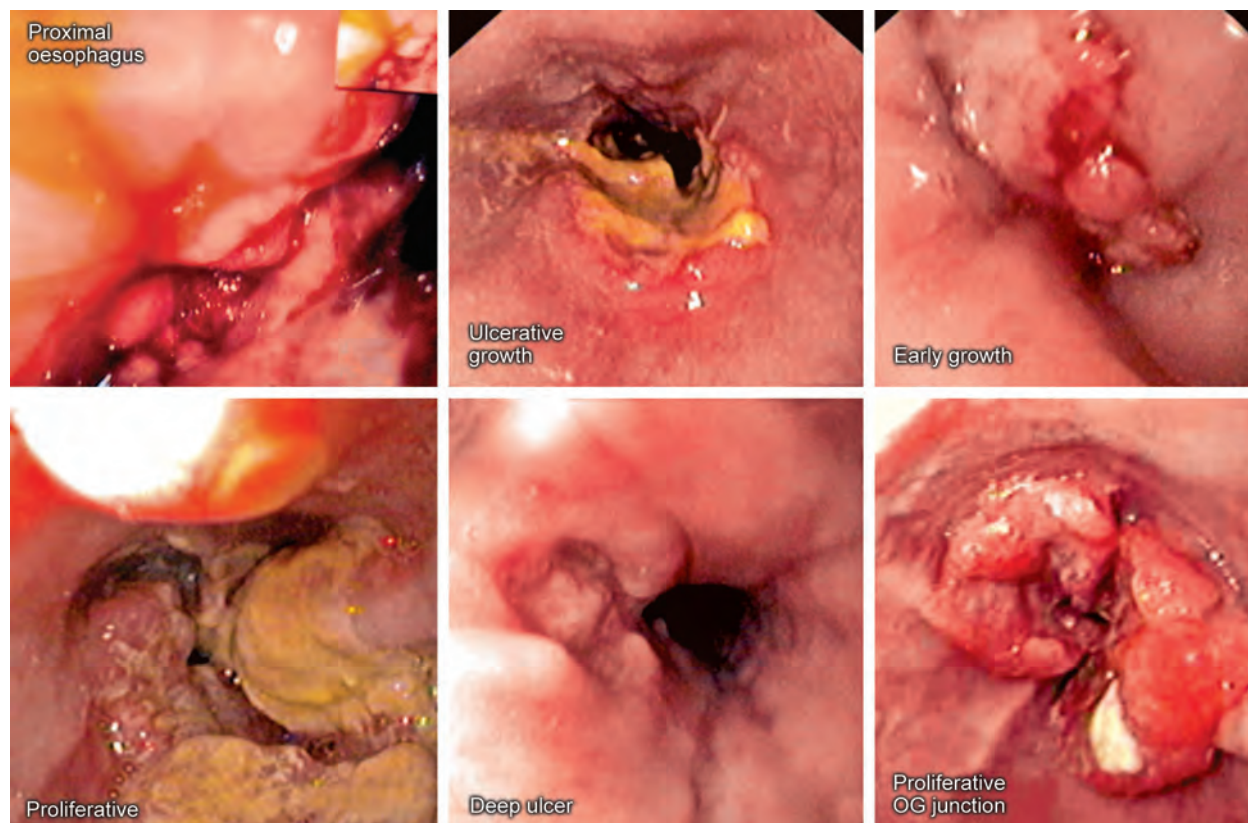


**Figs 19.32A and B:** Barium swallow showing irregular filling defect and shouldering sign in middle third oesophagus.



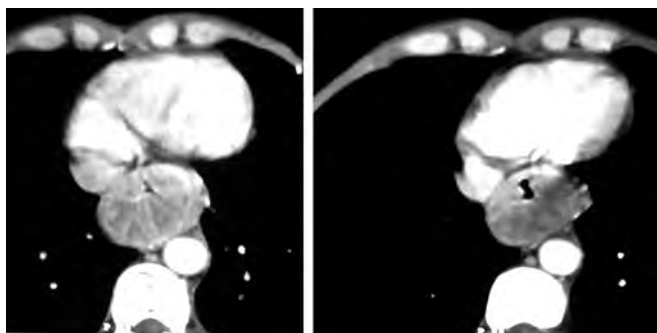
**Figs 19.33A to D:** Barium swallow X-rays showing irregular filling defect at different levels—feature of carcinoma of oesophagus.

- ◆ *Biopsy*—for histological type and confirmation.
- ◆ *Chest X-ray*—to look for aspiration pneumonia.
- ◆ *CT scan* (95% accuracy)—to look for local extension, nodal status, perioesophageal/diaphragmatic/pericardial (1%)/vascular infiltration, obliteration of mediastinal fat and status of tracheobronchial tree in case of upper third growth.
- ◆ *Bronchoscopy* to see invasion in the upper 1/3rd carcinoma of oesophagus; *laryngoscopy* to identify vocal cord palsy.



**Fig. 19.34:** Endoscopic views of oesophageal carcinomas—at different levels and different gross types.

- ◆ *Chromoendoscopy, magnification endoscopies* are newer methods. Local topical application of different stains will improve the tissue (tumour) localization, features and diagnoses. Different stains that are used like *absorptive* (Lugol's, methylene blue – get absorbed by specific cell membranes), *contrast* (indigocarmine – permeate into the mucosal crevices showing irregularity and topography) or *reactive* (Congo red, phenol red – shows colour change due to reaction with cell chemicals). Biopsy is done in these selected areas.
- ◆ *Oesophageal endosonography*—to look for the involvement of layers of oesophagus, nodes, cardia and left lobe of the liver. Nodes smaller than 5 mm can be very well visualised by EUS which may be missed in CT scan. EUS guided transmucosal nodal needle aspiration cytology can also be done.
- ◆ *Ultrasound abdomen*—to look for liver and lymph nodes status in abdomen.
- ◆ *Endoscopic oesophageal staining* with labelled iodine results in normal mucosa being stained brown, but remains pale in carcinoma (as mucosa in carcinoma will not take up iodine).
- ◆ *Blood tests:* Haematocrit; ESR; Liver function tests.
- ◆ *Laparoscopy:* It is useful to see peritoneal spread, liver spread and nodal spread. It is the only reliable method to detect peritoneal seedlings. Biopsy from different places can also be taken. It will prevent unnecessary laparotomy for anticipated surgical resection.
- ◆ *PET scan* using 18 F-fluorodeoxyglucose (FDG): 18 FDG is given to the patient. FDG enters highly active cells and gets phosphorylated to FDG 6 phosphate. It stays in the cell as end product and gets polarised there. PET with CT scan is used to see response for therapy.



**Fig. 19.35:** CT scan chest and abdomen is essential investigation in carcinoma oesophagus to identify operability, nodal status.

- ◆ *Video-assisted thoracoscopic approach*—to stage oesophageal carcinoma and to identify the operability, nodal status.
- ◆ *Endoscopic mucosal resection (EMR)* is done using double channeled endoscope with tip having a soft plastic cap. Cap is firmly placed over the lesion and suction is created; a snare is brought over the lesion; biopsy specimen is snared off 1.5 cm in size containing mucosa and submucosa. It is basically a diagnostic biopsy tool; but can be therapeutic in early and premalignant lesion. Endoscopic submucosal dissection (ESD, Japan) is now devised using hook cautery and scissors to remove the lesion up to muscularis propria.

- ◆ *Newer modalities of evaluation* – Flow cytometry, p53 immunohistochemistry, optical coherence tomography, spectroscopy, etc.

## Treatment

*Gastrostomy* should not be done as a palliative procedure.

## Principles

### Indications for curative treatment

1. Early growth when patient is fit.
  2. When there is no involvement of adjacent periesophageal structures, bronchus, liver or distant organs.
- ◆ Only 20% of oesophageal cancers present early and becomes *curable*. In such early growths confirmed with absence of nodal spread, curative surgery is the main approach—*radical oesophagectomy*. Proximal extent of resection should be 10 cm above the macroscopic tumour and distal extent of resection is 5 cm from macroscopic distal end of tumour. Proximal stomach has to be removed commonly especially in lower 1/3rd of tumour. Sufficient removal of contiguous structures may be needed in curative resection.
  - ◆ If nodes are present, then multimodal approach should be used like—curative resection; radiotherapy and chemotherapy. Outcome of surgery depends on location of tumour; number, location and size of nodes; tumour grading.
  - ◆ Lymph node involvement more than 5 carries poor prognosis. If 5 or less nodes are involved then, it is called as curative resection.
  - ◆ Neoadjuvant therapy by chemotherapy and/or radiotherapy prior to surgery may improve the survival.
  - ◆ Aggressive chemoradiation also may be used as curative therapy in some patients especially upper 1/3rd growths and in patients who are unfit for surgery.
  - ◆ In remaining patients (80%) *palliation* is the main modality of treatment. Palliation therapy is done if patient is not fit for major surgery; if there is blood spread; if there is spread to adjacent organ; if there is peritoneal/liver spread. It is to relieve pain and dysphagia and also to prevent aspiration and bleeding.

### Palliative therapy (80% cases)

#### Indications where probably curative therapy is not possible

Nodes >5 involvement  
 Invasive, poorly differentiated grade  
 Length of involvement >8 cm  
 Abnormal oesophageal axis in barium study  
 Horner's syndrome  
 Loss of weight >20%  
 Metastatic disease

#### To palliate

Pain  
 Dysphagia  
 Prevent bleeding  
 Prevent aspiration

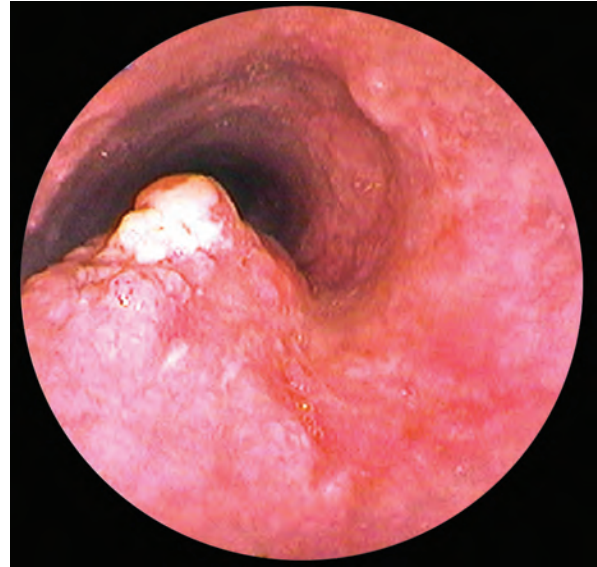


Fig. 19.36: Carcinoma oesophagus (Endoscopic view).

## Approaches for Different Level Tumours

### Post-cricoid tumour (Squamous cell carcinoma):

- ◆ Treated mainly by radiotherapy. Radical radiotherapy— 5000–6000 rads.
- ◆ Often pharyngolaryngectomy is done along with gastric or colonic transposition. But complications are more in this procedure. Free jejunal transfer is the other option.

### Upper third growth (Squamous cell carcinoma):

- ◆ Treated mainly by radiotherapy.
- ◆ Commonly it is advanced with left recurrent laryngeal nerve palsy and bronchial invasion.
- ◆ If it is early and operable, *McKeown three phased oesophagectomy* and anastomosis is done in the neck. Initially laparotomy is done to mobilise the stomach. Then thoracotomy through right 5th space is done and oesophagus is mobilised. Through right side neck approach, oesophagus with growth is removed. Anastomosis between pharynx and stomach is done in the neck.
- ◆ Split sternum approach oesophagectomy is also practiced.

### Middle third growth (Squamous cell carcinoma):

*Ivor Lewis operation (Lewis-Tanner two-phased oesophagectomy):* After laparotomy stomach is mobilised. Pyloroplasty is done. Through right 5th space thoracotomy is done and growth with tumour is mobilised. Partial oesophagectomy and oesophagogastric anastomosis is done in the thorax. Intercostal tube drainage is placed during closure. Right gastroepiploic vessels should be retained safely (essential). Azygos vein should be ligated securely. Mediastinal nodes should be dissected. Thoracic duct should be ligated if needed. Feeding jejunostomy is better to maintain nutrition.

*Complications of Ivor Lewis operation*—Pulmonary (bronchopneumonia, empyema), anastomotic leak, mediastinitis, oesophagitis and sepsis.

If the growth is inoperable, palliative radiotherapy is given.

### Lower third growth (Squamous cell carcinoma + adenocarcinoma):

- ◆ Here through left thoracoabdominal approach, partial oesophago-gastrectomy is done with oesophagogastric anastomosis. Often jejunal Roux-en-Y loop anastomosis is done.
- ◆ *Orringer approach*, i.e. *transhiatal blind total oesophagectomy* with anastomosis in the left side of the neck. Through laparotomy, stomach and lower part of the oesophagus are mobilised. Through left sided neck approach, upper part of the oesophagus is mobilised using finger. Blind dissection is completed by meeting both fingers above and below in the thorax. Later oesophagus is pulled up out above through the neck wound and removed. Continuity is maintained in the neck. It is a *palliative* surgery.



Fig. 19.37: Transhiatal blind oesophagectomy—on table surgical specimen.

### Other Approaches

- ◆ *Thoracoscopic-laparoscopic oesophagectomy* and lymphadenectomy is becoming popular, safer and effective.
- ◆ *Radical oesophagectomy with 3-field clearance* of abdominal/thoracic and cervical nodes is also practiced in many centres. 3-Field clearance (coeliac, thoracic and neck) is done for mainly squamous cell carcinoma as spread in SCC is upwards. In adenocarcinoma 2-field clearance is sufficient (abdominal—coeliac and thoracic) as spread is downwards.

#### Note:

When oesophagus is removed totally or subtotally an interposition is required between cervical oesophagus/pharynx and distal stomach. Different parts of GI is used for the same.

#### Oesophageal substitutes:

- ▶ **Stomach:** It is preferred one and is based on right gastric and right gastroepiploic arteries. It needs only one anastomosis and take up is well due to good vascularity. But it can cause postprandial fullness with bile or acid regurgitation (>50%). It also needs a pyloroplasty for gastric drainage as vagotomy is done. Entire stomach or tubed part or reverse tubed part can be transposed.
- ▶ **Colon:** It is better as there are less postprandial problems. But it needs 3 anastomoses. *Left colon* is used with ascending branch of left colic artery as *isoperistaltic* loop. *Right colon* is used with middle colic artery as base as *antiperistaltic* loop.

Complications are leak, fistula formation, delayed emptying, redundancy, peptic ulceration, stricture formation. Colonic polyp and diverticulosis are contraindications for colonic conduit.

- ▶ **Jejunum:** Isolated required length of pedicled jejunum is transposed. Jejunal free transfer is also tried; vessels are sutured to internal mammary vessels or to the vessels available the neck. Pedicled jejunum is also *supercharged* with microvascular anastomoses with internal mammary vessels. It is used as a last option only.

*Transposition* is done through posterior mediastinum (*shortest route*), right pleural space (transpleural), retrosternal or subcutaneous route.

- ◆ *Skinner en bloc resection* used to be of practice in olden days in which tumour with oesophagus is resected along with thoracic duct, azygos vein, intercostal vessels crossing the vertebral bodies, pericardium and mediastinal pleura. There is no survival benefit with this procedure.
- ◆ *Vagal sparing oesophagectomy* with HSV is tried to preserve pylorus functioning with avoiding pyloroplasty to reduce the chances of postprandial fullness. But it is technically tedious.
- ◆ *Lymphadenectomy* in carcinoma oesophagus:
  - ▶ *Standard:* Nodes removed are—paratracheal, parabronchial, carinal, paraoesophageal, posterior mediastinal, paracardial, left gastric, along lesser curve of stomach.
  - ▶ *Extended/three field/ultraradical:* As like standard above, with bilateral cervical lymphadenectomy, removal of upper mediastinal, coeliac, retroperitoneal, subhepatic nodes.

#### Surgical approaches

- ❖ Ivor-Lewis 2-phase oesophagectomy
- ❖ McKeown 3-phase oesophagectomy
- ❖ Left abdominothoracic approach for lower oesophagus—*Sweet* approach
- ❖ Thoracoscopic—laparoscopic
- ❖ Transhiatal blind approach—Orringer's

### Postoperative Management

- ◆ Fluid and electrolyte management.
- ◆ Antibiotics and proper analgesia.
- ◆ Respiratory care; ICT care; physiotherapy.
- ◆ Prevention of DVT—elevation, exercises, heparin.
- ◆ Monitoring for bleeding, sepsis, leak, oxygen saturation.
- ◆ TPN only during initial postoperative period and *early jejunosomy feeding* for nutrition.

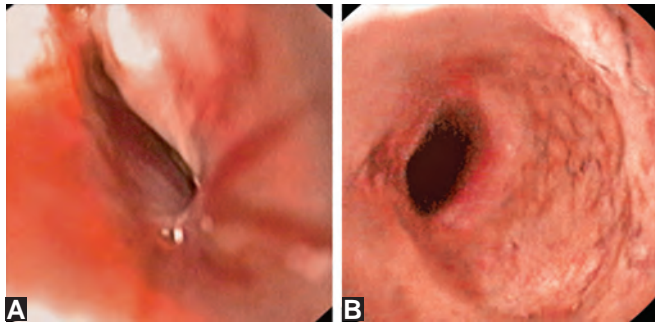
### Palliative Treatment

80% of patients with carcinoma oesophagus, when present first, have fairly advanced tumour and so they are amenable for only palliative treatment. It is to *relieve pain, dysphagia and to prevent aspiration and bleeding*. Palliation therapy is done –

- ◆ If patient is not fit for major surgery.
- ◆ If there is blood spread.
- ◆ If there is adjacent organ spread.
- ◆ If there is peritoneal/liver spread.

**Different methods are:**

- ◆ **Palliative external radiotherapy**
  - ▶ 3000 Rads. Severe mucositis, stricture and fistula formation are the complications.
- ◆ **Intraluminal RT**
  - ▶ Brachytherapy (radiation intraluminally). Loading catheter is placed using endoscope and applicator is fixed to mouth to give 1500 cGy radiation with least systemic effects.



**Figs 19.38A and B:** (A) Stricture oesophagus after radiotherapy given for carcinoma oesophagus; (B) Oesophageal stent *in situ*—a look endoscopically.

- ◆ **Chemotherapy**
  - ▶ Cisplatin; methotrexate; 5 FU; **palcitaxel**, etoposide, bleomycin. **Platinum based chemotherapy** is beneficial especially in advanced adenocarcinoma of oesophagus.

◆ **Intubation**

Intubation was described by Symmonds in 1887. It is commonly used method. Guidewire is passed across the growth under X-ray screening or C-arm guidance; flexible introducer and prosthetic tube is pushed across the tumour along the guidewire. It carries 90% success rate. Problems are—tube intolerance, poor drainage, airway compression, reflux, aspiration, displacement, food blockage, tumour overgrowth beyond the prosthesis causing its failure.

Intubation is used for *tracheo-oesophageal fistula* or external compression. Prosthesis with a sponge-filled balloon is used for fistula closure. Standard tube wrapped with multilayered polyvinyl sponge is other option. It is less expensive, single time, rapid acting.

They can be traction or pulsion tubes. Perforation chance is 10%.

**Different tubes used are:**

- ▶ **Atkinson tube.**
- ▶ **Celestin tube** (armoured rubber tube with a long tail)—ideal, commonly used tube. It is wider proximally. It can be passed through endoscopy or laparotomy.
- ▶ **Souttar tube** (coiled German silver wire)—block is first dilated with bougies; tube is passed over small sized bougie and pushed across the block. It is mainly useful for lower oesophagus.
- ▶ **Mousseau-Barbin tube**—cheaper but needs laparotomy. After laparotomy, anterior wall of the stomach is opened. MB tube is passed from mouth with the help of anesthetist by stitching its tip to nasogastric tube and pulled down into the stomach. Tip is cut near the cone part. It is sutured to anterior wall of the stomach. Gastrostomy is closed.
- ◆ **Endoscopic therapy:**
  - ▶ **Self-expanding metal stents (SEMS)** are passed through endoscope under C-arm guidance. It is the *ideal method of palliation*. Stent is collapsed during insertion and released once it is placed in proper position. There is no need to dilate

oesophagus more than 8 mm to pass this expanding stent and so chances of perforation is minimal.

**Uncovered SEMS**—here tissues project through the mesh to have a better grip with less chances of migration. But stent occlusion is more.

**Plastic covered SEMS**—it shows less stent occlusion and less friction. Stent migration is more.

**SEMS may be**—stainless wall stent; knitted nitinol Strecker stent; stainless steel covered *Gianturco-Rosch* stent.

**Problems of stents** are—aspiration, displacement, erosion, bleeding, tumour growth across or beyond mesh, food bolus obstruction, retrosternal pain, need for reinsertion (40%). Mortality is 1–2%.

- ▶ **Endoscopic laser** is used to core a channel through the tumour to improve dysphagia (Nd YAG laser; Diode laser). It causes thermal destruction of tumour. It improves dysphagia but needs repeated laser ablation. It may be used more effectively to remove tumour block in previously placed stents.

Exophytic tumour less than 6 cm is *suitable* for laser.

**Noncontact high power Nd:YAG 50-100 W laser** from distal to proximal end facilitates visualisation of lumen and also reduces the chances of perforation.

**Contact low power Nd:YAG 10-20 W laser** is used for fully occluded tumour with less smoke formation and less perforation chance.

**Success rate** of palliation is 85%.

**Problems are**—fever, chest pain, 3% mortality, perforation (2%) and fistula formation—5%, costly, takes one week to relieve dysphagia

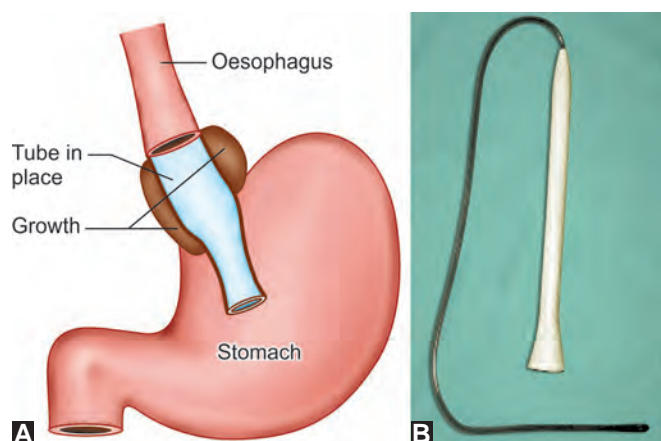
- ▶ **Endoscopic bipolar diathermy** using a olive tip; argon beam plasma coagulation; endoscopic alcohol injection into the tumour.
- ▶ **Endoscopic photodynamic therapy (PDT)** is used to destruct tumor and to relieve dysphagia. It is often used as a therapy in early cancer. Photosensitive haematoporphyrin agent is injected intravenously 48 hours before endoscopy. It is activated over tumour using laser. Visible infrared light also can be passed to tumour endoscopically to create tumour necrosis by released cytotoxic singlet oxygen through photosensitiser. Sunburn, fever, perforation, pleural effusions are complications. It is effective only to superficial cancers; effects will be seen only after 1 week; need to avoid direct sunlight exposure by the patient for one month is the drawback.

◆ **Surgery**

- ▶ **Transhiatal Orringer's blind oesophagectomy** is a palliative surgical procedure.
- ▶ **Kirschner palliative gastric bypass** done in advanced carcinoma oesophagus wherein mobilised stomach is brought to neck via retrosternal or subcutaneous route and anastomosed to divided cervical oesophagus. Lower cut end of oesophagus is anastomosed to a jejunal loop. Here oesophagus is not addressed (left alone).

**Palliative procedures**

- ❖ External or intraluminal RT (Brachytherapy)
- ❖ **Traction tubes** like Celestin or MB tubes through open surgery
- ❖ **Pulsion tubes** like self-expandable metal stents through endoscopes using C-arm
- ❖ Endoscopic laser
- ❖ Chemotherapy
- ❖ Transhiatal oesophagectomy—Orringer



**Figs 19.39A and B:** (A) Mousseau-Barbin tube placed as a palliative method for carcinoma oesophagus; (B) Mousseau-Barbin tube.

### Complications of oesophagectomy

- ❖ 5–10% mortality
- ❖ Haemorrhage
- ❖ Respiratory infection, often severe
- ❖ Septicaemia
- ❖ Chylothorax, injury to thoracic duct
- ❖ Anastomotic leak—thoracic leak is most dangerous (5–10%)
- ❖ Hoarseness due to recurrent laryngeal nerve palsy
- ❖ Stricture formation (40%)
- ❖ Gastro-oesophageal reflux in gastric transfer
- ❖ Conduit necrosis due to ischaemia either stomach or colon
- ❖ Colonic dysmotility causing partial obstruction in colon transfer

### Terminal Events in Carcinoma Oesophagus

- ◆ Cancer cachexia.
- ◆ Sepsis, mediastinitis.
- ◆ Immunosuppression.
- ◆ Malignant tracheo-oesophageal fistula (causes severe respiratory infection and death. Here expansile (self-expandable) *endoluminal stents* are used at the site of fistula to have temporary benefit).
- ◆ Erosion into major blood vessel—bleeding.

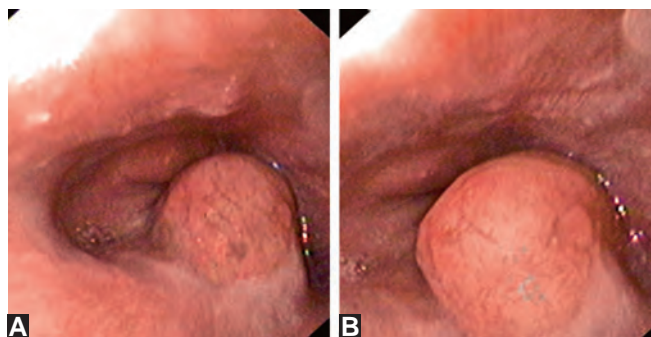
### Prognosis

- ◆ Not good because of early spread, longitudinal lymphatics, aggressiveness, difficult approach, late presentation.
- ◆ Nodal involvement carries bad prognosis.
- ◆ 5-year survival rate is only 10%.

### BENIGN TUMOURS OF THE OESOPHAGUS

- ◆ *Benign tumours* of the oesophagus are rare (0.5–1% of all oesophageal tumours).
- ◆ It grows slowly like a balloon by expansion, compressing surrounding structures. It never infiltrates or spreads.
- ◆ It can be solid, cystic, polypoid.
- ◆ It is usually in submucosal plane.
- ◆ It can cause obstruction/regurgitation/aspiration/ mediastinal compression.
- ◆ It can be squamous papilloma/polyp/inflammatory pseudo tumour/*leiomyoma* (commonest benign tumour of oesophagus—65%)/neurofibroma/rhabdomyoma/lipoma. True adenoma in oesophagus is very rare.

- ◆ Features may be asymptomatic (85%—identified incidentally during contrast X-ray/endoscopy); dysphagia/airway obstruction/pneumonia/spluttering during swallowing; stridor/regurgitation.
- ◆ **Leiomyoma** (commonest—65%) is smooth, sessile, lobulated, firm, with grey-white whorled appearance.
  - ▶ Only when leiomyoma reaches 5 cm in size, it causes obstruction.
  - ▶ Multiple localised leiomyomas can occur which can be enucleated independently.
  - ▶ *True diffuse leiomyomas* can occur occasionally in females (4%) in lower oesophagus, as diffuse hyperplasia and thickening of both muscular layers; often as part of the Alport's syndrome which needs total oesophagectomy with gastric pull up, even though benign.
  - ▶ Benign leiomyoma of oesophagus rarely turns into leiomyosarcoma.
  - ▶ 90% of oesophageal leiomyomas occur in *lower third of the oesophagus*.
  - ▶ Leiomyomas are common in men in 5th decade.
  - ▶ Leiomyoma which expresses the c-kit oncogene (CD117) is considered as GIST.
- ◆ *Investigations*—barium swallow X-ray (smooth circular outline/eccentric filling defect)/oesophagoscopy/endosonography/CT scan.
- ◆ *Treatment*—if tumour is more than 5 cm/symptomatic tumour/intraluminal tumour/when diagnosis is doubtful surgical enucleation is indicated. Enucleation is the therapy of choice. Ideally it should be done through right-sided thoracotomy. Occasionally oesophageal resection is needed if tumour is very large/tumour with mucosal ulceration/if tumour is near OG junction. Thoracoscopic resection can be done. Leak, empyema, sepsis and stricture are the occasional complications.



**Figs 19.40A and B:** Oesophageal submucosal tumour—endoscopic view—leiomyoma.

#### Note:

Unlike in the stomach and intestine (gastric leiomyoma more than 6 cm/intestinal leiomyoma more than 4 cm are potentially malignant) increased size of the oesophageal leiomyoma does not predispose the malignant transformation.

#### Oesophageal cysts

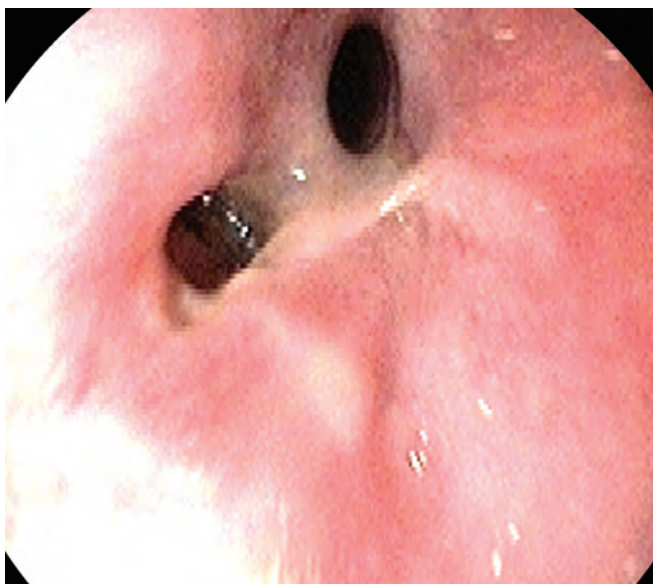
- ▶ It is 2nd commonest benign tumour of oesophagus.
- ▶ It can be congenital or acquired. Congenital is derived from foregut. It contains mucus. It is lined by ciliated columnar epithelium. In infants, it is common in upper third of oesophagus; often with a fistula into airway. It can cause obstruction.
- ▶ Acquired cyst is from obstruction of the excretory ducts of oesophageal glands.
- ▶ *Treatment:* Enucleation or resection. If fistula is present it should be ligated and divided.

*Truth, like surgery, may hurt, but it cures.*

## ■ OESOPHAGEAL PERFORATION

### Causes

- ◆ Instrumental injuries—commonest cause, 75% commonest site is just above the level of cricopharyngeus.
- ◆ Foreign bodies.
- ◆ Alkali injuries.
- ◆ Carcinoma oesophagus 1%.
- ◆ Boerhaave's syndrome 15%.
- ◆ Trauma 9%.
- ◆ Surgical trauma (Vagotomy, thyroidectomy, Heller's operation, pneumonectomy, spine surgery).



**Fig. 19.41:** Oesophageal perforation with mediastinitis and empyema; perforation is after eating large chicken bone.

### Clinical Features

Chest pain, vomiting, shock, subcutaneous emphysema.

#### Investigations

- ❖ Chest X-ray—shows pneumomediastinum
- ❖ CT scan

#### Complications

- ❖ Mediastinitis
- ❖ Septicaemia
- ❖ Empyema, ARDS

### Treatment

- ◆ *Conservative treatment:* It is advocated in small perforations due to instrument where there is minimal air leak and contamination of mediastinum with less septic load. Crepitus should be absent; pleura should be clear and without any obstruction. Treatment is—antibiotics, nutrition (TPN/enteral through tube), fluid management, proper observation and monitoring the patient by repeated blood counts, and imaging. Biodegradable removable self-expanding stents also can be used. It may also act as a bridge therapy for eventual major surgical exploration. Stents which are used for carcinomas cannot be used as they cannot be removed.
- ◆ *Thoracotomy,* proper saline wash to pleura, mediastinum and repair with buttressing the area using *pedicled intercostal musculopleural flap* is done. Nasogastric tube for long duration, jejunostomy tube for feeding, ICT for drainage is essential. Often in late cases decortication of lung is needed to achieve full expansion of the lung.
- ◆ Repair over T-tube so as to create a controlled fistula along with feeding jejunostomy and ICT on both sides.
- ◆ Intraluminal stents/mediastinal irrigation and drainage.
- ◆ Resection of oesophagus with gastric pull up. As condition is an emergency situation and with sepsis it carries high mortality.
- ◆ Oesophageal exclusion with cervical oesophagostomy above and feeding jejunostomy below.
- ◆ Diversion surgeries using colon/stomach/jejunum.

#### Foreign body oesophagus

##### Common foreign bodies:

- ❖ Coins, metals, plastics
- ❖ Dentures
- ❖ Pins, toothpicks, batteries
- ❖ Fish or meat bones—dangerous—40%
- ❖ Food (meat—common/vegetables) impaction—45%

##### Sites of impaction in oesophagus:

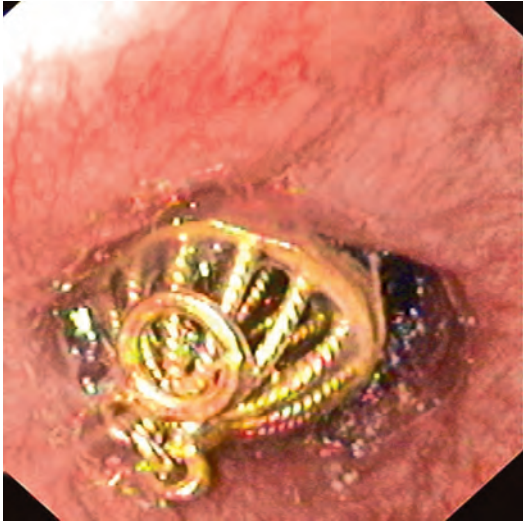- ❖ Cervical constriction—C6
- ❖ Broncho-aortic constriction—T4
- ❖ Diaphragmatic constriction—T10
- ❖ Pre-existing malignancy or inflammatory stricture site

##### Features:

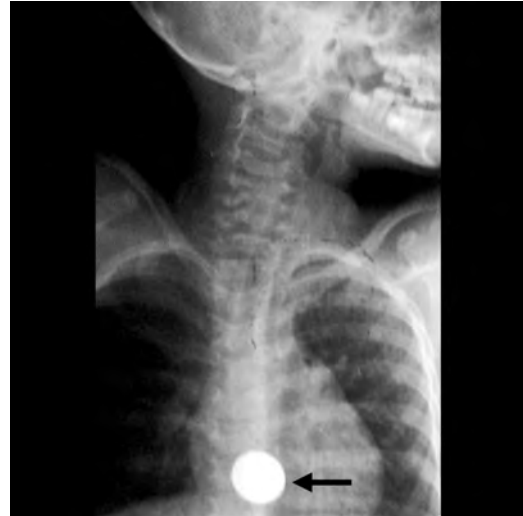- ❖ Sudden dysphagia with chest pain and breathlessness
- ❖ Later features of shock, sepsis, mediastinitis, empyema

##### Management:

- ❖ X-ray shows site and level of the foreign body (FB)
- ❖ Endoscopic removal can be tried.
- ❖ Impacted large FB should be removed by thoracotomy
- ❖ Antibiotics, jejunostomy, TPN, ICT are also required



**Fig. 19.42:** Foreign body in the oesophagus.



**Fig. 19.43:** Foreign body (COIN) in the lower oesophagus. Usually it can be removed by endoscope.



# Chapter 20

## Stomach

### CHAPTER OUTLINE

- ❖ Anatomy
  - Blood Supply of Stomach
  - Nerve Supply of Stomach
  - Histology
  - Lymphatic Drainage of Stomach
  - Duodenum
- ❖ Gastric Physiology
- ❖ Gastric Function Tests
- ❖ Gastrin
- ❖ Barium Meal Study
- ❖ Gastroscopy
- ❖ *Helicobacter pylori*
- ❖ Congenital Hypertrophic Pyloric Stenosis
- ❖ Gastritis
- ❖ Acute Peptic Ulcer
- ❖ Gastric Ulcer
- ❖ Duodenal Ulcer
- ❖ Pyloric Stenosis due to Chronic Duodenal Ulcer
- Electrolyte Changes in Pyloric Stenosis
- ❖ Perforated Peptic Ulcer
  - Perforated Duodenal Ulcer
  - Perforated Gastric Ulcer
  - Perforated Stomal Ulcer
  - Dry Perforation
- ❖ Bleeding Peptic Ulcer
  - Bleeding Duodenal Ulcer
  - Bleeding Gastric Ulcer
- ❖ Haematemesis
- ❖ Complications of Gastric Surgery
  - Duodenal Blow-out
  - Recurrent Ulcer
  - Dumping Syndrome
  - Roux Stasis Syndrome
  - Gastrojejunocolic Fistula
- ❖ Trichobezoar
- ❖ Chronic Duodenal Ileus
- ❖ Dunbar's Syndrome
- ❖ Acute Gastric Dilatation
- ❖ Gastric Volvulus
- ❖ Gastric Polyp
- ❖ Menetrier's Disease
- ❖ Duodenal Diverticula
- ❖ Carcinoma Stomach
- ❖ Gastric Lymphoma
  - Primary Gastric Lymphoma
  - Secondary Gastric Lymphoma
- ❖ Gastric Sarcomas
- ❖ Gastrointestinal Stromal Tumours
- ❖ Pyloroplasty
- ❖ Gastrostomy
- ❖ Gastrectomy
- ❖ Gastrojejunostomy
- ❖ Retrograde Jejunogastric Intussusception
- ❖ Vagotomy

### ANATOMY

The stomach contains four anatomic regions:

1. Fundus.
2. Cardia.
3. Body.
4. Pyloric part contains pyloric antrum, pyloric canal.

The *duodenum* is 20–30 cm in length. It extends from pyloric sphincter to *ligament of Treitz*. It is divided into four parts.

Ninety per cent of duodenal ulcer occurs in the 1st part of duodenum (duodenal bulb/cap).

CBD and pancreatic duct merges to form *ampulla of Vater* and enter the 2nd part of duodenum. The 3rd part of duodenum is wedged between aorta and superior mesenteric artery.

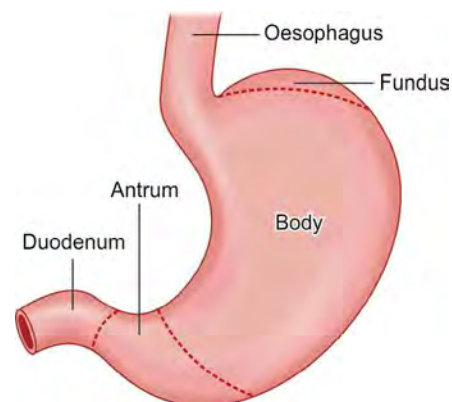


Fig. 20.1: Parts of stomach.

## BLOOD SUPPLY OF STOMACH

### Arterial Supply

- ◆ Left gastric artery, a branch of coeliac artery (Smallest branch of coeliac axis).
- ◆ Right gastric artery, a branch of hepatic artery.
- ◆ Gastroduodenal artery, a (largest) branch of hepatic artery.
- ◆ Right gastroepiploic artery, a branch of gastroduodenal artery.
- ◆ Left gastroepiploic artery, a branch of splenic artery.
- ◆ Short gastric arteries, branches of splenic artery.

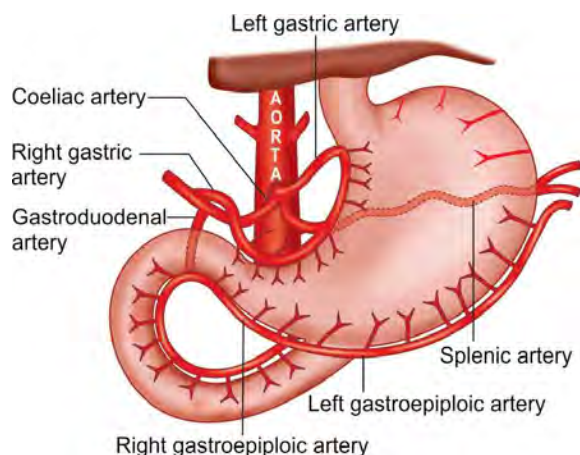


Fig. 20.2: Blood supply of the stomach.

### Venous Drainage

- ◆ Right and left gastric veins drain into portal vein.
- ◆ Right gastroepiploic vein drains into superior mesenteric vein.
- ◆ Left gastroepiploic vein and short gastric veins drain into splenic vein.
- ◆ Prepyloric vein of Mayo distinguishes pyloric canal from the first part of duodenum.

## NERVE SUPPLY OF STOMACH

- ◆ Intrinsic innervation occurs through myenteric plexus of Auerbach and submucous plexus of Meissner.
- ◆ Right vagus is posterior and left vagus is anterior.
- ◆ Posterior vagus gives *criminal nerves of Grassi*, which supply lower oesophagus and fundus of stomach, which, if not cut properly during vagotomy, may lead to recurrent ulcer.
- ◆ Vagus also gives splanchnic branches (*hepatic and coeliac branches*), ends as *nerve of Latarjet* which supplies the antrum and maintains the antral pump.
- ◆ Parietal branches help in HCl secretion, which is an important concept in vagotomy that is done as a treatment in duodenal ulcer.
- ◆ *Truncal vagotomy* with posterior gastrojejunostomy is done for chronic duodenal ulcer with pyloric stenosis.
- ◆ *Highly selective vagotomy (HSV)* is done in case of uncomplicated chronic duodenal ulcer which is not responding to available medical line of treatment. In HSV, nerve of Latarjet is retained so as to retain antral pump and no drainage is required. Here only the fibres entering the stomach are ligated close to the lesser curve to reduce the acid secretion.

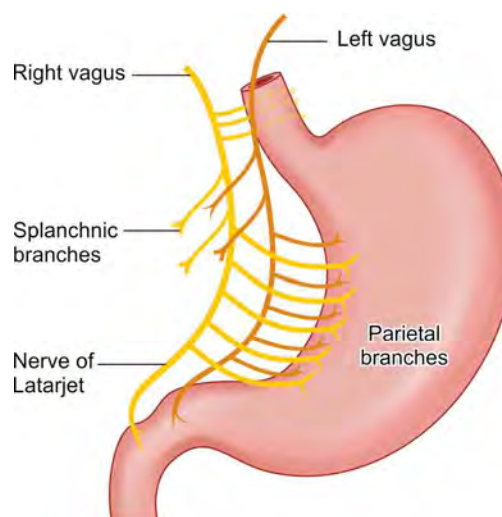


Fig. 20.3: Anatomy of nerve supply of stomach.

- ◆ In *selective vagotomy* splanchnic branches are retained but it is presently not done.
- ◆ Gastroduodenal pain is sensed via sympathetic fibres (T<sub>5</sub>–T<sub>10</sub>).

## HISTOLOGY

- ◆ The fundus and body contains parietal and chief cells.
- ◆ *Parietal cells* secrete acid and intrinsic factor.
- ◆ *Chief cells* produce pepsinogen. There are two types of pepsinogen secreted by chief cells—I and II. Pepsinogen I is produced only in stomach. In gastric atrophy pepsinogen I is decreased.
- ◆ In the antrum, *endocrine cells* produce gastrin (G cells) and somatostatin (D cells).
- ◆ 12% of epithelial cells of stomach are parietal (oxyntic) cells; 45% chief (zymogenic cells); 40% mucous cells; 3% endocrine cells.
- ◆ Pyloric sphincter is a thick circumferential layer of smooth muscle.
- ◆ Submucosa is strongest, collagen rich layer of gastric mucosa.
- ◆ Gastric mucus is a mucosal barrier containing mucopolysaccharides which maintains the integrity of gastric mucosa.

## LYMPHATIC DRAINAGE OF STOMACH

- ◆ Lymphatics of proximal half of stomach drain into left gastric, splenic, and superior pancreatic lymph nodes. From antrum, it drains into right gastric, right gastroepiploic, and subpyloric lymph nodes. From pylorus, it drains into right gastric and subpyloric lymph nodes.
- ◆ Efferent lymphatics from suprapyloric region drain into para-aortic lymph nodes and so into left supraclavicular lymph nodes. Efferent lymphatics from subpyloric lymph nodes drain into superior mesenteric lymph nodes. Lymphatics near *oesophagogastric (OG)* junction communicate with oesophageal lymphatics.
- ◆ In carcinoma stomach if upper lymphatics are blocked, retrograde spread through lower lymphatics can occur.
- ◆ Presently in carcinoma stomach different resections are classified as R0, R1, R2, R3, or D1, D2 (dissection) based on levels of lymph nodes in the abdomen in relation to the stomach. R0 is *no residual disease*; R1 is *microscopic residual disease*; R2 is *macroscopic residual disease*; R3 is *inoperable*.

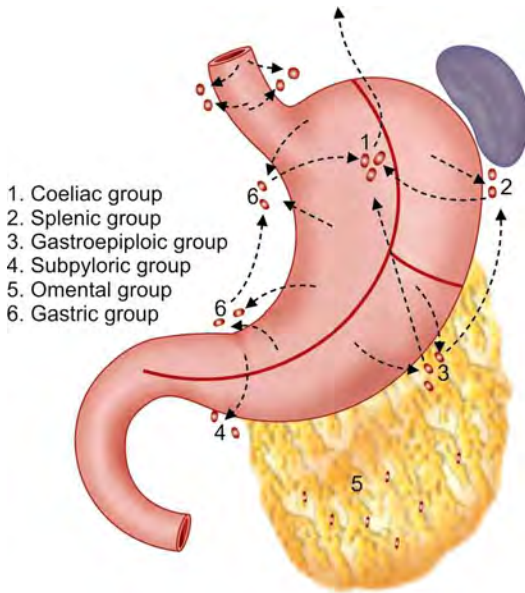


Fig. 20.4: Lymphatic drainage of stomach.

## DUODENUM

### Arterial Supply

It is mainly supplied by superior and inferior pancreaticoduodenal arteries. First part also gets supply from right gastric artery, supraduodenal artery, a branch of hepatic artery.

### Venous Drainage

Drains into the splenic, superior mesenteric and portal veins.

### Nerve Supply

- ◆ Sympathetic from spinal segments T<sub>8</sub> and T<sub>10</sub>.
- ◆ Parasympathetic from vagus.

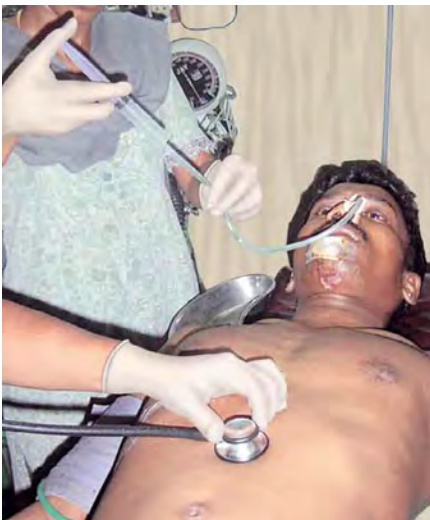

Fig. 20.5: After passing the Ryle's tube to the stomach, air from the syringe should be infused through the tube. When auscultated gush of air into the stomach can be heard which confirms that tube tip is in the stomach.

## Lymphatic Drainage

Drains mainly to pancreaticoduodenal nodes present along the inside of the curve of duodenum.

## GASTRIC PHYSIOLOGY

- ◆ *Gastric function* is regulated by hormonal and neural methods. Hormonal mediators control function through endocrine (through release into blood), paracrine (diffusion across interstitial space) and neurocrine (diffusion across synapsed target cell and receptor binding).
- ◆ *Gastric acid secretion* is regulated by acetylcholine, histamine and gastrin. Acetylcholine is the principal mediator of acid release through vagal parasympathetic ganglion cells. Vagus innervates parietal, G and *enterochromaffin-like* (ECL) cells. Basal acid secretion is 10% of maximal acid output (1-5 mmol/hour). It is reduced by 90% after vagotomy or H<sub>2</sub> receptor blockage. **Phases of acid secretion** are—(1) *Cephalic phase*—through central mediation (smell/sight/taste → vagus → acetylcholine → muscarinic receptors). (2) *Gastric phase*—food enters the stomach → antral G cells → acid release though gastrin (gastric distension causes direct acid release). Gastric phase lasts until stomach is empty and releases 70% of total acid release. (3) *Intestinal phase*—it is 10% of acid release and is mediated by chyme entering the small bowel—nongastrin related.
- ◆ *Receptors of acid secretions* are—(1) Gastrin—CCK receptors: Two types are present in parietal cell; Gastrin CCK type A receptor has high affinity for CCK but less to gastrin; Gastrin CCK type B receptor has got high affinity for both CCK and gastrin. (2) Muscarinic receptor (parietal cell)—its M<sub>3</sub> type is mediator for acetylcholine. (3) Histamine receptor (parietal cell)—H<sub>2</sub> subtype binds to histamine to cause effect. (4) Somatostatin receptor—these are 5 subtypes. Its inhibitory action is through parietal cell subtype. (5) Second messengers involved are intracellular cAMP and calcium.
- ◆ *Luminal gastric pH* is 2. The pH at surface epithelial cells is 7. These cells secrete bicarbonate continuously into the lining mucus gel to keep the pH of surface mucus at 5. Bicarbonate in mucus barrier reduces once luminal pH reduces below 1.4.
- ◆ *Functions of gastric acid*: Conversion of pepsinogen to pepsin which in turn hydrolyses proteins into polypeptides; promotes release of duodenal secretin; prevents bacterial colonisation of upper GIT; formation of food chyme which contains food particles of 1 mm size or less.
- ◆ *Gastric juice* contains HCl, mucus, swallowed saliva, reflux content from duodenum. Parietal cells secrete electrolytes of 160 mmol/L. They also secrete *intrinsic factor*, a mucoprotein which is essential for absorption of vitamin B<sub>12</sub> in ileum; its secretion is independent of acid secretion from parietal cell and is not influenced by PPIs. Pepsinogen is a proteolytic proenzyme (42,000 mol wt). Type I is secreted from chief cells and mucous neck cells of only acid secreting part of the stomach (acid secreting mucosa). Type II is secreted from surface epithelial cells of entire stomach and proximal duodenum. Mucous is secreted by surface mucous cells and mucous neck cells from acid secreting area of stomach and antrum. Gel like viscous mucous contains 85% water and 15% glycoproteins. It contains bicarbonate secreted from surface epithelial cells. Mucous is strong gastric barrier. Mucous secretion is inhibited by anticholinergics and NSAIDs. *H. pylori* break the mucin and so barrier.
- ◆ *Gastric motility* begins from *pacemaker cell of Cajal* located at proximal stomach. Special myoelectric migrating complex slow

waves with electric spikes maintain gastric motility in three phases. Immediately after food intake resting tone of fundus and proximal stomach decrease causing receptive relaxation and gastric accommodation mediated by vagus. Vagotomy eliminates this causing early fullness, early satiety and rapid gastric emptying. Delayed gastric motility occurs in diabetes, *H. pylori* infection and after vagotomy. Many factors like stress, hormones increase the gastric motility. Prokinetics, erythromycin helps in gastroparesis.

- ◆ **Mucosal defense factors** are—mucous production, mucosal  $\text{HCO}_3^-$ , mucosal blood flow, growth factors, cell renewal, endogenous prostaglandins, epithelial barrier (hydrophobic phospholipids, restitution, NO, epidermal growth factor and microcirculation). **Aggressive factors** are—*H. pylori*, HCl secretion, pepsin, smoking, alcohol, duodenal bile reflux, ischaemia, NSAIDs.

## GASTRIC FUNCTION TESTS

### Gastric function tests

- ❖ Pentagastrin test/Kay's augmented histamine test
- ❖ Hollander's insulin test
- ❖ Radioisotope labelled gastric emptying study
- ❖ 24 hours intragastric pH monitoring
- ❖ Gastrin level estimation

### Peak Acid Output Test (Pentagastrin/Augmented Histamine Test)

Initially stomach is emptied completely. Basal acid level of aspirated stomach content (aspiration is done for 1 hour on empty stomach) is analysed. Pentagastrin—6  $\mu\text{g}/\text{kg}$  or histamine 2  $\mu\text{g}/\text{kg}$  is injected IV/SC/IM and 15 minutes samples for subsequent hours (usually 1 hour) are collected and analysed. Peak acid output level is calculated. Test is useful in Zollinger-Ellison (Z-E) syndrome, duodenal ulcer and gastric ulcer. Basal acid output (BAO) is 2–3 mEq/h. Peak acid output (PAO) is highest rate of secretion obtained in any of the 15 minutes samples following stimulation. Maximal acid output (MAO) is obtained by averaging the output of two final 15 minutes samples. In duodenal ulcer and Z-E syndrome basal and stimulated acid is increased; in pernicious anaemia, gastric atrophy and gastric cancer both are decreased.

	Basal	Peak
Normal	5 mmols	25–27
Gastric ulcer	2	15
Duodenal ulcer	6	35–38
Z-E syndrome	Very high	> than 60

*Achlorhydria* is defined as a condition in which stomach cannot produce secretions with a pH of less than 7.0 even after maximal stimulation. It is seen in 20% of carcinoma stomach.

#### Note:

Achylia means—no pepsin in the gastric juice.

### Insulin Test (Hollander)

- ◆ This test is useful postoperatively to confirm the completeness of vagotomy. 0.2 units/kg body weight of insulin is injected intra-

venously to a fasting patient so as to create hypoglycaemia of below 35 mg%, which in turn stimulates the parietal cells through hypothalamus and through vagus to cause increased acid secretion. Patient who had undergone complete vagotomy does not show increase in acid secretion.

- ◆ **Early response** signifies incomplete vagotomy wherein there is increase in acid concentration in first hour of >20 mmols/L.
- ◆ **Delayed response** signifies an increase in acid concentration in between first and second hours, and is probably due to vagal gastrin release.

## GASTRIN

- ◆ Gastrin is secreted by the G-cells from gastric antrum.
- ◆ **Types of gastrin** are—**Big gastrin** ( $\text{G}_{34}$ ); **little gastrin** ( $\text{G}_{17}$ )—most common 90%; **mini gastrin** ( $\text{G}_{14}$ ). Pentapeptide at the C terminal end of  $\text{G}_{17}$  is active part which is identical to CCK. Luminal peptides and amino acids are most potent stimulator of gastrin release. Luminal acid is the most potent inhibitor of gastrin release.
- ◆ **Gastrin promotes** the release of acid and also regulates it. It also maintains mucosal defense, has trophic effects on parietal and ECL cells (enterochromaffin like cells).
- ◆ Number of G-cells are increased in duodenal ulcer, G-cell hyperplasia, but not in gastric ulcer. Normal plasma value is 50 ng/L of plasma (fasting). It is analysed by radioimmunoassay.
- ◆ It increases to many 1000's in gastrinomas.
- ◆ **Hypergastrinaemia** can occur in **ulcerogenic conditions** like— antral G cell hyperplasia, retained excluded antrum, Z-E syndrome, short gut syndrome, gastric outlet obstruction; **nonulcerogenic conditions** are—PPIs, pernicious anaemia (–ve feedback), vagotomy, atrophic gastritis (hypochlorhydria), *H. pylori*, chronic renal failure.
- ◆ Gastrin is raised very high in **gastrinomas**.

### Gastric hormones

- ❖ **Gastrin**
- ❖ **Somatostatin**—2 types, 14 and 28. In stomach, type 14 is common; from D cells of gastric mucosa of fundus and antrum. Antral acidification is the main stimulus; vagal acetylcholine inhibits its release. It has **paracrine** effect inhibiting acid secretion from parietal cell, gastrin release from G cell and histamine release from ECL cell. *H. pylori* decrease antral D cells and so somatostatin, leading into increased gastrin release
- ❖ **Gastrin releasing polypeptide** (GRP, Bombesin)—it stimulates gastrin and somatostatin release by binding to receptors on G and D cells. It is released from sympathetic nerve terminals of the gastric mucosa of body and antrum. Its half-life is 1½ minutes
- ❖ **Histamine** is stored in ECL and mast cells. Its release is stimulated by gastrin, acetylcholine and epinephrine
- ❖ **Ghrelin** (28 amino acids) is mainly secreted from endocrine cells of gastric mucosa. It has mainly got growth hormone releasing action; prolactin, ACTH, cortisol, aldosterone release is also promoted. Its action on islet cells reduces insulin release. **Ghrelin** stimulates appetite. Gastric bypass, gastrectomy reduces the appetite.

### Investigations for gastroduodenal diseases

- ❖ Gastroduodenoscopy is ideal and most common investigation used to visualise mucosa. Lesions if any biopsy is taken for *H. pylori* and carcinoma. Also often used for endotherapy
- ❖ Endosonography (EUS) is very sensitive method to assess tumours, visualise stomach layers (90% accuracy), lymph nodes (80%), and to detect early liver metastasis which may not be identified by CT especially from left lobe
- ❖ CT scan is good imaging method to detect the stage, spread, nodal status, liver secondaries, and status of lungs
- ❖ CT and PET scan (together) using FDG is better to assess early spread
- ❖ Laparoscopy is very good investigating tool to identify peritoneal secondaries, and to stage the disease. Laparoscopic US is very sensitive to detect the liver secondaries
- ❖ Barium meal studies are used to detect hiatus hernia
- ❖ Celiac angiography is useful in bleeding ulcers, both for diagnostic and therapeutic purpose (therapeutic embolisation)

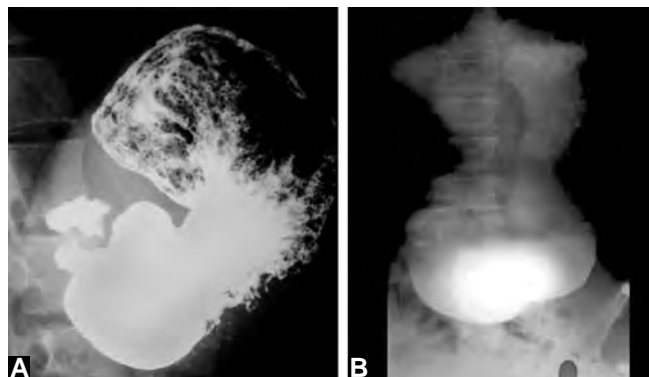
## BARIUM MEAL STUDY

### Indications

1. Gastric ulcer—shows a *niche* which is the ulcer crater, a *notch* which is due to spasm of circular muscle on the greater curvature.
2. Chronic duodenal ulcer—shows absence or deformed duodenal cap (due to spasm of 1st part of duodenum, barium will not stay and so cap will not be formed).
3. Gastric outlet obstruction—the cause may be chronic duodenal ulcer with pyloric stenosis or carcinoma pylorus. Features are:
  - ▶ Enormous dilatation of stomach.
  - ▶ Greater curvature below the level of iliac crest.
  - ▶ Absence of duodenal cap.
  - ▶ No filling of dye in 2nd part of duodenum.
  - ▶ Mottled appearance of stomach because of retained food particles.
  - ▶ Evidence of gastritis.
4. Carcinoma stomach—irregular filling defect.
5. Pseudocyst of pancreas—widened vertebrogastric angle.
6. Stomal ulcer in previous gastrojejunostomy.
7. In chronic duodenal ileus (*Wilkie's syndrome*)—shows dilatation of stomach, 1st and 2nd parts of duodenum, proximal portion of 3rd part of duodenum.
8. Others—gastric volvulus, duodenal diverticula, trichobezoar, gastric fistulas, diaphragmatic hernias when stomach is the content.
9. Carcinoma of head of pancreas shows "*pad sign*"; in periampullary carcinoma—*reverse '3' sign*.  
*Frostberg's reverse '3' sign* (inverted '3' sign).  
*Rose thorn duodenum* in carcinoma head of pancreas.
10. Hiatus hernia.

### Procedure

- ◆ Barium sulphate solution is used [Barium is neurotoxic, but in sulphate media it will not get absorbed and so barium sulphate is used (Barium phosphate is not used)].
- ◆ About 300 ml solution is given to the patient to drink and its flow down to the stomach is observed under fluoroscopic guidance. Films are taken as required. Commonly oblique views are taken.
- ◆ Microcrystallised barium sulphate (*Microbar solution*) is better as it does not get precipitated.



**Figs 20.6A and B:** Barium meal X-rays showing normal picture in one and dilated stomach with features of gastric outlet obstruction in another.

### Complication

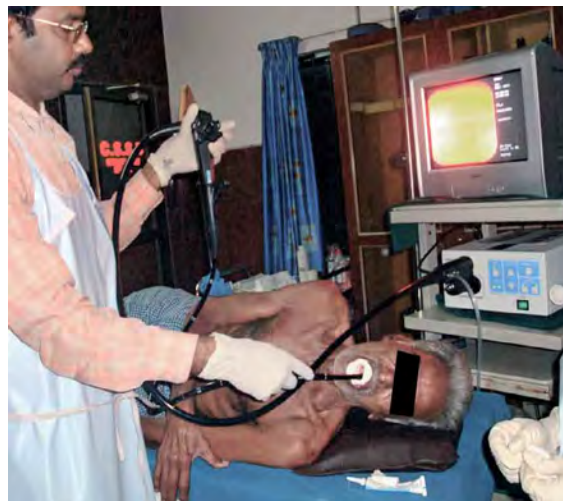It may precipitate intestinal obstruction.

## GASTROSCOPY

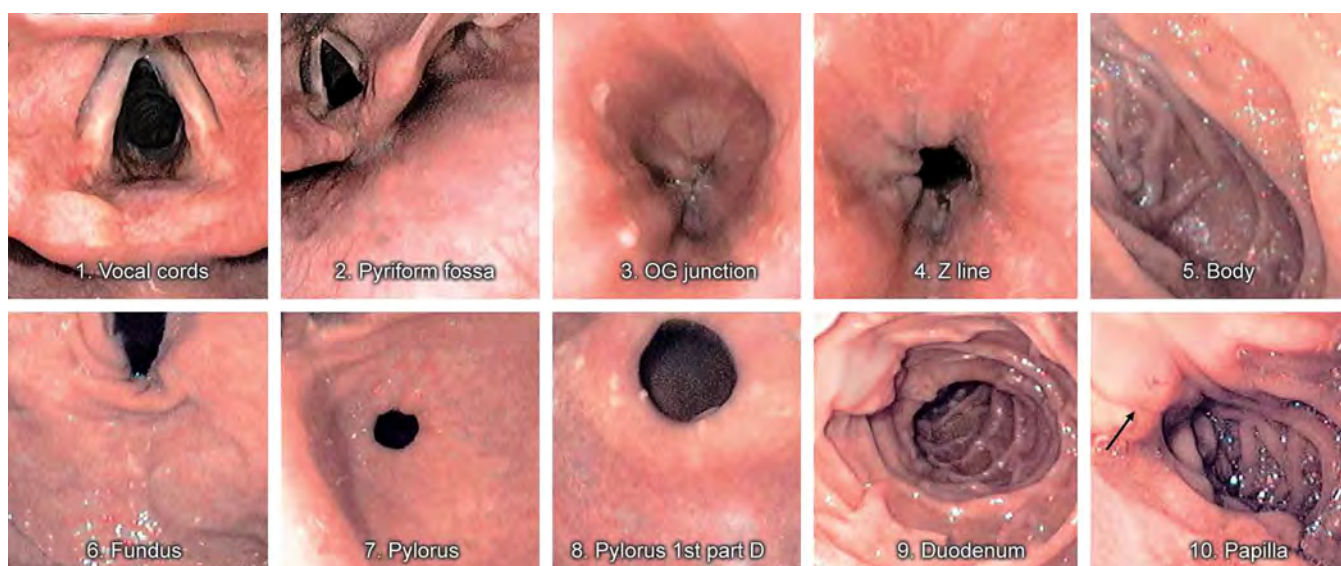
It is visualisation of interior of stomach, duodenum, oesophagus. It can be done as OP procedure.

### Uses

1. For diagnosing any pathology, e.g.
  - ▶ Gastric ulcer.
  - ▶ Duodenal ulcer.
  - ▶ Gastritis.
  - ▶ Stomal ulcer.
  - ▶ Carcinoma stomach.
  - ▶ Oesophagitis.
  - ▶ Varices.
  - ▶ Biopsies from the suspected cases of malignancy or for *Helicobacter pylori* can be taken.
    - **Endosonography** can be done to assess the staging, operability of carcinoma stomach or oesophagus.
    - Presently fibreoptic, flexible, or video gastroduodenoscopy is used.



**Fig. 20.7:** Technique of doing gastroscopy using videoendoscope.



**Fig. 20.8:** Gastrosopic views of different parts—vocal cords; pyriform fossa; oesophagus; oesophagogastric (OG) junction; body, fundus and pylorus of stomach, duodenum with clearly visible duodenal papilla (Courtesy: Dr Tantry and Dr Sandeep Gopal, Gastroenterologists, KMC, Mangaluru).

## 2. Therapeutic


- ▶ **Videoendoscopy** is used not only for diagnosis but also mainly for therapeutic procedures.
- ▶ Both end viewing and side viewing gastroscopes are available.
- ▶ For therapeutic procedures and ERCP, side viewing gastroscope is required.

### Therapeutic procedures done are:

- ❖ Variceal injection or ligation or glueing or banding
- ❖ Stenting of pseudocyst of pancreas through gastroscopy
- ❖ Polyp removal
- ❖ Submucosal resection
- ❖ For ERCP diagnostic and therapeutic procedures
- ❖ Percutaneous gastrostomy (PEG)

## Procedure

Gastroscopy is done following eight hours of fasting. After lignocaine spray into the oral cavity, gastroscope is passed gently down the oesophagus when the patient does the swallowing action. Once the scope is inside the stomach, air is inflated and different parts of the



**Fig. 20.9:** Endosonography of stomach showing different layers with echogenicity.

stomach is visualised. Fundus is visualised by retropulsion. Scope is passed through the pylorus to see the 1st and 2nd parts of duodenum and looked for any pathology. If required biopsy is taken.

Often sedation with midazolam is beneficial to have an easy passage.

- ◆ *Buscopan* is used to relax stomach wall.
- ◆ *Z-line* signifies squamocolumnar junction.
- ◆ *Multi-byte biopsy forceps* is used.

## Complications

- ◆ Bleeding.
- ◆ Aspiration.
- ◆ Perforation (rarely). Perforation occurs mainly in therapeutic procedures like oesophageal dilatation, endoscopic mucosal resection (EMR). It is common in proximal and middle oesophagus but can occur anywhere. Patient presents with hypotension, tachycardia, sudden severe pain in chest, abdomen, neck and surgical emphysema.

## HELICOBACTER PYLORI

- ◆ It is gram –ve spiral like flagellated organism, first studied by Warren and Marshall (both got Nobel prize), which is commonly present in stomach. It is involved in pathogenesis of duodenal ulcer, gastric ulcer, gastritis (type B) and gastric cancer.

### *H. pylori*

- ❖ Duodenal ulcer—95%
- ❖ Gastric ulcer—70%
- ❖ Gastritis—70–90%
- ❖ Gastric cancer—No. 1 carcinogen
- ❖ Gastric MALTOMA (mucosa-associated lymphoid tissue lymphoma)

*The stomach you can hear, the stomach you can see, the stomach you can feel.*—Sir James Walton

### Control of *H. pylori* Infection

It is treated with antibiotics and other drugs with different combinations

Clarithromycin 500 mg BD	Metronidazole 400 mg BD	Omeprazole 20 mg BD
OR	OR	OR
Amoxicillin 500–750 mg BD	Tinidazole 600 mg BD	Lansoprazole 30 mg BD
OR		OR
Tetracyclines, or Bismuth.		Pantoprazole 40 mg BD

The above regime is given for 7–14 days and then only proton pump inhibitors are continued.

## Pathogenesis

- ◆ It is the most common bacterial infection in the world. Rhesus monkey is the only natural reservoir. Its incidence increases with age.
- ◆ It releases enzymes like *urease* that hydrolyses urea so as to release ammonia which through negative feedback mechanism increases the gastrin release from G-cells.
- ◆ Infection occurs in stomach, i.e. body, fundus, antrum, disrupts the mucosal barrier, causes chronic inflammatory response leading to gastritis, gastric ulcer.
- ◆ Other than urease it also secretes dehydrogenase (converts alcohol to aldehyde which is toxic to mucosa), endopeptidase (disrupts mucosal barrier). Urease creates alkaline environment around it in mucus layer of gastric epithelium. It can survive only in gastric epithelium or gastric metaplasia in duodenum or Barrett's oesophagus or in heterotopic gastric mucosa in Meckel's diverticulum or rectum. It is because receptors for organisms to adhere into mucosa are available only in gastric mucosa.
- ◆ *H. pylori* impair mucosal healing, cause degranulation of eosinophils. It releases various protease and lipases that break mucus and so strong protective mucus barrier.
- ◆ It also secretes *cytotoxins* (cagA and vacA) which may also be involved in inflammatory reaction or malignancy.
- ◆ Even though normal duodenum cannot harbour the *Helicobacter*, duodenum with gastric metaplasia can very well get infected by *Helicobacter* which explains why *Helicobacter* is involved in duodenal ulcer.
- ◆ *Helicobacter* is normally not found in saliva.
- ◆ Infection is transmitted through faeco-oral route, with a infection rate of 80–90% in a population (common and high).
- ◆ It is more common in lower socioeconomic group.
- ◆ It is considered to be a **carcinogen for stomach**. It is not linked with carcinoma of OG junction.

### Enzymes and toxins released by *H. pylori*

- ❖ Urease
- ❖ Dehydrogenase
- ❖ Endopeptidase
- ❖ Vacuolising cytotoxin–Vac A exotoxin
- ❖ Haemolysin
- ❖ CagA–cytotoxin-associated gene A

It is identified by:

- a. Rapid urease test (cod liver oil test/CLO test)—noninvasive.
- b. C13–C14 breath tests (labelled urea breath test)—noninvasive.
- c. Biopsy from the different parts of the stomach and staining to identify the organism—invasive.

For *H. pylori* three biopsies are taken one each from antrum, body and fundus.

### Tests for *H. pylori*

- ❖ Rapid urease test—90% sensitivity, 98% specificity
- ❖ C13/ C14 breath tests—95% sensitivity and specificity—'gold standard'
  - C13 requires spectrometry and costly
  - C14 uses radioactivity
- ❖ Serology to identify IgG antibody—ELISA test with 90% sensitivity and specificity
- ❖ Biopsy and culture—very costly
- ❖ Warthin's starry silver stain, acridine orange are special stains used
- ❖ Newer methods—special fluorescent technique, PCR products of *H. pylori*—urease gene, 16S rRNA identified using specialised probes when organisms are in less number

## Treatment

Therapy consists of antimicrobials combined with suppression of gastric acid. Various combinations like *triple regimes* are used to control and eradicate the infection. Clarithromycin, amoxicillin, tetracyclines, bismuth and metronidazole/tinidazole with omeprazole/lansoprazole/pantoprazole (proton pump inhibitors) combinations—are used. Triple regime is given for 7–14 days. After that PPI should be continued for 6–12 weeks. Follow-up confirmation of the eradication of the infection is needed often. Quadruple therapy using PPI twice daily, bismuth 2 tablets 4 times daily, metronidazole 250–400 mg three times daily, tetracycline 500 mg 4 times daily is used for 7–14 days.

## ■ CONGENITAL (INFANTILE) HYPERTROPHIC PYLORIC STENOSIS

It is hypertrophy of musculature of pyloric antrum, especially the circular muscle fibres, causing primary failure of pylorus to relax. Duodenum is normal.

There is increased risk of developing the condition if newborn gets erythromycin or azithromycin in first 14 days after birth.

## Clinical Features

- ◆ Common in first born *males* (4:1).
- ◆ Incidence is 4 in 1000 births.
- ◆ It is familial.
- ◆ It is seen between 3rd and 6th weeks of age of an infant, the time taken by the hypertrophied muscle to cause complete obstruction.
- ◆ Vomiting—forcible, *projectile and non-bilious*.
- ◆ Visible gastric peristalsis (VGP).

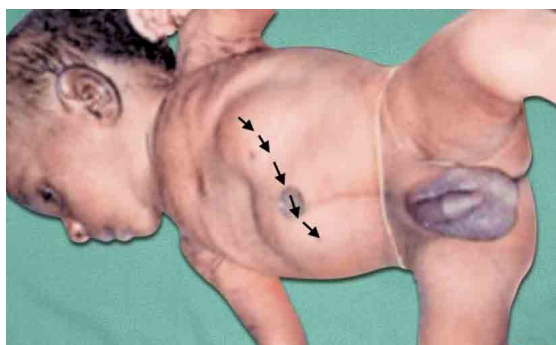


Fig. 20.10: Visible gastric peristalsis.

- ◆ Palpable lump of hypertrophied pylorus which is better felt from left side, as a mobile, smooth, firm, *olive like* mass, with all borders well made out, moves with respiration, with impaired resonance on percussion. It is the most important clinical feature (95%).
- ◆ Constipation.
- ◆ Dehydration and loss of weight.
- ◆ Electrolyte imbalance—hypokalaemic metabolicalkalosis.

### Clinical features of congenital pyloric stenosis

- ❖ Vomiting
- ❖ VGP
- ❖ Palpable mass
- ❖ Constipation and dehydration

#### In premature infants:

- ◆ VGP and mass is better seen and felt.
- ◆ Vomiting is regurgitant.
- ◆ Anorexia is common.

#### Diagnosis is established by:

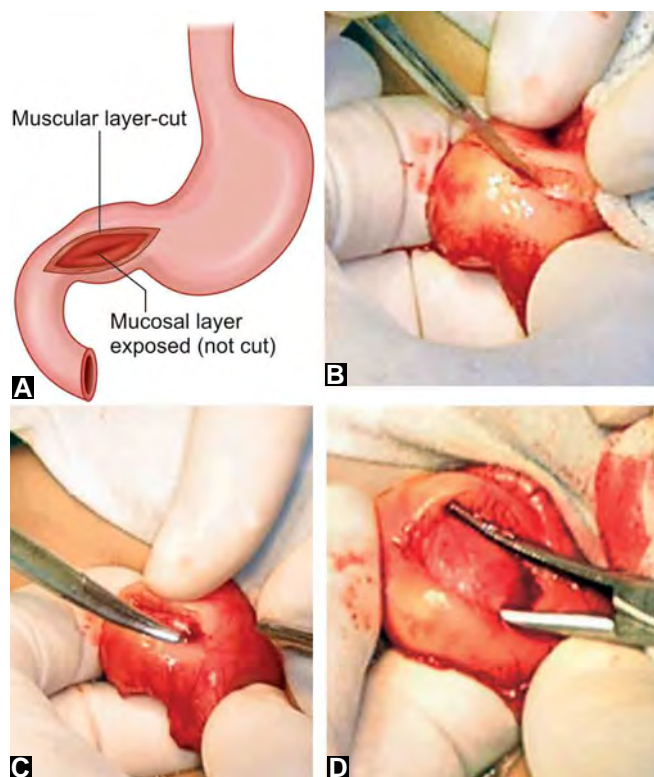
- ◆ Clinical examination.
- ◆ Ultrasound abdomen (very useful)—*Doughnut sign*.
  - ▶ Pyloric muscle 4 mm or more in thickness.
  - ▶ Length of pyloric canal >14 mm.
  - ▶ Cervix sign on long axis, target sign on short axis.
- ◆ Barium meal shows obstruction. Contrast study is not commonly done; but when it is done, it shows ‘string sign’ or ‘railroad track sign’ or ‘double track sign’ with pyloric obstruction.

## Differential Diagnosis

- ◆ Duodenal atresia (Bilious vomiting is present).
- ◆ High intestinal obstruction (e.g. volvulus neonatorum).
- ◆ Intracranial haemorrhage.

## Treatment

1. Correction of dehydration and electrolyte imbalance.
2. **Surgery:**
  - ▶ *Ramstedt's operation*—After laparotomy, hypertrophied muscle is cut along the whole length adequately until the mucosa bulges out. Mucosa should not be opened (pyloromyotomy). If mucosa is injured, it should be sutured horizontally using interrupted vicryl or silk sutures.
  - ▶ *Laparoscopic pyloromyotomy* is becoming popular.
3. *Endoscopic pyloromyotomy* is also tried (alike POEM for achalasia cardia).
4. Balloon dilatation is tried but results are not optimum like surgery or myotomy.



FIGS 20.11A to D: (A) Ramstedt operation for congenital hypertrophic pyloric stenosis. Note that here muscular layer is cut but not mucosal layer; (B to D) *Ramstedt pyloromyotomy* for congenital hypertrophic pyloric stenosis. Only muscular layer is cut to allow mucosa to bulge out.

### Complications of surgery

- ❖ Postoperative pyrexia (Hyperthermia).
- ❖ Gastroenteritis
- ❖ Electrolyte imbalance



**Note**

- **Medical treatment:** Not advisable as cure is not guaranteed. Atropine methyl nitrate orally is tried to relax the pylorus muscle.

**GASTRITIS****Types**

1. Type A gastritis.
2. Type B gastritis.
3. Reflux gastritis.
4. Erosive gastritis.
5. *Others:* Stress gastritis, lymphocytic gastritis, granulomatous gastritis, phlegmonous gastritis.

**Type A Gastritis**

- ◆ Autoimmune disease.
- ◆ There is formation of antiparietal cell antibodies.
- ◆ Parietal cell dysfunction occurs causing achlorhydria and vitamin B<sub>12</sub> deficiency.
- ◆ Antrum is not affected.
- ◆ 'G' cell hyperplasia occurs with raised serum gastrin level.
- ◆ There is formation of microadenoma of enterochromaffin like cells (ECL cells) with predisposition to gastric carcinoma.

**Type B Gastritis**

- ◆ Occurs due to *Helicobacter pylori* infection.
- ◆ Antrum is affected.
- ◆ Peptic ulcer is common.
- ◆ *Helicobacter* related pangastritis commonly occurs which may turn into gastric cancer.

**Reflux Gastritis**

- ◆ Usually occurs after gastric surgeries.
- ◆ Prokinetic drugs are useful—metochlopramide, domperidone, cisapride, mozapride.

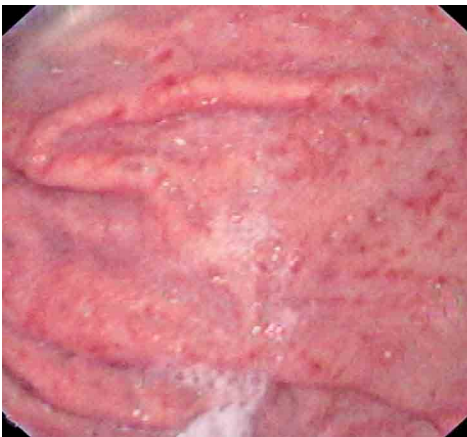**Erosive Gastritis**

- ◆ Occurs due to disturbed gastric mucosal barrier.
- ◆ Induced by NSAIDs/alcohol.

**Stress Gastritis**

Treatment:

- ◆ IV ranitidine 50 mg 8th hourly.
- ◆ IV omeprazole/pantoprazole.
- ◆ Sucralfate orally.



**Fig. 20.12:** Endoscopic view of erosive gastritis.

- ◆ Due to inhibition of cyclo-oxygenase type 1 (COX-1) receptor enzyme, resulting in decreased prostaglandin production (Prostaglandin is cytoprotective).
- ◆ COX-2 mediated NSAIDs will not cause erosive gastritis.

**Lymphocytic Gastritis**

It is associated with *H. pylori* infection.

**Granulomatous Gastritis**

It is seen in Crohn's disease and tuberculosis.

**Phlegmonous Gastritis**

It is due to severe bacterial infection of stomach. It is rare but dangerous.

**Nonulcer dyspepsia**

- ❖ Symptom complex with pain and discomfort in the upper abdomen
- ❖ It is intermittent upper abdomen pain in the absence of peptic ulceration
- ❖ It occurs in 25% of population—large number
- ❖ Anatomical or biochemical abnormalities are not discovered in this condition
- ❖ *H. pylori* is not associated with this condition
- ❖ Often it lasts for long time decreasing the quality of life
- ❖ Differential diagnosis—GERD/acid peptic diseases/gallstones/pancreatitis/carcinoma
- ❖ *H. pylori* eradication is not required and there is no surgical role

**ACUTE PEPTIC ULCER (DUODENAL OR GASTRIC ULCER)**

They are usually multiple erosions due to disruption of the mucosal barrier.

**Causes**

Stress, drugs like analgesics, steroids, surgeries.

**Clinical Features**

- ◆ Sudden onset of acute pain and tenderness in epigastric region.
  - ◆ Vomiting with or without haematemesis.
  - ◆ Often acute peptic ulcers can lead to perforations.
    - ▶ Acute ulcers after cerebral trauma or neurosurgeries are called as *Cushing's ulcers*.
    - ▶ Acute ulcers after major burns are called as *Curling's ulcers*.
- Diagnosis is by gastroscopy.

**Treatment**

- ◆ Intravenous ranitidine 50 mg, 8th hourly.
- ◆ IV fluids. IV pantoprazole/rabeprazole/omeprazole.
- ◆ Blood transfusions if there is bleeding.

Most of the time surgery is not required for acute ulcers. During follow-up patients are advised to take antiulcer drugs for 4-6 weeks—ranitidine, omeprazole or lansoprazole.

**Curling's Ulcers**

- ◆ They are acute ulcers which develop after major burns, presenting as pain in epigastric region, vomiting or haemate-

mesis. Treatment is conservative—IV ranitidine. IV pantoprazole 80 mg in 100 ml DNS—slow, later 40 mg IV maintenance.

- ◆ Curling's ulcer occurs when burn injury is more than 35%. It is observed in the body and fundus not in antrum and duodenum.

### Cushing's Ulcers

They are acute ulcers which develop after cerebral trauma or after neurosurgical operations. It is commonly single, deeper ulcer more frequently perforates. It can occur in oesophagus and duodenum also. Treatment is conservative by IV ranitidine.

## ■ GASTRIC ULCER

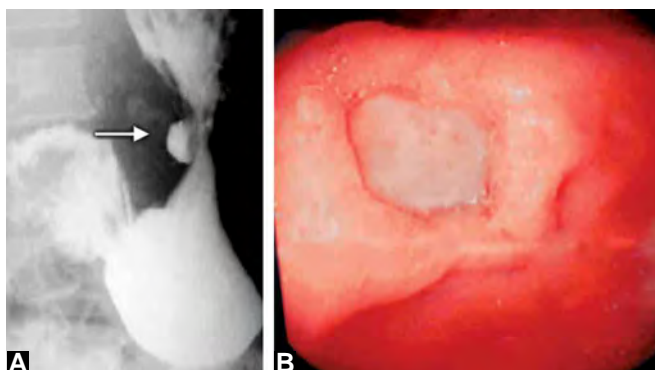
### Aetiology

It occurs due to imbalance between protective and damaging factors of gastric mucosa.

- ◆ Atrophic gastritis, duodenogastric bile reflux, gastric stasis, abnormalities in acid and pepsin secretion. Acid becomes ulcerogenic even to normal gastric mucosa.
- ◆ Smoking, alcohol, NSAIDs, steroids.
- ◆ *Helicobacter pylori* infection (70%).
- ◆ There is either normochlorhydria or hypochlorhydria.
- ◆ Altered mucosal barrier mechanism.
- ◆ Lower socioeconomic group.

### Factors Involved in Gastric Ulcer Formation

- ◆ Duodenogastric reflux—reflux containing bile salts and lysolecithin break the mucosal barrier making it more vulnerable for injury, action of drugs and pepsin injury.
- ◆ Gastric stasis.
- ◆ Ischaemia of the gastric mucosa.
- ◆ Type II and III gastric ulcers show acid hypersecretion.



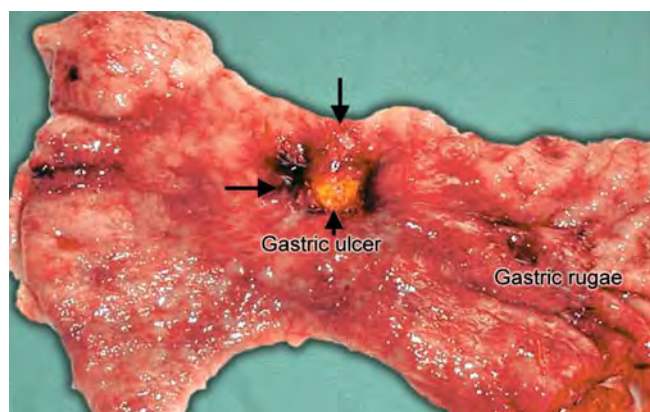
**Figs 20.13A and B:** (A) Barium meal showing *Niche* in the lesser curve as benign gastric ulcer; (B) Benign gastric ulcer endoscopic view. Biopsy is a must. Ideally 10 biopsies should be taken from the edge.

### Pathology

- ◆ Gastric ulcer is large in size, usually lies in the lesser curvature, its floor being formed by the muscular layer.
- ◆ Posteriorly it may penetrate into the pancreas; it may cause torrential bleeding by eroding left gastric (commonly) vessels or splenic vessels or vessels in the gastric ulcer wall.
- ◆ Anteriorly it may perforate or penetrate into the liver. It may lead into *hour glass contracture*, or *tea-pot deformity*.

- ◆ Microscopically, it shows ulcer crater with chronic inflammatory cells and granulation tissue, endarteritis obliterans and epithelial proliferation.

(Ulcer to the right of the incisura is malignant unless proved otherwise).



**Fig. 20.14:** Specimen of stomach (identified by the mucosal pattern and rugae) showing deep ulcer near lesser curvature. Margin of the ulcer is clear, not everted with gastric mucosal folds converging towards the base of the ulcer. 95% of benign gastric ulcer occurs towards lesser curve. Benign gastric ulcer is more common in lesser curvature, as it takes more burden of passage of food and so more of wear and tear. Benign gastric ulcer is rare in greater curvature, fundus and cardia. Histologically it shows destruction of epithelial lining; proliferation of margin; destruction of the part of the muscle layer; granulation tissue in the floor; infiltration with chronic inflammatory cells; endarteritis and fibrosis in the base.

- ◆ Gastric ulcer >3 cm is called as *giant gastric ulcer*. It has got 6–23% chances to turn into malignancy. Incidence of *perforation and bleeding* is also very high. Endoscopy and biopsy should be done to rule out malignancy. Follow-up endoscopy is a must if drug therapy is used for treatment to confirm the complete healing of the ulcer. If complete remission has not occurred then partial gastrectomy should be done.
- ◆ Grossly, margin of the benign gastric ulcer is clear; deep; near lesser curve; edge is not everted with gastric mucosal folds *converging* towards the base of the ulcer.
- ◆ Ninety-five per cent of benign gastric ulcer occurs towards lesser curve, as it takes more burden of passage of food and so more of wear and tear. Benign gastric ulcer is rare in greater curvature, fundus and cardia.
- ◆ **Acute ulcer:** It is confined to mucosa and submucosa. It is commonly due to NSAIDs.
- ◆ **Chronic ulcer:** It penetrates muscularis layer of stomach.

### Clinical Features

- ◆ Equal in both sexes. It is becoming more common in females.
- ◆ Common after the age of 40 years.
- ◆ *Pain* in epigastric region after taking food, lasting up to two hours. Pain is uncommon during night. It is relieved by vomiting or by inducing vomiting.
- ◆ *Periodicity:* Symptom free interval may be 2–6 months. Often with seasonal variation.
- ◆ *Vomiting* relieves pain and often it is induced by the patient for relief of pain.

**Types of gastric ulcer (Daintree Johnson)**

Type	Location	Incidence	Acid level
Type I	In the antrum, near the lesser curve	55%	Normal
Type II	Combined gastric ulcer (in the body) with duodenal ulcer	25%	High
Type III	Prepyloric ulcer	15%	High
Type IV	Gastric ulcer in the proximal stomach or cardia	5%	Normal

- ◆ *Haematemesis and melaena*: Haematemesis is more common.
- ◆ Appetite is good but hesitant to eat, because eating induces pain and that results in loss of weight. But once complications occur, appetite decreases. Aversion to spicy, fried foods occurs.
- ◆ On deep palpation, tenderness is felt in epigastric region.

**Note:**

- Often in lesser curve, saddle-shaped ulcer can occur.
- Type V gastric ulcer is – ulcer anywhere in the stomach associated with NSAIDs.

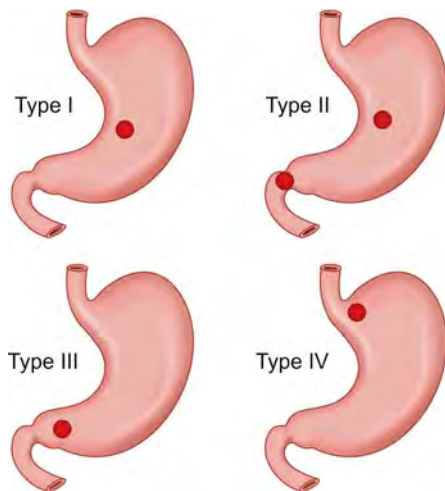


Fig. 20.15: Types of gastric ulcer (Daintree Johnson).

**Differential diagnosis**

- ❖ Hiatus hernia
- ❖ Cholecystitis
- ❖ Chronic pancreatitis
- ❖ Chronic gastritis
- ❖ Dyspepsia
- ❖ Carcinoma stomach.

**Investigations**

- ◆ Barium meal X-ray to see *niche and notch*.

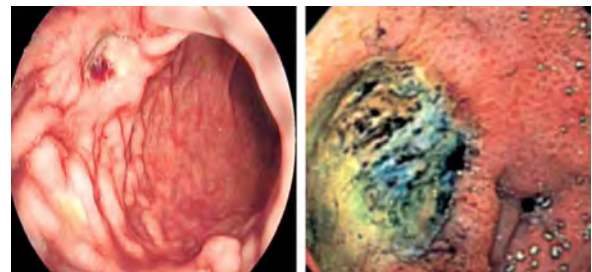
**Barium meal X-ray features of benign gastric ulcer**

- ❖ *Niche* on the lesser curve with *notch* on the greater curvature
- ❖ Ulcer crater projects beyond the lumen of the ulcer
- ❖ Regular/round margin of the ulcer crater—*stomach spoke wheel pattern*
- ❖ Overhanging mucosa at the margins of a benign gastric ulcer—projects inwards towards the ulcer—*Hamptom's line*
- ❖ Converging mucosal folds towards the base of the ulcer
- ❖ Symmetrical normal gastric mucosal folds

- ◆ Gastroscopy is done to see the location, type of ulcer and also to take biopsy (10 biopsies).
- ◆ Ultrasound abdomen mainly to rule out other diseases and to confirm associated diseases.

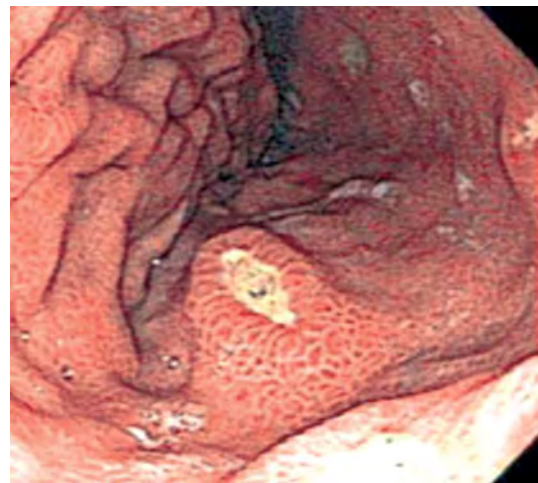

Fig. 20.16: Multiple ulcers visualised on gastroscopy.



Figs 20.17A and B: (A) Gastric ulcer in the body of the stomach; (B) Gastric ulcer in prepyloric region.

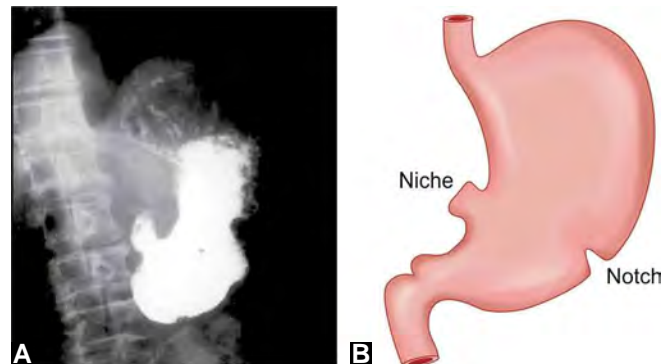
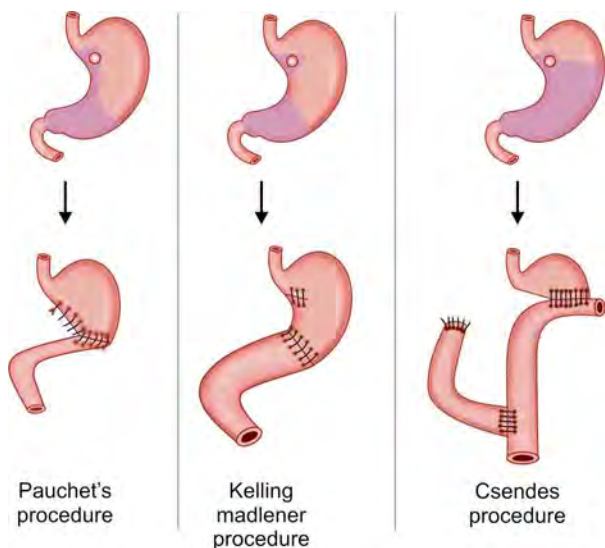


Fig. 20.18: Barium meal study showing *niche and notch*—gastric ulcer.

## Treatment

- ◆ Drugs like H<sub>2</sub> blockers, proton-pump inhibitors, carbenoxolone (biogastrone, sucralfate, prostaglandins which coats the ulcer and so creates a mucosal barrier) helps in reducing or eliminating the symptoms.
- ◆ But asymptomatic ulcer may exist silently and may turn into malignancy.
- ◆ **So surgery is the preferred line of treatment. Partial gastrectomy and Billroth I gastroduodenal anastomosis is done.**
- ◆ Type IV proximal gastric ulcer is difficult to manage. It is treated by subtotal gastrectomy. Often distal gastrectomy with selective sleeve like extension cut along the lesser curve to remove the ulcer is done—*Pauchet's procedure*.
- ◆ **Other surgical procedures:**
  1. *de Miguel's antrectomy*: Distal antrectomy, pylorotomy with excision of ulcer along with gastroduodenal anastomosis is done. It preserves gastric reservoir function, shows less recurrence rate and less operative morbidity.
  2. *Maki's pylorus preserving gastrectomy*: Hemigastrectomy with excision of pyloric ulcer but retaining 2 cm pre-pyloric stomach. It is only used in type I gastric ulcer. Even though it has got fewer incidences of postoperative diarrhoea and dumping, it has got high recurrence rate.



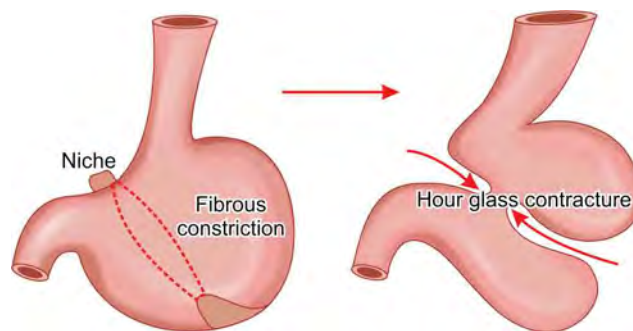
**Fig. 20.19:** Diagram showing Pauchet's, Kelling Madlener, Csendes operations for proximal Type IV benign gastric ulcer.

3. *HSV with excision of ulcer*.
4. *Kelling Madlener procedure*: It is antrectomy and excision of proximal gastric ulcer Type IV.
5. *Csendes procedure*: It is subtotal gastrectomy with sleeve extended resection along the lesser curve for type IV proximal gastric ulcer.

## Complications of Gastric Ulcer

1. **Hour glass contracture**: It, occurs exclusively in **women**, is due to cicatricial contracture of lesser curve ulcer.
  - ▶ Here stomach is divided into two compartments.
  - ▶ **Clinical features**
    - Loss of periodicity.

- Persistent pain.
- Vomiting.
- Loss of appetite and weight.



**Fig. 20.20:** Hour glass contracture.

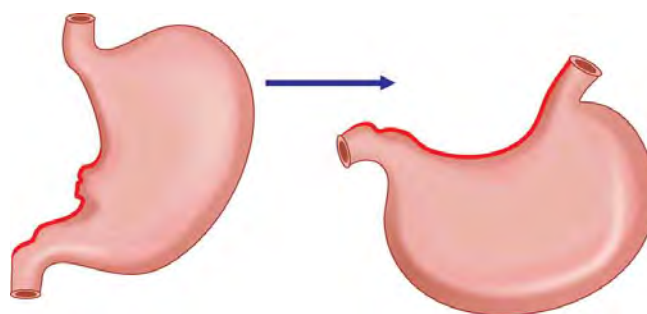
### ▶ Diagnosis

- *Barium meal*: It shows filling only in the proximal stomach or double pouched stomach.
- Gastroscopy.

### ▶ Treatment

Partial gastrectomy wherein gastric ulcer with lower compartment of the stomach is removed and Billroth I anastomosis is done.

2. **Tea-pot deformity (Hand-bag stomach)**: It is due to cicatrization and shortening of the lesser curvature.
  - ▶ They present with features of pyloric stenosis.
  - ▶ Treatment is partial gastrectomy with Billroth I anastomosis.
3. **Perforation**—most frequent.
4. **Bleeding** by erosion into the left gastric and rarely splenic vessels or to vessels in the wall of ulcer—35%. It is common in type II and III gastric ulcers.



**Fig. 20.21:** Tea-pot deformity.

5. **Penetration** posteriorly into pancreas, anteriorly into liver.
6. **Malignant transformation** usually into **adenocarcinoma of stomach** (5–10%).

## ■ DUODENAL ULCER

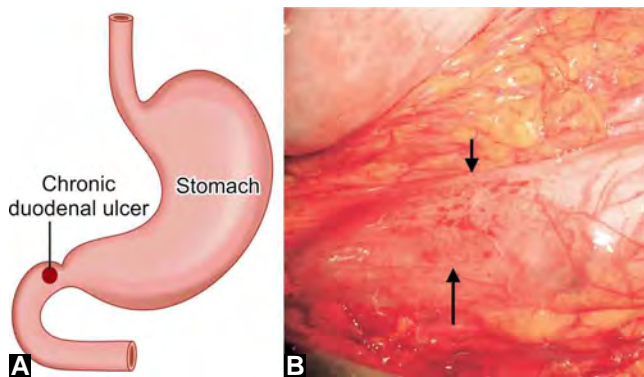
### Aetiology

- ◆ Common in people with blood group O +ve.
- ◆ Stress, anxiety—'hurry, worry, curry'.
- ◆ *Helicobacter pylori* infection is an important aetiology for duodenal ulcer (90%).

*It is consequences which are more important than rewards or punishments.*

	<i>Benign gastric ulcer</i>	<i>Malignant gastric ulcer</i>
Mucosal folds	Converging mucosal folds up to the margin	Effacing mucosal folds
Site	95% lesser curve	Greater curvature
Margin	Regular margin	Irregular margin
Floor	Granulation tissue in floor	Necrotic slough in floor
Edge	Not everted; punched or sloping	Everted edge
Surrounding area	Surrounding area and rugae are normal	Surrounding area shows nodules, ulcers and irregularities
Size and extent	Small, deep up to part of muscle layer	Large and deep

- ◆ NSAIDs, steroids.
- ◆ Endocrine causes: Zollinger-Ellison syndrome, MEN syndrome, hyperparathyroidism.
- ◆ Other causes: Alcohol, smoking, vitamin deficiency.
- ◆ *Dragstedt dictum*: “No acid – No ulcer”.



**Figs 20.22A and B:** (A) Anatomical location of chronic duodenal ulcer; (B) Serosal surface in a chronic duodenal ulcer. It appears like *cayenne pepper*.

## Pathology

- ◆ Ulcer occurs in the first part of duodenum, usually within the first inch, involving the muscular layer.
- Sites:*
  - a. In the bulb (bulbar)—95%.
  - b. Post-bulbar (5%).
- ◆ Eventually it shows cicatrization causing pyloric stenosis. Serosa overlying the site of duodenal ulcer shows petechial haemorrhages with speckled red dots, appearing like sprinkled *cayenne pepper*.
- ◆ Microscopically, ulcer with chronic inflammation with granulation tissue, gastric metaplasia of duodenal mucosa, endarteritis obliterans are visualised.
- ◆ Sometimes two opposing ulcers, i.e. over anterior and posterior surfaces of duodenum are present and are called as *kissing ulcers*.
- ◆ An anterior ulcer *perforates* commonly, posterior ulcer *bleeds or penetrates* commonly.

## Clinical Features

- ◆ In India, ratio of duodenal ulcer (DU) to gastric ulcer is 30 : 1. A very high incidence.
- ◆ It is common in all socioeconomic group, more with stressed professionals (Type A personality).

- ◆ *Pain* is more before food, in early morning and decreases after taking food. It is classically called as *hunger pain* as it is relieved by taking food. Night pains are common.
- ◆ Common in *males*.
- ◆ *Periodicity* is more common than in chronic gastric ulcer with seasonal variation.
- ◆ *Water-brash, heart burn, vomiting* may be present.
- ◆ *Melaena* is more common, *haematemesis* also can occur.

### Differences between clinical features of gastric ulcer and duodenal ulcer

<i>Gastric ulcer</i>	<i>Duodenal ulcer</i>
Pain after food intake	Pain before food intake
Periodicity less common	Periodicity more common
Haematemesis more common	Melaena more common
Weight loss occurs	Weight gain occurs
Equal in both sexes	Common in males

- ◆ Appetite is good and there is gain in weight. It decreases once stenosis develops.
- ◆ Eats more frequently without any restriction.
- ◆ Chronic duodenal ulcer can be *uncomplicated or complicated*.

## Complications of Duodenal Ulcer

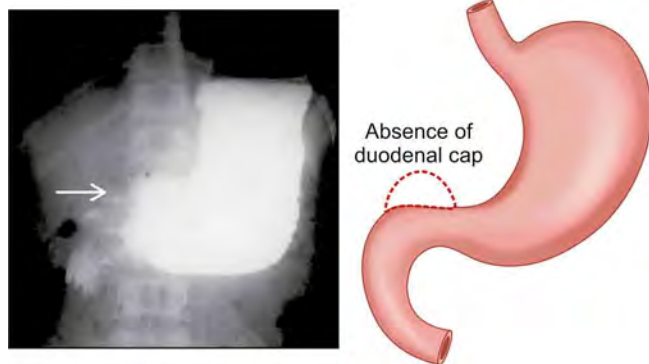
1. Pyloric stenosis: Due to scarring and cicatrization of first part of the duodenum.
2. Bleeding (10%).
3. Perforation (5%). Both acute and chronic ulcers can perforate. Anterior ulcers perforate.
4. Residual abscess.
5. Penetration to pancreas.

### Note:

- Chronic duodenal ulcer will not turn into malignancy.
- Ulcer which is more than 2 cm is called as *giant* duodenal ulcer.

## Investigations

- ◆ Barium meal X-ray shows deformed or absence of *duodenal cap* (because of spasm). Appearance of '*trifoliate*' duodenum is due to secondary duodenal diverticula which occurs as a result of scarring of ulcer.

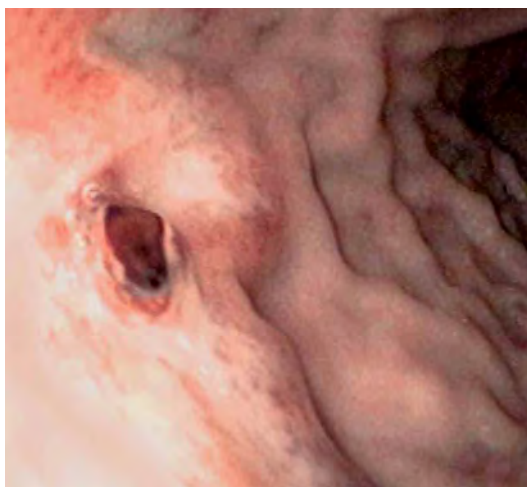


**Fig. 20.23:** Absence of duodenal cap—chronic duodenal ulcer.

- ◆ Gastroscopy reveals the type, location of ulcer, narrowing if any. Biopsy also can be taken to look for the presence of *Helicobacter pylori*. Usually biopsies are taken from duodenum, pylorus, antrum, body, fundus, and confirmed by rapid urease test or C13 or C14 breath tests.
- ◆ Estimation of serum gastrin level, serum calcium level.

#### Differential diagnosis

- ❖ Carcinoma stomach (pylorus)
- ❖ Dyspepsia due to other causes
  - Hiatus hernia
  - Oesophagitis
  - Cholecystitis
  - Chronic pancreatitis



**Fig. 20.24:** Endoscopic view of duodenal ulcer.

## Treatment

### Aim of therapy:

To relieve symptoms; to heal ulcer; to prevent recurrence.

#### I. General measures:

- ▶ Avoid alcohol, NSAIDs, smoking, spicy foods. Have more frequent food.

#### II. Specific measures:

- ▶ Intra-gastric pH should be maintained above 5.

## Drugs

#### 1. $H_2$ Blockers:

- ▶ Promotes ulcer healing in 4–8 weeks, by reducing acid secretion.
  - Tab cimetidine.
  - Tab ranitidine (300 mg HS or 150 mg BID), (IV preparation is available).
  - Tab famotidine (IV is available) *Most potent  $H_2$  blocker.* Dose is 20–40 mg/day.
  - Tab roxatidine.
  - Tab nizatidine.

#### 2. Proton-pump inhibitors:

- ▶ Inhibit parietal cell  $H^+$ ,  $K^+$  ATPase enzyme responsible for acid secretion. They are used for 6–12 weeks. They stop acid secretion completely.
  - Omeprazole 20 mg OD 1 hour before food—IV preparation is available.
  - Esomeprazole 40 mg.
  - Lansoprazole 30 mg, Ilaprazole 10 mg
  - Pantoprazole 40 mg—IV preparation available.
  - Rabeprazole 20 mg—IV preparation available.

#### 3. Antacids:

- ▶ Neutralises the HCl to form water and salt and also inhibits peptic activity.
- ▶ Aluminium hydroxide and magnesium trisilicate are commonly used.
- ▶ Dose is 2 grams 2 hours *after food*.
- ▶ Aluminium hydroxide causes constipation, magnesium trisilicate causes diarrhoea. Osteomalacia, milk alkali syndrome, rebound ulcer due to gastrin release are other complications.

#### 4. Sucralfate

- ▶ It is an aluminium salt of sulfated sucrose which provides a protective coat to ulcer crater thereby promotes healing. It inhibits peptic activity.
- ▶ It binds to ulcer bed and stays for 12 hours; prevents back diffusion of hydrogen ion; raises endogenous prostaglandin level in tissues; binds bile acid and pepsin; prevents colonisation of gastric mucosa by bacteria.
- ▶ Dose is 1 g qid for 6 weeks (before food). It is an effective drug.

#### 5. Anti-*Helicobacter pylori* regime:

- ▶ It is very useful, given for 7–14 days—later the proton-pump inhibitors are continued.
- ▶ *Triple or quadruple* (tetracycline, bismuth, tinidazole, pantoprazole) regimes are used.

6. *Colloid bismuth sulphate* is a good drug for ulcer, but it stains the oral cavity and mucosa.

7. Misoprostol (200 mg tid) is the only prostaglandin agonist accepted.

- ▶ PG E1 (mesoprostol) and E2 increase mucus and bicarbonate secretion, improves mucosal blood flow, but reduces acid secretion.

**Anti-Helicobacter regime (Triple regime)**

Clarithromycin 500 mg BD	Metronidazole 400 mg BD	Omeprazole 20 mg BD
OR	OR	OR
Amoxicillin 500–750 mg BD	Tinidazole 600 mg BD	Lansoprazole 30 mg BD
OR		OR
Tetracyclines, or Bismuth, etc.		Pantoprazole 40 mg BD

**Follow-up gastroscopy** is a must, to confirm that ulcer has healed.

**Note:**

Antacids and H<sub>2</sub> blockers should not be used along with PPI as these drugs will reduce the action of PPIs by creating alkaline media.

**Surgery for Uncomplicated Duodenal Ulcer**

**Indications for surgical intervention for chronic DU** (Uncomplicated DU):

1. Uncomplicated DU, not responding to drug therapy of 8–12 weeks—**intractable duodenal ulcer**
  2. Repeated recurrences
- Presently most of the uncomplicated DU does not require surgery

♦ *Highly selective vagotomy (HSV).*

- ▶ In HSV, only fibres supplying the parietal cells are ligated. Nerve of Latarjet which supplies the antrum pump is retained and so no drainage procedure is required in HSV. HSV is also called as *parietal cell vagotomy or superselective vagotomy*. Here nerve fibres in last 6 cm of stomach, just proximal to pylorus are preserved (Crow's foot). Vagotomy reduces acid secretion, hence ulcer heals. *No acid, No ulcer.*
- ▶ HSV was first described by *Amdrup and Johnston* in 1969.
- ▶ Distal 6 cm oesophageal nerve fiber clearance is essential. Fibers up to 6 cm proximal to pylorus in stomach are cleared; nerve of Latarjet is preserved; adequate distal greater curve clearance is essential.
- ▶ *Intraoperative test for completion of vagotomy* should be done—*Grassi test or insulin test.*
- ▶ It has got distinct *advantages*—low operative mortality (0.2%) and postoperative morbidity (0.5%); post-vagotomy diarrhoea and dumping syndrome is very low; chances of developing anaemia, weight loss, osteoporosis, tuberculosis, and carcinoma are very less.
- ▶ *Problems*—lesser curve necrosis due to ischaemia; recurrent ulcer 10–15% in 10 years.

- ♦ *Selective vagotomy with pyloroplasty (SV + P).*
- ♦ *Truncal vagotomy with gastrojejunostomy (TV + GJ).*
- ♦ *Posterior truncal vagotomy with anterior seromyotomy—Taylor's operation.* It can be done through laparoscopy.
- ♦ *Vagotomy with antrectomy:* Gastrin producing antrum, vagal cholinergic pathway from ulcer bearing area is removed with gastroduodenal anastomosis. Ulcer recurrence is very low but has got morbidity.
- ♦ *Posterior truncal vagotomy* with HSV without drainage procedure (Kim's) often through laparoscopy is also done.
- ♦ *Linear gastrectomy* with posterior truncal vagotomy through laparoscopy.

- ♦ Most of these procedures presently can be done through *laparoscopy*.

**Note:**

- Presently, there is *no role of gastrectomy or gastrojejunostomy (Just GJ) for uncomplicated DU.*
- A *peptic ulcer* is an excavated defect in the gastric or duodenal mucosa that extends through the muscularis mucosa into the deeper layers of the wall.
- A *refractory peptic ulcer* is defined as an endoscopically proven ulcer greater than 5 mm in diameter that does not heal after 12 weeks of treatment with a proton-pump inhibitor.
- A *recurrent peptic ulcer* is defined as an endoscopically proven ulcer greater than 5 mm in diameter that develops following complete ulcer healing.

**■ PYLORIC STENOSIS DUE TO CHRONIC DUODENAL ULCER****Pathology**

Chronic DU after many years undergoes scarring and cicatrization causing total obstruction of the pylorus, leading to enormous dilatation of stomach.

**Clinical Features**

- ♦ Pain is severe, persistent, in epigastric region, and also with feeling of fullness.
- ♦ Vomiting—large quantity, foul smelling and frothy, vomitus contains food consumed on previous day (partially digested or undigested food).
- ♦ Loss of periodicity.
- ♦ Loss of appetite and weight.
- ♦ *Visible gastric peristalsis (VGP)*—may be elicited by asking the patient to drink a cup of water.
- ♦ *Positive succussion splash* which is done with 4 hours empty stomach, by placing a stethoscope over the epigastric region and shaking the patient adequately.
- ♦ *Auscultation test* shows dilated stomach. Test is done by placing a stethoscope over the epigastric region. Skin is scratched from left side downwards, at several points away from the epigastrium (towards left side) using finger and these points are joined. Normally greater curvature of stomach is above the level of umbilicus (midway between the umbilicus and epigastrium). In gastric outlet obstruction it lies below the level of the umbilicus (Stomach we see; stomach we feel; stomach we hear).
- ♦ Confused status because of alkalosis and electrolyte changes.

- ❖ **Electrolyte changes:** Because of vomiting, *hypochloraemic, hyponatraemic, hypokalaemic, hypocalcaemic, hypomagnesaemic alkalosis* occurs. It causes **paradoxical aciduria**.
- ❖ Mass is never palpable.
- ❖ **Goldstein saline load test**—half an hour after installation of 750 ml of saline, if volume remained and if more than 250 ml, suggest obstruction.

## Investigations

1. **Barium meal study:**
  - ▶ Absence of duodenal cap.
  - ▶ Dilated stomach where greater curvature is below the level of iliac crest.
  - ▶ Mottled stomach.
  - ▶ Barium will not pass into duodenum.
2. Gastroscopy to rule out carcinoma stomach and to visualise the stenosed area.
3. Electrolyte study for correction of electrolyte imbalance.
4. ECG to check for hypokalaemia.

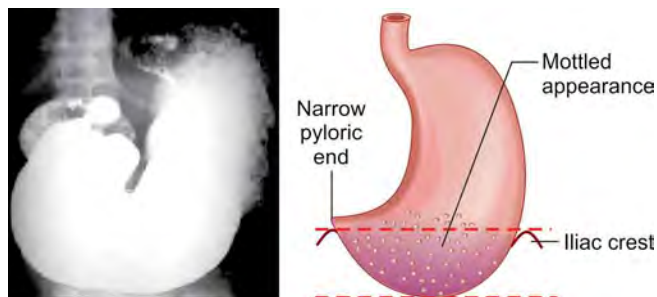
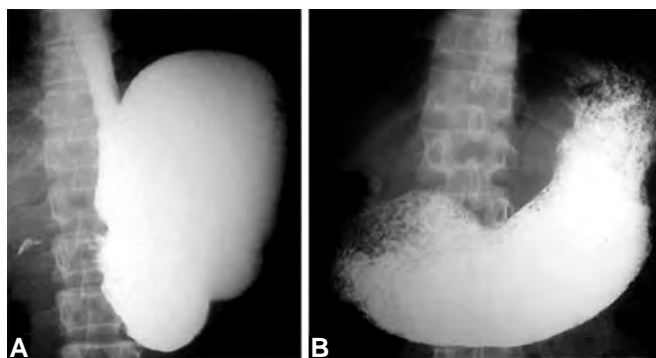


Fig. 20.25: Pyloric stenosis with gastric dilatation.



Figs 20.26A and B: Barium meal pictures showing gastric outlet obstruction.

## Differential Diagnosis

Carcinoma pylorus—here mass may be palpable.

### Pyloric stenosis—causes

- ❖ Congenital
- ❖ Chronic DU—fibrosed/cicatrised
- ❖ Carcinoma pylorus
- ❖ Adult pyloric stenosis—it is treated by pyloroplasty (not by pyloromyotomy)
- ❖ Pyloric mucosal diaphragm—it should be excised surgically or endoscopically

## Treatment

- ❖ Correction of dehydration and electrolytes by IV fluids—normal saline or double strength saline, calcium, potassium, magnesium.
- ❖ Blood transfusion is given if there is anaemia.
- ❖ TPN support.
- ❖ Stomach wash to clean the stomach contents (using normal saline) is given using stomach tube like Eswald's. It also reduces the oedema of stomach wall and improves gastric emptying time by increasing the gastric muscle tone.
- ❖ **Surgery**
  - ▶ *HSV with gastrojejunostomy* is present recommendation even though it is technically difficult. HSV is better than TV as it maintains the nerve supply of the chronically obstructed antrum and so may eventually reduce the chronic emptying problems.
  - ▶ Truncal vagotomy along with gastrojejunostomy of *Mayo (posterior; vertical/oblique, short loop, retrocolic, isoperistalsis) is done—ideal, commonly advocated procedure.*
  - ▶ Vagotomy, antrectomy (acid secreting area) with Billroth I anastomosis along with feeding jejunostomy for nutrition is the other option.

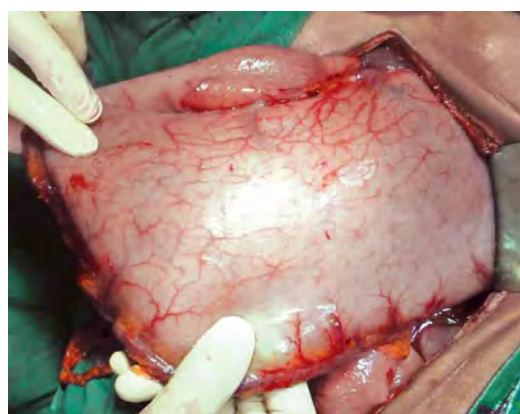

Fig. 20.27: Gastric outlet obstruction showing dilated stomach on table.

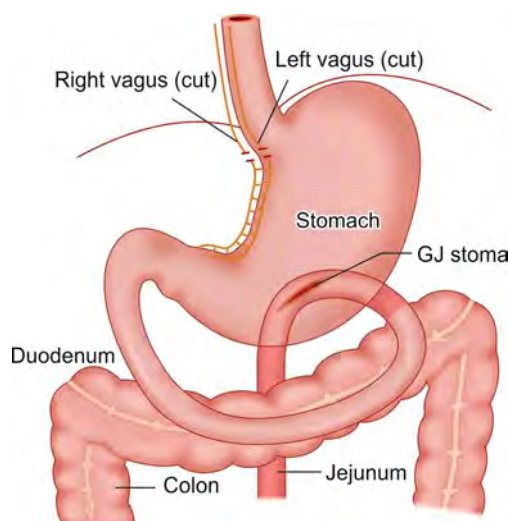


Fig. 20.28: Truncal vagotomy and gastrojejunostomy. It is posterior, vertical, short loop, retrocolic, isoperistaltic GJ of Mayo.

Patients with peptic ulcer were regularly “milked” for acid, which was used for patients suffering from hypochlorhydria.

— Albert E Coates



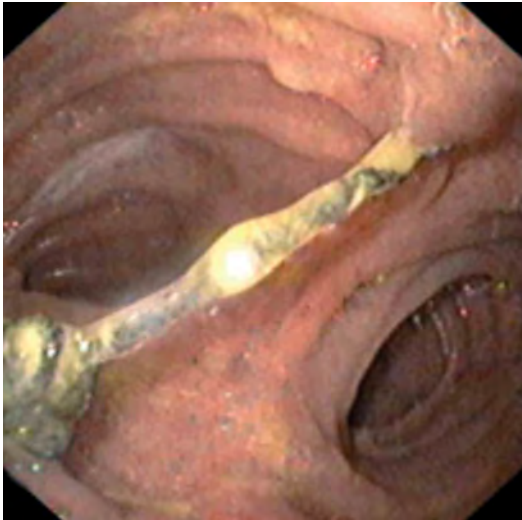


Fig. 20.29: Gastrojejunostomy stoma view on endoscopy.

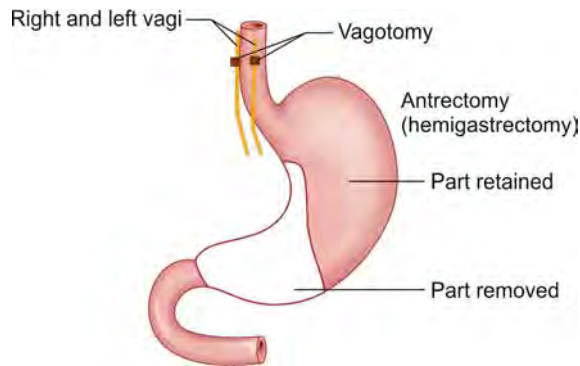


Fig. 20.30: Vagotomy and antrectomy. It is occasionally used for intractable resistant duodenal ulcer or chronic duodenal ulcer with obstruction. HSV is commonly used in intractable cases. GJ with vagotomy is commonly used in pyloric stenosis due to chronic duodenal ulcer.

**Note:**

- Often gastric emptying may be delayed for 2–4 weeks after surgery in pyloric stenosis. It usually recovers in 7 days.
- After recovery eradication of *H. pylori* infection is routinely done even though infection may not be evident in many of patients with outlet obstruction.
- No role of pyloroplasty or only HSV in a scarred duodenum—as it can cause disruption and bile leak.
- Gastrectomy and other procedures are usually not necessary in pyloric stenosis.
- Endoscopic balloon dilatation of the stenosed area benefits only temporarily with high recurrence rate.

### ELECTROLYTE CHANGES IN PYLORIC STENOSIS

- ◆ Hyponatraemia.
- ◆ Hypokalaemia.
- ◆ Hypomagnesaemia.
- ◆ Hypochloraemia.
- ◆ Metabolic alkalosis.
- ◆ Paradoxical aciduria.

Because of severe vomiting which contains acid as well as undigested retained food, sodium, chloride, potassium, magnesium levels

drop, causing metabolic alkalosis. Alkalosis can lead to hypocalcaemia causing tetany. It is called as '*gastric tetany*'.

To control alkalosis, kidney secretes excess bicarbonate (In alkalosis without hyponatraemia, bicarbonate is secreted along with sodium). Here, due to hyponatraemia, body conserves sodium and so bicarbonate is secreted along with hydrogen ion. So urine becomes acidic. It is called as *paradoxical aciduria*.

### Clinical Features

- ◆ Irritability, confused status, dehydration.
- ◆ Often convulsions can occur.
- ◆ Features of alkalosis like rapid breathing—Cheyne-Stokes breathing and tetany.

### Investigations

- ◆ Serum electrolytes.
- ◆ Arterial blood gas analysis.
- ◆ Serum calcium level estimation.

### Treatment

- ◆ Double strength normal saline.
- ◆ IV potassium given slowly under ECG monitoring.
- ◆ The cause is treated.
- ◆ IV magnesium.

**Note:**

Metabolic changes are not severe in carcinoma pylorus as it is seen in pyloric stenosis due to chronic duodenal ulcer because in carcinoma stomach often there is hypochlorhydria or achlorhydria.

## ■ PERFORATED PEPTIC ULCER

- ◆ It is the terminology used for *perforation of duodenal ulcer or gastric ulcer or stomal ulcer*. Otherwise all clinical features and management are similar.
- ◆ Perforation is common in duodenal ulcer (75% of perforated peptic ulcers). Mortality is more in gastric ulcer perforation and perforation in elderly.

### A. PERFORATED DUODENAL ULCER

- ◆ It is common in males (8:1) between 35–45 years of age group, but can occur in any age group.
- ◆ *Anterior ulcer* perforates, commonly
  - ▶ In 80% of cases, there is a history of chronic DU.
  - ▶ In 20% cases, it is silent perforation.
- ◆ Perforation can occur in acute ulcers or in acute presentation of a pre-existing chronic ulcer.
- ◆ Perforation may be precipitated by steroids, analgesics (NSAIDs), alcohol, antimalarials.
- ◆ Overall incidence is 5%.
- ◆ Active ulcers perforate commonly.
- ◆ Duodenal ulcer with *H. pylori* infection causes perforation more commonly, especially in young individual; NSAID-induced ulcer causes perforation in elderly.
- ◆ *Mortality* in perforated duodenal ulcer is 10% (in gastric ulcer it is more—20%).

## Stages of Perforation

- ◆ **Stage of chemical peritonitis:**
  - ▶ Once perforation occurs, stomach contents escape into the peritoneal cavity. The acid from the stomach causes chemical peritonitis leading to severe pain in epigastric region, vomiting, tenderness, guarding, rigidity, tachycardia, sweating.
- ◆ **Stage of reaction (Stage of illusion):**
  - ▶ Peritoneum secretes lots of fluid to neutralise the escaped content and so temporarily the pain reduces, and the patient feels better. This phase lasts for about 6 hours.
- ◆ **Stage of diffuse bacterial peritonitis:**
  - ▶ After about six hours, bacteria from GIT (escape) migrate from the site of perforation causing diffuse peritonitis.

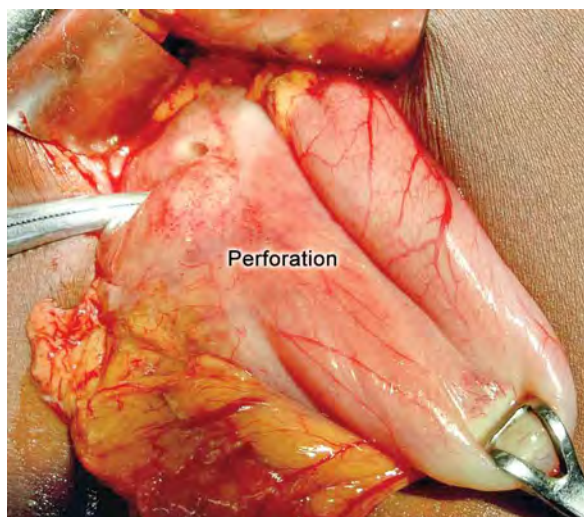


Fig. 20.31: Duodenal perforation—on table look.

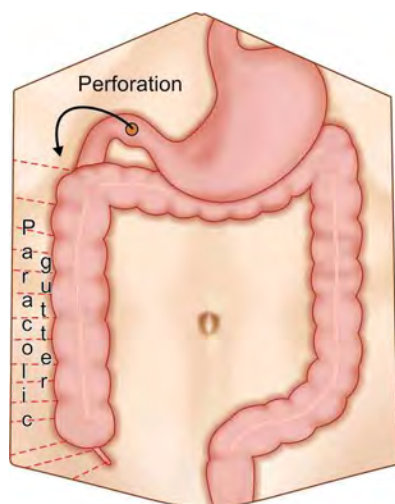


Fig. 20.32: Spread in DU perforation.

## Clinical Features

- ◆ Presents with *severe persistent pain* in the epigastrium initially, later in the right side abdomen (as the inflammatory fluid spills along the right paracolic gutter) and finally becomes generalised. Pain is of sudden in onset, is due to

contact of expelled gastric contents with the parietal peritoneum. Pain often radiates to right scapular region. Pain becomes more on movements.

- ◆ Tenderness and rebound tenderness is seen (*Blumberg sign*) all over the abdomen.
- ◆ Fever, vomiting, dehydration, oliguria occurs.
- ◆ Patient is toxic, with tachycardia, hypotension, tachypnoea.
- ◆ Abdominal distension occurs.
- ◆ Guarding and rigidity, initially in the epigastrium but later all over the abdomen.
- ◆ Dullness over the flank because of fluid.
- ◆ *Obliteration of liver dullness*—as a result of collection of escaped gas under the diaphragm.
- ◆ Silent abdomen with absence of bowel sounds.
- ◆ Tenderness felt on per rectal examination.
- ◆ Sometimes fluid from supracolic region slowly trickles down along the right paracolic gutter and collects in right iliac region causing pain and tenderness in RIF mimicking appendicitis.
- ◆ Often slow, small perforation presents with subacute features, but diffuse peritonitis eventually sets in 24–48 hours.

### Terminal stage:

Patient may have oliguria, septicaemia, shock, *Hippocratic facies* (sunken eyes, cold periphery and shallow rapid breathing, ill look), with MODS (Multiorgan dysfunction syndrome).

### Note:

*Valentino's syndrome* is perforated peptic ulcer mimicking acute appendicitis. Rudolph Valentino, in 1926 died of appendicitis and peptic ulcer due to sepsis.

## Investigations

- ◆ *Chest X-ray with abdomen in erect posture (plain X-ray):* Shows gas under diaphragm in 70% of cases. In 30% of cases, there is no gas under diaphragm. It may be due to, either the gas leak is less than 1 ml or due to previous surgery causing adhesions between liver and diaphragm, or sealed peptic ulcer. (*Chilaiditi's syndrome* is the interposition of the colon in front and above the liver. It is common in children and elderly. It may be mistaken for gas under diaphragm in plain X-ray abdomen).

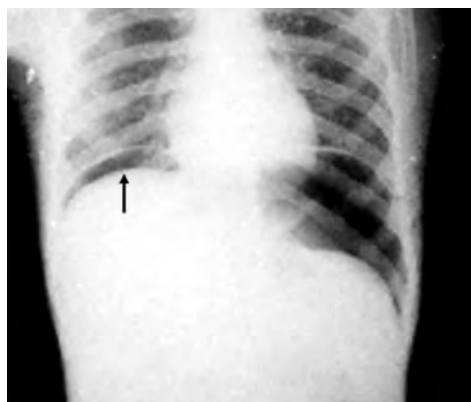
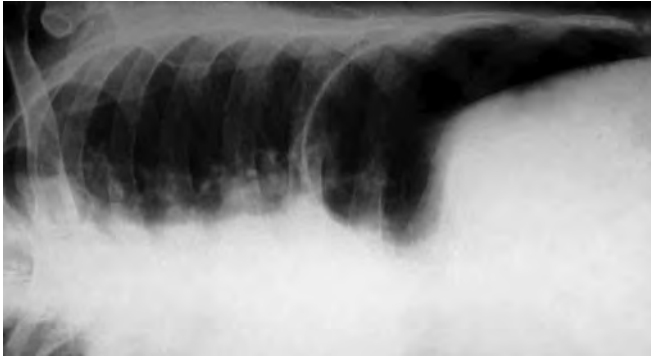


Fig. 20.33: Plain X-ray abdomen in erect position with ground-glass appearance and gas under diaphragm—perforation.



**Fig. 20.34:** Lateral (Left) decubitus X-ray showing air under diaphragm. This is done when patient is critically ill and cannot make the patient stand in erect posture.

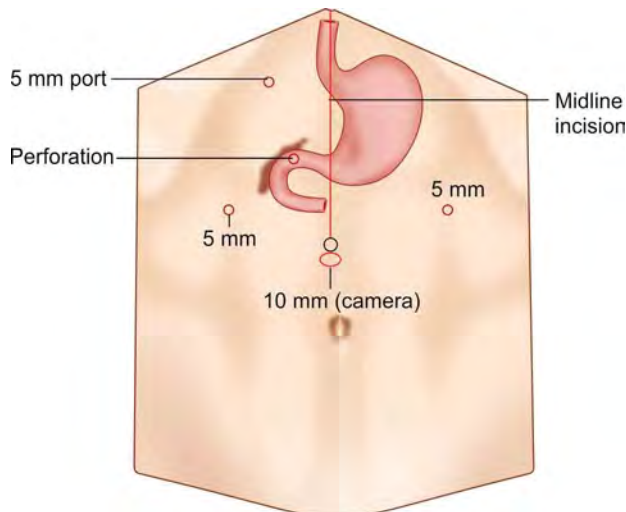
- ◆ Ultrasound abdomen shows free fluid and often gas.
- ◆ Blood urea, serum creatinine, total count, electrolytes, are helpful.
- ◆ *CT scan abdomen is very sensitive investigation* whenever there is absence of gas under diaphragm. It rules out other conditions like pancreatitis. Gastrograffin upper GI study also confirms the perforation.

#### Differential diagnosis

- ❖ Acute appendicitis
- ❖ Acute pancreatitis
- ❖ Acute cholecystitis
- ❖ Ruptured aortic aneurysm
- ❖ Myocardial infarction
- ❖ Mesenteric ischaemia
- ❖ Pneumonia

#### Treatment

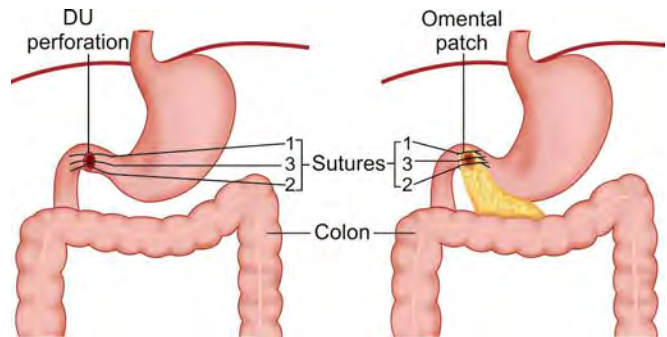
- ◆ Patient is advised admission.
- ◆ IV fluids—Ringer lactate, normal saline, dextrose saline.
- ◆ Antibiotics—Cefotaxime, metronidazole, amikacin.
- ◆ Catheterisation.
- ◆ Ryle's tube aspiration.



**Fig. 20.35:** Approaches to manage duodenal ulcer perforation can be either open (upper midline incision) laparotomy incision or laparoscopic.

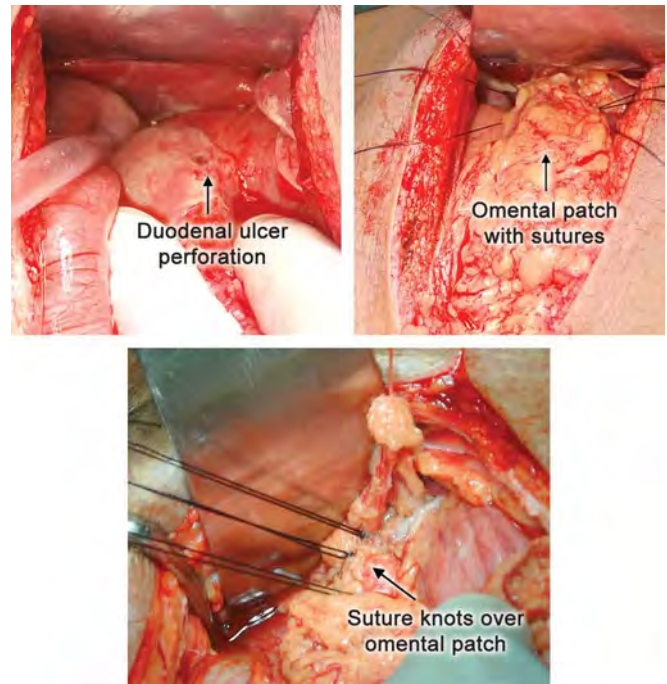
#### ◆ Surgery:

- ▶ Emergency laparotomy through upper midline incision is done.
- ▶ All infected fluid is sucked out.
- ▶ Perforation is identified and closed with interrupted, horizontal sutures using *either silk or vicryl*. Omental patch is placed *before suturing*—it is called as **Rosoe-Graham Operation**. Because of its *adhesion property* it seals perforation; good vascularity and lymphatics promote the healing effectively.



**Fig. 20.36:** Duodenal ulcer perforation closed horizontally using interrupted silk/vicryl sutures with omental patch over it.

- ▶ Peritoneal wash (toilet) using 5–10 litres of saline is given.
- ▶ Drain is placed and abdomen is closed, often if required with *tension sutures*. Drain is removed in 3–5 days. During discharge, patient is advised to avoid alcohol and to take H<sub>2</sub> blockers or proton pump inhibitors for 6–12 weeks.
- ▶ After 12 weeks *follow-up gastroscopy must be done*.



**Fig. 20.37:** Closure of duodenal ulcer perforation using interrupted silk/vicryl sutures over a omental pedicle patch—Rosoe Graham's operation.

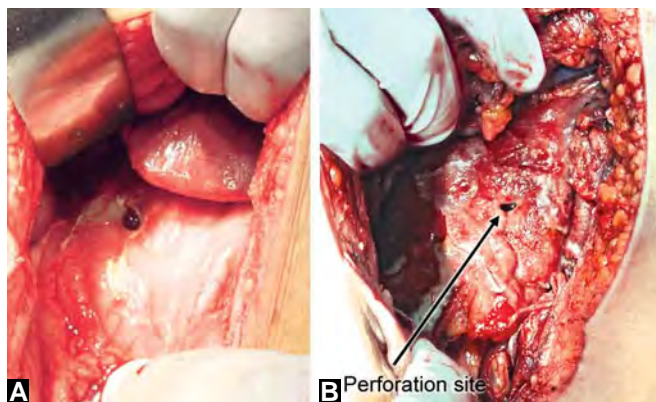
#### Note:

- Very rarely, in elderly people or in cases of subacute perforation which gets sealed on its own, *conservative treatment* is tried with careful observation, i.e. by giving IV fluids, antibiotics, Ryle's tube aspiration, maintenance of urine output and electrolytes. It is called as *Hermen-Taylor regime*. But it should not be a standard treatment.

- Laparoscopy is beneficial for both diagnoses, as well as for therapy for perforation closure using omental patch. It is proposed and widely used for early duodenal perforation. It can be useful for most of the duodenal ulcer perforations. If it is problematic, conversion options should always be kept in mind.
- Once perforation is closed, either by open or laparoscopic method, after recovery patient should be advised, *anti-Helicobacter pylori* therapy (triple regime for 14 days) with PPI for 3 months. It reduces rate of re-perforation and ulcer recurrence in duodenal ulcer.
- In patients with severe peritonitis and critically ill, after perforation closure it is better to insert a nasojejunal tube or feeding jejunostomy for nutrition in postoperative recovery period. Even if patient develops a temporary duodenal leak, this supports nutrition well until the leak stops.
- Occasional large perforated duodenal ulcer with oedema which cannot be closed is managed by serosal patch/duodenal drainage and pyloric exclusion/gastrostomy, duodenostomy and jejunostomy/Roux-en-Y jejunal patch over the perforation.
- *Manheim peritonitis index* or *APACHE II* scoring system is used to assess the patient properly.
- Doing concomitant acid reducing surgical procedure like HSV is under debate and not used routinely (not advised) even though some centers advocate. HSV may be done if there is not much contamination of the peritoneal cavity or in early perforation of a chronic duodenal ulcer.

## B. PERFORATED GASTRIC ULCER

- ◆ Commonly ulcer in the lesser curve near the antrum perforates. Amount of gas escaped is more than the perforated DU. Malignancy should always be suspected and so *biopsy from the edge is a must*.
- ◆ Mortality in gastric ulcer perforation is high (20%).
- ◆ Commonly they are prepyloric in position.
- ◆ Primary closure with an edge biopsy is commonly used. Distal gastrectomy, including ulcer area is better option if patient's general condition is favourable.
- ◆ Posterior gastric ulcer perforation is often difficult to diagnose both clinically and radiologically.



**Figs 20.38A and B:** (A) Gastric ulcer perforation on table finding; (B) Malignant gastric ulcer showing perforation.

## C. PERFORATED STOMAL ULCER

*In perforation of stomal ulcer, often undoing of GJ or partial gastrectomy may be required.*

## D. DRY PERFORATION (Perforated Duodenal Ulcer Sealed by Omentum)

- ◆ Patient is ambulatory.
- ◆ Vomiting is absent.
- ◆ Rigidity confined to epigastrium and right hypochondrium.

### Different signs in X-ray in perforation

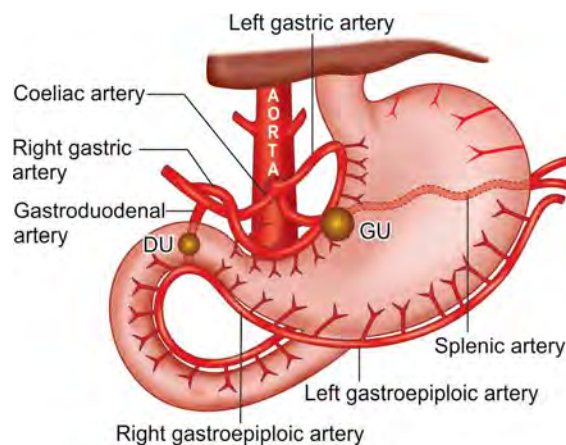
- ❖ *Cupola sign*—crescent shaped radiolucency under the diaphragm
- ❖ *Riglers sign*—visualisation of both aspects of the bowel wall being outlined by gas on either side
- ❖ *Inverted V sign*—gas on either sides of the falciform ligament
- ❖ *Football sign*—collection of gas in the center of the abdomen like a foot ball
- ❖ *Triangle sign*—gas between bowel loops

### Conditions which mimic pneumoperitoneum—pseudopneumoperitoneum

- ❖ Subpulmonary pneumothorax
- ❖ Chillarditi syndrome
- ❖ Subphrenic abscess due to infections by gas forming organism like *Clostridium Welchii*
- ❖ Subdiaphragmatic fat or omental fat under the diaphragm may rarely mimic gas under the diaphragm

## BLEEDING PEPTIC ULCER

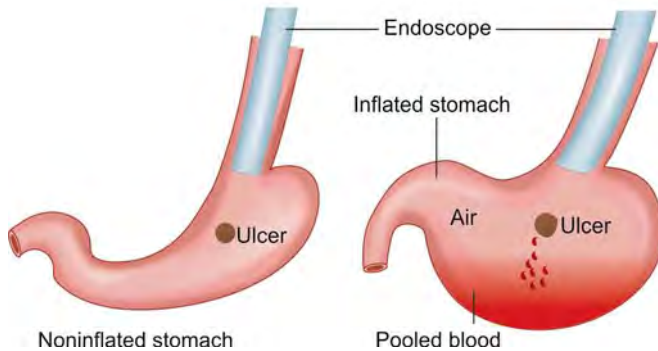
- ◆ It is **bleeding either from duodenal ulcer, or gastric ulcer or stomal ulcer**.
- ◆ In bleeding from stomal ulcer, partial gastrectomy is required.
- ◆ Mortality in bleeding peptic ulcer is high (20–30%). Elderly age, associated systemic diseases increase the mortality.
- ◆ NSAIDs and *H. pylori* infection, coagulopathy, and anticoagulant drugs are common precipitating factors. Concomitant use of NSAID and steroids increase risk by 10-fold.
- ◆ Need of more than 5 units of blood transfusion during hospital stay is called as *massive haemorrhage*.



**Fig. 20.39:** Sites of gastric ulcer and duodenal ulcer bleeding. Note GU can erode into the left gastric artery. DU can erode into the gastroduodenal artery.

### A. BLEEDING DUODENAL ULCER

- ◆ 10% common.
- ◆ Risk of bleeding in chronic duodenal ulcer increases to 35% if patient has not taken specific anti-*Helicobacter pylori* therapy and PPI.



**Fig. 20.40:** In bleeding ulcer during endoscopy stomach should be inflated with air adequately so that bleeding ulcer is visualised well.

#### Precipitating causes

- ❖ Alcohol
- ❖ NSAIDs, steroids
- ❖ Excessive fibrosis
- ❖ Atherosclerotic disease

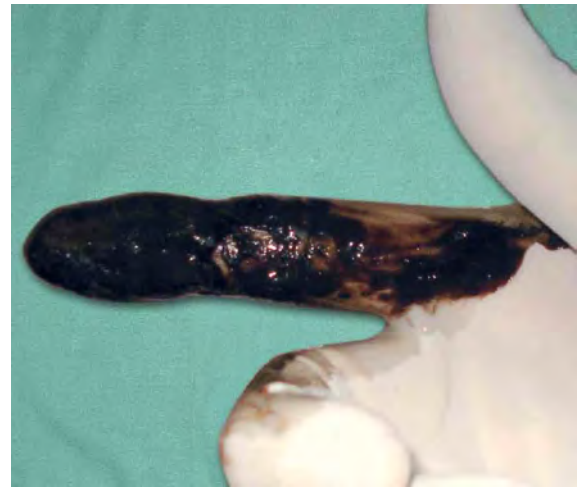#### Forrest classification of bleeding or bled ulcer

- Ia Spurting and bleeding
- Ib Nonspurting but active bleeding
- IIa Visible vessel with red or blue protrusion or pulsatile pseudoaneurysm
- IIb Nonbleeding ulcer with clot overlying
- IIc Ulcer with haematin base
- III Clean ulcer—no clot, no vessel

- ◆ Bleeding from DU is either from the *small vessels in the wall of ulcer crater* or due to erosion into the *gastroduodenal artery*.
- ◆ Usually *posterior* duodenal ulcer bleeds.
- ◆ Bleeding from small vessels in the wall of ulcer is due to sloughing of the ulcer. It is less severe, gradual and most often well-controlled by conservative treatment.
- ◆ Bleeding from erosion of gastroduodenal artery is severe, torrential and almost always needs early surgical intervention.

### Clinical Features

- ◆ *Haematemesis and melaena*.
- ◆ Features of shock: Pallor, tachycardia, sweating, hypotension, tachypnoea, dry tongue, cold periphery.
- ◆ Past history of chronic DU may be present. But it is not always necessary in every patient, as some may have a silent ulcer which may present as bleeding and haematemesis to begin with.
- ◆ History of pain and tenderness in epigastric region which has increased in intensity recently.



**Fig. 20.41:** Melaena—typical *black, tarry* coloured *foul* smelling stool. It signifies upper GI bleed. At least 50 ml bleeding should be there to cause melaena.

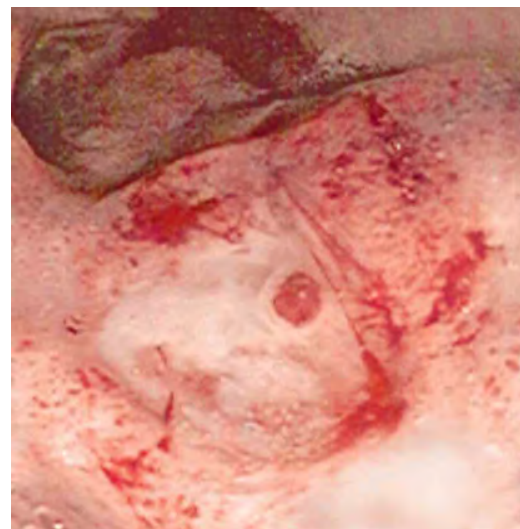#### Differential diagnosis

- ❖ Erosive gastritis
- ❖ Oesophageal varices
- ❖ Carcinoma stomach
- ❖ Bleeding gastric ulcer
- ❖ Mallory-Weiss syndrome
- ❖ Gastric polyps
- ❖ Bleeding disorders

### Investigations

#### To look for in endoscopy, in bleeding ulcer

- ❖ Spurter
- ❖ Clot
- ❖ Visible vessel
- ❖ Aneurysmal dilatation of the arteriole in the wall of ulcer
- ❖ Ooze



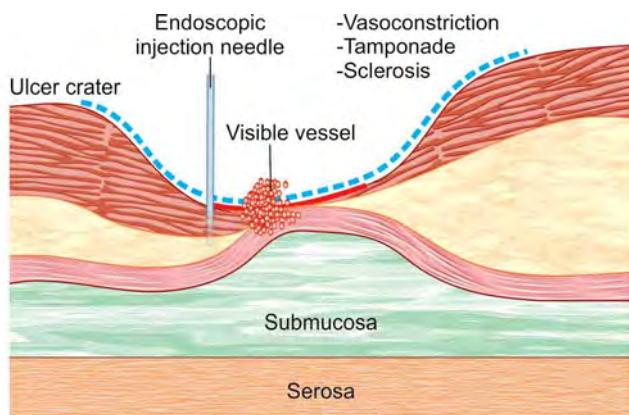
**Fig. 20.42:** Bleeding duodenal ulcer endoscopic view.

- ◆ *Gastroscopy is confirmative*—it is a must. It identifies ulcer bleed in 90% of cases clearly. Possibility of rebleed is also assessed by endoscopy. A flat clear based ulcer is less likely to rebleed. Active ulcer/fresh clot/visible vessel/pseudoaneurysm/large ulcer are more likely to rebleed. *Rockall scoring system* is used to predict rebleed.
- ◆ *Coeliac angiogram* to identify the bleeder may be helpful.
- ◆ Hb% and PCV—should be repeated at regular intervals (once in 2–3 hours).
- ◆ Blood group and cross-matching.
- ◆ Estimation of serum electrolytes, blood urea, serum creatinine, platelet count.

## Treatment

Seventy percent of bleeding duodenal ulcers are treated conservatively.

- ◆ The shock is corrected initially by:
  - ▶ Foot end elevation.
  - ▶ IV fluids, plasma expanders (haemaccel, dextran, crystalloids). CVP line is better in these patients.
  - ▶ Sedation.
  - ▶ Catheterisation—to assess urine output.
  - ▶ Blood transfusion to replace the lost blood.
- ◆ Stomach wash is given—1 : 2,00,000 adrenaline in saline wash is given to the stomach through Ryle's tube.
- ◆ IV ranitidine 50 mg 6th or 8th hourly. IV famotidine.
- ◆ IV pantoprazole 80 mg in 100 ml dextrose saline is given slow IV as starting dose and later 40 mg in dextrose saline IV OD/BD. Slow continuous infusion of pantoprazole 40 mg in dextrose saline, 500 ml IV can also be given.
- ◆ *Endoscopic cauterisation* of small vessel with either gastroscopic bipolar cautery or through Laser (*Nd: YAG*) or through heater probe or through haemoclips can be tried to stop the bleeding.
- ◆ *Sclerotherapy*—ethanolamine oleate, distilled water. *Epinephrine injection* is also used commonly. Other agents used are absolute alcohol, polidocanol.
- ◆ Observation
  - ▶ Patients with bleeding from small vessels in the wall of DU will commonly respond to conservative treatment.
- ◆ *Angiographic embolisation of gastroduodenal artery.*
- ◆ *Haemoclips placement* over the bleeding point endoscopically.



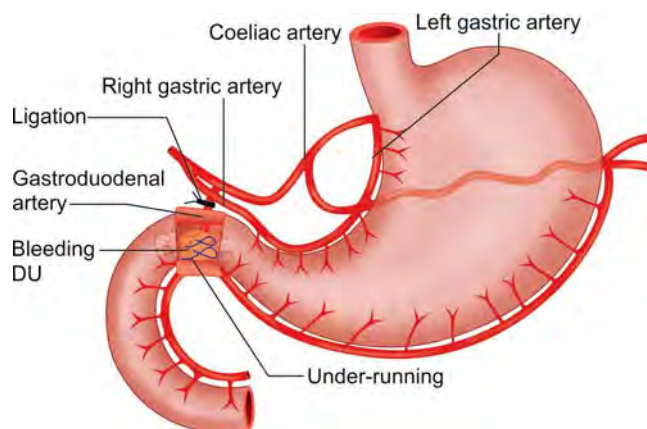
**Fig. 20.43:** Sclerosants like ethanolamine oleate or distilled water are used through endoscopy to control bleeding ulcer. It causes tamponade, vasoconstriction, sclerosis. It is the best method to control the bleeding.

## Indications for surgical treatment

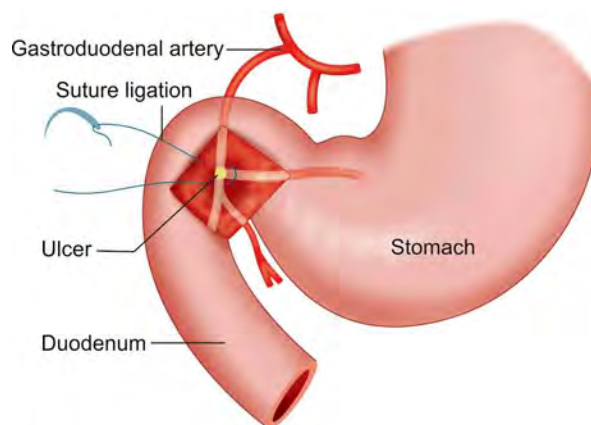
- ❖ In spite of conservative treatment condition of patient deteriorates
- ❖ Bleeding from gastroduodenal artery
- ❖ Recurrent bleeding
- ❖ Elderly patient
- ❖ If more than 4 units of blood required immediately

## ◆ Surgery

- ▶ After laparotomy, pyloric channel and first part of the duodenum (gastroduodenum) is opened longitudinally, bleeder is identified. *Underrunning* of the bleeding area with vicryl is done.



**Fig. 20.44:** Gastroduodenal artery ligation is required in case of severe massive upper GI duodenal ulcer bleed.



**Fig. 20.45:** Underrunning of the bleeding duodenal ulcer at ulcer bed is done to control haemorrhage. After that duodenum is closed with Finney's pyloroplasty.

- ▶ If the bleed is from gastroduodenal artery, then it has to be ligated to stop the bleeding. Opened gastroduodenum is closed by *Finney's pyloroplasty*.
- ▶ Truncal vagotomy may be done together, if the general condition of the patient is good.

## ◆ Further treatment

- ▶ During discharge, patient is advised to take *anti-Helicobacter pylori* (triple) therapy, proton pump inhibitors for 6–12 weeks (Omeprazole, or Lansoprazole).

65% of haematemesis is due to bleeding peptic ulcer. Among peptic ulcer, duodenal ulcer (35%) is the most common cause.

- ▶ Healing of ulcer can be confirmed by doing a gastroscopy after 6–12 weeks.

#### Treatment schedule for bleeding duodenal ulcer

- ❖ Treatment of shock
  - ❖ Blood transfusion
  - ❖ Stomach wash with—1 : 2,00,000 adrenaline saline
  - ❖ IV ranitidine, famotidine, pantoprazole, omeprazole
  - ❖ Endoscopic sclerotherapy using ethanolamine oleate or distilled water
  - ❖ Endoscopic bipolar cauterisation, laser therapy, heater probe, haemoclips
  - ❖ Angiographic embolisation of gastroduodenal artery
  - ❖ Open surgery and underrunning of the bleeding ulcer bed
  - ❖ Ligation of gastroduodenal artery and then Finney's pyloroplasty
  - ❖ Proton pump inhibitors during discharge
  - ❖ Follow-up gastroscopy after 3 months
- Sclerotherapy is the most popular endoscopic method used at present*

## B. BLEEDING GASTRIC ULCER

- ◆ It is similar to bleeding DU. Bleeding may be either from the ulcer bed or from the erosion of gastric vessels commonly but occasionally splenic vessels. They commonly present with severe haematemesis and shock.
- ◆ Bleeding is much more severe than bleeding DU.
- ◆ Surgery is the main treatment:  
After initial resuscitation, blood transfusion and a trial of conservative management, laparotomy is done.

On laparotomy one of the following procedures is done:

Underrunning of the ulcer bed.

OR ligation of splenic vessels with splenectomy with or without partial gastrectomy and gastroduodenostomy.

Postoperative management and follow-up is same like bleeding DU.

#### Treatment for bleeding gastric ulcer

- ❖ Underrunning of the ulcer bed
- ❖ Partial gastrectomy with Billroth I anastomosis
- ❖ Vagotomy with antrectomy
- ❖ Occasionally splenic vessel ligation with splenectomy may be required

## HAEMATEMESIS

### Causes:

- ◆ Chronic peptic ulcer (duodenal + gastric) (65%).
- ◆ Acute peptic ulcer.
- ◆ Acute erosive gastritis (Steroids, NSAIDs).
- ◆ Oesophageal varices.
- ◆ Mallory-Weiss syndrome (5-15%)
- ◆ Carcinoma stomach (5%)
- ◆ Gastric polyps, lymphomas, leiomyomas.
- ◆ Portal gastropathy.
- ◆ Bleeding disorders.
- ◆ Pernicious anaemia.
- ◆ Thrombocytopenia.

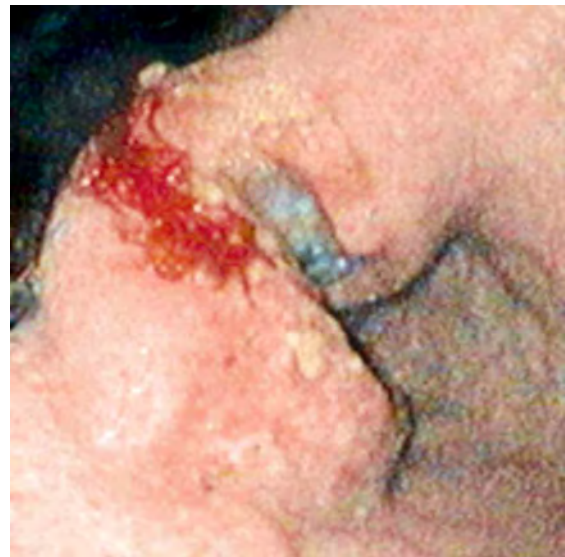

Fig. 20.46: Gastroscopy showing carcinoma stomach which is bleeding. Note the slough and everted edge.

1. Chronic DU
2. Gastric ulcer
3. Oesophageal varices
4. Erosive gastritis
5. Mallory-Weiss
6. Carcinoma stomach
7. Gastric polyp
8. Carcinoma oesophagus
9. Leiomyoma/GIST
10. Gastric lymphoma
11. Dieulafoy's
12. Stomal ulcer

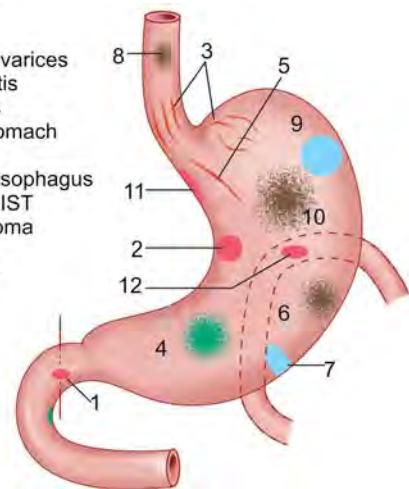


Fig. 20.47: Various causes of haematemesis.

### ◆ Gastric antral vascular ectasia

- ▶ It is a rare endoscopically confirmed condition which shows segmented dilated vessel meshes in the antral mucosa (*watermelon/tiger stripe stomach*).
- ▶ It is often associated with achlorhydria and hypergastrinaemia.
- ▶ It is *common* in middle aged females; *common* in liver diseases (25%) and autoimmune connective tissue disorders.
- ▶ *Pathologically* it shows mucosal fibromuscular hyperplasia and hyalinisation.
- ▶ After confirmation with *gastroscopy*, often *antrectomy* is needed.
- ◆ Osler-Weber-Rendu syndrome, aortoduodenal fistula, Crest syndrome are rare causes.
- ◆ **Dieulafoy's disease**
  - ▶ A gastric arteriovenous malformation which is covered by apparently normal mucosa.
  - ▶ It occurs in proximal stomach near OG junction (within 6 cm) along lesser curve (80% of cases).
  - ▶ Bleeding often may be severe and torrential.

- ▶ Vasculitis or atheroma are absent in the vessel.
- ▶ It is 5% of nonvariceal upper GI bleed.
- ▶ A large 1–3 mm tortuous abnormal submucosal artery (AVM) is the cause, which due to its pulsation erodes the mucosa to expose itself to acid which further erodes the artery causing bleeding.
- ▶ Endoscopy and endoscopic therapy or excision of the lesion is required.
- ▶ Angiography can be done to confirm the disease and to do therapeutic embolisation using gel foam.
- ▶ Failure of endoscopic or angiographic therapy needs gastrotomy and excision of the entire lesion—*gastric wedge resection*. It can be done by open/laparoscopic approach. Prior endoscopic tattooing is mandatory to identify the lesion during resection.

## Management of Haematemesis

- ◆ *Evaluation of patient* by measuring BP, pulse, respiration looking for features of shock, oxygen saturation, investigating for Hb%, blood grouping, blood urea, serum creatinine, LFT, prothrombin time, platelet count, arterial blood gas analysis, gastroscopy.
- ◆ *Initial treatment* is central line insertion, fluid and blood replacement; catheterisation; IV PPI; nasogastric tube placement (controversial but now universally accepted); FFP, platelet transfusion if needed; gastroscopic sclerotherapy, banding, laser, haemoclip application; SB tube for varices; pharmacotherapy.
- ◆ *Further treatment*—critical care (ICU); antibiotics; treatment of complications like sepsis, DIC, ARDS.
- ◆ *Specific treatment*—open surgery for uncontrolled bleeding, ligation of gastroduodenal artery and underrunning of ulcer bed with pyloroplasty, gastrectomy, ligation of varices with devascularisation.
- ◆ *Definitive surgery* for underlying cause—shunt surgery; vagotomy and GJ; gastrectomy; TIPSS; splenectomy, etc.

## COMPLICATIONS OF GASTRIC SURGERY

- ◆ Haemorrhage.
- ◆ Stomal obstruction.
- ◆ Biliary fistula.
- ◆ Injury to CBD.
- ◆ Duodenal blow out—on 4th postoperative day.
- ◆ Pancreatitis.
- ◆ Recurrent ulcer/stomal ulcer.
- ◆ Gastrojejunal fistula.
- ◆ Dumping syndrome (Postcibal syndrome).
- ◆ Nutritional disturbances, diarrhoea.
- ◆ Pulmonary tuberculosis.
- ◆ Carcinoma in gastric remnant (after 10–15 years).
- ◆ Gallstone formation.
- ◆ Alkaline gastritis.
- ◆ Afferent and efferent loop syndrome.
- ◆ Afferent loop obstruction—*common*.
- ◆ Efferent loop obstruction.

**Complications may be classified as:**

**Intraoperative**—bleeding, injury to spleen, pancreas, CBD.

**Early postoperative**—bleeding either intraluminal (from stomal site) or extraluminal; leak along anastomotic line; delayed opening of stoma; gastroparesis; duodenal stump blow out; lesser curve necrosis; fistula formation—gastric/duodenal/jejunal; omental infarction.

**Late postoperative**—reflux gastritis, recurrence of ulcer; dumping syndrome; malnutrition; gastrojejunal fistula; motility disorders; small stomach syndrome; afferent or efferent loop obstruction; retrograde jejuno gastric intussusception; remnant carcinoma; gallstones; pulmonary or GIT tuberculosis; bezoar formation.

### Stomal obstruction after gastric surgeries is due to:

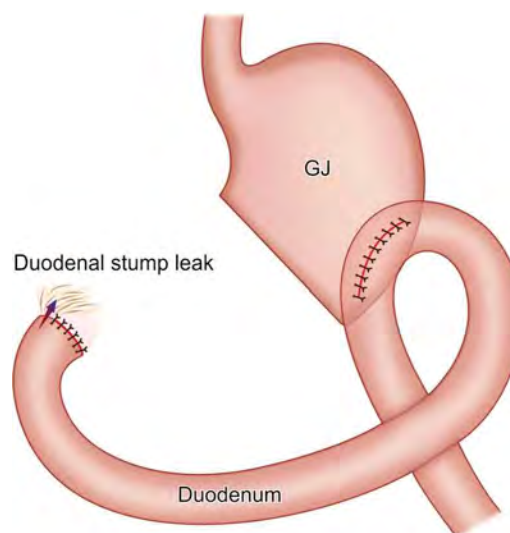
- ❖ Mucosal oedema—usually subsides eventually
- ❖ Retrograde jejuno gastric intussusception
- ❖ Hypertrophied stomal mucosa causing ball-valve mechanism
- ❖ Efferent loop obstruction
- ❖ Gastric atony even though there is wide patent stoma causing apparent stomal obstruction

### Nutritional deficiencies following gastrectomy

❖ Iron deficiency anaemia	40%
❖ Megaloblastic anaemia (after 5 years)	25%
❖ (100 µg B <sub>12</sub> is given IM weekly, later monthly)	
❖ Vitamin B deficiency	10%
❖ Calcium deficiency	40%
❖ Calcium deficiency with bone changes (after 5 years)	5%

## A. DUODENAL BLOW-OUT

- ◆ It is a very serious complication of Billroth II gastrectomy, occurs usually on 4–5th day after surgery.



**Fig. 20.48:** Duodenal blow-out after Billroth II anastomosis usually occurs 4 days after the surgery. It is often life-threatening condition.

- ◆ Here contents in the afferent loop are not having free flow which in turn increases the pressure in the duodenal 'C' loop leading to giving way of the closed duodenal stump.
- ◆ It is due to improper closure of duodenal stump, oedematous inflamed duodenum, afferent loop block, distal obstruction, ischaemia of least vascular duodenum and sepsis. Often there will be *local pancreatitis* which may cause disruption of the stump by its enzymes.



## Features

- ◆ Sudden, severe pain abdomen postoperatively with features of shock.
- ◆ Forming a duodenal fistula through the drain placed.
- ◆ May cause peritonitis.
- ◆ Severe electrolyte imbalance.
- ◆ Features of biliary peritonitis, septicaemia.
- ◆ Skin excoriation and its problems.
- ◆ CT scan is ideal to identify the leak.

## Treatment

- ◆ *Conservative therapy* with nasogastric aspiration, IV fluids, TPN, antibiotics. Usually, patient will recover in 40–60 days.
- ◆ *Surgery is indicated* when there is peritonitis, fistula not responding, when there is distal obstruction.
- ◆ *Surgeries are*—afferent and efferent loop connection, relieving the obstruction distally, serosal patch over the duodenal stump after excision of the fistula, creating a controlled fistula after placing a tube into the duodenum. (**Duodenostomy**). Duodenostomy reduces the intraluminal pressure; duodenostomy may be end, lateral, retrograde (tube) types.

### Duodenal fistula

#### Causes

- ❖ Due to duodenal blow out—ischæmia, afferent loop obstruction, sepsis
- ❖ After closure of perforated DU
- ❖ Injury to duodenum by trauma, surgeries like hemicolectomy, renal surgeries, pancreatic surgeries, etc

#### Types

- ❖ Low output - < 250 ml/24 hours
- ❖ Moderate output 250–500 ml/24 hours
- ❖ High output > 500 ml/24 hours

#### Features

- ❖ Pain abdomen
- ❖ Bile leak through the drain site or fistula track
- ❖ Skin excoriation
- ❖ Electrolyte imbalance
- ❖ Malnutrition, anaemia
- ❖ Recurrent infection

#### Investigations

- ❖ Electrolyte estimation, haematocrit
- ❖ CT fistulogram

#### Treatment

- ❖ TPN, feeding through jejunostomy
- ❖ Management of anaemia, electrolytes
- ❖ Blood transfusion
- ❖ Antibiotics whenever sepsis is suspected
- ❖ Care of skin—zinc oxide cream application, controlled fistula by placing a Foley's catheter into the fistula track
- ❖ Usually responds well by conservative therapy in 8–12 weeks
- ❖ If not improved then surgery is needed—*anastomosis between afferent and efferent loops (jejuno-jejunostomy)*; serosal patch techniques; surgical closure of fistula, Roux-en-Y patch over fistula

## B. RECURRENT ULCER

It is a wide terminology which includes stomal ulcers, recurrence of ulcer in the original ulcer site or different parts of stomach/duodenum or jejunum after a therapeutic surgical procedure.

**Stomal ulcer** can occur in gastrojejunostomy stoma or in gastroduodenostomy stoma. GJ stomal ulcer *per se* can occur after only gastrojejunostomy or after partial gastrectomy with Billroth II anastomosis. Recurrent ulcer at the original site is commonly referred to *ulcer recurrence* (after HSV commonly).

Recurrent ulcer is 3–7%. It may be after:

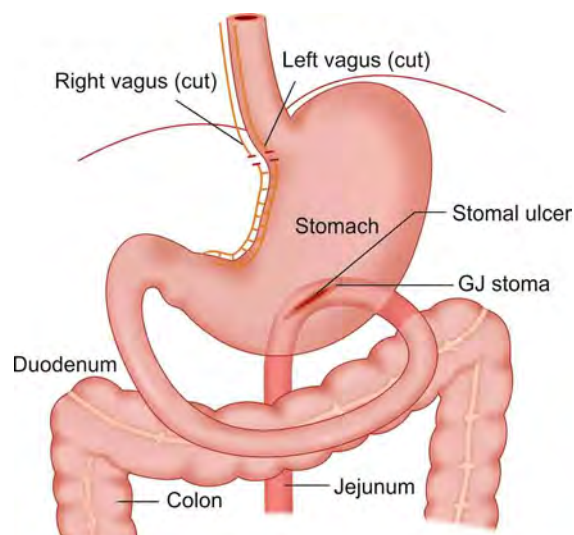
- ◆ Gastrojejunostomy.
- ◆ Billroth I or Billroth II anastomosis.

It may be:

- ❖ Gastrojejunostomy stomal ulcer
- ❖ Gastroduodenostomy stomal ulcer
- ❖ Jejunal ulcer
- ❖ Gastric ulcer
- ❖ *Ulcer recurrence*—10%

## Causes

- ◆ Incomplete vagotomy.
- ◆ Zollinger-Ellison syndrome, gastrinomas.
- ◆ Alcohol, smoking, NSAIDs.
- ◆ Hyperparathyroidism.
- ◆ *H. pylori infection*.
- ◆ Gastrojejunostomy when done without vagotomy—40%.
- ◆ After HSV—10%.



**Fig. 20.49:** Stomal ulcer after GJ may be due to incomplete vagotomy, Zollinger-Ellison syndrome.

## Clinical Features

- ◆ Pain in the umbilical and left hypochondrium (severe, persistent).
- ◆ Back pain.
- ◆ Haematemesis.
- ◆ Anaemia, loss of weight.
- ◆ Features of obstruction—10%.

#### Note:

Stomal ulcer may complicate to gastrojejunocolic fistula, perforation, bleeding, obstruction, penetration.

## Investigations

- ◆ Barium meal.
- ◆ Gastroscopy.
- ◆ Hollander's insulin test.
- ◆ Pentagastrin test.
- ◆ Gastrin level estimation.
- ◆ Serum calcium and parathormone (PTH) to rule hyperparathyroidism.
- ◆ *Visick grading* is used to assess the response to therapy to various procedures (Grades 1, 2, 3, 4 and 5).

## Treatment

- ◆ Complete the vagotomy.
- ◆ Undoing of GJ.
- ◆ Conversion into another procedure, Roux-en-Y procedure.
- ◆ Treat hypergastrinaemia, hyperparathyroidism.
- ◆ Eradication of *H. pylori* infection using triple regime for 2 weeks and then continuation of therapy using PPI for 3 months.
- ◆ Subtotal gastrectomy in resistant recurrent ulcer cases.

### Stomal ulcer

- ❖ It is the ulcer in anastomotic site of GJ/GD
- ❖ Overall incidence is 10% in 10 years after surgery
- ❖ It is common on jejunal side but can occur on gastric side or both sides or at junction

#### Causes

- ❖ After only gastrojejunostomy procedure—40%
- ❖ After vagotomy and GJ—5–7%
- ❖ After partial gastrectomy and gastroduodenostomy—Billroth I—3%
- ❖ After partial gastrectomy and GJ—Billroth II—3%
- ❖ Other causes like gastrinomas, hyperparathyroidism, incomplete vagotomy, smoking, alcohol

#### Features

- ❖ Pain and haematemesis/melaena is the main presentations
- ❖ Pain is persistent, severe over left upper abdomen often radiating to back
- ❖ Pain may be in the chest if it is antecolic anastomosis
- ❖ Weight loss and features of obstruction can occur

#### Investigations

- ❖ Acid tests (Hollander's), gastroscopy, tests specific for the cause
- ❖ Serum gastrin/calcium assay

#### Complications

- ❖ Bleeding stomal obstruction
- ❖ Perforation
- ❖ Gastrojejunocolic fistula
- ❖ Nutritional deficiency

#### Treatment

- ❖ Completion vagotomy
- ❖ Subtotal gastrectomy/revision gastrectomy
- ❖ Roux-en-Y anastomosis
- ❖ Treat the cause

## C. DUMPING SYNDROME (Post-cibal Syndrome)

It is common in *females*, seen after Billroth II surgery.

### Types

#### 1. EARLY DUMPING SYNDROME:

- ❖ It is common and more severe type
- ❖ Incidence is 10%
- ❖ Vasomotor symptoms appear immediately after food, lasts for 30-40 minutes, aggravated by bulky food. It is relieved by lying down, aggravated by more food

#### Clinical features:

- ❖ Sweating, tachycardia, colicky pain and diarrhoea
- ❖ Hypotension and features of hypovolaemia

**Pathogenesis:** It is a *primary disorder of carbohydrate metabolism* wherein initial transient hyperglycaemia, prevents further absorption of glucose, which in turn draws fluid from the bowel wall by high osmolarity resulting in increased intestinal activity, resulting in diarrhoea and fall in blood volume

**Treatment:** Small, dry, more frequent food, with avoidance of carbohydrates. Octreotide 100 µg given subcutaneously before meals is found to be beneficial

#### Surgical treatment:

- ❖ Conversion of Billroth II to Billroth I
  - ❖ Interposition of reversed jejunal loop (*Henley's loop*)
- Early dumping syndrome can last for long time (many years)

#### 2. LATE DUMPING SYNDROME:

- ❖ It is of less severe type
- ❖ Incidence is 5%
- ❖ It usually occurs 2 hours after meal
- ❖ It is relieved by glucose and aggravated by exercise

**Pathogenesis:** Due to initial hyperglycaemia insulin secretion is stimulated which in turn leads to hypoglycaemia

#### Clinical features:

- ❖ Tremor, fainting, nausea
- ❖ Features of hypoglycaemia

**Treatment:** Symptoms are less severe and so treated conservatively, by giving glucose and food

## D. ROUX STASIS SYNDROME (Matias, 1985)

- ◆ It is occurrence of *gastric atony* after subtotal or partial gastrectomy if Roux-en gastrojejunostomy is done.
- ◆ They present with fullness, vomiting, loss of appetite and weight, early satiety, abdominal pain, bloating sensation after eating.
- ◆ It occurs in 25% of Roux-en-Y GJ. It is common in *females*.
- ◆ It is common in Roux-en-Y limb if *more* than 40 cm. It is late complication seen in months or year.
- ◆ Transection of the jejunum during the construction of the Roux limb separates the limb from the natural small intestinal pacemaker located in the duodenum causing appearance of ectopic pacemakers in the limb triggering retrograde contractions in its proximal portion. These contractions slow transit through the limb and result in Roux stasis.
- ◆ There may be dysfunction of both gastric remnant and Roux limb. It is due to *ectopic pacemaker* in *Roux limb* which delays the gastric emptying.

### Treatment

- ▶ Completion total gastrectomy is the choice.
- ▶ Isolated jejunal loop interposition of 40 cm length— Henley's loop.
- ▶ Intestinal pacing, OR usage of '*uncut Roux*' limb.
- ▶ Octreotide, tegaserod drugs are found useful.

### E. GASTROJEJUNOCOLIC FISTULA

It is a complication of gastrojejunal ulcer (stomal ulcer), wherein ulcer penetrates and erodes into the transverse colon leading to gastrojejunocolic fistula, a dreaded complication.

Inadequate vagotomy or inadequate gastrectomy or inadequate therapy for *H. pylori* infection or development of carcinoma at stoma or formation of stomal ulcer, elderly malnourished people are the causes of developing GJC fistula.

#### Clinical Features

- ◆ Sudden onset of severe diarrhoea after every meal with past history of GJ done and past history of gastrojejunal ulcer.
- ◆ Foul gas eructation.
- ◆ Dehydration.
- ◆ Rapid loss of weight, anaemia, cachexia, hypoproteinaemia (bacteria from colon enters the jejunum disrupting the absorptive mechanism).
- ◆ Steatorrhoea.
- ◆ Rarely faecal vomiting.
- ◆ Marshall and Knud-Hansen triad of GJC fistula are - diarrhea, weight loss and eructation of fecal-smelling gas. Often immediate diarrhea after oral intake may suggest GJC fistula with undigested food in the stool if the size of a GJC fistula is large.

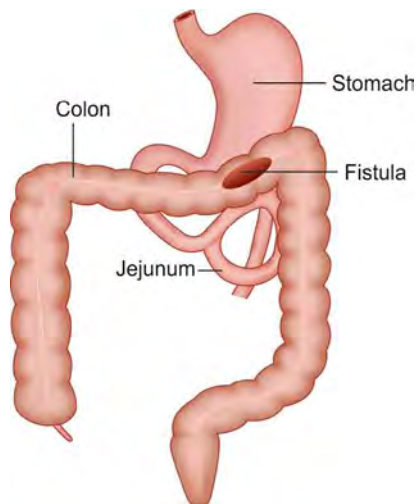


Fig. 20.50: Gastrojejunocolic fistula.

#### Investigation

Barium enema - 95% sensitivity (not barium meal). CT scan, endoscopy (upper and lower).

#### Treatment

- ◆ IV fluids.
- ◆ Total parenteral nutrition (TPN).
- ◆ Blood transfusions.
- ◆ Antibiotics.
- ◆ Rehydration, electrolyte management.
- ◆ Surgery:
  - ▶ Single stage resection of the *involved stomach, jejunum and colon* is commonly done maintaining the corresponding anastomotic continuity—*triple resection*.

- ▶ A two staged procedure (Lahey's procedure) can be done in critical patients with triple resection and colostomy; later closure of colostomy after 3 months. But with the advent of proper fluid and nutrition therapy and antibiotics, single stage procedure is more popular.

**It has got high mortality.**

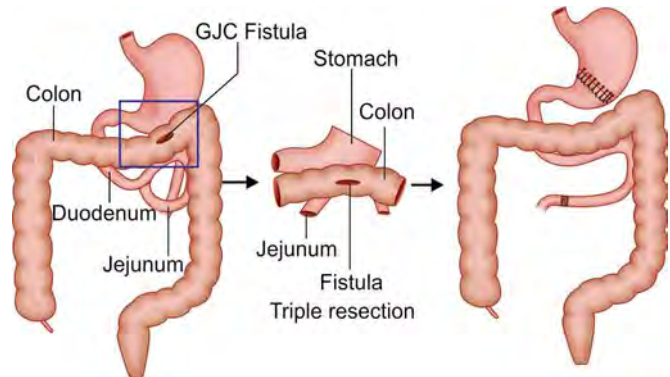


Fig. 20.51: Resection of the gastrojejunocolic fistula (removal of involved parts of the stomach, jejunum and colon—triple resection) with maintaining the continuity.

### ■ TRICHOBEZOAR (Rapunzel Syndrome)

- ◆ It is a hair-ball commonly seen in stomach of *females with psychiatric illness*, who swallow hair regularly.
- ◆ It forms a ball like mass occupying the full stomach.
- ◆ When this hairball extends into the duodenum and jejunum it is called as *Rapunzel syndrome*.

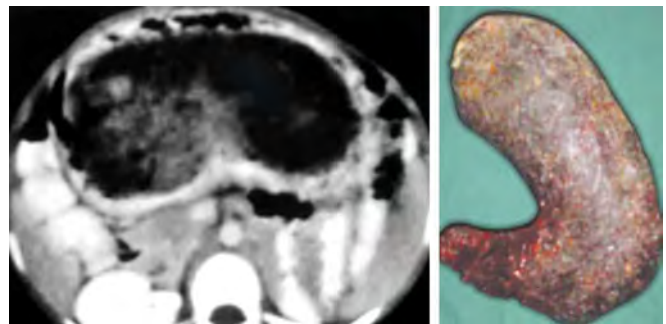


Fig. 20.52: Trichobezoar—CT and hair ball mass (Courtesy: Dr (Professor) BM Nayak, KMC, Mangaluru)

#### Clinical Features

- ◆ Epigastric pain, early satiety.
- ◆ Haematemesis.
- ◆ Features of gastritis.
- ◆ Loss of appetite.
- ◆ Perforation.
- ◆ Epigastric mass.

#### Investigation

- ◆ Barium meal and endoscopy is confirmative.
- ◆ CT scan is very useful.

## Treatment

- ◆ Gastrostomy and removal of hairball. Duodenum and small bowel should be examined on table for additional bezoars in these sites.
- ◆ Psychiatric counselling.
- ◆ Enzymatic digestion and endoscopic breaking of the bezoars is also tried.
- ◆ It can also be removed by laparoscopy.

### Phytobezoar

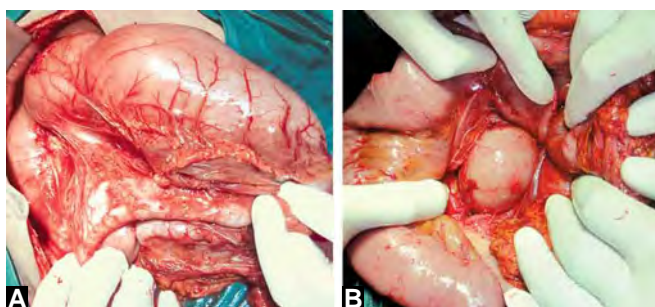
- ▶ It is due to solid ball formation in the stomach comprising plant fibres and seeds.
- ▶ Phytobezoar is common in gastric remnant after partial gastrectomy and in diabetics with autonomic neuropathy.
- ▶ *Enzymatic digestion* can be tried using papain (found in Adolph's meat Tenderizer, as one tsp in 300 ml of water taken orally many times a day to fragment bezoar), cellulase substance. If fails, removal by gastrostomy.

## CHRONIC DUODENAL ILEUS (WILKIE'S SYNDROME)

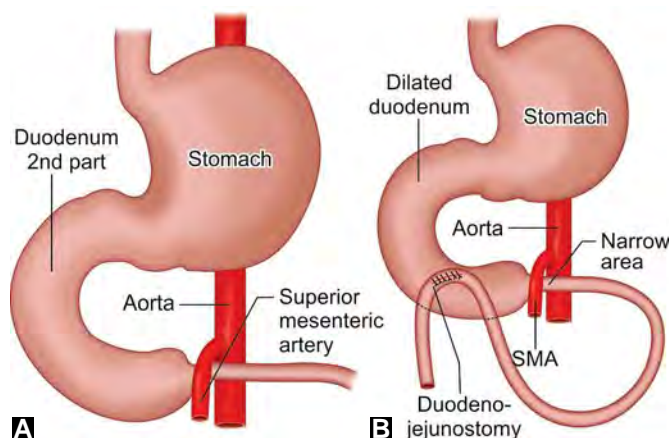
- ◆ It is also called as *superior mesenteric artery (SMA) syndrome*.
- ◆ It is due to obstruction of the 3rd part of the duodenum due to decreased angle between SMA and aorta.
- ◆ There will be narrowing of aortomesenteric angle, becoming less than  $15.2^\circ$ ; aortomesenteric distance becoming less than 10 mm with abnormally low origin of SMA.
- ◆ It can be congenital or due to low insertion of SMA or high insertion of duodenal end or due to traumatic aneurysm of SMA.
- ◆ It can be aggravated by plaster casts, lordosis, pancreatic tumour, enlarged lymph node in the 3rd part of duodenum (*Cast syndrome*).

## Features

- ◆ Bilious vomiting.
- ◆ Upper abdominal fullness.
- ◆ Visible peristalsis.
- ◆ Dehydration.
- ◆ *Differential Diagnosis*
  - ▶ Pyloric stenosis with gastric outlet obstruction.
  - ▶ Annular pancreas.



**Figs 20.53A and B:** Superior mesenteric artery—SMA (Wilkie's syndrome) showing site of obstruction and dilated proximal gastrooduodenum.



**Figs 20.54A and B:** (A) Wilkie's syndrome; (B) Duodenojejunostomy, in case of chronic duodenal ileus.

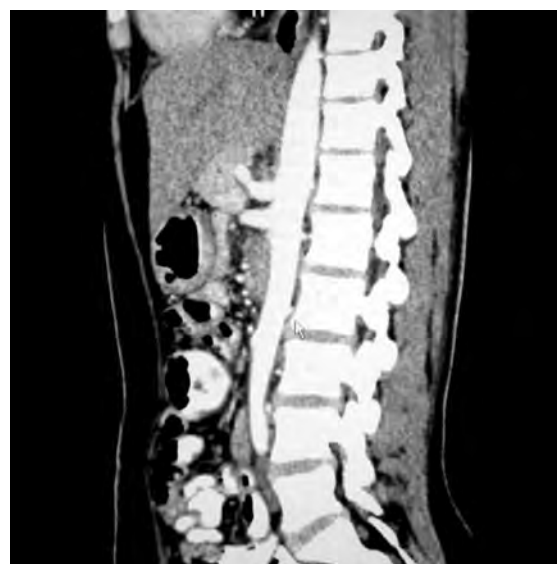- ◆ *Investigation*
  - ▶ Barium meal is diagnostic.
  - ▶ CT scan abdomen.
- ◆ *Treatment*
  - ▶ *Duodenojejunostomy* with division of the *ligament of Treitz* is the most common and most successful procedure done.
  - ▶ *Strong's operation*—division of ligament of Treitz and transposition of the SMA.
  - ▶ Anterior transposition of the 3rd part of the duodenum.

### Note:

Gastrojejunostomy should not be done.

## DUNBAR'S (MALS) SYNDROME (Harjola—Marable Syndrome)

- ◆ Condition is also called as *median arcuate ligament syndrome (MALS)* or *coeliac artery syndrome* or *coeliac band syndrome*.
- ◆ There is a connecting band between right and left crura which causes compression of coeliac artery and SMA.



**Fig. 20.55:** CT scan showing coeliac artery syndrome.

- ◆ It may cause foregut ischaemia due to inadequate collaterals, or midgut ischaemia due to diversion of blood to foregut.
- ◆ Presentation—chronic abdominal pain after food, murmur in epigastric region, weight loss.
- ◆ It is often difficult to diagnosis. CT scan, CT angiogram may show poor perfusion. MRI may be useful. *GDA clamp test and intra operative Doppler* is very useful.
- ◆ Treatment—cutting/excising the fibrous band, with removal of the celiac ganglion through laparotomy or laparoscopy. Coeliac angioplasty, aortocoeliac bypass, coeliac endostenting and coeliac reimplantation are also tried.

## ACUTE GASTRIC DILATATION

- ◆ It is an enormous acute dilatation of stomach with atonic gastric wall without peristalsis.
- ◆ Stomach distends enormously occupying most of the abdomen and pelvis causing sequestration of lots of fluid resulting in hypovolaemia.

### Causes

- ◆ After major surgery (abdomen, neurosurgery).
- ◆ Trauma, burns.
- ◆ Retroperitoneal haematoma.
- ◆ Electrolyte imbalance.
- ◆ Other causes: Anorexia nervosa, bulimia, polyphagia, drug abuse, diabetes, anaesthesia, debilitating diseases, spinal cord diseases, muscle dystrophy.

### Clinical Features

- ◆ Features of hypovolaemia and shock.
- ◆ Vomiting, hiccough. Vomits large quantity of brownish black fluid like “*the storm water of a peat-laden stream.*” Vomitus when placed in a test tube and held in a strong light, myriads of small particles may be suspended in the fluid.
- ◆ Dilated stomach confirmed by ausculto percussion test.
- ◆ Positive succussion splash.
- ◆ Electrolyte imbalance is seen.

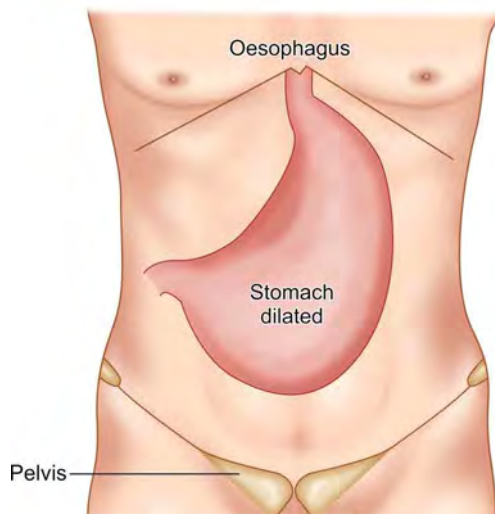


Fig. 20.56: Acute gastric dilatation showing dilated stomach occupying entire abdomen and also pelvis.

## Investigations

Plain X-ray abdomen, serum electrolytes, U/S abdomen.

## Treatment

- ◆ Conservative treatment is given initially.
  - ▶ Large amount of intravenous fluids.
  - ▶ Ryle's tube aspiration.
  - ▶ Electrolyte management, blood transfusion.
- ◆ The cause is treated.
- ◆ Rarely, surgical decompression is required. Condition has got high mortality.

## Complications

- ◆ Aspiration pneumonia (*Mendelson syndrome*).
- ◆ Severe hypovolaemia and electrolyte imbalance.
- ◆ Raised intragastric pressure causes *venous congestion*, venous infarction, necrosis and perforation. *Gastric ischaemia and perforation has got reportedly 80% mortality.*

## GASTRIC VOLVULUS

It is twist in the axis of the stomach.

- ◆ Rotation occurs around the axis made by two fixed points—cardia and pylorus.
- ◆ It can be idiopathic (Type 1—65%) or secondary (Type 2—35%) to—hiatus hernia, left sided eventration, adhesions or pyloric obstruction with long-standing gastric dilatation.

Twist may be:

- ◆ **Organo-axial:** Common in elderly—horizontal.
- ◆ **Mesenterico-axial:** Common in children—vertical.
- ◆ Combined.

## Pathology

- ◆ Here stomach twists upwards between oesophagogastric junction and pyloroduodenal junction. Colon along with omentum also moves upwards initially.
- ◆ It is often associated with rolling hiatus hernia or diaphragmatic eventration.

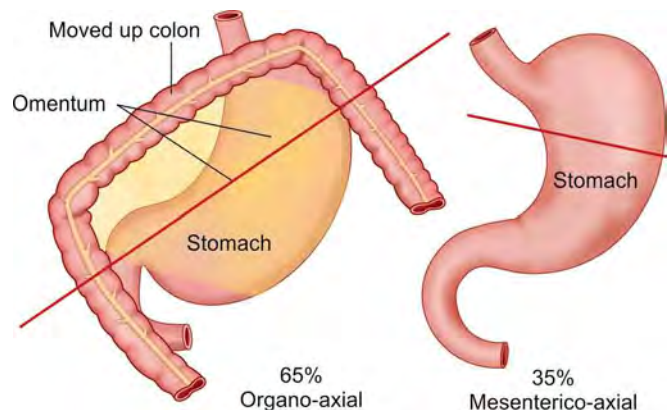


Fig. 20.57: Types of gastric volvulus.

## Clinical Features

### Borchart's triad

- ❖ Acute epigastric pain
- ❖ Violent ineffective vomiting-retching
- ❖ Inability to pass a nasogastric tube

## Types

- ◆ Acute.
- ◆ Chronic recurrent. It is common type.

## Complications

- ◆ Perforation.
- ◆ Gangrene of the stomach.
- ◆ Bleeding.

## Investigations

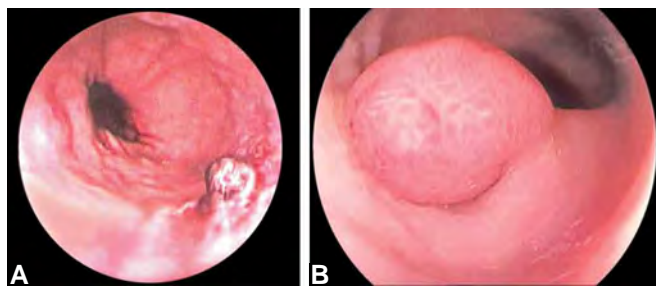
- ◆ Plain X-ray chest and abdomen in erect posture will show retro-cardiac gas filled viscous with dilated bowel loop in the abdomen.
- ◆ Barium meal X-ray.
- ◆ CT scan abdomen.

## Treatment

- ◆ Untwisting of the volvulus and gastropexy by fixing the anterior wall of the stomach to anterior abdominal wall.
- ◆ Gastrojejunal fixation (gastrojejunostomy without a stoma).
- ◆ Gastrectomy when stomach is gangrenous.
- ◆ Treating hiatus hernia or eventration.
- ◆ Displacing colon downwards by dividing gastrocolic omentum—*Tanner's operation*.

## GASTRIC POLYP

Gastric polyps are observed in 3% of total gastroscopies. 45% of them are found in fundus which does not show any malignant potential. These polyps are often associated with FAP or Gardner's syndrome and colorectal neoplasms; but these gastric polyps perse are non-neoplastic.



**Figs 20.58A and B:** (A) Gastric polyp in prepyloric region; (B) Polyp in the duodenum first part.

## Types

1. Hyperplastic polyp—75% common, minimal risk of malignancy (2%). Size usually is <1 cm.

2. Adenomatous polyp (10%)—neoplastic in origin. Size >2 cm is potentially malignant (25% chance).

## Features

- ◆ *Hyperplastic polyp* is randomly distributed throughout the stomach. They are usually less than 2 cm in size, often multiple. Spontaneous regression can occur. Often it is associated with *H. pylori* infection.
- ◆ *Adenomatous polyp* is usually single. It is common in antrum. It can be sessile (common) or pedunculated. It is usually 2 cm or more (80%). It has got hyperchromatic nuclei arranged in a picket fence pattern. Size more than 2 cm has got high malignant potential.
- ◆ Inflammatory, hamartomatous and heterotrophic are other gastric polyps of negligible malignant potential.
- ◆ 50% are asymptomatic.
- ◆ Fundal polyps are associated with PPI therapy and familial polyposis.
- ◆ Gastric carcinoids arise from enterochromaffin like cells (ECL). They usually present as small polyps with pernicious anaemia.
- ◆ It may present with pain, haematemesis and gastric outlet obstruction. Gastroscopy is diagnostic.

## Management

- ◆ Gastroscopic biopsy is a must. Barium study shows soap bubble or paint brush look.
- ◆ It depends on the size, number, location, type and presence of symptoms.
- ◆ *H. pylori* eradication should be done in all hyperplastic polyps.
- ◆ Endoscopic resection is used in hyperplastic type more than 1 cm; pedunculated polyps. Snare polypectomy is done.
- ◆ Gastrotomy and resection is needed in endoscopically failed or difficult cases and polyps >5 cm – open or laparoscopic sleeve resection.
- ◆ Partial gastrectomy of multiple polyps bearing area is needed in multiple polyps.
- ◆ Small polyps can undergo surveillance at regular intervals through endoscopy.
- ◆ All gastric adenomatous polyps should be resected due to their high potential for malignancy.

## MENETRIER'S DISEASE

- ◆ It is an acquired condition with giant gastric mucosal folds (hypertrophic gastropathy) in the fundus and body of the stomach—'*cobblestone appearance*'. Common in males.
- ◆ Histologically, it shows hyperplasia, mucosal thickening and gastric gland atrophy.
- ◆ Hypoalbuminaemia, anaemia and hypochlorhydria is common.
- ◆ Antrum is not involved.
- ◆ There is over expression of transforming growth factor alpha (TGF $\alpha$ ) peptide which binds to epidermal growth factor (EGF).
- ◆ There is foveolar surface mucus cell hyperplasia with absence of *parietal cells* causing excessive mucus production, protein loss and achlor/hypochlorhydria.
- ◆ It is associated with CMV infection in children and *H. pylori* infection in adult.

## Clinical Features

- ◆ Epigastric pain, anaemia and weight loss, melaena.

*Carcinoma stomach is the commonest cause of Krukenberg's tumour.*

## Investigations

- ◆ Serum total proteins, albumin.
- ◆ Gastric function tests.
- ◆ Barium meal studies, gastroscopy.

### Menetrier's disease

- ❖ Giant folds in fundus and body
- ❖ Gastric gland atrophy
- ❖ Hypochlorhydria
- ❖ Hypoalbuminaemia
- ❖ It may turn into malignancy
- ❖ Antral sparing

## Treatment

- ◆ High protein diet, H<sub>2</sub> blockers or PPIs, prednisolone, anticholinergics, antibiotics (for *H. pylori*), drugs for CMV infection, cetuximab – a EGFR blocker, a monoclonal antibody – are all tried.
- ◆ *Total gastrectomy* is the treatment if there is massive protein loss or dysplasia or carcinoma.

*Menetrier's disease may turn into malignancy.*

## DUODENAL DIVERTICULA

It is outpouching/prolapse of the duodenal mucosa. It may be mucosal outpouching of mucosa only through muscularis propria or of all layers. They are quiet common; 25% asymptomatic; only < 10% need surgical intervention. Duodenum is the 2nd most common site of diverticulum in the GIT after colon. It is common in periampullary region; common in females.

Diverticulum can be congenital which is true one involving all layer diverticulum or acquired which is mucosal outpouching through muscular layer. But this classification is conflicting and confusing.

*It can be:*

**Extramural diverticulum**—protrudes outside; it can be –

- ◆ **Primary**—is usually mucosal; common on the medial wall of the 2nd (60%) or 3rd (30%) part of the duodenum. It is usually acquired one. It is diagnosed by barium fluoroscopic study / CT scan or MRI. It is treated with surgical excision of the diverticula from outside through laparotomy or laparoscopy - diverticulectomy.
- ◆ **Secondary**—always acquired; occurs in 1st part of the duodenum; is usually due to cicatrised chronic duodenal ulcer. Barium meal shows 'trifoliate duodenum'. Endoscopy should be done. It is treated by truncal vagotomy and posterior gastrojejunostomy.

**Intramural diverticulum**—protrudes inward into the lumen (*Windsock diverticulum*). Intramural diverticula are usually congenital. It shows 'Windsock sign' in barium study. When it is close to the ampulla of Vater, it can precipitate biliary stasis and stone formation with cholangitis, cholecystitis, pancreatitis and occasionally obstruction. It often can cause mechanical obstruction. It is diagnosed by contrast CT or MRI. It can be usually treated by endoscopy.

**Complications of diverticula**—diverticulitis, *haemorrhage* (most usual), perforation, abscess formation, *Lemmel syndrome* (compression of the intrahepatic CBD by the diverticula causing intra- and extrahepatic biliary dilatation with no biliary calculi). Adenocarcinoma can occur within the diverticulum.

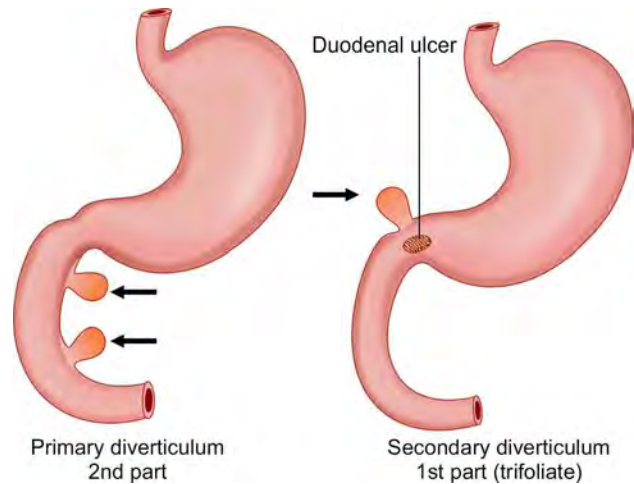
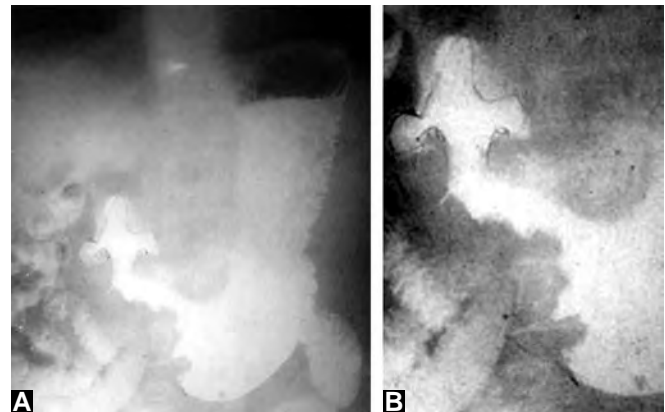


Fig. 20.59: Primary and secondary diverticula of the duodenum.



Figs 20.60A and B: Barium meal picture showing trifoliate duodenum as secondary diverticulum due to chronic duodenal ulcer.

## CARCINOMA STOMACH

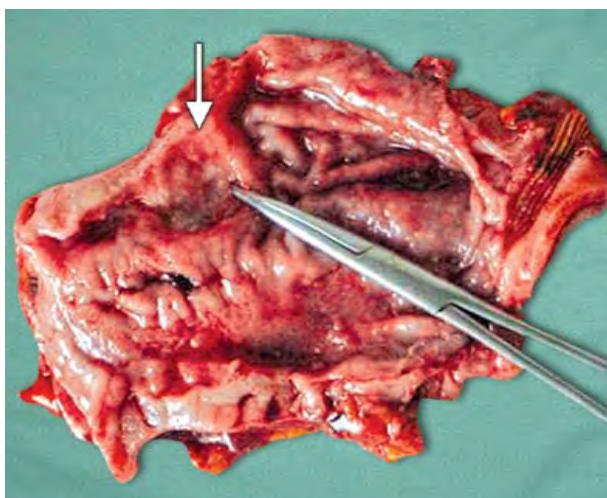
*My kinsman, Antonio Bruno, retained the food he had eaten for too short a time, and then threw it up undigested.... His body wasted away through lack of nourishment till little more than skin and bone remained. At last, he was brought to his death. The body was cut open for reasons of public welfare. It was found that the opening of his stomach had closed up and it had hardened...with the result that nothing could pass through to the organs beyond, and death inevitably followed.*

—Antonio Benivieni, 1507

- ◆ 'It is the captain of men of death'.
- ◆ It is more common in Japan—70 per 1,00,000 population.
- ◆ It is more common in males 2:1.
- ◆ Decrease incidence in western world (Western Europe and US)—last four decades. But this decrease is confined to distal gastric cancers. Incidence of proximal gastric cancer is increasing. Carcinoma proximal stomach is not associated with *H. pylori* infection unlike cancers of body and distal stomach.

## Risk Factors (Aetiology)

- ◆ **Familial**—10%. Napoleon and many members of his family died of carcinoma stomach. *Familial gastric cancer* is associated with mutation of *e-cadherin gene* (90% risk). It causes hereditary diffuse gastric cancer. Relatives of such family show mutation of this gene. Whether prophylactic total gastrectomy is needed or not in these high-risk individuals is a debate.
- ◆ **Inactivation of p53, over expression of growth factors, bcl-2 gene mutations** are other genetic causes.
- ◆ **HNPCC, Li-Fraumeni syndrome.**
- ◆ Gastric mucosa of people with **blood group 'A'** is more susceptible for carcinogens—diffuse type. It is due to different mucopolysaccharide secretion in stomach of blood group A patients who are more susceptible for carcinogens.
- ◆ **Gastric polyps, adenomatous polyp >2 cm.**
- ◆ **Pernicious anaemia**—high-risk 6 times.
- ◆ **Gastric remnant**—15 years after gastrectomy and GJ.



**Fig. 20.61:** Gastrectomy specimen showing ulcerative gastric carcinoma.

- ◆ **Diet**—high salt diet, food with more nitrosamines increases the risk. Smoked salmon fish increases the risk. They release polycyclic hydrocarbons. Ingested nitrates and nitrites from preserved food are converted to nitrosamines by GI bacteria.
- ◆ Fruits and vegetables rich in vitamin 'C' protect from carcinoma stomach.
- ◆ **Chronic gastritis (atrophic, autoimmune), intestinal metaplasia.** Type A causes proximal gastric cancer. Type B causes distal gastric cancer.
- ◆ **Gastric dysplasia:** Chronic gastritis → gastric atrophy → intestinal metaplasia → dysplasia → carcinoma *in situ* → carcinoma—this cycle occurs in body and distal stomach and is often called as *Correa cycle*.
- ◆ Smoking, alcohol.
- ◆ **Helicobacter pylori infection**—high-risk (Cag A strain) 6-fold increase in incidence. It causes intestinal type of gastric cancer.

- ◆ Agammaglobulinaemia—high-risk (2–5%).
- ◆ Chronic benign gastric ulcer. Carcinoma arising from benign gastric ulcer is called as *ulcer cancer* of stomach.
- ◆ Giant hyperplasia of gastric mucosal folds (*Menetrier's disease*).
- ◆ Carcinoma in proximal stomach is common in young and upper socioeconomic group.
- ◆ Carcinoma in distal stomach is common in old and lower socioeconomic groups.
- ◆ In western countries, carcinoma stomach is more common in proximal, near OG junction. Obesity, young individual, white people, smoking, alcohol intake, gastro-oesophageal reflux, higher social status, high calorie diet and probably genetic factors are the causes for proximal gastric cancers. It is more aggressive, spreads early due to thin muscularis mucosa. It is often diagnosed late. Signet ring type is common. It carries poor prognosis. It needs oesophageal resection.
- ◆ In Asian countries, it is still common in distal stomach.
- ◆ In India, it is common in south India (4 times than North India).
- ◆ Epstein-Barr virus, radiation exposure.
- ◆ Occupational—Rubber workers, coal workers.
- ◆ Zinc, lead, talc, asbestos all can cause carcinoma stomach.

## Precursor Lesions of Carcinoma Stomach

- ◆ **Chronic atrophic gastritis:** It is the most common precursor lesion mainly intestinal subtype. In Japan 95% of atrophic gastritis develop early gastric cancer. Incidence is higher in elderly and in those associated with *H. pylori* infection.
- ◆ **Adenomatous gastric polyps.**
- ◆ **Intestinal metaplasia:** Risk of carcinoma depends on extent of metaplasia in mucosa. *H. pylori* eradication is important here. Based on histological and biochemical nature, two types are found:
  - ▶ **Complete:** Glands are completely lined with goblet cells and intestinal absorptive cells indistinguishable histologically and biochemically from their small bowel counterparts.
  - ▶ **Incomplete:** It contains columnar cells, goblet cells but without intestinal absorptive cells.

It also can be:

- ▶ **Type I**—Mature; goblet cells secrete sialomucin.
- ▶ **Type II**—Cells in different levels of dedifferentiation. Cells secrete sialomucin and an abnormal sialomucin (sulphomucin)—a small quantity.
- ▶ **Type III**—Marked dedifferentiation of cells, secreting mainly sulphomucin.
- ◆ **Menetrier's disease.**
- ◆ **Benign gastric ulcer:** Here risk is 2-5%. But it is related to the size, extent and duration of the benign gastric ulcer. Giant gastric ulcer has got as high as 6–23% risk. Cancer developing in a pre-existing benign gastric ulcer is called as *ulcer cancer*.
- ◆ **Stomach remnant (stump carcinoma):** It can occur after Billroth II gastrojejunostomy (common) or vagotomy GJ. It takes around 15 years or more to develop cancer. Common site is close to the stoma. Atrophic gastritis—metaplasia—dysplasia and carcinoma develops. Altered acid level, enterogastric bile refluxes are the pathogenesis which increases the peptic activity causing mucosal metaplasia and dysplasia. Earlier history of gastric surgery, recent history of loss



of appetite and decreased weight with often a palpable mass are the features. Liver secondaries, ascites may develop in late cases. Gastroscopy with biopsy and CT scan confirms the diagnosis. Treatment is gastrectomy with nodal clearance.

### Aetiology for gastric cancer

Environmental/ occupational/diet/habits	Genetic and familial
<ul style="list-style-type: none"> <li>Smoking/alcohol/obesity</li> <li>Low vegetables, diet with low vitamin A and C</li> <li>Consuming red meat, smoked salmon fish, cabbage, diet rich in nitrosamines, lead</li> <li>Viral infections like EB virus</li> <li>Occupational—rubber/coal workers</li> <li>Lower social status—distal cancers</li> <li>Higher social status—proximal cancers</li> </ul>	<ul style="list-style-type: none"> <li><i>E-cadherin</i> gene mutation in diffuse cancers</li> <li>Mutation in APC gene for <math>\beta</math>-catenin in intestinal cancers—50%</li> <li>Inactivation tumour suppressor gene p53 in 30% cases</li> <li>Loss of heterozygosity in the BCL2 gene, an inhibitor of apoptosis (intestinal type)</li> <li>Amplification/over expression of different growth factor receptors</li> <li>HNPCC—carries 5–10% risk of gastric cancer</li> <li>Li Fraumeni syndrome</li> <li>Blood group A</li> <li>First degree relative carries 3–6 folds increased risk of gastric cancer.</li> <li>Monozygotic twins carry more risk than dizygotic</li> <li>When both parents have gastric cancer, the siblings are at risk of diffuse proximal gastric cancer</li> <li>FAP—10-folds more risk of gastric cancer</li> <li>Mutation of H-ras oncogene and over expression of c-erb B2 gene</li> </ul>
<p><b>Precancerous lesions:</b></p> <ul style="list-style-type: none"> <li><i>H. pylori</i> infection, chronic gastritis</li> <li>Pernicious anaemia</li> <li>Intestinal metaplasia</li> <li>Adenomatous polyps more than 2 cm</li> <li>Agammaglobulinaemia</li> <li>Benign gastric ulcer</li> <li>Previous gastric surgery</li> <li>Menetrier's disease</li> </ul>	

## Pathology

### I. Gross types:

Cauliflower type  
Ulcerative type  
Leather-bottle (Linitis plastica)

### II. Lauren's classification (DIO classification):

- Intestinal type (53%):**
  - Has got favourable prognosis.
  - Polypoid and superficial types are intestinal varieties—common in *H. pylori* induced. Gland formation and definite cellular architecture are the features.
  - Synchronous/polypoid/superficial types are common.
  - Gastric mucosa is replaced with epithelium that resembles small bowel mucosa.
  - It is common in men and aged individuals, probably has environmental factors, commonly shows haematogenous spread, *microsatellite instability*, APC gene mutations, p53, p16 inactivation.
- Diffuse type (33%):**
  - It has got poor prognosis. Common in blood group A, familial type, young people and females.

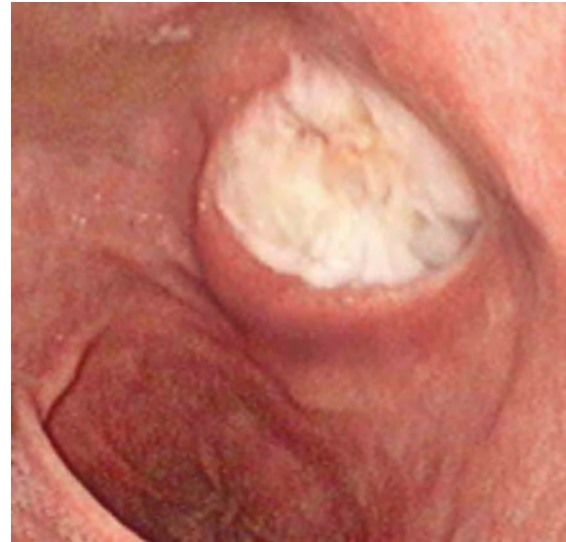

Fig. 20.62: Endoscopic view of carcinoma of stomach.

- It is usually poorly differentiated/signet type with early gastric wall penetration and both submucosal and subserosal lymphatic spread.
- Linitis plastica, ulcerative growth without glandular formation is common in this type.
- It shows decreased *E-cadherin* with p53, p16 inactivation.

c. *Others*—Unclassified (14%).

### III. Depending on the depth of invasion:

- Early gastric cancer** is defined as involvement of *mucosa and/or submucosa* only with or without involvement of lymph nodes – T1 + any N.

It is being classified as:

#### (Japanese's classification)

- Protruded.
- Superficial—elevated (a), flat (b), depressed (c).
- Excavated.

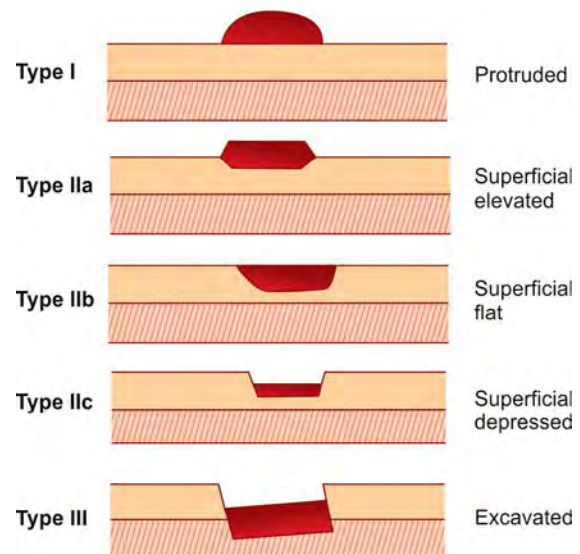


Fig. 20.63: Japanese's classification for early gastric cancer.

It is:

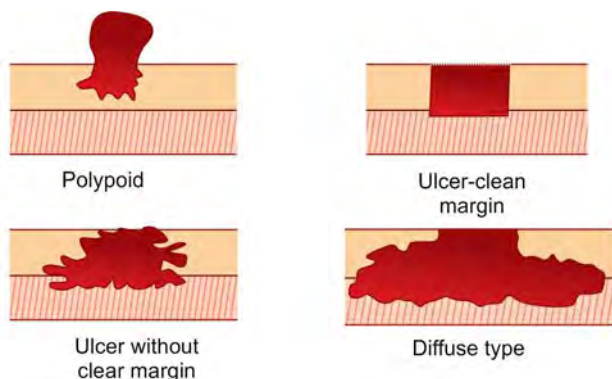
- More common in Japan—50% of gastric cancers treated are early gastric cancers. In USA—20%.
- 10% of early gastric cancers will have nodal metastases. 3% in only mucosal lesions. 20% in submucosal lesions.
- Nodal spread in early gastric cancer depends on tumour size (>2 cm) and differentiation.
- About 70% are well-differentiated.
- Endoscopic mucosal resection (EMR) is possible in cancer of only mucosal lesions.
- Overall cure rate with adequate gastric resection and lymphadenectomy—95%.

b. *Advanced gastric cancer* is defined as involvement of *muscularis and/or serosa* with or without involvement of lymph nodes.

It is classified as:

**(Borrmann's classification):**

- I. Single, polypoid carcinoma.
- II. Ulcerated carcinoma with clear cut margin.
- III. Ulcerated carcinoma without clear cut margin.
- IV. Diffuse carcinoma—linitis plastica.
- V. Unclassified.



**Fig. 20.64:** Borrmann's classification of the advanced gastric cancer.

**IV. Ming's classification:**

- ▶ Expanding—favourable prognosis.
- ▶ Infiltrative—unfavourable, poor prognosis.

**V. WHO histological classification of gastric cancer (microscopic)**

- ▶ Adenocarcinoma—most common.
  - Papillary adenocarcinoma—most common type.
  - Tubular adenocarcinoma.
  - Mucinous adenocarcinoma.
  - Signet-ring carcinoma
- ▶ Adenosquamous carcinoma.
- ▶ Squamous cell carcinoma—rare, when occurs it is common near OG junction.
- ▶ Undifferentiated carcinoma.
- ▶ Others—unclassified carcinoma.

**VI. Proximal gastric adenocarcinoma (Siewert classification)**

*Type 1:* Carcinoma in Barrett's oesophagus/true oesophageal carcinoma extending to GE junction. Here total oesophagectomy with gastric pull through to neck is needed.

*Type 2:* Tumour within 2 cm of squamocolumnar junction. Here total gastrectomy with Roux-en-Y oesophagojejunostomy is needed.

*Type 3:* Tumour in subcardial region. Here total gastrectomy with Roux-en-Y oesophagojejunal anastomosis is done.

**Note:**

Not commonly used are:

**VII. Morphovolumetric classification:**

It is based on ratio of invasion into muscle to mucosa in advanced carcinoma as:

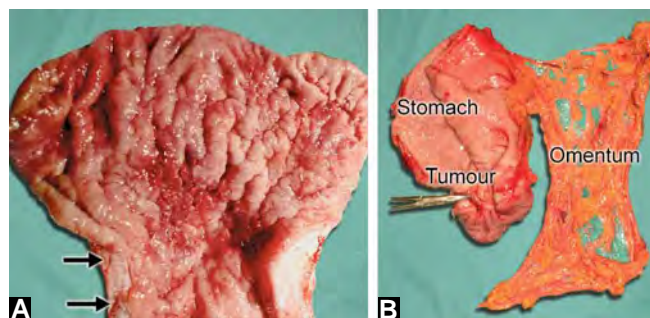
- ▶ *Funnel type*—mucosa involvement is more compared to muscle with a ratio of <0.15. It carries better prognosis.
- ▶ *Columnar type*—equal involvement in ratio of 0.75-1.25.
- ▶ *Mountain type*—muscle invasion is more with ratio < 1.25.

**VIII. Morson and Dawson classification:**

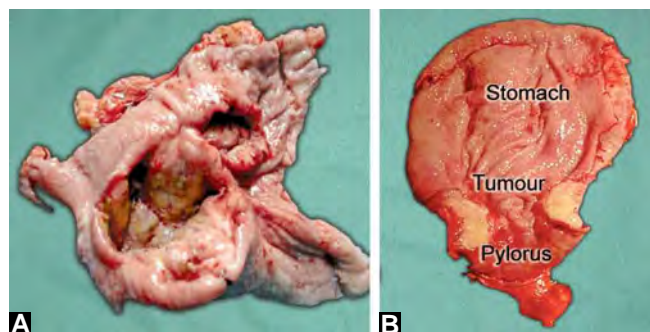
- ▶ Nodular.
- ▶ Ulcerated.
- ▶ Fungating.
- ▶ Linitis plastica.

**IX. Kajitani classification:**

- ▶ Localised.
- ▶ Intermediate.
- ▶ Infiltrating.



**Figs 20.65A and B:** Specimen of stomach showing thickening of wall of part of the stomach with loss of rugosity. Omentum, proximal parts are also seen. Thickening is extending into serosa.

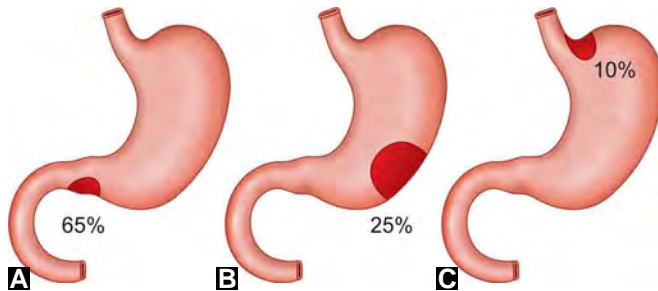


**Figs 20.66A and B:** (A) Specimen of stomach showing large ulcerative deep lesion in the stomach with raised and everted edge. Loss of rugosity also observed; (B) Specimen of stomach showing thickening of pylorus—feature of carcinoma stomach. In Asian countries, pylorus is the most common site. In Western countries proximal stomach is the most common site.

### Common Site of Occurrence

- ◆ Pyloric and pyloric region (65%) (most common site)
- ◆ Body (25%).
- ◆ Fundus, OG junction.

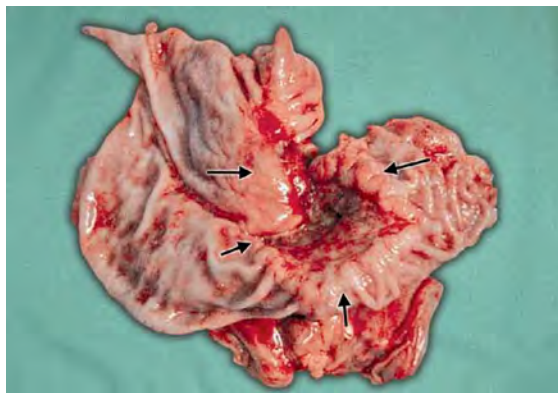
But now the incidence of growth in the upper part, near oesophago gastric (OG) junction is increasing.



**Figs 20.67A to C:** Common sites of carcinoma stomach:  
(A) Pylorus; (B) Body; (C) Fundus.

#### Note:

- *Synchronous gastric cancer* (Moertel) is histologically proved malignant conditions separated by normal stomach wall. Local extension and secondaries should be ruled out.
- *Distal gastric cancers* are diet related, environmental, epidemic, intestinal type, have better prognosis, with 30% resectability, treated with distal subtotal gastrectomy.
- *Proximal gastric cancers* are not diet related, not environmental, endemic, diffuse type, carries poor prognosis, with less than 20% resectability, treated with total gastrectomy.



**Fig. 20.68:** Ulcerative lesion with everted edge in the gastrojejunostomy stoma. It usually occurs only after 15 years of gastrojejunostomy surgery.

### Spread (Biological Behaviour)

- ◆ **Direct spread:**
  - ▶ *Horizontal submucosal spread* along stomach wall.
  - ▶ *Vertical spread by invasion* across to adjacent structures like—pancreas, colon, mesocolon, liver.
- ◆ **Lymphatic spread:**
  - ▶ Spread occurs by permeation and embolisation through lymphatics to subpyloric, gastric, pancreaticoduodenal, splenic, coeliac, aortic, and later to left supraclavicular lymph nodes (Virchow's lymph node—*Troisier's sign*).

- ▶ Retrograde spread to mesenteric nodes of small and large bowel can occur which signifies poor prognosis.

#### Zones of lymphatic drainage in stomach: Four zones.

**Zone 1** lies in gastrocolic omentum along the right gastroepiploic vessels, draining pyloric portion of the greater curve to pyloric, coeliac and aortic lymph nodes.

**Zone 2** lies in gastrocolic and gastrosplenic omentum along the left gastroepiploic vessels draining from upper half of greater curve to pancreaticosplenic and aortic lymph nodes.

**Zone 3** is drainage from proximal two thirds of the stomach and the upper lesser curve along the left gastric artery. Zone 3 drains into perioesophageal lymph nodes

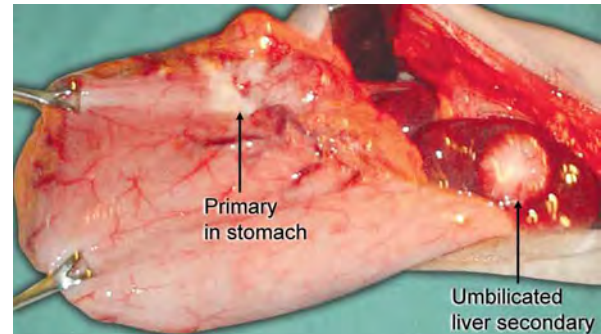
**Zone 4** is from distal portion of lesser curve and pylorus along hepatic artery into para-aortic nodes.

#### Lymph node groups

- ❖ *Group I:* Perigastric nodes
- ❖ *Group II:* Along the root of major vessels
- ❖ *Group III:* At the root of superior mesenteric artery and hepato duodenal ligament
- ❖ *Group IV:* Distant lymph nodes

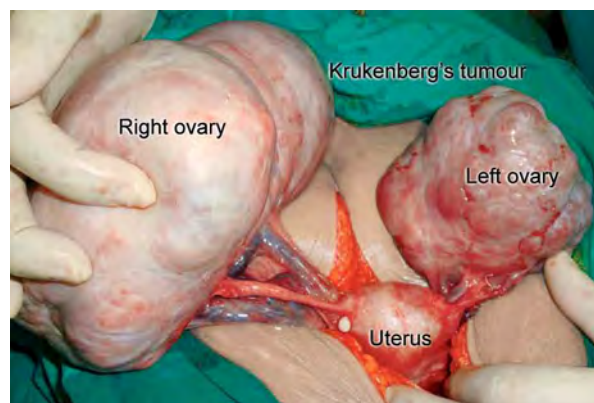
#### ◆ Blood spread

- ▶ It occurs to liver (most common) causing multiple liver secondaries presenting as multiple, hard, nodules with umbilications due to central necrosis.



**Fig. 20.69:** Carcinoma stomach showing umbilicated secondaries in liver.

- ▶ Later lungs and bones can get involved.
- ◆ **Transperitoneal spread**
  - ▶ It can cause peritoneal seedlings (leading to ascites) and also can cause *Krukenberg's tumours in ovary* in menstruating age group (Commonly seen in colloid carcinoma of stomach).
  - ▶ Krukenberg's tumour can often occur without ascites. This is explained by possible *retrograde lymphatic spread* from stomach to ovary. This is favoured by absence of ascites, no denudation/implantation/adhesions on the ovarian surface. Through lymphatic spread, even early gastric cancer can cause *Krukenberg's tumour*. In Japan, 17% of ovarian tumours is Krukenberg's secondaries from carcinoma of stomach. Occasionally Krukenberg's tumour can arise from carcinoma breast (lobular), other abdominal organs also.
  - ▶ Rectal secondaries (*Blumer shelf*), *Sister Mary Joseph* umbilical secondaries are through transperitoneal spread.
  - ▶ Transperitoneal spread is best identified through laparoscopy and confirmed by laparoscopic biopsy.



**Fig. 20.70:** Krukenberg's tumour involving both ovaries from carcinoma of stomach. It is due to transcoelomic spread or through peritoneal lymphatics or blood spread. It usually occurs during ovulation period.

## TNM Staging of Carcinoma Stomach

### TNM Staging, 7th edition, 2010

#### Tumour – T

- Tx—tumour cannot be assessed
- T0—no evidence of tumour
- Tis—carcinoma *in situ*, intraepithelial tumour without invasion
- T1a—invades lamina propria or muscularis mucosa
- T1b—invades submucosa
- T2—invades muscularis propria
- T3—invades subserosal connective tissue without invasion of visceral peritoneum or adjacent structures
- T4a—invades serosa/visceral peritoneum
- T4b—invades adjacent structures

#### Nodes – N

- Nx—cannot be assessed
- N0—no nodal spread
- N1—1–2 regional nodes
- N2—3–6 regional nodes
- N3a—7–15 regional nodes
- N3b—16 or more nodes

#### Metastases – M

- M0—no distant spread
- M1—distant spread present

#### Staging

- 0—T<sub>is</sub> N<sub>0</sub> M<sub>0</sub>
- IA—T<sub>1</sub> N<sub>0</sub> M<sub>0</sub>
- IB—T<sub>1</sub> N<sub>0</sub> M<sub>0</sub> / T<sub>2</sub> N<sub>0</sub> M<sub>0</sub>
- IIA—T<sub>1</sub> N<sub>2</sub> M<sub>0</sub>; T<sub>2</sub> N<sub>1</sub> M<sub>0</sub>; T<sub>3</sub> N<sub>0</sub> M<sub>0</sub>
- IIB—T<sub>1</sub> N<sub>3</sub> M<sub>0</sub>; T<sub>2</sub> N<sub>2</sub> M<sub>0</sub>; T<sub>3</sub> N<sub>1</sub> M<sub>0</sub>; T<sub>4a</sub> N<sub>0</sub> M<sub>0</sub>
- IIIA—T<sub>2</sub> N<sub>3</sub> M<sub>0</sub>; T<sub>3</sub> N<sub>2</sub> M<sub>0</sub>; T<sub>4a</sub> N<sub>1</sub> M<sub>0</sub>
- IIIB—T<sub>3</sub> N<sub>3</sub> M<sub>0</sub>; T<sub>4a</sub> N<sub>2</sub> M<sub>0</sub>; T<sub>4b</sub> N<sub>0-1</sub> M<sub>0</sub>
- IIIC—T<sub>4a</sub> N<sub>3</sub> M<sub>0</sub>; T<sub>1</sub> N<sub>2-3</sub> M<sub>0</sub>
- IV—Any T Any N M<sub>1</sub>

Stage I, II—*locoregional disease*

Stage IV—*systemic disease*

### Japanese classification in staging of gastric carcinoma (JCGC)

It includes following *principles*:

- ❖ Basic rules for clinical, surgical, pathological, and final features
- ❖ Specific rules for histology
- ❖ Gastric biopsy specimen group classification
- ❖ Chemo RT response

#### Nodal spread as per JCGC:

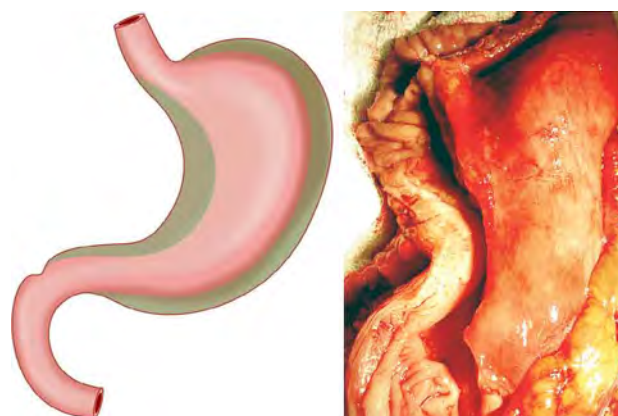
- N<sub>x</sub>—Nodes unknown/cannot be assessed
- N<sub>0</sub>—No nodal spreads
- N<sub>1</sub>—Group I nodes only involved
- N<sub>2</sub>—Group II nodes are involved but not group III
- N<sub>3</sub>—Group III nodes are involved

### Birmingham staging

- 1—Confined to mucosa/muscularis propria
- 2—Muscularis/serosal involvement
- 3—Nodal spread
- 4a—Residual disease; 4b—metastatic disease

## Leather-Bottle Stomach (Linitis Plastica) (7–10%)

- ◆ It is an aggressive diffuse type of carcinoma stomach wherein there is enormous proliferation of fibrous tissue involving submucosa of stomach which is thickened, (*Mother of pearl appearance*) but mucosa looks and feels normal.
- ◆ It is type IV gastric carcinoma.
- ◆ It is *poorly differentiated* type *lacking* glandular formation, showing clusters of small uniform cells often with *signet ring* cells.
- ◆ It spreads *submucosally* without much inflammatory cells.
- ◆ Transmural, lymphatic, intraperitoneal spread and early metastasis is common.
- ◆ *Common* in young, females, blood group A and is familial.



**Fig. 20.71:** Specimen showing features of Linitis plastica—a diffuse type of carcinoma stomach mainly involving submucosa and deeper layer (mother of pearl appearance). It carries poor prognosis. It is type IV gastric carcinoma. It may be generalized or localized. It is also called as leather-bottle stomach.

#### Clinical features:

- ▶ Loss of appetite and weight. Later, mass may be palpable from the body of the stomach.

- ◆ **Investigation:**
  - ▶ Small sized stomach in barium meal study.
  - ▶ Endosonography is also diagnostic.
- ◆ **Treatment:**
  - ▶ Total gastrectomy with oesophagojejunal anastomosis.
  - ▶ Prognosis is poor.
  - ▶ It may be occasionally localised linitis plastica in pyloric antrum which is better operable.

#### Colloid carcinoma of stomach

- ❖ It is 6% common among all gastric cancers, wherein tumour cells contain *colloid* which is histologically typical
- ❖ It also signifies *poorer prognosis*
- ❖ Common in women

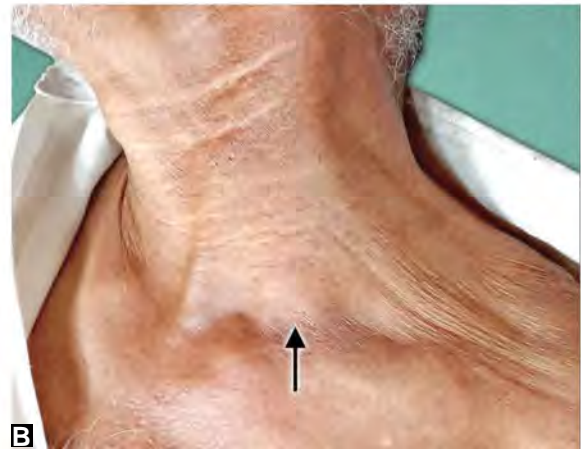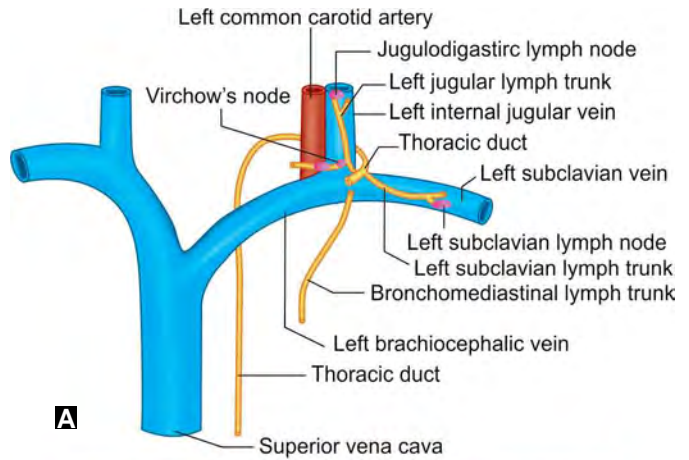
### Presentations of Carcinoma Stomach

- ❖ *Asymptomatic* in early gastric cancer or often in cancer of body of stomach.
- ❖ *Nonspecific symptoms*—indigestion/vague epigastric discomfort, constant nonradiating pain which is not related to food intake.
- ❖ *Specific symptoms* depend on the site of tumour—obstruction, dysphagia, mass, etc.
- ❖ *Metastatic disease*—liver secondaries, ascites, secondaries in ovary, rectovesical pouch, umbilicus, supraclavicular nodes, lung and bone secondaries.
- ❖ *Unusual presentations*—acanthosis nigricans, Irish nodes in the axilla.

### Clinical Features

- ◆ Recent onset of loss of appetite and weight, early satiety, fatigue. *Microcytic, hypochromic anaemia* (iron deficiency) is common (40%).
- ◆ Upper abdominal pain.
- ◆ Vomiting with features of gastric outlet obstruction, i.e. [VGP +ve, +ve ausculto-percussion test, +ve succussion splash (to be checked with 4–6 hours empty stomach)].
- ◆ *Mass abdomen*: Mass in pylorus lies above the umbilicus, nodular, hard, with impaired resonance, mobile, moves with respiration, all border well made out.
- ◆ Dysphagia with mass in upper epigastrium.
- ◆ When it arises from the body of stomach, it may present as only mass abdomen.
- ◆ Along with jaundice, liver may be palpable with secondaries which are hard, nodular (50%) with umbilication.
- ◆ Ascites.
- ◆ +ve Troisier's sign.
- ◆ +ve rectovesical secondaries. (Blumer shelf) on per rectal examination.
- ◆ +ve *Trousseau sign*—migrating thrombophlebitis, also seen in carcinoma pancreas.
- ◆ Anaemia, cachexia.
- ◆ Haematemesis (15%), melaena.
- ◆ Occasionally carcinoma stomach can present as *perforation* with (4%).
- ◆ Rarely as secondaries in the liver with silent primary in stomach.

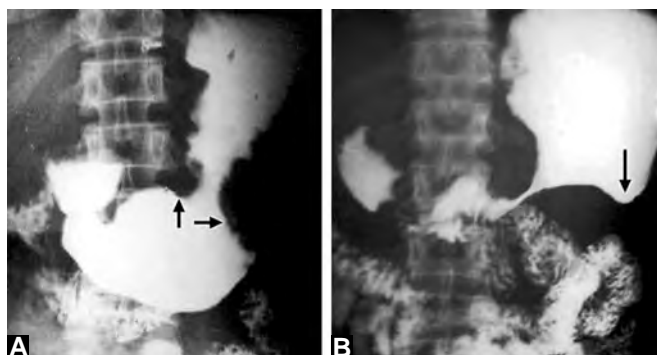
- ◆ Secondaries in umbilicus, as Sister Joseph's nodules (spread through ligamentum teres).
- ◆ Cutaneous secondaries.
- ◆ Krukenberg tumours.



**Figs 20.72A and B:** Anatomy of Virchow's node. It is located under the lateral head or in between the two heads of the sternocleidomastoid muscle just above the angle of the clavicle.

#### Virchow's node

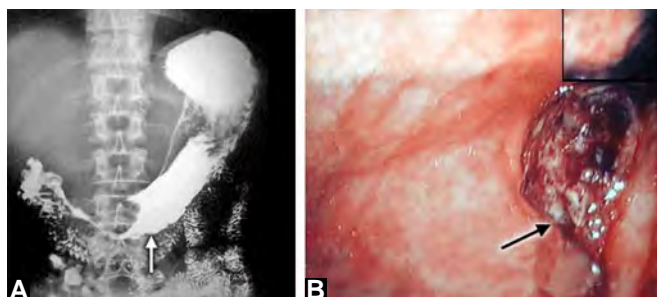
Rudolf Ludwig Karl Virchow, in 1849, noted the involvement of left supraclavicular node in relation to the junction of the thoracic duct, adjacent to medial to the IJV; this *end node* drains through few lymphatics into the left jugular trunk and to thoracic duct. Reflux from thoracic duct into this node occurs easily in abdominal malignancy. 40 years later, *Troisier* reported many abdominal cancers presenting with left supraclavicular lymph node involvement as *external indicator* and so coined the term *Virchow's node* and sign is called as *Troisier sign*. At the level of left C7 transverse process, thoracic duct arches behind the carotid sheath and IJV and joins the junction of IJV and left subclavian vein; this Virchow's (end node along the thoracic duct) is located medial to this junction behind the muscular lateral head of the left sternocleidomastoid muscle or in between the two heads. *Virchow's node* is also called as '*signal node*' or '*seat of the devil*' node. Virchow's node is actually part of the lower deep cervical node (level IV). *Its surface marking* almost corresponds to end of the thoracic duct i.e. just above the sternal angle of the clavicle 1.5 cm left of the midline. Node is just medial to this point.



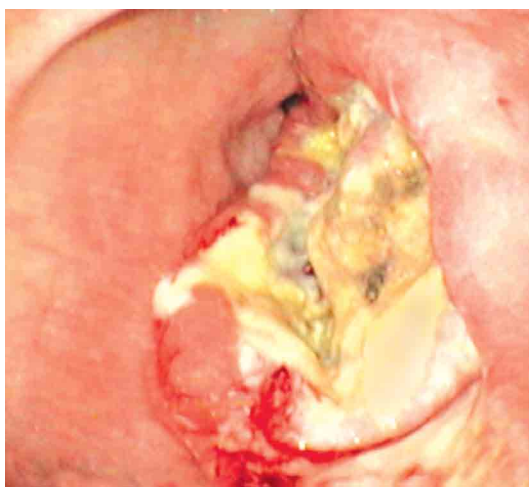
**Figs 20.73A and B:** (A) Barium meal showing irregular filling defect in the body of the stomach suggestive of carcinoma stomach; (B) Barium meal showing irregular filling defect in the pylorus suggestive of carcinoma pylorus.

#### Differential diagnosis

- ❖ Acid peptic disease; pyloric stenosis with gastric outlet obstruction
- ❖ Gastritis
- ❖ Pancreatic mass—carcinoma
- ❖ Transverse colon mass—carcinoma
- ❖ Advanced fixed stomach mass may mimic retroperitoneal or nodal mass.



**Figs 20.74A and B:** Polypoid carcinoma stomach seen in barium meal picture and also through endoscopy.



**Fig. 20.75:** Ulceroproliferative growth in the antrum—an endoscopic view.

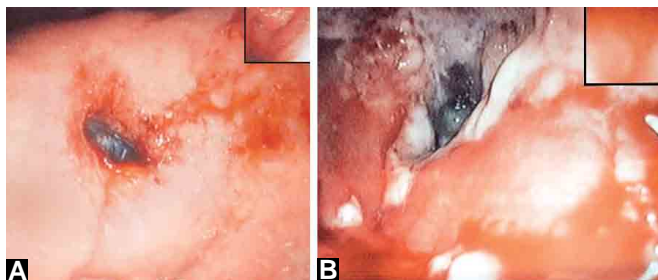
#### Investigations

- ◆ Hb%, haematocrit.
- ◆ Barium meal (Irregular filling defect).
- ◆ Single contrast barium studies—sensitivity is 75%.
- ◆ *Double contrast barium studies*—sensitivity is 90–95% in the detection of gastric cancer, comparable to endoscopy.

#### Barium meal findings in carcinoma stomach

- ❖ Irregular filling defect
- ❖ Loss of rugosity
- ❖ Delayed emptying
- ❖ Dilatation of stomach in carcinoma pylorus
- ❖ Decreased stomach capacity in linitis plastica
- ❖ Margin of the lesion projects outward from the ulcer/lesion into the gastric lumen—*Carmann's meniscus sign*

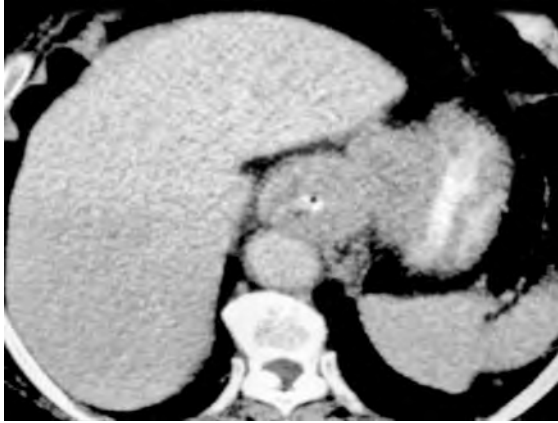- ◆ *Gastroscopy with biopsy*—10 targeted biopsies.
- ◆ *Endosonography*: EUS is useful to detect the involvement of layers of the stomach, nodal status and to define whether tumour is early or advanced. All 5 layers are visualised as alternate hypo- and hyperechogenic areas. It gives 90% accuracy for T staging and 80% of nodal staging.



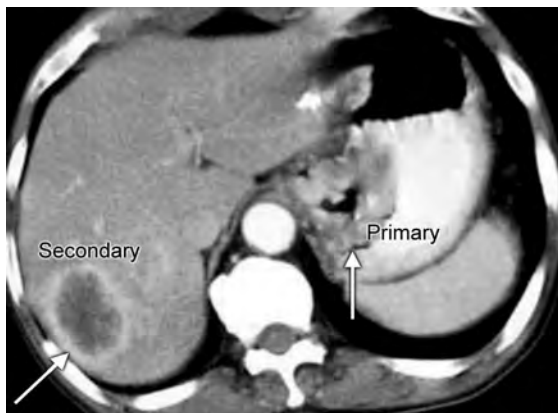
**Figs 20.76A and B:** (A) Endoscopic view of the growth in the pylorus; (B) Carcinoma stomach endoscopic view showing irregular tumour.

- ◆ *Ultrasound abdomen* to see liver secondaries, ascites, nodes, ovaries. It is not as sensitive as EUS and CT scan.
- ◆ CT scan abdomen and CT thorax in proximal tumours to see size, extent, infiltration, LN status, secondaries and operability (*Refer Figs 20.77 to 20.79*).
- ◆ Liver function tests and prothrombin time. Secondaries in liver can cause hepatic dysfunction and liver cell failure. Enlarged hepatic nodes can compress CBD and cause obstructive jaundice also.
- ◆ Often FNAC from left supraclavicular lymph node when it is significantly palpable.
- ◆ *Laparoscopy* to stage disease. Laparoscopy will pick up peritoneal secondaries; detect occult metastases, organ invasion. Guided biopsy of peritoneum and nodes, peritoneal lavage for cytology and laparoscopic US can be done. It will avoid unnecessary laparotomy. *Signs of inoperability will be better identified like*—peritoneal deposits (CT may miss), fixity, liver secondaries, fixed coeliac nodes, para-aortic nodes, ascitic fluid positivity on analysis. It is more accurate than CT.
- ◆ *Tetracycline fluorescence test*—gastric cancer cells take up tetracycline given orally which becomes yellow in colour. Under UV light it shows yellow fluorescence.
- ◆ CA 72-4 is important tumour marker to evaluate the relapse. CEA, CA 19-9, CA 12-5 are other markers.

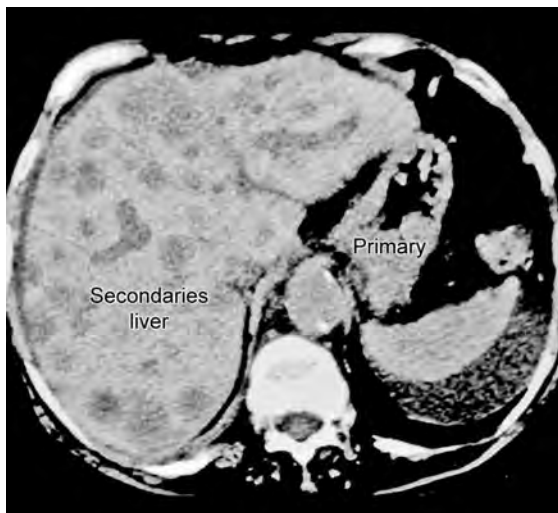
- ◆ Combined *PET*—*CT* scan is useful. It is to evaluate metabolic, physiologic and functional activity. It is mainly useful to identify recurrent gastric cancer.
- ◆ *Sentinel node biopsy*—<sup>99m</sup>Tc colloid peritumoral injection during gastrectomy. It has got sensitivity—80%, specificity—100% but not widely used.



**Fig. 20.77:** CT scan showing carcinoma pylorus with luminal obstruction.



**Fig. 20.78:** CT scan showing primary tumour in the stomach with secondaries in the right lobe of the liver. Secondaries are commonly multiple; only occasionally it will be solitary.



**Fig. 20.79:** CT scan showing multiple secondaries in liver with primary in the stomach.

**Note:**

*PET* scan and *EUS* do not form part of the staging of the gastric cancer.

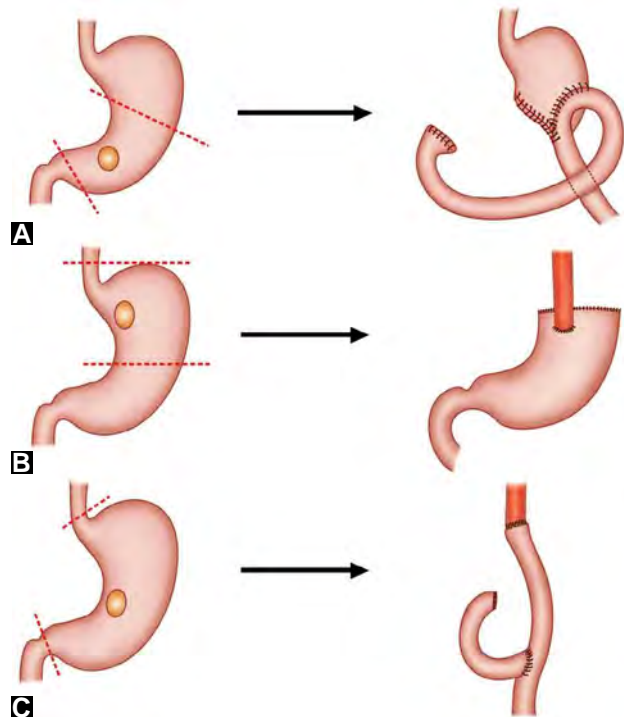
**Treatment**

*Surgery* is the treatment of choice for carcinoma stomach.

**Preoperative preparation**

- ❖ Correction of anaemia, nutrition, fluid and electrolyte
- ❖ Cardiac, respiratory and renal status assessment
- ❖ Stomach wash using normal saline
- ❖ Prophylactic antibiotic as achlorhydria in gastric lumen allows colonisation of *Streptococcus faecalis*, *E. coli*, bacteroides, *Staphylococcus ablus*
- ❖ Blood/FFP may be needed preoperatively and for surgery

1. If it is an early growth, as in case of pylorus, *lower radical gastrectomy* with proximal 5 cm clearance is (*Subtotal gastrectomy*), along with removal of greater omentum, lesser omentum, all lymph nodes, spleen (to clear splenic lymph nodes), tail of pancreas (when required); and later Billroth II anastomosis.
2. In case of growth in the OG junction or upper part of the stomach, *upper radical gastrectomy* is done along with removal of spleen, both omentum, lymph nodes; and later *oesophago gastric* anastomosis. *Total gastrectomy* is ideal here.
3. In case of growth in the body or *linitis plastica*, *total gastrectomy (radical)* with oesophagojejunal anastomosis is done.



**Figs 20.80A to C:** Gastrectomies for carcinoma stomach: (A) Lower radical gastrectomy; (B) Upper radical gastrectomy; (C) Total radical gastrectomy.

**Note:**

- In tumours of antrum or body of the stomach, *subtotal gastrectomy* is ideal. Total gastrectomy is not done.

- *Total gastrectomy* with reconstruction is better option for *proximal growth, aggressive growth from body or linitis plastica*. It reduces heartburn, dumping, improves appetite better with better functional outcome. Roux-en-Y oesophagojejunostomy is the reconstruction done.
- *Distal clearance* towards duodenum is 1 cm from tumour end; proximal clearance is 5 cm.
- *D1 gastrectomy* is clearance of perigastric nodes; *D2 gastrectomy* is clearance of nodes along major vessel trunks—along coeliac and splenic arteries. D2 is always better than D1.
- **D2 gastrectomy and adjuvant chemoradiation is ideal present concept therapy in operable carcinoma stomach.** *D2 gastrectomy includes*—removal of stomach with growth, omental bursa, greater and lesser omentum, anterior layer of mesocolon, anterior pancreatic capsule, D2 lymphadenectomy.
- Prophylactic splenectomy once practiced is no longer found useful. It is done only if the tumour is adherent to spleen or its vessels.
- In early well circumscribed lesion, clearance of 2.0 is adequate but infiltrating tumours need 5 cm clearance.
- D2 dissection is better than D1 dissection of lymph nodes.
- *Omentectomy* (both greater and lesser) and *bursectomy* (removal of outer leaf of transverse colon bearing colic vessels) should be added.
- Absolute curative resection is done—when there is absence of serosal, peritoneal, hepatic spread; with free adequate resection margin, with adequate nodal clearance (D dissection exceeds one level more the N nodal involvement).
- In operable cases, *neoadjuvant chemotherapy* improves the survival.
- Ideal reconstruction is either directly into the duodenum or in total gastrectomy using jejunal interposition with creation of reservoir. In distal gastrectomy Polya reconstruction is used.
- When the tumour is located upper or middle posterior wall of the stomach with serosal involvement without distant metastases *left upper abdominal evisceration* can be done. This *extended combined resection* includes—total gastrectomy, pancreaticosplenectomy, transverse colectomy always, occasionally may include left hepatectomy, left nephrectomy, and left adrenalectomy with resection of part of the left diaphragm. Its significance is doubtful.
- *Extended resection* means total gastrectomy with distal pancreatectomy with splenectomy.
- Para-aortic dissection is removal of fatty tissue and nodes from aortic hiatus to origin of inferior mesenteric artery often with left adrenalectomy to clear area adjacent to left renal artery.
- Recommendation is that, at least 15 lymph nodes should be removed. More than 5 positive nodes signify poor prognosis.

Presently newer staging for dissection is practiced in Japan—D1, D2, D3, D4 depending on levels of lymph nodes cleared ('D' for dissection). D1 or D2 dissections are commonly done.

- ◆ **D1** is done when nodes are N<sub>0</sub>. It is removal of nodes along the lesser and greater curves and pylorus (Group I: stations 3–6).
- ◆ **D2** is done when nodes are N<sub>1</sub>. Here nodes like left gastric/common hepatic/splenic/retropancreatic are removed. Splenic nodes can be cleared with or without splenectomy along with removal of tail of pancreas. Here node stations 1–11 are removed. Stations 12–18 are not removed. Average 27 nodes are removed.
- ◆ **D3** is done when nodes are N<sub>2</sub>. Nodes removed for clearance are hepatoduodenal, nodes along mesentery, middle colic (1–16 stations). Average 43 nodes are removed.
- ◆ **D4** is not commonly advocated. It is removal of stations 1–18.

**D1**—involvement of group I lymph nodes

**D2**—involvement of group I and II lymph nodes

**D3**—involvement of group I, II and III lymph nodes

**D4**—involvement of group I, II, III and para-aortic nodes

#### Note:

All lymph nodes are numbered differently as 'stations' or 'echelons'.

#### Lymph node stations in gastric carcinoma (Japan)— 18 stations are there

1. Right paracardial
2. Left paracardial
3. Along lesser curve: 3a—nodes along the left gastric vessels; 3b – nodes along right gastric vessels
4. Nodes along the greater curvature: 4sa—along short gastric vessels; 4sb - long left gastroepiploic vessels; 4sd—along the right gastroepiploic vessels—4d
5. Suprapyloric nodes
6. Infrapyloric nodes
7. Along left gastric artery
8. Along common hepatic artery: 8a—anterosuperior; 8b—posterior group
9. Along celiac axis
10. At splenic hilum
11. 11p: Along proximal splenic artery: 11d—along distal splenic artery
12. At hepatoduodenal ligament. 12a—along hepatic artery; 12b—along the bile duct; 12p—behind portal vein
13. LN along posterior surface of the pancreatic head
14. At root of mesentery: 14v—along SMV; 14a—along SMA
15. Around middle colic vessels
16. Paraaortic nodes: 16a1—along the aortic hiatus; 16a2—from upper margin of celiac trunk to lower margin of left renal vein; 16b1—from lower margin of left renal vein to upper margin of IMA; 16b2—from upper margin of IMA to aortic bifurcation
17. Along the anterior surface of the pancreatic head
18. Along the inferior margin on the pancreas
19. Infradiaphragmatic
20. In the oesophageal hiatus of the diaphragm
  - No 110 – Paraoesophageal nodes in lower thorax
  - No 111 – Supradiaphragmatic
  - No 112 – Posterior mediastinal

#### Note:

15 lymph nodes must be removed for adequate staging of nodes

#### 4. Endoscopic mucosal resection (EMR)

- ▶ It is practiced in Japan in early gastric cancer. Tumour less than 2 cm, elevated, well-differentiated tumours without nodal disease is the ideal selection for EMR. Proper regular endoscopic surveillance is essential in these patients after EMR.
- ▶ Lesion is elevated by injecting normal saline submucosally and elevated lesion with adjacent mucosa is resected using cautery up to muscularis propria; later with clips defect is apposed.
- ▶ It is done in protruded early gastric cancer or ulcer-free depressed cancer which is well-demarcated.

#### 5. Photodynamic therapy

- ▶ Intravenous injection of haematoporphyrin derivative photosensitiser is given initially; 48 hours later laser light is delivered to tumour through an endoscope to create interaction between two, releasing highly reactive singlet O<sub>2</sub> which causes tumour necrosis.

## Adjuvant Therapy

### Chemotherapy

- ◆ Mitomycin 10 mg IV single dose in monthly cycles.
- ◆ 5-fluorouracil, 250–500 mg IV in 5% dextrose daily for 5 days.



- ◆ Cisplatin and epirubicin, adriamycin, oxaliplatin, capecitabine are other drugs used at present.  
(*FAM regime* is 5-fluorouracil, adriamycin, mitomycin C).
- ◆ Chemotherapy is also used as palliation in inoperable cases/metastatic cases whether surgical palliation (if obstruction or bleeding is present) is needed or not.
- ◆ Neoadjuvant chemotherapy to downstage the tumour is also used to make it operable later. ECF (Epirubicin, cisplatin, 5 FU), EAP (Epirubicin, adriamycin, cisplatin), FDT (% FU, doxorubicin, triazinate) are used.
- ◆ *Bevacizumab* (anti-VEGF) is currently under trial.
- ◆ Instillation of mitomycin C impregnated charcoal intraperitoneally is done to control lymphatic disease (Japan). It specifically kills the malignant cells in lymphatics and lymph nodes in the abdomen.
- ◆ EOC – Epirubicin, oxaliplatin, capecitabine regime is also used.
- ◆ EOC, EOX (O–oxaliplatin; X–capecitabine), ECF, ECX, EOF, EOX regimes are used in metastatic disease as palliative therapy or occasionally as neoadjuvant therapy.

### Chemoradiotherapy

- ◆ Postoperative radiotherapy (RT) with chemotherapy using 5 FU and leucovorin. Chemoradiation has become the *standard* adjuvant treatment.
- ◆ Some benefits are shown but controversial. It is said to be better than adjuvant chemotherapy alone.

#### Note:

- Very less role for radiotherapy at present. Many radiosensitive structures in the gastric bed prevents tumour to have effective RT. RT is used as palliative method for painful bone secondaries.
- *Molecular targeted therapy* using trastuzumab monoclonal antibody against HER2 is also tried.
- *Intraperitoneal chemotherapy (IPC)* where high doses of chemotherapy is directly administered into the peritoneal cavity; it may be combined with hypothermia (HIPC); it may be done directly administering after surgery itself as in early postoperative intraperitoneal chemotherapy (EPIC). Oxaliplatin is instilled intraperitoneally for 30 minutes.

### Immunochemotherapy as an Adjuvant

- ◆ It is given in *stage III* carcinoma after radical gastrectomy. It starts from 5th postoperative day to the end of 2 years.
- ◆ It is based on the fact that preoperative T cell counts, percentage, are reduced which can be improved/modulated by this therapy.
- ◆ Residual cancer cells or micrometastases can be eradicated by this therapy.
- ◆ *Regime contains*—initially *immunotherapy* using weekly intramuscular injections of Picibanil (*Streptococcus pyogenes* derived) immune agent 1.0 clinical unit is given on 5th postoperative day. Later from 10th postoperative day onwards, *chemotherapy* regime consisting of mitomycin C and 5 FU is used as follows—mitomycin C 4 mg/50 kg IV twice weekly for 2 weeks, then weekly for 6 weeks; 5 FU as 500 mg/50 kg IV twice weekly for 2 weeks, then weekly for 6 weeks, then 600 mg/50 kg orally daily for 2 years.

#### Signs of inoperability

- ❖ Adherent to pancreas or colon or mesocolon
- ❖ Ascites
- ❖ Para-aortic lymph nodes
- ❖ Secondaries in liver
- ❖ **Palpable mass is incurable but can be resectable surgically**
- ❖ Blumer shelf
- ❖ Left supraclavicular nodes
- ❖ Sister Mary Joseph nodule
- ❖ Irish node (Left axillary lymph node secondaries)

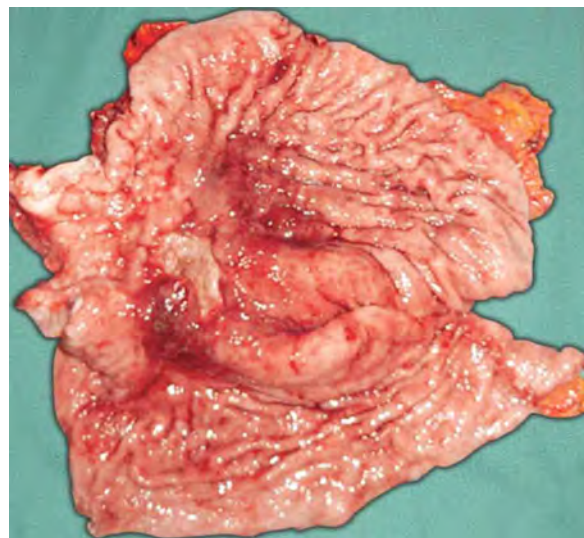


Fig. 20.81: Carcinoma stomach resected specimen.

#### Management of gastric carcinoma

- ❖ *Early growth in pylorus*: Lower radical gastrectomy with removal of tumour, proximal 5 cm clearance, nodal clearance, greater and lesser omentum, distal pancreas and spleen (now not regularly removed; it is removed to clear splenic nodes—one of the node stations) and Billroth II anastomosis or Roux-en-Y anastomosis is done. Postoperatively adjuvant chemotherapy should be given—5-fluorouracil, mitomycin, epirubicin, cisplatin, oxaliplatin, capecitabine
- ❖ *D1 or D2 nodal dissection* should be done for adequate clearance in curative surgery
- ❖ *Growth in body, proximal growth, diffuse carcinoma and generalised linitis plastica* are the indications for total radical gastrectomy with oesophagojejunal anastomosis.
- ❖ Neoadjuvant chemotherapy in advanced gastric cancer prior to surgery and later gastrectomy.
- ❖ Instillation of mitomycin C impregnated charcoal intraperitoneally to control lymphatic disease (Japan)
- ❖ Palliative procedures like *palliative partial gastrectomy*, anterior gastrojejunostomy, Devine's exclusion procedure, luminal stenting in proximal inoperable growths, chemotherapy are used in inoperable cases
- ❖ In early carcinoma proper lymph nodal clearance is important

### Palliative Treatment

- ❖ To palliate pain
- ❖ To palliate vomiting
- ❖ When there is bleeding
- ❖ To improve appetite
- ❖ *Partial gastrectomy (palliative) is the best method*

### Palliative Procedures

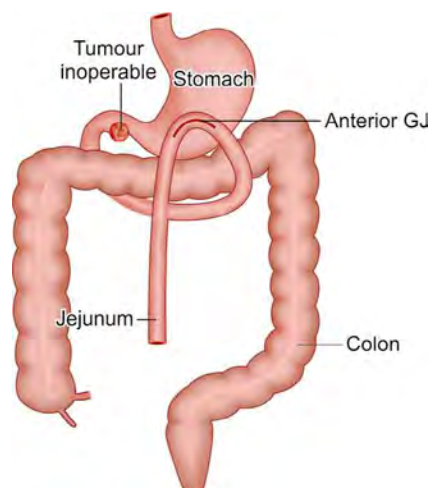
*Palliative partial/total gastrectomy* is the best palliation whenever possible.

- ◆ Palliative anterior gastrojejunostomy with jeuno-jejunostomy.
- ◆ *Devine's exclusion procedure* wherein instead of removal of tumour, it is excluded with Billroth II anastomosis.
- ◆ For unresectable growth in upper part of the stomach, palliation can be attained by inserting tubes through the oesophagus to the stomach like Mousseau-Barbin tube, Celestin tube (like in carcinoma oesophagus). Endoscopic stenting can also be tried.

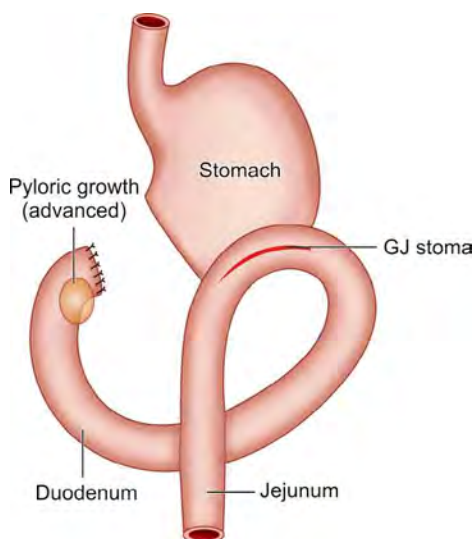
- ◆ Palliative chemotherapy is used in advanced stage.
- ◆ RT and analgesia like morphine is used to relieve pain.
- ◆ Surgery/endothrapy is used to relieve obstruction. Palliative partial gastrectomy (limited local resection), anterior GJ, laser, stenting are different options.
- ◆ Surgery (partial gastrectomy) or endothrapy is required in bleeding.
- ◆ Palliation for ascites is difficult even though repeated tapping and chemotherapy is done.

#### Palliative procedures for carcinoma stomach

- ❖ Palliative partial gastrectomy is the best palliation
- ❖ Palliative anterior gastrojejunostomy with jejunio-jejunostomy
- ❖ Devine's exclusion procedure
- ❖ M-B tube/Celestin tube insertion for proximal stomach growths
- ❖ Endoscopic stenting/dilatation
- ❖ Laser recanalisation
- ❖ Palliative chemotherapy—FAM regime



**Fig. 20.82:** Anterior gastrojejunostomy is one of the palliative procedures used in case of inoperable carcinoma stomach. It is anterior, antecolic GJ.



**Fig. 20.83:** Devine's exclusion procedure. Here inoperable pyloric tumour is left and excluded. Proximal stomach is transected and used for Billroth II like gastrojejunostomy.

#### Prognosis

- ◆ In early gastric cancer which has undergone good surgical resection, 5-year survival rate is 70–90% in Japan. In India, 5-year survival rate is 20%.
- ◆ In advanced gastric cancer it reduces to 20–25% in Japan. In other countries it is still worse.
- ◆ Overall prognosis is worse in carcinoma stomach.
- ◆ When serosa is not involved 5-year survival is 50%. When serosa is involved it is 20%.
- ◆ Nodal spread is a bad prognostic factor.
- ◆ Involvement of more than 4 nodes carry poor prognosis.
- ◆ In Japan, prognosis is better due to early diagnosis and better technical and staging approach.
- ◆ Early gastric cancer has got better prognosis.
- ◆ Intestinal type has better prognosis than diffuse type.
- ◆ Size of the tumour (2 cm); tumour depth; and histological type and grading.

#### Prognostic factors

- ❖ Early or advanced
- ❖ Histological grading
- ❖ Staging
- ❖ Gross types
- ❖ Lymph node status
- ❖ Liver secondaries
- ❖ Serosal involvement—an important factor
- ❖ Intestinal type—got better prognosis than diffuse type
- ❖ Ascites
- ❖ Response to treatment

#### Note:

- Recurrence rate is very high in first 3 years after therapy.
- If primary tumour can be removed surgically, it is called as *resectable tumour*. Resectability can be for palliation or along with radical surgery for cure.
- *Operable tumour* means radical gastrectomy with (amenable for) nodal clearance.
- *Inoperable tumour* means not amenable for radical surgery.
- Inoperable tumour can be resectable for palliation.
- **R<sub>0</sub>** is resection with complete clearance—no *residual disease*. **R<sub>1</sub>** is resection but with microscopic residual tumour. **R<sub>2</sub>** is resection with macroscopic residual tumour, **R<sub>3</sub>** is unresectable.
- D1 and D2 dissections are different for proximal and distal tumours.
- In early gastric cancers, laparoscopic endoluminal transgastric mucosal resection of the lesion is under trial now.
- Adjuvant chemoradiation (RT with 5-FU as radiosensitiser) is also under trial for proximal tumour, undifferentiated high-grade tumour.
- Antrectomy is also called as *hemigastrectomy*. Removal of 60–75% stomach is called as *partial gastrectomy*. Removal of more than 80% of stomach is called as *subtotal gastrectomy*.
- Perforation in gastric cancer has got high mortality.
- Most common site of recurrence is stomach bed, then lymph node and anastomotic site.
- Will Roger's stage migration phenomenon is thorough staging with stage for stage to improve the outcome.

#### ■ GASTRIC LYMPHOMA

There are two types of gastric lymphomas.

- ◆ Primary.
- ◆ Secondary.

*Without human being this world would have been heaven. Production of noble human being was the Perfect Tragedy to this world !!*

**Note:**

- Gut lymphomas are 10% of all lymphomas. It is common in males (2:1). Coeliac disease, alpha chain disease, ulcerative colitis, HIV, transplantation—are the aetiology in general for gut lymphomas. *H. pylori* is relevant for gastric lymphoma.
- It occurs in stomach (55%), small bowel (30%), colon (10%), ileocaecal region (5%).

**A. PRIMARY GASTRIC LYMPHOMA**

- ◆ Primary gastric lymphoma is the most common one among GI primary lymphomas.
- ◆ It is the second most common malignant neoplasms of the stomach (5% of gastric malignancies).
- ◆ It is common in elderly men and common in the antrum of the stomach.
- ◆ It can be infiltrative, ulcerative, nodular, polypoid or combined.
- ◆ Gastric lymphomas are commonly of non-Hodgkin's type (NHL—B cell type 98%).
- ◆ It is arising from B cells—derived from mucosal-associated lymphoid tissue (MALT). So often called as MALTOMA
- ◆ Diffuse mucosal thickening which eventually ulcerates—is the pathology.
- ◆ Disease remains in the stomach for long time and later spreads to liver and other lymph nodes.
- ◆ Association of primary gastric lymphoma with *H. pylori* is well-established. Normal gastric mucosa does not contain lymphocytes but mucosa with *H. pylori* infection contains lymphocytes.
- ◆ Usually disease is localised to stomach without any other lymph nodes in the abdomen or mediastinum with normal liver, spleen, bone marrow and total count.
- ◆ It is basically a localised disease of stomach to begin with but later to have systemic spread.
- ◆ *Main presentation* is mass abdomen, pain, vomiting and loss of weight. Perforation, bleeding, obstruction, gastrocolic fistula are also not uncommon.
- ◆ *Dawson's criteria for primary GI lymphoma* (NHL): No palpable superficial lymph nodes; no thoracic lymph nodes in CT scan; normal WBC count and bone marrow; predominant bowel pathology; liver, spleen are normal.
- ◆ *Ann Arbor staging*: Stage IE—confined to GIT; IIE – GIT + regional nodes; IIIE – GIT + nodes away from and beyond regional; IVE – GIT + other intra-abdominal organs or extra-abdominal.
- ◆ *It can be*—B cell, T cell, low grade, high grade, pure centroblastic, unclassified.
- ◆ *Lugano staging system* is widely accepted one for MALToma—*Early*: Single primary lesion or multiple noncontiguous primary lesions confined to GI tract with or without nodal involvement; *Advanced*: Disseminated extranodal spread or supradiaphragmatic spread.

**Clinical Features**

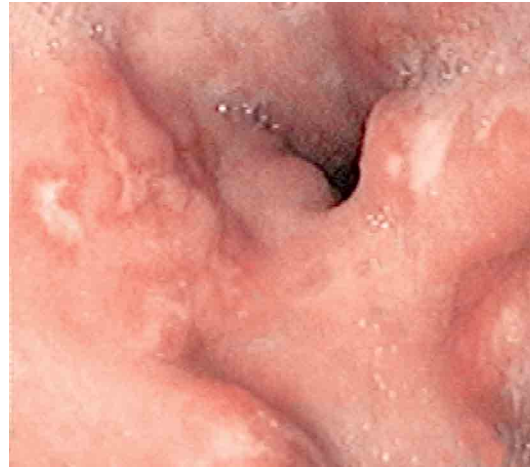- ◆ Pain abdomen, melaena and mass abdomen which is smooth and firm.
- ◆ Loss of weight, loss of appetite.

**Gastric lymphoma is associated with:**

- ❖ Wiskott Aldrich syndrome
- ❖ Klinefelter syndrome
- ❖ HIV, *H. pylori* (75%)
- ❖ Ataxia telangiectasia
- ❖ SLE
- ❖ Chronic gastritis
- ❖ MALT

**Complications**

- ◆ Obstruction.
- ◆ Perforation.
- ◆ Bleeding.
- ◆ Spread to other lymph nodes and liver—only late event.



**Fig. 20.84:** Gastric lymphoma, endoscopic view. It can be primary or secondary. Secondary is common. Primary occurs first in stomach and later other lymphatic system are involved. Gastrectomy is the treatment with chemotherapy.

**Investigations**

- ◆ Gastroscopy and biopsy.
- ◆ Endosonography.
- ◆ Peripheral smear, bone marrow aspiration.
- ◆ CT abdomen and CT chest and mediastinum.

**Treatment**

- ◆ *Primary chemotherapy* with anti-*Helicobacter pylori* regime, often with RT is the standard treatment. *H. pylori* regime with immunotherapy (rituximab with fludarabine) and chemotherapy (oral cyclophosphamide or oral chlorambucil; IV cladribine, bortezomib) is used.
- ◆ Palliative gastrectomy in case of bleeding, perforation and obstruction is needed.
- ◆ Radical gastrectomy is done in diseases which are confined to stomach only in selected individuals—when primary lymphoma is in antrum, radical subtotal gastrectomy is done. When it is in proximal stomach, radical total gastrectomy is done.

**B. SECONDARY GASTRIC LYMPHOMA**

- ◆ It is the most common type of lymphoma occurring in stomach. It differs from primary in many aspects.
- ◆ Here mainly systemic lymph nodes are involved first and the disease begins in lymph nodes at different regions, later to occur in stomach.
- ◆ Peripheral smear shows lymphocytosis; bone marrow shows changes; CT abdomen and chest shows multiple nodal enlargement.
- ◆ It is basically a systemic disease extending to stomach.
- ◆ Perforation and bleeding are the complications.
- ◆ Treatment is mainly chemotherapy—CHOP/ABVD/ MOPP/ BACOP and other regimes.
- ◆ Surgery is not done unless any local complications occur.

### Gastrointestinal mesenchymal tumours

- ❖ *GIST*—CD 117; CD 34; smooth muscle actin
- ❖ *Smooth muscle tumours*—CD 34; smooth muscle actin; Desmin
- ❖ *Neural tumours*—S-100; CD 34

## GASTRIC SARCOMAS

- ◆ Stomach is the most common site of GI sarcoma.
- ◆ Leiomyosarcoma is the most common type of gastric sarcoma. Other type is malignant leiomyoblastoma.
- ◆ Leiomyosarcoma is common in proximal stomach.
- ◆ It attains enormous size with rubbery consistency.
- ◆ Mainly spreads through the blood to the liver.

### Features

- ◆ Pain, vomiting, anorexia.
- ◆ Mass in upper abdomen.
- ◆ *Complication*
  - ▶ GI bleeding.
- ◆ *Investigations*
  - ▶ Ultrasound abdomen and CT scan.
  - ▶ Gastroscopy is useful in less than 50% of cases.
- ◆ *Treatment*
  - ▶ Subtotal gastrectomy.
  - ▶ Chemotherapy.

*Leiomyosarcoma has got better prognosis compared to adenocarcinoma and lymphoma of stomach.*

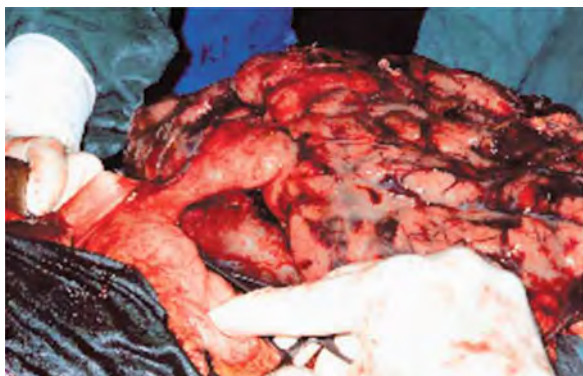

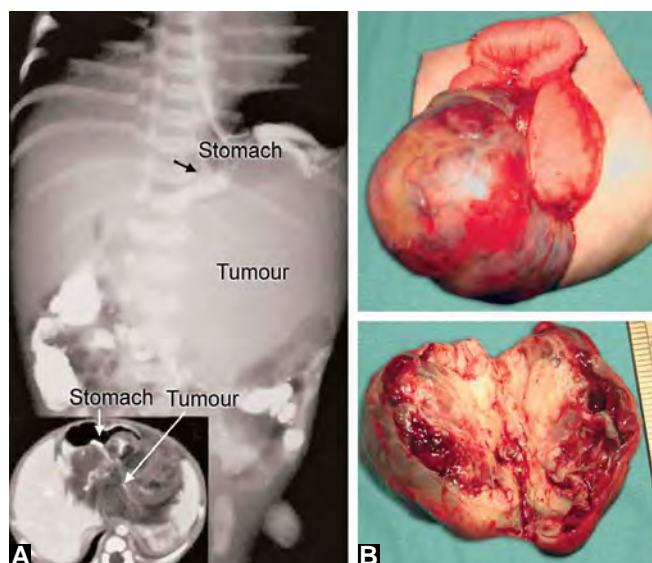
Fig. 20.85: Gastric sarcomas.

## GASTROINTESTINAL STROMAL TUMOURS (GISTS)

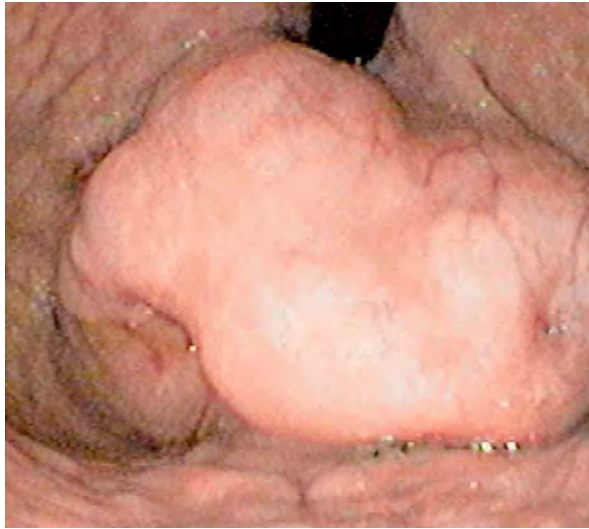
- ◆ It is a rare tumour of GI tract—0.2% of all GI tumours.
- ◆ But it is the most common nonepithelial tumour of the gastrointestinal tract. *Stomach is the most common site of all GISTs—50%; 25% of all GISTs are from small bowel; rectum—15%; colon—10%.*
- ◆ Equal in both sexes and common in 50–70 years age group.
- ◆ GIST arises from interstitial cell of Cajal (pacemaker cell which intercalates between smooth muscle cells and intra-

mural neurons). Mutation of tyrosine kinase and platelet derived growth factor alpha (PDGF $\alpha$ ) are the newer pathogenetic theories.

- ◆ GIST is classified as very low-risk (2 cm); low-risk (2–5 cm); intermediate risk (5–10 cm) and high-risk (>10 cm) based on *tumour size* and *mitotic activity* of cells.
- ◆ 95% of GISTs express c-kit – CD117 mutations – a specific molecular marker.
- ◆ *Kit protein* (CD117, stem cell factor receptor) is a transmembrane tyrosine kinase receptor which is detected by immunohistochemistry. It distinguishes from true smooth muscle neoplasms. 80% of GISTs are positive for CD34—haematopoietic progenitor cell antigen.
- ◆ Mutations occur in KIT (c Kit) as exon 11 (70%), or exons 8,9, 13, 17; it can occur as mutation in PDGFRA (platelet-derived growth factor receptor alpha) in exons 12, 14 and 18.
- ◆ Familial GIST occurs as autosomal dominant with mutation of germline gene KIT or PDGFRA; multiple GISTs in small bowel, colon, stomach are common. It is associated with urticaria and hyperpigmentation.
- ◆ Abdominal pain; weight loss; *GI bleed* (most common presentation) and large mass abdomen are typical. Mass is extraluminal as it is of submucosal origin but expands and compresses the mucosa. 50% of GIST can present as metastatic disease to liver and peritoneum (ascites).
- ◆ GISTs almost *never* metastasise to regional lymph nodes.
- ◆ It can be spindle shaped (70%); epithelioid (25%); combination.
- ◆ *Carney's triad*—extra-adrenal paraganglioma; pulmonary chondroma; gastric GIST.



Figs 20.86A and B: Barium meal X-ray showing gastric teratoma presenting as a large mass lesion compressing gastric lumen. Inset shows CT picture also. Operated specimen is also shown.



**Fig. 20.87:** Gastric leiomyosarcoma near the fundus—endoscopic view. It is now classified under GIST.

#### Investigation:

- ◆ Mainly CT scan. CT shows ulceration, calcification, necrosis, cystic areas, spread, metastases, ascites, etc.
- ◆ Tumour/molecular marker to differentiate it from sarcomas (immunohistochemistry).
- ◆ Endosonography guided biopsy/guided FNAC are important to get histological confirmation.
- ◆ 18 FDG PET scan is very useful adjunct to CT but reserved for difficult/equivocal cases.

#### Treatment:

- ◆ Surgical resection of the tumour with part of the adjacent bowel. *Resection should be* – R0, with intact pseudocapsule, without rupture.
- ◆ *Imatinib mesylate*—a specific oral drug (year 2000) that inactivates tyrosine kinase kit and so prevents phosphorylation of the receptor and proliferation of tumour is very much beneficial in advanced cases. Now it is also used if tumour size is more than 10 cm; in intraperitoneal rupture/spillage; haemorrhage in GIST; multifocal occurrence. Duration of imatinib is usually one year. Dose is 400 mg/day. Imatinib can also be used as *neoadjuvant drug* (6–12 months) for advanced GIST to initial downsizing.
- ◆ Newer drug—*SU11248* inhibits tyrosine kinase receptor as well as blocks PDGFRA. Another newer derivative—*sunitinib* and *dasatinib* are used in imatinib refractory cases. *Regorafenib* are used in imatinib/sunitinib resistance cases as 160 mg/day for 3 weeks with one week no treatment with repetition of such cycles for 3–6 months. Still more newer drugs are under trial but not approved yet.
- ◆ Doxorubicin ± ifosfamide is tried in metastatic disease but with only 5% response rate.

#### Prognostic factors:

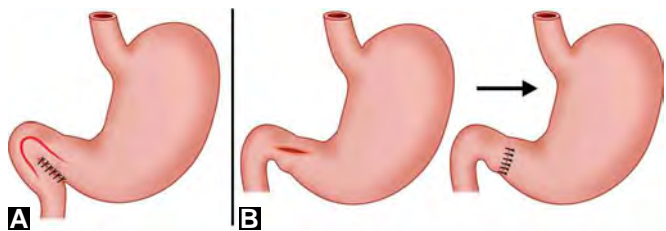
- ◆ Size of GIST more than 5 cm, male sex.
- ◆ High mitotic activity (>15 mitoses per 30 high power field), mixed pathology (spindle + epithelioid).
- ◆ Liver spread.
- ◆ KIT exon 9 mutation which is more aggressive than KIT exon 11 mutations—carries poor prognosis.
- ◆ *Ruptured GIST*—nearly all ruptured GISTs show abdominal metastases.

### GIST

- ❖ GIST is the most controversial topic.
- ❖ Primary nonepithelial tumours are classified as: Group I—smooth muscle type expressing smooth muscle actin and desmin; Group II—gastrointestinal autonomic nerve tumours (GANs/myenteric plexus tumour/plexosarcomas) express neuron specific enolase and s-100 and are aggressive; Group III—dual differentiation; Group IV—uncommitted type.
- ❖ GIST can be benign, intermediate/borderline, or malignant. Size and mitotic activity are main factors of malignancy; others are—necrosis, haemorrhage, hypercellularity.
- ❖ GIST is common in fundus of stomach. It can be submucosal (60%), subserosal (30%), intramural. Fundal GIST carries better prognosis than small bowel GIST.
- ❖ Small bowel GIST is common in jejunum (40%), ileum and duodenum. It can be submucosal or subserosal. It presents with GI bleed, abdominal pain, intestinal obstruction, mass abdomen, intussusception, perforation and cachexia. It often produces HCG causing hyperemesis.
- ❖ *GISS*—is gastrointestinal stromal sarcoma. It is common in stomach (50%), small bowel. GISS accounts for 2% of soft tissue sarcomas. 70% of them are symptomatic at early stage. Surgical resection is the treatment.

### PYLOROPLASTY

- ◆ *Indications*
  - ▶ Bleeding duodenal ulcer.
  - ▶ As a drainage procedure after vagotomy in uncomplicated- DU which is not responding to medical line of treatment.
  - ▶ As a part of procedure like Ivor-Lewis operation and Sigmoid-Futagawa operation.
- ◆ *Contraindications*
  - ▶ Duodenal ulcer with cicatrization and scarring.
- ◆ *Types*
  - ▶ Finney's pyloroplasty.
  - ▶ Heineke-Mikulicz pyloroplasty.
- ◆ *Complications*
  - ▶ Duodenal leak—very dangerous one.
  - ▶ Later reflux.



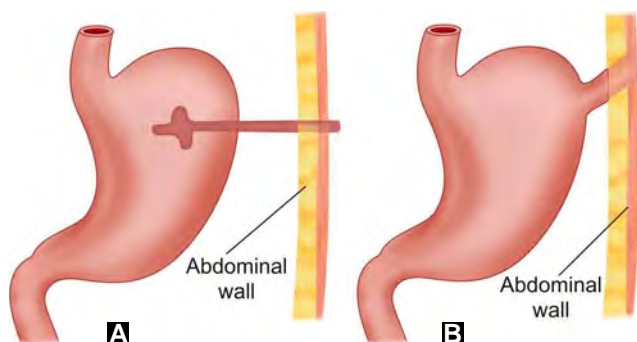
**Figs 20.88A and B:** Types of pyloroplasty. (A) Finney's pyloroplasty; (B) Heineke-Mikulicz pyloroplasty.

### GASTROSTOMY

- ◆ It is the procedure wherein a tube is passed into the stomach per abdominally for the purpose of enteral feeding.
- ◆ It can be *temporary or permanent*.

#### Types

- A. *Serosus lined*—for temporary gastrostomy.
- B. *Mucosa lined*—for permanent one.



**Figs 20.89A and B:** Types of gastrostomy. (A) Temporary gastrostomy; (B) Permanent gastrostomy.

After minilaparotomy, gastrostomy is done. Foley's or Malecot's catheter is placed in the stomach. It is fixed to parietal peritoneum through two circular purse string sutures.

### Other Types

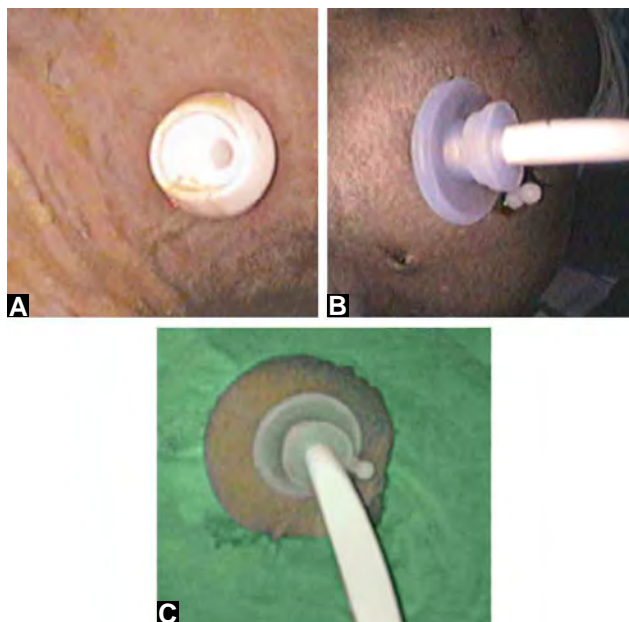
- ◆ Stamm's temporary gastrostomy.
- ◆ Kader-Senn temporary gastrostomy.
- ◆ Janeway's permanent gastrostomy.
- ◆ *Endoscopic percutaneous gastrostomy*—becoming popular (PEG).

### Indications

- ❖ Oesophageal strictures.
- ❖ Any conditions where tube feeding is required for more than 4 weeks (e.g. burns, severe sepsis).
- ❖ Major neck surgeries.

### Contraindications

- ◆ Previous gastrectomy.
- ◆ Gastric diseases with impaired gastric emptying.
- ◆ Intestinal obstruction.



**Figs 20.90A to C:** Percutaneous endoscopic gastrostomy (PEG). It is easier and acceptable method and less invasive.

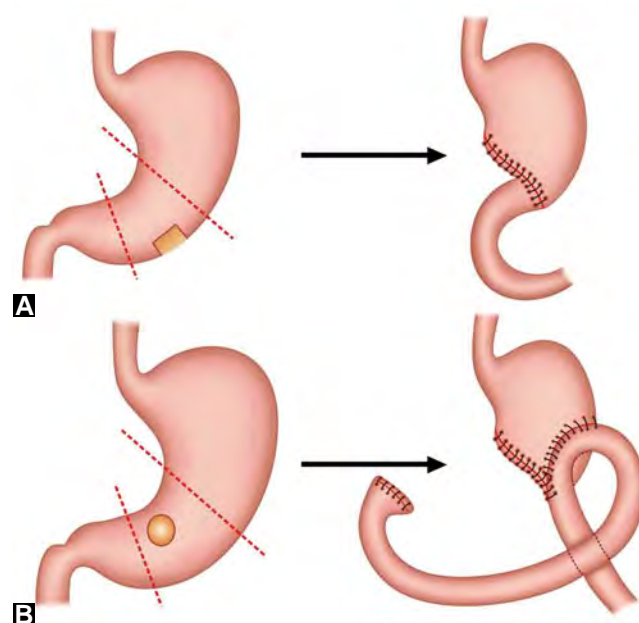
### Complications

- ❖ Infection
- ❖ Trauma to other organ, e.g. colon
- ❖ Leak from gastrostomy site
- ❖ Aspiration pneumonia
- ❖ Blockage.

## GASTRECTOMY

### Types

1. *Billroth I* is done for benign condition. Here along with partial gastrectomy, gastroduodenostomy is done.
2. *Billroth II* is done for carcinoma stomach. After partial gastrectomy, gastrojejunostomy is done and duodenal stump is closed.



**Figs 20.91A and B:** Types of gastrectomy. (A) Billroth I anastomosis; (B) Billroth II anastomosis.

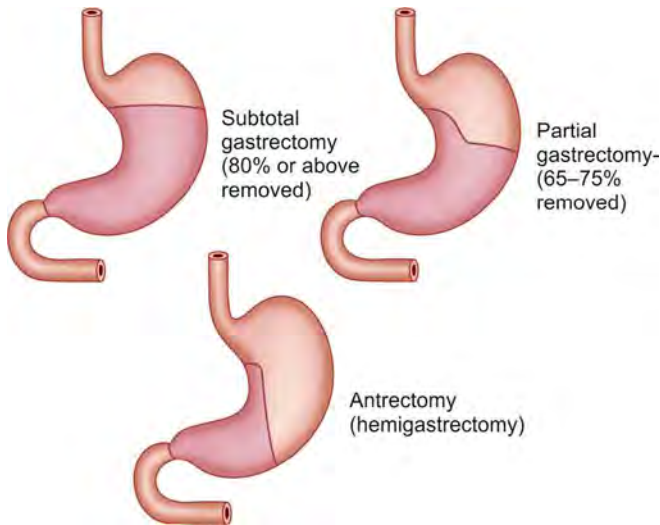
3. *Lower radical gastrectomy* is done in early carcinoma pylorus. Here along with the growth and proximal 5 cm of stomach, omentum, lymph nodes, spleen with tail of pancreas are removed and Billroth II anastomosis is done.
4. In growth of upper part or OG junction, *upper radical gastrectomy* is done along with *oesophago gastric anastomosis*.
5. In some cases like linitis plastica, *total gastrectomy* along with *oesophagojejunal anastomosis* is done.

### Indications

- ❖ Chronic benign gastric ulcer
- ❖ Benign tumours of stomach (Leiomyoma)
- ❖ Carcinoma stomach
- ❖ Stomal ulcer
- ❖ Bleeding ulcer
- ❖ Leiomyosarcoma, gastric lymphoma
- ❖ Menetrier's disease.

### Complications

- ❖ Bleeding
- ❖ Bile leak
- ❖ Duodenal blow-out
- ❖ Gastric fistula
- ❖ Dumping syndrome
- ❖ Anaemia.



**Fig. 20.92:** Different types of gastrectomy. Subtotal—more than 80% of stomach is removed; partial—60–75% removed.

## GASTROJEJUNOSTOMY (GJ)

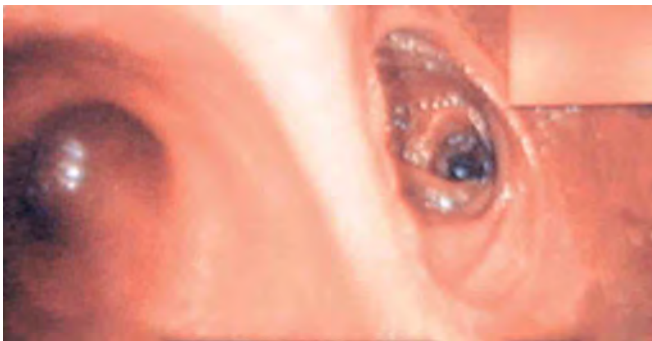### Types

1. Anterior GJ.
2. Posterior GJ.

Anterior gastrojejunostomy is done as a palliative procedure in case of advanced inoperable (adherent posteriorly) carcinoma pylorus to palliate vomiting. It is anastomosis between jejunum and anterior surface of stomach, in front of transverse colon (antecolic).

Posterior GJ is done along with truncal vagotomy, in pyloric stenosis due to chronic duodenal ulcer. *It is posterior, vertical, retrocolic, short loop, isoperistaltic (of Mayo).*

GJ is also done as part of the Billroth II gastrectomy.

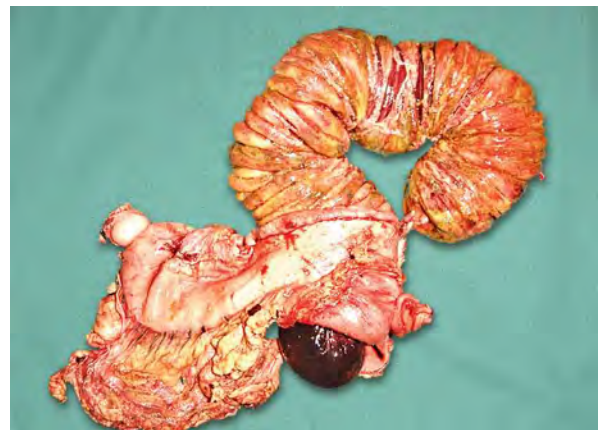

**Fig. 20.93:** Gastrojejunostomy stoma view on endoscopy.

### Problems with GJ

- ❖ Stomal obstruction
- ❖ Afferent or efferent loop obstruction
- ❖ Dumping syndrome
- ❖ Duodenal blow-out
- ❖ Retrograde intussusception
- ❖ Reflux gastritis.
- ❖ It is a rare entity occurs after gastrojejunostomy
- ❖ It can occur immediately, in weeks or in months.

## RETROGRADE JEJUNOGASTRIC INTUSSUSCEPTION



**Fig. 20.94:** Retrograde jejuno-gastric intussusception with gangrene—resected specimen.

- ❖ *Jejuno-gastric intussusception* is rare but definitive complication which occurs in loop (omega) gastrojejunostomy only; not in Roux en Y type. 80% cases efferent limb intussusception occurs; 20% cases afferent; rarely both. It can present as acute with features of obstruction or strangulation or intermittent with repeated episodes of symptoms.
- ❖ Presents with *pain* above and left of the umbilicus, *haematemesis*, firm, tender *mass* above and towards the left side. Patient becomes better in erect posture.
- ❖ Condition causes stomal obstruction.
- ❖ Barium meal shows *coiled spring look* within the stomach remnant. *Gastroscopy* is diagnostic.
- ❖ It is treated by open reduction of the intussusception with anchoring stitch to the bowel or enteroanastomosis. When gangrenous, resection and *Roux-en-Y anastomosis* is done.

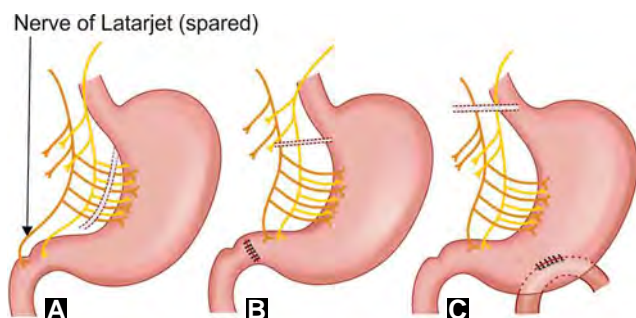
## VAGOTOMY

*In an inquiry which I had formerly instituted, respecting the functions of the stomach, I divided these nerves (the vagi) in the neck of a dog, for the purpose of ascertaining the influence which they possess on the secretion of the gastric juice. . . . We may conclude that the suppression of the secretions. . . sufficiently demonstrate, that the secretions of the stomach and intestines are very much under the control of the nervous system.*

—Benjamin Collins Brodie, 1814

## Types

1. **Truncal vagotomy** along with GJ as drainage procedure, is done in case of pyloric stenosis due to chronic DU.



**Figs 20.95A to C:** Types of vagotomy. (A) Highly selective vagotomy; (B) Selective vagotomy with pyloroplasty; (C) Truncal vagotomy with gastrojejunostomy.

Complications of vagotomy	
Intraoperative	Late complications
Injury to spleen/ oesophagus/liver/ pancreas/thoracic duct stomach Bleeding from phrenic veins/gastric vessels/ perioesophageal vessels	<ul style="list-style-type: none"> <li>• Vagotomy diarrhoea—20%               <ul style="list-style-type: none"> <li>– Most common complication of vagotomy</li> <li>– Gastric stasis</li> <li>– Hypoacidity with fermentation with bacterial over-growth causing enteritis</li> </ul> </li> </ul>

Contd...

Contd...

Pneumothorax	– Alteration in intestinal villi and enzyme content, altered small bowel motility due denervation
Oesophagogastric disconnection	– Altered biliary and pancreatic exocrine function
Early postoperative Gastric atony	– Cholestyramine 4 gram tid/ reverse jejunal loop is the treatment for intractable case
Lesser curve necrosis in HSV	• Reflux oesophagitis
Transient dysphagia	• Oesophageal stricture
	• Gallstones—due to bile stasis and gastric atony—15%

In uncomplicated DU, with failure of medical treatment and when HSV cannot be done, then truncal vagotomy with pyloroplasty is done.

2. **HSV (Highly selective vagotomy)** or **Parietal cell vagotomy** or **Super selective vagotomy** is done in case of uncomplicated DU where medical treatment fails. Here only fibres entering the stomach is divided both anteriorly as well as posteriorly. Nerve of Latarjet is retained to supply antrum and so *no drainage procedure is required* (Amdrup). It has got 10% recurrence rate.
3. **Selective vagotomy** is at present not done often. Here along with a drainage procedure, either GJ or pyloroplasty, vagotomy is done with retaining of coeliac and hepatic branches. It has got 10% recurrence rate.



# Chapter 21

## Small Intestine

### CHAPTER OUTLINE

- ❖ Anatomy
- ❖ Meckel's Diverticulum
- ❖ Regional Enteritis
- ❖ Surgical Complications of Typhoid
- ❖ Surgical Complications of Round-worm
- ❖ Pneumatosis Cystoides Intestinalis
- ❖ Mesenteric Vessel Ischaemia
- ❖ Necrotising Enterocolitis
- ❖ Small Bowel Tumours
- ❖ Benign Tumours of Small Bowel
- ❖ Malignant Tumours of Small Bowel
- ❖ Carcinoid Tumour
- ❖ Short Bowel Syndrome
- ❖ Massive Bowel Resection
- ❖ Small Bowel Enema
- ❖ Capsule Endoscopy
- ❖ Small Bowel Enteroscopy
- ❖ Enteric/Gastrointestinal Fistula

### ANATOMY

The small intestine is 6 m in length. This includes upper fixed (duodenum, 25 cm), lower mobile part (proximal 2/5th is jejunum and distal 3/5th is ileum).

### Differences between the Features of Jejunum and Ileum

	<i>Jejunum</i>	<i>Ileum</i>
1.	Long and few vasa rectae	Short and numerous vasa rectae
2.	Long plicae	Small plicae
3.	Thick wall, wider—4 cm	Thin wall—3 cm
4.	Mesentery transparent	Mesentery contains fat
5.	Peyer's patches are scanty	Peyer's patches are abundant, located in the antimesenteric border
6.	Villi, leaf like and more abundant	Villi, finger like and less abundant.
7.	Proximal 40% of small bowel—deep red	Distal 60%—pale pink

Mesentery attaches the small intestine to the posterior abdominal wall, contains blood vessels, lymphatics, fat.

*Mesentery* at its root is attached to L2 vertebra on the left side at duodenojejunal junction, running obliquely downwards and right towards right sacroiliac joint at ileocaecal junction. Mesentery is 25 cm in length at its root and spreads like a wide fan when it reaches to small bowel wall becoming 5–6 meters in length. It crosses the

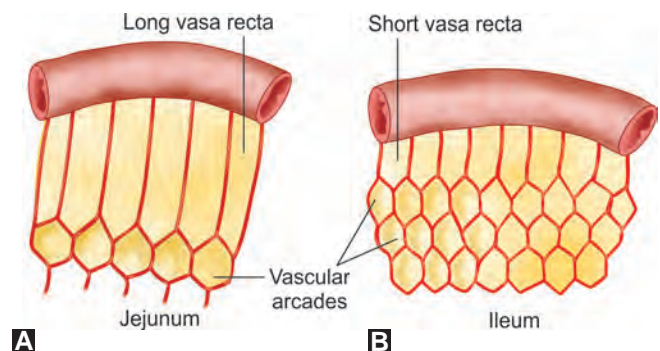
duodenum, aorta, IVC, right ureter, right psoas major muscle, right gonadal vein. Mesenteric cyst, mesenteric lymph nodes, mesenteric tear, mesenteric inflammations are of surgical importance. SMA, SMV and their branches and tributaries pass through it. During small bowel resection, mesentery should be ligated using surgical ligatures or energy sources and later anastomosis is done.

### Nerve Supply

Sympathetic supply is from T<sub>9</sub>-T<sub>11</sub> and parasympathetic supply is from vagus. Both pass through coeliac and superior mesenteric plexus.

Bowel wall contains the myenteric plexus of Auerbach which lies between the circular and longitudinal muscle coats; and submucous plexus of Meissner.

Sympathetic nerves are motor to sphincter, inhibitory to peristalsis; parasympathetic nerves are inhibitory to sphincter and stimulates peristalsis.



**Figs 21.1A and B:** Vascular pattern in (A) jejunum, (B) ileum.

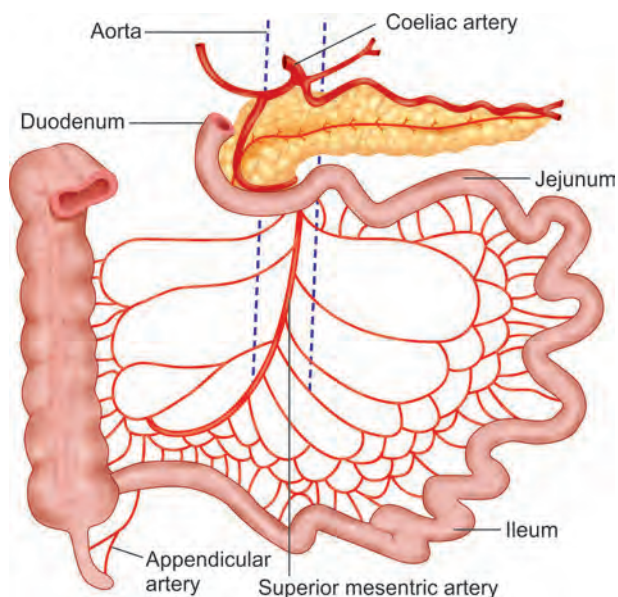


Fig. 21.2: Blood supply of the small bowel.

#### Normal GIT secretions

Saliva—1000 ml  
 Gastric—1500 ml  
 Intestinal—4000 ml  
 Bile—1000 ml  
 Pancreas—1500 ml

Cell type	Function
Goblet cells	Mucous
Paneth cells	Lysozyme, tumour necrosis factor, cryptidins
Enterocytes	Absorption
Enteroendocrine cells	Different hormones

#### Investigations for small bowel diseases

- ❖ Barium meal follow through
- ❖ Small bowel enema (*Enteroclysis*)
- ❖ Plain X-ray abdomen to see intestinal obstruction
- ❖ Selective splanchnic angiography to see vascular bleed or malformation (DSA)
- ❖ Isotope scintigraphy to see Meckel's diverticulum
- ❖ Estimation of faecal fat in 24 hours—normal is less than 7 gram
- ❖ *Schilling test* to find out the absorption of vitamin B<sub>12</sub> from terminal ileum
- ❖ SeHCAT bile acid absorption test (selenium labelled) to find out the absorption of bile acids from the terminal ileum
- ❖ Many different breath tests are used to find out malabsorption, bacterial overgrowth and transit time
- ❖ Jejunal biopsy
- ❖ CT scans to see fistula, tumour, and spread
- ❖ Capsule endoscopy is very useful

### MECKEL'S DIVERTICULUM

*It appears at a specific site in the ileum and the wall contains each of the several layers of the intestinal tract.... The proof that the diverticulum is a residuum of the communication between the intestinal canal and the umbilical stalk rests in the findings which I have observed in three stillborn, full-term fetuses.*

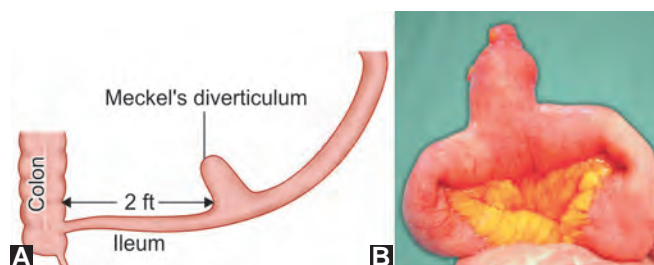
—Johann Friedrich Meckel, 1809

It is a congenital diverticulum arising from the terminal ileum and is part of the unobliterated proximal portion of the vitellointestinal duct.

It is:

- ❖ 2% common.
- ❖ 2 feet from the ileocaecal valve.
- ❖ 2 inch in length.
- ❖ 2% of Meckel's diverticulum only will be symptomatic.
- ❖ 50% of symptomatic are below 2 years of age.
- ❖ 20% heterotopic epithelium.
- ❖ 2:1 female preponderance is seen.

- ❖ It is congenital, results from incomplete closure of vitello-intestinal duct.
- ❖ It is the most common congenital anomaly of small intestine.
- ❖ Arises from the antimesenteric border of the ileum, containing all three layers of the bowel with independent blood supply.
- ❖ In 20% of cases mucosa contains heterotopic epithelium like gastric (commonest—50%), colonic and pancreatic tissues (5%).
- ❖ It may be connected to or communicated with the umbilicus through a band or fistula.
- ❖ It may be associated with oesophageal atresia, exomphalos, and anorectal malformations.



Figs 21.3A and B: (A) Anatomy of Meckel's diverticulum; (B) Meckel's diverticulum.

### Presentations in Meckel's Diverticulum

- ❖ Asymptomatic—in majority cases.
- ❖ Severe haemorrhage most common, seen in children aged 2 years or younger (*Maroon-coloured blood*).
- ❖ Intestinal obstruction due to bands/adhesions/ intussusception.
- ❖ Perforation.
- ❖ Intussusception, volvulus of small bowel.
- ❖ Peptic ulceration.
- ❖ Diverticulitis (20%)—features mimic acute appendicitis.
- ❖ *Littre's hernia*—it is presence of Meckel's diverticulum in hernial sac as content. It is observed in inguinal/femoral hernia.

*One cannot love what he cannot respect, whether it be himself or another.*

- ◆ Silent Meckel's diverticulum found during laparotomy or laparoscopy or by radioisotope study.
- ◆ Carcinoid or GIST can occur in Meckel's diverticulum.

**Note:**

"Meckel's diverticulum frequently suspected; often sought; seldom found"—Charles Mayo.

**Diagnosis**

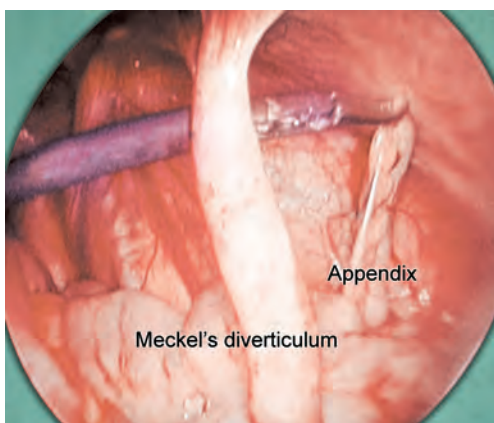
- ◆ Technetium ( $Tc^{99}$ ) radioisotope scan is very useful (90–95% accuracy). 90% of heterotrophic gastric mucosa can be identified in Meckel's diverticulum by radioisotope study. It can detect Meckel's diverticulum with minimal bleeding also (0.1 ml/minute). So it is very useful investigation in children presenting with bleeding.
- ◆ X-ray abdomen to see complications like obstruction, perforation.
- ◆ *Laparoscopy is very useful.*
- ◆ Enteroclysis/small bowel enema under fluoroscopy may show the Meckel's diverticulum. It is probably the most accurate investigation.

**Treatment**

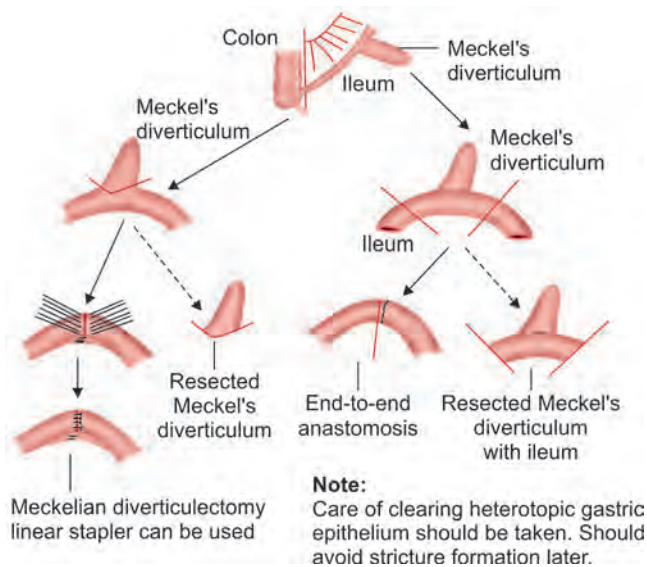
- ◆ Asymptomatic Meckel's diverticulum can be left alone when identified during laparotomy.
- ◆ *Resection of a short segment of ileum containing Meckel's diverticulum and end-to-end anastomosis is done.*
- ◆ *Meckelian diverticulectomy with closure of enterotomy also can be done, but chances of retaining heterotopic tissues and stenosis are higher.*

**Indications for surgery**

- ❖ Surgery is done whenever the base is narrow, and in lengthy diverticulum.
- ❖ Presence of adhesions or band which may precipitate obstruction, intussusception or volvulus.
- ❖ Symptomatic patients or presence of complications.
- ❖ If it is found in children below 2 years.



**Fig. 21.4:** Laparoscopic view of Meckel's diverticulum. Patient presented with features of acute appendicitis. On laparoscopy, Meckel's diverticulum which was adherent to umbilicus by a cord was found. Appendix was identified separately. Appendicectomy and Meckelian diverticulectomy was done.



**Fig. 21.5:** *Meckel's diverticulum*—surgical treatment. Meckelian diverticulectomy is done by obliquely clamping beyond the base of the Meckel's diverticulum. Care should be taken not to retain heterotopic gastric (or other) epithelium which can be felt-like indurated area. Enough precaution should be taken so that stricture will not form later. When heterotopic tissues extend beyond the Meckel's diverticulum into the ileum, then resection of ileum with Meckel's and anastomosis is done. Clamping distal to the base of the Meckel's diverticulum like appendicectomy should not be done. It will cause stricture, leak or retaining heterotopic tissues in the part.

- ❖ *Duodenal diverticulum* is the most common acquired diverticulum of small bowel.
- ❖ *Meckel's* is the most common true congenital diverticulum of small bowel.
- ❖ *Duodenal diverticulum:*  
It is common in females; 65% occur within 2 cm of ampulla. Commonly they are asymptomatic; < 5% need surgery. It can be congenital/acquired; true/false; intra- or extraluminal. Biliary obstruction, pancreatitis, cholangitis, haemorrhage are *complications*. Diverticulectomy; duodenotomy and invagination of diverticulum when it is very close to ampulla embedded in pancreas; sphincteroplasty are the *treatment*. Perforated diverticulum is treated with serosal jejunal patch/duodenal diversion/duodeno- or gastrojejunostomy. Trifoliate diverticula is an acquired one, occurs in chronic duodenal ulcer.
- ❖ *Jejunioileal diverticula:*  
It is rare (0.1%). It is false type, common in elderly. They are common in jejunum, often multiple, protrudes from mesenteric border. Chronic pseudo-obstruction, vague pain, malabsorption, haemorrhage, perforation can occur occasionally. Diverticulitis leads into perforation and peritonitis or abscess. Bile salt deconjugation with steatorrhoea, megaloblastic anaemia (vitamin  $B_{12}$  deficiency) can occur. *Treatment*—enterotomy with removal of enterolith or resection and anastomosis.

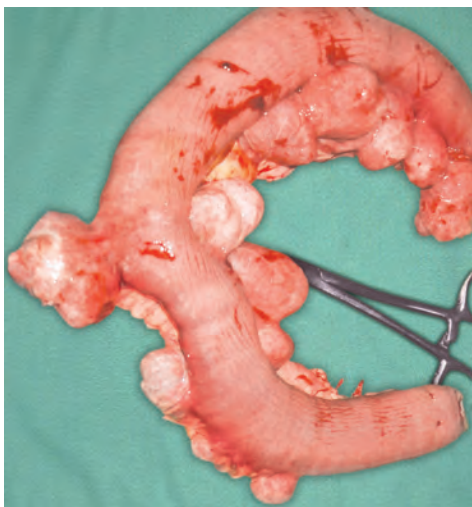

Fig. 21.6: Jejunal diverticula are rare. Often can cause obstruction, haemorrhage. It needs surgical resection.

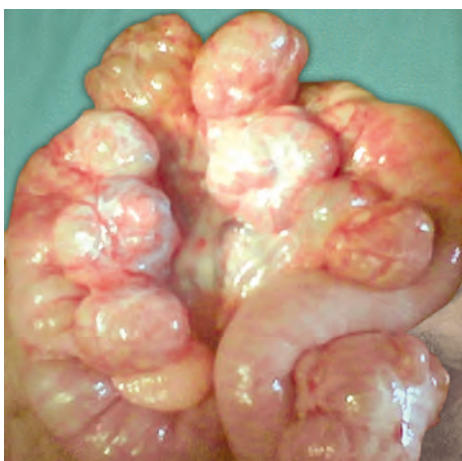

Fig. 21.7: Jejunal diverticula—multiple.

## REGIONAL ENTERITIS (Crohn's Disease)

*We propose to describe, in its pathologic and clinical details, a disease of the terminal ileum, affecting mainly young adults, characterised by a subcutate or chronic necrotising and cicatrising inflammation. The ulceration of the mucosa is accomplished by a disproportionate connective tissue reaction... a process which frequently leads to stenosis of the lumen of the intestine, associated with the formation of multiple fistulas.*

—Burrill Bernard Crohn, Leon Ginzburg,  
Gordon D Oppenheimer, 1932

- ◆ It is a *granulomatous, noncaseating (transmural) inflammatory condition of the ileum commonly and of the colon often.*
- ◆ It is independent of age, sex, socioeconomic status and geographic areas.
- ◆ Rarely other parts of the GIT like colon, jejunum, stomach, duodenum, oesophagus can get involved. Small bowel alone is involved in 30% cases; in 50% cases both small and large bowels are involved. *Terminal ileum is most commonly*

*involved (60%).* In 75% cases perianal is involved (fissure in ano).

- ◆ Incidence is 5/1,00,000; prevalence is 50/1,00,000. It is common in North America and North Europe.

## Aetiology

- ◆ Unknown, but a familial and infective nature is thought of.
- ◆ Increased autoantibodies.
- ◆ Diet and food allergy.
- ◆ It is slightly more common in females.
- ◆ DNA of *Mycobacterium paratuberculosis* was found in intestines of 60% of patient's with Crohn's disease but antituberculous drug therapy has not helped them.
- ◆ Focal ischaemia as a vasculitis may be the cause.
- ◆ 10% of first degree relatives; 50% of monozygotic twins develop Crohn's disease. Genes *NOD2/CARD15* in chromosome 16q12 has got strong association with Crohn's disease. *CARD15* is expressed in Paneth cells of the ileum.
- ◆ Smoking is related to Crohn's disease as aetiology, as for relapse and for exacerbations.

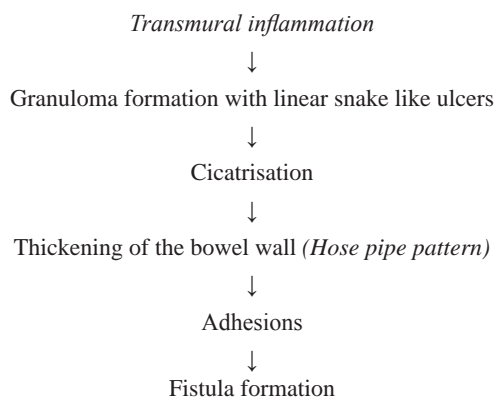
### Causes for Crohn's

- ❖ *Infectious*—*Mycobacterium paratuberculosis* and atypical mycobacteria. It causes *Johne's disease* in cattle
- ❖ *Immunologic*
- ❖ *Genetic*—chromosome 16q—IBD with *CARD15/NOD2* gene (40 fold risk)
- ❖ *Environmental*
- ❖ *Jews* are more prone
- ❖ Smoking, diet, OCPs (controversial), psychosocial factors

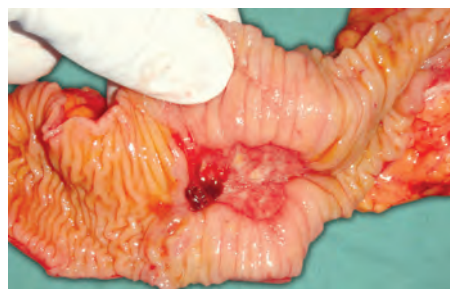

Fig. 21.8: Multiple ulcers in the jejunum—Crohn's or tuberculosis.

## Pathology



*Happiest people are not only happy in themselves; they are the cause of happiness to others.*

- ◆ There is increased mucous membrane permeability → antigen-induced cell-mediated inflammatory response → release of cytokines like TNF, interleukin 2 → defect in suppressor T cell → granuloma and other pathology.
- ◆ Fibrosis, stricture formation, deep ulcers, oedema of mucosa between ulcer areas which looks like 'cobble stone', skipped normal areas in between, serosal opacity, mesenteric fat stranding, enlarged mesenteric lymph nodes, abscesses in the mesentery, fistula are the pathology. Small mucosal aphthous ulcers are earliest gross feature.
- ◆ Disease may be *inflammatory, stricturing or perforating types*.
- ◆ Noncaseating giant cell granuloma with chronic inflammation of all layers; focal arterial blocks in muscularis propria are the microscopic features.
- ◆ Extensive *fat wrapping around bowel* which is been thickened, firm, rubbery, incompressible, segmental is typical.

#### Main features of Crohn's disease

- ❖ Ileum—most common site of occurrence—60%
- ❖ Rectal sparing is usual and common
- ❖ Skip lesion
- ❖ Hose-pipe pattern
- ❖ Linear ulcers and cobblestone appearance of mucosa
- ❖ Transmural

- ◆ Mesentery is thickened, oedematous, with enlarged lymph glands which will neither break nor calcify.
- ◆ Rarely jejunum, stomach and other parts of GIT like oral cavity, oesophagus are involved.
- ◆ In colon (30%), it is commonly observed in caecum and ascending colon.
- ◆ Toxic megacolon with acute colitis even though rare, can occur in Crohn's disease.

#### Note:

- Anal fissure is most common anal problem in Crohn's disease. It may lead into perianal abscess and fistula.
- Cytokine response in Crohn's disease is associated with Th17.

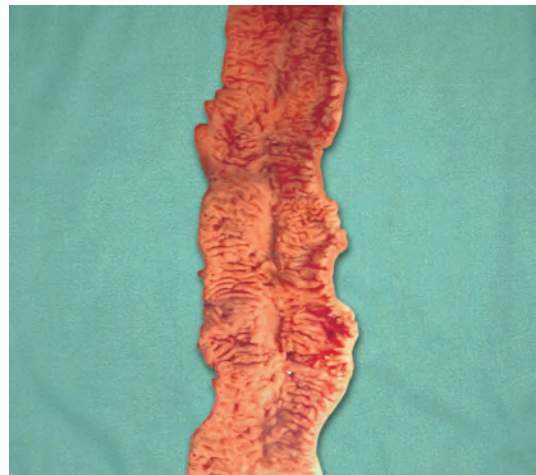
#### Vienna classification of Crohn's disease

- ❖ *Age in years:*
  - A<sub>1</sub>: < 40; A<sub>2</sub>: ≥ 40
- ❖ *Behaviour:*
  - B<sub>1</sub>: Nonstricturing, nonpenetrating
  - B<sub>2</sub>: Stricturing
  - B<sub>3</sub>: Penetrating
- ❖ *Location:*
  - L<sub>1</sub>: Terminal ileum
  - L<sub>2</sub>: Colon
  - L<sub>3</sub>: Ileocolon
  - L<sub>4</sub>: Upper GIT

### Clinical Features

- ◆ It is common in young age group.
- ◆ Abdominal pain and diarrhoea is the initial slow insidious presentation. There is also asymptomatic period in between.
- ◆ Diarrhoea is usually less severe without blood, pus or mucus.

- ◆ Mild fever, weight loss, lethargy.
- ◆ Crohn's disease may present as tender, firm, resonant mass in right iliac fossa
- ◆ Obstruction, fistula formation, often perforation.
- ◆ Bleeding which is usually chronic but occasionally massive can occur.
- ◆ Perianal disease with fissure, fistula, and abscess can occur in 25% of patients with small bowel Crohn's. It can be the only presentation of Crohn's in 5% of cases. 50% of colonic Crohn's will have perianal disease.
- ◆ Extraintestinal manifestations occur in 30% of Crohn's disease.



**Fig. 21.9:** Crohn's disease in small bowel. It is transmural full thickness disease. In 30% cases colon is involved. Skip lesion, stricture, fistula are common. It can involve any part of GIT occasionally.

### Presentations

#### a. Acute presentations (5%):

It mimics acute appendicitis with severe diarrhoea. Often there will be localised or diffuse peritonitis.

#### b. Chronic Crohn's:

*First stage*—Mild diarrhoea, colicky pain, fever, anaemia, mass in right iliac fossa which is tender, firm, nonmobile along with recurrent perianal abscess.

*Second stage* is either acute or chronic intestinal obstruction due to cicatrisation with narrowing.

*Third stage*—Fistula formation—enterocolic, enteroenteric, enterovesical, enterocutaneous, etc.

It is *precancerous condition but not as much as ulcerative colitis*.

#### Extraintestinal manifestations of Crohn's disease

- ❖ Skin: Erythema nodosum, pyoderma gangrenosum—most common
- ❖ Eyes: Iritis, uveitis
- ❖ Joints: Arthritis, ankylosing spondylitis, sacroiliitis
- ❖ Sclerosing cholangitis, gallstones
- ❖ Nephrotic syndrome, renal stones
- ❖ Pancreatitis, chronic active hepatitis
- ❖ Amyloidosis, aphthous ulcers
- ❖ Blood: Anaemia, thrombocytosis, DVT, arterial thrombosis.

## Investigations

- ◆ Plain X-ray abdomen, ultrasound abdomen.
- ◆ *Barium meal follow through or small bowel enema shows:*
  - ▶ Straightening of valvulae conniventes.
  - ▶ Multiple defects (*cobblestone* appearance).
  - ▶ Cicatrisation of ileum (*string sign of Kantor*).
  - ▶ *Rose-thorn appearance of the bowel wall*.
  - ▶ Radiologically Crohn's disease is classified as non-stenosing type or *stenosing type*.
- ◆ *CT scan and CT fistulogram* is useful method.
- ◆ *Colonoscopy* usually shows normal rectum; with colon showing aphthoid like ulcers and reddened mucosal margin. Deep ulcers, stricture and fistula will be evident in late cases. Colonoscopy also shows segmental, deep, cobblestone look.
- ◆ Blood tests for anaemia, protein loss, mineral and trace element loss like magnesium, zinc, and selenium. There will be raised *C reactive protein and orosomucoid* in active disease.
- ◆ *Capsule endoscopy* is useful investigation, but when stricture is present capsule may get stuck in the narrow part.
- ◆ MRI to diagnose anal disease. *MR enteroclysis* is very useful to demonstrate fistula.
- ◆ *Serum markers:* 90% of patients with Crohn's disease show ASCA (anti-saccharomyces *cerevisiae* antibody)-positive and pANCA (perineural antineutrophil cytoplasmic antibody)-negative, whereas in 98% of patients with ulcerative colitis, ASCA is negative but pANCA positive.

### Complications of Crohn's

- ❖ Intestinal obstruction
- ❖ Stricture
- ❖ Bleeding
- ❖ Fistula formation
- ❖ Carcinoma small and large bowel
- ❖ Perianal abscess
- ❖ Peritonitis
- ❖ Pericolonic abscess

## Differential Diagnosis

- ◆ Radiation enteritis and *Yersinia enterocolitica*.
- ◆ Ulcerative colitis, acute appendicitis.
- ◆ Intestinal tuberculosis, *Salmonella*, *Shigella*, CMV
- ◆ Carcinoma ileum or caecum.
- ◆ Differential diagnosis for mass in the right iliac fossa (carcinoma caecum, actinomycosis, appendicular mass, ileocaecal TB, ectopic kidney, mesenteric lymphadenitis).

## Treatment

### Medical

- ◆ *Cessation of smoking*
- ◆ Bed rest, protein and vitamin supplementations. Often nasogastric tube nutrition or TPN is required.
- ◆ *Steroids* are mainly used to induce remission of the disease in initial phase. It is less useful for maintenance. Dose is 20–40 mg/

day of prednisolone (0.5 mg/kg/day) for 3–6 weeks. Methylprednisolone infusion IV 60 mg/day for 5–7 days can be given initially. *Budesonide*, a newer steroid shows high first phase metabolism in liver and so in high dose achieves targeted delivery into the intestine. It is often combined with mesalamine or used as an alternate first line therapy.

- ◆ *Azathioprine* is used for maintenance therapy. It inhibits the cell-mediated immunity. 6-mercaptopurine and cyclosporine are also used. *Tacrolimus* (FK-506) inhibits production of IL<sub>2</sub> and is effective in improving fistula.
- ◆ Short course intravenous cyclosporin can also be used to induce remission.
- ◆ *Salazopyrines* are mainly used in acute ileitis and colitis. It is not useful in inducing remission. 5-aminosalicylic acid (5-ASA) and sulfasalazine are also used. 5-ASA inhibits leukotriene, TNF, interleukin production. It acts mainly on colonic and partly on small bowel mucosa. *Mesalamine* which causes slow release of 5ASA is better with a dosage of 4 gram/day. It is released throughout its passage along the small and large bowel. Mesalamine remains the *first line therapy* for Crohn's disease.
- ◆ *Metronidazole* is useful in reducing the anal and colonic pathology by suppressing the cell-mediated immunity and also as antibacterial. It is not beneficial for small bowel disease.
- ◆ Monoclonal antibody like *infliximab* (Murine chimaeric monoclonal antibody) is used in severe refractory cases which act against tumour necrosis factor alpha (TNF $\alpha$ ). Single dose is used for induction. Later given after 2nd week, 6th week and then once in 8 weeks at a dose of 5 mg/kg. It is also useful in promoting closure of fistula in 60–80% cases. But its long-term side effects are not confirmed.
- ◆ Anti-IL<sub>1</sub>, anti-IL<sub>12</sub>, anti-IL<sub>18</sub>, anti-interferon- $\gamma$  antibodies are tried. *Natalizumab* is recombinant human monoclonal antibodies against  $\alpha$  integrin. *Adalimumab*, a human monoclonal antibody is also effective. Monoclonal antibodies cannot be used in patients with tuberculosis or associated malignancy. They are expensive; relapse can occur after cessation of the therapy.
- ◆ *Antibiotics* (Ciprofloxacin) are useful in controlling sepsis in fistula, colitis.

### Medical therapy

- ❖ To induce remission—steroids
- ❖ For maintenance—immunomodulating drugs like azathioprine
- ❖ Antibiotics, metronidazole (as immunomodulator)
- ❖ Monoclonal antibody—infliximab
- ❖ Nutritional support

#### Note:

Patients with Crohn's disease should avoid NSAIDs.

## Surgery

### Indications

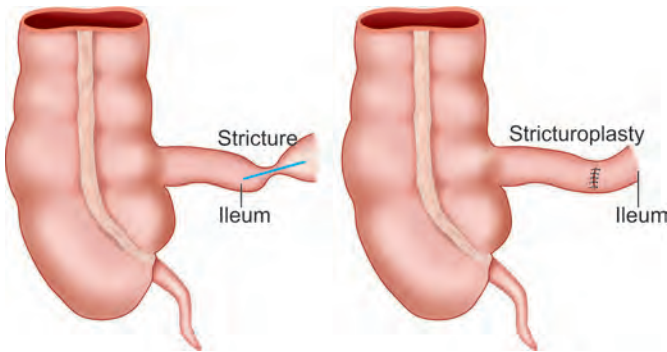
- ◆ Failure of medical treatment.
- ◆ If patient cannot be weaned off systemic steroid after 6 months.
- ◆ Intestinal obstruction—*most common indication*.
- ◆ Fistula formation, bleeding, malignant change.
- ◆ Perforation, fulminant colitis.
- ◆ Perianal problems.
- ◆ Crohn's disease children with growth retardation.

#### Note:

Surgery is not to cure the disease, but to correct complications. Recurrence of complications and relapse of disease can occur even after surgery. Patient should be on postoperative azathioprine/6 MP/5ASA.

### Surgeries

- ◆ **Ileocaecal resection** (common procedure done because commonly ileocaecal region is involved).
- ◆ Segmental resection—conservative resection is better.
- ◆ Total colectomy and ileorectal anastomosis. It is only done in extensive colonic Crohn's. Ileoanal anastomosis with pouch is not done after total proctocolectomy or continent ileal pouch is not done as disease may later recur in the pouch itself.
- ◆ Stricturoplasty.
- ◆ Temporary ileostomy.
- ◆ Right hemicolectomy is done occasionally.
- ◆ Emergency colectomy may be needed in 8% of patients with extensive severe colitis but with rectal sparing.
- ◆ Laparoscopic resection is good alternative.
- ◆ Occasionally if rectum is diseased or anal disease is severe then total proctocolectomy with ileostomy is done.
- ◆ Corrective surgery for anal diseases like fissure, abscess and fistula.
- ◆ Definitive procedures for internal fistulas like ileovesical, ileocolic with faecal and urinary diversions.
- ◆ Bypass and exclusion procedures are not commonly used at present.
- ◆ In free perforation and peritonitis ileostomy is needed. But later, it is difficult to decide the timing of closure of ileostomy as disease is extensive; it is wiser to do right ileocolic resection or right hemicolectomy in these patients.
- ◆ Enterocutaneous fistula is treated with excision of fistula with resection and anastomosis of that particular segment. Organ fistulas are also treated with resection of adherent bowel and closure of organ like urinary bladder wall.
- ◆ Small bowel Crohn's causes chronic bleeding; colonic Crohn's often may cause massive bleed. In massive bleed, angiographic control or colonoscopy is needed.



**Fig. 21.10:** Stricturoplasty can be done in Crohn's disease in case of short strictures in the absence of active inflammation.

#### Note:

**Appendicectomy** should not be done in acute phase of Crohn's disease as it may lead to external faecal fistula; if there is no acute inflammation, *elective appendicectomy can be/should be done* as it eliminates appendix as a source of future abdominal pain.

## SURGICAL COMPLICATIONS OF TYPHOID

- ◆ Typhoid (Enteric fever) is caused by organism—*Salmonella typhi*.
- ◆ Mode of transmission is faecooral route.
- ◆ Presents initially with fever, chills, abdominal pain.

### Typhoid

- ❖ *S typhi, S paratyphi A, B and C*
- ❖ Gram-negative flagellated bacilli
- ❖ Faeco-oral route is commonest mode of spread
- ❖ Asymptomatic human carriers are most important reservoirs (*Typhoid Mary*)
- ❖ Peyer's patches, mesenteric lymph nodes, gallbladder, spleen, liver and bone marrow are commonly involved

### Complications of typhoid

- ❖ Paralytic ileus is the *most common* complication
- ❖ Intestinal haemorrhage—as the Peyer's patches in terminal ileum are enlarged and ulcerated—20%. Usually blood transfusion and antityphoid therapy is sufficient to control bleeding. Rarely in massive bleed resection anastomosis is needed
- ❖ Perforation
- ❖ Cholecystitis and carrier stage
- ❖ Venous thrombosis particularly of common iliac vein is known
- ❖ Typhoid cystitis, bacilluria, epididymo-orchitis
- ❖ Arthritis
- ❖ Typhoid osteomyelitis (granular sequestrum)
- ❖ Typhoid perichondritis and laryngitis leading to airway obstruction
- ❖ Typhoid abscess in liver, spleen, brain and parotid
- ❖ Myositis, myocarditis, meningitis

## Typhoid (Enteric) Perforation

*Perforation usually occurs in 3rd week of the infection:*

- ◆ Ulcers are multiple, arranged in parallel and in antimesenteric border of the ileum.
- ◆ One or more ulcers might perforate and many ulcers may be on impending perforation.
- ◆ Patient is toxic, presents with:

- ❖ *Severe diarrhoea*
- ❖ *Relative bradycardia*
- ❖ *Soft abdomen*
- ❖ *Obliterated liver dullness*
- ❖ *Abdomen without guarding and rigidity (because of Zenker's degeneration)*
- ❖ *Initial history of fever for few days then pain abdomen and tenderness, which is progressive*

### Associated features

- ❖ Splenomegaly
- ❖ Fever, headache
- ❖ Rose spots in the skin

### Investigations

- ◆ Possibility of missing typhoid perforation is very high.
- ◆ X-ray in erect posture shows gas under diaphragm.
- ◆ Widal test is positive.
- ◆ Neutropenia is seen in blood.
- ◆ Blood culture (90% + ve) and stool cultures are often required. Marrow culture is useful.

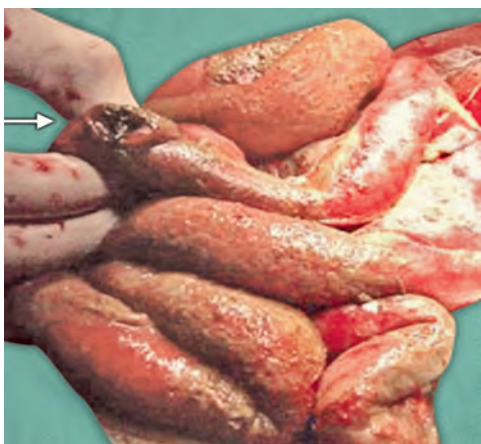- ◆ Identification of specific and sensitive markers (to detect Ig G/ IgM). These tests are positive even when blood culture is negative.
- ◆ PCR assay for typhoid infection is also useful.

#### Note:

- Incidence of typhoid perforation is 2% of total cases.
- 75–80% of perforations are single which needs simple closure after taking biopsy from the edge of ulcer.
- 20–25% of perforations are multiple which requires either resection or exteriorisation as ileostomy.
- In paratyphoid B fever colon perforation can occur.
- CT scan abdomen is ideal investigation to detect early pneumoperitoneum and fluid collection.

#### Treatment

- ◆ Antityphoid drugs (Quinolones, chloramphenicol, ceftriaxone sodium) are started.
- ◆ Later laparotomy is done to close the perforation.
- ◆ Ulcers which are on impending perforation should be sutured with serosa.
- ◆ Presently, resection and anastomosis is also accepted as treatment when multiple perforated ulcers are present.
- ◆ ZIP technique (laparostomy) to reopen the abdomen whenever required is also beneficial.
- ◆ Exteriorisation of ileum is ideal in a critically ill patient. Once patient recovers properly after 6–12 weeks closure and continuity is maintained.
- ◆ Closure of perforation with ileotransverse anastomosis is the other option, but not ideal.
- ◆ ICU care, TPN/enteral feeding/monitoring/blood transfusion/fluid and electrolyte management/ prevention or management of other complications like DVT/DIC/ARDS/septicaemia.

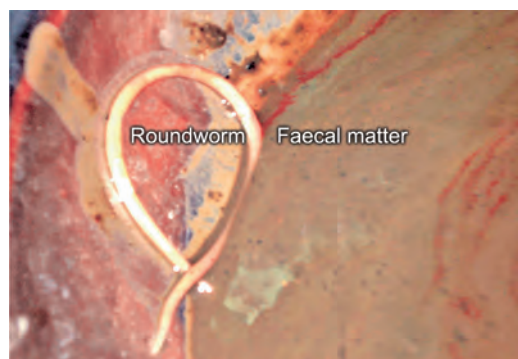

**Fig. 21.11:** Enteric perforation is often severe causing faecal peritonitis. Resection/exteriorisation may be needed in severe cases.

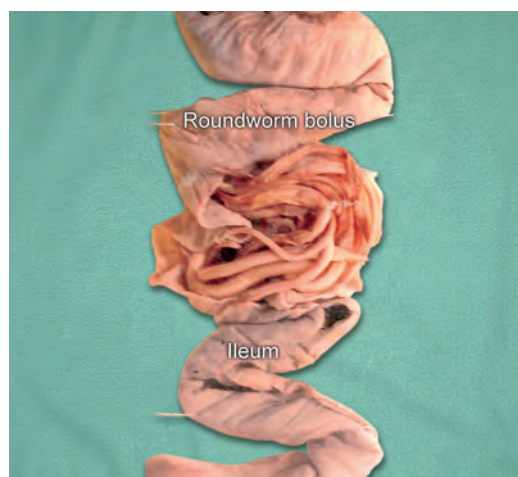## ■ SURGICAL COMPLICATIONS OF ROUNDWORM (*Ascaris lumbricoides*)

### Life Cycle

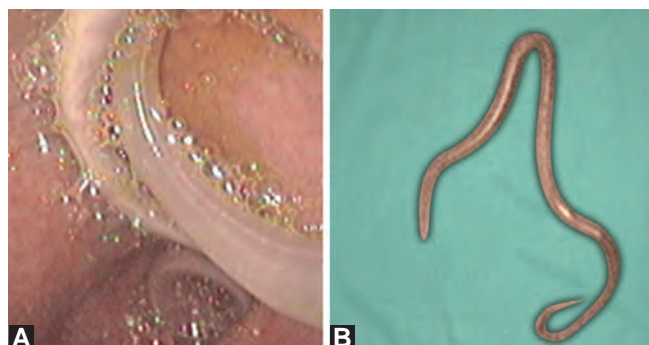Eggs → faeco-oral route → larvae → portal circulation → liver → hepatic veins → IVC, heart, pulmonary artery → lungs → maturation of larvae (8 weeks) → alveoli, tracheobronchial tree → coughed out or swallowed to intestine → adult roundworms → male + female worms union → release of eggs → stool → reinfection.



**Fig. 21.12:** Roundworm removed from peritoneal cavity. Note the faecal contamination.



**Fig. 21.13:** Specimen of ileum showing roundworm *bolus*. Bolus causes intestinal obstruction, commonly near terminal ileum.



**Figs 21.14A and B:** Gastroduodenoscopy view of roundworm. It was removed through endoscopy. Roundworm in proximal bowel can cause pancreatitis, cholangitis. Vomiting of roundworms signifies intestinal obstruction. It need not be due to roundworm obstruction. Because of the obstruction and proximal bowel irritation, worms move proximally into stomach and come out through the mouth (Courtesy: Dr Tantry and Dr Sandeep Gopal, Gastroenterologists, KMC, Mangaluru).

### Features

- ◆ Worm colic.
- ◆ Toxicity—fever, tachycardia.

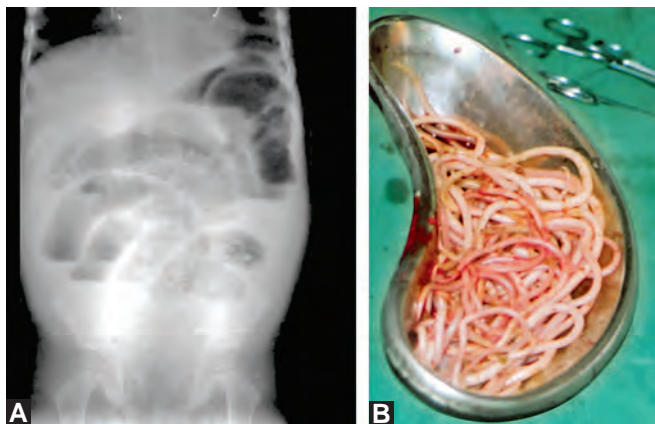


- ◆ Subacute intestinal obstruction.
- ◆ Acute intestinal obstruction with palpable roundworm bolus per abdomen.
- ◆ Perforation—common in the ileum.

**Note:**

Perforation usually occurs at the site of pre-existing disease like nonspecific ileal ulcer, amoebic ulcer, typhoid ulcer, and suture line.

- ◆ Intraoperative abscess.
- ◆ Dyspepsia, malabsorption, iron deficiency anaemia.
- ◆ Due to migration of worm into the CBD/pancreatic duct causes ascending cholangitis with fever, jaundice and upper abdominal pain or features of pancreatitis.
- ◆ *Loeffler's syndrome* is due to larvae in the alveoli causing fever, dry cough, chest pain, dyspnoea.



**Figs 21.15A and B:** (A) Plain X-ray abdomen in a child showing features of intestinal obstruction due to roundworms in the bowel; (B) Roundworm obstruction. Worms removed through an enterotomy.

**Investigations**

- ◆ Small bowel enema/barium meal follow through may show roundworms in the ileum.
- ◆ US can demonstrate the worms/worm bolus/worm in CBD or pancreatic duct.
- ◆ Blood may show eosinophilia, anaemia, hypoalbuminaemia. LFT for worm in CBD.
- ◆ Chest X-ray may show bronchitis.
- ◆ Sputum or bronchial wash may show larvae or Charcot-Leyden crystals.
- ◆ Stool examination may show ova.
- ◆ CT/MRI will show worms/obstruction/worm in CBD or pancreatic duct.

**Treatment**

- ◆ Antihelminthic drugs like piperazine citrate 60 ml is given immediately if there are features of obstruction, otherwise at night time. Albendazole, mebendazole are other drugs used. Proper nutrition is important.
- ◆ Nasogastric aspiration; IV fluids; observation is sufficient in most of the situations. In 48 hours, obstruction will be relieved and child passes worm bolus per anally.
- ◆ Occasionally laparotomy and milking of the worm bolus into the caecum without enterotomy is needed. Once worms are in the

colon, hypertonic saline wash per anum makes them to disperse and pass outside.

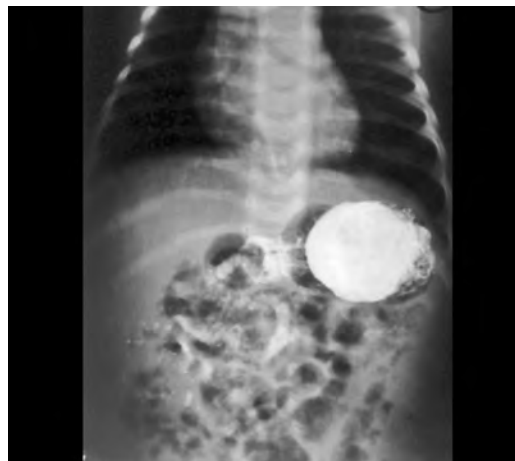
- ◆ Removal of worms by enterotomy is rarely done. Enterotomy should be *securely sutured using silk otherwise reperforation* from sutured site can occur by worm toxins or by worm activity and migration.
- ◆ If there is perforation (common site is ileum) or gangrene with peritonitis, peritoneal worms should be essentially removed. Ideally ileum should be exteriorised to prevent suture line breakdown after closure due to worms. Once patient recovers bowel ends are sutured to maintain the continuity and abdomen is closed. Even though it is *ideal method*, it is not commonly performed.
- ◆ ERCP, worm extraction and stenting is done for worm in CBD/pancreatic duct.

**Treatment of roundworm obstruction**

- ❖ Drugs—piperazine citrate, mebendazole, albendazole
- ❖ Most often by conservative treatment, worms get dispersed and passed per anally. But patient requires nasogastric aspiration, IV fluids, antibiotics, and observation
- ❖ If patient is not responding then laparotomy is done. *Worm bolus* in the distal ileum is milked into the caecum. Often enterotomy and removal of worms is required
- ❖ Perforation due to worm requires immediate laparotomy, removal of worms and closure of perforation
- ❖ Only rarely, resection and exteriorisation is required

**PNEUMATOSIS CYSTOIDES INTESTINALIS**

- ◆ It is transient, thin cysts containing nitrogen in submucosa and subserosa of ileum.
- ◆ It is due to increased intraluminal pressure, which forces N<sub>2</sub> through the layers of the bowel due to hyperperistalsis.
- ◆ It is associated with chronic duodenal ulcer, chronic pulmonary disease, bowel obstruction.
- ◆ It can be associated with connective tissue disorder like scleroderma.
- ◆ In neonates it is associated with necrotising enteritis.
- ◆ It is common in subserosal and submucosal planes. Cysts contain nitrogen and hydrogen.
- ◆ They can occur anywhere in GIT but commonly seen in jejunum. Later in ileocaecal and colon region.



**Fig. 21.16:** Pneumatosis cystoides intestinalis.

- ◆ Mesentery and peritoneum may also be involved.
- ◆ It is equal in both sexes.
- ◆ These gas-filled cysts in small bowel may rupture into peritoneal cavity to cause *sterile pneumoperitoneum*. Peritonitis is unusual.
- ◆ Abdominal pain, distension, bowel disturbances, vomiting are the presentations.
- ◆ Intestinal obstruction, haemorrhage, perforations are complications.

## Treatment

- ◆ *Oxygen therapy* by 70% oxygen for 5 days or hyperbaric oxygen 2.5 atmospheres for 2 hours daily for 3 days.
- ◆ Metronidazole therapy.
- ◆ Treating the cause; resection only in refractory cases.

### Small bowel strictures

#### Causes

- ❖ Tuberculosis of ileum/jejunum
- ❖ Crohn's disease
- ❖ Radiation enteritis
- ❖ Ischaemic strictures—after bowel ischaemia, necrotising enterocolitis
- ❖ Nonspecific causes
- ❖ *Garrey's stricture* following long standing irreducible hernia occurs after reduction and surgery (due to constriction band causing ischaemia at the site)

#### Management

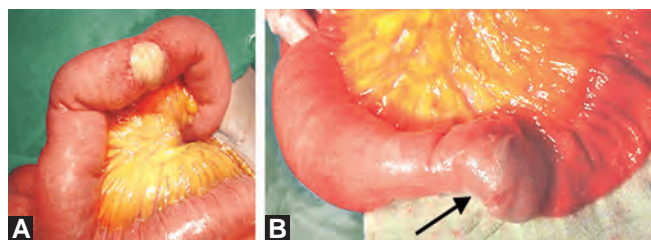
- ❖ Small bowel enema/capsule endoscopy/CT scan—investigations
- ❖ *Treatment:* Treating the cause; resection anastomosis, and stricturoplasty

## MESENTERIC VESSEL ISCHAEMIA

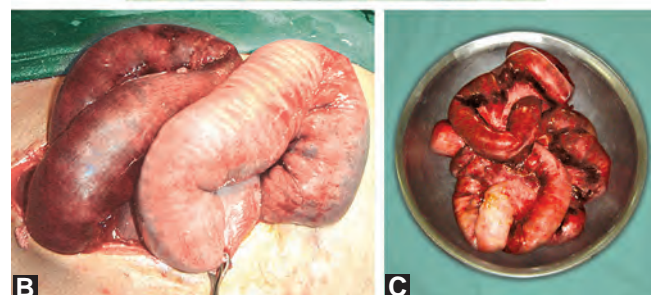
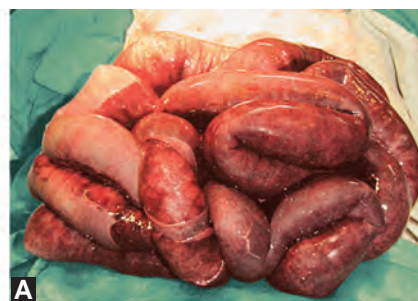Superior mesenteric artery is commonly involved than inferior mesenteric artery. Often superior mesenteric vein can also get involved.

### Causes

- ◆ *Embolism (50%)—Sources*
  - ▶ From left auricle, as seen in atrial fibrillation.
  - ▶ A mural infarct.
  - ▶ Atheroma from aorta or aneurysm.
  - ▶ Endocarditis vegetations.
  - ▶ Left atrial myxoma.
- ◆ *Thrombosis*
  - ▶ It may block the origin of the superior mesenteric artery and can cause ischaemia of full length of small bowel. It is life-threatening.
  - ▶ It may be due to atherosclerosis or occasionally TAO.
  - ▶ Often all main splanchnic vessels—coeliac, superior and inferior mesenteric arteries may be involved by atherosclerosis.
- ◆ *Nonocclusive*
  - ▶ It is due to hypotension/hypoperfusion.
  - ▶ It is due to *vasospasm* due to shock—*nonocclusive mesenteric ischaemia (NOMI)*.
- ◆ *Superior mesenteric vein thrombosis*, occurs in patients with portal hypertension, portal pyaemia, sickle cell disease, women with contraceptive pills (OCP).



**Figs 21.17A and B:** Ischaemic bowel necrosis. It will lead to perforation and peritonitis. So always requires surgical resection.



**Figs 21.18A to C:** Acute extensive mesenteric ischaemia causing small bowel gangrene. Patient will develop short gut syndrome.

### Pathology

- ◆ Bowel and mesentery will be oedematous, friable, discoloured, and collected with fluid and blood.
- ◆ Once gangrene sets in, perforation can occur leading to peritonitis.

### Clinical features

#### In acute

- ◆ *Abdominal pain that is out of proportion* in relation to tenderness; pain is around umbilicus to begin with later diffuse.
- ◆ Persistent vomiting, bloody diarrhoea; later shock and toxicity.
- ◆ Initially abdomen will be soft but later develops tenderness, rebound tenderness, distension, guarding and rigidity.
- ◆ Rectal examination shows bloody stool.

#### In chronic

- ◆ *Post-prandial abdominal pain* is the most important symptom with aversion to food and weight loss.
- ◆ *Abdominal angina*—recurrent colicky pain, diffuse in nature occurs with or without food intake.
- ◆ *Bloody diarrhoea*—it is a feature of both acute and chronic and is confirmed by rectal examination.
- ◆ Later, once severe infarction of bowel occurs; it may present with acute features.

## Types

### It can be:

- ◆ *Acute type*, sloughing of intestinal mucosa occurs in 3 hours; infarction of entire thickness of bowel occurs in 6 hours.
- ◆ *Chronic type*, it is slow and gradual process.

### It can also be:

- ◆ *Extensive* involving large segment of bowel, small or large.
- ◆ *Localized*:
  - ▶ Colonic localised ischaemia at splenic flexure—the most common.
  - ▶ Focal segmental ischaemia often with necrosis in small bowel.
  - ▶ Chronic mucosal infarction.

## Specific Features of Mesenteric Ischaemia

- ◆ It is often considered as intestinal failure.
- ◆ It can be *thrombotic; embolic; and nonocclusive* (low flow status—is due to reduced SMA perfusion by underlying causes like cardiogenic shock, mesenteric vasoconstriction or part of systemic disease. There is no documented thrombosis or embolus).
- ◆ It is rapidly progressive causing early mortality.
- ◆ Clostridium, anaerobic and streptococci infections are evident.
- ◆ *Gas bubble in the mesenteric vein* is pathognomonic sign of irreversible mesenteric ischaemia.
- ◆ CT/CT angiogram is very useful. An occlusion at the ostium of SMA signifies thrombosis. Embolic occlusion is smooth filling defect, usually distal to origin of middle colic artery sparing proximal small bowel, right side colon and transverse colon. Emboli can be fragments causing multiple patchy necrosis of bowel at different sites.
- ◆ Decreased blood volume; poor tissue perfusion; metabolic acidosis; myocardial depression by depressant factor; endotoxaemia; ARDS; renal failure; septicaemia and MODS are the pathological events.
- ◆ On laparotomy—*musty smell and dusky look of extensive gangrenous bowel is typical*. When in doubt, ischaemia should be confirmed by oxygen support; warming; on table Doppler.

## Investigations

- ◆ Plain X-ray in erect posture and US of abdomen.
- ◆ CT scan is the investigation of choice.
- ◆ Angiogram or CT angiogram is the *most reliable* investigation especially in NOMI. It is also *ideal* for chronic ischaemia.
- ◆ Angiogram—on-table angiogram
- ◆ Doppler study—on table.
- ◆ *Blood tests*: Total count is raised with drop in haemoglobin. Raise in blood urea and serum creatinine is common. Serum phosphate level is increased very early in 4 hours as small bowel is rich in phosphate. Arterial blood gas analysis is often essential. Blood culture may be needed.

## Treatment

- ◆ *Emergency laparotomy* is done. With the help of Doppler the block is identified and the vessel is opened. The block is removed and the bowel is reperfused.
- ◆ If patient has presented after 24–48 hours, gangrene might have already occurred, then resection and anastomosis is done.

- ◆ If patient presents within 6 hours, it is possible to prevent gangrene and to salvage the bowel. Emergency SMA angiography is done. Papaverine is injected for vasodilatation (by many studies its benefit is not confirmed). Often heparin (20,000 units loading dose and then maintenance dose of 5000–10000 units 6th hourly) or thrombolytics are injected. Immediate laparotomy is done. SMA is opened (arteriotomy) over the obstruction and thrombus/embolus is removed using Fogarty catheter. Perfusion is maintained. Close monitoring is essential for possibility of formation of bowel gangrene and if it is so relaparotomy should be done for bowel resection.
- ◆ In acute condition, *thrombolysis* using streptokinase, urokinase and recombinant tissue plasminogen activator can be tried. It should be done within 8 hours of onset of pain.
- ◆ NOMI is often treated with *selective infusion of vasodilator papaverine* into SMA. It is also used in all types of mesenteric ischaemia. Catheter is placed into SMA under guidance; 45 mg of papaverine given as a bolus initially, later 30 mg/hour continuous infusion with 1 mg/ml concentration. Catheter is usually kept for 2 weeks and repositioning with regular angiographic confirmation is needed. Papaverine being a vasodilator increases the bowel perfusion through end arteries as well as collaterals.
- ◆ *Chronic mesenteric arterial ischaemia* is treated with *surgical revascularisation* using aortomesenteric bypass graft and mesenteric endarterectomy. It also can be treated with *PTA with or without stenting*. PTA should not be done if there is bowel infarction. It is done through transfemoral or transaxillary route; balloon should be longer than the lesion and 10% wider than the arterial diameter.
- ◆ *Chronic mesenteric vein thrombosis* is treated with anticoagulation or propranolol or oesophageal variceal banding or portocaval shunt.
- ◆ Eventually patient requires *oral anticoagulant therapy* using warfarin for 12 months.
- ◆ Repeated *post-therapy angiography* is needed in all patients.
- ◆ Steroids are given to reduce lysosomal membrane destruction and effects of endotoxins; to maintain arterial resistance and complement activity. High dose hydrocortisone is used.
- ◆ Higher generation antibiotics; critical care; ventilator, fluid, electrolytes and nutritional support (TPN) are essential.

### Note:

- Minimum bowel length required to be retained is 1.2 meters, otherwise the patient will have high mortality (due to short bowel syndrome).
- Small bowel transplantation is under trial for the same.
- Mesenteric bowel ischaemia has got very high mortality.
- Development of septicaemia, ARDS, DIC, postoperative leak are common.

## ■ NECROTISING ENTEROCOLITIS

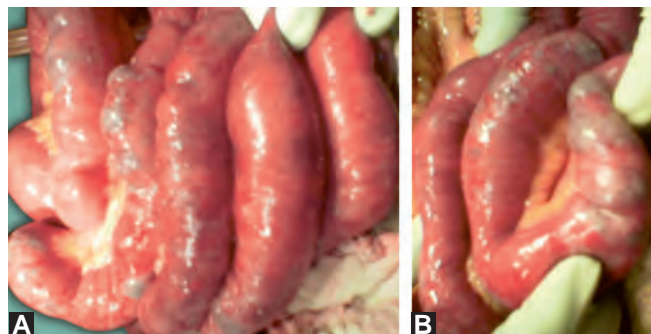
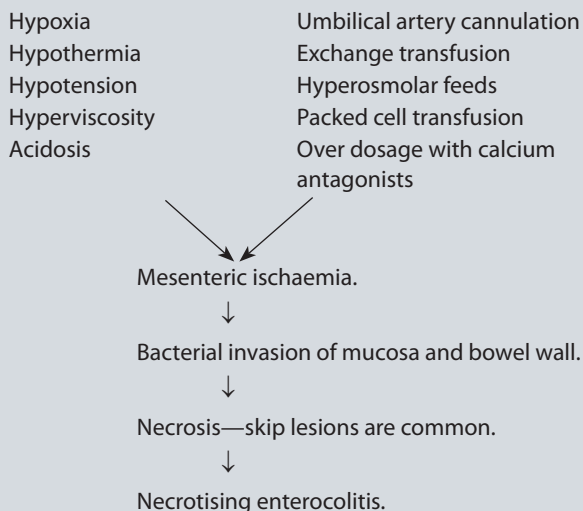
- ◆ Necrotising enterocolitis is an acquired inflammatory disease commonly seen in infants and newborn but occasionally can occur in children and adults. It is more commonly seen in premature babies. It is more common in formula fed babies than breastfed babies. Reduced gut flora make virulent pathogens to act and cause sepsis.

- ◆ Common site is terminal ileum, caecum and ascending colon. Often it can involve entire small bowel.
- ◆ Gas in the bowel wall and often in portal vein is typical.

## Incidence

- ◆ Often associated with low birth weight babies.
- ◆ Preterm babies 90%.
- ◆ Term babies 10%.

### Pathogenesis



**Figs 21.20A and B:** Necrotising enterocolitis. Skin necrotic lesions are typical. It is common in infants and children but can be seen in adolescents occasionally (*Courtesy: Dr Rupen, MS, KMC, Mangaluru*).

## Investigations

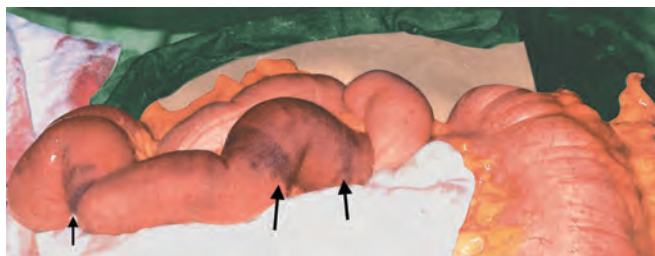
- ◆ Plain X-ray abdomen:
  - ▶ Linear gas shadow in bowel wall.
  - ▶ Free intraperitoneal air implies perforation.
- ◆ Blood examination—leukocytosis, anaemia, hyperkalemia, metabolic acidosis.

### Complications

- ❖ Stricture—small bowel.
- ❖ Perforation—peritonitis.
- ❖ Colonic stricture can develop lately after healing of ischaemic area. It is seen in 10% of cases.

## Sites

- ◆ Common in small bowel.
- ◆ Terminal ileum and caecum.



**Fig. 21.19:** Necrotising enteritis. Note the segmental involvement of the disease.

## Clinical Features

Most babies present with:

- ◆ Bilious vomiting.
- ◆ Abdominal distension, guarding and rigidity.
- ◆ Bradycardia.
- ◆ Apnoea, lethargy.
- ◆ Gross or occult blood in stool (75%).
- ◆ Erythema and oedema of anterior abdominal wall—late feature.
- ◆ DIC.
- ◆ Mortality is 20%.

## Management

### I. Medical therapy

- ▶ Nasogastric aspiration.
- ▶ Broad spectrum IV antibiotics.
- ▶ TPN for 10–14 days.
- ▶ Oxygen supplement is required.

### II. Surgery

#### Indications

1. Pneumoperitoneum.
2. An abdominal mass.
3. Dilated intestinal loops.

#### Procedures done

- ◆ Bowel necrosis and perforation—resection with stoma.
- ◆ Localised disease—resection and primary anastomosis.

*Complication:* Extensive bowel resection—short bowel syndrome.

## SMALL BOWEL TUMOURS

- ◆ They are rare neoplasms—3% of all GI tumours (Even though 80% total length and 90% of mucosal surface area of the GIT is small bowel).
- ◆ Common in elderly men.
- ◆ Common in New Zealand and Hawaii.
- ◆ It can be benign or malignant.
- ◆ Early diagnosis is difficult.
- ◆ Presentations are vague initially.

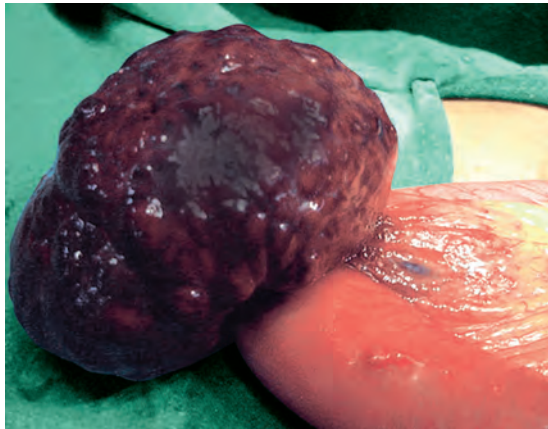


Fig. 21.21: Jejunal haemangioma. Surgical resection cured the condition.

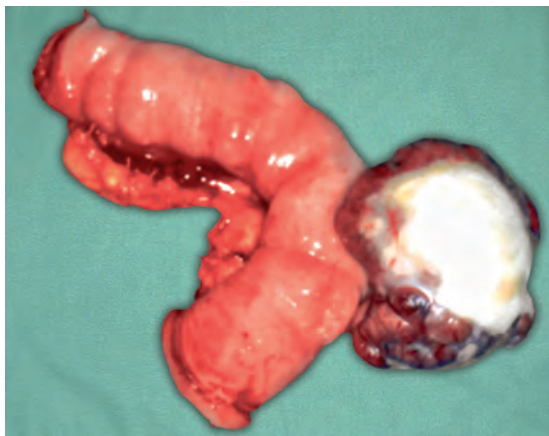

Fig. 21.22: Jejunal tumour.

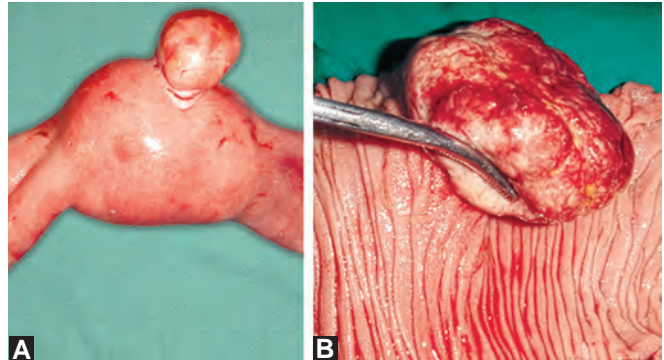
**Reasons why malignancy is uncommon in the small bowel (even though it comprises 75% of length and 90% of GI mucosa):**

- ◆ Rapid transit time, 30 minute to 2 hours. So exposure of mucosa to toxins and metabolites is less.
- ◆ Alkaline mucus rich luminal content is protective.
- ◆ Cells of small bowel produce the enzyme benzopyrene hydroxylase which detoxifies the carcinogen—benzopyrene.
- ◆ High levels luminal IgA provides immunity.
- ◆ Plenty of lymphoid tissue in the wall provides immunity.
- ◆ Healthy small bowel has got less bacterial load and so their toxic metabolites (as compared to colon).

**Risk factors implicated are:**

- ❖ Bile acids and their metabolites
- ❖ Post-cholecystectomy status
- ❖ Familial adenomatous polyposis (FAP) especially with duodenal adenomas has got very high chance of developing adenocarcinoma
- ❖ Crohn's disease has got 100 times increase in incidence of adenocarcinoma
- ❖ Celiac disease increases the risk of lymphoma
- ❖ Peutz-Jegher's syndrome has got increased risk of small bowel adenocarcinoma

- ❖ Patients with chronic immunosuppression have very high-risk of developing NHL (PTLD—post-transplant lymphoproliferative disorder, HIV) or sarcoma
- ❖ Patient with von Recklinghausen's disease of neurofibromatosis is prone to develop GI neurofibroma or neurofibrosarcoma
- ❖ Smoking, red meat, alcohol, salt food



Figs 21.23A and B: Jejunal tumour coming out of serosa.

## Presentations

- ◆ Asymptomatic initially.
- ◆ Features of obstruction/intussusception/bleeding.
- ◆ Vague abdominal discomfort.

## Investigations

- ◆ Often it is very difficult to assess small bowel. It may be on table finding during surgery, while presenting as complication like obstruction.
- ◆ Small bowel enteroclysis.
- ◆ CT abdomen is better investigation to assess bowel/ nodes/organs. *CT enteroclysis* shows 90% accuracy.
- ◆ Video capsule endoscopy enables to visualise small bowel mucosa properly.
- ◆ CT angiography is useful in identifying vascular tumours.
- ◆ Enteroscopes (push type or Sonde pull enteroscopes) are technically difficult.
- ◆ Intraoperative enteroscopes are useful.

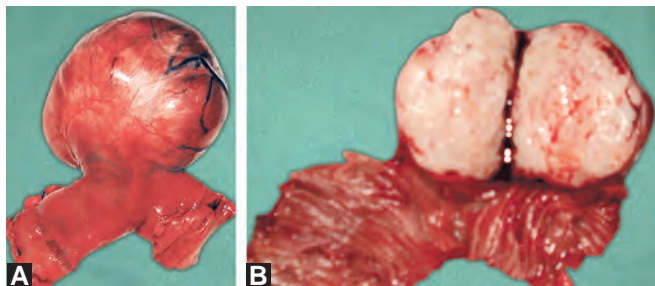
## BENIGN TUMOURS OF SMALL BOWEL

- ◆ Benign tumors of small bowel are 50% of primary small bowel tumours.
- ◆ Adenoma can be potentially malignant.

## Types

### *Leiomyoma or GIST*

- ◆ It is the most common symptomatic benign tumour of small bowel.
- ◆ It arises from interstitial cell of *Cajal*. It can be spindle cell type (70%) or epithelioid type.
- ◆ Commonly they are benign in small bowel.
- ◆ GIST express CD117 (90%), the c-kit proto-oncogene protein membrane receptor for stem cell growth factor and CD34 (80%), a human progenitor cell antigen.



**Figs 21.24A and B:** Leiomyoma of jejunum.

### Adenomas

- ◆ It is 15% of all benign small bowel tumours.
- ◆ 50% are in ileum; 30% in jejunum; 20% in duodenum.
- ◆ Commonly single but can be multiple when familial or associated with FAP.
- ◆ Commonly presents as bleeding and obstruction.

### Adenomas can be:

- ◆ **Brunner gland adenoma**
  - ▶ It occurs as benign hyperplastic tumour in proximal duodenal submucosa which secretes alkaline bicarbonate rich fluid.
  - ▶ Bleeding is the usual problem.
  - ▶ It is treated by endoscopic resection.
  - ▶ It never turns into malignancy.
- ◆ **Villous adenoma**
  - ▶ It can occur anywhere in small bowel presenting as intestinal obstruction or haemorrhage.
  - ▶ But commonly seen in periampullary region presenting as obstructive jaundice, upper abdominal pain.
  - ▶ Size more than 3 cm can lead into adenocarcinoma with an adenoma—carcinoma sequence.
  - ▶ EUS is ideal tool to assess size and depth.
  - ▶ ERCP is done to relieve obstruction, to biopsy and to remove if it is small in size.
  - ▶ Malignant potentiality is very high—50%.
  - ▶ Transduodenal excision/pancreaticoduodenectomy are the surgical options. Small bowel adenomas are treated by resection.
- ◆ **True adenomas**
  - ▶ It can be tubular or tubulovillous.
  - ▶ It is usually single.
  - ▶ Endoscopic excision is the treatment; resection/pancreaticoduodenectomy is done if there is invasive lesion.
- ◆ **Familial adenomas**
  - ▶ It is associated with FAP with 5% risk for adenocarcinoma in duodenum.
  - ▶ It is diffuse throughout the duodenum.
  - ▶ *Spigelman classification* is used for assessment of FAP related duodenal adenomas. Villous adenomas larger than 3 cm or suspicious lesions identified on endoscopy are biopsied.
  - ▶ *Screening endoscopy* to be done every year.
  - ▶ Endoscopic or open polypectomy; argon beam or photodynamic therapy is tried in benign lesions.
  - ▶ Pancreaticoduodenectomy is done in high grade, carcinoma in situ, Spigelman IV classification.

### Spigelman classification of duodenal adenomatosis

Parameter about polyps	Point 1	Point 2	Point 3
Number	1–4	5–20	More than 20
Size	1–4 mm	5–10 mm	More than 10
Histology	Tubular	Tubulovillous	Villous
Dysplasia	Mild	Moderate	Severe
<b>Stage</b>	<b>Points</b>		
0	0		
1	1–4		
2	5–6		
3	7–8		
4	9–12		

### Lipoma

- ◆ It mainly causes intussusception.
- ◆ It is common in *elderly men*.
- ◆ It is usually *single intramural submucosal* lesion.
- ◆ Lipoma *does not* have malignant potential.

### Peutz-Jegher's Syndrome

- ◆ Autosomal dominant condition with melanotic pigment patches and GI polyps.
- ◆ Brown black pigments of 1–2 mm diameter in circumoral face, cheek, forearms, palms, soles, digits, perianal region.
- ◆ Hamartomas are located in entire jejunum and ileum; 50% of colorectum; 25% of stomach.
- ◆ Intussusception, bleeding, anaemia—presentations.
- ◆ Cancer of small intestine, stomach, pancreas, ovary, lung, uterus and breast can occur.
- ◆ Cure is not possible. Segment which is causing complication is resected.

### Haemangioma

- ◆ It is 4% of all small bowel benign tumours.
- ◆ They are multiple in 60% of patients.
- ◆ They are usually submucosal abnormal proliferative vessels.
- ◆ Jejunum is the commonest site.
- ◆ They are often seen in association with *Osler Weber Rendu disease*, *Turner's syndrome*.
- ◆ It presents as small bowel bleed.
- ◆ It can be diagnosed by angiography,  $^{99m}\text{Tc}$  RBC scanning or capsule endoscopy.
- ◆ *Treatment:* Endoscopic sclerotherapy or angiographic embolisation or resection of bowel segment.

### General Features

- ◆ They cause haemorrhage, colicky pain, and intussusception.
- ◆ Diagnosis is by suspicion. Small bowel enema, capsule endoscopy, radioisotope study, CT scan or MRI may help in identifying the disease. Laparoscopy and proceed may be useful.
- ◆ Commonly it is on table finding during exploration for acute presentations.
- ◆ Adenomas are potentially malignant depending on the size (> 3 cm).

## Treatment

- ◆ It depends on type, number, nature, size of the tumour.
- ◆ Resection and anastomosis cures the condition.
- ◆ Surgery is not done for Peutz-Jegher's syndrome unless it presents with complications.

## MALIGNANT TUMOURS OF SMALL BOWEL

### 1. Adenocarcinoma

- ◆ Its incidence is 40% of small bowel tumours.
- ◆ It is most common primary malignant small bowel tumour.

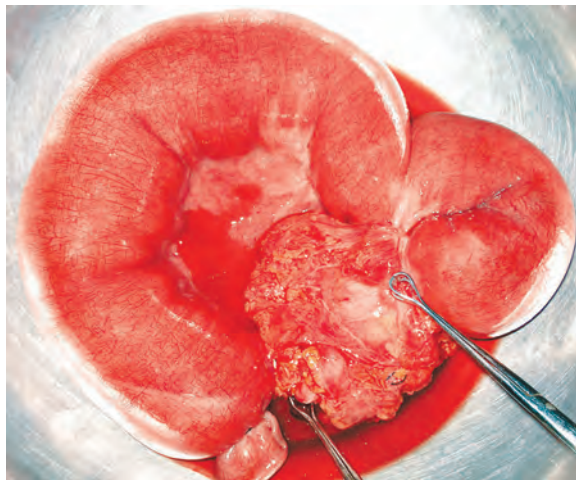


Fig. 21.25: Resected small bowel specimen showing small bowel adenocarcinoma.

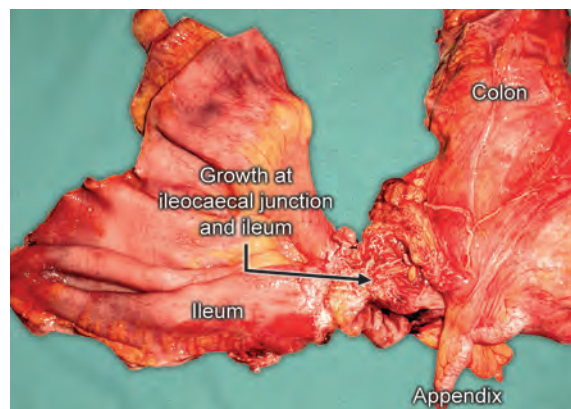


Fig. 21.26: Carcinoma ileum near ileocaecal junction. It (adenocarcinoma of ileum) carries poor prognosis. It is often on table diagnosis.

- ◆ In 80% cases it is in the duodenum and jejunum.
- ◆ FAP, adenoma, Crohn's, coeliac diseases are the causes.
- ◆ Adenocarcinoma in *Crohn's disease* occurs in younger age group and commonly in ileum (70%).
- ◆ Nonspecific features, anorexia, crampy pain abdomen, bleeding and diarrhoea, obstruction or features of metastases (liver).

- ◆ CT scan, capsule endoscopy are the investigations.
- ◆ TNM system is used for staging.
- ◆ Nodal spread is the important prognostic factor.
- ◆ Surgical resection is the choice of therapy. *Pancreaticoduodenectomy* is done for duodenal tumour; for ileal/jejunal site tumours *radical resection* with 10 cm margin with adjacent mesenteric clearance is done. Adenocarcinoma of terminal ileum is treated with *right hemicolectomy*.
- ◆ RT and chemotherapy are less beneficial.
- ◆ It carries a poor prognosis.

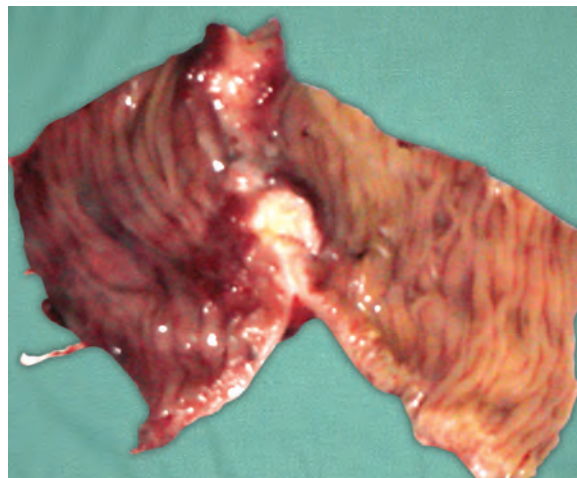


Fig. 21.27: Jejunal adenocarcinoma presenting as stricture with features of proximal small bowel obstruction.

### 2. Non-Hodgkin's lymphoma (NHL)—25%

- ◆ GI is the commonest extranodal site of NHL (20%), with small bowel (primary intestinal NHL) as second common site (30%) for extranodal site of NHL (First common site is stomach—60%).
- ◆ Lymphadenopathy/mediastinal lymph node enlargement are absent. Normal spleen, liver, blood peripheral smear are observed.
- ◆ B cell type is the commonest type 75%. It is common in ileum.
- ◆ T cell type (25%) carries poor prognosis.
- ◆ Presentations are malabsorption, obstruction, perforation, haemorrhage or palpable mass.
- ◆ In children lymphomas are the most common intestinal neoplasm.
- ◆ 25% of patients develop perforation.
- ◆ Fever when present suggests systemic spread.
- ◆ CT scan with CT guided biopsy or laparoscopic biopsy is needed.
- ◆ Surgical resection and chemotherapy are the treatment.
- ◆ Prognosis is poor.

### 3. Carcinoid tumour—30%.

### 4. GIST (gastrointestinal stromal tumour)

- ◆ It is rare but most common nonepithelial small bowel tumours.

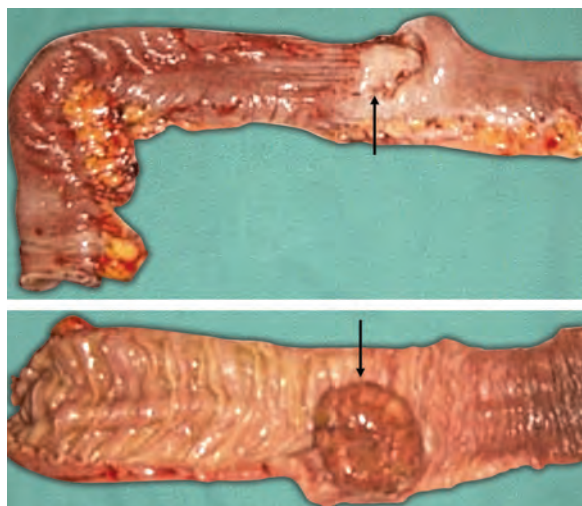


Fig. 21.28: Gross look of small bowel lymphoma.

- ◆ 25% of GIST occurs in small bowel (stomach—50 to 60%). It is 0.2% of all GI tumours.
- ◆ It is equal in both sexes.
- ◆ It arises from interstitial cell of Cajal.
- ◆ More than 95% show c-kit (transmembrane receptor tyrosine kinase) mutation.
- ◆ Many mesenchymal tumours of small bowel are now classified as GIST. GIST attains massive size when presenting clinically.
- ◆ Palpable mass, compression, haemorrhage are the features; has *less affinity* for lymphatics.
- ◆ CT is diagnostic. Histochemistry and tumour markers are needed.
- ◆ GIST can be low risk or high-risk group based on tumour size and mitotic index.
- ◆ Surgical wide resection is the treatment.
- ◆ Imatinib mesylate a KIT kinase inhibitor is used successfully. SU11248 with similar effect is also used.

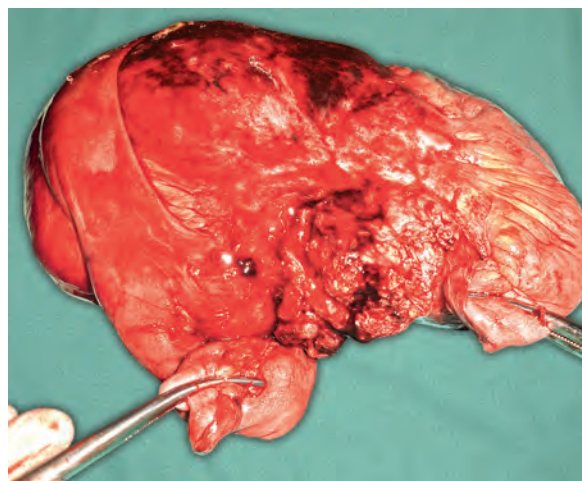


Fig. 21.29: GIST of small bowel  
(Courtesy: Dr Chinivalar, MS, Surgeon).

## 5. Liposarcoma and myxoliposarcoma.

## 6. Secondaries in small bowel

They are very rare—if it is present, primary being commonly melanoma.

### Malignant tumours of small bowel

- ❖ Adenocarcinoma is commonest—40%. Order of occurrence—duodenum, jejunum and ileum
- ❖ GIST is new entity comprising smooth muscle tumours also
- ❖ Carcinoid and lymphoma has got better prognosis
- ❖ Adenocarcinoma and GIST has got poor prognosis
- ❖ Presentations are pain, diarrhoea, weight loss, anaemia, melaena, palpable mass, intestinal obstruction and metastatic features
- ❖ Bleeding and perforation are common in lymphoma and sarcoma
- ❖ Enteroclysis/capsule endoscopy/CT scan/histochemistry are needed to diagnose
- ❖ Surgery is the main therapy
- ❖ Imatinib is used in GIST with favourable results

## CARCINOID TUMOUR

- ◆ The term '*Karzinoids*' was coined by Oberndarger in 1907.
- ◆ They arise from the enterochromaffin cells (Kulchitsky cells) found in the crypts of Lieberkuhn.
- ◆ These cells are capable of APUD (Amine precursor uptake and decarboxylation) and can secrete vasoactive peptides.
- ◆ It commonly occurs in appendix (45%), ileum (25%) and rectum (15%). Other (15%) sites are—other parts of GIT (including pancreas and biliary tract), bronchus and testis. In the ileum it is almost always in the terminal 2 feet.
- ◆ Metastasis occurs in 3% of appendiceal carcinoid; 35% of ileum.
- ◆ 75% of carcinoids are less than 1 cm and 2% of them will spread; carcinoid of 1–2 cm shows 50% chances of spread; more than 2 cm shows 85% chances to spread.
- ◆ 75% of carcinoids are asymptomatic and found incidentally.
- ◆ It secretes amines (**5 HT**, 5 HIAA, 5 HTP—85%, histamine, and dopamine), tachykinins (kallikrein, substance P, neuropeptide k), peptides (**chromogranins**—100%, pancreatic polypeptide—40%, neurotensin, HCG  $\alpha$ , HCG  $\beta$ , motilin), prostaglandins.
- ◆ 10% of cases are associated with MEN syndrome type I.
- ◆ Pathologically it is smooth, firm, yellowish submucosal nodule seen in antimesenteric border of bowel with mesenteric nodal mass having desmoplastic reaction.
- ◆ Carcinoid in appendix is usually single. But commonly it causes luminal obstruction and so presents with features of appendicitis. Common site is at tip/distal 2/3rd.
- ◆ Small bowel carcinoids are multiple in 40% cases. In 50% of cases other primary malignancy is observed like of breast and colon.
- ◆ Small bowel carcinoids (jejunoileal) < 1 cm incidence, of nodal and liver spread is 20–30%. If it is 1–2 cm, nodal spread is 60–80% and spread to liver is 20%. If it is > 2 cm, nodal spread is more than 80% and spread to liver is 50%.



## Types of Carcinoids

1. *Foregut carcinoids* (Bronchial, thymic, gastroduodenal, pancreatic): Produce low levels of serotonin, but may secrete 5 HPT (5 hydroxy tryptophan) and ACTH.
2. *Midgut carcinoids* (Jejunal, ileal, appendiceal, right colic): Secrete high levels of serotonin.
3. *Hindgut carcinoids* (Distal colon, rectum): Rarely produce serotonin, but produce somatostatin and peptide YY. They present as submucosal nodules without ulcer. Hormonally inactive.

*Foregut carcinoids*—argyrophillic (cells can be stained with metallic silver only in the presence of reducing agent)

*Midgut carcinoids*—argentaffin (stained with metallic silver without a reducing agent) and argyrophillic both

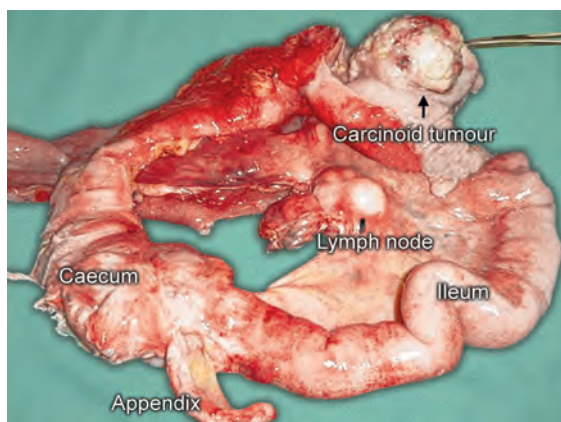
*Hindgut carcinoids*—do not stain with silver

### Features of small bowel carcinoids

- ❖ Primary tumour is usually small < 1 cm
- ❖ Age: Seen in 50–60 years
- ❖ May be multicentric in small bowel—40%
- ❖ May coexist with synchronous adenocarcinoma of small or large bowel (10%)
- ❖ Highest propensity to metastasise to liver to produce carcinoid syndrome

## Clinical Features

- ❖ Most often asymptomatic—an incidental finding.
- ❖ May present with abdominal pain, features of intestinal obstruction, diarrhoea.
- ❖ Hindgut carcinoids present with constipation, bleeding per rectum, rectal tenesmus.
- ❖ Once secondaries develop in the liver (which is yellowish) **Carcinoid syndrome** develops (10%), which is due to release of 5-HT, kinins, prostaglandins, histamine and indoles causing flushing, diarrhoea, cyanosis, asthmatic attacks, hepatomegaly, cardiac lesion on right side.
- ❖ *Attacks can be induced by alcohol.*



**Fig. 21.30:** Carcinoid of ileum. It often presents when liver secondaries develop as carcinoid syndrome. Resection and anastomosis is the treatment.

## Investigations

- ❖ *Urine shows increased 5-hydroxyindoleacetic acid (5HIAA) levels (Normal value—2–8 mg/24 hours).*
- ❖ <sup>111</sup>In-octreotide scintigraphy to detect the tumour.
- ❖ CT scan is very useful for evaluation.
- ❖ <sup>131</sup>I MIBG scan is also done.
- ❖ *Plasma level of chromogranin A* will be elevated in 80% of patients.
- ❖ Provocative tests using pentagastrin, calcium or epinephrine may be used.
- ❖ PET scan using <sup>11</sup>C 5 HTP and <sup>18</sup>F L DOPA isotopes when fused with CT scan will give the best image; with urine 5 HIAA and serum chromogranin A, diagnosis will be accurate.

## Treatment

- ❖ If it is in the tip of the appendix (*tip is common*), appendectomy and regular follow up with urine 5HIAA is sufficient.
- ❖ If it is in the base of appendix or appendicular lesion >2 cm size or terminal ileum, right hemicolectomy is required.
- ❖ In small bowel, if the primary tumour is <1 cm, with no lymph nodes, then segmental intestinal resection and anastomosis is sufficient. Radical resection of bowel is necessary in case of large, multiple carcinoids, with involvement of lymph nodes.
- ❖ In liver secondaries, along with surgical debulking hepatic resection, hepatic artery ligation or embolisation is tried.

### Surgical treatment

- ❖ *Appendix*
  - Tip/lesion less than 2 cm but not involving base—appendectomy
  - Lesion more than 2 cm/involving base—right hemicolectomy
- ❖ *Gastroduodenum*
  - Less than 1 cm—endoscopic resection
  - More than 1 cm—subtotal gastrectomy/pancreaticoduodenectomy
- ❖ *Small bowel lesion*
  - Less than 1 cm—segmental resection
  - More than 1 cm—radical resection with adjacent mesentery
  - Terminal ileum—right hemicolectomy
- ❖ *Rectal lesion*
  - Less than 1 cm—endoscopic resection
  - 1 cm invasive—wide excision
  - More than 1 cm—anterior resection

### Medical treatment

- ❖ Mainly symptomatic
- ❖ Long-acting somatostatin analogue—octreotide can be given—90% symptom palliation is achieved
- ❖ Slow release formulation of octreotide (*Sandostatin LAR*) is also used
- ❖ *Pasireotide* is 2nd generation octreotide which has got wide somatostatin receptor inhibition action (40 fold than octreotide) is said to be very effective

- ❖ Ketanserin (to control diarrhoea), cyproheptadine, ondansetron are also effective
- ❖ Bevacizumab (antiangiogenesis factor), sunitinib (Tyrosine kinase inhibitor), everolimus (m TOR inhibitor) are other agents tried
- ❖ Others: Serotonin antagonists, antihistamines, alpha methyl dopa, 5-fluorouracil
- ❖ Bromocryptine, streptozocin, doxorubicin, dacarbazine, 5 FU, methylsergide, diphenoxylate hydrochloride, interferon
- ❖ Radiolabelled somatostatin analogue
- ❖ Indium-111 labelled pentetretotide is also effective

**Note:**

- Methysergide causes retroperitoneal fibrosis and so not used now.
- Anaesthesia may precipitate carcinoid syndrome during surgical treatment; IV octreotide infusion 50 µg/hour with steroid and antihistamines are needed in such patients.

**Carcinoid Syndrome**

- ◆ It occurs in 10% of carcinoid tumours.
- ◆ It is common in small bowel carcinoid, but can occur in other sites also—bronchus, pancreas, testis, ovary.
- ◆ It is the (first pass metabolism site) *liver secondaries* which cause the *carcinoid syndrome*. Carcinoids of ovary, testis and retroperitoneum bypass the first pass metabolism in liver and so causes syndrome without liver secondaries. Rarely carcinoid syndrome develops in noncarcinoid malignant tumour and dermatomyositis.
- ◆ Syndrome is due to release of 5 HT, 5 HTP, histamine, dopamine, bradykinin, prostaglandin, kallikrein and substance P.
- ◆ **Presentations**
  - ▶ *Vasomotor*: Flushing (80%) is the *commonest manifestations* which may be short lived, *diffuse, erythematous* involving face, neck and upper chest; longer, often permanent *cyanotic violaceous flush* with watery eyes; *prolonged flush* for 3 days affecting entire body with oedema face and hypotension; *red patchy flush* seen in carcinoid stomach.
  - ▶ *GIT*: Diarrhoea (75%) is next common which is episodic, watery, explosive occurs after meals and is due to raised serotonin level. Hepatomegaly (70%) is common.
  - ▶ *Cardiac*: Pulmonary stenosis (90%), tricuspid insufficiency (45%), tricuspid stenosis (40%) are features of right valvular fibrosis—due to serotonin. Bronchospasm (asthma—25%) is due to serotonin and bradykinin.
  - ▶ *Diversion of dietary tryptophan causes malabsorption and pellagra*.
- ◆ Symptoms are precipitated by intake of alcohol, cheese, chocolate and red wine.
- ◆ Severe bronchospasm, circulatory collapse, when not diagnosed can lead into '*carcinoid crisis*'.
- ◆ **Treatment**
  - ▶ Assessment by 5 HIAA, and other methods mentioned above.
  - ▶ IV octreotide infusion, management of circulatory failure effectively using critical care.
  - ▶ Treatment of hepatic secondaries—embolisation, chemotherapy, TACE (transarterial chemoembolisation), hepatic artery ligation, radiofrequency ablation.

**Prognosis**

- ◆ Prognosis is very good for carcinoid of appendix. 5-year survival is 90% and commonly appendiceal carcinoid is identified incidentally; they are commonly in the tip or distal 2/3rd of the appendix; nodal spread and liver spread is rare; 75% are less than 1 cm. Two histological types of carcinoid *appendix are goblet cell and classical type*. Goblet cell type carries poor prognosis.

- ◆ Small bowel carcinoid has got poorer prognosis compared to carcinoid of appendix. Prognosis depends on size of primary tumour; nodal spread; multicentricity; hepatic spread. Carcinoid has better prognosis than adenocarcinoma of small bowel.

**SHORT BOWEL SYNDROME (Short Gut Syndrome)**

- ◆ It is the symptom complex after massive small bowel resection, i.e. *resection more than 70% of the bowel*. Minimum bowel required is 1.2 meters.
- ◆ Proximal jejunal resection is better tolerated than distal ileal resection.
- ◆ Ileum is more adaptive and has got capacity to increase the absorption capacity more efficiently. So in massive resections, patients with retained ileum will do better. Adaptation is better if ileum and caecum is preserved.

**Causes**

- ◆ Massive small bowel resection as in superior mesenteric artery ischaemia.
- ◆ Multiple sequential resections.
- ◆ Recurrent Crohn's disease—common cause.
- ◆ Necrotising enterocolitis in neonates and children.
- ◆ Intestinal atresia.
- ◆ Midgut volvulus.
- ◆ Radiation enteritis.

**Adaptive changes in the retained small bowel**

- ❖ Villous hypertrophy and hyperplasia
- ❖ Increased absorptive surface
- ❖ Increased capacity of small bowel
- ❖ Lower transit time of bowel content

**Factors Deciding the Outcome in Short Gut Syndrome**

- ◆ Age—infants tolerate massive resection better.
- ◆ Retaining ileocaecal valve shows better outcome. Ileocaecal resection interrupts the enterohepatic circulation of bile salts which in colon get metabolised into secondary bile salts. Secondary bile salts block the absorption of water and electrolytes.
- ◆ Delayed clearance of gastrin causes hyperacidity and peptic ulcer.
- ◆ Adaptability of the small bowel. Adaptation is better if ileum and caecum are preserved.
- ◆ Additional colectomy increases the morbidity. In such occasion retained jejunum will function as either of two ways. '*Net absorbers*' have adequate absorption of water and sodium and usually will have more than 100 cm of retained jejunum. '*Net secretors*' have less than 100 cm of jejunum and lot of sodium and water are secreted into the lumen from plasma. These patients should avoid hypotonic solutions like water/tea; instead should take hypertonic saline with glucose containing 90 mmol sodium/L. WHO cholera fluid is ideal (contains 90 mmol sodium/L).

### Clinical features

- ❖ Diarrhoea
- ❖ Fluid and electrolyte deficiency
- ❖ Severe malnutrition
- ❖ Recurrent bacterial enteritis

### Outcome of Short Bowel Syndrome

- ◆ Severe malabsorption.
- ◆ Severe dehydration.
- ◆ Gallstone formation due to altered bile metabolism.
- ◆ Urinary calculi due to increased oxalate level.
- ◆ Water and electrolyte imbalance.
- ◆ Diarrhoea is common.
- ◆ Recurrent bacterial enteritis.
- ◆ Fulminant hepatic failure often can occur.
- ◆ Osteomalacia, tetany, hypomagnesaemia.
- ◆ Bleeding diathesis, peripheral neuropathy.

### Massive bowel resection

- ❖ Resection of *more than 200 cm* of small bowel is called as massive resection.
- ❖ *Metabolic sequelae* in massive resection depend on—extent and anatomical site of resection; functional capacity and adaptation of the small or large bowel; cause for the resection. It causes gastrin hypersecretion, increased parietal cell mass in stomach, peptic ulceration; increased endocrine pancreatic secretion; hypoalbuminaemia, oedema.
- ❖ *Resection of more than 100 cm of distal ileum* causes diarrhoea and steatorrhoea (steatorrhoea is faecal fat > 6 gram/day); increases bile lithogenicity; causes deficiency of vitamins A, D, E, K; colonic bacteria converts unabsorbed fatty acids and conjugated bile salts into hydroxy fatty acids and deconjugated bile salts.
- ❖ *Ileum* maintains enterohepatic circulation of bile salts, absorption of vitamin B<sub>12</sub> and vitamin D. Resection of middle part of small bowel is better tolerated.
- ❖ *Removal of ileocaecal valve* reduces the intestinal transit time; reduces absorption of vitamin B<sub>12</sub>, calcium, magnesium, zinc; increases diarrhoea and contamination of shortened small bowel by bacteria.
- ❖ In massive resection, *colonic bacteria* degrade fatty acids into lactate and short chain fatty acids; lactate reduces colonic pH which inhibits bacteroides; due to this acid resistant anaerobes will increase in colon which produces large amount of D lactate which is absorbed causing *D lactic acidosis* presenting with confusion, ataxia and nystagmus.
- ❖ *TPN* was introduced by Dudrick. It is very useful in short gut syndrome.

### Treatment

#### Early phase

- ◆ Total parenteral nutrition.
- ◆ Fat and fibre free but protein rich liquid diet with essential fatty acids.
- ◆ Diarrhoea is controlled by loperamide/codeine phosphate.
- ◆ Oral cholestyramine to bind bile salts is needed in massive resection which includes ileum.
- ◆ Parenteral vitamin B<sub>12</sub> injection regularly.
- ◆ H<sub>2</sub> antagonists/PPIs/somatostatin (to reduce secretions from stomach, liver and pancreas).
- ◆ Octreotide reduces the secretion and reduces GI motility.

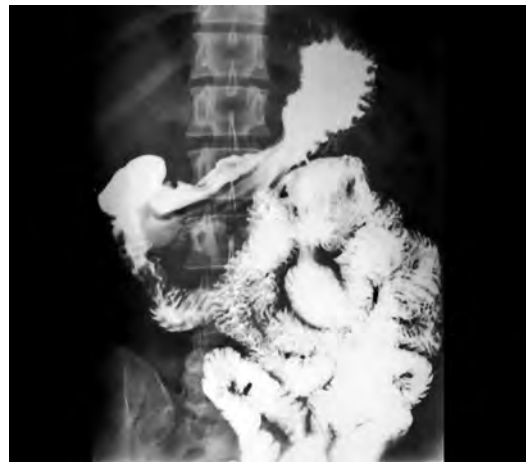
- ◆ Fluid and electrolyte management.
- ◆ Control of diarrhoea.

#### Late phase

- ◆ Enteral nutrition to stimulate intestinal adaptation.
- ◆ TPN supplement—often permanently required.
- ◆ *Home parenteral nutrition* is universally used method in western countries. But in Asian countries it is yet not practicable.
- ◆ Hormones and glutamine administration are under trial.
- ◆ Surgical techniques to delay the intestinal transit time or small bowel transplantation are under trial but with less success.
  - ▶ *Reversal of 10 cm intestinal segment* to delay transit time.
  - ▶ *Intestinal lengthening* to delay transit time and increase the absorption surface.
  - ▶ *Small bowel transplantation*, ideal but graft rejection and failure is the problem.
  - ▶ Antiperistaltic colonic interposition into the small bowel segment.
  - ▶ Regeneration of intestinal mucosa over denuded serosa.
  - ▶ Longitudinal splitting of the intestine and closing of these as separate tubes which are anastomosed to each other to achieve lengthening—*Binachi's surgery*.
  - ▶ Mucosal *stem cell transplantation using enterocytes* without lymphoid tissue.
  - ▶ Seeded mucosal autografts in a prosthetic tubes.

### SMALL BOWEL ENEMA (Enteroclysis)

It is the contrast study of the small bowel by infusing contrast agent either high density microbar solution with methyl cellulose or water soluble iodine dye through Nolan intestinal tube.



**Fig. 21.31:** Enteroclysis X-ray film showing entire small bowel. It is still commonly used investigation to assess small bowel pathology.

### Indications

- ◆ Small bowel tumours.
- ◆ Stricture small bowel.
- ◆ Congenital anomalies.
- ◆ Crohn's disease, intestinal tuberculosis.

### Findings to look for

- ❖ Narrowing
- ❖ Filling defects, irregular or regular
- ❖ Mass lesions

### Problems

- ❖ Poor patient acceptance
- ❖ Technically difficult

## CAPSULE ENDOSCOPY

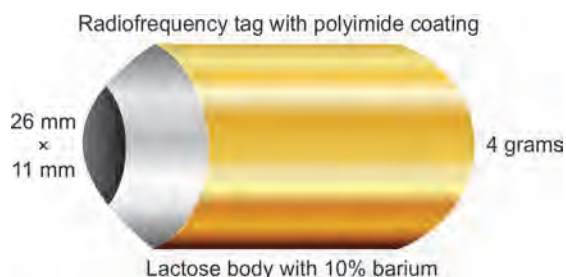


Fig. 21.32: Capsule endoscopy—diagrammatic look.

- ◆ It is a type of endoscopy wherein highly sensitive miniature video-camera which after activation is swallowed by the patient. It is 26 mm × 11 mm in size. It weighs 4 grams.
- ◆ It contains single use video-camera, with 6 light emitting diodes, a lens, a colour camera chip, two batteries, radiofrequency transmitter with an antenna. Capsule takes 2 pictures per second which is transmitted to a worn recording device through radiofrequency. From the recording device data is downloaded to special computer.
- ◆ It is swallowed with 12 hours fasting.
- ◆ After activation it functions for 8 hours. It is mainly used to study small bowel diseases like vascular malformations, narrowing, tuberculoses, ulcers and tumours.
- ◆ This capsule camera sends signals and endopictures at regular intervals to the receiver (digital recorder) tied over the patient's waist.
- ◆ This receiver is later attached to specialised computer software to get different level pictures for study.
- ◆ Capsule gets deactivated in 8 hours and is passed out in the stool.
- ◆ It is available only at few centers and is costly.
- ◆ Capsule retention is the complication in 5% cases.
- ◆ It may not give proper evaluation in obstructive pathology and motility disorders of small bowel.

## SMALL BOWEL ENTEROSCOPY

It is a difficult technique done to visualise the small bowel.

### Indications

- ◆ Occult or obscure GI bleed. 5% of GI bleed is not diagnosed by any methods like gastroduodenoscopy, colonoscopy, contrast imaging. Angiodysplasia and ectasias are common causes for such type.
- ◆ Small bowel tumours.
- ◆ Crohn's disease.
- ◆ Celiac disease.
- ◆ Refractory sprue.
- ◆ HIV related small bowel diseases.
- ◆ Intraoperative enteroscopes to assess lumen on table.

## Technique

### Push Enteroscopy

- ◆ It is easier and faster. It reaches 60 cm beyond the ligament of Treitz.
- ◆ Flexible enteroscopes or paediatric colonoscopes are used.
- ◆ Simethicone is given prior to enteroscopy.
- ◆ BT, CT, LFT and prothrombin time should be checked. Aspirin should be stopped 5 days prior if patient is taking it.
- ◆ Oesophageal overtube is used to pass the enteroscopes through upper GI.
- ◆ Enteroscopes is passed through overtube into stomach, duodenum, and jejunum. Proper evaluation of the mucosa is done during withdrawal. If there is a bleeder point, it is fulgurated.

### Sonde Enteroscopy

- ◆ It is a 5 mm diameter, 275 cm enteroscope passed through nose by a piggyback technique with a paediatric colonoscope. Its two internal channels are for air inflation and for balloon inflation. Biopsy or working channel is not there.
- ◆ Scope is passed through pylorus and further it is moved with subsequent inflation of balloon and distal progression by peristalsis. Distal position is confirmed by fluoroscopy. It takes 6 hours to pass through the entire small bowel.
- ◆ Once it is in the terminal part of the small bowel, small bowel is inflated with air and mucosa is inspected.

### Intraoperative enteroscopy

- ◆ Abdomen is opened. By a small enterotomy scope is passed into the lumen. It is guided manually by compression and release to visualise entire mucosa of small bowel.

### Complications and problems

- ❖ Epistaxis due to nasal irritation.
- ❖ Perforation.
- ❖ Pancreatitis.
- ❖ Failure to pass enteroscopes as needed.
- ❖ Time consuming and not acceptable by the patient.

## ENTERIC/GASTROINTESTINAL FISTULA

Enteric fistula is a challenging problem due to its high mortality of 30%, management of electrolyte imbalance, malnutrition, and sepsis.

An enterocutaneous fistula is an abnormal communication between the mucosal epithelium of the intestine and skin surface.

### Classifications

#### Anatomical

- ◆ *External*: They are **enterocutaneous fistulas** which are discussed in detail here.
  - ▶ 75% of enteocutaneous fistulas are of *postoperative* cause due to disruption of the anastomotic site.
  - ▶ 25% are *spontaneous* due to malignancy, radiotherapy, inflammatory bowel disease (most common in spontaneous cause), diverticular disease and bowel ischaemia.
  - ▶ 70% of external fistula will close spontaneously.

◆ *Internal*

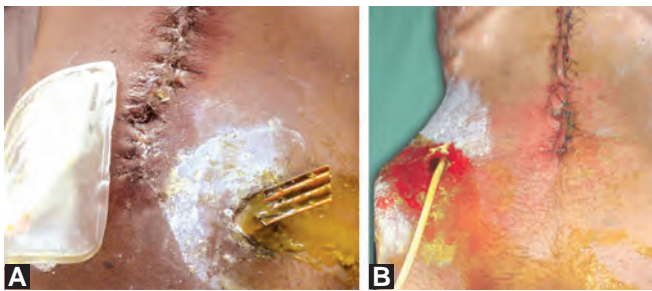
- ▶ Most of the internal fistula need surgical correction, if they are symptomatic or causing complications.

**Aetiological**

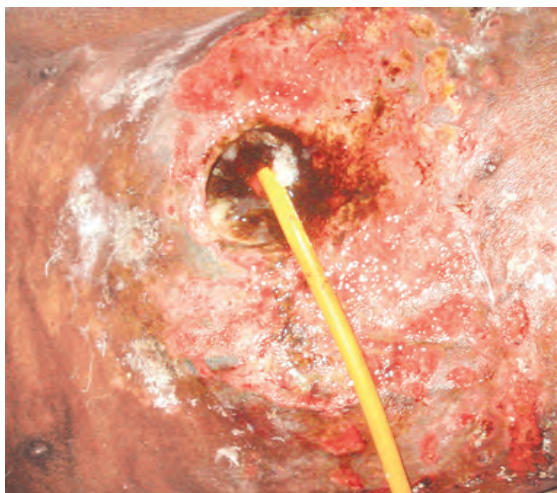
- ◆ Anastomotic disruption in postoperative period.
- ◆ Trauma to normal bowel—inadvertent enterotomy/injury.
- ◆ Disease of the bowel extending into the adjacent structures.
- ◆ Disease outside the bowel extending into the normal bowel.

**Depending on the site**

- *Oropharyngeal*
- *Oesopharyngeal*
- *Gastric*: Commonest cause is the site of gastrostomy tube, either with tube *in situ* or after tube removal. Other causes are—post-gastrectomy and anastomotic leak after surgery for carcinoma stomach, surgeries for benign gastric diseases, reflux diseases, and obesity.
- *Duodenal*: It occurs after surgery for pancreas, biliary system, duodenal stump leak, gastroduodenal anastomosis, renal, aortic, colonic surgeries. Spontaneous fistula occurs in Crohn's, ulcers, malignancy and trauma. It can be duodenal stump fistula which often closes spontaneously; lateral duodenal fistula which less commonly closes spontaneously.

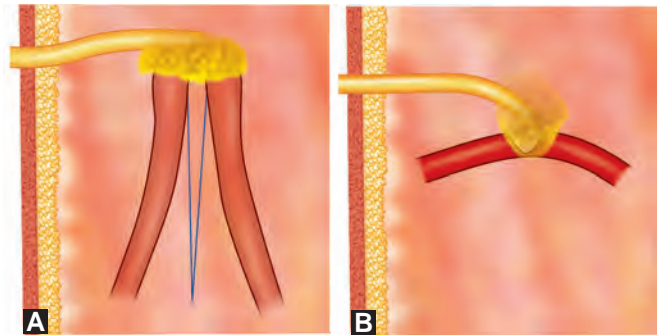


**Figs 21.33A and B:** Enterocutaneous fistula in two different patients.

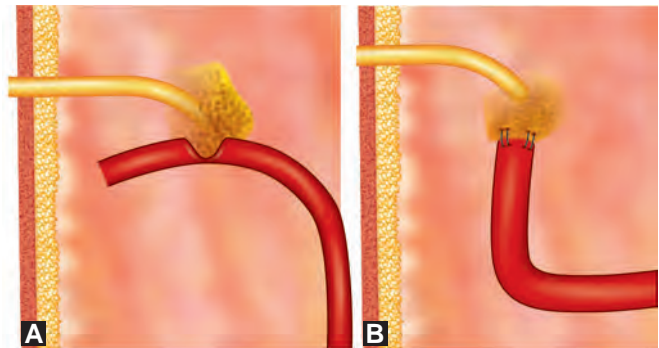


**Fig. 21.34:** Fistula at gastrostomy site. This is becoming the common cause.

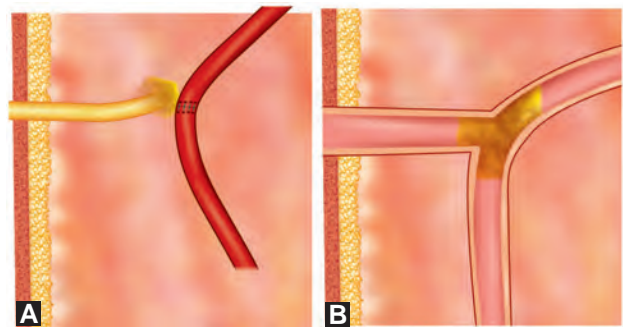
- *Small bowel*: It is the commonest site of GI fistula. More than 75% are postoperative. Crohn's disease is the most common cause of spontaneous small bowel fistula in which 50% each are internal and external.
- *Colonic*: It can be due to postappendicectomy, postcolonic surgeries. It is common after emergency surgeries, and surgeries in unprepared bowel. Appendicectomy in acute phase of Crohn's may cause fistula due to adhesion of inflamed terminal ileum to abdominal wall wound, not from appendicular stump. Spontaneous fistula even though rare, occurs in diverticulitis, malignancy, ulcerative colitis, radiation and pancreatitis.



**Figs 21.35A and B:** (A) Complete disruption of the anastomotic site causes fistula which is unlikely to close spontaneously; (B) Partial disruption also is equally problematic.

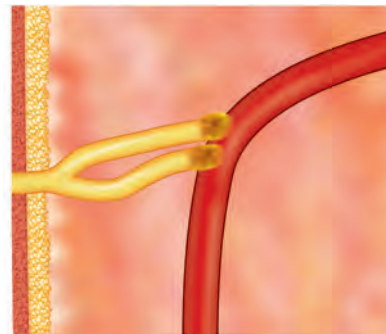
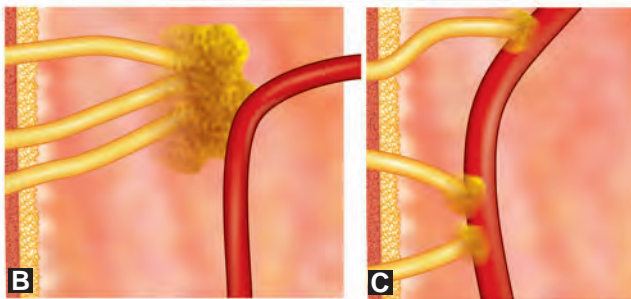
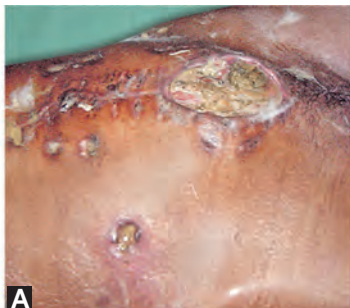

**Figs 21.36A and B:** (A) Distal obstruction precipitates fistula formation and also prevents its closure; (B) End fistula. It is seen in duodenal stump leak.



**Figs 21.37A and B:** (A) Lateral fistula is seen in anastomotic leak from suture line; (B) Epithelialisation of the fistula track prevents spontaneous closure.

<p><b>Fistula may be due to:</b></p> <ul style="list-style-type: none"> <li>• Complete disruption of anastomotic site</li> <li>• Partial disruption</li> <li>• Lateral fistula with distal obstruction</li> <li>• Fistula in stricture bowel</li> </ul>	<p><b>Physiological—based on quantity of daily output:</b></p> <ul style="list-style-type: none"> <li>• <i>High output</i>—&gt; 500 ml/day—usually small bowel; 50% mortality; less chance of spontaneous closure.</li> <li>• <i>Moderate output</i>—200–500 ml/day—colonic and small bowel mixed.</li> <li>• <i>Low output</i>—&lt; 200 ml/day—colonic; mortality is 15%; more chance of spontaneous closure.</li> </ul>	<p><b>Fistula may be:</b></p> <p><i>Favourable:</i></p> <ul style="list-style-type: none"> <li>• Site—oropharyngeal, oesophageal, duodenal stump, pancreaticobiliary, jejunal, colonic.</li> <li>• Cause—postoperative, appendicitis, diverticulitis.</li> <li>• Low output, absence of sepsis, transferrin level more than 200 mg/dl.</li> <li>• Healthy adjacent tissues with intestinal continuity, without distal obstruction.</li> <li>• Fistula track more than 2 cm; bowel wall defect less than 1 cm<sup>2</sup>.</li> </ul> <p><i>Unfavourable:</i></p> <ul style="list-style-type: none"> <li>• Site—gastric, lateral duodenal, ileal.</li> <li>• Cause—malignancy, inflammatory bowel disease.</li> <li>• High output, poor nutrition, sepsis, transferrin &lt; 200 mg/dl.</li> <li>• Diseased adjacent bowel, presence of distal obstruction, large abscess, complete bowel disruption, radiation.</li> <li>• Track &lt; 1 cm; bowel wall defect &gt; 1 cm<sup>2</sup>. Track epithelialisation, presence of foreign body.</li> </ul>
<p><b>Fistula may be:</b></p> <ul style="list-style-type: none"> <li>• <i>End fistula</i></li> <li>• <i>Lateral fistula</i></li> </ul> <p><b>Fistula may be:</b></p> <ul style="list-style-type: none"> <li>• Single</li> <li>• Multiple</li> </ul>	<p><b>Fistula stoma categories:</b></p> <p><i>Category 1:</i> A single orifice fistula through an intact abdominal wall or healed scar with normal skin adjacent</p> <p><i>Category 2:</i> Single or multiple fistulas passing through abdominal wall close to bony part or umbilicus or surgical scar</p> <p><i>Category 3:</i> Fistula through a small dehiscence through the main wound</p> <p><i>Category 4:</i> Fistula through a large dehiscence through main wound or dehiscence at the bottom of wound</p>	
<p><b>Fistula may be:</b></p> <ul style="list-style-type: none"> <li>• <i>Simple</i></li> <li>• <i>Complicated</i>—if multiple tracks, track with an abscess, communication to more sites or more than one viscus.</li> </ul> <p><b>Note:</b> Fistula of duration of more than 3 months is called as <i>chronic fistula</i></p>		



**Fig. 21.39:** Fistula can have multiple tracks even though it is opening at one point in the skin.

**Figs 21.38A to C:** Multiple enterocutaneous fistulas can occur from same site or from different sites.

**Factors Precipitating the Fistula Formation**

- ◆ *Patient factors:* Anaemia, malnutrition, sepsis, hypotension, hypothermia, poor oxygen saturation, associated respiratory diseases/failure, emergency surgeries, specific diseases like malignancy, Crohn's, tuberculosis, adhesions.
- ◆ *Technical factors:* To reduce the chances of fistula formation technical care is essential like—proper mobilisation, meticulous dissection, tension free anastomosis, proper secure anastomosis, most important is proper blood supply at the bowel cut edges, care to avoid cautery injury as bowel is very sensitive to heat/cautery injury, proper prior preparation of patient and bowel.

<b>Problems with enterocutaneous fistulas</b>	<b>Factors which prevents spontaneous closure of fistula</b>
<ul style="list-style-type: none"> <li>• Skin excoriation</li> <li>• Electrolyte imbalance</li> <li>• Severe malnutrition</li> <li>• Recurrent sepsis—locally and systemic like pneumonia, candida, varicella</li> <li>• Pellagra, osteomalacia, zinc deficiency</li> </ul>	<ul style="list-style-type: none"> <li>• <i>Distal obstruction</i></li> <li>• Foreign body in the track</li> <li>• Abscess in the track, infection</li> <li>• Definitive disease like carcinoma, Crohn's, tuberculosis</li> <li>• Epithelialisation of the track</li> <li>• Anaemia, hypoalbuminaemia (2.5 g/dl)</li> <li>• Complete disruption of anastomotic site</li> </ul>

**Management of Fistula**

**Phase 1**

- ◆ *Resuscitation and restoration* of volume with crystalloids and colloids, blood transfusion to achieve haematocrit of 30%, maintenance of albumin level at 3.0 gm/dl with albumin infusion.

*You cannot bring about prosperity by discouraging thrift. You cannot strengthen the weak by weakening the strong. You cannot help the poor by destroying the rich.*

- ◆ *Sepsis control* with antibiotics, percutaneous drainage of abscess under guidance or open drainage.
- ◆ *Skin care* to prevent excoriation using Karya powder, zinc oxide cream/powder, ion exchange resins, stoma adhesive and controlled fistula drainage using sump constructed suction catheter drain system or vacuum assisted closure (VAC) system or silicone barrier or created inverted cone system.
- ◆ *Reduction of output of fistula*—proton-pump inhibitors, histamine antagonists, sucralfate, octreotide, infliximab (in fistula in Crohn's patients). Long-term nasogastric aspiration should be avoided.
- ◆ *Nutrition*: Nutritional status should be assessed by clinical (weight, anthropometry), biochemical methods. 30 Kcalories/kg/day; 1.5 g/kg/day of protein is the basic need. Initially TPN is used. Once patient tolerates oral, enteral feeding should be started ideally. Enteral feeding (oral/gastrostomy/jejunostomy) is contraindicated in presence of distal obstruction. Enteral feeding reduces the sepsis, improves the bowel activity, caliber, thickness and ability to hold sutures. It also avoids TPN related problems.

### Phase 2

- ◆ *Investigations* are done to assess fistula and its causes. It is done in 7–10 days of fistula formation.
- ◆ *Fistulogram* using water soluble contrast, *CT fistulogram* to see the pathological anatomy of fistula—site, number, length, status of bowel, distal obstruction, presence of abscess cavity.
- ◆ *Biochemical analysis* (electrolytes, haematocrit and albumin) and renal, hepatic, respiratory, cardiac status should be assessed carefully.

### Phase 3

- ◆ *Decision* by observation and assessment, whether fistula will close spontaneously or not. Favorable fistulas are likely to close spontaneously but not unfavorable.
- ◆ *Definitive procedure* is done for fistula only after 6 weeks. Mortality and recurrence is higher if operated prior to 6 weeks due to obliterative peritonitis.
  - ▶ *Definitive surgical procedure* is lengthy, complex and *team work*. Optimum nutrition, proper planning, prophylactic antibiotics are needed.
  - ▶ *Reopening* should be done through a *new distant* often transverse incision.
  - ▶ *Bowel refunctionalisation* by freeing entire bowel from ligament of Treitz to rectum should be done to clear adhesions and obstructions and all areas of sepsis and abscesses. *Sharp dissection* using scissor should be done to clear adhesions. As much as possible bowel injury should be avoided; if occurs it should be closed transversely using interrupted 3 zero silk sutures.
  - ▶ *Resection of the bowel adjacent to fistula* with track is the ideal procedure with end-to-end meticulous two layered closure using interrupted 3 zero silk sutures.
  - ▶ When it is not possible, fistula area bypass, Roux-en-Y drainage, serosal patch technique is used. Duodenal fistula is better managed by bypass using gastrojejunostomy and vagotomy without intervening the fistula.
  - ▶ *Proper irrigation of abdominal cavity* with saline and antibiotics during procedure, omental flap around the anastomosis, various solutions to prevent repeat adhesions are also often

done. Supportive jejunostomy may be added for enteral feeding.

- ▶ *Abdominal wall closure* is important by primary closure or by using myocutaneous flap. Mesh should not be used for closure as *recurrent fistula* may occur.

### Phase 4

- ◆ Treatment during recovery and healing time also should be adequate and optimum.
- ◆ Supplementing of nutrition, protein, vitamins and essential element are important.
- ◆ Physical, psychological therapy is needed.

## Important Measures in Enterocutaneous Fistula

*Sepsis control* is a *absolute need* in all fistulas. Sepsis is the commonest cause of death in fistulas.

*Prevention or treatment of abdominal compartment syndrome* should be remembered.

*Assessing the fistula type and anatomy, nutrition, skin care, fluid and electrolyte therapy* are essential. Normally 7 litres of fluid is secreted into the GIT lumen in one day; it is absorbed in distal ileum and colon. Fistula output more than 1000 ml will need TPN and is unlikely to close spontaneously. Fistula output less than 500 ml is more likely to close spontaneously. Fluid should be restricted to 1500 ml/24 hours with 1000 ml should be hypertonic content. PPI decreases gastric secretion; loperamide (4 mg qid) and codeine phosphate (60 mg qid) is useful drug to reduce the output. Octreotide 200 ug tid subcutaneously for 48 hours is shown to decrease the pancreatic and small bowel secretion.

*Monitoring should be done* by urine output (>1 litre/day), urinary sodium more than 20 mmol/litre, serum magnesium > 0.7m mol/litre. Proper nutrition, avoiding weight loss is important. Liver, renal functions, haematocrit should be assessed.

*Assessing the fistula* as favorable and unfavorable is important. (on page 883). Decision for surgical intervention and timing of surgery should be judicial. Usually surgical intervention when needed is done after 12 weeks.

## Surgery

- ◆ Surgery is done if fistula is not healing spontaneously or in high out or unfavourable fistula. It is *resection of fistula* tract with adjacent bowel and anastomosis or creation of stomas like ileostomy, gastrostomy, colostomy, depending on anatomical location of the fistula. In small bowel fistula, after excising the fistula track with its adjacent skin, entire small bowel along its length should be mobilized after adhesiolysis. Restoration of normal continuity is the goal at a later period.
  - ◆ *Reconstruction of the abdominal defect* is also equally important. Reconstruction of the abdominal wall is done by primary closure, or compartment separation technique (Ramirez) with use of biological mesh like decellularised collagen mesh as inlay or onlay. Initial vacuum-assisted dressings, packing are other options.
- Recurrence of fistula* after proper therapy is 15–20%. Disruption, distal obstruction, specific causes, malnutrition, old age, immunosuppression are different causes.

# Chapter 22

## Large Intestine

### CHAPTER OUTLINE

- |                                                   |                                     |                                          |
|---------------------------------------------------|-------------------------------------|------------------------------------------|
| ❖ Anatomy                                         | – Benign Tumours/Polyp of the Colon | ❖ Angiodysplasia of Colon                |
| ❖ Hirschsprung's Disease                          | – Juvenile Polyps                   | ❖ Ogilvie's Syndrome                     |
| ❖ Diverticular Disease of the Colon               | – Metaplastic/Hyperplastic Polyp    | ❖ Colostomy                              |
| ❖ Ulcerative Colitis                              | – Peutz-Jegher's Polyp              | ❖ Stoma Care                             |
| ❖ Ischaemic Colitis                               | – Adenoma of Colon                  | ❖ Stoma Appliances                       |
| ❖ Pseudomembranous Colitis                        | – Familial Adenomatous Polyp        | ❖ Faecal Fistula                         |
| ❖ Surgical Complications of Intestinal Amoebiasis | – Gardner's Syndrome                | ❖ Preparation of Large Bowel for Surgery |
| ❖ Tumours of Colon                                | ❖ Carcinoma Colon                   | ❖ Surgical Pouches                       |
|                                                   |                                     | ❖ Barium Enema                           |

### ANATOMY

- ◆ The colon (large intestine) is 135 cm long, and is divided into caecum, ascending colon, transverse colon, descending colon and sigmoid colon.
- ◆ The wall of the colon is composed of mucosa, submucosa, inner-circular muscle layer and outer longitudinal muscle layer which, in turn, is concentrated into 3 separate longitudinal strips—*taeniae coli*.
- ◆ Small pockets of fat filled peritoneum—*appendices epiploicae* is scattered all over the colon except appendix, caecum and rectum.
- ◆ *Haustra* are sacculations between the *taeniae*.
- ◆ All the 3 above are important features of colon.
- ◆ *Ileocaecal valve* serves as a sphincter to prevent the back reflux to terminal ileum.

### Blood Supply

- ◆ Ileocolic, right colic, and middle colic arteries which are branches of superior mesenteric artery supply the colon from caecum to splenic flexure.
- ◆ Left colic, sigmoid, superior rectal arteries which are branches of inferior mesenteric artery supply the descending and sigmoid colon.
- ◆ The anastomotic arcade formed between the branches of superior and inferior mesenteric arteries is called '*arc of Riolan*'.
- ◆ Venous drainage occurs into superior mesenteric vein (which joins the splenic vein to form the portal vein) and inferior mesenteric vein (drains into the splenic vein).

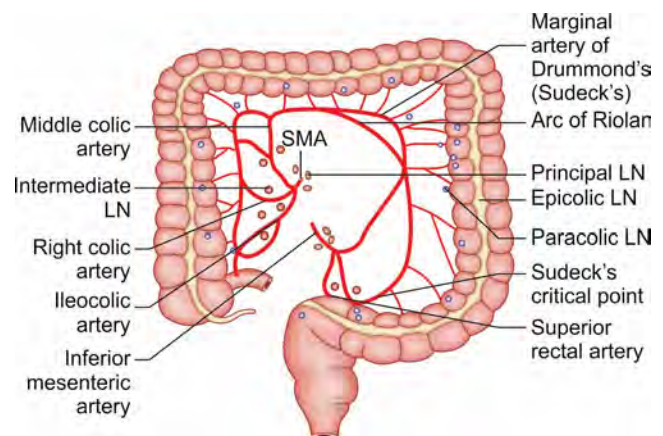


Fig. 22.1: Arterial supply and lymphatic drainage of colon.

### Lymphatic Drainage

- ◆ Mucosa contains no lymph channels, so mucosal cancers rarely metastasize.
- ◆ Nodes are *epicolic* (located in the colonic wall), *paracolic* (located along the inner margin), *intermediate* (located near mesenteric vessels), *principal* (located near main mesenteric vessels).

### Nerve Supply

- ◆ Colonic motility is under control of autonomic nervous system; parasympathetic via vagi and pelvic nerves, sympathetic via superior and inferior mesenteric ganglia.



- ◆ The effect of meal on colonic activity is termed as *gastrocolic reflex*.

## HIRSCHSPRUNG'S DISEASE (CONGENITAL MEGACOLON)

*My first specimen is a colon, but a colon of such a size that it will no doubt surprise you to learn that it comes from a child only 11 months old when it died.... Only (the) rectum was not dilated, nor indeed subject to any obstruction.*

—Harald Hirschsprung, 1888

- ◆ It is a congenital, familial condition, occurring in newborn due to the *absence of ganglion cells*—Auerbach's and Meissner's plexus in anorectum, which may extend proximally either a part or full length of the colon.
- ◆ It always involves the anus, internal sphincter and rectum (partly or entirely).
- ◆ There is narrow, spasmodic, non-relaxing pathological segment.
- ◆ Transitional zone proximal to it contains only few ganglion cells with formation of cone.
- ◆ Still proximal to it, colon is dilated enormously with hyperaemia, multiple ulcers and hypertrophied circular muscle fibres.
- ◆ It is one of the causes of neonatal intestinal obstruction.
- ◆ Severe enterocolitis can occur which may be fatal. Perforation, peritonitis and septicaemia can occur.
- ◆ Often there will be a chronic course of the disease with malnutrition, abdominal distension.

### Types

1. *Ultrashort segment HD*—only anal canal and terminal rectum is aganglionic.
2. *Short-segment HD*—anal canal and rectum is completely involved (80%).
3. *Long-segment HD*—anal canal, rectum and part of the colon is involved (10%).
4. *Total colonic HD*—anal canal, rectum and full length of the colon is involved—10%.

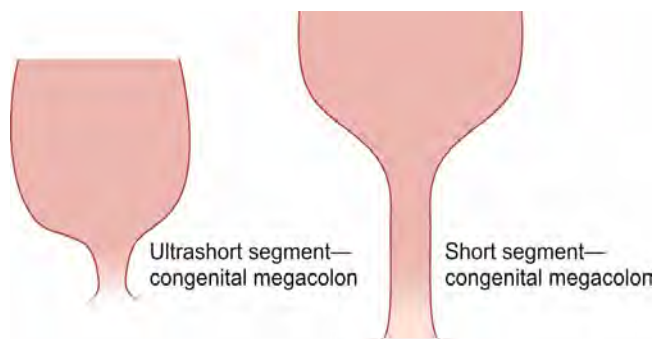


Fig. 22.2: Types of Hirschsprung's disease.

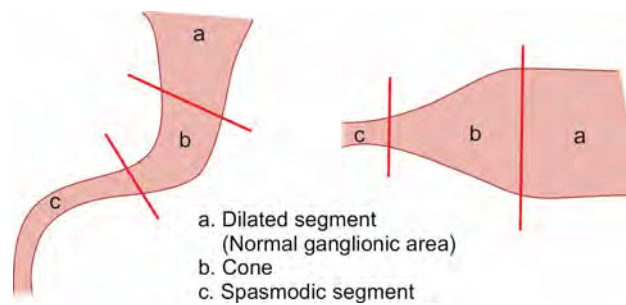


Fig. 22.3: Zones in Hirschsprung's disease.

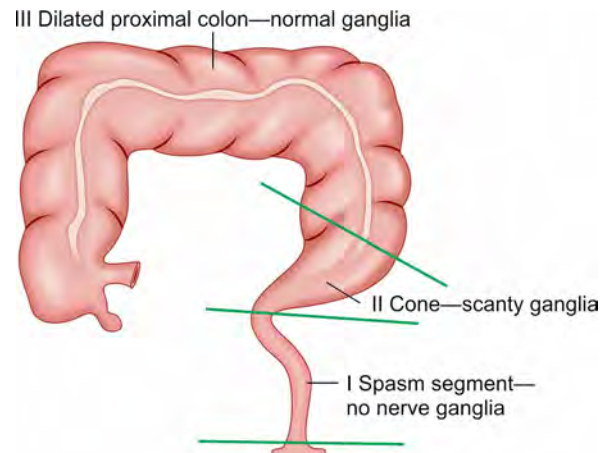


Fig. 22.4: Congenital megacolon showing spasmodic aganglionic segment, coning (transitional zone), and proximal dilated normal ganglionic segment.

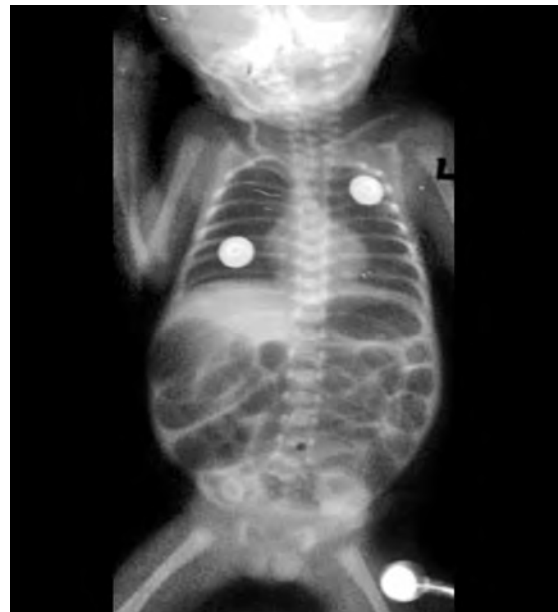
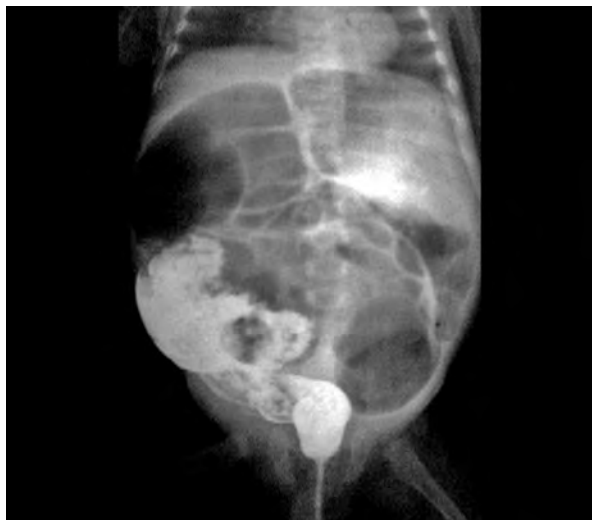
Fig. 22.5: Newborn with Hirschsprung's disease with intestinal obstruction (Courtesy: Dr Vivek Prabhu, MCh, Mangaluru).

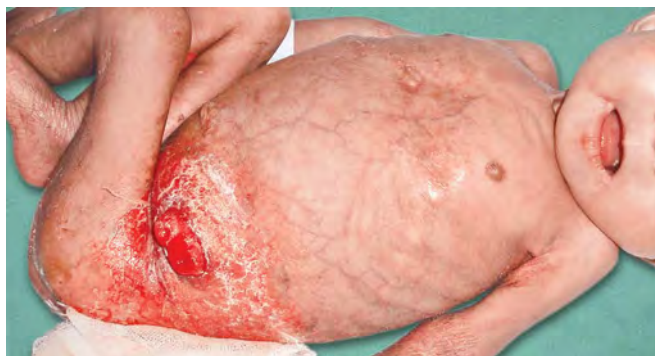

**Fig. 22.6:** Barium enema X-ray showing parts of congenital megacolon—spasmodic area, cone, proximal dilated segment.

It has got **three zones**:

- I. *Distal immobile spastic segment*, i.e. aganglionic zone.
- II. Proximal, *middle transitional zone* of about 1–5 cm length with less, sparse number of ganglions (*cone*).
- III. A still more proximal, *hypertrophied dilated segment* is actually the normal ganglionic area.

### Clinical Features



**Fig. 22.7:** Child suffering from Hirschsprung's disease undergone initial sigmoid colostomy.

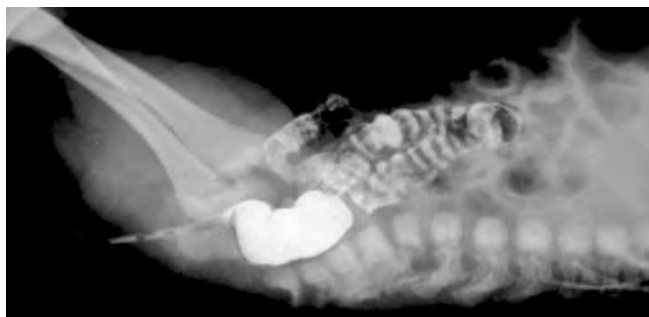**Presentations:** Acute, recurrent, chronic.

- ◆ It is common in males (80%).
- ◆ Its incidence is 1 in 5000 live births.
- ◆ It is common in infants and children, occasionally it occurs in adults also.
- ◆ Often it is associated with Down's syndrome (10%). (Commonest association).
- ◆ In 90% of cases, symptoms appear in early neonatal period, i.e. within three days of birth. *The child fails to pass meconium*. After introducing finger into the rectum, child passes *toothpaste like stool*, with evidence of straining. Distension of the abdomen with features of intestinal obstruction is seen.

- ◆ In children, there is passage of *goat pellet* like stools, malnutrition, abdominal distention—chronic type. Constipation, with history of passing stools once in 3–4 days with straining is seen throughout the childhood and also in adolescent period. Occasionally, condition can cause intestinal obstruction.
- ◆ 10% familial.
- ◆ Gene mutation can occur in chromosome no. 10 commonly; occasionally in chromosome no. 13.
- ◆ **Rectal examination** shows tight sphincter with empty rectum. Child passes lot of gas and meconium.

### Diagnosis

- ◆ History of failure of passing meconium.
- ◆ Plain X-ray abdomen—shows intestinal obstruction. Useful in case of perforation.
- ◆ **Biopsy** from all three zones to study the *ganglions and hypertrophic nerve terminals* in spasmodic segment. Starting from 2 cm above the dentate line, a full thickness rectal biopsy is ideal.
- ◆ **Barium enema** is done to look for the extent of disease and three zones. *Foley's catheter should not be used while doing barium enema in case of Hirschsprung's disease*.
- ◆ **Anorectal manometry**—shows the absence of rectoanal reflex in Hirschsprung's disease, which is diagnostic.
- ◆ **Acetylcholine esterase staining** shows *hypertrophied nerve bundles*.



**Fig. 22.8:** Barium enema X-ray showing features of Hirschsprung's disease in a newborn.

#### Complications

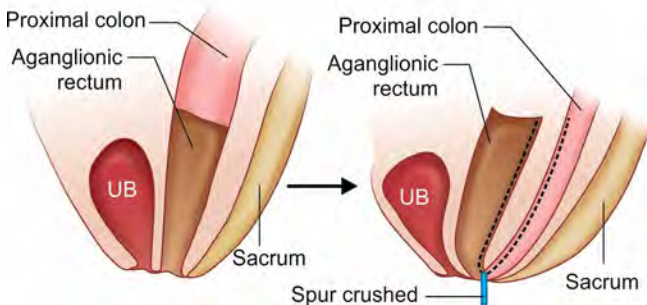
- ◆ Colitis (Intramucosal gas in plain X-ray). Enterocolitis may be fulminant and fatal.
- ◆ Intestinal obstruction.
- ◆ Growth retardation.
- ◆ Constipation.
- ◆ Perforation, peritonitis, septicaemia.

#### Differential diagnosis

- ◆ Total neuronal dysplasia
- ◆ Acquired megacolon—rectum is loaded with stool
- ◆ Anorectal malformations (ARM)
- ◆ Hypothyroidism
- ◆ Meconium plug syndrome

## Treatment

- ◆ Initially, colostomy is done either transverse or transitional, so to have normal bowel function.
- ◆ Nutritional supplementation.
- ◆ Once the child attains 10 kg of weight, definitive procedure is done, i.e.
  - a. Excision of aganglionic segment (spasmodic segment).
  - b. Maintenance of continuity by doing coloanal anastomosis.
  - c. Closure of colostomy later.
 Common procedures done are:
- ◆ **Modified Duhamel operation**—resection of upper part of the rectum and a part of colon; anastomosis of colon to posterior part of the lower rectum and crushing the spurs to create the rectal pouch. It is *technically easier and a retro-rectal pull through*. New pouch is created by anterior part of the aganglionic rectum and by ganglionic proximal pulled down colon. Biopsy should be taken from proximal pulled down colon to look for evidence of ganglions. Pulled down proximal colon is sutured to full thickness posterior anal canal just above the dentate line. Spur between these two segments is crushed by Kocher's forceps or specialized instrument to create a single pouch.
- ◆ **Soave's mucosectomy** and pull through operation.
- ◆ Coloanal anastomosis after proctocolectomy.
- ◆ Total proctocolectomy with ileo-anal anastomosis in case of total colonic HD.
- ◆ **Swenson's operation**—through abdomino-anal approach, aganglionic segment is resected and colo-anal anastomosis is done.
- ◆ **Anorectal myectomy** is found to be very useful for ultrashort segment and short-segment Hirschsprung's disease. Mucosa is incised horizontally 1 cm proximal to mucocutaneous junction. A strip of muscularis with part of internal sphincter is excised with both muscle layers of the rectum for about 6–10 cm length. Mucosa is sutured back. Complications are abscess formation and failure.



**Fig. 22.9:** Modified Duhamel operation. Normal colon is brought behind the aganglionic rectum and anastomosed just above the dentate line.

### Complications of surgery

- ❖ Severe colitis
- ❖ Faecal fistula
- ❖ Stenosis
- ❖ Stunted growth

### Acquired megacolon

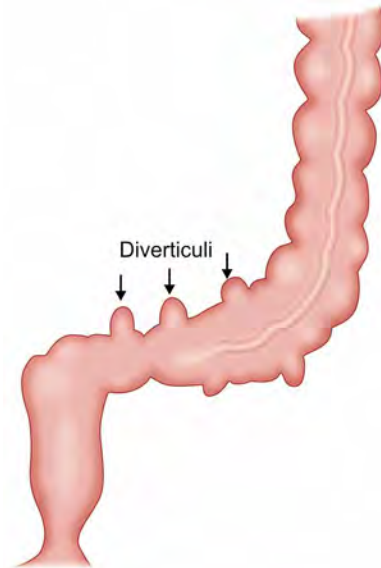
- ❖ No contracted segment in rectum
- ❖ Seen in children with faulty toilet training
- ❖ Rectum and sigmoid colon are dilated
- ❖ Normal ganglions in all levels
- ❖ Improper bowel habit causing chronic bowel dilatation
- ❖ Repeated enemas, manual evacuation, toilet training, educating the parents are required
- ❖ Should be differentiated from Hirschsprung's disease

## DIVERTICULAR DISEASE OF THE COLON

- ◆ They are acquired herniations of colonic mucosa through circular muscles at the points where blood vessels penetrate (points of least resistance).
- ◆ It is more commonly localised to *sigmoid colon (90%)* but occasionally seen in full length of the colon.  
*Rectum is not affected.*

### Saint's triad (5%)

- ❖ Diverticulitis, hiatus hernia, gallstones
- ◆ It is rare in Asian and African countries because of the high fibre diet. It is common in western countries.
- ◆ Colonic diverticulosis is usually of false type with only mucosal herniation.

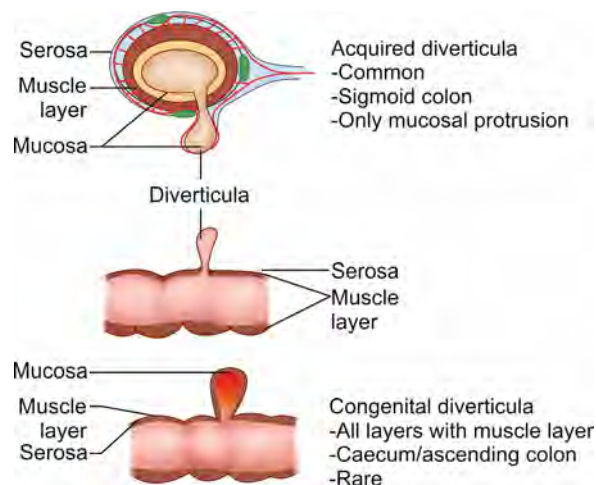


**Fig. 22.10:** Diverticular disease of the colon.

## Aetiology

- ◆ **Diet**—it is the main factor. Low fibre diet increases the stool transit time, reduces the stool weight, reduces the bulkiness of stool which increases the intraluminal pressure and muscle hypertrophy. High fibre diet prevents this.
- ◆ Disease is more common in females. It is more common in aged.

- ◆ It is more common in non-vegetarian than in vegetarian.
- ◆ NSAID intake by inhibiting prostaglandin synthesis may cause diverticular disease. It is more common in individuals with steroid therapy or immunocompromised people.
- ◆ Smoking and alcohol.
- ◆ Long-standing constipation increases the stool transit time and causes diverticulosis.



**Fig. 22.11:** Diagram showing the formation of diverticula. Note the difference between congenital and acquired diverticula.

## Types

### Diverticulosis

These false diverticula occur at the site where arteriole perforates the muscular wall; so they occur on the mesenteric side of the anti-mesenteric taenia; they do not occur on the antimesenteric border. Diverticula are common in sigmoid colon (50%), descending colon (40%), rarely in the other parts of the colon; muscular wall thickening with hypertrophy limits to sigmoid colon only. Sigmoid gets narrowed due to spasm with mucosal false diverticula adjacent to lateral taenia with raise in intraluminal pressure 90 mmHg or more. There will be muscular incoordination, segmentation, causing episodic spasmodic left iliac fossa pain—painful diverticular disease. Here luminal perforation with peridiverticulitis is not observed.

### Peridiverticulitis (Diverticulitis)

Diverticulitis is a misnomer; actually it is perforation through the diverticula with peridiverticulitis; if extraluminal extraperitoneal perforation with only pericolic infection it is called as *uncomplicated*; if there is pericolic abscess or fistula or intraperitoneal perforation with peritonitis it is called as *complicated*.

- ◆ *Uncomplicated type (75%)* is—actually peridiverticulitis with extraluminal pericolic infection caused by luminal perforation into pericolic area without formation of fistula or abscess or intraperitoneal perforation. Presentations are—pain in the left iliac fossa and left groin persistent or recurrent, fever, loose stool, tender palpable thickened colon, urinary urgency, radiating pain towards back and suprapubic region.
- ◆ *Complicated type (25%)* shows—abscess or fistula into urinary bladder (commonly) or small bowel (occasionally), intraluminal perforation and peritonitis, haemorrhage (it is common due to close proximity of diverticula to perforating arterioles).

### Diverticula-associated Colitis (DAC)

It is distinct entity herein diverticula is associated with colitis. It presents tenesmus, diarrhoea, haematochezia. There is segmental colitis.

## Pathology

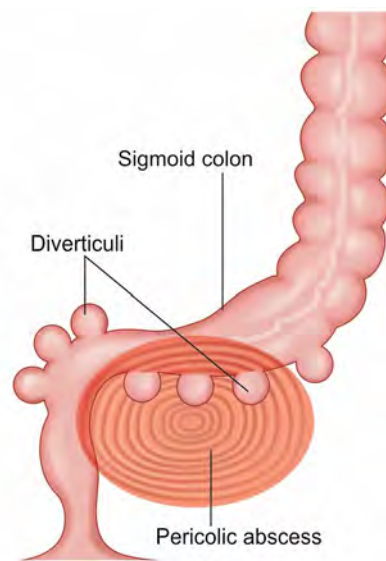
There is hypertrophy and thickening of the muscle layer with progressive colonic narrowing and segmentation with raised intraluminal pressure causing pulsion diverticula of only mucosa adjacent to taenia in antimesenteric region. Pathology is common in sigmoid colon.

## Features of Diverticular Disease

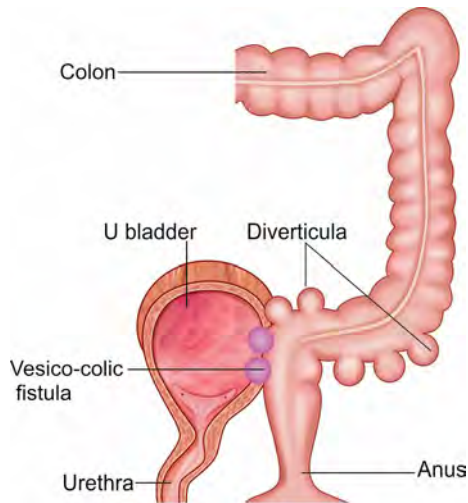
- ◆ In western countries, 50% risk to develop diverticular disease for an individual is at the age of 60 years. Only 15% of patients with diverticulosis develop diverticulitis. 75% of patients with diverticulitis have uncomplicated course with features of only diverticulitis. 25% of patients with diverticulitis develop complications like abscess, stenosis and fistula. Abscess can be commonly pericolic and pelvic, rarely in buttock and ischioanal fossa.
- ◆ *Features of diverticulosis*—fullness of abdomen, bloating, flatulence, vague discomfort.
- ◆ *Features of diverticulitis*—pain in left iliac fossa which is constant radiates to back and groin, tenderness, bloody stool, often massive haemorrhage, fever, rigidity and mass in left iliac fossa. Mass is usually tender, firm, resonant, non-mobile.
- ◆ *Features of fistula*—colovesical is the commonest type of fistula. It causes passage of gas in the urine (*pneumaturia*) commonly and occasionally faeces.

### Complications of diverticulitis

- ❖ Perforation with pericolic abscess or peritonitis
- ❖ Progressive stenosis and intestinal obstruction
- ❖ Profuse colonic haemorrhage (17–20%)
- ❖ Fistula formation (5%)—vesicocolic, vaginocolic, enterocolic, colcutaneous



**Fig. 22.12:** Sigmoid diverticula causing pericolic abscess as a known complication.



**Fig. 22.13:** Diverticular disease causing colovesical fistula. Patient will have urine stained with faecal matter and severe urinary infection. Contrast dye study, CT scan is required. Initial colostomy as diversion is required before definitive procedure.

**Note:**

*Diverticulitis is not a precancerous condition.*

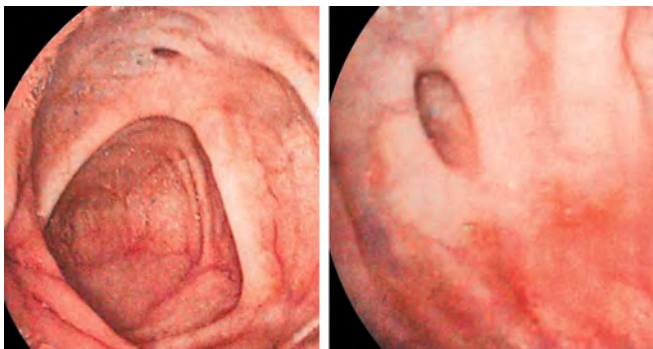
It may coexist with malignancy, irritable bowel syndrome, Crohn's disease.

**Hinchey's classification of diverticulitis**

- ❖ Stage I: Pericolic or mesenteric abscess
- ❖ Stage II: Walled off pelvic abscess
- ❖ Stage III: Generalised purulent peritonitis
- ❖ Stage IV: Generalised faecal peritonitis

**Investigations**

- ◆ *Barium enema (best method to diagnose)* shows 'saw-teeth' appearance. *Champagne glass sign*—partial filling of diverticula by barium with stercolith inside—seen in sigmoid diverticula.
- ◆ *Sigmoidoscopy* is useful but should not be done in acute stage. Once acute stage subsides, barium enema, sigmoidoscopy, colonoscopy can be done (To rule out associated malignancy).
- ◆ *CT scan* in acute phase to see pericolic abscess.



**Fig. 22.14:** Colonoscopic view of sigmoid diverticula.

- ▶ CT scan shows thickening of muscle layer, abscess, perforation, fistula, involvement of organs like urinary bladder and associated pathology. CT scan is the ideal investigation.
- ◆ *Cystoscopy and colonoscopy* in case of fistula. *Ureteric stenting* is needed to make eventual surgery easier.

**Differential diagnosis**

- ❖ Carcinoma sigmoid colon
  - ❖ Amoebic colitis, ulcerative colitis, ischaemic colitis and Crohn's disease
  - ❖ Tuberculosis
- Coexistence of carcinoma and diverticulitis can occur in 12% of cases

**Treatment**

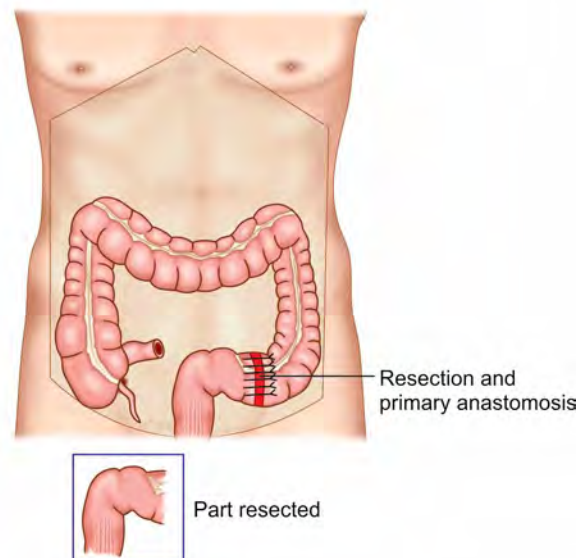
**Medical treatment**

- ❖ High fibre diet
- ❖ Antibiotics
- ❖ Bulk purgatives
- ❖ Avoid constipation
- ❖ Regular follow-up of the progress of disease and onset of complications
- ❖ Abscess can be drained by CT guided aspiration or percutaneous drainage tube

- ◆ In acute stages, conservative treatment like bowel rest, antispasmodics, antibiotics are advised.
- ◆ *Guided aspiration* of the abscess is sufficient if abscess is small. Proper antibiotics are needed.
- ◆ Later, surgery is required. *Resection of sigmoid colon and anastomosis (colorectal)* is done.

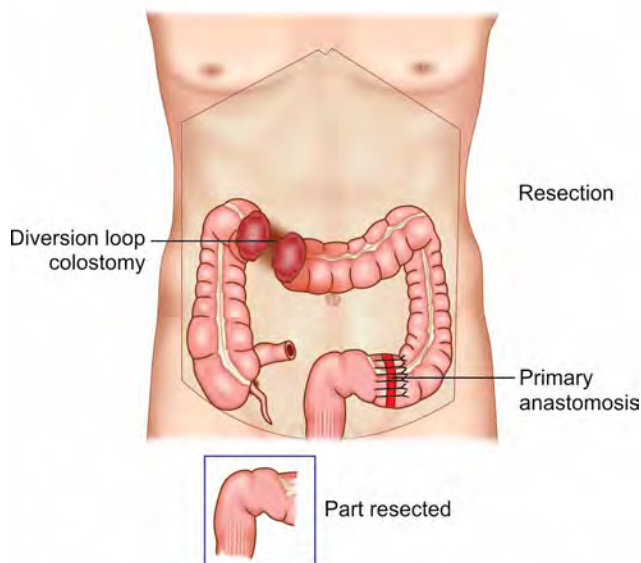
**Indications for surgery**

- ❖ Recurrent diverticulitis
- ❖ Diverticulitis with complications



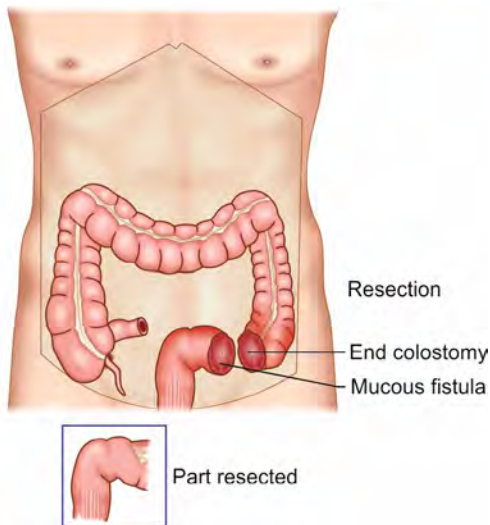
**Fig. 22.15:** Resection and primary anastomosis can be done in sigmoid diverticula after proper bowel preparation electively.

- ◆ If colon is loaded with faecal matter, initially a transverse colostomy is done. Then resection and anastomosis; later colostomy closure is done as a staged procedure.



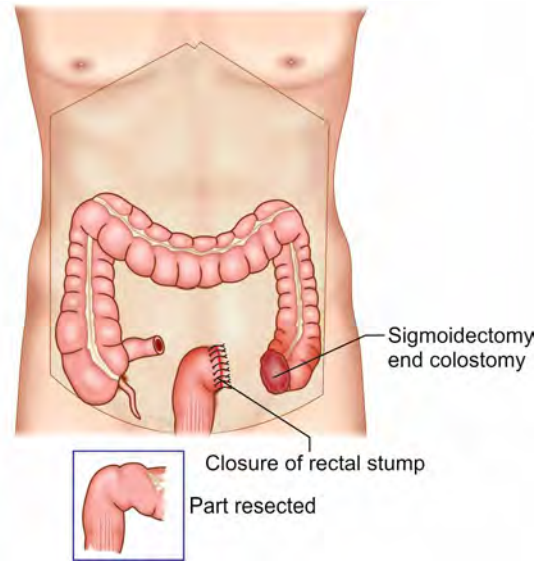
**Fig. 22.16:** Resection of sigmoid colon for sigmoid diverticula with primary anastomosis and defunctioning diversion colostomy.

- ◆ In case of perforation, proximal colostomy and exteriorisation of the affected bowel with later resection and anastomosis is done as it has high mortality.



**Fig. 22.17:** Resection and formation of end colostomy and mucous fistula for acute sigmoid diverticulitis.

- ◆ Occasionally, Hartmann's procedure (combination of sigmoidectomy, end colostomy and closure of rectal stump) is better and life saving.
- ◆ Fistulas are treated by resection of the diseased bowel and closure of the fistula along with diversion procedures like colostomy, cystostomy, ureterostomy.
- ◆ In certain cases of diverticulosis, a longitudinal incision through the taenia and muscular layer without opening the mucosa is sufficient (like Heller's/Ramstedt's myotomy)—*Reilly's sigmoid myotomy*.



**Fig. 22.18:** Hartmann's operation for acute diverticulitis with sepsis/perforation/peritonitis. Here after resection proximal colon is exteriorised as end colostomy. Distal rectal stump is closed.

#### Note:

- It is basically a **benign condition**, therefore the prognosis is good. High fibre diet is advised.
- Complications like *perforations, fistulas are dangerous and life threatening*.
- *Right-sided diverticulum* in the caecum and ascending colon is usually *solitary and congenital*.

#### Myotomy

- ❖ Heller's myotomy—achalasia cardia
- ❖ Ramstedt's myotomy—congenital pyloric stenosis
- ❖ Reilly's myotomy—diverticulosis

#### ULCERATIVE COLITIS

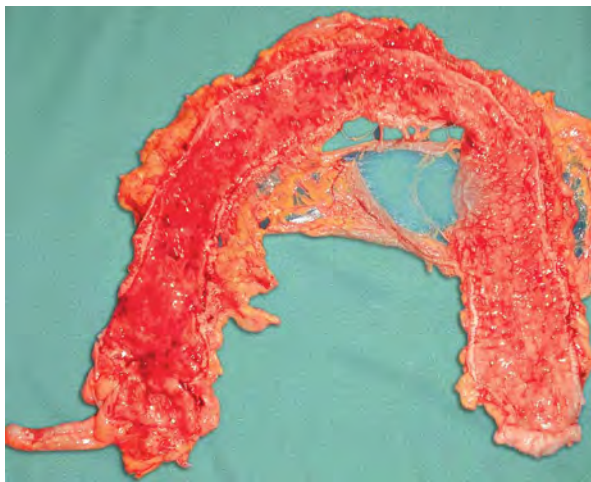
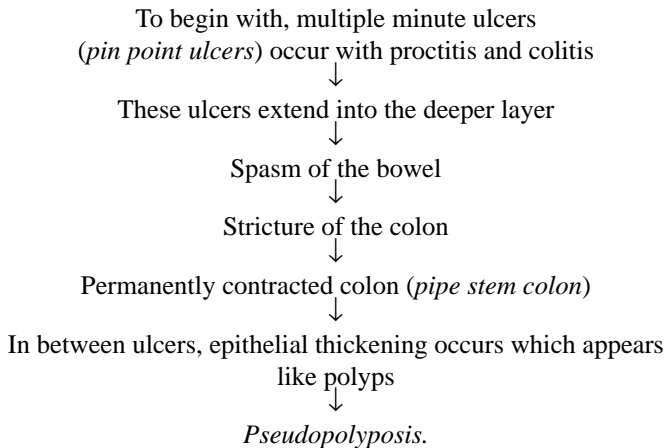
- ◆ It is an inflammatory condition of rectum and colon of unknown aetiology perhaps related to stress, westernized diet, autoimmune factor, familial tendency, allergic factor.
- ◆ Disease commonly starts in the *rectum*, spreads proximally to the colon and often into the ileum as **back wash ileitis** (5%).

#### Aetiological Factors

- ◆ Westernized diet, red meat; less common in vegetarians.
- ◆ Defective mucin production in the colonic mucosa and mucosal immunological reaction.
- ◆ Autoimmune factors—cytotoxic T lymphocytes against colonic epithelial cells and presence of anticolon antibodies. Association with HLA DR2 is observed in ulcerative colitis. DR 1501 is associated with less severe type' DR 1502 is associated with more severe form.
- ◆ Appendicectomy and smoking protects ulcerative colitis especially from extraintestinal features and from postoperative complications.
- ◆ Familial in nature.

- ◆ Allergy to milk (cow milk) and other dietary factors.
- ◆ Excess reactive oxidative metabolism in ulcerative colitis.
- ◆ Psychological aspects, stress, lifestyle, personality disorders.

## Pathology



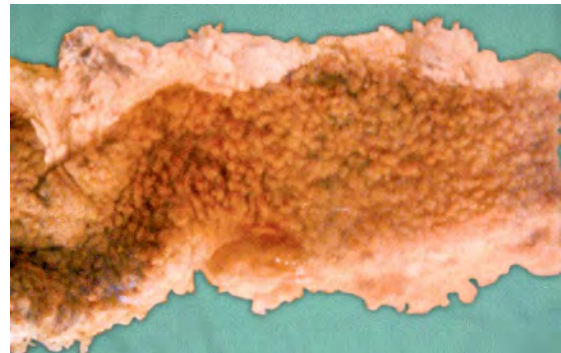
**Fig. 22.19:** Operated specimen showing colon with features of ulcerative colitis.

- ◆ It is a disease confined to mucosa and submucosa.
- ◆ There is no bowel wall thickening and no granuloma formation.
- ◆ There are no skip lesions. Rectum is always involved. Distal bowel is involved to begin with, then spreads proximally. Distal involvement is more severe. Entire colon including caecum and appendix may be involved.
- ◆ Only rectum involvement, as proctitis occurs in 25% cases. Such patients will have 5% risk of developing rectal cancer. In 15% cases, it is left sided ulcerative colitis presenting with severe recurrent diarrhoea. In 25% patients, total proctocolitis is the presentation. Bloody diarrhoea, malnutrition, complications like *toxic megacolon*, perforation (steroid may mask the features) and carcinoma are common here.
- ◆ Pseudopolyps are of inflammatory in nature. Absence of normal mucosa between these pseudopolyps is important to differentiate it from neoplastic polyps.
- ◆ Intense inflammation in the *mucosa and submucosa* with typical feature like:

- ▶ *Multiple crypt abscesses*
- ▶ *Sparing of the deeper layers* of the colonic wall
- ▶ *Inflammatory pseudopolyps*
- ▶ *Multiple pinpoint ulcers*
- ▶ Increase in *substance p containing nerve fibres*
- ▶ *Lymphoid hyperplasia* in mucosa and submucosa (25%)
- ▶ Presence of *anti neutrophil cytoplasmic antibodies* with a perinuclear staining pattern (86%)
- ▶ Decreased goblet cell mucin
- ◆ Only in **toxic megacolon** (1.5–2.5%) there is acute inflammation extending to entire thickness of the colonic wall including the serosa. It is not the colon that is toxic but it is the patient who is toxic, hence the name. It is precipitated by non specific causes, during barium enema study, due to drugs like opiates, antidiarrhoeal drugs and anticholinergics. Toxic megacolon commonly affects the *transverse colon* which will be more than 6 cm in diameter. Left colon or entire colon also may be involved. Caecum when rarely involved; becomes more than 10 cm in diameter. Colon will be like *wet blotting paper*. It is prone for perforation, peritonitis which carries high mortality (25-50%). C-reactive protein will be increased. It needs emergency laparotomy with total colectomy/proctocolectomy with ileostomy. Occasionally toxic megacolon can occur in pseudomembranous colitis, amoebic colitis or typhoid colitis.
- ◆ **Carcinoma in ulcerative colitis** is more prevalent than in Crohn's disease.

### Factors involved are:

- ▶ *Extent* of involvement (more in total colonic).
- ▶ *Duration* of the disease; *continuous active disease* than intermittent disease.
- ▶ Incidence is 5% when duration is 15 years; 25% in 25 years; 35% in 30 years; 45% in 35 years; 65% in 40 years.
- ▶ Incidence of developing cancer in left sided colitis is 10 years later than universal ulcerative colitis.
- ▶ Incidence of carcinoma developing in ulcerative colitis is *equal* in both sexes.
- ▶ Carcinoma in ulcerative colitis is commonly *aggressive and poorly differentiated, multicentric, synchronous, infiltrative and scirrhous*; half the patients will have colloid carcinoma (signet ring), more advanced at the time of presentation, *dysplasia* developing into cancer is common.
- ▶ Ulcerative colitis with primary sclerosing cholangitis has still increased risk of developing cancer.
- ▶ In ulcerative colitis, dysplasia is very important factor to transform into carcinoma. It may be mild, moderate or marked. It is often called as *dysplasia associated lesion or mass* (DALM).



**Fig. 22.20:** Multiple pseudopolyposis involving entire colon in ulcerative colitis. Disease involves only mucosa and submucosa.

## Clinical Features

Disease usually begins in rectum as **proctitis** later becomes **left sided colitis** and eventually causes severe **total proctocolitis**.

- ◆ More common in females (2:1), begins in 3rd decade.
- ◆ Watery diarrhoea, mucus or blood stained discharge per rectum.
- ◆ Colicky pain, spasms.
- ◆ Decreased appetite and loss of weight.
- ◆ Relapses and remissions at regular intervals.

Clinical grading of ulcerative colitis			
	Mild	Moderate	Severe
Stool frequency	<4	4–6	>6
Pulse	< 90	90–100	>100
Haematocrit	Normal	30–40	<30
Weight loss in %	None	1–10%	>10%
Temperature	Normal	99–100	>100
ESR	<20	20–30	>30
Albumin	Normal	3–3.5	<3.0

Two types of presentations:

a. **Fulminant type**, 5% common:

- ▶ It is a severe form, with continuous diarrhoea with passage of blood, mucus and pus.
- ▶ Patient is ill and dehydrated.
- ▶ Mimics fulminant amoebic colitis; severe typhoid and dysentery.
- ▶ Fever, hypokalaemia, acidosis, dehydration and shock.
- ▶ Abdominal distension occurs.
- ▶ *Acute toxic dilatation* (1.5%) of *transverse colon* may occur where the diameter of transverse colon >6 cm. It has high mortality and requires *emergency surgery*, i.e. either colostomy or resection with ileostomy and later ileo-anal anastomosis. Here colon is like *wet blotting paper*.

b. **Chronic type** (95%):

- ▶ Lasts for months to years with diarrhoea, blood loss, anaemia, invalidism, abdominal discomfort and pain.
- ▶ Severe malnutrition and hypoproteinaemia.

**Note:**

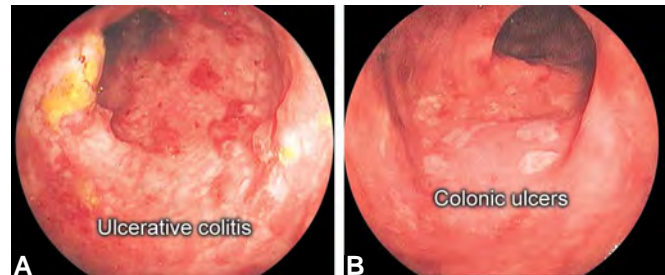
- Prevalence is 40–100/1,00,000.
- It is common before 30 years.
- Smoking increases Crohn's but protects ulcerative colitis.
- Incidence of colonic stricture is 10% in ulcerative colitis and is due to muscular hypertrophy. Strictures are usually benign. But 60% stricture appear after 20 years; 80% of stricture occur proximal to splenic flexure; stricture causing obstruction are likely to be malignant.
- *Perinuclear staining antinuclear cytoplasmic antibodies (pANCA)* are seen in 85% of patients with ulcerative colitis and is diagnostic test to differentiate from Crohn's.
- Arthritis (20%), ankylosing spondylitis (5%), erythema nodosum (15%), pyoderma gangrenosum are extraintestinal features which resolve after total colectomy.
- Primary sclerosing cholangitis (PSC, 5%) is common in ulcerative colitis before 40 years of age; common in males; related to HLA B<sub>8</sub> and HLA DR<sub>3</sub> (10 times). Malignant transformation in colon is

5 times more in these patients compared with ulcerative colitis without PSC. It causes pain abdomen, obstructive jaundice, later liver cirrhosis and failure. Total colectomy *will not resolve* PSC.

- *Surveillance colonoscopy* to identify transformation to carcinoma in ulcerative colitis is done as follows – Every year from 8 years after the onset of pancolitis and 15 years after the onset of left sided colitis. 10–30 random biopsies should be done. No dysplasia (less chance of carcinoma)/low grade dysplasia (10% chance)/high grade dysplasia (40% chance)/DALM (50% chance). All dysplasia types need proctocolectomy. Flow cytometry of biopsy specimens to study DNA aneuploidy or polyploidy is needed for further confirmation. 30% of high grade dysplasias show invasive carcinomas.
- Sacroiliitis and ankylosing spondylitis are 20 times more common in patients with ulcerative colitis and is associated with HLA B27.

## Investigations

- ◆ *Barium enema*—shows loss of haustrations, narrow contracted colon (*hose pipe colon*), mucosal changes, pseudo-polyps. *It is avoided in fulminant cases*.
- ◆ *Sigmoidoscopy and biopsy*.
- ◆ *Colonoscopy* is also required. *Due to very high incidence of malignant transformation in ulcerative colitis (10–20%), multiple biopsies should be taken from suspected areas of the colon*. Risk increases with age of the patient and duration of the disease (20%).



**Figs 22.21A and B:** Colonoscopic view of ulcerative colitis and multiple ulcers.

### Sigmoidoscopic grading of ulcerative colitis

- 0—Normal mucosa
- 1—Loss of vascular pattern
- 2—Granular, non-friable mucosa
- 3—Friability on rubbing
- 4—Spontaneous bleeding, ulcerations

- ◆ Plain X-ray abdomen is useful in obstruction, toxic megacolon, perforation.
- ◆ C-reactive protein will be very high in acute phase.

### Differential diagnosis

- ❖ Crohn's disease
- ❖ Ischaemic colitis
- ❖ Irritable bowel syndrome
- ❖ Amoebic colitis
- ❖ Bacillary dysentery
- ❖ Carcinoma colon
- ❖ Collageous colitis in females
- ❖ Infectious colitis by *Clostridium difficile*, *Campylobacter jejuni*

*Hard work doesn't guarantee success, but improves its chances.*



## Differences between Crohn's disease and ulcerative colitis

Crohn's disease	Ulcerative colitis
• It affects ileum and often colon but can involve any part of GIT—rectal sparing is common	• It affects rectum and colon from distal to proximal
• Full thickness—transmural disease	• It affects mucosa and submucosa—not deeper
• Skip lesions are typical	• Skip lesions are not observed
• Granulomatous lesion on histology—deep ulcers; pseudopolyps are not found	• Not a granulomatous lesion—superficial ulcers, pseudopolyps are present
• Stricture and fistula are common	• Narrowing can occur but not very common
• Anal fissure and perianal abscess are more common	• Fissure and perianal disease can occur but not as common as in Crohn's disease
• May mimic appendicitis	• Will not mimic appendicitis
• Bleeding is not common	• Bleeding is common
• Fever is common	• Fever is uncommon
• Mass in RIF is common	• Mass is not a common feature
• Anal pathology very common	• Anal pathology is rare
• Discontinuous segmental asymmetrical colitis	• Continuous mucosal disease—colitis
• Toxic megacolon is rare	• Toxic megacolon is common
• Normal vascular pattern	• Distorted vascular pattern
• Fistula is very common	• Fistula is uncommon
• Recurrence is common after resection	• Total proctocolectomy cures the disease

## Complications

## GIT

- ❖ Pseudopolyposis
- ❖ Turning into malignancy
- ❖ Stricture formation, commonly in recto sigmoid and anal canal—10%
- ❖ Toxic megacolon in transverse colon
- ❖ Massive haemorrhage—1%
- ❖ Fistula in ano—20%
- ❖ Perforation—10-20%

## Extraintestinal

- ❖ Severe malnutrition
- ❖ Liver cirrhosis (50%)
- ❖ Skin lesions—pyoderma, erythema nodosum
- ❖ Arthritis, iritis, ankylosing spondylitis—common
- ❖ Sclerosing cholangitis, carcinoma of bile duct

## Treatment

## General

- ❖ Correction of anaemia
- ❖ Fluid and electrolyte supplementation
- ❖ Nutrition (high protein, carbohydrate, vitamin, but low fat diet), TPN
- ❖ Sedatives and tranquillisers
- ❖ Psychological counselling

## Drugs

In active disease, drugs are used to *induce remission*. Later drugs also should be given for *maintenance* of remission and to prevent relapses.

- ❖ *Salazopyrine/sulfasalazine* splits into 5 amino-salicylic acid and sulphapyridine in colon. It is used as *first line therapy*. Its dose is 2–4 gm/day. It is mainly used to induce remission. It suppresses PG E1 and PG E2 to reduce the inflammation, inhibits proteolytic enzymes and also causes immunosuppression. 5 ASA is the most active ingredient. Side effects are skin rashes, bone marrow suppression, folic acid deficiency, haemolysis in glucose 6 phosphate dehydrogenase deficiency patients, temporary fertility problems in men.
- ❖ *5 ASA (Mesalamine)* is also used in active disease as *first line therapy*. It is used with an azo bond to prevent its absorption in small bowel. Its induction of remission is same as sulfasalazine. Idiosyncrasy and temporary infertility is not present in mesalamine. Its *oral* dose is 2–4 gm/day. It is also used as *retention enema* which is better than steroid enema in left sided ulcerative colitis/proctitis. But mesalamine enema (4 gm in 100 ml saline) is costly. Enema is combined with oral mesalamine or oral steroid in acute cases. Mesalamine 500 mg *suppository* is also used in BID doses. Daily oral (1.6 gm) and topical 4 gm enema, twice weekly is often used for maintenance therapy. Headache, dyspepsia and myocarditis are the complications.
- ❖ *Steroids* are used in cases where salazopyrine fail to induce remission. It is a drug for *refractory cases*. Oral prednisolone 60 mg/day tapering in 4 weeks is the dose. Intravenous hydrocortisone 100 mg 8th hourly is used in acute cases. 100 mg hydrocortisone enema/40 mg methylprednisolone enema (steroid retention enema) are used for 2 weeks in acute active diseases. Most patients with moderate to severe disease need steroid therapy. *Budesonide* is a newer steroid hydrocortisone analogue is also equally effective with lesser side effects and less adrenal suppression.
- ❖ *Immunomodulators* are used often to induce remission and for maintenance. *Azathioprine* and *6-mercaptopurine* are used. They act at DNA level (purine ribonucleotide) and inhibit lymphocyte function (of T cells). But this action is slow.
- ❖ *Cyclosporin* is used in refractory, fulminant severe ulcerative colitis as a reserve drug. Dose is 4 mg/kg/day IV.
- ❖ *Mebeverine HCl* and *Tegaserod* (6 mg) are the other drugs used in ulcerative colitis. Other measures are using sucralfate, short chain fatty acids, probiotics, antidiarrhoeal drugs (diphenoxylate, loperamide, codeine), avoiding milk products, fibre, fruits.
- ❖ Antitumour necrosis factor alpha—*Infliximab* is also used selectively (in some studies). It is given intravenously at interval of 6 weeks. It shows 70% remission in ulcerative colitis.
- ❖ Newer drugs with a targeted delivery into the colon is used nowadays, e.g. Olsalazine (azobond); Balsalazine (4 aminobenzoyl carrier).

## Management of severe ulcerative colitis

- ❖ It is more than 6 stools per day, with cramping pain, toxicity, fever, raised ESR, anaemia, tachycardia, more than 10% weight loss, hypoalbuminaemia less than 3.5 gm%
- ❖ It always needs hospitalisation
- ❖ IV corticosteroids [hydrocortisone] 300 mg/day/oral prednisolone/5 ASA orally or as enema
- ❖ IV cyclosporine with azathioprine or 6 mercaptopurine
- ❖ Fluid and electrolyte management
- ❖ TPN/enteral nutrition
- ❖ Proper monitoring of the patient for complications
- ❖ Surgery

## Indications for Surgery—30% Cases

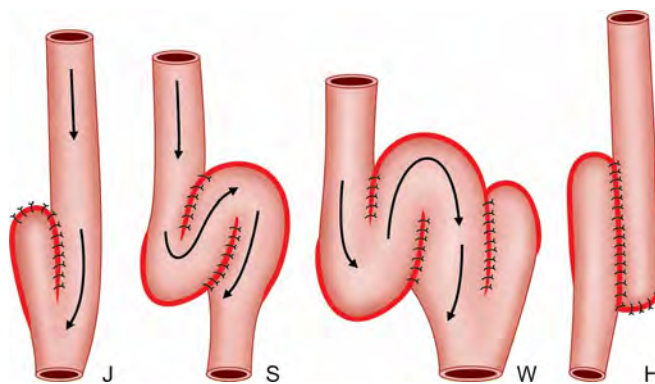
- ❖ Intractability—commonest indication
- ❖ Toxic dilatation
- ❖ Perforation
- ❖ Haemorrhage
- ❖ Risk of malignant transformation, dysplasia (DALM)
- ❖ Onset at early age
- ❖ Chronic invalidism
- ❖ Progressive disease with stricture, abscess, fistulae
- ❖ Steroid dependency, persistent active disease
- ❖ Malignancy
- ❖ Severe extraintestinal manifestations
- ❖ Growth retardation in children

### Toxic megacolon

- ❖ 1.5% incidence
- ❖ Common in transverse colon
- ❖ Colon is more than 6 cm in diameter
- ❖ Colon is like wet blotting paper
- ❖ Commonly seen in ulcerative colitis
- ❖ Can occur in bacterial colitis, pseudomembranous colitis, fulminant amoebic colitis
- ❖ May be precipitated by antidiarrhoeal drugs
- ❖ IV fluids, blood transfusion, antibiotics, steroids are also needed
- ❖ Can be life threatening
- ❖ Plain X-ray is very useful
- ❖ Emergency surgery, colectomy, colostomy/ileostomy may be required
- ❖ In olden days *blow hole procedure* was advocated for toxic megacolon, may be still useful in severe cases. Skin level transverse colostomy, sigmoid colostomy and a loop ileostomy is done to decompress entire small and large bowel. After many months (6–8 months) once patient recovers from acute illness, total proctocolectomy with ileal pouch anal anastomosis is done

## Surgeries

- ◆ *Total proctocolectomy with ileo-anal anastomosis with pouches as reservoir* (“J”, “S”, or “W” pouches). It is called as *restorative proctocolectomy with ileal pouch anal anastomosis (IPAA)*. It is *ideal curative procedure* for ulcerative colitis. Anal sphincter complex is preserved. 30 cm ileal pouch is created either hand sewn or with stapler. Created ileal pouch reservoir is anastomosed just above the anal canal using end to end stapler. Diameter of the pouch should be twice the diameter of the ileum. Obstruction (25%), diarrhoea, *pouchitis* (25%), leak, sepsis, incontinence are the complications.
- ◆ Total proctocolectomy with ileostomy (permanent, continent Kock’s ileostomy, with one way valve is done). It is used at present only *in revision surgery* when needed after restorative proctocolectomy.
- ◆ *Total proctocolectomy with end non continent ileostomy* was the earliest operation done for ulcerative colitis. It is now *reserved only* for ulcerative colitis complicated with carcinoma of rectum. *Ileostomy site* should be marked in standing and sitting position. Stoma should be within the right rectus abdominis muscle at the summit of infraumbilical fat, away from midline incision, bony prominences and umbilicus.



**Fig. 22.22:** Different pouches are used after restorative proctocolectomy and during ileoanal anastomosis. Pouch acts as reservoir and reduces the frequency of stool. It avoids ileostomy with natural stool passage with continence. Pouchitis can occur with diarrhoea, blood in stool, perianal pain. Occasionally, redoing or conversion may be required. J type is commonly used.

- ◆ *Total colectomy* with ileorectal anastomosis. Proper follow-up at regular intervals by regular sigmoidoscopy evaluation should be done as rectum is also diseased and vulnerable for complications. It is *not commonly* practiced now.
- ◆ Total colectomy with rectal mucosectomy and anastomosis above the dentate line on posterior aspect is also occasionally used.

### Ileostomy

It is usually end ileostomy. But often loop ileostomy is also done

#### Indications:

- ❖ After total proctocolectomy for ulcerative colitis, total colonic Hirschsprung’s diseases, Crohn’s disease (occasionally), and total colectomy for carcinomas
- ❖ Loop ileostomy is done in critically ill patient with acute ileal conditions like multiple ileal perforations, ileal gangrene or distal fistulas or sepsis. It is temporary ileostomy
- ❖ Ileostomy is *placed in right iliac fossa* through the right rectus muscle.
- ❖ Ileostomy may be temporary (loop) or permanent (end)
- ❖ Brooke’s classic end non continent ileostomy or Kock’s continent ileostomy (with continent intra-abdominal pouch) are used
- ❖ Ileum should project as a spout at least 4 cm above the skin surface, which facilitates the effluent to pass directly into the bag
- ❖ Ileostomy usually acts in 48 hours
- ❖ Ileostomy bag, ileostomy care, nutrition and electrolyte management are important
- ❖ **Complications** like prolapse, stenosis, haemorrhage, retraction can occur

## Complications of Surgery for Ulcerative Colitis

- ◆ *Pouchitis* (20%) with pain, diarrhoea, fever, bleeding, toxicity, pouch—vaginal fistula, fecal incontinence (5%). Pouchitis disease activity scoring index is at present used which is based on clinical, endoscopic and histological inflammatory features.
- ◆ *Stenosis, pelvic abscess formation.*
- ◆ *Leak, fistula formation.*
- ◆ *Problems with ileostomy*—psychological trauma, skin excoriation, retraction, stenosis (25%), prolapse, bleeding, enteritis, ileal

*God gives every bird its food, but he does not throw it into the nest.*

necrosis, ileal volvulus, paraileostomy hernia, paraileostomy abscess.

- ◆ *Sexual dysfunction* following proctocolectomy by nerve injury.
- ◆ *Persistent perineal sinus* after total proctocolectomy.
- ◆ Risk of cancer persists if only total colectomy is done.

## ■ ISCHAEMIC COLITIS

It occurs in **splenic flexure** where blood supply is precarious. Splenic flexure is the *water shed* area of colon, receiving blood supply from terminal branches of superior and inferior mesenteric arteries.

- ◆ Ischaemic colitis is common in females; common in aged.
- ◆ It is related to atherosclerosis, emboli, vasculitis, diabetes, chronic renal failure, autoimmune diseases, polycythaemia, haemodialysis, etc.
- ◆ *Water shed point*—Griffith's point in artery of Riolan gets poor perfusion by arterial disease/low perfusion pressure/altered viscosity causing ischaemic colitis.

### Types (Marston's Classification)

1. Gangrenous type—*ischaemia of full thickness* colon causing peritonitis.
2. Stricture type—*ischaemia of muscularis* layer causing scarring.
3. Transient type—most vulnerable layer, *mucosal* involvement usually recovers completely.

### Clinical Features

- ◆ Pain in left iliac fossa and left hypochondrium.
- ◆ Vomiting, diarrhoea.
- ◆ Passing blood in the stool.

#### Differential diagnosis

- ❖ Carcinoma colon
- ❖ Ulcerative colitis
- ❖ Crohn's disease
- ❖ Tuberculosis

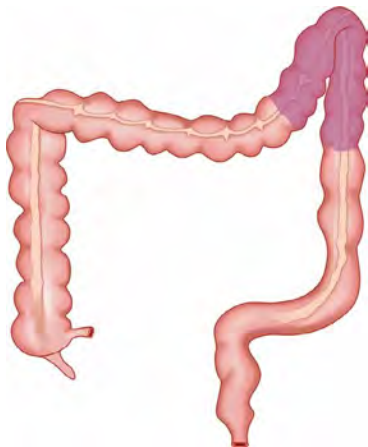


Fig. 22.23: Ischaemic colitis in splenic flexure.

### Investigation

- ◆ *Plain X-ray* reveals '*thumb printing sign*' due to mucosal oedema and submucosal haemorrhage. Perforation is also diagnosed.

- ◆ *CT scan* shows colonic wall thickening with posterior fat shadowing. Angiography is not helpful.
- ◆ *In acute stage*, barium enema or contrast study or sigmoidoscopy or colonoscopy is avoided due to risk of perforation.
- ◆ *In chronic stage*, colonoscopy and contrast study is a must.

### Treatment

- ◆ 80% of patients will recover from conservative treatment—bowel rest, fluids, antibiotics, adequate perfusion.
- ◆ Surgery is indicated in gangrene and peritonitis, stricture (15%), segmental ischaemia (20%).
- ◆ Laparotomy, resection and anastomosis (splenic flexure) is done.
- ◆ In acute phase with peritonitis (covering), diversion colostomy is needed.

#### Colonic ischaemia

- ❖ Colon is the *commonest* site of intestinal ischaemia
- ❖ Most of colonic ischaemia results from *small vessel occlusion* or low flow ischaemia.
- ❖ Vascular diseases, vasculitis, diabetes, hypotension, aortic surgery with ligation of inferior mesenteric artery, aortic atherosclerosis blocking opening of IMA, OCP intake, cocaine abuse, coagulopathies, CMV, *E. coli* infections, long distance running—are the causes
- ❖ *Splenic flexure* is the most common site; but any segment like sigmoid colon can be involved
- ❖ Rectum is *spared* due to rich collaterals

## ■ PSEUDOMEMBRANOUS COLITIS

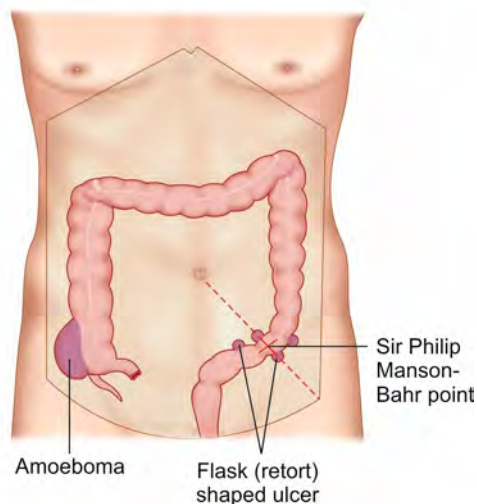
- ◆ It is an acute diarrhoea due to toxins produced by the overgrowth of *Clostridium difficile* after antibiotic therapy (usually after clindamycin).
- ◆ *Clostridium difficile* is a Gram positive, anaerobic, spore forming bacillus. It produces toxin A (enterotoxin) and toxin B (cytotoxin, more potent).
- ◆ It is also often seen in immunocompromised patients and patients who are on cancer chemotherapy.
- ◆ Incidence is 2%. Mortality is 30%.
- ◆ Stool cytotoxin assay is highly sensitive and specific. ELISA test for toxins is also useful.
- ◆ Colonoscopy is ideal as right side involvement is more common.
- ◆ It can occur up to 6 weeks after stopping the drug.
- ◆ Diarrhoea, toxæmia, perforation, haemorrhage also can occur.
- ◆ *Treatment*
  - ▶ IV vancomycin 500 mg 8th hourly.
  - ▶ IV metronidazole 8th hourly.

## ■ SURGICAL COMPLICATIONS OF INTESTINAL AMOEBIASIS

Trophozoites of *Entamoeba histolytica* by digesting mucosa, submucosa of *rectosigmoid* (75%) region commonly or *ileocaecal* region of the colon, causes *retort shaped amoebic ulcers* which exudes blood, pus and necrotic material.

- ◆ Cyst is the infective agent. It enters through faeco oral route. It forms trophozoite which multiplies and causes inflammation and *flask shaped ulcers* in the rectosigmoid, caecal and often in the terminal ileal region.
- ◆ It causes blood with mucus diarrhoea, toxæmia, secondary bacterial infection, fulminant colitis, perforation and peritonitis, rarely toxic megacolon, extraintestinal amoebiasis.

- ◆ Amoebic liver abscess is the *commonest form* of extra-intestinal amoebiasis. Others are cutaneous amoebiasis, amoebic empyema, and very rarely amoebic brain abscess, amoebic pericarditis.
- ◆ *Chronic amoebiasis* causes vague abdominal pain, decreased appetite, intestinal colic and psychological trauma to the patient.



**Fig. 22.24:** Amoebic ulcer is common in left side (sigmoid colon). Amoeboma can occur in caecal region where it forms granuloma in pericolic area presenting as mass abdomen. Amoebic ulcers are classically flask/retort shaped.

## Presentations

1. *Amoebic dysentery* with diarrhoea, colicky pain, tenderness in left iliac fossa (in “*Sir Philip Manson-Bahr amoebic point*”).
2. *Amoebic typhlitis* (inflammation of caecum) presentation with pain and tenderness in right iliac fossa and often also as a *mass in the right iliac fossa mimicking carcinoma caecum* called as **amoeboma** (amoebic granuloma) (1.5%).

### Differential diagnosis for amoeboma

- ❖ Appendicular mass
- ❖ Ileocaecal tuberculosis
- ❖ Carcinoma colon
- ❖ Retroperitoneal tumour
- ❖ Lymph node mass

3. *Acute fulminant amoebic colitis* is a severe type with sloughing of colonic and rectal mucosa causing torrential bleeding, toxicity which can be life-threatening.

### Investigations for intestinal amoebiasis

- ❖ Saline wet mount of fresh stool—trophozoites in 90% cases
- ❖ Serology—indirect haemagglutination test
- ❖ PCR
- ❖ P/R and proctoscopy

### Complications of amoebic colitis

- ❖ *Amoeboma*—right side common
- ❖ Perforation in rectosigmoid/caecal region bleeding, peritonitis
- ❖ Stricture rectum and colon
- ❖ Intestinal obstruction
- ❖ Pericolic, paracolic, ischioirectal abscess and fistula formation
- ❖ Amoebic typhlitis, amoebic liver abscess

## Treatment

- ◆ In acute cases, hospitalization and proper rehydration is done.
- ◆ Antispasmodics to alleviate pain is given.
- ◆ Metronidazole IV or metronidazole retention enema is given. It is very effective in both intestinal and extraintestinal amoebiasis.
- ◆ In less severe disease, tab metronidazole (400–800 mg) 3 times daily is given for 10 days or tab tinidazole 2 gm daily for 3 days.
- ◆ Diloxanide furoate is very effective in chronic amoebiasis and cyst passers. Dose is 500 mg, 3 times daily for 10 days.
- ◆ Other drugs used are—paromomycin, iodoquinol.

## TUMOURS OF COLON

### BENIGN TUMOURS/POLYP OF THE COLON

- ◆ *Polyp* is a tumour/swelling arising from mucosal surface with a pedicle/stalk. ‘*Poly*’ means many; ‘*pous*’ means foot in Greek.
- ◆ *Polyp* is a mass projecting into the bowel lumen beyond the surface epithelium.

### Classification

#### Inflammatory

- ◆ Ulcerative colitis.
- ◆ Segmental colitis.
- ◆ Crohn’s disease.
- ◆ Diverticulitis.
- ◆ Dysenteric colitis.

#### Hyperplastic (Metaplastic)

- ◆ Also called as metaplastic mucosal polyps.

#### Hamartomatous

- ◆ Peutz-Jegher’s syndrome.
- ◆ Juvenile polyp.
- ◆ Cronkhite—Canada syndrome.

#### Neoplastic

- ◆ Tubular—pedunculated.
- ◆ Villous—sessile.
- ◆ Tubulo—villous.
- ◆ FAP—familial adenomatous polyposis.

Polyps			
Inflammatory	Hyperplastic	Hamartomatous	Neoplastic
Ulcerative colitis	(Metaplastic)	Peutz-Jegher syndrome	Adenomatous
Segmental colitis		Juvenile polyp	– Tubular
Dysenteric colitis		Cronkhite-Canada syndrome	– Tubulovillous
Crohn's disease			– Villous
Diverticulitis			Malignant (carcinomatous)

### Others

- ◆ Lipoma, haemangioma, leiomyoma.

### JUVENILE POLYPS

- ◆ *Commonest* polyp of colorectum in *infants and children*.
- ◆ Can cause intussusception, prolapse through rectum, bleeding.
- ◆ Colonoscopic polypectomy is done.
- ◆ Not a premalignant condition.

### METAPLASTIC/HYPERPLASTIC POLYP

- ◆ Metaplastic—indicates a difference in appearance from normal mucosa.
- ◆ Very minute in size—1–2 mm. Multiple.
- ◆ Common in rectum. Also occurs in other parts of colon. It is most common colonic polyp.
- ◆ Contains columnar epithelium, cystic dilatation, goblet cells, and lymphocytes.
- ◆ Not a pre-malignant entity.

### PEUTZ-JEGHERS POLYP

- ◆ It is common in *small intestine* (jejunum) but can also occur in large intestine.
- ◆ **Features** are multiple, familial, hamartomatous intestinal polyps.
- ◆ Associated with *melanosis* of the oral mucosa, lips (lower lip) and occasionally digits (*not in tongue*).
- ◆ Microscopically it contains tree like branching filaments of mucosa with smooth muscle wall.
- ◆ It can occasionally turn into malignancy.
- ◆ It is autosomal dominant disease with germline defect in suppressor serine threonine kinase 11 (STK11).

### Complications

Bleeding or intussusception, when occurs requires surgery either resection—*anastomosis* or colonoscopic removal.

### ADENOMA OF COLON

- ◆ It can be *tubular*, *villous*, *tubulovillous* (histologically). Tubular is the commonest—70%. 25% tubulovillous; 5% villous.

- ◆ It also can be *solitary or multiple*, sessile or pedunculated.
- ◆ Tubular is commonly 1–2 mm sized and sessile is 3–4 mm sized.

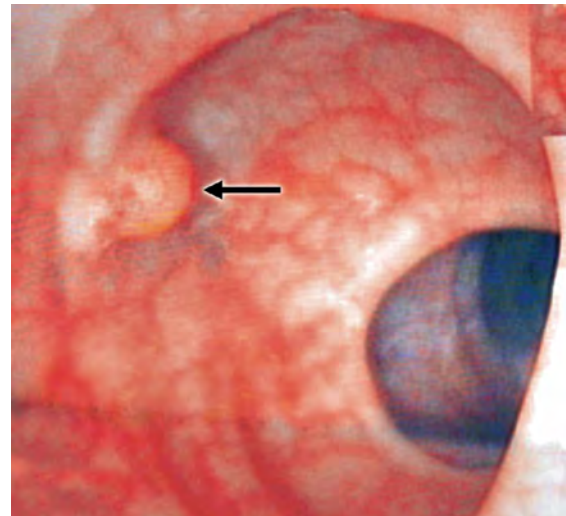


Fig. 22.25: Colonoscopic view of colonic polyp.

- ◆ **It has malignant potential.**

Potentiality increase with:

- ▶ *Size, is an important factor* in causing carcinoma. If size of adenoma is >2 cm—30–50% chances of developing carcinoma; 1–2 cm —10% chances of carcinoma; <1 cm —1–5% chances of carcinoma.
- ▶ Sessile nature.
- ▶ Villous architecture.
- ▶ Dysplasia.

#### Grading of adenoma

- ❖ I: Minimal hyperplasia, no cellular atypia
- ❖ II: Mild hyperplasia, cellular atypia
- ❖ III: Moderate hyperplasia, cellular atypia
- ❖ IV: Severe hyperplasia, cellular atypia
- ❖ V: Carcinoma *in situ*

### Features of Adenoma

- ◆ Can be asymptomatic.
- ◆ Bleeding per anum is usually chronic but rarely can be acute.
- ◆ Anaemia
- ◆ Prolapse—common in tubular type.
- ◆ Diarrhoea common in villous type; mucus discharge.

- ◆ Tenesmus, colicky abdominal pain.
- ◆ Spurious diarrhoea.
- ◆ Poor general health.
- ◆ Electrolyte imbalance—*hypokalaemia*.
- ◆ Per-rectal examination should be done to feel the adenoma/polyp.
- ◆ Carcinomatous changes.

### Investigations

- ◆ Serum electrolytes.
- ◆ *Barium enema* study—shows filling defect—usually multiple.
- ◆ *Colonoscopy—biopsy is a must.*
  - ▶ Size should be noted.
  - ▶ Texture—harder tumour more likely to be malignant.
  - ▶ Colour of the lesion—pale is benign, pink, red and active—could be carcinoma.
  - ▶ Ulceration on the surface if it has turned into malignancy.

### Treatment

- ◆ Colonoscopic polypectomy using snare. Any adenoma more than 5 mm in size should be removed colonoscopically.
- ◆ Diathermy excision/coagulation with sigmoidoscope.
- ◆ Per-anal polypectomy.
- ◆ Per-anal excision with clear margin of the rectal sessile adenoma.
- ◆ Open-abdominal colotomy and polypectomy in case of huge adenoma.
- ◆ Segmental resection of the colon if polyps/adenomas are limited to one segment of the colon confirmed by colonoscopy.
- ◆ Total colectomy/proctocolectomy if multiple polyps present all over colorectum and if associated with FAP.
- ◆ Blood transfusions, correction of electrolytes, protein supplements.

#### Problems in therapeutic colonoscopy

- ❖ Perforation due to necrosis
- ❖ Haemorrhage—secondary
- ❖ Intracolonic explosions
- ❖ Sepsis

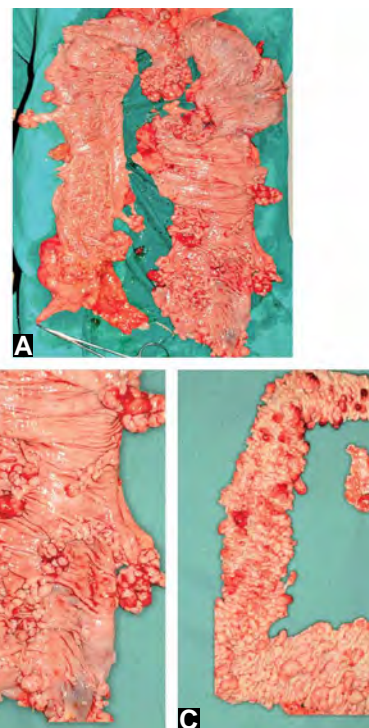
### FAMILIAL ADENOMATOUS POLYP (FAP)

- ◆ It is inherited as an autosomal dominant neoplastic condition (chromosome no. 5q21).
- ◆ It presents in younger age group—15–20 years.
- ◆ Incidence is equal in both sex, involving commonly the large intestine but can also occur in stomach, duodenum and small intestine.
- ◆ It is familial with a *high potential for malignant transformation*. If there is no adenoma at the age of 30 years, then it is not FAP of colon.
- ◆ It can be associated with duodenal or ampullary carcinomas, *Gardner's syndrome* [desmoid tumour in the abdomen, osteomas (75%) and epidermoid cysts] and also *Turcot's syndrome* [FAP + brain tumour (medulloblastoma or gliomas)] or sarcoma of bone.

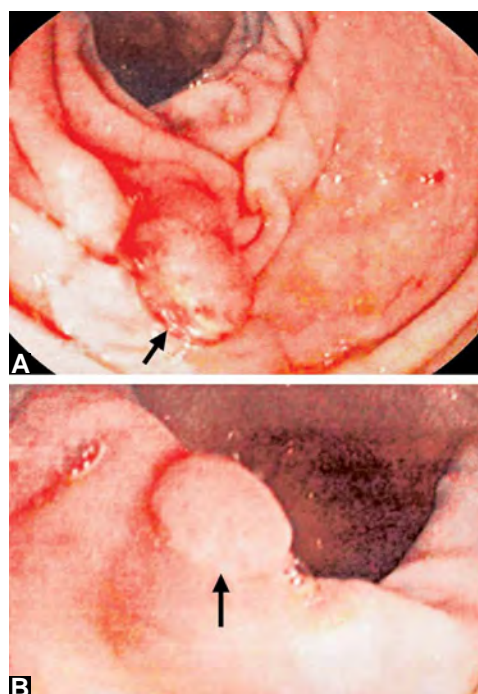
- ◆ Usually multiple (over 100).
- ◆ Presents with lower abdominal pain, loose stools with blood and mucus, weight loss.

### Investigations

- ◆ Double contrast barium enema.
- ◆ Colonoscopic biopsy.



Figs 22.26A to C: Multiple polyps extensively involving the colon.



Figs 22.27A and B: Colonoscopic view of polyp colon in two different patients.

- ◆ Screening of *all the members of the family is a must*.  
Pigment spots in retina (Congenital hypertrophy of the retinal pigmented epithelium of the iris, CHRPE / CHIRPES) and DNA tests for FAP are good screening methods, but cost and availability limits its use.
- ◆ Patients with FAP will develop colorectal cancer almost 100% in the absence of surgical intervention.

## Treatment

1. *Proctocolectomy with ileoanal anastomosis with ileal pouch* is commonly done.
2. Alternatively a conservative *total colectomy* with ileo rectal anastomosis can be done, but with a regular follow-up with sigmoidoscopy for any *rectal polyps*. If present *snaring of polyps* should be done.  
*Sulindac* (NSAID) 300 mg BD/*aspirin* 325 mg OD is given to these patients, causes disappearance of polyps in the rectum.

### Gardner's syndrome

- ❖ It is commonly associated with FAP—10%.
- ❖ Presents with bone, skin, soft tissue and dental abnormalities. Jaw osteomas are very common. Other features are epidermoid cysts (50%), exostoses, fibromas, lipomas.
- ❖ Associated with desmoid tumours seen in the scar, abdomen, intraabdominal region and mesenteric fibromatosis.
- ❖ Congenital hypertrophy of pigment layer of retina (seen as pigment spots)—commonly seen.
- ❖ Often associated with MEN IIb syndrome.

### Turcot's syndrome

- ❖ Autosomal recessive disorder
- ❖ Colonic polyps + brain tumours like medulloblastoma or gliomas
- ❖ Often associated with FAP

### Cronkhite-Canada syndrome

- ❖ Polyps in stomach, duodenum and colorectum. No polyps in oesophagus, small intestine
- ❖ Intractable diarrhoea, pigmentation, cachexia, alopecia, onychodystrophy
- ❖ In females
- ❖ 15% will have malignancy

### Cowden syndrome

#### (multiple hamartoma—neoplasia syndrome)

- ❖ Autosomal dominant
- ❖ Penetrance at age 20 with PTEN suppressor gene mutation
- ❖ Benign ectodermal tumour—tricholemmoma—80%
- ❖ Macrocephaly—40%
- ❖ GI polyposis—35% and no risk of GI malignancy
- ❖ 10% risk of thyroid cancer
- ❖ 30–50% risk of breast cancer

### Bannayan-Riley-Ruvalacaba syndrome (Ruvalacaba Myhre Smith)

- ❖ Autosomal dominant
- ❖ GI hamartomatous polyp
- ❖ Macrocephaly, mental retardation
- ❖ Delayed psychomotor development
- ❖ Lipid storage myopathy
- ❖ Hashimoto's thyroiditis
- ❖ Hyperpigmentation of penile skin
- ❖ No risk for GI or extra GI malignancy

## CARCINOMA COLON

- ◆ It is commonly *adenocarcinoma*.
- ◆ Very rarely adenosquamous, squamous carcinoma can occur.

### Adenocarcinoma

- ◆ Sigmoid colon (21%) is the most common site of malignancy after rectum (38%).
- ◆ In caecum it is 12% common.

### Aetiology

- ◆ **Diet:**
  - ▶ Red meat and saturated fat increases the incidence of colonic cancer.
  - ▶ Cholesterol increases the bile acid concentration in the intestinal lumen which acts as cocarcinogen.
  - ▶ High fibre diet protects the colon against cancer.
  - ▶ Calcium in diet prevents colonic cancer by combining with bile salts and reducing bile salt concentration in the colon. It directly acts on the colonic mucosal cells to reduce their proliferative potential.
  - ▶ Diet with lack of fibre increases the risk. Diet with high fat increases the risk.
  - ▶ Dietary vitamins A, C, E and zinc reduces the risk.
- ◆ **Genetic:**
  - ▶ Carcinoma colon is more common in individuals with *adenoma colon* or with *familial adenomatous polyposis (FAP)*, Gardner's syndrome, Turcot's syndrome.
  - ▶ Relatives of colonic cancer patient have got 2–4 times increased risk of developing carcinoma of colon.
- ◆ Long standing *ulcerative colitis*, *Crohn's disease* has high risk of colonic cancer. Crohn's disease is a premalignant condition but not as much as ulcerative colitis.
- ◆ *Alcohol and cigarette smoking increases the risk*.
- ◆ *Hereditary nonpolyposis colonic cancer (HNCC)* has got high incidence (25%) of synchronous and metachronous growth, so total colectomy is needed.
- ◆ After cholecystectomy and ileal resection there is increased bile salts and so more prone for carcinoma colon.
- ◆ Radiation increases the risk (mucinous type).
- ◆ Ureterosigmoidostomy increases the risk by 100–500 times.
- ◆ Acromegaly may increase the risk.

**Note:**

Aspirin, calcium and other NSAIDs protect against colonic cancer.

**Pathogenesis**

- ◆ Adenoma—carcinoma sequence
  - ▶ Most of the colonic carcinoma develops from polyp/adenoma pathway.
  - ▶ Normal epithelium → initiation by 5q loss APC gene → dysplasia (hyperproliferative) → DNA methylation → early adenoma → 12p activation K ras → intermediate adenoma → 18q loss DCC → late adenoma → action by 17p loss p53 → carcinoma → spread .
- ◆ 80% of colorectal cancer arises from *loss of heterozygosity (LOH) pathway*. LOH pathway is due to APC gene defects (in FAP), K ras mutation altering the cell cycle [K ras binds to GTP (guanosine triphosphate) hydrolyse to GDP which inactivates G protein normally; K ras mutation blocks GTP hydrolyse leading into permanently active form of G protein causing carcinoma]; loss of DCC tumour suppressor gene; mutation of tumour suppressor gene p53. LOH pathway is microsatellite stable (MSS) and carries poor prognosis compared with MSI.
- ◆ 20% of colorectal cancer develops from mutation from *RER (Replication Error Repair) pathway* wherein repair mechanism of DNA replication error is lost. It causes microsatellite regions of genome to have repeated sequences leading into error and is called as *microsatellite instability (MSI)*. In colon, it is seen in right side growths and is associated with better prognosis.

**Colonic cancer may be:****Nonhereditary colon cancer**

- ◆ It can be sporadic colon cancer—60%.
- ◆ It can be familial colon cancer—30%. Common in Ashkenazi – Jewish population.

**Hereditary colon cancer**

- ◆ FAP.
- ◆ HNCC.
- ◆ Peutz Jeghers syndrome—2–3% risk of cancer colon.
- ◆ *Cronkite—Canada syndrome*.
- ◆ *Juvenile polyposis syndrome*—it differs from isolated juvenile polyps discussed earlier. It is an autosomal dominant condition,

occurs in children and adolescent. Germ line mutation of SMAD-4 gene is observed. It increases the risk of colonic cancer.

**HNCC (Hereditary Nonpolyposis Colonic Cancer)**

- ❖ No polyps. Autosomal dominant
- ❖ Three members of the family have colonic cancers
- ❖ Two first degree relatives will have same cancer
- ❖ Two consecutive generations observed
- ❖ One relative with less than 50 years age will have colonic cancer
- ❖ *Lynch syndrome I* is site specific—commonly right sided, occurs in early age group, 40% are metachronous
- ❖ *Lynch syndrome II* has other malignancy in, stomach, breast, ovary, endometrium and urinary bladder. It is cancer family syndrome
- ❖ Microsatellite instability (MSI) at DNA level occurs in HNCC
- ❖ Accounts for 3–5% of colonic cancers
- ❖ Amsterdam criteria I (1990); Amsterdam criteria II (1999) and revised Bethesda guidelines (2002) are used to diagnose HNCC

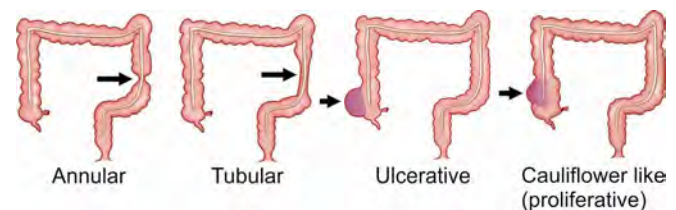
**Types**

Patient can have *de novo multiple primary* carcinomas in different parts of the colon at the same time, i.e. **synchronous (5–10%)**, or can present with growth in different parts of the colon in different periods, i.e. **metachronous (10–20%)**.

**Gross types:** *Annular, tubular, ulcerative, cauliflower like.*

*Annular (stenosing) type:*

- ◆ It is more common on left side.
- ◆ Here the growth spreads round the internal wall and so it often presents with intestinal obstruction.



**Fig. 22.28:** Gross types of carcinoma colon. Annular and tubular types are common in left side, ulcerative and proliferative are common in right side.

<b>Amsterdam criteria</b>	<b>Bethesda criteria</b>
<ul style="list-style-type: none"> <li>• At least 3 relatives of common cancer</li> <li>• One affected person is 1st degree relative of other two affected persons</li> <li>• Two successive generations affected</li> </ul>	<i>Amsterdam criteria and one of the following:</i> <ul style="list-style-type: none"> <li>• 2 cases of HNPCC associated cancer in one patient including synchronous or metachronous cancer</li> <li>• Colon cancer and 1st degree relative with HNPCC associated cancer and or colonic adenoma</li> <li>• Colon or endometrial cancer diagnosed before the age of 45</li> <li>• Right sided colon cancer that has an undifferentiated pattern or signet cell type before the age of 45</li> <li>• Adenoma diagnosed before 45</li> </ul>
<b>Modified Amsterdam criteria</b> Same as Amsterdam except cancer must be associated with HNPCC (colon, endometrium, small intestine, renal pelvis and ureter) instead of specifically colon cancer	

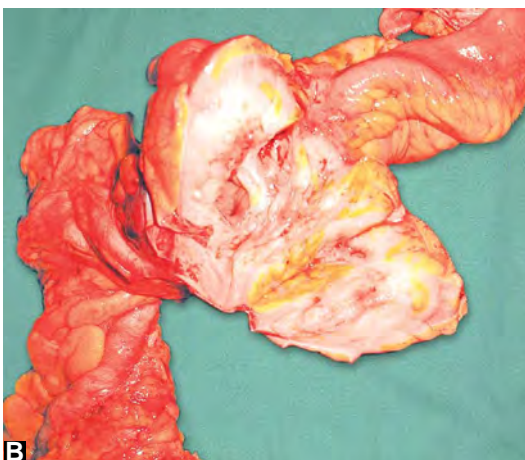
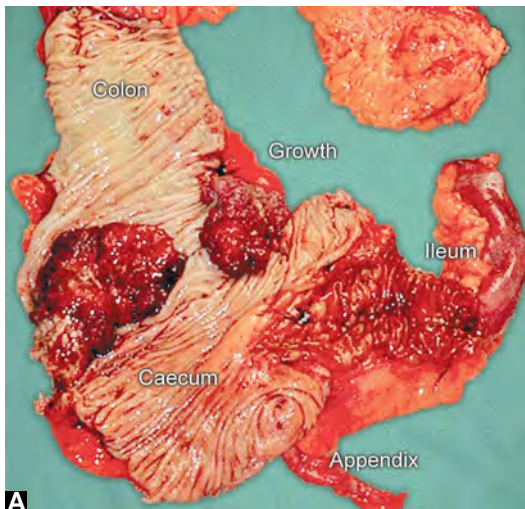

*Ulcerative type:*

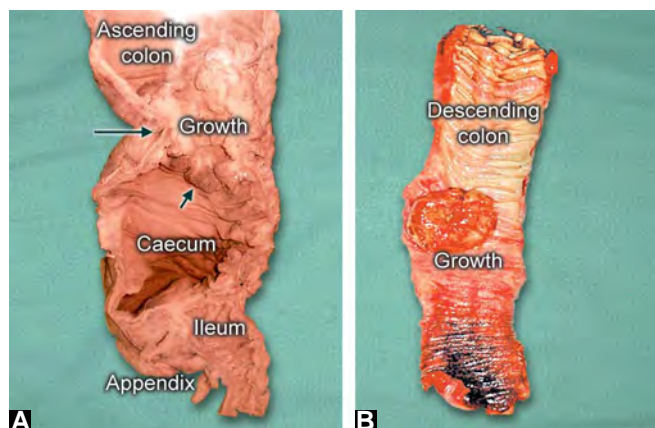
- ◆ It is common on right side.

*Proliferative type:*

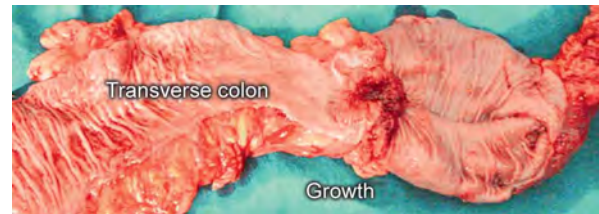
- ◆ Common in right side. It is fleshy, bulky and polypoid. It is less malignant.



**Figs 22.29A and B:** (A) Carcinoma caecum showing proliferative lesion; (B) Thickening of the wall is seen.



**Figs 22.30A and B:** (A) Carcinoma ascending colon. Note the growth, caecum and ileum. It is proliferative type; (B) Carcinoma descending colon. Note the proliferative tumour. Commonly it is stricture type/annular type on left side.



**Fig. 22.31:** Carcinoma transverse colon. It is ulceroproliferative lesion.

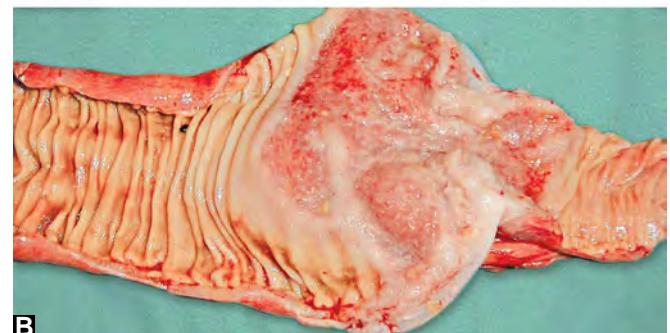
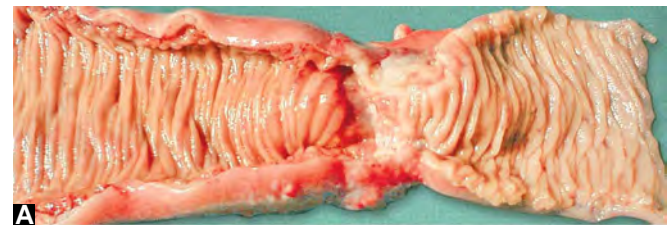
**Histology (WHO)**

- ◆ Adenocarcinoma—90%.
- ◆ Mucinous adenocarcinoma—5–10%.
- ◆ Signet ring cell carcinoma.
- ◆ Small cell/oat cell carcinoma—rare—extremely poor prognosis.
- ◆ Squamous cell carcinoma.
- ◆ Undifferentiated carcinoma.

*Duke's histological grading of carcinoma colon (now modified Morson-Dawson)*

- ◆ Grade I—low grade.
- ◆ Grade II—average grade.
- ◆ Grade III—high grade.
- ◆ Grade IV—anaplastic.

*Carcinoma confined to muscularis mucosa does not metastasize.*



**Figs 22.32A and B:** Annular type of growth observed in left sided/sigmoid colon.

**Haggitt's invasion of malignant polyp***In pedunculated polyp*

- Level 0—noninvasive carcinoma over the summit
- Level 1—invasion to head of the pedunculated polyp
- Level 2—invasion to neck of the pedunculated polyp
- Level 3—invasion to stalk of the pedunculated polyp
- Level 4—invasion to base of the pedunculated polyp

*In sessile polyp*—all lesions are level 4

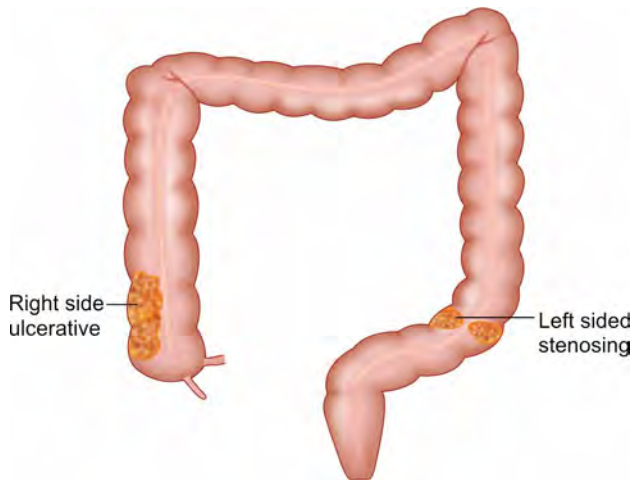


Fig. 22.33: Carcinoma colon—types.

### Sessile Malignant Polyp Invasion

Sm 1: Submucosal invasion into upper 1/3rd (superficial/ inner).

Sm 2: Submucosal invasion into middle 1/3rd (inner 2/3rd).

Sm 3: Submucosal invasion lower 1/3rd (deep).

#### Staging of carcinoma colon

##### Duke's

- A. Confined to bowel wall, mucosa and submucosa
- B. Extends across the bowel wall to the muscularis propria with no lymph nodes involved
- C. Lymph nodes are involved

##### Modified Duke's

- A. Growth limited to rectal wall
- B. Growth extending into extrarectal tissues but no lymph node spread
  - B1: Invading muscularis mucosa
  - B2: Invading into or through the serosa
- C. Lymph node secondaries
- D. Distant spread to liver, lungs, bone, brain

##### Astler-Coller's grading of colorectal/rectal cancer

- A. Intramucosal
- B1 Involvement up to muscularis propria
- B2 Spread through the wall in to peritoneum
- C1 B1 + involvement of lymph nodes
- C2 B2 + involvement of lymph nodes
- D Distant spread

### Spread

#### Direct spread:

- ◆ Locally it can invade the bladder, obstruct ureter and so cause hydronephrosis.
- ◆ Can perforate and cause peritonitis/pericolic abscess/faecal fistula.
- ◆ Growth may get adherent to psoas muscle posteriorly.
- ◆ Carcinoma sigmoid colon can infiltrate and cause colovesical or colovaginal fistula. It can infiltrate ureter, ovary, uterus etc. It can cause pericolic abscess or abscess in lateral abdominal wall.

#### Lymphatic spread:

- ◆ Growth through lymphatics spreads to pericolic, epicolic, intermediate and principal group of lymph nodes.

#### Groups of lymph nodes draining colon

- ◆ N1: Nodes immediately adjacent to bowel wall.
- ◆ N2: Nodes along ileocolic/right colic/middle colic/ left colic/ sigmoid arteries.
- ◆ N3: Nodes near the origin of SMA and IMA.
- ◆ Nodal spread in carcinoma colon is sequential from N1 → N2 → N3.

#### Blood spread:

- ◆ 40% of carcinoma colon spreads to liver via portal veins.
- ◆ Secondaries may be either solitary or multiple, present as liver with hard, umbilicated nodules.
- ◆ Rarely it spreads to bone, lung, skin.

#### Cunderson-Sosin staging

- A – Lesion limited to mucosa
- B<sub>1</sub> – Through mucosa, still within bowel wall
- B<sub>2</sub> – Through entire bowel wall
- B<sub>3</sub> – Adherent to or invading adjacent organs
- C<sub>1</sub> – Limited to bowel wall but node +ve
- C<sub>2</sub> – Through entire bowel wall, node +ve
- C<sub>3</sub> – Adherent, invasion to adjacent organs with node +ve
- D – Distant spread / locally unresectable tumour

#### TNM staging of colorectal cancer

##### Tumour—T

- T<sub>x</sub> – Primary tumour cannot be assessed
- T<sub>0</sub> – No evidence of tumour
- T<sub>is</sub> – Carcinoma *in situ*—intraepithelial/invasion into lamina propria
- T<sub>1</sub> – Invasion into submucosa
- T<sub>2</sub> – Invasion into muscularis propria
- T<sub>3</sub> – Invasion into pericorectal tissues/fat
- T<sub>4a</sub> – Invasion into surface of the visceral peritoneum
- T<sub>4b</sub> – Direct invasion or adherent to adjacent structures/organs

##### Regional nodes—N

- N<sub>x</sub> – Nodes cannot be assessed
- N<sub>0</sub> – No nodal spread
- N<sub>1</sub> – Regional nodes 1–3 involved
  - N<sub>1a</sub> – 1 regional node
  - N<sub>1b</sub> – 2 to 3 regional nodes
  - N<sub>1c</sub> – Tumour deposits in serosa/mesentery/nonperitonealised pericolic or perirectal tissues without regional nodes
- N<sub>2</sub> – Regional nodes 4 or more involved
  - N<sub>2a</sub> – 4–6 regional nodes
  - N<sub>2b</sub> – 7 or more regional nodes

##### Distant metastases—M

- M<sub>0</sub> – No distant spread
- M<sub>1</sub> – Distant spread present
  - M<sub>1a</sub> – Spread confined to one organ or site—liver/lung/ovary/nonregional nodes;
  - M<sub>1b</sub> – Spread to more than one organ or site/peritoneum.

Contd...

Contd...

**Histological grade—G**

- G<sub>x</sub> – Grade cannot be assessed
- G<sub>1</sub> – Well differentiated
- G<sub>2</sub> – Moderately differentiated
- G<sub>3</sub> – Poorly differentiated
- G<sub>4</sub> – Undifferentiated

**Residual tumour—R**

- R<sub>0</sub> – No residual tumour after resection
- R<sub>1</sub> – Microscopic residual tumour after resection
- R<sub>2</sub> – Macroscopic residual tumour after resection

**Stage Group**

- 0 – T<sub>is</sub> N<sub>0</sub> M<sub>0</sub>
- I – T<sub>1</sub> N<sub>0</sub> M<sub>0</sub>; T<sub>2</sub> N<sub>0</sub> M<sub>0</sub>
- IIA – T<sub>3</sub> N<sub>0</sub> M<sub>0</sub>
- IIB – T<sub>4a</sub> N<sub>0</sub> M<sub>0</sub>
- IIC – T<sub>4b</sub> N<sub>0</sub> M<sub>0</sub>
- IIIA – T<sub>1-2</sub> N<sub>1-1c</sub> M<sub>0</sub>; T<sub>1</sub> N<sub>2a</sub> M<sub>0</sub>
- IIIB – T<sub>3-4a</sub> N<sub>1-1c</sub> M<sub>0</sub>; T<sub>2-3</sub> N<sub>2a</sub> M<sub>0</sub>; T<sub>1-2</sub> N<sub>2b</sub> M<sub>0</sub>
- IIIC – T<sub>4a</sub> N<sub>2a</sub> M<sub>0</sub>; T<sub>3-4a</sub> N<sub>2b</sub> M<sub>0</sub>; T<sub>4b</sub> N<sub>1-2</sub> M<sub>0</sub>
- IVA – Any T Any N M<sub>1a</sub>
- IVB – Any T Any N M<sub>1b</sub>
- V<sub>0</sub> – No venous invasion; V<sub>1</sub>—Presence of venous invasion
- L<sub>0</sub> – No lymphatic vessel invasion; L<sub>1</sub>—Presence of lymphatic vessel invasion

**Clinical Features**

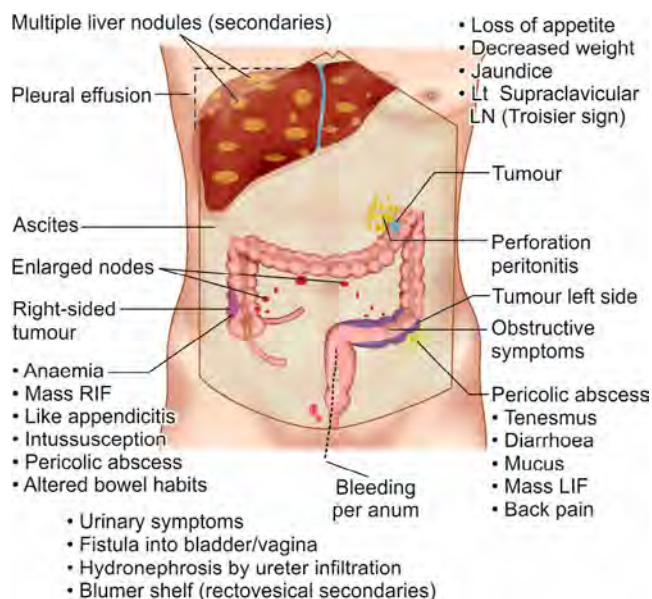
- ◆ Occurs usually after 50 years. Familial type can present in younger age group. Common in males (M : F :: 3 : 2).
- ◆ Commonly present with loss of appetite and weight, anaemia, abdominal discomfort and mass per abdomen.
- ◆ 20% of cases present as an acute intestinal obstruction.
- ◆ 20% of colonic/colorectal cancer has stage IV disease at the time of first presentation.
- ◆ **Right sided growth** commonly presents with *anaemia, palpable mass* in the right iliac fossa, which is not moving with respiration, mobile, nontender, hard, well-localised with impaired resonant note.

**Differential diagnosis for mass in the right iliac fossa**

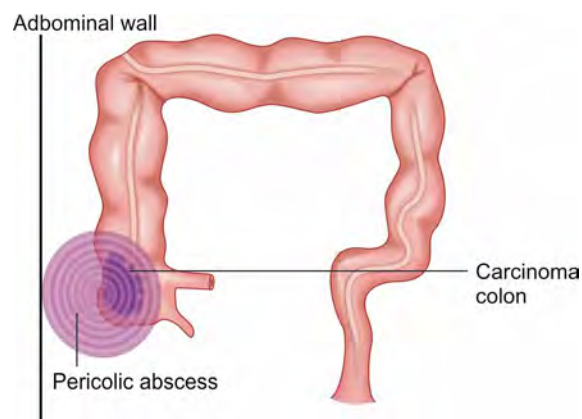
- ❖ Ileocaecal tuberculosis
- ❖ Appendicular mass
- ❖ Actinomycosis
- ❖ Ectopic kidney
- ❖ Mesenteric lymph nodes
- ❖ Ovarian tumour in females
- ❖ Retroperitoneal tumour
- ❖ Amoeboma

Carcinoma caecum occasionally presents like acute appendicitis or intussusception with intestinal obstruction.

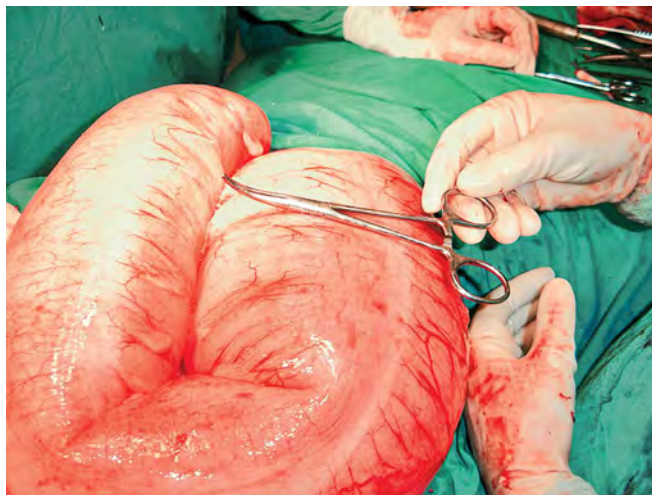
- ◆ **Left sided growth** presents with *colicky pain, altered bowel habits (alternating constipation and diarrhoea)*, palpable lump, distension of abdomen due to *subacute/chronic obstruction*. Later may present like complete colonic obstruction. Tenesmus, with passage of blood and mucus, with alternate constipation and diarrhoea, is common. Bladder symptoms may warn colovesical fistula.
- ◆ Features of pericolic abscess/obstruction (15%)/perforation/peritonitis may be the first presentation.



**Fig. 22.34:** Clinical features of carcinoma of colon—diagrammatic representation.

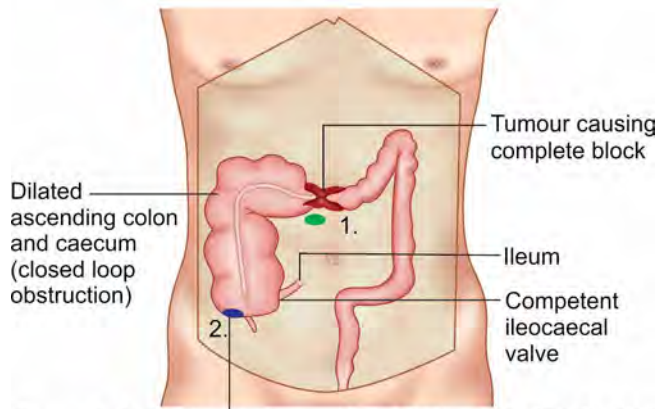


**Fig. 22.35:** Carcinoma with pericolic abscess right sided. Mass here will be tender and localised. Patient may be having fever, tachycardia. Associated obstruction may be there occasionally.



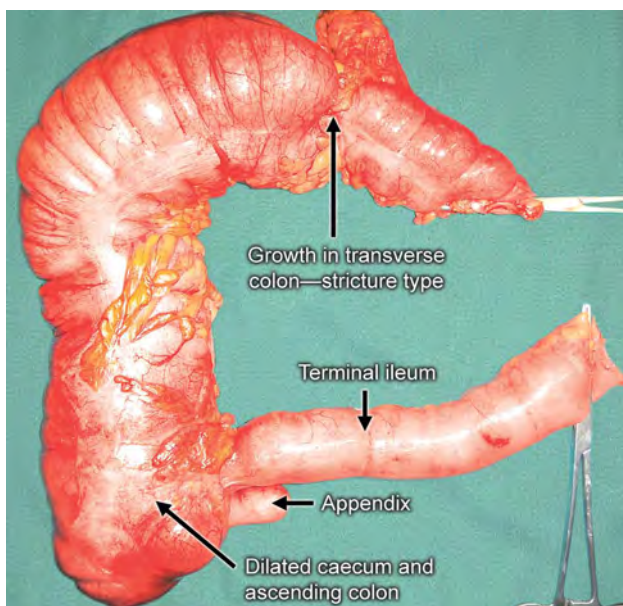
**Fig. 22.36:** Dilated colon in colonic growth with obstruction.

- ◆ *Closed loop obstruction* can occur in transverse colon growth (stricture type causing block) with competent ileocaecal valve. Enormously dilated right sided colon is prone for *stercoral ulcer*, perforation and faecal peritonitis.
- ◆ Enlarged liver with multiple umbilicated hard secondaries, ascites, rectovesical secondaries, palpable left supraclavicular lymph nodes are other presentations.
- ◆ Faecal strength of *Streptococcus bovis* bacteria increases many fold in patients with colonic cancer compared to individuals without colonic cancer.



Stercoral ulcer in the caecum 1 and 2 are sites of perforation

**Fig. 22.37:** Carcinoma transverse colon or near hepatic flexure can cause complete block, leading into the enormous dilatation of caecum. If ileocaecal valve is competent, then there will be closed loop obstruction of right-sided colon causing *stercoral ulcer* due to pressure ischaemia over the summit of the caecum. Perforation can occur in stercoral ulcer or in growth site itself. It is treated by emergency surgery with resection and temporary ileostomy.



**Fig. 22.38:** Closed loop obstruction specimen showing in a operated patient with growth in mid-transverse colon. Extended right hemicolectomy was done.

### Local complications of carcinoma colon

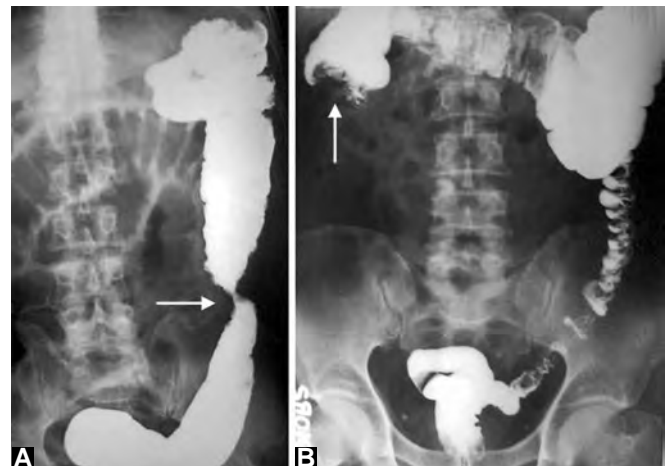
- ❖ Intestinal obstruction
- ❖ Closed loop obstruction
- ❖ Perforation and peritonitis
- ❖ Vesicocolic fistula
- ❖ Invasion of ureter
- ❖ Pericolic abscess

### Investigations

#### Screening and surveillance for colon cancer

- ❖ *Faecal occult blood test (FOBT)*—it is nonspecific test for peroxidase contained in haemoglobin. It is simple but with low specificity
- ❖ *Flexible sigmoidoscopy*—once in 5 years to identify the adenoma; it is often combined with FOBT
- ❖ *Colonoscopy* is the most accurate and most complete method for evaluating the entire colon. It allows identification of small polyps (<1 cm), allows biopsy, polypectomy, control of bleeding, stricture dilatation if needed. Problem as a screening method is—prior need for mechanical bowel preparation
- ❖ *Air contrast barium enema (ACBE)* detects polyps greater than 1 cm. Its accuracy is more in proximal colon than in sigmoid colon as one may misinterpret a polyp for diverticulosis
- ❖ *CT colonography (virtual colonoscopy)*—it is helical CT 3 dimensional intraluminal colon imaging. It needs bowel preparation, air insufflation, CT imaging

- ◆ *Barium enema:* Shows irregular filling defect and ‘apple core’ lesion (in left sided carcinoma). It also helps in finding colonic polyps (*air-contrast barium enema*).
- ◆ *Colonoscopy and biopsy* confirms the diagnosis.
- ◆ *Virtual colonoscopy (CT colonography)* is also useful to visualize entire colon.



**Figs 22.39A and B:** X-rays with barium enema showing narrowing in sigmoid region (A) and irregularity (B).

- ◆ US, to see secondaries in liver, peritoneum, lymph node status, rectovesical secondaries.
- ◆ **CEA (carcinoembryonic antigen):**
  - ▶ It is a *cell surface glycoprotein* discovered by Gold and Freedman.

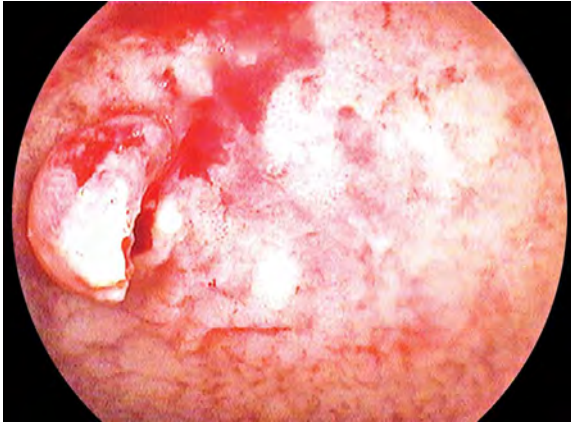


Fig. 22.40: Carcinoma colon—colonoscopic view.

- ▶ It is normally produced by colonic epithelium.
- ▶ Its serum  $\frac{1}{2}$  life is up to 10 days and is cleared by liver through Kupffer cells. So its  $\frac{1}{2}$  life prolongs in cholestasis and hepatocellular dysfunction.
- ▶ Normal level is  $<2.5$  ng/ml. Level  $>5$  ng/ml is significant.
- ▶ Even though it is a widely used tumour marker, it has got low sensitivity.
- ▶ CEA is primarily associated with colorectal cancers, but it can also increase significantly in pancreatic, gastric, lung, breast carcinomas. Often its level also increases in nonmalignant conditions like pancreatitis, hepatitis, obstructive jaundice, BPH.
- ▶ *Uses in colorectal cancers are:*
  - a. Preoperative levels  $>7.5$  ng/ml signifies poor prognosis.
  - b. If postoperative level does not fall, it indicates either incomplete resection, or occult metastasis elsewhere.
  - c. Increase CEA during follow-up indicates recurrence or secondaries.

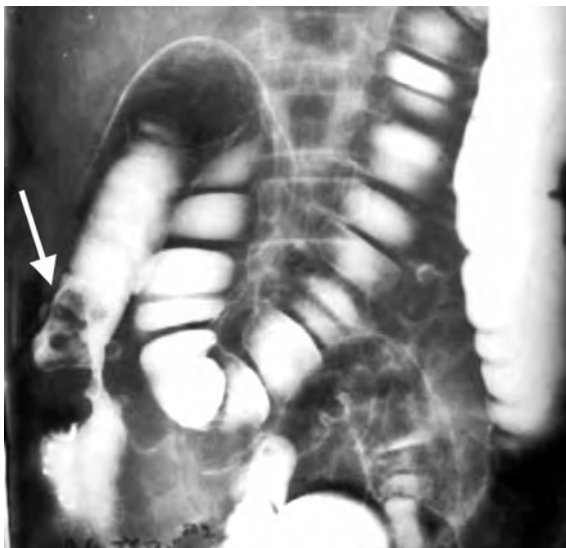

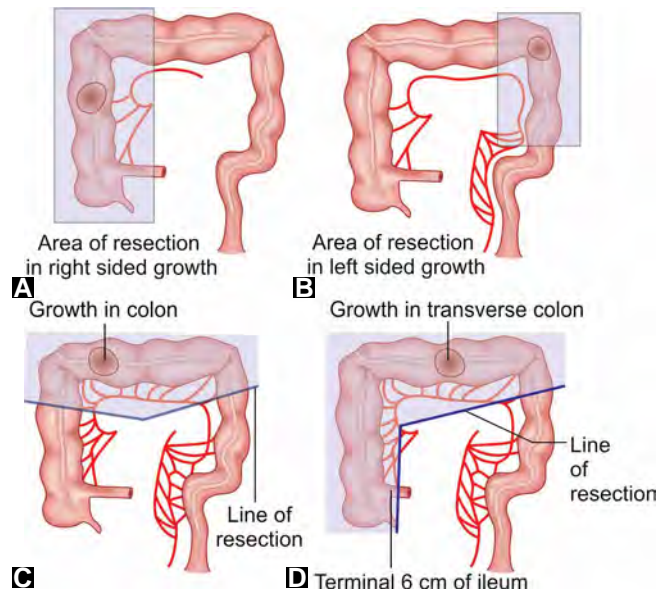
Fig. 22.41: Barium enema X-ray showing irregular filling defect in caecum—feature of carcinoma colon.

- ▶ A slow rise indicates loco regional disease.
- ▶ A rapid rise signifies metastasis.
- ▶ It is not useful in assessing follow-up in poorly differentiated adenocarcinoma as such tumour will not produce CEA.
- ◆ *CT scan abdomen and pelvis*—to see local spread, invasion, size and extent, stage, nodal status and liver secondaries.
- ◆ Left supraclavicular lymph node if palpable, its FNAC may clinch the histological diagnosis.
- ◆ Hb%, PCV, haematocrit, ESR. Look for *occult blood in stool* is the initial test for anaemia.
- ◆ LFT—mainly enzyme studies like alkaline phosphatase, SGPT.

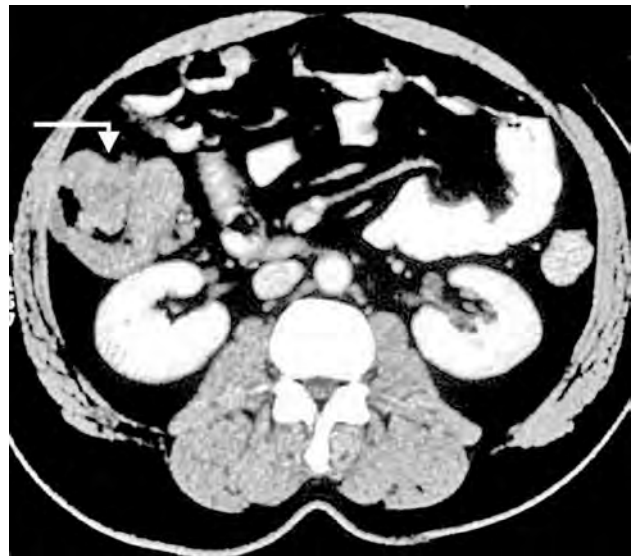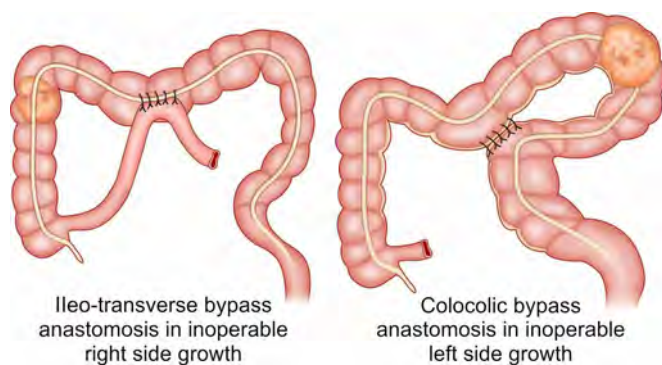


Fig. 22.42: CT scan picture showing growth in the right side colon.

## Treatment



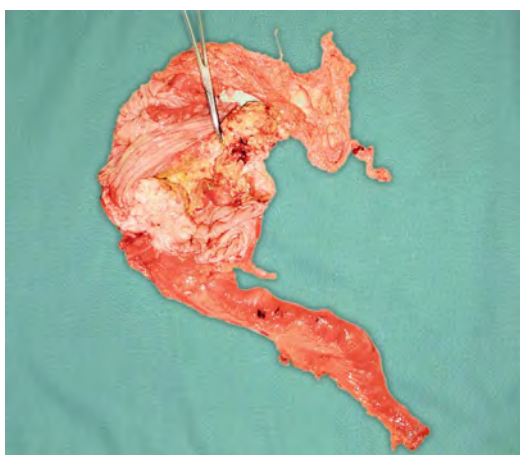
Figs 22.43A to D: (A to C) Levels of resection in growths in different portions of the colon; (D) Diagram showing extended right hemicolectomy.



**Fig. 22.44:** Ileo-transverse anastomosis in case of inoperable hepatic flexure growth. Colosigmoid bypass in case of inoperable growth in splenic flexure.

### Mainly Surgical

- ◆ *Right-sided early growth:*
  - ▶ *Right radical hemicolectomy* with ileo-transverse anastomosis is done. Structures removed are terminal 6 cm of ileum, caecum and appendix, ascending colon, 1/3 of transverse colon, lymph nodes (epicolic, paracolic, intermediate).
  - ▶ In inoperable right sided growth, *ileo-transverse anastomosis* is done as a by-pass procedure.



**Fig. 22.45:** Specimen of hemicolectomy done for carcinoma caecum. Note the different parts—terminal ileum, ascending colon, hepatic flexure and omentum.

- ◆ *Transverse colon growth:*
  - ▶ *An extended right hemicolectomy* is the procedure done for transverse colon growth which includes division of right colic, middle colic arteries at their origin, with removal of terminal 6 cm ileum, ascending and transverse colon; anastomosing terminal ileum and proximal part of the descending colon—*ileocolic*.
  - ▶ Alternatively, in mid-transverse colon growth, transverse colon with both flexures can be removed; anastomosing cut ends of ascending and descending colon—*colocolic*.
- ◆ *Left-sided early growth:*
  - ▶ Left radical hemicolectomy is done, where in left 1/2 of transverse colon and descending colon is removed along with lymph nodes.

- ▶ *Left-sided stenosing type of growth* can present with acute intestinal obstruction, in which case initially colostomy is done. Later, after 3–6 weeks, following proper preparation, required formal procedure is done, followed by colostomy closure after 8 weeks (*3 stage operation*).
- ▶ Often growth in the transverse or left sided colon, which is stenosing or obstructive type, can cause *closed loop obstruction* because of the competent ileocaecal valve. As a result, pressure increases in the caecum eventually leading to its perforation. Perforation can also occur occasionally at the site of tumour. They need *emergency intervention*—caecostomy or colostomy, or ileostomy with resection and anastomosis. If severe peritonitis sets in, it may be life-threatening.
- ▶ Left-sided colon growth with *obstruction* can be treated with resection of tumour, saline lavage and cleaning the rest of the colon by passing a catheter through the appendix into the caecum followed by primary anastomosis thus avoiding colostomy.
- ▶ In severely *obstructed sigmoid growths* are often alternatively treated as tumour resection with removal of entire proximal colon and continuity is maintained with ileo sigmoid/ileorectal anastomosis. It also avoids diversion.
- ▶ During exploration, presence of any synchronous growths has to be looked for. Now it is found that carcinoma colon can be *associated with tuberculosis or lymphoma of colon*. So this association is also looked for.
- ▶ In acute left sided growths, *trans anal self-expanding metal stents* can be used instead of defunctioning colostomy.
- ▶ *Turnball's 'No touch technique'*: Here the vessels are ligated at its origin, at the beginning, in order to prevent the tumour spread—due to tumour handling.
- ◆ *Multiple synchronous primaries* in the colon:
  - ▶ *Total abdominal colectomy* with ileorectal anastomosis is done if there are multiple primary tumours or in HNPCC. Significant chronic diarrhoea is the problem due to defective water absorption.
- ◆ *Surgical treatment of liver secondaries:*
  - ▶ In *solitary liver secondary*, segmental hepatic resection is useful.
  - ▶ In case of multiple secondaries confined to one lobe of the liver, *hemihepatectomy* can be tried.
  - ▶ *Metastasectomy*—it is done in one secondary/one lobe secondaries/less than 3 metastases in both lobes/without any extrahepatic spread.
- ◆ 'A *second look operation*' is most often helpful in carcinoma of colon, to resect the residual or recurrent tumours (*Owen Wangensteen's Second look surgery*).
- ◆ If there are synchronous growths or growth with other area having multiple potential polyps, then total colectomy with colorectal anastomosis is done.
- ◆ Recurrent tumour should be treated by re-exploration and resection with adjuvant chemotherapy of different regime.
- ◆ Laparoscopic evaluation and resection is becoming popular. Laparoscopic assisted colonic resection is also done [*Hand assisted laparoscopic surgery (HALS)*].

#### Note:

- *Caecum and ascending colon*—right radical hemicolectomy (terminal ileum to mid transverse colon); *hepatic flexure and transverse colon*—extended right radical hemicolectomy (terminal ileum to

proximal descending colon); *splenic flexure*—extended left radical hemicolectomy (hepatic flexure to rectosigmoid); *descending colon and sigmoid*—left radical hemicolectomy ( splenic flexure to rectosigmoid).

- Minimum 5 cm margin clearance at colonic side/sides is needed; 6 cm terminal ileum clearance is sufficient in case of right sided growth.
- Duodenum, ureter, IVC, superior mesenteric vein should be taken care of during dissection in right hemicolectomy; spleen, stomach, tail of the pancreas should be taken care of in left hemicolectomy.
- It is *ideal* to mobilize both flexures adequately in all colonic surgeries to reduce the anastomotic tension.
- Bleeding at *anastomotic site edges* should be adequate; in emergency obstructive situation, better to do temporary covering colostomy or ileostomy to prevent anastomotic leak.
- On table and postoperative *hypoxia and hypotension* should be prevented to minimize anastomotic leak.
- Preoperative mechanical bowel preparation earlier once said to be important is questioned now; it was practiced in elective colonic resection using polyethylene glycol, mannitol, oral bowel antiseptics like neomycin / streptomycin / gentamicin and metronidazole.
- Infiltration into adjacent local structures is *not a contraindication* for surgical resection.
- At least 12 nodes should be examined during histology after resection.
- *Blood transfusion* before or during surgery for colonic cancer may alter the immunological aspect of the colonic cancer and may increase the recurrence rate and so may alter the prognosis. It is presently not very well-proved. *Reason thought is*—blood transfusion raises the suppressor T cells leading into immunosuppression. So autologous blood transfusion is better when in case of need.
- Antibiotic prophylaxis; DVT prophylaxis by crepe bandage or stockings bandage, heparin or low molecular weight heparin.
- Pulmonary function tests and pulmonary exercise preoperatively as well as postoperatively.
- Urinary catheterisation, nasogastric tube placement.
- Postoperative proper care with fluid, electrolyte, drain care, early mobilisation, monitoring.
- Complications of surgery are leak (fecal fistula), bleeding, infection like intraperitoneal/pelvic abscess, respiratory problems, DVT, wound infection, burst abdomen.

## Adjuvant Therapy

### Chemotherapy

#### Indications for chemotherapy

- ◆ Positive nodes.
- ◆ T4 lesions.
- ◆ Venous (microscopic) spread.
- ◆ Signet cell type.
- ◆ Poorly differentiated tumour/aneuploidy.
- ◆ Changes in CEA level.

Postoperative chemotherapy is used commonly. Occasionally also given preoperatively.

#### Regimes are:

- ◆ 5 fluorouracil (5 FU) with folinic acid (leucovorin/ LV) is the most commonly used regime for 6 months as monthly cycles. Folinic acid potentiates the action of 5 FU.
- ◆ Levamisole 150 mg/day for 3 days given once in 15 days for one year with intravenous 5 FU monthly for one year.
- ◆ Irinotecan/5 FU/LV—IFL regime is also used.
- ◆ Folinic acid (LV)/5 FU/oxaliplatin—FOLFOX regime is also used. It is becoming treatment of choice.
- ◆ Irinotecan/oxaliplatin—IROX regime is used in previously untreated metastatic colonic cancer.
- ◆ Capecitabine (xeloda) an oral drug which generates 5 FU at tumour tissue, shows significantly greater response than 5 FU/LV regime.
- ◆ Phase II trials are going on for capecitabine/oxaliplatin and capecitabine/irinotecan combination regimes.

- ◆ 5 FU infusions into the portal vein during and immediately after surgery have shown benefits in terms of outcome and recurrence.

**EGFR and VEGF blockers** (EGFR is epithelial growth factor receptor; VEGF is vascular endothelial growth factor):

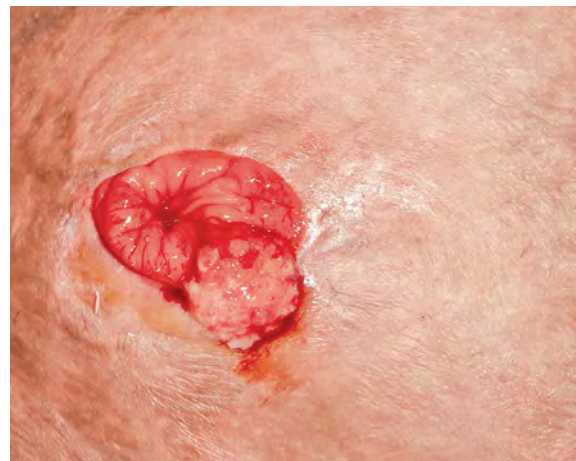- ◆ They are used as single agent and also in combination with chemotherapy drugs in phase II and III trial.
- ◆ Drugs are monoclonal antibody, cetuximab which blocks EGFR, bevacizumab which binds VEGF.
  - ❖ Dose of 5 FU is 400 mg/m<sup>2</sup>/day IV × 5 days once in 3-4 weeks for 6-12 months
  - ❖ Dose of leucovorin is 20 mg/m<sup>2</sup>/day × 5 days once in 3-4 weeks for 6 months
  - ❖ Dose of levamisole is 150 mg/day × 3 days once in 2 weeks for one year
  - ❖ Capecitabine is given orally 1250 mg/m<sup>2</sup> twice daily

### Radiotherapy (RT)

- ◆ Usually there is no role for RT as tumour is radioresistant.
- ◆ It is often used in locally advanced tumour, infiltrating the psoas major muscle or lateral abdominal wall, left sided colonic growth.
- ◆ It is also used in inoperable recurrent tumour.

### Follow-up of Carcinoma Colon

- ◆ For 3 years at regular intervals, once in 3–6 months.



**Fig. 22.46:** Patient has undergone left hemicolectomy earlier for sigmoid growth with a colostomy; now presenting as recurrence at colostomy site. It could be recurrence of original disease or could be new metachronous disease in the mucosa of the colostomy site. CT scan/CEA/PET scan will help to differentiate. Re-excision can be done if it is metachronous local growth.

#### This is by:

- ❖ Regular CEA analysis
  - ❖ Ultrasound abdomen
  - ❖ Barium enema X-ray
  - ❖ Colonoscopy
- Rise in CEA is a definite indicator of recurrence or secondaries  
In patients with raised CEA, radioisotope antibody study will show the site of recurrence or secondaries
- ❖ Serum alkaline phosphatase

#### Note:

- **Local recurrence:** Incidence of local recurrence after radical resection is 15%. 85% of recurrence is detected in 2 years. It is more in colocolic

and colorectal anastomosis than ileocolic. *Recurrence may be*—local/locoregional/regional/metastatic. *Recurrence may be*—true recurrence at anastomotic site, probably mucosal; adjacent and close to anastomotic site, at the original primary tumour bed; peritoneal recurrence; recurrence in adjacent organ. It is due to implantation of spilled tumour cells during easier surgery, incomplete resection, metachronous new lesion, retrograde lymphatic spread. It is identified by CEA, CT scan, radioisotope/radioimmuno assay, colonoscopy. It is treated by curative surgery with clearance, chemotherapy, RT.

- Colonoscopy after 1 year to see anastomotic site, new / missed polyp/metachronous growth.
- Later colonoscopy is done once in 3-5 years unless there is a family history (here yearly colonoscopy is needed).
- CEA estimation once in 3 months for 2 years. If there is a raise any time, further screening is done for recurrent/metastatic disease by CT/MRI/PET scan.

## Prognosis

Depends on:

- ◆ *Site*—left sided tumours has got better prognosis as they present early.
- ◆ *Type*—colloid carcinoma has got poorer prognosis.
- ◆ *Size* of the tumour.
- ◆ *Lymph nodes status*: Number of lymph nodes involved decides the prognosis.
- ◆ *Liver secondaries* has poor prognosis.
- ◆ *Age of the patient*.
- ◆ Associated diseases like *HIV*.
- ◆ *Stage* of the tumour.
- ◆ Presence of complications, perforation, peritonitis.

On the whole, it is a curable malignancy with proper surgery and adjuvant therapy.

5 year survival is:

Stage I – 90%.

Stage II – 75%.

Stage III – 50%.

Stage IV – less than 5%.

## ANGIODYSPLASIA OF COLON

- ◆ It is a vascular ectasia seen *commonly in right side* colon.
- ◆ It is uncommon in healthy individual.
- ◆ It is commonly seen in elderly of 70 years age. It is acquired malformation of aging.
- ◆ It is not common in left side colon. It is often associated with calcified aortic stenosis; and ectasia bleeding if present, stops once aortic stenosis is corrected.
- ◆ Common cause of rectal bleed in adults and elderly.
- ◆ *An acquired condition seen in caecum* and ascending colon due to degeneration of the mucosal and submucosal vessels of the colon.
- ◆ Diagnosis is by mesenteric angiography. *Angiographic criteria in angiodysplasia*—early and prolonged filling of draining veins; cluster of small arteries; visualisation of vascular tuft.
- ◆ Colonoscopic fulguration or resection is the treatment.
- ◆ Therapeutic embolisation is useful in 85% of cases.

## OGILVIE'S SYNDROME

- ◆ Described by Sir William Heneage Ogilvie in 1948.

- ◆ Also called as *colonic pseudo-obstruction* caecum more than 10 cm in diameter. Splenic flexure and descending colon goes for functional atony.
- ◆ Severe colonic ileus occurs without any mechanical obstruction.
- ◆ *Tympanic, nontender, distended* abdomen and bowel sounds will be normally present—are the clinical features. Features of causative etiology may be present.
- ◆ Occurs in critically ill patients.
- ◆ Due to sacral parasympathetic nerve dysfunction.
- ◆ Commonly seen in *right and transverse colon*.
- ◆ Due to sacral parasympathetic malfunctioning, there is atony of descending colon causing functional obstruction. Splenic flexure will be the junction of dilated and collapsed parts of the colon wherein parasympathetic supply of vagus ends and of sacral parasympathetic begins. Increased sympathetic activity causes colonic dilatation.

❖ It is seen in:

- Scleroderma, SLE, dermatomyositis
- Chaga's disease
- Myotonic dystrophy, multiple sclerosis
- Neuropathies
- Myopathies
- Hypothyroidism, diabetes mellitus
- CRF, renal transplantation
- Poisoning, sepsis, hypoxia
- Radiotherapy, orthopedic procedures
- Psychiatric disorders, drug abuse
- Retroperitoneal irritation by blood, urine, pancreatic enzymes
- Lumbar spine and pelvic trauma, shock, stroke
- Septicaemia, burns, MI
- Can be *idiopathic* also

- ◆ It is often seen as reactivation of Varicella zoster infection in the enteric ganglia causing dilatation of the colon.

◆ *Investigations*:

- ▶ Plain X-ray abdomen shows dilatation of colon.
- ▶ Barium enema will be normal.
- ▶ Careful gentle colonoscopy is useful as therapeutic also.
- ▶ CT abdomen to rule out mechanical obstruction of large bowel.

## Treatment

- ◆ Mainly conservative.
- ◆ Motility enhancing drugs like neostigmine and erythromycin are used. *Neostigmine* is given 2.5 mg IV for 3 minutes, showing response in 10 minutes in 90% of patients. But bradycardia should be watched for and atropine should be kept ready.
- ◆ Prokinetic drugs like cisapride/mosapride are used.
- ◆ Ceruletide decapeptide 0.3 µg/kg IM is used to stimulate intestinal motility.
- ◆ Ryle's tube aspiration.
- ◆ Flatus tube insertion. It is not very useful as disease is common in proximal colon.
- ◆ *Epidural anaesthesia* causes sympathetic blockade relieving pseudo-obstruction.
- ◆ *Colonoscopic decompression* is also useful.
- ◆ Correction of electrolyte imbalance.
- ◆ Sodium enema.



Caecal diameter more than 12 cm (critical) on X-ray indicates surgical exploration.

- ◆ Tube caecostomy; resection and exteriorisation.

## COLOSTOMY

It is an artificial opening made in the colon to the exterior (skin) to divert faeces and flatus.

### Types

1. **Temporary:** Is done in conditions wherein diversion is required to facilitate healing distally in the rectum or distal colon. And this is closed once the purpose is over.

Site of temporary colostomy is usually right hypochondrium and left iliac fossa.

It can be *loop colostomy* or *Devine's double-barrel colostomy* (wherein there is a gap between the two openings of colostomy which prevents spillage into the distal loop).

2. **Permanent** colostomy is always *end colostomy* placed in left iliac fossa, 6 cm above and medial to the anterior superior iliac spine.

Indications	
Temporary	Permanent
Congenital megacolon	AP-Resection.
Anorectal malformations	Carcinoma anal canal.
Sigmoid volvulus	After Hartmann's operation
Perforation of left sided colon	
Left sided colonic growth	
High anal fistula	
Trauma to left sided growth	

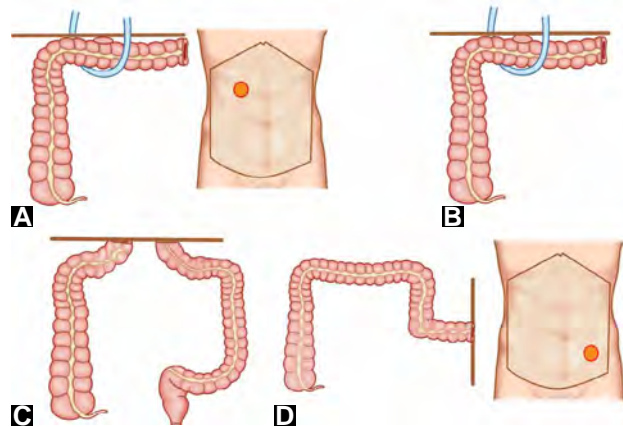
### Colostomy can be:

- ◆ Loop, end, double barrel.

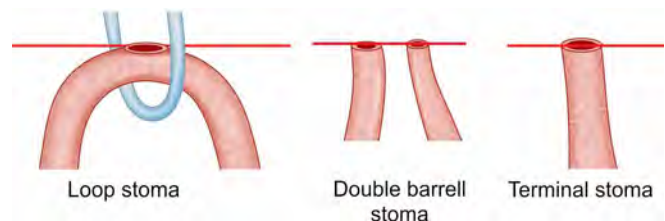
It can be:

- ◆ **Diversion colostomy:** It is done when there is breach in bowel wall, trauma, destruction, sphincter injuries, Crohn's, carcinoma rectosigmoid. It is usually brought out as an end colostomy with a mucus fistula or with a Hartmann's resection. It can be at sigmoid, descending and transverse colon.
- ◆ **Decompression colostomy:** It is done for obstructive lesions in rectosigmoid, toxic megacolon. Types—(1) *Blow hole* procedure is done as a single or multiple small stomas onto the skin to decompress colon in acutely ill patients with massively dilated or impending perforation of colon. Problems are—remaining possible ischaemic parts of the colon is not identified still risking perforation; peristomal skin complications and mucosal prolapse is common. (2) *Tube caecostomy*—It is technically easier without much complications; but tube getting blocked limits its use regularly. (3) *Loop transverse colostomy*—It serves as decompressing and diverting long stoma without getting blocked. It is done only in mobile colon.
- ◆ **Irrigation colostomy:** It avoids need for appliance wear; reduces the passage of uncontrolled gas with less leak of

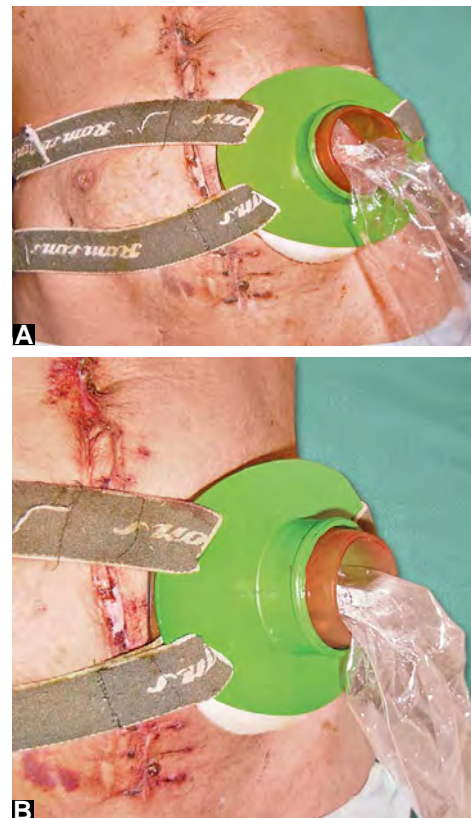
stools. But it is time consuming with chance of water intoxication due to excess water absorption during irrigation.



**Figs 22.47A to D:** Types of colostomy. (A) Temporary colostomy; (B) Loop colostomy; (C) Devine's double barrel colostomy; (D) Permanent colostomy.



**Fig. 22.48:** Different types of stomas used in colostomy.



**Figs 22.49A and B:** Diagram of colostomy in a patient with colostomy bag.

### Complications of colostomy

- ❖ Prolapse of mucosa (prolapse of distal loop mucosa is common)—commonest complication
- ❖ Retraction
- ❖ Necrosis
- ❖ Stenosis
- ❖ Herniation
- ❖ Bleeding
- ❖ Diarrhoea
- ❖ Enteritis
- ❖ Skin excoriation

Educating the patient regarding the proper usage of colostomy bags and proper care of the colostomy is very essential.

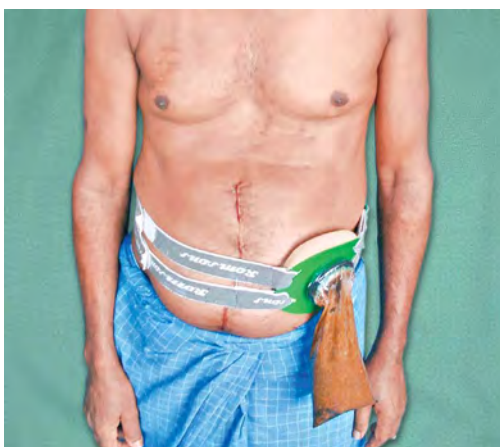### Colostomy Care

- ▶ Similar to stoma care.
- ▶ Initially stoma bag should be transparent as content is liquid stool but later it can be opaque.
- ▶ Regular consultation with stoma therapist.
- ▶ Care of the skin.
- ▶ Training for managing colostomy, its care to prevent leak, odour, and discomfort.

### Closure of Colostomy

*Criteria for temporary colostomy closure:*

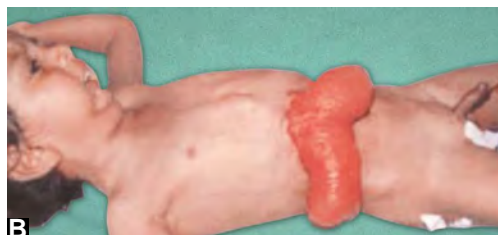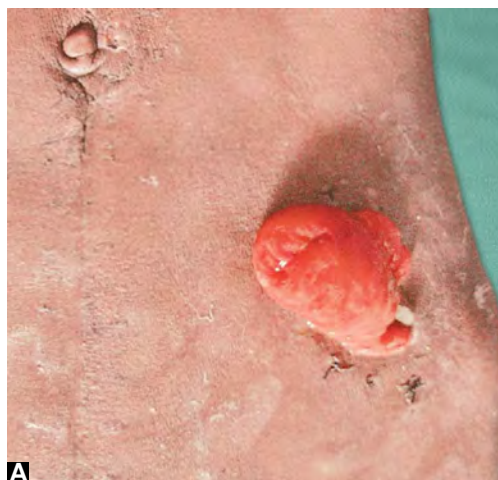- ◆ Integrity of distal colon should be normal and adequate.
- ◆ Anorectal sphincter should be normal.
- ◆ Cause for construction of colostomy is cured completely without any suspicious of recurrence of same disease distally.
- ◆ When temporary colostomy is done, it is closed usually after 3 months.
- ◆ *Two types of closure are present*—extraperitoneal and intraperitoneal type. *Now intraperitoneal closure is done.* Earlier extraperitoneal closure was done in loop colostomy by placing a spur in between and closing the antimesenteric part of the colon. It prevents the peritoneal contamination. But inadequate closure, leak, adhesions are the problems. *Intraperitoneal closure*—commonly advocated technique now, is done by placing a circumferential incision over the margin with skin edge. Incision is deepened to enter the peritoneum and pull out the colostomy stoma. Part adjacent to the



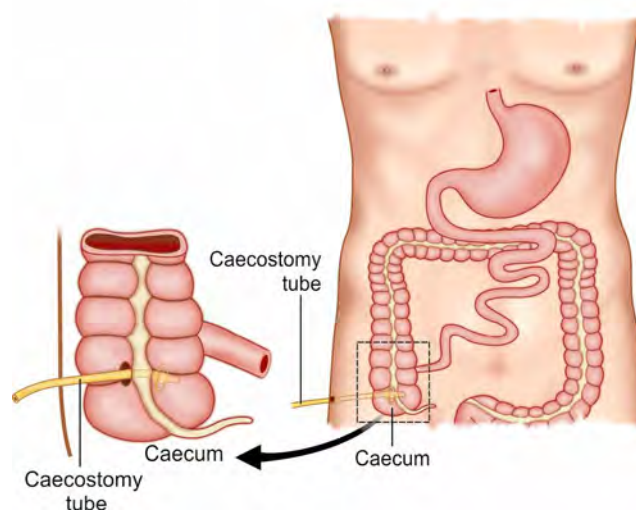
**Fig. 22.50:** Patient with colostomy bag. He has undergone abdominoperineal resection (APR) for carcinoma rectum.

skin is resected and anastomosed using silk/vicryl. Sutured bowel is placed into the peritoneal cavity. Drain is placed into the peritoneal cavity. Abdomen is closed in layers.

- ◆ Closure of colostomy is done after proper bowel preparation, under general or spinal anaesthesia.
- ◆ Proper postoperative care is important.
- ◆ Patient should perform anal sphincter exercises to prevent sphincter atrophy and to maintain sphincter tone.



**Figs 22.51A and B:** Prolapse of colostomy is a common complication.



**Fig. 22.52:** Caecostomy is often done in acute colonic conditions as diversion procedure after surgery distally like perforation closure and resection. But it is not as popular as colostomy because it may not function adequately, may get displaced or blocked. But it is technically easier and usually done by doing appendicectomy and passing Malecot's tube through appendicular stump. Removal is easier without any surgical intervention.

*The most vital test of a man's character is not how he behaves after success, but how he sustains defeat.*

## STOMA CARE

### Definition of Stoma

*Stoma* is an artificial opening or 'mouth like' to the exterior, the abdominal wall so as to drain the content from the tubular structures inside, like bowel or ureter. It is done for diversion of urine or faecal matter in case of malignancy, trauma, and sepsis or after surgery.

### Types

- ◆ **Ileostomy**—terminal 5 cm ileum is projected out, on to the skin of abdominal wall to drain semi-liquid, faecal matter.
- ◆ **Colostomy**—colon at different levels, can be brought out to the skin as required as colostomy, to divert faecal matter.
- ◆ **Cutaneous ureterostomy**—cut ends of one or both ureters are apposed to the skin of abdominal wall.
- ◆ **Ileal urinary conduit**—segment of isolated ileum can be used to drain urine from the ureter as urinary ileal conduit. Ureters are anastomosed to a closed ileal conduit. Ileal stoma is brought out as stoma. Different types of continent ileostomies are in use to prevent leak, soakage and discomfort.
- ◆ **Vesicostomy**—it is done in children. Here anterior wall of bladder is brought out and bladder mucosa is sutured to the skin of abdominal wall.

Stoma created may be *round* (commonly) or *square* in shape.

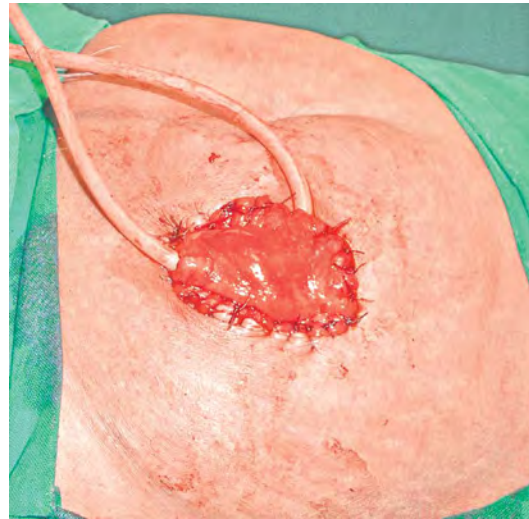### Preparation and Counselling of the Patient for Stoma

- ◆ To certain extent stoma of any type causes psychological and physical trauma to the patient, as it is nonphysiological, distressing and socially not acceptable.
- ◆ Patient should be explained about the procedure and should be convinced and consoled about the stoma.
- ◆ Detailed meaning, explanation and after care of the stoma should be discussed.
- ◆ Indication for the stoma and consent for the same should be taken.
- ◆ Reassurance about the stoma, its care, and its position should be diagrammatically explained to the patient and his close relative.
- ◆ In case of obstructive disease, stoma is done as an inevitable procedure to relieve the obstruction, often it may be temporary.
- ◆ Proper bowel preparation by bowel wash, gut irrigation is required before surgery.
- ◆ *The surgeon selects the site of the stoma.*
  - ▶ Stoma is usually sited midway between anterior superior iliac spine and umbilicus.
  - ▶ It should be away from the belt line.
  - ▶ It should be away from the scar, creases, and bony points.
  - ▶ Patient should be assessed for proper size, adequacy for stoma in lying down, sitting, and standing positions.
  - ▶ Proper stoma appliances should be decided after thorough check-up and discussion with patient and patient's relative.
  - ▶ Stoma site should be marked properly before surgery.
  - ▶ Ileostomy is usually sited in the right iliac fossa, colostomy in left iliac fossa.
  - ▶ Allergy for the particular appliances should be checked for.
  - ▶ The patient should consult stoma therapist.

### Postoperative Care for the Stoma

- ◆ Stitches are removed in 6–10 days.

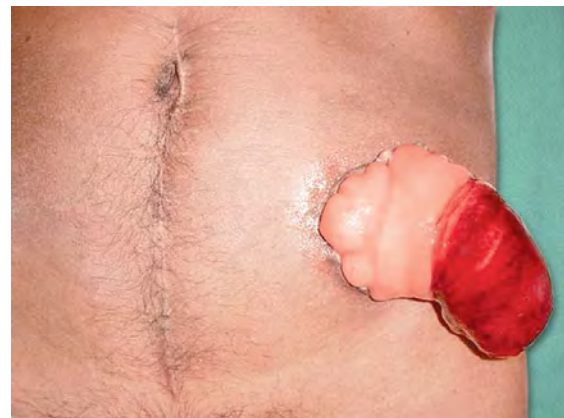- ◆ Dressing should be done first over the stoma and after placement of appliance, laparotomy wound is dressed otherwise stoma appliance will not sit properly.
- ◆ Patient should be observed for any complications.
- ◆ Once wound has healed patient can take bath by removing the appliances. After bath skin is dried up and stoma appliances can be fit again.
- ◆ Patient should be taught about the stoma care and its appliances.
- ◆ Care and prevention of skin excoriation due to leak is also looked into.
- ◆ Psychotherapy is given for the patient.
- ◆ Skin should be *absolutely dry* prior to placing the stoma appliances.



**Fig. 22.53:** Right sided temporary loop colostomy. Note the tube kept in between.

### Complications of Stoma

- ◆ Skin excoriation.
- ◆ Mucosal prolapse—common complication.



**Fig. 22.54:** Colostomy prolapse is the common complication.

- ◆ Stenosis and block.
- ◆ Infection either bacterial or candidal.
- ◆ Diarrhoea due to irritation.
- ◆ Leak due to improper fitting of the appliances, scar, irregularity of stoma, prolapse.

- ◆ Bleeding from the stoma edge.
- ◆ Herniation of the abdominal contents adjacent to stoma.

### Skin Excoriation

It is a major problem in stoma patients. It is basically due to leak adjacent to appliances.

### Causes for Excoriation

- ◆ Leak due to improper appliances.
- ◆ Wet skin before placing the appliance.
- ◆ Inadequate stoma hole.
- ◆ Improper and inadequate adhesive sheet usage.
- ◆ Allergy.
- ◆ Infection like of bacteria and candida.
- ◆ Altered weight of the patient.
- ◆ Stoma bag is overfilled or kinked or air in the stoma bag.

### Treatment of Excoriation

- ◆ Control of infection by antibiotics and control of moniliasis.
- ◆ Allergy has to be confirmed, and if it is the cause, the agent is found out and treated as required.
- ◆ Zinc oxide cream application.
- ◆ Change of the type of appliance.
- ◆ Refashioning of the stoma.

## STOMA APPLIANCES

Stoma appliances are devices, which are used to collect and dispose the effluent materials which come out of the stoma.

### Ideal stoma appliance is:

- ❖ Leak proof
- ❖ Should not damage the stoma and surrounding skin
- ❖ Should prevent odour
- ❖ Should be available
- ❖ Easier to use

## Types of Appliances

It can be:

- ◆ *Closed type* is discarded when full and is used in patients with well-formed stool.
- ◆ *Drainable type* is used in patients with loose liquid stool. It can be emptied and retained and reused. Immediately after colostomy, drainable appliance is used. Later, it can be changed over to closed type.

It can also be:

- ◆ *One-piece stoma* appliance as a bag with adhesive system attached which adheres to skin around the stoma.
- ◆ *Two-piece stoma* appliance has got a flange with adhesive system and a bag over it, which can be removed and replaced with a new one without disturbing the flange underneath.

Bag can be:

- ◆ *Transparent*, in which fluid can be visualised. It is used in initial period of the stoma.

- ◆ *Opaque*, in which fluid cannot be visualised. It is used eventually later.

## General Care and Advice to Patients with Stoma

- ◆ Patient can have normal diet. Diet, which regulates the bowel action, is better. Plenty of water is advisable.
- ◆ Patient can go for normal work, exercise like sports, swimming, tennis. Stoma appliances suitable for these works are available.
- ◆ Antidepressants, anticholinergics might cause constipation. So these drugs should be taken carefully.
- ◆ Using irritant solutions near stoma should be avoided. It may lead to dangerous complications.
- ◆ Patient can have normal sexual activity.
- ◆ Patient should have additional stoma bags in hand so as to use if required urgently.
- ◆ Patient should be aware of different appliances available and should be well-versed with its use. He can take the help of the stoma societies.

## FAECAL FISTULA

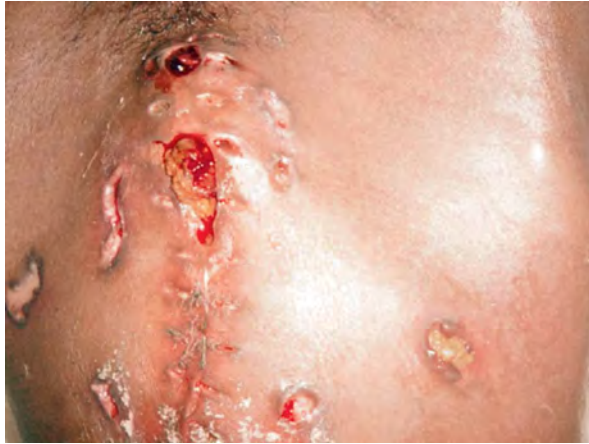- ◆ This is a dangerous entity.
- ◆ It commonly occurs after appendectomy (gangrenous), ileal resection, colonic surgery, malignancy, ileocaecal TB, actinomycosis and Crohn's disease.
- ◆ It may be from the ileum or the colon.
- ◆ It may be single or multiple openings.
- ◆ More proximal the fistula, more is the severity in fluid and electrolyte imbalance.
- ◆ It may be from the main incision wound or from the drain wound.
- ◆ If there is no distal obstruction, the fistula will heal spontaneously, but may take a longer time.
- ◆ *Fistulogram* often delineates the track.
- ◆ CT fistulogram with CT scan abdomen is essential.
- ◆ Often gastrograffin study is also useful to study the fistulous track in detail.

### Factors preventing closure (FRIENDS)

- ❖ F : Foreign body in fistula tract
- ❖ R : Radiation enteritis
- ❖ I : Inflammatory bowel disease
- ❖ E : Epithelialisation of tract
- ❖ N : Neoplasm
- ❖ D : Distal obstruction
- ❖ S : Sepsis

### Factors preventing spontaneous closure of faecal fistulas

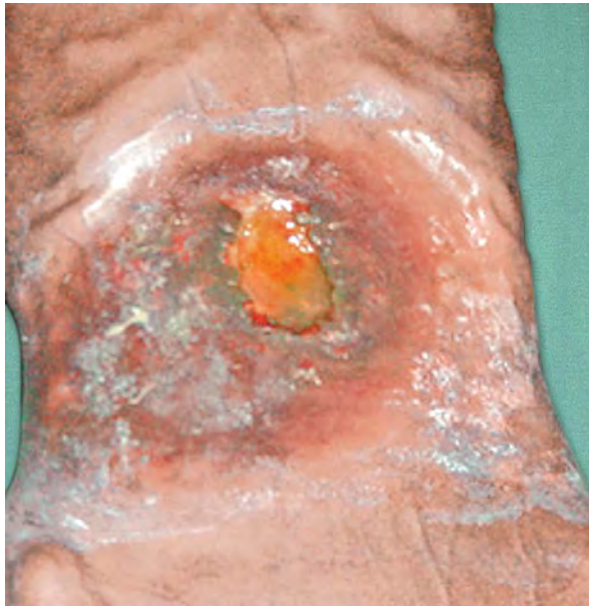- ❖ High output > 500 ml/24 hr
- ❖ Distal bowel obstruction
- ❖ Sepsis, inflammatory bowel disease
- ❖ Tuberculosis
- ❖ Cancer
- ❖ Radiation enteritis
- ❖ Foreign body in fistula tract
- ❖ Epithelialisation of tract



**Fig. 22.55:** Multiple faecal fistulous openings in the abdominal wall. Patient has undergone laparotomy for acute peritonitis.

#### Investigations for faecal fistula

- ❖ Fistulogram using gastrograffin
- ❖ CT scan and CT fistulogram
- ❖ Barium enema study



**Fig. 22.56:** Gastrointestinal faecal fistula after an emergency surgery for ileal perforation with severe peritonitis. Patient recovered after long-term stay in the hospital.

### Treatment

- ◆ TPN and blood transfusion may be required to improve the nutritional status of the patient.
- ◆ Sepsis is controlled with proper antibiotics.
- ◆ Management of fluid and electrolyte loss.
- ◆ Skin is protected from excoriation by using zinc oxide cream.
- ◆ If it persists, later exploration and resection is done.
- ◆ The cause is treated.
- ◆ Bypass may be required. (*Most of the time, the decision is, taken on table during surgery*).

## ■ PREPARATION OF LARGE BOWEL FOR SURGERY

### Principle Behind Bowel Preparation

Colon contains large amount of bacteria up to  $10^9$  / ml of faeces. Most common anaerobe is bacteroides; commonest aerobe is *Escherichia coli*; *Pseudomonas*, *Enterococcus*, *Proteus*, *Klebsiella*, *Streptococcus* are other organisms. Bowel preparation is done to clear this bacterial load to reduce postoperative complications.

### Methods Used

#### 1. Mechanical bowel preparation

- ▶ *Polyethylene glycol (PEG)* is a non-absorbed sodium sulphate solution, 2–3 litres of which is asked to drink by the patient along with plenty of additional fluids orally. It cleans the bowel by passing loose stool for 10–15 times in 12 hours. It acts by its hygroscopic action. *Side effects* are—nausea, vomiting, and abdominal cramps. Antiemetics are often needed. It is ideal in renal failure, ascites, cirrhosis, CCF.
- ▶ *Sodium phosphate* is an alternative to PEG as smaller volume is sufficient to take. But it causes electrolyte imbalance. Its efficacy is similar to PEG. But patient compliance is better with sodium phosphate. It can cause hyponatraemia, hypocalcaemia, hypocalcaemia and hypophosphataemia in case of renal dysfunction. In such patients it is contraindicated.
- ▶ *Other methods*—(1) *Total gut irrigation* daily using 200 ml of *oral mannitol* or through nasogastric tube for 3 days prior to surgery. (2) *Bowel wash* daily for 3 days prior to surgery using 2 litres of normal saline (not water as it will cause water intoxication); it cleans entire large bowel. (3) Senna, castor oil, bisacodyl. (4) Repeated enemas. *PEG or sodium phosphate has taken over all this methods.*

*Contraindications* for mechanical bowel preparation: Complete bowel obstruction and perforation.

#### 2. Antibiotics—parenteral and as bowel antiseptics

- ▶ *Oral neomycin* (gentamycin, streptomycin were used in olden days) 1 gram, *erythromycin* 1 gram, is used 3 days prior to surgery. Alternatively *ciprofloxacin* and *metronidazole* are used. IV fluids should be given in addition to these patients to maintain adequate hydration.
- ▶ *IV antibiotics 4 hours before making incision*, reduces the incidence of sepsis. Usually cephalosporins are given.

### Controversies

- ◆ There is doubt about the advantages of preoperative mechanical bowel preparation even though it is practiced universally.
- ◆ Oral antibiotics to reduce the bacterial load in the colon is also controversial. However, preoperative single dose parenteral antibiotic improves the result and reduces the sepsis.

### Indications for Large Bowel Preparation

- ◆ Carcinoma colon (especially left sided).
- ◆ Anorectal malformations.
- ◆ Megacolon.
- ◆ Carcinoma rectum.
- ◆ Surgery for ulcerative colitis.

Pathological pouches	Experimental physiological pouches	Natural pouches
<ul style="list-style-type: none"> <li>• <i>Zenker's diverticulum</i> causing pharyngeal pouch</li> <li>• <i>Physick's pouch</i> in the rectal wall in between rectal valves</li> <li>• <i>Hartmann's pouch</i> is protruded pathological gallbladder infundibulum</li> </ul>	<ul style="list-style-type: none"> <li>• <i>Heidenhein pouch</i>: To study gastric physiology done in stomach</li> <li>• <i>Pavlov pouch</i>: Gastric pouch created with retaining <i>vagii</i> to study gastric physiology</li> </ul>	<ul style="list-style-type: none"> <li>• <i>Rathke's pouch</i> in pituitary</li> <li>• <i>Seessel's pouch</i> in pharynx</li> <li>• <i>Morrison's hepatorenal pouch</i></li> <li>• Rectouterine pouch of <i>Douglas</i></li> </ul>

- ◆ FAP.
- ◆ Diverticulitis.
- ◆ High pelvirectal fistulas.
- ◆ Before colonoscopy.

## ■ SURGICAL POUCHES

Pouches are created as reservoir whenever needed as a replacement for the existing reservoir like stomach, rectum, and urinary bladder.

### Types

- ◆ *Jejunal pouches*: It is used for stomach. Hunt Lawrence pouch, omega loop, Roux en loop are the examples. It is commonly used after total gastrectomy. Hunt Lawrence pouch is 15 cm in length.
- ◆ *Ileal pouch*: It is used as rectal reservoir, urinary reservoir, ileostomy reservoir. Examples are—J, S, W, H pouches after proctocolectomy with ileo anal anastomosis; Koch's pouch for ileostomy; Ileal pouch for bladder replacement or cutaneous ureterostomy.
- ◆ *Colonic*: Sigmoid reservoir or caecal/ileocaecal reservoir is often used to replace urinary bladder.

### Principles

- ◆ Blood supply should be preserved.
- ◆ Mesentery should extend adequately.
- ◆ Bowel is opened on the antimesenteric border and sutured using vicryl posterior and anteriorly.
- ◆ Created pouch is anastomosed to the required area from its summit or from open end.

### Complications

- ◆ Obstruction (25%) is the common complication. It may be due to stomal stricture, internal hernia, volvulus and adhesions.
- ◆ Pouch disruption and leak can occur which is usually treated conservatively.
- ◆ Pelvic abscess formation in ileoanal pouch is confirmed by clinical features of fever, back pain, raised total count, CT scan. It is treated with antibiotics, drainage per abdomen or reservoir excision and ileostomy.
- ◆ Pouchitis: It is the common problem (20%). Tenesmus, bloody diarrhoea, spasm, back pain, fever, cramps, dehydration are the presentations. It is treated conservatively with antibiotics, hydration, *probiotics*.
- ◆ Vaginal fistula formation.
- ◆ Anal canal stricture formation.
- ◆ Faecal incontinence.
- ◆ In urinary conduits, sepsis, acidosis, electrolyte imbalance, stone formation, urine leak are the complications.

### Note:

Pouch is contraindicated in *Crohn's disease*.

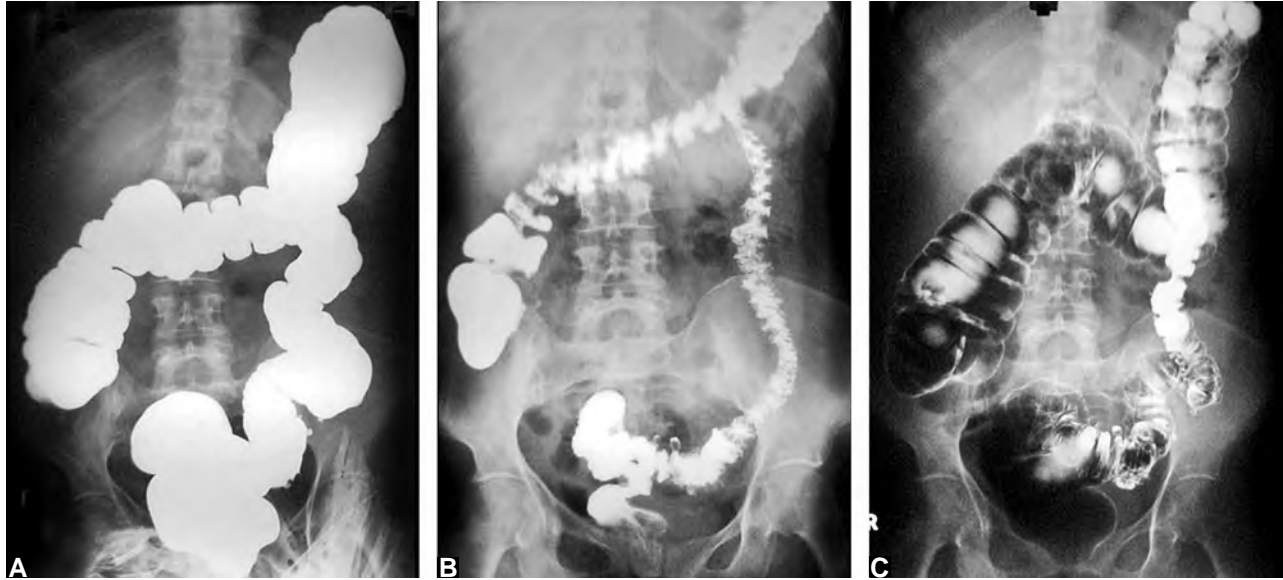
## ■ BARIUM ENEMA

- ◆ It is the contrast X-ray done to visualise large bowel.
- ◆ Therapeutic barium enema is done in intussusception in children.

Barium enema	
Indications	Finding
Carcinoma colon	Irregular filling defect
Ileocaecal tuberculosis	Pulled up caecum, obtuse ileocaecal angle
	Filling defect, incompetent ileocaecal valve
Ulcerative colitis	Loss of haustrations, lead pipe appearance
Colonic polyps	Smooth, regular filling defect
Congenital mega colon	Narrow zone, zone of cone, dilated proximal segment
Diaphragmatic hernia	Colonic shadow in the left thoracic cavity
Gastrojejunocolic fistula	Leak into the stomach from colon

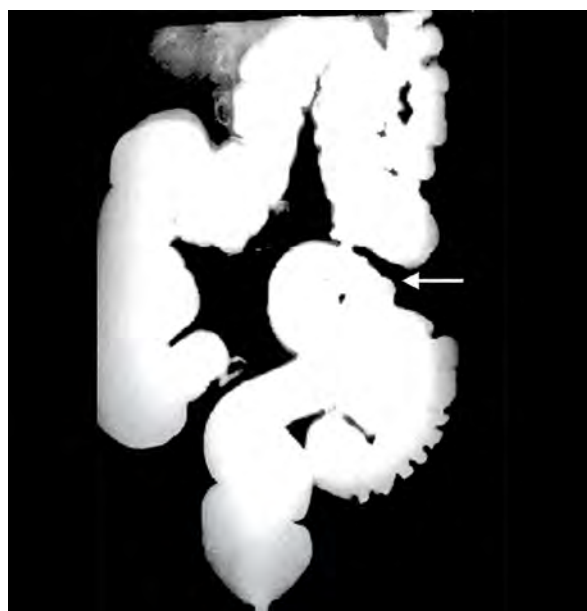

Fig. 22.57: Barium enema showing normal peristaltic movement.



**Figs 22.58A to C:** Barium enema X-ray in different indications should be taken with complete filling, postevacuation and after air-contrast.

### Procedure

Laxative is given previous evening. Enema is given on same day before doing the procedure. About one litre of barium sulphate solution is infused into the colorectum per anally through enema tube. In children 12F Foley's catheter is used. Once complete filling occurs, X-ray is taken. Patient is asked to evacuate the

barium and postevacuation film is taken. After that, air is inflated into the colon which gives a better contrast to visualise thin mucosa of the colon (**air-contrast barium enema**).

### Contraindications

Acute colonic conditions.

# Chapter 23

## Intestinal Obstruction

### CHAPTER OUTLINE

- ❖ Intestinal Obstruction
- ❖ Dynamic Obstruction
- ❖ Duodenal Atresia
- ❖ Small Intestine Atresia
- ❖ Malrotation
- ❖ Meconium Ileus
- ❖ Intussusception
- ❖ Volvulus
- ❖ Sigmoid Volvulus
- ❖ Paralytic Ileus
- ❖ Adhesions and Bands
- ❖ Internal Hernias

### ■ INTESTINAL OBSTRUCTION: TYPES

#### Classification I: Depending on Aetiopathology

- A. *Dynamic*.
- B. *Adynamic*.

#### Classification II: Depending on Type of Obstruction

1. *Acute*: Common in small bowel.
2. *Chronic*.
3. *Acute on chronic*: Common in large bowel.
4. *Closed loop* obstruction.

	<b>Dynamic</b>		<b>Adynamic</b>
	<i>In the wall</i>	<i>In the lumen</i>	
<i>Outside the wall</i>			
Hernia—25% Adhesions—40% Volvulus Intussusception	Tuberculous stricture Crohn's disease Malignancy	Gallstones Roundworm Inspissated faeces Meconium ileus	Cessation of peristalsis Postoperative period Electrolyte imbalance Spinal injuries Uraemia Diabetes mellitus Retroperitoneal—haematomas and surgeries Renal surgeries Mesenteric ischaemia Pseudo-obstruction

#### Classification III: Depending on Site of Obstruction

	<b>Proximal small bowel</b>	<b>Distal small bowel</b>	<b>Large bowel</b>
<i>Site of obstruction</i>	<i>Duodenum and jejunum</i>	<i>Ileum</i>	<i>Anywhere in large intestine</i>
Causes:	Congenital Lipomas Leiomyomas Malignancy Bands and adhesions	Tuberculosis strictures Malignancy Crohn's Gallstones Hernias—common cause Roundworm Congenital	Malignancy Tuberculous stricture Anorectal malformation Volvulus Congenital megacolon Bands

Contd...



Contd...

	<b>Proximal small bowel</b>	<b>Distal small bowel</b>	<b>Large bowel</b>
Clinical features:	Severe vomiting, dehydration, no or less distension, colicky pain	Central distension, vomiting, dehydration Central abdominal pain	Constipation, distension— early; Late vomiting less pain
Special features:			
Plain X-ray	Valvulae conniventes	Characterless Central fluid level	Dilatation and haustration

## Classification IV

- A. Congenital.  
B. Acquired.

<b>Congenital</b>	<b>Acquired</b>
Anorectal malformations	Hernia (commonest)
Congenital megacolon	Postoperative
Adhesions	Intussusception
Duodenal atresia	Roundworm
Intestinal atresia (ileal)	Gallstones
Bands and adhesions	Tuberculosis
Malrotation	Malignancy
Volvulus neonatorum	Internal hernias

### Bolus obstruction

- ❖ Worms
- ❖ Gallstones
- ❖ Trichobezoars
- ❖ Phytobezoars
- ❖ Meconium pellets
- ❖ Foreign body
- ❖ Food bolus
- ❖ Stercoliths

*Intestinal obstruction* still is a challenging, commonly acute condition in surgical practice. *Adhesions* are becoming the more common cause of intestinal obstruction than hernia nowadays. Common causes for adhesions are gynaecologic surgeries, appendectomy, colonic and pelvic surgeries. 20% cases of intestinal obstruction are due to malignancy or its peritoneal *carcinomatosis* spread. More than 50% of intestinal obstruction in Western countries are due to adhesions; 20% due to malignancies; 10–15% due to hernias. Crohn's disease is also becoming a common cause of obstruction.

### Note:

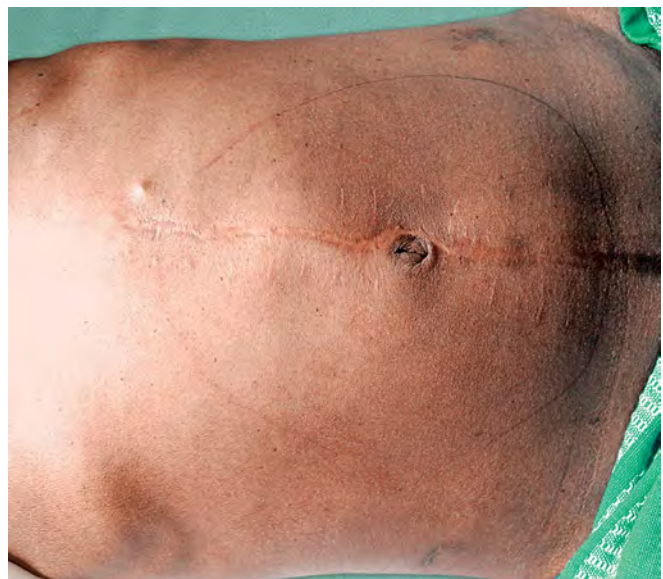- Adhesions and hernias are most common causes of intestinal obstruction
- Depending on **degree of block** intestinal obstruction can be *complete, partial or partial circumferential*. *Subacute obstruction* implies incomplete obstruction.
- Depending on the **vascular compromise** it can be – simple obstruction with intact blood supply or *strangulated* with compromised blood supply.
- 80% of intestinal obstruction is in small bowel; 80% of small bowel obstructions are due to benign cause. 70–80% of large intestine obstruction is due to malignancy, others being volvulus and tuberculosis.

## ■ DYNAMIC OBSTRUCTION


- ◆ It is mechanical blockage of normal propulsion and passage of intestinal contents.
- ◆ Obstruction may be external/internal; partial (incomplete or subacute)/complete; acute/acute on chronic/or chronic; simple/closed loop/strangulation; congenital/acquired; proximal/distal.
- ◆ Earlier, hernia was the commonest cause of intestinal obstruction. Now adhesions (40%) are the commonest cause especially in developed countries and hernia being 15–25% common. In developing countries both adhesions and hernia are the common causes of intestinal obstruction.
- ◆ *Adhesions* commonly cause small bowel obstruction than large bowel.
- ◆ Eighty per cent of intestinal obstruction occurs in small bowel; 20% in colon. 70% of colonic obstruction is due to malignancy. Other 30% is due to volvulus; diverticulitis, inflammatory cause like tuberculosis, etc.
- ◆ Mortality is 3% in obstruction without strangulation; 30% in obstruction with strangulation.
- ◆ Recurrent obstruction is more common in adhesions.

## Pathology and Pathogenesis

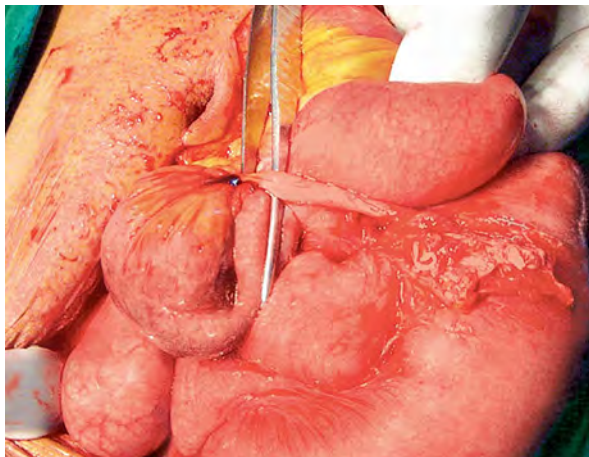
- ◆ *Changes proximal to the bowel obstruction:*



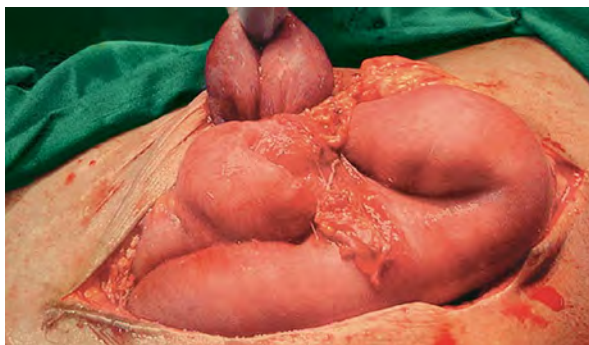**Fig. 23.1:** Step ladder peristalsis with visible dilated bowel loop in intestinal obstruction due to adhesions – post-laparotomy patient.



- ▶ Fluid collects just proximal to the obstruction which is derived from saliva, stomach, pancreas and intestine. Because of oedema and inflammation absorption decreases, sequestration of fluid from the circulation into the lumen occurs and bacteria (*E. coli*, *Klebsiella*, anaerobes, bacteroides and other organisms) multiply, toxins are released—*toxaemia* occurs. This leads to severe dehydration, electrolyte imbalance.



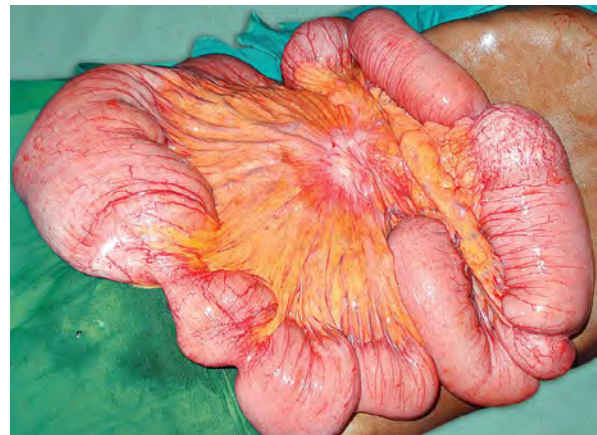
**Fig. 23.2:** Intestinal obstruction due to band. Note the ischaemic bowel under the band.



**Fig. 23.3:** Postoperative internal hernia with obstruction.

- ▶ Proximal to the collected fluid, air accumulates (derived from *swallowed air* (70%), diffusion from blood into the lumen (20%), from digested product and bacterial action (10%)), in which, main component is nitrogen (90%) and also hydrogen sulphide. During vigorous peristalsis, air enters the distal fluid, results in *churning*, is the reason to cause *multiple air-fluid levels in plain X-ray abdomen*.

- ▶ *Defective absorption*, decreased fluid intake, loss of fluid by vomiting, sequestration of fluid into the bowel lumen—leads into severe dehydration, fluid and electrolyte imbalance.
- ▶ Inflammatory response in the bowel wall (*intramural inflammation*) causes accumulation of activated neutrophils and macrophages in the muscle wall which release reactive enzymes and cytokines. These substances damage secretory and motor process of muscle leading into dilatation of the bowel. Increased release of *nitric oxide* in muscle wall and production of intramural reactive oxygen metabolites alter gut motility and permeability.
- ▶ *Intestinal wall hypoxia* is also the cause for dilatation.
- ▶ In first 12 hours of obstruction, there is *only decreased absorption* which causes accumulation of fluid and electrolytes in the lumen.
- ▶ After 12 hours, there is also *increased intestinal secretion* causing further accumulation of the fluid.
- ▶ Accumulation of bacterial toxins, bile salts, prostaglandins, and mucosa-derived free radicals, VIP—all increase the luminal secretion of fluid in obstructed bowel.
- ▶ Dilatation of bowel wall increases *intraluminal pressure* which exceeds the bowel wall *venous pressure* causing ischaemia which causes further dilatation and *ischaemic injury*. This leads into eventual blockage of arterial perfusion causing bowel wall necrosis/gangrene.
- ▶ *Increased bacterial colony* in the bowel (Normal flora is less than  $10^6$  colonies/ml in jejunum and  $10^8$  colonies /ml in the ileum) due to altered luminal content and environment → multiplication → toxins → further mucosa damage → disrupted mucosal defense/barrier/integrity → *translocation of bacteria across mucosa* into submucosa and also absorption of bacterial and other toxins into the circulation → bacteraemia/toxaemia/septicaemia/SIRS/MODS.



**Fig. 23.4:** Multiple strictures in the small bowel with dilated bowel – intestinal obstruction probably due to tuberculosis.

#### Factors causing systemic problems in intestinal obstruction

- ❖ Dilatation of the bowel
- ❖ Decreased absorption across mucosa
- ❖ Increased secretion into the lumen
- ❖ Intramural inflammation and hypoxia
- ❖ Increased intraluminal pressure
- ❖ Venous congestion and increased venous pressure
- ❖ Disrupted mucosal barrier → bacterial translocation

*The coexistence of intestinal colic and borborygmi, establishes the diagnosis of obstruction of the small intestine in more than 9 out of 10 cases.*

—Clarence Dennis

◆ **Changes at the site of the obstruction:**

Initially venous return is impaired

↓  
Congestion, oedema of bowel wall occurs which turns purple.

↓  
Later this jeopardizes the arterial supply.

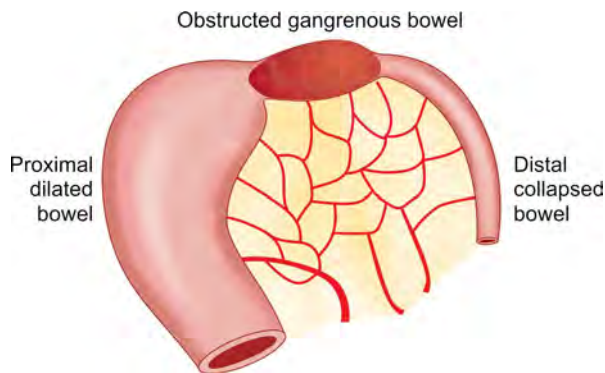↓  
Loss of shininess, blackish discolouration, loss of peristalsis.

↓  
**Gangrene.**

↓  
Perforation occurs.

↓  
Bacteria and toxins migrate into the peritoneum.

↓  
**Peritonitis.**



**Fig. 23.5:** Gangrenous bowel with proximal dilated and distal collapsed bowel segments.

**Note:**

- Causes for strangulations are—external like hernia (by constriction ring of the sac), adhesions, bands; compression in the wall causing mechanical block and compromised blood supply like in volvulus, intussusception; increased intraluminal pressure like closed loop obstruction; mesenteric ischaemia.
- Morbidity, poor outcome and mortality are more common in intraperitoneal strangulation than in strangulation of hernia as it is localised with less fluid loss.
- Outcome also depends on age of the patient, extent of the disease and time at which patient reaches for therapy.
- **Massive 3rd space fluid loss**, dehydration, hypovolaemia, hypotension, hypochloroemia, hypokalaemia, metabolic alkalosis, oliguria, azotemia, haemoconcentration (after fluid therapy haematocrit falls indicating the need for blood transfusion).
- **Translocation of bacteria** across oedematous small bowel wall causes septicaemia.

◆ **Closed loop obstruction:**

- ▶ When there is obstruction in the large bowel, with ileocaecal valve competence (40%), pressure increases in the caecum.

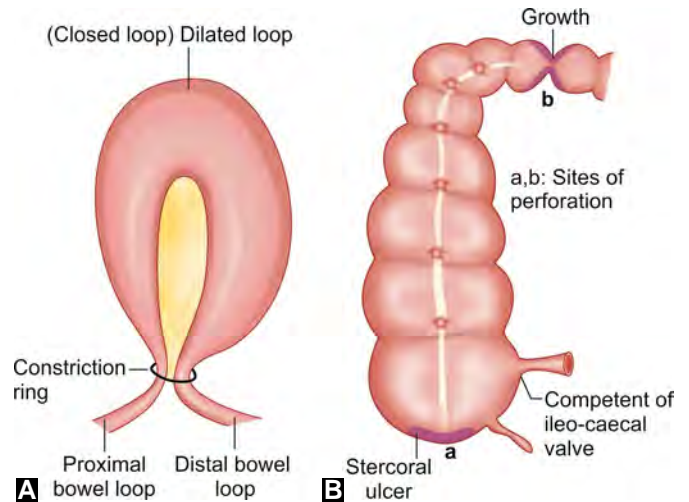
↓  
Stercoral ulcer in the caecum.

↓  
Gangrene.

↓  
Perforation.

↓  
Peritonitis (Faecal).

- ▶ Perforation also can occur at the site of obstruction due to the malignant growth.



**Figs 23.6A and B:** (A) Closed loop obstruction. Here loop of the bowel is obstructed at its point of entry and exit creating closed loop; (B) Closed loop obstruction of ileo-caecal region.

- ▶ Closed loop obstruction also can occur when bowel get obstructed at both proximal and distal parts of the loop of the bowel. It can occur in external or internal hernias, volvulus, etc. Necrosis and perforation are both common at obstructed site and over the convex summit of the bowel content.

◆ **Bowel distal to the obstruction is inactive and collapsed.**

**Changes in intestinal obstruction**

**Proximal to obstruction**

❖ **Distension of bowel –**

- By gas due to *swallowed air* (70%), from blood in the lumen (20%), from bacterial action and digestion (10%); mainly N<sub>2</sub> and H<sub>2</sub>S.
- *Due to fluid* mainly of digestive juices which normally get absorbed, but in obstruction absorption ceases and accumulated fluid causes bowel distension (1500 ml saliva, 2000 ml gastric juice, 1000 ml bile, 1500 ml pancreatic juice and 3000 ml from small intestine [succus entericus]); often oedematous bowel wall further secretes more fluid into the lumen aggravating the distension. This fluid is toxic with high bacterial load.

❖ **Peristalsis** initially increases (*borborygmi*) to overcome obstruction; but later fatigue develops and peristalsis ceases.

**Distal to the obstruction** – bowel initially empties the content and become collapsed and contracted remaining silent.

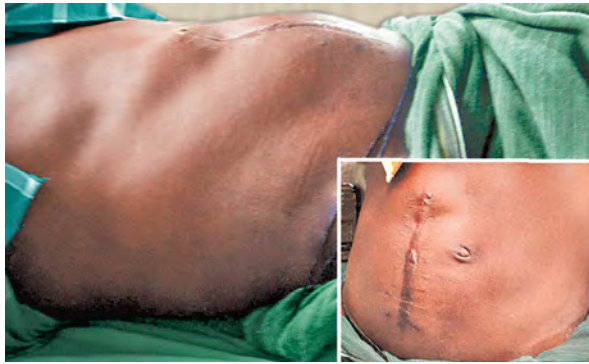**At the level obstruction** depends on cause strangulation, perforation, peritonitis can occur.

**Systemic features** – Toxaemia, septicaemia, renal failure, ARDS, SIRS, MODS can occur.

**Clinical Features**

◆ **Abdominal pain:**

- ▶ Initially colicky and intermittent: later continuous and severe.
- ▶ Pain is the first symptom to develop which is sudden and severe. Initial colicky pain suggests obstruction and eventual diffuse persistent pain suggests strangulation. Pain begins usually around umbilicus in small bowel obstruction.



**Fig. 23.7:** Step ladder peristalsis seen in small bowel obstruction. Note the previous laparotomy scar signifies obstruction is due to adhesions. Laparoscopy and proceed—is the needed management.

- ▶ In small bowel obstruction, it is crampy, recurrent paroxysms occurring as short crescendo/decrecendo episodes (of 30 seconds).
- ▶ In large bowel obstruction, it is of longer episodes of minutes (In paralytic/adynamic ileus, pain is diffuse and mild).
- ◆ **Vomiting:**
  - ▶ In *jejunal* obstruction, it is early and persistent.
  - ▶ In *ileal* obstruction, it is recurrent occurring at an interval; initially bilious later faeculent.
  - ▶ In *large bowel* obstruction, vomiting is a late feature.
- ◆ **Distension:**
  - ▶ It is absent or minimal in case of *jejunal* obstruction
  - ▶ Obvious with visible intestinal peristalsis (VIP) and borborygmi sounds in case of *ileal* obstruction—*Step ladder peristalsis*.
  - ▶ It is enormous in case of *large bowel* obstruction.
- ◆ **Constipation:**
  - ▶ It is *absolute*, i.e. neither faeces nor flatus is passed.

#### Exceptions

- ❖ Richter's hernia obstruction
- ❖ Gallstone obstruction
- ❖ Mesenteric vascular occlusion
- ❖ Intestinal obstruction with a pelvic abscess

- ◆ **Dehydration:**
  - ▶ Leads to oliguria → renal failure.
- ◆ **Features of toxemia and septicaemia:**
  - ▶ Tachycardia, tachypnoea, fever, sunken eyes, cold periphery.
- ◆ **Abdominal tenderness:**
  - ▶ It is initially localised but later becomes diffuse—is a feature of intestinal obstruction. Rebound tenderness and guarding will not be present in simple obstructions which are features of strangulation.
- ◆ **Features of strangulation:**
  - ▶ Continuous severe pain, shock, tenderness, rebound tenderness (*Blumberg's sign*).
  - ▶ Guarding and rigidity, absence of bowel sounds.

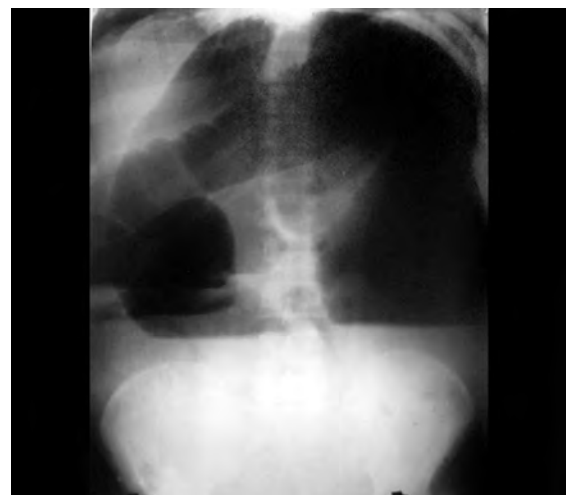- ▶ In case of strangulated hernia, a swelling which is tense, tender, rigid, irreducible, no expansile impulse on coughing and history of recent increase in size is seen.
- ◆ **Temperature:**
  - ▶ Fever signifies inflammation in the bowel wall/ ischaemia/perforation.
  - ▶ Hypothermia can occur when septicaemia develops due to lack of pyrogenic response. It suggests poor prognosis.
- ◆ **Bowel sounds:**
  - ▶ They are increased—high-pitched metallic (rushes and groans) sounds followed by metallic tinkling sounds of dilated bowel. Eventually once fatigue occurs or gangrene develops, bowel sounds are not heard—silent abdomen of peritonitis develops (in paralytic ileus, there are only continuous metallic sounds of dilated bowel).
- ◆ **Per-rectal examination:**
  - ▶ Shows *empty, dilated rectum*, often with tenderness. If rectal growth is the cause for obstruction, it may be palpable.

#### Cardinal features of intestinal obstruction

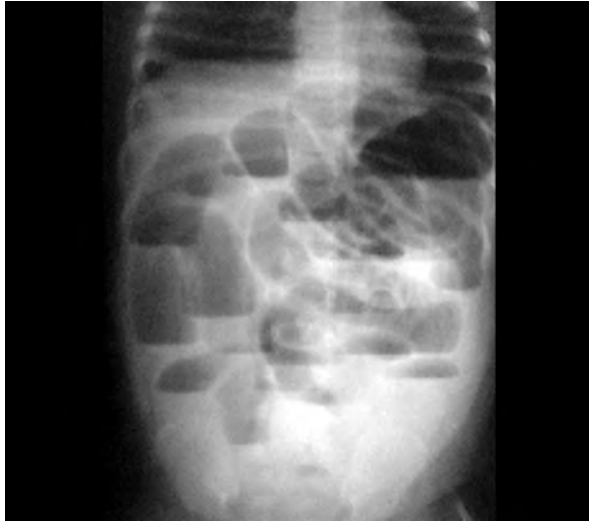**Colicky abdominal pain; vomiting; distension; constipation later.**  
*In high jejunal obstruction*—no distension (scaphoid abdomen), severe bilious vomiting, no peristalsis, without constipation initially.  
*In ileal obstruction*—central moderate distension, bilious and faeculent vomiting, intermittent crescendo colicky pain, step ladder peristalsis, constipation at a later period.  
*In low/colonic obstruction*—variable colicky pain, right to left peristalsis, marked enormous distension, constipation to begin with, late feculent vomiting.

#### Investigations

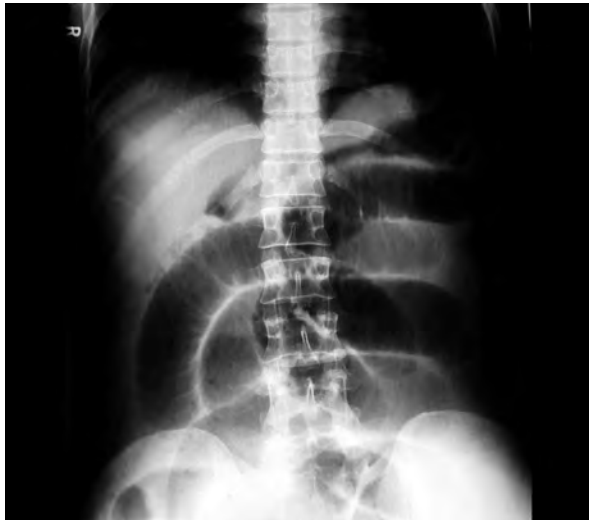- ◆ **Plain X-ray abdomen:** (initially supine abdominal X-ray is taken; later if needed, X-ray in erect posture is taken if perforation is suspected).
  - ▶ *Multiple air-fluid levels.*
  - ▶ Proximal the obstruction → Lesser the air fluid level.
  - ▶ Distal the obstruction → More the air fluid level.



**Fig. 23.8:** Plain X-ray abdomen in erect posture showing dilated bowel and colon—a feature of intestinal obstruction.



**Fig. 23.9:** Plain X-ray abdomen showing multiple air fluid levels due to bowel obstruction.



**Fig. 23.10:** Plain X-ray showing valvulae conniventes with intestinal obstruction.

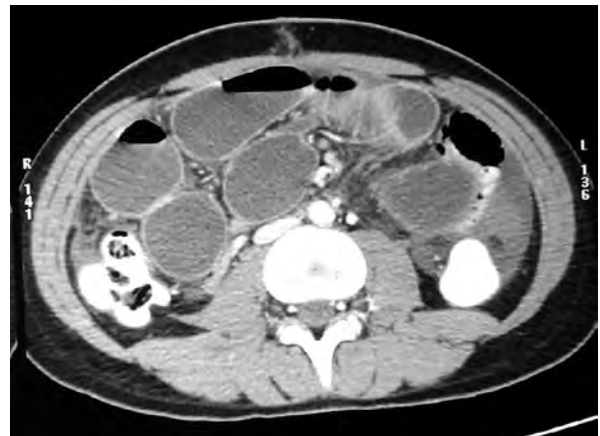Normally, *three fluid levels can be seen* in plain X-ray film—at fundus of stomach, at duodenum and often at caecum.

- ▶ *Jejunum shows concertina effect* due to *valvulae conniventes (Herring bone pattern)*—by the *valves of Kerckring*.
- ▶ *Ileum is smooth and characterless* (by Wangenstein).
- ▶ *Large bowel shows haustration*.
- ▶ *Pneumobilia* (gas in biliary tree) may be due to gall-stone ileus.
- ▶ Distended caecum is shown as round gas shadow in the right iliac fossa. Dilated caecum signifies large bowel obstruction.
- ▶ Small bowel >3 cm diameter; proximal large bowel >9 cm; transverse colon >5.5 cm; sigmoid colon >5 cm are suggestive of intestinal dilatation. But this increased diameter need not suggest intestinal obstruction everytime.

#### Triad of small bowel obstruction in plain X-ray

1. Dilated small bowel loops > 3 cm
2. Multiple air fluid levels in erect X-ray
3. Paucity of air in the colon

- ◆ *CT scan is very reliable investigation* for intestinal obstruction. It has got 93% sensitivity; 94% accuracy and 100% specificity. In CT scan, small bowel loop >2.5 cm suggests dilatation. It can show dilated loop, transition zone and collapsed part which are definitive features of intestinal obstruction. It can also give idea of changes in the bowel wall, ischaemia, strangulation, mesenteric oedema and thickening. It also shows *bowel wall gas, portal venous gas* and mass lesion.
- ◆ *Barium (micro bar solution) enema or gastrografin contrast enema X-ray* is useful in intussusception. [*Barium meal is usually contraindicated in acute intestinal obstruction*. However dilute (micro bar) barium meal/gastrografin meal follow through X-ray may be done with caution in suspected subacute/partial intestinal obstruction under fluoroscopy, otherwise it may precipitate complete obstruction or may cause perforation and barium peritonitis which is very dangerous].
- ◆ Haematocrit, blood urea and serum creatinine; arterial blood gas analysis (acidosis is common), LFT, platelet count (in severe sepsis, there will be altered LFT with thrombocytopenia).
- ◆ *Serum electrolytes estimation*. Hypokalaemia is common.
- ◆ Total count is increased. But can be significantly low in severe stage of sepsis.
- ◆ Estimation of serum D lactate, CPK-BB isoenzyme, intestinal fatty acid binding proteins are different investigations may be useful to predict bowel ischaemia/gangrene.
- ◆ *US abdomen* is useful to see dilated bowel and fluid in the peritoneal cavity. It is better than X-ray but not as good as CT scan. It has got 95% sensitivity; 80% specificity; 80% accuracy. Doppler US is useful in detecting strangulation.
- ◆ Basic electrical rhythm of small bowel will be changed in ischaemia. It can be determined by noninvasive method using *superconducting quantum interference device (SQUID)*.



**Fig. 23.11:** CT abdomen showing dilated bowel loop; CT is ideal investigation for intestinal obstruction.

#### Complications of intestinal obstruction

- ❖ Peritonitis
- ❖ Hypovolaemic and septic shock
- ❖ Renal failure
- ❖ ARDS
- ❖ Intra-abdominal abscess formation
- ❖ Moribund status

### Differential diagnosis

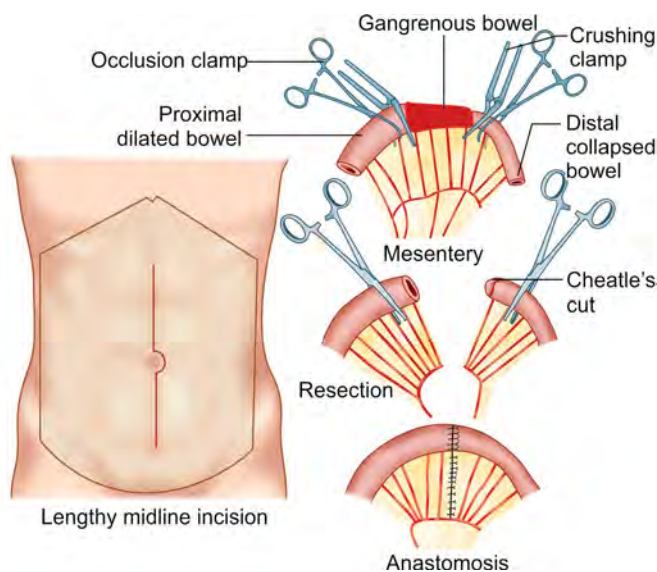
- ❖ Paralytic obstruction
- ❖ Pseudo-obstruction
- ❖ Ascites

### Treatment

- ◆ **Nasogastric aspiration:** To reduce toxic effects, to reduce bowel distension which indirectly improves pulmonary ventilation and to reduce possibility of aspiration pneumonia.
- ◆ **Replacement of fluid and electrolytes.**
- ◆ **Antibiotics:** Ampicillin, gentamicin, metronidazole, cephalosporins.
- ◆ **Blood transfusion:** FFP or platelet transfusions are often needed in critical patient.
- ◆ **ICU critical care:** Systemic management of complications like ARDS, DIC, SIRS are important. If there is hypotension, dopamine/dobutamine are also needed.
- ◆ **CVP for fluid and monitoring:** PCWP (pulmonary capillary wedge pressure) monitoring are often needed in haemodynamically unstable patient.
- ◆ **Surgery:**
  - ▶ **Immediate laparotomy** is done and the site (by finding the junction of dilated proximal and collapsed distal bowel) and cause of the obstruction is identified. The obstruction is relieved.

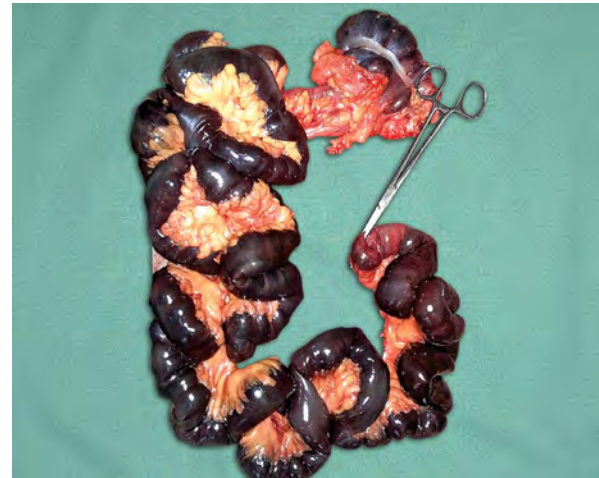### To check for viability of bowel, look for:

- ❖ Peristalsis
- ❖ Pulsations
- ❖ Bleeding in mesentery and bowel wall
- ❖ Friability—friable, flabby muscle is seen in ischaemia
- ❖ Colour (black/pink)—dull and lusterless serosa is seen in ischaemia
- ❖ Serosal shining



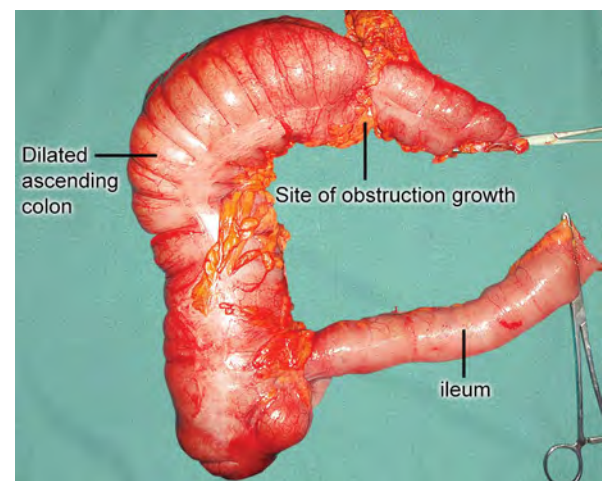
**Fig. 23.12:** Bowel resection and anastomosis for gangrene in case of intestinal obstruction. Cheate's cut on the antimesenteric margin of the collapsed distal segment is often needed to avoid discrepancy in luminal width. Single layer interrupted (silk/vicryl) or two layered continuous sutures can be used. Single layer is better in acute conditions.

- ▶ **Warm-saline soaked mop** is placed over the doubtful area with 100% oxygen inhalation for 20 minutes; if colour becomes normal with peristalsis then bowel is viable.
- ▶ **On table Doppler study** may be useful.
- ▶ **Fluorescein fluorescence study** may be helpful on table to check the viability. 1000 mg of *fluorescein* is injected into the peripheral vein and bowel is inspected under Wood's *UV light*; nonviable loops are identified which requires resection and anastomosis.
- ▶ If bowel is not viable, **resection and anastomosis is done**. A good peritoneal wash is given and the abdominal cavity is drained.



**Fig. 23.13:** Gangrenous bowel-resected specimen in a case of mesenteric ischaemia.

- ▶ Abdomen is closed in layers using nonabsorbable sutures (polyethylene, polypropylene, nylon). Often tension sutures are required.
- ▶ Small bowel can be decompressed using *Savage's decompressor*.
- ▶ In case of **right-sided colonic obstruction**, **right hemicolectomy with ileocolic anastomosis** is done.



**Fig. 23.14:** Colonic obstruction due to stricture/growth in the transverse colon; right hemicolectomy is done.

- ▶ In case of *left-sided colonic obstruction*, *left hemicolectomy* (resection) and *colo-colic anastomosis* is done with a *defunctioning colostomy* (right-sided transverse) which is closed after 6 weeks.
- ▶ Obstruction due to *rectosigmoid growth* with patient being severely ill—*Hartmann's operation* can be done to save the life of the patient wherein distal stump after removal of the growth is closed, proximal colon is brought out as *end colostomy*.
- ▶ *Second look operation* may be needed in doubtful cases or multiple segment obstructions in 24–48 hours to confirm viability.
- ▶ *Laparoscopic approach* may be useful in partial obstruction, proximal obstruction, obstruction due to band. Conversion when needed, should be done without hesitation.
- ▶ *Acute postoperative obstruction* is difficult to identify and manage. CT is very useful. Initially it is treated conservatively (90%), but suspected ischaemic cases or persistent obstruction becomes an indication for surgery. Resection with exteriorization may be the choice.

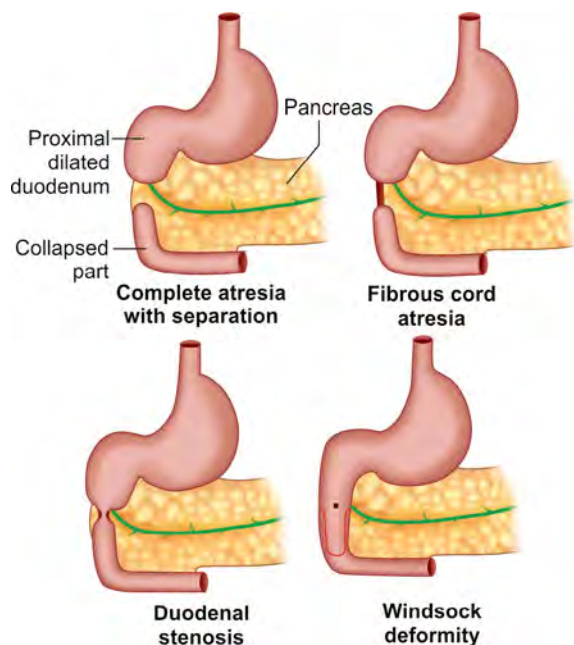
#### Postsurgery complications

- ❖ Pelvic abscess
- ❖ Subphrenic abscess
- ❖ Biliary or faecal fistulas
- ❖ Burst abdomen
- ❖ Bands and adhesions
- ❖ Incisional hernias.

## DUODENAL ATRESIA

- ◆ It is the commonest site of intestinal atresia.
- ◆ It is usually a complete stenosis of the second part of duodenum at the level of ampulla of Vater.
- ◆ It is defective fusion of foregut and midgut with failure of recanalisation.
- ◆ Incidence is 1 in 10,000 live births.

### Types



**Fig. 23.15:** Types of duodenal atresia—complete; fibrous cord; duodenal stenosis and windssock deformity.

- ❖ Type 1: Duodenal complete atresia: It is the commonest type (50%). It is usually complete separation with intact wall. In 25% cases, complete separation with wall also occurs.
- ❖ Type 2: Fibrous cord.
- ❖ Type 3: Incomplete or partial obstruction. It can be stenosis or web with an aperture.

- ◆ Duodenal diaphragm/web can present as complete; incomplete with a fenestra; incomplete diaphragm with central aperture which causes '*windssock*' deformity due to proximal dilatation. Here actual diaphragm will be proximal to the site of obstruction.
- ◆ Duodenal atresia may be *preampullary* (nonbilious vomiting) or *postampullary* (bilious vomiting). Postampullary is common (80–90%).

### Associations

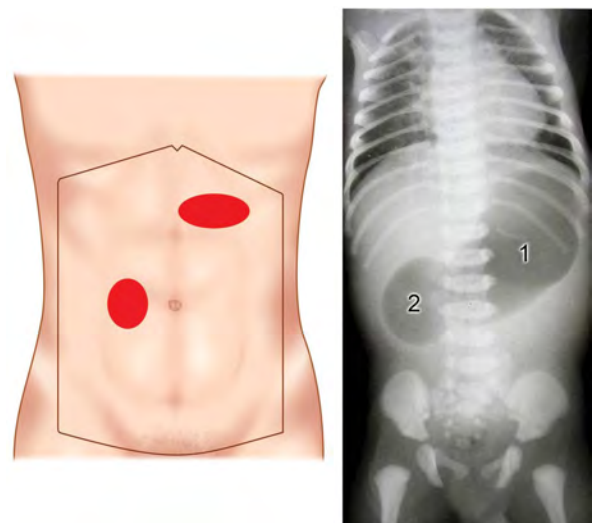
- ◆ Duodenal stenosis is often associated with annular pancreas.
- ◆ It can be isolated duodenal atresia or in association with Down's syndrome (30%)/incomplete rotation of gut (20%)/congenital heart diseases (30%)/trisomy (30%)/anorectal malformations (10%), etc.
- ◆ It is commonly associated with maternal polyhydramnios (50%). Antenatal US can confirm it. 50% infants are premature.

### Features

- ◆ Jaundice.
- ◆ Bilious/nonbilious vomiting immediately after birth.
- ◆ Features of gastric outlet obstruction.
- ◆ Dehydration. Electrolyte changes are common.
- ◆ Growth retardation of newborn due to deprived nutrition (by swallowed amniotic fluid in fetus).

### Investigations

- ◆ Plain X-ray shows classic *double-bubble sign* with absence of air in the distal part.



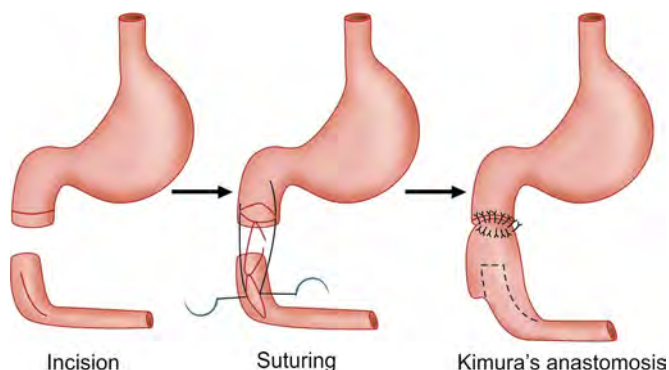
**Fig. 23.16:** Double-bubble sign in duodenal atresia.

- ◆ In partial obstruction, air may be present in distal loop and so contrast study has to be done. Risk of aspiration in newborn infant should be remembered.

- ◆ US will show distended stomach and proximal duodenum, *rail road track* duodenum and features of associated anomalies. Maternal and fetal ultrasound in pregnancy may identify the pathology and also maternal polyhydramnios.

### Treatment

- ◆ Proper preoperative preparation like correction of fluid and electrolytes; gastric decompression; TPN; injection vitamin K; evaluation for associated anomalies.
- ◆ *Duodenoduodenostomy* is done. Associated malrotation should be corrected in these patients (*Ladd's operation*). Side-side duodenoduodenostomy may cause dilated duodenum (megaduodenum—30%); anastomotic dysfunction; and delayed transit of the content.
- ◆ *Kimura's diamond-shaped anastomosis* between transversely opened proximal pouch and longitudinally opened distal pouch reduces the problems of anastomosis. Presence of bile in the duodenum and proximal and distal patency should be confirmed by saline irrigation.
- ◆ Transanastomotic nasojejunal or gastrostomy tube for feeding purpose is needed as prolonged postoperative ileus is the usual problem.



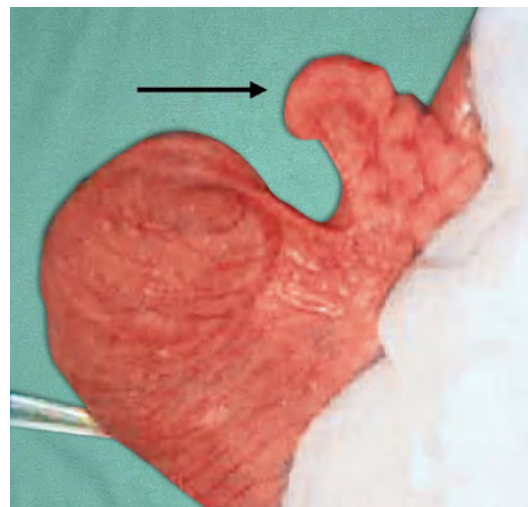
**Fig. 23.17:** Duodenoduodenostomy is ideal in duodenal atresia. Kimura's modification has got lesser chance of developing side effects like gastroparesis.

#### Note:

- Duodenojejunostomy may cause blind loop problems. Gastrojejunostomy should not be done due to high incidence of marginal ulceration and bleeding.

### SMALL INTESTINE ATRESIA (INTESTINAL ATRESIA)

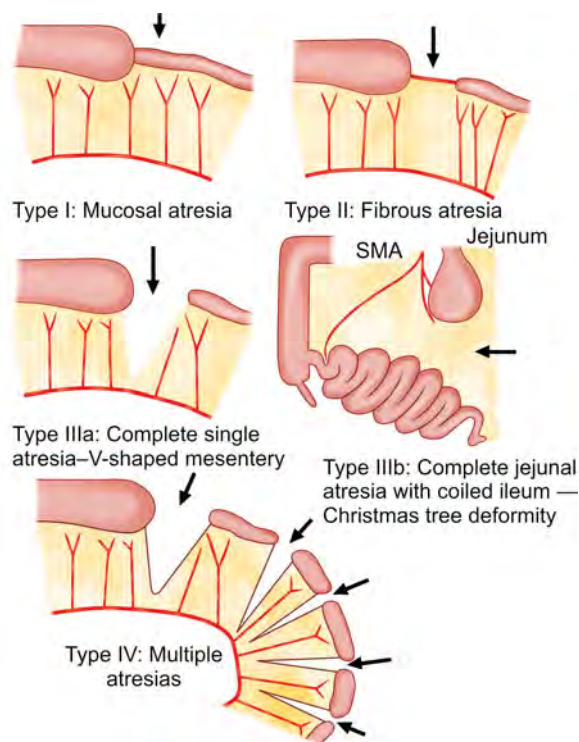
- ◆ It is jejunoileal atresia.
- ◆ It is due to intrauterine mesenteric vascular accidents (occlusion) of the segments affected. V-shaped mesentery; presence of bile pigments in the distal segments suggesting earlier period of patency—are supportive for the above theory.
- ◆ It is often associated with malrotation, gastroschisis, volvulus—20%.
- ◆ Common site is proximal jejunum; next common is distal ileum.
- ◆ Maternal polyhydramnios occurs in 35% of jejunal atresia.
- ◆ Proximal bowel wall is dilated with hypertrophy but villi are normal. Distal bowel is collapsed but with hypertrophied villi. Narrow collapsed large intestine (microcolon) is seen in proximal atresia.



**Fig. 23.18:** Typical intestinal atresia.

#### Griesfield modification of martin's classification of intestinal atresia

- ❖ Type I: Membranous/mucosal with normal mesentery—20%.
- ❖ Type II: The lumen is atretic—fibrous cord between proximal and distal parts of the segment involved (only one atretic segment) but mesentery is normal—40%.
- ❖ Type III (a): Atresia with complete separation of proximal and distal ends and V-shaped defect of mesentery—35%.
- ❖ Type III (b): Atresia with Christmas tree-shaped defect in mesentery with distal bowel being supplied by single artery—right colic/ileocolic/superior mesenteric—*apple peel atresia*.
- ❖ Type IV: Multiple atresias—5%.



**Fig. 23.19:** Types of intestinal atresia.

*If the hand is kept flat upon the abdomen the underlying coil may be felt to harden and soften alternately much like in a pregnant uterus, in a case of intestinal obstruction.*

— Arthur H Burgess



## Clinical Features

- ◆ Equal in both sexes.
- ◆ Commonly infant is of low birth weight.
- ◆ Bilious vomiting with features of intestinal obstruction like distension.
- ◆ Features of associated anomalies.
- ◆ Respiratory distress.
- ◆ Jaundice.

## Investigations

- ◆ Plain X-ray abdomen shows—*triple-bubble appearance* in jejunal atresia; multiple air fluid levels in ileal atresia.
- ◆ Barium enema may show narrow microcolon. Calcification suggests antenatal fetal bowel perforation.
- ◆ US abdomen to confirm associated anomalies.

## Differential Diagnosis

- ◆ Other causes of neonatal intestinal obstruction like duodenal atresia, malrotation, volvulus of midgut.

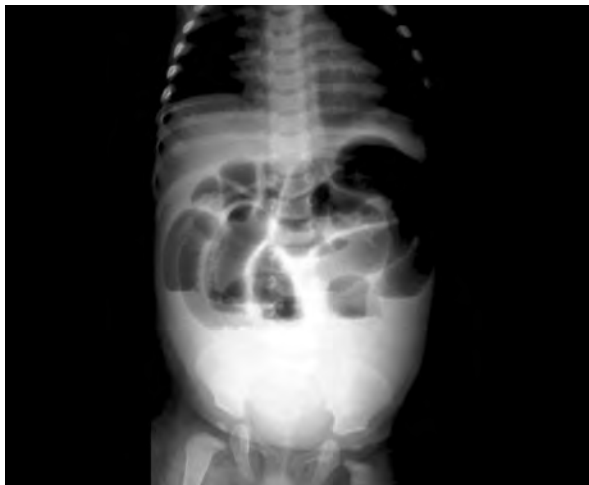

Fig. 23.20: X-ray abdomen of a patient with intestinal obstruction in a newborn as neonatal intestinal obstruction.

## Treatment

- ◆ Resection and anastomosis is the choice of therapy.
- ◆ Treatment of associated anomalies.
- ◆ Tapering proximal jejunoplasty is done if extensive length of jejunum is involved.
- ◆ Prognosis depends on length of atretic bowel; multiple atresias; associated anomalies.

## MALROTATION

It is interference in the process of normal rotation of midgut in fetus and its mesenteric fixation.

### Stages of normal rotation of midgut

- ❖ *Stage 1:* In 4th-8th week of intrauterine period, midgut supplied by superior mesenteric artery (SMA) grows rapidly. As coelomic cavity cannot accommodate growing midgut during that period, it protrudes into the umbilical cord as *physiological hernia*.
- ❖ *Stage 2:* In 10th-12th week, midgut migrates into coelomic cavity. First, small bowel returns towards the left side of the abdomen. Then caecocolic loop returns to left lower abdomen. It rapidly rotates 270° counterclockwise to reach right iliac fossa. Then duodenojejunal segment rotates 270° counterclockwise to reach left of SMA and behind the colon.
- ❖ *Stage 3:* Fusion of different parts of mesentery and posterior peritoneum.

## Different Errors of Rotation

- ◆ *Stage 1:* Exomphalos major/minor or gastroschisis.
- ◆ *Stage 2:* Errors of rotation in this stage is important and is usually considered under malrotation.
  - ▶ *Nonrotation:* Causing small bowel in right side; colon in left side; caecum in midline as suspension.
  - ▶ *Incomplete rotation:* It is the *most common type* of malrotation. Caecum is located in subhepatic right hypochondrium. *Ladd's peritoneal band* connects from caecocolic loop to posterior abdominal wall compressing the 2nd part of the duodenum. Entire midgut is hanging down along with SMA with a narrow-based mesentery causing midgut volvulus.

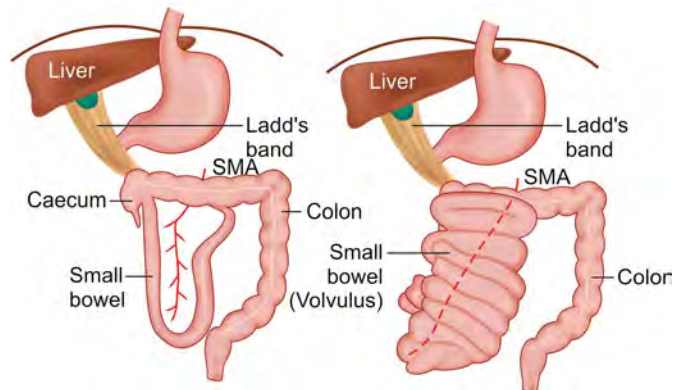


Fig. 23.21: Diagram showing incomplete gut rotation and small bowel volvulus.

- ▶ *Reverse rotation:* Final 180° rotation occurs clockwise bringing colon posterior to duodenum and SMA.
- ▶ *Hyper-rotation:* Rotation up to 360° or 450° causing caecum on left side of the abdomen.
- ▶ Encapsulated small bowel occurs while fetal midgut returns into coelomic cavity.
- ◆ *Stage 3:* Final defect in fixation causes mobile caecum and ascending colon leading into caecal volvulus.

### Associated anomalies (20%)

- ❖ Congenital diaphragmatic hernia of Bochdalek
- ❖ Prune belly syndrome
- ❖ Duodenal atresia
- ❖ Oesophageal atresia

## Presentations

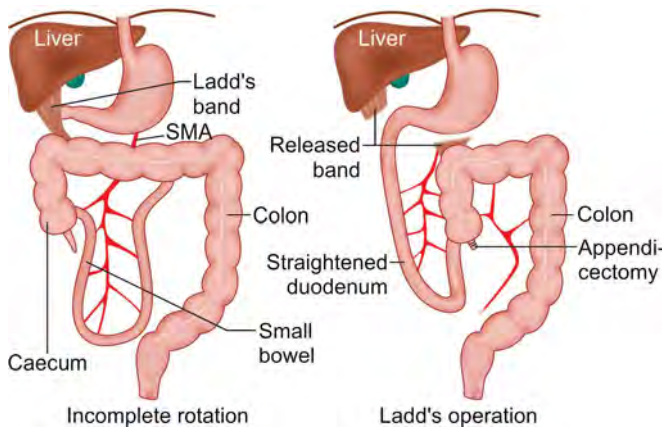
- ◆ Acute/recurrent/subacute intestinal obstruction.
- ◆ Midgut volvulus (30%) (usually clockwise rotation) with features of strangulation, perforation, peritonitis.
- ◆ Shock, septicaemia, passage of dark blood per rectum, oedema and erythema of anterior abdominal wall.
- ◆ In children—failure to thrive, recurrent abdominal pain, cyclical vomiting, constipation and diarrhoea.

## Investigations

- ◆ Plain X-ray abdomen shows air fluid levels.
- ◆ Barium meal (dilute/microbarium) and follow through X-ray is the investigation of choice.
- ◆ US abdomen/CT abdomen, if needed.
- ◆ Haematocrit, serum electrolytes estimation.

## Treatment

- ◆ Resuscitation, antibiotics, fluid and electrolytes, blood transfusion.



**Fig. 23.22:** Ladd's operation for incomplete gut rotation. Ladd's band is released. Duodenum is straightened. Appendectomy is done.

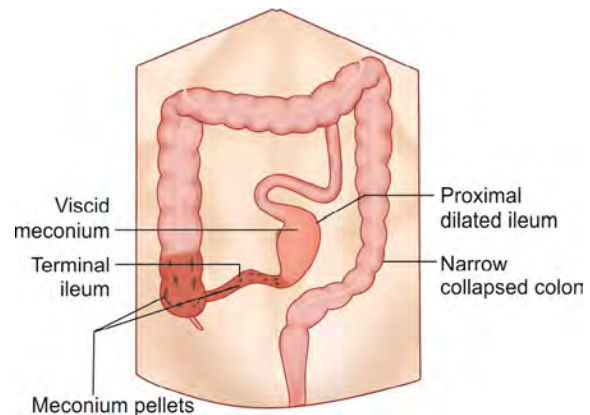
- ◆ *Laparotomy* through horizontal incision is done. Clockwise rotated midgut which is congested and cyanotic is identified. Untwisting of the midgut in counterclockwise direction is done. Viability of bowel is confirmed (colour, vessels in mesentery, peristalsis, on table Doppler). *Ladd's band* is divided *large bowel is repositioned in left side*. The entire duodenum is *Kocherised* and the ligament of Treitz is divided so that *duodenum becomes straight towards right iliac fossa*. This achieves *wide root of the mesentery* and places the *small bowel in the right side of the abdomen* thus preventing further volvulus. A *complementary appendectomy* is done—*Ladd's operation*.
- ◆ After laparotomy, if bowel is gangrenous, it is resected and remaining parts of the bowel are exteriorised as enterostomies. A second look operation is done to look for viability of remaining bowel and also to maintain the continuity. Often it will be extensive bowel resection leading into poor prognosis.

## MECONIUM ILEUS

- ◆ It is neonatal manifestation of fibrocystic disease of the pancreas wherein thick meconium, which is viscid and paste-like, gets collected in the terminal ileum. Because of

inspissation it forms a firm bolus leading to obstruction of the ileum.

- ◆ Neonates present with features of ileal obstruction as well as respiratory dysfunction, exocrine pancreatic insufficiency, and high salt in the sweat ( $\text{Na}^+$  and  $\text{Cl}^-$  more than 90 mmol/L).
- ◆ Meconium ileus occurs in 15% of patients with cystic fibrosis. Cystic fibrosis is an autosomal recessive disease involving bronchioles, exocrine pancreas and sweat glands. Condition is common in Caucasians. Exocrine pancreatic insufficiency and malabsorption is seen in 90% of patients with cystic fibrosis.
- ◆ There is hypertrophy and dilatation of the proximal ileum containing thick, viscid, tenacious dark green meconium. Distal ileum and colon are narrow and contracted having grayish meconium pellets. Meconium gets calcified very rapidly. Gangrene, perforation, volvulus can occur in 50% of cases.
- ◆ Intrauterine perforation causes fetal meconium peritonitis which leads to dense adhesions and calcification in peritoneum. Fetal meconium peritonitis is sterile.



**Fig. 23.23:** Pathology of meconium ileus. Note the meconium pellets in the distal ileum and colon; thick viscid meconium in proximal ileum.

- ◆ Plain X-ray shows calcified meconium pellets with multiple air fluid levels which appear as 'soap-bubbles' (*Neuhauser sign*).
- ◆ Vomitus of the patient which does not contain trypsin, when poured on the exposed X-ray film, will not digest the gelatin of the film whereas the vomitus of individual with normal pancreas will digest the gelatin of X-ray film—*very useful test*.
- ◆ Pilocarpine, a cholinergic drug is injected into skin to stimulate the sweating and collected sweat (100  $\mu\text{g}$  sweat) is analysed for sodium and chloride.
- ◆ Elevated albumin level in meconium, sodium level assay in nail clipping and serum immune active trypsin assay are other investigations.

### Meconium ileus

- ❖ Commonly associated with cystic disease of pancreas but not necessarily always
- ❖ Respiratory dysfunction
- ❖ Exocrine pancreatic insufficiency
- ❖ High salt in the sweat >90 mmol/L
- ❖ Ileal obstruction
- ❖ Soap-bubble appearance in X-ray
- ❖ Gelatin in X-ray film will not get digested by patient's vomitus
- ❖ Bishop-Koop operation, ileostomy, dissolving ileal meconium pellets are required

*The remedy for injuries is not to remember them.*

### Complications of meconium ileus

- ❖ Intestinal bolus obstruction
- ❖ Perforation and peritonitis
- ❖ Gangrene, volvulus formation

### Treatment

#### Nonoperative measures

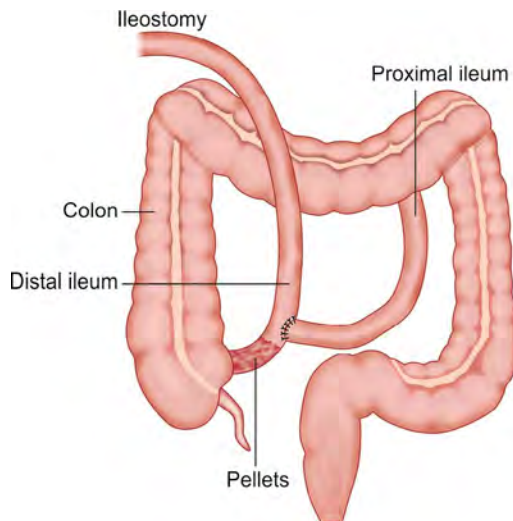
- ◆ Dissolution through enema can be tried using *gastrografin* which is hyperosmolar and contains Tween 80 as dissolving agent. *Gastrografin* is diatrizoate meglumine with Tween 80 (polysorbate 80) as dissolving agent. N acetylcysteine 10% also can be used for irrigation per-anally.
- ◆ N acetylcysteine 10% wash through nasogastric tube also can be used—5–10 ml 6th hourly.
- ◆ Treatment for cystic fibrosis.

#### Operative Measures

**Present standard surgical approach**—Enterotomy with irrigation using warm normal saline or 4% N acetylcysteine and complete evacuation of all meconium pellets (or can be pushed down into large bowel manually) closure of the enterotomy is present standard method. N acetylcysteine, by breaking the disulphide bonds of the meconium, separates it from intestinal mucosa allowing its retrieval. A T tube can be placed in the small bowel through which N acetylcysteine wash can be given repeatedly if further meconium needs dissolution.

#### Other Methods

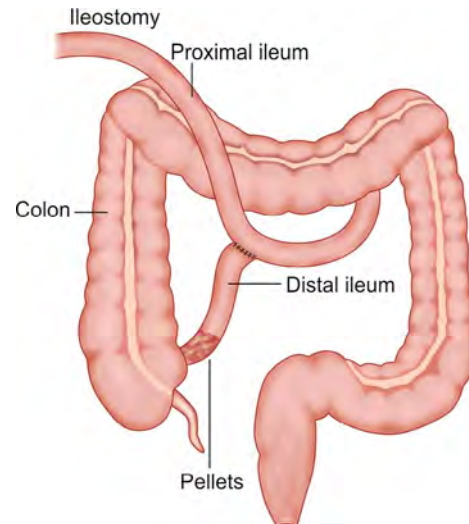
- ◆ When patient's condition is critical with obstruction, *Bishop-Koop operation* is done. Proximal dilated segment is resected and resected end is anastomosed to the side of the distal collapsed ileum. End of the distal ileum is brought out as ileostomy. Through the ileostomy *gastrografin* or acetyl cystine wash is given regularly to dissolve meconium pellets. This ileostomy can be kept for long time. Continuity is maintained at later period.
- ◆ *Santulli operation* is done where proximal ileum is brought as ileostomy for irrigation using a fine tube and distal ileum is sutured to proximal ileum as end to side anastomosis.
- ◆ *Resection and anastomosis* is ideal if patient is fit and if proximal bowel is suitable for anastomosis.



**Fig. 23.24:** *Bishop-Koop operation*. Here distal ileum is brought as ileostomy and proximal part sutured to distal bowel.

### Management of meconium ileus

- ❖ *Nonoperative wash per rectally* using acetyl-cysteine or *gastrografin* through Foley's catheter passed per anally. Acetyl cysteine can also be passed for irrigation per orally through a Ryle's tube as 10 ml 6th hourly.
- ❖ *Bishop-Koop and Santulli operations* done in very sick neonates.
- ❖ *Resection and anastomosis* is ideal when child is adequately fit.



**Fig. 23.25:** *Santulli operation* done for meconium ileus wherein proximal ileum is brought out as ileostomy. Distal ileum is sutured to proximal.

### Causes of neonatal intestinal obstruction

- ❖ Hirschsprung's disease
- ❖ Duodenal atresia
- ❖ Intestinal atresia
- ❖ Malrotation
- ❖ Midgut volvulus/volvulus neonatorum
- ❖ Meconium ileus
- ❖ Anorectal malformation

## INTUSSUSCEPTION (ISS)

### Definition

It is telescoping or invagination of one portion (segment) of bowel into the adjacent segment.

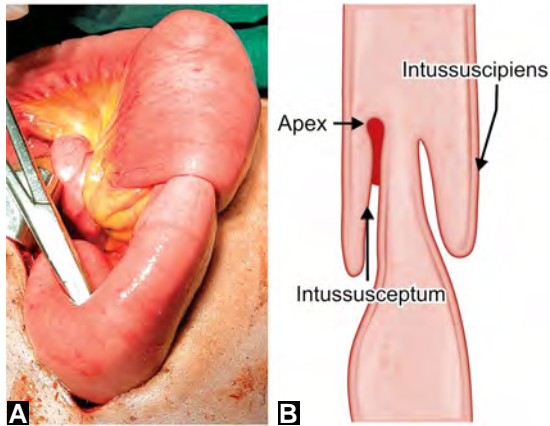
### Types

1. **Antegrade:** Most common.
2. **Retrograde:** Rare (jejuno gastric in gastrojejunostomy stoma).

#### In elderly intussusception:

- ❖ Colocolic is most common type
- ❖ Apex is formed usually by growth
- ❖ No role of hydrostatic reduction

- ◆ It can be single or multiple (rare).
- ◆ It can be *ileo-colic* (most common type, 75%), colocolic, ileoileocolic, colocolic.
- ◆ It is common in weaning period of a child (common in male), between the period of 6–9 months.
- ◆ It is the *commonest cause* of intestinal obstruction in children of 6–18 months age.



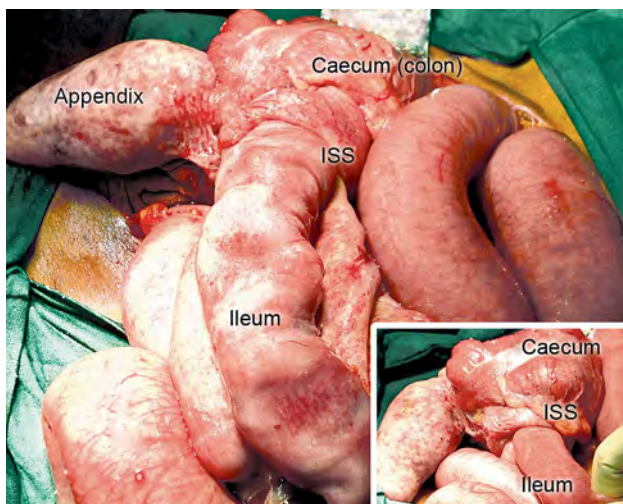
**Figs 23.26A and B:** (A) Typical intussusception—on table look; (B) Parts of intussusception.

### Aetiology

- ◆ Idiopathic ISS is common in children, occurs in terminal 50 cm of ileum.
- ◆ During weaning, change in diet causes inflammation and oedema of Peyer's patches—may stimulate ISS.
- ◆ Upper respiratory tract viral infection which causes oedema of Peyer's patches is also thought as an aetiology for intussusception in children.
- ◆ Other causes in adolescents and adults are submucous lipoma, leiomyoma, polyps in jejunum (Peutz-Jegher syndrome), other polyps and carcinomas with papillary projections.

#### Causes

- ❖ Change in diet during weaning
- ❖ Upper respiratory tract viral infection
- ❖ Intestinal polyps
- ❖ Submucous lipoma
- ❖ Leiomyoma of intestine
- ❖ Meckel's diverticulum
- ❖ Carcinoma
- ❖ Purpuric submucosal haemorrhages



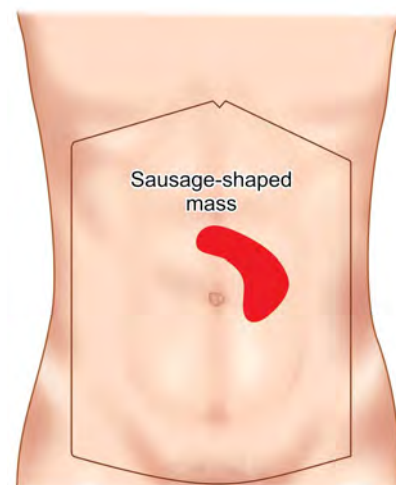
**Fig. 23.27:** Intussusception. Different parts and apex point is also clearly seen.

### Pathology

- ◆ **Apex** is the one which advances;
- ◆ **Intussusciens** is the one which receives (outer sheath);
- ◆ **Intussusceptum** are the tubes which advance (middle and inner sheath).
  - ▶ Apex and inner tubes will have compromised blood supply which leads to gangrene.
  - ▶ Because of ischaemia, apex sloughs off and bleeds, which mixes with the mucus to produce the classic *red-currant jelly* that is passed per anum.
  - ▶ Gangrene which sets in leads to perforation and peritonitis.
  - ▶ Red currant jelly is not commonly observed in ISS in adult, but it can occur.

### Clinical Features

- ◆ Common in males (3:2).
- ◆ Common in 6–9 months. But can also occur at later age-grouped children.
- ◆ Common in spring and winter, coinciding with the gastroenteritis and respiratory infections in respective periods.
- ◆ Commonest cause of intestinal obstruction in infancy.
- ◆ Initial colicky abdominal pain (75%) which eventually becomes severe and persistent.
- ◆ Sudden onset of pain in a male child, with progressive distension of the abdomen, vomiting, with passage of “*red-currant-jelly*” stool. It is usually not found in adult ISS.
- ◆ Often ISS is recurrent, when it gets reduced, child automatically becomes asymptomatic (Mother often complains “*Bachha rotha he, Bachha sotha he*”). It means child cries during an episode and sleeps peacefully once it gets reduced).



**Fig. 23.28:** Sausage-shaped mass of intussusception.

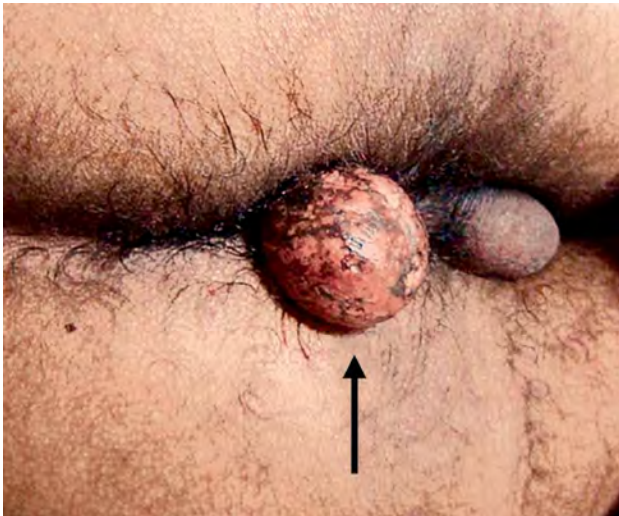- ◆ *On examination*, a mass is felt either on the left or right of the umbilicus which is sausage shaped with concavity towards umbilicus, smooth, firm, resonant, not moving with respiration, mobile, *contracts under the palpating fingers*. Often mass appears and disappears.

*In the field of observation, chance favours only the prepared mind.*

- ◆ Right iliac fossa is empty (*Sign of Dance*).
- ◆ After 24–48 hours, abdominal distension appears and increases progressively with features of intestinal obstruction.
- ◆ Features of intestinal obstruction with *step-ladder peristalsis*.
- ◆ Blood-stained stool is often obvious on digital examination of the rectum. Occasionally ISS can be seen per anally and felt with a long mesentery.
- ◆ Eventually, gangrene and perforation occurs with features of the peritonitis.

#### Abdominal palpatory findings in ISS

- ❖ Palpable mass (85%)
  - Sausage-shaped smooth, firm mass
  - Mass does not move with respiration
  - Mobile in all directions
  - Resonant
  - Mass contracts under the palpating fingers
  - Mass appears and disappears
- ❖ Empty right iliac fossa
- ❖ Features of intestinal obstruction/peritonitis—later



**Fig. 23.29:** A rare condition where colonic intussusception has occurred through rectum, coming out per anally. Part is already gangrenous.

#### Complications

- ❖ Intestinal obstruction
- ❖ Perforation
- ❖ Peritonitis

#### Differential Diagnosis

- |              |                                   |
|--------------|-----------------------------------|
| In children: | Acute gastroenteritis.            |
|              | Purpura with intestinal symptoms. |
| In adults:   | Carcinoma colon.                  |
|              | Mesenteric mass.                  |

#### Investigations

- ◆ Barium enema shows typical *claw sign* or *coiled spring* sign (Pincer end).
- ◆ Ultrasound shows *target sign* or *pseudokidney sign* or *bull's eye sign*, which is diagnostic.
- ◆ Doppler may show mass with *doughnut sign* and is useful to check *blood supply* of bowel.
- ◆ Plain X-ray abdomen shows *multiple air fluid levels*.
- ◆ CT abdomen is needed.

#### Treatment

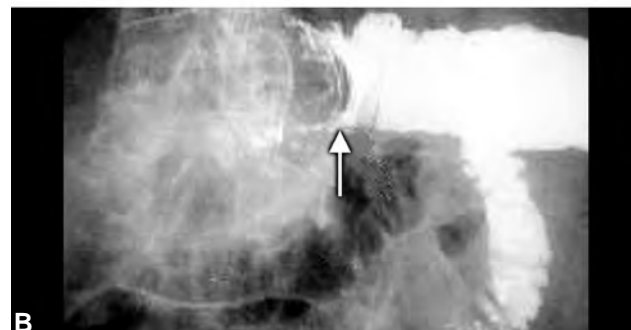
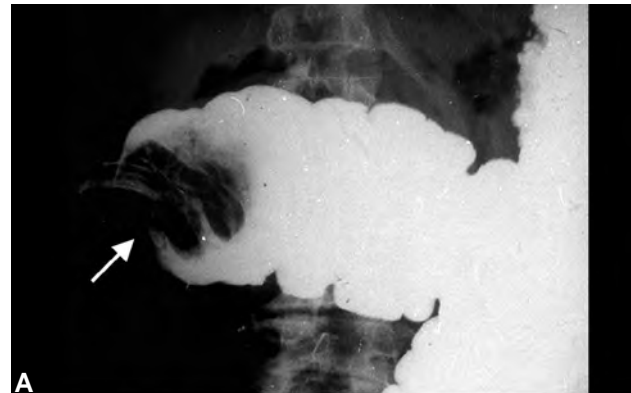
##### Initial management

- ❖ Ryle's tube aspiration
- ❖ IV fluids
- ❖ Antibiotics
- ❖ Catheterisation.

##### Later management

##### Nonoperative management

- ◆ *Reduction by hydrostatic pressure* using either *warm saline* or *microbarium sulphate solution* or *air* (popular in **China**). Barium or saline is infused into the rectum through a catheter (Foley's catheter). Under fluoroscopy, reduction can be observed. Child will pass large quantity of air and faeces; distension reduces; child shows recovery and stops crying. Air or contrast enters the proximal bowel freely. *Palpable abdominal mass disappears*. Rare complication is perforation of colon. It is done in early stage within 24 hours of presentation. 70% cases of ISS will respond to nonoperative method. It is *contraindicated* in complete obstruction; perforation and peritonitis.



**Figs 23.30A and B:** Barium enema showing the typical 'Claw sign' of intussusception.

### Indications for surgery in ISS

- ❖ ISS more than 48 hours
- ❖ Features of perforation, strangulation, peritonitis
- ❖ Recurrent ISS
- ❖ In adult commonly, resection is required

### Surgery

- ◆ *Cope's method*: If reduction does not occur, *laparotomy* is done under G/A. By gently *milking out* the intussusception with warm packs, it is reduced. After reduction, viability of the bowel is checked carefully. If manual reduction is not possible, it is understood that the bowel is likely to be gangrenous which requires resection and anastomosis. In case of viable bowel, often terminal ileum is anchored to the ascending colon and *Jackson veil band* is cut. Patient also requires nasogastric tube aspiration, IV fluids, antibiotics. *Appendectomy should be done* after reduction of the intussusception.
- ◆ Laparoscopic approach may be used to reduce the intussusception.
- ◆ If intussusception persists for more than 48 hours or intussusception in adult requires resection.
  - ▶ Ileocolic resection is sufficient.

### Recurrence rate

- ❖ In hydrostatic reduction—10%
- ❖ In open manual reduction—2%
- ❖ In resection—very less <1%.

## VOLVULUS

### Definition

It is the *twist (rotation)* in the axis of the loop of the bowel either clockwise or anticlockwise.

- ◆ 15% of large bowel obstruction is due to volvulus.
- ◆ *Sigmoid colon is the commonest site (anticlockwise)*—65%.
- ◆ **Caecal volvulus**
  - ▶ Caecum is the second common site (*clockwise*) (C for C)—30%.
  - ▶ It is common in females, present as intestinal obstruction.
  - ▶ *Caecal bascule* is the presence of constricting band across the ascending colon (*Bascule—French—see-saw and balance*).
  - ▶ Caecum will be markedly distended and found in the centre of the abdomen.
  - ▶ It is due to lack of fixation of the caecum—*mobile caecum*.
  - ▶ Occasionally, it is associated with malrotation.
  - ▶ Caecal volvulus is the commonest cause of large bowel obstruction in pregnancy.
  - ▶ X-ray shows *round gas shadow* in right iliac region. CT scan is very useful. Barium enema is also helpful.
  - ▶ *Resection and anastomosis (surgery)* is the only treatment.
- ◆ *Volvulus of small intestine* (midgut), *volvulus neonatorum*, *gastric volvulus* are other volvulus which can occur.

## SIGMOID VOLVULUS (Volvulus of Pelvic Colon)

- ◆ It is common in Asia, common in India (7% of intestinal obstruction) and especially South India because of high fibre diet.
- ◆ It is very common cause of large bowel obstruction in Peru and Bolivia due to high altitude.
- ◆ More common in males and old age.
- ◆ It is common in patients with chronic constipation with laxative abuse.

### It is common in:

- ❖ Ogilvie's syndrome
- ❖ Mentally-retarded individuals
- ❖ Chaga's disease
- ❖ Hypothyroidism
- ❖ Anticholinergic drugs
- ❖ Multiple sclerosis
- ❖ Scleroderma
- ❖ Parkinson's disease

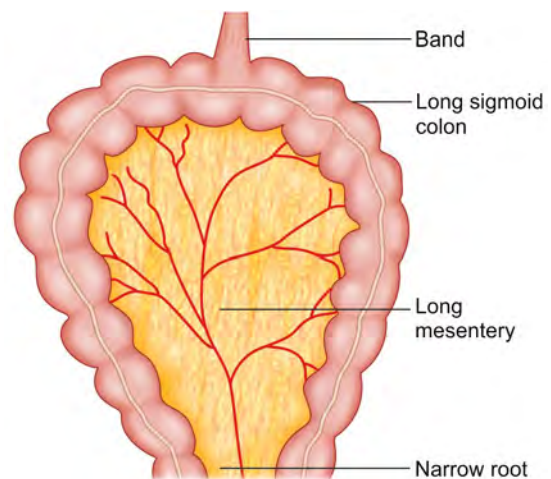


Fig. 23.31: Causes of sigmoid volvulus.

### Predisposing factors

- ❖ Adhesions
  - ❖ Peridiverticulitis
  - ❖ Overloaded redundant pelvic colon
  - ❖ Long pelvic mesocolon
  - ❖ Narrow attachment of sigmoid mesocolon
- ◆ Always rotation is *anticlockwise*.
  - ◆ It requires *one and half turn* of rotation to cause vascular obstruction and gangrene which eventually leads into perforation either at the root or at the summit of the sigmoid loop.
  - ◆ Enormous distension of the colon occurs. Sometimes ileum comes to the root of the sigmoid volvulus and encircles it

causing *compound volvulus* in which case knotted small bowel also becomes gangrenous—*ileosigmoid knotting*.

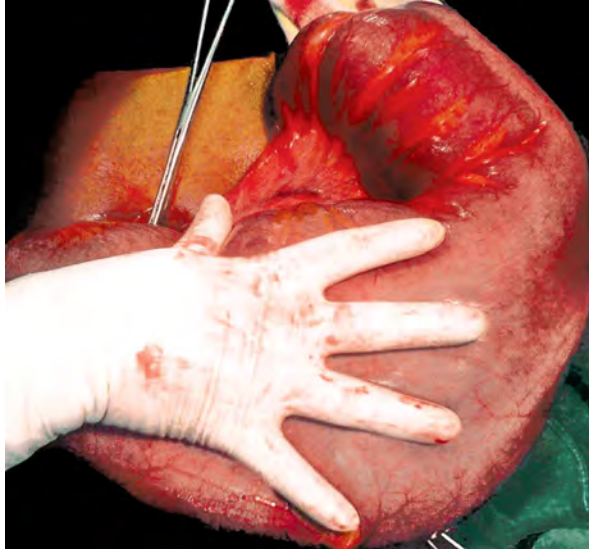


Fig. 23.32: Sigmoid volvulus. Note the dilated sigmoid colon.

### Types

1. Acute.
2. Recurrent.

### Clinical Features

- ◆ Pain in the abdomen—initially left sided, eventually all over.
- ◆ Absolute constipation (*obstipation*—no faeces, no flatus).

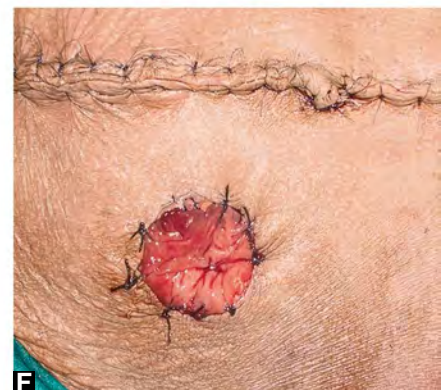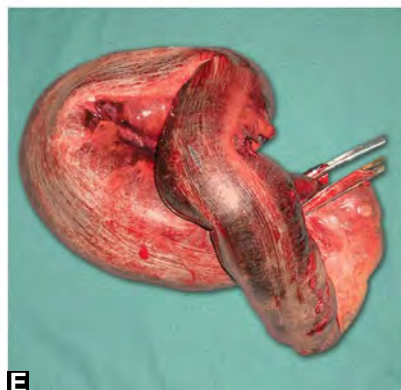
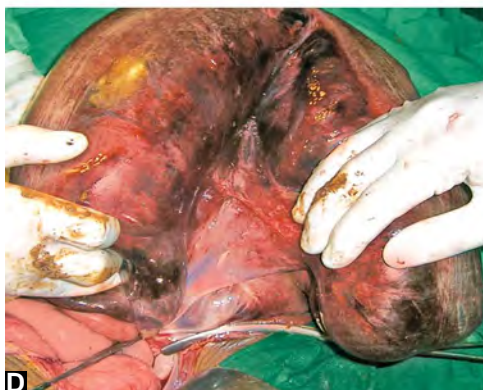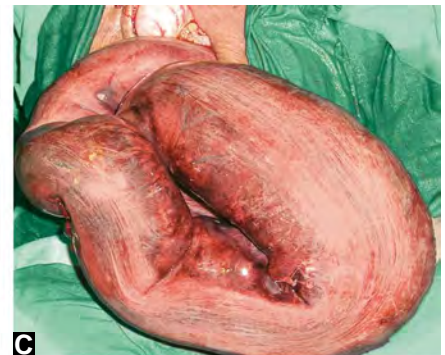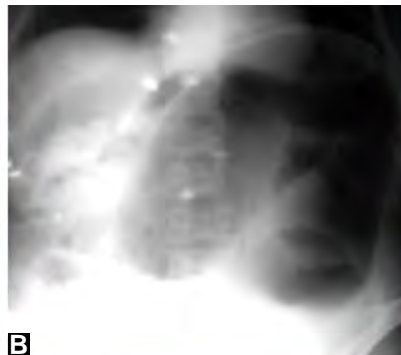
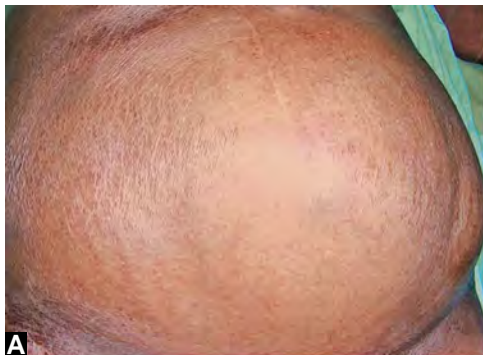- ◆ Enormous distension of abdomen, starting from left iliac fossa extending to the whole of the abdomen (*Tympanic abdomen*).
- ◆ Late vomiting and eventually dehydration.
- ◆ Features of peritonitis.
- ◆ Hiccough and retching can occur.
- ◆ *Tyre like feel* of the abdomen is diagnostic.

### Differential diagnosis

- ❖ *Ogilvie's syndrome*: It is acute colonic pseudo obstruction. It is due to malfunctioning sacral parasympathetic nerves. Splenic flexure is the junction of collapsed and dilated large bowel. Descending colon is atonic causing acute functional obstruction. It may be due to trauma, retroperitoneal irritation, antidepressants, uraemia, diabetes, myxoedema, hypokalaemia, etc. Prokinetic drugs, colonoscopic decompression, tube caecostomy are the treatment.
- ❖ Faecal impaction.
- ❖ Carcinoma rectosigmoid region.
- ❖ Idiopathic megacolon.

### Investigations

1. **Plain X-ray**: (diagnostic in 70–80%)
  - ▶ *Ω sign (omega sign)*—single, grossly distended loop of colon arising out of the pelvis and extending towards the diaphragm.
  - ▶ *Coffee-bean sign* or *Bent-inner tube sign*.
2. **Contrast enema**: (dilute barium/water soluble contrast media is used):
  - Birds beak sign* (ace of spades appearance)—Upper end of barium column tapers into the spirally twisted distal sigmoid colon.



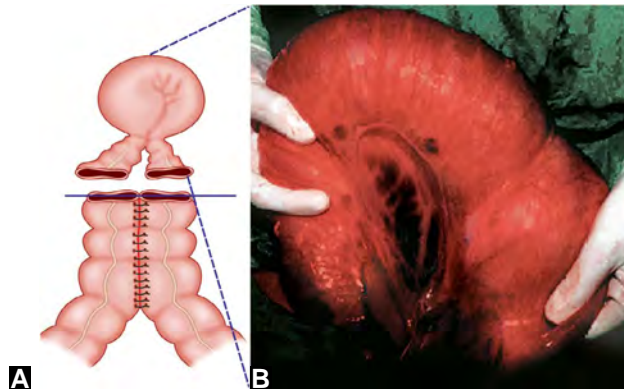
Figs 23.33A to F: Sigmoid volvulus—note distended tympanic abdomen; X-ray showing typical sigmoid volvulus; on table gangrenous sigmoid volvulus; underwent resection with colostomy and mucous fistula (exteriorisation).

3. **CT scan** (for difficult cases): Shows characteristic whirl pattern.
4. **Blood**—Haematocrit, renal function tests, serum electrolytes.

### Treatment

- ◆ RT aspiration.
- ◆ IV fluids.
- ◆ Catheterisation.
- ◆ Antibiotics.
- ◆ *A flatus tube or Sigmoidoscope* is passed in operation theatre (proper care is taken otherwise it leads to perforation). If it derotates, patient will pass flatus and faeces; and distension reduces.
- ◆ If derotation does not occur, laparotomy through midline incision should be done. Dilated sigmoid colon is derotated manually and checked for viability. If viable, it can be fixed to the lateral wall of abdomen or pelvis—**sigmoidopexy**.
- ◆ If sigmoid colon is gangrenous, it is resected and proximal cut end is brought out as colostomy and distal end is brought out as mucous fistula, from the rectum (**Paul-Mikulicz Operation**). Later after 6 weeks, continuity is maintained after proper preparation.
- ◆ Resection of the gangrenous sigmoid done; proximal cut is brought out as end colostomy: distal end closed—**Hartmann's operation**. Later in 6–12 weeks colorectal anastomosis is maintained.
- ◆ Primary resection and anastomosis is not advisable because of the contamination and anastomotic leak.

**Mortality** in sigmoid volvulus is due to *perforation, peritonitis and septicæmia*.



Figs 23.34A and B: Paul-Mikulicz operation.

### PARALYTIC ILEUS

#### (Adynamic Intestinal Obstruction)

- ◆ It is a state in which intestines fail to transmit peristalsis due to failure of neuromuscular mechanism, i.e. Auerbach's and Meissner's plexus.
- ◆ It may be localised or generalised.

#### Causes

- ❖ Postoperative
- ❖ Infective—pus, blood, bile, toxins, enteritis
- ❖ Uraemia
- ❖ Hypokalaemia
- ❖ Spinal injury
- ❖ Retroperitoneal haemorrhage
- ❖ Spinal surgery
- ❖ Plaster jacket

### Clinical Features

- ◆ No passage of flatus.
- ◆ No bowel sounds.
- ◆ Marked abdominal distension.
- ◆ Vomiting of large volume of fluid.
- ◆ Tachycardia.
- ◆ Respiratory distress due to pressure over the diaphragm.
- ◆ High-pitched tinkling note '*like bells at evening pealing*'.
- ◆ Dull abdominal pain (not colicky).
- ◆ Features of fluid/protein/electrolyte imbalance.

### Investigations

- ◆ Serum electrolyte estimation: Especially serum potassium.
- ◆ ECG.
- ◆ X-ray abdomen.
- ◆ Ultrasound abdomen to find out the possible cause of ileus, e.g. sepsis.

### Treatment

- ◆ Nasogastric aspiration.
- ◆ The primary cause is treated.
- ◆ IV fluids.
- ◆ Electrolyte management.
- ◆ Catheterisation and urine output measurement.
- ◆ *Do not stimulate the peristalsis* ("*Don't flog a tired horse*").
  - ▶ **Measurement of abdominal girth** is necessary to see whether patient is recovering or not.
  - ▶ Decompression of the large bowel can be tried by inserting a flatus tube per anally into the rectum and keeping in place for few hours.
  - ▶ Most often, patient recovers in 3–6 days by conservative treatment.
  - ▶ In prolonged, life-threatening paralytic ileus, laparotomy is done and bowel is decompressed with *Savage's decompressor* and closed with tension sutures.
- ◆ *Catchpole regime*: Adrenergic blocking agent along with cholinergic stimulant (neostigmine) is used rarely only in resistant cases as medical therapy.

### ADHESIONS AND BANDS

Adhesions and bands are the most common causes of intestinal obstruction in Western countries. In India, hernia and then adhesions are the two common causes of intestinal obstruction.

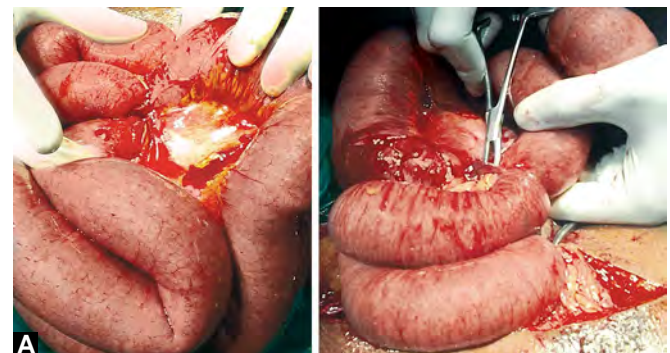


Fig. 23.35A



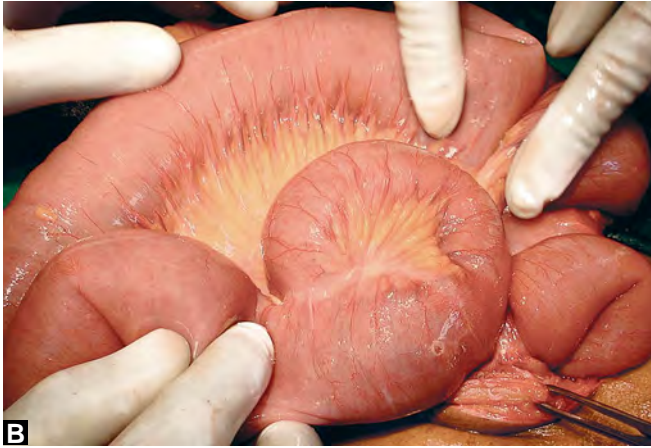
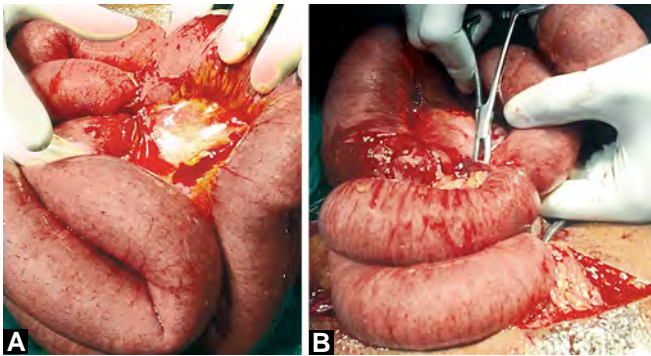


Fig. 23.35B

Figs 23.35A and B: Adhesions causing intestinal obstruction.



Figs 23.36A and B: Congenital band causing intestinal obstruction. These bands are often vascular.

## Causes

- ◆ Infection due to peritonitis, appendicitis, post-laparotomy, and other acute infective abdominal conditions.
- ◆ Materials used during surgery can cause dense inflammatory reactions—suture materials like silk, thread, and foreign body, mop, and gauze, talc powder, drugs like sulphonamides and penicillins.
- ◆ Ischaemia of bowel due to poor blood supply, sepsis.
- ◆ Gynaecological conditions, bowel injury, radiation-induced enteritis, Crohn's disease, other inflammatory bowel diseases.
- ◆ Specific conditions like tuberculosis, malignancy.

### Note:

- It is often called as *adhesive small bowel obstruction* (ASBO). 80% cases showed earlier laparotomies; 35% multiple laparotomy. 75% of surgeries in such patients are emergency one.
- *Causes may be classified as—Congenital adhesions; Ischaemic—*Reduced blood supply of the bowel, *Traumatic—*Patients have undergone laparotomies for intra-abdominal injuries; *Irritants—*Talc powder used for gloves, starch, antibiotics, nonabsorbable suture materials, gauze and cotton filaments, barium; *Inflammatory: Appendicitis, cholecystitis, pelvic infection, Crohn's disease, tuberculosis; Others—*Serosal denudation during surgery precipitates adhesions.
- Initial cause ischaemia/injury → inflammatory exudates → fibrinous adhesions → fibrous adhesion → fibrinolysis. Fibrinous adhesion is avascular. Often thick vascular adhesions develops. Adhesions can be localized or extensive.

## Types

*Type I—Fibrinous* adhesions occur during 5–10th post-surgical period. It usually gets resolved completely. It is avascular and flimsy.

*Type II—Fibrous* adhesions. Due to lack/poor blood supply, bowel gets attached to part of peritoneum or omentum or other parts of the bowel with dense vascular adhesions to maintain blood supply. It will persist and precipitate intestinal obstruction, often-subacute and recurrent type.

*Adhesions due to tuberculosis are severe, dense and difficult to separate.*

### Clinical features

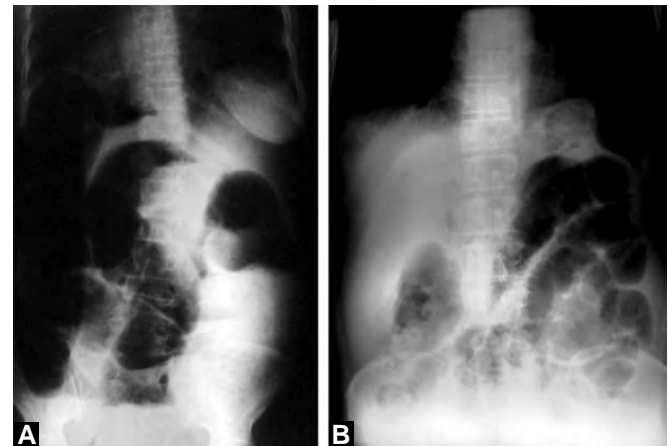
- ❖ Pain abdomen—colicky type and recurrent and episodic
- ❖ Distension, vomiting
- ❖ Constipation
- ❖ Reduced bowel sounds on auscultation
- ❖ Previous surgical scars commonly observed
- ❖ Dehydration, tachycardia, hypotension
- ❖ Commonest symptom in adhesions is **pain** which is sharp, sudden, recurrent, episodic and colicky. Colicky pain is more common in mid-level obstruction. *Gilroy Bevan triad* of adhesive pain is—(1) Pain may get aggravated or relieved on change of posture. (2) Pain in the region of old abdominal scar. (3) Tenderness is elicited by pressure over the scar
- ❖ Lower adhesions will have more distension compared to proximal adhesion
- ❖ Presents with features of obstruction initially, later features of strangulation (toxicity, fever, tachycardia, guarding, rigidity, rebound tenderness)
- ❖ Adhesions may be asymptomatic for many years but later become symptomatic

## Investigations

- ◆ Plain X-ray abdomen shows dilated bowel loops.
- ◆ Oral contrast with CT scan is very useful.
- ◆ In partial obstruction only enteroclysis with water-soluble iodine dyes can be done.

Level of obstruction should be assessed probably by X-ray and CT scan.

- ◆ CT may show radiological features of strangulation -
  - ▶ Intramesenteric fluid.
  - ▶ Mesenteric oedema, congestion.
  - ▶ Bowel wall thickening more than 2 mm.
  - ▶ Reduced mural enhancement in strangulated bowel compared to adjacent bowel.



Figs 23.37A and B: X-ray showing small bowel obstruction with multiple air fluid levels.

- ▶ Small bowel loop may go for volvulus showing *Whirl sign* in CT scan with whirlpool mesentery of that part of the bowel.

- ◆ Electrolyte estimation, total count, serum creatinine, blood grouping.

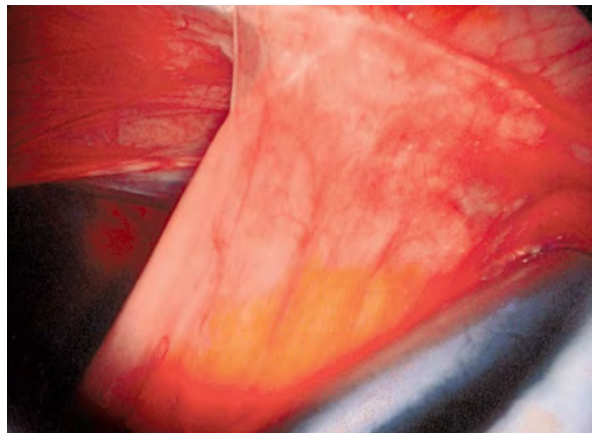
**Treatment**

*Initial Treatment*

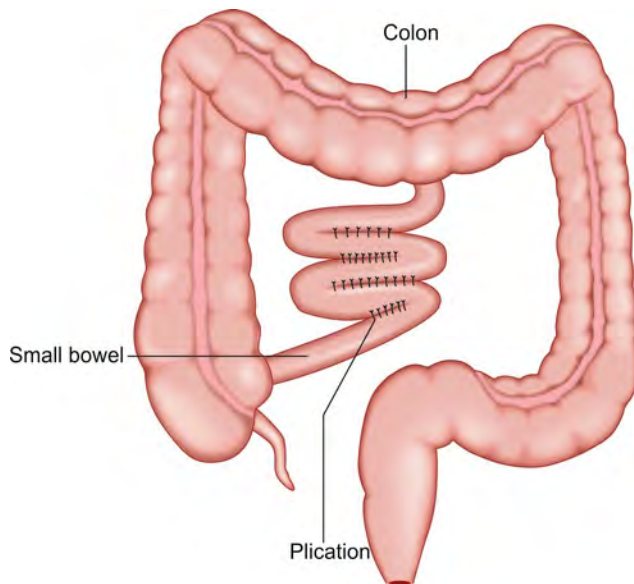
- ◆ IV fluids.
- ◆ Nasogastric aspiration.
- ◆ Antibiotics.
- ◆ Often per anal flatus tube insertion.
- ◆ Commonly patient responds in 4–5 days of therapy.

*Later Treatment*

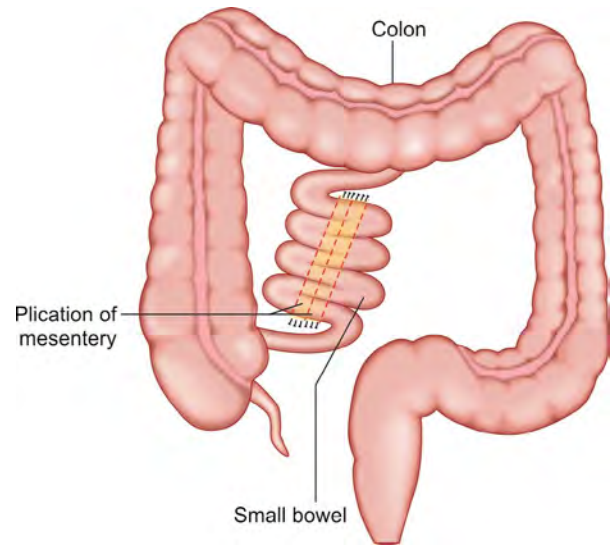
- ◆ Open surgical adhesiolysis using fingers gently.
- ◆ *Laparoscopic adhesiolysis* is becoming popular, safer, ideal with less recurrent adhesion rate and gives good results.



**Fig. 23.38:** Laparoscopic view of dense adhesions—postoperative cause.

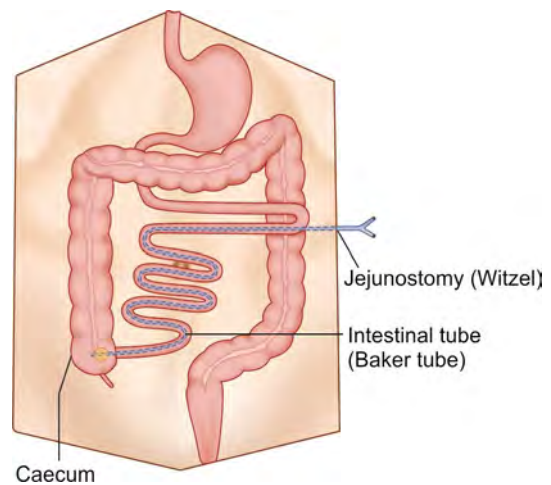


**Fig. 23.39:** Methods used to prevent recurrent adhesions and so to reduce the chances of intestinal obstruction. *Nobles plication* is plication of intestines.



**Fig. 23.40:** *Childs-Phillips operation* done to prevent adhesive obstruction by plicating mesentery.

- ◆ *Noble’s plication* of intestines—wherein adjacent coils of small bowel are sutured to prevent in-going for further recurrent adhesions.
- ◆ *Childs-Phillips mesenteric plication* is similar way of plication of intestinal mesentery, which will prevent crumpling of bowel and adhesion formation.
- ◆ Passing long stiff tube from exterior through an opening in the proximal bowel up to the entry into the large bowel, which acts as intraluminal splinting.
  - ▶ Intestinal intubation is technically difficult with chances of perforation and fistula formation.
  - ▶ *Baker’s tube* insertion through *jejunostomy* site; *Stewardson insertion of Baker tube* through nasogastric route; In *Nelson and Nyhus* method, 2nd balloon to Baker tube 25 cm proximal to the first to facilitate easier insertion of the tube—are different tubes and techniques used.



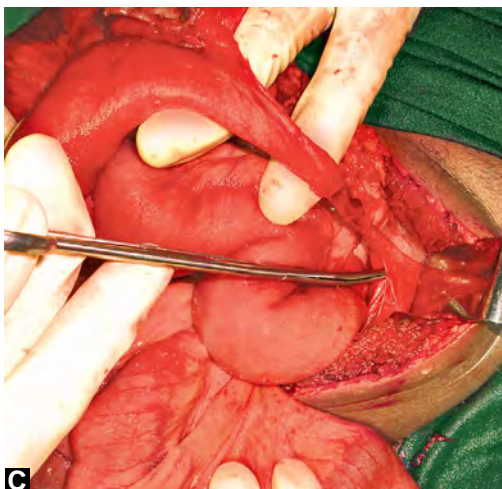
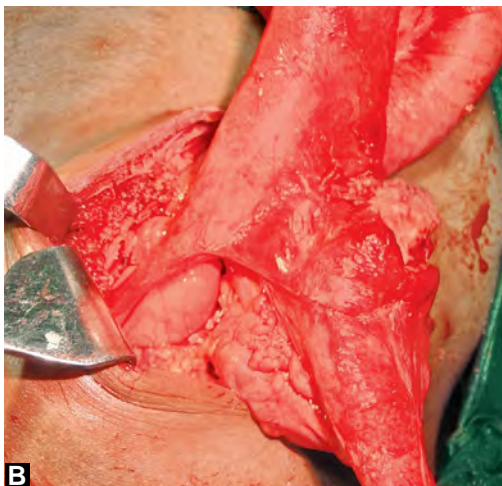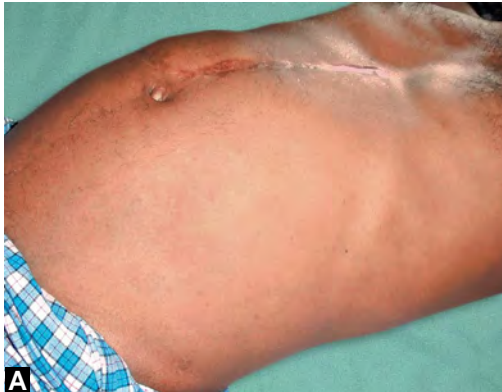**Fig. 23.41:** Intestinal intubation via a jejunostomy tube used for adhesions.

- ◆ Expandable PTFE membrane barriers or hyaluronic acid and carboxymethyl cellulose membrane barriers are also used.

*It is never too late to give up your prejudices.*

### Prevention of adhesions

- ❖ Instilling drugs like hyaluronidase, steroids, dextrans, dextrans, polyvinyls, silicone, fibrinolysins, chondroitins, streptomycins
- ❖ Gentle handling of the bowel
- ❖ Prevention of spillage of contents like bile, faeces
- ❖ Ideal peritoneal wash using 8–10 liters of saline before closing the abdomen
- ❖ Careful placing of the drains
- ❖ *Laparoscopic procedures have got lesser chance of getting adhesions than open method*



**Figs 23.42A to C:** Postoperative adhesions have become commonest cause of intestinal obstruction. Note the abdominal distension in a previous laparotomy patient and on table adhesions.

## Obstruction due to Bands

- ◆ These are *dense fibrous strings* attached from one portion of the abdomen to another area or bowel causing entrapment of intestines leading into obstruction and often dangerous *strangulation*.
- ◆ Common causes are vitellointestinal duct, Ladd's band, omental band, postsurgical fibrous band, tuberculous band.
- ◆ Clinical features are like of intestinal obstruction.
- ◆ Management is release of the band either through laparoscopy or through laparotomy.

## INTERNAL HERNIAS

- ◆ It is rare entity.
- ◆ A portion of small bowel gets entrapped in one of the retroperitoneal fossae or congenital internal defects (e.g. mesenteric defect).

### Sites

- ◆ Mesenteric defect; defect in transverse mesocolon.
- ◆ Foramen Winslow.
- ◆ Diaphragmatic hernia.
- ◆ Hernia through duodenal/caecal/appendiceal/ intersigmoid retroperitoneal fossae.
- ◆ Hernia through broad ligament.

**Mesocolic/paraduodenal hernias:** They are rare congenital small bowel herniation behind the mesocolon due to midgut malrotation. It can be right or left types. In right type small bowel is right of the superior mesenteric artery (SMA is medial to neck of the sac) behind right side colonic mesentery with ileocolic, right colic, middle colic vessels in front in the sac. Left type is commonest (75%) with herniation of small bowel between inferior mesenteric vessels and attachment of descending mesocolon. Presentation is acute intestinal obstruction. Contrast CT is diagnostic. Often condition is diagnosed on table during surgery. Incising peritoneum sac adjacent to vessels carefully and adequately is the needed surgical treatment. Malrotation should be surgically corrected.

**Mesenteric defect hernias** (small bowel mesentery/mesocolon) even though can occur anywhere, are common near ileocolic junction.

**Acquired internal hernias** occur through defects developed after surgeries like gastrojejunostomy (*Stammer's hernia*); colostomy; ileostomy; surgeries for morbid obesity.

### Features

- ◆ Herniation occurs in these sites whenever there are adhesions.
- ◆ Features of intestinal obstruction—acute/subacute/recurrent.
- ◆ Diagnosis is usually on table. But enteroclysis, contrast CT scan are useful.

### Treatment

- ◆ Release of adhesion, reduction of hernia, if bowel not viable resection and anastomosis.
- ◆ Often major vessels may be present adjacent to the constriction ring which may get injured while releasing causing torrential haemorrhage. Decompression is first done prior to reduction.

# Chapter 24

# Appendix

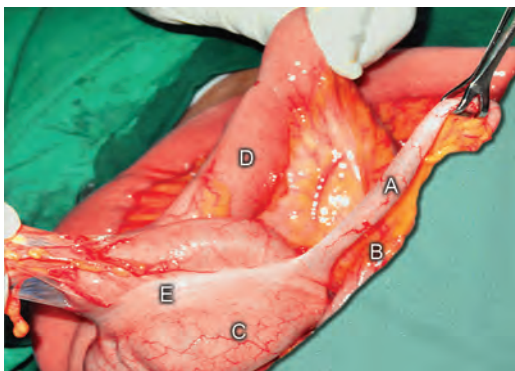
## CHAPTER OUTLINE

- ❖ Surgical Anatomy
- ❖ Acute Appendicitis
- ❖ Duplication of Appendix
- ❖ Incidental Appendicectomy
- ❖ Appendicular Mass
- ❖ Appendicular Abscess
- ❖ Faecal Fistula after Appendicectomy
- ❖ Mucocele of Appendix
- ❖ Neoplasms of the Appendix
- ❖ Laparoscopic Appendicectomy

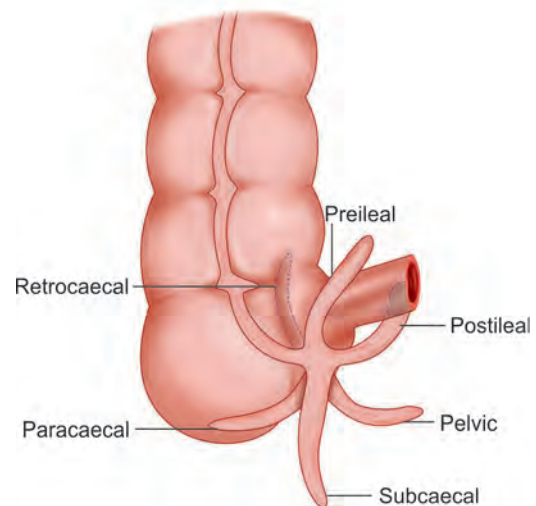
### SURGICAL ANATOMY

It is located at the terminal end of the caecum where three taeniae join, about 2 cm below the ileocaecal orifice. Usually, around 5–10 cm in size but can be variable. Size of its lumen is that of matchstick. Diameter of appendix is 3–8 mm; diameter of lumen is 1–3 mm (matchstick).

Mesoappendix is extension of the mesentery contains appendicular artery, a branch of ileocolic artery. Often an accessory appendicular artery (*of Seshachalam*) may be present. Thrombosis of these vessels leads to gangrenous appendicitis.



**Fig. 24.1:** On table demonstration of mesoappendix with appendicular artery. Note the appendix (A); mesoappendix (B); caecum (C); ileum (D); taenia (E).



**Fig. 24.2:** Different anatomical positions of the appendix.

### DUPLICATION OF APPENDIX (Wallbridge classification) (Fig. 24.3)

- Type A: Partial duplication in a single caecum.
- Type B: Two separate appendices in a single caecum.
- Type C: Double caecum with each one having one appendix.

- ◆ **Most common position** is retrocaecal (75%). Next common is pelvic (21%).

Other sites are:

- ❖ Preileal (anterior)—rare (1%)
- ❖ Postileal (splenic)—rarest
- ❖ Paracaecal
- ❖ Subcaecal –2%
- ❖ Subhepatic

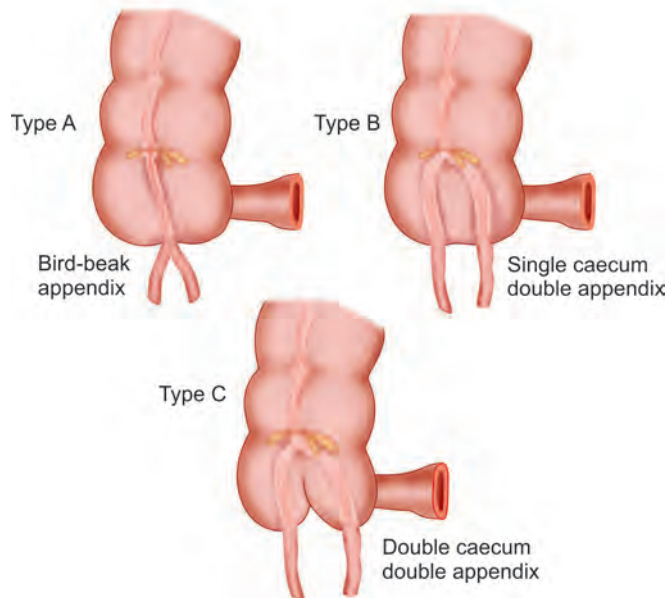


Fig. 24.3: Duplication of appendix.

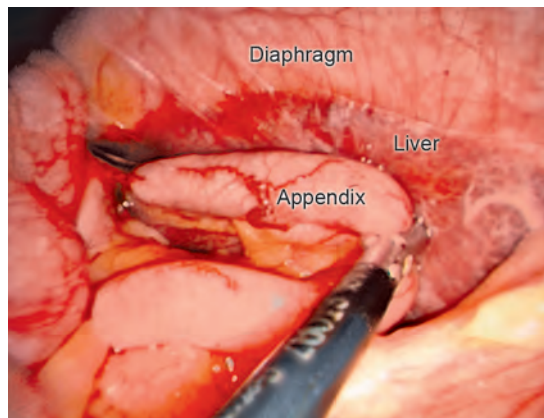


Fig. 24.4: Laparoscopic view of subhepatic appendix.

- ◆ Often it may be in subserosal plane leading to difficult dissection during appendicectomy.
- ◆ In *situs inversus* appendix is on the left side.
- ◆ Mucosa of appendix is lined by columnar cells with crypts.
- ◆ Submucosa contains numerous lymphatic aggregations (follicles)(*abdominal tonsil*).
- ◆ Opening of the appendix into caecum is guarded by 'valve of Germalch'.

## ACUTE APPENDICITIS

The partial inflammation of the peritoneum, in the liac fossa, is sometimes set up by disease in the Appendix caeci.... The appendix having been perforated by ulcerations, occasioned by the lodgement of the faecal concretions in its cavity, extravasation takes place, and inflammation of a more severe and serious kind is originated.... Nature sometimes succeeds in limiting the inflammation to a part of the right side; but it is at other times diffused over the whole abdomen ...and quickly proves fatal.

—Thomas Hodgkin, 1836

### Aetiology

- ◆ It is common in young males.
- ◆ It is common in white races.
- ◆ Fibre rich diet prevents appendicitis. Less fibre diet increases chance of appendicitis.
- ◆ It is common in May and August—seasonal variation—often called as *epidemic appendicitis*.
- ◆ Viral infection may cause mucosal oedema and inflammation which later gets infected by bacteria causing appendicitis.
- ◆ Family history may be relevant in 30% of appendicitis in children with appendicitis occurring in first degree relatives.
- ◆ Obstruction of the lumen of appendix causing obstructive appendicitis.
  - ▶ Blockage occurs due to—faecoliths, stricture, foreign body, round worm or threadworm.
  - ▶ Adhesions and kinking—carcinoma caecum near the base, ileocaecal Crohn's disease.
- ◆ Distal colonic obstruction.
- ◆ Abuse of purgatives.
- ◆ Faecolith is the *most common* cause.

### Organisms:

*E. coli* (85%), enterococci, (30%), streptococci, *Anaerobic streptococci*, *Cl. welchii*, bacteroides.

*Pseudoappendicitis* is appendicitis due to acute ileitis following Yersinia infection. It is often due to Crohn's disease.

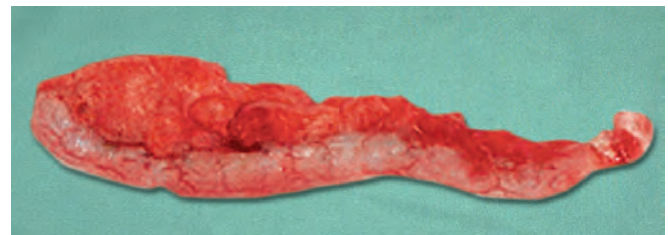
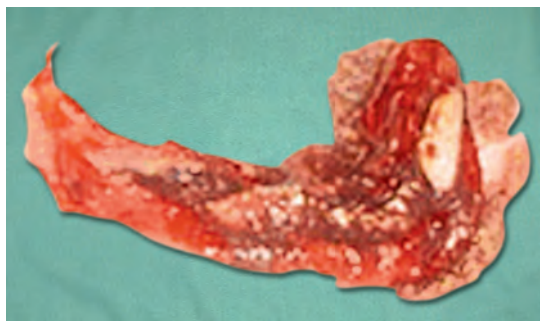


Fig. 24.5: Removed appendix with its mesoappendix.

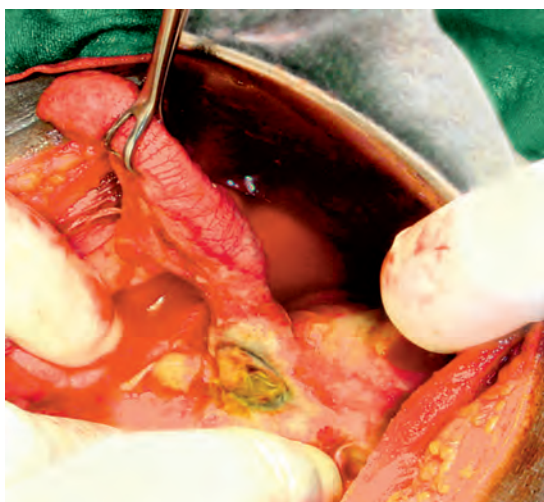
### Pathogenesis

- ◆ Acute inflammation of the mucus membrane with secondary infection without obstruction causes *acute nonobstructive appendicitis*. It may lead into resolution, fibrosis, recurrent appendicitis or eventual obstructive appendicitis.

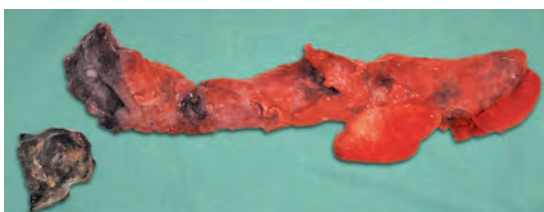


**Fig. 24.6:** Severely infected appendix with faecolith inside. Faecolith is one of the causes of obstructive appendicitis.

- ◆ Luminal obstruction by faecolith, lymphoid hyperplasia, pinworm (*oxyuris vermicularis*), other worms, foreign body, carcinoma/Crohn's disease → mucus and inflammatory fluid collects inside the lumen → increases intraluminal pressure → leads to blockage of lymphatic and venous drainage → resulting in increased oedema of mucosa and wall → causes mucosal ulceration and ischaemia → bacterial translocation → bacterial spread through submucosa and muscularis propria → *acute obstructive appendicitis* → thrombosis of appendicular artery → ischaemic necrosis of full thickness of the wall of the appendix → gangrene of the appendix → perforation at the tip or at the base → peritonitis.
- ◆ After perforation → localisation by greater omentum and dilated ileum occurs → with suppuration and pus inside forming *appendicular abscess*.



**Fig. 24.7:** Laparotomy showing perforated appendix with peritonitis.



**Fig. 24.8:** Appendicolith with appendicitis.

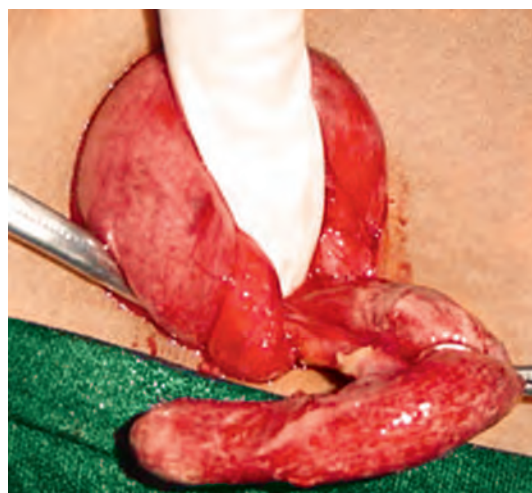- ◆ In severe acute appendicitis → localisation can occur by omentum and dilated ileum without pus inside → forming *appendicular mass*.
- ◆ Acute appendicitis with blockage at the opening of the lumen → inflammation rarely subsides → mucus collects inside the lumen of the appendix resulting in its enlargement → *Mucocele of the appendix*.

## Types

### 1. *Acute nonobstructive appendicitis (catarrhal) (mucosal appendicitis):*

Inflammation of mucous membrane occurs with redness, oedema and haemorrhages which may go for following courses:

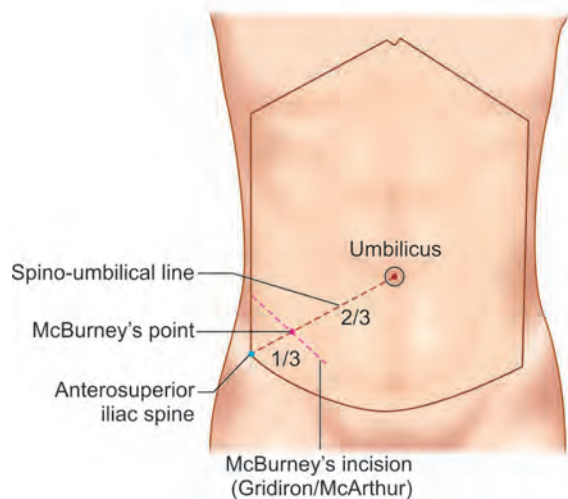
- ❖ Resolution
- ❖ Ulceration
- ❖ Fibrosis
- ❖ Suppuration
- ❖ Recurrent appendicitis
- ❖ Gangrene—rare initially in nonobstructive type but later can occur
- ❖ Peritonitis.



**Fig. 24.9:** Gangrenous obstructive appendicitis—on table.

2. *Acute obstructive appendicitis:* Here pus collects in the blocked lumen of appendix which is blackish, gangrenous, oedematous and rapidly progresses leading to perforation either at the tip or at the base of appendix. This leads to peritonitis, formation of appendicular abscess or pelvic abscess. Most often, there will be thrombosis of the appendicular artery.
3. *Recurrent appendicitis:* Repeated attacks of nonobstructive appendicitis leads to fibrosis, adhesions causing recurrent appendicitis.
4. *Subacute appendicitis* is milder form of acute appendicitis.
5. *Stump appendicitis* is retained long stump of appendix after commonly laparoscopic appendicectomy.

## Clinical Features



**Fig. 24.10:** *McBurney's point* is junction of lateral 1/3rd and medial 2/3rd of spino-umbilical line. *McBurney's/Gridiron's/McArthur's* incision is perpendicular to this line in this point.

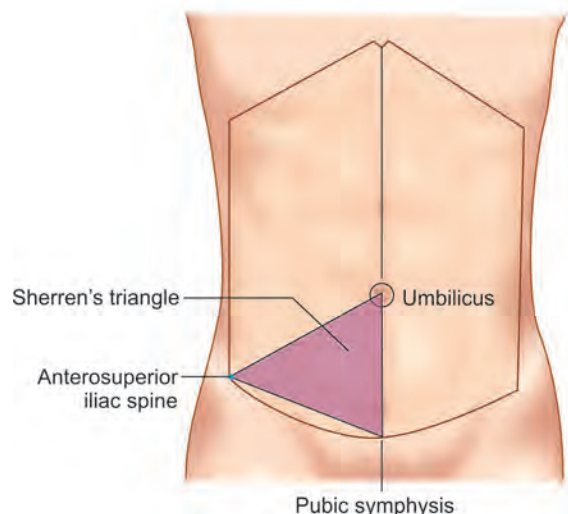
- ◆ It is rare before the age of two, common in children and other age groups.
- ◆ **Pain:** It is the earliest symptom. Visceral pain starts around the umbilicus due to distension of appendix, later after few hours, somatic pain occurs in right iliac fossa due to irritation of parietal peritoneum due to inflamed appendix. Pain eventually becomes severe and diffuse which signifies spread of infection into the general peritoneal cavity.
- ◆ **Vomiting:** Due to reflex pylorospasm.

### Murphy's triad

- ❖ Pain—first
- ❖ Vomiting—next
- ❖ Temperature—last

- ◆ **Constipation** is the usual feature *but diarrhoea* can occur if appendix is in postileal or pelvic positions.
- ◆ **Fever, tachycardia, foetor oris** are other features.
- ◆ **Urinary frequency:** Inflamed appendix may come in contact with bladder and can cause bladder irritation.
- ◆ Tenderness and rebound tenderness at *McBurney's point* in right iliac fossa (*release sign—Blumberg's sign*) are typical.
- ◆ **Rovsing's sign:** On pressing left iliac fossa, pain occurs in right iliac fossa which is due to shift of bowel loops which irritates the parietal peritoneum.
- ◆ Hyperextension (in case of retrocaecal appendix—*Cope's psoas test*) or internal rotation (in case of pelvic appendix—*obturator test*) of right hip causes pain in right iliac fossa due to irritation of psoas muscle and obturator internus muscle respectively.
- ◆ **Baldwing's test** is positive in retrocaecal appendix—when legs are lifted off the bed with knee extended, the patient complains of pain while pressing over the flanks.

- ◆ P/R examination shows tenderness in right side of the rectum.
- ◆ Hyperaesthesia in '*Sherren's triangle*'. This triangle is formed by anterosuperior iliac spine, umbilicus, pubic symphysis.



**Fig. 24.11:** *Sherren's triangle*. It is area of hyperaesthesia found in acute appendicitis between anterosuperior iliac spine; umbilicus and pubic symphysis.

Often infection gets localised by omentum, dilated ileum and parietal peritoneum leading to *appendicular mass*. Often suppuration occurs in the localised area resulting in *appendicular abscess*.

### Clinical signs in appendicitis

- ❖ Rovsing's sign
- ❖ Blumberg's sign (Release sign)
- ❖ Cope's psoas test
- ❖ Obturator test
- ❖ Baldwin's test
- ❖ Bastede sign
- ❖ *Dumphy's* cough tenderness sign (Refer fascinating signs for detail)
- ❖ Bapat bed shaking test
- ❖ Heel Drop test

- ◆ **Acute appendicitis in infancy:**
  - ▶ Even though it is rare, when it occurs, it has got 80% chances of perforation with high mortality (50%).
- ◆ **Acute appendicitis in children:**
  - ▶ Here localisation is not present, and so peritonitis occurs early.
  - ▶ It *requires early surgery*. Dehydration, septicaemia are common.
- ◆ **In elderly:**
  - ▶ Gangrene and perforation are common. Because of lax abdominal wall, localisation is poor and so peritonitis sets in early.
- ◆ **In pregnancy:**
  - ▶ **Incidence** is 1 in 2,000 pregnancies. It is more common in 1st and 2nd trimesters.
  - ▶ Appendix shifts to upper abdomen. So pain is higher and more lateral.

- ▶ Rebound tenderness and guarding *may not* be evident.
- ▶ TC will be very high with neutrophilia.
- ▶ Risk of *premature labour* is 15%.
- ▶ *Foetal death* in early appendicitis is 5% but becomes 29% once appendix perforates in pregnancy.
- ▶ After 6 months, maternal mortality increases by 10 times than usual and also leads to premature labour.
- ▶ Appendicitis is the most common non-gynaecologic surgical emergency during pregnancy.
- ▶ Incidence of perforation is highest in 3rd trimester.
- ▶ Surgery is the treatment.

## Differential Diagnosis for Acute Appendicitis

Many conditions mimic acute appendicitis. It differs in children, adult, elderly and females.

- ◆ *Perforated duodenal ulcer*: In duodenal ulcer perforation, fluid trickles down along right paracolic gutter and mimics appendicitis. Upper abdominal pain, obliterated liver dullness, gas under diaphragm in X-ray and CT scan differentiate it from acute appendicitis.
- ◆ *Acute cholecystitis*: Pain in right upper abdomen, fever, jaundice, upper abdominal guarding are the features of acute cholecystitis. US; HIDA scan, LFT will differentiate it from acute appendicitis.
- ◆ *Acute pancreatitis*: Pain in epigastrium, radiating to back, raised serum amylase and lipase, CT abdomen with a history of alcohol intake often are diagnostic.
- ◆ *Right ureteric colic*: Pain is colicky in nature which often refers to genitalia. Haematuria, urinary symptoms are common. It mimics retrocaecal/pelvic acute appendicitis. Often in ureteric stone, abdomen is soft and nontender. CT is the important way to differentiate.
- ◆ *Acute typhlitis*: Inflammation of caecum is called as typhlitis. Often it is difficult to differentiate it from acute appendicitis. Intravenous/oral metronidazole completely controls the disease.
- ◆ *Acute bacterial enterocolitis*: It presents with pain abdomen, diarrhoea, toxæmia, dehydration. Often it is difficult to differentiate from acute appendicitis.
- ◆ *Acute mesenteric lymphadenitis* is difficult to differentiate from acute appendicitis. It is treated conservatively. CT may be helpful to identify it. Laparoscopic evaluation is ideal.
- ◆ *Right sided acute pyelonephritis*: Here there will be pain and tenderness in loin. Urine analysis, US are diagnostic. Often DTPA scan may be needed.
- ◆ *Crohn's disease* presenting with acute symptoms will have similar features of acute appendicitis.
- ◆ *Pelvic inflammatory disease* like salpingo-oophoritis mimics acute appendicitis. Twisted/haemorrhagic/ruptured ovarian cyst/ruptured ectopic gestation/endometriosis/tubo-ovarian abscess mimics acute appendicitis. US, laparoscopy helps to differentiate it from others. *Mittelschmerz* is lower abdominal pain due to rupture of follicular cyst during midcycle. It subsides on its own. There are no systemic features.
- ◆ *Meckel's diverticulitis* presents clinically like acute appendicitis. It is not possible to differentiate between two clinically.
- ◆ *Intussusception* mimics acute appendicitis in children. ISS is common before the age of 2 years. Acute appendicitis is rare before the age of 2 years. Palpable mass, features of intestinal obstruction, barium enema X-ray, US are useful methods to differentiate.
- ◆ *Worm infestation (round worm bolus/ball)*: It often presents as pain in right iliac fossa. Features of intestinal obstruction are common here.
- ◆ *Right-sided lobar pneumonia* and pleurisy are often not easy to differentiate from acute appendicitis. Pleural rub, change in breath sounds, chest X-ray can identify pneumonia.
- ◆ *Testicular torsion/acute severe orchitis* often look like acute appendicitis. Referred pain in iliac fossa, and if scrotum is not palpated clinically these conditions are mistaken for acute appendicitis. These problems are much more obvious if *testis is undescended* one.
- ◆ *Sigmoid diverticulitis* in elderly with loop lying towards right side may present as pain in the right iliac fossa.
- ◆ *Carcinoma caecum* may present with features of acute appendicitis without any earlier typical features.
- ◆ *Ruptured aortic aneurysm, acute intestinal obstruction, mesenteric ischaemia* may present like acute appendicitis.
- ◆ Rare conditions like preherpetic pain of the right 10th and 11th dorsal nerves may mimic acute appendicitis. Guarding and rigidity will not be present. There will be significant hyperaesthesia.
- ◆ Tabetic crisis, tuberculosis of spine, secondaries in spine, multiple myeloma, osteoporotic pain often can mimic acute appendicitis.
- ◆ Acute crisis of porphyria and diabetes mellitus mimic acute appendicitis with severe abdominal pain.

### Differential diagnosis

- ❖ Perforated peptic ulcer
- ❖ Ruptured or twisted ovarian cyst
- ❖ Acute cholecystitis
- ❖ Right ureteric colic
- ❖ Enterocolitis
- ❖ Right acute pyelonephritis
- ❖ Mesenteric lymphadenitis
- ❖ Lobar pneumonia
- ❖ Crohn's disease
- ❖ Acute pancreatitis
- ❖ Meckel's diverticulitis
- ❖ Acute crisis of porphyria
- ❖ Salpingitis
- ❖ Diabetic abdomen
- ❖ Ectopic gestation—ruptured
- ❖ Typhlitis

### Differential diagnosis in children

- ❖ Meckel's diverticulitis
- ❖ Acute colitis
- ❖ Acute iliac lymphadenitis
- ❖ Intussusception
- ❖ Roundworm colic
- ❖ Lobar pneumonia

### Differential diagnosis in females

- ❖ Ruptured ectopic gestation
- ❖ Mittelschmerz rupture of ovarian follicle during mid-menstrual period
- ❖ Ovarian cyst torsion
- ❖ Salpingo-oophoritis

### Differential diagnosis in elderly

- ❖ Acute diverticulitis
- ❖ Carcinoma caecum—acute features
- ❖ Mesenteric ischaemia
- ❖ Intestinal obstruction
- ❖ Aortic aneurysm leak
- ❖ Crohn's disease

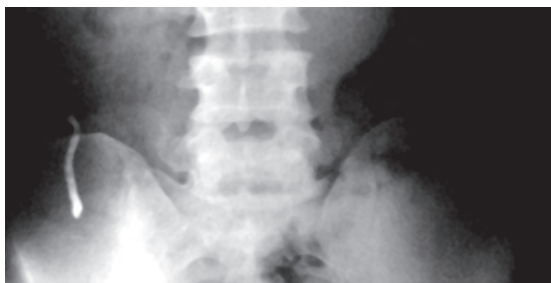*Appendices epiploicae are absent in rectum, appendix and caecum.*



### Sequelae of acute appendicitis

- ❖ Resorption
- ❖ Relapse and recurrent appendicitis
- ❖ Appendicular mass
- ❖ Appendicular abscess
- ❖ Perforation—has got 20% mortality
- ❖ Peritonitis, septicaemia
- ❖ Portal pyaemia
- ❖ *Intestinal obstruction* due to obstructive ileus, inflammatory adhesion, formation of band between appendix and omentum or between appendix and small bowel

### Investigations

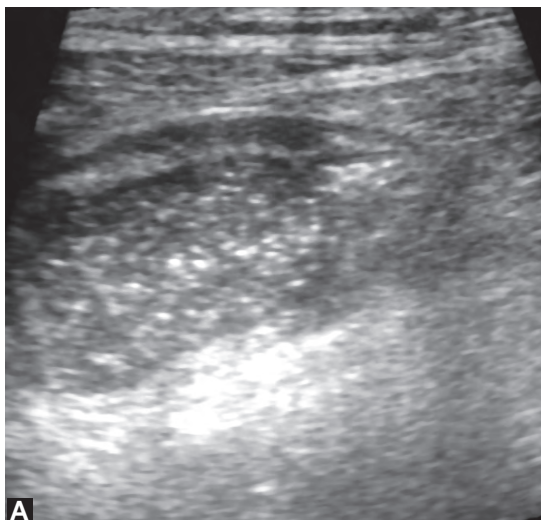


**Fig. 24.12:** Radio-opaque appendix in a plain X-ray. It could be calcified or have calcified content.

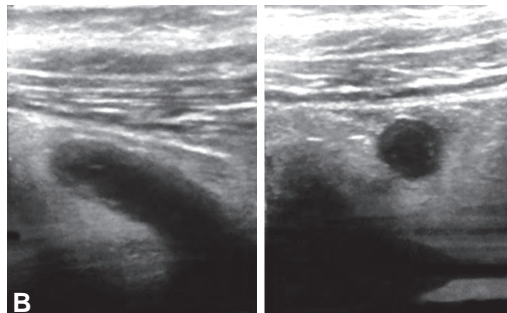
- ◆ Total leucocyte count is increased.
- ◆ *Ultrasound* is done to rule out other conditions like ureteric stone, pancreatitis, ovarian cyst, ectopic pregnancy and also to confirm appendicular mass or abscess.
- ◆ Laparoscopy is the most useful method.

### Sonographic criterias for appendicitis (85% Specificity)

- ◆ Noncompressible appendix of size > 6 mm AP diameter, hyperechoic thickened appendix wall > 2 mm—*target sign*.
- ◆ Appendicolith.
- ◆ Interruption of submucosal continuity.
- ◆ Periappendicular fluid.



**Fig. 24.13A**



**Fig. 24.13B**

**Figs 24.13A and B:** Ultrasound showing dilated noncompressible appendix in two different patients.

- ◆ *Contrast CT scan* is very much useful when diagnosis is difficult especially in old people. Dilated appendix; dilated lumen; thickened wall; nonfilling of the lumen by contrast or air; periappendicular fluid collection; presence of mass/abscess/associated pathology like carcinoma can be identified. It has 95% sensitivity and specificity with 95% accuracy. *Dirty fat thickened mesoappendix*, appendicular *phlegmon*, appendicular *faecolith* and thickened caecum funneling contrast into the orifice of the appendix as *arrowhead sign*—are all relevant features in CT scan.
- ◆ *C-reactive protein*, even though nonspecific increases in acute phase. *<sup>99mTc</sup> HMPAO labeled leukocyte* imaging may give guidance in deciding the management.
- ◆ MRI is very useful tool in pregnancy.
- ◆ *Plain X-ray* may show lumbar scoliosis towards right due to psoas spasm which is not uncommon; faecolith on the right side; obliteration of preperitoneal fat line due to retrocaecal appendicitis; segmental ileus in caecum and terminal ileum; speckled extraluminal gas in right iliac fossa, gas in appendix, pneumoperitoneum (very rare); intestinal obstruction (occasionally only); soft tissue mass in mass or abscess of appendix—all these features are very much nonspecific. X-ray is useful to rule out DU perforation, intestinal obstruction, ureteric stone.

### Different Scoring Systems Used

<i>Alvarado scoring for appendicitis (1986):</i>	<b>Score</b>
<i>Migrating pain</i>	1
<i>Anorexia</i>	1
<i>Nausea and vomiting</i>	1
<i>Tenderness in right iliac fossa</i>	2
<i>Rebound tenderness</i>	1
<i>Elevated temperature</i>	1
<i>Leucocytosis with count more than 10,000</i>	2
<i>Shift to left with neutrophilia in peripheral smear</i>	1
<b>Total score</b>	<b>10</b>
Score less than 5: Not sure.	
Score between 5–6: Compatible.	
Score between 6–9: Probable.	
Score more than 9: Confirmed.	

- ◆ *Kalam modified Alvarado scoring system* (1994) where shift to left is removed.
- ◆ *Tzanakis scoring system* 2005—lower abdominal tenderness—4; rebound tenderness—3; total count > 12,000/cm—2; USG features—6.
- ◆ *RIPASA scoring system* (2010)—with 15 parameters.
- ◆ *Anderson scoring system*—8 parameters.

## Treatment

### Surgery-Appendicectomy:

#### Approaches

1. **Gridiron incision:** Incision is placed perpendicular to the right spinoumbilical line at the McBurney's point (i.e. at the junction of lateral one-third and medial two-third of spinoumbilical line). (Gridiron is a frame of cross beams to support a ship during repairs. This incision was first described by *McArthur*).
2. **Rutherford Morison's muscle cutting incision** (*Muscles are cut upwards and laterally*).
3. **Lanz crease incision** centering at McBurney's point—cosmetically better.
4. **Right lower paramedian incision/lower midline incision**—when in doubt or when there is diffuse peritonitis.
5. **Laparoscopic approach:** Becoming popular and better.
6. **Fowler-Weir approach** by cutting muscle medially over the rectus.

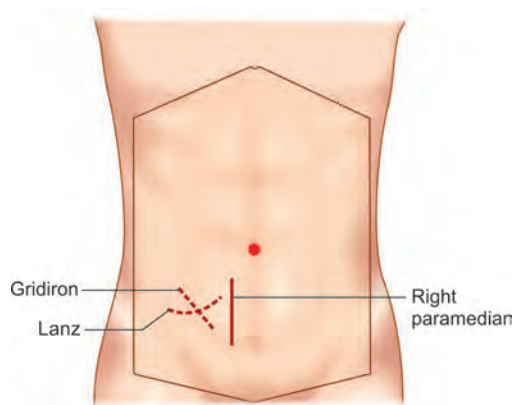


Fig. 24.14: Approaches for appendicectomy.

## Procedure

- ◆ Under general anaesthesia, skin is incised. Two layers of superficial fascia are cut. External oblique aponeurosis is opened in the line of incision. Internal oblique and transverse muscles are split in the line of fibres. Peritoneum is opened in the line of incision. Caecum is identified by taeniae, and ileocaecal junction. Omentum when adherent is separated. Appendix is held with Babcock's forceps. Mesoappendix with appendicular artery is ligated. Using thread or silk, a purse—string suture is placed around the base of the appendix. Base of the appendix is crushed with artery forceps and transected using vicryl (absorbable). Appendix is cut distal to the suture ligature and removed. Stump is cleaned with antiseptics. Purse string suture is tightened so as to bury the stump.

- ◆ In difficult cases—*Retrograde appendicectomy* can be done. In presence of pus or burst appendix, the peritoneal cavity is drained.
- ◆ Postoperatively, IV fluids, antibiotics are given. Once bowel sounds are heard, oral diet is started.

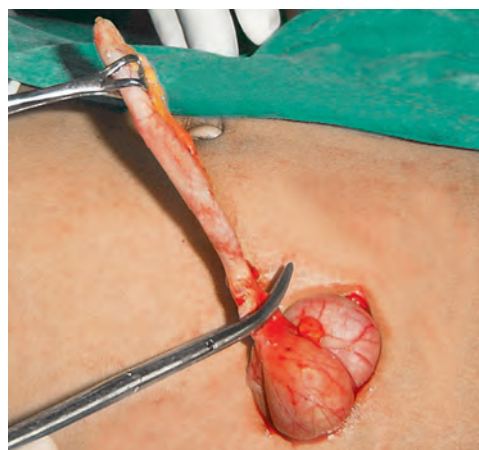
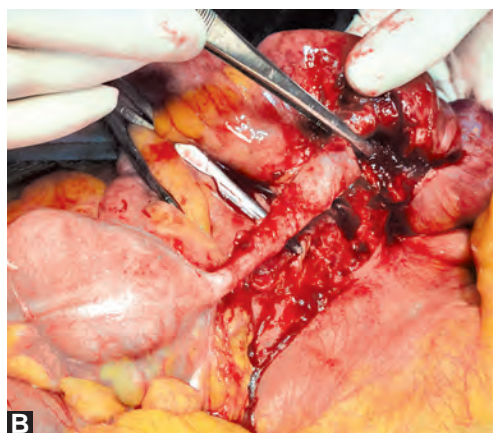
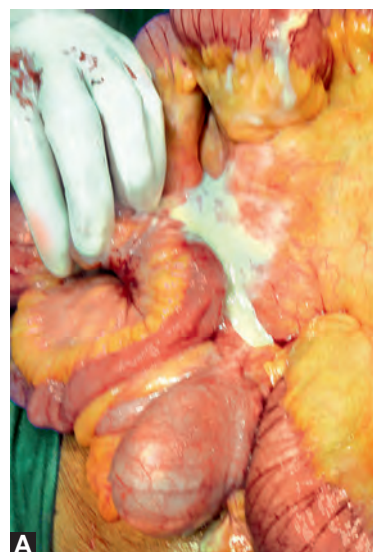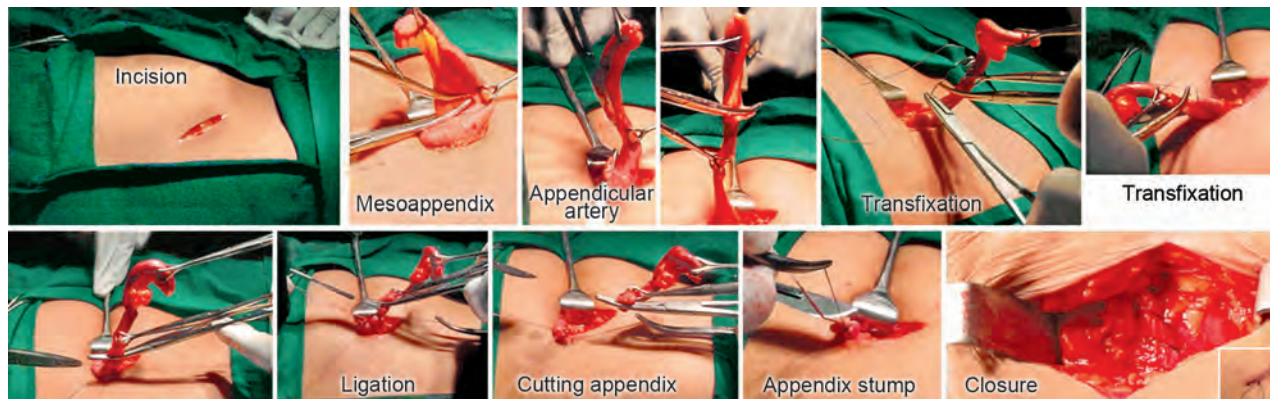


Fig. 24.15: Appendix, on table during appendicectomy.



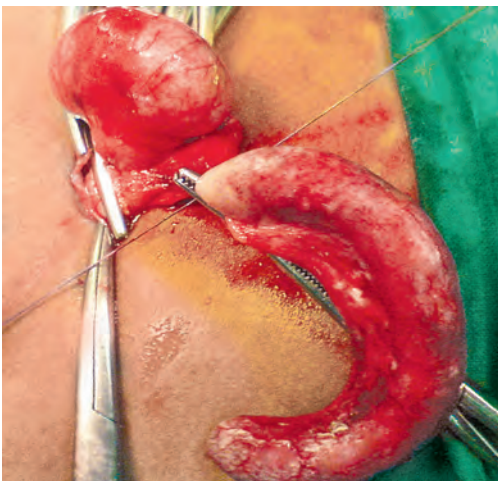
Figs 24.16A and B: Burst appendicitis showing pus. Tip of appendix is burst causing collection of pus adjacent. Usually proximal site of appendix just distal to the site obstruction will burst.



**Fig. 24.17:** Steps in open appendectomy. Note the base of appendix, mesoappendix; its ligation; transfixation of the base using 2 zero vicryl; cutting of appendix and closure of the wound. Burying is not essential; it is optional. Burying is done using silk/vicryl using purse string suture.

#### Complications after appendicectomy

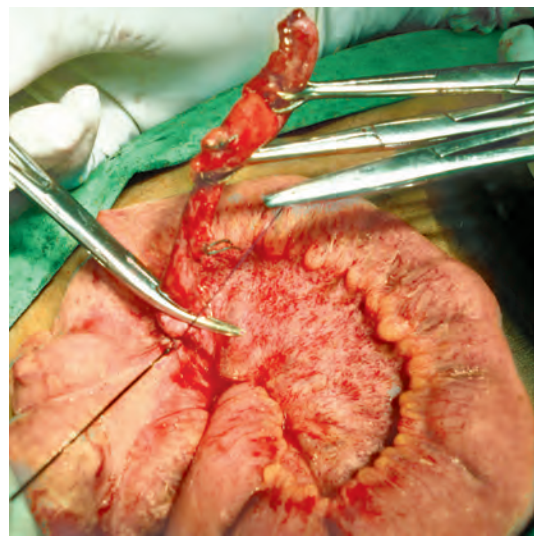
- ❖ Paralytic ileus
- ❖ Reactionary haemorrhage due to slipping of ligature of the appendicular artery
- ❖ Residual abscess (pelvic, paracolic, local, subdiaphragmatic)
- ❖ Pylephlebitis (portal pyaemia)
- ❖ Adhesions, kinking and intestinal obstruction
- ❖ Right inguinal hernia (*direct*)—due to injury to ilioinguinal nerve
- ❖ Wound sepsis 10%
- ❖ Faecal fistula
- ❖ Respiratory problems and DVT



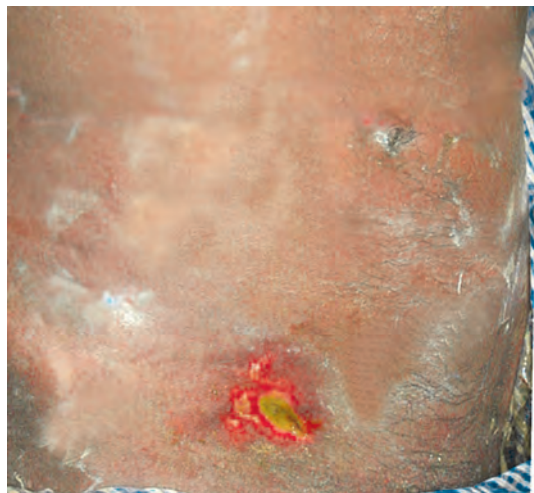**Fig. 24.18:** Gangrenous appendix. It is gently ligated at the base using 2 zero vicryl. It is not buried as stump will be friable (burying is not necessary to any appendicectomy).

#### Portal pyaemia

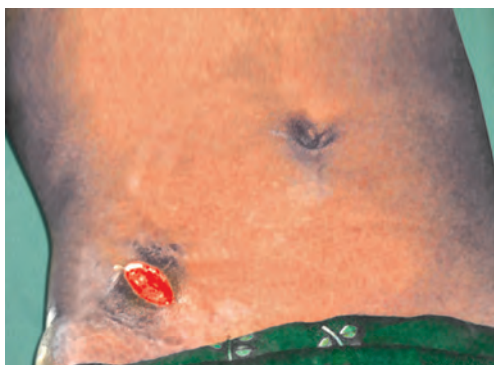- ❖ It is rare nowadays
- ❖ It is septic portal system thrombosis
- ❖ Commonly seen in immunosuppressed individuals
- ❖ Infection spreads to liver through portal vein causing rapid multiplication of virulent organisms leading into septicaemia (toxaemia with hypotension, tachycardia), jaundice, tender palpable liver. Patient will be drowsy
- ❖ Treatment—antibiotics like cefoperazone, amikacin, metronidazole, meropenem; fluid management; ventilator support
- ❖ It carries poor prognosis



**Fig. 24.19:** Transfixation of the base of appendix using 2 zero vicryl is an important step after secured ligation of appendicular artery.



**Fig. 24.20:** Faecal fistula after appendicectomy. Most of the time faecal fistula subsides by conservative treatment unless there is distal obstruction or specific causes like Crohn's, tuberculosis or malignancy.



**Fig. 24.21:** Wound infection after appendicectomy in patient with burst appendicitis.

## Troubles in Appendicectomy

- ◆ During surgery if appendix is found normal, other cause for symptoms should always be looked for like Meckel's diverticulum, Crohn's disease, ovarian/pelvic causes in females, malignancy, etc.
- ◆ Appendicular tumour may be found. If it is in the tip, appendicectomy is sufficient. It could be carcinoid tumour. If it is in the base right hemicolectomy is done.
- ◆ Absence of appendix—a rare occasion can occur. Caecum and taeniae should be traced properly before finalising it.
- ◆ Appendicular abscess/pelvic abscess formation.
- ◆ Malignancy in the caecum is identified on table—right hemicolectomy should be done.
- ◆ If Crohn's disease is identified during surgery, appendicectomy can be done with care, if base of the appendix is normal. But in rare occasion where appendix is involved by Crohn's disease, appendicectomy should not be done but treated only with antibiotics and steroids, otherwise fistula can develop.

## INCIDENTAL APPENDICECTOMY

- ◆ Here removal of normal appendix is done at laparotomy for other conditions, e.g. hysterectomy.
  - ◆ It is done in vague lower abdominal pain of doubtful severity.
  - ◆ It is a useful procedure to tackle 'Munchausen syndrome', i.e. the patient is always worried of pain abdomen and gets relieved after the procedure (psychological benefit).
- Baron Hieronymus Munchausen (1797)* was a German officer who fought with Russians against Turks and returned to tell tall stories. Patient presents with various stories of pain, bleeding, earlier medical or surgical therapies.
- ◆ It is done along with Ladd's procedure for malrotation.
  - ◆ It is also done during on table colonic lavage (*Doodleys lavage*).
  - ◆ It is not done in Crohn's disease (during acute phase), post-radiation, immunosuppression, aortoiliac grafts.

### Remember

- ❖ Appendicitis is common in white races, young males and in those who are on westernised diet
- ❖ It most commonly affects individuals of age group 10-20 years. 2/3rd will develop perforation due to rapid progression and poor localisation
- ❖ Gangrene, perforation and peritonitis are rare in nonobstructive type; but recurrent appendicitis of nonobstructive origin can cause perforation

Contd...

- ❖ Pneumoperitoneum is not common in appendicular perforation
- ❖ Appendicular artery which is an end artery can undergo infective thrombosis and can cause gangrene and perforation
- ❖ In retrocaecal appendicitis rigidity is not common; psoas spasm is known to occur
- ❖ Pelvic and post-ileal appendicitis can cause diarrhoea. Post ileal appendicitis is difficult to diagnose
- ❖ It is difficult to remove subhepatic appendix through McBurney's incision
- ❖ Pain will be above and lateral in appendicitis in pregnant women. Appendicitis is the most common acute abdominal condition in pregnancy (1:1500 pregnancies). Incidence of foetal loss is 5% without perforation and it becomes 20% if there is perforation. It is better to do laparotomy to remove the appendix in pregnancy
- ❖ In elderly atypical features are more common and so diagnosis is often missed. Gangrene and perforation are common in elderly. Often it mimics subacute obstruction
- ❖ In obese patients diagnosis is often difficult
- ❖ Appendicitis is rare before 2 years. But when it occurs perforation and peritonitis are common carrying poor prognosis
- ❖ *Negative appendicectomy*—incidence is 30%
- ❖ *Reginald Fitz of Boston* coined the term appendicitis. *McBurney* described clinical features; *Claudius Amyand* (1736) did first appendicectomy
- ❖ Appendix is found on the *left side in situs inversus* patient. Situs inversus may be *both thoracic and abdominal or only abdominal*
- ❖ Acute pancreatitis (straw/haemorrhagic chicken broth fluid), DU perforation (bile fluid), perforated Meckel's diverticulum, twisted ovarian cyst/ectopic pregnancy (bloody fluid) are *important life-threatening conditions* which may be missed for appendicitis and patient might undergo appendicectomy as a wrong procedure in these patients
- ❖ **Simple appendicitis** is one where the symptoms are of less than 48 hours duration with imaging studies showing appendicitis without abscess or phlegmon
- ❖ **Chronic appendicitis** earlier this term was not used, but is presently accepted terminology; few attacks of recurrent appendicitis will lead into chronic appendicitis. It presents with episodic often vague discomfort with colicky pain in RIF, anorexia, malaise, pain with movement and is often called as *grumbling appendicitis*. TC, US, CT scan may be normal in these patients
- ❖ *Perforation rate* in appendicitis is 25% in general; in children and elderly it becomes 45-50%. *High fever* more than 102°F, *TC* > 18,000/- are suspected features of rupture
- ❖ *Mortality rate of appendicectomy* is less than 1%. Morbidity and complications are more after surgery for perforated appendicitis
- ❖ *Surgical site infection* is 5% in uncomplicated appendicitis; 20% in perforated appendix after surgery
- ❖ *Small bowel obstruction* postoperatively is 1% with simple appendicitis; 3-5% in perforated appendicitis after surgery. More than 50% of obstruction occurs in first year of postoperative period
- ❖ In children with appendicitis, there is poor localisation and so peritonitis is common. So conservative therapy should be avoided. Surgery is the only choice of treatment otherwise early peritonitis is the danger.
- ❖ Appendicular mass is initially treated with *Ochsner Sherren* regime. After 6 weeks, *interval appendicectomy* is done.
- ❖ Children, old age, faecolith, laxative abuse, diabetes mellitus, immunosuppression and pelvic appendix are high-risk factors for perforation in appendicitis
- ❖ In pelvic and retrocaecal appendicitis, adjacent ureteral inflammation can occur in which urine on analysis shows blood cells and pus cells

Contd...

Contd...

Poverty knows how extremely expensive it is to be poor.

Contd...

- ❖ Incidence of removal of normal appendix is 30%
- ❖ *Stump appendicitis* is inflammation and infection in the remaining portion of the appendix in the stump after appendicectomy. It is a rare entity
- ❖ On table during surgery, normal appendix if found, it is called as '*Lily white appendix*'. Then other pathology like Meckel's, ileal/mesenteric lymph node/ovarian disease has to be looked for

## APPENDICULAR MASS (Periappendicular Phlegmon)

- ◆ It is the localisation of infection occurring 3 to 5 days after an attack of acute appendicitis.

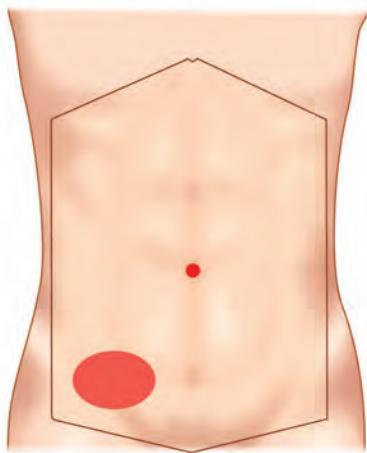


Fig. 24.22: Appendicular mass—a well localised one.

- ◆ Inflamed appendix, greater omentum, oedematous caecum, parietal peritoneum and dilated ileum (ileus) forms a mass in the right iliac fossa.
- ◆ This mass is tender, smooth, firm, well localised, not moving with respiration, not mobile, all borders well made out (well localised) and resonant on percussion. Patient may have fever and features of toxicity.

### Differential diagnosis

- |                        |                              |
|------------------------|------------------------------|
| ❖ Carcinoma caecum     | ❖ Actinomycosis              |
| ❖ Crohn's disease      | ❖ Mesenteric lymphadenitis   |
| ❖ Ovarian disease      | ❖ Ruptured ectopic pregnancy |
| ❖ Twisted ovarian cyst | ❖ Ileocaecal tuberculosis    |

## Investigations

- ◆ TC is increased.
- ◆ Ultrasound confirms the mass.

## Treatment

Conservative (*Ochsner-Sherren Regimen*), as nature has already localised the infection, if now disturbed will cause faecal fistula.

Includes observation:

- ◆ Temp, BP, pulse chart.

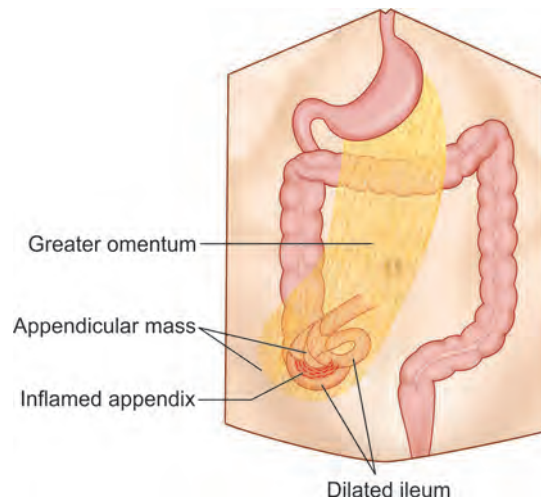


Fig. 24.23: Appendicular mass is formed by dilated ileum; greater omentum; inflamed appendix and caecum. It is resonant, smooth, firm, and tender with well defined borders which does not move with respiration and does not have mobility.

- ◆ *Marking the mass to identify the progression/regression.*
- ◆ Antibiotics (ampicillin, metronidazole, gentamicin, or other drugs given depending on severity and requirement).
- ◆ IV fluids.
- ◆ Analgesics.
- ◆ Initial nasogastric aspiration.
  - ▶ Patient usually shows response by 48 to 72 hours and mass reduces in size, temperature and pulse becomes normal. Appetite is regained. 90% of patients respond to conservative therapy.
  - ▶ Patient is discharged and advised to come for *interval appendicectomy* after 6 weeks.

## Contraindications for Ochsner-Sherren regimen

1. When diagnosis is in doubt.
2. In acute appendicitis in children and elderly.
3. In burst, gangrenous appendicitis.
4. In patients in whom diffuse peritonitis sets in.

### Criteria to discontinue Ochsner-Sherren regimen

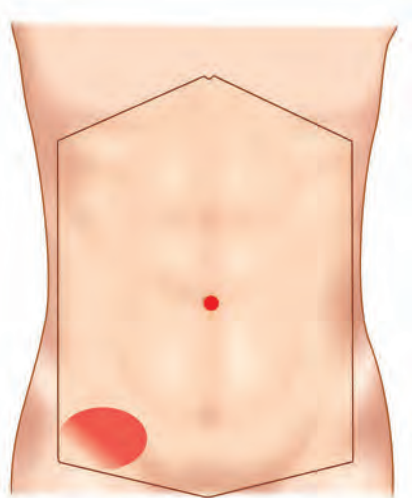
- ❖ Patient becomes more toxic (tachycardia, high fever)
- ❖ Persistent vomiting
- ❖ Increase or spread of pain abdomen (means onset of diffuse peritonitis)
- ❖ Increased size of the mass
- ❖ Suppuration (abscess formation) in the mass

In these patients the regimen is discontinued. The patient is taken for immediate surgery, either through laparotomy or through classic approaches

## APPENDICULAR ABSCESS

- ◆ It occurs due to suppuration in an acute appendicitis or suppuration in an already formed appendicular mass.
- ◆ Abscess commonly *occurs in retrocaecal* region but often can occur in subcaecal, preileal lumbar or postileal regions.

- ◆ *Pelvic abscess is also common after an attack of acute appendicitis.*



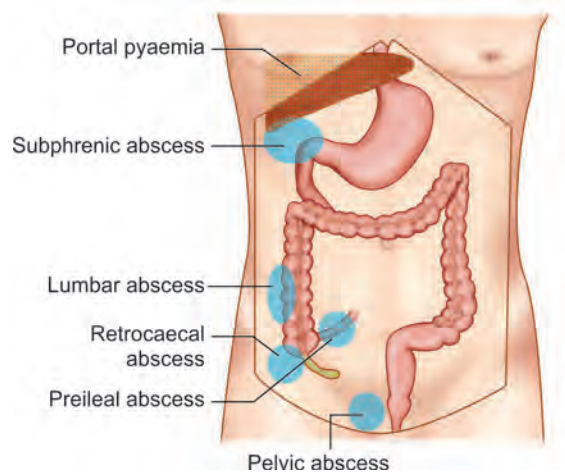
**Fig. 24.24:** Appendicular abscess. Swelling with ill-defined lower border.

### Clinical Features

- ◆ High fever, features of toxicity, tender, smooth, dull (to percuss), soft swelling in right iliac fossa which lies towards right lateral and lower side with clear upper margin but indistinct lower margin.
- ◆ Ultrasound confirms the diagnosis.

### Treatment

- ◆ Antibiotics are started.
- ◆ *CT-guided aspiration or catheter drainage* is done often as initial therapy.
- ◆ Under G/A, incision is made in the lower lateral aspect of the swelling above the inguinal ligament. Skin, external oblique muscle is cut. Abscess cavity is opened and pus is drained *extra-*



**Fig. 24.25:** Different sites where abscess can occur after appendicitis retrocaecal, appendicular; pelvic; subphrenic; preileal and lumbar. Portal pyaemia can occur with multiple pyaemic abscesses in the liver.

*peritoneally*, which is sent for culture and sensitivity. Wound is closed. A drain is placed through a separate incision. Antibiotics are continued.

- ◆ *Interval appendicectomy is done after 3 months.*  
Pelvic abscess is drained per-rectally or through posterior colpotomy (in females).

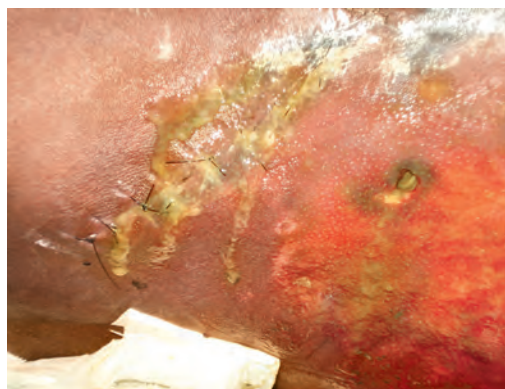## FAECAL FISTULA AFTER APPENDICECTOMY

### Causes

- ◆ It can occur when appendicectomy is done in gangrenous/perforated/friable base appendix.
- ◆ It can occur after drainage of appendicular abscess.
- ◆ It can occur if appendicectomy is done/attempted in appendicular mass.
- ◆ If there is underlying additional pathology like Crohn's disease/carcinoma/ileocaecal tuberculosis/actinomycosis during appendicectomy, fistula can occur.

### Features

- ◆ Faeculent, foul smelling discharge from either main wound or drain site.



**Fig. 24.26:** After appendicectomy fistula can occur. Note the faecal discharge.

- ◆ Features of infection.
- ◆ Skin excoriation.
- ◆ Features suggestive of cause.

### Investigations

- ◆ CT fistulogram to delineate the track.
- ◆ CT scan abdomen to find out the other pathology.
- ◆ Other relevant investigations, Hb%, albumin level, etc.

### Treatment

- ◆ Conservative—antibiotics, IV fluids, dressing, zinc oxide cream over the skin, observation.
- ◆ Most of the time fistula subsides provided there is no distal obstruction by adhesions or kinking or specific causes like carcinoma or tuberculosis.

- ◆ If persists even after 6 weeks, resection of ileocaecal segment and anastomosis is done.

## MUCOCELE OF APPENDIX

- ◆ It can be neoplastic or non-neoplastic.
- ◆ It occurs when proximal end of the lumen of appendix gets slowly and completely occluded, usually by a fibrous stricture causing collection of sterile fluid (mucus) in the lumen. It is a retention cyst.
- ◆ Appendix is grossly enlarged with features of sub-acute appendicitis.
- ◆ Mucocele can get infected leading to *emphyema* of appendix.
- ◆ Rupture of mucocele can lead to *pseudomyxoma peritonei*. Neoplastic type causes generalised pseudomyxoma peritonei; non-neoplastic type causes localised pseudomyxoma peritonei. (Other cause for pseudomyxoma peritonei is ruptured mucinous carcinoma of ovary).
- ◆ Often mucocele of appendix is also caused by a mucus secreting adenocarcinoma and if it is so right hemicolectomy is done.
- ◆ **Clinical features:** Colicky pain in right iliac fossa, Tenderness in the right iliac fossa.
- ◆ **Investigations:** Ultrasound abdomen.
- ◆ **Treatment:** Appendicectomy.

### Pseudomyxoma peritonei

- ❖ Jelly like mucoid yellowish-brown substance accumulates in peritoneal cavity
- ❖ Due to ruptured adenocarcinoma appendix/mucocele or mucinous carcinoma of ovary
- ❖ Common in females
- ❖ Painless progressive distension of abdomen with intestinal obstruction occurs eventually
- ❖ Shifting dullness is absent
- ❖ Surgical debulking, oophorectomy, appendicectomy, omentectomy are often done
- ❖ Chemotherapy is useful—cisplatin
- ❖ Carries poor prognosis

#### Note:

Pseudomyxoma peritonei is presently considered to be due to neoplastic adenocarcinoma of appendix with gelatinous fluid collection in the peritoneal cavity. It is also seen in cystadenocarcinoma of ovary. Treatment is surgery and chemotherapy.

## NEOPLASMS OF THE APPENDIX

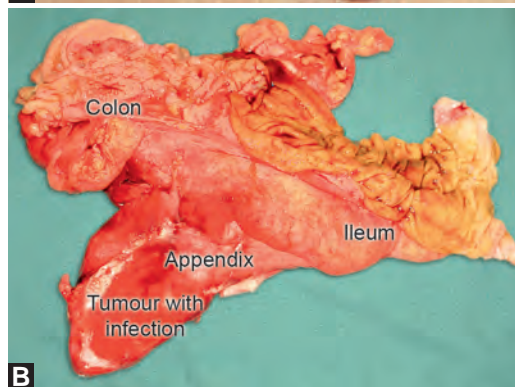
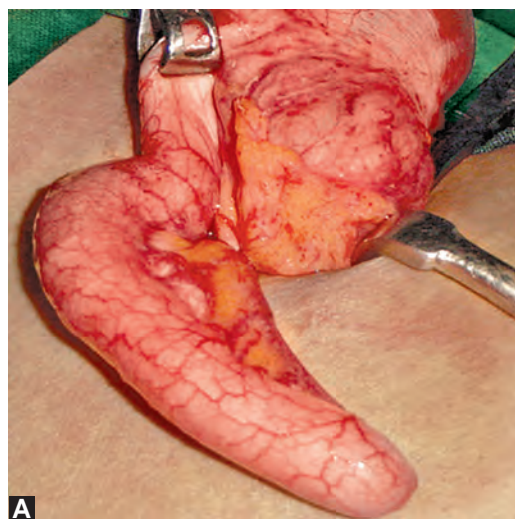
- ◆ It is rare.
- ◆ It is often postappendicectomy histological diagnosis.
- ◆ **Cystic neoplasms of appendix:** Simple cyst (non-neoplastic mucocele); mucinous cystadenoma; mucinous cystadenocarcinoma (most common form of cystic neoplasms); pseudomyxoma peritonei. Simple cyst is non-neoplastic obstruction of the lumen and is less than 2 cm in size which contains mucin. Mucinous cystadenoma attains progressively large size of up to 8 cm with CT showing calcification of the wall. Laparoscopic appendicectomy is not used in mucinous cystadenoma. Hemicolectomy is done in mucinous cystadenocarcinoma and cystadenoma of large size and if base is involved.
- ◆ **Carcinoid tumour** is the most common type. It is less aggressive. It is often incidentally found. It is arising from Kulchitsky cells

in crypts of Lieberkuhn (argentaffin tissue). It is ten times more common than other types (One in 400 appendices). Commonly its location is in the tip. 75% are less than 1 cm; 15% are 1–2 cm; 10% are > 2 cm in size. It stains chromograninB immunohistochemically. Distant and nodal spread occurs if tumour is more than 2 cm. Carcinoid of appendix may be goblet cell type or classical type histologically. Goblet cell has got more mortality than classic type. Treatment is appendicectomy. Right hemicolectomy is done if base is involved or size is more than 2 cm or nodes are involved. 5-year survival is 90%.

- ◆ **Primary adenocarcinoma of the appendix** is rare. It can be mucinous (common) or colonic (less common) type. Acute presentation as appendicitis is common in colonic type. It is staged as Duke's staging A, B, C and D. 5-year survival rate for each is 100%; 65%; 50% and 5% respectively. Mucinous type has got better prognosis. 5-year survival for mucinous type is 70% and colonic type is 40%. Mucinous type can rupture into the peritoneal cavity and can cause pseudomyxoma peritonei.

### Tumours of the appendix

- ❖ Carcinoid tumour—most common site is appendix
- ❖ Primary adenocarcinoma of appendix
- ❖ Mucocele of appendix leading into pseudomyxoma peritonei



**Figs 24.27A and B:** Carcinoid tumour in two different patients. If it is in the tip or away from the base, then appendicectomy is sufficient. If it is in the base or extending into the caecum then right hemicolectomy is needed.

## LAPAROSCOPIC APPENDICECTOMY

This is newer, popular and ideal method of appendicectomy. *It has become gold standard method of treatment.*

### Advantages

- ◆ Diagnosis is confirmed.
- ◆ Other parts of the abdomen are visualised.
- ◆ In females pelvic structures are assessed properly.
- ◆ Trauma of access is less.
- ◆ Faster recovery.
- ◆ Laparoscopic appendicectomy is definitely better whenever there is vague abdominal pain; atypical pain; situs inversus; in women; subhepatic appendix and as interval appendicectomy.

### Disadvantages

- ◆ Technical difficulties especially in burst appendix.
- ◆ Cost factor and availability.

#### Note:

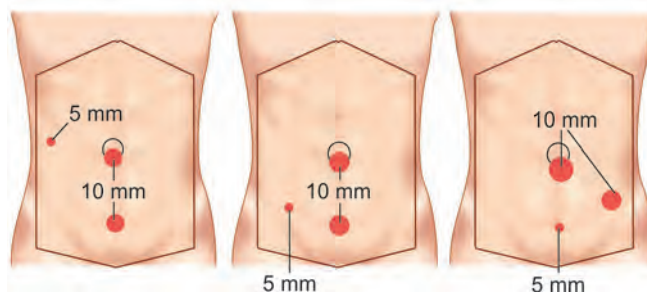
Consent for conversion should be taken.

### Technique

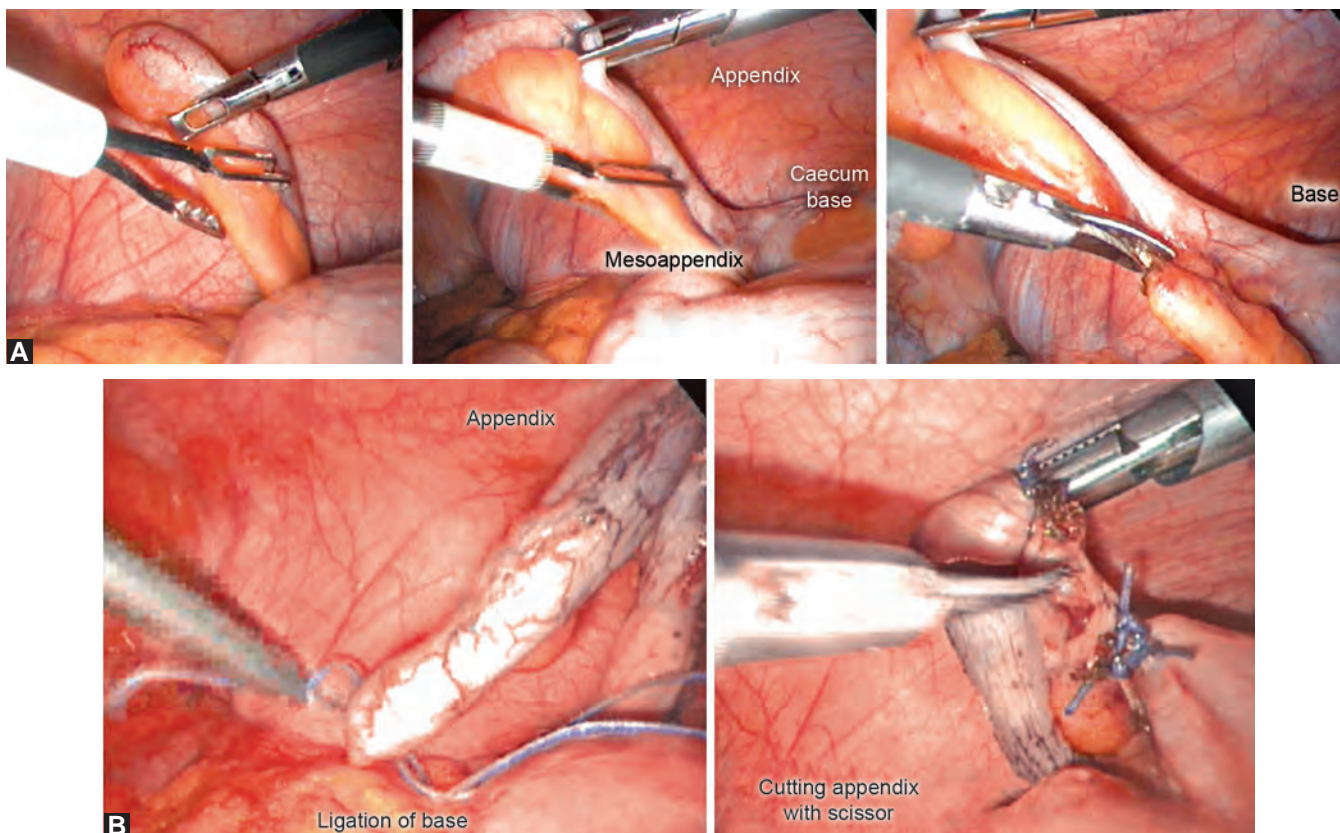
- ◆ Procedure is done under general anaesthesia. Head down position with right tilt is needed. Surgeon and camera man stands on the

left side. Scrub nurse on the right side. Monitor is kept on the foot end right side.

- ◆ 10 mm camera port is placed at the umbilicus. Working ports are two 5 mm, one on each side of lower abdomen or one on left side and another on the lower midline. One of the working ports can be 10 mm in difficult appendectomies.
- ◆ Pneumoperitoneum is created using CO<sub>2</sub>.
- ◆ Appendix is held with grasper or *Babcock's forceps*. Mesoappendix is cauterised by bipolar or unipolar cautery.
- ◆ Appendix is dissected up to the base of the appendix.
- ◆ Base of the appendix is ligated with loop ligature. Intracorporeal ligature also can be placed using vicryl 2 zero suture material. Appendix is removed through 10 mm working port along with reducer. Often retrieval bag can be used to remove the appendix.

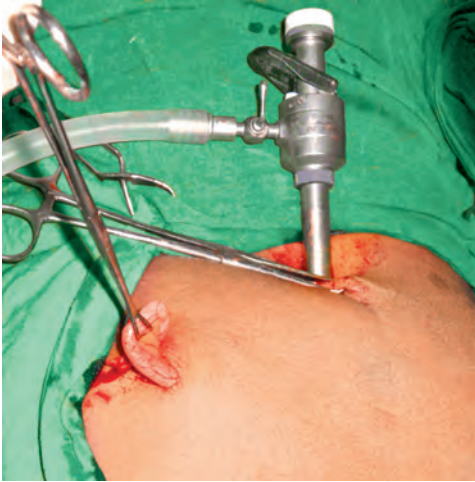

**Fig. 24.28:** Different possible port placements for appendicectomy.



**Figs 24.29A and B:** Laparoscopic appendicectomy. Note the mesoappendix is being cauterised. Ligation of the appendix is done using vicryl (Courtesy: Dr Keshava Prasad, MS, KMC, Mangaluru).





**Fig. 24.30:** Laparoscopic assisted appendectomy.

- ◆ Umbilical port is closed in two layers. Other ports are closed by skin sutures. If gangrenous or burst appendix drain can be placed through one of the ports.
- ◆ Oral food is started in 12 hours.

*Laparoscopic assisted appendectomy* can be done if caecum is mobile without much adhesions and mobilised appendix can be delivered through the 10 mm umbilical port. As in regular laparoscopic procedure, appendix is identified and mobilised. Appendix which is not friable and not turgid can be delivered through umbilical port gently. During this procedure gas flow should be stopped so that all gas in the cavity will be empty. Mesoappendix is ligated. Appendix is transfixed like in open method and removed. Stump is pushed back into the place. Telescope is passed again to confirm the position and security of the stump. Advantage is that it is faster.

### Complications

- ◆ Injury to bowel, vessels while passing the ports.
- ◆ Complications of pneumoperitoneum.
- ◆ Accidental cautery injury to bowel, vessels and other vital structures.
- ◆ Bleeding.
- ◆ Bowel perforation, peritonitis.
- ◆ Ligature slipping, leak, peritonitis, fistula formation.

# Chapter 25

## Rectum and Anal Canal

### CHAPTER OUTLINE

- ❖ Anatomy
- ❖ Per-rectal Examination
- ❖ Proctoscopy (Kelly's)
- ❖ Sigmoidoscopy
- ❖ Colonoscopy
- ❖ Carcinoma Rectum
- ❖ Solitary Ulcer Syndrome
- ❖ Rectal Prolapse
- ❖ Anorectal Malformations
- ❖ Pilonidal Sinus
- ❖ Piles/Haemorrhoids
  - External Piles
- ❖ Anal Fissure
  - Sentinel Pile
- ❖ Anorectal Abscess
- ❖ Fistula-in-Ano
- ❖ Anorectal Strictures
- ❖ Condyloma Acuminata
- ❖ Anal Intraepithelial Neoplasia
- ❖ Malignant Tumours of Anal Area
- ❖ Sacrococcygeal Teratoma
- ❖ Anal Incontinence
- ❖ Descending Perineal Syndrome
- ❖ Proctitis
- ❖ Proctalgia Fugax
- ❖ Hidradenitis Suppurativa of Anal Region
- ❖ Pruritus Ani
- ❖ Gastrointestinal Haemorrhage
  - Upper GI Bleed
  - Lower GI Bleed
  - Obscure GI Bleed

### ANATOMY

#### Rectum

- ◆ It is the distal portion of the large gut, placed between the sigmoid colon above and anal canal below; in front of last three pieces of sacrum and coccyx (From S3).
- ◆ The three cardinal features of large intestine (sacculaton, appendices epiploicae and taeniae) are absent.
- ◆ The upper third of rectum is covered by peritoneum on front and sides, mid third only on the front, lower third is infraperitoneal.
- ◆ The rectum is pulled forward by the puborectalis muscle forming the anorectal sling which is primarily responsible for rectal continence.
- ◆ It has got three lateral flexions left, right and left from below upwards (*Valves of Houston*).
- ◆ Rectum is supplied by rich network of vessels that originates from superior and middle rectal arteries and median sacral artery.
- ◆ Lymphatic drainage from upper half of rectum is to inferior mesenteric nodes; from lower half to internal iliac nodes.
- ◆ It is innervated by autonomic nervous system; sympathetic (L<sub>1</sub>, L<sub>2</sub>) is motor to sphincter and inhibitory to musculature; parasymp-

thetic (S<sub>234</sub>) is motor to musculature and inhibitory to sphincter. Sensation of distension is carried through parasympathetic; pain sensation is carried by both.

#### Rectosigmoid Junction

- ◆ Implies a segment of bowel comprising the last seven centimetre of sigmoid colon and upper five centimetre of rectum.
- ◆ On sigmoidoscopic examination it is taken as a point 15 cm from the anal verge.

#### Supports of Rectum

- ◆ Pelvic floor.
- ◆ *Fascia of Waldeyer*: It is the condensation of pelvic fascia behind rectum, contains superior rectal vessels and lymphatics.
- ◆ *Lateral ligaments of rectum*: It is the condensation of pelvic fascia, attaches rectum to the posterolateral wall of lesser pelvis.
- ◆ *Denonvillier's fascia*: It is the fascial condensation which separates rectum from prostate in males and vagina in females.

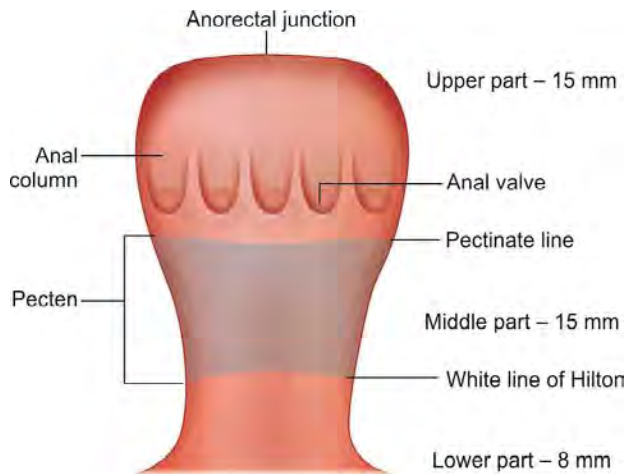


Fig. 25.1: Interior of the anal canal.

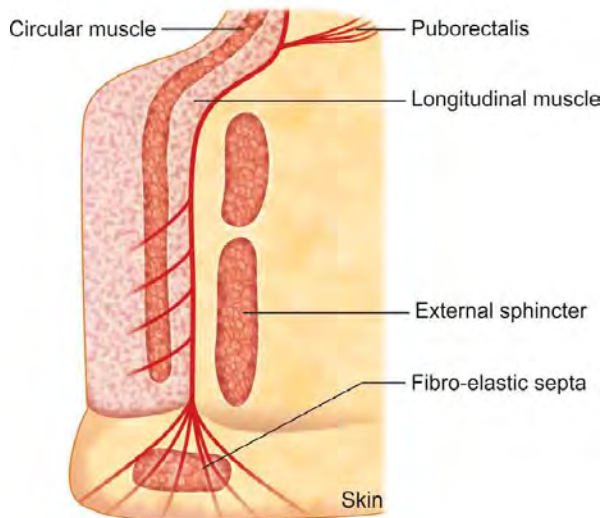


Fig. 25.2: Sphincters of anal canal.

## Anal Canal

- ◆ It is 4 cm long, extends from levator ani muscle to anal verge.
- ◆ The *dentate line* represents the former site of the embryonic anal membrane.
- ◆ The lining of the canal above this line is columnar epithelium and below is skin.
- ◆ The mucosa above this line has an autonomic nerve supply, below is by pudendal nerve.
- ◆ The venous drainage above this line is by inferior mesenteric and portal circulation, whereas below to systemic venous circulation.
- ◆ Internal haemorrhoids develop above this line.

## Sphincters of Anal Canal

**Internal sphincter:** Downward extension of circular muscle of rectum, under control of autonomic nervous system.

**External sphincter:** Surrounds the internal and continuous with the levator muscle.

Blood supply is from inferior rectal artery.

**Venous drainage:** Internal rectal venous plexus lies in the submucosa of the anal canal. It drains mainly into the superior rectal vein but communicates freely with external plexus. It is an important site of portosystemic communication. They are situated in anal column at 3,7,11 o'clock. Their saccular dilatation forms 'primary internal piles'.

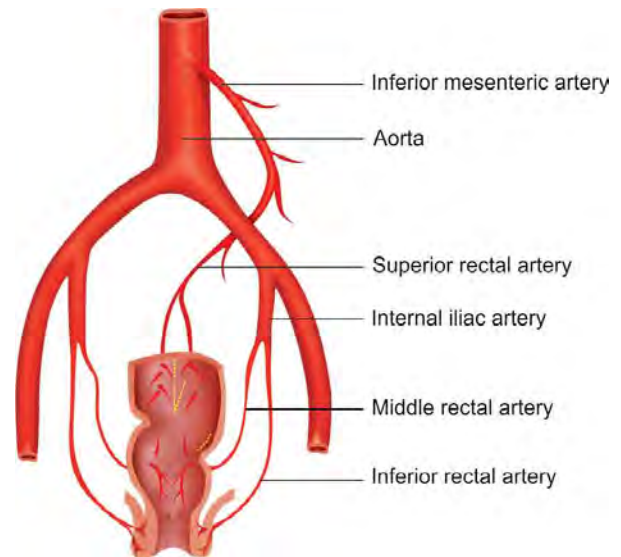


Fig. 25.3: Blood supply of rectum.

## PER-RECTAL EXAMINATION (Digital Examination of the Rectum Refer Chapter 16)

*We had almost come to the conclusion that the case (of vasovesiculitis) was one of acute appendicitis, but decided to make a rectal examination for the sake of completeness.*

—Ulysses Grant Dailey, WS Grant, 1924

No abdominal examination is complete without a per-rectal examination.

- a. It is done to palpate.
  1. Carcinoma rectum.
  2. Stricture rectum.
  3. Polyps.
  4. Thrombosed piles.
  5. BPH and carcinoma prostate.
  6. Secondaries in the rectovesical pouch (Blumer shelf).
  7. Sphincter tone.
  8. Pelvic abscess (is felt as boggy swelling).
- b. To feel the internal opening of anal fistulas.
- c. In bimanual palpation of the bladder or pelvic tumours.
- d. In acute abdominal conditions—it reveals dilated empty rectum with tenderness.

### Positions for Per-rectal Examination

- ❖ Right lateral position.
- ❖ Left lateral position.
- ❖ Dorsal position in ill-patients.
- ❖ Lithotomy position.
- ❖ Knee-elbow position.

Contd...

Contd...

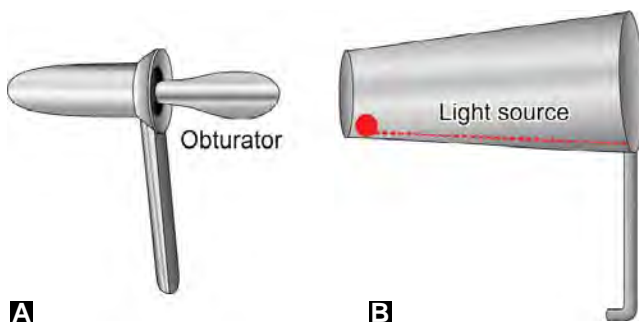
- ❖ Picker position: Patient in standing position leans forward by grasping a chair or stool. This method is used to palpate seminal vesicles which is involved by tuberculous seminal vesiculitis (as craggy feeling) or in trichomonas vaginalis infestation of seminal vesicle.

*Per-rectal examination is contraindicated in acute fissure-in-ano.*

## ■ PROCTOSCOPY (KELLY'S)

### Indications

- Diagnostic*—piles, fissure in ano, polyps, stricture, etc.
- Therapeutic*—injection therapy for partial prolapse or piles, cryo-therapy for piles, polypectomy, biopsy for carcinoma rectum or anorectum.



**Figs 25.4A and B:** Types of proctoscopes: (A) Non-illuminating; (B) Illuminating.

### Types

- Illuminating.
- Nonilluminating.

### Parts (10 cm)

*Proctoscope* is conical shape, with proximal diameter more than the distal, so as to illuminate the light at the required site properly. *Obturator* is the inner part which allows the easy insertion of the proctoscope.

### Positions for Proctoscopy

- ◆ Left lateral position (common).
- ◆ Right lateral.
- ◆ Lithotomy.
- ◆ Knee-elbow position.

### Technique of Proctoscopy

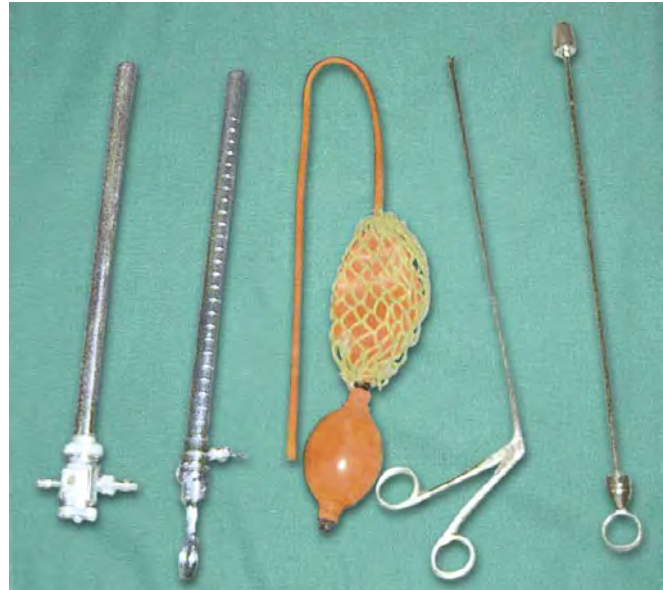After doing digital examination, proctoscope with the obturator is introduced inside, through the anal canal in the direction towards the umbilicus. The obturator is removed. Proctoscope is withdrawn and during the course of withdrawal, any pathology has to be looked for.

*Acute anal fissure is contraindication for proctoscopy.*

## ■ SIGMOIDOSCOPY

*Annual sigmoidoscopy for all, after their fortieth birthday: something to look forward to.*

— Henry George Miller, 1968



**Fig. 25.5:** Rigid sigmoidoscope with inflation balloon and biopsy forceps.

- ◆ It is used to visualize rectum and sigmoid colon, take biopsies from suspected lesions and do therapeutic procedures (polypectomy, control of bleeding, etc.).
  - ◆ There are *two* types:
    1. **Rigid**—25 cm long, with illumination.
    2. **Flexible**—60 cm long.
  - ◆ In lateral position as in P/R examination or proctoscopy, sigmoidoscope with obturator is passed into the rectum and obturator is removed. Rectosigmoid is inflated with air and scope is negotiated into the sigmoid through *Alpha (α) manoeuvre*. Looked for any disease, biopsies are taken and also any required procedure is done.
- Precaution:** Care should be taken in acutely inflamed sigmoid colon, because chance of perforation is high.

## ■ COLONOSCOPY

- ◆ It is 160 cm long, flexible.
- ◆ Technique is same as sigmoidoscopy, but is passed up to the caecum.

### Technique

It is often done under GA using propofol or with laryngeal mask airway (LMA). It can be also done under high sedation. But patient finds difficult to tolerate pain and distension. Passage by *elongation*; *looping with a manoeuvre*; *dither-torquing* (clockwise-anticlockwise rotations) methods are used. Difficulty is encountered while passing through

sigmoid colon, splenic flexure, and hepatic flexures. Continuous air inflation is important. It is better to visualise the lumen and then pass the colonoscope. Often it can also be negotiated into the terminal ileum. Changing position, abdominal pressure is required for better negotiation of the colonoscope. Technique differs in patients after haemicolectomy or through colostomy.

## Indication

- ◆ Bleeding per rectum, resistant anaemia.
- ◆ To take biopsies from different parts of the bowel.
- ◆ To identify synchronous growths, ulcerative colitis.
- ◆ To remove polyps.
- ◆ When barium enema shows irregularity.
- ◆ For therapy—colonoscopic polypectomy, dilatation of stricture colon, fulguration.

### Contraindication

- ❖ Acute ulcerative colitis.

### Advantage

- ❖ It helps to visualise full length of the colon. GA is not used, except in children.

### Disadvantage

- ❖ Takes a long time and requires expertise to do the same.

### Hazards

- ❖ Perforation of bowel, splenic flexure is the commonest site.
- ❖ Trauma to anorectum.
- ❖ Sepsis.
- ❖ Haemorrhage.
- ❖ Problems of incomplete therapeutic procedures.

## CARCINOMA RECTUM

*Bubo is an apostem breeding within the anus in the rectum with great hardness but little aching. This I say, before it ulcerates, is nothing else than a hidden cancer.... Out of bubo (cancer) goes hard excretions and sometime they may not pass, because of the constriction caused by the bubo, and they are retained firmly within the rectum.... I never saw nor heard of any man that was cured... but I have known many that died of the foresaid sickness.*

—John of Arderne, 1414

- ◆ It is common in females.

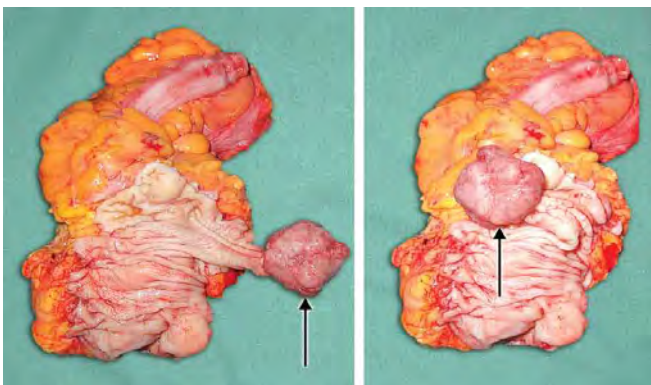


Fig. 25.6: Rectal polyp—it is premalignant condition.

- ◆ In 3% of cases, it occurs in multiple sites (synchronous).
- ◆ Usually originates from a pre-existing adenoma or papilloma (tubular polyp).
- ◆ Any tumour within 15 cm proximal to the anal margin is called as rectal tumour/cancer. More than 95% are adenocarcinoma. It is characterized by chromosomal instability. Microsatellite instability (MSI) is rare in rectal cancer.

## Aetiology

- ◆ Red meat and saturated fatty acids increase the risk.
- ◆ High fibre diet reduces the risk.
- ◆ Alcohol and smoking increases the risk.
- ◆ FAP and adenomas are more prone to carcinomas.

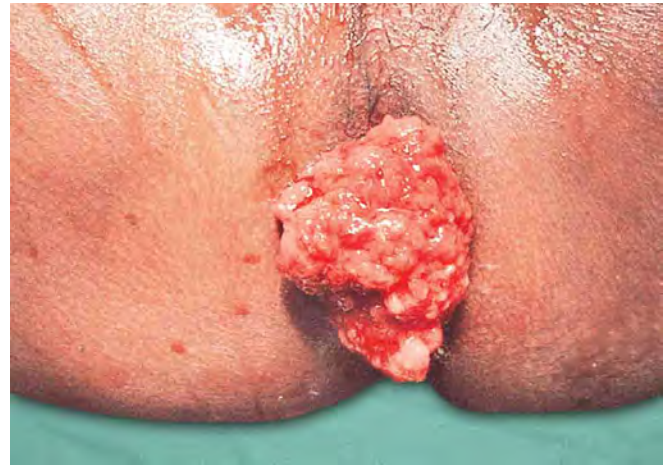

Fig. 25.7: Large rectal polyp which has come out of the anal canal. It is potentially malignant.

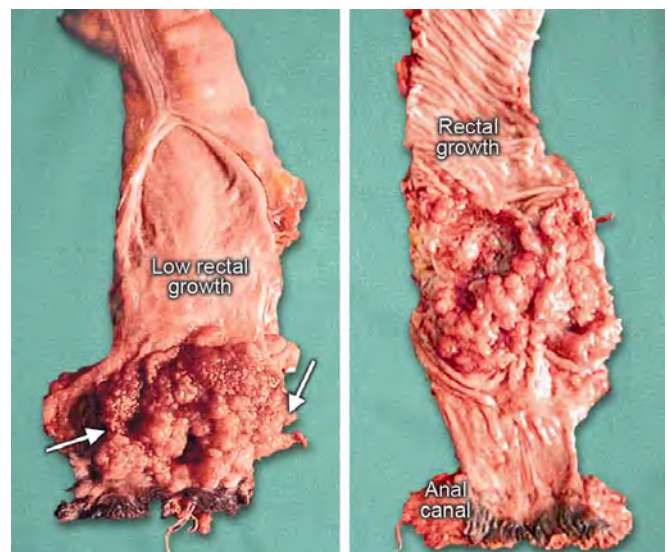


Fig. 25.8: Pathological specimens of anal canal, rectum and sigmoid colon after abdominoperineal resection for low rectal carcinoma and midrectal carcinoma.

- ◆ Villous adenoma has 40% chance of turning malignancy, size more than 2 cm is at high-risk.
- ◆ Ulcerative colitis; Crohn's disease; HNPCC carries higher incidence of carcinoma of rectum.

- ◆ Family history of rectal cancer—any first degree relative of a person with rectal cancer will show two times increased risk of carcinoma rectum.
- ◆ Risk of developing other cancers like of endometrium (40%); stomach (20%); biliary tree (20%); ovary (10%) in the same patient also increases.
- ◆ ‘Adenoma—carcinoma sequence’ like in carcinoma of colon is known common method of occurrence.

**Gross:** It can be:

- ❖ *Ulcerative*
- ❖ *Papilliferous*
- ❖ *Infiltrative*
- ❖ *Annular:* It is common in rectosigmoid junction.
- ❖ *Diffuse type:* Often observed in patients with ulcerative colitis which carries poor prognosis

**Histologically:** It is *adenocarcinoma* which may be:

- ❖ *Well-differentiated*—10%
- ❖ *Moderately differentiated*—65%
- ❖ *Undifferentiated*—25%

**Colloid carcinoma of the rectum**

It is 12% common in young people

**Types**

- ❖ Primary and secondary
- ❖ *Secondary* colloid carcinoma is common type and is due to mucoid degeneration of adenocarcinoma itself.

*Primary* is mucus within the cell with displaced nucleus (*signet ring*).

*Primary type has got poorer prognosis compared to secondary.*

**Spread**

- ◆ *Local spread:* Initially, it spreads, locally circumferentially (takes 12–18 months to complete the circumference of the bowel). Later spreads out to the muscular coat and peri-rectal tissue. Then to prostate, bladder, seminal vesicles in males, and uterus and vagina in females. Posteriorly into the sacrum and sacral plexus, laterally into the ureters.

**Haggitt's invasion of malignant polyp (Similar to carcinoma colon)***In pedunculated polyp*

Level 0—noninvasive carcinoma over the summit  
 Level 1—invasion to head of pedunculated polyp  
 Level 2—invasion to neck of the pedunculated polyp  
 Level 3—invasion to stalk of the pedunculated polyp  
 Level 4—invasion to base of pedunculated polyp

*In sessile polyp*—all lesions are level 4

**Duke's staging of carcinoma rectum**

- Confined to bowel wall, mucosa and submucosa
- Extends across the bowel wall to the muscularis propria with no lymph nodes involved
- Lymph nodes are involved

**Modified Duke's staging**

- Growth limited to rectal wall (15%)
- Growth extending into extra-rectal tissues but no lymph node spread (35%)
  - Invading muscularis mucosa
  - Invading in to or through the serosa
- Lymph node secondaries (50%)
- Distant spread to liver, lungs, bone, brain

**Note:**

- Astler-Coller's grading (Refer Chapter 22).
- Primary rectal cancers are divided *into 4 groups* – very early; early; intermediate; locally advanced.
- For sessile adenoma, Kikuchi sm (submucosal invasion) classification is used (in T1) depends on depth of submucosal invasion: sm1—upper (inner) 1/3rd; sm2—middle 1/3rd; sm3—lower 1/3rd.
- *Lymphatic spread:* Above the peritoneal reflection, spread occurs upwards along the colonic lymph nodes. In mid-rectum, into the para-rectal and mid-rectal lymph nodes. Downward spread is rare occurs when growth is close to the anal canal into the inguinal lymph nodes. Obturator nodes may be involved in 8% of lower rectal growths.
- *Venous spread* occurs to the *liver 35%, lungs 20%, adrenals 10%* and other areas.
- *Perineural spread* carries poor prognosis.

**Clinical Features**

- ◆ Bleeding per rectum/anum (may mimic haemorrhoids)—earliest symptom.
- ◆ *Spurious diarrhoea:* It occurs in *early morning* due to overnight mucus accumulation in the rectum causing urgency for defecation, but results in spurious diarrhoea with incomplete evacuation.

**TNM Classification of rectal cancer—7th edition, 2010****Tumour:**

Tx—Primary not assessed

T0—No primary tumour

Tis—Carcinoma in situ: intraepithelial or invasion of lamina propria

T1—Submucosa

T2—Muscularis propria

T3—Subserosa/perirectal tissue; T3a <1 mm; T3b 1–5 mm; T3c 5–15 mm; T3d 15+ mm

T4—Perforation into visceral peritoneum (a) or invasion to other organs (b)

**Nodes:**

N1—1–3 regional nodes involved; N1a—one LN; N1b—2–3 LN; N1c Small deposits in the fat

N2—4 or more regional nodes involved; N2a—4–6 LN; N2b—7 or more LNs

*In the case of acute abdomen, it is more important to insert the finger into the lower end than to put the thermometer into the upper end of the alimentary tract.*

— sir zachary cope

**Metastases:**

M0—No distant metastases

M1—Distant metastases; M1a One distant organ or set of lymph node; M1b More than one organ or to the peritoneum

**Stage grouping:**

I—1–2, N0, M0

IIA—T3, N0, M0

IIB—T4a, N0, M0

IIC—T4b, N0, M0

IIIA—T1–2, N1/N1c, M0; T1, N2a, M0

IIIB—T3–T4a, N1/N1c, M0; T2–T3, N2a, M0; T1–2, N2b, M0

IIIC—T4a, N2a, M0; T3–4a, N2b, M0; T4b, N1–2, M0

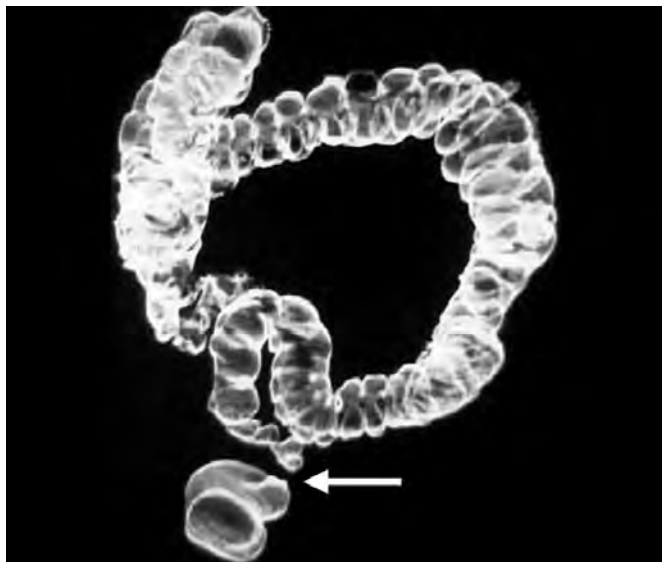
IVA—T1–4, N1–2, M1a; IVB T1–4, N1–2, M1b

- ◆ *Tenesmus*: It is painful incomplete defecation with bleeding.
- ◆ *Bloody slime*: Mucus with blood in stool.
- ◆ Sense of incomplete evacuation, constipation.
- ◆ Presenting as piles due to proximal venous congestion by tumour or as fistula in perianal region (which itself is tumour extension into the anal canal).
- ◆ Anaemia, malnutrition, loss of appetite and weight.
- ◆ Altered bowel habits.
- ◆ Urinary symptoms are due to infiltration of bladder or prostate.
- ◆ Back pain, due to invasion of sacral plexus.
- ◆ Ascites, liver secondaries, urinary symptoms.

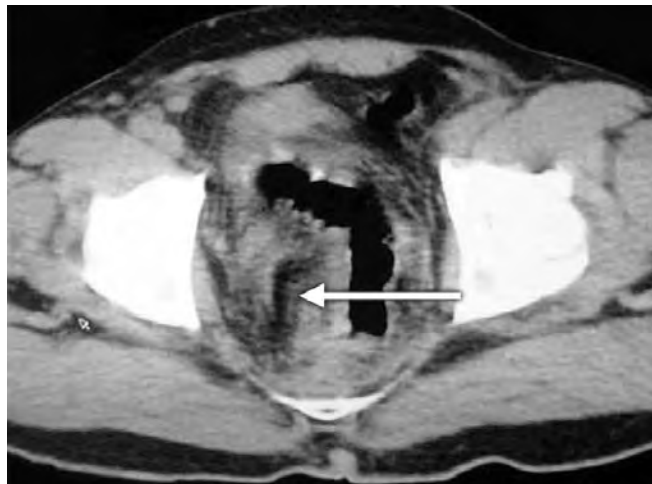
*Ninety per cent of rectal growths can be felt by per-rectal examination.* Depth of tumour penetration can be assessed through digital examination as superficial tumours are mobile; deep penetrating tumours are not mobile.

**Investigations**

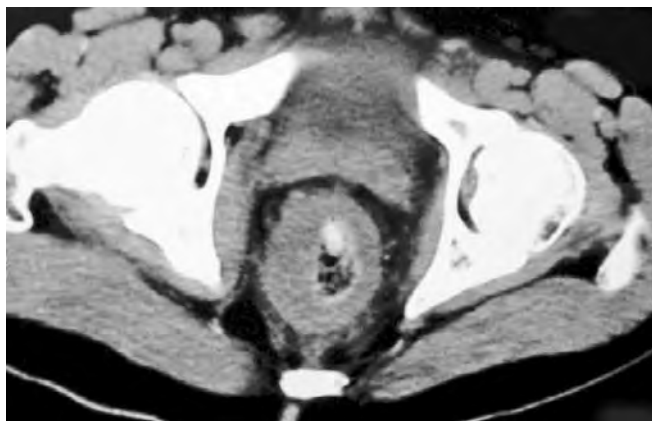- ◆ Proctoscopy.
- ◆ Sigmoidoscopy.



**Fig. 25.9:** Air-contrast CT of colon and rectum showing significant narrowing in rectosigmoid junction.



**Fig. 25.10:** CT picture of carcinoma rectum. CT is useful in evaluating the extent, nodal status and operability.

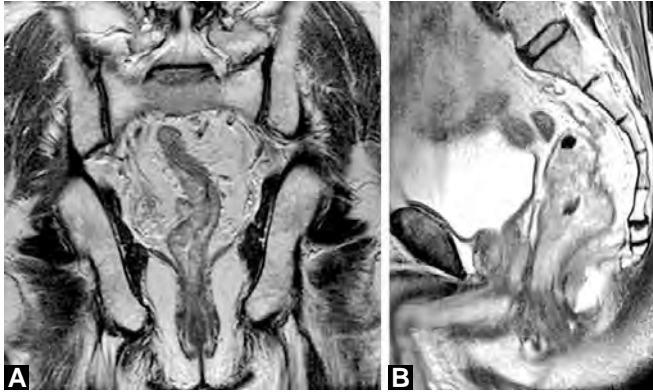


**Fig. 25.11:** CT scan showing carcinoma of rectum.

- ◆ Biopsy using *Yeoman's* forceps.
- ◆ Barium enema in case of FAP and synchronous growths.
- ◆ Colonoscopy is ideal to rule out presence of any synchronous growths proximally (5%) or polyps.
- ◆ Even though *colonoscopy* is done *rigid proctosigmoidoscopy* is a must to identify the precise location of the tumour and to measure the tumour distance from anal sphincter accurately.
- ◆ Ultrasound abdomen—to look for secondaries in liver, ascites.
- ◆ CT scan to see operability, local extension, size, nodal status, ureteral involvement, presence of perforation or fistula. CT is very useful to assess *nodal status*. Local extension is better assessed by TRUS. Any mesorectal node detected in CT is considered as malignant spread. Liver secondaries are well-identified in CT. Ureteral involvement in CT scan signifies requirement of stenting prior to surgery. Chest CT is essential to look for secondaries.
- ◆ *Endorectal ultrasonography*—very useful to assess the local extent of the tumour. *Transrectal ultrasound (TRUS)/endorectal ultrasound* gives more accurate picture of primary tumour, layers, perirectal tissues and nodes. TRUS is superior in T staging of rectal cancers. Its accuracy is 95%

compared to MRI (85%); and CT (75%). Endorectal US based T staging and N staging used now depends on layers involved and presence of nodes. TRUS detects nodes more or equal to 5 mm size.

- ◆ **Endorectal coil MRI (EC MRI)** is very useful as it gives larger field of view compared to TRUS; extent, adjacent organ spread are better assessed by MRI. Recurrent tumour is better assessed by MRI.



**Figs 25.12A and B:** MRI showing carcinoma of rectum and adjacent structures. MRI is good method to evaluate the spread and staging.

- ◆ **Fluorine—18 fluorodeoxyglucose PET scan** is useful to detect recurrent local tumours; metastatic disease; to detect pathologic response in preoperative chemoradiation. PET is not accurate for nodal spread.
- ◆ Blood tests like haematocrit; CEA; blood urea and serum creatinine; serum electrolytes and proteins for management purpose. **CEA estimation**—it is raised in metastatic disease. It is important during follow-up after treatment.

#### Differential diagnosis

- ❖ Inflammatory stricture
- ❖ Amoebic granuloma
- ❖ Tuberculosis
- ❖ Carcinoid
- ❖ Solitary ulcer syndrome

## Treatment

### Surgery

#### Principles

- ◆ Surgery is the main method of treatment. Preoperative chemoradiotherapy is often used if growth is invading into adjacent tissues (T4). Adjuvant chemotherapy and radiotherapy is a must.
- ◆ Genetic, morphologic, biologic features of rectal cancers are similar to colonic cancers.
- ◆ But **anatomical factors** make it more complex than colonic cancers, like its location deep in the pelvis, relation to important structures like ureters, bladder, genital, autonomic nerves and anal sphincters. So surgical approach is very difficult.
- ◆ **Avascular endoplevic fascial plane** is important during dissection to avoid injury laterally to autonomic nerves (will cause impotence in men and bladder dysfunction in both sexes); more medial dissection leads into incomplete clearance and high local recurrence.
- ◆ **Abdomino perineal resection (APR)** is the gold standard. But if tumour is well-differentiated and if there is adequate margin above the anal canal, a sphincter saving **anterior resection (AR)** can be done. **Low anterior resection (LAR)** is possible if EEA stapler is used for anastomosis. But anterior resection should not be done by compromising the adequacy of tumour clearance. Tumour clearance is still the priority in rectal cancer as it decides the eventual outcome.
- ◆ **Total mesorectal excision (TME)** should be the goal in all procedures as mesorectum contains nodes and lymphatics, clearance of which gives better result.
  - ▶ It is a **sharp dissection** (not blunt) in avascular areolar plane between fascia of rectum which encroach the mesorectum and parietal pelvic wall fascia.
  - ▶ Mesorectum should not be breached.
  - ▶ Absolute haemostasis, **preservation of autonomic nerves** and dissection under vision are the essential principles.
  - ▶ Both layers of membranous anterior Denonvillier's fascia should be dissected off the prostate and seminal vesicles in male to have proper clearance.
  - ▶ In TME for middle and lower rectum, entire mesorectum should be removed.
  - ▶ For upper rectal tumors, TME is done 5–6 cm below the lower margin of the tumour.
  - ▶ TME improves the quality of life in relation to **impotence, retrograde ejaculation and urinary incontinence**. These complications are around 50% or more in APR whereas in TME it is less than 20%.
- ◆ Recommended **distal rectal margin clearance** is 5 cm, however 2 cm distal margin is an **acceptable** clearance.
- ◆ **Circumferential resected margin—CRM (radial margin, > 2 mm)** is more important than proximal and distal margin. A 5 cm clearance of mesorectum from the primary tumour is essential as tumour implants can occur only for up to 4 cm from primary tumour margin.
- ◆ **Principles to be followed**—adequate lymphatic and vascular clearance; en bloc resection of primary tumour; no/less touch technique; avoiding spillage; adequate radical surgery. **At least 12 lymph nodes' examination is recommended.**
- ◆ **Ultra low anterior resection or intersphincteric resection** (Turnball–Cutait) can be considered in low rectal tumours.
- ◆ After resection (on table) **irrigation of rectal bed** with cetrimide or hypertonic solution like distilled water is often practiced as they are tumoricidal.
- ◆ Selection of the procedure AR or APR is decided by proper staging using TRUS and MRI.
- ◆ Neoadjuvant chemotherapy or neoadjuvant chemoradiotherapy is often used in T3 lesions which also may avoid APR; and AR may be sufficient.
- ◆ Local wide excision approaches are often used when tumour is <4 cm; <40% circumference involved; T1 N0/T2 N0 tumour:
  - ▶ **Transanal approach** is used in small tumours that is 3–5 cm above the dentate line but within 10 cm from the anal verge
  - ▶ **Transcoccygeal Kraske's approach** for posterior wall rectal tumours (dangerous posterior faecal fistula can occur)
  - ▶ **Transanal endoscopic microsurgery** (Buess) using operating microscope and videoscope can also be done. This **endosurgical device** is 4 cm in diameter, specialized sealed proctoscope with



ports for CO<sub>2</sub> insufflation, water irrigation, and suction and for monitoring intrarectal pressure. CO<sub>2</sub> insufflation distends the rectum and local excision is done with proper positioning of the device.

- ◆ In females, partial vaginectomy with or without hysterectomy and bilateral oophorectomy may be needed in T4 lesions to achieve surgical resection. Removal of uterus and ovaries prevents patient from developing possible associated cancers of these organs. Carcinoma rectum also spreads to ovaries commonly which can be prevented by oophorectomy.
- ◆ Often resection of liver secondaries can be undertaken in selected patients when one lobe is involved or solitary secondaries are present.
- ◆ *Laparoscopic APR/AR* is becoming popular.  
*Features are:*
  - ▶ Dissection will be more meticulous.
  - ▶ Less blood loss, less postoperative pain.
  - ▶ Early bowel function.
  - ▶ Clearance is same as open method in relation to primary tumour and nodes.
  - ▶ Short hospital stay, mortality and morbidity are similar to open method.
  - ▶ Port site recurrence chances are 0.5–2% (Earlier it was higher; now it has reduced due to proper technique, careful handling of the specimen, specimen isolation prior to extraction, trocar site irrigation with cytotoxic agents and povidone iodine).
- ◆ For carcinoma rectum presenting with obstruction, an initial proximal colostomy is done. Neoadjuvant chemoradiation is given. Patient is reassessed for operability. Then APR is done with permanent colostomy.
- ◆ Incidence of *local recurrent rectal cancer* is 30%.
  - ▶ Eighty per cent of local recurrence occurs within 2 years of surgery.
  - ▶ Common site of recurrence is in the pelvic wall. It also can occur at distal anastomotic margin.
  - ▶ Intractable pelvic pain, urinary symptoms, sepsis, bleeding, perineal sinus, swelling and induration, bowel disturbances are the features.
  - ▶ It is evaluated by CEA, biopsy, CT abdomen, MRI of pelvis and PET scan.
  - ▶ It is often difficult to manage.
  - ▶ Incidence of recurrence will come down to 5% in proper TME.
  - ▶ Palliative chemoradiation, end colostomy, ureteral stenting are the palliation. RT controls pain and bleeding.
  - ▶ Extensive radical surgery like removal of tumour with pelvic structures can be undertaken with diversions but with a high mortality rate and failure rate.
- ◆ Proper *preoperative bowel preparation* is a must in all rectal cancers which reduces the postoperative problems like sepsis, leak and increases the early chance of recovery.
  - ▶ Bowel preparation by polyethylene glycol; electrolytes *orally*; bowel wash *per anally*; bowel antiseptics like neomycin 1 g tid previous day/erythromycin 1 g tid/metronidazole tid *orally*.
- ◆ Systemic antibiotics like cefazolin, metronidazole, gentamicin.
- ◆ Prophylactic heparin or low molecular weight heparin.
- ◆ Foley's catheterisation and nasogastric tube should be passed.
- ◆ Preoperative adequate hydration using IV fluids.
- ◆ Blood grouping and crossmatching and required bottles of blood should be reserved if needed to transfuse during the procedure.

#### *Different surgeries for carcinoma rectum are:*

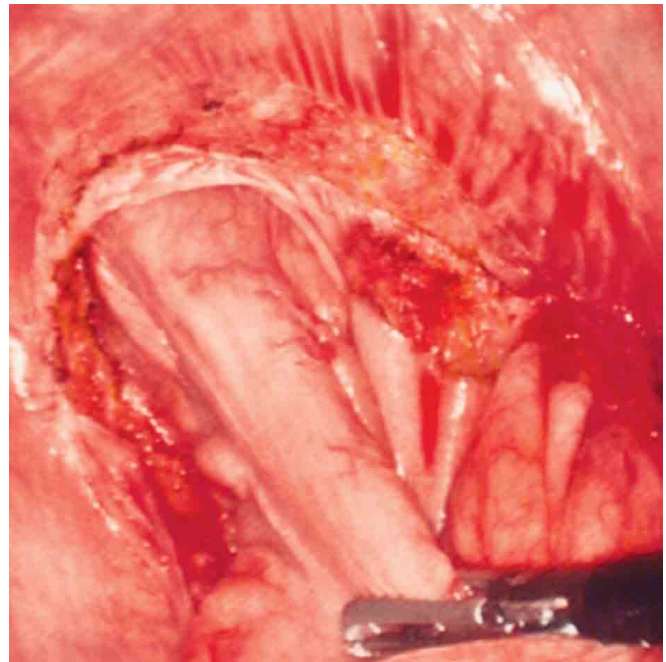
1. **Abdominoperineal resection** (A-P resection) (APR) wherein sigmoid, descending colon and upper rectum is

mobilised per abdominally. Anal canal with perianal and perirectal tissues are dissected per anally. Retained colon is brought out as *end colostomy in left iliac fossa*.

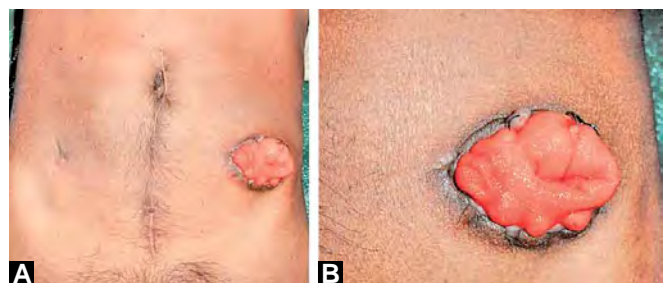
#### APR—types

- ❖ *Miles*—abdomen first, perineum later
- ❖ *Gabriel*—perineum first, abdomen later
- ❖ *Lloyd-Davies*—synchronised (together), (combined)

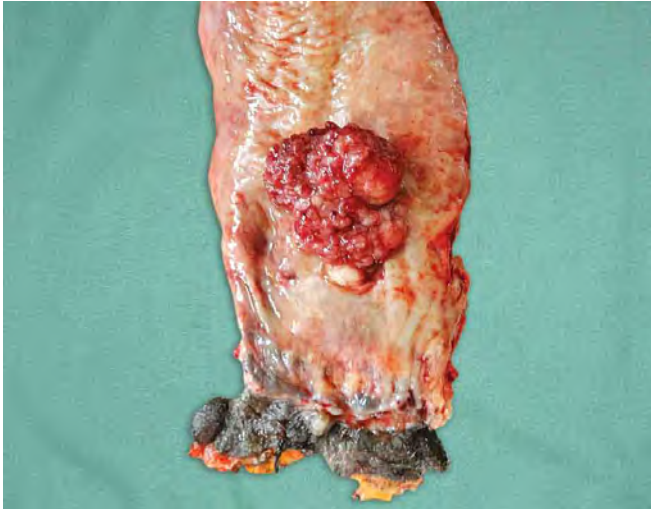- ◆ APR is done through lower midline incision in lithotomy position. Left-sided colon and entire rectum is mobilised from above. Rectum is mobilised posteriorly in avascular plane in front of nerve plane (hypogastric nerve) between mesorectum and sacrum. Inferior mesenteric artery is ligated high proximal (as lymphovascular ligation) at its origin or just beyond its first branch. Colon is transected and proximal cut end is fashioned for end colostomy in *left iliac fossa*. Through perineum, a purse string suture is placed around anal margin. Circumferential incision is placed around the anus. Dissection is deepened using scissor and cautery into the perineal body, coccyx, ischial tuberosity, ischioanal fossa. First posterior and lateral dissections are undertaken until it reaches above. Lastly, anterior dissection is done to reach above and specimen is removed through perineal wound. Perineal wound is closed in layers often with a drain. Abdomen drain is placed. Colostomy is created by suturing skin to mucosa using silk.



**Fig. 25.13:** Laparoscopic view of mobilised rectum in APR.



**Figs 25.14A and B:** Colostomy done in left iliac fossa after APR. Colostomy care is important.



**Fig. 25.15:** APR specimen showing carcinoma rectum; note the clearance margin.

- ❖ **Complications of APR are:**
  - Bleeding
  - Infection of perineal wound
  - Complications of colostomy like prolapse, stenosis, and infection
  - Injury to urinary system, ureter, impotence, urinary incontinence
  - Operative mortality is less than 2%

APR is the treatment of choice when mesorectum is involved or when it is poorly differentiated tumour or when nodes are involved. It gives adequate clearance.

- ◆ **Sphincter saving APR with coloanal anastomosis:** It is done in operable distal rectal tumour in young individual wherein within oncological principle anal sphincter need not be sacrificed but adequate oncological tumour clearance can be achieved. Here a permanent colostomy stoma is avoided. Approach is both abdominal and perineal. Initial dissection of rectal mobilisation is done from above; dissection of rectal mucosa from the anal sphincter at the level of dentate line and complete dissection of distal rectum is done through anal canal. Entire rectosigmoid is removed retaining only the anal sphincter. Colonic J pouch or coloanal reservoir is created in the mobilised descending colon; coloanal anastomosis is done per anally using hand sutures under direct visualisation.
  - ◆ **APR with neo sphincter reconstruction** is also occasionally sought; but technically difficult with complications. Perineal colostomy is done with gracilis muscle wrap which is made to produce sphincter like muscle twitch using an implanted pacemaker.
2. **Anterior resection** (Abdominal radical restorative operation) is done in growths located in the mid and upper part of the rectum, which is well-differentiated, small-sized and with a clear adequate length for anastomosis after resection.
- ◆ **Anterior resection** is also called as *anterior proctosigmoidectomy* through *abdominal* approach wherein rectum *above* the peritoneal reflection is resected with colorectal anastomosis.
  - ◆ **Low anterior resection (LAR)** is resection of rectum *below* the peritoneal reflection along with the sigmoid colon (as sigmoid

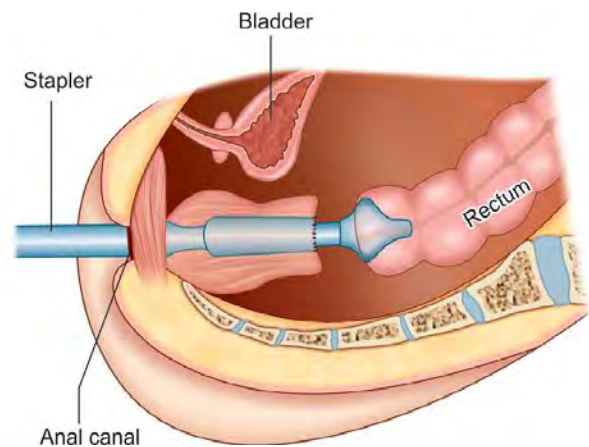
should be removed due its precarious blood supply after dissection), with total mesorectal excision (TME) through *abdominal approach* (laparotomy) and *colorectal anastomosis* using circular stapler device (EEA stapler). Stoma should be inspected using proctoscope for integrity and when in doubt a covering temporary proximal colostomy should be done. LAR often leads into frequent small bowel movements causing more frequent stools called as *low anterior resection syndrome (LAR syndrome)/clustering*. It can be avoided by creating reservoir either by doing *colonic J pouch* or by doing *colooplasty* 6 cm from proximal divided end of colon (longitudinal colotomy between taeniae of 10 cm which is sutured horizontally).

#### Criteria for anterior resection—(Low anterior resection, LAR)

- ❖ Upper and middle third rectal growth
- ❖ Above peritoneal reflection
- ❖ Well-differentiated tumour
- ❖ <4 cm size tumour
- ❖ In females, growth 7 cm above the anal verge
- ❖ T1 N0/T2 N0 tumour
- ❖ Tumour without lymphatic or venous spread

#### Advantages:

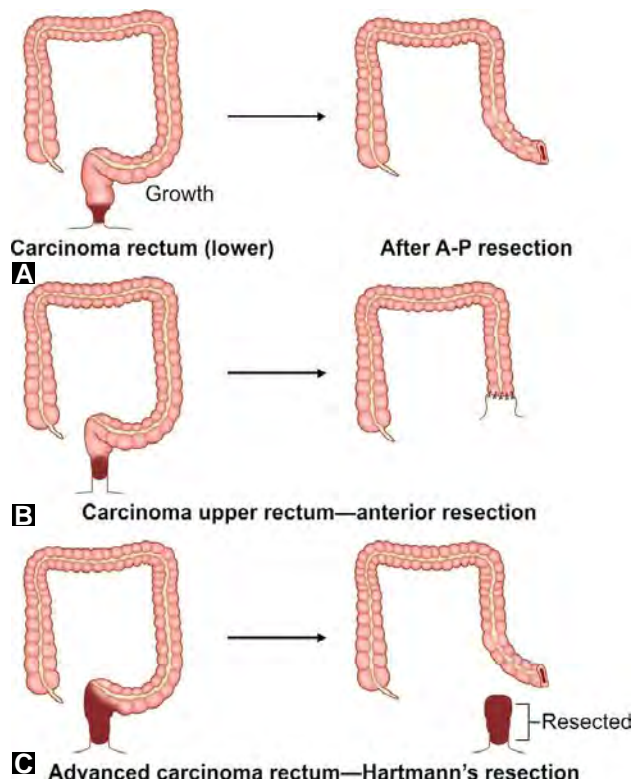
- ▶ Avoids permanent colostomy.
- ▶ Sphincter is retained.
- ▶ Patient's acceptance.



**Fig. 25.16:** Anterior resection for carcinoma upper rectum using stapler device.

#### Disadvantages:

- ▶ Uncertainty of clearance which is very important in cancer surgeries and so chances of **local recurrence** is high.
  - ▶ Anastomotic leak, infection; stenosis.
3. **Hartmann's operation** is an excellent palliative procedure—done in elderly people who are not fit for major surgery like AP resection and also in locally advanced tumours. Here rectal growth is resected and upper end of the rectum is closed completely. Proximal colon is brought out as *end colostomy*.
4. **Pelvic evisceration (Brunschwig's operation):** It is removal of rectum with the tumour, all the lymph nodes, urinary bladder, fat, fascia, uterus, vagina, with colostomy and urinary diversion. It is neither favourable nor popular.



**Figs 25.17A to C:** Surgeries for Ca rectum (A) A-P resection; (B) Anterior resection, (C) Hartmann's resection.

5. **Palliative colostomy** is done in advanced unresectable growth which presents with intestinal obstruction.

### Radiotherapy

It is beneficial in carcinoma rectum showing increased survival rate. It is useful when growth is below the level of peritoneal reflection.

#### Radiotherapy in carcinoma rectum

- ❖ Only rectal adenocarcinoma in GIT responds well for RT
- ❖ Preoperative RT can be given to down stage the tumour so as to make it amenable for APR or make it for anterior resection
- ❖ Postoperative RT is commonly used
- ❖ In small well-differentiated growths *papillon's* intracavitary curative RT can be tried with proper follow-up
- ❖ Palliative RT
- ❖ IORT (Intraoperative RT) is used in pelvic wall disease. It can cause peripheral neuropathy and ureteral stenosis
- ❖ As a component of chemoradiation
- ❖ Short course 25 Gy in 5 fractions in 5 days
- ❖ Long course 40–50 Gy in 28 fractions in 6 weeks
- ❖ RT sterilises field; causes down staging of tumour; preserves sphincter

### Chemotherapy

- ▶ Capecitabine, oxaliplatin are newer drugs used (refer chapter large intestine for detail). Indications are positive nodes; T2 stage; blood spread; for chemoradiation; recurrent tumour; advanced/ metastatic disease.
- ▶ Biologic agents:
  - Bevacizumab VEGF receptor antagonist.
  - Cetuximab EGFR antagonist.

It has been tried using endoxan, 5 FU, semustine also with leucovorin (Folinic acid) or levamisole.

### Other Methods

- ▶ Electrocoagulation and decoring of the tumour, as a palliative procedure; stenting.
- ▶ Laser photocoagulation, cryotherapy.
- ▶ *Portal vein infusion*; hepatic artery infusion for metastases.
- ▶ *Tumour vaccines*: Tumour antigen does not elicit immune response *in situ*; but vaccines are injected to evoke immune response. (1) BCG with irradiated tumour cells (2) Monoclonal antibodies 17-1A [Murine Ig G2A] (3) CEA vaccines.

### Chemoradiation in Carcinoma Rectum

- ◆ It is very useful *adjuvant therapy*.
- ◆ To prevent recurrence after anterior resection.
- ◆ Neoadjuvant (preoperative) chemoradiation can be used in tumour like T3 to downstage the disease and make it possible for AR.
- ◆ Post-operative chemoradiation.
- ◆ Palliative chemoradiation in locally advanced disease or metastatic disease also.
- ◆ Recurrent local carcinoma of rectum.
- ◆ In carcinoma of rectum presenting with obstruction, chemoradiation is given after loop colostomy.

#### Prognosis in carcinoma rectum

5-year survival is	Prognostic factors are	Follow-up
<ul style="list-style-type: none"> <li>• Stage I 90%</li> <li>• Stage II 75%</li> <li>• Stage III 40%</li> <li>• Stage IV 5%</li> </ul>	<ul style="list-style-type: none"> <li>• Size of the tumour</li> <li>• Differentiation</li> <li>• Mesorectal involvement</li> <li>• Stage of the disease</li> <li>• Nodal status, perineural spread</li> <li>• Distant spread</li> <li>• Circumferential resected margin</li> <li>• Adjuvant therapy used</li> </ul>	<ul style="list-style-type: none"> <li>• Regular colonoscopy</li> <li>• CEA assessment</li> <li>• PET scan</li> <li>• CT/MRI</li> <li>• Colostomy care in APR</li> </ul>

### SOLITARY ULCER SYNDROME

- ◆ It is mainly thickening and disorganisation of muscularis mucosa with superficial ulceration.
- ◆ It is usually 4–12 cm from the anal verge in the anterior wall of the rectum. But often can occur in sigmoid colon.
- ◆ Attempt to defaecate in the closed pelvic floor causes funneling of the rectum and descent of the anterior rectal wall. Raised intrarectal pressure and hidden intussusception is the cause. It is often seen in sexual abused individuals. Often typical crater like ulcer is seen/felt on the *anterior rectum*. Chronic ischaemia at that point may be the cause.
- ◆ In 30% cases, there are multiple ulcers.
- ◆ Often there will be inflammation and induration of the area without an ulcer.
- ◆ **Presentations are:** Common in young females, constipation, bleeding, mucosal prolapse, chronic pain in the anal canal, incontinence. But sphincter tone on rectal examination is usually normal.

- ◆ **Investigations:** Defaecography shows nonrelaxing persistent puborectalis impression waves. EMG shows decreased electrical activity. Colonoscopy should be done to rule out other conditions like neoplasm, ulcerative colitis. Colonic transit time shows rapid filling of the rectum but delayed clearance of 7 days from the rectum.
- ◆ Condition is commonly associated with rectal prolapse.
- ◆ **Differential diagnosis** are carcinoma, tuberculosis, ulcerative colitis.
- ◆ **Treatment:**
  - ▶ High fibre diet.
  - ▶ Treatment for rectal prolapse.
  - ▶ Avoid surgical excision in solitary ulcer syndrome as much as possible.

## RECTAL PROLAPSE

- ◆ It is *circumferential descent* of rectum (bowel) through the anal canal.
- ◆ It is commonly seen in infants, children and elderly individual.
- ◆ It is common in females (6 : 1).
- ◆ *Faecal incontinence* is very common feature; urinary incontinence occurs in 35% of patients; 15% of patients are associated with vaginal vault prolapse.
- ◆ Rectal prolapse can be:
  - ▶ *Partial.*
  - ▶ *Complete.*
  - ▶ *Hidden/concealed:* It is internal intussusception of the sigmoid into the rectum or part of the rectum distally; they do not come out of the anal orifice. Here only mucosa and submucosa separates from muscularis layer and descends.

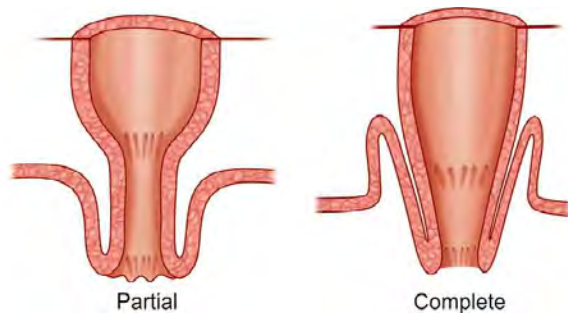


Fig. 25.18: Rectal prolapse.

## Aetiology

- ◆ *Alexis Moschowitz* put his theory of 'rectal prolapse is due to sliding herniation of the pouch of Douglas through pelvic floor fascia into the anterior aspect of the rectum'.
- ◆ *Broden and Snellman* proposed that 'procidentia is a full thickness rectal intussusception starting approximately 7.5 cm above the dentate line which is extending beyond the anal verge'.
- ◆ Decreased sacral curvature and decreased anal canal tone are the probable causes in infants.
- ◆ *Chronic constipation* with straining is the common cause.
- ◆ Diarrhoea, cough, malnutrition are the additional factors in children.
- ◆ It may be due to reduced ischiorectal fossa fat, neurological causes, fibrocystic disease of pancreas or poorly developed pelvis.

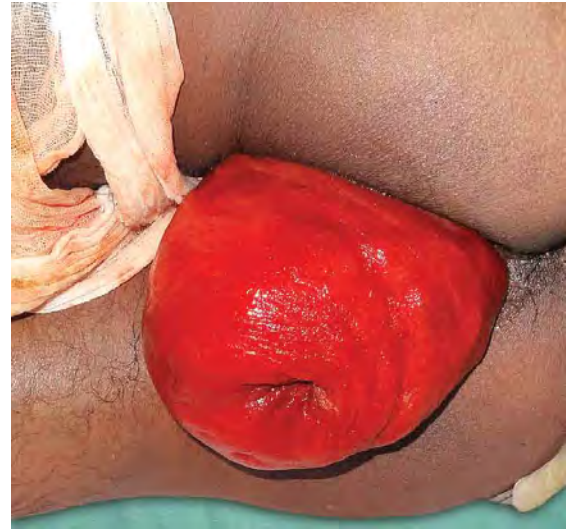

Fig. 25.19: Complete rectal prolapse. It is the circumferential descent of the rectum through anal canal.

- ◆ There is diastasis of the levator ani, abnormally deep cul de sac, redundant sigmoid colon, patulous sphincter, loss of rectal sacral support, lax and atonic pelvic floor musculature.
- ◆ *Pudendal nerve damage* is said to be the cause for pelvic floor and anal sphincter weakness. It may be due to obstetric injury, diabetes, sacral nerve damage.
- ◆ In adults, it is common in females, common in multipara—repeated birth injuries to perineum results in damage to the perineal nerve supply.
- ◆ Additional factors are due to increased intra-abdominal pressure due to any cause like chronic cough, stricture urethra.

## Types

### Partial Rectal Prolapse

Here only mucosa and submucosa of the rectum descends, not more than 3.75 cm. There is no descent of the muscular layer. It is the *commonest type of rectal prolapse*.

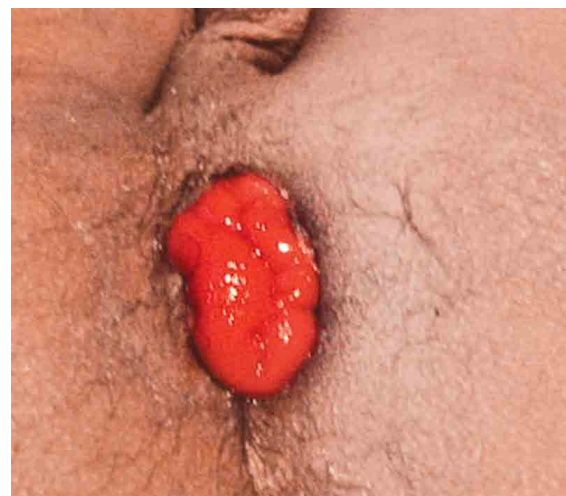

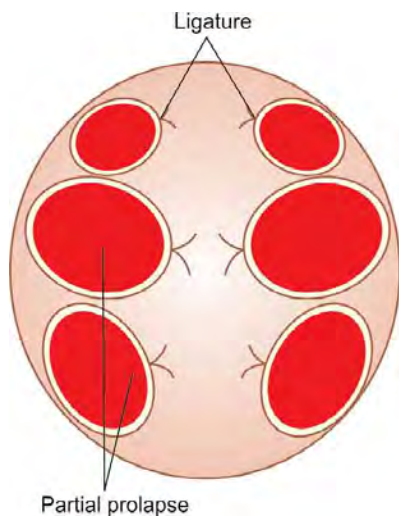
Fig. 25.20: Partial rectal prolapse is less than 3.75 cm and only mucosal.

### Clinical features of partial rectal prolapse

- ◆ History of mass per anum, which can be observed when child is allowed to strain in squatting position.
- ◆ It is *pink in colour and circumferential*.
- ◆ It differs from *piles* (differential diagnosis), the piles are not circumferential and *are plum or blue coloured (not pink)*.

### Treatment for partial prolapse

1. The nutrition of the child is improved and digital repositioning is tried. *Correction of constipation* is important.
2. Submucosal injections of 10 ml of 5% phenol in almond oil or ethanalamine oleate is given into the apex of the prolapse under. G/A so as to create an aseptic inflammation leading to tethering of mucosa to the underlying muscular coat. Injection can also be given at the base or both at the apex and base.
  - ▶ Alternatively 30 ml of tetracycline or oxytetracycline or hypertonic saline injection can also be used. Initial injection is supported by *Thiersch wiring* using (temporary) chromic catgut until adhesion occurs between the mucosa and muscular layer (in 3 weeks).
  - ▶ In adults, injection therapy is tried for partial prolapse, results are not as good as in children.
3. Thiersch wiring alone is tried with good success rate in children.
4. *Goodsall's operation* is excision of the prolapsed mucosa at its base, usually in three positions.
5. Stapled transanal rectal resection surgery (*STARR*) is also often used.



**Fig. 25.21:** Goodsall's ligature for partial prolapse. Prolapsed mucosa is ligated at different positions using nonabsorbable suture material often with double needed. Usually, it is done for one side in three portions.

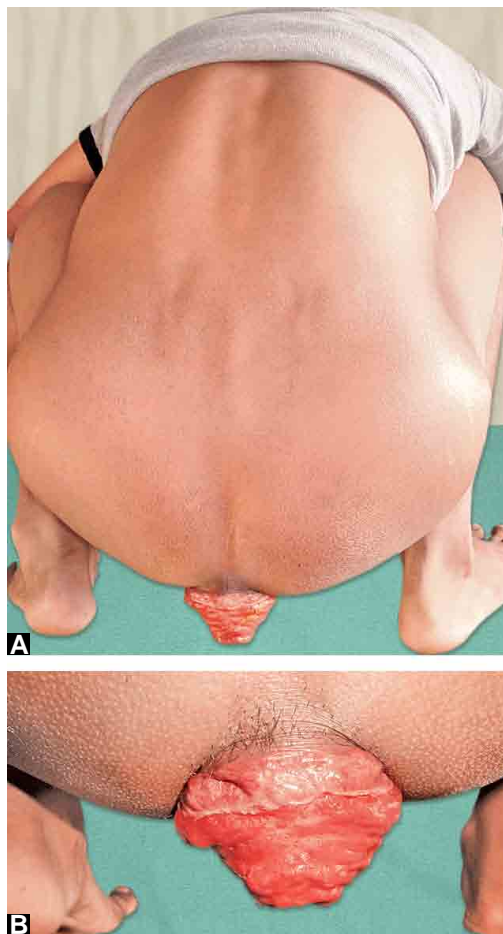
### Complete Rectal Prolapse

- ◆ Also called as *procidentia*, is *less common than partial prolapse*.

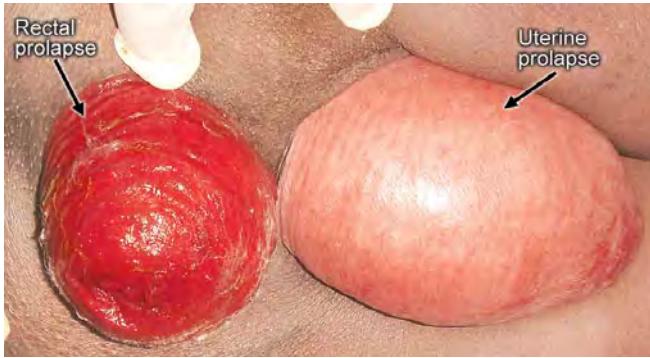
- ◆ It is common in females (6 : 1 :: female : male).
- ◆ It is due to weakened levator ani and supporting pelvic tissues.
- ◆ The descent is always more than 3.75 cm, contains all layers of the rectum (i.e. including muscular layer). Often descends down up to 10–15 cm.
- ◆ It is often associated with the uterine descent (*uterine prolapse*).
- ◆ It is also thought to be as an intussusception of the rectum.
- ◆ Once complete prolapse is more than 5 cm, anteriorly it drags peritoneum as pouch which often contains small intestine. On digital pushing it reduces with gurgling.
- ◆ Patulous anal sphincter is typical with mucus discharge and faecal incontinence.
- ◆ Mucosa of the chronic rectal prolapse is *thickened, ulcerated, bleeds*, and often *incarcerated* below the level of anal verge.

### Aetiological factors

- ❖ Weak anus, external sphincter and pelvic muscle
- ❖ Lax, mobile rectum
- ❖ Obliterated ano-rectal angle
- ❖ Abnormally mobile rectum with descent



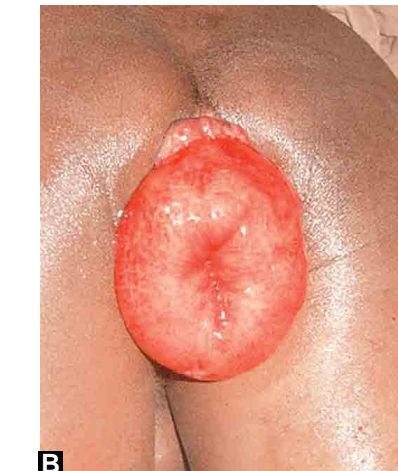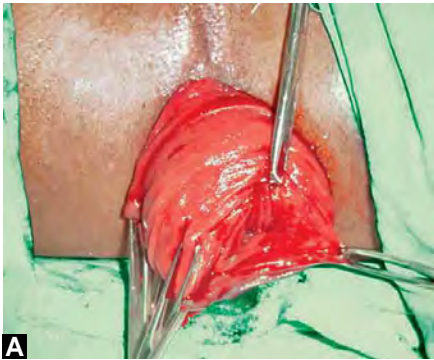**Figs 25.22A and B:** Complete rectal prolapse. It should be confirmed by observing the patient during straining in squatting position.



**Fig. 25.23:** Female patient presented with both complete uterine and rectal prolapse (Procidentia).

### Clinical features of complete rectal prolapse

- ◆ Complete descent of rectum as mass per anum circumferentially which is red in colour. Mass is usually reducible and painless. Incarcerated or infected rectal prolapse is painful.
- ◆ Rectal prolapse may be associated with the *uterine prolapse* (uterine procidentia) in females.
- ◆ Faecal incontinence (75%) is very common. It is due to disruption of the anal sphincter and prolapsed rectal mucosal discharge.
- ◆ Bleeding can occur because of the congestion.
- ◆ Sepsis, discharge, fever, anaemia are other features.
- ◆ P/R examination shows lax sphincter. Anteriorly, peritoneal sac comes down as a pouch which may contain small bowel.



**Figs 25.24A and B:** Complete rectal prolapse. It is more than 3.75 cm, prolapse of mucosa with muscular layer.

### Differential diagnosis

*Rectosigmoid* intussusception, third degree piles, large rectal polyp.

*Folds* in rectal prolapse are *concentric* and *red* in colour; in piles there are *radial nonconcentric* invaginations of haemorrhoidal cushions which are *plum* coloured with a cutaneous component.

### Complications of rectal prolapse

- ❖ Ulceration, bleeding, anaemia
- ❖ Proctitis, sepsis
- ❖ Irreducibility, gangrene
- ❖ Rupture with evisceration

### Investigations

- ◆ Defecography reveals increased mobility of the rectum from sacral fixation point with redundant mesorectum and funnel formation. It is fluoroscopic and spot filming in lateral projection after instilling radio-opaque material into the rectum done in sitting posture over a radiolucent commode.
  - ▶ Cinedefecography, triple contrast cinedefecography, dynamic MRI defecography, colpocystodefecography are helpful to delineate complex pelvic floor problems.
  - ▶ *Defecography detected abnormalities*—megarectum, incontinence, nonrelaxing puborectalis, abnormal perineal descent (2.5 cm), mucosal prolapse, solitary ulcer rectocoele, enterocoele.
  - ▶ *Preprolapse* (in defecography): Rectum is funnel shaped, lack of fixation to sacrum, excessive rectosigmoid mobility, ring pocket formation, intussusception.
  - ▶ *Rectal prolapse* (in defecography): Redundant sigmoid colon, wide deep pouch of Douglas.

### Defecographic grading of rectal prolapse

- N—normal rectal fixation and sphincter relaxation and rectal emptying
- 1—nonrelaxed puborectalis
- 2—mild intussusception
- 3—moderate intussusception
- 4—severe intussusception
- 5—prolapse
- R—rectocoele

- ◆ *Sigmoidoscopy*: It is to detect the tumour in the intussuscepted prolapsed rectum which is an occasional cause.
- ◆ *Anal manometry*: *Resting* (40 mmHg of internal sphincter) and *squeeze* (80 mmHg, external sphincter) pressures at various points in anal canal is measured by placing water filled balloons attached to catheters and transducers placed in the anal canal.
- ◆ *Pudendal nerve latency study*: *Specialized transducer* attached to a glove like device is to be worn on the finger through which digital rectal examination is done. Electrode in the finger is directed over the right and left levator ani complex to measure pudendal nerve terminal motor latency (PNTML) which is normally 1.8–2.2 msec. It is prolonged in pudendal nerve damage.
- ◆ *Electromyography study* of the puborectalis muscle tone is also very useful.

### Treatment for complete prolapse

#### Aim of treatment

- ◆ To *control* the prolapse; to *restore* continence; to *prevent* constipation.

- ◆ In young males, abdominal repair should be avoided as it injures pelvic nerves leading to sexual impotency. So perineal approach is better.
- ◆ Rectopexy is fixing the rectum to sacrum by sutures or mesh after complete mobilisation of the rectum. Laparoscopic rectopexy using polypropylene mesh and sutures gives good result and has become very popular.
- ◆ *Delorme's operation* is better option in young individual with complete prolapse.
- ◆ In elderly perineal proctectomy with anterior and posterior reefing of the sphincter muscle is accepted method now. It is similar to Altemeier technique (It is perineal rectosigmoidectomy). Here entire prolapsed rectum and redundant sigmoid is resected through perineum prior to reefing of the sphincter.
- ◆ Anal encircling surgeries using synthetic wires/mesh/suture materials are limited to extremely ill patients and elderly who will not withstand perineal proctectomy.
- ◆ *Choice of procedure* depends on age, sex, operative risk, pelvic floor defect, degree of incontinence, history of constipation.

## Surgery—Types

### Abdominal Procedures

#### Laparoscopic rectopexy

- ◆ It is ideal and good approach to fix the rectum to sacrum.
- ◆ *Laparoscopic posterior mesh rectopexy (LPMR)* is the procedure done. Prior bowel preparation is needed. Head down, low lithotomy position is needed. Ports are placed as shown in diagram. Sigmoid colon is held with left sided port. Surgeon does dissection from right side. Peritoneum on the right of the rectum is opened from sacral promontory downwards to reach presacral avascular plane. Care should be taken to avoid injury to autonomic nerves, ureters. Dissection is extended down as posterior mobilisation into the pelvis with adequate mobilisation of the rectum. Lateral ligaments are either divided or left alone. *Anterior mobilisation* is also important. Anterior mobilisation along the Denonvillier's fascia is done 5 cm below the peritoneal reflection. 10 × 6 cm polypropylene mesh is placed in the presacral space deep to rectum which is fixed to presacral fascia along the sacrum and sacral promontory. Mesh is sutured to rectal wall also on both sides using interrupted polypropylene sutures. Only partial wrapping of mesh is done. Peritoneum is closed using vicryl.

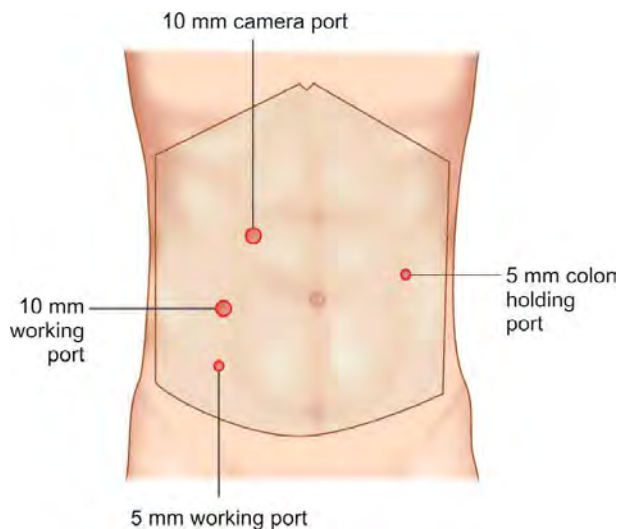


Fig. 25.25: Laparoscopic rectal prolapse—ports.

- ◆ Many advocate laparoscopic mobilisation and fixation of mobilised rectum to sacral promontory using polypropylene sutures without mesh.
- ◆ *Laparoscopic sigmoid resection and rectopexy* (Laparoscopic resection rectopexy, LRR) is done when there is rectal prolapse with constipation, with excess redundant sigmoid colon with kinking.

#### Well's operation

- ◆ *Polyvinyl alcohol sponge* is wrapped around the mobilised rectum and is fixed to sacrum. Infection, fistula formation is high.
- ◆ Polypropylene mesh is used as a modification now instead of polyvinyl sponge; wrapping is only partially done to reduce the incidence of constipation.

#### Ripstein operation

After mobilisation of the rectum, 5 cm width Teflon mesh sling is passed around the rectum to fix it behind to fascia 5 cm below and in front of the sacral promontory. Sling is also fixed in front and laterally to rectum.

#### Goligher's operation

Rectum is entirely mobilised up to anorectal ring and its posterior muscular layer is fixed to presacral fascia using interrupted polypropylene sutures.

#### Devadhar rectal plication

Through abdominal approach, junction between thicker lower part and thinner upper part of the intussusception is identified. A purse string suture using silk is placed in front and laterally; further 3-4 interrupted submucosal Lambert sutures are placed to create reverse intussusception.

#### Lahaut's operation

Rectosigmoid is mobilised fully; mobilised loop of rectosigmoid is passed in front through posterior rectus sheath behind the rectus muscle; extraperitonealisation is done to pull the rectus forward to prevent descent.

#### Rosoe Graham operation

- ◆ After mobilisation of the rectum, levator muscles are exposed and sutured in front of the rectum along with removal of pouch of Douglas.
- ◆ In *Dumphy operation*, it is done through combined abdominoperineal approach with perineal rectosigmoidectomy. Both procedures control prolapse well but not incontinence.

#### Muir low anterior resection

In a redundant rectosigmoid with prolapse, rectosigmoid resection is done; excision of redundant pouch of Douglas is done; rectum is fixed to sacrum behind.

### Perineal Procedures

#### Delrome's operation (Mucosal sleeve resection and plication)

After prior bowel preparation, under spinal anaesthesia, in lithotomy position, completely prolapsed rectum is held with Babcock's forceps. 1 in 2,00,000 adrenaline solution is injected into the submucosal plane of the rectum to cause haemostasis. By making longitudinal incision, with sharp scissor and cautery dissection, mucosa is stripped off from the deeper muscular layer from 1 cm below the anal margin to the apex of the prolapsed rectum. Muscular layer of rectum is plicated using absorbable vicryl 2 zero interrupted sutures

all around; approximately 12–15 plication stitches are needed. These sutures are tied after finishing the passage of all sutures. Cut end of the mucosa of the apex is sutured to anal margin using interrupted vicryl sutures. It is technically easier. But incontinence may persist and recurrence chance is high.

**Perineal posterior fixation of the rectum of Lockhardt-Mummery**  
Retrorectal space is dissected through perineal approach and posterior rectal wall is sutured to sacrum and coccyx, additionally placing a retrorectal gauze pack to stimulate adhesions.

#### Wyatt operation

Through perineal post anal approach dissected retrorectal space is placed with a Marlex/mersilene mesh which is sutured high to the sacral promontory and rectal wall laterally.

#### Mickulicz Miles perineal transanal rectosigmoidectomy/ amputation of prolapse

Prolapsed rectum is excised and sigmoid is sutured to the anal margin.

#### Altemeier's rectosigmoidectomy

After rectosigmoidectomy, colonic anastomosis and pelvic floor is supported by suturing puborectalis muscle in front of the rectum using nonabsorbable sutures.

#### Anal encircling

- ◆ In 1891, Thiersch did anal encircling using silver wire to provoke inflammatory fibrosis as well as to give mechanical support to the anal orifice—*Thiersch wiring*. It is done under local anaesthesia. Two small incisions are made at lateral parts of the anal canal. Silver wire is passed around deeper to these incisions and tied after placing the *index finger* into the anal canal. Wire can be removed after 12 months. Polypropylene, nylon are the other materials that can be used. *Complications*: Pain due to wire erosion, infection, faecal impaction, incarceration, high recurrence of 50% or more. In children with rectal prolapse, *temporary wiring* along with Goodsall's ligature or injection sclerotherapy using thick catgut are often advocated.
- ◆ *Suprlevator high encirclement of anal orifice* (of Notaras) is done above the level of levator muscles by placing Teflon or nylon ribbons through anterior and posterior incisions. It gives better support and will not cut through. *Thoralsksen* modified this by placing plastic/mersilene tape around the bowel high up.

#### Procedures for repair of rectal prolapse

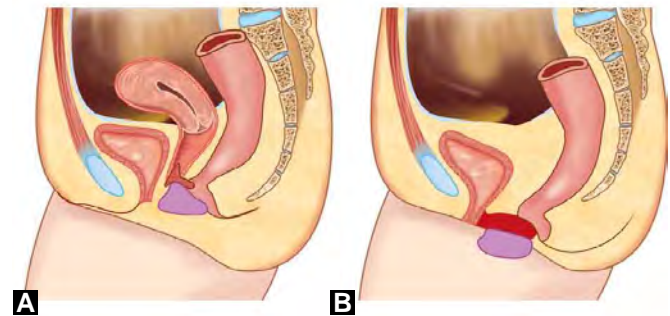
Perineal operations	Abdominal operations: Open/Laparoscopic
• Mucosal sleeve resection ( <i>Delrome's</i> )	• Suture rectopexy—Goligher, Lahaut, Devadhar, Rosoe Graham
• Perineal rectosigmoidectomy ( <i>Altemeier's</i> )	• Prosthetic or mesh rectopexy—anterior/posterior—Well's, Ripstein
• Posterior fixation of the rectum of Lockhardt-Mummery	• Resection rectopexy—Muir's
• Wyatt operation	• Anterior resection
• Mickulicz Miles perineal transanal rectosigmoidectomy/ amputation of prolapse	• Lahaut's operation
• Anal encircling (Thiersch)	

## Complications of Surgery

- ◆ Injury to hypogastric nerve causing impotence.
- ◆ Bladder dysfunction.
- ◆ Bleeding from sacral venous plexus.
- ◆ Injury to rectum and colon causing faecal fistula.
- ◆ Constipation after rectopexy is a known complication.
- ◆ Recurrence of prolapse.
- ◆ Improper correction of continence occurs in 50% cases.
- ◆ Infection—proctitis/pelvic abscess, etc.

## ANORECTAL MALFORMATIONS (ARM)

- ◆ It is due to imperfect fusion of the post-allantoic gut with the proctodaeum.
- ◆ Incidence is one in 4500 newborns.



**Figs 25.26A and B:** Anorectal malformation with fistula in (A) Females; (B) Males.

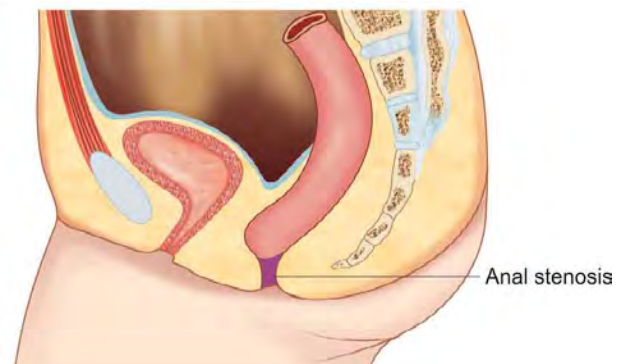
#### Note:

#### Present classification of ARM—

- **Nonsyndromic ARM**
- *Nonsyndromic ARM with fistula*
  - ▶ Recto-perineal
  - ▶ Recto-urinary (with bladder neck, bulbar or prostatic urethra) in males
  - ▶ Rectovestibular, rectovaginal, cloacal in females.
- *Nonsyndromic ARM without fistula* – imperforate anus
- *Nonsyndromic complex fistula*—cloaca with short common channel <3 cm; cloaca with long common channel >3 cm; H shaped rectovaginal fistula; rectal duplication.
- **Syndromic ARM**—associated with different syndromes.

## Clinical Features

- ◆ Newborn presents with inability to pass meconium, abdominal distension, features of intestinal obstruction, improper anal dimple, sometimes with complaints of passing meconium per urethra.



**Fig. 25. 27:** Anal stenosis.



### Wingspread classification of anorectal malformations ('Wingspread'—name of the place where the conference was held)

Low	Intermediate	High
It is below the level of pelvic floor, (Puborectalis). Easy to diagnose and treat with good outcome. It may be—	It occurs at the level of puborectalis, with or without fistula	It can be with or without a fistula into the bladder urethra, uterus, vagina It may be:
– Covered anus		– Anorectal agenesis
– Anovestibular fistula		– Rectal atresia
– Anal stenosis		– Cloaca (only in females, with confluence of rectum, vagina, bladder and urogenital sinus)
– Anal membrane.		

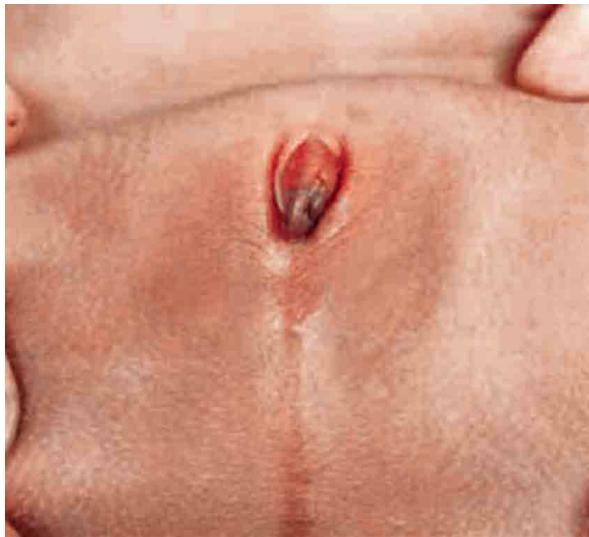

Fig. 25.28: Anorectal malformation, Cloaca type.

- ◆ It can be associated with—cardiac anomaly, tracheo-oesophageal fistula, renal anomalies, spinal anomalies. VATER/VACTERL anomaly.
- ◆ Most common ARM in boys is *rectobulbar fistula* with fistula beginning distal to puborectalis from distal rectum to bulbar urethra.
- ◆ Most common ARM in females is *rectovestibular fistula*.

### Investigations

1. *Wangenstein's invertogram*: Usually done 6–12 hours after birth, so as to allow air to reach the rectal pouch. A metal coin (marker) is strapped at the presumed site of anus and X-ray is taken. Length between the rectal pouch and anal dimple marker is more than 2.5 cm in high anal fistula.
  - a. In *low fistula*, rectal pouch is distal to the *Stephen's line* (*Pubococcygeal line*).
  - b. In *intermediate*, pouch is at the level of ischial spine (*Kelly's point*).
  - c. In *high fistula*, rectal pouch is proximal to the Stephen's line.
2. *Murugassu's technique*: Through visible anal dimple, meconium is aspirated by passing a needle into the rectal pouch in sitting propped up position. Watersoluble iodine dye is injected. Lateral X-ray is taken to study the level through Stephen line and Kelly's point.

3. US abdomen.
4. Evaluation of cardiac function is also important.
5. MRI spine.

### Treatment

1. In *low fistula*, single stage reconstruction is done under GA with very good results.
  - i. Anoplasty.
  - ii. Anovestibuloplasty.
  - iii. Anal dilatation.
  - iv. Incision of anal membrane.

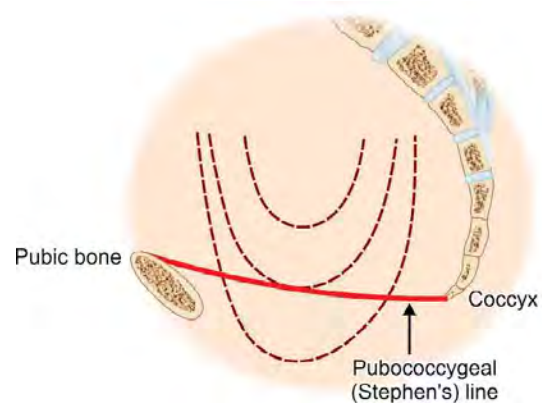


Fig. 25.29: Stephen's line.

2. In *high fistula*, initial colostomy is done. Later definitive procedure, i.e. *Pull through operation* through puborectalis and anastomosis of rectal pouch to create the anal canal is done. Closure of colostomy is done later.
  - ▶ *Posterior sagittal anorectoplasty* is commonly done procedure.

#### Note:

Level of rectal pouch and normal/abnormal sacrum are the deciding factors for good results.

### Complications

- ❖ Infection
- ❖ Faecal fistula
- ❖ Stenosis
- ❖ Colitis
- ❖ Malnutrition
- ❖ Faecal incontinence

## ■ PILONIDAL SINUS/DISEASE (Jeep Bottom; Driver's Bottom)

*Pilus—hair; Nidus—nest*

- ◆ It is *epithelium lined tract*, situated short distance behind the anus, containing hairs and unhealthy diseased granulation tissue. It is due to penetration of hairs through the skin into subcutaneous tissue. It forms granuloma/unhealthy granulation tissue in the deeper plane. It is of infective origin and occurs in sacral region between the buttocks, umbilicus, axilla.
- ◆ It is common in hair dressers (seen in interdigital clefts), jeep drivers.
- ◆ *Types of hair (H)*, *force of hair insertion* into subcutaneous tissue (F), *vulnerability of the skin (V)* are the three factors that cause pilonidal sinus. Number of hairs collected, acuteness of root end of hairs, type of hair—tough/silky, shape of hair—straight/curled, scaliness of hair are the deciding features of hair. Cut hairs from above descend into cleft and stay there to get buried deep into pilonidal sinus. Depth, narrowness, friction movements in the natal cleft; soft/macerated skin with erosions, splits, wide skin pores, wounds, presence of moisture and sweat are other factors.
- ◆ It is common in 20–30 years of age. It is common in males and mostly affects hairy men.

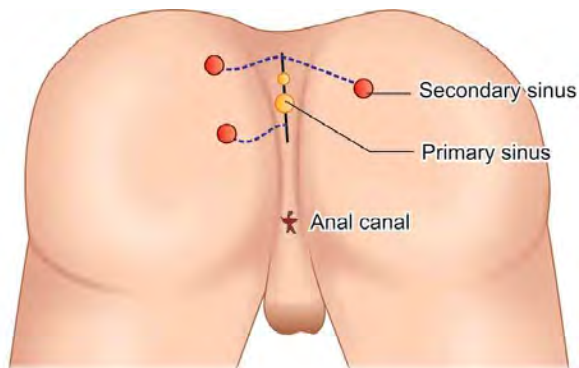


Fig. 25.30: Site and types of pilonidal sinus.

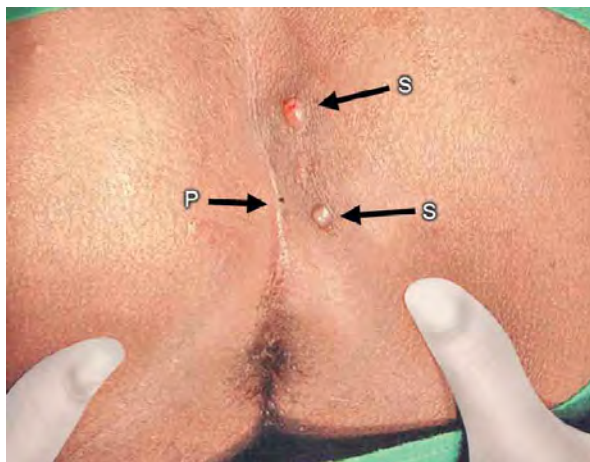


Fig. 25.31: Typical site of pilonidal sinus in the sacral region. Note the primary and secondary sinuses.

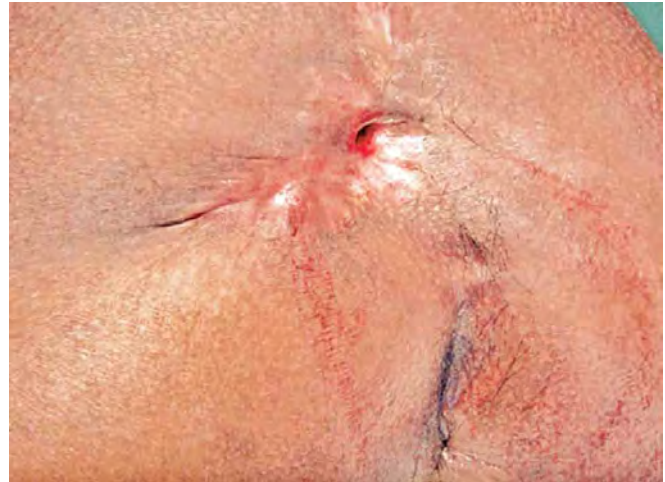

Fig. 25.32: Recurrent pilonidal sinus. 25–40% of pilonidal sinuses can recur.

**Commonest site:** Interbuttock sacral region.

### Pathology

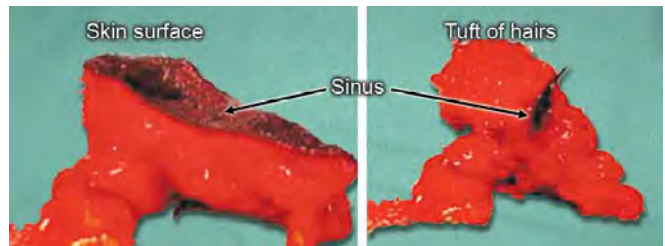
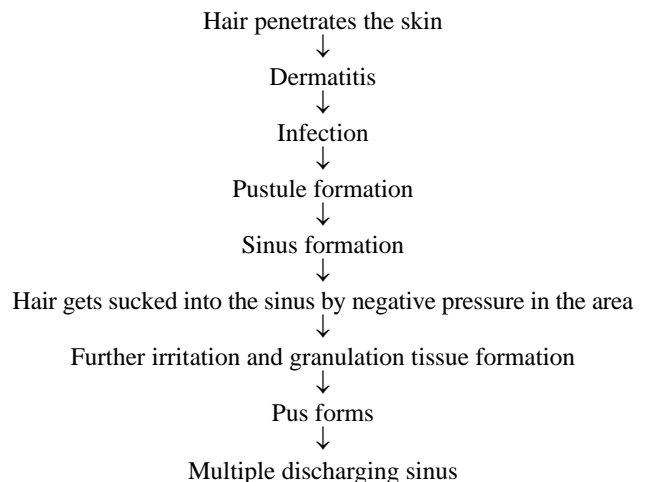


Fig. 25.33: Specimen of typical excised pilonidal sinus. Note the tuft of hair.



*Primary sinus* occurs in the midline.

*Secondary sinus* occurs laterally (paramedian).

#### Note:

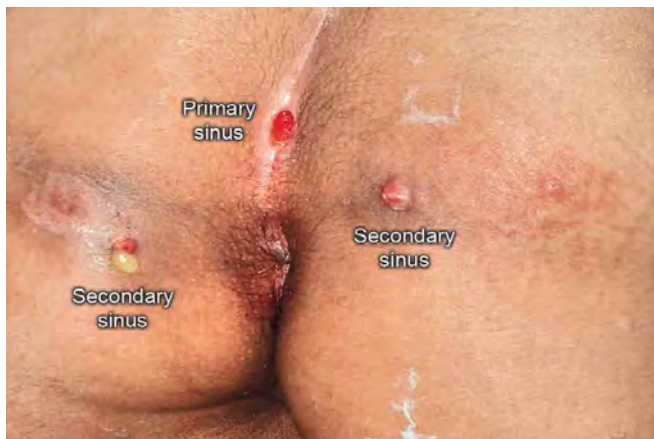Theories like Preen gland, medullary canal vestige, traction dermoid, inclusion dermoid are no longer accepted. Now it is considered as *acquired condition*.

### Remember about pilonidal sinus

- ❖ Congenital theory is no longer considered; it is an acquired entity
- ❖ Hair follicles have never been demonstrated in the wall of the sinus (only hairs have found)
- ❖ Number, sharpness, nature, shape of hairs; depth and narrowness of the natal cleft; friction movements; nature of the skin, moisture and sweating are the factors predisposing pilonidal sinus
- ❖ Hair need not be local, tract always traverses cephalad
- ❖ Male preponderance—74%, male sex hormone effect, hairy body, more sweat and maceration
- ❖ Occurs in young—20–29 years, who are having active pilosebaceous glands
- ❖ Dark haired—stiff hairs, rare in Negroes
- ❖ Obese and overweight—deep natal cleft
- ❖ Prolonged sitting
- ❖ Many procedures for treatment are available with each one having their own advantages and disadvantages

### Clinical Features

- ◆ *Discharge*—either sero sanguinous or purulent.
- ◆ *Pain*—throbbing and persistent type.
- ◆ *A tender swelling* seen just above the coccyx in the midline (*primary sinus*); and on either sides of the midline (*secondary sinus*).



**Fig. 25.34:** Pilonidal sinus—primary and secondary sinuses are clearly seen.

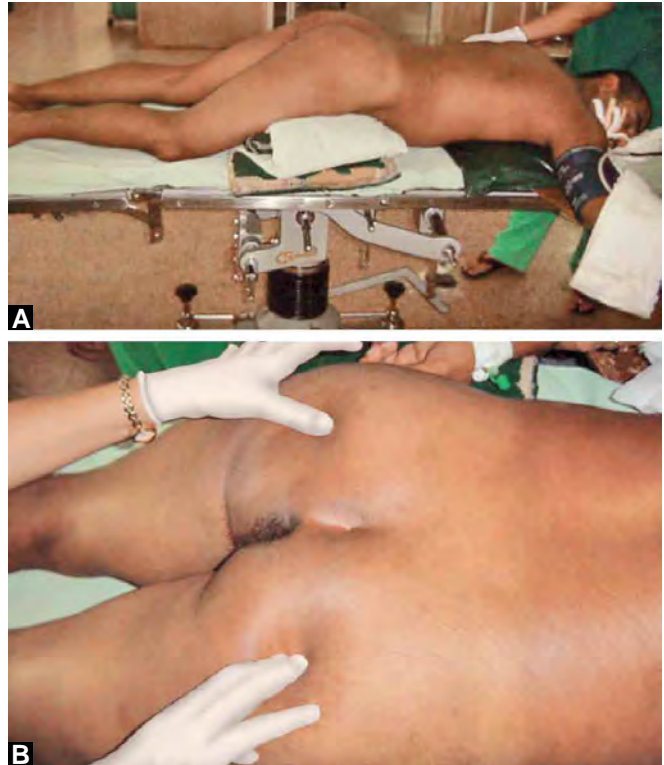
- ◆ Tuft of hairs may be seen in the opening of the sinus.
- ◆ Presentation may be as an acute exacerbation (abscess), or as a chronic one.
- ◆ It causes recurrent infection, abscess formation which bursts open forming recurrent sinus with pain, discharge and discomfort.

### Complications

- ◆ Chronic pilonidal sinus can cause occasionally sacral osteomyelitis, necrotising fasciitis and rarely meningitis.
- ◆ It is not a life-threatening condition but often it can be a morbid disease because of high recurrence rate.

### Treatment

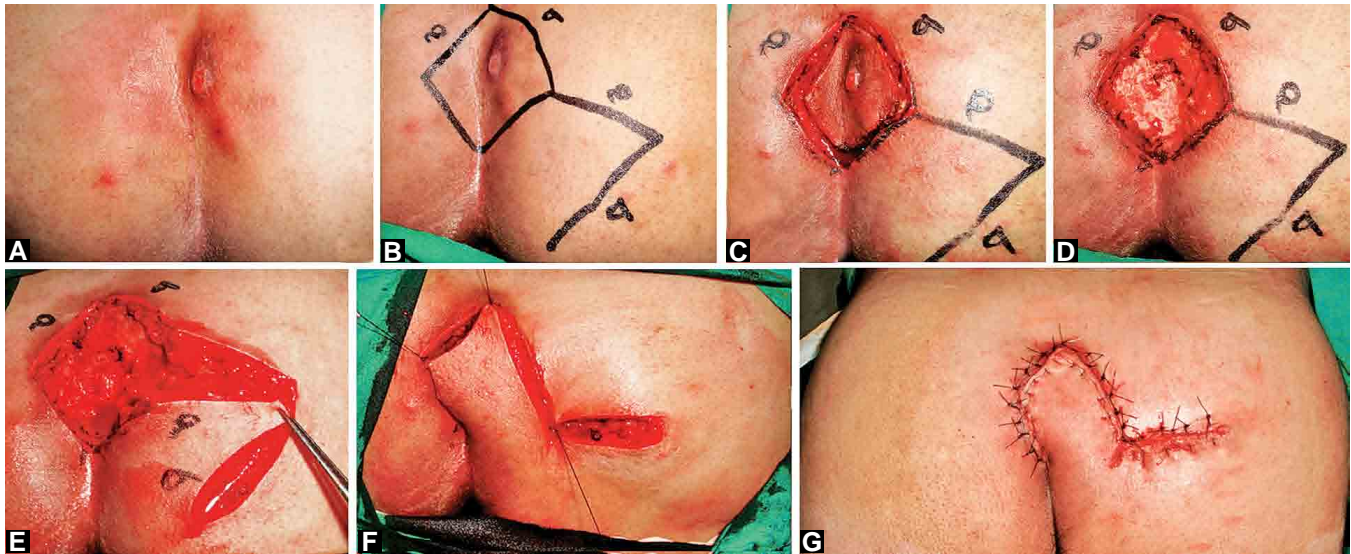
*In acute phase initially*—drainage of the abscess and antibiotics; later definitive treatment is undertaken.



**Figs 25.35A and B:** Pilonidal sinus—operative jack knife position.

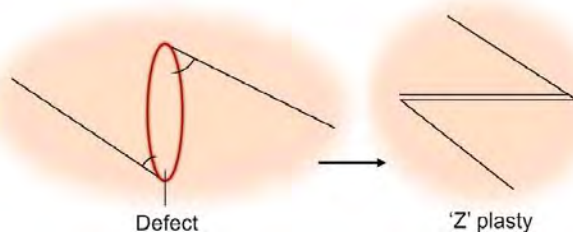
### Definitive treatment:

- ◆ In prone position (*jack knife* position, i.e. prone with buttocks elevated) excision and primary closure is done under general anaesthesia or local anaesthesia. All sinus tracks, unhealthy granulation tissues with hairs are removed completely. Methylene blue is injected to demonstrate the multiple tracks properly.
- ◆ Excision and skin grafting—has got high recurrence rate.
- ◆ Excision with Z plasty—good result.
- ◆ Excision with multiple Z plasty.
- ◆ Karydakis excision through a semilateral incision and lateralised suturing of the wound away from the midline gives good result.
- ◆ Excision with closure using Limberg (Rhomboid) buttock flap (single or double rhomboid flaps)—good result.
- ◆ V-Y gluteal advancement flap.
- ◆ *Bascom technique* of excision through lateral approach is a good method. Through small lateral incision or multiple small lateral incisions 2–4 mm sized sinus is approached and pus is drained; hairs are removed with only minimal excision of sinus done. Cavity walls are not excised. Lateral small wounds are either sutured or left open for spontaneous healing.
- ◆ *Lahey and Cattell's relaxing skin incisions* on one buttock to relieve tension on main wound sutures with later closure of secondary wounds by sutures or advancement.
- ◆ *Davies and Starr buttock skin flap rotation* into the defect and secondary defect is closed at a later period.
- ◆ After excision of entire sinus completely, wound is left open to granulate and heal by epithelialisation with regular dressings.
- ◆ *Buie's marsupialisation of the sinus track*—after making incision on the sinus track, edge of the laid opened area is sutured to the skin edge all round using silk or vicryl. This reduces healing time and promotes healing.



**Figs 25.36A to G:** Rhomboid-Limberg flap for pilonidal sinus. It gives good result.

- ◆ *Lord and Millar's limited excision of primary track* for 0.5 cm depth with removal of tuft of hairs, debris and unhealthy granulation tissue using tiny brush and nylon bristle.
- ◆ *Injection of phenol to the track* destroys the epithelium after removal of the tufted hairs. Phenol is allowed to be in contact with epithelium for 3 minutes to create a blanch in the track orifice.



**Fig. 25.37:** 'Z' plasty is done for pilonidal sinus. It gives good result. Multiple Z plasties are also used.

#### **Nonoperative treatment/prevention of recurrence after surgery:**

- ◆ Regular shaving of natal cleft to have meticulous hair control. *Laser, depilatory cream, electrolysis* are other methods used.
- ◆ Proper perineal hygiene.

#### **Causes for high recurrence rate**

- ❖ Improper removal
- ❖ Overlooking of existing diverticulum
- ❖ Entry of new tuft of hairs
- ❖ Breakage of scar

Note: Condition has got high recurrence rate (20%)

## **PILES/HAEMORRHOIDS**

*If bile or phlegm be determined to the veins in the rectum, it heats the blood in the veins: and these veins becoming heated attract blood from the nearest veins, and being gorged the inside of the gut swells outwardly, and the heads of the veins are raised up, and being at the same time bruised by the faeces passing out, and injured by the blood collected in them, they squirt blood, most frequently along with the faeces, but sometimes without faeces.*

—Hippocrates, (460–375 BC)

*Piles = a ball or mass, Haemorrhoids = blood to ooze, Figs = a fruit (Anjoora).*

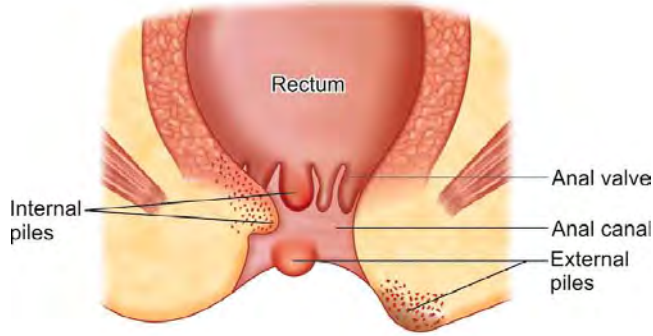
- ◆ The word '*Haemorrhoids*' is derived from Greek word Haima (bleed) + Rhoos (flowering), means bleeding. The *pile* is derived from the Latin word '*Pila*' means Ball.
- ◆ It is downward sliding of anal cushions abnormally due to straining or other causes.
- ◆ *Anal cushions* (Thomson, 1975) are aggregation of blood vessels (arterioles, venules), smooth muscles and elastic connective tissue in the submucosa that normally reside in left lateral, right posterolateral and right anterolateral anal canal.
- ◆ Piles can be mucosal or vascular (Graham Stewart, 1963). Vascular type is seen in young; mucosal is seen in old.
- ◆ *Present concept* is weakening of Park's ligament which is the lower end of the external sphincter.

### **Types**

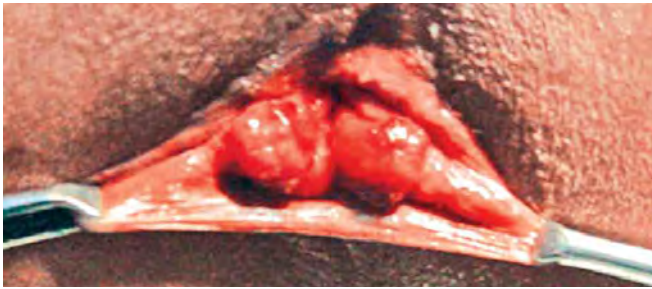**Internal**—above the dentate line, covered with mucous membrane.

**External**—below the dentate line, covered with skin.

**Interno-external**—together occurs.



**Fig. 25.38:** Anatomical locations of internal and external piles.

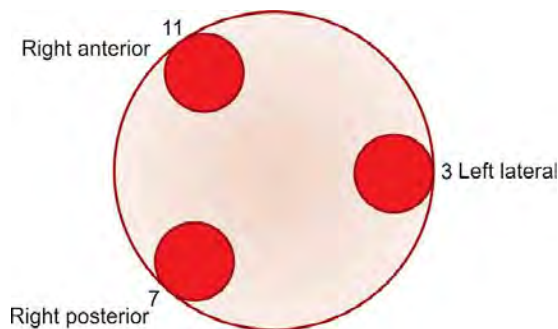


**Fig. 25.39:** Parts of piles—plum coloured internal part and black cutaneous external component.

## Classification I

**Primary haemorrhoids:** Located at 3, 7, 11 o'clock positions, related to the branches of the superior haemorrhoidal vessel which divides on the right side into two; left side it continues as one.

**Secondary haemorrhoids:** One which occurs between the primary sites.



**Fig. 25.40:** Positions of haemorrhoids.

## Classification II

### First degree haemorrhoids

Piles within that may bleed but does not come out

### Second degree haemorrhoids

Piles that prolapse during defaecation, but returns back spontaneously

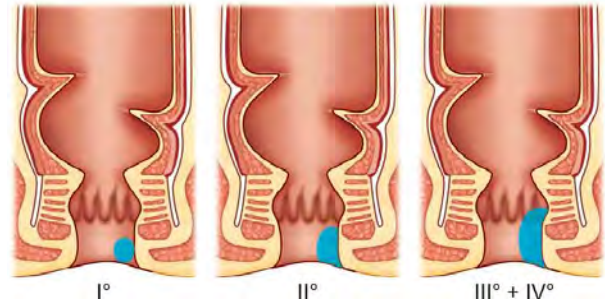
### Third degree haemorrhoids

Piles prolapsed during defaecation, can be replaced back only by manual help

### Fourth degree haemorrhoids

Piles that are permanently prolapsed

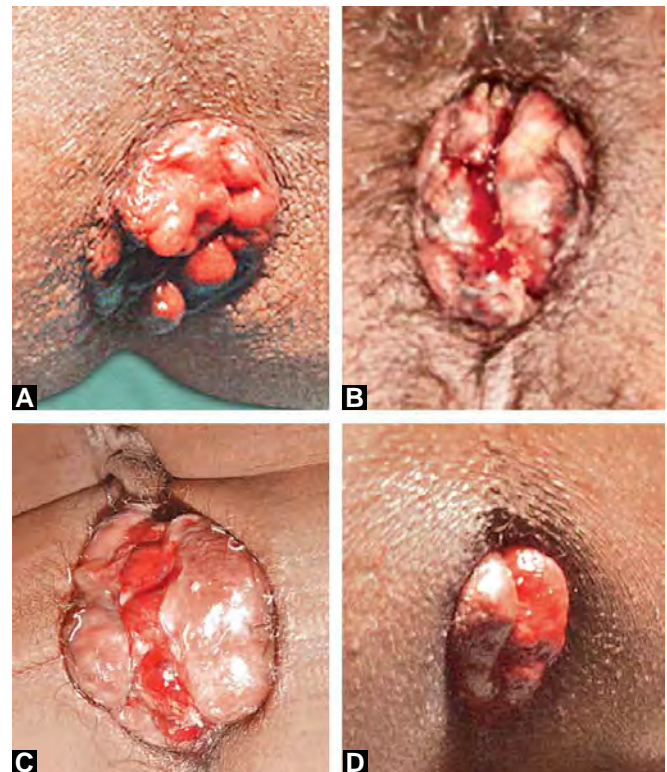
Piles begin as pedicle and it is located at the origin of the internal pile, i.e. at the level of ano-rectum.



**Fig. 25.41:** Degrees of haemorrhoids.

## Aetiology

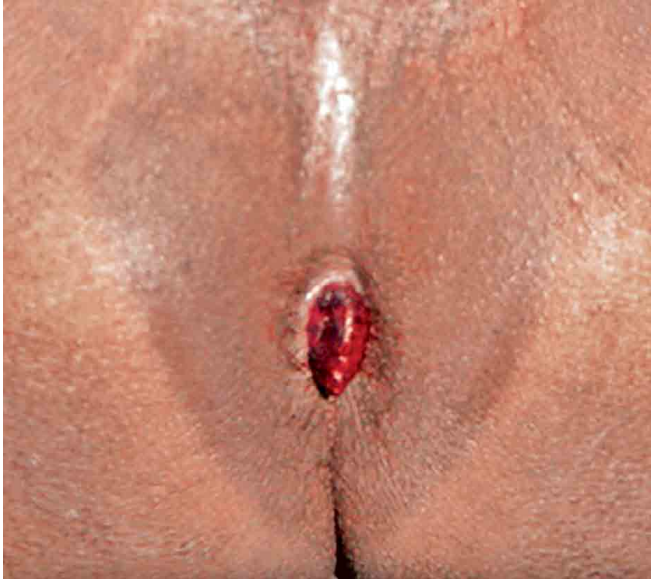- ◆ Hereditary.
- ◆ Morphological—weight of the blood column without valves causes high pressure. Veins in the lower rectum are in loose submucosal plane, but the veins above enter the muscular layer, which on contraction increases the venous congestion below (more prevalent in patients with constipation). Superior rectal veins have no valves (as they are tributaries of portal vein) and so more congestion.
- ◆ Other causes are straining, diarrhoea, constipation, hard stool, low fibre diet, overpurgation, carcinoma rectum, pregnancy, portal hypertension (rare cause). *During pregnancy* factors causing haemorrhoids—raised progesterone relaxes the venous wall and reduces its tone, enlarged uterus compresses the pelvic vein, and constipation is common problem.
- ◆ *Bulging of haemorrhoidal plexus (anal corpus cavernosum, by Stelzner)* occurs due to raised luminal pressure and transmission



**Figs 25.42A to D:** Different types of prolapsed piles.

of arterial pressure; pressure in *rectal ampullary pump* (Wannas) during straining raises the portal as well as systemic pressure causing obstruction to venous outflow causing haemorrhoids. *Disruption of suspensory tissues* which hold plexus in position (*sliding lining theory*); raised *basal anal pressure*; unsupported superior haemorrhoidal vein in the loose submucosal connective tissue in the anorectum when passes through the muscular coat gets *constricting effect* leading into congestion of haemorrhoidal plexus—are the *other theories* of haemorrhoid formation.

- ◆ *Idiopathic cause*: It is very difficult to pinpoint the cause for production of piles.



**Fig. 25.43:** Thrombosed prolapsed pile. Note the colour of the thrombosed pile. It is very painful and tender.

**Note:**

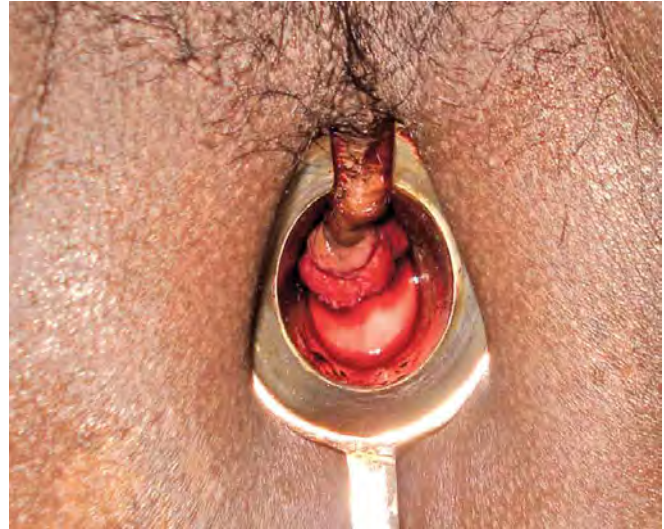- **An arterial pile** is haemangiomas condition of superior rectal artery entering the pedicle of internal haemorrhoid which will bleed profusely.

**Clinical Features**

- ◆ The *prevalence rate* of piles is 4.4% in the world, in about 10 million people.
- ◆ It may occur at any age but mostly seen in the age between 30 to 65 years.
- ◆ Incidence is equal in both the sexes.
- ◆ *Bleeding*—1st symptom—‘Splash in the pan’—‘bright red and fresh’—occurs during defecation.
- ◆ Mass per anum.
- ◆ Discharge—a mucoid discharge.
- ◆ Pruritus.
- ◆ Pain—may be due to prolapse, infection or spasm.
- ◆ Anaemia—secondary.
- ◆ On inspection, prolapsed piles will be visualized.
- ◆ On P/R examination, only thrombosed piles can be felt.
- ◆ Through *proctoscopy*, exact position can be made out as a bulge into the proctoscope.

◆ *Points to be noted during proctoscopy:*

- ▶ The numbers, degrees and size.
- ▶ The surface and appearance of piles.
- ▶ Features chronicity of the prolapse.



**Fig. 25.44:** Proctoscopic view of the internal pile (grooved proctoscope).

**Causes for bleeding per anum**

Piles	Carcinoma rectum
Fissure-in-ano	Carcinoma colon
Polyps	Diverticulitis
Ulcerative colitis	Intussusception
Amoebic colitis	Vascular anomaly of the colorectum
Fistula-in-ano	Mesenteric ischaemia

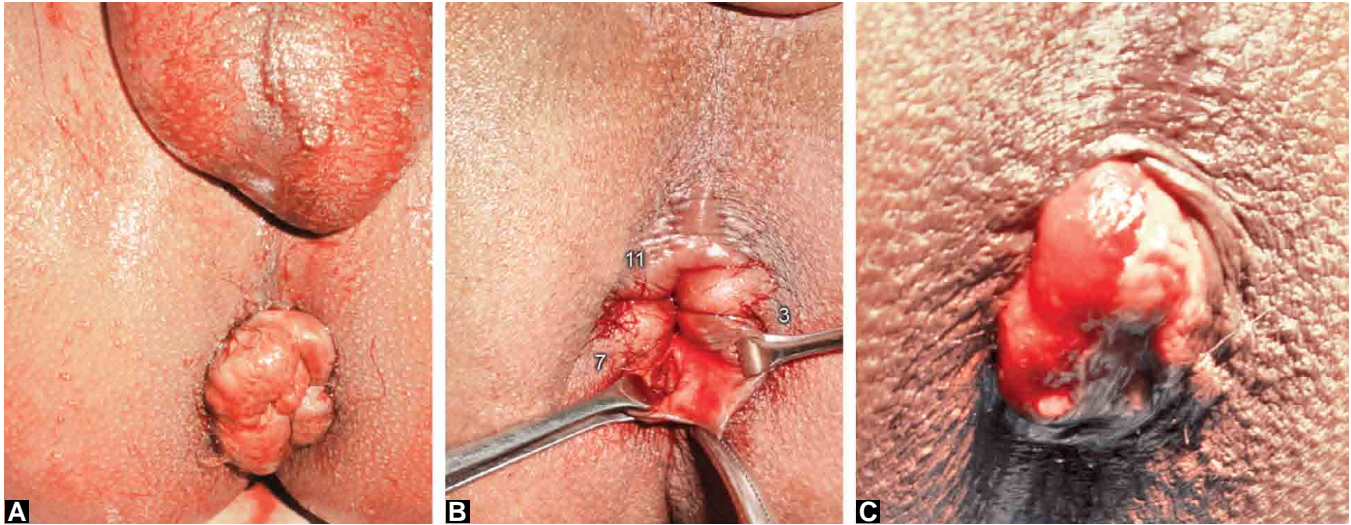
- ▶ One should look for other rectal lesion such as external tags, anal papillae and fissure, proctitis.
- ▶ Any gynaecological, genitourinary or abdominal conditions like—carcinoma of rectum, polyps, tumours, features of ulcerative colitis should be identified.
- ▶ Presence of other discharge like blood, pus, mucous.
- ◆ *Sigmoidoscopy* or colonoscopy or barium enema should be done if there is any suspicion of associated malignancy.

**Differential diagnosis**

- ❖ Carcinoma
- ❖ Rectal prolapse
- ❖ Perianal warts

**Investigations**

- ❖ Haematocrit
- ❖ Colonoscopy to evaluate proximally for any cause
- ❖ Barium enema X-ray



Figs 25.45A to C: Different positions of piles and parts.

## Complications

- ◆ Profuse haemorrhage which may require blood transfusion.
- ◆ Strangulation—piles is being gripped by anal sphincter.
- ◆ Thrombosis—piles appear dark purple/black, feels solid and tender.
- ◆ Ulceration.
- ◆ Gangrene.
- ◆ Fibrosis.
- ◆ Stenosis.
- ◆ Suppuration, leads to perianal or submucosal abscess.
- ◆ Pylephlebitis (Portal pyaemia) is rare, but can occur in 3rd degree piles after surgery.

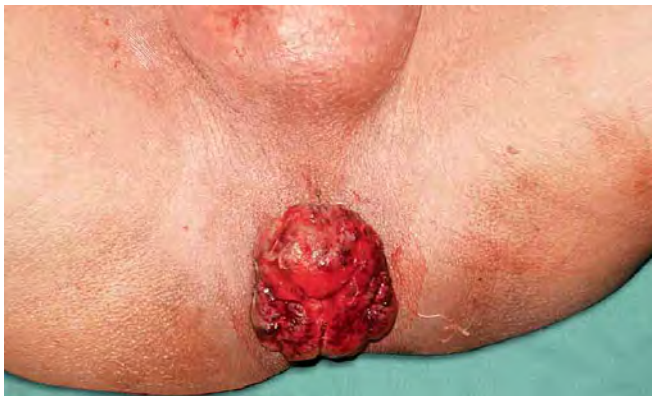

Fig. 25.46: Prolapsed, strangulated piles.

## Treatment

Preventive	Therapeutic/curative
Diet—more fibre/liquid Laxatives	<b>Medical</b> —local applications; sitz bath, diet, laxatives, drugs—analgesics <b>Parasurgical</b> <ul style="list-style-type: none"> <li>• Sclerotherapy</li> <li>• Banding</li> <li>• Cryotherapy</li> </ul>

Contd...

Contd...

- Infrared coagulation (IRC)
- Laser therapy
- Doppler-guided haemorrhoidal artery ligation (DGHAL)

### Surgical

- Open haemorrhoidectomy
- Closed haemorrhoidectomy
- Stapled haemorrhoidopexy
- Anal stretching—Recamier, Lord's

### 1. Nonoperative:

- ◆ *Sitz bath*—means the patient has to sit in warm water with the anal region dipped in water for 20 minutes, 2–3 times a day. This reduces the oedema, pain and promotes healing.
  - ◆ *Local applications* to reduce pain, itching and oedema can be used.
  - ◆ Antibiotics, laxatives, anti-inflammatory drugs are beneficial.
  - ◆ Fibre diet 35 g/day, plenty of water. *Fibre alternatives* (bulk-forming agents, e.g. ispaghula husk, sterculia, methylcellulose) can be used to supplement a high-fibre diet; squatting position may reduce the incidence of piles; plenty of liquid intake.
  - ◆ *Laxatives* such as lactulose solution which soften bowel motions and relieve the constipation. Bulk laxatives such as psyllium muciloid, Konsyl or polycarbophil may be necessary.
2. **In case of inflamed, permanently prolapsed, oedematous piles**, initially, manual stretching of the anal canal sphincter is tried. This prevents congestion of anal cushions and relaxes the anal sphincter, as a result of which the prolapsed piles gets reduced—*Lord's dilatation (8 fingers)*. Once oedema subsides, in 1–2 weeks, formal procedure is done.

### Complications of anal dilatation (3–4 fingers dilatation)

- ❖ Incontinence—rectal—usually temporary
- ❖ Infection
- ❖ Haemorrhage/haematoma
- ❖ Prolapse rectum

### 3. Injection-Sclerosant therapy:

- ◆ It is done in 1st degree and early 2nd degree piles (internal)—outpatient procedure.

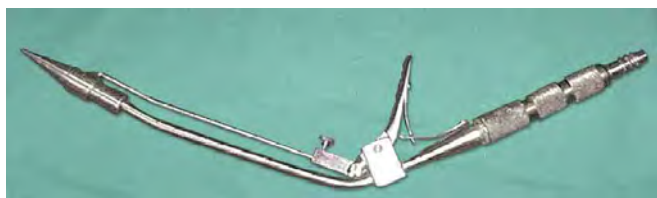- ◆ Using proctoscope and Gabriel syringe, 3–5 ml of 5% phenol in almond oil is injected into the submucosal plane just above the anorectal ring to the pedicle. All three piles can be injected separately—3–5 ml to each site in single sitting. Technique can be repeated after 6 weeks. This technique is not done in the presence of sepsis or prolapse.
- ◆ The drug causes fibrosis in the submucosal region (sclerosis leading to mucosal fixation on to deeper planes and occlusion of lakes) and thereby fixation of the anal cushions which do not prolapse, causes strengthening of the vessel wall and obliteration of the vessel lumen.
- ◆ It is quick and painless; gives 95% cure rate in 1st degree piles; done on OP basis.
- ◆ *Contraindications are*—thrombosed/prolapsed piles, presence of proctitis/fissure/fistula-in-ano, pregnancy and diabetes mellitus.
- ◆ Sclerotherapy has not gained popularity, oily solution is difficult to handle and inject.
- ◆ *Complications*—recurrence (15%), hypochondriac pain due to entry of drug into the portal system, tenesmus, mucosal sloughing/ulceration, submucosal abscess, anal canal pain, anal stricture.
- ◆ Inadvertent deep injection can precipitate pelvic abscess, prostatitis, impotence, rectovaginal fistula.



**Fig. 25.47:** *Gabriel syringe*—It is used for injection sclerotherapy for internal piles using 5% phenol in almond/olive oil (almond/vegetable oil acts as a vehicle which holds phenol for long period of action). It is a stainless steel syringe with two metallic finger brims near the proximal end. One more metallic finger brim is present on the proximal end of the piston to place thumb while injecting.

#### 4. *Barron's banding:*

- ◆ It is done for 2nd degree piles. It causes ischaemic necrosis and piles fall off.
- ◆ At one time only two piles can be banded. Repeat banding can be done only after 3 weeks.
- ◆ Band should be placed 2 cm above the dentate line.
- ◆ Usually 2 bands are used for pile mass to take care of breakage. Tissue sloughs off in 1–2 weeks leaving an ulcer which heals by scarring.
- ◆ Equipment is inexpensive, simple to perform; done without anaesthesia on OP basis; results are consistent, stops bleeding and tackles the prolapsing anal cushion.



**Fig. 25.48:** *Barron's band* instrument for 1st and early 2nd degree piles.

- ◆ It is contraindicated in fissure/fistula/proctitis.
- ◆ *Complications:* if applied low into skin it causes severe pain; discomfort; secondary haemorrhage, ulceration.

#### **Note:**

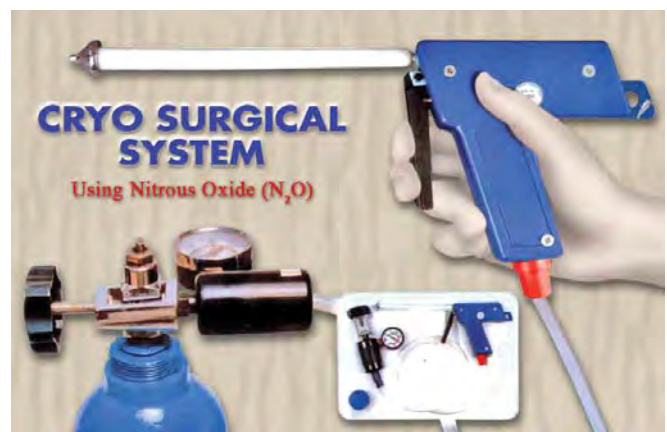Suction banding is used presently. Suction is used to suck the internal pile into the banding gun.

#### 5. *Cryosurgery:*

- ◆ Using nitrous oxide (–98°) or liquid nitrogen (–196°), extreme cold temperature is used to coagulate and cause necrosis of piles which gets separated and falls off subsequently.
- ◆ It is relatively painless and can be done on OP basis.
- ◆ All masses can be tackled at one sitting.
- ◆ This is carried out with the help of a *cryoprobe*. Nitrous oxide is preferred since it produces adequate freezing. Nitrous oxide delivery system/cryoprobe does not require special rewarming circuit. Liquid nitrogen produces quick destruction and damage of sphincter muscle; also needs special rewarming circuit for its release and is costlier.
- ◆ The patient is put in lithotomy position; cryoprobe is applied in the longitudinal axis of internal pile above the dentate line; the pressure must be maintained above 700 lb continuously; the rapid adhesion with freezing (white area formation on piles) occurs; traction and slight rotation in both directions is done to draw entire pile mass to come in contact with the probe; when entire tissue is frozen in 20–30 seconds, the probe is detached after warming (defrosting/thawing). Procedure is repeated on other pile masses.

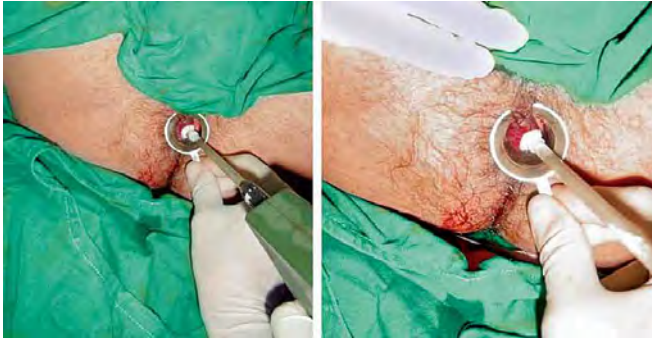


**Fig. 25.49:** Cryosurgery instrument set up for cryohaemorrhoidectomy.



**Fig. 25.50:** Cryoinstrument for cryosurgery.





**Fig. 25.51:** Cryosurgery for piles. Note the probe, grooved proctoscope, freezing the internal pile mass.

- ◆ **Advantages:** It is reasonably painless, simple, safe, can be done on OP basis, with less bleeding.
- ◆ **Disadvantages:** It causes *profuse watery discharge*, itching, pain if skin is frozen; marked oedema of adjacent skin, incontinence occasionally.

#### 6. **Infrared coagulation:**

- ◆ Here heat is used to burn the piles so as to allow it to fall off.
- ◆ Pulses of infrared radiation are applied through a handheld applicator. The specific infrared wavelengths produce chemical changes that cause blood coagulation within the haemorrhoid itself, which causes the haemorrhoid to seal, shrivel, shrink or slough off. Source of infrared rays of 14 volt Wolfram halogen lamp with a gold plated reflector rays are transmitted from fiber optic cable which terminates in a probe or pistol for coagulation.
- ◆ In left lateral position, the probe is applied at the base of pedicle above the dentate line and bursts are given in clover leaf fashion. Timer is set at 2 secs giving a depth of 2 mm; total time taken 2–5 minutes. It is done in 1st, 2nd, and 3rd degree piles.
- ◆ It produces a discrete area of necrosis (coagulates tissue proteins and evaporates water from the cells) which heals to form a scar; reduces or eliminates blood flow through the haemorrhoid thereby shrinking it and mucosa becomes fixed to the underlying tissue.
- ◆ Often 3 or 4 sittings are needed at 1 month intervals.
- ◆ It does not cause noncontact coagulation; does not cause interference with electromagnetic devices such as pacemakers. It is *contraindicated* in external pile, proctitis. Long-term results are not good. Equipment is expensive; multiple sessions are needed.

#### 7. **Laser therapy for piles**—for 3rd degree piles.

- ◆ Nd-YAG, diode and carbon dioxide lasers can be used but are expensive and tedious.
- ◆ The intense beam of light interacts with tissue and can be used to cut, coagulate or ablate the tissue, sealing off nerves and tiny blood vessels can be done by laser beam. By sealing superficial nerve endings patients have minimum postoperative discomfort. Laser is used for dissecting and excising pile masses.
- ◆ It is done for internal haemorrhoids.
- ◆ **Advantages**—less operative time; less intraoperative and postoperative bleed and pain; rapid healing; quick recovery; done under LA/SA; less complications; minimal pain, constipation and urinary retention.
- ◆ **Disadvantages**—needs skill; sphincter should be taken care of; non-contact burning can occur; secondary haemorrhage can occur due to heat tissue destruction; and also injury to sphincter can occur.

#### 8. **Doppler guided haemorrhoidal artery ligation (DGHAL)**

- ◆ DGHAL is an advanced instrument that works under Doppler guided ultrasound. It is painless, 20-minute procedure that cures all degrees of haemorrhoids. It causes choking and blocking of the

blood supply of piles. It is done using proctoscope with an incorporated Doppler probe.

- ◆ This proctoscope is inserted and used to locate the haemorrhoidal arteries by an audible signal. Once located, a needle holder is inserted into the lumen of the proctoscope and the artery ligated with a 'figure of eight' absorbable suture into the submucosa. The procedure is repeated until no more Doppler signals are identified.
  - ◆ **Advantages:** Anaesthesia is not needed; blood loss, pain, residual problems are minimal; done as day care surgery; early return for work; may be safe in diabetic, cardiac, old age patients, and in pregnancy.
  - ◆ It is under trial and too early to confirm the efficacy.
- #### 9. **Stapled haemorrhoidopexy (Antonio Longo)**
- ◆ It is circumferential excision of the mucosa and sub-mucosa 4 cm above the dentate line using circular haemorrhoidal stapler passed per anally (MIPH—minimally invasive procedure for haemorrhoids).
  - ◆ **Advantages** are—it is less painful; less blood loss; faster recovery; short hospital stay and equally efficacious.
  - ◆ It is done only for prolapsed piles.



**Figs 25.52A and B**

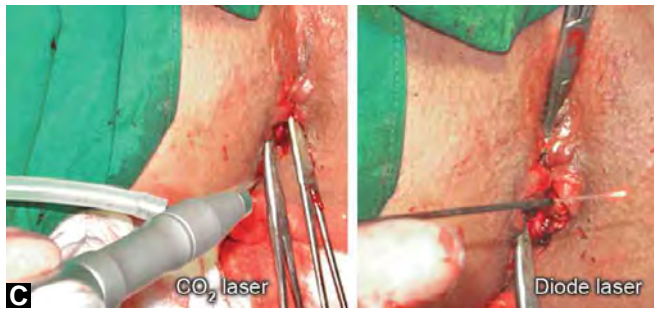
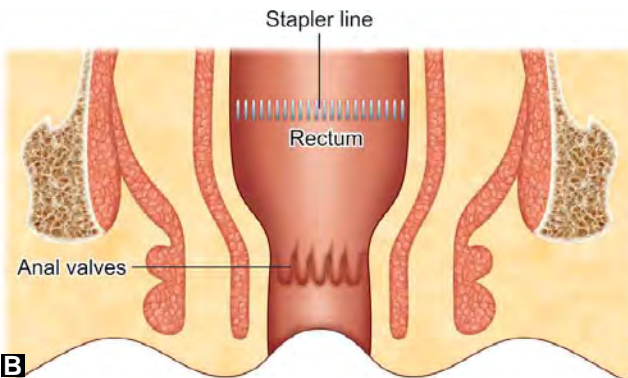
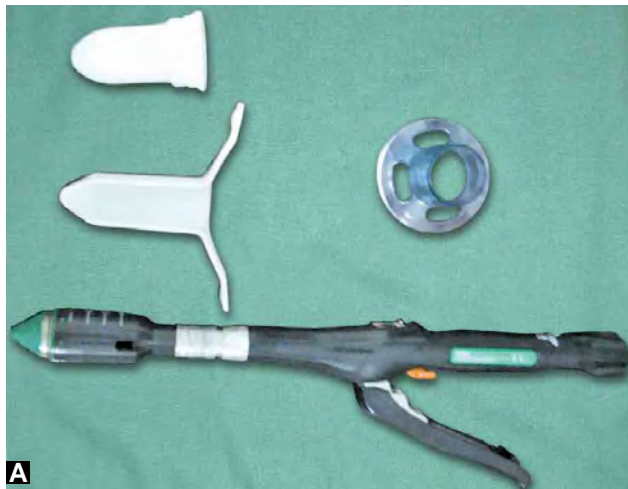

Fig. 25.52C

Figs 25.52A to C: Laser surgery for piles—CO<sub>2</sub> laser and diode laser.



Figs 25.53A and B: Stapler haemorrhoidopexy. It is minimally invasive procedure for haemorrhoids. It is high mucosal rim excision including vascular pedicles using circular (single use) staplers. It is done for prolapsed piles.

- ▶ This procedure avoids wound in the sensitive peri of anal skin thereby reducing the postoperative pain. Using stapling gun, a unique circular stapler which reduces the degree of prolapsed piles by excising a circumferential strip of mucosa from the proximal anal canal. The strip of mucosa and sub mucosa is excised circumferentially above the dentate line. The veins leading to the haemorrhoids are thus incorporated in this excision. Activation of the gun also simultaneously recovers the cut mucosa and sub mucosa by stapling the edges together.
- ▶ **Disadvantages**—need for experience in advanced surgical skill; costlier; may cause a full-thickness excision of the rectal

wall; may injure the anal sphincter. *Improper purse string* can cause incomplete doughnut leading to severe haemorrhage.

- ▶ **Contraindication:** Associated anorectal disease like fissure, fistula in ano.

#### Note:

- Doughnut should be *sent for histology* for muscular layer; proper doughnut should not contain muscular layer.

#### 10. Open operative methods: Still gold standard.

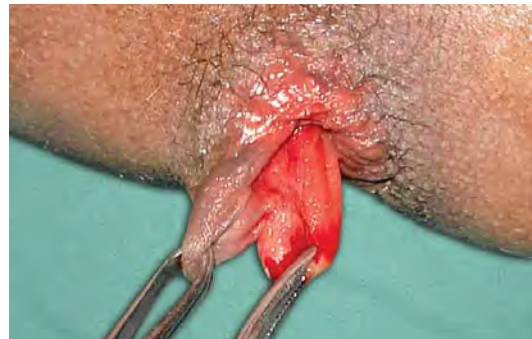#### Indications

- ❖ 3rd degree piles
- ❖ Failure of nonoperative methods
- ❖ Fibrosed piles

**Haemorrhoidectomy** is the best treatment for haemorrhoids. The haemorrhoidectomy is performed using an open or closed technique. The open technique is commonly used in UK and is known as *Milligan-Morgan operation*. The *closed technique (Hill Ferguson)* is more popular in USA. Both involve ligation and excision of the haemorrhoid, but in the open technique the anal mucosa and skin are left open to heal by second intention, and in the close technique the wound is sutured. Efficacy of surgery is 95% with 2–5% recurrence rate.

#### Methods are:

- ◆ **Ligation and excision of piles**—commonly done procedures (*Milligan-Morgan (Open method)*).
  - ▶ Under anaesthesia, in lithotomy position, initially the sphincter should be dilated to reduce the postoperative pain. Later skin is held with Allis forceps, internal pile is held with artery forceps. Skin is cut in “V” shaped manner and internal sphincter is separated and pushed up. Pedicle is transfixed with vicryl or catgut and distal part is excised. All the three piles can be dealt in a single sitting.
  - ▶ Postoperatively, *sitz bath*, antibiotics, laxatives, analgesics, local applications are given. Often few finger dilatation of the anal canal is required to prevent stenosis.
- ◆ **Submucosal haemorrhoidectomy of ‘Parks’**—approach is above the skin through submucosal plane.
- ◆ **Hill-Ferguson closed method:** Here patient in prone position, under GA/caudal anaesthesia, retraction is done using Hill-Ferguson retractor. Incision is made around pile mass, pedicle is dissected to its proximal base; it is ligated with transfixation using 2 zero vicryl or silk; mucosa and anal skin is sutured using 3 zero vicryl/dexon after proper haemostasis using cautery.



**Fig. 25.54:** During haemorrhoidectomy, skin part is held with Allis forceps; internal pedicle is held with artery forceps. A ‘V’ cut is placed over the outer skin up to mucocutaneous junction. Dissection is deepened to visualise the internal sphincter. Once pedicle is dissected, it is transfixed using vicryl suture material. Distal tissue is excised. Technique is repeated on other sites also.

*We do not see things as they are, we see them as we are.*

### Postoperative complications

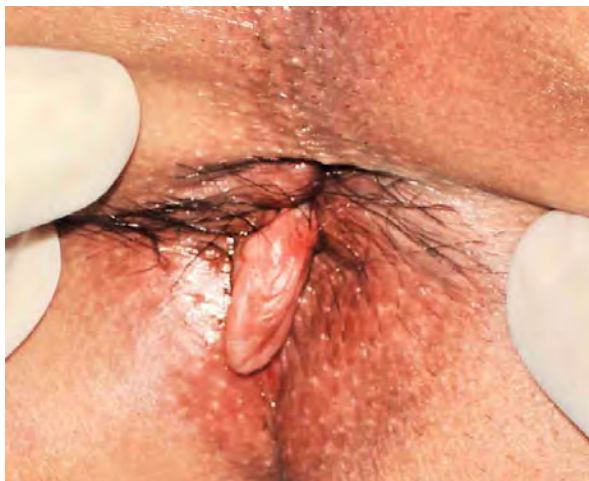- ❖ Pain—due to spasm, nerve irritation, muscle injury
- ❖ Retention of urine—commonest—50%
- ❖ Reactionary or secondary haemorrhage
- ❖ Anal stricture
- ❖ Anal fissure
- ❖ Recurrence
- ❖ Anal discharge for sometime
- ❖ Incontinence for faeces or gas
- ❖ Ectropion (Whitehead deformity)

11. **Management of strangulated/thrombosed/gangrenous piles:** Here initially conservative treatment is done using warm water sitz bath; antibiotics; elevation; bed rest; saline compression dressing; analgesics. This reduces the oedema and piles shrink. Later in 4–5 days haemorrhoidectomy is done. Doing haemorrhoidectomy immediately may precipitate portal pyaemia and also increases risk of developing anal stricture.

12. **Newer methods:** Using ultrasound or controlled electric energy (Harmonic scalpel or ligasure), haemorrhoidectomy can be done with less post-operative pain. But tissue charring may precipitate secondary haemorrhage.

### EXTERNAL PILES

- ❖ **Causes:** As a part of internal piles, Sentinel pile associated with anal fissure, Anal skin tags.
- ❖ **Treatment:** The cause is treated, Sitz bath, Excision.



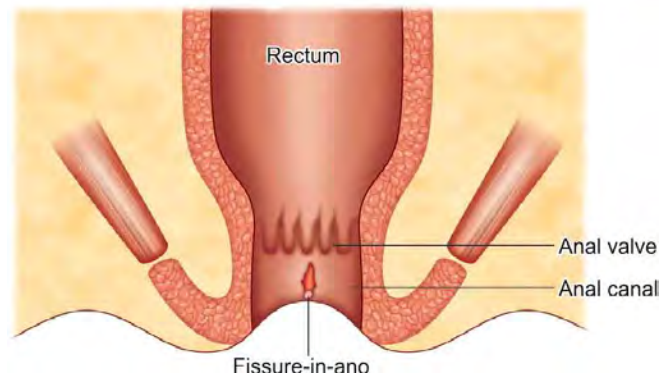
**Fig. 25.55:** Typical external pile. It causes haematoma, abscess, pain, itching.

- ❖ **Problems:** Pruritus ani, Perianal haematoma, Perianal abscess formation.

### ANAL FISSURE (FISSURE-IN-ANO)

- ❖ It is an ulcer in the longitudinal axis of the lower anal canal.
- ❖ Commonly it occurs in the *midline, posteriorly* (more common in males), but can also occur in the midline anteriorly (more common in females).

- ❖ Ninety five per cent of anal fissures in men are posterior; 5% are anterior. Eighty per cent of anal fissures in females are posterior; 20% are anterior. Anterior anal fissure is common in females.
- ❖ It is superficial, small but distressing lesion.
- ❖ Fissure ends above at the *dentate line*.



**Fig. 25.56:** Anatomy of anal canal with fissure-in-ano. It is commonly posterior.

### Internal Sphincter

- ❖ The internal sphincter is formed from a thickening of the smooth muscle of circular coat of upper end of anal canal. Circular muscle is the continuation of the inner coat of the rectum. This involuntary muscle commences where the rectum passes through the pelvic diaphragm and ends just within the anal orifice, where its lower border can be felt.
- ❖ The internal anal sphincter is 2.5 cm long and 2 to 4 mm thick. The internal sphincter is closed by a sheath of striped muscle.
- ❖ Spasm and contracture of this muscle play a major part in fissure and several other anal infections.

### External Sphincter

It can be divided into three parts—deep, superficial and subcutaneous portion. It is considered to be one muscle.

- ❖ Deep part encircles the upper end of anal canal and has no bony attachment.
- ❖ Superficial part is attached posteriorly to the coccyx, anteriorly inserted into the mid-perineal point in the male, in female it fuses with the sphincter vagina.
- ❖ Subcutaneous part encircles the lower end of the anal canal and has no bony attachment.

### Causes

- ❖ Because of the curvature of the sacrum and rectum, hard faecal matter while passing down causes a tear in the anal valve leading to posterior anal fissure.
- ❖ Anterior anal fissure is common in females due to lack of support to pelvic floor.
- ❖ Hard stool; diarrhoea; *increased sphincter tone; local ischaemia; trauma; sexually transmitted diseases.*
- ❖ *Other causes*—haemorrhoidectomy, Crohn's disease, venereal disease, ulcerative colitis, tuberculosis.

## Types

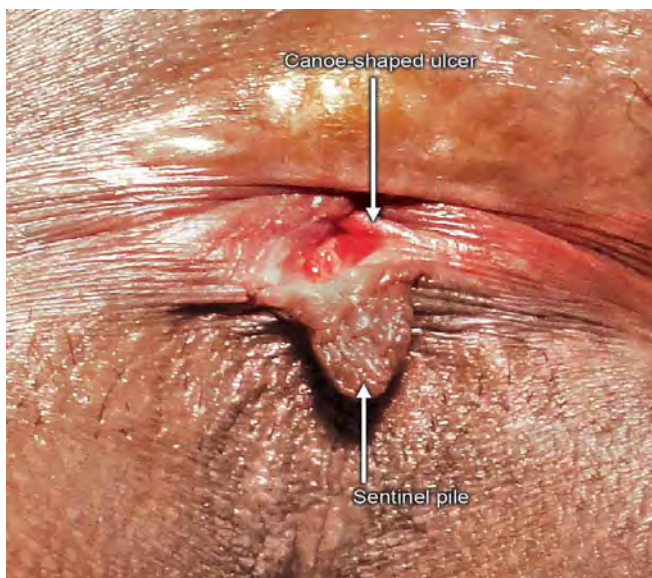- ◆ Anal fissure can be *acute or chronic*.

### Acute Anal Fissure

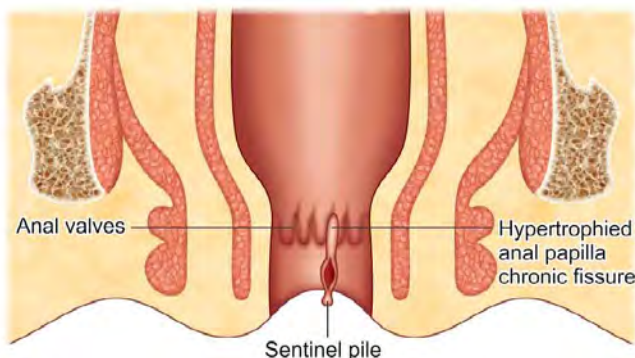
- ◆ It is a deep tear in the lower anal skin with severe sphincter spasm without oedema or inflammation.
- ◆ It presents with *severe pain and constipation*.

### Chronic Anal Fissure

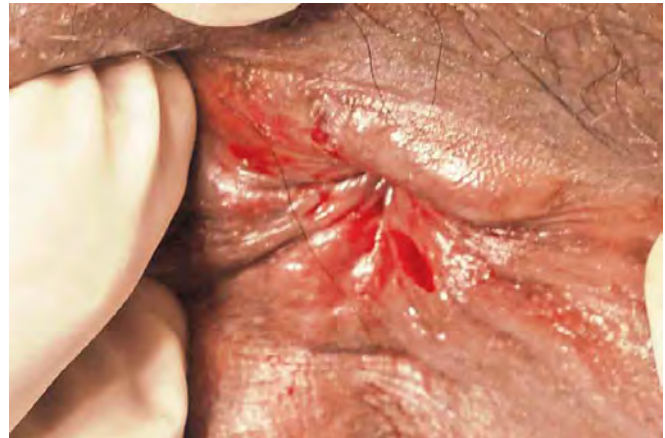- ◆ It has got inflamed, indurated margin with scar tissue.
- ◆ Ulcer at its inferior margin is having a skin tag which is oedematous, acts like a guard—*sentinel pile*.
- ◆ Proximally *hypertrophied anal papilla* is observed.
- ◆ It can cause repeated infection—fibrosis—abscess formation—fistula formation.
- ◆ Chronic fissure is less painful than acute one.
- ◆ Multiple fissures are seen in inflammatory bowel disease, homosexuals and venereal diseases.
- ◆ Chronic fissure can cause *complications* like—abscess, fistula formation.



**Fig. 25.57:** Chronic fissure-in-ano with ulcer and sentinel (pile) skin tag.



**Fig. 25.58:** Parts of chronic fissure-in-ano. Ulcer in the lower anal canal; sentinel pile below and hypertrophied papilla above.



**Fig. 25.59:** Lateral fissure-in-ano.

## Clinical Features

- ◆ Common in middle aged women, not in elderly.
- ◆ Pain is severe in nature in acute type, whereas less severe in chronic.
- ◆ Constipation, bleeding and discharge.
- ◆ P/R examination and proctoscopy is not possible in acute fissure-in-ano. General anaesthesia is required for examination.
- ◆ In chronic fissure, ulcer is felt with button like depression, induration and often sentinel pile.

## Differential Diagnosis

- ◆ Carcinoma anal canal.
- ◆ Inflammatory bowel disease.
- ◆ Venereal diseases.
- ◆ Anal chancre (painful).
- ◆ Tuberculous ulcer.
- ◆ Proctalgia fugax.

## Treatment

### In an acute case

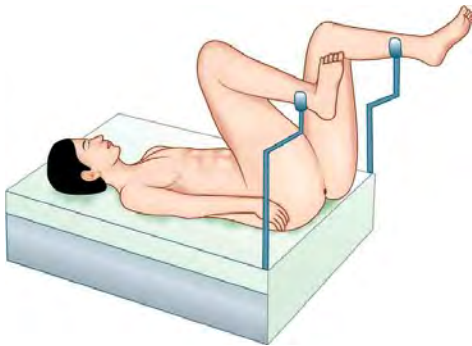
- ◆ *Stretching of the anal sphincter* (Recamier, 1829) using *two fingers of each hand (4 fingers)* under anaesthesia is also an alternative one. It is better than Lord's dilatation as complications are less.
- ◆ *Lord's dilatation* is done under G/A to relax the sphincter. It is the *manual dilatation* (Lord, 1969) of the anus under general anaesthesia with relaxation using *four fingers of each hand (8 fingers)* to cause vigorous stretching of the anal canal to break the circular constricting band in the wall of the anorectum.

### General measures for anal fissure

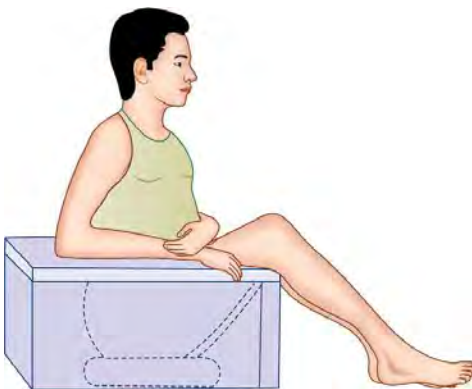- ❖ Adequate fluid intake (6–8 glasses of liquids)
  - ❖ Fiber rich diet (vegetables, fruits, brown rice)
  - ❖ Bulk forming agents (psyllium husk, bran)
  - ❖ Stool softeners (lactulose)
  - ❖ Local anaesthetic agents (lignocaine 5%)
  - ❖ Sitz bath
  - ❖ Avoid constipation
  - ❖ Once recovers, regular anal dilatation
- ◆ Later, use of laxatives, xylocaine surface anaesthetic application, and anal dilatation with finger can be carried out for certain period.
  - ◆ Bed rest; 2% nifedepine ointment.

**For chronic fissure**

- ◆ *Dorsal fissurectomy with sphincterotomy* is done under anaesthesia. Specimen should be sent for biopsy to rule out carcinoma, tuberculosis, etc. Here transverse fibres of internal sphincter is divided in the floor of the fissure.
- ◆ *Lateral anal sphincterotomy*
  - ▶ Here internal sphincter is divided partially away from the fissure either in right or left lateral positions (also gives a good result).
  - ▶ Here *closed or open methods* (Notaras) are used. Sphincterotomy is done below the dentate line. In *closed method* no 11 blade is inserted into the intersphincteric groove to pass upwards. Blade is moved medially to cut lower 1/3 or 1/2 of the internal sphincter. In *open method* skin is incised laterally, external to anal verge. Hypertrophied band of lower part of internal sphincter is dissected and divided. Wound is left open.
  - ▶ Haematoma, perianal abscess, bruising, fistula, incontinence are the complications of lateral sphincterotomy.
- ◆ Topical nitroglycerine 0.2% is also used to relax the sphincter. It causes severe headache.
- ◆ Botulinum toxin 25 units injected into the internal sphincter. It causes temporary denervation of the internal sphincter; reducing its tone, improving the blood supply and control of ischaemia. It causes temporary incontinence for flatus (10%).
- ◆ Diltiazem (2%), L arginine are the other agents used.
- ◆ Regular anal dilatation is also often important to prevent recurrence.
- ◆ *Anal advancement flap* is more effective especially in females.



**Fig. 25.60:** Lithotomy position used for all perineal surgeries like for fissure, piles, fistula, and APR.

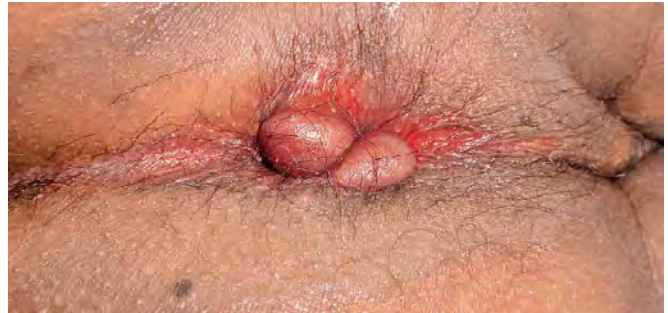

**Fig. 25.61:** Sitz bath is used after perineal surgeries like for piles, fissure, and fistula. Patient sits in warm water bath with perineum dipped in the water. Often small quantity of antiseptics or  $\text{KMnO}_4$  is added.

**SENTINEL PILE**

(‘sentinel’ means guard)

- ◆ It is commonly associated with *Fissure-in-ano* of chronic type wherein, in the lower part of fissure, skin enlarges and appears like guarding the fissure.

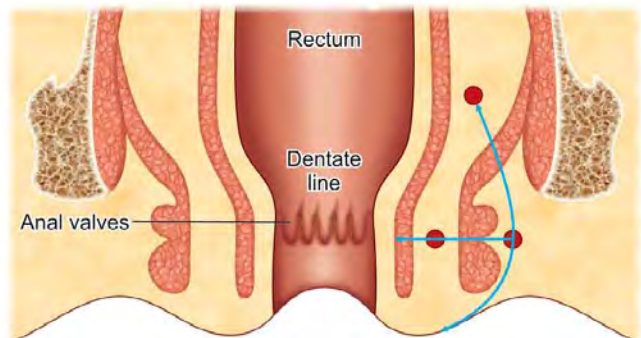


**Fig. 25.62:** Perianal haematoma—it should be drained to remove clot. Small haematoma may resolve on its own. Larger one if not drained will form an abscess.

- ◆ It can cause *perianal haematoma*, *abscess formation*, discomfort.
- ◆ The chronic fissure is treated along with excision of the sentinel pile.
- ◆ There may be low grade *infection* and *lymphatic oedema*. Haematoma/abscess can develop in it.

**ANORECTAL ABSCESS**

- ◆ Most common causative organism is *E. coli* (60%). Others are *Staphylococcus*, *Bacteroides*, *Streptococcus*, *B. proteus*. Commonly occurs due to infection of anal gland in perianal region. 95% of anorectal abscesses are due to infection of anal glands in relation to crypts—*cryptoglandular disease*.
- ◆ Common in diabetics and immunosuppressed.



**Fig. 25.63:** Anatomy of anorectal abscess.

**Other causes:**

- ▶ Injury to anorectum.
- ▶ Cutaneous infection (e.g. Boil).
- ▶ Blood born infections.
- ▶ Many anorectal abscesses are associated with anal fistulas.
- ▶ Fissure-in-ano.
- ▶ Perianal haematoma.
- ▶ Post-anorectal surgery.
- ▶ Crohn’s disease.
- ▶ Tuberculosis.

### Differential diagnosis of anorectal abscess

- ❖ Periurethral abscess
- ❖ Bartholin abscess
- ❖ Tuberculous abscess

### Investigations

- ◆ MRI is the *investigation of choice* for anorectal abscess.
- ◆ *Perineal and anal US* is also very useful.
- ◆ Investigations relevant to specific cause may be done.
- ◆ Proctosigmoidoscopy is needed to identify secondary cause in anorectum.

### Classification

- ❖ Perianal
- ❖ Ischiorectal
- ❖ Submucous
- ❖ Pelvirectal
- ❖ *Fissure abscess* (in relation to fissure-in-ano).

### Perianal Abscess (60%)

- ◆ This usually results due to suppuration of anal gland or suppuration of thrombosed external pile or any infected perianal condition.
- ◆ It lies in the region of subcutaneous portion of external sphincter.

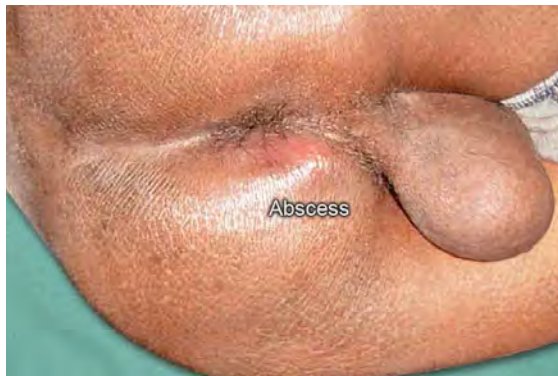

Fig. 25.64: Perianal abscess. Note the swelling and inflammation.

### Clinical Features

- ◆ Severe pain in perianal region with difficulty to sit.
- ◆ Tender, smooth, soft swelling in the region.

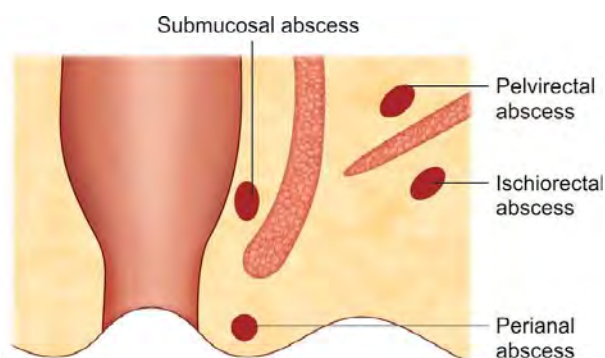


Fig. 25.65: Sites of anorectal abscess.

### Treatment

- ◆ Sitz bath, antibiotics, analgesics, local application of anaesthetic agents and laxatives.
- ◆ Drainage under G/A.

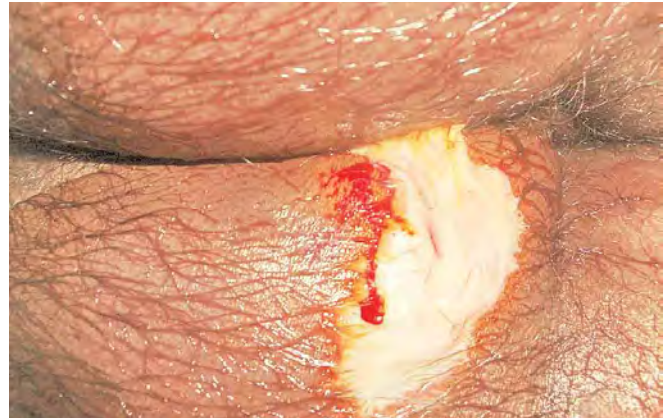

Fig. 25.66: Perianal abscess showing pus oozing out.

### Ischiorectal Abscess (30%)

#### Surgical Anatomy

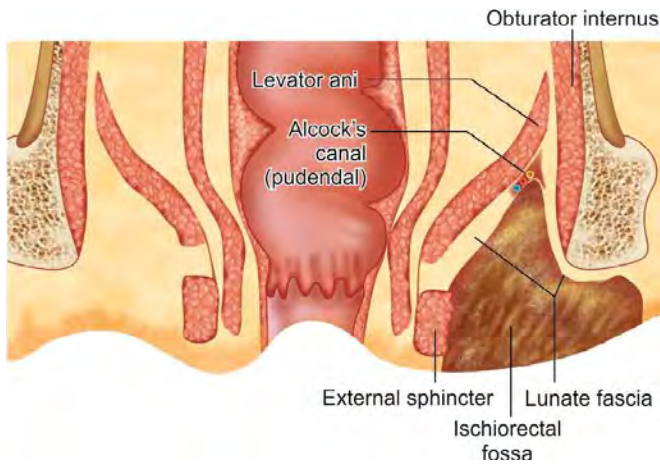
Ischioanal fossa (pyramidal shape 5 cm depth and 2 cm width) lies between anal skin and levator ani. Right and left communicates with each other. Laterally, it is related to fascia covering obturator internus; medially to levator ani and external sphincter; posteriorly sacrotuberous ligament and gluteus maximus; anteriorly urogenital diaphragm; below, the floor by skin. Above it is related to lunette fascia and pudendal neurovascular bundle in pudendal canal (Alcock's canal).

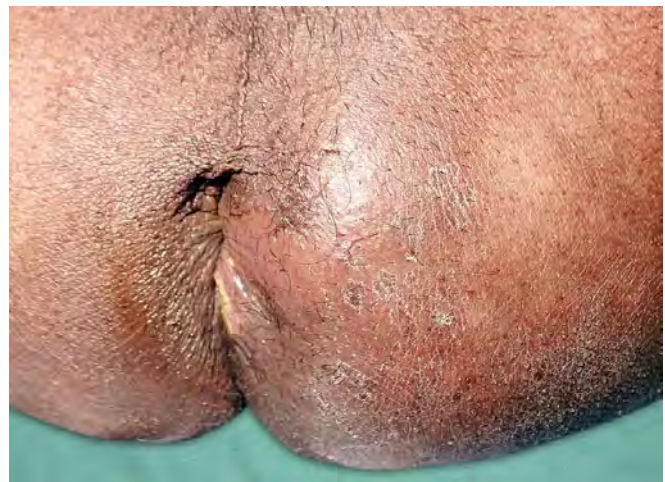

Fig. 25.67: Ischiorectal abscess—left side.

### Causes

- ◆ Commonly, it is due to extension of low intermuscular anal abscess, laterally through external sphincter.
- ◆ But often it can be blood or lymphatic born.
- ◆ Fat in the fossa is more prone for infection because it is least vascularised.



**Fig. 25.68:** Anatomy of ischioanal fossa. Note the boundaries and Alcock's canal.

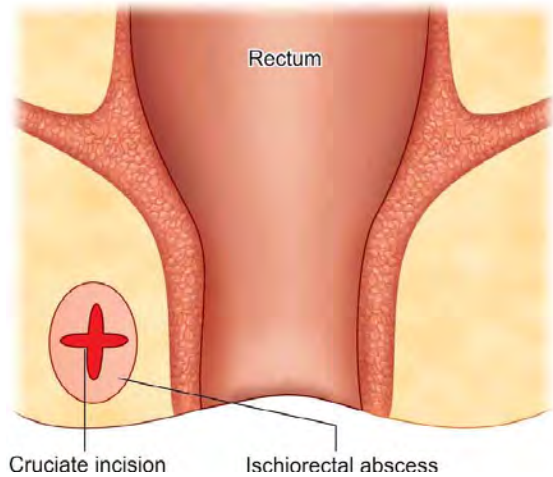
- ◆ Fossa communicates with that of opposite side through post-sphincteric space and so *horse-shoe like* abscess can occur.
- ◆ It presents with tender, indurated, brawny swelling in the skin over the ischioanal fossa with high fever.
- ◆ *Swelling is not well-localised and fluctuation is absent in ischioanal abscess.*

#### Treatment

Under G/A in lithotomy position, through a cruciate incision a portion of skin is excised (de roofing) and pus is drained. Pus is sent for C/S and presence of any internal opening to rectum should be looked for (for possibility of an existing fistula).

#### Submucous Abscess (5%)

- ◆ It occurs above the dentate line, which can be drained with sinus forceps, through a proctoscope.
- ◆ Aching pain in the anorectum with significant perineal discomfort.
- ◆ On digital examination (P/R), tender, soft, smooth swelling in the lower rectum and anal canal.
- ◆ It may be missed clinically as there is no obvious swelling externally.
- ◆ *Treatment* is proper antibiotics; incision and drainage under general anaesthesia.



**Fig. 25.69:** Cruciate incision is used for drainage of ischioanal abscess.

#### Pelvirectal Abscess

- ◆ It is situated between the upper surface of levator ani and pelvic peritoneum. It is almost like a pelvic abscess, occurs secondary to appendicitis, salpingitis, diverticulitis, Crohn's.
- ◆ US abdomen is done to rule out the above factors.
- ◆ Treated accordingly, after thorough investigations for diabetes, Crohn's and other conditions.

#### Problems with anorectal abscess

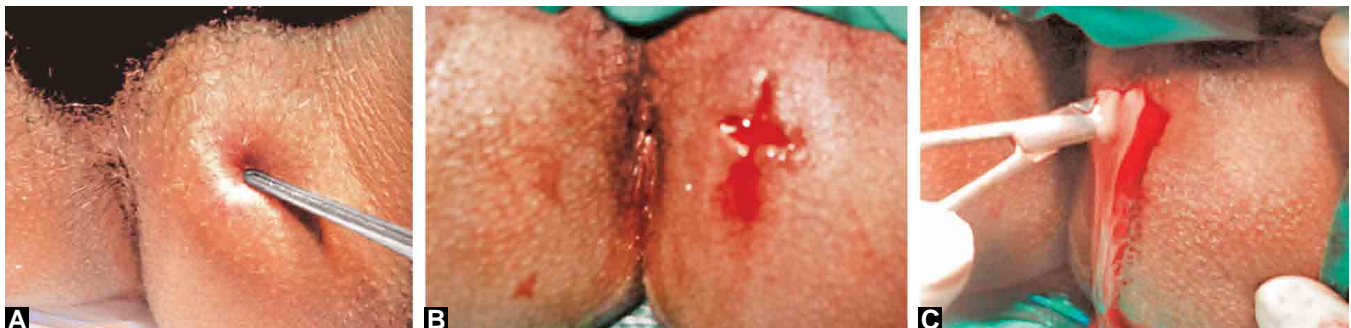- ❖ Recurrent abscess formation
- ❖ Fistula formation

#### FISTULA-IN-ANO

- ◆ It is a track lined by granulation tissue which connects perianal skin superficially to anal canal; anorectum or rectum deeply.
- ◆ It usually occurs in a pre-existing anorectal abscess which burst spontaneously.

#### Fistula-in-ano can be:

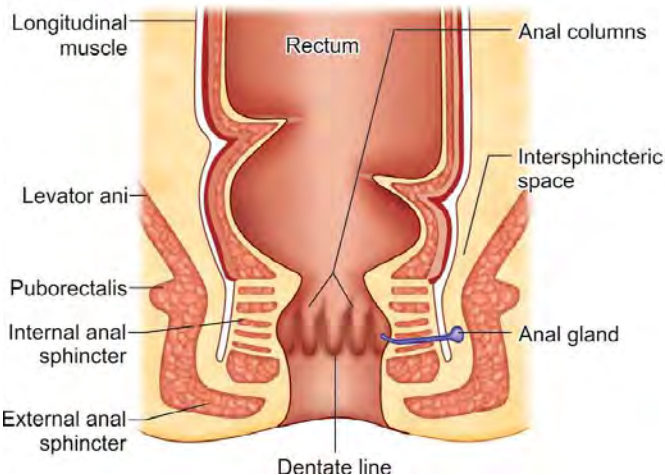
- ◆ Cryptoglandular—90%.
- ◆ Non-cryptoglandular (other causes)—10%.



**Figs 25.70A to C:** Ischioanal abscess drainage done under general anaesthesia. Note the cruciate incision placed and pus gushing out.

**Cryptoglandular Hypothesis**

- ◆ The intersphincteric space is the surgical plane between the internal and external sphincters and is found between the longitudinal muscle and external sphincter, where it exists as a sheet of fat containing loose areolar tissue. The fat-filled ischioanal fossa lies lateral to the sphincter complex and is traversed by a network of fibroelastic connective tissue. Proximal half of the anal canal is characterized by longitudinal mucosal folds, the anal columns of Morgagni. The distal aspect of each column is linked to its neighbour by a small semilunar fold (the anal valves), which in turn forms small pockets (the anal sinuses, or *crypts of Morgagni*). The distal undulating limit of these valves is the dentate (pectinate) line, which also marks the most distal aspect of the anal transitional zone, a histologic junction between anal squamous and rectal columnar epithelium. The dentate line lies 2 cm proximal to the anal verge and is important landmark in fistula-in-ano because the anal glands empty into the crypts that lie proximal to the valves. These glands secrete mucus to lubricate anus, and are the source of infection. These glands present in the subepithelium, internal sphincter, and two-thirds of these glands are located within the intersphincteric space. It is the infection of these intersphincteric glands that initiates the fistula in ano, known as the “*cryptoglandular hypothesis*”.
- ◆ These glandular infection leads into an intersphincteric abscess due to blockage of the draining duct by infected debris. This abscess may resolve by spontaneous drainage into the anal canal or may progress to an acute anorectal abscess. Treatment of this abscess is incision and drainage; but source of infection in the intersphincteric space persists, leading into development of a fistula in ano. Acute anorectal abscess and fistula in ano are believed to be acute and chronic manifestations, respectively of the same disease.
- ◆ While most fistulas start as a *simple single primary* tract, recurrent infection eventually causes formation of *extensions (secondary tracts)*. Extensions may be intersphincteric, ischioanal, or supralevator (pararectal). The ischioanal fossa is the commonest site for an extension. Extensions also occur in the horizontal plane known as “horseshoe” if there is ramification on each side of the internal opening.

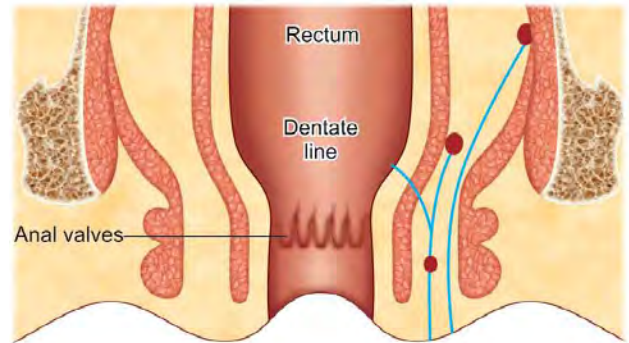


**Fig. 25.71:** Anatomy of anal glands (Cryptoglands of Morgagni).

**Other causes are (Non-cryptoglandular)**

- ❖ Tuberculosis
- ❖ Carcinoma
- ❖ Crohn’s disease
- ❖ Ulcerative colitis
- ❖ Lymphogranuloma venereum
- ❖ Hydradenitis suppurativa
- ❖ Traumatic

*Plenty of lymphoid aggregates* surround the anal glands, which explain the high incidence of anal fistula in *Crohn’s disease*.



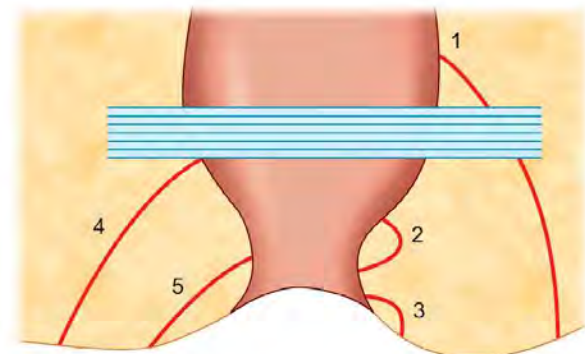
**Fig. 25.72:** Anatomy of fistula-in-ano.

**Classifications**

<b>Standard (Milligan Morgan, 1934; Goligher 1975)</b>	<b>Park’s classification (1976)</b>
<ul style="list-style-type: none"> <li>• Subcutaneous commonest</li> <li>• Low anal—common</li> <li>• Submucous</li> <li>• High anal</li> <li>• Pelvi rectal</li> </ul>	<ul style="list-style-type: none"> <li>• Intersphincteric—commonest 70%</li> <li>• Transphincteric 25%</li> <li>• Supralevator/suprasphincteric 4%</li> <li>• Extrasphincteric 1%</li> </ul>

**It can be:**

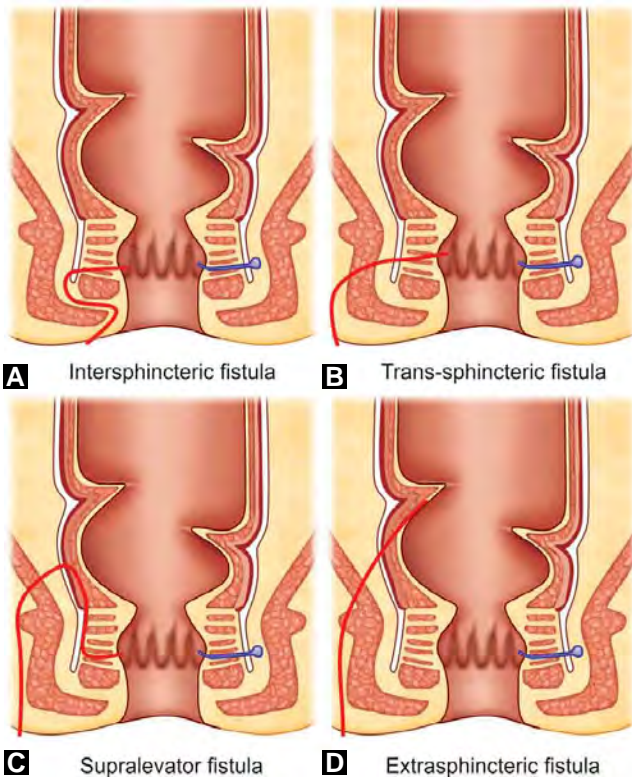
1. **Low level fistulas**—these open into the anal canal below the internal ring.
2. **High level fistulas**—these open into the anal canal at or above the internal ring.



1. Pelvi-rectal fistula
2. Submucosal fistula
3. Subcutaneous fistula
4. High-anal fistula
5. Low-anal fistula

**Fig. 25.73:** Classification of fistula-in-ano (*Standard classification*).





**Figs 25.74A to D:** Park's classification of fistula-in-ano—(A) Intersphincteric fistula; (B) Transsphincteric fistula; (C) Supralelevator fistula; (D) Extrasphincteric fistula.

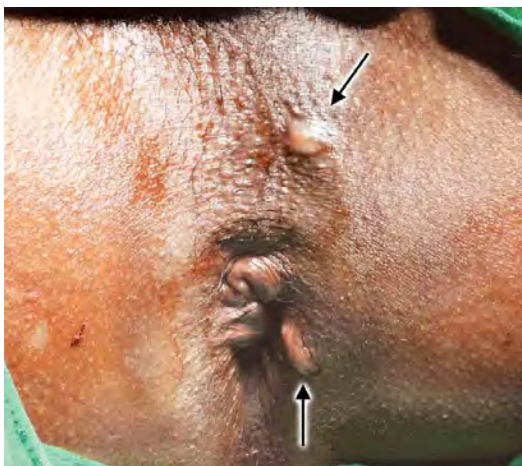**It can be:**

- ◆ Simple fistula without extensions.
- ◆ Complex fistula with extensions.

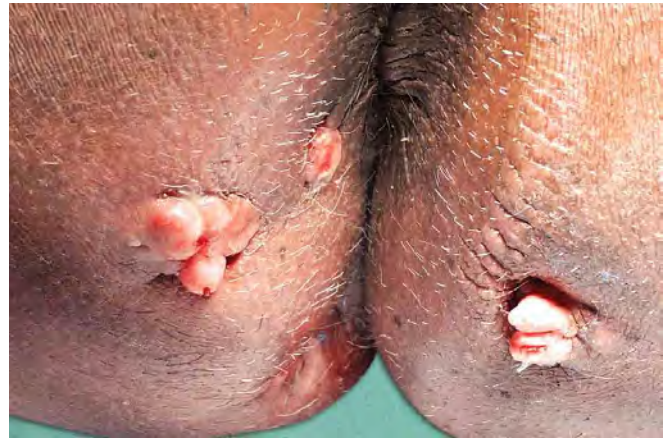**It can be with:**

- ◆ Single external opening.
- ◆ Multiple external openings which are often seen in tuberculosis, ulcerative colitis, Crohn's disease, LGV, hidradenitis suppurativa, actinomycosis.

The term *complex fistula* means—the track crosses >50% of the external sphincter, anterior in females, multiple tracks, recurrent, or the patient has preexisting incontinence, local irradiation, or Crohn's disease.



**Fig. 25.75:** Fistula in ano both anterior and posterior (Multiple).

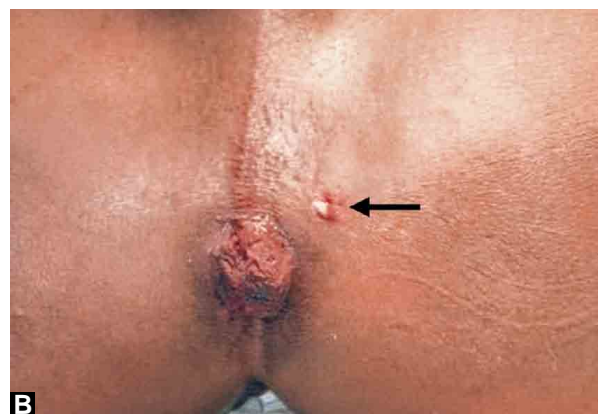
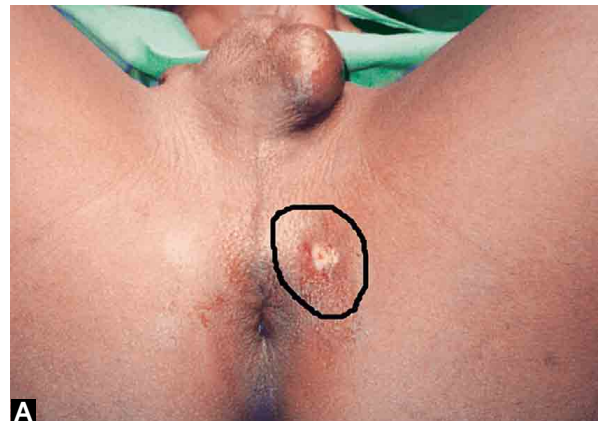

**Fig. 25.76:** Complex fistula in ano both sides of long duration.

**LOW-LEVEL FISTULAS**

**Clinical Features**

- ◆ It has a prevalence of 0.01% and is common in young adult males (2:1, male to female).
- ◆ It presents with seropurulent discharge (65%), along with skin irritation and one or more external opening may be present with induration of the surrounding skin.



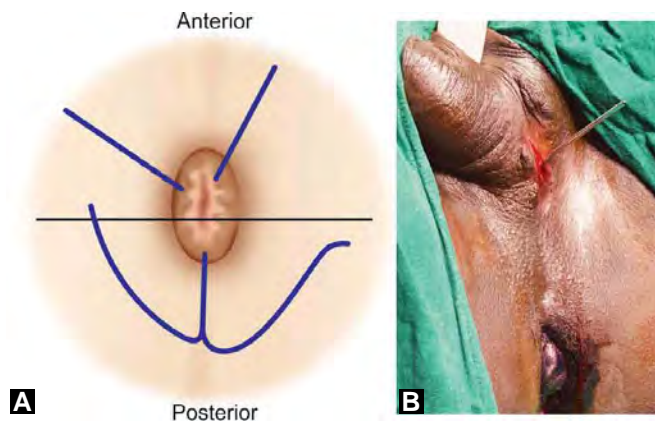
**Figs 25.77A and B:** Fistula-in-ano (*simple type*)—typical look and site.

- ◆ Often it may heal superficially but pus may collect beneath forming an abscess which again discharges through same or new opening.

- ◆ Ischiorectal fossa on each side, most often communicates with each other behind the anus causing *horseshoe* fistula.

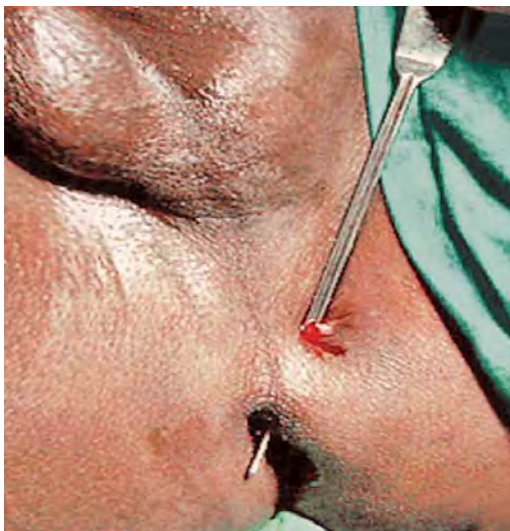#### Goodsall's (1900) Rule

- ❖ Fistulas with an external opening in relation to the anterior half of the anus is of direct type.
- ❖ Fistulas with external openings in relation to posterior half of the anus, has a curved track may be of horse-shoe type, opens in the midline posteriorly and may present with multiple external opening all connected to a single internal opening.



**Fig. 25.78A and B:** (A) Goodsall's rule. Anterior fistulas are having straight track. Posterior fistulas are having curved track with internal opening in the posterior midline; (B) Complex fistula-in-ano.

- ◆ P/R examination shows indurated internal opening usually in the midline posteriorly.
- ◆ Most of the fistulas are on posterior half of anus.
- ◆ Probing in the ward and fistulogram in the ward before surgery using Lipiodol is not advisable as it may cause recrudescence of inflammation. It can be done with adequate precaution. Probing is done under *general anaesthesia* gently with care without creating extensions.

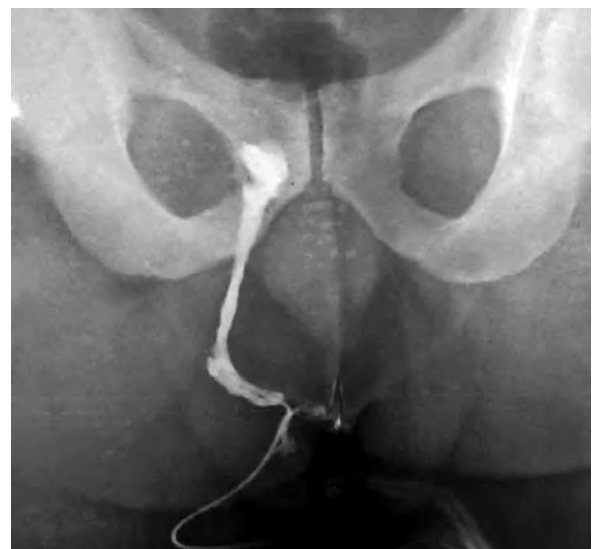

**Fig. 25.79:** Anterior fistula-in-ano with probe in place. Anterior low fistula has got straight track. Both internal and external openings are seen.

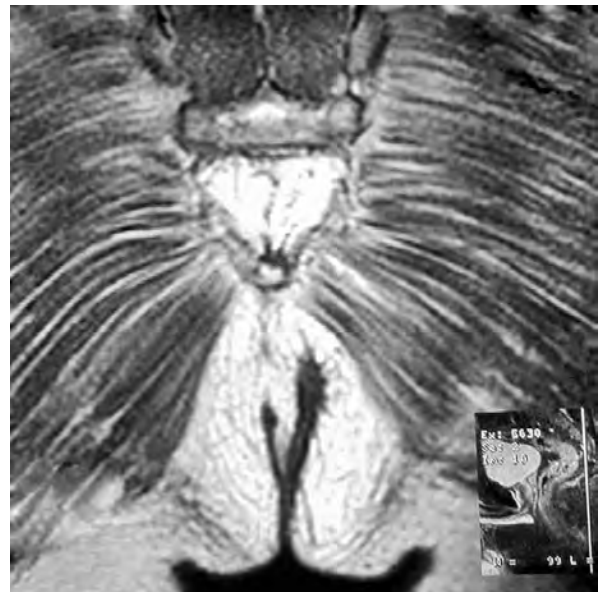*Tuberculous fistulas do not have induration*, will have pale granulation tissue with watery discharge and they are most often multiple. Here, the infection occurs in lymphoid tissue over the lower part of anal canal, around anal gland opening.

#### Investigations

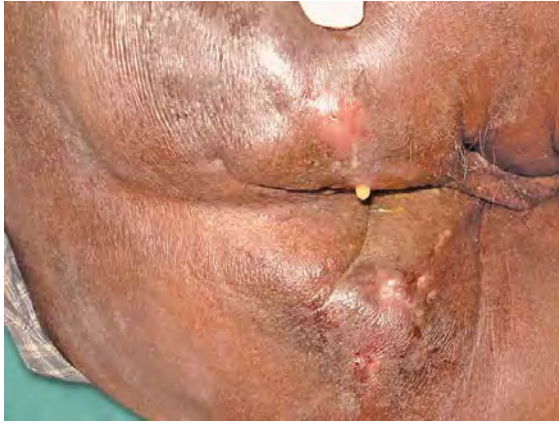- ◆ Chest X-ray, ESR and barium enema X-ray.
- ◆ *If required fistulogram is done only under anaesthesia.*
- ◆ **MRI/MRI fistulogram** ideal.
- ◆ Endorectal ultrasound (US perineum) is useful to assess deeper plane.
- ◆ Discharge study, methylene blue dye study, biopsy.
- ◆ Colonoscopy often when ulcerative colitis/Crohn's is suspected.
- ◆ Specific blood test.



**Fig. 25.80:** Fistulogram X-ray showing track.



**Fig. 25.81:** MR fistulogram.



**Fig. 25.82:** Multiple fistulas-in-ano. It may be Crohn's disease; carcinoma or HIV. Biopsy should be done prior to formal therapy. MRI of perineum is of great help in such patients to anatomically evaluate the fistula-in-ano.

#### Differential diagnosis for fistula-in-ano

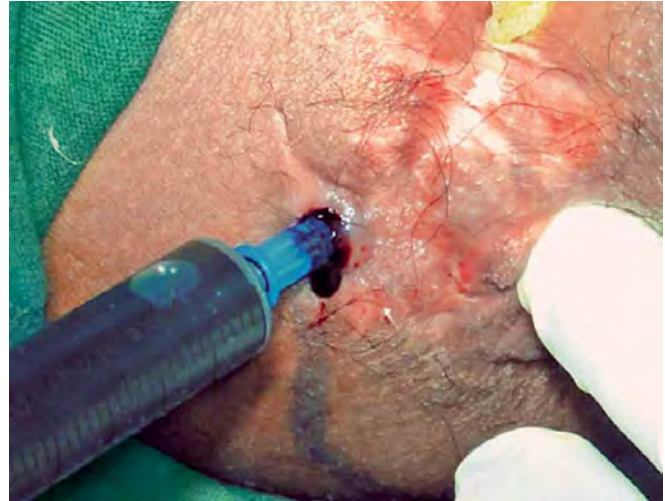
- ❖ Urethral fistula in male
- ❖ Chronically infected Bartholin's gland
- ❖ Pilonidal sinus
- ❖ Hidradenitis suppurativa
- ❖ Carcinoma
- ❖ Crohn's tuberculosis, ulcerative colitis

### Treatment

#### ◆ *Fistulectomy*

- ▶ Under G/A or spinal anaesthesia, probe is passed through external opening up to the internal opening which is felt as an induration. Fistula is opened along the probe using a knife. Fibrous track along with unhealthy granulation tissue and additional external openings are excised. Specimen is always sent for histopathology.

Principles in management	Procedures
<ul style="list-style-type: none"> <li>• Identify the cause—cryptoglandular or other</li> <li>• Delineate exactly the fistula anatomy — MRI/EUS</li> <li>• Identify relation of fistula to anal sphincter</li> <li>• Drain all sites of infection</li> <li>• Eradicate <b>track</b> and secondary <b>extensions</b></li> <li>• Preserve anal continence function</li> </ul> <p>The <i>primary objectives</i> are to eradicate the tract and drain all associated sites of infection while simultaneously preserving anal continence</p>	<ul style="list-style-type: none"> <li>• Laying open the fistula—fistulotomy with curetting</li> <li>• Fistulectomy</li> <li>• Gluing of fistula—not much useful</li> <li>• Mucosal flap procedure</li> <li>• Fistulectomy with primary repair</li> <li>• Fistulectomy with primary repair with episioectomy</li> <li>• Fistulectomy with secondary repair</li> <li>• Anal fistula plug repair (AFP)</li> <li>• LIFT Technique (Ligation of intersphincteric fistula track)</li> <li>• Seton technique (Latin—seta—a bristle)</li> <li>• Colostomy—lay open, fistulectomy, later closure of colostomy—for high type</li> <li>• VAAFT procedure (Video assisted anal fistula track ligation)</li> </ul>



**Fig. 25.83:** Methylene blue injection to delineate track on table in fistula-in-ano.

- ▶ Postoperatively—sitz bath, antibiotics, analgesics, laxatives are given.
- ▶ *Fistulectomy for low level fistulas do not cause rectal incontinence.*
- ▶ Proper curetting of the infected anal gland area is essential.

#### ◆ *Fistulotomy*

It is done in low anal fistula. It is technically easier. After passing the probe through the entire fistulous track, incision is made over the probe to cut and lay open the fistulous track. It is allowed to granulate and heal from the floor/surface. Technique is safer, easier and can be done on outpatient basis.

- ◆ *Advancement flaps* are used occasionally to get better result—mucosal flap procedure.
- ◆ *Gluing of the fistula track* is tried but success rate is not good. Fibrin glue is a multicomponent system containing mainly human plasma fibrinogen and thrombin. Once prepared it is injected into the fistula track which hardens in few minutes and fills the entire track. Success rate is 70%.
- ◆ *Anal fistula plug (AFP) repair:* Surgisis anal fistula plug (*porcine small intestine submucosa, SIS*) is used with 85% success rate in simple fistula. It contains naturally derived extracellular matrix which acts as scaffolding, ingrowth of tissue, remodeling.
- ◆ *LIFT technique* (Ligation of intersphincteric fistula track): Under anaesthesia in lithotomy position, intersphincteric space is reached through a transverse incision. Fistula running across is identified and ligated using vicryl on either side. Part is excised; outer part is curetting through external opening.
- ◆ *VAAFT procedure* (Video assisted anal fistula track ligation): Fine specialized endoscope is passed through the outer opening into the fistula track; with continuous irrigation fistula track is cleaned and wall is cauterized. Inner opening is ligated through vicryl from luminal side.
- ◆ *Fistula clip closure*—closure of the internal fistula opening with a superelastic clip made of nitinol (over-the-scope clip - OTSC) – by German surgeon Ruediger Probst.

### HIGH-LEVEL FISTULAS

- ◆ Its upper opening is at or above the anorectal ring. It is difficult to treat.

**Common causes are:**

- ❖ Crohn's disease
- ❖ Ulcerative colitis
- ❖ Trauma
- ❖ Carcinomas
- ❖ Foreign body

- ◆ Incontinence may follow after lay opening of these fistulas.

**Investigations**

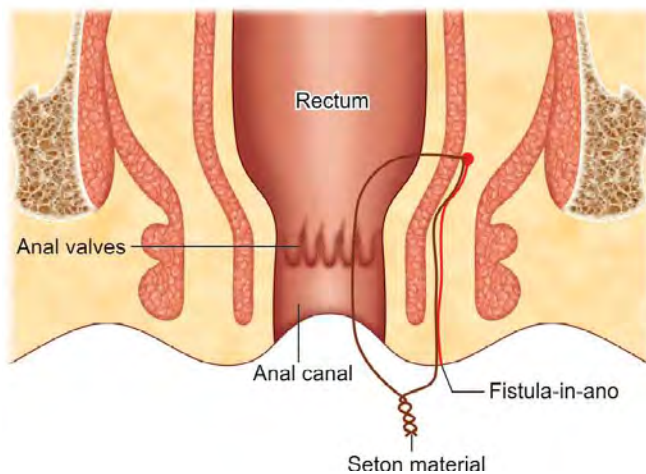
- ◆ Barium enema X-ray, colonoscopy, chest X-ray, biopsy.

**Treatment**

- ◆ Requires staged procedure—*initial colostomy* is done followed by definitive procedure. This prevents sepsis and promotes faster healing.
- ◆ Later closure of colostomy is done.

**Seton Technique**

- ◆ A *silk or linen ligature* is passed across the fistula and left in place with a tie.
- ◆ *Striated muscle* superficial to fistula track is encircled with Seton material and tied securely and left *in situ* to create ischaemic necrosis, dividing the muscle slowly without allowing it to spring apart avoiding gutter deformity. Even though internal sphincter is divided in this, causing adequate laying open of entire fistula track, it will well-preserve the sphincter function and pressure.
- ◆ This allows the fistula to granulate and heal from above and to close completely. Usually takes longer duration to heal.
- ◆ It is done for intermediate and intersphincteric fistula. It is used prior to definitive procedures like fistulectomy or advancement flap. *It is staged fistulotomy.*



**Fig. 25.84:** Seton technique for intersphincteric fistula-in-ano. It is kept for 3 months. It can be tight or loose seton depending on the indications. It promotes formation of granulation tissue, healing by fibrosis and track recedes downwards.

- ◆ Seton can be kept for 3 months. It can be regularly replaced by new silk or any material by rail road technique without anaesthesia.
- ◆ *Two types of setons are present.*

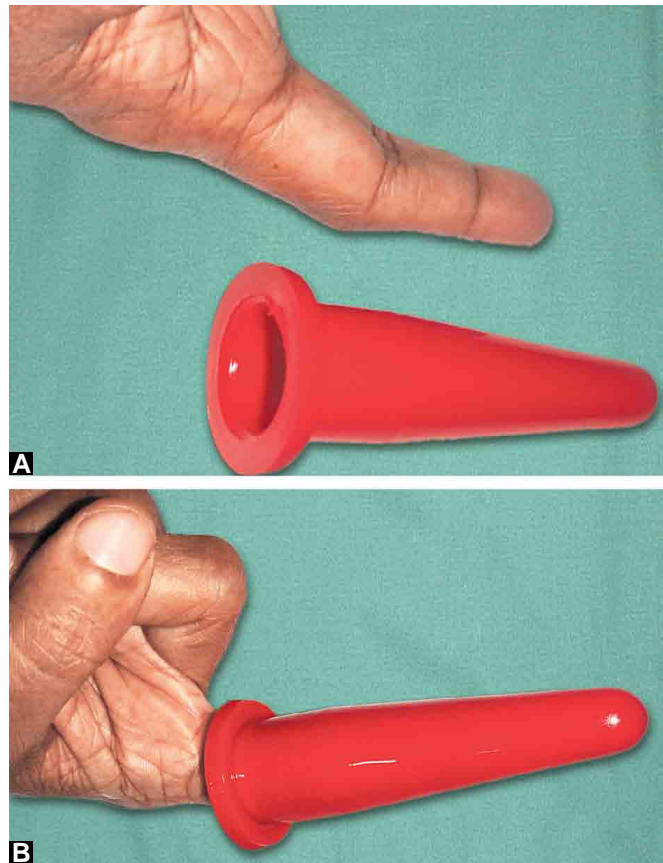
- ▶ Loose setons are used mainly to drain for long period in recurrent/postoperative fistulas and due to specific causes like Crohn's. There is no tension in seton.
- ▶ Cutting setons are used when enclosed muscle is needed to cut (cheese wiring through ice effect). It is placed tight.

**ANORECTAL STRICTURES****Causes**

- |                                                           |                      |
|-----------------------------------------------------------|----------------------|
| ❖ Congenital                                              | ❖ LGV (in females)   |
| ❖ Fibrotic anal fissure                                   | ❖ Ulcerative colitis |
| ❖ Irradiation                                             | ❖ Crohn's disease    |
| ❖ Senility                                                | ❖ Carcinomas         |
| ❖ Postoperative (surgery for piles, coloanal anastomosis) |                      |

**Features**

- ◆ Progressive constipation.
- ◆ On P/R examination, stricture can be felt as a tight ring.
- ◆ Features relevant of specific cause.



**Figs 25.85A and B:** Anal dilator. Many proctology surgeries require regular anal dilatation postoperatively. Note how to hold the dilator to pass into the anus after applying lubricant.

- ◆ *Investigations:* Barium enema X-ray, biopsy, colonoscopy.

**Treatment**

- ◆ The cause is treated.
- ◆ Dilatation of the anal canal under general anaesthesia.
- ◆ Resection in severe recurrent cases.

*Two types of mankind are there; Hosts and Guests; on either way you are in trouble.*

- ◆ *Anal reconstruction*—anoplasty is technically demanding with preservation of continence along with prevention of restenosis is important.

### CONDYLOMA ACUMINATA

- ◆ It is most common sexually transmitted anal disease. It is common in homosexual men.
- ◆ Penile warts or female genital warts may be present.
- ◆ It is caused by Human Papilloma Virus (HPV).
- ◆ Pruritus, discharge, pain and bleeding are the features.
- ◆ Large wart may block the anal canal orifice.
- ◆ Whitening occurs on applying acetic acid on it.
- ◆ Biopsy confirms the diagnosis.
- ◆ Treatment is local application of 25% podophyllin cream; surgical excision of the wart; intralesional injection of interferon  $\alpha$  2b.
- ◆ Malignancy should be ruled out by histology.

#### Note:

- *Buschke – Lowenstein disease* (1925, giant condyloma acuminata) is a slow-growing, locally destructive verrucous plaque but seldom metastasizes that typically appears on the penis but may occur elsewhere in the anogenital region. It is commonly considered to be a regional variant of verrucous carcinoma.
- It is common in the penis but can also occur in anal region, vagina and scrotum. It is common in males. HPV 6, 11 and HIV infections may commonly coexist.
- Biopsy and MRI confirms the diagnosis. Giant condyloma acuminatum is differentiated histologically from ordinary condyloma acuminata by its thicker stratum corneum and the presence of an endophytic downgrowth, along with a tendency to invade deeper.
- Treatment—surgical wide excision, topical podophyllin, 5 FU, interferon, cidofevir gel, bleomycin are different treatment modalities. HPV vaccine (Gardasil) may prevent the disease.
- A combination of radiofrequency surgical dissection and oral acitretin is used in perianal Buschke-Lowenstein tumor with good success. The use of acitretin may eliminate the residual disease that was not removed by surgery.

### ANAL INTRAEPITHELIAL NEOPLASIA (AIN)

- ◆ It is dysplasia of anal or perianal epidermis.
- ◆ It is seen in individuals with HIV infection; HPV infection (16, 18); individual who do anorectal intercourse.

#### Classification:

AIN I—absence of keratocyte maturation and cellular atypia observed in outer 1/3rd of epithelium—low grade.

AIN II—cellular atypia observed in middle 1/3rd—low grade squamous intraepithelial neoplasia.

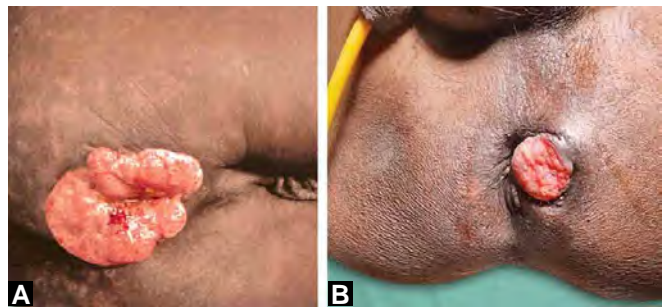AIN III—cellular atypia full thickness—high grade squamous intraepithelial neoplasia.

- ◆ Thirty per cent of anal warts will show AIN.
- ◆ It is raised scaly white/pigmented/cracked lesion.
- ◆ Biopsy confirms the disease.
- ◆ Treatment: Excision; topical imiquimod, 80% trichloroacetic acid and oral retinoids.

### MALIGNANT TUMOURS OF ANAL AREA

- ◆ *Anal malignant tumours* are < 2% of large bowel tumours. It can be below the dentate line (SCC, 80% of anal tumours); above the dentate line (Basaloid/transitional/cloacogenic).

- ◆ Causes may be HPV infection; HIV infection; AIN (Anal intraepithelial neoplasia); organ transplant recipients; immunosuppression.
- ◆ *Anal canal tumours* arise from the anorectal ring proximally to the anal verge distally, and include the anal transition zone and the non-hair or gland-bearing squamous tissue comprising the anoderm. *The anal margin* is defined as the hair and gland-bearing skin lateral and up to 5 cm away from the anal verge. This distinction between anal canal and anal margin malignancies is important as anal canal lesions are more aggressive and are treated differently. The incidence of anal canal lesions is significantly higher (5 times) than that of anal margin lesions.
- ◆ *Epidermoid carcinoma* is the most common type of anal canal malignancy—85% of all lesions. This includes squamous cell carcinoma and its variants—cloacogenic, basaloid, and transitional carcinomas.
- ◆ Twenty to twenty five per cent cases metastases occur to inguinal lymph node.
- ◆ Anal canal tumours are common in *females*.



**Fig. 25.86A and B:** (A) Anal canal carcinoma. Squamous cell carcinoma is commonest type—80%; (B) Carcinoma anal region—looks like anal margin tumour;

#### Classification of tumours of anal area

##### It can be:

- ❖ Benign
- ❖ Malignant

##### It also can be:

- ❖ Tumour of the anal canal (proximal to dentate line)—SCC, adenocarcinoma, melanoma
- ❖ Anal margin tumour (distal to dentate line)—ANI, Bowen's disease, Paget's disease, BCC, anal margin SCC

### Types

1. *Squamous cell carcinoma* is the commonest type. Predisposing causes: Papilloma, irradiation, dermatitis, long standing fistula-in-ano.
2. Basaloid carcinoma—it is rare, non-keratinising squamous cell carcinoma. Highly malignant.
3. Muco-epidermoid carcinoma—arises near squamo-columnar junction.
4. Basal cell carcinoma.
5. Melanoma—blue/black in colour mistaken for thrombosed pile—poor prognosis (5 years—10%).
6. Adenocarcinoma from the anal glands in a pre-existing fistula-in-ano.

Features	Investigations
• Ulceration	• Biopsy from anal region
• Bleeding	• FNAC of inguinal node
• Pain, pruritus and discharge	• US abdomen
• Irregular indurated mass	• MRI perineum is very useful
• Anovaginal fistula in females	• <i>P/R is a must to assess upper extent of the growth</i>
• Faecal incontinence in late cases	<i>AJCC staging</i> Tis—carcinoma <i>in situ</i>
• Inguinal node—hard, non-tender	T1—tumour <2 cm T2—tumour 2-5 cm
• Iliac nodes	T3—tumour >5 cm T4—invasion into adjacent organs like vagina/urethra
• Later—late constipation—obstruction	N1—perirectal nodes + N2—unilateral internal iliac/inguinal nodes N3—perirectal + inguinal/iliac or bilateral nodes M 0—no distant spread M1—distant spread present

- ◆ **Squamous cell carcinoma of anal canal**, usually present as a fungating or ulcerative growth, which spreads to inguinal lymph nodes.
  - ▶ Biopsy and FNAC of lymph nodes are the essential investigations.
  - ▶ **Treatment:** Wide excision of the lesion with 3 to 5 cm clearance and ilioinguinal block dissection for lymph nodes are done. Follow-up radiotherapy is also often given.
  - ▶ Nigro regime

## Nigro Regime

### Nigro Regime for Anal Carcinoma (Norman Nigro, et al. 1974)

- ❖ Initial radiotherapy for 3 weeks 3000 rads (30 Gy total) to perineum and pelvis
- ❖ Then chemotherapy—5 FU, for 4–5 days; is a radiosensitizer, started on 1st day of RT as 1000 mg/m<sup>2</sup> continuous infusion. Mitomycin C is 15 mg/m<sup>2</sup> as single dose on 1st day of RT
- ❖ Later after 3 weeks abdominoperineal resection (APR)
  - ▶ **Chemoradiation** is becoming popular for carcinoma of anal canal.
  - ▶ Drugs used for chemotherapy are 5 FU, bleomycin, vincristine, adriamycin.
  - ▶ If persistent or recurring disease presents following combined modality therapy (CMT—*chemoradiotherapy*), APR with colostomy is indicated.
  - ▶ Neoadjuvant chemotherapy using 5 FU, cisplatin and mitomycin C is also commonly used.
  - ▶ In advanced growths radiotherapy is the only treatment.

- ◆ **All other tumours:** *Abdominoperineal resection with permanent colostomy is done.*

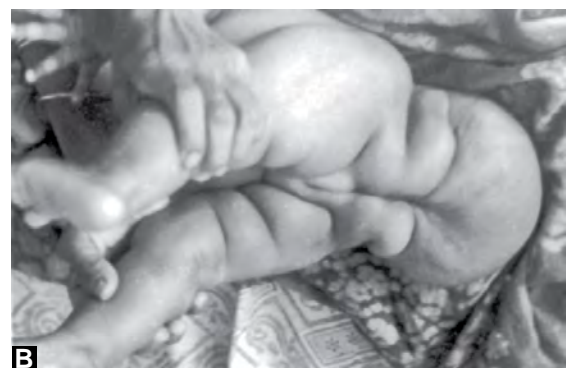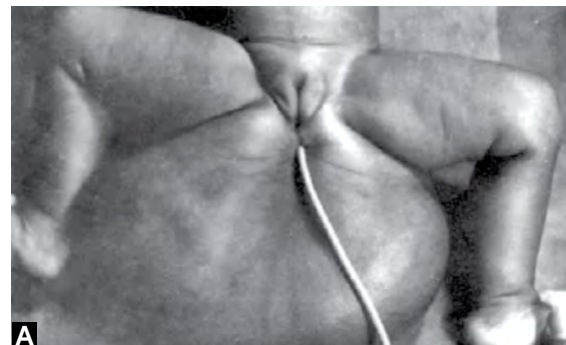
### Paget's

- ❖ Paget's disease of breast
- ❖ Paget's disease of anal margin—of apocrine glands
- ❖ Paget's disease of penis
- ❖ Paget's test
- ❖ Paget's disease of bone

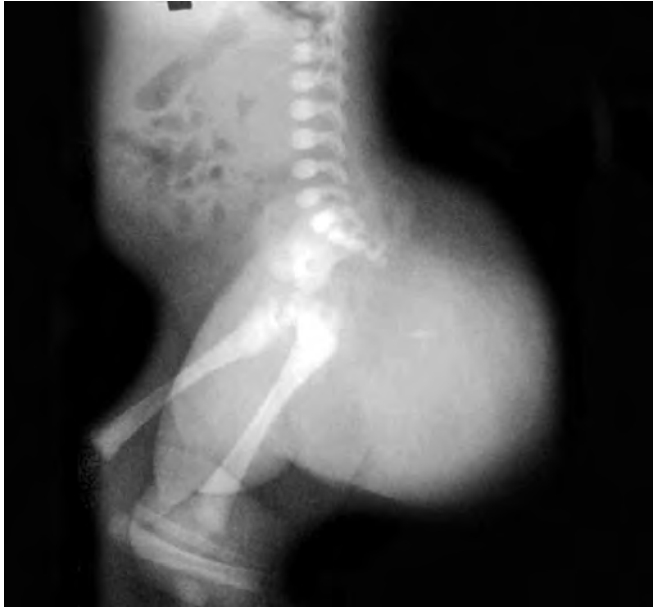## SACROCOCCYGEAL TERATOMA

- ◆ It is an uncommon tumour, but most common of the large tumours in first 3 months of life.
- ◆ More common in females.
- ◆ Retention of large amount of primitive toti-potential cell in this region may be the reason for this tumour.
- ◆ It occurs between coccyx and rectum
- ◆ It is attached to coccyx, extends commonly downwards as a huge mass, occasionally upwards into the pelvis.
- ◆ It is a congenital condition arising from totipotent cells.
- ◆ X-ray and CT scan are must.
- ◆ **Treatment:** Excision soon after birth.

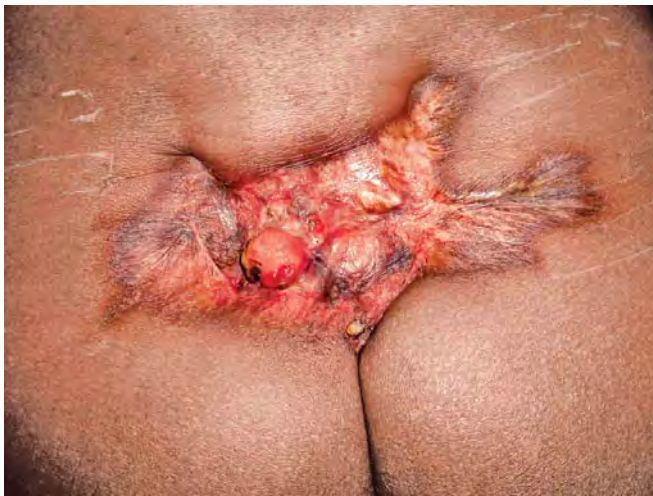Complications	Differential diagnosis
Ulceration	Sacral meningocele
Infection	Sacral chordoma
Urinary obstruction	Postanal dermoid
Malignant changes	



**Figs 25.87A and B:** Sacrococcygeal teratoma, typical site (Courtesy: Professor Suresh Kamath, MS, Mangaluru).



**Fig. 25.88:** X-ray of a patient with sacrococcygeal tumour (Courtesy: Professor Suresh Kamath, MS, Mangaluru).



**Fig. 25.89:** Recurrent chordoma of sacrum.

## ANAL INCONTINENCE

Continence of anal canal is maintained by two factors:

- ◆ Normal rectal and colonic pressure and activity.
- ◆ Normal pelvic floor function.

### Types

- ◆ *Urge incontinence*—here rectal and colonic pressure and activity is increased but normal pelvic floor.
- ◆ *True incontinence*—here rectal and colonic pressure and activity is normal but defective pelvic floor function.
- ◆ *Full incontinence*—here rectal and colonic pressure and activity is reduced and also defective pelvic floor function.
- ◆ *Temporary*—treated by reassurance. Often seen after Lord's dilatation.
- ◆ *Permanent*—needs definitive therapy.

## Causes

### Causes of anal incontinence

- ❖ Denervation—spinal injury, spina bifida
- ❖ Damage—childbirth, wounds, surgeries
- ❖ Descent—rectal prolapse, perineal descent
- ❖ Debility—old age, diseases
- ❖ Destruction—RT, malignancy
- ❖ Dementia—senility, psychosis
- ❖ Deficiency—congenital anomalies

- ◆ Irritable bowel syndrome, severe diarrhoea.
- ◆ Prolapsed piles, rectal prolapse.
- ◆ Old age, malnutrition, debilitating illness.
- ◆ Congenital anomalies.
- ◆ Trauma, surgeries, injury during childbirth in females.
- ◆ Spina bifida, spinal tumours, spinal injuries and surgeries.
- ◆ Malignancy, postirradiation.
- ◆ Psychological causes.

### Evaluation of the patient

- ❖ For specific causes
- ❖ Anorectal manometry
- ❖ Per-rectal examination
- ❖ Sigmoidoscopy
- ❖ Electromyography
- ❖ Defaecography
- ❖ Perineometer to assess level and angle of anorectal junction

## Treatment

- ◆ Suturing of the torn sphincter.
- ◆ Repair of puborectalis muscle and plication of external sphincter.
- ◆ Encircling operations around anal canal to give support using gracilis sling or mersiline sutures.
- ◆ Electrical stimulation of the puborectalis.
- ◆ *Secca therapy*: Temperature controlled radiofrequency energy in the anal canal and distal rectum to create scarring and fibrosis of internal sphincter and adjacent tissues.

## DESCENDING PERINEAL SYNDROME

- ◆ When a healthy person increases the intra-abdominal pressure and relaxes the pelvic floor muscles, there will not be any changes in the concavity of the perineum.
- ◆ In chronic ill-patients, malnourished, and people with preprolapse, perineal descent can occur with obliteration of the normal concavity of the perineum. It is called as *descending perineal syndrome*.
- ◆ Levators got injured directly or indirectly causing weakening of pelvic floor.
- ◆ Anal canal is situated many centimeters below the pubo coccygeal line. Usually 3–4 cm low during straining.
- ◆ *Defaecography* is ideal to evaluate such patients. Perineometer is also used.
- ◆ Presentations are tenesmus; incomplete evacuation; incontinence.
- ◆ *Treatment* is diet, laxatives, avoiding straining, and suppositories.
- ◆ Restoration of pelvic floor by various surgical methods may be needed often with rectal resection and suspension.
- ◆ Total pelvic marlex mesh repair; transcoccygeal posterior hitching of the rectum (Kraske); correction of cystocele, rectocele and enterocele.
- ◆ Results are *not very good* as recurrence or residual problems may persist.

## PROCTITIS

It is inflammation of rectal mucosa often with the inflammation of colon and anal canal.

### Types

- ◆ Acute.
- ◆ Chronic.
- ◆ Nonspecific—common.
- ◆ Ulcerative proctocolitis as part of ulcerative colitis.
- ◆ Specific
  - ▶ Bacillary dysentery.
  - ▶ Amebic proctitis—common.
  - ▶ Combined amoebic and bacillary.
  - ▶ Gonococcal proctitis.
  - ▶ Lymphogranuloma inguinale (LGV).
  - ▶ Tuberculous proctitis.
  - ▶ Bilharzial proctitis due to schistosoma haematobium.
  - ▶ Enema induced proctitis especially of herbal enemas.

#### Clinical features

- ❖ Pain per rectum and anum
- ❖ Tenesmus
- ❖ Passage of mucus and blood
- ❖ Frequent urge to pass stool
- ❖ Fever, loss of appetite
- ❖ Pain and tenderness in left lower abdomen
- ❖ P/R is tender

### Investigations

- ◆ Sigmoidoscopy is more relevant than just proctoscopy.
- ◆ Stool study, stool culture.
- ◆ Mucosal biopsy.
- ◆ Serological tests.
- ◆ Relevant investigations like ESR, blood smear, and chest X-ray.

### Treatment

- ◆ Antibiotics, antiamoebic drugs like metronidazole.
- ◆ In severe cases, retention enema using metronidazole, prednisolone, salazopyrin.
- ◆ IV fluids, IV antibiotics and IV metronidazole are often required.
- ◆ Treating the specific causes like tuberculosis, gonococcal infection and bilharzial infection.

## PROCTALGIA FUGAX

- ◆ It is sudden severe recurring pain in the rectum of unknown cause with segmental pubococcygeal spasm.

### Features

- ◆ It is common in young people may be due to stress, straining.
- ◆ Common at night, starts suddenly, lasts for few minutes and then subsides spontaneously.
- ◆ Pain is unbearable and severe with often constipation.
- ◆ Gradually subsides on its own.

- ◆ Occasionally, only cutting of puborectalis muscle is required but with danger of developing incontinence.

## HIDRADENITIS SUPPURATIVA OF ANAL REGION

- ◆ It is a chronic suppurativa condition of apocrine glands of the skin in axilla/perineum/mons pubis/ thighs/scrotum, etc.
- ◆ Apocrine gland duct obstruction → bacterial infection → multiple glands involvement → secondary infection (*Staphylococcus aureus*, streptococci) → skin oedema, multiple raised pustules → multiple communicating fistulae formation.
- ◆ Disease does not extend above dentate line or into sphincter.
- ◆ It is common in young obese females.
- ◆ Sinus; scarred areas; discharge; skin changes; pain and tenderness; foul smelling fluid are the presentations.
- ◆ *Differential diagnosis* are—Crohn's disease; fistula-in-ano; pilonidal sinus; tuberculosis; actinomycosis; LGV.
- ◆ *Treatment:*
  - ▶ Weight reduction; proper hygiene.
  - ▶ Antibiotics; analgesics.
  - ▶ Incision and drainage of abscess.
  - ▶ Laying open of all communicating tracks and regular dressing.
  - ▶ Radical local excision of entire apocrine bearing perineal skin with reconstruction using flap.
  - ▶ Recurrence is known to occur.

## PRURITUS ANI

- ◆ It is intractable itching in and around anal canal.
- ◆ Skin is reddened, hyperkeratotic, cracked and moist.

### Causes

- ◆ Poor hygiene.
- ◆ Anal discharge due to fissure/fistula/piles/warts/ polyp.
- ◆ Trichomonas vaginalis infection of vagina in females.
- ◆ Parasites.
- ◆ Epidermophytosis.
- ◆ Allergic cause.
- ◆ Dermatitis/psoriasis.
- ◆ Intertrigo/erythrasma (*Corynebacterium minutissimum*).
- ◆ Diabetes mellitus; psychological cause.

### Treatment

Proper cause should be assessed and treated. Good hygiene; local steroid application; topical xylocaine; strapping of the buttocks are needed.

## GASTROINTESTINAL HAEMORRHAGE (GI BLEED)

GI bleed is classified as upper GI and lower GI bleed.

- ◆ *Upper GI bleed* is bleeding above the level of ligament of Treitz.
- ◆ *Lower GI bleed* is bleeding below the level of ligament of Treitz.



*Ligament of Treitz* is a fibromuscular band, which extends from right crus of diaphragm to duodenojejunal flexure with upper part made up of striped muscle fibres, lower part smooth muscle fibres and middle part with elastic fibres.

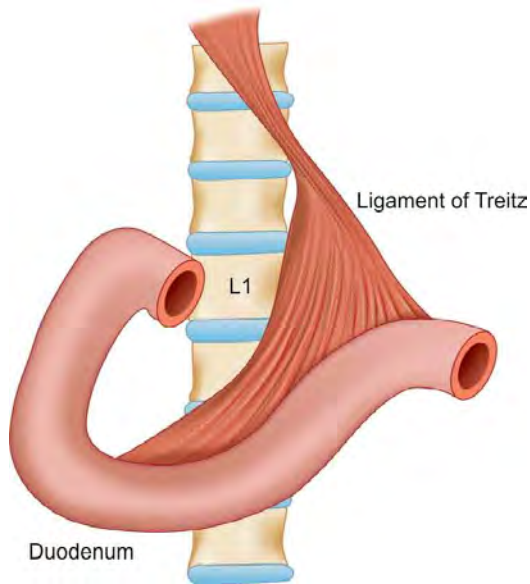


Fig. 25.90: Anatomy of ligament of Treitz.

## UPPER GI BLEED

### It is considered as:

- ◆ Variceal.
- ◆ Nonvariceal.

### Causes

- ◆ Peptic ulcer 55%. Ulcer bleeding is precipitated by NSAIDs, steroids, alcohol. Ulcer bleeding is overall common in men. But NSAID induced ulcer bleeding is common in females. *Duodenal ulcer* (35%) more commonly bleeds than *gastric ulcer* (20%)
- ◆ Gastroduodenal erosions.
- ◆ Oesophageal varices.
- ◆ Oesophagitis and erosions.
- ◆ Carcinoma stomach—5%
- ◆ Mallory-Weiss syndrome—5–15%.
- ◆ Vascular anomalies—Dieulafoy's syndrome (A-V malformation in the fundus of the stomach), Osler-Weber-Rendau syndrome, Ehlers-Danlos syndrome.
- ◆ Aortoduodenal fistula.
- ◆ Bleeding disorders.
- ◆ H/o drug intake—anticoagulants, clopidogrel, ecospirin.

### Factors which aggravate the bleeding

- ❖ Gastric acid which inhibits the platelet aggregation
  - ❖ Pepsin, by its proteolytic action causes erosion of the ulcer into the vessel. It also digests the clot, so as to aggravate the bleeding
  - ❖ Mucosal blood supply pattern
  - ❖ Gastric motility
  - ❖ Alcohol, drugs
- Major haemorrhage occurs when erosion of gastroduodenal artery or left gastric artery or splenic artery occurs or when bleeding occurs from varices

## Clinical Features

### Acute Bleed

- ◆ Features of shock.
- ◆ Haematemesis.
- ◆ Melaena.

### Chronic Bleed

- ◆ Hypochromic microcytic anaemia, glossitis, koilonychia, congestive cardiac failure.
- ◆ Mortality in upper GI bleed is 10%.

## Investigations

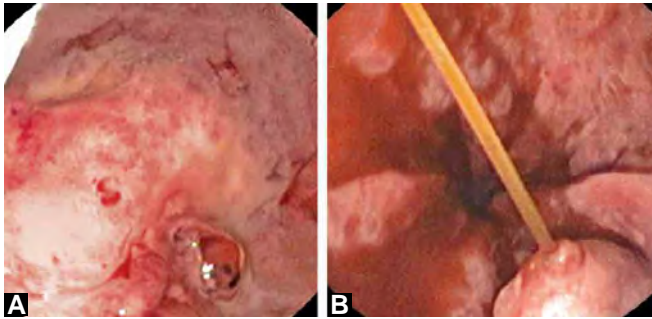
- ◆ *Gastroscopy* to see the spurting vessel, oozing, clot in the ulcer, collected blood in the lumen of the stomach.
- ◆ CT angiography of coeliac trunk and SMA.
- ◆ Hb%, packed cell volume, CVP measurement, blood grouping and crossmatching. Ultrasound abdomen.
- ◆ LFT; prothrombin time; platelet count; blood urea and serum creatinine; serum electrolytes.
- ◆ *Modified Forrest classification* (refer Chapter 20—Stomach) and *Rockall scoring system* (better) is used. In **Rockall scoring system** parameters used are—age (60 [0], 60–79 [1], >79 [2] Years); shock (none [0], plus >100 [1], plus >100 with hypotension [2]); comorbidity (none [0], IHD [2], renal/liver failure/advanced malignancy [3]); condition diagnosed (Mallory Weiss [0], all but malignancy [1], upper GI malignancy [2]); endoscopic finding (none [0], dark spot, blood/clot/visible vessel [2]). Score: <3 low-risk; 3–8 moderate; >8 high.

## Treatment

### Treatment of upper GI bleed

- ❖ General
- ❖ Medical—PPI/tranexamic acid/octreotide
- ❖ Endoscopic
- ❖ CT angiography guided embolisation
- ❖ Surgical

- ◆ General: IV fluids, catheterisation, Ryle's tube aspiration, blood transfusion.
- ◆ Injection ranitidine IV 50 mg 8th hourly, or famotidine IV, omeprazole IV, pantoprazole IV.
- ◆ Antifibrinolytics like tranexamic acid, EACA.
- ◆ Somatostatin or octreotide, PPI infusion.
- ◆ *Endoscopic therapy* (tamponade, laser, haemoclip, banding, sclerotherapy, etc.) is the first line of therapy in all upper GI bleed. *CT angiography guided transcatheter embolisation* of artery (gastroduodenal) is very useful in bleeding duodenal ulcer if endoscopic therapy fails. *Persistent recurrent bleeding* needs surgical intervention.
- ◆ For varices, vasopressin, propranolol, isosorbide dinitrate, Sengstaken tube tamponade, sclerotherapy, Boerema-cricle operation, Hasaab operation (devascularisation with splenectomy), oesophageal transection, Siguiria-Futagawa operation or TIPSS.
- ◆ For peptic ulcer, saline wash with 1 : 2,00,000 adrenaline, Nd:YAG laser therapy, cautery coagulation, thrombin injection, Finney's pyloroplasty, partial gastrectomy, ligation of gastroduodenal or left gastric artery, cytoprotectant mesoprostil injection.
- ◆ The cause is treated, once acute episode is under control.



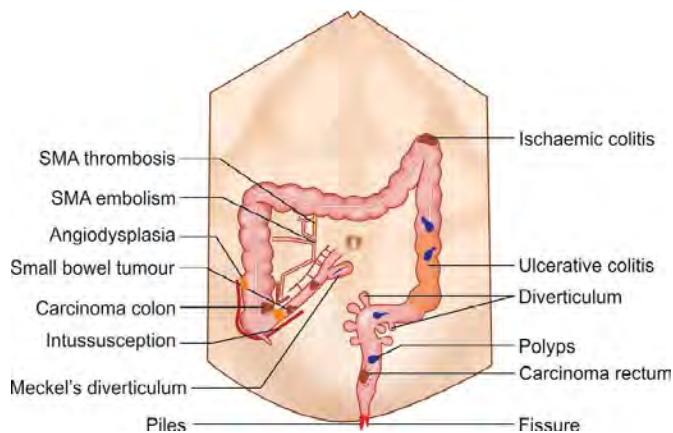
**Figs 25.91A and B:** Bleeding peptic ulcer (duodenal ulcer) is the commonest cause of upper GI bleed. Oesophageal varix causes dangerous severe life-threatening bleed.

## Prognosis

- ◆ Varices and gastric ulcer bleed has higher mortality.
- ◆ Bleeding duodenal ulcer has got better prognosis.

## LOWER GI BLEED

- ◆ Bleeding in the GIT below the level of the ligament of Treitz.
- ◆ Normal faecal blood loss is 1.2 ml/day. A loss more than 10 ml/day is significant.



**Fig. 25.92:** Causes of lower GI bleed.

## Causes

- ◆ Angiodysplasia.
- ◆ Diverticular disease—commonest cause in Western countries.
- ◆ Tumours of colon or small bowel.
- ◆ Anorectal diseases—haemorrhoids, fissure-in-ano.
- ◆ Ulcerative colitis, Crohn's disease.
- ◆ Colorectal polyps; rectal carcinomas.
- ◆ Intussusception.
- ◆ Tumours, either benign or malignant of colon or small bowel.
- ◆ Meckel's diverticulum.
- ◆ Ischaemic colitis.
- ◆ Stercoral ulcer.
- ◆ Infectious colitis.
- ◆ Mesenteric artery occlusion.

### Lower GI bleed can be:

- ❖ Occult bleed: >10 ml/day but not revealed
- ❖ Overt bleed: Bleeding which is revealed
  - Overt acute
  - Overt acute massive (bleed >1.5 litre/day)
  - Overt chronic

### Common causes

- ❖ Internal piles
- ❖ Diverticular disease
- ❖ Neoplasia
- ❖ Inflammatory bowel diseases
- ❖ Angiodysplasia

## Classification

### I. Bleeding may be:

**Small bowel bleed:** Polyp, Meckel's diverticulum, mesenteric ischaemia, intussusception; small bowel tumor.

**Large bowel bleed:** Angiodysplasia, carcinoma, colitis, diverticulitis, carcinoma.

**Anorectal diseases:** Piles, fissure-in-ano, carcinomas.

### II. Bleeding may be:

**Congenital:** Polyp's, Meckel's diverticulum.

**Inflammatory:** Ulcerative colitis, infective, amoebic, Crohn's disease.

**Neoplastic:** Adenomas, carcinomas, polyps.

**Vascular:** Angiodysplasia, mesenteric artery ischaemia, colitis.

**Others:** Piles, fissure-in-ano.

Angiodysplasia is common in caecum and ascending colon.

Bleeding more than 1.5 litres per day is called as *acute massive GI bleed*.

### Acute bleed occurs in:

- ❖ Mesenteric ischaemia
- ❖ Angiodysplasia
- ❖ Ischaemic colitis
- ❖ Meckel's diverticulum
- ❖ Intussusception
- ❖ Acute episodes of ulcerative colitis
  - 80% of acute bleed regress spontaneously
  - 20% will become either massive or recurrent

## Presentations

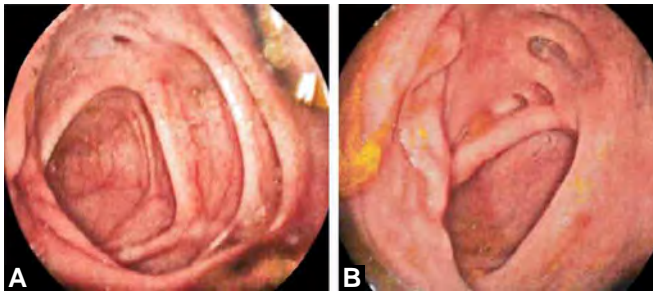
- ◆ Acute bleeding presents with features of shock.
- ◆ Chronic blood loss occurs in piles, fissures, colitis. Presents with hypochromic, microcytic anaemia.
- ◆ Tenesmus, subacute obstruction, loss of appetite, decreased weight, bloody diarrhoea is seen in carcinoma distal, large bowel.
- ◆ Per-rectal examination is a must which may reveal polyp, growth, ulcerations.

- ◆ Haematochezia.
- ◆ Mass palpable per abdomen in left or right iliac fossa or mass of intussusception.

- ❖ *Blood with mucus*—colitis, carcinoma
- ❖ *Fresh blood as splashes in the pan*—piles
- ❖ *Maroon coloured stool*—Meckel's diverticulum
- ❖ *Red currant jelly in stool*—intussusception
- ❖ *Bright red blood in stool*—polyps

## Investigations

- ◆ Hb%, packed cell volume, ESR.
- ◆ Bleeding time; clotting time; prothrombin time; platelet count; blood urea and serum electrolytes.
- ◆ Occult blood in the stool—positive faecal blood test using Guaiac reagent.
- ◆ Barium enema.
- ◆ Proctoscopy for piles and sigmoidoscopy for rectosigmoid diseases.
- ◆ Colonoscopy for colitis, carcinomas, polyps.
- ◆ Small bowel enema (enteroclysis).



**Figs 25.93A and B:** Sigmoid diverticula on colonoscopy. It is the common cause of lower GI bleed in Western countries.

- ◆ US abdomen.
- ◆ Mesenteric angiogram is very useful investigation in acute bleed, especially in angiodysplasia.
- ◆ Technetium scan for Meckel's diverticulum.
- ◆ Capsule endoscopy.

## Treatment

- ◆ Endoscopic fulguration or therapeutic embolisation or right hemicolectomy (for angiodysplasia).
- ◆ Endoscopic polypectomy for polyps.
- ◆ Treatment for ulcerative colitis with mesacal enema or drugs or total proctocolectomy with ileo-anal anastomosis.
- ◆ Surgical resection of colonic carcinoma.
- ◆ Massive resection of small bowel in mesenteric ischaemia.
- ◆ Sigmoid colectomy in sigmoid diverticula.
- ◆ Cause is treated.
- ◆ Proper exploration through a lengthy midline incision is essential.

## OBSCURE GI BLEED

- ◆ It is intermittent GI bleed for which *no source has been found* endoscopically/radiologically.
- ◆ It is 5% common.

- ◆ Commonly, it is due to either missed common cause or angiodysplasia.
- ◆ If it is angiodysplasia, angiography, nuclear scintigraphy, capsule endoscopy; then angiographic embolisation or resection of the part of the bowel is done.
- ◆ Enteroscopy, upper and lower GI scopes are needed in other conditions.
- ◆ All other conditions are treated accordingly.

## Investigations for GI bleed

### Blood

- ❖ Haematocrit, LFT, blood urea, serum creatinine
- ❖ Serum ferritin, iron, binding capacity
- ❖ Coagulation profile—platelet count, BT, CT, PT, APTT

### Occult stool blood test (1–2 ml/day)

- ❖ Benzidine test
- ❖ Guaiac test
- ❖ Haemoccult—guaiac impregnated electrophoresis paper
- ❖ Fecal test
- ❖ Immunological test

### Endoscopy

- ❖ Gastroduodenoscopy
- ❖ Proctosigmoidoscopy
- ❖ Colonoscopy—often difficult in acute bleed for clarity visualisation, if bleeding point is seen it can be controlled by cautery, laser, haemoclips, injection sclerotherapy, heater probe etc. But still it becomes the test of choice once bleeding has controlled/stopped temporarily
- ❖ Small bowel endoscopy—push type (160 cm); Sonde enteroscope (275 cm, 5 mm diameter with balloon tip) are used. Entire small intestine is visualised while withdrawing but therapy or biopsy is not possible

### Angiography

- ❖ It identifies when bleeding rate is 0.5 ml / min; useful in active bleed; in therapeutic embolisation, injection vasopressin can be done. Embolisation of small bowel vessel may cause bowel infarction which is dangerous and resection is needed in such situation. Visualisation in angiography can be improved by selective infusion of vasodilators like tolazoline and prostaglandins, using magnification films, using vasoconstrictor drugs
- ❖ *Angiographic criteria in angiodysplasia are*—early and prolonged filling of draining veins; cluster of small arteries; visualisation of vascular tuft

### Nuclear scintigraphy

- ❖ Identifies 0.1 ml/min of bleed ; *Tc sulphur colloid scan* is very sensitive and is completed in 1 hour but increased uptake in spleen and liver obscures bleeding point and needs repeated administration due to rapid clearance; *Tc labeled RBC* recirculates and so effective for 1 day with better localisation
- ❖ *Advantages are*—high-sensitivity even with active continued bleed; screening test prior to angiography
- ❖ *Problems are*—no specificity; therapy is not possible

### Other methods

- ❖ CT angiography; MR angiography
- ❖ Aortography for aortoenteric fistula
- ❖ *Intraoperative localisation*—on table enteroscopy; on table Doppler; on table bowel lavage and colonoscopy

# Chapter 26

## Urology

### A. Kidney

*It is no exaggeration to say that the composition of the blood is determined not by what the mouth ingests but by what the kidneys keep; they are the master chemists of our internal environment, which, so to speak, they synthesize in reverse.*

—Homer William Smith, 1939

#### CHAPTER OUTLINE

- ❖ Anatomy of Kidney and Ureter
- ❖ Plain X-ray—Kidney, Ureter and Bladder
- ❖ Intravenous Urogram
- ❖ Retrograde Pyelography
- ❖ Renal Angiogram
- ❖ Micturating Cystourethrography
- ❖ Ascending Urethrogram
- ❖ Isotope Renography
- ❖ Cystoscopy
- ❖ Catheters
  - Foley’s Catheter
  - Malecot’s Catheter
- Red Rubber Catheter
- ❖ Nephrostomy
- ❖ Suprapubic Cystostomy
- ❖ Haematuria
- ❖ Horseshoe Kidney
- ❖ Cystic Diseases of the Kidney
  - Polycystic Kidney Disease
  - Solitary Renal Cyst
- ❖ Duplication of Renal Pelvis and Ureter
- ❖ Retrocaval Ureter
- ❖ Uretrocele
- ❖ Injuries to Kindney
- ❖ Renal Tuberculosis
- ❖ Hydronephrosis
- ❖ Pyonephrosis
- ❖ Carbuncle of Kidney
- ❖ Perinephric Abscess
- ❖ Renal Calculus
- ❖ Ureteric Calculi
- ❖ Staghorn Calculus
- ❖ Benign Tumours of Kidney
- ❖ Wilms’ Tumour
- ❖ Renal Cell Carcinoma
- ❖ Approaches to Kidney

#### ANATOMY OF KIDNEY AND URETER

##### KIDNEY—ANATOMY

- ◆ They are a pair of excretory organs situated retroperitoneally, on the posterior abdominal wall; one on each side of vertebral column.
- ◆ Vertically it extends from the upper border of T<sub>12</sub> vertebra to the centre of the body of L<sub>3</sub> vertebra. The right kidney is slightly lower than the left, left kidney is slightly nearer to the median plane.
- ◆ Each kidney is about 11 cm long, 6 cm broad, 3 cm thick. Lateral border is convex. Medial border is concave with a hilum. Structures seen in the hilum are (from anterior to posterior)—(1) renal vein, (2) renal artery, (3) renal pelvis.
- ◆ Upper pole is related to suprarenal gland; lower pole lies 1 inch above the iliac crest.

- ◆ Capacity of renal pelvis is 10 ml.
- ◆ The angle between the 12th rib and the outer border of the sacrospinalis is the kidney angle. Kidney pain is usually referred here and pressure over this point elicits pain in kidney lesions.
- ◆ Hepatorenal pouch is a peritoneum lined deep recess, related to the upper pole of kidney. It is the lowest site when the body is in horizontal position, excluding the pelvis. Collection of extravasated fluid is likely to occur in this pouch following surgeries to liver and biliary tract.

##### Capsules of Kidney

1. *Proper capsule*—fibrous membrane which can easily be stripped off from the organ.

*The remedy for injuries is not to remember them.*

2. *Perirenal fat* is in the space of Gerota.
3. *Renal fascia of Gerota*—has got anterior layer (*Fascia of Toldt*) and posterior layer (*Fascia of Zuckerkandl*).
4. Pararenal body of fat.

## Structure of Kidney

### Gross

Coronal section shows outer brownish cortex, inner pale medulla, renal sinus.

Renal sinus is a space that extends into the kidney from hilum. It contains (1) branches of renal artery, (2) branches of renal vein, (3) renal pelvis.

The pelvis divides into 2–3 major calyces which, in turn divides into 7–13 minor calyces.

### Histology

Each kidney is composed of 1–3 millions of uriniferous tubules; each of which has a collecting part (*collecting tubules*) and secretory part (*nephron*).

### Blood Supply

It is from renal artery, which arises from the aorta at right angles, at the level of intervertebral discs between L<sub>1</sub> and L<sub>2</sub> vertebrae. About 95% of abdominal aortic aneurysm arises below the level of origin of renal artery.

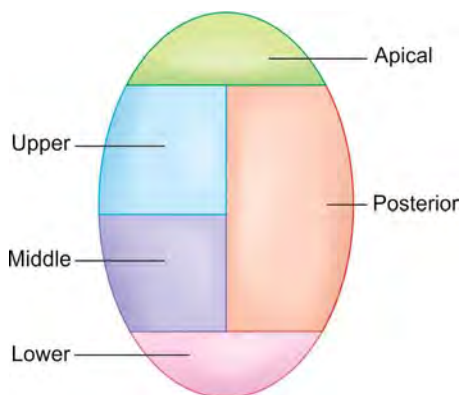


Fig. 26.1: Segments of kidney.

The kidney is divided into anatomic segments based on blood supply. In the hilum, the main artery divides into anterior and posterior divisions. The anterior division supplies the apical, upper, middle and lower segments; posterior segment is supplied by the posterior division. The knowledge of this is important in the operation of anastrophic nephrolithotomy, where a functionally *avascular plane (Brodel)* between the posterior segment and the upper and middle segments exist on the posterior half of the kidney, about two-thirds of the way from the hilum to the lateral margin of the kidney.

### Nerve Supply

T<sub>10,11,12</sub> through the lesser and lower splanchnic nerves.

### Lymphatics

They are drained into para-aortic nodes. Perinephric fat is removed during nephrectomy (for malignancies), as intrarenal lymphatics freely communicate with the plexus in the perinephric fat.

## URETER—ANATOMY

- ◆ Each ureter is 25–30 cm long. It begins within the renal sinus as a funnel-shaped dilatation called renal pelvis.
- ◆ It enters the bladder wall obliquely to open at the lateral angle of the trigone.
- ◆ It lies in the retroperitoneal space not attached to any fixed structures, so can be displaced or obstructed by retroperitoneal masses like tumours or aneurysms.
- ◆ Abdominal portion of ureter lies on the medial portion of psoas major muscle near the tips of transverse processes of lumbar vertebra (which is very well seen in IVP).
- ◆ The ureter enters the pelvis crossing the end of common iliac or beginning of external iliac artery.
- ◆ In females, uterine artery crosses the ureter from lateral to medial side, about 2 cm lateral to the cervix (this has to be remembered while ligating the uterine arteries in hysterectomy).

**Normal sites of constrictions:** (1) PUJ, (2) At the brim of lesser pelvis, (3) Along its passage through the bladder wall

- ◆ **Arterial supply:** Upper segment of ureter receives blood supply from branches of renal and adrenal arteries; the middle portion from the branches of arteries of posterior abdominal wall; the pelvic portion from the branches of internal iliac arteries.
  - ▶ Vessels reach the abdominal portion of ureter on the medial side; whereas the pelvic portion receives on the lateral side (This has to be remembered while mobilising the ureter). The vessels form an anastomotic plexus in the adventitia of the ureter, which is found to be deficient in 10–15% of individuals leading to necrosis of cut ends of ureter following extensive mobilisation.

## PLAIN X-RAY—KIDNEY, URETER AND BLADDER (KUB)

- ◆ Preparation of the patient: Enema/bowel wash/laxative is given on the previous day and the patient is asked to fast in order to reduce the bowel gas shadows in X-ray.
- ◆ High penetration X-ray is taken in supine position which covers *pubic symphysis and lower two ribs*.
- ◆ Interpreting the film:
  - a. First bony parts are looked for, i.e. the hip, pelvis, lumbar vertebrae for fractures, scoliosis, spina bifida, secondaries in the spine.
  - b. **Kidney shadow:** Kidney shadows are visualised in plain X-ray KUB due to difference in the density between kidney (high vascularity) and perinephric fat (low vascularity). Findings noted are size, location, calcification and stones. In children, perinephric fat is absent and so kidney shadows are not visualised.
  - c. **Psoas shadow:** It is visualised well in normal KUB.

### Psoas shadow is obliterated in:

- ❖ In enlarged kidney
- ❖ In scoliosis due to inflammatory or infiltrative causes
- ❖ In malignancy
- ❖ Tuberculous spine with cold abscess (psoas abscess)
- ❖ Splenic injury—in left-sided shadow
- ❖ Retroperitoneal tumours

d. **Ureteric line:** It is looked for any radio-opaque shadow (ureteric stone). It runs along the tips of the *transverse processes of the lumbar vertebrae*, crosses the *sacroiliac joints* and reaches up to a point medial to the *ischial spine*.

e. Bladder, prostate and urethral areas are visualised for any lesion.

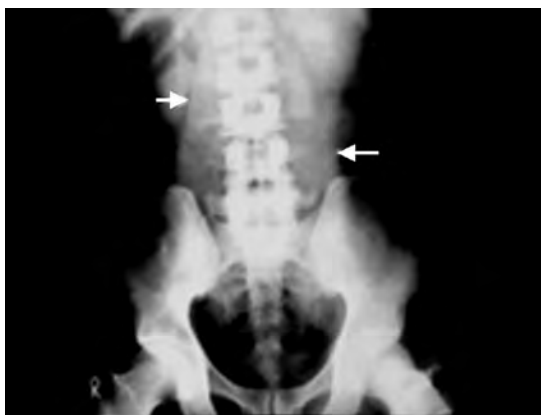

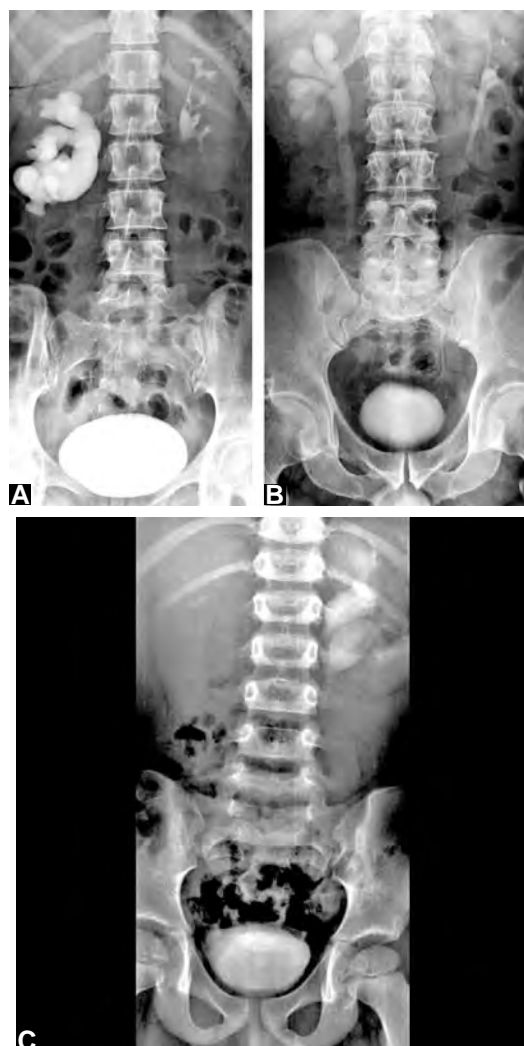
Fig. 26.2: Plain X-ray KUB AP-view. Note the psoas shadow.

## INTRAVENOUS UROGRAM (IVU)

### Procedure

Renal function must be normal.

- ◆ Overnight fasting for 8 hours is advised. Laxatives are given to reduce bowel shadow and get a good quality film.
- ◆ First, a plain X-ray KUB is taken (IVU should not be read without doing KUB).
- ◆ Then 1 ml test dose of **sodium diatrizoate (Urografin)** or **meglumine iothalamate** is injected IV and waited for 5–10 minutes for any reaction. If no adverse reaction occurs, then full dose 1 ml/kg body weight, IV urografin is given (40–50 ml).
- ◆ X-ray is taken in 1–5 minutes, which shows the nephrographic and secretory function of the kidneys.
- ◆ Later 15 minutes and then 20–30 minutes films are taken.
- ◆ Further films are taken depending on the need.
- ◆ Film can be taken as late as 72 hours. Late films show bladder pathology as well as residual urine.
- ◆ In case of *renal failure* with high blood urea, dose of dye is increased to 2 ml/kg body weight to get a better film—**Infusion IVU**. Often diuretics are used in these patients to have better secretion.
- ◆ Lower abdominal compression is done for 10 minutes to have better definition of calyces, but not done in children and patients with abdominal aortic aneurysm.
- ◆ **Minute IVU:** In case of renal artery stenosis, within first minute many films are taken to see nephrographic shadow (where a small, concentrated kidney is seen).
- ◆ **Nonvisualization of kidney:** No contrast is seen in the film even after 12 hours.



Figs 26.3A to C: IVU showing hydronephrosis with clubbing of calyces and dilatation. Delayed post-lasix film often should be taken whenever there is poor secretion in initial films. Film can be taken as late as 72 hours. This delayed film shows dilatation (Courtesy: Dr Navinchandra Shetty, MD, HOD of Radiology, KMC, Mangaluru).

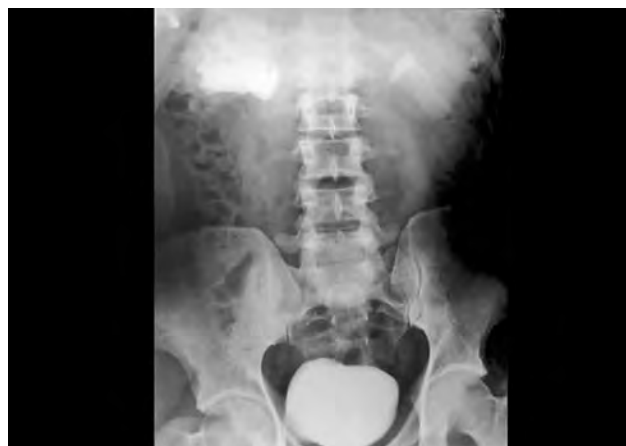
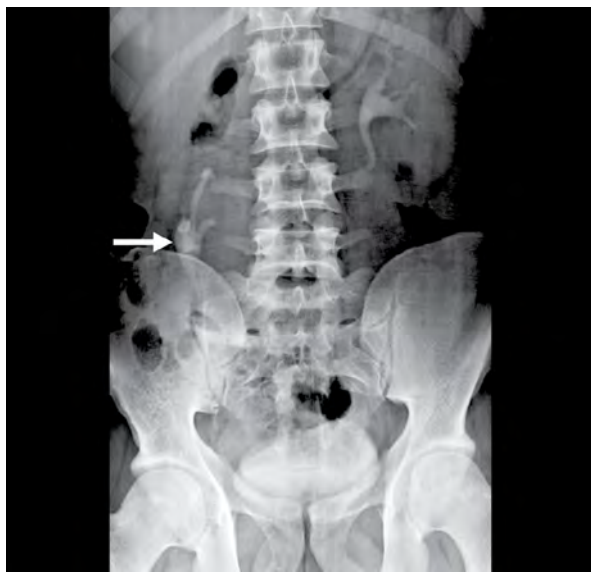
Fig. 26.4: IVU showing hydronephrosis on right side; normal secretion on left side; with bladder filling

**Intravenous Urogram (IVU)**

	<b>Indications</b>	<b>Findings</b>
1.	Hydronephrosis	Clubbing of calyces
2.	Congenital anomalies	
	a. Horseshoe kidney	Flower vase appearance
	b. Duplex kidney and double ureter	
	c. Ureterocele	Adder (cobra) head appearance
	d. Polycystic kidney disease	Spider leg appearance
	e. Retrocaval ureter	Reverse 'J' sign with hydronephrosis
3.	Renal cell carcinoma	Irregular filling defect; spider leg appearance
4.	To see the function of the kidneys in bilateral diseases	Bilateral stones, obstructive uropathy
5.	After surgery for urinary diseases	To see the function of kidneys and outcome of the surgery
6.	Renal injury	To see the function of other kidney (a very specific investigation)
	<b>Contraindications</b>	

1. Iodine sensitivity—may go for anaphylaxis. Hence, all precautions must be taken and essential drugs should be available while doing IVU
2. Multiple myeloma and hypergammaglobulinaemias (Acute renal failure may be precipitated due to dehydration)
3. Toxic thyroid



**Fig. 26.5:** Ectopic kidney right sided IVU picture. It is un-ascended kidney. It often presents as mass in the right iliac fossa. CT scan is diagnostic. Differential diagnoses for masses in right iliac fossa are nodal mass; carcinoma caecum; tuberculosis; psoas abscess; retroperitoneal tumour. Sepsis; stones; tumour; can occur in ectopic kidney. Management of whatever problems arise is done through open method. Bilateral ectopic kidney may lead into eventual renal failure. Isotope scan is diagnostic.

**RETROGRADE PYELOGRAPHY (RGP)****Indications**

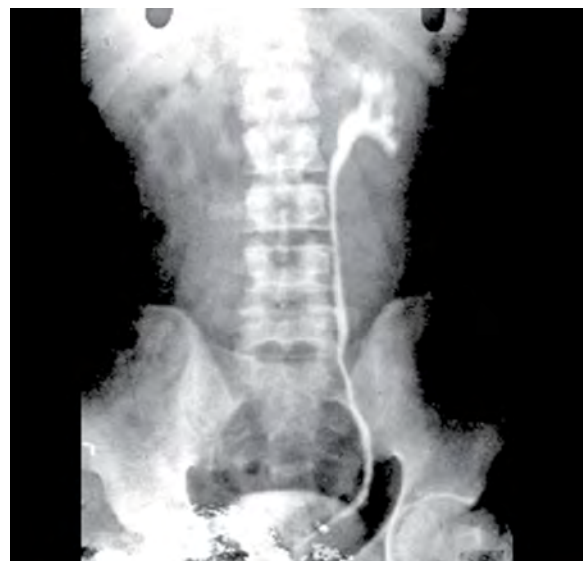- ❖ Failure of showing any secretions in an IVU as late as 72 hours film
- ❖ Urinary tuberculosis
- ❖ Urothelial tumours from the renal pelvis

**Procedure**

- ◆ Under G/A, cystoscope is passed. Ureteric orifice is visualised.
- ◆ Ureteric catheter is passed. Dye, sodium diatrizoate is injected.
- ◆ Patient is put in 15° head down position to allow the dye to reach upper urinary system.
- ◆ X-ray is taken.

**Advantages**

- ◆ Prior to dye injection selective urine sample can be taken from each ureter.
- ◆ Brush biopsy from suspected urothelial tumours of upper urinary tract can be taken.
- ◆ Better-delineation of anatomy (due to more concentration of dye).



**Fig. 26.6:** Left RGP—normal study.

## Disadvantage

Anaesthesia is required and is laborious.

## RENAL ANGIOGRAM

### Indications

- ❖ Renal artery stenosis
- ❖ Renal artery atheroma
- ❖ Renal artery aneurysm
- ❖ Occasionally renal cell carcinoma
- ❖ Arterial anomalies

## Procedure

*Retrograde Seldinger technique:*

- ◆ Through femoral artery, using Seldinger's needle selective angiogram is done to visualise tumour vascularity, narrowing, anomalies. Dye used is Hypaque. Dose: 6–7 ml.
- ◆ Therapeutic embolisation, transluminal balloon angioplasty for renal artery stenosis can also be done by this approach.
- ◆ Translumbar approach for angiogram (through aortogram) is also used. Hypaque used is 30 ml.

### Complications

- ❖ Paraplegia
- ❖ Embolism
- ❖ Dissecting aneurysm
- ❖ Bleeding
- ❖ Renal tubular necrosis

*Renal pharmacangiogram:*

- ◆ Noradrenaline is injected along with the dye. Normal vessels will constrict in response to noradrenaline. But since tumour is autonomous, vessels in renal cell carcinoma do not respond to noradrenaline and so *tumour blush* is seen.

## MICTURATING CYSTOURETHROGRAPHY (MCU)

### Indications

- a. Vesicoureteric reflux.
- b. Posterior urethral valve.

### Procedure

Catheter is passed into the bladder. Dilute iodine dye is infused. X-ray is taken during micturition. *Free reflux* is looked for. Applying pressure over the suprapubic region, X-ray is taken. *Pressure reflux* is studied.

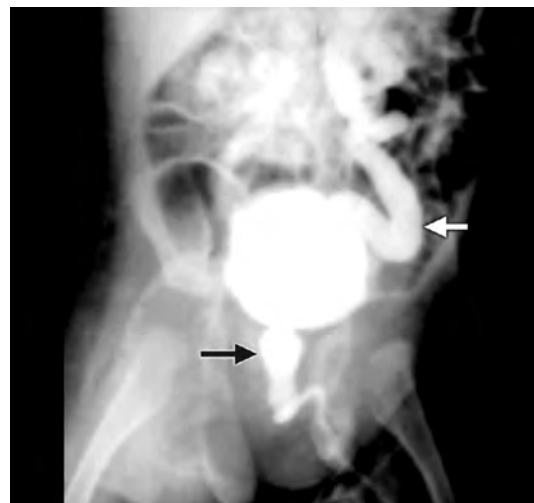**Vesicoureteric reflux** is graded depending on the severity of the reflux—as:

- I—Ureters seen
- II—Ureters and pelvis are seen
- III—Ureters, pelvis, calyces are seen
- IV—With grossly distended calyces
- V—Tortuous elongated serpentine ureters

It can be unilateral or bilateral. Often it is associated with posterior urethral valve. It is often complicated by infection, pyonephrosis and renal failure

*Investigations:* MCU, IVU, U/S, blood urea and serum creatinine

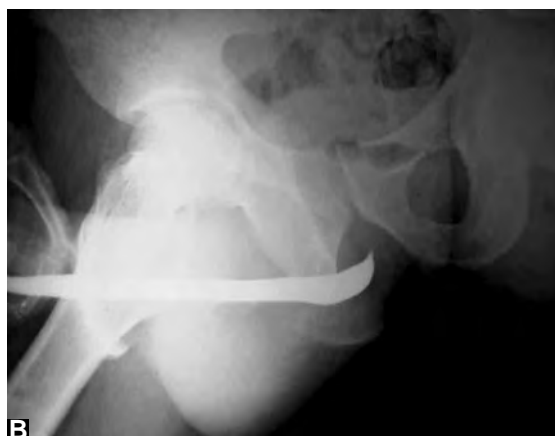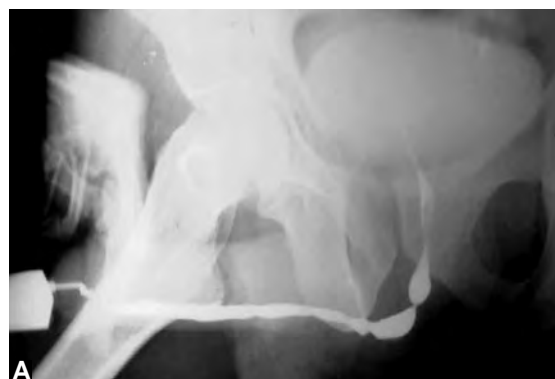
*Treatment:* Tailoring of ureter with reimplantation



**Fig. 26.7:** Micturating cystourethrogram showing concomitant existence of posterior urethral valve (causing dilatation of proximal urethra) and vesicoureteric reflux (left side).

## ASCENDING URETHROGRAM

- ◆ It is the investigation of choice for *stricture urethra*.
- ◆ Red rubber catheter is passed into the external meatus.
- ◆ Water-soluble iodine dye is injected through the catheter.
- ◆ Oblique X-ray films are taken to visualise the urethra.
- ◆ Site, size, extent of stricture and extravasation can be found out in urethrogram.



**Figs 26.8A and B:** Ascending urethrogram showing stricture urethra.

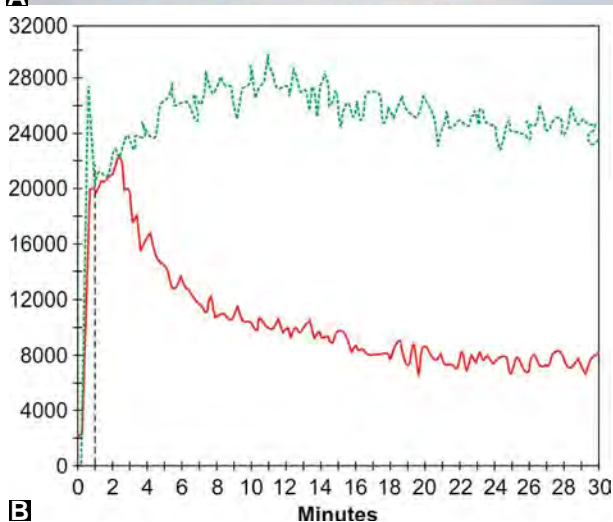



## ISOTOPE RENOGRAPHY

- ◆ A measure of individual kidney function is obtained by this method using a gamma camera.
- ◆ Radiolabelled Technetium 99m **DMSA** (Dimercapto- succinic acid) or **DTPA** (Diethylenetriamine-penta acetic acid) is given intravenously.

DTPA—renal function.

DMSA—renal parenchymal changes.



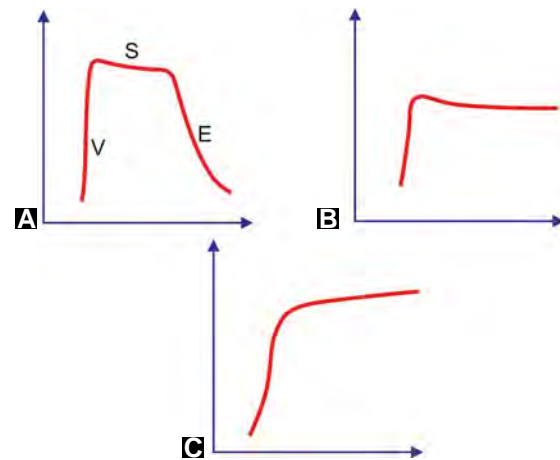
**Figs 26.9A and B:** Isotope renogram showing reduced secretion on right side.

It shows:

- ◆ *Early* vascular phase.
- ◆ *Then* secretory phase.
- ◆ *Later* excretory phase.
  - ▶ This allows the assessment of renal plasma flow to each kidney and the efficiency and effectiveness of pelvicalyceal excretion also.
  - ▶ Secretion <20% is precarious.

## Problems

1. Positioning of counters.
2. Often difficult to differentiate from muscle mass. It is only a supportive investigation.



**Figs 26.10A to C:** Renography showing; (A) Normal study; (B) Hydronephrosis; (C) Renal failure.

## CYSTOSCOPY

### Uses

- ❖ To examine urethra, bladder, ureteric orifice for any pathology (tumour, infection)
- ❖ To visualise any bladder fistulas
- ❖ To treat
  - Urethrotomy (in stricture urethra)
  - TURP for BPH and carcinoma prostate
  - Bladder tumour resection
  - Bladder stone removal (cystolithotripsy, cystolitholapaxy)
  - Ureteric catheterisation
  - Fulguration of posterior urethral valve

**Contraindication:** Acute cystitis and prostatitis

## Types

- ◆ *Rigid.*
- ◆ *Flexible.*

## Procedure

- ◆ Patient is placed in lithotomy position.
- ◆ Under G/A or spinal anaesthesia after cleaning and draping, through urethra, cystoscope is passed using continuous *glycine irrigation* (to avoid TURP syndrome).

- ◆ The parts of the urethra are visualised while passing the cystoscope.
- ◆ Once bladder is reached, it is looked for diverticula, hypertrophy and other pathologies.
- ◆ Ureteric orifices are visualised.

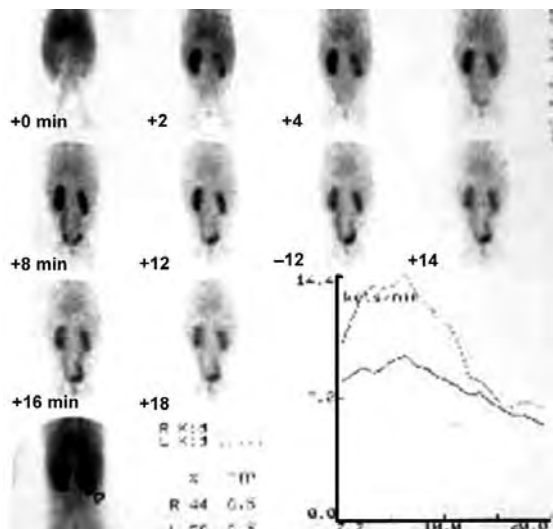


Fig. 26.11: Isotope renogram showing kidney function.

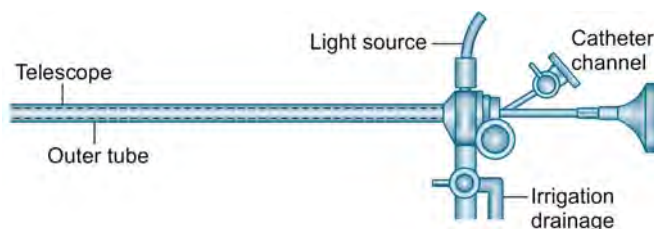


Fig. 26.12: Cystoscope.

**Complications**

- ❖ Urethral injury
- ❖ Bleeding
- ❖ Water intoxication.

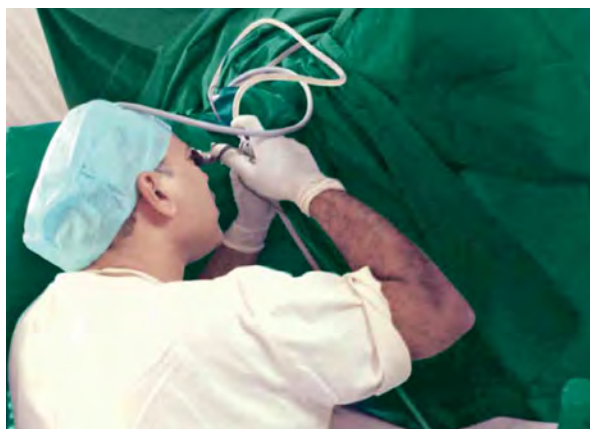

Fig. 26.13: Cystoscopy is being done for different procedures like TURP; diagnostic, etc. (Courtesy: Dr Ashok Pandit, MCh, Urologist, Mangaluru).

**CATHETERS**

They are hollow tubes used to relieve urinary retention, obtain urine for analysis, irrigate bladder and to instill drugs into bladder.

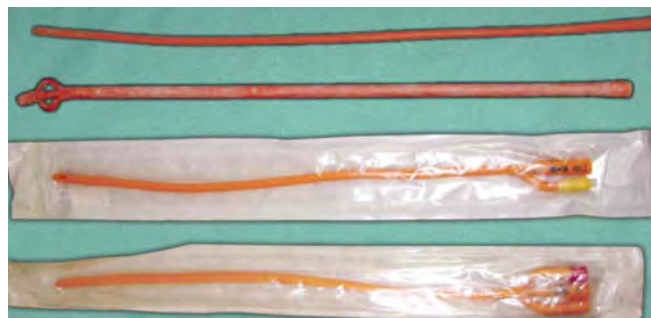

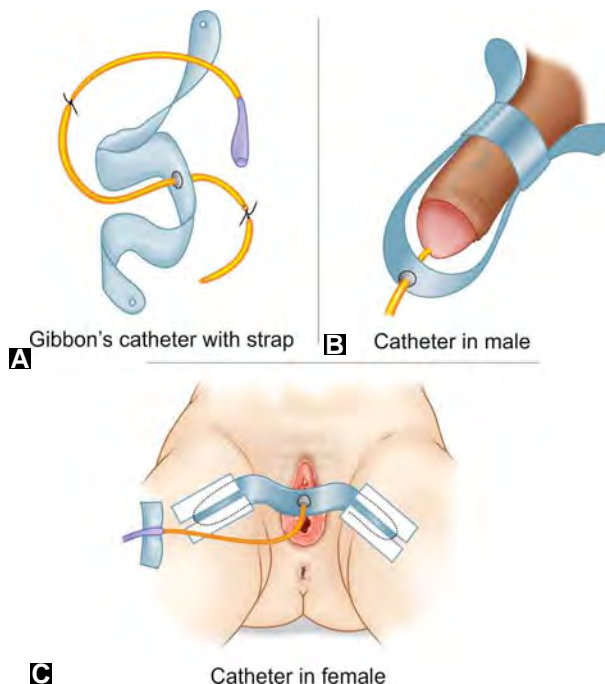
Fig. 26.14: Photo showing red rubber catheter; Malecot's catheter and Foley's catheters.

**Types**

- a. **Nonself-retaining catheter:** Simple red rubber catheter.
- b. **Self-retaining catheter:** Foley's catheter, Malecot's catheter, Gibbon's catheter, De-Pezzer catheter.

**Types of Catheterisation**

- a. **Indwelling catheterisation:** When a catheter is left behind in bladder and remains so it is called an indwelling catheter.



Figs 26.15A to C: Gibbon's catheter. Note the look and method of fixing in male and female. It is a self-retaining catheter made up of plastic with a stillete in it which makes its passage easier through urethra. Sizes differ for males and females because of the difference in length of the urethra in male and female. Catheter has two ribbons attached which can be used to fix to the genitalia by adhesive plaster. Gibbon's catheter is least irritant to urethra.

*If someone is greedy, bribe him, if someone is foolish, advise him; if someone is wise, listen to him.*

It is achieved by:

- ▶ Balloon tip of catheter—Foley's catheter.
- ▶ Flower tip of catheter—Malecot's catheter, De- Pezzers.
- ▶ Strapping catheter externally—Gibbon's catheter.

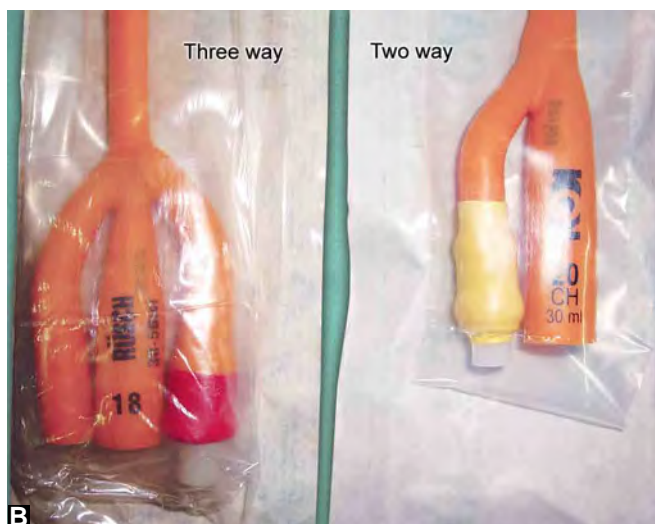b. **Intermittent catheterisation:** A sterile catheter is introduced intermittently by the patient or by others.

### FOLEY'S CATHETER (Fredrick Eugene Basil Foley—American Urologist)

It is a *self-retaining* urinary catheter made of *latex*. It has got a balloon near the tip into which distilled water is infused to make it *self-retainable*. Usually, Foley's catheter is kept for 7 days. Sterilized by  $\gamma$ -radiation.

**Size:** Adults—16 F.  
Children—8 F or 10 F.

(F—French unit, Charriere unit, where each unit equals 0.33 mm). 16 F means circumference of the catheter is 16 mm. Diameter is one-third of circumference).



**Figs 26.16A and B:** Foley's catheter. Two way/three way Foley's catheters are available.

### Uses

- ◆ To pass per urethrally in retention of urine of any cause (BPH, stricture, trauma).
- ◆ To measure the urine output in renal failure, postoperative patients, terminally ill patients.
- ◆ Percutaneous cystostomy.
- ◆ Cholecystostomy.
- ◆ To drain fistulas.

### Types

- ◆ Two-way Foley's.
- ◆ Three-way Foley's—to give bladder irrigation, e.g. following TURP.
- ◆ Silicone coated Foley's—to reduce reaction and so as to keep for longer period (3 months).

### Procedure

- ◆ After cleaning under strict asepsis, lignocaine gel is lubricated onto the urethral meatus. Catheter is passed into the urethra.
- ◆ Sometimes *Maryfield introducer* is used to pass Foley's catheter.
- ◆ Once catheter is in the bladder, urine flows out. It is now connected to a *urosac bag*.
- ◆ Balloon is inflated with 20–30 ml (amount is written on the catheter) of distilled water to make it self-retainable.
- ◆ During removal of the catheter, same amount of water should be removed from the balloon before pulling out the catheter.

### Complications

- ❖ Infection
- ❖ Encrustation
- ❖ Bleeding
- ❖ Stone formation
- ❖ Blockage
- ❖ Stricture
- ❖ Difficulty in removal of the catheter due to blockage of the balloon channel. Here bulb of Foley's can be punctured either from above under US guidance or injecting ether into the balloon so as to burst it but may cause chemical cystitis or passing a stilette into the channel

### MALECOT'S CATHETER

- ◆ Self-retaining urinary catheter with an umbrella or flower at the tip. It is made of red rubber, contains sulphur and so it is radio-opaque.
- ◆ It is never introduced per urethrally.
- ◆ It is sterilised by boiling.



**Fig. 26.17:** Malecot's catheter—photo.



Fig. 26.18: Malecot's catheter—diagram.

#### Uses

- ❖ Suprapubic cystostomy (SPC)
  - In case of urinary retention when Foley's catheterisation fails (after two trials)
  - For diversion of urine following bladder, prostate or urethral surgeries
- ❖ Perinephric abscess
- ❖ Pyonephrosis
- ❖ Cabot's nephrostomy
- ❖ Subphrenic abscess
- ❖ Cholecystostomy
- ❖ Infected pseudocyst of the pancreas
- ❖ Amoebic liver abscess
- ❖ Gastrostomy

#### Advantages:

- ▶ Malecot's catheter can be kept for a longer duration (3 months).
- ▶ It drains fluid adequately.
- ▶ Less infection rate.
- ▶ Removal is easier.


- ❖ **Disadvantage:** Surgery (open method) is required to insert the catheter.

### RED RUBBER CATHETER

- ❖ It is a non self-retaining urinary catheter.
- ❖ Its tip is blunt. It has got only side opening.

#### Uses

- ❖ Used to drain urine from the bladder temporarily.
- ❖ To find out residual urine. After passing urine, catheter is introduced into the bladder. The amount of retained urine is measured. If it is more than 30–50 ml it signifies obstruction. It often increases up to 200–300 ml in conditions like BPH.
- ❖ Other uses
  - ▶ To administer nasal oxygen.
  - ▶ For throat suction.
  - ▶ As a tourniquet for venesection and surgeries of fingers and toes.



- Only opening at the side wall near to tip
- No opening at the tip
- Non self-retaining
- Rounded tip

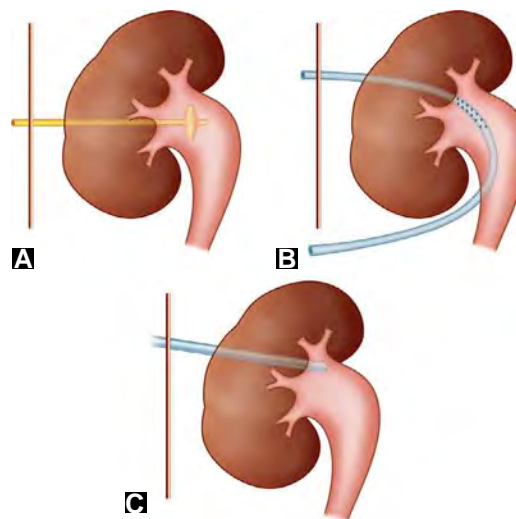
Fig. 26.19: Simple red rubber catheter. It has got only side opening. No opening in the tip (Flatus tube has got opening on both sides as well as at the tip).

### NEPHROSTOMY

Nephrostomy is diversion of urine by passing a tube through the kidney into the calyces.

#### Indications

- ❖ Pyonephrosis
- ❖ Severe hydronephrosis
- ❖ Postoperative—following renal surgeries
- ❖ Obstruction in ureters



Figs 26.20A to C: Nephrostomy types: (A) Cabot's nephrostomy; (B) Tresidder's nephrostomy; (C) Percutaneous nephrostomy.

#### Types

1. **Cabot's nephrostomy:** Malecot's catheter is placed into the calyces.

*The skilful doctors know what is wrong by observing alone, the middling doctor by listening and the inferior doctor by feeling the pulse.*  
—Chang Chung-Ching

2. **Tresidder's through and through loop nephrostomy:** Loop tube is placed with central part in the kidney and ends outside percutaneously to drain urine. This achieves double drainage. New tube can be placed using rail road technique.
3. **Percutaneous nephrostomy:** Done under US guidance using guidewire and dilators.

#### Complications of nephrostomy

- ❖ Bleeding
- ❖ Sepsis
- ❖ Blockage

### SUPRAPUBIC CYSTOSTOMY (SPC)

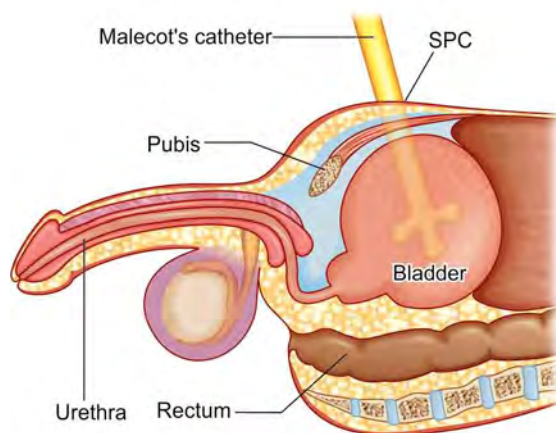
- ◆ It is placing of Malecot's catheter into the bladder above the pubis by open method, or percutaneously under the guidance using Foley's catheter.
- ◆ It is a temporary opening through the abdominal wall into the bladder.

#### Prerequisite

Bladder must be full and is confirmed by dullness below the umbilicus or by ultrasound.

#### Indication

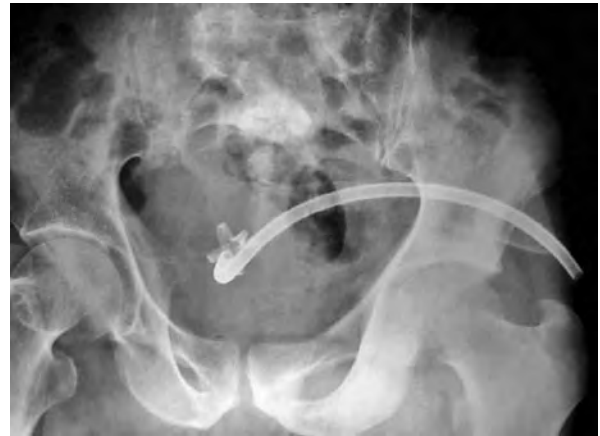Retention of urine, when urethral catheterisation fails.



**Fig. 26.21:** Suprapubic cystostomy (SPC). Malecot's or Foley's catheter can be used.

#### Procedure

- ◆ Under local anaesthesia (Xylocaine 2% above the pubis, in the midline) or G/A, a vertical midline incision of 3 cm in length is placed through linea alba. Skin, fascia, anterior rectus sheath are incised. Recti are retracted. In extraperitoneal space, peritoneum with pad of fat is reflected upward.
- ◆ Bladder is identified by the pattern of detrusor muscle and vesical venous plexus and is also confirmed by aspirating urine through a syringe.



**Fig. 26.22:** X-ray showing radio-opaque Malecot's catheter.

- ◆ The bladder is opened near the fundus. Urine is aspirated. Bladder wall is inspected for any pathology.
- ◆ Malecot's catheter is straightened using artery forceps and placed in the bladder. Sutures are placed around the Malecot's catheter. Wound is closed in layers.
- ◆ In percutaneous SPC, Foley's catheter is passed into the bladder using trocar and cannula.

#### Complications

- ◆ Injury to bowel, peritoneum.
- ◆ Infection.

### HAEMATURIA

#### Types

- ◆ *Gross* (visible to unaided eye).
- ◆ *Microscopic* (>5 RBC's/HPF).

- ❖ *Early* (initial) haematuria: Urethral origin, distal to external sphincter
- ❖ *Terminal* haematuria: Bladder neck or prostate origin
- ❖ *Diffuse* (total) haematuria: Source is in the bladder or upper urinary tract
- ❖ *False haematuria:* Discolouration of urine from pigments such as food colouring and myoglobin.
- ❖ *Silent haematuria* is due to tumours of kidney or bladder unless proved otherwise.

#### Causes

- ❖ Renal injury
- ❖ Urinary stones
- ❖ Wilm's tumour
- ❖ Tuberculosis
- ❖ Renal cell carcinoma
- ❖ Cystitis
- ❖ Bladder tumour
- ❖ Urinary bilharziasis
- ❖ BPH, carcinoma prostate
- ❖ Renal infarct
- ❖ Glomerulonephritis
- ❖ Blood dyscrasias

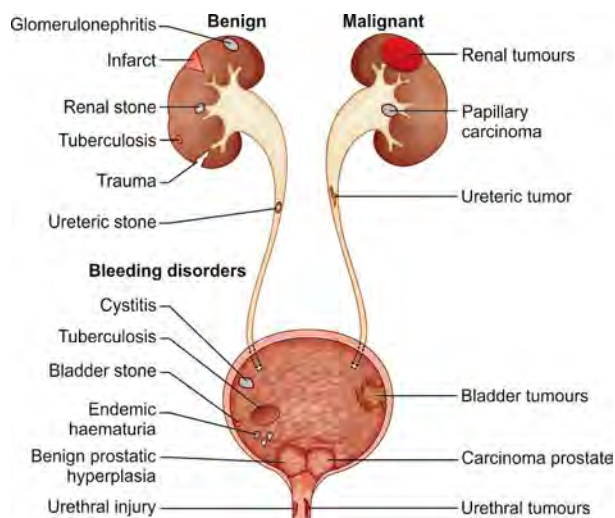


Fig. 26.23: Causes of haematuria.

## Investigations

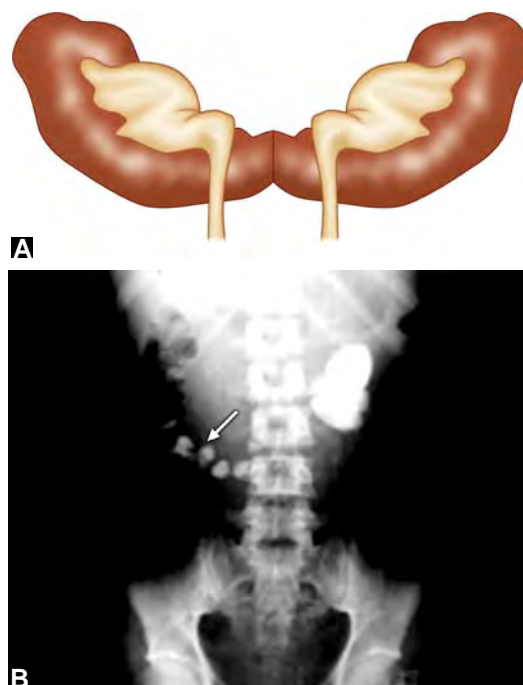
- ◆ Urine culture and sensitivity (urine test for haematuria—*Benzidine test*).
- ◆ Ultrasound to look for the stone, tumour in the urinary tract.
- ◆ Cystourethroscopy to look for bladder or urethral pathology.
- ◆ IVU look for function of the kidneys.
- ◆ Urinary cytology for diagnosing urothelial malignancy.
- ◆ Bleeding time; clotting time; prothrombin time; platelet count.
- ◆ CT abdomen.
- ◆ Renal function tests—blood urea, serum creatinine.

## Management

- ◆ Cause should be identified and treated.
- ◆ Blood transfusion.
- ◆ Antibiotics.
- ◆ Nephroureterectomy for RCC; removal of stone from kidney, ureter, urinary bladder.
- ◆ Treatment of bladder tumour by cystoscopic resection; intravesical chemotherapy using BCG; radiotherapy; systemic chemotherapy.
- ◆ Treatment of medical causes like glomerulonephritis.
- ◆ Correction of BPH.
- ◆ Correction of bleeding diathesis.

## HORSESHOE KIDNEY

- ◆ It is a developmental anomaly where there is failure of complete ascent of kidneys with the fusion of lower or upper poles. It is due to fusion of subdivisions of mesonephric duct, when the embryo is as early as 30–40 days old.
- ◆ This condition is common in males.
- ◆ Fusion of lower pole is common (rarely upper poles).
- ◆ Most common site is in front of 4th lumbar vertebrae. The part in front of the vertebra is called as *isthmus*. It has blood supply which freely communicates one kidney to other. Isthmus usually lies in front of aorta.



Figs 26.24A and B: (A) Horseshoe kidney and (B) Plain X-ray KUB showing horseshoe kidney with renal stones.

## Clinical Features

- ◆ Presents as a fixed, nonmobile, firm mass in the midline at the level of 4th lumbar vertebra which is resonant on percussion.
- ◆ It is more prone for infection, stone formation, hydronephrosis, tuberculosis.

## Diagnosis

- ◆ IVU—medialisation of lower calyces and curving of ureter like a '*flower vase*'.
- ◆ Ultrasound abdomen.

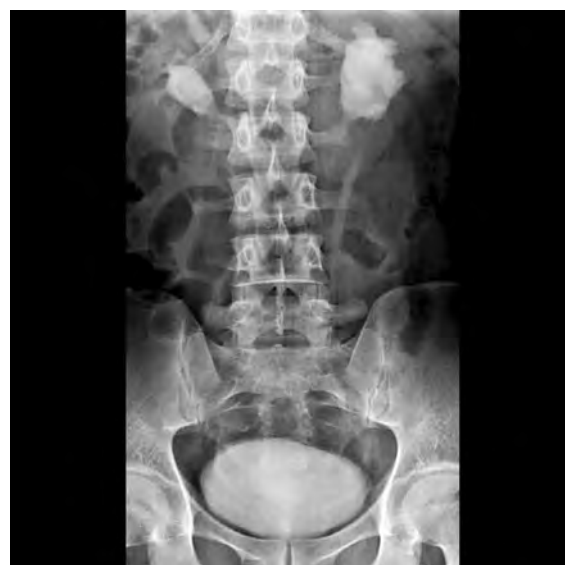

Fig. 26.25: IVU showing flower vase appearance of horseshoe kidney.

*When the patient dies the kidneys may go to the pathologist, but while he lives the urine is ours. It can provide us a serial story of the major events going on within the kidney.*  
—Thomas Addis

- ◆ Urine analysis, blood urea and serum creatinine are supportive investigations.
- ◆ CT abdomen, CT angiogram.

### Treatment

- ◆ Whatever the complication occurs in horseshoe kidney, it is treated accordingly.
- ◆ *Per se* separation of isthmus is not indicated, unless to approach aorta for aortic diseases.

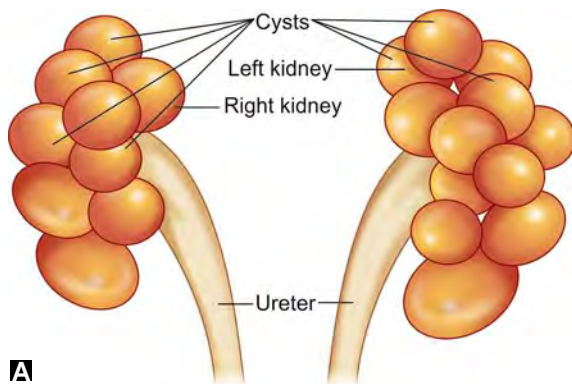
## ■ CYSTIC DISEASES OF THE KIDNEY

### Types

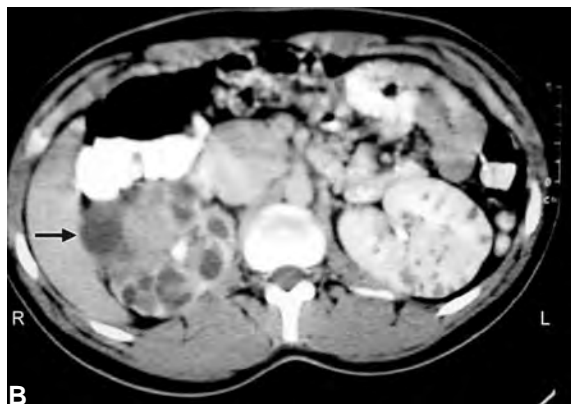
- ◆ **Genetic**
  - ▶ Adult polycystic kidney disease (Autosomal dominant).
  - ▶ Infantile polycystic kidney disease (Autosomal recessive)—fatal.
- ◆ **Nongenetic:** Simple cyst, multicystic kidney, medullary sponge kidney.
- ◆ **Acquired renal cystic disease** may develop in patient on long-term dialysis.

### POLYCYSTIC KIDNEY DISEASE (PCKD)

- ◆ Adult PCKD is inherited as autosomal dominant disease. It is common in females.
- ◆ It is bilateral and presents in third decade. One side presents little earlier than other side.



**A**



**B**

**Figs 26.26A and B:** Polycystic kidney disease, picture and CT scan. It is bilateral, multiple.

- ◆ **Associations**
  - ▶ Polycystic diseases of liver (18%), pancreas and lungs.
  - ▶ Berry aneurysm in the circle of Willis.
- ◆ Cyst formation occurs at the junction of the distal tubule and the collecting duct.
- ◆ Grossly it contains multiple cysts with a clear or brownish fluid (due to haemorrhage).

#### Clinical features

- ❖ Bilateral palpable renal mass
  - ❖ Loin pain
  - ❖ Haematuria
  - ❖ Infection
  - ❖ Hypertension
  - ❖ Uraemia
- ◆ Renal mass, which is lobular, firm, mobile, moves with respiration, ballotable, with dull renal angle and resonant band in front.
  - ◆ Pain, which is due to stretch of renal capsule or haemorrhage into a cyst.
  - ◆ Haematuria (25%), due to overdistended cyst rupturing into the renal pelvis.
  - ◆ Infection is due to stasis.
  - ◆ Hypertension (75%).
  - ◆ Uraemia occurs in late stage due to renal failure.

#### Differential diagnosis

- ❖ Renal cell carcinoma
- ❖ Hydronephrosis
- ❖ Solitary renal cyst

### Investigations

- ◆ Ultrasound confirms the presence of cysts.
- ◆ IVU—*Spider leg pattern* with an elongated compressed renal pelvis, narrowed and stretched calyces.
- ◆ Blood urea and serum creatinine.
- ◆ Urine shows low specific gravity.

### Treatment

- ◆ Wait and watch policy.
- ◆ If one of the cysts overdistends causing pain, haemorrhage, infection, then surgical intervention is required.
- ◆ **Rovsing operation:** The kidney is exposed. The cyst is opened. The fluid is evacuated. The cut edge is marsupialised.
- ◆ Presently US-guided aspiration is done as a simpler approach.
- ◆ Laparoscopic/retroperitoneoscopic aspiration/de-roofing of the renal cyst.
- ◆ Once renal failure sets in, then initial haemodialysis followed by bilateral nephrectomy, is done and later renal transplantation should be planned for.

### SOLITARY RENAL CYST

- ◆ Solitary renal cyst is never congenital.
- ◆ It is due to an earlier trauma or infection resulting in blockage of tubule, leading to cyst formation.
- ◆ It is usually unilateral, presents as a renal mass which is smooth, often tender if infected or haemorrhagic.

## Differential Diagnosis

- ◆ Renal neoplasm.
- ◆ Hydronephrosis.
- ◆ Polycystic disease.
- ◆ Hydatid cyst.

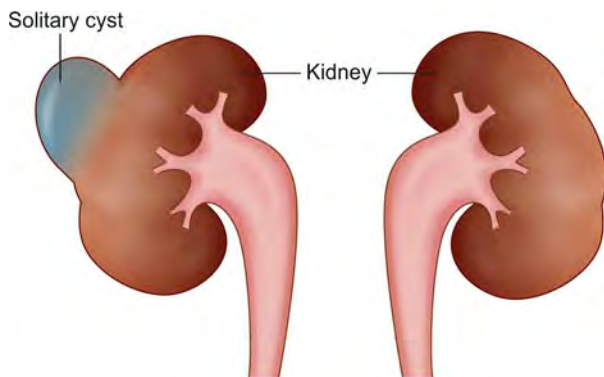


Fig. 26.27: Solitary renal cyst. It is acquired, unilateral.

## Investigation

- ◆ Ultrasound and IVU confirms the diagnosis.
- ◆ CT scan.

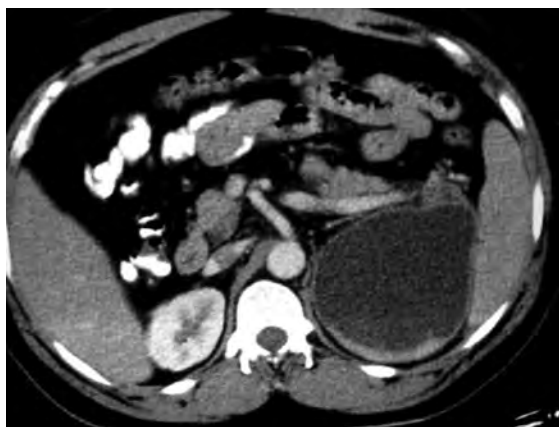

Fig. 26.28: Left side renal cyst—CT picture. It could be solitary renal cyst. It can be aspirated or de-roofed by laparoscopy/retroperitoneoscopy.

## Treatment

- ◆ Kidney is exposed. The cyst is aspirated and a portion of the cyst wall is removed (*Kirwin's operation*) and cavity is filled with perinephric fat.
- ◆ Occasionally if the cyst is in one of the poles, partial nephrectomy is done.
- ◆ Laparoscopic approach.

## DUPLICATION OF RENAL PELVIS AND URETER

- ◆ It is most common congenital anomaly of the upper urinary tract (4%).

- ◆ Usually unilateral. Common on the left side.
- ◆ In 3% of cases, it is associated with duplication of ureter.
- ◆ Upper renal pelvis is small, drains the upper calyces. Lower renal pelvis is larger, drains the middle and lower calyces.
- ◆ Double ureter when associated, may be *partial* where two ureters join in lower third or *complete* where upper ureter opens into the bladder at a lower level and lower ureter opens into the bladder at the upper, normal ureteric orifice. This is called as "*Weigert Meyer Law*".
- ◆ In partial duplex, there is reno-renal reflux resulting in infection, stone formation and hydronephrosis.

## Investigations

- ◆ IVU—diagnostic.
- ◆ US to look for complications.
- ◆ Cystoscopy shows **double ureteric orifices** on the same side.
- ◆ DTPA scan to see the function.

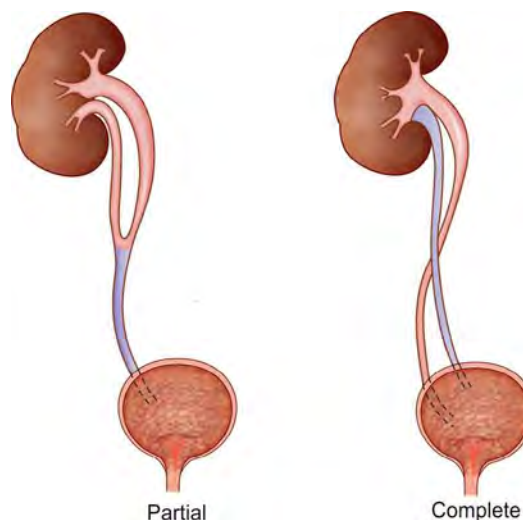
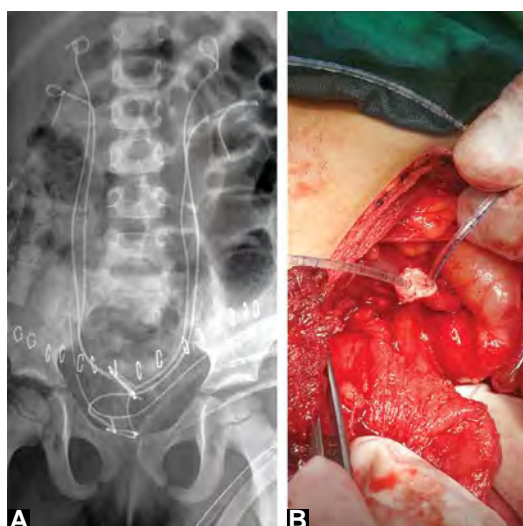


Fig. 26.29: Duplex renal system.



Figs 26.30A and B: Bilateral complete duplex kidney on table look and X-ray postoperatively. Both duplex ureters are reimplanted into the urinary bladder.



## Treatment

- ◆ Ureteric meatotomy is done if there is narrowing of the orifice.
- ◆ The co-existing complications are treated.

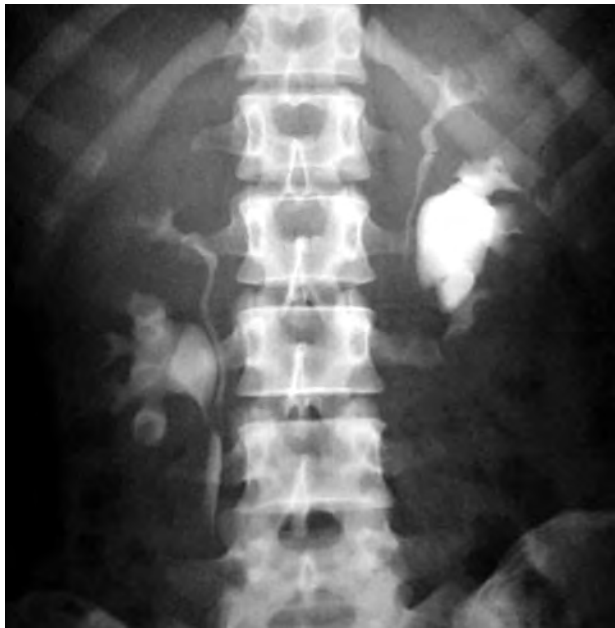

Fig. 26.31: IVU showing bilateral duplex kidney.

- ◆ Often heminephrectomy including removal of corresponding ureter may be essential as treatment.
- ◆ In females with complete duplication, lower ureteric orifice is ectopic, causing urinary incontinence which needs partial nephrectomy or ureteric reimplantation.

## RETROCAVAL URETER

- ◆ It is due to developmental defect of IVC, as a result of which right ureter passes behind the IVC, causing right-sided hydronephrosis with upper third hydroureter.

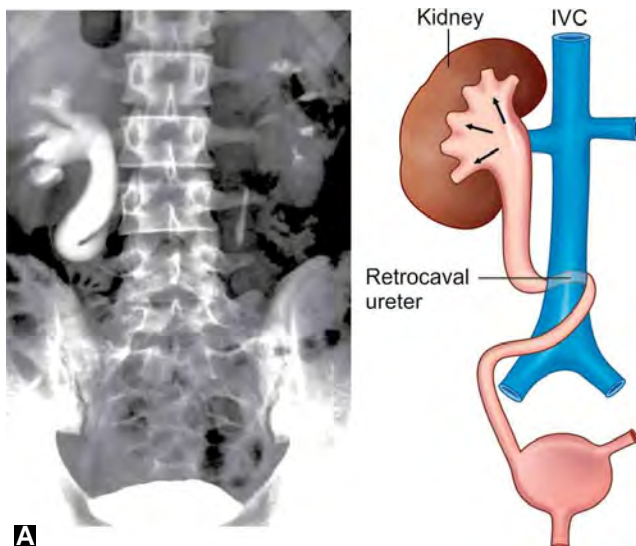


Fig. 26.32A

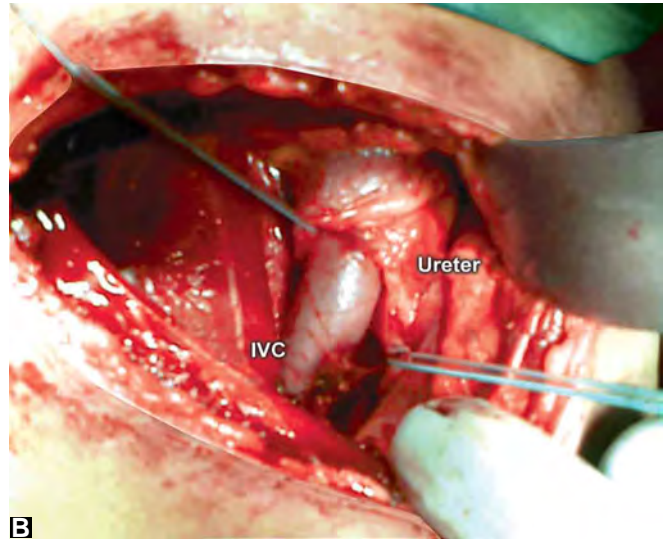


Fig. 26.32B

**Figs 26.32A and B:** Retrocaval ureter—IVU picture showing reverse J sign. On table finding of retrocaval ureter. It is treated by Anderson's Hynes operation. It causes hydronephrosis. It is due to anomalous development of IVC.

- ◆ IVU shows hydronephrosis with 'reverse J sign'.
- ◆ *Treatment:* Anderson Hynes' operation.

## URETEROCELE

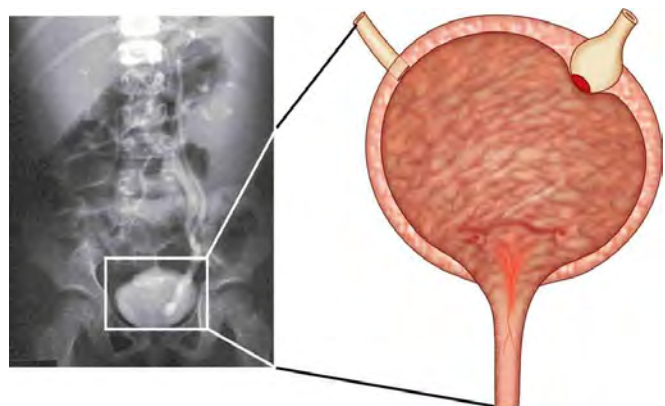
- ◆ It is a *cystic enlargement of the intramural portion of ureter* due to congenital atresia of the ureteric orifice. Its wall contains mucous membrane only.
- ◆ It is common in females, often bilateral (10%).

### Complications

- ❖ Stone formation
- ❖ Recurrent infection
- ❖ Hydronephrosis

### Stephen classification

Stenotic, sphincteric, sphincterostenotic



**Fig. 26.33:** IVU reveals left-sided ureterocele with duplex kidney. Note the characteristic Cobra (Adder) head pattern of left ureterocele.

## Investigations

- ◆ IVU—shows *Adder head* appearance or *cobra head* appearance.
- ◆ Cystoscopy—shows translucent cyst which is thin walled surrounding the ureteric orifice.

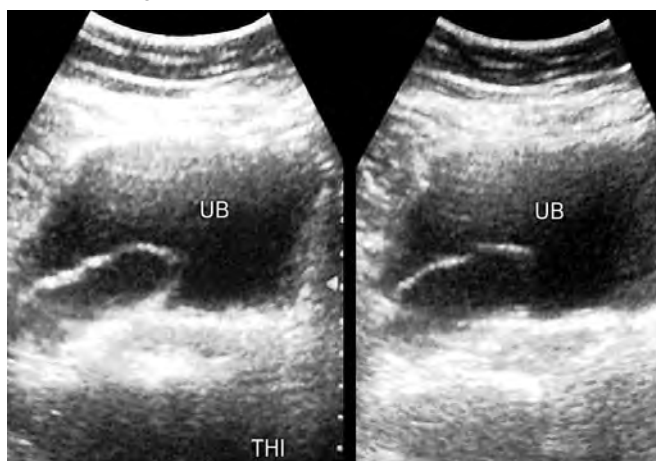


Fig. 26.34: Ultrasound picture of ureterocele—Adder head appearance.

## Treatment

- ◆ *Cystoscopic ureteric meatotomy* with the removal of cyst wall.
- ◆ In addition to that co-existing complications should be treated.
- ◆ Often ureteric reimplantation is needed.

## INJURIES TO KIDNEY

- ◆ Commonly, it is due to a blunt injury.
- ◆ Often it is associated with other abdominal injuries—of liver, spleen, bowel, mesentery, etc.
- ◆ *Per se renal injury is extraperitoneal.*

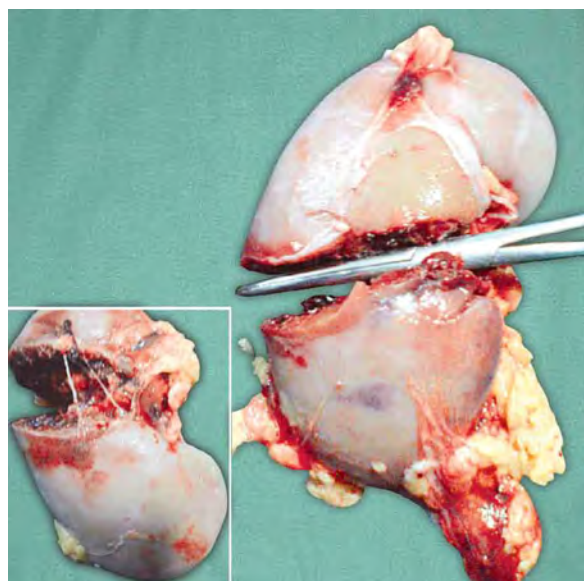


Fig. 26.35: Renal trauma causing extensive laceration. Patient underwent nephrectomy (Courtesy: Dr Ashfaque Mohammed, DNB; KMC, Mangaluru).

## Types

1. Small subcapsular.
2. Large subcapsular.
3. Cortical laceration.
4. Laceration with perinephric haematoma.
5. Medullary laceration with bleeding into the renal pelvis.
6. Corticomedullary complete rupture.
7. Hilar injury (most dangerous).

### Grading of renal injury

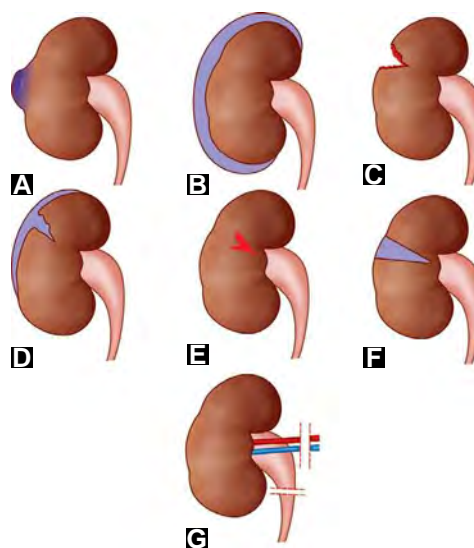
1. Subcapsular nonexpanding haematoma without parenchymal laceration
2. Cortical laceration <1 cm of parenchymal depth, no extravasation; perirenal haematoma
3. Cortical laceration >1 cm depth; no urine extravasation
4. Parenchymal laceration extending through cortex and medulla with collecting system; with extravasation of urine; expanding subcapsular haematoma
5. Renal pedicle avulsion; shattered kidney

## Clinical Features

- ◆ Features of *shock*.
- ◆ *Haematuria*—may be mild to profuse depending on the type of injury.
- ◆ *Sudden delayed profuse haemorrhage* causing haematuria can occur between 3rd day to 3rd week after trauma.
- ◆ *Clot colic*.
- ◆ Bruising, swelling and tenderness in the loin.
- ◆ Paralytic ileus with abdominal distension occurs due to retroperitoneal haematoma implicating splanchnic nerves.

## Investigations

- ◆ *CT scan is the investigation of choice.* It gives the grading of the renal injury; identifies the associated injuries; gives idea about the function of the kidney reasonably.



Figs 26.36A to G: (A) Small subcapsular; (B) Large subcapsular; (C) Cortical laceration; (D) Laceration with perinephric haematoma; (E) Medullary laceration with bleeding into the renal pelvis; (F) Corticomedullary complete rupture, (G) Hilar injury (most dangerous).

- ◆ *Ultrasound abdomen* is also important initial tool to identify the site and type of injuries, haemoperitoneum and associated injuries. It is very useful tool to check the response for conservative therapy by repeating it at regular intervals.
- ◆ *IVU* is also useful to see the function of the injured kidney as well as opposite kidney; often it is possible that opposite renal artery goes for reflex spasm, temporarily ceasing the function of the opposite kidney. This may lead into uraemia with raised blood urea and serum creatinine and often needs haemodialysis for few times. Presently, IVU is not an essential investigation; but often done for documentation.
- ◆ *Renal function tests* at regular intervals; serum electrolyte estimation, haematocrit assessment, blood grouping—are other needed investigations.
- ◆ Chest X-ray, CT scan chest, plain X-ray abdomen often may require to be done.

### Treatment

- I. *Initially always conservative:*
  - ▶ Catheterise and watch the urine colour and output.
  - ▶ Blood transfusion.
  - ▶ Strict observation with regular monitoring of the pulse, BP, temperature, *U/S follow-up daily*.
  - ▶ Sedation, analgesic and antibiotics.
  - ▶ 75% of patients respond to conservative management.
  - ▶ While treating conservatively, regular monitoring of blood urea and serum creatinine is a must.
  - ▶ If the patient goes in for renal failure, haemodialysis should be done for 6–8 weeks. Meanwhile, other kidney starts functioning again and patient recovers without any further problem.
- II. *Indications for surgical intervention:*
  - ▶ When there are signs of progressive blood loss with the condition of the patient deteriorating.
  - ▶ Formation of progressive perinephric haematoma (*pulsatile haematoma*).
  - ▶ When there are associated other injuries.
  - ▶ Hilar injury with PUJ disruption.

### Surgery (Only in 10–20% of Patients)

#### Options:

- ◆ Gentle suturing of the laceration. Often kidney is friable, this is not possible.
- ◆ Then nephrostomy (Cabot's) is done.
- ◆ When the injury is in the poles, partial nephrectomy is done.
- ◆ In *hilar injury and severe laceration, nephrectomy is the only choice*.

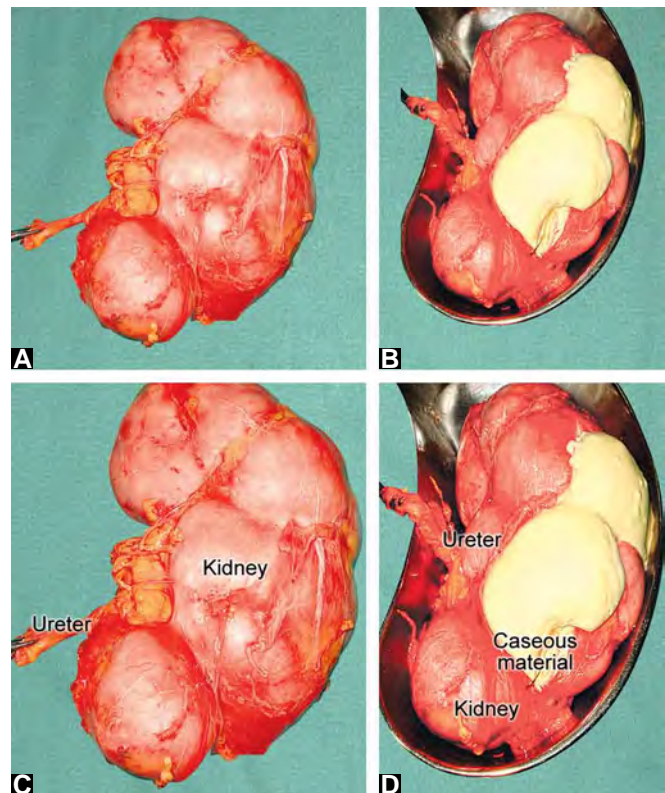
	Types	Treatment
I	Only bruise/contusion	Conservative
II	Breach in calyceal system rupture of one of the small branches of renal artery	Conservative/ nephrectomy
III	Rupture of pelvi-calyceal system/ renal substance	Nephrectomy

### Complications

- ❖ Clot retention in the bladder and may go for renal failure
- ❖ Pararenal pseudo hydronephrosis
- ❖ Infection
- ❖ Perinephric abscess
- ❖ Aneurysm of the renal artery
- ❖ Renal failure
- ❖ Hypertension occurs 3 months later

### RENAL TUBERCULOSIS

- ◆ Commonly it is *secondary*. Primary may be in the lung.
- ◆ Tuberculous bacilluria occurs with an early lesion in the renal cortex, and the disease spreads along the ureter causing tuberculous ureteritis and stricture ureter.
- ◆ Tuberculous kidney results in any of the following pathological types.



**Figs 26.37A to D:** Specimen of kidney showing dilatation and caseous material as content. It is tuberculous pyonephrosis. Ureter is visualised in the specimen. Often there may be ureteric stricture due to tuberculosis.

### Pathological Types

Through blood, bacteria reach the glomeruli causing caseating granuloma with Langhan's type of giant cells and epithelioid cells. These granulomas coalesce to form a papillary ulcer and other consecutive different forms.

- ◆ *Tuberculous papillary ulcer.*
- ◆ *Cavernous form.*
- ◆ *Hydronephrosis.*
- ◆ *Pyonephrosis* [due to (secondary) superadded infection by *E. coli*, *Klebsiella*].
- ◆ *Tuberculous perinephric abscess.*
- ◆ *Calcified tuberculous area* (mimics calculi, hence called as pseudocalculi).
- ◆ *Caseous kidney*—often called as *putty kidney* or *cement kidney* (it goes for autonephrectomy).
- ◆ *Miliary tuberculosis.*
- ◆ Tuberculous bacilluria occurs from an early stage of the disease which causes tuberculous ureteritis and stricture ureter. Most common site is *ureterovesical junction*; second common site is pelviureteric junction.
  - ▶ Tuberculous cystitis eventually results in *golf hole ureter* and *thimble bladder* (cystoscopic findings). This is due to fibrosis causing rigid withdrawn dilated ureteric orifice looking like *golf hole*. Entire urinary bladder gets fibrosed, stiff and unable to dilate and accommodate urine causing *thimble systolic bladder*.
  - ▶ Tuberculous prostatitis, seminal vesiculitis (P/R—palpable seminal vesicle), tuberculous epididymitis and funiculitis are other associations. Thickened epididymis with ulcer on the posterior aspect of the scrotum may often be found. Tuberculous funiculitis with beaded, thickened vas deferens.

## Clinical Features

- ◆ Common in males.

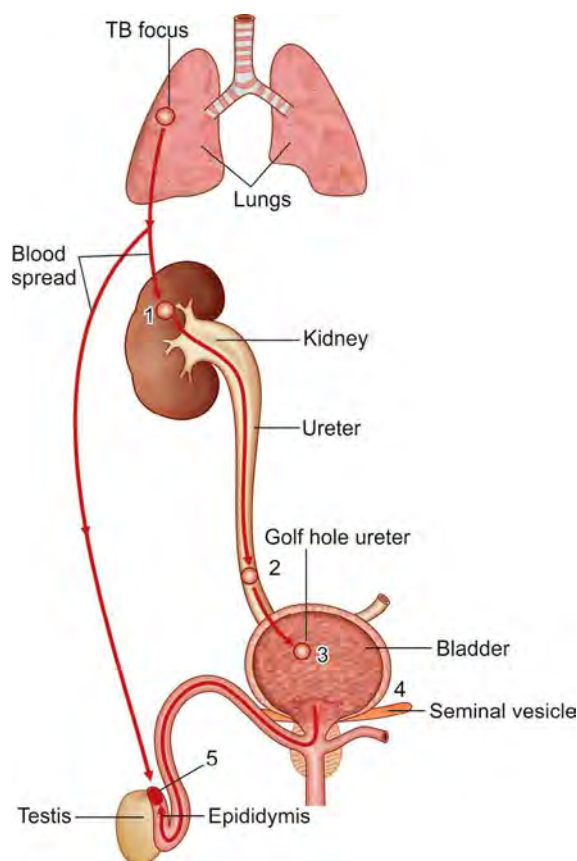


Fig. 26.38: Mode of spread in urinary tuberculosis.

- ◆ Common on right side.
- ◆ Frequency—both day and night.
- ◆ Polyuria.
- ◆ *Sterile pyuria*: Urine is pale and opalescent with presence of pus cells without organisms in an acid urine—*abacterial aciduria* (Other causes: Interstitial cystitis, chlamydia).
- ◆ *Painful micturition with often haematuria*. Haematuria may be overt or microscopic (50%).
- ◆ Renal pain and suprapubic pain. Suprapubic pain is more common due to cystitis.
- ◆ *Tuberculous kidney is rarely palpable* unless there is hydronephrosis or perinephric abscess.
- ◆ Enlarged prostate and seminal vesicle, thickened beaded vas, thickened epididymis, impotence, infertility are other features.
- ◆ Presentation like acute pyelonephritis.
- ◆ Features of urinary stones; recurrent urinary tract infection; renal failure if both kidneys are diseased; hypertension.
- ◆ Haemospermia; pelvic pain.
- ◆ Dyspareunia; menstrual dysfunction; vaginal discharge; infertility in females.
- ◆ Fever and weight loss.
- ◆ Often cough with expectoration and haemoptysis may be present.

## Investigations

- ◆ ↓Hb%.
- ◆ ↑ESR. Mantoux skin test is usually positive.
- ◆ Chest X-ray.
- ◆ U/S abdomen.
- ◆ *Three consecutive early morning samples of urine (EMSU)* are collected and sent for microscopy (Ziehl-Neelsen staining), culture (L-J media) or guinea pig inoculation.
- ◆ Plain X-ray KUB—shows calcification.
- ◆ CT scan of abdomen and pelvis to see hydronephrosis, shrunken kidney, stricture, necrosis.
- ◆ IVU—hydrocalyx, narrowing of calyx, stricture ureter which are often multiple with dilatations in between.
- ◆ Often RGP is very useful, as better definition of ureter, pelvis, calyces and selective sampling of urine are possible.

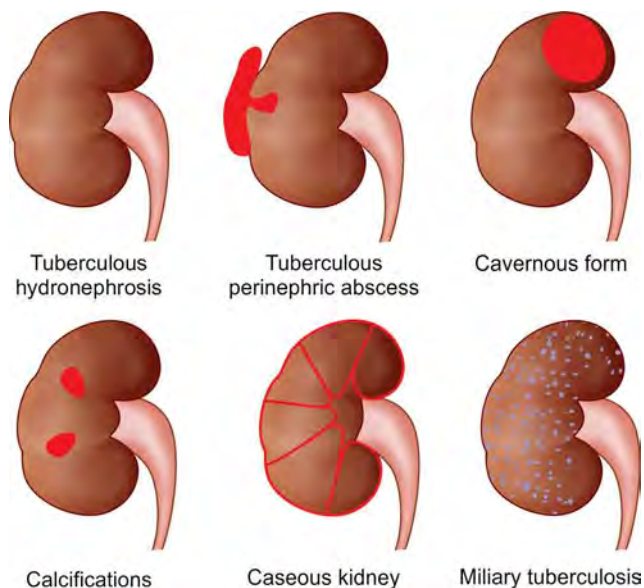
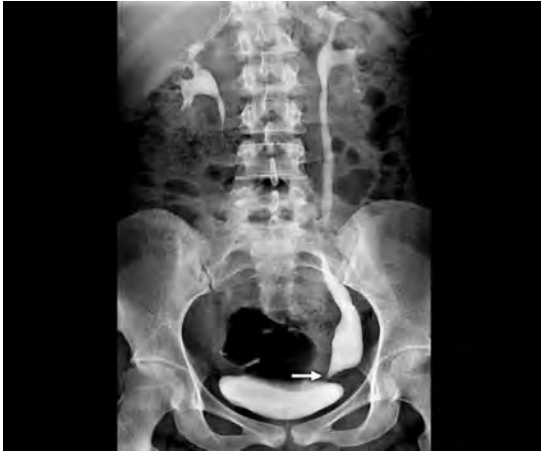

Fig. 26.39: Renal tuberculosis types.

*Always make a total effort even when the odds are against you.*



**Fig. 26.40:** Stricture of left ureter lower part—IVU picture. Common cause is tuberculosis of ureter.

- ◆ Cystoscopy reveals multiple tubercles, bladder spasm, oedema of ureteric orifice eventually forming “*golf hole ureter*”, scarring, ulceration, bleeding, stone formation.
- ◆ Polymerase chain reaction (PCR) for tuberculosis. Radioisometric culture.
- ◆ Voiding cystourethrography (MCU) to see ureteric stricture and reflux.

### Treatment

- ◆ Antitubercular therapy is started. INH, rifampicin, ethambutol and pyrazinamide. Duration of treatment is *one year*.
- ◆ After 6–12 weeks of drug therapy, surgical treatment is planned. Kidney is exposed. Pyocalyx is drained. Cut edge of the capsule is sutured—*Hanley's renal cavernostomy*.
- ◆ Hydronephrosis—*Anderson Hynes* operation or nephrostomy or stenting (“*J*” stent) of ureter is done.
- ◆ Renal tuberculous abscess not resolving for 2 weeks should be drained.
- ◆ Ureteral stricture—stenting/reimplantation of the ureter into the bladder/psoas hitch/Boari's flap/ileal conduit (*Koch's ileal conduit*).
- ◆ Thimble bladder—hydraulic dilatation/ileocystoplasty/caecocystoplasty/sigmoid colocoloplasty is done.
- ◆ In unilateral lesion, with gross impairment of renal function—*nephroureterectomy* is done.

#### Indications for nephroureterectomy

- ❖ Nonfunctioning kidney
- ❖ Disease extensively involving the kidney
- ❖ Disease causing hypertension and severe obstruction
- ❖ Tuberculous pyonephrosis
- ❖ Coexisting renal cell carcinoma

### HYDRONEPHROSIS (HN)

It is an *aseptic dilatation* of pelvicalyceal system due to *partial or intermittent obstruction* to the outflow of urine.

#### Aetiology

It can be unilateral or bilateral.

#### Unilateral

##### A. Extramural:

1. Aberrant renal vessels (vein or artery). It is common on *left side*.
2. Compression by growth (carcinoma cervix, carcinoma rectum).
3. Retroperitoneal fibrosis.
4. Retrocaval ureter.

##### B. Intramural:

1. Congenital PUJ obstruction.
2. Ureterocele.
3. Neoplasm of ureter.
4. Narrow ureteric orifice.
5. Stricture ureter following removal of stone, pelvic surgeries or tuberculosis of ureter.

##### C. Intraluminal:

1. Stone in the renal pelvis or ureter.
2. Sloughed papilla in papillary necrosis.

#### Bilateral

##### A. Congenital:

- ▶ Congenital stricture of external urethral meatus, pin-hole meatus.
- ▶ Congenital posterior urethral valve.

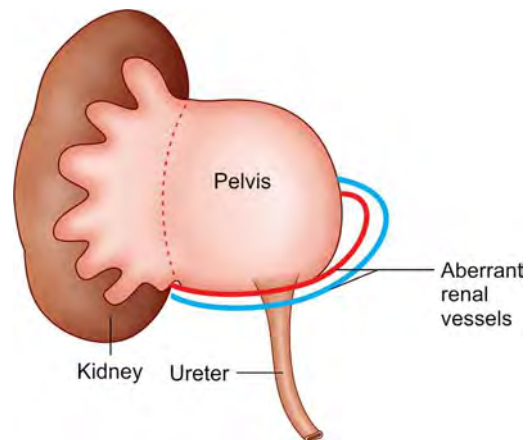
##### B. Acquired:

- ▶ BPH.
- ▶ Carcinoma prostate.
- ▶ Postoperative bladder neck scarring.
- ▶ Inflammatory/traumatic urethral stricture.
- ▶ Phimosis.
- ▶ Carcinoma cervix.
- ▶ Bladder carcinoma.

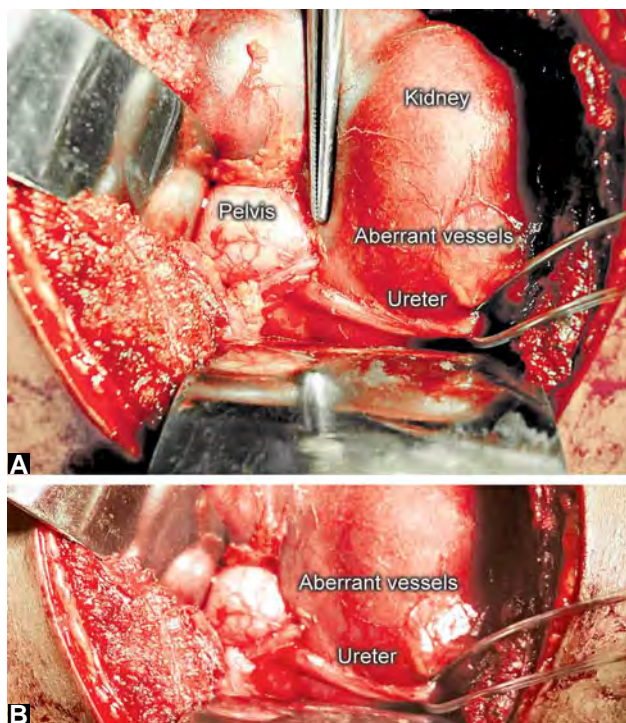
◆ *Congenital PUJ is the most common cause of HN.*

◆ Often it is bilateral and presentation on one side is earlier than the other side.

◆ **Aberrant renal artery or vein** in the lower pole of kidney can compress the PUJ causing HN. Renal angiogram confirms the diagnosis.



**Fig. 26.41:** Aberrant renal vessels are one of the known causes of hydronephrosis.



**Figs 26.42A and B:** Aberrant renal vessels causing obstruction and hydronephrosis. As this often supplies lower pole of kidney exclusively, it needs to be retained.

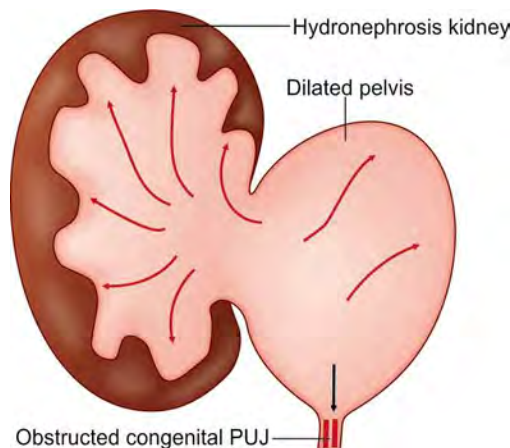
*Treatment of aberrant renal vessels*

If it is a vein, it can be ligated safely. But if it is an artery, it exclusively supplies the lower pole of the kidney and so cannot be ligated. So kidney is mobilised; upper and lower poles are approximated together so that artery is made to slip away from the site of compression—*Hamilton Stewart operation*.

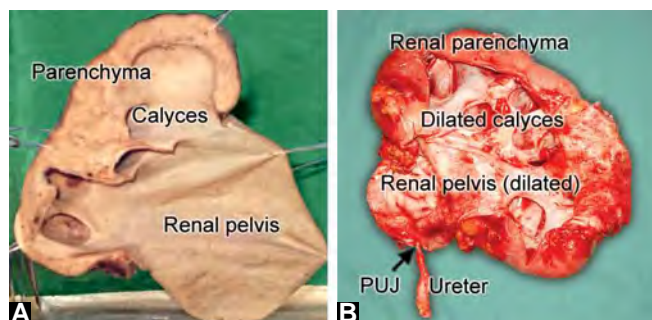
- ◆ **In pregnancy** dilatation of ureters and both pelvis occur due to atony of ureteric musculature by progesterone. It starts as early as in the first few weeks of pregnancy and lasts until few weeks after delivery. Involution occurs 2–12 weeks after delivery.

**Pathology**

- ◆ Initially pressure burden is taken up by the pelvis; later calyces and renal parenchyma. Gradually, parenchyma thins out due to destruction and it dilates. Eventually leading to compromised secretory function. Parenchymal thickness of less than 2 mm is unlikely to function. In bilateral cases such patients will go for renal failure.



**Fig. 26.43:** Hydronephrosis due to congenital PUJ obstruction. It is the common cause of hydronephrosis.



**Figs 26.44A and B:** Specimens showing hydronephrosis.

**Classifications**

*Classification I*

- ❖ Unilateral HN
- ❖ Bilateral HN without renal failure
- ❖ Bilateral HN with renal failure

*Classification II*

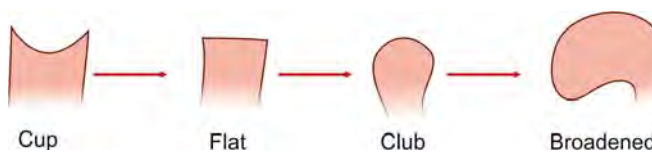
- ❖ *Intermittent HN:* Obstruction occurs, swelling and pain appear in the loin. After sometime, patient passes large amount of urine following which swelling and pain disappear—*Dietl's crisis*
- ❖ *Persistent HN:* It is due to persistent partial obstruction

*Classification III*

- ❖ HN only
- ❖ HN with hydroureter

*Classification IV*

- ❖ Extrarenal pelvic HN (80%)
- ❖ Intrarenal pelvic HN (20%). Destruction of kidney is earlier and severe here, as compared to extrarenal pelvic HN



**Fig. 26.45:** Stages of HN.

**Clinical Features**

*A. In unilateral cases:*

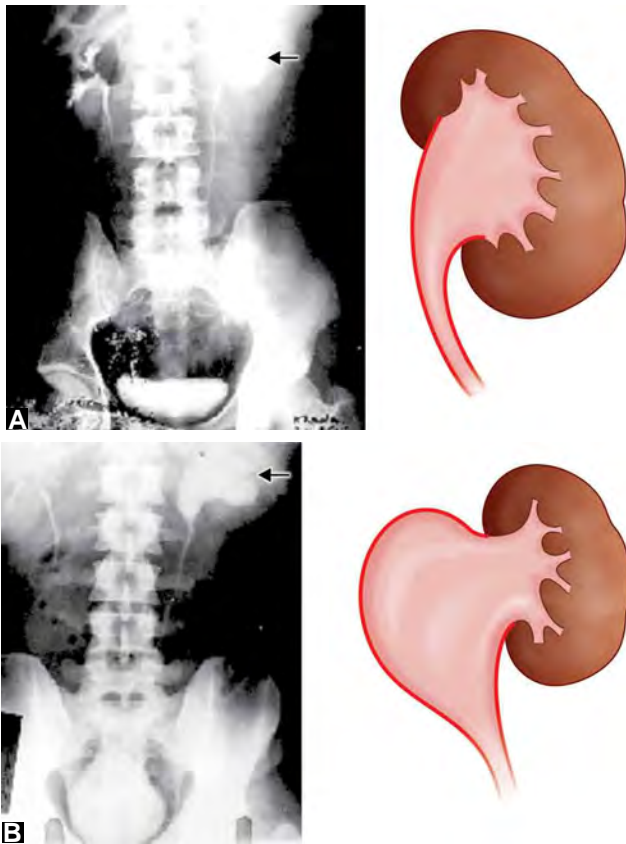
- ▶ Congenital PUJ obstruction and calculus are the most common causes.
- ▶ M : F : : 2 : 1.
  - Right side kidney is affected more commonly.
  - Dull aching loin pain with dragging sensation or heaviness.

*Variability is the law of life, and so no two faces are the same, so no two bodies are alike, and no two individuals react alike and behave alike under the abnormal conditions which we know as disease.* —William Osler

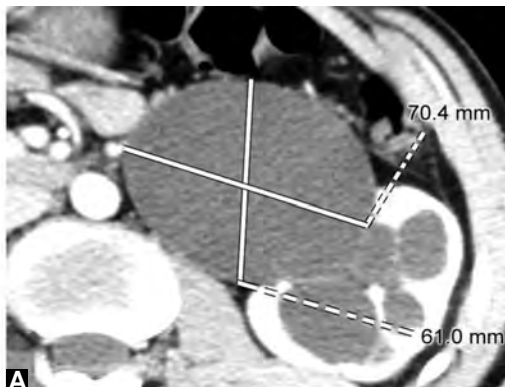
- Mass in the loin which is smooth, mobile, ballotable, moves with respiration with dullness in renal angle and a band of colonic resonance in front.
- Attacks of acute renal colic.
- Often patient may be having *Dietl's crisis*—after an acute attack of renal colic, swelling in the loin is seen which disappears after sometime following passage of large volume of urine.
- Dysuria, haematuria, if infected fever and tenderness in renal angle.
- Occasionally hypertension.

B. In bilateral cases:

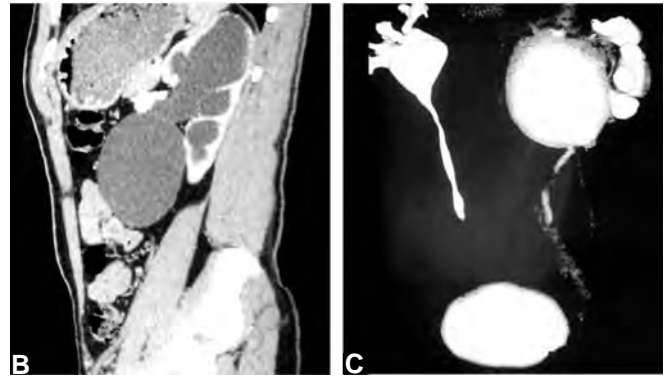
- ▶ From lower urinary tract obstruction.



**Figs 26.46A and B:** Types of renal pelvis: (A) Intrarenal; (B) Extrarenal.



**Fig. 26.47A**



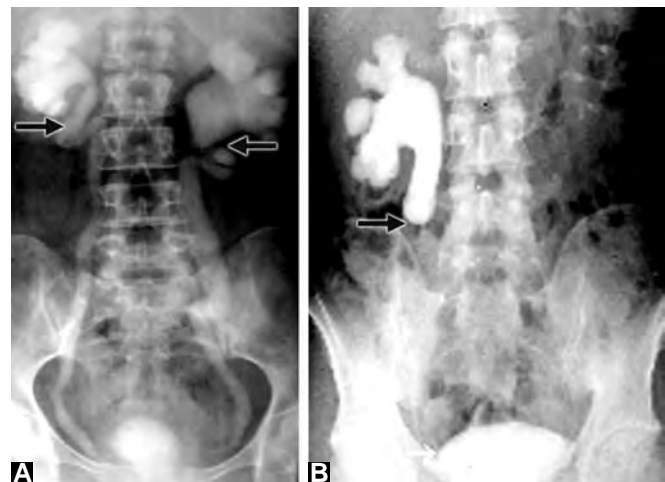
**Figs 26.47B and C**

**Figs 26.47A to C:** CT scan showing hydronephrosis of left kidney with extrarenal pelvis. Patient underwent laparoscopic pyeloplasty (Courtesy: Dr Ashok Padit, MCh, Urologist, Mangala Hospital, Mangaluru).

- ❖ Loin pain
- ❖ Features of bladder outlet obstruction—frequency, hesitancy, poor stream
- ❖ Kidneys are often not palpable if renal failure develops early

- ▶ From bilateral upper urinary tract obstruction.

- ❖ Loin pain, mass in the loin, attacks of renal colic
- ❖ In bilateral cases, when it is severe, features of renal failure like oliguria, oedema, hiccough may be present



**Figs 26.48A and B:** (A) IVU showing bilateral hydronephrosis and hydroureter; (B) IVP showing right hydronephrosis. Note the dilated right renal pelvis and delay in the excretion of the dye from the affected kidney.)

### Complications

1. Pyonephrosis.
2. Perinephric abscess.
3. Renal failure in bilateral cases.

### Investigations

- ◆ Blood urea and serum creatinine.
- ◆ Urine for microscopy.
- ◆ Ultrasound abdomen: Investigation of choice.

Type of pelvis, thickness of parenchyma, site of obstruction, and cause of obstruction, e.g. stones, can be made out.

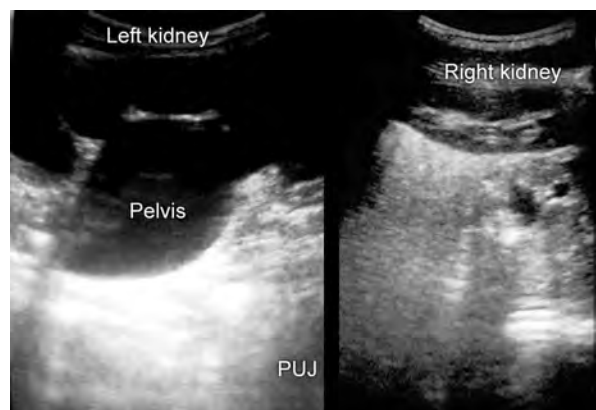


Fig. 26.49: Ultrasound picture of hydronephrosis showing dilated pelvis.

- ◆ **IVU:** To find out the function of diseased as well as opposite kidney. Normal calyx is *cup* shaped. It gets *flattened* and later *club shaped* which eventually becomes *broadened* in hydronephrosis.
- ◆ **CT scan** is diagnostic.

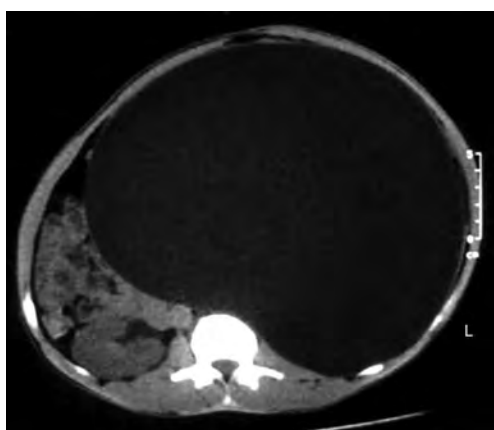
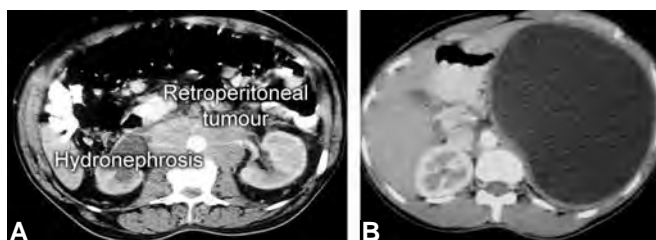

Fig. 26.50: Hydronephrosis as seen in CT scan.

- ◆ **Isotope renography** is also useful to study the function of the kidney before and after the surgical treatment and also to see the efficacy of surgery as far as function is considered—DTPA scan.



Figs 26.51A and B: (A) Retroperitoneal tumour causing ureteral obstruction with hydronephrosis; (B) CT scan showing bilateral hydronephrosis. One side large (left side); another side early hydronephrosis.

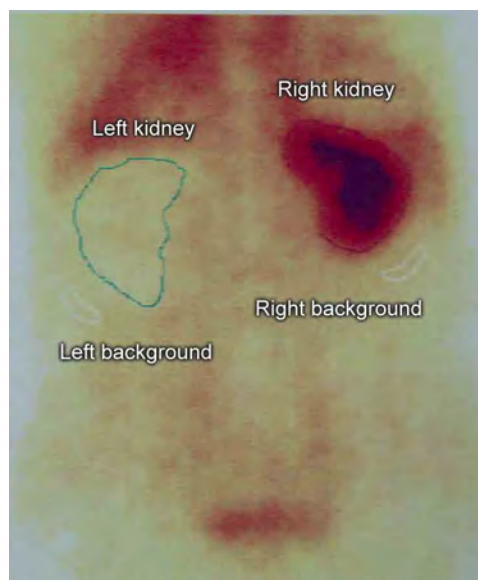


Fig. 26.52: Isotope scan showing hydronephrosis on the left side.

- ◆ **Whitaker test:** A fine needle is passed into the renal pelvis through loin. Pelvis is perfused with saline at a rate of 10 ml/minute. Normally, initially the pressure increases and later it will remain constant. Persistent increase in pressure suggests HN.

### Treatment

- ◆ Always conservative surgeries which are aimed at conserving the kidneys are done. Nephrectomy is not done unless indicated.
- 1. The cause is treated: Stone, congenital anomaly, aberrant renal vessels, stricture urethra (dilatation, urethrotomy, urethroplasty); phimosis (circumcision); BPH (TURP); posterior urethral valve (cystoscopic fulguration of valve).

**Note:**

Please refer respective topics and highlight the individual treatment.

- 2. **Anderson-Hyne's operation (Dismembered pyeloplasty):** In congenital PUJ obstruction, the spasmodic segment and redundant pelvis are excised. A new pelvis is created and the cut end of pelvis is anastomosed to the ureter in the *dependent* position.

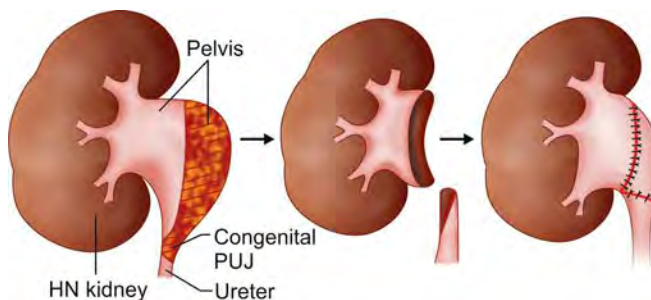


Fig. 26.53: Anderson-Hyne's operation.



3. *Davis T-tube ureterostomy*: Placement of T-tube in the ureter by making longitudinal incision.
4. *Non-dismembered pyeloplasties*: Here PUJ is not transected. Reconstruction is done without PUJ transection by different methods, e.g. **Foley's Y-V plasty**.
5. In bilateral HN, without renal failure, *kidney which is functioning better should be operated first*. Three months later, otherside kidney is dealt with.
6. In bilateral HN with renal failure, *bilateral nephrostomy and haemodialysis* support is required initially. After 3–6 weeks IVU is done and the functions of both kidneys are looked for. If they function, then treated accordingly by Anderson-Hyne's operation.  
*If kidneys are still not functioning (renal function <20% on isotope study) then nephrectomy and renal transplantation is the only option left.*
7. *Laparoscopic or retroperitoneoscopic pyeloplasty* is becoming popular but is expensive and time consuming. It gives good result as well.
8. *Endoscopic pyelolysis*, even though technically easier, results are not assured.

## PYONEPHROSIS

It is collection of pus in pelvicalyceal system, which is converted into a multiloculated sac. Occurs due to:

- a. Infection of pre-existing hydronephrosis.
- b. Following acute pyelonephritis.
- c. As a complication of renal calculus—either stone in the renal pelvis or staghorn calculus.

## Clinical Features

- ◆ Usually unilateral.

### Triad

- ❖ Anaemia
- ❖ Fever
- ❖ Loin swelling

- ◆ Tender mass in the loin which is smooth, soft, not mobile, not moving with respiration.
- ◆ Patient may also have cystitis, pyuria, burning micturition.
- ◆ Features of toxicity such as fever with chills and rigors.

## Investigations

- ◆ Plain X-ray, KUB, may show renal calculus.
- ◆ IVU shows HN poor secretion.
- ◆ *Cystoscopy* reveals cystitis with *efflux of purulent pus* through the ureteric orifice.
- ◆ Ultrasound shows dilatation.
- ◆ DTPA scan later.

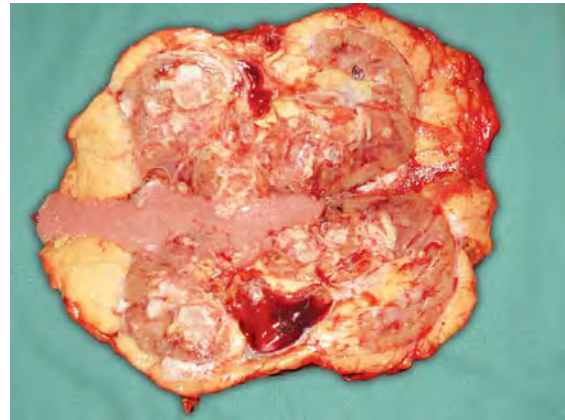
## Treatment

- ◆ After starting antibiotics, pus is immediately drained from the kidney through a loin incision and *nephrostomy* tube (Cabot's nephrostomy) (Malecot's catheter) is placed.

- ◆ If kidney is totally destroyed, *subcapsular nephrectomy* is done. This also prevents other kidney from getting infected through perirenal lymphatic connections.
- ◆ In bilateral pyonephrosis, *bilateral nephrostomy* is the only choice. '*J*' stenting is done often to keep the ureters patent.

## CARBUNCLE OF KIDNEY (RENAL CARBUNCLE)

- ◆ A localised inflammatory necrotic mass of tissue involving renal parenchyma, caused by *Staphylococcus aureus* and coliform organisms, source of which is cutaneous infections like boil and carbuncle.
- ◆ It presents as ill-defined tender swelling in the loin, with pyrexia and leucocytosis.



**Fig. 26.54:** Cut section of specimen of kidney showing pus, necrotic area, and multiple infected abscesses—renal carbuncle with multiple abscesses. Condition is common in diabetics.

- ◆ Staphylococci can be isolated from the urine.
- ◆ IVU shows obliteration of group of calyces, *mimics renal cell carcinoma*.
- ◆ **Treatment:** Antibiotics, drainage of carbuncle, with placement of Malecot's catheter.
- ◆ Often, in severe type nephrectomy may be needed.
- ◆ Severe septicaemia may occur in renal carbuncle.

### Renal abscess/renal carbuncle

- ❖ A localised inflammatory necrotic mass of tissue involving renal parenchyma, caused by *Staphylococcus aureus* and coliform organisms, source of which is cutaneous infections like boil and carbuncle. Eventually infection may spread to entire kidney causing multiple abscesses
- ❖ It presents as ill-defined tender swelling in the loin, with pyrexia and leucocytosis
- ❖ Staphylococci can be isolated from the urine
- ❖ IVU shows obliteration of group of calyces, *mimics renal cell carcinoma*
- ❖ Treatment: Antibiotics, drainage of carbuncle with Malecot catheter placement
- ❖ Often, nephrectomy may be needed in severe type
- ❖ Life-threatening septicaemia can occur which often needs not only nephrectomy but also higher antibiotics like meropenem, linezolid, and intensive critical care, ventilator support

## PERINEPHRIC ABSCESS

### Causes

- ◆ Infection of a perinephric haematoma.
- ◆ Perforation through renal capsule from pyonephrosis or renal carbuncle.
- ◆ Tuberculous perinephric abscess.
- ◆ Extension of cortical abscess.
- ◆ Haematogenous spread.
- ◆ Extension of appendicular abscess.
- ◆ Periureteral lymphatic spread.

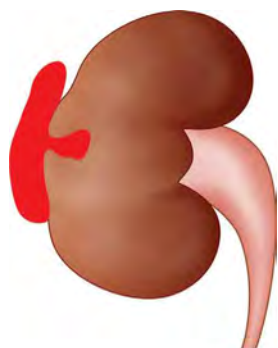


Fig. 26.55: Perinephric abscess.

### Clinical features

- ❖ High fever
- ❖ Fullness in the loin
- ❖ Tenderness and rigidity
- ❖ Scoliosis with concavity towards the side of abscess

### Investigations

- ◆ Total count is increased.
- ◆ Plain X-ray KUB—obliteration of psoas shadow, scoliosis, elevation of hemidiaphragm.
- ◆ IVU—two films taken one in lying-down position and another in erect posture.

Normally in erect posture, downward displacement of the kidney is seen. Downward displacement is not seen in case of perinephric abscess—*Mathe's sign*.

- ◆ U/S abdomen.
- ◆ CT scan is diagnostic.

### Treatment

1. Antibiotics are started.
2. Under G/A through loin approach (lumbar incision), pus is drained adequately. Pus is sent for culture and sensitivity. Collection in the cortex of the kidney should also be drained. A Malecot's catheter is kept in place.

## RENAL CALCULUS

*The Times wheret you often in a day have the Urinary Excretion performed with Ease, are times which invite you very frequently to lift up your Hearts unto God with such an Acknowledgment as This; 'O, My most merciful God, I bless thee, that the grinding Torments of the Stone, are not now grinding of me'*

—Cotton Mather, 1724

It is more common in males; 90% are radio-opaque (gallstones are more common in females; 90% are radiolucent).

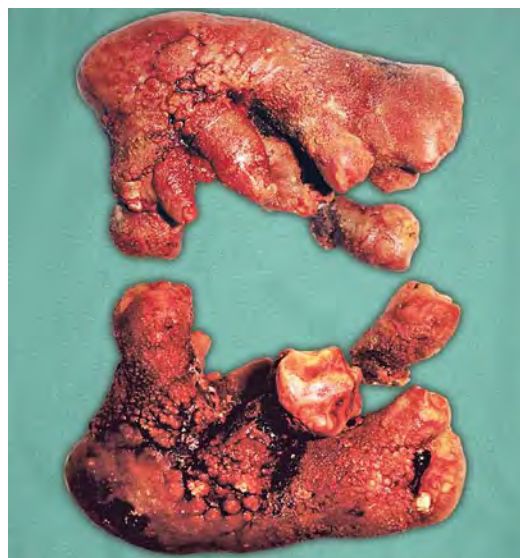

Fig. 26.56: Large staghorn calculus—both surfaces of the stone were shown.

### Aetiology

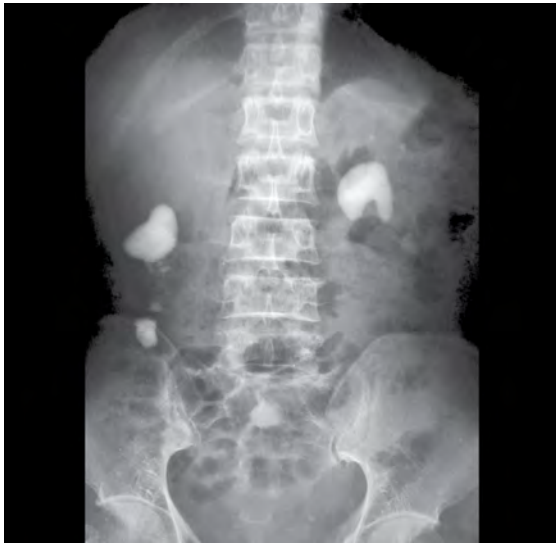- ◆ *Diet*: Vitamin A deficiency—it causes desquamation of epithelium which acts as a nidus for stone formation.
- ◆ *Climate*: In hot climate urinary solutes will increase with decrease in colloids, which leads to chelation of solute with calcium forming a nidus for stone.
- ◆ *Citrate level* in urine (300–900 mg/24 hours) maintains the calcium phosphate and carbonate in soluble state and any decrease in citrate level in urine causes stone formation.
- ◆ *Infection* in kidney: Urea splitting organisms commonly cause stone formation, i.e. *E. coli*, *Staphylococcus*, *Streptococcus*, *Proteus*.
- ◆ *Prolonged immobilisation* causes decalcification of bones and so hypercalciuria leading to stone formation.
- ◆ *Hyperparathyroidism* causes hypercalciuria causing multiple bilateral stones or often bilateral nephrocalcinosis (5%).
- ◆ *Hyperoxaluria*, as a result of altered glycine metabolism.
- ◆ *Cystinuria* (Autosomal recessive).
- ◆ *Stasis* due to obstruction to urine flow.
- ◆ *Medullary sponge kidney*.
- ◆ *Randall's plaque theory* is erosion and deposition of urinary salts as Randall's plaque at the apex of renal papillae.
- ◆ *Carr's postulates* states that minute concretions called as microliths normally develop in the subendothelial part of the tubule which will be carried away as particles by renal lymphatic network vessels. If these lymphatics are blocked, microliths enlarge and act as nidus for stone formation.
- ◆ *Others*: Sarcoidosis, myelomatosis, gout, idiopathic hypercalciuria, hypervitaminosis D, neoplasms on treatment, hypomagnesuria ( $Mg^{++}$  in urine acts as a complexing agent and prevents nucleation normally).

- ◆ *Renal tubular acidosis*: Commonly causes calcium phosphate stone (10%).

#### Stages of stone formation

- I. Supersaturation
- II. Nucleus formation
- III. Crystallisation
- IV. Aggregation
- V. Matrix formation
- VI. Stone

**Epitaxy:** Growth of one type of stone on another type.



**Fig. 26.57:** Plain X-ray KUB showing bilateral large renal stones and right ureteral stone.

### Types

1. *Oxalate stones (75%)*: Also called as *mulberry stone* as it is brown in colour, with sharp projections. It is invariably calcium oxalate stone, shows *envelope crystals in urine*.
2. *Phosphate stones (10–15%)*: It is either calcium phosphate or calcium, magnesium, ammonium phosphate stone usually occurring in an infected urine. It is smooth and white in colour. In an alkaline urine, it enlarges rapidly, filling renal calyces taking their shape called as *staghorn calculus*. It is radio-opaque and attains a large size.
3. *Uric acid stones (5%)* are smooth, hard, yellowish, multiple and radiolucent. They are seen in gout, hyperuricosuria, altered purine metabolism.
4. *Urate stones*.
5. *Cystine stones (2%)* occur in *cystinuria* where there is defective absorption of cystine from the renal tubules (autosomal recessive condition).  
It is seen in young girls, occurs only in *acidic urine*. It is multiple, soft, yellow in colour and the colour changes to

*greenish hue* on exposure. It attains large size. It is radio-opaque because it contains sulphur.

6. *Xanthine stones* are very rare, smooth, brick red in colour, due to altered xanthine metabolism.  
Here there is deficiency in xanthine oxidase enzyme.
7. *Indigo stones*: Very rare. Blue in colour.
8. *Struvite stone*: It is compound of magnesium, ammonium phosphate mixed with carbonate. It occurs in presence of ammonia and urea splitting organisms in urine, e.g. *Proteus*; *Klebsiella*.

### Shapes of Stone Crystals in Urine

	Type of crystal	Shape of crystal
a.	Calcium oxalate monohydrate	Dumbbell shaped
b.	Calcium oxalate dihydrate	Envelope shaped
c.	Uric acid	Yellowish of varying size and shape
d.	Cystine	Hexagonal, very soft stones
e.	Triple stone	Coffin lid shaped

### Clinical Features

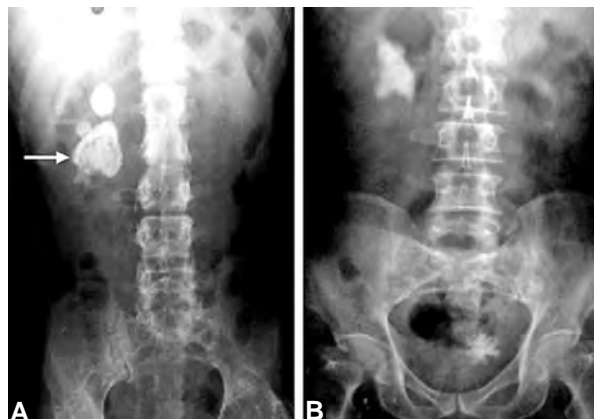- ◆ *Pain—renal pain* is located over renal angle, hypochondrium and lumbar region. Often severe radiating to groin and testis in male, with vomiting due to pylorospasm. Pain worsens on movements.
- ◆ *Haematuria* is common.
- ◆ Pyuria.
- ◆ Fever.
- ◆ Tenderness in renal angle, with often a mass in the loin due to hydronephrosis which moves with respiration and is bimanually palpable, ballotable, smooth, soft.
- ◆ As urinary tract infection.
- ◆ Incidental finding.
- ◆ Often hypertension.

#### Note:

Food rich in oxalates are, spinach, tea, cola, alcohol, citrus fruits.

### Investigations

- ◆ *Blood*: ESR, serum calcium, phosphate, creatinine, blood urea, uric acid, PTH level.
- ◆ *Urine*: Calcium, urate, cystine if suspected only, pH, specific gravity.
- ◆ *Plain X-ray, KUB*: To see kidney shadow, stones (90%—*radio-opaque*).
- ◆ IVU to see renal functions and HN.
- ◆ RGP if required.
- ◆ Ultrasound abdomen—can detect even radiolucent stones and gives information about the changes in renal parenchyma.
- ◆ Urine analysis and C/S to identify bacteria.
- ◆ *CT scan* will identify the small missed stones in ureter.



**Figs 26.58A and B:** Plain X-ray KUB showing: (A) Multiple stones in the right kidney; (B) Phosphate stone in the kidney and oxalate stone in urinary bladder.

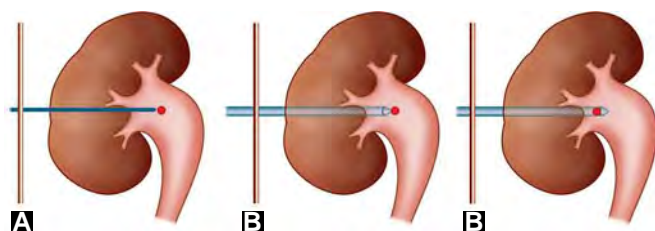
## Treatment

### 1. PCNL (Percutaneous Nephrolithotomy).

#### Indications

- ❖ Stones more than 2.5 cm in size
- ❖ Multiple stones
- ❖ Stones not responding for ESWL

**Procedure:** Initially cystoscopy is done and ureteric stent/catheter is placed and renal pelvicalyceal system is identified under C-arm guidance. Under the guidance of C-arm or U/S, needle puncture is made in the loin percutaneously. Through kidney, calyx and pelvis are approached. Guidewire is passed. Graduated dilators are passed and so track is widened. Then through that, a nephroscope is passed. After fragmentation, stone is removed using different methods [Laser (Holmium), pneumatic, ultrasonic or electrohydraulic].



**Figs 26.59A to C:** Stages in PCNL.

#### Complications of PCNL

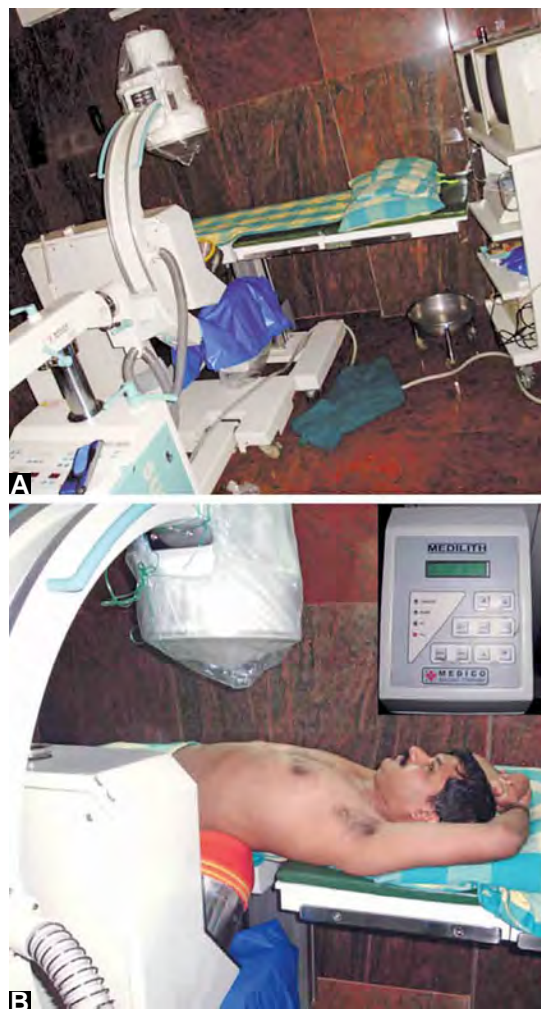- ❖ Haemorrhage
- ❖ Perforation of collecting duct causing extravasation of irrigation fluid
- ❖ Injury to colon or pleura while creating initial track for nephroscope

### 2. ESWL (Extracorporeal Shock Wave Lithotripsy):

- ❖ Piezo-Ceramic or Electromagnetic shock waves are passed to the stone through water bath or water cushion which acts as a media.

Shocks are produced at 2/sec. 1000–4000 shocks are required for each stone.

- ❖ *Dornier Lithotripter* is used for fragmenting stones.



**Figs 26.60A and B:** ESWL table and machine used for renal stones. It needs C-arm to guide the exact point of stone to be fragmented.

- ❖ Stone is located and observed through fluoroscope (C-arm) or ultrasound. Shock waves are triggered to create *compressive waves* over the stone, to *fragment* it. These fragments are flushed out later.

#### Advantages

- ❖ No anaesthesia is required
- ❖ Can be done as an OP procedure
- ❖ Less than 2.5 cm sized stones are well fragmented
- ❖ Hard stones, oxalate stones are better eliminated by ESWL
- ❖ ESWL can be done repeatedly in different sittings
- ❖ If it is not successful one can switch over to PCNL

#### Complications

- ❖ Renal haematoma
- ❖ Severe haematuria
- ❖ Injury to adjacent structures
- ❖ Fragmented stone retains in the ureter

*In the case of perinephric abscess bending the trunk away from the side of the abscess may produce pain, whereas the patient can bend his body towards the lesion without much discomfort.*

—George S

### Contraindications

- ❖ Pregnancy
- ❖ Bleeding disorders
- ❖ Patients with abdominal aneurysms
- ❖ Sepsis and renal failure (Serum creatinine more than 3 mg%)

### 3. Conservative treatment:

- ▶ Flush therapy—mainly used for lower ureteric stones.
- ▶ IV fluids.
- ▶ Inj frusemide 60–80 mg IV.
- ▶ Anti-inflammatory and antispasmodic agents are given to relieve the pain.

4. **Surgery for renal stones:** Presently most of the renal stones can be removed without open surgery (PCNL, ESWL, URS). But limiting factors are cost and availability.

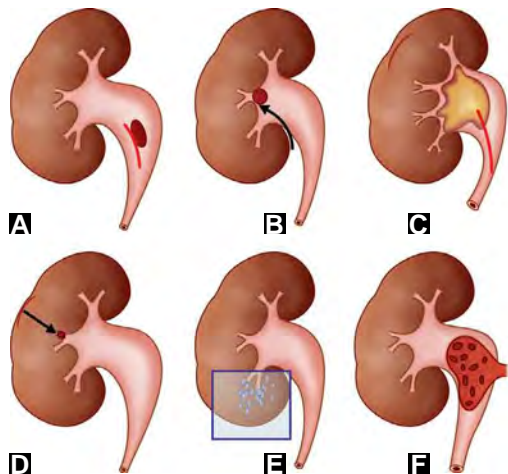
### Surgeries

#### 1. Pyelolithotomy.

- ▶ Suitable for stones in extrarenal pelvis.

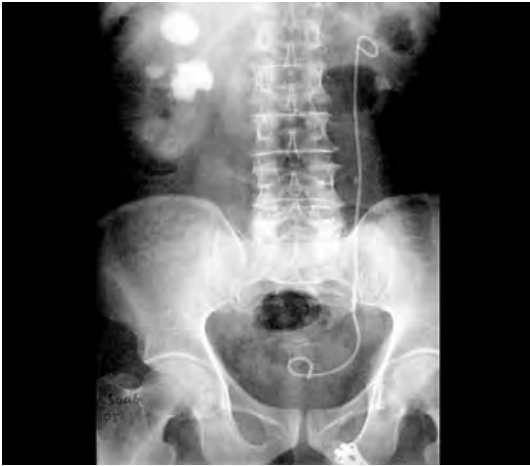

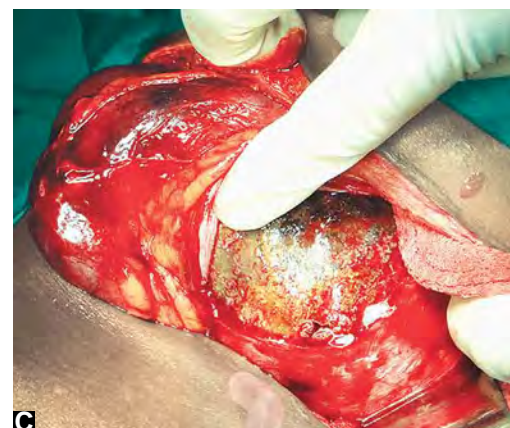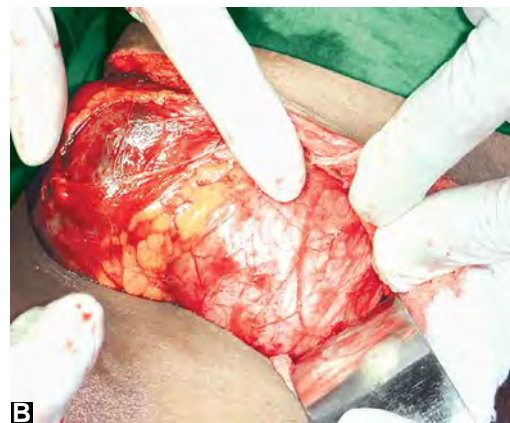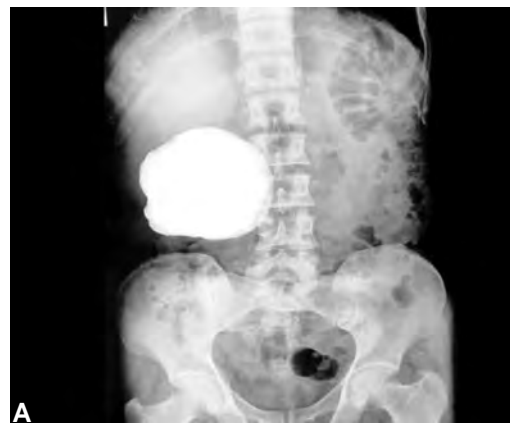Fig. 26.61: Plain X-ray showing right-sided renal stone with 'J' stent on left side.



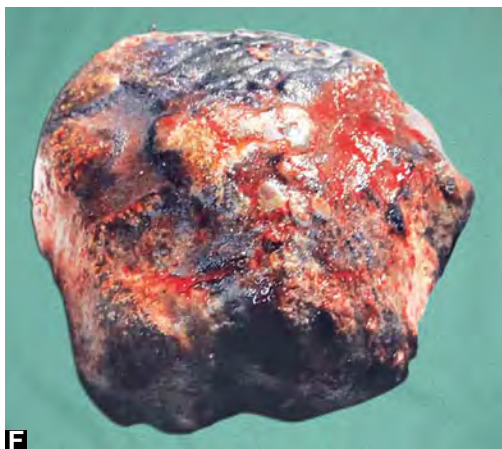
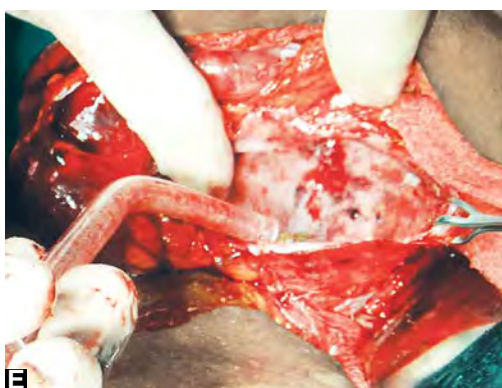
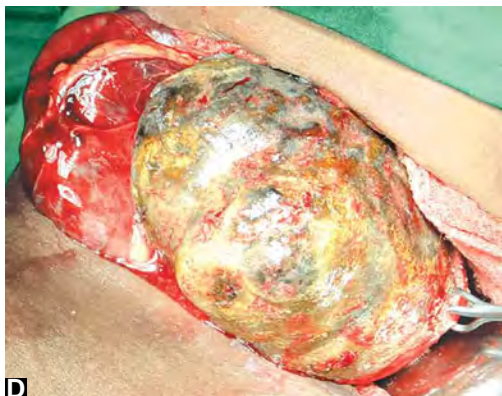Figs 26.62A to F: Surgeries for renal stones. (A) Pyelolithotomy; (B) Extended pyelolithotomy; (C) Nephropylolithotomy; (D) Nephrolithotomy; (E) Partial nephrectomy; (F) Coagulum pyelolithotomy.

- ▶ By loin (posterior subcostal) incision, kidney is approached.
- ▶ Renal pelvis is opened, the stone is removed and the pelvis is closed. A drain is placed and wound is closed.

2. **Extended pyelolithotomy (Gil-Vernet):** In case of intrarenal pelvis, incision is done on the hilum between the pelvis and kidney over the renal sinus, dissection is carried out so as to remove the stones from pelvis as well as calyces.
3. **Nephrolithotomy:** By placing incision just behind the most convex surface (*Brodell's line*), stone is removed.
4. **Nephropylolithotomy:** By making incisions both over the kidney and pelvis, stone/stones are removed. It is often done in *staghorn calculus*.
5. **Partial nephrectomy:** Done when there are multiple stones occupying a pole, usually lower pole of the kidney or when there is damage to the calyx, if not removed, may encourage further stone formation.
6. **Bench surgery:** Kidney is removed out temporarily, cooled by ice packs or inosine or liquid nitrogen. Stones are searched and removed completely. Later kidney is replaced in right iliac fossa.



Figs 26.63A to C



**Figs 26.63D to F**

**Figs 26.63A to F:** Very large renal pelvic stone of more than 8 cm in size weighing 610 grams. It is one of the largest renal stones extracted (Courtesy: Dr Ashok Padit, MCh, Urologist, Mangala Hospital, Mangaluru).

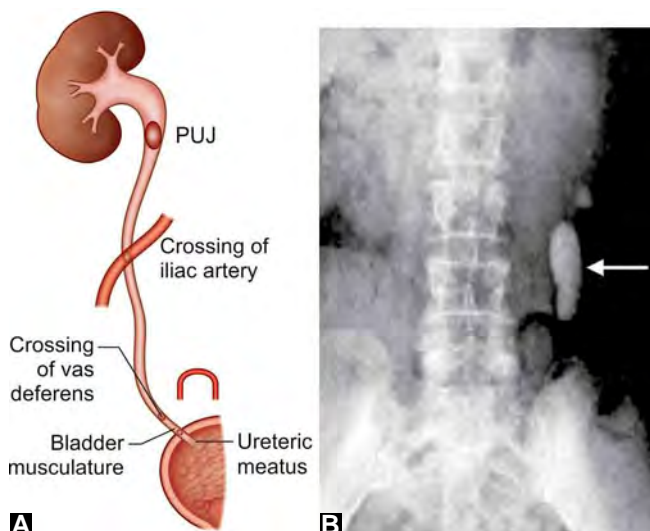
7. *Coagulum pyelolithotomy*: Coagulum solution which contains fibrinogen is poured into the renal pelvis. It is activated so that it solidifies, meanwhile entangling the stones in renal pelvis. This entangled mass is removed en masse.
8. *Anatrophic pyelolithotomy*: After exposing the kidney, it is cooled with ice packs for 20 minutes and posterior branch of the renal artery is clamped temporarily using bull-dog clamp. The most avascular plane behind the Brodel's line is thus visualised properly. Kidney is opened through this line and stone/stones are removed (anatrophic means "to prevent atrophy").

## URETERIC CALCULI

- ◆ Always of renal origin.
- ◆ Nature of stones are same as that of renal stones.
- ◆ They are commonly of elongated shape.
- ◆ They can get impacted at various narrow junctions.

### Sites

- ◆ Pelvi-ureteric junction.



**Figs 26.64A and B:** (A) Sites of ureteric narrowing; (B) A plain X-ray, KUB, showing left ureteric calculi.

- ◆ Where ureter crosses the iliac vessels.
  - ◆ Where ureter crosses vas deferens/broad ligament.
  - ◆ Where ureter penetrates outer layer of bladder muscle.
  - ◆ In the intramural portion of ureter near the ureteric orifice.
- Stones less than 5–8 mm size may pass spontaneously.

### Problems with ureteric stones

- ❖ Obstruction
- ❖ Hydronephrosis
- ❖ Infection
- ❖ Impaction
- ❖ Ureteral stricture

### Clinical Features

- ◆ *Pain*—it is of colicky type and radiates from loin to groin often to the tip of the genitalia, testis in males, labia majora in female (referred along the genitofemoral nerve).  
It is severe in intensity, increases with exercise.  
It mimics *appendicitis*, *cholecystitis*, *ovarian* or *tubal pathology*.
- ◆ Nausea, vomiting, sweating due to pain and reflex pylorospasm.
- ◆ Haematuria, dysuria, frequency, strangury.
- ◆ Tenderness in iliac fossa and renal angle (no rebound tenderness).

### Investigations

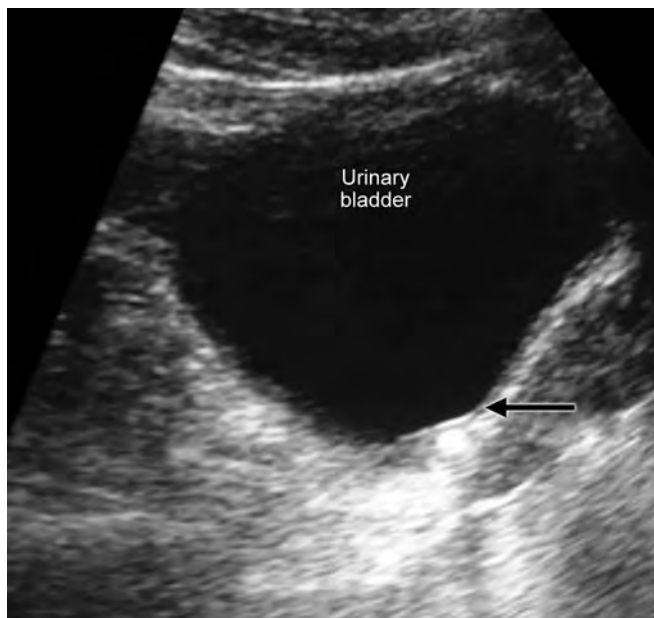
- ◆ Urine—microscopy, C/S.
- ◆ Plain X-ray, KUB—radio-opaque stones are visible in 90% of cases—in the line of ureter (near the tips of transverse processes of lumbar vertebrae, sacroiliac joint and medial to ischial spine).

Lateral or oblique films are required to differentiate from other opacities which mimic stone.

- ◆ IVU shows hydronephrosis and hydroureter. Function may be accurately assessed by isotope renogram.
- ◆ Blood urea, serum creatinine, serum calcium, uric acid level.
- ◆ Ultrasound is useful.
- ◆ CT scan is *diagnostic*.

#### Differential diagnosis

- ❖ Appendicitis
- ❖ Cholecystitis
- ❖ Ovarian cyst
- ❖ Tubo-ovarian disease
- ❖ Mesenteric adenitis
- ❖ Ruptured ectopic gestation



**Fig. 26.65:** USG showing vesicoureteric junction (VUJ) stone which needs cystoscopic meatotomy and extraction.

### Treatment

- ◆ Plenty of water orally.
- ◆ Diuretic—oral frusemide to flush the stone.
- ◆ Suitable antibiotics to control sepsis; antispasmodics to relieve pain.
- ◆ IV fluids—fast infusion of about 1.5 to 2 litres and injection frusemide 60 to 80 mg. Usually given for 3 to 5 days.
- ◆ Surgical intervention for ureteric stones:

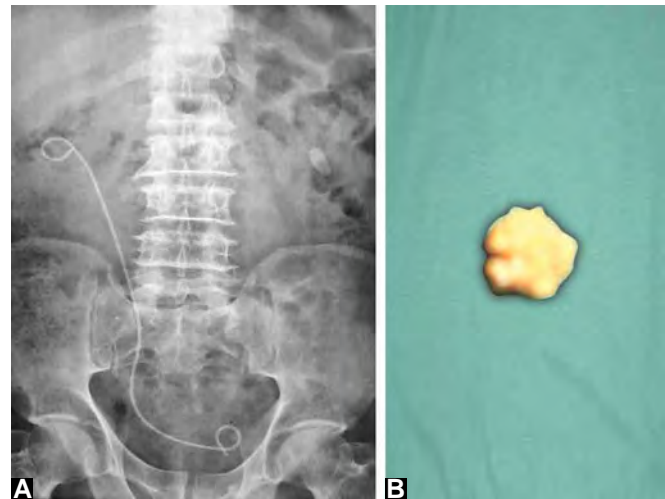
#### Indications

- ❖ Size of the stone more than 5 to 8 mm
- ❖ IVU showing deterioration of function
- ❖ Co-existing infection
- ❖ If stone is impacted in the ureter with persistent symptoms

### Procedures

*Upper third stone:*

- ◆ ESWL for stone in upper third ureter.
- ◆ The stone is pushed into the renal pelvis and then PCNL is done.



**Figs 26.66A and B:** (A) J`stent right side—used after URS (ureterorenoscopy) in ureteric stone extraction; (B) Removed ureteric stone.

◆ URS—*Ureterorenoscopic stone removal:*

- ▶ Through ureteroscope, stone is visualised and often fragmented using pneumatic bombardier. It is then extracted by ureteroscope.
- ▶ Complications are perforation of ureter and extraperitoneal leakage of urine, bleeding.

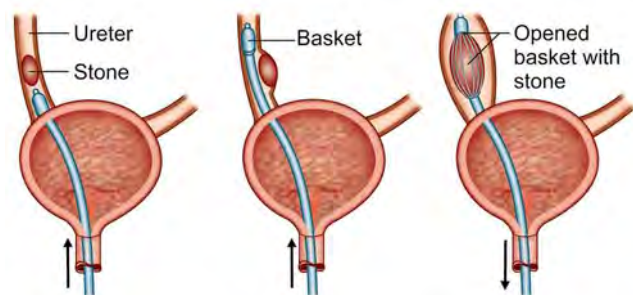
◆ Open *ureterolithotomy* through loin incision.

*Stone in middle third ureter:*

- ◆ URS.
- ◆ Open ureterolithotomy.

*Stone in lower third ureter:*

- ◆ URS.
- ◆ *Dormia* basketing:



**Fig. 26.67:** Dormia basket is used to remove the stone in the lower ureter. Single stone less than 1 cm can be removed.

#### Indications for Dormia basketing

- ❖ Stone in lower third ureter
- ❖ Stone below pelvic brim
- ❖ Stone less than 10 mm size
- ❖ Single stone

Basket is passed into the proximal ureter beyond the stone and opened. The stone is then pulled out.

#### Complications of Dormia basket

- ❖ Stone dislodgement
- ❖ Urethral injury
- ❖ Avulsion of ureter
- ❖ Stricture ureter

- ◆ Open ureterolithotomy.
- ◆ Using cystoscope under general anaesthesia, *ureteric meatotomy* is done for stones impacted at the ureteric orifice. It is released by cutting the orifice at upper and lateral aspects.

**Note:**

All ureteric stones can be removed through laparoscopy or retroperitoneoscopy.

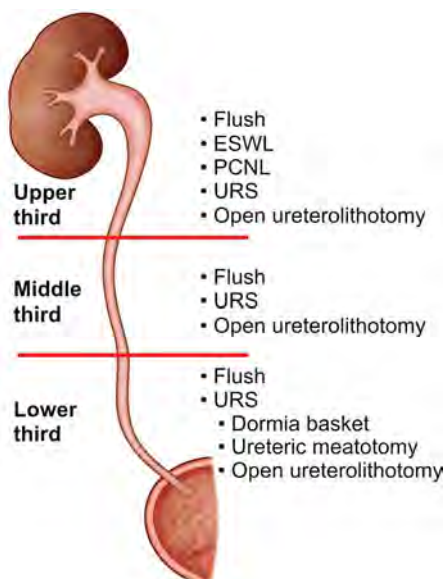


Fig. 26.68: Approaches for removal of ureteric stones.

## RECURRENCE OF STONES

### Types of recurrence:

- False recurrence—during intervention, tiny fragments may be left behind.
- True recurrence—recurred again once all stones are cleared by intervention.

### Causes for recurrence:

Existing causes like hyperparathyroidism, hypercalciuria, hyperuricaemia, gout, cystinuria.

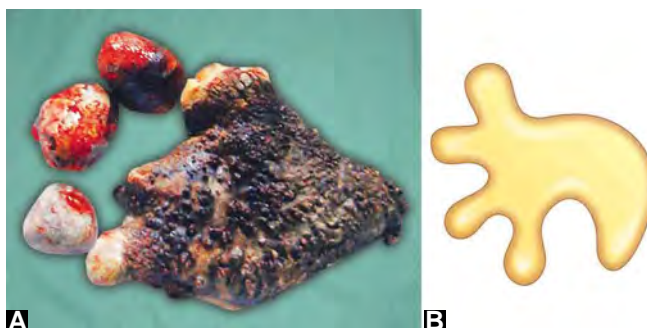
### Prevention and advice

- ◆ Hydration is the main method of prevention. Per day 3 to 4 litres of fluid should be taken.
- ◆ Diet:
  - ▶ Avoid diets rich in calcium oxalate, sodium (natriuresis causes hypercalciuria) and vitamin C (gets converted into oxalate).
  - ▶ Increased intake of dietary fibre—binds with intestinal calcium and decreases the calcium absorption. *Sodium cellulose phosphate* is used for the same.
- ◆ *Allopurinol* reduces the uric acid level and so uric acid stone. It also reduces the oxalate level.
- ◆ Diet rich in *magnesium* makes calcium oxalate less soluble.
- ◆ *Aluminium gel* or *ammonium chloride* prevents the excessive alkalinity and so prevents the recurrence of phosphate stones.
- ◆ *Penicillamine* or *alpha-mercaptopyranyl-glycine* may reduce the recurrence rate of cystine stones.

- ◆ In idiopathic hypercalciuria, strict low calcium diet along with 5 mg bendrofluzide which reduces loss of calcium in urine or indomethacin 25 mg tds which reduces the calcium secretion or sodium phytate can be given.
- ◆ Acetohydroxamic acid due to structural similarity to urea is a potent inhibitor of urease and so reduces the bacterial originated stone.

## STAGHORN CALCULUS

- ◆ It is the stone occupying the renal pelvis and calyces.
- ◆ It is usually phosphate or ammonium, magnesium phosphate (*Triple phosphate*) stone.
- ◆ It is white in colour, soft, smooth, occurs in pre-existing infection (commonly *E. coli*).
- ◆ It can be *unilateral* or *bilateral*. Patient with *bilateral* stones may go in for *renal failure*.



Figs 26.69A and B: (A) Staghorn calculus; (B) Diagrammatic representation.

### Presentation

- ❖ Pain in loin
- ❖ Fever
- ❖ Burning micturition
- ❖ Haematuria
- ❖ In bilateral cases, symptoms are bilateral and often with features of renal failure (hiccough, oedema feet, oliguria, anaemia)

### Investigations

- ◆ Ultrasound abdomen.
- ◆ Plain X-ray, KUB.
- ◆ IVU to see the renal function.
- ◆ Blood urea and serum creatinine.
- ◆ Urine microscopy and urine C/S.
- ◆ Isotope renogram—DTPA.

### Treatment

Antibiotic is started.

- ◆ *Unilateral stone* is removed by *nephropyelolithotomy*. Multiple incisions are made over the Brodel's line (avascular plane) and assisted by pelvic incision. Stone is removed. Blood transfusion may be necessary as bleeding can occur.

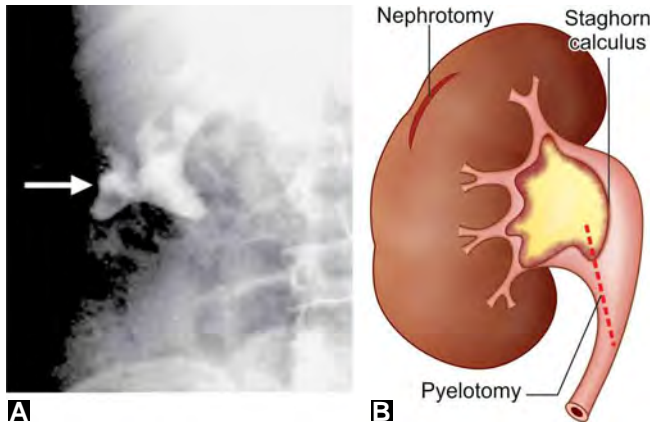
After that, nephrotomy and pyelotomy incisions are sutured with chromic catgut or vicryl.



- ◆ In *bilateral cases*, IVU is very essential. The kidney which is functioning better should be treated first. After 3 months, the other side kidney should be operated upon.
- ◆ If there are *bilateral staghorn calculi with pyonephrosis*, then initially bilateral nephrostomy is done using Malecot's catheter (*Cabot's nephrostomy*). IVU is done later to see the renal function. If function is present, then both the kidneys are operated one after the other in a gap of 3 months. They often need *haemodialysis*.
- ◆ Sometimes in case of severe infection *nephrectomy* is required. Presently, *PCNL is becoming a popular procedure for unilateral or bilateral staghorn calculi*.  
But when required, *conversion to open nephropylolithotomy* should be considered.

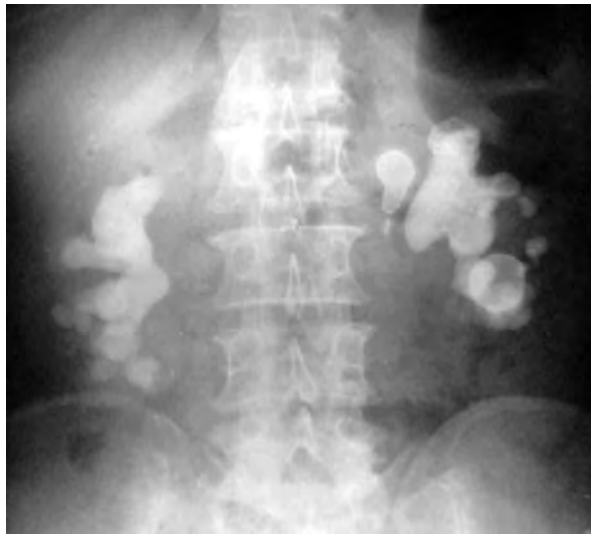

Fig. 26.70: Bilateral staghorn calculi



Figs 26.71: (A) Nephropylolithotomy. Note the incisions placed; (B) A plain X-ray, KUB, revealing staghorn calculus on right side.

#### Complications of staghorn calculus

- ❖ Pyelonephritis
- ❖ Pyonephrosis
- ❖ Perinephric abscess
- ❖ Renal failure

#### Differential diagnosis for radio-opaque shadow which mimics renal stone

- ❖ Calcified lumbar or mesenteric lymph node
- ❖ Gallstone (10% are radio-opaque)
- ❖ Concretion in appendix
- ❖ Phleboliths
- ❖ Ossified tip of 12th rib
- ❖ Chip fracture of transverse process of vertebra
- ❖ Calcified renal tuberculosis
- ❖ Calcified suprarenal gland
- ❖ Drugs or foreign body in the alimentary canal

#### BENIGN TUMOURS OF KIDNEY

They are rare.

##### Types

- ◆ *Renal papillary adenoma*: Small discrete adenoma arises from tubular epithelium, <5 mm in size, cortical, yellow circumscribed tumour. It is potentially malignant, may turn into papillary type of RCC, especially if size >3 cm.
- ◆ *Angiomyolipoma*: It contains fat, vessels and smooth muscles. It is commonly associated with tuberous sclerosis (50%). Tumour is susceptible for spontaneous haemorrhage.
- ◆ *Oncocytoma*: It is an epithelial tumour arising from intercalated cells of collecting ducts. Its cells show large nucleoli. These large eosinophilic cells contain numerous mitochondria. Tumour is homogeneous well encapsulated tan coloured. It can attain large size and can be multicentric.

#### WILMS' TUMOUR (NEPHROBLASTOMA)

*The patient was a 3-year-old girl with a kidney tumour which had grown to immense proportions in a short time. The child, anemic and emaciated, was admitted with an enormous mass in the right abdomen and with definite ascites. After nephrectomy, the little child recovered uneventfully. A few months later, however, a recurring abdominal mass was again palpable and shortly afterward the child died.*

—Max Wilms, 1899

- ◆ It arises from embryonic connective tissue containing epithelial and connective tissue elements.
- ◆ It is located in one of the poles of the kidney.
- ◆ It is bilateral in 5% cases. It is common in first 4 years of life.

##### Pathology

###### Gross

It is smooth, soft, fleshy, pinkish white in colour, often with haemorrhagic areas.

###### Microscopically

Malignant primitive glomeruli and primitive tubules, with epithelial and connective tissue cells exist side by side, one of the types is usually prominent.

### Types

- Favourable histology (FH)—Wilms'—means without anaplastic features
- Unfavourable histology (Un FH) —Wilms'—means with anaplastic features

## Histological Types

- ◆ Cystic nephroma.
- ◆ Mesoblastic nephroma.
- ◆ Nephroblastoma.

## Spread

Mainly through blood into the lungs, liver and rarely to bones.

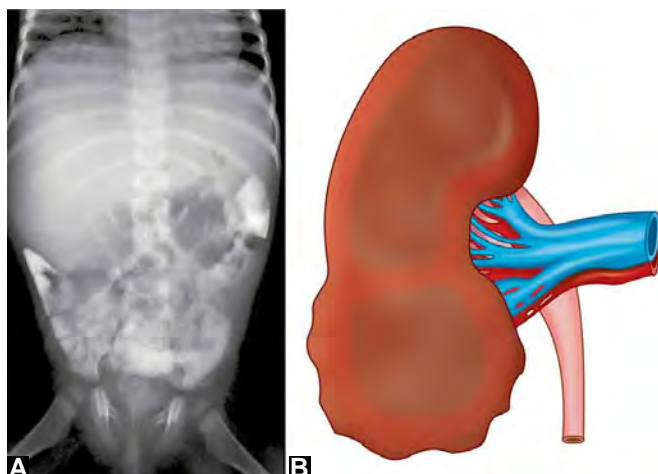
## Clinical Features

- ◆ Incidence is equal in both sexes.

### Triad

Mass, fever, haematuria

- ◆ *Mass abdomen is commonest presentation.* Mass is smooth, mobile, firm or hard, lobular, located in the loin, moves with respiration, bimanually palpable, ballotable, with dullness in renal angle and with resonant band in front. It does not cross the midline (Differential diagnosis is adrenal neuroblastoma which is knobby and nodular, does not move with respiration and crosses the midline).



**Figs 26.72A and B:** (A) X-ray showing mass lesion in right abdomen. It could be Wilms' tumour; (B) Location of tumour.

- ◆ *Fever*—may be due to tumour necrosis.
- ◆ *Haematuria* is a grave sign as it signifies rupture of tumour into the renal pelvis.
- ◆ *Hypertension*—in 25% cases.
- ◆ 12% of cases are associated with congenital anomalies and syndromes (Glaucoma, aniridia, Beckwith syndrome).

### Staging of Wilms'

- Disease confined to kidney and completely resectable
- Tumour extends beyond kidney, but can be excised completely
- Residual disease after resection with positive lymph nodes and massive spillage
- Blood-borne metastasis
- Bilateral disease

## Investigations

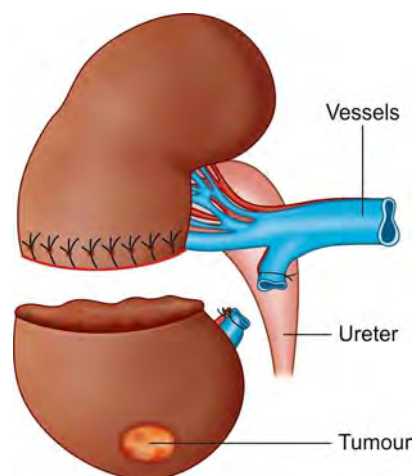
- ◆ U/S abdomen, CT scan abdomen.
- ◆ IVU.
- ◆ Renal angiography.
- ◆ X-ray, abdomen—*eggshell* peripheral calcification is diagnostic.
- ◆ MRI.

### Differential diagnosis

- ❖ Adrenal tumour
- ❖ Retroperitoneal tumour
- ❖ Renal cyst
- ❖ Polycystic kidney disease

## Treatment

- ◆ *Nephrectomy and postoperative radiotherapy in case of unilateral tumours.*
- ◆ In bilateral cases, either bilateral partial nephrectomy or nephrectomy on one side with partial nephrectomy on the other side is done (*Nephron-sparing surgery*).



**Fig. 26.73:** Partial nephrectomy.

- ◆ *Chemotherapy:* Actinomycin D, vincristine, doxorubicin.
- ◆ Preoperative RT in locally inoperable cases—later surgery and then chemotherapy is given.

## Prognosis

Five years survival rate is 80% under the age of one year. Recurrence rate is high within one year.

*You may be disappointed if you fail, but you are doomed if you don't try.*

## Prognostic Factors

Age, bilaterality, size of the tumour, presence of haematuria, spread of tumour, histology type.

## RENAL CELL CARCINOMA (RCC)

Also known as *Hypernephroma*—(it is a misnomer), *Grawitz tumour*, *clear cell carcinoma*, *Internist tumour*:

- ◆ It is an adenocarcinoma arising from renal tubular cells, most common site is proximal renal tubule. More common in males; more common in 5th–6th decade of life.
- ◆ It is 3% of all adult malignancies.
- ◆ **RCC types:**
  - ▶ *Clear cell* (75%)—nonpapillary, associated with loss of sequence in short arm of chromosome no.3. It can be sporadic (common, 95%) or familial.
  - ▶ *Papillary* (15%)—multifocal commonly, with papillary pattern.
  - ▶ *Chromophobe RCC* (5%)—arising from intercalated cells of collecting duct; shows halo around the nucleus; carries excellent prognosis.
  - ▶ *Collecting duct of Bellini carcinoma* (1%)—arises from collecting duct of medulla; tumour with fibrous stroma typically in medullary location.

### Aetiology

- ❖ It is associated with von Hippel-Lindau disease (cerebellar haemangioblastoma, retinal angiomas, tumour or cysts of pancreas). Here RCC is commonly bilateral
- ❖ Diet high in animal fat
- ❖ Environmental factors like asbestos, lead, cadmium and tobacco
- ❖ Cigarette smoking
- ❖ Chromosomal aberration, tuberous sclerosis
- ❖ Acquired cystic kidney disease after long-term dialysis
- ❖ *Birt-Hogg-Dube syndrome* with hereditary chromophobe RCC and oncocytoma
- ❖ Cortical renal adenoma could be RCC by itself
- ❖ Analgesic nephropathy

## Pathology

### Gross

It attains a large size. Commonly located in *upper pole*, sometimes in lower pole but rare in the middle. Cut-section is *yellowish* due to lipid content with areas of haemorrhage and necrosis. This noncapsulated tumour is very vascular.

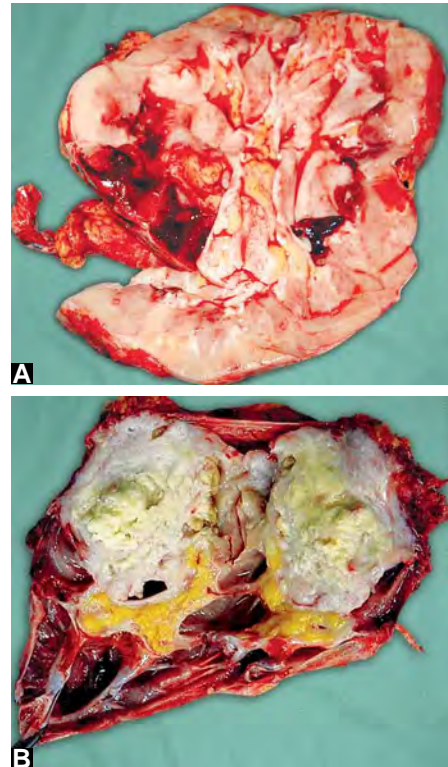
### Microscopy

Malignant cells which are cubical or polyhedral containing lipid, cholesterol and glycogen.

*Histological types*—clear (75%), granular, spindle, sarcomatoid, papillary (15%)

### Spread

1. *Local*: Into the perinephric pad of fat, calyces and renal pelvis.



**Figs 26.74A and B:** Renal cell carcinoma in upper pole of kidney—resected specimen. It is from two different patients.

2. *Blood spread*: RCC enters the renal vein as *proliferating tumour thrombus*, which extends into the IVC and later gets detached causing “*cannon ball secondaries*” in the lung, which are often calcified. Once primary tumour is removed, secondaries may regress due to tumour immunity. Occasionally, secondaries occur in bone, liver and brain. Left testicular vein which drains into left renal vein may get blocked by proliferating tumour thrombus resulting in *irreducible-left sided varicocele*. *More than 50% spread to lungs; 30% to bones*; then liver, adrenal and brain.
3. *Lymphatic spread*: To hilar lymph nodes, para-aortic lymph nodes.

### AJCC (American Joint Committee on Cancer) Staging: TNM Staging

- Tx: Primary tumour cannot be assessed  
 T0: No primary tumour  
 T1: Tumour less than 7.0 cm size, limited to kidney  
 T1a is tumour 4 cm or less; T1b is tumour 4–7 cm in size  
 T2: Tumour more than 7.0 cm size, limited to kidney T2a is 7–10 cm; T2b is >10 cm  
 T3: Tumour extends into major veins, adrenals, perinephric fat but not into the Gerota's fascia  
 T3a: Into perinephric tissue or renal vein  
 T3b: Into IVC below diaphragm or adrenal gland  
 T3c: Tumour extends into IVC above the diaphragm  
 T4: Tumour invades Gerota's fascia and extends beyond  
 N0: No lymph nodes  
 N1: Spread to single regional lymph nodes  
 N2: Spread to more than one regional lymph nodes  
 M0: No blood spread  
 M1: Distant spread to—lungs (75%); soft tissues (25%); bones (20%); liver (15%); CNS (8%); skin (8%)

**Robson-Flocks and Kadesky staging**

Stage 1	Tumour confined to renal parenchyma
Stage 2	Tumour invasion to perinephric fat but confined within Gerota's fascia
Stage 3	a. Tumour invasion to renal vein or IVC b. Invasion to regional lymph nodes c. Both a + b
Stage 4	Invasion to adjacent organs other than adrenal Distant metastasis

**Note:**

- 45% present as early disease; 25% as locally advanced disease; 30% as metastatic disease.

**Clinical Features**

- ◆ M : F :: 2 : 1.
- ◆ Haematuria—30%.
- ◆ Clot colic.
- ◆ Dragging discomfort in the loin.
- ◆ Mass in the loin which moves with respiration, mobile, nodular, hard, with dull renal angle and resonant band in front.
- ◆ Left-sided *varicocele* which is *irreducible* in left-sided RCC.

**Triad of RCC**

- ❖ Pain
- ❖ Haematuria
- ❖ Palpable renal mass

**Atypical presentations: 25%**

- ◆ Due to secondaries:
  1. Pathological fractures.
  2. Persistent cough and haemoptysis.
- ◆ *Persistent pyrexia* with no evidence of infection (*Pyrexia of Unknown Origin*)—20%
- ◆ *Constitutional symptoms*: Malaise, lethargy and severe anaemia.
- ◆ *Polycythemia*: 4%—due to increased secretion of erythropoietin.
- ◆ Hypercalcaemia, hypertension. Hypercalcaemia due to PTH like hormone secretion, hypertension is due to increased secretion of renin from kidney tissue adjacent to tumour.

**Surgical renal conditions associated with hypertension**

- ❖ Polycystic kidney disease
- ❖ Renal cell carcinoma
- ❖ Renal artery stenosis

- ◆ *Nephrotic syndrome*: Very rare.
- ◆ *Stauffer's syndrome*: Nonmetastatic reversible liver dysfunction which gets corrected after nephrectomy. It is 7% common. It carries poor prognosis.
- ◆ Cushing's syndrome.
- ◆ Leukaemoid reaction due to bone marrow stimulation.
- ◆ Secondary amyloidosis 5%.

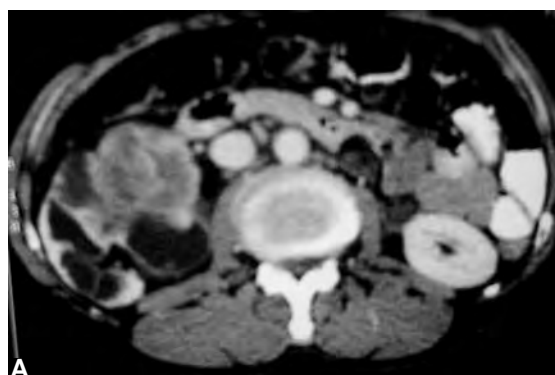
**Investigations**

- ◆ Urine microscopy for RBCs.

- ◆ IVU—shows mass lesion and irregular filling defect.
- ◆ Ultrasound abdomen—to know the size, extension, lymph node involvement, spread to the liver, status of renal vein and IVC.
- ◆ *CT scan*: It is confirmatory and also helps to know the status of renal vein and IVC. Multi-detector CT and CECT (contrast enhancement CT) are very useful in detecting early lesion/function/spread/venous status. Lymph node status, tumour extension are well made out with CT. Contrast enhancement CT scan helps to find out function of opposite kidney and tumour thrombus in renal vein or IVC.

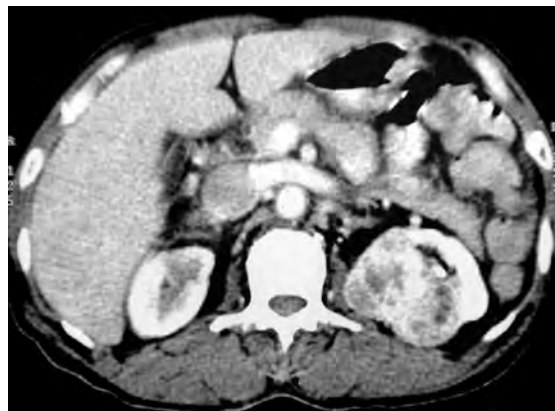
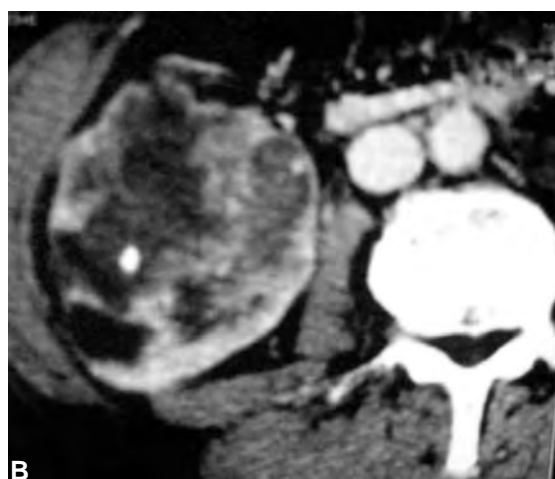
Fig. 26.75: CT scan showing RCC—left sided.



Figs 26.76A and B: CT scan showing features of renal cell carcinoma.

- ◆ *CT chest is ideal and more reliable.*
- ◆ *Renal angiogram* through Seldinger technique via transfemoral route, to see the vascularity. *Pharmacangiogram* (Inject noradrenaline along with dye while doing angiogram). As tumour vessels are autonomous they will not constrict whereas adjacent normal vessels will constrict, so *tumour blush* is visualised. Through angiogram therapeutic embolisation of tumour can be done to reduce the vascularity of tumour.
- ◆ Chest X-ray shows *cannon ball* secondaries. Often it is *calcified*.
- ◆ Bone scan to see bone secondaries.
- ◆ Peripheral smear, serum calcium, haematocrit and ESR.
- ◆ *Inferior vena cavagram* to assess the tumour extension through renal vein into IVC and extension in the IVC infra-or supradiaphragmatic.
- ◆ MRI is diagnostic to assess the tumour thrombus in IVC. MRI/MR angiogram is unique in identifying the spread into IVC especially in the thorax. In such occasion oesophageal endosonography is also useful to visualise thoracic extension of the tumour thrombus.

#### Differential diagnosis

- ❖ Polycystic kidney disease
- ❖ Solitary cyst of kidney
- ❖ Adrenal tumour
- ❖ Retroperitoneal tumour
- ❖ Carcinoma colon

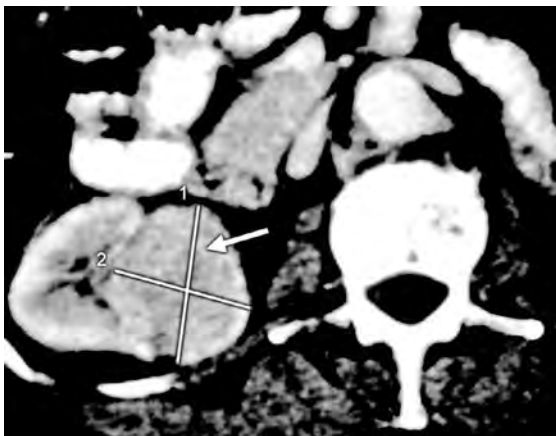


Fig. 26.77: CT scan of carcinoma right kidney.

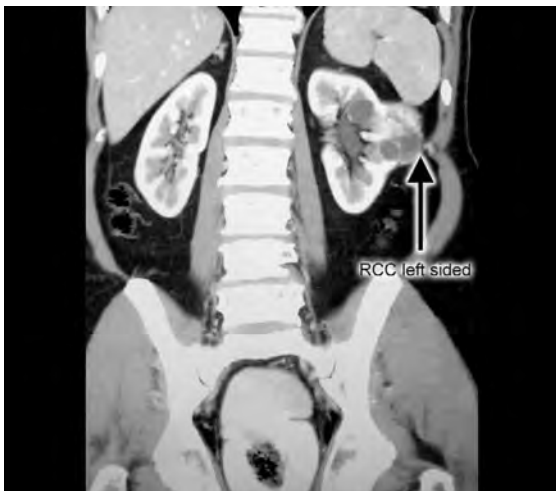

Fig. 26.78: MRI showing carcinoma left kidney; nephron sparing nephrectomy was done in this patient.

## Treatment

Surgery is the treatment of choice.

- ◆ **Nephron sparing nephrectomy** has become the standard treatment in large number of cases. Proper CT imaging is a must to plan the resection. Using cystoscopy ureteric catheter is placed initially. Through rib cutting loin incision (11th rib), kidney is approached. Vascular control is achieved (both renal artery and vein). While applying individual Satinsky clamps, time should be noted. By 15 minutes ischaemic time, resection should be completed; or else by placing icepacks on the kidney prior to vascular clamping for 10 minutes ischaemic time can be prolonged to 30 minutes. Using monopolar cautery scoring is done keeping adequate margin for clearance of 5–10 mm. With blade or cautery resection is done; care should be taken not to enter tumour capsule. After resection, bleeders are ligated using 3 zero vicryl or bipolar cautery. Dilute methylene blue is injected through ureteric catheter below to identify any calyceal tear; if present, it should be sutured using 3 zero vicryl. Tissue should be sent for margin clearance. Renal capsule is approximated using interrupted vicryl sutures after placing oxidized regenerated cellulose (surgicel). Vascular clamps are released; again renal surface haemostasis is achieved. After lowering the kidney bridge, drain is placed and wound is closed.

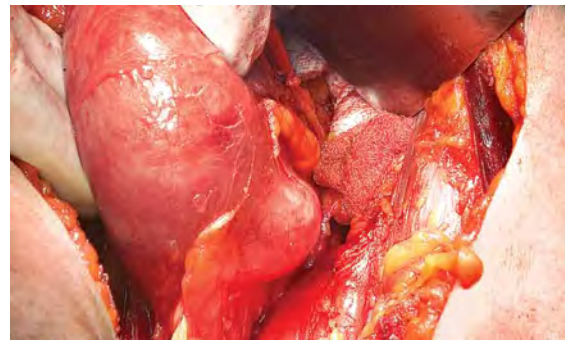


Fig. 26.79: RCC on table look prior to nephron sparing nephrectomy.

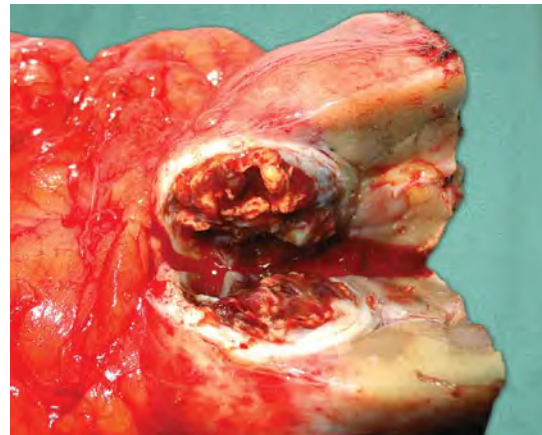


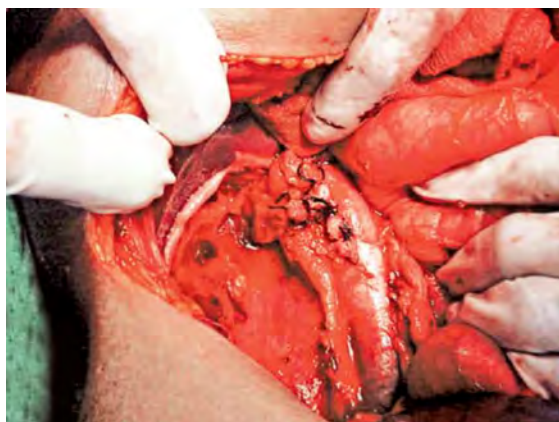Fig. 26.80: Specimen showing RCC after nephron sparing nephrectomy.

- ◆ **Radical nephrectomy:**

#### Structures removed are:

- ❖ Entire kidney along with tumour
- ❖ Perinephric tissue
- ❖ Ipsilateral adrenal gland
- ❖ Proximal 2/3rd ureter/as low as possible
- ❖ Lymph nodes from crus of diaphragm to aorta bifurcation with renal hilar nodes

- ▶ Transperitoneal approach is often used. Retroperitoneal/Nagamatsu (resection of 11th ribs) approach/thoracoabdominal approach/posterior vertical are other approaches used. Patient will be in lateral position. After laparotomy, colon is mobilised medially. Vessels are identified and dissected and ligated securely (transfixation and three ligatures proximally using nonabsorbable silk/polypropylene sutures).
- ▶ Preoperative renal artery embolisation can be done to decrease vascularity and to facilitate the removal of entire tumour.
- ▶ Always renal vein is ligated early so as to prevent tumour dislodgement (But early ligation of renal vein may cause congestion and torrential bleeding and so renal artery is ligated first commonly in practice). But usually renal artery which is posterior is dissected and clamped or ligated in continuity; then renal vein is ligated and divided; later ligated renal artery is divided. In case of IVC extension, after applying an oblique vascular clamp, IVC is opened, tumour thrombus is removed and IVC is sutured. In supradiaphragmatic vena caval extension of thrombus, cardiopulmonary bypass is necessary. First renal vessels (artery and vein) should be ligated to prevent tumour dissemination and bleeding.



**Fig. 26.81:** Renal cell carcinoma, on table after nephrectomy. Note the vascular pedicles.

- ◆ Even in large fixed tumour, palliative nephrectomy or debulking is advised as it may cause regression of secondaries.
- ◆ *No role for radiotherapy.*
- ◆ *Chemotherapy:* Vinblastine and progesterone can be tried. RCC is a remarkably refractory solid tumour—chemoresistant.
- ◆ Interferons and interleukins have shown beneficial effects.
- ◆ Preoperative renal artery embolisation can be done to decrease the vascularity of the tumour (Using clot, gelfoam, spheres).
- ◆ Antiangiogenic drugs like endostatin and angiostatin are under trial. RCC is highly vascular and there is highly angiogenic environment to give possible benefit by anti-angiogenesis.
- ◆ Patient with solitary lung metastasis may get benefited by wide resection of the secondary.
- ◆ Humanised monoclonal antibodies like bevacizumab which neutralises VEGF are under trial.

#### Note:

- Laparoscopic approach is becoming popular. Here renal artery is ligated first.
- **Sisitnab**, a multitargeted tyrosine kinase inhibitor prevents angiogenesis and tumour proliferation is said to be useful.
- FDA has approved the anti PD-1 immunotherapy using nivolumab for the treatment of metastatic RCC. This drug is also used in metastatic melanoma and small cell lung cancer.

#### Prognosis

- ◆ Five-year survival rate is 40%.
- ◆ In early localised disease, it is 70–90%. In advanced and metastatic disease it is 10–15%
- ◆ 5-year survival is 65% for stage I and II; 40% for stage III; 10% for stage IV

#### Prognostic factors are:

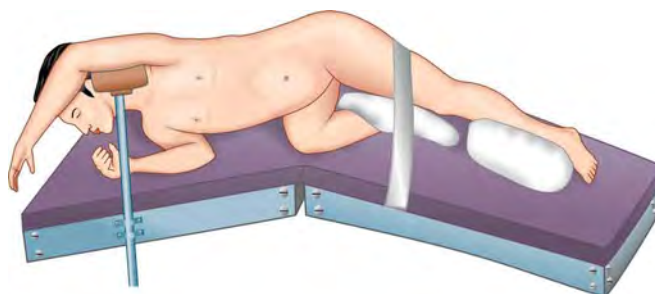
- ❖ Tumour size more than 4 cm carries poor prognosis
- ❖ Extension into the renal vein
- ❖ Presence of secondaries
- ❖ Differentiation
- ❖ Local extension
- ❖ Hypercalcaemia and Stauffer's syndrome carry poor prognosis

#### Note:

- Most common type of renal pelvis and ureteric tumours is transitional cell carcinoma (90%).
- Renal pelvic tumours account for 5% of renal tumours. It is common in Taiwan.
- It is more aggressive.
- Treatment is radical nephroureterectomy with removal of cuff of bladder adjacent to ureteric orifice.

#### APPROACHES TO KIDNEY (SURGICAL)

- ❖ *Posterior subcostal* (oblique lumbar incision).
- ❖ *Laparotomy approach* (anterior approach).
- ❖ *Thoracoabdominal approach.*
- ❖ *Nagamatsu approach* (approach following excision of 11th rib in case of upper pole tumour).
- ❖ *Posterior vertical lumbotomy approach* (Gilvernet's approach).
- ❖ *Laparoscopic approach.*
- ❖ *Retroperitoneoscopic approach.*



**Fig. 26.82:** On table position to approach kidney surgically.

## B. Urinary Bladder

### CHAPTER OUTLINE

- |                         |                               |                         |
|-------------------------|-------------------------------|-------------------------|
| ❖ Anatomy               | ❖ Schistosoma Haematobium     | ❖ Malakoplakia          |
| ❖ Ectopia Vesicae       | ❖ Thimble or Systolic Bladder | ❖ Neurogenic Bladder    |
| ❖ Urachal Anomalies     | ❖ Bladder Tumours             | ❖ Vesicoureteric Reflux |
| ❖ Vesical Calculus      | ❖ Transitional Cell Carcinoma | ❖ Bladder Diverticula   |
| ❖ Cystitis              | ❖ Ureterosigmoidostomy        | ❖ Urinary Diversion     |
| ❖ Recurrent Cystitis    | ❖ Rupture Bladder             | ❖ Urinary Fistulas      |
| ❖ Interstitial Cystitis | ❖ Residual Urine              |                         |

### ANATOMY

- It is a muscular reservoir of urine situated in the pelvis, posterior to the pubic bone from which it is separated by the retropubic space.
- The size, shape, position of bladder depends on the amount of urine it contains.
- In females, the peritoneum is reflected from the superior surface of the bladder onto the anterior wall of the uterus close to the junction of the body of the uterus and cervix.
- In males, the peritoneum is reflected from the superior surface of the bladder over the superior surface of the ductus deferens and seminal vesicles.
- The neck of the bladder is the most fixed part, lies 3–4 cm behind the pubic symphysis. In males it lies on the prostate and in females it rests on the anterior vaginal wall which is also supported by the levator ani muscle.

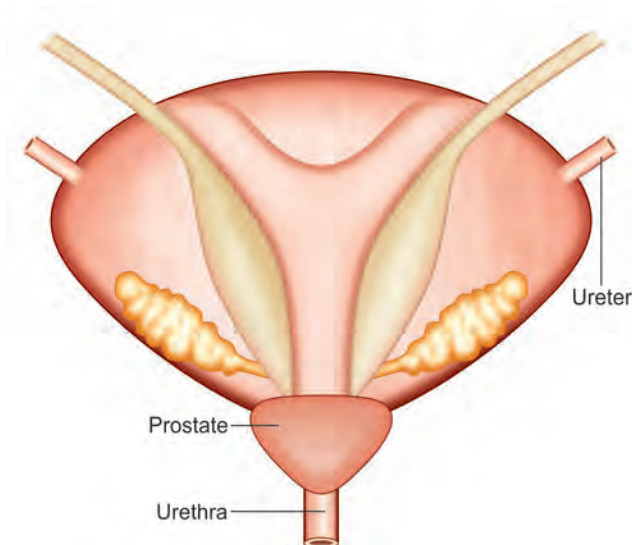


Fig. 26.83: Anatomy of urinary bladder—posterior aspect.

### Structure of the Bladder

- The bladder wall consists of interlacing fibres of smooth muscle. The urothelium consists of transitional epithelium which is loosely attached and easily separated from the bladder wall except over the *trigone*.
- Trigone* is a triangular area over the lower part of the base of the bladder. The ureters opens into the posterolateral angles of the trigone. The internal urethral orifice opens at the inferior angle of trigone.

### Sphincters

- Internal sphincter*: Smooth muscle, situated at the neck of the bladder, micturition follows its relaxation. It is innervated by autonomic nervous system.
- External sphincter*: It consists of striated muscle, innervated by the perineal branch of pudendal nerve (S<sub>2</sub>,S<sub>3</sub>).

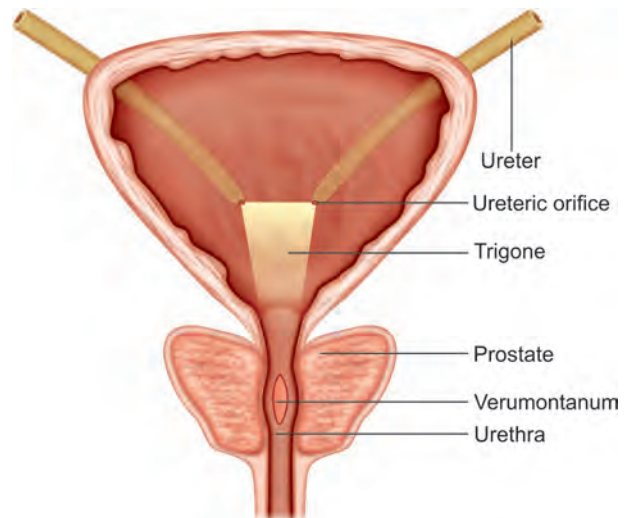


Fig. 26.84: Urinary bladder—inner anatomy.

## Blood Supply

- ◆ Superior vesical artery, a branch of internal iliac artery.
- ◆ Inferior vesical artery:
  - ▶ Venous drainage is by the vesical plexus of veins, which drains into the internal iliac veins. These veins connect directly to veins of hip bones, the heads of femoral and vertebral bodies. This accounts for the site of occurrence of bony metastasis in carcinoma of the bladder and prostate.

## Lymphatic Drainage

Lymphatics drain into internal iliac and external iliac nodes.

## ■ ECTOPIA VESICAE (Extrophy of the Bladder)

- ◆ It is incomplete development of the infraumbilical part of the anterior abdominal wall and anterior wall of the bladder. It is of embryological origin.
- ◆ It is often associated with the spina bifida and other congenital anomalies.
- ◆ It is more common in males (4 : 1).
- ◆ Red mucus membrane of posterior bladder wall protrudes out with visible urine efflux from ureteric orifice.
- ◆ Umbilicus is absent.
- ◆ There is separation of pubic bones.
- ◆ In males, *epispadias* is commonly present with rudimentary prostate and seminal vesicle.

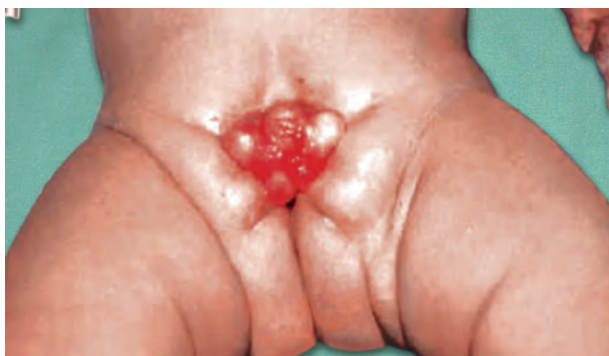

Fig. 26.85: Child showing extrophy bladder.

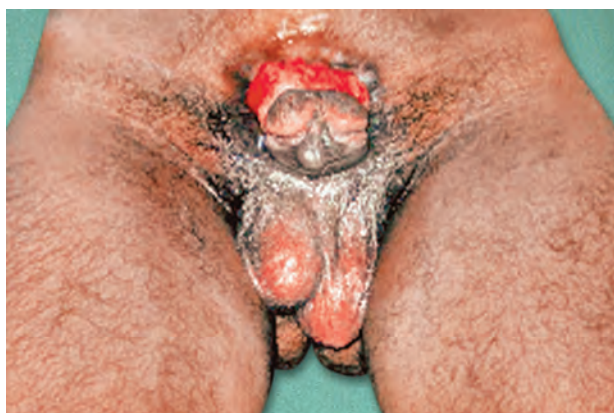

Fig. 26.86: Ectopia vesicae in a man of 25 years old.

- ◆ Testes are normal.
- ◆ Bilateral inguinal hernias are common.
- ◆ In females defective external genitalia is common.

### Problems

- ❖ Repeated soakage
- ❖ Ulceration
- ❖ Pain
- ❖ Recurrent pyelonephritis
- ❖ Renal failure
- ❖ Metaplastic changes in mucosa can lead into *adenocarcinoma*
- ❖ **50%** of patients die of renal failure

## Treatment

- ◆ Staged procedure.
- ◆ Initial diversion of urine to colon/rectum.
- ◆ Iliac osteotomy and closure of the abdominal wall.
- ◆ Correction of epispadias.
- ◆ Sometimes cystectomy and permanent ureterosigmoid diversion is required.
- ◆ Condition has got high mortality due to infection and renal failure.

## ■ URACHAL ANOMALIES

- ◆ *Patent urachus with urine leak*: It signifies obstruction distal to bladder.
- ◆ *Urachal sinus with discharge*.
- ◆ *Urachal cyst*: Present as immobile, fluctuant swelling in the abdominal wall. Sepsis, tuberculosis, adenocarcinoma, can occur in patent urachus.

## ■ VESICAL CALCULUS

*The signs of a stone in the bladder are, great and frequent irritations to make water, a stoppage in the middle of making it, and a pain with heat just after it is made; a tenesmus, pain in the extremity of the urethra, incontinence or suppression of urine, together with a quiet pulse, and the health in no bad state.*

—William Heberden, 1802

## Types

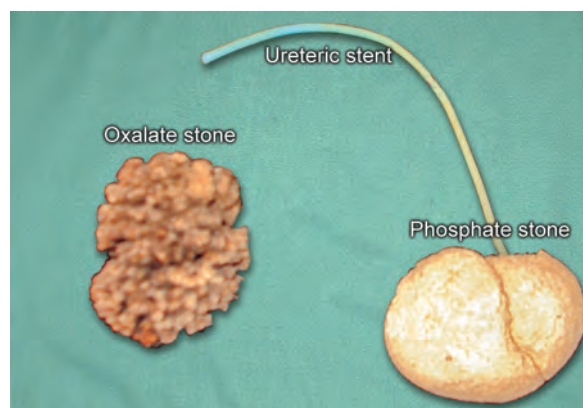


Fig. 26.87: Bladder stones—oxalate and phosphate. Phosphate stone has occurred in an indwelling J ureteric stent.

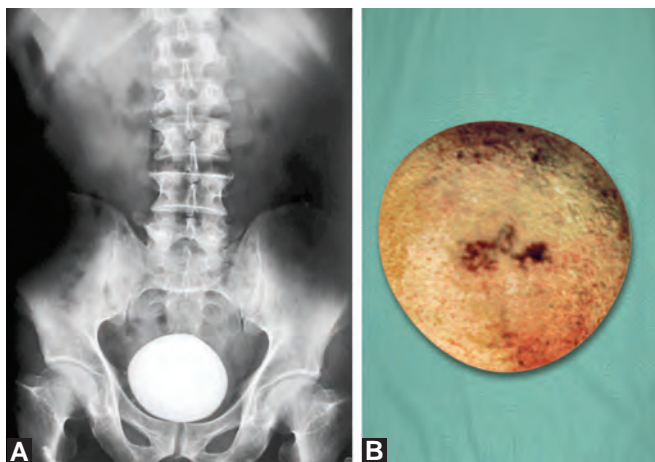
*Retrograde cystogram is the most reliable investigation in case of bladder rupture.*



- ◆ **Primary vesical calculus:** Occurs in sterile urine.
  - ▶ Usually comes down from kidney through ureter into the bladder and it gets enlarged here. It is usually *oxalate* stone (Jack stone).
  - ▶ Oxalate stone is usually single, primary stone, brownish black in colour (due to deposited blood pigment over the surface), hard and with spikes over the surface which irritates bladder mucosa causing haematuria (*mullberry stone*).
- ◆ **Secondary vesical calculus:** Occurs in the presence of infection. Most common bladder stone.
  - ▶ It is usually *phosphate stone*, occurs in bladder only.
  - ▶ Phosphate stone is smooth, soft, ivory-white in colour. It is either calcium phosphate or ammonium, calcium and magnesium phosphate (*triple phosphate stone*).
  - ▶ *E. coli* is the common organism.
- ◆ **Uric acid and urate stones** are single or multiple, primary, nonradio-opaque, smooth, pale yellow in colour.
- ◆ **Cystine calculus:** Occurs in cystinuria and is radio-opaque due to high sulphur content.

#### Aetiology

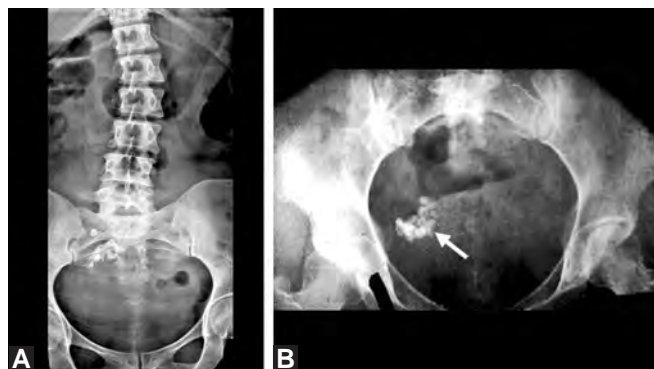
- ❖ Infection
- ❖ Hypercalciuria of any cause
- ❖ Hyperoxaluria
- ❖ Cystinuria
- ❖ Bed ridden and paraplegic patients
- ❖ Gout and other hyperuricaemic patients
- ❖ Diverticula bladder
- ❖ Obstruction to urine flow by BPH, urethral stricture, bladder neck obstruction
- ❖ Neurogenic bladder
- ❖ Schistosomiasis
- ❖ Foreign body in bladder



**Figs 26.88A and B:** (A) Plain X-ray KUB showing large bladder stone; (b) Large bladder stone removed by open suprapubic extraperitoneal cystolithotomy.

## Clinical Features

- ◆ Common in males. Often occurs in children.
- ◆ **Frequency** is more during day than night, because during day, due to ambulation stone comes in contact with the trigone of the bladder and irritates, whereas during night, stone slips towards the fundus, away from the trigone and so less frequency and pain.
- ◆ **Pain:** More during day which is referred to the tip of penis or labia. Also increases during jolting movements. Suprapubic pain and tenderness may be present.
- ◆ **Haematuria:** Often terminal.
- ◆ Interruption of urinary stream and often acute urinary retention.
- ◆ Features of cystitis: Burning micturition, fever, pain.
- ◆ P/R or P/V: Large stone may be palpable.
- ◆ Stone may be identified incidentally in plain X-ray, KUB or U/S, abdomen.



**Figs 26.89A and B:** (A) Plain X-ray showing dermoid cyst of ovary with Calcification. It is teratoma of ovary; (B) Dermoid cyst ovary. Note the radio-opaque teeth.

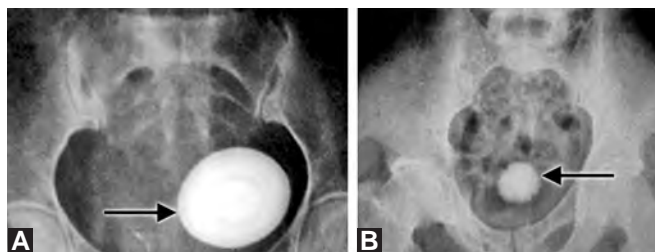
## Investigations

- ◆ Urine microscopy
  - ▶ Envelope crystals in oxalate stone,
  - ▶ Hexagonal type in cystine stone.
- ◆ Urine C/S.
- ◆ Blood urea, serum creatinine, serum calcium, inorganic phosphate, uric acid.
- ◆ Plain X-ray, KUB shows radio-opaque stones—90% are radio-opaque.

#### Radiological differential diagnosis for vesical calculi in females:

- ❖ Calcified fibroid uterus
- ❖ Dermoid cyst ovary

- ◆ IVU to see function of the kidney.
- ◆ Ultrasound abdomen is diagnostic.
- ◆ Cystoscopy to see radioluscent stone.



**Figs 26.90A and B:** A plain X-ray, pelvis showing: (A) Phosphate stone. Note the laminations; (B) Oxalate stone. Note the spiculated margins.

## Treatment

### 1. Cystoscopic litholapaxy

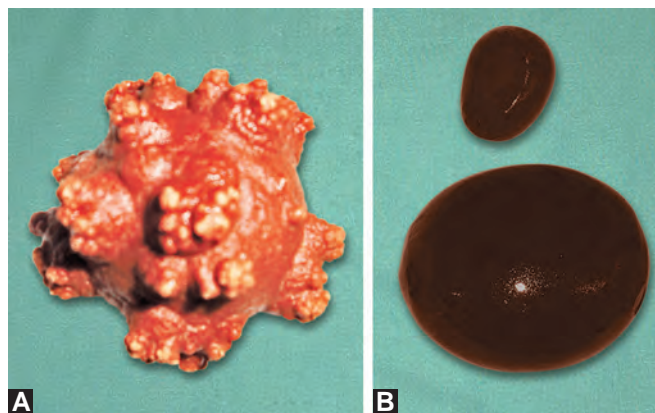
Under GA, cystoscope is passed and the stone is visualised. It is fragmented by pneumatic, laser, electromagnetic waves or mechanohydraulic lithotripsy. The bladder is flushed using an irrigator (Freyer's evacuator or irrigator or Ellik's evacuator).

#### Contraindications

- ❖ Too large stone
- ❖ Too small stone. Too soft stone. Too many stones
- ❖ Stone in bladder diverticula
- ❖ Bladder tumour
- ❖ Contracted bladder
- ❖ Patient's age below 10 years
- ❖ When patients general condition is poor, as the procedure takes a longer duration it is avoided and open removal is advised

### 2. Suprapubic open cystolithotomy

Through Pfannenstiel incision, bladder is approached extra-peritoneally. Bladder is identified by its detrusor muscle



**Figs 26.91A and B:** Two types of bladder stones—one with surface projections, other with smooth surface.

pattern, which is criss-cross and also its venous pattern. Bladder is opened near the fundus and stone is removed. Bladder is closed often with SPC using Malecot's catheter and Foley's catheter is passed per urethra. Wound is closed in layers with a drain.

### 3. Suprapubic percutaneous litholapaxy

This procedure is becoming popular. When cystoscope cannot be passed per urethra, bladder is approached suprapubically. Through a needle, guidewire and dilators, a track is created through which a nephroscope is passed to remove the stone after fragmenting.

The cause is treated.



**Fig. 26.92:** Asepto syringe used for bladder wash in patients with urinary catheter which has been blocked; or when haematuria is noticed in the catheter. It is also used to fill the bladder with saline.

## ■ CYSTITIS

Inflammation of the bladder mucosa due to different causes.

#### Causes

- ❖ Acute bacterial cystitis
- ❖ Chronic cystitis due to tuberculosis, syphilis
- ❖ Interstitial cystitis
- ❖ Radiation cystitis
- ❖ Cystitis due to schistosomiasis
- ❖ Postmenopausal atrophic cystitis

### Predisposing Factors

- ◆ Congenital urinary tract anomalies
- ◆ Short urethra in females may cause ascending infection and cystitis.
- ◆ Initial period of sexual contact in females can cause cystitis—Honeymoon cystitis.
- ◆ Catheters, instrumentation.
- ◆ Bladder stone.
- ◆ BPH, carcinoma prostate.
- ◆ Cystocele, bladder diverticulum.
- ◆ Stricture urethra, bladder neck obstruction.
- ◆ Bladder tumours.
- ◆ Pregnancy.
- ◆ CNS diseases, spinal injury.

### Organisms

- ◆ *E.coli*, *Klebsiella*, *Pseudomonas*, *Staph. aureus*, *Staph. albus*, *Proteus*.
- ◆ *Candida albicans*, fungal infection.

### Features

- ◆ Painful urination, frequency, strangury, incomplete emptying, with often retention.
- ◆ Occasionally haematuria can occur.
- ◆ Burning urine, discoloured foul smelling urine.

- ◆ Fever, chills, rigors, suprapubic pain and tenderness and often loin pain.
- ◆ Septicaemia can develop in severe cystitis.

## Investigations

- ◆ Total count will be raised.
- ◆ Urine will show pus cells and culture will reveal the organisms.
- ◆ X-ray may show a stone. IVU, cystogram are also helpful.
- ◆ U/S abdomen will show thickening of bladder mucosa, stone, tumour.
- ◆ Cystoscopy reveals bladder inflammation, mucosal changes.

## Treatment

- ◆ Appropriate antibiotics like quinolones, aminoglycosides, cephalosporins.
- ◆ Plenty of water intake to flush the bacteria from the bladder.
- ◆ Often admission and parenteral antibiotics may be needed.
- ◆ Evaluation and therapy for cause should be done.
- ◆ Strict aseptic precaution is used while catheterisation, cystoscopy.
- ◆ Often long-term antibiotics are needed to prevent recurrent infection.

## ■ RECURRENT CYSTITIS

### Causes

- ◆ Failure of early treatment for acute cystitis
- ◆ Reinfection by same or different organisms.

### Types

- ◆ Chronic cystitis.
- ◆ Phosphate deposition in the ulcerated mucosa causing encrusted cystitis.
- ◆ Proliferation of mucosa and submucosa causing proliferative cystitis. It may be cystitis follicularis, cystitis polyposa, cystitis glandularis, cystitis cystica.
- ◆ Gas filled cysts in the submucosa causing cystitis emphysematosa.
- ◆ Necrosis of bladder wall can occur leading to gangrenous cystitis.

## Management

- ◆ Urine microscopy and culture.
- ◆ Antibiotic and urinary antiseptics like hippuric acid, mandelic acid.
- ◆ Proper hygiene.
- ◆ Plenty of oral fluid intake and frequent emptying of the urine.

## ■ INTERSTITIAL CYSTITIS (Hunner's Ulcer, Elusive Ulcer)

- ❖ It is common in females
- ❖ Common in western countries
- ❖ Common in psychic females

## Pathology

There is pancystitis with fibrosis of vesical musculature along with linear ulcers in the bladder mucosa. Microscopically, severe inflammation of all layers of bladder with fibrosis is observed. Bladder eventually

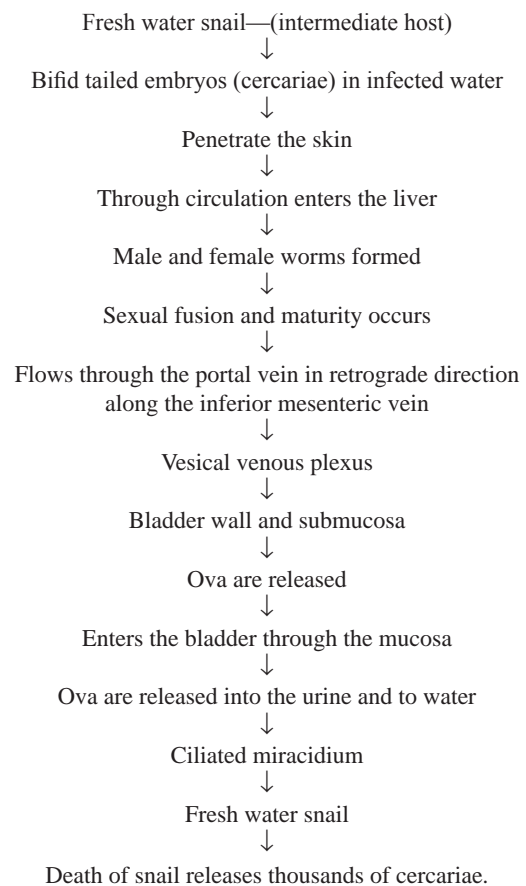
becomes **thimble (systolic) bladder** with decreased bladder capacity up to 30–60 ml (less than 100 ml).

## Features

- ◆ Pain.
- ◆ Decreased bladder capacity.
- ◆ Pain increases with bladder distension.
- ◆ Frequency and often haematuria.
- ◆ *Differential diagnosis*: Other causes for thimble bladder.
- ◆ *Investigation*: Cystography and cystoscopy are diagnostic.
- ◆ *Treatment*
  - ▶ Hydrostatic dilatation.
  - ▶ Instillation of dimethyl sulphoxide (Rimso 50).
  - ▶ Ranitidine instillation.
  - ▶ Ileocystoplasty or caecocystoplasty, to increase the bladder capacity.
  - ▶ Urinary diversion.

## ■ SCHISTOSOMA HAEMATOBIIUM (Endemic Haematuria, Urinary Bilharziasis) (Swimmer's Itch)

### Life Cycle



## Pathology in the Bladder

- ◆ Bilharzial pseudotubercles—earliest sign.
- ◆ Nodules.

- ◆ Sandy patches—calcified dead ova with degeneration of overlying epithelium.
- ◆ Granulomas.
- ◆ Ulceration and papilloma.
- ◆ Fibrosis and thimble bladder formation.
- ◆ In due course of time, development of *squamous cell carcinoma*.
- ◆ Other pathologies: Ureteral and urethral stricture, recurrent UTI, bladder calculi, urinary fistula.

### Clinical Features

- ◆ Initially cutaneous lesions like urticaria develops lasting for few days.
- ◆ Then after a period of 4–8 weeks, fever, along with features of eosinophilia develops.
- ◆ Eventually, after many months it causes intermittent, painless, *terminal haematuria*.

### Investigations

- ◆ Cystoscopy and biopsy.
- ◆ IVU.
- ◆ Cystography.
- ◆ Urine microscopy: Last few ml of early morning urine sample is collected to see for ova and RBCs.

#### Differential diagnosis

- ❖ Tuberculosis
- ❖ Recurrent cystitis
- ❖ Malignancy

### Treatment

- ◆ Long-term *Praziquantel* or metrifonate.
- ◆ Surgery for thimble bladder—ileo- or caecocystoplasty.
- ◆ Cystoscopic diathermy fulguration of papillomas.
- ◆ Radical cystectomy, if it is squamous cell carcinoma of the bladder.

## THIMBLE OR SYSTOLIC BLADDER

It is inability of the bladder to relax and distend and so inability to retain the urine as required.

#### Causes

- ❖ Tuberculous cystitis
- ❖ *Schistosoma haematobium*
- ❖ Interstitial cystitis
- ❖ Radiotherapy
- ❖ Malignancy
- ❖ Previous bladder surgery

- ◆ Bladder is fibrotic and contracted, with difficulty in dilating and accommodating urine as needed.
- ◆ Bladder capacity is less than 100 ml (60 ml).

### Clinical Features

- ❖ Features of decreased bladder capacity
- ❖ Frequency of urine
- ❖ Features of recurrent cystitis

### Investigations

- ◆ Cystoscopy.
- ◆ Cystography.
- ◆ IVU.
- ◆ Urine C/S.
- ◆ Specific diagnostic tests.

### Treatment

- ◆ The cause is treated.
- ◆ Hydrostatic dilatation.
- ◆ Augmentation of bladder by doing ileocystoplasty or *caecocystoplasty* or *sigmoidocystoplasty*.
- ◆ Steroids are also tried.

## BLADDER TUMOURS

They are urothelial tumours. They are commonly malignant. Benign tumours are rare. Transitional cell carcinoma (TCC) is the most common.

### 1. Primary

- Epithelial**
  - ▶ *Transitional cell carcinoma* (90%).
  - ▶ *Adenocarcinoma*, arising from urachal remnant or in exstrophy bladder or from glandular metaplasia (2%).
  - ▶ *Squamous cell carcinoma* originates from bilharzial infection (5%) or calculus.
- Connective tissue tumour:**
  - ▶ Myoma, angioma, fibromas, sarcomas.
  - ▶ Extra-adrenal pheochromocytoma.

### 2. Secondary

From adjacent organs like sigmoid colon, rectum, uterus, ovary, prostate.

## TRANSITIONAL CELL CARCINOMA (TCC)

- ◆ It is the most common type of bladder tumour.
- ◆ It is the 4th most common nondermatological cancer in man.

### Aetiology

#### 3C's

- ❖ Chemical carcinogens.
- ❖ Cigarette smoking.
- ❖ Cyclophosphamide.

- ◆ Chemical carcinogens are the main factor. 2-Naphthylamine, aminobiphenyl, benzidine, chloro-O-toluidine, chloro-aniline, other dyes.
- ◆ Occupation wise it is common in textile, dye, cable, tyre, petrol, leather workers, painters, chemical workers, sewage workers.
- ◆ Abnormal tryptophan metabolism can cause bladder cancer.
- ◆ *Schistosoma haematobium*; chronic irritation, etc.

*Men take only their needs into consideration, never their abilities.*

## Classification I

1. **Nonmuscle invasive tumour without involving lamina propria:** Has got excellent prognosis (70%).
2. **Nonmuscle invasive tumour with involvement of lamina propria.**
3. **Muscle invasive type (25%):** Carries poor prognosis.
4. **Carcinoma in situ (flat noninvasive—5%):**
  - ▶ Contains irregularly arranged cells with large nuclei, with high mitotic index, replacing normal urothelium.
  - ▶ This may occur alone—*Primary carcinoma in situ*.
  - ▶ It may occur in association with a new tumour—*Concomitant carcinoma in situ*.
  - ▶ It can occur in a patient who had a previous tumour—*Secondary carcinoma in situ*.
  - ▶ It has got high malignant potential with 50% mortality rate.
  - ▶ It was called earlier as 'malignant cystitis' as it causes severe dysuria, suprapubic pain and frequency (terminology not used presently).



Fig. 26.93: Pathology specimen of bladder (tumour) showing multiple papillary tumours projecting into the lumen.

## Classification II

- a. **Superficial bladder tumour:**
  - ▶ It may be *papillary*, pedunculated with narrow stalk, which is often multiple.
  - ▶ It may be *sessile* with a wide base, can be single or multiple, and has got tendency to invade the muscle earlier.
  - ▶ Mucosa in and around the tumour is oedematous, red, with dilated vessels, often with encrustations. It is 70% common. Less than 5% of superficial TCC develop metastatic carcinoma.
- b. **Muscle invasive TCC:**
  - ▶ Almost always they are solid, sessile, with a broad base and with irregular ulcerated surface.
  - ▶ It may spread through lymphatics to pelvic lymph nodes or through blood to the lung, liver and bones.
  - ▶ It has got poor prognosis.
- c. **Carcinoma in situ:**
  - ▶ Bladder tumor can be papillary or villous type. It can be low grade or high grade.

## Staging

### Jewett-Strong-Marshall staging

- I Tumour confined to subepithelial connective tissue
- II Muscle infiltration superficially
- III Full thickness muscle and perivesical tissues infiltrated, but mobile
- IV Fixed to adjacent organs
  - IVa (prostate)
  - IVb (pelvic wall)

- ▶ Staging is done by bimanual palpation under G/A.

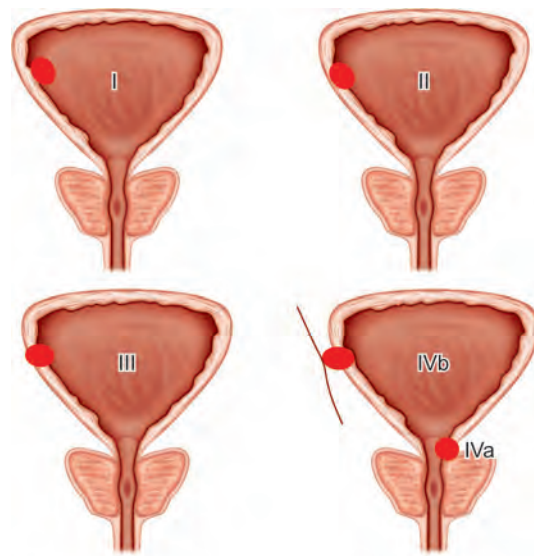


Fig. 26.94: Staging of bladder tumour.

## Sites

- ◆ *Lateral wall*—most common (35%).
- ◆ *Trigone*—next common (32%).

## TNM staging (AJCC) of bladder tumours

### Tumour—by clinical, imaging; cystoscopy

- Tx—Primary cannot be assessed
- T0—No evidence of tumour
- Tis—Carcinoma in situ
- Ta—Noninvasive papillary tumour
- T1—Invading only lamina propria
- T2—Tumour invading muscularis propria
  - pT2a—Invading the inner half of the muscle
  - pT2b—Invading the outer half of the muscle
- T3—Invading perivesical tissues
  - pT3a—Microscopic invasion
  - pT3b—Macroscopic invasion
- T4—Invasion into prostate/uterus/vagina/pelvic or abdominal wall
  - T4a—Invasion into prostate/uterus/vagina
  - T4b—Invasion into pelvic/abdominal wall

### Nodal—by clinical and imaging

- Nx—Regional nodes cannot be assessed
- N0—No nodal spread
- N1—Single regional node in true pelvis (hypogastric, obturator, external iliac, presacral)
- N2—Multiple regional nodes in the true pelvis
- N3—Spread to common iliac nodes

Contd...

Contd...

#### Metastases—by clinical, imaging

M0—No distant spread

M1—Distant metastases present

#### Stage groups

Stage 0a: T<sub>a</sub>,N0,M0

Stage 0is: T<sub>is</sub>,N0,M0

Stage I: T<sub>1</sub>,N0,M0

Stage II: T<sub>2a</sub>,/T<sub>2b</sub>,N0,M0

Stage III: T<sub>3a</sub> /T<sub>3b</sub> / T<sub>4a</sub>,N0,M0

Stage IV: T<sub>4b</sub>,N0,M0; Any T,N1–3,M0; Any T, any N, M1

## Clinical Features

- ◆ Painless haematuria anaemia.
- ◆ Features of cystitis, with suprapubic pain, frequency, dysuria.
- ◆ Hydronephrosis can occur when tumour obstructs the ureteric orifice.
- ◆ Pain in groin, back, perineum, when tumour invades the pelvic wall.
- ◆ Common in males—3:1.

## Investigations

- ◆ Urine microscopy: For RBC's and malignant cells.
- ◆ Blood: Hb%, blood urea, serum creatinine.
- ◆ IVU: Shows filling defect with distortion and often hydronephrosis.
- ◆ Cystoscopy and biopsy/resection.
- ◆ Bimanual examination under G/A—to stage the tumour.
- ◆ U/S abdomen to see bladder wall, pelvis, liver, lymph nodes.
- ◆ CT scan to evaluate the extension.
- ◆ MRI to see invasion and pelvic wall status.

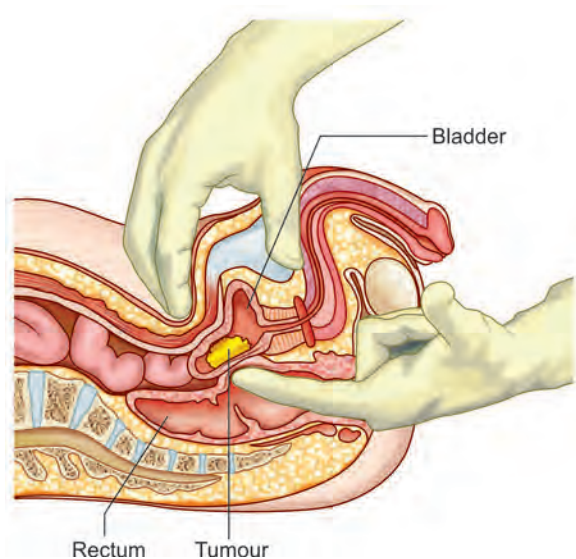


Fig. 26.95: Bimanual palpation is done for bladder tumour under general anaesthesia to evaluate the tumour.

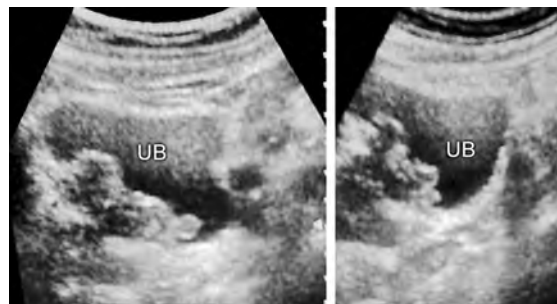
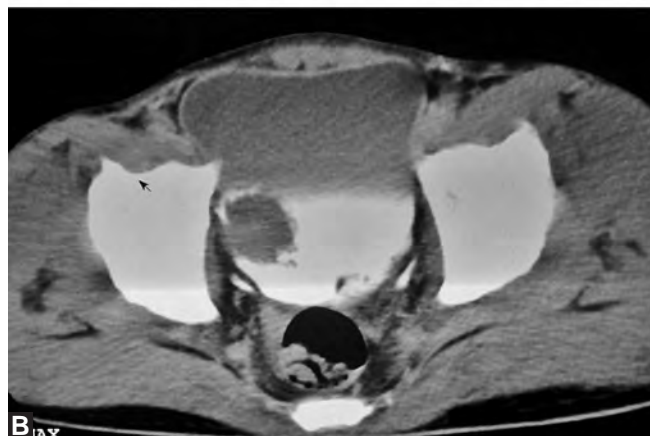
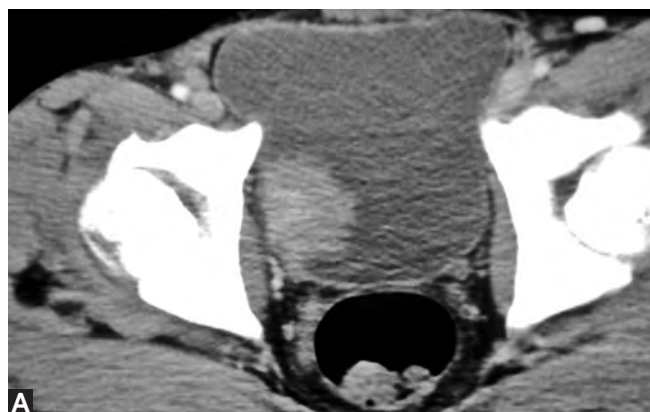


Fig. 26.96: Carcinoma urinary bladder—ultrasound picture.



Figs 26.97A and B: CT scan showing bladder tumour.

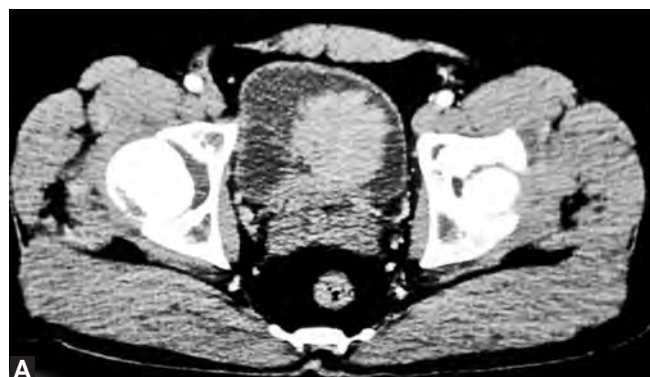

Fig. 26.98 A

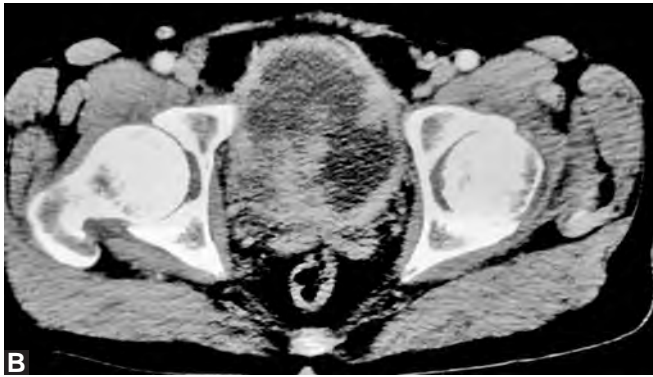

Fig. 26.98B

**Figs 26.98A and B:** CT scan picture showing irregularity in bladder mucosa—carcinoma urinary bladder.

## Treatment

### a. Noninvasive tumour:

- ▶ **Endoscopic resection** of tumour.
- ▶ **Intravesical chemotherapy** using BCG (Dose: 120 mg in 150 ml of normal saline weekly for six weeks), mitomycin C, epirubicin, adriamycin, thiotepa, methotrexate can be given especially for carcinoma *in situ*.
  - BCG is very useful. Very rarely *BCG provocation* can occur. Fever, joint pain, granulomatous prostatitis, sinus formation, disseminated tuberculosis are the features. Dysuria, frequency and urinary irritation can occur. BCG is *live attenuated vaccine*; its advertent IV entry can be *life threatening* and so if there is haematuria its infusion should be postponed.
  - Mitomycin C causes skin desquamation and rash.
- ▶ **Systemic chemotherapy:** Using cisplatin, 5 FU, adriamycin, mitomycin.
- ▶ **Helmstein balloon degeneration** for large papillary tumour. Balloon is passed into the bladder and inflated so as to cause pressure necrosis of the summit of the tumour. Later remaining part of the tumour can be resected easily through cystoscopy.

### b. Invasive bladder tumour:

- ▶ **Curative interstitial radiotherapy** using implantation of radioactive gold grains (Au 198) (half life is two and half days), or radioactive tantalum wires (Ta 182) (half life is 4 months).
- ▶ **Radical deep external beam radiotherapy** (45 Gy) using cobalt 60 is useful, as bladder is retained and so normal act of micturition and potency can be maintained. Complication is that it may eventually lead to formation of thimble bladder.
- ▶ **Surgery:**

#### Indications for surgery

- ❖ Multiple bladder tumours
- ❖ Sessile tumours
- ❖ Recurrent tumours
- ❖ Poorly differentiated tumours
- ❖ *In situ* carcinomas
- ❖ Squamous cell carcinoma
- ❖ Adenocarcinomas

- **Partial cystectomy** done when tumour is confined to fundus of the bladder and is single, with a margin of clearance of 2.5 cm. External beam RT and chemotherapy should be given.
- **Radical cystectomy:** CT scan is a must before doing radical cystectomy to see the pelvis and lymph node status. Here urinary bladder, urethra, paravesical tissues, lymph nodes (pelvic) are removed. In females hysterectomy with removal of part of the vagina is done. After surgery urinary

diversion is done either by doing continent ileal conduit, or ureterosigmoidostomy or by creating rectal urinary pouch.

- ▶ **Intravesical chemotherapy** by BCG, mitomycin C, adriamycin and interferons.
- ▶ **Systemic chemotherapy** by cisplatin, adriamycin, mitomycin, vinblastine—adjuvant therapy. Neoadjuvant cisplatin based chemotherapy is beneficial improving survival by 7%. MVAC regime is methotrexate; vinblastine; adriamycin and cisplatin.

## Prognosis

- ◆ Depends on type, differentiation, location, stage, invasion, number, lymph node status, pelvis involvement and response to treatment.
- ◆ TCC alone—85%; TCC with SCC or adenocarcinoma—6%; SCC/adenocarcinoma alone—3%; spindle cell carcinoma—2%.

## URETEROSIGMOIDOSTOMY

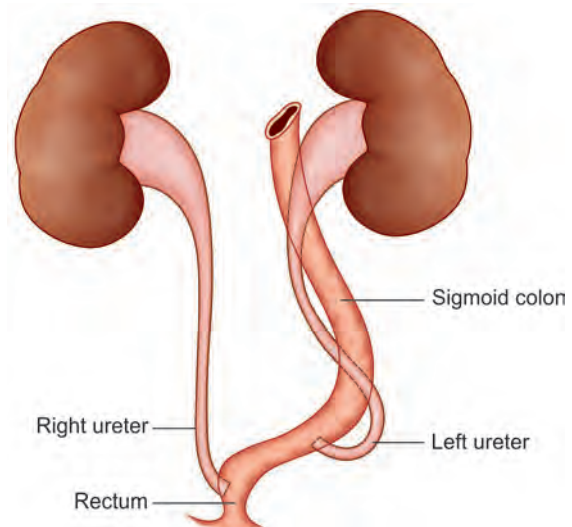
- ◆ It is a procedure done for urinary diversion after radical cystectomy or as a permanent diversion for many other causes, e.g. bladder dystrophy.
- ◆ *Left ureter is implanted to the sigmoid colon, right one to the upper rectum or rectosigmoid junction.*

## Complications

- ◆ Because the pressure in sigmoid colon is more, it causes *pyelonephritis* and recurrent upper urinary tract infection.
- ◆ Because of diarrhoea it causes *hypokalaemia*.
- ◆ Because of reabsorption of chloride, *hyperchloraemic acidosis* occurs.

## Treatment

- ◆ IV sodium bicarbonate (8.4%) with slow IV potassium.
- ◆ IV antibiotics.
- ◆ Patient is advised to take potassium citrate and sodium bicarbonate and to **avoid salt**.
- ◆ In many cases conversion to *ileal conduit* may be required.

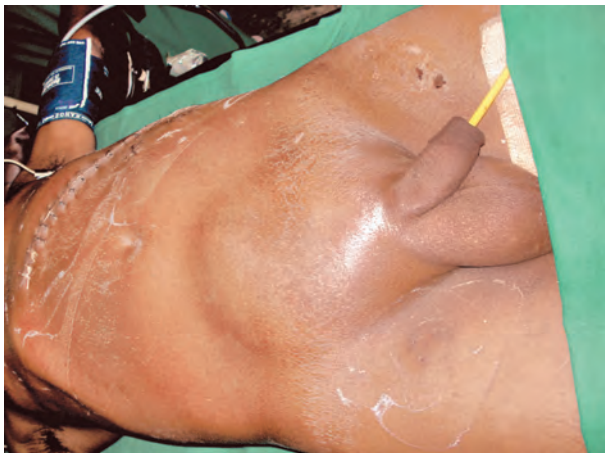

**Fig. 26.99:** Ureterosigmoidostomy.

## RUPTURE BLADDER (BLADDER INJURY)

### Causes

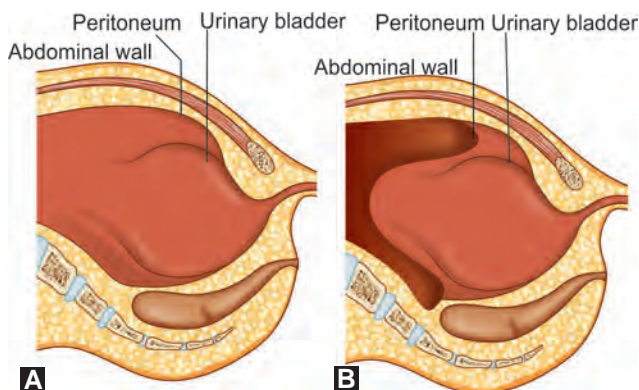
- ❖ Blow, kick or fall
- ❖ Road traffic accidents
- ❖ Stabs, gunshot injuries
- ❖ Endoscopic trauma
- ❖ Diathermy
- ❖ Instrumentations



**Fig. 26.100:** Rupture urinary bladder causing extravasation and lower abdominal swelling. It needed surgical intervention, repair of bladder; suprapubic cystostomy.

### Types

- I. *Intraperitoneal rupture*—20% common.  
Occurs in fully distended bladder due to blow, kick, or fall.
- II. *Extraperitoneal rupture*—80% common.  
Due to road traffic accidents, golf playing, fall over the manhole.  
Its features and management are same as rupture of posterior (membranous) urethra.



**Figs 26.101A and B:** (A) Intraperitoneal rupture; (B) Extraperitoneal rupture.

#### I. Intraperitoneal Rupture

- ◆ It is 20% common.
- ◆ It occurs in full bladder.

#### Clinical features

- ◆ Sudden pain in suprapubic region.
- ◆ Shock and syncope.
- ◆ Diffuse abdominal pain.
- ◆ Urine leaks into the abdominal cavity causing distension of abdomen.
- ◆ Later it causes features of peritonitis, with guarding, rigidity, tenderness and rebound tenderness, dull flank.
- ◆ *Patient does not have the desire to micturate.*

#### Investigations

- ◆ Plain X-ray shows ground glass appearance.
- ◆ Peritoneal tap is done to confirm urine.
- ◆ Cystogram: After passing a small catheter gently per urethra, water soluble iodine dye is passed to visualise the tear in the bladder and entry of the dye into the free peritoneal cavity. This can be done now through C-Arm image intensifier easily.
- ◆ Ultrasound abdomen to look for other injuries in the abdomen.
- ◆ CT scan abdomen.

#### Treatment

- ◆ *Surgery is the only treatment for intraperitoneal rupture of the bladder.* Emergency laparotomy is done.
- ◆ Bladder tear is sutured in two layers using **vicryl**. Peritoneal wash is given.
- ◆ Malecot's catheter is placed from above as SPC.
- ◆ Prevesical space and peritoneal cavity are drained separately.
- ◆ Foley's catheter from below is also passed.
- ◆ Adequate specific antibiotics are given to prevent sepsis.

### Complications of rupture bladder

- ❖ Cystitis and pyelonephritis
  - ❖ Peritonitis
  - ❖ Pelvic abscess
  - ❖ Fistula formation (vesicovaginal or rectovesical)
  - ❖ Paralytic ileus
  - ❖ Haemorrhage
- Without surgery mortality is 100%

#### II. Extraperitoneal Rupture of the Bladder

- ◆ It is 80% common.
- ◆ Occurs in road traffic accidents, in a nondistended bladder.

#### Clinical features

- ◆ There is collection of urine and blood in the extraperitoneal space in front, with fullness, diffuse pain and tenderness in lower abdomen.
- ◆ Swelling in the scrotum or labia, and abdominal wall.
- ◆ Strangury and inability to pass urine.
- ◆ Often blood in the external meatus is noted.
- ◆ Features of shock and of other associated injuries may be noted.

#### Investigations

- ◆ Plain X-ray pelvis shows fracture pelvis.
- ◆ Cystogram shows leak from the bladder.

*A great man is always willing to be little. Man's greatness is not in what he is but in what he makes possible.*



**During cystoscopy**

- ❖ Bladder cannot be distended
  - ❖ Endoscopy light may be shining through the abdominal wall
  - ❖ Irrigating fluid cannot be retrieved back
- Associated urethral injury is looked for

**Treatment**

- ◆ The bladder is exposed extraperitoneally, the tear is identified and sutured. The extraperitoneal space is irrigated with saline. Bladder is closed with a SPC using Malecot's catheter and a drain is placed in prevesical space (cave of Retzius).
- ◆ If there is urethral injury it should be treated accordingly.

**Note:**

- **Bladder injury can also occur** during hysterectomy (both abdominal and vaginal), surgery of colon or rectum, repair of direct inguinal or femoral hernias.

**RESIDUAL URINE**

- ◆ It is the amount of urine retained in the bladder after voiding (at the end of completion of the act of micturition).
- ◆ Normal value is 30 ml.
- ◆ Amount more than 50 ml is significant. It signifies obstruction in the urethra like BPH.
- ◆ Residual urine more than 200 ml in BPH indicates the need for surgical intervention.
- ◆ High residual urine is also seen in different types of neurogenic bladder.
- ◆ Residual urine precipitates infection because of stasis.

*Residual urine is assessed by the following methods:*

- ◆ The patient is asked to pass urine and then a red rubber catheter is passed to empty the retained urine which is measured to quantify.
- ◆ Ultrasound for evaluation of the bladder after voiding urine.
- ◆ Intravenous urogram (IVU)—postmicturition film.

**MALAKOPLAKIA**

- ◆ It is usually associated with chronic cystitis of unknown aetiology causing greyish raised patches in the bladder mucosa.
- ◆ Microscopically it shows infiltration of submucosa with lymphocytes, plasma cells and large multinucleated malakoplakia giant cells with concretions, called as *Michaelis Gutmann bodies* present both inside the giant cell as well as outside.
- ◆ It does not turn into malignancy.
- ◆ It presents as cystitis.
- ◆ Management is urine analysis; culture; antibiotics; urinary antiseptics like pyridium; cystoscopic evaluation and biopsy to rule out other causes.

**NEUROGENIC BLADDER**

It is the altered bladder function due to defects anywhere in the pathway of micturition reflex.

**Causes**

- |                            |                     |
|----------------------------|---------------------|
| ❖ Spinal cord trauma       | ❖ Tabes dorsalis    |
| ❖ Disc prolapse            | ❖ Diabetes mellitus |
| ❖ Spina bifida             | ❖ Cerebral diseases |
| ❖ Spinal cord root lesions | ❖ Poliomyelitis     |

**Types****Uninhibited Neurogenic Bladder**

- ◆ It occurs in CNS diseases due to block in the corticospinal tract.
- ◆ There is increased frequency, urgency and incontinence.
- ◆ There is early desire to micturate with inability to hold urine.
- ◆ Bladder capacity is decreased.
- ◆ Awareness of filling and distension, and voiding pressure is normal.
- ◆ No residual urine.

**Reflex Neurogenic Bladder (Automatic bladder)**

- ◆ Lesion here is above the level of micturition centre  $S_2, S_3$  and  $S_4$ .
- ◆ There is no desire to micturate.
- ◆ No awareness of filling or distension.
- ◆ Bladder capacity is normal or increased.
- ◆ Voiding pressure varies.
- ◆ Residual urine present.
- ◆ Infection is common.

**Autonomous Bladder**

- ◆ Here micturition centre is destroyed ( $S_2, S_3, S_4$ ). Both sensory and motor parts are destroyed.
- ◆ There is no awareness of filling.
- ◆ Bladder is incapable of contraction and so bladder capacity is increased.
- ◆ No voiding pressure.
- ◆ High residual urine and infection.
- ◆ Stress incontinence is present.
- ◆ Patient empties the urine by manual pressure.

**Sensory Paralytic Bladder**

- ◆ Here sensation from the bladder to micturition centre is selectively affected.
- ◆ It is common in tabes dorsalis and pernicious anaemia.
- ◆ There is complete loss of awareness of filling.
- ◆ Varying voiding pressure.
- ◆ Increased bladder capacity and residual urine.
- ◆ Infection is common.

**Motor Paralytic Bladder**

- ◆ It is due to selective destruction of motor pathway from the micturition centre to the bladder.
- ◆ It is seen commonly in polio, tumours, trauma.
- ◆ There is normal awareness of filling and painful distension.
- ◆ Voiding pressure is zero. It is atonic bladder.
- ◆ There is residual urine with normal bladder capacity.

**Investigations**

- ◆ Spine X-ray.
- ◆ Micturating cystogram.
- ◆ Urodynamic studies.
- ◆ Ultrasound abdomen to find out residual urine.
- ◆ Urine culture and microscopy.

## Treatment

- ◆ The cause is treated.
- ◆ Condom drainage.
- ◆ Intermittent catheterisation.
- ◆ Drugs like carbachol, distigmine can be given.
- ◆ Alpha adrenergic agents.
- ◆ Physiotherapy and pelvic exercises.
- ◆ Electrical stimulation of perineal muscles.
- ◆ Treating the stress incontinence surgically.
- ◆ Antibiotics whenever there is infection.

## ■ VESICoureTERIC REFLUX

- ◆ Normal flow of urine is always from ureter to bladder through ureteric orifice. It is called as efflux.
- ◆ If urine enters the ureter from the bladder through ureteric orifice, it is called as reflux. It is always *pathological*.

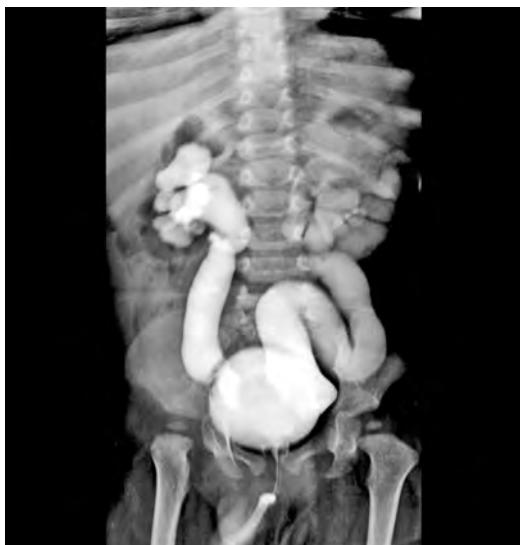

Fig. 26.102: Micturating cystourethrogram (MCU) showing gross vesicoureteric reflux on both sides.

## Causes

- ◆ *Congenital*: It is commonly associated with posterior urethral valve.
- ◆ *Acquired*: Trauma, after surgery or intervention.
  - ▶ Reflux has got **5 grades** depending on the amount of reflux (for grades refer back—MCU).
  - ▶ Reflux can be unilateral or bilateral.

## Features

- ◆ Features of recurrent urinary tract infection.
- ◆ Renal failure in bilateral cases.
- ◆ Palpable kidney mass in the loin.
- ◆ *Investigations*
  - ▶ Urine microscopy and C/S.
  - ▶ Blood urea and serum creatinine.
  - ▶ IVU.
  - ▶ Micturating cystourethrogram (MCU).

## ◆ Treatment

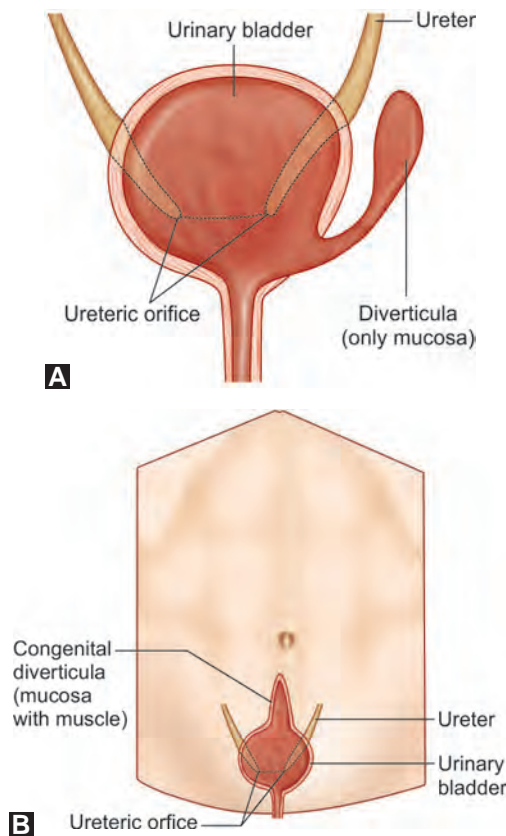
- ▶ Tailoring of the ureter with ureteric re-implantation.
- ▶ Antibiotics.
- ▶ In severe cases nephrectomy, renal transplantation are required.

## ■ BLADDER DIVERTICULA

Normal intravesical pressure is 30–50 cm of water. Pressure reaches as high as 150 cm of water in obstruction. This causes hypertrophy of bladder mucosa → saccule formation → diverticulum.

### Diverticula can be:

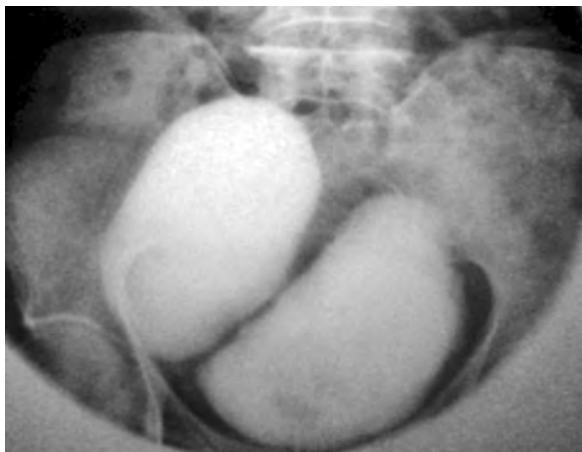- ❖ *Acquired*—common
  - Pulsion diverticulum occurs due to increased intravesical pressure
  - Traction diverticula occurs due to traction into a hernial sac in the groin—often as a sliding hernia
- ❖ *Congenital*—due to remnant urachus in midline



Figs 26.103A and B: Diverticula bladder. In acquired type only mucosal protrusion is seen in paraureteric orifice region. In congenital type it is full thickness protrusion, commonly over the dome of the bladder.

### 1. Congenital diverticula:

- ▶ It occurs over the dome of the bladder.
- ▶ It is due to unobliterated end of the urachus.
- ▶ As it contains muscle in the wall and it contracts during micturition.
- ▶ Rare type.

2. *Acquired diverticula:*

**Fig. 26.104:** X-ray showing bladder diverticula. It can be pulsion or traction diverticula. It can be congenital or acquired. Acquired occurs in paraureteric region. Congenital occurs in midline over the dome of the urinary bladder.

- ◆ They are more common.
- ◆ It occurs as a result of chronic urinary obstruction like BPH.
- ◆ It occurs adjacent to ureteric orifice and contains only mucosa (above and outer to ureteric orifice).
- ◆ It is prone for stasis, sepsis, stone formation, metaplasia and malignancy.
- ◆ Common in males (95%). Common in adults of 50 years.
- ◆ Haematuria (30%); fever; pyelonephritis.
- ◆ Micturition twice in rapid succession to empty the diverticular urine—is often typical.

#### Complications of bladder diverticula

- ❖ Recurrent infection
- ❖ Bladder stone formation
- ❖ Obstructive uropathy
- ❖ Malignant transformation—less than 5%

### Investigation

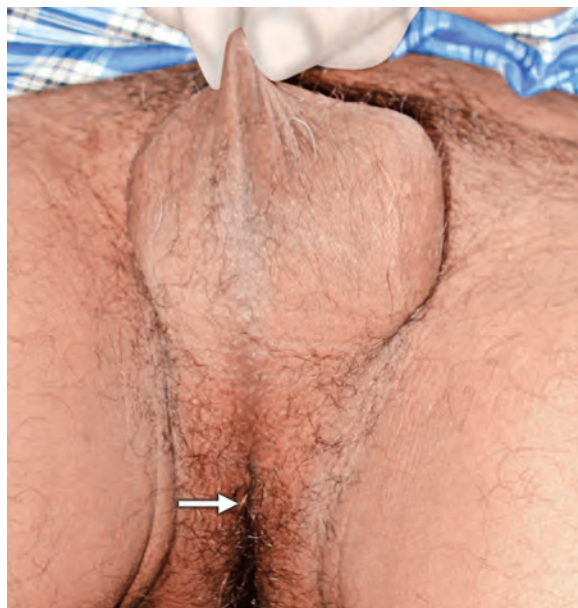- ◆ Urine C/S, cystoscopy, cystogram, IVU, ultrasound abdomen.
- ◆ CT scan abdomen.

### Treatment

- ◆ Removal of the diverticula through open surgery.
- ◆ Approach is combined intravesical and extravesical. Through cystoscopy, ureteric stent is placed. Suprapubic transverse extraperitoneal open approach is used. Anterior wall of bladder is vertically opened in midline. Diverticulum is packed with gauze. Junction between urinary bladder and diverticulum is dissected from outside; transected and diverticulum is excised. Bladder surface is closed with vicryl 2 zero single layer sutures. Midline vesicotomy is closed with a Malecot's catheter. Retropubic space is drained. Indwelling urinary catheter is kept *in situ* for 7–10 days.

## ■ URINARY DIVERSION

- ◆ It is diversion of urine temporarily or permanently, proximal to the site of obstruction.
  - ▶ Temporary type is done in benign conditions and distal obstructions, to promote healing.
  - ▶ Permanent type is done in advanced malignancies which block the urine flow distally, after radical cystectomy, after radiotherapy with frozen pelvis, etc.



**Fig. 26.105:** Perineal urethrostomy after total amputation of penis.

### Temporary Diversions

- ◆ Suprapubic cystostomy (SPC).
- ◆ Vesicostomy in children in ectopiae vesicae, epispadias, urethral anomalies.
- ◆ Ureteric J stent—pigtail stents kept for 3 months.
- ◆ Urethrostomies.
- ◆ Nephrostomies in pyonephrosis and high obstructive uropathies.
- ◆ Pyelostomy.

### Permanent Diversions

#### External Diversions

- ◆ *Noncontinent ileal conduit*  
Here 20 cm of vascularised distal ileum (30 cm from IC valve) is prepared. Ureters are re-implanted over the ileum. Other end of ileum is brought out as a 3 cm stoma in right iliac fossa. Patient has to wear a bag over it.
- ◆ *Continent ileal conduit* is similar conduit with creation of specialised valve (Koch's continent) within, using ileal mucosa or appendix. Patient has to empty the conduit by passing self catheters once in 6 hours.
- ◆ Cutaneous ureterostomy/cutaneous ring ureterostomy.

#### Internal Diversions

- ◆ Ureterosigmoidostomy (*Leadbetter-Palitano*).

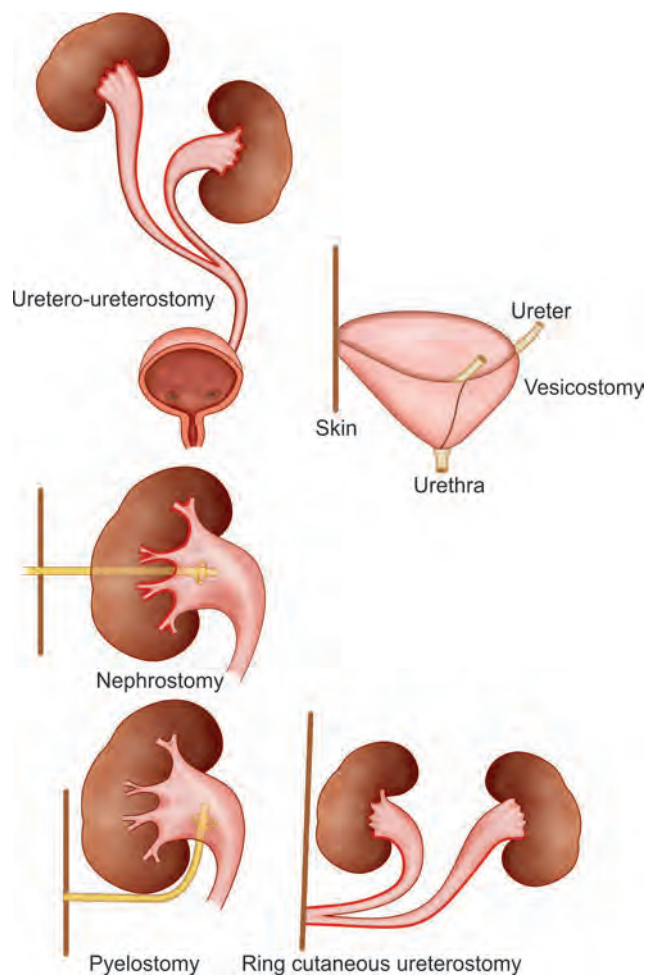


Fig. 26.106: Types of urinary diversions.

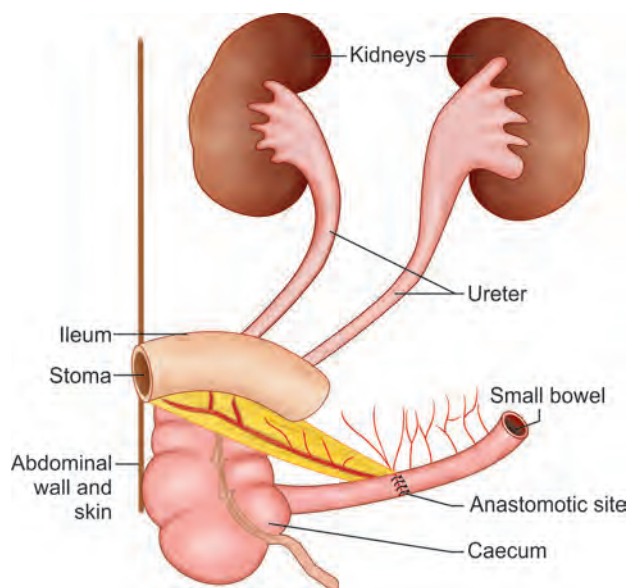


Fig. 26.107: Ileal conduit as urinary diversion.

- ◆ Rectal bladder creation.
- ◆ Ileocystoplasty.
- ◆ Caecocystoplasty/sigmoidocystoplasty.
- ◆ Creation of neobladder using ileum/caecum/sigmoid colon which is sutured to urethra.

#### Types of urinary diversions

- ❖ Nephrostomy
- ❖ Pyelostomy
- ❖ Cutaneous ureterostomy
- ❖ Cutaneous ring ureterostomy
- ❖ Suprapubic cystostomy
- ❖ Vesicostomy in children
- ❖ Urethrostomy
- ❖ Ureterosigmoidostomy
- ❖ Rectal bladder
- ❖ Urinary ileal conduit (Koch's conduit)

#### Complications of Diversions

- ◆ Urine leak, faecal leak, intestinal obstruction, sepsis.
- ◆ Hyperchloraemic hypokalaemic metabolic acidosis.
- ◆ Pyelonephritis.
- ◆ Osteomalacia, growth retardation.
- ◆ Calculi formation—4%.
- ◆ Continent failure, blockage of diversion stoma (stenosis).
- ◆ Reflux of urine.
- ◆ Vitamin B<sub>12</sub> and folate deficiency due to absence of ileum.
- ◆ Complications of stoma.
- ◆ Renal failure.
- ◆ Metaplasia and adenocarcinoma especially at uretero sigmoidostomy junction.

#### URINARY FISTULAS

It is the leak of urine at abnormal sites.

#### Causes

##### Congenital

- ◆ Patent urachus.
- ◆ Ectopiae vesicae.
- ◆ In association with anorectal malformation—rectovesical fistula.

##### Acquired

- ◆ Trauma to perineum.
- ◆ Pelvic surgery.
- ◆ *Vesicovaginal fistula*—due to obstructed labour; after hysterectomy, bladder may get injured while pushing it down; anterior colporrhaphy in elderly after vaginal hysterectomy; radiation induced; infiltrating carcinoma cervix. Usually it takes one week to cause necrosis and present as fistula. Features are—passage of urine per vagina, dribbling of urine in vagina on per speculum examination, *swab test is positive* (Methylene blue is injected through urethra after placing a swab in the vagina. Swab turns blue if there is fistula). Treatment is difficult. Surgical exploration—transvaginal repair in low fistula. Suprapubic repair if fistula is high. Often urinary diversion is needed.

- ◆ Specific causes like tuberculosis.
- ◆ Staghorn calculi can cause fistula after nephrostomy.
- ◆ Fistula can develop after surgery of renal pelvis, ureter, bladder.  
It will persist if there is distal obstruction like stricture urethra, otherwise it will subside spontaneously.
- ◆ Renal pelvis involved by Crohn's disease.

### Investigations

- ◆ Discharge study for creatinine level.
- ◆ Urine C/S; leaking fluid for C/S.

- ◆ Ultrasound abdomen; CT scan.
- ◆ MR fistulogram.

### Treatment

- ◆ Correction of cause.
- ◆ Urinary diversion in initial period.
- ◆ Excision of fistula track and repair.
- ◆ Fistula can recur based on cause, nutrition, local blood supply, specific causes.

# C. Prostate

## CHAPTER OUTLINE

- ❖ Anatomy
- ❖ Acid Phosphatase
- ❖ Prostate Specific Antigen
- ❖ Benign Prostatic Hyperplasia
- ❖ Prostatitis
- ❖ Bladder Outlet Obstruction
- ❖ Carcinoma Prostate

### ANATOMY

It is an accessory gland of male reproductive system. It is composed of glandular tissue embedded in fibromuscular stroma. It surrounds the first 3 cm of the urethra.

### Lobes

- ◆ It is composed of 5 lobes—anterior, posterior, 2 lateral, 1 middle/median lobe.
- ◆ Primary carcinoma is said to begin in posterior lobe. Middle lobe produces an elevation in the lower part of the trigone of bladder (*uvula vesicae*). Adenoma is more common here due to more amount of glandular tissue.

### Capsules

1. *True capsule*: Formed by the condensation of the peripheral part of the gland; continues with the stroma of the gland.
2. *False capsule*: Derived from the pelvic fascia. On each side prostatic venous plexus are embedded in it.

### McNeal Divided Prostate into Three Zones

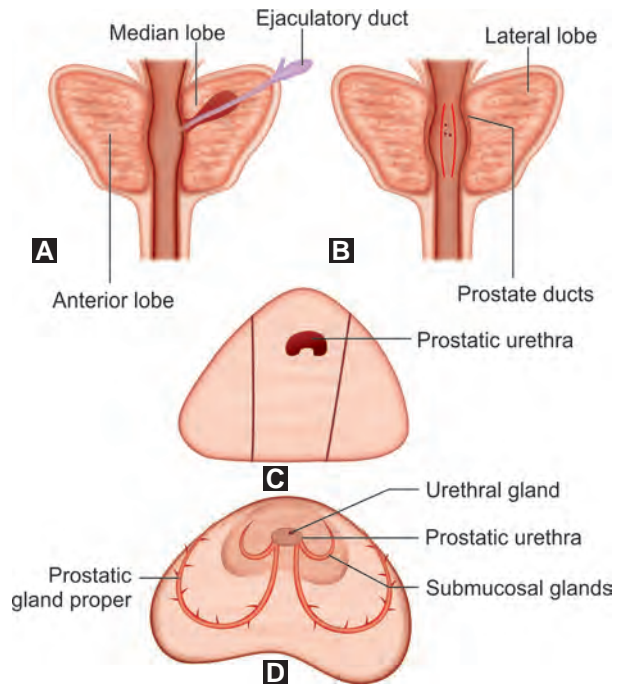
- ◆ *Peripheral zone*—prone for carcinoma.
- ◆ *Periurethral transition zone* where BPH arises.
- ◆ *Central zone*.

#### Note:

- Prostate carcinoma develops in prostatic gland proper.
- BPH develops in submucosal glands.

### ACID PHOSPHATASE

- ◆ It is the enzyme that splits organic phosphates.
- ◆ It is found in many human tissues, but more concentrated in prostate.
- ◆ It is active at pH 5.
- ◆ Acid phosphatase secreted by prostate drains into the urethra through prostatic ducts and so blood levels of this enzyme remain low.
- ◆ Serum acid phosphatase estimation should be done **on empty stomach** because heavy meals alter the level of the acid phosphatase.
- ◆ Normal value is 0–5 King Armstrong units per 100 ml of serum.



Figs 26.108A to D: Parts of prostate.

- ◆ It is raised significantly in carcinoma prostate with metastases.
- ◆ *It does not increase in BPH.*
- ◆ Slight increase in acid phosphatase level occurs in acute prostatitis, Paget's disease of bone and hepatic cirrhosis.
- ◆ Prostatic fraction of acid phosphatase is more relevant in carcinoma prostate.

### PROSTATE SPECIFIC ANTIGEN (PSA)

- ◆ It is a protease, produced from the prostatic epithelium secreted in the semen to cleave and liquefy the seminal coagulum formed after ejaculation.
- ◆ PSA is organ specific. *Normal value is 4 ng/ml of plasma. More than 10 ng/ml is significant.*
- ◆ PSA elevation occurs not only in carcinoma but also in prostatic hyperplasia and prostatitis.
- ◆ But the increase is much more in carcinoma than in benign conditions.

- ◆ PSA is in two forms: *Major*, bound form and *minor*, free form.
- ◆ Major, bound form increases in carcinoma. Minor, free form is increased in benign conditions.
- ◆ PSA density, i.e. PSA level per gram of prostate tissue is more relevant.
- ◆ *Pro PSA*, initial inactive part, the assessment of which is often more useful in prostatic cancer along with PSA. When PSA is 4–10 ng/ml form of pro PSA (-2) assay is useful to decide whether prostate biopsy is essential or not.
- ◆ PSA is sensitive for carcinoma prostate but not specific; *PSA velocity* (>2 ng/ml/year [rate of change in PSA in one year]); *PSA Doubling Time* (<12 months [time period where man's PSA doubles]); *free to total PSA ratio* (% free PSA <25); PSA density (>0.5 ng/ml/gm) and assessment of *PSA isomers* – are different forms of PSA assay.
- ◆ Serial estimation of PSA is very useful to suspect spread and recurrence after treatment—PSA velocity estimation.
- ◆ 25% of men with PSA 4–10 ng/ml show prostate carcinoma.
- ◆ 20% of men with normal PSA (1–4 ng/ml) will show prostate carcinoma.
- ◆ PSA more than 10 ng/ml is suggestive of carcinoma prostate.
- ◆ PSA more than 35 ng/ml is almost diagnostic of advanced carcinoma of prostate.
- ◆ Decrease in PSA after therapy suggests adequate ablation.
- ◆ Men aged >50 years with PSA  $\geq 3$  ng/ml should undergo prostatic biopsy.

#### Prostatic calculi

It is the calcification of corpora amylacea which contains calcium phosphate, protein and fat.

### BENIGN PROSTATIC HYPERPLASIA (BPH)

*He was very often, both in the Day and the Night, forced to make Water, seldom in any Quantity, because he could not retain it long enough.*

—Edward Hyde (first Earl of Clarendon), 1759

It is benign enlargement of prostate which occurs after 50 years, usually between 60 and 70 years. BPH affects both glandular epithelium and connective tissue stroma.

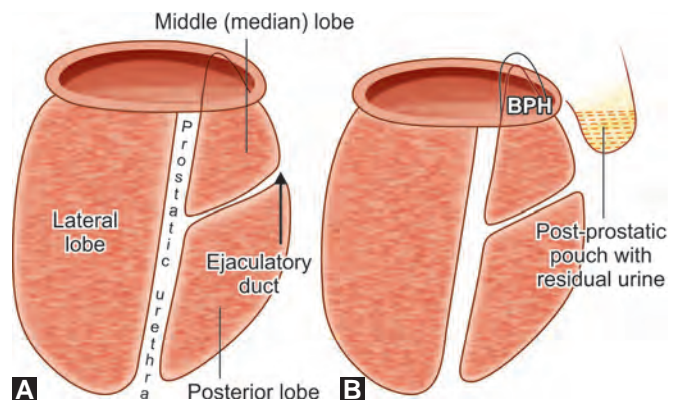
### Aetiology

#### Theories

- ◆ It is involuntary hyperplasia due to disturbance of the ratio and quantity of circulating androgens and estrogens.
  - ◆ Hypothalamus → pulsatile release of LHRH → release of luteinising hormone (LH) from anterior pituitary → stimulates Leydig cells of testes → releases testosterone (TS) → reaches prostate → releases 5 $\alpha$  reductase type II of prostate → converts TS to DHT (dihydrotestosterone) for its effects. DHT is five times more potent than TS. 90% TS is from testes. Remaining 10% TS is from adrenal cortex.
  - ◆ With age TS level drops slowly. But fall of oestrogen level is not equal. So prostate enlarges through intermediate peptide growth factor.
  - ◆ BPH is a benign neoplasm, also called as *fibromyoadenoma*. The neoplastic theory is old one—not universally accepted now—under debate.
- ◆ BPH arises from submucosal glands of periurethral transitional zone with stromal proliferation and adenosis. It eventually compresses the peripheral zone and enlarges as lateral lobe.
  - ◆ BPH arising from subcervical glands of central zone enlarges as middle lobe projecting up into the bladder.

### Pathology

- ◆ BPH usually involves median and lateral lobes or one of them.
- ◆ It involves adenomatous zone of prostate, i.e. submucosal glands.
- ◆ Median lobe enlarges into the bladder.
- ◆ Lateral lobes narrow the urethra causing obstruction.
- ◆ *Urethra above* the verumontanum gets elongated and narrowed.
- ◆ *Bladder* initially takes the pressure burden causing *trabeculations*, *sacculations* and later *diverticula* formation.
- ◆ Enlarged prostate compresses the prostatic venous plexus causing congestion, called as *vesical piles* leading to *haematuria*.



**Figs 26.109A and B:** (A) Prostate anatomy; (B) Retention of urine in bladder due to BPH.

- ◆ Incrimination of BPH as the source of haematuria before excluding other causes is termed as “*Decoy prostate*”.
- ◆ *Kidney and ureter:* Backpressure causes *hydronephrosis* and *hydronephrosis*.
- ◆ Secondary ascending infection can cause *acute* or *chronic pyelonephritis*.
- ◆ Often severe obstruction can lead to obstructive uropathy with *renal failure*.
- ◆ BPH causes *impotence*.

### Clinical Features

- ◆ Frequency occurs due to introversion of sensitive urethral mucosa into the bladder or due to cystitis and urethritis.
- ◆ Urgency, hesitancy, nocturia.
- ◆ Overflow and terminal dribbling.
- ◆ Difficulty in micturition with weak stream and dribble.
- ◆ Pain in suprapubic region and in loin due to cystitis and hydronephrosis respectively.
- ◆ Acute retention of urine.

- ◆ Chronic retention also can occur in BPH.
- ◆ Retention with overflow. High pressure chronic retention with functional obstruction.
- ◆ Impaired bladder emptying with its problems like cystitis, urethritis, stone formation and residual urine.
- ◆ Haematuria.
- ◆ Renal failure.
- ◆ *Prostatism* is a combination of symptoms like frequency both at day and night, poor stream, delay in starting and difficulty in micturition.
- ◆ Tenderness in suprapubic region, with palpable enlarged bladder due to chronic retention. Hydronephrotic kidney may be palpable.
- ◆ **Per rectal examination shows enlarged prostate. It should be done when bladder is empty.**
- ◆ Features of urinary infection like fever, chills, burning micturition.
- ◆ International prostate symptom score is available now.

Lower urinary tract symptoms (LUTS)	
Symptoms of voiding	Symptoms of storage
<ul style="list-style-type: none"> <li>• Hesitancy</li> <li>• Poor flow not improving by straining</li> <li>• Dribbling even after micturition</li> <li>• Intermittent stream—stops and starts</li> <li>• Poor bladder emptying</li> <li>• Episodes of near retention</li> </ul>	<ul style="list-style-type: none"> <li>• Frequency</li> <li>• Nocturia</li> <li>• Urgency</li> <li>• Urge incontinence</li> <li>• Nocturnal incontinence</li> </ul>

## Differential Diagnosis

- ◆ Stricture urethra.
- ◆ Bladder tumour, carcinoma prostate.
- ◆ Neurological causes of retention of urine like diabetes, tabes, disseminated sclerosis, Parkinson's disease.
- ◆ Idiopathic detrusor activity.
- ◆ Bladder neck stenosis; bladder neck hypertrophy.

## Investigations

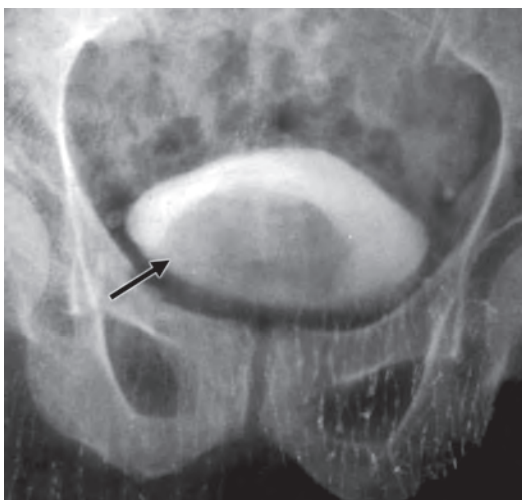


Fig. 26.110: IVU showing bladder with enlarged median lobe of prostate.

- ◆ Urine for microscopy and C/S.
- ◆ Blood urea and serum creatinine.
- ◆ Ultrasound abdomen—look for presence of residual urine.
- ◆ Urodynamics.
  - ▶ Urine flow rate >15 ml/sec is normal. 10–15 ml is equivocal; <10 ml is low.
  - ▶ Voiding pressure <60 cm of water is normal; 60–80 is equivocal; >80 is high.
- ◆ Cystoscopy.
- ◆ Transrectal US (TRUS) is useful to find out nodules/possibility of carcinoma prostate. It is not done routinely.
- ◆ Acid phosphatase.
- ◆ Prostate specific antigen (PSA).
- ◆ IVU—to see kidney function.
- ◆ Serum electrolytes.

### Note:

Normal peak urine flow rate is 20 ml/sec. In obstruction, it is less than 10 ml/sec.

## Management

- ◆ Patient with *acute retention* of urine requires *urethral catheterisation*.
- ◆ If urethral catheterisation fails, then *suprapubic cystostomy (SPC)* is done.
- ◆ If patient presents with *uraemia*, then urethral catheterisation is a must. That allows the kidney to function adequately and further obstructive damage is prevented.
- ◆ Serum electrolytes should be corrected properly in these patients.

## Indications for Surgery

- ◆ Prostatism (frequency, dysuria, urgency).
- ◆ Acute retention of urine.
- ◆ Chronic retention of urine with residual urine more than 200 ml.
- ◆ Complications like hydronephrosis, stone formation, recurrent infection, bladder changes.
- ◆ Haematuria.

## Surgeries

1. *Transurethral resection of prostate (TURP)*:
  - ▶ Using cystoscope with fluid like glycine irrigating continuously, enlarged prostate is identified and resected using a loop with a hand control. Resection is done using high frequency diathermy current, above the level of verumontanum.
  - ▶ After surgery, continuous bladder irrigation using normal saline is done using three way Foley's catheter. Antibiotics should be given. Catheter is removed within 72 hours.

### Postoperative complications are:

- ❖ Water intoxication with congestive cardiac failure—TURP syndrome
- ❖ Hyponatraemia
- ❖ Haemorrhage
- ❖ Infection

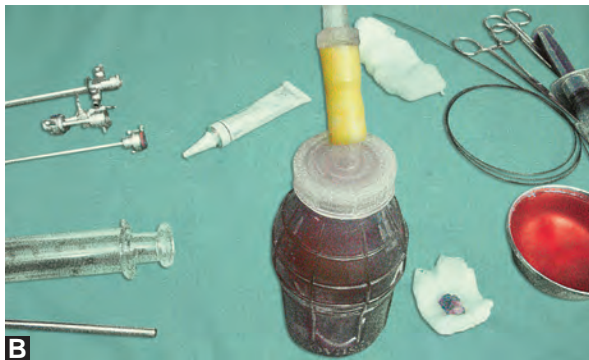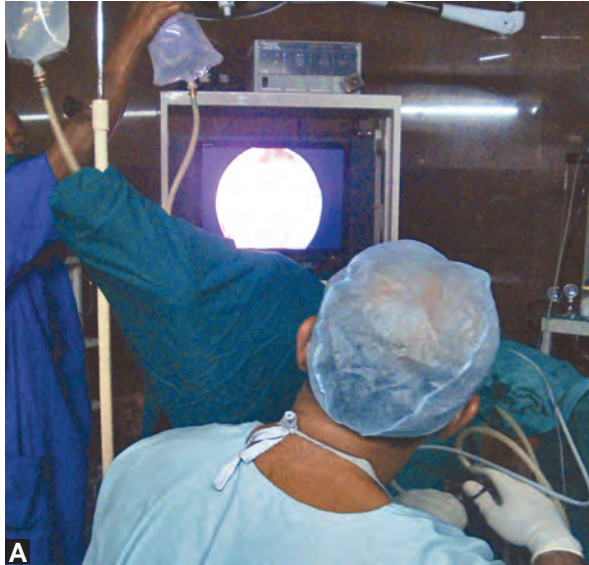Contd...

In cases of complete intrapelvic rupture of the urethra, the tip of the catheter can be felt per rectum protruding from the urethral tear as a longitudinal cord lying beneath the anal canal. —Wallace



Contd...

- ❖ Incontinence
- ❖ Perforation of the bladder or prostatic capsule
- ❖ Stricture urethra
- ❖ Retrograde ejaculation and impotence
- ❖ Recurrence



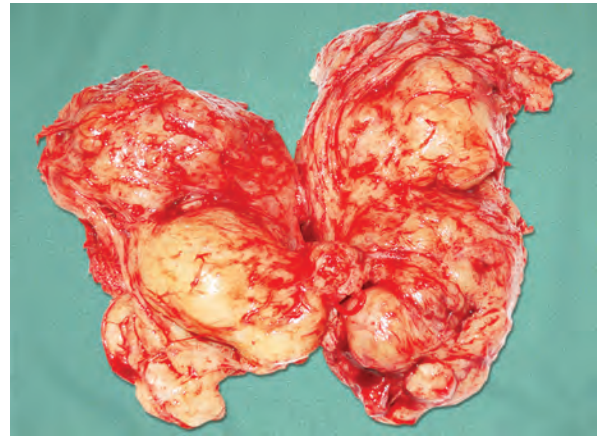
**Figs 26.111A and B:** Endotherapy for BPH—TURP is the most common procedure; laser (holmium), stenting—are different procedures. TURP set is shown on the table with evacuator to remove fragmented prostate tissue.

#### Transurethral resection of prostate

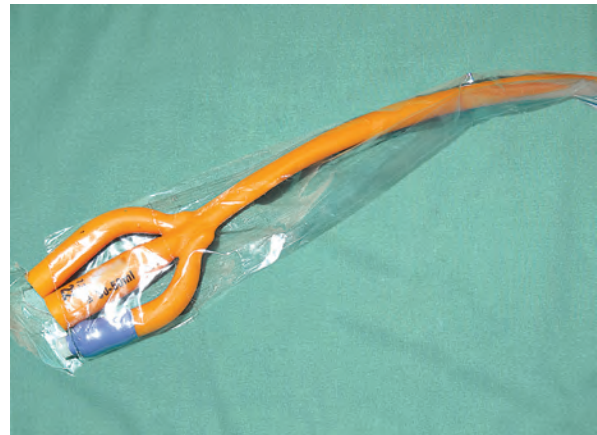- ❖ No suprapubic incision
- ❖ Most common and popular method
- ❖ Done using resectoscope
- ❖ Recurrence may occur in large prostate
- ❖ TURP syndrome can develop
- ❖ Continuous postoperative irrigation using glycine solution is needed for 72 hours
- ❖ Faster recovery and early discharge is possible

#### 2. Freyer's suprapubic transvesical prostatectomy.

Before TURP, it was a popular and was the procedure of choice for enlarged prostate.



**Fig. 26.112:** Large prostate in BPH removed through open suprapubic transvesical approach.



**Fig. 26.113:** Three-way Foley's catheter is used for continuous irrigation after prostatectomy for 1–2 days.

Complications are haemorrhage, infection, stricture urethra, incontinence, impotence, bladder neck contracture.

#### 3. Millin's retropubic prostatectomy.

It is done without opening the bladder (It is not commonly practiced).

#### 4. Young's perineal prostatectomy through perineal approach.

#### 5. Microwave hyperthermia treatment with temperature of 45–50 degree.

#### 6. Laser treatment is becoming popular, using holmium laser.

#### 7. High energy electromagnetic treatment.

#### 8. Placement of intraurethral stents at prostatic urethra.

#### 9. Placement of extraurethral stents which are inert.

#### 10. Transurethral balloon dilatation of the prostate.

#### 11. If patient presents with acute retention of urine, initial urethral catheterization is done. If not possible then *suprapubic trocal cystostomy* ideally or formal open SPC is done. Once patient's obstructive uropathy is under control, TURP is done after 7–14 days after evaluation.

### Specific Problems after Surgical Intervention of Prostate

- ◆ Retrograde ejaculation—65%.
- ◆ Erectile dysfunction—5%.

- ◆ Failure, recurrence of symptoms and enlargement—10%.
- ◆ Need for ref TURP/surgery in 10 years—15%.
- ◆ Severe sepsis—6%.
- ◆ Recurrent late urinary infection—20%.
- ◆ Postoperative haematuria—3% needs transfusion.
- ◆ Mortality in TURP is 0.5%.

#### Other methods used for BPH

- ❖ Transurethral incision of prostate—TUIP
- ❖ Laser ablation
- ❖ Transurethral microwave therapy—TUMT
- ❖ Transurethral needle ablation using high frequency radio-waves—TUNA
- ❖ High intensity US energy
- ❖ Water induced thermotherapy—through a balloon placed in prostatic urethra
- ❖ Prosthetic stents
- ❖ Balloon dilatation

## Drugs Used for BPH

- ◆ *Alpha 1 adrenergic blocking agents*—which inhibit smooth muscle contraction of prostate. They reduce the bladder neck resistance so as to improve the urine flow.
  - ▶ Short acting drugs are *prazosin* and *indoramin*.
  - ▶ Long acting drugs are *terazosin* and *doxazosin*.
  - ▶ Selective  $\alpha_{1A}$ —adrenoceptor blocking agent: *Tamsulosin* 0.2 to 0.4 mg OD for 12 weeks.
- ◆ *5-alpha reductase inhibitor* inhibits conversion of testosterone to dihydrotestosterone.
  - ▶ It is effective in palpably enlarged prostate.
  - ▶ Drug used is *finasteride* 5 mg daily. Duration of treatment is about 6–8 months.
  - ▶ It is contraindicated in obstructive uropathy or carcinoma prostate.

## PROSTATITIS

### Types

Acute or chronic.

#### Acute Prostatitis

*Causes:*

- ◆ Due to instrumentation.
- ◆ Ascending infection from below.
- ◆ Haematogenous.
- ◆ Descending infection from above.

*Bacteria involved:*

- ◆ *E. coli*, *Klebsiella*, *Proteus*.
- ◆ *Staphylococcus*.
- ◆ *Streptococcus faecalis*.
- ◆ *Gonococcus*.

*Clinical features:*

- ◆ Pain, frequency, fever with chills and rigors.
- ◆ Retention of urine.

#### Perineal heaviness, pain on defaecation.

- ◆ Tender prostate on per rectal examination.
- ◆ Initial fraction of urine is turbid which is sent for culture and sensitivity.

*Investigations:*

- ◆ Urine C/S.
- ◆ Ultrasound abdomen.

*Treatment:*

- ◆ Prolonged rigorous antibiotics—for 2 months.
- ◆ Avoidance of alcohol and sexual intercourse for 6 weeks.

#### Complications

- ❖ Formation of single or multiple abscess. It is common in diabetics
  - ❖ Chronic prostatitis
  - ❖ Retention of urine
- Prostatic abscess has to be drained—through perineal approach under ultrasound guidance

### Chronic Prostatitis

- ◆ Caused by *E. coli*, *Staphylococcus*, *Streptococcus*, *Trichomonas*, *Chlamydia*.
  - ▶ There is always associated posterior urethritis.
  - ▶ Epididymitis.
  - ▶ Pain in the perineum, rectum, low back pain, leg pain.
  - ▶ Fever.
  - ▶ Sexual dysfunction.
  - ▶ Per rectal examination shows tender prostate.
  - ▶ Prostatic fluid obtained by prostatic massage shows 15 or more pus cells/HPF.
  - ▶ In three glass urine test—first glass contains prostatic threads.
- ◆ *Treatment:* Antibiotics—Co-trimethoxazole, trimethoprim, doxycycline.

### Prostatic Abscess

- ◆ It is infection, suppuration and pus formation in the prostate gland.
- ◆ Presentation is fever, rigors, perineal pain, urinary disturbances, and tender soft fluctuant swelling in the prostate on rectal examination.
- ◆ Often presentation may be retention of urine.
- ◆ Total count will be increased.
- ◆ Urine will show pus cells.
- ◆ US is diagnostic. US is often done over perineum also.
- ◆ Treatment is antibiotics; US guided aspiration transperineally in lithotomy position or transperineal incision and drainage.
- ◆ Suprapubic cystostomy is better in case of retention of urine.
- ◆ After drainage antibiotics are needed for longer period of 6 weeks to prevent recurrent infection.

### BLADDER OUTLET OBSTRUCTION (BOO)

- ◆ It is low urinary flow rate with the presence of high voiding pressure. It is an urodynamically confirmed entity.
- ◆ It is diagnosed by urodynamic pressure flow study.

*Do all the good you can, by all the means you can, in all the ways you can, in all the places you can, at all the times you can, to all the people you can, as long as ever you can—*

- ◆ Flow rate will be less than 10 ml/second with voiding pressure more than 80 cm of water.
- ◆ Eventually detrusor inefficiency occurs causing significant residual urine.
- ◆ *Causes of BOO*—BPH; bladder neck hypertrophy or stenosis; carcinoma of prostate; urethral stricture; functional bladder neck obstruction.
- ◆ *Effects of BOO*—acute retention of urine; chronic retention of urine; impaired bladder emptying; uraemia; infection; stone formation, haematuria.
- ◆ US; renal function tests; IVU; PSA are the investigations.
- ◆ *Management* is by treating the cause by cystoscopic bladder neck incision, urethrotomy; TURP, etc.

#### Evaluation of patient with lower urinary tract infection (LUTI)

- ❖ Urine analysis and culture
- ❖ Hemoglobin, total count, ESR, blood urea and serum creatinine
- ❖ Digital examination of rectum (P/R)
- ❖ CNS examination
- ❖ PSA, acid phosphatase
- ❖ Uroflowmetry, flow rate assessment, residual urine analysis
- ❖ US abdomen, IVU to see upper urinary tract, CT abdomen in selected patients only
- ❖ Cystoscopy, transrectal US (TRUS)
- ❖ Prostatic abscess aspiration/drainage through perineal approach under guidance.

## CARCINOMA PROSTATE

*During the last six months, (IB) had suffered ...excruciating pain in the region of the kidneys and bladder, attended with almost constant desire to void urine, which was effected with the greatest difficulty.... An examination per rectum proved that there existed an enlarged... prostate gland, and slight pressure occasioned great pain.... The bladder was found (at autopsy) to contain a tumour as big as a large orange...discovered to derive its origin from the prostate gland.... The fungus ...plugged up both ureters.... In the liver there were several tumours (and) several...in the lungs.*

—George Langstaff, 1817

- ◆ It is the *most common malignant tumour* in men over 65 years.
- ◆ Carcinoma prostate occurs in peripheral zone in prostatic gland proper, i.e. *commonly in posterior lobe*. So prostatectomy for BPH does not confer protection against development of carcinoma prostate.
- ◆ Incidence of prostate cancer in men over 80 years is 70%.

#### Types of carcinoma prostate

- ❖ Microscopically latent
- ❖ Tumours incidentally found either by TURP or by PSA estimation
- ❖ Early localised carcinoma
- ❖ Advanced local prostatic carcinoma
- ❖ Metastatic carcinoma either into the bone commonly or other organs

#### Histology

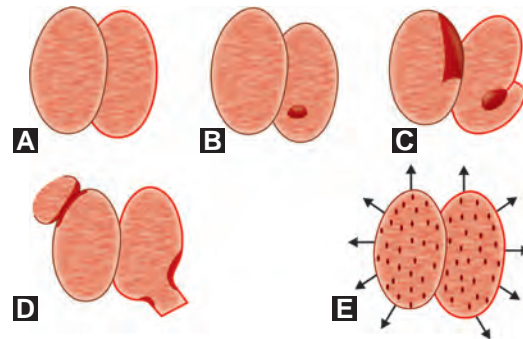
It is an *adenocarcinoma*, wherein there is loss of myoepithelial cell layer which normally surrounds the prostatic glands (Gleason). Glands here appear in confluence. *Grading of carcinoma* is based on dedifferentiation as proposed by Gleason.

#### Note:

- **Gleason Grade** (1–5) is as follows—1. Small uniform glands; 2. More stroma between glands; 3. Distinctly infiltrative margins; 4. Irregular masses of neoplastic glands; 5. Only occasional gland formation (undifferentiated).
- **Gleason Score** (Gleason grade of most frequent field type + that of second most frequent), e.g. 3 + 4 = 7. Score—< 7 good; 7 or more carries poor/worse prognosis. *Gleason Score* 3 + 4 = 7 worse than 4 + 3 = 7.
- **Prostatic Intraepithelial Neoplasia (PIN)** is another important histology to be remembered. PIN is a precancerous condition. It is not detected by rectal examination (DRE) or TRUS or MRI; does not cause raise in PSA level. It is identified usually after TURP for BPH with final histology or by prostatic biopsy. *Low and high grade types* are identified. High grade carries the risk of carcinoma prostate; but low grade not much. In high grade PIN, treatment is controversial. Regular screening with DRE, PSA, TRUS and if needed biopsy during follow-up; finasteride drug therapy are the methods. Radical surgery or RT is not used in high grade PIN.

#### Staging of carcinoma prostate

Occult—Diagnosed after investigation due to suspicion  
 Stage I—Tumour confined to prostate/local nodule  
 Stage II—Tumour involving capsule or diffuse type  
 Stage III—Tumour involving seminal vesicle  
 Stage IV—Extension into adjacent tissue



**Figs 26.114A to E:** Staging of carcinoma prostate: (A) Occult; (B) Stage I; (C) Stage II; (D) Stage III; (E) Stage IV.

#### d'Amico's risk stratification

Criteria	Low-risk	Intermediate risk	High-risk
Clinical stage	T1a-cN0M0; T2aN0M0	T2b-cN0M0	T3–4N0M0
PSA	<10 ng/ml	10–20 ng/ml	>20 ng/ml
Gleason score	<6	7	>7
Treatment	Watchful wait/active surveillance and radical prostatectomy (RP)	RP + hormone therapy for 6 months	RP + hormone therapy for 2 years + adjuvant therapy

### TNM staging

#### T—Primary Tumour

Tx cannot be assessed

T1 not palpable/visible by imaging

❖ T1a—Incidental histological finding in 5% or less of resected tissue

❖ T1b—Incidental histological finding in > 5% or less of resected tissue

❖ T1c Tumor identified by needle biopsy (due raised PSA)

T2 Tumour confined to prostate

❖ T2a—tumour in one half of one lobe or less

❖ T2b—tumour in more than half of one lobe (but NOT both lobes)

❖ T2c—tumour involves both lobes within the capsule

T3 Tumour extends through prostatic capsule

❖ T3a—Extracapsular extension (unilateral or bilateral) including microscopic bladder neck involvement

❖ T3b—involving one or both seminal vesicles

T4—Fixed tumor invades adjacent rectum/pelvic floor or wall

#### N—Regional Lymph Nodes

Nx—Regional nodes cannot be assessed

N1—Regional nodes involved

#### M—Distant Metastasis

M0—No distant metastases

M1—Distant metastases present

❖ M1a—Non-regional lymph node(s)

❖ M1b—Bone(s)

❖ M1c—Other site(s)

#### Gleason grading and scoring

Gx—Cannot be assessed

G1—Score 2–4

G2—Score 5–6

G3—Score 7

G4—Score >7

#### Stage groups

Stage I—T1aN0M0G1; T1aN0M0G2—4; T1bN0M0 AnyG

Stage II—T1c/T2N0M0 AnyG

Stage III—T3/T4N0M0 AnyG

Stage IV—Any TN1M0 AnyG; Any T, any N, AnyG

#### Note:

Whitmore Jewett system staging is also used with stages as—A, B, C and D.

### Note

For T1a progress rate is slow—15–20% in 8 years

For T1b and T2 it is 35%

For T3/T4 M0 it is 50% in 5 years with bone spread

For M1 average survival is 3 years

## Spread

### Local spread:

- ❖ Upward into seminal vesicles, bladder neck, trigone, later into both ureters causing anuria. Downward into distal sphincter.

### Blood spread:

- ❖ Into the bones commonly—pelvic bones, lumbar vertebrae, femoral head, ribs, skull—in that order.
  - ▶ Pathological fractures can occur in long bones and vertebrae.
  - ▶ Paraplegia may occur if spine is involved.
  - ▶ Rarely spread to liver and lung can occur.

### Lymphatic spread:

- ▶ Into the obturator lymph nodes, then to internal iliac lymph nodes.
- ▶ Through seminal vesicles, into external iliac and retro-peritoneal lymph nodes.
- ▶ Eventually mediastinal, left supraclavicular lymph nodes get involved.

### Clinical features

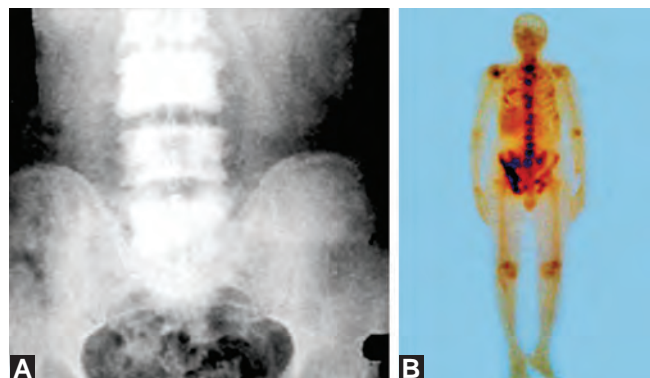
- ❖ Commonly asymptomatic
- ❖ Bladder outlet obstruction and so retention of urine
- ❖ Haematuria, frequency
- ❖ Pelvic pain, back pain, arthritic pain in sacroiliac joint—features of secondaries
- ❖ On per rectal examination, prostate feels hard, nodular, irregular often with loss of median groove
- ❖ Incidental carcinoma after TURP or after PSA analysis
- ❖ Features of renal failure
- ❖ Anaemia secondary to extensive bone marrow invasion and also due to renal failure.

## Differential Diagnosis

- ◆ Are other causes of retention of urine and other causes of back pain.

## Investigations

- ◆ Hb%, peripheral smear. In metastatic disease, there may be leukoerythroblastic reaction with bone marrow invasion causing anaemia, thrombocytopenia, DIC and increased fibrinogen degradation products (FDP). Anaemia may also be due to renal failure.
- ◆ Prostate specific antigen (PSA): More than 10 ng/ml is suggestive.
- ◆ Prostatic fraction of acid phosphatase is increased.
- ◆ Blood urea, serum creatinine, liver function tests.
- ◆ Transrectal ultrasound (TRUS) is very useful.
- ◆ Transrectal prostatic biopsy. 10 biopsy cores are taken.
- ◆ Plain X-ray, KUB, may show *dense coarse sclerotic* secondaries. Osteolytic or combination of lytic and sclerotic lesions are also often seen.



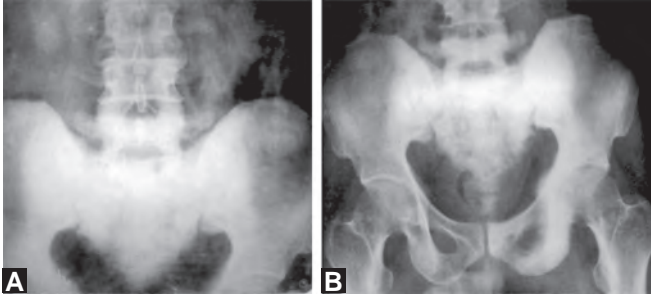
**Figs 26.115A and B:** (A) A plain X-ray AP view of lumbar spine in a patient with carcinoma prostate. Note the typical osteosclerotic secondaries; (B) Carcinoma prostate showing skeletal secondaries in bone scan.

*Look at happiness and misery the same; Look at success and failure the same. —True way of life it is called as.*

- ◆ Technetium radioisotope bone scan to see secondaries.
- ◆ Ultrasound abdomen, to see the tumour extension into the bladder and to see kidneys for hydronephrosis.
- ◆ MRI/CT scan is better for staging the disease. MRI is ideal. It can be combined with TRUS to have an accurate staging.

**Note:**

Osteoblastic secondaries occasionally can be seen in carcinoma breast.



**Figs 26.116A and B:** Osteoblastic secondaries in pelvic bones and lumbar spine.

**Remember**

- ❖ What we taught and thought as carcinoma prostate is slow growing, easy to manage, will not kill the patient is not right; actual fact is there is increase in incidence, inexorable progression despite proper treatment, with increased mortality.
- ❖ Cure is possible only when disease is organ confined.
- ❖ 45% of men over 50 years have carcinoma prostate on autopsy; but only detected in 17%.
- ❖ Most men die with carcinoma prostate, not of carcinoma prostate.
- ❖ It will take 8–10 years for carcinoma prostate to progress to metastasis.
- ❖ Even indolent carcinoma prostate can rapidly progress after 10 years.
- ❖ Metastatic disease becomes Castrate Resistant Prostate Cancer (CRPC) in 1.5–3 years. In CRPC death occurs in 1.5–3 years.
- ❖ Treatment of metastatic disease does not increase survival.
- ❖ Disease should be identified early – by PSA, digital rectal examination (DRE), transrectal US (TRUS).
- ❖ Staging work-up is done using – MRI, PET scan (choline), MDP bone scan.

**Treatment**

*In prostatic cancer with marked elevation of acid phosphatase, castration or injection of large amounts of estrogen caused a sharp reduction of this enzyme to or towards the normal range.... In 3 patients with prostatic cancer, androgen injections caused a sharp rise of serum acid phosphatase.*

—Charles Brenton Huggins, Clarence Vernard Hodges, 1941

- ◆ **Radical prostatectomy** is done in early growth with removal of prostate, seminal vesicle, distal sphincter along with reconstruction of the urethra. Open/laparoscopic/robotic assisted/nerve sparing approaches are used nowadays.
- ◆ **Radical radiotherapy** for early carcinoma prostate can be given using both interstitial and external radiation.
- ◆ **Pelvic lymph node dissection with  $I^{125}$  radiation seeds implantation.**

- ◆ **Bilateral subcapsular orchidectomy** is done to reduce the testosterone level. Very useful method. First started by **Charles Huggins**—Urologist (*Nobel Prize winner*). (Other condition where orchidectomy is done is carcinoma of male breast.)

- ◆ **TURP + Bilateral orchidectomy + External radiotherapy for bone secondaries + Flutamide or Honvan**—commonly advocated method.

**Drugs:**

- ▶ Phosphorylated diethylstilbestrol (**Honvan**)—initially given intravenously and later orally. It is very effective. Complications are cardiac congestion, DVT, gynaecomastia.

**Phosphorylated diethylstilbestrol**

- ❖ Initially IV 100 mg/daily later orally 100 mg/daily
  - ❖ Can cause cardiac congestion, DVT, gynaecomastia
  - ❖ Prior RT to breasts to prevent gynaecomastia often advocated
  - ❖ Response starts appearing in 48 hours.
- ▶ LHRH agonists (Medical castration)—Leuprolide, Goserelin.
  - ▶ Androgen receptor blocking agents like flutamide, bicalutamide.
  - ▶ Cyproterone acetate (also has got progestogenic effect).
- ◆ In elderly people with early carcinoma prostate *inactivity with wait and watch policy* is practised.
  - ◆ Sometimes permanent suprapubic cystostomy (SPC) is required in these patients.
  - ◆ **Castrate Resistant Prostate Carcinoma (CRPC) – Abiraterone**—Cytochrome P 17 (17 Hydroxylase and 17, 20 Lyase) inhibitor—used with **prednisolone**—to prevent hypokalaemia and fluid overload due to mineralocorticoid excess. Chemotherapy using docitaxel, cabazitaxel, prednisolone is also tried.
  - ◆ **Tumour vaccines**—Sepuleucel-T—Autologous peripheral blood mononuclear cells harvested and activated with prostatic acid phosphatase construct (increase in survival 4 months). Allogenic cell line based vaccines, Peptide and mRNA vaccines (CV9103).
  - ◆ T-cell checkpoint inhibitors (Ipilimumab – CTLA 4 inhibitor).
  - ◆ **Bone secondaries** are treated using—Radioactive strontium 89 (Metastron)/Samarium 153/Radium 223; Palliative RT to specific bone involved; Bisphosphonates – Zoledronic acid; Denosumab (RANKL inhibitor – down-regulation of osteoclasts); calcium, vitamin D<sub>3</sub>.

**Remember**

- ❖ Wait and watch policy is ideal in elderly patient with early carcinoma (P/R; PSA) above 70 years.
- ❖ TURP if there is obstruction with bilateral subcapsular orchidectomy; LHRH agonists; androgen blockage.
- ❖ Radical prostatectomy/radical RT in young T1a or T1b—early disease. The criteria for radical prostatectomy—life-expectancy should be more than 10 years; PSA <20 mmol/ml; bone scan should be negative.
- ❖ Brachytherapy using guided RI seeds of  $I^{125}$  and palladium
- ❖ Orchidectomy; LHRH agonists (Leuprolide); androgen receptor blockade (flutamide, bicalutamide); TURP if needed—commonly done procedure.
- ❖ External RT/IV radiopharmaceutical Strontium 89 (bone seeking isotope) for bone secondaries—used.

## D. Urethra

### CHAPTER OUTLINE

- ❖ Anatomy
- ❖ Urethral Injury
- ❖ Stricture Urethra
- ❖ Hypospadias
- ❖ Epispadias
- ❖ Posterior Urethral Valve
- ❖ Urethral Calculi
- ❖ Urethritis
- ❖ Extravasation of Urine
- ❖ Retention of Urine

### ANATOMY

#### Posterior urethra:

- ▶ Prostatic urethra.
- ▶ Membranous urethra.

#### Anterior urethra:

- ▶ Bulbar urethra.
- ▶ Penile urethra.

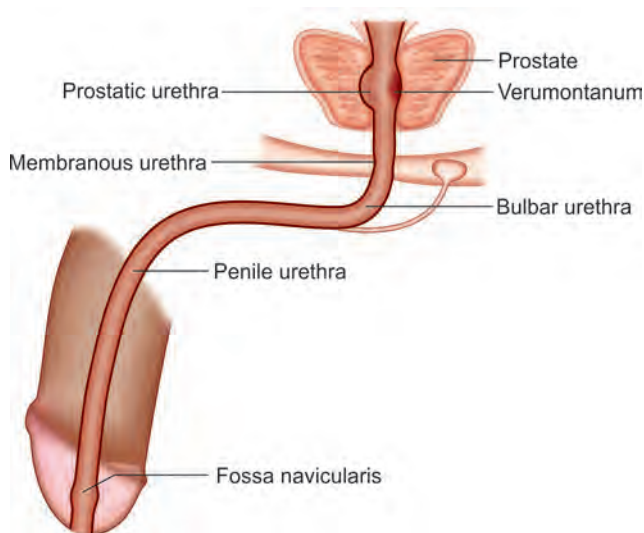


Fig. 26.117: Anatomy of urethra.

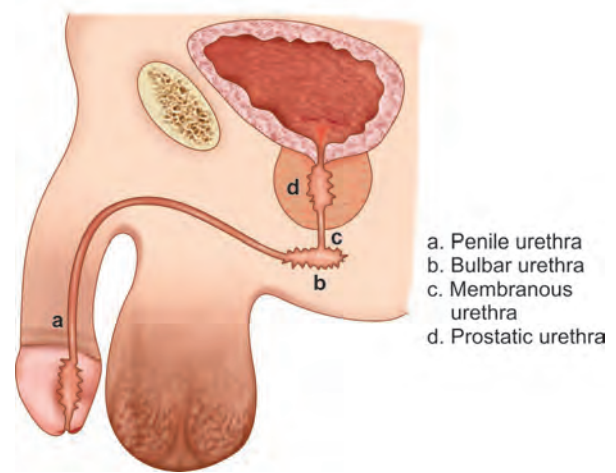


Fig. 26.118: Common sites of urethral injuries.

### RUPTURE OF MEMBRANOUS URETHRA AND/OR PROSTATIC URETHRA (Posterior Urethra)

#### Causes

- ❖ It is usually associated with pelvic fracture, commonly due to road traffic accidents
- ❖ Injury can also occur during instrumentation
- ❖ Calculus passage and catheterisation
- ❖ In prolonged labour, due to long-standing pressure on the urethra by foetal head

### URETHRAL INJURY

#### Classification

##### I. Depending on site of rupture:

1. Rupture of the membranous urethra.
2. Rupture of the bulbous urethra.

##### II. Depending on circumference of the urethral wall involved:

1. Complete.
2. Incomplete.

##### III. Depending on the thickness of the urethra involved:

1. Total.
2. Partial.

- ◆ Prostate is attached to pubis by puboprostatic ligament and disruption of puboprostatic ligament with complete rupture of urethra can lead to *floating prostate—Vermooten's sign*.
- ◆ Injury can lead to incomplete rupture of urethra or may be associated with extraperitoneal rupture of bladder.

**Based on ascending urethrogram, posterior urethral injury is classified as (McCallum-Colapinto classification).**

**Type I:** Elongation of posterior urethra, but intact

**Type II:** Prostate "plucked off" membranous urethra with extravasation of urine above sphincter only—*Floating prostate*—*Vermeulen's sign*

**Type III:** Total disruption of urethra with extravasation of urine both above and below the sphincter

## Clinical Features

- ◆ Blood in external meatus. Failure or difficulty in passing urine.
- ◆ Extravasation of urine to scrotum, perineum and abdominal wall.
- ◆ *Shock* with pallor, tachycardia, hypotension.
- ◆ Features of associated injuries like head injury, thorax and or abdominal organs which take priority in initial phases of management.
- ◆ On persectal (PR) examination, prostate may be felt high or may not be palpable at all. Signifies *floating prostate*.

## Investigations

- ◆ X-ray pelvis to see for fracture.
- ◆ Ultrasound abdomen to see pelvis and other injuries.
- ◆ *Urethrogram* is done to see the site and type of tear (often reserved to do at later stage).

## Treatment

The shock and associated injuries are treated.

- ◆ In *floating prostate*:
  - ▶ As *rupture is complete*, bladder is opened from above. A metal bougie is passed from above through the bladder and one more metal bougie is passed from below through urethra and both are manipulated so as to meet each other.
  - ▶ Lower bougie is negotiated along the upper one and so into the bladder. Red rubber catheter is tied to the tip of the lower (urethral) bougie which has already entered into the bladder. When lower bougie is pulled out per urethrally, catheter tied to it will pass through urethra from above, to which Foley's catheter is tied and pulled up, so as to keep it in position.
  - ▶ Bladder is closed with a SPC using Malecot's catheter—*Rail-road technique*.

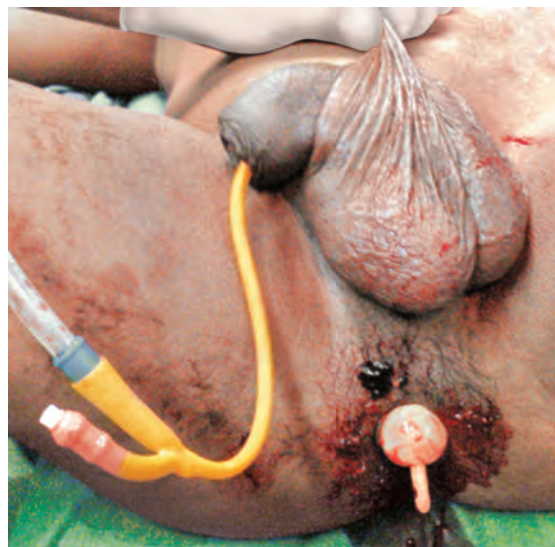
In *incomplete rupture*: *Two approaches*:

- ◆ *First approach proposed by Mitchell*:
  - ▶ Do not pass catheter from below as it may further damage the urethra and also may damage sphincter mechanism and so may cause incontinence later. Here SPC is done using Malecot's catheter.
  - ▶ After three to six weeks, an urethrogram is done. Using endoscope or along with open method Foley's catheter is passed, often after dilatation.
- ◆ *Second approach advocated by Blandy*:
  - ▶ *Single attempt to pass a small soft catheter per urethrally* gently may lead into the bladder, which will be kept *in situ*, to maintain the continuity.
  - ▶ If this fails SPC is done. On second day, in operation theatre (OT), bladder is opened from above and flexible cystoscope is passed from below and using this, catheter is passed from below.
  - ▶ Bladder is closed with a SPC.

- ◆ If patient with incomplete rupture presents later, then it is managed once a stricture forms, accordingly as stricture urethra, after 3 months. Until then patient may require SPC.
- ◆ *Other measures*: Antibiotics, blood, fluid replacement, treatment of other injuries.

### Complications

- ❖ Urinary incontinence
- ❖ Impotence
- ❖ Stricture urethra
- ❖ Infection



**Fig. 26.119:** Penetrating injury in the perineum causing rectal and urethral injury which is communicating. Note the catheter passed per urethra has gone into the rectum and come out through the anal canal. It needed colostomy and suprapubic cystostomy diversions. (Courtesy: Dr Ashfaque Mohammad, DNB, KMC, Mangaluru)

## RUPTURE OF BULBOUS URETHRA (Anterior Urethra)

- ◆ Usually, due to a fall astride a projecting object, like in sailing ships, cycling, over loose manhole cover, gymnasium.

### Clinical features: Triad

- ❖ Blood in external meatus (Urethral haemorrhage)
- ❖ Perineal haematoma
- ❖ Retention of urine

- ◆ Rupture may be *complete* or *incomplete*.
- ◆ *Total* or *partial*.

## Investigations

X-ray pelvis, and US abdomen. Condition is diagnosed clinically.

## Treatment

- ◆ *Patient should be told not to try to pass urine*, if passed, then extravasation of urine occurs.
- ◆ In operation theatre, *one attempt of urethral catheterisation is tried gently*. If able to pass a catheter, then it is left in place.

- ◆ Often perineal haematoma which occurs, has to be drained.
- ◆ Antibiotics should be given to prevent sepsis.
- ◆ *If catheter fails to pass*, then under general anaesthesia, in lithotomy position, SPC is done. Bulbous urethra is exposed through perineal midline incision and tear is sutured with an indwelling Foley's catheter. Drain is then placed into the perineum.
- ◆ If suturing is not possible (sometimes), then *perineal urethrostomy* is done and at later stages continuity is maintained (usually after 3 months).

#### Complications

- ❖ Infection
- ❖ Extravasation of urine
- ❖ Stricture urethra

### STRICTURE URETHRA

#### Classification I: Aetiologically.

1. Congenital.
2. *Inflammatory*:
  - a. Post-gonococcal is most common (70%).
    - Gonococcal stricture occurs one year after infection.
    - Retention develops only 10–15 years later.
    - Common in the bulb of urethra especially in the roof.
    - Here multiple strictures are common, proximal stricture is the narrowest.
  - b. Tuberculous.
  - c. Other infection (urethritis).
3. *Traumatic*: Bulbous, membranous.
4. *Post-instrumentation*: Catheter, dilator, cystoscope.
5. *Postoperative*: Prostate surgery (4%), urethrostomy.

#### Classification II:

1. *Proximal*: Common in *bulbous urethra* (70%).
2. *Distal*: Congenital (in the external meatus). Often traumatic in children.

#### Classification III:

1. *Permeable*: Permits urine to pass.
2. *Impermeable*.

#### Classification IV:

1. *Passable*: Allows catheter to pass.
2. *Impassable*.

#### Classification V: It can be single or multiple.

#### Classification VI: According to the part involved. In the roof (most common) or in the floor.

#### Clinical features

- ❖ Poor urinary stream
- ❖ Forking and spraying of the stream
- ❖ Incomplete emptying
- ❖ Frequency, dysuria
- ❖ Retention and often with overflow
- ❖ Pain, burning micturition, suprapubic tenderness
- ❖ Thickening and button-like feeling in bulbar urethra (Bulbous urethra is felt clinically by lifting the scrotum in midline in the perineum)

### Investigations

- ◆ Urine microscopy and culture.

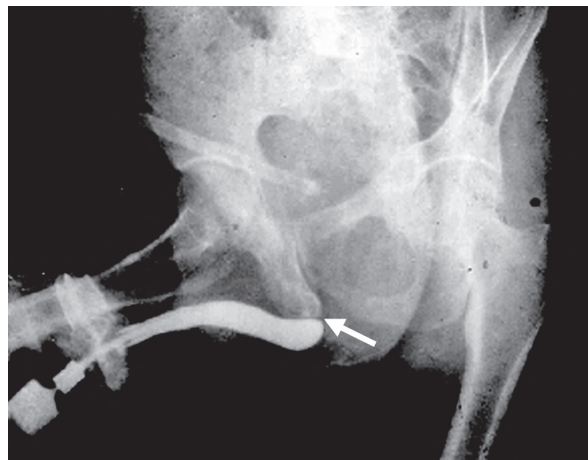


Fig. 26.120: Ascending urethrogram showing failure of dye to pass due to stricture urethra.

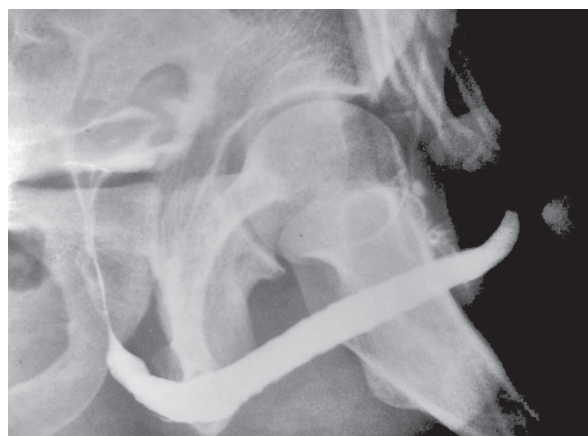

Fig. 26.121: Ascending urethrogram showing stricture urethra.

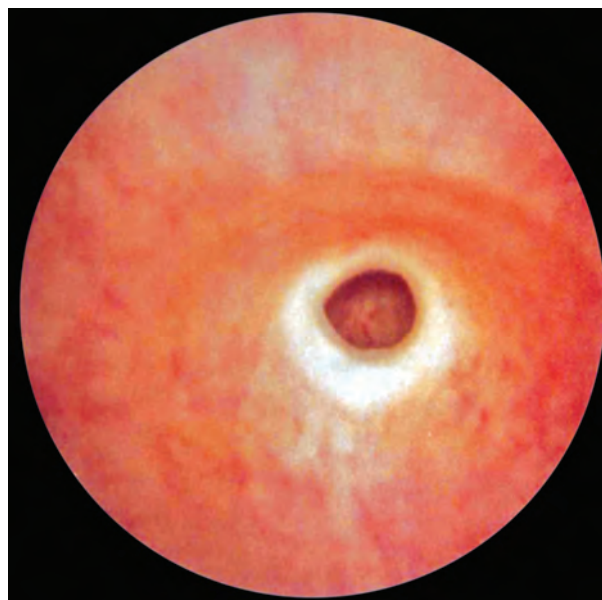


Fig. 26.122: Cystoscopic view of urethral stricture.



- ◆ Blood urea and serum creatinine.
- ◆ IVU to see hydronephrosis and function of kidney.
- ◆ Ultrasound abdomen.
- ◆ X-ray of pelvis to see old fracture with history of trauma.
- ◆ *Ascending urethrogram* is an essential investigation to see the site, type, extent and false passage.
- ◆ The dye is injected through suprapubic needle puncture into the bladder and visualisation is done using C-Arm image intensifier.
- ◆ Urodynamic studies.
- ◆ Urethroscopy.

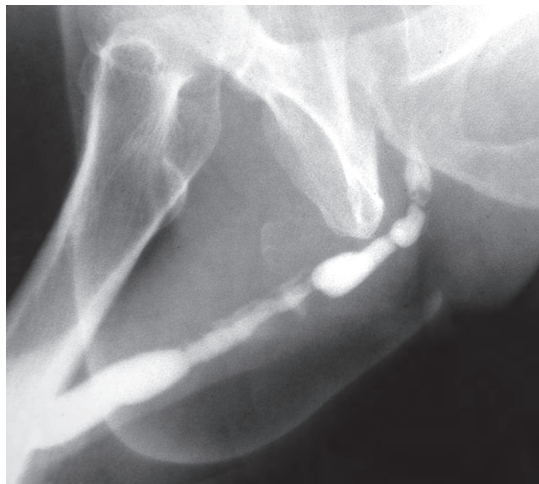


Fig. 26.123: Ascending urethrogram showing multiple urethral stricture.

## Treatment

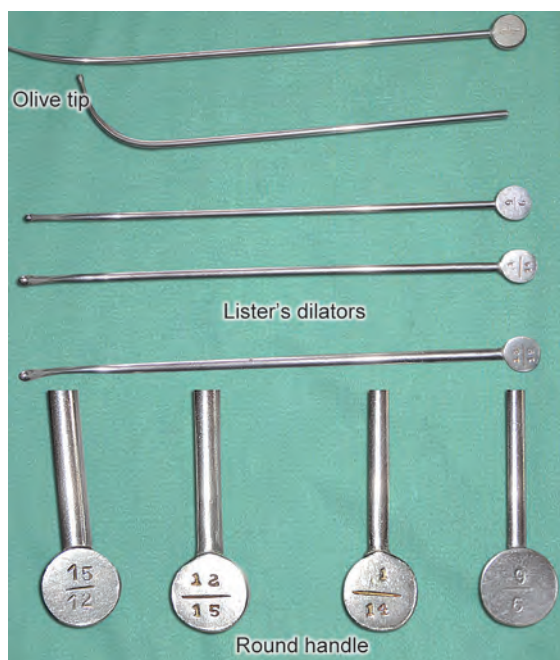


Fig. 26.124: Lister's urethral dilator. It shows olive tip (blister). Circumference proximally and at tip is same; just prior to tip it is narrow; difference in circumference is 3 mm in Lister's dilators. Handle is circular.

### 1. Intermittent dilatation:

Gradual dilatation, initially with thin dilators, later with thicker dilators of increasing size. Dilatation should be done in OT under aseptic precaution.

*Should avoid forcible dilatation or over dilatation.*

Dilatation is done "*Once a week for one month, once a month for one year, and later once a year (on his birthday)*".

*Dilators used:*

- a. Lister's dilator [has got olive tip (blister)].
- b. Clutton's dilator.
- c. Filiform bougies.

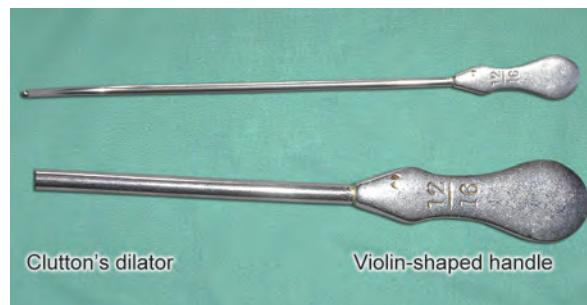


Fig. 26.125: Clutton's dilator. It is violin shaped; does not have olive tip; gradually narrows towards tip; difference in circumference proximal to distal is 4 mm; handle is violin like.

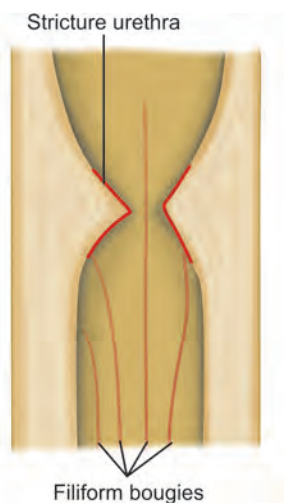


Fig. 26.126: Filiform bougies are used to dilate narrow stricture urethra. One of the bougies will be passed into the urethra.

### Complications of dilatation

- ❖ Infection and bleeding due to trauma
- ❖ False passage
- ❖ Fistula formation

### 2. Visual internal cystoscopic urethrotomy or stricturotomy:

- ▶ Here using cystoscope, stricture is visualised and is cut at 12 o'clock position, until it bleeds (fibrous tissue is cut completely).
- ▶ After that Foley's catheter is passed and kept in position for 48 hours.

3. **External urethrotomy** by open method. Presently not commonly done as cystoscopic urethrotomy is more popular. It is presently done as an initial stage surgery for urethroplasty (*Wheelhouse's operation*).
4. **Urethroplasty:** Stricture is excised and urethra is reconstructed using *prepuceal skin* or *scrotal skin* (*Johanson's urethroplasty*).

#### Problems in urethroplasty

- ❖ Staged procedure and so prolonged hospitalisation
- ❖ Infection
- ❖ Necrosis of skin flap
- ❖ Leak and fistula formation
- ❖ Restenosis

#### Complications of stricture urethra

- ❖ Retention of urine
- ❖ Urethral fistula
- ❖ Infection—urethritis, cystitis, pyelonephritis
- ❖ Urethral diverticula
- ❖ Periurethral abscess
- ❖ Bilateral hydronephrosis
- ❖ Stone formation
- ❖ Renal failure
- ❖ Due to straining—hernia, haemorrhoids, rectal prolapse

## HYPOSPADIAS

It is the most common congenital malformation of urethra wherein external meatus is situated *proximal* than normal, over the *ventral* (under) aspect of the penis.

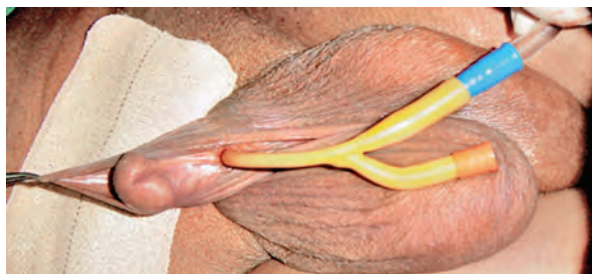
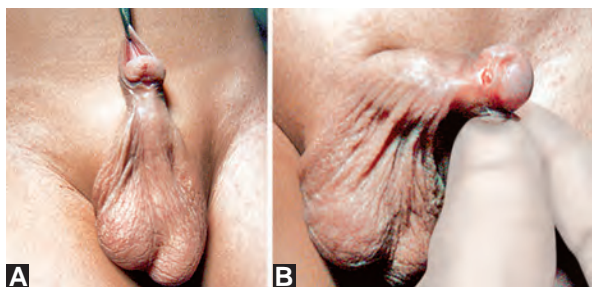
Fig. 26.127: Hypospadias.



Figs 26.128A and B: Hypospadias in coronal region of glans penis with typical chordee.

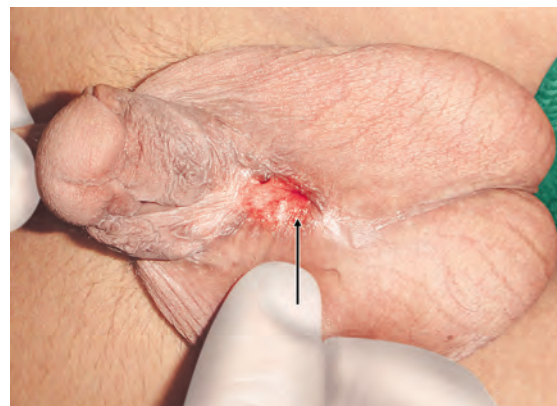

Fig. 26.129: Penoscrotal hypospadias.

#### Classification

- ❖ *Glandular:* Meatal opening in glans. It is the most common type
- ❖ Coronal
- ❖ Penile
- ❖ Penoscrotal
- ❖ Perineal with split scrotum. This is associated with bilateral undescended testes

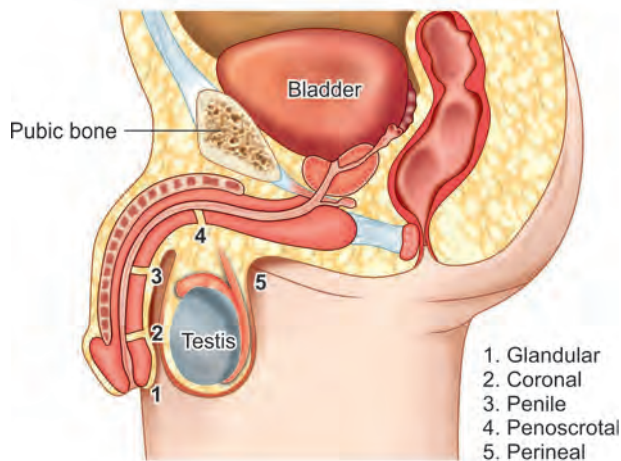


Fig. 26.130: Types of hypospadias.

#### Features

- ◆ Incidence is 1 in 350 males.
- ◆ Absence of urethra and corpus spongiosum distal to abnormal urethral orifice.
- ◆ Bowing or bending of penis distal to abnormal urethral opening (*chordee*), with poorly developed prepuce over inferior aspect.
- ◆ Urine soilage over the scrotum with dermatitis and infection.
- ◆ Associated congenital anomalies are known to exist.
- ◆ Karyotyping is needed to rule out associated intersex anomaly.

#### Treatment: Staged Procedure

- I. At the age of one and half years, surgical correction of the chordee is done.

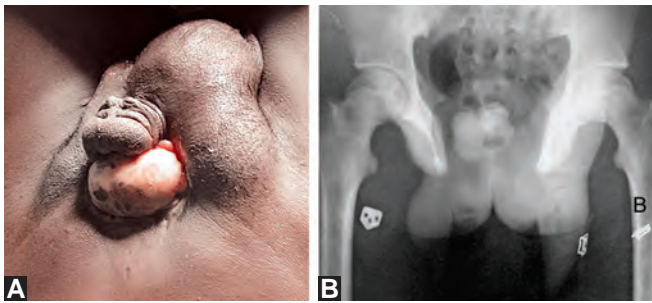
II. At the age of 5–7 years, reconstruction of urethra is done using *prepuccial skin* (ideal) or scrotal skin if the patient has been circumcised. Best is prepuccial skin.

- ◆ *Perineal urethrostomy is done for diversion.*
- ◆ Perineal urethrostomy should be there until reconstruction of urethra takes up well (*Denis-Browne procedure*).
- ◆ *MAGPI repair:* Meatal advancement glandular repair—for glandular hypospadias.

*In hypospadias, circumcision is contraindicated as prepuccial skin is required for future urethroplasty.*

## ■ EPISPADIAS

- ◆ Here the urethra opens on the dorsum of the penis, proximal to the glans.
- ◆ Most common site is at the abdominopenile junction.
- ◆ It is associated with a dorsal chordee, ectopia vesicae, urinary incontinence, separated pubic bones.
- ◆ It is uncommon in females.
- ◆ *Treatment*
  - ▶ Correction of incontinence of urethra.
  - ▶ Urinary diversion.



**Figs 26.131A and B:** Bladder extrophy. X-ray pelvis showing separation of pubic bones. Epispadias is the common association.

## ■ POSTERIOR URETHRAL VALVE

- ◆ They are congenital symmetrical valves in the posterior urethra, just below the verumontanum.
- ◆ It allows the passage of catheter without obstructing its ingress. But it obstructs the outflow of urine.
- ◆ Proximal urethra is enormously dilated with obstructive pathology in the bladder (sacculations and diverticula formation).
- ◆ Bladder wall is thickened and hypertrophied so much so that it is palpable in suprapubic region as a firm swelling (*cricket-ball bladder*).
- ◆ There is poor urinary stream, with hydronephrosis, often with infection.
- ◆ Child finds difficult to pass urine.
- ◆ Often it is associated with vesicoureteral reflux.
- ◆ Renal failure and atrophy of kidney occurs due to back pressure.

### Investigations

- ❖ *Micturating cystourethrography (MCU)* is diagnostic. It shows dilated proximal urethra
- ❖ Ultrasound abdomen
- ❖ Blood urea and serum creatinine
- ❖ IVU
- ❖ Antenatal US shows fetal urinary tract dilatation.

## Differential Diagnosis

- ◆ *Marion's disease:* Bladder neck obstruction due to hypertrophied interureteric bar. MCU differentiates it from posterior urethral valve. Treatment is Y-V plasty (*Bonin's Y-V Plasty*).
- ◆ Neurogenic bladder.

## Treatment

Initial SPC and later cystoscopic resection of the posterior valves is done usually after several weeks.

## ■ URETHRAL CALCULI

Stone from the bladder is commonly passed out through urethra if it is small, but the stone can get impacted due to a *stricture* or *urethral diverticulum*.

### Sites of impaction

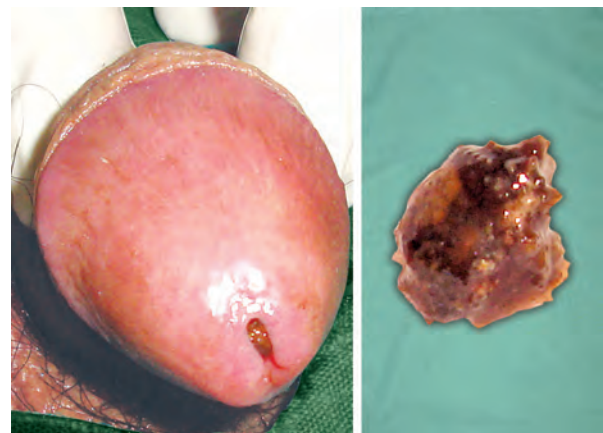
- ❖ Prostatic urethra
- ❖ Bulbous urethra
- ❖ Fossa navicularis
- ❖ External meatus

## Clinical Features

- ◆ Painful urination with thin stream and forking of urine.
- ◆ Retention of urine.
- ◆ Lower urinary tract infection.
- ◆ Haematuria.
- ◆ Pain in the penis and perineum.
- ◆ Stone may be palpable when it is in the bulbar or penile urethra.

## Investigations

- ◆ Plain X-ray, KUBU (kidney, ureter, bladder urethra).
- ◆ Ultrasound abdomen.
- ◆ Urine examination.

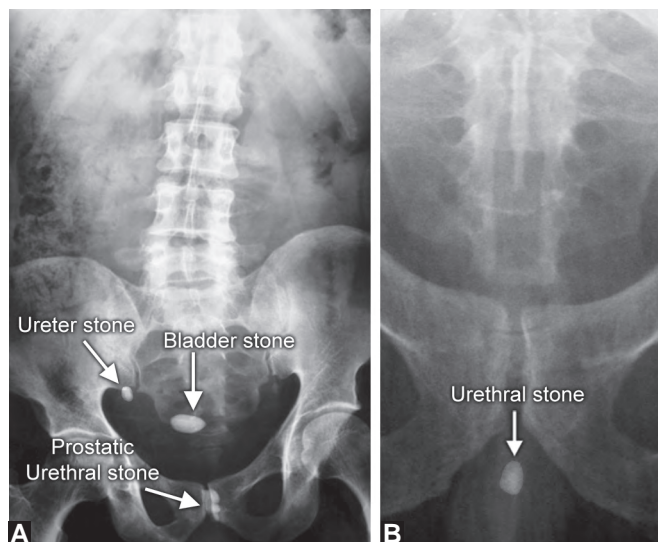


**Fig. 26.132:** Stone at urethral meatus (external meatus) which is extracted.

## Treatment

- ◆ If it is impacted in the external meatus or fossa navicularis, meatotomy and extraction of the stone is done (Meatotomy is cutting and widening of external meatus so as to have an easy stone extraction).

- ◆ If it is impacted in other parts of the urethra, urethroscopy and removal of stone from urethra is done or through a cystoscope the stone is pushed into the bladder and then extracted.
- ◆ In case of retention of urine, initial suprapubic cystostomy is required before removal of the stone.
- ◆ Diverticulum and stricture urethra should be treated accordingly.



**Figs 26.133A and B:** (A) Plain X-ray KUB showing stone in the bladder; stone in the terminal end of ureter; stone in the prostatic urethra; (B) X-ray showing urethral stone.

## Complications

Bleeding, stricture urethra and infection.

## ■ URETHRITIS

### Causes

- ◆ Gonococcal urethritis.
- ◆ *Nongonococcal urethritis:*
  - ▶ Trichomonal urethritis.
  - ▶ Lymphogranuloma venereum (LGV).
  - ▶ Mycoplasma.
  - ▶ Ureaplasma urealyticum.
  - ▶ *Candida*.
- ◆ Trauma, catheters, cystoscopes, stones.
- ◆ Chemical urethritis.
- ◆ *Reiter's disease:* Arthritis, conjunctivitis, urethritis.
- ◆ Allergy.

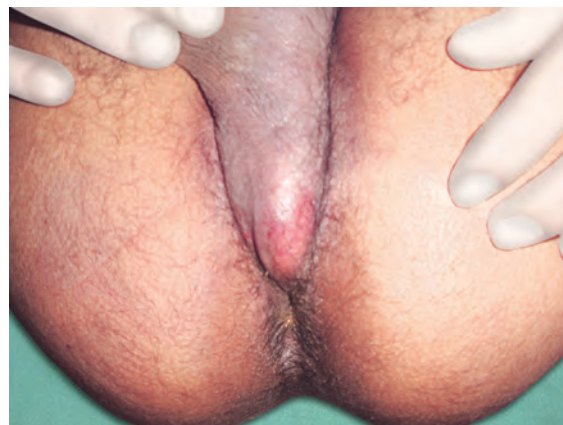### Reiter's syndrome

- ❖ Nongonococcal urethritis
- ❖ Conjunctivitis
- ❖ Arthritis

### Features

- ◆ Urethral discharge, dysuria, burning micturition, haematuria and increased frequency.

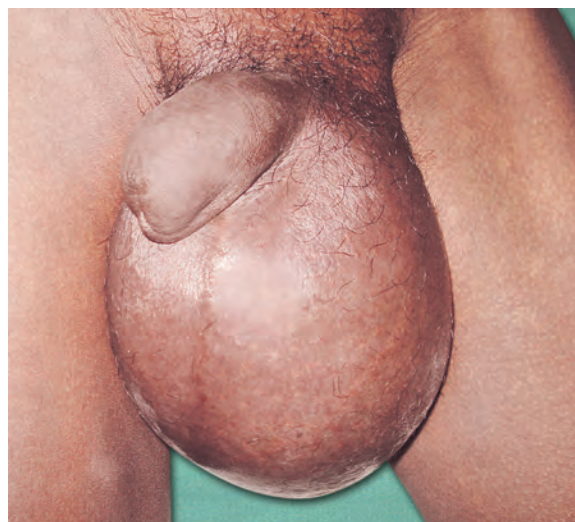
- ◆ Perineal pain, tenderness over the site.
- ◆ Suprapubic pain and tenderness.
- ◆ *Investigations:*
  - ▶ Urine microscopy and culture.
  - ▶ Ultrasound abdomen.
- ◆ *Treatment:*
  - ▶ Antibiotics given according to culture and sensitivity.
  - ▶ The cause is treated.



**Fig. 26.134:** Periurethral abscess.

## ■ EXTRAVASATION OF URINE

Urine extravasates from the bladder or urethra and collects in the layers of the perineum or in the prevesical space (cave of Retzius).



**Fig. 26.135:** Extravasation of urine showing the collection of urine in the scrotum and perineum after trauma.

### Causes

- ◆ Trauma to bladder or urethra.
- ◆ Instrumentation like dilatation, catheterisation, cystoscopy.
- ◆ Infection like *Gonococcus* (*water can perineum*).

## Types

It may be superficial or deep.

1. **Superficial:** It is due to either bulbar urethral injury or due to bursting of periurethral abscess after urethral stricture. Once urine extravasates due to full thickness disruption of the urethra anteriorly, it collects in superficial perineal space. This space is a closed cavity all round except anteriorly where it communicates with scrotal subcutaneous tissue deep to fascia Colles, penis between superficial fascia and deeper Buck's fascia, in the anterior abdominal wall deep to Scarpa's fascia. It does not spread to thigh and ischioanal space as Scarpa's fascia is attached firmly to fascia lata of thigh. Superficial perineal space is closed above by inferior fascia of perineal membrane; below by fascia of Colles; laterally by ischiopubic rami. It is open and communicating only anteriorly. Entire scrotum, penis and often lower abdominal wall are swollen containing urine. It is painful; patient cannot pass urine through urethra; severe pain and shock due to pelvic injury. Often sepsis occurs and skin sloughs of leading into urinary fistulas.
2. **Deep:** Urine spreads upwards into the extraperitoneal space of the pelvis around the bladder and prostate into the anterior abdominal wall causing deep extravasation of the urine. Here rupture of urethra is at membranous part of the urethra much more proximal than superficial type.

### Clinical Features

- ❖ Pain, swelling in the perineum
- ❖ Retention of urine
- ❖ Suprapubic pain, tenderness and fullness.

## Treatment

- ◆ The cause is treated:
  - ▶ Antibiotics.
  - ▶ Suprapubic cystostomy.

Often multiple incisions may be placed in the perineum to evacuate the extravasated urine.

## Complications

Abscess formation, sinus/fistula formation.

### RETENTION OF URINE

- ◆ It is *accumulation of urine* in the urinary bladder. Kidneys excrete urine in normal quantity. But patient passes only small amount of urine or does not pass urine at all causing *distended bladder*. In anuria due to renal failure, patient does not pass urine as kidney does not secrete any urine and bladder is not distended.
- ◆ Retention can be *acute; chronic; retention with overflow*. Retention differs in male, female and in infants and children.
- ◆ Chronic retention is due to BPH, bladder neck contracture, urethral stricture, etc. and is painless with suprapubic dullness.
- ◆ It is one of the common conditions seen in surgical casualty.

## Causes

Urethral injury	Prostatic hyperplasia (BPH)
Stricture urethra	Carcinoma prostate
Stone in the urethra	Bladder tumour near bladder neck
Phimosis with meatal stenosis	Bladder neck hypertrophy
Posterior urethral valve	Prostatitis or urethritis

Neurogenic causes like head and spinal injuries  
 Postoperative period following pelvic and perineal surgeries  
 Drug-induced retention of urine: Anticholinergics, anti-histamine drugs, antidepressants

### In males

- ◆ BPH in old.
- ◆ Stricture urethra in young.
- ◆ Trauma—urethral/pelvic.
- ◆ Postsurgical—perineal surgeries like haemorrhoidectomy; fistulectomy; fissurectomy; pelvic surgeries; surgeries for fracture hip/fracture pelvic bone.
- ◆ Bladder outlet obstruction.
- ◆ Carcinoma of prostate.

### In females

- ◆ Uterine prolapse.
- ◆ Urethral stricture.
- ◆ Uterine/Ovarian surgeries.

### In infants and children

- ◆ Posterior urethral valve.
- ◆ Meatal stenosis.

## Clinical Features

- ◆ Pain and swelling (fullness) in the suprapubic region.
- ◆ Inability to pass urine.
- ◆ Smooth, soft, tender swelling in hypogastric region which is dull on percussion.
- ◆ Features relevant of specific causes.
  - ▶ Per rectal examination to see prostate and other causes. In full bladder often prostate cannot be assessed properly.

### Types

- ❖ Acute
- ❖ Chronic
- ❖ Retention with overflow

**Acute retention:** It is rare. It is sudden inability to pass urine. It is painful distension of the bladder. It is seen in urethral trauma, due to anaesthesia, or surgery (perineal/abdominal). There is increased desire to pass urine.

**Chronic retention** is gradual collection of urine in the bladder due to ineffective emptying of the bladder completely. Bladder is distended and is painless. It is common in elderly. Frequency,

difficulty in urination, overflow incontinence is common. Infection in such chronic retention makes it painful.

*Acute on chronic retention:* Patient is having chronic obstructive condition like BPH; due to infection and acute inflammation and oedema of mucosa of urethra sudden total blockage sets in causing acute on chronic retention of urine.

### Investigations

- ◆ Ultrasound abdomen.
- ◆ Blood urea, serum creatinine.
- ◆ Urine microscopy.

### Treatment

- ◆ Urinary catheterisation using Foley's catheter.
- ◆ If it fails then suprapubic cystostomy (SPC) using Malecot's catheter is done.

- ◆ The cause is treated.
- ◆ Intermittent catheterisation in case of neurogenic bladder.

#### Management of retention of urine

- ❖ Clinical and sonological assessment of kidney, ureter and bladder
- ❖ Evaluation for cause
- ❖ Evaluation for obstructive uropathy and renal function
- ❖ Urinary catheterisation by Foley's catheter/red rubber catheter/metallic catheter. SPC with Malecot catheter by open method or using Foley's catheter by trocal puncture method
- ❖ Intermittent catheterisation
- ❖ Vesicostomy in children
- ❖ Treating the cause
- ❖ Postoperative retention is a common cause. It is treated by reassurance, placing hot water bag over suprapubic region, change of position or standing, only occasionally by catheterisation

## E. Penis

*The functioning role of the penis is as well established as that of any other organ in the body. Ironically, there is no organ about which more misinformation has been perpetrated. The penis constantly has been viewed but rarely seen. The organ has been venerated, reviled, and misrepresented with intent in art, literature, and legend through the centuries.*

—William H Masters, Virginia E Johnson, 1966

### CHAPTER OUTLINE

- ❖ Phimosis
- ❖ Paraphimosis
- ❖ Circumcision
- ❖ Balanoposthitis
- ❖ Chordee
- ❖ Priapism
- ❖ Peyronie's Disease
- ❖ Ram's Horn Penis
- ❖ Carcinoma Penis
- ❖ Buschke-Lowenstein Tumour

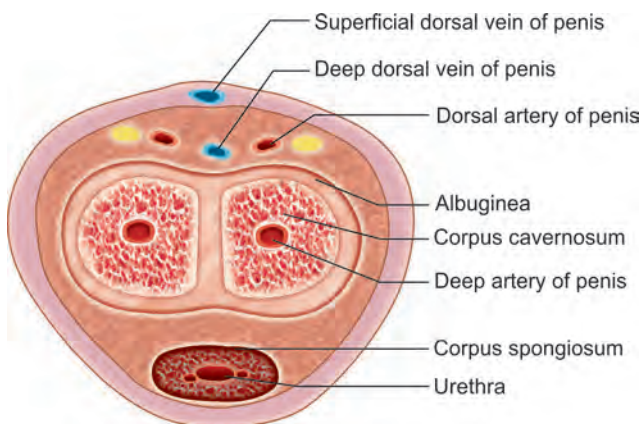


Fig. 26.136: Anatomy of penis.

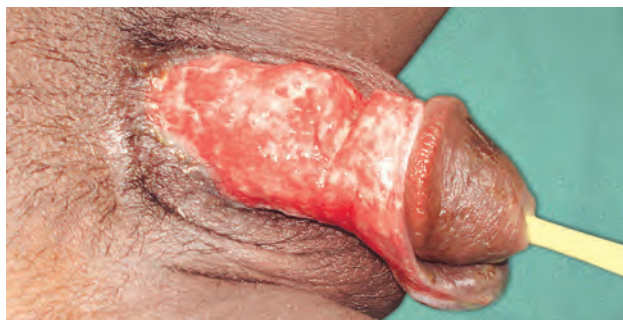

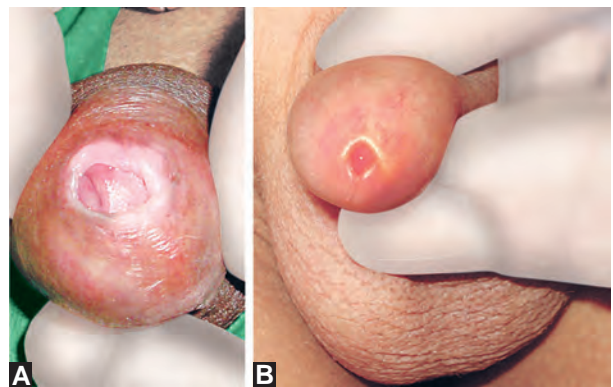
Fig. 26.137: Degloving injury of penis which needed skin grafting later.

### ■ PHIMOSIS

It is inability to retract the prepuce over the glans.

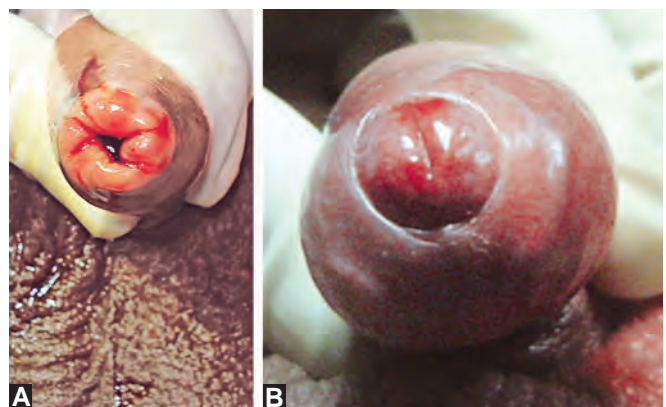
#### Causes

1. Congenital—in which case the child has pinhole meatus and ballooning of prepuce occurs when the child urinates.



Figs 26.138A and B: Pinhole meatus with phimosis. It is an indication for circumcision. Often clinically there will be ballooning of the prepuce during urination.

2. Balanitis (inflammation of glans) and balanoposthitis (inflammation of glans, prepuce and sac). Common in diabetics.



Figs 26.139A and B: (A) Posthitis and balanoposthitis are common causes of phimosis in adult. It may be common in diabetics. Carcinoma should also be ruled out. Specimen should be sent for histology after circumcision; (B) Phimosis. It is inability to retract prepuce over glans.

Patients with phimosis are more prone for recurrent infection, smegma collection and *carcinoma penis*.

## Treatment

*Circumcision.*

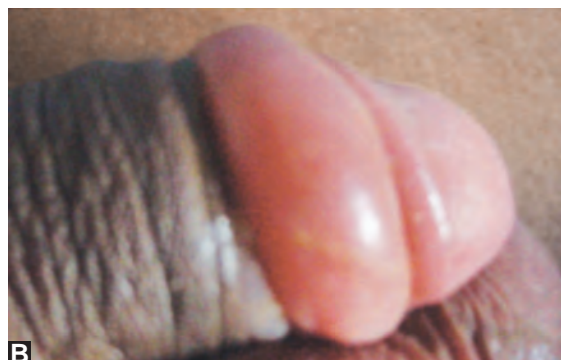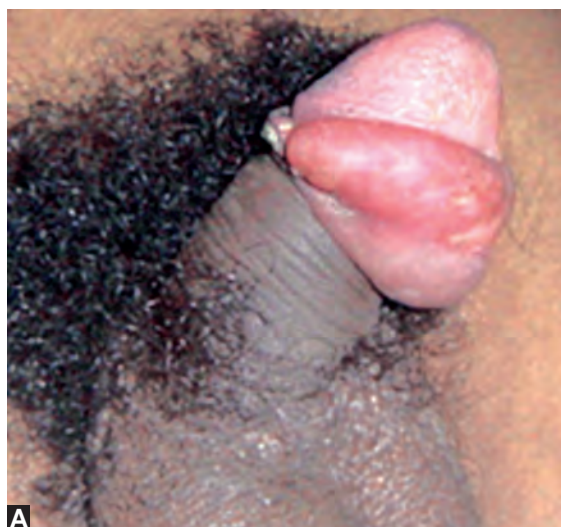### Problems due to phimosis

- ❖ Recurrent balanoposthitis
- ❖ Paraphimosis
- ❖ Ballooning of prepuceal skin
- ❖ Retention of urine
- ❖ Prepuceal calculi formation due to smegma collection in prepuceal sac
- ❖ Carcinoma of penis later

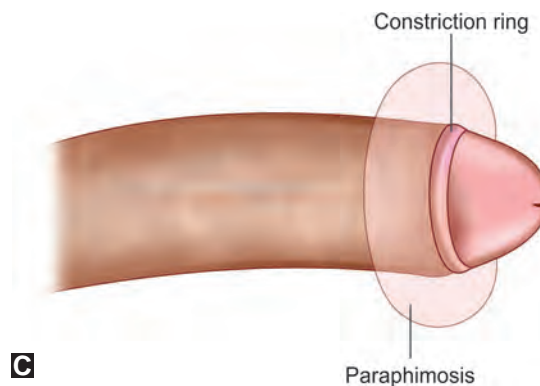
## PARAPHIMOSIS

- ◆ Inability to place back (cover) the retracted prepuceal skin over the glans is called as paraphimosis.
- ◆ It causes ring like constriction proximal to the corona and prepuceal skin.
- ◆ As a result the glans will be swollen, oedematous with severe pain and tenderness.
- ◆ Often glans will undergo necrosis or becomes gangrenous.

Paraphimosis is precipitated after sexual intercourse or iatrogenically after urethral catheterisation.



Figs 26.140A and B



Figs 26.140C

Figs 26.140A to C: Paraphimosis is inability to place back the retracted prepuce.

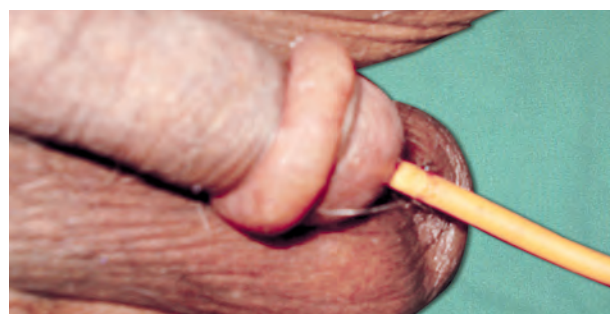

Fig. 26.141: Paraphimosis developed after catheterisation due to failure of replacing back of the prepuce.

## Treatment

- ◆ Manual reduction of prepuceal skin is to be tried.
- ◆ If not possible, *initial dorsal slit* is made to relieve the oedema and compression. Antibiotics and analgesics are given. *Circumcision* is done after 3 weeks.
- ◆ Sedation and hyaluronidase injection in 10 ml saline into the constriction ring or multiple needle punctures over the oedematous part, reduces the oedema and makes the paraphimosis to get reduced. Later circumcision should be done.

## CIRCUMCISION

*And God said to Abraham, "As for you, you shall keep my covenant, you and your descendants after you throughout their generations. This is my covenant.... Every male among you shall be circumcised. You shall be circumcised in the flesh of your foreskins, and it shall be a sign of the covenant between me and you. He that is eight days old among you shall be circumcised."*  
—The Bible, date unknown

### Indications

- ❖ Religious
- ❖ Phimosis
- ❖ Paraphimosis after doing initial dorsal slit
- ❖ Balanitis and balanoposthitis (common in diabetics)
- ❖ Early carcinoma of prepuce or glans penis—both diagnostic as well as therapeutic purpose
- ❖ Certain sexually transmitted diseases, e.g. herpes infection

*If you want to advance in life, make sure that your WANTS don't advance.*



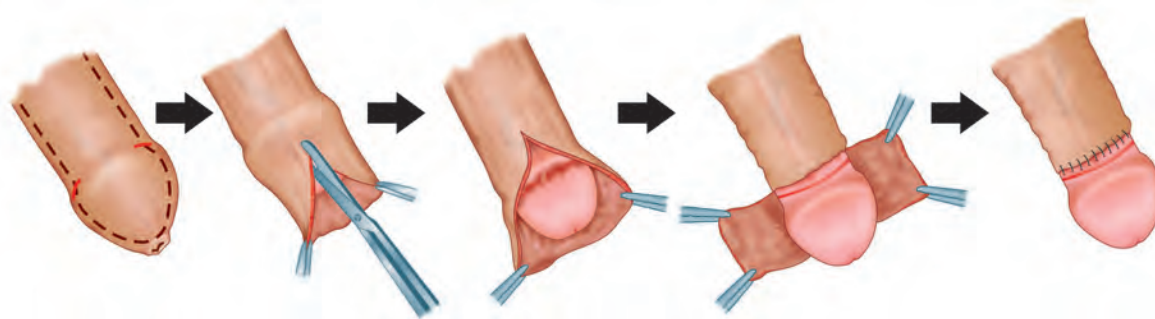


Fig. 26.142: Operative steps of the circumcision.

## Procedure

- ◆ In children, it is done under G/A. In adults, it is done under local anaesthesia.
- ◆ After cleaning and draping, LA [1% lignocaine (*plain*) injected circumferentially near the root of the penis] is given (ring block).
- ◆ Dorsal skin is cut up to the corona and later circumferentially and ventrally.
- ◆ The skin is cut with inner layer.
- ◆ Care is taken to see that optimum (less) skin is cut ventrally to prevent the occurrence of *chordee*.
- ◆ Frenular artery is transfixed and ligated ventrally using chromic catgut (2-0 or 3-0). Small bleeders are also ligated.
- ◆ Skin is apposed to the cut edge of corona using interrupted chromic catgut sutures.
- ◆ Postoperatively, antibiotics and analgesics are given.

## Complications

- ❖ Reactionary haemorrhage due to slipping of ligature from frenular artery and dorsal vein
  - ❖ Infection
  - ❖ Stricture urethra near the external meatus in *children*
  - ❖ *Chordee* due to removal of excess skin on the ventral aspect
  - ❖ Rarely priapism can occur
- ◆ *Hollister Bell cap technique* (Plastibel device): This specially devised plastic cap can be fitted over the glans penis and prepuce is rolled over it. A tight ligature is tied over it near base of the prepuce. In 7 days skin and prepuce sloughs off and sheds with the cap. Bleeding will not occur due to thrombosis of prepuceal vessels. Technique can be used for religious circumcision/balanoposthitis without phimosis. It is contraindicated in phimosis and paraphimosis.

## Note:

- Circumcision *by guillotine* is a method done by pulling and stretching the prepuceal skin beyond the glans and cutting the prepuce. It should be condemned and not be done as injury to glans is common. It is practiced in religious circumcision.
- **Monopolar cautery should not be used** in circumcision.

## BALANOPOSTHITIS

- ◆ It is inflammation of glans and prepuce—(Inflammation of prepuce is posthitis; of the glans is balanitis).

## Causes

- ❖ Diabetes mellitus
- ❖ Candidiasis
- ❖ Venereal diseases like syphilis, herpes. It can cause phimosis, carcinoma penis.

- ◆ *Clinical features:* Pain, swelling, discharge.

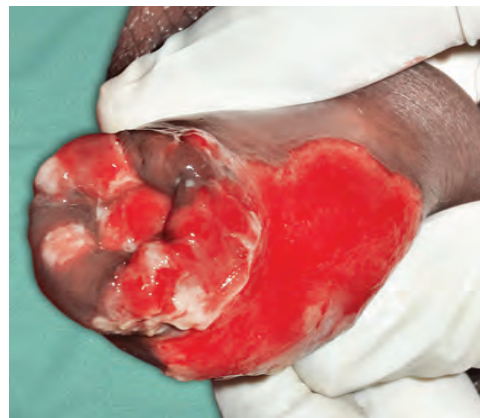

Fig. 26.143: Extensive balanoposthitis in a diabetic patient.

- ◆ *Treatment:*
  - ▶ Antibiotics.
  - ▶ Circumcision.
  - ▶ The diabetes is controlled.

## CHORDEE (CORDEE)

It is fixed bending of glans penis, more obvious during erection.

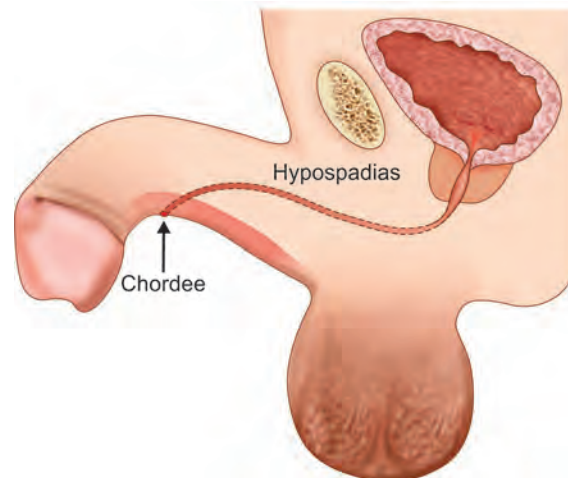


Fig. 26.144: Chordee.

## Types

- ◆ Ventral.
- ◆ Dorsal.

## Causes

- ◆ Hypospadias, where urethra opens more proximally than normal (*ventral cordee*).
- ◆ After circumcision, if more skin is cut over the ventral aspect (*ventral cordee*).
- ◆ In epispadias *dorsal cordee* occurs.

## Treatment

- ◆ Chordee due to hypospadias is corrected during staged procedure.
- ◆ In chordee following circumcision, initially stilbestrol 6 mg daily is given. Later chordee is corrected surgically by excising fibrous tissue and later doing skin grafting. More often they require surgical intervention.

## ■ PRIAPISM

- ◆ It is persistent, painful erection of penis.
- ◆ Corpora cavernosa are filled with blood due to defective venous drainage. Glans and corpus spongiosum are not involved.

### Causes

- ❖ Idiopathic *thrombosis of corpora cavernosa*
- ❖ Idiopathic thrombosis of prostatic venous plexus
- ❖ Sickle cell disease
- ❖ Leukaemia
- ❖ Secondary deposits in corpora cavernosa
- ❖ Spinal injury or diseases

- ◆ It can be *ischaemic* (low flow), *non-ischaemic* (high flow) and *stuttering/intermittent*.

## Investigations

- ◆ Relevant for specific causes.
- ◆ Doppler duplex US scan is done. Arteriogram often with embolization is often done.

## Treatment

- ◆ Doppler guided aspiration; intracavernous injection of adrenergic agonists like phenylephrine are nonsurgical methods.
- ◆ Anastomosis between corpora cavernosa and saphenous vein.
- ◆ Anastomosis between corpora cavernosa and corpus spongiosum.

## ■ PEYRONIE'S DISEASE (Induratio-penis Plastica)

- ◆ It is development of fibrous tissue plaque on the covering of corpus cavernosum and later involving its full extent resulting in induration of corpus.
- ◆ It is a slowly progressive disease of uncertain aetiology, may be due to old trauma, often associated with *Dupuytren's contracture*, *retroperitoneal fibrosis* and *plantar fasciitis*.
- ◆ Initial active phase has painful erection with changing deformity of penis.
- ◆ Later quiescent phase has disappearance of painful erection with development of deformity which is painless.

- ◆ Later erectile dysfunction; penile shortening occurs.
- ◆ Indurated plaque is noticed in the penis.

## Treatment

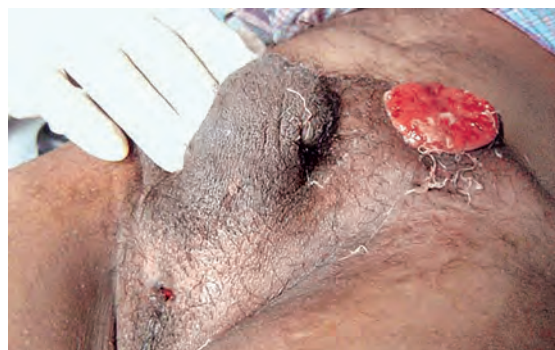- ◆ Some cases resolve spontaneously.
- ◆ Drugs
  - ▶ Steroids.
  - ▶ Vitamin E.
  - ▶ Potassium amino benzoate 12 mg/day.
  - ▶ Tamoxifen 20 mg daily.
  - ▶ Terfenadine and fexafenadine.
  - ▶ Colchicine therapy.
  - ▶ Intralesional injection of verapamil 10 mg once in 2 weeks—12 injections.
- ◆ Surgery is needed in many cases
  - ▶ Excision and plication to opposite side—*Fitzpatrick operation*.
  - ▶ Multiple incisions over the fibrous plaque and temporal fascia bridging—*Gelhard's operation*.
  - ▶ Excision of fibrous plaque and corporotomy is covered with overlay flap like tunica vaginalis flap (*Lockhart's*)/dermal flap (*Devine and Horton's*).
  - ▶ Intracorporeal penile prosthesis placement.

## ■ RAM'S HORN PENIS

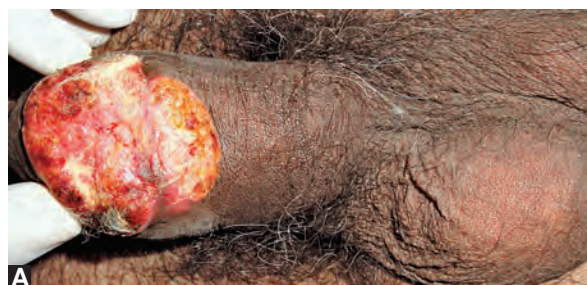Filarial involvement of penis where it becomes thick, distorted and resembles horn of a ram.

## ■ CARCINOMA PENIS

- ◆ It is commonly *squamous cell carcinoma*, but melanoma, adenocarcinoma from Tyson's gland, basal cell carcinoma and secondaries may also occur.



**Fig. 26.145:** Carcinoma penis earlier operated by total amputation of penis has now developed secondaries in inguinal lymph nodes which has already fungated. Note the perineal urethrostomy done.



**Fig. 26.146A**

*When you burn with the fire of anger, smoke gets in your eyes.*

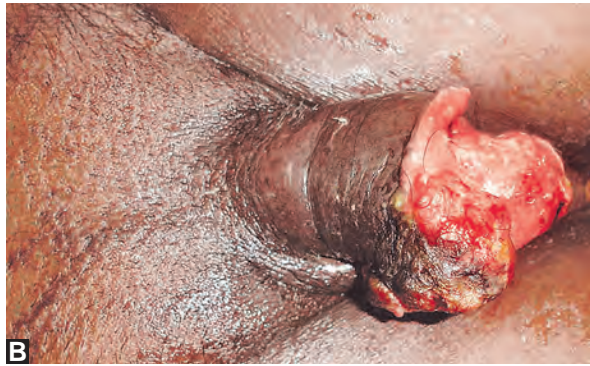

Fig. 26.146B

Figs 26.146A and B: Carcinoma penis in two different patients.

**Aetiology**

- ◆ Chronic balanoposthitis, phimosis.
- ◆ Sexually transmitted diseases.
- ◆ Leukoplakia of glans.
- ◆ Long-standing genital warts.
- ◆ *Paget's disease* of penis.
- ◆ Erythroplasia of Querat is persistent rawness of glans penis.

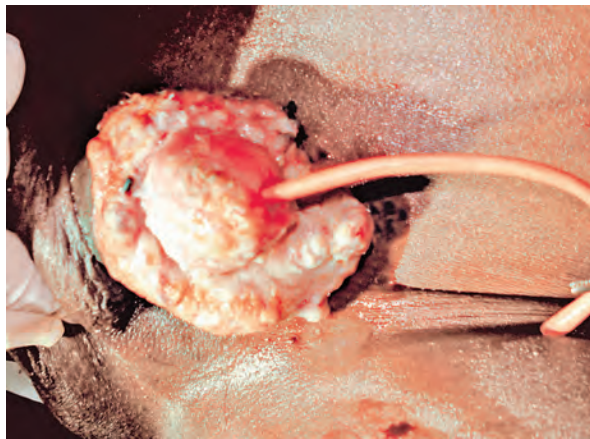


Fig. 26.147: Carcinoma penis—circumferential proliferative exophytic lesion.

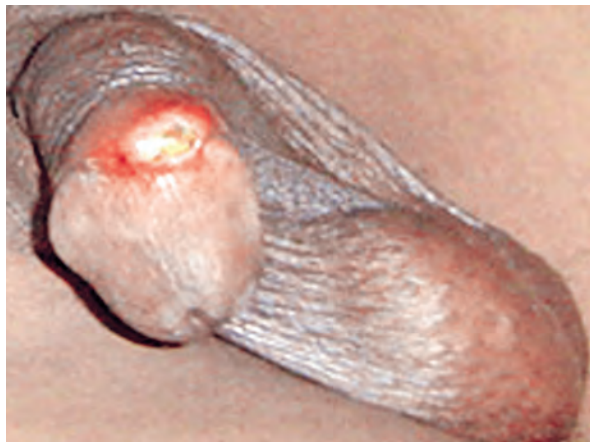

Fig. 26.148: Small ulcerated lesion over glans penis—carcinoma.

- ◆ Condyloma acuminata (by human papilloma virus), balanitis xerotica obliterans.

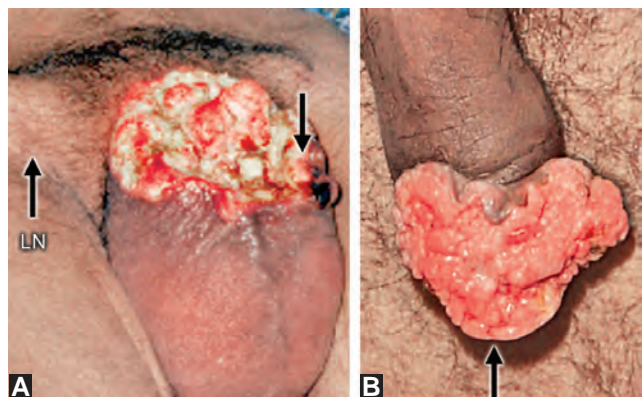
- ◆ HIV infection—HPV-16.
  - ▶ Circumcision during infancy confers total immunity against carcinoma penis.
  - ▶ It is common in Asia and Africa.

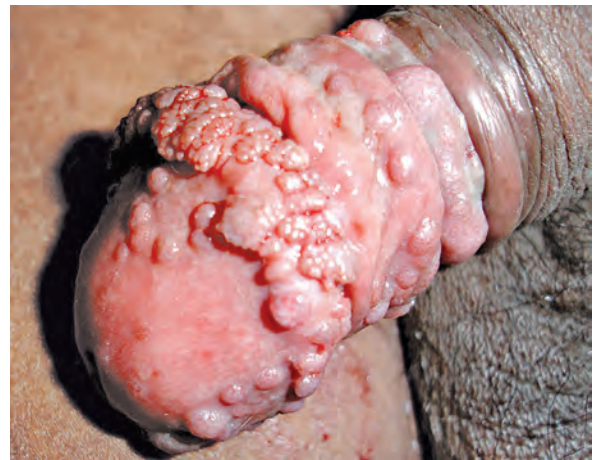
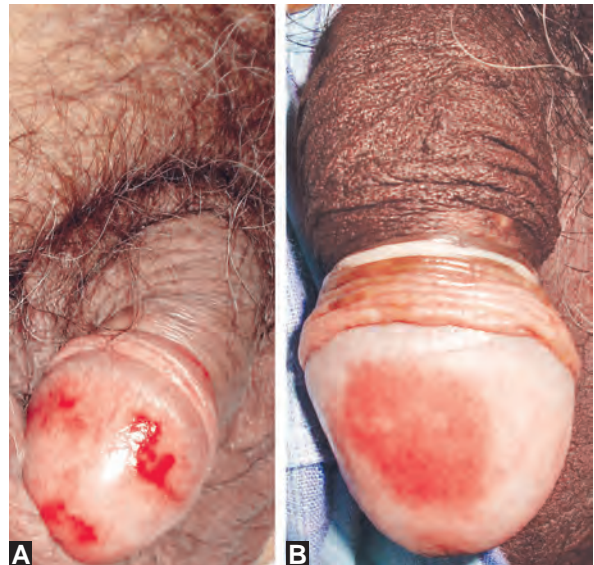
Fig. 26.149: Genital warts—in glans penis. It is a premalignant condition. Biopsy, excision and podophyllin application is needed.



Figs 26.150A and B: Erythroplasia of glans penis. It is a premalignant condition.



Figs 26.151A and B: (A) Carcinoma of penis causing destruction of entire penis; (B) Carcinoma penis with proliferative lesion.

## Pathology

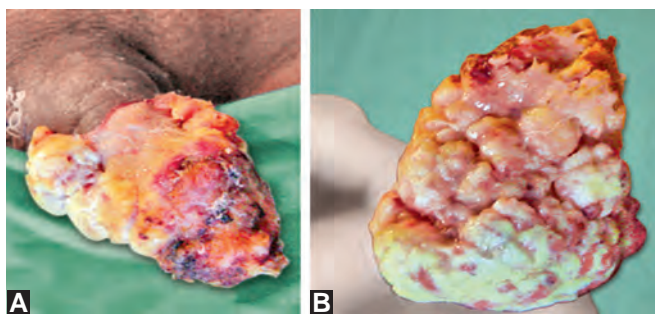
- ◆ *Infiltrating type* occurs in a preexisting leukoplakia. It often presents as indurated area.
- ◆ *Papilliferous type* eventually attains a large size forming a fungating foul smelling lesion which often gets infected.
- ◆ *Ulcerative type.*
  - ▶ Glans penis is the most common site (coronal sulcus for basal cell carcinoma).
  - ▶ 80% are of low grade tumours.

## Spread

- ◆ Through lymphatics, it spreads to the horizontal group of inguinal lymph nodes which become nodular and hard. Lymph nodes on both sides can get involved. Later, external iliac group are involved (above and on medial aspect of the inguinal ligament).
- ◆ Once inguinal lymph nodes are fixed, it causes severe excruciating pain and lymphoedema. *Fixed lymph node status indicates the advancement of the disease.* It may erode into the femoral vessels causing torrential haemorrhage and death. Fungation can occur.
- ◆ From glans, it also spreads to Cloquet lymph node which is located in femoral canal.
- ◆ Carcinoma from shaft of penis can spread directly to the external iliac lymph nodes.
- ◆ It spreads proximally to the body of penis causing induration.
- ◆ Urethral meatus may get involved causing alteration in urinary stream. *It is a locoregional malignant disease.*
- ◆ *Blood spread is rare.*

## Clinical Features

- ◆ In an adult, recent onset of phimosis should raise the suspicion of carcinoma penis.



**Figs 26.152A and B:** Verrucous carcinoma of penis.

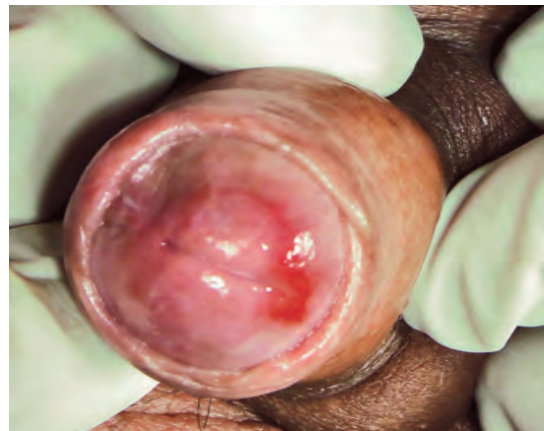- ◆ Lesion is painless initially but later becomes painful due to secondary infection, often accompanied by discharge which is foul smelling, purulent and irritating.
- ◆ Altered urinary stream.
- ◆ Fungation and induration, everted edge, often extending into the body of penis.
- ◆ Palpable hard, nodular inguinal lymph nodes on both sides may be present. External iliac lymph nodes may be palpable.
- ◆ Pain, oedema, tenderness, redness develops once infection occurs.

## Investigations

- ◆ *Wedge biopsy* from the lesion shows squamous cell carcinoma with epithelial pearls.

### Broder's grading

- ❖ Very well differentiated (75% epithelial pearls)
- ❖ Well differentiated (50–75%)
- ❖ Moderately differentiated (25–50%)
- ❖ Undifferentiated (<25%)



**Fig. 26.153:** *In situ* carcinoma penis over the glans.

- ◆ *FNAC of lymph nodes* (No open biopsy for lymph nodes).
- ◆ Ultrasound abdomen, to look for involvement of external iliac lymph nodes.
- ◆ *SLNB—Cabana sentinel node* is located above and medial to the junction of saphenous and femoral vein. It is the first node to get involved in carcinoma penis. So this Sentinel Lymph Node Biopsy (SLNB) after isosulphan blue dye injection in to the primary is done to decide for the necessity for ilioinguinal block dissection.

## Staging of Carcinoma of Penis

### Jackson's staging of carcinoma penis

Stage I—Tumour involving only glans/prepuce/both	90% five-year survival
Stage II—Tumour extending into body of penis	70%
Stage III—Tumour having mobile inguinal nodes	50%
Stage IV—Tumour spreading to adjacent structures/fixed nodes	5%

### TNM Staging of carcinoma penis (AJCC, 2013, 7th edition)

- TX: Primary tumour cannot be assessed
- T0: No evidence of primary tumour
- Tis: Carcinoma *in situ* (cancer that is only in the top layers of skin). This is called as *erythroplasia of Queyrat* when it occurs on the glans of the penis; it can be called *Bowen disease* when it occurs on the shaft of the penis.
- Ta: Verrucous (wart-like) carcinoma that is only in the top layers of skin (*non-invasive*)
- T1: Tumour has grown into the tissue below the top layers of skin (called the *subepithelial connective tissue*)
- T1a: The cancer has grown into the subepithelial connective tissue, but it has not grown into blood or lymph vessels. The cancer is grade 1 or 2.
- T1b: The cancer has grown into the subepithelial connective tissue and either it has grown into blood and lymph vessels OR it is high-grade (grade 3 or 4).
- T2: Tumour has grown into one of the internal chambers of the penis (the corpus spongiosum or corpora cavernosum)

*Contd...*

*The hand will not reach for whom the heart does not long for. Hand is the reflection of the heart.*

Contd...

T3: Tumour has grown into the urethra  
 T4: Tumour has grown into the prostate or other nearby structures  
 NX: Nearby lymph nodes cannot be assessed  
 N0: No spread to nearby lymph nodes  
 N1: The cancer has spread to a single lymph node in the groin (inguinal lymph node)  
 N2: The cancer has spread to more than 1 inguinal lymph node  
 N3: The cancer has spread to lymph nodes in the pelvis and/or the cancer in the lymph nodes has grown through the outer covering of the lymph node and into the surrounding tissue (fixed uni- or bilateral lymph nodes).

M0: The cancer has not spread to distant organs or tissues  
 M1: The cancer has spread to distant organs or tissues (such as lymph nodes outside of the pelvis, lungs, or liver)

#### Staging:

Stage 0: Tis or Ta, N0, M0

Stage I: T1a, N0, M0:

Stage II: Any of the following: T1b, N0, M0; T2, N0, M0; T3, N0, M0

Stage IIIa: T1 to T3, N1, M0. Stage IIIb: T1 to T3, N2, M0

Stage IV: Any of the following: T4, any N, M0; Any T, N3, M0; Any T, any N, M1

## Treatment

- ◆ If growth involves the glans without extending into the proximal part of shaft of the penis, then *partial amputation of the penis* is done. A length of 2.5 cm stump is retained. Clearance of 2 cm from the proximal extended part of the tumour is needed. Advantage is proper streaming of the urine is possible.
- ◆ Partial amputation of penis with bilateral ilioinguinal lymph node block dissection is called as *Young's operation*.
- ◆ If tumour involves the proximal part of the body of penis or if it is anaplastic/poorly differentiated tumour *total amputation of penis* is done with *perineal urethrostomy*. Problems with perineal urethrostomy are scrotal ammoniacal dermatitis and stricture at urethrostomy site. Dermatitis is prevented by asking the patient to urinate in sitting position lifting the scrotum upwards. Stricture needs dilatation.
- ◆ Total scrotoectomy with orchidectomy is done along with total amputation of the penis—*Sir Piersey Gold operation*. It prevents frequent dermatitis of the scrotal skin because of the perineal urethrostomy and also reduces the sexual desire.

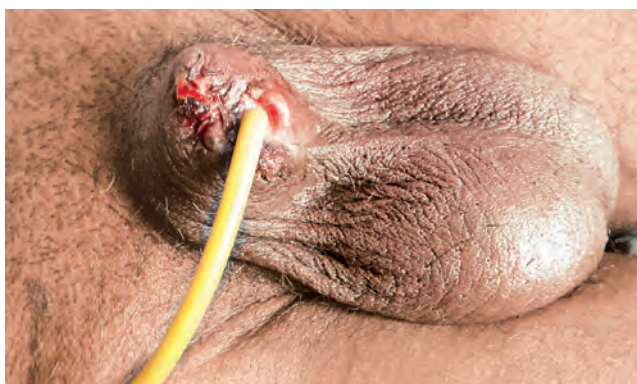

Fig. 26.154: Partial amputation of penis with catheter *in situ*.

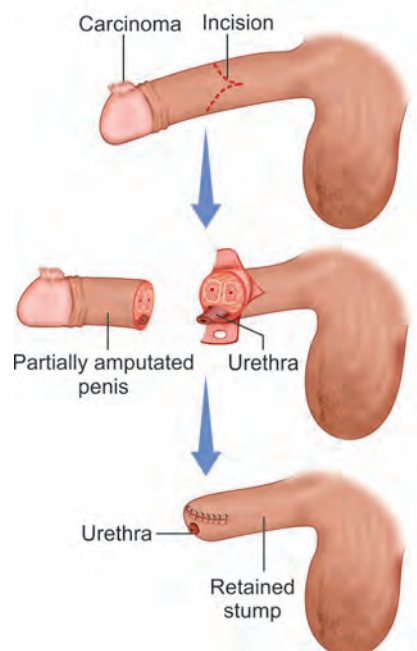


Fig. 26.155: Partial amputation of penis is done in penile carcinoma in the glans not extending into the body of the penis.

- ◆ In case of carcinoma *in situ*, T<sub>1</sub> lesion of glans penis or well differentiated tumour in young individual, circumcision and curative radiotherapy to the penis can be given using radioactive tantalum wire implantation (6000 cGy in 7 days) or by wearing radium penile mould continuously or intermittently (6000 cGy in 7 days) or by linear accelerator external beam radiotherapy (6000 cGy in 5 weeks). Involvement of nodes in these patients is less than 10%.
- ◆ When lymph nodes are involved and are mobile, *bilateral ilioinguinal nodal dissection* is done.
  - ▶ *Primary inguinal block* is doing block dissection within 4 weeks of surgery for primary tumour.
  - ▶ *Secondary inguinal block* is doing block dissection after 4 weeks of surgery for primary disease. Only 50% of palpable inguinal nodes are involved by metastatic spread. So often a course of antibiotic is given and waited for 4–6 weeks. Complications of ilioinguinal block dissection are *flap necrosis*, lymphoedema of lower limb, femoral blow out, infection, lymphorrhoea and haemorrhage.

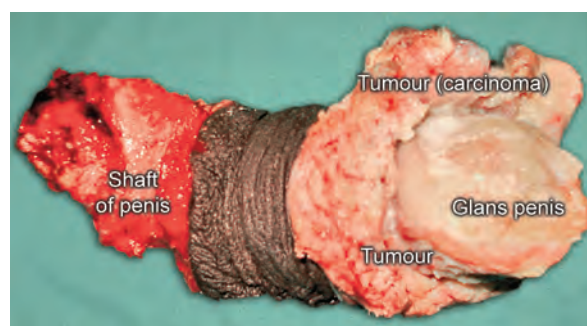
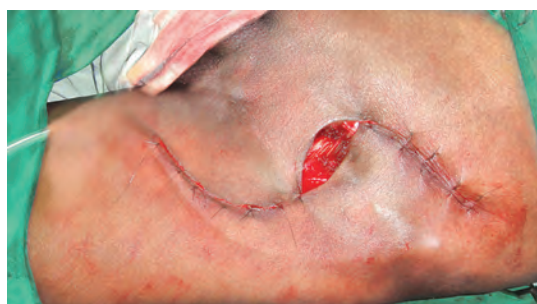

Fig. 26.156: Specimen of total amputation of penis done for carcinoma of penis.

- ▶ If primary tumour is poorly differentiated, and if tumour is T<sub>2</sub> or above, chances of inguinal nodal spread is more than 50% and so a prophylactic inguinal nodal dissection is done.
- ▶ Often, involvement of inguinal nodes may be due to infection. So a trial of antibiotic therapy is given for 4–6 weeks to reduce the size of the inguinal node.
- ▶ Removal of iliac nodes does not alter the outcome. It is done to confirm the spread, so that further therapy can be planned and prognosis can be predicted.
- ◆ Postoperative radiotherapy to inguinal region is often given.
- ◆ In advanced fixed inguinal nodes palliative external radiotherapy is given. It is to palliate pain, fungation and anticipated erosion into femoral vessels.
- ◆ Topical 5 FU cream or imiquimab or Mohs surgery or limited wide excision or Nd:YAG laser photoirradiation is useful in carcinoma *in situ*.
- ◆ **Chemotherapy:**  
5 FU; methotrexate, bleomucin, cisplatin and vincristine. MBP/VBM combinations are used.  
Bleomycin is a radiosensitiser and so beneficial if RT is planned later.

**Note:**

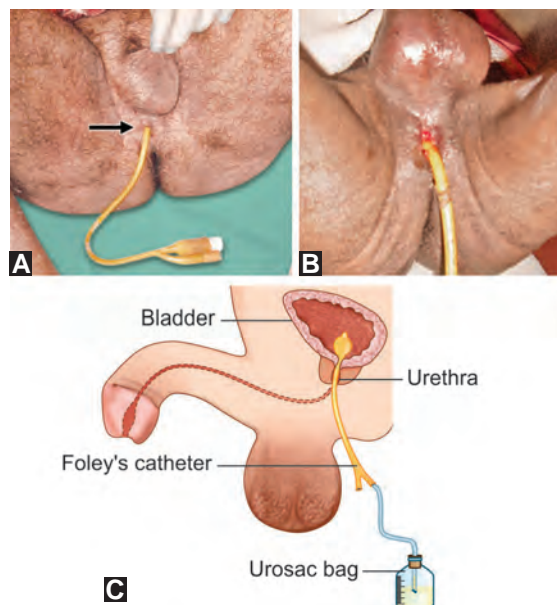
- **Dresslers quadrangle**—upper border is formed by line joining anterosuperior iliac spine and pubic tubercle; laterally line joining anterosuperior iliac spine and a point 20 cm below it; medially pubic tubercle and a point 15 cm below it. Nodal block dissection for carcinoma penis should cover this area adequately.
- **Elective prophylactic inguinal block** is done in high-risk group—*invasive carcinoma*; T<sub>2</sub> and T<sub>3</sub> tumours; with vascular invasion.
- **Therapeutic inguinal block** is done whenever FNAC of node shows positive tumour.
- **Superficial lymph node block** is dissection superficial to fascia lata in N<sub>0</sub> disease. It should undergo frozen section biopsy. If nodes are positive, then formal block dissection should be done.
- **Standard inguinal lymphadenectomy**—is classical block dissection.
- **Modified inguinal block dissection (Catalona)**—small incision, limited dissection, preservation of saphenous vein.



**Fig. 26.157:** S-shaped incision for ilioinguinal block dissection. Many modification incisions are also used.

**Role of radiotherapy in carcinoma penis**

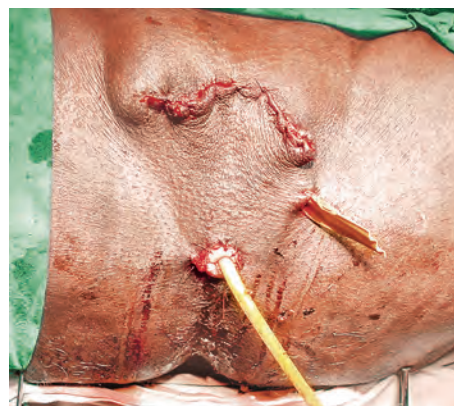
- ❖ Carcinoma *in situ*
- ❖ Small lesion less than 2 cm
- ❖ Lesion confined to glans
- ❖ Small lesion in young individual
- ❖ Advanced inoperable disease
- ❖ Palliation to inoperable inguinal nodes in groin
- ❖ Postoperative RT



**Figs 26.158A to C:** Perineal urethrostomy is done for urethral injury, urethral surgeries like urethroplasties as diversion and after total amputation of penis in carcinoma penis.

**Complications of inguinal block dissection**

- ❖ Haemorrhage
- ❖ Lymphorrhoea
- ❖ Lymphoedema
- ❖ Infection
- ❖ Flap necrosis—*common*



**Fig. 26.159:** Total penectomy for carcinoma penis. Note the drain placed; sutures; urethrostomy site.

**BUSCHKE-LÖWENSTEIN TUMOUR**

It is verrucous carcinoma of penis (5–15% common).

- ◆ *It is a curable malignancy.*
- ◆ It is locally destructive, locally invasive.
- ◆ It is often large, exophytic, dry, verrucosa-like growth.
- ◆ Neither spreads through lymphatics nor blood.
- ◆ After biopsy and confirmation, surgical excision or partial amputation is the treatment of choice.
- ◆ Radiotherapy should not be given.
- ◆ Virus aetiology is proposed—HPV—6 and 11.
- ◆ Systemic interferon α therapy and Nd:YAG laser therapy is successful.

## F. Scrotum

### CHAPTER OUTLINE

- ❖ Anatomy
- ❖ Fournier's Gangrene
- ❖ Hydrocele
  - Primary Vaginal Hydrocele
  - Secondary Vaginal Hydrocele
- ❖ Haematocele
- ❖ Pyocele
- ❖ Cyst of Epididymis
- ❖ Spermatocele
- ❖ Varicocele

### ANATOMY

It is a cutaneous bag containing the right and left testis, epididymis and lower part of spermatic cord.

#### Layers (from without inwards)

1. Skin
2. Dartos muscle
3. External spermatic fascia
4. Cremasteric fascia
5. Internal spermatic fascia

### Blood Supply

From external pudendal, deep external pudendal and internal pudendal arteries.

### Nerve Supply

- ◆ Anterior 1/3rd portion by ilioinguinal nerve and genital branch of genitofemoral nerve.
- ◆ Posterior 2/3rd portion by posterior scrotal branch of pudendal nerve and perineal branch of posterior cutaneous nerve of thigh.
- ◆ Dartos is supplied by sympathetic nerve.

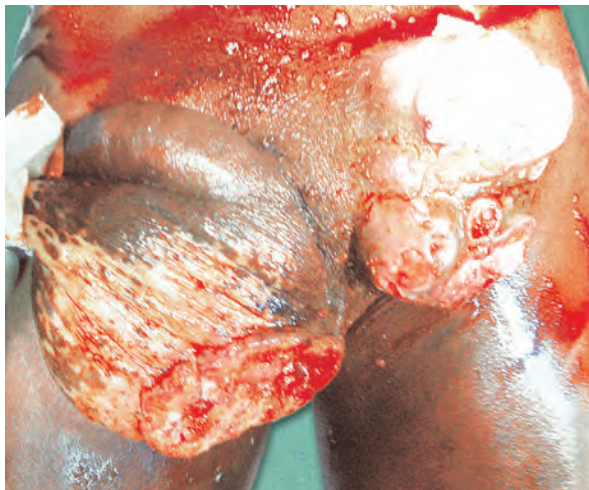

Fig. 26.160: Carcinoma of scrotum with inguinal node secondaries.

### FOURNIER'S GANGRENE

- ◆ It is also called as *idiopathic gangrene of the scrotum*.
- ◆ It is a *vascular gangrene of infective origin*, caused by haemolytic streptococci, microaerophilic streptococci, staphylococci, *E. coli*, *Cl. welchii*, *Bacteroides fragilis*.
- ◆ There will be fulminant inflammation of the scrotal skin and subcutaneous tissues resulting in *obliterative arteritis* of the arterioles of the scrotal skin leading into cutaneous gangrene.
- ◆ It is common in diabetics, old age, malnourished, immunosuppressed individuals.

### Clinical Features

- ◆ Condition is common in old age.
- ◆ Sudden pain in the scrotum, fever, severe toxicity.
- ◆ Very fast spreading cellulitis of scrotal skin, extending to the groin and often to anterior abdominal wall.
- ◆ Extensive skin sloughing occurs *leaving normal testis exposed*.
- ◆ Sometimes toxicity is so severe that they may go for renal failure and other complications.
- ◆ Sometimes the condition may worsen rapidly leading to death (25% mortality).

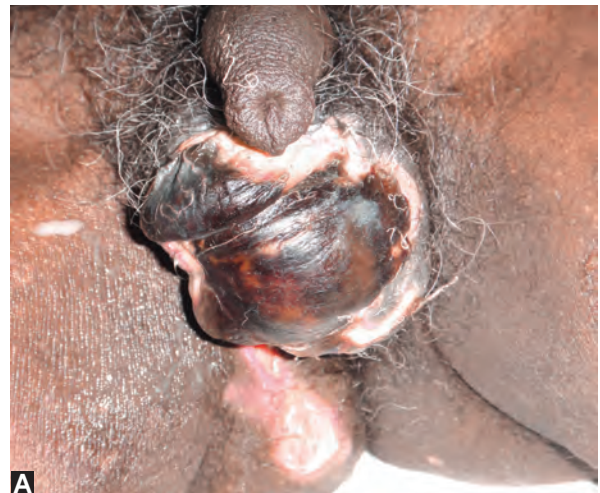

Fig. 26.161A

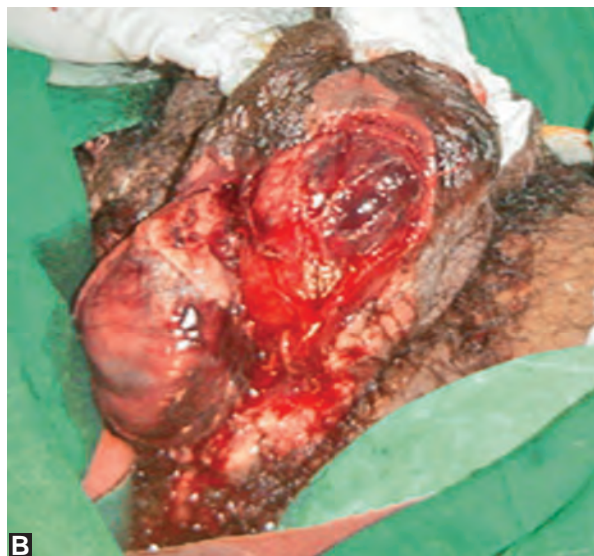

Fig. 26.161B

**Figs 26.161A and B:** Fournier's gangrene. Testes are normal. It is an infective gangrene of scrotum, rapidly spreading.

### Treatment

- ◆ Treated as an in-patient always.
- ◆ IV fluids and catheterisation—for maintenance of urine output.
- ◆ Antibiotics, blood transfusion.
- ◆ Nutritional support (TPN, enteral).
- ◆ Liberal excision of all slough.
- ◆ Once patient recovers and wound granulates well, *skin grafting is done*.
- ◆ **Orchidectomy is not necessary as testis is normal and viable.**
- ◆ Testis can be placed in the pouch in medial aspect of the thigh.

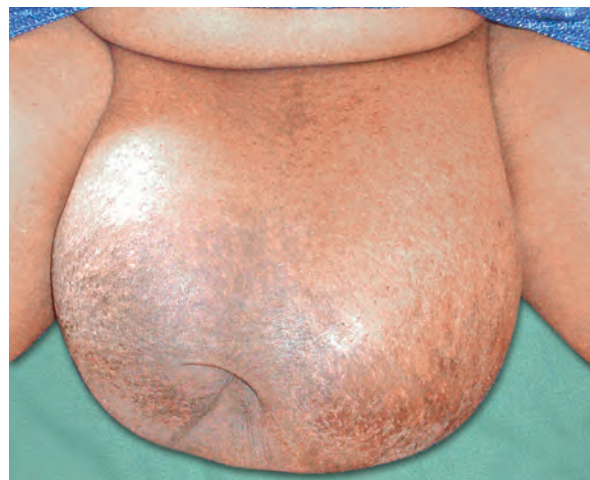### HYDROCELE

It is the collection of fluid between the two layers of tunica vaginalis of testis.

Types	
❖	Congenital
❖	Acquired
–	Primary
–	Secondary

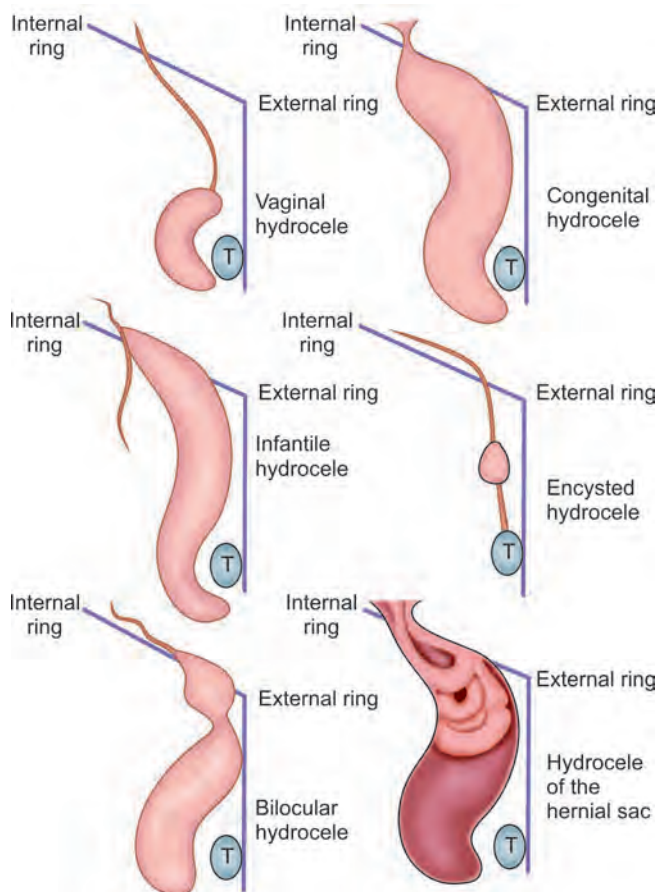
### Aetiology

- ◆ Defective absorption of fluid by the tunica vaginalis, probably due to damage to the endothelial wall by low-grade infection.
- ◆ Excessive production of fluid as in secondary hydrocele.
- ◆ Interference with drainage of fluid by lymphatic vessels of the cord.
- ◆ Communication with the peritoneal cavity.



**Fig. 26.162:** Massive hydrocele wherein penis is buried completely within the hydrocele area.

*Hydrocele fluid* is amber-coloured with specific gravity of 1.022 to 1.024. It contains water, salts, albumin, fibrinogen. Per se, hydrocele fluid does not clot, but if it comes in contact with the blood, fibrinogen gets activated and clots firmly. Often fluid contains cholesterol and tyrosine crystals.



**Fig. 26.163:** Types of hydrocele.



### Cysts which contain cholesterol crystals

- ❖ Vaginal hydrocele
- ❖ Branchial cysts
- ❖ Dentigerous cyst

### PRIMARY VAGINAL HYDROCELE

- ◆ Occurs in middle-aged, common in tropical countries.
- ◆ Testis is not palpable as it usually attains a large size (unlike secondary hydroceles which are small, except in filarial hydrocele).
- ◆ *Fluctuant* (elicited by, fixing the hydrocele with hand and feeling for the fluid movement using fingers placed in *two perpendicular directions*).
- ◆ *Initially transilluminant* (elicited in front of the swelling, side to side), but long-standing hydrocele is nontransilluminant (due to thickened dartos, thickened spermatic fascia, thickened hydrocele sac, infected content, chylous fluid, often filarial hydrocele, haematocele).
- ◆ *Can get above the swelling* (you can feel only cord structures and nothing else at the root of the scrotum, unlike in hernia).
- ◆ Testicular sensation can be elicited in vaginal hydrocele by transmitting the pressure sensation through the fluid.

#### Note:

- A relaxed muscle can demonstrate fluctuation in one direction even though there is *no fluid* in it.

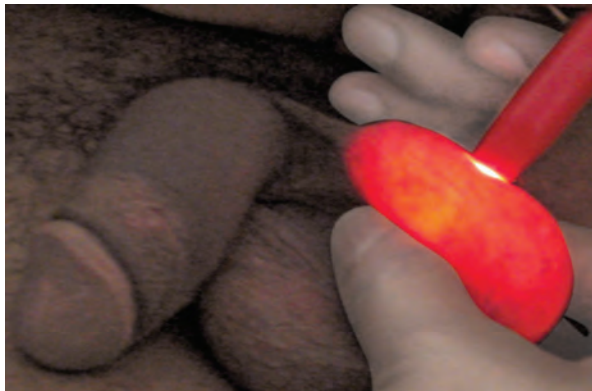

Fig. 26.164: Hydrocele which is brilliantly transilluminant.

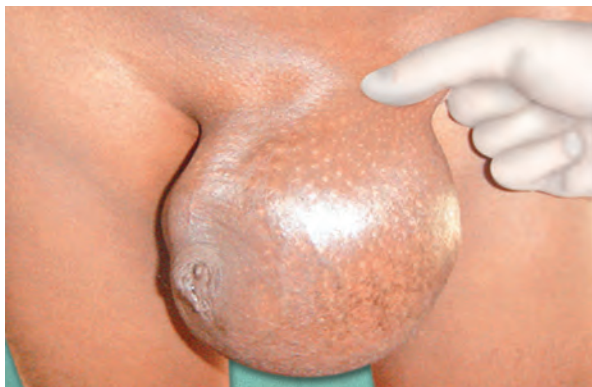

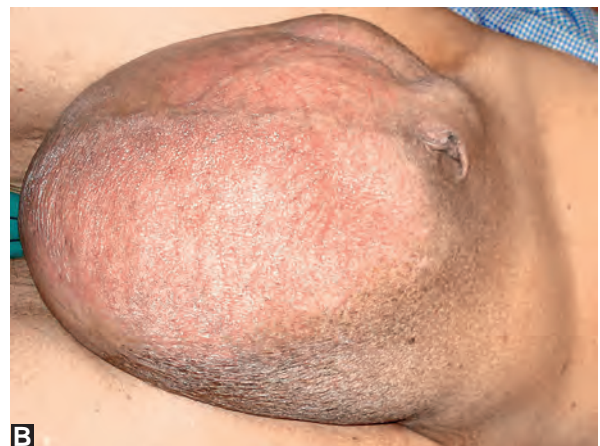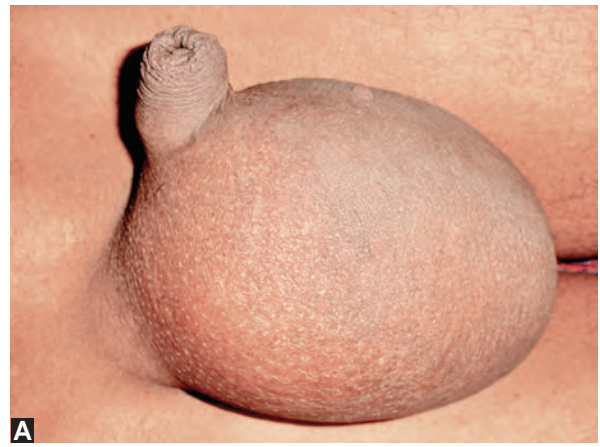Fig. 26.165: Get above the swelling is possible in case of hydrocele.

### Swellings which are brilliantly transilluminant

- ❖ Vaginal hydrocele
- ❖ Epididymal cyst
- ❖ Cystic hygroma
- ❖ Ranula
- ❖ Meningocele



Fig. 26.166: Hydrocele is transilluminant. It may be negative in long-standing hydrocele, thick sac, thick dartos, thick skin and infected fluid or chylous.



Figs 26.167A and B: Hydrocele in two different patients. One is average sized; another is large and penis is buried into the hydrocele swelling.

## Infantile Hydrocele

Here tunica and processus vaginalis (hydrocele) are distended up to internal ring, but sac has no connection with the general peritoneal cavity.

## Congenital Hydrocele

- ◆ Processus vaginalis communicates with the peritoneal cavity.
- ◆ As this communicating orifice is too small, bowel does not descend and so hernia usually will not develop. While lying down, fluid disappears gradually and while standing fluid recollects.
- ◆ Hydrocele cannot be emptied by digital pressure as it causes “*inverted ink bottle*” effect. Ascites, tuberculous peritonitis are the aetiologies for the same.

## Encysted Hydrocele of the Cord

- ◆ It is the *fluid collection* in a portion of patent funicular process part of the tunica vaginalis; but closed above and below; located in inguinal/inguinoscrotal/scrotal part which is fluctuant and transilluminant.
- ◆ On gentle traction to the testis, the swelling becomes less mobile (*traction test*).
- ◆ *Differential diagnosis*: Epididymal cyst, inguinal hernia, lipoma of cord, varicocele.
- ◆ *Treatment* is excision under local anaesthesia.

## Hydrocele-en-bisac (Bilocular Hydrocele)

Hydrocele has got two intercommunicating sacs, one above and one below the neck of the scrotum. Upper one lies superficial or in the inguinal canal or may insinuate itself between the muscle layers—*cross-fluctuant*.

### Other conditions where cross-fluctuation is elicited

- ❖ Plunging ranula
- ❖ Compound palmar ganglion
- ❖ Psoas abscess

## Hydrocele of the Canal of Nuck

It occurs in females, in relation to the round ligament, always in the inguinal canal.

## Hydrocele of the Hernial Sac

It is due to adhesions of the content of hernial sac. Fluid secreted collects in the hernial sac and forms hydrocele of the hernial sac.

## SECONDARY VAGINAL HYDROCELE

### Causes

It is usually small, lax and testis is usually palpable (unlike primary hydrocele). *Exception is, secondary hydrocele due to filariasis*. It can be very large.

Infection: Filariasis

Tuberculosis of epididymis—30% cases have secondary hydrocele  
Syphilis

Injury: Trauma, postherniorrhaphy hydrocele

Tumour: Malignancy

Secondary hydrocele rarely attains large size

## Postherniorrhaphy Hydrocele

It is a secondary hydrocele occurring after the surgery for inguinal hernia. It is due to the damage to lymphatic vessels of the tunica vaginalis and is 0.2% common. It is treated like any hydrocele but usually after about 6 months.

## Filarial Hydrocele and Chylocele

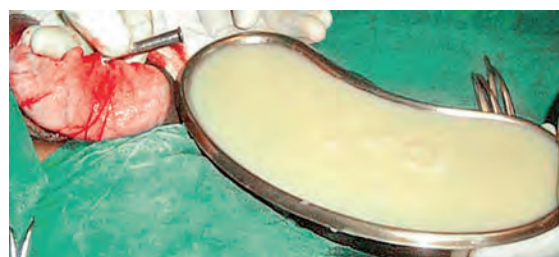


Fig. 26.168: Chylocele.

- ◆ Occurs commonly in coastal region, and in and around the equator.
- ◆ Usually occurs after repeated attacks of filarial epididymitis.
- ◆ Hydrocele is usually of large size and the sac is thickened.
- ◆ Fluid contains fat, rich in cholesterol, and is derived from ruptured lymph varix into the tunica.
- ◆ It is often difficult to differentiate from primary hydrocele.

### Complications of hydrocele

- ❖ Infection
- ❖ Pyocele
- ❖ Haematocele
- ❖ Atrophy of testis
- ❖ Infertility
- ❖ Hernia of hydrocele sac (rare)

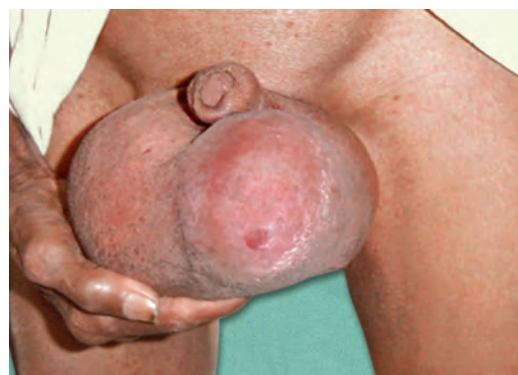

Fig. 26.169: Hernia of hydrocele is a rare complication of hydrocele. Herniation occurs through dartos.

### Differential diagnosis

- ❖ Inguinal hernia
- ❖ Epididymal cyst
- ❖ Spermatocele
- ❖ Testicular tumour
- ❖ Scrotal oedema

### Treatment for Hydrocele

#### Surgery

- ❖ Sub-total excision
- ❖ Partial excision and eversion (Jaboulay's operation)
- ❖ Evacuation and eversion
- ❖ Lord's plication

### Procedure

- ◆ Under GA or spinal or LA, after cleaning and draping, vertical incision of about 6–8 cm in length is made over the scrotum, anteriorly 1 cm lateral to the median raphe.
- ◆ Skin, dartos, external spermatic fascia, internal spermatic fascia are incised. *Bluish* hydrocele sac is identified, i.e. parietal layer of the tunica vaginalis of testis. Fluid is evacuated using trocar and cannula. Sac is opened.


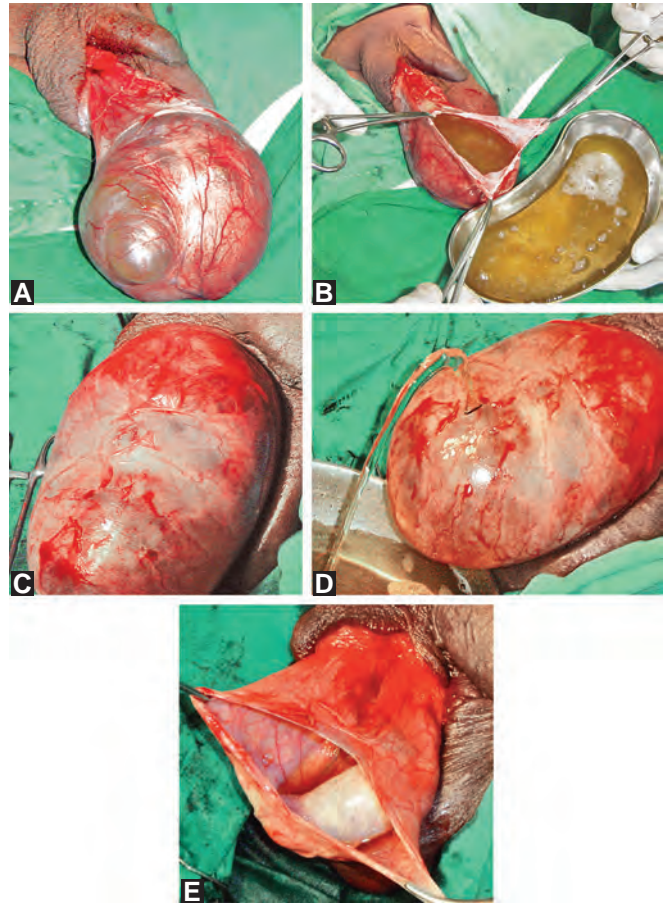


Fig. 26.170: Trocar and cannula used to evacuate the hydrocele fluid.



Fig. 26.171: Trocar and cannula used for hydrocele surgery.

- ◆ If the sac is small, thin and contains clear fluid, either *Lord's plication*, i.e. tunica is bunched into a "ruff" by placing series of multiple interrupted chromic catgut sutures so as to make the sac to form fibrous tissue (It is relatively avascular and so haematoma will not occur).
- ◆ Or *evacuation and eversion* of the sac behind the testis (after eversion, everted sac is sutured with chromic catgut by continuous sutures) is done.
- ◆ If the sac is thick, in large hydrocele and chylocele, *subtotal excision of the sac* is done (as tunica vaginalis is reflected on to the cord structures and epididymis posteriorly, total excision leads to orchidectomy with division of cord).
- ◆ Often the sac is excised partially and then eversion is done, which is called as *Jaboulay's operation*.
- ◆ After evacuation, the sac with the testis is placed in a newly created pocket between the fascial layers of the scrotum (*Sharma and Jhaver's technique*).



Figs 26.172A to E: Bluish hydrocele sac and hydrocele fluid in the sac.

- ◆ *Aspiration must be avoided as much as possible* as it is only a temporary measure (recurrence occurs very early) and chances of haematocele, infection are higher.
- ◆ A drain is placed near the root of the scrotum on the lateral aspect because it becomes the most dependent portion, when scrotal support is given. Scrotal support is given to reduce the scrotal oedema.
- ◆ Wound is closed in layers.
- ◆ Drain is removed in 48 hours.

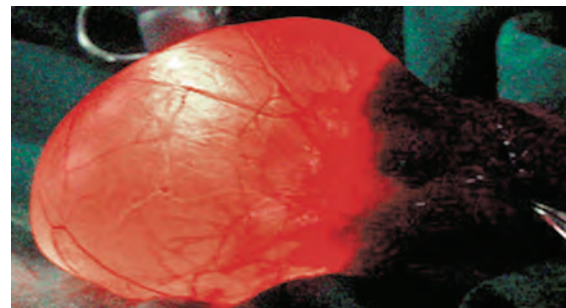
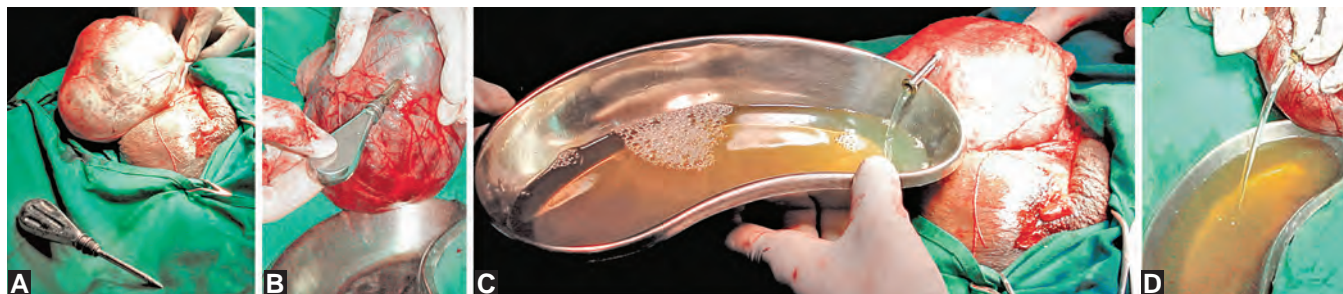


Fig. 26.173: Transillumination of hydrocele sac during surgery just prior to placing the trocar for evacuation after exposing the sac.

### Surgeries for hydrocele

- ❖ Subtotal excision of the sac
- ❖ Jaboulay's operation
- ❖ Evacuation and eversion
- ❖ Lord's plication
- ❖ Sharma and Jhaver's technique



Figs 26.174A to D: Hydrocele surgery showing sac; trocar and cannula; its insertion and evacuation of fluid.

**Complications of surgery**

- ❖ Reactionary haemorrhage
- ❖ Infection
- ❖ Pyocele
- ❖ Sinus formation
- ❖ Recurrent hydrocele

**Conditions which cause loss of testicular sensation**

- i. Testicular tumour
- ii. Lepra orchitis
- iii. Syphilitic orchitis
- iv. Chronic haematocele

**Conditions where orchidectomy is done in hydrocele**

- ❖ Pyocele with testicular destruction
- ❖ Clotted haematocele with testicular destruction

- ◆ Often it may occur following aspiration of a hydrocele.
- ◆ It may be precipitated by trauma also.

*Clinical features:*

- ◆ Sudden onset of pain and swelling after an history of trauma.
- ◆ It is tender, warm, fluctuant, but nontransilluminant.
- ◆ Occasionally aggressive testicular tumour mimics the presentation of acute, recent haematocele.
  - ▶ Ultrasound of the scrotum is done in such suspected cases to rule out neoplasm and also to find out the viability of testis.

**Complications**

- ❖ Chronic (old clotted) haematocele
- ❖ Infection
- ❖ Pyocele

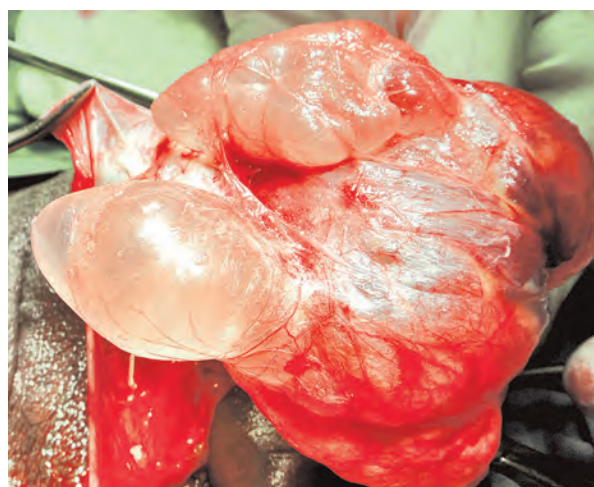

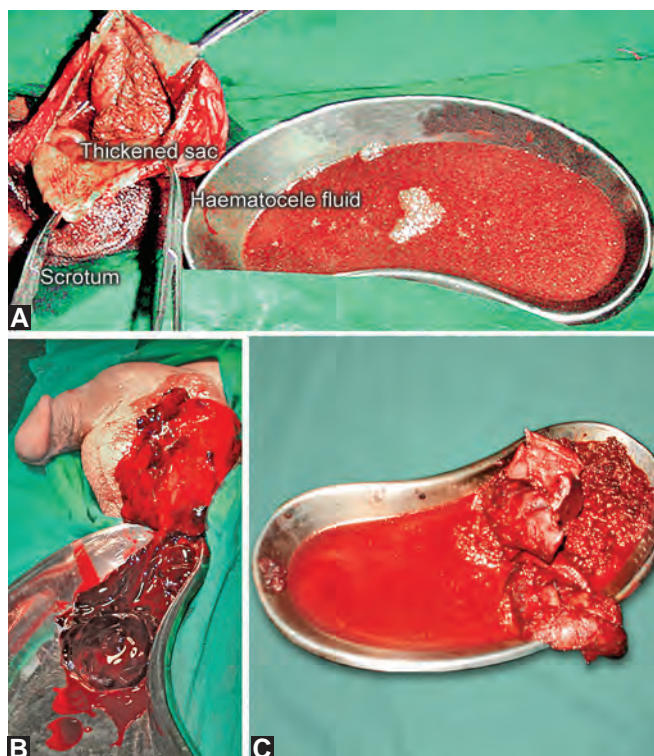Fig. 26.175: Multiloculated hydrocele—on table look.

**HAEMATOCELE**

**Types**

*a. Recent Haematocele*

- ◆ It is due to rupture of one of the vessels in the tunica causing bleeding into the sac.



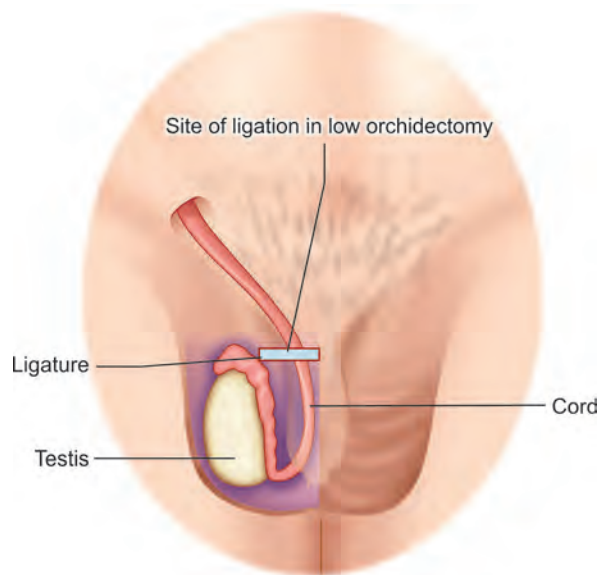
Figs 26.176A to C: Haematocele in different patients. Orchidectomy is often required in these patients, if testis is not viable.

*In early testicular tuberculosis there is often a loss of cutaneous elasticity as shown by smoothing out of rugae consequent upon wasting of the cellular tissue beneath the dermis.*  
**—A Clifford Morson**

*Treatment:* The scrotum is explored under general anaesthesia. The clot is evacuated and the wound is closed with a drain.

### b. Chronic or Old Clotted Haematocele

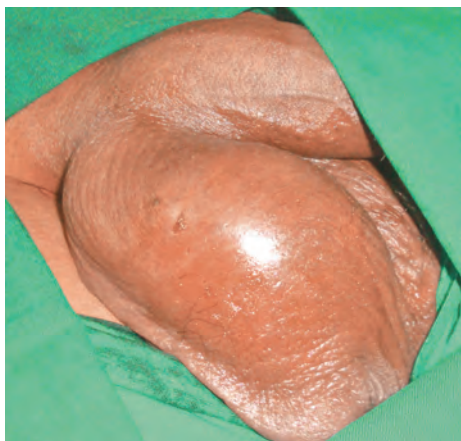
- ◆ It is usually due to slow, spontaneous haemorrhage into the tunica vaginalis, without any proper history of trauma.
- ◆ It is painless, hard, nontender, nonfluctuant, often calcified swelling, with *loss of testicular sensation*.
- ◆ Because of the constant pressure, testicular function and so testicular sensation is lost. It mimics testicular tumour in many aspects.
- ◆ Ultrasound of the scrotum is done.
- ◆ **Treatment** is *orchidectomy*, as testis is functionless (Low orchidectomy through scrotal approach).



**Fig. 26.177:** Low orchidectomy is done in case of haematocele, pyocele. Here incision is in the scrotum. Cord is doubly ligated using thick chromic catgut.

### ■ PYOCELE

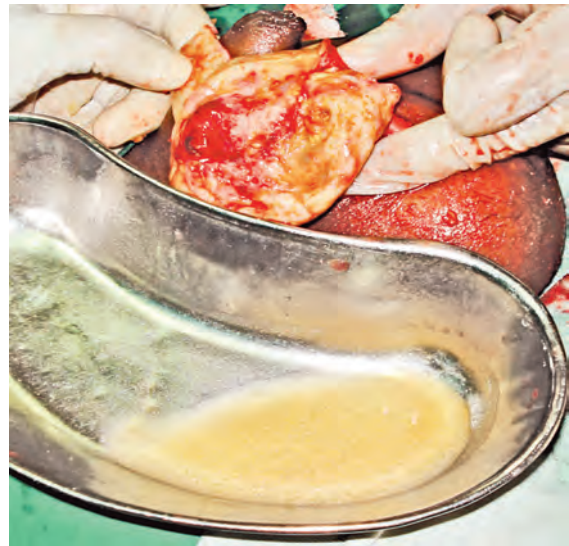- ◆ It is collection of pus in the layers of tunica vaginalis.
- ◆ It can occur in a previously normal tunica or in a pre-existing haematocele or hydrocele (which gets infected).



**Fig. 26.178:** Pyocele—clinical look. US confirms the diagnosis. TC will be raised.

### Features

- ◆ Fever, toxicity, tender swelling in the scrotum, with scrotal wall oedema.
- ◆ Often in young individuals, it may be difficult to differentiate this from the torsion testis.
- ◆ Pus under tension eventually causes infective thrombosis of testicular vessels, leading to nonviability of the underlying testis or testicular gangrene.



**Fig. 26.179:** Pyocele of scrotum. It is pus collection in the tunica vaginalis testis. It needs immediate exploration; drainage; often orchidectomy.

### Treatment

- ◆ Antibiotics are started.
- ◆ Scrotum is explored immediately and pus is evacuated.
- ◆ Viability of the testis is checked.
- ◆ If viable, pus is evacuated and sent for CS, wound is closed with a drain.
- ◆ If the testis is not viable, then *orchidectomy* is done (after taking consent).
- ◆ When in doubt, always testis is left in place and observed. Often, testis will show signs of viability. If not, then orchidectomy is done at a later stage.

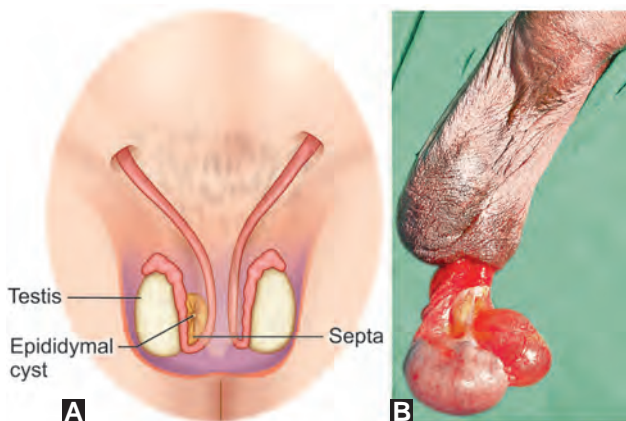
### ■ CYST OF EPIDIDYMS

It is due to the cystic degeneration of:

- ❖ Paradiidymis (organ of Giralde)—is the most common cause
- ❖ Appendix of the epididymis
- ❖ Appendix of the testis
- ❖ The vas aberrans of Haller

- ◆ Even though it is of congenital origin, it occurs in middle age.
- ◆ It is tensely cystic, contains clear fluid.
- ◆ Often bilateral.
- ◆ They are aggregation of number of small cysts and so *multiloculated*.
- ◆ They feel like 'bunch of tiny grapes' situated behind the body of the testis.
- ◆ It is situated behind the body of testis.

- ◆ Because of numerous septae they are finely tessellated and so are brilliantly transilluminant, appear like ‘chinese lantern pattern’.



**Figs 26.180A and B:** (A) Epididymal cyst showing multiloculated ‘Chinese lantern’ pattern. Its location is behind the body of testis; (B) Epididymal cyst.

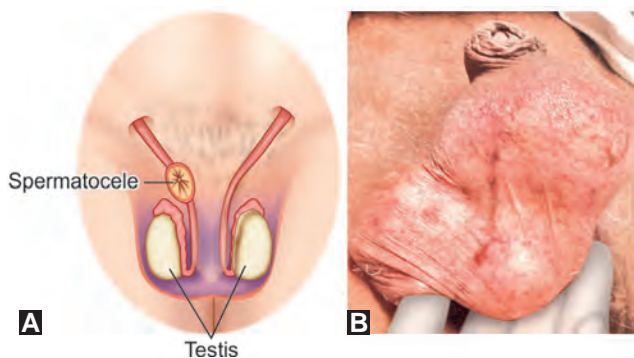
- ◆ **Differential diagnosis:**
  - ▶ Spermatocele.
  - ▶ Encysted hydrocele of the cord.
- ◆ **Treatment:**
  - ▶ Avoid excision as much as possible as it results in infertility due to blockage.
  - ▶ In old age, excision can be done.

**SPERMATOCELE**

It is a *unilocular, acquired retention cyst* derived from blockage of some portion of the sperm conducting mechanism of the epididymis.

- ◆ It is situated in the head of the epididymis, above and behind the body of the testis.
- ◆ Swelling contains *barley water like fluid*, which contains spermatozoa.
- ◆ It is soft, cystic and transilluminant. It is often considered by the patient as having an additional testis.
- ◆ Aspiration cytology confirms the diagnosis.
- ◆ **Differential diagnosis:**
  - ▶ Epididymal cyst.
  - ▶ Hydrocele.

**Treatment:** It can be left alone. If it is large, excision is done.

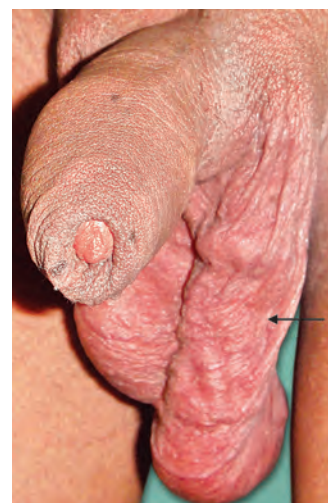

**Figs 26.181A and B:** (A) Spermatocele occurs behind and above the testis. It is *unilocular containing ‘barley’ like fluid*; (B) Spermatocele. It was earlier mistakenly called as 3rd testis.

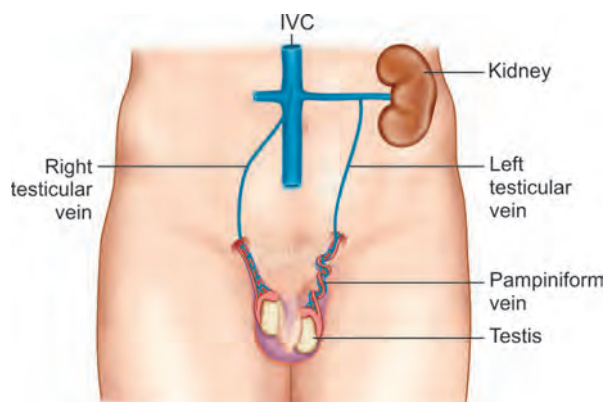
Epididymal cyst	Spermatocele
Congenital	Acquired retention cyst
Behind the body of the testis	Behind and above the testis
Multilocular	Unilocular
Bunch of grapes appearance	Looks like 3rd testis
Clear fluid as content	Barley water fluid contains sperms
Brilliantly transilluminant	Transilluminant
Excision should be avoided in young	Can be excised

**VARICOCELE**

- ◆ It is dilatation and tortuosity of the pampiniform plexus of veins and so also the testicular veins. Normally, there will be numerous plexus of veins (pampiniform) in the scrotum, which all join together to form about 4–8 veins in the inguinal canal. Above, in the abdominal cavity, in the posterior abdominal wall all join to form a single testicular vein. On left side, it drains the left renal vein; on the right side it drains the inferior vena cava.
- ◆ Varicocele is common in *tall, thin young men*.
- ◆ More common on the *left side*, but often can be bilateral.



**Fig. 26.182:** Clinical photo of left-sided varicocele—‘bag of worms’ look.



**Fig. 26.183:** Anatomy of testicular veins. Left testicular vein joins into left renal vein in perpendicular fashion. Right vein joins IVC directly.

*In transposition of the viscera (situs inversus) the right testis hangs lower—C Allan Birch*

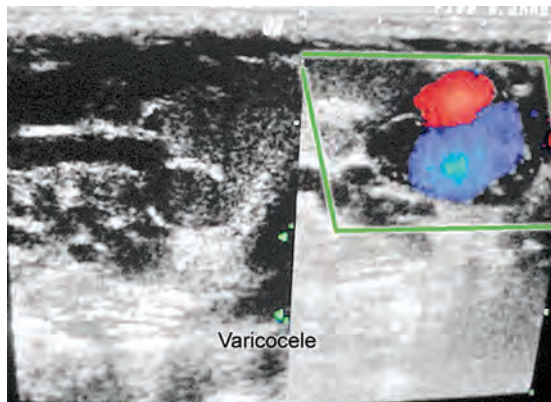
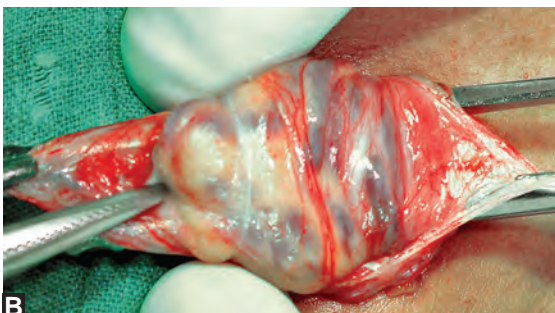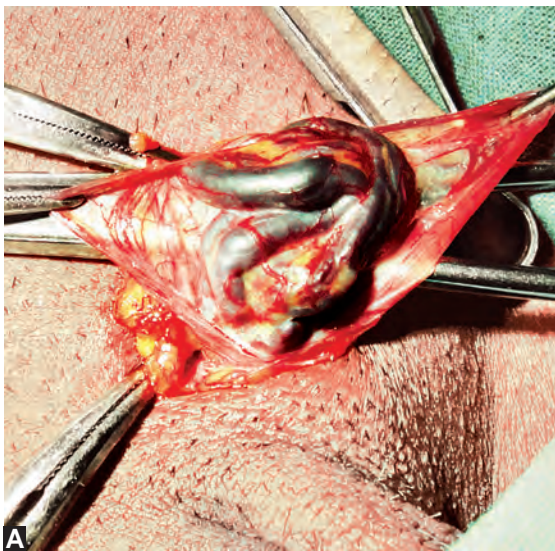


Fig. 26.184: Scrotal ultrasound showing varicocele.

- ◆ Commonly, it is idiopathic in origin, may be due to absence or incompetent valve at the junction of left testicular vein and left renal vein causing inefficient drainage of blood. Other reason is, due to perpendicular (right angle) entry of the left testicular vein into the left renal vein.
- ◆ In left-sided renal cell carcinoma, tumour proliferates into the left renal vein and blocks the entry of left testicular vein causing varicocele on left side which is *irreducible*.
- ◆ Varicocele causes increased temperature in the scrotum which depresses the spermatogenesis and so causes *infertility* (correctable infertility).



Figs 26.185A and B: Varicocele—on table look of tortuous pampiniform plexus of veins.

#### Note:

- *Subfertility/infertility* are observed even in unilateral varicocele. It is a debate whether it really causes subfertility. Possible causes are:
  - Altered heat exchange mechanism of the scrotum due to varicocele → hyperthermia → inhibition of spermatogenesis.
  - Increased blood flow → increased temperature in the testes → increases the metabolic activity using glycogen storage → depletion of glycogen → injury of parenchyma of testes → oligospermia.
  - Hypoxia of testes.
  - Same cause leads into Leydig cell dysfunction, decreasing testosterone levels.
  - Final effect is maturation arrest → poor spermatogenesis.

### Types of Varicocele

- ◆ *Primary/idiopathic*—95%: No cause is found. There is incompetence of valves of the testicular vein. It is common on left side because left testicular vein joins left renal vein perpendicularly and left side vein is longer and liable to get compressed by loaded sigmoid colon. Left renal vein is often compressed between aorta and SMA.
- ◆ *Secondary*—due to specific cause like left-sided renal carcinoma with a tumour thrombus in left renal vein causing obstruction to venous flow of left testicular vein.

#### Clinical features

- ❖ Swelling in the root of the scrotum
- ❖ Dragging pain in the groin and scrotum
- ❖ "Bag of worms" feeling
- ❖ Impulse on coughing
- ❖ On lying down, it gets reduced (except in renal cell carcinoma)

*Bow sign:* After holding the varicocele between thumb and fingers, patient is asked to bow. Varicocele gets reduced in size. Bowing reduces the blood flow of testicular vein and pampiniform plexus causing reduction in size.

#### Grading of varicocele

- I. Small
- II. Moderate
- III. Large
- IV. Severely tortuous

### Differential Diagnosis

- ◆ Hydrocele.
- ◆ Inguinal hernia.
- ◆ Lymph varix.
- ◆ Lipoma of the cord.

### Investigations

- ◆ Venous Doppler of the scrotum and groin.
- ◆ Ultrasound abdomen to look for kidney tumour.
- ◆ Semen analysis.

## Treatment

- ◆ **Palomo's operation:** Suprainguinal extraperitoneal ligation of the testicular vein.
- ◆ **Inguinal approach (Ivanissevich approach):** Easier and safer.
- ◆ **Subinguinal approach (Marc-Goldstein):** It is subinguinal approach at superficial inguinal ring outside the external oblique aponeurosis without opening the external oblique aponeurosis. Here cord is easily identified through a small incision.
- ◆ **Scrotal approach:** In case of grade IV, veins have to be excised through this approach.
- ◆ **Laparoscopic approach:** Presently, accepted—controversial?

### Indications for surgery

- ❖ Pain
- ❖ Oligospermia—usually in 6–12 weeks oligospermia improves very well and also the conception rate

### Complications of varicocele surgery

- ❖ Haemorrhage and scrotal haematoma
- ❖ Infection, pyocele
- ❖ Injury to testicular artery
- ❖ Injury to ilioinguinal nerve and pain
- ❖ Recurrence—5–10%

*When the scrotal skin of the affected side is less rugose than the normal side, it is probable that, that half of the scrotum never contained a testis. W*

—Kenneth I Macrosson



## G. Testis

The stones are called in Latin, *Testes*, that is witness because they witness one to be a man, ask the Pope else, he will tell you I say true.... I need not tell you where they are placed, for every boy that knows his right hand from his left, knows that.... The use of the stones is, 1. To convert blood spirit into seed for the procreation of man...2. They add heat, strength, and courage to the body.

—Nicholas Culpeper, 1660

### CHAPTER OUTLINE

- ❖ Anatomy
- ❖ Undescended Testis
- ❖ Ectopic Testis
- ❖ Retractable Testis
- ❖ Torsion of the Testis
- ❖ Testicular Tumours
- ❖ Paratesticular Tumours
- ❖ Orchitis
- ❖ Epididymitis

(*Testis* = was so-called because, in olden days men were *testifying* by holding the genitalia)

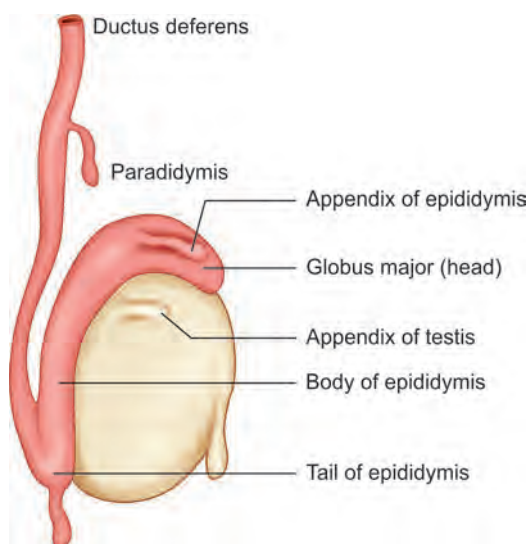


Fig. 26.186: Anatomy of the testis.

### ANATOMY

It is the male gonad. It is suspended in the scrotum by the spermatic cord. It lies obliquely such that its upper pole is tilted forwards and laterally.

It is 1½ inches long, 1 inch broad, ¾ inch thick. Epididymis lies along the lateral part of the posterior border.

### Coverings of the Testis

1. Tunica vaginalis—lower persistent portion of processus vaginalis.
2. Tunica albuginea—dense, white fibrous coat covering the testis; the posterior border of which is thickened to form the mediastinum testis. Numerous septa extend from it into the inner surface.
3. Tunica vascularis.

### Structure of Testis

Contains 200–300 lobules, each containing 2–3 seminiferous tubules.

### Arterial Supply

Testicular artery, a branch of abdominal aorta.

### Venous Drainage

By pampiniform plexus of veins which ultimately fuse to form single vein, which drains into IVC on right side, renal vein on left side.

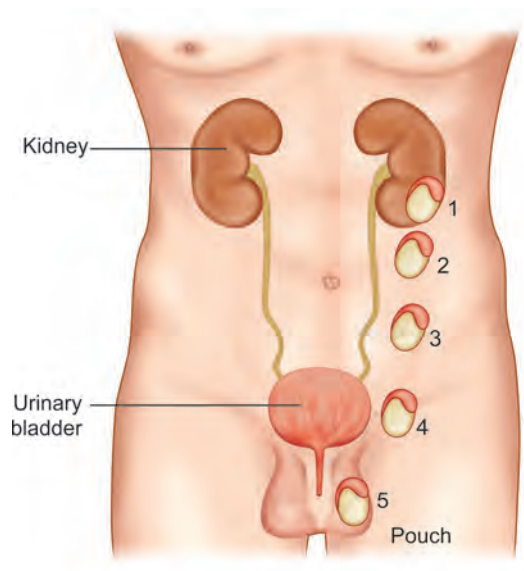


Fig. 26.187: Stages of testicular descent.

### Lymphatic Drainage

*Para-aortic group* of nodes at the level of L<sub>2</sub> vertebra.

### UNDESCENDED TESTIS

- ◆ It results from arrest of descent of the testis in some part along its pathway to the scrotum.
- ◆ Bilateral undescended testis is called *cryptorchidism* (means hidden testis).

**Anorchism:** Here there is complete agenesis of testis. These two can be differentiated by HCG test.

**Note:**

- *Maldescended testis* is one that cannot be made to touch the bottom of the scrotum. It can be undescended testis, cryptorchidism, ectopic testis or anorchism.
- *Vanishing testis:* Testis develops but disappears before birth probably due to prenatal torsion.
- *Cryptorchidism* may be associated with Klinefelter’s syndrome, hypogonadotrophic hypogonadism, Prune-Belly syndrome, renal agenesis, bladder extrophy, gastroschisis, horseshoe kidney, anorectal malformations.

**Embryology (Normally Kidney Ascends, Testis Descends)**

- ◆ Primitive testis develops from the genital fold which is attached to the posterior abdominal wall by mesorchium. It lies below the developing kidneys.
- ◆ Wolffian duct develops into epididymis and *vas deferens*. A fold of peritoneum develops at the junction of *vas deferens* and epididymis which can be traced down up to the developing phallus (scrotum) and is called as *gubernaculum*.
- ◆ Along with some hormonal factors, the muscular fibres in the gubernaculum assist in the descent of testis.
- ◆ During 9th month of gestation, testis reaches deep inguinal ring. Later, just before or after delivery it descends into the scrotum.
- ◆ Increased intra-abdominal pressure, differential growth of the abdominal wall are other mechanical factors.
- ◆ Müllerian inhibiting substance from fetal Sertoli cells; androgens and HCG are hormonal factors.

**Aetiology**

- ❖ Gubernacular dysfunction
- ❖ Lack of gonadotrophin (HCG)
- ❖ Lack of ‘*Calcitonin Gene Related Peptide (CGRP)*’ produced by genitofemoral nerve responsible for testicular descent
- ❖ *Prune-Belly syndrome*—due to weak abdominal wall
- ❖ Familial
- ❖ Retroperitoneal adhesions
- ❖ Short *vas deferens*/short testicular vessels
- ❖ Altered hypothalpituitary—gonadal axis; testosterone (androgen) deficiency; deficiency of Müllerian inhibiting substance which is secreted by fetal Sertoli cells which is essential for testicular descent—are other factors

**Incidence**

- ◆ In premature infants—30%.
- ◆ In full-term infants—4%.
- ◆ In later childhood—2%.
- ◆ Right testis alone is involved commonly in 50% cases, left alone in 30% cases, bilateral in 20% cases.

**Pathology**

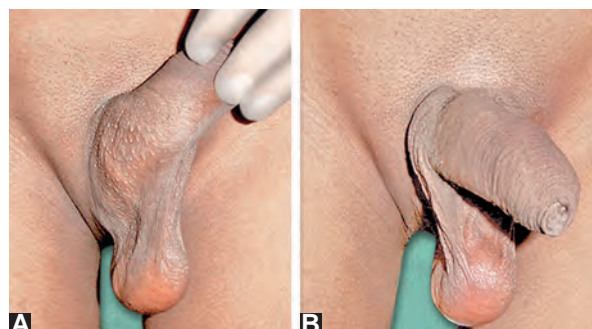
Up to the age of 6, microscopic changes are uncommon. After that, testis gradually atrophies, reduces its external as well as internal secretory activity. Eventually, grossly immature epithelial elements with irreversible destructive changes of the germinal epithelium occur.

**Different Positions**

1. In the abdomen just above the internal ring, extraperitoneally.
2. In the inguinal canal.
3. In the superficial inguinal pouch.

Bilateral undescended testes which are clinically impalpable is called as *cryptorchidism*.

- ◆ Scrotum is not fully developed and testis cannot be brought down manually to the bottom of the scrotum in undescended testis.



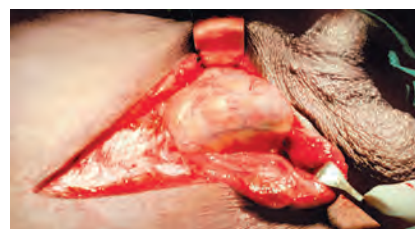**Figs 26.188A and B:** Undescended testis right-side. Inguinal region is normal without any swelling. Note the poorly developed scrotum on right side. Testis is probably intra-abdominal in this patient.

**Differential Diagnosis**

- ◆ Retractable testis.
- ◆ Other causes of groin swelling – lymph nodes, soft tissues, hernia, etc.

**Complications of Undescended Testis**

- ◆ Sterility.
- ◆ Trauma and pain.
- ◆ An associated indirect inguinal hernia (70%).
- ◆ Torsion testis.
- ◆ Epididymo-orchitis (as the pain will be high up it mimics acute appendicitis).
- ◆ Testicular atrophy.
- ◆ *Malignant transformation in undescended testis is 20 times more common than normally descended testis.*
  - ▶ It is higher in abdominal than in inguinally located testis.
  - ▶ *Seminoma* is the most common malignancy in undescended testis.
  - ▶ The testis which has normally descended on other side testis (in case of unilateral undescended testis), is also more prone for malignant transformation than normal individual.



**Fig. 26.189:** Undescended testis which has turned into seminoma testis.

### TESTIS

- ❖ Torsion
- ❖ Epididymo-orchitis
- ❖ Sterility
- ❖ Trauma
- ❖ Inguinal hernia
- ❖ Seminoma

### Investigations

- ◆ Ultrasound abdomen, intra-abdominal testis is difficult to detect in US.
- ◆ Assessment of FSH, HCG. If FSH is high in a young boy, that means there is bilateral anorchia.
- ◆ CT scan.
- ◆ Gonadal venogram.
- ◆ Laparoscopy—quite useful and therapeutic also.
- ◆ Blind ending *vas deferens* in laparoscopy is called as *vanishing testis*. It means testis is completely atrophied.

### Treatment

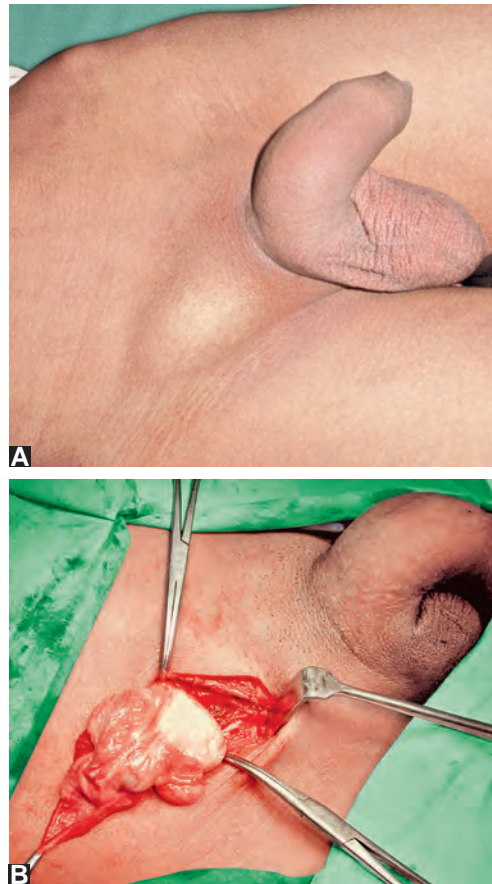
Always surgery. Surgery is done between two and four years of age.

### Principles

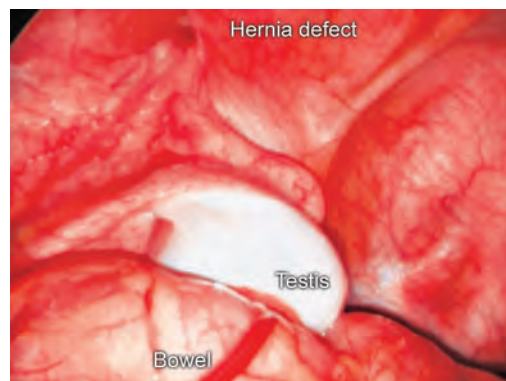- ❖ Mobilisation of cord
- ❖ Repair of associated hernia
- ❖ Adequate scrotal fixation without tension

### Mobilisation of spermatic cord:

- ◆ Inguinal canal is opened.
- ◆ Herniotomy is done as hernia is a common association.
- ◆ Inferior epigastric vessels are ligated to lengthen the cord.
- ◆ If length is still required, vas and testicular vessels are mobilised retroperitoneally.
- ◆ If further length is required, then a soft clamp is applied to the testicular artery and the viability of testis is checked. If it is viable that means it is also receiving blood supply from the artery of vas or cremaster vessels. Then testicular artery can be ligated safely so that adequate length can be achieved to bring down the testis to the scrotum—*Stephen-Fowler's technique*.
- ◆ **Proper scrotal pouch** is created by finger dissection.
- ◆ **Fixation of the testis** into the scrotum is done using nonabsorbable interrupted sutures (prolene). In bilateral cases, testis is passed into the opposite scrotum through an opening in the scrotal septum—*Ombredanne's operation*.
- ◆ If the testis is totally atrophied, *orchidectomy* should be done after taking consent, because even though this is a nonfunctioning testis, it is highly prone for malignant transformation.
- ◆ **Role of hormone therapy: Not much.** Only indications are cryptorchidism associated with hypogonadism and obesity and doubtful retractile testis. It should be given at or after the age of eight.
  - ▶ HCG (human chorionic gonadotrophin) 1000 I/U—twice weekly for maximum of 10 weeks (not more than 10 weeks). It stimulates Leydig cells to produce testosterone.
  - ▶ GnRH—1.2 mg/day as nasal spray for one month.



**Figs 26.190A and B:** Undescended testis in the inguinal region. Right-sided scrotum is underdeveloped. On table finding seen in the same patient. Hernia is the common association.



**Fig. 26.191:** Laparoscopic view of undescended testis (abdominal testis). Note the inguinal hernial defect. Laparoscopic approach is becoming popular.

### Note:

- In bilateral case surgery is done with an interval of 6 months.
- *Ladd and Gross procedure:* After placing the testis in the scrotal pouch, it is fixed by a polypropylene suture into tunica albuginea, across scrotal skin and into the thigh skin outside. This suture is removed in 14 days.
- *Keetley-Torek procedure:* Testis is mobilised and is brought into the scrotal pouch first. Then it is brought out through scrotal skin. A pouch is created on the medial aspect of the thigh outer to fascia

lata, deep to thigh skin after making skin incision. Testis delivered from scrotal pouch is placed into the thigh pouch. Scrotal and thigh incisions are sutured around the cord inside. After 6 months scrotal sac with cord and testis is separated and placed in the scrotal pouch.

- **Laparoscopic approach:** Orchidopexy has become popular and accepted method.
- Orchidopexy may not alter the chances/risk of developing carcinoma of testis. But it makes easy observation and evaluation by US to detect the possible changes early.
- Orchiectomy is considered if there is atrophy; torsion; inability to bring down abdominal testis.
- Testicular biopsy in infertility to study spermatogenesis is sent in *Bouin's fluid*—picric acid (75%); acetic acid (25%). It should not be sent in usual formalin.

**Surgeries in undescended testis**

- ❖ External anchorage—Ladd and Gross
- ❖ Ombredanne's procedure
- ❖ Denis-Browne operation—narrowing of the neck and external anchorage
- ❖ Keetley-Tosek procedure into the thigh
- ❖ Dartos pouch creation and placing the testes
- ❖ Stephen-Fowler's technique
- ❖ Silbar procedure—autotransplantation with microvascular anastomoses into inferior epigastric vessels

**ECTOPIC TESTIS**

- ◆ **Lockwood theory:** Even though there are multiple gubernaculum, scrotal tail normally gets activated better and so testis is brought down to the scrotum.
- ◆ In ectopic testis, scrotal tail weakens or ruptures and so one of the other accessory tails will act and pulls the testis in direction according to its site.

**Different sites**

- ❖ Superficial inguinal pouch
- ❖ Perineum
- ❖ Root of the penis
- ❖ Femoral triangle (thigh)

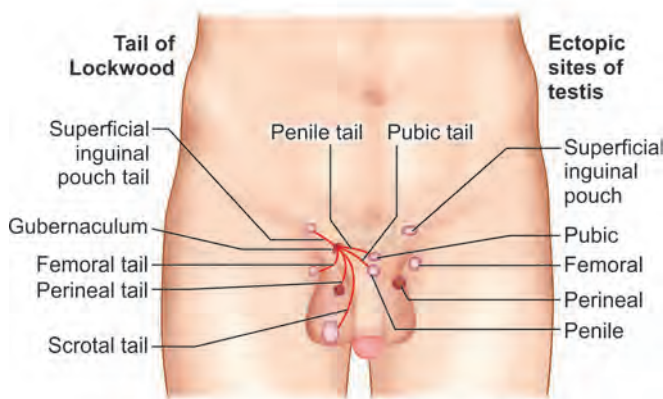


Fig. 26.192: Tails of Lockwood and ectopic testes.

- ◆ Testis, here is functioning normally and of normal size. It is more prone for trauma and can cause psychological problem.

- ◆ *Superficial inguinal pouch* is space between external oblique and Scarpa's fascia. On raising the legs, ectopic testis in superficial inguinal pouch becomes more prominent but not in case of undescended testis located in inguinal canal.

**Treatment**

- ◆ Mobilisation and creation of a new scrotal pouch.
- ◆ Then placement and fixation.

**RETRACTILE TESTIS**

- ◆ It is due to the overaction of cremaster. Testis is pulled up, to stay near the external ring and often mistaken for undescended testis.
- ◆ Here, testis is normally developed, can be pulled down to the bottom of the scrotum properly. Scrotum is also fully developed.
- ◆ Child is made to sit on a chair with feet kept on the chair; knees fully flexed and brought over to the chest wall; causing pressure on the inguinal canal downwards, pushing retractile testis down into the scrotum—*Orr Chair test*.

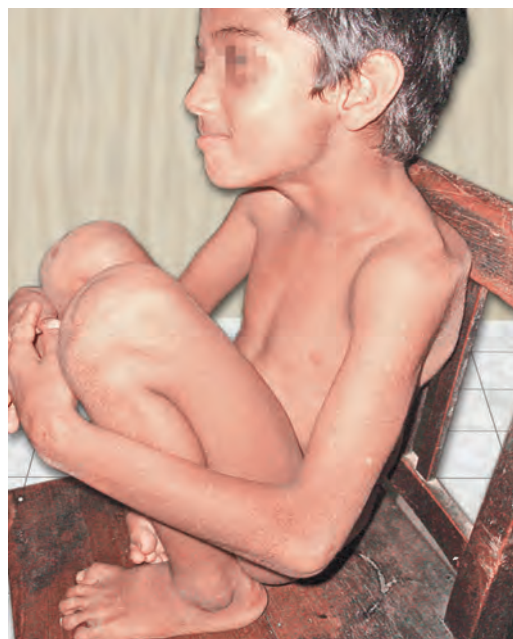

Fig. 26.193: Orr chair test.

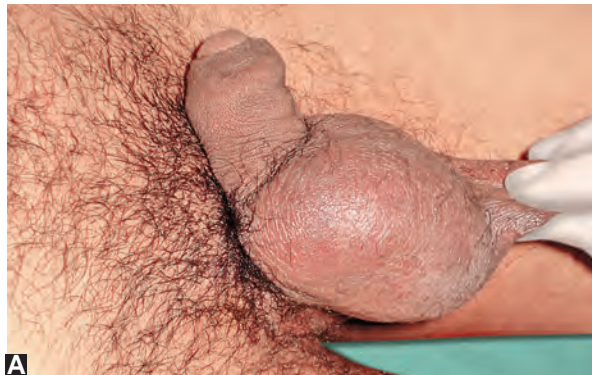- ◆ **Treatment:** Usually *no treatment* is required. Often hormone therapy is given (HCG).

**TORSION OF THE TESTIS**

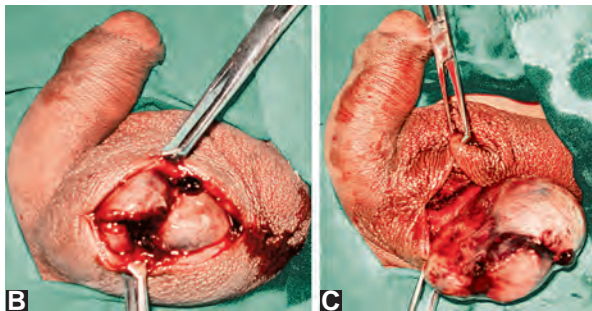
- ◆ It is an emergency condition of the testis, wherein the testis twists (rotates) in its axis compromising its blood supply. If not intervened and rectified within 12–24 hours, testicular gangrene may occur.
- ◆ Right testis rotates in clockwise direction where as left testis rotates in anticlockwise.

### Predisposing factors

- ❖ Inversion of the testis
- ❖ High investment of the tunica vaginalis which acts like a mesentery through which testis rotates. Here testis hangs like a *clapper in bell*
- ❖ Presence of gap between the body of the testis and epididymis, as a result of which testis twists over epididymis
- ❖ Heavy straining often precipitates torsion due to vigorous contraction of the cremaster which is attached spirally

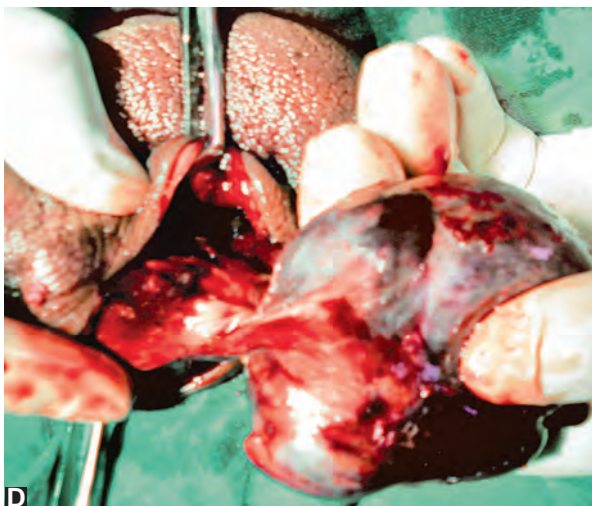


A



B

C

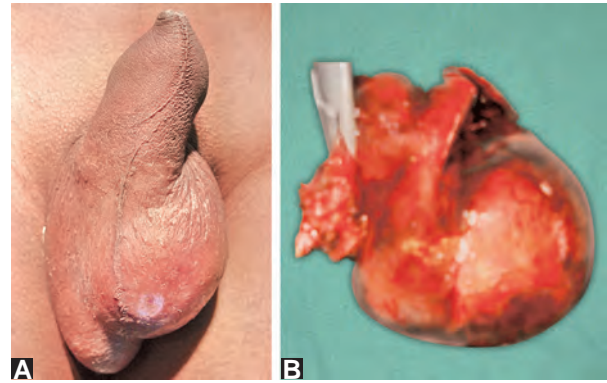


D

**Figs 26.194A to D:** Clinical look of torsion testis. On table finding showing torsion and gangrene of testis. Patient underwent orchidectomy and fixation of opposite testis.

### Clinical Features

- ◆ Occurs in children and adolescents.
- ◆ Presents with sudden onset of pain in the scrotum, groin and lower abdomen.

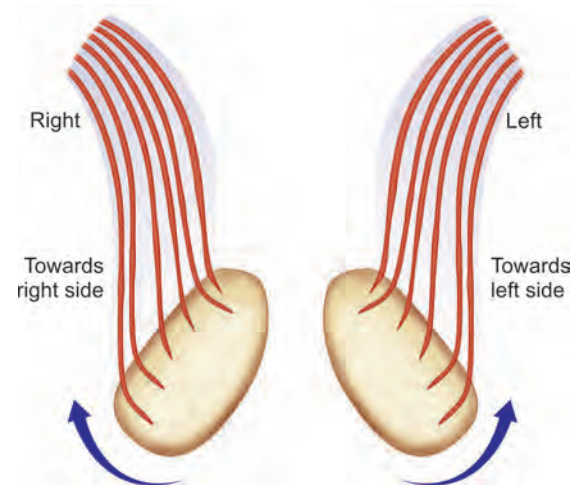


A

B

**Figs 26.195A and B:** Torsion testis left sided—clinical look. Removed orchidectomy specimen.

- ◆ Vomiting due to pylorospasm.
- ◆ Tenderness, redness and oedema of the scrotal skin.
  - ▶ *Deming's sign:* Affected testis is positioned high because of twisting of cord and spasm of cremaster muscle.
  - ▶ *Angell's sign:* Opposite testis lies horizontally because of the presence of mesorchium.



**Fig. 26.196:** Torsion testes.

### Differential Diagnosis

- ◆ *Acute epididymo-orchitis*—elevation of the scrotum for one hour, relieves the pain of acute epididymo-orchitis but aggravates in case of torsion testis (*Prehn's sign*).
- ◆ *Strangulated inguinal hernia:* Torsion of incompletely descended testis resembles strangulated inguinal hernia but the scrotum on that side is empty.
- ◆ Other structure in scrotum which can undergo torsion is '*Appendage of testis*'. If the patient is able to walk to clinician with feature of torsion, then this condition has to be thought of, whereas in torsion testis the pain is so severe that the clinician is summoned to the patient's bed.

### Investigations

- ◆ Total WBC count.
- ◆ Doppler study of scrotum to look for the testicular artery pulsation.
- ◆ Ultrasound abdomen.

## Treatment

- ◆ *Emergency exploration of the scrotum and untwisting of the torsion testis is done.* Then viability of testis is checked. Once confirmed, the testis is fixed to the scrotal sac using 2–3 interrupted nonabsorbable sutures (Prolene).
- ◆ If surgery is done within 12–24 hours, viability of the testis may be retained. If delayed, testis becomes gangrenous and *orchidectomy* is done after taking informed consent.
- ◆ *When in doubt, testis is retained and orchidectomy can be postponed to later period* so as to give a chance to have a viable testis.
- ◆ Here *early exploration is an important aspect.*
- ◆ When diagnosis is in doubt, exploration is advised.
- ◆ Postoperatively, a repeat Doppler study helps to confirm the viability. As often the condition is *bilateral, other side testis should also be fixed to prevent the torsion.*

## TESTICULAR TUMOURS

- ◆ 1% of all malignant tumours.
- ◆ 99% of testicular tumours are malignant.
- ◆ *Life time prevalence* of getting testicular tumour is 0.2%.
- ◆ *Very common* in Scandinavia; least common in Africa and Asia.
- ◆ More common in *higher socioeconomic* group.
- ◆ 4 times common in *whites* than blacks.

*Predisposing factors:* Undescended testis and testicular atrophy.

## Aetiology

- ◆ *Cryptorchidism*—it is *probably due to* abnormal germ cell agenesis, gonadal dysgenesis, rise in temperature, change in blood supply and endocrine dysfunction.
- ◆ *Klinefelter's syndrome*—testicular atrophy, absence of spermatogenesis, eunuch, gynaecomastia—features. These patients are prone to seminoma testis.
- ◆ *Testicular atrophy.*

### Classification

1. Seminoma—40%
2. Teratoma—32%
3. Seminoma + teratoma—14%
4. Interstitial tumours—1.5% [Leydig cell tumour (musculinises), Sertoli cell tumour (feminises)]
5. Lymphomas—7%
6. Others

## Histological Classification

- ◆ *Germ cell tumour (95%)*
  - ▶ Seminomatous—classic; spermatocytic; anaplastic.
  - ▶ Nonseminomatous type—embryonal carcinoma; teratomas; choriocarcinoma; yolk sac tumour (endodermal sinus tumour contains *Schiller-Duval bodies*).
- ◆ *Nongerm cell tumour (5%)*
  - ▶ *Sex cord stromal tumours*—Leydig cell tumour; Sertoli cell tumour; granulosa cell tumour.

- ▶ *Combined germ cell and gonadal stromal tumour*—gonadoblastoma.
- ▶ *Miscellaneous tumours:* Adenocarcinoma of rete testis; mesenchymal neoplasm.
- ◆ *Adnexal and paratesticular tumours*—mesothelioma; sarcomas.
- ◆ *Others*—carcinoids; lymphomas.
- ◆ *Secondaries.*

*Other classifications used* are—Dixon and Moore; WHO; British tumour panel.

## Seminoma Testis

- ◆ Starts in the mediastinum of testis and lower pole.
- ◆ Grossly it is lobulated, fleshy, homogeneous, creamy or pinkish in colour and it compresses adjacent testicular tissue.
- ◆ Histologically, malignant cells resemble spermatocytes which are cells containing clear cytoplasm with large nucleus, and are arranged in sheets with fibrous stroma in between which is in turn infiltrated by lymphocytes.
- ◆ It spreads through testicular lymphatics into the para-aortic lymph nodes and then to left supraclavicular lymph node. Through blood, it spreads to lungs, bone, brain, liver.

## Types of Seminoma

- ◆ *Typical/classic form*—it is most common type; occurs in middle age; syncytiotrophoblastic type (15%) occurs and produces high levels of beta HCG.
- ◆ *Spermatocytic seminoma*—occurs in older people with different phases of spermatogonia. Spread in this type is very rare.
- ◆ *Anaplastic type* has got high mitotic index/nuclear pleomorphism/anaplasia with high potentiality to spread.
- ◆ *Atypical form* of seminoma shows cytoplasmic expression of low molecular weight keratin type 1 precursor to blood group antigen where typical seminoma stains negative.

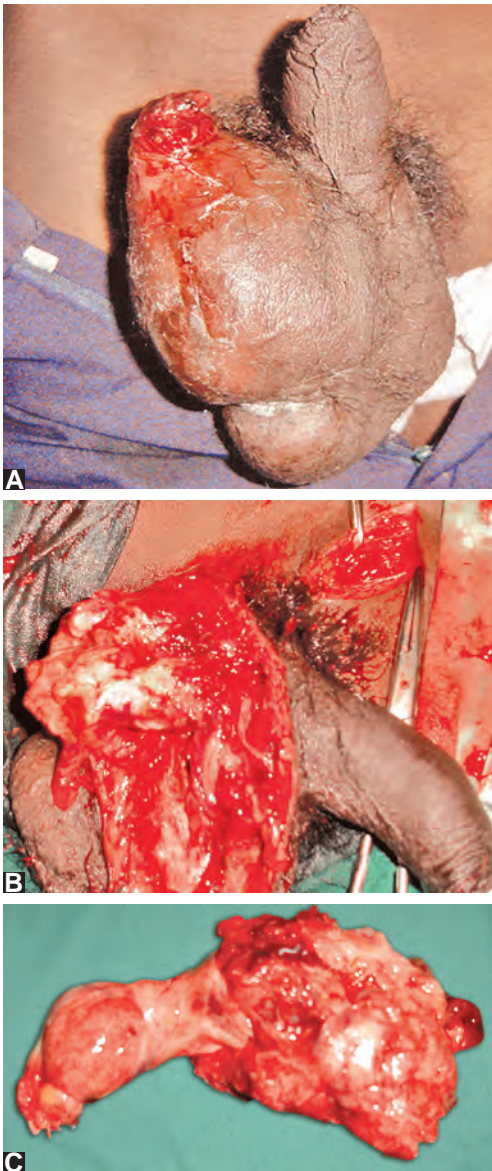
## Teratoma

- ◆ It arises from totipotent cells, i.e. ecto, meso, endoderms.
- ◆ Grossly tumour surface is irregular, cut section shows solid and cystic spaces with areas of haemorrhage. It often contains gelatinous fluid and cartilaginous nodules.
- ◆ Teratoma spreads mainly through blood, less commonly through lymphatics.
- ◆ Teratoma can be mature; immature; choriocarcinoma or mixed germ cell tumour.

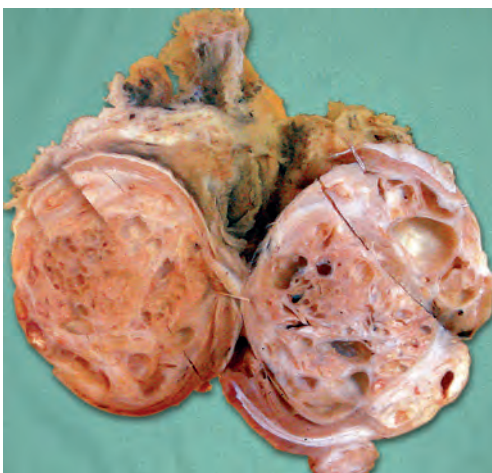
*Histologically, there are four types:*

1. *Teratoma differentiated* (1%)
2. *Teratoma intermediate* (30%) common
  - Two subtypes are A and B. Type A contains matured cells but type B is more malignant consisting of less proper differentiated tissues.
3. *Teratoma anaplastic* (15%)
  - Secretes alpha-fetoprotein (AFP)
4. *Teratoma trophoblastic* (1%)

It shows high levels of beta-HCG (normal level is 100 IU)



**Figs 26.197A to C:** Teratoma testis which is fungating through scrotal skin. On table during orchidectomy and specimen of the same.



**Fig. 26.198:** Specimen of testicular tumour. Note the cystic and solid areas of teratoma.

## Interstitial Cell Tumour

- ◆ *Leydig cell tumour* (2%): Masculinises. Prepubertal tumour shows excessive output of androgens causing sexual precocity, extreme muscular development often mimicking infant hercules. They are relatively benign, spread occurs to lymph nodes and lungs. It is treated by surgery. It is radioresistant and chemoresistant.
- ◆ *Sertoli cell tumour* (1%): Feminises. Postpubertal tumour commonly arising from Sertoli cells causes feminising effect with gynaecomastia, loss of libido and aspermia. It may be classic/large cell type; calcifying/sclerosing. Surgery is the treatment.

## Spread of Testicular Tumour

### Local

- ◆ To epididymis, cord, tunica albuginea, scrotum and so inguinal nodes.

### Lymphatic Spread

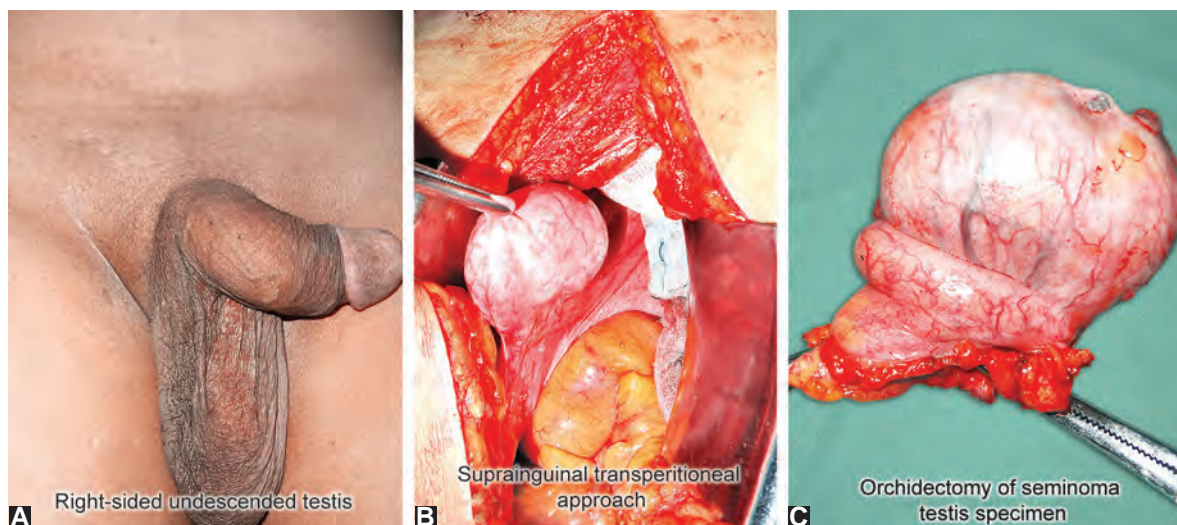
- ◆ Lymphatics drainage of testis is through its mediastinum along the gonadal vessels to para-aortic and retroperitoneal nodes. Through the lymphatics along the medial side of testis may run with the artery of vas draining into the common iliac nodes at the bifurcation of common iliac artery. Spread mainly occurs to *para-aortic*; often to retroperitoneal and common iliac nodes. Malignancy spreads to inguinal nodes, only if scrotal skin is involved.
- ◆ *Right testicular tumour* spreads to interaortocaval nodes immediately below the renal vessels as *primary landing zone* (L2 level), then to para-aortic nodes. Paracaval, preaortic, common iliac nodes are also can be involved.
- ◆ *Left testicular tumour* spreads to true para-aortic nodes to begin with just below the renal vessels; then to preaortic and common iliac nodes.
- ◆ From retroperitoneal and para-aortic nodes spread occurs to left supraclavicular nodes and posterior mediastinal nodes.
- ◆ Seminoma mainly spreads through lymphatics than teratoma.

### Extranodal Spread

- ◆ To lungs, liver, brain, bone, kidney, adrenals in frequency order.

## Clinical Features

- ◆ Enlargement of testis.
- ◆ Fullness and heaviness in the scrotum.
- ◆ Pain in the testis (30%).
- ◆ Testis is enlarged, firm, heavy, with loss of testicular sensation (*in early stage only*).
- ◆ Secondary hydrocele is common.
- ◆ Cremaster is hypertrophied and thickened.
- ◆ Vas, prostate and seminal vesicles are normal.
- ◆ Often in epigastric region para-aortic lymph nodes may be palpable as hard, nodular, nontender, nonmobile, vertically placed, resonant mass (not moving with respiration).



**Figs 26.199A to C:** Undescended testis which was in retroperitoneum which has turned into seminoma testis; orchidectomy is done through suprainguinal approach.

- ◆ Haemoptysis, altered breath sounds and pleural effusion.
- ◆ Bone pain and tenderness due to secondaries in bone.
- ◆ Nodular secondaries in the liver.
- ◆ Occasionally, it may mimic acute epididymo-orchitis or acute haematocele.
- ◆ Gynaecomastia may be present in few teratomas—5%. It is due to raised  $\beta$ -HCG.
- ◆ *Hemiscrotum* with absence of rugae with suspicious mass in the groin with suspicious mass in the groin suggests undescended testis with testicular tumour.
- ◆ 3% of testicular tumours are bilateral.
- ◆ Inguinal nodes are involved if tumour breaches the tunica albuginea to spread to scrotum; previous surgeries like testicular fixation, hernia surgery can also predispose inguinal node spread.
- ◆ CNS/spinal cord may be involved by secondaries.
- ◆ In 10% of cases it present as asymptomatic, identified incidentally.
- ◆ *Hurricane type* is very aggressive, highly malignant testicular tumour which is more often fatal in few weeks.
- ◆ Rarely, if tumour comes out of the tunica albuginea (tunica albuginea is resistant for malignant cell infiltration), then scrotum gets infiltrated and spread can occur to inguinal lymph nodes.

#### Differential diagnosis

- ❖ Acute and chronic haematocele
- ❖ Acute epididymo-orchitis
- ❖ Syphilitic orchitis
- ❖ Lepra orchitis

*Sign of vas:* To differentiate tumour from infection—in testicular tumours vas is normal, cord structures may become bulky because of cremasteric hypertrophy whereas in infection vas is thickened, beaded, tender.

#### Staging of testicular tumours (Refer Fig. 26.200)

- I. Lesion confined to testis
- II. Nodes involved below the diaphragm
- III. Nodes involved above the diaphragm
- IV. Distant (blood) spread

#### TNM staging

- T<sub>0</sub> – No evidence of tumour  
 T<sub>is</sub> – Carcinoma *in situ*  
 T<sub>1</sub> – Tumour limited to testis and epididymis. Vascular/lymphatic invasion not present. Tumour may invade tunica albuginea but not tunica vaginalis  
 T<sub>2</sub> – Tumour limited to testis and epididymis with vascular/lymphatic invasion. Or tumour extends through the tunica albuginea with involvement of tunica vaginalis  
 T<sub>3</sub> – Tumour invades to spermatic cord with or without vascular/lymphatic invasion  
 T<sub>4</sub> – Tumour invades to scrotum with or without vascular/lymphatic invasion  
 N<sub>0</sub> – Regional nodes not involved  
 N<sub>1</sub> – Single/multiple nodes—not more than 2 cm in size  
 N<sub>2</sub> – Regional nodes—between 2–5 cm  
 N<sub>3</sub> – Regional nodes >5 cm  
 M<sub>0</sub> – Distant spread not present  
 M<sub>1</sub> – Distant spread present  
 M<sub>1a</sub> – Distant spread to nonregional nodes or to lungs  
 M<sub>1b</sub> – Distant spread to other than nonregional nodes or lungs

#### Serum tumour markers (S)

- S<sub>x</sub> – Marker study not done  
 S<sub>0</sub> – Normal marker study  
 S<sub>1</sub> – LDH <1.5 × N (upper limit of normal) and HCG <5000 mIU/ml and AFP <1000 ng/ml  
 S<sub>2</sub> – LDH 1.5–10 × N or HCG 5000–50000 mIU/ml or AFP 1000–10000 ng/ml  
 S<sub>3</sub> – LDH >10 × N or HCG >50000 mIU/ml or AFP >10000 ng/ml

*In torsion testis, affected testis lies higher than its fellow.*—Clyde L Deming



### Stage groups in testicular tumour

Stage 0—Tis N0 M0 S0  
 Stage I—T1–4 N0 M0 Sx  
 Stage IA—T1 N0 M0 S0  
 Stage IB—T2–4 N0 M0 s0  
 Stage IS—Any T N0 Mo S1–3  
 Stage II—Any T N1–3 M0 Sx  
 Stage IIA—Any T N1 M0 S0–1  
 Stage IIB—Any T N2 M0 S0–1  
 Stage IIC—Any T N3 M0 S0–1  
 Stage III—Any T Any N M1 Sx  
 Stage IIIA—Any T Any N M1a S0–1; Any T N1–3 M0 S2  
 Stage IIIB—Any T Any N M1a S2; Any T N1–3 M0 S3  
 Stage IIIC—Any T Any N M1a S3; Any T Any N M1b Any S

## Investigations

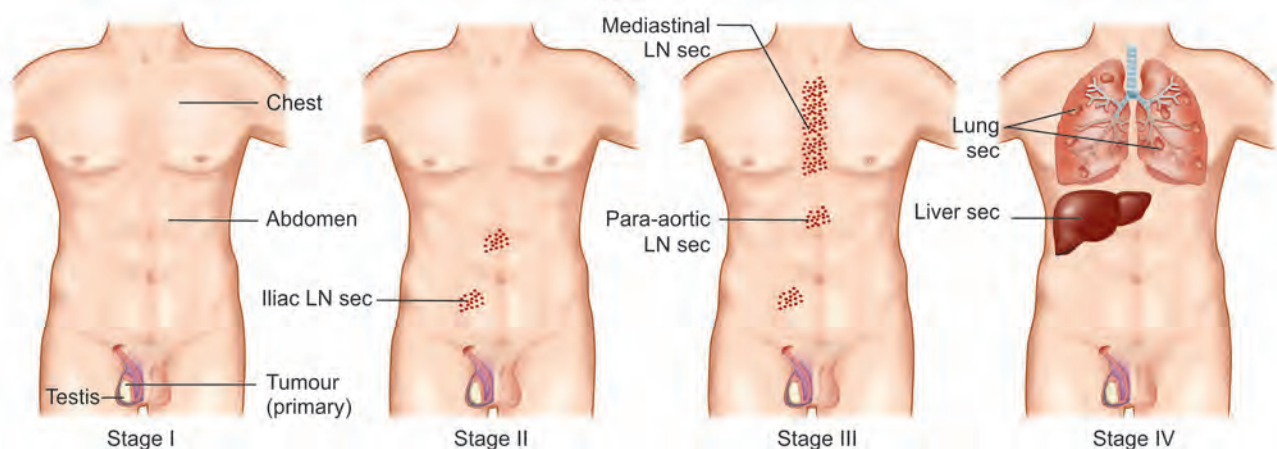
**No FNAC; No scrotal approach; No incision biopsy.**

- ◆ Through inguinal approach, cord and testis are exposed. A soft clamp is applied to the cord at or above the level of the deep ring so has to prevent dissemination through blood. Frozen section biopsy is done from the suspected area. If tumour is positive, *high orchidectomy is done (Chevassu manoeuvre)*.
- ◆ **Measurement of tumour markers ( $\beta$ -HCG, AFP, LDH).**
  - ▶ AFP and  $\beta$ -HCG are elevated in nonseminomatous germ cell tumours (teratomas)—65%.
  - ▶ Raised AFP always indicates teratomatous tumour. *AFP level increase is not seen in pure seminomas.*
  - ▶  $\beta$ -HCG may be elevated in *advanced* cases of seminomas (10%).
  - ▶ LDH level depends on growth rate/cellular proliferation/tumour burden. LDH is increased in 80% of advanced seminomas and 60% of nonseminomatous germ cell tumour.
  - ▶  $\beta$ -HCG is never found in normal individual. It is secreted by syncytiotrophoblasts. Half life is 18–36 hours. It is increased in choriocarcinoma (100%); embryonal carcinoma (65%); teratoma testis; recurrent or residual disease in testicular tumour after therapy.

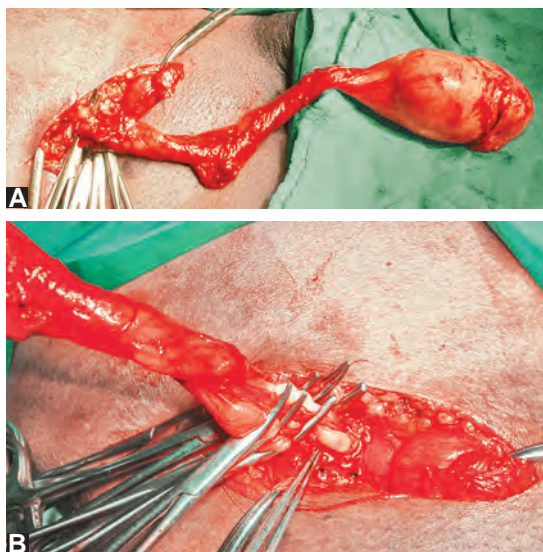
- ▶ Placental alkaline phosphatase (PLAP) is increased in seminoma.
- ◆ *Chest X-ray* to look for lung secondaries. HRCT scan is ideal.
- ◆ *Ultrasound abdomen* to see nodal status like para-aortic nodes and liver secondaries. CT abdomen is better.
- ◆ *Ultrasound scrotum* to see echogenicity of testis and tumour within.
- ◆ *CT scan abdomen* and pelvis to look for secondaries, iliac and para-aortic nodes.
- ◆ CT chest is needed to confirm lung secondaries.
- ◆ Based on presence of AFP;  $\beta$ -HCG; LDH; Nonpulmonary visceral secondaries (bone/liver/brain), germ cell tumour risk group classification is done to both seminomatous germ cell tumour (SGCT) and also to nonseminomatous germ cell tumour (NSGCT).
  - ▶ Good risk and intermediate risk group for SGCT.
  - ▶ Good risk; intermediate risk and poor risk for NSGCT.

## Treatment

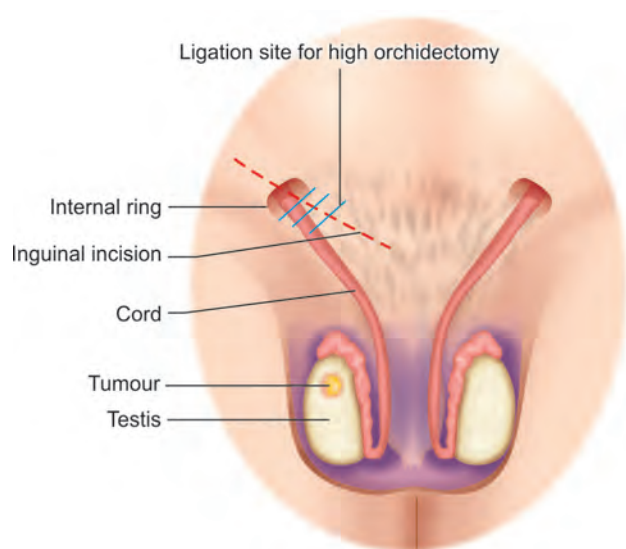
- ◆ *Seminomas* are radiosensitive. So after high orchidectomy, *radiotherapy* is given to increase the cure rate and also to reduce relapse. It is *the treatment of choice* in stage I seminomas. Opposite testis should be shielded during radiotherapy.
  - ▶ Seminomas with high levels of tumour marker are treated as nonseminomatous tumours.
  - ▶ Chemotherapy is also effective. *Cisplatin* is very useful drug in seminoma.
- ◆ *In teratoma, Retroperitoneal Radical Lymph Node Dissection (RPLND)* is beneficial after high orchidectomy. Even in stage I disease, chances of existing retroperitoneal spread is 30%. So, RPLND (infrahilar) has a major role especially in teratomas which are relatively radioresistant. It involves removal of precaval, retrocaval, paracaval, interaortocaval, retroaortic, para-aortic, common iliac nodes along with removal of gonadal vein and adjacent fibrofatty tissues from internal ring level to its insertion into renal vein on left side and inferior vena cava on right side. Commonly bilateral RPLND is done as contralateral nodes also can be



**Fig. 26.200:** Staging of testicular tumour.



**Figs 26.201A and B:** High orchidectomy showing testis with cord structures which is ligated at or above the internal ring; it is done through inguinal approach.



**Fig. 26.202:** High orchidectomy is done for testicular tumour through inguinal approach. Not through scrotal incision. Cord is ligated at the level of the internal ring.

involved. Mortality in RPLND is only 1%. RPLND may cause ejaculatory problems. Nerve sparing RPLND is ideal, if technically possible. Nerve sparing dissection is done on opposite side of the tumour. Laparoscopic RPLND is also advocated safely.

*Modified RPLND* is same side lymph node dissection both above and below the inferior mesenteric artery (IMA); opposite side dissection is limited to above the level of IMA so that sympathetic chain on opposite side is preserved to retain ejaculation.

- ▶ **Complications:** Haemorrhage; injury to main structures like major vessels/ureter/bowel; chylous ascites; lymphocele; retrograde ejaculation.
- ▶ Radiotherapy is not beneficial in teratoma.
- ▶ Chemotherapeutic drugs for teratoma are *cisplatin*, *bleomycin*, *vinblastine*, *etoposide*, *ifosfamide*, *mesna*, *paclitaxel*. BEP regimen is commonly used.

### Follow-up

- ◆ Measurement of tumour markers at regular intervals for 5 years and yearly after 5 years.
- ◆ CT abdomen and chest once a year.

### Factors Affecting the Prognosis

- ◆ Histological appearance of tumour.
- ◆ Staging of the tumour: II—90%; III—70% 5-year survival.
- ◆ Age of the patient, younger the age group poorer the prognosis.
- ◆ Seminoma has got better prognosis than teratomas.
- ◆ Spermatocytic seminoma has got good prognosis.
- ◆ Hurricane type has got worst prognosis.
- ◆ Seminoma responds well to RT (melts-like snow). Teratoma is less sensitive RT.

## ■ PARATESTICULAR TUMOURS

### Types

- ◆ Adenomatoid.
- ◆ Cystadenoma of epididymis.
- ◆ Mesenchymal neoplasms.
- ◆ Mesotheliomas.
- ◆ Metastases.

### Features

- ◆ Generally sarcomatous.
- ◆ Rhabdomyosarcoma occurs in 40% cases. Occurs during first two years of age. It can be localised or with distant spread (lungs).
- ◆ US scrotum; CT scan.
- ◆ Treatment—radical orchidectomy and chemotherapy.

## ■ ORCHITIS

- ◆ It is an inflammation of the testis. It is commonly associated with inflammation of the epididymis. Hence, called as epididymo-orchitis.
- ◆ Orchitis is due to infection through blood, lymphatics or epididymis.

### Causes

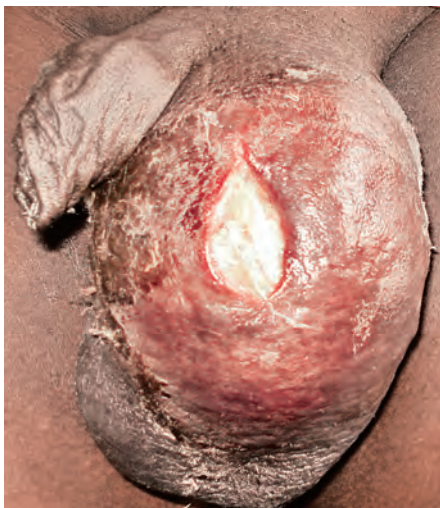- ◆ Viral infection—mumps.
- ◆ Filarial disease.
- ◆ Leprosy.
- ◆ Bacterial.
- ◆ Brucellosis.
- ◆ Infectious mononucleosis.

- ◆ It can be precipitated by retrograde spread due to stricture urethra, after prostate or bladder surgery, after instrumentation.
- ◆ Syphilis involves testis—causing formation of gummatous ulcer *on front of the scrotum*.

### Syphilitic orchitis

Syphilis involves *only testis*; never vas deferens. It can be:

- ❖ **Bilateral interstitial orchitis seen in congenital syphilis** causing *pigeon—egg testes* in infants; if infant becomes syphilitic boy, then he becomes *lame* (Clutton's joints), *deaf* (neurolabyrinthitis), *blind* (interstitial keratitis), *impotent* (atrophy of testes)
- ❖ **Interstitial fibrosis**, bilateral causing gradual destruction of the seminiferous tubules with loss of testicular sensation without any enlarged testes. Testis is dense, rounded hard and mobile—*billiard testis*'
- ❖ **Gumma of testis** is most common type of presentation with unilateral painless slowly enlarged hard testis with loss of testicular sensation. Testis is adherent to anterior part of the scrotal skin leading to softening and gummatous ulcer formation. Shotty groin, epitrochlear and popliteal lymph nodes may be palpable



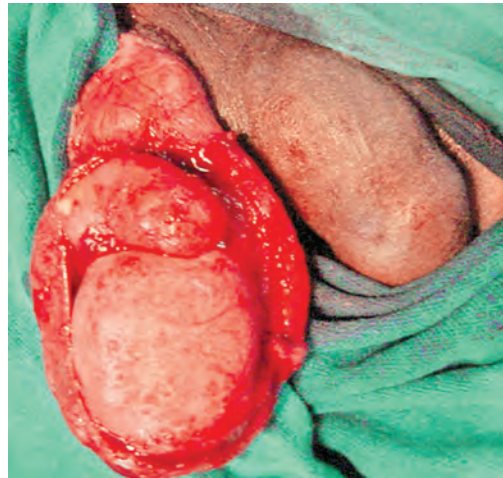**Fig. 26.203:** Ulcer scrotum—it could be nonspecific. Syphilitic ulcer develops in front (gumma); but nowadays it is very rare.

### Features

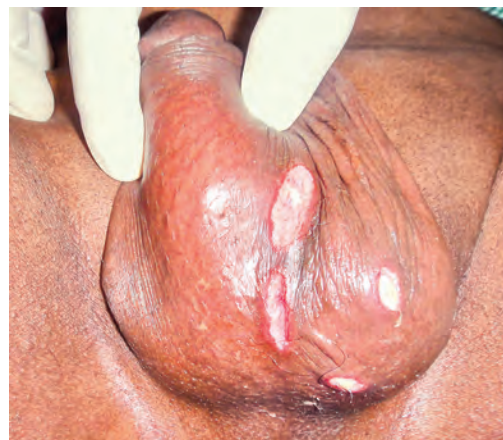- ◆ Pain in the testis often radiates into groin due to associated funiculitis.
- ◆ Fever, tenderness in the testis.
- ◆ Secondary hydrocele is common.
- ◆ Urinary infection often noticed.
- ◆ **Differential diagnosis:**
  - ▶ Torsion testis.
  - ▶ Testicular tumour.
- ◆ **Treatment:**
  - ▶ Antibiotics, analgesics, DEC.
  - ▶ Treating the cause.

## ■ EPIDIDYMITIS

Inflammation of epididymis is commonly associated with orchitis—*epididymo-orchitis*.



**Fig. 26.204:** On table operated hydrocele case—showing thickened epididymis.



**Fig. 26.205:** Tuberculous epididymitis presenting as multiple ulcers on the posterior aspect.

### Causes

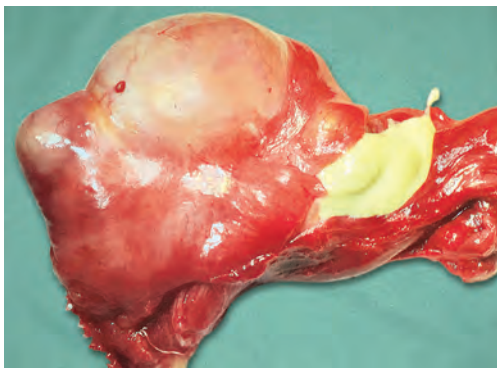
- ◆ Nonspecific, viral like mumps.
- ◆ Bacterial.
- ◆ Filarial.
- ◆ **Tuberculosis:** It involves mainly epididymis not testis and so ulcer/sinus occurs over *the posterior aspect of the scrotum not in front*.
- ◆ Gonococcal.
- ◆ Schistosomiasis.  
It can be acute or chronic.

### Features

- ◆ Pain and tenderness in the epididymis.
- ◆ Swollen, tender epididymis.
- ◆ Thickened epididymis.
- ◆ Often secondary hydrocele may be present.
- ◆ Beaded vas with craggy epididymis—in *tuberculosis*.

### Treatment

- ◆ Analgesics, antibiotics, diethyl carbamazine citrate (DEC) 100 mg for 3 weeks.



**Fig. 26.206:** Tuberculous epididymitis.

- ◆ Specific cause should be ruled out.
- ◆ Long-term epididymitis causes real psychological disturbance to the patient and so reassurance is required.

#### Tuberculous epididymitis

- ❖ It is commonly due to retrograde spread from tuberculous cystitis. It involves globus minor (tail) first and later entire epididymis and testis is involved in late stage. Blood spread from lungs directly involves globus major first. Thickened, craggy, firm nodular epididymis is common.
- ❖ Cold abscess, sinus or undermined ulcer may be present on the posterior aspect of the scrotum. Lesion will be on the anterior aspect in anteverted testis. Scrotal skin loses its normal rugosity with wasting of the tissue under the skin.
- ❖ There is restricted mobility (upward and downward) of testis. Thickened beaded vas (due to tubercles) is typical.
- ❖ Secondary hydrocele develops in 30% cases. 60% will be having renal tuberculosis.
- ❖ Digital examination of rectum (P/R) shows tender thickened palpable seminal vesicles and irregular prostate.
- ❖ Pulmonary tuberculosis is evident in 50% of cases.

*The young patient is asked to sit on a chair and hug his knees to the chest. Pressure then directed on the inguinal canal causes a retractile testis to descend into the scrotum.*

— Louis Orr

# Chapter 27

## Neurosurgery

### CHAPTER OUTLINE

- ❖ Head Injuries
- ❖ Extradural Haematoma
- ❖ Subdural Haematoma
- ❖ Subarachnoid Haemorrhage
- ❖ Fracture Skull
- ❖ Depressed Skull Fracture
- ❖ CSF Rhinorrhoea
- ❖ Hydrocephalus
- ❖ Intracranial Abscess
- ❖ Intracranial Aneurysms
- ❖ Intracranial Tumours
- ❖ Pituitary Tumours
- ❖ Craniopharyngiomas
- ❖ Spinal Dysraphism
- ❖ Meningocele
- ❖ Spina Bifida
- ❖ Intervertebral Disc Prolapse
- ❖ Tuberculosis of Spine
- ❖ Spinal Tumours

### HEAD INJURIES

*Now as soon as thou findest that smash which is in his skull like those corrugations which form on molten copper, (and) something therein throbbing and fluttering under thy fingers like the weak place of an infant's crown before it knits together-when it has happened there is no throbbing and fluttering under thy fingers, until the brain of his (the patient's) skull is rent open- (and) he discharges blood from both his nostrils and both his ears, (and) he suffers stiffness in his neck.*

— (Anonymous), circa 2500 BC

Head injuries are one of the *common causes of death* in road traffic accidents. Young males are commonly affected.

It can be *open or closed injuries* depending on whether there is fracture skull with meningeal injuries causing *CSF leak or not*. CSF (Cerebrospinal fluid) can leak through scalp wound or through ear or nose depending on site of injury. Open injury has more risk of intracranial infection including meningitis. In closed head injury CSF leak is not present. Otherwise both are equally dangerous depending on the extent of intracranial injury. *Intracranial haematomas/haemorrhages* can be extradural or subdural or intracerebral or subarachnoid.

*Scalp injury* can be incised/lacerated/multiple/or scalp avulsion or degloving. Blood vessels in the scalp are attached to galea and so once galeal aponeurosis disrupts profuse bleeding from the scalp is common. Fracture skull can occur at various bones which may be indirect evidence about the extent, type and side of intracranial injury. Scalp should be sutured including galea as interrupted sutures. Bleeding can be controlled by catching galea using series of arteries. Loss of scalp skin with periosteum of the skull bone is difficult to

manage which may require creation of multiple perforations on the outer table of the skull to facilitate the formation of adequate granulation tissue over which skin grafting can be done at a later ideal period.

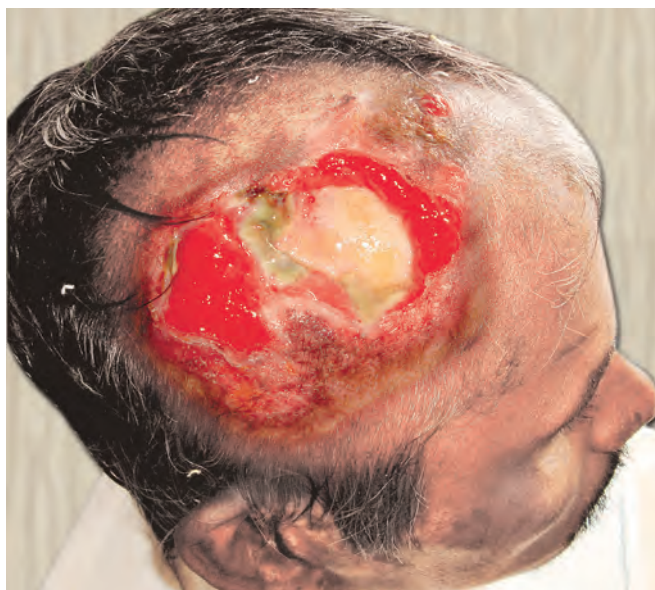*Injuries can be blunt or sharp (heavy) or missile injuries.*

*Complicated head injury* is one which shows life-threatening secondary changes; whereas *uncomplicated head injury* does not show life-threatening secondary changes but should be observed for.

Features of *malignant cerebral oedema* wherein it shows diffuse cerebral oedema with intracranial hypertension (ICP). It has got high mortality (>90%). It is treated by steroids, mannitol, ventilator support and symptomatic management including prevention of sepsis.

### Mechanism

- ◆ *Distortion of the brain:* Brain is a soft structure, therefore has a 'mobility' and readily distorts. This distortion and mobility is accentuated by CSF and vascular components. Any impact creates shearing forces in the brain causing damage to neurons, supporting tissues and blood vessels. This leads to loss of consciousness, focal neurological deficits. Such distortive damage may be temporary or permanent.
- ◆ *Mobility of the brain in relation to the skull and membranes* causes cerebral damage and bleeding in dural spaces from torn vessels in the dura, commonly the veins. In old age, the brain shrinks, as a result of which 'mobility' of brain increases favouring rupture of veins which cross the subdural space.
- ◆ *Configuration of interior of skull:* Damage is less severe over the smooth area but is more severe over the rough and sharp areas. So the damage is severe over the anterior cranial fossa, over the falx, and over the tentorium.



**Fig. 27.1:** Exposed skull after trauma with sepsis. It needs multiple burr holes to allow granulation tissue formation from depth. Later skin grafting can be done. Otherwise local rotation flap is needed.

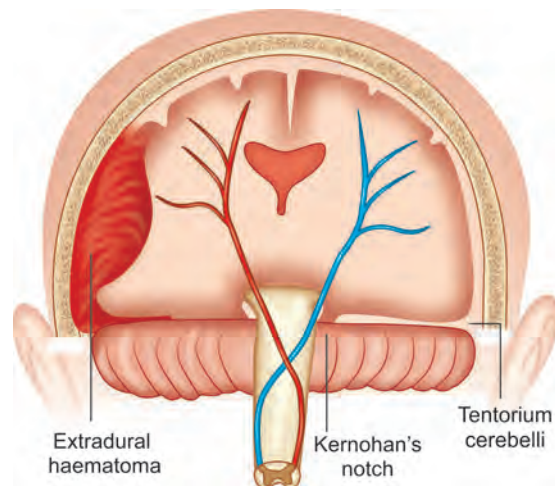
- ◆ *Deceleration and acceleration injuries:* *Deceleration injuries* occur when moving head strikes an immovable object (like in road traffic accidents). *Acceleration injuries* occur when stationary skull is struck by a moving object (like in assault).
- ◆ *Cerebral concussion* is slight distortion causing temporary physiological changes leading to transient loss of consciousness with complete recovery.
- ◆ *Cerebral contusion* is more severe degree of damage with bruising and cerebral oedema leading to diffuse or localised changes.
- ◆ *Cerebral laceration* is tearing of brain surface with collection of blood in different spaces and with displacement of dural parts.

### Effects of Brain Injuries

- ◆ *Brain oedema* is accumulation of fluid, both intracellular and extracellular. It is due to congestion and dilatation of blood vessels. It may be diffuse or localised.
- ◆ *Brain necrosis* is of severe variety with destruction and is due to haemorrhagic infarction.
- ◆ *Extradural haematoma* occurs usually in temporoparietal region. It is commonly due to tear in middle meningeal veins and often middle meningeal artery. It causes intracranial hypertension, displacement, Kernohan's effect and often death.
- ◆ *Subdural haematoma* is due to tear of veins between cerebrum and dura due to shearing forces. It is diffuse and commonly associated with cerebral injury.
- ◆ *Intracerebral haematoma* can occur in different parts of cerebrum may be in frontal lobe, temporal lobe.
- ◆ *Intraventricular haemorrhage* is very severe type of haemorrhage.
- ◆ *Brain ischaemia* is due to increased pressure. This in turn leads to alteration in the perfusion of brain which itself aggravates the ischaemia and this forms a vicious cycle, causing progressive diffuse ischaemia of brain.
- ◆ *Coup injury* occurs on the side of the blow to the head. *Contre-coup injury* occurs on the side opposite to the blow on the head.

- ◆ *Coning:* It is due to raise in intracranial pressure causing either:
  - i. Herniation of contents of supratentorial compartment through the *tentorial hiatus* or
  - ii. Herniation of the contents of infratentorial compartment through the *foramen magnum*.

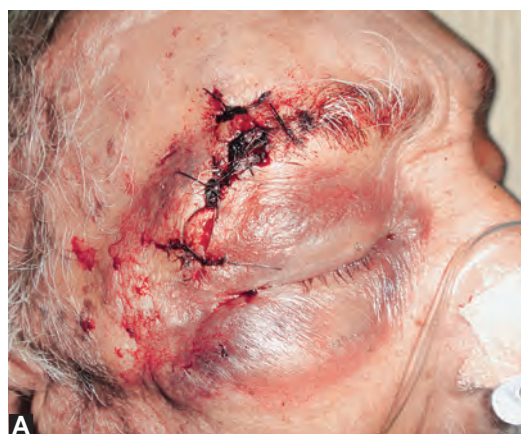In supratentorial herniation, there is compression of ipsilateral third cranial nerve and midbrain. Midbrain is displaced away from the mass (haematoma) and midbrain is pressed by the sharp edge of tentorium cerebelli of opposite side leading to dysfunction of corticospinal fibres (which after decussation supplies the opposite side of the body, i.e. same side of the injury).



**Fig. 27.2:** Coning with Kernohan's notch.

This leads to:

- a. Deterioration in the level of consciousness.
  - b. Dilatation of pupil on the side of compressing mass (haematoma).
  - c. Hemiparesis on the same side of the mass lesion (haematoma) due to compression of the contralateral corticospinal tract. This effect is called as "**Kernohan's notch**".
- Herniation of infratentorial contents through the foramen magnum causes obstruction of cerebral aqueduct which further damages the brain function.
- ◆ *Respiratory failure* altering  $PO_2$  and  $PCO_2$  levels.



**Fig. 27.3A**

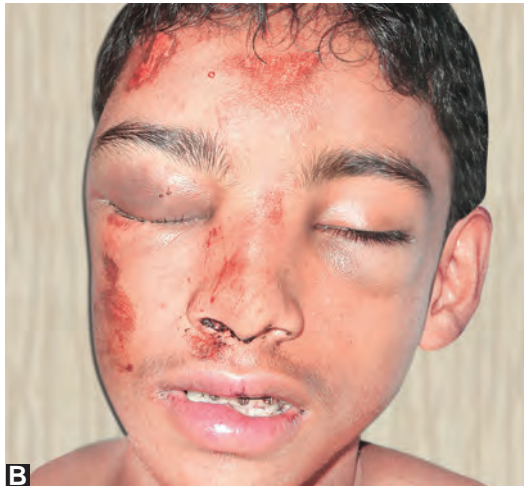

Fig. 27.3B

Figs 27.3A and B: Black eye in two different patients.

- ◆ *Raised intracranial pressure* causing bradycardia, hypertension, vomiting. Raised intracranial pressure may precipitate coning and thus aggravates brain ischaemia.
- ◆ *Fluid and electrolyte imbalance.*
- ◆ *Hyperpyrexia.*
- ◆ *Convulsions* due to irritation of grey matter.
- ◆ *CSF rhinorrhoea or CSF otorrhoea.*

### Pathology of Head Injury

Primary lesions	Secondary lesions
<ul style="list-style-type: none"> <li>• Diffuse neuronal damage</li> <li>• Shearing lesions</li> <li>• Contusions</li> <li>• Lacerations</li> </ul>	<ul style="list-style-type: none"> <li>Brain swelling</li> <li>• Oedema, venous congestion, hypoxia</li> <li>Intracranial haemorrhage</li> <li>• Extradural</li> <li>• Subdural</li> <li>• Intracerebral</li> <li>Infections</li> <li>• Open head injury               <ul style="list-style-type: none"> <li>– Generalised meningitis</li> <li>– Subdural empyema</li> </ul> </li> <li>• Closed head injury               <ul style="list-style-type: none"> <li>– Pott's puffy tumour</li> </ul> </li> </ul>
Cerebral concussion	Cause of death in head injury
<ul style="list-style-type: none"> <li>• Temporary physiological paralysis of nervous system</li> <li>• Loss of consciousness</li> <li>• Post-traumatic amnesia</li> <li>• Full recovery is expected</li> <li>• Residual complications may develop</li> </ul>	<ul style="list-style-type: none"> <li>• Brain hypoxia</li> <li>• Coning</li> <li>• Diffuse severe irreversible neuronal injury</li> <li>• Death may be due to other injuries like abdominal/thoracic</li> <li>• Metabolic changes</li> <li>• Aspiration in unconscious patient</li> </ul>

#### Other features

- ❖ CSF leak or bleeding from nose
- ❖ Blood collection in the orbit
- ❖ Black eye
- ❖ *Battle's sign*—ecchymosis over the mastoid
- ❖ Haematoma of scalp
- ❖ *Panda sign*—bilateral black eye

### Clinical Approach of a Patient with Head Injury

1. Detail history of injury has to be taken and also the process of deterioration—rapid or gradual.
2. History of alcohol intake: Alcohol intake mimics head injury and alcoholism itself may mask the features of head injury.
3. *Neurological assessment:* By

- ❖ Level of consciousness
- ❖ Glasgow coma scale
- ❖ Pupillary reaction to light and size
- ❖ Pulse
- ❖ Temperature
- ❖ Blood pressure
- ❖ Respiratory rate
- ❖ Reflexes
- ❖ Limb movements—normal/mild weakness/ severe weakness/ spastic flexion/extension/no response

4. Status and protection of airway.
5. General assessment and other injuries like fractures, abdominal organ injuries, thoracic injuries are looked for.
6. Presence of any scalp haematoma, fractures of skull bone which may be depressed has to be looked for.
7. Any blood from nose or ear, CSF rhinorrhoea or CSF otorrhoea has to be looked for.

### Indications for Hospitalisation

- ❖ Any altered level of consciousness
- ❖ Skull fracture
- ❖ Focal neurological features
- ❖ Persistent headache, vomiting, systolic hypertension, bradycardia
- ❖ Alcohol intoxication
- ❖ Bleeding from ear or nose
- ❖ Associated injuries

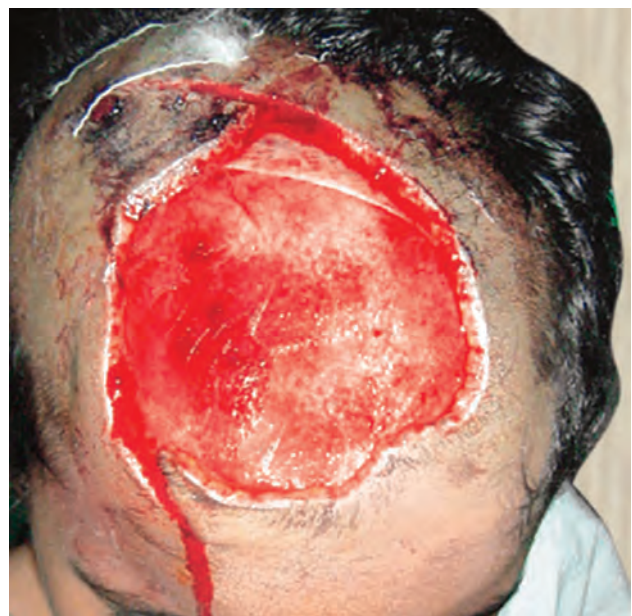

Fig. 27.4: Degloving injury scalp. Note all layers of the scalp stripped off.

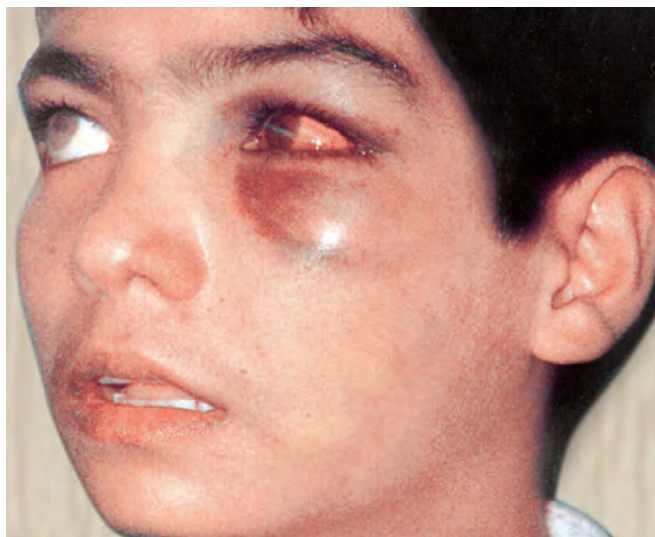

Fig. 27.5: Patient with head injury having black eye.

#### Adelaide coma scale

It is used in children

Scores for eye opening and motor responses are same as Glasgow coma scale

But *verbal response score differs*—Oriented-5. Words-4. Vocal sounds-3. Cries-2. Nil-1

*Orientation cannot be evaluated below 5 years. For first 6 months, the best verbal response is CRY*

#### Investigations

- ◆ X-ray skull: To look for fracture, relative position of the calcified pineal gland, presence of intracranial air.
- ◆ Serum electrolyte measurement.
- ◆ Blood grouping and cross matching.
- ◆ CT scan: Plain (not contrast) to look for cerebral oedema, haematomas, midline shift, fractures, ventricles, brainstem injury.
- ◆ Carotid arteriography.
- ◆ Investigations for other injuries like ultrasound of abdomen.
- ◆ Monitoring of intracranial pressure.

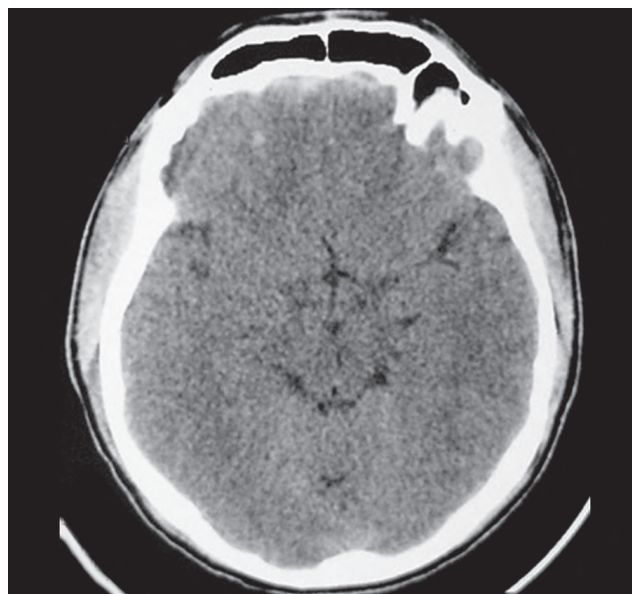


Fig. 27.6: CT scan head showing scalp haematoma on both sides. There is no internal injury.

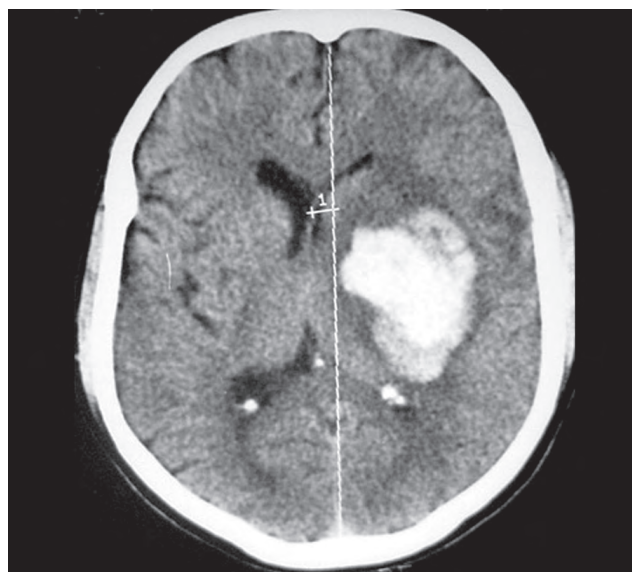


Fig. 27.7: CT scan head showing intracerebral haematoma.

#### Glasgow coma scale

Eye opening		Verbal response		Motor response	
Spontaneous	–4	Oriented	–5	Obeys commands	–6
To speech	–3	Confused	–4	Localises pain	–5
To pain	–2	Inappropriate words	–3	Flexion to pain	–4
None	–1	Incomprehensible words	–2	Abnormal flexion	–3
		None	–1	Extension to pain	–2
				None	–1

Total score: 15

Mild head injury: score 13–15

Moderate head injury: 9–12

Severe head injury: less than 8 (3–8)



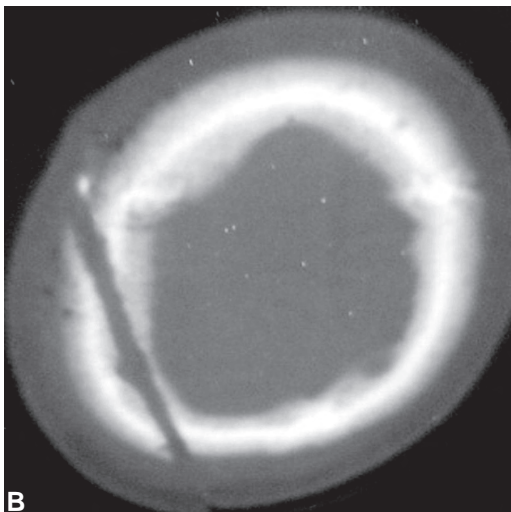
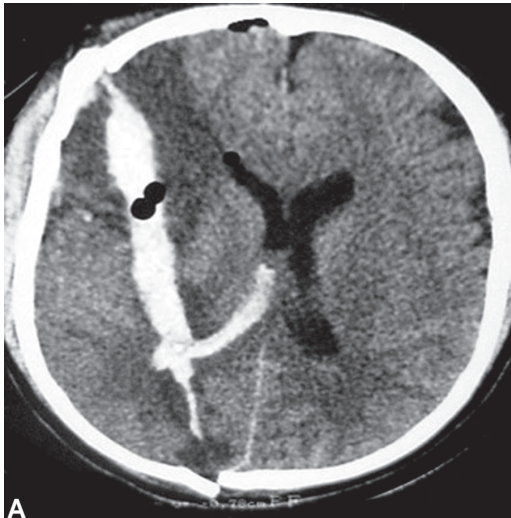
## Treatment

### General

- ◆ Protection of airway using mouth gag, endotracheal intubation or tracheostomy, whenever required.
- ◆ Throat suction, bladder and bowel care and good nursing are very essential.
- ◆ Nasal oxygen, or often ventilator support.
- ◆ IV fluids initially, later Ryle's tube feeding has to be done.
- ◆ Electrolyte maintenance.

### Drugs

- ◆ Sedation is avoided.
- ◆ Analgesics and anticonvulsants like phenytoin or phenobarbitone is started.
- ◆ Diuretics are given to reduce cerebral oedema—either mannitol 20%, 200 ml IV 8th hourly or frusemide 40 mg IV 8th hourly. It should not be given in case of intracranial haematoma.
- ◆ Antibiotics like penicillins, ampicillins are given to prevent the onset of meningitis.



**Figs 27.8A and B:** CT scan head showing sharp head injury causing through and through cut across skull and brain. Patient survived and went home.

- ◆ Corticosteroids, either dexamethasone or betamethasone is used commonly, but its beneficial effect is not confirmed.

### Indications for surgery

- ▶ Acute extradural haematoma.
- ▶ Acute subdural haematoma.
- ▶ Depressed skull fracture.

## Procedure

Craniotomy is done and cranial flap is raised. Clot is evacuated followed by applying *hitch stitches* between dural layer and scalp. Postoperative antibiotics, analgesics, anticonvulsants are given.

## Complications of Head Injuries

### Early

- ◆ Brainstem injury—due to coning.
- ◆ Compression over cerebellum and medulla.
- ◆ **CSF rhinorrhoea:** Due to communication between intracranial cavity and the nose. There is a tear in the dura following the fracture involving the sinuses—frontal, ethmoid, sphenoid sinuses. Meningitis is the common complication of CSF rhinorrhoea.

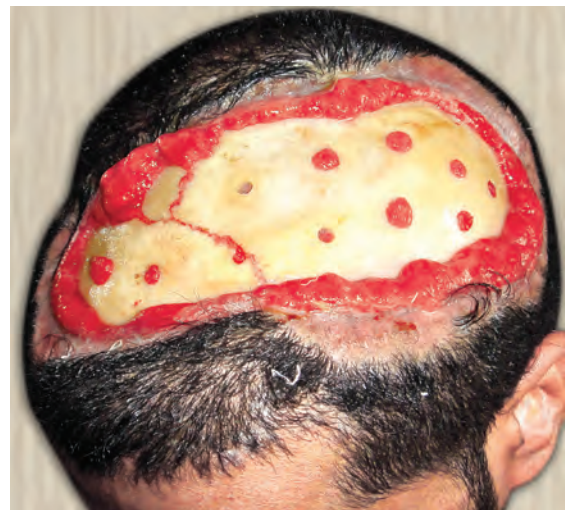*Treatment:* Initial management is only conservative, for 10 days—by antibiotics and observations.

### Indications for surgical intervention

- ❖ Fracture of middle third face
- ❖ CSF rhinorrhoea persisting for more than 10 days
- ❖ Fracture of sinuses
- ❖ An aerocele
- ❖ An attack of meningitis

### Surgeries:

- i. Reduction of fracture of middle third face.
  - ii. Exploration of anterior cranial fossa.
- ◆ Meningitis—common.
  - ◆ Pituitary damage and endocrine failure—requires high dose of hydrocortisone 200 mg, 6th hourly.
  - ◆ Aerocele.
  - ◆ CSF otorrhoea.



**Fig. 27.9:** Multiple burr holes done to promote formation of granulation tissue from vascular diploe of the skull. Once granulation tissue covers the entire defect, skin grafting can be done.

- ◆ Depressed fractures, often causes injury to dural venous sinuses and may lead to torrential haemorrhage, which may be life threatening. So such depressed fractures should never be elevated.

### Late

- ◆ Chronic subdural haematoma.
- ◆ Early post-traumatic epilepsy—they need anticonvulsants for 3 years.
- ◆ Late post-traumatic epilepsy is due to scarring and gliosis of cerebrum.
- ◆ Post-traumatic amnesia.
- ◆ Post-traumatic hydrocephalus.
- ◆ Post-traumatic headache.

## EXTRADURAL HAEMATOMA

- ◆ It is collection of blood in the extradural space between the dura and skull.
- ◆ Most common site is *temporoparietal* region. It can be *unilateral or bilateral*.

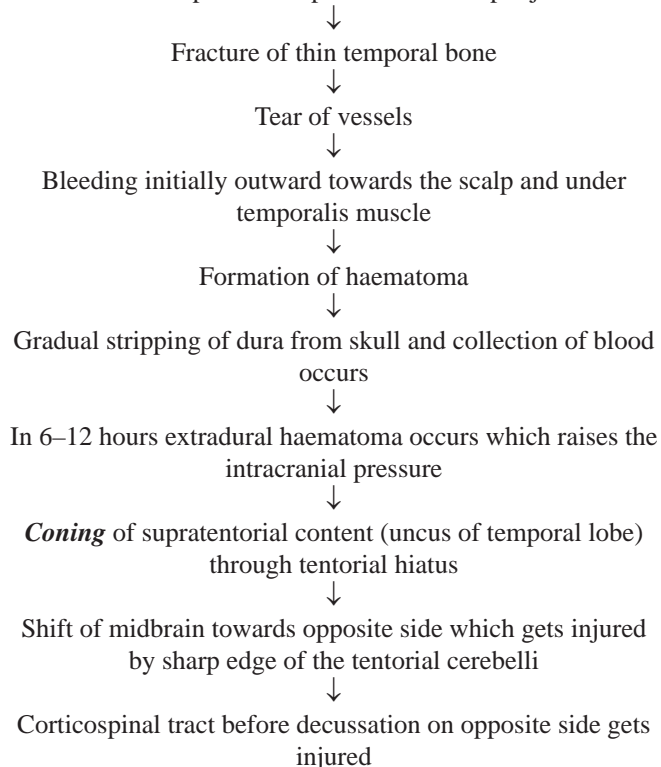
### Vessels commonly involved

- ❖ Middle meningeal veins
- ❖ Anterior branch of middle meningeal artery
- ❖ Posterior branch of middle meningeal artery

Usually, it is associated with fracture of temporoparietal region.

### Pathology

Direct blow, like from cricket ball or road traffic accidents or fall and impact or coup and contre-coup injuries



↓

So hemiparesis, and pupillary changes occur on the same side of haematoma

↓

This effect is called as **Kernohan's notch effect**.

- ◆ Immediately after injury, there is transient loss of consciousness and the patient soon becomes normal. Later after 6–12 hours, he again falls ill and the condition deteriorates. This is the time taken to develop raised intracranial pressure, coning and its effects. This crucial time gap which is unnoticed and often missed is called as "**lucid interval**".

### Clinical Features

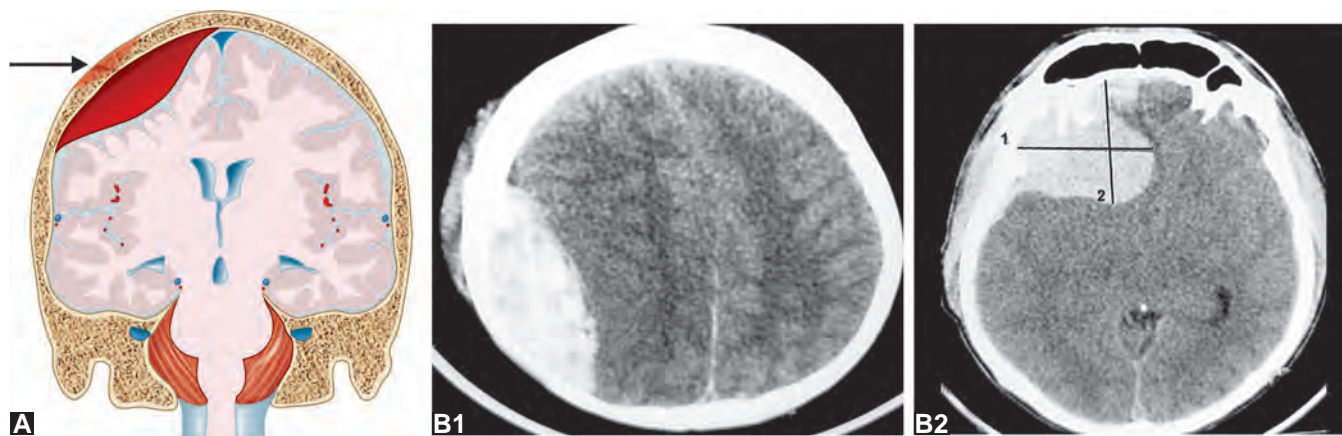
- ◆ History of transient loss of consciousness following a history of blow or fall.
- ◆ Patient soon regains consciousness and again after 6–12 hour starts deteriorating (**Lucid interval**).
- ◆ Later the patient presents with confusion, irritability, drowsiness, hemiparesis on same side of the injury. Initially pupillary constriction and later pupillary dilatation occurs on the same side, finally becomes totally unconscious—*Hutchinsonian pupils*. Initial pupillary constriction is due to irritation of the ipsilateral 3rd cranial nerve (*oculomotor*) by the herniation of the temporal lobe at the tentorial hiatus. But eventually pupillary dilatation occurs by constrictor paralysis due to persistent compression of ipsilateral 3rd cranial nerve. There is ischaemia of the nucleus of 3rd nerve at midbrain due to compression of the posterior cerebral artery. So burr hole decompression is done on the side of *Hutchinsonian pupil*.
- ◆ Death can occur if immediate surgical intervention is not done.
- ◆ *Features of raised intracranial pressure* like high blood pressure, bradycardia, vomiting is also seen. Occasionally, *convulsions* may be present.
- ◆ *Wound and haematoma in the temporal region of scalp* may be seen.
- ◆ *Glasgow coma scale* gives clear idea about the neuronal injury.
- ◆ Autonomic disturbances with bradycardia, systolic hypertension, deep, slow respiration and later Cheyne Stokes ventilation. *Cushing's triad of raised intracranial pressure* is obvious—bradycardia; hypertension; respiratory irregularities.
- ◆ Features like—restlessness, irritability, headache, vomiting, progressive deterioration—are common.

### Investigations

- ◆ X-ray skull may show fracture of temporal bone.
- ◆ Electrolyte estimation.
- ◆ CT scan head is diagnostic. Extradural haematoma shows *biconvex* lesion.

*Fourth nerve when paralysed causes diplopia when going downstairs (that is on looking downwards).*

—Sir Benjamin W Ryeroff



**Figs 27.10A and B:** (A) Extradural haematoma. Note the biconvex configuration of the haematoma; (B1 and B2) CT scan head showing extradural haematoma with biconvex lesion.

## Treatment

**Immediate surgical intervention is a must to save the life of the patient.**

- ❖ Craniotomy is done and cranial flaps are raised. The dura is not opened and the clot is evacuated. The dura is fixed to galea using interrupted sutures—*Hitch stitches*.
- ❖ Antibiotics and anticonvulsants are given postoperatively.
- ❖ Recovery is good after surgery.

### Treatment of extradural haematoma

- ❖ Earliest surgery and evacuation is the need
- ❖ 5 cm vertical incision in parietal region above the zygoma
- ❖ Galea is incised. Skull is opened using perforator and burr
- ❖ Meninges are kept aside
- ❖ *Black currant jelly clot* is evacuated
- ❖ Bleeding vessels are cauterized—bipolar cautery
- ❖ Dural hitch stitches are placed
- ❖ Opposite side if needed should be evacuated
- ❖ Antibiotics; anticonvulsants
- ❖ Analgesics
- ❖ General measures—catheter; fluid therapy
- ❖ Prevention post-traumatic complications

### Complications

- ❖ Post-traumatic epilepsy
- ❖ Meningitis
- ❖ Post-traumatic amnesia

## SUBDURAL HAEMATOMA

### Types

- ❖ Acute
- ❖ Chronic

#### Acute Subdural Haematoma

- ❖ It is a collection of blood between the brain and dura. It is due to injury to the cortical veins and often due to laceration

of cortex of brain which bleeds and blood gets collected in the subdural space forming a haematoma.

- ❖ Here haematoma is extensive and diffuse. There is no lucid interval. There is severe primary brain damage.
- ❖ Haematoma may be of coup and contre-coup type.
- ❖ Loss of consciousness occurs immediately after trauma and is progressive.
- ❖ Convulsion is common.
- ❖ Features of raised intracranial pressure is obviously seen—high BP, bradycardia, vomiting.
- ❖ Focal neurological deficits or hemiparesis can occur.
- ❖ CT scan shows concavo-convex lesion.

#### Treatment

- ❖ Antibiotics, anticonvulsants.
- ❖ *Surgical decompression is done by craniotomy.*

#### Chronic Subdural Haematoma

- ❖ It is due to the rupture of veins between dura and brain (cerebral hemispheres), causing gradual collection of blood in subdural space.
- ❖ It is commonly seen in elderly people following any minor trauma like fall, slipping (which might have gone unnoticed).
- ❖ In elderly people, brain atrophies and even minor injuries can cause shearing and bleeding from these veins.
- ❖ Blood collects gradually over 2–6 weeks. Plasma and cellular components get separated. Eventually cellular part gets absorbed leaving only fluid component. It is called as *chronic subdural hygroma*.
- ❖ Usual haematoma collection is 60–120 ml. Often in 50% of cases, it is bilateral.

#### Clinical Features

- ❖ Common in old age, with history of minor trauma.
- ❖ Patient presents with confusion, disorientation, gradually with altered level of consciousness and drowsiness.

- ◆ Later convulsions, features of intracranial hypertension, features of coning develops.
- ◆ Extensor plantar response and pupillary changes develop eventually.

### Investigations

- ◆ CT scan (shows *concavo-convex* lesion).
- ◆ Serum electrolytes.
- ◆ Blood grouping and cross matching.

### Differential Diagnosis

- ◆ Electrolyte imbalance.
- ◆ Intracranial space occupying lesion.

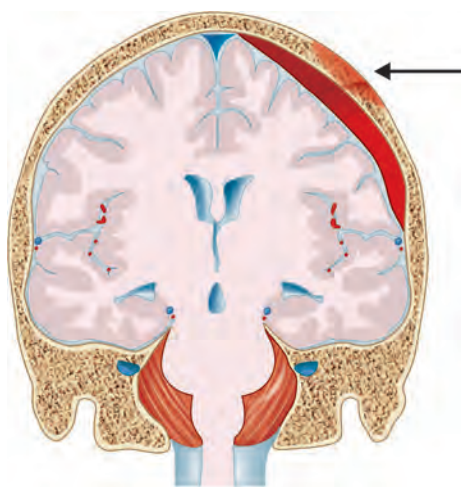


Fig. 27.11: Subdural haematoma. Note the *concavo-convex* configuration of the lesion.

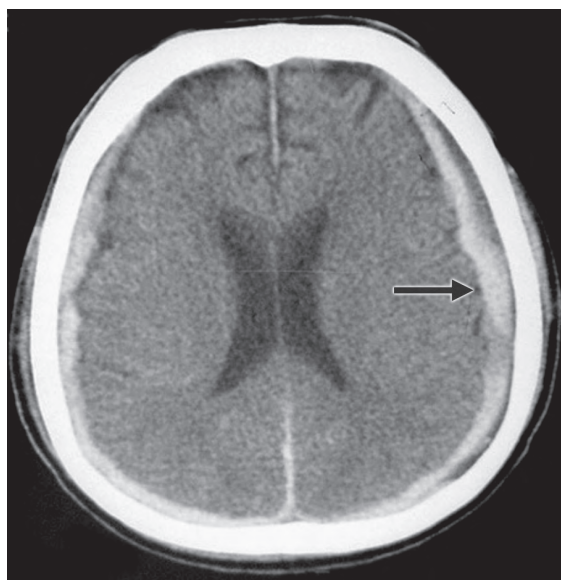

Fig. 27.12: CT scan head showing subdural haematoma with *concavo-convex* lesion.

### Treatment

- ◆ Craniotomy and evacuation of clot is done when required on both sides.
- ◆ Antibiotics.
- ◆ Anticonvulsants for 3 years.

#### Complications

- ❖ Epilepsy
- ❖ Meningitis
- ❖ Coning
- ❖ Neurological deficits

### Chronic Subdural Empyema

- ◆ It may be primary infection of subdural space from sinusitis focus causing suppuration and pus formation.
- ◆ It can be complication of the chronic subdural haematoma.
- ◆ It is due to secondary bacterial infection of collected clot/fluid.
- ◆ Infection is from sinusitis scalp (common)/through earlier trauma wound/haematogenous.
- ◆ Commonly Gram positive organisms cause empyema like streptococci (viridans/milleri) but other virulent organisms like Gram negative bacteria occasionally can cause.
- ◆ There is cortical venous thrombophlebitis and cortical infarction.
- ◆ Headache, fever, meningism and convulsions are the features.
- ◆ MRI is ideal than CT to diagnose.
- ◆ *Treatment:* Antibiotics, craniotomy and drainage; anticonvulsants, ICU care, proper monitoring, regular follow up.
- ◆ Condition has got 10% mortality.

### SUBARACHNOID HAEMORRHAGE (SAH)

*The Abbot by chance wished to decide with him the fate of the servants, found (him) prostrate upon the ground, insensible to shouts, to shaking and pinching of the body...senseless.... I saw him livid from pallor, deprived of all sensation and animate motion.... The first hour after midday of the same day he ceased to live.... By the indulgence of the Most Reverend Lord Abbot... I opened the head.... Much blood flowed from the space.... The (blood) covered (the brain) all over.... The ventricles laid open I found them all filled up with blood.*

—Johann Jakob Wepfer, 1658

It is a type of intracranial haemorrhage into the subarachnoid space usually from basal cisterns.

It may be spontaneous or following trauma.

#### Causes

- ❖ Intracranial aneurysms—commonest cause (50%)
- ❖ Hypertension
- ❖ A-V malformations
- ❖ Blood dyscrasias
- ❖ Anticoagulant drugs
- ❖ Brain tumours (malignant)

*Two black eyes following one injury indicate fracture of the base of skull.—Sir Earnest Finch*

## Clinical Features

- ◆ Sudden onset of severe headache with vomiting.
- ◆ Features of raised intracranial pressure.
- ◆ Photophobia.
- ◆ Neck stiffness.
- ◆ Focal neurological deficits: hemiplegia, dysphasia.
- ◆ Eye changes: ptosis, dilated pupil, changes in the eyeball movements.
- ◆ Sudden loss of consciousness.
- ◆ Features of brain oedema and cerebral ischaemia.

In 40% of recovered patients, rebleeding occurs in 6–8 weeks which is commonly fatal.

### Hunt and Hess grading for subarachnoid haemorrhage

- Grade 1: Asymptomatic
- Grade 2: Severe headache and neck stiffness
- Grade 3: Drowsy, confused or mild focal deficit
- Grade 4: Stupor, hemiparesis
- Grade 5: Decerebrate rigidity, coma

### Fischer grading of SAH

- I—minimal <8 mm size
- II—moderate 8–15 mm size
- III—severe >15 mm size

## Differential Diagnosis

- ◆ Meningitis.
- ◆ Coning due to any cause.

## Investigations

- ◆ *Lumbar puncture* should be done to differentiate from meningitis. It has to be done carefully as it may precipitate coning. In subarachnoid haemorrhage, blood stained CSF is collected.
- ◆ CT scan.
- ◆ Carotid and vertebral angiogram.

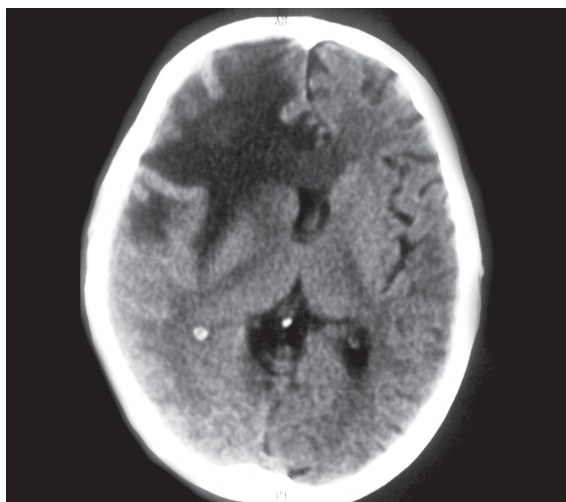


Fig. 27.13: CT scan showing intracerebral brain haemorrhage.

## Treatment

- ◆ Clipping, or wrapping the aneurysm.
- ◆ Craniotomy and proceed.
- ◆ Ligation of common carotid artery—there is risk of hemiplegia.
- ◆ Therapeutic embolisation.
- ◆ Excision of vascular malformations.
- ◆ Coiling of aneurysm with instruments.

## ■ FRACTURE SKULL

Fracture skull is important as by itself may cause different problems and often it may be an indicator of the site of intracranial injury. It may be fracture of both tables of the skull or depressed fracture which is common in children but do can occur in adult. Fracture site may be single or multiple. It may be in anterior or middle or posterior cranial fossa. Fracture segments adjacent to dural venous sinuses may tear them causing life-threatening haemorrhage which is difficult to manage.

**Anterior cranial fossa fracture**—Here cribriform plate may be fractured causing CSF rhinorrhoea; subconjunctival haemorrhage can develop when fracture extends to orbit. Anosmia due to olfactory nerve injury, blindness either partial or complete due to optic nerve injury or oculomotor nerve palsy can also occur.

**Middle cranial fossa fracture**—Here maxillary or sphenoid or other sinus cavities can get fractured causing epistaxis, CSF otorrhoea, abducent (6th), facial (common, 7th), and vestibulo-cochlear (8th) nerve palsies can occur.

**Posterior cranial fossa fracture**—It can cause glossopharyngeal, vagus or spinal accessory nerve palsies with boggy swelling in the nape of the neck.

## Clinical Features

- ◆ Features of brain injury with altered Glasgow coma scale, convulsions, localizing signs depends on the location of the fracture and amount of intracranial injury.
- ◆ Cranial nerve palsies as mentioned earlier.
- ◆ Features of raised intracranial pressure (ICP—normal is 8–12 mmHg) when present – vomiting, systolic hypertension, headache, bradycardia, altered level of consciousness.

## Investigations

- ◆ CT head, CT angiogram (carotid/vertebral if indicated only).
- ◆ Serum electrolytes, haematocrit.

## Treatment

If there is no intracranial injury fracture segment can be treated conservatively. Fracture site close to the dural venous sinuses are usually treated conservatively as intervention may cause more damage.

Often it needs formal craniotomy and elevation of the fracture segment.

## Complications

- ◆ Haemorrhage.
- ◆ Meningitis.
- ◆ Post-traumatic epilepsy.

## DEPRESSED SKULL FRACTURE

- ◆ It is a common neurosurgical problem among the head injuries.
- ◆ It means fracture depression is more than the depth of inner table of the skull.
- ◆ *Investigations:* CT scan.

### Problems in depressed fracture

- ❖ Tear in the dura beneath
- ❖ Haematoma in the deeper plane
- ❖ Injury to the cerebrum
- ❖ Injury to the venous sinuses—may cause life-threatening haemorrhage. *Fracture should not be elevated* in such occasion, as it itself can precipitate bleeding
- ❖ Convulsions
- ❖ Meningitis

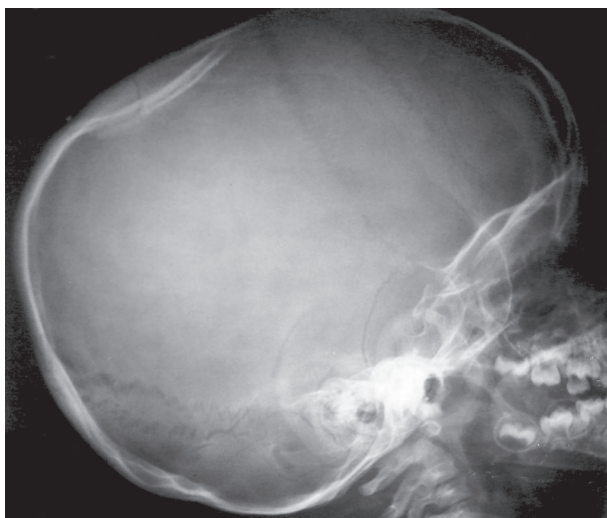

Fig. 27.14: Depressed skull fracture.

## Treatment

- ◆ Antibiotics, anticonvulsants.
- ◆ *Elevation of the depressed fracture:* Burr holes are made in the adjacent normal skull. Fracture is elevated. Bony fragments and necrotic materials are removed. Dural tear is closed with interrupted sutures.

## CSF RHINORRHOEA

It is the CSF leak through the nose due to communication between subarachnoid space and nasal cavity. It is due to tear in the dura of various causes. CSF normally is produced by choroid plexus and absorbed by arachnoid villi. Normally CSF production is 20 ml/h or 500 ml per day. 150 ml of CSF is on circulation in CNS.

Anterior or middle cranial fossa injury with *fracture cribriform plate* or injury to paranasal sinuses can tear dura causing CSF leak and rhinorrhoea.

## Causes

- ◆ Traumatic.
- ◆ Iatrogenic during base of skull surgeries or other neurosurgical procedures. It occurs in 5–7 days after the procedure usually. Nasal surgeries like FESS or septoplasty can cause CSF rhinorrhoea.
- ◆ Spontaneous/idiopathic—Due to high pressure hydrocephalous or congenital.
- ◆ Tumour related causes which erode the bony plate to create communication.

## Features

- ◆ Rim of blood in the linen or filter paper with a layer of clear fluid—*ring/double ring/halo sign*.
- ◆ Change in position causes gush of CSF—*reservoir sign*.
- ◆ CSF leak may be *immediate (within 48 hours)* or *delayed*. Delayed leak occurs as initial haematoma prevents leak but haematoma dissolves or reduces CSF leak begins.
- ◆ CSF rhinorrhoea may be *unilateral or bilateral or paradoxical* (due to injury to midline structures like crista galli or vomer wherein CSF leaks into opposite nostril).
- ◆ Salty or *metallic taste* is typical.
- ◆ Anosmia, features of other cranial nerve palsies, infection or *meningitis or pneumocephalous* may be present.
- ◆ Traumatic leak resolves spontaneously in 70% of cases and will not recur; whereas nontraumatic leak is unlikely to resolve which requires intervention either endoscopically or by open method.

### Note:

CSF mixed with blood will not clot.

- ◆ Complications: meningitis, persistent leak for long time due to prevention of dural healing by brain matter interposition. *Streptococcus pneumoniae* and *Haemophilus influenzae* are most common bacteria causing meningitis.
- ◆ **Beta 2 transferrin assay** is best method to identify the CSF leak. It is produced by neuraminidase in CNS. It is present only in CSF, perilymph and aqueous humor. 0.5 ml of leak fluid is assayed by electrophoresis. Beta trace proteins, glucose test of leak fluid are other less sensitive methods.
- ◆ *CT head* confirms the site of injury. MRI head or CT or MR cisternography or injection of intrathecal fluorescein are different methods used to identify the site of leak.

## Treatment

- ◆ *Avoid straining*, coughing, sneezing, nasal blowing as much possible as with *head end 30° elevation*.
- ◆ *Acetazolamide* 250 mg tid reduces the CSF volume and hence the leak.
- ◆ *Antibiotics* coverage to prevent ascending meningitis.
- ◆ *Surgical treatment*—CSF leak which doesn't stop, needs surgical intervention. Dural flap or muscle patch or mucosal graft or bone graft is used to cover the defect at the site of leak. Approaches may be intracranial, external approach through paranasal sinuses or *endoscopic approach*.

- ◆ *Lumbar drainage* as an adjuvant therapy can be used with drainage of 5–10 ml/h for 48 hours.

## ■ HYDROCEPHALUS

*The heads of children sometimes grow enormously large, the sutures give way, and the membranes of the brain are pushed up with the water within, and make a soft tumour rising above the edges of the sutures.... They daily become more and more stupid, with a pulse not above seventy-two.*

—William Heberden, 1802

It is dilatation of ventricles due to blockage of cerebrospinal fluid flow (CSF) or due to increased secretion or due to defective absorption of CSF.

### Classification I

- ◆ **Communicating type:** Ventricles communicate freely into the subarachnoid space.  
Here there is defective absorption of CSF following any inflammation, subarachnoid haemorrhage or trauma.
- ◆ **Noncommunicating type:** Obstruction is in the ventricle or its exit, due to any tumours or any inflammatory process.  
*CSF drains* from lateral ventricle to 3rd ventricle through foramen of Monro; from 3rd ventricle to 4th ventricle through aqueduct of Sylvius; from 4th ventricle through foramen of Lushchka and Magendie to reach over the convexity to get absorbed by arachnoid tissue.

### Clinical Features

- ◆ Large head often causes obstructed labour. There will be raised head circumference more than 2 cm/month and craniofacial disproportion.
- ◆ Bulging of anterior fontanelle which is more prominent on crying, engorged scalp veins, scalp is thin and shiny, suture line separation.
- ◆ Decreased upward gaze (*sunsetting sign*); on percussion cracked pot sound due to dilated ventricle (*Macewen's sign*).
- ◆ Delayed milestones, mental retardation and difficulty in retaining feeds.
- ◆ Features on raised ICP mainly in adult, lethargy, irritability, ataxia, papilloedema, blindness due to ophthalmoplegia, abducens palsy and respiratory failure.

### Investigations

- ◆ CT scan; MRI brain, CT or air ventriculography.
- ◆ Evaluation for the cause.

### Treatment

**Drugs**—acetazolamide, frusemide, isosorbide, glycerol.

### Classification II

<b>Congenital</b>	<b>Acquired</b>
Associated with spina-bifida and myelomeningocele. It is due to:	May be unilateral or bilateral (midline obstruction), due to:
• Failure of formation of CSF pathways	• Chronic meningitis
• Arnold-Chiari malformation	• Trauma
• Congenital stenosis of aqueduct of Sylvius	• Subarachnoid haemorrhage
• Presents with widening of sutures, tense fontanelles and decreased cortical thickness	• Brain tumours—(pineal/cerebellar/craniopharyngiomas)
• Enlargement of head occurs, either prenatal (can cause obstructed labour) or postnatal	• Colloid cyst of 3rd ventricle
	• Arachnoid cysts

### Surgery

- ◆ Tapping of the lateral ventricles.
- ◆ Ventriculocysternostomy using polythene catheters— *Torkildsen operation*.
- ◆ Ventriculo-atrial (VA) or ventriculo – peritoneal (VP) shunts.
- ◆ *Complications of shunt surgery* – obstruction or infection of the shunt; subdural haematoma, convulsions, spontaneous pneumothorax, ascites.

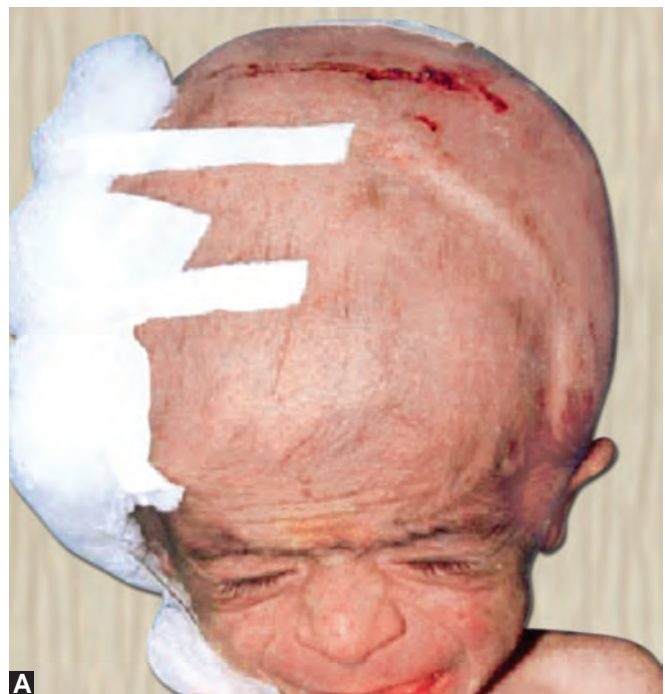

Fig. 27.15A

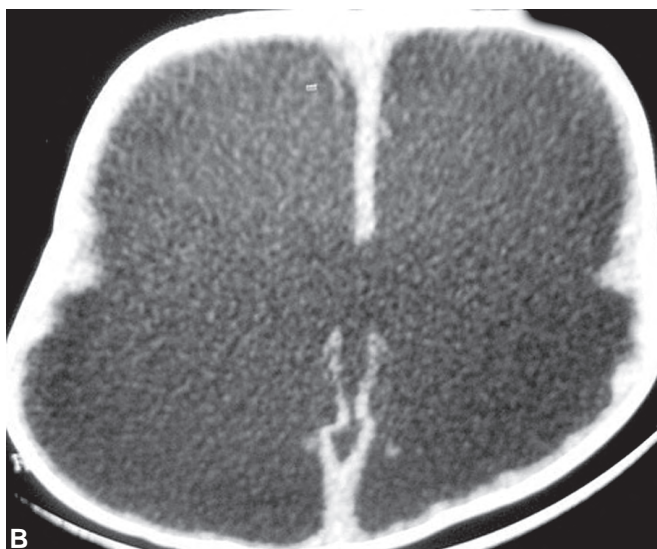


Fig. 27.15B

Figs 27.15A and B: Hydrocephalus child. CT scan head picture in hydrocephalus.

## ■ INTRACRANIAL ABSCESS

### Types

- ◆ **Extradural abscess:** Caused by:
  - ▶ Osteomyelitis of skull.
  - ▶ Middle ear infection.
  - ▶ Frontal sinusitis.

*Pott's puffy tumour* is subperiosteal swelling with infection and inflammation of the scalp. There is acute localised headache and tenderness in the skull, localised pitting oedema of the scalp usually in the frontal region.

- ◆ **Subdural abscess:** is caused by septic thrombophlebitis from the frontal sinusitis or other infections. It is often very severe with extension into the venous sinuses.
- ◆ **Intracerebral abscess:** is caused by
  - ▶ Extension from middle ear or sinuses.
  - ▶ Blood-born infection.
  - ▶ After intracranial injuries.

*Common sites:* Temporal lobe, cerebellum, frontal lobe.

It can be:

- a. **Acute**—There is acute septic encephalitis without pus formation. It may cause ventriculitis or localized abscess formation
- b. **Subacute**—Occurs in 3 weeks, by the formation of a glial wall, i.e. thickness is more near the cortex and less towards ventricle
- c. **Chronic**—Occurs in 6 weeks with thick wall which may persist or may get enlarged behaving like a space occupying lesion
- d. **Metastatic**—Abscess in brain occurs either in cerebrum (parietal or temporal lobes) or in ventricles (Ventriculitis is more dangerous and often fatal)

### Clinical Features

- ◆ Evidence of focus of infections are seen, i.e. middle ear (CSOM), sinusitis.
- ◆ Focal neurological features are seen, depending on the location of abscess. In temporal lobe abscess features of dysphasia, contralateral hemiparesis are seen; in cerebellar abscess, all cerebellar symptoms are seen.
- ◆ Epilepsy.
- ◆ Features of raised intracranial pressure: (a) slow pulse, (b) rising BP, (c) headache and vomiting, (d) papilloedema, (e) deterioration in level of consciousness, (f) visual disturbances.

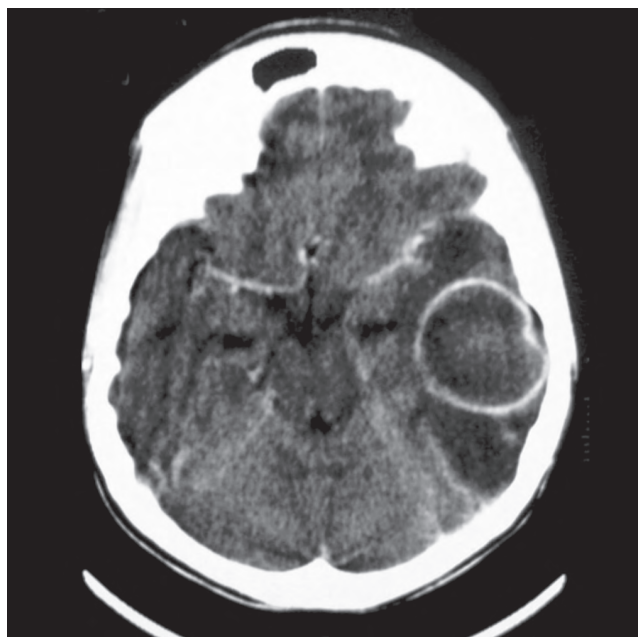
### Differential Diagnosis

- ◆ Intracranial tumour.
- ◆ Tuberculoma.
- ◆ Meningitis.

### Investigations

- ◆ CT scan.
- ◆ MRI.
- ◆ Carotid angiogram.
- ◆ Ventriculography.
- ◆ EEG.
- ◆ Isotope brain scan.
- ◆ Total count, ESR.
- ◆ Investigation specific for focus of infection.

Lumbar puncture should be avoided in acute abscess as coning can occur.



**Fig. 27.16:** Intracranial abscess. It needs drainage. It could be tuberculosis. It is a space occupying intracranial lesion, mimics malignancy often.



## Treatment

- ◆ Antibiotics—high dose penicillins, benzyl penicillins are given.
- ◆ Burr hole exploration is done and Dandy's brain cannula is placed. Pus is aspirated and sent for culture and cytology.
- ◆ In case of chronic abscess, exploration of cranial cavity and excision of brain abscess is done.

### Complications

- ❖ Intracranial hypertension
- ❖ Coning
- ❖ Neurological deficits

## INTRACRANIAL ANEURYSMS

### Types

- ◆ **Subclinoid type** occurs in the internal carotid artery within the cavernous sinus. It causes ptosis, defective external ocular movements, 5th nerve palsy. It can cause carotid-cavernous fistula.
- ◆ **Supraclinoid type** is commonest type.
  - ▶ **Berry aneurysms:** A congenital type occurs in circle of Willis in relation to internal carotid artery [40% (most commonly at the origin of posterior communicating artery)], anterior communicating artery, middle cerebral artery, vertebralbasilar artery. It occurs due to weakness in the media of major arteries.
  - ▶ **Acquired aneurysms** due to atheromas, hypertension.
  - ▶ **Mycotic aneurysms** occurs due to infection in the wall of cerebral vessels, as a result of any bacteraemia.

Common sites are peripheral branches of middle cerebral artery.

### Presentations

- ❖ Subarachnoid haemorrhage
- ❖ Pressure effects
- ❖ Convulsions
- ❖ Eye and pupillary signs

## Investigations

- ◆ CT scan.
- ◆ Carotid and vertebral angiogram.

## Treatment

- ◆ Clipping or wrapping of aneurysms.
- ◆ Therapeutic embolisation.
- ◆ Open neurosurgical approaches.

## INTRACRANIAL TUMOURS

*There was discovered on (the corpus callosum) of the brain a remarkable round fleshy tumour like an acorn. It was hard and full of holes and was as large as a medium-sized apple. It was covered with its own membrane and was entwined with veins. . . . We perceived that this ball by compressing the brain and its ducts with its mass and by flooding them, had been the occasion of the lethargy and listlessness and finally of death.*

—Felix Platter, 1614

**Secondaries are the commonest malignant tumour in the brain. Metastasis occurs usually from lung (commonest), nasopharynx or from any other organ in the body.**

### Secondaries in brain

- ❖ Commonest malignant brain tumour
- ❖ Primary are—lungs (40%), breast (30%), melanoma (15%), others (15%)
- ❖ Usually multiple
- ❖ Headache, focal lesions, convulsions, hypertension, altered level of consciousness are the features
- ❖ CT scan, CT chest or evaluation of primary—needed
- ❖ Radiotherapy and chemotherapy of particular primary is treatment
- ❖ Solitary metastasis can be removed surgically
- ❖ Steroids reduce the cerebral oedema and so symptoms

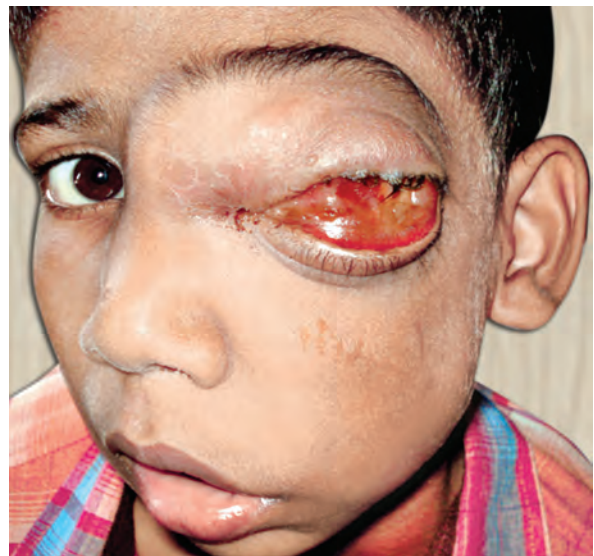

Fig. 27.17: Orbital secondaries from adrenal neuroblastoma.

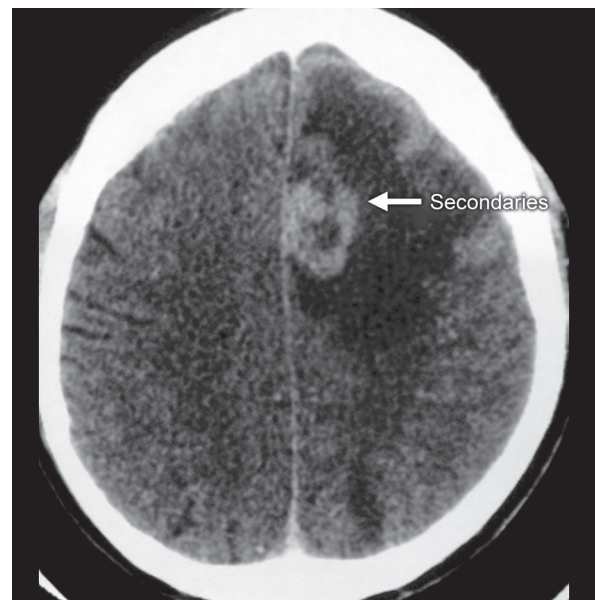


Fig. 27.18: CT scan head showing brain secondaries.

## Primary Brain Tumours

### 1. Gliomas (43%).

a. *Astrocytomas* are the commonest type. They are usually malignant. They can occur anywhere in the cerebral hemispheres, medulla, brainstem. Peak incidence is in 4th decade.

They can be *diffuse, solid or cystic*. They contain star-shaped cells resembling adult neuroglial cells. Astrocytic gliomas are graded as *Grades I, II, III, IV based on the quantity of adult and primitive cells*.

Grade I—Cystic

Grade II—Diffuse

Grade III—Anaplastic

Grade IV—**Glioblastoma multiforme**—It is high grade aggressive type of astrocytoma. It is treated by surgical removal/debulking; high dose radiotherapy, chemotherapy with carmustine inserted into the surgical cavity and oral temozolomide. Median survival is 12 months; 2-year survival rate is 25% or less.

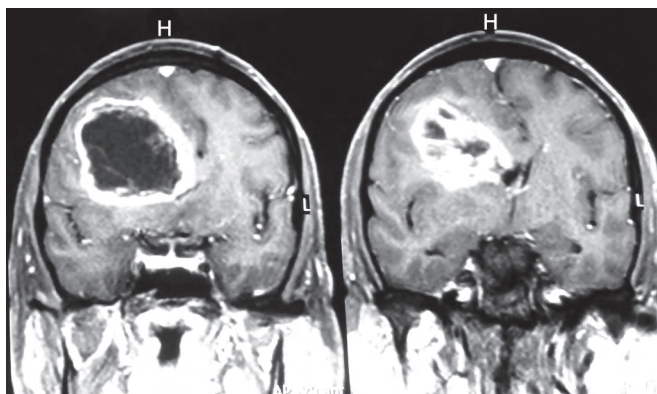


Fig. 27.19: CT scan showing astrocytoma – aggressive variety—grade IV—glioblastoma multiforme.

b. *Oligodendrogliomas*: They are slow growing tumour commonly arising from frontal lobes, lasts for years; shows calcification.

c. *Spongioblastoma polare*: They arise from primitive spongioblasts, affects optic chiasma, 3rd ventricle, hypothalamus. They are both operable and radiosensitive.

d. *Medulloblastoma*: It is highly malignant embryonal tumour grouped under PNETs (primitive neuroectodermal tumours) arising from primitive cell nests; common in children (*medulloblastoma is the most common brain tumour in children*) and young individuals. It often spreads within the brain itself causing *sugarcoat metastases* which may extend across the spinal canal.

e. *Ependymomas*: Here cells resemble ependymal cells; can occur throughout the hemispheres. They arise from cells lining the ventricles of the brain and central canal of the spinal cord. They are common in *4th ventricle*; common in *younger individual*; blocks CSF circulation causing hydrocephalus.

2. **Meningiomas (18%)**: They are usually globular, arising from the arachnoids. Tumour gets attached to the dura. It gets blood supply from dural arteries and veins, from emissary veins and veins of diploe and scalp. Along these veins tumour cells invade the bone, causing bone destruction and reactive hyperostosis.

Meningiomas are *classified as fibroblastic, endothelial and angioblastic*.

#### Sites

- ❖ Parasagittal
- ❖ Frontobasal
- ❖ Posterior fossa
- ❖ Choroid plexus

#### Microscopic:

It contains whorls of spindle cells, with central hyaline material, with *psammoma bodies*.

#### Meningioma

- ❖ 18% common
- ❖ Arising from arachnoids
- ❖ 80% are supratentorial; but occasionally can occur in the sphenoid wing, olfactory groove or lateral ventricle
- ❖ Common in females of middle aged
- ❖ Multiple meningiomas may be present in patients with neurofibromatosis type 2
- ❖ Gets blood supply from dural vessels
- ❖ Invades the skull bone through emissary and diploe veins
- ❖ Destruction and reactive hyperostosis of bone is common
- ❖ *Psammoma bodies* are often seen histologically
- ❖ CT/MRI diagnostic
- ❖ Surgery is the choice therapy
- ❖ It has got good prognosis

3. **Schwannoma (8%)**: Common in auditory nerve, also called as *acoustic neuroma*.

Occurs in the internal auditory meatus which projects into the cerebellopontine angle (C- P angle), compressing 5, 6, 7, 8th nerves. It presents with compressive features like unilateral deafness, trigeminal neuralgia, squint, cerebellar compression syndrome.

4. **Pituitary tumours (12%)**.

5. **Craniopharyngiomas (5%)**.

6. **Blood vessel tumours (2%)**.

## Clinical Features

- ◆ Initial period of silent growth.
- ◆ Focal syndromes with epilepsy.
- ◆ Raised intracranial pressure with headache, vomiting, deterioration of level of consciousness, altered vision, slow pulse, high BP, papilloedema.
- ◆ Brain displacement and stage of coning.

#### Note:

First sign in acoustic neuroma is loss of corneal reflex.

*A very bold surgeon is the one who realise that, his patient takes all the risks.*

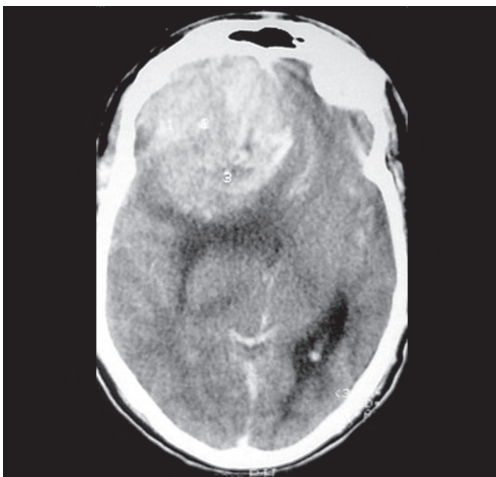
## Specific Features

- ◆ Frontal lobe tumours: Personality and emotional changes, epilepsy of generalised type, contralateral facial weakness.
- ◆ Parietal lobe tumours: Jacksonian epilepsy, progressive hemiparesis, astereognosis, acalculia.
- ◆ Occipital lobe tumours: Aura of flashing of light in contralateral field, homonymous hemianopia.
- ◆ Temporal lobe tumours: Progressive aphasia, visual, auditory, smell and taste hallucinations, hemiparesis, superior quadrantic hemianopia.
- ◆ Midline tumours: Produces bilateral hydrocephalus.
- ◆ Tumours of the third ventricle (colloid cyst is common): Causes bilateral hydrocephalus, progressive cerebral atrophy, dementia, sexual precocity, endocrine disturbances.
- ◆ Pineal tumours: Causes precocious puberty.
- ◆ Cerebellar vermis tumours: Usually medulloblastomas, occur in young children, presents with progressive hydrocephalus and features of herniation of cerebellar tonsils through foramen magnum.
- ◆ Cerebellar hemisphere tumours: Commonly are astrocytomas, produce cerebellar syndromes, nystagmus.

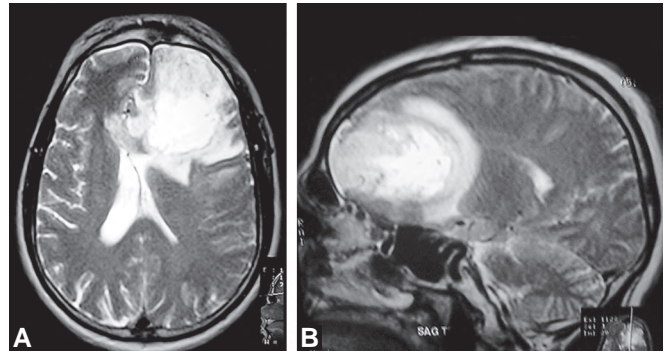
- ❖ Incidence of malignant brain tumour is 8%
- ❖ In adult brain tumours are commonly (60%) are supratentorial; in children infratentorial – posterior cranial fossa
- ❖ 50% present with headache which is often (10%) worsening at early morning. Headache is due to raised ICP; focal or generalised convulsions (25%); progressive neurological deficit (65%) motor (mainly and sensory; visual disturbances; cranial nerve palsies; mental changes; drowsiness and irritability – are presentations
- ❖ Features may suddenly worsen or progress when there haemorrhage in the tumour

## Investigations

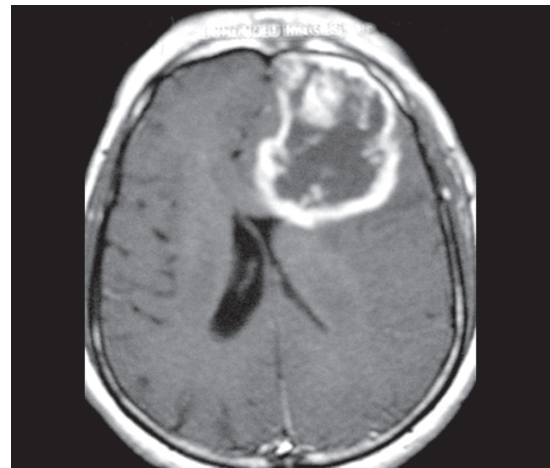
- ◆ X-ray skull:
  - ▶ Calcifications like in meningiomas, craniopharyngiomas.
  - ▶ Separation of sutures.
  - ▶ A beaten silver appearance.
  - ▶ Lateral displacement of pineal body.
  - ▶ Hyperostosis, expansion, destruction in skull bones.



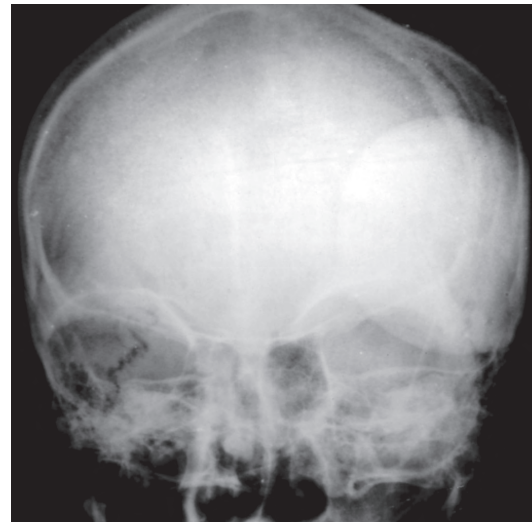**Fig. 27.20:** CT scan head showing large meningioma frontal region.



**Figs 27.21A and B:** MRI brain showing glioma brain.



**Fig. 27.22:** MRI brain showing glioblastoma multiforme. It is very aggressive malignant tumour.

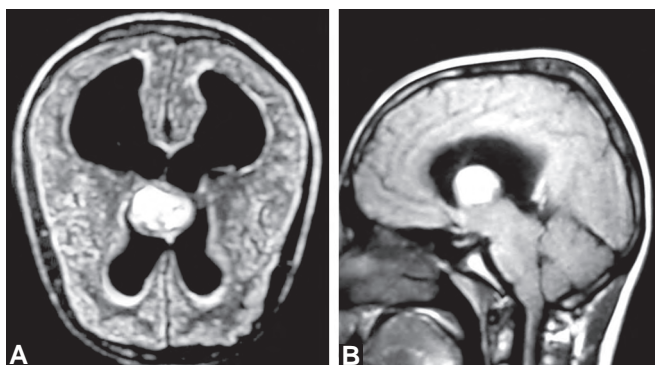


**Fig. 27.23:** Skull X-ray showing mass calcified lesion. It could be meningioma, dermoid extending intracranially.

- ◆ Isotope scan.
- ◆ CT scan.
- ◆ MRI.
- ◆ Positron Emission Tomography (PET).
- ◆ Carotid angiogram (Introduced by Egas Moniz).
- ◆ Ventriculography.
- ◆ EEG.

## Treatment

- ◆ Relief of raised intracranial pressure:
  - a. Ventricular tap and drainage through a posterior parietal burr hole.
  - b. Tapping of cystic tumours and abscesses.
  - c. Administration of mannitol.
  - d. Emergency decompression by partial removal of tumour.
  - e. Steroid therapy—dexamethasone.
- ◆ Establishment of pathological diagnosis:
  - a. Burr-hole and biopsy.
  - b. Craniotomy and biopsy using brain cannula.
  - c. Frozen section biopsy.
  - d. CT guided stereotactic biopsy.
- ◆ Removal of benign tumours—by different craniotomy approaches.
- ◆ Decompressive surgeries for malignant tumours.
- ◆ Shunt surgeries to drain CSF—ventriculoperitoneal shunt or ventriculoatrial shunt.
- ◆ Radiotherapy—external radiotherapy is used as primary treatment or as an adjuvant therapy after surgery.
- ◆ Chemotherapy is occasionally used—*Temozolamide*.



Figs 27.24A and B: Craniopharyngioma from sellar region.

## Prognosis

Tumour which is benign and surgically accessible has better prognosis.

## PITUITARY TUMOURS

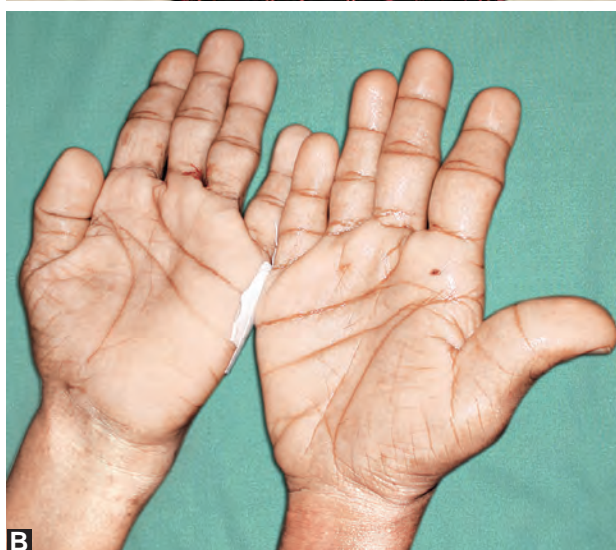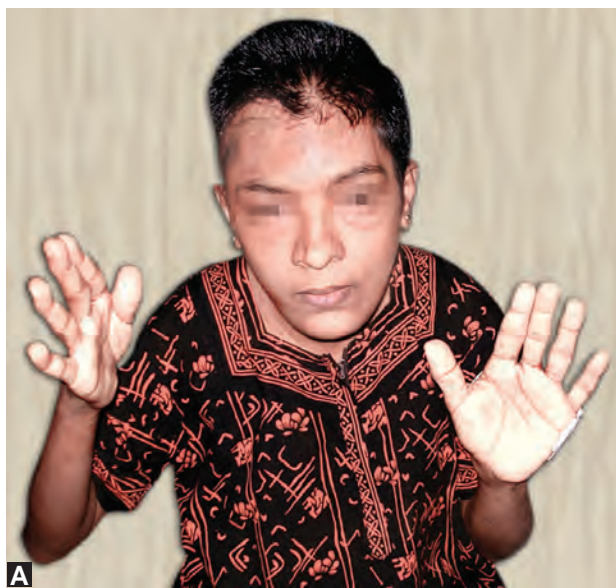*A young student...suddenly (sleepy and lethargic) died in convulsions within two weeks. In his brain the ventricles were found swollen with blood... which had gone down to the base of the skull....The olfactory bulbs were not swollen at all. The pituitary gland...was completely blocked by a...viscous and gelatinous mass about the size of a small bean... Hence a dropsy of the brain ensued.*

—Richard Lower, 1672

## Classifications I

1. **Eosinophil (Acidophil) adenomas:** Tumour is usually small. Rarely it causes compressive features.

It secretes excess growth hormone causing acromegaly in adults and gigantism in children.



Figs 27.25A and B: Acromegaly due to pituitary tumours. Note the operated scar in the frontal region.

2. **Chromophobe adenomas** are common in females and in the age group—20–50 years.

Initially, it is *intrasellar* and after sometime becomes *suprasellar*. Later, it extends *intracranially* often massively, causing features of intracranial space occupying lesion. It presents with myxoedema, amenorrhoea, infertility, headache, visual disturbances, bitemporal hemianopia, blindness, intracranial hypertension, epilepsy.

*Differential diagnosis:* Meningiomas, aneurysms. CT scan, angiogram, X-ray skull are diagnostic.

Treatment is surgical decompression by craniotomy through subfrontal approach or trans-sphenoidal approach. Deep external radiotherapy and steroids are also used.

3. **Basophil adenomas** are usually small. They secrete ACTH and presents as Cushing's disease with all its features.
4. **Prolactin-secreting adenomas** causes infertility, amenorrhoea and galactorrhoea.

*Truth always exists; only lies are invented.*

**Classification II**

- ❖ Hypersecreting
- ❖ Hyposecreting by compression and atrophy

**Classification III**

- ❖ Micronodular: Tumour size less than 10 mm
- ❖ Macronodular: Tumour size more than 10 mm

**Stages**

- ❖ Stage of intrasellar development
- ❖ Stage of suprasellar extension
- ❖ Stage of massive intracranial extension

**Investigations**

- ◆ X-ray skull—shows calcifications, destruction of sella turcica, mass lesion, enlarged pituitary fossa.
- ◆ CT scan.
- ◆ MRI.
- ◆ Hormone assay—like serum prolactin, growth hormone, ACTH, steroids, sex hormones, etc.

**Treatment**

- ◆ Surgery: By subfrontal craniotomy approach or transphenoidal approach.  
Care should be taken not to injure optic chiasma, arteries, cavernous sinus.
- ◆ External radiotherapy.

**CRANIOPHARYNGIOMAS**

They are large masses with cystic cavities, lined by ciliated epithelium containing cholesterol crystals. Areas of calcifications may be present and coral-like masses may be formed. They are adherent to the basal arteries and adjacent nerves. They are *irremovable*. They are tumours of sellar region.

**Clinical Features**

- ◆ *Intrasellar craniopharyngiomas* inhibits sexual maturation causing obese, impotent dwarf with bitemporal hemianopia (due to compression of optic chiasma)—**Frolich's syndrome**.
- ◆ *Suprasellar craniopharyngiomas* produces Frolich's syndrome; pressure on hypothalamus which controls sleep and water metabolism (causes somnolence and diabetes insipidus).
- ◆ *Massive intracranial extension* causes intracranial hypertension and also hydrocephalus by obstructing CSF flow.

**Investigations**

- ◆ Skull X-ray shows calcification.
- ◆ CT scan is diagnostic.

**Treatment**

- ◆ Through craniotomy or through trans-sphenoidal approach cystic tumours are evacuated.
- ◆ Ventriculoatrial shunt has to be done to drain CSF in case of hydrocephalus.

- ◆ Ventriculocisternostomy—*Torkildsen's operation* is done in cases of large masses blocking the 3rd ventricle obstructing the CSF outflow.
- ◆ Radiotherapy.

**SPINAL DYSRAPHISM**

It is posterior midline congenital deformity of spine due to incomplete fusion of ectodermal, mesodermal or neuroectodermal elements either singly or in combination. It is due to arrest of closure of neural tube.

**Types****Myelocele**

There is failure of closure of neural as well as vertebral arch. There is raw oval defect uncovered over central canal which is incompatible with life and newborn infant dies soon. Loss of lower limb power, incontinence of urine, talipes, CSF discharge, and meningitis is common. Very occasional infant who survives develop a skin coverage from periphery but neurological problems are irreversible. It is common but least survival chance.

**Syringomyelocele**

It is rarest type. Central canal of spinal cord is dilated with bulging out of the canal under the skin of the dilated central canal as thin cystic sac containing cord with meninges and nerve roots. Gross paralysis is common. It is identified on table as it is difficult to differentiate from myelomeningocele clinically.

**Myelomeningocele**

It occurs 2 in 1000 live births. Here part of the cord or cauda equina or both present as median cystic swelling at back. It is not transilluminant. It is common in lumbosacral region. Adhesion of spinal cord or cauda equina to sac causes neurological deficit. Kinking, compromised blood supply causes neurological deficit (30%). Monoplegia, paraparesis, paraplegia, talipes and incontinence are the features. It is almost always associated with Arnold Chiari syndrome or Dandy Walker syndrome (atresia of foramina Lushka and Magendie).

**Meningocele**

Protrusion of spinal meninges through a congenital defect in the spinal lamina defect.

**Spina Bifida**

Neural arches failure to unite over a limited area and externally there is no protrusion but there is obvious defect.

**MENINGOCELE**

It is the herniation of meninges through a weak point of spine where bony fusion has not taken place effectively.

Swelling is covered with pia mater and arachnoid mater without dural covering and contains CSF.

**Clinical Features**

- ◆ Present since birth.

- ◆ Soft, cystic, fluctuant with transillumination.
- ◆ Signs of compressibility.
- ◆ Expansile impulse when asked to cough or when child cries.

**Location**

- ◆ *Lumbosacral—commonest.*
- ◆ *Occipitocervical—2nd most common.*

**Investigations**

- ◆ CT scan head to look for hydrocephalus.
- ◆ MRI spine.

**Treatment**

Excision as early as possible. Transverse elliptical incision. Closure of defect by plication. Approximation of muscles.  
Early closure prevents infection.

**Complications**

- ◆ Ulceration.
- ◆ Haemorrhage.
- ◆ Closure may cause hydrocephalus which needs shunting of CSF.

<i>Meningocele</i>	<i>Meningomyelocele</i>
<ul style="list-style-type: none"> <li>• Membranes content</li> <li>• Soft, cystic</li> <li>• Brilliantly transilluminant</li> <li>• Longitudinal furrow absent</li> <li>• No neurological defect</li> <li>• Good prognosis after repair</li> </ul>	<ul style="list-style-type: none"> <li>• Membranes with nerve roots</li> <li>• Soft to firm</li> <li>• Nontransilluminant</li> <li>• Longitudinal furrow is seen due to adherence of nerve roots</li> <li>• Trophic ulcer, bowel/urine incontinence, motor problems</li> <li>• Neurological deficit present</li> <li>• Not good results</li> </ul>

**SPINA BIFIDA**

- ◆ It is also classified under *spinal dysraphism*.
- ◆ It is failure of enfolding of nerve elements within the spinal canal during developmental period.
- ◆ It is usually seen in lumbosacral region. There is failure of fusion of one or more posterior vertebral arches.
- ◆ It is often associated with other anomalies.

Sites
<ul style="list-style-type: none"> <li>❖ Lumbosacral</li> <li>❖ Thoracolumbar</li> </ul>

**Types**

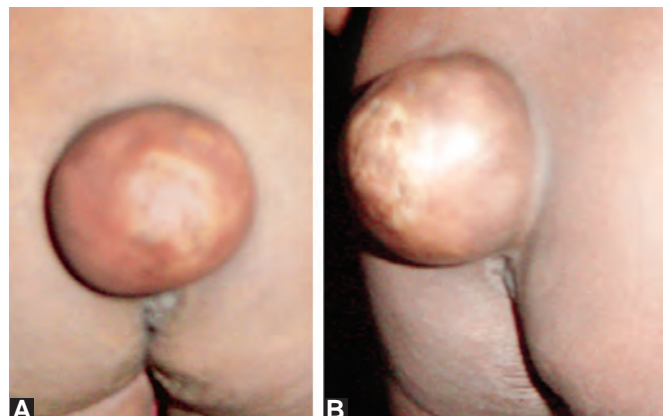
1. *Spina bifida occulta*—commonest type
  - ▶ There is dimpling of skin with dermoids, lipomas in the site. Impulse on coughing can be seen.

- ▶ Initially there is no neurological deficit but later due to tethering, traction on dura, infection, can lead neurological deficits.
2. *Spina bifida aperta*
    - ▶ Here neurological deficit is present. It may be *myelomeningocele* wherein spinal cord and nerve roots are in the sac. It may be *meningocele* wherein sac consists of meninges and fluid only.
    - ▶ Meningocele is brilliantly transilluminant. Myelomeningocele is not transilluminant.

Clinical features
<ul style="list-style-type: none"> <li>❖ Motor paralysis</li> <li>❖ Sensory paralysis</li> <li>❖ Visceral paralysis with incontinence of urine and faeces</li> <li>❖ Swelling in the spine at the site of the lesion, may be lipoma or dermoid, with impulse on coughing</li> <li>❖ Bony defect at the site</li> <li>❖ Hydrocephalus</li> </ul>

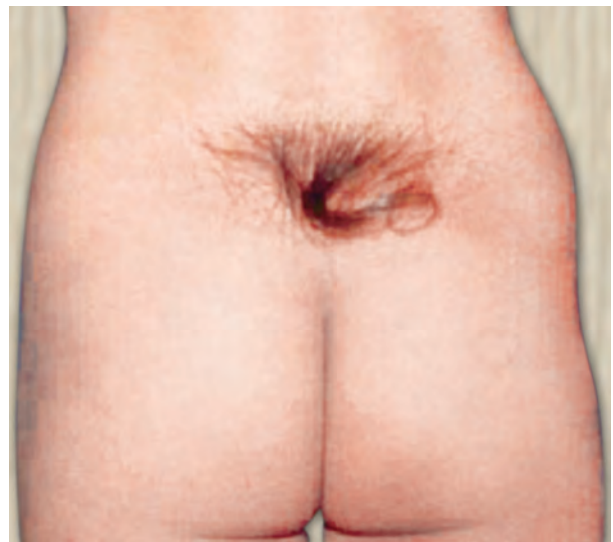

Fig. 27.26: Spina bifida occulta. Note the dimple and tuft of hair.



Figs 27.27A and B: Spina bifida with protruding dermoid through the defect.

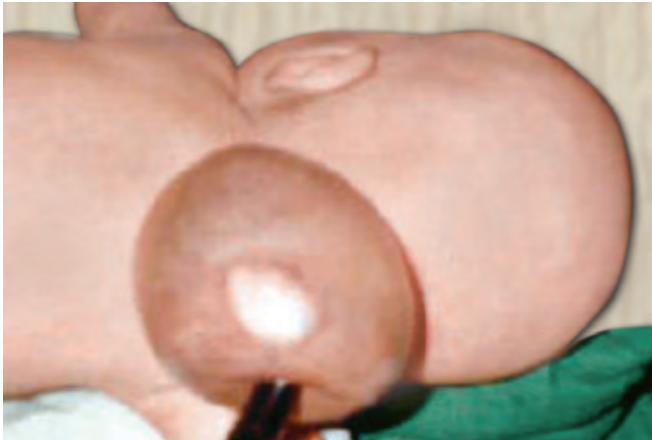**Investigations**

- ◆ Plain X-ray of the spine.
- ◆ CT scan/MRI of spine and head.

*The first sign of Pott's disease is deepened midline spinal sulcus at about T10 level due to increased muscular tonicity of sacrospinalis muscle. It is a NATURE'S PLASTER CAST.*  
—Francis E Jardine

## Treatment

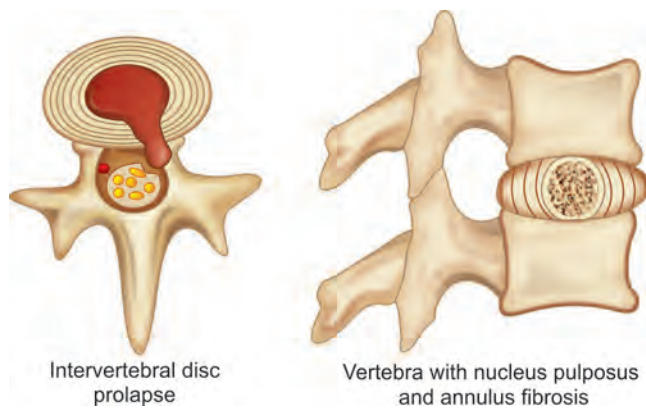
- ◆ Correction of deformity.
- ◆ Maintaining the visceral function.
- ◆ Development of limb function.
- ◆ Ventriculoperitoneal shunt or ventriculoatrial shunt surgery for hydrocephalus.



**Fig. 27.28:** Infant with encephalocele. It is non-transilluminant whereas meningocele is brilliantly transilluminant.

## INTERVERTEBRAL DISC PROLAPSE (IVDP)

- ◆ Herniation of part of the gelatinous nucleus pulposus through a rent in the annulus fibrosus, commonly at postero-lateral part which is a weak point.
- ◆ **In cervical spine** discs between C5 and C6; C6 and C7 are commonly affected impinging 6th and 7th nerves respectively.
- ◆ **In lumbosacral region**, discs between L5 and S1; L4 and L5 are commonly affected impinging first sacral nerve and 5th lumbar nerve respectively.
- ◆ Initially protrusion bulges through the pain sensitive posterior longitudinal ligament causing back pain.
- ◆ Later it herniates through the posterior ligament compressing the nerve causing typical root pain.



**Fig. 27.29:** Intervertebral disc prolapse.

## Types

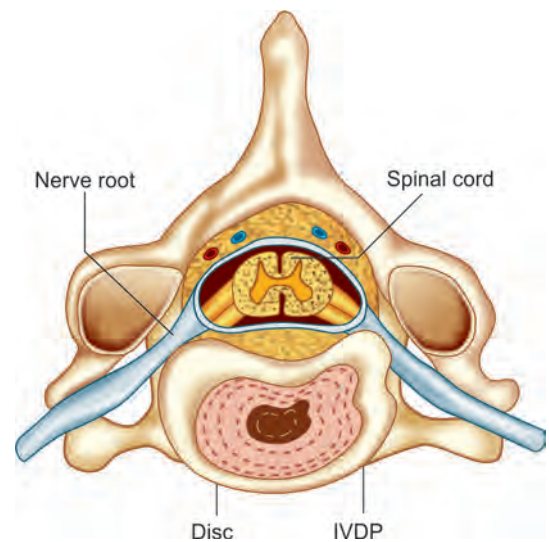
- ◆ Posterolateral is common.

- ◆ Central-posterior is not common. It is due to trauma. It is severe type, even though rare.

*Secondary changes: Osteoarthritis of joints.*

## Clinical Features

- ◆ Pain in the distribution of the root which gets aggravated by straining, coughing, twisting, stooping.
- ◆ Pain radiates along the distribution of the nerve with tingling and numbness.
- ◆ Lumbar scoliosis is significant.
- ◆ Restricted forward flexion but free lateral flexion.
- ◆ Positive straight leg raising on the affected side with positive Lasegue's manoeuvre.
- ◆ Wasting in the muscles with blunting of sensation, with absence knee and ankle jerks.
- ◆ Loss of bladder sensibility and retention of urine.



**Fig. 27.30:** Intervertebral disc prolapse.

## Differential Diagnosis

- ◆ Spinal cord tumours.
- ◆ Tuberculosis of the spine.
- ◆ Osteoarthritis.
- ◆ Ankylosing spondylitis.
- ◆ Spondylolisthesis.
- ◆ Vascular problems.
- ◆ Retroperitoneal and pelvic tumours.

## Investigations

- ◆ X-ray spine both AP and lateral. It is not useful in acute prolapse.
- ◆ Myelography or radiculography.
- ◆ CT scan.
- ◆ MRI is very useful method.

## Treatment

- ◆ Rest in bed.
- ◆ Spinal jacket.

- ◆ Continuous or intermittent traction.
- ◆ Analgesics and relaxants.
- ◆ Intradiscal injection of the chymopapain enzyme which dissolves the fibrocartilaginous tissue and nucleus pulposus.
- ◆ Surgical treatment:

*Indications:*

- ▶ Persistent pain for 12 weeks which is not relieved by drugs.
- ▶ Severe neurological disturbances like involvement of bladder, bowel or sexual functions.

*Surgery:* Discectomy.

## ■ TUBERCULOSIS OF SPINE (CARIES SPINE)

- ◆ It is commonly of *secondary* type.
- ◆ Primary focus is in the lungs or lymph nodes.
- ◆ Commonly involved vertebra is dorsilumbar vertebra T10.

*Mode of infection:* Mainly haematogenous.

### A. Tuberculosis of Cervical Vertebra

Common in C6 and C7 vertebra.

#### Clinical Features

- ◆ Pain in the neck, often referred to occipital region through suboccipital or posterior auricular nerves.
- ◆ Pain, when referred through anterior cervical primary rami causes *brachial neuralgia*.
- ◆ Rigidity in the neck.
- ◆ Patient supports the chin on the palm of his hand (*Rust sign*).
- ◆ Tenderness and paraspinal spasm with rigidity of the skull muscles.
- ◆ All passive and active movements of spine are painful and restricted.
- ◆ Cold abscess may be present in the neck, posterior to sternomastoid muscle or in the retropharyngeal region or in the axilla.
- ◆ Chronic tuberculous retropharyngeal abscess in midline, situated behind the prevertebral fascia. It is painless, soft, often causing dysphagia and dyspnoea.

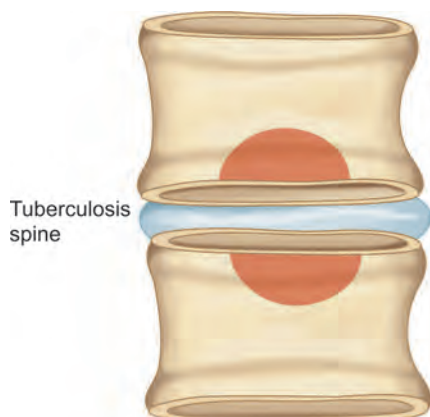


Fig. 27.31: Tuberculosis of spine.

#### Differential diagnosis

- ❖ Cervical spondylosis
- ❖ Congenital torticollis
- ❖ Secondaries
- ❖ Spinal cord tumours

#### Investigations

- ◆ X-ray cervical spine, chest X-ray.
- ◆ MRI is ideal.

#### Treatment

- ◆ Antitubercular drugs.
- ◆ Anterolateral decompression of vertebra.
- ◆ Drainage of cold abscess.

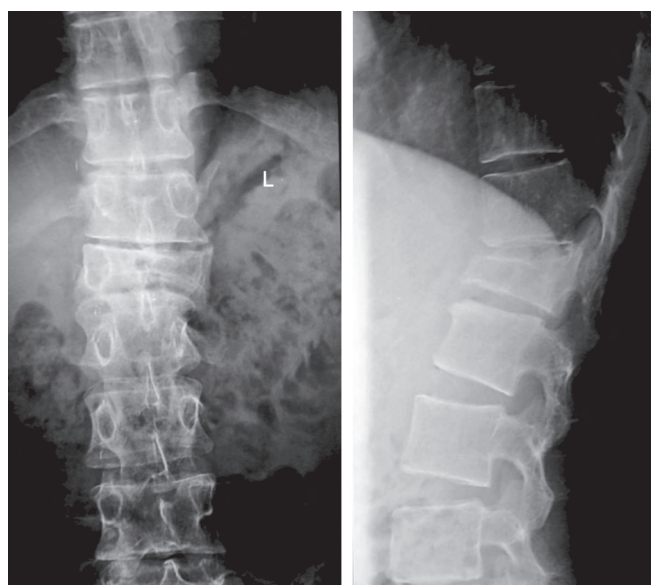


Fig. 27.32: Compression fracture spine—traumatic, pathological.

### B. Tuberculosis of Thoracolumbar Vertebra (Pott's Disease, Caries Dorsilumbar Spine)

*Commonest site is dorsilumbar region—T10.*

#### Reasons

- ❖ It is the junction of fixed (thoracic) and mobile (lumbar) segments of spine
- ❖ It bears the maximum stress
- ❖ It has got large amount of cancellous bone
- ❖ Bulky nucleus pulposus
- ❖ Relative avascularity of the body of dorsilumbar vertebra
- ❖ Close proximity to the thoracic duct through which infection can occur
- ❖ Adjacent prevertebral veins

#### Types

- ◆ *Tuberculosis of the body of vertebra*
  - ▶ *Tuberculous metaphysitis*—Here contiguous surfaces of the vertebra are involved. It is the most common type in children.



- ▶ *Tuberculous osteomyelitis* (central type—through central artery of the vertebra)—It occurs in the centre of the body of vertebra.
- ▶ *Tuberculous periostitis* (peripheral or periosteal)—It is seen in adults. It is situated deep to the anterior longitudinal ligament.

#### ◆ Tuberculosis of the appendages

- ▶ Spinous process.
- ▶ Pedicle.
- ▶ Transverse process.
- ▶ Lamina.

### Features

- ◆ Contiguous surfaces of paired vertebra are involved.
- ◆ Lower half of one vertebra and upper half of adjacent vertebra below, with intervertebral joints are involved as they share a common blood supply.

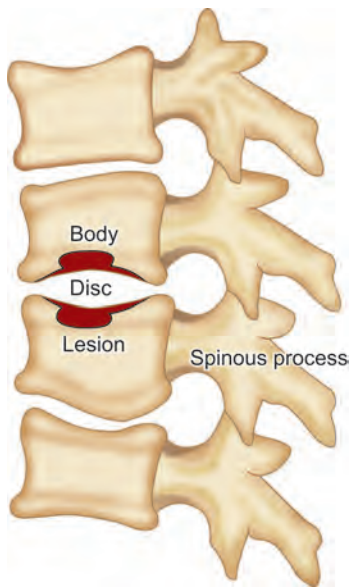

Fig. 27.33: Tuberculosis of spine. Note the area of involvement.

- ◆ Destruction of the vertebra and intervertebral disc; collection of caseous material behind the anterior longitudinal ligament.

### Pathology

- ❖ Tuberculous endarteritis
- ❖ Decreased blood supply
- ❖ Formation of tubercles with caseation
- ❖ Destruction of bone
- ❖ Failure of subperiosteal new bone formation

### Effects

1. Deformity—*Kyphosis (Gibbus)* is excessive posterior curvature of the spine. It is due to complete anterior collapse of the vertebra.
2. *Cold abscess* formation:
  - a. Close to the midline, when caseating material passes through the medial dorsal cutaneous nerves.
  - b. Away from the midline, when caseating material passes through the lateral cutaneous nerve.
  - c. Cold abscess may form in relation to psoas muscle (in dorsi-lumbar or lumbar).

It passes through psoas sheath. It causes psoas spasm causing flexion of hip with inability to extend. If abscess extends below the inguinal ligament, then it is cross-fluctuant.

3. Spinal cord involvement—causes *paraplegia* (10%). This is common in thoracic spine, as the spine is narrow.

- a. *Early paraplegia* ('Paraplegia in flexion', 'paraplegia with active disease').

It is due to:

- Pressure by caseating material, granulation tissue and sequestrum.
- Tuberculous meningitis.
- Spinal cord oedema.
- Endarteritis of segmental spinal artery.
- Pressure from distended disc.

- b. *Late paraplegia* ('Paraplegia with a healed disease', 'paraplegia with extension').

It is due to:

- 'Gibbus' causing stretching of the spinal cord.
- Longitudinal shrinkage of the spinal cord due to gliosis.

### Clinical Features

- ◆ Pain in the back, often with tingling sensation along the distribution of nerve roots.
- ◆ In upper thoracic tuberculosis, typical '*military attitude*' with raised shoulder which is drawn backwards is seen.
- ◆ *Kyphosis (gibbus)* is the commonest deformity. It can be angular but also can be rounded.
- ◆ Tenderness in the spine with paraspinous spasm.
- ◆ All active and passive movements of spine are restricted.
- ◆ '*Coin test*'—inability to pick up a coin is positive.
- ◆ Weakness and decreased power in the limb muscles, with altered sensation.

### Investigations

- ◆ X-ray spine shows:
  - ▶ Narrowing of the disc space.
  - ▶ Wedging of the vertebra.
  - ▶ Rarefaction of the adjacent vertebra.
  - ▶ Soft tissue shadow of cold abscess.
- ◆ Chest X-ray PA view.
- ◆ ESR.
- ◆ Radioisotope bone scan.
- ◆ CT scan or MRI of spine.

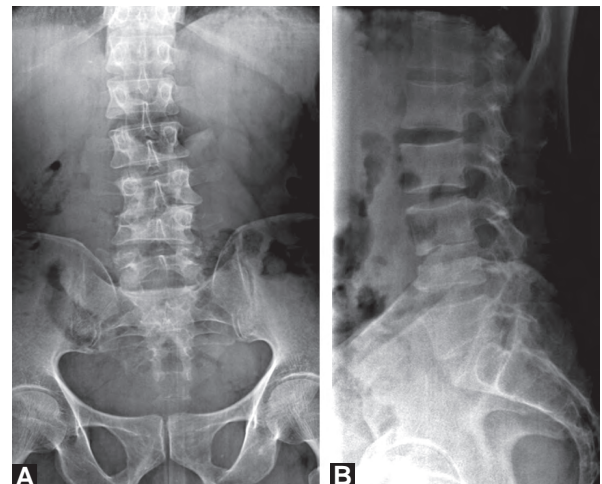


Fig 27.34A and B: Typical tuberculosis of spine involving L4 and L5 spine X-ray features.

## Differential Diagnosis

- ◆ Secondaries in the spine.
- ◆ Spinal tumours.
- ◆ Scheuermann's disease (osteochondritis).
- ◆ Old compression fracture of the vertebra.
- ◆ Ankylosing spondylitis.

### Complications of Pott's spine

- ❖ Kyphosis
- ❖ Cold abscess
- ❖ Paraplegia
- ❖ Sinus formation
- ❖ Dissemination

## Treatment

- ◆ Anti-tuberculous drugs for one year.
- ◆ Rest with plaster jacket (SPICA).  
Patient gains weight, X-ray shows re-calcification and healing. ESR becomes normal. Pain and spasm disappears.

### Indication for surgery

- ❖ When the disease is progressive
- ❖ When there is neurological manifestation
- ❖ Cold abscess formation

## Surgeries

### Note:

No posterior approach, no laminectomy for TB spine.

- Anterolateral approach and costotransversectomy with removal of all caseating material with bone grafting.
- Drainage of cold abscess.
- Posterior spinal fusion using bone graft. Bone graft is taken from the iliac crest.

## SPINAL TUMOURS

### Classification

#### A. Extradural tumours

- ▶ Commonest is secondaries.
  - They lie between the dura, bone and ligamentum flavum.
  - Primary sites are bronchus, breast, prostate, kidney. Rare extradural tumours are sarcomas, osteoclastoma, chondroma, lipoma.

#### B. Intradural tumours

1. *Extramedullary* (75% of intradural)
  - Neurofibromas are the commonest, more common in males.
    - Arises from the posterior nerve root. It can be 'dumb-bell' tumours.
  - Spinal meningiomas are seen exclusively in females.

2. *Intramedullary* (25% of intradural)
  - Commonest is diffuse gliomas (50%). Others are ependymomas, vascular malformations.
  - Common in cervical cord.

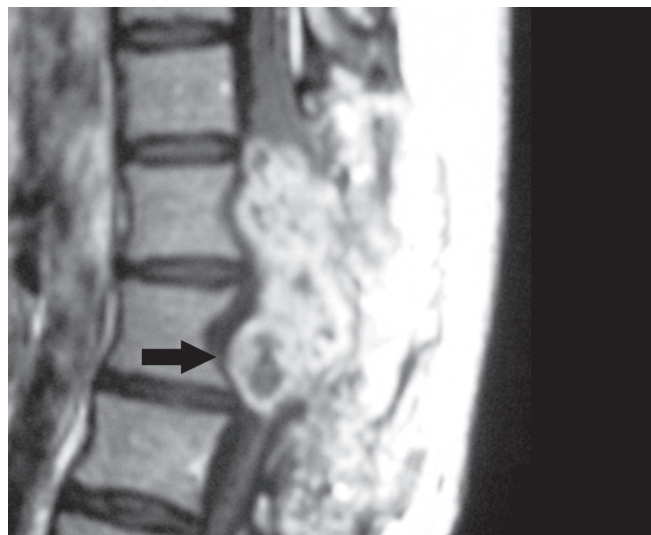


Fig. 27.35: MRI spinal cord showing spinal cord tumour—ependymoma.

## Clinical Features

- ◆ Weakness of limbs, often with paraplegia.
- ◆ Tingling and numbness.
- ◆ Disturbance in micturition.
- ◆ Changes in tendon reflexes.
- ◆ Pain in the back.

*Spinal cord or cauda equina compression is a surgical emergency.*

## Investigations

- ◆ X-ray shows widening of space and destruction.
- ◆ Myelography.
- ◆ Lumbar puncture *per se* has no role, as it is dangerous.
- ◆ CSF below the block may be yellow and proteinaceous and is called as 'Froin's syndrome'.
- ◆ Protein levels in lumbar CSF is usually raised in the presence of lumbar tumours, commonly 'Schwannomas'.
- ◆ CT scan.
- ◆ MRI.

## Surgery

- ◆ Surgery is the main treatment—*Decompression of spinal cord and removal of tumour* by doing laminectomy.
- ◆ Adjuvant therapy: Radiotherapy and chemotherapy.
- ◆ Intrathecal methotrexate is also beneficial.

*No head injury is so slight that it should be neglected, or so severe that life should be despaired of.*

—Hippocrates, Father of Medicine

# Chapter 28A

## Thorax

### CHAPTER OUTLINE

❖ Chest Injuries	❖ Shock Lung	❖ Cardiac Tamponade
❖ Fracture Ribs	❖ Pulmonary Embolism	❖ Diaphragmatic Hernia
❖ Flail Chest and Stove in Chest	❖ Surgical Emphysema	❖ Pulmonary Complications during Postoperative Period
❖ Pneumothorax	❖ Lung Cysts	❖ Surgical Management of Pulmonary Tuberculosis
❖ Tension Pneumothorax	❖ Mediastinal Tumours	❖ Video-assisted Thoracoscopic Surgery
❖ Haemothorax	❖ Thymomas	
❖ Pleural Tap	❖ Lung Cancers	
❖ Bronchoscopy	❖ Pancoast Tumours	
❖ Empyema Thoracis	❖ Chest Wall Tumours	
❖ Empyema Necessitans	❖ Pericarditis	
❖ Lung Abscess	– Acute Pericarditis	
❖ Intercostal Tube Drainage	– Chronic Constrictive Pericarditis	
	❖ Pericardial Tap	

### ■ CHEST INJURIES

#### Types

- ◆ Crush injuries involving lung, pleura, ribs.
- ◆ Single rib fracture.
- ◆ Two or more rib fractures.
- ◆ *Steering wheel injury*—causes multiple rib fractures, bilaterally often with flail chest, with fracture dislocation of upper end of sternum.
- ◆ Stove in chest or flail chest.
- ◆ Traumatic pneumothorax.
- ◆ Haemothorax, haemopneumothorax, with fracture ribs.
- ◆ Tension pneumothorax.
- ◆ Pericardial, cardiac injuries and rupture of bronchus.
- ◆ Associated injuries in liver, spleen, diaphragm, major vessels.

#### Causes

- ◆ Road traffic accidents.
- ◆ Industrial accidents.
- ◆ Blast injuries.
- ◆ Crush injuries.
- ◆ Stab injuries.

- ▶ In children, ribs are malleable and so fracture ribs are rare.
- ▶ In elderly because of rigid ribs fracture is common.
- ▶ First and second ribs are protected by clavicle and so their fracture is uncommon.
- ▶ 11th and 12th ribs are floating ribs and so their fracture is rare.

#### Classification of Chest Injuries

As per the *American College of Surgeons Committee on Trauma* chest injuries are classified as (deadly dozen):

1. Immediately life-threatening injuries.
2. Potentially life-threatening injuries.

<b>Immediately life-threatening injuries</b>	<b>Potentially life-threatening injuries</b>
• Airway obstruction	• Tracheobronchial disruption
• Tension pneumothorax	• Aortic disruption
• Open pneumothorax	• Diaphragmatic disruption
• Massive pneumothorax	• Esophageal disruption
• Cardiac tamponade	• Cardiac contusion
• Flail chest	• Pulmonary contusion

## Pathological Effects of Chest Injuries

Immediate	Late
Hypoxia	Empyema, fibrothorax
Hypercarbia	Lung abscess
Acidosis	Mediastinitis
Hypovolemic shock	Cardiac arrhythmias
Bronchospasm	

## Clinical Features of Thoracic Injuries

- ◆ History of trauma, painful breathing, cough, haemoptysis, pain in the chest wall, sometimes external wound may be present (in communicating wounds).
- ◆ Features of shock when major vessels are involved, i.e. tachycardia, hypotension, cold periphery.
- ◆ Respiratory distress—tachypnoea, cyanosis, respiratory difficulties.
- ◆ Tenderness over the fracture site.
- ◆ Dullness on percussion with decreased breath sounds signifies haemothorax. Resonant with decreased breath sound confirms pneumothorax.
- ◆ Surgical emphysema with palpable crepitus may be present.

## Investigations

- ◆ Chest X-ray shows haemothorax, pneumothorax, fracture ribs.
- ◆ Hb%, PCV to assess blood loss.
- ◆ Blood grouping and cross matching.
- ◆ Blood gas analysis, i.e. PO<sub>2</sub> and PCO<sub>2</sub>.
- ◆ Ultrasound abdomen to look for associated abdominal injuries. FAST (Focused abdominal sonar trauma).
- ◆ CT chest and CT abdomen.

## Treatment

### Initial First Aid

- ◆ **Airway:** Prevention of aspiration, plastic airway, intubation, tracheostomy.
- ◆ **Breathing:** ICT placement, supportive measures.
- ◆ **Circulation:** Fluid therapy, CVP line, blood transfusion.
- ◆ Look for disability.
- ◆ Expose the patient properly for proper breathing and assisting.
- ◆ Assess the patient properly.
- ◆ Examine the patient thoroughly.
- ◆ Evaluate the patient for associated injuries like of head, abdomen, fracture limbs, spine.

### Further Treatment

- ◆ Fracture rib without complication is treated with analgesics and rest.
- ◆ Haemothorax, pneumothorax should be treated with **intercostal tube drainage** (ICT) with underwater seal.
- ◆ Flail segment should be treated accordingly.
- ◆ Blood transfusion is done whenever required.
- ◆ Antibiotics like penicillin, cefotaxime, etc. to prevent infection.
- ◆ Nasal oxygen, throat suction.

- ◆ Ventilator support with IPPV (Intermittent positive pressure ventilation), with regular monitoring of blood gas.
- ◆ Tracheostomy/endotracheal intubation is done whenever required.
- ◆ Antibiotics, bronchodilators, often steroids are other supportive measures required.

### Indications for thoracotomy

- ◆ Haemothorax more than 1500 ml found when ICT is placed or hourly collection in ICT is 200–300 ml
- ◆ ICT placed shows persistent drainage of blood
- ◆ Diaphragmatic injury
- ◆ When associated with liver and spleen injuries
- ◆ Bronchus and major vessel injuries
- ◆ Haemopericardium
- ◆ Oesophageal and thoracic duct injuries

## Principles of Management of Chest Injuries

- ◆ Pulmonary physiotherapy.
- ◆ Aspiration of secretions—trachea, nasotracheal, oral, pharyngeal.
- ◆ Pain relief—oral narcotics, intercostal nerve block, epidural anaesthesia.
- ◆ Respiratory supports—encourage coughing, chest percussion, deep inspiration efforts, humidification, mobilisation.
- ◆ ICT placement for haemo/pneumothorax.
- ◆ Management of shock.
- ◆ Focused abdominal sonography on trauma (FAST).
- ◆ Surgery when indicated—thoracotomy and proceed.
- ◆ Management of complications—DVT and embolism, tracheostomy problems, ICT problems, sepsis, ARDS, empyema treatment, bronchopleural fistula, bronchial stenosis, chylothorax, clotted haemothorax, atelectasis.

## Complications

- ◆ Infections—empyema, lung abscess, pneumonia, septicaemia.
- ◆ Respiratory failure.
- ◆ Traumatic asphyxia.
- ◆ Traumatic shock lung.
- ◆ Disseminated intravascular coagulation (DIC).
- ◆ ARDS (Adult respiratory distress syndrome).

### Note

- Incidence of thoracic injury is 25% of all injuries.
- 75% to 80% of them are managed nonoperatively—transfusion, ICT placement, critical care.
- Mortality due to thoracic injury is 20% to 25%.
- **Chest X-ray** is the *immediate (first choice) investigation* required; chest X-ray may be required to be repeated in 12–24 hours even if earlier X-ray is apparently normal. Pneumothorax, haemothorax, diaphragmatic hernia with bowel in the thoracic cavity are identified in chest X-ray.
- Imaging thorax (USG chest) during ultrasound abdomen (FAST) is also useful in initial assessment.
- CT scan is the *most reliable investigation* in major thoracic injury. It reveals injuries to lungs, major vessels, pericardium, oesophagus, bronchi, etc.
- ICT placement is the *most common intervention* done and life-saving procedure in majority of thoracic injuries. In emergency situation one should not wait for chest X-ray or ultrasound chest

if it causes delay instead should place ICT at the earliest. ICT is diagnostic and therapeutic.

- *Sucking chest wound* should not be closed without any ICT placement to avoid formation of unstable tension pneumothorax.
- Often bleeding may be due to injury to intercostal vessels or internal mammary vessels mainly in blunt injury chest; it is managed by ICT placement and ligation of the specific vessels.
- Blood transfusion may be required in massive haemothorax.
- *Associated injuries* like fractures, spine injury, head and abdominal injuries should be looked for.
- *Diaphragmatic injury is often silent.* Serial chest X-rays, CT chest, video-assisted thoracoscopy (VATS) with laparoscopy gives the diagnosis. Immediate surgery is required. Nasogastric tube should be passed. Through thoracotomy or laparotomy approach contents are reduced; diaphragm is sutured using interrupted nonabsorbable sutures—number one polypropylene mattress sutures are usually placed. ICT is placed:
- **Deadly dozen chest injuries** should be remembered. They are:
  - *Immediately life-threatening injuries are*—Airway obstruction; tension pneumothorax; open pneumothorax; massive haemothorax; flail chest; pericardial tamponade.

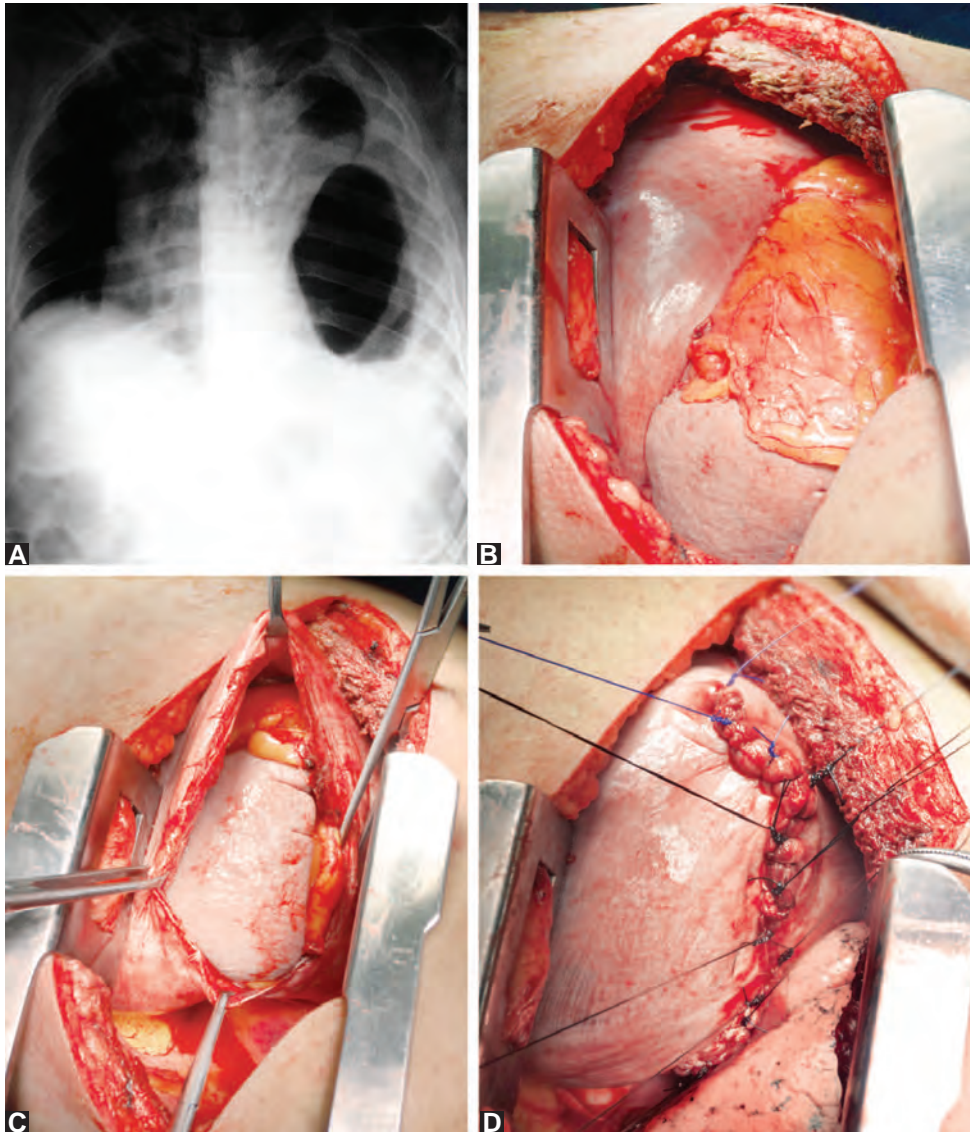
- *Potentially life-threatening injuries are*—Aortic and tracheobronchial injuries; myocardial contusion; rupture of diaphragm; oesophageal injuries; pulmonary contusion.
- ◆ Emergency thoracotomy is required to have internal cardiac massage, to control major bleed from lungs, heart or major vessels, oesophageal injury, massive air leak.

## ■ FRACTURE RIBS

- ◆ Rib fractures are rare in children as ribs are malleable.
- ◆ Fracture ribs are common in elderly as ribs are rigid and nonmalleable.
- ◆ 1st and 2nd ribs are covered by clavicle and so rarely fractures.
- ◆ Floating 11th and 12th ribs rarely get fractured.

## Causes for Fracture Ribs

- ◆ Road accidents, chest injuries.
- ◆ Direct trauma.
- ◆ Blast injuries.



**Figs 28.1A to D:** Traumatic diaphragmatic hernia—chest X-ray showing stomach in the left hemithorax; on table finding of injury to the diaphragm; repaired diaphragm.

## Features of Rib Fracture

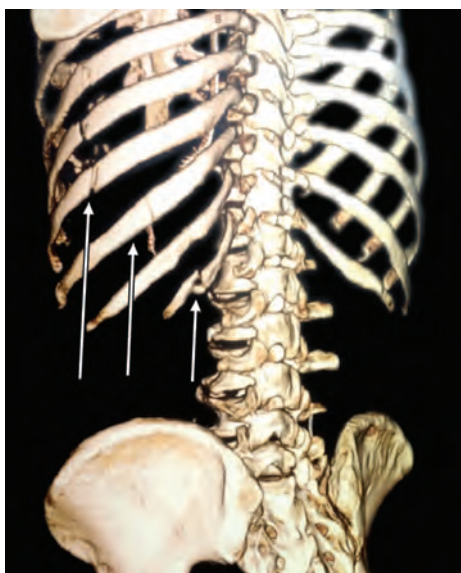
- ◆ Difficulty and pain during breathing.
- ◆ Tenderness over fracture site.
- ◆ Spring test is positive.
- ◆ Propped up position is more comfortable than lying down.
- ◆ Features of haemothorax, lung injuries.
- ◆ Features of abdominal injuries like of liver and spleen injuries.

## Problems in Fracture Ribs

- ◆ Surgical emphysema.
- ◆ Haemothorax, pneumothorax.
- ◆ Cardiac and or major vessel injury.
- ◆ Diaphragmatic injury.
- ◆ Flail chest.
- ◆ Asphyxia, cyanosis, respiratory failure.
- ◆ Pneumonia.

## Investigations

- ◆ Chest X-ray is diagnostic.
- ◆ CT chest or abdomen to check deep or solid organ injury.
- ◆ Arterial blood gas analysis.



**Fig. 28.2:** CT reconstruction image of thoracic cage showing fracture lower ribs—left sided; haemothorax, splenic injury, diaphragmatic injury should be suspected.

## Treatment

- ◆ Control of pain.
- ◆ Prevention of infection.
- ◆ Respiratory physiotherapy.
- ◆ Treatment for definitive conditions like flail chest, ICT placing for haemo/pneumothorax.

### Non-traumatic rib fracture

- ❖ Stress fracture
- ❖ Metastatic fracture
- ❖ Metabolic cause like hyperparathyroidism
- ❖ Osteogenesis imperfecta
- ❖ Child abuse
- ❖ Old age—osteoporosis

## FLAIL CHEST AND STOVE IN CHEST

- ◆ It is fracture of *two or more consecutive ribs*, with each rib having *two or more* fracture sites. Such segment is called as **flail segment**.
- ◆ **Stove in chest** is depression of a portion of chest wall due to severe chest injury, otherwise features and management are like flail chest.

## Pathophysiology

Flail segment moves independent of the adjacent thoracic cage. During inspiration flail segment moves inwards (unlike normal thoracic cage which moves outward), and during expiration the segment moves outwards (unlike normal cage which moves inward) causing pathophysiological derangements.

- ◆ This *paradoxical respiration* causes reduction in ventilatory lung surface and so respiratory dysfunction.
- ◆ *Mediastinal flutter*: Movement of mediastinum during different phases of respiration occurs, often causing kinking of great vessels and sudden cardiac arrest.
- ◆ *Pendular movement of air* from one lung to other occurs, and thus preventing atmospheric air to get into both injured and otherside normal lung leading to respiratory failure.
- ◆ All these derangements gets aggravated by *haemothorax*, *pneumothorax* and other associated injuries.
- ◆ There is *hypoventilation*: Carbon dioxide retention and respiratory failure.

### Flail chest

Derangements	Types	Problems
<ul style="list-style-type: none"> <li>• Paradoxical respiration</li> <li>• Mediastinal flutter</li> <li>• Pendular movement of air</li> <li>• Pulmonary contusion</li> </ul>	<ul style="list-style-type: none"> <li>• Anterior—near costochondral junction</li> <li>• Lateral—in rib shafts</li> <li>• Posterior—safer, due to support of scapula</li> </ul>	<ul style="list-style-type: none"> <li>• Cardiac arrest</li> <li>• Respiratory failure</li> <li>• Haemothorax</li> <li>• Infection</li> <li>• ARDS</li> </ul>

### Note

Flail chest is a clinical diagnosis.

## First Aid

The paradoxical movement of flail segment is prevented by applying pressure over it using hand or clothes (It is often life saving.) It makes other lung function adequately.

## Investigations

- ◆ Chest X-ray—to identify the fracture segment.
- ◆ Blood grouping.
- ◆ Arterial PO<sub>2</sub> and PCO<sub>2</sub> and serum electrolytes.

## Treatment

- ◆ Intercostal tube drainage.
- ◆ Applying clips to fracture ribs and fixing above and below to normal ribs.
- ◆ Antibiotics like penicillins, cefotaxime.
- ◆ Blood transfusion, IV fluids.
- ◆ Bronchodilators, steroids.
- ◆ Ventilator support with IPPV—IPPV is treatment of choice. Assisted ventilation is required for several days until the chest wall stabilises. If ventilator support is required for more than 10 days, then tracheostomy is done to prevent laryngeal stenosis which can occur due to prolonged endotracheal intubation.
- ◆ Thoracotomy—when required only.

## PNEUMOTHORAX

*The means we possess of reducing (a diseased lung) to a state of collapse, or of divesting it for a time of its peculiar functions, are equally simple and safe. In those cases in which the disease is placed in one of the lungs only, the remedy (i.e. induced pneumothorax) would appear to be simple, safe, and complete*

—James Carson, 1820

It is the presence of air between the layers of pleura.

### Classification I

- a. Pneumothorax.
- b. Hydropneumothorax.
- c. Pyopneumothorax.
- d. Haemopneumothorax.
- e. Artificial pneumothorax.
- f. Tension pneumothorax.

### Classification II

- a. Open pneumothorax
- b. Closed pneumothorax
  - ▶ Simple
  - ▶ Tension

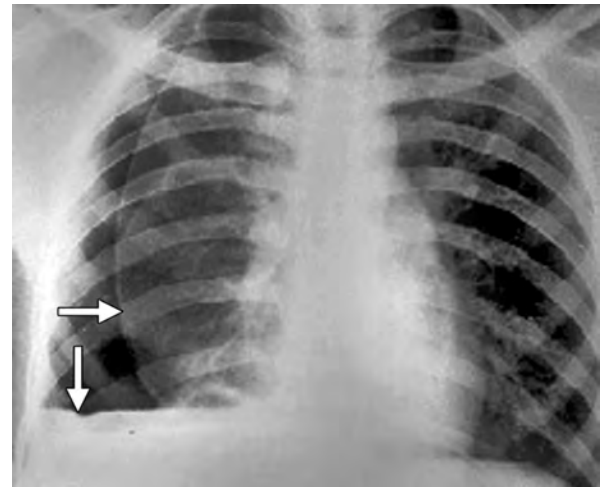
*Open pneumothorax* is a sucking chest wound, with wound usually more than 3 cm in size. Here lung collapses and causes severe hypoventilation. A large sized chest tube should be placed; sucking wound is closed with creation of three side flutter valve. Often thoracic tube may be connected to suction apparatus with a low pressure to facilitate lung expansion.

Additional drain is often justified. Respiratory care, early mobilization and physiotherapy is useful.

## Causes

- ◆ Traumatic.
- ◆ Spontaneous.
  1. Tuberculous.
  2. Non-tuberculous:
    - a. Rupture of emphysematous bullae.
    - b. Rupture of solitary lung cyst.
    - c. Honeycomb or cystic lung.
    - d. Idiopathic.

*Spontaneous pneumothorax can be acute, chronic, recurrent.*



**Fig. 28.3:** Plain X-ray chest PA-view showing air-fluid level and collapsed lung margin (Hydropneumothorax)

## Clinical Features

Hyperresonant, absence of breath sounds, tracheal deviation.

### Chest X-ray reveals

- ❖ Radiolucency on the affected side
- ❖ Absence of lung markings
- ❖ Collapsed lung margin

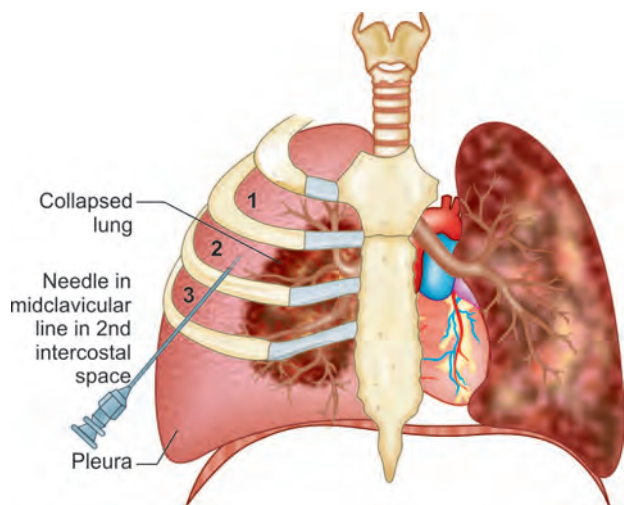
## Treatment

- ◆ In tension pneumothorax, emergency needle aspiration is done followed by ICT placement.
- ◆ ICT placement.
- ◆ The cause is treated.
- ◆ Often thoracotomy is required, if there is persistent broncho-pleural fistula or ruptured cyst or bullae.

## TENSION PNEUMOTHORAX

- ◆ During inspiration, air is pumped into the pleural cavity through a valvular opening in the visceral pleura and underlying injured lung.
- ◆ Lung collapses first, and as air continuously collects in the pleural cavity, mediastinum shifts towards the opposite side, further decreasing the volume of the functioning lung.

- ◆ Further increase in the pleural pressure, reduces the venous return, atrial filling, and ventricular filling and so cardiac output and cardiac function.



**Fig. 28.4:** Emergency decompression through 2nd intercostal space.

*It causes sudden death and hence emergency treatment is required.*

**Clinical features**

- ❖ Tachypnoea and tachycardia
- ❖ Decreased/absent breath sounds
- ❖ Resonant on percussion with severe mediastinal/tracheal shift
- ❖ Cyanosis and hypotension
- ❖ Chest pain, distended neck veins

**Management**

- ◆ *Once clinically diagnosed, a wide bore needle is immediately placed in the second intercostal space in midclavicular line, and a sterile glove is kept on the hub (blunt) end of the needle to create a valve so as to prevent inward sucking of air from outside—thoracocentesis.*
- ◆ Nasal oxygen is used.
- ◆ Once patient is better, chest X-ray is done.
- ◆ Later an intercostal tube is passed (ICT placement).
- ◆ Antibiotic, analgesics are given.
- ◆ In severe cases ventilator support with IPPV is required.

**HAEMOTHORAX**

It is blood in pleural cavity. It causes pain, shock, as it is very irritant to pleural cavity.

It is a good culture media for bacteria and so infection is quite common.

**Causes**

- ◆ Trauma.
- ◆ Postoperative: Pulmonary, cardiac, oesophageal surgeries, cervical sympathectomy, leak from CVP monitor line.

- ◆ Tumours of lung, mediastinum, pleura.
- ◆ Leaking aneurysms.
- ◆ Spontaneous.  
There may be rib fractures in traumatic haemothorax.

**Clinical features**

- ❖ Pain in the chest, tenderness
- ❖ Difficulty in breathing, dullness on percussion diminished breath sounds
- ❖ Features of shock

**Investigations**

- ◆ Chest X-ray.
- ◆ Aspiration (pleural tap).
- ◆ Chest CT scan.

**Treatment**

1. ICT placement in the mid-axillary line in the 6th intercostal space.
2. Antibiotics, bronchodilators.
3. Thoracotomy:

**Indications of thoracotomy**

- ❖ Initial chest tube output of 1500 ml of blood or persistent drainage of 200–300 ml/hr.
- ❖ Clotted haemothorax is difficult to manage. It requires thoracotomy, evacuation and decortication of lung. Initially liquefaction of the clot is tried by infusing of streptokinase and trypsin into the pleural cavity

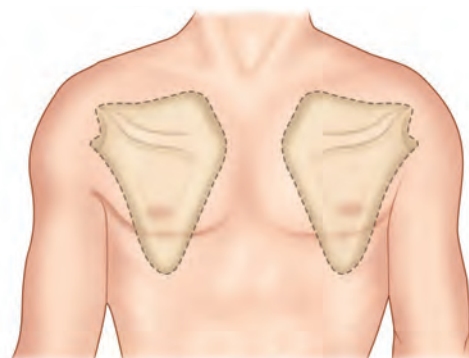
**Complications**

- ◆ Infection and empyema.
- ◆ ARDS: respiratory failure.

**PLEURAL TAP**

**Indications**

- ◆ Pleural effusion—both for diagnostic as well as therapeutic purpose. The fluid is sent for culture, cytology, microscopy, specific gravity, biochemical analysis of proteins for diagnosis of tuberculosis, malignancy.
- ◆ In empyema thoracis, for diagnostic purpose before placing an ICT.



**Fig. 28.5:** Sites of pleural tap.



## Position

In sitting position, leaning forward over a wooden support.

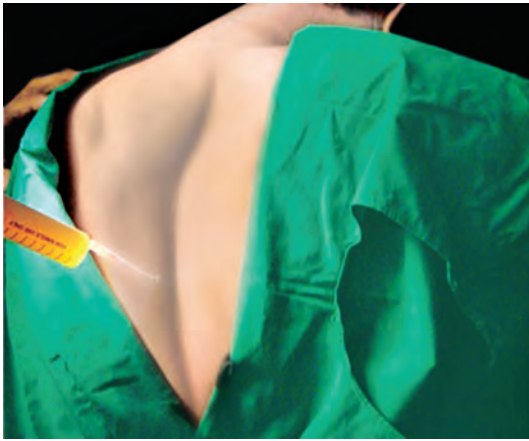
## Site

Tip of scapula at 7th intercostal space (posteriorly).

Under local anaesthesia wide bore needle (Abraham needle) is passed to tap the fluid.

### Complications

- ❖ Infection
- ❖ Dry tap or bloody tap
- ❖ Sudden vagal shock
- ❖ Pain and respiratory distress



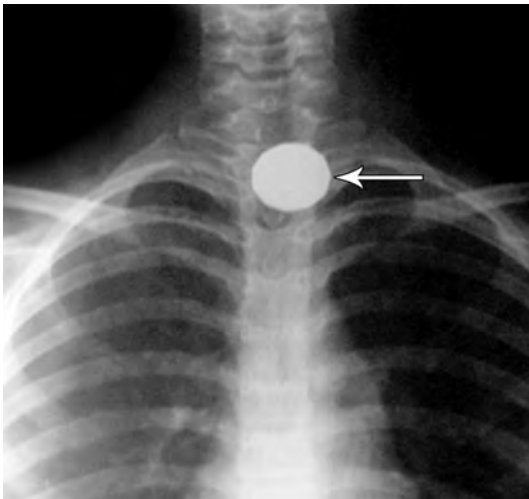
**Fig. 28.6:** Position for pleural tap is sitting and leaning forward over a support. Site is below the scapula, posteriorly through the seventh intercostal space.

## BRONCHOSCOPY

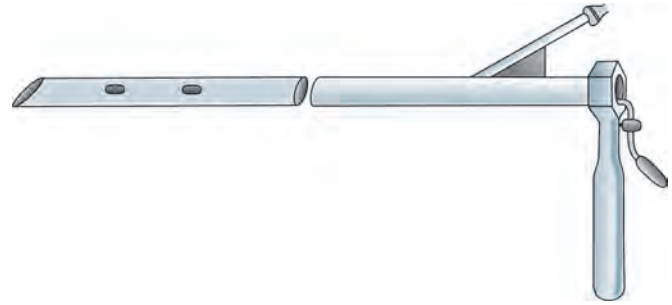
### Indications

*Diagnostic:* To take biopsy in conditions like carcinoma lung, lung abscess, pulmonary tuberculosis.

*Therapeutic:* To remove foreign body, to suck out the bronchial secretions.



**Fig. 28.7:** Foreign body in trachea. This can be removed using a bronchoscope. Patient may develop collapse of lung, pneumonia, respiratory failure and ARDS.



**Fig. 28.8:** Bronchoscope.

### Types

- ◆ *Rigid bronchoscopy*—it is used for removal of foreign body and bronchial wash. It reaches up to third generation bronchioles. It is used to take biopsy from carcinoma of proximal divisions but not from carcinoma of peripheral lung. Rigid scope has got multiple holes to allow ventilation during the procedure (Oesophagoscope does not have side holes). It is done under general anaesthesia.
- ◆ *Flexible bronchoscopy*—it reaches up to 5th generation bronchioles. It can be done under local anaesthesia. It is mainly used for diagnosis and biopsy.

### Complications

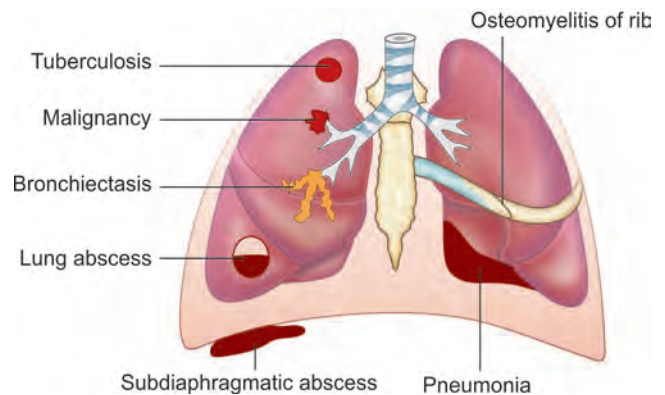
- ❖ Bleeding
- ❖ Infection
- ❖ Perforation
- ❖ Bronchospasm

## EMPHYEMA THORACIS

*The pleurisia is an inflammation of the membrane, investing the ribs, caused by subtle and choleric blood.... If it tend to suppuration, it commonly infers a pricking pain, a fever and difficulty of breathing.... If nature being too weak...the disease is turned into an empyema, wherefore the Chirurgeon must then be called, who...may make a vent between the third and fourth true and legitimate ribs.... The pus or matter must be evacuated by little and little at several times; and the capacity of the chest cleansed from the purulent matter.*

—Ambroise Paré, 1575

It is collection of pus in pleural cavity.



**Fig. 28.9:** Causes of empyema.

## Causes

An empyema is never primary.

Secondary causes are:

- ◆ From chest wall: Wounds, osteomyelitis of ribs.
- ◆ From lung: Pneumonia, abscess, bronchiectasis, tuberculosis, growth.
- ◆ Postoperative: After thoracotomy.
- ◆ From oesophagus: Perforations, carcinoma.
- ◆ From below diaphragm: Subphrenic abscess.

Tuberculosis and pneumonia are common causes in developing countries.

## Pathology

- ◆ Initially serous fluid collects, which eventually becomes purulent. Intrapleural clotting of pus occurs with thickening of pleura and later fibrinous adhesion forms resulting in matured empyema.
- ◆ Chest is withdrawn inwards and is immobile, mediastinum is drawn inwards, diaphragm gets elevated.
- ◆ It leads to rigid contracted immobile chest with functionless lung underneath—*frozen chest*. Often pus perforates through intercostal space and forms *empyema necessitans*.

### Stages of empyema

- ❖ Acute empyema
- ❖ Subacute empyema
- ❖ Chronic empyema

### Organisms:

Initially staphylococci, streptococci, pneumococci, and later *Entamoeba coli*, *Pseudomonas*, drug-resistant staphylococci.

### Clinical types

- ❖ Acute empyema
- ❖ Acute fulminant toxic empyema
- ❖ Subacute empyema
- ❖ Chronic empyema
- ❖ Latent empyema
- ❖ Persistent empyema
- ❖ Empyema necessitans
- ❖ Chronic empyema with sinus
- ❖ Interlobar empyema

### Pathological types

- ❖ Exudative
- ❖ Fibrinopurulent
- ❖ Organising

### Anatomical types (Depending on the anatomical location)

- ❖ Apical
- ❖ Mediastinal
- ❖ Interlobar
- ❖ Diaphragmatic
- ❖ Lateral

## Clinical Features

- ◆ Pain in the chest, tenderness, fever.
- ◆ Difficulty in breathing.
- ◆ Features of toxicity in acute type of empyema.
- ◆ Dullness on percussion, absence of breath sounds.
- ◆ Decreased chest wall movement.

### Complications

- ❖ Frozen chest (functionless lung)
- ❖ Empyema necessitans
- ❖ Osteomyelitis/chondritis of ribs or vertebra
- ❖ Pericarditis
- ❖ Mediastinitis
- ❖ Bronchopleural fistula
- ❖ Dissemination of infection

## Investigations

- ◆ Chest X-ray, ESR.
- ◆ Peripheral smear.
- ◆ Diagnostic aspiration.
- ◆ Pus C/S, AFB.
- ◆ Bronchoscopy.
- ◆ CT scan and MRI for carcinoma bronchus.

## Treatment

### Stage 1

- ◆ Antibiotics.
- ◆ Repeated aspirations.
- ◆ Intercostal tube drainage.
- ◆ Antituberculous drugs.

### Stage 2

- ◆ ICT drainage.
- ◆ Rib resection (*Eloiser's method*).
- ◆ Antibiotics, antituberculous drugs.
- ◆ Respiratory physiotherapy.

### Stage 3

- ◆ **Decortication** is very useful and favourable method. Here, thickened pleural sac is stripped off from the lung through thoracotomy approach.
- ◆ Often **lobectomy** may be required, rarely pneumonectomy is done.
- ◆ Physiotherapy, antibiotics, ATD'S are also essential.

## EMPYEMA NECESSITANS

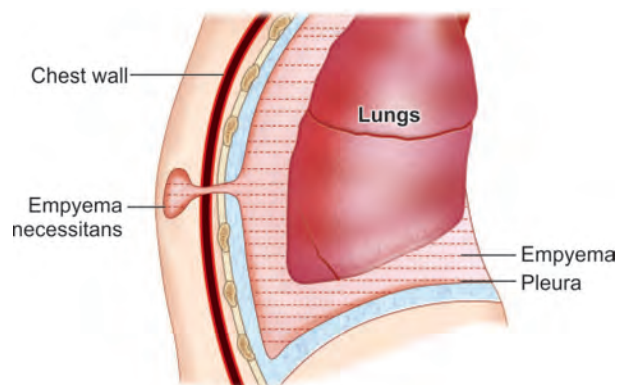


Fig. 28.10: Empyema necessitans.

It is a complication of empyema thoracis, *wherein empyema* which is not drained perforates through the chest wall presenting as subcutaneous collection of pus communicating directly or often with a tortuous route with the pleural cavity.

### Causes

- ◆ Neglected empyema either of tuberculous or nontuberculous aetiology.
- ◆ Following incomplete aspiration of pus of empyema through a thin needle—needle track itself allows pus to form a track and leads to *empyema necessitans*.

### Clinical Features

A diffuse, tender, smooth, soft, fluctuant, swelling in the intercostal space having *impulse on coughing*.

#### Features of empyema necessitans

- ❖ Bulge in the intercostal space
- ❖ Restricted movement of chest wall
- ❖ Tenderness
- ❖ Dullness on percussion without breath sounds
- ❖ Impulse on coughing

### Investigations

- ◆ Chest X-ray.
- ◆ Total count is increased.
- ◆ ESR.

### Treatment

- ◆ Antibiotics.
- ◆ Empyema is drained by placing an ICT. Pus is sent for C/S and AFB.
- ◆ If it is tuberculous, antitubercular drugs are started.
- ◆ Empyema necessitans subsides on its own when empyema is treated.
- ◆ But often may require separate incision and drainage when track is tortuous.

## LUNG ABSCESS

- ◆ It is localised suppuration in the lung with tissue necrosis.
- ◆ It is end-stage of suppurative pneumonitis with thrombosis of associated artery.

### Aetiology

- ◆ Pneumonias due to *Streptococcus*, *Pneumococcus*, *Haemophilus*, *Staphylococcus*, anaerobic and other bacteria.
- ◆ Bronchial obstruction due to tumours or foreign body.
- ◆ Chronic upper respiratory infection due to sinusitis, tonsillitis and dental infection (anaerobic infection).
- ◆ Septicaemia.
- ◆ Aspiration.

As pus accumulates, tension increases inside the abscess cavity causing spread into other areas of the lung or may rupture into the bronchus.

#### Note:

Lung abscess secondary to aspiration is commonly seen in apical lower lobe.

#### Clinical features

- ❖ Acute onset of fever, but often it is recurrent in nature
- ❖ Cough with expectoration
- ❖ Haemoptysis with foul smelling sputum
- ❖ Chronic illness with debilitation
- ❖ Pleuritic pain

### Complications

- ◆ Spread into other areas of the lung.
- ◆ *Metastatic cerebral abscess*—Lung abscess is the *commonest* focus for metastatic cerebral abscess. Occurs as a result of pyaemic emboli through paravertebral veins.
- ◆ Haemorrhage, may be torrential due to erosion of the vessel in the abscess wall.
- ◆ Empyema thoracis.

### Differential Diagnosis

- ◆ Pulmonary tuberculosis.
- ◆ Carcinoma lung.
- ◆ Fungal infections like aspergillosis.
- ◆ Pneumoconiosis.
- ◆ Lung cysts.

### Investigations

- ◆ Chest X-ray shows localised opacity with smooth margin and fluid level.
- ◆ Bronchoscopy and biopsy is done to rule out carcinoma.
- ◆ Sputum for culture, AFB and cytology.
- ◆ CT scan.

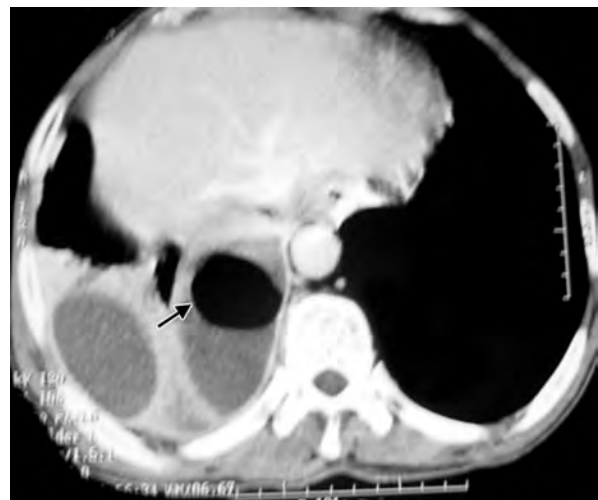

Fig. 28.11: CT scan of lung showing right-sided lung abscess with fluid level.

### Treatment

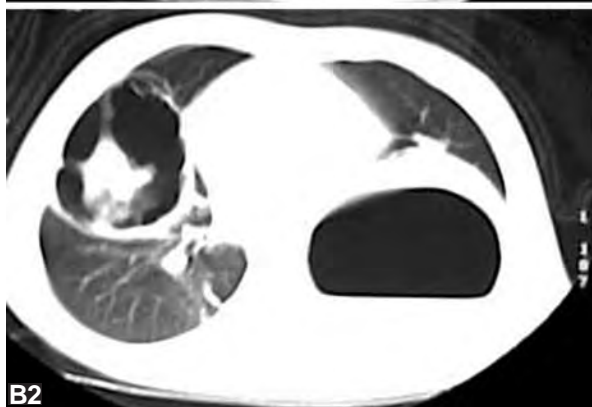
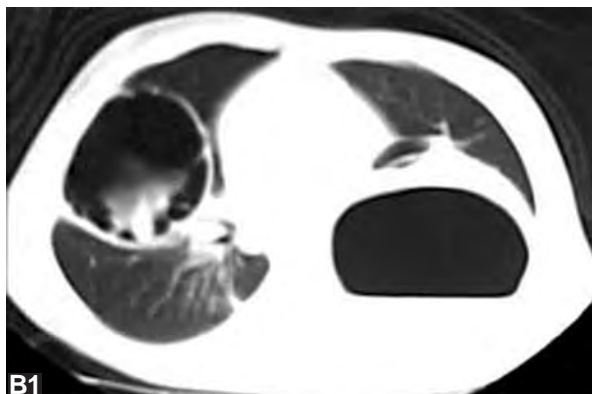
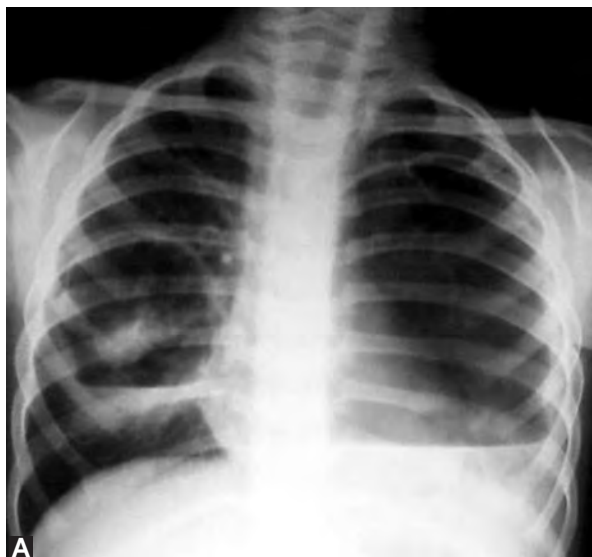#### Medical

- ◆ Appropriate *high dose antibiotics* are started depending on sputum culture like penicillins, third generation cephalosporins like cefoperazone, ceftriaxone for 3–6 weeks.
- ◆ *Postural drainage* for 2–3 hours, 3 times daily.

- ◆ *Periodic culture* of sputum is done to study the response of treatment.
- ◆ 80–90% of acute abscesses resolve by medical therapy.

### Surgical

- ◆ External surgical drainage with rib resection is done in severe acute lung abscess only. Not commonly used procedure.
- ◆ *Lobectomy* is done when medical treatment fails.



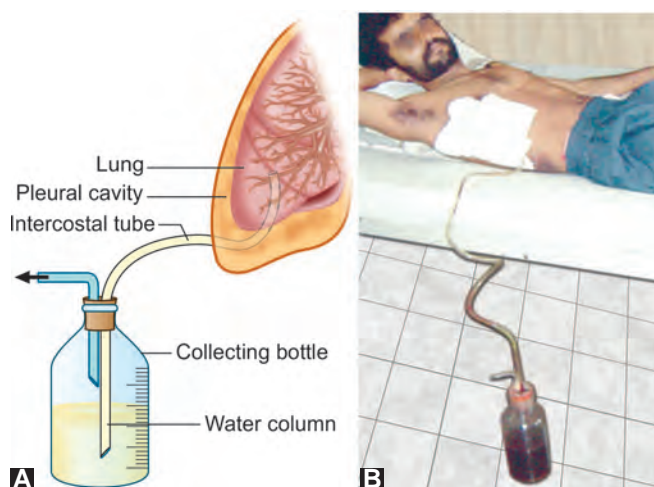
**Figs 28.12A and B:** Lung abscess X-ray picture and CT of the same patient.

## ■ INTERCOSTAL TUBE DRAINAGE

It is the method of draining fluid/blood/air collected in the pleural cavity safely, so as to allow the underlying lung to expand.

### Indications

- ❖ Haemothorax, hydrothorax, chylothorax
- ❖ Pneumothorax
- ❖ Haemopneumothorax
- ❖ Empyema thoracis
- ❖ Traumatic lung contusion
- ❖ After thoracotomy, to drain pleural cavity



**Figs 28.13A and B:** (A) Intercostal tube drainage under water seal; (B) Intercostal tube drainage showing haemothorax.

### Procedure

- ◆ Technique is also called as *tube thoracostomy*; tube is called as chest or intercostal tube or drain (Bulau drain). Concept was first introduced by Hippocrates but popularized by Dr C Pope in 1922.
- ◆ *Chest tube* is made up of clear plastics or PVC; it has got multiple fenestrations on the side which resides inside the thoracic cavity. Ranges from 6 French to 40 French sizes are available. Tube has got a radio-opaque strip. Silastic channel styled chest drains (Blake drains) are available which drain through capillary action and suction; it is less painful.
- ◆ *Drainage canister* is used to collect the blood, air, fluid and so on through a water seal apparatus. *Triple chamber canisters* are often used for better function; here first chamber collects the fluid content. Second chamber acts as water seal which allows the air escape acting as one way valve; it also indicates the air leak from pleura or lung. Third chamber is the suction control chamber; height of water column in

*Clubbing is frequently present in those with a chronic discharging empyema sinus.*

—Hippocrates, Father of Medicine

this regulates the negative pressure so controls the suction system. Only water seal and water column regulator system is 'wet' type; water seal with mechanical regulator is 'wet-dry' type; system without water seal but uses mechanical check valve and mechanical regulator is called as 'dry' system.

- ◆ **Site: Triangle of safety**—British Thoracic Society describes the *safe zone* as—bounded by the lateral border of pectoralis major, a horizontal line inferior to the axilla, the anterior border of latissimus dorsi and a horizontal line superior to the nipple; commonly the tube is inserted into the 5th intercostal space slightly anterior to the midaxillary line; but it may be 6th space below in haemothorax or empyema or it may be upwards in 4th space in pneumothorax. In this point muscle bulk is less and so easy to pass the intercostal tube.
- ◆ **Position:** Patient is kept in supine (with head end up if possible 45°) position. Arm should be abducted and externally rotated with palm of the hand is kept over the patient's head. Cleaning and draping is done. Local anaesthesia xylocaine 1% or 2% is injected at the site of insertion of the tube in the space under the skin, muscle and to parietal pleura; site is just above the rib, i.e. in the lower part of the intercostal space so as to avoid injury to neurovascular bundle which are located in the groove in the lower part of the rib close to the upper part of the intercostal space.
- ◆ **Horizontal skin incision** is made using no 11 blade, 4 cm in length; fascia and intercostal muscles are opened and separated; adequacy of the separation should be confirmed using finger tip; fenestrated end of the selected (No. 28 in adult; No. 18 in children; No. 12 in infants; No. 10 in neonates) chest tube is held firmly using long curved haemostat (Kelly's clamp); outer end is clamped which will be released later; tube is gently forced across the parietal pleurae which gives 'a given way' feel. Tube is easily pushed into the thoracic cavity. Air or blood or fluid will pass through the tube; tube is connected to under water seal apparatus which should be filled with sterile normal saline up to the mark in the canister (Tube is often clamped prior to insertion and released after that). ICT is sutured to the skin using nonabsorbable polyethylene suture; often additional suture bites are taken around and kept untied which will be tied immediately firmly after removal of the ICT (central vertical mattress suture—*sealing suture*). Air tight plaster dressing is placed around to keep the ICT in position.
- ◆ **Movement of the air column** during respiration (and during the act of coughing) should be checked; quantity of fluid or blood collecting also should be observed. *Check chest X-ray* should be taken *immediately* to assess the position of the ICT. O<sub>2</sub> supplementation is often needed; patient should be monitored throughout.
- ◆ Canister or underwater seal bottle or bag should be kept 100 cm below the patient level.
- ◆ Trocar ICT or guide wire directed ICT placement is also used in few centres but they are not popular.

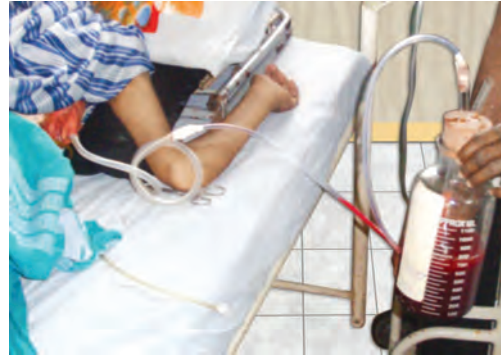

Fig. 28.14: ICT bottle with blood—haemothorax.

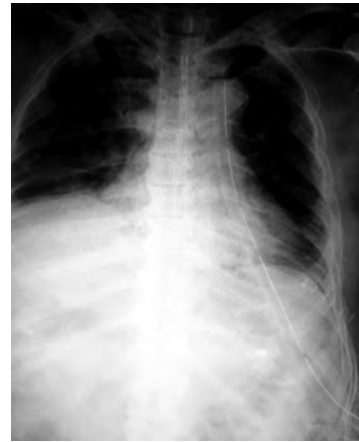

Fig. 28.15: Immediate check chest X-ray should be done to confirm the position of the ICT.

### Postoperative Care

- ◆ **ICT care** is crucial. Movement of the column, quantity of fluid collected should be observed. *Mechanical manipulation* (tapping, milking) gently may be done to correct kinking, clot inside or to facilitate free flow of fluid but they are painful.
- ◆ **Closed chest tube clearing device** using sterile magnetically wired loops can prevent clogging and blocking of the tube so as to prevent formation of retained blood syndrome (haemothorax, pleural effusion, tamponade, atrial fibrillation).
- ◆ Lung expansion should be checked at regular intervals.
- ◆ Usually ICT is placed for 3–5 days for pneumothorax until lung expands adequately which should be confirmed by chest X-ray; for haemothorax for 4–7 days. For bronchopleural fistula ICT should be kept for longer period.
- ◆ **Respiratory physiotherapy** using spirometer or football balloon and breathing exercise should be done.




Fig. 28.16: Spirometer. Respiratory physiotherapy should be done using spirometer.

## ICT Removal

- ◆ It is done once chest X-ray confirms that lung gas has expanded properly, pleural fluid drain becomes serous and less than 25 ml/day for 3 consecutive days, water column movement becomes less than 1 cm.
- ◆ It is removed under all aseptic precaution; suture is removed; patient is asked to take deep inspiration; often outer end of the tube may be connected to low volume suction. At the summit of deep inspiration, tube is pulled out; wound is cleaned quickly and if sealing suture is present it should be tied firmly; sealed plaster dressing is placed to avoid re-entry of air into the plural cavity.

### Contraindications for ICT placement

- ❖ Traumatic diaphragmatic hernia
- ❖ Refractory coagulopathy
- ❖ Pleural adhesions
- ❖ Emphysematous bullae

### Complications

- ❖ *Clogging of the ICT* (40%) is the main complication which commonly goes unnoticed as the part inside the thoracic cavity is gets often clogged. It can cause retained blood syndrome, tension pneumothorax, effusion, haemothorax.
- ❖ *Injury* to intercostal nerve and vessels, diaphragm, liver, spleen, aorta and heart can occur.
- ❖ *Improper placement of the tube.*
- ❖ *Re-expansion pulmonary oedema* can occur if large quantity of fluid or pus drained in effusion or empyema; it may cause sudden onset cough, breathlessness and respiratory arrest (potentially fatal). In such situation gradual decompression is better.
- ❖ Subcutaneous haematoma, seroma, *subcutaneous emphysema* can occur.
- ❖ Displacement, pain, intercostal neuralgia, dyspnoea, cough, infection can occur.

## SHOCK LUNG (Stiff lung)

### Causes

- ◆ Major chest trauma.
- ◆ Septicaemia.
- ◆ Massive blood transfusions.
- ◆ DIC.

### Pathogenesis

Development of microthromboembolism in small lung vessels following extensive intravascular coagulation, leading to pulmonary consolidation, which reduces the lung compliance markedly, causing severe depression of gas exchange in the lung—a *stiff lung*.

It has got high mortality as lung cannot expand at all. Outcome is fatal if emergency treatment is not given.

### Treatment

- ◆ Endotracheal intubation.
- ◆ Ventilator support with IPPV.

- ◆ Antibiotics.
- ◆ High dose of steroids.
- ◆ Monitoring the patient with PCWP and cardiac monitor.
- ◆ Bronchodilators.
- ◆ The cause is treated.

## PULMONARY EMBOLISM (PE)

*From my Stanford days... I had known that excessive bed rest gave rise to thromboembolic complications.... The death rate from thromboembolism was always much less at the County Hospital than it was at Stanford Hospital.... When (the County Hospital patients) got up to go to the bathroom, (they) dislodged only tiny clots from their veins and these did not harm them when they got to the lungs and were dissolved, while the wealthier patients (at Stanford) who remained in bed and formed large clots in their legs and pelvises suffered the major consequences of large pulmonary emboli.*

—William Dock, 1984

- ◆ It is due to deep venous thrombosis (DVT) which gets detached to cause pulmonary embolism.
  - ◆ It may be from femoropopliteal or ileo-femoral region.
- The thrombi most commonly develop in the leg veins due to stasis and hypercoagulable state. They subsequently enlarge and propagate proximally, dislodge to form emboli.

### Types

- ◆ **Small emboli:** Causes pulmonary hypertension of features of bronchopneumonia.
- ◆ **Medium emboli** lodges in branches of pulmonary artery causing chest pain, haemoptysis, dyspnoea.
- ◆ **Large (massive) emboli** causes block at bifurcation of pulmonary artery trunk or right/left pulmonary artery leading to sudden chest pain, severe dyspnoea, shock, raised venous pressure and *sudden death*.

### Effects of pulmonary embolism

- ❖ Decreased cardiac output
- ❖ Pulmonary vasospasm and pulmonary hypertention
- ❖ Bronchospasm
- ❖ Defective oxygenation of blood

### Risk Factors

- ◆ Postoperative and trauma patients who are bed ridden.
- ◆ Pregnant women.
- ◆ Old age.
- ◆ Obesity and heart disease.
- ◆ Varicose veins.
- ◆ All aetiologies which cause DVT.
- ◆ Carcinoma.

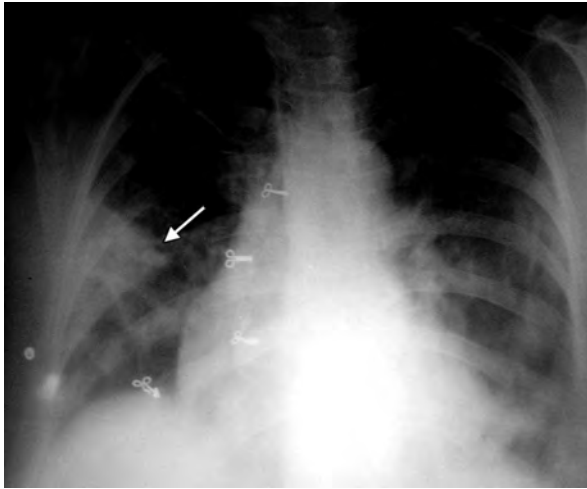
### Clinical features

- ❖ Dyspnoea, chest pain and haemoptysis
- ❖ Tachycardia, tachypnoea and cyanosis
- ❖ Pleural rub and cardiac gallop

*The patient dyspnoeic due to pulmonary embolism prefers to lie flat.—Ronald Gibson*

## Investigations

- ◆ Chest X-ray PA view—hyperlucency in an area of oligaemia—*Westermark sign*.
- ◆ CT scan and MRI—can detect PE.
- ◆ Pulmonary angiography: It is diagnostic (100%).
- ◆ Arterial blood gas analysis.
- ◆ Isotope radionuclide ventilation—perfusion (V/Q) lung scanning: While normal scan rules out PE, evidence of V/Q mismatch is highly suggestive of pulmonary embolism.
- ◆ Doppler study and venography—To rule out DVT.



**Fig. 28.17:** Chest X-ray showing wedge shaped pulmonary infarct.

## Management

- ◆ Thrombolytics: Streptokinase, 6 lakhs units to begin with and later one lakh units hourly.
- ◆ Pulmonary embolectomy with or without bypass by immediate thoracotomy.
- ◆ Venous thrombectomy using Fogarty catheter.
- ◆ Ventilator support.
- ◆ To prevent further embolisation of embolus into the lungs, IVC filters can be placed.
- ◆ Treatment of DVT.

### Note:

*Heparin should not be combined with thrombolytics.*

## ■ SURGICAL EMPHYSEMA

It is collection of gas/air in the subcutaneous or and fascial planes.

### Causes

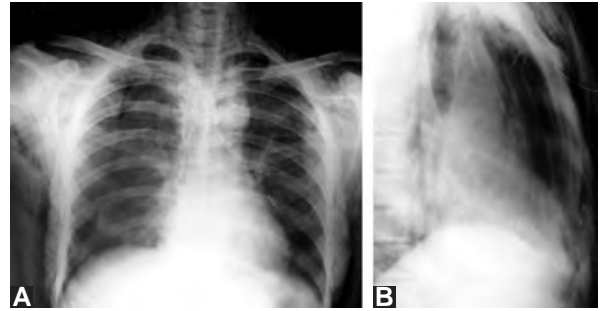
- ◆ Lung injury.
- ◆ Tracheal injury.
- ◆ Chest wall injury.
- ◆ After laparoscopic procedure.

### Types

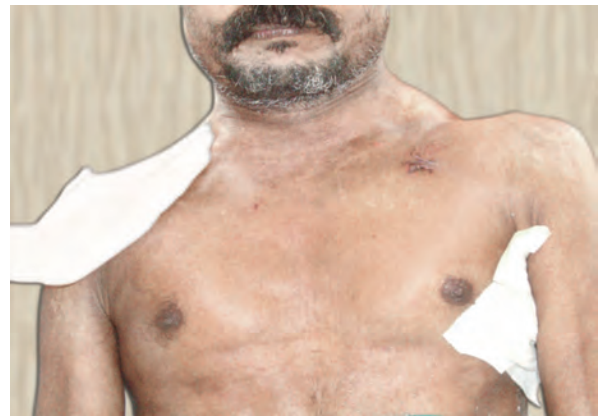- ◆ Localised—observed at the site of trauma.
- ◆ Generalised—extensive in the neck, face, eyelids, chest wall, etc.—in the injury of bronchus, oesophagus and mediastinum.

## Features

- ◆ Pain, diffuse swelling of the subcutaneous region.
- ◆ Palpable *crepitus* is diagnostic.
- ◆ X-ray chest and neck is confirmatory.



**Figs 28.18A and B:** Chest X-ray PA and lateral views showing surgical emphysema.



**Fig. 28.19:** Surgical emphysema. Note the demonstration of crepitus.

## Treatment

- ◆ Conservative treatment—treat the cause.
- ◆ In severe cases—ICT one side or both sides placement.

## ■ LUNG CYSTS

### Types

- ❖ Epithelial cyst
- ❖ Emphysematous cyst
- ❖ Parasitic cyst (Hydatid cyst)
- ❖ Pseudocyst of the lung

### Epithelial Cyst

- ◆ It is of *developmental* origin.
- ◆ It can be large single cyst or small, multiple cysts.
- ◆ It is lined by *respiratory epithelium*.
- ◆ It is often associated with cervical rib or cardiac anomalies.
- ◆ It is common in *infants and children*.
  - ▶ Usual *clinical features* are dyspnoea and chest pain. When infected, presents with fever, cough and haemoptysis.
  - ▶ *Treatment* is excision of the cyst. Antibiotics are given when infected.
  - ▶ *Here spontaneous pneumothorax is uncommon. Infection and haemorrhage are common.*

### Emphysematous Cyst

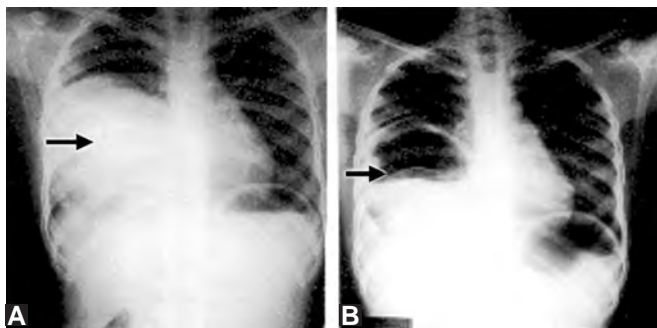
- ◆ It is a progressive disease of lung with rupture of alveolar wall and distension with air.
- ◆ It is an acquired condition.
- ◆ Cyst does not have epithelial lining.
- ◆ Compression of adjacent lung tissue with poor gaseous exchange is common.

Usual *clinical features* are dyspnoea and severe, persistent cough.

*Pseudocyst of the lung*: It occurs in a cavity due to tuberculosis, lung abscess or *Staphylococcus pneumonia*.

### Complications

- ◆ Spontaneous pneumothorax.
- ◆ Severe chronic bronchitis.



**Figs 28.20A and B:** (A) Hydatid cyst in lung; (B) Ruptured hydatid cyst with water-lily sign.

### Treatment

- ◆ Localised cyst is excised.
- ◆ Generalised cysts are treated conservatively.
- ◆ Pleurodesis is often required.

Here spontaneous pneumothorax is very common. Infection and haemorrhage are uncommon.

### Hydatid Cyst of the Lung

- ◆ It is caused by the parasite, *Echinococcus granulosus*.
- ◆ It is often associated with hydatid cysts of the liver.
- ◆ Incidence is 15%.
- ◆ It is usually single. But multiple hydatids can occur.

### Presentations

- ◆ Dyspnoea, chest pain and haemoptysis.
- ◆ Rupture into bronchial tree causes anaphylaxis.
- ◆ Rupture also causes expectoration of fluid and grape skins (vesicles).
- ◆ Fever, cough and expectoration due to secondary infection.
- ◆ Asymptomatic hydatid, identified during chest X-ray.

### Investigations

- ◆ Chest X-ray:
  1. Dense homogenous opacity.
  2. Collapsed laminated membrane produces an irregular projections in a fluid level due to rupture of the cyst—*Water-lily* appearance.
  3. *Crescentic cap of air*, when it communicates into bronchial tree.
- ◆ Positive Casoni's test.
- ◆ Blood shows eosinophilia.

- ◆ Complement fixation test.
- ◆ Indirect haemagglutination test.
- ◆ CT scan—diagnostic.

### Complications

- ❖ Rupture of the cyst
- ❖ Anaphylaxis
- ❖ Secondary infection
- ❖ Collapse of lung
- ❖ Pleural effusion
- ❖ Secondary pleural hydatid formation
- ❖ Hepatobronchial fistula formation (produces bilious sputum)

### Differential diagnosis

- ❖ Lung abscess
- ❖ Epithelial lung cysts
- ❖ Aspergillosis

### Treatment

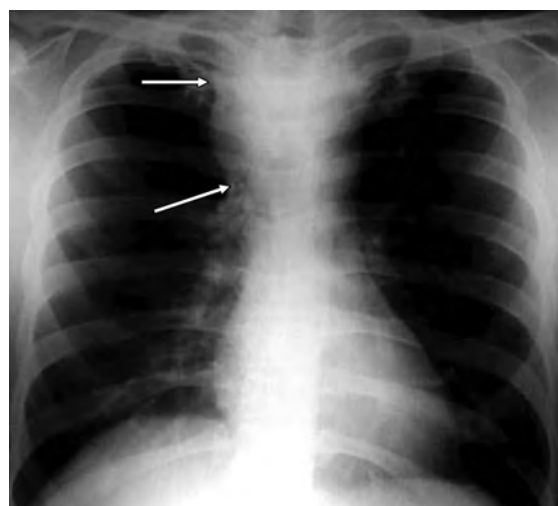- ◆ Thoracotomy and *enucleation of the cyst*: It is achieved by taking a good anaesthetist's help by creating positive pressure ventilation. Cyst extrudes intact. It should not be held with forceps to avoid rupture.
- ◆ *Lobectomy* is done in cases with difficulty and complications.
- ◆ Drugs like *praziquantel* or *albendazole* is given for a long period.

## MEDIASTINAL TUMOURS

- ◆ It occurs at any age group, in both sexes.
- ◆ It is often identified on a routine chest X-ray, as about 50% are symptomless.

### Presentations

- ◆ Chest pain and back pain.
- ◆ Respiratory distress.
- ◆ Venous congestion (SVC syndrome).
- ◆ Hoarseness of voice (due to compression over recurrent laryngeal nerve).
- ◆ Dysphagia, due to oesophageal compression.



**Fig. 28.21:** Superior mediastinal tumour—could be thymoma, nodal mass.



- ◆ *Horner's syndrome*, due to compression over sympathetic chain.
- ◆ Scabbard trachea.
- ◆ Later diaphragmatic paralysis may occur.
- ◆ Pleural effusion.
- ◆ Haemorrhage, due to erosion of major vessels by malignant tumour.

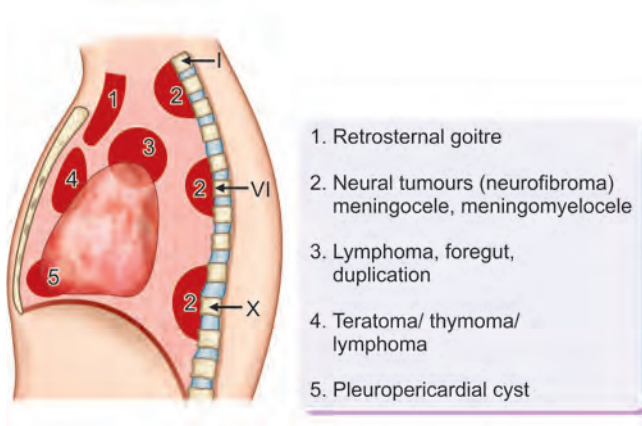
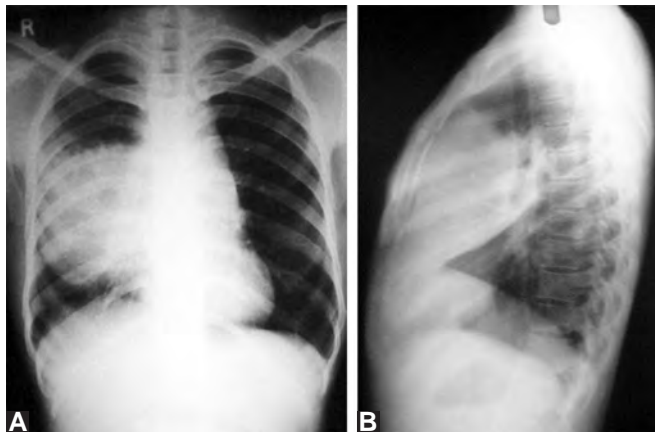


Fig. 28.22: Sites of mediastinal tumours.

**Classification**

- Superior mediastinal tumour:** Retrosternal goitre.
- Anterior mediastinal tumours**
- ❖ Retrosternal goitre, aortic arch aneurysm lymph node enlargement.
  - ❖ Thymic tumours—thymomas are commonly associated with myasthenia gravis.
  - ❖ Teratomas and dermoids.
  - ❖ Pleuro-pericardial cyst (*spring water cyst*).
- Midmediastinal tumours**
- ❖ Lymphadenopathies of all causes—secondaries, lymphomas, tuberculosis—common.
  - ❖ Foregut duplication cysts.
  - ❖ Lipomas.



Figs 28.23A and B: Chest X-ray showing mediastinal tumour.

**Posterior mediastinal tumours**

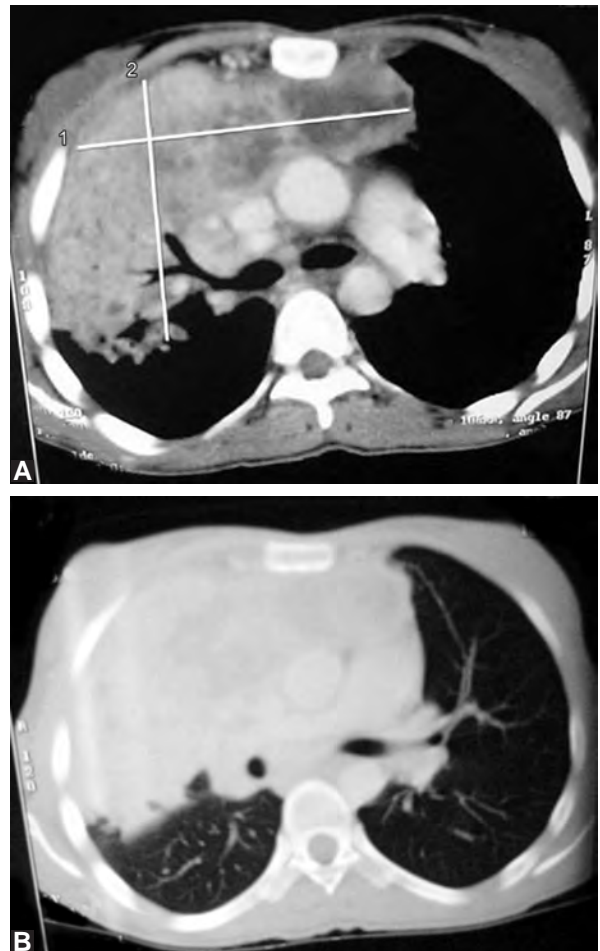
- ◆ Neurofibromas—commonest, 75%.
- ◆ Ganglioneuromas.
- ◆ Aneurysm of descending aorta.
- ◆ Lymph node mass.

**Investigations**

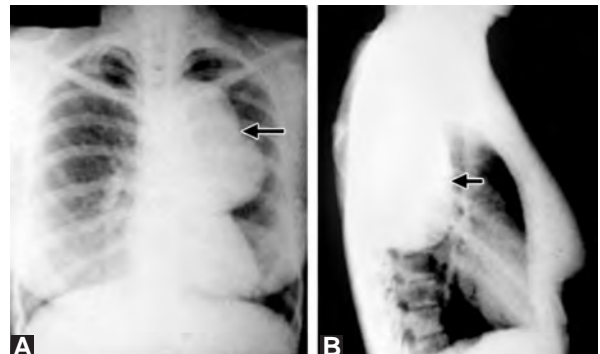
- ◆ Chest X-ray, both PA view and lateral view.
- ◆ CT scan.
- ◆ MRI.
- ◆ Mediastinoscopy and biopsy.

**Treatment**

- ◆ Thoracotomy and removal of tumour.
- ◆ If malignant, adjuvant therapy like radiotherapy and chemotherapy are given.
- ◆ Sternotomy for superior and anterior mediastinal tumours.
- ◆ Thoracoscopic and mediastinoscopic approaches.



Figs 28.24A and B: CT scan showing mediastinal tumour.



Figs 28.25A and B: Plain X-ray chest showing posterior mediastinal mass.

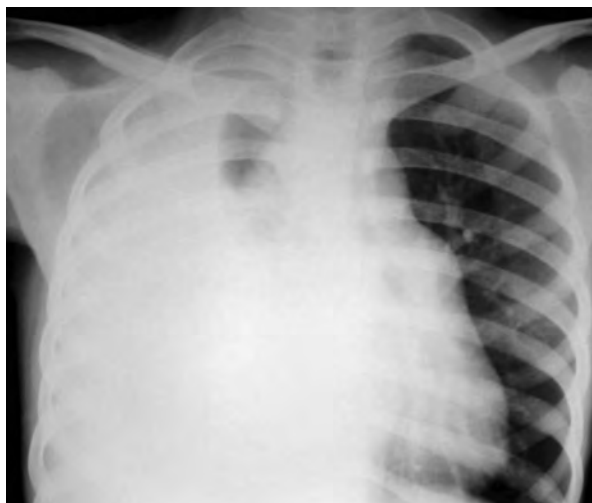

Fig. 28.26: Malignant effusion—right-sided.

## THYMOMAS

- ◆ Thymomas are the most common tumours of the anterosuperior mediastinum in the adult.
- ◆ They are most common in the fifth and sixth decades of life. Both sexes are equally affected.

### Histological types

- ❖ Epithelial cell—has poor prognosis
  - ❖ Lymphocytic
  - ❖ Mixed
  - ❖ Spindle—has better prognosis
- 50% of thymomas are malignant

### Staging

- I — Confined to the capsule
- II — Tumour spread to periglandular fat
- III — Tumour spread to adjacent tissue

## Clinical Features

- ◆ Asymptomatic—50%.
- ◆ 30-40% of thymomas have associated myasthenia gravis.
- ◆ Chest pain.
- ◆ Dysphagia and dyspnoea.
- ◆ Superior vena caval obstruction.

## Investigations

- ◆ *Tensilan diagnostic test*: By injecting 10 mg IV to symptomatic myasthenia will be relieved in one minute temporarily.
- ◆ Chest X-ray, lateral view shows opacity in the mediastinum.
- ◆ CT scan.

## Treatment

- ◆ *For myasthenia*—tablet neostigmine bromide 15 mg tds, daily.
- ◆ *Thymectomy* is very useful.
  - ▶ When the disease is less than 5 years.
  - ▶ Myasthenia gravis without thymoma.
  - ▶ In young, females.

### Features of myasthenia gravis

- ❖ An autoimmune disease
- ❖ Presence of antibodies to acetylcholine receptors in NMJ resulting in reduced muscular contraction
- ❖ Weakness of muscle on exertion
- ❖ Ptosis, diplopia, dysarthria, dysphagia
- ❖ Drooping of jaw
- ❖ Paralysis of respiratory muscle
- ❖ Periodic remission

## LUNG CANCERS

- ◆ Lung cancers are either secondary or primary.
- ◆ *Secondaries* are commonly from breast, thyroid, sarcomas, kidneys and bones. They usually show typical cannonball secondaries. Primary should be evaluated by CT scan, endoscopies, tumour markers. PET scan is useful investigation. It is treated with chemotherapy, RT.

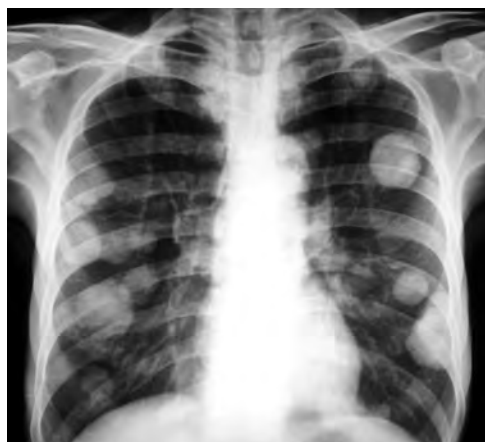

Fig. 28.27: Multiple cannonball secondaries in lung. Primary sites are—breast, kidney, sarcomas, testis, prostate, thyroid.

- ◆ *Bronchogenic carcinoma* is the commonest primary; common in smokers and males. Cough, chest pain, haemoptysis, loss of weight and appetite, features of metastases and paraneoplastic syndromes are—common presentation. It is evaluated with chest X-ray, CT chest and metastatic work up, tumour

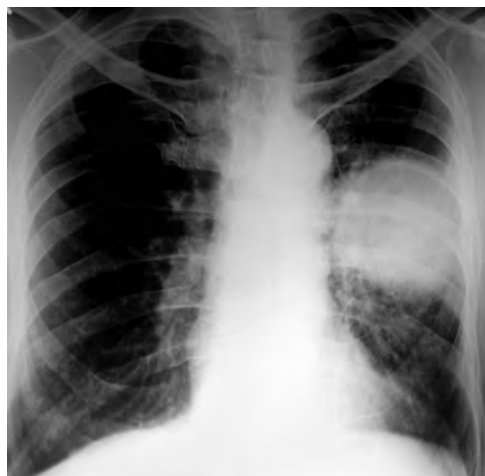

Fig. 28.28: Bronchogenic carcinoma—X-ray picture.

markers, sputum cytology and bronchoscopy. Commonly it is advanced when present with. When operable, pneumonectomy is done provided opposite lung is normal. Inoperable cases as commonly are managed with chemotherapy, radiotherapy and symptomatic measures. Condition carries poor prognosis.

## ■ PANCOAST TUMOURS (Superior sulcus tumour)

*When the tumour extends its feet from all sides of its body into the veins, the sickness produces the picture of a crab.*

—Galen, (130-200)

- ◆ It is a type of peripheral lung carcinoma arising from the apex of the lung (5% of lung cancers).

### Features

- ◆ It invades brachial plexus, sympathetic chain, upper ribs and vertebrae.
- ◆ Intractable pain in upper chest, arm and also weakness in the arm.

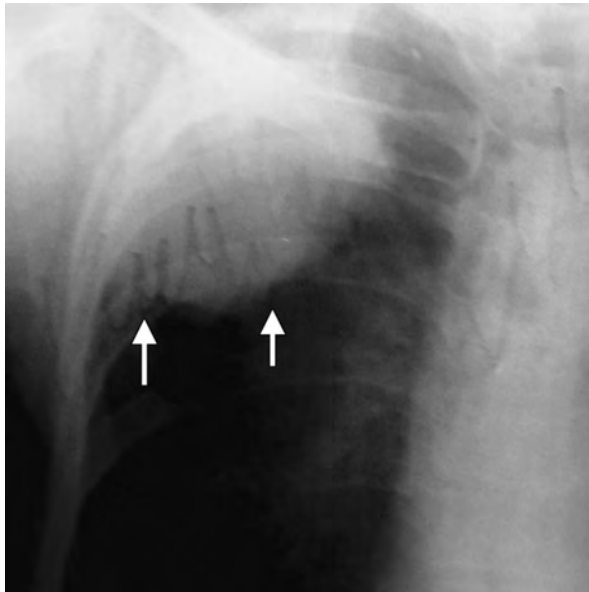


Fig. 28.29: X-ray showing right sided Pancoast's tumour.

### Presentations

#### Pancoast's syndrome

- ❖ Lower brachial plexus palsy
- ❖ Horner's syndrome
- ❖ Rib erosion
- ❖ Apical shadow

#### Horner's syndrome

- ❖ Miosis
- ❖ Enophthalmos
- ❖ Anhydrosis
- ❖ Ptosis
- ❖ Loss of spino-ciliary reflex

### Investigations

- ◆ Chest X-ray.
- ◆ CT scan.
- ◆ Bronchoscopy and biopsy.
- ◆ CT-guided biopsy.
- ◆ MRI is better than CT in Pancoast tumour as brachial plexus and sympathetic chain is involved which better visualised in MRI.

### Treatment

- ◆ Lobectomy/pneumonectomy.
- ◆ Radiotherapy—external tele cobalt.
- ◆ Chemotherapy—methotrexate.

**Prognosis:** Poor.

## ■ CHEST WALL TUMOURS

- ◆ Tumours arising from the chest wall components like muscles or ribs. They can be benign or malignant.

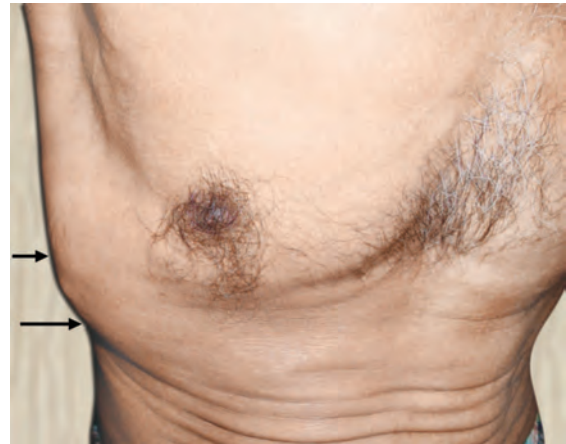

Fig. 28.30: Chest wall tumour. Benign tumours are usually chondromas.

- ◆ Commonest benign tumour is chondroma arising from ribs.
- ◆ Malignant tumours are *secondaries* (commonest), chondrosarcoma arising from ribs (common among primary malignant tumours), rhabdomyosarcoma from muscles, fibrosarcoma from ribs/muscles/ other soft tissues, Ewing's sarcoma and invasion from other tumours like from pleura or lungs or breast.

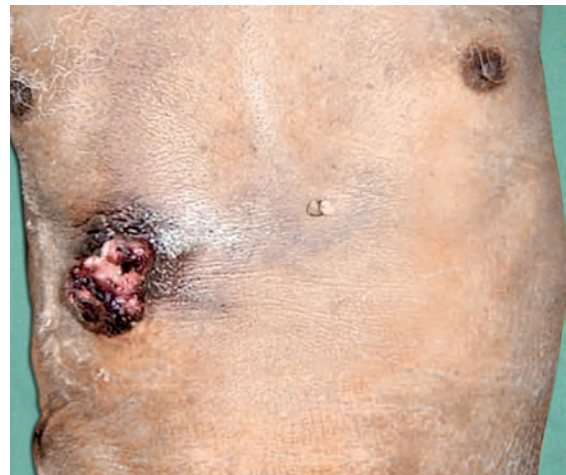

Fig. 28.31: Fungating tumour invading chest wall.

## Benign Tumours

- ◆ They are slow growing, nonmobile, painless and usually from the rib cartilage, near costochondral junction.
- ◆ X-ray is diagnostic, shows rib expansion with intact cortex.
- ◆ One or more ribs can be involved. Treatment is rib resection.

## Primary Malignant Tumour

- ◆ It has got all features of sarcoma—progressive rapid enlargement, attaining large size, warm, vascular, nonmobile, often extends into the thoracic cavity or with skin ulceration.
- ◆ Secondaries in lung/brain/liver can occur.
- ◆ Chest X-ray, CT chest, US abdomen should be done to see secondaries.
- ◆ CT scan can also give idea about the tumour extension and operability.
- ◆ Open incision/trucut biopsy is essential for histological confirmation.
- ◆ Treatment is wide excision with chest wall reconstruction using different osteomyocutaneous flaps, rib grafts, mesh or acrylic plates.
- ◆ Postoperative adjuvant chemotherapy is always needed to prevent relapse. In advanced cases radiotherapy to chest wall is advised.

## PERICARDITIS

*Water contained in the sac of the heart, likewise if the sac contain within either a fluid putrid and smelling badly, or stones, it causes throbbing.... Adhesions of the pericardium to the body of the heart itself... was observed in two dropsical patients.*

—Guillaume de Baillou (Ballonius), 1735

## Types

1. Acute pericarditis.
2. Chronic pericarditis.
3. Chronic constrictive pericarditis.

## ACUTE PERICARDITIS

Usually by bacteria like *Staph. aureus*, *H. influenzae*, *Streptococci*, *Neisseria*. It is uncommon at present, because of availability of good antibiotics.

### Other causes

- ❖ Viral infection
  - ❖ Uraemia
  - ❖ Trauma
  - ❖ Malignancy
  - ❖ Connective tissue disorders
- ◆ Here pus collects in the pericardial space causing decreased cardiac function and toxicity.

## Treatment

- ◆ Antibiotics.
- ◆ Pericardial aspiration.
- ◆ Drainage of purulent fluid by open pericardiotomy.

## CHRONIC CONSTRICTIVE PERICARDITIS (Pick's Disease)

- ◆ Here pericardium is thickened, fibrosed and calcified. Heart is encased in a rigid cavity which decreases the cardiac function as well as the venous return.

## Causes

- ◆ Tuberculous pericarditis is the commonest cause.
- ◆ Trauma.
- ◆ Viral pericarditis.
- ◆ After cardiac surgery.

## Clinical Features

- ◆ Decreased cardiac output and tachycardia.
- ◆ Dyspnoea on exertion, easy fatigability.
- ◆ Raised jugular veins, hepatomegaly, ascites and oedema feet.

## Investigations

- ◆ ECG.
- ◆ Echocardiography.
- ◆ Chest X-ray.
- ◆ CT scan.

## Treatment

- ◆ Pericardiotomy with biopsy.
- ◆ Pericardiectomy.
- ◆ Antitubercular drugs is started when tuberculosis is the cause.

## PERICARDIAL TAP

### Indications

- ❖ Pericardial effusion due to any cause—viral, tubercular
- ❖ Haemopericardium
- ❖ Purulent pericardium

### Procedure

A 16 or 18-gauge needle is passed into the pericardium just below the Xiphoid process, directing upwards and backwards, towards left side with an angle of 45° to the surface.

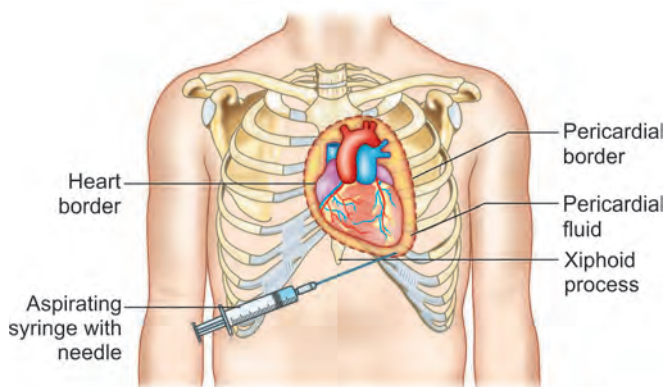


Fig. 28.32: Pericardial tap for pericardial effusion/tamponade.

*Don't let the skin stand between you and the diagnosis.*

**This site is used because:**

- ❖ Most dependent aspiration
- ❖ Unlikely to traumatise heart
- ❖ Pleura is not punctured
- ❖ Coronary vessels are not interfered

Presently US guided aspiration is commonly done.

**Complications**

- ◆ Injury to heart.
- ◆ Infection.

**CARDIAC (PERICARDIAL) TAMPONADE**

Rapid accumulation of fluid or blood in the pericardial space causing increase in the *intrapericardial pressure* is called as cardiac tamponade.

This results in compression of cardiac chambers.

↓  
↓ venous return  
↓  
↓ cardiac output

**Causes**

- ❖ Trauma
- ❖ Progressive pericardial effusion due to tuberculosis, viral, bacterial infections
- ❖ Often, uraemia can cause significant pericardial effusion

**Features**

- ◆ Hypotension.
- ◆ Widened cardiac dullness.
- ◆ Muffled or decreased heart sounds.
- ◆ Increased venous pressure with raised jugular veins.
- ◆ Pulsus paradoxus (pulse becomes weaker on inspiration than expiration).
- ◆ In severe cases, heart is unable to expand causing *shock and often sudden death*.

**Beck's triad**

- ❖ Hypotension
- ❖ Muffled heart sounds
- ❖ Raised jugular venous pressure

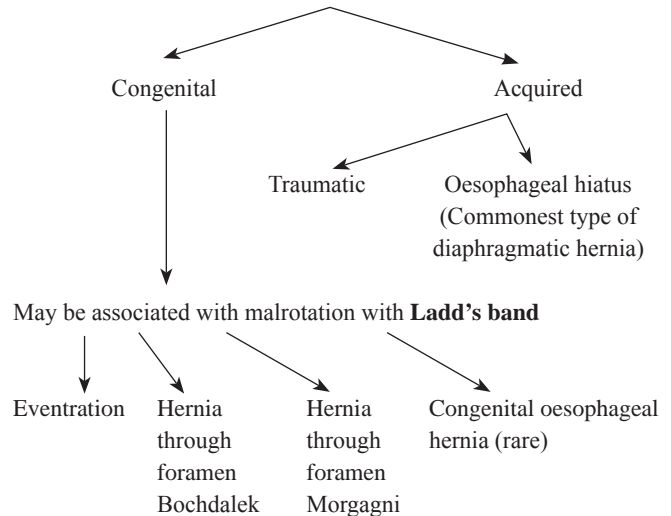
- ◆ *Investigation:* Chest X-ray and US confirms the diagnosis.
- ◆ *Differential diagnosis:* Tension pneumothorax.

**Treatment**

- ◆ *Pericardial tap* is done for immediate temporary relief under US guidance—needle pericardiocentesis.
- ◆ But eventual *open pericardiotomy* (occasionally pericardiectomy) and drainage is required in most of the patients.

**DIAPHRAGMATIC HERNIA**

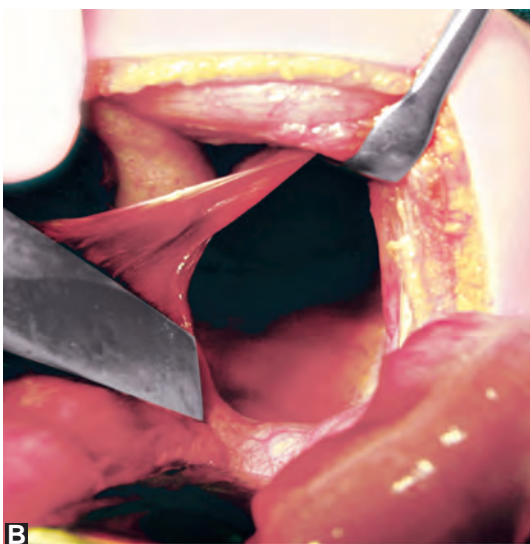
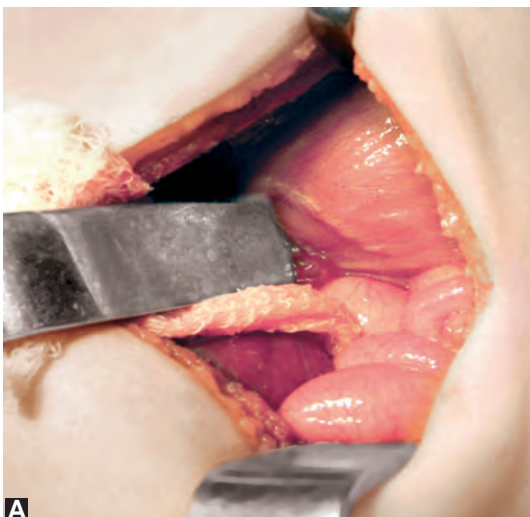
It is herniation of abdominal content through diaphragm into the chest.

**Etiology of congenital diaphragmatic hernia**

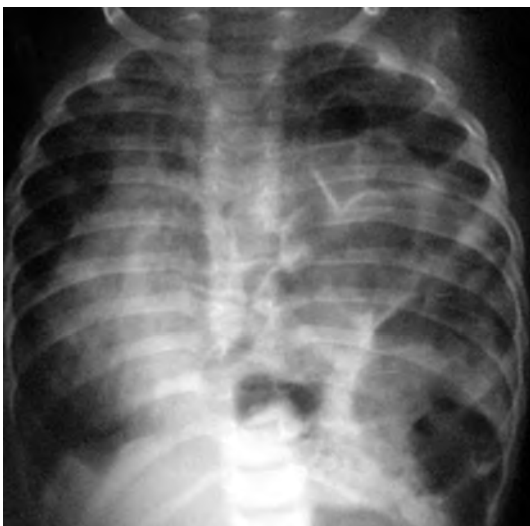- ❖ Genetic
- ❖ Decreased lung fluid pressure
- ❖ Failure of the closure of pleuroperitoneal canal (foramen of Bochdalek)
- ❖ Early return of bowel into peritoneal cavity from physiological hernia

**Eventration**

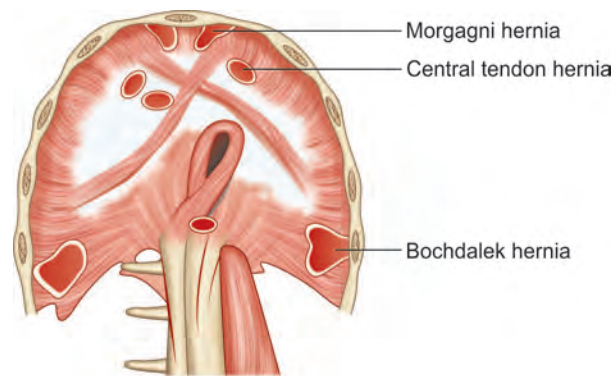
- ◆ It is weakening of diaphragm due to atrophy and loss of muscle of a part or all of one leaf of the diaphragm, with thin fibrous tissue formation, covered with pleura and peritoneum on either side.
- ◆ Diaphragm is *attenuated and inactive*.
- ◆ *Classification of eventration:*
  1. *Congenital*—marked decrease in the muscle fibres in the diaphragm, clinically it may mimic CDH with sac.
  2. *Acquired* or secondary—(a) Phrenic nerve palsy due to trauma (with Erb's palsy); viral—usually in adults (Polio, Herpes zoster, Influenza, Diphtheria). (b) Neoplasia. (c) Autoimmune neuropathy involving diaphragm or phrenic nerve. (d) Iatrogenic.
- ◆ Most of them present in the infancy and childhood. A few of them escape to adulthood.
- ◆ This thin diaphragm is raised higher and immobile. It is actually not a true herniation. But features mimic hernia.
- ◆ *Presentation:* Asymptomatic, wheezing, recurrent LRTI, exercise intolerance, extreme respiratory distress.
- ◆ Symptomatic patients have functional deficit in ventilation perfusion (V/P) ratio because lung growth is affected.
- ◆ Larger the defect more the hypoplasia. More the hypoplasia lesser the perfusion and severe the symptoms.
- ◆ Paradoxical movement compromises the gas exchange.
- ◆ *Sniff test*—fluoroscopic evaluation for paradoxical movement.
- ◆ Chest X-ray (CT scan/MRI) shows the abnormality
- ◆ Differential diagnosis are diaphragmatic hernia through foramen Bochdalek.
- ◆ Condition causes respiratory embarrassment.



**Figs 28.33A and B:** Eventration of diaphragm on table look (Courtesy: Dr Sadashiva Rao, MCh, Paediatric Surgeon, KMC, Mangaluru).

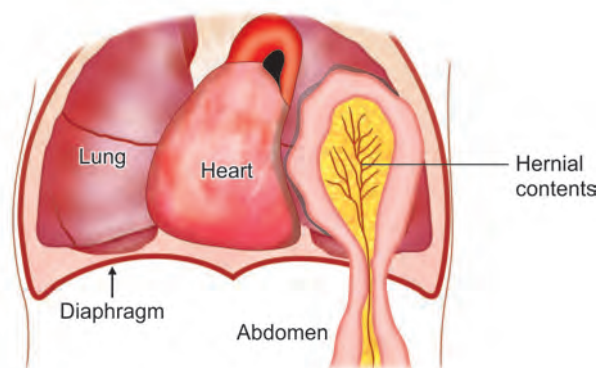


**Fig. 28.34:** Chest X-ray showing left sided diaphragmatic hernia. Note the bowel shadows in the left side thorax.



**Fig. 28.35:** Anatomy of diaphragm showing different sites where hernia can occur.

## Types



**Fig. 28.36:** Diaphragmatic hernia.

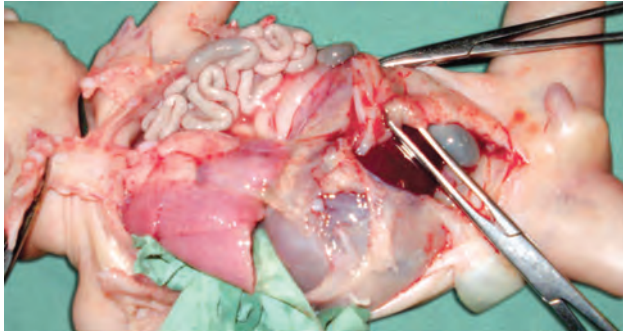
**Treatment** is plication of diaphragm through laparotomy.

### Indications for surgery

- ❖ Symptomatic patients
- ❖ Decreased ventilation perfusion ratio
- ❖ Prolonged (>3 to 6 months) exertional dyspnoea
- ❖ Impairing daily activity in idiopathic/viral
- ❖ Phrenic nerve palsy

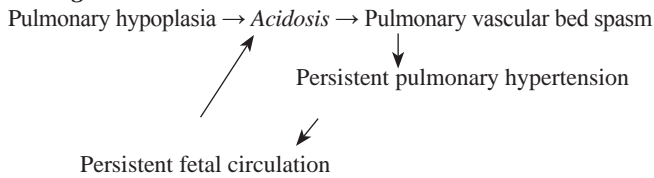
### *Hernia Through Foramen Bochdalek (Through Pleuroperitoneal Canal) (95% Left Sided, Only 5% Right Sided)*

- ◆ It is commonest congenital diaphragmatic hernia.
- ◆ This is a developmental defective condition, due to failure of fusion of pleuroperitoneal canal leaving a direct communication between pleura and peritoneum on left side. This allows herniation of contents of abdomen into the left side thorax.
- ◆ Common content is *colon*. Occasionally small bowel, stomach are the contents.
- ◆ 80% cases do not have hernial sac. Only 20% cases has got sac.



**Fig. 28.37:** Postmortem look of a newborn baby with classical diaphragmatic hernia (Courtesy: Dr Subramanya Bhat K, Sonologist Kanhangad). Note the entire bowel occupying the left side thorax.

### Pathogenesis



- ◆ Hypoplasia not only on left side, it may be bilateral.
- ◆ Generations of bronchial branches decreased.
- ◆ Extension of tunica media beyond respiratory bronchioles.
- ◆ Decreased total lung mass
- ◆ Incidence: 1 in 3000 live births, M:F—2:1.
- ◆ 90% present in newborn period.
- ◆ 90% of CDH are Bochdalek hernias
- ◆ Left—80%, right—15%, bilateral—5%.
- ◆ Defects are large in babies and small in adults.
- ◆ Associated anomalies—10 to 50%, commonest—nonfixation/midgut malrotation. Other anomalies—CNS, cardiac are known to occur and commoner with large/bilateral CDH.
- ◆ Very small percentage of patients escape and pass on to adulthood. Incidence—0.17 to 6%
- ◆ Incidental detection while evaluating for some other problem. So usually they are asymptomatic.

### Poor prognostic criterias in Bochdalek hernia

- ❖ Early antenatal detection (before 5th month)
- ❖ Small left ventricle
- ❖ Large diaphragmatic defect / hemiagenesis
- ❖ Stomach in chest
- ❖ Polyhydramnios

### Clinical features

- ❖ Respiratory embarrassment
- ❖ Scaphoid abdomen
- ❖ Bowel sounds in left side of chest
- ❖ Mediastinal shift towards right side
- ❖ Occasionally features of intestinal obstruction

**Investigations:** Chest X-ray, *barium enema* (common) or barium meal, *arterial blood gas analysis* (ABG).

### Treatment

- ◆ Laparotomy and dissection of the sac (when present) and closure of the defect in the diaphragm (using nonabsorbable suture material).

### Note:

Persistent fetal circulation is the major problem in these newborns. It aggravates the postsurgical mortality.

## Management

Antenatal	Postnatal
<ul style="list-style-type: none"> <li>• Fetal interventions</li> <li>• Discontinue the pregnancy (poor prognosis)</li> <li>• Continue pregnancy and observation</li> <li>• Shift the mother to higher centre</li> <li>• Mode of delivery—LSCS/normal</li> </ul>	<ul style="list-style-type: none"> <li>• Stabilise the neonate</li> <li>• Do not resuscitate with Ambu bag</li> <li>• Tracheal intubation and ventilation</li> <li>• Pass nasogastric tube</li> </ul> <p><i>Surgical correction of CDH after stabilisation</i></p>

### Triad of congenital diaphragmatic hernia (CDH)

- ❖ Respiratory distress
- ❖ Scaphoid abdomen
- ❖ Mediastinal shift (Pseudodextrocardia)

### Association of CDH

- ❖ Pulmonary hypoplasia with persistent fetal circulation—is the actual cause for hernia
- ❖ Respiratory acidosis

### Hernia through Foramen of Morgagni

- ◆ The defect lies between the sternal and costal attachments of diaphragm and is situated in front, towards right. Colon is commonest content. Usually, it is symptom free.

### Oesophageal Hiatus Hernia

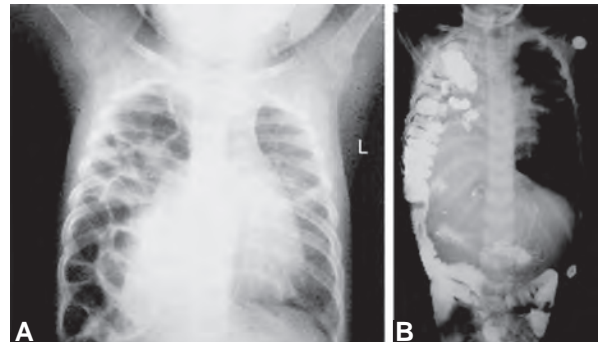
- ◆ Oesophageal hiatus hernia can be congenital or acquired (common).

### Traumatic Diaphragmatic Hernia

- ◆ Either on right or left side, resulting from road traffic accidents, crush injuries, penetrating injuries, or blunt injuries.
- ◆ Patient is under shock.
- ◆ On right side along with the liver, the intestines may also get herniated.
- ◆ Patient is pale, presents with respiratory distress, guarding and rigidity over the abdomen.

## Investigations

- ◆ X-ray chest and abdomen.
- ◆ US abdomen.
- ◆ Often CT scan of abdomen and chest is done.



**Figs 28.38A and B:** (A) Plain X-ray chest; (B) Barium enema, showing bowel loops within thoracic cavity on the right side (diaphragmatic hernia).

## Treatment

- ◆ Immediate laparotomy and exploration is done. Tear in the diaphragm is sutured.
- ◆ Associated injuries in liver or spleen or bowel are treated accordingly.
- ◆ Adequate blood transfusion and antibiotics is required.
- ◆ Ventilator support is often necessary.

## ■ PULMONARY COMPLICATIONS DURING POSTOPERATIVE PERIOD

### Precipitating Factors

- ◆ Age: Common in infants and elderly.
- ◆ Sex: Common in males.
- ◆ Common in *smokers*.
- ◆ Common in people with chronic bronchitis, asthma, tuberculosis or COPD.
- ◆ Postoperative pain.
- ◆ Deep venous thrombosis and pulmonary embolism.
- ◆ Type of surgery: Common in thoracic or upper abdomen surgeries.
- ◆ Septicaemia.
- ◆ Paralytic ileus.
- ◆ Anaesthetic complications.
- ◆ Aspiration and its problems.
- ◆ Obesity.

### Complications

- ◆ Bronchopneumonia.
- ◆ Lung collapse.
- ◆ Bronchitis.
- ◆ Lung abscess.
- ◆ *Adult respiratory distress syndrome (ARDS)*.
- ◆ *Respiratory failure*.
- ◆ Alkalosis.
- ◆ Pleural effusion or empyema.

### Investigations

- ◆ Chest X-ray.
- ◆ Arterial blood gas analysis.

### Management

- ◆ Suction—aspiration of tracheobronchial tree.
- ◆ Respiratory physiotherapy.
- ◆ Analgesics to control pain.
- ◆ Ventilator support with endotracheal intubation.
- ◆ Tracheostomy.
- ◆ Control of sepsis by proper antibiotics.

## ■ SURGICAL MANAGEMENT OF PULMONARY TUBERCULOSIS

### Indications for Surgery

- ◆ Failure of medical therapy.
- ◆ Tuberculoma.
- ◆ Tuberculous bronchiectasis.
- ◆ Destruction of lobe.
- ◆ Persistent foci, persistent cavity.
- ◆ Empyema thoracis.
- ◆ Presence of neoplasm with tuberculosis.

### Surgeries Done

- ◆ Pleural tap.
- ◆ Intercostal tube drainage for empyema.
- ◆ Rib resection and Eloisier's drainage.
- ◆ Lung resection is undertaken when medical treatment fails or when there is tuberculoma. It is commonly used method.
- ◆ Lobectomy or pneumonectomy.
- ◆ Decortication.
- ◆ Thoracoplasty collapse therapy—it causes elastic relaxation of lung around the lesion leading to closure of cavity.
- ◆ Creation of artificial pneumothorax (nitrogen is used).
- ◆ Temporary phrenic nerve palsy.
- ◆ Extrapleural pneumothorax.
- ◆ **Plombage:** It is extrapleural pneumolysis using lucite spheres.

## ■ VIDEO-ASSISTED THORACOSCOPIC SURGERY (VATS)

It is visualisation and doing surgical procedures through video thoracoscopy.

*It can be:*

- ◆ Diagnostic—lung cyst, pleural pathology, malignancy, tuberculosis, lung abscess, emphysematous bullae.
- ◆ Therapeutic—cervical sympathectomy, oesophageal mobilisation for carcinoma of oesophagus, lung resection, excision of lung cysts, etc.

### Requirements

- ◆ Expert skilled personal.
- ◆ Double lumen endotracheal tube for one lung anaesthesia.
- ◆ Instruments.

### Advantages

- ◆ Open thoracotomy and its complications are avoided.
- ◆ Less painful, fast recovery.
- ◆ Magnification and precise dissection.

### Disadvantages

- ◆ Injury to major structures.
- ◆ Longer duration of surgery.
- ◆ Learning curve.



## B. Cardiac Surgery

### CHAPTER OUTLINE

- ❖ Anatomy
- ❖ Preoperative Assessment and Preparation of the Cardiac Patient
- ❖ Cardiopulmonary Bypass
- ❖ Congenital Heart Diseases
- ❖ Patent Ductus Arteriosus
- ❖ Coarctation of Aorta
- ❖ Atrial Septal Defect
- ❖ Ventricular Septal Defect
- ❖ Pulmonary Stenosis
- ❖ Transposition of Great Vessels
- ❖ Tetralogy of Fallot
- ❖ Acquired Heart Disease
- ❖ Mitral Regurgitation
- ❖ Aortic Stenosis
- ❖ Aortic Regurgitation
- ❖ Valve Replacement Surgery
- ❖ Ischaemic Heart Disease
- ❖ Cardiac Pacemakers
- ❖ Postoperative Care

### ANATOMY

Heart consists of right and left atrium, right and left ventricle with mitral (bicuspid) valve between left atrium and left ventricle and tricuspid valve between right atrium and right ventricle. Aorta begins from the left ventricle to have systemic circulation. Superior vena cava (SVC) and inferior vena cava (IVC) enters the right atrium to return venous blood. From right ventricle, pulmonary artery begins which transport the unoxygenated venous blood into the lungs. From lungs, four pulmonary veins collect the oxygenated blood to reach left atrium and to complete the cycle.

Pressure in the right ventricle is low. Pressure in the left ventricle is high.

Chordae tendinae act as guy ropes which connect valves (mitral and tricuspid) to heart through papillary muscles.

Aortic and pulmonary valves are semilunar valves.

**First heart sound** is produced by closure of atrioventricular valves.

**Second heart sound** is produced by closure of semilunar valves. Valvular heart disease may be congenital or acquired. Rheumatic heart disease is the commonest acquired cause for valvular disease. Mitral stenosis is the commonest type.

Right and left ventricles are separated by interventricular septum. Right ventricle is thinner than left ventricle. SVC and IVC opens into right atrium.

Heart derives its blood supply from two **coronary arteries—right and left**. Left coronary artery once origins at ostium runs for 2 cm, divides into **anterior descending and circumflex artery**. Anterior descending artery runs in the anterior interventricular groove to reach apex and ascends short distance in posterior interventricular groove. **The circumflex artery** runs around the base of left ventricle. Right coronary artery through atrioventricular groove reaches the posterior interventricular groove and runs along it.

**Right coronary artery** supplies right atrium, entire right ventricle except anterior part, posterior part of the interventricular septum, conducting system except left branch.

**Left coronary artery** supplies left atrium, entire left ventricle except posterior part, anterior part of the interventricular septum.

There are collaterals within the heart and extracardiac but is not sufficient enough to maintain the adequate perfusion in case of coronary block to the dynamic heart leading into myocardial infarction.

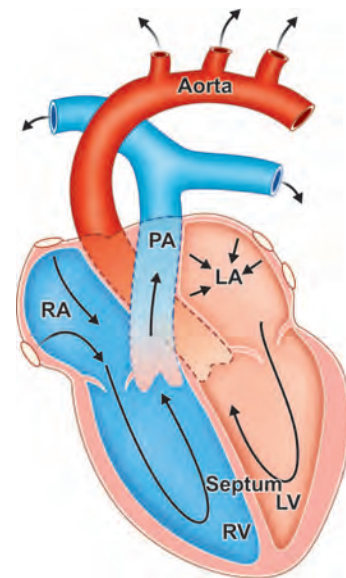


Fig. 28.39: Normal heart anatomy.

**Venous drainage of heart** is through superficial and deep veins. Superficial veins (great cardiac, middle cardiac, small cardiac, oblique and posterior veins) form **coronary sinus** ending at right atrium. Deep veins directly enter the heart called as **Thebesian veins**.

First blood passes to the elastic vessels then resistant vessels and capillaries later to veins and then back to heart. In capillary because of great cross-sectional area, rapid transfer of substances across tissues occur.

Flow of blood from left side heart through aorta and its branches to capillaries and return to right heart is called as **systemic circulation**.

Blood from right heart through pulmonary artery to lungs and from lungs through pulmonary veins to left heart is called as **pulmonary circulation**.

**Conduction system of heart** consists of **SA node** (Sinu atrial node) which is pacemaker of the heart, **AV node** (Atrio-ventricular node) located in lower part of the atrial septum, **AV bundle** (Atrio-ventricular bundle) with right and left branches and terminal **Purkinje fibres** in subendocardial region.

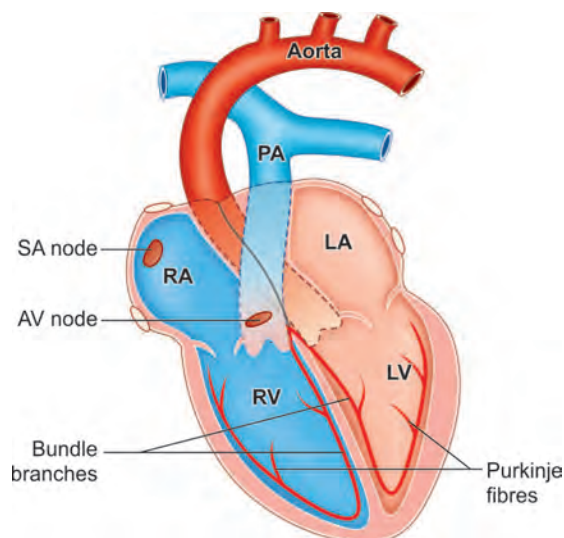


Fig. 28.40: Conduction system of heart.

**Surface marking of the heart:** Upper border is between 2nd and 3rd costal cartilage at the level of sternum. Lower border is from 2 cm to the right of sternal margin at 6th costal cartilage to the apex of heart at 5th intercostal space 9 cm from the midline.

## PREOPERATIVE ASSESSMENT AND PREPARATION OF THE CARDIAC PATIENT

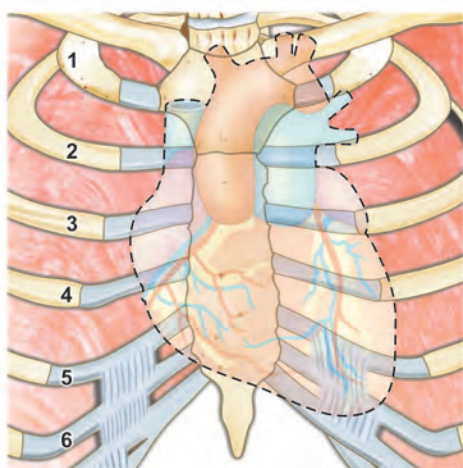


Fig. 28.41: Surface marking of the heart.

- ◆ Since cardiac surgery is a major surgery, proper evaluation is essential. Consent, explanation, discussion in initial phases is absolute need.
- ◆ Patient will be anxious. He needs proper consolation, moral support.
- ◆ Proper history related to smoking, alcohol intake, diabetes, previous cardiac surgery, drug intake is essential.
- ◆ ECG, chest X-ray, haemoglobin, haematocrit, blood urea, serum creatinine, blood sugar, lipid profile, blood grouping are essential basic investigations.
- ◆ **Echocardiography** is ultrasound examination of heart. Heart chambers, pericardium, pumping capacity, valves and their structure,

ejection fraction are found through this. Usually cardiologists do this test and give opinion about it.

- ◆ **Treadmill stress test** to find out the response of heart to work.
- ◆ **Coronary angiogram** is done to find out the amount of coronary function or its block. Special coronary artery catheter is passed through the brachial or femoral artery like in seldinger angiogram. This catheter is negotiated into the coronary arteries both right and left. Radio-opaque water soluble dye is injected into the catheter and coronaries. X-ray film will confirm the status of the coronaries. Procedure is done under guidance using C-arm. Amount of block is assessed and categorised.
- ◆ **Cardiography** is the procedure wherein dye is injected into the heart chambers using specialised catheters and size, shape, presence of clot in the chambers, valvular incompetence are studied.
- ◆ **Cardiac catheterisation** is done to get cardiac **oximetry and pressures** in different chambers of the heart. Cardiac catheter is flexible 100 cm long tube passed to the heart under guidance. Right and left sides are assessed separately. Catheter is infused with heparinised solution to prevent intravascular clotting during procedure.
- ◆ **Catheter to the right side** of the heart is passed through the cubital vein, subclavian vein, SVC. Pressures at systole and diastole are studied in right atrium, right ventricle, pulmonary artery. Blood samples are collected from these three levels to study **oxygen saturation (oximetry)**.
- ◆ **Left side of the heart** is approached by two approaches—one is through the right atrium penetrating the atrial septum, catheter reaches the left atrium, and so to left ventricle and aorta. Pressure is recorded in each chambers. Blood samples are collected for oxygen saturation.
- ◆ **Pressure** will alter in valvular diseases like stenosis or regurgitation.
- ◆ **Oxygen saturation** is altered in shunts between right and left sided. Shunt occurs between systemic and pulmonary circulation.
- ◆ **Cardiac isotope scanning.**

- ❖ Pressure in atrium is low 0–10 mmHg. Right atrium is little lower than left
- ❖ Pressure in the right ventricle is 15–30 mmHg systolic and 0–8 diastolic
- ❖ Pressure in pulmonary artery is 15–30 mmHg systolic and 3–12 diastolic
- ❖ Pressure in left ventricle is 100–140 systolic and 3–12 mmHg diastolic
- ❖ Pressure in aorta is 100–140 systolic and 10–80 mmHg diastolic

- ◆ Pulmonary function study is done by chest X-ray, spirometry, blood gas analysis.
- ◆ Focus of infection should be looked for like dental infection, throat infection, skin infection.

## CARDIOPULMONARY BYPASS

Here functions of the heart and lungs are temporarily replaced by heart-lung machine which acts as a pump and oxygenator to the body. Heart is exposed through a midline sternotomy incision.

Venous blood from the SVC and IVC is diverted to the heart lung machine by placing tubes to them.

From the heart-lung machine, oxygenated blood is pumped through a tube which is passed to the ascending aorta so as to bypass the heart and lungs with retaining the function so tissues will have adequate required perfusion. Blood should be heparinised to prevent clotting. Often venous tube is placed in the right atrium.

Temperature is lowered over the heart by pouring cold saline. Ventilation is discontinued.

Once procedure in the heart is over, air in the chambers of the heart is cleared. Coronary artery perfusion is restored and heart is made to beat spontaneously or using DC shock. Acidosis and hypocalcaemia is corrected. Patient is warmed.

Heart is allowed to fill gradually and slowly heart lung machine blood flow is reduced. Cannulas are removed from the veins (SVC and IVC) and also from the aorta. Protamine sulphate is given to reverse the effect of heparin.

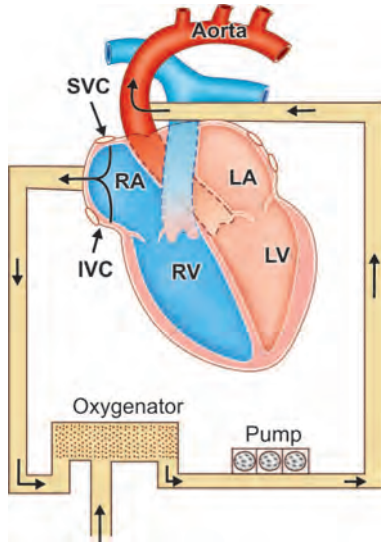


Fig. 28.42: Figure showing cardiopulmonary bypass.

#### Myocardial protection is achieved by:

- ❖ Infusion of solution with 20 mmol/litre of potassium into the coronaries
  - ❖ Cooling cardioplegic infusate to 6°C
  - ❖ Surface of the heart is sprayed with 4°C Hartmann's solution
  - ❖ Body temperature is reduced to 20–27°C
- Heart can be kept arrested for 2 hours.

## ■ CONGENITAL HEART DISEASES

**Left-to-right shunt**—It leads into overloading of the pulmonary circulation. Usually it is acyanotic.

PDA—patent ductus arteriosus.

ASD—atrial septal defect.

VSD—ventricular septal defect.

**Right-to-left shunt**—Blood from the systemic veins enter the systemic arteries bypassing the lungs allowing severe hypoxic blood to enter the systemic circulation. It will cause cyanosis. Examples are tetralogy of Fallot and transposition of great vessels.

**Conditions without shunts**—Coarctation of aorta, aortic stenosis, pulmonary stenosis.

Also classified as *cyanotic and acyanotic heart diseases*.

## ■ PATENT DUCTUS ARTERIOSUS (PDA)—10%

Ductus arteriosus is essential in foetal life wherein blood from pulmonary artery reaches the aorta through this ductus arteriosus by passing the lung. Once child is born, this ductus closes because of the beginning of the lung function. Prostaglandin prevents closure. Indomethacin promotes closure. If it persists in child it is called as PDA.

In PDA, part of the blood from aorta flows back to pulmonary artery because of high pressure in aorta (left-to-right shunt). This causes pulmonary hypertension.

Occasionally, pressure is so severe that flow may reverse and deoxygenated blood from pulmonary artery may flow towards aorta causing reversal of left-to-right shunt converting acyanotic shunt to a cyanotic one. It is called as *Eisenmenger's syndrome*. It can occur in other left-to-right shunt also (ASD, VSD).

Child presents with dyspnoea, chest pain, machinery murmur.

*Aortogram* and echocardiography are diagnostic.

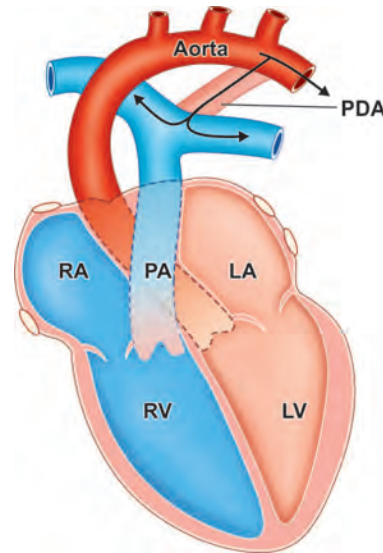


Fig. 28.43: Patent ductus arteriosus.

**Treatment**—closure of the PDA either through interventional cardiology or more conveniently through open surgery.

**Complications of PDA**—congestive cardiac failure, bacterial endocarditis.

## ■ COARCTATION OF AORTA—5%

Narrowing of the aorta just distal to the origin of left subclavian artery. It is often associated with PDA, VSD.

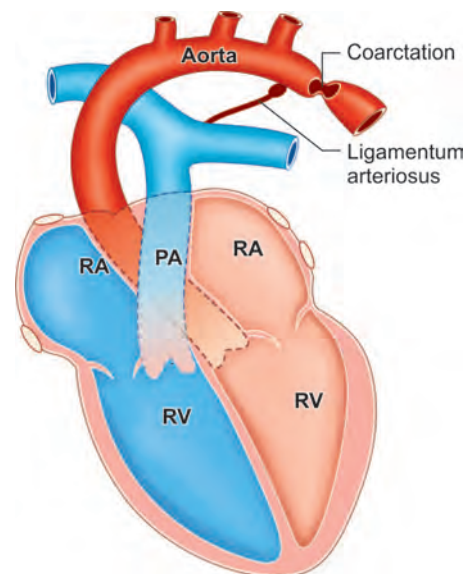


Fig. 28.44: Coarctation of aorta.

There is increased perfusion of upper limb, cranium, face. But less blood supply occurs to lower limb, kidneys.

## Types

- ◆ It can be preductal or postductal depending on relation to the ligamentum/ductus arteriosus.

## Features

- ◆ It causes left ventricular hypertrophy, differential blood pressure (pressure upper limb is higher but pressure in lower limb is lower). Often there is differential cyanosis.
- ◆ Visible dilated intercostal vessels through collateral perfusion is more obvious when patient leans forwards.
- ◆ X-ray will show dilated proximal aorta, notching of ribs due to erosion of the intercostals vessels.
- ◆ Aortogram is diagnostic.

**Treatment** is widening of the narrowed segment of aorta with Dacron patch graft, or removal of stenosed segment and arterial graft.

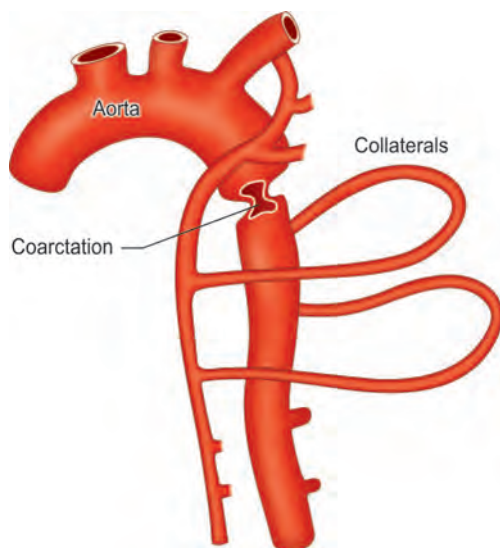


Fig. 28.45: Collaterals development in intercostal vessels in coarctation of aorta.

## Complications

- ◆ Congestive cardiac failure, bacterial endocarditis, aortic rupture.

## ■ ATRIAL SEPTAL DEFECT (ASD)—7%

- ◆ An ASD is the hole in the atrial septum, thus causing communication between left and right atrium.

### Types

- ❖ **Secundum type** is the commonest one. It is elliptical, in the middle of the atrial septum and is due to defect in the site of foramen ovale
- ❖ **Primum type** is lower part. It is rare
- ❖ **Sinus venosus type** is near SVC opening

## Features

- ◆ There is shunting of blood from left atrium to right atrium. It causes left ventricular hypertrophy, pulmonary hypertension, eventually occasionally reversal of shunt as right to left leading into cyanosis.
- ◆ Dyspnoea, fixed split of second heart sound, systolic murmur due to increased blood flow through the pulmonary valve are the clinical features.
- ◆ It is diagnosed by echocardiography, cardiac catheterisation and angiocardiogram.

## Treatment

- ◆ Closure of the defect by direct suturing or using patch either pericardium or Dacron.

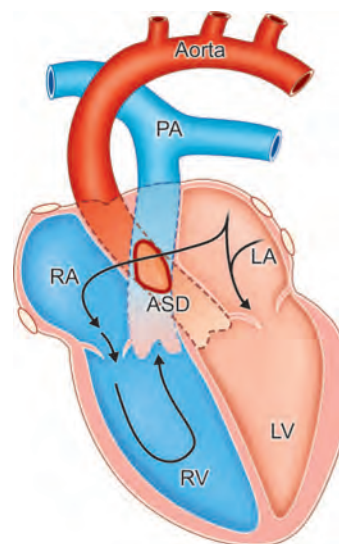


Fig. 28.46: Atrial septal defect.

## ■ VENTRICULAR SEPTAL DEFECT (VSD)—15%

- ◆ VSD is defect in the ventricular septum causing left-to-right shunt. There is pulmonary hypertension, ventricular hypertrophy.

## Types

- ◆ Four types of VSD are present depending on location of the defect. Defect can be small or large.
- ◆ It may be associated with tetralogy of Fallot.
- ◆ *Severe cases of shunt become reversal causing Eisenmenger's syndrome.*

## Clinical Features

- ◆ Pansystolic murmur, palpable thrill, split second sound with pulmonary accentuation, recurrent respiratory infections.
- ◆ 40–50% of defects especially when they are small, will close spontaneously. Spontaneous closure will not occur after the age of 6.

## Investigations

Echocardiography, cardiac catheterisation.

*When man is hungry he dreams food. Hunger is the greatest anarchist in man, next to egoism.*

## Treatment

Closure of the defect using pericardial patch or Dacron. While suturing care should be taken not to injure atrioventricular conduction system.

## Complications of VSD

Recurrent respiratory infection, pulmonary hypertension, cardiac failure.

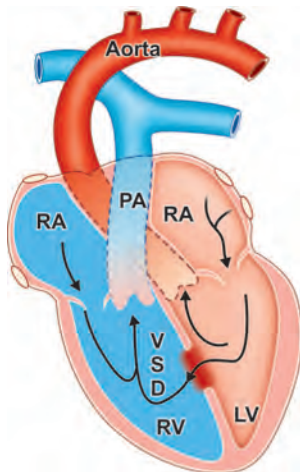


Fig. 28.47: Ventricular septal defect.

## PULMONARY STENOSIS

It is narrowing of the pulmonary valves due to fusion of cusps. Narrowing may be as less as 2–4 mm. Patient develops right ventricular hypertrophy and later right ventricular failure. Pressure in the right ventricle is higher, in pulmonary artery is lower. Treatment is pulmonary valvotomy.

## TRANSPOSITION OF GREAT VESSELS

Here aorta begins from right ventricle and pulmonary artery begins from left ventricle. So venous blood enters the aorta and causes hypoxia and cyanosis. It is usually not compatible with life but often through bronchial collaterals communication may develop and become compatible. When it is often associated with ASD or VSD or PDA mixing occurs and is compatible.

It is cyanotic heart disease.

It is diagnosed by an emergency echocardiography and aortocardiogram.

## Treatment

- ◆ Immediate palliative method is *Rashkind balloon septostomy*. A balloon is passed into the right atrium and through the septum into the left atrium. Balloon is inflated and rapidly pulled out through the atrial septum causing widening of the defect in the septum. It allows flow of oxygenated blood from pulmonary veins through the septum and so to the right ventricle and aorta.
- ◆ *Albert-Mustard atrial redirection of flow of blood*: Atrial septum is excised and using either pericardial or Dacron patch left atrial blood is directed to the right ventricle and right atrial blood is directed to the left ventricle.
- ◆ Later definitive correction is done either at atrial level or at great arterial level.

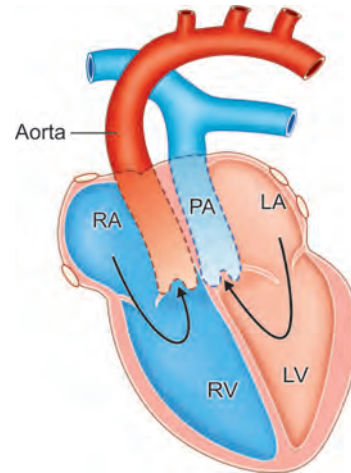


Fig. 28.48: Transposition of great vessels.

## TETRALOGY OF FALLOT

It is a cyanotic congenital heart disease.

### Components

- ❖ Ventricular septal defect
- ❖ Infundibular and pulmonary stenosis causing right ventricular outflow obstruction
- ❖ Right ventricular hypertrophy
- ❖ Dextroposition of aorta

Because of right ventricular outflow obstruction venous blood gets diverted through the existing VSD into the left ventricle and so to the aorta. So systemic circulation is provided with unoxygenated venous blood causing cyanosis.

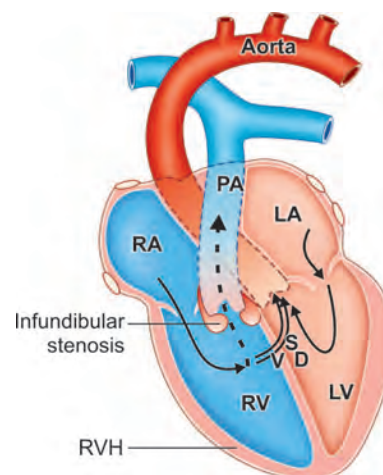


Fig. 28.49: Tetralogy of Fallot.

## Features

- ◆ Cyanosis with dyspnoea. Ejection systolic murmur which diminishes during cyanotic attack.
- ◆ Echocardiography, cardiac catheterisation are the essential investigations.

## Treatment

- ◆ **Blalock-Taussig operation**—it is done as initial treatment in newborn baby with Fallot's tetralogy. Left subclavian artery and pulmonary artery is connected using a graft which allows the pulmonary arterial perfusion.
- ◆ **Second stage definitive correction** by relieving the right ventricular outflow obstruction completely and closure of VSD using Dacron patch.

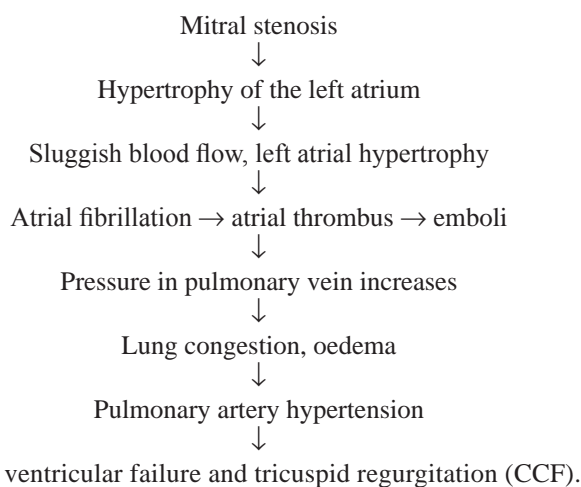
## ACQUIRED HEART DISEASE

### Mitral Stenosis

Commonest acquired heart disease. Valve here cannot open completely during left atrial contraction.

It is scarring and thickening of the mitral valves due to inflammation of valves with valve area less than  $2.5 \text{ cm}^2$  (normal is  $4\text{--}6 \text{ cm}^2$ ). It will later lead into fusion of chordae tendinae, calcification of the valve cusps. It is commonly due to rheumatic fever with streptococcal pharyngitis.

### Features



#### Mitral stenosis—clinical features and investigations

- ❖ Dyspnoea, orthopnoea
- ❖ Cough, haemoptysis
- ❖ Mid-diastolic murmur, with loud heart sound
- ❖ Features of atrial fibrillation
- ❖ Chest X-ray shows straightening of the left border of the heart
- ❖ ECG and echocardiography will demonstrate mitral stenosis, clot
- ❖ Cardiac catheterisation shows increased right atrial pressure
- ❖ Pulmonary capillary wedge pressure (PCWP) shows increased left atrial pressure

#### Indications for surgery

- ❖ Severe stenosis
- ❖ Calcification of cusps
- ❖ Clot in the left atrium
- ❖ Right ventricular hypertrophy

### Surgeries for mitral stenosis

- ◆ Closed mitral valvotomy—through left thoracotomy incision, heart is exposed. Left atrium is opened with purse string suture so as to

allow the finger to pass inside. Left ventricular tip is incised with a purse string suture and Tubb's valve dilator is passed. Under finger guidance through left atrial purse string wound, valve and cusps are separated using **Tubb's dilator**.

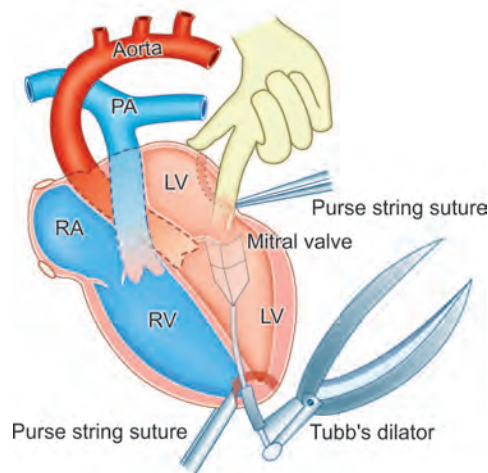


Fig. 28.50: Mitral valvotomy using Tubb's dilator.

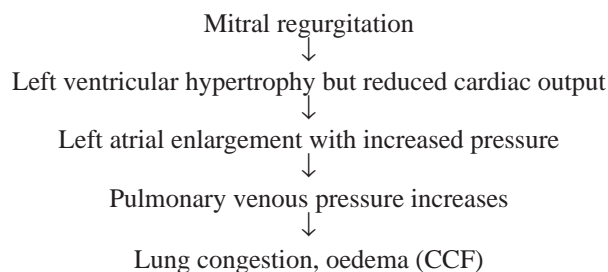
- ◆ **Open mitral commissurotomy**—it is done with cardiopulmonary bypass, left atrium is opened, valve and commissures are separated, valve is dilated using finger, clot in the left atrium is removed.
- ◆ Open valvuloplasty by doing repair of the valve.
- ◆ Percutaneous balloon valvotomy.
- ◆ Valve replacement surgery.

## MITRAL REGURGITATION

Mitral valve here cannot close completely during left ventricular contraction. It can be associated with mitral stenosis also.

### Causes

- ◆ Rheumatic heart disease causing fibrosis, rigidity and shortening of chordae tendinae leading to inability to close the mitral valve.
- ◆ Myxomatous degeneration of the valve.
- ◆ Marfan's syndrome.
- ◆ Connective tissue disease.
- ◆ Sarcoidosis.



### Features

- ❖ Cough, haemoptysis, chest pain, dyspnoea
- ❖ Pansystolic murmur
- ❖ Features of failure
- ❖ Often associated features of mitral stenosis
- ❖ Features of associated diseases
- ❖ Echocardiography, cardiac catheterisation and PCWP are the investigations

## Treatment

Valve replacement surgery.

### AORTIC STENOSIS

Narrowing of the aperture of aorta is due to rheumatic heart disease, bicuspid stenosis, calcification. Valve is thickened, fibrosed, calcified and narrowed.

## Features

- ◆ There is left ventricular hypertrophy with reduced left ventricular capacity.
- ◆ Because of the narrowing of the valve, cardiac output decreases.
- ◆ Systolic murmur is better heard over aortic area.
- ◆ Later may lead into failure.
- ◆ Echocardiography is diagnostic.

## Treatment

Valve replacement surgery.

### AORTIC REGURGITATION

There is incompetence of aortic valve.

## Causes

- ◆ Rheumatic disease.
- ◆ Connective tissue disorder.
- ◆ Marfan's syndrome.
- ◆ Tertiary syphilis.
- ◆ Endocarditis.
- ◆ Aortic dissection.

## Features

- ❖ There is left ventricular hypertrophy, and cardiac failure later
- ❖ Early diastolic murmur is characteristic
- ❖ Collapsing pulse
- ❖ Dyspnoea, chest pain
- ❖ Echocardiography is diagnostic
- ❖ It may be associated with ischaemic heart disease

## Treatment

Valve replacement surgery.

### VALVE REPLACEMENT SURGERY

#### Indications

- ❖ Severe valvular disease with fixity, stenosis
- ❖ Valve disease with thrombosis like in mitral stenosis
- ❖ Multivalvular disease

## Types

1. **Biological valves**—Capentier's glutaraldehyde preserved porcine valve with a sewing ring and frame is used. It is not thrombogenic. So, it is used in child bearing age and in whom warfarin is contraindicated. But its life span is less. So it is useful in elderly.

2. **Mechanical valves**

- ▶ Starr-Edwards ball—valve prosthesis.
- ▶ Bjork-Shiley tilting disc—valve prosthesis.

Mechanical valves are long lasting but they are thrombogenic. Embolic phenomenon can occur. Patient requires oral anticoagulant to keep prothrombin time twice normal. If anticoagulants cannot be used, then aspirin, dipyridamole can be used.

#### Problems with mechanical valves

- ❖ Thrombogenic
- ❖ Require warfarin anticoagulant therapy
- ❖ Prone for severe epistaxis, intracranial haemorrhage while on warfarin therapy
- ❖ Prone for infections by bacteria, fungi, yeasts
- ❖ Mechanical haemolysis and anaemia
- ❖ Valve malfunction may occur

3. **Free homograft valve.**

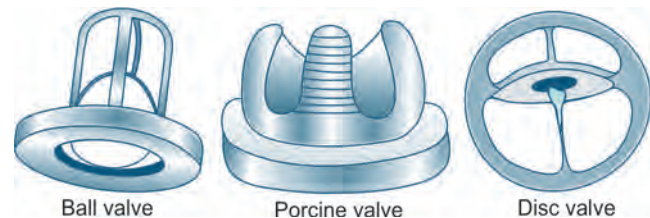


Fig. 28.51: Different types of valve prosthesis.

### ISCHAEMIC HEART DISEASE (IHD)

Main major arteries of the heart are right coronary, left coronary and circumflex artery. Blockage can occur in one or two or all three vessels. Involvement of all three vessels is called as triple vessel disease.

IHD presents as *asymptomatic* with sudden massive cardiac ischaemia with sudden death.

Or *symptomatic angina*, is progressive if not treated and eventually may lead in to severe MI.

*Atherosclerosis is the commonest cause.*

#### Risk factors are:

- ❖ Hypercholesterolaemia
- ❖ Cigarette
- ❖ Diabetes mellitus
- ❖ Hypertension
- ❖ Family history and age

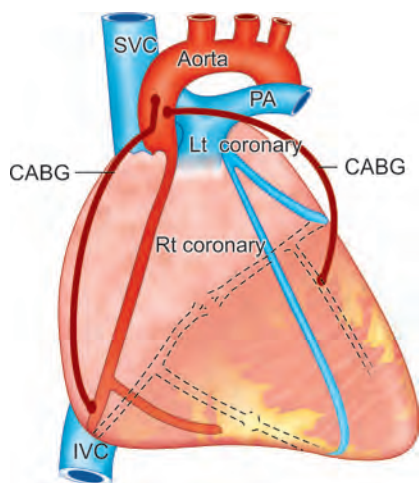
Atheroma plaques deposits in the coronary artery and narrows it. Block above 70% is called as critical block. Angina is initially treated with calcium antagonists, beta blockers, nitrates.

## Investigations

- ◆ ECG.
- ◆ Coronary angiography is diagnostic.
- ◆ Echocardiography.
- ◆ Lipid profile (done on empty stomach).

## Treatment

1. **Coronary balloon angioplasty** is done in case of angina, only one or two vessels are involved. It is done by interventional radiologists



**Fig. 28.52:** Coronary artery: Anatomy and sites of CABG.

in presence of cardiologists. Balloon tip catheter is passed through femoral or radial artery to reach proximal aorta and entered into the coronary artery opening. Coronary angiogram is done after injecting the dye. Balloon tip of the catheter is passed across the site of the block. Balloon is inflated to crush the atheroma.

#### Problems with angioplasty

- ❖ Restenosis
- ❖ May precipitate block

2. Coronary artery stenting after balloon angioplasty.
3. Coronary artery bypass graft (CABG).

#### Indications

- ❖ Triple vessel stenosis
- ❖ Left main stem stenosis
- ❖ Chronic stable angina
- ❖ Angina with persistent chest pain
- ❖ Block more than 70%

### Grafts Used

- ◆ Patient's own long saphenous vein—*commonly used graft*.
- ◆ Patient's own internal mammary artery—*choice graft* as it is reliable, less occlusion, long-term patency. Usually 3–4 grafts are used.

**Technique**—It is done under cardiopulmonary bypass. Aortic cross clamps are used to help proper graft anastomosis.

#### Complications of CABG

- ❖ Graft thrombosis
- ❖ Narrowing
- ❖ Atherosclerosis in the graft
- ❖ Respiratory infection

### CARDIAC PACEMAKERS

Cardiac rate is made regular using specialised device which stimulates the heart and acts as pacemaker.

#### Temporary Pacing

It is done in myocardial infarction, arrhythmias, and cardiac surgery.

*Contd...*

*Contd...*

#### Permanent Pacing

It is done in congenital and acquired atrioventricular block, sick sinus syndrome (SA node dysfunction), atrial fibrillation, certain tachycardia.

### Routes of Pacing

**Transvenous route** is commonly used. A needle is passed into the subclavian vein and guide wire is passed through the needle into SVC. Dilators are passed through the guide wire. Then sheath is passed. Electrode is passed into the atrium or ventricle. It is endocardial pacing.

**Transthoracic pacing**—it is not commonly used. It requires open thoracotomy. One lead is placed to the atrium and two other to ventricle.

Pacemaker may be **external** usually used as temporary.

**Internal** pacemaker is placed in the upper chest wall below the middle of the clavicle in subfacial plane under local anaesthesia (pacemaker pocket).

### POST-OPERATIVE CARE

- ◆ Proper monitoring and ICU care is essential.
- ◆ ECG, temperature, BP, CVP, cardiac monitor, urine output has to be assessed regular intervals.
- ◆ Serum electrolytes, blood gas analysis, assessment of isoenzymes, haematocrit, blood urea, creatinine.
- ◆ Acidosis and hypercalcaemia to be corrected early.

#### Complications of pacing

- ❖ Arrhythmias
- ❖ Infection
- ❖ Phlebitis, haematoma, thrombosis, bleeding
- ❖ Failure of battery, electrode
- ❖ Electrode displacement

#### Types of electrode activity

- ❖ Fixed rate—ventricular pace—no sensing
- ❖ Demand release—ventricular pace—sensing-triggered mode
- ❖ Inhibited rate—ventricular pace—sensing-inhibited mode

- ◆ *Pacemakers are sensitive to electromagnetic interference.*
- ◆ Drains from pericardium, mediastinum should be assessed carefully.
- ◆ Hypovolaemia, cardiac tamponade, myocardial infarction, hypoxia, acid-base imbalance has to be corrected.
- ◆ Dopamine, dobutamine, isoproterenol are the drugs used when there is low cardiac output.
- ◆ Digoxin, pacing, cardioversion may be required if there is cardiac arrhythmias.
- ◆ Management of respiratory system—when the patient is alert and having adequate cough reflex, endotracheal tube is removed. Breathing exercises, physiotherapy, observation for respiratory distress, prevention of pneumonia to set in are important care required.
- ◆ Care of the endotracheal tube, suctioning, checking the parameters in intermittent positive pressure ventilation (IPPV).
- ◆ Neurological system should be observed—alertness, speech, level of consciousness, any deficits are looked for.
- ◆ Strict asepsis is undertaken in cardiac postoperative period by avoiding unnecessary visitors, separate dress in postoperative ward, wearing gloves, cap, masks while attending the patient.

*Perfection is the best excuse.*



# Chapter 29

## Adjuvant Therapy

### CHAPTER OUTLINE

- ❖ Radiotherapy
- ❖ Chemotherapy
- ❖ Cell Cycle
- ❖ Antimalignancy Drugs
- ❖ Hormone Therapy in Cancer
- ❖ Immunosuppression
- ❖ Immunotherapy
- ❖ Hybridoma
- ❖ Gene Therapy

### RADIOTHERAPY

*The effect of radiations on living cells is the more intense: (1) the greater their reproductive activity, (2) the longer their mitotic phase lasts, and (3) the less their morphology and function are differentiated.*

—Jean Alban Bergonié, Louis Mathieu Frédéric Adrien Tribondeau, 1906

- ◆ Radiotherapy is the use of ionizing radiation as therapy, mainly in malignant conditions.
- ◆ Megavoltage X-rays or gamma rays which generates energy greater than  $1 \times 10^6$  V are used.

### Principles and Factors in Radiotherapy

- ◆ Penetration of the beam into the deep seated tumour.
- ◆ Building of the radiation dose under the skin over the tumour tissue so as to minimize the skin reactions.
- ◆ Precise targeting of radiation towards the tumour.
- ◆ Radiosensitivity, tumour volume and tumour size are the factors which determine the radiation efficacy.

### Physicochemical Effects of the Radiation

- ◆ Direct action on the target tissues.
- ◆ Indirect action, by releasing free radicals which cause cell destruction.
- ◆ It acts on the different phases of cell cycle to destroy the cell.

### Changes in the Tumour Cells after Irradiation

1. Repair of the damaged but retained cells.
2. Repopulation is by proliferation and reproduction of the retained cells.

3. Redistribution of the cells. Cells in the 'S' phase of the cell cycle (where DNA is being synthesised) are radioresistant. These, cells after radiotherapy will go to 'G<sub>2</sub>' or 'M' phase.
4. Reoxygenation of the cells which were hypoxic at the time of radiotherapy. Hypoxic tumour cells are radioresistant. About 10% of tumour cells are in hypoxic state.

Thus, fractionation of the radiotherapy allow retained cells to go for active and sensitised phase making radiotherapy more effective.

**Oxygen is a good radiosensitiser.** So hyperbaric oxygen is used many times as radiosensitiser.

### Radiation Unit

It is called as grey unit. It is defined as the absorption of 1 J of radiation energy by 1 kg of tissue.

### Types of Radiotherapy (Therapeutic)

1. **Curative (radical) radiotherapy:** It is given in early malignancies as a curative or primary method to tumours which are radiosensitive.
2. **Palliative radiotherapy:** It is used to alleviate the symptoms when the tumour is beyond cure.

*Symptoms are:*

- ◆ **Pain** in secondaries in the bone
  - ▶ Myeloma.
  - ▶ Carcinoma breast.
  - ▶ Advanced lymph node metastasis.
- ◆ **Bleeding**
  - ▶ Carcinoma oral cavity, cervix.
  - ▶ Carcinoma bladder, rectum.
  - ▶ Advanced secondaries in the lymph nodes.

### Common tumours

- ❖ Seminoma testis
- ❖ Hodgkin's lymphoma
- ❖ Squamous cell carcinoma
- ❖ Ewing's sarcoma
- ❖ Carcinoma lung
- ❖ Gliomas
- ❖ Bladder tumours
- ❖ Carcinoma cervix, vagina, nasopharynx, head and neck, oesophagus
- ❖ Basal cell carcinoma

Dose is 60 Gy in 30 fractions over 6 weeks.

- ◆ **Fungation**
  - ▶ Breast carcinoma.
  - ▶ Rectal carcinoma.
- ◆ **Obstruction**
  - ▶ Bronchogenic carcinoma obstructing inferior vena cava.
  - ▶ Carcinoma cervix causing obstruction to the ureter.
- ◆ **Pathological fracture** due to secondaries.
- ◆ **Spinal cord compression** due to secondaries.

Dose is 10–25 Gy in 1 to 5 fractions.

## Principle

**Radiation** is used to kill actively proliferating malignant cells at their mitotic level.

### Common malignancies which are radiosensitive

- ❖ Squamous cell carcinoma
- ❖ Basal cell carcinoma
- ❖ Bladder tumours
- ❖ Carcinoma cervix
- ❖ Seminoma testis
- ❖ Hodgkin's lymphoma

### Other areas where radiotherapy is used commonly:

- ◆ In carcinoma breast during postoperative period: For secondaries in bone, sometimes as preoperative radiotherapy, as part of *QUART Regime*.
- ◆ In follicular carcinoma of thyroid: For secondaries radioactive  $I^{131}$  5 m curies is given orally. External radiotherapy is also given for bone secondaries along with internal fixation if there is pathological fracture.
- ◆ Malignant brain tumours like astrocytomas.
- ◆ Many sarcomas.
- ◆ Carcinoma prostate.
- ◆ Carcinoma oesophagus.
- ◆ Carcinoma lung.
- ◆ Fixed secondaries in neck as palliation to palliate pain, fungation and erosion into major vessels.
- ◆ Multiple myelomas.

## Radioresistant Tumours Include

- ◆ All GI malignancies.
- ◆ Melanoma.
- ◆ Medullary carcinoma of the thyroid.

## Source of Radiotherapy

- ◆ Cobalt-60 machine—most commonly used.

- ◆ Kilovoltage machines.
- ◆ Linear accelerator.
- ◆ Betatron/Microtron.
- ◆ Radioactive materials like Cesium 137 (pellets), Iridium 192 (wire), Gold 198 (seeds), Iodine 125 (seeds).

## Measurement of Ionising Radiation

**Roentgen unit** is a measure of ionisations produced per unit volume of air by X-rays and gamma rays but it is not used for photon energies above 3MeV. SI unit for exposure is Coulomb per kg.

## Radiation Absorbed Dose (RAD)

Absorbed dose is De/dm. It is mean energy imparted by the ionizing radiation to material of mass dm.

Old unit is *rad* which is equivalent to 100 ergs of energy per gram.

## Newer International Unit is Presently Used

One Grey (*Gy*) is one joule of energy deposited per kilogram of material. One Gy = 100 rads = 100 cGy. 1 cGy = 1 rad.

## Radiotherapy Plan

Type and doses of radiotherapy is decided by following factors:

- ◆ Site of tumour.
- ◆ Lymphatic field.
- ◆ Tumour size and extent.
- ◆ Histological type and grading.

### Types of radiotherapy (Technical)

- ❖ Superficial X-ray therapy (100 KV)
- ❖ Orthovoltage X-ray therapy (200/300 KV)
- ❖ Caesium ( $^{137}\text{Cs}$ ) or cobalt ( $^{60}\text{Co}$ ) teletherapy
- ❖ Intracavitary or intralesional radiotherapy (Brachytherapy)
- ❖ Radioactive  $I^{131}$  therapy for follicular carcinoma thyroid

## Brachytherapy

- ◆ It is radiation given with source close to the tumour.
- ◆ It is given using iridium<sup>192</sup> caesium<sup>137</sup>.
- ◆ It is curative radiotherapy.
- ◆ It is used in carcinoma oral cavity, penis, breast, cervix and bladder.
- ◆ Radiation material placed in the cavity is called *intracavitary* RT.
- ◆ Radiation material is inserted into the tissues—*interstitial* RT.
- ◆ Implants can be kept permanently or temporarily.
- ◆ Radioactive material is placed into the cavity/tissue through applicators under general anaesthesia.
- ◆ Intraoperative radiotherapy is also becoming popular.
- ◆ It has only localised effect with adjacent tissue being spared.

### External beam radiation:

Given using cobalt 60 teletherapy or X-ray source.

*Advantages*—Deep penetration, skin sparing, better dose distribution.

### Internal radiation:

Used for diagnostic and therapeutic purpose, e.g. in carcinoma thyroid for treatment of secondaries.

*“Cancer” word itself is lethal many times than cancer.*

Radiotherapy sources	Classification	Efficacy depends on:
<ul style="list-style-type: none"> <li>X-rays, electrons—from high energy X-ray machine, i.e. Linear accelerator</li> <li>Gamma and beta rays from radioactive isotopes like Cobalt-60, Caesium 137, Iridium 197</li> <li>Protons, neutrons and heavy ion nuclei from cyclotrons</li> </ul>	<ul style="list-style-type: none"> <li><i>Low LET</i> (Low Energy Transfer) radiation—X-rays, gamma rays, electron</li> <li><i>High ET</i> radiation—Neutrons, protons, alpha particles and negative ions. It has heavier mass with dense localisation and hence biologically more effective</li> </ul>	<ul style="list-style-type: none"> <li>Cell cycle phase</li> <li>Oxygen content of cells</li> </ul> <p><i>Methods of delivery</i></p> <ul style="list-style-type: none"> <li>External beam radiation (Teletherapy)</li> <li>Brachytherapy</li> <li>Systemic irradiation using radioisotopes like I<sup>131</sup></li> </ul>
<p><i>Preoperative radiotherapy</i></p> <p><i>Advantages</i></p> <ul style="list-style-type: none"> <li>Down-stage the tumour and reduces the tumour bulk</li> <li>No change in oxygenation of tissues</li> <li>Blockage of lymphatics by RT prevents tumour spread during surgical dissection</li> <li>Reduces the chances of microscopic spread</li> </ul> <p><i>Disadvantages</i></p> <ul style="list-style-type: none"> <li>Delayed healing due to reduced vascularity</li> <li>Flap necrosis, fistula formation</li> <li>Carotid blow-out</li> </ul>	<p><i>Postoperative radiotherapy</i></p> <ul style="list-style-type: none"> <li>More effective and extent of RT is well-defined</li> <li>Flap necrosis, fistula complications are less</li> </ul> <p><i>Indications</i></p> <ul style="list-style-type: none"> <li>When resected margin is positive for tumour</li> <li>When bone/cartilage are involved</li> <li>Extracapsular nodal spread</li> <li>Multiple neck nodes/node more than 3 cm in case of neck disease</li> <li>Poorly differentiated tumour</li> </ul>	<p><i>Radiotherapy and chemotherapy combined</i></p> <ul style="list-style-type: none"> <li>Commonly used before or during RT</li> <li>Chemotherapy after RT is not commonly followed</li> <li>Chemotherapy before RT is called as <i>induction chemotherapy</i> which reduces the bulk of tumour without altering the vascularity</li> <li>Chemotherapy with RT is called as <i>concomitant RT</i> which improves the effect of RT. Methotrexate and bleomycin are radio sensitisers</li> </ul>

## Complications of Radiotherapy

- Oral mucosal oedema, ulceration, dysphagia, dyspnoea, loss of taste, oral thrush.
- Bone marrow suppression.
- Oophoritis in women and oligospermia in men.
- Affecting lens, eyelashes and lacrimal glands causing dryness, cataract.
- Mucosa in GIT is very sensitive causing nausea, vomiting and diarrhoea.
- Radiation dermatitis, pigmentation in skin.
- Radiation myelitis of the spinal cord—causing hemiplegia, paraplegia.
- Radiation pneumonitis and pulmonary fibrosis.
- Radiation nephritis and renal failure.
- Radiation osteomyelitis.
- Radiation-induced malignancies.
- Radiation-induced thimble bladder.
- Radiation-induced frozen pelvis.
- Infection—bacterial, viral, candidial (*oral thrush*).

## CHEMOTHERAPY

- Chemotherapy, today is an important modality of treatment in managing a case of cancer.
- It is the main modality of treatment in most of the advanced malignancies.
- It is used preoperatively to downstage the tumour so as to increase the possibilities of surgical resection.
- When used postoperatively it reduces the rate of recurrence.
- It is the primary treatment for NHL, leukaemia.
- These drugs mainly act by blocking the mitotic activity in the nucleus in different phases of the cell cycle.
- It is given either oral, intravenous (*systemic*), intra-arterial, intrathecal and intravesical (*regional*) or as isolated limb perfusion.
- Intra-arterial chemotherapy is used in head and neck cancers and hepatic cancers.
- Isolated limb perfusion* is used in melanoma.

## Brachytherapy

Type	Advantages	Disadvantages
<ul style="list-style-type: none"> <li><i>Intracavitary</i> like in uterus, urinary bladder, maxillary antrum, bronchial or oesophageal tree</li> <li><i>Interstitial</i> wherein radioactive needles/wires/ribbons/seeds are inserted into the tumour area like in bladder or oral cavity</li> <li><i>Surface brachytherapy</i> using moulds like in tumours of skin/eye/breast</li> <li>Radionuclides used are Caesium 137 (Cs<sup>137</sup>), Iridium 192 (Ir<sup>192</sup>), Gold 198 (Au<sup>198</sup>) and Iodine 125 (I<sup>125</sup>)</li> <li>Brachytherapy is often combined with external beam radiotherapy</li> </ul>	<ul style="list-style-type: none"> <li>High, localised, single continuous dose of RT</li> <li>Deeper and adjacent tissues are spared</li> <li>High dose rate with short time</li> <li>Less side effects</li> <li>Curative and effective in early cancers</li> <li>After loading devices are available which reduces personal exposure</li> <li>Surgery is avoided and part is retained</li> </ul>	<ul style="list-style-type: none"> <li>Technically difficult</li> <li>Availability of the facility</li> <li>Local complications like displacement/erosion</li> </ul>

## CELL CYCLE

The cell cycle is composed of:

1. 'G<sub>0</sub>'—resting phase or nonproliferative phase.
2. Presynthetic phase (G<sub>1</sub>)—resting cells that are not preparing for cell division are said to be in this subphase G.
3. 'S' phase—DNA synthesis takes place during this phase.
4. 'M' phase—formation of mitotic spindle, i.e. period of mitosis.
5. Postsynthetic phase (G<sub>2</sub>)—premitotic interval, which follows the termination of DNA synthesis.

Most potent cytotoxic agents act by damaging DNA. Their toxicity is high during the DNA synthetic phase, 'S' phase of the cell. Some agents block the formation of mitotic spindle in M phase (vinka alkaloids and taxanes). So the agents have activity only against cells that are in the process of division. Hence, tumour with high fraction of actively dividing cells are more susceptible to chemotherapeutic agents.

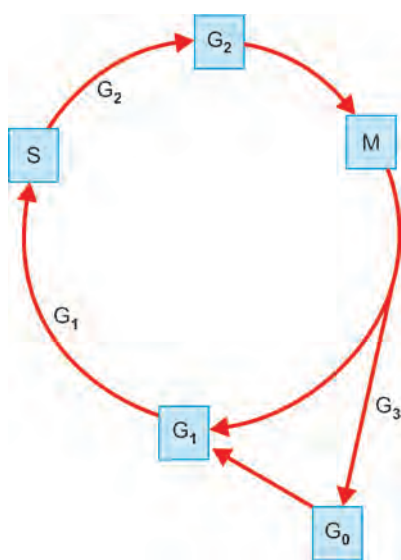


Fig. 29.1: Cell cycle.

When chemotherapy is given with interferons and interleukins, it is called as **biochemotherapy**.

## ANTIMALIGNANCY DRUGS

### I. Classification

1. *Alkylating agents*:
  - a. Nitrogen mustards: Mechlorethamine (mustine hydrochloride), cyclophosphamide, chlorambucil, melphalan.
  - b. Ethylenimines.
  - c. Alkylsulfonates—busulfan.
2. *Antimetabolites*:
  - a. Folic acid antagonists—methotrexate.
  - b. Purine antagonists—azathioprine, 6-mercaptopurine.
  - c. Pyrimidine antagonists—5-fluorouracil.
3. *Antibiotics*: Actinomycin-D, mitomycin, doxorubicin, bleomycin.
4. *Vinca alkaloids*: Vincristine, vinblastin.
5. *Miscellaneous*: Cisplatin, procarbazine.

### II. Classification of antimalignancy drugs based on the action on cell cycle

*S-phase specific agents*: Cytosine arabinoside, hydroxyurea, 6-mercaptopurine.

*M-phase specific agents*: Vincristine, vinblastine, paclitaxel.

*Phase nonspecific agents*: Alkylating agents, nitrosoureas, antitumour drugs, procarbazine, cisplatin, dacarbazine.

### Mode of Action

These drugs damage the active cells by affecting the process of cell division. Hence, they also affect haemopoiesis, cellular activity, epithelial tissues and gonads. They also suppress the immune system.

### Adverse Effects in General

Bone marrow suppression, alopecia, hepatotoxicity, nephrotoxicity, damage to gonads, damage to GI mucosa and ulceration.

## HORMONE THERAPY IN CANCER

### Ablative Procedures

- ◆ Oophorectomy and adrenalectomy in carcinoma breast.
- ◆ Orchidectomy in carcinoma prostate.

### Added Hormone

- ◆ Prednisolone, progestogens, estrogens and androgens.

### Hormone Antagonists

- ◆ Tamoxifen is estrogen receptor antagonist. Estrogen receptor level is assayed. If it is more than 10 units/g of tissue, it is called as ER positive and if less than 10 units, it is called as ER negative.
- ◆ Cyproterone acetate, competes with testosterone for binding receptors.
- ◆ LHRH analogue—Goserelin (Zoladex) acts as an antagonist to carcinoma breast.
- ◆ Phosphorylated diethylstilbestrol (Honavan) is used in carcinoma prostate.

### Drugs that Interfere with Hormone Synthesis or Release

- ◆ Aminoglutethimide is an adrenal inhibitor. It is also an aromatase inhibitor inhibiting the peripheral conversion of androstenedione to estrogen.
- ◆ *Papillary carcinoma of thyroid is (TSH) hormone dependent.* TSH can be very well-suppressed by giving L-thyroxine, suppressive dose, daily 0.3 mg for life long.

**Steroids (corticosteroids)** are used as component of chemotherapy regime. They also improve the anorexia and also control hypercalcaemia seen in patients with malignancies on treatment. They reduce cerebral oedema in intracranial malignant neoplasms.

	<b>Drugs</b>	<b>Used in</b>	<b>Adverse effects</b>
1.	Mustine hydrochloride	Hodgkin's lymphoma	Alopecia, bone marrow suppression
2.	Cyclophosphamide: Dose: 3 mg/kg IV daily for 5 days in dextrose, as monthly cycle for 6 months Orally as 50 mg tablets	Ovarian carcinoma, lymphomas, colonic and bronchogenic carcinoma	Alopecia, bone marrow suppression, haemorrhagic cystitis
3.	Melphalan: Dose: 10 mg daily × 3 weeks Available as 2 mg tablets	Multiple myeloma and melanoma	
4.	Busulfan: 10 mg for 3 weeks	Chronic myeloid leukaemia	Pulmonary fibrosis
5.	Chlorambucil: 10 mg for 3 weeks	Chronic lymphatic leukaemia	
6.	Methotrexate: 2.5–5 mg/d orally; 10 mg intrathecally 1–2 times a week	Choriocarcinoma, ALL, soft tissue sarcoma, breast cancer	Oral and GIT ulceration, bone marrow suppression, hepatic damage
7.	6-Mercaptopurine: Dose: 2.5 mg/kg/d orally	Leukaemias and choriocarcinoma	Hyperuricaemia
8.	5-Fluorouracil Dose: 15 mg/kg/d IV	Adenocarcinomas of GIT, breast cancers and cancer cervix	Neurotoxicity, stomatitis, bone marrow suppression
9.	Vinca Alkaloids. Vincristine: Dose: 1.5 mg/sq.m Vinblastine: Dose: 0.1 mg/kg body weight	Leukaemia Hodgkin's lymphoma	Neurotoxic Bone marrow toxicity
10.	Rubidomycin: Dose: 40 mg/m/day IV	Acute myeloblastic leukaemia	Myocardial depressant
11.	Adriamycin: 60 mg/m <sup>2</sup> IV	NHL, hepatoma, medullary carcinoma thyroid, osteosarcoma and soft-tissue sarcomas	Cardiotoxic
12.	0'-p DDD(Mitotane): Dose: 10 gm orally for 8 weeks	Carcinoma adrenal cortex	
13.	Bleomycin: 20 units IV or IM	Squamous cell carcinoma of skin and other regions and lymphomas	Pulmonary fibrosis
14.	Cytosine arabinoside: Dose: 4 mg/kg IV	Leukaemias and lymphomas	Leukopenia and thrombocytopenia
15.	Lomustine (CCNU) and Carmustine (BCNU)	Brain tumours and lymphomas	
16.	Procarbazine	Hodgkin's lymphoma and oat cell carcinoma lung	Bone marrow and CNS depression
17.	Cisplatin: Dose: 20 mg/m <sup>2</sup> /d	Testicular and ovarian tumours	Nephrotoxicity
18.	Etoposide: Dose: 100 mg/sq.m	Testicular tumour, bladder tumour, lymphomas	
19.	Hydroxyureas	Myeloma, leukaemias	

## ■ IMMUNOSUPPRESSION

- ◆ It is mainly used in transplantation to prevent graft rejection, e.g. in transplantation of kidney, liver, heart, small bowel, pancreas.

Drugs used are:

- ◆ *Azathioprine* (Imuran, Purine analogue): Inhibits purine synthesis.
- ◆ *Cyclosporine*: It is a very good immunosuppressant, derived from fungus. It causes inhibition of lymphocytic activity, delayed hypersensitivity, interleukins, memory cells, etc. It binds to cyclophilin, decreases IL-2 and other cytokine release from T cells. It is initially given intravenously and later given orally. It is given usually for long duration, for 12–24 months. It is *nephrotoxic* as well as *bone marrow suppressant*. So, constant monitoring by blood urea, serum creatinine, blood count, Hb% at regular intervals is required. Dose should be adjusted depending on these parameters. Cyclosporine is very effective immunosuppressant in transplantation.
- ◆ *Antilymphocytic globulin*: Antibodies against T-cell receptors (CD2, CD3, CD4, CD8), B-cells and macrophages.
- ◆ *Steroids (methylprednisolone)*: Alters transcription and translation, affects T-cells and macrophages.
- ◆ *Cytosine arabinoside*: Anti-inflammatory and immunosuppressive effect.
- ◆ *Tacrolimus (FK506)*: Bind to FK binding proteins, effects are similar to cyclosporine.
- ◆ *OKT3*: Acts against CD3 and T-cells.
- ◆ *Mycophenolate mofetil*: Inhibits inosine monophosphate, affects lymphocytes.

## Types of Immunosuppression

1. *Induction regimens*: Mainly aims to avoid rejection and to establish a good graft function during the immediate post-transplant weeks (2 weeks). Antilymphocytic sera, along with either cyclosporine or azathioprine or steroids are used here.
2. *Antirejection regimens*: It aims at reversing the acute rejections. High dose steroids and antilymphocytic sera are used here.
3. *Maintenance therapy*: Using cyclosporine or FK506 along with steroids and azathioprine.

### Complications

- ❖ Infection—commonest
- ❖ Malignancy—squamous cell carcinoma, lymphoma, Kaposi's sarcoma
- ❖ Nephrotoxicity
- ❖ Bone marrow toxicity
- ❖ GIT toxicity
- ❖ Neurotoxicity

## IMMUNOTHERAPY

It is enhancing the host response of patient whenever required, commonly against malignant cells. Often it is used in other conditions also, where there is severe immunosuppression due to any reason like bone marrow suppression or in specific conditions like severe hepatitis.

### Immunotherapy can be:

- ❖ Active
- ❖ Passive
- ❖ Restorative
- ❖ Adaptive

### Immunotherapy agents

- ◆ Monoclonal antibodies.
- ◆ Bone marrow transplantation.
- ◆ Cell transfer.
- ◆ Lymphokines.
- ◆ Thymic hormones.
- ◆ Levamisole and BCG (as immunomodulators).
- ◆ Prostaglandins.
- ◆ Interferons, interleukins.
- ◆ Immunoglobulins.
- ◆ Antibody derived specific to certain tumour like melanoma.

### Tumours where immunotherapy is used

- ❖ Melanoma
- ❖ Bladder tumour
- ❖ Carcinoma colon
- ❖ Renal cell carcinoma
- ❖ In many tumours it is under trial

## Disadvantages

- ◆ Very costly.
- ◆ Nonavailability.
- ◆ Effect is not 100%.

## HYBRIDOMA

- ◆ It is a biotechnological process wherein *multiplication* property of *Myeloma cells* is combined with *synthetic* property of some other required cells, to *achieve rapid* and large quantity manufacturing of required chemical.
- ◆ Myeloma cells with only retained multiplication activity is fused with human cells or lymphocytes or other cells (of nature to produce the required product) by *hybridisation*. The resulting cell has got the capacity to multiply rapidly and to produce required product in large quantity. It is called as *hybridoma*.
- ◆ It is used to generate monoclonal antibodies, insulin and many other antibodies, immunoglobulins, etc.

### Monoclonal antibodies are used for

- ❖ Immunodiagnosis—for radioimmunoassay, radionuclide scan
- ❖ Antibody for detection of tumour antigen
- ❖ For cancer therapy
- ❖ For serotherapy
- ❖ As conjugates (with drugs, toxins, isotopes)
- ❖ For production of other chemicals and as a *research tool*

## GENE THERAPY

The ability to alter specific genes of interest is, nowadays an exciting and powerful tool in the potential management of a wide range of diseases. Instead of giving a patient a drug to treat or control the symptoms of the genetic disorder, physicians may be capable of treating the basic problem by altering the genetic makeup of the patient's cell.

Typically, two methods have been considered: Germ line and somatic cell gene therapy.

- ◆ *Germ cell therapy* involves insertion of a gene into fertilised egg for the correction of a genetic disease. Because these genes are dispersed throughout the tissues of the egg, they end up in the germ cells of the foetus, and hence are passed on to the future generations.
- ◆ *Somatic cell therapy* involves the insertion of genes or otherwise manipulating the gene machinery of a cell to treat a disease. In this case the cells are restricted to the population that has been treated and any genetic change remains restricted to these cells and is not passed onto the germ cell line.

The goals of human somatic therapy are usually one of the following:

- ◆ To repair or compensate for a defective gene.
- ◆ To enhance the immune response directed at a tumour or pathogen.
- ◆ To protect vulnerable cell populations against treatments such as chemotherapy.
- ◆ To kill tumour cells directly.

Several single gene disorders are candidates for gene therapy and in addition, current thinking has expanded to include treatment of AIDS and atherosclerosis using gene therapy techniques.

Vectors used for gene therapy fall into *two main classes*—*Viral and nonviral*.

- ◆ **Viral**: Initially retroviruses were used as vectors. Other potential vectors include Adenovirus, Herpes virus and Vaccinia virus.

### Nonviral systems

- ▶ Liposome mediated DNA transfer.
- ▶ DNA protein conjugates.

However exciting and appealing the prospects of gene therapy may appear, this technique is still in the experimental stages.

# Chapter 30

## Anaesthesia

*It has long been an important problem in medical science to devise some method of mitigating the pain of surgical operations. An efficient agent for this purpose has at length been discovered. A patient has been rendered completely insensible during an amputation of the thigh, regaining consciousness after a short interval.*

—Henry Jacob Bigelow, 1846

### CHAPTER OUTLINE

- ❖ Preoperative Assessment
- ❖ General Anaesthesia
  - Anaesthetic Agents
  - Oxygen
  - Muscle Relaxants
  - Reversal Agents
  - Instruments in Anaesthesia
  - Complications of General Anaesthesia
- Postoperative Care
- Monitoring the Postoperative Patient
- ❖ Regional Anaesthesia
  - Topical Anaesthesia
  - Infiltration Block
  - Field Block
  - Nerve Block
- Intravenous Regional Anaesthesia
- ❖ Spinal Anaesthesia
  - Saddle Block
- ❖ Epidural Anaesthesia
  - Caudal Anaesthesia

### ■ PREOPERATIVE ASSESSMENT

#### History

- ◆ Chronic cough, smoking, alcohol, drug intake, drug allergy.
- ◆ Any previous diseases like hypertension, diabetes mellitus, epilepsy, bronchial asthma, tuberculosis, hepatitis, cardiac diseases.
- ◆ Drug therapy: Steroids, antihypertensives, sedatives, antibiotics, antiepileptics.

#### Examination

**General:** Posture, teeth, mouth opening, dilated veins, neck movements, tremor, airway, anaemia, oedema, jaundice, cyanosis.

**Respiratory system:** To look for asthma, tuberculosis, emphysema, COPD.

**Airway:** Mouth opening, Mallampati scoring, thyromental distance, temporomandibular joint assessment.

**Thyromental distance:** It is the distance between mentum and thyroid

cartilage, measured externally. If it is more than 6.5 cm (i.e. more than 4 fingers breadth) intubation is easier, if it is less than 6.5 cm intubation is difficult.

**Cardiovascular system:** Hypertension, ischaemic heart disease, arrhythmias, cardiac failure, valvular diseases.

**Spine:** Curvature, intervertebral space, skin over the area for any infection.

**Other systems:** Abdomen, skeletal system.

#### Scoring to assess intubation

##### Mallampati scoring:

Class I — Faucial pillar, soft palate, uvula are seen

Class II — Faucial pillar, soft palate are seen

Class III — Only soft palate is seen

*Samsons Young modification:*

Class IV — Only hard palate seen

Class I, II: Easy intubation

Class III, IV: Difficult intubation

## Preoperative Investigations

Haematocrit, blood sugar, blood urea, serum creatinine, electrolytes, chest-X ray, ECG, blood grouping, blood-gas analysis, cardiac assessment.

## Preoperative Treatment

- ◆ Control of respiratory and cardiac diseases.
- ◆ Improvement of Hb% status, if anaemia is present.
- ◆ Preoperative antibiotics are given.
- ◆ Blood should be kept ready for major cases.
- ◆ Starvation for 4 hours for liquids and 6 hours for solids.
- ◆ Bladder and bowel should be emptied to prevent soiling on the operation table. Urinary catheter may be passed and enema may be given.
- ◆ Dentures, contact lenses, jewellery must be removed.
- ◆ Surgical area should be cleaned and properly prepared.

## GENERAL ANAESTHESIA

It means abolition of all sensations, i.e. touch, pain, posture and temperature with a state of reversible loss of consciousness.

It has got three components:

(1) Analgesia; (2) Hypnosis; (3) Muscle relaxation.

## ANAESTHETIC AGENTS

- ◆ **Volatile anaesthetics:** They vaporise in room air.
  - ▶ Agents used are: Ether, trichloroethylene, halothane, enflurane, isoflurane, sevoflurane.
  - ▶ Ether which is irritant, unpleasant, flammable, is commonly used agent in developing countries.
  - ▶ Enflurane and isoflurane are non-inflammable, non-explosive, non-irritant and stable. Here anaesthesia is rapid with faster recovery.
- ◆ **Gaseous anaesthetics:**
  - ▶ Nitrous oxide: It is non-inflammable, non-irritant, good analgesic but weak anaesthetic agent. It is given along with 30–50% oxygen for balanced anaesthesia (blue coloured cylinder in India).
  - ▶ Cyclopropane is highly flammable.
- ◆ **Intravenous anaesthetics:**
  - ▶ Thiopentone: It is ultrashort acting barbiturate which causes hypnosis during induction of anaesthesia. It does not have analgesic effect. It causes hypotension, respiratory depression, laryngeal and bronchospasm. Recovery is rapid. Extravasation of drug can cause skin ulceration. Intra-arterial injection causes vasospasm and gangrene. Dose: 4–7 mg/kg. Methohexitone sodium. Propanidid: 4–7 mg/kg. It can cause anaphylaxis.
  - ▶ Ketamine: Dose: 2 mg/kg IV. It is a good analgesic. It causes dissociative anaesthesia. It can lead to hypertension, apnoea, laryngospasm. In children it can be given IM-5 mg/kg. It does not require intubation for small procedures.
  - ▶ Propofol: It is widely used induction agent which has got predictable onset and recovery. It has got least side effects on CVS and respiratory system. It is also used for total IV anaesthesia. Dose: 1–2.5 mg/kg.

- ▶ Fentanyl is neuroleptanalgesic. It causes sedation, catatonia, dissociation, hypotension and preferred in asthmatics.

## OXYGEN

- ◆ Oxygen is given through Boyles apparatus (33.3%).
- ◆ Oxygen in high concentration is respiratory depressant and also affects eyes.
- ◆ A 5% CO<sub>2</sub> mixture in oxygen is called as carbogen.
- ◆ Oxygen is available in black and white coloured cylinder.

## MUSCLE RELAXANTS

### Depolarising Muscle Relaxants

They act at the level of acetylcholine receptors which widens the refractory period after depolarisation causing paralysis. It is short-acting muscle relaxant.

- a. *Suxamethonium chloride (scoline):*
  - ▶ It lasts for 2–4 minutes.
  - ▶ It causes muscle twitching—fasciculations—paralysis.
  - ▶ It is metabolised by plasma pseudocholinesterase. Atypical or deficiency of this enzyme prolongs the action of the scoline.
  - ▶ Side effects are hyperkalaemia, myotonia, apnoea and cardiac arrest.
- b. *Suxthonium bromide.*

### Non-depolarising Muscle Relaxants

They block the channels of entry of acetylcholine. They are long acting relaxants.

1. *Tubocurarine:* It lasts for 45 minutes. 30 mg is the dose.
2. *Gallamine. (Flaxedil):* Dose is 1–2 mg/kg. It is cheaper. It is contraindicated in renal diseases.
3. *Pancuronium bromide (Pavulon):* It is synthetic steroid muscle relaxant. Its action lasts for 45 minutes. Dose is 0.08–0.1 mg/kg.
4. *Vecuronium bromide:* It is a steroid muscle relaxant, given at a dose of 0.05–0.1 mg/kg.
5. *Rocuronium* is short-acting steroid muscle relaxant. It starts its action in one minute.
6. *Atracurium:* It lasts for 20–30 minutes. Dose is 0.6 mg/kg.
7. *Mivacurium:* Dose is 0.15–0.25 mg/kg.

## REVERSAL AGENTS

They are anticholinesterase drugs which increase the acetylcholine, and thus act as antagonising agents for non-depolarising muscle relaxants. They cause bradycardia.

*Neostigmine (2.5 mg)* is used commonly along with atropine (1.2 mg).

Edrophonium (short acting) and pyridostigmine (long acting) are other drugs.

## INSTRUMENTS IN ANAESTHESIA

1. **Boyle's apparatus:**
  - It consists of:
    - a. Cylinders for N<sub>2</sub>O and O<sub>2</sub>.
    - b. Pressure gauge—to know the amount of gas remaining.
    - c. Pressure regulator—to regulate the pressure of gas used.
    - d. Rotameter—to know the flow of gas.
    - e. Vapouriser.

*When giving mouth-to-mouth resuscitation, the important thing to remember is to remove your denture first.*

—WU McClenahan





Fig. 30.1: Different sized airways have different colours.

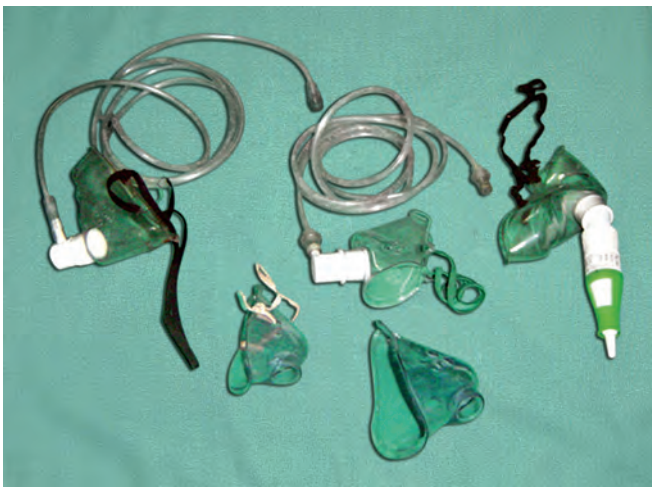

Fig. 30.2: Different sized masks used during anaesthesia.



Fig. 30.3: Boyle's apparatus used for anaesthesia.

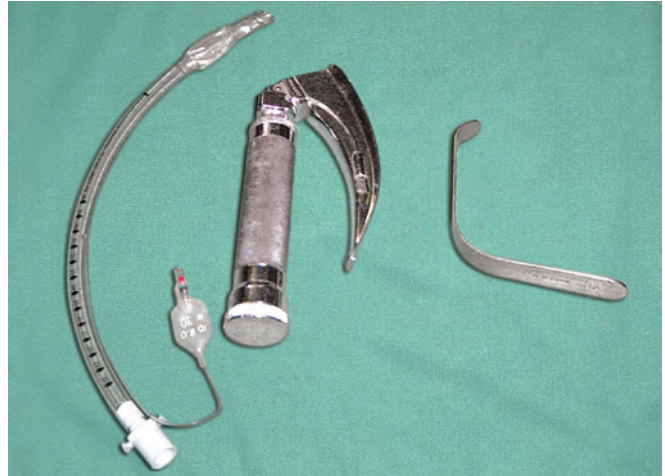


Fig. 30.4: Direct laryngoscope with endotracheal tube and tongue depressor.

**Note:**

- **Pin index code:** It is safety mechanism to fix gas cylinder onto the Boyle's machine. Different gases have different pin index codes, so that interchanging of cylinders does not take place.
- Pin index code for  $N_2O$  is 3, 5.
- Pin index code for  $O_2$  is 2, 5.
- Pin index code for air is 1, 5.

2. **Endotracheal tube:** These are tubes inserted into the trachea and is used to conduct gases and vapours to and from the lungs. Depending on the diameter, it is available in various sizes. It has a cuff at one end which, when inflated stabilises the tube in position and also prevents regurgitation. Non-cuffed tubes are also available. The other end near the mouth is connected to the breathing circuit through which anaesthetic gases are delivered. The tube is inserted using a direct laryngoscope. The proper placement in the airway is confirmed by auscultating for the breath sounds over the chest when the gases are delivered.

**Complications**

- ❖ Postoperative sore throat
- ❖ Hoarseness after intubation
- ❖ Upper airway oedema

3. Magill's forceps.
4. Mouth gag.

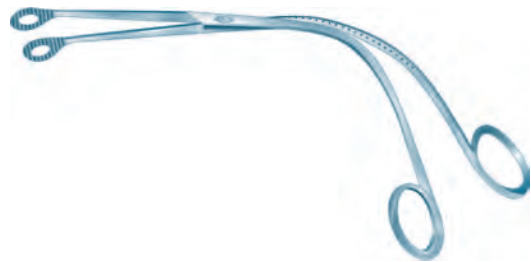

Fig. 30.5: Magill's forceps.

5. Laryngoscope.
6. Connectors.

### 7. Laryngeal mask airway (LMA):

- ▶ Laryngeal mask consists of a wide bore tube whose proximal end connects to breathing circuit and distal end is attached to an elliptical cuff which can be inflated.
- ▶ These come in various sizes for various age groups. It is made up of silicone rubber.
- ▶ The deflated cuff is lubricated and inserted into the hypopharynx, so that once inflated, the cuff forms a low pressure seal around the entrance into the larynx.

#### Advantages

- ❖ Does not require laryngoscope for insertion
- ❖ Does not cause irritation of airway
- ❖ Less incidence of laryngospasm
- ❖ In case of inability to intubate can save the life of the patient

#### Contraindications

- ❖ Pharyngeal pathology
- ❖ Full stomach as it can cause aspiration
- ❖ Bronchospasm

#### Components of general anaesthesia

- ❖ Premedication
- ❖ Induction
- ❖ Maintenance
- ❖ Recovery

## Premedication

It is given one hour before surgery:

- ◆ For sedation and relief of anxiety. Pethidine 50 mg/ morphine 10 mg/diazepam 10 mg, midazolam 1–2.5 mg.
- ◆ To suppress vagal activity. Atropine 0.6 mg IM.
- ◆ To reduce vomiting. Promethazine (phenargan) 12.5 mg.

**Induction:** Patient is preoxygenated with 100% oxygen for 3 minutes then induced with IV thiopentone, given 4–5 mg/kg. Patient loses consciousness. Induction is maintained by 67% nitrous oxide and 33% oxygen.

Scoline is given IV to relax muscles so as to facilitate *endotracheal intubation*.

Once intubated, *ventilation* can be either *controlled* using muscle relaxants or *spontaneous* using a volatile anaesthetic agent.

**Reversal** is done using neostigmine and atropine or glycopyrrolate.

## COMPLICATIONS OF GENERAL ANAESTHESIA

- ◆ Intra-arterial injection of the drug.
- ◆ Myocardial depression and cardiac arrest.
- ◆ Hypertension.
- ◆ Laryngeal and bronchial spasm.
- ◆ Cardiac arrhythmias.
- ◆ Respiratory failure.
- ◆ ARDS.
- ◆ **Mendelson's syndrome:** It is due to regurgitation of the acid from the stomach causing aspiration of acid leading into bronchospasm, pulmonary oedema and circulatory failure. This is treated with oxygen, suction, hydrocortisone, aminophylline, antibiotics, Ryle's tube aspiration and ventilator support.
- ◆ Hypoxia.

- ◆ Pneumothorax.
- ◆ Anaphylaxis.
- ◆ **Malignant hyperthermia:** It is an inherited myopathic disorder occurs under anaesthesia due to drugs like halothane, scoline. There is marked increase in metabolic rate, with rise of temperature. There is high levels of CPK enzyme. Condition will cause metabolic acidosis and hyperkalaemia. It has got high mortality. Treatment is IV dantrolene, cooling, oxygen and cold IV fluids.
- ◆ Hypothermia.

## POSTOPERATIVE CARE

Immediate postoperative period is important and critical, because patient may not be fully conscious. Patient should be kept in recovery room until he/she recovers from anaesthesia.

1. *Care of respiratory system:* Adequate breathing is important, otherwise hypoxia sets in, which gradually leads to cardiac arrest.

#### Respiratory problems may be:

- ❖ Laryngeal spasm
- ❖ Falling of tongue backwards blocking the airway
- ❖ Aspiration
- ❖ Bronchospasm
- ❖ ARDS
- ❖ Respiratory failure

Oxygen supplement through mask, observation, proper positioning are the treatment.

2. Hypercarbia.
3. Circulatory problems:

- ❖ Hypotension
- ❖ Arrhythmias
- ❖ Hypertension
- ❖ Cardiac arrest

4. GIT:

- ❖ Vomiting
- ❖ Regurgitation
- ❖ Mendelson's syndrome

5. *Renal problems:* Oliguria, i.e urine output is less than 30 ml/hour. It may be due hypovolaemia, hypotension, acidosis, sepsis, transfusion reaction, toxins.

The ratio of urine/plasma osmolality of 2:1 signifies pre-renal failure. Ratio of 1.7:1 indicates renal failure.

Blood urea and serum creatinine is done at regular intervals.

Fluid and electrolyte imbalance, if any is corrected.

100 ml 20 % mannitol or frusemide 40–80 mg are often required.

6. Other problems:

Restlessness, shivering, pain.

## MONITORING THE POSTOPERATIVE PATIENT

- ◆ Pulse, temperature, BP chart.
- ◆ Breathing type.
- ◆ Level of consciousness.
- ◆ Urine output.
- ◆ Oxygen saturation and heart rate using pulse oximeter.
- ◆ Checking and encouraging limb movements.
- ◆ Skin colour, tongue colour for adequacy of oxygenation.

*The future belongs to those who believe in the beauty of their dreams.*

- ◆ Tongue for hydration.
- ◆ Cardiac monitor.
- ◆ Blood gas analysis in case of patient on ventilator.
- ◆ Serum electrolytes assessment.

## REGIONAL ANAESTHESIA

Carl Koller, an ophthalmologist introduced cocaine as local anaesthetic in ophthalmic practice.

*Mode of action:* It causes temporary conduction block of the nerve, thus preventing the propagation of nerve impulse.

*Advantages of local anaesthetic agent:*

- ◆ Technically simpler.
- ◆ General anaesthesia is avoided.
- ◆ Consciousness is retained.
- ◆ Patient can have food earlier after surgery.

*Drugs used:*

- ◆ Cocaine, procaine, cinchocaine—amino esters.
- ◆ Lignocaine, prilocaine, bupivacaine, ropivacaine—amino amides.

**Lignocaine/Lidocaine/Xylocaine:** It is the commonest local anaesthetic agent used. It is available as 0.25–5% concentrations.

It is metabolised in the liver and excreted in the kidney as xylidines. It is also an antiarrhythmic drug and so commonly used in cardiology and cardiac surgery.

*Side effects:* Giddiness, headache, postural hypotension, tinnitus, circumoral anaesthesia.

**Dose:** 4 mg/kg effect lasts for 90 minutes.

*Uses*

- ◆ Topical: 4%.
- ◆ Infiltration block: 0.25%.
- ◆ Field block: 0.5%.
- ◆ Nerve block: 1.0 %.
- ◆ Epidural: 1.5, 2.0%.
- ◆ Spinal: 5%.

It can be used with or without adrenaline.

Xylocaine with adrenaline has got longer duration of action. It creates relatively bloodless field.

But it should not be used in places where end arteries are present like glans penis, ear lobule, tip of the nose, lip, fingers and toes.

**Bupivacaine (Marcaine):** It has got prolonged action. It is a vasodilator also.

- ◆ Dose: 3 mg/kg.
- ◆ Epidural block: 0.5%
- ◆ Spinal: 0.5% 3 ml.

## TOPICAL ANAESTHESIA

- ◆ It is used for minor surgeries of eye, laryngoscopy, bronchoscopy, cystoscopy, gastroscopy.
- ◆ It is available as instillation, spray, viscous, ointment, gel, EMLA (Eutectic mixture of local anaesthetic).

## INFILTRATION BLOCK

Direct injection of local anaesthetic under the skin for small procedures.

## FIELD BLOCK

It is achieved by blocking the entire field of excision where lesion is located.

## NERVE BLOCK

- ◆ Block of inferior dental nerve and lingual nerves in the region of the mental foramen for extraction of teeth.
- ◆ Finger block of digital nerves. Here plain xylocaine is used (without adrenaline).
- ◆ Intercostal block.
- ◆ Ankle block.
- ◆ Median and ulnar nerve block.
- ◆ Brachial plexus block (*Winnie's block*).

It can be given through:

- ▶ Interscalene.
- ▶ Axillary.
- ▶ Supraclavicular approaches.

Supraclavicular approach is commonly used. 1 cm above the mid-point of the clavicle, needle is passed downwards, backwards and medially towards first rib. Once needle hits the first rib, 15–20 ml of 1.5% xylocaine is injected (with walking or stepping over the first rib). Complications are pneumothorax and injury to the great vessels.

*Other blocks:*

- ◆ Cervical plexus block.
- ◆ Sciatic nerve block.
- ◆ Femoral nerve block.

## INTRAVENOUS REGIONAL ANAESTHESIA (BIER'S BLOCK)

Limb is exsanguinated and occluded with tourniquet. Pressure in the tourniquet must be 30 mmHg more than the systolic pressure of the patient. Needle is placed in the selected vein. 40 ml of 0.5% xylocaine for upper limb and 80 ml of 0.25% of xylocaine for lower limb is injected into the vein. *Xylocaine with adrenaline should not be used.* It gives very good analgesia for 2 hours.

*Side effects:* Sudden release of drug into the circulation can cause hypotension, convulsions and often death.

Bupivacaine should not be used.

## Indications

For upper and lower limb surgeries, it can be used without G/A or S/A.

## SPINAL ANAESTHESIA

It is the injection of local anaesthetic into the subarachnoid space causing loss of sympathetic tone, sensation and motor function. The sympathetic block is 3 segments higher than sensory block, motor block is 3 segments lower than sensory block.

*Position:* Lateral decubitus position with head, hips and knees being fully flexed so as to open the inter-laminar spaces. Highest point of iliac crest corresponds to 4th lumbar vertebra.

*Drugs used:*

- ◆ Lignocaine 5% in 6% dextrose, 2 ml.
- ◆ Bupivacaine 0.5% in 5% dextrose, 3 ml.
- ◆ Cinchocaine 0.5% in 6% dextrose, 2 ml.

*Technique:* 24–26 gauge needle with stillette is used. Needle is passed through the interspinous space and ligamentum flavum to reach the subarachnoid space to get clear fluid (0.5 ml/sec). Needle is rotated 360 degrees and drug is injected slowly. Patient is repositioned to supine. Drug takes 15 minutes to act.

## Types

1. Caudal (up to L<sub>5</sub>)
2. Low spinal (up to L<sub>1</sub>)
3. Mid-spinal (up to T<sub>10</sub>)
4. High spinal (up to T<sub>6</sub>)
5. Unilateral spinal

## Advantages

- ❖ Economical
- ❖ Hypotension reduces the bleeding
- ❖ Adequate relaxation is achieved
- ❖ Respiratory complications are less

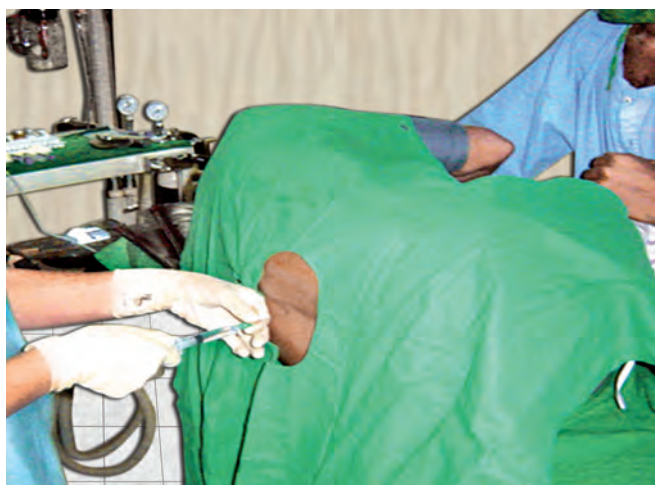

Fig. 30.6: Spinal anaesthesia being given. Note the position of the patient.

## Disadvantages and Complications

- ❖ CSF leak and aseptic inflammation of meninges causing headache.
- ❖ Meningism.
- ❖ Infection.
- ❖ Paraplegia. It is very rare.
- ❖ Occasionally, it can become total spinal which requires intubation and ventilator support.

### Contraindications

- ❖ Cardiac patient
- ❖ Allergy
- ❖ Increased intracranial pressure. It may precipitate coning
- ❖ Sepsis
- ❖ Spinal tumours
- ❖ Back pain and spinal diseases
- ❖ Neurological conditions like syringomyelia
- ❖ Kyphosis, scoliosis

## SADDLE BLOCK

- ❖ It is used for surgeries in perineal and anorectal region.

- ❖ It is spinal anaesthesia using xylocaine or bupivacaine given in sitting position.

## EPIDURAL ANAESTHESIA

- ❖ It is a potential space between dura anteriorly and ligamentum flavum posteriorly which has got negative pressure inside. It extends from foramen magnum to sacral hiatus.
- ❖ *Touhy needle* is used for epidural anaesthesia. Once the needle is in the space there will be sudden indrawing of air or saline drop.
- ❖ An epidural catheter is placed in the space and fixed. 2% xylocaine with adrenaline or 0.5% bupivacaine is injected into the space to achieve anaesthesia up to the desired level.

## Advantages

- ❖ It can be used for continuous repeated prolonged anaesthesia.
- ❖ It can be used for postoperative analgesia.
- ❖ It can be kept for several days.

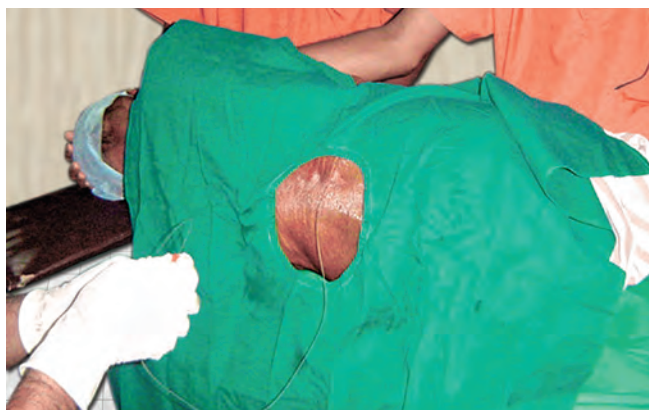

Fig. 30.7: Epidural anaesthesia with epidural catheter placed.

## CAUDAL ANAESTHESIA

Caudal space is the sacral component of epidural space and access is through the sacral hiatus.

## Indications

- ❖ Haemorrhoidal surgery
- ❖ Circumcision
- ❖ Small procedures in the perineum like cystoscopy

## Procedure

It is given in lateral position. Needle is inserted through the sacral hiatus to enter the caudal epidural space. Drug is then injected into the space.

## Complications

- ❖ Trauma to anal canal
- ❖ Intravascular injection
- ❖ Failure of caudal block

# Chapter 31

## Advanced Imaging Methods

*What would it be like in a radiologist's shoes? To spend most of my day dealing with images of people: plain black-and-white X-ray images, or speckled images caused by sound waves bouncing off organs, or images caused by dyes outlining arteries and veins, or contrast medium filling loops of bowel, or images reconstructed by computers into cross sections of the body—all without speaking to a patient.*

—Abraham Verghese, 1994

### CHAPTER OUTLINE

- |              |                              |                                     |
|--------------|------------------------------|-------------------------------------|
| ❖ Ultrasound | ❖ CT Scan                    | ❖ Radionuclide Imaging              |
| ❖ Doppler    | ❖ Magnetic Resonance Imaging | ❖ Positron-emission Tomography Scan |

### ■ ULTRASOUND

Ultrasound contains waves with a frequency of more than 20,000 cycles/second which the human ears cannot hear.

In medical sonography, frequencies used are commonly 2–10 MHz. The transducer or the probe works as both transmitter of *sound waves* and receiver of *echoes*. The piezoelectric crystal is the producer of ultrasound waves. Received signals from the patient are fed into the computer which forms the image.

There are three types of ultrasound image display.

1. **A-mode:** Only one dimensional static display as spikes are obtained. It is used only in eye scan.
2. **B-mode:** Two dimensional real-time images in the form of grains. It is most widely used type. Using this mode *Transverse, Longitudinal or Oblique* sections can be taken.
3. **M-mode:** Here images are recorded as dots. It is mainly used in moving parts like echocardiography. M-mode is also called as TM mode, i.e. *Time Motion Mode*.

### Uses

- ◆ Used in all abdominal and pelvic conditions, often in thoracic conditions.
- ◆ *Ultrasound of thyroid* is very useful method to differentiate between solid and cystic lesions.
- ◆ Ultrasound is used in testicular tumours, epididymoorchitis, trauma to testis, erectile dysfunction, etc.

- ◆ Ultrasound breast is used to differentiate solid from cystic tumours.
- ◆ Soft tissue and musculoskeletal ultrasound.
- ◆ Ocular ultrasound is ideal method to image eye and intraocular structures.

### Advantages

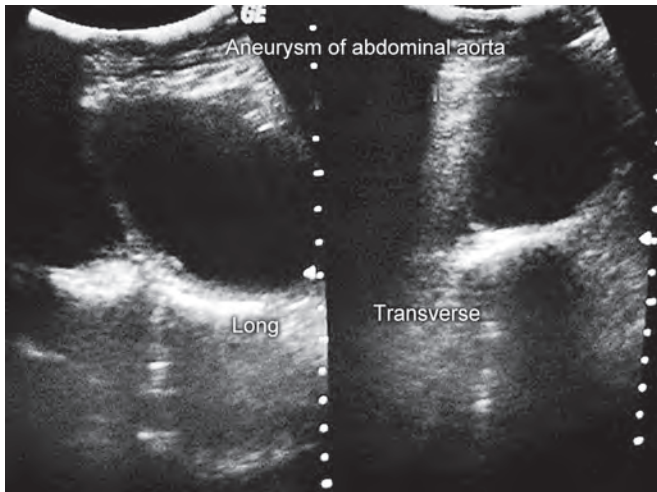
- ❖ No radiation
- ❖ Noninvasive
- ❖ Effective with efficiency
- ❖ Painless
- ❖ Low cost
- ❖ Available even as portable machines
- ❖ Stones are well-visualised with *acoustic shadow*

### Disadvantages

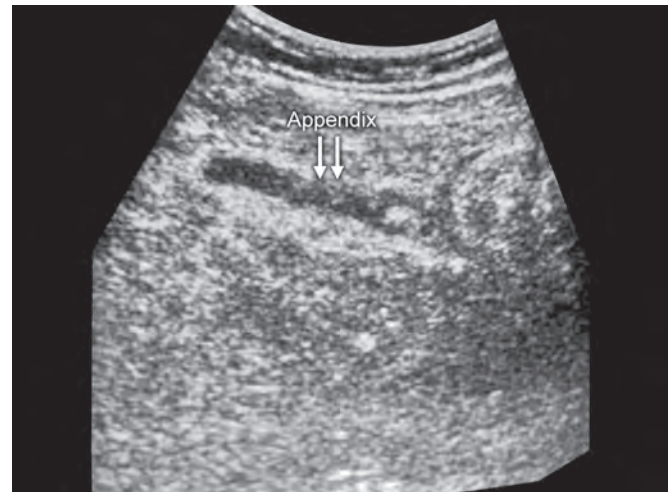- ❖ Interpretation can be inadequate
- ❖ Bowel shadow may prevent proper visualisation
- ❖ In obese patient image will be inadequate
- ❖ **Interpretation** is based on echogenicity either *hyperechogenic* or *hypoechoogenic*

### Advanced ultrasound techniques

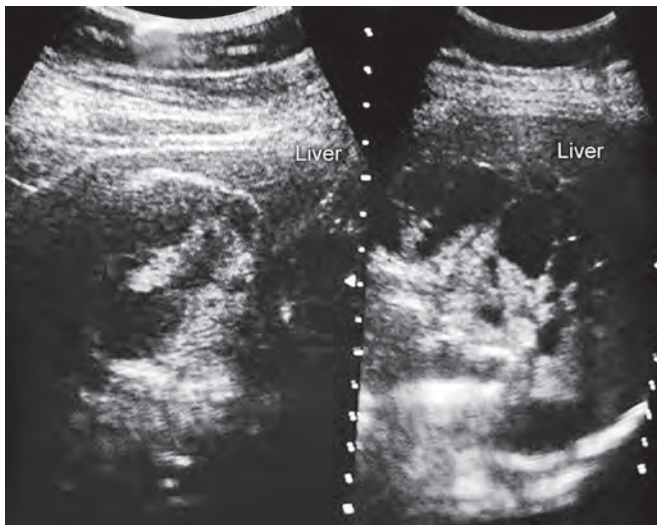
- ❖ Endosonography (EUS) is used in visualisation of walls of oesophagus or stomach through gastroscopy
- ❖ Transvaginal ultrasound
- ❖ Transrectal ultrasound to see prostate
- ❖ Doppler ultrasound to study arterial and venous diseases



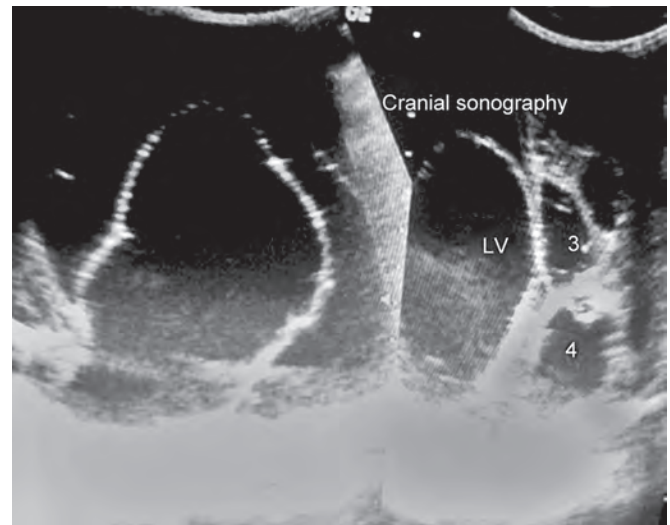
**Fig. 31.1:** US showing abdominal aortic aneurysm.



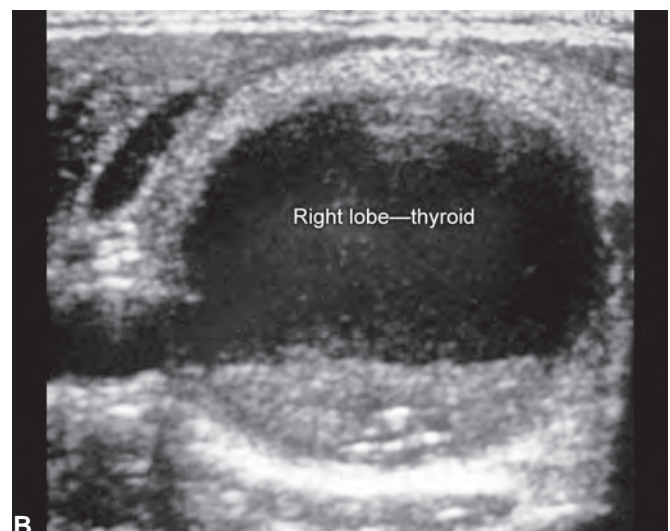
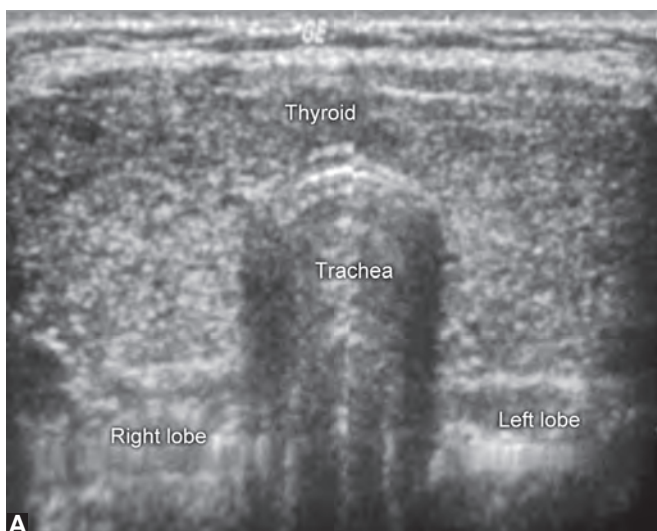
**Fig. 31.2:** US showing appendix—appendicitis.



**Fig. 31.3:** US showing liver mass.



**Fig. 31.4:** Cranial sonography is done to see intracranial problems through suture lines—usually done in infants and children.



**Figs 31.5A and B:** US thyroid showing thyroid both lobes in one; solid and cystic components in another.

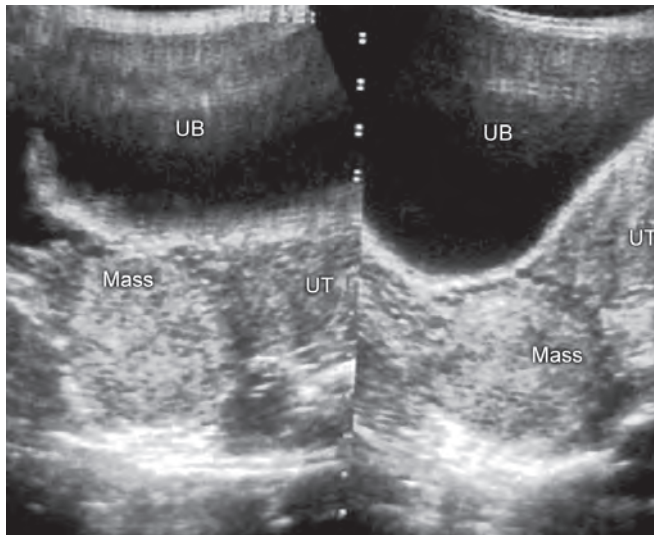


Fig. 31.6: US picture of a pelvic mass.

#### Ultrasound as therapeutic use

- ❖ To guide aspiration of amoebic liver abscess, pericardial tap
- ❖ On table ultrasound can be done to assess the operability of tumour. (During laparotomy to assess the extent of tumour, lymph node status, etc.)

### DOPPLER

**Doppler effect** is a change in the perceived frequency of sound emitted by a *moving source*. So it measures blood flow. Spectral Doppler wave form and ultrasound image are combined in **Duplex scanning**.

#### Types

1. Continuous waves.
2. Pulsed waves.

Doppler will provide both audio and video signals.

**Colour Doppler imaging displays** flowing blood as *red* when direction of flow is towards the transducer. Image will be *blue* if flow is away from transducer.

#### Uses

- ◆ To study cardiovascular system.
- ◆ To study vascularity of tumours.
- ◆ To study blood flow and velocity in arterial diseases so as to assess stenosis (its extent, cause, etc.) like in atherosclerosis, TAO, cervical rib, aneurysm, A-V fistulas.
- ◆ To find out deep venous thrombosis (DVT), varicose veins, perforator incompetence.
- ◆ To study grade of varicocele in males.

#### Advantages

- ◆ It has replaced venogram and angiogram in many places as a diagnostic tool.
- ◆ It is reliable and non-invasive.

### CT SCAN

Computerised tomography scan was invented by **Godfrey Hounsfield** in 1963. He was a physicist. He received **Nobel prize** (1972) for the same. The first CAT scan is in the London museum.

Narrow X-ray beams are passed from rotating X-ray generator through **the gantry** where patient is placed. When X-rays pass through the tissues, some of the X-rays get absorbed and some pass through, depending on the tissue density. The different grades of absorption in different tissues are detected through sensitive detectors which are translated to a Grey scale image by a computer.

- ❖ Density of tissues is numbered as **Hounsfield Number (HN)**
- ❖ Water—Zero HN
- ❖ Air—Minus 1,000
- ❖ Bone—Plus 1,000

The density of other tissues come in between air and bone with different HNs

**Presently spiral CT scan** has become popular. They are faster and in a single breath holding time, whole CT scan can be taken.

Both plain and contrast CTs are done whenever required.

#### Contrast Agents

- ◆ **Ionic:** Water soluble iodide dyes like *Sodium diatrizoate*, *Meglumine iothalamate* (*Conray*, *Urograffin*, *Angiograffin*). They are cheaper but often toxic and cause anaphylaxis.
- ◆ **Non-ionic** are safer but expensive, like *Iohexol* (*Omnipaque*), *Iopamiro*.

In abdominal CT, contrast agents can be given orally to delineate bowel properly.

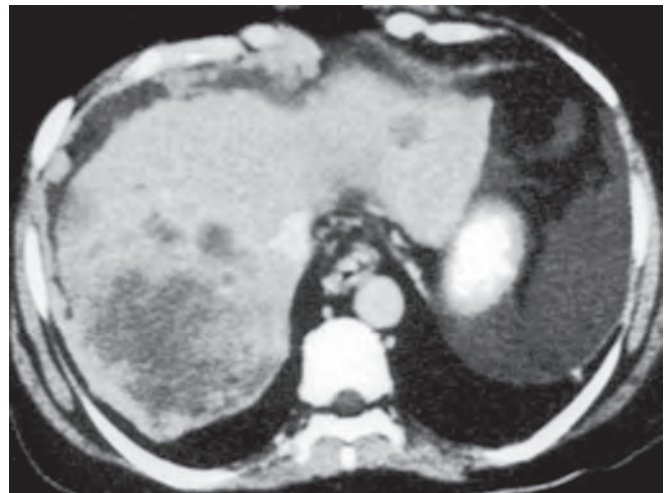


Fig. 31.7: CT scan picture showing liver secondaries.

#### Indications

- ◆ **Trauma** like head injury, chest injury, abdomen trauma. In trauma *only plain CT scan* is taken.
- ◆ **Neoplasms:** To see the exact location, size, vascularity, extent and operability. For example, brain, abdominal, retroperitoneal, thoracic and spinal tumours.

- ◆ **Inflammatory conditions**, in various sites.  
For example, psoas abscess, pseudocyst of pancreas.

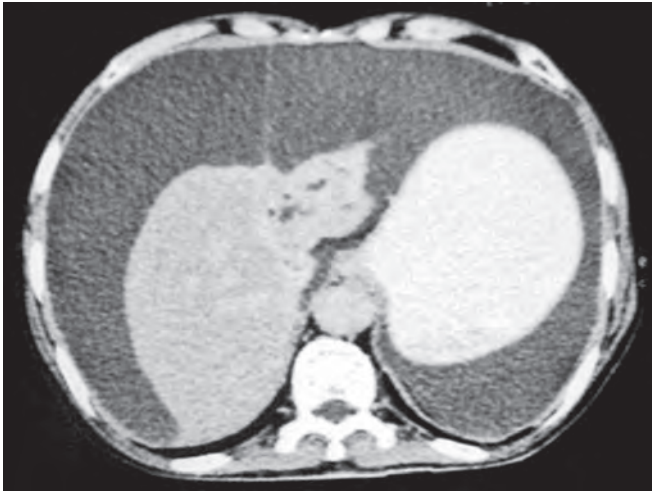


Fig. 31.8: CT scan showing ascites (gross).

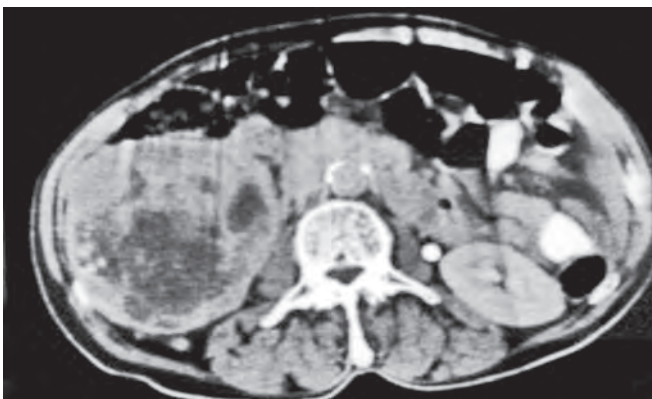

Fig. 31.9: CT scan abdomen showing right renal mass (RCC).

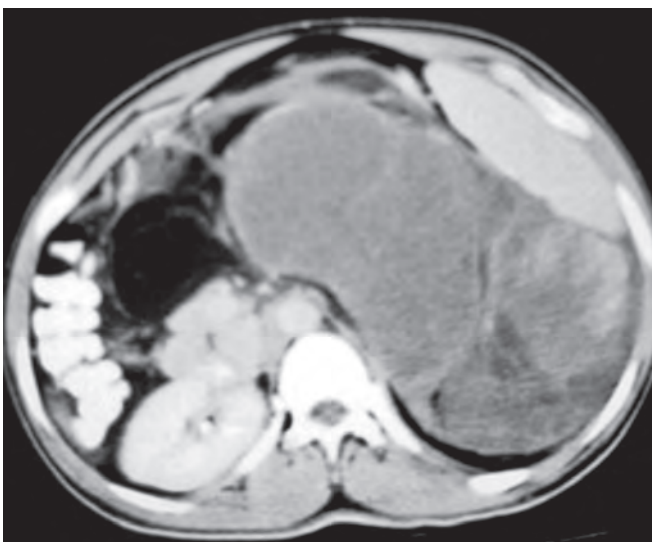


Fig. 31.10: CT scan showing retroperitoneal tumour.

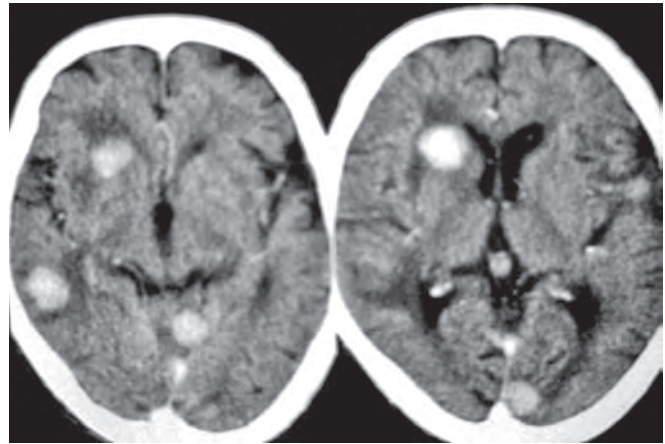


Fig. 31.11: CT scan showing brain secondaries. Secondaries are the commonest malignant tumours of brain. Breast is the common site of primary.

#### Advantages of CT scan

- ❖ One to two mm sized sections are possible
- ❖ Amount of exposure to radiation is less
- ❖ More accurate, sensitive, and specific
- ❖ Small lesions are also detected
- ❖ CT-guided biopsies are done at present, safely

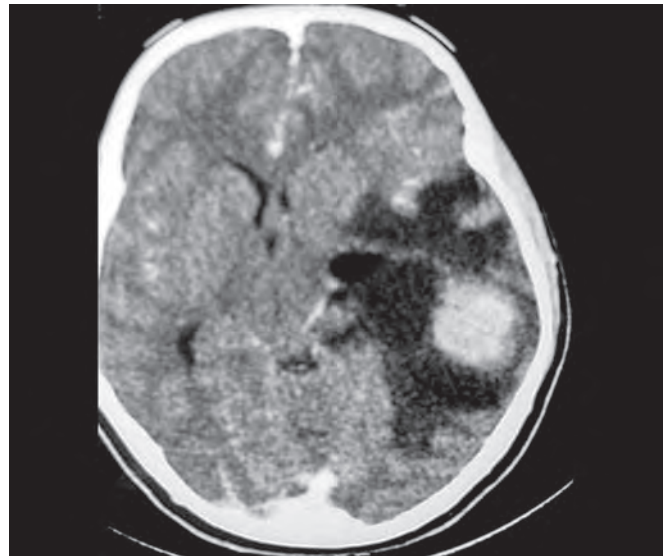


Fig. 31.12: CT picture showing astrocytoma.

#### Disadvantages

- ❖ **Interpretation** by an experienced radiologist is important
- ❖ **Artefacts** can be present
- ❖ **Cost factor** and **availability**

#### Findings

- ◆ Extradural haematoma—*Biconvex lesion*.
- ◆ Subdural haematoma—*Concavoconvex lesion*.

*Ultrasound and CT scan are conveyors of morphological information.*



- ◆ Smooth margin in benign condition.
- ◆ Irregular margin in malignant condition.

#### Advantages of spiral CT scan

- ❖ Reduced scan time. Useful in children and critically-ill patients
- ❖ Imaging in both arterial and venous phases is possible
- ❖ Improved lesion detection. Missing a lesion is uncommon
- ❖ Multiplanar and 3-dimensional analysis like CT angiography, complex joint imaging, facial bone imaging is possible

**High resolution CT (HRCT)** is a CT technique used in chest scan where thin sections are taken to have better quality images.

### MAGNETIC RESONANCE IMAGING (MRI)

Earlier, named as *Nuclear magnetic imaging*, the term is not used now.

It can be **Plain MRI** or **Contrast MRI**. Contrast agent is *Gadolinium*, given intravenously.

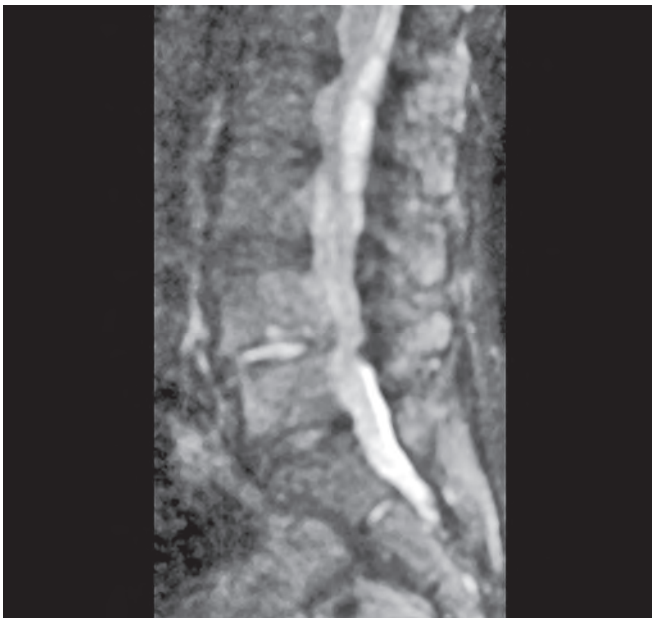#### Principle

When patient is placed in an *external high magnetic field*, protons of hydrogen atoms rotate in phase with each other and gradually return to their original position releasing small amounts of energy which is detected by sensitive coils. Proton density and relaxation time are assessed by radiofrequency pulse and the computer generates a grey scale image from this data.

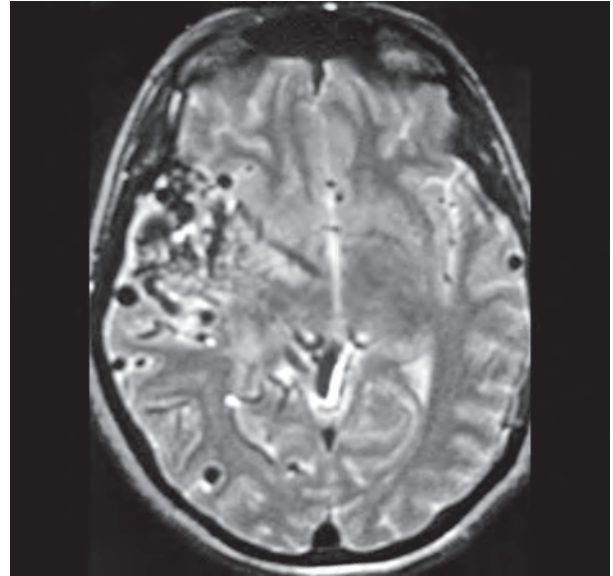
**T1 relaxation time** is the time taken to return to original axis. *T1 images* are used to find out *normal anatomical details*. It has got high soft tissue discrimination. Here fluid (CSF) looks black.

**T2 relaxation time** is the time taken by the proton to diphas. It is used to assess *pathological processes*. In *T2 images* fluid looks white.

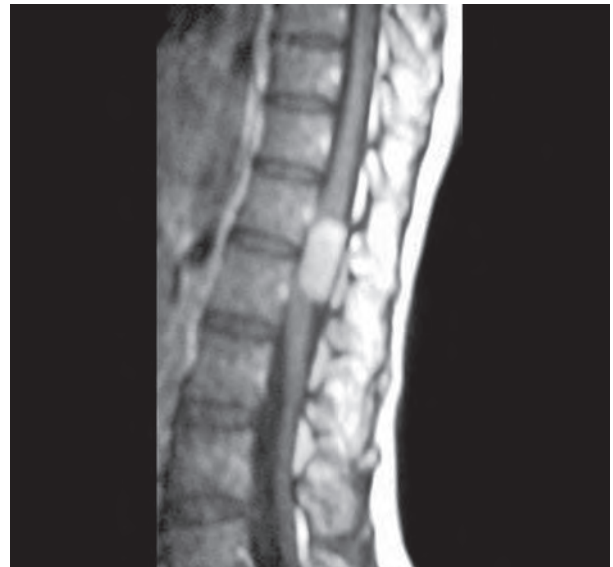In **proton density images** fluid looks in between black and white.



**Fig. 31.13:** MRI showing spine tuberculosis. Note the lesion and vertebral collapse.



**Fig. 31.14:** MRI showing AV malformation.



**Fig. 31.15:** MRI picture, which shows extradural schwannoma.

#### Uses of MRI

- ◆ It is very useful in intracranial, spinal and musculoskeletal lesions including *joint pathologies*.
- ◆ It gives direct anatomical sections of the area, with lesions at a high resolution.
- ◆ **MR angiogram** is done without injecting IV contrast agents.
- ◆ **Cardiac MRI** is very useful.
- ◆ **Breast MRI** is used in multifocal recurrent cancers.
- ◆ **Magnetic resonance cholangiopancreatography (MRCP)** is a very useful noncontrast diagnostic tool which may replace diagnostic ERCP.
- ◆ **MR spectroscopy** is chemical analysis of elements in a tissue to differentiate between tumour, inflammation, and degeneration.

## Advantages

- ◆ Artefacts are not common.
- ◆ More sensitive and specific than CT scan.

### Contraindications

Patients with **prosthesis in the body, metallic foreign bodies, pacemakers, cochlear implants, cranial aneurysm clips should never** undergo MRI

### Precaution

Before entering the MRI room, the patient and other personnel should remove all magnetically attractive materials

## Disadvantages

- ◆ *Availability and cost factor.*
- ◆ It is time consuming.
- ◆ Patient compliance is poor.
- ◆ It is not feasible in patients suffering from *Claustrophobia*.
- ◆ It is not ideal in emergencies and critically-ill patients.
- ◆ It is not useful in lung pathology and subarachnoid haemorrhage.

## RADIONUCLIDE IMAGING

- ◆ It represents function of an organ than morphology.

Rays:

- ◆  $\alpha$ -particles are emitted by the natural radionuclides like radium, which are no longer used in medicine.
- ◆  $\beta$ -particles are useful for therapy but not for diagnosis.
- ◆  $\gamma$ -rays pass out of the body and so used for the diagnostic purpose.
- ◆ Mapping is done using sophisticated gamma camera.

## Technetium 99<sup>m</sup>

- ◆ It is commonest radionuclide used (99- is mass number; m- meta-stable.).
- ◆ It is administered IV.
- ◆ Pure  $\gamma$ -rays emitter.
- ◆ Short half-life.
- ◆ Widely used gamma ray detectors are specified to Tc<sup>99m</sup>.

### Uses

Tc <sup>99m</sup>	labelled serum albumin is used to detect pulmonary emboli
Tc <sup>99m</sup>	labelled phosphate is used to image bone
Tc <sup>99m</sup>	labelled sulphur colloid is used to detect the functions of liver, spleen, bone marrow
Tc <sup>99m</sup>	labelled HIDA (Hippuric immuno diacetic acid) or PIPIDA is used to study the functions of hepatocytes and biliary tract

Tc <sup>99m</sup>	labelled DMSA (Dimercapto succinic acid) which is taken up by the renal cortical cells, is used in renal function tests
Tc <sup>99m</sup>	labelled DTPA (Diphenyl triamine penta acetic acid) measures GFR
Tc <sup>99m</sup>	labelled HMPAO (Hydroxy methyl propylamine oxime) is used in Alzheimer's disease and schizophrenia as it crosses the blood brain barrier

Other radionuclides used:

- ◆ Thallium 201 chloride for cardiac imaging.
- ◆ Gallium 67 nitrate to detect tumours and inflammation.
- ◆ I<sup>123</sup>

Advantages	Disadvantages
Safer	Availability
Easier	Cost factor
No side effects	Not specific
	Fast half-life

## POSITRON-EMISSION TOMOGRAPHY (PET Scan)

- ◆ It is a non-invasive diagnostic method to assess the biochemical and physiological status of a tissue.
- ◆ It is used in complimentary with CT scan and MRI.
- ◆ Two protons are used, they are positive electrons (*positrons*).
- ◆ Most clinically used positron emitting radionuclides is fluoro-deoxyglucose (FDG), others are <sup>82</sup>Rb, <sup>15</sup>O, <sup>13</sup>N.
- ◆ Detectors used are bismuth germanate (BGO) crystals or sodium iodide crystals.
- ◆ Principle of *electronic collimation* is used to produce images from the radiation emitted from positron emitting tracers.

## Uses

- ◆ To assess myocardial perfusion (<sup>82</sup>Rb) and viability (FDG) study.
- ◆ Epilepsy—To localise temporal lobe epilepsy (FDG).
- ◆ Cancer imaging—Lung cancer (detection and staging).
- ◆ Colorectal cancer.
- ◆ Melanoma.
- ◆ Head and neck cancer and breast cancer.
- ◆ Musculoskeletal tumours.
- ◆ Thyroid cancer (I<sup>131</sup>).

## Advantage

Very specific.

## Disadvantage

Very expensive and limited availability.

### Note:

- Most of the U/S pictures, CT and MRI pictures in this book are from Balmatta Scan Centre, Mangalore, I am thankful to consultants Dr Raghavendra Bhat and Dr Ravichandra there.

# Chapter 32

## Operative Surgery

### A. Asepsis and Sterilisation

*Bearing in mind that it is from the vitality of the atmospheric particles that all the mischief arises, it appears that all that is requisite is to dress the wound with some material capable of killing these septic germs, provided that any substance can be found reliable for this purpose, yet not too potent as a caustic.*

—Joseph Lister, 1867

#### CHAPTER OUTLINE

- ❖ Sterilisation
- ❖ Disinfection
- ❖ Antisepsis
- ❖ Asepsis
- ❖ Different Methods of Disinfection/ Sterilisation

#### ■ STERILISATION

- ◆ It is freeing an article by removing or killing all bacteria, spores, fungi and viruses.

#### ■ DISINFECTION

- ◆ It is killing of all bacteria, fungi and viruses but not spores.

#### ■ ANTISEPSIS

- ◆ It is inhibition of growth of microorganisms.

#### ■ ASEPSIS

- ◆ Asepsis means—organisms are prevented to access the patient or individual.

#### ■ DIFFERENT METHODS OF DISINFECTION/ STERILISATION

##### Physical Agents

- ◆ **Burning or incineration** is used to disinfect contaminated articles like dressings.

- ◆ **Hot-air oven:** Here temperature used is 160 to 180 degree for one hour.

- ◆ **Boiling:** It kills bacteria but not spores and viruses. Temperature is between 90 to 99 degree. It is used to disinfect syringes, utensils. It is not useful for gloves, rubber materials.

- ◆ **Autoclave:** It is steam under pressure. Temperature attained is between 120–135 degree. It is sterilised for 20 minutes with 15 pounds/sq. inch pressure. It kills all organisms including spores. Completeness of sterilisation is confirmed by using specific gelatin protein which precipitates only in steam underpressure for 20 minutes. Green coloured strip turns to black if autoclave is complete (*signaloc*). Surgical gloves, linen, cotton, dressings, surgical instruments are sterilised by this method. Sharp and plastic instruments cannot be sterilised by this method. *Bacillus thermophilus* spores are used to assess the completeness of the sterilisation in mass scale. Double autoclaving is done for instruments of orthopaedic or ophthalmic surgeries.

- ◆ *The Bowie-Dick* method is also used to check the completeness of sterilisation.

- ◆ **Radiation: Ionising type of radiation:** Atomic gamma radiation is used as commercial method to sterilise suture materials, disposable materials in packets. It is viable, safe and cheaper.

- ◆ **Non-ionizing radiation** either infrared radiation or ultraviolet radiation is used to reduce the bacteria in air, water. Bacteria and

<b>Materials</b>	<b>Method of sterilisation</b>
• All theatre appliances	Autoclave
• Sharp instruments (scissors, needles, blades) plastic materials	Glutaraldehyde 2%, lysol
• Endoscopes	Glutaraldehyde
• Rubber equipments	Glutaraldehyde
• Syringes	Autoclave, hot air oven, gamma radiation
• Heart-lung machine	Ethylene oxide
• Disposable articles	Gamma radiation
• Operation theatre and rooms	Ideally by U-V radiation or by formaldehyde
• Sera and biological materials	Filtration
• Lab glassware	Hot-air oven
• Ward, sick room, furniture	Formaldehyde, iodophor spray, glutaraldehyde
• Clothes, bed sheets especially for burns patients	Autoclaving
• Soiled dressings, materials, animal carcasses	Incineration, lysol, iodophors
• Excreta	Lysol, iodophors
• Cleaning of skin before surgery	Iodophors 2%, savlon, spirit
• For cleaning infected wounds	Iodophors, acriflavine, savlon, H <sub>2</sub> O <sub>2</sub>
• To remove slough from the wounds	EUSOL, H <sub>2</sub> O <sub>2</sub>
• Before injection	Spirit is used to clean the skin
• Cleaning the ward	Phenol, cresol, lysol
• Hand wash	Chloroxylenol, savlon, spirit, iodophors
• Bladder wash	0.1% potassium permanganate solution (Condy's lotion), solution of acetic acid and silver nitrate
• Water	Chlorination, potassium permanganate
• Fruits, vegetables	Potassium permanganate

virus are vulnerable to ultraviolet rays below 3000Å. Exposure to eyes and skin can cause burn injury.




Fig. 32.1: Autoclave machine for sterilisation.



Fig. 32.2: Signaloc used for confirmation of completion of proper sterilization.


### Chemical Agents

- ◆ **Phenol:** It is used as standard to compare the efficacy of other agents.
- ◆ **Cresol** is more powerful and nontoxic. 5% solution is used.
- ◆ **Lysol** is emulsified cresol with soap. 2% solution is effective.
- ◆ **Chlorhexidine (hibitane)** is useful antiseptic.

- ◆ **Hexachlorophane:** It is not used in infants and children because it can get absorbed through intact skin in this age group causing severe neurotoxicity.
- ◆ **Dettol (chloroxylenol)** 5% solution is used.
- ◆ **Cetrimide** is cationic surfactant (cetavlon) 2% solution is used.
- ◆ **Savlon** is combination of cetrimide and hititane. It is very commonly used antiseptic in operation theatres, wards.

## Halogens

- ◆ Bleaching powder.
- ◆ Sodium hypochlorite.
- ◆ **EUSOL: Edinburg University Solution** contains sodium hypochlorite, boric acid and calcium hydroxide.  
*EUSOL bath* is dipping the ulcer bearing part in dilute EUSOL solution for 30 minutes 2–3 times a day.
- ◆ Iodine
- ◆ **Iodophors:** These are antiseptics and also sporicidals. They are non-irritant and do not stain skin. **Povidone-iodine** is a good example which is commonly used.
- ◆ **Alcohols:** Ethyl or isopropyl alcohols are used.
- ◆ **Formaldehyde:** It is useful to disinfect the rooms like operation theatre. It is effective at a high temperature and humidity of 80–90%. It is commonly used to fumigate the room. 500 ml of formalin with one litre of water is boiled to get formaldehyde vapour. Formaldehyde vapour can be created by adding potassium permanganate to the same solution. Room is kept closed for 12 hours.
- ◆ **Glutaraldehyde (cidex 2%):** It is used to sterilise sharp instruments. Instrument should be dipped for 10 hours to achieve complete steri-



**Figs 32.3A and B:** Operation theatre mop rack to keep 'used mops' during surgery after use.

- lisation. It is potent bactericide, sporicide, fungicide and viricide.
- ◆ **Hydrogen peroxide ( $H_2O_2$ ):** It is used as topical oxygen therapy. Because of its effervescence and release of nascent oxygen it removes the tissue debris. It is used to clean wounds, cavities, ulcers, as mouth wash and as ear drops to clear earwax.
- ◆ **Acriflavine and proflavine** are orange-red coloured dyes used as antiseptics. It is effective against Gram-positive and few Gram-negative organisms. It retains its activity in pus and body fluids.

# C. Suture Materials

## CHAPTER OUTLINE

- ❖ Classification I
- ❖ Classification II

- ❖ Classification III
- ❖ Classification IV

- ❖ Classification V

### Features of ideal suture material

- ❖ Adequate tensile strength
- ❖ Good knot holding property
- ❖ Should be least reactive
- ❖ Easy handling property
- ❖ Should have *less memory*
- ❖ Should be easily available and cost effective

### Uses of absorbable suture materials

- ❖ In bowel anastomosis like gastrojejunostomy, resection and anastomosis. Vicryl is used
- ❖ In cholecystojejunostomy (CCJ), choledochojejunostomy (CDJ), pancreaticojejunostomy. Vicryl is used
- ❖ In suturing muscle, fascia, peritoneum, subcutaneous tissue, mucosa
- ❖ In ligating pedicles. 1-zero chromic catgut or vicryl are used, e.g. ligation of pedicles during hysterectomy
- ❖ In circumcision, usually 3-zero plain or chromic catgut are used

## CLASSIFICATION I

### Absorbable Suture Materials

- ◆ **Plain catgut** is derived from submucosa of jejunum of sheep.
  - ▶ It is yellowish white in colour.
  - ▶ It is absorbed by inflammatory reaction and phagocytosis—absorption time is 7 days.
  - ▶ It is used for subcutaneous tissue, muscle, circumcision in children.
- ◆ **Chromic catgut** is catgut with chromic acid salt.
  - ▶ It is brown in colour.
  - ▶ Its absorption time is 21 days.
  - ▶ It is used for suturing muscle, fascia, external oblique aponeurosis, ligating pedicles, etc.
- ◆ **Vicryl** (Polyglactic acid):
  - ▶ It is synthetic absorbable suture material.
  - ▶ It gets absorbed in 90 days.
  - ▶ Absorption is by hydrolysis.
  - ▶ It is violet in colour (braided).
  - ▶ It is multifilament and braided.
  - ▶ It is very good suture material for bowel anastomosis, suturing muscles, closure of peritoneum.
- ◆ **Dexon** (Polyglycolic acid) is synthetic absorbable suture material like vicryl. It is creamy yellow in colour (braided).
- ◆ **Maxon** (Polyglyconate) monofilament.
- ◆ **PDS** (Poly Dioxanone Suture material) is absorbable suture material. It is creamy in colour with properties like vicryl. It is costly but better suture material than vicryl.
- ◆ **Monocryl** (Polyglecaprone) monofilament.
- ◆ **Biosyn** (Glycomer) monofilament.

Absorbable suture materials should not be used for suturing tendon, nerves, vessels (vascular anastomosis).

### Non-absorbable Suture Materials

- ◆ **Silk** is natural, multifilament, braided, non-absorbable suture material derived from cocoon of silkworm larva. It is black in colour. It is coated suture material to reduce capillary action.
- ◆ **Polypropylene** (Prolene) is synthetic, monofilament suture material. It is blue in colour. It has got high memory. (*Memory of suture material* is recoiling tendency after removal from the packet. Ideally suture material should have low memory.) (Prolene mesh used for hernioplasty is white in colour).
- ◆ **Polyethylene** (Ethylene) is synthetic monofilament nonabsorbable suture material. It is black in colour.
- ◆ **Cotton** is twisted multifilament natural nonabsorbable suture material. It is white in colour.
- ◆ **Linen** is derived from bark of cotton tree.
- ◆ **Steel, polyester, polyamide, nylon** are other nonabsorbable suture materials.

### Uses of non-absorbable suture materials

- ❖ In herniorrhaphy for repair
- ❖ For closure of abdomen after laparotomy
- ❖ For vascular anastomosis (6-zero), nerve suturing, tendon suturing
- ❖ For tension suturing in the abdomen
- ❖ For suturing the skin

## CLASSIFICATION II

### Natural

- ◆ Catgut.
- ◆ Silk.
- ◆ Cotton.
- ◆ Linen.

### Synthetic

- ◆ Vicryl, dextron, polydioxanone suture (PDS), maxon.
- ◆ Polypropylene, polyethylene, polyester, polyamide.

## CLASSIFICATION III

- ◆ **Braided:** Polyester, polyamide, vicryl, dextron, silk.
- ◆ **Twisted:** Cotton, linen.

## CLASSIFICATION IV

- ◆ **Monofilament:** Polypropylene, polyethylene, PDS, catgut, steel.
- ◆ **Multifilament:** Polyester, polyamide, vicryl, dextron, silk, cotton.

## CLASSIFICATION V

- ◆ Coated.
- ◆ Uncoated.

### Numbering of Suture Material

2-Thick. For pedicle ligation.

1-

0-zero.

1-zero.

2-zero. For bowel suturing.

3-zero.

4-zero.

5-zero. For vascular anastomosis.

6-zero.

7-zero.

8-zero.

9-zero. For ophthalmic surgery. Requires operating microscope.

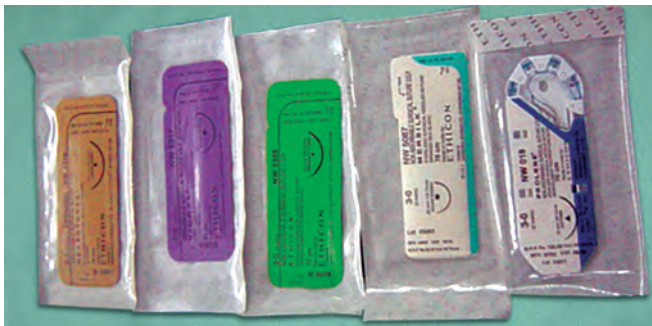

Fig. 32.45: Photo showing different types of suture materials (with pack).

### Types of suturing

- ❖ Continuous suturing
- ❖ Interrupted simple suturing
- ❖ Interrupted mattress suturing
- ❖ Subcuticular suturing
- ❖ Horizontal tension suturing
- ❖ Vertical tension suturing

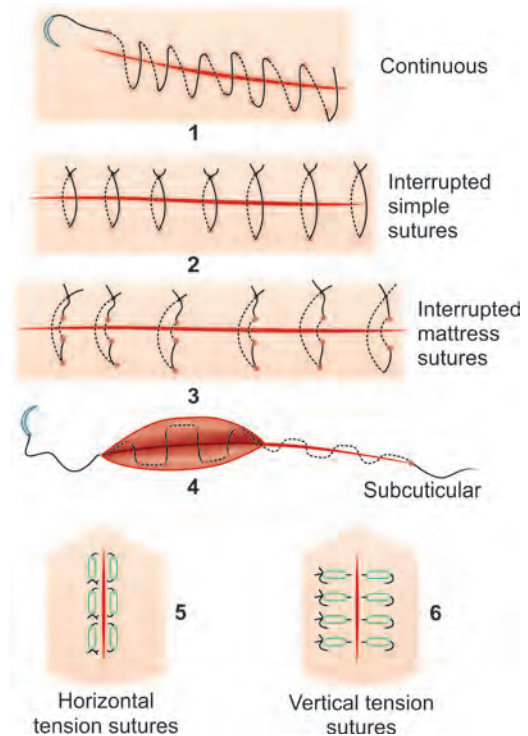


Fig. 32.46: Types of suturing.

### Types of knots

- ❖ Reef knot
- ❖ Granny knot
- ❖ Surgeon's knot

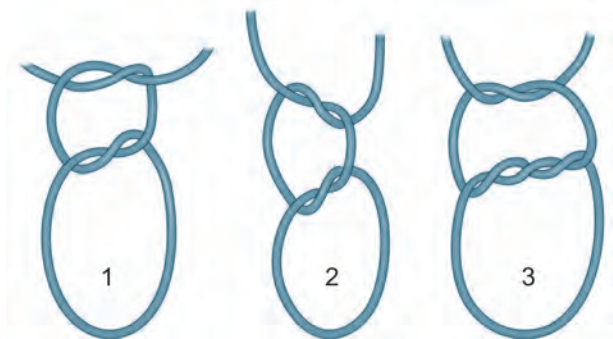


Fig. 32.47: Types of knots.

## D. Diathermy (Electrocautery)

It is the method to control bleeding or to cut the tissues during surgery.

### TYPES

*Based on type of current used:*

- ◆ Unipolar cautery.
- ◆ Bipolar cautery. It is safer because its effect is seen only in between electrode points. Adjacent tissues will never get damaged.

*Based on type of action:*

- ◆ **Coagulation cautery** which causes haemostasis by tissue coagulation. Here temperature is 100 degree (blue switch).
- ◆ **Cutting cautery**: Here temperature is 1,000 degree which disintegrate the tissues. It is not haemostatic (yellow switch).
- ◆ **Blended current** is combination of both coagulation and cutting.

### Differences Between Unipolar and Bipolar Cautery

<b>Unipolar cautery</b>	<b>Bipolar cautery</b>
<ul style="list-style-type: none"><li>• Can be used for both coagulation and cutting</li></ul>	<ul style="list-style-type: none"><li>• Only for coagulation</li></ul>
<ul style="list-style-type: none"><li>• Conducting plate should be kept</li></ul>	<ul style="list-style-type: none"><li>• No need</li></ul>
<ul style="list-style-type: none"><li>• Cannot be used in patient with artificial valves</li></ul>	<ul style="list-style-type: none"><li>• Can be used</li></ul>
<ul style="list-style-type: none"><li>• Should be careful about adjacent tissues</li></ul>	<ul style="list-style-type: none"><li>• Adjacent tissues will never get damaged</li></ul>

### Uses

- ◆ For coagulation of bleeders during surgery to achieve haemostasis.
- ◆ To cut muscles, fascia, etc.
- ◆ It is essential for laparoscopic surgical procedures. Bipolar is commonly used.
- ◆ It is used to remove small cutaneous lesions, to control bleeding duodenal ulcer.

### Disadvantages

- ◆ Infection.
- ◆ Cauterisation of normal tissues.
- ◆ Problem of explosion.
- ◆ Diathermy burn to the patient at the site where diathermy plate is kept.
- ◆ Burn injury or electrical shock to surgeon and assisting personnel.

### Precautions

- ◆ Proper earthing.
- ◆ Avoid loose contact of electrodes.
- ◆ It should be kept off when not in use during procedure.



Fig. 32.48: Diathermy machine with plate, foot switch for use.



## E. Operative Procedure

### CHAPTER OUTLINE

- ❖ Abdominal Incisions
- ❖ Vasectomy
- ❖ Circumcision
- ❖ Hydrocele
- ❖ Inguinal Hernia
- ❖ Appendicectomy
- ❖ Thyroidectomy
- ❖ Tracheostomy
- ❖ Cryosurgery
- ❖ Lasers in Surgery
- ❖ Staplers in Surgery
- ❖ Nasojejunal Tube Feeding
- ❖ Gossypiboma

### ABDOMINAL INCISIONS

#### Principles

- ◆ Incision should be long enough for a good exposure.
- ◆ Splitting the muscle is better than cutting, except rectus muscle.
- ◆ Avoid cutting nerves and vessels in the abdominal wall.
- ◆ Retract muscle, abdominal organs towards the neuro-vascular supply.
- ◆ Insert a drainage tube through a separate incision.
- ◆ Transverse incisions are better than vertical incisions.
- ◆ Close the wound layer by layer.

#### Requirements

- ❖ Accessibility
- ❖ Extensibility
- ❖ Security

#### Factors affecting the strength of the scar

- ❖ Type of surgery (acute abdomen, surgery for malignancy, major surgery)
- ❖ Obesity
- ❖ Pregnancy
- ❖ Straining
- ❖ Cough
- ❖ Ascites
- ❖ Nutrition
- ❖ Diabetes
- ❖ Immunosuppression
- ❖ Type of incision

#### Complications of Abdominal Incision

- ◆ Wound infection.
- ◆ Burst abdomen.
- ◆ Fistula formation.
- ◆ Wound pain.
- ◆ Incisional hernia.
- ◆ Adhesion and its complication.

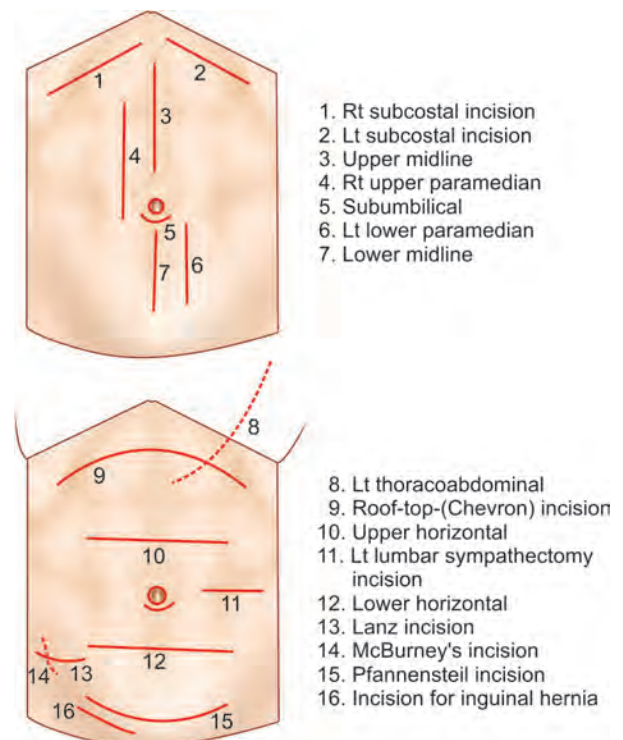


Fig. 32.49: Different incisions in the abdomen.

*Different abdominal incisions are:*

- ◆ Upper midline.
- ◆ Upper right paramedian.
- ◆ Upper left paramedian.
- ◆ Kocher's incision (right subcostal).
- ◆ Left subcostal.
- ◆ Bucket handle.
- ◆ Upper horizontal.
- ◆ Thoracoabdominal.
- ◆ Subumbilical.
- ◆ Incision for lumbar sympathectomy.
- ◆ Lower midline.
- ◆ Lower right or left paramedian.
- ◆ Incisions for appendicectomy—McBurney's, Rutherford Morrison's, Lanz, laparoscopic.

*Surgery is an irreversible repair but often it can be irreversible damage also !!!*

- ◆ Pfannenstiel incision.
- ◆ Lower horizontal.
  - ▶ Upper incisions are always better.
  - ▶ Horizontal incisions are better.
  - ▶ Paramedian is better than midline.

## ■ VASECTOMY

### Indications

- ◆ Family planning (parents should have two healthy children, consent should be obtained).
- ◆ After prostatectomy, vasectomy is done to prevent retrograde infection of testes.

### Procedure

#### Types

- ◆ Classical method – Scalpel technique.
- ◆ No scalpel technique (Shunqiang Li- China).

#### Classical method

After cleaning and draping the scrotum, 2–5 ml of xylocaine plain 1% is injected into root of the scrotum on lateral aspect. Skin, dartos are incised (1–2 cm vertical incision). Once spermatic fascia is incised cord structures are identified. Vas deferens is seen and felt as thickened whitish cord like structure. It is dissected using mosquito artery forceps. It is held using Babcock's forceps as loop outside the wound. Vas is clamped in two different places with a gap in between using two artery forceps. A piece of the vas (5–10 mm) is excised. Cut ends are ligated using non-absorbable sutures like silk. Skin is closed with sutures. Procedure is repeated on the other side. Dressing is placed. Sutures removed after 7 days.

#### No Scalpel Technique

Two special instruments are used here. An extracutaneous ring clamp and Chongqing's sharpened curved mosquito clamp. After cleaning and draping, xylocaine 2% of 2–3 ml is injected under the skin of midline raphe proximal aspect. Vas deferens of one side is felt and pushed under the raphe. It is carefully held with extracutaneous ring clamp. Skin is incised using sharp tip of the curved mosquito clamp. Whitish cord like vas which is held with ring clamp is dissected → clamped → a small piece of 5 mm is cut. Cut ends are ligated using silk. Opposite vas is also similarly brought into the same wound by manipulation and clamped and ligated after cutting. Skin is not closed. It gets apposed automatically and heals on its own. Post-operatively antibiotics and analgesics are given. It is a *single incision procedure* also.

### Advice

To avoid sexual contact or to use contraception for 3 months.

#### Complications

- ❖ Haematoma
- ❖ Haematocele
- ❖ Infection
- ❖ Pyocele
- ❖ Sperm granuloma
- ❖ Recanalisation occurs rarely but dangerous

- ◆ When there is hernia or hydrocele, vasectomy is done along with specific procedures for hernia or hydrocele.
- ◆ *No scalpel vasectomy*, using specialised instruments is becoming popular. Procedure does not require any suturing.

## ■ CIRCUMCISION

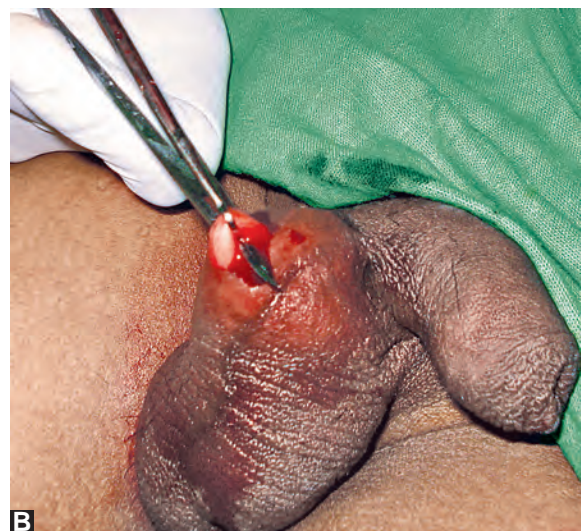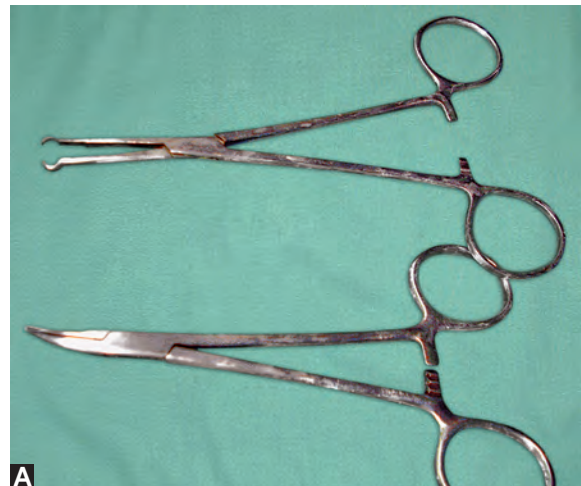### Indications

- ◆ Religious.
- ◆ Phimosi.
- ◆ Paraphimosis after doing initial dorsal slit.
- ◆ Balanitis and balanoposthitis (common in diabetics).
- ◆ Early carcinoma of prepuce or glans penis—both diagnostic as well as therapeutic purpose.
- ◆ Certain sexually transmitted diseases, e.g. herpes infection.

### Procedure

In children, it is done under General Anaesthesia (G/A). In adults, it is done under local anaesthesia.

After cleaning and draping, LA (1% lignocaine *plain*) is injected circumferentially near the root of the penis (ring block). Dorsal skin is cut up to the corona and later circumferentially and ventrally. The



Figs 32.50A and B: No scalpel vasectomy instruments and technique.

skin is cut with inner layer. Care is taken to see that optimum (less) skin is cut ventrally to prevent the occurrence of *chordee*. Frenular artery as well as dorsal vein is transfixed and ligated ventrally using chromic catgut (2-0 or 3-0). Small bleeders are also ligated. Skin is apposed to the cut edge of corona using interrupted chromic catgut sutures.

Postoperatively, antibiotics and analgesics are given.

#### Note:

*Monopolar cautery should not be used during circumcision as penis may go for necrosis. Bipolar cautery can be used judiciously.*

## Complications

- ◆ Reactionary haemorrhage due to slipping of ligature from frenular artery and dorsal vein.
- ◆ Infection.
- ◆ Stricture urethra near the external meatus in *children*.
- ◆ Chordee due to removal of excess skin on the ventral aspect.
- ◆ Rarely priapism can occur.

## HYDROCELE

### Types of Surgery

- ◆ Subtotal excision.
- ◆ Partial excision and eversion (Jabouley's operation).
- ◆ Evacuation and eversion.
- ◆ Lord's plication.
- ◆ Sharma and Jhawers technique.


### Procedure

- ◆ Under G/A or spinal or L/A, after cleaning and draping, vertical incision of about 6–8 cm in length is made over the scrotum, anteriorly 1 cm lateral to the median raphe.
- ◆ Skin, dartos, external spermatic fascia, internal spermatic fascia are incised.

*Bluish* hydrocele sac is identified, i.e. parietal layer of the tunica vaginalis of testis.

Fluid is evacuated using trocar and cannula. Sac is opened.

- ◆ *If the sac is small, thin and contains clear fluid*, either *Lord's plication*, i.e. tunica is bunched into a "ruff" by placing series of multiple interrupted chromic catgut sutures so as to make the sac form a fibrous tissue which is relatively avascular and so haematoma will not occur, or *evacuation and eversion* of the sac behind the testis (after eversion, everted sac is sutured with chromic catgut by continuous sutures) is done.
- ◆ *If the sac is thick, in large hydrocele and chylocele*, *subtotal excision of the sac* is done (as tunica vaginalis is reflected on to the cord structures and epididymis posteriorly, total excision of the sac leads to orchidectomy with division of cord).
- ◆ Often the sac is excised partially and eversion is done, which is called as *Jabouley's* operation.



**Fig. 32.51:** Trocar and cannula used for tapping hydrocele. It prevents spillage of fluid.

- ◆ After evacuation, the sac with the testis is placed in a newly created pocket between the fascial layers of the scrotum (*Sharma and Jhawer's technique*).
- ◆ *Aspiration must be avoided as much as possible* as it is only a temporary measure (recurrence occurs very early) and chances of haematocele, infection are higher.
- ◆ A drain is placed near the root of the scrotum on the lateral aspect because, it becomes the most dependent portion once scrotal support is given. Scrotal support is given to reduce the scrotal oedema.
- ◆ Wound is closed in layers.
- ◆ Drain is removed in 48 hours.

### Surgeries for hydrocele

- ❖ Subtotal excision of the sac
- ❖ Jabouley's operation
- ❖ Evacuation and eversion
- ❖ Lord's plication
- ❖ Sharma and Jhawer's technique

### Complications of surgery

- ❖ Reactionary haemorrhage
- ❖ Infection
- ❖ Pyocele
- ❖ Sinus formation
- ❖ Recurrent hydrocele

### Conditions where orchidectomy is done in hydrocele

- ❖ Pyocele with testicular destruction
- ❖ Clotted haematocele with testicular destruction

## INGUINAL HERNIA

Surgery is the treatment of choice for inguinal hernia.

In infants, whether it is hernia or hydrocele, only *herniotomy* is done through inguinal approach (*Michaelis plank operation*).

In adults: It includes *herniotomy*, i.e. excision of hernial sac and *herniorrhaphy* (strengthening of the posterior wall of inguinal canal either by repair or mesh).

### 1. Herniotomy

*Anaesthesia:* Spinal or General

*Procedure:* After cleaning and draping, skin is incised 1.25 cm above and parallel to the medial two-third of inguinal ligament. Two layers of superficial fascia (outer Camper's fascia and inner Scarpa's fascia) are incised. External oblique aponeurosis is incised. Upper leaf is reflected above and lower leaf is reflected downwards to visualise and expose the inguinal ligament. Ilioinguinal nerve is safeguarded. Cremasteric muscle is opened. Cord structures are dissected. Sac which is anterior and lateral to cord is identified and is pearly white in colour. Dissection is usually started from the fundus and extended towards the neck which is identified by extraperitoneal fat. The neck is narrow and is lateral to inferior epigastric artery. Sac is opened at the fundus. Finger is passed to release any adhesions. Sac is twisted so as to prevent the contents from coming back. It is transfixed using absorbable suture material (chromic catgut 2-0) and is excised distally.

## 2. Modified Bassini's Herniorrhaphy

Conjoined tendon and inguinal ligament are approximated using interrupted nonabsorbable monofilament sutures [polypropylene (prolene, blue in colour)]; medial most stitch is taken from the periosteum of pubic tubercle (*called as key or Bassini's stitch*); external oblique is closed and other layers are closed.

### Complications of herniorrhaphy

- ❖ Haemorrhage
- ❖ Haematoma
- ❖ Infection
- ❖ Haematocele
- ❖ Postherniorrhaphy hydrocele
- ❖ Hyperaesthesia over the medial side of inguinal canal due to injury to ilioinguinal nerve
- ❖ Recurrence
- ❖ Osteitis pubis

## Hernioplasty

Prolene mesh is used for hernioplasty (white in colour). Other materials which can be used are Dacron, tensor fascia lata, skin.

### Relation of sac to the cord

- ❖ Indirect inguinal hernia—anterolateral
- ❖ Direct inguinal hernia—posteromedial

## APPENDICECTOMY

*Approaches:*

- ◆ **Grid-iron incision** (*McBurney's incision*): Incision is placed perpendicular to the right spino-umbilical line at the McBurney's point, i.e. at the junction of lateral one-third and medial two-third of spino-umbilical line.
- ◆ **Rutherford Morison muscle cutting incision** (*Cut upwards and laterally*).
- ◆ **Lanz crease incision** centering at McBurney's point—cosmetically better.
- ◆ **Right lower paramedian incision**—when in doubt or when there is diffuse peritonitis.
- ◆ **Laparoscopic approach**: Becoming popular.
- ◆ **Fowler-Weir approach**: Medial muscle cutting incision.

## Procedure

Under general anaesthesia, skin is incised. Two layers of superficial fascia are cut. External oblique aponeurosis is opened in the line of incision. Internal oblique and transverse muscles are split in the line of fibres. Peritoneum is opened in the line of incision. Caecum is identified by taeniae, and ileo-caecal junction. Omentum when adherent is separated. Appendix is held with Babcock's forceps. Mesoappendix with appendicular artery is ligated. Using thread or silk, a purse-string suture is placed around the base of the appendix. Base of the appendix is crushed with artery forceps and transfixed using vicryl (absorbable). Appendix is cut distal to the suture ligature and removed. Stump is cleaned with antiseptics. Purse-string suture is tightened so as to bury the stump.

In difficult cases *Retrograde appendicectomy* can be done. In presence of pus or burst appendix, the peritoneal cavity is drained.

Postoperatively, IV fluids, antibiotics are given. Once bowel sounds are heard, oral diet is started.

## Complications after Appendicectomy

- ◆ Paralytic ileus.
- ◆ Reactionary haemorrhage due to slipping of ligature of the appendicular artery.
- ◆ Residual abscess (pelvic, paracolic, local, subdiaphragmatic).
- ◆ Pylephlebitis (Portal pyaemia).
- ◆ Adhesions, kinking and intestinal obstruction.
- ◆ Right inguinal hernia (*direct*) due to injury to ilioinguinal nerve.
- ◆ Wound sepsis.
- ◆ Faecal fistula.

## THYROIDECTOMY

### Types

- ◆ **Hemithyroidectomy**: Along with removal of one lobe, entire isthmus is removed. It is done in benign diseases of only one lobe.
- ◆ **Subtotal thyroidectomy**: Commonly done in toxic thyroid either primary or secondary and also often for nontoxic multinodular goitre. Here about 8 grams or a tissue, size of pulp of the finger is retained at the lower pole, one or both sides and rest of the thyroid gland is removed.
- ◆ **Partial thyroidectomy** is removal of the gland in front of trachea after mobilisation. It is commonly done in nontoxic multinodular goitre.
- ◆ **Near total thyroidectomy**: Here both lobes, except the lower pole which is very close to recurrent laryngeal nerve and parathyroid is removed. It is done in case of papillary carcinoma of thyroid.
- ◆ **Total thyroidectomy**: Entire gland is removed. It is done in case of follicular carcinoma of thyroid, medullary carcinoma of thyroid.

### Procedure

**Position**: Under general anaesthesia patient is put in supine position, with neck hyperextended by placing a sand bag under shoulder—with table tilt of 15 degree head up to reduce venous congestion.

**Incision**: Horizontal crease incision is done, two finger breadth above the sternal notch, extending from sternomastoid of one side to the other.

Skin and platysma are incised—upper flap raised up to thyroid cartilage, lower flap up to sternoclavicular joint. Deep fascia is opened vertically in the midline. Strap muscles are retracted or cut in between two Kocher's forceps. Pretracheal fascia is opened to mobilise the thyroid. First, short stout middle thyroid vein is ligated, then superior thyroid pedicle is ligated close to the gland so as to avoid injury to external laryngeal nerve. Inferior thyroid artery is ligated away from the gland so as to avoid injury to recurrent laryngeal nerve. Mobilised gland is removed. Bed is sutured with catgut so as to prevent bleeding. Drain is placed. The wound is close in layers.

**Thyroid steal**: Patient with thyrotoxicosis is taken to operation theatre daily for few days before doing surgery so as to reduce the anxiety of the patient.

## Complications of Thyroidectomy

- ◆ **Haemorrhage**: May be due to slipping of ligatures, either of superior thyroid artery or other pedicles. It causes tachycardia,

hypotension, breathlessness and compression over the trachea which intum may cause severe stridor, respiratory obstruction. As a first aid, immediate release of sutures including that of deep fascia has to be done and pressure over the trachea is released. Then patient is shifted to operation theatre and under general anaesthesia exploration is done and bleeders are ligated. Blood transfusion may be required.

- ◆ **Respiratory obstruction:** It may be due to haematoma (if it is so, the haematoma has to be evacuated), or due to laryngeal oedema. For laryngeal oedema, *immediate emergency endotracheal intubation* is done along with steroid injections. Often emergency tracheostomy may be required as a life-saving procedure.
- ◆ **Recurrent laryngeal nerve palsy:** It can be transient or permanent. Transient is 3% common. They usually recover in 3 weeks to 3 months. Often they require steroid supplement and speech therapy. Permanent paralysis is rare.
- ◆ **Hypoparathyroidism** is rare (0.5%). Mostly it is temporary due to vascular spasm of parathyroid glands, occurs in 2nd–5th postoperative day. Presents with weakness, +ve Chvostek's sign, carpopedal spasm, convulsions. Serum calcium estimation is done and then 10 ml of 10% calcium gluconate—is given IV 8th hourly. Later supplemented by oral calcium 500 mg 8th hourly. After 3–6 weeks, patient is admitted, drug is stopped and serum calcium level is repeated.
- ◆ **Thyrotoxic crisis (Thyroid storm):** Occurs in a thyrotoxic patient inadequately prepared for thyroidectomy and rarely a thyrotoxic patient presents in a crisis following an unrelated operation or stress. They present in 12–24 hours with severe dehydration, circulatory collapse, hypotension, hyperpyrexia and often cardiac failure. *Treatment* is injection hydrocortisone, oral antithyroid drugs, tepid sponging of whole body, beta blocker injection, oral iodides, large amount of IV fluids for rehydration, digitoxin. Cardiac monitor, often ventilator support with close observation is necessary. It has got high rate of mortality with critical period of 72 hours. Correction of fluid and electrolyte imbalance and cardiac monitoring are the important aspects of management.
- ◆ **Injury to external laryngeal nerve** causes weakness of cricothyroid muscle leading to alteration in pitch of voice.
- ◆ **Hypothyroidism:** Revealed clinically after 6 months.
- ◆ Wound infection, stitch granuloma formation.
- ◆ Keloid formation.

## ■ TRACHEOSTOMY

### Types

- ◆ Emergency tracheostomy.
- ◆ Elective tracheostomy.

### Tracheostomy Tube

- ◆ **Fuller's bivalved tracheostomy tube:** It has got outer tube and inner tube. Outer tube is biflanged and so insertion is easier. Inner tube is longer with an opening on its posterior aspect. Inner tube can be removed and re-inserted easily whenever required.
- ◆ **Jackson's tracheostomy tube:** It has got outer tube, inner tube and an obturator.

- ◆ Red rubber tracheostomy tube.
- ◆ Polyvinylchloride tracheostomy tube.

Modern tracheostomy tubes are made of plastic. They are soft, least irritant and disposable. They have inflatable cuff which makes it easier to give assisted ventilation. Cuff should be deflated at regular intervals to prevent tracheal pressure necrosis. (For assisted ventilation endotracheal tube can be kept for 7 days. Beyond that period patient needs tracheostomy for further ventilation.)

#### Indications for tracheostomy

- ❖ In head, neck and facial injuries
- ❖ Tetanus
- ❖ Tracheomalacia after thyroidectomy
- ❖ Laryngeal oedema/spasm/surgeries
- ❖ Major head and neck surgeries like commando's operation, block dissection, etc.
- ❖ ICU ventilation after 7 days

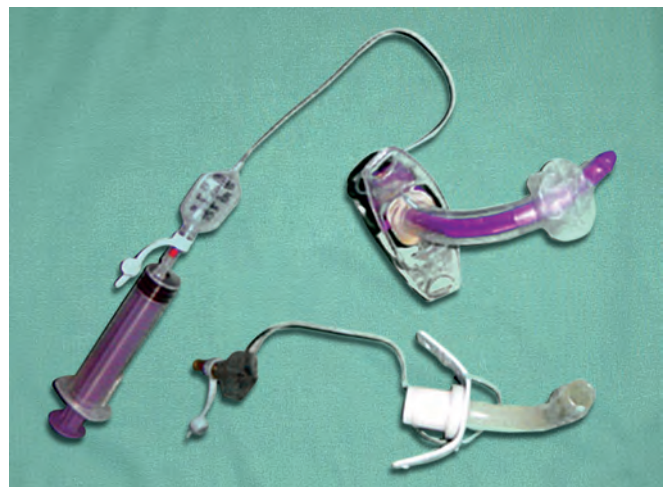

Fig. 32.52: Tracheostomy tube with inflation part and syringe (Inflated with air)

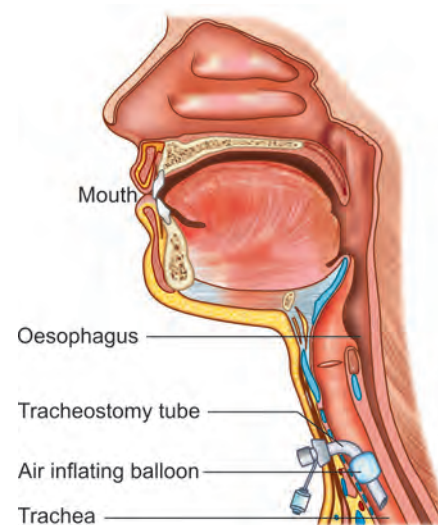
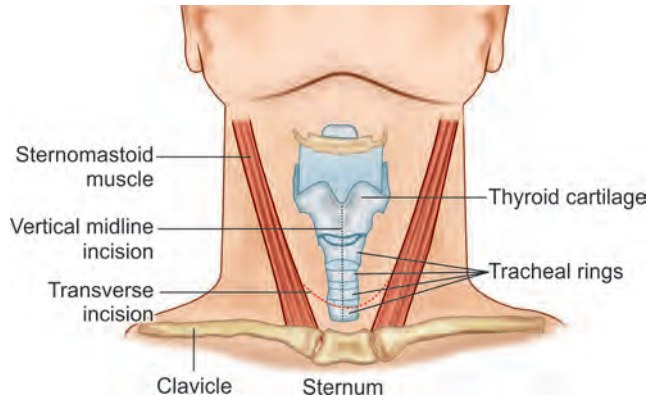


Fig. 32.53: Figure showing the position of tracheostomy tube.



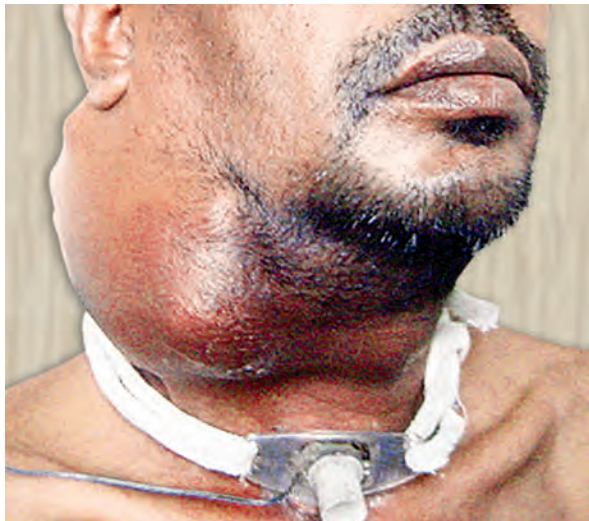**Fig. 32.54:** Vertical midline or transverse incisions are used for tracheostomy. **Vertical midline** extends from cricoid cartilage to sternal notch. It is used both in emergency and elective tracheostomy and commonly used incision. It gives rapid access with less dissection but leads into poor scar. **Transverse incision** can be used in elective tracheostomy. It is placed two finger breadths above the sternal notch with a length of about 5 cm transversely. It has got a better cosmetic scar.

### Technique of Tracheostomy

Neck of the patient is hyperextended by placing sand bags under the shoulder. Vertical (midline) or horizontal incision is made. Deep fascia is opened. Strap muscles are retracted laterally. Isthmus is divided or retracted below. 2nd and 3rd tracheal rings are opened and circular opening is made. Tracheostomy tube is placed. It is tied around the neck.

#### Note:

Endotracheal tube can be kept *in situ* only for 7 days.



**Fig. 32.55:** Advanced secondaries in neck with tracheostomy tube to control respiratory stridor.

### Tracheostomy Care

- ◆ Regular suctioning of the tube.
- ◆ Cleaning of tracheostomy tube.
- ◆ Humidification of the inspired air.

### Complications of tracheostomy

- ◆ Tracheal stenosis
- ◆ Bleeding
- ◆ Aspiration
- ◆ Pneumothorax
- ◆ Surgical emphysema in the neck
- ◆ Mediastinal emphysema
- ◆ Tracheostomy dependency

### CRYOSURGERY

- ◆ It is the destruction of tissues by **controlled cooling**.
- ◆ System contains an automatic defrosting device with a cryoprobe.

#### Gases used are:

- ◆ Nitrous oxide—minus 98°C temperature.
- ◆ CO<sub>2</sub>—minus 60°C.
- ◆ Liquid N<sub>2</sub>—minus 180°C.
- ◆ Freon—minus 190°C.

Commonly nitrous oxide is used as it is easily available, cheaper and achieves optimum temperature required for different procedures.

### Mode of Action

- ◆ It produces intracellular crystallisation, dehydration and denaturation of proteins and cell death.
- ◆ It causes the obliteration of microcirculation and so cell death.

### Indications

- ◆ To remove warts and lesions in the skin.
- ◆ Cryotherapy for piles.
- ◆ For chronic cervicitis.

### Advantages

- ◆ Relatively bloodless and painless.
- ◆ Adequate control of extent and depth in freezing.
- ◆ Equally effective.

### Disadvantages

- ◆ Infection.
- ◆ Discharge from the site.

### LASERS IN SURGERY

It is **Light Amplification Stimulated Emission of Radiation**. Electrons in high energy status leave towards excited level from ground state and eventually return to ground state releasing its energy as photon particle of light. This laser light has got one specific wavelength and is monochromatic. Laser light is unidirectional with one specific colour and is coherent with a tight, strong and concentrated beam.

Power density and laser energy are two important parameters. Power density is the measure in unit beam area; it is Watts/cm<sup>2</sup>. Laser energy is power delivered/second.

Molecules are placed in a compact area and power is passed through this so as to activate the molecules. Molecules get activated at different periods and move in different directions, which they hit each other releasing energy; this energy is allowed to act through optical system to area wherever required. Depending on the molecules used laser is being named like Nd YAG (Neo dymium Ytrium Aluminum Garnet **Laser**), CO<sub>2</sub>, Neon, Holmium, Erbium, etc.

### Types Based on Generation of Power

1. *Continuous wave laser*: Generates continuous power for longer duration; it is commonly used in medical field.
2. *Pulsed laser*: Generates high power for short intervals in pulses. Nd YAG pulsed laser is used in ophthalmology; diode pulsed laser is used in varicose veins.

### Types, Based on Material Used

- ◆ *Solid state laser*: Nd YAG laser (infrared light of 1064 wavelength). Nd YAG laser is invisible which is absorbed easily by tissues; requires a visible guiding beam like red helium or neon beam; it penetrates tissues deeply for 5 mm; easily and effectively vaporizes tissues; it is used in endoscopic procedures, LITT (light induced thermal therapy).
- ◆ *Gas lasers*: helium, neon, CO<sub>2</sub> lasers are gas lasers. CO<sub>2</sub> laser has got wavelength of 10.6 mm; it penetrates tissues very poorly; it is absorbed rapidly by water in the tissues; it is invisible and needs helium or neon beam; it is used I surface lesions of skin and for haemorrhoids.
- ◆ *Dye lasers*: Rhodamine organic dye laser.
- ◆ *Semiconductor lasers*: They are diode lasers use low power.
- ◆ *Excited dimer (Excimer) lasers*: Argon, Krypton, Xenon which are mixed with chlorine or fluorine creating dimer. Argon laser has got two wavelengths 514 (green) and 488 (blue); it is absorbed by haemoglobin red pigment; tissue vaporization is poor; has got limited penetration and so useful for surface lasers in skin, eye; it is useful in photodynamic therapy also.

### Applications

- ◆ Focused heat beam of laser light is used to coagulate, excise, vaporize the tissues.
- ◆ It is used to cut tissues, cauterize blood vessels, photocoagulation.
- ◆ Photodynamic or photoradiation therapy using dye or diode laser after injecting photosensitizer photofrin intravenously.

### Uses in Surgery

- ◆ In gastroenterology—piles; debulking luminal malignancies like oesophagus, rectum; arrest gastrointestinal bleeding; to remove small tumour or angiodysplasias.
- ◆ In urology—to remove superficial low grade bladder tumours.
- ◆ In eye—in retinopathy, laser photocoagulation, retinal detachment, in glaucoma. Lasik surgery is done for myopia using microkeratome to reshape the cornea. It is laser- induced keratoplasty.
- ◆ In ENT – removal of small mucosal lesions
- ◆ In skin – argon or CO<sub>2</sub> lasers are used. Used in removal of tattoos (Ruby laser, pulsed); excision of small lesions, haemangiomas.
- ◆ Vascular – Laser angioplasty can be done.

- ◆ In gynaecology—in endometrial ablation, in removing precancerous lesion of cervix, adhesiolysis, fimbrioplasty.

### Advantages

It is bloodless, small incision, fast recovery.

### Complications

Damage to normal tissues, adjacent bowel, vessels.

Problem to operating beam—injury to skin, eyes causing corneal or retinal damage, cataract formation.

### Precautions

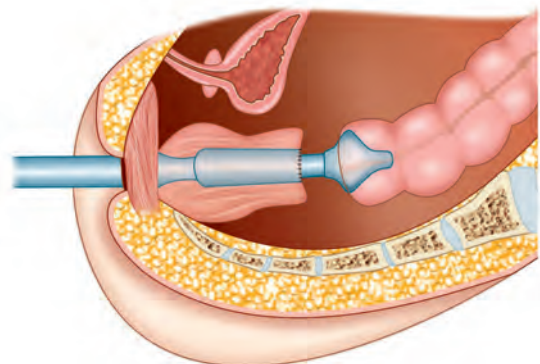
- ◆ All operating team staff should wear safety goggles.
- ◆ Drapes should be wet; dry materials should be used.
- ◆ Instruments ideally should be non-reflective (coated to avoid reflection).
- ◆ Audible signals should be used.
- ◆ Emergency shutter devices should be present.

## ■ STAPLERS IN SURGERY

Staplers are used for apposition of tissues. Used in skin, bowel, lungs, etc.

### Types

- ◆ **Cutaneous staplers** give clean apposition. It is faster and technically easier. Problem is removal requires specific instrument and costlier than sutures.
- ◆ **Linear staplers** are used to close the bowel either completely or partially.
- ◆ **Circular staplers** also called as EEA stapler—End to End Anastomosis. It is commonly used for colorectal anastomosis in anterior resection for carcinoma rectum, oesophagogastric anastomosis after oesophagogastric resection in case of carcinoma at O-G junction.



**Fig. 32.56:** Circular stapler for colorectal anastomosis.

**Parts:** Stapler gun, and cartridge with two rows of stapler pins for apposition. Loaded cartridge is detachable. Cut ends of bowel are placed over gun and cartridge. Once gun is shot, cartridge moves to the gun and creates anastomosis.

*Remember, the most important person in an operation theatre is the patient.*

—Berkehy George Andrew Moynihan

- ◆ **GIA stapler** (Gastrointestinal anastomosis stapler) for *side to side* anastomosis, like small bowel or ileocolic anastomosis.
- ◆ **Stapler for lung apposition.**
- ◆ **Endostaplers:** These are used during laparoscopic surgeries. It is commonly used for bowel anastomosis. **Endovascular staplers** are used to ligate vascular pedicles like renal pedicles during laparoscopic nephrectomy.
- ◆ Stapled haemorrhoidopexy—costly.

**Disposable staplers** are available but are costly.

**Advantages:** Technically easier and faster.

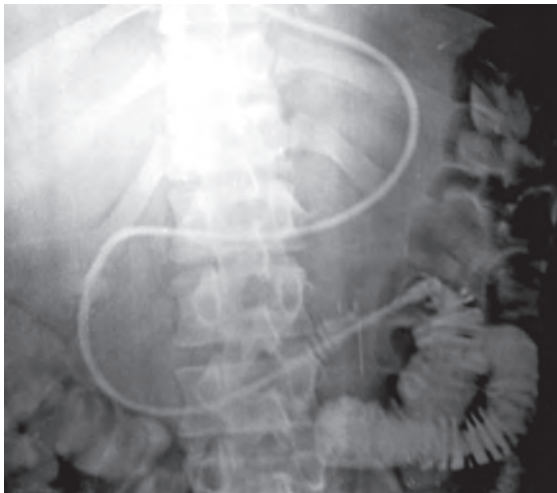**Disadvantages:** Cost factor, availability.

**Problems with staplers:**

- ◆ It is not completely haemostatic and so bleeding can occur.
- ◆ Leak from anastomosis, improper apposition.
- ◆ Intestinal obstruction.

## ■ NASOJEJUNAL TUBE FEEDING

- ◆ It is one of the methods of *enteral nutrition*. It is commonly used in acute pancreatitis. It is also useful in other enteral nutrition needs.



**Fig. 32.57:** X-ray showing nasojejunal tube for enteral nutrition purpose. It is useful and effective method of enteral nutrition. Its passage needs expertise, C-ARM guidance. It can be kept for long time for 3 months. Its position often to be confirmed by X-ray.

- ◆ It is passed under C-ARM guidance per nasally. It is passed up to the first loop of the jejunum across the duodenal C loop. It should be fixed properly to the nostril. Its position should be confirmed by X-ray. One should take care not to displace the tube.
- ◆ **Advantages** are—it is safer, easier and can be kept for 3 months. Complications of long-term TPN are not there.
- ◆ **Disadvantages**—irritation by tube, displacement, aspiration.

## ■ GOSSYPIBOMA

### (Gossypiboma—Cotton Based in Latin)

- ◆ By definition, it is the presence of *cotton based foreign body* that is in place of concealment following surgery.
- ◆ Forgotten foreign bodies (mop, gauze, etc.) intraoperatively especially in *abdominal cavity* (can occur in any cavities (thorax, pelvis) cause adhesions, provoke sepsis, often get encapsulated.
- ◆ It may cause an inflammatory mass, bowel erosion/perforation/peritonitis, intra-abdominal abscess, septicaemia, fistula formation.
- ◆ **Presentations** may be as—asymptomatic, pseudotumour, abscess, septicaemia, fistula.
- ◆ Often foreign body erodes and enters the bowel lumen and with peristalsis reaches ileocaecal valve causing intestinal obstruction. There are incidences patient has passed the foreign body like mop per anally few months after surgery (in 6% gossypiboma).
- ◆ Ultrasound, *CT scan* and MRI identifies the foreign body (gossypiboma). Plain X-ray is of less value.
- ◆ Incidence of gossypiboma is 1 in 3,000 surgeries. Migration commonly occurs into intestine either small or large but can occur into urinary bladder or stomach.
- ◆ 70% of retained foreign bodies are sponges/mops; 30% are instruments.
- ◆ **Commonest site** is abdominal cavity 55%, vagina (20%), thorax (10%) and rest on other cavities.
- ◆ Commonly gossypiboma present 3–12 weeks; rarely it can present as later as 5–7 years.
- ◆ It is more commonly observed in emergency surgery, trauma, and surgery for malignancies.
- ◆ **Treatment:** Surgical exploration and extirpation of the foreign body, antibiotics.
- ◆ **Legal problem:** Gossypiboma amounts for criminal negligence. Surgeon or team or hospital can be sewed for negligence either in consumer court or criminal court.



## F. Laparoscopic Surgery

### CHAPTER OUTLINE

- ❖ Advantages of Laparoscopic Surgery
- ❖ Laparoscopic Cholecystectomy
- ❖ Laparoscopic Appendicectomy
- ❖ Advanced Laparoscopic Surgeries
- ❖ Diagnostic Laparoscopy
- ❖ Retroperitoneoscopy
- ❖ Natural Orifice Transluminal Endoscopic Surgery

### History

First laparoscopic cholecystectomy was done by Muhe of Germany in 1985 and by Mouret in Lyon in 1987.

McKeran and Saye performed the first laparoscopic cholecystectomy in USA in 1988.

First laparoscopic appendicectomy was done by Semm as prophylaxis.

First laparoscopic appendicectomy for acute appendicitis was done by Schreiber in 1987.

Semm changed 75% open gynaecological surgeries into laparoscopic surgeries.

Professor TE Udawadia, Mumbai did first laparoscopic cholecystectomy in India.

### ADVANTAGES OF LAPAROSCOPIC SURGERY

- ◆ Relatively less painful compared to open surgery. Trauma of access is very less.
- ◆ Shorter hospital stay and early return to work.
- ◆ Faster postoperative recovery.
- ◆ Better visualisation of the anatomy, i.e. better approach for dissection and visualisation of other parts of abdomen for any other pathology.
- ◆ Instrumental access to different abdominal locations is many times better compared to open method.
- ◆ Minimal scar on the abdomen.

### Instruments Used

- ◆ Zero degree laparoscope is commonly used. Side viewing scopes are also used to have better visualisation 30°.
- ◆ Cold light source either halogen lamp or xenon lamp is used. Halogen lamp is used commonly and is cheaper. Xenon lamp gives high visualisation.
- ◆ Camera: 3 chip camera is commonly used with high resolution.
- ◆ Video-monitor to display images.
- ◆ CO<sub>2</sub> insufflator.
- ◆ Long fine dissectors like in open surgical techniques.
- ◆ Hooks and spatulas are used along with cautery for dissection.
- ◆ Clip applicators.
- ◆ Needle holders.
- ◆ Endostaplers.
- ◆ Veress needle.
- ◆ Suction-irrigation apparatus.
- ◆ Trocars of different sizes—10 mm, 5 mm.
- ◆ Reducers to negotiate smaller instruments through larger ports.



**Figs 32.58A and B:** Laparoscopic set showing trolley, telescope and monitor instruments.

### Preparation

Always general anaesthesia. Other preparations are same as for open method.

### Technique

Pressure bandages are applied to both legs to improve the venous return and to decrease the stasis.

Head end of the table is lowered to have easier insertion of veress needle and scope.

Ryle's tube and Foley's catheter are essential before insertion of the trocars.

Pneumoperitoneum is created using veress needle through umbilical incision. Access can be achieved by open method through an umbilical incision.

#### CO<sub>2</sub> is commonly used to create pneumoperitoneum as:

- ❖ It is readily available
- ❖ It is cheaper
- ❖ It suppresses the combustion
- ❖ It is easily absorbed by tissues
- ❖ It has a high diffusion coefficient
- ❖ It is quickly released via respiration

*Other gases used are:* Air, nitrous oxide, helium, argon.

Pneumoperitoneum is created upto a pressure of 15 mmHg which distends the abdominal cavity adequately to have proper visualisation of the abdominal contents.

*A quiet, vacant mind is distressed, depressed mind.*

Laparoscope is inserted through the umbilical port (10 mm). Abdomen is evaluated for any pathology. Liver, gallbladder, pelvic organs are visualised.

Additional ports (3–4) through trocars are placed depending on the procedure to be done. It may be either 5 mm port or 10 mm port. These ports are placed in such a way to have a proper triangulation of instruments for dissection.

To use clip applicator 10 mm port is required.

### Physiologic Changes due to Pneumoperitoneum

- ◆ CO<sub>2</sub> causes hypercarbia, acidosis and hypoxia.
- ◆ Pneumoperitoneum exerts pressure on the IVC, decreases the venous return and so the cardiac output.
- ◆ It increases the arterial pressure also.
- ◆ It compromises the respiratory function by compressing over the diaphragm impairing the pulmonary compliance.

### Complications

- ◆ CO<sub>2</sub> narcosis and hypoxia.
- ◆ Sepsis—subphrenic abscess, pelvic abscess, septicaemia.
- ◆ IVC compression.
- ◆ Bleeding.
- ◆ Leak from the site, e.g. bile leak.
- ◆ Organ injury during insertion of ports, e.g. major vessels, bowel, mesentery, liver.
- ◆ Subcutaneous emphysema and pneumomediastinum.
- ◆ Gas emboli, though is rare but fatal.
- ◆ Postoperative shoulder pain due to irritation of diaphragm.
- ◆ Cardiac dysfunction due to decreased venous return.
- ◆ Injury to the abdominal wall vessels and nerves.
- ◆ Cautery burn to abdominal structures.
- ◆ Abdominal wall hernias.
- ◆ Wound infection.
- ◆ Mortality—0.5%.

### Relative Contraindications

- ◆ Patients with compromised cardiac status.
- ◆ Peritonitis.
- ◆ Previous abdominal surgeries.
- ◆ Bleeding disorders.
- ◆ Morbid obesity.
- ◆ Third trimester pregnancy.
- ◆ Portal hypertension.

### Basic Laparoscopic Surgeries

- ◆ Laparoscopic cholecystectomy.
- ◆ Laparoscopic appendectomy.

## LAPAROSCOPIC CHOLECYSTECTOMY

It is becoming popular method of treatment.

#### Indications

- ❖ Gallstones—symptomatic
- ❖ Cholecystitis
- ❖ Biliary colic

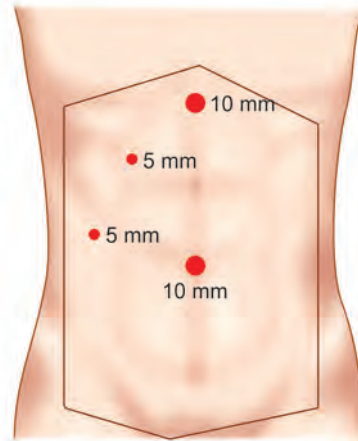


Fig. 32.59: Portals for laparoscopic cholecystectomy.

### Relative Contraindications

- ◆ End stage cirrhosis, ascites or portal hypertension.
- ◆ Cholangitis: Cholecystectomy should be done after the control of cholangitis.
- ◆ CBD stones: Here, initially ERCP and stone extraction is done from CBD, then laparoscopic cholecystectomy is done.

### Technique

After pneumoperitoneum, patient is placed in head up and slight left tilt position so as to make bowels to fall below and towards the left side. One 10 mm trocar is placed at umbilicus and through this umbilical port, laparoscope is passed. One 10 mm port in the epigastric region and two 5 mm ports in the right subcostal line are placed for grasping the gallbladder and for dissection. Initially, through the working channel gallbladder is held and Calot's triangle is dissected. Cystic duct and cystic artery are clipped.

An intraoperative cholangiogram is done with C-arm. Through the epigastric port, clips or ligatures are applied to the cystic duct and cystic artery, close to the gallbladder. Care should be taken to avoid bleeding and not to injure or clip the CBD or hepatic ducts. Gallbladder is separated from its bed using cautery and spatula and removed through the epigastric port. Abdomen may be drained. Patient is discharged after 48–72 hours.

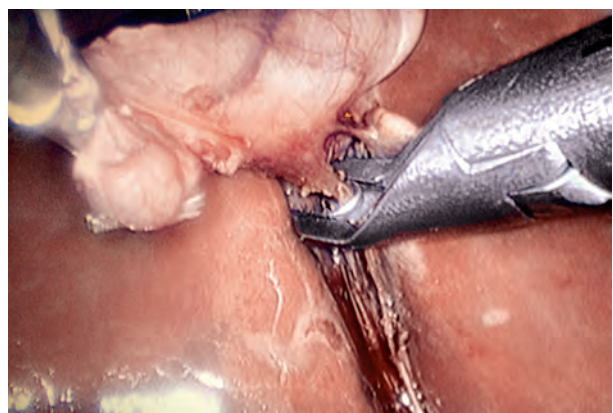

Fig. 32.60: Laparoscopic cholecystectomy. Applying clip to cystic duct is shown.

### Complications

- ❖ Common bile duct (CBD) injury
- ❖ Bile leak
- ❖ Haemorrhage
- ❖ Postoperative jaundice
- ❖ Subphrenic and other intra-abdominal abscess
- ❖ Septicaemia

When problem arises, one should be ready to convert into open cholecystectomy. Conversion rate to open cholecystectomy is 2–10%. It is indicated when there is uncontrolled bleeding, dense adhesions, suspected CBD injury, when anatomy is indistinct.

When required one should not be hesitant to do conversion.

## LAPAROSCOPIC APPENDICECTOMY

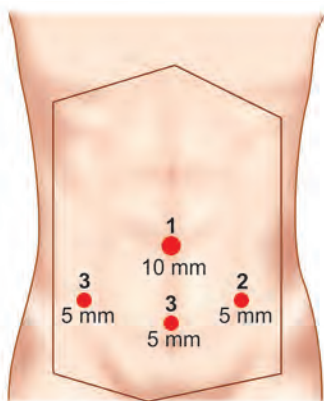
### Indications

Acute appendicitis. Here main advantage is confirmation of the diagnosis. Other parts of the abdomen are also visualised.

### Relative Contraindications

Appendicular mass and abscess.

**Technique:** Laparoscope is passed through the umbilical port. Two additional ports are placed, one in lower midline (5 mm), another at right lumbar region. Mesoappendix is clipped or cauterized, using bipolar cautery. Appendix base is clipped or ligated using Roeder knot and ligature.



**Fig. 32.61:** Ports used for laparoscopic appendectomy. 10 mm umbilical camera port (1); 5 mm working left lower abdominal port (2); another 5 mm port (3) either in suprapubic midline or right lower abdomen.

### Complications

- ❖ Appendicular stump leak.
- ❖ Pelvic abscess.
- ❖ Bleeding.
- ❖ Injury to caecum, ileum.

## ADVANCED LAPAROSCOPIC SURGERIES

- ❖ Presently most of the abdominal surgeries can be done through laparoscopy.
- ❖ It requires advanced technology and skill. Surgeon should be expert in doing intracorporeal and extracorporeal knotting.

*When light pressure is exerted over area of surgical emphysema, a sensation similar to that of likewise palpating a horse hair mattress is experienced.*

—Denis Dooley

## Procedures

- ❖ Laparoscopic hernia repair.
- ❖ Laparoscopic splenectomy.
- ❖ Laparoscopic fundoplication.
- ❖ Laparoscopic vagotomy and gastrojejunostomy.
- ❖ Laparoscopic Nissen's fundoplication.
- ❖ Laparoscopic colectomy.
- ❖ Laparoscopic hysterectomy. It is becoming very popular.
- ❖ Laparoscopic urologic surgeries.
- ❖ Laparoscopic paediatric surgeries.

## Laparoscopic Inguinal Hernia Repair

It is becoming popular method, lately. It is a skilled laparoscopic surgery.

1. *Transabdominal preperitoneal repair (TAPP repair):* Through abdomen, using laparoscope Hesselbach's triangle is exposed and mesh is placed in the preperitoneal space. Peritoneum is sutured back or stapled.
2. *Totally extraperitoneal repair (TEP repair):* Through sub-umbilical incision, preperitoneal space is created with the help of a balloon. Laparoscope is passed to this space. Inguinal canal is dissected and mesh is placed.

*Triangle of 'Doom':* It is bounded by ductus deference medially, testicular vessels laterally, with apex at internal ring. This is dangerous area in laparoscopic hernia repair as dissection may injure iliac vessels and cause torrential haemorrhage.

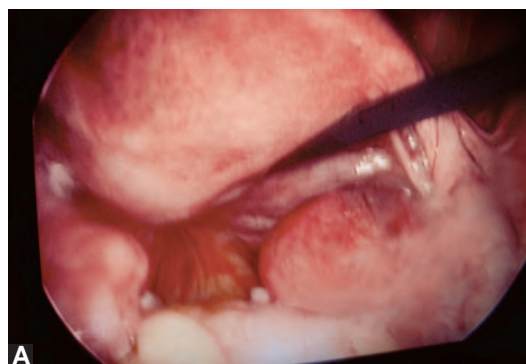### Complications

- ❖ Subcutaneous emphysema.
- ❖ Abdominal wall haematoma.
- ❖ Injury to major vessels.
- ❖ Recurrence.

## DIAGNOSTIC LAPAROSCOPY

### Indications

- ❖ Acute pelvic conditions.
- ❖ Tubal pregnancy.
- ❖ Ovarian diseases.
- ❖ Infertility.
- ❖ Staging of the malignancy.
- ❖ Biopsy from the tumours.
- ❖ In chronic pain abdomen where ultrasound, endoscopies, barium studies are negative, then diagnostic laparoscopy is useful.



**Fig. 32.62A**

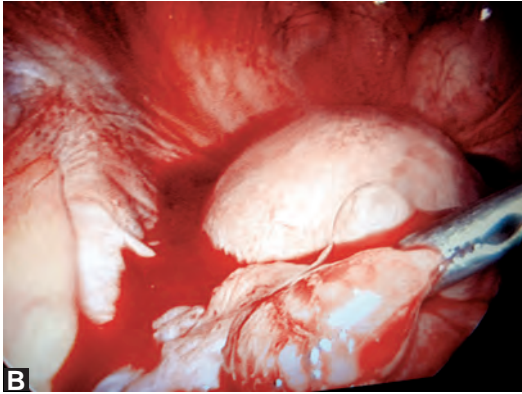


Fig. 32.62B

**Figs 32.62A and B:** Diagnostic laparoscopy showing ectopic pregnancy in right fallopian tube. It is removed by salpingectomy through laparoscopy.

*Needle laparoscopy of 2 mm sized becoming popular (especially for diagnostic purpose).*

### Advantages

- ◆ Laparotomy is avoided.
- ◆ Once diagnosis is made, therapeutic procedure also can be carried out in the same sitting.

### RETROPERITONEOSCOPY

- ◆ It is becoming popular in urology to assess kidney, ureter, adrenals for various urologic procedures.
- ◆ Through a small loin approach, retroperitoneum is expanded by inflating balloon in the space. Once space is created, different ports are placed to do dissections.

#### Procedures done through retroperitoneoscopy are:

- ❖ Nephrectomy
- ❖ Pyeloplasty
- ❖ Adrenalectomy
- ❖ Pyelolithotomy
- ❖ Uretero-lithotomy
- ❖ Retroperitoneal lymph node dissection (RPLND)

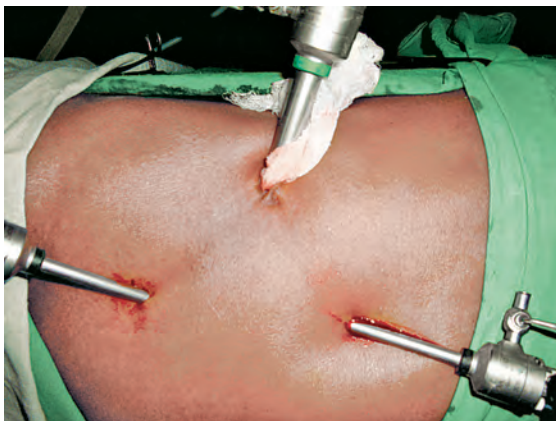


Fig. 32.63: Port positions for retroperitoneoscopy.

### Complications

- ◆ Injury to vessels.
- ◆ Paralytic ileus.
- ◆ Bowel (colon) injury.

### Advantage

- ◆ Complications of pneumoperitoneum is not present and so respiratory reserve is well-maintained.

### NATURAL ORIFICE TRANSLUMINAL ENDOSCOPIC SURGERY (NOTES)

It is an experimental surgical technique whereby “scar less” abdominal operations can be performed with an *endoscope* passed through a *natural orifice* (mouth, urethra, anus, etc.) then through an internal incision in the stomach, vagina, bladder or colorectum, thus avoiding any external incisions or scars.

- ◆ This technique has been used for diagnostic and therapeutic procedures in animal models, including transgastric (through the stomach) organ removal. The transvesical and the transcolonic approaches are also used. Transgastric and transvesical combined approach is also used to increase the feasibility of moderately complex procedures such as cholecystectomy.
- ◆ NOTES was originally described in animals by researchers at Johns Hopkins University (Dr Anthony Kalloo, et al.), and was recently used for transgastric appendectomy in humans in India (by Dr GV Rao and Dr N Reddy).
- ◆ On June 25, 2007, Swanstrom and colleagues reported the first human transgastric cholecystectomy. In late 2008, surgeons from Johns Hopkins School of Medicine removed a healthy kidney from a woman donor using NOTES. The surgery was called transvaginal donor kidney extraction.
- ◆ The *transvaginal access* to NOTES seems to be the *safest and feasible*. In 2007, the NOTES Research Group in Rio de Janeiro, Brazil, lead by Dr Ricardo Zorron, performed the first series of transvaginal NOTES cholecystectomy in four patients. With fewer potential complications, the procedure has a disadvantage of being possible only in women.
- ◆ Proponents and researchers in this field recognize the potential of this technique to revolutionize the field of minimally invasive surgery by eliminating abdominal incisions. NOTES could be the next major paradigm shift in surgery, just as laparoscopy was the major paradigm shift during the 1980s and 1990s.
- ◆ **Advantages are**—lower anaesthesia requirements; faster recovery and shorter hospital stays; avoidance of the potential complications of transabdominal wound infections (e.g. hernias); less immunosuppression; better postoperative pulmonary and diaphragmatic function; and the potential for “scar less” abdominal surgery.
- ◆ **Disadvantages are**—it is single port surgery and difficulty in visualisation of the area in need from all directions which is essential for proper surgical dissection. Poor manoeuvrability is the problem. Sepsis through this potentially infected area into sterile peritoneal cavity is a real risk. After procedure non closure of the port site opening in these approach sites or if closing their inadequacy are the real risk in NOTES.
- ◆ The general impression is that NOTES will be accepted as the newest frontier in minimally invasive surgery. As of today non-Bariatric minimally invasive surgery fellowships offer the best opportunity to train in this new approach.

# G. Dressings and Bandages

## CHAPTER OUTLINE

❖ Dressings

❖ Bandages

### DRESSINGS

They are the materials used to cover wounds, ulcers to provide support and to encourage healing.

#### Advantages

- ❖ It covers the wound and so prevents further contamination.
- ❖ It gives comfort to the patient.

#### Disadvantages

- ❖ It may get soaked.
- ❖ It may delay the epithelial layer formation.

#### Types

- ❖ *Dry dressings*: It is used in clean, sutured operated wound. It is not changed at regular intervals.
- ❖ *Wet dressings*: It is used in ulcers and wounds. Dressings are made wet by using jelly or sofra tulle sheets.

#### Components of Dressing

- ❖ *Inner contact layer*: It is non-absorbent and only allows secretion to pass into the absorbent layer. It does not allow penetration of granulation tissue. It is usually kept wet. Either mesh gauze or sofra tulle is used.
- ❖ *Intermediate absorbent layer* made up of cotton which absorbs the secretions.
- ❖ *Outer layer as supportive* is made up of gauze.

#### Dressings are fixed to the place by:

- ❖ Bandages
- ❖ Plasters
- ❖ Dynoplast
- ❖ Crepe bandages

Depending on the condition and amount of discharge from the wound/ulcer it is changed as required—twice a day/once a day/once in two days.

Small dressings are done without anaesthesia.

Large areas like burn wounds or dressing in children require general anaesthesia.

### BANDAGES

Technique of bandaging is called as *Dysmergia*.

#### Indications

- ❖ To reduce the swelling like in lymphoedema
- ❖ To keep dressings in position
- ❖ To support splints
- ❖ To stop bleeding/oozing

#### Types of Bandages

##### a. Roller bandages

- ▶ It is a continuous roll of material, which is rolled over the part to cover the area.
- ▶ It is used in limbs.
- ▶ It is available in different lengths and widths—1 inch, 2 inches, 4 inches or 6 inches.
- ▶ It is used in different ways.
  - *Circular turns*: Continuous rolls placed over the same place.
  - *Spiral turns*: After the initial turn of the bandage, it ascends proximally overlapping the distal 2/3 of the previous turn.
  - *Reverse spiral turn*: Here each spiral turn is reversed in opposite direction so as to attain uniform pressure. It is used in limbs and areas which end as cones.
  - *Figure eight turn*: It is used in knee, elbow, wrist, ankle and for clavicle.
  - *Recurrent turn*: It is used in head, amputation stump. Here initially circular rolls are made and over that half turns are made to cover other parts of the area required.
  - *Spica bandage*: It has got ascending and descending turns, with each turn overlap and cross each other. It is used in hip, groin, shoulder, breast or thumb. *Spica means eye of a bean*.

##### b. 'T' bandages: It is used in perineum and groin.

##### c. Tailed bandages: It may be four tailed bandages or many tailed bandages. It is used to support dressings on a wide area like in burns dressing, over abdomen or chest wall.

##### d. Tubular bandages: These are stockings which are unrolled over the limb to give pressure effects. It is used in lymphoedema, varicose veins and in the postoperative period following surgeries of the limb (Tubifix, Tubipress).

##### e. Triangular bandage: These are used for supporting the elbow or forearm. Here a wide gauze is used to cover the arm, forearm and elbow, which again winds around the neck.

##### f. Cravat bandages: It is a folded type of triangular bandage, which is used as sling around the neck, when elbow requires to be rested.

#### Principles of Bandaging

- ❖ Bandage is applied to the part from distal to proximal end.
- ❖ Proper positioning of the limb is a must before bandaging.

*Genius is one percent inspiration 99% perspiration.*

- ◆ After initial few circular turns, the required type of bandaging is then done.
- ◆ Bandage is unrolled outwards.
- ◆ During bandaging, latter turn should overlap 2/3rd of earlier turn.
- ◆ Firm, adequate pressure should be used during bandaging.
- ◆ After completing the procedure, the knot should not lie over the area or over the bony points or over the back.
- ◆ It should not cause venous or arterial compression.
- ◆ Digits should be left open and circulation in the digits should be observed for:

<b>Anatomical place</b>	<b>Types of bandage</b>
• Finger/toe	• 1 inch
• Arm	• 2 and 1/2 inches
• Leg	• 4 inches
• Thigh	• 6 inches
• Trunk	• 6 inches
• Head	• 4 inches

# H. Day Care Surgery

## CHAPTER OUTLINE

❖ Day Care Surgery

❖ Surgical Audit

❖ Surgeon and Law

### DAY CARE SURGERY

- ◆ *Day care surgery* is discharge within 23 hours (USA); surgery done without night stay (UK).
- ◆ *Day care surgery means* patient is fit to return home in 23 hours usually with overnight stay. *Ambulatory surgery means* patient recovers after surgery and returns home on the same evening. *Office surgery means* patient recovers from surgery and returns home in few hours. *Outpatient surgery* is different from day care surgery in that, patient is not previously fully assessed in outpatient surgery. Only minor procedures are done in this. Patient is not admitted in outpatient surgery. In day care and ambulatory surgery patient is admitted in the hospital.
- ◆ *Day care surgery* has been defined by *the Royal College of Surgeons* as when the surgical day case patient is admitted for investigation or operation on a planned non-resident basis and who nonetheless requires facilities for recovery. This definition excludes upper and lower GI endoscopies, outpatient procedures such as flexible cystoscopy, and minor superficial surgery under local anaesthetic, none of which require full day case facilities for recovery.
- ◆ *Day care surgery* is an upcoming field in surgical practice. It is a unique method wherein general practitioner, nurse at day care ward and theatre, surgeon, anaesthetist work in hand so that hospital stay and so the cost is reduced.
- ◆ Patient comes to hospital at morning for surgery and leaves the hospital on same day evening.

#### Advantages

- ❖ Minimal hospital stay
- ❖ Becomes cheaper
- ❖ Patient acceptance

- ◆ *Contraindications* for day care surgery are—age >70 years; high-risk cardiac and respiratory patients; patients with bleeding disorders.

#### Basic Requirements are:

- ◆ In house anaesthesiologist; recovery room; theatre and recovery room/ward nurse; all essential surgical set up including monitor, ventilator.
- ◆ *Alertness; ambulation; analgesia and alimentation—basis* for day care of surgery.

#### Assessment Done Prior to Surgery are by:

- ◆ *Pre-anaesthetic clinics* with system evaluations; *health questionnaire* by surgeon and physician; *telephonic interviews*.

- ◆ Patient selection, patient information, patient acceptance are important parts in day care surgery.

### Selection Criteria are

American Society for Anesthesiologist (ASA) category I and II patients can be taken up for day care surgery. ASA III/or beyond are contraindicated for day care surgery.

#### ASA (American Association of Anesthesiologists) grading of the patient for surgery

- ❖ Normal individual
- ❖ Mild-moderate systemic disease—diabetes and hypertension under control
- ❖ Severe systemic disease—uncontrolled diabetes and hypertension
- ❖ Incapacitating systemic disease
- ❖ Moribund status
- Class E—emergency surgery

#### Exclusion criteria for day care surgery are:

- ❖ ASA grade beyond III or more
- ❖ Obesity (BMT >35). Hypertension—not controlled
- ❖ Surgery requiring more than one hour
- ❖ Surgery with anticipation of major fluid/blood loss or needs post-operative critical care
- ❖ Preterm babies and infants less than 3 month's age
- ❖ Patient living in far and not easily reachable or able transport easily
- ❖ Unstable psychiatric illness
- ❖ If proper caregiver is not available
- ❖ Uncontrolled diabetes, alcohol abuse, Chronic obstructive pulmonary disease (COPD), severe asthma, epilepsy
- ❖ Pregnancy

### Levels of day Care Surgery

*Three levels* are used but minor procedures in outpatient clinic, accident cases are not included.

- ◆ Minor ambulatory surgery.
- ◆ Major ambulatory surgery.
- ◆ Inpatient surgery—patient stays overnight and get discharged within a day.

*Day care surgery unit (DSU)* is present in many centres. It may be hospital integrated or hospital based or free standing or officer based. It should have a separate dedicated unit with reception, surgery team, theatre, recovery unit, anaesthetist. Patient selection is done prior to surgery including all evaluations.

*So long as enthusiasm lasts, so long is life still with us.*

Many surgeries are done as day care surgery—hernia, haemorrhoidal procedures, laparoscopic surgeries, excisions, biopsies, laparoscopic cholecystectomy, appendicectomy, ovarian cystectomy, varicose vein surgery, all endoscopies, circumcision, orchidectomy, hydrocele surgery, vasectomy, renal stone procedures like ESWL, skin grafting, liposuction, fracture manipulation, arthroscopy, surgical decompression of carpal tunnel syndrome, most of the eye surgeries, tympanoplasties, myringoplasty, adenoidectomy, laryngoscopy, orthodontic surgeries, laparoscopic sterilization etc.

Any surgery which has got low-risk with less bleeding and early ambulation can be done as day care surgery with fulfilling the selection criteria.

**Advantages are**—less infection, home food, less chance of DVT, early ambulation, reduced cost, reduced waiting list, early return to work, psychological benefit.

**Guidelines for safe discharge**—stable vitals; proper orientation and recovery of the patient; tolerant for oral food adequately; ability to pass urine; able to move with or without support; no features of vomiting, nausea, severe pain, swelling or bleeding. Responsible relative to take care of the patient at home should be present.

#### Problems

Postoperative nausea and vomiting (50%); postoperative pain and postoperative drowsiness/dizziness (50%) are the *common complications* in day care anaesthesia.

### Precautions

- ◆ Patient should be assessed properly before sending to day care surgery.
- ◆ The nurse should give proper instruction to the patient as patient stays in the hospital for a short period.
- ◆ Patient should be warned about possible problems like bleeding, vomiting, pain, discomfort, and sedation.
- ◆ Before discharging, patient should be seen by the doctor for the fitness.
- ◆ All records should be carefully documented.
- ◆ Patient should be advised to rush to hospital if any problems arise or to communicate immediately.
- ◆ Now hernia; small gynaecology procedures; ENT, cataract surgeries are done as day care procedures.

*Nurses hold an important role in day care surgery.*

## ■ SURGICAL AUDIT

'Clinical audit' is a process used by clinicians who intend to improve the patient care. The process involves comparing various aspects of

patient care that includes *structure, process and outcome* against *explicit criteria*.

### Aspects of Patient Care

- ◆ Structure—includes what is there in that place—the people in place, their training and knowledge, the equipments and facilities provided, the organization, management and their payment, etc.
- ◆ Process—includes what procedure is followed in that place in managing referred patients, what antibiotics used, what diagnostic tests done, use of ICU facilities, use of postoperative rehabilitation care, what procedure used for discharge of patients, etc.
- ◆ Outcome—includes the overall results that include the morbidity, mortality, readmission, improvement /deterioration of the patient's condition.

### Explicit Criteria

Proposal for changes can be made in the care of the patient if it falls short of the criteria chosen which can be undertaken at one or more levels:

- ◆ Individual level—more training can be given to the doctors.
- ◆ Infrastructure—upgrading of the newer diagnostic tools.
- ◆ Team level—nurses getting more trained in handling the procedures along with the doctors.
- ◆ Institution—change in the treatment strategy, or antibiotic policy.
- ◆ Regional level—providing a good referral centre with all facilities and trained personnel.
- ◆ National level—introduction of screening programmes and health campaigns.

*Surgical audit* is a systematic, critical analysis of the quality of surgical care that is reviewed by peers against explicit criteria or recognised standards, and then used to further inform and improve surgical practice with the ultimate goal of improving the quality of care for patients.

In surgical practice, there will be definitely variations in the results of the surgery done by a trainee or an experienced surgeon, variations in outcome of the operation done in peripheral setup and in referral institutions, usage of modern equipments and technique used.

#### Step 1

##### Determine scope

It should be clearly defined, otherwise results in ineffective/inappropriate data collection.

It should also be relevant, easily measurable.

Common areas in scope of an audit include—duration of hospital stay/unplanned admissions/readmissions/operative specific complications/30 days mortality /morbidity/investigations done/management strategy/patient satisfaction.

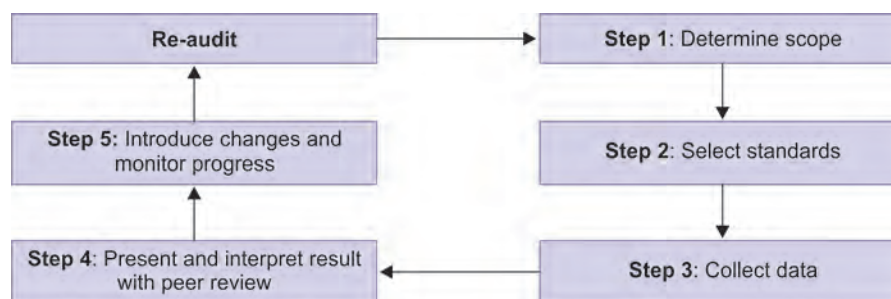


Fig. 32.64: Surgical audit cycle



**Step 2****Select standards**

Standards for the selected topic/practice area is decided based on relevant information obtained from:

- ◆ Evidence-based research and guidelines.
- ◆ Local guidelines for local relevance.
- ◆ New guidelines developed based on references from a library.

The standard which was already existing or developed must be clearly described, measurable, specific, and realistic.

**Step 3****Collect data**

It is important aspect of the audit which has to be informative for the audit to be successful. The best quality data collected depends on by whom it is being collected; when—retrospective/prospective collected; how—on form/PDA/computer; at/fter the time of surgery; follow-up data when collected; patient identification in a prospective/retrospective study.

Collected data must be relevant to the objectives of the surgical audit. Sometimes, the standards may need to be expanded or reduced/ or the data collection methods may need to be modified.

**Step 4****Present and interpret result with peer review**

Audit aims in continuous improvement by experience and by making changes which is ultimately rewarding.

The outcome of the audit should be presented and discussed in a clinical meeting. It should undergo peer review. It involves viewing and analyzing one's outcome by one's own peers who are none other than other experienced trained surgeons. It should be conducted in an atmosphere of confidentiality, trust and teamwork, should not be an opportunity to blame or brag but exchange of frank, non-confrontational discussions between the colleagues. Mortality/morbidity meetings, grand rounds are one form of peer review.

**Step 5****Introduce changes and monitor progress**

Based on the conclusion of the audit and meetings certain changes to be made in respect to the patient care are decided and all the personnel involved in the process are informed or educated. The outcome due to changes made are monitored by follow-ups either by reauditing the whole process/ or only the part that has been changed.

**■ SURGEON AND LAW**

- ◆ It is important to a surgeon to know legal aspects in relation to his profession. Consumer Protection Act and criminal negligence

are the two things surgeons are regularly worried about and face often problems.

- ◆ It is better to have a fair idea about Consumer Protection Act in relation to patient treatment.
- ◆ Surgeon should keep all documents regarding the patient with him or in the hospital.
- ◆ Case sheet should be written in detail. Daily follow-up should be written with date and time of visit with progress about the patient.
- ◆ It is better to take detailed consent after proper explanation about the disease and treatment protocol to patient and his close attender/relative. It is better to get signature about discussion given from them with date and time. In many centres, it is practiced to record the explanation part to keep it as document.
- ◆ Surgical method, its problems, risks due to anaesthesia, high-risk if any, risk of bleeding, complications, duration of hospital stay should be discussed.
- ◆ One should make sure that anaesthetist will do preanaesthetic check up prior to surgery; he should also write his preoperative/operative/postoperative anaesthetic notes.
- ◆ Daily information sheet should be used wherein patient or party should be informed about the condition of the patient. Timing of this and signature of surgeon and party should be taken.
- ◆ After surgery detailed surgical procedure technique should be written in case sheet and should be informed to patient. Specimens should be shown to patient party and should be sent for histology.
- ◆ Approximate cost of the procedure and entire bill in the hospital should be informed. One should also inform that it may change depends on complications, number of days in ICU, critical care, need for higher antibiotics, etc.
- ◆ Negligence about retaining mops/instruments are legally not acceptable; it is better to take care of enough precautions about that.
- ◆ Surgeon has got vicarious liability about the mistakes done by ward boys, nurses, theatre nurses, etc. So it is better to train them for proper care in OT, postoperative wards and ICU.
- ◆ It is ideal to show all reports to patient party and discuss/brief with them about the condition especially when patient is in ICU.
- ◆ If patient or party become arrogant or aggressive it is better to make a note of it in case sheet and inform police people about the same.
- ◆ It is better to make a professional indemnity insurance policy always to cover these problems in case if needed.
- ◆ It is again ideal to have an advocate to discuss these matters whenever needed.
- ◆ It is care which surgeon gives not cure always.

# Chapter 33

## Miscellaneous

### A. Fascinating Signs in Surgery

*“If it is a question of doubt in diagnosis, you may often observe that one man solves the doubt when the others could not, and the way in which one man happened to solve it is this: he applied to the diagnosis of the case some method of examination which others had not applied.”*

—Charles Barrett Lockwood, 1856–1914

**SIGN:** Sign is an indication of existence of an objective evidence of a disease, i.e. such evidence as is perceptible to the examining physician, as opposed to the subjective sensation (symptoms) of the patient.

**PATHOGNOMONIC SIGN** (patho = disease, gnoma = signature, pathognomonic = signature of the disease): Specially distinctive or characteristic sign of a disease or pathological condition on which a diagnosis can be made.

**ACCESSORY SIGN** (Assident sign): Any nonpathognomonic sign of disease, which adds on to the surety of the diagnosis when present.

**ANTECEDENT SIGN:** Any precursory indication of an attack of disease. These signs are to be identified at the earliest.

1. **Aaron’s sign:** A sensation of pain and/or distress in the epigastric or precordial region on pressure over McBurney’s point in appendicitis.
2. **Abadie’s sign:**  
Charles Abadie—Spasm of levator palpebrae superioris muscle—A sign of Graves’ disease.  
Jean Abadie—Insensibility of Achilles tendon to pressure, seen in tabes dorsalis.
3. **Air cushion sign** (Syn: Klemm’s sign): In the radiograph of chronic appendicitis, there is often an indication of tympanitis in the right lower quadrant.
4. **Alder’s sign** of shifting tenderness: This sign is useful to diagnose acute appendicitis in pregnancy. Locate the most tender spot and mark it on the skin. Now request the patient to turn on the left side and wait for a full minute. If the tenderness is of uterine origin it will shift with the uterus while the position remain constant in case of appendicular origin.
5. **Angell’s sign:** Helpful in diagnosing “*Torsion testis*” due to developmental anomaly—The presence of mesentery between the testis and the epididymis is invariably bilateral.  
The sign is usually obscured on the affected side and can be made out by examining the patient in the standing position wherein the opposite testis will be found to lie horizontally instead of in the normal vertical position.
6. **Anghelescus’ sign:** Seen in Pott’s disease of spine (TB spine) wherein the victim is unable to bend the spine while lying on the back so as to rest on the head and heel alone.
7. **Argyll Robertson pupil sign:** Typically described for neurosyphilis wherein light reflex is lost while accommodation reflex is retained. Such an eye responds poorly to mydriatics. This is due to destruction of fibres between pretectal nucleus and Edinger-Westphal nucleus. Other conditions where this sign may be seen—encephalitis, vascular and traumatic lesions, cerebral tumours, diabetes mellitus and chronic alcoholism.
8. **Auenbrugger’s sign:** Bulging of the epigastrium due to massive pericardial effusion. This sign highlights the importance of examining thorax in patients with abdominal symptoms.
9. **Babinski’s sign** (Not syn with Babinski’s reflex):
  - a. Loss or weakening of the Achilles tendon reflex in sciatica. This sign helps distinguish true sciatica from hysterical sciatica.
  - b. In hemiplegia the contraction of platysma muscle in the healthy side is more pronounced than on the affected side. It can be elicited by asking the patient to open the mouth, whistling, blowing, etc.

- c. When a hemiplegic patient is lying with arms crossed upon the chest and makes an effort to sit up, the thigh on the paralyzed side is flexed upon the pelvis and the heel lifted from the floor while limb on the healthier side does not move.
- d. When the paralyzed forearm is placed in supination it turns over to pronation. It is seen in organic paralysis and is also called 'Pronation sign'.
10. **Baid sign:** Described for pseudocyst of pancreas and is well appreciated in thin individuals. When Ryle's tube is passed into the stomach, it may be palpated over the swelling because the stomach is displaced anteriorly by the pseudocyst pancreas.
11. **Ballances' sign:** Seen in about 25% of ruptured spleen. There is a dull note in both the flanks due to haemoperitoneum. The dullness on the right side can be made to shift, but that on the left side remains constant/fixed because the blood in the vicinity of the ruptured spleen gets coagulated soon.
12. **Ballet's sign:** This sign is helpful in Graves' disease and hysteria wherein there will be persistence of involuntary pupillary and reflex eye movements with loss of all voluntary eye movements (external ophthalmoplegia).
13. **Bamberger's sign:** A sign described in pericardial effusion—Presence of signs of consolidation at the angle of scapula which disappears when the patient leans forwards.
14. **Banana sign:** An ultrasonographic sign described for Arnold-Chiari deformity—a cause for congenital hydrocephalus. Sonography of the fetal skull reveals flattened and curved (banana like) shape of the cerebellar hemisphere.
15. **Bastede's sign:** A sign described in a case of appendicitis—Mentioned to be condemned—when colon is inflated with air through a rectal tube, pain and tenderness can be elicited in the right iliac fossa in a suspected case of appendicitis. Such manoeuvre carries risk of perforation and hence should not be entertained.
16. **Battle's sign:** It is relevant in middle cranial fossa fracture—bruising/ecchymosis over the mastoid process in the line of posterior auricular artery is a tell-tale sign of underlying middle cranial fossa fracture (temporal bone fracture).
17. **Bergman's sign:** A urologic radiographic sign:
  - a. The ureter is dilated immediately below an obstructing neoplasm rather than collapsed as seen in cases of obstructing stones.
  - b. The ureteral catheter passed in such cases tends to coil in this dilated portion of the ureter.
18. **Berry's sign:** Indicated by the absence of carotid artery pulsation in a patient presenting with goitrous swelling, is an ominous sign of thyroid malignancy (due to carotid sheath infiltration by the malignant tissue).
19. **Bezold's sign:** Described in a case of mastoiditis—An inflammatory swelling seen below the apex of the mastoid process.
20. **Biederman's sign:** A dark colour instead of normal pink colour of the anterior pillar of the throat is seen in some patients with syphilis.
21. **Bird's sign:** Described for hydatid disease of lung wherein a definite zone of dullness with absence of the respiratory sounds may be appreciated.
22. **Biernacki's sign:** Analgesia of ulnar nerve in general paresis and tabes dorsalis.
23. **Blatin's sign** (Syn: Hydatid thrill): A sign elicited in cases of hydatid cystic disease. It is due to displacement of daughter cysts in the fluid of the mother cyst.
24. **Boas sign:** An area of hyperaesthesia, posteriorly extending 2.5 cm lateral to the spinous process of vertebrae to the posterior axillary line and vertically from the level of the 11th dorsal to the 1st lumbar spine—A definitive sign of the presence of cholecystitis.
25. **Blumberg sign** (Syn: Rebound tenderness; Release sign): It is a sign of peritonitis due to presence of an inflamed organ underneath it.
26. **Bonnet's sign:** Pain on thigh adduction in sciatica.
27. **Boston's sign** (Syn: von Graefe's sign): It constitutes the lid lag elicited in cases of thyrotoxicosis.
28. **Bowler's hat sign** (Syn: Double ring sign): A radiological sign which describes the appearance of a gastric polyp seen on end-on position in a double contrast barium meal study. There will be a central lucency with two rims of barium around. May also be seen in cases of sessile intestinal polyp or a diverticulum.
29. **Boyce's sign:** A gurgling sound heard on pressure by the hand on the side of neck, in cases of oesophageal diverticulum.
30. **Bozzolo's sign:** A visible pulsation of the arteries in the nostrils. A sign believed to indicate the presence of aneurysm of the thoracic aorta.
31. **Branham sign** (Syn: Nicoladoni sign): This sign is elicited when arteriovenous fistula is suspected. A pressure on the artery proximal to the fistula will cause:
  - a. Reduction in size of the swelling.
  - b. Disappearance of bruit.
  - c. Fall in pulse rate.
  - d. Pulse pressure returns to normal.
32. **Brodie's sign:** A black spot on the glans penis—a sign of gangrene due to urinary extravasation into the corpus spongiosum.
33. **Bald fundus sign:** A radiological sign described for atrophic gastritis. The fundus of the stomach looks like a small dome with absence of mucosal pattern indicated by a very thin smooth appearing gastric wall.
34. **Bent inner tube sign:** A radiological sign described for sigmoid volvulus—an important diagnostic sign. A plain X-ray abdomen taken in the supine position reveals a massively distended ahaustral sigmoid colon arising from the pelvic loop.
35. **Bird of prey sign:** A radiological (Barium enema) sign which helps in confirming the diagnosis in doubtful cases of sigmoid volvulus. Barium enema reveals a smooth tapered narrowing at the point of torsion of the colon. Mucosal folds show a screw pattern around the point of twist.
36. **Border sign:** Describes the appearance of ventral hernia in barium study follow through done in suspected cases, in the postoperative period. Lateral and inferior border of the hernia are sharply outlined while the medial and upper border blends with the abdominal shadows.

37. **Cardarelli's sign:** Transverse pulsations in the laryngotracheal tube in suspected cases of aneurysms and dilatation of the aortic arch.
38. **Chvostek's sign** (Syn: Chvostek Weiss sign; Schultze's sign): A clinical sign typically described for hypocalcaemic tetany. The sign is elicited by tapping over the muscles and/or superficial nerves to induce the muscle spasm. It may be:
  - a. **Facial sign:** A light tap over the facial nerve branches in front of the ear lobe causes muscular twitching over the whole of that side of the face.
  - b. **Peroneal sign:** Tapping the peroneal nerve near the fibular neck will cause dorsiflexion and abduction of the foot.
39. **Cobra head sign** (Adder head appearance): A radiological sign seen in cases of ureterocele—congenital dilation of lower end of ureter. Urography done in suspected cases produces a characteristic appearance which resembles a cobra head and hence the name.
40. **Crescent sign:** A radiological sign described in relation to two different conditions affecting the lungs and the kidneys:
  - a. In plain chest X-ray taken in a patient suspected of hydatid disease or aspergilloma (fungus ball) of the lung reveals a crescent of air in the shadow of partially ruptured hydatid cyst or in the cavity containing fungus ball.
  - b. On IVP, the nephrogram reveals a crescent sign in cases of congenital hydronephrosis.
41. **Cullen's sign** (Syn: Cullen Hofstatter sign): A clinical sign which was typically and initially described for ruptured ectopic pregnancy wherein there is discolouration (ecchymosis) of the umbilicus and the surrounding skin (aptly referred to as umbilical black eye). It is due to haemoperitoneum and may be seen in conditions like ruptured ectopic pregnancy (a bluish tinge), acute haemorrhagic pancreatitis (a yellowish tinge).
42. **Carman's sign** (Syn : Carman-Kirklin meniscus sign): A radiographic sign helpful in the analysis of gastric ulcers in barium meal study. It is a reliable indicator of malignancy. Nonprojecting ulcers lying intraluminal in all projections surrounded by an elevated rim of tumour produces a curval interface resembling a meniscus and is called Carman's meniscus sign. Whether the meniscus is convex or concave towards the lumen is mainly dependent upon the site of ulcer in relation to incisura angularis. Meniscus is concave towards the lumen in cases of ulcer being proximal to the incisura while it is convex when the ulcer is distal to the incisura.
43. **Carnett's sign:** A clinical sign which helps differentiate the plane of abdominal swelling. The abdominal wall muscle is made tense by asking the patient to raise both the legs with knee extended. If the lump is intraperitoneal it disappears or becomes less prominent, while it becomes prominent or persists when the lump arises from the abdominal wall.
44. **Chilaiditi's sign** (Syn: Chilaiditi's syndrome; Hepatoptosis): A radiological sign seen in plain X-ray abdomen which is helpful in the diagnosis of this syndrome wherein there is interposition of colon between liver and diaphragm. It needs to be differentiated from the conditions causing gas under the diaphragm. The presence of haustrations in the gas shadow in a plain X-ray abdomen tilts the favour in the diagnosis of Chilaiditi's syndrome.
45. **Coiled spring sign:** A radiological sign (Barium enema) classically described for intussusception. The passage of barium beyond the apex of the intussusception into the intussusciptien gives a coiled spring appearance. The sign may also be seen in cases of:
  - a. Post-traumatic haematoma of duodenum.
  - b. Acute appendicitis.
  - c. Mucocele of appendix.
  - d. Endometriosis of appendix.
  - e. Intestinal carcinomas.
46. **Coles' sign:** A radiological sign. Barium meal follow through study reveals deformity of the duodenal contour in the presence of duodenal ulcer.
47. **Colon cut off sign:** A radiographic sign of appendicular perforation or colonic spasm. Absence of gas and feces in the right lower quadrant, reflex dilatation of transverse colon and sharp cut-off of gas at the hepatic flexure. This sign is also seen in acute pancreatitis
48. **Coopermail's sign:** Ecchymosis on the perineum and scrotum/labia. A sign of fracture pelvis.
49. **Cope's sign** (Syn: Psoas sign): Clinical signs which are relevant in cases of acute appendicitis. This has two tests:
  - a. **Cope's psoas test:** In acute appendicitis there is psoas muscle spasm secondary to the inflamed organ and hence the patient keeps the thigh in a flexed position. This pain can be aggravated by passively hyper-extending the hip joint which stretches the psoas muscle.
  - b. **Cope's obturator test:** Principles are same as above except the muscle involved is obturator internus which is passively stretched by internally rotating the right leg which is flexed at the hip and knee.
50. **Cupola sign:** A radiological sign helpful in the diagnosis of pneumoperitoneum. A plain X-ray abdomen (erect position) reveals gas under the diaphragm when there is relatively large amount of air in the peritoneal cavity—Cupola sign.
51. **Crow foot sign** (Syn: Mercedes Benz sign; Seagull's sign): A radiological sign described in relation to cholelithiasis (Gallstones). Nearly 80–90% of the gallstones are radiolucent with only 10–20% being radio-opaque. However, rarely a non-opaque gallstone can be diagnosed in plain radiography by the presence of gas containing crevices within the stone. These radiolucent crevices give the appearance of the crow foot; Hence the name crow foot sign, Mercedes Benz sign or the Seagull's sign.
52. **Courvoisier's sign** (Syn; Courvoiser's law): In a patient with obstructive jaundice, if the gallbladder is palpable it is not due to gallstones.
53. **Cowen's sign:** A clinical sign elicited in cases of Graves' disease. In response to a light shone on one eye there is jerky constriction of the contralateral pupil.
54. **Crowe's sign:** Refers to axillary freckling seen in neurofibromatosis.
55. **Cruveilhier's sign** of the saphena varix: A clinical sign elicited in cases of varicose veins (Saphena varix). A thrill is felt over the saphena varix when the patient is asked to perform a Valsalva manoeuvre/cough in an erect position and is due to a jet of blood entering and filling the pouch.
56. **Coleman's sign:** Helps in the clinical evaluation of fracture mandible. There is obvious swelling and bruising over the bony injury and a haematoma in the floor of the mouth if the body of the mandible is fractured.

57. **(Meniscus) Claw sign:** A radiological sign (Barium study) diagnostic of ileo-colic intussusception. The barium in the intussuscipten is seen as a claw around the negative shadow of the intussusceptum.
58. **Coffee bud sign:** It is a radiological sign seen in volvulus of sigmoid colon.
59. **Dalrymple's sign:** It is one of the manifestations of Graves' ophthalmopathy. It consists of retraction of the upper eyelid so that the palpebral opening is abnormally wide and upper sclera is visible.
60. **Delbet's sign:** A prognostic indicator in cases of aneurysm of the main artery of the limb. If the nutrition of the part distal to the aneurysm is maintained then the collateral circulation is said to be sufficient even though the distal pulse is not felt.
61. **de Musset's sign:** Rhythmical jerking movement of the head with each heart beat and is seen in cases of aortic insufficiency and aortic aneurysm.
62. **Dance sign** (Syn: Signe de Dance): A feeling of emptiness in the right iliac fossa—A sign of intussusception.
63. **Demarouay's sign:** Fixation or lowering of larynx during phonation and deglutition. A sign of syphilis of trachea.
64. **Dew's sign:** A clinical sign described in relation to the diaphragmatic hydatid abscess beneath the right cupola of the diaphragm. The area of resonance moves caudally with the patient in knee-elbow position.
65. **Dixon Mann's sign** (Syn: Mann's sign): In case of Graves' orbitopathy the two eyes appear not to be on the same level.
66. **Dorendorf's sign:** The sign identifies the fullness in the supraclavicular groove on one side in aneurysm of aortic arch.
67. **Double bubble sign:** A radiological sign described in cases of duodenal obstruction. A plain X-ray abdomen reveals two foci of gas, one in the stomach and the other in the duodenum—a sign of duodenal atresia. A similar feature is observed in the foetus in ultrasonography done in the antenatal period.
68. **Drummond's sign:** A whiff sound heard over the open mouth during respiration in cases of aortic aneurysm.
69. **DTP sign** (Syn: Distal tingling on percussion; Tinel's sign; Formication sign): A prognostic indicator which is helpful in the evaluation of nerve recovery following nerve injury. If percussion over the site of nerve injury causes tingling sensation in the distal end of the limb it suggests that the nerve injury was a partial one or it heralds the recovery from the nerve injury—a good prognostic sign.
70. **Dubois sign:** Shortness of the little finger in congenital syphilis.
71. **Duchenne's sign:** This clinical sign identifies the sinking of the epigastrium during inspiration (a paradox). It is classically seen in cases of paralysis of the diaphragm and in certain cases of hydropericardium (Pericardial effusion).
72. **Dupuytren's sign:** It is described in two conditions:
  - a. A crackling sensation on pressure over a sarcomatous bone.
  - b. In congenital hip dislocation, it refers to free up and down movement of the head of the femur.
73. **Dott's sign:** It is helpful in differentiating pain due to acute appendicitis and basal pneumonia with pleuritis. Compression of lower thorax from side to side elicits obvious distress when the lesion is above the diaphragm whereas in appendicitis it has no effect.
74. **Dock sign:** A radiological sign described in relation to coarctation of aorta. A chest X-ray PA view reveals rib notching on the inferior margins of 3rd-9th ribs while sparing the first two ribs and is indicative of collateral circulation developed in coarctation of aorta.
75. **De Weese sign:** A clinical sign helpful in cases presenting with history suggestive of intermittent claudications with palpable peripheral pulses. The patient is asked to exercise by walking or running sufficiently to bring on the pain. If prompt re-examination reveals absence of peripheral pulses it suggests that the pain was truly due to intermittent claudication.
76. **Echo sign:** A percussion sound resembling an echo which is heard over a hydatid cyst.
77. **Elliot's sign:** Refers to presence of indurated edge of a syphilitic skin lesion.
78. **Enroth's sign:** Identifies the abnormal fullness of the eyelids—a manifestation of Graves' orbitopathy.
79. **Escherich's sign** (Syn: Escherich's reflex): Described in relation to tetany, where percussion of the inner surface of the lips or tongue produces contraction of lips, tongue and masseter muscles.
80. **Ewart's sign:** It is said to be positive in cases of pericardial effusion if there is bronchial breathing and dullness on percussion at the lower angle of the left scapula and is due to pressure and collapse of the lingular lobe due to enlarged pericardial sac.
81. **E-sign** (Syn: Reverse 3 sign): A radiological sign seen on barium swallow radiograph in patient suspected of coarctation of aorta and is due to indentation produced on the barium filled oesophagus by the aorta.
82. **Figure of three sign:** A radiological sign seen in the plain chest X-ray PA view in patient with coarctation of aorta. A pair of bulges is seen in the wall of the aortic arch one above and one below the aortic knuckle and is due to pre- and post-stenotic dilatation of the aorta.
83. **Frostberg's sign:** A radiological sign seen in barium study in carcinoma of the head of pancreas involving the duodenum. In carcinoma of the head of the pancreas, there is widening of the 'C' loop of the duodenum and with the involvement of the ampulla of Vater, the expanded loop assumes a reversed 3 configuration—Frostberg's sign. Once the carcinoma of the head affects the duodenum the surgical cure is remote.
84. **Fox sign:** Discolouration near the inguinal ligament—seen in few cases of haemorrhagic pancreatitis.
85. **Fuchsig's sign** (Syn: Crossed leg test): This sign is more relevant when popliteal artery is not clinically palpable along with absent distal pulses. The patient is made to sit with his legs crossed. Normally, oscillatory movements of the foot occur synchronously with the pulse if the popliteal artery is patent while a negative result is more suggestive of popliteal artery block in a patient with absent distal pulses.
86. **Federici's sign:** An interesting sign described in relation to pneumoperitoneum (due to intestinal perforation) wherein on auscultation of the abdomen, the cardiac sounds can be heard.
87. **Flush tank sign:** A clinical sign described in relation to hydronephrosis. The patients classically present with features suggestive of Dietle's crisis, i.e. passage of a large amount of urine with consequent disappearance of a lumbar swelling—Flush tank sign.

88. **Flare sign:** The precursor of varicose ulcer is a splay of fine venules that courses from the medial (sometime the lateral) malleolus, and spreads out to be lost beneath the thick skin of the heel and is known as the “Flare sign”.
89. **Gifford’s sign:** A clinical sign which helps in differentiating unilateral exophthalmos and proptosis due to intraorbital tumours. If the upper eyelids cannot be easily everted on the affected side, the exophthalmos is more likely to be due to thyrotoxicosis, whereas if the lid is easily everted it is more likely due to an intraorbital mass.
90. **Grey Turner sign:** Skin discolouration (bruising) in the left flank (left costovertebral angle) in cases of acute haemorrhagic pancreatitis.
91. **Gilbert’s sign:** Opsuria indicative of hepatic cirrhosis (opsuria means excretion of urine more rapidly during fasting than after a meal).
92. **Glasgow’s sign:** A clinical sign—presence of systolic murmur over the brachial artery is found in latent aortic aneurysm.
93. **Griffith sign:** It is one of the clinical signs of Graves’ orbitopathy wherein there is lower lid lag on upward gaze.
94. **Guyon’s sign:** Ballottement and palpation of a floating kidney.
95. **Gaur sign:** A clinical sign seen in femoral hernia. Distension of superficial epigastric and/or circumflex iliac veins on the affected side due to pressure on these vessels by the hernial sac.
96. **Guerin’s sign:** Haematoma at greater palatine foramen seen in maxillary fracture.
97. **Homan’s sign:** Pain on sudden dorsiflexion of the foot—a sign of deep vein thrombosis of calf veins.
98. **Hamilton Bailey sign:** A clinical sign described for intussusception. A sausage shaped mass with concavity towards the umbilicus which is felt to harden as a wave of peristalsis commences.
99. **Hall’s sign:** This sign identifies a tracheal diastolic shock felt in the aneurysm of aorta.
100. **Hatchcock’s sign:** Refers to the tenderness towards the angle of the jaw in mumps.
101. **Haudek’s sign** (Haudek’s niche): A radiological sign identified in barium meal X-ray done in patient suffering from gastric ulcer. It describes a projecting shadow (niche) in radiographs due to settlement of barium in pathological niches of stomach wall.
102. **Hitzelberger’s sign:** A clinical sign described in case of acoustic neuroma wherein there is anaesthesia of medial, posterior or superior areas of the external auditory canal because of the tumour tissue compressing on the facial nerve.
103. **Hook sign:** This clinical sign identifies flexion of fingers in a case of acute suppurative tenosynovitis.
104. **Horn’s sign:** This sign identifies the pain produced by traction on the right spermatic cord in acute appendicitis.
105. **Howship Romberg sign:** A sign described in the patients suffering from obturator hernia. The patient complains of pain passing down the inner side of the knee due to pressure on the obturator nerve by the hernial sac.
106. **Harvey’s sign:** Two index fingers are placed by the side on a vein. The fingers are now pressed firmly and the finger near the heart is moved proximally keeping the steady pressure on the vein so as to empty the short length of vein between the two fingers. The distal finger is now released. This will allow venous refilling to be observed which will be poor in ischemic limb and increased in arteriovenous fistula.
107. **Hamman’s sign** (Syn: Hamman’s mediastinal crunch or murmur): A clinical sign—precordial crunching, clicking or knocking sound synchronous with each heart-beat heard on auscultation in conditions such as:
  - ▶ Acute mediastinitis
  - ▶ Pneumomediastinitis
  - ▶ Pneumothorax.
108. **Inflammatory signs** (Syn: Cardinal signs in inflammation):
  - ▶ Rubor—Redness
  - ▶ Calor—Temperature
  - ▶ Dolor—Pain
  - ▶ Tumour—Oedema/swelling
  - ▶ Functio lesa—Loss of function
109. **Jendrassik’s sign:** Paralysis of extraocular muscles—A manifestation of Graves’ orbitopathy.
110. **Jugular sign** (Syn: Quekenstedt’s sign; Tobey Ayer test): On spinal canal block (e.g. spinal tumour) when pressure is applied over jugular veins, in the manometer connected to LP needle, either pressure will not raise or if raises falls slowly.
111. **Joffroy’s sign:** Absence of wrinkling of the forehead when the head is bent down and the patient is asked to look upwards—A sign of Graves’ ophthalmopathy.
112. **Kernig’s sign:** A sign which is positive in meningitis. With the hip flexed, the knee is extended, normally it can be done upto 175°. In meningitis it is restricted due to spasm of the hamstrings.
113. **Kaposi Stemmer sign:** Failure to pick up or to pinch a fold of skin at the base of the second toe. It is characteristic of lymph oedema.
114. **Kocher sign** (Syn: Mean’s sign): A sign of Graves’ orbitopathy. The examiner places one hand on a level with the patient’s eye and then lifts it higher. The upper eyelid springs up more quickly than the eyeball.
115. **Kanavel sign:** This sign is useful in the diagnosis of ulnar bursitis. In case of ulnar bursitis the site of maximum tenderness is over that part of the ulnar bursa lying between the transverse palmar creases.
116. **Kantor’s sign** (String sign of Kantor): A radiological sign described in barium enema follow through in patients suffering from Crohn’s disease. A string like configuration of contrast material through a filling defect is seen in the radiography.
117. **Kehr sign:** This sign identifies the pain elicited in the left shoulder in patients with suspected splenic rupture. The pain (referred pain) experienced by the patient is due to blood in the peritoneal cavity irritating the diaphragm.
118. **Klemm’s sign:** It is the radiological sign found in chronic appendicitis where there is often an indication of tympanitis in the right lower quadrant.
119. **Knie’s sign:** Unequal dilatation of the pupils—a sign of Graves’ orbitopathy.
120. **Krisowski’s sign:** Cicatricial lines radiating from the mouth in congenital syphilis.

121. **Kenawy's sign:** A clinical sign usually associated with bilharzial fibrosis of liver (Egyptian splenomegaly) but may be present in any type of portal hypertension. Auscultation over the xiphoid process reveals a venous hum (splenic vein engorgement) which becomes prominent on inspiration.
122. **Klein's sign** (of shifting tenderness): A clinical sign useful in acute nonspecific mesenteric lymphadenitis. When patient is shifted to left lateral position, point of maximum tenderness also gets shifted to the left side in contrast to acute appendicitis. It may also be positive in Meckel's diverticulitis.
123. **Lemon sign:** A radiological sign of Arnold-Chiari deformity. There is scalloping of the frontal bones giving the skull a lemon shaped configuration in sonography of the fetal skull during second trimester of pregnancy.
124. **Lenhoff's sign:** A furrow appearing on deep inspiration below the lower rib and above an echinococcal cyst of liver.
125. **Sign of Leser Trelat:** Sudden appearance and rapid increase in size and number of seborrhoeic keratoses, a sign of internal malignancy of the GIT.
126. **Lloyd's sign:** A clinical sign elicited in a patient with renal calculus. Pain elicited in the loin on deep percussion over the kidney even when there is no pain on applying deep pressure.
127. **London's sign:** It is useful in ruptured intestine suspected in an accident case. The presence of pattern of bruising of the skin (i.e. an imprint of the clothing is noted on the skin) indicates that a crushing force has been applied sufficient to rupture the bowel against the vertebral column. This sign is a strong indication to carry a laparotomy.
128. **Mallet Guy's sign:** A clinical sign identified in chronic relapsing pancreatitis. It is elicited by placing the patient in the right lateral position with the patient's hip and knee flexed and deeply palpating the abdomen in the epigastric and the left subcostal region. This will evoke tenderness in chronic relapsing pancreatitis.
129. **McBurney's sign:** Finger tip pressure is made over the McBurney point elicits severe tenderness in patients with appendicitis.
130. **Murphy's sign** (Moynihan's method): This clinical sign is classically described in patients suffering from cholecystitis. It is elicited by asking the patient to breath deeply while exerting moderate pressure with the left hand such that thumb lies over the fundus of the gallbladder. The patient catches his breath as the inflamed gallbladder which is pushed down by the diaphragm gets imposed against the thumb.
131. **McEwen's sign:** A clinical sign elicited in children with hydrocephalus. On percussion of skull behind the junction of frontal, parietal and temporal bones and auscultation over opposite mastoid bone there is a more resonant note than normal, seen in internal hydrocephalus and cerebral abscess in children (syn: cracked pot sign, cranial cracked pot sound).
132. **Meniscus sign:** Refer No. 57.
133. **Moebius sign:** Inability to keep the eyeballs converged due to insufficiency of medial rectus muscle— A clinical sign of Graves' ophthalmopathy.
134. **Milian's ear sign:** A clinical sign which is useful to differentiate facial erysipelas from cellulitis. Erysipelas being a cuticular lymphangitis spreads from the face to the pinna while the cellulitis which is spreading inflammation of the subcutaneous tissue stops short of pinna because of close adherence of the skin to cartilage.
135. **Mahler's sign:** A steady increase of pulse rate without corresponding increase of temperature seen in thrombosis.
136. **Mann's sign** (Syn: Dixon Mann's sign): In Graves' disease the two eyes appear not to be on the same level.
137. **Marie's sign:** Tremors of body extremities in Graves' disease and other types of hyperthyroidism.
138. **Mean's sign** (Syn: Kocher's sign): Refer No. 114.
139. **Medusa Lock sign:** A radiological sign described in patients with intestinal obstruction due to roundworm infestation. A plain X-ray erect film of the abdomen reveals trapped intestinal gas within the worm mass giving a characteristic appearance of coiled locks of hair—Medusa Lock sign.
140. **Meitzer's sign:** Loss of normal second heart sound on auscultation of the heart after swallowing. Seen in occlusion or contraction of lower part of oesophagus.
141. **Mercedes Benz sign** (Syn: Crow foot sign): Refer No. 51.
142. **Mexican hat sign:** A radiological sign described in barium enema (filling defect) done in patients with pedunculated polyp of the inferior wall of the colon.
143. **Maulage sign:** Waxy cast appearance of bowel segments—A radiographic sign of coeliac disease.
144. **Mose's sign:** A clinical sign suggestive of deep vein thrombosis. It is elicited by squeezing the relaxed calf muscles from side to side which is painful in case of deep vein thrombosis.
145. **Niche sign** (Syn: Haudek's sign): Refer No. 101.
146. **Nicoladoni's sign** (Syn: Branham's sign): Refer No 31.
147. **Oliver's sign** (Syn: Porter's sign; Tracheal tug): Tracheal tug is seen in:
  - ▶ Aneurysm of the aorta.
  - ▶ Neoplasm which fixes bronchus to aorta.
148. **Omega sign:** A radiological sign observed in patient suspected of sigmoid volvulus on the X-ray. A plain X-ray abdomen taken in the supine position shows a massively distended sigmoid colon with haustrations arising from the pelvis resembling Greek letter 'omega' ( $\omega$ ).
149. **Payr's sign:** Pressure over the sole of the foot elicits severe pain in cases of thrombophlebitis.
150. **Peroneal sign:** Tapping the peroneal nerve near the fibular neck causes dorsiflexion and abduction of foot in hypocalcaemic tetany.
151. **Perez's sign:** A friction sound heard over the sternum when the patient raises and drops his arms. A sign of mediastinal tumour or aneurysm of arch of aorta.

152. **Parrot's sign** (Syn: Parrot's nodes, hot cross bun skull, Natiform skull): Bony nodes on the outer table of the skull of infants with congenital syphilis, so that it has a hot cross bun or buttock shape.
153. **Pfuhl sign**: A clinical sign which helps in differentiating between subphrenic abscess and pyopneumothorax. Inspiration increases the force of flow in paracentesis in subphrenic abscess, but lessens in case of pyopneumothorax. This distinction is however lost in cases where diaphragm is paralyzed.
154. **Pitre's sign**: Hypoaesthesia of scrotum and testes in tabes dorsalis.
155. **Plummer's sign** (Syn: Quadriceps sign): Inability to step up onto the chair or to walk up steps seen in Graves' disease and other forms of hyperthyroidism.
156. **Pool Schlesinger's sign**: In tetany if patient's leg is held at the knee joint and flexed strongly at the hip joint, within a short time there will be an extensor spasm at the knee joint with extreme supination of foot.
157. **Porter's sign**: Tracheal tugging in aneurysm of aortic arch and neoplasms which fix the left bronchus to aorta.
158. **Potain's sign**: Extension of percussion dullness over the arch of the aorta from the manubrium to the third costal cartilage on the right side—seen in cases of dilatation of the aorta.
159. **Prehn's sign**: Elevation and support of the scrotum will relieve the pain in epididymo-orchitis but not in torsion testis.
160. **Psoas sign** (Syn: Cope's test): Refer No. 49.
161. **Puddle sign**: Describes a clinical method to detect small amount of ascites (150–500 ml). Patient lies prone for 5 minutes and then goes for knee-elbow position. In this position dullness is elicited in the umbilicus in case of minimal ascites.
162. **Pemberton's sign**: This sign refers to symptoms of faintness with evidence of facial congestion and external jugular vein distension when the arms are raised above the head touching the ears. This manoeuvre reduces the thoracic inlet thereby hampering venous drainage of the face in the presence of retrosternal thyroid.
163. **Pointing sign**: Ask the patient to point to the site of maximum pain. If this proves to be the site of localized tenderness it is also certainly the site of diseased organ, e.g. appendicitis.
164. **Patel's sign**: It is important in paralytic ileus. Apply the stethoscope firmly to the skin just below and right of the umbilicus for full 3 minutes. In paralytic ileus there will be ominous silence, broken by patient's own heart sounds believed to be transmitted via the over distended coils of the intestine with added succussion splashes if the patient moves and very occasionally by faint tinkles.
165. **Pad sign**: A radiological sign identified in patients with carcinoma of the head of pancreas wherein the 'C' loop of barium filled duodenum may be widened.
166. **Panda sign** (Raccoon sign, Spectacle haematoma, Black eye): Haemorrhages in soft tissues around the eye and in the eyelids is known as Panda sign as it resembles panda eyes. It is caused by:
1. Direct trauma, such as punch to the eye.
  2. Blunt impact to the forehead, the blood gravitating downwards over the supraorbital ridge.
  3. Fracture of the floor of the anterior fossa of the skull.
167. **Queckenstedt's sign** (Jugular sign; Tobey Ayer test): Refer No. 110.
168. **Quenu Muret sign**: A prognostic indicator. In aneurysm, when the main artery of the limb is compressed and a puncture is made at the periphery, if the blood flows, then the collateral circulation is probably established.
169. **Rat-tail sign**: A radiological sign described in relation to oesophageal carcinoma.
170. **Ridge sign**: A clinical sign of dehydration. In considerable dehydration if the skin is picked up in between the thumb and fingers and then released, instead of it springing back with normal elasticity, a ridge is formed that subsides slowly.
171. **Rovsing sign**: In acute appendicitis, when left iliac fossa is pressed; pain is felt in right iliac fossa.
172. **Release sign** (Syn: Rebound tenderness; Blumberg's sign): Refer No. 25.
173. **Reversed 3-sign**: Refer No. 81.
174. **Reisman sign** (Syn: Snellen's sign): The bruit heard over the closed eye in Graves' disease.
175. **Rocher's sign**: A clinical sign which helps in the differentiation of epididymitis from torsion of the testes. In torsion testes, the epididymis cannot be distinguished from the body of the testes, whereas in epididymitis the body of the testes can be felt in the enlarged crescent of epididymis.
176. **Rommelaere's sign**: An abnormally small proportion of normal phosphates and of sodium chloride in urine in cancerous cachexia.
177. **Rotch sign**: A clinical sign identified in case of pericardial effusion. Dullness is felt on percussion on the right 5th intercostal space.
178. **Rovighi's sign**: A fremitus felt on percussion and palpation of the superficial hepatic hydatid cyst.
179. **Raccoon sign** (Syn: Panda sign, Spectacle Haematoma, Black Eye): Refer No. 166.
180. **Sign of splashing** (Syn: Succussion splash): Seen in gastric outlet obstruction.
181. **Saegesser's sign**: A clinical sign identified in patients with splenic rupture. An excruciating tenderness is elicited in the Saegesser's point or splenic point (seen in the lower part of the posterior triangle of the neck between the left sternomastoid and scalenus medius muscle above the clavicle).
182. **Sternomastoid sign** (Syn: Trail's sign): The sternal head of the sternomastoid muscle will become more prominent on the side to which trachea is deviated.
183. **Saenger's sign**: Refers to the light reflex of the pupil that has ceased, returns after a short stay in the dark. Observed in cerebral syphilis but not in tabes dorsalis.
184. **Sansom's sign**: Described in two separate contexts:
- ▶ Marked increase in the area of dullness in the second and third intercostal space – Due to pericardial effusion.
  - ▶ A rhythmical murmur heard with a stethoscope applied to the lips in aneurysms of the thoracic aorta.
185. **Schlesinger's sign** (Syn: Pool's phenomenon): Refer No. 156.
186. **Schultze sign** (Syn: Schultze Chvostek sign): Refer No. 38.



187. **Silex's sign:** Furrows radiating from the mouth in congenital syphilis.
188. **Sisto's sign:** Constant crying in infancy—a sign of congenital syphilis.
189. **Setting sun sign:** A clinical sign described in patients suffering from raised intracranial tension. There is downwards deviation of the eyes so that each iris appears to set beneath the lower eyelid with white sclera exposed between it and the upper lid. This sign is observed in cases:
- ▶ Hydrocephalus
  - ▶ Intracranial haemorrhage
  - ▶ Brain tumours
190. **Snellen's sign** (Syn: Reisman sign): Refer No. 174.
191. **Summer's sign:** This sign is said to be positive when there is increase in the tone of the abdominal muscle on gentle palpation of the right iliac fossa. It may indicate:
- ▶ Appendicitis
  - ▶ Right ureteric or renal stones
  - ▶ Torsion ovarian cyst.
192. **Simon's sign:** Identifies absence of usual correlation between the movements of diaphragm and thorax, seen in early cases of meningitis.
193. **Stierlin's sign:** A radiological sign observed in barium enema study of the colon where there is absence of normal shadow due to an indurating or ulcerative process such as tuberculosis of caecum or colon.
194. **String sign** (Syn: Kantor's sign): Refer No. 116.
195. **Suker's sign:** Deficient complementary fixation in lateral eye rotation—a manifestation of Graves' orbitopathy.
196. **String of beads sign:** A series of round shadows resembling a string of beads or pearls, seen on a radiograph of small intestine, indicating of trapped gas surrounded by the fluid of obstructed and distended bowel.
197. **Stellwag's sign:** Identifies the widening of palpebral fissures (staring look) due to retraction of upper eyelids, an early sign of Graves disease.
198. **Stemmer sign** (Kaposi Stemmer sign): Refer No. 113.
199. **Slip sign:** A clinical sign which helps in differentiating a solid swelling, e.g. lipoma, from a cystic swelling. Here, when the edge of the swelling is palpated, the margin of the solid swelling does not yield but slips away from it unlike a cystic swelling which yields to the pressure of the palpating finger and does not slip away.
200. **Solius sign:** A radiological finding observed in a chest X-ray lateral view in patient's with enlarged thymus. An enlarged thymus being a firm swelling does not get flattened against sternum by the pressure of heart and great vessels.
201. **Shrinkage sign:** A radiological sign of thymus enlargement. In a chest X-ray there is a paradoxical alteration of the shape of the chest with respiration (Decrease in transverse diameter with deep inspiratory film than the expiratory film).
202. **Seagull sign:** Refer No. 51.
203. **Suzmann's sign:** A clinical sign described in patient with coarctation of aorta. The collaterals which develop display visible and palpable pulsations together with thrills and murmurs which are most obvious in the inter-scapular and infra-scapular regions of the back. The Dock sign is the radiological counterpart of this sign.
204. **Trail's sign** (Syn: Sternomastoid sign): Refer No. 182.
205. **Tap sign** (Syn: The percussion sign; Chevrier's sign): If the valves are incompetent an impulse will be felt by the fingers overlying the long saphenous vein when the varicosities are percussed below.
206. **Thornton's sign:** Refers to the severe pain complained by the patient in the region of the flanks in nephrolithiasis.
207. **Tinel's sign** (Syn: DTP sign; Formication sign): Refer No. 69.
208. **Tresilian sign:** This sign identifies reddish appearance (congestion) in opening of Stensen's duct in cases of mumps.
209. **Trimadeau's sign:** A radiological sign identified in barium swallow X-ray done in patient's with dysphagia. If the dilatation above an oesophageal stricture is conical, the stricture is fibrous; while it is cup shaped (shouldering) it is likely to be malignant.
210. **Tanyol's sign:** In ascites umbilicus shifts downwards and in mass arising from pelvis it shifts upwards.
211. **Troisier's sign:** Identifies enlargement of left supraclavicular lymph node (Virchow's node). Seen in:
- ▶ Ca stomach
  - ▶ Ca testes
  - ▶ Ca bronchus
  - ▶ Malignancy of any other abdominal organ.
212. **Trousseau's sign:** This sign is described under two different context:
- ▶ The blood pressure cuff is applied to the arm and inflated to pressure above systolic pressure for 3–5 minutes. This will elicit typical carpopedal spasm (obstetrician's hand) in cases of hypoparathyroidism and other conditions associated with hypocalcaemia.
  - ▶ Migrating superficial thrombophlebitis—a sign of visceral carcinomas especially of pancreas or the stomach.
213. **Tracheal fluctuation sign:** A unique sign elicited in patients suffering from achalasia cardia.
214. **von Graefe's sign** (Syn: Graefe's sign): Persistent lagging of upper lid behind the corneoscleral limbus when patient is asked to follow the finger moved up and down several times. Seen in Graves' disease.
215. **Vermooten's sign:** A clinical sign helpful in the intrapelvic rupture of urethra. On per rectal examination, the prostate cannot be felt but in its position a doughy swelling (blood and urine) is felt. If prostate is felt, it is displaced upwards.
216. **Vas sign:** This sign is helpful in differentiating testicular neoplasm and an inflammatory lesion of the testes. Inflammatory lesions causes vas deferens to become considerably thickened which remains normal in cases of neoplasm.

217. **Vein sign:** A bluish cord along the mid-axillary line formed by the swollen junction of the thoracic and superficial epigastric vein. Seen in:
- ▶ Tuberculosis involving the bronchial glands
  - ▶ Superior vena cava obstruction.
218. **Wegner's sign:** A postmortem finding—A broadened discoloured appearance of the epiphyseal line in infants who have died from congenital syphilis.
219. **Wilder's sign:** An early clinical sign of Graves' disease consisting of slight twitch of the eyeball when it changes its movement from adduction to abduction or vice versa.
220. **Wimberger's sign:** Symmetrical erosions of the proximal tibia seen radiographically in infants with congenital syphilis.
221. **Water lily sign** (Syn: Lily pad sign): A radiological sign identified in cases of hydatid cyst of the lung. When the hydatid cyst ruptures, the daughter cyst floating within the cavity appear like a water lily hence the name water lily sign.
222. **Smith's sign:** Murmur heard in cases of enlarged bronchial lymph nodes on auscultation over the manubrium with the patients head thrown backwards.
223. **'H' Bomb sign:** A radiological sign seen in cases of atrophic gastritis. The gastric folds within fundus and the body of stomach are very thin and the thin walled fundus becomes distended with air (in erect posture) or with barium contrast.

## B. Triads in Surgery

- Saint's triad:**
  - Diverticulosis of colon
  - Gallstones
  - Hiatus hernia.
- Whipples' triad:** Seen in insulinoma.
  - Features of hypoglycaemia
  - Blood sugar less than 45 mg%
  - Symptoms are relieved by glucose.
- Charcot's triad:** Seen in ascending cholangitis.
  - Intermittent fever
  - Intermittent pain
  - Intermittent jaundice.
- Virchow's triad:**
  - Change in the vessel wall
  - Diminished rate of blood flow
  - Increased blood coagulability.
- Murphy's triad:** Seen in acute appendicitis.
  - Pain in right iliac fossa
  - Vomiting
  - Temperature.
- Hutchinson's triad:** Seen in late congenital syphilis
  - Interstitial keratitis
  - 8th nerve deafness
  - Hutchinson's teeth.
- Trotter's triad:** Seen in nasopharyngeal carcinoma.
  - Conductive deafness
  - Elevation and immobility of same side soft palate
  - Pain in the side of the head.
- Tillaux's triad:** Seen in mesenteric cyst.
  - Soft fluctuant swelling in the umbilical region
  - Freely mobile in the direction perpendicular to mesentery
  - Zone of resonance all around.
- Triad of portal hypertension:**
  - Varices
  - Splenomegaly
  - Ascites.
- Cushing's triad:** In intracranial hypertension.
  - Increased blood pressure
  - Decreased pulse rate
  - Decreased respiratory rate.
- Triad of renal cell carcinoma:**
  - Anaemia
  - Haematuria
  - Mass in the loin.
- Borchardt's triad:** Seen in gastric volvulus
  - Acute epigastric pain
  - Violent vomiting
  - Inability to pass nasogastric tube.
- Beck's triad:** Seen in cardiac tamponade.
  - Muffled heart sounds
  - Distended neck veins
  - Hypotension.
- Pancoast's triad:** Seen in Pancoast tumour.
  - Excruciating pain in the arm
  - Horner's syndrome
  - Erosion of ribs.
- Prune-Belly triad:** Seen in Prune-Belly syndrome.
  - Cryptorchidism
  - Abdominal wall defects
  - Genitourinary defects.
- Mackler's triad:** Seen in Boerhaave's syndrome.
  - Vomiting
  - Chest pain
  - Subcutaneous emphysema.
- Triad of Sandblom:** Seen in haemobilia
  - Jaundice
  - Pain
  - Melaena.
- Galezia triad:**
  - Dupuytren's contracture
  - Retroperitoneal fibrosis
  - Peyronie's disease of penis.
- Dieulafoy's triad:** Seen in appendicitis
  - Hypersensitiveness of skin
  - Reflex muscular contraction
  - Mac Burney's tenderness.
- Triad of congenital diaphragmatic hernia**
  - Respiratory distress
  - Apparent dextrocardia
  - Scaphoid abdomen.
- Carney's triad**
  - Functioning adrenal para ganglioma—nonfamilial
  - Gastric leiomyosarcoma—GIST
  - Pulmonary chondroma.
- Triad of Ohashi in IPMN in ERCP**
  - A bulging ampulla of Vater
  - Mucin secretion
  - Dilated main pancreatic duct.
- Haimovici triad of revascularisation of an acutely ischaemic limb**
  - Muscle infarction
  - Myoglobinuria
  - Acute renal failure.
- Triad of small bowel obstruction in plain X-ray**
  - Dilated small bowel loops >3 cm
  - Multiple air fluid levels in erect X-ray
  - Paucity of air in the colon.
- Gilroy Bevan triad of adhesive pain is**
  - Pain may get aggravated or relieved on change of posture
  - Pain in the region of old abdominal scar
  - Tenderness is elicited by pressure over the scar.

## C. Misnomers in Surgery

1. *White bile*: It is neither white nor bile. It is opalescent. It contains mucous. It signifies severe obstructive jaundice due to which secretion of bile from liver is stopped. Mucous is derived from biliary tree lining.
2. *Mycotic aneurysm*: It is not due to fungal infection. It is due to bacterial infection.
3. *Lateral aberrant thyroid*: It is not an aberrant thyroid. It is secondaries in neck lymph node from occult primary in the thyroid, i.e. papillary carcinoma thyroid.
4. *Adenolymphoma of parotid gland*: It is not lymphoma. It is a benign tumour of the parotid. It never turns into malignancy.
5. *Pre-tibial myxoedema*: It is not seen in myxoedema. It is seen in thyrotoxicosis.
6. *Sternomastoid tumour*: It is not a tumour. It is due to birth trauma which causes organised haematoma in sternomastoid muscle.
7. *Dissecting aneurysm*: It is aortic dissection, not dissecting aneurysm.
8. *Malignant hydatid*: It is not malignant. It is due to *Echinococcus alveolaris*. It behaves like a malignant condition.
9. *Malignant exophthalmos*: It is due to primary thyrotoxicosis. It is not a malignant condition.
10. *Spina ventosa*: It is tuberculous dactylitis. It is not related to spine.
11. *Mycosis fungoides*: It is cutaneous "T" cell lymphoma. It is not due to fungal infection.
12. *Hypernephroma*: It is renal cell carcinoma. It is not above the kidney.
13. *Hepatoma*: It is hepatocellular carcinoma. It is not benign tumour.
14. *Melanoma*: It is melanocarcinoma. It is not benign.
15. *Surgical ganglion*: It is arising from the synovial sheath. It is not from nerve ganglion.
16. *Brain fungus*: It is not a fungal infection. It is seen in cranial injury wherein due to injury brain protrudes out of the wound as fungus.
17. *Cock's peculiar tumour*: It is not a tumour. It is ulcerated sebaceous cyst. It mimics SCC of skin.
18. *Pott's puffy tumour*: It is not a tumour. It is osteomyelitis of the frontal bone with cellulitis of the frontal region of the scalp. It may spread intracranially through emissary veins which endangers the life of the patient.
19. *Tumour alba*: It is tuberculosis of synovial sheath of knee joint.
20. *Umbilical adenoma*: It is not a tumour. It is prolapse of mucosa of cutaneous end of vitello-intestinal duct
21. *Madelung's deformity*: It is not associated with any of the conditions in the lung. It is a congenital subluxation or dislocation of the lower end of the ulna, from malformation of the bones.
22. *Ray fungus*: Actinomycoses, a bacteria infection.
23. *Malignant pustule*: Anthrax infection.
24. *Malignant oedema*: Gas gangrene.
25. *Juvenile melanoma*: It is not a melanoma. It is benign SPITZ naevus.
26. *Hydrocele of the neck*: It is cystic hygroma
27. *Kuttner tumour*: It is chronic sclerosing sialadenitis of submandibular salivary gland.
28. *Aneurysmal bone cyst*: It is not related to artery. It is expanding lesion in the bone containing blood mixed fluid of unknown aetiology.
29. *Hairy leucoplakia*: It is hairy leucoplakia with white confluent patches of fluffy / hairy hyperkeratotic thickening almost always situated in the lateral border of the tongue. It is not hair in tongue; not related hair diseases; not structurally hair component.

## D. Triangles in Surgery

- Hesselbach's triangle:** The medial border of the triangle is formed by the rectus sheath, superolateral border by the inferior epigastric artery, inferior border by the inguinal ligament.

*Importance:* Helps in differentiating direct from indirect hernias.
- Bryant's triangle:** Patient lies in supine position, three lines are drawn, one from the anterior superior iliac spine vertically down to the bed; another from the tip of the greater trochanter to join the first line at the right angles; third line from anterior superior iliac spine to the tip of the greater trochanter—this forms a triangle.

*Importance:* Diminution in the length of the second line indicates upward displacement of the greater trochanter. Third (oblique) helps determine the anteroposterior displacement of the greater trochanter.
- Triangle of Doom:** Bounded by the ductus deferens medially, spermatic vessels laterally in the male and the apex of the triangle is at the level of internal inguinal ring.

*Importance:* External iliac artery and vein, femoral nerve are located in the triangle and so stapling is avoided in this triangle while doing laparoscopic preperitoneal repair for hernia.
- Calot's triangle:** Formed medially by the common hepatic artery, laterally by the cystic duct and the apex is formed by the junction of the cystic and the hepatic ducts. Base is formed by the cystic artery.

*Importance:* Cystic lymph node of 'Lund' is present in the fork created by the junction of the cystic and common hepatic artery.
- Anal triangle and urogenital triangle:** A transverse line joining the anterior parts of the ischial tuberosities and passing immediately anterior to the anus divides the perineum into two triangles, anal and urogenital triangle. Anal triangle contains the termination of the anal canal in the median plane and an ischiorectal fossa on each side.

*Importance:* Both the perineal and ischiorectal spaces in the anal triangle are common sites of abscess.
- Femoral triangle:** It is triangular depression on the front of the upper one-third of the thigh below the inguinal ligament, bounded medially by the medial border of adductor longus, laterally by the medial border of sartorius, apex is formed by the meeting point of the medial and lateral boundaries.

*Importance:* Femoral vein in this site is most suitable for intravenous injection in the infants; femoral artery pulsations are an important aid for clinicians (in diagnosing peripheral vascular disease).
- Lumbar triangle:**

  - Inferior lumbar triangle of Petit**—bounded by the crest of ilium below, external oblique laterally and medially by the latissimus dorsi.

*Importance:* Most primary lumbar hernia occur through this triangle.
  - Superior lumbar triangle of Grynfelt**—bounded by the 12th rib above, medially by the sacrospinalis and laterally by the posterior border of the inferior oblique.

*Importance:* Grynfelt hernia appears through superior lumbar triangle.
- Triangle of auscultation:** This is a small triangular interval bounded medially by the lateral border of the trapezius, laterally by the medial border of the scapula and inferiorly by the upper border of latissimus dorsi. Floor of the triangle is formed by the 7th rib, 6th and 7th intercostal spaces and *rhomboids minor*.

*Importance:* This is the only part of the back which is not covered with muscles. Respiratory sounds are better heard with a stethoscope here than that heard elsewhere in the back.

On the left side, the cardiac end of the stomach lies deep to this triangle and in days before X-rays were discovered, sounds of swallowed liquids were auscultated over this triangle.
- Simon's triangle:** Bounded anteriorly by the recurrent laryngeal nerve, posteriorly by the common carotid artery and base is formed by the inferior thyroid artery.

*Importance:* Aids in identification of the recurrent laryngeal nerve.
- Lumbosacral triangle of Marcille:** It is a triangular interval on each side of the body of the 5th lumbar vertebra, bounded medially by the body of the 5th lumbar vertebra, laterally by the medial border of the psoas muscle, apex by the junction of the psoas major muscle and the body of the 5th lumbar vertebra. Base is formed by the upper surface of the ala of the sacrum and floor by the transverse process of the 5th lumbar vertebra and the iliolumbar ligament.

*Importance:* Ureter crosses the common iliac vessels at the lateral angle of the triangle.
- Retromolar trigone:** Base overlies the ascending ramus of the mandible from the last molar, apex terminates at the maxillary tuberosity, laterally continuous with the buccal mucosa and medially blends with the anterior tonsillar pillar.

*Importance:* Common site for oral malignancy.
- Sherren's triangle:** Bounded by the umbilicus, symphysis pubis and the anterior superior iliac spine.

*Importance:* Indicates the area of hyperaesthesia in an acute episode of appendicitis.
- Scalene triangle:** Bounded by scalenus anticus anteriorly, scalenus medius posteriorly and first rib inferiorly.

*Importance:* Subclavian artery and trunks of the brachial plexus pass through the scalene triangle where they may be compressed causing thoracic outlet syndrome.

## E. Drugs at a Glance

*Remember how much you do not know. Do not pour strange medicines into your patients.*

—William Osler, 1903

### ■ ANTIBACTERIALS

*It seems likely that in the next few years a combination of antibiotics with different antibacterial spectra will furnish a “cribrum therapeuticum” from which fewer and fewer infecting bacteria will escape.*

—Alexander Fleming, 1946

### ■ SULFONAMIDES

They act by inhibiting folic acid synthetase which converts PABA to folic acid.

*Side effects:* Intolerance, crystalluria, agranulocytosis, goitre, neuritis, jaundice.

---

#### *Drugs*

Sulfadiazine: 1 gm 6th hourly.

Sulfamethizole: 200 mg 6th hourly.

Sulfadimidine: 1 gm 6th hourly.

Sulphamethoxazole:

Sulfaguanidine: 3 gm 6th hourly.

Sulfamethoxale: 1 gm 6th hourly.

Used in meningitis, UTI, chancroid, trachoma, ulcerative colitis, toxoplasma, Bacillary dysentery.

Silver sulphadiazine cream 1% for burns.

Sulphacetamide as ophthalmic solution.

---

**Cotrimoxazole:** Combination of trimethoprim and sulfamethoxazole in a ratio of 1 : 5 in different strengths

Trimethoprim inhibits dihydrofolate reductase enzyme which converts dihydrofolate into tetrahydrofolate. It has got synergistic action with sulphamethoxazole.

It is used as BID dose in typhoid, plague, UTI, prostatitis.

*Side effects:* Severe skin reactions, megaloblastic anaemia.

### ■ QUINOLONES

They act by interfering with the synthesis of DNA.

They are useful against gram-negative organisms, enteric fever, respiratory infections, gastroenteritis, urinary infections, tuberculosis.

*Side effects:* Allergic reactions, CNS manifestations, hallucinations, nephritis, arrhythmias.

---

#### *Drugs*

Nalidixic acid 1 gm 6th hourly.

Norfloxacin 400 mg BD for 10 days.

Ciprofloxacin 500 mg BD for 10–14 days.

Pefloxacin 400 mg BD.

Ofloxacin 200 mg OD or BD for 10–14 days.

Lomefloxacin 400 mg OD.

Sparfloxacin 200 mg BD.

Levofloxacin 500 mg OD for 7–14 days.

Gatifloxacin 200 mg OD.

---

### ■ PENICILLIN

It acts by interfering with the cell wall synthesis of bacteria.

Used in *Streptococcus*, *Pneumococcus*, *Meningococcus* and gonococcal infections, syphilis, tetanus, gas gangrene, actinomycosis, plague.

It is also used as prophylaxis in rheumatic fever. It is used in pelvic infections, lymphoedema.

*Side-effects:* Anaphylaxis, serum sickness, Jerisch-Herxheimer reaction.

**Drugs:**

Benzyl penicillin. 4–10 lakhs 4th or 6th hourly intravenously after test dose.

Procaine-penicillin 4–10 lakhs IM after test dose OD for 7–14 days.

Benzathine penicillin 12–24 lakhs deep IM into the buttocks after test dose once in 3 weeks.

**■ AMPICILLIN/AMOXYCILLIN/TALAMPICILLIN/PIVAMPICILLIN**

Used in respiratory infections, meningitis, endocarditis, cutaneous infections.

It is not useful in penicillin-resistant staphylococci infections.

*Dose:* 500 mg 6th hourly.

**■ METHICILLIN**

It is a penicillin group of antibiotic which is used in penicillin resistant staphylococcal infections.

*Dose:* 1–2 gm. IM 6th hourly.

1 gm in 5–10 ml normal saline can be used as intrapleural or intra-articular therapy.

**■ CLOXACILLIN/DICLOXACILLIN/FLUCLOXACILLIN**

These drugs are used in penicillin resistant staphylococcal infections.

*Dose:* 500 mg 6th hourly.

**■ CARBENICILLIN/TICARCILLIN**

It is used in septicaemias, urinary tract infections mainly due to *Pseudomonas* and *Proteus* infections.

*Dose:* 1 gm 6th hourly IV.

**■ PIPERACILLIN/AZOCILLIN/MEZLOCILLIN**

It is active against *Pseudomonas*.

*Dose:* 2 gm 4th–6th hourly.

**■ CLAVULANIC ACID**

It is a beta lactamase inhibitor used against beta lactamase producing bacteria.

It is used along with amoxicillin/ticarcillin/ampicillin.

**■ SULBACTAM**

It is a beta lactamase inhibitor.

It is combined with ampicillin.

**■ TAZOBACTAM**

It is a beta lactamase inhibitor combined with piperacillin.

**■ CARBAPENEM/IMIPENEM/MEROPENEM**

These are bactericidal beta lactam antibiotic.

They are used in septicaemia, *Pseudomonas*, *Klebsiella* and *Proteus* infections.

**■ LINCOMYCIN/CLINDAMYCIN**

They act on bacterial ribosomal RNA.

*Side effect:* Pseudomembranous colitis.

*Dose:* 500 mg tds.

**■ VANCOMYCIN/TEICoplanin**

It inhibits cell wall synthesis.

*Side effects:* Nephritis, ototoxicity.

Used in pseudomembranous colitis.

*Dose:* 500 mg 6th hourly IV.

*He is the best physician who knows the worthlessness of many medicines.—Benjamin Franklin*

## ■ CEPHALOSPORINS

They are bactericidal. They inhibit bacterial cell wall synthesis.

Useful in most of the bacterial infections.

*Side effects:* Anaphylaxis, Hepatotoxicity, Nephrotoxicity.

<i>Ist Generation</i>	<i>IInd Generation</i>
Cephalexin 500 mg TDS oral. Cephadroxy 500 mg BD oral. Cephadrine 250 mg QID oral. Cephazolin 1 gm BD IV. Cephalothin 2 gm 6th hourly. Cepharin 2 gm 6th hourly.	Cefuroxime 500 mg BD oral. Cefaclor 500 mg 8th hourly. Cefamandone 2 gm 6th hourly. Cefoxitin 2 gm 8th hourly. Cefonicid 2 gm 6th hourly. Ceforanide 2 gm 12th hourly.
<i>IIIrd Generation</i>	<i>IVth Generation</i>
Cefetoxime 1 gm 6th or 8th hourly. Ceftriaxone 1 gm 12th hourly. Ceftizoxime 2 gm 8th hourly. Ceftazidime 2 gm 8th hourly. Cefaperazone 2 gm 12th hourly. Cefixime 200 mg BD orally.	Cefepime 200 mg BD orally. Cefpodoxime 200 mg BD orally.

## ■ MACROLIDES

They act by inhibiting protein synthesis and also by blocking ribosomal activity.

*Side effects:* Allergic reactions, gastric irritation, cholestasis.

*Uses:* Respiratory infections, skin infections.

*Drugs:*

Erythromycin: 500 mg QID.

Roxithromycin: 150 mg BD.

Azithromycin 500 mg OD before food for 3 days.

Clarithromycin 500 mg BD. It is also used as anti-*Helicobacter pylori* in treating duodenal ulcer.

Spiramycin 1–5 millions BD.

## ■ AMINOGLYCOSIDES

They block the RNA-ribosome combination and also inhibits the enzymes involved in Krebs' cycle.

*Side effects:* Ototoxicity (vestibular), nephrotoxicity.

Aminoglycoside will not get absorbed through the GIT because of high pH. So they are given either IM or IV. As bowel antiseptic they can be given orally.

*Drugs:*

1. Streptomycin: 0.75 gm IM OD for 3 months. Used in tuberculosis, plague, chancroid, granuloma inguinale, brucellosis, respiratory infections, gut sterilisation during large bowel preparation.
2. Kanamycin: 1.5 gm/day. It is more cochlear toxic.
3. Gentamicin: 80 mg BD IM or IV. 1 mg/kg body weight. Antipseudomonal drug.
4. Tobramycin 5 mg/kg body weight. More effective against *Pseudomonas* than gentamicin.
5. Amikacin 250 mg BD IM/IV. 15 mg/kg body weight.
6. Netilmycin: 3–6 mg/kg body weight.
7. Neomycin 1 gm 6th hourly. Mainly used in hepatic failure and in gut sterilisation.
8. Framycetin as 0.5% ointment.
9. Paromomycin: 2 gm QID. Used in amoebic dysentery.

## ■ TETRACYCLINES

They are bacteriostatic.

They act by inhibiting enzyme system, protein synthesis and ribosomal activity.

*Side effects:* Hepatic dysfunction, gastric irritation, permanent yellow staining of teeth, suppresses the bone growth.

*Uses:* Plague, cholera, sexually transmitted diseases like syphilis, gonorrhoea, chancroid, actinomycosis.

It is also used to identify malignant cells as brilliant yellow fluorescence under UV light after giving tetracycline for 5 days.

*Dose:* 500 mg QID.

Doxycycline: 100 mg OD/BD for 10–14 days.



## ■ CHLORAMPHENICOL / THIAMPHENICOL

It interferes with protein synthesis.

*Side effects:* Bone marrow suppression, Grey-baby syndrome, liver damage.

*Uses:* Typhoid fever, meningitis, plague.

*Dose:* 2 gm/day.

## ■ DRUGS FOR TUBERCULOSIS

### RIFAMPICIN:

It inhibits DNA-dependent RNA polymerase. It is bactericidal.

*Side effects:* Hepatotoxicity, orange-red coloured urine, flu-like syndrome.

*Uses:* Tuberculosis.

*Other uses:* Leprosy, Meningococcal carrier, brucellosis, mycetoma, Q-fever, *Legionella*, *Chlamydia*.

*Dose:* 450–600 mg/day (OD) before food.

**RIFABUTIN:** 150 mg/day.

### ISONICOTINIC ACID HYDRAZINE (INH):

It inhibits the synthesis of phospholipid synthesis of cell wall of bacteria. It is bactericidal.

*Side effects:* Intolerance, Neuritis, Hepatitis.

It crosses the blood-brain barrier and placenta.

*Dose:* 300 mg orally OD.

**ETHAMBUTOL:** It is bacteriostatic.

*Side effects:* Gastric intolerance, retrobulbar neuritis (green colour vision is defective).

It crosses the blood-brain barrier and concentrates in CSF.

*Dose:* 25 mg/kg body weight. 800 mg OD after food.

**PYRAZINAMIDE:** It is bactericidal.

It acts on dormant bacteria, bacteria inside the macrophages and caseating material.

*Side effects:* Hepatotoxicity, hyperuricaemia, photosensitivity.

*Dose:* 1.5 gm OD after food or 750 mg BD after food for 2 months.

**MORPHAZINAMIDE:** 3 gm/day.

**STREPTOMYCIN.**

**CYCLOSERINE:** 2 gm daily. It is a reserve drug.

**VIOMYCIN:** 1 gm twice a week. IM. It is used in multi-drug-resistant tuberculosis.

**AMIKACIN/KANAMYCIN.**

**CAPREOMYCIN.**

**PAS:** Para-amino salicylic acid: It interferes with PABA metabolism of the bacteria.

*Side effects:* GIT intolerance, hepatotoxicity, blood abnormalities.

**ETHIONAMIDE and PROTHIONAMIDE.**

**CLARITHROMYCIN.**

**AZHITHROMYCIN.**

## ■ ANTIAMOEBIIC DRUGS

### DEHYDROEMETINE:

It acts on the trophozoite. But not on the cyst.

It is used for extra-intestinal amoebiasis.

*Side effects:* Myocarditis, myalgia.

*Dose:* 60 mg deep IM OD for 10 days given under monitor.

**DIIDOHYDROXYQUINOLINE:** 2 gm/day. It is more useful against trophozoites.

**IDOCHLOROXYQUINOLINE:** 0.75 gm/day. It is more useful in cyst passers.

**CHLOROQUINE:** Used for only extra-intestinal amoebiasis.

500 mg BD for 2 days.

250 mg BD up to 3 weeks.

### METRONIDAZOLE:

400–800 mg tds for 10 days. Or 500 mg (1 mg/ml) tid IV.

It is used for intestinal and extra-intestinal amoebiasis.

**TINIDAZOLE:**

300–600 mg tid for 3–5 days.

**SECNIDAZOLE:**

2 gm single dose after food for intestinal amoebiasis.

2 gm OD for 5 days.

**ORNIDAZOLE:****DILOXANIDE FUROATE:**

500 mg tid for 10 days.

Used in cyst passers and chronic carriers.

**TETRACYCLINES:**

2 gm/day for 10 days.

It is used only as an adjuvant drug.

## ■ IMPORTANT ANTIHELMINTHICS

**PIPERAZINE CITRATE:**

*Dose:* 5 gm single dose. 1 ml = 150 mg.

Used for Ascariasis.

*Side effects:* Cerebellar ataxia, vertigo, convulsion.

**TETRAMISOLE:** 150 mg for adult, 50 mg for children. Used in ascariasis and ankylostomiasis.

**MEBENDAZOLE:** 100 mg BD for 3 days. 600 mg tid for 21 days.

Used in Ascariasis, Ankylostomiasis, Trichuris trichura, hydatid cyst.

**ALBENDAZOLE:** 400 mg single dose.

**PRAZIQUANTEL:** 500 mg tid for 15 days.

**THIABENDAZOLE:** 25 mg/kg for 3 days.

**PYRANTEL PALMOATE:** 11 mg/kg. 15 ml. (1 ml = 50 mg).

**LUCANTHONE** 1 gm tid for 3 days. **HYCANTHONE** 4 mg/kg orally for 4 days.

Used in *S. haematobium*, *S. mansoni*.

**METRIFONATE:** 7.5 mg/kg for 3 days.

**NIRIDAZOLE:** 25 mg/kg. Used in schistosomiasis.

**ANTIMONY COMPOUNDS:** Given intramuscularly.

Used in *S. haematobium* and leishmaniasis.

**DIETHYL CARBAMAZINE CITRATE (DEC):** 100 mg tid for 21 days.

Used in Filariasis, tropical eosinophilia, larva migrans.

**LEVAMISOLE:** 150 mg OD.

Used in ascariasis, hookworms, strongyloidosis, as immunomodulator in cancer.

## ■ ANTICOAGULANTS

**HEPARIN:** 10,000 units IV and later 5,000 subcutaneously 8th hourly.

*Uses:* DVT, pulmonary embolism, DVT prophylaxis.

Heparin therapy should be monitored by partial thromboplastin time (PTT).

*Side effects:* Haemorrhage, alopecia.

Protamine sulphate neutralizes the action of heparin. It is given IV slowly. Dose should not exceed 50 mg.

**LOW MOLECULAR WEIGHT HEPARINS:**

It has got longer duration of action. Monitoring is not required. Given as once a day regime.

Dalteparin 2500–10,000 IV- SC/IV.

Enoxaparin: 40 mg SC.

Parnaparin.

Fraxiparin.

**WARFARIN SODIUM:**

It is an oral anticoagulant. It is monitored using prothrombin time.

Available as 5 mg tablets.

*Dose:* 10 mg OD.

It causes haemorrhage and drug interactions.

## OTHER DRUGS

- ◆ **VITAMIN K:** 10 mg OD IM for 3–5 days. It is used in bleeding disorders, Vitamin K deficiencies in children, liver disorders.
- ◆ **ERYTHROPOIETIN:** 500 IU/kg thrice a week. It is used in chronic renal failure.
- ◆ **BROMOCRIPTINE:** *Dose:* 20 mg/day.  
It is used to suppress lactation, galactorrhoea, hyperprolactinaemia, parkinsonism, acromegaly.
- ◆ **CLOMIPHENE CITRATE:** Used in infertility.  
*Dose:* 50 mg for 5 days from 5th day of menstruation.
- ◆ **OCTREOTIDE:** 0.1 mg BD. Used after pancreatic surgeries in haematemesis, gut endocrine tumours.
- ◆ **VASOPRESSIN:** 20 IU IV/SC. Used in bleeding oesophageal varices.  
DESMOPRESSIN 4 microgram/day-SC-IV-NASAL SPRAY.  
TERLIPRESSIN: 2 mg IV.
- ◆ **L-THYROXINE:** 25, 50, 100, 200 microgram tablets.  
*Uses:* Myxoedema, cretinism for maintenance therapy after total thyroidectomy, as suppressive therapy in papillary carcinoma thyroid (300 µgm) in physiological goitre, in dysmorphogenesis.
- ◆ **ANTITHYROID DRUGS:** *Side effects:* Agranulocytosis and alopecia.  
CARBIMAZOLE: 5–20 mg daily exactly 8th hourly.  
METHIMAZOLE: 5–20 mg daily.  
PROPYLTHIOURACIL: 600 mg tid. Used in pregnancy and children.
- ◆ **DANAZOL:** It is used in fibrocystic disease of breast, gynaecomastia, mastalgia, infertility, precocious puberty.  
*Dose:* 800 mg OD.
- ◆ **ANTACIDS:** Aluminium hydroxide, magnesium trisilicate, sodium bicarbonate.  
*Dose is variable.*
- ◆ **CARBENOXOLONE:** 100 mg tid. It is used in peptic ulcer.  
It causes water and sodium retention, hypokalaemia.
- ◆ **H<sub>2</sub> RECEPTOR BLOCKERS:** Used in peptic ulcer.  
Cimetidine 1000 mg/day.  
Ranitidine 150 mg BD or 300 mg at bed time. Injection ranitidine 50 mg IV 6th–8th hourly.  
Famotidine: 40 mg OD.  
Roxatidine 75 mg OD.  
Nizatidine.
- ◆ **PROTON PUMP INHIBITORS:** Used in peptic ulcer.  
Omeprazole: 20 mg OD/BD 1 hour before food.  
Lanzoprazole: 30 mg OD before food.  
Esomeprazole 40 mg OD.  
Pantoprazole 40 mg OD before food.
- ◆ **PIRENZEPINE:** 50 mg BD. Used in peptic ulcer.
- ◆ **BISMUTH COLLOIDS:** Used in peptic ulcer. It is also anti-*Helicobacter pylori*.  
It stains the oral mucosa.
- ◆ **SUCRALFATE:** Used in peptic ulcer.  
*Dose:* 1 gm tid.
- ◆ **ONDANSETRON:** 8 mg BD. Orally or IV. It is used to prevent vomiting before starting chemotherapy.
- ◆ **LAXATIVES:**  
Castor oil: 16 ml HS.  
Phenolphthalein 300 mg HS.  
Bisacodyl 5 mg orally. HS or 100 mg as rectal suppositories.  
Isabgol as bulk laxative. 15 mg HS.  
Liquid paraffin: 30 ml HS.
- ◆ **ANTIDIARRHOEAL:**  
Bismuth kaolin.  
Diphenoxylate, atropine.  
Loperamide 2–4 mg 8th hourly or as required up to maximum of 16 mg/day dose.
- ◆ **PROKINETIC DRUGS:**  
Metoclopramide: Used in vomiting, dyspepsia, hiccough. It causes extra-pyramidal reactions.  
Domperidone: *Dose:* 10 mg tid before food. It does not cause extra-pyramidal reaction as it does not cross the blood-brain barrier.  
Cisapride: 10–40 mg/day before food. It can cause cardiac arrhythmias.  
Mosapride.
- ◆ **POTASSIUM:** It should be given only in IV drip slowly. *IV Bolus should not be given.* 2 mEq/ml.  
*Dose:* 20–40 m equivalents. IV should be given under ECG monitoring.
- ◆ **SODIUM BICARBONATE:** 7.5% w/v in correction of acidosis.

*It seems likely that in the next few years a combination of antibiotics with different antibacterial spectra will furnish a “cribrum therapeuticum” from which fewer and fewer infecting bacteria will escape.* —Alexander Fleming

# Appendix

## Important Laboratory Values

### URINE

Specific gravity:

Normal: 1.010 to 1.025. Low: less than 1.010. High: more than 1.025.

Fixed: 1.010 to 1.014.

Reaction: Acidic with a pH of 6.0.

Colour: Clear and amber coloured.

Parameter	Values
Aldosterone	2–10 µg/day
Nitrogen	0.4–1.0 gm/day
Amylase	30–250 Somogyi units/hour
Calcium	<3.8 mmol/day
Catecholamines	<100 U/day
Copper	<25 µg/day
Creatinine	1.0–1.6 gm/day
Creatinine clearance	140–150 ml/min in males 105–130 ml/min in females
Estrogens	4–25 µg/day in males 5–100 µg/day in females. Very high in pregnancy
17–hydroxy corticosteroids	2–10 mg/day
5–HIAA	2–9 mg/day
17–ketosteroids	7–25 mg/day in men 4–15 mg/day in women
Magnesium	6.0–8.5 mEq/24 hours
Metanephrines	1.3 mg/day
Urine osmolarity	38–1400 mOsm/kg water
Phosphorus	0.9–1.3/day
Porphyryns	
Coprophyrin	50–250 µg/day
Uroporphyrin	10–30 µg/day
Potassium	25–100 mmol/day
Protein	<150 mg/day
Sodium	100–250 mEq/day
Urobilinogen	1–3.5 mg/day
VMA	<8 mg/day

### BLOOD

Acetoacetic acid	<0.3 mmol/litre
Acid phosphatase	1.0–5.0 King–Armstrong units
Alkaline phosphatase	20–90 IU/litre
Amino nitrogen	3.5–5.5 mg/dl
Amylase	60–180 Somogyi units
Ascorbic acid	0.4–1.0 mg/dl
Bicarbonate	23–29 mmol/litre

Bilirubin	Total 0.3–1.0 mg/dl. Direct 0.1–0.3 mg/dl Indirect 0.2–0.7 mg/dl
Calcium	9–11 mg/dl
Ionised	4.5–5.6 mg/dl
CO <sub>2</sub> in plasma	20–30 mmol/L. (50–70 volume %)
CO <sub>2</sub> tension in artery	35–45 mmHg
Ceruloplasmin	27–37 mg/dl
Chlorides	98–106 mmol/L
Cholesterol—total	150–250 mg%
Copper	115 + or –15 µg/dl
Cortisol	5–20 µg/dl
Creatine phosphokinase (CPK).	25–90 units/ml in males. 10 m–70 units/ml in females
Creatinine	<1.5 mg/dl
Free fatty acids	0.7 mmol/litre
Gastrin	40–200 mg/dl
Glucose	70–110 mg/dl
17–OH corticosteroids	2–10 mg/day
IgG	800–1500 mg/dl
IgM	40–150 mg/dl
IgA	90–320 mg/dl
Insulin	6–26 µU/ml
17–keto steroids	7–25 mg/day in males. 4–15 mg/day in females
Lipase	1.5 units
Magnesium	0.8–1.3 mmol/litre
5' nucleotidase	0.3–2.6 Bodansky units/dl
Osmolality	280–300 mOsm/kg of water
Oxygen.	17–21 volume % in arterial blood 10–16 volume % in venous blood
Oxygen saturation	97% in arterial blood. 60–85% in venous blood
pH of blood	7.36–7.44
Phosphorus, inorganic	1–1.4 mmol/litre
Potassium	3.5–5.0 mmol/litre
Protein—total	5.5–8.0 gm/dl
Albumin	3.5–5.5 gm/dl
Globulin	2.0–3.5 gm/dl
Sodium	136–145 mmol/litre
Sulphate inorganic	0.8–1.2 mg/litre
Testosterone	<100 ng/dl in females. 300–1000 ng/dl in males
TSH	0–5 IU/ml plasma
Thyroxine (T4)	5–12 µg/dl
Triiodo thyronine (T3)	80–200 ng/dl
SGOT/AST	6–18 units/litre
SGPT/ALT	3–26 units/litre
Uric acid	2.5–8.0 mg/dl in males 1.5–6.9 mg/dl in females
Urea nitrogen (BUN)	10–20 mg/dl
<hr/>	
RBC count	4.6–6.2 millions/mm <sup>3</sup> in males 4.2–5.4 millions/mm <sup>3</sup> in females 4.5–5.1 millions/mm <sup>3</sup> in children
Reticulocyte count	25,000–75,000/mm <sup>3</sup>
WBC count	4,300–10,000/mm <sup>3</sup>
Platelet count	1,50,000–4,40,000/cu mm
Bleeding time	1–4 minutes
Haematocrit	40–54 ml/100 ml
Clotting time	2–15 minutes

Clot retraction time	Apparent in 60 minutes, complete in 24 hours
Plasma fibrinogen	Usually <6 hours
Partial thromboplastin time	160–400 mg/dl
	68–82 seconds
	Activated is 32–46 seconds
Prothrombin time	11–15 seconds
Haemoglobin	14–18 gm/dl males
	12–16 gm/dl females
	11–16 gm/dl children
	16–19 mg/dl newborn
Fetal haemoglobin	<2%
Haemoglobin A2	1.5–3.5%
Osmotic fragility	Begins in 0.45–0.39% NaCl and completes in 0.33–0.30%
Sedimentation rate (ESR)	<10 mm in one hour in males
	<20 mm in one hour in females

## ■ STOOL EXAMINATION

Bulk	100–200 gm
Water	75%
Osmolarity	250 mOsm/L
Colour	Brown
pH	7.0–7.5
Fat	<7 gm/day
Stercobilinogen	50–280 mg/day
Urobilinogen	30–200 mg/100 gm
Nitrogen	<2.5 gm/day
Calcium	0.6 gm/24 hours
Trypsin	20–90 units/gram