

Eastern
Economy
Edition

A Textbook of Ophthalmology

Second Edition

E. Ahmed



Rs. 450.00

A TEXTBOOK OF OPHTHALMOLOGY, 2nd ed.
by E. Ahmed

© 2001 by Prentice-Hall of India Private Limited, New Delhi. All rights reserved. No part of this book may be reproduced in any form, by mimeograph or any other means, without permission in writing from the publisher.

ISBN-81-203-1916-8

The export rights of this book are vested solely with the publisher.

Published by Asoke K. Ghosh, Prentice-Hall of India Private Limited, M-97, Connaught Circus, New Delhi-110001 and Printed by Rajkamal Electric Press, B-35/9, G.T. Kamal Road Industrial Area, Delhi-110033.

Brief Contents

<i>Preface</i>	xxv
<i>Acknowledgements</i>	xxvii
<i>Abbreviations</i>	xxix

PART ONE—ANATOMY AND EMBRYOLOGY **1–51**

1. Anatomy of the Orbit 3–11
2. Anatomy of the Eyelid 11–15
3. Anatomy of the Lacrimal Apparatus 15–18
4. Anatomy of the Conjunctiva 18–21
5. Anatomy of the Cornea 21–24
6. Anatomy of the Sclera 24–25
7. Anatomy of the Uveal Tract 25–29
8. Anatomy of the Crystalline Lens and Suspensory Ligament 29–30
9. Anatomy of the Vitreous Humour 30–31
10. Anatomy Related to Glaucoma 31–33
11. Anatomy of the Retina 33–88
12. Anatomy of the Visual Pathways 38–43
13. Anatomy of Extraocular Muscles of the Eye 43–46
14. Embryology and Postnatal Development of the Eye 46–51

PART TWO—OCULAR PHYSIOLOGY **53–74**

15. The Aqueous Humour 55–56
16. The Intraocular Pressure 56–57
17. Ocular Circulations 57–59
18. Physiology of the Cornea 59–61
19. Physiology of the Crystalline Lens 61–62
20. Physiology of the Vitreous Humour and Retina 62–63
21. Accommodation 63–65
22. Convergence 65–67
23. Binocular Vision 67–68
24. The Reactions of Light on the Eye 68–70
25. Colour Vision 70–72
26. Visual Sensation and Adaptation 72–73
27. Neurology of Vision 73–74

PART THREE—MICROBIOLOGY **75–87**

28. Bacterial Infections 77–80
29. Viral and Chlamydial Infections 80–82
30. Mycotic and Parasitic Infections 82–87

PART FOUR — OCULAR THERAPEUTICS, OPTICAL DEFECTS AND OCULAR EXAMINATIONS	89–146
<u>31. Ocular Therapeutics 91–104</u>	
<u>32. Optics and Refractions 104–128</u>	
<u>33. The Examination of the Eyes 128–146</u>	
PART FIVE—OCULAR DISEASES AND OCULAR AFFECTIONS IN SYSTEMIC DISEASES	147–441
<u>34. Diseases of the Orbit 149–164</u>	
<u>35. Diseases of Eyelids 164–180</u>	
<u>36. Diseases of the Lacrimal Apparatus 180–189</u>	
<u>37. Diseases of the Conjunctiva 189–211</u>	
<u>38. Diseases of the Cornea 211–240</u>	
<u>39. Diseases of the Sclera 241–244</u>	
<u>40. Diseases of the Uveal Tract 244–264</u>	
<u>41. Pupillary Disorders 264–269</u>	
<u>42. Diseases of the Crystalline Lens 269–277</u>	
<u>43. Diseases of the Vitreous 277–282</u>	
<u>44. Glaucoma 282–309</u>	
<u>45. Diseases of the Retina 309–355</u>	
<u>46. Diseases of the Visual Pathways 355–366</u>	
<u>47. Strabismus 366–390</u>	
<u>48. Ocular Manifestations of Systemic Diseases 390–420</u>	
<u>49. Tumours 420–429</u>	
<u>50. Ocular Injuries 429–441</u>	
PART SIX—SURGICAL PROCEDURES	443–499
<u>51. Ophthalmic Surgery 445–499</u>	
PART SEVEN—MISCELLANEOUS ASPECTS	501–545
<u>52. Genetics and Paediatric Ophthalmology 503–512</u>	
<u>53. Immunology Related to Ocular Disorders 512–515</u>	
<u>54. Prevention and Rehabilitation of Blindness 515–517</u>	
<u>55. Eye Hygiene 517</u>	
<u>56. Modern Advances in Ophthalmology 518–537</u>	
<u>57. Syndromes in Ophthalmology 537–545</u>	
<i>Appendix I: Formulary of Topical Ophthalmic Preparations</i>	547–549
<i>Appendix II: Ophthalmic Instruments</i>	550–558
<u>Glossary</u>	559–571
<u>Index</u>	573–600

Contents

<i>Preface</i>	xxv
<i>Acknowledgements</i>	xxvii
<i>Abbreviations</i>	xxix
PART ONE—ANATOMY AND EMBRYOLOGY	1–51
1. Anatomy of the Orbit	3–11
<u>Walls of the Orbit</u>	3
<u>Ophthalmic Artery</u>	5
<u>Superior Ophthalmic Vein</u>	6
<u>Inferior Ophthalmic Vein</u>	6
<u>Ciliary Ganglion</u>	7
<u>Surgical Spaces in the Orbit</u>	7
<u>Tenon's Capsule or the Fascia Bulbi</u>	7
<u>Cranial Nerves in the Orbit</u>	8
<u>Sphenopalatine (Pterygopalatine) Ganglion</u>	11
<u>Paranasal Sinuses in Relation to the Orbital Walls</u>	11
<u>Further Reading</u>	11
2. Anatomy of the Eyelids	11–15
<u>Muscles of the Eyelids</u>	13
<u>Glands of the Eyelids</u>	13
<u>Further Reading</u>	14
3. Anatomy of the Lacrimal Apparatus	15–18
<u>The Lacrimal Gland</u>	15
<u>The Lacrimal Passages</u>	17
<u>Further Reading</u>	18
4. Anatomy of the Conjunctiva	18–21
<u>The Palpebral Conjunctiva</u>	18
<u>The Bulbar Conjunctiva</u>	19
<u>The Fornix</u>	19
<u>Further Reading</u>	21
5. Anatomy of the Cornea	21–24
<u>Structure of the Cornea</u>	22
<u>The Epithelium</u>	22
<u>Bowman's Membrane</u>	22
<u>Substantia Propria</u>	22
<u>Descemet's Membrane</u>	23
<u>Endothelium</u>	23
<u>Limbus</u>	23
<u>Further Reading</u>	24

6. Anatomy of the Sclera	24–25
<i>Further Reading</i> 24	
7. Anatomy of the Uveal Tract	25–29
<i>Iris</i> 25	
<i>Ciliary Body</i> 26	
<i>Choroid</i> 27	
<i>Further Reading</i> 28	
8. Anatomy of the Crystalline Lens and Suspensory Ligament	29–30
<i>Suspensory Ligament of the Lens</i> 30	
<i>Petit's Canal</i> 30	
<i>Further Reading</i> 30	
9. Anatomy of the Vitreous Humour	30–31
<i>Further Reading</i> 31	
10. Anatomy Related to Glaucoma	31–33
<i>Anterior Chamber</i> 31	
<i>Posterior Chamber</i> 31	
<i>Angle of the AC or the Filtration Angle</i> 32	
<i>The Outflow Apparatus</i> 32	
<i>Inner Canals or Afferent Communications</i> 33	
<i>Further Reading</i> 33	
11. Anatomy of the Retina	33–38
<i>Optic Disc</i> 33	
<i>Central Retina or Macula Lutea</i> 34	
<i>Peripheral Retina</i> 34	
<i>Further Reading</i> 38	
12. Anatomy of the Visual Pathways	38–43
<i>Optic Nerve</i> 39	
<i>Localization of the Fibres in the Visual Pathways</i> 40	
<i>Optic Chiasma</i> 41	
<i>Optic Tract</i> 42	
<i>Lateral Geniculate Body</i> 42	
<i>Optic Radiations</i> 42	
<i>Striate Cortex</i> 43	
<i>Extrastriate System</i> 43	
<i>Further Reading</i> 43	
13. Anatomy of Extraocular Muscles of the Eye	43–46
<i>Extrinsic Muscles</i> 43	
<i>Basic Eye Movements</i> 45	
<i>Further Reading</i> 45	
14. Embryology and Postnatal Development of the Eye	46–51
<i>Embryology of the Eye</i> 46	
<i>Embryology of Neuroectodermal Structures</i> 48	
<i>Embryology of Mesodermal Structures</i> 49	
<i>Further Reading</i> 51	

PART TWO—OCULAR PHYSIOLOGY	53–74
15. The Aqueous Humour	55–56
<i>Further Reading</i>	<i>56</i>
16. The Intraocular Pressure	56–57
Physiological Variations	56
Nervous Control of the IOP	57
Normal IOP and Hypertensive Eyes	57
<i>Further Reading</i>	<i>57</i>
17. Ocular Circulations	57–59
Pulsation in the Retina	57
Measurement of Ocular Blood Flow	58
Control of Ocular Circulation	58
<i>Further Reading</i>	<i>59</i>
18. Physiology of the Cornea	59–61
Nutrition of the Cornea	59
Metabolism of the Cornea	59
Corneal Permeability	60
Transparency of the Cornea	60
<i>Further Reading</i>	<i>61</i>
19. Physiology of the Crystalline Lens	61–62
Lens Metabolism	61
<i>Further Reading</i>	<i>62</i>
20. Physiology of the Vitreous Humour and Retina	62–63
Physicochemical Properties of Vitreous	62
Metabolism of the Vitreous	62
Transparency of the Vitreous	63
Retinal Pigment Epithelium (RPE)	63
Metabolism of the Retina	63
<i>Further Reading</i>	<i>63</i>
21. Accommodation	63–65
Theories of Accommodation	64
Physical and Physiological Accommodation	64
Range and Amplitude of Accommodation	64
Anomalies of Accommodation	64
<i>Further Reading</i>	<i>65</i>
22. Convergence	65–67
Pathway for Convergence	65
Measurement of Convergence	65
Range and Amplitude of Convergence	66
Association between Accommodation and Convergence	66
Anomalies of Convergence	66
Presbyopia	66
<i>Further Reading</i>	<i>67</i>

23. Binocular Vision	67–68
<u>Anatomical Factors</u>	67
<u>Physiological Factors</u>	67
<u>Grades of Binocular Vision</u>	67
<u>Tests for Binocular Vision</u>	68
<u>Depth Perception</u>	68
<u>Further Reading</u>	68
24. The Reactions of Light on the Eye	68–70
<u>Light</u>	68
<u>Transmission, Reflection and Absorption of Light</u>	69
<u>Effects of Radiant Energy</u>	69
<u>Photochemistry of Vision</u>	69
<u>Visual Pigments</u>	69
<u>Electrical Changes in the Retina</u>	70
<u>Further Reading</u>	70
25. Colour Vision	70–72
<u>Purkinje Phenomenon</u>	70
<u>Scotopic Luminosity Curve</u>	70
<u>Theories of Colour Vision</u>	70
<u>Colour Cells</u>	71
<u>Colour Deficiency</u>	71
<u>Tests for Colour Vision</u>	71
<u>Further Reading</u>	72
26. Visual Sensations and Adaptation	72–73
<u>Visual Sensations</u>	72
<u>Light Threshold</u>	72
<u>Successive Contrast</u>	72
<u>Simultaneous Contrast or Spatial Induction</u>	73
<u>Further Reading</u>	73
27. Neurology of Vision	73–74
<u>Visual Pathways</u>	73
<u>Pupillary Pathways</u>	73
<u>Sympathetic Pupillary Pathways</u>	74
<u>Further Reading</u>	74
PART THREE—MICROBIOLOGY	75–87
28. Bacterial Infections	77–80
<u>Staphylococci</u>	77
<u>Streptococci</u>	77
<u>Pneumococci</u>	78
<u>Neisseria</u>	78
<u>Mycobacteria</u>	78
<u>Haemophilus</u>	79
<u>Treponema</u>	79

<u>Corynebacterium</u>	79
<u>Diphtheroids</u>	79
<u>Pseudomonas (Ps.) Pyocyanea</u>	79
<u>Morax–Axenfeld Diplobacilli</u>	80
<u>Further Reading</u>	80
29. Viral and Chlamydial Infections	80–82
<u>Viral Infections</u>	80
<u>Chlamydial Infection</u>	81
<u>Further Reading</u>	82
30. Mycotic and Parasitic Infections	82–87
<u>Mycotic Infections</u>	82
<u>Rhinosporidiosis</u>	83
<u>Aspergillosis</u>	83
<u>Sporotrichosis</u>	83
<u>Moniliasis or Candidosis</u>	84
<u>Actinomycosis</u>	84
<u>Streptothrix</u>	84
<u>Parasitic Infections</u>	84
<u>Parasites causing Ocular Affections</u>	85
<u>Toxoplasmosis</u>	85
<u>Acanthamoebiasis</u>	86
<u>Malaria</u>	86
<u>Leishmaniasis</u>	86
<u>Giardiasis</u>	86
<u>Taeniasis and Cysticercosis</u>	86
<u>Echinococcosis</u>	86
<u>Toxocariasis</u>	86
<u>Onchocerciasis</u>	
<u>Rare Helminthic Infections</u>	87
<u>Further Reading</u>	87
PART FOUR—OCULAR THERAPEUTICS, OPTICAL DEFECTS AND OCULAR EXAMINATIONS	89–146
31. Ocular Therapeutics	91–104
<u>Autonomic Drugs</u>	91
<u>Miotics</u>	93
<u>Mydriatics</u>	93
<u>Anaesthesia in Ophthalmology</u>	93
<u>Chemotherapeutic Agents and Antibiotics</u>	94
<u>Sulphonamides</u>	95
<u>Antibiotics</u>	95
<u>Antiviral Agents</u>	95
<u>Antifungal Agents</u>	98
<u>Steroids</u>	98

<u>Enzymes in Ophthalmology</u>	100
<u>Anticoagulant Therapy</u>	100
<u>Carbonic Anhydrase Inhibitors (CAIs)</u>	100
<u>Hyperosmotic Agents</u>	100
<u>Immunosuppressive Agents</u>	101
<u>Nonsteroidal Antiinflammatory Drugs (NSAIDs)</u>	102
<u>Viscoelastic Agents</u>	102
<u>Toxic Effects of Ocular Drugs</u>	102
<u>Toxic Effects of Systemic Drugs</u>	103
<u>Other Therapeutic Measures</u>	103
<u>Further Reading</u>	104
32. Optics and Refraction	104–128
<u>Geometrical Optics</u>	104
<u>Reflection at Uniformly Curved Surfaces: Spherical Mirrors</u>	104
<u>Spherical Lens</u>	106
<u>Astigmatic Lens</u>	106
<u>Meniscus Lens</u>	107
<u>Transposition of Spherocylindrical Lenses</u>	108
<u>Prism</u>	108
<u>Vergence and Dioptre</u>	109
<u>Front and Back Vertex Powers</u>	109
<u>Aberrations in Lenses</u>	110
<u>Prismatic Effects of the Lenses</u>	110
<u>Decentration of the Lenses</u>	110
<u>Homocentric or Coaxial Lens System</u>	111
<u>Refraction in the Normal Eye</u>	111
<u>Reduced Eye or Schematic Eye</u>	111
<u>Optical Aberrations of the Eye</u>	111
<u>Catoptric Images (Purkinje–Sanson Images)</u>	112
<u>Hypermetropia or Hyperopia</u>	113
<u>Myopia</u>	114
<u>Astigmatism</u>	116
<u>Anisometropia</u>	119
<u>Aniseikonia</u>	119
<u>Aphakia</u>	119
<u>Transient Changes in Refraction</u>	120
<u>Contact Lens</u>	120
<u>Visual Aids</u>	122
<u>Special Lenses</u>	123
<u>Tinted Glasses</u>	124
<u>Frames</u>	125
<u>Verification of Spectacle Lenses</u>	125
<u>Optical Centre of the Lens</u>	125
<u>Instruments used in Refraction Work</u>	126
<u>Further Reading</u>	127

33. The Examination of the Eyes	128–146
<u>Basic Equipments</u>	128
<u>History of the Case</u>	128
<u>External Examinations</u>	129
<u>Examination in Dark Room</u>	131
<u>Visual Acuity</u>	135
<u>Functional Examinations</u>	135
<u>Special Examinations</u>	135
<u>Visual Field</u>	139
<u>Hemianopia</u>	142
<u>Quadrantanopia</u>	142
<u>Scotomata</u>	143
<u>Visual Field Changes in Different Ocular Disorders</u>	143
<u>Toxic Effects on the Retina and Optic Nerves</u>	144
<u>Optic Nerve Affections</u>	144
<u>Chiasmal Affections</u>	144
<u>Infrachiasmatic Lesions</u>	145
<u>Suprachiasmatic Lesions</u>	145
<u>Vascular Lesions</u>	145
<u>Retrochiasmal Lesions</u>	145
<u>Further Reading</u>	146

PART FIVE—OCULAR DISEASES AND OCULAR AFFECTIONS IN SYSTEMIC DISEASES

147–441

34. Diseases of the Orbit	149–164
<u>Proptosis or Exophthalmos</u>	149
<u>Investigations</u>	150
<u>Special Radiological Techniques</u>	151
<u>Enophthalmos</u>	152
<u>Acute Orbital Cellulitis (Postseptal Cellulitis)</u>	152
<u>Preseptal (Periorbital) Cellulitis</u>	152
<u>Chronic Orbital Cellulitis</u>	153
<u>Tenonitis</u>	153
<u>Osteoperiostitis</u>	153
<u>Cavernous Sinus Thrombosis</u>	153
<u>Nasal Sinusitis</u>	154
<u>Pseudotumours of the Orbit</u>	154
<u>Dysthyroid Exophthalmos</u>	155
<u>Thyrotoxic Exophthalmos (Graves' Disease)</u>	156
<u>Orbital Tumours</u>	157
<u>Primary Tumours</u>	157
<u>Tumours of the Optic Nerve Sheaths</u>	158
<u>Superior Orbital (Sphenoid) Fissure Syndrome</u>	159
<u>Meningioma of the Sphenoid Ridge</u>	159
<u>Metastatic Tumours</u>	159
<u>Manifestations in General Diseases</u>	159

	Orbital Cysts	160	
	Dermoid Cysts	160	
	Vascular Disturbances	160	
	Caroticocavernous Fistula	161	
	Orbital Varix	161	
	Developmental Anomalies of the Orbit	162	
	Dysostoses of the Skull	162	
	Facial Dystrophies	162	
	Orbital Meningocele and Cephalocele	163	
	Further Reading	163	
35.	Diseases of Eyelids		164–180
	Diseases of the Lacrimal Gland	180	
	Diseases of the Skin of Eyelids	164	
	Disorders of the Eyebrows and Eyelashes	167	
	Tumours of Eyelids	174	
	Carcinoma of the Lid	175	
	Neurofibromata or von Recklinghausen's Disease	177	
	Malignant Melanoma of the Eyelid	177	
	Abnormal Lid Movements	178	
	Abnormalities of the Palpebral Aperture	179	
	Developmental Abnormalities of Eyelids and Palpebral Fissure	179	
	Oedema of the Lids	180	
	<i>Further Reading</i>	180	
36.	Diseases of the Lacrimal Apparatus		180–189
	Diseases of the Lacrimal Gland	180	
	Hypersecretion of Tears	181	
	Paradoxical Lacrimation	181	
	Dry Eye	181	
	Acute Dacryoadentitis	181	
	Chronic Dacryoadentitis	182	
	Atrophy of the Lacrimal Gland	182	
	Dislocation of the Lacrimal Gland	182	
	Tumour of the Lacrimal Gland	182	
	Benign Mixed Tumour of the Lacrimal Gland	182	
	Miscellaneous Tumours	183	
	Cysts of the Lacrimal Gland	183	
	Sjögren's Syndrome	183	
	Diagnostic Tests for Dry Eye	183	
	Diseases of the Lacrimal Passages	184	
	Tumours of the Lacrimal Sac	186	
	Developmental Abnormalities of the Lacrimal Apparatus	187	
	Anomalies of Secretory System	188	
	Anomalies of Excretory System	188	
	Congenital Obstruction of the Nasolacrimal Duct	188	
	<i>Further Reading</i>	189	

37. Diseases of the Conjunctiva	189–211
<u>Anomalies of the Vascular System</u>	189
<u>Conjunctivitis</u>	190
<u>Bacterial Flora of the Conjunctival Sac</u>	191
<u>Acute Infective Conjunctivitis</u>	191
<u>Acute Purulent Conjunctivitis</u>	192
<u>Membranous Conjunctivitis</u>	193
<u>Chronic Catarrhal Conjunctivitis</u>	194
<u>Rare Types of Conjunctivitis</u>	195
<u>Follicular Conjunctivitis</u>	195
<u>Béal's Syndrome</u>	196
<u>Epidemic Viral Keratoconjunctivitis</u>	196
<u>Epidemic Haemorrhagic Conjunctivitis</u>	196
<u>Adenoviral Keratoconjunctivitis</u>	197
<u>Epidemic Keratoconjunctivitis</u>	197
<u>Pharyngoconjunctival Fever</u>	197
<u>Nonspecific Follicular Conjunctivitis</u>	197
<u>Other Viruses causing Conjunctivitis</u>	197
<u>Tuberculosis of the Conjunctiva</u>	201
<u>Ulceration of the Conjunctiva</u>	202
<u>Allergy of the Conjunctiva</u>	202
<u>Allergic Conjunctivitis</u>	202
<u>Keratoconjunctivitis Associated with Diseases of the Skin and Mucous Membranes</u>	205
<u>Degeneration of the Conjunctiva</u>	205
<u>Transposition of Pterygium</u>	207
<u>Conjunctival Cysts</u>	209
<u>Tumours of the Conjunctiva</u>	209
<u>Pigmentation of the Conjunctiva</u>	210
<u>Developmental Anomalies of the Conjunctiva</u>	210
<u>Further Reading</u>	210
38. Diseases of the Cornea	211–240
<u>Equipments and Methods of Examination</u>	212
<u>Injury to the Cornea</u>	212
<u>Healing of Corneal Wounds</u>	213
<u>Keratitis</u>	213
<u>Bacterial Corneal Ulcer</u>	214
<u>Hypopyon Corneal Ulcer</u>	217
<u>Rosacea Keratitis</u>	219
<u>Diffuse Superficial Keratitis</u>	219
<u>Herpes Simplex</u>	220
<u>Herpes Zoster Ophthalmicus</u>	222
<u>Adenoviral Keratitis</u>	223
<u>Molluscum Contagiosum</u>	223
<u>Thygeson's Superficial Punctate Keratitis</u>	223
<u>Theodore's Superior Limbic Keratoconjunctivitis</u>	223

	<u>Exposure Keratitis (Keratitis Lagophthalmo)</u>	224
	<u>Neurotropic Keratitis</u>	224
	<u>Neuroparalytic Keratitis</u>	224
	<u>Nutritional Ulcers</u>	225
	<u>Keratitis Sicca (Keratoconjunctivitis Sicca)</u>	225
	<u>Interstitial Keratitis (IK)</u>	225
	<u>Disciform Keratitis</u>	226
	<u>Mycotic Corneal Ulcer</u>	226
	<u>Noninfectious Corneal Ulcers</u>	227
	<u>Corneal Degenerations</u>	227
	<u>Keratoconus or Ectatic Corneal Dystrophy or Conical Cornea</u>	233
	<u>Corneal Pigmentations</u>	235
	<u>Corneal Deposits</u>	236
	<u>Corneal Oedema</u>	236
	<u>Secondary Oedema</u>	236
	<u>Essential Oedema (Diffuse Epithelial Keratopathy)</u>	237
	<u>Bullous Keratopathy</u>	237
	<u>Filamentary Keratopathy</u>	237
	<u>Folds in Bowman's Membrane</u>	237
	<u>Ruptures in Bowman's Membrane</u>	237
	<u>Folds in Descemet's Membrane</u>	238
	<u>Ruptures in Descemet's Membrane</u>	238
	<u>Developmental Anomalies of the Cornea</u>	238
	<i>Further Reading</i>	239
39.	Diseases of the Sclera	241–244
	Episcleritis	241
	Scleritis	241
	Scleromalacia Perforans	243
	Necrosis of the Sclera	243
	<i>Further Reading</i>	244
40.	Diseases of the Uveal Tract	244–264
	Uveitis	244
	<u>Iridocyclitis (Anterior Uveitis)</u>	250
	<u>Acute Iritis</u>	250
	<u>Chronic Iridocyclitis</u>	251
	<u>Cyclitis</u>	251
	<u>Choroiditis</u>	251
	<u>Pars Planitis</u>	252
	<u>Panophthalmitis</u>	252
	<u>Uveitis in Bacterial Infections</u>	253
	<u>Tuberculosis of the Uveal Tract</u>	253
	Syphilis of the Uveal Tract	254
	Gonococcal Iritis	254
	Herpetic Keratoiridocyclitis	254
	Herpes Zoster Uveitis	254

<u>Toxoplasmosis</u>	254
<u>Uveitis in Noninfective Systemic Diseases</u>	255
<u>Uveitis due to Hypersensitivity</u>	256
<u>Lens-induced Uveitis</u>	256
<u>Idiopathic Specific Uveitis Syndrome</u>	256
<u>Uveitis in Children</u>	258
<u>Heterochromic Cyclitis of Fuchs</u>	258
<u>Pseudoglioma</u>	259
<u>Endophthalmitis</u>	259
<u>Iris Cysts</u>	260
<u>Disturbances of Circulation</u>	260
<u>Rubeosis Iridis</u>	260
<u>Masquerade Syndromes</u>	260
<u>Uveal Effusion</u>	260
<u>Neovascularization in the Posterior Segment</u>	261
<u>Haemorrhage in the Uvea</u>	261
<u>Degenerative Changes in the Uvea</u>	261
<u>Congenital Anomalies of the Uvea</u>	262
<u>Further Reading</u>	263
41. Pupillary Disorders	264–269
<u>Pupillary Pathways</u>	264
<u>Pupillary Reflexes</u>	265
<u>Abnormal Pupillary Reflexes</u>	265
<u>Neurologic Significance of the Abnormalities in the Pupil</u>	266
<u>Further Reading</u>	269
42. Diseases of the Crystalline Lens	269–277
<u>Developmental Abnormalities of the Lens</u>	269
<u>Cataract</u>	270
<u>Cataract Associated with Systemic Diseases</u>	275
<u>Iatrogenic Cataract</u>	276
<u>Aftercataract</u>	276
<u>Displacement of the Lens</u>	276
<u>Further Reading</u>	277
43. Diseases of the Vitreous	277–282
<u>Fluidity of the Vitreous</u>	277
<u>Vitreous Opacities</u>	278
<u>Muscae Volitantes or Vitreous Floaters</u>	278
<u>Asteroid Hyalopathy or Benson's Disease</u>	278
<u>Synchysis Scintillans</u>	279
<u>Vitreous Haemorrhages</u>	279
<u>Vitreous Degenerations</u>	280
<u>Vitreous Detachments</u>	280
<u>Proliferative Vitreoretinopathy</u>	280
<u>Congenital Deformities in the Vitreous</u>	281
<u>Massive Vitreous Retraction (MVR)</u>	281
<u>Further Reading</u>	281

44. Glaucoma	282–309
Investigation of Glaucoma	282
Chronic Simple Glaucoma (Simple Glaucoma, Open-angle Glaucoma)	289
<u>Closed-angle Glaucoma</u>	293
Treatment of Glaucoma	297
<u>Congenital Glaucoma</u>	301
<u>Absolute Glaucoma</u>	302
<u>Secondary Glaucomas</u>	302
<u>Lens-induced Glaucomas</u>	303
<u>Secondary Glaucomas following Ocular Trauma</u>	304
<u>Neovascular Glaucoma (Haemorrhagic Glaucoma)</u>	304
<u>Glaucoma in Aphakia and Pseudophakia</u>	305
<u>Malignant Glaucoma</u>	305
Iatrogenic Glaucoma	306
Pigmentary Glaucoma	306
Glaucoma Capsulare	306
Epidemic Dropsy Glaucoma (Bengal Glaucoma)	306
<u>Juvenile-onset Open-angle Glaucoma</u>	307
<u>Normal-tension (Low-tension) Glaucoma</u>	307
<u>Unilateral Glaucoma</u>	307
<u>Glaucoma in Developmental Disorders</u>	307
<i>Further Reading</i>	308
45. Diseases of the Retina	309–355
<u>The Normal Fundus</u>	309
<u>Investigations for Retinal Diseases</u>	310
<u>Miscellaneous Diagnostic Procedures</u>	311
<u>Electrodiagnostic Methods in Retinal Disorders</u>	311
Common Developmental Abnormalities of the Fundus	314
<u>Pseudoneuritis</u>	315
<u>Central Serous Retinopathy (CSR)</u>	317
<u>Central Chorioretinopathy</u>	317
<u>Cystoid Macular Oedema</u>	317
<u>Haemorrhages in the Fundus</u>	318
Anomalies of Retinal Blood Vessels	319
Exudates	319
Central Retinal Artery Obstruction (CRAO)	320
Ophthalmic Artery Occlusion	322
Central Retinal Vein Thrombosis (CRVT)	322
<u>Neovascularization of the Fundus Oculi</u>	325
<u>Inflammation of the Retina</u>	325
<u>Senile Changes in the Retina</u>	328
<u>Retinal Degenerations</u>	328
<u>Developmental Variations in the Peripheral Part of the Fundus</u>	330
<u>Disorders of Bruch's Membrane</u>	330
<u>Macular Lesions Secondary to Choroidal Vascular Affections</u>	332
<u>Circinate Retinopathy</u>	332

Macular Disorders	333
Retinal Dystrophies	334
Flecked Retina Syndrome	339
Vascular Retinopathies	339
Retinal Manifestations of Vascular Disease	339
Involutionary Sclerosis or Senile Arteriosclerosis	340
Diabetic Retinopathy	342
Chronic Arteriolar Capillaropathies in Retina	345
Retinal Changes in Blood Diseases	345
Retinal Changes in Hyperlipidaemia	347
Inflammatory Retinopathy	347
Anomalies of Fundus Pigmentation	347
Retinal Detachment	347
Coats' Disease	351
Phakomatoses or Hamartomous Syndromes	351
Tuberous Sclerosis or Bourneville's Disease	351
Neurofibromatosis or von Recklinghausen's Disease	352
Sturge-Weber Syndrome	352
von Hippel-Lindau Disease	352
Cysts of the Retina	353
Further Reading	353
46. Diseases of the Visual Pathways	355-366
Optic Neuritis	355
Optic Atrophy	359
Compressive Optic Neuropathy	362
Disorders of Optic Chiasma and Optic Tract	362
Disorders of Optic Radiations and Visual Cortex	363
Symptomatic Visual Disturbances	363
Further Reading	365
47. Strabismus	366-390
Strabismus or Squint	368
Diplopia	368
Confusion	369
Suppression	369
Amblyopia	369
Abnormal Retinal Correspondence (ARC)	372
Investigations for Squint	372
Paralysis of the Ocular Muscles	374
Ophthalmoplegia	375
Paralytic Squint	376
Cranial Nerve Palsy	377
Palsy Involving Extrinsic Ocular Muscles	378
Congenital Paralytic Strabismus	378
Concomitant Squint	379
Extropia	380

<u>Vertical Squint</u>	382
<u>Gaze Palsy</u>	384
<u>Orthoptic Instruments</u>	384
<u>Pleoptic Instruments</u>	387
<u>Nystagmus</u>	387
<u>Further Reading</u>	389
48. Ocular Manifestations of Systemic Diseases	390–420
<u>Ocular Involvement in Affections of the Nervous System</u>	390
<u>Intracranial Tumours</u>	391
<u>Demyelinating Diseases</u>	394
<u>Inflammatory Diseases of the Brain and Meninges</u>	395
<u>Vascular Disorders</u>	396
<u>Cervical Vascular Diseases</u>	399
<u>Metabolic Disorders</u>	400
<u>Disorders of Lipoprotein</u>	403
<u>Sphingolipidoses</u>	403
<u>Disorders of Glycoprotein Metabolism</u>	404
<u>Disorders of Mineral Metabolism</u>	405
<u>Senile Changes in the Eyes</u>	405
<u>Tuberculosis</u>	405
<u>Syphilis</u>	407
<u>Parasitic Infection of the Eyes</u>	408
<u>Toxoplasmosis</u>	408
<u>Acquired Immuno Deficiency Syndrome (AIDS)</u>	410
<u>Diseases of the Blood and Reticuloendothelial System</u>	411
<u>Skin and Mucous Membrane Diseases Related to Ophthalmology</u>	411
<u>Connective Tissue Disorders</u>	413
<u>Diseases of the Muscles</u>	415
<u>Miscellaneous Disorders</u>	419
<u>Further Reading</u>	419
49. Tumours	420–429
<u>Tumours of the Cornea</u>	420
<u>Pigmented Tumours</u>	421
<u>Tumours of the Uveal Tract</u>	422
<u>Tumours of the Retina</u>	426
<u>Secondary Tumours of the Retina</u>	428
<u>Tumours of the Optic Nerve and Sheaths</u>	428
<u>Further Reading</u>	429
50. Ocular Injuries	429–441
<u>Contusion and Concussion Injuries</u>	430
<u>Posttraumatic Retinal Detachments</u>	432
<u>Perforating Injuries</u>	433
<u>Nonmechanical Injuries</u>	437
<u>Orbital Fractures</u>	439
<u>Further Reading</u>	440

PART SIX—SURGICAL PROCEDURES	443–499
51. Ophthalmic Surgery	445–499
<u>Surgery of the Eyelids</u> 446	
<u>Entropion</u> 447	
<u>Ectropion</u> 448	
<u>Ptosis</u> 449	
<u>Canthotomy</u> 451	
<u>Canthoplasty</u> 451	
<u>Surgery of the Lacrimal Passages</u> 451	
<u>Other Operations</u> 454	
<u>Surgery of the Conjunctiva</u> 455	
<u>Corneal Surgery</u> 456	
<u>Keratoplasty or Corneal Transplantation</u> 457	
<u>Eye Bank</u> 457	
<u>Postoperative Treatment</u> 460	
<u>Lamellar Keratoplasty</u> 461	
<u>Surgery of the Iris</u> 462	
<u>Iridotomy</u> 464	
<u>Surgery for Iridodialysis</u> 464	
<u>Cataract Surgery</u> 464	
<u>Ocular Diseases Posing Problems for Surgery</u> 465	
<u>Intracapsular Extraction of the Lens</u> 468	
<u>Discission for Developmental Cataract</u> 476	
<u>Curette Evacuation or Linear Extraction</u> 477	
<u>Intraocular Lens Implantation</u> 477	
<u>Phacoemulsification</u> 479	
<u>Operations for Glaucoma</u> 480	
<u>Surgery on the Trabeculum</u> 484	
<u>Operations for Squint</u> 487	
<u>Retinal Detachment</u> 490	
<u>Cryosurgery in Ophthalmology</u> 492	
<u>Photocoagulation</u> 493	
<u>Intravitreal Procedures</u> 495	
<u>Pars Plana Surgery</u> 495	
<u>Vitreous Surgery</u> 496	
<u>Enucleation of the Eyeball</u> 496	
<u>Further Reading</u> 498	
PART SEVEN—MISCELLANEOUS ASPECTS	501–545
52. Genetics and Paediatric Ophthalmology	503–512
Basic Aspects of Genetics and Inheritance 503	
Sex-linked or X-linked Disorders and Ocular Affections 503	
<u>Chromosomal Aberrations</u> 504	
<u>Paediatric Ophthalmology</u> 504	
<u>Defects of the Globe as a Whole</u> 506	

<u>Abnormal Skull and Face Development</u>	506
<u>Abnormalities of the Vitreous</u>	508
<u>Abnormalities of the Optic Disc</u>	508
<u>Abnormalities of the Choroid and Retina</u>	508
<u>Paediatric Inflammations</u>	509
<u>Inherited Metabolic Disorders</u>	509
<u>Miscellaneous Disorders</u>	509
<u>Glaucoma in Childhood</u>	510
<u>Tumours in Childhood</u>	510
<u>Prematurity and Ocular Abnormalities</u>	510
<u>Further Reading</u>	512
53. Immunology Related to Ocular Disorders	512–515
<u>Cellular Components</u>	512
<u>Human Leucocyte Antigens</u>	512
<u>Immunologic Responses</u>	513
<u>Autoimmune Diseases</u>	514
<u>Immunologic Aspects of Certain Ocular Affections</u>	514
<u>Further Reading</u>	515
54. Prevention and Rehabilitation of Blindness	515–517
<u>Preventive Ophthalmology</u>	515
<u>Blindness in India</u>	516
<u>Further Reading</u>	517
55. Eye Hygiene	517
<u>The Visual Tasks</u>	517
<u>The Environment</u>	517
<u>Further Reading</u>	517
56. Modern Advances in Ophthalmology	518–537
<u>Improved Diagnostic Facilities</u>	518
<u>Pachometry (Pachymetry)</u>	518
<u>Fluorophotometry</u>	518
<u>Specular Microscopy</u>	519
<u>Computer-assisted Keratometry</u>	519
<u>Specialized Contact Lenses in Fundus Examinations</u>	519
<u>High-power Plus Lenses</u>	519
<u>Transillumination Ophthalmoscopy</u>	519
<u>Equator Plus Ophthalmoscope and Camera</u>	519
<u>Scanning Laser Ophthalmoscope</u>	519
<u>Confocal Scanning Laser Ophthalmoscope</u>	520
<u>Optic Nerve-head Imaging</u>	520
<u>Sensory Diagnostic Tests in Strabismus</u>	520
<u>Fundus Fluorescein Angiography</u>	521
<u>Indocyanine Green Angiography</u>	525
<u>Ultrasonography</u>	525
<u>Computed Tomography</u>	528

<u>Magnetic Resonance Imaging</u>	528
<u>Improved Modes of Treatments</u>	528
<u>Laser Therapy</u>	529
Automated Perimetry	531
Keratorefractive Surgery	531
<u>Adhesives in Ophthalmology</u>	534
<u>Pneumatic Retinopexy</u>	535
<u>Further Reading</u>	535
57. Syndromes in Ophthalmology	537–545
<i>Further Reading</i>	545
<i>Appendix I: Formulary of Topical Ophthalmic Preparations</i>	547–549
<i>Appendix II: Ophthalmic Instruments</i>	550–558
<u><i>Glossary</i></u>	559–571
<u><i>Index</i></u>	573–600

Preface

This book was originally published in 1993. Since the first edition, many important advances have been made in the science of ophthalmology. The primary objective of bringing out the second edition remains still the same as the original edition. It is to provide an accurate, complete and up-to-date textbook on the subject of ophthalmology for the students both at the undergraduate and postgraduate levels. The second edition takes due account of the developments in ophthalmology, and records state-of-the-art advances in all aspects of this science—basic, investigative, clinical, and management.

Today, diagnostic techniques such as automated perimetry, fluorescein fundus angiography, digital imaging, computer-assisted procedures, specialized lenses and ophthalmoscopes are being increasingly employed. Newer drugs are available with better therapeutic results. Intraocular lens implantation, phacoemulsification, keratorefractive surgery, vitreoretinal procedures are also being increasingly practised. All these new techniques and practices have been fully described in this completely revised and updated edition. The book can thus also fulfil the need for a valuable work of reference of lasting usefulness to practising ophthalmologists.

The text, as in the first edition, is organized into several parts dealing with anatomy and embryology, ocular physiology, microbiology, ocular therapeutics, optical defects and ocular examinations, ocular diseases and ocular affections in systemic diseases, and surgical procedures, etc. This organization of the book is based on the premise that the aetiopathological processes and the fundamental principles of optics and refraction should be understood first. Next, it is essential to be familiar with the methods of clinical examinations. Finally, it is the study of different ocular diseases and their differentiation from allied disorders. The treatment, depending on the case may be medical or if necessary surgery may have to be resorted to.

I gratefully acknowledge, as in the first edition, many authors, editors and publishers of textbooks from which I have collected text matters and some illustrations.

I express my sincere thanks to Prof. Ranabir Mukherjee, Prof. I.S. Roy, Prof. K.S. Mehra, Prof. K.N. Sahoo, Prof. P.K. Mukherjee, Dr. G.N. Rao, and many others for their helpful criticism of the first edition of the book, which has resulted in significant improvements in this edition. I am thankful to my younger colleagues and to my son, Dr. Imtiaz Ahmed, for assisting me in creating this new edition. I also owe a debt of gratitude to Appasamy Associates of Chennai and Modern Surgical of Kolkata for allowing me to use a number of quality photographs of several eye equipment and instruments.

I gratefully acknowledge the sincere support and help received from the staff of my publishers, Prentice-Hall of India, New Delhi. I am indebted to all of them for their unending patience and courtesy. Finally, I express my deep appreciation and heartfelt thanks to my family members for their patience, perseverance and encouragement, and for supporting me throughout the fulfilment of this arduous task of revision.

E. AHMED

Acknowledgements

acknowledges the authors, editors and publishers of the following textbooks from
which have been borrowed. *Parsons' Diseases of the Eye*: Churchill Livingstone, London;
The Eye: Williams and Wilkins, Baltimore; *May and Worth's Manual of*
Ophthalmology: Cashell, London; *Wolff's Anatomy of the Eye and Orbit*, H.K.
Lewis, London; *Ophthalmic Operations*, Bailliere, Tindall and Cox, London;
University Press, London; *Pauchet and Dupret's*
Ophthalmology: The Essentials of Perimetry, Oxford
Ophthalmology, Butterworths, London;
Ophthalmology, Association;



Acknowledgements

The author gratefully acknowledges the authors, editors and publishers of the following textbooks from which some illustrations have been borrowed. *Parsons' Diseases of the Eye*: Churchill Livingstone, London; *May's Manual of the Diseases of the Eye*: Williams and Wilkins, Baltimore; *May and Worth's Manual of the Diseases of the Eye*: Bailliere Tindall and Cashell, London; *Wolff's Anatomy of the Eye and Orbit*, H.K. Lewis, London; Philps and Foster: *Ophthalmic Operations*, Bailliere, Tindall and Cox, London; *Cunningham's Manual of Practical Anatomy*: Oxford University Press, London; *Pauchet and Dupret's Pocket Atlas of Anatomy*: Oxford University Press, Hong Kong; Reed: *The Essentials of Perimetry*, Oxford University Press, London; Duke-Elder and Wybar: *Duke-Elder's System and Ophthalmology*, Vol. 6. *Ocular Motility and Strabismus*, Kimpton, London; Sorsby: *Modern Ophthalmology*, Butterworths, London; Lombardi: *Radiology in Neuro-Ophthalmology*, Williams and Wilkins, Baltimore; Wybar: *Ophthalmology*, Bailliere-Tindall, London; Mann: *Developmental Abnormalities of the Eye*, British Medical Association; Mcpherson: *New and Controversial Aspects of Retinal Detachment*, Harper and Row, New York; Scheje and Albert: *Textbook of Ophthalmology*, W.B. Saunders, Philadelphia; Berens and Zuckerman: *Diagnostic Examination of the Eye*; J.B. Lippincott, Philadelphia; Whittington: *The Art of Clinical Refraction*, Oxford University Press, London; Perkins: *Uveitis and Toxoplasmosis*, J&A Churchill, London; *Stallard's Eye Surgery*, John Wright and Sons, London; Trevor-Roper: *The Eye and Its Disorders*, Blackwell Scientific Publications, Oxford; Trevor-Roper: *Lecture Notes in Ophthalmology*, Blackwell Scientific Publications, Oxford; *Gifford's Textbook of Ophthalmology*, W.B. Saunders, Philadelphia; Parr: *Introduction to Ophthalmology*, Oxford University Press, New Zealand; Galbraith: *Basic Eye Surgery*, Churchill Livingstone, Edinburgh; Brian and Walton: *Brain's Diseases of The Nervous System*, Oxford University Press, London; Whitnall: *The Anatomy of the Human Orbit*, Oxford Medical Press, London; Hollwich, F.: *Ophthalmology*, 2nd revised ed., English translation by F.C. Blodi, Thieme and Stratton, 1985; Peyman, G.A., Sanders, D.H. and Goldberg, M.F. (Eds.): *Principles and Practice of Ophthalmology*, W.B. Saunders, Philadelphia, 1980; Snell, R.S. and Lewp, M.A.: *Clinical Anatomy of the Eye*, 2nd ed., Blackwell Science, 1998.

The author is thankful and he also acknowledges permission to reproduce certain illustrations as follows: A.J. Bron of University of Oxford for some illustrations in *The Unquiet Eye* published by Glaxo Laboratories; American Cyanamid Company, for two coloured photographs; Nicholas division of Indian Schering Ltd; Appaswamy Associates, Chennai and Ankur Metal Works, West Bengal. The author's gratitude is no less in the case of help received from his esteemed colleagues.

Although every effort has been made to trace copyright holders of material printed in this book, in some cases it has not proved possible. The publisher will be glad to hear from such copyright holders, which will be acknowledged in the next edition.

E. AHMED

Abbreviations

A	Accommodation	C	Candida
Å	Angstrom, a unit of measurement	C/D ratio	Cup/disc ratio
AC	Anterior chamber	C₈	Cervical vertebra 8
AC/A ratio	Accommodation-convergence/accommodation ratio	CAB	Cellulose acetate butyrate
ACE	Angiotensin-converting enzyme	CAI	Carbonic anhydrase inhibitor
ACTH	Adrenocorticotrophic hormone	CAT	Computerized axial tomography
ACV	Acyclovir	CCC	Continuous curvilinear capsulorrhexis
ADCC	Antibody-dependent cell-mediated cytotoxic	CCT	Computerized coronal tomography
AIDS	Acquired immuno deficiency syndrome	CEA	Carcinoembryonic antigen
AION	Anterior ischaemic optic neuropathy	CF	Complement fixation
AK	Astigmatic keratotomy	CFF	Critical fusion frequency
AKC	Atopic keratoconjunctivitis	CHED	Congenital hereditary endothelial dystrophy
ALT	Argon laser trabeculoplasty	CLV	Corrected loss variance
AMP	Adenosine monophosphate	CMI	
ANA	Antinuclear antibodies	response	Cell-mediated immunity response
APMPPE	Acute posterior multi-focal placoid pigment epitheliopathy	CMO	Cystoid macular oedema
Ara-A	Adenine arabinoside	CMV	Cytomegalovirus
ARC	Abnormal retinal correspondence	CNS	Central nervous system
ARMD	Age-related macular degeneration	Coryn	Corynebacterium
AS	Ankylosing spondylitis	CP angle	Cerebellopontine angle
Asb	Apostilbs, a term used in automated perimetry	CPC	Central posterior curve, of the cornea
ASFA	Anterior segment fluorescein angiography	CPK	Combined epithelial and subepithelial punctate keratitis
ATP	Adenosine triphosphate	CR length	Crown-rump length
AV crossing	Arteriovenous crossing	CRAO	Central retinal artery occlusion
AZT	Azidothymidine	CRVT	Central retinal vein thrombosis
B	Bacillus	CSLO	Confocal scanning laser ophthalmoscope
B-cells	Lymphocytes, bone-marrow derived	CSMO	Clinically significant macular oedema
BCG	Bacille Calmette-Guérine	CSR	Central serous retinopathy
BDR	Background diabetic retinopathy	CT	Computerised tomography
BMR	Basal metabolic rate	Cyl	Cylinder
BP	Blood pressure	D	Dioptre, unit of a lens
BRVT	Branch retinal vein thrombosis	dB	Decibel, term used in automated perimetry
BSS	Balanced salt solution	DCG	Dacryocystography
BSV	Binocular single vision	DCR	Dacryocystorhinostomy
BUT	Breakup-time of tear	DEAE-D	Diethyl aminoethyl-dextran
BVA	Binocular visual acuity	DEK	Deep epithelial keratopathy
BVDU	5-(2-bromovinyl)-2-deoxyuridine	DFP	Diisopropyl fluorophosphate
'C'	Coefficient of aqueous outflow	DHPG	9-(1,3-dihydroxy-2-propoxymethyl) guanine
		DIT	Diniodotyrosine
		DLT	Differential light threshold
		DMSO	Dimethyl sulphoxide
		DNA	Deoxyribonucleic acid
		DOCA	Deoxycorticosterone acetate
		DSG	Dacryoscintillography

E	Emmetropia	HLA	Human leucocyte antigen
EBV	Epstein-Barr virus	HM	Hand movements
ECCE	Extracapsular cataract extraction	Hm	Hypermetropia, manifest
ECF	Eosinophil chemotactic factor	HMS	Hexose monophosphate shunt
ED glaucoma	Epidemic dropsy glaucoma	HSV	Herpes simplex virus
EDMA	Ethylene glycol dimethacrylate	Ht	Hypermetropia, total
EDTA	Ethylenediamine tetraacetic acid	HZO	Herpes Zoster ophthalmicus
EEG	Electroencephalography		
EHC	Epidemic haemorrhagic conjunctivitis	Ia antigen	Immune-associated antigen
EIA	Enzyme immuno assay	ICCE	Intracapsular cataract extraction
EKC	Epidemic keratoconjunctivitis	ICG	Indocyanine green
EKP	Epikeratoprosthesis	IDDM	Insulin dependent diabetes mellitus
ELISA	Enzyme-linked immuno assay	IDU	5-iodo-2-deoxyuridine
EMBP	Eosinophil major basic protein	IF	Immunofluorescence
EMG	Electromyography	IFA	Indirect fluorescent antibody
EOG	Electrooculography	Ig	Immunoglobulin
EPS	Exophthalmos-producing substance	IHA	Immune adherence haemoagglutination
ERG	Electroretinography	IK	Interstitial keratitis
ERP	Early receptor potential	INH	Isonicotinic acid hydrazide
ESR	Erythrocyte sedimentation rate	IO	Inferior oblique
ETDRS	Early treatment diabetic retinopathy study	IOL	Intraocular lens
		IOP	Intraocular pressure
		IPK	Interstitial punctate keratitis
5-FU	5-fluorouracil	IR	Inferior rectus
F₁, F₂	Focal points	IRBP	Interphotoreceptor retinal binding protein
F₃T	Trifluorothymidine	IRMA	Intraretinal microvascular abnormalities
Fab	Fragment antigen binding		
FAMA	Fluorescent antibody to membrane antigen	J₁, J₂	Sizes of the print in Jaeger's near vision chart
FAZ	Foveal avascular zone	JCA	Juvenile chronic arthritis
FC	Finger counting	JOAG	Juvenile open-angle glaucoma
Fc	Fragment crystallisable	JRA	Juvenile rheumatoid arthritis
FFA	Fluorescein fundus angiography		
FNAB	Fine-needle aspiration biopsy	'K'	Reading in keratometry indicating the radius of the curvature of the front surface of the cornea
FTA-ABS	Fluorescein treponemal antibody absorption	K-cell	Killer cell
		KP	Keratic precipitate
G	Gutta, i.e. drop	KW	
GANDA	Guanethidine + adrenaline	syndrome	Kimmelstiel-Wilson syndrome
GCV	Ganciclovir	KWC	Koch-Weeks' conjunctivitis
GHPC	Geographic helicoid peripapillary choroidopathy		
GM	Gangliosidosis	Laser	Light amplification by stimulated emission of radiation
GMP	Guanosine monophosphate	LASIK	Laser-assisted keratomileusis
GPC	Giant papillary conjunctivitis	LATS	Long-acting thyroid stimulator
		LCAT	Lecithin cholesterol acyl transferase
H	Hypermetropia	LDH	Lactic dehydrogenase
H.	Haemophilus	LED	Light emitting diode
HA	Haemoagglutination		
HEMA	Hydroxy ethyl methacrylate		
HI	Haemoagglutination inhibition		
HIV	Human immunodeficiency virus		
HI	Hypermetropia, latent		

LGV	Lymphogranuloma venereum	OU	Oculus uterque (both eyes)
LK	Lamellar keratoplasty		
LR	Lateral rectus		
LRP	Late receptor potential	pp,	Punctum proximum (near point)
LTF	Long-term fluctuations	pr,	Punctum remotum (far point)
		P ₀	Initial intraocular pressure in tonography
		P ₁ and P ₂	Principal points
M	Myopia	P ₁	Resultant elevated pressure in tonography
m.a.	Metre angle	PABA	Paraamino benzoic acid
mA	Milliampere	PACG	Primary angle-closure glaucoma
MAO	Monoamine oxidase	PAF	Platelet-activating factor
MD	Mean defect	PAM	Potential acuity meter
MDCG	Macrodacryocystography	PAS	Paraamino salicylic acid
MEWDS	Multiple evanescent white dot syndrome	Pas	Peripheral anterior synechia
MIF	Microimmunofluorescence	PBI	Protein-bound iodine
MIT	Monoiodotyrosine	PCF	Pharyngoconjunctival fever
MK medium	McCarey-Kaufman medium	PCM	Protein-calorie malnutrition
ML	Mucopolysaccharidosis	PD	Pupillary distance
MLD	Margin limbal distance	PDMS	Polydimethyl siloxane
MMC	Mitomycin C	PDR	Proliferative diabetic retinopathy
MPP	Massive preretinal proliferation	PEE	Punctate epithelial erosions
MPR	Massive preretinal retraction	PEK	Punctate epithelial keratitis
MPS	Mucopolysaccharidoses	PHEMA	Polydihydroxymethyl methacrylate
MR	Medial rectus	PHPV	Persistent hyperplastic primary vitreous
MRD	Margin reflex distance	PI	Peripheral iridectomy
MRI	Magnetic resonance imaging	PK	Penetrating keratoplasty
MVR	Massive vitreous retraction	PL	Perception of light
Myco.	Mycobacterium	PMMA	Polymethyl methacrylate
		POAG	Primary open-angle glaucoma
		POB	Punctate opacification of Bowman's membrane
N.	Neisseria	PPDR	Preproliferative diabetic retinopathy
N ₁ &N ₂	Nodal points	PR	Projection of rays
N ₅ to N ₄₈	5-point to 48-point sizes of near vision chart standardized by Faculty of Ophthalmologists	PRK	Panretinal photocoagulation
NADPH	Nicotinamide adenine dinucleotide phosphate	Ps.	Pseudomonas
NANA	N-acetyl neuraminic acid	PSK	Punctate subepithelial keratitis
NCL	Neuronal ceroid lipofuscinosis	PTK	Phototherapeutic keratectomy
NIDDM	Non-insulin-dependent diabetes mellitus	PUGH	Pigment-uveitis-glaucoma-hyphaema syndrome
NK cells	Natural killer cells	PVD	Posterior vitreous detachment
nm	Nanometer	PVP	Polyvinyl pyrrolidone
NPA	Near point of accommodation	PVR	Proliferative vitreoretinopathy
NPC	Near point of convergence		
NRC	Normal retinal correspondence	RA	Rheumatoid arthritis
NSAID	Nonsteroidal antiinflammatory drug	RAI	Radioactive iodine
NVD	Neovascularization at the disc	RAPD	Relative afferent pupillary defect
NVE	Neovascularization elsewhere	RB inj.	Retrobulbar injection
		RBN	Retrobulbar neuritis
OA	Optic atrophy	RBP	Retinol-binding protein
OD	Oculus dexter (right eye)	RD	Retinal detachment
OS	Oculus sinister (left eye)	RLF	Retrolental fibroplasia

RMS	Root mean square, a term in automated perimetry	T-cell	Thymus-derived cell
RNA	Ribonucleic acid	TEM	Triethylene melamine
RNFL	Retinal nerve fibre layer	TF	Total fluctuations
ROP	Retinopathy of prematurity	THIOTEPA	Triethylene thiophosphoramidate
RPE	Retinal pigment epithelium	TL	Total loss, a term in automated perimetry
		TRD	Traction retinal detachment
		TRH	Thyrotropin-releasing hormone
		TRIC	Trachoma inclusion conjunctivitis virus
Sc.inj.	Subconjunctival injection	TSCA	Tumour-specific cytoplasmic antigen
SLE	Systemic lupus erythematosus	TSH	Thyroid-stimulating hormone
SLO	Scanning laser ophthalmoscope	TSTA	Tumour-specific transplantation antigen
SO	Superior oblique		
Sph	Spherical	UGH	Uveitis-glaucoma-hyphaema syndrome
SPK	Superficial punctate keratitis	Ung.	Unguentum (ointment)
SR	Superior rectus		
SRF	Subretinal fluid	VA	Visual acuity
SRK formula	Sanders, Retzlaff and Kraff formula	VDRL	Venereal disease research laboratory
SRNVM	Subretinal neovascular membrane	VER	Visual evoked response
SRS-A	Slow release substance of anaphylaxis	VF	Visual field
Staph.	Staphylococcus	VISC	Vitreous infusion suction cutter
STF	Short-term fluctuations	VSR	Venous stasis retinopathy
Strepto.	Streptococcus	VZV	Varicella-Zoster virus
T₁,T₂ etc.	Thoracic vertebrae 1,2, etc.	YAG laser	Yttrium-aluminium-garnet laser
TAA	Tumour-associated antigens		
TB	Tuberculosis		
TCA cycle	Tricarboxylic acid cycle		

Part One

Anatomy and Embryology

Each eyeball or globe, with the anteroposterior, vertical and horizontal diameters of 24 mm, 23 mm and 23.5 mm respectively, occupies the anterior part of the bony orbit. The eyeball comprises three concentric coats—outermost, middle and innermost. The outermost coat, protective in function, contains the opaque sclera in its posterior five-sixth portion and the transparent cornea in its anterior part. The anterior part of the sclera is covered by the conjunctiva which also covers the back surface of the eyelids. The middle coat of the globe, vascular and nutritive, is made up of the iris, ciliary body and choroid—all three constituting the uveal tract. The innermost coat is the retina. The ocular appendages are the eyelids, eyebrows, conjunctiva and lacrimal apparatus. There are two sets of muscles—extrinsic, six in number, and intrinsic, three in number. The extrinsic muscles comprise four recti and two obliques, while the intrinsic muscles are the sphincter pupillae, dilatator pupillae and ciliary muscle. Aqueous humour, the intraocular fluid, occupies the anterior and posterior chambers. The posterior four-fifth of the globe is occupied by the vitreous humour. The crystalline lens is placed behind the iris and in front of the vitreous body.

This section deals with the orbit and its contents, eyelids, lacrimal apparatus, conjunctiva, cornea, sclera, uveal tract, retina, visual pathways, extrinsic muscles and with the parts involved in glaucoma.

Certain basic aspects of the embryology of the eye should also be understood since there are lot of developmental anomalies in each tissue of the eyeball and its appendages.

1. ANATOMY OF THE ORBIT¹⁻³

Seven bones contribute to the formation of the pear-shaped orbit: the frontal, sphenoid, maxillary, palatine, zygomatic, ethmoid and lacrimal. It has a base, margin, apex and four posteriorly converging walls. The orbital cavity is directed forward, outward and slightly downward.

Base. The base of the orbit represents the anterior open end.

Margin. This is made up of three bones: the frontal, zygomatic and maxilla. There are four portions: superior, inferior, medial, and lateral.

Apex. The apex corresponds to the optic foramen.

Average dimensions. Table 1.1 indicates average dimensions of the orbit.

Table 1.1
Average Dimensions of the Orbit

Each orbital margin	40 mm
Width of orbital opening	40 mm
Height of orbital opening	35 mm
Interorbital distance	25 mm
Extraorbital distance	100 mm
Length of sphenoid fissure	22 mm
Distance between	
intracranial openings of 2 optic canals	25 mm
orbital openings of 2 optic canals	30 mm
Orbital volume	30 ml

Orbital index. It is the ratio of the height to the width $\times 100$. There are three types of orbital index:

- (i) *mesosemes* (intermediate): index between 83–89
- (ii) *megasemes* (large): index more than 89
- (iii) *microsemes* (small): index less than 83.

Walls of the Orbit (Fig. 1.1)

Roof. This is approximately triangular and consists, anteriorly of the orbital plate of the frontal bone—the major contribution; and posteriorly, the lesser wing of the sphenoid bone.

Floor. This is roughly triangular and consists centrally, of the orbital plate of the maxilla, anterolaterally of the zygomatic bone, and posteriorly of the orbital process of the palatine bone.

Medial wall. This is quadrangular and is the thinnest of all the walls, 0.2–0.4 mm. It consists, in the main central part, of the lamina papyracea of the ethmoid; superoanteriorly, of the frontal process of the maxilla; inferoanteriorly, of the lacrimal bone; and posteriorly, of the lateral aspect of the body of the sphenoid.

Lateral wall. This in triangular is shape and is the strongest of all the walls. Both lateral walls form an angle of about 90° to each other. Each wall forms an angle of about 45° with the median

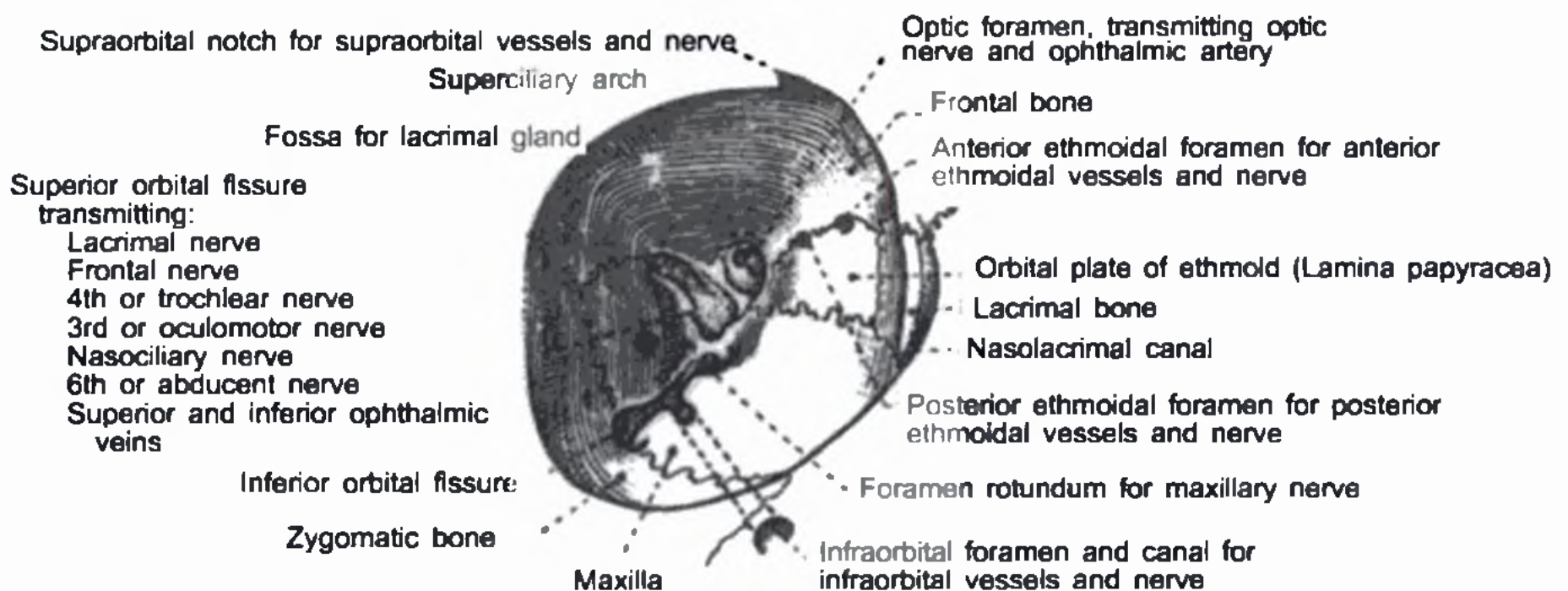


Fig. 1.1 Right orbit (Pauchet and Dupret).

sagittal plane. Each is made up of the orbital surface of the zygomatic in the anterior one-third, and that of the greater wing of the sphenoid in the posterior two-thirds.

Relations are shown in Table 1.2.

Table 1.2
Relations of the Orbit

Relations	Structures
Superior	Anterior cranial fossa Frontal sinus Supraorbital sinuses
Medial	Ethmoid air cells Nasal cavity Sphenoid sinus
Inferior	Maxillary antrum Palatine air cells
Lateral	Middle cranial fossa Temporal fossa Pterygopalatine fossa

Landmarks

Superior orbital or sphenoid fissure (Fig. 1.2). Between the greater and lesser wings of the sphenoid there lies an anterolaterally directed oblique gap about 2 cm long, situated between the

roof and the lateral wall of the orbit, having two segments. The wide medial segment communicates with the middle cranial fossa, while the narrow lateral segment is closed by the dura mater. Through the wide part the following structures pass: (a) the three branches of the ophthalmic division of the trigeminal nerve, (b) the III, IV and VI cranial nerves, (c) the ophthalmic vein or veins, (d) the orbital branch of the middle meningeal artery and the recurrent meningeal branch of the lacrimal artery and (e) the sympathetic fibers from the cavernous plexus. A tendinous ring known as *annulus tendinous communis of Zinn* surrounds the optic canal and part of the medial segment of the superior orbital fissure.

Optic foramen and canal. The optic foramen is the vertically oval opening at the apex of the orbit and marks the orbital end of the optic canal. The optic canal, about 4–9 mm long and 4–6 mm wide, lies between the two roots of the lesser wing of the sphenoid bone. It is directed posteromedially and makes an angle of about 36° with the median sagittal plane. The canal transmits (a) the optic nerve, (b) the ophthalmic artery, (c) the branches of the sympathetic carotid plexus, and (d) the prolongations of the optic nerve sheaths.

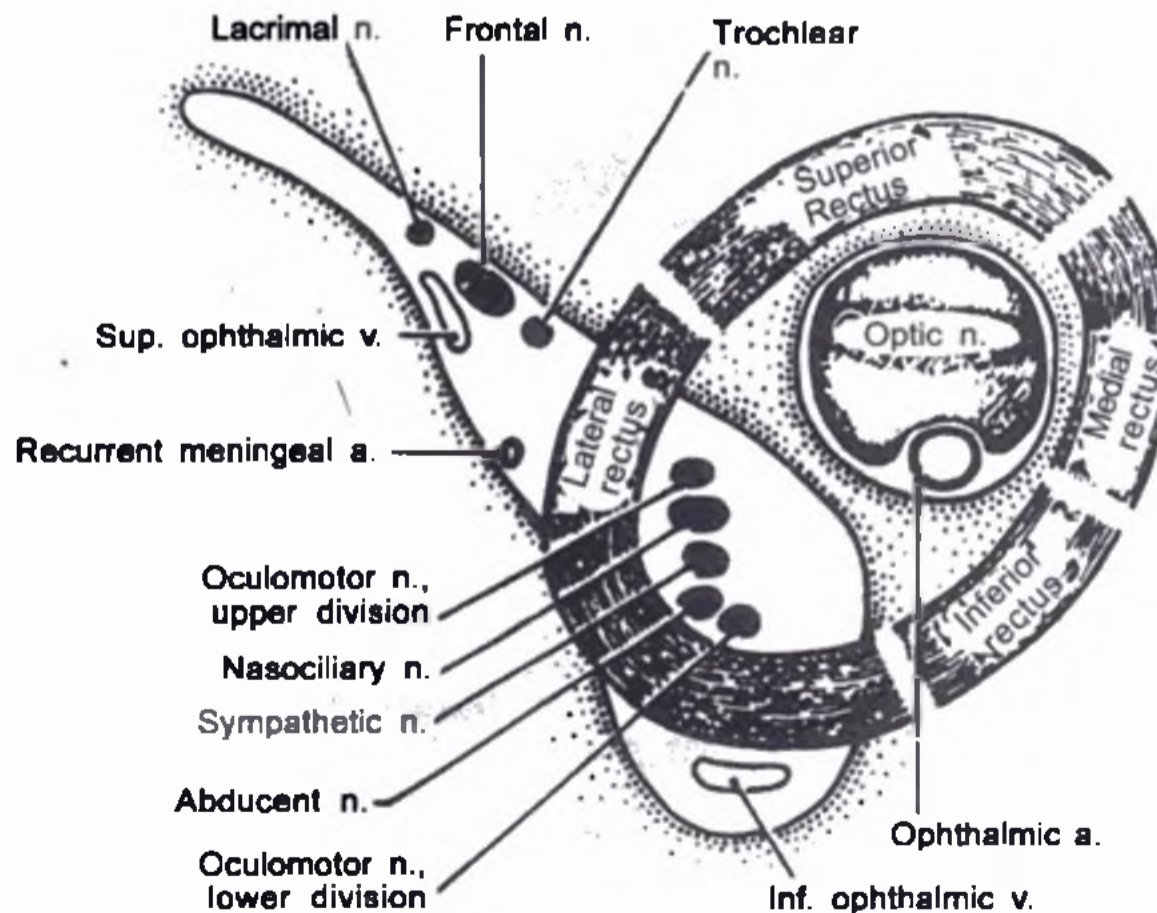


Fig. 1.2 Anatomical relations at the apex of the right orbit (Reed).

Fossa for the lacrimal gland. This is on the frontal bone and is situated at the anterolateral angle of the orbit.

Trochlear fossa. This is on the frontal bone, 5 mm behind the anteromedial angle of the orbit. It contains the pulley of the superior oblique muscle.

Zygomaticofrontal suture. This lies between the roof and the lateral wall of the orbit.

Supraorbital notch and canal. This is at the junction of the medial third and lateral two-third of the superior orbital margin and transmits the supraorbital nerve and vessels.

Orbital tubercle of the zygomatic bone. This is 11 mm below the frontozygomatic suture. The structures attached to it are: (a) the check ligament of the lateral rectus, (b) the suspensory ligament of the eyeball, (c) the lateral palpebral ligament and (d) the aponeurosis of the levator palpebrae superioris. The combined attachment of these structures is called the *lateral retinaculum*.

Zygomatic canal. This is in the lateral wall. It transmits the zygomatic nerve and branches of the infraorbital artery.

Meningeal foramen. This is in the lateral wall. It transmits the orbital branch of the middle meningeal artery with the accompanying vein.

Lacrimal fossa. This lodges the lacrimal sac in the medial wall, and is situated between the anterior and posterior lacrimal crests.

Inferior orbital or sphenomaxillary fissure. This is about 2 cm long and is situated between the floor and posterior two-third of the lateral orbital wall. It transmits these structures: (a) the maxillary division of the V cranial nerve; (b) the infraorbital artery; (c) the zygomatic nerve; (d) the branches of the inferior ophthalmic vein to the pterygoid plexus; and (e) the branches of the sphenopalatine ganglion.

Fossa at the anteromedial angle of the floor. The inferior oblique muscle originates from this fossa.

Contents

Apart from the eyeball which occupies most of its space the orbit contains the following:

(a) **Muscles.** Six extrinsic, lid muscles and plane muscles of the orbit.

(b) **Arteries.** Two sources—ophthalmic and terminal branch of the external carotid.

(c) **Veins.** Superior ophthalmic, inferior ophthalmic and central retinal.

(d) **Nerves.** II, III, IV, VI, first two divisions of the V cranial; sympathetic fibres to the eyeball, the lacrimal gland, the plane muscle of the orbit and to the blood vessels; and parasympathetic fibres to the lacrimal gland through the VII cranial.

(e) **Orbital fascia.**

(f) **Ciliary ganglion.**

Ophthalmic Artery (Fig. 1.3)

Ophthalmic artery arises from the anteromedial aspect of the internal carotid artery, just medial to the anterior clinoid process. The artery has three parts: one part lying inferolateral to the optic nerve; the second crossing the optic canal to lie on the

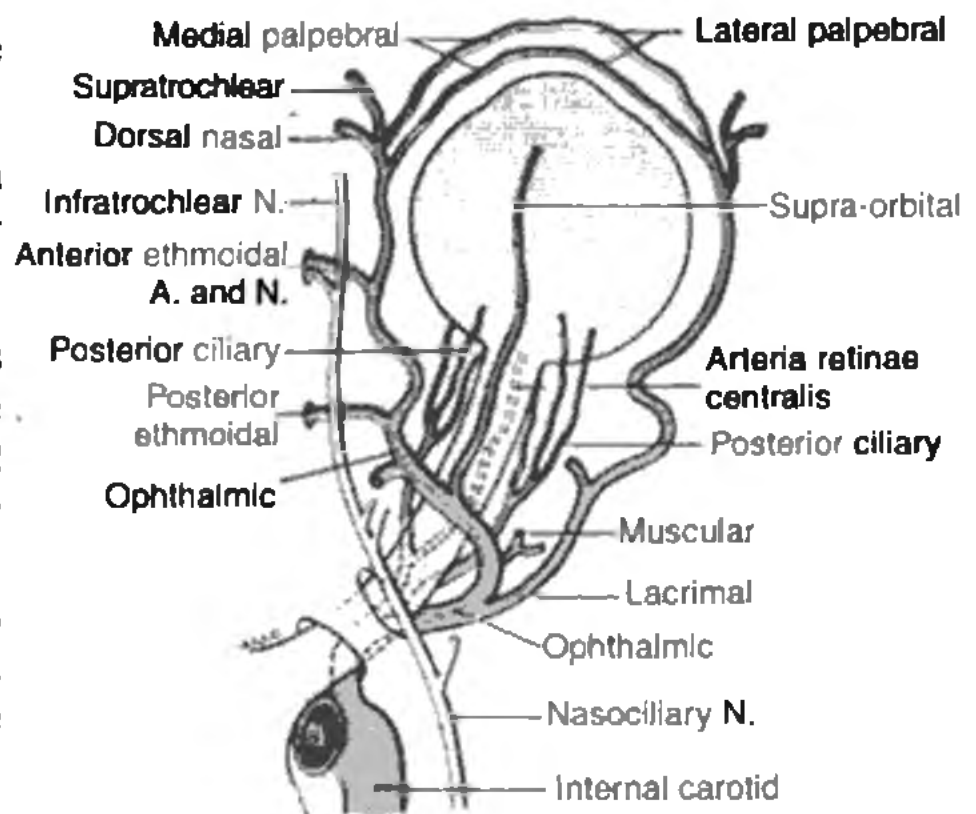


Fig. 1.3 Illustration of the ophthalmic artery and its branches (Cunningham).

lateral side of the optic nerve; and the last lying medial to the optic nerve. Leaving the dural sheath, it lies within the muscle cone, crosses the optic nerve usually above, and runs towards the medial side of the orbit. Running forward between the superior oblique and the medial rectus, ophthalmic artery ends by splitting into two terminal branches—the frontal and the dorsal nasal.

The branches of the ophthalmic artery are listed in Table 1.3.

Superior Ophthalmic Vein (Fig. 1.4)

It is the largest vein in the orbit and originates at the junction of the angular and supraorbital veins. It runs alongside the ophthalmic artery and receives several tributaries such as the inferior ophthalmic, the central retinal, the anterior ciliary via the muscular veins, the anterior and posterior ethmoidal, two vorticose and the lacrimal. It finally drains into the cavernous sinus.

Inferior Ophthalmic Vein

This vein (Fig. 1.4) arises in the floor of the orbit

Table 1.3

Branches of the Ophthalmic Artery

<i>Central retinal</i>	
superior and inferior papillary	
nasal and temporal branches	
<i>Lacrimal</i>	
lateral palpebral	
zygomatic	
recurrent meningeal	
<i>Muscular (7)</i>	
anterior ciliary	
<i>Posterior ciliary</i>	
long (2)—medial and lateral	
short (15–20)	
<i>Anterior ethmoidal</i>	
<i>Posterior ethmoidal</i>	
<i>Pial</i>	
<i>Supraorbital</i>	
<i>Medial palpebral</i>	
<i>Anterior meningeal</i>	
<i>Central artery of the optic nerve</i>	
<i>Supratrochlear (frontal)</i>	} terminal branches
<i>Dorsal nasal</i>	

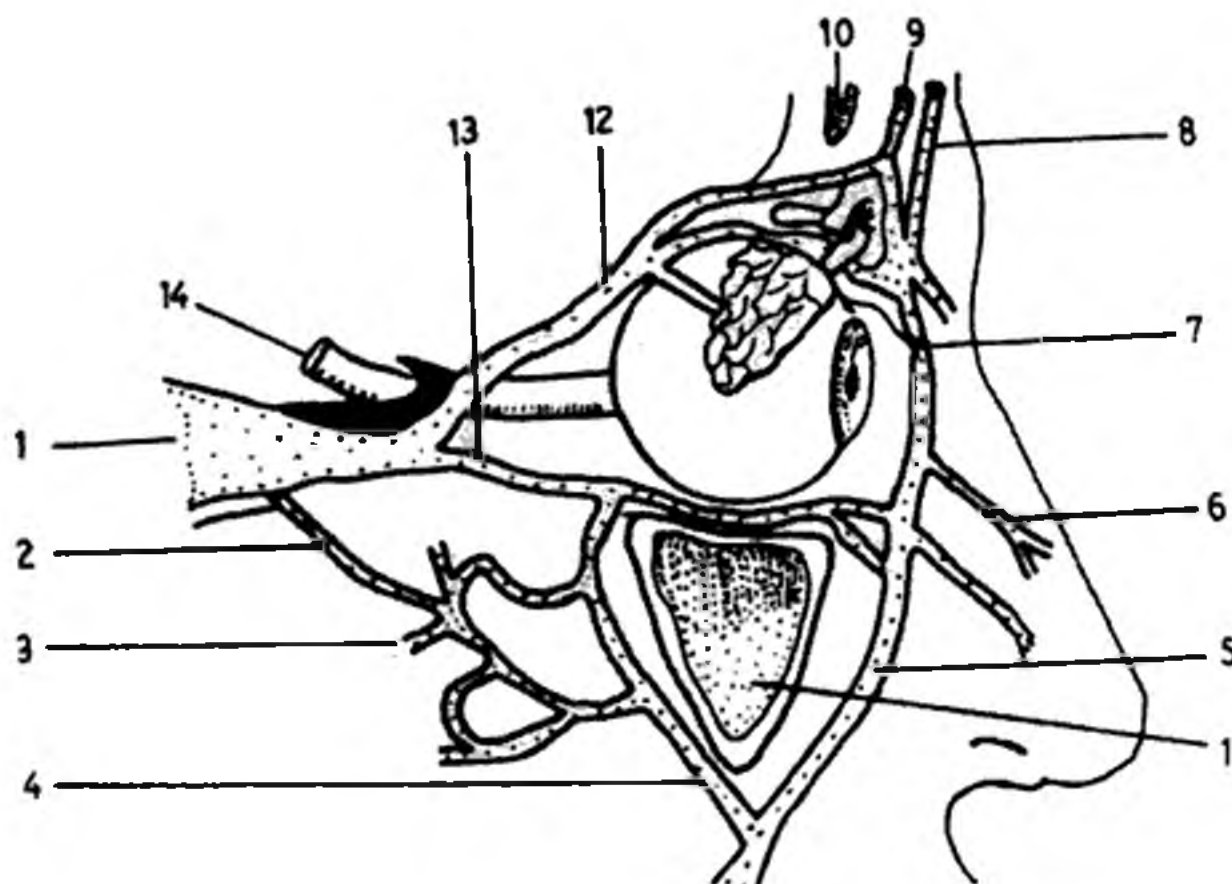


Fig. 1.4 Diagrammatic representation of the orbital veins: 1, cavernous sinus; 2, vein of Vesalius; 3, pterygoid venous plexus; 4, deep facial vein; 5, facial vein; 6, nasal vein; 7, angular vein; 8, frontal vein; 9, supraorbital vein; 10, frontal sinus; 11, maxillary sinus; 12, superior ophthalmic vein; 13, inferior ophthalmic vein; and 14, optic nerve.

as a plexus, runs alongside the inferior rectus, and joins either the superior ophthalmic vein or drains directly into the cavernous sinus.

Ciliary Ganglion (Figs. 1.5 and 1.6)

A small, rectangular body 2 mm horizontally and 1 mm vertically situated at the apex of the orbit within the loose fatty tissue, it lies about 1.5 cm behind the globe, nesting between the optic nerve and the lateral rectus and on the lateral side of the

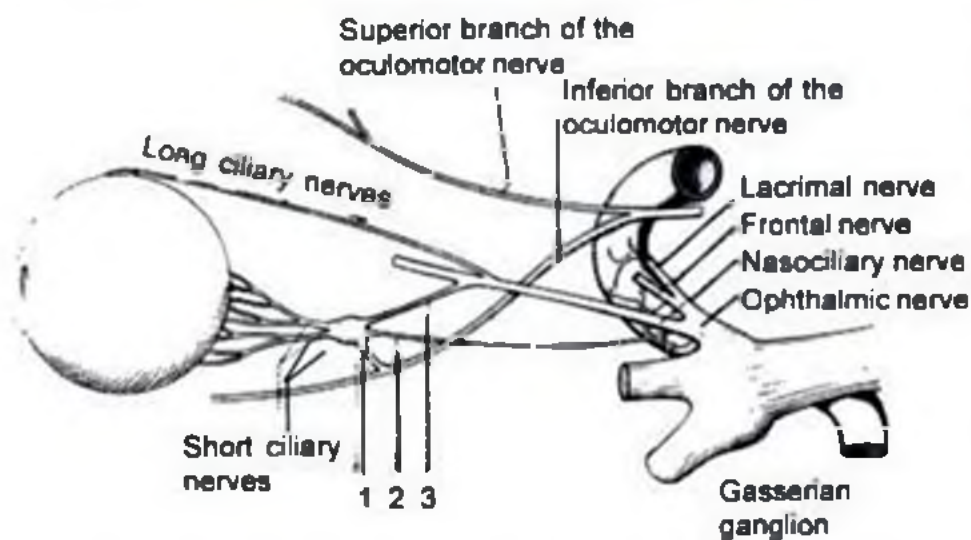


Fig. 1.5 Roots of ciliary ganglion 1, short root; 2, sympathetic root and 3, long root (Hollwich).

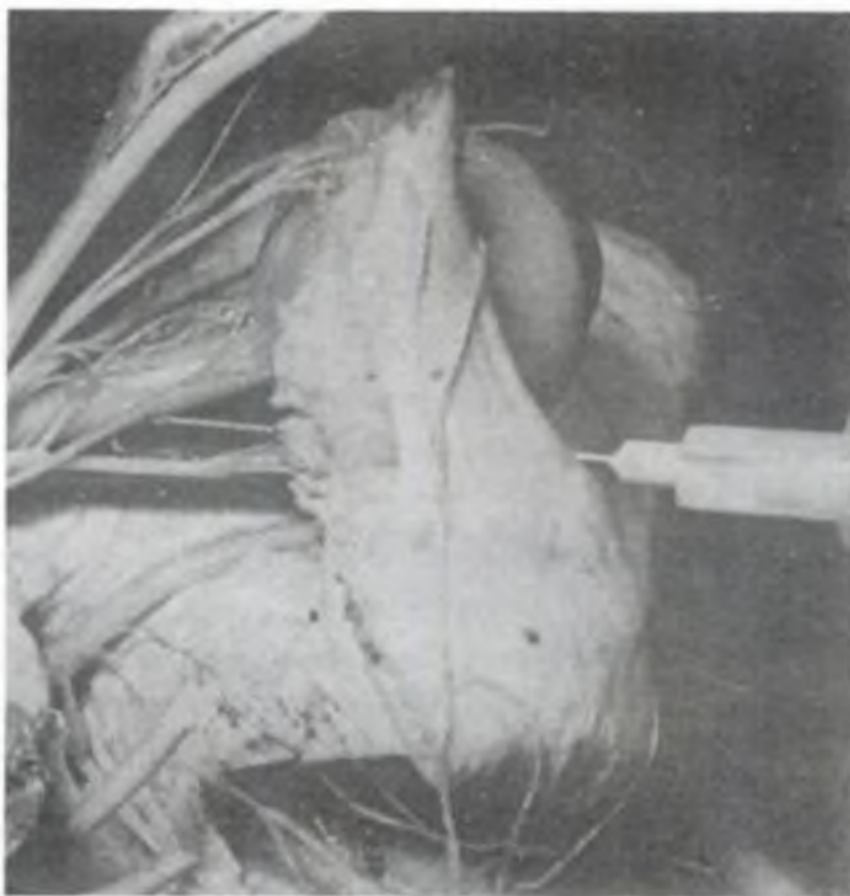

Fig. 1.6 A lateral view of the orbit showing the position of the needle when the injection commences. (Note that the extraocular muscles and lateral wall of the orbit have been removed in this model. (Courtesy: J.E.K. Galbraith)

ophthalmic artery. Essentially, a cell-station of the parasympathetic elements of the III cranial nerve, it has three roots which enter its posterior aspect: (a) the short motor or parasympathetic—from the nerve to the inferior oblique, (b) the long sensory—from the nasociliary branch of the ophthalmic division of the V cranial, and (c) the sympathetic—from the internal carotid plexus.

Variations in the ciliary ganglion are common, e.g. multiplicity or absence of a root.

Accessory ciliary ganglia. Thirty or more in number, these are associated with the ciliary nerves and may be concerned with the contraction of the pupil or convergence.

Surgical Spaces in the Orbit

1. Subperiosteal space is situated between the orbital wall and the periorbita.
2. Peripheral space is bound internally by the extrinsic muscles with their fascial expansions, peripherally by the periorbita, anteriorly by the septum orbitale, and it merges posteriorly with the retrobulbar space.
3. Retrobulbar (central) space, also called *muscle cone*, is a cone-shaped space limited anteriorly by the globe, posteriorly by the annulus tendinous communis of Zinn and laterally by the extraocular muscles.
4. Episcleral (Tenon) space lies round the eyeball between the sclera and Tenon's capsule.

Tenon's Capsule or the Fascia Bulbi (Fig. 1.7)

Tenon's capsule or fascia bulbi is a thin fibrous membrane consisting of the outer parietal and inner visceral layers. It extends from the limbus to the optic nerve and blends anteriorly with the subconjunctival connective tissue and posteriorly with the dural sheath of the optic nerve. It is attached to three structures: the globe, the extrinsic muscles, and the sclera and is pierced by three major sets of structures: six extrinsic muscles, venae vorticosae, and the optic nerve with surrounding ciliary arteries and nerves. Each extrinsic muscle

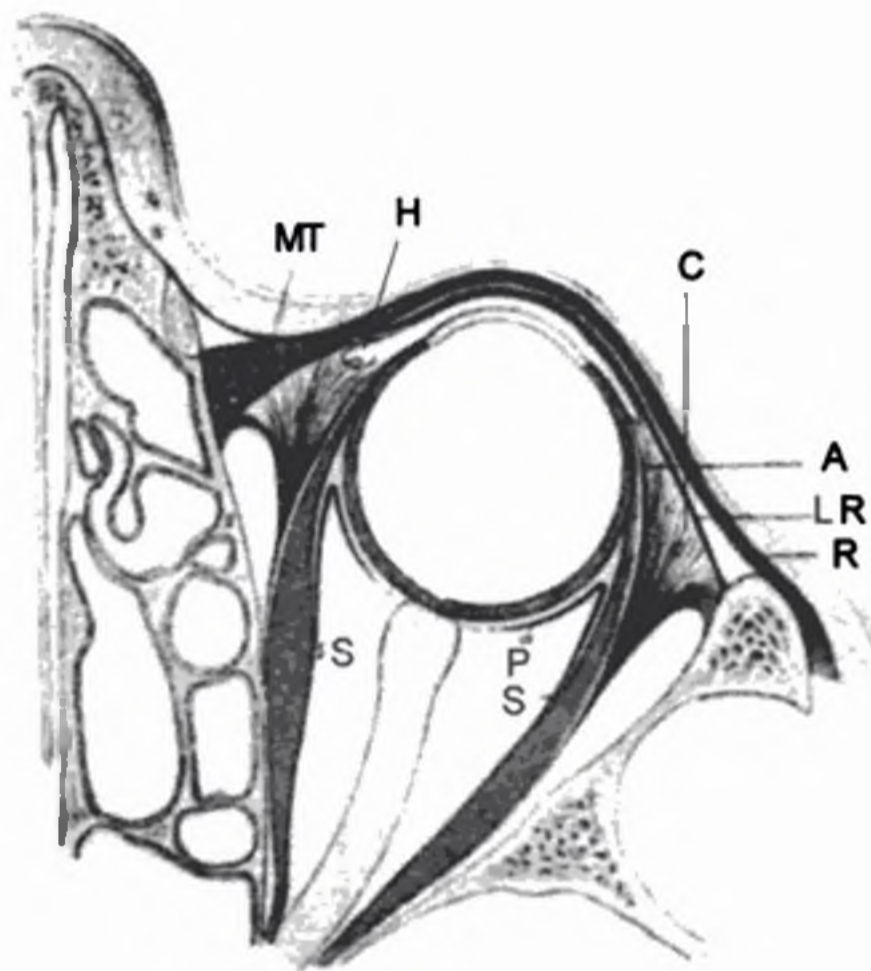


Fig. 1.7 Schematic view of a horizontal section through the right orbit to illustrate the fascia of the orbit. The fascia bulbi or Tenon's capsule, is shown by A, its anterior part, and P, its posterior part. The fascial sheaths of the muscles are marked by S, and their offshoots form the lateral, C, and the medial, H, "check ligaments." The drawing also illustrates certain points in the anatomy of the eyelids. MT, the medial palpebral ligament with its two limbs passing in front of and behind the fossa for the lacrimal sac; LR, the lateral palpebral ligament; and the lateral palpebral raphe (Whitnall: *Anatomy of the Human Orbit*. Oxford Medical Press, London).

is clothed by a tubular reflection from Tenon's capsule. The lateral and medial recti receive such capsular expansion which partly limits some action of either of the two muscles. This is known as the *check ligament*. The reflection from the superior oblique and the inferior oblique muscles are respectively attached to the trochlear pulley and the outer part of the floor of the orbit.

The lower part of Tenon's capsule, the *ligament of Lockwood*, is especially thickened forming a hammock in which the globe rests.

Cranial Nerves in the Orbit^{1,2}

Of the 12 cranial nerves, the following are the main nerves concerned with the structures in the orbit.

The optic nerve. The anatomy of the optic nerve has been described under anatomy of the visual pathways (see Chapter 12).

The third, fourth and sixth nerves (Fig. 1.8). The nuclei of the third and fourth nerves lie in the mid-brain just anterior to the cerebral aqueduct at the level of the superior colliculi. The nuclei of the sixth nerve lie in the pons beneath the floor of the upper part of the fourth ventricle. The third nerve nucleus is divided as follows (Fig. 1.9).

Table 1.4 and Fig. 1.9 give a brief account of this nuclear complex.

Table 1.4

Subdivisions of the Oculomotor Nuclear Complex

Parts of the nucleus	Supply to
<i>Paired</i>	
Dorsolateral	ipsilateral inferior rectus
Intermediate	ipsilateral inferior oblique
Ventromedial	ipsilateral medial rectus
<i>Unpaired</i>	
Caudal central	levator palpebrae superioris
Edinger-Westphal	preganglionic parasympathetic fibres in ciliary ganglion
Perlia	possible role in convergence
Large multipolar	contralateral superior rectus

The *third nerve* emerges from the brain and passes between the superior cerebellar and posterior cerebral arteries. It runs forward and pierces the dura mater on the lateral side of the posterior clinoid process. It traverses the lateral wall of the cavernous sinus and divides into superior and inferior divisions which enter the orbit through the superior orbital fissure. The plan of the oculomotor nerve has been shown in (Fig. 1.10).

The *fourth nerve* is the largest cranial nerve. The fibres of this most slender nerve first run downward and laterally through the tegmentum and then turn backward and at the anterior medullary velum the nerve fibres decussate with the corresponding fibres of the other side and cross the median plane to emerge just behind the inferior colliculi. The nerve passes round the cerebral peduncle just above the pons and pierces the tentorium cerebelli to enter the cavernous sinus. It

then enters the orbit through the superior orbital fissure, and runs along the orbital roof to supply the SO.

The fifth (trigeminal) nerve. This arises from the undersurface of the pons on its lateral aspects by two roots—a large sensory and a small motor and

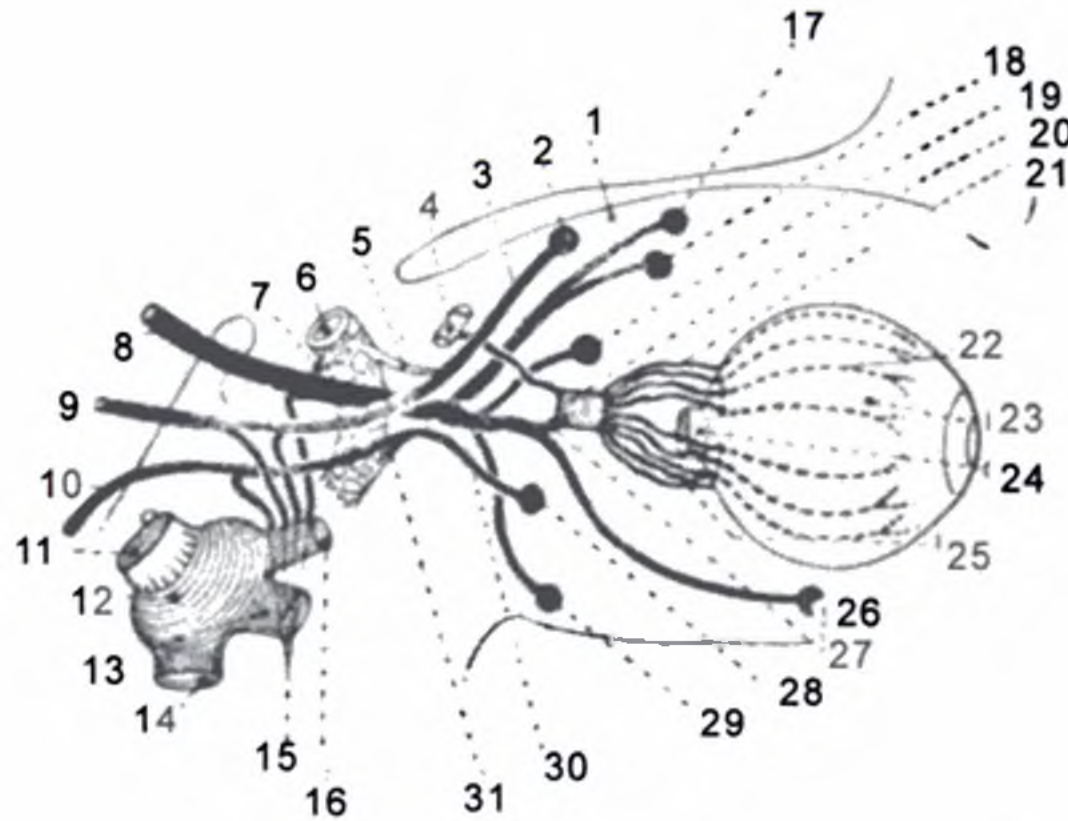


Fig. 1.8 Nerves to the muscles of the eyeball: III, IV and VI cranial nerves 1, orbital cavity; 2, trochlear nerve, to superior oblique; 3, oculomotor nerve, superior division; 4, nasociliary nerve: branch of ophthalmic nerve, giving the sensory root (radix longa ganglii ciliaris) to the ciliary ganglion; 5, sympathetic root; 6, internal carotid artery; 7, sympathetic root; 8, oculomotor nerve; 9, trochlear nerve; 10, abducent nerve; 11, trigeminal nerve; 12, trigeminal ganglion (g. semilunaris); 13, maxillary nerve; 14, mandibular nerve; 15, communicating branches of ophthalmic nerve; 16, ophthalmic nerve; 17, N. to levator palpebrae superioris; 18, N. to superior rectus; 19, N. to medial rectus; 20, ciliary ganglion; 21, efferent branches from the ganglion (short ciliary nerves, upper group); 22, intra-ocular course of ciliary nerves; 23, eyeball (bulbus oculi); 24, optic nerve, cut across; 25, short ciliary nerves, lower group; 26, N. to inferior oblique; 27, motor or short root of ciliary ganglion; 28, N. to lateral rectus; 29, N. to inferior rectus; 30, inferior division of oculomotor nerve; 31, sympathetic root (Pauchet and Dupret).

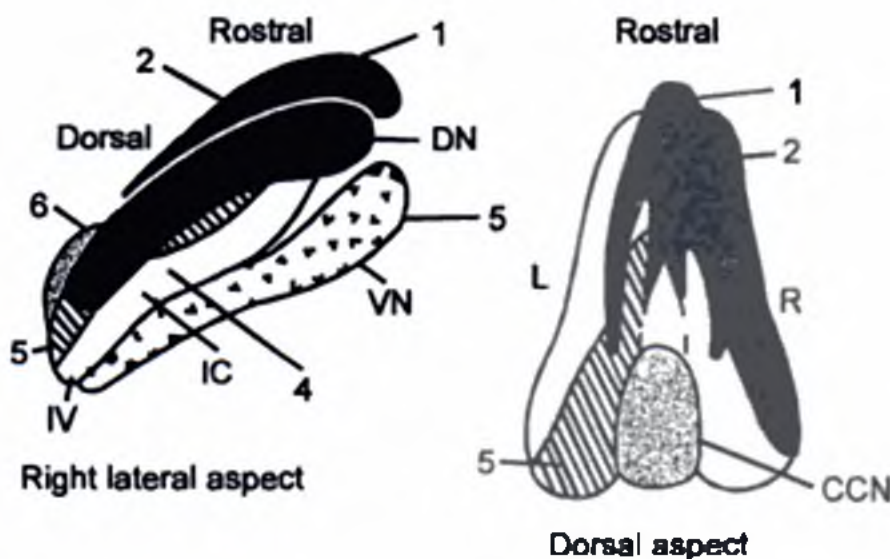


Fig. 1.9 Topographic organization within the oculomotor nucleus. 1, viscerai nucleus; 2, inferior rectus; 3, medial rectus; 4, inferior oblique; 5, superior rectus; 6, levator palpebrae superioris. L = left; R = right; CCN = caudal central nucleus; D = dorsal nucleus; VN = ventral nucleus; IC = intermediate nucleus; IV = trochlear nucleus (Warwick).

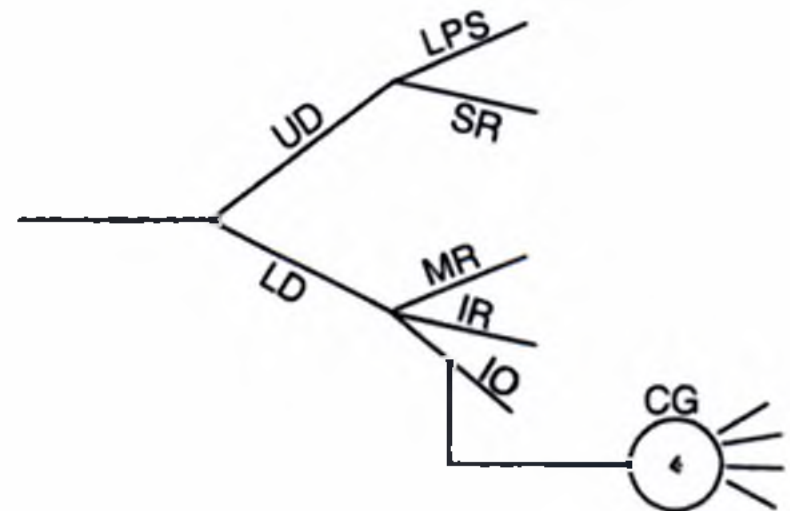


Fig. 1.10 Distribution of the oculomotor nerve. UD, upper division; LD, lower division; CG, ciliary ganglion; LPS, nerve to levator palpebrae superioris; MR, nerve to medial rectus; SR, nerve to superior rectus; IR, nerve to inferior rectus; and IO, nerve to inferior oblique.

passes forward in the posterior fossa to pierce the dura mater to reach the apex of the temporal bone. The sensory root expands and forms the trigeminal ganglion (*Gasserian ganglion*) which splits into three divisions: (a) the ophthalmic, (b) the maxillary, and (c) the mandibular. The motor root emerges under the ganglion and becomes continuous with the mandibular division. Table 1.5 enumerates the branches.

Table 1.5
Branches of the Trigeminal Nerve

<i>Ophthalmic division (sensory)</i>	
Nasociliary	
Long ciliary	
Infratrochlear	
Anterior ethmoidal	
Posterior ethmoidal	
Long root of ciliary ganglion	
Frontal (largest branch)	
Supratrochlear	
Supraorbital	
Lacrimal (smallest branch)	
<i>Maxillary division (sensory)</i>	
Infraorbital	
Middle superior alveolar	
Anterior superior alveolar	
Middle meningeal	
Zygomatic	
Zygomaticofacial	
Zygomaticotemporal	
Pterygopalatine	
<i>Mandibular division (sensory and motor)</i>	
Sensory	
Auriculotemporal	
Inferior alveolar	
Lingual	
Buccal	
Motor	
Supply to muscles of mastication	

The ophthalmic nerve lies in the lateral wall of the cavernous sinus, and then it enters the orbit through the superior orbital fissure. It supplies the skin of the face and scalp, and supplies sensory fibres to the conjunctiva, cornea, iris and possibly secretory fibres to the lacrimal gland. The lacrimal, frontal and nasociliary are its three branches.

The maxillary nerve passes through the foramen rotundum into the pterygopalatine fossa and enters the orbit through the inferior orbital fissure. It has

four groups of branches: (a) in the cranium, (b) in the pterygopalatine fossa, (c) in the infraorbital canal, and (d) on the face.

The mandibular nerve is made up of two roots—the large sensory and the small motor. It descends through the foramen ovale of the sphenoid bone. It supplies the teeth and gums of the mandible, skin of the temporal region, lower part of the face, muscles of mastication, etc., as also mucous membrane of the anterior two-third of the tongue and floor of the mouth.

The sixth nerve. The fibres leave the nucleus just below the floor of the fourth ventricle, and pass forward through the pons to emerge at its lower border. The nerve follows a long course along the base of the brain and pierces the dura mater lateral to the dorsum sellae to enter the cavernous sinus. It then follows the same route as that of the third and fourth nerves.

The facial (VIIth) nerve [Fig. 1.11]. The facial nerve has got two roots—the motor and the sensory.

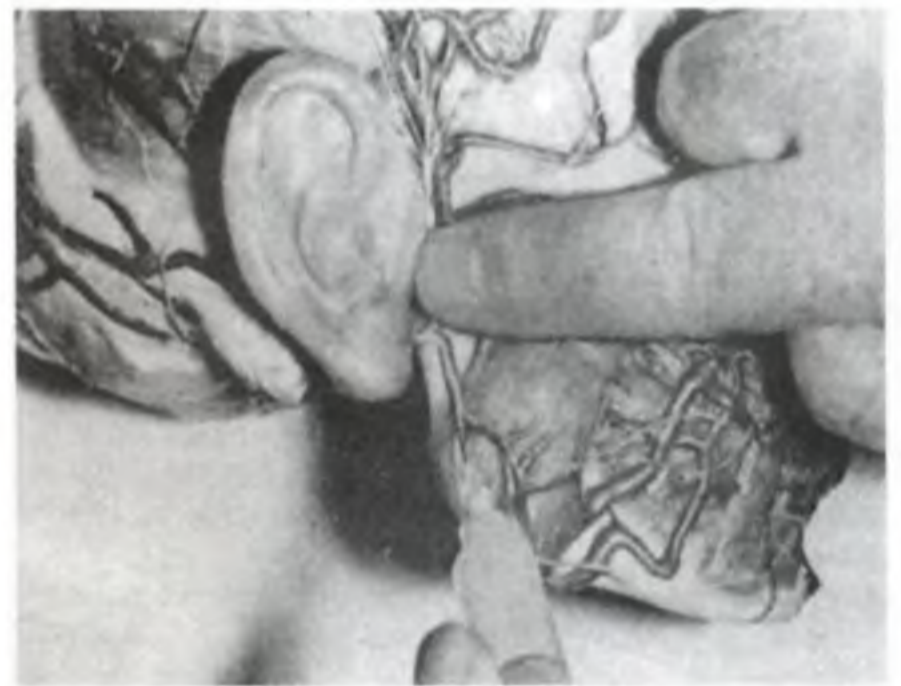

Fig. 1.11 The relation of the facial nerve to the neck of the mandible shown on a model (*Courtesy: J.E.K. Galbraith*).

The two roots arise at the lower border of the pons. The nerve passes laterally and anteriorly (with the auditory nerve) to the internal auditory meatus. It enters the facial canal and finally descends to reach the stylomastoid foramen. It continues to the substance of the parotid gland and divides behind the ramus of the mandible into branches.

The branches are listed in Table 1.6.

Table 1.6
Branches of the Facial Nerve

<i>Within the facial canal</i>
Greater petrosal nerve
Tympanic
Nerve to stapedius
Chorda tympani
<i>At the exit from the stylomastoid foramen</i>
Posterior auricular
Nerve to digastric
Nerve to stylohyoid
<i>On the face</i>
Temporal
Zygomatic
Buccal
Mandibular
Cervical

Sphenopalatine (Pterygopalatine) Ganglion

The largest peripheral ganglion of the parasympathetic system, connected functionally with the seventh nerve, is situated just below the maxillary nerve and is deeply placed in the pterygopalatine fossa. It has two roots, parasympathetic and sympathetic.

Parasympathetic fibres derived from lacrimatory nucleus of the facial nerve are preganglionic and relayed in this ganglion. They follow a complicated course and supply secretomotor fibres to the lacrimal gland. Postganglionic sympathetic fibres reach this ganglion and follow also a complicated course.

Paranasal Sinuses in Relation to the Orbital Walls

Frontal sinuses. The septum between the two frontal sinuses is frequently not strictly median. The sinus opens into the anterior part of the middle meatus.

Ethmoidal sinuses. These are numerous thin-walled sinuses within the ethmoid bone and on

each side there are three groups: the anterior and middle groups enter the middle meatus, while the posterior groups open into the superior meatus, forming a medial relation to the optic canal.

Sphenoidal sinuses. These two sinuses lie within the body of the sphenoid bone and relate superiorly to the optic chiasma and the pituitary body laterally to the internal carotid artery and the cavernous sinus.

Maxillary sinuses. These are the largest accessory paranasal sinuses situated in the body of the maxilla. The roof of the sinus is often ridged by the infraorbital canal.

Further Reading

1. Bron, A.J., Tripathi, R.C., Tripathy, B.J. (Eds.), *Wolff's Anatomy of the Eye and Orbit* (8th ed.), Chapman and Hall, London, 1997.
2. Duke-Elder, S., *System of Ophthalmology*, Vol. II: *The Anatomy of the Visual System*, Duke-Elder, S. and Wybar, K. (Eds.), Kimpton, London, 1961.
3. Gray, H. *Gray's Anatomy* (35th ed.), Warwick, R. and Williams, P.L. (Eds.), Longman, London, 1973.

2. ANATOMY OF THE EYELIDS¹⁻³

The eyelids (Fig. 2.1) are movable folds to protect the eye from external injury, excessive light and undue exposure, to facilitate the distribution of tear and glandular secretions, and to help in the regulation of the amount of light reaching the retina. The palpebral fissure is an elliptical space, 30 mm long × 10 mm wide, between the upper and lower lid margins when the eye is open.

The eyelids unite laterally at an acute angle lying in direct continuity with the globe (lateral canthus) and medially at a rounded angle (medial canthus) in which there are two structures namely the *caruncle* and *plica semilunaris*.

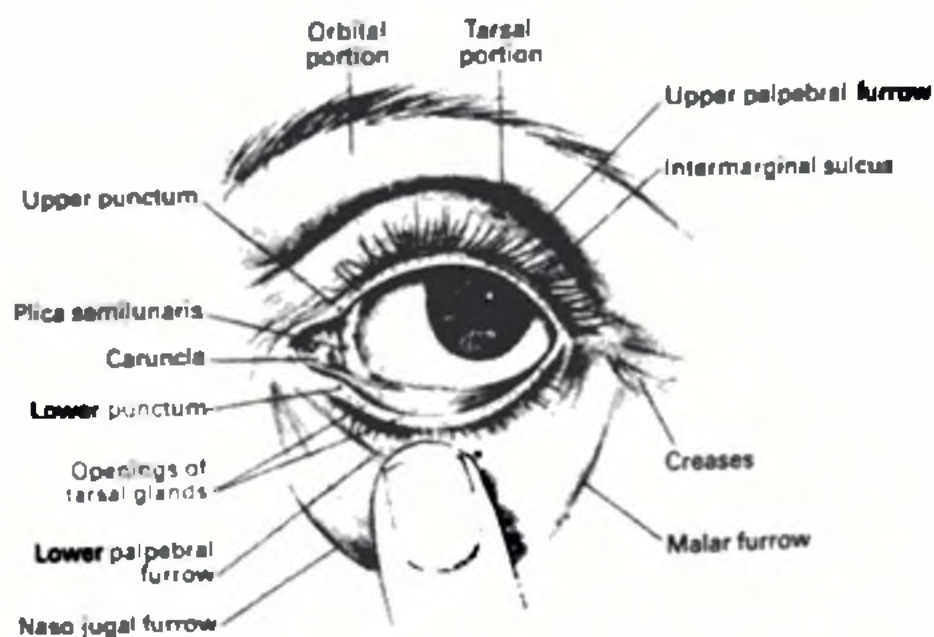


Fig. 2.1 The surface anatomy of the eye and eyelids (Trevor-Roper and Curran).

The eyelid margin, 2 mm broad, is divided by the lacrimal punctum into the large ciliary portion, of the anterior border from which the eyelashes arise and the small lacrimal portion, having neither cilia nor Meibomian ducts. The posterior border of the lid margin is sharp and is in contact with the globe. *Grey line* is midway between the anterior and posterior borders of the lid margin and lies anterior to the openings of Meibomian ducts and through it lid—halving between the orbicularis and the tarsus is possible.

Structure (Fig. 2.2)

The layers of an eyelid are disposed anteroposteriorly as follows:

1. The skin
2. The subcutaneous areolar layer
3. The layer of striated muscle—orbicularis oculi
4. The submuscular areolar tissue
5. The fibrous layer made up of tarsus and septum orbitale
6. The layer of unstriated muscle—Müller's muscle
7. The palpebral conjunctiva.

The skin is extremely thin and is marked by furrows—the superior and inferior palpebral sulci—when the eyes are open. The subcutaneous tissue

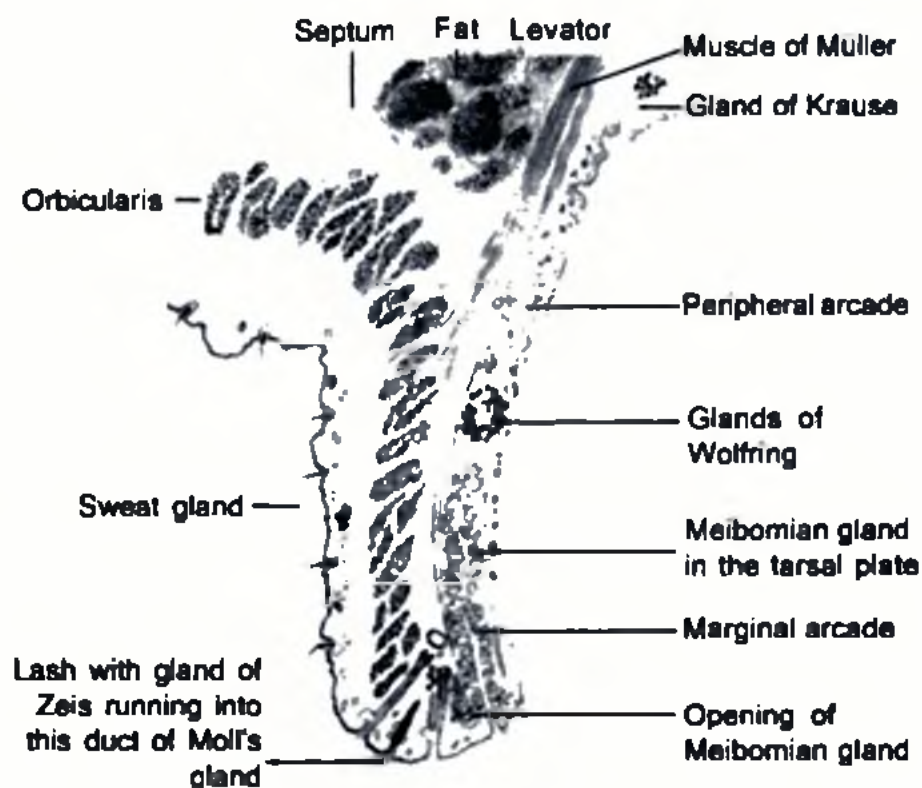


Fig. 2.2 Structures seen in a vertical section of the upper lid: 1, skin; 2, eyelashes with gland of zeis; 3, orbicularis oculi; 4, levator palpebrae superioris; 5, Meibomian glands; 6, opening of Meibomian gland; 7, Krause's glands; 8, glands of Wolfring; and 9, conjunctiva.

is loose and delicate, containing no fat. The palpebral fibres of the orbicularis oculi run parallel to the palpebral fissure. The submuscular areolar tissue communicates with the subaponeurotic layer of the scalp. It is traversed by the fibres of the levator, palpebrae superioris and the nerves to the eyelids, and through this plane the lid can be halved into an anterior and posterior portion. The fibrous layer consists of the thickened tarsal plate and peripheral part, the palpebral fascia (*septum orbitale*).

Septum orbitale (*palpebral fascia*) arises at the orbital rim from the thickened periosteum called *arcus marginale*. It is attached to the anterior and posterior lacrimal crests. It is fused above with the levator aponeurosis and below with the capsulopalpebral fascia. This fascia is pierced by the following structures: (i) lacrimal vessels and nerve, (ii) supratrochlear nerve, (iii) supraorbital vessels and nerve, (iv) frontal artery, (v) infratrochlear nerve, (vi) anastomosis between angular and ophthalmic veins, (vii) superior palpebral arteries, (viii) inferior palpebral arteries, (ix) levator palpebrae superioris, and (x) expansion of inferior rectus.

The fusion of this fascia with the fibres of the orbicularis oculi on the lateral side forms the *lateral palpebral raphe*.

The tarsus constitutes the form and support of the eyelid and is made up of thickened fibrous tissues encircling the acini of the tarsal or Meibomian glands. About 29 mm long and 1 mm thick, its shape resembles the letter "D" placed on its side. It is made up of two surfaces—the anterior and posterior, two borders—the attached is continuous with the septum orbitale, and the free and two extremities—the medial and lateral.

The superior unstriped muscle (Müller's muscle) takes origin from the levator fibres, while the inferior is from the inferior rectus; they are inserted to the corresponding tarsus and supplied by the sympathetic.

The palpebral conjunctiva is subdivided into three portions—marginal, tarsal, and orbital.

Muscles of the Eyelids

Levator palpebrae superioris. The muscle originates from the undersurface of the lesser wing of the sphenoid bone, above and in front of the optic foramen. The muscle ends anteriorly in a wide aponeurosis, the extremities being called the *lateral and medial "horns"*.

The muscle is intersected by three slips: (a) anteriorly it traverses between the fibres of the orbicularis and these muscle fibres are attached to the skin, (b) centrally it is inserted at the upper border of the tarsus, and (c) posteriorly, it is inserted at the upper fornix. The lateral horn is attached to the orbital tubercle of the zygomatic bone and lateral palpebral ligament. The medial horn is attached to the frontonasal suture and medial palpebral ligament. The muscle is supplied by the oculomotor nerve. It acts as an elevator (10 mm) of the upper lid and as a direct antagonist of the orbicularis oculi.

Orbicularis oculi. This is a broad, flat, elliptical sheet of concentric muscle fibres covering the eyelids and circumference of the orbit. It spreads over the temporal region downward toward the cheek. It is supplied by the facial nerve.

The orbicularis is subdivided into three parts.

- (a) Palpebral part
 - Pretarsal or marginal (muscle of Riolan)
 - Preseptal or peripheral
- (b) Orbital part
- (c) Lacrimal part (Homer's muscle).

The palpebral part forms two half ellipses, one on each lid. It arises from the medial palpebral ligament and the bone immediately above and below this ligament and sweeps across the eyelids to finally form the lateral palpebral raphe. Its action is essentially a sphincter of the eyelid. The other actions of the muscles are variable depending upon the part of the muscle brought into play, e.g. the orbital part acts during forcible closure of the eyelids and causes expansion of the lacrimal sac during stretching of the lacrimal diaphragm in a lateral direction.

Müller's muscle. This consists of the unstriped muscle fibres derived from the expansion of the levator in the upper lid and that of the inferior rectus in the lower lid. Each muscle is inserted into the proximal edge of the tarsus and is supplied by the sympathetic. This muscle causes 2-mm elevation of the upper lid.

Glands of the Eyelids

Meibomian glands. These are about 20 to 40 highly developed sebaceous glands within the tarsus extending from its upper to lower border, and each opens by a single vertical duct on the free margin of the eyelid. The lower lid has lesser glands than the upper. The oily meibomian secretion mixes with tear and does not allow it to overflow, thus, guarding against xerosis of the conjunctiva and cornea.

Zeis's glands. These are minute sebaceous glands connected with the eyelashes.

Moll's glands. These are minute sweat glands opening between the two eyelashes or into the duct of Zeis's gland.

Arterial supply (Fig. 2.3)

The superficial structures of the eyelids are supplied by a free anastomosis derived from two sources.

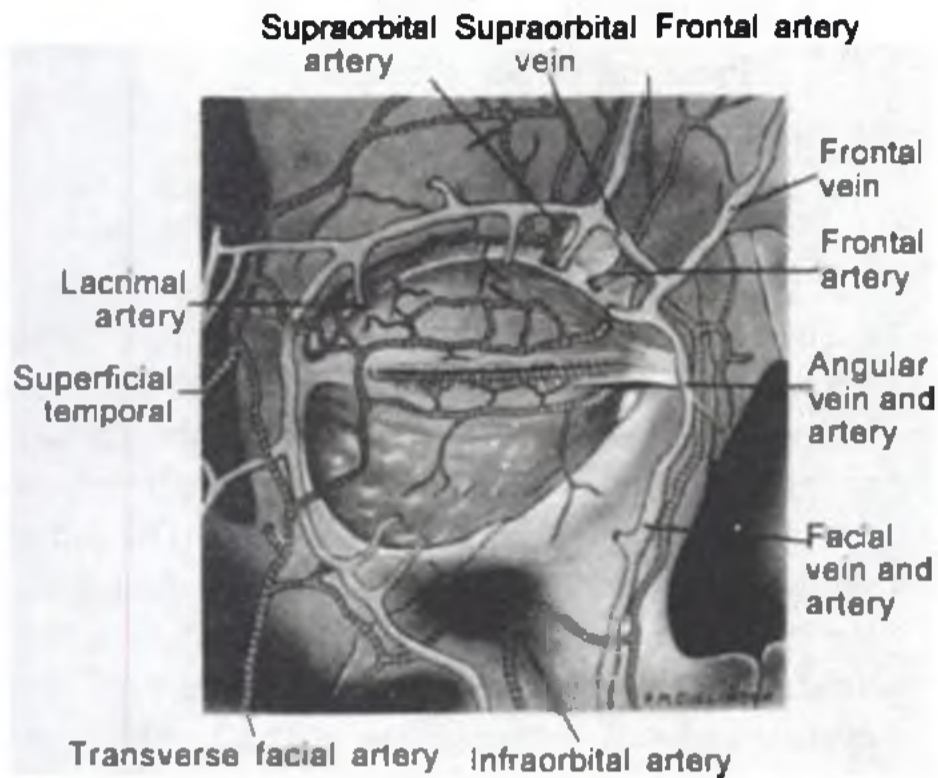


Fig. 2.3 The blood supply of the eyelids (Wolff).

The *facial* system is composed of (a) the facial artery, (b) the superficial temporal artery consisting of the transverse facial, the frontal and the zygomaticoorbital, and (c) the infraorbital artery.

The *orbital* system or the branches of the ophthalmic artery consists of (a) the dorsal nasal artery, (b) the frontal artery, (c) the supraorbital artery, and (d) the lacrimal artery.

The deeper structures are supplied by four palpebral arcades, two in each lid and one at either border of the tarsus: (a) the medial palpebral—from the dorsal nasal branch of the ophthalmic artery, and (b) the lateral palpebral—from the lacrimal artery, branch of the ophthalmic.

Both anastomose and form two arterial arcades in each lid. Of the marginal and peripheral arcades, the former is the larger and runs 3 mm from the free border of the lid.

Venous drainage

The superficial or *pretarsal* vein drains into the anterior facial which in turn drains into the internal jugular and the superficial temporal which in turn drains into the external jugular.

The deep or *posttarsal* drains into the orbital which drains into the cavernous sinus and the deep facial which drains into the pterygoid plexus.

The two systems of veins meet in the angular vein, the nodal point of the entire venous system of the eyelids. The angular vein is situated at the inner canthus 8 mm away from the medial angle of the lids and lateral to the corresponding artery.

Lymphatic drainage

From the lateral side, the lymph vessels drain into the preauricular and parotid lymph glands. From the medial side, the lymph vessels drain into the submaxillary lymph nodes.

Nerve supply (Fig. 2.4)

It is divided into three groups: (a) motor—the facial and oculomotor, (b) the sensory—from the trigeminal and (c) the sympathetic—supplying Müller's muscle.

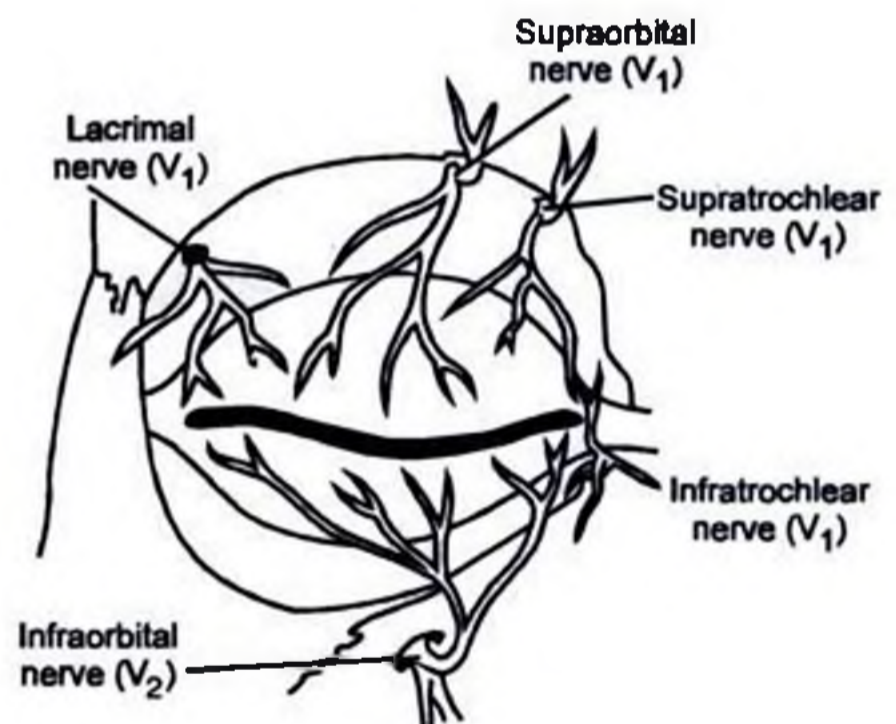


Fig. 2.4 Sensory supply to the eyelid: 1, lacrimal nerve; 2, supraorbital nerve; 3, supratrochlear nerve; 4, infratrochlear nerve; and 5, infraorbital nerve (Snell and Lemp).

Further Reading

1. Bron, A.J., Tripathy, R.C. and Tripathy, B.J. (Eds.), *Wolff's Anatomy of the Eye and Orbit*, (8th ed.), Chapman and Hall, London, 1997.

2. Duke-Elder, S., *System of Ophthalmology*, Vol. II: *The Anatomy of the Visual System*, Duke-Elder, S. and Wybar, K. (Eds.), Kimpton, London, 1961.
3. Gray, H. *Gray's Anatomy* (35th ed.), Warwick, R. and Williams, P.L. (Eds.), Longman, London, 1973.

3. ANATOMY OF THE LACRIMAL APPARATUS^{1,4}

The lacrimal apparatus consists of the lacrimal gland that is the secretory part and the lacrimal passages which form the collecting part.

The Lacrimal Gland (Fig. 3.1)

The lacrimal gland consists of the major—the orbital part, and the minor—the palpebral part which is about one-third of the size of the orbital part, the two parts being continuous behind and separated in front by the expansion of the aponeurosis of the levator muscle. The palpebral part can be seen after everting the upper lid while the eye looks down.

The orbital part. The orbital part has two surfaces—the superior and inferior, two borders—the anterior and posterior and two extremities—the medial and lateral. Relations are as follows:

- (a) The superior surface connects the fossa for the lacrimal gland with the intervening periosteum.

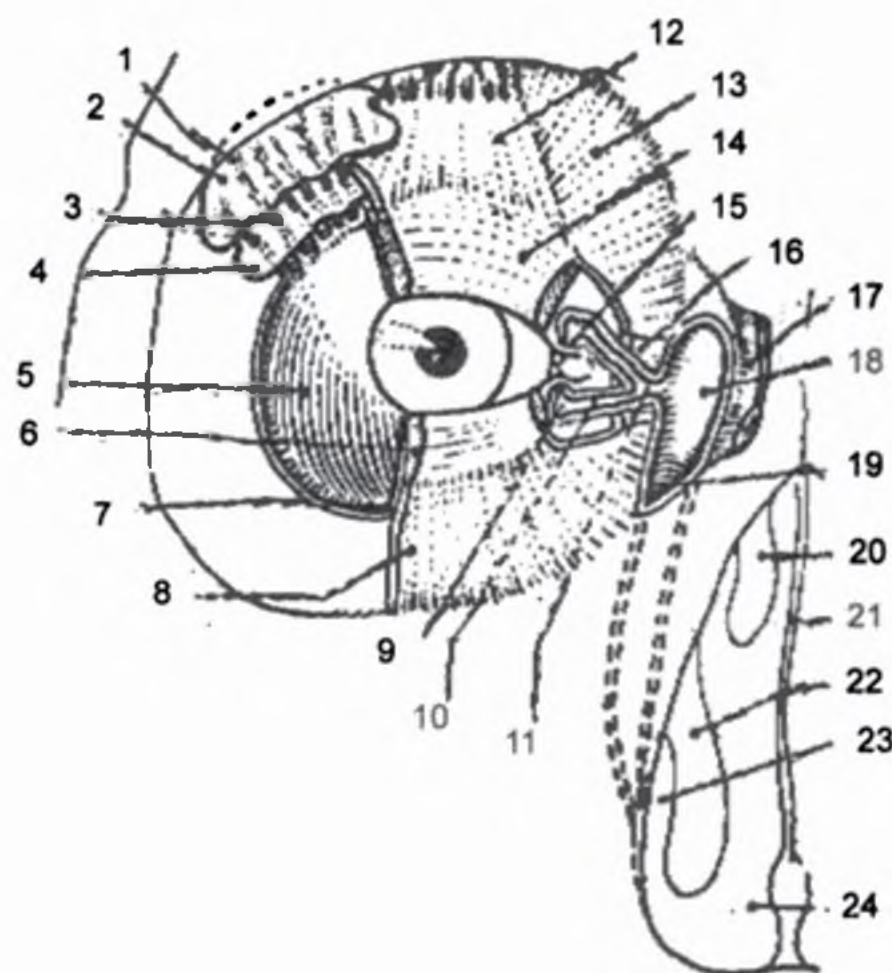


Fig. 3.1 Lacrimal apparatus: 1, lacrimal gland; 2, superior portion; 3, lacrimal ducts opening in superior fornix; 4, palpebral portion of lacrimal gland; 5, eyeball covered with conjunctiva; 6, inferior tarsus; 7, inferior fornix; 8, palpebral fascia of lower lid; 9, lower lacrimal canaliculus opening at punctum lacrimale on papilla lacrimalis; 10, horizontal portion of same; 11, portion formed by upper and lower canaliculi, opening into the lacrimal sac; 12, levator palpebrae superioris; 13, palpebral fascia of upper lid; 14, superior tarsus; 15, superior lacrimal canaliculus; 16, tendon of orbicularis oculi, posterior part; 17, tendon of orbicularis oculi, anterior part; 18, lacrimal sac; 19, upper orifice of naso-lacrimal duct, which runs in a bony canal; 20, middle nasal concha; 21, septum nasi; 22, inferior nasal concha; 23, lower opening of naso-lacrimal duct in anterior quarter of inferior meatus of nose; 24, right nasal cavity (Pauchet and Dupret).

- (b) The inferior surface is related to the levator, expansion of the levator and the lateral rectus in this order.
- (c) The anterior border is related to the septum orbitale.
- (d) The posterior border is related to the orbital fat.
- (e) The medial extremity is related to the levator palpebrae superioris.
- (f) The lateral extremity is related to the lateral rectus.

The palpebral part. Since all the 10 to 12 lacrimal ducts, at first intralobular, then extralobular and finally lacrimal ducts traverse this part to finally reach the superolateral aspect of the conjunctival sac, excision of this part of the gland virtually leads to complete nonfunctioning of the gland.

Accessory lacrimal glands are described under the conjunctival glands.

Structure

Lacrimal gland is a branched tubuloalveolar type of gland. Each tubule when cut in section forms an acinus. The acini are lined by pyramidal secretory cells, the cells containing many secretory granules toward the lumen. The secretory tubules are surrounded by a dense basement membrane and they converge to form an intralobular duct, the latter emptying into larger interlobular duct. The interlobular and interacinous connective tissue contains many vessels, non-myelinated nerves and plasma cells. Most of the plasma cells secrete immunoglobulin A into the interstitial space.

Ultramicroscopy. Each acinar cell contains a well-defined basal nucleus and number of electron-dense secretory granules. The secretory cells are joined near their lumen by junctional complexes and they have many microvilli projecting into the lumen.

Arterial supply

The lacrimal artery runs along the lateral orbital wall at the upper margin of the lateral rectus to

reach the lacrimal gland. The infraorbital sometimes contributes.

Nerve supply (Fig. 3.2)

Nerve supply consists of two groups of nerves—the afferent or sensory, from the trigeminal, and the efferent or motor, which is contributed by both sympathetic and parasympathetic.

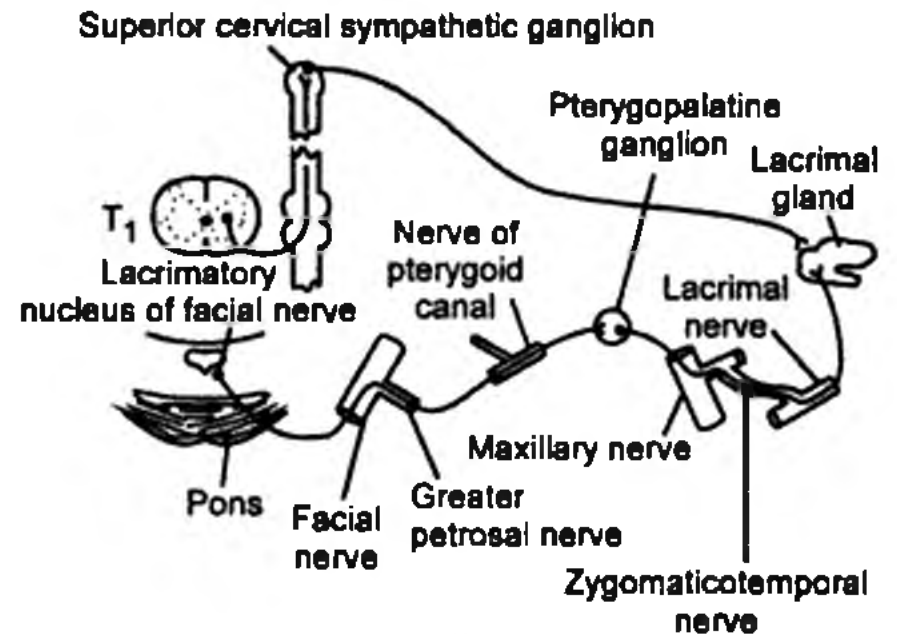


Fig. 3.2 Sympathetic and parasympathetic supply to the lacrimal gland (Snell and Lemp).

The *afferent* or *sensory* supply to the lacrimal gland is from the lacrimal nerve, a branch of the ophthalmic division of the trigeminal nerve.

The lacrimal nerve continues to run along the lateral wall of the orbit. After entering the gland it divides into superior and inferior divisions—the inferior division joins the zygomaticotemporal branch of the maxillary division of the trigeminal.

Sympathetic. The sympathetic fibres are derived from the postganglionic fibres associated with the internal carotid artery. The fibres then run in the nerve of the pterygoid canal (*vidian nerve*) which is formed by the junction of the deep petrosal nerve, from the internal carotid plexus, with the greater petrosal nerve, from the facial nerve to the sphenopalatine ganglion, from the latter the nerve fibres reach the lacrimal gland either with the zygomatic nerve or along with the lacrimal artery.

Parasympathetic. The fibres are derived from the facial nerve nucleus, superior lacrimal, in the brain-

stem. Leaving the brain stem the fibres depart the facial nerve in the greater superficial petrosal nerve and reach the sphenopalatine ganglion. A relay takes place in the ganglion and the postganglionic fibres reach the lacrimal gland through the zygomatic branch of the maxillary nerve or directly to the gland.

Tear.⁶ Tear, which is slightly alkaline, is composed of 98.2 per cent water and 1.8 per cent solids. The solid components of tear have been listed in Table 3.1.

Table 3.1
The Solid Components of Tear

Glucose	approx. 5 mg/dL
Proteins	0.6%
Tear-specific prealbumin	
Albumin	
Immunoglobulins	
Lysozyme	
Lactoferrin	
Glycoprotein	
Potassium	} in higher concentrations than in plasma
Sodium	
Chloride	
Urea	0.04 mg/dL

Tear is secreted by the lacrimal gland and collected by 10 to 12 lacrimal ducts extending toward the superior conjunctival fornix.

Mechanism of secretion.² Two pathways are involved in the secretion of water and electrolytes: cholinergic-activated, and vasoactive intestinal peptide-activated. Three pathways involved in the secretion of protein are: cholinergic agonist-activated, alpha adrenergic agonist-activated and AMP-dependent.

Normal secretion is sufficient to keep the eyeball moist. The collection near the inner canthus, *lacus lacrimalis*, and movement into the lacrimal passages are caused by: (a) capillarity, (b) gravity, (c) blinking due to orbicularis contraction, (d) dilatation of the lacrimal sac occurs due to pull on the lacrimal fascia owing to the contraction of Horner's muscle and tear is drawn into the resulting vacuum and (e) movement of tear into the

nasolacrimal duct is due to relaxation of the negative pressure within the sac when the eyes are open.

In the lacrimal secretory system, there are two types of secretors.⁵

Basic—the fundamental and indispensable part.

(i) Mucin secretors

Goblet cells
Crypts of Henle
Glands of Manz

(ii) Lacrimal secretors

Glands of Krause
Glands of Wolfring

(iii) Oil secretors

Meibomian glands (sebaceous)
Glands of Zeis (sebaceous)
Glands of Moll (sweat)

Reflex—the lacrimal gland.

Tear film⁶ is made up of three layers:

- external lipid produced by Meibomian glands
- middle aqueous formed primarily by the lacrimal and accessory lacrimal glands
- innermost mucous secreted by the goblet cells.

Table 3.2 lists important measurements.

Table 3.2
Measurements Related to Tear Film³

External lipid layer	0.1 micron
Middle aqueous layer	7 microns
Innermost mucous layer	0.02–0.05 microns
Thickness of tear film	7–9 millimicrons
Volume of tear film	7 microlitres
Osmolarity of tear film	303–6 mOsm/L
Average tear flow	0.5–2.2 microlitres/min

The Lacrimal Passages (Fig. 3.1)

The lacrimal passages begin at each punctum and terminate at the inferior meatus of the nose. These are made up of the puncta, canaliculi, lacrimal sac, nasolacrimal duct and inferior meatus of the nose.

The punctum. This is a patent ring of dense fibrous tissue around which are the fibres of the orbicularis oculi. It is relatively pale because of its avascularity and is situated on each lid margin. The upper and the lower ones are 6 and 6.5 mm away from the medial canthus. It is normally not visible unless the lid is averted.

The canaliculus. This consists of vertical, about 2 mm, and horizontal, about 6 to 8 mm, portions. It is lined by stratified epithelium, and both canaliculi join to form a small diverticulum just before opening into the sac.

The lacrimal sac. The membranous sac, 15 mm long vertically and 5 mm wide when distended, is situated in the lacrimal fossa. It is closed above but continuous below with the nasolacrimal duct, and has three parts—the fundus, the body and the neck.

Relations are as follows:

Medially—where the ethmoid air cells and the middle meatus are situated and laterally it is related to the skin, the orbicularis muscle, the medial palpebral ligament (across the fundus of the sac) and the lacrimal fascia and posteriorly—to the lacrimal fascia and Horner's muscle.

The lacrimal sac has a fibroelastic coat lined internally by mucous membrane, the latter being continuous with the conjunctiva through the canaliculi and with the nasal cavity through the nasolacrimal duct.

The nasolacrimal duct. This is a membranous canal, 12 to 24 mm long and consists of two portions, the intraosseous—within the bony nasolacrimal canal, and the intrameatal membranous portion.

The mucous lining of the lacrimal sac and the duct is covered with columnar epithelium.

Arterial supply

The sources of supply are from the ophthalmic through its superior and inferior medial palpebral branches—the angular branch of the facial artery; the maxillary through its infraorbital branch; and the nasal branch of the sphenopalatine artery.

Nerve supply

Nerve supply is divided in three groups: (a) the sensory—from the trigeminal, (b) the motor—from the facial, and (c) the sympathetic outflow to the orbit.

Further Reading

1. Bron, A.J., Tripathy, R.C. and Tripathy, B.J. (Eds.), *Wolff's Anatomy of the Eye and Orbit* (8th ed.), Chapman and Hall, London, 1997.
2. Dartt, D.A., Signal transduction and activation of the lacrimal gland. In *Principles and Practice of Ophthalmology: Basic Sciences*, Albert, D.M. and Jacobiec, F.A. (Eds.), W.B. Saunders, Philadelphia, 1994, p. 458.
3. Gilbard, A.P., Dry eye disorders. In *Principles and Practice of Ophthalmology: Clinical Practice*, Albert, D.M. and Jacobiec, F.A. (Eds.), W.B. Saunders, Philadelphia, 1994, p. 257.
4. Gray, H., *Gray's Anatomy* (35th ed.), Warwick, R. and Williams, P.L. (Eds.), Longman, London, 1973.
5. Jones, L.T., The lacrimal secretory system and its treatment, *Am. J. Ophthalmol.*, 62: 47, 1966.
6. Lamberts, D.W., Physiology of the tear film, in *The Cornea*, Smolin, G. and Thoft, R.A. (Eds.), Little, Brown and Co., Boston, 1983.

4. ANATOMY OF THE CONJUNCTIVA^{1,2}

The conjunctiva (Lat. *conjunctivus*, serving to connect) is a thin and transparent mucous membrane, conjoining the eyelid to the globe and its epithelium is continuous with that of the cornea. It is divided into three parts: palpebral, bulbar and fornix.

The Palpebral Conjunctiva (Fig. 4.1)

The palpebral conjunctiva is subdivided into three parts.

- (a) The marginal which is the transition zone between the skin and the conjunctiva

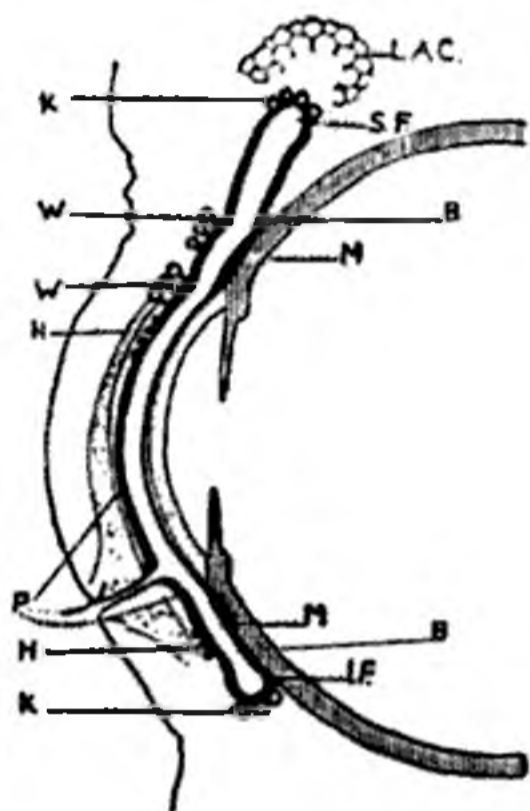


Fig. 4.1 Scheme of a sagittal section through the eyelids and eyeball to show the conjunctival sac and the position of its glands. SF, IF, the conjunctiva of the superior and inferior fornices respectively. B, the bulbar conjunctiva. P, the palpebral conjunctiva. LAC, the lacrimal gland proper. K, the accessory lacrimal glands of Krause, and W, those of Wolfring. H, the crypts of Henle. M, the glands of Manz, (After Dubreuil, 1908. From Whitnall: *Anatomy of the Human Orbit*, Oxford Medical Press, London.)

proper, extending from the anterior lid margin to a groove, *sulcus subtarsalis*, situated 2 mm behind the posterior lid margin.

- (b) The tarsal which is thin, vascular and intimately adherent to the underlying tarsus.
- (c) The orbital which is loose with horizontal folds overlying Müller's muscle.

The Bulbar Conjunctiva

The bulbar conjunctiva is a loose sheet overlying the episclera and the tendons of the four recti. Because of its looseness, chemosis commonly affects this zone.

The Fornix

The fornix represents the junction between the palpebral and bulbar conjunctiva and is a circular

cul-de-sac interrupted on the medial side by (a) the caruncle (Lat. *caro*, flesh) which is a small, fleshy ovoid, modified skin containing sebaceous, sudorific and modified lacrimal glands; and (b) the plica semilunaris (Lat. *plica*, to fold) contains the plain muscles and thickened epithelium having many goblet cells. The inferior, superior and lateral fornices are 8 mm 9 mm and 14 mm from the limbus respectively.

Structure

Histologically, the layers are the epithelium and the substantia propria, which is subdivided into the superficial, i.e. adenoid layer and the deep, i.e. the fibrous layer. The structure varies in different portions.

The epithelium. The free margin of the lid is covered by keratinized stratified epithelium. The mucocutaneous junction lies at the level of the posterior margin of the openings of Meibomian glands and at this region there are about five layers of non-keratinized squamous epithelium, the most superficial cells being nucleated.

The tarsal conjunctiva of the upper lid has two layers, the deeper cubical and the superficial cylindrical. The tarsal conjunctiva of the lower lid is rarely two-layered as in the upper, but contains three or four layers of cells. Sometimes there may be five layers. There are three sets of cells—deepest cubical, polygonal and superficial cone-shaped.

The fornix shows three layers, the deepest layer contains cubical, intermediate polyhedral and superficial cylindrical cells.

The bulbar conjunctiva consists of several layers including additional polyhedral layers between the superficial and deep cells. The superficial cells are flatter and the deep cells taller.

In the limbus, there are several layers. The deepest of them are basal cells containing melanin pigment. A few layers of polygonal cells are also present. Superficially, one or two layers of flattened cells are noticed. Conjunctival polygonal cells do not show any prickle while corneal polygonal cells show prickles.

The substantia propria. The adenoid layer is absent at birth, starts developing about the third month of life and is most developed in the fornix conjunctiva.

The fibrous layer, formed mainly by the expansions of muscle tendons and Tenon's capsule, contains the blood vessels and nerves.

Ultramicroscopy. The following important characteristics are seen.

1. The superficial cells are joined at their anterior contiguous borders by junctional complexes.
2. The apical cytoplasm of the surface cells contains numerous subsurface vesicles.
3. The cell membrane is anchored to the cytoskeleton by actin filaments passing from the microvilli to the horizontal condensation (terminal web).

Conjunctival glands

The distinguishing features of the conjunctival glands are indicated in Table 4.1.

Table 4.1

Distinguishing Features of Conjunctival Glands

	<i>Krause's glands</i>	<i>Glands of Wolfring</i>	<i>Henle's glands</i>
Nature of glands	Accessory lacrimal	Accessory lacrimal	Not true glands but transversely cut mucous folds
Number	42 in the upper and 6 to 8 in the lower lids	2 to 5 in the upper, and 2 in the lower lids	—
Situation	In subconjunctival connective tissue	At both borders of the tarsus	—

Goblet cells. These occur throughout the conjunctiva, more abundant in the fornices and the plica semilunaris. They decrease as the limbus is approached. They are large, oval, fat-looking cells, unicellular mucous glands which secrete mucin which moistens and protects the epithelium of the conjunctiva and cornea.

Arterial supply (Fig. 4.2)

The deeper structures of the eyelid and the whole of the conjunctiva barring 3 to 6 mm of the paralimbal zone are supplied by four palpebral arcades, two in each lid, one at either border of the tarsus. The medial palpebral is formed from the dorsal nasal and the lateral palpebral from the lacrimal arteries.

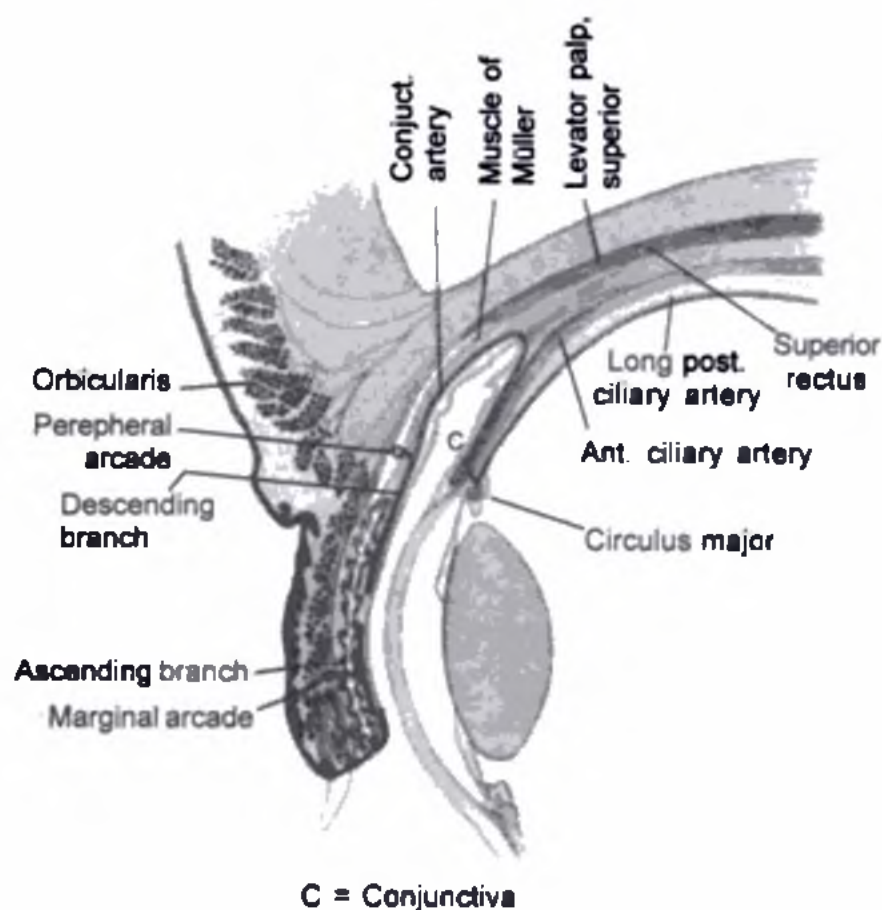


Fig. 4.2 Section of the upper lid and anterior portion of the eye to show the blood supply to the conjunctiva (Wolff).

Along each border of the tarsal plate two arterial arcades, the marginal and the peripheral are formed. The marginal arcade is the larger of the two arcades and runs 3 mm from the free border of the eyelid. The peripheral arcade is smaller and inconstant. It is situated at the peripheral margin of the tarsus, i.e. the upper border of the upper tarsus and the lower border of the lower tarsus. Small twigs pass from the marginal to the peripheral arcade and vice versa, and two arterial plexuses, the pretarsal and the posttarsal, are formed in front and behind the tarsus. The posttarsal plexus supplies the major part of the conjunctiva. The ascending branches of the peripheral arcade run upwards to the fornix, bend round it and pass under the bulbar conjunctiva as the posterior conjunctival arteries.

The anterior ciliary arteries are continuation of the muscular arteries to the recti and are derived from the ophthalmic artery. These arteries give off the anterior conjunctival arteries. The anterior ciliary arteries on the surface of the sclera divide into three branches, the episcleral, the intrascleral and the perforating. The episcleral twigs give off two sets of branches, terminal and recurrent; the terminal branches run anteriorly into the limbus, while the recurrent branches run away from the cornea as the anterior conjunctival arteries and anastomose with the terminal branches of the posterior conjunctival arteries.

The arterial supply of the entire conjunctiva (Table 4.2) is derived from three sources: (a) the marginal arterial arcade, having marginal and tarsal branches, (b) the peripheral arterial arcade, having descending and ascending branches or the posterior conjunctival and (c) the episcleral twigs of the anterior ciliary arteries having two sets—terminal and recurrent branches.

Table 4.2

Details of the Arterial Supply of the Conjunctiva

Zone of conjunctiva	Arterial supply
Marginal	Marginal branches of the marginal arcade
Tarsal	Tarsal branches of the marginal and descending branches of the peripheral arcade
Orbital, fornix and bulbar (except 3–6 mm paralimbal zone)	Ascending branches of the peripheral arcade, i.e. the posterior conjunctival arteries
Paralimbal 3–6 mm zone	Anterior conjunctival derived from the episcleral twigs of the anterior ciliary arteries

Venous drainage

The conjunctival veins are larger, darker and more tortuous than the corresponding arteries.

Lymphatic drainage

There are two groups of lymphatic networks, the superficial and the deep. The medial one-third of

the upper and lateral two-third of the lower conjunctiva drain into the submaxillary, while the remaining portions drain into the preauricular gland.

Nerve supply

There are three groups: (a) the sensory, branches of the ophthalmic division of the V cranial, (b) the sympathetic supplying the conjunctival glands and (c) the parasympathetic supplying the accessory lacrimal glands.

The sensory supply is as follows:

- upper palpebral and fornix from the frontal
- outer part of bulbar conjunctiva from the lacrimal
- remaining part of bulbar conjunctiva from the long ciliary branches of the nasociliary nerve
- lower fornix from the infraorbital nerve.

Further Reading

1. Bron, A.J., Tripathy, R.C. and Trepthy, B.C. (Eds.), *Wolff's Anatomy of the Eye and Orbit (8th ed.)*, Chapman and Hall, London, 1997.
2. Duke-Elder, S. *System of Ophthalmology*, Vol. II: *The Anatomy of the Visual System*, Duke-Elder, S. and Wyber, K. (Eds.), Kimpton, London, 1961.

5. ANATOMY OF THE CORNEA¹⁻³

The shiny and transparent cornea, having slightly greater curvature than the rest of the globe, constitutes the anterior one-sixth of the outer coat of the eyeball. The horizontal diameter, 11.7 mm is greater than the vertical diameter, 10.6 mm. The cornea is more curved and thinner 0.58 mm centrally, while its peripheral part is less curved and thicker, i.e. 1 mm. Anteriorly it looks elliptical, while it is circular posteriorly. The radii of curvature of the anterior and posterior surfaces are

7.8 mm and 6.6 mm respectively. The cornea can be divided into the cornea proper—transparent and avascular and the limbus—1 mm transition zone, richly vascular [*Limbus, seam, i.e. the line of junction between two edges*].

Structure of the Cornea (Fig. 5.1)

The cornea proper shows five layers disposed anteroposteriorly behind the precorneal tear film.




Fig. 5.1 The microscopic appearance of the cornea: 1, epithelium; 2, Bowman's membrane; 3, stroma; 4, Descemet's membrane; and 5, endothelium.

The Epithelium

The epithelium is the forward extension of the conjunctival epithelium. It is 50 millimicron thin and consists of three types of cells disposed in 5–6 layers.

The basal cells. This is a single layer of cells, the germinal cell layer, standing in a palisade-like manner on the basement membrane. The cells are columnar with rounded heads and flat bases and have an oval nucleus near the head. The cells are interconnected by fine denticulations.

The wing or umbrella cells. These are 2–3 layers of polyhedral cells and have concave bases fitted over the rounded heads of the basal cells. These rounded heads project anteriorly. Each cell has an oval nucleus whose long axis is parallel to the corneal surface. They are so named because of the presence of intercommunicating processes, the wings, between them.

The surface cells. These constitute the most superficial layer. The cells are flattened and nucleated. They do not show any keratinization normally.

It must be stressed that there are lymph spaces between the cells, best distinguished between the basal cells and gradually disappearing between the surface cells.

Basal membrane. A part of the epithelium, it is of even thickness and is osmophilic. This merges with Bowman's membrane.

Bowman's Membrane

Bowman's membrane is a 8–14 millimicron homogeneous sheet interposed between the basement membrane and the substantia propria, separated from the epithelium by a sharply defined border. It is demarcated from the stroma by an ill-defined line. Peripherally, it terminates in a rounded border. It does not regenerate if it is damaged. It does not contain any elastic tissue.

Substantia Propria

The substantia propria is made up of a modified connective tissue whose components have almost the same refractive index. There are three components.

The lamellae. These are made up of 200 to 250 fine collagen fibrils arranged parallel to the corneal surface. Each lamella is about 2 millimicron thin and 10 to 25 millimicron wide. Only a few of the fibres are oblique, probably in relation with the entrance of the corneal nerves. They are clearly distinguished by electron microscopy.

The cells. These are of two types, 'fixed' or keratocytes and 'wandering' or histiocytes.

The ground substance. This is made up of acid mucopolysaccharides. It holds the cells and the fibres and forms a gel.

Descemet's Membrane

Descemet's membrane is a strong, homogeneous membrane of 10–12 millimicron. There is a line of demarcation between it and the stroma, the line being utilized during lamellar keratoplasty. At its periphery the posterior surface of the membrane shows some round elevations, *Hassall-Henle bodies*, having a tendency to increase with age.

Endothelium

The endothelium is the posteriormost layer and consists of a single layer of flattened epithelium-like cells, continuous round the angle of the anterior chamber with the endothelium of the iris. It can be visualized by a slit-lamp.

Specular microscopy, first used by Maurice in 1968, can evaluate the morphological and functional aspects of the endothelium. The cells can be examined at a very high magnification ($\times 500$). The examination is possible with corneas *in vitro* and *in vivo*. The introduction of noncontact and wide-angle instruments has widened its sophistication.

The study of corneal endothelium is of vital significance because: (a) corneal transparency is dependent on the integrity of the endothelium, (b) the endothelium is the site of metabolic process which maintains the deturgescent state of the cornea, (c) the efficacy of drug therapy and (d) the success of keratoplasty.

Limbus

There are two layers only: (a) the epithelium, having ten or more layers of irregularly disposed cells and (b) the stroma which lacks the uniformity of the structure that is present in the cornea proper, but contains numerous capillary loops.

Ultramicroscopy

The ultramicroscopic features have been summarized below.

Epithelial cells. They contain: (i) usual organelles of actively metabolizing cells, (ii) tonofibrils, (iii) desmosomes, (iv) zonulae occludentes (tight junctions), (v) microvilli and microplicae (fused microvilli), and (vi) dendritic cells.

Basal membrane. Two layers are seen, lamina densa and lamina lucida. This membrane is anchored to the underlying Bowman's membrane by short filaments.

Bowman's membrane. It consists of felted meshwork of fine collagen fibrils of uniform size 24 to 27 nm.

Stroma. Each lamella contains a band of collagen fibrils (64 nm) arranged in parallel rows. The lamellae cross each other approximately at right angles. Keratocytes are mostly interlamellar and occasionally intralamellar.

Descemet's membrane. There are two portions: anterior, banded showing interdigitations between the fine filaments, the foetal part, constituting one-third portion. The posterior two-third, the postnatal part, forms the nonbanded zone showing a granular appearance.

Endothelium. There are 500,000 cells, each of 5 millimicron thin and 10–20 millimicron wide. These are extremely metabolically active cells. Large numbers of mitochondria are found particularly around the nucleus. The lateral borders of the cells show marked convolutions forming complex interdigitations with the neighbouring cells. The anterior (basal) cell membrane is anchored to Descemet's membrane by modified desmosomes. The posterior (apical) cell membrane shows microvilli projecting into the anterior chamber and pinocytic vesicles.

Nerve supply

The cornea is richly supplied by the long ciliary nerves from the nasociliary branch of the ophthalmic division of the trigeminal. Most of the nerves enter the cornea from the sclera and, the remaining from the subconjunctival and episcleral

tissues 70 to 80 nerves run radially into the stroma and most of them lose their myelin sheaths 0.3–0.5 mm from the limbus. These nerves form plexuses within the epithelium, under Bowman's membrane and within the stroma. There is no innervation of Descemet's membrane.

Further Reading

1. Bron, A.J., Tripathy, R.C and Tripathy, B.J. (Eds.), *Wolff's Anatomy of the Eye and Orbit* (8th ed.), Chapman and Hall, London, 1997.
2. Hogan, M.J., Alvarado, J.A. and Weddell, J.E., *Histology of the Human Eye*, W.B. Saunders Co., Philadelphia, 1971.
3. Smelser, G.K. and Ozanics, V., New concepts in anatomy and histology of the cornea, in *The Cornea: World Congress*, King, J.H. and McTigue, J.W. (Eds.) Butterworths, London, 1965.

6. ANATOMY OF THE SCLERA¹⁻³

The dull-white and inelastic sclera form the tough posterior five-sixth of the outermost protective coat of the eyeball. Anteriorly, it is continuous with the cornea; and posteriorly, it is continuous with the dural sheath of the optic nerve. The outer surface is covered by Tenon's capsule and the conjunctiva, connected by a loose connective tissue, i.e. the episclera. The inner surface is covered by the lamina fusca of the choroid. The average thickness is 0.8 mm. It is thickest at the posterior part, 1 mm, thinner anteriorly and thinnest at the insertions of the recti, 0.3 mm.

Weak spots in the sclera. As 3 mm medial to and slightly above the posterior pole, the sclera becomes sieve-like, *lamina cribrosa*, through the holes of which traverse the fibre of the optic nerve. At this weakest spot, excavation of the optic disc occurs typically in long-standing chronic simple glaucoma.

Variation in colour. In childhood and in pathological state, the sclera appears bluish owing to the visibility of the uvea through the thinned-out sclera. In old age it may appear yellowish due to the deposition of fat.

Structure (Fig. 7.3)

The sclera is relatively avascular, almost acellular, and it consists of highly compact thick collagen bundles of varying sizes between 400 and 3300 Å and easily separable with the intervening elastic tissues.

Orientation of the fibres. The anterior part is strictly circular at the insertions of the extrinsic muscles. There are two strata at the posterior part: the outer like a net around a balloon and the inner fanwise. Hence, owing to the increased ocular tension the elastic fibres become tense, while the wavy connective tissues become straight.

Dense cross-linking of the large diameter fibrils results in greater tensile strength of the sclera. The scleral resistance is due to greater surface area of contact with the encircling matrix and greater amount of interaction with proteoglycans by the small-diameter fibrils³.

Arterial supply

The sclera is almost avascular except for the vessels which pass through it. Two vascular networks are present: the circle of Zinn-Haller (Chapter 11, p. 37 of Part One) and the episcleral plexus situated at the insertions of the recti.

Nerve supply

The sclera is innervated by the branches of the short posterior ciliary nerves posteriorly behind the equator, and by those of the long posterior ciliary nerves.

Further Reading

1. Duke-Elder, S., *System of Ophthalmology*, Vol II: *The Anatomy of the Visual System*, Duke-Elder, S. and Wybar, K. (Eds.), Kimpton, London, 1961.

2. Gray, H., *Gray's Anatomy* (35th ed.), Warwick, R. and Williams, P.L. (Eds.), Longman, London, 1973.
3. Marshall, G.E., Konstas, A.G.P. and Lee, W.R. Collagens in ocular tissues. *Br. J. Ophthalmol.* 77: 515, 1993.

7. ANATOMY OF THE UVEAL TRACT¹⁻³

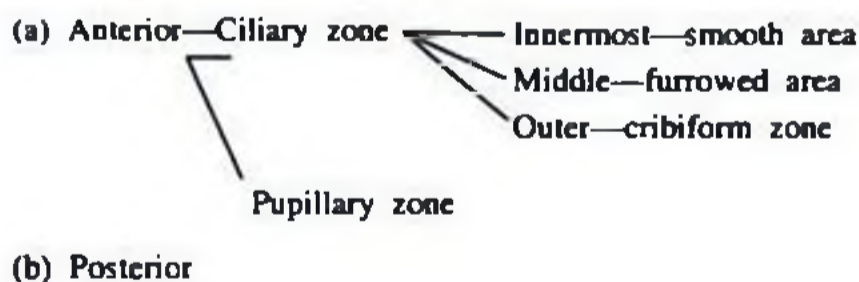
The middle coat of the eyeball is presumed to be a dark sphere (Gk. *uva*) hanging from the optic nerve.

The middle coat, which is also vascular and nutritive, consists of three portions: the choroid or the posterior uvea, the iris, and the ciliary body which together form the anterior uvea.

Iris

The iris is a thin average 3–4 mm in diameters, circular, coloured disc depending upon the amount of pigment, with a central, slightly nasal, perforation called the *pupil*. It is attached at its periphery or *root*, i.e. the thinnest part to the middle of the anterior surface of the ciliary body. The pupillary margin is free and it glides over the anterior capsule of the lens.

The iris has two surfaces:



Between the ciliary and pupillary zones, about 1.5 mm from the pupillary margin, there lies the *collarette* or *iris frill* (Fig 7.1), the thickest part.

Posterior. This is relatively smooth surface (Fig. 7.2).

Structure

The layers of the iris from anterior to posterior are:

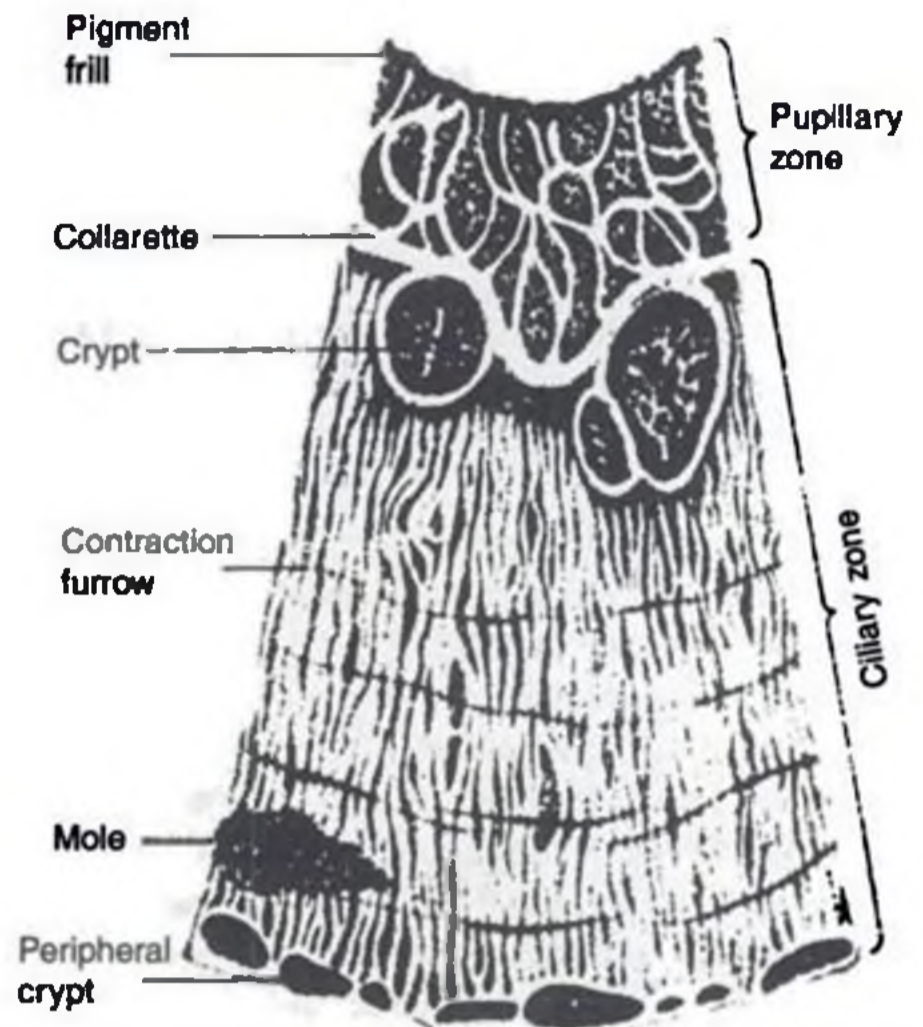


Fig. 7.1 The surface anatomy of the front of the iris (Wolff).

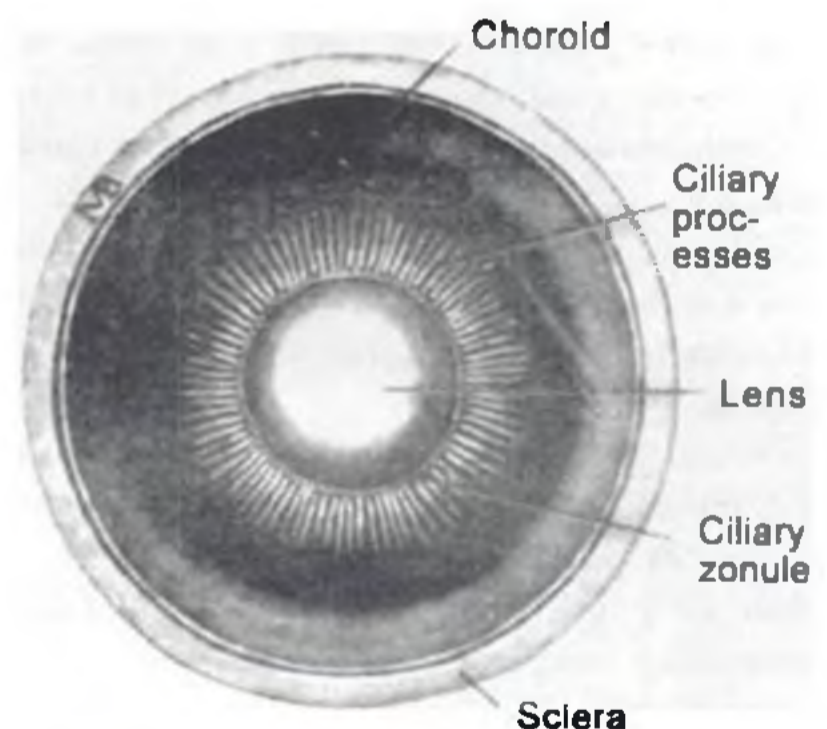


Fig. 7.2 Anterior half of the interior of the eyeball viewed from behind after removal of the vitreous (Cunningham).

1. Anterior border layer
2. Stroma
3. Anterior epithelium
4. Posterior pigment epithelium.

The *anterior border layer* is a condensation of connective tissue and pigment cells of the anterior stroma. This contains fibroblasts, melanocytes, collagen fibres, nerve filaments and capillaries. This layer exhibits crypts where it is not continuous. The colour of the iris depends on the thickness of this layer and the number of melanocytes. The fibroblasts project their microvilli and cilia into the anterior chamber.

The *stroma* forms the bulk of the iris. This is a loosely arranged collagenous network containing blood vessels, nerves, pigmented and nonpigmented cells, and sphincter pupillae.

Blood vessels are radial with a slightly sinuous course to allow movements of the pupil. They straighten during constriction and become wavy during dilatation of the pupil.

Nerves are derived from the long and short ciliaries and they accompany the corresponding arteries.

Melanocytes are distributed around the vessels along with fibroblasts. Clump cells are mostly pigment-laden macrophages found especially near the pupillary margin. Mast cells are also seen.

Sphincter pupillae constitutes a 0.75-mm wide and 0.17-mm thick, smooth, annular band of muscle fibres encircling the pupillary margin. The muscle fibres are separated by collagenous septa containing blood vessels and nerves.

The *anterior epithelium* is 12.5 millimicron thick and essentially containing smooth muscle, dilatator pupillae.

Dilatator pupillae 60 millimicron long and 7 millimicron wide, is a radially oriented smooth muscle. At places this muscle merges with the sphincter pupillae or the iris stroma causing pigmented projections (spurs) as follows.

- (i) *Fuchs' spur*—in the vicinity of the sphincter pupillae
- (ii) *Michel's spur*—at the periphery of the sphincter pupillae
- (iii) *Grunert's spur*—by the fusion of dilator fibre with the stroma at the root of the iris.

The *posterior pigment epithelium* is the forward continuation of the ciliary epithelium and pars ciliaris retinae. The cells are heavily pigmented.

This is made up of two layers: narrower anterior and wider posterior, connected laterally by desmosomes. The apical surfaces of the epithelial cells form microvilli interdigitating with those of the anterior epithelium.

Ciliary Body

The ciliary body is the region beyond the *ora serrata*, the jagged line marking the termination of the retina and the beginning of the ciliary body. It forms a ring 5.9 mm wide nasally and 6.7 mm temporally. Its colour is black. Its inner surface which faces the vitreous can be divided into two zones: the peripheral part or the *pars plana* which is relatively the smooth two-third part, and the inner part, the *pars plicata* or the *corona ciliaris* which shows about 70 longitudinal ridges of various sizes called the ciliary processes, each 0.8 mm high \times 1 mm wide. On the sagittal section the ciliary body appears triangular with these three sides (Fig. 7c.1)

- (a) The anterior side from whose middle the iris arises. The outer part contributes to the formation of the angle of the anterior chamber, and the remainder opens in the posterior chamber.
- (b) The lateral side is adjacent to the sclera and corresponds to the ciliary muscle.
- (c) The medial side corresponds to the ciliary processes.

Structure

The suprachoroidal space intervenes between the sclera and ciliary body proper.

From outside to inwards the layers are as follows:

The *ciliary muscle* 6 mm broad, is a circular band of unstriped fibres. It constitutes the main framework of the ciliary body and has mainly two groups of fibres, longitudinal (Brucke's muscle) and circular, each 0.8 mm high \times 1 mm wide (Müller's muscle) and some junctional oblique fibres. The outer, longitudinal fibres originate from the scleral spur and extend posteriorly even beyond

the equator ending in 'muscle-stars'-branched, star shaped figures. The inner, circular fibres form a sort of ring.

The ciliary muscle has two important actions: (a) the pull of the muscle fibres slackens the suspensory ligament and there is decreased tension on the lens capsule following which the anterior surface of the lens becomes more convex during accommodation, and (b) backward pull on the scleral spur opens up the trabecular spaces and facilitates the drainage of the aqueous humour.

The *ciliary process* consists essentially of the blood vessels and constitutes the most vascular region of the whole eye.

Bruch's membrane is the forward continuation of that of the choroid. In the choroid there are two strata, the outer elastic and inner cuticular; while in the ciliary body there are three strata: the outer elastic, intermediate connective tissue and inner cuticular.

The *epithelium* consists of two layers, the outer pigmented cells and inner nonpigmented cells. Retinal detachment does not spread beyond the ora serrata because here the pigmented and nonpigmented layers are firmly united.

The *internal limiting membrane* is said to be absent over the pars plana.

It must be emphasized that the structure of the ciliary body is the continuation of the layers of the choroid and the retina. The ciliary muscle, ciliary processes and Bruch's membrane are the continuation of the choroid. The epithelium and internal limiting membrane continue with those of the retina.

Ultramicroscopy. The features are summarized below.

Ciliary muscle. The characteristic features are as follows:

1. There is abundance of mitochondria and endoplasmic reticulum.
2. More well-developed Golgi apparatus is seen.
3. Muscle cells are arranged in bundles surrounded by a sheath of fibroblasts.
4. The fibres are filled with actin filaments, and many pinocytotic vesicles.

Ciliary epithelium. The cells are rich in organelles. The cytoplasm of the cells of the pigment epithelium is more electron-dense than that of nonpigmented epithelial cells. Zonulae occludentes occlude the lateral surfaces of the nonpigmented cells close to their apices. Gap junctions connect the lateral surfaces of both pigmented and less frequently nonpigmented cells. Desmosomes attach the lateral sides of the nonpigmented cells to each other.

Choroid

The dark-brown choroid, nourishing the outer part of the retina, extends from the margin of the optic nerve to the ora serrata. Because of its extreme vascularity, its thickness cannot be assessed accurately, although it is thicker posteriorly, 1/4 mm than anteriorly, 1/10 mm. There are two sites at which the choroid is adherent, at the margin of the optic nerve, and at the scleral spur.

Structure (Fig. 7.3)

From outside to inward the layers are as follows.

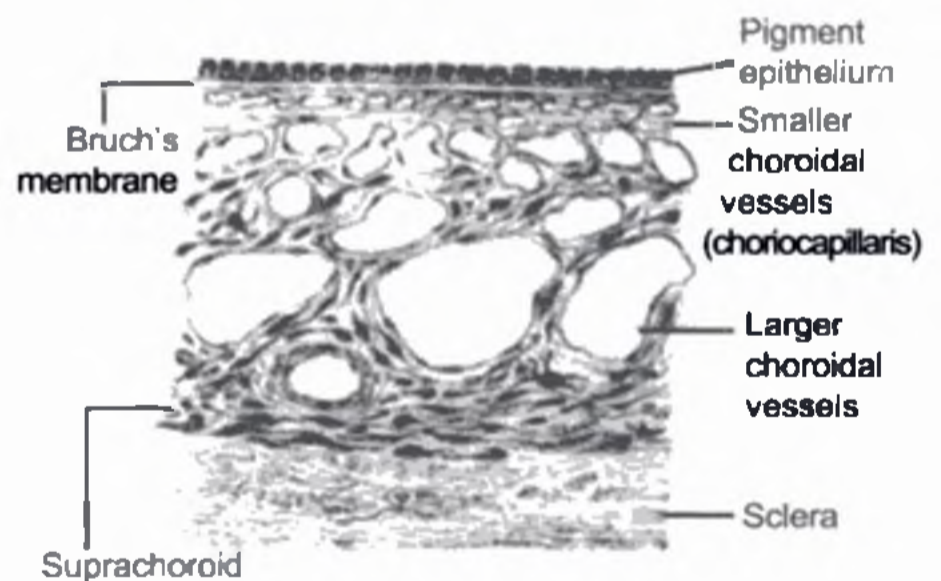


Fig. 7.3 Choroid, transverse section (Wolff).

(a) *The suprachoroid or epichoroid* is a potential space between the sclera and the choroid, consisting of interwining flattened laminae through which run or lie: (i) the long and short posterior ciliary arteries and nerves; (ii) the elastic fibres; (iii) the chromatophores; (iv) the muscle-stars; and (v) the multipolar ganglia at the nerve endings, probably vasomotor.

(b) *The layer of large vessels, Haller's layer.*

(c) *The layer of medium-sized vessels, Sattler's layer.*

(d) *The choriocapillaris* are capillaries of unusual bore, packed closely together. They end at the ora serrata, whereas the other layers continue on the the ciliary body.

(e) *Bruch's membrane* or the *lamina vitrea* is a thin 1.5 micron membrane firmly attached to the pigment epithelium of the retina. It acts as a filtering meshwork for the metabolic exchange between the choriocapillaris and the pigment epithelium of the retina.

Electronmicroscopically, it is found to be made up of five layers:⁴ (i) the basement membrane of the retinal pigment epithelium; (ii) the inner collagenous zone; (iii) the elastic layer; (iv) the outer collagenous zone; and (v) the basement membrane of the capillaries.

Blood supply to the uveal tract (Fig. 7c.2)

Blood is supplied to the uveal tract by these two arterial systems:

- (a) The posterior ciliaries— Short, Long
- (b) The anterior ciliaries—through the perforating branches.

The short posterior ciliary arteries. Ten to twenty arteries perforate the sclera in a circular zone around the optic nerve-head. They divide dichotomously and eventually break up into choriocapillaris.

The long posterior ciliary arteries. The nasal and temporal arteries pierce the sclera on either side of the optic nerve anterior to the short posterior ciliary arteries. They pass through the scleral canal, reach the suprachoroidal space and end into the ciliary muscle. They do not give off any branch till they reach the ciliary muscle.

The perforating branches of the anterior ciliary arteries. These perforate the sclera about 5 mm away from the limbus, enter the ciliary body, and at the anterior end of the ciliary muscle anastomose

with branches of the long posterior ciliary arteries to form the major arterial circle of the iris—the *circulus arteriosus iridis major*. The major arterial circle gives off muscular—to the ciliary muscle, ciliary—to the ciliary processes, recurrent ciliary—the other recurrent branches are from the long posterior ciliary and perforating branches of the anterior ciliary arteries, and branches to the iris. The majority of the arterial branches run to the pupillary margin, while others divide and subdivide to finally form an incomplete circle at the collarette—the minor arterial circle of the iris or *Circulus arteriosus iridis minor*.

The *venous return* of the uveal tract is practically through four to seven *venae vorticosae*, so named because of its whorled appearance. The radial veins of the iris run posteriorly, receive tributaries from the ciliary processes, and finally reach the choroid to form large anterior tributaries of the *venae vorticosae*. The veins from the outer part of the ciliary body run anteriorly and unite to form the ciliary venous plexus. This plexus drains into the anterior ciliary and episcleral veins.

Nerve supply

Parasympathetic. The postganglionic fibres from the ciliary ganglion run in 8 to 10 short ciliary nerves, penetrate the sclera to reach the suprachoroidal space and supply the sphincter pupillae and ciliary muscle.

Sympathetic. The postganglionic fibres from the superior cervical ganglion run along the internal carotid artery via the nasociliary→two long posterior ciliary nerves→and finally penetrate the sclera to reach the dilator pupillae and possibly also the ciliary muscle.

Sensory. The supply is through the long ciliary nerves.

Further Reading

1. Bron, A.J., Tripathy, R.C. and Tripathy, B.J. (Eds.), *Wolff's Anatomy of the Eye and Orbit* (8th ed.), Chapman and Hall, London, 1997.

2. Duke-Elder, S., *System of Ophthalmology*, Vol III: *The Anatomy of the Visual System*, Duke-Elder, S. and Wybar, K. (Eds.), Kimpton, London, 1961.
3. Gray, H., *Gray's Anatomy*, (35th ed.), Warwick, R. and Williams, P.L. (Eds.), Longman, London, 1973.
4. Hogan, M.J. Bruch's membrane and diseases of the macula: role of elastic tissue and collagen, *Tr. Ophthalmol. Soc. UK*, **87**: 113, 1967.

8. ANATOMY OF THE CRYSTALLINE LENS AND SUSPENSORY LIGAMENT

The crystalline lens in the adult is transparent, biconvex and semisolid. It is spherical and soft in the fetus, and flattened and sclerosed in the old. It is placed behind the pupillary border of the iris and on the anterior surface of the vitreous to which it is attached by *Wieger's hyaloideocapsular ligament*, with the intervening hyaloid fossa and the retrolental *space of Berger* which is a capillary space behind the lens. The lens is suspended from the ciliary body by the suspensory ligament or *zonule of Zinn*. It is enclosed by a capsule. Its axial thickness is 3.6 mm and has a variable diameter between 9 and 10 mm. The radius of the anterior surface is 9 mm, while that of the posterior surface is 5.5 mm. Its refractive index is 1.39.

The crystalline lens (Fig. 8.1) has: (a) two parts, the central or nucleus and the peripheral or cortex; (b) two surfaces, the anterior and posterior; and (c) two poles, the anterior and posterior.

The equator of the lens having a dentate surface corresponds to the junction between two surfaces and is about 0.5 mm behind the ciliary processes.

The lens is avascular and its nutrition is maintained by the metabolic exchange between it and the aqueous humour.

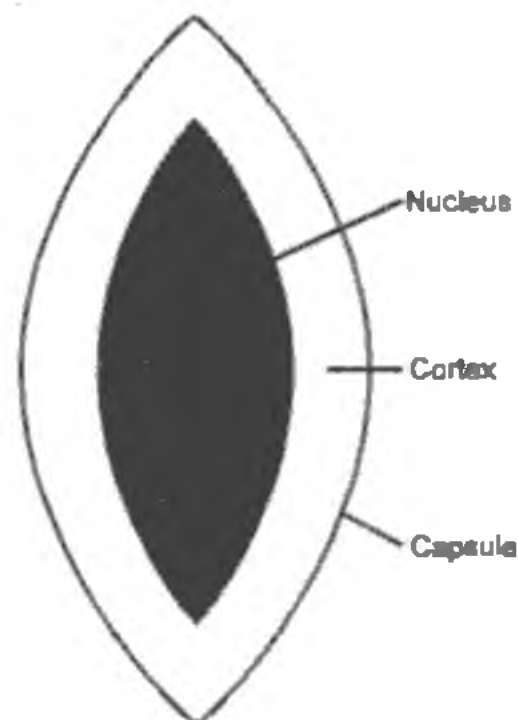


Fig. 8.1 Parts of the human lens, diagrammatic.

Structure

The crystalline lens is comprised of the following.

(a) The *capsule* is an elastic, homogeneous envelope with varying thickness at different regions, thicker anteriorly, thickest at the equator and thinnest at the posterior pole. It has two portions: superficial, i.e. the delicate zonular lamellae and the deep, i.e. capsule proper, which is homogeneous. With an increase of age the capsule becomes thicker.

(b) The *anterior epithelium* which consists of a single layer of cubical cells interposed between the anterior capsule and the main substance of the lens. There is no posterior epithelium, since the cells of this portion have developed into lens fibres during intrauterine life.

(c) The *cement substance* is present in different places: subcapsular, subepithelial and central.

(d) The *lens fibres* are hexagonal, 2100 to 2300 in number, flat, 5 to 7 millimicron wide and 8 to 12 millimicron long. During development they run from one pole to another initially, and from the equator to the anterior epithelium at a later stage. Newly-formed fibres are successively laid upon the older ones, pushing the older fibres towards the centre.

Ultramicroscopy. Electron microscopy of the cells of the lens epithelium shows few organelles lying in a coarse cytoplasm, endoplasmic reticulum, ribosomes, small mitochondria and golgi complex. The cytoskeletal elements of the cells include proteins, actin, intermediate filaments, microtubular protein, spectrin, alpha actin and myosin. The basal aspects of the cells are attached to the anterior capsule by hemidesmosomes, while their lateral aspects are attached to each other by desmosomes. The superficial lens fibres are roughly hexagonal having two long and four short sides. The fibres meet forming a series of 'ball and socket-like' joints. In the deepest layers of the cortex and nucleus, the ball and socket-like joints are supplemented by 'tongue and groove' joints. These interlockings are essential for continuing transparency of the lens and accommodation.

Suspensory Ligament of the Lens^{1,2} (Syn. Ciliary zonule or zonule of Zinn)

Suspensory ligament suspends the crystalline lens and allows the ciliary muscle to act on it particularly during accommodation. Most of the fibres appear triangular in a meridional section having apex, base, anterior (outer) and posterior (inner) surfaces. The *apex* corresponds to a point on the ora serrata. The *base* is at the equator of the lens spreading towards both anterior and posterior surfaces. The *anterior surface* forms part of the posterior wall of the posterior chamber, while the *posterior surface* lines the anterior limiting membrane of the vitreous. There are two types of fibres: the main and the auxiliary.

The *main fibres* are subdivided into four groups depending upon the site of attachment, and these are:

1. Orbiculoposterior capsular
2. Orbiculoanterior capsular
3. Cilioposterior capsular
4. Cilioequatorial fibres.

The *auxiliary fibres* are fine and they anchor the main fibres providing strength to the latter. A zonular fibre having a diameter of 0.35 to 1

micron is made up of microfibrils of 8 to 40 nm diameter.

Petit's Canal

Petit's canal is the triangular space between the crystalline lens and the zonular fibres.

Further Reading

1. Bron, A.J., Tripathy, R.C. and Tripathy, B.J. (Eds.), *Wolff's Anatomy of the Eye and Orbit* (8th ed.), Chapman and Hall, London, 1997.
2. Nema, H.V., *Anatomy of the Eye and Its Adnexae* (2nd ed.), Jaypee Bros, New Delhi, 1991.

9. ANATOMY OF THE VITREOUS HUMOUR¹⁻³

The vitreous humour is a perfectly transparent, roughly spherical and gelatinous structure occupying the posterior four-fifth of the globe. The volume of the vitreous is about 4 ml.

Its outermost condensation is called the *hyaloid membrane*. The *base* of the vitreous is the region where it is attached to the pars plana and ora serrata, and is 1.5 mm broad. The potential space between the posterior lens surface and the anterior hyaloid membrane is called *Berger's space* and the connections between the two is by *hyaloideo-capsular ligament of Weiger*. *Cloquet's canal* or the *hyaloid canal* indicates the potential space running from the funnel-shaped space in front of the optic disc (*area of Martegiani*) to the posterior lens capsule, left behind by the hyaloid artery.

Structure (Fig. 9.1)

A combination of gel containing 99% water and cells the vitreous humour consists of these major macromolecular components: (a) the collagen—which is the main structural basis and is filled up

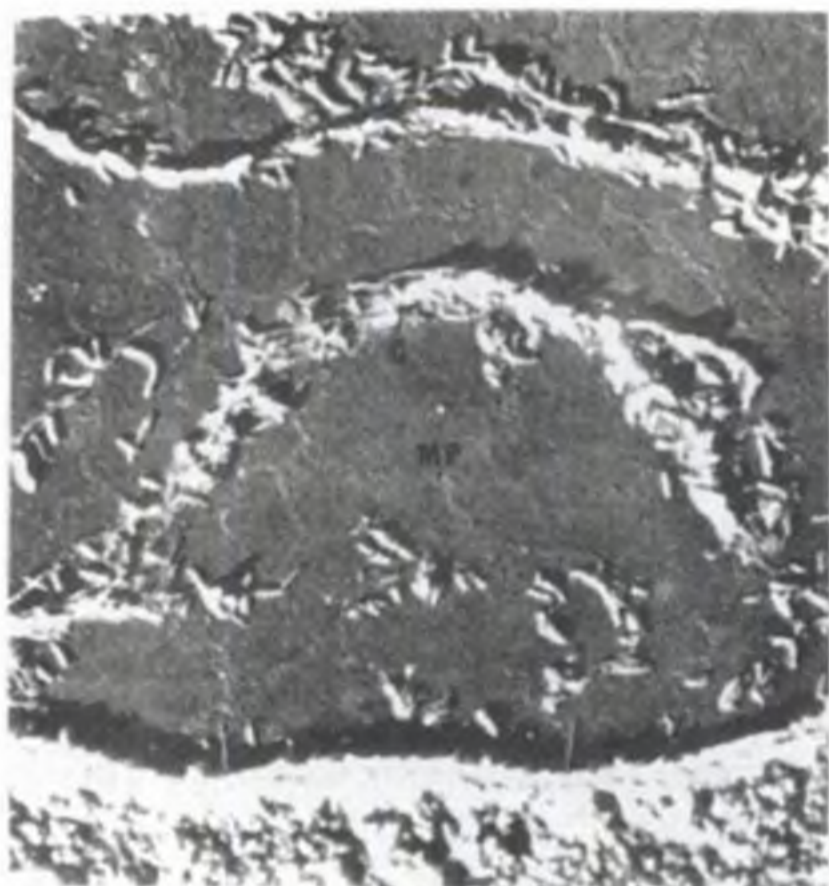

Fig. 9.1 Electron micrograph showing drying pattern of vitreous acid mucopolysaccharides, MP, between the aggregates of delicate collagenous filaments, C, of the vitreous framework. Below lies the inner surface of the retina (arrows) ($\times 24,000$) (Courtesy: B.S. Fine; Scheie & Albert).

with hyaluronic acid, (b) hyaluronic acid which protects the gel against cellular invasion and is condensed at the periphery as a surface layer and (c) soluble proteins. In the normal eyes, the vitreous cells called the *hyalocytes* which are mainly histiocytes, appear to help in the synthesis of acid mucopolysaccharides and vitreous fibrils.

It acts as an intervening medium in the light-pathway between the lens and the retina.

Vitreous attachments

The vitreous is firmly adherent at certain regions, viz., the vitreous base, margin of the optic disc and macula, and overlying retinal vessels. Elsewhere the attachment is loose.

Ultramicroscopy. The fibrils in the cortical vitreous insert into the internal limiting membrane of the retina posteriorly, blending with the basal lamina of Müller's cells or with that of the ciliary body anteriorly. The hyalocytes show large electron-dense inclusions.

Further Reading

1. Bron, A.J., Tripathy, R.C. and Tripathy, B.J. (Eds.), *Wolff's Anatomy of the Eye and Orbit* (8th ed.), Chapman and Hall, London, 1997.
2. Duke-Elder, S., *System of Ophthalmology*, Vol. 11: *The Anatomy of the Visual System*, Duke-Elder, S. and Wybar, K., (Eds.), Kimpton, London, 1961.
3. Nema, H.V., *Anatomy of the Eye and Its Adnexae* (2nd ed.), Jaypee Bros., New Delhi, 1991.

10. ANATOMY RELATED TO GLAUCOMA^{1,2}

Anterior Chamber

The anterior chamber (AC) is bound in front by the posterior surface of the cornea and peripherally by the angle recess. The apex of the angle is formed by the anteriormost part of the ciliary body. It is also limited behind by the anterior surface of the iris and the lens exposed in the pupillary area. The average diameter is 11 to 12 mm and its average axial depth is 3 to 3.5 mm. Its volume is 0.2 to 0.3 mm. The shallowest part is at the iridocorneal junction and the deepest part is in the pupillary area.

The causes of deep AC include (a) aphakia; (b) buphthalmos; (c) sometimes myopia; and (d) vitreous degeneration.

The causes of shallow AC include (a) intumescence of lens; (b) closed-angle glaucoma; (c) sometimes hypermetropia; and (d) old age.

AC is deep in the centre and shallow at the periphery as in iris bombe. AC is deeper at one side than on the other as in subluxation of the lens.

Posterior Chamber

The posterior chamber is the space demarcated in front by the iris, at the back by the lens and the suspensory ligament. Its base is formed by the ciliary processes, while its apex is formed by the

pupillary margin of the iris. The volume of this chamber is 0.06 ml.

This chamber consists of three compartments: prezonular (posterior chamber proper), zonular and retrozonular.

The *prezonular* part is triangular on cross-section. Its apex is formed by the point of contact between the pupillary margin of the iris and the anterior surface of the lens. The base is formed by the ciliary processes. The anterior and posterior walls are respectively formed by the pigment epithelium of the iris and by the lens with zonules.

The *zonular* compartment lies within the zonule of Zinn.

The *retrozonular* compartment (Petit's canal) is situated in between the posterior aspect of the zonular fibres and the anterior hyaloid face.

Angle of the AC or the Filtration Angle

This is bound behind by the root of the iris and in front by the corneoscleral trabeculum and anteriormost part of the ciliary body. The corneoscleral trabeculum or the meshwork of the angle is made up of three structures: (i) Descemet's membrane breaking up into bundles; (ii) scleral meshwork; and (iii) uveal meshwork. Descemet's membrane connects the scleral and uveal meshworks.

The Outflow Apparatus

The outflow apparatus consists of the trabecular meshwork, canal of Schlemm and collector channels.

The trabecular meshwork (Fig. 7c.2). This spongework connective tissue beams are arranged as superimposed perforated sheets. It arises just before the apparent termination of Descemet's membrane. The beams run posteriorly to the anteromedial border of the scleral spur and junctions of the iris and ciliary body. It shows two portions: inner uveal meshwork and outer corneoscleral meshwork. The *uveal meshwork* contains one or two layers which branch and

interlace but tapering anteriorly. The sheets converge anteriorly and join the periphery of Descemet's membrane, inner part of Schwalbe's ring and corneoscleral trabeculae. The *corneoscleral meshwork* is made up of 8 to 15 layers with a total width of 120 to 150 millimicrons.

Ultramicroscopy. The trabeculae are made up of central core, middle layer of basement membrane and the surrounding endothelial layer containing numerous pinocytic vesicles. The central core is formed by collagen types I, II and IV, fibronectin, chondroitin sulphate, elastic tissue, etc. The trabecular cells made up of basal laminar, collagen and glycosaminoglycans (mucopolysaccharides have important functions like secretion and pigment phagocytosis).

Canal of schlemm. It is a slightly irregular, annular, endothelial-lined canal. This is about 36 mm in circumference and is situated in the outer portion of the internal scleral sulcus. This canal conducts the aqueous humour from the trabecular meshwork to the episcleral venous network via the collector channels. Microscopically there are zones: the endothelial lining, basement membrane, and pericanalicular connective tissue.

Ultramicroscopy. There is direct communication between the extracellular spaces of the trabeculum and Schlemm's canal. The single-layered endothelial spindle cells line the canal. These cells are connected to each other by poorly tight junctions and their cytoplasm shows usual organelles. The luminal surface of the cells show sparse microvilli, but the prominent feature is the presence of *giant vacuoles*. These vacuoles are globular invaginations of the basal plasmalemma of endothelial cells. The vacuoles are 25 millimicron long \times 6 millimicron wide. About 2% of these vacuoles communicate with Schlemm's canal via a luminal pore (*transcellular channels*). Following aqueous drainage there is occlusion of the basal infoldings resulting in a nonvacuolated state.

The collector channels. They originate at irregular intervals from the outer wall of Schlemm's canal.

They are 25 to 35 in number. They drain into: (i) deep scleral plexus, (ii) intrascleral (midscleral) plexus and (iii) episcleral plexus. The deep plexus made up of branches of the anterior ciliary veins drains into the intrascleral plexus. The intrascleral plexus drains posteriorly into the episcleral plexus, and the latter finally into the anterior ciliary veins.

Aqueous veins are those 8 collector channels that directly drain into the episcleral plexus. They are seen with a slit-lamp biomicroscope either as clear vessels showing bilaminar flow of blood and aqueous, about 2 mm away from the limbus usually located anteromedially.

Inner Canals or Afferent Communications

These are fine, tortuous, endothelial-lined, oblique spaces within the meshwork.

Further Reading

1. Bron, A.J., Tripathy, R.C. and Tripathy, B.J. (Eds.), *Wolff's Anatomy of the Eye and Orbit* (8th ed.), Chapman and Hall, London, 1997.
2. Sugar, H.S., *The Glaucomas*, Paul B. Hoeber, New York, 1957.

11. ANATOMY OF THE RETINA¹⁻⁷

The retina (Lat. *rete*, net) is the innermost (nervous) coat of the eyeball which is the receptor of the light stimuli. It is a delicate, transparent membrane, purplish red in colour due to rhodopsin. It is very thin approximately 0.5 mm at the posterior pole, 0.2 mm at the equator and 0.1 mm at the ora serrata. It is thickest near the optic disc and becomes thinner towards the periphery. It is attached at two places—the ora serrata and the optic disc. Externally, the retinal pigment epithelium is in contact with Bruch's membrane of the choroid. The internal limiting membrane of the retina separates it from the vitreous. Anteriorly, the pigment epithelium

extends into the ciliary body. Posteriorly, all the retinal layers except the nerve fibre layer terminate at the optic disc and being separated from the disc by a layer of glial tissue, the *intermediary tissue of Kuhnt*. The retina and the vitreous humour are in intimate contact especially at the ora serrata and in a 4 mm zone posterior to the ora serrata.

Optic Disc

The optic disc is round or vertically oval, 1.5 mm in diameter with a depression at the centre. The depression is due to atrophy of the fetal vascular elements called the *physiologic cup*. At this region the nerve fibres become continuous with the optic nerve and the central retinal artery with its branches enters here. The central retinal vein with its tributaries exits here. It is made up of axons of the ganglion cells of the retina. The term 'papilla' used as a synonym is a misnomer since the disc is not raised from the surface but at the same level as that of the rest of the retina. While charting the visual field the 'blind spot' corresponds to the optic disc, because of absence of the rods and cones. The optic disc is considered the retinal aspect of the head or intraocular portion of the optic nerve.

Table 11.1 gives an account of retinal elements.

Table 11.1

The Elements of the Retina

Neuroepithelial layer
Rods
Cones
Cerebral layer
Direct conducting elements
Bipolar cells
Ganglion cells
Association and sustentacular elements
Müller's cells
Horizontal cells
Amacrine cells
Other cells like astrocytes and spongioblasts

There are three neurons and the layers of the retina are grouped under them as indicated in Table 11.2.

Table 11.2
Three Neurons in the Retina

Neuron I (percipient elements)
Layer of rods and cones
External limiting membrane
Outer nuclear layer
Outer plexiform layer
Neuron II (conduction and association elements)
Inner nuclear layer
Inner plexiform layer
Neuron III (purely conduction elements)
Ganglion cell layer
Nerve fibre layer
Internal limiting membrane

The retina proper can be broadly subdivided into two parts: the central or macular and the peripheral.

Central Retina or Macula Lutea

Macula lutea (Lat. *macula* a spot; *lutea*, yellow, the specialized region of the retina is 3 mm or 2-disc diameter temporal to the optic disc. Since this area is avascular, its nutrition is derived from the choroid. The central retina can be subdivided into three areas, the fovea, parafovea and perifovea.

The *fovea centralis* (Lat. *fovea*, pit) is a central depression in the macula lutea. It shows a bright reflex seen by the ophthalmoscope. It is the most sensitive part of the retina and contains only cones.

The *parafovea* is a 2.1 mm wide area all round the fovea and contains both rods and cones arranged alternately.

The *perifovea* is 1.5 mm wide area around the parafovea and at this region there are two rods between each cone.

Peripheral Retina

The peripheral retina may be divided into four zones: (a) the near periphery; (b) the mid periphery; (c) the far periphery; and (d) the ora serrata or extreme periphery.

The near periphery. The near periphery is the 1.5 mm wide area around the macula characterized by the absence of Henle's fibre layer and the presence of thicker cones surrounded by a collar of rods.

The mid periphery. It is 3 mm wide. It is characterized by interrupted ganglion cells and thicker cones, the cones being separated from each other by at least three rods.

The far periphery. This is 9 to 10 mm wide temporally and 16 mm wide nasally. At this region there are large and widely-spaced ganglion cells and the number of cones reduced, the cones having shorter outer segments.

The ora serrata. The ora serrata is 2 mm wide temporally and 0.7 mm wide nasally. There is gradual disappearance of the rods and replacement with malformed cones, disappearance of the outer molecular layer and fusion of the rods and cones. At 0.5 mm before the termination of the retina the rods and cones, ganglion cells and nerve fibre layer cease.

Ora serrata is the anteriormost end of the retina where it continues as the nonpigmented ciliary epithelium of the pars plana. The serrated appearance is due to anteriorly directed projections, about 40 in number. These projections are called *dentate processes* or *oral teeth*. The scalloped areas between them are called *oral bays*.

Structure (Fig. 11.1)

The retina has ten layers from outside to inwards. These are as follows:

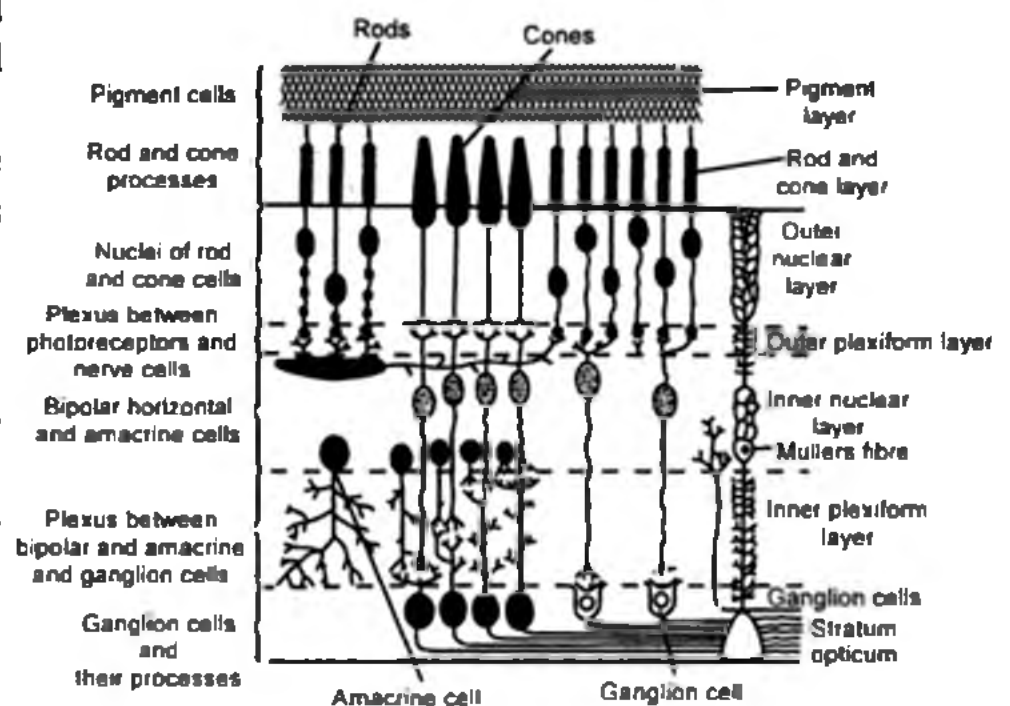


Fig. 11.1 Diagram of the structure of the retina (Sorsby)

The pigment epithelium. This consists of a single layer of flattened hexagonal cells (each cell consists of a dome, base and fine contractile pigment processes insinuating between adjacent rods and cones), each cell having a nucleus and large amount of dense pigment, *fuscina*. In senile eyes there is less dense pigment, *lipofuscin*.

Electron microscopically, the cytoplasm shows three zones: (a) the outermost which contains the mitochondria and basal membrane infoldings; (b) the intermediate which contains the nucleus and endoplasmic reticulum; and (c) the innermost which contains melanin granules and ribonucleoprotein particles.

Layer of rods and cones. This represents the true light-perceiving layer. The rods are maximum at the periphery, and at the fovea there are only cones. Each visual cell, either a rod or a cone, has the following components (Fig. 11.2): (a) an outer segment, which is thicker than the inner one, (b) a cilium connecting the outer and inner segments,

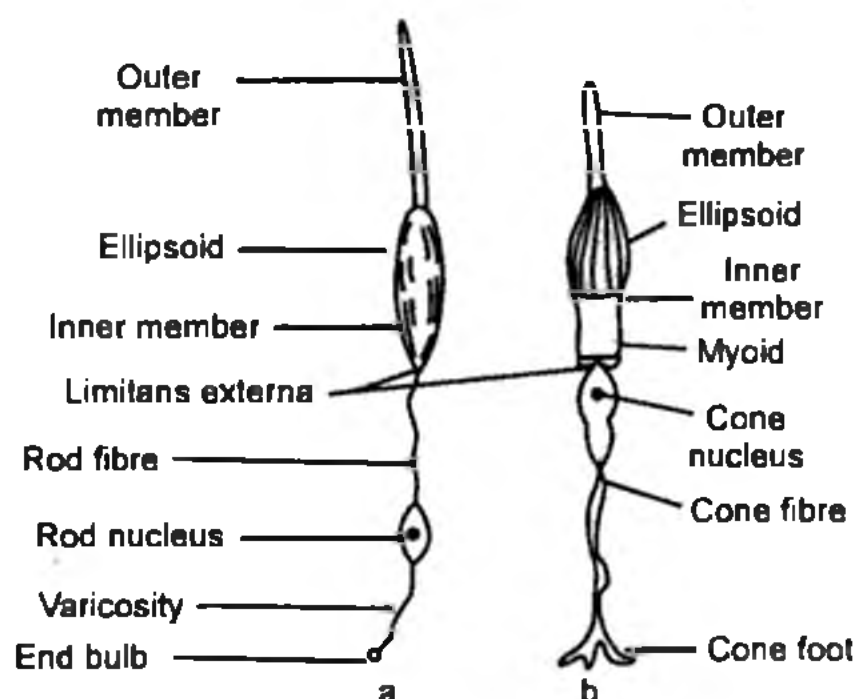


Fig. 11.2 Diagram showing parts of (a) rod and (b) cone of the human retina.

(c) an inner segment which consists of the ellipsoid containing the mitochondria and the myoid containing glycogen, (d) a connecting fibre between the inner segment and the cell body, (e) the cell body contains the large nucleus and small amount of cytoplasm, and (f) the inner rod or inner cone fibre: the rod fibre ends in a spherule and the cone fibre in feet.

The distinguishing features of the photoreceptors (rods and cones) are listed under Table 11.3.

Table 11.3

Distinguishing Features of the Retinal Rods and Cones

Points	Rods	Cones
Total number	77.9–103.3 millions	4.08–5.29 millions
Distribution	Absent at fovea	Maximal at fovea
Outer segment	Lesser in number	More, 1000–1200/cone discs
Ending	Spherule	Feet
Plasma membrane	Discs within it	Discs not separated from it
Relation with colour vision	No	Yes

Electron microscopy shows (Fig. 11.3) the essential structure of the outer segments of both rods and cones consisting of about 600 to 1200 highly regular lamellae packed in a columnar manner. In a cone the discs have a greater diameter. The inner segment is connected to the outer by a short area of relatively featureless cytoplasm. The inner segment contains many mitochondria, Golgi apparatus and a granular endoplasmic reticulum, along with ribosomes and neurotubules.

The external limiting membrane. This is formed by Müller's fibres and fenestrated by the fibres of the rods and cones. The cone openings are larger than the rod openings.

The outer nuclear layer. This layer consists essentially of the nuclei of the rods and cones.

The outer plexiform (molecular) layer. This contains the axons of the rods and cones arborizing with the dendrites of the bipolar cells, as well as with those of the horizontal cells and amacrine cells. This layer is thickest at the macula, but almost disappears at the fovea.

The inner nuclear layer. This layer consists of: (a) the bipolar cells, (b) the nuclei of Müller's fibres, (c) the horizontal cells, (d) the amacrine cells, and (e) the capillaries of the central retinal vessels.

The bipolar cells (Table 11.4) are of two types,

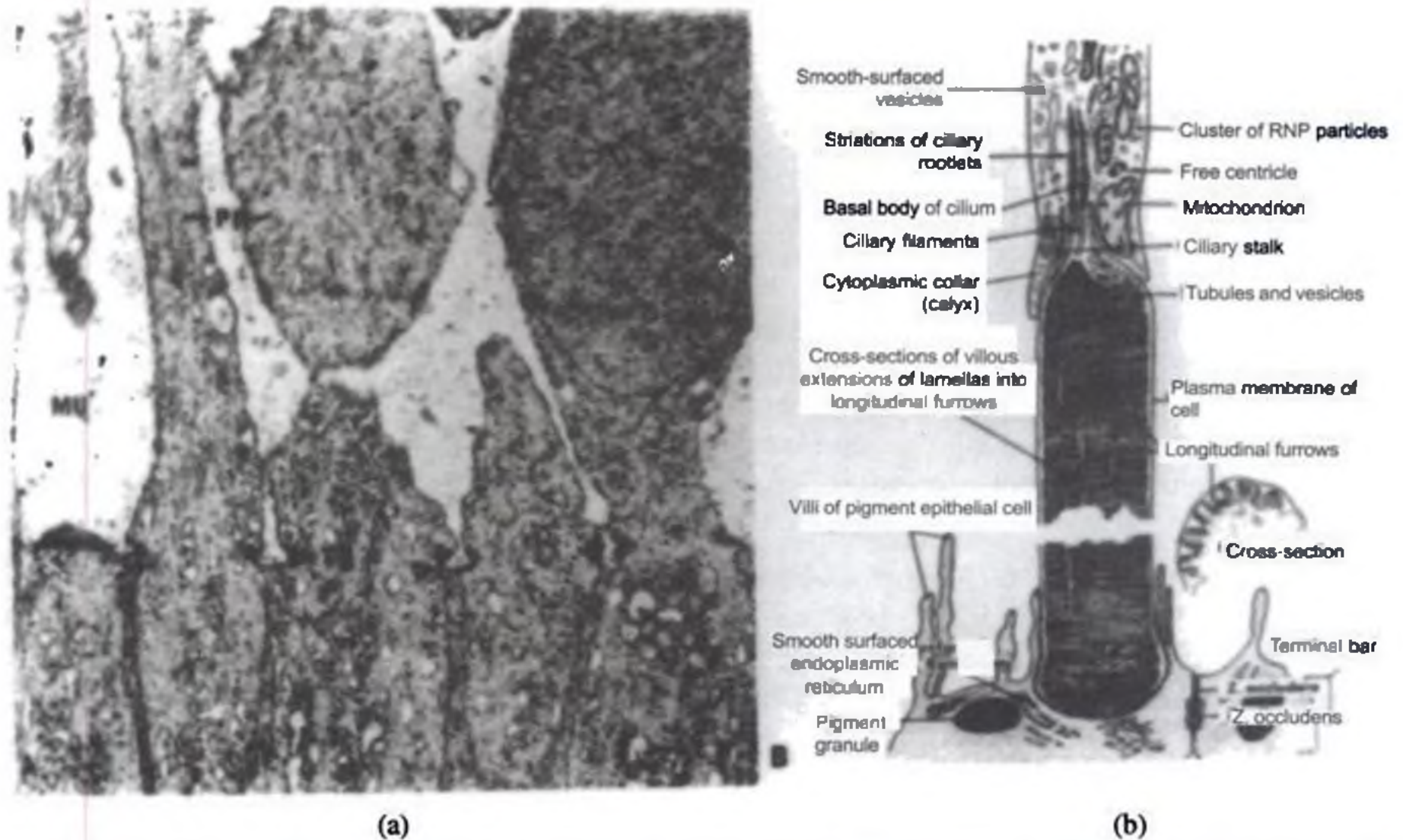


Fig. 11.3 (a) Electron micrograph showing external limiting membrane made up of terminal bars, TB. Internally, Müller's cell cytoplasm, MU is easily distinguished from the photoreceptor cells, PH, in the outer unclar layer ($\times 7,000$). (b) Diagram showing parts of the photoreceptors that extend beyond (are external to) the external limiting membrane (Courtesy: B S Fine; McPherson).

Table 11.4 Classification of Bipolar Cells

Rod or mop bipolar
Cone bipolar
Monosynaptic (midget)
Invaginating
Flat
Diffuse
Invaginating (brush)
Flat
Giant
Flat

diffuse and *midget* or monosynaptic; the diffuse bipolar again may be subdivided into *mop* and *brush* types. The mop bipolar cells connect with both rods and cones. The brush bipolar cells connect with the cones only. The axons of the midget bipolar run into the inner plexiform layer and connect with the dendrites of the midget ganglion cells. There are equal number of cones,

midget bipolar cells and monosynaptic ganglion cells, and this arrangement causes one-to-one connections between the cones and the optic nerve fibres.

Ultramicroscopy. Ultrastructures of all types of bipolar cells are similar. They contain round or oval nucleus, prominent Golgi apparatus, ribosomes, endoplasmic reticulum, mitochondria and microtubules.

The *horizontal cells* connect the cones of one part of the retina with the rods and cones of adjacent parts.

The *amacrine cells* are also laterally communicating neurons like the horizontal cells. The name 'amacrine' was given to these cells from the incorrect assumption that they had no axons. In fact, these cells have single processes.

Müller's fibres are the main supporting elements of the retina and they extend throughout the retina except at the fovea. Each fibre has a nucleus, cell

body and long processes. They have the capacity of storage and synthesis of glycogen.

The inner plexiform layer. This consists essentially of the arborizations of the axons of the bipolar cells with the dendrites of the ganglion cells along with Müller's fibres, distal processes of the amacrine cells and branches of the retinal vessels.

The ganglion cell layer. It consists of Müller's fibres, neuroglia, branches of the retinal vessels and a single row of ganglion cells except near the fovea where 8 layers are present.

Ganglion cells are flask-shaped consisting of the axons, forming the nerve fibre layer, and the dendrites, extending into the inner plexiform layer. Each cell is multipolar with a large nucleus, several nucleoli and Nissl granules. The ganglion cells are the neurons of the second order. Their axons make a cell station in the lateral geniculate body.

The nerve fibre layer. This consists essentially of the axons of the ganglion cells. The other elements of this layer are the centrifugal fibres, Müller's fibres, the neuroglia and the retinal blood vessels.

The arrangement of the nerve fibres (Fig. 11.4) is an important consideration while dealing with papilloedema and various field defects. All the fibres converge towards the optic disc. The fibres

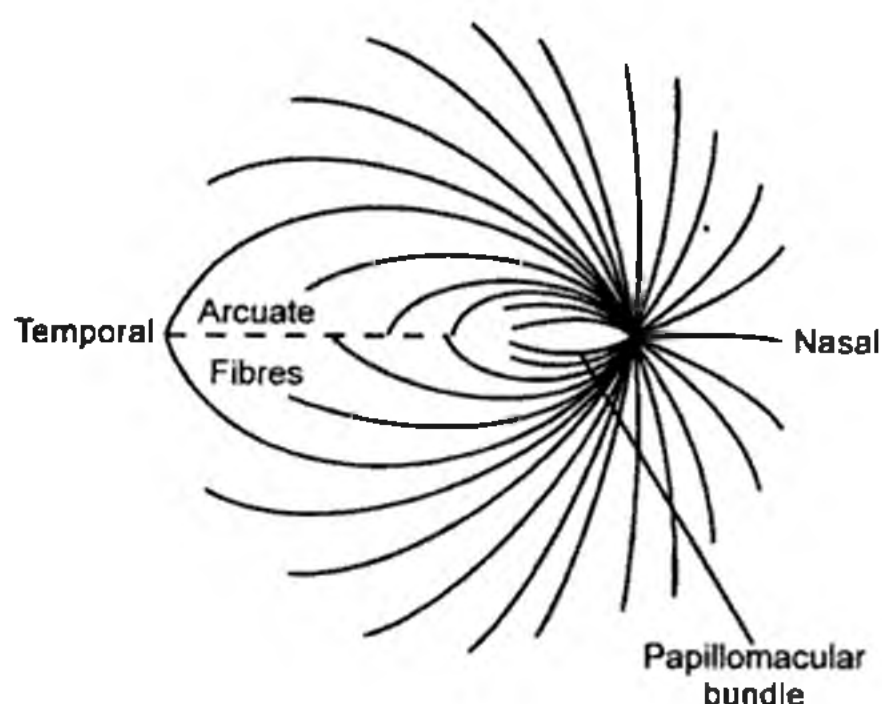


Fig. 11.4 Distribution of the retinal nerve fibres.

from the macula itself run straight towards the outer side of the optic disc, the *papillomacular bundle*. The fibres from the outer side of the disc arch above and below the macula, the arcuate fibres, while those from the inner side reach the disc without any interruption.

The nerve fibre layer is thinnest in the zone of the papillomacular bundle, next in thickness are the outer quadrants followed by the thickest inner quadrants. The relative thickness is the factor which determines the onset of papilloedema, and papilloedema initially involves the inner quadrant.

The internal limiting membrane. This separates the retina from the vitreous and is formed by the terminal expansions of Müller's fibres. It merges at the optic disc and becomes continuous with the neuroglia constituting the connective tissue meniscus of Kuhnt. Neuroglia are derived from both ectoderm and mesoderm. It may be broadly divided into astrocytes and oligodendrocytes derived from the ectoderm, and microglia derived from the mesoderm.

Arterial supply (Fig. 45c.1)

The retina gets its main arterial supply from the central retinal artery, a branch of the ophthalmic artery. The central artery of the retina is divided into four branches: superior temporal, superior nasal, inferior temporal, and inferior nasal.

The branches arise in the physiologic cup of the optic disc, then they divide in a dichotomous manner and all the four quadrants of the retina receive the blood supply in an even manner. The retinal arterioles are end-arteries.

The cilioretinal artery is an inconstant branch appearing at the temporal side of the disc coursing towards the macula. It is derived from the circle of Zinn-Haller, called the *circulus vasculosus nervi optici* which is the circular anastomosis between 2,4 or more of the short posterior ciliary arteries, the circle lying close to the optic nerve.

The retina has a double blood supply. The central retinal artery extends between the internal limiting membrane and the inner nuclear layer. The outer plexiform layer is fed partly from the retinal

arterioles and the choriocapillaris. The remaining layers namely the outer nuclear layer, the layer of rods and cones, the external limiting membrane, and the pigment epithelium are supplied by the choriocapillaris.

Venous drainage

The veins at the retinal periphery do not follow the course of the arteries, but in the central part the veins follow the course of the arteries. Four veins, the superior temporal, superior nasal, inferior temporal and inferior nasal unite to form the central retinal vein. The central retinal vein drains into the cavernous sinus, and sometimes into the superior and inferior ophthalmic veins.

Capillary distribution

Basically, there are two networks, superficial and deep—the former is in the outer parts of the nerve fibre layer and the latter in the zone intervening between the inner nuclear layer and the outer plexiform layer. This basic pattern of distribution is modified at the following regions: (a) at the extreme margin of the retina, the avascular zone; (b) at the retinal periphery, the single capillary net; (c) at the equator, the double capillary net; (d) around the macula, the triple capillary net and most superficial retinal net disappears; and (e) around the disc, four layers, the superficial net becomes three-dimensional.

Further Reading

1. Bron, A.J., Tripathy, R.C. and Tripathy, B.J. (Eds.), *Wolff's Anatomy of the Eye and Orbit* (8th ed.) Chapman and Hall, London, 1997.
2. Dacheux, R.P. and Raviola, E., Functional anatomy of the neural retina. In *Principles and Practice of Ophthalmology: Basic Sciences*, Albert, D.M. and Jacobiec, F.A. (Eds.), W.B. Saunders, Philadelphia, 1994, p. 285.
3. Duke-Elder, S., *System of Ophthalmology*, Vol. II: *The Anatomy of the Visual System*, Duke-Elder, S. and Wybar, K. (Eds.), Kimpton, London, 1961.

4. Fine, B.S., Retinal Structure: light and electron microscopic observations. In *New and Controversial Aspects of Retinal Detachment*, McPherson, A. (Ed.), Hoeber, Harper & Row, New York, 1968.
5. Hogan, M.J., Alvarado, J.A. and Weddell, J.E., *Histology of the Human Eye*, W.B. Saunders, Philadelphia, 1971.
6. Pahwa, J.M. and Billore, O.P., *Retinal Diseases*, Oxford and IBH, New Delhi, 1978.
7. Roof, D.L. and Heth, C.A., Photoreceptors and retinal pigment epithelium transduction and renewal mechanism. In *Principles and Practice of Ophthalmology: Basic Sciences*, Albert, D.M. and Jacobiec, F.A. (Eds.), W.B. Saunders, Philadelphia, 1994, p. 309.

12. ANATOMY OF THE VISUAL PATHWAYS¹⁻³

The visual pathway from the retina has been divided into six parts (Fig. 12.1): (a) the optic nerve, (b) the optic chiasma; (c) the optic tract, (d) the

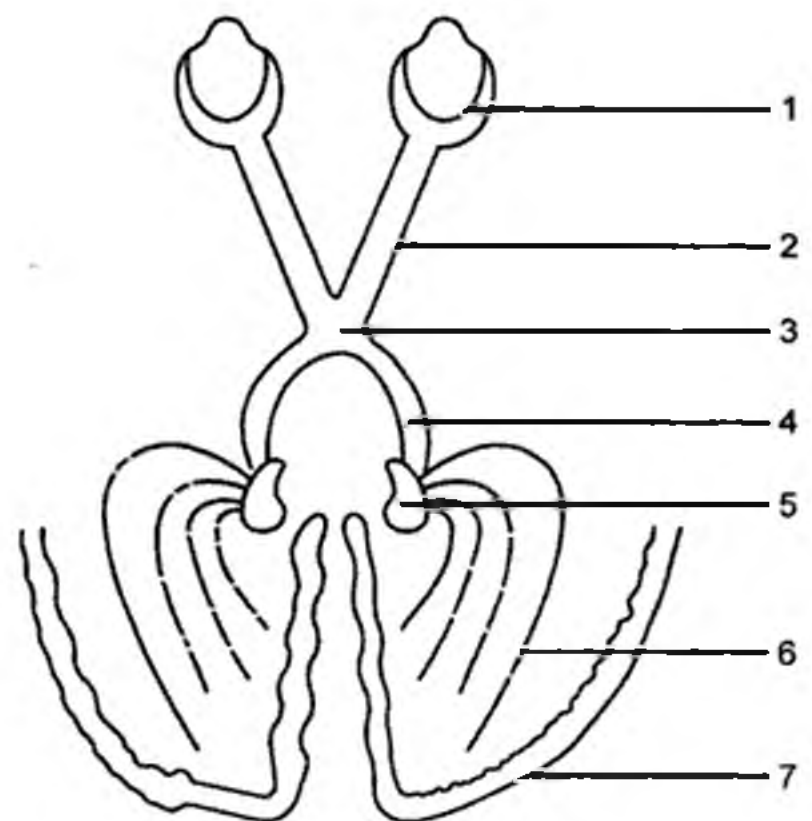


Fig. 12.1 Anatomy of the visual pathways: 1, retina; 2, optic nerve; 3, optic chiasma; 4, optic tract; 5, lateral geniculate body; 6, optic radiations; and 7, visual cortex.

lateral geniculate body, (e) the optic radiations, and (f) the visual cortex.

In the visual path, the end-organ is the sensory epithelium of the rods and cones. Three sensory neurons can be recognized between the retinal receptors and the visual cortex and they start as follows.

The first neuron. The bipolar cell in the retina one cone receptors are connected with a single bipolar cell.

The second neuron. The ganglion cells of the retina.

The third neuron. The axons of the lateral geniculate body.

Optic Nerve

Ontogenetically, morphologically and functionally a tract of the central nervous system, the optic nerve extends from the retina to the chiasma, and it has the following characteristics: (a) no sheaths and cells of Schwann are present, (b) neuroglial cells in the interstices are seen, and (c) it is clothed by coverings of the brain. The length varies between 35 and 55 mm, and the diameter of the intracranial part is between 4 and 7 mm and that of the intraorbital part is between 3 and 4 mm. The optic nerve is divided in several parts.

- (a) The intraocular or head, 1 mm in length. This is subdivided into three parts: retinal, choroidal and scleral.
- (b) The intraorbital, 25 mm in length, after leaving the retina through the lamina cribrosa.
- (c) The intraosseous or canalicular, 4 to 10 mm in length.
- (d) The intracranial, 10 to 23 mm in length. The part starting beyond the optic foramen is the intracranial portion.

Relations

These are extremely important.

Intraorbital. It is surrounded by the origin of the extrinsic muscles. The ciliary ganglion is situated lateral to the nerve between it and the

lateral rectus. The posterior ciliary arteries gradually surround the nerve when it is approaching the eyeball.

Intraosseous or canalicular. The ophthalmic artery crosses below the nerve in the dural sheath to the lateral side and leaves the dura near the canal. The sphenoidal air sinus is separated from the optic nerve by a thin plate of bone.

Intracranial. The nerve lies successively on the diaphragma sellae and the anterior part of the cavernous sinus, and below the anterior perforated substance and the medial root of the olfactory tract. The internal carotid artery, as also the ophthalmic artery, is at first below and then lateral to the intracranial part of the nerve. Between the two optic nerves in front of the chiasma, there is a variable part of the pituitary gland covered by the diaphragma sellae.

The other important structures are described in connection with the sphenoidal fissure.

Type of fibres

There are over one million axons and five types of fibres: (a) the visual (afferent), 80%, the fibres reaching the lateral geniculate body, (b) the pupillary (afferent), the fibres running to the tectum, (c) the efferent fibres (of unknown function) to the retina, (d) the photostatic fibres to the superior colliculus, and (e) the autonomic fibres.

Arterial supply

The intraocular part (Fig. 12.2). Arterial supply to the intraocular part of the optic nerve is derived from these.

From the ciliary circulation: (a) the circle of Zinn, (b) the anterior part of the arterial plexus in the pia mater, (c) the short posterior ciliary arteries, and (d) the choroidal arteries.

From the retinal circulation: (a) the intraneural part of the central retinal artery; and (b) the anterior division of the central artery of the optic nerve.

The intraorbital part. The peripheral system is derived from the pial plexus of vessels

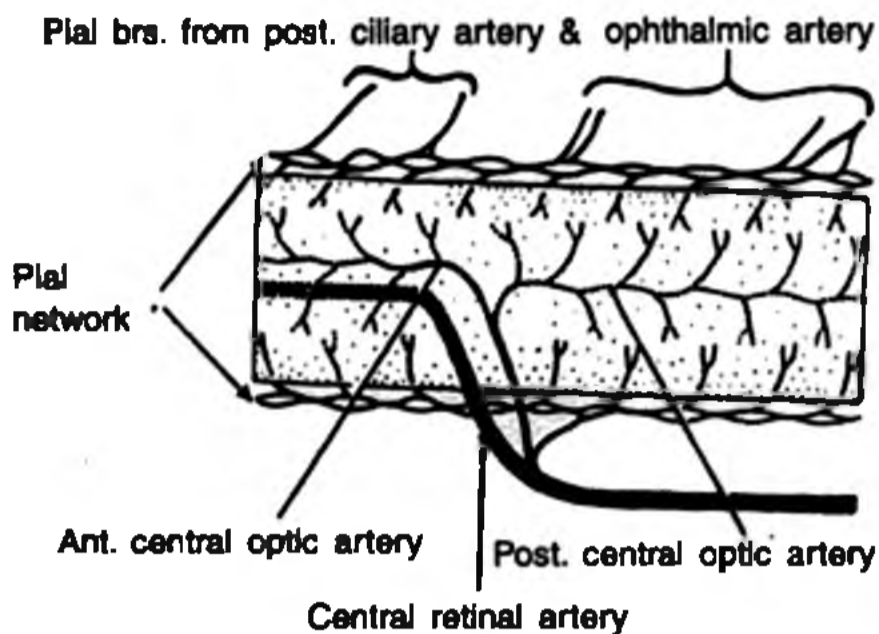


Fig. 12.2 Blood supply of the optic nerve (Reed).

supplemented by the ophthalmic, posterior ciliary, circle of Zinn and central retinal artery; and the axial system is derived from the central retinal, central artery of the optic nerve and central retinal collateral branches.

The intracanalicular part. It is supplied by the ophthalmic artery. The axial system disappears proximal to the optic foramen.

The intracranial part. The supply is derived from the pial plexus and supplemented by the internal carotid, anterior cerebral, ophthalmic and anterior communicating arteries.

Localization of the Fibres in the Visual Pathways (Fig. 12.3)

It is essential to be familiar with the arrangement of the fibres in the visual pathways as it is helpful in the localization of a lesion.

In the retina. This has already been described (see Fig. 11.4 on p. 37).

In the optic nerve. In the distal part, the macular fibres, about one-third of the nerve occupy a wedged area in the lateral part of the nerve. The peripheral fibres from the temporal side and those from the nasal side occupy the same side. In the proximal part, i.e. the part near the chiasma the macular fibres occupy the central position of the nerve.

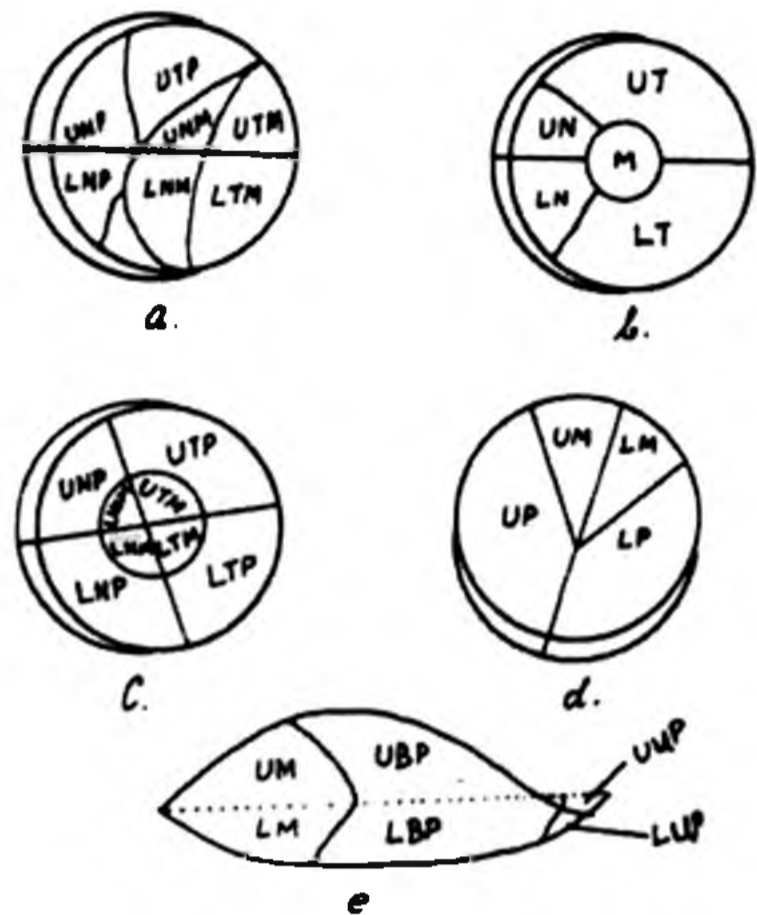


Fig. 12.3 Diagram to show the posterior view of the distribution of the visual fibres in (a) right optic nerve near the disc; (b) the region midway between the right optic nerve-head and the optic chiasma; (c) the optic chiasma; (d) the right optic tract; (e) the right striate area. U, upper; L, lower; T, temporal; N, nasal; P, peripheral; M, macular; B, binocular; and U, unocular.

In the chiasma. There is partial decussation of the fibres of both optic nerves. The temporal fibres pursue a direct ipsilateral course, while the fibres from the nasal hemiretina cross over to the optic tract of the opposite side. The arrangement of the fibres has been described on p. 42 and shown in Fig. 12.5.

In the optic tract. The macular fibres both crossed and uncrossed, are placed dorsolaterally. The lower peripheral fibres occupy the lateral position and the upper peripheral fibres occupy the medial position.

In the lateral geniculate body. The upper retinal fibres reach the medial part of the lateral geniculate body. The macular fibres occupy the posterior two-third.

In the optic radiations (Fig. 12.1). The upper and lower retinal fibres form corresponding parts of the radiations and reach the upper and lower

lips of the calcarine fissure. The macular fibres occupy the middle position.

In the visual cortex. There is a point-to-point localization of the retina in the visual cortex.

Optic Chiasma

Optic chiasma it is a transversely oval structure 12 mm in transverse diameter, 8 mm sagittally and 3 to 5 mm dorsoventrally covered by pia mater and represents the junction between the termination of the optic nerves anteromedially and emergence of the optic tracts.

Relations

They are important and of much clinical significance.

Superiorly. They are the lamina terminalis and floor of the third ventricle. The chiasma is also related to the hypothalamus.

Inferiorly. Relations vary according to its position. It usually rests on the diaphragma sellae and is related closely to the pituitary gland. However, the optic chiasma may be *prefixed* 5% or *postfixed* 4% depending upon whether the chiasma is lying in front or behind the pituitary gland.

Laterally. It is related especially to the termination of the internal carotid artery.

Posteriorly. It is related to the tuber cinereum and the infundibulum which connects the pituitary to the base of the brain.

Arterial supply

Arterial supply is by the vessels on all free aspects. It should be remembered that these are the main branches (Fig. 12.4).

(a) The superior part is supplied from the: (i) anterior cerebral and (ii) the anterior communicating arteries.

(b) The inferior part is supplied from the: (i) the internal carotid (ii) the anterior superior hypophysial and (iii) the posterior communicating arteries.

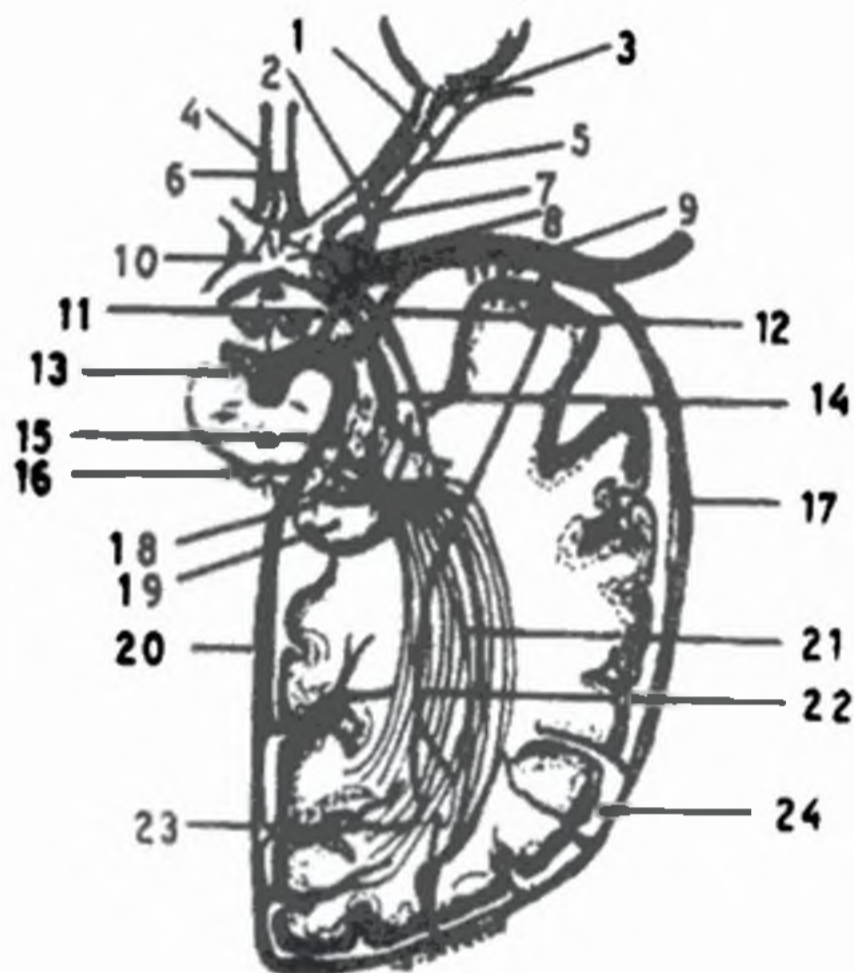


Fig. 12.4 Parts of the visual pathways and their arterial supply. 1, central retinal artery; 2, optic nerve; 3, ciliary arteries; 4, anterior cerebral artery; 5, central artery of the optic nerve; 6, anterior communicating artery; 7, ophthalmic artery; 8, internal carotid artery; 9, middle cerebral artery; 10, optic chiasma; 11, posterior communicating artery; 12 anterior choroidal artery; 13, basilar artery; 14, optic tract; 15, choroid plexus; 16, posterior choroidal artery; 17, middle cerebral artery; 18, lateral geniculate body; 19, thalamus; 20 posterior cerebral artery; 21, optic radiations; 22, deep optic branch to middle cerebral artery; 23, calcarine artery; 24, cerebral cortex.

Arrangement of the fibres (Fig. 12.5)

The fibres, from the nasal half of each retina including the nasal half of the macula decussate and cross over to the contralateral optic tract. The temporal fibres pursue a direct ipsilateral course.

The fibres, coming from the lower medial quadrant of the retina, cross in the lower part of the front of the chiasma. The uncrossed fibres, after crossing, loop forward into the terminal portion of opposite nerve before reaching the inferomedial part of the tract. The fibres, coming from the upper medial quadrant of the retina, cross in the middle and posterior parts of the chiasma, while the more

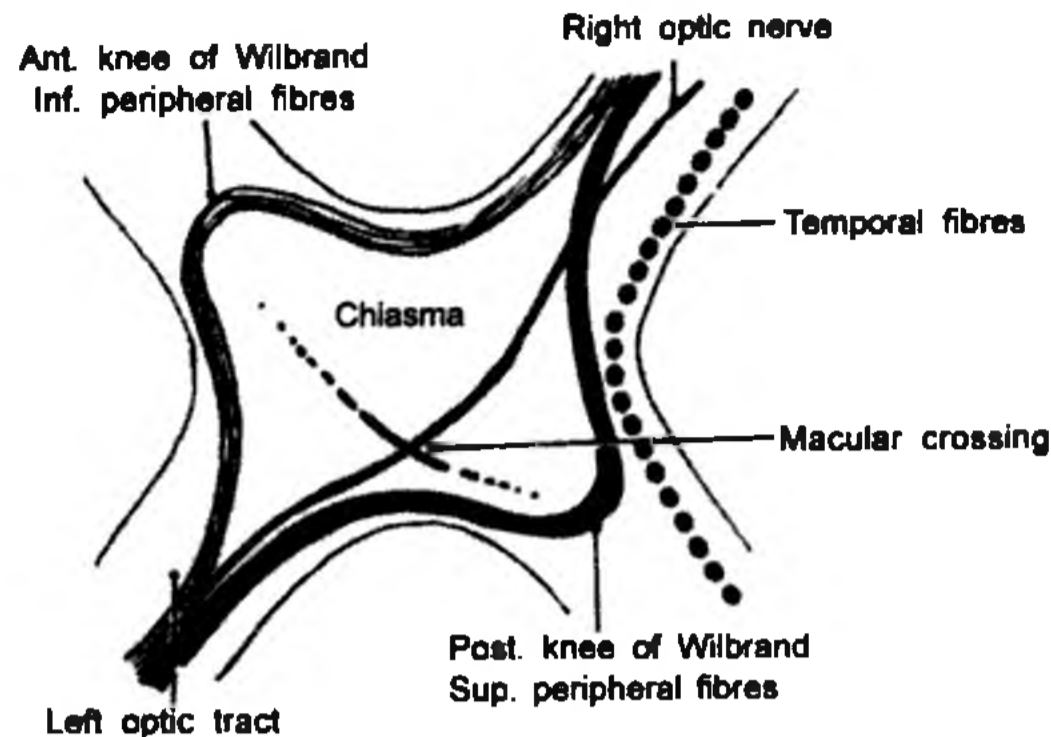


Fig. 12.5 Arrangement of the fibres in the optic chiasma

posteriorly disposed fibres cause a detour at the commencement of the ipsilateral optic tract before reaching the contralateral optic tract.

Optic Tract

The optic tract originates at the posterolateral angle of the optic chiasma, appears round at first between the tuber cinereum and the anterior perforated substance, and flat subsequently. It sweeps round the side of the cerebral peduncle and finally divides into two roots: (a) the larger lateral, and (b) the smaller medial. The majority of the former terminates into the lateral geniculate body and some reach the pretectal region and superior colliculus, and the latter into the medial geniculate body. The superior colliculus is the part of the midbrain and serves possibly as a centre of vertical gaze in man.

Arterial supply (Fig. 12.4)

Optic tract is supplied by the pial network, the vessels derived from: (a) the anterior choroidal, (b) the middle cerebral, (c) the posterior communicating, and (d) the posterior cerebral arteries.

Lateral Geniculate Body

Lateral geniculate body acts as the 'relay station' in the afferent visual pathway, and derives its name

'geniculate' because of its configuration, i.e. it is bent upon itself so that its dorsal surface is convex medially and the ventral surface is concave medially. It has two nuclei, dorsal and ventral, the former being phylogenetically more recent. Six layers are described, of which 1, 4 and 6 receive contralateral optic fibres, while the other layers receive ipsilateral optic fibres.

Arterial supply

Lateral geniculate body is supplied mainly by the posterior cerebral and to some extent by the anterior choroidal arteries.

The external striate artery termed the 'artery of cerebral haemorrhage' passes near the lateral geniculate body.

Optic Radiations

Fresh relay of fibres originates in the lateral geniculate body, pass forward and laterally forming the optic peduncle. It lies anterior to the lateral ventricle and in the retrolenticular part of the internal capsule behind the sensory and medial to the auditory radiations. It fans out to form the medullary optic lamina and then terminates into the fourth layer of the ipsilateral visual cortex. The lower fibres spread out forward around the inferior horn of the lateral ventricles (*Meyer's loop*).

Arterial supply

Optic radiations receive their supply from: (a) the anterior choroidal through the perforating branches, (b) the calcarine branch of the posterior cerebral, and (c) the middle cerebral arteries through the deep optic branches.

Striate Cortex

Striate cortex is also called *primary visual area* or *area 17* of Brodmann. This is characterized by *white lines of Gennari*. There are six layers in the cerebral cortex:

- Layer 1—molecular layer
- Layer 2—outer granular layer
- Layer 3—pyramidal layer
- Layer 4—inner granular layer
- Layer 5—ganglion layer
- Layer 6—polymorphous layer.

In the striate cortex the layer 4 (inner granular layer) is enormously expanded and the layer 5 (ganglion layer) contains solitary pyramidal *cells of Meynert*.

The primary visual area (area 17) is situated mainly in the medial aspect of the occipital lobe, around and in the calcarine sulcus with extensions into the lingual and conous gyrus. It is the main receptor area for the optic radiation from the lateral geniculate body. There is a point-to-point localization of the retina in the visual cortex and pyramidal association areas.

The *functions of the visual cortex* are: (a) to appreciate visual sensation, (b) to differentiate colours, (c) to fuse two separate images in binocular vision, (d) to perceive form and contour, and (e) to coordinate relative localization in space.

Arterial supply

Striate cortex receives its blood supply chiefly from the occipital branch of the posterior cerebral artery through its calcarine branches and to a less extent through the temporal and parieto-occipital branches of the posterior cerebral arteries.

Extrastriate System

This includes visual association with the parastriate or *area 18* of Brodmann and peristriate or *area 19* of Brodmann. These two are: the visuopsychic, area, and the area anterior to the former, i.e. in the region of the angular and supramarginal gyri and the temporal lobe. Area 18 does not show stria of Gennari. Area 19 does not show pyramidal cells in layer 5. The frontal eye fields, superior colliculus, oculomotor and other nuclei are connected with area 19.

Further Reading

1. Bron, A.J., Tripathy, R.C. and Tripathy B.J. (Eds.), *Wolff's Anatomy of the Eye and Orbit* (8th ed.), Chapman and Hall, London, 1997.
2. Duke-Elder, S., *System of Ophthalmology*, Vol. II: *The Anatomy of the Visual System*, Duke-Elder, S. and Wybar, K. (Eds.), Kimpton, London, 1961.
3. Gray, H., *Gray's Anatomy* (35th ed.), Warwick, R. and Williams, P.L., (Eds.), Longman, London, 1973.

13. ANATOMY OF EXTRAOCULAR MUSCLES OF THE EYE¹⁻³

The extraocular muscles are divided into three major groups: extrinsic muscles, muscles of the eyelid, and plane muscles of the orbit.

Extrinsic Muscles

For descriptive purpose these are described under five headings: origin, insertion, course, actions and nerve supply (Table 13.1).

Origin

The four recti originate from a tendinous ring surrounding the optic foramen and part of the

Table 13.1
Details and Actions of the Six Extrinsic Muscles of the Eye

Muscle	Length of muscle (in mm)	Distance of insertion from the cornea (in mm)	Length of the tendon (in mm)	Nerve supply (cranial nerve)	Actions	
					Main	Subsidiary
Medial rectus	40.8	5.5	3.7	III	Adduction	None
Lateral rectus	40.6	6.9	8.8	VI	Abduction	None
Superior rectus	41.8	7.7	5.8	III	Elevation	Adduction and intorsion
Inferior rectus	40.0	6.5	5.5	III	Depression	Adduction and extorsion
Superior oblique	60.0 (40 direct and 20 reflected part)	—	—	IV	Intorsion	Depression and abduction
Inferior oblique	37.0	—	—	III	Extorsion	Elevation and abduction

medial end of the superior orbital fissure. The ring is known as *annulus tendinous communis of Zinn*. The origin of the superior oblique is by a narrow tendon above and medial to the optic foramen, partially overlapping that of the levator palpebrae superioris.

The inferior oblique originates from a rounded tendon from a depression on the orbital plate of the maxilla just outside the passage of the nasolacrimal duct.

Insertion

The recti are inserted into the sclera in an area lying anterior to the equator, while the obliques are inserted into the sclera in an area lying posterior to the equator.

The inserted tendons can be distinguished from the scleral fibres. The tendons have parallel arrangement of fibres and the scleral fibres at this region show more irregular pattern.

Course

The superior rectus (SR) passes forward and outward lying under the levator forming an angle of 25° with the visual axis.

The inferior rectus (IR) similarly passes in the same direction as the SR but along the floor of the orbit, and also makes an angle of 25° . The medial (MR) and lateral rectus (LR) pass forward along the corresponding walls.

The superior oblique (SO) about 10 mm behind the trochlea or pulley forms a rounded tendon which hooks round the trochlea, passes downward, backward and outward at an angle of 55° (Fig. 13.1)

The inferior oblique (IO) passes backward and outward lying below the IR.

Actions of the muscles

Rotation of an eyeball is possible around three axes: vertical, transverse and anteroposterior—whose centre of rotation corresponds roughly to the centre of the eyeball.

In elevation the SR and IO act together; the SR is responsible for elevation of the abducted eye, and the IO for elevation of the adducted eye (Fig. 13.2).

In depression the IR and SO act together. Intorsion is produced by the SO and SR. Extorsion is produced by the IO and IR. During abduction the main action of the vertical recti (SR and IR)

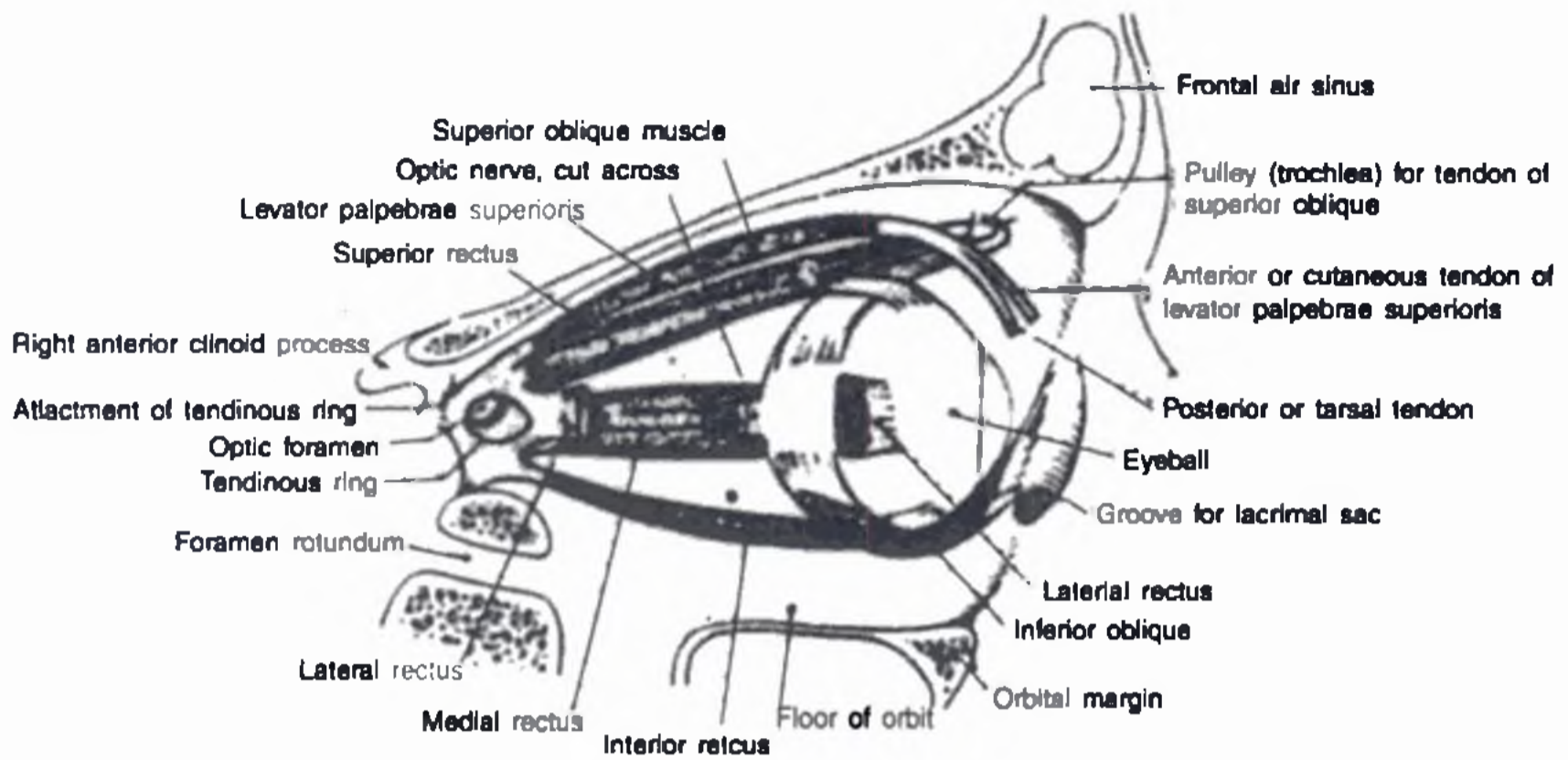


Fig. 13.1 Muscles of the right orbit (Pauchet and Dupret).

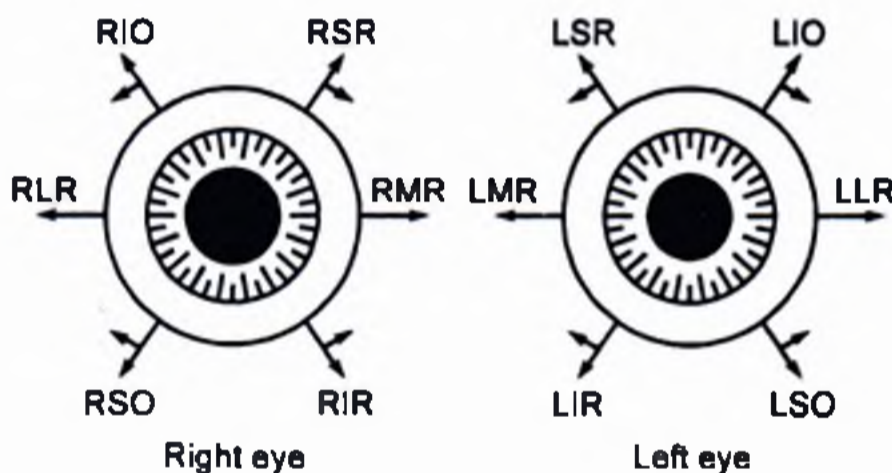


Fig. 13.2 Diagram showing possible actions of the extrinsic muscles. The direction towards which the eye moves is indicated by the straight arrows, while the torsional movement is shown by the curved arrows.

increases, while during adduction the main action of the obliques (SO and IO) increases. The subsidiary actions of the vertical recti increase during adduction, while those of the obliques increase during abduction.

Basic Eye Movements (Table 13.2)

Vestibuloocular reflex has a latency of 15 m, seconds and it starts in three pairs of semicircular canals. It shows two phases: a phase interrupted by a quick phase (saccadic) and resets the eye in more central position. This reflex is present at birth.

Table 13.2

Classification of Basic Eye Movements³

<i>Reflexive</i>
Vestibuloocular reflex
Opticokinetic nystagmus
<i>Voluntary</i>
Saccades
Smooth pursuit

Opticokinetic nystagmus is a reflexive ocular movement in response to a large moving stimulus, and can be elicited in newborn infant.

Saccades are eye movements of short, 20 to 100 m seconds', duration and of high velocity, 20 to 600 degrees/second peak velocity. They shift the direction of gaze from one target to another. Both saccades and smooth pursuit movements depend largely on attention.

Smooth pursuit movements are low velocity ocular movements.

Further Reading

1. Duke-Elder, S., *System of Ophthalmology*, Vol II: *The Anatomy of the Visual System*, Duke-Elder, S. and Wybar, K. (Eds.), Kimpton, London, 1961.

2. May, C. and Worth, C., *Manual of the Diseases of the Eye* (13th ed.), Keith Lyle, T., Cross, A.G., and Cook, C.A.G. (Eds.), Bailliere, Tindall and Cashell, London, 1968.
3. Hansen, R.M., Development of oculomotor control systems. In *Principles and Practice of Ophthalmology: Basic Sciences*, Albert, D.M. and Jacobiec, F.A. (Eds.), W.B. Saunders, Philadelphia, 1994, p. 608.

14. EMBRYOLOGY AND POSTNATAL DEVELOPMENT OF THE EYE¹⁻³

The two eyes develop from the pair of diverticula from the sides of the forebrain and the neighbouring mesodermal and ectodermal elements. A short discussion about the development of the central nervous system (CNS) and the brain in this connection is thus important.

The ectoderm of the embryonic plate anterior to the primitive streak is the source of the development of the major part of the CNS. It runs longitudinally over the caudal part of the dorsal surface. The *neural plate* is formed at this region by proliferation and thickening of the cells. The *neural groove* is the median longitudinal groove in the neural plate and the two parallel neural folds are the result of proliferation of the neural ectoderm one on each side of the groove. Along the margin of each neural fold a ridge of ectodermal cell, *neural crest*, is formed. Posteriorly, the neural folds fuse in the midline to convert the neural groove into the *neural tube* during the fourth week of intrauterine life. Prior to the closure of the *neural tube*, the neural folds expand in the cephalic end to outline the primordial brain and subsequent expansions form the three parts, the hindbrain, the midbrain, and the forebrain.

Embryology of the Eye (Tables 14.1 and 14.2 and Fig. 14.1)

The cells of the neural crests migrate to the

Table 14.1
Principal Landmarks in Ocular Growth (Mann)³

<i>Structures undergoing change</i>	<i>Approximate age at end of period</i>
Optic pit changing into optic vesicle	3-4 weeks
(a) Appearance of lens pit and vesicle	
(b) Formation of the optic cup by invagination of the optic vesicle	end of 4th week
(c) Appearance of pigment in the outer layer of the optic cup	
(a) Closure of the foetal tissue	
(b) Formation of primary lens fibres	6th week
(c) Beginning of retinal differentiation	
(d) Beginning of tunica vasculosa lentis	
(a) Beginning of secondary lens fibres	
(b) Completion of tunica vasculosa lentis	3rd month
(c) Development of lid folds	
(d) Beginning of ectodermal layers of the iris	
(a) Beginning of retrogression of posterior vascular capsule of the lens	
(b) Appearance of ciliary muscles, muscles of the iris and outer layer of the choroid	5th month
(a) Retrogression of pupillary membrane	7th month
(b) Beginning of medullation of the optic nerve	
(a) Disappearance of hyaloid artery	9th month
(b) Medullation reaching lamina cribrosa	
Full differentiation of macula lutea	4-6 months after birth
Growth of whole eye	25 years

dorsolateral aspects of the cephalic end of the neural tube and cause a depression on either side known as the *optic pit*, the first evidence of the rudiments of the eyes. The peripheral cells of the optic pits become thickened to form the *optic plates*. The optic plates themselves grow outward towards the surface to form the *primary optic vesicle*. The primary optic vesicles are connected to the forebrain on each side by the *optic stalk*.

The two eyes develop from the primary optic vesicles along with the neighbouring mesodermal and ectodermal structures. At the 4 to 5 mm stage

Table 14.2

Approximate Relationship between Age and Crown-Rump Length (CRL) of the Embryo and Fetus (Duke-Elder)¹

	Age (in weeks)	CR length* (in mm)
Embryo	4th	1-25 Somites
	5th	3-8
	6th	8-15
	7th	15-22
	8th	22-30
Fetus	9th	30-40
	10th	40-50
	11th	50-60
	12th	60-70
	16th	70-110
	20th	110-150
	24th	150-200
	28th	200-230
	32th	230-265
	36th	265-300
40th	300-335	

*The CRL is the end-to-end length without considering the curvature and without taking account of the legs.

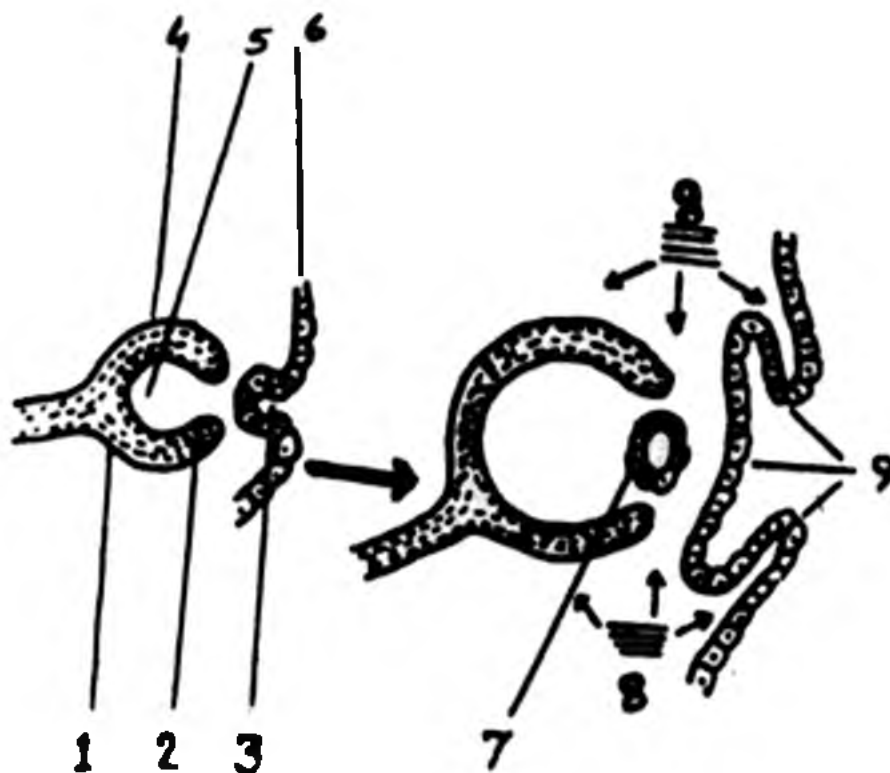


Fig. 14.1 Drawings to depict the development of the human eye. 1, pigment layer of the retina; 2, nervous layer of the retina; 3, lens pit; 4, neural ectoderm; 5, optic cup; 6, surface ectoderm; 7, lens; 8, mesoderm; 9, developing anterior surface of the eyelids and cornea.

the primary optic vesicle begins to invaginate the surface ectoderm simultaneously from below and laterally thus forming the *optic cup* or the *secondary optic vesicle*, and the groove foetal, *embryonic* or *choroidal fissure*—at the lower part. The fissure allows the passage of the vascular mesoderm to eventually form the hyaloid system. The inner layer of the optic cup forms the main structure of the retina, while the outer layer of the cup forms the pigment epithelium. From the anterior border of the narrow space representing the original optic vesicle between the two layers of the cup, parts of the iris and ciliary body develop. The mesoderm surrounding the cup differentiates to form coats of the eyes and the structures within the orbit. The development of the crystalline lens occurs from the lens vesicle.

Table 14.3 gives an account of the embryonic origins of various ocular tissues.

Table 14.3

Embryonic Origins of Different Ocular Tissues

Neural ectoderm

- Neural retina
- Optic nerve
- Epithelium of iris and ciliary body
- Pupillary muscles

Combined ectoderm and mesoderm

- Vitreous humour

Surface ectoderm

- Epithelium of
 - Conjunctiva
 - Cornea
 - Lacrimal gland
- Lacrimal sac and nasolacrimal duct
- Eyelid epidermis and lashes
- Crystalline lens

Mesoderm

- Stroma, Descemet's membrane and endothelium of cornea
- Sclera
- Stroma of iris and ciliary body
- Choroid
- Ciliary muscle
- Extraocular muscles
- Schlemm's canal
- Trabecular meshwork
- Vascular endothelia
- Meninges of optic nerve
- Orbital cartilages and bones

Embryology of Neuroectodermal Structures

The retina. This develops from two layers of the optic cup, the inner one forming the nervous elements and the sustentacular fibres, while the outer layer gives rise to the pigment epithelium.

There are four stages in the development of the retina.

Stage I (4th–5th week). Initial differentiation of two zones—outer nucleated and inner nonnucleated marginal.

Stage II (6th–12th week). Differentiation into three temporary zones of the inner non-nucleated zone and inward migration of the outer nucleated zone.

Stage III (3rd–7th month). Differentiation into various layers. The marginal zone has been subdivided into three layers: the inner neuroblastic; the intermediate (*layer of Chievitz*); and the outer neuroblastic. The inner neuroblastic layer gives rise to the ganglion cells; the amacrine cells; and Müller's fibres. The intermediate layer disappears. The outer neuroblastic layer gives rise to the horizontal cells; and the nuclei of rods and cones. The processes extending from the ganglion cells constitute the nerve fibre layer. The terminal expansions of Müller's fibres develop into the two limiting membranes.

Stage IV (7th–13th month). Final organization of layers occurs. All the layers of the adult retina are formed by the fifth month. Vascularization in the inner retinal layers develops at the eighth month. Macula develops between 3 and 8 months.

The optic nerve. The optic nerve is formed by the growth of nerve fibres from the axons of the ganglion cells of the retina into the cavity of the optic stalk and its subsequent obliteration at the 25 mm stage. They consist mostly of centripetal fibres from the retina and a few centrifugal fibres from the nerve cells of the brain.

The vitreous humour. It is developed from both the ectoderm and mesoderm. The development is in three stages:

The primary stage (3–6 weeks). This stage or the hyaloid vitreous develops from the extensions of the protoplasmic conical processes of both lens cells and retinal cells, the latter group being predominant. As the lens capsule develops, the lens cells lose contact with the vitreous. At the same time, the hyaloid artery enters and embryonic fissure along with mesodermal fibrils.

The secondary stage (6–10 weeks). In this stage the secondary vitreous is avascular and is secreted from the inner layers of the optic cup. This surrounds the primary vitreous and gradually increases in volume. The thickening of the secondary vitreous forms the hyaloid membrane. The remnants of the primary vitreous surrounding the hyaloid artery persists as the hyaloid canal, extending from the retrolental space towards the optic disc.

The tertiary stage (10 weeks onwards). The tertiary vitreous is secreted from the ciliary epithelium appearing as fibrils extending from the ciliary body to the equator of the lens. The zonule of Zinn in adult is formed from these fibrils.

Epithelium of the iris, of the ciliary body and pupillary muscles. During the third month the rim of the optic cup grows forward in front of the lens. The inner layer forms the nonpigmented epithelium of the ciliary body and the posterior epithelial layer of the iris. The outer layer gives origin to the anterior epithelial layer of the iris. The sphincter pupillae and dilator pupillae (after 6th month) develop from the anterior epithelial layer of the iris.

Conjunctival and corneal epithelium. The lens vesicle perhaps induces a differentiation of the surface ectoderm into the corneal epithelium by means of thin protoplasmic bridges running between the lens vesicle and the epithelium. The epithelium at the 14 mm stage is seen to have two cell layers. By the 30 mm stage, three of the five layers of the epithelium are fairly well differentiated.

Epithelium of the lacrimal gland. This is derived from the ectoderm of the superior conjunctival fornix.

The lacrimal sac and the nasolacrimal duct. At first a solid cord of ectodermal cells, evident at 6 weeks in the embryo, becomes buried in the mesoderm at the junction of the maxillary and lateral nasal processes. By the twelfth week, canalization starts at the upper end by disintegration of its central cells and gradually descends downward towards the inferior meatus. At about the second week of life, the communication at the inferior meatus is fully established by lysis of cells of opposed mucosal lining of the nasal cavity and the lower end of the nasolacrimal duct.

Other structures developing from the surface ectoderm are the eyelashes and the lining cells of the tarsal and other glands opening on the lid margin.

The crystalline lens (Table 14.4). This is developed (Fig. 14.2) from the invagination of the surface ectoderm whose communication with the surface is cut off.

Table 14.4

Important Phases of Lens Development (Mann³)

Lens plate—2 weeks
Lens vesicle—4 weeks
Primary lens fibres, beginning—5 weeks
Secondary lens fibres, beginning—7 weeks
Y-sutures, recognizable—8½ weeks
Vascular capsule fully developed—9 weeks
Retgression of vascular capsule complete—at or before birth
Lens capsule—3 months
Nuclei of the lens
(i) Embryonic—1 to 3 months
(ii) Foetal—2 to 6 months
(iii) Infantile—continues up to puberty
(iv) Adult—20 to 25 years
Cortex-forms throughout life

The lens pit deepens to form the lens vesicle which is attached to the surface by the lens stalk. Subsequently, the lens vesicle separates. Primary lens fibres begin to form from the cells of the posterior subcapsular epithelium of the lens vesicle. These fibres obliterate the lumen of the vesicle and meet its anterior wall which persists as the anterior epithelium. After the completion of




Fig. 14.2 Development of crystalline lens. A, lens plate; B, lens pit; C, lens pit closing; D, lens vesicle; E, primary lens fibres beginning; F, primary lens fibres complete; and G, secondary lens sutures (Ida Mann).

development of primary lens fibres, secondary lens fibres start forming. Y-sutures (upright anterior 'Y' and inverted posterior 'Y') are seen when the opposing fibres meet along these lines.

In the embryonic life, the lens is enclosed by a vascular capsule, *tunica vasculosa lentis*, which totally disappears at or before birth.

The lens capsule develops from two sources—the deeper layer from the cells of the lens vesicle, and the superficial layer from the suspensory ligament of the lens.

Embryology of Mesodermal Structures (Fig. 14.3)

The cornea. The endothelium, Descemet's membrane and stroma of the cornea originate from the mesodermal cells growing between the surface ectoderm and the lens vesicle. At the 12 mm stage the mesodermal cells give rise to the corneal endothelium. The second layer of the mesodermal cells then grows between the surface ectoderm and the cells destined to develop into the corneal endothelium. This forms the stroma between 25 and 30 mm stage. By the fifth month, Bowman's membrane appears. Subsequently Descemet's membrane elaborated by the endothelium develops.

The sclera and extraocular muscles. They develop from the condensed mesoderm encircling the optic

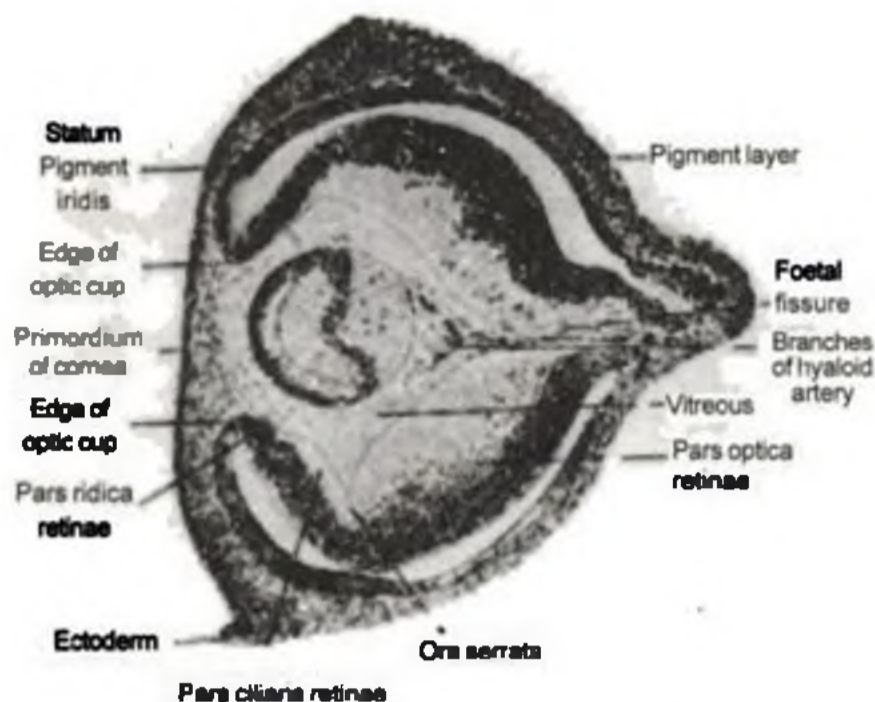


Fig. 14.3 Section through the eye and foetal fissure of 13.5 mm embryo ($\times 157$). Note the eversion of the inner layer of the optic cup at the posterior (proximal) end of the foetal fissure (After Fischel; Wolff).

cup and at the 20 mm stage the differentiation sets in. By the fifth month development of these structures is well marked.

The eyelids. The lid buds appear at the 16 mm stage in front of the growing eye where they fuse at the 37 mm stage. During the fifth month they separate, while the ectodermal structures of the eyelids, i.e. the eyelashes and lining cells of different glands, develop.

Anterior and posterior chambers. A thin cleft appears in the mesoderm separating the future corneal endothelium and the iris stroma and forms the anterior chamber (AC). After the fifth month there is marked deepening and development of the anterior ocular segment. Schlemm's canal is present after the second month and the trabecular meshwork starts appearing in the sixth month.

The choroid. At the 5 to 6 mm stage with the appearance of the endothelial spaces choriocapillaris develop in the mesoderm surrounding the optic vesicle. The cuticular layer of Bruch's membrane appears at the 14 to 18 mm stage. The elastic layer of this membrane is seen at the 70 mm stage. The inner cuticular layer is ectodermal and the outer elastic layer is mesodermal in origin.

Large venous channels make their appearance during the third month. By the fifth month chromatophores appear.

The ciliary body and iris. During the third month the paraxial mesoderm outside the anterior rim of the optic cup shows a tendency for condensation. The mesoderm external to the epithelial layers fills the spaces behind the folds and ridges produced by the epithelial layer, and forms the stroma of the corona ciliaris. The posterior leaf of the mesodermal portion of the iris is formed, while there is forward and axial extension of the neural ectoderm.

The ciliary muscle is developed by the specialized condensation of the mesoderm encircling the optic cup.

Hyaloid system of vessels. This constitutes an important aspect in the embryology of the eye. The hyaloid artery, a branch of the primitive dorsal ophthalmic artery, reaches the posterior pole of the lens vesicle (6 to 7 mm) through the foetal fissure. At the posterior pole of the lens vesicle it unites with the tunica vasculosa lentis.

Soon after the 10 mm stage the hyaloid system communicates with the annular vessel to form the capsulopupillary portion of the *tunica vasculosa lens*. The annular vessel develops at the 8 to 9 mm stage along the anterior margins of the foetal fissure. At the 2.5 mm stage small buds appear in the annular vessel to form the anterior portion of the tunica vasculosa lentis.

The hyaloid system starts disappearing at the 60 mm stage of differentiation.

Postnatal development

Postnatal development occurs through first few years of life.

Eyeball. The anterior segment of a neonatal eye is about 75 to 80 per cent of that in adult, while the posterior segment at birth is less than 50 per cent of the size of a normal adult eye. The size increases due to expansion of the scleral surface area of the posterior segment and this continues till 13 years of age, but most dramatic changes involving 50 per cent increase occur within first six months of life.

The length of an eyeball in a neonate is 16 mm, but this is 22.7 mm in the age group of 5 to 13 years.

Orbit. With the growth and development of the skull and facial bones orbital anatomy undergoes significant changes. The roof becomes flatter and larger in infants than in adults. The inner angle becomes more divergent as age advances.

Palpebral fissure. The length and height are 18.5 to 19 mm and 10 mm respectively, while those in an adult eye they are 28 to 30 mm and 14 to 15 mm respectively.

Lacrimal apparatus. Both secretory and excretory functions are operational at birth. The development of the nasolacrimal duct is complete at birth.

Conjunctiva is thicker and tougher in a child. There is a gradual increase in size over 10 years of age.

Cornea. The newborn child has a relatively large cornea which reaches adult size by 2 years of age. During the first year the changes include enlargement, flattening, thinning and increase in transparency.

Anterior chamber (AC). The angle of the AC undergoes differentiation during first year of life. Shortly after birth the endothelial cell lining of the angle becomes fenestrated.

Iris and pupil. At birth, the anterior surface of the iris shows very little or no pigment. The colour of the iris changes within first 6 months of life.

The size of the pupil is 3.6 ± 0.9 mm and there is no pupillary response to light.

Intraocular pressure (IOP) in an infant is lower than in an adult.

Extraocular muscles. Their development continues after birth. The insertions of the medial rectus and lateral rectus are quite close to the equator, and those of the superior oblique and inferior oblique are closer to one another than in the adult eye.

Retina. The macula lutea is least well-developed at birth. The foveal reflex is fully established by 42 weeks of gestational age.

Crystalline lens. At birth it is almost spherical and soft in consistency.

Refractive error. About 80 per cent of children are born hypermetropic. Seventy-one per cent of them have + cylinder at 180°.

Further Reading

1. Duke-Elder, S., *System of Ophthalmology*. Vol. III: *Normal and Abnormal Development*. Part I: *Embryology*, Duke-Elder, S. and Cook, C. (Eds.), Kimpton, London, 1963.
2. Eustis, H.S., Postnatal development. In *Pediatric Ophthalmology*, Wright, K.W. (Ed.), C.V. Mosby, St. Louis, 1995, p. 45.
3. Mann, I., *The Development of the Human Eye* (3rd ed.), British Medical Association, London, 1964.

Oops, page PA53 was not yet downloaded :(

Part Two

Ocular Physiology

The eye is the organ of vision. To enable the eyes to do so, its parts must be in perfect condition to attain perfect vision. The physiology of the eye differs from that of the other organs of the body. The particular aspects related to the eyes include the formation of the intraocular fluid, maintenance of the intraocular pressure, metabolism of the avascular tissues of the eyeball, accommodation and convergence.

15. THE AQUEOUS HUMOUR¹⁻³

The aqueous humour comprises about 4 per cent of the total volume of the eye and represents the ocular tissue fluid. It maintains the intraocular pressure and supplies nutrition to the avascular structures, namely the cornea and lens. It has a specific gravity of 1.005, slightly higher than water and a low refractive index of 1.336. The aqueous humour is a refractive medium. It is composed of water—99.69 per cent and solids. The solid constituent is as follows: (a) diffusible crystalloids made of electrolytes containing positively-charged or cations—sodium, potassium, magnesium and calcium and negatively-charged or anions—chlorides, phosphates, sulphates and bicarbonates, nonelectrolytes—glucose, urea, lactate and pyruvate; (b) nondiffusible colloids made of proteins, immune bodies and enzymes as well as (c) ascorbic acid and hyaluronic acid. The cations are in lesser concentrations and the anions in higher concentrations in the aqueous humour than in blood plasma. This is due to the retention of cations by the negatively-charged blood colloids.

The concentrations of glucose and urea are higher in blood plasma. The aqueous humour has a higher concentration of lactate. It contains 0.02 gm/per cent of proteins in comparison to that of blood which is 7 gm/per cent. There is a low concentration of immune bodies and only traces of enzymes. The presence of ascorbic acid, in the region of 12 to 20 mg per 100 ml, is 18 times higher than that of blood plasma.

Hyaluronic acid is present only in the aqueous and not in the blood.

Formation

Aqueous humour is formed by the ciliary body and the following mechanisms are responsible:

- Secretion—approximately 80 per cent
- Ultrafiltration
- Diffusion.

Secretion is the active transport of certain substances from the blood into the posterior chamber. It is an active energy-dependent transport

of ions by the enzymes: carbonic anhydrase, sodium-potassium ATPase, and others. This occurs in the region of nonpigmented cells of the ciliary body containing numerous mitochondria.

Ultrafiltration means dialysis in the presence of hydrostatic pressure. When a combined protein and salt solution is separated from pure water by means of membrane impermeable to protein, transference of salt and water through the membrane occurs. The passage of water into the protein-containing solution is called *dialysis*.

In the eye, protein-free filtrate derived from the plasma passes inward and outward between the uveal and retinal capillaries and forms the intraocular fluid. Because of the anatomical peculiarity in the ciliary body, the most vascular region of the eye, the transference is largely carried out by this region.

Diffusion is the process of uniform molecular distribution of a gas or solution throughout the space in which it is present.

In the eye, diffusion of nonelectrolytes occurs across the blood—aqueous barrier, i.e. the walls of the capillary beds act as semipermeable membrane and separate the blood from the ocular cavity. Diffusion of electrolytes occurs according to the 'Gibbs-Donnan theory'. According to the theory, the product of the diffusible ions on one side of the membrane is equal to the product of the diffusible ions on the other side, and the sum of the cations on any one side is equal to the sum of the anions on the same side.

Circulation

The aqueous humour, formed by the ciliary body, comes to the posterior chamber, flows between the iris and lens into the anterior chamber, and finds its exit at the angle of the anterior chamber.

There are two types of circulation: the small mass movements of aqueous humour due to change in the hydrostatic-osmotic pressure relationship, e.g. during eye movements, compression of the lids, etc., and thermal circulation due to the difference in temperature. Aqueous humour is constantly heated by the blood in the iris vessels and so it tends to rise. When it comes in contact with the

back surface of the cornea, which is cooled by evaporation and the precorneal tear film, it tends to sink. Thus, a constant cycle is established.

Drainage

There are two modes of drainage:

- Conventional or pressure-dependent—85 to 95%
- Uveoscleral or pressure-independent—5 to 15%

Conventional. It is principally dependent on the relationship between the intraocular pressure (IOP) and pressure in the exit veins situated at the angle of the AC, in the vorticoses veins, and in the veins at the optic disc. The walls of the veins traversing the sclera are quite compressible, thus, when the IOP rises above the venous pressure the veins are constricted, the venous pressure behind the constriction rises until it reaches above the IOP. The venous pressure in the exit veins normally remains just above the IOP, and there is a sudden fall of pressure beyond these points.

The aqueous from the angle of the AC filters through the trabecular meshwork.⁴ It reaches the canal of Schlemm, showing a vacuolization cycle, and then the aqueous veins and flows into the venous system at a point beyond which there is a rapid drop of pressure. Free drainage is thus established. It is estimated that about 1% of the fluid in the AC drains away per minute. When the IOP rises, there is concomitant rise of venous pressure within the sclera. There is also a bigger difference of venous pressure between the intrascleral and episcleral veins, and hence there is enhanced aqueous drainage.

Uveoscleral. The drainage occurs through the stroma and vessels of the iris root and ciliary body, and flows backward to leave the eye via supraciliary and suprachoroidal spaces to finally reach the orbital vessels.

Glass-rod or compression phenomenon. A laminated stream is often found in a confluent vessel made up of a blood vein and an aqueous vein. When such a confluent vessel is compressed, stratification is present after the compression. The

fluid flows from whichever vessel is at a higher pressure into the other, i.e. the glass-rod phenomenon. Depending on the higher pressure, there is either 'blood influx' into the aqueous vein seen in the rising phase of high ocular tension, or 'aqueous influx' into the blood vein, seen in the falling phase of ocular tension.

Further Reading

1. Adler, F.H., *Physiology of the Eye* (6th ed.), Moses, R.A., (Ed.), C.V. Mosby, St. Louis, 1975.
2. Parsons, J.H., *Diseases of the Eye* (18th ed.), Miller S.J.H. (Ed.), Churchill Livingstone, London and ELBS, 1990.
3. Podos, S.M. and Yanoff, M. (Eds.), *Textbook of Ophthalmology*, Vol. VII, *Glaucoma*, C.V. Mosby, St. Louis, 1994, p. 1.23, 1.30.
4. Tripathi, R.C., Mechanism of aqueous outflow across the trabecular wall of Schlemm's canal, *Exp. Eye Res.*, II: 111, 1971.

16. THE INTRAOCULAR PRESSURE^{1,4}

The factors responsible for the maintenance of the normal intraocular pressure are: (a) elasticity of the sclera and cornea—a rigid coat gives rise to higher pressure; (b) the volume of the intra-ocular contents which is composed of solid i.e. the lens, vitreous, uvea and retina and fluid i.e. the aqueous humour; the volume of the aqueous humour is the principal determinant of normal IOP; and (c) the difference in the osmotic pressure of plasma and aqueous humour—if the osmotic pressure of the aqueous is raised or that of the blood lowered, there is a rise of the IOP.

Prolonged changes in the maintenance of IOP are chiefly due to two factors—variation in the formation of the aqueous, and variation in the resistance to the outflow.

Physiological Variations

Physiological variations have been subdivided by Duke-Elder² into two groups:

Rhythmic variations. (a) Cardiovascular—1 to 2 mm, (b) respiratory—as much as 5 mm and (c) diurnal—normally not in excess of 5 mm.

Acute variations. (a) Blinking, (b) action of extraocular and intrinsic muscles, and (c) physical effort.

Diurnal variation. The normal IOP is highest in the early morning and lowest in the evening hours. The cause of this variation is still not clear, but is probably either due to change in the secretory activity of the ciliary body or to extrinsic factors like action of extraocular muscles, postural changes involving vascular factor, intake of food and drink and loss of fluid throughout the day.

Nervous Control of the IOP

It is known that the stimulation of the parasympathetic causes raised intraocular pressure (IOP) while that of the sympathetic reduces IOP.

In addition, there is also local nervous control mediated through axon reflexes from the trigeminal nerve, an action resembling the triple response of Lewis.

The intraocular pressure may be raised or lowered in several conditions (Table 16.1).

Table 16.1

Various Conditions Influencing Intraocular Pressure³

- Those causing raised pressure*
- Elevated episcleral venous pressure
 - Squeezing of the eye
 - Elevated body temperature
 - Mydriatics
 - Steroids
 - Dysthyroid exophthalmos
 - Depolarizing muscle relaxants
 - Ketamine—dissociative anaesthesia

- Those causing reduced pressure*
- General anaesthesia
 - Prolonged physical exercise
 - Systemic acidosis
 - Alcohol

Normal IOP and Hypertensive Eyes

The mean average IOP measured by applanation tonometer is 15.4 mm with a standard deviation of ± 2.5 mm Hg. The normal eye will tolerate an IOP 20 mm of Hg indefinitely without any bad effect, but in high myopia, such normal IOP may produce pathological effects.

The IOP which can be higher than the normal range, may not produce any pathological signs or symptoms. If there is no rise of pressure on provocation then those eyes with normal aqueous outflow facility are hypertensive.

Further Reading

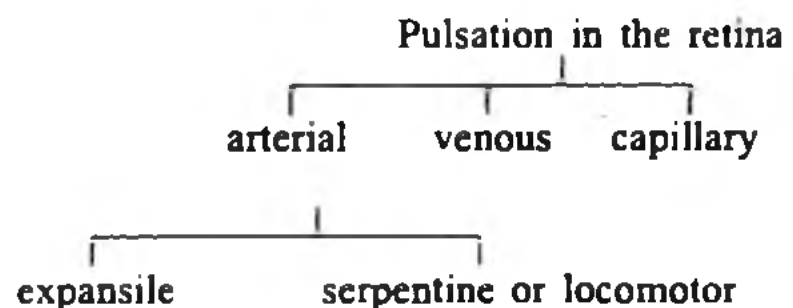
1. Adler, F.H., *Physiology of the Eye* (6th ed.), Moses, R.A. (Ed.), C.V. Mosby, St. Louis, 1975.
2. Duke-Elder, S., *System of Ophthalmology*. Vol. IV: *The Physiology of the Eye and of Vision*, Duke-Elder, S., Gloster, J. and Weale, R.A. (Eds.), Kimpton, London, 1968.
3. Krupin, T., *Manual of Glaucoma: Diagnosis and Management*, Churchill Livingstone, New York, 1988.
4. Sugar, H.S., *The Glaucomas*, Paul B. Hoeber, New York, 1957.

17. OCULAR CIRCULATION^{1,2}

There are two systems of blood vessels in the interior of the eye—retinal and uveal. These have already been described.

Pulsation in the Retina

It can be classified as under



Arterial pulsation. This is due to the rhythmic variations of pressure within the artery. In the *expansile* pulsation, the artery itself enlarges and collapses during the systole and the diastole respectively. This pulsation is due to transmission of a pressure-pulse from the heart through the large arteries to the retinal arterioles. Two factors favour its appearance, namely the fall in the BP and rise in the IOP.

In the *serpentine* or *locomotor* pulsation, there are rhythmic side-to-side movements of the part of the artery at each heartbeat. The factors that favour its appearance include tortuosity, dilatation and pliable wall of the arteries, high systolic pressure and low peripheral resistance.

Venous pulsation. This occurs at the optic disc and is viewed by an ordinary ophthalmoscope. It is perhaps due to transmission of pulse from the arteries to the veins. In a large number of normal eyes there is spontaneous venous pulsation, which is exhibited by the slightest pressure on the eyeball. It is made to stop by compression of the jugular veins.

Capillary pulsation. This has also been reported.

Average pressure in vessels of the eye has been indicated in Table 17.1.

Table 17.1

Average Pressure in Different Vessels of the Eye

Pressure in the central retinal artery	systolic, 65–70 mm Hg diastolic, 35–45 mm Hg
Pressure in the retinal arterioles	systolic, 88 mm Hg diastolic, 64 mm Hg
Pressure in the intraocular veins	about 2 mm Hg higher than IOP
Pressure in the intrascleral veins	7 to 8 mm Hg
Pressure in the vortex vein	8.5 mm Hg
Pressure in the episcleral veins	11 mm Hg
Pressure in the choroid capillaries	about 55 mm Hg
Pressure in the retinal capillaries	lesser than 55 mm Hg

Measurement of Ocular Blood Flow

Only the clinical methods are mentioned below:

1. Fluorescein angiography
2. Indocyanine green angiography

3. Laser Doppler velocimetry

4. Blue field entoptoscopy.

Fluorescein angiography. With this, measurements of various aspects of local retinal blood flow can be done.

Indocyanine angiography is more suitable for studying choroidal circulation.

Laser doppler velocimetry. A bidirectional system has been introduced for absolute measurements of flow velocity in large retinal vessels.

Blue field entoptoscopy provides a retinal shadow due to leucocytes flowing through the paramacular capillaries.

Control of Ocular Circulation

The blood flow is influenced by vascular pressure, tone in the vasoactive nerves, vasoactive substances and metabolic activity.

Perfusion pressure is the difference between the pressure in the arteries and the veins. The pressure in the ocular arteries can be recorded by ophthalmodynamometry, while that in the veins leaving the eye can be assessed by tonometry. The ocular perfusion pressure ($P_a - P_v$) can be reduced by either reduction of arterial pressure or increase in intraocular pressure.

Nervous control. Both sympathetic and parasympathetic nerves innervate various ocular vessels, though the role of the latter is less clear. The sympathetic system helps autoregulation system in maintaining the intraocular flow and volume-constant.

Vasoactive substances. The vascular endothelium is involved in the regulation of vascular tone, platelet activity and vascular permeability. This endothelium maintains vascular tone by releasing potent vasoactive agents.

Metabolic activity. Breathing pure oxygen constricts the retinal vessels and increases the oxygen tension of choroidal venous blood. Inhalation of 7 per cent carbon dioxide and 21 per cent oxygen moderately dilates the retinal blood vessels.

Further Reading

1. Alm, A., Ocular circulation. In *Adler's Physiology of the Eye* (9th ed.), Hart, W.M., Jr. (Ed.), Mosby Year Book, 1992, p. 198.
2. Trevor-Roper, P.D. and Curran, P.V., *The Eye and Its Disorders* (2nd ed.), Blackwell Scientific, Oxford, 1984.

18. PHYSIOLOGY OF THE CORNEA¹⁻⁶

The normal water content of the cornea is between 75 to 80 per cent.

The solid constituents are as follows:

- (a) *Proteins*—18 to 20 per cent.
 - (i) Collagen is present in large quantities in the corneal lamellae, although reported to be present in Bowman's membrane and Descemet's membrane. It is essential in the healing of wound.
 - (ii) Mucopolysaccharide (MPS) forming 4 per cent of the corneal dry weight is the polysaccharide of mucoïd. Mucoïd is an ester of hyaluronic acid and is hydrolyzable by hyaluronidase. Polysaccharide present in interlamellar spaces plays an important role in the maintenance of transparency and swelling pressure of the cornea. There are three fractions of MPS: (a) keratan sulphate (50%); (b) chondroitin (25%) and (c) chondroitin sulphate A (25%).
 - (iii) Elastin.
 - (iv) Nucleoprotein is found mostly in the epithelium as DNA and RNA.
 - (v) Albumin and globulin.
- (b) *Lipids* are in greater concentration: 5.4 per cent of the dry weight of the epithelium, about 100 times more in the epithelium than in the stroma.
- (c) *Minerals*, e.g. sodium, potassium, copper, iron, zinc, etc.

(d) *Enzymes*, necessary for different pathways of corneal metabolism, are mostly seen in the epithelium and endothelium.

(e) *Ascorbic acid*. It is indirectly responsible for formation of collagens, and hence, is effective in the healing of deep corneal ulcer. It is twice greater in the epithelium, 47 to 94 mg/100 gm, than in the stroma.

(f) *Glutathione*. The possible functions include: (i) its involvement in hexose monophosphate shunt and in regulation of adenosine triphosphatase activity as in endothelium pump function as well as (ii) removal of toxic peroxides.

Nutrition of the Cornea

Nutrition of the cornea is derived from three sources: (a) aqueous humour; (b) exudation from the perilimbal vessels; and (c) precorneal tear film.

Precorneal tear film. The optical interface between the anterior surface of the cornea and the air is formed by the tear film. Oxygen is derived from the tear film by diffusion.

Metabolism of the Cornea

Metabolism of the cornea is modified by the structural peculiarities in the cornea and they are: (a) avascularity of the cornea proper, while the limbus is richly vascular; (b) bathing of corneal surfaces by fluids; and (c) three sources of corneal nutrition. The metabolism of glucose is the chief source of energy required for transparency, cellular activity and growth of the cornea. Glucose is stored in the epithelium as glycogen which in state of emergency, e.g. wound healing, breaks down again into glucose.

There are two different processes of catabolism of glucose: (a) aerobic, through—(i) Krebs' tricarboxylic acid (TCA) cycle, and (ii) hexose monophosphate shunt (HMS); (b) anaerobic.

Aerobic. TCA cycle is not very active because of less abundant mitochondria in the corneal epithelium, since this cycle takes place in mitochondria. About 35 per cent of glucose used by the epithelium passes through the HMS.

The breakdown of glucose produces adenosine triphosphate (ATP) and nicotinamide adenine

dinucleotide phosphate (NADPH), high energy elements utilized in cellular processes.

Anaerobic glycolysis produces pyruvate and lactate and these under aerobic condition break down into carbon dioxide and water. Carbon dioxide is eliminated across both epithelium and endothelium. Lactate is unable to permeate the epithelium but diffuses through the stroma and endothelium into the aqueous humour. There is accumulation of lactate during hypoxia or other corneal stress causing corneal oedema.

Glycolysis, i.e. the breakdown of glucose into lactic or pyruvic acid, the process may be aerobic or anaerobic, e.g. use of tight contact lens.

Respiration, i.e. oxidation of lactic acid into carbon dioxide and water is always aerobic.

In the cornea, glucose derived mainly from the aqueous humour is utilized mainly by anaerobic or *Embden-Meyerhof pathway*, 65 per cent and partly by aerobic or *phosphogluconate pathway*, i.e., 'shunt', 35 per cent.

Glycolysis occurs both in the corneal epithelium and stroma. Respiration only occurs in the epithelium. The stroma contains chiefly a dehydrogenase system and the epithelium contains cytochrome oxidase.

Protein synthesis

There are two types of proteins in the cornea—structural and enzymes.

Ribonucleic acid (RNA) acts as a template for protein synthesis, the two other constituents are amino acids and adenosine triphosphate (ATP).

Corneal Permeability^{3,6}

Normally, corneal hydration *in vivo* is maintained by the following factors.

1. Structural rigidity due to presence of the corneal layers and restriction of swelling by sclera.
2. The epithelium and endothelium act as barriers to rapid fluid passage, especially by high resistance to diffusion of electrolytes rather than

resistance to water flow. The movement of the ions is restricted, because of unusual resistance of the epithelium, which is about 200 times that of the stroma, to ions, and hence the resulting osmotic pressure retains the water in the corneal stroma.

3. Balance of normal swelling tendency of the cornea caused by excretion of the fluid and dehydration by evaporation. This tendency is called *stromal swelling pressure*.
4. Relatively slow movement of the fluid from the cornea.
5. The corneal endothelium has a pump activity. If this is decreased there is stromal swelling.
6. Intraocular pressure can only produce oedema of the epithelium in presence of defective endothelium.

Transparency of the Cornea

Transparency is dependent on two factors, viz. anatomical and physiological.

The *anatomical factors* are:

- (a) Avascularity.
- (b) Regular arrangement of epithelial layers on its outer surface and absence of its cornification.
- (c) Single layer of endothelium.
- (d) Stromal collagen fibres disposed regularly and in parallel strata. Maurice reported that they form a lattice structure, so arranged that scattering of light is eliminated by mutual interference from individual fibrils.

More recent view indicates that regular lattice arrangement of collagen fibres is not necessary for transparency. The corneal stroma does not scatter light because its collagen fibrils are small in diameter (300 Å) and closely packed.

- (e) Presence of mucopolysaccharide gel in which the stromal fibres are immersed.
- (f) Absence of pigment.

The physiological factors are:

- (a) The state of deturgescence. The stroma has a tendency to swell, which is counteracted by a process of fluid transport through the limiting membranes.
- (b) Metabolic process.

Further Reading

1. Adler, F.H., *Physiology of the Eye* (6th ed.), Moses, R.A. (Ed.) C.V. Mosby, St. Louis, 1975.
2. Arffa, R.C. (Ed.), *Grayson's Diseases of the Cornea* (4th ed.), C.V. Mosby, St. Louis, 1997.
3. Dohlman, C.H., Physiology of the cornea: corneal oedema. In *The Cornea*, Smolin, G. and Thoft, R.A. (Eds.), Little, Brown and Co., Boston, 1983.
4. Friend, J., Physiology of the cornea: metabolism and biochemistry. In *The Cornea*, Smolin, G. and Thoft, R.A. (Eds.), Little, Brown and Co., Boston, 1983.
5. Maurice, D.M., The Structure and transparency of the cornea. *J. Physiol.* 136: 263, 1957.
6. Maurice, D.M., The regulation of corneal hydration. In *The Cornea: World Congress*, King, J.H. and McTigue, J.W. (Eds.), Butterworths, London, 1965.

19. PHYSIOLOGY OF THE CRYSTALLINE LENS^{1,2}

The chemical composition of the normal lens is:

(a) *Water*. The water content in the adult lens is 65 per cent of its total weight. There is relative dehydration of the lens as age advances.

(b) *Proteins*. They form the 34 per cent balance of the composition and are divided in two groups:

Major	{	Soluble-85%	{	alpha-crystallin-55%
				beta-crystallin-15%
				gamma-crystallin-15%
		Insoluble or albuminoid-15%		

The amount of beta-crystallin is double that of alpha-crystallin. As the lens ages, alpha-crystallin is gradually converted into insoluble albuminoid.

The minor group consists of nucleoprotein, phosphoprotein, and mucoprotein.

The lens protein is organ-specific and not species-specific. An animal immunized against lens protein reacts to the subsequent injection of the same irrespective of the species from which it is obtained.

(c) *Salt content*. This is 0.5 to 0.75 per cent of the weight of the lens. The salts include sodium, potassium, calcium, magnesium and chloride. Sodium and chloride are present chiefly in the fluid surrounding the lens fibres, while potassium is found within the fibre. As the lens ages potassium content decreases. Calcium helps in the permeability of the cell membrane.

(d) *Lipids*. These include phospholipids and cholesterol.

(e) *Ascorbic acid*. This is present in both oxidized and reduced forms, 30 mg/100 gm of lens. The source of ascorbic acid is by direct synthesis by the lens and by the ciliary epithelium. Dihydroascorbic acid oxidizes glutathione and hydrogen thus released reduces nicotinamide adenine dinucleotide phosphate (NADP) or diphosphopyridine nucleotide (DPN).

(f) *Glutathione*. Gamma-glutamylcysteinyl glycine is synthesized by the crystalline lens. It protects the lens enzymes and proteins against oxidative damage. It is decreased in advanced age and cataract.

Lens Metabolism

The lens subserves the following functions which are dependent on the lens metabolism.

- (a) Maintenance of transparency. This depends on the physiochemical state of the lens proteins.
- (b) Development and growth of new lens fibres.
- (c) Maintenance of elasticity of the capsule.
- (d) Permeability, diffusion and transport.

There are two elements involved in lens metabolism.

Lens proteins. Electrophoretic study reveals different types of proteins with different electrophoretic motility, antigenicity and structure.

Carbohydrates. The metabolic pathways of carbohydrate metabolism are:

(a) *Anaerobic glycolysis*. It accounts for about 85 per cent of glucose metabolism of the lens. Glucose is phosphorylated by ATP to form glucose-6-phosphate → through various steps → pyruvic acid → oxidized → which in the lens is reduced to lactic acid.

(b) *The hexose monophosphate pathway*. Glucose is phosphorylated → oxidized → oxidative decarboxylation → production of carbon dioxide.

(c) *The citric acid cycle*. Glucose → pyruvic acid → some enters Krebs citric acid cycle.

(d) *The sorbitol pathway*. If glucose is excessive it is converted into sorbitol with the help of enzyme aldose reductase coupled with diphosphopyridine nucleotide and then to fructose.

The energy of the lens is derived from glucose metabolism.

The maintenance of constant water-content is also an energy-consuming process.

Further Reading

1. Adler, F.H., In *Physiology of the Eye* (6th ed.), Moses, R.A. (Ed.), C.V. Mosby, St. Louis, 1975.
2. Newell, F.W., *Ophthalmology: Principles and Concepts* (8th ed.), C.V. Mosby, St. Louis, 1997.

20. PHYSIOLOGY OF THE VITREOUS HUMOUR AND RETINA¹⁻⁴

The vitreous body is a medium which maintains the light path between the lens and the retina. It is jelly-like occupying the major cavity of the globe. It is essentially acellular and has a low metabolic activity.

Vitreous cells

They are chiefly histiocytic and they normally help in the synthesis of acid mucopolysaccharide, pathologically they behave as phagocytes.

Composition

The vitreous has a near similar composition as the aqueous but for the following differences: (a) an excess of collagen; (b) an excess of hyaluronic acid; and (c) a slightly less amount of glucose.

Physicochemical Properties of Vitreous

There are three macromolecular components: (a) collagen—which is the main structural basis; (b) soluble proteins; and (c) hyaluronic acid, which occupies the intervening spaces of interlacing collagen fibrils. It acts as a stabilizer which protects the gel against cellular invasion. The concentration of low molecular weight constituents is usually similar to that in aqueous humour.

According to Balazs¹ there are four basic physicochemical properties: (a) frictional interaction; (b) vitreous expansion and contraction; (c) the excluded volume concept; and (d) the molecular sieve concept.

A precise balance between the collagen and hyaluronic acid (acid MPS) is responsible for: (a) the maintenance of the integrity of the structure of the vitreous; (b) viscoelasticity of the vitreous gel; (c) volume change characteristics; (d) cell distribution and (e) its transport. Any breakdown of the delicate balance between the two can cause a lesion.

Metabolism of the Vitreous

The vitreous humour serves the following functions:

1. It is a repository for the retina, hyalocytes and surrounding tissues
2. It is a depository for metabolic wastes like lactic acid
3. It plays an important role in the movements of solutes and solvents within the eye

4. Hyaluronic acid offers the major resistance against the transvitreal flow of water and decreases transvitreal transport of macromolecules.

Transparency of the Vitreous

Transparency of the vitreous is due to the presence of an extremely low concentration of macromolecular solutes.

Retinal Pigment Epithelium (RPE)⁴

The functions of the RPE are as follows:

1. It plays a major role in maintenance of the blood-retinal barrier
2. It cooperates with the photoreceptor to maintain the light sensitivity of the retina
3. It is involved in the removal of photoreceptor protein and membrane components.

Disc shedding and phagocytosis. Each RPE cell is in contact with as many as 200 photoreceptor outer segments. Phagocytosis of the rod outer segment is mediated by a specific receptor present on the apical membrane of the RPE. This is followed by generation of a transmembrane signal across the plasma membrane of the RPE with production of a second messenger. Finally the shed disc membranes are pulled into the RPE cell cytoplasm as *phagosomes*. The phagosomes quickly fuse with lysosomes forming *phagolysosomes*. The process of disc shedding, phagocytosis and formation of phagolysosomes is complete within 5 minutes of exposure to light.

Disc synthesis and assembly. The molecular mechanism is obscure, but some facts are known. The discs of the outer segment of the rods arise by evaginations of the plasma membrane of the connecting cilium region. The disc assembly is initiated within one hour of exposure to light and continues throughout the light period.

Axoplasmic transport. Axoplasmic transport is the passage of the metabolic substances from the body of the nerve cell to its axon.

Metabolism of the Retina^{3,4}

The retina has got an unusual active metabolism. It has different physiologic activities like biosynthesis of cellular elements, ion transport and axonal transport. Retinal capillaries supply glucose and oxygen which are metabolized in the inner layers. The retinal photoreceptors receive these two from the choroidal vessels. Müller's cells containing glucose-6-phosphatase activity have some glycogen. Most of the oxygen utilized in the retina are consumed. Most of the ATP are produced by combustion of pyruvate into carbon dioxide and water. The excess pyruvate is converted into lactic acid.

Further Reading

1. Balazs, E.A., *The Molecular biology of the Vitreous*. In *New and Controversial Aspects of Retinal Detachment*, McPherson, A. (Ed.), Harper & Row, New York, 1964.
2. Duke-Elder, S., *System of Ophthalmology*, Vol. IV: *The Physiology of the Eye and of Vision*, Duke-Elder, S., Gloster, J. and Weale, R.A. (Eds.), Kimpton, London, 1968.
3. Marmour, M.F., *Clinical physiology of the retina*. In *Principles and Practice of Ophthalmology*, Peyman, Sanders and Goldberg (Eds.), W.B. Saunders, Philadelphia, 1980.
4. Roof, A.J. and Heth, C.A., *Photoreceptors and retinal pigment epithelium: transduction and renewal mechanism*. In *Principles and Practice of Ophthalmology: Basic Sciences*, Albert, D.M. and Jacobiec, F.A. (Eds.), W.B. Saunders, Philadelphia, 1994, p. 309.

21. ACCOMMODATION¹⁻⁴

Accommodation is the mechanism of an eye by which the rays coming from a near object are brought to a focus on the retina.

The changes that occur during accommodation are: (a) an increase in the thickness of the lens causing diminution of the diameter of the lens;

(b) the anterior surface of the lens moves towards the cornea, making the AC shallow, while its posterior surface remains comparatively stationary; (c) contraction of the ciliary muscle; (d) relaxation of the zonule of Zinn and (e) the lens capsule becomes lax and folds upon itself.

Theories of Accommodation

The *Helmholtz theory of relaxation* states that the zonule is relaxed on contraction of the ciliary muscle and diminishes the tension on the capsule. The lens now freed of any compressing force becomes spherical. The objections to this theory are that the lens is not an elastic body, but a semisolid mass. The choroid being a vascular structure cannot constantly stretch without showing pathologic changes. So, it is unlikely that the choroid can act as a counteracting force. When the ciliary muscle contracts the choroid is pulled forward which releases the tension of the zonule. To overcome the objections of this theory, *Henderson* suggested that the traction of the zonule is borne by both the radial and longitudinal fibres of the ciliary muscle. *Fincham* supported the theory but postulated that the lack of uniform thickness throughout its entire extent determines the increased curvature of the lens and the conoidal form assumed by the lens.

The *Tscherning's theory of increased tension*, rejected by many, assumes that following compression of the lens at the equator there is increased curvature especially of the anterior pole.

Nervous pathway

The parasympathetic supply is the main effector, and the sympathetic perhaps plays only a minor part. The peripheral cell station is the ciliary ganglion and perhaps also in the accessory ciliary ganglion. The fibres run along the short ciliary nerves. The stimulation of the accommodation centre located near or in Brodmann's area 22 in the cerebral cortex.

Physical and Physiological Accommodation

Though contraction of the ciliary muscle chiefly determines the activity of accommodation, the lens also takes part in it. The physical accommodation is an expression of the physical deformation of the lens expressed in dioptres, while the physiological accommodation is related to the contractile power of the ciliary muscle expressed in myodiotres. Decreased physical accommodation is seen in presbyopia, while decreased physiological accommodation occurs in a state of debility.

Range and Amplitude of Accommodation

The furthest distance at which an object can be seen clearly is called the far point or *punctum remotum*. The nearest point at which an object can be seen clearly exerting maximum accommodation is called the near point or *punctum proximum*. The distance between the far point and the near point is called the range of accommodation. The amplitude of accommodation is the difference of refractivity of the eye in two different conditions—static and dynamic refraction, expressed by the formula $A = P - R$, where

A = amplitude of accommodation,

P = refractive power of the fully accommodated eye, and

R = refractive power of the eye at rest.

In emmetropia, R is nil.

AC/A ratio is the ratio between accommodative convergence and accommodation. It is an expression of how much convergence the subject associates with a given amount of accommodation.

Anomalies of Accommodation

The following are the anomalies of accommodation: (a) excessive accommodation; (b) spasm of accommodation; (c) insufficiency of accommodation; (d) ill-sustained accommodation; and (e) paralysis of accommodation.

Excessive accommodation. It occurs in young hypermetropes to gain clear vision, myopes doing too much close work, in early presbyopia, using ill-fitted glasses or in debility. Cardinal symptoms are blurring of vision and those of accommodative asthenopia, i.e. headache, feeling of discomfort, etc. The latter is caused by excessive accommodation and marked dissociation between accommodation and convergence. Normally, the refraction becomes +1 D after complete cycloplegia, but in excessive accommodation there is a greater difference than normal.

Treatment. Close work should be forbidden initially and curtailed thereafter, general health should be attended to.

Spasm of accommodation. True spasm of the ciliary muscle is rare and may occur in hysteria or following instillation of eserine. Treatment involves complete cycloplegia for about 4 weeks.

Insufficiency of accommodation. In childhood the amplitude of accommodation is 14 D, the near point at 7 cm; at 36 years the amplitude is 7 D, near point at 14 cm; at 45 years amplitude is 4 D and near point at 25 cm. In insufficiency, the accommodation is always below the lower limit of normal variation. This is due to lental sclerosis and/or weakness of the ciliary muscle. All the features of asthenopia and eye strain are present. Asthenopia is due to enhanced muscular work and eye strain is caused by fatigue. Near vision is blurred and test of amplitude of accommodation reveals insufficiency.

Treatment. Rectifying glasses, which also provide weakest convex glass give adequate vision and near correction, are essential. Proper base-in prisms are added in associated convergence insufficiency. Exercises with the help of an accommodation card are also beneficial, e.g. a black vertical line over a white card.

Ill-sustained accommodation. It is essentially the same as insufficiency but less accentuated.

Paralysis of accommodation. It may be static, i.e. presbyopia and dynamic. The failure of accommodation may be inertia or total paralysis.

Paralysis is caused by drugs, e.g. cycloplegics, and infections like diphtheria, toxic conditions, etc. Treatment of the cause is essential.

Further Reading

1. Adler, F.H., *Physiology of the Eye* (6th ed.), Moses, R.A. (Ed.), C.V. Mosby, St. Louis, 1975.
2. Agarwal, L.P. *Principles of Optics and Refraction*, Medical Publication, New Delhi, 1962.
3. Duke-Elder, S., *The Practice of Refraction*, 9th ed. Revised by Abrams, D. Churchill Livingstone, Edinburgh, 1978.
4. Trevor-Roper, P.D. and Curran, P.V. *The Eye and Its Disorders* (2nd ed.), Blackwell Scientific, Oxford, 1984.

22. CONVERGENCE^{1,2}

Pathway for Convergence

The path is not definitely known. The centre for voluntary convergence is situated in the oculogyric area, i.e. area 8. Afferent fibres from the medial recti run centrally, probably by the oculomotor nerve to the mesencephalic nucleus of the fifth nerve, to a presumptive convergence centre. Perlia's nucleus, the lower convergence centre, is connected by the occipitomesencephalic and corticomesencephalic tracts. From Perlia's nucleus, the fibres run to Edinger-Westphal nucleus. The efferent path is through the parasympathetic fibres in the oculomotor nerve.

Measurement of Convergence

Measurement of convergence is done by using metre angle, i.e. *ma* unit. When the eyes are directed to an object situated at 1 metre distance, the visual axes make an angle with this line. This angle is called the *metre angle*. This angle is inversely proportional to the distance in metres.

The convergence can also be measured in prism dioptres.

Clinically, it can be measured roughly by asking the patient to look at a pencil or finger which is gradually brought nearer to the eyes in the middle line.

Range and Amplitude of Convergence

The range of accommodation is the distance between the far point and near point of convergence. The amplitude of convergence is the difference in convergence between the far point and the near point. The amplitude of convergence consists of:

(a) the *positive*, i.e. that part of the range of convergence between the eye and infinity, and (b) the *negative*, i.e. that part beyond infinity. This is also called relative divergence.

Association between Accommodation and Convergence

Accommodation, convergence and contraction of the pupil form normally a synkinesis.

In emmetropia, the eye needs for each distance of binocular vision, as many dioptries of accommodation as it does metre angles of convergence, e.g. to see an object placed at 1 metre, one metre angle of convergence and 1 dioptry of accommodation are needed.

Near reflex consists of two parts, convergence reflex and accommodation reflex.

The different types of convergence are: (a) voluntary—that can be induced at will; (b) reflex, which may be (i) tonic—not dependent upon fusion or proximity of fixation (ii) proximal—dependent on proximity of fixation (iii) fusional—related with fusion of disparate stimuli (iv) accommodative; (c) tonic—that part of convergence which is not dependent on fusion or proximity of the fixation and (d) fusional—that is related with fusion of disparate retinal stimuli.

Anomalies of Convergence

Anomalies of convergence may be either insufficiency or excess of convergence.

Insufficiency of convergence. The causes include anatomical, e.g. wide interpupillary distance, uncorrected refractive errors, i.e. myopia, hypermetropia and presbyopia. In the former, it is caused by lack of use of accommodation and in the latter two due to insufficiency of accommodation, systemic diseases and weakness of the medial recti, e.g. myasthenia gravis. Diagnosis is clinched by remoteness of the near point, beyond 9.5 cm, in the presence of orthophoria in the distance. Treatment comprises correction of refractive error, orthoptic exercises and advice in the training of voluntary convergence. Occasionally base-in prisms are advocated.

Convergence excess. There are three types: (a) associated with increased accommodation, (b) associated with attempted clear near vision, and (c) primary or irritative lesion, e.g. meningitis. Symptoms in mild cases include headaches and blurring of the prints. In severe cases close work is impossible and diplopia occurs. The principles of treatment are elimination of the causative factor, curtailing of close work, orthoptic exercises and divergence exercises with the amblyoscope.

Presbyopia

Presbyopia is the decreased ability of the eye to alter its focus as age advances, because of progressive diminution of power of accommodation. The process is considered physiological unless it is premature, e.g. in premature sclerosis of the lens or development of cataract.

Close work is usually done about 28 to 30 cm from the eyes and when the near point is about 40 to 50 cm there is onset of presbyopia.

The onset of presbyopia depends on the age and the state of refractive error. In hypermetropia it usually sets in earlier than 40 years of age, in emmetropia later than 40, and much later in myopia.

The symptoms are as follows:

- (i) small prints appear indistinct especially in relative lack of bright light,
- (ii) running together of the lines,

- (iii) holding of the book more distally to get a clear view, and
- (iv) tiring of the eyes, etc.

Treatment. This consists of the provision of convex lenses depending on the age, state of refraction and working habits of the individual.

In general the following schedule may be followed:

40 years	+1 D
45 years	+1.5 D
50 years	+2 D
55 years	+2.5 D

Further Reading

1. Agarwal, L.P., *Principles of Optics and Refraction*, Medical Publication, New Delhi, 1962.
2. Parsons, J.H., *Diseases of the Eye* (18th ed.), Miller, S.J.H. (Ed.), Churchill Livingstone, Edinburgh and ELBS, 1990.

23. BINOCULAR VISION¹⁻³

Binocular vision is the coordinated use of both eyes so as to produce a single mental impression. It depends on anatomical and physiological factors. Under normal conditions, the binocular vision becomes established during the first few years of life.

Anatomical Factors

There is poor visual perception, because there is no full development of the retina and fovea just after birth. The child attains 6/6 vision at about the age of 5. At 6 months there is enough structural development in the eye to have rudimentary binocular vision.

Physiological Factors

At birth the single unconditioned reflex links the two eyes. As the child grows, they are linked by a series of conditioned reflexes—from 6 months to 2 years in a state of 'flux', from 2 to 5 years in

a state of 'diminished flux,' and in 'fixed' state by the age of 8 years.

Binocular reflexes are as follows:¹

At birth. Compensatory fixation reflex keeps the eye in a fixed position in spite of movement of the head and neck.

At 2 to 3 months. (a) Orientational reflex; (b) re-fixation reflex relates to the eyes to take up original orientational point, i.e. passive re-fixation or new orientational point, i.e. active re-fixation; (c) pupillary reflex—direct and consensual; and (d) vergence reflex is established by the age of 6 months

At 2 to 3 years. (a) Accommodation reflex, and (b) fusional vergence reflex.

Grades of Binocular Vision

Binocular vision was divided by Worth into three grades (Fig. 23.1).

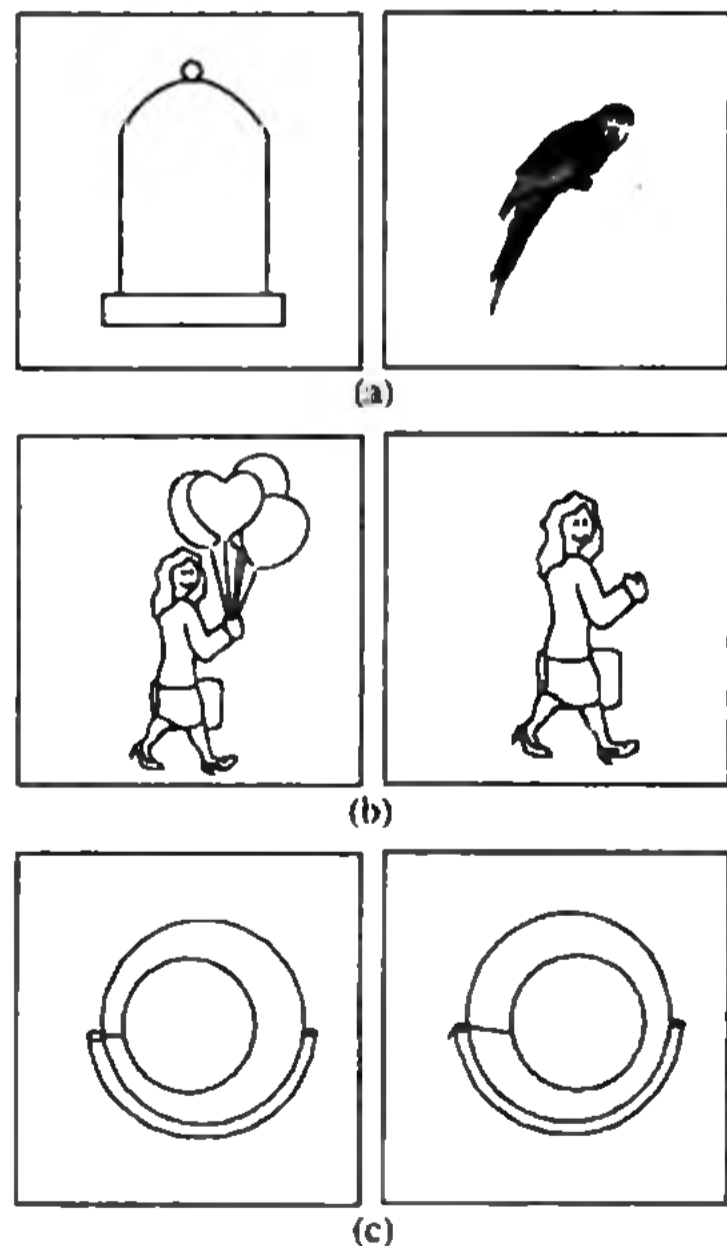


Fig. 23.1 Slides for testing: (a) simultaneous macular perception, (b) fusion and (c) stereopsis.

Grade I. Simultaneous perception, i.e. the faculty to view two images, one on each retina simultaneously. This grade, i.e. the simultaneous foveal, macular or paramacular, of binocular vision is proved by the presence of normal retinal correspondence (NRC).

NRC is the fusion of two monocular images, and the two foveae are the corresponding points, i.e. they are points on the two retinae from which images are projected to the same place in the common visual pathway. In NRC the subjective and objective angles of deviation are the same. The angle of deviation is the difference between the visual and optic axes. The *horopter* is an imaginary line in space, all points on which stimulate corresponding retinal elements. Around the horopter is 'Panum's fusional space', narrow at the centre and wider at the periphery.

Grade II. Fusion—faculty of viewing two similar images and blending them as one.

Grade III. Stereopsis—ability of seeing two slightly dissimilar images and blending them as one along with an appreciation of depth.

The advantages of binocular vision are: (a) the field of vision is larger; (b) the combined binocular visual acuity is slightly greater than the visual acuity of one eye; (c) optical defects present in one eye are made less evident by the normal image of the opposite, involving the use of the blind spot of each eye; and (d) stereoscopic vision and depth perception occur accurately.

Stereopsis can be subdivided into two components: *fine parvocellular* or *static* and *coarse magnocellular* or *motion*. The location of static stereopsis is foveal and it persists in the presence of chromatic equiluminance. The parvocellular stream of retinal ganglion cells (beta cells), concentrated in the fovea are concerned with static stereopsis. The location of motion stereopsis is parafoveal. It is not colour sensitive. This is related to magnocellular stream of retinal ganglion cells (alpha cells), found more toward the near periphery.

Tests for Binocular Vision

The presence of fusion is detected by Worth's four-

dot test. The degree of stereopsis is estimated by measuring the disparity required to produce the impression of depth. Two tests may be employed: *Titmus stereo test* for near, and *vectograph* used for distance.

Depth Perception

Depth perception is the third-dimension in space, and this is dependent on a number of factors. Apart from stereopsis there are other clues, monocular and binocular.

Monocular clues. These include apparent size, interposition of one object in front of another, aerial perspective, shading, geometric perspective, relative velocity and motion parallax.

Binocular clues include stereopsis, efforts of convergence and accommodation.

Further Reading

1. Cashell, G.T. and Durrant, I.M., *Handbook of Orthoptic Principles*, E&S Livingstone, Edinburgh 1967.
2. Tycheson, L. Binocular vision. In *Adler's Physiology of the Eye* (9th ed.), Hart, W.M., Jr. (Ed.), Mosby Year Book, St. Louis, 1992, p. 773.
3. Walonker, A.F., Clinical assessment of binocular vision. In *Adler's Physiology of the Eye* (9th ed.), Hart, W.M., Jr. (Ed.), Mosby Year Book, St. Louis, 1992, p. 183.

24. THE REACTIONS OF LIGHT ON THE EYE^{1,3}

Light

Light is the energy spectrum in wavelengths that evokes a retinal response to cause a sensation.

Light sense

The faculty to see the gradations of intensity is called light sense.

Light minimum

Light minimum is the gradual reduction of the intensity of light reaching the retina to a point which can be just perceived.

Luminous intensity

Luminous intensity is the amount of light radiated. It is estimated in units of candles. A *foot candle* is one lumen per square foot. *Lumen* is the unit of luminous flux. A *lambert* is one lumen per square cm.

Transmission, Reflection and Absorption of Light

The visible spectrum has a span of 400 to 700 millimicrons ($m\mu$) or roughly 400 nm at the violet end and 700 nm at the red end. One millimicron or one millimicromillimetre is equal to one nanometer (nm), i.e. 10^{-6} . Beyond the red end are infrared rays known as heat rays which cause a rise of temperature. Beyond the violet end are ultraviolet rays capable of causing chemical action such as ultraviolet burn.

The ocular media uniformly allow the visible rays at 390 to 660 nm to permeate, whereas the nonvisible spectrum is reflected maximally. The cornea absorbs rays shorter than 295 nm, and the lens rays shorter than 350 nm. Ordinary spectacle glasses absorb rays beyond 350 nm. Thus, it appears that only a few of the longest ultraviolet rays reach the retina and are relatively harmless.

Infrared rays at 700 to 1100 nm can almost uninterruptedly reach the retina, and 'eclipse burn' at the macula occurs.

Effects of Radiant Energy³

The effects can be grouped as:

Thermal. These effects are caused by infrared rays. They especially involve the pigmented structures, i.e. the iris and retinal pigment epithelium causing necrosis.

Chemical. This results usually from short ultraviolet rays, i.e. below 300 nm.

Fluorescence. This is caused by the larger ultraviolet rays.

Specific effects. The specific effects cause: (i) structural changes in the retina; (ii) bleaching of the visual pigments; and (iii) electrical changes in the retina.

Photochemistry of Vision (Fig. 24.1)

The stimulation of the visual pigments of the retina by light causes photochemical, photomechanical or structural and electrical changes. The photomechanical change is insignificant in man.

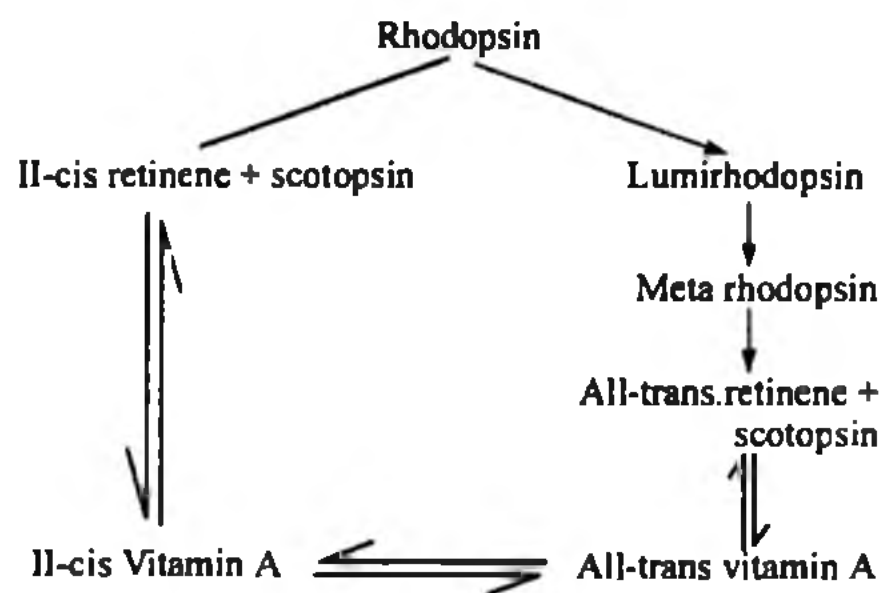


Fig. 24.1 Breakdown and reformation of rhodopsin

Visual Pigments¹

(a) *Rhodopsin*. It is a magenta-coloured pigment. On exposure to light, it is converted into retinene, which in turn is converted to vitamin A. Retinene is an aldehyde of vitamin A and opsin is the protein component. When opsin is found in rods, it is called *scotopsin*. *Photopsin* is found in cones.

(b) *Idopsin*. Retinene₁ combined with photopsin is found in cones.

(c) *Porphyropsin*. Retinene₂ combined with scotopsin is found in rods.

(d) *Cyanopsin*. Retinene combined with photopsin is found in cones.

(e) *Xanthophyll*. Yellow carotenoid pigment of

vegetable origin also enters the human body through food products.

There are three types of cone pigments: blue (*cyanolabe*), red (*erythrolabe*) and green (*chlorolabe*).

Electrical Changes In the Retina

The process by which the light is converted to an electrical signal is called *phototransduction*, which is primarily performed by photoreceptors and assisted by the retinal pigment epithelium. The outer part of the photoreceptor in the light (photon)—capturing part. The rod cells are highly sensitive even in a single incident photon under dim illumination.²

There are three types of potential differences: (a) action potential in the optic nerve fibres, (b) steady corneoretinal potential; and (c) phasic potential produced by light stimulus.

The fleeting electrical disturbances following excitation of a nerve or muscle by action currents are called *action potentials*.

Recordings show a single fibre of the crab 'limulus' in which each of the light-sensitive cells is connected to a single nerve fibre. This ends into a central ganglion without any intervening neuron.

Hartline recorded intermittent and evenly spaced impulses of the same height in all of them. He found three types of fibres in frog's eye:

1. simple intermittent response, i.e. 20 per cent 'on-fibre' as in limulus;
2. initial outburst to onset and final outburst to cessation of illumination, i.e. 50 per cent 'on- and off-fibres'; and
3. response only to cessation of illumination, i.e. 30 per cent 'off-fibres'.

It has been found that in mammals 'on-fibres' are present in rod-rich retinae and 'on-off fibres' in cone-rich retinae.

Further Reading

1. Pahwa, J.M. and Billore, O.P., *Retinal Diseases*, Oxford and IBH, New Delhi, 1978.

2. Roof, D.J. and Heth, C.A., Photoreceptors and retinal pigment epithelium: transduction and renewal mechanism. In *Principles and Practice of Ophthalmology: Basic Sciences*, Albert, D.M. and Jacobiec, F.A. (Eds.), W.B. Saunders, Philadelphia, 1994, p. 309.
3. Trevor-Roper, P.D. and Curran, P.V., *The Eye and Its Disorders* (2nd ed.), Blackwell Scientific, Oxford, 1984.

25. COLOUR VISION

The three important factors in colour vision are:¹ (a) wavelength; (b) luminosity or brightness; and (c) saturation or calorimetric purity which indicates the ratio of mixing with white light. Pure colour means unmixed white. When red, green and violet portions of the spectrum mix and evoke a sensation of white, they are called *primary* colours.

Certain colours admix to produce white and these are known as *complementary* colours, e.g. red + greenish blue, greenish-yellow + violet.

Purkinje Phenomenon

Purkinje phenomenon is the shift in relative colour values from photopic to scotopic vision, e.g. a red light may be strong enough to permit reading as well as to allow unimpaired dark adaptation. Rods are much more sensitive to low illumination than cones, while in bright illumination cones come into play, and under the respective states the vision is called 'scotopic' and 'photopic'. In man, they are both present.

Scotopic Luminosity Curve

The curve obtained by measuring the minimal amount of energy of light from the different portions of the spectrum just perceptible to a dark-adapted subject is called scotopic luminosity curve.

Theories of Colour Vision

The *Young-Helmholtz theory* states the existence of three colour-transmitting mechanisms. This is

really the basis of trichromatic theory of colour vision.

In human, the presence of three kinds of pigments in the cones has been established which lends support to this theory.

The *Hering's opponent-colour theory* proposes the presence of three photochemical substances in the retina that can be both broken down and re-synthesized by three sets of complementary colours (white-black, red-green and yellow-blue). The theory is against the doctrine that the same nerve fibre cannot signal two different sensations to the brain.

The *Granit's theory* proposes that the rods, i.e. the 'dominators' respond in the dark only, and both 'dominators' and 'modulators', i.e. the three groups—red, green and blue come into play in light adaptation.

There are several other views regarding the mechanism of colour vision. The trichromatic theory may account for the phase of reception. Hering's theory may explain the neural interaction at the higher visual levels.

Colour Cells³

Both opponent and double opponent colour cells are found in the visual pathways, the former in the ganglion cells of the retina and lateral geniculate body, and the latter in the striate cortex. The opponent colour cells are involved in successive contrast and the double opponent cells in simultaneous contrast.

Colour Deficiency^{2,3,4}

The normal subject who needs a minimum of three primary colours is a trichromat. Those who need two primary colours to match the spectrum are dichromats, and those who need only one are monochromats. In the anomalous trichromat, the colour mixtures differ from those of the normal trichromat.

Classification

This may be classified into:

Developmental

A. Anomalous trichromats

- (a) Protanomalous—1–1.5%
- (b) Deuteranomalous—2–4%
- (c) Tritanomalous—0.0001%

B. Dichromats

- (a) Protanopia—one colour is defective, 1 per cent, red-blind, confusing blue-green with red.
- (b) Deuteranopia—two colours are defective, 1.4 per cent, green-blind, confusing blue-green with purple.
- (c) Tritanopia—three colours are defective, 0.0001 per cent, confusing yellow with blue.
- (d) Tetratanopia—in which the confusion runs between yellow and blue.

C. Monochromats

These are very rare, rod monochromatism in 0.003 per cent and cone monochromatism in 0.000001 per cent

Blue blindness is acquired.

Tests for Colour Vision

Most commonly by *Ishihara's pseudoisochromatic chart* (Fig. 25.1) which contains bold numerals shown in dots of various tints which are not confusing to the trichromat but to those whose colour vision are defective.




Fig. 25.1 Ishihara's pseudoisochromatic colour vision chart.

For precise diagnosis, an *anomaloscope* is more suitable. This is a device wherein a variable mixture of two coloured lights is compared with and matched with another colour.

The *Farnsworth–Munsell 100 hue test* involves the discrimination of hue of specially prepared coloured discs.

The *Edridge–Green lantern test* is practical test cases where recognition of colour signals is required. Other tests include electroretinograph and microspectrophotometry.

Further Reading

1. Adler, F.H., *Physiology of the Eye*, (6th ed.), Moses, R.A. (Ed.), C.V. Mosby, St. Louis, 1975.
2. Majji, A.R., Sharma, Y.R., Rajsekhar, Y.L., et al. Colour vision and colour blindness. In *Modern Ophthalmology*, Dutta, L.C. (Ed.), Jaypee Bros., New Delhi, 1994, p. 777.
3. Duke-Elder, S., *System of Ophthalmology*, Vol IV: *The Physiology of the Eye and of Vision*, Duke Elder, S., Gloster, J. and Weale, R.A. (Eds.), Kimpton, London, 1968.
4. Parr, J., *Introduction to Ophthalmology*, (2nd ed.), Oxford University Press and ELBS, Oxford, 1982.

26. VISUAL SENSATIONS AND ADAPTATION¹⁻³

The effects of a single flash of light of moderately high intensity (Fig. 26.1) causes a retinal response. The response has:¹ (a) a latent period of 50 to 200 m seconds; (b) a primary image of 50 to 200 m. seconds; and (c) after-images, consisting of



Fig. 26.1 Afterimages. Following fading of primary image there are three positive and three negative afterimages.

alternation of three positive and three negative images becoming progressively longer and less intense.

Effects of intermittent stimuli. When the rate of alternation is increased, a flickering occurs, and on further increase, the difference between successive sensations lessens and suddenly ceases at a certain rate. This is the *critical fusion frequency* (CFF).

Visual Sensations

Visual sensations consist of three senses: (a) light; (b) form; and (c) colour.

Light sense. Light sense is the property to perceive gradations in intensity of illumination and can be tested by determining light minimum and light difference. Light minimum or intensity threshold for light is the lowest limit of illumination at which an object is discernible. Light difference or differential threshold for light is the faculty of distinguishing different intensities of light.

Form sense. Form sense is the faculty of perceiving the form or shape of an object and is expressed in terms of visual acuity.

Visual acuity is a measure of the smallest retinal image of which the form can be appreciated. It is dependent on factors like area of the retina stimulated, intensity and distribution of illumination and spectral nature of illumination.

Colour sense. Colour sense is the faculty of differentiating between colours.

Light Threshold

Light threshold depends on several factors like: (i) nature, duration and size of the stimulus; (ii) quadrant of the retina stimulated; (iii) state of adaptation; and (iv) nature of the surrounding field.

The peripheral rays that reach the retina most obliquely are less effective in stimulating vision. This is called the *Stiles–Crawford effect*.

Successive Contrast

The single stimulus evoking after-images inhibits

subsequent similar stimuli and enhances dissimilar stimuli. This phenomenon is called successive contrast or *temporal induction*. The familiar example is the appearance of a dark square when a white square is briefly projected on the white wall.

Simultaneous Contrast or Spatial Induction

Simultaneous contrast or spatial induction improves the definition of the contour of the visual image and is the result of a single stimulus. An example is the appearance of a grey square as almost white and almost black against black and white backgrounds respectively.

Adaptation

The adjustability of the eye to light of different intensities is called adaptation, either dark or light adaptation. The rods operate best at low illumination, *scotopic vision*. The cones are more sensitive to light and act effectively in bright illumination, *photopic vision*. These two types, scotopic and photopic, form the basis for duplicity theory of vision.

Dark adaptation. The visual sensitivity increases when the eyes remain in darkness. The pupil dilates and there are neural and biochemical changes. There are two phases: the initial phase lasting for 5 to 9 minutes and the second lasting for 30 to 45 minutes; the first phase is rapid and the second slower. In the first phase there is regeneration of cone pigments, while regeneration of rhodopsin occurs in the next phase. The bleaching and regeneration can be measured by reflection densitometry. The dark adapted retina is most sensitive in the region 2.5 mm away from the fovea. Dark adaptation can be tested by Goldmann-Weekers' adaptometer.

Light adaptation. The visual sensitivity decreases when the eye is exposed to a strong source of light. This is primarily a neural phenomenon and is complete within 2 to 3 minutes, but whole process of light adaptation takes about 30 minutes.

Loss of 7 per cent rhodopsin causes cone function to play its role.

Further Reference

1. Hart, W.M., Jr. (Ed.), *Adler's Physiology of the Eye* (9th ed.), Mosby Year Book, St. Louis, 1992, p. 502.
2. Marmour, M.F. Clinical physiology of the retina. In *Principles and Practice of Ophthalmology*, Peyman, G.A., Sanders, D.R. and Goldberg, M.F. (Eds.), W.B. Saunders, Philadelphia, 1980, p. 823.
3. Trevor-Roper, P.D. and Curran, P.V., *The Eye and Its Disorders* (2nd ed.), Blackwell Scientific, Oxford, 1984, p. 146.

27. NEUROLOGY OF VISION¹

The neurology of vision is associated with the study of visual pathways and pupillary pathways and reflexes.

Visual Pathways¹

Three neurons link the retina to the occipital cortex. The sensory end-organs, the rods and cones of the retina respond to adequate light stimulus. The first neuron is the bipolar cell with its axon in the inner plexiform layer. The second neuron starts at the ganglion cell of the retina and runs to the lateral geniculate body. The third neuron transmits the impulse from the lateral geniculate body to the occipital cortex. Each neuron is made up of a cell body containing the nucleus, dendrites and an axis cylinder or axon. The terminal ramifications are called *teledendrones*. The teledendrones synapse with the dendrites of the other cells.

The nerve message received through the dendrites is transmitted by the cell body and is discharged to the next receiving neuron through the teledendrones.

Pupillary Pathways

There are two separate pathways that control

pupillary constriction and dilatation, the former by the parasympathetic and the latter by the sympathetic pathways. Parasympathetic pupillary pathways (light, near and accommodation reflexes).

Afferent pathway. The afferent pupillary fibres start in the photoreceptors → pass through the retina to reach the optic nerve → partially decussate in the optic chiasma like the visual fibres → run along with the visual fibres to reach the posterior third of the optic tract → then leave the tract as a separate bundle of fibres to enter the brachium of the superior colliculus → pass into the midbrain to reach the pretectal nucleus → partially cross to reach Edinger-Westphal nucleus.

Efferent pathway. The fibres start in Edinger-Westphal nucleus. This nucleus is linked with the frontal cortex, occipital cortex and hypothalamic sympathetic centre. There is *excitatory control* from the frontal and occipital cortex. The *inhibitory control* is from the frontal cortex and the hypothalamic centre. The course of the efferent pathway is summarized as follows: Edinger-Westphal nucleus → the oculomotor nerve → the nerve to the inferior oblique → short root of the ciliary ganglion → sphincter pupillae. Three processes, viz, miosis, convergence and accommodation occur together. The pathway for

convergence is described on p. 65, and for accommodation is described on p. 63.

Sympathetic Pupillary Pathways

There are three neurons: central, preganglionic and postganglionic. *Central neuron* originates in the posterior hypothalamus. The fibres pass caudally and ipsilaterally through the brain stem into the upper spinal cord to synapse in the *ciliospinal centre of Budge*.

Preganglionic neuron leaves the spinal cord by ventral roots of C8 to T2 to reach the sympathetic chain and finally the superior cervical ganglion.

Postganglionic neuron has the following course: the fibres enter the skull with the carotid plexus → reach the cavernous sinus → pass over Gasserian ganglion → run along the ophthalmic nerve → nasociliary nerve → long ciliary nerve → sympathetic root of the dilatator ganglion → short ciliary nerve → reach the dilatator pupillae.

Pupillary reflexes (See p. 265)

Further Reading

1. Parsons, J.H., *Diseases of the Eye* (18th ed.), Miller, S.J.H. (Ed.), Churchill Livingstone, Edinburgh, ELBS, 1990.

Part Three

Microbiology

The eye is vulnerable to infection—especially exogenous. There are three chief groups of infection: bacterial, viral and fungal. A description of the offending organisms causing ocular lesions is helpful in understanding the pathogenesis.

28. BACTERIAL INFECTIONS¹⁻²

Bacterial infections in the eyes (Figs. 28c. 1-7) are caused by cocci or bacilli, both of them are gram-positive or gram-negative organisms.

Staphylococci

Staphylococci are among the most common group of human bacteria, normally found on the mucous membranes and skin surfaces.

Microscopic appearance. *Staphylococcus* (*Staph.*) is a coccus of about 1 micron in diameter, nonsporing, nonmotile, usually noncapsulate, gram-positive, and they are arranged in grapebunch-like clusters from which it derives its name.

Cultural characteristics. They grow abundantly on all ordinary media under aerobic condition. There are also facultative anaerobes. The colonies on blood-agar may have white (*Staph. albus*), lemon yellow (*Staph. citreus*) or golden (*Staph. aureus*) pigmentation. The *Staph. epidermidis* strains are usually nonhaemolytic and nonpigmented.

Coagulase test. The pathogenic strains of staphylococcus produce a prothrombin-like enzyme.

The test is done as follows. To 0.5 ml of citrated rabbit or human plasma diluted 1:10 in sterile saline, 0.1 ml of an overnight broth culture of the *Staphylococcus* is added. The mixture is incubated at 37°C for 6 to 12 hours, and is inspected hourly for coagulation.

Coagulase-positive staphylococci are pathogenic and are called *Staph. pyogenes* i.e. *Staph. aureus*, and occasionally *Staph. albus* and *Staph. citreus*.

There are three species of coagulase-positive and 13 species of coagulase-negative staphylococci.

Pathogenecity. This is dependent on the presence of toxins and enzymes liberated by staphylococcus (Table 28.1).

Table 28.1

Toxins and Enzymes Produced by Staphylococci

Toxins

Haemolytic: alpha, beta, delta and gamma
Enterotoxins—A, B, C and E
Epidermolytic
Toxic shock syndrome toxin I

Enzymes

Coagulase
Hyaluronidase
Lysozyme
Fibrinolysin
Others—lipase, protease, gelatinase, nuclease, etc.

Alpha-haemolytic toxin (dermatonecrotxin) is found to be associated with chronic staphylococcal conjunctivitis. Beta-haemolytic toxin is cytotoxic to different types of cells and damaging to plasma membrane of RBCs.

Of the enzymes, coagulase is the most important. Hyaluronidase probably helps in dissemination of staphylococci. The other significant enzyme is lysozyme.

Staph. aureus causes several local infections such as boils, carbuncles and wound infection.

Ocular infections. Staphylococci are present as commensals in the healthy conjunctival sac, usually *Staph. albus*. In more than 50 per cent of the population, the anterior nares are the reservoir of *Staphylococcus* from where they spread to the skin of the lids especially the lower.

The various forms of exogenous staphylococcal conjunctivitis are: (a) chronic catarrhal; (b) chronic allergic; (c) blepharo-conjunctivitis; and (d) rarely, purulent or pseudomembranous conjunctivitis.

Staph. pyogenes can also cause central corneal ulcer or superficial punctate keratitis due to staphylococcal hypersensitivity, the latter variety being accompanied by blepharo-conjunctivitis.

Streptococci

Microscopic appearance. They are approximately 1 micron in diameter, spherical, arranged in chains of varying lengths, gram-positive, nonmotile, nonsporing, capsulate in certain conditions and

they stain well with basic aniline dyes. Pathogenic streptococci are usually arranged in long chains.

Cultural characteristics. *Streptococci* (*Strepto.*) are aerobes and facultative anaerobes. They grow best on 5 per cent blood agar and cause three types of haemolysis. When *Streptococcus* is surrounded by a narrow halo of greenish grey discoloration it is called alpha-haemolysis (*Strepto. viridans*). When *Streptococcus* is surrounded by a wider zone of clearing of the red cells it is called beta-haemolysis and when there is nonhaemolysis it is called gamma-haemolysis.

Pathogenicity. There are three toxins liberated by *Strepto. pyogenes*: (a) streptolysin O, (b) streptolysin S, and (c) erythrogenic toxin, the first two being cytolytic. Two of the enzymes, hyaluronidase and streptokinase are related to pathogenicity.

Strepto. pyogenes the beta-haemolytic streptococci, has the characteristic property of extreme invasiveness probably because of production of hyaluronidase and streptokinase, the latter causing fibrinolysis.

Ocular infections. Streptococci are present in 1 to 4 per cent of normal eyes. It may cause erysipelas, wound infection and conjunctivitis. They may give rise to endogenous infection.

Pneumococci (*Streptococcus pneumoniae*)

Pneumococci are commensals in the nasopharynx and throat in about 40 per cent of the population and in the nose in about half this number.

Microscopic appearance. These are about 1 micron in length, arranged in pairs. They are gram-positive, nonmotile, capsulate and nonsporing.

Cultural characteristics. They grow poorly on ordinary media, but can grow well on blood or serum media. They are facultative anaerobes.

Biochemical reactions. Of which bile solubility and optochin sensitivity are important.

Antigenic structure. Over 70 different types of pneumococcus have been identified.

Ocular infections. The lacrimal sac, when infected, is said to be a potent reservoir of pneumococci. The other ocular lesions are: (a) the various clinical types of conjunctivitis—acute catarrhal, haemorrhagic, purulent, pseudomembranous, ulcerative and lacrimal; and (b) the central corneal ulcer. A haemolytic toxin that can cause toxic effect on the cornea has been reported.

Neisseria (N.)

The genus *Neisseria* comprises a few members which are commensals in the nasopharynx. Two of them are of ophthalmologic importance, namely *N. catarrhalis*, and *N. gonorrhoeae* (gonococci).

Microscopic appearance. Less than 1 micron in diameter, they are arranged in pairs with the long axes parallel and concavity of their opposed surfaces. They are gram-negative, noncapsulate and nonsporing.

Cultural characteristics. They grow on ordinary agar, but their growth is much improved by adding blood or serum.

Biochemical reactions. All *Neisseriae* give a positive oxidase reaction, which is especially needed to detect *N. gonorrhoeae*. 1 per cent freshly prepared oxidase reagent is applied over the culture plate, the colonies of *N. gonorrhoeae* rapidly turn a deep purple colour.

Ocular infections. *N. catarrhalis* may cause chronic conjunctivitis, but is rarely found in acute conjunctivitis.

N. gonorrhoeae causes typically ophthalmia neonatorum, acute purulent conjunctivitis and corneal complications. Rarely it causes a metastatic conjunctivitis associated with arthritis in adults.

Mycobacteria (Myco.)

Two of the species of the genus *Mycobacterium* are of importance in ophthalmology: *Mycobacterium tuberculosis* and *Myco. leprae*.

Myco. tuberculosis. The human and bovine types of *Myco. tuberculosis* cause human tuberculosis.

Microscopic appearance. They are approximately 3 microns by 0.3 microns, straight or slightly curved bacilli, arranged like small 'chinese letters'. They are nonmotile, nonsporing and noncapsulate. Ziehl-Neelson stain shows that they are acid-fast and alcohol-fast. When stained they resist decolourisation with 25 per cent sulphuric acid.

Cultural characteristics. They are strictly aerobic. They grow on enriched media—egg yolk or serum.

Myco. leprae

Microscopic appearance. They are similar in size and shape to *Myco. tuberculosis*. They are acid-fast but non-alcohol-fast. The bacilli are intracellular and are arranged in bundles. The bacilli cannot be cultivated.

Haemophilus (H.)

This genus comprises of 13 species including *H. influenzae* and *H. aegyptius* or Koch-Weeks bacilli.

H. aegyptius. is for all practical purposes identical with *H. influenzae*. They are gram-negative, slender rods 1.5 microns by 0.5 microns in size, nonmotile, noncapsulate and nonsporing. They require blood-containing media (haemophilic) for growth and are aerobic. It produces 'pink eye'.

Treponema (T.)

T. pallidum is a purely human parasite and the causative agent for syphilis.

Microscopic appearance. They are delicate spiralled filaments of about 0.2 microns by 4 to 14 microns with pointed and tapering ends. In the unstained preparation, they require dark-ground illumination. They cannot be cultivated.

Serological reaction. They give a positive complement-fixation test or Wassermann reaction.

Corynebacterium (C.)

Corynebacterium has been so named because of its club-like shape. The commensal species, *C. xerosis*

and *C. hofmanni*, of corynebacteria are called diphtheroids.

Microscopic appearance. *C. diphtheroid* are very pleomorphic. They are usually slender, slightly curved, with club-shaped ends and show 'chinese letter' arrangement. They are gram-positive bacilli, nonmotile, noncapsulate and nonsporing. Stained with methylene blue, they stain irregularly with metachromatic granules at either end of the bacteria.

Cultural characteristics. Their growth occurs in enriched media such as Löffler's serum medium.

Diphtheroids

Diphtheroids rarely show metachromatic-granules. They readily grow on ordinary media and on Tellurite media. *C. xerosis* produces jet black and *C. hofmanni* produces greyish-white colonies.

Pseudomonas (Ps.) Pyocyanea

Ps. pyocyanea (*Ps. aeruginosa*) occurs as commensal in the human intestine or on the skin.

Microscopic appearance. They are small, nonsporing, gram-negative bacilli, 1.5 microns to 3 microns in length, motile and flagellate.

Cultural characteristics. They grow readily on ordinary media at room temperature.

The pigments and toxins produced by pseudomonas are listed in Table 28.2.

Table 28.2

Pigments and Toxins Produced by Pseudomonas

Pigments

Pyocyanin—blue
Pyoverdin—yellow
Pyomelanin—brown
Fluorescein—yellowish

Toxins

Haemolysin
Exotoxin—A, B and C

Pyocyanin inhibits oxygen uptake by tissue cells, haemolysin contributes to invasiveness, and exotoxin A can destroy polymorphs.

Morax–Axenfeld Diplobacilli (Moraxella)

There are three species which are important in ophthalmology: *M. lacunata*, *M. liquefaciens* and *M. catarrhalis*.

They are human parasites and cause angular conjunctivitis.

Microscopic appearance. They are diplobacilli 1 by 2 to 3 microns, nonsporing, noncapsulate and gram-negative.

Cultural characteristic. It grows best on serum media.

Further Reading

1. Brinser, J.H., Ocular bacteriology. In *Infections of the Eye*, Tabbara, K.F. and Hyndiuk, R.A. (Eds.), Little, Brown and Co., Boston, 1986, p. 115.
2. Burd, E.M., Bacterial keratitis and conjunctivitis: bacteriology. In *The Cornea: Scientific Foundations and Clinical Practice* (3rd ed.), Smolin, G. and Thoft, R.A. (Eds.), Little, Brown, Boston and Co., 1994, p. 115.

29. VIRAL AND CHLAMYDIAL INFECTIONS

Viral Infections^{2,4} (Table 29.1)

Structure of a virus. There are diverse groups of viruses of different shapes and sizes. The viral particles contain *genomes* or *nucleocapsids*, which may be helical (tubular) or icosahedral (isometric). Helical nucleocapsids contain structural units called *capsomeres* bound to helical form of nucleic acid. Many viruses contain a protein or lipid envelope.

Characteristics of viruses Viruses are strict parasites. They contain a single nucleic acid RNA or DNA, and a protein coat. The majority of them are ultramicroscopic. Because of their size 10 to 15 millicrons in diameter, they are filter-passing.

Table 29.1

Viruses Causing Various Ocular Affections⁴

DNA viruses	RNA viruses
Papovavirus	
Orthomyxovirus	
Adenovirus	Influenza
Herpes virus	Paramyxovirus
Herpes simplex	Measles
Varicella-zoster	Mumps
Cytomegalovirus	Newcastle disease
Epstein-Barr	Picomavirus
Pox virus	Enterovirus 70
Small pox	Coxsackie virus
Vaccinia	Togavirus
Molluscum contagiosum	Rubella
	Arbo
	Retrovirus
	Human immuno deficiency virus

Proliferation of viruses involves complex relationships with their host cells. They do not grow in non-living culture media.

Life cycle of a virus. The following stages are generally evident.

(a) Penetration. There is specific attachment between the virus protein and 'surface receptor' on the cell membrane, following which nucleic acid goes to the interior of the cell leaving the protein envelope outside.

(b) 'Eclipse phase'. True viruses always pass through this phase in which the intracellular nucleic acid loses its identity.

(c) Maturation and replication. The characteristic change is the release of mature virus particles, i.e. elementary bodies from the infected cell. They now involve further cells. Large aggregations of elementary bodies are called inclusion bodies. They are either intracytoplasmic or intranuclear, basophilic or acidophilic.

(d) Assembly of the virus particles.

(e) Release of infective virus particles then occurs and the cycle is repeated.

Synthesis.² The synthesis of the viral components and ingredients can be divided into three stages.

(1) Synthesis of messenger RNA on viral DNA as a template. Viruses provide DNA, while the

cells provide purine and pyrimidine bases, phosphate, energy and enzymes, which lead to synthesis of messenger RNA.

(2) Synthesis of viral protein on the code of viral messenger RNA. The ribosomes are the centres for synthesis of protein within the cell. Viral messenger RNA is synthesized in the infected cell, while the host cell provides amino acids, phosphate and energy. The amino acids are transported by transfer RNA to the ribosomes and there is synthesis of viral protein on the code of messenger RNA.

(3) Synthesis of DNA. This occurs due to virus-specific enzymes.

Structural characteristics of different viruses are described under Table 29.2.

Rubella virus, a member of togavirus, causes German measles producing developmental cataract and other congenital defects.

Cytomegalovirus (CMV) may cause retinitis.

Laboratory diagnosis. These include:

Rapid antigen detection. The tests include immunofluorescence (IF) and enzyme immuno assay (EIA).

Serologic analysis. The tests include neutralization, complement fixation (CF), immuno adherence haemoagglutination (IHA), haemoagglutination inhibition (HI), fluorescent antibody to membrane antigen (FAMA) and enzyme-linked immunosorbent assay (ELISA).

Table 29.2

Structural Characteristics of Different Viruses⁴

<i>Virus</i>	<i>Envelope</i>	<i>Genome form</i>	<i>Capsid shape</i>	<i>Size (nm)</i>
Papovavirus	No	ssDNA, circular	Icos	45
Adenovirus	No	dsDNA, linear	Icos	70-90
Herpes virus	Yes	dsDNA, linear	Icos	150-200
Pox virus	Yes	dsDNA, linear	Brick	300-450 × 170-260
Orthomyxovirus	Yes	ssRNA, segmented	Helical	90-100
Picornavirus	No	ssRNA	Icos	25-30
Toga virus	Yes	ssRNA	Icos	60-70
Retrovirus	Yes	ssRNA	Icos and helical	80-130

Icos = icosahedral, ss = single stranded, ds = double stranded.

Ocular lesions. They are summarized below.

Molluscum contagiosum produces eyelid lesions.

Papovavirus causes warts on the lid margin.

Herpes simplex virus (HSV). Ocular HSV infection is caused primarily by type I (oral) and occasionally by type II (genital).

For ocular lesions, see Table 38.5, p. 220.

Adenovirus. There are 47 serotypes. Three major ocular affections are epidemic keratoconjunctivitis, pharyngoconjunctival fever and nonspecific follicular conjunctivitis.

Enterovirus 70, a member of picornavirus causes epidemic haemorrhagic conjunctivitis.

Nucleic acid hybridization. This is a highly specific technique of viral identification. Viral DNA from the specimen is spotted onto a nitrocellulose filter. The DNA is denatured with alkali and exposed to radioactive recombinant viral DNA fragment probes.

Chlamydial Infection¹

Chlamydia (C) or Bedsonia was included under psittacosis-lymphogranuloma-trachoma (PLT) virus. Recently, they are described as a separate group occupying a taxonomic position midway

between bacteria and viruses. They show the following characteristics:

1. They contain both DNA and RNA
2. They replicate by binary fission
3. They possess a cell wall
4. Their replication is inhibited by some antibiotics.

Morphology and life cycle of *C. trachomatis*. The elementary body is the infectious particle of chlamydia. The diameter of the elementary body is about 300 nm. The life cycle starts with attachment of the elementary body to the susceptible host cells, followed by its entrance into the cell. About 8 hours after its entrance, the elementary body reorganizes into a *reticulate body*. This process leads to flexible and permeable cell wall. About 48 hours after attachment, the cell and one or more intracytoplasmic inclusions rupture releasing newly-formed elementary bodies, the latter affecting other cells or new host.

Laboratory diagnosis (Table 29.3). There are 15

Table 29.3

Methods of Laboratory Diagnosis of
*C. Trachomatis*¹

Cytologic examination

Yolk sac of embryonated eggs
McCoy cells
He La cells

Antigen detection

Fluorecein staining
Conjugated monoclonal antibody
Enzyme immuno assay

Nucleic acid hybridization

Serologic tests

Complement fixation
Micro immunofluorescence testing
Enzyme-linked immuno assay

serotypes (*serovars*) of *C. trachomatis*. Only three serotypes L₁, L₂, L₃ readily infect the cell culture. The pretreatment of He La cells and uncentrifused McCoy cells with diethyl aminoethyl (DEAE)-

dextran enhances susceptibility of the cells to infection.

Further Reading

1. Heggie, A.D. and Lass, I.H., Chlamydial disease. In *Principles and Practice of Ophthalmology: Basic Sciences*, Albert, D.M. and Jacobiec, F.A. (Eds.), W.B. Saunders, Philadelphia, 1994, p. 840.
2. Jones, B.R., Prospects in treating viral diseases of the eye, *Tr. Ophthalmol. Soc., UK*, 87, 537. 1967.
3. Kelly, L.D. and Dunkel, E.C., Ocular virology. In *Principles and Practice of Ophthalmology: Basic Sciences*, Albert, D.M. and Jacobiec, F.A. (Eds.), W.B. Saunders, Philadelphia, 1994, p. 891.
4. Kichington, P.R., Viral keratitis and conjunctivitis: virology. In *the Cornea: Scientific Foundations and Clinical Practice* (3rd ed.), Smolin, G. and Thoft, R.A. (Eds.), Little, Brown and Co., Boston, 1994, p. 169.

30. MYCOTIC AND PARASITIC INFECTIONS

Mycotic Infections^{1,3,4}

Certain terms used in relation to mycotic (fungal) infection are described below.

Mycology is the science that deals with fungi, either moulds or yeasts.

Molds are multicellular, filamentous organisms.

Yeasts are usually single celled and capable of reproducing by budding process.

Hyphae are multicellular, long, cellulose-like tubes produced by moulds.

Pseudohyphae are elongated buds of some yeasts.

Mycelium is the network composed of hyphae.

Conidiophore is a special hyphal branch connecting the spores (conidia).

There are about 200,000 species of fungi and of these about 175 can cause ocular infection. The cell-mediated immune system offers protection against a fungal infection. Debilitating diseases, breach of anatomic continuity, prolonged use of antibiotic, steroid or both predispose to fungal infection. Table 30.1 lists the fungi responsible for ocular lesions.

Table 30.1
Fungi Causing Ocular Lesions

<i>Candida albicans</i>
<i>Penicillium</i>
<i>Aspergillus (A) fumigatus, A. flavus, A. niger</i>
<i>Fusarium (F) solani, F. oxysporium</i>
<i>Sporothrix schenckii</i>
<i>Rhinosporidium seeberi</i>
<i>Cephalosporium</i>
<i>Actinomyces bovis</i>
<i>Histoplasma capsulatum</i>

Rhinosporidiosis

Rhinosporidiosis is a chronic disease of the nasal and conjunctival mucosa due to *Rhinosporidium seeberi*. The lesion is polypoid in appearance. The disease is present in the Asian subcontinent and South America.

Ocular lesions

(a) In the conjunctiva the presence of reddish, polypoid, single or multiple papilloma-like elevations with characteristic white dots are noticed. The lesion bleeds easily. (b) In the lacrimal sac it presents a picture of nonspecific dacryocystitis. (c) The eyelids may show some tumour-like masses. Diagnosis is confirmed by histopathological examination of the mass and nasal polyps which shows characteristic sporangia of rhinosporidium (Fig. 30.1).

It is best treated by excision of the polypoid lesion followed by cauterization.

Aspergillosis

Aspergillosis is caused by *Aspergillus fumigatus* (Fig. 30.2)

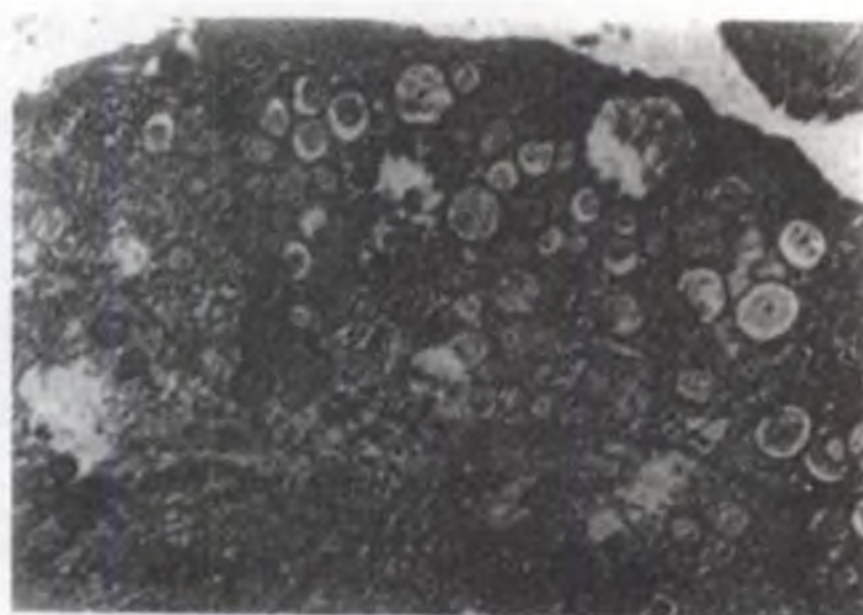

Fig. 30.1 Photomicrograph of the sporangia of rhinosporidiosis (Dr. E. Ahmed and Dr. S.N. Roy).



Fig. 30.2 *Aspergillus* sp. colony showing conidiophores (×320) (Dr. A. Roychowdhury).

Ocular lesions. (a) The cornea is the principal site in the eye. Following injury and contamination, the fungus causes a superficial localized ulcer with soap-lather appearance and a dry surface. It is surrounded by a yellowish demarcation line which gradually deepens to form a furrow. The ulcer has a slow progress. It is usually accompanied by hypopyon. (b) From the cornea the fungus spreads to the conjunctiva. It is usually treated by amphotericin B.

Sporotrichosis

Sporotrichosis is mostly caused by *Sporotrichum schenckii*. It may involve the skin, lungs and central nervous system. In the eye, the lesions are in the eyelids—presenting multiple bead-like

nodules, with a tendency to ulcerate involving the eyelids or eyelid margins, conjunctiva—presenting erythematous or granulomatous lesions; and very rarely, other structures.

Monilliasis or Candidosis

Moniliasis or Candidosis is usually caused by *Candida albicans*. The infection is usually from the mouth, rectum and vagina. The predisposing factors include diabetes, pregnancy and the use of antibiotics or steroids. It may occur in subjects otherwise immuno compromised.

Ocular lesions

(a) Obstruction of the nasolacrimal duct may be caused by the fungi. (b) Corneal lesions caused by *Candida albicans* follow injury and are deep ulcers with undermined edges and dry surfaces. They are frequently accompanied by hypopyon and iritis. (c) The conjunctiva and other structures may be rarely affected.

Actinomycosis

Actinomycosis is usually caused by *Actinomyces bovis*. The species are similar to anaerobic bacteria. The infection spreads from the mouth to the soft tissues of the face forming small abscesses with fistulae. Because of the presence of granules on their surface the infecting agents present a star-shaped appearance from which the name 'actinomyces' is derived.

Ocular lesions

(a) The eyelid is involved next after the face and it shows similar lesions. (b) In the conjunctiva there may be inflammation, pseudomembrane formation and nodular lesions. (c) The cornea may show ulcer with hypopyon. (d) In the lacrimal canaliculi, the lower canaliculus is commonly affected. The canaliculus is filled up with soft yellowish cheese-like material, which later on becomes hard with presence of concretions. (e) Other structures in the eye and orbit are rarely affected.

Streptothrix

This word is occasionally used as a synonym for both aerobic and anaerobic actinomyces. Streptothrix is studied in material collected from the concretions of canaliculitis. The characteristic manifestation is that of mycotic canaliculitis. It usually occurs in females and is unilateral involving chiefly the lower canaliculi. It is evidenced by mild inflammation with copious yellowish material within the canaliculus.

Among the fungi that cause occasional eye lesions are *trichophyllum* which causes ringworm, *Histoplasma capsulatum*—histoplasmosis, *Mucoraceas*—mucormycosis, *Nocardia asteroides*—nocardiosis, *Cephalosporium*—cephalosporiosis and *Fusarium oxysporum* and *solani*—fusariosis.

Laboratory diagnosis is difficult. This can be described as under:

(i) *For superficial infection*

- Scraping of surface lesions and identification either by direct staining of smear or culture.

(ii) *For deep keratitis or intraocular infection*

- Biopsy of deep corneal lesion and use of special stains

- Culture of the aspirate.

Examination of direct smear is done by potassium hydroxide (KOH) or calcofluor white. Fifteen per cent KOH is instilled on gently teased tissue and examined under a microscope to demonstrate hyphae. Staining is done with Gram stain, Giemsa or PAS (Periodic acid-Schiff). Culture is done with Saboraud's media, blood agar or brain-heart infusion broth medium.

Parasitic Infections¹⁻⁴

A parasite is a living organism which receives nourishment and shelter from another organism where it lives.

The terms related to parasitology are briefly described.

Symbiosis denotes close association between the dissimilar organisms. In case of parasitism this association is advantageous to the parasite but detrimental to the host.

Horizontal transmission denotes all types of transfer of infection between the individuals except transfer that occurs from the parents.

Vertical transmission. This mode refers to congenital transfer from a parent to progeny via transplacental route.

Vectors are carriers that transfer parasite from one host to another.

Zoonosis is a disease of the animals that can be transmitted to humans.

Definitive host is one in which a parasite passes its adult and sexual existence.

Intermediate host is one in which a parasite passes its larval or nonsexual existence.

Protozoa is a unicellular structure which performs all the functions and is composed of cytoplasm and nucleus.

Helminths are multicellular, bilaterally symmetrical showing three germ layers and grouped into two phyla: nematodes and platyhelminths.

Parasites causing Ocular Affections

Parasites causing ocular affections belong to four phyla of animal kingdom: protozoa, platyhelminths, nemathelminths, and arthropods. (Table 30.2).

Table 30.2

Parasitic Infections Causing Ocular Manifestations

Protozoal

Toxoplasmosis
Acanthamoebiasis
Malaria
Leishmaniasis
Giardiasis
Amoebiasis

Platyhelminths

Cysticercosis
Taeniasis
Echinococcosis (hydatid cyst)
Schistosomiasis (bilharziasis)

Nemathelminths

Onchocerciasis
Ancylostomiasis (hookworm)
Ascariasis (roundworm)
Dracontiasis (guineaworm)
Gnathostomiasis

Arthropods

Ophthalmia nodosa
Phthiriasis
Ophthalmomyiasis

Toxoplasmosis

Toxoplasmosis is caused by *Toxoplasma* (T.) (Gk. *toxos*, arc) *gondii*. *T. gondii* is an intracellular protozoan with a crescent shape measuring 3×6 millimicron having a well-defined round nucleus. This has two phases: proliferative (tachyzoites) and cystic (bradyzoites). Cats are known definitive hosts. The intermediate hosts include rodents, birds and humans. The life cycle is divided into intestinal (sexual) and tissue (asexual) phases. Cats are infected by ingestion of bradyzoites → rapidly transform into tachyzoites, the latter enter the cat's intestinal mucosa, undergo sexual proliferation and develop into oocysts. The oocysts detach from the intestinal epithelium and are voided with the faeces. These oocysts enter the human system through contaminated food → bradyzoites transform into tachyzoites → reach intestinal lymphatics → disseminate to the cerebrum, liver, lungs, muscles and eyes. Host immunity is initiated and the organisms encyst.

Ocular manifestations. Refer to Table 48.7, pp. 407–8.

Laboratory diagnosis. The tests are as follows.

Sabin-Feldman dye test. A suspension of live toxoplasma is added to the patient's serum to which saturated alcoholic solution of alkaline methylene blue is mixed. If there is no staining of the cytoplasm it indicates the presence of antibody against toxoplasmosis in the patient's serum. But if there is staining it indicates the absence of antibodies and there is no toxoplasmosis. This test is positive as early as the fourth day and it persists longer. False-positive reaction may be seen in other parasitic infections. However, if this test is positive with a titre of 1:128 it is suggestive of an active toxoplasmosis.

Complement fixation test is positive 3 to 4 weeks after an infection. This test utilizes a soluble parasitic antigen derived from chick embryo cultures. A titre less than 1:8 is not indicative of active toxoplasmosis infection.

Haemo agglutination test. The lysed organisms are coated onto the RBCs indicating a positive result.

Indirect immunofluorescent assay. The killed parasites are added to the patient's serum and antihuman globulin labelled with fluorescein. Now they are examined under a fluorescent microscope. This test has now largely replaced the dye test used for detection of antitoxoplasma I_gM or I_gG antibodies. Both false-positive and false-negative may be present.

Enzyme-linked immunosorbent assay (ELISA) is a specific and sensitive test for detection of toxoplasmosis. The patient's serum is incubated with parasitic antigen followed by incubation with enzyme-linked second antibody. Measurement of enzyme activity indicates specific antibody concentration. In recurrent cases measurement of I_g and I_gM points toward an active infection.

Acanthamoebiasis

Ocular acanthamoebiasis is presumably due to direct ocular invasion by free living soil amoeba, *Acanthamoeba*. The portal of entry is the nose or the cornea. This parasite has two stages: trophozoite and cyst. The use of steroids, injury, herpetic infection, contaminated water, vegetable matter, etc. may predispose to this infection.

Ocular lesions

Ocular infection is unusual, keratitis cases being reported. This keratitis is characterized by remissions and exacerbations, pain, insidious lesion and features resembling those of herpetic or fungal keratitis.

Laboratory diagnosis. Clinically involved epithelium and stroma are scraped vigorously with a sharpened Kimura or Bard Parker No. 15 blade. If the initial cultures are negative or if there is deep stromal involvement with intact epithelium, a corneal biopsy may be necessary to obtain the infected tissue. Smears are examined for cysts. The trophozoites stained with calcofluor white are viewed with ultraviolet light under a fluorescent microscope. Cultures are plated on 1.5 per cent non-nutrient agar with an *E. coli* overlay for an optimal growth.

Malaria

Malaria is caused by *Plasmodium*. Occasionally the following complications may be encountered: dendritic keratitis, unilateral IK, conjunctival pigmentation and retinal haemorrhages.

Leishmaniasis

In India, visceral leishmaniasis or kala-azar caused by *L. donovani* is not rare. Other two forms are: cutaneous and mucocutaneous leishmaniasis. Gross anaemia in kala-azar results in retinal haemorrhages.

Giardiasis

Giardiasis is due to *Entamoeba histolytica*. It is not certain whether uveitis associated with this affection is caused by amoebiasis or is a coincidence.

Taeniasis and Cysticercosis

Taeniasis is caused by *T. solium* and *T. saginata*. Cysticercosis is caused by larva of the tapeworm *T. solium* called *Cysticercus cellulosae*. Terminal gravid segments of this worm containing 50,000 to 100,000 eggs are voided in the faeces. The eggs are ingested by intermediate hosts like cattle, pig or human, and hatching of the eggs occurs producing larvae.

Ocular lesions (see p. 409)

Echinococcosis (Hydatid Cyst)

Echinococcosis is due to *Echinococcus*, usually *E. granulosus*. Definitive hosts, dogs or cats, pick up infection by eating sheep's or pig's viscera. Humans are contaminated by ingesting eggs shed in dog's faeces.

Toxocariasis

Toxocariasis is caused by *Toxocara canis* or *catis*. It is transmitted to humans by ingestion of eggs from the soil contaminated with dog's or cat's faeces. The larvae reach the eye via choroidal circulation.

Ocular lesions (see p. 410)

Onchocerciasis

Also called *river blindness*, it is caused by *Onchocerca volvulus*. The affection is common in Africa, central and north America. The vector is the black fly, *Simulium*. When a black fly bites an infected individual the microfilariae enter the fly. The pathologic changes are the direct or indirect result of local death of microfilariae.

Ocular lesions (see p. 410)

Rare Helminthic Infections (Table 30.3)

Arthropods

The notable arthropod infections are briefly described. *Phthiriasis* (refer to p. 166) is caused by *Phthirus pubis*, a lice infestation. *P. pubis* is 1.5 to 2 millimicron long with a crab-like

appearance. Nits or lice eggs cases are cemented to the hair shafts of the eyelashes.

Myiasis is caused by maggots (larvae) of *Diptera* flies. There are three types: ocular surface, intraocular and orbital. *Ophthalmia nodosa* (see p. 195) is caused by caterpillar hairs.

Further Reading

1. Chatterjee, K.D., *Parasitology* (12th ed.), Chatterjee Medical, Calcutta, 1980.
2. De Freitas, D. and Dunkel, E.C., Parasitic and rickettsial infections. In *Principles and Practice of Ophthalmology: Basic Science*, Albert, D.M. and Jacobiec, F.A. (Eds.), W.B. Saunders, Philadelphia, 1994, p. 865.
3. Rodger, F.C., *Eye Diseases in Tropics*, Churchill Livingstone, Edinburgh, 1981.
4. Tabbara, K.F. and Hyndiuk, R.A. (Eds.), *Infections of the Eye*, Little, Brown and Co., Boston, 1986.

Table 30.3

Rare Helminthic Infections Causing Ocular Lesions

Helminths	Disease	Ocular lesions
<i>Ascaris lumbricoides</i>	Roundworm	Hypersensitivity, uveitis
<i>Ancylostoma duodenale/americanans</i>	Hookworm	Evidence of anaemia, xerosis
<i>Dracunculus medinensis</i>	Guineaworm	Worms detected in lid, conjunctiva, orbit
<i>Gnathostoma spinigerum</i>	Gnathostomiasis	Larva in anterior chamber, uveitis
<i>Schistosoma haematobium</i>	Bilharziasis	Oedema of lid, conjunctival nodule
<i>Thelazia callipoeda</i>	Thelaziasis	Chemosis, corneal haze, worm in AC, etc.

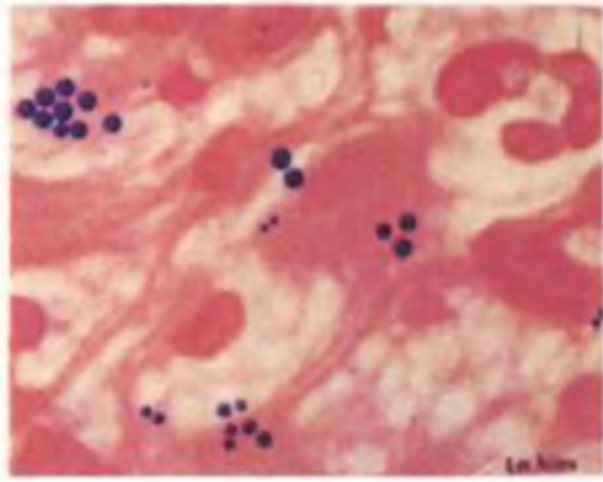


Fig. 28c.1 Staphylococci from conjunctival smear (May).

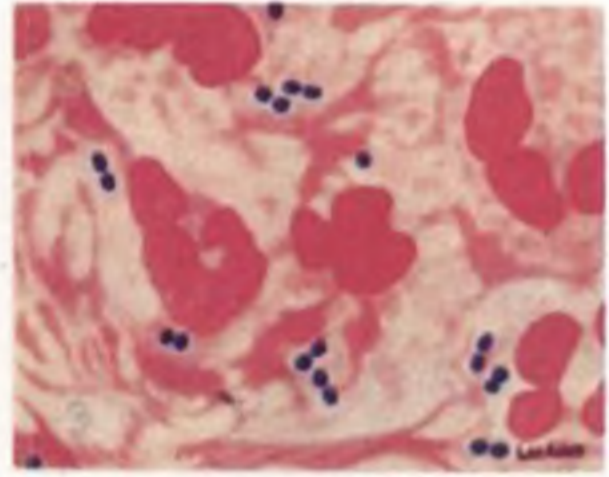


Fig. 28c.2 Pneumococci from conjunctival smear (May).

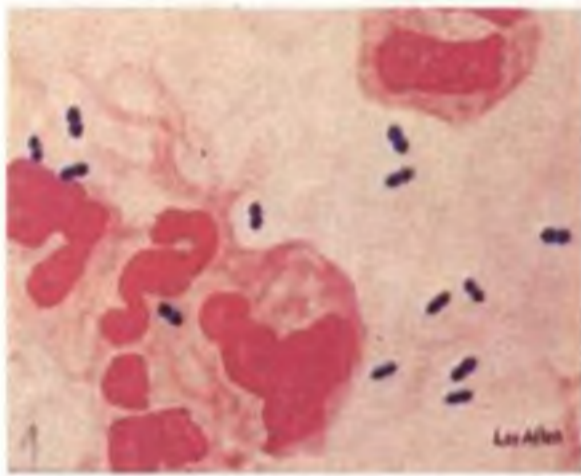


Fig. 28c.3 Streptococci from conjunctival secretion (May).

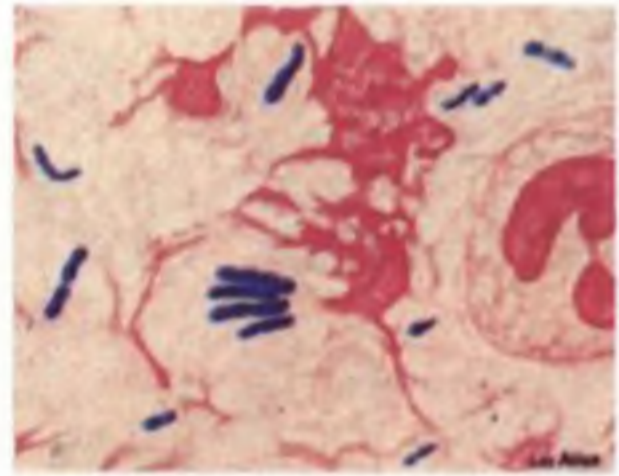


Fig. 28c.4 *Corynebacterium diphtheriae* conjunctival scraping (May).

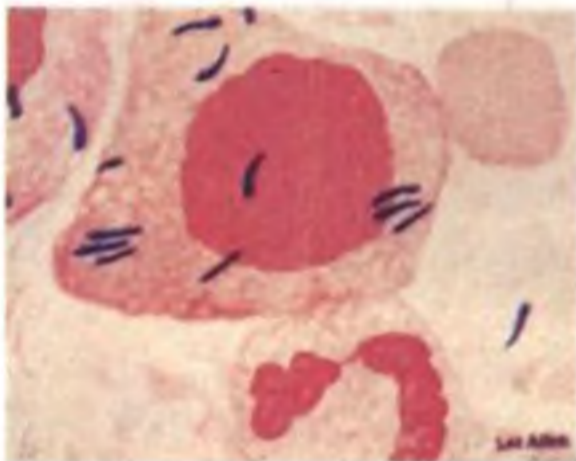


Fig. 28c.5 *Corynebacterium xerosis* from conjunctival scraping (May).

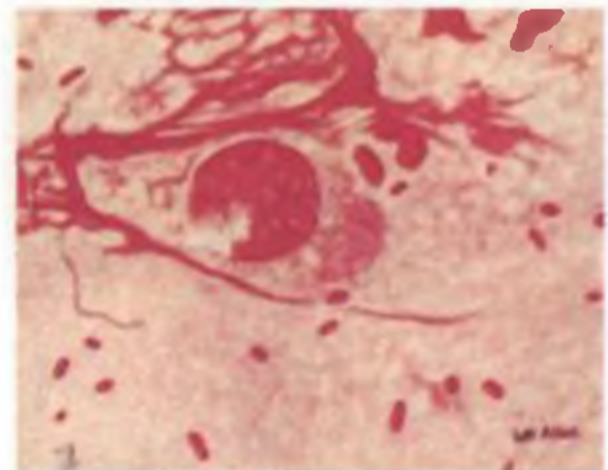


Fig. 28c.6 *Neisseria gonorrhoeae* (May).

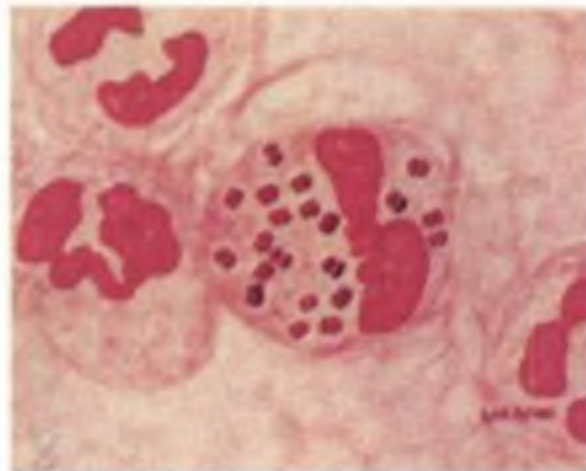


Fig. 28c.7 *Pseudomonas aeruginosa* (May).

Part Four

Ocular Therapeutics, Optical Defects and Ocular Examinations

Three important subjects have been grouped under this section.

In ocular therapeutics emphasis has been laid only on those aspects of pharmacology and therapeutics which are related to ocular disorders.

The physiological optics include correction of refractive errors with lenses, optical defects of the normal eye and accommodation. The determination of the refractive state is one of the procedures followed in ophthalmology, and is perhaps more an art than a science. Accommodation is a true physiologic process and has already been dealt with.

Lastly in examining a case, it is essential to elicit the history, perform routine clinical examination, and if necessary conduct special investigations.

31. OCULAR THERAPEUTICS

The basic study in ocular therapeutics² considered includes the following:

Ophthalmic solutions

The problems involved are: (i) tonicity—the eye tolerates solutions with sodium chloride equivalent to 0.7 to 2 per cent; (ii) pH of 6.6 to 7.8 is well tolerated; (iii) stability; (iv) sterility—is the most important attribute; and (v) preservatives, e.g. benzalkonium chloride.

Ophthalmic ointments

The base is a bland, non-irritating one. It may be: (i) simple—either oils or mucilages, and (ii) compound—either oil-in-water type or water-in-oil type. The compound base is more useful. The mixture containing 10 per cent liquid paraffin, 10 per cent wool-fat and 80 per cent soft yellow paraffin is the most convenient base.

Chief methods of administration

(i) Solutions; (ii) ointments; (iii) subconjunctival injections; (iv) retrobulbar injections; and (v) systemic therapy.

Agents needed for special effects

(i) Hypertonic substances, e.g. glycerine for purpose of reducing corneal oedema; (ii) lubricants, e.g. methyl cellulose, 1 or 2 per cent; (iii) staining agents, e.g. fluorescein and rose Bengal; (iv) epitheliolytes, e.g. iodine and alcohol; (v) chelating agents, e.g. ethylene diamine tetraacetate (EDTA) sodium to remove calcium deposits as in band-shaped keratopathy; (vi) tattooing, e.g. gold and platinum; (vii) irritants, e.g. ethylmorphine hydrochloride or dionin. The value of using irritant is doubtful.

Surface effectors

They may be grouped as (i) mechanical cleansers, e.g. normal saline lotion and sodabcarb lotion; (ii) demulcent or soothing agent, e.g. liquid

paraffin; (iii) emollient or softening agent, e.g. liquid paraffin and glycerine; (iv) irritants, e.g. dionin; (v) astringents, e.g. zinc, boric and acetic acid; (vi) corrosives; (vii) caustic agents, e.g. carbolic acid, trichloroacetic acid and iodine. The salts of a few heavy metals such as mercury, zinc, silver and copper are used as astringents, irritants and corrosives; and (viii) antiseptics act in one of the three following ways: (a) by coagulation of protein, (b) by disruption of cell membrane, and (c) act as strong oxidizing agents. Antiseptics used in the eyes include mercurochrome, protargol, argyrol and zinc sulphate.

Autonomic Drugs

Autonomic drugs may be cholinergic or adrenergic. Tables 31.1 and 31.2 give a list of these drugs.

Table 31.1
Cholinergic Agents

<i>Cholinergic-stimulating (agonists) or parasymphomimetics</i>
Direct-acting
Acetylcholine
Pilocarpine nitrate or hydrochloride
Methacholine chloride
Carbachol (Glaucostat)
Cholinesterase-inhibiting or anticholinesterases
Physostigmine (Eserine) salicylate
Demecarium bromide (Humorsol)
Edrophonium chloride (Tensilon)
Ecothiophate iodide (Phospholine)
Neostigmine bromide (Prostigmine)
Di isopropyl fluorophosphate (DFP)
<i>Cholinergic-blocking (antagonists) or parasymphatholytics</i>
Muscarinic antagonists
Atropine sulphate
Homatropine hydrobromide or hydrochloride
Scopolamine sulphate (Hyoscine)
Cyclopentolate hydrochloride
Tropicamide
Ganglion stimulators
Hexamethonium chloride
Pentolinium

Cholinergic agents. Acetylcholine is the effector substance or the chemical mediator in the

Table 31.2
Adrenergic Agents

Stimulators (agonists) or sympathomimetics	
Direct-acting	
Epinephrine (adrenaline) hydrochloride, borate or bitorate	
Phenylephrine	
Dipyvalyl epinephrine	
Apraclonidine	
Indirect-acting	
Cocaine hydrochloride	
Hydroxyamphetamine (Paredrine)	
Brimonidine	
Blockers (antagonists) or sympatholytics	
Direct-acting	
Alpha-antagonists	
Thymoxamine	
Dapiprazole	
Beta-antagonists	
Timolol	
Betaxolol	
Laevobunolol	
Metipranolol	
Carteolol	
Atenolol	
Pindolol	
Indirect-acting	
Guanethidine	

cholinergic system. Acetylcholine is formed from choline and acetylcoenzyme A in the presence of the enzyme cholineacetylase. It is released at cholinergic nerve endings where it is rapidly hydrolyzed and inactivated by the enzyme acetylcholinesterase, present on the neuron and membrane of the receptor cell, into acetic acid and choline. Traditionally, acetylcholine has a *muscarinic* effect on the smooth muscle, cardiac muscle and glands and a *nicotinic* effect on the skeletal muscle and ganglia.

The different sites of stimulation and blockade of cholinergic system have been shown in Fig. 31.1. Parasympathomimetics are essentially used as miotics and parasympatholytics as mydriatics—cycloplegics.

Adrenergic agents In the adrenergic system there are two chief effector substances, norepinephrine and epinephrine and both are catecholamines. These two substances are inactivated by two

Sites of actions of drugs on parasympathetic system

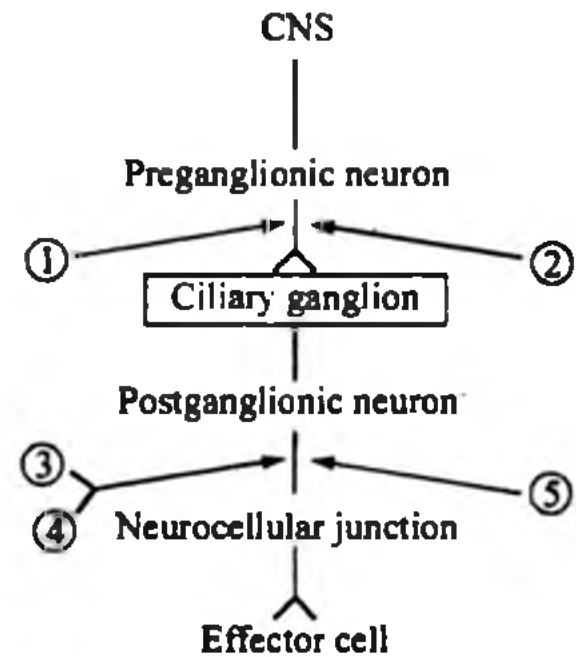


Fig. 31.1 Sites of actions of the drugs on the parasympathetic system. 1, ganglion stimulation by the drugs like acetylcholine and tetramethylammonium; 2, ganglion stimulation by the agents like hexamethonium and pentolinium; 3, direct peripheral stimulation by the drugs like pilocarpine, methacholine and acetylcholine, 4, indirect peripheral stimulation by the drugs like physostigmine, ecothiophate, edrophonium and iso fluorophate and 5, cholinergic peripheral block by such drugs like atropine, homatropine, eucatropine, scopolamine and cyclopentolate.

enzymes—catechol-o-methyl transferase and monoamineoxidase (MAO).

The different sites of adrenergic system stimulation and blockade have been shown in Fig. 31.2.

In the eye there are two types of receptors: alpha (postsynaptic, type 1 and presynaptic, type 2) and beta (type 1 and type 2).

Alpha-receptors are present in the arterioles, outflow channels, dilatator pupillae and Müller's muscle. Hence, their stimulation causes enhanced aqueous outflow, mydriasis and lid retraction.

Beta-receptor type 1 is present in the cardiac muscle.

Beta-receptor type 2 is present in bronchial muscles, blood vessels of the anterior ocular segment, outflow channels and ciliary body. Stimulation of beta-receptor type 1 causes tachycardia and enhanced cardiac output. Stimulation of beta-receptor type 2 causes bronchial dilatation and increased aqueous secretion.

Sites of actions of drugs on sympathetic system

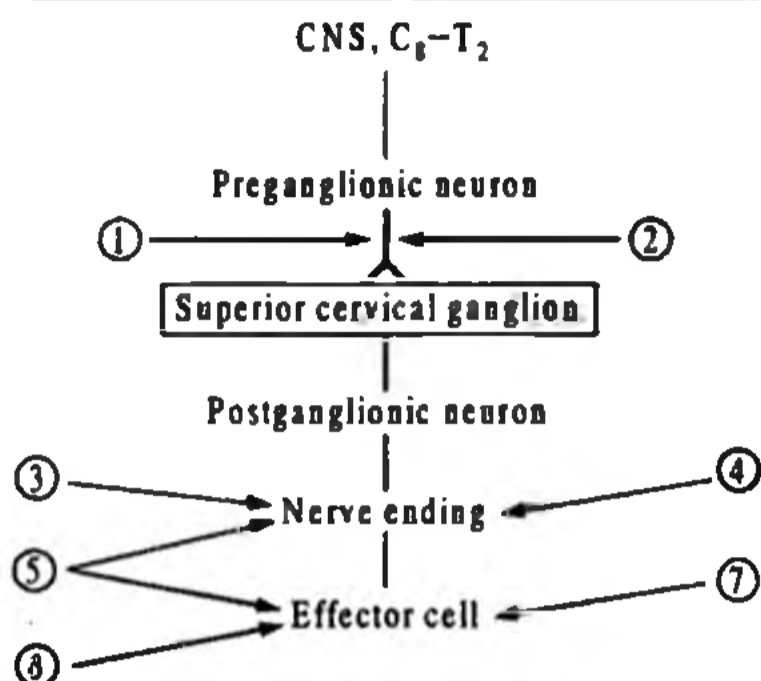


Fig. 31.2 Sites of actions of the drugs on the sympathetic system. 1, ganglion stimulation by the cholinergic drugs; 2, ganglion block by the cholinergic drugs; 3, adrenergic peripheral stimulation by the drugs like hydroxyamphetamine; 4, adrenergic peripheral block by the drugs like reserpine, guanethidine and methyldopa; 5, direct cell stimulation by the drugs like phenylephrine and ephedrine; 6, stimulation of the effector cell by the agent like epinephrine; and 7, blocking of the effector cell by the drugs like tolazoline and dibenzylene.

Adrenergic agents. See p. 299.

Miotics

Miotics are drugs which constrict the pupil.

Pilocarpine. This is the drug of choice used in glaucoma. It may be used as a 1 per cent drop if the tension is below 30 mm Hg Schiötz, as a 2 per cent drop if the tension is well above 30 mm Hg Schiötz and a 4 per cent drop in very high tension. The 2 per cent drop is the most effective strength. It is used as nitrate or hydrochloride. It acts within 15 minutes of instillation and lasts for about six hours and sometimes longer. Maximum drop of IOP occurs within one hour.

Eserine (Physostigmine). It is used as salicylate, usually as 0.25 per cent or 0.5 per cent drops. It is a stronger miotic than pilocarpine and accommodative spasm is commoner than in pilocarpine. The action starts within 5 minutes and miosis disappears within 2 to 3 days. Blocking of

the ciliary ganglion causes the pupil unresponsive to eserine.

For details about miotics (see Table 44.5, p. 299).

Mydriatics

Mydriatics are agents needed to dilate the pupil, while cycloplegics cause paralysis of the ciliary muscle and accommodation. Some mydriatics are also cycloplegics, e.g. atropine and homatropine.

Atropine. This is the longest-acting parasympatholytic drug. A 1 per cent drop or ointment causes mydriasis within 15 minutes which peaks in about 30 minutes and lasts for 12 days or more. Cycloplegia starts around 25 minutes, begins to decline in 3 to 5 days but lasts for 2 to 3 weeks. Evidence of acute poisoning includes dryness of the mouth and skin, flushing of the face, fever, and tachycardia.

Homatropine. A 1 or 2 per cent solution induces a mydriasis within 15 minutes, and reaches its peak within 1 hour. It lasts for about 24 hours.

Scopolamine (Hyoscine), 0.25 per cent or 0.5 per cent drops cause mydriasis within 1/2 hours and maximum cycloplegia in less than 1 hour. Mydriatic-cycloplegic action lasts for 3 to 7 days.

Cyclopentolate. This is used as a 0.5 or 1 per cent solution. Mydriasis develops in 45 minutes and cycloplegia in 60 minutes. The action lasts for 12 to 24 hours.

Tropicamide. This is used as a 0.5 or 1 per cent solution. Full cycloplegia occurs in 20 minutes. The action lasts for about 6 hours.

Phenylephrine. This is an alpha-receptor stimulant but with little beta activity. A 10 per cent drop is often sufficient for effective mydriasis within 30 minutes. The action lasts for 3 to 4 hours. It should never be used in the presence of angle closure.

Anaesthesia in Ophthalmology

The essential prerequisite for a successful surgical

procedure is an effective anaesthesia. Local anaesthesia is sufficient for the vast majority of cases. General anaesthesia is resorted to nervous and apprehensive patients, children and evidently in prolonged surgical procedures.

Local anaesthetics include: (a) surface anaesthetics and (b) infiltration and regional anaesthetics.

The common surface anaesthetics used are:

(i) *Amethocaine or tetracaine hydrochloride* (1/2%), a novocaine substitute, readily soluble in water, effective within minutes and produces burning sensation and slight hyperaemia.

(ii) *Lignocaine hydrochloride or Xylocaine* (4%).

(iii) *Cocaine hydrochloride* (1 to 4%) is effective within 2 minutes. It causes vasoconstriction, mydriasis, desquamation of corneal epithelium, and occasionally toxic reactions.

Toxic reactions may be local, determined by: (i) nature of the drug; (ii) solubility; and (iii) concentration.

Infiltration and regional anaesthetic

Mixtures of lignocaine and bupivacaine have become popular because the former has rapid onset but short duration of action, while the latter has slow onset but long duration of action (Table 31.3).

General manifestations are varied and include: (a) in normal subjects: (i) central nervous system

Table 31.3

Drugs Used for Infiltration and Regional Anaesthesia

Drug	Concentration (%)	Maximum dose (mg)	Onset of action (minutes)	Duration of action (hours)
Lignocaine (Xylocaine)	2	500	4-6	1/2-1
Procaine (Novocaine)	1-4	500	6-8	1/2-3/4
Mepivacaine (Carbocaine)	1-2	500	3-5	1-1/2-2
Bupivacaine (Marcaine)	0.25-0.75	175	3-5	4-12

(CNS) effects—stimulation or depression; (ii) peripheral nervous system effects; and (iii) cardiorespiratory effects, and (b) abnormal responses, e.g. allergic responses such as idiosyncrasy.

Sedatives and analgesics. They are often used as pre- or postanaesthetic drugs: (a) to allay or prevent nausea and vomiting; and (b) to avoid side effects of anaesthetics.

Chemotherapeutic Agents and Antibiotics

These are primarily classified as:

(a) *Bacteriostatic*—sulphonamides, tetracyclines, chloramphenicol, erythromycin in low dose, paraaminosalicylic (PAS) acid etc.

(b) *Bactericidal*—penicillins, cephalosporins, aminoglycosides, e.g. streptomycin, neomycin and kanamycin as well as cotrimoxazole, erythromycin in high concentration and isoniazid.

They can also be arranged according to mechanism of action:

(a) *Inhibition of biosynthesis of the cell.* The peptidoglycan component of the cell wall of the bacterium is essential for the integrity. The growth of bacteria causes lysis of the wall, e.g. by penicillins and cephalosporins.

(b) *Inhibition of protein synthesis.* Tetracyclines, streptomycin, chloramphenicol and erythromycin interfere with the production of the peptide chains on ribosomes.

(c) *Alteration of the permeability of the cell wall.* Agents like colistin and amphotericin cause such alteration.

(d) *Interference with the intermediary metabolism.* PAS, sulphonamides, trimethoprim and isoniazid interfere with bacterial metabolism.

(e) *Interference with nucleic acid metabolism.* RNA and DNA metabolism may be affected by nalidixic acid, rifampicin and actinomycin.

The different chemotherapeutic agents used in ocular infections include sulphones, PAS acid, isoniazid and cotrimoxazole.

Sulphonamides

Sulphonamides act by competitive action. They chemically almost resemble para-aminobenzoic acid (PABA), the latter being a precursor of folic acid. Folic acid is needed for the growth of many bacteria. When sulphonamides are administered they compete with PABA, but their slight difference in chemical structure does not allow the bacteria to synthesize folic acid.

Ocular uses. They are used topically as sodium sulphacetamide (Albucid) 10%, 20% and 30% drops or 6% ointment, and occasionally as sulphisoxazole drop with a wetting agent.

Being lipid-soluble they are at times suitable for controlling intraocular infections, but hypersensitivity and toxic reactions must be considered. Slowly-excreted sulphonamides, e.g. sulphamethoxypyridazine (Lederkyn or Midikel), sulphaphenazole (Orisul), sulphadimethoxine (Madribon) are preferred in conditions like trachoma.

Cotrimoxazole. (Septran or Bactrim) is a chemotherapeutic agent which comprises sulphamethoxazole and trimethoprim. A tablet contains 400 mg of sulphamethoxazole and 80 mg of trimethoprim. It is reported that the concentration in the aqueous is higher than any other sulphonamide.

Antibiotics^{2,4}

Local route of administration is preferable to systemic administration, provided the antibiotic is able to reach the site of infection. Newly developed antibiotics should only be used in infections by organisms resistant to older antibiotics.

As the use of antibiotics is essential the following factors should be considered: (a) the predisposition of the patient; (b) the disease; (c) the responsible pathogen; and (d) the antibiotic. Patients with apparently similar infections react differently. The dose and the type of antibiotic may have to be modified if the liver or kidney is involved. Full bacteriological assessment is the basis of definitive therapy.

Antibiotics therapy may not respond because of these factors: (a) wrong diagnosis; (b) wrong selection of the drug; (c) wrong dosage; (d) development of drug resistance; (e) presence of pus; and (f) infection with multiple organisms.

Use of antibiotics in ocular disorders. The external infections of the eye respond favourably to antibiotic therapy. The control of intraocular infection by antibiotics appears to be a problem because of relative impermeability of the blood-aqueous barrier. The lipid-soluble substances such as chloramphenicol are more permeable than water-soluble substances such as penicillin and streptomycin. In inflammations the blood-aqueous barrier is more permeable.

Topical uses. The usual methods of local therapy include instillation of drops and suspensions, application of ointments or applicap and occasionally subconjunctival or retrobulbar injections.

Antimicrobial spectrum of antibiotics

It shown in Table 31.4.

Topical preparations. Table 31.5 lists the major topical antibiotics.

Doses of subconjunctival injections of antibiotics are indicated in Table 31.6.

Antiviral Agents^{1,4,6}

There are two groups:

- (a) Nonselective
 - Idoxuridine (IDU)
 - Trifluorothymidine (F₃T)
 - Vidarabine (Ara-A)
 - Cytarabine (Ara-C)
 - Methisazone
 - Amantadine, rimantadine, tromantadine
- (b) Selective
 - Acyclovir (ACV)
 - Ganciclovir (GCV)
 - Bromovinyl deoxyuridine (BVDU)
 - Foscarnet trisodium
 - Azidothymidine (Zidovudine)

Table 31.4
Antibiotics with General Antimicrobial Spectrum

Antibiotics	Effective predominantly against
Penicillins	
Benzyl (Penicillin G)	Staphylococci
Penicillinase-resistant	<i>Staph.</i> and <i>Strepto. haemolyticus</i>
Methicillin	
Cloxacillin	
Nafcillin	
Oxacillin	
Broad spectrum	Gram-positives
Ampicillin	
Amoxycillin	
Carbenicillin	
Cephalosporins	Both Gram-positives and negatives
Cephazolin	
Cephalothin	
Cephalexin	
Cephotaxime	
Aminoglycosides	
Streptomycin	<i>Myc. tuberculosis</i>
Framycetin	Gram-positive cocci and Gram-negative bacilli
(Soframycin)	
Amikacin	Both Gram-positives and -negatives
Tobramycin	As above
Sisomicin sulphate	As above
Spectinomycin	<i>N. gonorrhoeae</i>
Gentamicin	Both Gram-positives and -negatives
Neomycin	Gram-negatives
Chloramphenicol	Gram-positive cocci and Gram-negative cocci
Tetracyclines	Gram-positives and -negatives,
Lincomycin	Chlamydia, Rickettsiae
Macrolides	Gram-positives
Erythromycin	As that of penicillin
Spiramycin	<i>Toxoplasma gondii</i>
Azithromycin	<i>Chlamydia trachomatis</i> and
Roxithromycin	<i>Toxoplasma gondii</i>
Polymyxins	Chlamydial infections
Polymyxin B+	<i>Pseudomonas pyocyanea</i>
Gramicidin + Neomycin	
(Neosporin)	
Polymyxin B + Polymyxin E	
(Colistin)	
Fluoroquinolones	Staphylococci, <i>Pseudomonas pyocyanea</i>
Ciprofloxacin	<i>Moraxella</i> , <i>Haemophilus</i> and <i>N. gonorrhoeae</i>
Norfloxacin	
Ofloxacin	
Clindamycin	As that of lincomycin
Rifampin	<i>Myc. tuberculosis</i> and <i>leprae</i>
Fusidic acid (Fucidin)	Staphylococcal infection

Table 31.5

Topical Antibiotic Preparations Used in the Eye

Antibiotic	Preparations
Penicillin G	Sol 100,000 units/ml
Chloramphenicol	Sol 0.5%, oint 1%
Tetracycline	Sol or oint 1%
Chlortetracycline	Oint 1%
Oxytetracycline (Terramycin)	Oint 1%
Framycetin (Soframycin)	Sol or oint 1%
Ofloxacin	Sol 0.3%
Norfloxacin	Sol 0.3%
Ciprofloxacin	Sol 0.3%
Gentamicin	Sol 0.3%
Tobramycin	Sol or oint 0.3%
Sisomicin	Sol 3 mg/ml

Table 31.6

Doses of Antibiotics Given by Subconjunctival Injections

Antibiotic	Subconjunctival dose
Benzyl penicillin	300 mg/ml
Carbenicillin	100 mg/0.5 ml
Cephazolin	100 mg/0.5 ml
Gentamicin	40 mg/ml
Tobramycin	40 mg/ml
Vancomycin	25 mg/0.5 ml
Streptomycin	250 mg/0.5 ml

5-iodo-2 deoxyuridine or *idoxouridine (IDU)*. IDU molecule closely resembles thymidine and is incorporated into viral and host DNA instead of thymidine causing production of altered messenger RNA. This antimetabolite is used in treating epithelial HSV keratitis. The drug is poorly soluble. It is used as 0.1 per cent drops to be used every 2 hours during waking and 0.5 per cent ointment 4 to 5 times daily. The treatment should not exceed 3 weeks.

Trifluorothymidine, trifluridine (F₃T) or viroptic blocks DNA synthesis by inhibiting cellular thymidylate synthetase and is incorporated into viral DNA. It is soluble in water and fat and hence is more effective in controlling HSV keratitis, particularly epithelial lesions. It is used as 1 per cent solution, 5 to 9 times daily for 2 to 3 weeks.

Vidarabine (Vira-A) or adenine arabinoside (Ara-A) is a purine derivative, while IDU and F₃T are pyrimidine derivatives. It is phosphorylated without the help of thymidine kinase. It is said to be more effective than IDU but less effective than F₃T. It is used as 3 per cent ointment 5 times daily up to 10 days. The use should be reserved for cases allergic or resistant to IDU or F₃T.

Cytarabine or cytosine arabinoside inhibits synthesis of nucleic acid. It is used against herpes simplex and vaccinia. It is used as 0.5 or 1 per cent drops and 1 per cent ointment.

Acyclovir (ACV), acycloguanosine or Zovirax activates only in virus infected cells. At first there is conversion of ACV to ACV monophosphate. Then it enters preferentially into infected cells. The activated ACV, ACV triphosphate has a 30 times greater affinity for viral DNA polymerase and causes a 3000 times greater effect of ACV on HSV replication. It is used as 3 per cent ointment 5 times daily for 2 weeks. In HZO 500 mg 5 times daily for 2 or more weeks may be advocated.

Ganciclovir (GCV) or dihydroxy propoxymethyl guanine (DHPG) is structurally and pharmacologically related to ACV.

Bromovinyl deoxyuridine (BVDU) is most potent antiviral agent against HSV type 1 and HZO. Its action resembles that of ACV. It may be used as 0.1 to 0.2 per cent drops 5 to 8 times daily.

Foscarnet trisodium inhibits replication of all human herpes and retroviruses including HIV and may be used in ACV-resistant cases. It is given as IV injection, 2.4 mg in 0.1 ml, once a week.

Azidothymidine (AZT) or zidovudine prevents the production of viral DNA chains by inhibiting the reverse transcriptase of HSV type 1. It is recommended in treatment of AIDS and CMV retinitis. It is given 100 to 200 mg orally 5 to 6 times daily for 4 to 6 weeks.

Toxicity of antiviral agents, see Table 31.17.

Antifungal Agents^{1,4}

Table 31.7 gives an account of various antifungal drugs, their mode of administration and spectrum.

disadvantages. These are: (a) the activity is less intense than that of steroids; (b) there is metabolic upset; and (c) 25 units every 8 hourly can be given by IM or IV injection but not orally.

Table 31.7
Antifungal Agents, Their Mode of Administration and Effectivity

Antifungal agent	Mode of administration	Effective against
Polyenes		
Amphotericin B	Topical, SC, IV, intravit,	Keratomycosis and mycotic endophthalmitis Filamentous fungi and <i>C. albicans</i>
Natamycin (Pimaricin)	Topical	
Nystatin	Topical	<i>Candida</i>
Imidazoles		
Clotrimazole	Topical, oral, SC	<i>Acanthamoeba</i>
Miconazole	Topical, intravit, SC, IV	Yeasts and filamentous fungi
Econazole	Topical, IV, oral	<i>Aspergillus</i>
Ketoconazole	Topical, oral	<i>Candida, Fusarium, Penicillium</i>
Triazole		
Fluconazole	Topical, oral	<i>Aspergillus, Candida</i>
Pyrimidines		
Flucytosine	Topical, oral	<i>Candida</i>
Others		
Silver sulphadiazine	Topical	<i>Fusarium</i>

SC = Subconjunctival; IV = Intravenous; Intravit = intravitreal.

Preparations and doses of topical antifungals are listed in Table 31.8.

Table 31.8
Preparations and Doses of Topical Antifungals

Antifungal	Preparations	Daily dose
Amphotericin B	Drop, 50,000 U/ml	5 times
Clotrimazole	Suspension, 1%	2 hourly
Econazole	Suspension/oint., 1%	8 hourly
Fluconazole	Drop, 0.2%	5 times
Flucytosine	Drop, 1%	2 hourly
Miconazole	Suspension, 1%	2 hourly
Natamycin	Suspension, 5%	5 times
Nystatin	Ointment, 10000 U/g	2 hourly
Silver sulphadiazine	Drop, 1%	5 times

Steroids¹⁻³

Corticosteroids and adrenocorticotrophic hormone (ACTH) have remarkable anti-inflammatory effects. ACTH causes stimulation of the adrenal cortex to produce steroids. ACTH has certain

Deoxycorticosterone (DOCA) was the first synthetic adrenal compound. In 1950 hydrocortisone was discovered. Later more potent and synthetic preparations were introduced. While deciding about the use of steroids in ophthalmology the local hazards as well as general contraindications are to be considered.

There is a daily 10 to 15 mg secretion of hydrocortisone in the normal person and any increase in the secretion by the administration of steroids can cause a pharmacological effect.

Steroids are divided into three groups: (a) mineralocorticoids, e.g. deoxycorticosterone and fludrocortisone; (b) glucocorticoids—(i) natural, e.g. hydrocortisone; (ii) synthetic, e.g. prednisolone, methyl prednisolone, triamcinolone, betamethasone and dexamethasone; and (c) androgens.

Glucocorticoids fill a great need because of its valuable antiinflammatory action.

The antiinflammatory action of steroid is due to the following mechanisms.¹

1. Inhibition of vascular permeability
2. Stabilization of lysosomal membranes
3. Inhibition of intracellular lysosomal membranes
4. Inhibition or release of damaging enzymes
5. Inhibition of PMN (Polymorphonuclear neutrophil) cell degranulation and macrophage activity
6. Mobilization of PMNs from the bone marrow causing increased neutrophilic leucocytosis and preventing their adherence to the vascular endothelium.
7. Suppression of lymphocyte proliferation
8. Suppression of fibroplasia
9. Decompression of bacterial activity of monocytes and macrophages
10. Prevention of formation of prostaglandins and leucotriens through inhibition of phospholipase A₂ and release of arachidonic acid, affecting both cyclooxygenase and lipooxygenase pathways.

Therapeutic indications. See Table 31.9.

Table 31.9

Indications of Steroids in Ophthalmology

Allergic blepharitis
Allergic conjunctivitis
Contact dermatitis
Episcleritis
Scleritis
Interstitial keratitis
Scleritis
Uveitis
Optic neuritis
Retinal vasculitis
Postsurgery
Temporal arteritis
Pseudotumours of orbit
Mucocutaneous conjunctival affections
Chemical burns
Sympathetic ophthalmitis

Steroids can be administered orally, parenterally and topically (Table 31.10).

Table 31.10

Routes of Administration of Steroids

Systemic	Oral Parenteral
Topical	Solution Suspension Ointment Subconjunctival Repository

In addition to topical drops or ointments in severe forms of iridocyclitis and scleritis, subconjunctival injection and/or systemic administration are necessary. In inflammatory diseases of the posterior segment of the globe, optic nerve and the orbit, systemic administration of glucocorticoids or ACTH injection is valuable.

Retrobulbar injection of repository corticoids is effective in selected cases of posterior segment affection, the advantages of such therapy being high local concentration of the drug and avoidance of systemic side effects.

Dosage of systemic steroids. In severe cases daily dose of 40 to 80 mg of prednisolone or its equivalent is used. The reduction of the dose is done gradually over a period of days or weeks.

The doses of commonly used topical preparations of steroids are shown in Table 31.11.

Table 31.11

Showing Usual Strength of Topical Steroids

Topical steroids	Percentage
Hydrocortisone solution	0.2
Hydrocortisone ointment	0.5
Hydrocortisone acetate suspension	2.5
Prednisolone ointment	0.25
Dexamethasone phosphate solution (Decadron)	0.1
Betamethasone solution (Betnesol)	0.1
Triamcinolone acetonide ointment (Kenalog)	0.1
Medrysone suspension	1.0

The side effects include aggravation of herpetic infection, predisposition for fungal overgrowth, retardation of healing, glaucoma—in those subjects genetically predisposed to glaucoma, and cataract.

Enzymes in Ophthalmology³

These enzymes are proteolytic or fibrinolytic.

Alphachymotrypsin. This is a proteolytic enzyme prepared from mammalian pancreas. It is used for ease of intracapsular extraction of the lens.

The normal dosage is 750 units with 5 ml diluent yielding a 1:5000 solution. For irrigation of the posterior chamber, 1 to 3 ml for about 3 minutes is used. 0.5 ml or less of 1:10,000 solution may be quite effective. The possible side effects are keratopathy, delayed wound healing, transient rise of intraocular pressure and vitreous degeneration.

Hyaluronidase. It is an enzyme which depolymerizes the polysaccharide, hyaluronic acid found in the tissues. It is available in 150 unit ampoules. The usual dosage is 6 units per ml of anaesthetic solution. Addition to an anaesthetic solution for injection ensures increased tissue permeability, rapid spread and quicker absorption.

Urokinase. It is a fibrinolytic enzyme used for washing out the AC. It is indicated in hyphaema.

Anticoagulant Therapy³

Principally, there are two drugs, the heparin and the coumarin group of drugs.

Heparin should be given in the dosage of 7,500 to 10,000 units by IV injection since it causes a rather rapid effect. *Coumarin* drugs are started simultaneously as their action does not start before 12 to 96 hours. Heparin is withdrawn after 24 to 48 hours and coumarin drugs are given as maintenance therapy. Prothrombin time should always be checked. Important drugs for oral therapy are dicoumarol, phenindione (Dindevan) and biscoumacetate (Tromexan).

The dosage of dicoumarol is on the first day 300 mg; on second day 200 mg; and thereafter 50 to 75 mg daily. Prothrombin time should be maintained between 20 and 25 per cent of normal levels.

Contraindications include bleeding tendencies and hepatic disorder.

Withdrawal of oral therapy is made in about 6 weeks.

Antagonist to coumarin drugs. IV injection of vitamin K₁ reduces the prothrombin time to almost normal in 3 to 5 hours.

Carbonic Anhydrase Inhibitors (CAIs)^{2,3}

The enzyme *carbonic anhydrase* is present in the ciliary epithelium, corneal endothelium, lens and retina. CAIs inhibit this enzyme which catalyzes the reaction between carbon dioxide and water to form carbonic acid. This decreases the rate of aqueous humour secretion by 40 to 50 per cent. The pressure-lowering effect lasts for 3 to 5 days following cessation of therapy.

Doses. The doses of CAIs are follows:

Acetazolamide (Diamox, Actamid)—250 mg thrice daily in children 10 mg/kg body weight; 500 mg IV and 500 mg slow release capsule.

Methazolamide (Neptazane)—50 mg tablet twice daily.

Dichlorphenamide (Daranid)—50 mg tablet twice or thrice daily.

Ethoxzolamide (Cardase)—125 mg tablet 4 times daily.

Topical CAIs. These include sezolamide, acetazolamide and dorzolamide. Of these, *dorzolamide* 2 per cent was introduced in 1995; it is given thrice daily or twice daily as adjunctive instillation.

Systemic side effects are common and depend upon the agent administered and total dose given. Minor effects include paraesthesia of the fingers and toes, and area around the mouth. Major effects include drug allergy, gastrointestinal disorders, metabolic acidosis, potassium depletion and renal calculi. Potassium supplementation is essential to counteract these effects.

Hyperosmotic Agents

They lower intraocular pressure primarily by reducing the ocular volume.

Indications of the use of osmotic agents are:

angle-closure glaucoma, malignant glaucoma, secondary glaucoma, hyphaema with secondary glaucoma likely to produce blood staining of cornea, and orbital exploration.

Contraindications are severe renal, cardiac or hepatic damage.

Doses and methods of administration of osmotic agents are shown in Table 31.12.

Table 31.12

Dosage and Mode of Administration of Osmotic Agents

Osmotic agents	Dosage	Route of administration
Glycerol	1.5 gm/kg, 50% glycerol dissolved in 0.9% saline	Oral
Urea	0.5–1 gm/kg as a 30% solution, dissolved in 10% inert sugar	IV
Mannitol	2 g/kg as a 20% water solution	IV
Ascorbate	0.5–1 gm/kg in 20% solution	IV
Isosorbide	1.5 gm/kg of 50% solution	Oral

Side effects may be headache, nausea, vomiting and other hazards at the site of injection. Oral agents have their onset of action within 1/2 hour of administration, maximum effect within 2 hours and duration of action for 4 to 5 hours.

Intravenous hyperosmotic agents have more rapid onset of action, 10 to 20 minutes after IV injection, and greater hypotonic effect, 5 to 6 hours, than oral agents. The drugs should be used with caution in elderly subjects and in patients suffering from cardiac, renal and hepatic disorders.

Side effects. The common side effects are headaches, backache, nausea and vomiting. The severe effects seen after IV injection are chest pain, pulmonary oedema, congestive cardiac failure, agitation, disorientation and urinary retention.

Immunosuppressive Agents

These agents are listed in Table 31.13.

Table 31.13

Various Immunosuppressive Agents

Alkylating agents
Busulphan or myeleran
Chlorambucil
Cyclophosphamide or endoxan
Thiotepa
Antimetabolites
Methotrexate
Mercaptopurine
Azathioprine
5-fluorouracil (5-FU)
Vincristine
Cyclosporine
Antimicrobial
Mitomycin C (MMC)
Alkaloid
Bromocriptine
Pulsed steroid therapy: high dose of IV steroid.

Table 31.14 enumerates the possible indications of different immunosuppressive agents.

Table 31.14

Indications of Immunosuppressive Agents

Agents used	Clinical condition
5-fluorouracil	Filtering operation
Mitomycin C	Filtering operation, pterygium operation
Cyclosporine A	Behcet's syndrome, Vogt-Koyanagi-Harada syndrome
Methotrexate	Uveitis, necrotizing scleritis, sympathetic ophthalmitis, scleritis
Chlorambucil	Sympathetic ophthalmitis
Azathioprine	Uveitis, Wegener's granulomatosis, cicatricial pemphigoid
Cyclophosphamide	Uveitis, Mooren's ulcer, necrotizing scleritis.

These drugs are toxic and may cause bone marrow suppression, hepatotoxicity and nephrotoxicity.

5-fluorouracil is used after filtering surgery, it is administered by subconjunctival injection, 5 mg twice daily for one week and then once daily for another week.

Mitomycin C is given as 0.02 to 0.05 per cent drops post pterygium surgery for one week. During filtering surgery it is instilled as 0.02 to 0.05 per cent drops on the scleral surface.

Nonsteroidal Antiinflammatory Drugs (NSAIDs)

Mechanism of action. Arachidonic acid is the primary precursor of prostaglandins, leucotriens and related compounds. Cyclooxygenase is responsible for conversion of arachidonic acid to endoperoxidase. Nonsteroidal antiinflammatory drugs exert inhibitory effects on cyclooxygenase and thereby block prostaglandin biosynthesis. Table 31.15 lists the important NSAIDs.

Table 31.15

Nonsteroidal Antiinflammatory Drugs

For systemic use

Aspirin
Mefenamic acid
Indomethacin
Phenylbutazone
Ibuprofen
Naproxen
Diclofenac sodium
Piroxam

For ophthalmic use

Indomethacin 1%
Flurbiprofen sodium 0.03%
Sodium cromoglycate 2%
Diclofenac sodium 0.1%
Ketorolac tromethamine 0.5%
Suprofen 1%

Indomethacin and diclofenac sodium drops are used in episcleritis or scleritis.

Sodium cromoglycate drops are used in vernal conjunctivitis.

Flurbiprofen acts on the receptors of arachidonic acid and controls prostaglandin formation. This drug is used in inflammatory affections and for maintaining intraoperative miosis.

Viscoelastic Agents¹

Viscoelastic agents have been increasingly used during past few years. An ideal agent should be:

1. Solution of high viscosity
2. Elastic quality enabling it to rebound following mechanical stress and compression

3. Pseudoplasticity, i.e. ability to pass through small channel

4. Noninflammatory

5. Nonpyogenic

6. Nontoxic

8. Nonantigenic.

Mode of action. These agents act by coating the surfaces thus protecting them, maintain or increase tissue spaces within the eye, separate tissue planes, form temporary blockade and prevent capillary oozing.

Preparations. Healon appears to be safest and easiest to handle because of its smooth transition from viscous to elastic nature. Others are shown in Table 31.16.

Table 31.16

Viscoelastic Agents and Their Composition

Viscoelastic Agent	Composition	Concentration (Percentage)
Healon	Sodium hyaluronate	1
Armvisc	Sodium hyaluronate	1.2
Armvisc plus	Sodium hyaluronate	1.6
Visilon or Viscomet	Hydroxypropyl methyl cellulose	2
Viscoat	Sodium hyaluronate +	3
	Chondroitin sulphate	4

Indications. These agents are used during cataract surgery, keratoplasty, trabeculectomy and other filtering operations, retinal surgery, after vitreous loss and during repairing injury.

Side effects are rare if the viscoelastic is meticulously washed off after completion of surgery. Otherwise there is chance of secondary rise of IOP and postoperative inflammation.

Toxic Effects of Ocular Drugs^{5,7}

The toxic effects of commonly-used topical preparations have been indicated in Table 31.17.

Table 31.17
Toxic Effects of Common Topical Drugs

Drug	Systemic effects	Ocular effects
Antibiotics	Allergic reaction, gastrointestinal upsets, etc.	Allergic dermatconjunctivitis, folliculosis, etc.
Antivirals	Hypersensitivity	Superficial punctate keratitis, canalicular block, thickening of lid margin, etc.
Atropine	Dry mouth and skin, flushing of face, fever, delirium, etc.	Allergic dermatconjunctivitis, folliculosis, etc.
Miotics	Perspiration, diarrhoea, increased salivation, nausea, vomiting, etc.	Accommodative spasm, myopia, retinal detachment, etc.
Beta-blockers	Cardiac or/and respiratory trouble, confusion, impotence, etc.	Superficial punctate keratitis, decreased tear secretion, etc.
Steroids	Possible systemic absorption	Secondary glaucoma, cataract, reactivation of herpetic and fungal infection, corneal thinning, etc.

Toxic effects of Systemic Drugs^{5,7}

These have been indicated in Table 31.18.

Other Therapeutic Measures

1. Artificial tear, e.g. methylcellulose, isoptotear, tearisol, etc.

2. Lipotropic agents include atromid S.

Atromid-S (Clofibrate). It reduces elevated triglyceride and cholesterol level. It is used as an adjunct in the treatment of exudative form of diabetic retinopathy. The recommended dosage is 500 mg 4 times daily.

Table 31.18
Toxic Effects of Commonly-used Systemic Drugs

Drugs	Effects	Drugs	Effects
Aspirin	Rare. Excessive dosage causes acidosis and chance of decrease of IOP	Chloroquine	Corneal deposits and macular oedema
Anti-parkinsonian drugs	Mydriasis, paralysis of accommodation and precipitation of angle-closure glaucoma	Chloramphenicol	Optic neuritis
Atropine and related drugs like probanthine	Mydriasis, paralysis of accommodation and precipitation of angle-closure glaucoma, and visual hallucinations	Digitalis	Floating spots and yellow, blue or green vision
Acetazolamide (Diamox)	Paresthesia, numbness and tingling of extremities, potassium depletion and exfoliative dermatitis	Insulin	Overdosage leads to hypoglycaemia and may cause diplopia
Antihypertensives	Sudden lowering of BP may induce retinal ischaemia	Penicillin	Hypersensitivity reactions
Antihistamines	Impairment of accommodation	Salicylates	Retinal haemorrhages
Alcohol	Amblyopia, optic atrophy, visual field defects, etc.	Steroids	Cataract, glaucoma, activation of fungal and herpetic keratitis
Barbiturates	Impaired ocular motility, miosis or mydriasis, xanthopsia, transient loss of vision, etc.	Streptomycin	Optic neuritis
		Sulphonamides	Transient impairment of accommodation, erythema multiforme, etc.
		Ethambutol	Optic neuropathy and loss of visual acuity
		Tranquillizers	Pigment disturbances in the retina and uveal tract

3. Physiotherapy includes application of heat and cold, diathermy, electrolysis, ionization, β -rays, X-rays and radium therapy.

4. Protein shock therapy is the injection of non-specific protein, e.g. milk which induces production of antibodies within the body.

5. Tissue-therapy is the use of biogenic stimulator, e.g. injection of placenta extract. It was originally advocated in 1933 by Filatov. They are used in various degenerations and dystrophies. This therapy is doubtful.

6. Vasodilators include tolazoline hydrochloride (Priscol) and aminophyllin.

Further Reading

1. Albert, D.M. and Jacobiec, F.A. (Eds.), *Principles and Practice of Ophthalmology: Basic Sciences*, W.B. Saunders, Philadelphia, 1994.
2. Duke-Elder, S., *System of Ophthalmology*, Vol. VII: *The Foundations in Ophthalmology*, Kimpton, London, 1962.
3. Ellis, P.P. and Smith, D.L., *Handbook of Ocular Therapeutics and Pharmacology*, (3rd ed.), C.V. Mosby, St. Louis, 1969.
4. Fechner, P.U. and Teichmann, K.D., *Ocular Therapeutics*, Slack (1st Indian Ed.), Jaypee Bros, New Delhi, 1998.
5. Grant, W.M., Drug intoxication and chemical injuries, In *Modern Ophthalmology* (2nd ed.), Sorsby, A. (Ed.), Vol. II, Butterworths, London, 1972, p. 661.
6. Jones, B.R., Prospects in treating viral diseases *Tr. Ophthalmol. Soc.*, UK, 87: 537, 1967.
7. Martin-Doyle, J.L.C., *A Synopsis of Ophthalmology* (3rd ed.), John Wright and Sons, Bristol, 1967.
8. Newell, F.W., *Ophthalmology—Principles and Concepts*, (8th ed.), C.V. Mosby, St. Louis, 1997.

32. OPTICS AND REFRACTION

Geometrical Optics^{8,9}

Laws of reflection (Fig. 32.1). The incident ray, the normal and the reflected ray lie in one plane.

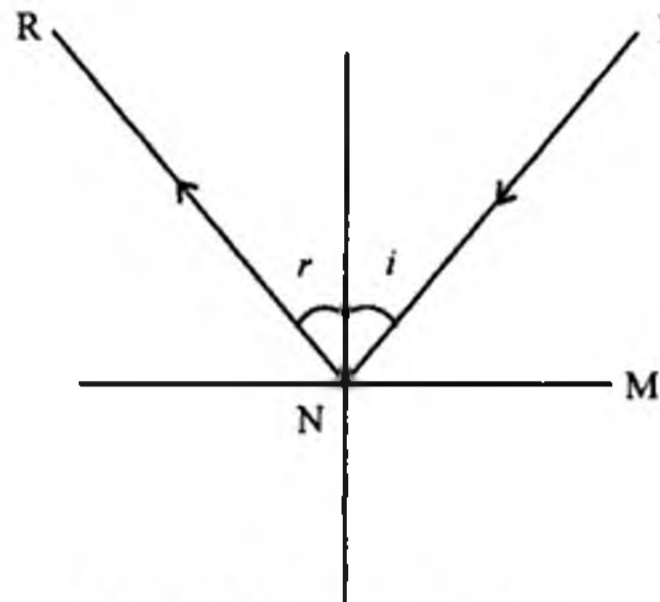


Fig. 32.1 Laws of reflection.

The angle of reflection is equal to the angle of incidence.

Rotation of a plane mirror (Fig 32.2). If the mirror is rotated in the plane of the incidence of light, the angle of reflection is twice that through which there is rotation of the mirror.

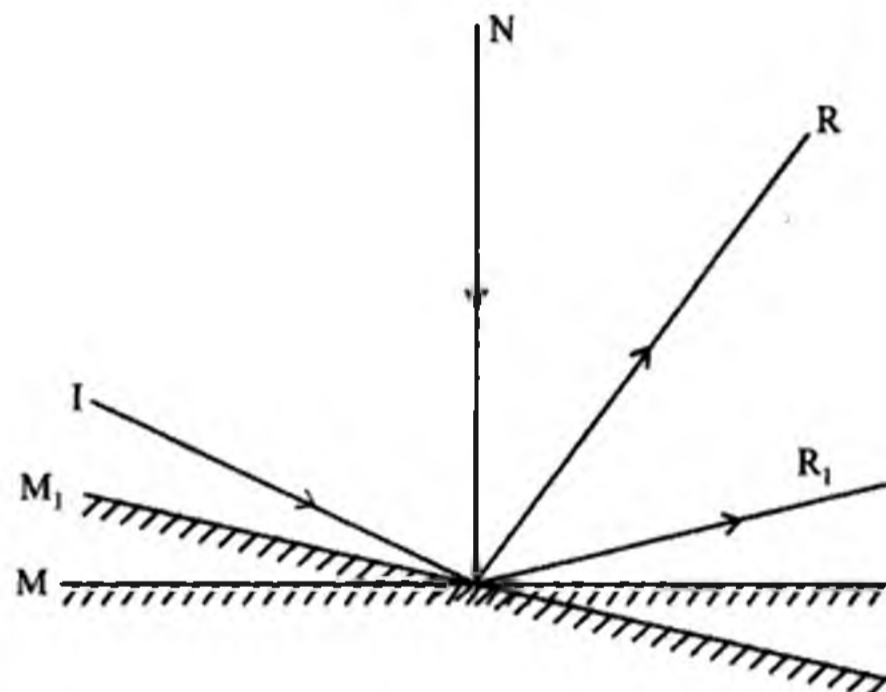


Fig. 32.2 Rotation of a plane mirror M: IN , the normal; the incident ray: R , the reflected ray; and M_1 , the mirror tilted.

Reflection at Uniformly Curved Surfaces: Spherical Mirrors⁶

The centre of curvature is the centre of the sphere of which the mirror is part.

The pole or vertex is the central point of the reflecting surface.

The radius of curvature is the radius of the sphere.

The axis is any line passing through the centre of curvature.

The principal axis is the axis passing through the pole (Fig. 32.3).

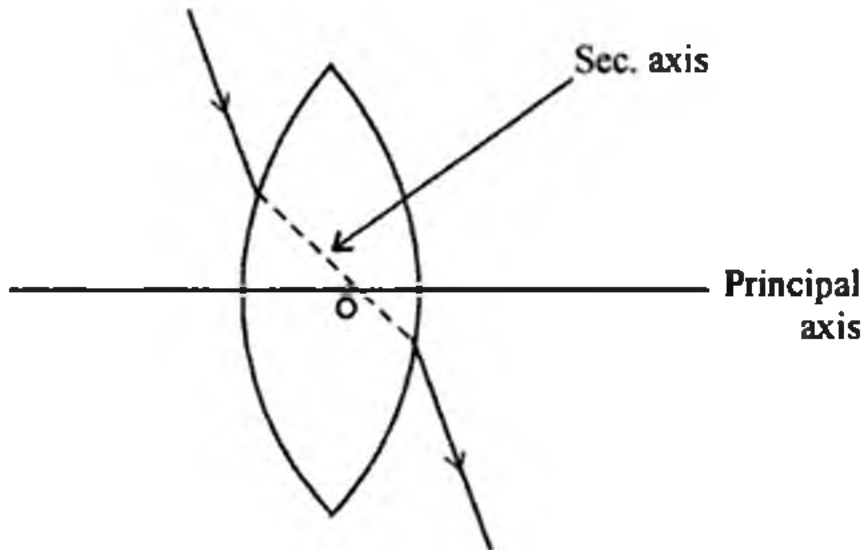


Fig. 32.3 Principal and secondary axes.

The subsidiary axis is any other axis other than the primary.

The sign conventions are all distances measured from the pole, those in the direction of incident ray are called *positive* and those against the incident ray *negative*.

The principal focus is the point where parallel rays are focused after refraction (Figs 32.4 and 32.5). There are two principal foci. Any ray passing through the first or anterior focus will emerge parallel to the principal axis. The second or posterior focus is the point on the principal axis at which parallel rays entering the lens reach a focus.

The focal length is the distance of the principal focus from the lens and is equal to half the radius of curvature.

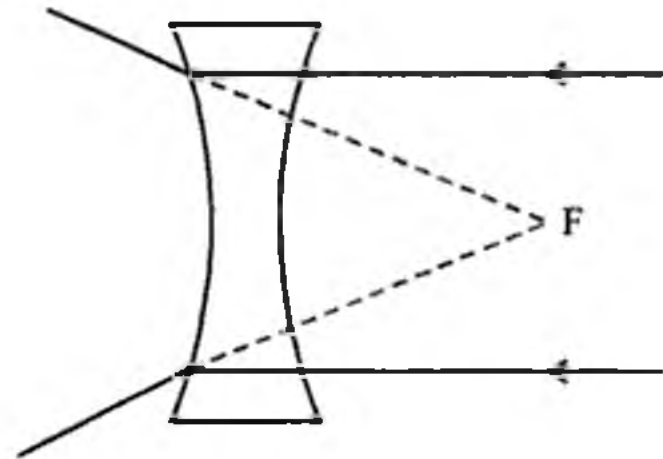


Fig. 32.4 Principal focus in a concave lens (F)

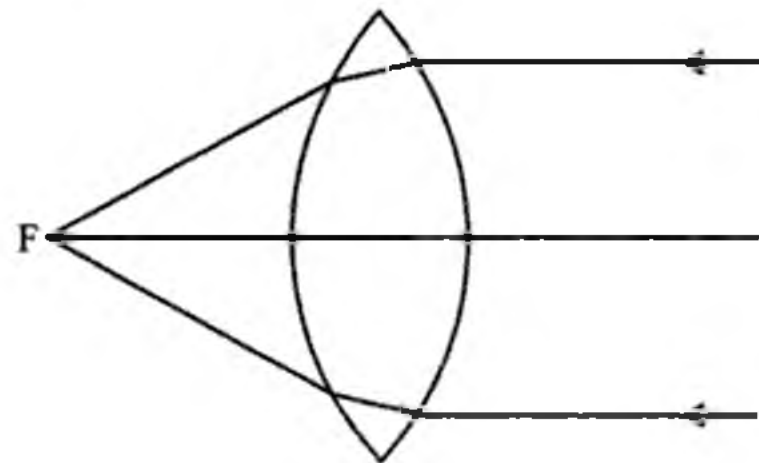


Fig. 32.5 Principal focus in a convex lens (F).

Focal planes are the planes passing through the focal points.

Conjugate foci are the positions of the object and image bearing a constant relation to each other.

Magnification is equal to the size of the image divided by the size of the object.

Position of images

In the convex lens the image is smaller, inverted and real, if the object is situated just beyond the principal focus (Fig. 32.6).

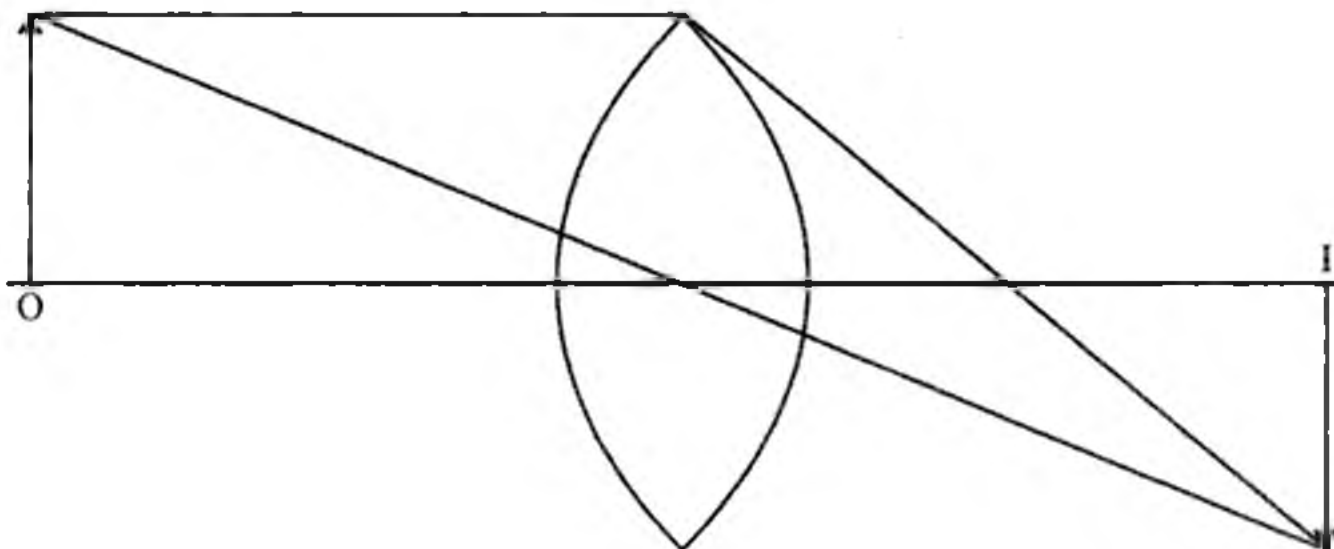


Fig. 32.6 Image formed by a convex lens when the object is at O.

In the concave lens the image is smaller than the object, erect and virtual (Fig. 32.7).

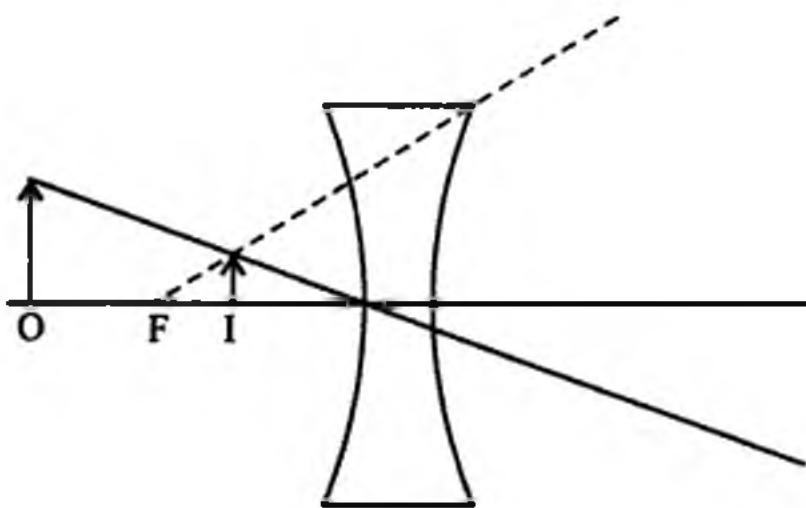


Fig. 32.7 Image formed by a concave lens when the object is outside the principal focus.

The image that can be seen on a screen is called a *real* image, and the one that cannot be seen is known as a *virtual* image.

Refraction⁸

When light rays pass from one transparent medium to another of different density bend, the phenomenon of bending of light rays is called *refraction*.

The *refractive index* is the measurement of the optical density by comparing the velocity of light in air, and that of a medium. It is inversely proportional to the wavelength of the refracted light.

Law of refraction (Snell's law) states that

$$n \sin i = n' \sin r$$

where

n = index of refraction of the initial optical medium

n' = index of refraction of the medium in which the refracted ray travels

i = angle of incidence

r = angle of refraction

The *critical angle* is the angle between the incident ray and the normal. The light is so refracted that the emerging ray becomes parallel to the surface separating the two media.

The internal reflection of light is caused by light incident at a greater angle to the critical angle.

Spherical Lens (Fig. 32.8)

The spherical lens is divided into two types:

- (A) *Convex* (converging)
 - (a) Biconvex
 - (b) Planoconvex
 - (c) Concavoconvex meniscus
- (B) *Concave* (diverging)
 - (a) Biconcave
 - (b) Planoconcave
 - (c) Convexoconcave meniscus.

A biconvex lens is formed by two prisms placed base to base, while a biconcave lens is formed by two prisms arranged apex to apex (Fig. 32.9).

All the rays passing through the *optical centre* of the lens remain undeviated (Fig. 32.10).

The *geometric centre* of the lens is the point in the middle of the lens.

Astigmatic Lens

These are of two types.

Cylindrical (Fig. 32.11). One surface is curved

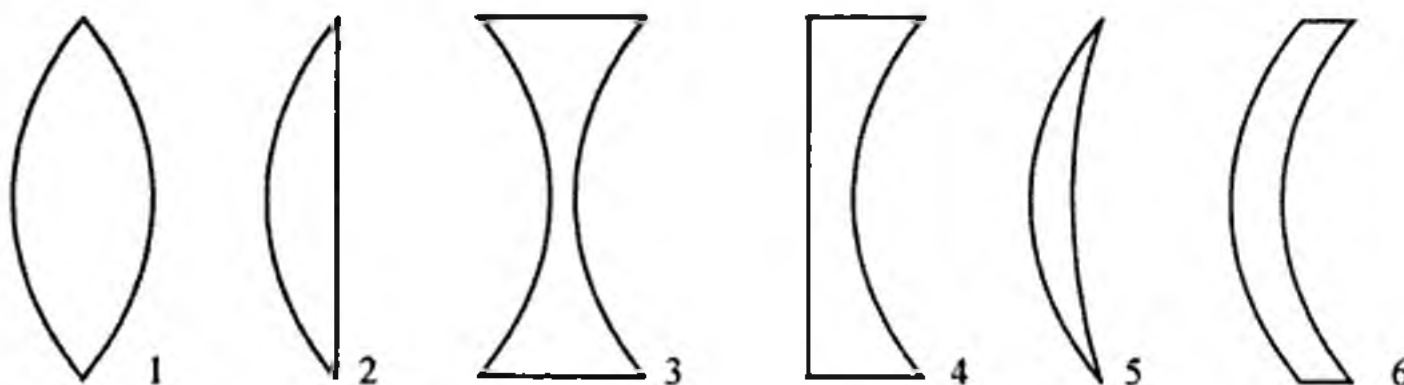


Fig. 32.8 Different types of spherical lenses: 1, biconvex; 2, planoconvex; 3, biconcave; 4, planoconcave; 5, convexoconcave; 6, concavoconvex.

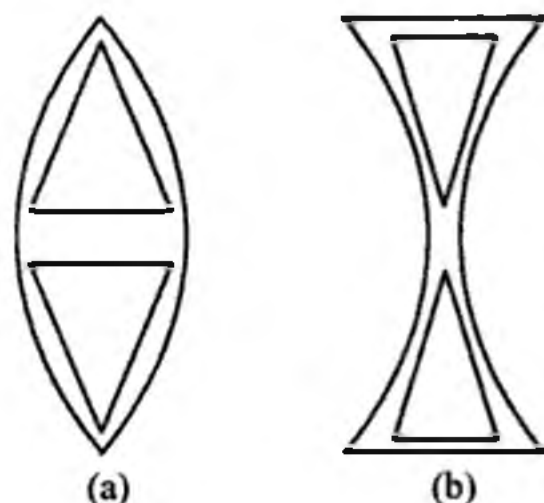


Fig. 32.9 Formation of (a) biconvex and (b) biconcave lenses.

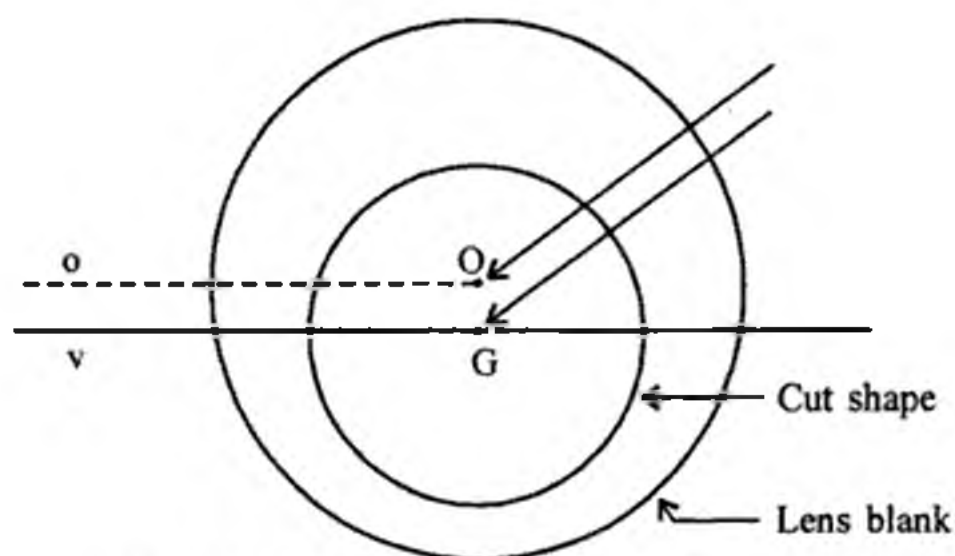


Fig. 32.10 Centres and axes of a lens.

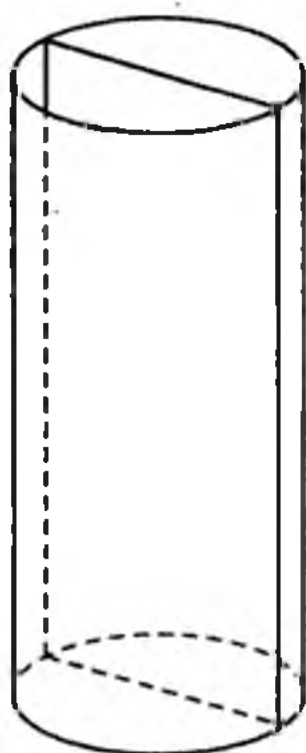


Fig. 32.11 Cylindrical lens.

while the other is plane. The cylindrical lens is a segment of a cylinder and axis of cylinder is parallel to that of the cylinder.

Toric (Fig. 32.12). A toric lens is a combination of a sphere and a cylinder. Both meridians are curved, but to a different degree. The numerically smaller power of the toric surface is called the *base curve*.

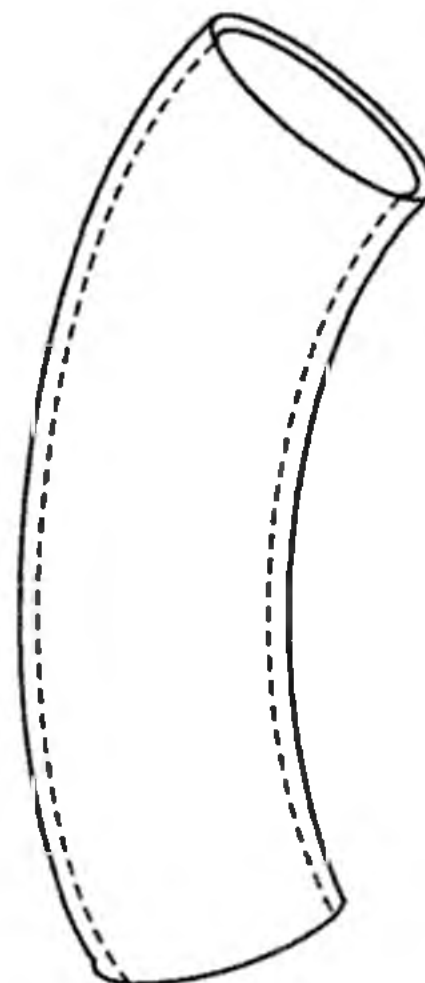


Fig. 32.12 Toric curve.

Meniscus Lens

The cylindrical curve is ground on the spherical surface on one side. Meniscus lens produces least aberration.

Thick lens^{4,5} (Fig. 32.13)

A thick lens is one with a finite thickness. The cardinal points of these lenses are: (a) focal points (F_1 and F_2); (b) nodal points (N_1 and N_2); (c) principal points (P_1 and P_2); and (d) principal planes.

There are two principal foci or focal points: first or anterior and second or posterior. There are two nodal points and these correspond to the optical centre of a simple lens. The principal points are those where two principal planes strike the principal axis. The principal or unit planes are conjugate planes where magnification is unity which means

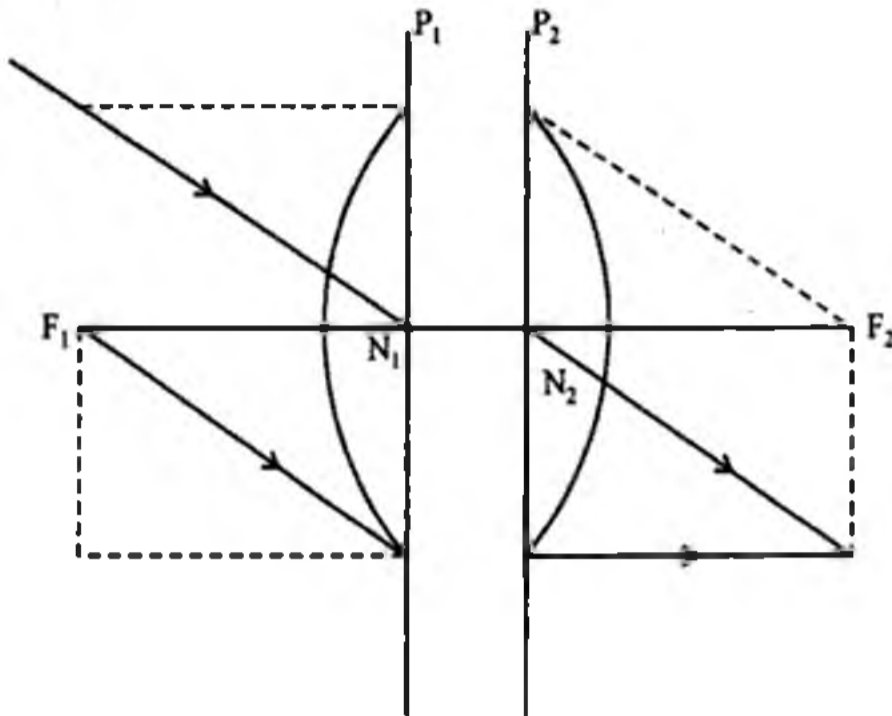


Fig. 32.13 Thick lens showing the cardinal points, F_1F_2 ; the nodal points, N_1N_2 and the anterior focal length, F_1N_1 .

an object located at one plane will produce an image of the same size in the second plane.

The equivalent power of a thick lens is dependent on the thickness of the glass, its refractive index and the refracting powers of the surfaces.

Between the first focal point and the principal plane is the first or anterior focal length and the latter is equal to the second or posterior focal length.

Thin lens

In a thin lens, the equivalent power is simply the addition of the front and back surface powers, the others are neglected, i.e. one principal plane instead of two and is situated at the centre of the lens, the anterior and posterior focal lengths are identical, and one nodal point instead of two.

Transposition of Spherocylindrical Lenses^{1,6,10}

Transposition means alteration of the power of lenses from one form to another equivalent form.

There are three types of transposition.

Simple. The steps are: (i) addition of numerical power of the cylinder to that of the sphere; (ii) change of the axis by 90° ; and (iii) alteration

of power sign of the cylinder.

$$\begin{aligned} \text{Transposition of } & \frac{+1.00 \text{ Dsph}}{-2.00 \text{ Dcyl } 90^\circ} \\ & = \frac{-1.00 \text{ Dsph}}{+2.00 \text{ Dcyl } 180^\circ} \end{aligned}$$

Toric transposition. The toric formula is written as a fraction, the numerator of which is a sphere, and the denominator consists of the base curve plus the necessary cylinder.

$$\frac{+1.00 \text{ Dsph}}{-2.00 \text{ Dcyl } 90^\circ}$$

By simple transposition it becomes

$$\frac{-1.00 \text{ Dsph}}{+2.00 \text{ Dcyl } 180^\circ}$$

Let us suppose that we are dealing with a lens with a base curve of -6 D . For toric transposition, subtract -6 D . Hence, the power of the spherical surface would be $-1.00 \text{ Dsph} - (-6 \text{ Dsph}) = +5 \text{ Dsph}$ while the cylindrical power is added to the base curve, i.e. $+2.00 \text{ Dcyl } 180^\circ + (-6.00 \text{ Dcyl } 180^\circ) = -4.00 \text{ Dcyl } 180^\circ$ and power sign of the cylinder is altered from 180° to 90° .

Therefore, the toric transposition would be:

$$\frac{+5.00 \text{ Dsph}}{-6.00 \text{ Dcyl } 90^\circ \text{ with } -4.00 \text{ Dcyl } 180^\circ}$$

Vertex (accurate) transposition. It is especially indicated in thick lenses and meniscus lenses. The steps are: (i) simple transposition for the front surface, (ii) obtain the focal length in mm by taking reciprocal of (i) $\times 1000$, (iii) divide the thickness in mm by the refractive index, (iv) ascertain the focal length of the front surface by adding (ii) and (iii), and finally (v) obtain the power of the front surface in D by taking the reciprocal of (iv) $\times 1000$.

Prism⁸

A *prism* (Fig. 32.14) is a portion of a refractive medium bounded by two plane refractive surfaces at an angle to each other. This angle is termed the angle of the prism, and the opposite the base of

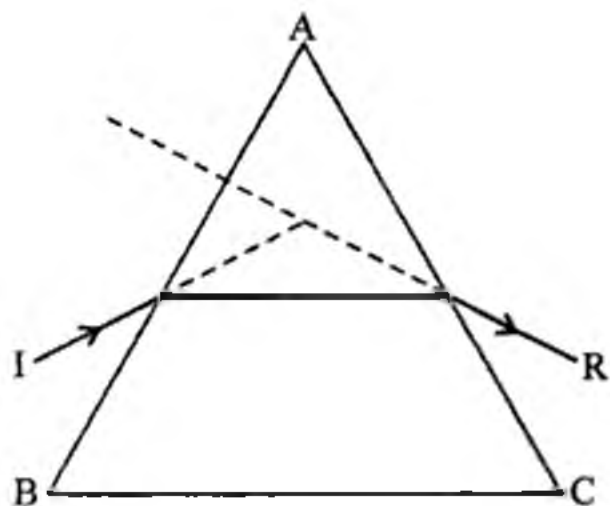


Fig. 32.14 Prism. ABC, the prism; BAC, the base of the prism; I, the incident ray and R, the refracted ray.

the prism. A line from the apex to the base forms the axis of the prism. The light is deviated towards the base. Prism dioptre (Δ) is the strength of the prism which produces a linear deviation of 1 cm of an object situated one metre away from the prism.

The uses of prisms are: (a) diagnostic, e.g. use of Maddox rod; (b) for treatment, e.g. to improve fusional reserve; and (c) incorporation in instruments, e.g. ophthalmoscope, applanation tonometer and keratometer.

Vergence and Dioptre^{4,6}

The term vergence means whether light is convergent, parallel or divergent. The unit of vergence is the dioptre. The reciprocal of the second focal length ($1/F_2$) of the spherical lens is the

verging power of the spherical lens. *Dioptre (D)* is defined as the reciprocal of the distance in metres from the reference light source. It is the unit of measurement of the refractive power of the lens and indicates the verging power of a lens with a focal length of 1 metre. An object situated 1 metre away will produce a divergence of $-1 D$, while 4 metres away will produce $-1/4 D$, and so forth. A convex or converging lens induces convergence, while a concave or diverging lens causes divergence (Figs 32.15 and 32.16).

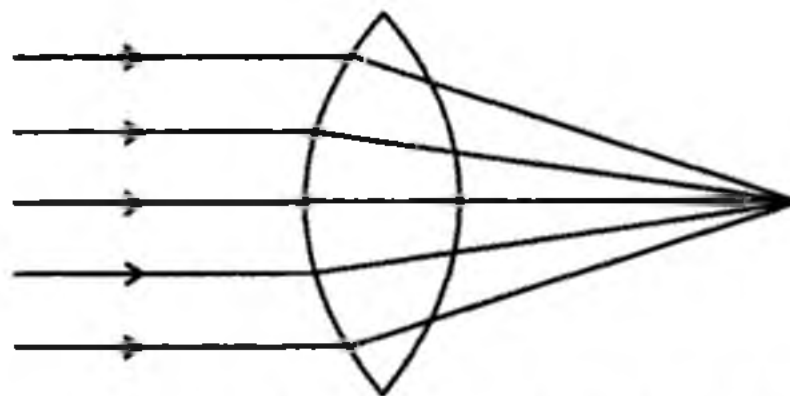


Fig. 32.15 Effect of biconvex lens on the parallel rays.

Front and Back Vertex Powers^{4,6}

The vertices or poles are the centres of the first and the last refractive surfaces of the optical system. The distance of the vertices from the focal points are called the anterior and posterior vertex focal lengths and their reciprocal is expressed in dioptres as the front and back vertex powers. The usual procedure of neutralizing the front vertex power of a thin lens is by using lenses from a trial case

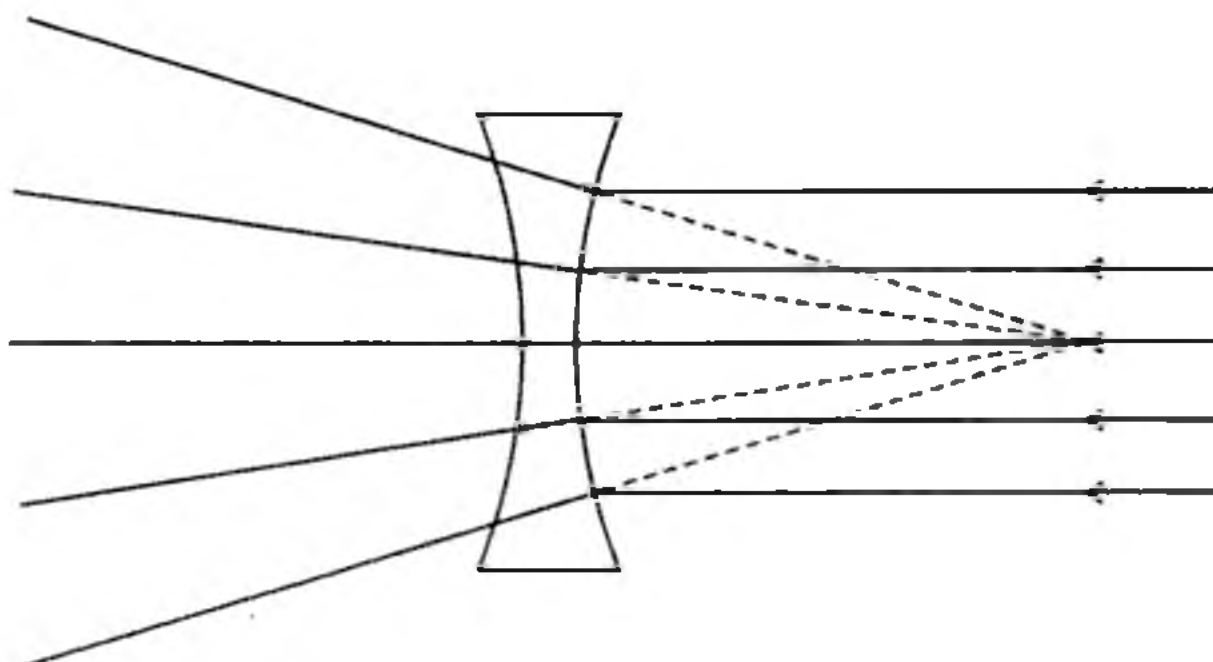


Fig. 32.16 Effect of biconcave lens on the parallel rays.

of lenses. In case of thick best-form lens neutralization in this manner is not possible. To determine the back vertex power a refractometer is used.

Aberrations In Lenses^{5,9}

The main aberrations in lenses are: spherical aberration, coma, oblique astigmatism and image distortion.

Lens aberrations are natural and they may be due to: actual lens form, lens curvature, lens thickness and the angle of the plane of the lens relative to the incident light and plane of the eye.

Spherical aberration (Fig. 32.17). It can be eliminated by grinding the optical lens so that its curvature decreases slightly at the periphery. These lenses are called *aplanatic*.

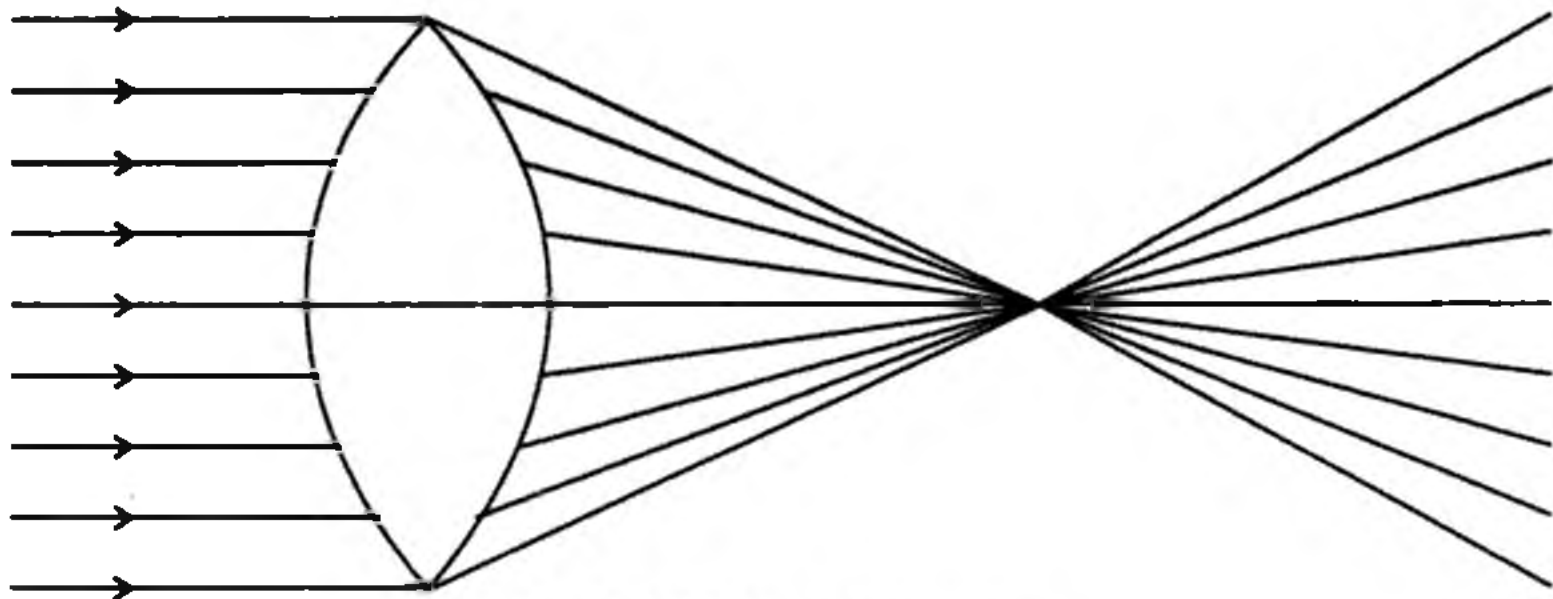


Fig. 32.17 Spherical aberration.

Coma. This is the spreading out of an image in a plane about 90° to the optic axis and following unequal magnification of different zones of the lens. This can be corrected by aplanatic lens.

Oblique astigmatism. This results from the plane of the lens being oblique to the incident rays. It can be avoided by using meniscus or best-form lens.

Image distortion. Different portions of the lens may show various magnification effects causing barrel distortion and pincushion distortion. If the peripheral parts of an object show lesser magnification than the axial parts then a barrel

distortion results. Pincushion distortion occurs if the axial parts of an object show lesser magnification than the peripheral parts.

Prismatic Effects of the Lenses⁴

These may arise from the following causes:

1. The spherical component of the distance lenses may be different.
2. The spherical component may be identical, but the power of the cylinder may differ.
3. The spherical and cylindrical powers may be similar, but the axes of the cylinder may be different.
4. The axes of the cylinder are parallel but oblique, e.g. right eye +2.00 Dcyl 75° ; left eye +2.00 Dcyl 75° .

Decentration of the Lenses

Decentration of the lens can be done by one of the two ways: displacement of the frame by lengthening or shortening of the nose-piece and displacement of the lens in its rim.

Decentration causes prismatic effect. Decentration of a convex lens inwards causes the effect of a base-in prism. That of the same outwards causes the effect of a base-out prism. Decentration of a cylindrical lens in the direction perpendicular to the axis has the same effect as in the case of a sphere.

Indications of decentration are: (a) to adapt a

pair of glasses to an asymmetrical face; (b) for close work; (c) in correction of heterophoria; and (d) for overcoming deficiency or excess of convergence.

Refraction by lens combinations. The effect of such combinations is additive, especially when the lenses are thin.

Homocentric or Coaxial Lens System

The component lenses when centred on a common optic axis form the coaxial or homocentric lens system. In the compound system such as the eye itself, there are three pairs of cardinal points as described by Gauss and Listing: (a) two principal foci; (b) two principal points; and (c) two nodal points.

Refraction in the Normal Eye

Light rays reach the retina after traversing the following structures: (a) the anterior surface of the cornea; (b) the substance of the cornea; (c) the posterior surface of the cornea; (d) the aqueous humour; (e) the anterior surface of the lens; (f) the substance of the lens; (g) the posterior surface of the lens; and (h) the vitreous humour.

In the cornea and lens, the substance of the cornea and lens may be neglected and their two surfaces are parallel. Thus, they may be considered as one.

Refractive indices of the aqueous and vitreous are 1.33, those of the cornea and crystalline lens are 1.33 and 1.43 respectively.

So, there are two chief elements: the cornea and the lens, both acting as convex lenses.

Reduced Eye or Schematic Eye⁵

The concept of reduced eye (Fig. 32.18) introduced by Donders has these particular features. It is an ideal spherical surface having: (a) radius of curvature which is 5.73 mm; (b) nodal point is 7.08 mm behind the anterior corneal surface; (c) anterior focal distance is 17.05 mm or 15.7 mm in front of the plane of the cornea; and

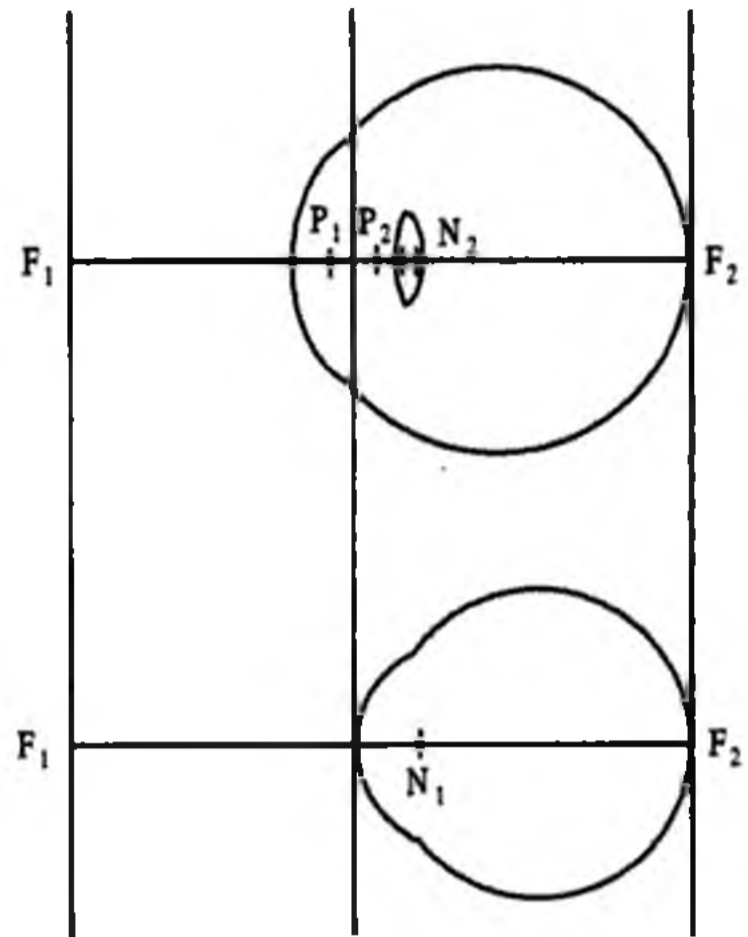


Fig. 32.18 Reduced eye. The lower figure represents the reduced eye. The upper figure represents the normal eye which shows two focal points, F_1 and F_2 ; two principal points, P_1 and P_2 and two nodal points, N_1 and N_2 .

(d) posterior focal distance is 22.78 mm or 24.13 mm behind the plane of the cornea.

Optical Aberrations of the Eye⁵

The eye is not a perfect optical instrument, and the optical aberrations are classified as:

Physiological. Aberrations depending upon the nature of light: (a) diffraction; and (b) chromatic.

Aberrations depending upon the optical instrument: (a) spherical; (b) decentring; and (c) peripheral.

Pathological. Refractive errors.

Diffraction of light. Deviation of the sides of the light wave occurs while travelling in space. The narrow wave produces more pronounced effect.

Chromatic aberration (Fig. 32.19)

During refraction of white light the short blue wavelengths are refracted most and they reach a

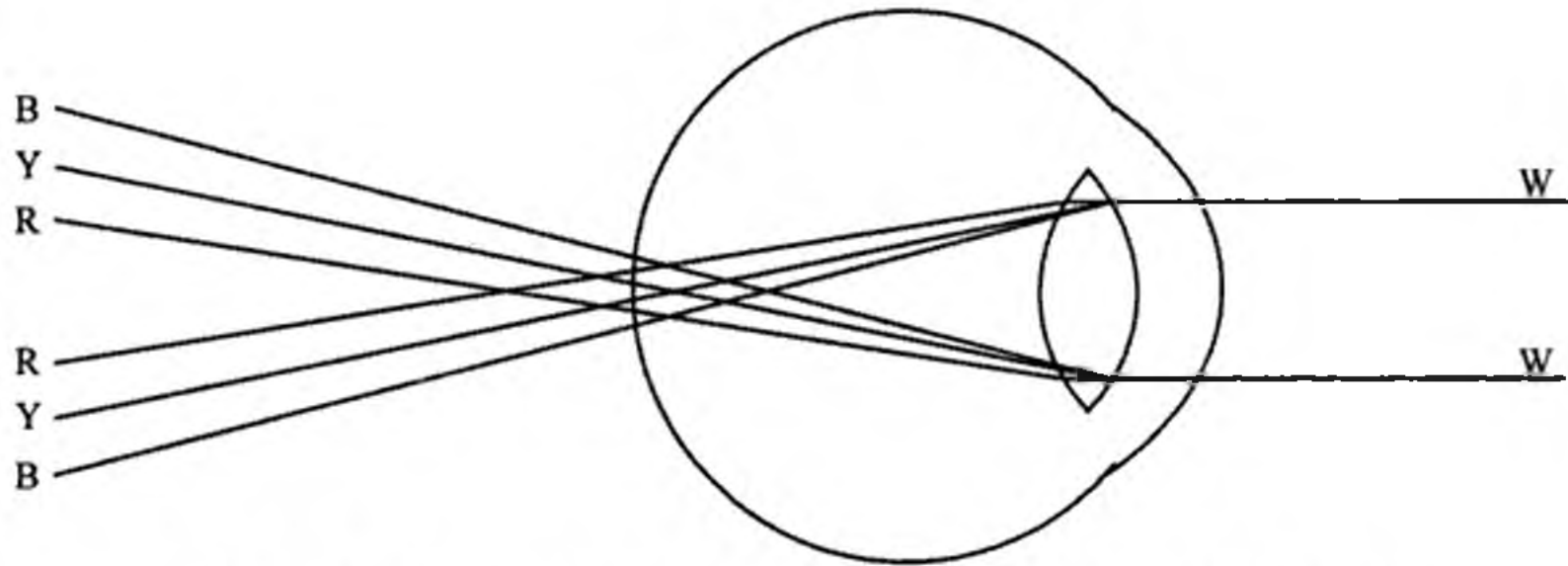


Fig. 32.19 Chromatic aberration. B, blue; W, white; Y, yellow and R, red.

focus in front of longer red rays. This process is enhanced when the pupil is dilated. An achromatic lens reduces this aberration.

Spherical aberration (see Fig. 32.17)

As there is higher refracting power in the periphery of the lens than in the central part, the peripheral rays are brought to a focus more quickly than the central ones. This process is also enhanced when the pupil is dilated. The aberration can be reduced by making the anterior surface of the lens more curved than the posterior one.

Peripheral aberrations

These include coma, oblique astigmatism and image distortion.

Catoptric Images (Purkinje–Sanson Images)

If a strong light such as a lighted candle falls on the eye, there are four images formed from: (a) the anterior surface of the cornea; (b) the posterior surface of the cornea; (c) the anterior surface of the lens, and (d) the posterior surface of the lens.

The first three of these images move in the same direction, while the fourth moves in the opposite direction, since the first three of the surfaces are convex and the fourth surface is concave.

Knapp's rule (Fig. 32.20). In refractive error of

pure axial nature when corrected by a lens placed at the anterior focal plane, the absolute size of the retinal image is identical to the image produced in emmetropia with comparable dioptric components.

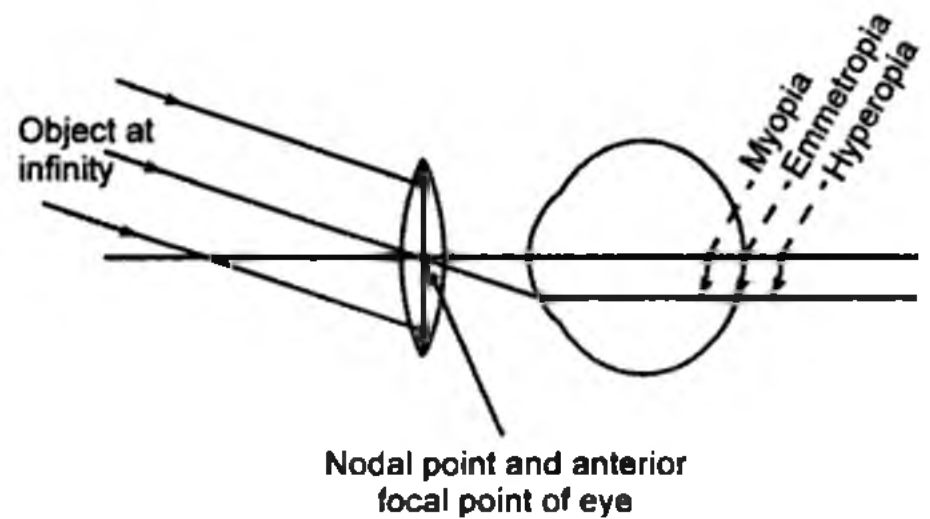


Fig. 32.20 Knapp's rule.

Badal's principle (Fig. 32.21). The retinal angular size subtended by an object situated at any position, O_1 , O_2 , O_3 along the optic axis does not vary when a biconvex lens is placed in front of the eye so that the posterior focal point of the corresponding lens coincides with the nodal point of the eye.

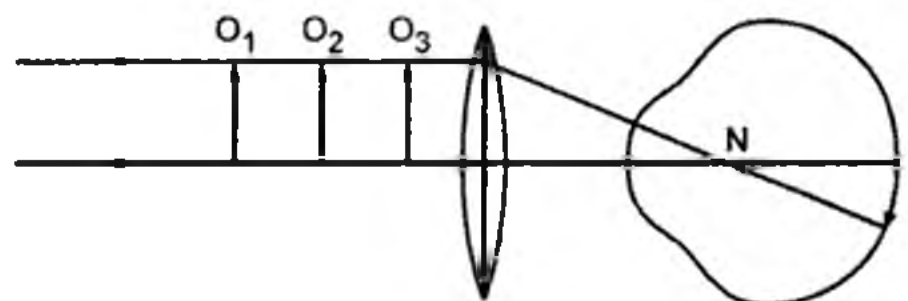


Fig. 32.21 Badal's principle.

Emmetropia

Emmetropia is a perfectly normal condition in which parallel rays of light are brought to a focus on the retina under physiological condition.

Refractive errors

Ametropia is relatively more common. The three subtypes are: hypermetropia, myopia and astigmatism.

Hypermetropia or Hyperopia⁵

The parallel rays of light are brought to a focus behind the retina, when the eye is at rest.

Aetiology. There are three types of hypermetropia.

Axial. This is the most common form, the eyeball being too short. 1 mm shortening represents +3 D of refractive change.

Curvature. This is caused by the flattening of the cornea. An increase of 1 mm radius of curvature of cornea causes an error of +6 D.

Index. It is present in diabetic cataract.

Most normal infants are born with hypermetropia of about +4 D because the eyeball is shorter, the corneal curvature flatter and the lens placed nearer the cornea. As the child grows hypermetropia tends to disappear or lessen. If it persists it is considered as delayed development.

Aphakia is a classical example of acquired high hypermetropia.

Optical condition (Fig. 32.22). (a) At rest, the parallel rays are brought to a focus behind the retina, causing a distorted image.

(b) Because the axis of the eye is shorter and the retina is nearer the nodal point, the image is smaller than in emmetropia.

(c) The rays from the near object will be increasingly divergent as they reach the eye and will be brought to a focus further behind the eye.

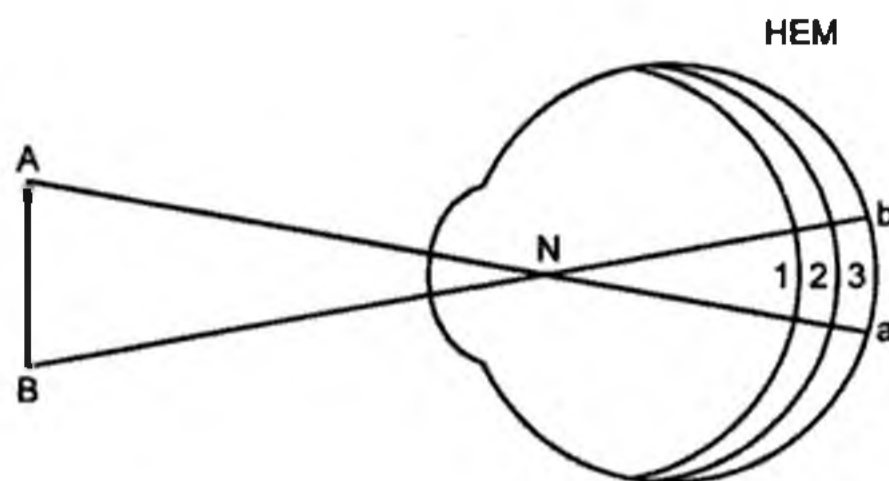


Fig. 32.22 In hypermetropia (H) the parallel rays meet behind the retina. In emmetropia (E) they are focused on the retina and in myopia (M) they are focused in front of the retina.

(d) To get a clearer and distinct image, the converging power of the optical system is increased and this is achieved in two ways: by increasing the curvature of the crystalline lens (Fig. 32.23), and by placing a convex lens in front of the eye (Fig. 32.24).

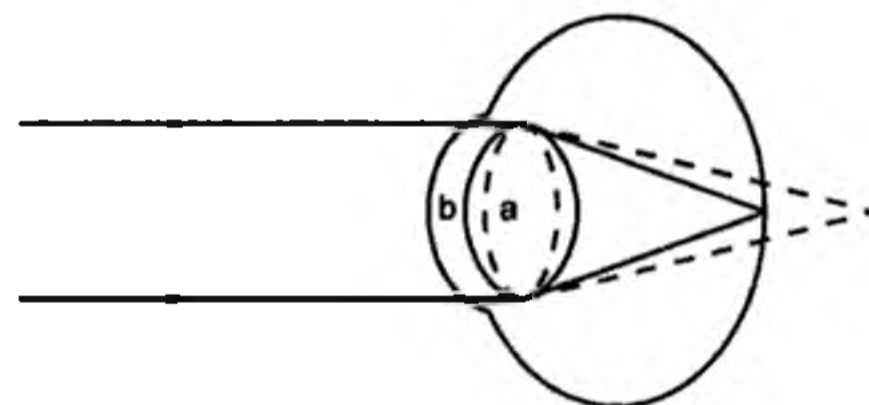


Fig. 32.23 Increased converging power in hypermetropia during accommodation. The dotted line indicates the normal lens and the solid line indicates the lens during accommodation.

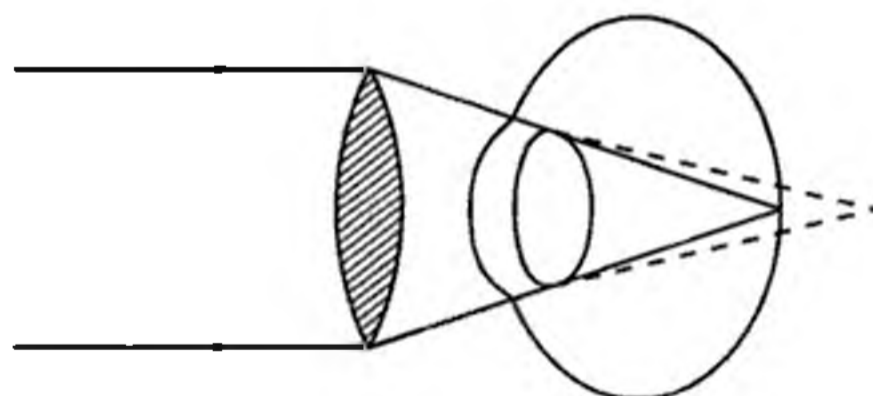


Fig. 32.24 Provision of biconvex lens in hypermetropia.

Accommodation in hypermetropia

Total hypermetropia is the entire amount detected

after accommodation is fully paralysed by cycloplegia and is made up of:

(a) *Latent hypermetropia* which is overcome by a normal tone of the ciliary muscle.

(b) *Manifest hypermetropia* which is detected without paralysing accommodation. It is measured by the strongest convex glass with which the maximum visual acuity is obtained. This may be:

(i) *Facultative*. When it can be overcome by the effort of accommodation. It can be measured by the fogging method or dynamic retinoscopy, which determines the difference between the strongest and weakest convex lens with which maximal visual acuity is achieved.

(ii) *Absolute*. When it cannot be overcome by the effort of accommodation. It is measured by the weakest convex lens with which maximum visual acuity is obtained.

Accommodation in hypermetropia is always in excess of convergence.

Clinical features. Patients are asymptomatic, when the degree of hypermetropia is less, the patients young and when the defect is overcome by the accommodative effort. In higher degrees, symptoms include indistinctness, obscurations of vision caused by temporary failure of the ciliary muscle, and symptoms of eye strain caused by accommodative asthenopia.

Ophthalmoscopically. In higher degrees of hypermetropia there may be: (a) water-silk appearance of the retina; (b) pseudoneuritis; and (c) frequently an inferior crescent.

Pathology. The eyeball is typically small in all directions, the cornea is small, and the anterior chamber is shallow.

Treatment. Treatment is unnecessary when: (a) the error is small; (b) visual acuity is normal; (c) there are no symptoms; and (d) there is no muscular imbalance.

Between 6-16 years of age. If any of the above conditions are violated, convex glasses are prescribed.

In older people. Glasses are only necessary if the degree of hypermetropia is high and it produces symptoms.

Correction of presbyopia by provision of near addition is recommended.

Occasionally contact lens is recommended and in selected cases keratamileusis may be advocated.

Myopia⁵

The parallel rays of light come to a focus in front of the retina, when the eye is at rest. The clinical types are: (a) congenital; (b) simple, usually starts between 4 and 7 years; (c) degenerative or progressive, i.e. myopia which steadily increases and exceeds -6 dioptres; and (d) acquired, e.g. in diabetes.

Aetiology. There are three aetiological types of myopia:

Axial. This is due to increase in the anteroposterior diameter of the eye in the majority of cases. Two types are known: simple and pathological or progressive.

Curvature. There may be increased curvature of the cornea.

Index. Increased refractive index of the nucleus or decreased index of the cortex of the lens may be present.

Pseudomyopia. Pseudomyopia occurs due to spasm of the ciliary muscle and of accommodation in uncorrected hypermetropia and early presbyopia.

Optical condition. (a) The parallel rays of light are brought to a focus in front of the retina (Fig. 32.25) and hence the image on the retina is by the diverging beam.

(b) Because the axis of the eye is longer and the retina is further away from the nodal point, the image is larger than in emmetropia (Fig. 32.23).

(c) If the rays are to be brought to a focus at the retina the parallel rays coming from a distance are rendered divergent by provision of a diverging or concave lens (Fig. 32.26).

Clinical features. Most commonly simple or school myopia starts manifesting between 7 and 10 years, and is bilateral. Primarily there is defective distant vision, the greater the degree of myopia, the greater the defect. In small degrees of

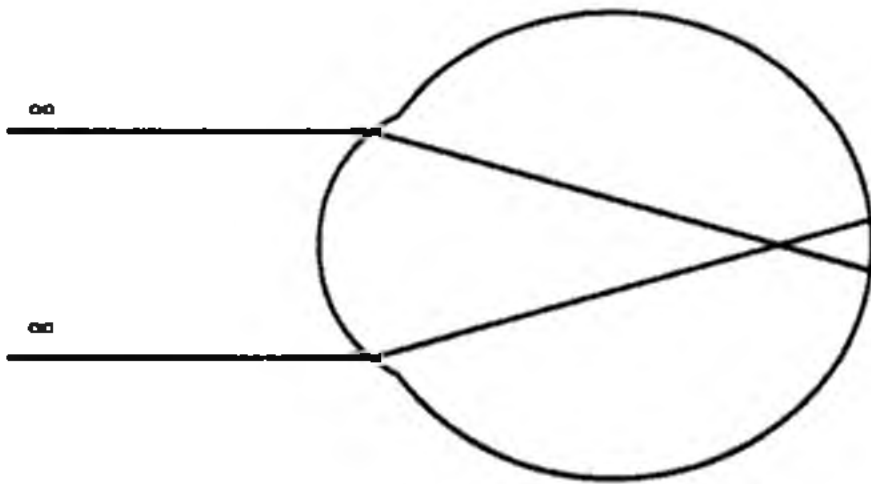


Fig. 32.25 Parallel rays meeting in front of the retina in myopia.

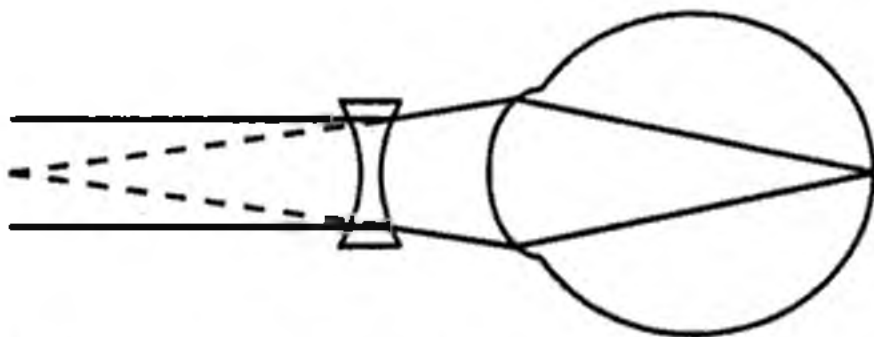


Fig. 32.26 Provision of biconcave lens in myopia.

error, symptoms of eye strain are present. In progressive myopia, visual impairment may be serious. Myopia progress is till late adolescence. In progressive myopia there may be pseudoproptosis with large pupil.

Ophthalmoscopically, the major findings especially in a progressive myopia are (Fig. 32c.1)

(a) Temporal crescent is present. The failure of the retinal pigment epithelium to extend to the temporal border of the disc leads to exposure of choroidal pigment and thus causes a choroidal crescent.

(b) Supertraction crescent: on the nasal side the retina extends over the disc margin causing a blurring at this region.

(c) Tigroid fundus in which there is loss of pigment from pigment epithelium of the retina and as a result the choroidal vessels are well seen.

(d) There are patches of choroidal atrophy especially in the posterior region. Myopic choroidal atrophy is present in high degree of myopia, but its severity is not necessarily parallel to that of myopia. It is genetically determined and is usually recessive.

(e) Vitreous opacities due to premature liquefaction and degeneration may be seen.

(f) Macular changes include atrophy, pigmentation or haemorrhage. Fuchs' spot, the dark pigmented macular lesion, results from combined effects of retinal pigment epithelial hyperplasia and pigments derived from haemorrhage.

(g) Rarely, posterior staphyloma may be present due to increased length of the anteroposterior diameter of the eyeball.

Complications. The following are present in progressive myopia:

(a) *Retina and choroid*—atrophy, haemorrhage, break, detachment of retina and macular degeneration.

(b) *Vitreous*—liquefaction, opacities and detachment.

(c) *Lens*—cataract.

(d) *Intraocular pressure*—high myopia is sometimes associated with chronic simple glaucoma.

Treatment. Optical correction consists of

(a) *Provision of appropriate concave lenses.* Glasses which give best vision with maximum comfort are prescribed. Full correction is advised in young patients with low degrees of myopia, up to -6 D. In adults, undercorrection is advised especially for reading because the ciliary muscle becomes unusually weak and cannot tolerate normal accommodative effort offered by the correcting lenses. In high myopia a full correction can be rarely tolerated.

(b) *Contact lens.* In very high degree of myopia where diminution in size of image and optical aberrations of the correcting glasses render it difficult for the full correction to be prescribed, contact lens is of real help. This eliminates prismatic effects and provides a greater field than the glasses.

(c) *Telescopic glasses.* This may be helpful in cases associated with macular degeneration.

(d) In progressive myopia, shortening of the axial length of the eye, i.e. scleral shortening operation is of some prophylactic value. Radial keratotomy is sometimes resorted to. Other measures include keratomileusis and excimer photorefractive keratectomy.

(e) Ocular hygiene includes good and adequate illumination, easy and natural posture, large and clear print, etc. Improvement of general health appears to be justified especially in growing children.

Astigmatism^{5,12}

Astigmatism (GK. *stigma*, point) is a form of ametropia where the formation of a point focus of light on the retina due to unequal refraction of light in the different meridians is absent.

Aetiology. An error which may be caused in the:

(a) *Curvature.* Chiefly in the cornea and also in the lens due to slight obliquity in placement. The most common is the error in which the vertical curve of the cornea is greater than the horizontal. This has been accepted as physiological. This type in which the astigmatism is corrected by a + cylinder near 90° is known as *astigmatism-with-the rule*. The opposite condition is called *astigmatism-against-the rule*.

(b) *Centring.* The defect may be slightly in oblique position of the lens or subluxation of the crystalline lens.

(c) *Index.* Because of uneven refraction of the lens.

Optical condition. (a) Those rays, which pass through the meridian of greater curvature, come to a focus sooner than those which pass through the meridian of lesser curvature.

(b) The focal lines are formed instead of a simple focal point. These two lines are separated by a focal interval (Sturm).

(c) The length of the focal interval is the degree of astigmatism.

(d) Fig. 32.27 shows refraction by an astigmatic lens (*Sturm's conoid*). This is further described below. At A, there is a horizontal oval ellipse. The vertical rays converge more rapidly than the horizontal ones. At B, there is a horizontal straight line. This indicates that only the vertical rays have come to a focus. At C, there is a horizontal oval ellipse. The vertical rays diverge, while the horizontal rays are still converging. At D, there is

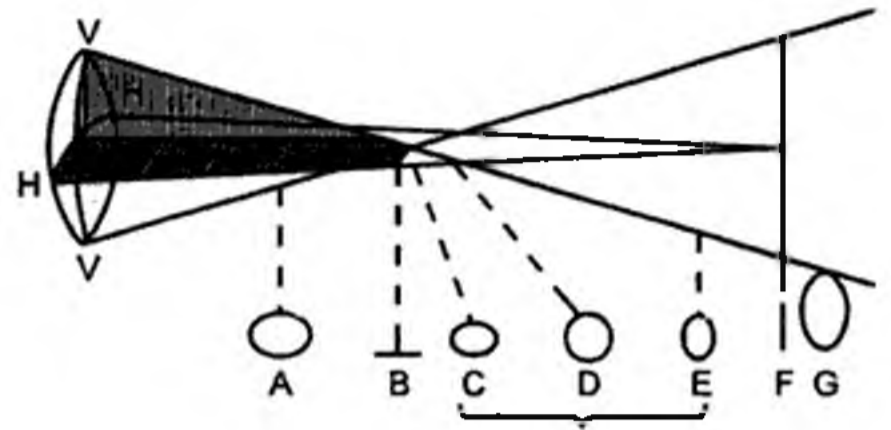


Fig. 32.27 Diagram of a spherocylindrical lens showing the more curved vertical meridian (VV) and the less curved horizontal meridian (HH) as well as the Sturm's conoid and the circle of least diffusion (D). A, B, C, D, E, F and G are the sections of the conoid, while B to F represents the focal interval.

a circle of least diffusion, where the processes at B and C are equal and opposite. At E, the long axis of the ellipse is vertical because of the preponderance of the divergent vertical rays. At F, there is a vertical straight line—this indicates that the horizontal rays have come to a focus. At G, beyond the point F where both sets are always diverging, there will be a gradual increasing of the vertical oval.

Types of astigmatism

Regular (Fig. 32.28). When two meridians are at right angles, one shows the maximum and the other the minimum refraction. These are called the *principal meridians*.

Simple. Where one of the foci falls upon the retina and the other either in front or behind the retina. Hence, one meridian is emmetropic and the other is either myopic or hypermetropic. These are respectively called simple myopic and simple hypermetropic astigmatism.

Compound. When neither of the foci is situated on the retina but in front or behind it. They are respectively known as compound myopic and compound hypermetropic astigmatism.

Mixed. When one axis is myopic and the other hypermetropic.

Oblique. When the two principal meridians are usually either symmetrical, e.g. both at 45° or complementary, e.g. at 45° and 135° respectively.

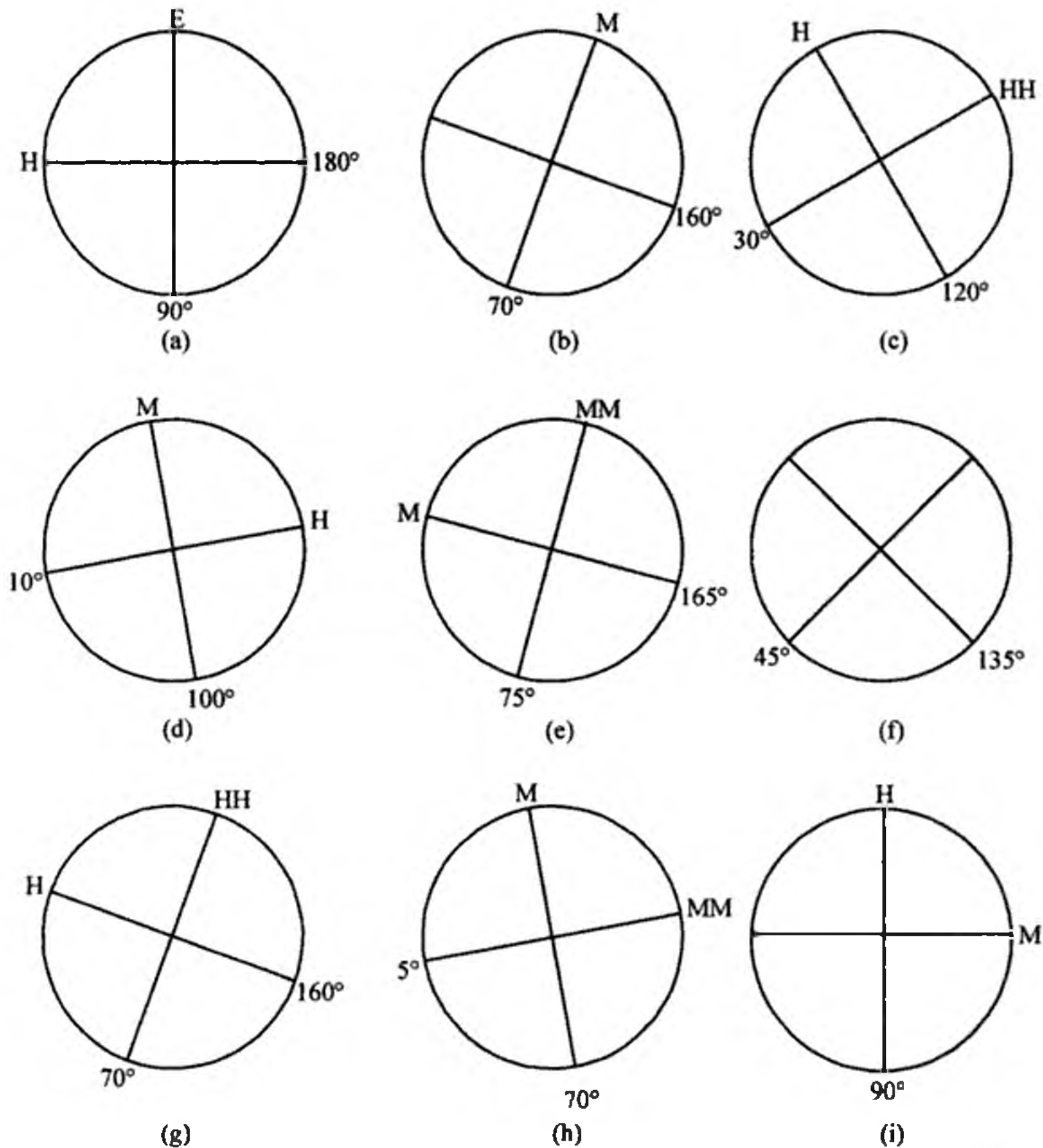


Fig. 32.28 Diagrams to show different types of regular astigmatism. a, simple hypermetropic; b, simple myopic; c, compound hypermetropic; d, compound myopic; e, mixed; f, oblique; g, compound hypermetropic; h, compound myopic and i, mixed. E=the emmetropic meridian; M=the myopic meridian; H=the hypermetropic meridian; MM=the more myopic meridian; HH=the more hypermetropic meridian. a, b, c, d and e represent astigmatism-with-the rule, while g, h and i indicate astigmatism-against-the rule.

They may be crossed obliquely, i.e. bioblique astigmatism.

Irregular. This is due to irregularities in the curvature of the meridians.

Clinical features. The symptoms are diminution of acuity of vision, both distant and near, proportional to the degree and type of astigmatism and those of asthenopia.

Diagnosis. There are two methods:

Objective method. Most accurate diagnosis is by retinoscopy. If corneal cause is suspected, keratometry may be needed.

Subjective methods. They include:

(a) **Persistent confusion** of verticals and horizontals or obliques of the letters HMN and T.

(b) *Astigmatic fan or dial* (Fig. 32.29). The line corresponding to the ametropic meridian is seen most distinctly while the one corresponding to the emmetropic meridian is seen least distinctly in simple astigmatism. These indicate the axes of the two principal meridians.

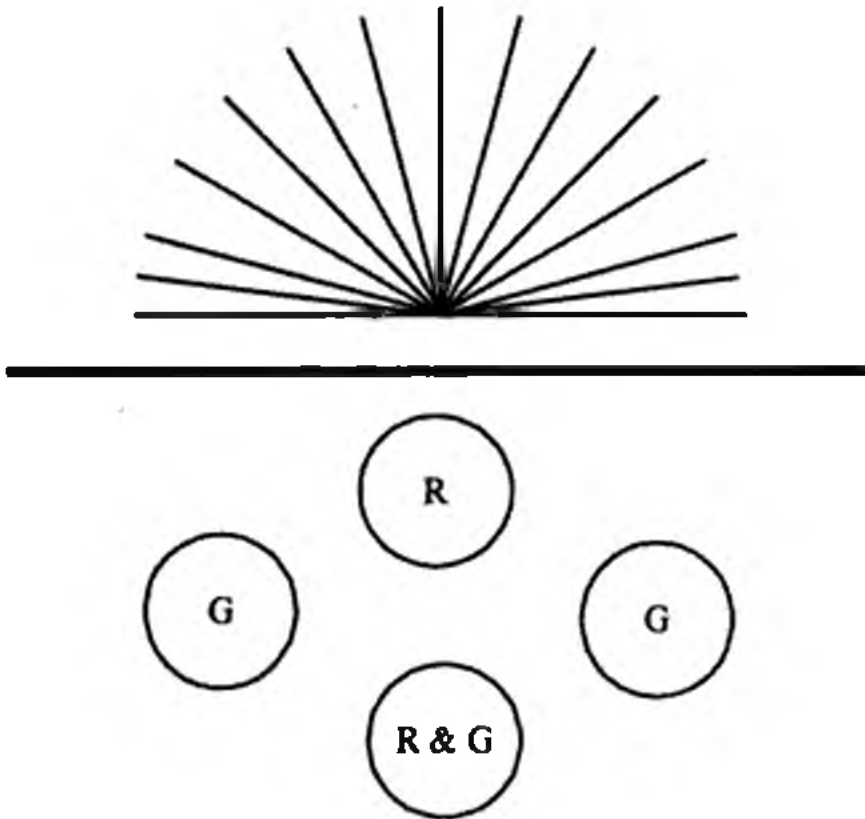


Fig. 32.29 Astigmatic fan (top) and Worth's four-dot test (down). R= red; G=green; R and G=red and green.

(c) *Stenopaecic slit*. The slit can be rotated in front of the eye and subjective testing of refraction done.

(d) *Cross cylinder* (Fig. 32.30). A mixed cylinder in which half the power of the sphere is diametrically to the other half of the cylinder with the axes at right angles, e.g. combination of a -0.25 D sphere with a $+0.25$ D cylinder.

Cross cylinder is used to check the strength of the cylinder and the axis of the cylinder. After the best possible spherical correction, the cross cylinder is placed in the trial frame with the axis of the plus cylinder at 90° and the axis of the minus cylinder at 180° . This is then rotated through 90° . If the visual acuity remains good, the cylinder in the trial frame is correct. If the visual acuity improves, corresponding correction is usually advised.

The cross cylinder is then placed in such a fashion that each axis is alternately 45° to either



Fig. 32.30 Cross cylinder.

side of the axis of the trial cylinder. If the visual acuity improves, the correcting cylinder is moved slightly in the direction of axis of the cylinder of the same denomination in the cross cylinder. This checking is repeated till rotation of the cross cylinder does not cause alteration in distinctness in either position.

(e) *Keratometer* (Fig. 32.31). Two illuminated 'mires' which are used as an object, are placed on a rotatable circular arc. The curvature of any diameter of the cornea is measured by viewing through a telescope. It measures the astigmatism of the front surface of the cornea at two points about 1.25 mm on either side of its centre.

Treatment. Treatment is essential when astigmatism causes asthenopic symptoms. Constant use of proper cylindrical lens is advocated. Contact lens is needed especially for irregular astigmatism. Irregular astigmatism due to corneal opacity may have to be treated by penetrating keratoplasty.




Fig. 32.31 Keratometer (Courtesy: Appasamy Associates, Chennai).

Anisometropia⁵

Anisometropia (Gk. *anisos*, unequal) is the unequal refraction in both the eyes.

Types. Anisometropia can be classified under these types.

(a) *Simple*—one eye is emmetropic, the other is ametropic, i.e. hypermetropic or myopic.

(b) *Compound*—both eyes are ametropic, i.e. hypermetropic or myopic.

(c) *Mixed*—One eye is myopic, and the other is hypermetropic.

Anisometropia may be congenital or acquired, e.g. unocular cataract extraction.

Treatment. (a) The provision of spectacle lenses to correct anisometropia is limited. A lens power difference of over 4 D can result in a difference in retinal image size of 7 per cent or more. But in case of myopic anisometropia a higher difference is often tolerated by a young individual.

(b) Contact lens is beneficial in high degrees of astigmatism.

(c) If one eye is myopic, the other hypermetropic and they do not cause any discomfort, the condition may be better left alone. Otherwise undercorrection of more ametropic and overcorrection of less ametropic eye have been advocated.

Aniseikonia⁵

Aniseikonia is a condition in which the two images presented to the visual cortex from the two eyes differ in size and shape.

Types. Aniseikonia is classified under two types:

(a) *Physiological or retinal disparity.* It is of very small degree, responsible for stereopsis.

(b) *Abnormal*

(i) *Optical.* Developmental and acquired, the latter is caused by lenses.

(ii) *Anatomical.* This is possibly determined by the density of the retinal mosaic.

Clinical features. A difference of size up to 5 per cent is tolerated, while higher difference is usually accompanied by symptoms. Usually asthenopic symptoms are present. Diagnosis is by eikonometer, with complicated units but it is of no clinical value.

Treatment. Specific iseikonic lenses are prescribed in certain cases.

Aphakia⁵

The absence of the crystalline lens causes the eye to become strongly hypermetropic. Parallel rays of light reach a focus about 31 mm behind the cornea. The average anteroposterior diameter of the eye is 23 to 24 mm.

The *optics* of the eye is essentially that of the corneal system, i.e. the refractive system is reduced to the refractive power of the cornea alone (+43.05 D). The total refractive power of the eye is +58.64 D.

Optical considerations are as follows.

(a) Astigmatism against the rule is usually present, because of a section in the upper half of the cornea. +8 or +10 D is needed in the first 8 to 10 days after an operation. +2 or +3 D cyl is needed 6 weeks after the operation.

Thus, it is safe to order an aphakic correction 6 weeks after an operation.

(b) The size of the image is an important consideration. At the usual spectacle distance the retinal image is about 25 per cent larger than in the phakic eye.

(c) A vision of 6/9 in a corrected aphakic eye corresponds to 6/12 in a normal phakic eye.

(d) Accommodation is absent.

(e) There is distortion if the patient does not look through the central portion of the aphakic lens.

(f) Visual field is limited and shows disturbing scotomata.

It must be emphasized that adaptation to the use of aphakic lens comes with time.

Clinical features. Postcataract surgery signs include:

(a) a linear scar corresponding to the section made in the proximity of the upper segment of the limbus; (b) the iris shows peripheral buttonhole iridectomy, or two iridectomies or complete iridectomy; (c) the anterior chamber is deep from lack of support of the iris by the lens; (d) there is often an iridodonesis for the same reason as the deep anterior chamber; (e) the pupil is jet black; (f) Purkinje third and fourth images are absent; and (g) there is gross dimness of vision because of acquired high hypermetropia following lens removal.

Optical correction of aphakia. There are 5 available methods: spectacle correction, contact lens, intraocular lens, epikeratophakia and keratophakia.

Transient Changes in Refraction

Changes in refraction are caused by local conditions such as orbital inflammation and lid tumour and general conditions like diabetes mellitus and drug toxicity. In diabetes the change may sometimes be sudden and bilateral, myopia is found in hyperglycaemia and hypermetropia in hypoglycaemia.

Contact Lens^{1-3,10}

The use of contact lens is getting more popular than ever and among its other benefits, the following factors are important: (a) cosmetic consideration; (b) elimination of corneal irregularities in such conditions as keratoconus and high astigmatism; (c) elimination of peripheral aberrations inherent in spectacle lenses; (d) a good substitute for heavy spectacles in the higher degree of refractive error; (e) allowance for a wide visual field; and (f) formation of the part of the optical system moving in conjunction with the eye.

Optical principles

(a) The refractive power of the cornea itself is greatly reduced, if not altogether eliminated.

(b) The front surface of the contact lens becomes the new corneal surface.

(c) The refractive power of the anterior surface of the contact lens consists of normal power of the cornea plus the correction for the refractive error.

Indications

They are listed in Table 32.1.

Table 32.1
Indications for Contact Lens

Optical	
(i) Irregular astigmatism	
(ii) High myopia	
(iii) Unilateral aphakia	
(iv) Anisometropia	
(v) Aniseikonia	
Therapeutic –	Principally for the protection of an exposed or insensitive cornea
Protective, e.g.	(i) Albinism (ii) Aniridia
Occupational	
Diagnostic, e.g.	(i) Gonioscopy (ii) Slit-lamp examination of posterior segment of the eye (iii) Fundus photography

(d) In case of substitution of spectacle lens by contact lens, decreased and increased

magnifications occur in hypermetropia and myopia respectively only because of slight displacement of the cardinal points of the combined optical system caused by the use of contact lens.

(e) In aphakia, the conventional lenses increase the size of the image by 33 per cent. Contact lenses increase it by 11.4 per cent. This tends to retain binocular vision in unocular aphakia.

Types of contact lens (Fig. 32.32)

Contact lenses may be blown or ground. They are made of glass and synthetics.



Fig. 32.32 Contact lens.

Blown and ground contact lenses have been discontinued. In ground lenses there were two curvatures, corneal and scleral or haptic.

Moulded lenses first made of dentacoll, an impression material made to fit the individual globe, were next in vogue. These have been further replaced by synthetics. Tuohy introduced the all plastic corneal contact lenses in 1948. Recently microlenses have been introduced. A microlens is a single curve lens with a diameter below 8.5 mm. The latest to be introduced are the soft hydrophilic contact lenses, some of which are semipermeable and can be worn continuously for a month, and gas-permeable lenses.

Hard (conventional) contact lens (Fig. 32.33)

Hard (conventional) contact lenses are made of polymethyl methacrylate (PMMA). They have excellent light transmission, its refractive index is

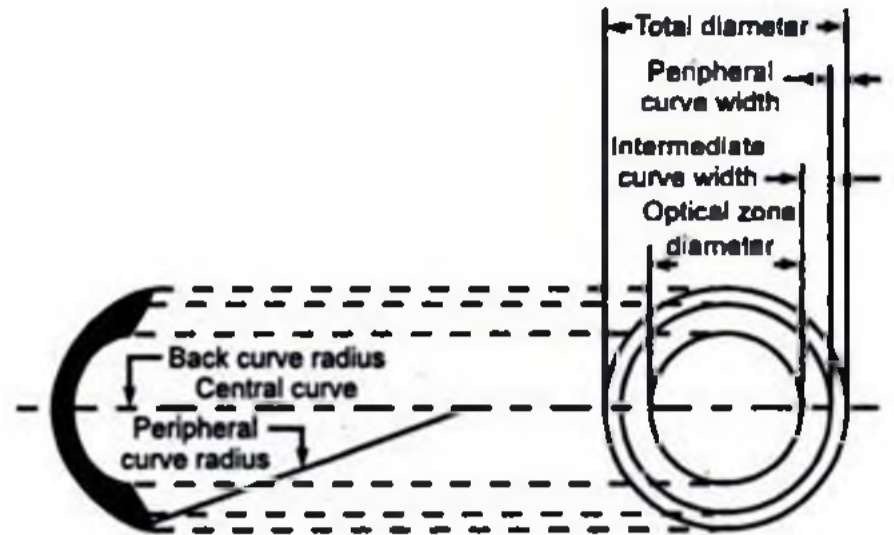


Fig. 32.33 Different measurements of hard contact lens.

1.49, and with a low toxicity. These are popular because they are: (a) lighter, (b) thin, (c) flexible, (d) unbreakable, (e) easier to wear and (f) easier to make.

Possible modifications in a contact lens. They are chiefly: (a) shape of the edge of the lens, (b) thickness (as thin as 0.3 mm), (c) diameter (average 8–10 mm), (d) dioptric power, (e) radii of peripheral curves, and (f) base curve of the central zone which is either parallel to or slightly shorter in radius than curvature of the cornea.

Fitting of a contact lens. Apart from knowledge of the patient's refraction this involves the following procedures.

(a) The measurement of the flattest meridian of the anterior surface of the cornea referred to as K is done by a keratometer. The central posterior curve (CPC) of the contact lens is determined in relation to K, steeper or flatter than K.

(b) A standard lens from a trial set of contact lenses of varying diameters and radii is fitted.

(c) The convenient method of determining the smooth and accurate corneal fit is by instillation of a drop of 2 per cent solution of fluorescein and the eye is examined by a cobalt blue light. Areas of contact are seen as blanched in contrast to brilliant fluorescence in the areas of separation.

(d) The patient is taught how to insert a contact lens cleaned in wetting solution containing methyl cellulose or polyvinyl alcohol and rinse it and to remove it.

Symptoms of contact lens postwearing

Symptoms of contact lens postwearing may be grouped as those which do not necessarily indicate specific modification, e.g. excessive lacrimation or blinking, photophobia, foreign body sensation, sensation of blurred vision and discomfort on upward gaze, and these disappear between 2 and 4 weeks; and which indicate specific modifications, e.g. persistent sense of scratching, blurred vision, glare and sensation of looseness of the lens.

Tolerance of contact lens. Improvement is possible by reducing the diameter of the lens, the thickness of the lens and the addition of intermediate curves between the peripheral curves.

Corneal changes in contact lens wear.¹¹ In the epithelium the sequence of events are: oedema—necrosis—scarring—ulceration—vascularization. In the stroma—oedema. In Descemet's membrane—folds.

Soft contact lens

Hydrophilic plastic, introduced in 1960, is a tridimensional co-polymer of ethylene glycol monomethacrylate with the addition of a little triethylene dimethacrylate collect ethylene glycol dimethyl acrylate (EDMA). The basic plastic that is polymerized in the soft lens is hydroxyethyl methacrylate (HEMA). The hydrocurve lens is made up of a polymer consisting of polyvinylpyrrolidone (PVP) and HEMA.

Physicochemical properties. The thickness determines the permeability of the lens, and the latter is dependent on the water-content of the and these are of three types: with more than 70 per cent water, with 45–70 per cent water and with 45 per cent water.

Diameter of the lens. This is determined by making a choice of diameter which is 2 mm larger than the corneal diameter.

Advantages of soft lens. The advantages are the comfort and ease of fit which are of special importance. Rapid adaptation is possible. There is

no spectacle blur. The lens can be worn intermittently. It provides a good protection for the cornea. It has property for minimal corneal damage and minimal dislodging.

Indications for its use. It is indicated in the following: aphakia, keratoconus, bullous keratopathy, 'dry eye' syndromes, lens use with supplementary drugs, alkali burn of the cornea and as 'bandage lens' for protection of the cornea.

Rigid gas-permeable lens

The materials used include cellulose acetate butyrate (CAB), siloxanyl methacrylate, silicone, fluorocarbon and styrene. A gas-permeable lens has a large optical zone, capacity of better centration and enhanced facility of oxygen transmission.

Complications. Complications are listed in Table 32.2.

Table 32.2

Possible Complications following Contact Lens Wear

In the conjunctiva
Giant papillary conjunctivitis
Infective conjunctivitis
In the cornea
Superficial punctate keratitis
Epithelial microcysts
Oedema
Ulcer
In the contact lens
Mechanical damage
Lens deposits
'Tight syndrome'

Other types of contact lens

Extended wear lens like 'Permalens' as well as disposable lens like 'Acuvue' are available.

Visual Aids^{1,2,7}

There are three groups of patients who need visual aids: (a) those who have affections causing subnormal vision, e.g. corneal opacity, corneal dystrophy and keratoconus; (b) those suffering from

dense opacities in the media or central retinal lesions, which need an enlarged retinal image; and (c) the patients who need a non-magnified, but sharper and more definite image.

Classification. Table 32.3. shows classification of optical aids.

Table 32.3
Classification of Optical Aids⁷

For distance:	1. Spectacles— (i) Conventional (ii) Telescopic (iii) Pin hole
	2. Spectacle modifications, e.g. clip-on monocular telescopic spectacle
	3. Contact lens
	4. Non-spectacle aids
For near:	1. Spectacles (i) Strong convex (ii) Best-form +16.00, +20.00 and +24.00 D (iii) Telescopic (iv) Specially designed
	2. Spectacle modifications, e.g. (i) Monocular telescopic clip-on (ii) Binocular head-borne loupe
	3. Non-spectacle magnifier — (i) Hand-held (ii) Stand with fixed object-to-lens distance (iii) Focusable stand
	4. Projection magnifiers

Magnifying lens. It consists of a convex lens placed at a distance within the anterior focal length from the object, so that there is formation of a virtual erect image.

Telescopic lens. This comprises a negative lens of short focal length and a positive lens separated by a distance equal to the difference in their focal lengths.

Telescopic spectacles. The galilean system as applied to the telescopic spectacles consists of a strong minus lens close to the eye or the eye-piece and a strong plus lens in front of it or the objective glass, these two lenses being separated by a distance equal to the sum of their focal

lengths. The anterior focus of the convex lens coincides with the posterior focus of the concave lens. These spectacles are especially helpful in high myopia with macular degeneration, and are used primarily for near vision.

Hand-held magnifiers are available in varying sizes and power between +4 and +20 D. Low power magnification lenses are preferable than high power magnification lenses since the latter cause disturbing optical aberrations like oblique astigmatism. The use of magnifier has a limited value because of its difficulty to maintain constant focus, and there is decreased magnification with increased lens diameter. The introduction of press-on *Fresnel lens*, which is light weight and membrane-like has overcome the problem of hand-held magnifier.

High plus reading lens offers larger field of view and greater depth of focus. Such lenses can be single vision or bifocal. The power varies between +4 and +20 D.

Pin hole spectacles are indicated with opacities of the media in the presence of good macular function.

Special Lenses¹²

Special lenses include the following:

Lenses—bifocals, trifocals and multifocals.

Frames—drop-on or 'Klipp-on' frames, reversible and frames for very young and school children.

Bifocals (Fig. 32.34)—In the bifocal there are two segments: the upper for distant focus and the lower for near. Straight-split bifocal was originally used. This was followed by cemented bifocal. Then invisible bifocals—either solid or fused—were introduced.

The main difficulty in using bifocals is the sudden jump of the image while changing the gaze from distance to near or the difficulty in going downstairs. This can be averted by: (i) making the lens unacentric or monocentric, i.e. coinciding the optical centres of the distance and reading segments; (ii) providing a twincentric bifocal,

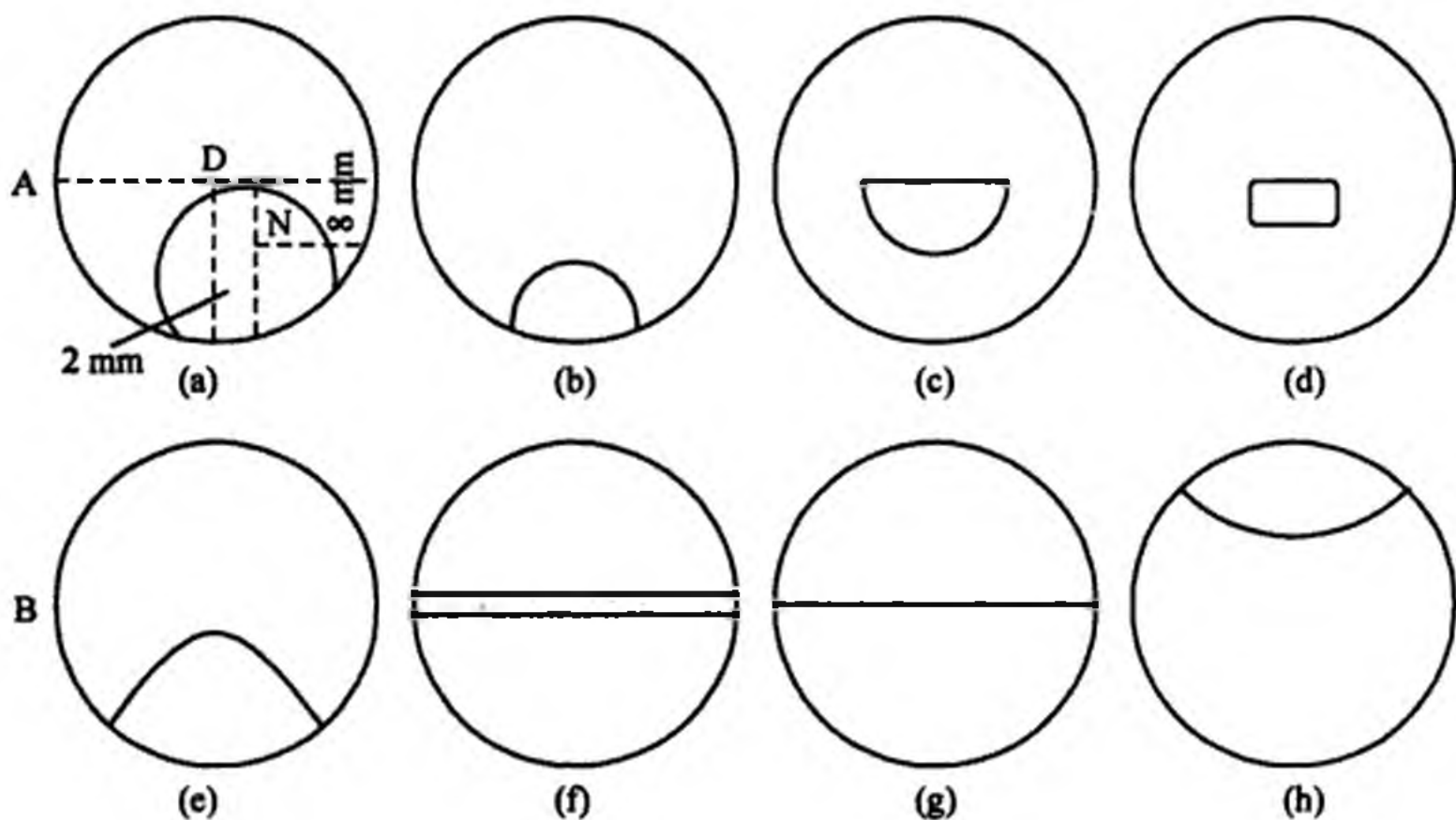


Fig. 32.34 Different types of bifocal lens. A; a, geometry of a bifocal lens showing the centre of the distance portion (D) and the centre of the near segment (N) which is 8 mm downward and 2 mm inward to D; b, round top; c, flat top; d, univis B; e, bifocal with a supplementary wafer; f, fused; g, executive and h, upcurve

where the centres of distance and reading—segments are on the same horizontal line, the centre of the reading portion being nearer the nose. The latter allows convergence.

Each case of reading addition is judged according to its own merit. In case of smaller reading portion there will be larger field for distance. If the reading portion of the bifocal is not up to the bottom of the spectacle frame, but there is a space of about 3 mm, the latter portion with distant correction aids in avoiding certain difficulty, e.g. going down the staircase.

Certain special varieties need a little description. Upcurve bifocals help the subject to do desk work with ease and while looking up can see people clearly. Raised lower segment (or strip bifocal) consists of an outer rim of distance correction around the supplementary segment, the outer rim helps to see low down objects beyond the reading range. 'Rising front' bifocal provides a device lifting the frame higher on the nasal bridge for near work, and helps in avoiding the difficulty while looking obliquely downwards during tiresome close work.

Half-eye glasses (Pantoscopic glasses). The subject sees through the lower half while reading or doing close work, while it is easy to look over them for distant vision.

Trifocals. These are useful particularly for presbyopic hypermetropes, the correction being almost similar in both eyes. There are three portions: (a) the distance segment; (b) the intermediate addition—for easier transition from reading to distance; and (c) the reading segment.

Multifocals. The reading portion of the lens has a continuously variable curve which gradually increases the power from the periphery to the centre. The system appears to be complex.

Tinted Glasses

Tinted glasses may be used for providing protection against glares, comfort, for cosmetic reason.

Sunglasses. They are commonly used to protect the eyes from ultraviolet, infrared rays as well as to absorb 60 to 80 per cent of the incident rays of

the spectrum. The green or grey tint is normally used. Glass is more effective than plastic in avoiding infrared rays.

Photochromic glasses. An ordinary glass absorbs considerable amount of ultraviolet, while photochromic can alter the capacity of ultraviolet absorption. They are not effective in shades.

Photogrey lenses. It is not effective as a sunglass. Its absorption varies between 15 and 45 per cent.

Photosun lenses. Its minimum absorption is 35 per cent and maximum is 80 per cent. They should not be used in night driving.

Tinted glasses for industrial concern. These glasses are meant for welders, glass blowers, steel industry, etc. and they cut down harmful infrared and ultraviolet rays.

Frames¹²

Frames may be metal, plastic, combination of metal and plastic, rimless and special frames.

Metal frames may be made up of gold-filled, nickel, and aluminium.

Plastic frames may be of two types— injection-molded and higher quality plastic (cellulose nitrate, cellulose acetate and lucite).

Combination frames are made up of metal chassis with plastic or both plastic and metal, along with two adjustable pads.

Rimless frames may be made up of metal or plastic.

Special frames include:

Frames for infants. Because of almost lack of bridge to the nose, the ordinary frames are not adjustable. So, a special nose-construction in the frame is incorporated.

Hemianopic glasses (right or left). In hemianopia of homonymous type one-half of the visual field is affected. Such glasses provide a semitransparent mirror hinged at the nose-bridge, which helps in averting difficulty.

Side shields. These are necessary to cover the eye between the frame and the eye.

Ptosis crutches. These are provided with metal extension arising from the inner part of the rim which supports the drooped upper lid.

Verification of Spectacle Lenses

Verification of spectacle lenses involves determination of: (a) type of the lens; (b) power of the lens; and (c) optical centre of the lens.

Types of lenses. There are several types of lenses: spherical, cylindrical, spherocylindrical, planoprismatic or prism combined. Their uses are determined by utilizing their prismatic power.

In case of the spherical lens, the object focused at a distance seems to move in opposite direction and appears enlarged as in the case of the convex lens or seems to move in the same direction and appears smaller as in the case of the concave lens. In case of the weak lens, the object appears to move slowly, while in case of the stronger lens it appears to move rapidly.

The object seen through the cylindrical lens becomes elongated in one meridian. This indicates the axis of astigmatism.

In case of incorporation of the prism, the object seen through it appears to be shifted to one side, i.e. towards its apex.

Power of the lens. (a) The most common method of determination of the power of the lens is of neutralization. Lenses of opposite power are placed against the lens being tested and both lenses are moved in front of the observer's eyes. The lens which stops all apparent movements of the subject is the neutralizing lens.

(b) *Geneva lens measure.* This quickly indicates the type and power of the lens.

(c) *Refractionometer or focimeter or lensometer* (p. 127).

Optical Centre of the Lens (Fig. 32.35)

Optical centre of the lens is the place in the lens which does not show any prismatic action. The optical centre does not necessarily correspond with

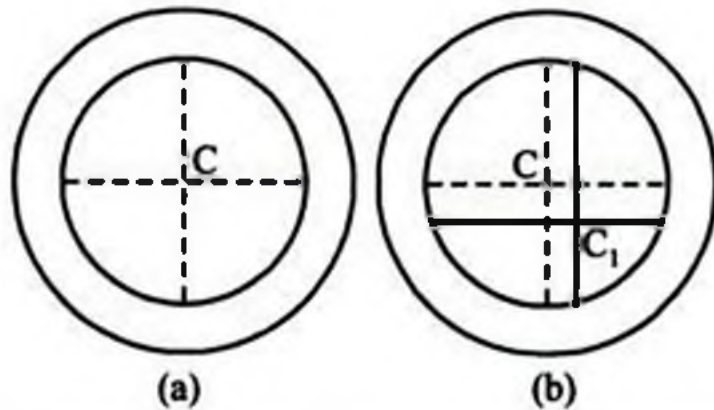


Fig. 32.35 a, The optical centre, vortex or pole (c) located at the centre of the frame; b, the optical centre decentered downward and inward (c1) for reading. A right spectacle is represented in both cases.

the centre of the spectacle frame, and this is the geometric centre

To determine the optical centre, two lines crossing each other at right angles are seen through the lens held a few inches above them, and the lens is moved in these two major opposite directions. The point of no prismatic deviation of the image and the axes are found out which is the pole or vertex, or the optical centre of the lens.

Instruments Used in Refraction Work

Retinoscope. This is the most important instrument in determining the refractive error of the eye. Retinoscopy is the accurate objective method of assessment of the total refractive error and is done by either of the following instruments:

- Retinoscopy mirror
 - Plane
 - Concave
- Streak retinoscope

Plane retinoscopy mirror. By tilting the mirror, the mirror image is situated as far behind the mirror as the light in front of it.

Concave retinoscopy mirror. The mirror image of the light source placed behind the patient's head is situated in front of the mirror in between the observer and the patient.

The mirror, concave or plane, has a central aperture (4 mm) approximating the size of the observer's pupil.

Streak retinoscope (Fig. 32.36). It is either illuminated by battery in the handle, or by electric currents from mains with a resistance. The linear

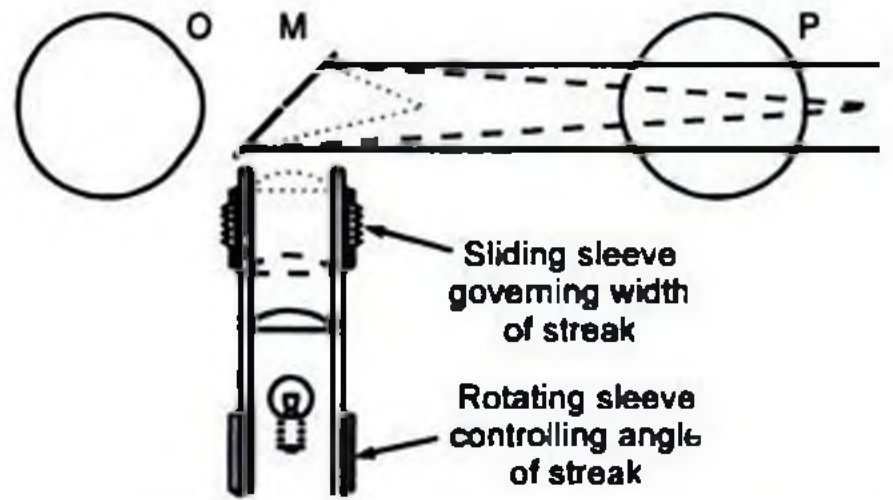


Fig. 32.36 Purvis streak retinoscope, with variable direction of the rays (Hamblin). O = observer; M = mirror; P = patient.

Diagram of head of the retinoscope. This is illuminated by battery in handle, or from mains with a resistance. The lamp has an exactly straight filament.

By sliding the projector-lens the direction of the rays reflected by the mirror is altered. When lens is at top (dotted outline), rays are convergent, as from powerful concave mirror; when in intermediate position (broken lines), the rays are focused on the eye and there is no moving light in the pupil; when slid further down (continuous line), the reflected rays are parallel, as from a plane mirror. Clinically, when working at 1 metre, the streak is first accurately focused on the patient's forehead, and then the projecting lens is slid further down to get the plane mirror effect (Whittington).

streak can be rotated and it disappears at the neutralization point. The streak effect is variable by sliding the projector lens upwards or downwards. Its special use is in the determination of the axis of astigmatism (Fig. 32.37).

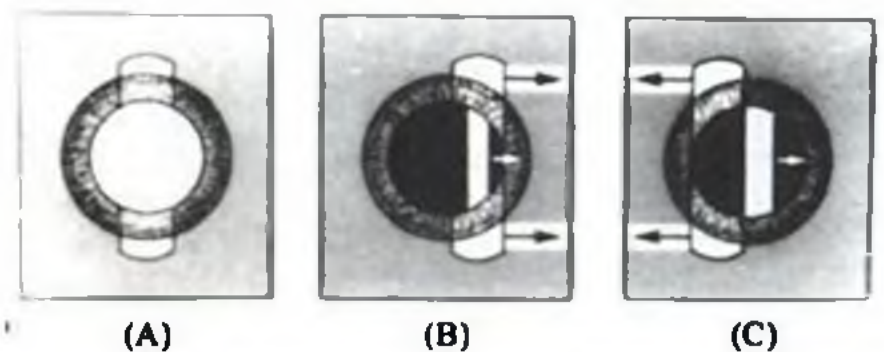


Fig. 32.37 Streak retinoscopy. A shows the reflex at the point of neutralization; B the reflex and streak in a 'with movement in hypermetropia' plane mirror; C the reflex and streak in an 'against movement in myopia' plane mirror (Parsons).

Trial frame and trial set of lenses (Fig. 32.38). A trial frame is needed during retinoscopy and during subjective method of estimation of visual acuity by test types and trial lenses. The trial set of lenses



Fig. 32.38 Trial set of lenses with trial frame.

is a box containing + and - spherical and cylindrical lenses arranged in pairs usually from 0.12 to 20.00 D, along with a set of prisms. The other contents are the occluder, the pinhole, the stenopeic slit, the Maddox rod, red and green glass, plane glass and also a trial spectacle frame.

Pinhole. A pinhole allows only the central rays through it and if the vision improves with it, the vision will improve with lenses.

Cross cylinder. This has already been discussed on p. 118, Fig. 32.30.

Lensometer or refractionometer. This is useful for determining the optical centre and axes of the cylinder, measuring the dioptré of the lens, and also direction of the prism. (Fig. 32.39)




Fig. 32.39 Lensometer (Courtesy: Appasamy Associates, Chennai).

The image of the target is seen through a telescope and focused by a standard lens. For measurement of the dioptric power of an unknown lens, it is placed into a special rack in between the standard lens and the telescope. The instrument must be set to 'O' before use. The target is then moved until the light rays reaching the telescope are parallel and the image is therefore in focus. The change in position of the target indicates the dioptric power of the unknown glass.

Placido's disc (or keratoscope). It is a centrally perforated disc, 25 cm in diameter, having alternating concentric black and white rings painted on its surface. The patient sits with his or her back towards light. The disc is held close to the eye and the observer looking through the hole will see the reflection of the concentric lines of the disc over the cornea. The patient is asked to rotate the eye and the reflections are noted. The rings visible may be circular, i.e. normal, elliptical as in regular astigmatism, distorted as in keratoconus or irregular astigmatism, or interrupted as in corneal foreign body.

Stenopeic slit. It is used either as an aid to refraction or at times to determine the clear part of the cornea affected by opacity before performing an optical iridectomy. It is a black disc which can be put in a trial frame and is provided with a slit, 1 mm wide and 6 mm long.

Further Reading

1. Agarwal, L.P., *Principles of Optics and Refraction*, Medical Publication, New Delhi, 1962.
2. Arora, R. and Gupta, A.K., Contact lens update. In *Current Topics in Ophthalmology*, Vol. I, Gupta, A.K. (Ed.), B.I. Churchill Livingstone, New Delhi, 1993, p. 132.
3. Buckley, R. and Morris, J., Contact lens practice. In *Recent Advances in Ophthalmology*, Vol. VIII, Davison, S.J. and Jay, B. (Eds.), Churchill Livingstone, Edinburgh, 1992, p. 19.

4. Davey, J.B., Ophthalmic optics. In *Modern Ophthalmology* (2nd ed.), Vol. I, Sorsby, A. (Ed.), Butterworths, London, 1972, p. 383.
5. Duke-Elder, S., *The Practice of Refraction* (9th ed.), Revised by Abrams, D., Churchill Livingstone, Edinburgh, 1978.
6. Duke-Elder, S., *System of Ophthalmology*, Vol. V: *Ophthalmic Optics and Refraction*, Duke-Elder, S. and Abrams, D. (Eds.), C. V. Mosby, St. Louis, 1970.
7. Fonda, G., *Management of the Patient with Subnormal Vision*, C.V. Mosby, St. Louis, 1970.
8. May, C. and Worth, C., *Manual of the Diseases of the Eye* (13th ed.), Keith Lyle, T., Cross, A.G. and Cook, C.A.G. (Eds.), Baillière, Tindall and Cashell, London, 1968.
9. Mittelman, D., Geometric optics. In *Principles and Practice of Ophthalmology*, Peyman, G.A., Sanders, D.R. and Goldberg, M.F. (Eds.), W.B. Saunders, Philadelphia, 1980, p. 174.
10. Ruben, M., Optics. In *May and Worth's Manual of the Diseases of the Eye* (13th ed.), Keith Lyle, T., Cross, A.G. and Cook, C.A.G. (Eds.), Baillière, Tindall and Cashell, London, 1968.
11. Ruben, M., Corneal changes in contact lens wear. *Tr. Ophthalmol. Soc.*, UK, 87: 27, 1967.
12. Whittington, T.H., *The Art of Clinical Refraction*, Oxford University Press, London, 1958.

33. THE EXAMINATION OF THE EYES

Basic Equipments

The basic equipments needed for ocular examinations include a good source of illumination, a monocular loupe or binocular loupe, adequately illuminated distant vision Snellen's charts, standard set of near vision charts, a trial set of lenses of good qualities with accessories such as pinhole,

stenopaic slit, Maddox rod, red-green glasses, prisms and cross cylinder, ophthalmoscope, retinoscopy mirror and streak retinoscope, tonometer, colour vision charts and a set of commonly used drugs, e.g. homatropine, pilocarpine, phenylephrine and lignocaine.

Other instruments for an ophthalmic clinic include a perimeter, Bjerrum's screen, a slit-lamp biomicroscope with accessories, a binocular indirect ophthalmoscope, synoptophore, Hess' screen, Maddox wing, transilluminator and keratometer.

The examination of the eyes and their disorders may be considered under the following broad headings:

- (1) History of the case
- (2) Ocular examinations
 - (a) Objective
 - (i) External
 - (ii) Examination in the dark room
 - (iii) Special examinations, if or when necessary
 - (b) Subjective (functional) and whenever needed
- (3) Systemic examinations
- (4) Laboratory investigations.

But in routine clinical practice, an ophthalmologist prefers to follow his or her own personal order to avoid omissions.

History of the Case^{6,10}

(1) The age of the patient is given due consideration chiefly because of some of these factors: (a) certain disorders relate to certain age-groups; (b) progress of refractive error, e.g. myopia; (c) treatment of amblyopia in children; and (d) onset of presbyopia.

(2) Correction of refractive error in relation to occupational hazards are important.

- (3) Onset, duration and course,
- (4) Hereditary factors,
- (5) Presenting symptoms such as
 - (a) Asthenopia
 - (b) Headache. If present, enquiry comprises:
 - (i) characteristics of onset; (ii) duration; (iii) severity; (iv) location; (v) quality; and (vi) relief with drugs or not.

(c) Pain. Enquiries are made regarding: (i) location; (ii) type—dull, throbbing, paroxysmal; (iii) duration; (iv) periodicity; and (v) aggravating and relieving factors.

(d) Visual deterioration/or loss: (i) onset; (ii) duration; (iii) progress

(e) Redness

(f) Conjunctival discharge

(g) Photophobia

(h) Haloes

(i) Spots before the eyes

(j) Diplopia

(k) Night blindness

(l) Physical signs described by the patient as: (i) red eye; (ii) new growth; (iii) abnormal position of the eyes or eyelids; (iv) protrusion of the globe; (v) widening or narrowing of the palpebral fissure; and (vi) pupillary abnormalities.

External Examinations¹¹

Careful and methodical examination of the eyes is of great significance.

Inspection in good diffuse light and oblique illumination—focal or lateral—by a condensing lens or a corneal loupe are simple but valuable clinical methods of examination.

Focal illumination. A corneal loupe and sometimes a +13 D condensing lens for further magnification of the illuminated area are used about two feet away from the patient's eye laterally and slightly in front. The light is held on a level with the eye. The corneal loupe is held in one hand and the light in the other hand. If both corneal loupe and condensing lens are used one hand holds the 10x loupe and the other the condensing lens, while the source of illumination is a lit electric bulb.

The various aids to produce magnification are shown in Fig. 33.1.

Ocular examinations may be done in the following order:

The face. The face is inspected for abnormalities like: (a) any bony abnormality; (b) asymmetry of the face such as in facial palsy; (c) head-tilt; (d) naevus, vesicles and scars; and (e) missing of the eyelashes and lashes of the eyebrows.



Fig. 33.1 Aids to produce magnification. 1, the 10x loupe used to examine the anterior segment of the eye; 2, inexpensive operating glasses (2x); 3, a simple magnifier with a head band; 4, the more sophisticated (and expensive) Keeler operating glasses (2x) (Galbraith).

The orbit. See p. 149.

The eyeball. The normal position of the eyeball can be assessed as follows. A vertical line passing through the midpoints of the upper and the lower orbital margin is tangential to the cornea. There is neither protrusion nor retraction. The ocular movements are tested unilaterally and binocularly. Cover test is important to diagnose a case of squint. Any involuntary oscillatory movement is noted.

The eyelids and palpebral fissures. In primary position of the eyes the upper lid margin covers about 2 mm of the cornea. On voluntary closure, there is no exposure of the sclera. Note whether there is any elevation or depression of each lid. The lid skin may show ecchymosis, pigmentation, oedema, eruption, scar, cyst and tumour. Observe whether there is any drooping, lagging, spasm, twitching and infrequent blinking. Both lids should elevate and drop nicely with upward and downward gaze respectively. Note the position of the lid margins and they remain in contact with the globe normally. The lid margin is also examined for any hyperaemia, scale, ulcer, crust, localized abscess around an eyelash, misdirected or missed cilia and abnormal Meibomian secretion.

The palpebral fissure in an adult is 28 to 30 mm in length, and 14 to 15 mm in height. These measurements are slightly lesser in children and old people.

The lacrimal gland. Look at the superotemporal part of the orbit for any evidence of swelling. The palpebral part is not visible on eversion of the upper lid under normal condition. It becomes visible only when swollen. Schirmer's test, a useful clinical examination, is described under 'Diseases of the Lacrimal Gland'.

The lacrimal passages. Normally both puncta remain in close contact with the eyeball. Note any swelling, redness, occlusion or its absence. The sac region is examined for presence of swelling, tenderness or any fistula. Note whether digital pressure over this region causes regurgitation of mucopus or pus through the puncta into the conjunctival sac. Syringing has been described in detail on p. 452. The other methods of investigations are described under 'Epiphora' (p. 186).

The conjunctiva. All parts of the conjunctiva are inspected. Place the base of the thumb near the lower lid margin, evert the lower lid to inspect the lower palpebral conjunctiva and fornix. Ask the patient to look upward, downward, outwards and inwards to examine the whole of the bulbar conjunctiva. Eversion of the upper lid is done in the following manner. Request the patient to look downward, gently grasp the lashes of the upper lid between the index finger and thumb of the left hand and pull the lid slightly downward and forward away from the globe. Then place the edge of the nail of the little finger of the right hand on the skin surface above the superior border of the upper tarsus and exert pressure backward and downward. Eversion is achieved if these two manoeuvres are carried out simultaneously.

Examination of the upper fornix is rather a difficult procedure. There are two methods. The first and better method is turning up of the everted upper lid by means of a lid retractor. The other method is the eversion of the upper lid with the left hand and exerting gentle pressure downward and backward on the skin surface above the tarsus with an applicator.

Look for any evidence of conjunctival congestion and discharge. Conjunctival congestion

needs to be differentiated from ciliary congestion (Table 37.1).

The sclera. Examination may reveal congestion, nodule, pigmentation, bulging and thinning.

The cornea. This is examined by diffuse illumination, focal illumination and slit-lamp biomicroscopy. Simple instrument like corneal loupe may be used to get a magnified view. Staining is at times essential.

Note whether the cornea is round or oval. Curvature may be abnormal. Look for disturbance of transparency, ulcer, vascularization, pigmentation and deposit. For testing its sensation the lids are held apart and lightly touch various parts of the cornea with a wisp of cotton drawn out into fine threads. Normally blinking is present for details seep.

The anterior chamber. Depth and content are the important factors. Normal depth in the axial region is 3 mm. Normal content is colourless aqueous humour. A light is focused from the temporal side perpendicular to the limbus. Note the distance between the back surface of the cornea and the front surface of the iris. The AC may be shallow or deep. If the depth is sufficient there will be uniform illumination, and if shallow the half of the AC near the light will be illuminated and thus the remaining half is in shadow. This is called the *eclipse test*. Abnormal contents include pus, blood, precipitates, lens matter, foreign bodies and parasites. The examination is facilitated by the use of a slit-lamp biomicroscope.

The iris. Observe its colour, texture and pattern. There may be evidence of synechia, nodule, coloboma, tear, atrophy and neovascularization.

The pupil. The pupil is single and is slightly inferonasal to the centre of the iris, measuring 2 to 4 mm. They are equal in both eyes. Three reactions are tested—direct, indirect and near. Abnormalities may involve number, position, shape, size, equality and reaction.

The swinging flash light test is performed with a bright flash light in a dim room. The pupils are

about 8 mm in diameter in darkness. The patient is asked to fix a distant target to avoid accommodation and convergence. Now the light is shown from below the eyes and is alternated from one eye to another every 2 to 4 seconds. Normally, the responses consist of constriction followed by redilatation till the pupils become 5 mm after a few oscillations.

In the presence of afferent pupillary defect both pupils become larger with stimulation of the defective side, but they become smaller with the stimulation of the sound eye.

The lens. Mydriasis is desirable in examination of the lens in detail. It is subjected to focal illumination with or without a magnifier, slit-lamp biomicroscope, retinoscope and an ophthalmoscope. Note whether there is any opacity, dislocation, absence and deposit over its anterior surface.

The ocular tension. A rough method to assess tension is digitally. For precision, a tonometer is used. The two index fingers of the examiner are placed on the upper lid close to one another while the patient looks downwards (Fig 33.2). A slight pressure is applied downwards by one index finger while the other index finger feels ocular tension. Tonometry is described in detail on p. 282.

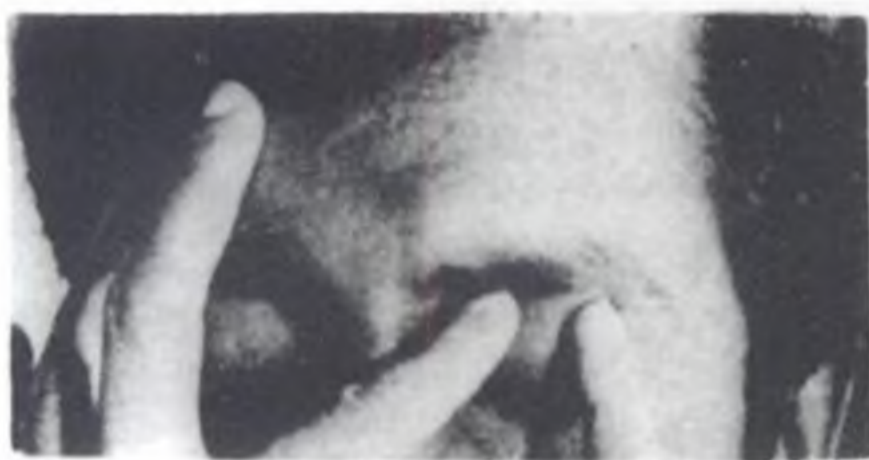

Fig. 33.2 Digital tonometry

Examination in Dark Room

Retinoscopy (Syn.: Skiascopy or shadow test) (Fig. 33.3)

Principle. An objective method is to find out the point of reversal or the myopic far point.

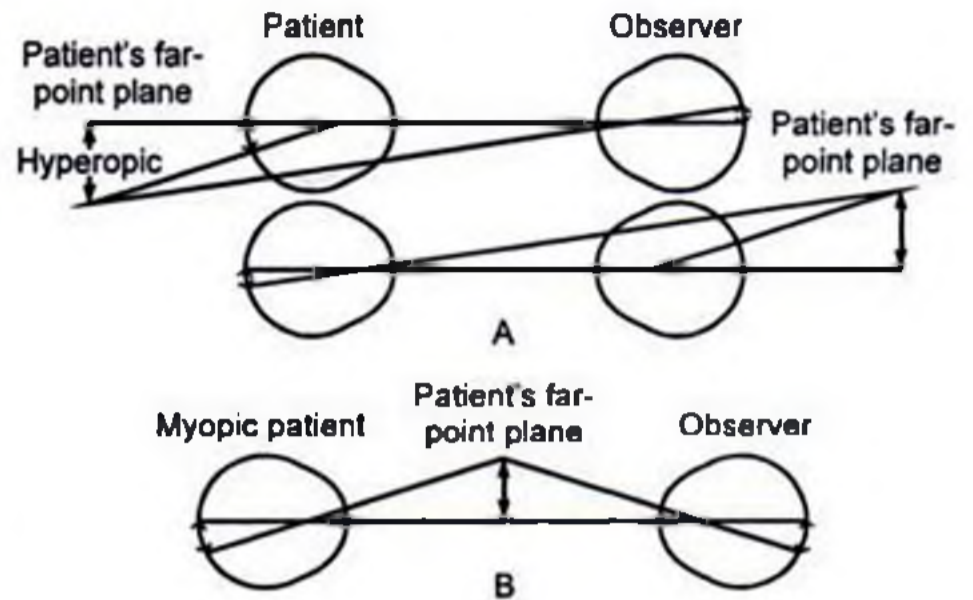


Fig. 33.3 Principle of retinoscopy: A, With motion if the far point is behind the observed eye or the observer; B, against motion is seen when the far point is situated between the observed eye and the observer. (Peyman, Sanders and Goldberg).

Dilatation of the pupils is essential for satisfactory examination of the interior of the eyes.

When a beam of light is reflected on to the pupil by a plane mirror (Fig. 33.4) held at a distance of 1 metre from the eye, lateral and




Fig. 33.4 Plane retinoscopy mirror

vertical movement of the mirror elicits corresponding movement of the shadow. If it is in the opposite direction, the refractive error is a myopia of more than $-1.00D$; if in the same direction—it may be hypermetropia, emmetropia or myopia of less than $-1.00D$. If there is no movement the subject has myopia of $-1.00D$. Neutralization of the movement of shadow is done by putting trial lenses in a trial frame. A postmydriatic test (PMT) is advised after the drug action completely disappears. Since there is residual impairment of accommodation for two or three days a period of four days is allowed in case of homatropine. Following retinoscopy under atropine ointment a three-week gap is allowed.

Dynamic retinoscopy. The method just described applies to measurement of static refraction for distance. For measurement of refraction of the eye focused for close work, retinoscopy is done with a self-luminous retinoscope on which a target is set. The patient looks and accommodates for the target. This method of retinoscopy for near vision is called dynamic retinoscopy.

Automated refraction. In recent years an autorefractometer has been introduced. This is a combination of electronic microcircuitry and computer technology. Certain preconditions for accuracy are good relaxation of accommodation and clear ocular media. However, accuracy is guarded (Fig. 33.5). Figure 33.6 shows a print out from a case.



Fig. 33.5 Autorefractometer.

Date: 03 OCT 1998
Name: M. Khatun

	SPH	CYL	AXIS	
R	-0.75	-2.75	111	
	-0.75	-2.75	111	
	-0.75	-2.75	111	
	-0.75	-2.75	111	
	-0.75	-2.75	117	
*	-0.75	-2.75	111	
L	+0.25	-1.00	73	
	+0.50	-1.25	75	
	+0.50	-1.25	75	
	+0.50	-1.25	75	
	+0.50	-1.25	75	
	+0.50	-1.25	75	PD 60

Fig. 33.6

Direct ophthalmoscopy

Though the first ophthalmoscope was described by Charles Babbage in 1847, the science of ophthalmology owes its inception in 1851 to von Helmholtz.

Examination with ophthalmoscope (Fig. 33.7) at a little distance reveals any haziness in the media.



Fig. 33.7 Direct ophthalmoscope (Courtesy: C. Davis Keeler Ltd).

The ophthalmoscope is held as close as possible in front of the eye. If the observer is ametropic, he or she must either wear correcting glasses or rotate a correcting lens into the aperture of the ophthalmoscope. When the patient is grossly ametropic, a suitable lens must similarly be rotated to place in the aperture. Magnification is about 15 times.

Optical principle of direct ophthalmoscopy (Fig. 33.8).⁹ The convergent light beam is reflected from the ophthalmoscopic mirror and the incident ray reaches the retina causing it to be illuminated. The emergent rays from the fundus then reach the retina of the observer through the hole in the mirror.

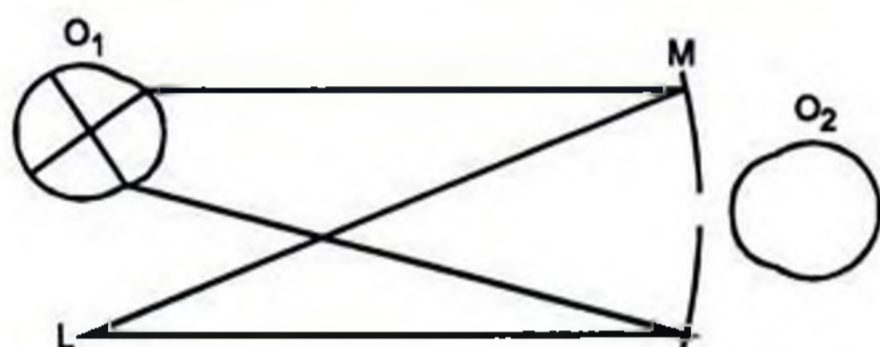


Fig. 33.8 Illumination of the ocular fundus and the area of the field of illumination in direct ophthalmoscopy. O_1 , the observed eye; O_2 , the observer's eye; M, mirror and L, light source.

If both observer and patient are emmetropic, the emergent rays become parallel and reach a focus on the retina of the observer.

If the patient is either hypermetropic or myopic, the emergent rays, divergent in case of hypermetropia, are made parallel by appropriate lenses so that they reach a focus on the retina of the observer (Fig. 33.9). The distinguishing features of direct and indirect ophthalmoscopy have been listed in Table 45.2.

Indirect ophthalmoscopy⁹

In the indirect method of examination by the ophthalmoscope a strong convex lens of +13 D is placed between the patient and the observer. The observer uses a concave mirror. In the binocular method (Fig. 33.10) the convex lens used are of +30 D, +20 D or +14 D. The advantages of the binocular method over the ordinary indirect method are: (a) stronger illumination; (b) superb

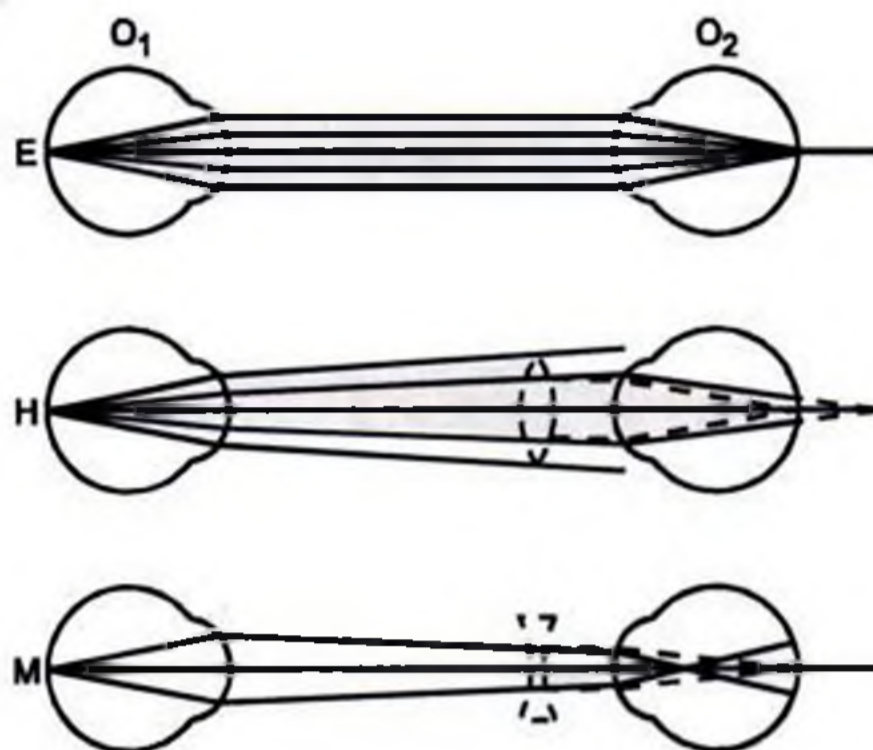


Fig. 33.9 Emergent rays from the observed eye, O_1 in emmetropia (E), hypermetropia (H) and myopia (M) forming the retinal image on the observer's retina, O_2 in direct ophthalmoscopy. In E, the emergent rays are parallel and are brought to a focus on the retina of O_2 under physiologic condition of rest. In H, the emergent divergent rays reach the observer's retina with the help of accommodation or biconvex lens placed before the patient's eye. In M, the emergent rays which are convergent reach O_2 by means of biconcave lens placed before his or her eye.




Fig. 33.10 Binocular indirect ophthalmoscope

binocularity and stereopsis; (c) both hands are free so that a scleral depressor may be used to observe the extreme retinal periphery; and (d) total retinal area and pars plana can be examined with scleral depression.

The indirect ophthalmoscope, either hand-held or spectacle-mounted type, has two systems illumination and viewing.

*Schepens indirect ophthalmoscope*⁸ consists of:

1. Indirect ophthalmoscope
2. Scleral depressor
3. Filters
4. Teaching mirror
5. Drawing board
6. Drawing chart
7. Colour pencils.

The usual condensing lens is +20 D lens with 50 mm diameter (Volk or Nikon). Other lenses are +14 D, +33 D or panfundus lens, all being aspheric lenses.

The examiner stands on the right side of the patient for observing the right fundus, the patient lying supine. The drawing chart is placed inverted over the patient's chest. The examiner now looks through the widely dilated pupil and the condensing lens having the surface with higher curvature facing the examiner gradually shifted away from the patient's eye till the clear fundus details are seen.

The indirect ophthalmoscope provides an inverted image which is magnified about 5 times.

*Optical principle of indirect ophthalmoscopy.*⁹

The convergent light beam is cast, say by a perforated concave mirror, and the patient's eye is made myopic by placing a +13 D convex lens between the observer and the patient. A real, inverted image of the fundus is formed between the lens and the observer (Fig. 33.11).

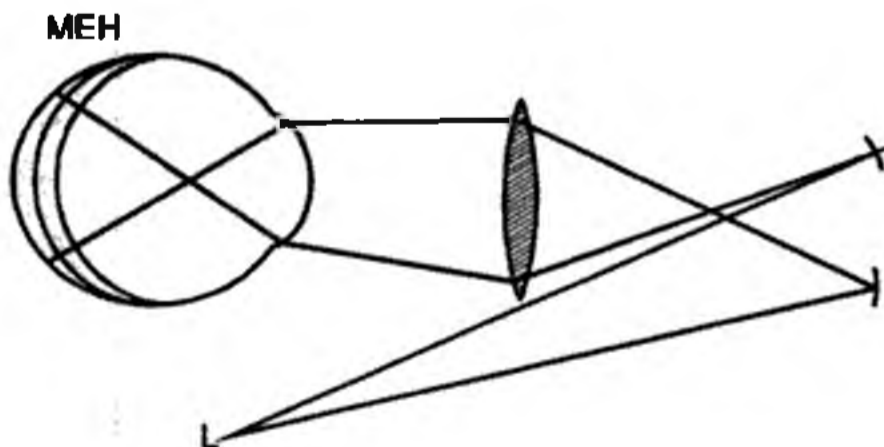


Fig. 33.11 Illumination of the fundus and the area of the field of illumination in indirect ophthalmoscopy.

In emmetropia, parallel emergent rays reach a focus by the strong lens at its principal focus.

In hypermetropia, the divergent rays reach a focus beyond the principal focus of the lens.

In myopia, the convergent rays reach a focus nearer to the lens and eye (Fig. 33.12).

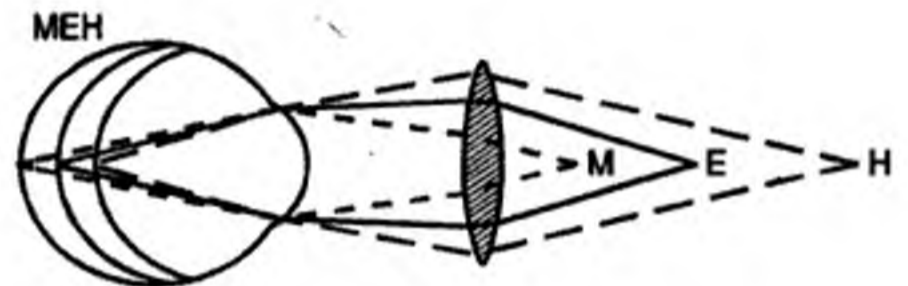


Fig. 33.12 Position of the image depending on whether it is emmetropic (E), myopic (M) or hypermetropic (H) in indirect ophthalmoscopy. The lens is placed at its focal distance. In E, the emergent parallel rays cross at the principal focus by the lens. In M, the emergent convergent rays and in H, the emergent divergent rays cross nearer to and cross further away from the principal focus respectively.

Transillumination¹¹

Transillumination is classified under these types:

- (a) Of the anterior ocular segment:
 - (i) Transpalpebrosclear
 - (ii) Transscleral
 - (iii) Transpupillary
- (b) Of the posterior ocular segment:
 - (i) Transpalpebrosclear
 - (ii) Transscleral
 - (iii) Oral
 - (iv) Transclero ophthalmoscopic examination (transillumination + ophthalmoscopy)
 - (v) Retrobuluar.

The two methods of transillumination are:

(a) *Direct.* An intense beam of light is thrown through the conjunctiva and sclera. Normally the pupil appears red. If it appears black it suggests the presence of an obstruction in the path of light.

(b) *Indirect.* An intense beam of light is placed in the mouth and the eyes are illuminated from behind. This method is less reliable.

Indications. The following are the indications:

- (a) detection of a solid mass; (b) differentiation

between a cyst and tumour; and (c) presence of opaque foreign body in a cataractous lens.

Visual Acuity

The plan of assessment is as follows:¹¹

1. Vision for distance:
 - (a) Vision without correction
 - (b) Pinhole vision without correction
 - (c) Vision with correction
 - (d) Pinhole vision with correction
2. Near vision and near point of accommodation. The following four should be checked:
 - (a) Near vision test with a near vision chart
 - (b) Punctum proximum
 - (c) Punctum optimum
 - (d) Punctum remotum.

Functional Examinations

(a) Distant central vision is tested by distant test charts. In *Snellen's test types* (Fig. 33.13) the letter at the top of the chart is of a magnification visible at 60 metres, the letters of the second row at 36 metres, and so on down the chart at 24, 18, 12, 9 and 6 metres respectively. The illumination should be adequate. The test is done by asking the

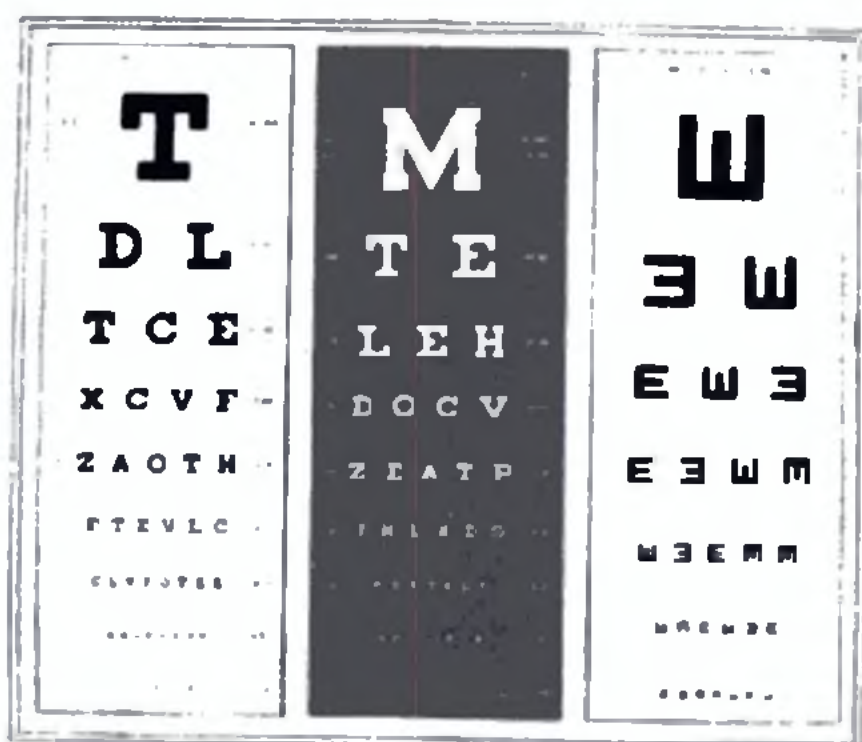


Fig. 33.13 Snellen's distant test types (reduced). The letters subtend a visual angle of 5 minutes at above distances.

patient to read the chart from a distance of 6 metres, each eye being tested separately.

If the patient cannot read the topmost line of the chart, his or her distant vision is less than 6/60; and accordingly his or her vision may be 3/60, 2/60, etc. The visual acuity may be still less, e.g. hand movements (HM) or perception of light (PL) and projection of rays (PR).

Principle. The whole letter subtends an angle of 5 minutes while the breadth of the letter subtends an angle of 1 minute at the nodal point of the eye.

(b) Near vision is tested by a *near vision chart*, e.g. Jaeger's chart. Near vision charts standardized by the Faculty of Ophthalmologists numbered from N₅ to N₄₈ are commonly used (Fig. 33.14). N₅ means numbers corresponding to the finest print which can be read. Each eye is to be tested separately.

(c) Field of vision. See pp. 139–40.

(d) Colour vision testing. See pp. 71–72.

(e) Light sense is the faculty to perceive light in all its gradations of intensity. It is tested by determining the light minimum by means of an adaptometer or photometer. Light minimum is the lowest limit of illumination with which an object can still be seen.

Adaptometer. The prerequisite is full dark adaptation by keeping in a dark room minimum for 20 minutes. Dark adaptation is tested with a Goldmann-Weeker adaptometer. The patient looks at the test light within the dome of the adaptometer. A series of light flashes are presented. The recording drum continuously keeps record of the patient's responses. The chief indication is its use in retinitis pigmentosa.

Special Examinations

Slit-lamp biomicroscope (Fig. 33.15)

Introduced by Gullstrand, a slit-lamp biomicroscopy is especially called for when minute examination is needed.

It provides a strong beam of light which, traversing the parts to be examined, shows them in

N 5

When I was ten years old, my father had a small estate near Satara where he used to take us during the holidays. It was situated in rough and uncultivated country and wild animals were often seen. Once we heard that there was a panther in the surroundings who was killing the cattle and attacking the villagers. Father had warned me not to wander far from home in the evening. I had made friends with a young villager called Ramu

throws supreme table porter worthy symbol

N 8

The cattle were slowly making their way home in front of us. The dog which helped Ramu ran barking at the hooves of the cows, who sometimes made a playful rush at the dog. Crows and mynas in flocks were passing home over our heads. We were passing a thick patch

vision receive noble elusive chief hinder preface

N 12

The cow was knocked over and I saw the tiger sitting over its white body. The cow kicked and struggled and the tiger found it difficult to get a grip.

theft heater abide defect endear

N 18

Ramu struck the tiger on the head with his stick.

decade employ flare

N 6

Ramu used to drive his cattle to graze and bring them back to shelter at the end of day. He was lean and of a short build and was barely fifteen. He used to be my companion whenever I met him winding his way home. One afternoon, just about five o'clock early in the month of March chance brought us together

frail elder preach forward tablet system

N 10

There was a rush of a wild animal from the bushes. It was a tiger, and I saw with terror that it sprang on the back of a white cow that had strayed behind the rest of the herd.

swich heaven party mirror carrier prank

N 14

I felt cold with fear but Ramu did not hesitate. Naked and with nothing but a lathi in his hand he rushed up to the struggling animals

Bottle measure assist clumsy

N 24

My eyes closed for a moment with fear

cart poet noble

N 36

I expected him to be torn apart

N 48

but it was the tiger that fled

Fig. 33.14 Near vision chart. Numbers N5 to N48 correspond to the modern time Roman types in various sizes from 5 pt. to 48 pt. (Courtesy: Nicholas, Indian Schering; reproduced with permission)

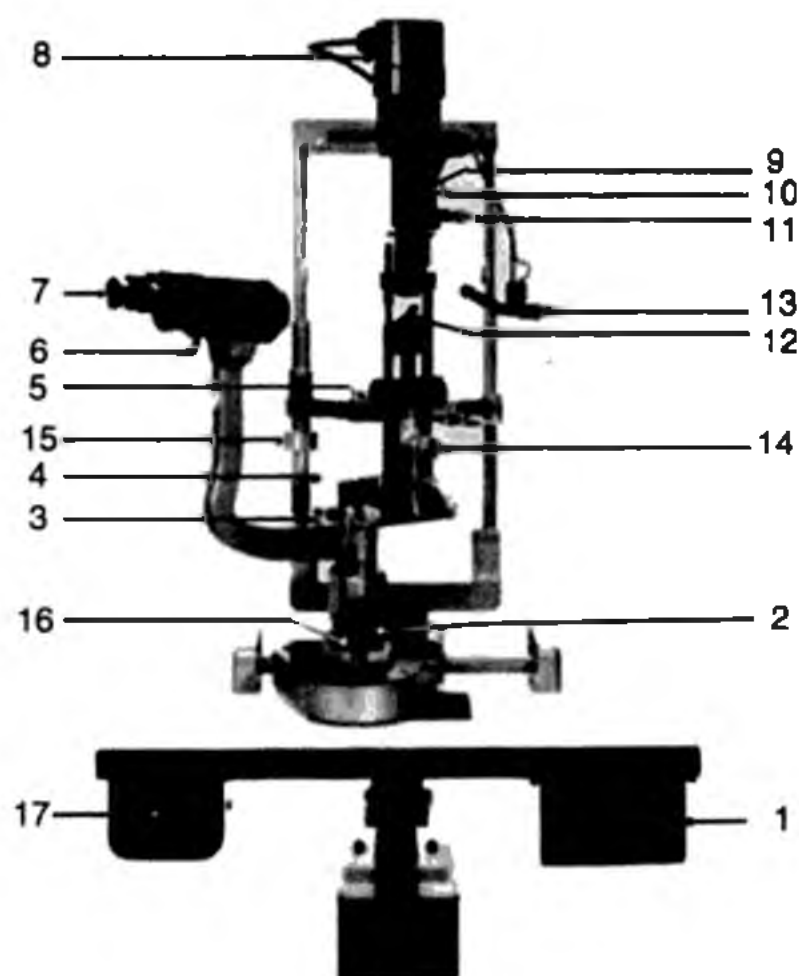


Fig. 33.15 The Haag-Streit slit-lamp 900:1, accessory box; 2, joy-stick lever for horizontal coarse and fine adjustments; 3, roll for setting the angle between microscope and illumination unit; 4, guide plate for preset lenses and applanation tonometer; 5, chin support; 6, lever for changing objectives; 7, interchangeable eye-pieces; 8, lamp casing; 9, lever for four different light filters; 10, lever for six different diaphragms; 11, ball-handle for turning slit-image; 12, interchangeable illumination mirror; 13, fixation lamp with annular fixation marker; 14, centring screw; 15, level adjustment control for chin support; 16, height adjustment control of slit-lamp; 17, transformer with switch (Parsons).

optical section, the area is then examined with a binocular microscope.

Principal methods of illumination employed in biomicroscopy are as follows¹:

- (a) Direct illumination
 - (i) with the broad beam
 - (ii) with the narrow beam
 - (iii) with the conical beam
- (b) Indirect illumination
- (c) Retroillumination
- (d) Oscillation
- (e) Examination in the zone of specular reflection
- (f) Sclerotic scatter

Technique of examination. (1) The setting of a biomicroscope includes the following:

(a) The illumination device must be checked and properly centred.

(b) Adjustment of the slit image and the binocular microscope is done so that there is a common axis of the illumination arm and the microscope arm.

(c) Checking of the dioptric adjustment of the eyepieces especially in relation to an ametropic observer.

(d) Height adjustment of the chin rest and head rest is checked.

(2) Examination of the anterior ocular segment:

(a) *Examination with a clear optical section.* The brilliant slit-beam is utilized for focusing directly upon an object such as a foreign body. For direct illumination, the optimal magnification is perhaps 10 times and 16 times. The short sections of the media are examined systematically. Large slits provide information about the size and shape of abnormalities of the cornea and lens, cloudiness of the aqueous, while narrow slits display abnormality in the layers, e.g. a corneal opacity.

(b) *Retroillumination.* The slit-beam is focused on reflecting surface behind the part under examination, the part being examined by transmitted light, e.g. for detection of KP.

(c) *Indirect illumination.* It is the examination of an area next to a focally illuminated area in its stray light, and is called for examination of an opaque structure, e.g. a blood vessel.

(d) *Zone of specular reflection.* Here the angle of the slit-beam and the line of the gaze of the patient are angled to the microscope axis. This method is employed to observe oedema of the epithelium and endothelium of the cornea, anterior and posterior surfaces of the lens.

(e) *Sclerotic scatter.* This is particularly indicated to detect epithelial oedema due to contact lens wear. The narrow beam is directed at the outer part of the limbus and the observer sets the microscope on the centre of the cornea.

Slit-lamp examinations of different structures.^{1,3,2}

Cornea. Cornea appears parallelepiped. Preliminary survey is best done by direct illumination with the broad beam. By narrowing the beam, an optical section providing a third dimension, which displays the depth, is obtained which shows: (i) a reduplicated anterior line which represents the corneal epithelium and Bowman's membrane; (ii) homogeneous interval, i.e., substantia propria; and (iii) a posterior line indicates Descemet's membrane.

Aqueous humour. Normally it appears clear. When floaters are present as in iridocyclitis, the aqueous becomes cloudy with the particles settling and the slit-beam reveals the so-called *aqueous flare* (Tyndall phenomenon).

Iris. Direct illumination displays the pupillary reflex, pupillary margin, crypts and collarettes, and hosts of pathological changes and developmental defects.

Crystalline lens. For examination of the anteroposterior plane, the narrow beam is used, and for that of coronal plane the broad beam is used; both beams provide a two-dimensional picture. The examination reveals: (a) anterior and posterior lens capsule; (b) beneath the capsule lies the cortex; clefts and globules may indicate early lental opacity; and (c) the innermost part is the nucleus comprising three outer layers indicating the adult, infantile and foetal nuclei within which there is a central dark interval, i.e. the embryonic nucleus (Fig. 33.16).

Vitreous humour. The anterior part of the vitreous can be examined without any accessories. For achieving this use the brightest beam and the narrow slit. The illumination is directed from the greatest angle possible.

It is difficult to examine the vitreous because of its low refractive index. Examination of the posterior segment requires the help of pre-set or contact lens, while that of the anterior does not. The use of contact lens has certain advantages: (a) good magnification; (b) appreciation of depth; and (c) ease of examination of the retinal

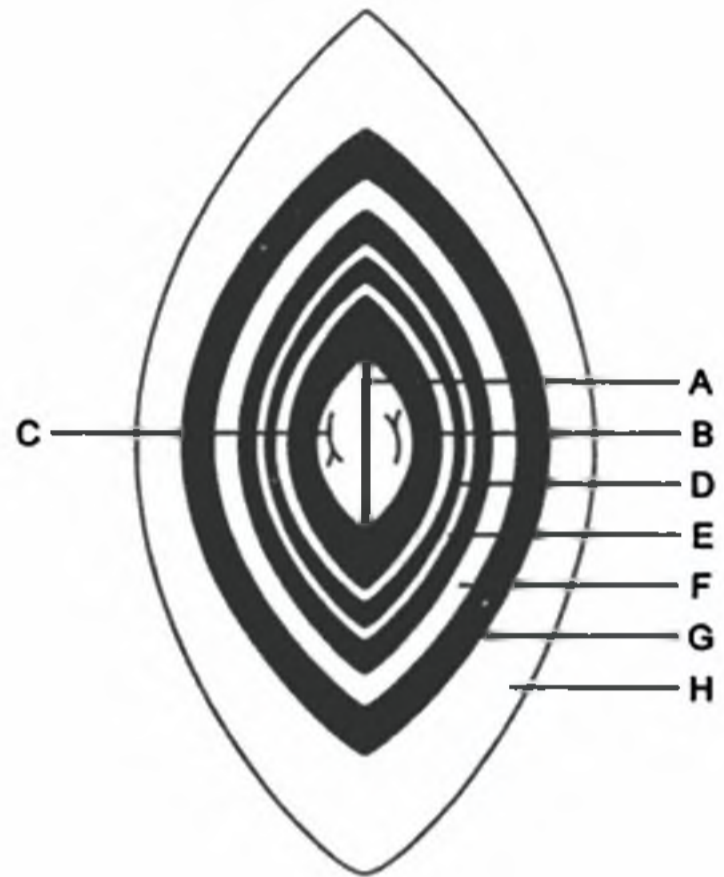


Fig. 33.16 Schematic representation of the biomicroscopic picture of the human lens: A, embryonic nucleus; B, anterior Y of the foetal nucleus; C, posterior Y of the foetal nucleus; D, foetal nucleus; E, infantile nucleus; F, adult nucleus; G, cortex and H, anterior capsule.

periphery. Its chief drawback lies in its inability to be used in a recently operated patient. Cloquet's canal is seen as an empty space situated posterior to the crystalline lens. At birth its course is straight and with age it becomes sinusoidal. In the eyes of young people, the vitreous sheets inserting into Cloquet's canal appear as 'bands'. The process of fibrous destruction progresses into cavity formation and is a normal ageing process. It also occurs prematurely in high myopia. Occasionally vitreoretinal adhesions are found especially at old choroiditic foci and in areas of cystic degeneration.

Angle of the AC. This is visualized by a slit-lamp with the aid of a gonioscopic lens. Refer to gonioscopy for detail (see pp. 285–86).

Biomicroscopy of the fundus oculi. This can be done by using

(a) *Hruby lens.* It is a planoconcave lens having a refractive power of -58.6 D attached with a special device to the slit-lamp. This neutralizes the total refractive power of the eye, $+ 60$ D. The corneal microscope is converted into a telescope.

(b) *Goldmann's three-mirror contact lens.* The three-mirror lens is made of organic glass. Through the centre of the contact lens the axial portion of the vitreous and the posterior pole of the fundus is seen. Inside the contact lens three mirror surfaces of different inclinations 59° , 67° and 73° are provided; these mirrors help in the detailed examinations of the entire retina. This lens replaces the refractive surface of the cornea with an afocal flat surface.

(c) *El Bayadi lens.* This is a +60 D lens used for indirect ophthalmoscopy with a slit-lamp. The real, inverted image of the retina is about 17 mm in front of this lens.

(d) Volk lens (see p. 311).

Gonioscopy (see pp. 285–86)

Fundus photography. Fundus photography is essential for: (a) permanent record; (b) minute lesions not seen by ophthalmoscopy; (c) assessment of treatment; (d) course of the disease; (e) review of the condition at intervals; and (f) fluorescein angiography.

A fundus photography can be taken commonly by: (a) fundus camera; (b) hand-held camera; and (c) slit-lamp camera.

Other special examinations indicated by history and clinical examination include: (a) exophthalmometry; (b) keratometry and keratoscopy; (c) tonography; (d) tear quantity and quality tests; (e) ultrasonography; (f) fluorescein angiography; and (g) radiologic studies.

Visual Field^{2,4}

According to Traquair, the visual field is considered to be an island of vision in a sea of blindness. Fovea centralis is imagined to be the mountain peak near the centre of the island, where the visual acuity is the highest, and the coastline is determined by perimetry.

Isoptres. They represent the limits of the field of vision with each target. If a 3 mm white test object is selected with a perimeter having a radius of 330 mm, the isoptre is recorded as the field for 3/330 white.

Methods for charting visual field. The central visual field has a radius of 30° around the fixation point, while the peripheral field is beyond 30° . The central field can be examined by confrontation tests, Amsler's grid, Bjerrum's screen, Goldmann's perimeter and automated perimeter. The peripheral field can be examined by either manual or automated perimetry.

Confrontation tests. A confrontation test is a simple, quick, rough, but useful qualitative test for detecting gross peripheral field defect. It is invaluable in bed-ridden patients. It is beyond 30° isoptre around the fixation point. After explaining the nature of the test to the patient, the examiner and the patient face one another about 2 feet apart. The patient has his or her back to the light source. The patient is asked to look straight into the examiner's uncovered eye which serves as the fixation point for the patient's eye. For examination of the patient's right visual field, the examiner covers his or her right eye with the right palm, while the patient covers his or her left eye with the left palm. Now the examiner moves his or her index finger in a plane halfway between themselves, the movements being from the periphery towards the centre.

The movements are repeated in at least four quadrants of the visual field.

Both eyes may be tested together in which the index finger of each hand is moved at the same time, and the patient consistently fixes on only one point. A homonymous hemianopia may be detected in this manner.

Abnormalities of the visual field are chiefly: (a) contraction; (b) depression; and (c) scotoma.

Perimetry may be static or kinetic, qualitative or quantitative, threshold or suprathreshold.

The static perimetry uses stimuli of varying luminance in the same position to produce vertical boundary of the visual field. This method is preferred in quantitative perimetry. The kinetic perimetry uses moving stimulus of known luminance or intensity from a non-seeing area to a seeing area until the patient is able to perceive the stimulus.

The qualitative perimetry detects a visual field defect and is utilized in the screening phase of glaucoma suspects.

The quantitative perimetry detects the severity of the visual field loss.

The threshold perimetry offers a quantitative information and is the most accurate method of follow-up of glaucomatous field defects. It involves the presentation of threshold luminance value of the patient in different areas of the visual field and compares the results with age-matched normal values.

The suprathreshold perimetry is a qualitative test and is used in screening glaucoma suspects. The stimuli at luminance levels above normal threshold values are presented in the different areas of the visual field. Then the patient sees the targets. The detection indicates normal visual function, but missing of targets indicates areas of decreased visual sensitivity.

Manual perimetry. The patient sits with the chin resting on the chin-rest of the perimeter (Fig. 33.17) and one eye occluded. He or she is asked to fix his

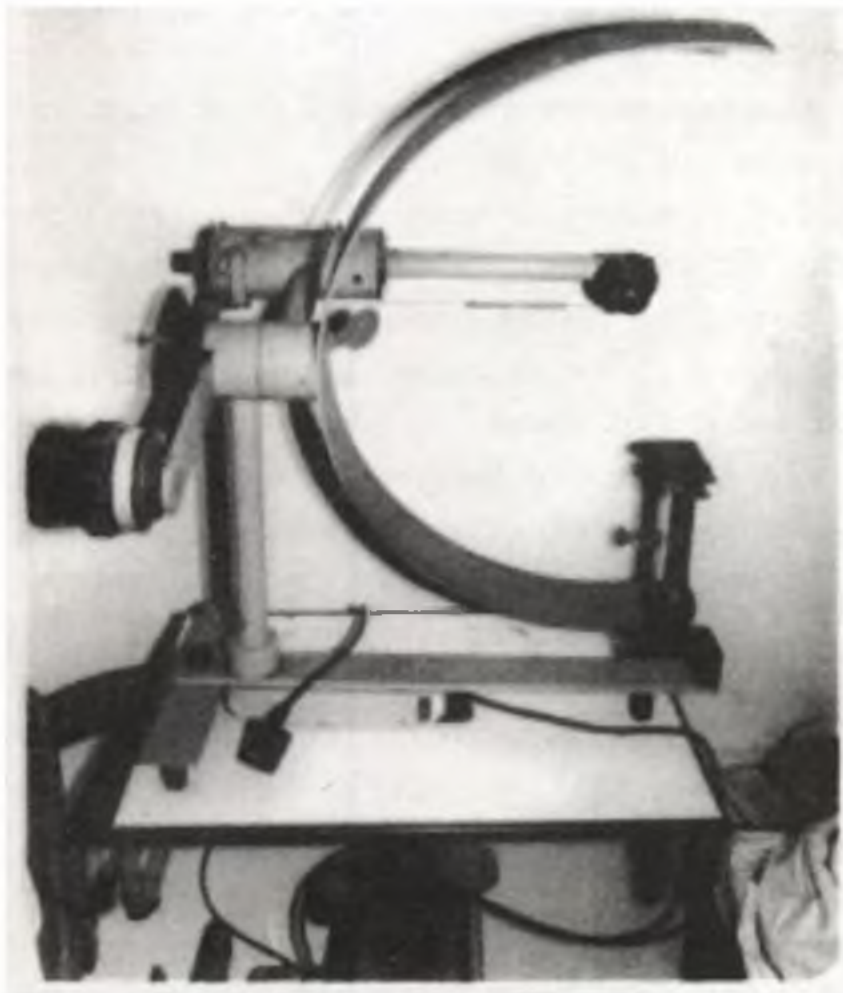


Fig. 33.17 Simplified perimeter.

or her attention to the central white dot of the arc having a radius of 330 mm from the eye. The arc, calibrated in degrees, can be rotated in a plane through its mid point. The test object is a disc usually 3 mm, which is movable along the arc and it is moved in from the periphery. The patient is asked to say when the test object is first seen by him or her while fixing his or her gaze towards the central dot. This is repeated using 16 positions of the arc. The least is eight positions. The test is then repeated with colour discs of the same size. Readings are recorded on a perimeter chart by perforations with a sharp point (Fig. 33.18).

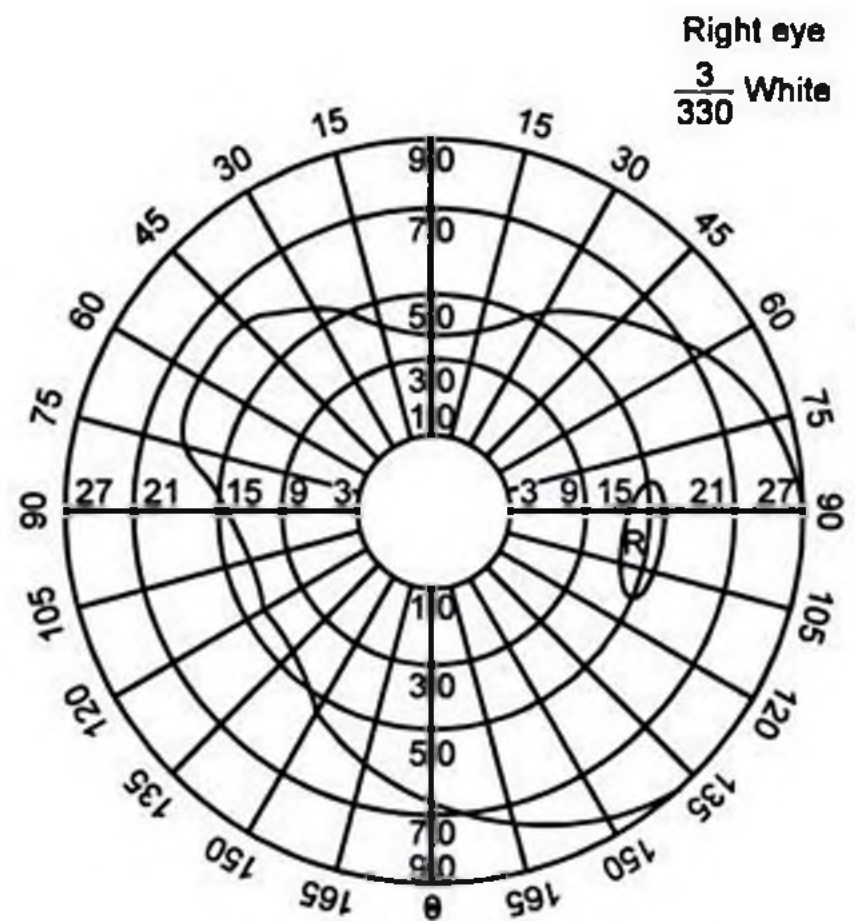


Fig. 33.18 A normal peripheral visual field. Right eye.

The main causes of peripheral field contraction are: (a) glaucoma; (b) optic atrophy; (c) papillitis; (d) peripheral retinochoroiditis; (e) retinitis pigmentosa; and (f) quinine or salicylate poisoning.

Scotometry by Bjerrum screen (Fig. 33.19). Bjerrum screen is a black square screen—2 × 2 metres marked with a central white spot and circles at 5°, 10°, 20° and 30° around the central point. The patient sits at 2 metres from the screen, with one eye occluded and fixing his or her gaze towards the central spot. At first the blind spot is charted




Fig. 33.19 Bjerrum screen

between 14° and 19° out along the horizontal equator and extends about 4° above and below it using a standard test object. *Blind spot of Mariotte* in the visual field corresponds with the optic disc.

A 5 mm white test object is used which is moved in from the periphery of the screen until seen by the patient. The position is indicated by placing a pin. The test is repeated till the charting is complete in all aspects.

If 5 mm object is not seen, a larger one is used.

In scotometry, several factors are important: (a) size of the test object; (b) distance from eye to screen; (c) illumination; and (d) background.

Causes of enlargement of the blind spot include: (a) papilloedema; (b) glaucoma; (c) progressive myopia with a temporal crescent; (d) juxtapapillary choroiditis; (e) medullated nerve fibres; and (f) drusen of the optic nerve-head, etc.

Bjerrum scotoma

Bjerrum scotoma affects the so-called Bjerrum area of the visual field which is 10° and 20° from the

fixation point. It is elliptical in shape simulating temporal nerve fibre bundles and usually crosses the vertical midline and producing a 'nasal step'.

Causes can be subdivided into three groups: (a) lesions at the optic disc are those of enlargement of the blind spot; (b) lesions in the anterior optic nerve, e.g. ischaemia and atrophy; and (c) lesions in the posterior optic nerve and optic chiasma, e.g. meningioma at the optic foramen or dorsum sella and pituitary adenoma.

Field defects

Reed⁷ considered field defects under four headings and their characteristics:

(a) Retinal lesion corresponding to the course of nerve fibres or blood vessels of the retina and crossing of the midline through the fovea.

(b) Retrobulbar lesions giving rise to central scotoma.

(c) Chiasmal lesions giving rise to bitemporal defects which is seldom symmetrical and is more advanced in one eye than the other.

(d) Lesions behind the chiasma producing homonymous hemianopia.

If the lesion is beyond the lateral geniculate body, two features are superadded, congruous homonymous hemianopia and macular sparing. When hemianopia is identical in both eyes it is called *congruous*.

Goldmann projection perimeter consists of a hemispherical bowl with a radius of 33 cm and a chin rest. It has a test object (circle of illumination) whose size, luminance and colour can be changed. The patient fixates the preset spot of light onto the bowl, while the observer monitors the patient's fixation through the central viewing aperture.

Tubinger perimeter. Facilitates the plotting of visual response along any meridian of the visual field. It can plot both central and peripheral fields, and can be used for static and kinetic perimetry, specifically for static.

Multiple pattern method for visual field examination (Fig. 33.20)

Multiple pattern method is not a substitute for standard perimetry but a simple screening device for the majority of field defects. There are 20 cards, 10 for each eye. Each card contains abstract patterns of dots and crosses on which the eye should concentrate. The central dot is black and the others are white fluorescent sulphide painted. The card is illuminated by ultraviolet radiation of quarter second duration when the pattern is distinctly visible against the white card. If there is any defect in any part of the visual field the stimulus of the pattern is not seen and so the patient describes it erroneously.

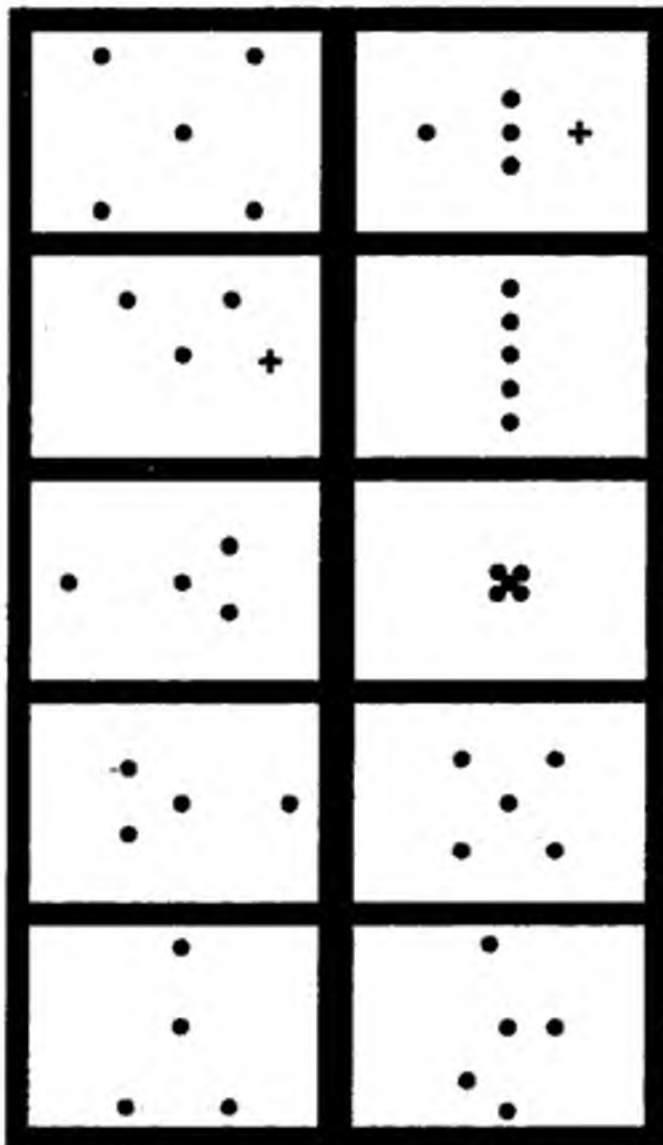


Fig. 33.20 Assessment of visual field by multiple pattern method.

Hemianopia (Fig. 33.21)

Hemianopia is the blindness of one-half of the visual field in one or both eyes. The classification has been shown in Table 33.1.

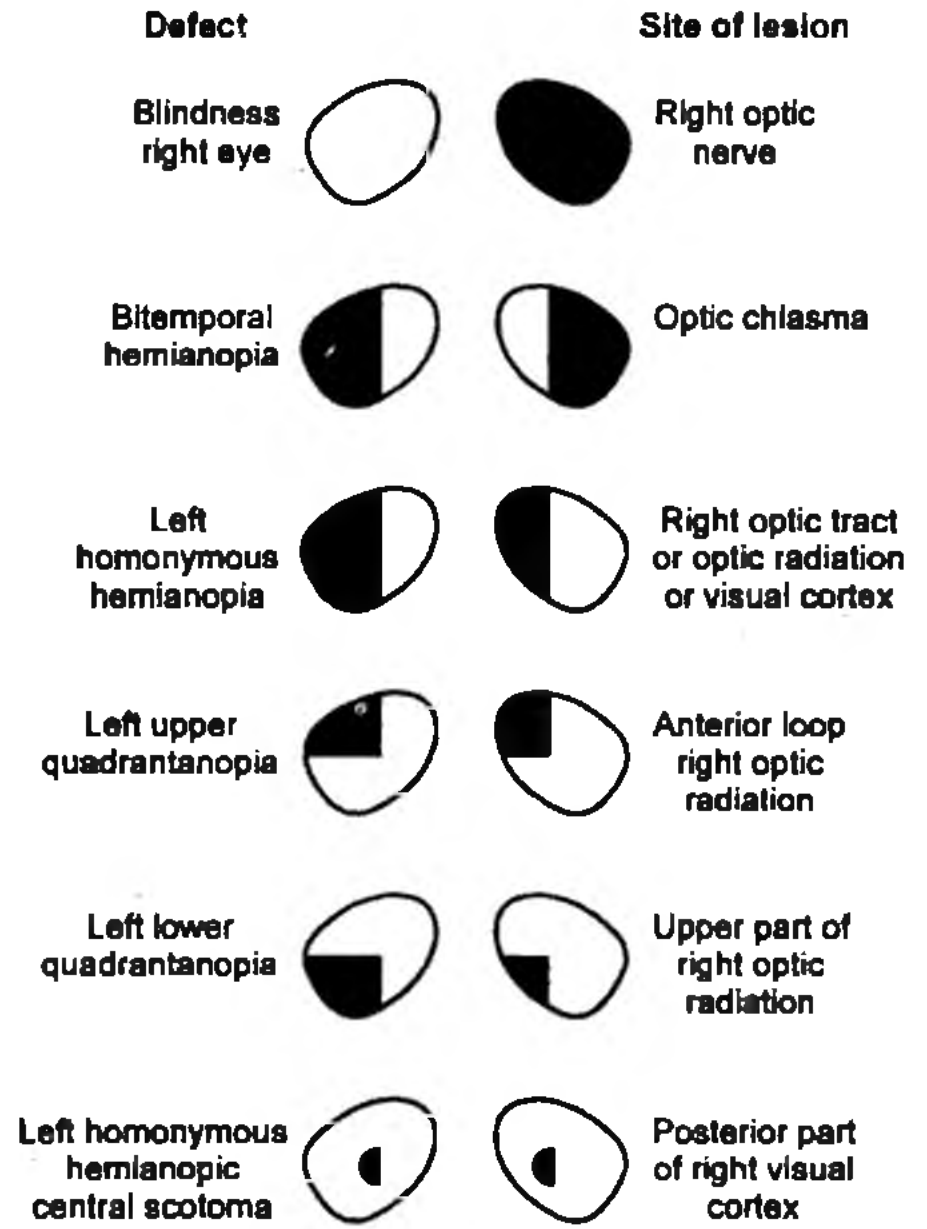


Fig. 33.21 Schematic edxamples of visual field defects (Parr).

Table 33.1
Classification of Types of Hemianopia

Unilateral	Temporal	
	Nasal	
	Superior altitudinal	
	Inferior altitudinal	
Bilateral	Homonymous	
	Heteronymous	— Bitemporal
		— Binasal

Quadrantanopia

Quadrantanopia is the sector-shaped defect limited by vertical and horizontal radii. A crossed quadrantanopia is one which involves one upper in one side and one lower in the other side. For clsssification, see Table 33.2.

Table 33.2
Classification of Quadrantanopia

Unilateral	
Bilateral	Bitemporal
Homonymous	Binasal
	Upper
	Lower
Crossed	

Table 33.3
Types of Scotomata

Central-	at the fixation point
Paracentral-	adjacent to the fixation point
Pericentral-	surrounding the fixation point
Pericaecal-	surrounding the blind spot
Paracaecal-	in the proximity of the blind spot
Centrocaecal-	between the fixation point and blind spot
Arcuate	
Annular or ring	
Peripheral	
Hemianopic	
Quadrantanopic	
Positive	
Negative	
Relative	

Scotomata (Figs. 33.22–33.24)

Scotoma is an area of depressed vision within the visual field. The different types are shown in Table 33.3.

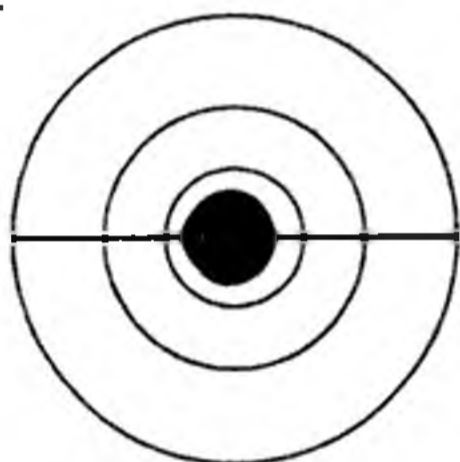


Fig. 33.22 Central scotoma.

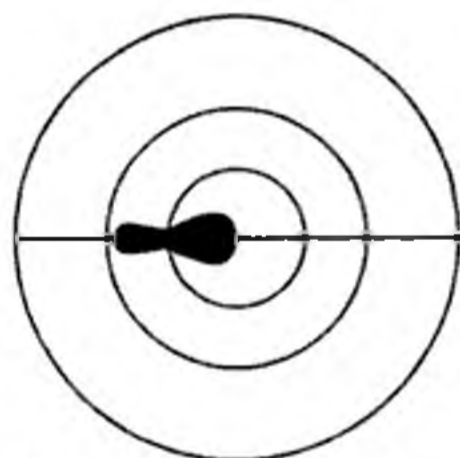


Fig. 33.23 Centrocaecal scotoma.

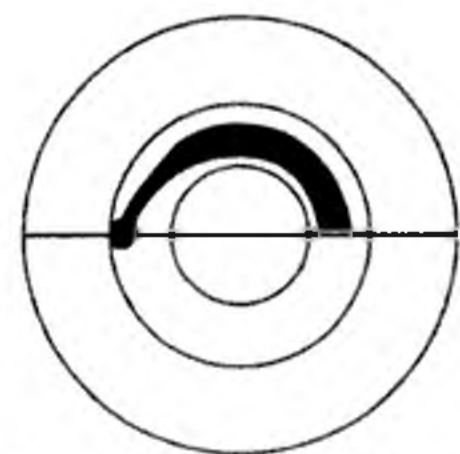


Fig. 33.24 Arcuate scotoma.

Positive scotoma is complained of by the patient. Negative scotoma is detected by the observer. Relative scotoma is the defective appreciation of colour. Altitudinal hemianopia means defect of the superior or inferior half-field bounded by the horizontal meridians. Junction scotoma is a temporal hemianopia involving the nasal fibres at the point where the optic nerve joins the optic chiasma.

Visual Field Changes in Different Ocular Disorders^{2,4}

The visual field changes in some groups of ocular conditions are now described.

Choroidal diseases

Choroiditis. Different morphological types of choroiditis may cause the following types of field changes: (a) scotomas—central, arcuate, sector, or multiple; (b) enlargement of the blind spot; and (c) general depression of all the isoptres of the field.

Central choroidal atrophy. It is due to myopic chorioretinal degeneration or obliterative vasosclerosis. It may cause a central scotoma.

Central areolar choroidal dystrophy causes an absolute central scotoma.

Coloboma of the choroid and retina. There is scotoma which corresponds with the coloboma more or less.

Retinal diseases

The field changes are seen in vascular lesions, inflammations, degenerations of the retina, retinopathies, injuries, tumours or detachment of the retina.

Occlusion of the central retinal artery. If complete, there is total blindness; with the presence of the cilioretinal artery, there is retention of central island of vision. In occlusion of the superior branch of the central retinal artery, there is loss of lower field.

Occlusion of the cilioretinal artery shows centrocaecal scotoma and a normal peripheral field.

In *central retinal vein thrombosis*, central scotoma of varying density and size may be detected.

In *central serous retinopathy* and *commotio retinae*, central scotoma is found.

Solar retinitis also produces central scotoma.

In *toxoplasmic retinochoroiditis* bilateral, central and paracentral scotomas are detected which correspond to the lesions visualized ophthalmoscopically.

In *pigmentary dystrophy of the retina* there is ring scotoma occupying the midperiphery of the visual field. The outer edge of the scotoma expands towards the periphery and the inner edge contracts towards the fixation point.

In *senile macular degeneration* central scotoma of varying density is detected.

Disciform degeneration causes irregular and dense central scotoma.

Toxic Effects on the Retina and Optic Nerves

Tobacco. Typically centrocaecal scotoma is seen in tobacco amblyopia.

Digitalis. Scotomas may be secondary to retrobulbar neuritis or toxic effects on the retinal receptors.

Streptomycin. The field changes are secondary to neuritis and include arcuate scotoma.

Isoniazid. This may cause bilateral central scotoma.

Optic Nerve Affections

Papilloedema. The early visual field change is a gradually developing concentric enlargement of the blind spot. A relative central scotoma in which there is blue blindness predominant may occur if the oedema involves the macular area.

When atrophy sets in there is also peripheral field contraction.

There may be additional field defects as a result of effect of an intracranial lesion on the visual pathways and centres.

Retrobulbar neuritis. The visual field changes are substantially the same in both acute and chronic cases. The changes are: (a) central scotoma is typically present; (b) centrocaecal scotoma and peripheral field contraction are also commonly present; and (c) rarely sector-shaped defects are seen.

Chiasmal Affections

The visual field changes are perhaps the result of ischaemia following constriction of the blood vessels supplying the region, evidenced by clear-cut margins of the defective field and rapid recovery of the defect on relief of pressure.

The important chiasmal lesions include vascular, i.e. intracranial aneurysm, arteriosclerosis and arterial compression, inflammatory lesions such as basal meningitis and neuritis, and tumours of the chiasma.

While considering chiasmal field defects one must consider the relation of optic chiasma with the neighbouring blood vessels and its varying relation with the sella turcica. It is absolutely essential to know the precise pattern of the arrangement of the fibres in the optic chiasma. There are six types of chiasmal field defects (Table 33.4).

Table 33.4

Types of Pressure on the Optic Chiasma and Visual Field Defects²

1. Median pressure:	Bitemporal hemianopia
2. Lateral pressure:	(a) Ipsilateral nasal hemianopia + diagonally quadrantic temporal defects (b) Then, ipsilateral blindness and contralateral temporal hemianopia
3. Anterolateral pressure:	(a) Ipsilateral nasal hemianopia + contralateral superotemporal quadrantanopia (b) Ipsilateral blindness + contralateral superior temporal quadrantanopia
4. Anteromedial pressure:	(a) Ipsilateral temporal hemianopia + contralateral superior temporal quadrantanopia (b) Then, ipsilateral blindness with contralateral superior quadrantanopia
5. Posterolateral pressure:	(a) Ipsilateral nasal hemianopia (b) Followed by contralateral hemianopia
6. Posteromedial pressure:	(a) Contralateral temporal hemianopia (b) Followed by ipsilateral hemianopia

Infrachiasmatic Lesions

A typical example is the *pituitary adenoma*, which presses the chiasma from below in the midline. Here it is stressed that the chiasma may be prefixed, in the middle position, or postfixed. Hence, the field defects may vary.

The classical field defect is a symmetric bitemporal hemianopia. As the chiasma is pushed superiorly, its anterior part along with two optic nerves may be compressed in between the tumour and two anterior cerebral arteries, consequently, the field changes appear in complex forms.

Suprachiasmatic Lesions

Broadly there are two groups of lesions—those involving the chiasma from the anterosuperior direction, and those from the posterosuperior.

(a) The *most important tumours attacking the anterosuperior aspect* are meningiomas of the olfactory groove, tuberculum sellae, or lesser wing of the sphenoid bone.

Olfactory groove meningioma is a midline tumour and spreads into the anterior chiasmal angle and causes symmetric bitemporal hemianopia. It can grow in an eccentric manner to involve one optic nerve or the other before reaching the chiasma.

Meningioma from tuberculum sellae produces similar change in the visual field as in olfactory groove meningioma.

Meningioma of the lesser wing of sphenoid bone shows irregular and asymmetric field changes caused by chiasmal compression.

(b) *Chiasmal compression* from the posterosuperior aspect is caused by craniopharyngioma and dilatation of the third ventricle. Craniopharyngioma produces bitemporal hemianopia, though it can cause variable changes like central, irregular and asymmetric bitemporal scotomas.

Vascular Lesions

The relation of the circle of Willis with the optic chiasma is an important consideration. The most common vascular lesion in this area is aneurysm of the internal carotid artery. The important field defects following an aneurysm are:

- Ipsilateral nasal defect with a scotoma
- Contralateral temporal defect
- Inferior bitemporal hemianopia
- Unilateral nasal hemianopia
- Homonymous hemianopia.

Retrochiasmal Lesions

Optic tract lesions produce homonymous hemianopia. The defect is incongruous. Such lesions may be caused by aneurysm of the internal carotid artery or the posterior communicating artery, craniopharyngioma, pituitary adenoma and demyelinating disease.

Temporoparietal lesions include vascular,

neoplastic or demyelinating diseases. Temporal lobe lesion at first affects the superior visual fields, while parietal lesions causes inferior field defects in the beginning.

Occipital lesions beyond the lateral geniculate body also produce homonymous hemianopia, but two features are characteristic—*congruity* and *sparing*. The lesions in this region include vascular affections, tumours, demyelinating diseases and injury.

Further Reading

1. Doggart, J.H., *Ocular Signs in Slit-lamp Microscopy*, Kimpton, London, 1949.
2. Duke-Elder, S., *System of Ophthalmology*, Vol VII: *The Foundations in Ophthalmology*, Kimpton, London, 1962.
3. Goldmann, H.; The diagnostic value of biomicroscopy of the posterior parts of the eye, *Br. J. Ophthalmol.*, 45: 449, 1961.
4. Harrington, D.O., *The Visual Fields: A Textbook and Atlas of Clinical Perimetry*, 3rd ed., C.V. Mosby, St. Louis, 1971.
5. Hruby, K., *Slit Lamp Examination of Vitreous and Retina* (English translation), Posner, A., Williams and Wilkins, Baltimore, 1967.
6. Newell, F.W., *Ophthalmology: Principles and Concepts*, 8th ed., C.V. Mosby, St. Louis, 1997.
7. Reed, H., *The Essentials of Perimetry*, Oxford University Press, London, 1960.
8. Schepens, C., *Retinal Detachment and Allied Diseases*, W.B. Saunders, Philadelphia, 1985.
9. Trevor-Roper, P.D. and Curran, P.V., *The Eye and Its Disorders*, 2nd ed., Blackwell Scientific, Oxford, 1984.
10. Vaughan, D., Asbury, T. and Tabbara, K.F. (Eds.), *General Ophthalmology* (12th ed.), Appleton and Lange, Connecticut, 1989.
11. Zuckerman, J., *Diagnostic Examination of the Eye*, 2nd ed., J.B. Lippincott, Philadelphia, 1964.

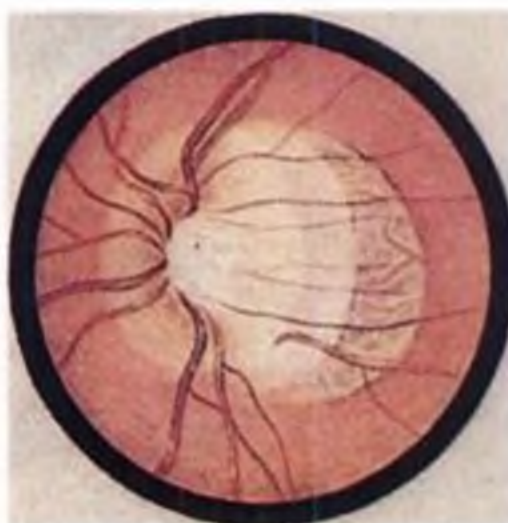

Fig. 32c.1 Myopic retraction and crescent (Parsons).

Part Five

Ocular Diseases and Ocular Affections in Systemic Diseases

There are several diseases that affect the eyes and ocular involvement in many systemic disorders is present. These will be discussed now.

34. DISEASES OF THE ORBIT

The relations and contents of the bony orbit are extremely important since the affections of the orbit follow those of the structures around or involve any of the contents. The fissures and foramina bear important relationship, e.g. there is intracranial communication through the optic foramen and sphenoid fissure. The affections may spread from the paranasal sinuses to involve the orbit or may spread far afield from the orbit through the venous channels, sometimes rapidly. Tenon's capsule, through which the extrinsic muscles are invaginated, forming a fibrous wall may be involved. Because of the unyielding bony walls any swelling causes a protrusion of the globe, i.e. proptosis.

Investigations in orbital disorders have been summarized in Table 34.1.

Table 34.1

Investigations of Orbital Disorders⁵

History
of proptosis, pain, vision changes
of head injury, injury to the orbit, fever
of associated systemic affections, thyroid disorder in family
Proptosis or exophthalmos
Visual acuity
Visual fields
Pupillary reactions
General inspection of the orbits
Palpation around the eyeball and the orbital rim
Evidence of congestion and inflammation
Examination of the lids
Ocular movements
Examination of the ocular fundi
Imaging studies
X-rays
Ultrasonography
Computerized tomography (CT)
Magnetic resonance imaging (MRI)
Examination of tissue specimens obtained by
Open biopsy
Tumour excision
Fine-needle aspiration biopsy

Proptosis or Exophthalmos^{1,6,9,20}

Though these two terms are used synonymously, they connote different meanings. Proptosis is the passive or mechanical protrusion of the eyeball, while exophthalmos is the active protrusion of the eyeball forward. A classic example of exophthalmos is a dysthyroid exophthalmos.

A true proptosis (Fig. 34.1) should be differentiated from a pseudo- or apparent proptosis.

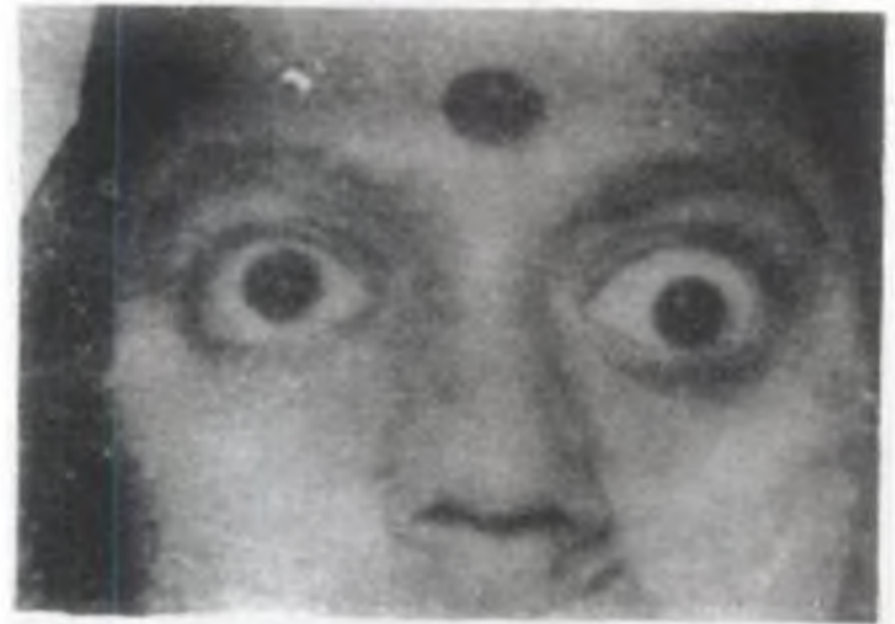

Fig. 34.1 Proptosis.

A pseudoproptosis occurs either due to enlargement of the eyeball or retraction of the eyelids; the causes include high myopia, asymmetry of the orbit, lid retraction, buphthalmos, shallow orbit, external ophthalmoplegia and contralateral enophthalmos. It is essential to note whether in primary position the upper lid margin rests at or above the limbus, i.e. lid retraction, or both upper and lower lids are equally withdrawn from the cornea as in exophthalmos, or the exposure of the sclera is asymmetrical, the distance of the upper lid margin from the limbus is greater than that of the lower as in simultaneous presence of exophthalmos and lid retraction.

Aetiology. Aetiology can be enumerated as follows:

Unilateral. Inflammatory, vascular, tumours, cysts and trauma.

Bilateral. Dysthyroid exophthalmos, cavernous

sinus thrombosis, congenital anomalies (e.g. oxycephaly), osteopathies, occasionally some tumours like multiple myeloma, and systemic affections like Wegener's granulomatosis.

Acute. Haemorrhage within the orbit and emphysema from the paranasal sinuses.

Pulsating. (a) True: typically in carotico-cavernous fistula and aneurysm of the internal carotid artery.

(b) Pseudo: e.g. frontal mucocele, angioma and neurofibroma.

Intermittent. Typical in orbital varix.

Investigations

History includes age of the patient, onset, fluctuation, duration, chronology of symptoms, local symptoms, history related to the thyroid gland, general symptoms, etc.

Clinical eye examinations

Inspection. The following plan of examinations may be followed:

(a) Unilateral or bilateral—more often proptosis is unilateral.

(b) True or pseudoproptosis.

(c) Presence of lid lag—if present a tumour can be ruled out.

(d) Direction of proptosis—axial or eccentric.

(e) Restriction of ocular movements.

(f) Presence of any swelling or fulness.

(g) Comparison of the level of the two eyes,

(h) Presence of inflammatory signs in the lid and conjunctiva.

(i) Presence of pulsation.

(j) Colour of the lid skin.

(k) Pupillary reactions.

(l) Inspection of the neighbouring area, e.g. shape of the skull, and fulness of the maxillary fossa.

Orbital palpation. This involves digital compression of the eyeballs backwards, palpation of the orbital rim, presence of any mass, bony defect and thrill.

Visual acuity. It may be emphasised that

anything which presses upon the optic nerve or causes defective blood supply to this nerve causes loss of vision.

Ophthalmoscopy. This is done for evidence of venous engorgement, haemorrhage and papilloedema.

Estimation of the degree of proptosis. (a) The observer stands behind the patient who is sitting, raises both upper lids while asking him or her to look downwards. Normally the cornea disappears from the view.

(b) In exophthalmometry, an exophthalmometer takes the measurement of the distance of the corneal apex which protrudes in front of the lateral orbital rim. Normally, this distance does not exceed 16 mm. A transparent plastic ruler with scale engraved on both sides and with a groove which can fit into the lateral margin of the bony orbit is commonly employed as an exophthalmometer.

Other examinations. These include orbitometry, visual field charting, tonometry, slit-lamp biomicroscopy, transillumination and auscultation.

General examination

General examination includes check-up for dysthyroid state, otorhinolaryngological conditions, blood picture, stool, urine and search for any primary neoplasm.

Plane X-ray of the orbit^{12,16}

X-ray of the eye and orbit is indicated in injury, foreign body and tumour. X-ray can be taken from different angles.

Caldwell view. This is a posteroanterior view, with the patient lying prone with his or her forehead and nose touching the X-ray table. It is needed to visualize the orbital rim and roof, the greater and lesser wings of the sphenoid, and the superior orbital fissure.

Waters view. Here in addition to Caldwell's the head is extended with the chin lying about 4 cm above the table. The areas seen are the inferior

orbital rim, the lateral orbital wall and the paranasal sinuses.

Oblique view. This is for better demonstration of the outer rim of the orbit.

Rhese position. This is needed to visualise the optic canal. The patient lies prone with the zygoma, nose, and chin resting on the table.

Lateral view. This is required in localizing foreign bodies.

Possible changes seen in plane X-rays

These include:

- (a) Alteration of general radiographic density of the orbit
- (b) Increased bone density
- (c) Symmetrical enlargement with a tumour within the muscle cone or asymmetrical with a tumour involving the orbital wall
- (d) Change in the shape of the orbit
- (e) Dehiscence in the bony wall
- (f) Change in the diameter of the sphenoidal fissure or optic canal.
- (g) Presence of calcification.

Special Radiological Techniques¹⁶

Carotid angiography (Fig. 34.2). This helps to demonstrate an orbital lesion in two ways: (a) the displacement of the ophthalmic artery and its branches; and (b) the demonstration of an abnormal vascular pattern. The common carotid artery is injected with an iodine-containing dye.

Orbitography. An orbitography can be done with either positive contrast or negative contrast, i.e. air. With positive contrast, 5 ml of a 20 per cent contrast medium is slowly injected retrobulbarly after a ciliary block and check-up of the needle by X-ray followed by withdrawing the needle and application of a tight pressure bandage. The pictures are then taken.

With negative contrast, the injected air is seen on X-ray as dark area, while the normal intraorbital structures are seen as areas of negative contrast. Abnormal appearances suggesting an orbital lesion

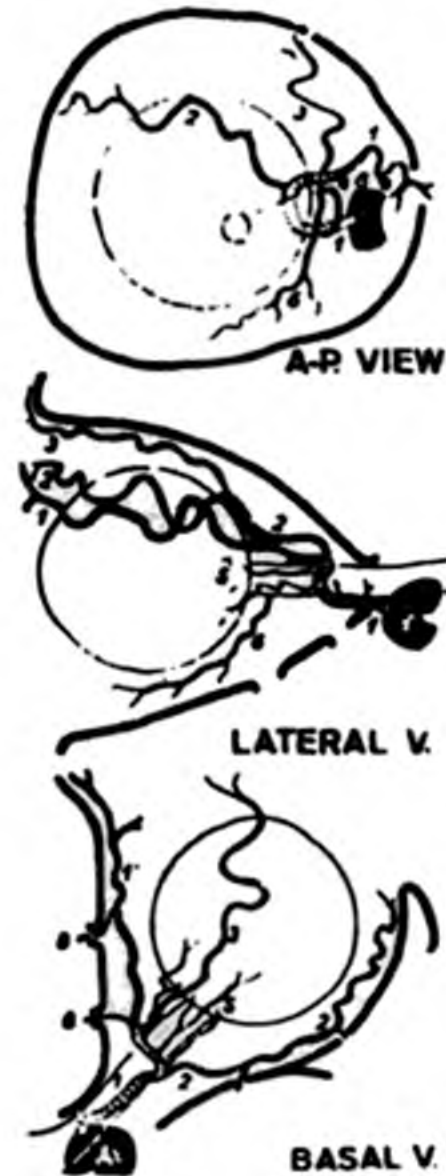


Fig. 34.2 Ophthalmic artery. Diagrams of the three orthogonal views: 1, ophthalmic artery; 2, lacrimal artery; 3, supraorbital artery; 5, ciliary arteries; 6, inferior maxillary; 8, ethmoidal arteries. [By courtesy of Dr G Salamon, from Salamon and Associates: *Ann Radiol* (Paris) 8: 557, 1965; Lombardi]

are obliteration of the fascial space and displacement of normal topography of structures. This is also referred to as *pneumo-orbitography*. An orbitography may cause discomfort and even visual impairment.

Orbital venography. Injection of a contrast medium is given through the frontal or supraorbital vein. In a frontal venography to prevent reflux of the contrast medium over the forehead a rubber band is placed around the hair-line and to prevent influx in the facial veins finger pressure is applied. For localization of an intraorbital lesion the following appearances should be noted—the displacement of the veins and the demonstration of abnormal veins.

Orbital tomography. This is a method in which

the superimposed structure in the neighbourhood are blurred for clear visibility of a given spot at a given depth. Two types—linear or *laminography* and hypocycloidal or *polytomography* are indicated in detection of orbital tumours and linear fractures.

Ultrasonography.⁴ This noninvasive technique confirms the diagnosis thus making X-ray unnecessary in some cases. A-scan provides information about the swollen optic nerve and extrinsic muscles. B-scan indicates the shape of the lesion and proximity of the lesion to the normal structures.

Computerized tomography.⁴ The bony and calcium-containing lesions are preferably evaluated by computerized tomography (CT). Hence, this is a preferred method of investigation in optic nerve sheath meningioma, orbital fractures and foreign bodies in the orbit.

Magnetic resonance imaging (MRI)⁴ appears to be the best mode of evaluation for various orbital and ocular diseases because of its high tissue contrast ability. All parts of the optic nerve can be clearly visualized. Certain lesions around the apex of the orbit, superior orbital fissure and optic canal can be better evaluated by MRI than by CT.

Therapeutic Trial with Steroids and Antibiotics. Retrogression indicates that certain inflammatory lesion is the cause of proptosis.

Surgical Exploration. Surgical exploration may be called for to determine the nature of the lesion. Occasionally biopsy is resorted to and depending on the report such treatment is suggested.

Enophthalmos

Enophthalmos is the retraction of the globe into the orbit. It is caused by blow-out fracture of the orbit, postsurgical shortening or postinflammatory scarring of the extrinsic muscles, maxillary hypoplasia, microphthalmos, etc.

Acute Orbital Cellulitis (Postseptal Cellulitis)

Acute orbital cellulitis is a purulent inflammation of the cellular tissues of the orbit.

Aetiology. Most commonly there is a spread of infection from the paranasal sinuses—ethmoid, frontal or maxillary. In children, ethmoiditis is very common. Infection reaches the orbit by two ways—through thrombophlebitis of the communicating veins, and rarely by bony dehiscences.

Infection may spread to the orbit from the teeth, the lacrimal apparatus or the skin.

A penetrating injury with retained foreign body in the orbit may sometimes provoke inflammation.

Pathology. The characteristics are those of inflammation, absence of lymphatics, digestive action of orbital fat and limitation of inflammation by fascial membranes.

Clinical features. In mild cases, there is slow development of insignificant constitutional signs, while in severe cases, the constitutional signs are marked.

Symptoms and signs in an advanced case are severe ocular pain, marked swelling of the lids and conjunctiva, axial and irreducible proptosis, restriction of all ocular movements and marked constitutional symptoms such as fever, headache, nausea and prostration. Vision may be reduced due to associated optic neuritis.

Complications. Complications are quite common and include exposure keratitis, papilloedema, optic neuritis leading to optic atrophy, septic uveitis, panophthalmitis, cavernous sinus thrombosis, rarely septicaemia and pyaemia.

Differential diagnosis. The condition should be differentiated from stye, suppurative chalazion, tenonitis, panophthalmitis and cavernous sinus thrombosis.

Treatment. The principles of treatment are adequate systemic antibiotics, local heat and treatment of the primary focus, e.g. drainage of pus from an infected paranasal sinus. An incision is sometimes done to drain the peripheral surgical space.

Preseptal (Periorbital) Cellulitis

Preseptal or periorbital cellulitis is an inflammation of the subcutaneous tissue of the eyelid in front of

the septum orbitale. The distinguishing features are depicted in Table 34.2.

Table 34.2

Distinguishing Features of Orbital and Periorbital Cellulitis

Features	Orbital cellulitis	Periorbital cellulitis
Age at presentation	Over 5 years	Younger than 5 years
Oedema of lid	Yes	Yes ++
Proptosis	Yes	Absent or minimum
Chemosis	Marked	Absent or mild
Ophthalmoplegia	Present	Absent
Visual acuity	May be reduced	Normal

Chronic Orbital Cellulitis¹⁸

Chronic orbital cellulitis may present clinically as pseudotumours of the orbit. It may be a sequel of tuberculous affection of the malar bone, syphilitic affection of the upper orbital margin or a nonspecific granuloma.

Tenonitis

Tenonitis may be serous, chiefly rheumatic and purulent. It is characterized by a sudden onset, pain, slight proptosis, lid oedema, chemosis, limitation of ocular movements and annular swelling around the muscle insertions. Treatment consists of local and systemic antibiotic therapy.

Osteoperiostitis

There are two types:

- (a) *Anterior*—involving the orbital margin.
- (b) *Posterior*—involving the apex of the orbit.

Aetiology. Tenonitis is caused by: (a) trauma; (b) extension from the neighbouring inflammation; and (c) specific granuloma, e.g. tuberculosis, syphilis, etc.

Clinical features. There are eccentric proptosis, focal tenderness plus other localizing signs.

In anterior periostitis, the sequences are oedema and tenderness→abscess→fistula→cicatrization.

Posterior periostitis is characterized by a triad of signs: (a) absolute immobility of the globe since the III, IV and VI cranial nerves are involved; (b) amaurosis where the II cranial nerve is involved; and (c) anaesthesia where the trigeminal nerve is involved.

Treatment. Most often it resolves with antibiotic therapy. But if there is suppuration, it should be drained. Occasionally in deep-seated inflammation, surgical exploration is called for.

Cavernous Sinus Thrombosis

The *anatomy* of the venous channels which communicate with the cavernous sinuses is of great importance in this connection. The cavernous sinuses (Fig. 34.3) lie on either side of the body of the sphenoid, between the two layers of the dura mater, extending from the superior orbital fissure backward for about 2 cm. They are formed by the superior ophthalmic, a tributary from the inferior

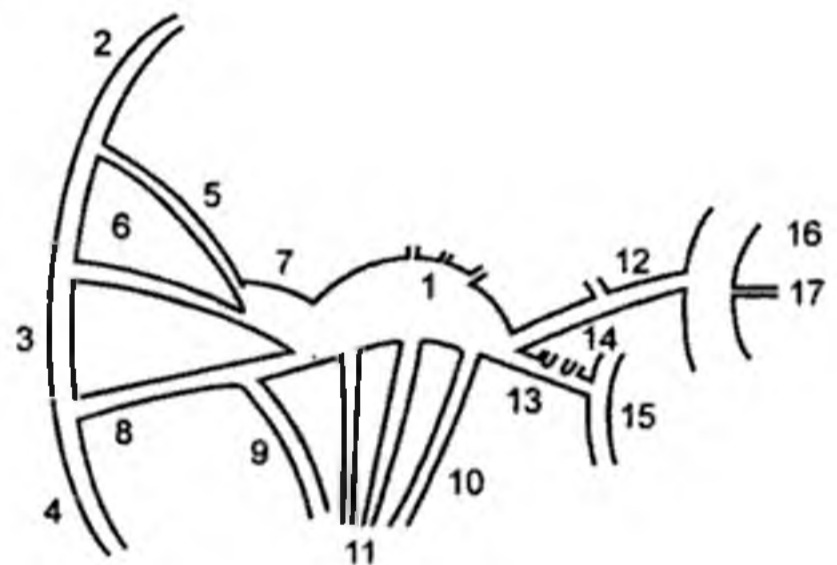


Fig. 34.3 Lateral view of the tributaries of the cavernous sinus. 1, cavernous sinus; 2, frontal vein; 3, angular vein; 4, facial vein; 5, supraorbital vein; 6, nasal vein; 7, superior ophthalmic vein; 8, inferior ophthalmic vein; 9, communicating vein; 10, middle meningeal veins; 11, pterygoid venous plexus; 12, superior petrosal sinus; 13, inferior petrosal sinus; 14, labyrinthine veins; 15, jugular vein; 16, lateral sinus and 17, mastoid emissary vein.

ophthalmic, central retinal veins, sphenopalatine sinus along with various emissary veins. Each sinus drains backwards through the superior and inferior petrosal sinuses into the sigmoid sinus and finally into the internal jugular vein. The cavernous sinuses also intercommunicate.

Contents (Fig. 34.4) are the internal carotid artery with accompanying sympathetic nerves within the sinus and in its lateral wall are the III, IV, VI and the first and second divisions of V cranial nerves.

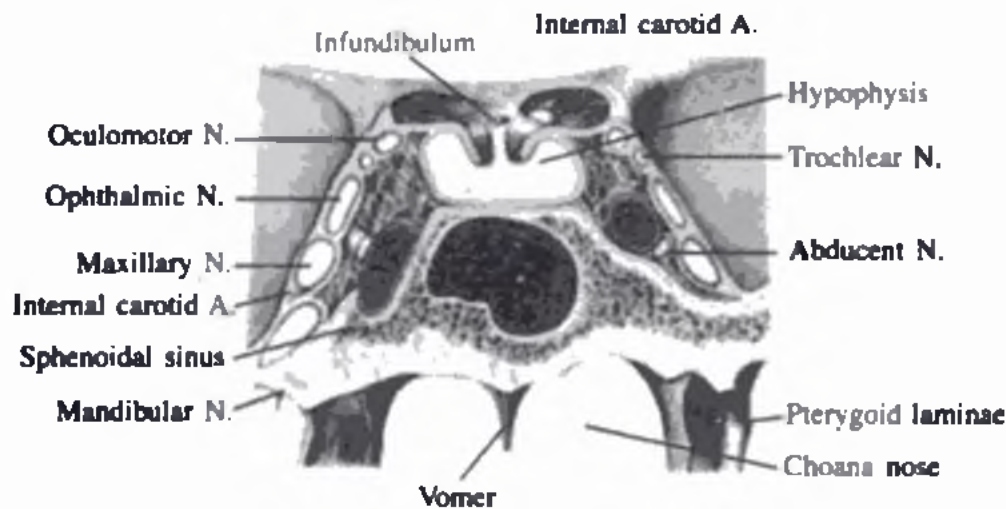


Fig. 34.4 Coronal section through the sella turcica and cavernous sinus (Cunningham).

Aetiology. Cavernous sinus thrombosis is caused by septic thrombophlebitis of the sinus from pyogenic foci in the face, mastoid region and sometimes from pyaemia.

Clinical features. Cavernous sinus thrombosis is characterized by a violent onset, bilaterality, rapid evolution of proptosis, marked constitutional upset, paralysis of the motor cranial nerves, a swelling of the skin over the mastoid process due to back pressure of the mastoid emissary vein, plus all the features of an acute orbital cellulitis. Simultaneous thrombosis of both cavernous sinuses with proptosis and papillitis occurs in diseases of the sphenoid sinuses.¹⁵

Treatment. The principle are: (a) intense systemic antibiotic therapy; and (b) intravenous anticoagulants to control the extension of the clot.

Nasal Sinusitis

Nasal sinusitis may affect the anteriorly-placed

sinuses causing mucocele and pyaemia, or the posteriorly-placed sinuses causing optic neuritis and myositis.

Pseudotumours of the Orbit^{2,17}

Birch-Hirschfeld (1930) coined the term. An orbital pseudotumour may be defined as a nonspecific, idiopathic and benign inflammatory process.

Pathology. In the acute form there is hypocellular polymorphous infiltrate made up of mature lymphocytes, plasma cells, polymorphonuclear neutrophils (PMNs), macrophages and eosinophils. In subacute and chronic forms, there are increasing amounts of fibrovascular stroma as well as replacement of normal muscle, fat and glandular elements by fibrous tissue.

Clinical features. The affection is usually unilateral. Onset may be acute, subacute or chronic. There is no sex predilection. The inflammation may be localized or diffuse; the localized form may involve either the anterior orbit or the posterior orbit, extraocular muscles or lacrimal gland. In acute case there are pain, swelling of the eyelid and redness. In chronic type there are progressive visual loss, diplopia and proptosis. Involvement of the *anterior orbit* causes the pattern of inflammation which is called periscleritis, sclerotenonitis or anterior inflammatory pseudotumour (see p. 242).

The *posterior* pattern of acute pseudotumour presents primarily with features of orbital apex syndrome (see p. 159).

Differential diagnosis (Table 34.3). The condition needs differentiation from other orbital conditions.

Investigations. Investigations include contrast-enhanced CT (CECT) scan of the orbit, ultrasonography (USG), fine-needle aspiration biopsy (FNAB), magnetic resonance imaging (MRI), occasionally electromyography (EMG) and forced duction test.

Table 34.3

Differential Diagnosis of Pseudotumour of Orbit

Dysthyroid ophthalmopathy
 Infections
 Granulomatous disease like sarcoidosis
 Vasculitis
 Foreign body reaction
 Ruptured dermoid cyst
 Neoplasia
 Vascular disorders

Treatment. Treatment is not definite, but various measures are: (a) systemic antibiotics; (b) steroids; (c) surgery; and (d) radiotherapy.

Antibiotics and steroids are used before and after an operation. Bilateral, diffuse infiltrative and those with severe inflammation should be treated with these agents. Surgery is particularly indicated in smaller and more circumscribed and accessible tumours located in the anterior part of the orbit. Radiotherapy including radioactive cobalt shows satisfactory resolution in benign lymphoid hyperplasia.

Dysthyroid Exophthalmos

Thyroid disorders in ophthalmology may be broadly grouped under two headings:¹³

(i) *Hyperthyroidism.* (a) with exophthalmos and (b) without exophthalmos.

(ii) *Hypothyroidism.* (a) in adults—myxoedema and (b) in infants—cretinism.

Synthesis of thyroid hormones. Synthesis of the thyroid hormones are as follows:

(a) The trapping of iodide by the thyroid cell and its oxidation into iodine.

(b) Iodine + tyrosine —Monoiodotyrosine (MIT).

(c) MIT + iodine —Diiiodotyrosine (DIT).

(d) MIT + DIT—Triiodothyronine (T_3).

(e) DIT + DIT—Thyroxine (T_4).

Relation with the pituitary gland. A low serum level of thyroxine induces an increased thyroid-stimulating hormone (TSH) which leads to enhanced thyroxine secretion and vice-versa.

Exophthalmos-producing substance (EPS). It is possibly a gamma globulin present in the serum and probably secreted by the anterior pituitary.

Long-acting thyroid stimulator (LATS). This is found to be present in about 80 per cent of patients with Graves' disease. It is a 7S globulin produced by lymphocytes in such patients. It acts as an antithyroid antibody. Thyroid microsome may act as an antigen.

Systemic manifestations of hyperthyroid state. They may be briefly grouped under two headings:

(a) *Epinephrine-like*, e.g. tremor, tachycardia and excessive sweating.

(b) *Hypermetabolic*, e.g. increased appetite and increased basal metabolic rate (BMR).

Tests of thyroid function^{16,19}. Tests of thyroid function are indicated to detect whether the patient is hyperthyroid, euthyroid or hypothyroid.

(a) Total serum thyroxine or T_4 has now become a routine thyroid function test, replacing protein-bound iodine (PBI) test. High T_4 values are indicative of hyperthyroidism.

(b) Total serum Triiodothyronine or T_3 is affected but in a lesser degree than T_4 .

(c) T_3 resin uptake.

(d) Radioiodine uptake. The uptake is high in hyperthyroidism.

(e) Serum thyroid-stimulating hormone. It is high in hyperthyroidism.

(f) Thyrotropin-releasing hormone test. It is particularly useful in cases where T_4 and T_3 levels are equivocal.

(g) Thyroid antibodies. Autoantibodies directed against thyroglobulin and complement fixing directed against the microsomal fraction of the thyroid cell.

(h) Thyroid scan. Thyroid scan using technetium (^{99m}Tc) is a useful test to differentiate between Graves' disease and secondary hyperthyroidism.

Dysthyroid ophthalmopathy. Pathogenesis¹⁴ is obscure. Two views are prevalent.

Humoral immunity to thyroglobulin. Thyroglobulin and the allied products perhaps reach

the orbit passing through the cervical lymphatic vessels. It is thought that an autoimmune reaction is provoked by thyroglobulin-antithyroglobulin complexes on the sarcolemma of the extrinsic ocular muscles.

Delayed hypersensitivity to thyroglobulin. The presence of thyroglobulin in the orbital tissues triggers an autoimmune reaction in which the sensitized thymus-dependent (T) cells interact with thyroglobulin, causing a delayed type of hypersensitivity.

The *anatomical pathology* occurring in dysthyroid exophthalmos is as follows:

(a) Slight elevation of the upper eyelid causing widening of the palpebral fissure is perhaps due to overaction of epinephrine on Müller's muscle and tethering of the inferior rectus to the inferior oblique on causing overaction of the levator palpebrae superioris.

(b) There is oedema involving fats, fascia, extrinsic muscles due to accumulation of material rich in mucopolysaccharides and diffuse round cell infiltration.

(c) Limitation of ocular movements (*restrictive myopathy*) is due to fibrosis and inelasticity of the opposite muscle.

(d) Involvement of the optic nerve is probably due to pressure by swollen muscles, infiltration and/or defective blood supply.

Clinical features. Two forms may be distinguished:

- (a) Mild (benign, thyrotoxic or dry)
- (b) Severe (malignant, thyrotropic or wet)

Thyrotoxic Exophthalmos (Graves' Disease)

Thyrotoxic exophthalmos is common in females of 30 to 40 years of age. There is a strong hereditary pattern.

Exophthalmos is noticed in about 25 per cent cases and in about 90 per cent cases of ophthalmic Graves' disease. Apart from this other signs are listed in Table 34.4.

Table 34.4

Eponyms of Major Clinical Signs in Ophthalmic Graves' Disease

Clinical signs	Eponyms
Upper lid retraction	Dalrymple sign
Upper lid lag on downgaze	von Graefe sign
Extrinsic muscle palsies	Ballet sign
Weakness of convergence	Mobius sign
Absence of normal forehead creases	Joffoy sign
Infrequent blinking reflex	Stellwag sign
Lower lid lag on upgaze	Griffith sign
Increased pigmentation of skin	Jellinek sign
Tremor of closed eyelids	Rosenbach sign
Oedema of lower lid	Enroth sign
Spasmodic upper lid retraction during fixation	Kocher sign
Nystagmoid jerks during abduction to adduction	Wilder sign

Eye changes in Graves' disease can be grouped into seven classes:²¹

Class 0—no ocular signs or symptoms

Class 1—upper lid retraction, with or without lid-lag and proptosis

Class 2—soft tissue involvement

Class 3—proptosis

Class 4—extrinsic ocular muscle involvement

Class 5—corneal involvement

Class 6—loss of sight (optic nerve involvement).

Two types of exophthalmos (Fig. 34.5)—mild and severe can be distinguished (Table 34.5).

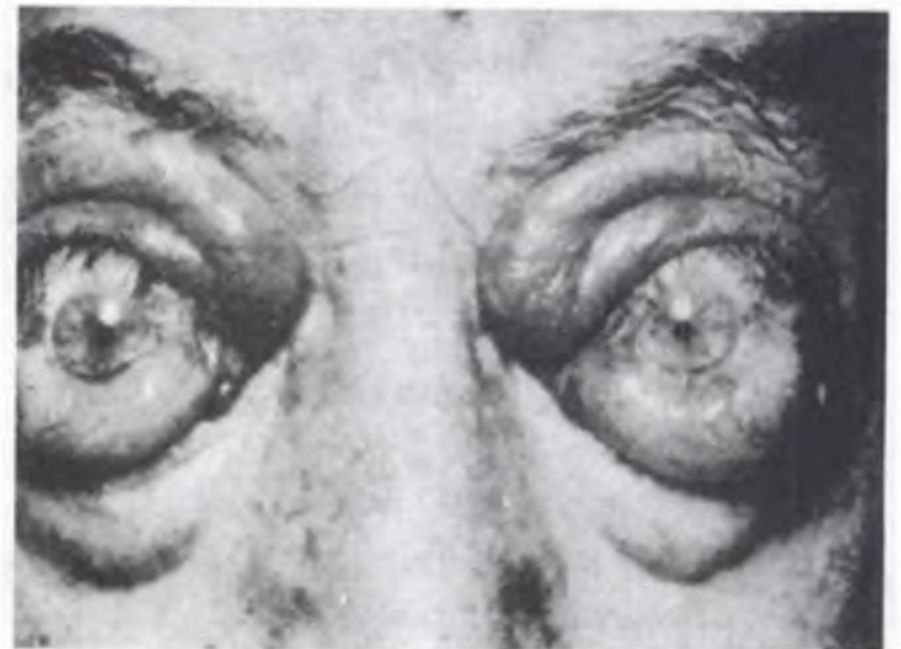


Fig. 34.5 Thyrotropic exophthalmos (Trevor-Roper and Curran).

Table 34.5

Distinguishing Features of Two Types of Exophthalmos

Points	Mild	Severe
Age	Usually adults	Usually elderly
Sex	Predominant in women	Equal or more in males
Thyroid state	Hyperthyroid	Any: hyper-, hypo- or euthyroid
Evidence of thyrotoxicosis	Yes and prominent	Minimal
Exophthalmos	Mild and reducible	Severe and often irreducible
Upper lid retraction	Variable in early stage	Slight
Ophthalmoplegia	Weak convergence	More prominent and may precede exophthalmos
Oedema	Slight in eyelids	Marked in eyelids and conjunctiva
Complications	Uncommon	Common and often severe

Differential diagnosis.³ The condition must be differentiated from a space-occupying lesion of the orbit (Table 34.6).

Table 34.6

Differentiation between Dysthyroid Exophthalmos and Space-occupying Lesion

Points	Dysthyroid exophthalmos	Proptosis due to a space-occupying lesion
Unilaterality	Rare	Usual
Evidence of thyrotoxicosis	Yes	No
Onset and progress	Insidious onset and slow progress	Rapidly progressive
Involvement of muscles supplied by oculomotor nerve	Unlikely	All muscles supplied by the nerve are likely to be affected together
Pupillary abnormality	No	Yes
Ptosis	Rare	Common
Optic disc changes	Rare	Common
X-ray	—	May be of value
Thyroid function tests	Revealing	Unrevealing

Treatment. Several measures have been suggested:

(a) Systemic iodide and antithyroid drugs like thiouracil—in mild type

(b) Systemic steroids help to reduce the oedema and infiltration

(c) Lid retraction may respond to guanethidine or Ismelin drops (10% or 5%)

(d) Protection of the cornea—if required, by tarsorrhaphy

(e) Orbital decompression—in rapidly progressing, irreducible proptosis with threatening involvement of the optic nerve.

Orbital Tumours^{6,8,10,11}

Classification. (a) Primary tumours of the orbital tissues

(b) Secondary tumours from the adjacent structures

(c) Metastasis from the distant organs

(d) Manifestations in general diseases.

Clinical features. All slow-growing tumours are asymptomatic except perhaps for vague discomfort or diplopia in their early stages, because the orbital contents adapt themselves well to the tumours.

A rapidly-growing tumour produces marked symptoms and signs owing to vascular disturbance and oedema.

Proptosis may be axial or eccentric. Apart from clinical assessment, exophthalmometry helps in estimating the progress of proptosis.

Oedema is a characteristic feature in rapidly-growing tumour. Immobility is caused earlier in a malignant tumour. Visual disturbance depends on the involvement of the optic nerve, the vascular supply and the eyeball itself.

Investigations are as those described under 'Proptosis'. It is mandatory to examine the neighbouring structures to determine whether the orbital invasion is primary or secondary.

FNAB is an important diagnostic aid.¹⁷

Primary Tumours

Benign. These tumours can be classified as follows (Table 34.7).

Table 34.7

Classification of Primary Benign Orbital Tumours

Vascular: haemangioma, haemangioendothelioma, haemangiopericytoma, vascular malformations, lymphangioma

Neural: neurofibroma

Mesenchymal: fibroma, lipoma, myxoma, chondroma, osteoma

Myomatous: rhabdomyoma, leiomyoma

Epithelial: typically from the lacrimal gland

Pigmented: melanoma

Haemangioma is usually of cavernous type. It produces variable proptosis. It is compressible and increases in size with certain physical acts such as crying, straining or stooping. It may produce pseudopulsation and cause visual loss by prolonged pressure on the optic nerve.

Neurofibroma affects the lids, orbit, face, scalp and skin in general. Its association with drusen of the optic nerve head or glioma has been recorded. Pressure-erosion of the bone wall caused by this tumour very rarely produces pseudopulsation.

The incidence of benign mesenchymal tumours is rare.

Table 34.8 lists the important distinguishing features of benign and malignant tumours of the orbit.

Table 34.8

Distinguishing Clinical Features of Orbital Tumours

Features	Benign	Malignant
Proptosis	Mild	Gross
Restricted ocular movements	Insignificant	Present
Visual impairment	No	Yes
Pain	No	Yes
Duration	Weeks	Months
Imaging studies	Intact bone circumscribed mass	Bone erosion, infiltrative mass

Malignant. Sarcoma may arise from any mesodermal constituent of the orbit. The affection is common in children or young adults and is terminal.

Rhabdomyosarcoma is the most common primary malignant tumour of the orbit in children. The tumour starts from the extrinsic muscles of the eye or the lid muscles. Lid swelling may be the first sign but rapid proptosis is the common presenting sign.

Lymphosarcoma and allied blood cell tumours occur usually in elderly persons. The types include: (a) lymphocytic cell sarcoma; (b) reticulum cell lymphosarcoma; (c) giant follicle lymphosarcoma; (d) Hodgkin's disease; and (e) lymphoma and chloroma.

Carcinoma of the lacrimal gland may present as adenocarcinoma, carcinoma or mixed tumour.

Apart from the conditions described above, the primary tumours of the orbit also include: (a) dermoid cyst; (b) phakomatoses; (c) epithelial tumours of the lacrimal gland; (d) pseudotumours; and (e) tumours from the fatty and fibrous tissues, muscle, nerve, cartilage, bone and reticuloendothelial system.

Tumours of the Optic Nerve Sheaths

Tumours of the optic nerve sheath include glioma, meningioma—arising from the arachnoid sheath, and fibroma—arising from the dura.

These tumours may be intraorbital or intracranial.

The intraorbital neoplasms are characterized by: (a) slowly progressive, axial and irreducible proptosis; (b) early and rapid visual loss; (c) usually there is evidence of vascular obstruction; (d) impairment of ocular mobility is late in onset; and (e) there is radiographic evidence of bone involvement, e.g. in glioma.

Glioma. Glioma is a benign astrocytic tumour arising from the intraorbital portion of the optic nerve near the optic foramen and spreading posteriorly. Histologically, there are irregular disposition of glial cells with areas of mucoid degeneration. There is associated proliferation of the connective tissue. This tumour is unilateral and occurs typically in the first decade of life. Early visual loss accompanied by gradual, painless, axial proptosis are characteristic features. Optic

atrophy is more common. X-ray shows an enlarged optic foramen with a polished border. CT especially helps in finding out any intracranial extension.

Meningioma. This arises from the arachnoid sheath of the optic nerve and invades the orbit and nasal fossae, spreading both anteriorly and posteriorly. The pia is rarely penetrated. Histologically, there are irregular lobules containing large syncytial cells. *Psammoma bodies* are characteristic. These are the hyaline masses formed by the collagenous material between the lobules (Fig. 34.6). Because of the late involvement of the nerve itself in the course of the disease, visual failure is characteristically late in its onset. Visual loss is associated with papilloedema or optic atrophy, and slowly progressive proptosis. The tumour can be evaluated by X-rays, ultrasonography and CT scan.

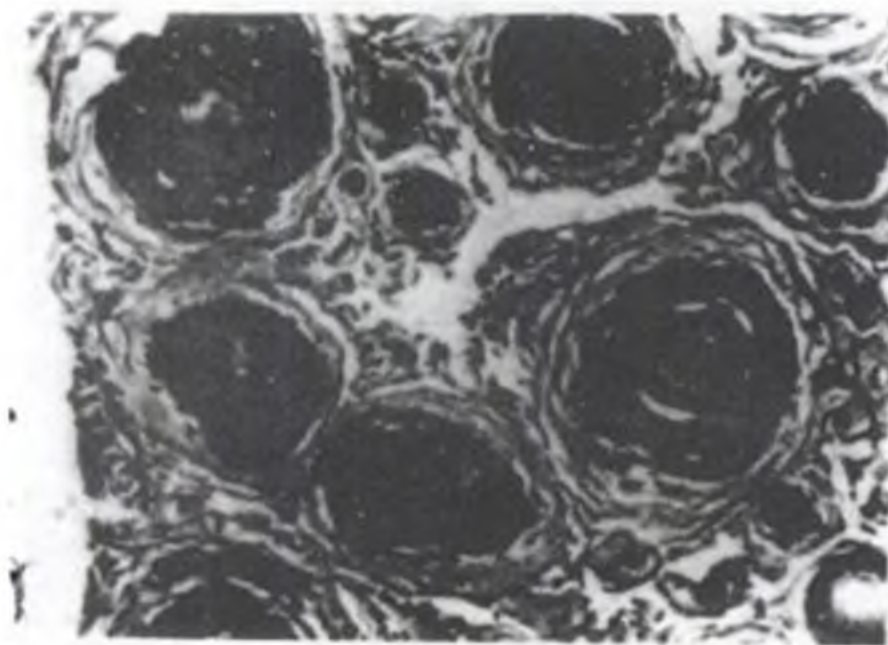


Fig. 34.6 Meningioma of the optic nerve sheath (Dr. I.S. Roy, and Dr. E. Ahmed).

Superior Orbital (Sphenoid) Fissure Syndrome

Superior orbital fissure or orbital apex syndrome is characterized by presence of unilateral paresis of III, IV and VI cranial nerves as well as that of the ophthalmic division of V cranial. There is lack of venous congestion, a feature which differentiates it from cavernous sinus syndrome.

Meningioma of the Sphenoid Ridge

Meningioma of the sphenoid ridge, e.g. extension from a retinoblastoma, nasopharyngeal carcinoma, is a secondary tumour. It may involve the inner third, middle third or lateral third of the ridge. More laterally placed neoplasms are frequently asymptomatic in their early stage.

However, an advanced case is characterized by: (a) unilateral proptosis; (b) oculomotor palsies; (c) optic atrophy; (d) anaesthesia in the distribution of the trigeminal nerve; and (e) X-ray shows two types of changes—osteolytic and hyperostotic, the latter being more common, involving the sphenoidal wings. The sphenoidal fissure may be enlarged.

Metastatic Tumours

Metastatic tumours may arise from neuroblastoma of the adrenal medulla or sympatheticoblastoma, leukaemia, lung carcinoma and carcinoma of the breast. Metastatic sympatheticoblastoma or neuroblastoma usually metastasizes to both orbits; it may present as proptosis associated with a mass in the cheek or temple area.

Manifestations in General Diseases

Lipodystrophies and osteopathies are among the manifestations in general diseases.

Lipodystrophies include typically Hand-Schüller-Christian disease, also known as 'diabetic exophthalmic dysostosis'. It is characterized by association of diabetes insipidus with xanthomatous deposits in the skull bones and the orbit in a physically and mentally handicapped child.

Osteopathies include bony hyperplasias, rickets and hydrocephalus.

Treatment of orbital tumours. The principles are:

- Benign—surgical excision
- Malignant
 - (a) Surgical excision

- (b) Radiotherapy
 - (i) Conventional
 - (ii) Teleradiation—cobalt-60
 - (iii) Intercavitary irradiation
- (c) Combinations.

Dermoid cyst and some other benign tumours can be removed without injuring the eyeball. If radical treatment is contemplated, surgical exploration and removal of a portion of the tumour for microscopic examination is essential.

Many of the malignant tumours tend not to metastasize, and thus they are treated by more conservative methods than are usual in other parts of the body. The majority of these tumours are treated by complete excision following orbitotomy. Occasionally for the sake of complete removal of the malignant tumour, even the eye may have to be excised. If the malignant tumour extends to the periorbita an exenteration operation is needed. Reticular tumours are especially responsive to radiation therapy.

Routes of surgical approach are the following:

(a) *Anterior orbitotomy*. Incision at the anterior orbital margin and access to the anterior half of the orbit.

(b) *Lateral orbitotomy (Krönlein)*. Incision outside the lateral canthus and access to the deeper parts of the orbit.

(c) *Transfrontal or Naffziger's operation*. This is for access to the apex of the orbit.

(d) *Lateral orbitocranial decompression*.

(e) *Transconjunctival orbitotomy*.

The additional space provided by the opening allows the orbital contents to expand reducing the risk of proptosis.

Orbital Cyst

Orbital cysts are relatively rare and divided into eight groups: (1) congenital e.g. dermoid cyst; (2) implantation; (3) haematic; (4) parasitic; (5) serous; (6) mucous cysts from paranasal sinuses; (7) dentigerous; and (8) cysts of intraorbital structures, e.g. lacrimal gland.

Dermoid Cyst (Fig. 34.7)

Dermoid cyst contains sebaceous material and hair follicles and is lined by the epithelium. It is most commonly found at the upper and outer angle of the orbit and less commonly at the other angles of the orbit. It presents as smooth, fluctuant and painless mass. It is free from the skin but is attached to the periosteum. It occasionally causes pressure—

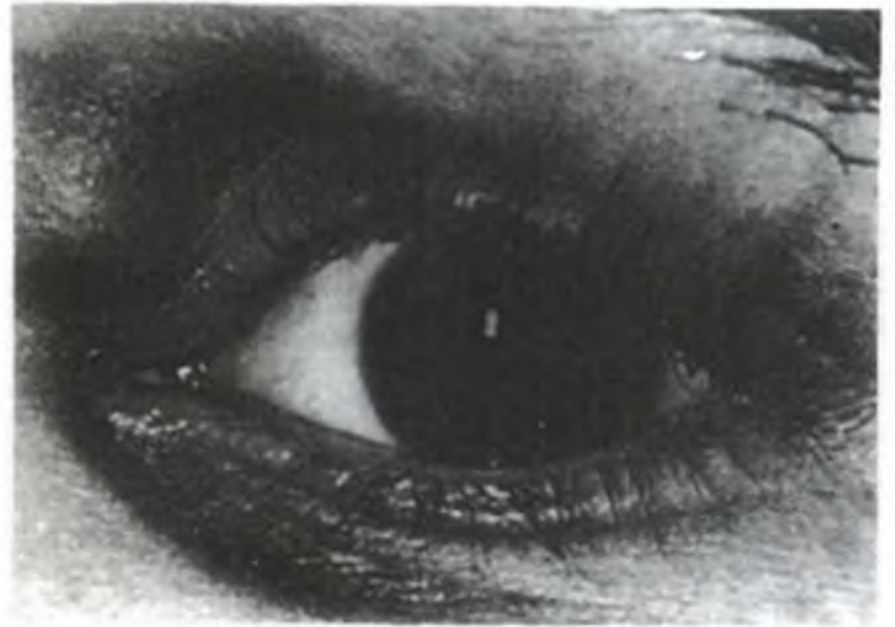

Fig. 34.7 Peribulbar dermoid.

absorption of the part of the wall. It rarely extends backwards to cause proptosis. The anteriorly-placed orbital cyst can be fully excised without much difficulty. A deeply-placed cyst can be removed with extreme difficulty.

Vascular Disturbances¹⁸

Haemorrhage

Aetiology. Haemorrhage may be caused by a blunt injury in the orbital region. Sometimes there may be spontaneous haemorrhage as in arteriosclerosis and blood dyscrasias.

Clinical features. Haemorrhage is characterized by variable degree of proptosis, subconjunctival haemorrhages, restriction of ocular movements which is dependent on the site of haemorrhage. If within the muscle cone all movements will be restricted and evidence of haematoma is present. The extravasated blood slowly disappears within a few weeks.

Carotidocavernous Fistula

Aetiology. (a) It is often traumatic. There is fracture of the base of the skull especially when the arteries are sclerotic.

(b) Occasionally there is spontaneous rupture of the carotid artery into the cavernous sinus which presents as 'pulsating exophthalmos'.

(c) There is rarely leaking aneurysm of the ophthalmic artery.

Clinical features. Carotidocavernous fistulae include sudden and marked proptosis, palpable and audible systolic pulsations caused by transmission of higher arterial pressure into low-pressure venous system, distended conjunctival vessel, chemosis and swelling of the lids, engorgement of the retinal veins, accompanied by pain and impairment of vision. Visual prognosis is guarded.

Diagnosis. Diagnosis is aided by pneumotonometry, angiography, ultrasonography, MRI and colour Doppler imaging.

Colour Doppler imaging is a noninvasive technique that provides a two-dimensional structural imaging and Doppler evaluation of the blood flow.

Treatment. Treatment is conservative. If the application of continuous pressure on the carotid stops pulsation, a cure may be affected by ligation of the carotid. The opposite carotid may also be tied at the expiry of some weeks after the first operation. This procedure may also fail. In this case intracranial ligation proximally and distally to the aneurysm is resorted to. Other methods include carotid embolization with muscle fragments and transcavernous electrocoagulation.

Orbital Varix

Orbital varix may be primary or secondary. A primary varix may be congenital and follow trauma or occur in association with a haemangioma. Secondary varices are due to either carotidocavernous fistula or an arteriovenous malformation (intraorbital).

Clinical features. Orbital varix causing intermittent proptosis (Figs. 34.8 and 34.9) is characterized by the following features:



Fig. 34.8 Orbital varix. Undisturbed eye.

- (a) Unilaterality—it is common on the left side.
- (b) Transient proptosis induced by bending the head forwards and pressure on the jugular veins.
- (c) Occasionally it pulsates and/or murmurs.
- (d) X-ray may show evidence of calcification due to phlebolith.
- (e) Diagnosis is confirmed by an orbital venography.
- (f) Colour Doppler imaging is a noninvasive method of evaluation.

Treatment. Many of the varices may eventually resorb or recanalize resulting in improvement of symptoms, and hence conservative treatment is suggested. Associated secondary glaucoma due to increased episcleral venous pressure should be medically treated. But surgery is indicated when there are intractable pain, gross degree of



Fig. 34.9 Appearance of proptosis after bending the head forward.

proptosis, compressive optic neuropathy or venous thrombosis. Carbon dioxide and yttrium-aluminium garnet (YAG) lasers may help in removal of superficial and subcutaneous varices.

Developmental Anomalies of the Orbit

Anomalies of the head and face include chiefly: (a) dysostoses of the skull; and (b) facial dystrophies.

Anomalies of the orbit include chiefly: (a) meningocele and cephalocele; (b) cysts—typically dermoids; and (c) tumours.

Dysostoses of the Skull

Dysostoses of the skull are perhaps due to premature closure of one or more sutures. Normally synostosis coincides with completion of growth of the brain.

Oxycephaly is caused by premature ossification of all the sutures. It is characterized by proptosis, divergent squint, restriction of ocular movements, primary optic atrophy and sometimes evidence of raised intracranial pressure, i.e. papilloedema, X-ray shows thinning and digitation of the bones.

It may be associated with syndactyly, *Apert's disease*.

Brachycephaly is short skull due to premature closure of the coronal suture.

Dolichocephaly is the increased anteroposterior diameter of the skull causing a long narrow head.

Scaphocephaly is the lop sided skull due to asynchronous fusion of the cranial bones.

Crouzon's disease. It is a craniofacial deformity characterized by brachycephaly or wide skull, shallow orbits, divergent squint, proptosis, greater breadth of the bridge of the nose, atrophy of the upper jaw, etc.

Facial Dystrophies⁶

The orbit is developed by the meeting and growth of the two mesodermal masses—the paraxial mesoderm of the head-fold and the maxillary process of the first visceral arch, between the 12 and 16 mm stage. Inhibition of the development of the first visceral arch leads to a deformity known as 'mandibulofacial dysostosis'.

Mandibulofacial dysostosis (Franceschetti). A fully developed case is bilateral and it is characterized chiefly by:

(a) Antimongoloid obliquity of the palpebral fissure with a coloboma usually in the outer part of the lower lid.

(b) Hypoplasia of the facial bones.

(c) Malformation of the ears, blind fistula between the angles of the mouth and the ears.

(d) Various other (facial and skeletal) anomalies.

Other anomalies include oculoauriculovertebral dysplasia (Goldenhar's syndrome), mandibulo-oculofacial dyscephaly, etc.

Orbital Meningocele and Cephalocele

There is protrusion of the portion of the contents of the skull into the orbit. They are encephalocele, hydroencephalocele and meningocele (rare).

The most common site is the inner angle of the orbit or at the root of the nose and corresponds to the suture-lines between the bones.

A typical anterior orbital cephalocele is characterized by a fluctuating cyst, reducible under pressure, and producing impulse on coughing. It is transparent and there is evidence of bone defect seen radiologically. Undue pressure may induce cerebral symptoms.

Treatment entails reposition of the hernia and repair of the bony defect, if necessary by dural substitute.

Further Reading

1. Ashworth, B., *Clinical Neuro-Ophthalmology*, Blackwell Scientific, Oxford, 1973.
2. Blodi, F.C. and Gass, G.D.M., Inflammatory pseudo-tumour of the orbit, *Br. J. Ophthalmol.*, 52:79, 1968.
3. Brain, R. and Walton, J., *Diseases of the Nervous System*, 7th ed., Oxford University Press, London and ELBS, 1969.
4. Choudhury, V. and Gulati, P., Ultrasonography, computed tomography and magnetic resonance imaging: efficiency and pitfalls in ophthalmology. In *Current Topics in Ophthalmology, I*, Gupta, A.K. (Ed.), B.I. Churchill Livingstone, New Delhi, 1993, p. 35.
5. Dallow, R.J. and Pratt, S.G., Approach to orbit disorders and frequency of disease occurrence. In *Principles and Practice of Ophthalmology: Clinical Practice*, Albert, D.M. and Jacobiec, F.A. (Eds.), W.B. Saunders, Philadelphia, 1994, p. 1881.
6. Duke-Elder, S., *System of Ophthalmology* Vol. XIII: *The Ocular Adnexa*, Part 2: *Lacrimal, Orbital and Para-orbital Diseases*, Duke-Elder, S. and MacFaul, P. (Eds.), Kimpton, London, 1974.
7. Duke-Elder, S., *System of Ophthalmology*, Vol III: *Normal and Abnormal Development*, Part 2: *Congenital Deformities*, Kimpton, London, 1963.
8. Henderson, J., *Orbital Tumours*, W.B. Saunders, Philadelphia, 1973, p. 139.
9. Jain, I.S., Diagnosis and investigations in proptosis. *Proc. All India Ophthalmol. Soc.*, 31:21, 1970.
10. Kanski, J.J., *Clinical Ophthalmology* (3rd ed.), Butterworth-Heinemann, London, 1994.
11. Levine, R.A., Orbital tumours. In *Principles and Practice of Ophthalmology*, Peyman, Sanders and Goldberg (Eds.), W.B. Saunders, Philadelphia, 1980.
12. Llyod, G.A.S., The radiological investigation of unilateral proptosis. In *Medical Ophthalmology*, Rose, F.C. (Ed.), Chapman Hall, London, 1976, p. 56.
13. Meadows, S.P., Endocrine Disorders. In *Modern Ophthalmology* (2nd Ed.), Sorsby, A. (Ed.), Vol. 2, Butterworths, London, 1972, p. 301.
14. Mulin, B.R., Dysthyroid exophthalmos. In *Pathobiology of Ocular Disease*, Garner, A. and Klintworth, G.K. (Eds.). Marcel Dekker Inc., New York, 1982, p. 1077.
15. Parsons, J.H., *Diseases of the Eye* (18th Ed.), Miller, S.J.H. (Ed.), Churchill Livingstone, Edinburgh and ELBS, 1990.
16. Pavan-Langstone, D. (Ed.). *Manual of Ocular Diagnosis and Therapy* (4th ed.) Little, Brown and Co., Boston, 1996.
17. Snebold, N.G., Noninfectious orbital inflammations and vasculitis. In *Principles and Practice of Ophthalmology: Clinical Practice*, Albert, D.M. and Jacobiec, F.A. (Ed.), W.B. Saunders, Philadelphia, 1994, 1923.

18. Trevor-Roper, P.D. and Curran, P.V., *The Eye and Its Disorders* (2nd ed.), Blackwell Scientific, Oxford, 1984.
19. Trevor-Roper, P.D. (Ed.), *Recent Advances in Ophthalmology*, No. 5, Churchill Livingstone, Edinburgh, 1975.
20. Vaughan, D., Asbury, T. and Tabbara, K.F. (Eds.), *General Ophthalmology* (12th ed.), Appleton and Lange, Connecticut, 1989.
21. Werner, S.C., Classification of the eye changes of Graves' disease, *J. Clin. Endocrin. Metabo.*, 29: 982, 1969.

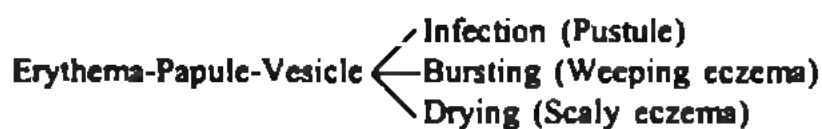
35. DISEASES OF EYELIDS

Apart from inflammations, motor and sensory disorders and tumours, the eyelids may be affected in circulatory, secretory, metabolic and congenital disorders. Diseases of the eyelashes and anomalies of the palpebral fissure are also considered.

Diseases of the Skin of Eyelids^{4,9,12}

The thinness and rich vascularity of the lid skin causes unusual distension, congestion and secondary infection involving the conjunctiva and other structures.

In an inflammatory lesion, the sequence of events are:



Dermatitis

Dermatitis may be: (a) irritant which is either contact or eczematous; and (b) infective. The contact and eczematous types are chiefly allergic in origin, where an exogenous allergy is mainly due to spectacle frames, by cosmetics, alkaloids, chemotherapeutic agents and antibiotics.

In infective type: (a) bacterial, e.g. erysipelas; (b) viral, e.g. typically in herpes zoster; (c) fungal like *pityrosporon* causing seborrhoeic and *tinea* causing ringworm dermatitis; and (d) parasitic, e.g. lice, are the main causes.

Treatment of irritant dermatitis consists of the removal of the cause and application of a steroid ointment. In infective type, treatment must be directed against the cause.

Ophthalmodermatozoosis¹

Dermatozoosis may involve any part of the exposed skin and is caused by the irritant secretion, possibly from the hindgut of the beetle of genus *Paederus* (*P. fusipes*).

Following insect hit, the insect is unintentionally squashed near the medial canthus liberating the irritant secretion. This is characterized by dermal lesions which involve the eyelids usually near the medial canthus and periocular region (Fig. 35c.1). The chain of events are: oedema → erythematous papules → vesicles → pustules → desquamation → cicatrization, often pigmented. The lesions persist for about one week.

Ocular lesions include conjunctivitis and corneal abrasions.

Treatment consists of local and systemic antibiotics for about a week. Occasionally antihistamines are of help.

All precautions must be taken in order that the lesions are not further aggravated.

Vesicular lid inflammations^{4,10}

Lid inflammations are occasionally present and the causes include: (a) acute viral inflammations, e.g. herpes simplex and herpes zoster; (b) Stevens-Johnson syndrome, (c) benign mucous membrane pemphigoid; (d) pemphigus vulgaris, and (e) drug-induced bullae.

In both primary and recurrent herpetic infection, crops of vesicles of pin-head size appear on the lid, particularly the lower. The lesions are typically unilateral.

The vesicles in herpes zoster make their appearance typically unilaterally. They rapidly become turbid and yellow. The latter burst within a short time.

The skin lesion of Stevens-Johnson syndrome is as follows. In the lids sharply defined erythematous patches are found which are symmetrically distributed. In a severe case they are turned into vesicular lesions.

In benign mucous membrane pemphigoid the bullae are subepidermal and the lids may be involved.

Pemphigus vulgaris affects older people, its incidence being rare. Crops of bullae appear on the apparently normal skin. There is no preceding erythema.

Blepharitis⁴

Blepharitis (Gk. *blepharon*, eyelid) is a chronic inflammation of the lid margin and is a very common condition. They are of two types—squamous and ulcerative.

Aetiology. Aetiology is often varied, involving both local and general factors. In the local factor, malfunctioning of the Meibomian glands, staphylococcal infection and parasitic infection, typically *Phthirus pubis* are noticed. In general, seborrhoeic dermatitis of the scalp and eyebrows and lowering of systemic resistance are noticed.

Pathology. Squamous blepharitis shows hyperaemia, oedema, desquamation, acanthosis, i.e. increased thickness of the prickle layer of the epidermis, parakeratosis, i.e. incomplete keratinization and infiltration.

Ulcerative blepharitis displays hyperaemia, oedema, infiltration and perifollicular abscesses.

Clinical features (Fig. 35c.2). There may be soreness, grittiness and discomfort along the lid margins. Two types—squamous and ulcerative can be distinguished (Table 35.1).

Staphylococcal blepharitis is characterized by: (a) chronic course; (b) periodic acute or subacute

Table 35.1

Differences between Squamous and Ulcerative Blepharitis

Features	Squamous	Ulcerative
Scales	White, fine, powdery and dry	Yellowish, coarse and wet
Ulceration	No	Yes
Bleeding	No	Yes
Alopecia of the lashes	Temporary and localized to few eyelashes	Permanent and almost all eyelashes are involved
Course	Mild	Progressive
Complications	Occasional	Usual and serious

exacerbations; (c) frequent association with other staphylococcal lesions, e.g. sycosis vulgaris; (d) hyperaemia of the lid margins; (e) eczematous changes of the skin of the lids at the angles of the lids; (f) onset with acute conjunctivitis; and (g) in severe exacerbations, presence of punctate epithelial keratitis.

Seborrhoeic blepharitis is characterized by: (a) persistent inflammation of the lid margins; (b) associated seborrhoeic dermatitis of the scalp and eyebrows; (c) presence of soft, oily flakes; and (d) fluctuations in severity.

Blepharitis may exist without conjunctivitis.

Complications and sequelae. If the treatment is inadequate, there is accompanying chronic blepharoconjunctivitis. In the ulcerative form the sequelae are serious. When the ulceration is deeper the eyelashes fall out which are either not replaced or replaced by a few small and scattered lashes, and the condition is called *madarosis*. These lashes are distorted and may be drawn out of place giving them a false direction. The misdirected and distorted cilia rub the cornea and this condition is termed *trichiasis*. A vicious cycle is formed when the lower lid tends to lose its contact with the eyeball causing *ectropion* which is the eversion of the lid margin. This leads to *epiphora*, which in turn worsens into an *eczema*. Two occasional sequelae are *tylosis*, i.e. hypertrophy of the lid margin and *milphosis*, i.e. permanent reddening of the lid margin.

Treatment. Treatment must aim at the symptomatic relief and eradication of the cause. As medication is retained in the organisms occupying the crypts of the folliculoglandular structures, the course of treatment is often prolonged.

Local treatment consists of an antibiotic-steroid ointment since it combats infection plus inflammation. This is perhaps more effective than other measures such as soaking and removal of the scales and application of an antiseptic ointment such as yellow oxide of mercury.

General treatment consists of eradication of associated scalp infection and enhancement of body resistance.

Phthiriasis palpebrarum infection is caused by numerous nits of pediculosis and crab-lice, which cling to the eyelashes. Treatment is frustrating and includes the removal of parasites by forceps, application of yellow oxide of mercury or application of eserine under direct observation and pyrethrum ointment.

Stye or hordeolum externum

Stye (Gk. *steigan*, to rise) is a suppurative inflammation of one or more of Zeis's glands and only occasionally of Moll's glands.

Aetiology. Styes are commoner in young adults and children, and there is often lowering of systemic resistance to *Staphylococcus aureus*. Recurrences are common.

Clinical features. The affection starts with pain and occasional fever in children. It is characterized by tenderness, oedema and finally suppuration localized around an eyelash (Fig. 35c.3). It, at times, involves the entire lid margin when it occurs near the canthi impairing the venous and lymphatic flow. In severe inflammation, preauricular lymphadenopathy and constitutional upsets are not uncommon.

Within three to six days, pus is discharged from the stye.

Treatment sometimes aborts it.

Complications though rare now-a-days are spreading cellulitis and rarer still cavernous sinus thrombosis.

Differential diagnosis. A stye should be differentiated from: (a) chalazion; (b) acute dacryocystitis; (c) orbital cellulitis; and (d) erysipelas.

Chalazion is asymptomatic unless it is suppurative. In a stye, history and presence of an eyelash differentiate it from a suppurative chalazion.

In acute dacryocystitis, epiphora and signs limited to the lacrimal sac region are present.

In orbital cellulitis, proptosis, chemosis, ocular immobility and marked constitutional upsets are present.

Erysipelas is a diffuse streptococcal inflammation along the cuticular lymphatics. Rapidly spreading erythema with irregular edges, and marked constitutional symptoms are characteristics.

Treatment. Treatment consists of localization in the early stage of the stye. This is achieved by fomentation accompanied with a short course of sulphonamides or antibiotics. A small incision may sometimes be needed to relieve the pus.

An antibiotic ointment is necessary after the stye discharges to prevent further infection of the other roots of the eyelashes.

In recurrent styes, correction of refractive error, treatment of debility, check-up for diabetes and enhancement of general body resistance are important measures.

Chalazion or Meibomian cyst

Chalazion (Gk. *chalza*, hailstone) is a chronic inflammatory granuloma of a meibomian gland.

Aetiology. There is retention of meibomian secretion due to obstruction or vicarious activity, with associated low-grade infection of the glands.

Pathology. Retention of the sebaceous secretion causes chemical irritation and subsequent reaction. The infiltration includes epithelioid, plasma, lymphoid and giant cells along with fibroblastic activity. A pseudocapsule forms around this granuloma whose central portion ultimately becomes gelatinous.

Clinical features (Fig. 35.1). Single or multiple chalazion often appears as a nodule of varying sizes, free from the skin but better seen as a pallid area of the conjunctiva when the lid is everted. Chalazion may progress towards the conjunctiva, the lid margin or the lid skin.

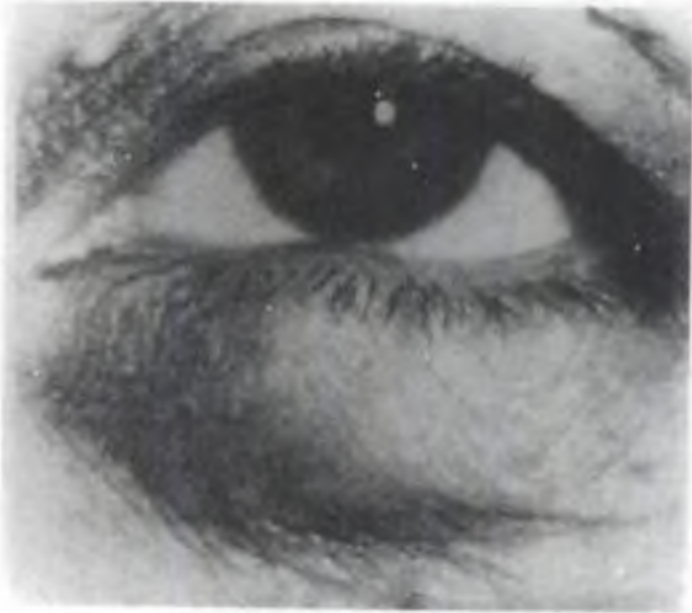

Fig. 35.1 Chalazion.

Course and complications. Chalazion may remain stationary, be infected and suppurated known as *hordeolum internum*. They at times abort. Recurrence is not uncommon. Malignancy is rare.

Treatment. Treatment includes an incision and evacuation of its content. Marginal chalazion with sprouting granulation tissue may need diathermy application, 20 to 30 milliamperes for a second.

Sudorific and sebaceous cysts

They are tiny cysts at the lid margin or scattered over the lid skin. Tiny sebaceous cysts are called *milia*.

Ankyloblepharon

Ankyloblepharon (Gk. *angkylos*, crooked) is the adhesion of the margins of both eyelids. It may be congenital or acquired often associated with symblepharon, partial or complete.

Treatment. is dependent on the amount of symblepharon. Operation is contraindicated in extensive cases. In other cases the lids are separated

and kept apart postoperatively. Covering with an epithelial graft is necessary when adhesion extends to the angle of the lids.

Symblepharon

Adherence of the eyelid to the eyeball is called symblepharon (Gk. *sym.*, with).

Aetiology. Caustics and mucocutaneous affections involving the conjunctiva are the causative factors. Apposition of two raw surfaces—palpebral and bulbar conjunctivae—causes adherence.

There are three types: (a) anterior—when the lid margin adheres to the bulbar conjunctiva; (b) posterior—when there is obliteration of the fornix; and (c) total—when the entire lid is fixed against the globe.

Treatment. If the case is inflammatory, treatment consists of topical and systemic medications, with this treatment it may resolve. But if the inflammation does not resolve with maximum therapy and the cicatrization is large, treatment is frustrating. In a stable and small cicatrization, glass rod separation may be helpful. In recurrent affection Z-plasty or mucous membrane graft is advocated. Following a mucous membrane graft either a silicone sleeve in moderately extensive surgical area or a scleral shell in extensive surgical area may be advised.

Disorders of Eyebrows and Eyelashes

Disorders of the eyebrows and eyelashes may be overgrowth of the lashes, *hypertrichosis*; or lack or absence of the lashes, *hypotrichosis*; or anomalies of pigmentation such as *poliosis*.

Trichiasis

Trichiasis (Gk. *thricks*, hair) is the inturning of the eyelashes which rub against the cornea. The lashes are seldom normal as they are stiff and distorted.

It may or may not be associated with an entropion.

Aetiology. Trichiasis may be due to: (a) trachoma;

(b) ulcerative blepharitis; and (c) deformity of the lid margin owing to inflammation, ulcer, trauma and burn.

Clinical features. Symptoms like irritation and persistent foreign body sensations are present.

Complications and sequelae. Complications and sequelae are recurrent corneal erosions, nebula and corneal vascularization.

Treatment. Treatment consists of epilation of the misdirected offending cilia, repetitions every few weeks are necessary and destruction of the cilia by electrolysis, diathermy or cryoapplication.

In electrolysis, the positive pole is wrapped round the arm, and the negative pole, whose terminals dipped into saline release hydrogen bubbles, is introduced into the hair follicle. A current of 2 milliamperes is applied for 5 to 10 seconds. Thus, a slight foam is produced, and the lash can be pulled out with ease.

In diathermy a current of 30 milliamperes is applied for 10 seconds. If associated with entropion, operative procedures for entropion are called for.

In cryoapplication the temperature falls to -20°C .

Entropion^{3,5} (Fig. 35.2)

Entropion (GK. *en*, inward; *trepein*, turn) is an inversion of the lid margin. It may be slight or severe, thus, the symptoms will vary from mild discomfort to severe keratitis. It is mostly acquired

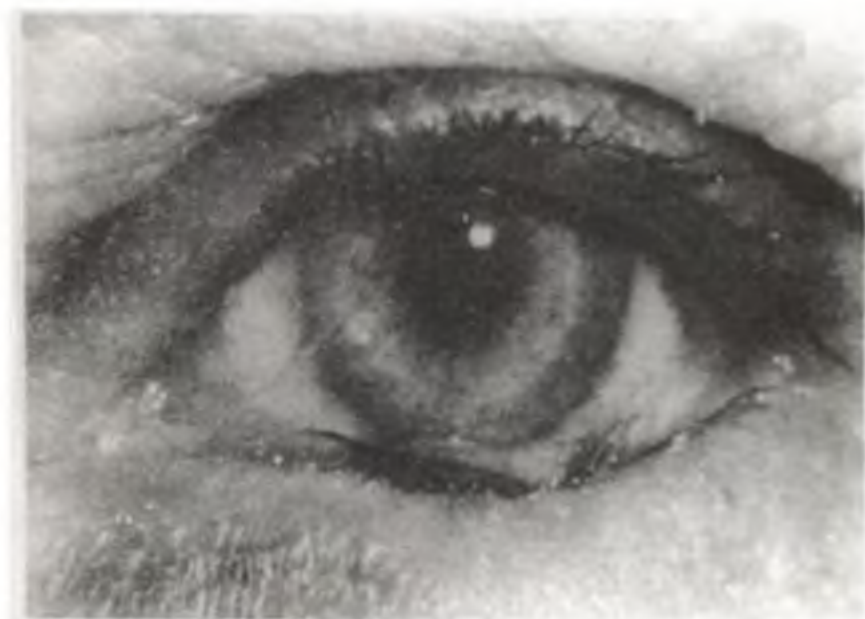

Fig. 35.2 Entropion.

and rarely congenital. Acquired entropion is classified under:

(a) *Acute spastic.* This is caused by ocular inflammation or prolonged bandaging. It involves mostly the lower lid and is usually a temporary condition.

(b) *Mechanical.* This is due to loss of support furnished to the lids by the globe—seen in anophthalmos and microphthalmos.

(c) *Cicatricial.* This may affect either the upper or lower lid. Trachoma is the most common cause; other causes include physical and chemical burns, and cicatrizing diseases of the conjunctiva.

(d) *Senile, involutinal or atonic.* This is the most common variety. It is unilateral or bilateral and involves either the lower or the upper eyelid. The contributory factors for its development are: (a) horizontal lid laxity, (b) laxity of lower lid retractors, (c) preseptal part of the orbicularis oculi overriding a portion of postseptal part, and (d) thinning and atrophy of the tarsus.

Treatment. Treatment of acute spastic entropion, caused by prolonged bandaging in an elderly patient, is to simply remove the bandage.

In mechanical entropion good prosthesis and measures to correct senile entropion are needed.

The surgical procedures adopted for correction of cicatricial entropion are indicated in Table 35.2.

When entropion is due to cicatricial contraction of the palpebral conjunctiva from burns, treatment consists of complete dissection of the scarred conjunctiva and subconjunctival fibrous tissue, followed by free conjunctival graft or very thin free mucous membrane graft.

In the lower lid excision of the skin and muscle may be effective.

In slight degree of senile entropion treatment consists of temporary measures which include application of adhesive plaster from the lower eyelid to the cheek and 5 to 6 cautery punctures at 3 mm intervals after a skin incision 3 mm below and parallel to the lash line, and full-thickness transverse sutures or everting sutures.

Permanent procedures. In the absence of

Table 35.2

Surgical Procedures in Different Types of Cicatricial Entropion³

Upper lid	
Mild	Anterior lamellar reposition
Moderate	
Thick tarsus	Tarsal wedge resection
Thin tarsus	Lamellar division with or without mucous membrane graft
Keratinization of tarsoconjunctiva	Rotation of terminal tarsus
Moderate lid contraction	
	Posterior lamellar advancement
Severe	Posterior lamellar graft or tarsal excision
Lower lid	
Mild/moderate	Wies' procedure
Severe	Posterior lamellar grafting

extensive lid laxity transverse lid split and everting sutures are advocated. In recurrent cases, plication of lid retractors is indicated.

Of the many operations indicated in senile type, skin-muscle is the simplest although result is unsatisfactory. There is chance of recurrence. So, operation of resection of the tarsus, skin and muscle has been designed to brace the atrophic tarsus and atonic orbicularis muscle.

For details of entropion surgery refer to the chapter on 'Surgery', p. 447.

Ectropion^{3,5}

Eversion (Gk. *ek*, out of; *trepein*) (Fig. 35.3) of the lid margin is called ectropion. It is classified as:

(a) *Acute spastic*. In young children or in elderly patients it occurs with proptosis. The condition is transient.

(b) *Mechanical*. This is caused by conjunctival hypertrophy.

(c) *Senile*. This is the most common form and affects the lower lid. There are five stages in its development: (i) loss of muscle tonus; (ii) eversion;

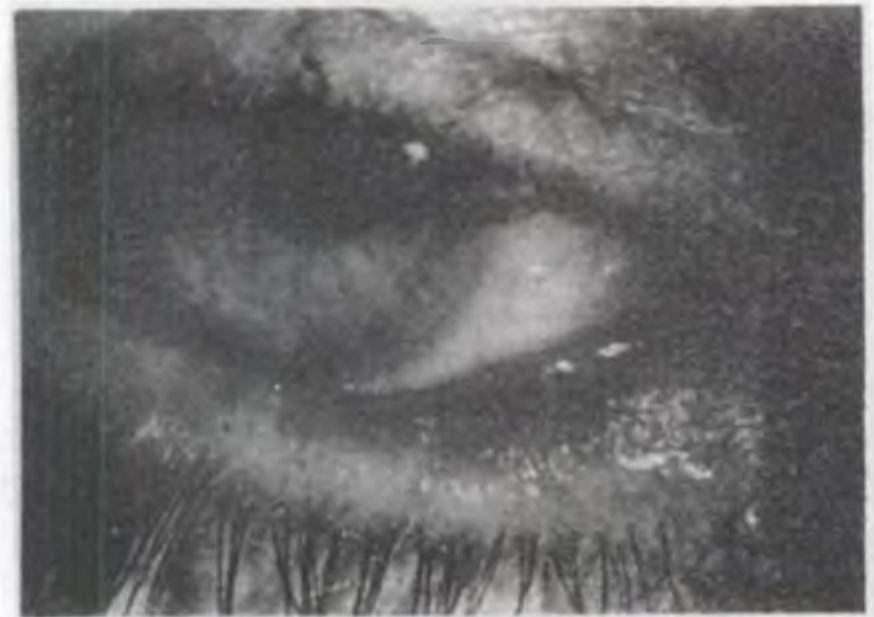

Fig. 35.3 Ectropion of the lower lid.

(iii) elongation; (iv) drooping of the lid; and (v) conjunctival hypertrophy and keratinization.

(d) *Paralytic*. Only the lower lid is affected, the upper lid being held in contact with the eyeball by its weight. It is due to paralysis of the orbicularis oculi.

(e) *Cicatricial*. This is due to scarring of the skin of the lid.

(f) *Congenital*.

Treatment. The treatment recommended in each case is as suggested.

In acute spastic, no treatment is needed except perhaps patching of the eye.

In mechanical, the offending factor needs attention.

In senile, the procedures are: (a) in early punctal eversion, localized cautery punctures are advocated; (b) in advanced punctal eversion, resection of a horizontal strip of the conjunctiva and the subconjunctival tissue below the punctum is done; (c) in still more advanced cases, cautery punctures along the whole length of the lid margin are required; (d) in slight degree, a V-Y operation has been advocated; and (e) in a fully established case, the principles are to counteract eversion and elongation and counteract laxity and sagging of tissues; hence, a combination of 'shortening' and 'raising' by a procedure known as the Kuhnt-Szymanowski operation is indicated.

In paralytic, a lateral tarsorrhaphy or canthoplasty is a lesser surgical procedure. In severe cases, fascia lata sling has been advocated.

In mild case of cicatricial, a V-Y operation is indicated. Two other procedures are lazy *T-procedure* in medial without medial canthal tendon laxity, and *medial canthal tendon plication* in severe medial ectropion.

Lagophthalmos

An incomplete closure of the palpebral fissure when an attempt is made to shut the eyes is called lagophthalmos (*Gk. lagos, hare; ophthalmos, eye*).

Aetiology. The causes are: (a) physiological—during sleep; (b) paralytic—in facial paralysis; (c) mechanical—due to proptosis; (d) ectropion—especially cicatricial; and (e) absence of reflex blinking—in an extremely ill patient.

Complications and sequelae. Epiphora, exposure keratitis and xerosis of the cornea are the usual complications.

Treatment. Treatment comprises essentially of the protection of the cornea. Temporary measure is an application of suture anchored to the medial palpebral ligament, threaded round both the upper and lower lid margins and fixed to the lateral canthus. In severe degree, the use of fascia lata sling is advised.

Ptosis^{2-5,8}

Ptosis (*Gk, ptosis, fall*) is the drooping of the upper lid. The majority of cases are congenital. It may be unilateral or bilateral, partial or complete. Table 35.3 gives a classification of ptosis.

Congenital ptosis

Majority of such cases follow dystrophy of the levator palpebrae superioris (dystrophic), while the remaining cases are due to aponeurotic defects and nerve palsies (nondystrophic). A congenital ptosis may be simple, complicated or synkinetic.

Simple congenital ptosis

It occurs in 75 to 80% of all cases and is often

Table 35.3
Classification of Ptosis

Congenital
Myogenic (dystrophic)
Aponeurotic (nondystrophic)
Acquired
Apparent
Mechanical
Myogenic
Paralytic
Pseudoparalytic
Atonic (senile)
Hypertonic
Sympathetic
Traumatic

bilateral. Heredity is an important factor. It is due mostly to either a weak levator or a weak levator plus superior rectus.

It may be emphasised that a child with congenital ptosis tries to overcome the difficulty by raising the eyebrow, wrinkling the forehead and tilting the head backwards when the eyeballs roll downwards.

Complicated congenital ptosis. A ptosis may occur along with ophthalmoplegia. There may be congenital aplasia of the oculomotor nerves. A ptosis may be associated with an epicanthus.

Marcus Gunn jaw-winking phenomenon (Figs. 35.4 and 35.5) are characterized by unilateral ptosis, the drooped lid rising above when the patient opens his or her mouth or moves the jaw to the other side. It is most likely due to abnormal nervous communication from the trigeminal to the levator muscle.

Apparent or pseudoptosis

Apparent or pseudoptosis is due to lack of support of the upper lid as occurs in microphthalmos, phthisis bulbi, empty socket, etc.

Mechanical ptosis

Mechanical ptosis follows a heavy upper lid due to inflammation, tumour, oedema or haemorrhage.



Fig. 35.4 Marcus Gunn syndrome. Left ptosis (Dr. A.K. Mitra).

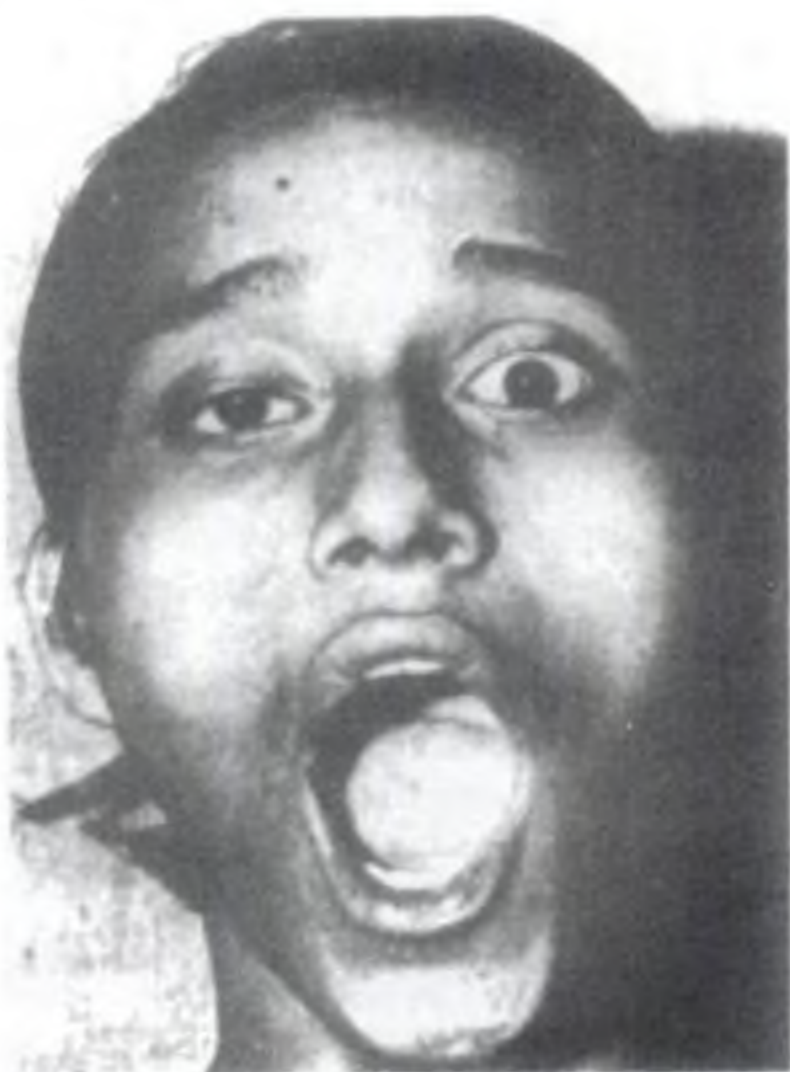

Fig. 35.5 Note the improvement of ptosis and apparent shooting up of the paretic upper lid on opening mouth (Dr. A.K. Mitra).

Myogenic ptosis

Myogenic ptosis due to myasthenia. Myasthenia gravis is characterized by its chronic course and tendency to relapse. It occurs usually in adults, and involves the extraocular and other muscles such as the bulbar, neck and shoulder muscles causing abnormal exhaustion especially detected by electromyography (EMG). Though it is generally known that the condition is due to a curare-like block at the myoneural junction, recent findings denote the condition may be due to the production of an antibody by the thymus against muscle end-plate protein. Persistent thymus is present in about one-third of the cases.

It is clinically characterized by ptosis (Figs. 35.6 and 35.7) increasing with fatigue, often asymmetrical and bizarre paresis of the extrinsic



Fig. 35.6 Ptosis in myasthenia gravis.

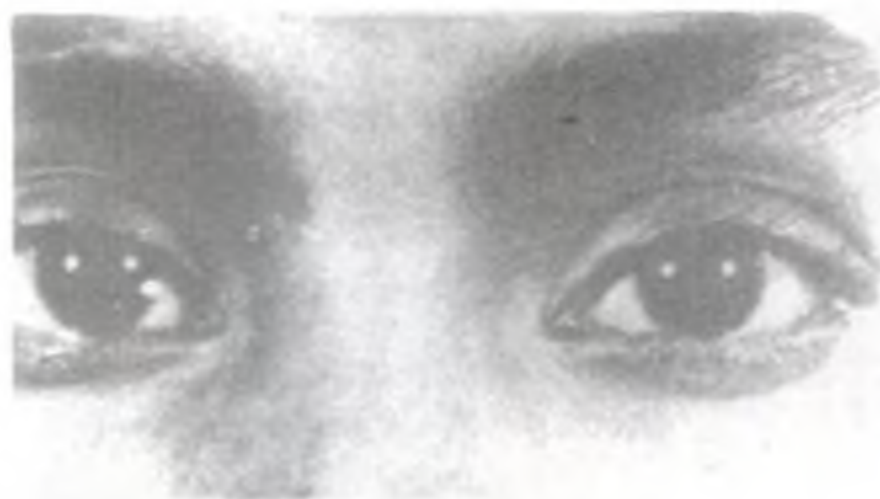

Fig. 35.7 Improvement of ptosis after prostigmine injection.

muscles, weakness of the orbicularis oculi and occasionally weakness of the muscles of the palate, pharynx, tongue and larynx. Injection of prostigmine intramuscularly or injection of a

quickly acting edrophonium hydrochloride (Tensilon) intravenously is of great diagnostic importance.

Myogenic ptosis due to myotonic dystrophy. Myotonic dystrophy is characterized by myotonia, i.e. excessive contractility but with poor tendency to relax and distal muscular dystrophy along with ptosis, myopathic facies, cataract, baldness, among others diagnosis is aided by EMG.

Paralytic ptosis

A palsy of the levator palpebrae superioris may be due to a lesion of the oculomotor nerve in any part of its course—supranuclear, nuclear and infranuclear.

The levator is the only extrinsic muscle having a separate representation in the parietal lobe of the cortex. So, an isolated ptosis can occur in a cortical lesion.

A unilateral ptosis with dilated pupil is seen in a temporal lobe tumour.

A midbrain lesion produces usually bilateral ptosis, with constricted pupil and often impaired elevation of the eyes. *Parinaud's syndrome*.

A supranuclear lesion causes ptosis but with parallelism of the eyes.

A nuclear lesion produces ptosis often with other muscle palsies.

A peripheral oculomotor lesion produces total and unilateral ptosis.

Pseudoparalytic ptosis

This may be: (a) atonic as atony of the levator in senility; and (b) hypertonic as in hysteria and parkinsonism.

Sympathetic ptosis (Horner's syndrome)

Sympathetic ptosis or Horner's syndrome is due to total or partial interruption of the sympathetic chain anywhere along its course between the hypothalamus and the eye. Among others the

causes may be aneurysm of the carotid, cervical cord injury or tumour, enlarged cervical lymph glands and mediastinal tumours.

Sympathetic ptosis is almost always a unilateral condition with the following features present on the affected side:

- (a) Slight ptosis due to paralysis of Müller's muscle
- (b) Smaller pupil
- (c) Pupil dilates less well with cocaine drops
- (d) Reduced sweating indicating preganglionic lesion
- (e) Elevation of the lower lid due to paralysis of smooth muscle attached to inferior rectus
- (f) Lighter colour of the iris in congenital cases.

Localization is possible with 1 per cent hydroxyamphetamine (Paredrine) instillation. After instillation in both eyes either both pupils dilate indicating central or preganglionic lesion, or the affected pupil does not dilate pointing towards a postganglionic lesion.

Traumatic ptosis

Traumatic ptosis may be due to the direct injury of the muscle or its nerve supply.

Investigations of ptosis. The following investigations are needed:

1. *History.* Time of onset, progress, fluctuation, any birth trauma and hereditary factors.
2. *Amount of ptosis in primary position.* This is roughly judged by measuring the width of the palpebral fissure in the primary position of the eyes. However, a better assessment is possible by measuring the distance from corneal light reflex to the upper eyelid in the primary position. This distance is called *margin reflex distance* which is 5 mm. In ptosis this distance is reduced.

3. *Amount of levator function.* The presence of folds in the upper lid is indicative of levator function. In order to assess the function, first press the patient's brow to eliminate the action of the frontalis muscle, and the patient is asked to look

downward and then upward. The amount of excursion is measured while holding the brow by the other hand. The function is graded as follows:

- 0.15 mm — normal
- 0.8 mm — good
- 0.5–7 mm — fair
- 0.4 mm or less — poor

Levator function may be assessed by measuring the *margin limbal distance* which is the distance from the 6° clock limbus to the central upper eyelid margin while the patient looks in extreme upgaze. Normally it is 8 mm. In ptosis it is reduced.

4. Visual acuity.

5. Examination of the eyes for ocular movements, presence of lid lag and Bell's phenomenon.

6. Pupillary reactions.

7. Check-up for normal tearing and normal corneal sensibility.

8. Any jaw-winking phenomenon.

Figure 35.8 presents the flow chart of diagnosis of ptosis.

Treatment. Treatment varies according to the cause and degree of ptosis.

The most common variety is simple congenital ptosis and the optimum time is decided by the droop of the upper lid. Operation is desirable at four or five years and even earlier in a bilateral ptosis covering the pupillary area by the drooped lids.

These operations perhaps occasionally achieve ideal results—strengthening of the levator, through the conjunctival surface or through the skin surface. This is indicated when levator function is present.

A plan for levator resection has been given in Table 35.4.

Table 35.4

Type of Levator Resection Depending on Levator Function³

Amount of levator function	Type of operation indicated
10 mm or more	Fasanella-Servat
Less than 10 mm with more than 2 mm ptosis	Aponeurotic
6 mm or more	Posterior approach lev. res.
4 mm or more	Anterior approach lev. res.
Less than 4 mm	Brow suspension

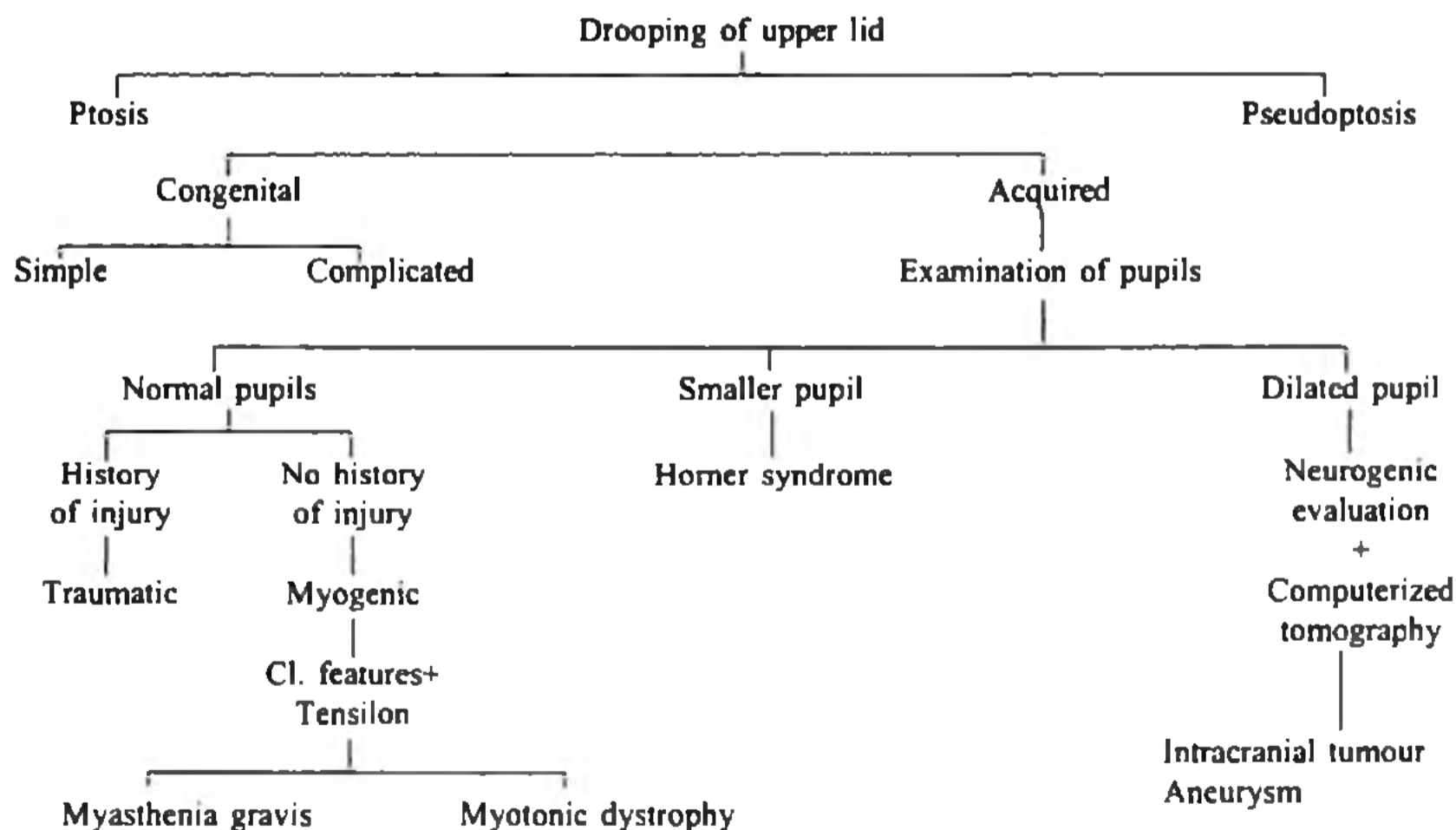


Fig. 35.8 Ptosis in myasthenia gravis⁷.

Motais' operation is the utilization of the superior rectus to elevate the lid, if the levator is paralysed but the superior rectus is active.

Hess' operation is the suspension of the upper lid from the frontalis muscle, when both the levator and superior rectus are paralysed.

In minimal degree of ptosis, the *Fasanella-Servat operation* is indicated in which the upper 4 to 5 mm of the upper tarsus with the palpebral conjunctiva, Müller's muscle and the levator are engaged in the jaws of artery forceps and excised.

Tumours of Eyelids^{4,11}

Tumours of the eyelids are classified as depicted in Table 35.5.

Table 35.5

Classification of the Tumours of the Eyelids

1. Epithelial	
Cutaneous	Benign: Papilloma, seborrhoeic keratosis, molluscum contagiosum, senile keratosis, trichoepithelioma, cornu cutaneum, keratoacanthoma and xanthelasma Malignant: Carcinoma, xerodermal pigmentosum
Glandular	Benign: Adenoma of sebaceous glands or of sweat glands Malignant: Adenocarcinoma
2. Mesenchymal	Benign: Fibroma, lipoma, myoma, myxoma and chondroma Malignant: Rhabdomyosarcoma, fibrosarcoma, myxosarcoma, liposarcoma, fibromyxosarcoma and leiomyosarcoma
3. Vascular	Haemangioma, lymphangioma
4. Melanotic	Benign: Naevus, melanoma Malignant: Malignant melanoma
5. Nerve tissue	Neurofibroma and neurilemmoma
6. Reticuloses	Lymphoma, reticulumcell sarcoma and lymphosarcoma
7. Developmental	Dermoids, teratoma and choristoma

Benign epithelial tumours

Benign epithelial tumours may arise from the skin or glands, or they may be noncystic or cystic.

The cystic benign tumours are adenoma of sebaceous glands, adenoma of sweat glands and milia.

Papilloma

Papilloma is the most common benign tumour of the eyelid. The number may be single or multiple. It may be sessile or pedunculated. It is usually found at the lid margin near the medial canthus. Its colour resembles that of the neighbouring skin.

Histology. There are papillae with vascularized connective tissue covered by acanthotic epithelium.

Treatment consists of excision. Recently, carbon dioxide laser ablation has been found to be effective in controlling the incision and haemostasis.

Seborrhoeic keratosis

Seborrhoeic keratosis is also called *basal cell papilloma*. Microscopically it is differentiated from a basal cell carcinoma by the deposition of keratin in crypts.

Molluscum contagiosum

Molluscum contagiosum is characterized by the presence of small, globular, umbilicated epithelial tumours of the skin.

Xanthelasma

Xanthelasma or xanthoma occurs in elderly women and sometimes associated with hypercholesterolaemia and diabetes. It is characterized by the presence of slightly raised, yellowish skin plaques on the inner parts of the upper and those of the lower lids (Fig. 35.9). They grow very slowly. Histologically there are lots of histiocytes distended with fat-forming foam cells. *Treatment* is needed when it causes disfigurement. The measures include full-thickness excision, sometimes advancement flaps, grafts or carbon dioxide laser application.

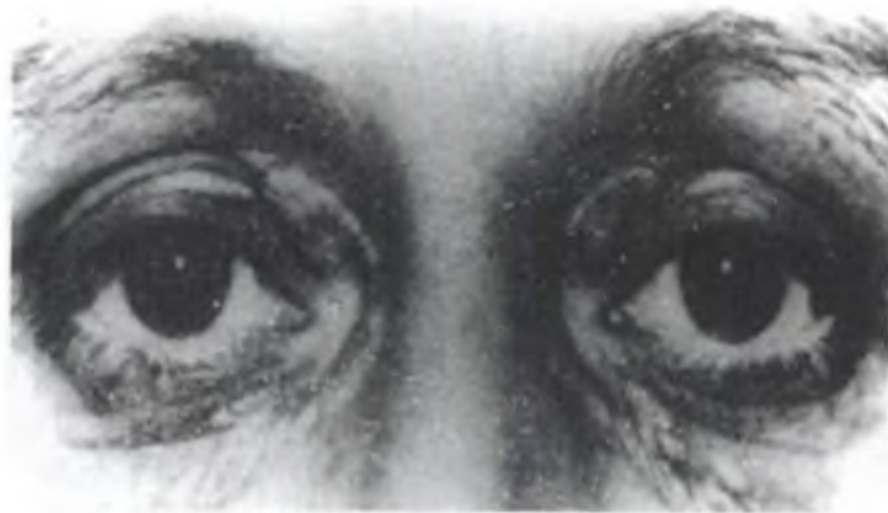

Fig. 35.9 Xanthelasma.

Senile keratosis

Also called *solar keratosis* is characterized by dry, wrinkled, hyperpigmented skin patches on exposed areas.

Trichoepithelioma

Trichoepithelioma is a rare lesion. It starts as wart-like growths in the regions of face, lids and eyebrows. It is basically a tumour of the hair follicle.

Keratoacanthoma

Also called *molluscum sebaceum* keratoacanthoma is particularly characterized by its rapid growth, maximally within 6 to 8 weeks. Keratin material is found within crater-like lesion.

Cornu cutaneum

Cornu cutaneum is a clinical term to describe a hyperkeratotic condition superadded on conditions like papilloma, senile or seborrhoeic keratosis and Bowen's disease.

Carcinoma of the Lid⁸

Broders' classification is as depicted in Table 35.6.

Table 35.6

Proders' Gradation of Malignant Tumours

	Differentiation (percentage)	De-differentiation (percentage)
Grade I	100-75	0-25
Grade II	75-50	25-50
Grade III	50-25	50-75
Grade IV	25-0	75-100

The usual locations are: (a) lower eyelid—54% (b) inner canthus—28%; (c) upper eyelid—13%; and (d) outer canthus—5%.

Three types are common: (a) basal cell—85%; (b) squamous cell—10%; and (c) adenoidal basal—5%.

It is common between 50 and 55 year and is predominantly in males.

Carcinomas arise in an otherwise normal skin without any apparent cause. Only at times chronic irritation is a precipitating factor.

Pathology. Basal cell carcinomas are locally malignant, and tend to form adnexal structures while squamous cell carcinomas are highly malignant with a tendency to metastasize and they tend to cause anaplasia.

There is epidermal invasion with downgrowth of columns of epithelial cells, the downgrowth showing secondary budding processes laterally and terminally (Table 35.7).

Table 35.7

Cellular Arrangement of Squamous Cell Carcinomas

Peripheral	Cylindrical cells
Intermediate	Prickle cells
Centre	Squamous cells

'Cell nests' are compressed squamous cells staining strongly with acid dyes, e.g. eosin. In basal cell carcinoma, the cells are basal cells of the epidermis taking basophilic stain, and do not show 'cell nests'.

Clinical features (Fig. 35.10). Carcinoma of the lid has a slow, insidious and painless onset. It occurs at or near the lid margin. At first there is



Fig. 35.10 Malignant tumour of left upper lid.

an indurated, elevated and sharply demarcated nodule with an irregular surface. There is infiltration into the skin. It is freely mobile over the underlying tissue unless strictly at the lid margin. The next stage is characterized by a thin and more glossy skin with development of an abnormal vascular pattern. Finally, it develops into a typical carcinomatous ulcer.

Diagnosis. The diagnosis is made from the clinical features and histological study using excisional biopsy in small tumours, incisional biopsy in large ones and fine-needle aspiration biopsy (FNAB).

Complications and sequelae. These include:

- (a) Occlusion of meibomian ducts
- (b) Erosion of the entire lid margin
- (c) Fungation
- (d) Involvement of the orbital tissues.

Treatment. The principles of treatment include the following measures:

Surgery. Most small basal cell carcinomas can be excised along with clinically normal tissue margin. The large lesions are dealt with wide excision followed by lid reconstruction. Exenteration is resorted to when there is orbital involvement.

Radiotherapy is indicated in cases which are unsuitable for operation and small basal cell carcinoma not affecting the medial canthus.

Cryotherapy is only tried in superficial, small basal cell carcinoma.

Chemotherapy helps in reducing the large size of basal cell carcinoma and is indicated when the patient refuses exenteration to be done.

Xeroderma pigmentosum

Aetiology. Xeroderma pigmentosum is presumably an actinodermatosis of alarming nature. Recessive trait is well documented, especially with a history of consanguinous marriage. It starts within the first decade of life.

Clinical features. The eyelids are frequently and primarily affected. The stages of affection are (a) acute erythema following exposure to sunlight; (b) diffuse pigmentation; (c) atrophy of the lid especially the lower with sequelae like entropion or ectropion; (d) exposure keratitis followed by ulcer; and (e) involvement of the orbit. The affection is fatal.

Mesenchymal tumours

Mesenchymal tumours are rather rare and they include myoma, rhabdomyoma of the orbicularis, leiomyoma, fibroma and lipoma.

Haemangioma

Haemangiomas are common tumours. Of the four types described below, the first two are rather common.

Capillary angioma or telangiectasia. It is histologically characterised by endothelial lined dilated capillaries with little connective tissue stroma. It is clinically exhibited as portwine spots involving small or large portions of the eyelid and the face, often following first and second divisions of the trigeminal nerve.

Naevus flammeus, the characteristic capillary angioma, forms one of the features of Sturge-Weber syndrome.

Cavernous haemangioma. It is histologically characterized by encapsulated masses of endothelial spaces in the subcutaneous tissue. Clinically it appears as a reddish elevated tumour, soft and compressible and increasing in size by venous congestion (by crying or bending the head). The tumour may spread to involve the cheek or even orbit.

Plexiform angioma. It occurs very rarely in infants and presents as nodular tumour with bleeding tendency.

Angioendothelioma. It is also very rare. There is proliferation of endothelial cells causing reduction of the blood space.

Treatment. If small, they may be treated by electrolysis or excision. Injection of sclerosing fluid such as 5 per cent sodium morrhuate may be given in large ones tumours.

They may be left untreated since some of them usually disappear.

Cryoapplication may be effective in destroying small superficial lesions.

Systemic steroids give sometimes dramatically successful results in orbital and adnexal haemangiomas. They perhaps exert an inhibitory action on immature vascular tissue or act as nonspecific antiinflammatory agents.

Carbon dioxide laser may be tried.

Lymphangioma

Its incidence in the lid is rare. It is slowly progressive. It may be simple capillary or cavernous type. Treatment is same as that of haemangioma.

Neurofibromata or von Recklinghausen's Disease

Neurofibromatosis causes lesions in the peripheral sympathetic nerves and the central nervous system, with *café-au-lait* pigmentation and hypertrophy of skin and subcutaneous tissues.

Three classical types of lid lesions are seen:

(a) *Plexiform neuroma* which affects usually the upper lid causing it to be thickened and pendulous in the advanced state;

(b) *Diffuse neurofibromatosis* which causes involvement of both lids and face; and

(c) *Molluscum fibrosum* which may appear as soft subcutaneous multiple tumours.

Association with buphthalmos and medullated nerve fibres has been noted. Orbits and skull bones

may be secondarily involved causing proptosis and pulsation.

Operative treatment may be advocated but it is always unsatisfactory.

Melanotic tumours

Normally the basal cells of the epidermis contain melanin derived from melanocytes.

Naevus or mole

Naevi occur at the lid margin, sometimes presenting as hairy mole (hairs arise from its surface) and sometimes as divided naevus, i.e. partly on the upper lid and partly on the lower, both together forming a complete one. They present as birthmarks, but develop actively at two stages of life—infancy and puberty.

Naevus is composed of naevus cells. These cells are small with deeply staining nucleus and scanty cytoplasm, arranged in nests, sheets or strands. They are divided into four groups: (1) junctional; (2) compound; (3) intradermal; and (4) blue, the former three from the epidermis and the remaining from the dermis.

Treatment is cosmetic.

Malignant Melanoma of the Eyelid

Malignant melanoma of the eyelid is rare before puberty. The majority often appear to develop in a preexisting naevus which has remained quiescent. However, it is signalled by the increase in size and pigmentation, consistency becoming harder and the fixity.

Pathology. Malignant melanoma of the eyelid shows all the features of malignancy: cellular pleomorphism, hyperchromatic nuclei, mitosis and usually areas of necrosis.

The changes that occur are: (a) the migration of epidermal pigment into the dermis and subsequent phagocytosis; (b) the increased number of clear cells in the basal layer of the epidermis; (c) the mild infiltration with chronic inflammatory cells in the superficial dermis;

(d) irregular deposits of clumped intradermal melanocytes and subsequent pleomorphism; and finally (e) the invasion of the dermis by malignant cells.

The cellular types are: (a) the epithelioid cells—more common types; (b) the naevoid cells; (c) the spindle cells; and (d) the bizarre cells.

Prognosis depends on the cellular content. Those with spindle cells is good while it is bad with epithelioid cells.

Treatment. Treatment of choice is wide surgical excision.

Abnormal Lid Movements⁹

The rate of blinking is on an average 3 to 7 times per minute.

The causes of abnormal lid movements are: (a) blinking; (b) squint; (c) tic; (d) blepharospasm; (e) blepharoclonus; (f) lid retraction; (g) lid lag; and (h) Bell's phenomenon.

Blinking. Blinking may be reflex, spontaneous, voluntary and spasmodic. Reflex blinking may be sensory reflex and optical blink reflex.

Spontaneous blinking occurs in waking hours.

Voluntary blinking or winking is usually unioocular. It is assisted by the orbicularis muscle.

Increased blink reflexes are due to any inflammation, fatigue, strenuous close work, psychopathic tic and blepharospasm. Decreased blanking occurs in dysthyroid ophthalmopathy and progressive supranuclear palsy.

Tic. This involves clonic contractures of isolated orbicularis fibres.

Blepharospasm. This is involuntary, persistent and strong orbicularis spasm causing firm closure of the eyelids lasting from few moments to few days. The causes include: (a) the most common is the reflex sensory irritation through the trigeminal; (b) stimulation of the facial nerve or its central connections; and among others (c) hysteria.

Treatment is always difficult and may need canthotomy or canthoplasty, injection of alcohol into the orbicularis, neurectomy of branches of

the facial nerve and resection of a band, about 8 mm of the orbicularis.

Blepharoclonus. This is the involuntary rhythmic contraction of the orbicularis fibres. It may involve the whole of the orbicularis oculi or some of its fibre bundles. When fibrillar twitching occurs in some fibre bundles especially near the outer canthus, this condition is termed *myokymia*. These involuntary contractions occur in fatigue and irritability.

Lid retraction. Normally in an adult the upper lid margin cuts the limbus 1 to 3 mm below its highest point, but if in the primary position of the eyes the upper lid margin so rests that a rim of the sclera is visible, lid retraction is said to be present (Fig. 35.11).

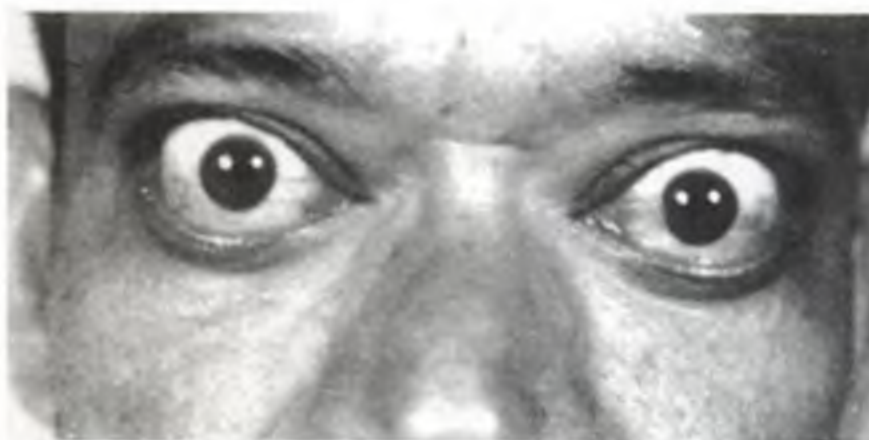

Fig. 35.11 Bilateral lid retraction and proptosis.

Aetiology. The main causes are listed in Table 35.8.

Table 35.8

Main Causes of Retraction of Upper Eyelid

Physiologic: in the newborn

Dysthyroid

Cicatricial

Posttraumatic

Postsurgical

Mechanical

Trachomatous upper lid

Proptosis

High myopia

Buphthalmos

Facial nerve palsy

Marcus Gunn syndrome

Drug induced

Phenylephrine, apraclonidine, etc.

Lid lag. When the upper lid lags behind during the downward movement of the eyeball, the condition is described as a lid lag. It is a characteristic feature of dysthyroid ophthalmopathy.

Bell's phenomenon. Physiologically there is synergistic up and out deviation of the eyeballs on lid closure, and this nociceptive reflex is called Bell's phenomenon. It occurs in sleep and coma, and also on attempted closure in facial paralysis. It may be absent in normal patients or in congenital supranuclear oculomotor paralysis. When the eyeballs deviate downwards it is called an inverse Bell's phenomenon or a perverse Bell's phenomenon.

Abnormalities of the Palpebral Aperture

The antagonistic muscles—the orbicularis oculi and levator palpebrae superioris—assisted by Müller's muscle determine the width of the palpebral aperture.

Widening of the fissure results from facial nerve palsy, exophthalmos, high myopia and buphthalmos.

Narrowing of the fissure occurs from ptosis, Horner's syndrome and enophthalmos.

Developmental Abnormalities of Eyelids and Palpebral Fissure

Colobomas. A coloboma is a notch primarily affecting the lid margin. One or all four lids may be involved. The degree of defect is variable. It may be a slight indentation of the lid margin to nearly complete absence of the lids (*ablepharon*). Abnormally small lids may be present, this condition is called *microblepharon*. When coloboma develops in the lower lid it usually affects the lateral side.

More commonly the medial part of the upper lid is affected. It may be associated with craniofacial dysostosis, *Treacher-Collins syndrome*.

The condition occurs due to injury from the amniotic bands or localized failure of the adhesion

of the lid-folds. Treatment is essential when there is corneal exposure due to a large defect. It consists of plastic repair and occasionally an end-to-end anastomosis.

Ankyloblepharon. It is the fusion of the upper and lower lid margins particularly at the lateral side. It should be separated surgically if it is disfiguring.

Ptosis. Most ptosis cases are congenital and are caused by a lack of peripheral differentiation or aplasia of the levator palpebrae superioris. The condition has been described with other types of ptosis.

Congenital entropion. This abnormality is a rare condition affecting the lower lid. It may be confused with an *epiblepharon*, the latter being characterized by redundant horizontal skin fold adjacent to the lower lid margin.

Congenital ectropion. This abnormality is also rare and may be associated with blepharophimosis.

Blepharophimosis syndrome. It exhibits bilateral ptosis, blepharophimosis, telecanthus, lower lid ectropion and epicanthus inversus.

Epicanthus. This is a semilunar skin-fold situated above and at times across the inner canthus. It is usually bilateral. It produces an apparent convergent squint. It is a racial characteristic of mongolism.

Telecanthus. It means increased width between the medial canthi. Unless it disappears with age operation such as Spaeth's Z-transposition or Mustardé's operation of producing a horizontal scar across the medial canthus is called for.

Epiblepharon. This is a prominent skin-fold in front of the lower tarsus usually at its medial margin. It usually resolves spontaneously.

Cryptophthalmos. This condition is rare. It is caused by the complete failure of the development of the lid folds. The skin passes continuously from the eyebrow over the hidden eye to the cheek.

Blepharochalasis. It is characterized by redundant skin of both upper lids hanging down over the eyes. It is often hereditary. Treatment is by surgical correction.

Blepharophimosis. This is the generalized narrowing of the palpebral fissure. It can be surgically dealt with.

Euryblepharon. This is the generalized enlargement of the palpebral fissure. Treatment is by lateral tarsorrhaphy.

Distichiasis. In this condition there are double rows of eyelashes, extra row situated in the line of the openings of the Meibomian glands. The extra lashes should be removed, otherwise they will irritate the cornea. Treatment consists of destruction of eyelashes by electrolysis or cryoapplication.

Dermochalasis. It occurs in senile eyes wherein there is redundancy of the lid skin associated with herniation through the orbital septum. Often there is a family history. Treatment is by blepharoplasty.

Oedema of the Lids

Oedema of the lids may be classified as: *inflammatory*—due to inflammations of the lids, conjunctiva, lacrimal sac, orbit and nasal sinuses; and *passive*—due to circulatory obstruction, e.g. renal diseases and cardiac failure.

Oedema of the eyelids is a common condition. The eye may be covered by profound oedema of the lids.

Angioneurotic oedema, perhaps due to vasomotor instability, is a condition where there is an intermittent acute oedema of the eyelids.

Further Reading

- Ahmed, E. and Roy, S.N., Ophthalmodermatozoosis: a study of fifty cases, *J. All India Ophthalmol. Soc.*, 17: 145, 1969.
- Beard, C., *Ptosis*, C.V. Mosby, St. Louis, 1969.
- Collin, J.R.O., *A Manual of Systematic Eyelid Surgery* (2nd ed.), Churchill Livingstone, Edinburgh, 1989.
- Duke-Elder, S., *System of Ophthalmology*, Vol. XIII, Part I: *Diseases of the Eyelids*, Duke-Elder, S. and MacFaul, P. (Eds.), Kimpton, London, 1974.
- Fox, S.A. *Ophthalmic Plastic Surgery* (4th ed.), Grune and Stratton, New York, 1970.
- Harley R.D. (Ed.), *Pediatric Ophthalmology*, W.B. Samelers, Philadelphia, 1975.
- van Heuven, W.A.G. and Swann, J.T. (Eds.), *Decision Making in Ophthalmology*, Mosby Year Book, St. Louis, 1992.
- Kanski, J.J., *Clinical Ophthalmology* (3rd ed.), Butterworth-Heinemann, London, 1994.
- Newell, F.W., *Ophthalmology: Principles and Concepts* (8th ed.), C.V. Mosby, St. Louis, 1997.
- Pau, H., *Differential Diagnosis of Eye Diseases*, trans. Cibis, G.W., W.B. Saunders, Philadelphia, 1978.
- Reese, A.B., *Tumours of the Eye* (2nd ed.), Hoeber Division, Harper and Row, New York, 1963.
- Trevor-Roper, P.D. and Curran, P.V., *The Eye and Its Disorders* (2nd ed.), Blackwell Scientific, Oxford, 1984.

36. DISEASES OF THE LACRIMAL APPARATUS

Diseases of the Lacrimal Gland

The various disorders may be enumerated as follows:

- Disorders of secretion
 - Hypersecretion
 - Paradoxical lacrimation
 - Hyposecretion
- Inflammation – acute and chronic dacryoadenitis
- Tumours
- Congenital anomalies
- Atrophy
- Involvement in systemic diseases
- Trauma

Hypersecretion of Tears^{1,11}

Excessive tears may be due to stimulation of the basic secretors or reflex secretors as in: (a) exposure to wind, cold or bright light; (b) inflammations of the conjunctiva, lids, orbit, cornea, uvea, and nasal sinuses; (c) lid lesions; and (d) parasympathetic stimulation.

Oversecretion of tears can be allayed by alcohol injection into the gland, by excision or irradiation.

Paradoxical Lacrimation

Also known as 'crocodile tears' it occurs as a sequel to facial nerve palsy. There is an aberrant regeneration of the nerve fibres. It is evidenced by hypersecretion of tears while eating. The affection is mostly unilateral and very rare.

Dry Eye^{7,10,11}

Aetiology. The causes include:

(a) Xerosis caused by cicatricial degeneration of the conjunctiva and other mucous tissues as in Sjögren's syndrome, Stevens-Johnson disease, trachoma and alkali burn

(b) Sensory lesions of the V cranial nerve

(c) Keratoconjunctivitis sicca—typically in Sjögren's syndrome

(d) Systemic diseases such as pemphigus and benign mucous membrane pemphigoid.

Clinically the patients complain of dry and gritty sensations. Investigations are described under Sjögren's syndrome.

Treatment. Several measures are advocated but none is particularly effective.

(a) *Artificial tears.* There are tears and lubricants available with methyl—or ethyl cellulose base, e.g. isoptotears, tearisol, etc.; hypoosmotic base; polyvinyl alcohol base; polyvinylpyrrolone polymer or other polymers.

(b) For prolonged action one 5 mg insert (lacrisert) is inserted every morning into the lower fornix and the insert swells up 10 times its original size by imbibition of fluid resulting in slow

release of hydroxypropyl methyl cellulose over 12 hours.

(c) Soft contact lens

(d) Temporary punctal occlusion. It can be done temporarily by agent like Teflon.

(e) Other measures include instillation of 10 to 20 per cent acetylcysteine 6 hourly, parotid duct transplantation which is often unsatisfactory, fitting of artificial tear tank, and 0.01 per cent topical vitamin A (Tretinoin) thrice daily.

Acute Dacryoadenitis¹

Incidence of acute dacryoadenitis is rare. Three types are known: (a) palpebral; (b) orbital; and (c) orbitopalpebral.

Aetiology. Acute dacryoadenitis may be primary or secondary. In the first instance the cause is not obvious. It occurs especially in children and adolescents, it is unilateral, mild and it affects the palpebral lobe. In the second instance the causes are local as in trauma and erysipelas, and metastatic, characteristically as in mumps which is the most common cause.

Pathology. The features include: (a) swelling and proliferation of the epithelium of the glandular ducts; (b) degeneration and casting off of the cells into the lumen; (c) surrounding of the remaining part by the infiltrative cells (lymphocytes, plasma cells, polymorphs, etc.); (d) vascular lesions which include thrombosis, necrosis, obliterative arteritis and phlebitis; (e) infiltration of the connective tissue between the alveoli, around the vessels and nerves; and (f) finally sclerosis, fibrosis and thickening.

Clinical features. Clinical features include: (a) oedema of the lids spreading towards the temple and cheek and causing mechanical ptosis with a S-shaped curve of the upper lid margin; (b) localised chemosis in the upper and outer quadrant; (c) conjunctival congestion; along with palpable and tender preauricular gland; and (d) constitutional upsets such as pain, fever and malaise. The orbital type produces less chemosis, more pain because of constriction of the orbital part by the fascia, and slight down and in proptosis.

Complications and sequelae. Acute dacryoadenitis usually resolves within one to two weeks. Suppuration may ensue in some cases leading to abscess and then fistula. Subacute dacryoadenitis may follow in other cases which resolves in one to three months. Sequelae include fistula, atrophy, cyst formation and hyposecretion.

Treatment. Treatment consists of heat, antibiotics and measures to allay the symptoms.

Chronic Dacryoadenitis¹

Aetiology. The various causes may be: (a) a sequel to acute dacryoadenitis; (b) trachoma; (c) tuberculosis; (d) leprosy; (e) syphilis; and (f) sarcoidosis.

Trachomatous dacryoadenitis. This may arise in two ways, by sclerosis of the gland secondary to trachomatous cicatrization of the subconjunctival tissues leading to obliteration of the ductules and by direct invasion of the gland by trachoma.

Tuberculous dacryoadenitis. This may be acute miliary and localized. A localized type may be either in the sclerotic form, forming a granuloma or in the caseous form.

Mikulicz syndrome is characterized by bilateral, chronic symmetrical enlargement of both lacrimal and parotid glands due to obscure aetiology but usually with lymphoid tissue hyperplasia.

Differential diagnosis. An acute dacryoadenitis should be differentiated from: (a) lid abscess; (b) sty; (c) a suppurative chalazion; (d) an acute purulent conjunctivitis; (e) an orbital cellulitis; and (f) an osteomyelitis of the frontal bone.

A chronic dacryoadenitis should be differentiated from: (a) tumours of the lacrimal gland; (b) dacryops; and (c) cysts of the lacrimal gland.

Atrophy of the Lacrimal Gland

Atrophy of the lacrimal gland may be senile, idiopathic and consecutive. The example of idiopathic atrophy is Sjögren's syndrome. The causes of a consecutive atrophy include acute

dacryoadenitis, tuberculous and malignant conditions.

Dislocation of the Lacrimal Gland¹

Dislocation of the lacrimal gland may be spontaneous or traumatic. The probable cause is a weakness of the orbitopalpebral fascia.

Tumours of the Lacrimal Gland^{1,2,4,11}

Lacrimal gland tumours are relatively rare. They may be benign or malignant, epithelial or non-epithelial. The important ones are pleomorphic or benign mixed tumours, adenocarcinoma and reticuloses. Epithelial tumours and lymphosarcoma comprise 50 per cent of the cases.

Clinical features. Clinical features include ptosis, raising of the eyebrow, palpable growth, displacement of the eyeball down and in, diplopia and occasional proptosis due to posterior extension of the tumour. In malignant tumours, other additional features may include enlargement of the neighbouring glands, swelling of the lids due to oedema or infiltration, and pain due to tumour involvement of the nerves.

X-ray shows an enlarged lacrimal gland fossa. In benign variety, the surrounding bones may show no evidence of involvement for a long time. In malignant tumours, early bone involvement, often hyperostosis and rarely erosion, is a characteristic feature.

Biopsy (by direct/or lateral approach) is an important diagnostic aid.

Treatment. Surgical interference may be of any degree ranging from local excision to exenteration.

Radiation and chemotherapy are relatively ineffective.

Benign Mixed Tumour of the Lacrimal Gland

Mixed tumour or *pleomorphic adenoma* is the most frequent variety, about 60 per cent, of epithelial tumours of the lacrimal gland. The usual age-group

affected is between the fourth and fifth decades. Onset is insidious and the progress is very slow.

Pathology. Basically it is an epithelial tumour derived from the ducts and is lined by a double layer of cuboidal cells. The inner secretes seromucinous material and the outer one often undergoes metaplasia forming connective tissue-like elements. The tissue elements show pleomorphism (myxomatous, fibroblastic, cartilaginous or osseous) and the appearance may vary in different areas of the tumour. Usually there is a pseudocapsule formed by the condensed connective tissue which may be adherent to the periosteum. The benign variety may turn into a carcinoma.

Carcinomas

Carcinomas form the remaining 40 per cent of epithelial tumours. These include the following varieties—adenoid cystic, mucoepidermoid and squamous cell carcinomas.

Miscellaneous Tumours

Other tumours include adenoma, fibroma, sarcoma and reticulosos.

Cysts of the Lacrimal Gland

Cysts of the lacrimal gland may be: (a) simple cyst of the palpebral lobe; (b) cyst of the orbital lobe; (c) parasitic; and (d) dermoid.

Dacryops is a retention cyst of the palpebral lobe of the lacrimal gland and it appears as a swelling at the outer part of the upper lid. It is painless, tense and mobile, the size varying between a pea and an egg. Sometimes there is a copious flow of tears following which the volume is reduced called an *intermittent dacryops*, and on occasion it may burst and it is known as a *fistulized dacryops*.

Sjögren's Syndrome^{1,11}

Aetiology. (a) It commonly occurs as a part of rheumatic diathesis. Most of the patients show rheumatoid factor in their serum.

(b) It may be a part of general glandular atrophy affecting the lacrimal and salivary glands.

(c) It may be an autoimmune disease. Many patients are found to have hypergammaglobulinaemia with increased IgG, IgM and sometimes IgA.

Pathology. The lacrimal glands show: (a) atrophy of the parenchyma of the glands; (b) replacement by the fibrous tissue; and (c) variable degree of infiltration, mainly lymphocytes and plasma cells. The bulbar conjunctiva shows oedema and vacuolation of the epithelial cells as well as oedema of the connective tissue. The corneal epithelium shows similar changes. Finally oedema subsides, the cells become flattened and localized degenerated areas appear in the cornea and sclera.

Clinical features. 'Every elderly arthritic woman who complains of conjunctival symptoms is said to be suspected of having keratoconjunctivitis sicca' (Sjögren).

The disease is characterized by: (a) Ocular features. Insidious onset, dry irritative conjunctivitis, mild ciliary congestion, desiccation of the conjunctiva and filamentary keratitis are characteristics. Three types of filaments are seen:¹⁰ (i) consisting entirely of mucus; (ii) entirely of epithelial cells; and (iii) consisting of epithelial cells and mucus.

(b) General features are dry mouth and tongue, dry cough, hoarse voice, anaemia, achlorhydria, rheumatoid polyarthritis (in about 50 per cent), splenomegaly and raised ESR.

Diagnostic Tests for Dry Eye^{1,10}

Rose bengal staining. 1 per cent rose bengal stains the desiccated conjunctival shreds; the test is more valuable than fluorescein staining, since the former indicates the state of dying tissue before its actual destruction. The damaged epithelial cells appear bright red.

Schirmer's test. This test is valuable for measuring the degree of tear secretion and is indicated in dry eyes.

A strip of filter paper 5 mm wide and 35 mm long is folded for 5 mm at one end at a right angle, and is placed in the outer half of the lower fornix. It is kept there for 5 minutes and the eyes are closed. The degree of wetting of the filter paper is noted. If it is more than 15 mm it can be considered normal, if more than 25 mm it indicates oversecretion and if it is less than 10 mm it indicates hyosecretion of both basic and reflex lacrimal secretors.

If hyosecretion is present the test may be repeated in a slightly darkened room after anaesthetizing the conjunctival sac and if the wetting is less than 10 mm, it indicates a hyosecretion of the basic secretors. This is the *basic secretion test of Jones*.

Schirmer's No. 2 test by smelling ammonia or onion. If the wetting is less than 15 mm the test may be repeated after abnormal stimulation of the mucosa of the middle turbinate. After 2 minutes the amount of wetting is noted.

If there is less than 15 mm wetting after this test it indicates a failure of the reflex secretor, i.e. the lacrimal gland. If the rate of wetting increases, it indicates a defect in the peripheral sensory pathway.

Break-up time (BUT) of tear film. The interval between the blink and appearance of first dry spot is called BUT. The patient is usually examined with a slit-lamp. He or she is requested to blink and then to keep the eyes wide open. Prior to this, instil a drop of fluorescein in the lower fornix. The time of appearance of small black spots in the blue-green field from the last blink gives the BUT. Normal range is more than 25 seconds. BUT less than 15 seconds indicates a tear film instability.

Fluorescein staining. The denuded conjunctiva will be stained.

Tear osmolarity. Normally, tear is isotonic—303 to 306 mos m/L. In Sjögren's syndrome, tear becomes hypertonic.

Tear lysozyme assay. It is done by turbimetric assays using *Micrococcus lysodeiktitus* and the

substrate after collecting tear samples on Schirmer's strips. In dry eye, tear lysozyme is low or absent.

Impression cytology. It involves counting conjunctival goblet cell density. Loss of goblet cell occurs in vitamin A deficiency, trachoma, Stevens-Johnson syndrome, Sjögren's syndrome and ocular pemphigoid.

Tear fern test⁶. This test involves drying of tear over slides and different patterns are seen. Uniform arborizations and numerous branchings with no space between the ferns are considered normal. Less branchings and larger spaces indicate abnormalities.

Treatment. Treatment is difficult and frustrating. The measures include:

(a) Conservation of small amount of tear that is present by occlusion of all four puncta.

(b) Use of artificial tears.

(c) Topical N-acetylcysteine drops (5%) may be used to decrease the viscosity of the mucus.

(d) Parotid duct transplantation though advocated by some, but is of no real value.

(e) Flush-fitting scleral or soft contact lens has recently been advocated.

Diseases of the Lacrimal Passages¹

They involve the puncta, canaliculi, lacrimal sac, and nasolacrimal duct.

Eversion of the lower punctum

Eversion of the lower punctum occurs due to the laxity of the lids as in old age, persistent blepharoconjunctivitis and ectropion.

Treatment in mild cases consists of cauterization of the area just behind and below the punctum. Localized cicatrization thus produced combats eversion. In a severe case, a conjunctivoplasty is advocated.

Occlusion of the puncta and canaliculi

Occlusion of the puncta may be cicatricial and rarely developmental. Occlusion of a canaliculus may be cicatricial and due to a foreign body. On inspection by a loupe there may or may not be trace of the punctum. Long-continued use of idoxuridine (IDU) drops may cause occlusion of the canaliculus. Masses of the mycelium of *Actinomyces* may also occlude a canaliculus.

Treatment. A canaliculotomy or three-snip operation (*see p. 453*) is indicated in the relief of punctal occlusion.

Treatment of canalicular occlusion is either conjunctivodacryocystorhinostomy if the block is medial (membranous) or canaliculodacryocystorhinostomy if the block is lateral (fibrous).

Canaliculitis

An uncommon, usually chronic, unilateral inflammation, the primary affection is more often mycotic, actinomycosis or sporotrichosis, involving more commonly the lower canaliculus and producing a cheesy-like material within the dilated canaliculus.

Treatment consists of the usual measures for combating infection and occasionally calls for dilatation, slitting, curettage and irrigation with antibiotic or touching with iodine.

Dacryocystitis

Dacryocystitis is the inflammation of the lacrimal sac and duct.

Classification. This is classified as:

- (a) Primary—chronic and Acute
- (b) Secondary—due to inflammation or injury in vicinity
- (c) Dacryocystitis neonatorum.

Chronic dacryocystitis

The affection is quite common, more so in females usually after about 40 years of age, and more often chronic. The structural configuration may be transmitted as a dominant characteristic, so heredofamilial incidence is not unlikely.

Aetiology. Aetiology is mostly unknown. Occasional causes include general infections, neighbouring infections and specific granulomata.

Pathology. Two factors, mutually forming a vicious circle, are of paramount significance and they are stasis and infection.

Stasis. The anatomical factors responsible for stasis are the narrower bony lumen of the nasolacrimal duct, the folds in the mucous membrane of the lacrimal passages and the presence of unusually rich vessels and lymphatics in the submucosa.

Infection. This may ascend from the nose, descend from the conjunctiva, and spread from the vicinity. Systemic infection may reduce the resistance so that there is ascent of pathogens from the nasopharynx.

Histological changes in chronic dacryocystitis are:

- (a) Lumen may be filled with mucinous fluid.
- (b) Lining epithelium shows hyperplasia, folds, etc.
- (c) There is infiltration with chronic inflammatory cells.
- (d) Finally there is picture of replacement fibrosis.

Clinical features. In chronic dacryocystitis the symptoms depend on the severity of the inflammation. Two clinical features are especially important: constant and persistent epiphora and intractable unilateral angular conjunctivitis. Three common types are—catarrhal, mucocele and suppurative.

Mucocele of the sac is evident by the presence of a swelling at the sac region and on application of pressure over the sac swelling mucopus or pus regurgitates through the puncta or rarely through the nose. When the signs are equivocal, a diagnostic syringing is called for.

The presence of an infected sac is a constant menace to the eye, because even a minor corneal abrasion may be infected from this potent reservoir of pyogenic infection.

Acute dacryocystitis¹ (Fig. 36.1)

Acute dacryocystitis occurs as an exacerbation of untreated chronic dacryocystitis and is characterized by a red tender swelling limited to the region of the lacrimal sac. It may lead to an abscess, which may perforate the skin below the medial palpebral ligament, resulting in a fistula.

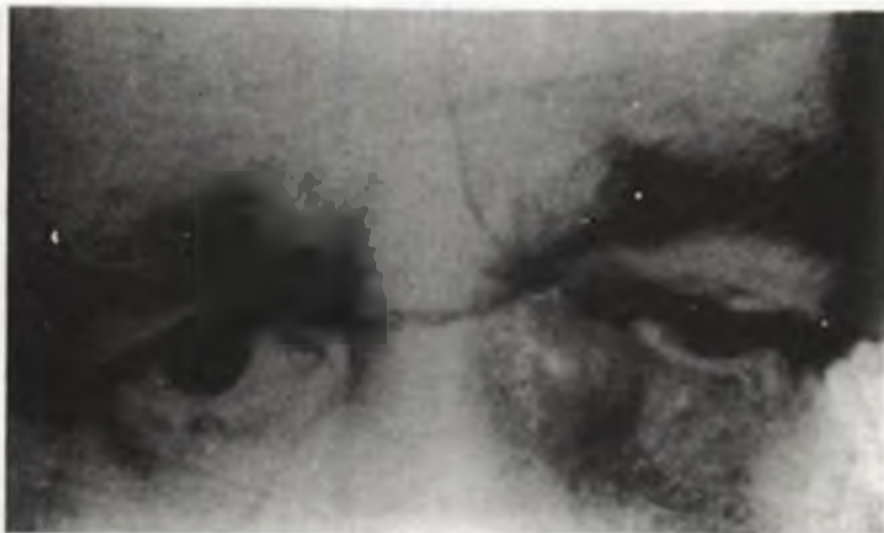


Fig. 36.1 Acute dacryocystitis.

Dacryocystitis neonatorum

Dacryocystitis neonatorum may present as an acute or chronic process, usually evident about the second week of life and occasionally as acute conjunctivitis in the first few days. Slight sticky discharge and persistent epiphora are two important signs.

Treatment of dacryocystitis. In chronic dacryocystitis conservative treatment is indicated in early cases. This may be: (a) Massage of the sac region followed by cleaning and instillation of sulphacetamide or antibiotic drops several times a day.

(b) Syringing is indicated for two purposes: diagnostic and therapeutic. Syringing is frequently curative in certain early cases. It may affect a cure by separating the oedematous mucosal walls sticking together and by clearing the mucosal debris.

Most cases are, however, obstinate and recalcitrant to conservative measures.

Surgical interference may be:

(a) Probing is unsuccessful in adults and is not advocated.

(b) Dacryocystorhinotomy (DCR) is the operation of choice in most cases. The obvious contraindications are recurrent lacrimal fistula, tuberculosis or malignancy of the sac, and occlusion of the puncta and canaliculi.

(c) Dacryocystectomy is indicated where DCR is contraindicated.

In acute dacryocystitis the treatment comprises heat and systemic antibiotics. A lacrimal abscess must be drained.

In dacryocystitis neonatorum treatment is at first essentially conservative. The child's mother is taught how to empty the lacrimal sac of purulent matter before each treatment and this is followed by instillation of antibiotic drops. If the conservative treatment fails, probing under general anaesthesia is done.

Tumours of the Lacrimal Sac

Tumours of the lacrimal sac may be classified as:

Primary—which may be: (a) epithelial such as papilloma, adenoma, pleomorphic and carcinoma; and (b) mesenchymal such as fibroma and sarcoma. Rarely, malignant melanoma, reticuloses and pseudotumours are seen.

Secondary—tumours that may spread to the lacrimal sac are from the skin, i.e. epithelioma of the lower lid; the nose, i.e. papilloma of the nose and the nasal sinuses, i.e. from the frontal and maxillary; and less commonly from the ethmoid.

Diagnosis. Epiphora in presence of a patent nasolacrimal passage is suspicious, while a hard irreducible mass is suggestive.

X-ray with a contrast medium reveals a filling defect in the lacrimal sac.

Treatment. It is treated on general principles.

Epiphora³

Epiphora means excessive watering of the

eyes due to some interference with the outflow of tears.

The following are the common causes:

(a) In the punctum and canaliculus—
inflammation, cicatrization, errant eyelash,
agenesis, etc.

(b) In the lacrimal sac—inflammation and
neoplasm

(c) In the nasolacrimal duct—postinflammatory
anatomic changes

(d) In the inferior meatus of the nose

(e) Distortion of the lid margin

(f) Paralysis or paresis of the orbicularis oculi.

Investigations. These investigations are recommended:

(a) History includes age, sex, mode of onset, precipitating causes (if any), family history, occupation, history of nasal or other disease and presence of irritative symptoms.

(b) Examinations include appearance and configuration of the face and nose, position of the eyeball, any position of the eyelids, tone of the orbicularis, position of the lower punctum, evidence of the lid lesion, direction of the eyelashes, hyperaemia of the conjunctiva and conjunctival discharge, swelling at the sac region, etc.

(c) *Dye test.* A drop of fluorescein is instilled into the conjunctival sac and a cotton-tipped applicator is inserted into the inferior meatus. Wait for 2 minutes. Nonstaining of cotton indicates obstruction in the nasolacrimal passage.

(d) *Syringing.* There are four possibilities:

(i) Freely patent to single syringing—
normal,

(ii) Freely patent to pressure syringing,

(iii) Patent, with difficulty to pressure
syringing, partial block,

(iv) Not patent at all—complete block,

(e) Rhinological check-up.

(f) Bacteriologic study.

(g) X-rays: 1. plane and 2. after injecting a contrast medium like lipiodol.

(h) *Dacryocystography*⁸. There are four types of dacryocystography (DCG).

Plane DCG. The dye (Lipiodol, Conray, Diagonal viscous, etc.) is introduced into the

lacrimal sac via the lower punctum by means of a cannula fitted with a syringe. Anteroposterior and lateral X-rays are taken after removing the cannula.

Distension DCG. The technique is same as that of plane DCG but the lacrimal passages are kept distended during taking X-rays. The size of the sac or the presence of diverticulum is assessed.

Macrodacryocystography (MDCG) is indicated in suspected canalicular obstruction. The technique is that of distended DCG but additionally a film cassette is placed under the X-ray table. Anteroposterior and lateral X-rays are taken immediately after the injection of the dye and again after 15 to 30 minutes.

Radioscintillography. A gamma camera is fitted with a pin hole collimeter at 5, 10, 15 and 25 minutes takes images of the eye after instillation of one drop of radioactive tracer technetium into the conjunctival sac of each eye. The tracer permeates through the lacrimal passages to reach the nasal cavity producing a continuous image. The lacrimal sac cannot be visualized if there is an obstruction. Persistent pulling of the dye into the sac indicates the presence of obstruction at the junction of the sac and the nasolacrimal duct.

Indications for surgery in various disturbing epiphora cases are as follows.⁵

(a) Eversion or phimosis of the punctum

(b) Neoplasms and incarcerated foreign body in the canaliculus

(c) Acute canalicular trauma

(d) Congenital absence, traumatic destruction or complete closure of both canaliculi

(e) Failure of conservative treatment

(f) Following a DCR.

Developmental Abnormalities of the Lacrimal Apparatus⁹

In general such abnormalities are infrequent, and anomalies of the lacrimal gland are rarer than those of the lacrimal passages.

Anomalies of Secretory System

Absence of the lacrimal gland. It is due to absence of the conjunctival sac. The lacrimal gland is present in anophthalmos, and is absent in cryptophthalmos.

Alacrima. It is seen in hereditary dysautonomia and probably due to neurogenic factor.

Aberrant lacrimal gland tissue. Aberrant lacrimal gland tissue may be present under the conjunctiva simulating an epibulbar tumour, and less commonly in the iris, ciliary body, sclera or cornea.

Congenital cysts. They develop in the orbital lobe of the lacrimal gland. The cyst may appear as a tense and fluctuating tumour under the lateral orbital margin. Sometimes it may cause ptosis and proptosis. Removal by Kronlein's operation may be necessary.

Fistula. Fistula occurs above the upper tarsal plate or at the lateral canthus. Treatment consists of transplantation of the fistula into the conjunctival sac or excision of the fistula with attached portion of the lacrimal gland.

Lacrimal hypersecretion. The incidence is very rare.

Anomalies of Excretory System

Anomalies of the punctum and canaliculus. There may be:

- (a) Total absence—usually the lower punctum
- (b) Atresia of the punctum or/and canaliculus is marked by a dimple
- (c) Supernumerary puncta and canaliculus. Usually the lower canaliculus is affected. The single accessory punctum most commonly lies nasally to the normal one; opening is at the lid margin, on the lid skin, in the conjunctival sac or in the caruncle. The supernumerary puncta may reach the sac or may end in a cul-de-sac
- (d) Slit or groove-like puncta
- (e) Variation in size and position of the puncta,

and length of the canaliculi e.g. Waardenburg's syndrome—characterized by lateralization of the puncta and lengthening of the canaliculi, accompanied by white forelock.

Treatment. Its treatment is difficult but the various measures advocated are:

(a) Passage of a sharp probe followed by dilatation with probes of increasingly large diameters.

(b) In absence of the punctum incision over the site of presumed canaliculus.

(c) In absence of the canaliculus conjunctivodacryocystorhinostomy may be tried.

Fistula of the lacrimal sac. It is usually secondary to a lacrimal abscess, and rarely due to mild persistence of the facial fissures. An external fistula is seen just below the level or medial palpebral ligament, it may end bluntly, but commonly connects the sac or nasolacrimal duct. An internal fistula extending from the sac ends in the nose. Treatment consists of excision, after proper evaluation of the anatomic communication of the fistula.

Obstruction of the nasolacrimal duct.

Congenital Obstruction of the Nasolacrimal Duct

Congenital obstruction of the nasolacrimal duct is the most common cause of epiphora in infants.

Aetiology. (a) Most commonly it is due to persistence of the membrane between the nasal cavity and the nasolacrimal duct beyond the second week of life.

(b) It may be due to obstruction caused either by epithelial debris in the lumen of the duct or by defective canalization of the duct.

(c) Very rarely it is due to defective development of the bony canal.

Treatment. (1) Conservative measures include regular digital massage and topical instillation of antibiotics. Most cases resolve by the sixth month of life.

(2) Probing under general anaesthesia is required

when the condition persists beyond 6 months or so. It should be done through the upper canaliculus. It is controversial whether the procedure should be followed by irrigation. When two or three correctly-performed probing fail to relieve the symptoms, dacryocystorhinostomy appears to be the procedure of choice.

Further Reading

1. Duke-Elder, S., *System of Ophthalmology*, Vol. XIII Part 2: *Lacrimal, Orbital and Para-orbital Diseases*, Duke-Elder, S. and MacFaul, P. (Eds.), Kimpton, London, 1974.
2. Forrest, A.W., Epithelial tumours of the lacrimal gland. In *The Lacrimal System: First International Symposium*, Veirs, E.R. (Ed.), C.V. Mosby, St. Louis, 1971, p. 19.
3. Jacobs, H.B., Symptomatic epiphora. *Br. J. Ophthalmol.*, 43:415, 1959.
4. Jones, I.S., Lacrimal gland tumours. In *The Lacrimal System: First International Symposium*, Veirs, E.R. (Ed.), C.V. Mosby, St. Louis, 1971.
5. Jones, L.T., The treatment of canalicular disorders. In *Corneo-Plastic Surgery*, Rycroft, P.V. (Ed.), Oxford, 1969, p. 113.
6. Kogbe, O. and Litotet, S., An interesting use of tear ferning pattern in contactology. *Ophthalmologica*, 194:150, 1987.
7. Lemp, M.A., Recent development of dry eye management. *Ophthalmology*, 84: 1299, 1987.
8. Mehrotra, A.S., Radiographic study of lacrimal passage. In *Modern Ophthalmology*, Dutta, L.C. (Ed.), Jaypee Bros., New Delhi, 1994, p. 169.
9. Pico, G., Congenital anomalies of the lacrimal system. In *The Lacrimal System: First International Symposium*, Veirs, E.R. (Ed.), C.V. Mosby, St. Louis, 1971, p. 3.
10. Tabbara, K.F., Tears. In *General Ophthalmology* (12th ed.), Vaughan, D., Asbury, T. and Tabbara, K.F. (Eds.), Appleton and Lange, Connecticut, 1989, p. 67.
11. Trevor-Roper, P.D. and Curran, P.V., *The Eye and its Disorders* (2nd ed.), Blackwell Scientific, Oxford, 1984.

37. DISEASES OF THE CONJUNCTIVA

Conjunctival diseases, especially inflammations, form the large proportion of all ocular affections. There are three ways through which the conjunctiva may be involved—mostly the affections are of exogenous origin, sometimes there is spread to the conjunctiva from the neighbouring tissues, and occasionally they may be endogenous. Fortunately the conjunctiva is accessible to culture test, cytologic and histologic studies.

Anomalies of the Vascular System⁷

Anomalies of the vascular system are mainly: (a) hyperaemia, (b) subconjunctival haemorrhages and (c) chemosis.

Hyperaemia (Fig. 37c.1)

Hyperaemia of the conjunctiva affects chiefly the fornix and palpebral conjunctiva. This may be active or arterial, and passive.

An active hyperaemia presents a bright pink colour, while a passive variety exhibits a dusky strangulated appearance.

Active hyperaemia is common. It is either transitory and may be due to a foreign body and trichiasis, or recurrent and chronic due to refractive error, and abuse of the eyes in faulty illumination.

Passive hyperaemia is due to an obstruction of the venous outflow, e.g. occlusion of the veins at the apex of the orbit and right-sided heart failure. Rarely, an increased blood viscosity as in polycythaemia, macroglobulinaemia and multiple myeloma may induce a passive hyperaemia.

Conjunctival congestion must be differentiated from ciliary congestion (Table 37.1).

Treatment consists of

- (1) Removal of the exciting factor; and
- (2) Mild astringent drop like G. zinc boric.

Table 37.1

Differences between Conjunctival and Ciliary Congestion

Points	Conjunctival congestion	Ciliary congestion
Site	More intense in the region of fornices	More intense in the pericorneal region
Colour	Bright red	Purple
Movement of vessels	Moves with the conjunctiva	Does not move
Discharge	Present	Lacrimation only
Direction of blood flow	Fornix to limbus	Limbus to fornix
Branching of the vessels	Individual vessels are seen, tortuous and anastomosing	Individual vessels are not seen, radial and nonanastomosing
Effect of vasoconstrictor (1:10,000 adrenaline)	Temporary disappearance	Injection persists
Possibility of extension into the cornea	Positive. May cause superficial vascularization	Negative. Stops at the limbus
Causes	Conjunctival irritation and inflammation	Keratitis, iridocyclitis and acute glaucoma
Involvement of the vessels	Posterior conjunctival	Episcleral twigs of the anterior ciliary

Subconjunctival haemorrhages

Subconjunctival haemorrhages appear as bright red patch and disappear slowly in course of two to three weeks.

Aetiology. The main causes are:

- (a) *Local.* It may be due to:
 - (i) Rupture of the small vessels due to injury
 - (ii) Severe acute conjunctivitis, e.g. acute haemorrhagic conjunctivitis and Koch-Weeks' conjunctivitis
 - (iii) Local vascular anomalies, e.g. varicosity and angiomatous tumour
 - (iv) Injuries to the orbit

(v) Following a subconjunctival injection.

(b) *General.* The causes are:

- (i) Systemic diseases, e.g. arteriosclerosis, hypertension and diabetes
- (ii) Severe and sudden venous congestion—typically, whooping cough in children
- (iii) Acute febrile conditions
- (iv) Blood dyscrasias.

Bleeding from the conjunctiva is very rare and may occur in a vascular tumour, haemophilia and severe anaemia.

Treatment is essentially that of the cause.

Chemosis (Fig. 34.5)

Chemosis (Gk. *cheme*, cockle; *osis*, condition) means oedema of the conjunctiva, and it involves the bulbar conjunctiva since it is loosely adherent to the underlying tissue.

The causes are:

(a) Severe acute inflammations, e.g. gonococcal conjunctivitis, stye, acute dacryocystitis, orbital cellulitis and panophthalmitis

(b) Allergy

(c) Obstruction to venous drainage within the orbit, e.g. malignant exophthalmos and orbital tumour

(d) Miscellaneous, e.g. myxoedema and nephrotic state.

Conjunctivitis

Inflammation of the conjunctiva may vary in its nature and severity. The degree of hyperaemia may be varied and so also the conjunctival discharge.

The *classification* of conjunctivitis should be ideally based on the cause that is responsible for it (Table 37.2). Broadly speaking, conjunctivitis may be infective or allergic in nature. In accurate diagnosis, both bacteriological and histological examination of the secretion and epithelial scraping are important.

Table 37.2
Aetiological Types of Infective Conjunctivitis

Bacterial:		
<i>Staph. aureus</i>	<i>N. catarrhalis</i>	<i>N. meningitidis</i>
Pneumococcus or <i>Diplococcus</i> <i>pneumoniae</i>	<i>H. influenzae</i>	<i>Corny. diphtheriae</i>
Gonococcus or <i>N. gonorrhoeae</i>	<i>Myco. tuberculosis</i>	<i>E. coli</i>
Koch-Weeks' bacillus or <i>H. aegyptius</i>	<i>B. proteus</i>	<i>Strepto. haemolyticus</i>
Morax-Axenfeld diplobacillus or <i>Moraxella lacunata</i>		<i>Ps. pyocyanea</i>
Viral and Bedsonian:		
Trachoma	Inclusion conjunctivitis	<i>Lymphogranuloma venereum</i>
Herpes simplex	Herpes zoster	Varicella
Adenovirus	Myxovirus	<i>Molluscum contagiosum</i>
Rickettsial:		
	<i>R. prowazeki</i>	<i>R. rickettsi</i>
	<i>R. mooseri</i>	<i>R. conori</i>
		<i>R. burneti</i>
Mycotic:		
<i>Candida albicans</i>	<i>Streptothrix</i>	
<i>Sporotrichum schenkii</i>	Others	
Parasitic:		
<i>Ascaris lumbricoides</i>	<i>Phthirus pubis</i>	Ocular myiasis
<i>Wuchereria bancrofti</i>		
<i>Taenia solium</i>	Filaria	
<i>Schistosoma haematobium</i>	<i>Onchocerca volvulus</i>	

Bacterial Flora of the Conjunctival Sac

The conjunctival sac in the newborn is sterile. Gradually organisms gain access to it. The healthy conjunctiva in an adult only occasionally remains sterile. The bacteria are mostly non-pathogenic, e.g. *Staph. albus* and diphtheroids.

The variation in the number, type and pathogenicity depends on climatic factors, habits and status of personal hygiene, and prolonged use of topical antibiotics.

Apart from constant washing by tears and relatively low temperature owing to evaporation, the presence of a bacteriostatic enzyme, lysozyme, as well as immunoglobins in the tear is an important factor in determining the sterile nature of the conjunctival sac.

In conjunctivitis, features occurring in organismal flora are the multiplication and mutation to pathogenicity of the normal inhabitants and the addition of new types of organisms.

Normal conjunctival sac is not said to harbour viruses, but fungi are found to be present in normal conjunctiva. Lindner believed that the only criterion for bacterial pathogenicity should be the presence of parasitic organisms on living cells.

Acute Infective Conjunctivitis⁷

The following are the clinical types: (a) mucopurulent or catarrhal; (b) purulent; (c) membranous; and (d) follicular (may be both acute and chronic), especially adenoviral conjunctivitis.

Acute mucopurulent conjunctivitis

Aetiology. The aetiology is varied. The common causes include:

- Staphy. aureus*—most common
- H. aegyptius* or Koch-Weeks' bacilli
- Pneumococcus
- Exanthemata like measles.

Staphylococcal conjunctivitis. Normally staphylococci are present in the anterior nares in more than 50 per cent of the healthy people. Coagulase-positive staphylococci are pathogenic.

Apart from acute mucopurulent conjunctivitis staphylococcal allergy produces characteristic clinical features: (a) chronic catarrhal conjunctivitis; (b) blepharitis; (c) superficial punctate keratitis with erosions involving the lower part of the cornea.

Pneumococcal conjunctivitis. Pneumococci are present as commensals in the throat and nasopharynx in about 40 per cent of healthy people. Association with pharyngitis or rhinitis, sometimes occurring in small epidemics and subsidence by a crisis between the 7th and 10th day are characteristics. The bacteria by this time are phagocytosed by the epithelial cells and hence the conjunctival secretion becomes sterile.

The different varieties of conjunctivitis caused by pneumococcus are: (a) acute catarrhal conjunctivitis; (b) haemorrhagic conjunctivitis; (c) pseudomembranous conjunctivitis; (d) lacrimal conjunctivitis.

Koch-Weeks conjunctivitis. These bacilli tend to cause widespread epidemics. They cause typical 'pink eye'.

Pathology. The features are hyperaemia, stasis, exudation of cells and proteinous fluid. In acute bacterial the cells are polymorphs; and in viral—mononuclear and multinucleated and/or epithelial.

Following epithelial desquamation, there is well-balanced regeneration to compensate for the loss.

Clinical features. Bacterial conjunctivitis affects both eyes. Generally the symptoms are smarting, burning or foreign body sensation due to mucous flecks and occasionally photophobia due to deposition of mucous flakes on the cornea.

In milder cases, there is hyperaemia of the palpebral and fornix conjunctiva with mucous flakes clinging to the eyelashes.

In severe cases, the whole conjunctiva is vividly red with grossly visible flecks of mucopus matting the eyelashes.

Examination of the lid margin after scrupulous cleansing can differentiate the condition from a blepharitis. Ecchymosis of the conjunctiva and chemosis is occasionally present.

Acute conjunctivitis reaches its peak on the third or fourth day. It usually clears away in 7 to 10 days, but occasionally causes marginal catarrhal ulcers of the cornea.

Differential diagnosis. Table 37.3 indicates the distinguishing features of three major types of conjunctivitis.

Treatment. There are two principles, irrigation and control of infection. Irrigation with warm normal saline or even pure water is done to wash out the conjunctival sac. It is done frequently if there is profuse discharge. Too much irrigation causes dilution of the bacteriostatic enzyme of the tear, lysozyme.

Table 37.3

Clinical Features of Three Major Types of Conjunctivitis

Features	Bacterial	Viral	Allergic
Conjunctival hyperaemia	Marked	Moderate	Mild to moderate
Conjunctival discharge	Profuse	Minimal	Minimal
Watering	Moderate	Excessive	Moderate
Papillae	Occasional	No except in TRIC	+
Follicles	No	Yes	No
Chemosis	Yes	Occasional	Yes
Preauricular Lymphadenopathy	+	++	No

TRIC—trachoma-inclusion conjunctivitis

Irrigation is followed by instillation of broad-spectrum antibiotic drops or application of an antibiotic ointment. Sulphacetamide or antiseptic drops may also be instilled, but they certainly are not so efficacious as an antibiotic.

The eyes should never be bandaged. Dark goggles relieve photophobia and are comforting to the patient.

Acute Purulent Conjunctivitis

Acute purulent conjunctivitis may occur in the newborn as ophthalmia neonatorum and in the adult as acute blennorrhoea (Gk. *blenna*, thick mucous discharge).

Ophthalmia neonatorum

Now rare incidence of this preventable disease is due to improved prophylactic measures before, during or after birth of the child.

In the newborn the two characteristic features are—the absence of the adenoid layer in the conjunctiva which causes the absence of mucin, thus, there is no protective action; the absence of tear causes lysozyme to be absent and therefore there is no bacteriostatic protection. Patrick¹³ observed that normal tear secretion is present on the first day of life.

Aetiology. Gonococcus is the main factor responsible and rarely the following cause it—*Staphylo. aureus*, *Diplococcus pneumoniae*, *Strepto. haemolyticus*, *E. coli*, and *Chlamydia oculogenitalis*. The incubation period is 18 to 72 hours in gonococcal but 4 to 14 days in nongonococcal case.

Pathology. Intense inflammation, exudation, oedema, infiltration involving the conjunctiva and also frequently the cornea are characteristics.

Clinical features. Watering from the eyes, usually on the second or third day of birth gives rise to suspicion. In ophthalmia neonatorum caused by rare groups of organisms, the affection is milder.

The affection is almost always bilateral.

In a typical gonococcal ophthalmia, the lids are at first swollen and tense (Fig. 37c.2). They become softer soon and so much so that the upper lid overhangs the lower, making separation of the lids difficult. Profuse, creamy-white, thick and frankly purulent discharge wells out from the edges of the lids. The conjunctiva is intensely congested and markedly chemosed. Corneal involvement is frequent and disastrous.

Complications and sequelae. Corneal complication is almost the rule and may reveal ulceration and perforation with attendant sequelae. Adherent leucoma follows a perforation. Other complications are nystagmus and metastatic such as arthritis. Nystagmus occurs due to serious visual impairment during first six weeks of life. Impairment is caused by bilateral corneal opacities.

Treatment. The prophylactic treatment consists of eradication of any suspected maternal infection during antenatal period. Strict asepsis is to be maintained during conduction of labour. The eyes of the newborn are opened after properly cleansing the face and the lids. A 1 per cent silver nitrate solution (*Credé's method*) or penicillin or other antibiotic drops are instilled. The baby's eyes are to be carefully watched for a week for evidence of watering or serous discharge.

Contamination should be strictly avoided by using protective goggles. In case of contamination,

prophylactic irrigation and instillation of antibiotic drops are prescribed.

The curative treatment consists of liberal irrigation of the conjunctival sac with normal saline lotion frequently, followed by $\frac{1}{2}$ to 1 hourly instillation of G. penicillin.

Fortunately most types of infection are amenable to penicillin therapy. In corneal involvement, a 1 per cent eye ointment of atropine sulphate is used. Control of infection occurs usually within forty eight hours of local penicillin therapy.

It is desirable to use penicillin intramuscularly and adopt measures to control fever and general ill-health.

Gentamicin 0.3% drops may be used in penicillin-allergic cases.

If properly treated prognosis is generally favourable.

Purulent conjunctivitis or acute blennorrhoea

Purulent conjunctivitis or acute blennorrhoea occurs in adult males at first unilaterally, the source of infection is from the genitals and is characterized by three stages.

Infiltration—is shorter in severe case,

Suppuration—lasts for two or three weeks,

Slow healing—lasts for two or three weeks.

The clinical features, complications and treatment are similar to those of ophthalmia neonatorum. Metastatic gonorrhoeal conjunctivitis of endogenous origin sometimes occurs in association with arthritis.

Membranous Conjunctivitis

There are two types: (a) diphtheritic or true which is rare, associated with pharyngeal diphtheria; and (b) pseudomembranous.

Causes of pseudomembrane are as follows:

(a) Bacteria, e.g. Streptococcus, pneumococcus, Staphylococcus, Meningococcus and Koch-Weeks bacilli

(b) Viruses, e.g. epidemic keratoconjunctivitis and herpes simplex

(c) Drugs

(d) Chemicals, e.g. acetic acid, ammonia, lime and copper sulphate

(e) Toxic factors, e.g. Stevens-Johnson syndrome and benign mucous membrane pemphigoid

(f) Vernal conjunctivitis.

Pathology of membrane formation. Exudation containing meshwork of fibrin which has a marked tendency to coagulate is its basis. This either covers the surface of the conjunctiva causing a pseudomembranous or croupous conjunctivitis, or penetrates the tissues of the conjunctiva causing a true membrane (Table 37.4).

Table 37.4

Differentiation between True and Pseudomembrane

True membrane	Pseudomembrane
Cannot be peeled off easily	Can be peeled off easily
Bleeding when separated	Bleeding very sparse
Pathologically, fibrinous exudate over and within the conjunctiva	Over the conjunctival epithelium

Clinical features. Any grade of severity may be met with and the severity bears no relation to the cause. Diphtheritic cases may be mild and severe cases may also be nondiphtheritic.

In mild cases there is mucopurulent or sanguinous discharge with membrane on the palpebral conjunctiva, disappearing within one to two weeks.

In severe cases three stages present themselves.

The stage of infiltration is characterized by brawny lids, congested and chemosed conjunctiva, with a tendency to necrosis of the conjunctiva due to compression of the vessels. This stage lasts for five to ten days.

The second stage is that of suppuration.

Finally in the stage of cicatrization formation of granulation tissue and an adhesion between the palpebral and bulbar conjunctivae, called symblepharon, are found.

Diagnosis is confirmed by bacteriologic examination.

Complications and sequelae. Complications and sequelae are corneal ulcer due to secondary infection, symblepharon and rarely postdiphtheritic paralysis of accommodation.

Treatment. All cases should be treated as diphtheritic unless proven to the contrary by negative bacteriological report. Antidiphtheritic serum combined with antibiotic should be administered, it should be withdrawn if the case is nondiphtheritic.

Chronic Catarrhal Conjunctivitis

Four subtypes have been described: (a) blepharoconjunctivitis; (b) angular conjunctivitis; (c) conjunctivitis meibomiana; and (d) lacrimal conjunctivitis.

Blepharoconjunctivitis

Aetiology. (a) Irritative factors—are most frequent causes, e.g. reflex eye strain, direct irritation, ill-ventilation, neighbouring infection (meibomian glands, lacrimal sac and nose).

(b) Infective—is typically due to *Staphylococcus aureus*.

(c) Allergy due to staphylococcal exotoxin or cosmetics.

Clinical features. Patients complain of burning and smarting sensations, heavy and sleepy feeling, watering and easy tiring of the eyes.

Congestion of the palpebral conjunctiva, papillae and occasional excoriation of the skin of the lid margin are seen.

Complications and sequelae. These include epiphora, ectropion and corneal ulcer.

Treatment. Treatment consists of elimination of the cause and use of astringent drops at times. Painting with a 1 per cent silver nitrate solution may afford relief in cases resistant to usual measures. If necessary it is to be repeated once or twice.

Angular conjunctivitis

Aetiology. *Morax-Axenfeld diplobacilli*. These are saprophytes, present in the nose of healthy people, and can act on dead tissues, hence, they are localized to the region of canthi where there is less tear. They liberate exogenously a proteolytic ferment which has the property of maceration of the epithelium.

Recent work suggests the association of the disease with staphylococci and vitamin B deficiency.

Clinical features. These are as follows:

- (a) Hyperaemia of the bulbar conjunctiva and intermarginal strip of the conjunctiva at the angles
- (b) Excoriation of the skin at the same site
- (c) Slight mucopurulent discharge.

Complications and sequelae. Complications and sequelae include blepharitis and marginal keratitis.

Treatment. This affection responds well to an oxytetracycline ointment. Zinc boric drop is less effective. Zinc acts by inhibiting the liberation of proteolytic ferment.

Rare Types of Conjunctivitis⁷

(a) A persistently chronic conjunctivitis due to abnormal Meibomian secretion, *conjunctivitis meibomiana*.

(b) *Lacrimon conjunctivitis* associated with chronic dacryocystitis.

(c) Conjunctivitis due to chemicals.

(d) *Ligneous conjunctivitis* is a rare bilateral recalcitrant or recurrent pseudomembranous, sometime membranous, conjunctivitis of unknown origin occurring in childhood and lasting for months or even years.

(e) In *conjunctivitis petrificans*, lime crystals, carbonate sulphate or phosphate, may be embedded in the conjunctiva and produce inflammation with infiltration. This is followed by epithelial exfoliation, necrosis, hyaline degeneration and extensive fibrosis.

(f) *Ophthalmia nodosa*.²¹ The irritant hairs of caterpillar may induce a nodular conjunctivitis. The

other ocular lesions caused by caterpillar hairs may be: (i) allergic dermatitis; (ii) marginal keratitis; (iii) keratitis; (iv) iridocyclitis; (v) nodule in the iris; and (vi) panophthalmitis.

Ophthalmia nodosa is treated on general principles.

Follicular Conjunctivitis

A follicular conjunctivitis may be acute or chronic.

Aetiology. The causes are listed in Table 37.5.

Table 37.5

Causes of Acute and Chronic Follicular Conjunctivitis³

Acute

- Epidemic keratoconjunctivitis
- Pharyngoconjunctival fever
- Haemorrhagic conjunctivitis
- Primary herpes
- Active trachoma
- Others like zoster, influenza virus, etc.

Chronic

- Trachoma
- Molluscum contagiosum
- Folliculosis
- Drug-induced, e.g. eserine, IDU, cosmetics, etc.

Follicles. Their characteristics and their differentiation from papillae are shown in Table 37.6.

Table 37.6

Distinguishing Features of Follicles and Papillae³

Follicles	Papillae
1. Discrete, round, raised dots	Elevated, polygonal, reddish areas
2. 0.5 to 5 mm diameter	0.3 to 2 mm diameter
3. Usually lower palpebral	Anywhere in the conjunctiva, sometimes in the upper palpebral
4. Represents hyperplasia of lymphoid tissue followed by accessory vascularization	Essentially vascular proliferation with superadded lymphocytic infiltration
5. No such	Connective tissue septa anchored into deeper tissues

This is a condition characterized by conjunctival congestion and discharge accompanied by formation of follicles. In conjunctival folliculosis also called 'School follicles' there is no accompanying conjunctivitis.

The affection is common in young children who are under or malnourished and not uncommonly associated with adenoid hypertrophy. The follicles appear as 1 to 2 mm round dots occurring especially in the lower fornix and at times at the corners of the upper tarsal conjunctiva.

Béal's Syndrome

Béal's syndrome is an acute follicular conjunctivitis with rapid onset, preauricular adenitis, mild symptoms but with rapid and complete recovery within a week or two.

Epidemic Viral Keratoconjunctivitis

The various features of epidemic viral and allied conjunctivitis have been summarized in the accompanying table (Table 37.7).

Epidemic Haemorrhagic Conjunctivitis^{16,20}

Attention to this condition was first drawn in 1970 by Chatterjee et al⁴ who reported a large number of cases from Ghana. Subsequently cases were reported from other parts of the world.

Aetiology. It is reported that the condition is due to a member of the picorna virus, called enterovirus 70. Contagion occurs rapidly and the incubation period is about 24 to 48 hours. It is at first unilateral and quickly becomes bilateral.

Clinical features. The characteristic symptoms are grittiness, watering, redness accompanied often by a painful puffy swelling of the eyelids and adjoining areas. Occasionally photophobia and rhinorrhoea are present. Some patients experience malaise and slight fever. Preauricular lymphadenopathy is common. Watery conjunctival discharge is frequently seen. Follicles are detected in the upper and lower palpebral conjunctiva. Not all cases show subepithelial punctate keratitis. But the most prominent sign is the presence of haemorrhage.

Table 37.7

Clinical and Epidemiological Features of Four Major Types of Haemorrhagic Conjunctivitis (After Maichuk¹¹)

Features	Epidemic haemorrhagic conjunctivitis (EHC)	Epidemic keratoconjunctivitis (EKC)	Adenovirus conjunctivitis	Koch-Weeks' conjunctivitis (KWC)
1. Causative agent	Picomavirus	Adenovirus type 8	Adenovirus types, 3, 7a, 4, 10	Koch-weeks' bacillus
2. Spread of infection	Typically epidemic,	Typically epidemic pandemic	Frequently epidemic, localised outbreak	Typically seasonal epidemic
3. Mode of transmission	Eye to eye contact	Eye to eye contact	Respiratory	Eye to eye contact
4. Incubation period	12 to 24 hours	6 to 10 days	4 to 8 days	12 to 24 hours
5. Preauricular adenopathy	Common	Very common	Frequent	Infrequent
6. Systemic symptoms	Not infrequent	Infrequent	Almost constant pharyngitis	Not infrequent
7. Lid oedema	Always severe	Mild to severe	Mild	Frequent, severe
8. Subconjunctival haemorrhage	Constant petechia to large haemorrhage	Multiple on tarsal conjunctiva	As in EKC	Frequent, pinpoint
9. Corneal involvement	Occasional epithelial punctate or sub-epithelial keratitis, corneal erosions	Constant—appears later; subepithelial infiltrates	Occasional epithelial punctate	Occasional epithelial punctate
10. Follicles	Frequent	Frequent	Occasional	Occasional
11. Clinical course	7 to 14 days	Few weeks	Few weeks	Few weeks
12. Cytology of exudate	Predominantly mononuclear	As in EHC	As in EHC	Predominantly neutrophils, many bacilli on or in epithelial cells

These subconjunctival haemorrhages are either petechial or blotchy and are seen mostly in the bulbar conjunctiva. The affection lasts for 3 to 9 days. Haemorrhage persists for 7 to 10 days. The severity is less marked in children than in elderly people.

Treatment is symptomatic.

Adenoviral Keratoconjunctivitis

Adenoviral infections are common and they produce acute follicular conjunctivitis. There are three basic types—(a) epidemic keratoconjunctivitis (EKC); (b) pharyngoconjunctival fever (PCF); and (c) acute nonspecific follicular conjunctivitis.

Epidemic Keratoconjunctivitis^{2,14}

Aetiology. Epidemic keratoconjunctivitis (EKC) is usually caused by adenoviruses 8 and 19, both having a tendency to cause widespread epidemic. Other sero types occasionally responsible are 2 to 4, 7 to 11, 14, 16 and 29.

Clinical features. The affection is common in young adults and is unilateral in two-third of patients. It is generally unaccompanied by any systemic upsets. About 8 days after exposure to this affection there is an acute onset with excessive watering, foreign body sensation, marked redness and mild photophobia.

There are two phases: conjunctival and corneal, each lasting for about one week (Table 37.8).

Table 37.8

Distinguishing Features of Epidemic Keratoconjunctivitis

Conjunctival phase

- Diffuse conjunctival congestion
- Papillae
- Follicles
- Tender preauricular lymph nodes

Corneal phase

- Stage 1—diffuse, superficial, fine PEK
- Stage 2—coalescence of above lesions causing focal PEE
- Stage 3—combined epithelial and subepithelial lesions
- Stage 4—subepithelial macular lesions

PEE—Punctate epithelial erosions.

PEK—Punctate epithelial keratitis.

Most cases of conjunctival phase of EKC resolve within 2 to 3 weeks, but keratitis may take months to years for its disappearance.

Pharyngoconjunctival Fever¹⁴

Pharyngo-conjunctival fever (PCF) is due to adenoviruses types 3, 4 and 7. Other types associated are types 4 to 6, and 14. The incubation period is 5 to 12 days. The affection is a highly infectious acute illness evidenced by 100 to 104° fever, pharyngitis, acute follicular conjunctivitis, and tender preauricular lymph nodes. There may be oedema of eyelids, chemosis and diffuse conjunctival congestion, and follicles particularly in the lower palpebral conjunctiva and fornix. Occasionally punctate keratitis may occur.

Nonspecific Follicular Conjunctivitis¹⁴

Nonspecific follicular conjunctivitis is a follicular conjunctivitis with or without keratitis.

Treatment of adenoviral diseases. Treatment is controversial. Antibiotics and antivirals are ineffective. In severe conjunctival reactions symptomatic relief is possible with topical steroid therapy.

Other Viruses causing Conjunctivitis

Other viruses causing conjunctivitis include herpes simplex, herpes zoster, varicella, smallpox, myxo- and paramyxoviruses.

Trachoma

*History.*⁷ Trachoma (kG. *trachys*, rough surface) was recorded by the Chinese as early as the 27 BC. The disease had been prevalent in Egypt in 19th, Greece in 5th and in Rome in 1st century BC.

The term 'trachoma' had been introduced by Pedanius Dioscorides AD 40–91. Celsus and Galen also described the clinical features of the affection.

The disease has been transmitted to the different parts of the world from time to time by travellers and invaders.

Halberstaedter and von Prowazek (1907) discovered the inclusion bodies. MacCallan (1908) divided the evolution of the affection into four distinct clinical stages.

T'ang et al. (1957) succeeded in successfully growing the causal virus, *Chlamydia trachomatis*. Continued interest and sophisticated investigations are still keeping apace.

Incidence. About one-fifth of the world's population is affected by trachoma.

In India its incidence is highest in the north and north-west, gradually declining towards the south and the east.

In hyperendemic area the disease is contracted during infancy.

The affection is also closely linked with overcrowding, illiteracy and poor personal hygiene.

Hyperendemic trachoma is prevalent in dry climate.

The onset is usually insidious in infants, while it is relatively acute in adults.

The incubation period is between 5 and 12 days.

Aetiology. Trachoma is due to *Chlamydia trachomatis*. It is now known that *Chlamydia trachomatis* includes TRIC & LGV agents.

Jones⁸ proposed the microbiological classification of ocular chlamydial agents in the following manner.

Trachoma inclusion conjunctivitis (TRIC):
(a) hyperendemic trachoma—A, B and C;
(b) paratrachomas—D, E, F, G, H, I, J and K; and they include inclusion conjunctivitis.

Lymphogranuloma venereum (LGV): L1, L2 and L3.

In the majority of the cases trachoma occurs due to direct person-to-person contact. Paratrachoma and LGV infections are rarely the result of contamination from patients suffering from nonspecific urethritis.

Pathology.⁷ Primarily there is an epithelial lesion of the conjunctiva and the cornea, and subsequently there is involvement of the subepithelial tissues.

(a) In the conjunctiva the following changes have been noticed.

Changes in the epithelium are seen in the very

early stage of trachoma and are characteristic. The changes are: (a) metaplasia; (b) degeneration of the nuclei; (c) proliferation; and (d) exfoliation. These increase with the progress of the disease.

Formation of papillae and pseudocysts are noticed as a result of proliferation of the epithelium. There is also downgrowth of the epithelium. Subsequently there is canalization of the solid downgrowth which becomes compressed all round by the dense cellular infiltrate leading to formation of pseudocysts. Formation of retention cysts occurs due to the increasing accumulation of the goblet cells in the sprouts of the epithelium growing downward.

Chronic inflammatory cell infiltration of the epithelium is also present.

Changes in the substantia propria include capillary dilatation and cellular infiltration.

Most characteristic histological change is the formation of *trachoma follicles*. A follicle is formed due to accumulation of lymphocytes, mononuclears, plasma cells, and histiocytes with a pseudocapsule around. Later on there are vessels at the periphery which make their way into the follicles. Trachoma follicles can be differentiated from nontrachoma follicles by the evidence of necrosis in the former.

In follicles especially trachomatous there is one characteristic cell which is very large, irregular-shaped with vacuolated cytoplasm, functionally, they are phagocytic. These cells are known as *Leber's cells*.

Other changes include xerosis and degenerations—epidermoid, hyaline and amyloid.

(b) The tarsus is thickened and fleshy in the early stage due to infiltration. Subsequently it softens and is destroyed. There is degeneration of the acini and the ducts of Meibomian glands.

(c) The changes in the cornea are early, typical and they occur simultaneously with conjunctival changes.

Avascular punctate epithelial and subepithelial keratitis is characterized by epithelial oedema along with cellular infiltration with polymorphs, splitting of Bowman's membrane and accumulation of polymorphs between the split layers.

Trachomatous pannus is the presence of

superficial vessels with cellular infiltration involving the upper part of the cornea. The capillaries become dilated, tortuous, elongated and give off new vessels. The new vessels are surrounded by cellular infiltration, at first between the epithelium and Bowman's membrane and afterwards underneath Bowman's membrane affecting the stroma. The new vessels are parallel.

There are three probable causes for the choice of the upper part of the cornea as the site of involvement:⁹

(i) intimate contact with the infected upper tarsal conjunctiva

(ii) the organisms can flourish easily because of warmth caused by covering of the region by the upper lid

(iii) the viruses are sensitive to light. So, relative lack of exposure to light enhances their growth.

(d) Changes in the other tissues may be dacryoadenitis and dacryocystitis.

Clinical features.^{7,15,20} The clinical features are widely variable.

Usually there is an initial phase, *trachoma dubium* which mimicks a bacterial conjunctivitis. Sometimes there is a mild inflammation with almost no distinguishing features. At times the diagnostic clues of an advanced state may be trichiasis and conjunctival scarring. Occasionally there may be acute onset with evidence of acute inflammation.

In 1908, MacCallan¹⁰ divided the evolution of trachoma into four stages based on the presence of follicular hypertrophy, papillary hypertrophy and conjunctival scarring. This classification was slightly modified later.

Stage I or TR I is characterized by the presence of lots of tiny red dots scattered on the upper palpebral conjunctiva (papillae), followed by the appearance of yellowish-white immature follicles in between the tiny capillaries. The proportion of papillae and follicles is variable, but both of them tend to spread involving the whole of the upper tarsal conjunctiva and the upper fornix. The cornea then shows greyish haziness in its upper part adjoining the limbus due to oedema and inflammatory cell infiltration. There is early pannus formation.

This stage ranges from 3 months to 3 years.

Stage II or TR II is characterized by the presence of all the signs of stage I but in greater proportions. The entire upper lid becomes thickened, upper tarsal conjunctiva intensely congested due to well-developed papillae. Mature trachoma follicles looking like 'sago grains' are grossly visible (Fig. 37c.3). The follicles are scattered over the congested conjunctiva and involve the upper fornix, lid margin, bulbar conjunctiva and limbus. The lower fornix, plica and caruncle are rarely involved.

Nontrachomatous follicles are smaller and do not show sago-like grains.

Trachoma follicles may resolve and atrophy. They may rupture. But intrinsically there is scarring which appears at a relatively early stage of the affection.

In the limbal region or in the peripheral part of the cornea the follicles are seen at a relatively early stage appearing as translucent and surrounded by fine capillaries. These are called *Herbert's rosettes*.

Trachomatous pannus (Lat. *pannus*, rug). A pannus is the superficial vascularization of the cornea with cellular infiltration.

Trachomatous pannus (Fig. 37.1) is primarily present in the upper part of the cornea. It may be progressive or regressive. A progressive pannus shows vessels spreading vertically downward parallel to each other with minimal anastomosis reaching up to an almost sharp horizontal line. In regressive pannus the vessels extend beyond the limit of infiltration.

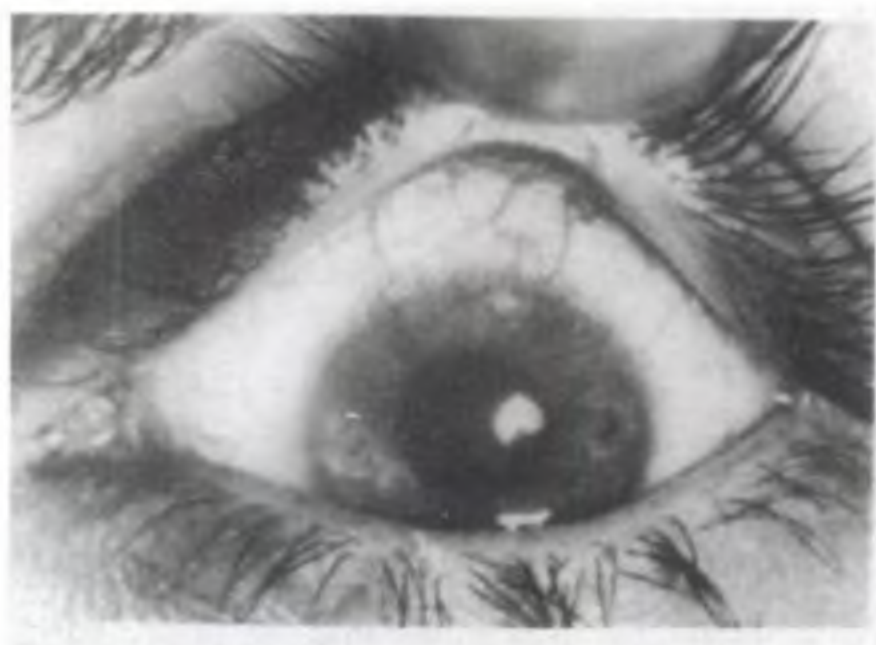

Fig. 37.1 Trachomatous pannus (Parsons).

A trachomatous pannus can be graded in the following manner.

Pannus tenuis which is recent and shows thin vessels.

Pannus vasculosus which is highly vascular.

Pannus crassus which contains thicker and irregular vessels.

Pannus siccus whose vessels show evidence of cicatrization.

A pannus may regress or resolve completely, but in severe cases there may be permanent scar formation.

Stage III or *TR III* is characterized essentially by the presence of cicatrization. Trachomatous scars which last for many years include:

Line of Arlt. The initial scar corresponds to the region where there is an anastomosis between the terminal capillaries of ascending and those of descending conjunctival arterioles. It appears as an ill-defined horizontal streak across the tarsal conjunctiva.

Stellate scars. More irregularly grouped scars appear till the whole upper tarsal conjunctiva becomes taut and anaemic.

Herbert's pits. Following rupture and cicatrization of the limbal follicles there is filling of the defect by epithelialization. They appear as clear cavities. They are the pathognomonic limbal signs of trachoma.

Stage IV or *TR IV* is characterized by the lack of inflammatory signs. There are widespread scars, pannus siccus and Herbert's pits. This stage lasts for life.

Grading of trachoma. WHO grading is shown in Table 37.9.

Diagnosis.^{8,20} Clinically, in the early stage diagnosis is difficult. Laboratory diagnosis is significant.

According to Dawson et al.,⁵ at least two of the following signs must be present, but pannus with any one of them may be considered pathognomonic; (a) follicles in the upper palpebral or limbal conjunctiva; (b) epithelial and subepithelial keratitis involving the upper part; (c) trachomatous cicatrization of the upper tarsal

Table 37.9

WHO Classification of Trachoma¹⁹

Stage	Name of clinical stage	Distinguishing features
I	Active trachoma with follicles (TF)	More than 5 follicles of larger than 0.5 mm on the upper tarsus
II	Trachomatous intense inflammation (TI)	Thickening of the conjunctiva obscuring more than 50 per cent of large, deep tarsal vessels
III	Trachomatous scarring (TS)	Scars on the upper tarsal conjunctiva
IV	Trachomatous trichiasis (TT)	At least 1 lash affected
V	Corneal opacities (CO)	Obscures at least part of the pupil with less than 6/18 visual acuity

conjunctiva; and (d) pannus affecting the upper half of the cornea.

Laboratory diagnosis. The smear from the upper tarsal conjunctiva is examined. The smear stained by Giemsa stain shows pleomorphism such as neutrophils, macrophages, plasma cells and lymphocytes.

Fluorescent antibody staining of smears prepared from scrapings can detect TRIC agents.

Chlamydial agents grow well in cell culture especially if penetration is enhanced by addition of agents like DEAE-dextran.

Microimmunofluorescence test can differentiate between the organisms of the subgroup A from those of subgroup B. It can as well classify subgroup A into 11 serotypes.

Trachoma should be differentiated from the allied lesions (Table 37.10).

Complications and sequelae. Complications and sequelae are as follows:

- (a) In the lids:
 - (i) Ptosis (mechanical) } due to infiltration
 - (ii) Ectropion } due to cicatrization
 - (iii) Entropion } due to cicatrization
 - (iv) Trichiasis } due to cicatrization
 - (v) Deformity of the lid margin.

Table 37.10
Differential Diagnosis of Trachoma

Points	Trachoma	Vernal conjunctivitis	Folliculosis and chronic follicular conjunctivitis
1. Age at presentation	Children and occasionally adults	6–20 years	Children
2. Laterality	Bilateral	Bilateral	Bilateral
3. Itching	May be present	Marked and characteristic	Nil
4. Season	Not related, but may have a peak	Related	Unrelated
5. Conjunctival discharge	Not specific	Minimal, whitish, ropy and alkaline	Not specific
6. Site of lesion	Upper tarsal conjunctiva and upper limbus	Upper tarsal conjunctiva and all round the limbus	Lower fornix. Occasionally at either angles of upper tarsal conjunctiva
7. Involvement of upper fornix	Marked	Not involved	Not involved
8. Involvement of cornea	Characteristic and marked	Rare and uncharacteristic	Not involved
9. Complications and sequelae	Many and common	Rare and minimal	Rare and minimal
10. Aetiology	Bedsonian virus	Exogenous allergy	Not specific

(b) In the conjunctiva:

- (i) Xerosis—due to destruction of the glands
- (ii) Symblepharon—due to apposition of raw surfaces of the bulbar and palpebral conjunctivae.

(c) In the cornea:

- (i) Neovascularization
- (ii) Ulcerations
- (iii) Opacities
- (iv) Xerosis
- (v) Keratectasia—due to a weak scar.

(d) In the lacrimal apparatus:

- (i) Dacryocystitis
- (ii) Dacryoadenitis.

(e) Miscellaneous—e.g. amyloid degeneration.

Treatment. The most effective treatment especially in its initial stage is perhaps a course of systemic sulphonamides supplemented by topical sulphacetamide or broad-spectrum antibiotic therapy. The topical therapy, however, is more valuable in the presence of concomitant bacterial conjunctivitis. The treatment should be started early, followed scrupulously for 3 to 6 months. Some cases do not materially respond to this treatment. Doxycycline, 100 mg oral twice daily for about 3 weeks, is recommended in active trachoma with genital tract infection.

Management of complications and sequelae of

trachoma is more difficult and uncertain. Such measures as excision of the upper fornix, peritomy and tarsectomy are hardly satisfactory.

Prophylaxis.^a The following measures are recommended.

(a) Massive topical antibiotic therapy to control infection, e.g. application of tetracycline eye ointment twice daily for 5 days each month quarterly or six monthly. The local therapy is supplemented with oral antibiotics, e.g. doxycycline, 5 mg/kg thrice a week for 3 weeks.

(b) Surgical corrections of the lid sequelae of trachoma.

(c) Provision of the primary health care.

(d) Health education to improve the personal hygiene and community sanitation.

(e) Measures to control flies.

Tuberculosis of the Conjunctiva

Tuberculosis of the conjunctiva is usually secondary to an extraocular lesion, but very rarely forms the primary focus. The affection occurs in young people and the course is chronic. The state of resistance and hypersensitivity determine the type of lesion. Two essential varieties are—tuberculoma and lupus vulgaris.

Several clinical forms of tuberculoma are met

with: (a) ulcerative; (b) polypoid; (c) nodular; and (d) gelatinous excrescences or hypertrophied papillary. Lupus vulgaris occurs rarely and is almost always due to a spread from a lesion of the lid skin in proximity.

Pathology. Scraping shows *Mycobacterium tuberculosis*. Section shows characteristic tuberculous lesion.

Treatment. The principles are: (a) instillation of streptomycin drops;

(b) systemic antituberculous therapy;

(c) excision/or scraping and diathermy cauterization.

Ulceration of the Conjunctiva

The causes are: (a) phlyctenulosis; (b) tuberculosis; (c) granulation tissue break, e.g. extrusion from a chalazion; (e) syphilis; and (f) broken-down carcinoma.

Allergy of the Conjunctiva

This was used to be classified as: (a) simple—immediate and delayed (contact or microbial); and (b) interstitial—endogenous and exogenous. But it may be better classified according to the type of hypersensitivity reactions (p. 454). There are three groups of mediators:¹ histamine and prostaglandins; eosinophil granule major basic protein (EMBP) and complement; and chemotactic factors.

Histamine is stored in basophil granules and mast cells. This is the central mediator of ocular allergy and inflammation. The conjunctiva has two histamine receptors, H₁ and H₂; type 1 causes itching and type 2 redness.

Prostaglandins (PG). PG D₂ and sometimes PG F take part in allergic diseases.

Eosinophil granule major basic protein (EMBP) is found to cause mast cell degranulation.

Chemotactic factors include eosinophils and macrophages to the site of inflammation.

Allergic Conjunctivitis

Four notable varieties are: phlyctenular; vernal; atopic; and giant papillary.

Phlyctenular keratoconjunctivitis

Phlyctenular (Gk. *phlyctaina*, blister) is chiefly an interstitial keratoconjunctivitis of endogenous type of allergy.

Aetiology. The various factors advocated are:

(a) Type IV allergic response. This is due to type iv hypersensitivity reaction to bacterial proteins. This may follow staphylococcal blepharitis.

(b) Hypersensitive reaction of the epithelium of the conjunctiva and cornea to protein substance following more often previous tuberculous infection.

(c) Septic foci. Attacks may follow rhinitis, eczema, etc. *Staph. aureus* may cause hypersensitive reaction in such cases.

(d) Helminthiasis. Association has been documented.

Pathology. The place of choice is at or near the limbus. Localized subepithelial infiltration consists of leucocytes, centrally—polymorphs, peripherally—mononuclears with occasional giant cells plus hyperaemia of the adjoining blood vessels. Usually necrosis ensues.

The epithelium remains uninvolved in the early stage. Secondary bacterial conjunctivitis not infrequently supervenes.

A corneal phlycten develops more slowly, spreads deeper and persists longer than a conjunctival phlycten.

Clinical features. Phlyctenular keratoconjunctivitis is common between the ages of 5 and 15 years. Patients are usually undernourished and often with enlarged neck glands, irritation, watering and photophobia.

Symptoms namely irritation, watering and photophobia are generally marked when the cornea becomes involved.

Conjunctival phlycten (Fig. 37c.4)

A conjunctival phlycten makes its appearance in a characteristic fashion. At first there is a pinkish elevation surrounded by a hyperaemic zone. In a

few days the nodule develops a crater at its apex which progresses till it involves the entire nodule and reaches the surrounding conjunctiva. Basically this ulcer remains localized and does not spread like an infected conjunctival ulcer. The ulcerated area soon epithelializes without a trace of the lesion.

The typical site is at, near or within the limbus. The number may be single or multiple and multiplicity is often a common feature. They are rarely found in the bulbar conjunctiva away from the limbus, in the palpebral conjunctiva and rarer still at the lid margin. When there is no superadded conjunctivitis the course is uncomplicated and there is good resolution, *simple phlyctenular conjunctivitis*.

Relapses are common. Occasionally there is a large phlycten which may develop into a *pustular conjunctivitis*. There is rarely involvement of the underlying sclera, *necrotizing phlyctenulosis* which persists and finally leads to permanent scar formation.

Its differential diagnosis is given in Table 37.11.




Fig. 37.2 Fascicular ulcer of the cornea. Diagramatic.

not perforate and its progress can be checked by cauterizing the leash of vessels carrying tuberculo-protein which sensitizes the superficial corneal layers.

Table 37.11
Differential Diagnosis of Phlycten

Points	Phlycten	Episcleritis	Limbal type of spring catarrh	Inflamed pinguecula
Age	5-15 years	Adult	Young	Adult
History	Nodule, redness, photophobia	Ache, nodule	Itching	Occasional disfigurement
Site	At or near the limbus	Away from limbus	Astride the limbus	Near but free from the limbus
Number	Single or multiple	Usually single	Irregular swelling all round	Single
Ulceration	Common	Uncommon	Does not occur	Does not occur

Complications and sequelae. Fascicular ulcer or wandering phlycten (Fig. 37.2) is a characteristic feature of the disease. Limbal infiltration and subsequent ulceration invade the cornea in a radial manner with a leash of nonanastomosing vessels derived from the limbal vessels over the furrow towards the centre of the cornea. The apex of this radial furrow, which corresponds to the advancing margin of the ulcer, is the densest, while the peripheral part heals. The superficial ulcer does

Marginal ulcer is superficial and occurs due to localized infiltration and ulceration.

The continuous infiltration at the limbus leads to formation of thin phlyctenular pannus at the corneal margin.

There may be many minute miliary ulcers scattered over a portion or whole of the cornea.

Ring ulcer is a very severe but rare condition, caused by conglomeration of multiple phlyctens at the limbus all round the cornea and their subsequent breakdown.

Marginal corneal opacities may occur as sequelae.

Treatment. The principles of treatment are:

Local—by combined steroid-antibiotic preparation. Steroid combats the hypersensitive reaction, while antibiotic controls the co-existent secondary conjunctivitis.

In corneal involvement 1 per cent atropine ointment and other routine measures are advocated.

General treatment is by enhancement of general body resistance by protein, calcium and vitamins. Antituberculous treatment is unnecessary unless there is active tuberculous focus elsewhere.

Vernal conjunctivitis (spring catarrh)

Vernal conjunctivitis occurs as a sporadic, noncontagious, bilateral conjunctivitis.

Age incidence. This varies between 6 and 20 years. The severity wanes as the age advances.

Sex incidence. In adult age group the affection is slightly more common in males.

Seasonal incidence. It occurs in summer months especially in tropics.

Aetiology. Exogenous allergy is not precisely known. It has been classified lately under type I allergy. It is mediated by IgE.

The reasons for considering the condition as allergic are: (a) tendency to attack the young; (b) virtual recurrence in each warm weather; (c) presence of occasional concomitant atopic allergy; (d) marked eosinophilic infiltration; and (e) response to steroid therapy.

Pathology. There are three chief histological features: (a) marked cellular mainly eosinophil infiltration of the conjunctiva. This occurs very early and is the last to disappear; (b) connective tissue proliferation followed by hyaline degeneration is the more characteristic change; and (c) epithelial proliferation occurs later and is the most prominent in the bulbar type of affection.

Clinical features. Clinical features is marked mostly by itching. Itching is due to alkaline conjunctival secretion. Its intensity does not

necessarily run parallel to the severity of the lesion. Occasionally there are lacrimation, irritation and photophobia.

Palpebral (tarsal) type (Fig. 37c.3) has the preference for the upper tarsal conjunctiva which becomes thickened, bluish white with formations of firm, flat polygonal vegetations. Sometimes the vegetations are unusually large as to produce mechanical ptosis and corneal damage.

Conjunctival discharge is thick, ropy, whitish and alkaline.

In bulbar (limbal) type bluish-white, diffusely spread, discrete vegetations in the pericorneal zone surrounded by dilated conjunctival vessels are present.

Diagnosis is fairly simple but in certain early cases slit-lamp biomicroscope may reveal engorged pericorneal vessels and marked increase in the number of aqueous veins. These cases subside in winter but recur every summer without any obvious sign of vernal conjunctivitis. This group becomes limbal occasionally in course of about three years.

The disease is self-limiting. When it begins early, its course is said to last longer. Relapses are common for some years. There is rarely superficial keratitis with micropannus.

Treatment. Treatment is symptomatic.

Topical steroid is quite effective. At first, frequent use of topical steroid is advocated till the symptoms subside. It should be continued usually thrice daily for about 4 to 6 weeks.

Following cessation of topical steroid therapy 2 per cent sodium cromoglycate 4 times daily may be used.

In recalcitrant cases, aspirin up to 200 mg daily in 4 divided doses, 0.3 per cent flurbiprofen drops, 0.5 per cent ketorolac tromethamine drops, acetyl cysteine drops, cryoapplications, etc. have been recommended.¹²

Atopic keratoconjunctivitis

Atopic keratoconjunctivitis (AKC) is due to type I allergy. Ocular symptoms are essentially similar to those of vernal conjunctivitis, but it typically affects

young men with preexisting atopic dermatitis for several years. Sodium cromoglycate drops 4 per cent are effective therapy of AKC.

Giant papillary conjunctivitis

Giant papillary conjunctivitis (GPC) is seen in contact lens wearer or postoperative exposed sutures. Ocular features resemble those of vernal conjunctivitis, but papillae are of greater diameter more than 0.3 mm, and there is excess mucus obscuring vision in GPC. Treatment consists of discontinuation of contact lens or replacement by improved design and polymer, and instillation of 4 per cent sodium cromoglycate drops.

Keratoconjunctivitis Associated with Diseases of the Skin and Mucous Membranes¹⁸

Chiefly they are: (a) mucocutaneous eruptions, e.g. erythema exudativum multiforme and ocular pemphigoid and (b) dermatoses, e.g. acne rosacea and xeroderma pigmentosum.

Stevens-Johnson syndrome (syn: *Erythema exudativum multiforme*)

It is characterized by exudative erythema, symmetrically distributed on the hands, forearms, neck and elsewhere and spreading to the mucous membranes. The affection is mostly in young adults. The cause is not definitely known. It may follow infections or drugs. Finally, the affection leads to shrinkage. HLA B 2 is seen in about 75 per cent of the cases.

Reiter's disease

It is characterized by the triad—conjunctivitis, urethritis and polyarthritis. HLA B 27 is seen in about 76 per cent of the cases.

Benign mucous membrane pemphigoid (syn: ocular pemphigoid, essential shrinkage of the conjunctiva)

It is rare without any known aetiology. It is a chronic affection in the elderly subject characterized by vesicles in the conjunctiva leading to progressive cicatrization of the conjunctiva and corneal opacification.

Allied aphthous lesions of the mucous membrane include: (a) erythema nodosum; (b) dermatitis herpetiformis; and (c) epidermolysis bullosa.

Scarring of the conjunctiva (Table 37.12)

Table 37.12
Causes of Scarring of the Conjunctiva

General	Typically in membranous conjunctivitis
Upper lid	Trachoma
Lower lid	e.g. Stevens-Johnson disease, ocular pemphigoid, chemical (especially alkali) injury and exfoliative dermatitis

Treatment of Shrinkage of the Conjunctiva.¹⁷ The following measures may be considered:

(a) Steroids. They must be used early and in adequate dosage. Saturation with steroids has a good effect.

(b) Cornea grafting. Since the corneal opacity is superficial, a lamellar graft is perhaps beneficial. Postoperative corneal vascularization causes gross visual disturbance.

(c) Fornix reconstruction. The reconstruction allows proper closure of the eyelids and retention of contact lenses. This is only attempted when the activity of the disease is latent.

(d) Parotid duct transplantation. It is of doubtful utility. This procedure provides tear but without the capacity of its retention.

(e) Occlusion of the puncta. It helps to conserve whatever amount of tear is present in the eyes.

(f) Contact lenses. A contact lens protects against trichiasis and causes retention of tear. It has both optical and therapeutic values. It can be used only in quiescent state.

Degenerations of the Conjunctiva

The following histological changes occur in the conjunctiva in advancing years making it less transparent and more rough:

- (a) Increased thickening of the epithelium
- (b) Tendency to keratinization
- (c) Atrophy of the subepithelial layers
- (d) Onset of hyaline degeneration and fatty degeneration
- (e) Disappearance of the elastic fibres.

Degenerative conditions of the conjunctiva include:

- (a) Concretions
- (b) Pinguecula
- (c) Pterygium
- (d) Other degenerative changes include hyaline, amyloid, and calcareous degenerations.

Concretions (Lithiasis)

Concretions are characterized by the presence of hard, yellow, projecting spots in the palpebral conjunctiva and these may scratch the cornea causing a foreign body sensation. There is never any calcareous deposits. The affection is due to deposition of epithelial cells and inspissated mucus in Henle's glands. They may be removed with a sharp surgical needle.

Pinguecula

Pinguecula (Lat. *pinguis*, fat) appears as a rough, triangular, yellowish, fatty looking area in the interpalpebral aperture near the limbus with its base towards the cornea. It becomes prominent when there is surrounding inflammation.

Pathology. There is elastotic degeneration of the collagen present in the substantia propria of the conjunctiva along with accumulation of amorphous hyaline material.

Treatment. If disfigurement is unusual surgical removal is indicated which leaves behind a scar.

Pterygium

Pterygium (Gk. *pterygion*, wing) is a triangular encroachment of the bulbar conjunctiva onto the cornea. It is found commonly in the sunny and sandy regions of the world.

Heredity has undoubtedly some influence. Inheritance is dominant with a low penetrance.

Aetiology. The cause is not precisely known. Environmental irritation is perhaps the most important factor.

Pathology. The earliest change is the appearance of small vesicle-like formation in the corneal margin. At these points, vascularized connective tissue starts growing under the epithelium and there is destruction of Bowman's membrane. There is same histologic change in the conjunctiva as those of pinguecula, namely elastotic degeneration of the collagen with deposition of amorphous hyaline material.

Clinical features (Fig. 37.3). Pterygium is unilateral or bilateral, most commonly seen on the nasal side in the interpalpebral area, and one or two in one eye or even four in both eyes.

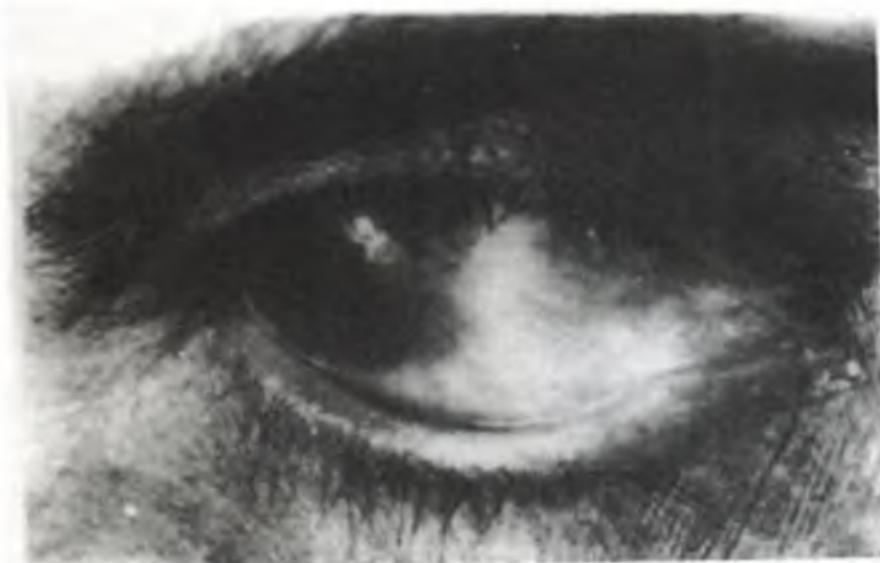

Fig. 37.3 A progressive pterygium.

The first change is the presence of grey circumscribed dots in the cornea near the limbus and simultaneously there is a tense conjunctiva opposite to the area of corneal affection and displacement of the plica. These conjunctival changes are the result of its shrinkage. Later on there is a wing-shaped extension of the fleshy growth of the bulbar conjunctiva on to the cornea.

A fully developed pterygium presents a well-formed 'apex', 'body' and 'neck'. The neck is between the apex and the body and situated over the limbus. The progressive pterygium is thick and vascular. A pterygium may cease to grow but it never disappears. When it ceases to grow it appears thin and anaemic.

Differential diagnosis. The condition should be differentiated from a pseudopterygium which is a fold of the chemotic conjunctiva being dragged over the marginal corneal ulcer, finally adhering to the cornea (Table 37.13).

Table 37.13
Differentiation between Pterygium and Pseudopterygium

	Pterygium	Pseudopterygium
History of corneal ulcer	Absent	Present
Age	Elderly usually but sometimes young	Any
Site	Interpalpebral region, nasal or temporal	Anywhere round the limbus
Progress	Progressive or stationary	Nonprogressive
Passing of a probe	Cannot be passed through and through	Can be passed under the neck

Treatment. A progressive pterygium should be excised, transposed or transplanted.

Dhanda⁶ has summarized various available methods of treatment under two broad headings:

(a) Nonsurgical:

- (i) No treatment, to wait and watch
- (ii) Topical thioTEPA, 1 in 2000 dilution for 6 weeks
- (iii) Subconjunctival steroids
- (iv) Beta-radiation, 2500–3000 rads
- (v) Cryoapplication.

(b) Surgical:

- (i) Excision
- (ii) Inversion
- (iii) Excision and transfixation
- (iv) Transplantation
- (v) Excision and mucous grafting
- (vi) Keratoplasty.

Recurrence is not unusual after excision and other measures.

Transposition of Pterygium

(Figs. 37.4–37.7)

After separation of the eyelids by a speculum and proper anaesthetization the conjunctiva is incised

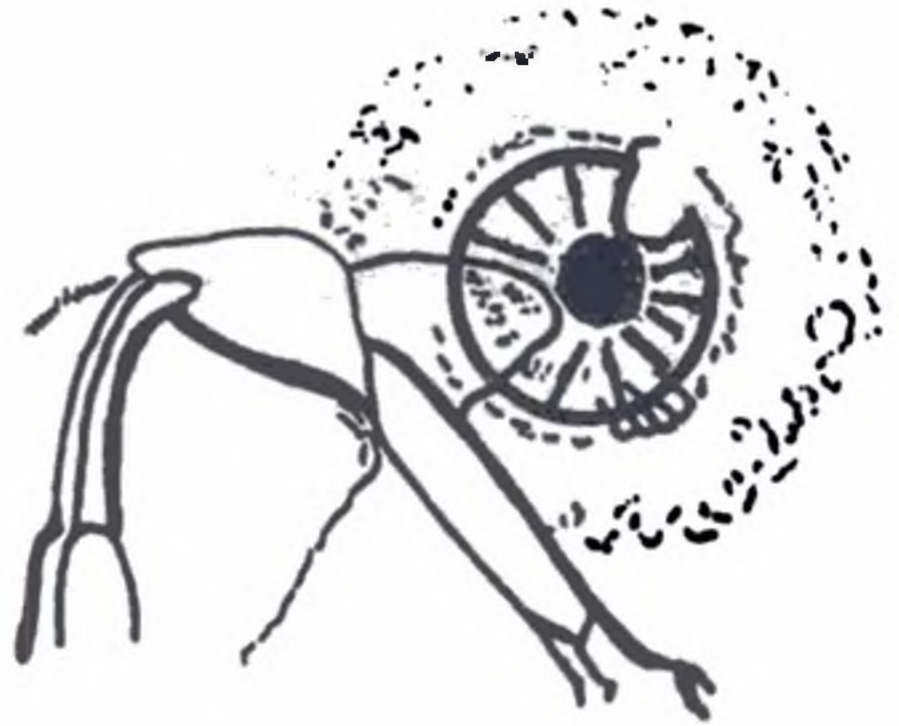

Fig. 37.4 The conjunctiva is incised along the limbus.

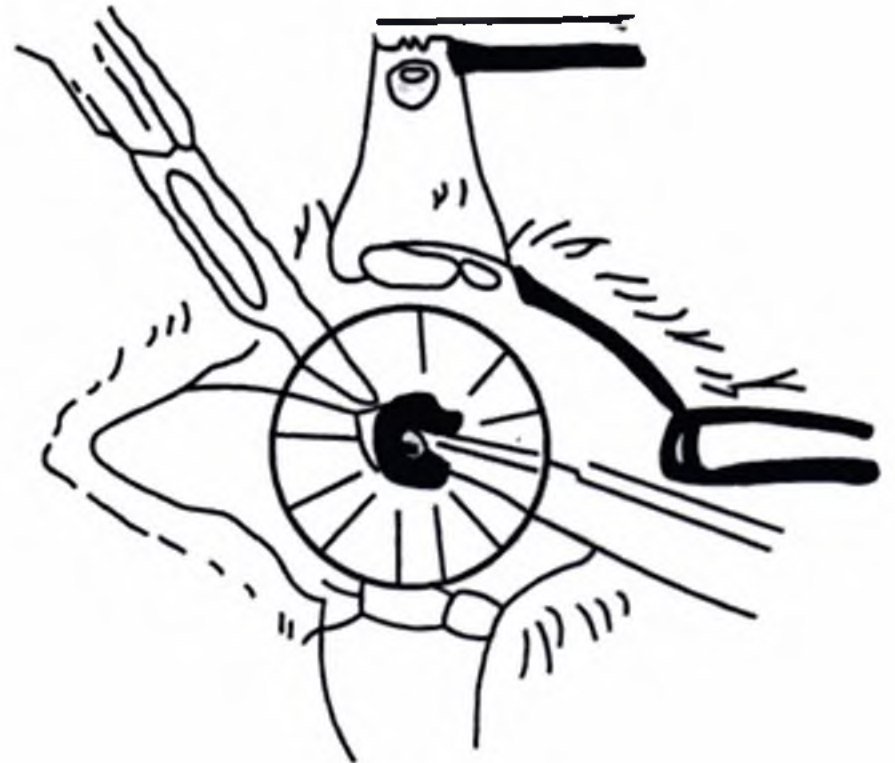


Fig. 37.5 Pterygium is dissected off from the underlying tissue.

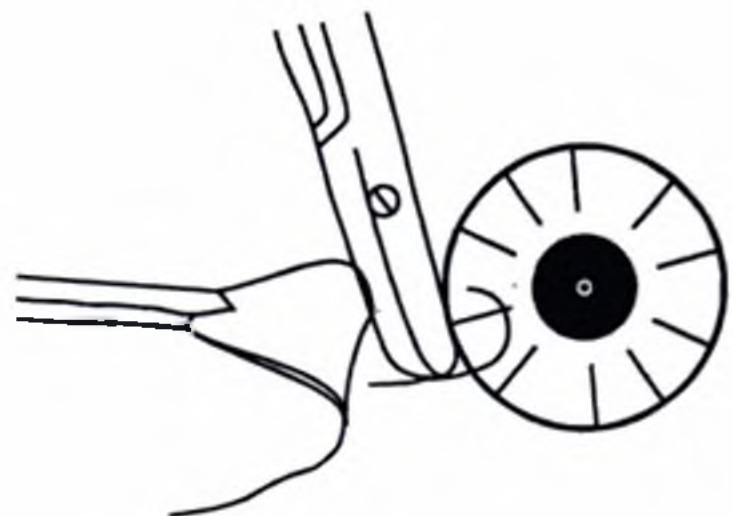


Fig. 37.6 A pocket is made in the lower part by separating the blades of the scissors.

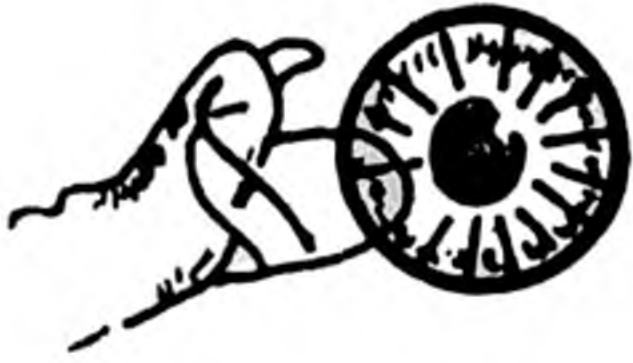

Fig. 37.7 Introduction of the apex of pterygium into the lower pocket and its fixation by the sutures.

at the limbus and along the upper and lower margins of the body of the pterygium. The area is now undermined, and a double-armed mattress suture is passed through the neck of the pterygium. The adjoining bulbar conjunctiva—either upward or downward—is picked and undermined toward the fornix with scissors. The two needles of the mattress suture are passed below the undermined conjunctiva and brought out at the distal part i.e. upper or lower limit, while the head of pterygium is introduced into the conjunctival pocket.

Excision of pterygium (Figs. 37.8–37.12).

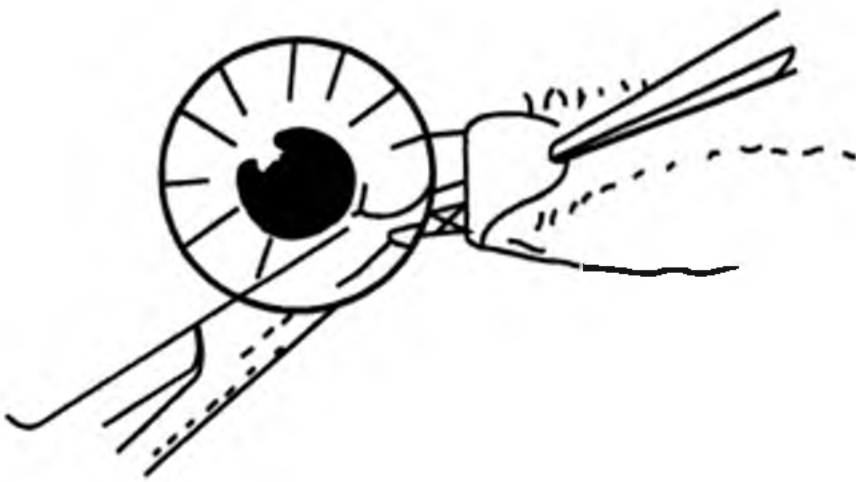


Fig. 37.8 Dissection of pterygium in excision.

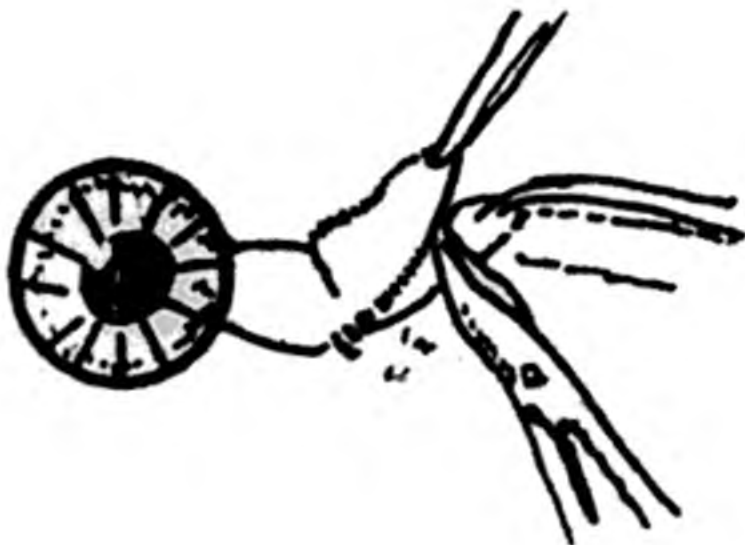


Fig. 37.9 Splitting of pterygium into two layers, superficial and deep.

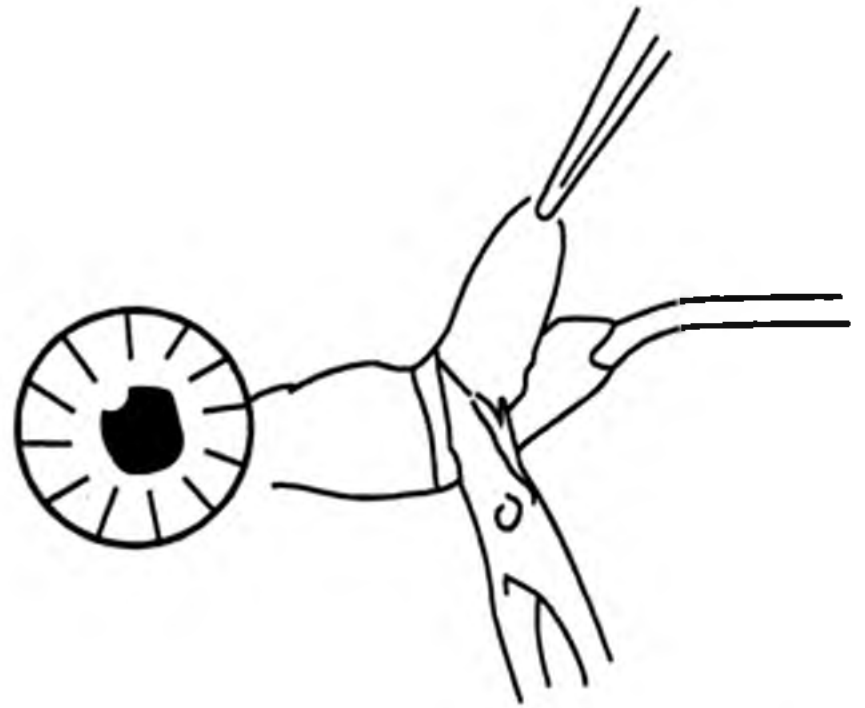


Fig. 37.10 Excision of the thick deeper layer from the base of pterygium.

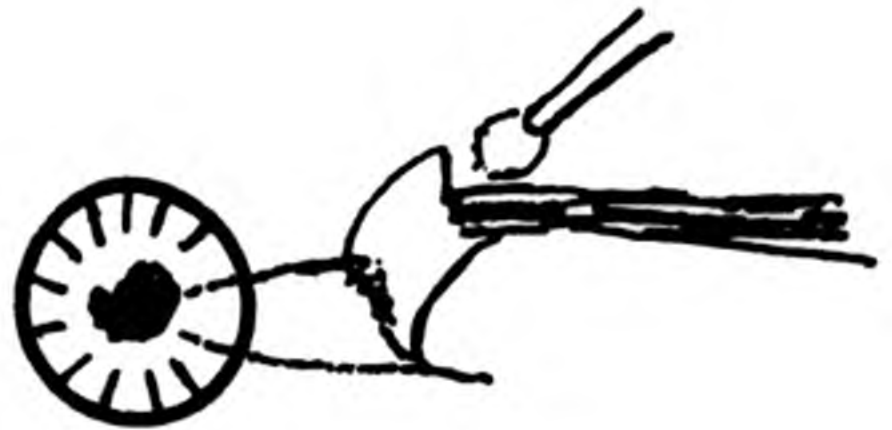


Fig. 37.11 Excision of the apex of the superficial layer.

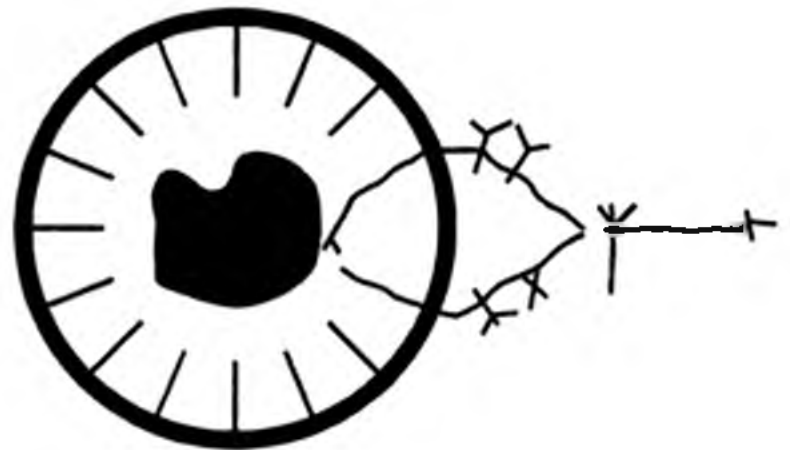


Fig. 37.12 Final closure of the conjunctival incision.

The steps have been shown in the figures and they are enumerated as: (a) the pterygium is undermined and the thick underlying tissue and dissected off extending as far as the caruncle; (b) the head of pterygium is shaved off from the corneal margin; and (c) the conjunctiva is pulled down to cover the dissected area and sutured.

Conjunctival Cysts

The following varieties are met with.

Lymphatic cysts are relatively common and are due to dilatation of lymph spaces. They may present as rows of fine cysts on the bulbar conjunctiva (lymphangiectasis) or rarely there may be a single multilocular cyst (lymphangioma).

Epibulbar dermoid may present itself in cystic form.

Traumatic cysts are formed as a result of submucous inclusion of the epithelium, followed by proliferation, degeneration and formation of central cystic space.

A cyst may follow injury or operation, e.g. squint surgery.

Epithelial cyst may occur in trachoma and pterygium.

Rarely cysts may be subconjunctival—cysticercus or hydatid cysts.

Congenital cyst is rather rare.

Tumours of the Conjunctiva

Tumours of the conjunctiva appearing as polypoid growth are not uncommon. They may be benign or malignant (Table 37.14).

Table 37.14

Classification of the Tumours of the Conjunctiva and Cornea

Epithelial
Benign: dermoid, dermolipoma, papilloma, adenoma, keratoacanthoma and others
Benign but potentially precancerous: leucoplakia and intraepithelial epithelioma
Malignant: epithelioma and pleomorphic adenoma
Mesoblastic
Benign: fibroma, lipoma and myxoma
Malignant: fibrosarcoma, liposarcoma and myxosarcoma
Vascular
Benign: haemangioma-plexiform, cavernous and telangiectatic, and lymphangioma
Malignant: angiosarcoma and Kaposi's sarcoma
Pigmented
Benign: naevus
Malignant: malignant melanoma and intraepithelial melanoma
Peripheral nerve tumours
Benign: neurofibroma, tuberous sclerosis and intrascleral nerve loops
Malignant: malignant schwannoma Reticuloses
Lymphoma, lymphosarcoma, mycosis fungoides

Benign. A *dermoid* (Fig. 37c.6) is a developmental tumour appearing as rounded, yellowish raised mass, usually astride the limbus and commonly at the outer side. Frequently hairs may protrude from the tumour. It has a tendency to grow at puberty. Treatment consists of removal. If the cornea is involved, after excision opaque cornea can be replaced by a lamellar graft.

Dermolipoma (Fig. 37c.7) is also a developmental tumour found at the outer canthus. Dermoid and/or dermolipoma along with accessory auricles and other congenital defects constitute *Goldenhar's syndrome* (Fig. 37.13). Treatment is only indicated when there is disfigurement. During its removal,

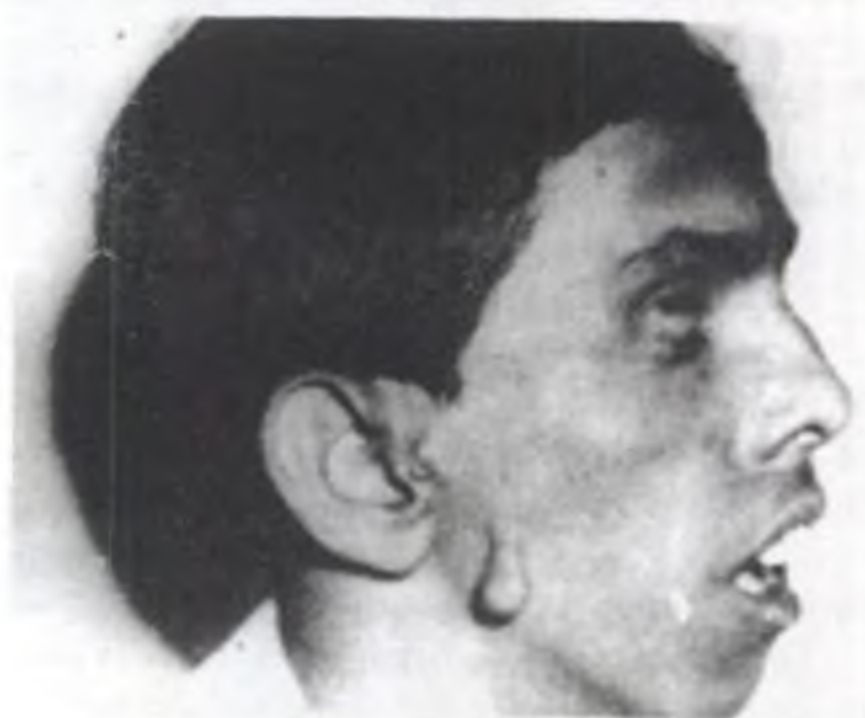

Fig. 37.13 Goldenhar's syndrome showing accessory auricles.

posterior dissection should be done with extreme care because dermolipoma is frequently continuous with the orbital fat.

Papilloma occurs at the inner canthus, in the fornices or at the limbus. It consists of multiple papillae with vascular connective tissue core. They are excised and their bases cauterized to prevent recurrences.

Granuloma consists of excess of granulation tissue. It occurs after squint surgery, at the site of a foreign body, in empty socket or from a chalazion. Treatment consists of its excision.

Naevi or conjunctival moles are relatively common. They have a preference for the limbus or plica semilunaris. They have a tendency to grow at puberty. Malignant change is rare.

Conjunctival *angioma* may take two forms—haemangioma and lymphangioma. Haemangioma may be plexiform, cavernous or telangiectatic in nature.

Junctional naevus and precancerous melanosis characterized by diffusely spreading pigmentation of the conjunctiva and also of the skin of the lids and cheek are precancerous.

Malignant. Epithelioma or squamous cell carcinoma arises most commonly from the limbus and appears as a small whitish elevation firmly adherent with the underlying tissue. It has a tendency to spread over the surface and into the fornices. Histologically, it consists of only squamous cells. If small, it may be excised completely and followed by diathermy cauterization of its base. If extension occurs enucleation is indicated. In case of recurrence, the orbit must be exenterated.

Intraepithelial epithelioma (Bowen's disease) is a rare condition of carcinoma *in situ*. It occurs as a flat growth, starting at the limbus and spreading to involve the cornea. It should be differentiated from Mooren's ulcer, pannus, filtering bleb, epithelial dystrophy of the cornea and fatty degeneration of the cornea.

The incidence of malignant melanoma is rare. It occurs in the elderly and the site is the limbus. This pigmented tumour spreads over the surface of the eyeball but rarely invades the interior of the eye. Treatment is either enucleation or exenteration depending upon the stage of the tumour.

Basal cell carcinoma may involve the eyelids and subsequently the conjunctiva.

Pigmentation of the Conjunctiva

The causes of the pigmentation of the conjunctiva are:

(a) Blood pigment, e.g. after subconjunctival haemorrhage. The conjunctiva becomes red.

(b) Bile pigment as in jaundice. The pigmentation is yellow.

(c) Melanin pigment, e.g. in vernal conjunctivitis, trachoma, xerosis of conjunctiva and

Addison's disease. The conjunctiva becomes blackish.

(d) Metallic, e.g. silver (argyrosis) where the colour becomes dark-brown, iron (siderosis) where the pigmentation becomes rust coloured, and copper (chalcosis).

(e) Benign melanosis.

(f) Naevus and melanotic tumours. The conjunctiva is brownish.

(g) Miscellaneous, e.g. eye cosmetics containing carbon black.

Developmental Anomalies of the Conjunctiva

Developmental anomalies of the conjunctiva are very rare. The conjunctiva may be absent as in cryptophthalmos. Hereditary haemorrhagic telangiectasia, also known as *Rendu-Osler-Weber syndrome*, may be met with. Congenital pterygium is known to occur. There may be apron-like conjunctival fold hanging from the inner tarsal surface of the lid, called *epiblepharon*.

Further Reading

1. Abelson, M.B., Udell, J.J., Allansmith, M.R., et al., Allergic and toxic reactions. In *Principles and Practice of Ophthalmology: Clinical Practice*, Albert, D.M. and Jacobiec, F.A. (Eds.), W.B. Saunders, Philadelphia, 1994, p. 77.
2. Ahmed, E. and Roy, S.N., A Study of fifty cases of keratoconjunctivitis. *Indian J. Ophthalmol.*, 21:23, 1973.
3. Arffa, R.C. (Ed.), *Grayson's Diseases of the Cornea* (4th ed.), Mosby, St. Louis, 1997.
4. Chatterjee, S., Quarcóopome, C.C. and Appenteng, A., Unusual type of epidemiological conjunctivitis in Ghana. *Br. J. Ophthalmol.*, 54:628, 1970.
5. Dawson, C.R., Jones, B.R. and Tarizzo, M.L., Guide to trachoma control in programmes for the prevention of blindness. *World Health Organization*, 1981.

6. Dhanda, R.P., Pterygium, *Acta XXII Concilium Ophthalmologicum*, Paris, Vol. 2: 1974, p. 742.
7. Duke-Elder, S., *System of Ophthalmology*, Vol. VIII, *Diseases of the Outer Eye*, Part I: *Diseases of the Conjunctiva and Associated Diseases of the Corneal Epithelium*, Kimpton, London, 1965.
8. Jones, B.R., The epidemiology of trachoma and other communicable ophthalmia. In *Scientific Foundations of Ophthalmology*, Perkins, E.S. and Hill, D.W. (Eds.), Heinemann Medical, London, 1977, p. 149.
9. Kamel, S., Trachoma and the cornea. In *The Cornea: World Congress*, King, J.H. and McTigue, J.W. (Eds.), Butterworths, London, 1965.
10. MacCallan, A., Epidemiology of trachoma. *Br. J. Ophthalmol.*, 15:369, 1931.
11. Maichuk, I.F., Clinical patterns of epidemic haemorrhagic conjunctivitis comparatively to other major epidemic conjunctivitis. *Bull. Ophthalmol. Soc., Egypt*, 66 17, 1973.
12. Myer, E., Kraus, F.E. and Zunis, S., Efficiency of antiprostaglandin therapy in vernal conjunctivitis, *Br. J. Ophthalmol.*, 71:497, 1987.
13. Patrick, R.K., Lacrimal secretion in full-term and premature babies: neonates do secrete tears. *Tr. Ophthalmol. Soc., UK*, 94, Part 1:283, 1974.
14. Pavan-Langstone, D., Viral diseases of the cornea and external eye. In *Principles and Practice of Ophthalmology: Clinical Practice*, Albert, D.M. and Jacobiec, F.A. (Eds.), W.B. Saunders, Philadelphia, 1994, p. 117.
15. Rodger, F.C., *Eye Diseases in the Tropics*, Churchill Livingstone, Edinburgh, 1981.
16. Roy, I.S., Roy, S.N. and Ahmed, E., Epidemic acute conjunctivitis. *Br. J. Ophthalmol.*, 56:501, 1972.
17. Taylor, R.F., Modern treatment of severe shrinkage of the conjunctiva. *Br. J. Ophthalmol.*, 51:31, 1967.
18. Thygeson, P., Muco-cutaneous ocular syndromes. In *Modern Trends in Ophthalmology*, (3rd series), Sorsby, A. (Ed.), Butterworths, London, 1955, p. 146.
19. Thylefors, B., Dawson, C.R., Jones, B.R., et al., A simple system for the assessment of trachoma and its complications, *Bull. World Health Organization*, 65:481, 1987.
20. Vastine, D., Infections of the ocular adnexa and cornea. In *Principles and Practice of Ophthalmology*, Peyman, G.A., Sanders, D.R. and Goldberg, M.F. (Eds.), W.B. Saunders, Philadelphia, 1980, p. 281.
21. Watson, P.G. and Sevel, D., Ophthalmia nodosa, *Br. J. Ophthalmol.*, 50:209, 1966.

38. DISEASES OF THE CORNEA

History³

According to Ebers, the Egyptians knew various affections of the eyes such as pinguecula, pterygium, leucoma, lid deformities and chemosis. As early as AD 508–575 Aetius described the corneal disease in the following manner ‘... On the cornea occur foggy and cloudy spots, tiny marginal ulcers, superficial ulcer, abscess, excavated ulcer, trough-like ulcer, rupture, etc. ...’. Hypopyon was first described by Galen. Lawrence was a pioneer in dealing with corneal affections. Wardrop (1808–18) coined the term *keratitis*. Hutchinson (1858) distinguished interstitial keratitis as one of the stigmata of congenital syphilis. In 1924, Holmes Spicer published a monograph on parenchymatous keratitis. The basis of fundamental pathologic processes in the cornea has been established by Ernst Fuchs. The aetiological basis of phlyctenular keratoconjunctivitis was propounded by von Pirquet (1903). Between 1890–1933 Groeneouw described several types of nodular dystrophy. Thygeson

contributed largely to bacterial and viral infections of the conjunctiva and cornea. Recently Dohlman has enriched the basic aspects of the cornea.

Introduction

The cornea proper is transparent and avascular. The transparency is impaired due to the disturbance of turgescence and regular arrangement of the lamellae. In other tissues these would not be so much visible, but the cornea shows even the earliest pathological change. Because of avascularity there is slow mobilization of leucocytes and fibroblasts derived from the pericorneal capillaries, hence, the corneal affection becomes chronic and sometimes intractable.

There are three groups of causes of corneal affection: (a) exogenous, which includes injury and primary infection; (b) spread from the conjunctiva, sclera and uveal tract; and (c) endogenous.

The corneal epithelium is vulnerable because of its exposed position and its delicate nature. It is not immune to virus and it is relatively impermeable to bacteria except gonococci and diphtheria bacilli.

The three embryologic layers of the cornea are the forward continuation of the conjunctiva, sclera and uveal tract. So, a conjunctivitis can cause a marginal keratitis, scleritis may develop into a sclerosing keratitis and an iridocyclitis may show keratic precipitates.

Equipments and Methods of Examination

These are indicated in Table 38.1.

External examination is carried out with pen light, magnifying loupe but best by slit-lamp biomicroscope.

Staining is essential for the detection of abrasions and minute foreign body. Sterile fluorescein strip is used to stain area of epithelial denudation. Rose Bengal stains areas of unhealthy epithelial cells, but the cells being still in place.

Corneal sensibility is examined with a wisp of cotton drawn out to a few threads and twisted. The sensibility should be tested before instillation of a surface anaesthetic. *Aesthesiometer* having retractable nylon thread may also be used.

Table 38.1

Investigations in Corneal Disorders¹⁴

History
External examination
Slit-lamp biomicroscopy—various types of illumination
Assessment of corneal surface
Staining—fluorescein and rose Bengal
Corneal sensibility
Measurement of corneal surface
Keratometry—Placido disc or computer-assisted corneoscope
Keratometer—manual and computer-assisted photokeratoscope
Measurement of corneal thickness
Pachymeter (pachometer)
Evaluation of precorneal tear film
Schirmer's test
Break-up time
Tear osmolarity
Measurement of lysozyme
Photography
External
Slit-lamp beam
Specular microscopic
Specular microscopy

Injury to the Cornea³

Injury to the cornea may be caused by extraocular foreign body. Oblique illumination, sometimes use of fluorescein and occasionally presence of a leash of blood vessels nearby are helpful in localization. Treatment is removal of the foreign body by spud or needle (even a hypodermic needle) after anaesthetization. Antibiotic ointment, and if necessary, a weak mydriatic are used.

Contusion injury to the cornea

Abrasion is evidenced by distortion of the corneal reflex and staining of the affected area by fluorescein. Antibiotic, pad and bandage for 24 to 48 hours are measures for the treatment.

Blood staining of the cornea

This is due to hyphaema, defined as blood into the anterior chamber, associated with secondary

glaucoma. Haemoglobin derivatives which enter either through the damaged endothelium or from the periphery accumulate in the corneal lamellae. The colour of the blood-stained cornea depends on the duration of the condition and hence varies between dark brown to greenish. The clearance of blood staining is a very slow process, starting at the periphery and progressing towards the centre. The treatment is unavailing. Evacuation of the blood and control of secondary glaucoma are the preventive measures.

Perforating injury

The involvement in the cornea may be linear or lacerated. If the wound is small, conservative treatment suffices. If it is large with an iris prolapse, abscission of the prolapsed iris is needed followed by repair of the cornea by sutures. The infected wound must be treated like an ulcer.

Healing of Corneal Wounds³

Healing of the corneal epithelium

Following an abrasion there is loss of continuity of the corneal epithelium and there are two processes involved in healing—migration of the epithelium in proximity and mitosis in which there is multiplication of surviving epithelial cells, the basal cells acting as the germinal layer. The rate of healing after a localized injury is rapid and there is no permanent defect left. There is regeneration even to cover the suppurative margin and floor of the ulcer.

The factors that inhibit epithelial healing are cooling of the eye, drops like argyrol, protargol, zinc sulphate and antibiotics. It appears that there is no serious inhibition of migration or mitosis.

Healing of the stroma

In an uncomplicated wound there is avascular healing, while in infective or destructive lesion healing occurs with vascularization.

In avascular healing, following corneal injury there are successive stages namely the activation

of enzymes, the liberation of polypeptides, the attraction of leucocytes to the injured area through the tear across the wound and migration from the perilimbal vessels, and changes in the stromal cells.

In a noninfective lesion there are destruction of the corneal corpuscles in the injured area and proliferation of these cells in the vicinity; also there is an attraction of monocytes of the blood to the injured area. The second invasion occurring after 48 hours and reaching its peak in one week consists of macrophages which at first act as scavengers and later form new corneal fibres. The newly-formed fibres are irregular in distribution. In presence of infection or destructive lesion healing occurs with appearance of blood vessels.

Repair of Descemet's membrane and the endothelium

As in the epithelium there are migration of the endothelial cells and mitosis. Normally there is regeneration of the endothelium by mitosis. In injury of Descemet's membrane, there is replacement with hyaline material derived from the proliferated endothelial cells.

Keratitis³

Keratitis means inflammation of the cornea. An inflammation of the cornea may be due to the following factors.

(a) Exogenous infection is the most common source of inflammation. There is primary infection of the cornea usually following a breach in the corneal epithelium.

(b) Spread from the neighbourhood. Three embryologic layers of the cornea, viz. the epithelium, substantia propria, and Descemet's membrane with endothelium are the forward continuation of the conjunctiva, sclera and uveal tract. So, the cornea may be involved secondarily in conjunctivitis, scleritis and uveitis.

(c) Endogenous. Because of avascularity, the cornea rarely participates in acute infections but it is liable to be involved in allergic conditions.

Aetiologic classification. There are six types of keratitis:

- (a) Infective: (i) bacterial; (ii) viral; (iii) mycotic; and (iv) parasitic
- (b) Allergic
- (c) Keratitis following skin and mucous membrane diseases
- (d) Keratitis as a manifestation of systemic diseases
- (e) Exposure, desiccation and neurotrophic keratitis
- (f) Of obscure aetiology.

Morphologic classification. Refer to Table 38.2.

Table 38.2

Morphologic Classification of Keratitis¹

Ulcerative
Infiltrative (suppurative)
Central
Marginal
Noninfiltrative (nonsuppurative)
Central
Marginal
Nonulcerative
Epithelial
Punctate erosions
Punctate keratitis
Deep epithelia:
Combined epithelial and subepithelial
Subepithelial infiltrative
Stromal
Interstitial
Disciform
Ring abscess
Stromal abscess
Endothelial, e.g. corneal graft rejection

Bacterial Corneal Ulcer³

Corneal ulcer. Corneal ulcer is defined as an epithelial break accompanied by underlying stromal necrosis.

Aetiology. The ulcer usually follows an exogenous infection after an injury to the corneal epithelium, the source of infection being an infected lacrimal sac, conjunctiva or lid margin.

Pathology. There are three stages and they are described.

(a) The first or *progressive* stage is characterized by oedema, infiltration of the epithelium and the stroma, followed by their necrosis. The chief causes of oedema are diminished function of the endothelium and the epithelium, and decreased pump-activity of the endothelium.

The chemotactic reaction of polypeptides released in response to injury attracts leucocytes to the site of injury. Normally, the corneal surface is constantly covered by a protective layer of mucosubstance, *glycocalyx*, of the precorneal tear film.

Glycocalyx of the injured epithelium or that of a few bacteria, such as, *pseudomonas* and *gonococcus* causes biological adhesion and subsequently liberates toxin and attracts polymorphs. The polymorphs phagocytose the bacteria and form phagosomes. The phagosomes in combination with the cytotoxic elements of lysozyme then produce phagolysosomes. The latter enzymes tend to destroy the bacteria as well as the corneal tissues.¹⁵

Necrosis occurs in the most anterior layers of the cornea, the desquamation of the epithelium and damage to Bowman's membrane are proportionately more than the ulcer. The walls of the ulcer overhang due to imbibition of fluid by the lamellae.

(b) The second or *regressive* stage is characterized by the subsidence of oedema, disappearance of infiltration and appearance of a line of demarcation between the normal and infected areas.

The pus cells in the ulcerated area are destroyed while the leucocytes survive in the periphery of the ulcer. The surviving cells digest and dissolve the necrosed tissue which is cast off. The ulcer at this stage becomes larger and clean associated with the subsidence of infiltration of the edges and base of the ulcer.

(c) The third or *healing* stage starts with a permanent covering of the defect by the growth of the epithelium over the edges. But the stage is essentially characterized by formation of scar tissue

due to the division of the corneal corpuscles, and invading monocytes which contribute two or three times more fibroblasts than the former and also the endothelial cells of the new vessels.

Clinical features. The symptoms are pain, watering and blepharospasm due to exposure of the terminal nerve fibrils of the ophthalmic division of the trigeminal nerve.

The onset of ulcer is by greyish infiltration of a localized area accompanied by the presence of ciliary congestion. Then suppuration ensues succeeded by the loss of tissue or ulceration. The ulcer is uneven with some slough. The floor is greyish. The surrounding is infiltrated and swollen. The walls are overhanging.

Fluorescein staining causes green staining of the ulcerated area.

Biomicroscopy is a valuable aid in the diagnosis. The size of the epithelial defect, size of the ulcer and infiltrate as well as its depth can be measured.

Diagnosis.¹⁵ Though the clinical features of an infective keratitis provide clues to arrive at a diagnosis, yet the confirmation depends on the isolation of the susceptible bacteria. Cultures are more sensitive than smears. Avoid using a surface anaesthetic while obtaining a culture from the conjunctiva, while it is essential to anaesthetize the cornea. Culture is obtained from the lids and conjunctiva of both eyes. In case of corneal ulcer, dry swab is used to clear the debris and exudates from the surface of the ulcer. This is followed by scraping by means of a standard Kimura spatula, C-streaking of the collected material on blood agar and Saboraud agar. The specimens are spread on sterile slides and stained with Gram and Giemsa stains.

Complications and sequelae. When the ulcer is small and superficial, it usually heals early with the subsidence of infiltration and oedema followed by cicatrization.

When Bowman's membrane is destroyed the opacity (Fig. 38.1) is always permanent. If the resulting opacity is slight and then it is called a *nebula*. If it is denser it is known as *macula*. The

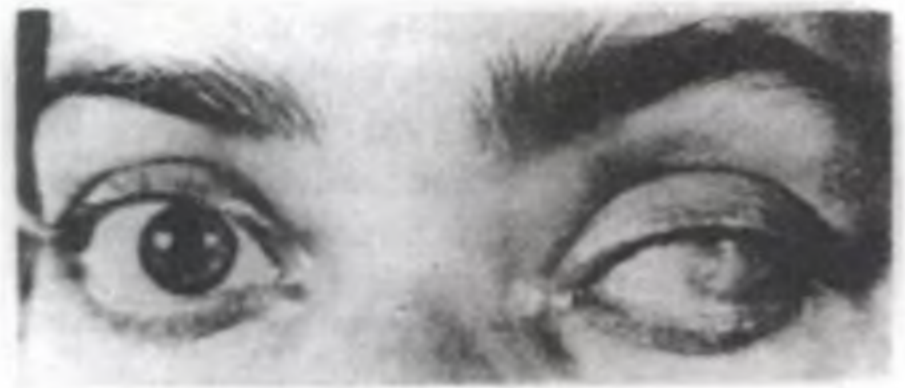

Fig. 38.1 Left corneal opacity. The affected eye is divergent.

very dense and white opacity is called *leucoma*. Sometimes there may be a depression or corneal *facet* at the site of the ulcer in which the scar is almost transparent. When the ulcer spreads superficially, there may be sloughing eventually involving the entire surface of the cornea.

When it spreads deeply, it extends through the stroma to reach up to Descemet's membrane, which offers great resistance till it yields to the intraocular pressure and leads to the bulging of this membrane through the ulcer appearing as a transparent vesicle, i.e. a *keratocele* or *descemetocoele*. It ultimately ruptures.

In the deeper spread of the ulcer other occasional complications like intracorneal abscess, posterior corneal abscess and ulcer may be seen. But the extreme complication is the perforation of the cornea.

Panophthalmitis may also occur.

Secondary glaucoma is due to hypopyon, perforation of the cornea or uveitis associated with corneal ulcer.

Corneal perforation. This occurs due to bursting of the weak floor of the ulcer induced by violent orbicularis spasm following some sudden exertion. Following perforation, there is loss of aqueous and loss of the anterior chamber.

Beneficial effects also occur and they are:

- (a) diminution of pain;
- (b) alleviation of pain;
- (c) halting of the progress of the ulcer; and
- (d) enhancement of healing.

Effects following perforation may depend on the site and size of perforation. In the small marginal, the iris glues itself to the area and forms anterior synechia. In the large marginal, prolapse of the iris occurs. In the small central, the pupillary margin of the iris approximates the edges of perforation and forms anterior capsular cataract. In the large central, subluxation and very rarely extrusion of the crystalline lens may occur.

Pseudocornea. There is an organization of the exudate and subsequent fibrosis at the site of iris prolapse, occurring under the growing conjunctival or corneal epithelium.

Keratectasia. Bulging of the scar, also called *ectatic cicatrix* occurs due to thinning of the cornea at the site of the ulcer due to loss of tissue.

Anterior staphyloma. It is an ectatic cicatrix in which the iris is incarcerated. It may be partial or total, the colour varying between slaty grey to black depending upon the amount of pigment engulfment, and the surface is lobulated due to irregular contraction of the fibrous bands. Following an iris prolapse the exudate covers the prolapsed area. Then the exudate becomes organized and forms a fibrous tissue layer over which the conjunctival and corneal epithelium grows. The cicatrix thus formed is too weak to withstand the intraocular pressure and bulges forward.

Corneal fistula. The opening becomes permanent.

Phthisis bulbi. There is destruction of the ciliary body leading to hypotony which sets in and the eyeball appears quadrilateral. The eyeball finally shrinks and degenerates.

Grading of the Severity of Corneal Ulcer. The following factors should be considered for grading of the severity: (a) area involved; (b) degree of oedema; (c) degree of necrosis; (d) AC signs like flare and cells; (e) degree of hypopyon; and (f) secondary rise of tension.

Treatment. Local measures: (1) Atropine 1 per cent drop or ointment twice or thrice daily is used for the control of coexistent anterior uveitis.

(2) Antibiotic is ideally selected on the basis of sensitivity. Penicillin G drops in staphylococcal and pneumococcal, cephalosporin drops in penicillin-resistant cases, and gentamicin or tobramycin drops in pseudomonas ulcer cases have been recommended. In some severe cases, subconjunctival injections of penicillin or gentamicin are added.

(3) Other measures are heat (to prevent stasis and encourage repair) and protection by pad occasionally (but never in the presence of conjunctival discharge) or dark glasses.

If the above measures are not successful in halting the progress, the procedures to be followed are:

(a) Cauterization may be performed with pure carbolic acid, trichloroacetic acid or iodine. Iodine cauterization should be reserved for a dendritic keratitis. Because of caustic and antiseptic properties a carbolic cautery is preferred in a progressive ulcer. It is done in the following manner. After proper anaesthetization the lids are held apart and the ulcer is scraped. The cornea around the ulcer is covered with blotting paper. The pointed end of a dried matchstick is dipped into carbolic acid and dripped dry. The ulcer is then touched over its entire extent by the matchstick till it becomes white. The process needs to be repeated two or three times at an interval of one or two days if the ulcer still persists.

(b) If the ulcer further persists and perforation seems inevitable paracentesis is called for.

General measures:

(a) Liberal use of vitamin A, vitamin C and also vitamin B complex.

(b) Correction of obvious malnutrition and enhancement of general body-resistance are also necessary.

Miscellaneous. Other local measures called for on occasions include:

(a) Conjunctival flap—in noninfective superficial ulcer resistant to other available therapeutic measures.

(b) Tarsorrhaphy—in exposure and neurotrophic keratitis and in recurrent ulcers.

(c) Tissue adhesives may be used in sealing a small, 1 mm or less perforation followed by covering with a soft contact lens.

(d) Therapeutic penetrating keratoplasty helps in debridement and in providing structural support.

Hypopyon Corneal Ulcer³

Aetiology. The widespread ulcer is caused by pneumococcus, while the most severe type is due to *Pseudomonas pyocyanea*. Other infective agents include *Moraxella liquefaciens*, *Staphylococcus aureus*, viruses and fungi (Table 38.3).

Table 38.3

Morphologic and Aetiologic Classification of Corneal Ulcers

Central	Marginal
a. Bacterial:	a. Bacterial:
<i>Staphylococcus aureus</i>	<i>Staphylococcus aureus</i>
Pneumococcus	Koch-Weeks' bacillus
<i>Pseudomonas pyocyanea</i>	Morax-Axenfeld diplobacillus
Streptococcus	<i>Haemophilus influenzae</i>
<i>Myc. tuberculosis</i>	b. Viral—trachoma
<i>Moraxella liquefaciens</i>	c. Parasitic: <i>Acanthamoeba</i>
<i>Escherichia coli</i>	d. Allergic—phlyctenular
<i>Proteus vulgaris</i>	e. Systemic disturbances:
b. Viral:	Collagen diseases
Herpes simplex	Hookworm
Herpes zoster	Influenza
Variola	Bacillary dysentery
Influenza	Rosacea
Vaccinia	f. Mooren's ulcer
Trachoma	
<i>Molluscum contagiosum</i>	
c. Mycotic:	
<i>Candida albicans</i>	
<i>Nocardia asteroides</i>	
<i>Aspergillus fumigatus</i>	
<i>Fusarium</i>	
<i>Cephalosporium</i>	
<i>Penicillium</i>	

Clinical features (Fig. 38.2). The liberated toxin is virulent and it causes corneal necrosis and exudation from the vessels of the limbus and

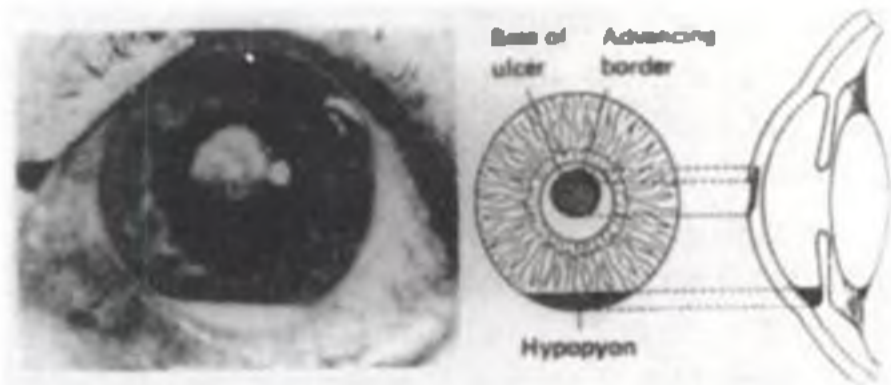


Fig. 38.2 Hypopyon corneal ulcer with severe inflammatory signs.

anterior uvea. Extensive migration of pus cells around the ulcer causes a greyish infiltration. Such migration into the anterior chamber occasionally along with erythrocytes, eosinophils and lymphocytes, causes *hypopyon*, i.e. pus in the anterior chamber (Fig. 38c.1). The development of hypopyon depends on the virulence of the organism and relative lack of tissue resistance. It remains sterile till Descemet's membrane is intact. Early hypopyon is small, and its upper margin is horizontal. Later it becomes semifluid owing to trapping of the cells by the fibrin meshwork, the level being higher up on the back of the cornea rather more in the proximity of the ulcer than on the anterior surface of the iris.

Posterior corneal ulcer

It occurs as a rare complication. The cells in hypopyon may macerate the endothelium and create a pathway facilitating the purulent process to involve the posterior layers of the cornea.

Pneumococcal ulcer

Syn. *Ulcus serpens*, typical hypopyon ulcer, acute serpiginous ulcer (Lat. *serpere*, to creep).

The characteristic changes are those of hypopyon ulcer. Pneumococci are seen in the necrosed area. The infiltration is minimum in the

middle layers and denser just opposite to Descemet's membrane. Posterior corneal abscess may develop due to massive infiltration between Descemet's membrane and the stroma or between layers of the posterior part of the stroma.

There is gross ulceration with infiltrated and oedematous floor and margins, increasing in depth and extent. It spreads irregularly having a tendency to extend in one direction at a time. Every now and then there is a change in the direction of the ulcer. This is due to migration of pneumococci in that particular direction. Hypopyon is typically present. There is concomitant iridocyclitis. Occasionally there may be posterior corneal abscess.

Pyocyaneal ulcer

An ulcer following infection with *Pseudomonas pyocyanea* is the most dreaded of all corneal infections, which leads to the loss of the eye if not adequately controlled. It primarily affects the corneal stroma. The ulcer invades rapidly, affects the deeper layers and causes a central necrosed area within 48 hours and a ring abscess around the corneal periphery. This is 2 to 3 mm internal to and concentric with the limbus. The pus is mucus in consistency and greenish in colour. Hypopyon is unusually large.

Staphylococcal ulcer

Staphylococcal ulcer occurs commonly in compromised cornea, e.g. dry eye, bullous keratopathy, chronic herpetic keratitis or rosacea keratitis. The ulcers tend to remain localized showing distinct borders with nonoedematous surrounding cornea. Occasionally they show multiple, stromal microinfiltrate satellites resembling mycotic lesions. Long-standing cases have a tendency to spread deeply to produce intrastromal abscesses.

Diplobacillary ulcer

Diplobacillary ulcer is due to *Moraxella liquefaciens*. It occurs after a minor injury. The ulcer has a tendency to penetrate deeply than

superficially and so perforation is rare. There may be a hypopyon.

Tuberculous ulcer

Tuberculosis of the cornea is almost secondary to conjunctivitis, scleritis or uveitis and very rarely primary. There are two types—ulcerative and infiltrative, the former being more common.

Marginal corneal ulcer

The incidence of marginal ulcers is more frequent than that of central ulcers. Because of anatomic continuity of the epithelium of the conjunctiva and the cornea, a marginal keratitis or ulcer may occur as a complication of conjunctivitis. Owing to the proximity of the limbal vessels the corneal periphery is prone to be affected by toxins or antigen-antibody reaction.

Catarrhal ulcer

Catarrhal corneal ulcer is a common complication of a chronic conjunctivitis in which at first there is infiltration and then there is ulceration at the periphery of the cornea. It is shallow and it heals rapidly. It tends to recur. Often there is superficial vascularization. It is commonly due to *Staph. aureus*. A staphylococcal infection produces blepharitis, chronic conjunctivitis and superficial punctate keratitis involving the lower part of the cornea. The ulcer is mostly sterile suggesting that it is toxic or allergic in nature.

Metastatic marginal ulcer

Metastatic marginal ulcer is characterized by marginal ulcer not associated with any conjunctivitis, occurring in old people and in patients having systemic diseases, such as influenza, bacillary dysentery and respiratory infections.

Superficial marginal keratitis

Superficial marginal keratitis is a bilateral affection occurring in old age and the aetiology is not known. It starts with marginal superficial infiltration at first

in one or more segments but eventually spreads all round. It makes slow progress. Recurrences and remissions are frequently seen. Ultimately it forms a ring ulcer.

Ring ulcer

Ring ulcers may develop either due to coalescence of multiple marginal ulcers or as a sequel to superficial marginal keratitis. They are commonly allergic and occasionally occur as a complication of collagen diseases.

Rosacea Keratitis

Rosacea keratitis is seen in acne rosacea occurring in women between third and fifth decades showing typical skin signs accompanied by keratitis in about 50 per cent cases. This keratitis may present as punctate epithelial erosions, peripheral corneal vascularization or thinning.

Infective superficial keratitis^{10,18}

Aetiology. Virus infection is the most common cause and three of them viz. herpes, zoster and adenovirus deserve special consideration. Other viruses, e.g. trachoma, measles and molluscum contagiosum also cause keratitis (Table 38.4).

While one virus may cause more than one type of lesion, it must be emphasized that the same clinical picture may be present in several viral infections.

Table 38.4

Causes of Viral Infections of the Cornea¹⁶

DNA viruses	Herpes simplex
	Herpes zoster
	Varicella
	Adenoviruses
	Molluscum contagiosum
RNA viruses	Enterovirus
	Measles
	Mumps
	Dengue
	Newcastle virus

Clinical features. In 1889 Fuchs for the first time described 'superficial punctate keratitis' (SPK) characterized by spots visible with the naked eye or a loupe. Renewed interest in the term SPK could be seen in Thygeson's description, which was later found to be an epidemic keratoconjunctivitis.

Today SPK is used as a morphological term embracing several varieties of keratitis essentially characterized by punctate dots.

Diffuse Superficial Keratitis

An acute diffuse superficial keratitis is usually secondary to bacterial infection, frequently *Staph. aureus*, and it shows fine epithelial opacities and erosions in the lower half of the cornea.

The lesions are the result of staphylococcal exotoxin. The affection occurs in association with an ulcerative blepharitis.

Chronic epithelial keratitis rarely occurs secondary to vernal conjunctivitis.

Punctate keratitis

Classification (Jones)¹⁰

1. Punctate epithelial erosions (PEE)
2. Punctate epithelial keratitis (PEK): (i) fine, (ii) coarse, (iii) areolar, (iv) stellate and (v) filamentary
3. Deep epithelial keratopathy (DEK)
4. Combined epithelial and subepithelial punctate keratopathy (CPK)
5. Punctate subepithelial keratitis (PSK)
6. Interstitial punctate keratitis (IPK)
7. Punctate opacification of Bowman's membrane (POB).

Punctate epithelial keratitis (PEK) differs from punctate epithelial erosions in that the spots are whitish and are seen without any staining. They are typically found in viral keratitis and staphylococcal and blepharoconjunctivitis.

Punctate epithelial erosions (PEE) appears as fine, depressed spots, staining brilliantly with fluorescein. They are due to disordered desquamation of superficial cells. The causes are varied and they include viral and bacterial

infections, chemicals, toxic causes such as molluscum contagiosum and trichiasis.

Deep epithelial keratopathy (DEK) involves the deeper layers without reaching the surface as occurring in rosacea.

Combined epithelial punctate keratopathy (CPK) is common in epidemic keratoconjunctivitis (EKC), pharyngoconjunctival fever and herpes.

Punctate subepithelial keratitis (PSK) occurs in viral keratitis such as EKC, zoster, herpes and bacterial keratitis such as leptotic.

Interstitial punctate keratitis (IPK) is rare and may occur in leprosy, zoster, herpes and rosacea.

Punctate opacification of Bowman's membrane (POB) may follow severe subepithelial keratitis.

The distributions of different types of superficial keratitis or keratopathy have been shown in Table 38.5.

Course of viral punctate keratitis. A punctate epithelial may develop into combined epithelial and subepithelial keratopathy. As healing of the epithelial component proceeds, punctate subepithelial keratitis tends to remain unchanged.

In others, after the healing of the epithelial keratitis, the subepithelial spots become swollen and they prevent the normal maturation of the overlying epithelium.

Treatment. Treatment is essentially symptomatic and includes atropine. Antibiotics are used to prevent secondary infection.

Herpes Simplex^{5,16}

Easty⁵ proposed the following classification.

Primary, which may be: (a) clinical disease—either type 1 or type 2; (b) subclinical disease; and (c) primary ocular disease—usually type 1, but type 2 in the newborn.

Primary infection usually occurs in children in whom there are no antibodies, and the characteristic manifestations include stomatitis and rarely severe follicular keratoconjunctivitis.

Subclinical infection is pretty common. Once infected, the person becomes a carrier, and immune bodies are present in 90 per cent of the population.

Table 38.5

Distribution of Different Types of Keratopathy^{1, 6}

<i>Lower third</i>
Staphylococcal blepharoconjunctivitis
Exposure keratitis
Entropion
Bacterial conjunctivitis
Drug toxicity
<i>Interpalpebral</i>
Neurotrophic keratitis
Keratitis sicca
Exposure keratitis
Photokeratopathy
<i>Upper third</i>
Trachoma
Inclusion conjunctivitis
Superior limbic keratoconjunctivitis
Vernal keratoconjunctivitis
Molluscum contagiosum
<i>Diffuse</i>
Early bacterial and viral infections
Toxic reaction to topical therapy
Vitamin A deficiency
<i>Random</i>
Trichiasis
Foreign body
Chemical injury
Herpes simplex keratitis

With a decline of body resistance, e.g. respiratory catarrh and systemic illness, there is occurrence of herpetic lesion.

Recurrent variety is due to conversion of the latent and noninfective virus into infectious form due to stress and fever, or due to persistence of the virus in some parts like the lacrimal gland, producing chronic infection.

Pathology. Herpes (Gk. *herpein*, to creep) virus typically produces intranuclear inclusion bodies. The cell ruptures with liberation of virus particles. In the cornea the changes include vacuolation and necrosis of the epithelium, disappearance of Bowman's membrane in places and infiltration and necrosis of the stroma.

The virus is readily grown on the chorioallantoic membrane or in tissue culture.

Clinical features. Recurrent herpetic infection involving the eye is characterized by entirely corneal changes. The affection is always unilateral. Though the corneal manifestations have been grouped under two categories—superficial and deep lesions, the former group is the more characteristic.

Table 38.6 gives a classification of HSV lesions in the anterior ocular segment.

Table 38.6

Classification of HSV Lesions in Anterior Ocular Segment¹⁶

Epithelial	
Infective:	dendritic keratitis
Noninfective:	keratitis metaherpetica (trophic keratitis)
Stromal	
Infective:	necrotizing keratitis
Noninfective	
Antigen-antibody complement-mediated	
	Interstitial keratitis
	Immune (Wessely) rings
	Limbal vasculitis
Lymphocyte-mediated	
	Disciform keratitis
	Endothelitis
	Iridocyclitis
	Trabeculitis

Dendritic keratitis (Fig. 38.3)

Dendritic keratitis (Gk. *dendri*, tree) is



Fig. 38.3 Diagrammatic representation of dendritic keratitis.

pathognomonic of herpes simplex corneae. There are linear, jagged ulcer with side branchings and bead-like nodes at the ends of branchings. Corneal sensibility is impaired. Fluorescein diffuses under the neighbouring epithelium. Double staining with fluorescein and methylene blue shows the actual ulcerated area as dark blue, while the neighbouring affected area shows a halo of green.

Complications and sequelae. These are as follows:

- (a) Disciform keratitis
- (b) Keratitis metaherpetica
- (c) Hypopyon
- (d) Bullous keratopathy
- (e) Herpetic iridocyclitis

Impaired corneal sensitivity even after primary healing of dendritic keratitis leads to a recurrence of an ulcer in which symptoms are less significant, ciliary congestion is minimum and there is diffusion of stain in the neighbouring area.

Keratitis metaherpetica (Syn. Metaherpetic or Trophic Keratitis)

Sometimes epithelial ulcers do not completely heal in spite of antiviral medication or they break down even after healing. So, they again appear as ovoid or dendritic. This is a sterile ulcer and follows defective basement membrane, impairment of sensibility and abnormal tear film stability. Healing of damaged basement membrane takes 12 to 15 weeks. Trophic ulcers have grey and thickened border made up of heaped up epithelium, while a dendritic keratitis have discrete and flat edges having tendency to change in configuration.

Antigen-antibody complement (AAC)-mediated keratitis

There are three affections under this heading: necrotizing interstitial keratitis (IK), immune rings and limbal vasculitis.

Necrotizing IK presents as single or multiple necrotic infiltrates and deep vascularization after a few weeks.

Immune (Wessely) rings are seen in the anterior stroma.

Limbal vasculitis is usually focal.

HSV disciform keratitis

HSV disciform keratitis is lymphocyte-mediated HSV stromal keratitis. This is a delayed hypersensitivity reaction to viral antigenic change of the surface membrane of the stromal cells and to the residual viral genome retained in the cornea. In benign form the lesion appears as focal, disc-shaped area of stromal oedema without any neovascularization. In moderately severe cases there are stromal oedema and folds in Descemet's membrane along with neovessels. In most severe type, the additional feature is necrosis.

HSV endothelitis and trabeculitis

Progressive endothelitis with or without iridocyclitis may be preceded by dendritic ulceration or secondary glaucoma a few weeks before the onset. The typical feature is the presence of a line of keratic precipitates marking oedematous and nonoedematous zones.

Treatment. In dendritic keratitis: Apart from the conventional treatment of keratitis by atropine and antibiotic, mechanical debridement of the affected region followed by cauterization with iodine is the effective remedy. In early cases before the viruses penetrate deep into the stroma, 0.5 per cent IDU or 3 per cent vidarabine ointment 5 times a day may also be advocated. The antiviral drugs may be used for 14 to 21 days.

One per cent trifluorothymidine (TFT) 1 to 2 hourly drops for two weeks can cure about 97 per cent of these cases, this agent is extremely potent and soluble having low incidence of viral resistance.

In *metaherpetic keratitis* treatment consists of antivirals, antibiotics, artificial tear, steroids, cycloplegics and soft contact lens.

In *stromal keratitis* treatment is by antivirals combined with steroids, antibiotics, cycloplegics with systemic steroids and acycloguanosine

(Acyclovir). But if the epithelium is ulcerated topical steroids should be reduced or withdrawn.

Herpes Zoster Ophthalmicus^{1,16}

Herpes zoster virus and varicella or chicken pox virus are believed to be identical. There are two theories regarding pathogenesis of zoster infection. There may be reactivation of the latent varicella-zoster virus left there during primary illness of chicken pox. Alternatively, there may be contact with exogenous virus.

The portal of entry is the skin via the sensory nerve to its chief focus, the Gasserian ganglion. From this ganglion the virus travels down any of the three divisions of the trigeminal nerve, the ophthalmic division is affected 20 times more than the other two.

Pathology. Herpes zoster produces an acute infection involving the first sensory neuron and the corresponding area of the skin. The main characteristics are:

- (a) inflammatory infiltration of the nerve cells, epidermis and dermis;
- (b) acidophil nuclear inclusion bodies in the cells of the vesicle—epithelium;
- (c) perivascular infiltration and
- (d) in a severe case, chromatolysis of the ganglion cells, fibrosis and secondary degeneration.

Clinical features (Fig. 38c.2). Herpes zoster is heralded by severe neuralgic pain and subsequently crops of vesicles limited to one half of the forehead make their appearance. Ocular complications occur in about 50% of all cases. Involvement of the eye is almost certain if the side of the tip of the nose presents herpetic vesicles, known as *Hutchinson's rule*. The whole cycle of affection lasts for about three to six weeks. When the skin vesicles rupture they form scabs. The latter separate and leave deep, permanent and pitted scars.

The corneal lesions include: (a) infiltration of the stroma; (b) epithelial vesicles; (c) disciform keratitis; (d) secondary infection of the vesicles; and (e) keratitis profunda.

Complications and sequelae. Complications and sequelae include iridocyclitis and hypotony in the early stage and later secondary glaucoma and scleritis as well as involvement of the III, IV, VI and VII cranial nerves. But at times there may be anaesthesia dolorosa and iris atrophy.

As iridocyclitis is a lymphocytic vasculitis there is often hypopyon or hyphaema.

In *anaesthesia dolorosa* there is a marked loss of skin sensation with severe and persistent neuralgia. This process is very obdurate and usually lasts for several months.

Treatment. The following therapeutic measures are recommended:

(a) acyclovir, 200 mg tablets, 4 tablets 5 times daily for 10 days; (b) topical antibiotics; (c) cycloplegics; (d) narcotic or non-narcotic analgesics usually on days 1 through 7 to 10 days; (e) artificial tears; (f) topical steroids in the presence of scleritis, stromal keratitis and iritis; and (g) treatment of posttherapeutic neuralgia by tricyclic antidepressants like cimetidine and capsaicin cream to periocular skin. Virus is said to be susceptible to 5-(2-bromovinyl)-2'-deoxyuridine (BVDU) orally.

Table 38.7 shows differences between herpes simplex and herpes zoster.

Table 38.7

Showing Differences between Herpes Simplex and Zoster Infections

Herpes simplex	Herpes zoster
Common in children	Mostly in adults
Follows illness which lowers the body-resistance	Arises independently usually from any preceding disease
No preceding neuralgia	Always preceding neuralgia
May follow the distribution of affected nerves, but not invariably	Always follows the distribution of affected nerves
Duration is short-lasting, a few days	Duration is about 3 to 4 months
No permanent scarring in the skin	Permanent scarring
Tendency for recurrence	One attack usually confers immunity

Adenoviral Keratitis^{1,16,23}

In EKC the incidence of keratitis is about 80 per cent and in PCF this is about 20 per cent. There are three stages:

- First stage of diffuse punctate epithelial keratitis
- Second stage of focal subepithelial opacities
- Third stage of anterior stromal infiltration.

Treatment is palliative comprising of mild topical steroids and antibiotics.

Molluscum Contagiosum

Molluscum contagiosum affects usually the lid margins. Other lesions include chronic follicular conjunctivitis, micropannus and fine epithelial keratitis. Treatment is by excision of skin nodules.

Thygeson's Superficial Punctate Keratitis

Thygeson's superficial punctate keratitis (SPK) is a bilateral affection, occurring more often in second and third decades, without a known cause but possibly viral. There is SPK without conjunctival or corneal stromal inflammation. The SPK affects more commonly the central part. It is evidenced by group of coarse, oval, slightly raised white or grey dots, a few to 50 in number, staining with fluorescein. Corneal sensation is normal or slightly impaired.

Individual attacks usually last for 4 to 8 weeks, go on remissions for 4 to 6 weeks and then recur. The affection may resolve after 2 to 4 years.

The symptomatic relief is possible by topical steroid therapy, usually low—concentration steroids twice or thrice daily for a few days to 2 weeks.

Theodore's Superior Limbic Keratoconjunctivitis

The cause is not precisely known. Possibly increased pressure of the upper lid over the upper bulbar conjunctiva as seen in thyroid disease is the responsible factor. The affection is a chronic,

recurrent keratoconjunctivitis. There is papillary hypertrophy and hyperaemia of the superior bulbar conjunctiva and superior limbus. In about 33 per cent cases there are filaments in the area of the superior limbus.

Diagnosis of the condition is difficult, and a high index of suspicion is essential to diagnose a case.

Treatment. They are treated with 0.5 to 1 per cent silver nitrate solution moistened applicators; if they fail, thermocauterization of the superior bulbar conjunctiva may be tried; if both of them fail, recession or resection of the superior bulbar conjunctiva may be recommended.

Exposure Keratitis (Keratitis Lagophthalmo)^{3,23}

An exposure keratitis is the result of desiccation which may occur in conditions where there is inadequate lid closure, e.g. lack of normal Bell's phenomenon, gross proptosis, facial palsy, coma and ectropion. If the lids are not properly closed the lower portion of the cornea becomes exposed to desiccation. It is more common in warm countries as rapid evaporation is the aggravating factor. It is further aggravated if there is corneal hypoaesthesia as in tuberculoid leprosy.

Clinical features. The affection starts deceptively.

Initially there are diffuse corneal haziness and desiccation of the exposed epithelium in the lower part of the cornea along with evidence of fine punctate epithelial keratitis. Then fissures and exfoliation of the epithelium make their appearance. Subsequently corneal stroma becomes hazy. Finally in absence of a superadded infection there is keratinization. But in presence of a secondary infection there is a torpid and infiltrative ulcer. Superficial corneal vascularization commonly occurs.

Treatment. In early state it is effective. Temporary measures include lubrication of the cornea, bandaging and a soft contact lens usually with a tarsorrhaphy.

For protecting the cornea either a lateral

tarsorrhaphy or a circumambulatory suture drawn taut under the skin around the palpebral fissure is needed.

In facial palsy—a temporalis-sling operation is called for.

Neurotrophic Keratitis³

Magendie was the first in 1824 to show that degenerative changes could occur in the cornea following denervation of the trigeminal nerve as in treatment of *tic douloureux*. Two important conditions are included under neurotrophic keratitis—diffuse vesicular keratitis or essential corneal oedema (see p. 236) and neuroparalytic keratitis.

Neuroparalytic Keratitis

Aetiology. The affection follows a lesion of the trigeminal nerve, semilunar ganglion or supraganglionic tracts, e.g. tumours, tuberculoma, basal meningitis, and injury.

Trophic disturbance such as loss of sensation (Table 38.8) in the ophthalmic division of the trigeminal nerve leads to unregulated accumulation

Table 38.8

Causes of Impairment of Corneal Sensibility

Neuroparalytic keratitis
Leprotic interstitial keratitis
Herpetic keratitis
Absolute glaucoma
Postkeratoplasty
Contact lens-wear
Atropine
Topical beta-blocker
Diabetes mellitus
Ageing

of metabolites causing tissue oedema and eventually leads to degeneration, desiccation and exfoliation of the corneal epithelium. Trauma and infection subsequently aggravate the condition.

Clinical features. Neuroparalytic keratitis presents

a clinical picture representing the extreme degree of neurotrophic disturbance. Degenerative changes in the cornea follow a trigeminal lesion—80 per cent within the first six months, 20 per cent within one week and sometime in acute cases within 1 to 2 days.

At first conjunctival congestion appears, lasts for 8 to 10 days and then disappears.

A coincident iritis may occur sometimes before and sometime after the corneal changes.

The cornea at first shows haziness with multiple punctate dots, followed by vesiculation. More often the vesiculation is followed by rapid and massive exfoliation of the epithelium, starting in the centre and spreading to involve the rest of the cornea except the peripheral rim. The denuded surface is dry, milky and hazy.

Secondary infection then supervenes leading to gross corneal ulcer with hypopyon.

Sometimes it does not progress much and resolves into a state resembling a diffuse vesicular keratitis.

The course is exceedingly slow, the ulcers showing little tendency to heal with conventional treatment.

Treatment. Apart from usual measures, tarsorrhaphy (minimum for 6 months and average 12 months) is the most important mode of treatment.

Nutritional Ulcers

Nutritional ulcers include keratomalacia and atheromatous ulcer.

Atheromatous ulcer occurs in old leucomata. Sequences are formation of hyaline and calcareous deposits. These act as foreign bodies which readily succumb to infection leading to ulceration which penetrates rapidly and deeply.

Keratitis Sicca (Keratoconjunctivitis Sicca)^{3,23}

Keratitis sicca constitutes one classical feature of Sjögren's syndrome. Keratitis develops insidiously and does not produce any symptom for a long

time. When the symptoms are present they are of a dry eye syndrome. The symptoms are relatively mild in the morning and become worse as the day progresses. Examination reveals diffuse conjunctival congestion, filamentary keratitis and stringy mucoid discharge. Microscopy reveals keratinization of the epithelium and lack of presence of leucocytes. It needs examination of conjunctival scrapings.

Treatment for the dry eye is discussed on pp. 183–84.

Interstitial Keratitis (IK)

Aetiology. About 90 per cent of the variety is syphilitic diffuse IK. Other causes include tuberculosis, leprosy, viral infections, sarcoidosis, Hodgkin's disease and filariasis.

Mostly bilateral which occurs in the age group of 5 to 15 years, the frequent cause is a violent corneal allergy which manifests itself later in life following an earlier treponemal infection and sensitization in the case of congenital syphilis. There is an interval of three or more weeks usually before the occurrence in the second eye.

Pathology. Basically it is keratouveitis. The characteristics include:

(a) Oedema involving: (i) the epithelium—this is seen as 'bedewing' by slit-lamp biomicroscope; (ii) the stroma; and (iii) the endothelium.

(b) Cellular infiltration especially in between the corneal lamellae just anterior to Descemet's membrane and chiefly around capillary vascularization.

(c) Vascularization: (i) chiefly deep, and in it radial, non-anastomosing vessels are present; and (ii) occasionally superficial which causes the limbal conjunctiva to be heaped up (*epaulet*).

(d) Bowman's membrane is wavy and irregular.

(e) Descemet's membrane is wrinkled.

Clinical features. Three stages are: (a) progressive stage lasting for 2 to 3 weeks; (b) florid stage for 2 to 3 months; and (c) regressive stage for 2 years or more.

After some irritative symptoms, ciliary congestion with hazy patches in the deeper layers

of the cornea make their appearance. These patches may be central or peripheral to start with, but by 2 to 4 weeks they spread out to involve the whole cornea (Fig. 38c.3).

Deep vascularization causes the colour of the vessels to appear dull reddish-pink (*salmon patches*). As soon as florid stage is reached, corneal oedema starts disappearing slowly from the periphery towards the centre of the cornea.

In its peak, the affection causes the visual acuity to deteriorate even to appreciation of hand movements.

Radial vessels finally remain as fine opaque lines throughout life as a stigma of the disease.

Diagnosis is based on: (a) clinical features; (b) general manifestations of congenital syphilis; and (c) positive serological reaction.

Treatment. Treatment of uveitis by atropine and steroid should be continued for at least one year after the ciliary congestion disappears.

Intensive penicillin therapy to shorten the aggravation of the disease is advised intramuscularly, a dose of one million unit a day for 10 days.

Table 38.9 shows distinguishing features of syphilitic and tuberculous IK.

Table 38.9

Showing Differentiation between Syphilitic and Tuberculous IK

Syphilitic	Tuberculous
Bilateral	Unilateral
Rapid onset	Slow onset
Whole cornea is involved	Involvement of the lower two-third of the cornea
Characteristic vascularization—deep	Irregular, superficial blood vessels, running in different directions
Eventual visual loss—less	Higher
Opacity—mostly central and deep	Opacity—superficial and widespread
Positive serological reaction to syphilis	Positive skin reaction to tuberculosis

Disciform Keratitis

Disciform keratitis is common in adults and unilateral. It may be herpetic or nonherpetic. It is caused either due to penetration of the viral antigen causing a delayed hypersensitivity or to the abuse of steroids in treating herpetic keratitis. The pathological changes are the same as in syphilitic interstitial keratitis, but in herpetic cases early destruction of the infected epithelium occurs.

Clinical features. The clinical features are the appearance of a central disc-shaped stromal oedema, absence of ulceration and vascularization, gross visual impairment and sometimes anaesthesia. In worst cases folds in Descemet's membrane and vessels in the cornea are present. Treatment consists of cycloplegics and sometimes tarsorrhaphy when there is corneal anaesthesia. In severe cases steroids are used along with antiviral drugs.

Mycotic Corneal Ulcer^{7,8,12}

The first case of fungal infection of the cornea was reported in 1879 by Leber due to aspergillosis. The incidence is sporadic, but in developed countries there is an increase in incidence with the advent and abuse of antibiotics and steroids. In India it appears to be an important ophthalmic problem.

More than 40 genera are said to be associated and of them only a few are human pathogens.

Aetiology. The common fungi include among others *Aspergillus fumigatus*, *Candida albicans* and *Nocardia asteroides*. The infection may follow an injury to the cornea by a foreign body often of a vegetable nature. It may also develop after a herpetic lesion.

Pathology. There are widespread necrosis, permeation with closely packed mycelium and leucocytic infiltration around the ulcer. Perhaps the enzymes—phospholipase, protease and pseudo-collagenase liberated by the fungus cause conglutative necrosis with loss of keratocytes and disruption of collagen lamellae. There is a complete and sharp line of demarcation around the ulcer and hypopyon.

Clinical features (Fig. 38.4). Subjective symptoms are minimal.




Fig. 38.4 Mycotic corneal ulcer.

Mycotic ulcer presents a typical picture. Following an epithelial injury there is appearance of a superficial ulcer, grey in colour with the surface dull and dry. Hypopyon is present which is at times massive.

The course is slow and torpid. The central part gradually acquires a laminated appearance with a crumbling surface. Spreading radial lines from the demarcation ring are noticed. After some weeks the line of demarcation is deepened into a furrow and there is sloughing of the infiltrated area.

Healing sets in after the sloughing of the sequestrum. Perforation is rare and vascularization is absent. Recurrences are noticed, the subsequent course being severe with a tendency for perforation.

Diagnosis. Diagnosis is dependent on suspicion, clinical picture and finally confirmation.

The possibility of one making a wrong diagnosis is present because of its rarity. Suspicion arises when there is a persistent torpidity of corneal ulcer in spite of routine treatment.

The clinical picture is characteristic and persistence of hypopyon in a relatively non-progressive corneal ulcer is also a clue. The diagnosis can be confirmed by histological examination of the central slough.

Treatment. Natamycin (pimaricin) suspension appears to be effective against superficial infections.

Noninfectious Corneal Ulcers¹¹

The causes are listed in Table 38.10.

Table 38.10

Causes of Noninfectious Corneal Ulcers

Local

Not immune-mediated

- Traumatic
- Postinfectious
- Postoperative
- Eyelash or eyelid abnormality
- Neurotrophic or neuroparalytic

Immune-mediated

- Mooren's ulcer
- Vernal keratoconjunctivitis
- Staphylococcal ulcer
- Suture irritation

Systemic

Not immune-mediated

- Keratomalacia

Immune-mediated

- Sjögren's syndrome
- Collagen vascular disease
- Atopic keratoconjunctivitis

Treatment. Treatment depends upon detection of precise aetiology. Various treatment modalities include: (a) debridement; (b) lubricant; (c) systemic and local vitamin C; (d) topical vitamin A; (e) extremely cautious instillation of steroid drops for 10 to 14 days after chemical injury; (f) therapeutic contact lens, (g) tissue adhesives in impending or less than 1 mm perforation of sterile ulcer; and (h) surgical procedures depending upon the cause; these include occlusion of the puncta, tarsorrhaphy, conjunctival resection, conjunctival flap and keratoplasty.

Corneal Degenerations

Corneal degenerations are classified as follows (Table 38.11).

Table 38.11
Classification of Corneal Degenerations¹⁷

Central:	
<i>Caused by ageing:</i>	
Cornea farinata	
Mosaic shagreen (Vogt)	
<i>Not caused by ageing:</i>	
Band-shaped keratopathy or calcific degeneration	
Salzmann's nodular degeneration	
Coats' white ring	
Hyaline degeneration	
Lipoid degeneration	
Amyloid degeneration	
Pigmentary degenerations—melanin and metal	
Peripheral:	
<i>Caused by ageing:</i>	
Arcus senilis	
Dellen	
Hassall-Henle bodies	
White limbal girdle (Vogt)	
Terrien's marginal degeneration	
Pellucid marginal degeneration	
Mooren's ulcer	
<i>Not caused by ageing:</i>	
Climatic keratopathy	
Peripheral pigmentary degenerations	

Cornea farinata

Under greater magnification fine dust-like opacities of the posterior part of the stroma are seen. The affection is asymptomatic.

Mosaic (crocodile) shagreen

The central part of Bowman's membrane in both eyes shows grey dots.

Band-shaped keratopathy

Band-shaped keratopathy is not an uncommon condition. The causes are multiple. Usually it is secondary to uveitis, either a long-standing case or chronic iritis associated with infantile polyarthritis (Still's disease); occasionally in hypercalcaemia and still rarely primary. Pathologic changes are granular deposition on the outer side of Bowman's

membrane, followed by degeneration of the epithelium and superficial parts of the stroma and finally there are fibrosis and hyaline degeneration. It starts as two grey bands, one at the medial and another at the lateral side near the limbus. This is always separated from the limbus by a clear zone because of better nutrition close to the limbal vessels. The bands spread during the next few years and finally meet together at the centre of the cornea as a continuous band in the interpalpebral area. Evaporation of water from this area leads to deposition of calcium. Treatment consists of dissolving the calcareous material by 0.05 ml, 15 per cent solution of neutral disodium ethylene diamine tetra acetate (EDTA) and removal by scraping, apart from cycloplegics, antibiotics and patching the eye.

Salzmann's nodular degeneration

Salzmann's nodular degeneration affects mainly females and is sometimes bilateral. It appears as sequel to phlyctenulosis, trachoma and vernal conjunctivitis. There are multiple bluish grey nodules either on the clear cornea or in the scarred area. Histopathological changes are degeneration and disintegration of the epithelium and Bowman's membrane, fibrillation of the lamellae and hyaline deposits. It may be treated by lamellar keratoplasty.

Coats' white ring

Coats' white ring usually follows an injury by metallic foreign body. There is deposition of iron in the superficial stroma or Bowman's membrane.

Pigmentary degenerations

Pigmentary degenerations may follow deposition of iron or other metal and melanin.

Hyaline degeneration

Hyaline degeneration is either secondary which is most often unilateral or primary which is usually bilateral. Secondary type may occur in conditions

like trachomatous pannus and old leucomata. The primary form is seen in granular, macular and lattice forms of dystrophy. Treatment, if needed, is by lamellar keratoplasty.

Lipoid degeneration

Lipoid degeneration is characterized by the appearance of fat in a vascularized area. It is disc-shaped if the vascularized area is localized, but is fan-shaped in the presence of widespread vascularization.

Amyloid degeneration

Primary localized corneal amyloidosis is usually secondary to conjunctival amyloidosis; secondary lesion may follow trachoma. There are three varieties of deposits: subepithelial, deep lamellar and perivascular. It may appear salmon pink to yellow white nodular mass.

Arcus senilis (Gerontoxon, Anterior embryotoxon)

This bilateral lipid infiltration appearing as annular grey line separated from the corneal margin by a relatively clear zone (lucid interval of Vogt) does not cause any visual defect, and is not associated with any serum lipid abnormality.

Hassall-Henle bodies (Descemet's warts)

Hassall-Henle bodies are hyaline excrescences all round the corneal periphery and projecting into the anterior chamber (AC).

Dellen (Fuchs' dimple or facet)

Dellen are small saucer-like depressions near the corneal margin occurring in old age and in perilimbal swellings such as pinguecula and pterygium.

White limbal girdle of Vogt

White limbal girdle of Vogt occurs usually after 40 years. It is characterized by symmetrical, half-

moon like girdle concentric with the limbus, situated in the interpalpebral area. Histopathologically, there is destruction of Bowman's membrane along with areas of hyaline and elastotic degeneration, calcium deposition also occurs.

Terrien's marginal degeneration

This rare condition occurs chiefly in males and at any age. It is usually bilateral. Degeneration starts at the upper and inner part evidenced by fine white epithelial and subepithelial opacities. These coalesce and cause thinning and vascularization of the corneal margin but always sparing the limbus. Histopathologically, Bowman's membrane and the stroma show fibrillation. Treatment consists of using a hand-fashioned lamellar graft.

Pellucid marginal degeneration

Degeneration starts near the inferior limbus but sparing the limbus. Possibly it follows depolymerization of corneal mucopolysaccharides. The age of presentation is between 20 to 40 years. It produces astigmatism against the rule.

Mooren's ulcer (Chronic Serpiginous Ulcer, Rodent Ulcer)

Aetiology. Degeneration of the cornea has been considered to be a significant factor. Evidences today are in favour of immune process and type 2 allergy or cytotoxic response is thought to be responsible.

Pathology. Polymorphonuclear leucocytes are attracted to the site of immune complex deposition, protease and collagenase liberated from PMNs induce corneal destruction. There is infiltration of the stroma with plasma cells having a property of producing immunoglobulins.

Clinical features (Fig. 38.5). Clinical features are classified under two types, typical and atypical. In typical there is a superficial ulcer, which starts at

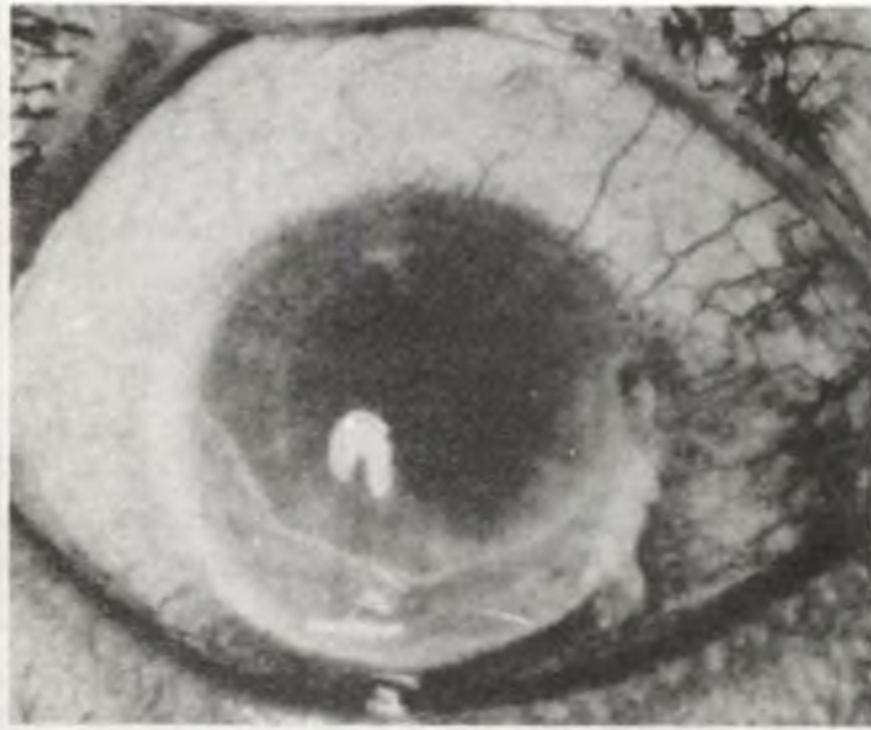


Fig. 38.5 Mooren's ulcer (Parsons).

the limbus, and spreads to involve the centre of the cornea. It starts with one or more grey infiltrates which breakdown, form small ulcers, coalesce and then undermine the epithelium and superficial layers of the stroma. Base of the ulcer is vascularized while the advancing edge is overhanging. It has very little tendency for perforation. The affection is chronic with a slow and relentless course.

Differential diagnosis is shown in Table 38.12.

Table 38.12

Differential Diagnosis of Mooren's Ulcer

Furrow degeneration
Terrien's degeneration
Pellucid degeneration
Peripheral corneal melting
Rheumatoid arthritis
Systemic lupus erythematosus (SLE)
Polyarteritis nodosa
Wegner's granulomatosis

Wood and Kaufman²⁴ described an atypical form. The features are listed in Table 38.13.

Treatment. Treatment is guarded.

The measures include:

- (a) Excision of the overhanging edge and cauterization of the ulcer
- (b) Covering with conjunctival flap

Table 38.13

Comparison of Clinical Features of two Types of Mooren's Ulcer

Features	Typical	Atypical
Age	Elderly	Young
Preceding history	—	Trauma
Pain	Moderate to severe	Variable
Bilaterality	25%	75%
Course	Slow progressive	May be rapid
Tendency for perforation	Uncommon	In one-third cases

(c) Diathermy application

(d) Cryoapplication

(e) Delimiting keratoplasty

(f) Conjunctival excision followed by use of soft contact lens

(g) Topical collagen inhibitor

(h) Subconjunctival heparin.

Climatic keratopathy

Climatic keratopathy is believed to result from the short ultraviolet rays from the sun. People living near the seashore are liable to be more affected. Proper diagnosis in the early stage is difficult. It first appears as opalescent droplets which takes a few years to form into a yellowish grey band beneath the epithelium. As there are progressively larger droplet aggregations the epithelium is elevated.

Corneal dystrophies^{17,22,23}

Table 38.14 shows the classification.

Recurrent corneal erosions

Recurrent corneal erosions may follow finger-nail injury of the cornea and may lead to dystrophy. This injury may act as a trigger in causing erosion. Usually the patient complains of pain, lacrimation, foreign body sensation and photophobia. Fluorescein staining indicates an epithelial defect. It heals within 24 to 36 hours. After a few weeks

Table 38.14

Classification of Corneal Dystrophies

Epithelial

- Recurrent corneal erosions
- Juvenile epithelial dystrophy (Meesman)
- Microcystic epithelial dystrophy (Cogan), also called finger print map-dot dystrophy or epithelial basement membrane dystrophy
- Bleb-like dystrophy
- Vortex dystrophy.
- Bowman's membrane dystrophy:
 - Ring-like dystrophy (Reis and Bücklers)
 - Superficial reticular dystrophy (Koby)
 - Anterior membrane dystrophy (Grayson and Wilbrandt), a variant of ring-like dystrophy

Stromal

- Granular dystrophy of Groenouw type I
- Lattice dystrophy
- Macular dystrophy or Groenouw type II
- Crystalline dystrophy (Schnyder)
- Central speckled (François and Neetens) or fleck dystrophy
- Marginal crystalline dystrophy (Bietti)
- Central cloudy dystrophy (François)
- Polymorphic amorphous dystrophy
- Polymorphic stromal dystrophy (Schlichting)
- Congenital hereditary stromal dystrophy

Endothelial

- Fuchs' epithelial-endothelial dystrophy
- Cornea guttata
- Congenital hereditary endothelial dystrophy (CHED)
- Posterior polymorphous dystrophy
- Ectatic dystrophies:
 - Keratoconus or conical cornea
 - Posterior keratoconus
 - Keratoglobus

or months, the lesions may reappear at the previous site or nearby.

Histopathologically, the epithelial cells become necrotic and oedematous and subsequently epitheliolysis occurs.

Each time treatment remains the same and it consists of antibiotics, homatropine and bandaging for 24 hours. Sometimes cauterization with chemical agent like alcoholic solution of iodine is advocated. In extreme cases even a lamellar keratoplasty may have to be resorted to.

Juvenile epithelial dystrophy

Juvenile epithelial dystrophy is a dominant hereditary condition. Dystrophy begins in infancy and increases with age. It is characterized by the presence of microvesicles in the epithelium and due to the degeneration of the epithelial cells and deposition of cell debris. If visual acuity has markedly deteriorated a lamellar keratoplasty may be considered. In milder cases soft lens may be given.

Epithelial basement membrane dystrophy

Hereditary tendency is not a predominant factor in such cases. Visual acuity is not disturbed and corneal sensation is normal. Because of its appearance it is also called fingerprint map-dot dystrophy.

Bleb-like dystrophy

Bleb-like dystrophy appears to be a variant of epithelial dystrophy.

Vortex dystrophy

This shows greyish epithelial deposits in a vortex fashion, may follow intake of chloroquine, indomethacin and chlorpromazine.

Ring-like dystrophy (Reis and Bücklers)

Ring-like dystrophy is characterized by the presence of irregular dense grey opacities arranged like a fishnet. These lie at the level of Bowman's membrane. Histopathologically, there is extreme degeneration of Bowman's membrane and its replacement by fibrous tissue.

Anterior membrane dystrophy

Anterior membrane dystrophy is a variant of ring-like dystrophy.

Granular, macular and lattice dystrophy

Granular, macular and lattice dystrophies form a distinct group known as hereditary corneal

dystrophies. The chief characteristics of the hereditary corneal dystrophies are as follows:

- (a) they are bilateral and symmetrical
- (b) they occur mainly in males and begin to appear in puberty
- (c) they have a preference for the central area
- (d) they are relatively asymptomatic
- (e) all of them show discrete areas of opacities in the superficial part of the stroma
- (f) there is no corneal vascularization
- (g) visual acuity generally deteriorates after the age of 40.

The clinical features of these three types have been shown in Table 38.15.

Lattice dystrophy

Lattice dystrophy is also an autosomal dominant dystrophy. There is deposition of amyloid material. Bowman's membrane may be present or absent and the basement membrane may be fragmented. The superficial stroma contains chiefly the amyloid.

Central crystalline dystrophy

Round or needle-shaped crystals appear early in the central part of the superficial stroma, reaching 80 per cent within 30 to 40 years of age. It is often associated with xanthelasma. The deposits in stroma and Bowman's membrane are fats. Treatment in a progressive case is penetrating keratoplasty.

Table 38.15
Essential Parenchymatous Corneal Dystrophy—Classical Varieties^{1a}

Features	Granular	Macular	Lattice
Transmission	Dominant	Recessive	Dominant
Age of onset	About 5 years	First decade	Usually second decade
Earliest signs	Small white dots in the cornea, some superficial and some fairly deep, may take the form of radiating lines from the centre	A thin superficial veil	A cobweb of delicate lines and when crossing each other produce lattice-like pattern
Course	Increase in size and number, lose radiating pattern and develop pattern figures of irregular shape and size	Increase in size	Increase in number and thickness
End-stage	Visible dots by about 40 years of age	Extensive opacity	Lattice pattern disappears and diffuse opacity appears

Treatment in an advanced case is penetrating keratoplasty.

Granular dystrophy

Granular dystrophy is an autosomal dominant dystrophy. Microscopically, there are small discrete hyaline excrescences of the axial part of the superficial stroma.

Macular dystrophy

The hereditary trait is autosomal recessive. The opacities are the result of storage of glycosaminoglycan in the keratocytes and between the corneal fibrils.

Fuchs' endothelial dystrophy

Fuchs' endothelial dystrophy is the most common type of endothelial dystrophies. The affection occurs in elderly people and is eventually always bilateral. There are four stages:³

- (a) The stage of cornea guttata
- (b) Endothelial and stromal oedema
- (c) Subepithelial connective tissue formation with vascularization
- (d) Stage of complication—infection or secondary glaucoma.

It is a primary dystrophy involving the endothelial surface of both cornea. In early cases slit-lamp examination shows the presence of golden

coloured bodies in the mosaic of endothelial cells. Treatment is difficult. Corneal grafting may be tried.

Keratoconus or Ectatic Corneal Dystrophy or Conical Cornea^{3,22}

Aetiology. Aetiology was once thought to be a degenerative process. It is now classified under dystrophy.

Pathology. The characteristics are:

- (a) fragmentation of the basal membrane
- (b) fibrillar degeneration of Bowman's membrane and stromal lamellae
- (c) folds in Descemet's membrane
- (d) from electron microscope study, Teng¹⁹ concluded that primary changes were degenerative in the basal cell layer of the epithelium.

Clinical features (Fig 38.6). Two types are encountered—anterior and posterior, the latter being very rare. The anterior is invariably bilateral and is common in females after puberty. Symptoms include photophobia, distortion of objects and visual deterioration.

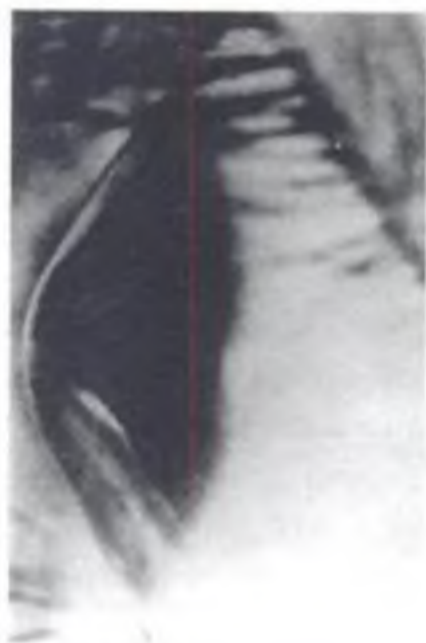

Fig. 38.6 Keratoconus.

There is unusual lustre of the central part of the cornea appearing as a drop of water on a glass surface. Sometimes this appearance may be missed, so an examination from the sides should also be done. Recognition of the cone is done by noting the angular curve of the lid margin due to unusual corneal curvature while the patient looks down

(*Munson's sign*). Translucency of the ecstatic site may be present.

Slit-lamp examination shows characteristic signs of:

- (a) thinning of the apex
- (b) ruptures in Bowman's membrane
- (c) vertical lines resulting from stretching in the deeper layers
- (d) increased visibility of the nerve fibres
- (e) ruptures in Descemet's membrane
- (f) appearance of the concavity of the cone
- (g) Fleischer's ring which is the haemosiderin ring round the base of the cone.

Placido's disc or keratoscope shows peculiar distortion of the rings. Keratometer indicates lack of parallelism of the images of the mires. Retinoscopy reveals myopic astigmatism. Ophthalmoscopy shows the appearance of an annular dark shadow.

In posterior keratoconus there is a dome-shaped posterior excavation of the cornea which is congenital, bilateral and stationary.

The conditions associated with keratoconus are listed in Table 38.16.

Table 38.16

Conditions Associated with Keratoconus¹

Pigmentary dystrophy of retina
Ectopia lentis
Aniridia
Developmental cataract
Retrolental fibroplasia
Blue sclera
Vernal keratoconjunctivitis
Marfan's syndrome
Down's syndrome
Ehlers-Danlos syndrome

Complications and sequelae. Most cases show a slow and gradual deterioration lasting 5 to 6 years followed by its arrest. Some cases at first remain stationary and soon after worsen. An abortive form has also been described.

Acute keratoconus is the rupture in Descemet's membrane followed by acute stromal oedema.

Treatment. Optical treatment consists of provision

of correction for myopic astigmatism by glasses and preferably contact lenses.

Keratoplasty is particularly successful and is indicated in a progressive case showing visual loss.

Keratoglobus

Keratoglobus is a developmental, bilateral, hemispherical protrusion of the whole cornea and is a hereditary trait.

Corneal vascularization^{3.20}

Corneal vascularization affects the superficial and the deeper layers of the cornea. The superficial layers are the anterior third and the deeper the interior two-third. Its advantages are enhanced metabolism, increased facility of transport of antibodies and drugs, and help in resolving inflammatory lesions. Its disadvantages are decreased visual acuity, increased opacification and vascularization of a graft.

The presence of a blood vessel in the cornea is always pathological.

Aetiology. Loss of compactness of the cornea may lead to vascularization.

Vasoformative factor is probably lactic acid. This has been emphasized by Imre⁹ because of the following reasons:

- (a) High concentration of lactic acid in the cornea
- (b) Experimental evidence of low lactic acid content in the avascular corneal oedema
- (c) Injection of lactic acid into a vascular tissue causing vascularization is done experimentally and experimental demonstration of moderate and minimal vascularization following intracorneal injections of l-lactate and k-lactate respectively.

The distinguishing features of two types of vascularization are indicated in Table 38.17, while the causes of superficial vascularisation with cellular infiltration (pannus) are listed in Table 38.18.

Structural barrier. The compact structure of the cornea prevents invasion by the blood vessels.

Hypoxia. It is a stimulus for corneal vascularisation.

Inflammation. Leucocytes liberate substances which induce vascular ingrowth.

In superficial vascularization the collateral channels contract to bypass the blood in the necessary direction and when there is no activity those vessels become obliterated.

Table 38.17

Distinguishing Features of Two Types of Corneal Vascularization.

Points	Superficial	Deep
Colour	Brick red	Purple
Distribution	Well-defined	Ill-defined and diffuse
Branching and course	Free arborization	Non-anastomosing and radial
Continuity with conjunctival vessels	Uninterrupted astride the limbus	Comes to an abrupt end at the limbus
Causes	Include phlyctenulosis, trachoma, leprosy, ariboflavinosis superficial ulcer	Include interstitial keratitis, disciform keratitis, sclerosing keratitis, deep corneal ulcer

It has been shown that oedema of the limbal cornea is a necessary factor for deep vascularization.

Vasoinhibitory factor. This is the presence of sulphate ester of hyaluronic acid in the cornea. Experiment has shown that depolymerization of this substance by hyaluronidase can abolish this inhibitory action. It prevents vascularization.

Superficial:

- (a) Pannus
 - (b) Fascicular—as in phlyctenular keratoconjunctivitis
 - (c) Epaulet—as a rare feature of IK
- Deep—chiefly may be
- (a) Arborescent
 - (b) Short loop

Table 38.18
Causes of Pannus

<i>Gross pannus</i> (vessels extending 2 mm or more beyond normal arcade)
Trachoma
Phlyctenular keratoconjunctivitis
Leprotic keratitis
Absolute glaucoma
Contact lens-wear
Trauma
<i>Micropannus</i> (vessels extending 1 to 2 mm beyond normal arcade)
Vernal keratoconjunctivitis
Staphylococcal blepharitis
Contact lens-wear
Superior limbic keratoconjunctivitis

(c) Brush

(d) Umbel (break-up of a large vessel with accompanying vein invading the cornea into star-shaped vessels).

Treatment. Ineffective measures are:

Steroids. Steroid acts as an anti-inflammatory agent in the active stage.

Radiation. The effect is due to endarteritis obliterans. Radiation is used at the early stage, for superficial vessels only. It is contraindicated in advanced stage, when radiation stimulates further neovascularization.

Surgical methods include:

(a) Thermocautery

(b) Cryoapplication when the neovessels are fairly localized

(c) Peritomy. Peritomy is the excision of about 5 mm rim of conjunctiva all round the limbus.

(d) In 1955 Leigh proposed the following procedures:

Application of a central lamellar graft is the first step. After 9 to 12 months following the central graft, an annular lamellar graft is placed in between the previous graft and the limbus. Finally a full-thickness graft is used for regaining vision.

Corneal Pigmentations³

Classification. Apart from developmental pigmentation, the causes are as follows:

- (a) Melanin Epithelial
 Stromal
 Endothelial
- (b) Haematogenous
- (c) Metallic.

Melanin pigmentation

Epithelial melanosis occurs in malignant melanoma at the limbus, trachoma and other inflammations, and this melanosis is by migration of melanoblasts present at the limbus. Superficial vascularization of the cornea is the probable factor responsible in the dissemination of pigments.

Stromal melanosis occurs in alkaptonuria.

Endothelial dystrophy, myopia, diabetes, senile cataract, simple glaucoma and senility are among the many factors that are responsible for endothelial melanosis. The pigment is derived from the iris and ciliary body. There are golden brown, small, scattered pigments occasionally grouped on the corneal endothelium.

Krukenberg's pigment spindle is a variety of endothelial melanosis in which the pigment deposition takes the form of a vertical spindle. This spindle is bilateral, small and is placed in the central part. This appears especially in senility and myopia.

Haematogenous pigmentation

Haematogenous pigmentation results from blood staining of the cornea but rarely from haemorrhage into the cornea due to the rupture of neovessels into the cornea. Pigmentation occurs after hyphaema, and subconjunctival haemorrhage at the limbus.

In blood staining of the cornea the pigmentation is due to absorption of disintegrated products of red blood corpuscles. These enter through the endothelium and perhaps also through the periphery of the cornea. At first there is rusty brown staining of the affected part which gradually becomes greenish yellow or grey.

Stähli-Hudson line

Stähli-Hudson line is linear brown pigmentation occurring in the cornea in a line parallel to the line

of the lid closure. This is perhaps due to localized aggregation of iron derived from blood and may be present in normal cornea of old people.

Metallic pigmentation

Metallic pigmentation may be due among others to copper, silver, gold, iron and bismuth.

Copper. Pigmentation may be: (a) direct—due to impaction of copper foreign body in the cornea (direct chalcosis); and (b) indirect—due to penetration of copper foreign body into the eyes. The reaction is variable as follows. If the metal is pure there is violent suppurative inflammation. If the metal is an alloy with less than 85 per cent of copper, chalcosis occurs forming corneal pigmentation and sunflower cataract.

Kayser–Fleischer ring is corneal pigmentation with copper occurring typically in Wilson's disease or hepatolenticular degeneration. The ring shows interplay of colours ranging between bright red to green or blue in the corneal periphery.

Corneal Deposits

Aetiology. The causes are listed in Table 38.19.

Table 38.19
Causes of Corneal Deposits

Iron	
Epithelial	
	In old age: Stähli–Hudson line
	Proximal to the apex of pterygium: Stocker's line
	At the corneal margin of filtering bleb: Ferry's line
	In keratoconus: Fleischer's ring
Stromal	
	Siderosis bulbi
	Following hyphaema
Silver	
	Argyrosis
Copper	
	Kayser–Fleischer's ring
	Sunflower cataract
Gold	
	Chrysiasis
Mucopolysaccharidoses	
Vortex dystrophy	
Fabry's disease	

Corneal Oedema²

The epithelium and the endothelium, especially the latter, regulate the passage of water and ions. The corneal stroma *in vivo* has a constant tendency to swell, but this tendency is neutralized by transport of fluid through the endothelium. The basis of the stromal swelling pressure is the polysaccharides.

Dohlman has summarized the mechanism of epithelial and stromal oedema in the following manner:

(a) **Epithelial oedema** is the result of positive stromal fluid pressure which occurs in poor dehydration activity of the endothelium or in high IOP. Localized oedema occurs in superficial corneal involvement. Normally there is a negative measure.

(b) **Stromal oedema.** Severe stromal oedema results from endothelial damage, either diminished barrier function or diminished pump activity of the endothelium. It affects the posterior part of the stroma. Stromal oedema following epithelial damage is not so pronounced.

The stroma greatly resists the flow of fluid from it and there is a slow equilibrium of fluid between oedematous and non oedematous parts of the cornea. This is responsible for localized oedema seen sometimes in an otherwise normal cornea.

Clinical features. The characteristic symptom is the presence of haloes. Visual disturbance is proportionate to the cause and degree of the lesion. Slit-lamp examinations reveal the following:

(a) Epithelial oedema when seen in the early stage presents as 'endothelial bedewing'.

(b) Vesicular keratopathy—is characterized by the presence of number of vacuoles.

(c) Epithelial bullae—are formed by coalescence of vacuoles.

(d) Striate keratopathy occurs in stromal oedema, greyish white in colour, with radial lines. The oedema is limited towards the posterior surface.

Secondary Oedema

Secondary oedema may follow:

(a) Injury to the epithelium—by mechanical

(e.g. contact lens wear) and physicochemical (e.g. exposure, chemicals, etc.) injury

(b) Injury to the endothelium as in buphthalmos and keratoconus

(c) Fuchs' corneal dystrophy

(d) Iridocyclitis

(e) Glaucoma—shows diffuse epithelial oedema in acute phase, but intractable bullous keratopathy in absolute glaucoma.

Essential Oedema (Diffuse Epithelial Keratopathy)

Essential oedema is episodic, often cyclic, and occurs without any apparent cause. Usually the attack occurs on waking, when the cornea shows fine spots like sands and the affection lasts for a few days.

Bullous Keratopathy

In bullous keratopathy, there is noninflammatory oedema representing the end stage of severe epithelial oedema, but its development essentially follows endothelial damage. The condition is seen in:

(a) Long-standing glaucoma

(b) Vitreous touching the corneal endothelium following cataract extraction

(c) Fuchs's corneal dystrophy

(d) After perforating wounds

(e) Prolonged inflammation of corneal stroma.

The characteristic clinical picture is the presence of epithelial bullae containing cloudy fluid. The bullae burst and then reappear, and this cycle is repeated.

Treatment of corneal oedema. (a) Treatment for removal of the cause, if feasible, e.g. control of inflammation, control of ocular tension, etc.

(b) Symptomatic measures include topical instillation of hyperosmotic agent and bandage soft contact lens.

(c) In severe case, especially bullous keratopathy—treatment is ineffective, but full-thickness corneal grafting may be tried.

Filamentary Keratopathy³

Aetiology. The causes are shown in Table 38.20.

Table 38.20

Causes and Usual Locations of Filamentary Keratopathy¹

Conditions causing filaments	Usual location
Neurotrophic keratitis	Interpalpebral
Keratoconjunctivitis sicca	Interpalpebral
Sutures or wound	Near suture or wound
After abrasion or erosion	Near abrasion or erosion
Herpes simplex infection	Usually single filament
Superior limbic keratoconjunctivitis	Upper third of cornea
Bullous keratopathy	Diffuse
Toxic reaction to topical therapy	Lower third of cornea

Pathology. Filaments are tags of epithelium arising from a triangular epithelial swelling which becomes coiled like an umbilical cord due to constant lid movements. The cells show elongation, vacuolation, hyaline or pigmentary changes. At the distal end of the filament, the cells become more and more degenerated.

Clinical features. An advanced stage shows semitransparent, white, several millimetre long tag with a freely movable bullous end and base fixed to the cornea. The bullous end can be stained with fluorescein. Treatment is directed towards the cause. Sometimes debridement may be needed.

Folds in Bowman's Membrane³

Folds in Bowman's membrane occur in cases of subnormal tension namely lowered IOP and lowered intracorneal pressure after subsidence of keratitis. They appear as glass-like ridges showing optically a double contour with nodes.

Ruptures in Bowman's Membrane³

Ruptures in Bowman's membrane may occur in acute inflammations, buphthalmos and keratoconus.

Folds in Descemet's Membrane²¹ (Fig. 38.7)

Folds in Descemet's membrane are relatively common, when there is hypotony, e.g. trauma, inflammation and diabetes. The folds are seen as broad interlacing bands of shifting light reflexes when examined biomicroscopically.



Fig. 38.7 Folds in Descemet's membrane seen in the slit-lamp beam as interlacing bands of shifting light reflexes (Trevor-Roper).

Ruptures in Descemet's Membrane²¹ (Fig. 38.8)

Ruptures in Descemet's membrane follow continued distension of the cornea such as in buphthalmos, keratoconus, high myopia and contusion of the eyeball. In the slit-lamp beam they appear as bright double band.

Developmental Anomalies of the Cornea^{1,4} (Fig. 38.9)

Developmental anomalies of the cornea may occur as: (a) anomalies in size; (b) anomalies of curvature; and (c) congenital opacification.

Anomalies in size

Microcornea. This term is used when the corneal



Fig. 38.8 Tears of Descemet's membrane seen in the slit-lamp beam. They appear as bright doubled band and well silhouetted by retroillumination against the iris (Trevor-Roper)

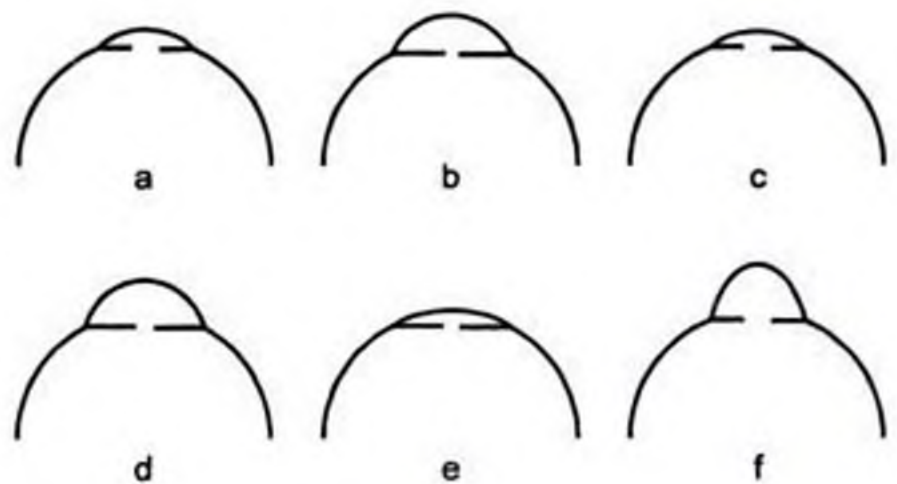


Fig. 38.9 Diagrams showing variations in the size and shape of the cornea (a) normal cornea; (b) megalocornea; (c) microcornea; (d) keratoglobus; (e) cornea plana and (f) keratoconus.

diameter in an otherwise normal sized eye is 10 mm or less. If the whole eye is small but otherwise normal, the condition is called *nanophthalmos*, while if the whole eye is small and malformed the term *microphthalmos* is used. Microcornea may be bilateral or unilateral. The inheritance is autosomal dominant or recessive.

Megalocornea. The term is used when the corneal diameter exceeds 13 mm in horizontal direction. It is usually bilateral, stationary and not associated with congenital glaucoma. The inheritance is most

often sex-linked recessive. The ocular associations include anterior embryotoxon, Krukenberg's spindle, pigment dispersion, hypoplasia of the iris stroma and ectopia lentis. Syndromes like Marfan's and Apert's may be found to be associated.

Anomalies in curvature

Keratoconus. See pp. 233–34.

Keratoglobus. It is a globular corneal bulging. The affection is bilateral with transparent cornea, normal diameter and normal IOP. High myopia and astigmatism are common. It may be associated with blue sclera, vernal keratoconjunctivitis and orbital pseudotumour.

Keratotorus. In this affection there is regular increase in curvature over a limited area of the cornea.

Cornea plana. This is possibly a form of sclerocornea with indistinct limbus, with curvature 30 to 35 D in most cases and shows shallow anterior chamber. The incidence of glaucoma is infrequent. The inheritance is autosomal dominant or recessive.

Corneal opacification at birth^{1,13}

Aetiology. The causes are listed in Table 38.21.

Table 38.21

Causes of Corneal Clouding at Birth

Congenital hereditary endothelial dystrophy
Posterior polymorphous dystrophy
Peter's anomaly
Sclerocornea
Congenital glaucoma
Birth trauma
Hurler's syndrome
Scheie's syndrome
Fabry's syndrome
Congenital rubella
Congenital syphilis

The distinguishing points for differentiating various conditions are: (a) laterality; (b) location of greatest opacity; (c) inflammation; (d) ocular tension;

(e) thickness of the cornea; (f) course of the disease; (g) inheritance; and (h) other associated abnormalities.

Congenital hereditary endothelial dystrophy (CHED) is a bilateral affection having usually autosomal recessive inheritance showing increased corneal thickness and central diffuse opacity. The condition may regress.

Posterior polymorphous dystrophy is a bilateral affection showing central corneal opacity at birth. The inheritance is autosomal dominant. The condition is progressive.

Peter's anomaly is either unilateral or bilateral affection showing central corneal opacity associated with posterior corneal defect, iris adhesions, glaucoma and many systemic anomalies.

Sclerocornea is bilateral, nonprogressive, noninflammatory opacification of the peripheral cornea, flattened cornea and vascularization being other characteristics of this condition.

Buphthalmos. See Table 44.9.

Birth trauma is characterized by unilaterality, focal haze of the cornea with signs of inflammation. The condition generally improves.

Hurler's and Scheie's syndromes are described on pp. 401–02.

Further Reading

1. Arffa, R.C. (Ed.), *Grayson's Diseases of the Cornea* (4th ed.), C.V. Mosby, St. Louis, 1997.
2. Dohlman, C.H., Endothelial function. In *The Cornea: Scientific Foundations and Clinical Practice* (3rd ed.), Smolin, G. and Thoft, R.A. (Eds.), Little, Brown and Co., Boston, 1994, p. 635.
3. Duke-Elder, S., *System of Ophthalmology*, Vol. VIII: *Diseases of the Outer Eye, Part 2, Diseases of the Cornea and Sclera, Epibulbar Manifestations of Systemic Diseases, Cysts and*

- Tumours*, Duke-Elder, S. and Leigh, A.G. (Eds.), Kimpton, London, 1964.
4. Duke-Elder, S., *System of Ophthalmology*, Vol. VIII: *Normal and Abnormal Development*, Part 2: *Congenital Deformities*, Kimpton, London, 1963.
 5. Easty, D.L., *Virus Diseases of the Eye*, Year Book Publishers, Chicago, 1985.
 6. Foulks, G.N. and Pavan-Langstone, D. Cornea and external diseases. In *Manual of Ocular Diagnosis and Therapy*, Pavan-Langstone, D. (Ed.), Little, Brown and Co., Boston, 1980, p. 69.
 7. Fine, B.S., Mycotic keratitis. In *The Cornea: World Congress*, King J.H. and Mctigue, J.W. (Eds.), Butterworths, London, 1965, p. 207.
 8. Fosters, C.S., Fungal keratitis. In *Principles and Practice of Ophthalmology: Clinical Practice*, Albert, D.M. and Jacobiec, E.A. (Eds.), W.B. Saunders, Philadelphia, 1994, p. 171.
 9. Imre, G., Neovascularization of the eye. In *Contemporary Ophthalmology, honoring Sir Duke-Elder*, Bellows, J.G. (Ed.), Williams and Wilkins; Baltimore, 1972, p. 80.
 10. Jones, B.R., The differential diagnosis of punctate keratitis. *Tr. Ophthalmol. Soc., UK*, 80: 665, 1960.
 11. Kenyon, K.R., Stark, T. and Wagoner, M.D., Corneal epithelial defects and Noninfectious Ulcerations. In *Principles and Practice of Ophthalmology: Clinical Practice*, Albert, D.M. and Jacobiec, E.A. (Eds.), W.B. Saunders, Philadelphia, 1994, p. 218.
 12. Koenig, S.B., Fungal keratitis. In *Infections of the Eye*, Tabbara, K.F. and Hyndiuk, R.A. (Eds.), Little, Brown and Co., Boston, 1986, p. 331.
 13. Laibson, P.R. and Waring, G.O., Diseases of the cornea. In *Pediatric Ophthalmology*, Harley, R.D. (Ed.), W.B. Saunders, Philadelphia, 1975, p. 273.
 14. Miller, D. and Greiner, J.V., Corneal measurements and tests. In *Principles and Practice of Ophthalmology: Clinical Practice*, Albert, D.M. and Jacobiec, F.A. (Eds.), W.B. Saunders, Philadelphia, 1994, p. 4.
 15. Ogawa, G.S.H. and Hyndiuk, R.A., Bacterial keratitis and conjunctivitis: clinical disease. In *The Cornea: Scientific Foundations and Clinical Practice* (3rd ed.), Smolin, G. and Thoft, R.A. (Eds.), Little, Brown and Co., Boston, 1994, p. 125.
 16. Pavan-Langstone, D., Viral keratitis and conjunctivitis. In *The Cornea: Scientific Foundations and Clinical Practice* (3rd ed.), Smolin, G. and Thoft, R.A. (Eds.), Little, Brown and Co., Boston, 1994, p. 183.
 17. Smolin, G., Corneal dystrophies and degenerations. In *The Cornea: Scientific Foundations and Clinical Practice* (3rd ed.), Smolin, G. and Thoft, R.A. (Eds.), Little, Brown and Co., Boston, 1994, p. 499.
 18. Sorsby, A. (Ed.), *Modern Ophthalmology* (2nd ed.), Vol. 3, Butterworths, London, 1972.
 19. Teng, C.C., Electron microscope study of the pathology of keratoconus. *Am. J. Ophthalmol.*, 55: 18, 1963.
 20. Thomas, C.I., Corneal inflammation and infection. In *The Cornea: World Congress*, King, J.W. and Mctigue, J.H. (Eds.), Butterworths, London, 1965, p. 169.
 21. Trevor-Roper, P.D. and Curran, P.V., *The Eye and Its Disorders* (2nd ed.), Blackwell Scientific, Oxford, 1984.
 22. Wadsworth, J.A.C., Pathology of corneal dystrophies. In *The Cornea: World Congress*, King, J.W. and Mctigue, J.H. (Eds.), Butterworths, London, 1965, p. 121.
 23. West, C. Corneal diseases. In *Principles and Practice of Ophthalmology*, Peyman, G.A., Sanders, D.R. and Goldberg, M.F. (Eds.), W.B. Saunders, Philadelphia, 1980, p. 398.
 24. Wood, T. and Kaufman, H., Mooren's ulcer. *Am. J. Ophthalmol.*, 71: 17, 1971.

39. DISEASES OF THE SCLERA

Scleral diseases are relatively uncommon because the sclera is inert, almost acellular and avascular, but essentially collagenous. For these reasons, too, the scleral disease tends to be torpid and chronic.¹

In both inflammatory and degenerative processes affecting the sclera, the essential lesion is a fibrinoid necrosis, a physically altered ground substance due to abnormal precipitation of mucopolysaccharides, resembling fibrin. In inflammatory process there occurs superadded infiltration by chronic inflammatory cells. Seldom acute inflammation and still very rarely suppuration occur. Healing after trauma depends upon the involvement of the neighbouring mesenchymal tissues.

The sclera is never involved in episcleritis, while the episclera is nearly always involved in scleritis.

Broadly the causes of episcleritis and scleritis may be grouped as: (a) allergic—to endogenous toxin; (b) systemic diseases like rheumatoid arthritis and gout; (c) secondary from the conjunctiva, cornea and uvea; (d) endogenous—pyogenic or non-pyogenic, rare; and (e) exogenous—following injury, rare.¹

Episcleritis^{1,2,4,6}

Aetiology. Episcleritis is more common in women. Systemic disease associated with episcleritis may suggest an acute hypersensitivity reaction. In less than 10 per cent of cases it is associated with a collagen disease. The condition is recurrent in nature.

Pathology. There is lymphocytic infiltration of the subconjunctival and episcleral tissues with accompanying oedema.

Types. Diffuse and nodular.

Clinical features. (a) Pain is localised to the area of redness and of varying severity from discomfort to actual pain.

(b) Injection—affects mostly the superficial episcleral plexus.

(c) Colour of the affected site is purple.

(d) Nodule. In nodular episcleritis the nodule

is tender with the conjunctiva freely moving over it, and is traversed by vessels of the superficial episcleral plexus (Fig. 39c.1). A nodule may persist for a few weeks. In *episcleritis periodica fugax*, fleeting and repeated attacks of episcleritis occur at times.

Complications and sequelae. Complications and sequelae are rather uncommon. Recurrent attacks may occur over years.

Differential diagnosis. Differential diagnosis include phlycten, inflamed pinguecula, scleritis and sclerosing keratitis.

Treatment. This consists of:

(a) Local soluble steroid.

(b) Oxyphenbutazone—400 mg daily in divided doses is effective, especially in recurrent cases.

(c) Instead of oxyphenbutazone, oral antiprostoglandins such as indomethacin, 50 mg twice daily may be used.

(d) Symptomatic measures.

Scleritis²⁻⁴

Aetiology. The condition is also often found in women. It is more commonly associated with a collagen disease in 50 per cent cases and chronic granulomatous conditions such as tuberculosis. The commonest association is rheumatoid arthritis.

Pathology. The histopathological changes are oedema of the middle layers of the sclera leading to breaking down and necrosis of the lamellae or dense lymphocytic infiltration of the layers of the sclera sometimes extending to the cornea and uveal tract. Finally there is a replacement fibrosis.

Clinical features. The features are as follows:

(a) Pain becomes generalized around the eye, constant ache or throb

(b) Injection affects mostly the deep episcleral plexus

(c) Colour of the affected site is bluish or dusky

(d) The presence of photophobia suggests involvement of the cornea or the posterior segment

(e) Nodule in nodular scleritis is diffuse and fixed (Fig. 39c.2).

Table 39.1 gives a classification of scleritis.

Table 39.1
Classification of Scleritis

<i>Anterior</i>
Diffuse
Nodular
Necrotizing with inflammation
Necrotizing without inflammation
<i>Posterior</i>

Investigations include erythrocyte sedimentation rate (ESR), chest X-ray, test for rheumatoid factor venereal disease research laboratory (VDRL), and antinuclear antibody test.

Table 39.2 lists the distinguishing features of nodular episcleritis and nodular scleritis.

Variants of scleritis¹

Involvement of the sclera all round the cornea, *annular scleritis*, may occur. A very severe form of diffuse annular scleritis, gelatinous in appearance and pitting on pressure occurs usually bilaterally in old woman with rheumatoid arthritis known as *brawny scleritis* or massive granuloma of the sclera.

Posterior scleritis (Syn.: Sclerotenonitis, periscleritis, anterior inflammatory pseudotumour)

Pathology. Tenon's capsule and periscleral tissues are primarily affected, but there may be scleral involvement.

Clinical features. The features include severe orbital pain, proptosis, restricted extraocular movements; sometimes there is presence of uveitis. The features depend upon the primary locus of inflammatory process. When the anterior orbital tissues are primarily affected, signs of ocular inflammation may dominate the clinical picture. In tenonitis chemosis spreads towards the limbus, but in sclerotenonitis there is hardly any involvement of the anterior ocular segment.

Ultrasonography often helps to arrive at a diagnosis.

Necrotizing inflammations

According to Duke-Elder and Leigh,¹ they are of three varieties:

- Rheumatic nodular episcleritis
- Necrotizing nodular scleritis
- Scleromalacia perforans (necrotizing without adjacent inflammation).

They are associated with collagen diseases characterized pathologically by fibrinoid necrosis plus chronic inflammatory cell infiltration; and clinically by the presence of single or multiple yellowish nodules around the limbus which

Table 39.2
Distinguishing Features of Nodular Episcleritis and Nodular Scleritis

Points	Nodular episcleritis	Nodular scleritis
Pain	Mild pain or discomfort	Generalized, periocular
Injection	Affects superficial episcleral plexus	Affects deep scleral plexus
Colour of the involved site	Purple	Bluish or dusky
Nodule	Conjunctiva freely mobile over it and traversed by vessels	Diffuse and fixed
Scleral affection	No	Yes, repeated attacks may lead to necrosis and ectasia
Corneal complications	Minimal	Seen in 30-40% cases
Uveitis	Occasional mild iritis	Present in 30% cases

ultimately lead to necrosis and perforation of the sclera.

Necrotizing nodular episcleritis and scleritis^{1,5}

Necrotizing nodular episcleritis shows similar picture as a nodular scleritis, but also shows evidence of necrosis, seen sometimes in rheumatic affection.

A necrotizing nodular scleritis is seen above the age of 50 and usually unilateral. Development of one scleral nodule is followed by appearance of others. Eventually it shows a picture of scleromalacia perforans.

Scleromalacia Perforans^{1,5}

Scleromalacia perforans is a rare disease, somewhat more common in elderly females, often with history of absence of symptoms in the early stages. A yellow necrotic scleral nodule appears between the limbus and the equator. After about 6 months or more, even 18 months there is sloughing of the area leaving behind a hole or depression. The condition is to be differentiated from necrotizing nodular scleritis, tuberculoma, gumma of the sclera, neurofibromatosis, spontaneous intercalary perforation, etc.

Types of keratitis associated with scleritis⁵ are:

- (a) Acute stromal keratitis
- (b) Sclerosing keratitis
- (c) Limbal guttering
- (d) Keratolysis—in severe cases of necrotising scleritis.

Complications and sequelae of scleritis. They are:

- (a) Keratitis
- (b) Uveitis
- (c) Scleral thinning
- (d) Exudative retinal detachment.

Treatment of scleritis. In severe and recurrent attacks nonsteroidal antiinflammatory drugs or immunosuppressive agents may be tried.

Local. Topical steroids and atropine are used along with symptomatic measures like hot fomentations.

General treatment appears to be more important.

Systemic steroids. 10 mg prednisolone four

times daily is recommended till the eye becomes free of gross objective signs. Then the dose is reduced to 10 mg daily till the inflammation is totally suppressed.

In severe and recurrent attacks oxyphenbutazone, 400 mg daily may be administered with systemic steroids. Indomethacin may be used.

Treatment of coexistent systemic disease by proper systemic therapy should also be advocated.

Necrosis of the Sclera

Common causes are as follows:

- (a) Tuberculoma
- (b) Necrotizing nodular scleritis
- (c) Scleromalacia perforans
- (d) Atypical epithelioma.

Staphyloma

Staphyloma means thinning and bulging of the sclera lined by the uveal tissue. They are situated: (a) behind the limbus (Fig. 39.1) it is called the *ciliary*; (b) at the lamina cribrosa, it is called *posterior*; (c) at the region of exit of the vortex vein, detected after enucleation, it is called *equatorial*; and (d) at the part of the sclera weakened by the passage of anterior ciliary vessels and presence of Schlemm's canal only proved by histological evidence is called *intercalary*.

Treatment. If it is associated with secondary

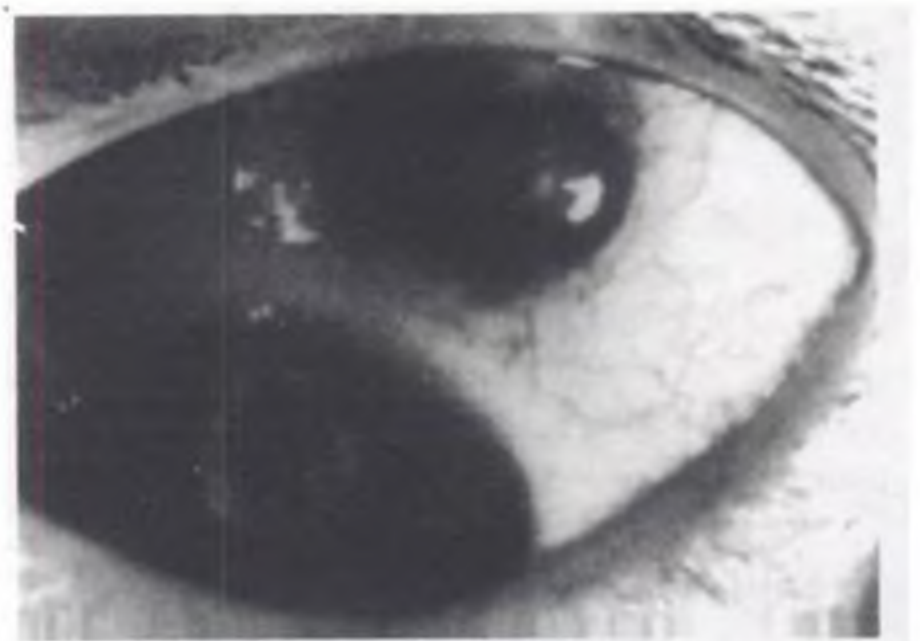


Fig. 39.1 Ciliary staphyloma.

glaucoma decompression operation causes relief. If painful and blind enucleation, operation is the only choice left.

Congenital anomalies

Blue Sclera. This is hereditary condition and often associated with abnormal fragility of the bones and deafness, *Van der Hoeve's syndrome*.

Further Reading

1. Duke-Elder, S., *System of Ophthalmology*, Vol. VIII, *Diseases of the Outer Eye, Part 2: Diseases of the Cornea and Sclera, Epibulbar Manifestations of Systemic Diseases, Cysts and Tumours*, Duke-Elder, S. and Leigh, A.G. (Eds.), Kimpton, London, 1964.
2. Lyle, A.J. and Pitkeathley, D.A., Episcleritis and scleritis. *Arch. Ophthalmol.*, 80:171, 1968.
3. Lyne, A.J., Scleritis and systemic disease. *Tr. Ophthalmol. Soc., UK*, 94:58, 1974.
4. Watson, P.G., Clinical manifestations of scleritis. *Tr. Ophthalmol. Soc., UK*, 94:74, 1974.
5. Watson, P.G. and Holt-Winston A.D., Corneal involvement in episcleritis and scleritis. *Tr. Ophthalmol. Soc., UK*, 94:46, 1974.
6. Watson, P.G. and Hayreh, S.S., Scleritis and Episcleritis. *Br. J. Ophthalmol.*, 60:103, 1976.

40. DISEASES OF THE UVEAL TRACT

Inflammation of the uveal tract is the chief affection and is of much importance because of the anatomic continuity of the iris, ciliary body and choroid. Other diseases include degenerations, dystrophies, vascular disturbances, tumours and congenital anomalies.

Uveitis

Uveitis is the inflammation of the uveal tract.

History related to uveitis.⁶ The Ebers Papyrus in 1500 BC indicated that the affection was known in ancient Egypt. Charles Saint Yves had described symptoms and signs of this affection. The name 'iritis' was coined by Schimdt, cyclitis by Bérard and a tentative description of 'choroiditis' was given by Maitre Jan. Ernst Fuchs (1889) described pure cyclitis, chronic in nature, characterized by the presence of keratic precipitates and vitreous opacities. Alan Woods' dealing with endogenous inflammation of the uveal tract still remains classic and integrated.

Uveitis is classified as follows (Table 40.1).

Table 40.1
Classification Schemes of Uveitis^{19,22}

Aetiologic
Infectious
Autoimmune
Systemic
Neoplastic
Idiopathic
Pathologic
Granulomatous
Nongranulomatous
Anatomic
Anterior
Intermediate
Posterior
Panuveitis
Clinical
Acute
Chronic
Recurrent

Aetiology. In a large proportion of cases, the cause remains conjectural. Inflammation of the mesodermal tissues in general may affect the uvea, since the uvea, except for its neural epithelium, is mesodermal in origin.

It may be associated with systemic diseases (Table 40.2).

Pathology.^{6,17} *Anterior uveitis (iridocyclitis).* Inflammation presents similar changes as occurring in other connective tissues but modified by two characteristic features in the iris, namely in vascularity and looseness of the stroma.

Table 40.2

Association of Systemic Diseases with Uveitis^{1,22}*Anterior uveitis*

HLA B 27-related

Ankylosing spondylitis

Ulcerative colitis

Reiter's syndrome

Crohn's disease

Psoriatic arthritis

Rheumatoid arthritis

Fuchs' heterochromic cyclitis

Herpetic or zoster uveitis

Leprosy

Tuberculosis

Posterior uveitis

Bacterial infections

Tuberculosis

Syphilis

Viral infections

Acquired immuno deficiency syndrome (AIDS)

Parasitic infections

Toxoplasmosis

Toxocariasis

Fungal infections

Presumed histoplasmosis

Panuveitis

Sarcoidosis

Behçet's syndrome

Vogt-Koyanagi-Harada syndrome

of the iris leads to formation of posterior synechiae, i.e. adhesions between the posterior surface of the iris and the anterior capsule of the lens and in long-standing cases also peripheral anterior synechiae.

(g) Oedema of the iris blurring its anterior surface as well as oedema and leucocytic infiltration of the ciliary body, more so in the ciliary process.

(h) Liberation of toxin on the nerve endings supplying the muscles.

Posterior uveitis (choroiditis). In the early stages there are congestion, infiltration and oedema. In purulent lesions-polymorphs continue to accumulate, in nongranulomatous type—lymphocytes predominate, and in granulomatous type—large mononuclear and epithelioid cells predominate. Break in Bruch's membrane and subsequent involvement of the retina and the vitreous then follow. In the later stages disappearance of oedema, atrophy of the choroid retina with pigment heaping around occur.

Uveal inflammation is mostly endogenous and Woods considered *endogenous uveitis* under two broad categories.²⁶

(a) *Nongranulomatous uveitis* which is essentially a hypersensitive reaction and is characterized by polymorphonuclear exudation in the initial stage predominantly involving the anterior uvea.

(b) *Granulomatous uveitis* which is due to invasion of the uveal tract by living and nonpurulent organisms. It is characterized by mobilization and proliferation of large mononuclear cells, the latter type being converted into epithelioid cells and subsequently giant cells form by fusion of epithelioid cells. This form has a special affinity for the posterior uvea. Table 40.3 gives its aetiological classification.

Clinical features.^{5,11,15,24} Clinical features may be enumerated as follows:

Pain. Pain is due to contraction of the ciliary muscle and stretching of the nerve fibres in the hyperaemic iris and ciliary body. This is proportional to the degree of involvement of the ciliary body. Sometimes it is due to involvement of the trigeminal nerve endings in cases associated

The important changes are:

(a) Dilatation of the blood vessels and changes in the capillary walls.

(b) Exudation of inflammatory cells occurs. The cells are polymorphs in acute purulent inflammation, lymphocytes in acute nongranulomatous uveitis and in chronic granulomatous uveitis large mononuclear and epithelioid cells predominate.

(c) Exudation of protein-rich fluid from the iris causes a plasmoid aqueous. Protein-rich fluid also reaches the posterior chamber. Exudation is found in the pars plana region.

(d) The cells reach the aqueous and the vitreous.

(e) There is deposition of cells on the back surface of cornea and on the anterior capsule of the lens.

(f) Fibrinocellular exudation binding the surfaces

Table 40.3

Aetiological Classification of Granulomatous Uveitis
(after Woods²⁶)

Bacterial	Viral
Tuberculosis	Herpes simplex
Syphilis	Herpes zoster
Leprosy	Vogt-Koyanagi-Harada syndrome
	Behçet's syndrome
Brucellosis	
<i>Protozoal</i>	<i>Mycotic</i>
Toxoplasmosis	Histoplasmosis
Trypanosomiasis	Actinomycosis
	Blastomycosis
<i>Helminthic</i>	<i>Unknown group</i>
Hookworm	Sympathetic ophthalmia
Onchocerciasis	Sarcoidosis
Cysticercosis	
Toxocariasis	

with corneal oedema. It is often a dull ache with occasional exacerbations. It frequently radiates to the same side of the head and face.

Photophobia and lacrimation. They are usually present in acute iridocyclitis and in associated keratitis.

Diminished vision. The causes may be as follows:

- (a) Exudation of cells in the aqueous and vitreous
- (b) Plasmoid aqueous
- (c) Keratic precipitates
- (d) Corneal oedema
- (e) Pigment deposition over the anterior capsule of the lens
- (f) Vitreous haze
- (g) Macular oedema
- (h) Papillitis
- (i) Secondary glaucoma
- (j) Scotoma due to chorioretinitis
- (k) In late cases there may be complicated cataract, macular pigmentation, etc.

Ciliary injection is dependent upon the spread of inflammation into and around the anterior ciliary vessels and their tributaries.

It is absent in chronic iridocyclitis and heterochromic iridocyclitis.

Flare and cells. Following increased vasodilation and permeability of the uveal vessels, there is increased protein content causing a plasmoid aqueous. This may contain particles of protein or floating cells. In slighter degrees, a slit-lamp examination reveals the presence of an aqueous flare. The cells are deposited at various sites such as on the corneal endothelium, at the angle, on the iris and ciliary body, on the lens and suspensory ligament, and in the vitreous. Flare can be graded—0, complete absence; 1+, faint; 2+, moderate with details of the iris and lens clear; 3+, marked; and 4+, intense. The cells per field can also be graded as 1+, 7–10 cells; 2+, 15–20 cells; 3+, 20–50 cells; and 4+, more than 50 cells.

Keratic precipitates (KPs) are deposits of inflammatory cells, pigments and other matters, though rarely RBCs and neoplastic cells are deposited on the corneal endothelium.

Keratic precipitates vary in number, size, character, composition and distribution. The deposition of the cells depends on the convection current of the aqueous. There is a thermal circulation of the aqueous which becomes warm, while it is against the iris due to vascularity and cool when it is on the back of the cornea due to exposure to atmosphere. The other factors on which deposition depends are the composition of the aqueous because plasmoid aqueous circulates poorly and damage to the corneal endothelium due to impairment of nutrition following plasmoid aqueous.

Morphologically, KPs may be any of the following types:

(a) Medium white and small KPs are considered pathognomonic of nongranulomatous uveitis, composed chiefly of lymphocytes and occasionally of plasma cells, and they tend to form a triangular pattern, occupying the inferior part.

(b) Pigmented KPs are those which either phagocytose pigment or are pigments liberated from the iris stroma.

(c) Mutton-fat KPs are characteristically present in granulomatous uveitis, consisting of chiefly macrophages with lymphocytes and plasma cells. They are so called because of this appearance. The

number varies between 10 and 15, and they are found in the mid and lower cornea.

(d) Stringy KPs are fibrin threads on the corneal endothelium present usually in plastic iritis.

KPs are arranged in several forms such as: (a) triangular (classical variety); (b) fusiform; (c) central; (d) peripheral; (e) linear; (f) disseminated; and (g) irregular.

Pupillary signs. The signs are constantly present in anterior uveitis and are diagnostic. The pupil is small, constricted and shows a sluggish reaction.

Small and contracted pupil is due to: (a) effects of toxin on the nerve endings, the sphincter being the more compact muscle there is pupillary constriction; (b) engorgement of sinuous, radial iris vessels; and (c) oedema and infiltration of the iris stroma.

Sluggishness of the pupil's reaction to light is due to oedema and infiltration of the stroma of the iris.

Irregularity of the pupillary margin is due to formation of posterior synechia.

Oedema of the iris. The actual pattern of the anterior surface becomes obscured.

Nodules of the iris. Most of them are evanescent, while few of them have characteristic features. They are as follows:

(a) **Koeppe nodules.** Normally in acute attacks they appear like mutton-fat KPs at the ectodermal border of the iris projecting into the pupil, and disappear within a few days.

(b) **Busacca nodules.** They are less transient than Koeppe nodules, are found about the iris collarette, and are of allergic diathesis.

(c) **Tuberculous nodules.** They appear to have a predilection for the iris root. The vessels surround and cross over the nodules. They need to be differentiated from the nodules due to other causes (Table 40.4).

(d) **Sarcoid nodules.** There are large, irregular, wart-like nodules in and on the iris. The nodules are multiple and they increase in size gradually. The vessels lie at the base and form an interlacing network into the nodules.

Vitreous changes include clouding, opacities and accumulation of inflammatory cells within the vitreous.

The site of the inflammation will determine the degree and type of vitreal involvement. In iritis the anterior vitreous is free of cells, while in cyclitis the density of cells in the anterior vitreous is much greater than that in the aqueous.

Vitreous opacities may be:

(a) Fine—predominantly the cells are lymphocytes, plasma cells, and macrophages

(b) Coarse—consist of tissue cells, macrophages and fibrin clumps

(c) Stringy—indicate posterior uveal involvement

(d) Snowball—large opacities, appear to be pathognomonic of sarcoidosis.

Retinal changes. Diffuse retinal and subretinal oedema may occur in anterior uveitis. Exudative bilateral retinal detachment is a characteristic of Vogt-Koyanagi-Harada syndrome. Anterior uveitis is often associated with perivasculitis.

Macular changes. Macular oedema is common in all forms of uveitis. Later, there are some pigmentary and cystic changes.

Table 40.4
Distinguishing Features of Nodules in the Iris

Points	Melanoma	Tuberculous	Syphilitic	Foreign body granuloma
Site	Anywhere	Near the ciliary margin	At the pupillary or ciliary margin	Anywhere
Colour	Black	Grey	Yellowish red	Reddish
Progress	Stationary or slow growth	Evanescent	May disappear with anti-syphilitic treatment	Slow growth
Vascularity	Not vascular in early stage	Usually absent	Slight	Very vascular

Optic nerve changes. They include papillitis and chorioretinitis.

Two major types of endogenous uveitis can be distinguished (Table 40.5).

Table 40.5
Distinguishing Features of Two Types of Endogenous Uveitis

	Granulomatous	Nongranulomatous
Anterior	<ol style="list-style-type: none"> 1. Slow and insidious onset 2. Chronic and protracted course with remissions and exacerbations 3. Features of low-grade inflammation 4. Mutton-fat KPs 5. Weak aqueous flare and few cells 6. Iris nodules common 7. Posterior synechiae are heavy and organized 	<ol style="list-style-type: none"> 1. Acute 2. Short course 3. Features of acute inflammation 4. Small KPs 5. Intense flare in active state with many cells 6. Does not occur 7. Evident in recurrent attacks
Posterior	<ol style="list-style-type: none"> 1. Heavy and veil-like opacities 2. Massive exudates 3. Slight localized retinal and subretinal oedema 	<ol style="list-style-type: none"> 1. Fine opacities 2. Not present 3. Marked and generalized

Diagnosis.^{2,22} Diagnosis should be based on history, ocular examination, occasionally review of various systems and laboratory tests whenever indicated (Tables 40.6 and 40.7).

The laboratory tests are more often expensive and hence they should be ordered according to the need of the patient (tailor-made) especially in cases which are recurrent, persistent or unresponsive to treatment.

Complications and sequelae (Table 40.8) of anterior uveitis. (i) Posterior synechiae (Fig. 40.1) are the adhesions of the posterior surface of the iris with the anterior capsule of the lens. They are present as characteristic diagnostic sign of iritis. If

Table 40.6

Clinical Investigations of Uveitis

History

Age, sex, personal history, past history of systemic diseases and family history like rheumatoid arthritis, ocular: present, past history, and history of injury or operation

Ocular examination

External examination

Visual acuity

Slit-lamp biomicroscopy of both anterior and posterior ocular segments

Direct and indirect ophthalmoscopy

Tonometry

Gonioscopy

Systemic examinations

Skin and hair

Rashes

Erythema nodosum

Alopecia, vitiligo, poliosis, etc.

Joints

Ankylosing spondylitis

Juvenile chronic arthritis

Mouth

Behçet's syndrome

Lungs

Sarcoidosis

such a case is not treated at all or is inadequately treated, these synechiae become extensive and use of mydriatic causes the pupil to assume a festooned appearance.

(ii) Seclusio pupillae or ring synechiae (Fig. 40.2) are caused by recurrent attacks of iritis or by a severe case of plastic iritis when there is profuse exudate covering the iris surface and the pupil. Subsequently the entire pupillary margin adheres with the anterior capsule of the lens.

(iii) Iris bombé is caused by the bowing of the iris forward as a result of the seclusion referred to above. The AC is deepest in the axial region and shallowest at the periphery.

(iv) Peripheral anterior synechiae are the adhesions caused by close contact of the peripheral part of the iris with that of the back surface of the cornea.

(v) Occlusio pupillae or the blocked pupil

Table 40.7

Investigations in Different Types of Uveitis

X-rays	
Chest	Tuberculosis, sarcoidosis
Affected joints	Ankylosing spondylitis
Hands and feet	Sarcoidosis
Mantoux test	Tuberculosis
Kveim test	Sarcoidosis
Rheumatoid factor	Sclerouveitis
Antinuclear antibodies	Juvenile rheumatoid arthritis and other collagen diseases
Angiotensin-converting enzyme	Sarcoidosis
HLA B 27	Ankylosing spondylitis, Reiter's syndrome
HLA B 5	Behçet's syndrome
VDRL and FTA ABS	Syphilis
ELISA	Toxoplasmosis, TB, toxocariasis
Iris angiography	Fuchs' cyclitis
Fundus fluorescein angiography	Acute multifocal pigment placoid epitheliopathy, white dot syndrome

(Fig. 40.3) is caused by the filling up of the pupillary area by a whitish membrane resulting from the organization of the extensive exudates.

(vi) Total posterior synechiae occur as a result of complete adhesion of the back surface of the iris with the anterior lens capsule. This causes retraction of the iris periphery. Thus, the AC becomes abnormally deeper at the periphery.

(vii) Secondary glaucoma may develop either during active stage of the disease, or later in chronic or recurrent cases. There are several causes. Commonly it may be caused by blockage of the drainage channels by inflammatory material. It is also due to oedema of the root of the iris causing an angle block. Other causes include seclusio pupillae, iris bombé and peripheral anterior synechiae. Rarely, it follows hypersecretion from the ciliary body and rubeosis iridis.

(viii) Cyclitic membrane is a membrane behind the lens occurring in a case of severe plastic iridocyclitis. There may be fanwise extension of the exudates into the anterior vitreous. It is better seen by an ophthalmoscope than by oblique illumination.

Table 40.8

Sequelae of Uveitis^{19,22}

Cornea	
Oedema	
Loss of endothelial cells	
Opacity	
Band keratopathy	
Neovascularization	
Iris	
Synechia	
Atrophy	
Neovascularization	
Scarring	
Ciliary body	
Atrophy	
Scarring	
Crystalline lens	
Complicated cataract	
Vitreous humour	
Cells	
Cyclitic membrane	
Intraocular pressure	
Secondary glaucoma	
Hypotony—occasional	
Retina	
Macular oedema	
Perivasculitis	
Retinal detachment	
Proliferation or hypoplasia of retinal pigment epithelium	
Optic nerve	
Atrophy	

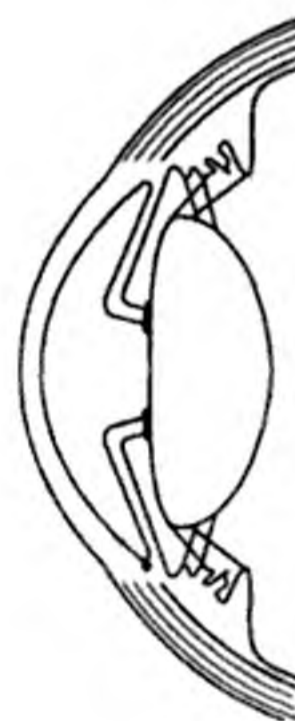

Fig. 40.1 Posterior synechia.

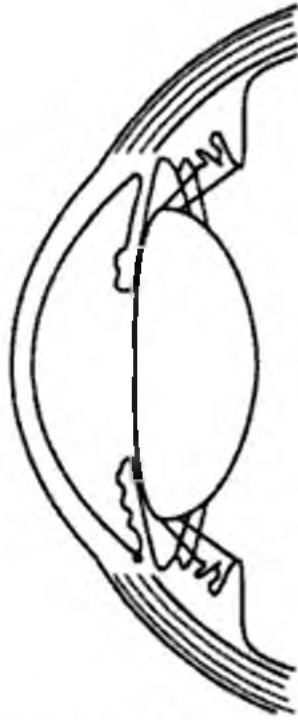


Fig. 40.2 Seclusio pupillae.

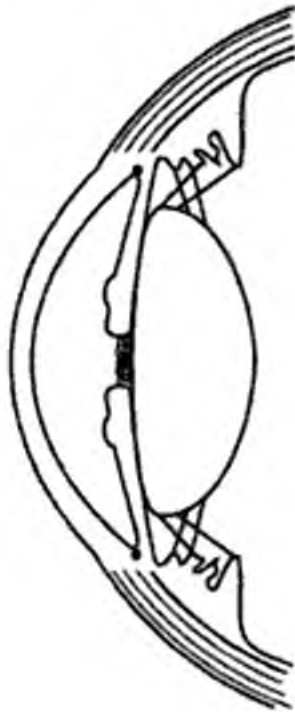


Fig. 40.3 Occlusio pupillae.

Complications and sequelae of posterior uveitis.

(i) Oedema of the optic disc and the macula may occur as a complication of a severe type of posterior uveitis. This is suspected when there is severe visual deterioration.

(ii) Retinal detachment may be either exudative as occurring in Vogt-Koyanagi-Harada syndrome, or traction following cyclitic membrane and vitreous shrinkage.

Treatment. Nonspecific. (a) Mydriatics and cycloplegics are most effective in the acute and exacerbation of chronic stage of anterior uveitis.

Atropine, 1 per cent drop or ointment

(if necessary, also by subconjunctival injection) is the most powerful, longest-acting and commonly used mydriatic and cycloplegic. It acts by:

- (a) putting the anterior uvea at rest
- (b) relaxing ciliary muscle spasm
- (c) dilating the pupil
- (d) preventing formation of or by breaking the posterior synechiae.

Initially it is used 4 hourly and when the pupil is fully dilated it is given twice daily. It is continued for 10 to 15 days after the eye appears to be quiet.

(b) Steroids are more effective in acute cases. Topical instillation or application, and if necessary subconjunctival injection of steroids are very effective in acute anterior uveitis, while systemic administration often with retrobulbar injection is necessary in posterior uveitis. They are essentially antiinflammatory agents, and they block the vascular and exudative reactions.

(c) Salicylates, phenylbutazone or derivatives, or antiprostaglandin agents like indomethacin are valuable in uveitis with rheumatoid affections.

(d) Symptomatic measures like hot formentations, dark glasses and analgesics, all provide relief from symptoms.

Specific measures. If aetiology is known then treatment of the cause like tuberculosis, leprosy and toxoplasmosis is essential.

Iridocyclitis (Anterior Uveitis)

The specific entities include:

- (a) HLA-related uveitis
- (b) Uveitis in juvenile rheumatoid arthritis
- (c) Infectious uveitis like tuberculosis, zoster, etc.
- (d) Traumatic uveitis
- (e) Glaucomatocyclitic crisis
- (f) Fuchs' heterochromic cyclitis

The chief varieties met with are acute iritis and chronic iridocyclitis.

Acute Iritis

There is sudden onset of a dull throbbing pain radiating to the periorbital region accompanied by

photophobia and lacrimation. There are marked ciliary injection and conjunctival hyperaemia. The cornea may be slightly hazy as a result of oedema and small keratic precipitates are common.

The aqueous is turbid and slit-lamp biomicroscopy reveals an aqueous flare. Because of obscuration of the crypts and collarettes the iris appears muddy. The pupil is constricted, sluggishly reacting and shows irregular pupillary margin with fine posterior synechiae. With adequate dilatation of the pupil these synechiae easily rupture. In a severe case the aqueous movement ceases and strands of fibrin accumulate over the anterior surfaces of the iris and the lens. This condition is called a *plastic iritis*.

An acute iritis needs to be differentiated from other conditions (Table 40.9).

Table 40.9
Differential Diagnosis of Acute Iritis

Points	Acute conjunctivitis	Acute iritis	Acute glaucoma
Onset	Gradual	Usually gradual	Acute
Pain	No	Moderate	Severe
Constitutional symptoms	Often absent	Occasionally present	Marked
Congestion	Conjunctival	Ciliary	Ciliary
Conjunctival discharge	Yes	No	No
Cornea	Clear	Usually KP	Hazy
Anterior chamber	Normal	Normal	Shallow
Pupil	Normal	Irregular	Dilated and fixed to light
Visual acuity	Normal	Impaired	Marked loss of vision
Ocular tension	Normal	Normal or subnormal	High

Attacks may last for 3 to 6 weeks. It subsides with almost no sequelae except some fine pigments over the anterior lens capsule.

Rothova et al²³ found the following characteristics in HLA B 27 positive cases of anterior uveitis:

- (a) Younger age group
- (b) More in males
- (c) Alternating recurrence

- (d) Unilateral
- (e) Plastic and fibrinoid aqueous
- (f) Absence of mutton-fat keratic precipitates (KPs)
- (g) More complications
- (h) Frequent association with spondyloarthropathy.

Chronic Iridocyclitis

Onset is insidious and the course is extremely chronic. There are a very few clinical signs, and hence the diagnosis is difficult. There are a few fine keratic precipitates disposed over a triangular area in the lower part. In a severe case the signs are as follows. There are slight ciliary congestion, ciliary tenderness, keratic precipitates and fine vitreous opacities. The anterior chamber deepens due to retraction of the iris by the synechiae.

If there is considerable visual deterioration without an obvious aetiology, an iridocyclitis should be suspected and a thorough slit-lamp examination is done.

Recurrence is common and every attack leaves a little permanent damage. Sometimes after many years the eye may turn phthisical. At other times there may be acute episode with aqueous flare, keratic precipitates and associated raised ocular tension. These features constitute the *Posner-Schlossman syndrome* of hypertensive iridocyclitic crises.

Cyclitis

A cyclitis of some degree is an invariable accompaniment of an iritis. Pain is more intense and ciliary tenderness is most marked. In a severe case there is profuse exudation from the ciliary body causing a plastic iridocyclitis and cyclitic membrane, later there is atrophy of the ciliary body resulting in ocular hypotony.

A chronic but characteristic form, *pars planitis*, has been described elsewhere in this chapter.

Choroiditis

Choroiditis may be classified as:

- (a) Nonsuppurative which may be granulomatous and exudative; and

(b) Suppurative.

Morphologically a nonsuppurative choroiditis may be: (a) diffuse—involving a large area; (b) disseminated—showing multiple, discrete areas of involvement; (c) circumscribed—frequently at the macula; and (d) juxtapapillary (Jensen)—besides the optic disc.

Clinical features. The symptoms include increasing blurring of vision, photophobia (fear of light), photopsiae (flashes of light) due to retinal irritation, micropsia (objects appearing smaller than they are) due to separation of the rods and cones, macropsia (objects appearing larger) due to crowding together of the rods and cones, and metamorphopsia (objects appearing distorted) due to alteration of the retinal contour, accompanied by scotomas (positive scotoma).

In the majority of choroiditis there is retinal involvement, *chorioretinitis*, while in some cases as in toxoplasmosis, the retinitis is primary and secondarily involves the choroid, *retinochoroiditis*. The affection is often bilateral and runs a chronic course.

An *active chorioretinitis* presents areas of greyish white patches with indistinct edges, lying at a deeper level than the retinal vessels, and often shows cloudy vitreous.

A *healed chorioretinitis* shows white areas due to fibrous tissue deposition and atrophy with pigment heaping around. Some specific lesions like toxoplasmosis and syphilis produce grossly visible pigmentation, while a severe lesion may show little pigmentation because of destruction of the pigment cells (Fig. 40c.1).

Pars Planitis^{1,3,5,10,19,22}

Syn. Intermediate uveitis, peripheral uveitis and chronic cyclitis.

Aetiology of pars planitis is precisely not known. Some of the cases are autoimmune in nature.

Pathology. It appears that the retinal venous system is the primary inflammatory focus. The vitreous shows fibroglial inflammatory exudate

(snow bank) with occasional neovascular element. The other changes include oedema and thickening of the pars plana with destruction of the pigment epithelium, vasculitis and perivasculitis, and nongranulomatous inflammation of the peripheral retina and choroid.

Clinical features. It is bilateral in about 70 per cent cases and occurs commonly in adults. The symptoms are insignificant and the signs are difficult to be elicited. It runs a mild course, hence, it is difficult to be diagnosed.

Slit-lamp biomicroscopy with contact lens, direct ophthalmoscopy and indirect ophthalmoscopy with scleral indentation may help in revealing the nature of the lesion.

Gelatinous exudate in the region of the ora serrata and pars plana particularly below, and the same in the region of the trabeculum, with vascular sheathing of the terminal vessels are characteristic.

The course may be variable. There may be gradual subsidence. Some cases develop chorioretinal detachment, cyclitic membrane and detachment of the retina. Sometimes there is occlusion of the retinal vessels. A chronic smoldering form is occasionally encountered which is characterized by multiple sequelae like peripheral anterior synechiae, posterior cortical cataract and retinal degeneration.

Treatment. Treatment is difficult. Kaplan¹⁴ advocated the following four-step approach:

Step 1—posterior subtenon injection of steroid

Step 2—if step 1 fails or the patient cannot tolerate steroid, cryotherapy of the vitreous base

Step 3—if step 2 fails, pars plana vitrectomy

Step 4—if above steps fail, immunosuppressive agents.

Panophthalmitis

There is an intense suppurative inflammation of the uveal tract with involvement of the whole eye.

Sometimes the suppurative inflammation may be limited to the choroid known as suppurative choroiditis, while rarely the purulent exudate may fill the vitreous causing a *vitreous abscess*.

Subacute endophthalmitis is rather common in children, and occurs due to infection elsewhere than the eye such as ear disease and specific fever.

Aetiology. Most commonly exogenous infection due to *Diplococcus pneumoniae*, *Strepto. haemolyticus*, *Staphylo. aureus*, and *Ps. pyocyanea* and less commonly endogenous conditions are causative factors.

Clinical features. These include: (a) severe pain, rapid loss of vision and constitutional symptoms; (b) features of severe proptosis with hazy vitreous; and pus usually pointing through the anterior part of the sclera.

Treatment. The principles are: (a) intense use of local and systemic antibiotics; (b) energetic treatment of uveitis; and (c) when the eye has no chance of survival an evisceration is the only choice left.

Uveitis in Bacterial Infections

Four important affections are described: leprosy, tuberculosis, syphilis and gonococcal infection.

Leprosy. Leprotic uveitis may manifest as acute iritis due to immune complex deposition or chronic iritis due to direct invasion of the iris by *Mycobacterium leprae*. The presence of *iris pearls* made up of histiocytes engulfing leprosy bacilli at the pupillary margin is the pathognomonic sign of lepromatous leprosy.

For details, see p. 406.

Tuberculosis of the Uveal Tract

Tuberculosis may affect any part of the uveal tract, is haematogenous in origin, and may affect either the anterior or the posterior uvea independently because of distinct blood supply to each part. This produces varying clinical pictures essentially determined by the degree of hypersensitivity and the degree of resistance.

Tuberculosis of the uveal tract may be divided into that of the anterior or posterior uvea. In the anterior uvea there may be: (a) granulomatous,

either miliary or conglomerate; and (b) exudative iritis. In the posterior uvea there may be: (a) acute or miliary; and (b) chronic which is diffuse, disseminated or conglomerate.

In the miliary type of iritis there are many small satellites which surround a yellowish-white nodule near the pupillary or ciliary margin of the iris. Presence of KPs indicates associated ciliary body involvement (Fig. 40.4). Occasionally there may be hyphaema or pseudohypopyon.

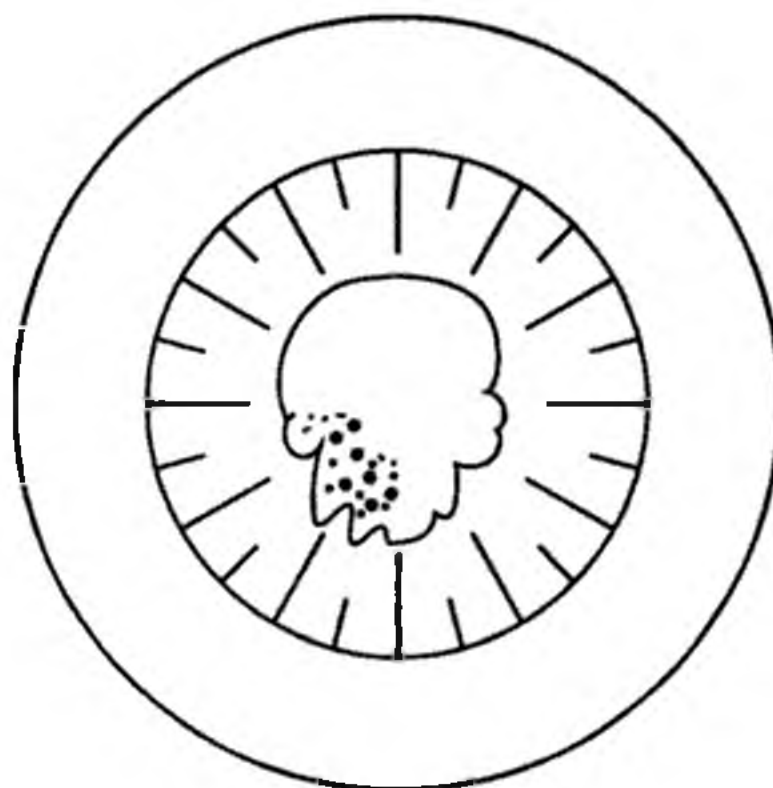


Fig. 40.4 Iridocyclitis. The pupil is irregularly dilated because of posterior synechiae. Several keratic precipitates are also seen.

Conglomerate tubercle shows less signs of iritis than the miliary form. Here there is a single, larger tubercle surrounded by the smaller satellites. Since it occurs at the sclerocorneal junction there is a chance of perforation at this region.

Exudative iritis follows tuberculous allergy. Its clinical features are no less different from those of any acute iritis. But two things are suspicious, mutton-fat KPs and Koeppe nodules.

Miliary tubercles of the choroid are found in acute miliary tuberculosis and tuberculous meningitis. Any portion of the choroid may be involved though the region near the optic disc is particularly prone. There are round yellow spots, widely variable in number.

There may be diffuse or disseminated choroiditis, but occasionally a conglomerate form may be detected. Perforation of the sclera may follow a conglomerate tubercle of the choroid.

Diagnosis. The features of granulomatous uveitis, chest X-ray, Mantoux test and tests for excluding sarcoidosis and syphilis are helpful. Negative Mantoux test is found in patients on systemic steroid therapy and in severe tuberculosis with presence of tuberculin anergy.

Treatment consists of isoniazid apart from local treatment of uveitis. Isoniazid combined with rifampin or ethambutol is more effective. If the eye is damaged and no treatment is feasible, excision may have to be resorted to.

Syphilis of the Uveal Tract²⁶

This may affect any part of the uveal tract.

Clinical features. These may be grouped under either those of (a) Iritis which is either congenital—an iritis is commonest in course of IK; or acquired. In secondary syphilis there are three types of lesions—*iritis roseata* showing small nets of capillaries, *iritis papulosa* showing highly vascular papules and *iritis nodosa* in which there are large yellowish-red nodules.

(b) Choroiditis. It is bilateral in 50 per cent cases and usually affects the midzone of the ocular fundus. It may be diffuse, disseminated or peripheral.

(c) Gumma of the ciliary body—rare.

Treatment. IM penicillin—600,000 units daily for 10 days.

Gonococcal Iritis

Gonococcal iritis is especially characterized by plastic exudate in the anterior chamber and rubeosis iridis. Treatment consists of intensive sulphonamide therapy apart from atropine and antibiotics.

Herpetic Keratoiridocyclitis⁶

The characteristic clinical picture of herpes simplex

is a dendritic keratitis which is usually associated with some iritis. Occasionally iridocyclitis may occur without any keratitis. Two types of keratoiridocyclitis are seen: (a) a mild iridocyclitis, probably toxic or allergic in nature; and (b) a severe exudative and haemorrhagic iridocyclitis, due to the virus invading the uvea.

Diagnosis is difficult in the absence of an associated keratitis. Sometimes there may be hyphaema. Sectorial atrophy of the iris pigment epithelium of small size near the pupillary margin and secondary glaucoma may occur.

Herpes Zoster Uveitis⁶

Iridocyclitis, which is almost invariable in herpes zoster ophthalmicus, usually appears synchronously with corneal involvement, but rarely it occurs late in the course of affection. Two types of iridocyclitis are met with: (a) a mild and transient variety, associated with corneal involvement; and (b) a severe diffuse exudative variety.

The pigment epithelium atrophy tends to occur near the iris root. Hyphaema may be present. Secondary glaucoma may ensue. Involvement of the posterior uvea is rare.

Toxoplasmosis

A focal necrotizing retinitis with solitary or multiple lesions is most characteristic. Ocular complications are liable to occur in association with the involvement of the central nervous system (CNS). Perhaps the chronic and progressively destructive lesions are the result of multiplication of this protozoa (sporozoa) in the retina. Toxoplasmosis is probably responsible for about 30 to 50 per cent of all posterior uveitis cases.

In infants the retinal involvement is primary in association with encephalitis.

In adults choroiditis is the primary event.

Clinical features (Fig. 40c.2). The clinical picture in infants is quite characteristic—bilateral, multiple, punched out chorioretinal lesions with heavily pigmented edges, especially affecting the macula.

Those children may present themselves with hydrocephalus, calcification in the brain and mental retardation. The newer lesions are satellites of the older lesions. An active toxoplasmic retinitis showed blurred margins. Recurrences are the result of rupture of the cysts of *toxoplasma* organisms. An acute acquired toxoplasmosis tends to produce lesion in one eye.

Uveitis in Noninfective Systemic Diseases¹³

The affections under this heading include ankylosing spondylitis, juvenile rheumatoid arthritis, Behçet's syndrome, sarcoidosis, Vogt-Koyanagi-Harada syndrome, multiple sclerosis and erythema nodosum.

Behçet's syndrome^{4,19}

Behçet's syndrome appears to be a virus infection of the neuroepithelium of the ciliary body and retina. Recently the virus has been isolated from the aqueous, buccal and genital ulcers, and from the blood during the viraemia stage. It is said to be associated with HLA-B5. CMI response is presumed to be responsible for tissue damage for this affection.

Clinical features may be enumerated as follows:

- (a) Severe iridocyclitis accompanied by hypopyon
- (b) Superficial corneal ulceration
- (c) Aphthous buccal ulcer
- (d) Genital ulcers and urethritis
- (e) Arthritis
- (f) Neurological signs.

Treatment consists of nonspecific measures like systemic steroids.

Reiter's syndrome

Associated with HLA B-27 this syndrome occurs in young males showing a triad of urethritis,

arthritis and conjunctivitis. An anterior uveitis is found to be associated in about 20 per cent cases.

Sarcoidosis^{12,13,24}

Sarcoidosis can cause ocular involvement in 25 to 50 per cent of cases. Almost any part of the eye and adnexa may be involved. This is responsible for about 4 per cent cases of uveitis. Uveitis occurring in association with skin plaques or erythema nodosum evokes suspicion of this affection. It is specially characterized by multiple iris nodules, gradually increasing in size on the surface and other manifestations of a granulomatous iridocyclitis. It sometimes causes bilateral panuveitis, involvement of the parotid glands and the cranial nerves, resulting in *Heerfordt's disease* or *uveoparotid fever*. Diagnosis is made from the clinical features, X-ray showing hilar adenopathy, non caseating granuloma seen by gland biopsy and sometimes by a positive Kveim test. Elevated serum lysozyme levels indicate such an affection when there is no systemic evidence of another granulomatous disease like tuberculosis.

Other diagnostic tests include biopsy of the skin and conjunctiva angiotensin-converting enzyme (ACE) level in the serum, the latter being raised in sarcoidosis.

Treatment Corticosteroids are the usual therapeutic weapon.

Vogt-Koyanagi-Harada syndrome^{17,24}

The cause is not precisely known. A viral aetiology is suspected. Zhang et al²⁷ have found this affection to be associated with HLA-DR in 75 per cent of cases.

The incidence is rare. The affection is common in young adults.

There are two phases in this disease, one occurring synchronously with or subsequently after the other: (a) *meningeal phase* is characterized by malaise, fever, headache and rarely manifestations of central nervous system involvement; and (b) *ophthalmic phase* is essentially characterized by bilateral, granulomatous panuveitis.

Some authors consider the cases under two groups: (a) involvement of the anterior uvea (Vogt-Koyanagi); and (b) involvement of the posterior uvea (Harada).

However, a typical case of Vogt-Koyanagi-Harada syndrome shows the following features: (a) bilateral uveitis, soon developing exudative retinal detachment in the inferior part; (b) poliosis of the hair and cilia; (c) vitiligo and dysacusia. The last two features are possibly related to pigment-metabolism disturbance.

Fluorescein angiography exhibits multiple discrete areas of subretinal haemorrhage.

Uveitis due to Hypersensitivity

Uveitis due to hypersensitivity is either due to autoantigens (lens or uveal pigment) or foreign antigens as in serum sickness.

Lens-induced Uveitis¹⁸

Chiefly there are two types, endophthalmitis phacoanaphylactica and phacotoxic uveitis.

Endophthalmitis phacoanaphylactica

In 1922 Verhoeff and Lemoine established this as a distinct clinicopathologic entity. Sometimes following operative procedures like extracapsular extraction of the lens and needling, and perforation of the lens due to trauma an inflammation may ensue after 24 to 48 hours. Histopathologically, the inflammatory reaction is located around the scattered lens fragments but chiefly in the anterior uvea. Clinical features include gross swelling of the lids and conjunctiva, mutton-fat KPs, and broad-based posterior synechiae. These may be sometimes accompanied by cyclitic membrane and corneal vascularization.

In a bilateral case differentiation needs to be done from sympathetic ophthalmitis. The first eye affected becomes usually inactive when inflammation starts in the second, while in a sympathetic ophthalmitis both eyes are highly inflamed.

Phacotoxic uveitis

Essentially phacotoxic uveitis occurs in an unopened eye and is due to toxic effects of the lens proteins. These proteins are liberated as a result of leakage through the lens capsule. The liberated substance mixes with the aqueous; it may be dissolved, digested and absorbed. In some cases it may combine with some adjuvant and become antigenic. Histopathologically, there is lens matter in the central part covered on its surface by the reactive cells. The cell types vary according to the severity of the inflammation. If the phacotoxic inflammation is more severe the cell necrosis is more.

Perhaps the chief reacting cell, lymphocyte, has antigen-recognition receptors and when it unites with a foreign matter like lens fragments it is sensitized to form autoantibodies and causes a violent inflammation.

The clinical features are less dramatic than those of endophthalmitis phacoanaphylactica. It chiefly affects the anterior ocular segment as evidenced by hazy cornea, secondary glaucoma apart from anterior uveitis. In a severe case there may be papillitis, retinal vasculitis and perivasculitis.

Treatment consists of removal of the lens matter along with use of atropine and topical steroids.

Idiopathic Specific Uveitis Syndrome^{1,19}

Idiopathic specific uveitis syndromes include:

- (a) Acute posterior multifocal placoid pigment epitheliopathy
- (b) Serpiginous peripapillary choroidopathy
- (c) Sympathetic ophthalmitis
- (d) Birdshot choroidoretinopathy
- (e) Recurrent multifocal choroiditis
- (f) Multiple evanescent white dot syndrome
- (g) Presumed ocular histoplasmosis
- (h) Retinal vasculitis.

Acute multiple placoid pigment epitheliopathy (AMPPE) (see p. 328)

Serpiginous peripapillary choroidopathy (see p. 328)

Sympathetic ophthalmitis^{1,24-26}

Sympathetic ophthalmitis is a very severe form of uveitis involving the previously normal eye due to a penetrating injury to the other eye. The injured eye is called 'exciting eye', while the uninjured one is called 'sympathizing eye'.

Aetiology. It is due to a penetrating injury involving chiefly the ciliary region, often with tissue incarceration (iris, ciliary body or lens).

The time interval between injury and onset of uveitis in the second eye is usually between three weeks to three months. It may be as early as 9 days and as late as 50 years.

The exact pathogenesis is not known. Normally there is no drainage of ocular antigens via the lymphatics. In sympathetic ophthalmitis following a penetrating injury, there is access to the conjunctival lymphatics. The inciting antigens are: (a) soluble (S) retinal antigen; (b) antigen from rhodopsin and (c) interphotoreceptor retinoid binding protein (IRBP). These three are able to produce a type of uveitis in experimental animals that clinically and histopathologically resembles sympathetic ophthalmitis.

In vitro tests such as lymphocytoblast transformation and leucocyte migration inhibition⁹ for demonstration of cellular immunity against the uvea in both sympathetic ophthalmitis and Vogt-Koyanagi-Harada syndrome have been reported.

Pathology. Histopathological features of both the exciting and sympathizing eyes are similar.²⁴

The following are characteristically present:

In early stage.

(a) Gross lymphocytic infiltration of the whole uvea

(b) Patchy aggregation of epithelioid cells

(c) Phagocytosis of the pigment. When small nodules of epithelioid cells containing phagocytosed pigment are found on the inner surface of Bruch's membrane which at this stage is intact, they are called *Dalen-Fuchs' nodules*.

In late stage.

(a) Sympathetic infiltration of the pigment epithelium of the anterior uvea

(b) The retina is not much involved because of intact Bruch's membrane.

Clinical features. When the symptoms persist and ciliary congestion does not disappear in the exciting eye suspicion for this affection arises.

Irritation and lacrimation appear in the sympathizing eye, and an early sign is the presence of an aqueous flare, followed by appearance of ciliary congestion and KPs. Sympathetic ophthalmitis is almost always a plastic iridocyclitis clinically differing in no respect from this form of iridocyclitis due to other causes. A chronic course runs for about six months to two years.

Treatment. Prophylactic treatment is more important. Excision of the severely injured eye earlier than 9 days after injury is indicated. Otherwise in an injured eye with relatively useful vision, treatment consists of that of iridocyclitis along with intensive steroid therapy.

If sympathetic ophthalmitis already develops treatment is difficult. Intensive topical, periocular and systemic steroid therapy combined with cycloplegics are essential. Seventy per cent of the cases improve with this therapy. The exciting eye may turn out to be better of the other, and therefore enucleation at this stage is not advocated.

Birdshot choroidoretinopathy

Birdshot choroidoretinopathy is a unilateral affection occurring in females between 30 and 70 years of age. In 80 to 90 per cent cases there is association with HLA A 29. Loss of vision is gradual. Ophthalmoscopically, there are multiple, cream coloured spots at the central and midperipheral zones of the fundus. The lesions are

located at the level of the RPE (retinal pigment epithelium). Treatment consists of systemic and periocular steroids.

Recurrent multifocal choroiditis

Recurrent multifocal choroiditis occurs in females between 20 and 40 years of age. There is relatively acute loss of vision. Multiple, small, discrete dots are found in the central and midperipheral zones of the fundus, the lesions being located at the level of the RPE. The sequelae include choroidal neovascular membrane and disciform scar.

Multiple evanescent white dot syndrome

Multiple evanescent white dot syndrome (MEWDS) occurs in young or elderly females and may follow a viral infection. Ophthalmoscopy exhibits multiple, 100 to 200 micron size, white dots commonly involving the posterior pole or perifoveal region sparing the fovea. The lesions are at the level of the RPE or deeper to the RPE. The spots clear in one area while making their appearance in another over a span of several days. Majority of the patients regain vision. The affection lasts for 3 to 10 years.

Presumed ocular histoplasmosis

Presumed ocular histoplasmosis is often due to *Histoplasma capsulatum*. About 62 per cent cases are bilateral. The fungi are inhaled into the lungs and they subsequently reach the blood stream. The ocular lesions include punched-out chorioretinal lesions, juxtapapillary changes and subretinal neovascular membrane (SRNVM). In acute cases high doses of steroids should be tried.

Uveitis in Children^{8,20}

This group comprises about 6 per cent of all uveitis cases, and in only about 50 per cent cases the causes are known.

Aetiology. The common causes of anterior uveitis in children are tuberculosis, rheumatoid affection and heterochromia.

The common causes of posterior uveitis in children are toxoplasmosis and tuberculosis.

Clinical features. The symptoms are mild and the signs are minimal. Two common clinical types are:

(a) Chronic iridocyclitis. The course is comparatively severe with the presence of broad posterior synechiae.

(b) Acute choroiditis. It presents with generalized subretinal oedema and papillitis.

Diagnosis. diagnostic procedures for uveitis in children should include:

- (a) Complete blood count
- (b) Urine examination
- (c) Erythrocyte sedimentation rate (ESR)
- (d) Total serum protein and albumin-globulin ratio
- (e) Serologic test for syphilis
- (f) Tests for toxoplasmosis—e.g. haemagglutination test
- (g) Skin tests—e.g. Mantoux test
- (h) Stool examination for ova, parasites and cysts
- (i) X-ray of the skull, chest and small bones
- (j) Lymph node and conjunctival biopsies.

Heterochromic Cyclitis of Fuchs

Aetiology.¹⁶ The cause is obscure. The affection has been presumed to be inflammatory rather than degenerative, while others consider it to be an immunologic response. It may be hereditary and developmental.

Clinical features. The condition is common between the age of 30 to 40 and is usually unilateral. The onset is insidious and the affection is essentially asymptomatic. The chief characteristics are heterochromia and absence of ciliary congestion as well as posterior synechia. Note that heterochromic iridum and heterochromic iridis are different conditions; in the former colour of one sector of the iris is different from the rest, and in the latter colour of two irides are different. Slit-lamp biomicroscopy reveals fine white KPs in the central or lower part of the cornea.

Diagnosis. Diagnosis is difficult. A retrospective diagnosis can be done while the patient presents with either secondary cataract even up to 70 per cent or secondary glaucoma (about 15–20%).

Treatment. Treatment is not needed unless there is secondary cataract or glaucoma. Steroids have very little influence.

Pseudoglioma

The term pseudoglioma can be applied to a variety of ocular affections that often mimic retinoblastoma by presenting a white reflex at the pupil (Fig. 40.5).

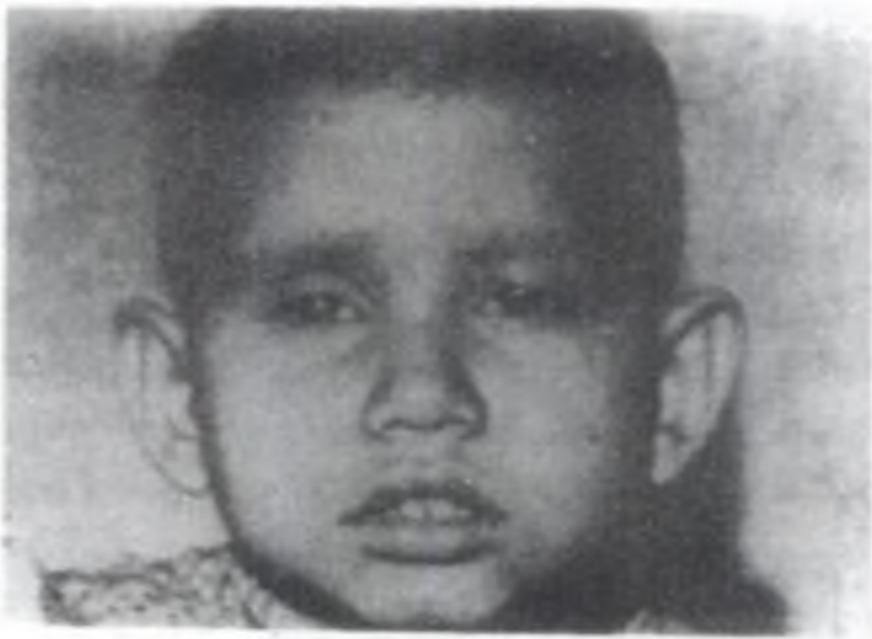

Fig. 40.5 White reflex at the pupil. Right eye (Dr. S. Banerjee).

Aetiology. (a) Endophthalmitis—the most important cause

(b) Cyclitic membrane—behind the lens, and it occurs in plastic iridocyclitis

(c) Conglomerate tubercle of the choroid

(d) Retrolental fibroplasia

(e) Persistent vascular sheath of the lens

(f) Coats' disease

(g) *Toxocara canis* infection

(h) Retinal dysplasia

(i) Retinoschisis

(j) Medulloepithelioma.

Endophthalmitis

Endophthalmitis is a severe condition characterized by inflammation of the intraocular tissues of the eye without extension of the inflammation beyond the sclera. But in panophthalmitis there is inflammation of the three coats of the eye and Tenon's capsule.

Aetiology. (a) Most commonly it is an acute process following an intraocular operation, the incidence rate varying between 0.05 per cent and 3 per cent. The aetiological factors are either bacterial such as *Staphylococcus aureus*, *Pseudomonas pyocyaneus*, pneumococcus and streptococcus, or fungal such as *Aspergillus fumigatus*, *Candida albicans* and *Nocardia asteroides*.

(b) Endophthalmitis may be a long-drawn inflammation, as after a filtering operation.

(c) It may follow a penetrating injury.

(d) It is sometimes metastatic from extraocular sources like otitis and septic arthritis.

Clinical features. The onset of symptoms and signs are variable depending upon the virulence of the organism. A bacterial endophthalmitis develops between 1 and 4 days, while a fungal endophthalmitis may ensue weeks to months after surgery.

In acute postoperative endophthalmitis there is pain and redness, the conjunctiva is somewhat chemosed, the cornea becomes hazy, as well as hypopyon and vitreous haze are present. There is also loss of vision.

Treatment. (a) Cultures done preferably from the aqueous and vitreous and sensitivity test to antibiotics are perhaps better performed.

(b) Treatment with suitable systemic antibiotics is recommended in addition to management of the primary condition.

(c) In the absence of a fungus infection, systemic steroids are safe and efficacious.

(d) Vitrectomy is indicated when all other attempts to control the inflammation fail.

Iris Cysts⁶

Aetiology. An iris cyst may be due to any of the following causes: (a) developmental; (b) traumatic implantation; (c) retention or exudative; (d) parasitic; (e) degenerative; (f) miotic; and (g) idiopathic.

Clinical features. The cysts are located in the stroma or in the epithelium near the pupil or root of the iris. The features are:

- (a) The cysts are often multiple
- (b) Tremulousness of the iris is sometimes observed
- (c) Loculation in the cyst may be found
- (d) Mobility of the pupil is disturbed
- (e) The cysts may appear translucent
- (f) Sometimes sequelae like iridocyclitis and secondary glaucoma may be found.

Diagnosis. Diagnosis is based on:

- (a) History—past history of trauma or operation, duration and rate of progress.
- (b) Clinical examinations—
 - (i) Thorough search for a perforating wound
 - (ii) Unusual pigmentation
 - (iii) Sluggish pupil reaction
 - (iv) Presence of neovascularization of the iris
 - (v) Proper mydriasis and full examination of the pupillary area are essential.
- (c) Special examinations include indirect ophthalmoscopy, gonioscopy and transillumination.

Treatment. Treatment depends on site, size and progress of the cyst.

- (a) An iridectomy is advocated if the cyst is small, if it is localised and if the tissues are not infiltrated.
- (b) Wide excision of the iris is recommended when diagnosis is more in favour of a neoplasm than that of a cyst.
- (c) Argon laser or xenon photocoagulation has also been advocated in some cases.

Disturbances of the Circulation⁶

Disturbances of the circulation include

neovascularization in the anterior and posterior uvea, haemorrhage, hyperaemia, anaemia, embolism and thrombosis.

Rubeosis Iridis

It may follow longstanding uveitis, diabetes mellitus, central retinal vein thrombosis, etc.

Rubeosis iridis (Lat. *ruber, red*) consists of new vessels in the iris, especially at its root and in the angle of the AC. The condition terminates in intractable secondary glaucoma.

The initial events are hypoxia of such a degree that cannot cause tissue destruction and venous stasis, which leads to exudation of some vasogenic substance.

Treatment is ineffective. The measures advocated are panretinal photocoagulation (PRP), goniophotocoagulation, trabeculectomy and cyclocryotherapy.

Masquerade Syndromes¹⁹

Masquerade syndromes indicated in Table 40.10 are said to masquerade as primary uveitis.

Table 40.10
Masquerade Syndromes

Intraocular lymphoproliferations
Retinoblastoma
Retinal detachment
Retinal degenerations
Intraocular foreign body
Pigment dispersion syndrome
Postoperative infection

Uveal Effusion¹

Aetiology. The causes are listed under Table 40.11.

Clinical features. In the anterior type the picture may vary depending on the cause, if it is inflammatory the signs are cells, keratic precipitates, fibrin, synechia and often lowered ocular tension. In the posterior type two common

Table 40.11
Causes of Uveal Effusion

Inflammatory
Trauma
Postoperative
Scleritis
Chronic uveitis
Sympathetic ophthalmitis
Vogt-Koyanagi-Harada Syndrome
Postcryo/postphotocoagulation
Hydrostatic
Hypotony
Wound leak
Idiopathic

features are nonrhegmatogenous retinal detachment and choroidal detachment.

Neovascularization in the Posterior Segment

Neovascularization in the posterior segment may be present in inflammatory and degenerative conditions. The choroidal vessels proliferate through dehiscences in Bruch's membrane to reach the retina. The causes include:

- (a) Long-standing diabetes
- (b) Central retinal vein thrombosis
- (c) Eales' disease
- (d) Chronic uveitis
- (e) Iris tumours like haemangioma
- (f) Coats' disease
- (g) Retinoblastoma
- (h) PHPV (persistent hyperplastic primary vitreous)
- (i) Vascular diseases like carotid artery affection and giant cell arteritis.

Haemorrhage in the Uvea⁶

Apart from an injury such a haemorrhage may be due to the following factors:

- (a) Overdistension of the vessels due to circulatory disturbance, e.g. central retinal vein thrombosis
- (b) Fragility of the vessels following vasosclerosis—atrophic and local

(c) Blood disorders as in anaemia, leucaemia, purpura and haemophilia

(d) Neovessels of the uvea

(e) Vascularized tumours as in angioma, lymphosarcoma and juvenile xanthogranuloma.

Degenerative Changes in the Uvea⁶

In the Iris

Apart from depigmentation and atrophy of the stroma, the rare but definite entity is essential atrophy of the iris. Still rarely there may be *iridoschisis* characterized by a localized cleavage of the stroma into two—anterior and posterior halves. The anterior leaf separates into fibrils.

Essential atrophy of the iris. Aetiology is unknown. It starts insidiously in early adult life and is usually unilateral. There is slow progressive iris atrophy, finally leading to formation of large lacunae in the iris and is often accompanied by secondary glaucoma. Glaucoma is due to downgrowth of an endothelial membrane over the tissues at the angle of the AC.

In the choroid

Degenerative changes are relatively common in the choroid. They may be:

(a) Primary is usually bilateral condition and includes:

- (i) Senile central choroidal atrophy
- (ii) Central areolar choroidal atrophy or sclerosis
- (iii) Myopic choroidoretinal degeneration
- (iv) Senile macular degeneration
- (v) Disciform degeneration of the macula
- (vi) Essential (gyrate) atrophy of the macula
- (vii) Choroideraemia
- (viii) Primary choroidal sclerosis
- (ix) Angioid streaks
- (x) Pseudoinflammatory macular dystrophy.

(b) Secondary—typically postinflammatory.

Senile central choroidal atrophy. Colloid bodies or drusens are hyaline excrescences on the surface of the choroid. These may accumulate in the macular area and when they occur in the elderly, they assume the form of 'central guttate choroidal atrophy' (Tay's choroiditis).

Central areolar choroidal atrophy (sclerosis). There is an oval patch of choroidal atrophy in the macular region, with visibility of the choroidal vessels and the sclera, accompanied by loss of vision and absolute central scotoma. It is often genetically determined.

Essential (gyrate) atrophy of the choroid. It involves practically the whole of the fundus except the macula. It is caused by defective activity of the enzyme, ornithine ketoacid aminotransferase. It is an autosomal recessive affection.

Choroideraemia is a hereditary affection and resembles clinically the terminal stage of essential atrophy of the choroid. Night blindness is a prominent symptom.

Primary choroidal sclerosis. Primary choroidal sclerosis occurring in two forms, diffuse and localized, is a degenerative condition associated with retinal degenerative and pigmentary changes. Histologically, there is atrophy or fibrous replacement of the muscular coat of the choroidal vessel wall. The localized type may affect peripapillary area or the central area. It is evidenced by tessellation of the fundus in which the affected choroidal vessels are seen along with pigment clumpings.

Treatment of choroidal degenerations. In the initial phase magnifying reading aids facilitate reading. Argon laser photocoagulation is indicated only in cases wherein there is a separation of pigment epithelium.

Pseudoinflammatory macular dystrophy. It is a heredodegenerative dystrophy symmetrically involving both maculae evidenced by oedema, haemorrhages and exudates. The condition finally turns into a generalized choroidal atrophy.

Congenital Anomalies of the Uvea⁷

These are:

- (a) Colobomata
- (b) Heterochromia
- (c) Albinism
- (d) Aniridia
- (e) Persistent pupillary membrane
- (f) Anomalies of the pupil, e.g. anisocoria or

unequal pupil, polycoria or multiple pupils, and corectopia or eccentric pupil

(g) Anomalies of pigmentation.

Colobomata. It results from defective closure of the foetal fissure situated in the inferior sector, possibly the defect being due to the presence of persistent fibrovascular sheath of the lens. If the defective closure occurs in later stage of intrauterine life, the coloboma is limited to the iris only.

They are usually bilateral and typical, pear-shaped and sometimes associated with other anomalies. Dominant hereditary inheritance has been documented.

Heterochromia. Two irides are significantly different in colours. Sometimes the condition may be associated with Horner's syndrome (sympathetic heterochromia) and iridocyclitis. There are five types: (a) simple; (b) sympathetic; (c) complicated; (d) associated with ocular disorders; and (e) associated with systemic disorders.

Albinism. This recessive hereditary condition leads to defective development of the pigment, which may be total or partial, the latter more common. It is characterized by nystagmus, photophobia, visual deterioration, pink iris and retina, gross visibility of the retinal and choroidal vessels and of the sclera. Treatment is palliative consisting of tinted glasses and optical aid.

Aniridia or irideraemia. The term is a misnomer, because rudimentary iris is always present. It is dominant hereditary and usually bilateral condition characterized by the presence of large pupil, photophobia, poor vision, nystagmus and is often accompanied by secondary glaucoma. The cause is possibly a primary defect in the neural ectoderm or aberrant development of the mesoderm.

Persistent pupillary membrane. Tunica vasculosa lentis, having anterior and posterior parts, totally disappears at or before birth. But sometimes there is failure of the normal atrophy of the anterior part of this vascular sheath resulting in persistent pupillary membrane. This occurs about the 7th or 8th month of foetal life. It is characterized by fine threads usually attached at the iris collarette,

unaccompanied by any evidence of inflammation and defective vision. The condition needs differentiation from posterior synechiae.

Anomalies of pigmentation. These anomalies are as follows:

- (a) Hypoplasia of the pigment layer
- (b) Hyperplasia of the pigment layer
- (c) Hyperplasia and ectropion of the pigment border
- (d) Entropion of the pupillary border of the iris
- (e) Reduplication of the pigment border of the iris.

Further Reading

1. Albert, D.M. and Jacobiec, F.A. (Eds.), *Principles and Practice of Ophthalmology: Clinical Practice*, W.B. Saunders, Philadelphia, 1994.
2. Biswas, J., Investigational approach in uveitis. In *Modern Ophthalmology*, Dutta L.C. (Ed.), Jaypee Bros., New Delhi, 1994, p. 520.
3. Brockhurst, R.J., Schepens, C.L. and Okamura, O.D., Peripheral uveitis-clinical description complications and differential diagnosis. *Am. J. Ophthalmol.*, 49:1257, 1960.
4. Charteris, D.G., Champ, C., Rosenthal, A.R., et al., Behcet's disease: Activated T lymphocytes in retinal perivasculitis. *Br. J. Ophthalmol.*, 76:499, 1992.
5. Coles, R.S., Uveitis. In *Modern Ophthalmology* (2nd ed.), Sorsby, A. (Ed.), Vol. 4:689, Butterworths, London, 1972.
6. Duke-Elder, S., *System of Ophthalmology*, Vol. IX: *Diseases of the Uveal Tract*, Duke-Elder, S. and Perkins, E.S. (Eds.), Kimpton, London, 1966.
7. Duke-Elder, S., *System of Ophthalmology*, Vol. III: *Normal and Abnormal Development*, Part 2: *Congenital Deformities*, Kimpton, London, 1963.
8. Hallet, J.W., Disorders of the uveal tract. In *Pediatric Ophthalmology*, Harley, R.D. (Ed.), W.B. Saunders, Philadelphia, 1975.
9. Hammer, H., Cellular hypersensitivity to uveal pigment confirmed by leucocyte migration test in sympathetic ophthalmitis and the Vogt-Koyanagi-Harada syndrome. *Br. J. Ophthalmol.*, 58:773, 1974.
10. Hogan, M.J., Kimura, S.J. and O'Connor, R., Peripheral retinitis and chronic cyclitis in children. *Trans. Ophthalmol. Soc., UK*, 85:39, 965.
11. Hogan, M.J., Kimura, S.J.T and Thygeson, P., Signs and symptoms of uveitis, Part I: Anterior uveitis. *Am. J. Ophthalmol.*, 47:155, 1959.
12. James, D.G., Anderson, R., Langley, D. and Ainslie, D., Ocular Sarcoidosis. *Br. J. Ophthalmol.*, 48:81, 1964.
13. Kanski, J.J., *Clinical Ophthalmology* (3rd ed.), Butterworth-Heinemann, London, 1994.
14. Kaplan, H.J., Intermediate uveitis (pars planitis, chronic cyclitis)—a four-step approach to treatment. In *Uveitis Update*, Saari, K.M. (Ed.), Excerpta Medica, 1984, p. 169.
15. Kimura, S.J., Thygeson P., and Hogan, M.J. Signs and symptoms of uveitis, Part II: Classification of the posterior uveitis. *Am. J. Ophthalmol.*, 69:1, 1970.
16. Lowenfeld, I.E. and Thompson, H.C., Fuchs heterochromic cyclitis: Critical review of the literature, II. Etiology and Mechanism. *Surv. Ophthalmol.*, 18:12, 1973.
17. May, C., *May's Manual of the Diseases of the Eye* (24th ed.), Allen, J.H. (Ed.), Williams and Wilkins, Baltimore, 1968.
18. Müller, H., Lens-induced uveitis (phacogenic ophthalmia). *Trans. Ophthalmol. Soc., UK*, 83:689, 1963.
19. Nussenblatt, R.B., Whitcap, S.M. and Palestine, A.C. (Eds.), *Uveitis: Fundamentals and Clinical Practice* (2nd ed.), Mosby, St. Louis, 1996.
20. Perkins, E.S., *Uveitis and Toxoplasmosis*, Churchill, London, 1961.
21. Perkins, E.S. Pattern of uveitis in children. *Brit. J. Ophthalmol.*, 50:169, 1966.

22. Podos, S. and Yanoff, M., *Textbook of Ophthalmology*, Vol. 2: *The Uvea*, Rao, N.A., Forster, D.J. and Augsburger, J.J. (Eds.), Gower Medical Publishing, New York, 1992.
23. Rothova, A., van Veenendol, W.G., Linsen, A., et al., Clinical features of acute uveitis. *Am. J. Ophthalmol.*, 103:137, 1987.
24. Tessler, H., Uveitis. In *Principles and Practice of Ophthalmology*, Peyman, G.A., Sanders, D.R. and Goldberg, M.F. (Eds.), W.B. Saunders, Philadelphia, 1980, p. 1554.
25. Wacker W.B., Experimental allergic uveitis. *J. Immunol.*, 199:1949, 1977 (Cited in. *Clinical Ophthalmology*, Duane, C.D. (Ed.), Vol. 4, Harper and Row, 1981).
26. Woods. A.C. *Endogenous Inflammations of the Uveal Tract*, Williams and Wilkins, Baltimore, 1961.
27. Zhang, Y.V., Wang, Y.M. and Hu, T.S., Profiling human leucocyte antigens in Vogt-Koyhanagi-Harada syndrome. *Am. J. Ophthalmol.*, 113:567, 1992.

41. PUPILLARY DISORDERS

The size and action of the pupils are the result of the combined actions of two physiologically antagonistic systems, the parasympathetic and sympathetic, the former always predominating.

Functions of pupillary contraction are:

- (a) regulation of the amount of light reaching the retina; (b) increase in the depth of focus for near objects, and (c) reduction of optical aberrations.

Pupillary Pathways^{1,4} (Fig. 41.1)

Pupillary pathways have been summarised as follows:

Parasympathetic. (a) Cortical control—

- (i) Excitatory—from the frontal and occipital cortex.
(ii) Inhibitory—from the frontal cortex.

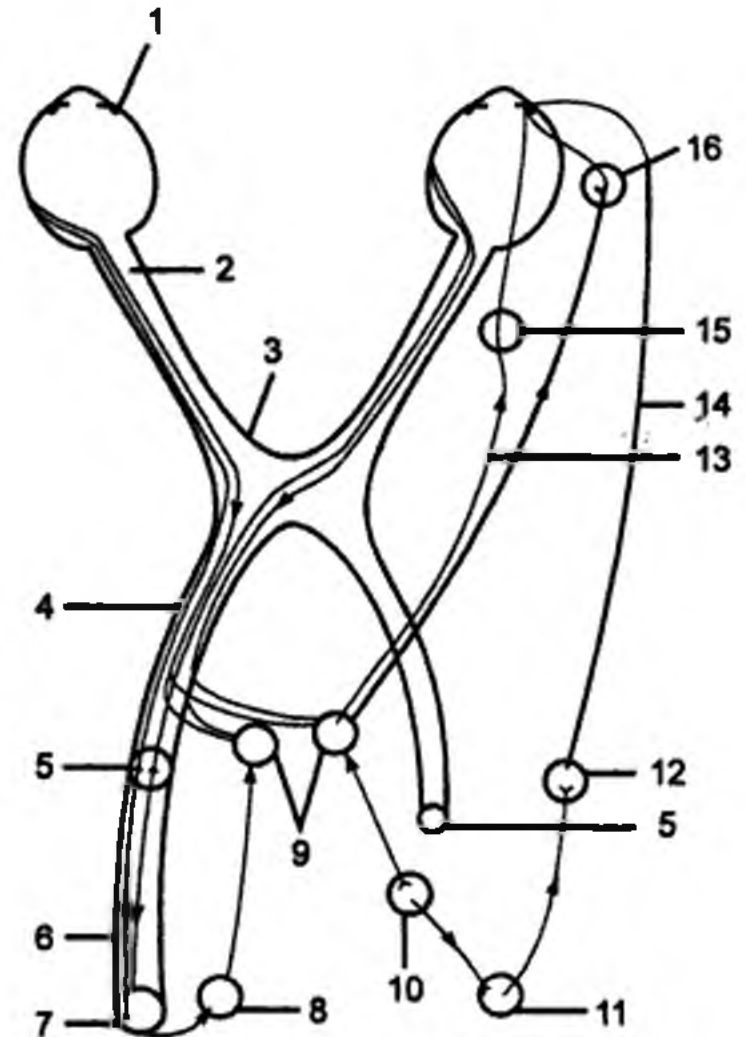


Fig. 41.1 The pathways of light and accommodation reflexes: 1, iris; 2, optic nerve; 3, optic chiasma; 4, optic tract; 5, lateral geniculate body; 6, optic radiations; 7, visual cortex; 8, centre in occipital cortex; 9, Edinger-Westphal nucleus; 10, hypothalamic sympathetic centre; 11, ciliospinal centre; 12, superior cervical ganglion; 13, oculo-motor nerve; 14, cervical sympathetic nerve; 15, ciliary ganglion; and 16, accessory ciliary ganglion.

(b) Sympathetic inhibitory control—from the hypothalamic centre.

(c) Pathways—

Edinger-Westphal nucleus→third nerve→inferior division→nerve to the inferior oblique.

(i) *Light reflex*—short root of ciliary ganglion→ciliary ganglion→short ciliary nerves→sphincter of the iris.

(ii) *Near reaction*—leaves the third nerve near at an unknown point→accessory ganglion→sphincter of the iris.

Sympathetic. The pupillodilatator tract probably starts in the hypothalamus and the fibres descend to the lateral columns in the cord known as the *ciliospinal centre of Budge*. They subsequently leave by ventral roots of C₈, T₁, T₂ and T₃, and enter the cervical sympathetic chain.

The postganglionic fibres from the superior cervical ganglion then enter the skull with the carotid plexus→cavernous plexus→along the first division of the trigeminal→nasociliary nerve→enter the globe→traverse the suprachoroidal space and terminate in dilatator pupillae.

Pupillary Reflexes

Classification. There are two types of reflexes:

- (a) Light reflex
- (b) Reflex to darkness, the *Marcus Gunn pupillary phenomenon* in which the consensual darkness reflex predominates when there is diminution or loss of pupillary activity of one eye
- (c) Near reaction
- (d) Trigeminal reflex
- (e) Psychosensory reflex

Light reflexes. When light enters an eye, it causes contraction of the pupil of the same side (direct light reflex) as well as that of the other side (consensual or indirect light reflex). The degree of constriction varies according to the intensity of the light and state of adaptation of the eye. On flashing a light there is a latent period, 0.2 to 0.5 seconds, followed by contraction having three phases—the primary lasting up to 0.4 seconds, the secondary varying between 0.3 and 0.4 seconds and the tertiary lasting for 0.3 and 0.4 seconds. On withdrawal of light there is a second latent period of 0.2 to 0.5 seconds followed by dilatation having three phases—small primary, fast secondary and slow tertiary.

Near reaction. Pupillary contraction occurs on looking at a near object, essentially a synkinesis occurring along with associated movements of the medial recti (convergence) and the ciliary muscle (accommodation). All the three processes are served by the third nerve.

Trigeminal reflex. Unilateral stimulation of the cornea, conjunctiva and eyelids causes both pupils to dilate slightly and then to constrict.

Lid-closure reflex or orbicularis reflex. This takes place in the presence of an active orbicularis muscle. There is pupillary constriction on attempt of closing the lids. Perhaps there are fibres in the orbicularis derived from the third nerve.

Psychosensory reflex. Here there is dilatation of the pupils due to stimulation of any sensory nerve with the exception of the fibres innervating the eye and the adnexa.

Mydriasis

Mydriasis is abnormal dilatation of the pupil. Chiefly the causes are:

- (a) Drugs—mainly:
 - (i) Parasympatholytics like atropine and homatropine
 - (ii) Sympathomimetics like phenylephrine and epinephrine
- (b) Third nerve lesion
- (c) Glaucoma, usually—(paralytic mydriasis) acute
- (d) Optic neuritis
- (e) Optic atrophy
- (f) Retinal detachment
- (g) Paralytic parasympathetic lesions
- (h) Irritative sympathetic lesions (spastic mydriasis)

Miosis

Miosis is abnormal constriction of the pupil. Chiefly the causes are:

- (a) Drugs mainly due to miotic therapy like pilocarpine and eserine.
- (b) Iritis
- (c) Irritative lesions of the parasympathetic spastic miosis
- (d) Paralytic lesions of the sympathetic pathways (paralytic miosis)

Abnormal Pupillary Reflexes

Abnormal pupillary reflexes include:

- (a) Adie's tonic pupil
- (b) Sluggish reaction in myotonic dystrophy
- (c) Tonohaptic reaction evidenced by extremely long latent period prior to both contraction and dilatation, and followed by short but prompt movement
- (d) Cog-wheel pupil reactions occur in a series of steps
- (e) Segmental contraction of the pupil

(f) Paradoxical pupillary reflexes or reverse pupillary reflexes either in the form of light reflex or near reflex may be found; in the former pupil dilates on illumination and contracts on withdrawal of light, and in the latter the pupil markedly dilates to convergence and constricts on looking at the distant object.

(g) Psychological associated reflexes.

Neurologic Significance of the Abnormalities in the Pupil

According to Hollenhorst,² there are five different groups:

1. Pupils of normal size

(a) Adie's pupil. One pupil reacts slowly to both light and accommodation.

(b) Lesion in afferent arc. Direct reaction is disturbed while consensual reaction persists.

(c) If both pupils react poorly or do not react to light and accommodation they indicate: (i) midbrain lesion; (ii) lesion in the afferent arcs for both eyes; or (iii) bilateral Adie's pupil.

2. Both pupils contracted

(a) But react well they suggest that either: (i) they are normal; or (ii) there is bilateral lesion of the midbrain, pons and medulla.

(b) React poorly to light but nicely to accommodation point to a lesion in the afferent arc at the pretectum.

(c) React poorly to accommodation but nicely to light indicates lesion in pathway between the convergence centre and the Edinger-Westphal nucleus.

3. Both pupils dilated

(a) React well they are probably not pathological, may accompany myopia.

(b) Wide dilatation plus sluggish or absent reaction occurs in a condition like diencephalic irritative lesion.

(c) React poorly to light or accommodation or both they point to: (i) bilateral afferent tract lesion; (ii) midbrain lesion; or (iii) bilateral Adie's pupil.

4. One pupil normal, the other small

indicates: (a) physiologic anisocoria; (b) Adie's pupil; (c) Horner's syndrome; or (d) pretectal lesion.

5. One pupil normal, the other dilated

indicates: (a) physiologic anisocoria; (b) unilateral III nerve lesion; or (c) Adie's pupil.

Anisocoria

Anisocoria means unequal size of the pupils. The normal difference in diameter is less than 1 to 2 mm. This is seen in about 20 per cent of apparently normal individuals, called *physiologic anisocoria*. The difference in size of the pupils persists in physiologic, but increases or decreases in *pathologic anisocoria*.

Aetiology (refer to Table 41.1).

Table 41.1

Causes of Pathologic Anisocoria

Iridocyclitis
Acute closed-angle glaucoma
Oculomotor nerve palsy
Optic neuritis
Adie's pupil
Argyll Robertson pupil
Homer's syndrome
Rupture of iris sphincter
Aniridia
Essential atrophy of the iris
Mydriatics
Miotics

Diagnosis. The following flow chart may help in arriving at a precise diagnosis (Fig. 41.2).

Leukocoria (Fig. 40.5) (Syn. White pupil, cat's eye reflex)⁶

Retinoblastoma. This usually occurs in infancy. It is bilateral in about 20 to 30 per cent of cases. It is sometimes hereditary with dominant mode of inheritance. The patient's parents notice a yellowish white reflex from the pupil, an amaurotic




Fig. 41.2 Flow chart for diagnosis of anisocoria.

cat's eye reflex. Ophthalmoscopic examination is mostly confirmatory.

Cataract. Cataract may be developmental, traumatic or due to other causes. History and clinical examination confirm the diagnosis.

Endophthalmitis. It is one of the causes of pseudoglioma. This is often confused with a retinoblastoma. In this affection there is usually among others history of infective fevers and ear infection. It is usually unilateral. In the advanced stage, there is involvement of the vitreous by massive exudation. Ocular tension is low.

Coats' disease. It produces white reflex at the pupil when the exudates in the retina lead to a retinal detachment. The other important finding is the presence of telangiectasia of the retinal vessels. The condition is invariably unilateral. It occurs commonly in young males.

Organized vitreous haemorrhage. There are varied causes of a vitreous haemorrhage. Apart from history and clinical examinations, indirect ophthalmoscopy is of significant help in localizing the haemorrhage which is more often in the inferior sector.

Retinal detachment. Diagnosis depends upon accurate clinical examinations, particularly by ophthalmoscopy can exclude retinoblastoma.

Exudative retinitis or chorioretinitis. An exudative lesion in the advanced stage causes exudation in the retina and vitreous, and produces marked vitreous haze.

Coloboma of the choroid and retina. Indirect ophthalmoscopy reveals a flat lesion with pigmented margins, while retinoblastoma always shows an elevated mass.

High myopia with chorioretinal degeneration. It rarely shows white reflex at the pupil.

Retrolental fibroplasia. The condition is bilateral and symmetrical, occurring in an immature infant who has received high concentrations of oxygen. The white reflex at the pupil is produced when the whole retina is detached and becomes vascularized, seen in the advanced stage of the affection.

Persistent hyperplastic primary vitreous (PHPV). In PHPV there is often an opaque retrolental mass. The distinguishing features by which it can be differentiated from retinoblastoma are enumerated below:

- (a) PHPV is almost always unilateral.
 (b) The affected eye is microphthalmic.
 (c) Retrolental mass is characteristic. In retinoblastoma it is present when the eye is filled up with the tumour.
 (d) There is early cataract. It is rare in retinoblastoma.
 (e) Elongated ciliary processes are seen. It is absent in retinoblastoma.
 (f) It is associated with hyaloid remnants, not so in retinoblastoma.

Retinal dysplasia. It is a gross retinal anomaly, developmental, bilateral and it occurs in an infant, particularly in association with trisomy 13 syndrome. The eyes are microphthalmic and there are multiple systemic abnormalities.

Angiomatosis retinae. It rarely produces leukocoria. Secondary retinal detachment occurring in late stage may give rise to white reflex at the pupil.

Larval granulomatosis is caused by *Toxocara canis*. This produces an elevated mass in the fundus with much vitreous reaction, occurring in young children. The condition is unilateral. It is contacted from a pet, usually a dog.

Irregular pupil (Fig. 41.3)

Causes are:

- (a) Posterior synechiae
- (b) Peripheral iridectomy
- (c) Sector iridectomy
- (d) Iridodialysis
- (e) Iris prolapse
- (f) Coloboma of the iris
- (g) Essential atrophy of the iris
- (h) Corectopia
- (i) Adherent leucoma.

Amaurotic pupil

When there is absence of light perception the pupil on the affected side shows the following characteristics:

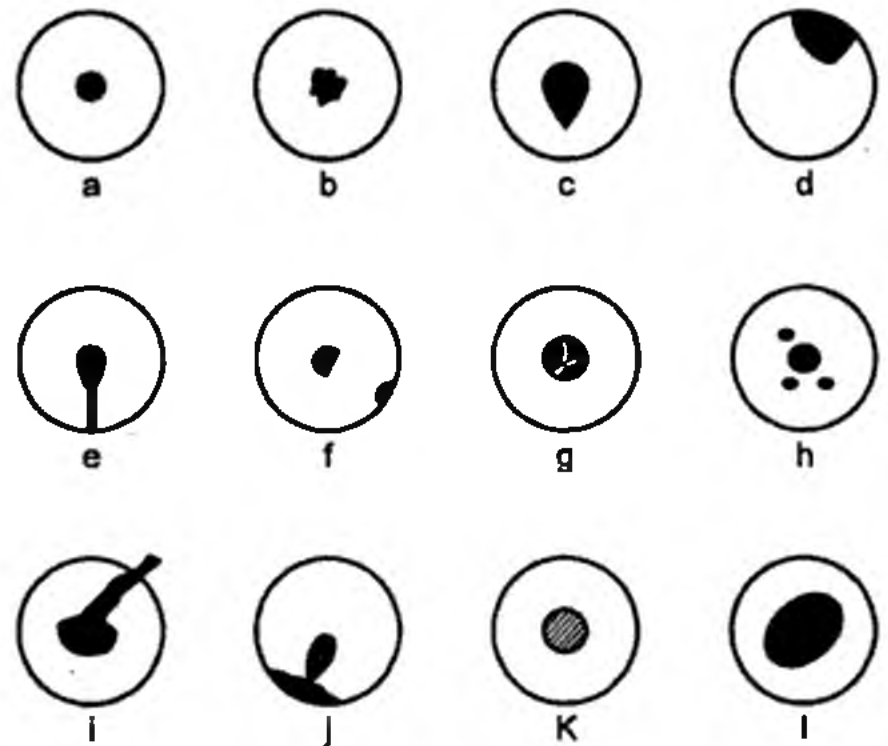


Fig. 41.3 Variations in the size and shape of the pupil: (a) normal; (b) irregular pupil due to posterior synechiae; (c) vertically oval and dilated pupil in acute congestive glaucoma; (d) pupil after broad iridectomy; (e) congenital coloboma of the iris; (f) D-shaped pupil in iridodialysis; (g) persistent pupillary membrane; (h) polycoria in essential atrophy of the iris; (i) iris prolapse; (j) pupil drawn toward corneal opacity in adherent leucoma; (k) occlusio pupillae; and (l) dilated pupil in optic atrophy.

(a) It does not show a direct pupillary reaction

(b) It shows a normal consensual reaction. When light is shone in the affected eye consensual pupillary reaction in the fellow normal eye is also absent.

Marcus Gunn pupil (Syn.: Relative afferent pupillary defect)^{5,7}

Relative afferent pupillary defect (RAPD) is seen in unilateral optic nerve or retinal disease but not severe enough to cause an absence of light perception. The testing of RAPD is done by swinging flash light test (see p. 187).

The causes are listed in Table 41.2.

Adie's pupil (Syn.: Tonic pupil, myotonic pupil)^{3,5}

The cause is unknown. Generally unilateral, about 80 per cent and in young women, the affected pupil

Table 41.2
Causes of Relative Afferent Pupillary Defect

Those often causing RAPD

Optic neuritis
Optic nerve tumours
Ischaemic optic neuropathy
Compressive optic neuropathy

Those sometimes causing RAPD

Macular disease
Retinal detachment
Branch retinal artery occlusion
Branch retinal vein thrombosis

is larger than its fellow, sluggishly reacting to light, slow tonic constriction on near stimulation and dilates fully with atropine.

The condition is associated with absent tendon reflexes in the lower limbs. Perhaps there is a neuronal degeneration in the ciliary ganglion.

Argyll Robertson pupil^{3,5}

Argyll Robertson pupil is characterized by small, unequal irregular pupil, with absence of light reaction but a normal near reaction. It dilates poorly with atropine. This condition may be unilateral or bilateral. It is often associated with tabes dorsalis. The site of lesion is in the connecting neuron between afferent pupillomotor fibres and Edinger-Westphal nucleus or in the ciliary ganglion. The impulses originating in the reticular activating system in the pons and medulla inhibit the Edinger-Westphal nucleus. When this inhibition is reduced as in Argyll Robertson pupil there is excessive parasympathetic activity with miosis.

Further Reading

1. Duke-Elder, S., *System of Ophthalmology*, Vol. IX: *Diseases of the Uveal Tract*, Duke-Elder, S. and Perkins, E.S. (Eds.), Kimpton, London, 1966.
2. Hollenhorst, R.W., Pupil in neurologic diagnosis. *M. Clin. North America*, 52:51, 1968.

3. Nieman, E.A., Disorders of the pupil. In *Medical Ophthalmology*, Rose, F.C. (Ed.), Chapman and Hall, London, 1976, p. 71.
4. Parsons, J.H., *Diseases of the Eye* (18th ed.), Miller, S.J.H. (Ed.), Churchill Livingstone, Edinburgh, ELBS, 1990.
5. Rosenberg, M.A., Neuroophthalmology. In *Principles and Practice of Ophthalmology*, Peyman, G.A., Sanders, D.R. and Goldberg, M.F. (Eds.), W.B. Saunders, Philadelphia, 1980, p. 1 & 17.
6. Sarin, L.K. and Shields, J.A., Differential diagnosis of leukokoria. In *Pediatric Ophthalmology*, Harley, R.D. (Ed.), W.B. Saunders, Philadelphia, 1975, p. 816.
7. Weinstein, J.M., The pupil. In *Podos and Yanoff's Textbook of Ophthalmology*, Vol. VI: *Neuroophthalmology*, Slamovitis, T.L. and Burde, R. (Eds.), Mosby Year Book, St. Louis, 1994, p. 51.

42. DISEASES OF THE CRYSTALLINE LENS

The crystalline lens is developed from the surface ectoderm and is avascular. There is only one disease which is of prime significance, i.e. cataract, the basic lesion being the loss of transparency.

Developmental Abnormalities of the Lens^{2,6}

Such abnormalities may be:

- (a) Defective formation, e.g. aphakia and lentoid formations
- (b) Defective size and shape, e.g. microphakia, spherophakia and lentiglobus
- (c) Defective position, e.g. ectopia lentis
- (d) Congenital marking on the capsule, e.g. hyaloid remnant
- (e) Developmental cataracts.

Congenital aphakia

There are two types—primary and secondary. In the primary type the lens does not develop at all and it occurs as a part of a generalized defect of the anterior part or whole of the eyeball. In the secondary type disorganization of the lens after its formation occurs.

Microphakia and spherophakia

Microphakia and spherophakia appear to be caused by defects in the zonule, a developmental arrest between 5 and 6 months of intrauterine life. These are bilateral and associated with high degree of myopia of even—20D. They are also associated with other anomalies such as ectopia lentis and megalocornea. The rim of a small-sized lens along with zonule is clearly seen through the fully dilated pupil. This small lens is also spherical in shape. In such a case use of a miotic evokes a rise of ocular tension, *inverse glaucoma*.

Lenticonus

Lenticonus is a conical protrusion of the posterior or the anterior surface of the lens. The posterior variety is more common than the anterior one. Retinoscopy reveals an appearance of an oil globule. It is confirmed by a slit-lamp biomicroscopy.

Lentiglobus

Lentiglobus is the spherical protrusion of the posterior part of the lens.

Ectopia lentis or congenital dislocation of the lens

Ectopia lentis is a partial displacement of the lens in usually up and in direction due to defective zonule in the lower part. It is bilateral and symmetrical. It is generally dominant. After dilating the pupils the condition can be easily detected. This often occurs along with arachnodactyly or homocystinuria.

Other causes of defect in the zonule. Apart

from Marfan's syndrome, the causes include Marchesani syndrome, homocystinuria, Ehlers-Danlos syndrome and osteogenesis imperfecta.

Marfan's syndrome (Fig. 42.1). The clinical features of Marfan's syndrome include ocular, skeletal, general and cardiac defects. Ectopia lentis is considered to be the hallmark of this syndrome. It is also associated with arachnodactyly.



Fig. 42.1 Marfan's syndrome with typical arachnodactyly.

Aetiology of this heredofamilial disorder remains still vague and may include defect in ectoderm, mesoderm or both elastic tissue and collagen.

Ectopia lentis is due to a defect in the zonule of Zinn, a modified collagen tissue. The defect is more common in the lower part, the stronger pull of the normal zonular fibres upward causes the displacement of the lens upward. It is to be differentiated from homocystinuria. Urinary nitroprusside reaction in Marfan's syndrome is normal but not so in homocystinuria.

Cataract

The history of cataract⁵ is about 4000 years old. Suśruta had described cataract as a derangement of intraocular fluid. Alexandrian school, represented by Celsus (25 BC to AD 50) and Galen (AD 131–210) had presumed it to be a collection of inspissated aqueous humour in the space between the pupil and the lens. This similar view was held

by the Arabian school. It was only in the middle of 17th century that Francois Quarre taught that cataract was an opacity of the lens.

Cataract is an opacity of the crystalline lens (Gk. *katarraktes*, waterfalls). The lens capsule does not change its transparency, but the so-called capsular cataracts occupy the inner surface of the capsule and start from the lens epithelium.

There are two types of cataracts—developmental and acquired.

Developmental cataract (Fig. 42.2)

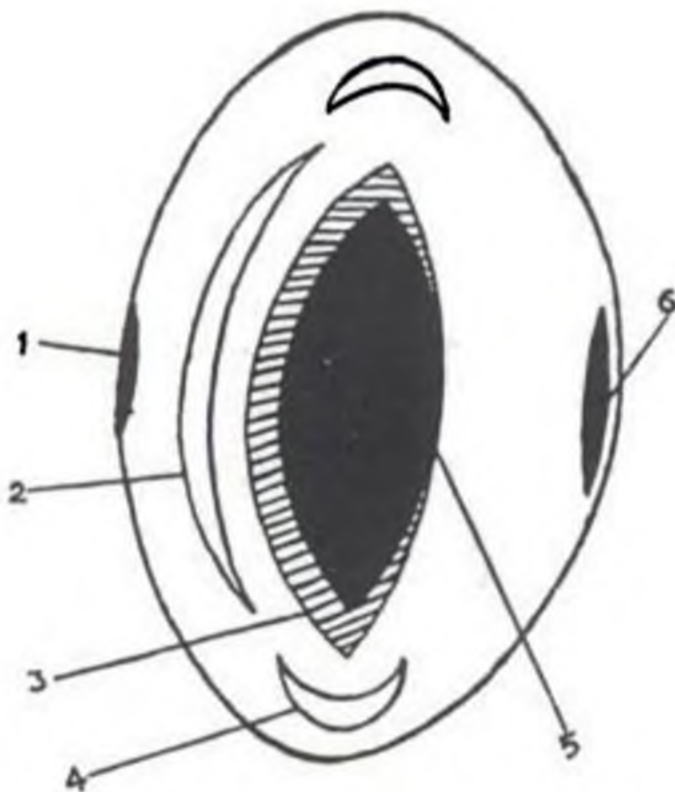


Fig. 42.2 Morphological types of developmental cataract. 1, posterior polar; 2, posterior capsular; 3, lamellar; 4, coronary; 5, nuclear; and 6, subcapsular.

Aetiology. Probable aetiological factors are as follows:

- (a) Heredity
- (b) Chromosomal aberration
- (c) Intrauterine inflammation
- (d) Prematurity
- (e) Inborn metabolic disorders
- (f) Associated ocular anomalies
- (g) Associated systemic disorders: metabolic, syndermatotic, muscular, bony and neurological.

Minute nonprogressive lenticular opacities are

not uncommon in general population. Developmental cataract tends to involve the particular layer of the lens which has developed at that state of intrauterine life when there is some developmental disturbance.

(a) *Anterior axial embryonic cataract.* There are small white opacities in close proximity to the anterior Y-suture. It is usually bilateral and stationary.

(b) *Sutural, stellate or triradiate cataract.* There are fine, white or bluish dots located in one or both the Y-sutures which may appear feathery. It is bilateral, stationary, and is autosomal dominant.

(c) *Zonular or lamellar cataract* (Fig. 42.3). Zonular cataract comprises 50 per cent of all developmental cataracts. There is possibly a temporary imbalance of parathyroid-calcium metabolism as evidenced also by the defective development of the enamel of the teeth and the presence of rickets. It is characterized by concentric zones of fine white opacities around the nucleus. When the pupil is dilated a clear peripheral rim of cortex is seen.



Fig. 42.3 Zonular cataract (Gifford).

If the diameter of the opacity is less than 5.75 mm which is the equatorial diameter of the lens in a newborn, the opacity is prenatal. If this is more than 5.75 mm the opacity is postnatal. There are a number of projections from the surface of a cataract

appearing as spokes of a wheel varying in shapes and sizes, these are called *riders*. The condition is bilateral and is inherited as autosomal dominant.

(d) *Coronary cataract*. The name is derived from 'corona' or club shape. There are peripheral opacities arranged like a crown found in juvenile age group and they can be visualized after full dilatation of the pupil. It is nonprogressive in nature. It shows a dominant inheritance. The incidence may even be up to 25 per cent.

(e) *Floriform cataract, axial or coralliform cataract*. The axial portion in the region of the anterior and posterior foetal sutures is affected. The axial opacity sometimes shows number of oval dots grouped together appearing as petals of flower. Inheritance is autosomal dominant.

(f) *Punctate or blue-dot cataract*. There are fine, round opacities bluish in appearance, disposed throughout the cortex of the lens. Unless large they rarely cause visual deterioration. Inheritance may be dominant.

(g) *Central pulverulent, embryonal nuclear, or Coppock's cataract*. The cataract is localized to the embryonic nucleus and is nonprogressive. There are discrete white dots appearing as a granular disc in each eye. Rarely vision is affected. Often it is bilateral. Most cases show autosomal dominant inheritance.

(h) *Anterior polar (pyramidal) cataract*. There are two types, congenital and postnatal. Postnatal type may occur as an occasional complication of corneal ulcer following perforation. It is due to close contact of the base of the ulcer with the anterior surface of the lens. An anterior polar opacity may also be associated with a persistent pupillary membrane or an anterior lenticonus. There is involvement of the anterior capsule by the opacity, also called *anterior capsular cataract*. It is visible to the naked eye. Sometimes there is a forward projection of the opacity into the AC like a pyramid known as *anterior pyramidal cataract*. Occasionally there is affection of the cortex lying underneath, *anterior cortical cataract*. It may so happen that there is growth of subcapsular epithelium between the capsular and cortical opacities following which there is growth of clear

lens fibres, so there is a buried opacity called an *imprint* and the two together form a *reduplicated cataract*.

These opacities are nonprogressive.

(i) *Posterior polar cataract*. It is a localized, saucer-shaped opacity occupying the posterior pole. Some workers consider this to be a mild form of persistent hyperplastic primary vitreous. There is considerable visual disturbance.

(j) *Mittendorf's dots with persistent hyaloid artery remnant*. About one mm size dot is seen at the posterior pole of the lens corresponding to the site of attachment of persistent hyaloid artery. A thread or number of corkscrew-shaped threads are seen hanging in the vitreous attached to the hyaloid face.

Investigations. Investigations include ophthalmoscopy through the dilated pupils, ultrasonography, preferential looking test of visual acuity in preverbal infants and pattern visual evoked potentials.

Treatment of developmental cataract. Early operation is recommended in advanced opacities and unioocular opacity with likelihood of developing stimulus-deprivation amblyopia.

The earliest age of operation may be as early as 2 to 3 months. Table 42.1 lists various treatment options.

Table 42.1

Various Methods of Treatment in Developmental Cataract

Needling (discission)
Aspiration
Limbal-based irrigation-aspiration
Pars plana lensectomy
Secondary intraocular lens (IOL) implantation
Epikeratophakia
Postoperative extended-wear contact lens

An ideal surgical procedure should have the following criteria:

(a) single procedure with the removal of the major portion, the rest of the residual lens matter will be absorbed; (b) no disturbance of the pupil,

posterior capsule and vitreous; and (c) minimum chance of postoperative glaucoma.

Acquired cataract

Degeneration of the lens fibres is the main cause. The reasons are not yet well clear and may probably be due to several causes.

An acquired cataract may be: (1) senile or primary: (a) cortical, (b) nuclear and (2) secondary: (a) traumatic, (b) inflammatory, (c) metabolic, (d) syndermatotic, (e) toxic, and (f) miscellaneous.

Senile cataract^{4,5}

Aetiology. Senile cataract is rare in persons under 50 and these disturbances occur: (a) impaired semipermeability of the capsule; (b) increased insoluble proteins; and (c) less effective autooxidative system.

Genetic influence plays a major role and in hereditary cases it manifests itself at an earlier age in following generations.

Pathology. The physiochemical changes are: (a) there is relative increase of water content in early cataract, but gradual decrease in advanced stage; (b) depletion of soluble proteins; (c) lowered potassium content; (d) increased calcium content; (e) marked reduction of ascorbic acid; and (f) glutathione is almost absent.

Nuclear cataract. There is pathologic sclerosis of the lens nucleus.

Cortical cataract. Histopathological features are as follows:

In the early stage: (a) vacuoles or globules; (b) separation of the lens fibres; (c) water-splitting of the sutures; and (d) cloudy swelling in the cortex.

In the advanced stage: (a) lens capsule—thinning, thickening or spontaneous rupture; (b) subcapsular epithelium—proliferation, cells in the equatorial regions making abortive attempt to form new fibres in the cortex and vesicular cells (bladder cells), etc.; and (c) cortex—necrosis, vacuolation, breakdown of the lens fibres producing round globules (Morgagnian globules).

Clinical Features. In the early stage the patient may complain of diplopia or polyopia and haloes due to irregular scatter of light rays by islands of opacities. Visual deterioration is the cardinal symptom in the advanced stage.

The incidence is common between the fifth and seventh decades and is almost always bilateral.

Senile cortical cataract can be classified in these stages:

(a) Incipient	Cuneiform Cupuliform
(b) Intumescent	
(c) Mature	
(d) Hypermature	Inspissated Morgagnian

Incipient cataract. In cuneiform cataract most frequently there are wedge-shaped, isolated, peripheral, spoke-like opacities extending from the equator to the centre and involving the anterior cortex as well the posterior cortex. In cupuliform cataract a saucer-shaped opacity usually develops in the central posterior cortex in front of the posterior capsule.

Intumescent (immature) cataract. The lens becomes white and swollen due to hydration. The AC becomes shallow.

Mature cataract (Fig. 42c.1). Stellate markings over the lens are still recognizable. Iris shadow is absent. There is normal depth of the AC. Visual acuity is reduced to only hand movement (HM) or perception of light (PL) and projection of rays (PR).

Hypermature cataract. A mature cataract may progress into stage of hypermaturity. There are two subtypes.

(a) **Inspissation hypermaturity.** Lens loses water in mature cataract and the process may further continue resulting in: (i) shrinkage of the lens; (ii) deep anterior chamber; (iii) tremulousness of the iris (iridodonesis); (iv) tendency for subluxation; and (v) deposition of calcium salts or cholesterol in the capsule and within the lens substance.

(b) **Morgagnian cataract.** If the tendency for the loss of water ceases at maturity, the opaque cortical matter disintegrates into a milky white fluid and the brown nucleus moves to the bottom. The

lens capsule becomes taut and slippery, while the anterior chamber becomes shallow.

Complications and sequelae. These include:

- (a) Hypermaturity
- (b) Secondary glaucoma
- (c) Exfoliation of the lens capsule
 - (i) True exfoliation—scroll-like exfoliation of the capsular lamellae
 - (ii) Pseudoexfoliation—a frost-like deposit on the anterior lens capsule
- (d) Dislocation of the lens.

Nuclear cataract. Nuclear cataract represents an exaggerated process of normal senile nuclear sclerosis (Fig. 42c.2). There is early visual deterioration, at first due to increased refractive index of the nucleus (index myopia) but later due to lenticular opacity occupying the axial area of the lens. The development of the opacity is remarkably very slow. Occasionally there is deposition of melanin pigment derived from the amino acids of the lens, *black cataract*. Ophthalmoscopy shows characteristic central opacity. The opacity takes years together to become mature. There is no hypermaturity in a nuclear cataract.

Diagnosis of cataract. In the early stage, neither the state of visual acuity nor oblique illumination helps in the detection. By oblique illumination a crescentic iris shadow is seen with concavity towards the pupil caused by the iris casting a shadow on the lental opacity. An iris shadow is absent in mature cataract and also in anterior capsular cataract. In the advanced stage, however, they are decidedly important.

More visual deterioration is caused by even a minute opacity in the axial area than a relatively large opacity at the periphery of the lens.

Retinoscopy and ophthalmoscopy are two chief diagnostic examinations. Normally in retinoscopy there is a red glow, in immature cataract black shadows interspere with red glow and in mature cataract there is total black shadow.

A slit-lamp biomicroscope affords accurate interpretation of especially early signs of cataract.

Treatment. Treatment is by cataract extraction. In early cataract, satisfactory visual improvement is sometimes possible by correction of refractive error, often index myopia. Aphakic correction is usually advised about six weeks after the operation. Aphakia is dealt with elsewhere.

Secondary cataract¹

Secondary cataract may be any of the following varieties:

- (a) Inflammatory
- (b) Metabolic
- (c) Syndermatotic
- (d) Toxic
- (e) Traumatic
- (f) Miscellaneous.

Inflammatory. It is secondary to uveitis (anterior and posterior), keratitis, scleritis, etc. see complicated cataract.

Metabolic. This group includes diabetic, galactosaemic, hypocalcaemic, hypothyroidic, myotonic, deficiencies and other metabolic anomalies.

Syndermatotic. This type may be associated with skin disorders like scleroderma, atopic dermatitis, Rothmund's syndrome and Werner's syndrome.

Toxic. It may follow steroids, chlorpromazine, miotics, radiation and electrical injury.

Traumatic cataract. A traumatic cataract (Fig. 42c.3) may result from physical injury (penetrating and nonpenetrating), heat or cold, radiant and electric energy, etc.

In concussion injury the possible effects on the lens are:

- (a) Rosette-shaped opacities affecting either the anterior or the posterior cortex is most characteristic;
- (b) Disseminated subcapsular opacities are less common;
- (c) *Vossius' ring* is a ring of pigmented opacity on the anterior capsule caused by impact and imprint of the constricted pupil; and
- (d) Displacement of the lens may be partial or complete.

Penetrating injury of the lens may be:

(a) Without retention of a foreign body. There may be either typical rosette-shaped cataract rapidly developing total opacity, or lens floccules causing iridocyclitis and secondary glaucoma. Occasionally the wound may be small involving the anterior capsule, in which it may be sealed by posterior synechiae or may cause localized haziness; and

(b) With retention of a foreign body.

Treatment consists of cycloplegic drug until all inflammatory signs have disappeared. If there is threatening secondary glaucoma rapid relief of the condition by operation is mandatory. Otherwise, the operative interference is needed after the eye becomes quiet.

Complicated cataract⁵

Complicated cataract results from disturbed nutrition of the crystalline lens chiefly due to inflammatory (uveitis, keratitis, scleritis, etc.) or degenerative (high myopia, retinitis pigmentosa, heterochromic iridocyclitis, old retinal detachment, etc.) and disease of the other parts of the eye. But broadly the term also includes those following systemic disorders, e.g. prematurity with retrolental fibroplasia and toxic cataracts.

The types seen are:

(a) Anterior segment type—involving the anterior capsule and anterior cortex

(b) Posterior segment type—involving the posterior cortex just in front of the posterior capsule.

Diagnostic clues are as follows:

(a) Unilateral involvement is suspicious.

(b) Spongy texture and extension of the opacity both outwards and inwards are characteristic especially in the posterior segment type

(c) A polychromatic lustre (normally there is an achromatic sheen) can be visualised

(d) Characteristic changes occur at the pupil in iridocyclitis

(e) Ocular tension is lowered in retinal detachment

(f) Projection of rays may be defective

(g) Examination of the iris may exhibit new

vessels and atrophy, and that of the cornea may show keratic precipitates.

Cataract Associated with Systemic Diseases

Diabetes. Two types are met with—(a) senile cataract associated with diabetes. It tends to occur at an earlier age and matures more rapidly than nondiabetic cases. (b) True diabetic cataract is rare. It occurs in a young diabetic with a history of diabetic coma. It presumably appears as reversible snow-flake subcapsular opacities and then rapidly spreading milky white opacities.

Parathyroid deficiency. In this disorder there is lowered blood calcium. It is characterized by tetany and cataract. The characteristic features of cataract in hypoparathyroidism are its slow onset even occurring years after the onset of hypoparathyroidism, bilaterality, presence of small discrete punctate cortical opacities with polychromatic lustre.

Myotonic dystrophy. It is a hereditary muscle dystrophy evidenced by myotonia, baldness, testicular atrophy in males, and cataract. Slit-lamp examination of the lens reveals iridescent dots in both anterior and posterior cortex.

Mongollism or Down's syndrome. Also known as *trisomy 21*, this is characterized by the presence of extra chromosome 21 free within the cell nucleus. The important ocular features are small and oblique palpebral fissures slanted up and outward, and cataract. The lental opacities resemble those of parathyroid deficiency.

Hypothyroidism. When it occurs in an adult it causes myxoedema. Cataract is occasionally present, and this is characterized by the presence of superficial cortical lens opacities.

Scleroderma. Occasionally lental opacities develop. The disturbance within the lens is closely similar to that within the skin.

Other systemic causes of cataract. The systemic causes apart from those described now are as

follows: hepatolenticular degeneration, galactosaemia, Lowe's syndrome, glycogen storage disease, Fabry's syndrome and mucopolysaccharidoses.

Drugs and Poisons causing Cataract¹ include:

- (a) Steroids
- (b) Miotics
- (c) Chlorpromazine
- (d) Antimitotic drugs
- (e) Dinitrophenol
- (f) Insecticides
- (g) Thallium
- (h) Triparanol.

Iatrogenic Cataract

The therapeutic use of a variety of chemical agents and drugs is found to occasionally result in the development of cataract. Of all of them, steroids are the most important, next in order are perhaps the miotic agents like ecothiophate iodide and demecarium bromide.

Long-term systemic or topical use of steroid may lead to posterior subcapsular lens opacity. Lens opacification develops about one year of steroid therapy, the incidence being dose-dependent. Anterior subcapsular cataract may occur after prolonged miotic therapy.

Aftercataract

Aftercataract is the remnant—capsular, capsuloenticular or an inflammatory membrane—left behind after an extracapsular extraction, needling or curette evacuation.

Clinical features. There are three varieties. Firstly, there may be only posterior capsular remnants. If they are slight in degree they are not visible usually by an ophthalmoscope but better visible by a slit-lamp biomicroscope; they do not cause visual loss. If these remnants are grossly visible they cause much visual deterioration. Secondly, there may be adhesion of the remnant of the anterior capsule with the posterior capsule with some cortical matter lying in the pocket between these two; this leads to production of abortive lens fibres from the

equatorial region. They form a dense ring behind the iris, called *Soemmerring's ring*. There is no visual disturbance unless the ring is displaced. In the third type, there is proliferation of the subcapsular cells forming balloon-like cells instead of lens fibres. These may project into the anterior chamber (AC) or may occlude the pupil. Vision is disturbed. These cells are known as *Elschnig's pearls*.

Treatment. Despite full course of treatment with atropine and steroid if the aphakic correction does not yield useful vision discission is indicated. The thick membrane can also be removed with vitreous cutter or vitreous scissors. An opening is also possible by YAG laser.

Displacement of the Lens (Fig. 42.4)

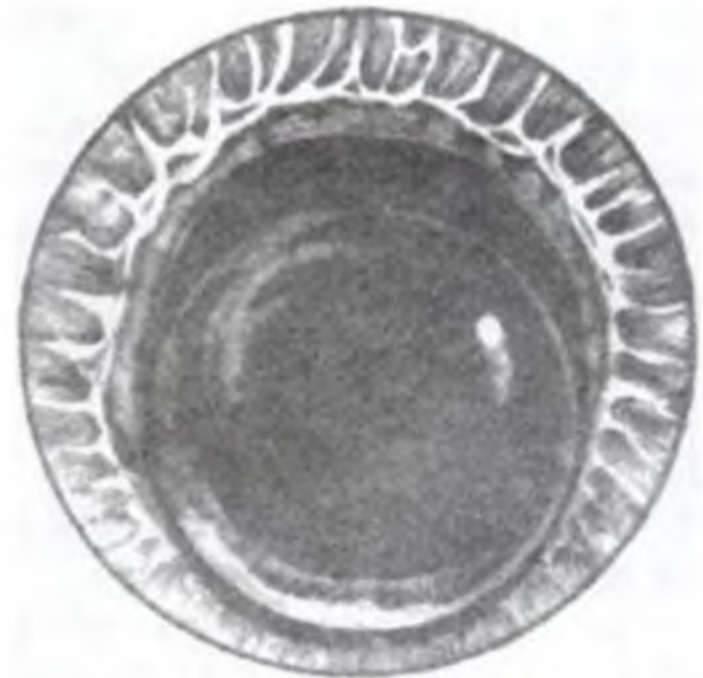

Fig. 42.4 Lens completely dislocated into the anterior chamber (Gifford).

Aetiology. Refer to Table 42.2.

Table 42.2

Causes of Displacement of Crystalline Lens

Ocular
Ectopia lentis
Aniridia
Injury
Coloboma
Systemic
Marfan's syndrome
Marchesani's syndrome
Homocystinuria

Clinical features. The displacement may be incomplete (subluxation) or complete (luxation). In subluxation the part of the lens is visible in the normal position, that is behind the pupillary area. The other features are monocular diplopia, astigmatism and iridodonesis. In luxation no part of the lens is seen in the normal position. The dislocated lens may come into the AC or become entangled in the pupil. In posterior dislocation the features are those of aphakia, but the lens can be better discovered by a slit-lamp examination. Rarely the dislocated lens may wander and reach the subretinal, subscleral or subconjunctival space.

Diagnosis. Diagnosis is based on history, complete ocular examination, retinoscopy, ultrasonography, systemic and laboratory tests related to clinical associations.

Complications and sequelae. The complications of anterior dislocation are secondary glaucoma, anterior uveitis and corneal damage due to contact of the lens with the corneal endothelium.

Treatment. Surgery is only indicated when the spectacle correction for the phakic or aphakic portion fails to improve vision. If the lens is cataractous, an operation is essential. If the lens is in the anterior chamber or trapped in the pupil it should be removed. If it is displaced into the vitreous with signs of early inflammation, the following techniques may be adopted:

- (a) if in the anterior vitreous—cataract extraction
- (b) if in the posterior vitreous—vitrectomy followed by lens extraction.

But a displaced lens into the vitreous not associated with any complication or fixed to the retina should be left as such.

Further Reading

1. Brown, N., Cataract and diseases of the lens. In *Medical Ophthalmology*, Rose, F.C. (Ed.), Chapman and Hall, London, 1976.
2. Cordes, F.C., Types of congenital and juvenile cataract. In *Symposium on Diseases and Surgery of the lens*, Haik, G.M. (Ed.), C.V. Mosby, St. Louis, 1957.
3. Cordes, F.C., Surgery of congenital cataracts. In *Symposium on Diseases and Surgery of the Lens*, Haik, G.M. (Ed.), C.V. Mosby, St. Louis, 1957.
4. Dobree, J.H., Cataract. In *Modern Ophthalmology* (2nd ed.), Vol. IV: Sorsby, A. (Ed.), Butterworths, London, 1972. p. 649.
5. Duke-Elder, S. *System of Ophthalmology*, Vol. XI: *Diseases of the Lens and Vitreous: Glaucoma and Hypotony*, Duke-Elder, S. and Jay, B. (Eds.), Kimpton, London, 1969.
6. Mann, I., *The Development of the Human Eye* (3rd ed.), British Medical Association, London, 1964.
7. McDonald, P.R., Disorders of the lens. In *Pediatric Ophthalmology*, Harley, R.D. (Ed.), W.B. Saunders, Philadelphia, 1975, p. 370.

43. DISEASES OF THE VITREOUS

Because of avascularity and acellularity the vitreous humour reacts by liquefaction or opacification. There may be degeneration due to various causes. The neighbouring inflammations or infections cause exudation and invasion by cells or infecting agents. Occasionally blood leaks into the vitreous as a result of disease or injury. Rarely there may be developmental anomalies.

Fluidity of the Vitreous

Fluidity of the vitreous is the most common degenerative change and occurs due to conversion of the colloid gel into a sol. The causes include senility, myopia, ocular inflammations, vitreous haemorrhage and trauma.

Floating opacities are seen by ophthalmoscopy and slit-lamp biomicroscopy. In addition, evidence of the responsible factor may be detected. Ocular tension is normal unless it occurs in a soft eye. In

such condition there are risks such as vitreous loss following cataract extraction and development of retinal detachment. It needs no treatment.

Vitreous Opacities^{1,3,4}

Vitreous opacities generally include those changes which disturb the transparency of the vitreous humour. These opacities can be classified both aetiologically and morphologically (see Table 43.1).

Dust-like opacities can only be detected by an ophthalmoscope with bright illumination. If they are numerous they produce generally cloudiness of the vitreous. They result from cells, debris, coagulum and fibrin.

Thread-like opacities occur in senility and they result from disorganization and thickening of the vitreous framework. They are associated with other senile degenerative changes. Discrete opacities are limited to the posterior hyaloid membrane.

Table 43.1

Aetiologic and Morphologic Classifications of Vitreous Opacities^{1,2}

Aetiologic:	
Congenital	Remnants of the hyaloid vascular system
Endogenous	Colloidal deposits Asteroid hyalopathy
	Crystalline deposits Synchysis scintillans
Exogenous	Protein coagulum
	Exudative cells
	Blood
	Tissue cells
	Tumour cells
	Pigments-melanotic and haematogenous
Morphologic:	
	Dust-like
	Thread-like
	Discrete
	Membranous
	Cord-like
	Haemorrhage into vitreous
	Exudation into vitreous
	Foreign body
	Parasitic cyst

Membranous opacities are found usually with posterior vitreous detachment (PVD).

Cord-like opacities are present as in retinitis proliferans. In both anterior and posterior uveitis vitreous opacities are common. There are four types of opacities—fine, coarse, stringy and snow-ball. The last three types occur especially in posterior uveitis.

Ultrasonography. The opacities may be so dense as to emit echoes.

Treatment. Minor cases do not need any treatment. In gross opacities treatment must be directed against the cause. When there is very little chance of regaining vision, a vitrectomy operation may have to be resorted to. The result of vitrectomy is not fully established as yet.

Muscae Volitantes or Vitreous Floaters^{1,2,6}

In elderly patients slit-lamp biomicroscopy shows coarse and visible vitreous sheets with cavities in between the coarser fibres. These cavities increase in size as age advances and these are seen as black specks floating in front of the eyes and especially visible on looking at a bright surface. The black specks are called muscae volitantes. These muscae are seen even by the normal persons under favourable optical conditions such as red blood cells passing through the retinal vessels.

Asteroid Hyalopathy or Benson's Disease (Fig. 43.1)

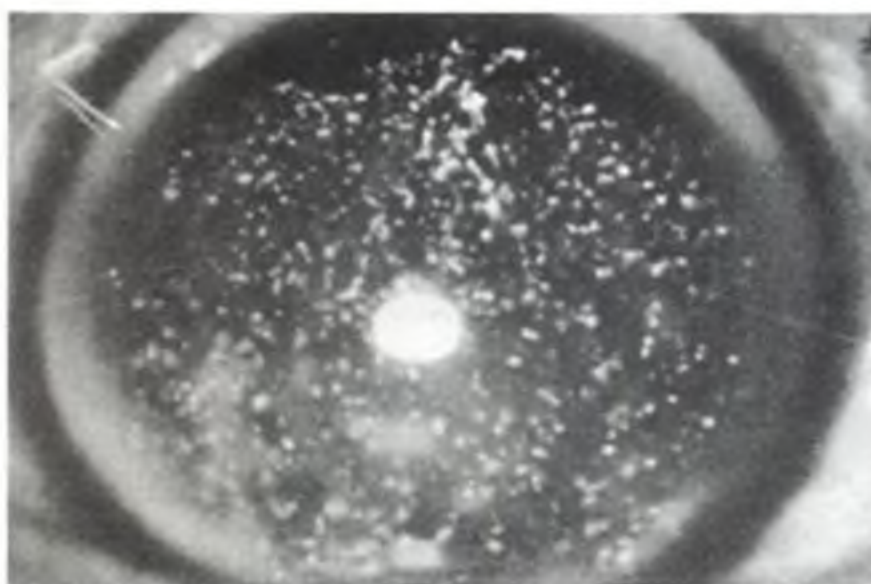


Fig. 43.1 Asteroid hyalosis (Scheie and Albert).

Asteroid hyalopathy is mostly unilateral, 75 per cent and is common in elderly males. It is occasionally associated with diabetes. It occurs in relatively normal eye. Pathologically, there are rounded accumulations of calcium soaps. Ophthalmoscopic examination shows small discrete bodies in a haphazard manner. They are white and shiny. They slowly move with movement of the eye.

Table 43.2 shows its differentiation from synchysis scintillans.

Table 43.2

Distinguishing Features of Two Types of Endogenous Vitreous Opacities¹

Points	Asteroid hyalopathy	Synchysis scintillans
Age	Senile	Usually under 35 years
Laterality	Usually unilateral	Usually bilateral
Shape	Globular strands	Fine flakes
Colour	White	Golden
Mobility	Less mobile	With movement of the eye, the particles which so long have been out of view, rapidly appear with characteristic colour and finally settle down again

Synchysis Scintillans (Fig. 43.2)




Fig. 43.2 Synchysis scintillans.

Synchysis scintillans occurs in younger subjects and is usually bilateral. It occurs in degenerative state of the eyeball. Pathologic characteristic is the deposition of cholesterol crystals. There are golden, flat and angular, innumerable crystals which remain hidden at the bottom of the vitreous. But they are clearly visible by ophthalmoscopy when they are stirred by movement of the eyes.

Vitreous Haemorrhages⁸

The chief causes are Eales' disease, retinal detachment, diabetic retinopathy, hypertensive retinopathy, central retinal vein thrombosis, proliferative or neovascular retinopathy, injury and active chorioretinitis. Vitreous haemorrhage may be intravitreal and preretinal or subhyaloid. They usually occur suddenly. A large intravitreal haemorrhage liquefies the vitreous gel and absorption of the blood is usually slow. Ophthalmoscopy reveals absence of red fundal glow in a large haemorrhage, but a small haemorrhage does not darken the red reflex and it can be seen. Visual acuity is reduced even to hand movements when there is a large accumulation of blood. When the amount is small it tends to sink down, and hence in such a case vision appears to be better on waking. If haemorrhage is within the liquefied vitreous it remains unclotted, shifts with gravity and settles in the lower part when the patient is in rest or his or her head is elevated. Visual disturbance increases immediately with stirring of blood.

The course of the affection is variable. Sometimes a little blood may be absorbed, while in other cases vitreous haemorrhage may persist indefinitely when it is in the formed vitreous gel. It tends to resolve more slowly. Repeated haemorrhage may occur. Since there are no fibroblasts in the normal vitreous, there is usually no organization and absorption is possible. Occasionally there is proliferation of fibroblasts from the retinal vessels leading to organization, as in retinitis proliferans.

The advent of ultrasonography has a distinct role in the diagnosis and in the evaluation of

prognosis of the case. Ultrasonographically, a dense haemorrhage can be visualized (Fig. 43.3). Sheets of blood will produce echoes. Ultrasonography also differentiates a vitreous haemorrhage from a retinal detachment. Retinal detachment will produce an ultrasonic image even at low sensitivity, but it disappears under similar condition in a vitreous haemorrhage. In retinal detachment the image will be continuous with the echo of the optic nerve, but it is not continuous in case of vitreous haemorrhage.

Treatment is initially conservative followed by finding out and dealing with the cause. If a retinal tear is detected it should be sealed and a new vessel should be coagulated. A closed vitrectomy is only considered when the visual acuity is less than 6/60 showing no sign of disappearance of blood even within 6 months.

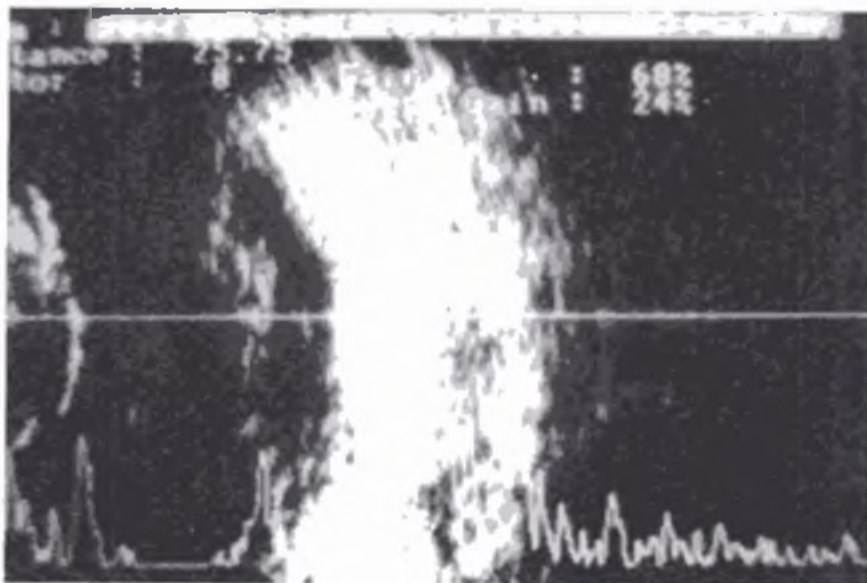


Fig. 43.3 B-scan in vitreous haemorrhage (Eye Care & Research Centre, Calcutta).

Vitreous Degenerations²

Vitreous degenerations may be senile, myopic, and may follow inflammations, retinal detachment and tumour.

It is not unusual to detect some degree of syneresis or liquefaction of the vitreous gel in old age. This is followed by cavity formation and the posterior vitreous detachment. Vitreous changes are diagnosed by ophthalmoscopy, slit-lamp biomicroscopy and ultrasonography.

In myopic degeneration liquefaction of the vitreous is most commonly seen especially at the posterior pole.

Any long-standing and severe intraocular inflammation shows vitreous degeneration. If a retinal detachment is old or is associated with senility and myopia then there is some degeneration.

Vitreous Detachments⁷

Liquefaction of the vitreous gel (syneresis) predisposes to vitreous detachment.

Classification (Table 43.3).

Table 43.3
Classification Vitreous Detachments^{1, 4}

Posterior
Total
Partial
Infundibular—in the region of vitreous base
Anterior
Retrolental
Retrozonular
Retrociliary
Combined

Posterior vitreous detachment (PVD). Its relationship with age is well established. Other contributory factors are degree of syneresis, aphakia, axial length of the eyeball, preexisting vitritis, diabetes, etc. The symptoms include vitreous floaters, photopsiae, distorted or blurred vision. In PVD, the vitreous is separated from the internal limiting membrane of the retina. The complications include retinal tears mostly seen in the upper quadrants, rupture of the vessels, retinal detachment, epiretinal membrane, etc. The case should be thoroughly evaluated by examination of the peripheral retina using scleral depressor, and B-scan ultrasonography. No treatment is needed if there is no associated retinal detachment.

Anterior vitreous detachments are those in which the vitreous is separated from the lens capsule.

Proliferative Vitreoretinopathy⁵

Proliferative vitreoretinopathy (PVR) is the growth and contraction of the cellular membranes within

the vitreous cavity and both surfaces of the retina following rhegmatogenous retinal detachment. The membrane in PVR consists of glial element derived from the extensions of Müller's cells and astrocytes, cells of the RPE, macrophages and collagens of usually types I to III.

A PVR can be graded as depicted in Table 43.4.

Table 43.4

Grading of Proliferative Vitreoretinopathy

Grade	Characteristics
A	Clumps of RPE in the vitreous and retina Protein flare in the vitreous
B	Surface wrinkling and rolled edge of tears
C	Full-thickness retinal folds
	Anterior
	Irregular equatorial
	Smooth circumferential
	Anterior displacement of peripheral retina
	Posterior
	Star folds
	Irregular fixed folds
	Elevated retinal fold without visible preretinal membrane

A posterior PVR is easily visualized, while it is more difficult to find out an anterior PVD.

Treatment. The surgical management of PVR can be divided into two groups

(a) Those in which surgical interference is likely to cause sustained closure of all retinal breaks

(b) Those in which there is possibility of recurrent traction inducing rhegmatogenous retinal detachment in spite of sealing the retinal breaks.

The operative procedures include scleral buckling, vitrectomy with or without silicone oil and vitrectomy.

Rare affections

Pus in the vitreous is seen in a case of panophthalmitis.

Parasites in the vitreous. Rarely cysticercus may be found in the vitreous.

Congenital Deformities in the Vitreous⁶

Persistent hyaloid artery. Having reached

the high stage of differentiation, the hyaloid system starts atrophy (60 mm stage). But rarely the hyaloid artery may persist and the possibilities are: (a) persistence of the entire length of the artery, (b) persistence of the posterior segment, and (c) persistence of the anterior segment.

Persistent hyperplastic primary vitreous (PHPV). It is characterized by the presence of the hyaloid artery with posterior vascular sheath associated with degeneration. The eye is microphthalmic and it shows white reflex at the pupil. The final picture is of retinal detachment, cataract and glaucoma.

Encephaloophthalmic dysplasia. PHPV is associated with anomalies in the central nervous system.

Massive Vitreous Retraction (MVR) (Syn.: Massive Preretinal Retraction)

Massive vitreous retraction is total PVD with vitreous collapse.

Further Reading

1. Duke-Elder, S., *System of Ophthalmology*, Vol XI: *Diseases of the Lens and Vitreous: Glaucoma and Hypotony*, Duke-Elder, S. and Jay, B.S. (Eds.), Kimpton, London, 1969.
2. Goldmann, H., The diagnostic value of biomicroscopy of the posterior parts of the eye. *Br. J. Ophthalmol*, 45:449, 1961.
3. Hruby, K., *Slit-lamp Examination of the Vitreous and Retina*, Posner, A., English translation, Williams and Wilkins, Baltimore, 1967.
4. Jaffe, N.S., *The Vitreous in Clinical Ophthalmology*, C.V. Mosby, St. Louis, 1969.
5. Lean, J.S., Proliferative vitreoretinopathy. In *Principles and Practice of Ophthalmology: Clinical Practice*, Albert, D.M. and Jacobiec,

- F.A. (Eds.), W.B. Saunders, Philadelphia, 1994, p. 1120.
6. Parsons, J.H., *Parsons' Diseases of the Eye* (18th ed.), Miller, S.J.H. (Ed.), Churchill Livingstone, Edinburgh, 1990.
 7. Podos, S.M. and Yanoff, M., *Textbook of Ophthalmology, Vol. IX, Retina and Vitreous*, Federman, J.J., Gouras, et al. (Eds.), Mosby Year Book, St. Louis, 1994.
 8. Scheie, H.G. and Albert, D.M. (Eds.), *Textbook of Ophthalmology* (9th ed.), W.B. Saunders, Philadelphia, 1977.

44. GLAUCOMA

History¹⁰

Hippocrates (5 BC) used the term *glaukos* while describing blindness in senile people—'if the pupil becomes sea-coloured sight is destroyed and blindness of the other eye often follows'. The first suggestion of the affection was found in Arabic (AD 10) writings and was described as 'migraine of the eye' or 'headache of the pupil'.

At the beginning of 19th century the first excellent description of glaucoma with raised ocular tension was given by Antoine-Pierre Demours. Guthrie (1823) recognized hardness of the eye as characteristic. The essential feature, raised ocular tension, was firmly proved by Mackenzie (1835). von Graefe (1857) divided the affection into three groups: acute, chronic, and secondary. Otto Barkan (1938) established the concept of acute glaucoma. He was mainly responsible for classification of primary glaucoma into two varieties, open-angle and closed-angle.

Definition

Glaucoma (Gk *glaukos*, sea green) is a state characterized by a persistent or intermittent elevation of the intraocular pressure from any cause

leading to a temporary or permanent functional and/or structural damage to the eye.²⁹

Classification

Primary glaucoma. This is not associated with other obvious ocular affections.

1. Adult primary glaucomas
 - (a) Chronic simple
 - (b) Closed angle
 This has four phases:
 - (i) Preglaucoma
 - (ii) Intermittent or subacute
 - (iii) Acute
 - (iv) Chronic
2. Infantile primary glaucomas
3. Juvenile primary glaucomas
4. Mixed primary glaucomas

Secondary glaucoma. This type is due to a specific anomaly or preexisting ocular disease.

Investigations of Glaucoma

Tonometry^{5,16,17,34}

Tonometry is the method of estimation of the intraocular pressure. It is classified as:

- (a) Digital
- (b) Instrumental
 - Impression
 - Applanation

Impression or indentation tonometry. Tonometry by means of a Schiötz tonometer (Fig. 44.1) is the most common clinical method of all the pressure-recording devices. This tonometer measures the depth of indentation of the cornea by the plunger while the tonometer is loaded with a given weight. After proper anaesthetization, and the patient lying on his or her back and fixing at a spot on the ceiling or at a finger, the tonometer is placed on the cornea. Scale reading taken from the tonometer is converted into corresponding mm Hg of tension by referring to a chart, e.g. 5/5.5 gm = 17.30 mm Hg Schiötz. The higher the tension, the lesser is the indentation and the lower the reading. The sources of error may be: (a) nonstandardized,




Fig. 44.1 Schiötz tonometer.

defective or dirty instrument; (b) muscular contraction; (c) improper application of the tonometer, e.g. tilting or undue pressure; (d) variation in the curvature of the cornea; and (e) lack of uniform thickness of the cornea.

The method of sterilization is commonly by ether or alcohol.

Normal IOP by Schiötz tonometry with a standard deviation is 16.1 ± 2.8 mm Hg.

Applanation tonometry. This method records the force necessary to flatten an area of the cornea, 3.06 mm in diameter, that is the pressure = force area. A *Goldmann applanation tonometer* is mounted on a Haag-Streit, Zeiss, or slit-lamp of other make. The tonometer has (Fig. 44.2): (a) an applanation prism; (b) a tension knob; and (c) a blue filter.

Technique. For the area of flattening involved, 1 gm of force is equivalent to 10 mm Hg of IOP. After proper anaesthetization a sterile fluorescein paper is placed in the lower fornix and removed after a few seconds. With conventional steps of slit-lamp biomicroscopy, the blue filter is swung




Fig. 44.2 Applanation tonometer.

into the open slit-beam and the beam is directed at the black line of the prism from a wide angle. In order not to startle the patient from rebounding from the cornea the measuring is set at 1 gm. The patient looks straight ahead, while the examiner uses the low power ($10\times$) of the microscope. The applanation prism is gently moved forward with the control stick till it touches the cornea. The flattened area is seen through the prism as two interlocking semicircles, the inner edge of the upper semicircle meeting the outer edge of the lower one symmetrically with each pulsation of the eye (Fig. 44.3). An estimate of the ocular tension in mm Hg is available from the reading on the drum

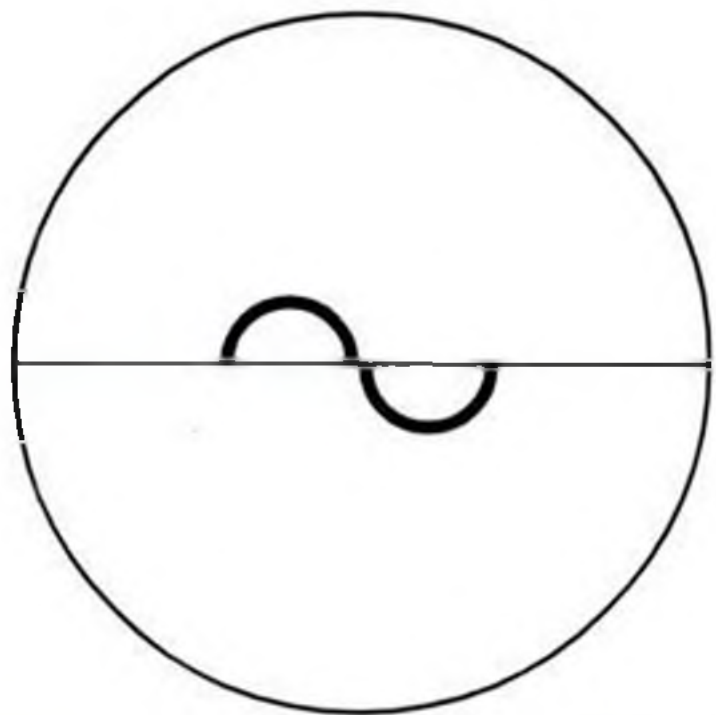


Fig. 44.3 Appearance of two semicircles when viewed from the applanation prism.

multiplied by 10. If the semicircles cannot be made to overlap, it indicates that the prism is too far away. If they cannot be separated, the prism is too far forward.

The normal IOP by applanation with a standard deviation is 15.4 ± 2.5 mm Hg. The values between 21–24 mm should arouse suspicion, while a pressure over 24 mm is taken as abnormal.

Mackay-Marg electronic tonometer. This records the pressure almost instantaneously on a continuously running tape. It is useful in scarred or oedematous cornea. It can also measure the IOP through soft contact lens. The device is less accurate than Goldmann's tonometer.

Langham pneumatic tonometer is an applanation type of tonometer which causes a graded flow of gas against a flexible diaphragm.

Noncontact applanation tonometer. Normally a blink takes 10 m secs. In this method a 3 m secs puff of air is blown against the cornea which produces temporary indentation of the cornea. The patient sits as in a slit-lamp examination and the examination does not need any surface anaesthesia. A monitoring system senses the light reflected from the surface of the cornea and records a maximal signal displayed on a digital read-out at the instant of applanation. The interval of time necessary for air puff to cause applanation is proportional to the IOP. The time-interval for an average noncontact tonometer measurement is 1 to 3 m secs.

Sources of error in applanation tonometry may be: (a) poor technique; (b) fluorescein—excess or inadequate; (c) corneal irregularities as in oedema and opacity; and (d) excess tearing.

Advantages of applanation tonometry. They are as follows:

(a) Recording of tension is possible while the patient is in sitting position

(b) Pressure is known immediately and no conversion table is needed

(c) There is no factor of scleral rigidity because of negligible volumetric displacement

(d) Tension recording is accurate

(e) Weight adjustments are not necessary.

Hand-held tonometers. These include:

Perkins' tonometer. This contains Goldmann prism, light source powered by battery and a base. The base contains batteries, adjustment knob and an IOP scale (Fig. 44.4).



Fig. 44.4 Perkins' hand-held tonometer.

Draeger tonometer. It has a prism of 3.06 mm diameter and an electrically powered light source. The applanation force is varied by an electric motor.

Tono-pen is a miniature, 18 cm long tonometer containing a central plunger of 1.02 mm diameter encircled by a 3.22 mm annulus, and a microprocessor. The microprocessor is capable of applanating the cornea. The IOP is converted to electric waves. A single chip computer in the tonometer now analyses the wave obtained from several corneal touches and displays it on the digital read-out (Fig. 44.5)

Pulsair is a noncontact applanation tonometer with automatic alignment activation device. This can be used with the patient both in the supine and upright positions.

Ophthalmoscopy

Ophthalmoscopy should be done routinely in all cases. Accurate ophthalmoscopy through an



Fig. 44.5 Tono-pen.

undilated pupil is however difficult to perform. Although direct ophthalmoscopy is most commonly done, indirect ophthalmoscopy and slit-lamp biomicroscopy will be helpful in the evaluation.

The features of a glaucomatous cup have been described in details on p. 290.

Perimetry and scotometry

Any subject with a suspicious glaucomatous cup should be examined for visual field defects. A glaucomatous cup is usually associated with characteristic nerve fibre bundle defect, but there may be only a glaucomatous cup with the absence of demonstrable field defect. Visual field changes in chronic simple glaucoma have been described in details on pp. 289-93.

Ocular rigidity

Ocular rigidity is the resistance to stretch the outer tunic of the eyeball. If the scleral rigidity is more the tension recorded by Schiötz tonometer will be higher than the real value. If the rigidity is less than the average normal tension recording by Schiötz method will be lower. So, in Schiötz tonometry the ocular rigidity must be taken into consideration. If the tonometric reading with

10 gm weight is consistently higher than with 5.5 gm weight, then the eye has a higher rigidity than normal. The rigidity is lower if this reading is consistently lower with 10 gm weight than that with 5.5 gm. In higher rigidity the actual IOP is lower. The scleral rigidity can be determined from two different weights of Schiötz tonometer, *differential tonometry*, with the help of Friedenwald's nomogram. Average normal coefficient of ocular rigidity is 0.0203 to 0.0217.

Gonioscopy^{5,24,34}

Gonioscopy is the examination of the angle of the anterior chamber by a gonioprism. Trantas coined the term gonioscopy. Two methods are as follows (Table 44.1).

Table 44.1

Distinguishing Features of Two Types of Gonioscopy

Direct gonioscopy	Indirect gonioscopy
Permits view of the whole circumference	Lower angle is seen when the mirror is up and so on
Time-consuming procedure	Not so
Not so	Optical superiority
Examination of the patient on the operating table is possible. The patient is in recumbent position	Not possible. The patient sits opposite a slit-lamp
Weight and unsteadiness of the hand-held microscope are the problems	Not so

The direct method. This is done by Koeppel contact lens, the front surface of which is curved more deeply than the cornea. Other lenses include Barkan, Richardson-Shaffer and Worst lenses.

The indirect method. This is possible by Goldmann (Fig. 44.6), Allen-Thorpe, or Zeiss four-mirror contact lens (Fig. 44.7). Smaller type of Goldmann lens with one or two mirrors and larger type containing three mirrors are available. The angle is examined with the reflected light. In Goldmann lens the mirror makes an angle of 64° with the front surface of the contact lens (Fig. 44.8). The indirect method is also known as *slit-lamp gonioscopy* because slit-lamp microscope is



Fig. 44.6 Goldman three-mirror lens (Dr. Sumit Chowdhury, Eye Care & Research Centre, Kolkata).



Fig. 44.7 Four-mirror goniolens (Dr. Sumit Chowdhury).

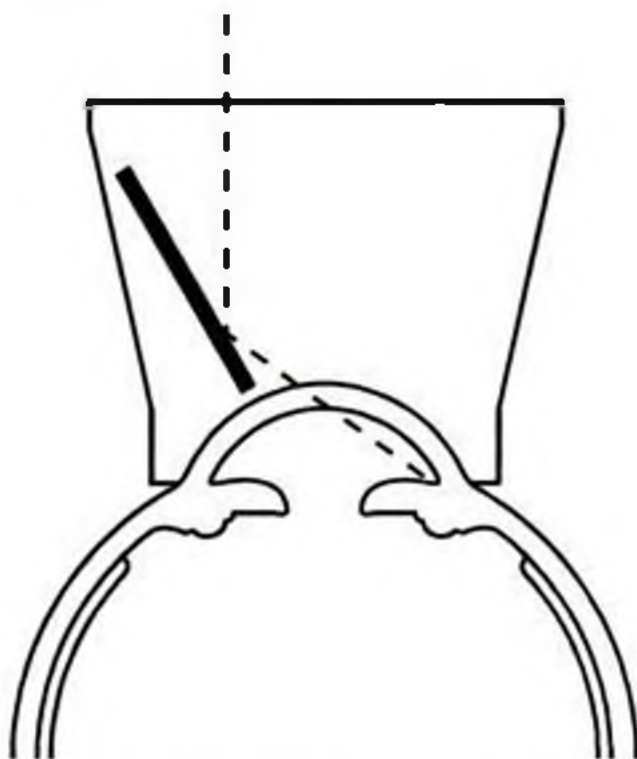


Fig. 44.8 The path of rays through Goldman contact lens in gonioscopy.

used to obtain magnification. Gonioscopy should be done after tonometry. Gonioscopy lowers the tension because it exerts external pressure upon the eyeball.

Technique. In a shallow AC with a narrow angle, miotic drop is instilled since it stretches the iris and widens the entrance to the angle and thus facilitates gonioscopy.

In an *indirect method* after proper anaesthetization, the contact lens, the concavity of which is filled up with a wetting solution, is inserted promptly and held by the observer between the thumb and the index finger. In the *direct method* the observer holds the microscope in one hand and light source in the other, or holds a goniolens with mounted light source. The lens can be rotated in any direction to bring all quadrants of the angle into view. In indirect gonioscopy, to avert the disadvantages—corneal distortion and difficulty of visualization of a narrow angle—newer designs of gonioprism have been introduced. The posterior radius of curvature is such that it comes closer to that of the anterior corneal surface. The mirrors are made taller.

The *direct method* utilizes the front curve of the contact lens to refract light rays at the lens air interface (Fig. 44.9).

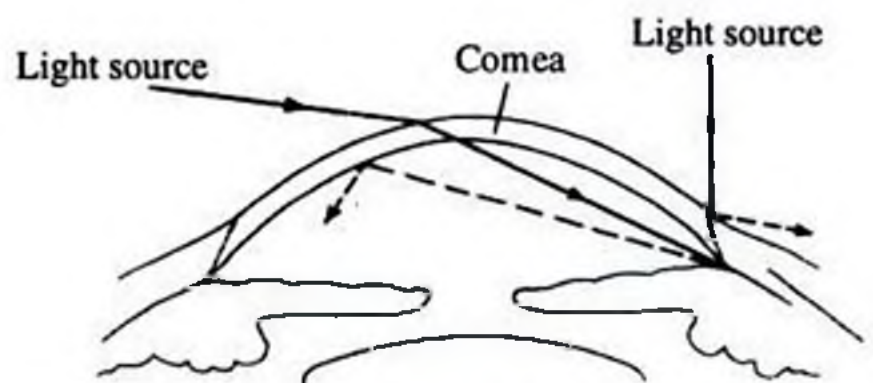


Fig. 44.9 Direct Gonioscopy.

Main features of gonioscopy in normal angle (Fig. 44.10). Starting from the back towards the front they are as follows:

- (a) Anterior surface of the iris
- (b) Anteromedial surface of the ciliary body
- (c) Scleral spur that is the white line marking the posterior border of the trabeculae.
- (d) Trabeculae covering the canal of Schlemm

controversial. Mechanical block is caused by fibrous, granuloamorphous and basement membrane material at the region. Malfunctioning of the endothelial lining is the result of attenuation of these cells and depletion of endothelial vacuoles. Many of the cells are phagocytosed by the pigment granules. There is also corresponding increase of the supporting element in the trabecular meshwork.

Pathology of Glaucoma.^{2,28-30} The pathologic alteration is governed by the severity and duration of raised ocular tension. The structural alterations in different tissues are as follows:

Cornea. There are oedema in all the layers, separation of the basal cells, presence of filaments, bullae and pannus. Degenerations may occur. Epithelial oedema occurs when the IOP exceeds 45 mm Hg.

Limbus. Distension of the vessels and formations of new anastomoses are common.

Trabecular-Schlemm's canal system. The changes include: (a) fragmentation of the collagens; (b) proliferation and foamy degeneration of the endothelial cells; (c) narrowing of the intertrabecular spaces; (d) abundance of acid mucopolysaccharides in the trabecular meshwork; (e) decrease or absence of the giant vacuoles in the inner wall endothelium of Schlemm's canal; and (f) collapse of Schlemm's canal.

Electron microscopy in advanced cases of primary open-angle glaucoma has shown extracellular plaques present in the trabecular meshwork and Schlemm's canal.

Uveal tract. This shows oedema followed by fibrosis.

Retina. Atrophy and cyst formation of the ganglion cells, degeneration of the plexiform layers, disintegration of the nuclear layer, matting and flattening of the rods and cones, and replacement of the nerve fibre layer by gliosis and haemorrhage from the sclerotic vessels are present.

Optic disc. Atrophy and cupping are characteristically present.

Sclera. Ectasia and staphyloma are seen.

Clinical features. Chronic simple glaucoma is a bilateral affection with a very slow progress and

is insidious in onset. The early symptoms include aches about the eyes and mild headaches. Any subject above the age of 40 years requiring especially frequent change in presbyopic glasses should be examined for any evidence of this affection. It must be noted that in some cases, signs of central retinal vein thrombosis may be the first evidence of the underlying glaucoma.

Diagnosis. Diagnosis essentially depends on the following investigations.

Ophthalmoscopic examination. It is rather difficult to distinguish early optic disc changes from a physiologic excavation of the disc especially when the latter is deep. Two marked changes in glaucoma of some duration are pallor and cupping. The possible variants are: (a) pathological cupping with atrophy; (b) pathological cupping without atrophy; (c) atrophy with minimal pathological cupping; and (d) atrophy with no pathological cupping.

Cupping possibly results from mechanical pressure and ischaemia. The pressure causes forcing the lamina cribrosa backwards leading to squeezing of the nerve fibres and then to disturbed axoplasmic flow.

Glaucomatous optic disc (Fig. 44c.1) should be assessed under the following headings:^{25, 28}

- (i) Cup diameter and extent
- (ii) Cup asymmetry
- (iii) Colour
- (iv) Depth of cupping
- (v) Displacement of the vessels
- (vi) Pulsation of the retinal arteries
- (vii) Peripapillary halo
- (viii) Fluorescein angiography.
- (ix) Retinal nerve fibre layer
- (x) Disc haemorrhages
- (xi) Digital imaging.

Cup diameter and extent. The edges of the glaucomatous cup may reach the disc margin. In its initial stage a glaucomatous cup preferentially affects the inferolateral quadrant of the optic disc. Cups with a vertical diameter greater than the horizontal are probably glaucomatous. The cup/disc diameter (C/D) ratio is a genetically determined

characteristic. In about 80 per cent of glaucomatous eyes this ratio is greater than 0.3. About 17 per cent of the general population have also a similar ratio of above 0.3.⁵

Cup asymmetry. It is a valuable sign, especially if it is marked.

Colour. The degree of pallor indicates the extent of atrophy. Glial atrophy is caused by ischaemia.

Depth of cupping. It may be quite deep, and it is usually measured by focusing a blood vessel at the edge of the cup and then on the floor.

Displacement of the blood vessels. They may be dragged on to the nasal side. In a deep excavation, they are seen at the edge of the cup and disappear below the overhanging edge till they are suitably focused on the floor of the excavation.

Pulsation of the retinal arteries. When the IOP has approached or exceeded diastolic pressure in the central retinal artery, an arterial pulsation is observed easily. It is not diagnostic of glaucoma, since it is present in other conditions like aortic regurgitation and aneurysm.

Retinal nerve fibre layer (RNFL). Normally RNFL appears as fine parallel lines crossing the larger retinal vessels and reaching the optic disc. These are best seen in darkly pigmented ocular fundus and visualized by red-free monochromatic light. In glaucoma these appear as slit-like grooves usually one disc diameter above and below the disc.¹

Disc haemorrhages. Splinter haemorrhages are sometimes seen over the optic disc.

Tonometry. Tonometry is the most commonly performed test for simple glaucoma. However, an applanation tonometer is more reliable than a Schiötz tonometer. A constant difference of 4 mm Hg ocular tension between the two eyes of an individual or a diurnal variation of more than 5 mm Hg Schiötz is suspicious. In simple glaucoma there are four types of diurnal variation: (a) rise of tension in the morning, 10 per cent; (b) rise of tension in the afternoon, 25 per cent; (c) biphasic variation, 55 per cent; and (d) the flat type, rarely seen. In glaucoma, the ocular tension remains normal between its diurnal variations in the early

stage, but as the disease progresses the variations increase and the tension rises further. A single tonometry reading is of no value.

Tonography. Though tonography was considered to be one of the most important tests in diagnosing early cases of simple glaucoma, but today many experts on glaucoma do not place so much importance to this test. The more the resistance to aqueous outflow the lesser the exit of aqueous from the eye, and subsequently there will be higher IOP. Normal coefficient of aqueous outflow is 0.20. If this is less than 0.16 it is suggestive of glaucoma, but if it is less than 0.13 it is indicative of glaucoma.

Visual field study (Fig. 44.11).^{8,10} Visual field study is a very valuable method of investigation essential for diagnosis, prognosis and assessment of efficiency of treatment. The field changes are the result of either individual nerve fibre bundle damage or of ischaemia.




Fig. 44.11 Visual field changes in chronic simple glaucoma; 1, baring of the blind spot; 2, Seidel's scotoma; 3, Bjerrum's scotoma; 4, Bjerrum's scotoma and Roenne's scotoma; 5, Roenne's nasal step connected with Bjerrum's scotoma; 6, final stage in visual field change showing remnant of the central field.

According to Hayreh¹⁴ ciliary circulation is the main source of vascular supply to the prelaminar, laminar and retrolaminar parts of the optic nerve. In raised IOP the vessels in the prelaminar part are most susceptible for obliteration and next in order comes the peripapillary choroid; retinal

circulation is not at all affected. On the basis of reduced fluorescence of the optic disc by fluorescence angiography in the patients with significant changes at the optic disc and visual field defects Hayreh has concluded that ischaemia produces the following lesions.

(a) At the optic disc—cupping of the disc, degeneration of the nerve fibre associated with visual field defects.

(b) In the peripapillary choroid—choroidal atrophy and enlargement of the blind spot.

(c) In the retrolaminar part—cavernous atrophy and peripheral constriction of fields.

Visual field defects in simple glaucoma

(a) The initial defect in the visual field in cases of simple glaucoma is variable.

(i) The earliest change in the visual field in co-operative patients is accentuation of the normal angioscotomata at the upper and lower poles of the blind spot (Evans).

(ii) A depression of the 1/2000 isoptre on the outer side of the blind spot is a further early sign. The isoptre passes to the nasal instead of the temporal side of the blind spot, barring the blind spot. Drance has contradicted and stated that barring of the blind spot also occurs in miosis, senility and lental changes—all these three accompanying simple glaucoma.

(iii) Enlargement of the blind spot is also an early sign. But this occurs in other conditions as well. Enlarged blind spot may be secondary to myopic conus. The enlargement of the blind spot occurs in a vertical direction, commonly above but sometimes above and below, and is called *Seidel's scotoma*. This scotoma in its early stage is inconstant and may disappear after instillation of miotic drops. Sometimes this is demonstrable in reduced illumination.

(b) Sector-shaped defects are due to nerve fibre bundle affection. *Bjerrum's scotoma* typically involves the Bjerrum region between 10 and 20° from the fixation area and causes a comet-shaped scotoma extending upward from the appropriate pole of the blind spot on the temporal side of the

central field. Sometimes other sector-shaped scotomata break through to the periphery. 'The shape of the sector-shaped scotomata corresponds exactly to the course of the nerve fibres' (Drance).⁸

(c) *Arcuate scotoma* is due to nerve fibre bundle defect (Bjerrum's scotoma is also called by some as arcuate scotoma) involving most commonly the arcuate fibres arching above and below the fovea. The arcuate scotoma is narrower on the temporal side and wider on the nasal side of the field because of disposition of the nerve fibres (Fig. 11.4), i.e. the fibres converging on to the optic disc. The scotoma may be relative or absolute. It extends towards the blind spot but it does not commonly arise from the latter. Sometimes there is a normal area between the scotoma and the blind spot.

(d) *Roenne's nasal step* corresponds to the horizontal meridian and follows extension of all complete arcuate scotomata.

(e) Progress of the visual field defects has been summarized by Drance⁸ in the following manner:

(i) There is aggregation of isolated paracentral scotomata due to nerve fibre bundle defects and conversion into arcuate scotomata.

(ii) There is widening of the original field defect due to damage to the adjoining nerve fibres.

(iii) There is breakthrough of scotoma towards the peripheral isoptres.

(iv) Fresh scotomata may occur in the previously unaffected area and spread towards the centre.

(v) There is preservation of central vision along with a patch in the temporal field, the latter disappearing before the central vision is eventually lost.

In central field charting, the target size and intensity, the pupil size, visual acuity and the refractive status should be noted. The field charting is repeated at the intervals of three months. If the changes are not progressive the frequency of testing may be reduced to 4 month, 6 month and yearly intervals.

Influence of miotics on visual field. Increased

mmosis for controlling glaucoma may increase the size of the sloping field defect, thereby, creating an impression that there is progressive field defect demanding surgical intervention.

Automated perimetry. An octopus perimeter may be used. The earliest change in POAG (primary open angle glaucoma) is a focal depression of more than 5 dB at one or more contiguous locations, repeated on retesting once or twice (Fig. 44.12).

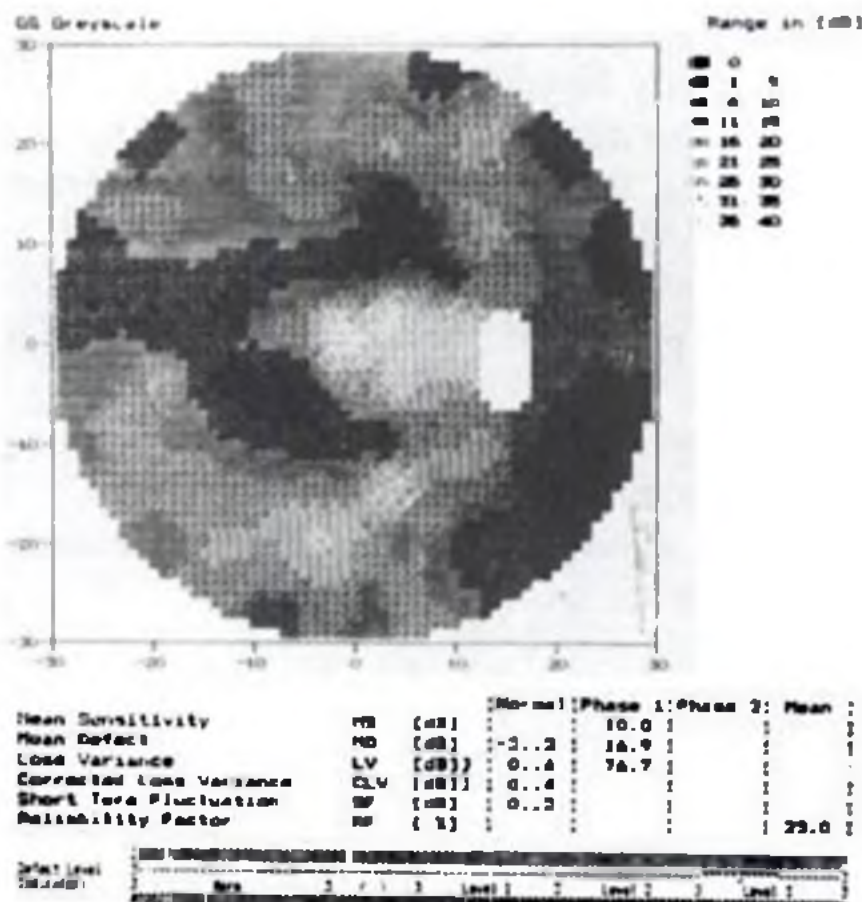


Fig. 44.12 Octopus perimetry showing double arcuate scotoma (Eye Care & Research Centre, Kolkata).

Provocative tests. Provocative tests have been referred to pp. 287–88.

Psychophysical tests.^{15, 30} Psychophysical tests include perimetry, colour vision tests, spatial and temporal contrast, contrast sensitivity, motion perception, visual-evoked response and pattern electroretinography (ERG). Unfortunately these tests are not specific for glaucoma.

(a) Colour vision defects are seen usually in the blue-yellow region of the spectrum.

(b) Loss of spatial contrast sensitivity and defective temporal contrast sensitivity are seen in both glaucoma and ocular hypertension.

(c) Motion perception is significantly decreased in both glaucoma and ocular hypertension.

(d) VER latency is increased in glaucoma and abnormality in visual pathway.

(e) There is selective decrease in the negative component of pattern ERG in glaucoma.

Glaucoma suspect. The following features should arouse suspicion of simple glaucoma:

(a) prominent cupping of the optic disc

(b) Schiötz scale reading 4 with 5.5 gm weight or less

(c) Applanation reading 21 mm Hg or higher

(d) Visual field changes

(e) Family history of glaucoma

(f) Association with high myopia

(g) IOP elevation following use of topical steroids

(h) Central retinal vein thrombosis

(i) Diabetes

(j) Pseudoexfoliation of the lens capsule

(k) Retinal detachment

(l) Pigmentary dystrophy of retina

(m) Dysthyroid disease.

The classical features of simple glaucoma are the following:¹⁰

(a) A cupped and atrophic disc

(b) A raised ocular tension

(c) A reduced facility of outflow

(d) Typical visual field defects

(e) Angle of the AC open.

Closed-angle Glaucoma^{5,6,17,18,28}

Closed-angle glaucoma may be primary, with either pupillary block or without, and secondary.

Primary closed-angle (angle-closure) glaucoma (Table 44.2)

Primary closed-angle glaucoma is variable in its severity differing from case to case. Most initial attacks go unnoticed but the angle-closure is often precipitated by specific and recognizable precipitating factors such as darkness, emotional crisis and prolonged visual concentration. Table 44.2 depicts its classification.

Age incidence. The age of presentation is between 50 and 60 years.

Shallow AC and narrow angle. Recognition of

Table 44.2

Classification of Primary Angle-closure Glaucoma
(After Campbell⁶)

According to location of pathologic process
Anterior
Posterior
According to course of disease
Acute
Intermittent
Chronic
According to type of angle closure
Appositional
Synechial
According to mechanism of angle closure
Relative pupillary block (RPB)
Plateau iris
Small eyeball
Mobile lens

shallow AC and narrow angle should be done as a routine.

Laterality. The other eye of the patient suffering from acute attack in one eye tends to develop similar episode in the other eye after an average interval of four years.

Heredity. The narrowed angle is dependent on the shallowness of the AC, both being the inherited characteristics. They are found to be present in many of the progenies of the patients with closed-angle glaucoma.

Depth of the AC. Primary closed-angle glaucoma is common with AC depths varying between 1.5 and 2 mm, the risk being more when it is less than 1.5 mm.

Corneal curvature. The radius of curvature of the cornea in acute glaucoma is about 4 per cent less than in normal eyes.

Refractive error. High hypermetropia is a common association. In such a case the eyes have shorter anteroposterior length and narrow AC.

Anatomic factors affecting the AC and depth of the angle

Shortness of the eyeball associated with high hypermetropia. In axial hypermetropia of high

degree, the root of the iris is inserted to the ciliary body further forward and consequently the angle is narrowed. The AC becomes shallow because of flattening of the cornea occurring in high hypermetropia.

Continuous growth of the crystalline lens. Due to this process the anterior diameter of the lens is increased which leads to decrease in the depth of the AC and increasing contact between the lens and the iris causing iris bombé.

The introduction of ultrasound biomicroscopy helps to study the angle struck in greater details.²²

In *anterior* type, there is contraction and pulling of the iris forward to cover the trabecular meshwork.

In *posterior* type, the forces posterior to the iris push the peripheral iris against the trabecular meshwork.

The *appositional* type shows the iris resting against the trabecular meshwork.

In *synechial* type, the iris is permanently adherent to the trabeculum.

Physiologic factors

Relative pupillary block. Normally there is slight contact between the pupillary margin of the iris and the anterior surface of the lens. In the eyes predisposed anatomically to closed-angle glaucoma the lens is relatively forward-placed inducing approximation of the pupillary border of the iris with the anterior surface of the lens. Hence, there is a pupillary block, which in turn results in an iris bombé, the latter finally causing an angle block.

Mydriasis. Pupil block occurs during mid dilatation of the pupil, while angle block is precipitated after maximal dilatation of the pupil. The thickness of the iris increases.

Neurovascular disturbance. Vasomotor instability following neurohumoral disturbance and stimulation of the sympathetic system results in vasocongestion, oedema involving especially the ciliary body, and increased secretion of the aqueous humour.

Mapstone¹⁹ has recently reviewed the subject and concluded that true angle closure is a two-

(f) Angle closure is always seen. Slit-lamp biomicroscopy reveals approximation of the iris with the periphery of the cornea. Within a few hours there is formation of peripheral anterior synechia evident gonioscopically.

(g) The pupil is dilated, vertically oval and fixed to light due to high ocular tension pressing on the iris, or perhaps due to diminished blood supply especially to the pupillary border of the iris, or formation of goniosynechiae in the lower part.

(h) Peripheral anterior synechia is characteristically present, but occasionally there may also be posterior synechia due to the congested iris becoming adherent to the anterior surface of the lens.

(i) The ocular tension is obviously very high, easily assessed by digital tonometry. An instrumental tonometry is never advocated because of risk of damaging the oedematous cornea.

(j) The optic disc changes are not seen easily because of the hazy cornea. The disc may be hyperaemic and little oedematous.

(k) Visual field changes are not diagnostic. It may show generalized contraction.

(l) The iris may occasionally exhibit sectorial atrophy usually in the upper part. This is due to localized interruption of the arterial supply causing ischaemia and finally leading to atrophy.

(m) The lens occasionally shows pseudoexfoliation of its capsule, *glaucomflecken* of Vogt.

(n) Vision may be totally lost if the ocular tension remains persistently high for a few days. But adequate control of tension sometimes causes remarkable visual regain. Occasionally following a single attack there may be abrupt total loss of vision, *glaucoma fulminans*.

Chronic angle closure glaucoma

A high base pressure is produced by closure of enough portion of the angle. Reduced aqueous outflow facility occurs permanently. It may follow any of the following: unrelieved attack of acute congestive glaucoma, intermittent angle closure and creeping angle closure.

Clinical features. The clinical picture is variable in three different states:

(a) In case of unrelieved glaucoma due to inadequate treatment or lack of treatment the classical signs of acute angle closure are present but the degree of severity is always less.

(b) In a case following prodromal attacks, the patient complains of periocular aches and haloes. There is slight ciliary congestion only during the episode, while tonography reveals proportionally decreased aqueous outflow.

(c) In a *creeping angle closure* there is never any sudden angle closure. A condition is described by Lowe¹⁸ in which there is insidious and asymptomatic angle closure in some shallow-chambered, narrow-angled eyes. In creeping angle closure followed by chronic angle-closure glaucoma, there is progressive elevation of tension to 40 to 60 mm Hg unaccompanied by evidence of congestive attack owing to closure of nearly two-third angle of the AC. Gonioscopically, there is a large area of contact between the iris and the trabecular meshwork, the process being initiated in the upper part of the angle.

Preglaucoma

Preglaucoma is characterized by narrow-angled eyes in which the other eye is involved by angle closure or in which there is a family history of angle-closure glaucoma.

Secondary angle-closure glaucoma with pupil block

Secondary glaucoma has been described on pp. 302-03. Only the causes of secondary angle closure with pupil block are enumerated.

- (a) Swollen lens
- (b) Iris bombe
- (c) Lens subluxation
- (d) Miotic-induced, especially by stronger miotics
- (e) Posterior synechia to vitreous in aphakia
- (f) Epithelial ingrowth
- (g) Scleral buckling
- (h) Malignant glaucoma.

Secondary angle-closure glaucoma without pupil block

Secondary angle-closure glaucoma without pupil block may be caused by the following:

- (a) Collapse of the AC and formation of peripheral anterior synechia
- (b) Tumours and cysts involving the ciliary body and peripheral iris
- (c) Iridocyclitis causing peripheral anterior synechia
- (d) Rubeosis iridis
- (e) Essential atrophy of the iris.

Primary angle-closure glaucoma (PACG) without pupil block

Primary angle-closure glaucoma without pupil block is very rare and occurs in plateau iris which is an abnormality of the iris that may be associated with angle closure but not with pupillary block.

Diagnosis of PACG. This depends on:

- (a) History
- (b) Clinical examinations
- (c) Biomicroscopy of the anterior chamber is to determine its depth and to find out any evidence of previous congestive attacks, e.g. pigment dispersion, segmental iris atrophy especially near the pupillary border, etc.
- (d) Tonometry
- (e) Gonioscopy shows peripheral anterior synechiae, the characteristic result of an acute angle-closure glaucoma. In noncongestive attack, during the phase of elevated tension, there is contact between the trabecular wall and the iris. In the congestive phase, the changes are the iris root pressed against the trabecular wall and oedema of the ciliary body with exudation.
- (f) Provocative tests are indicated in early stage of glaucoma. They are described on p. 287.

Two major types of glaucoma can be distinguished (Table 44.3).

Treatment of Glaucoma^{10,12,17,28}

Chronic simple glaucoma. Medical therapy is first line in early case. Though pilocarpine was the

Table 44.3

Differentiation of Two Major Types of Primary Glaucoma

Points	Closed angle	Chronic simple
1. Onset	Dramatic with severe ocular pain and loss of vision	Insidious, usually unaccompanied by symptoms
2. Prodromal stage	Present	Absent
3. AC depth	Shallow	Normal
4. Angle of AC	Closed	Open
5. Objective signs	Many including ciliary congestion, shallow AC, dilated and fixed pupil, and high rise of tension	A few which include raised ocular tension, glaucomatous cupping and visual field changes
6. Course	Turbulent	Slow and progressive
7. Tonography	Normal facility of aqueous outflow	Decreased aqueous outflow facility
8. Ophthalmoscopy	No cupping present. Cupping may develop years after the base pressure remains high for years	Glaucomatous cupping appears relatively early
9. Visual field defects	Appear late	Appear early but progress gradually
10. Treatment	Chiefly surgical but medical treatment is often essential prior to surgery	Usually medical but surgery may have to be resorted to

sheet anchor in its treatment, today most ophthalmologists prefer beta-blocker as the initial therapy.

In chronic simple glaucoma medical treatment should be continued

(a) As long as the patient is co-operative in using the miotic therapy;

(b) If the tension does not indicate persistent elevation;

(c) If cupping of the disc does not progress further; and

(d) If the visual field does not show progressive deterioration.

It is known that eyes with little or no cupping withstand the elevated pressure much more effectively than do eyes with gross field defects and glaucomatous cupping.

Closed-angle glaucoma. Surgical treatment is indicated irrespective of the stage of the disease, and medical treatment is only a prelude to surgery. Gonioscopy is an essential step in deciding the type of operation needed in a particular case. In acute attack instillations of pilocarpine 2 per cent drops every 10 to 15 minutes, acetazolamide 500 mg initially and then 250 mg 8–12 hourly, IV mannitol or oral glycerol along with symptomatic measures are essential.

But when ocular tension is as high as 60 mm Hg miotics become unresponsive. In such a case *thymoxamine*, which causes paralysis of dilatator pupillae, has been advocated.

Medical treatment. The various agents used for the control of glaucoma are:

1. Miotics
2. Sympathomimetics
3. Carbonic anhydrase inhibitors
4. Osmotic agents
5. Beta-blockers
6. Alpha-blockers
7. Prostaglandin analogue

Miotics. Miotics are drugs that constrict the pupil. There are two groups:

Cholinergic or direct-acting. The drugs act by stimulating the effect of acetylcholine at the motor end plate.

Anticholinesterases or indirect-acting. The agents inhibit cholinesterase reversibly or irreversibly and thus allowing local accumulation of acetylcholine. Miotics used for treatment of glaucoma are listed in Table 44.4.

In closed-angle glaucoma miosis causes a pull of the sphincter of the iris and this results in decreased volume of the iris in the angle of the AC. So, there is relief of obstruction caused by the peripheral iris blocking the trabecular meshwork.

In chronic simple glaucoma, as a result of

Table 44.4
Miotics used in Treatment of Glaucoma

Agents	Concentration (Percentage)	Administration
Pilocarpine nitrate	1,2,4	6 hourly
Pilocarpine hydrochloride	1,2,3,4	6 hourly
Pilocarpine membrane release (Ocuser)	20,40 microgram/hr	Every 5–7 day
Methacholine chloride (Mecholyl)	10–20	Every 5–10 minutes
Carbachol (Doryl, Glaucostat)	0.75,1,5,3	6 hourly
Physostigmine sulphate (Eserine)	0.25, 0.5	6 hourly
Ecothiophate (Phospholine) iodide	0.03–0.25	12 hourly
Demecarium bromide (Humorsol, Tosmilen)	0.03–0.25	Per day or every other day
Neostigmine bromide (Prostigmine)	2.5–5	8–12 hourly
Diisopropyl fluorophosphate (DFP)	0.01–0.1	Action lasts for 15 days after one instillation

contraction of the ciliary muscle there is a pull on the scleral spur or trabecular meshwork. Alternatively they may have direct cholinergic effects on that part of the meshwork which borders the canal of Schlemm and which forms the major site of resistance.

Pilocarpine. Pilocarpine, nitrate or hydrochloride, used as 0.5 per cent, 1 per cent, 2 per cent or 4 per cent drops, optimal strength being 2 per cent causes miosis within 15 minutes and the effect lasts for about 4 to 8 hours. It was the sheet anchor of treatment in both forms of primary glaucoma.

Eserine. 0.5 per cent or 0.25 per cent eserine salicylate is a stronger miotic. It starts its action within 5 minutes and reaches peak action within 30 minutes. The action on the pupil is for 2 to 3 days, while that on accommodation is for 1 to 2 days. It does not act after blocking the third nerve which pilocarpine does.

Methacholine chloride. This is a synthetic substitute of acetylcholine, used in 10 to 20 per cent concentration. In closed-angle glaucoma it is instilled every 5 to 10 minutes. The action lasts for less than 1 hour.

Apraclonidine has been advocated 1 hour before and immediately after laser posterior capsulotomy (YAG—yttrium-aluminium-garnet laser capsulotomy) or after argon laser trabeculoplasty. This prevents or controls secondary rise of IOP.

Brimonidine (Alphagan) is a selective alpha-2 adrenoceptor-agonist. It is said to reduce IOP peaks after argon laser trabeculoplasty, instilled as 0.4 per cent solution. It can also be used to control IOP in primary open-angle glaucoma.

Timolol is a beta-1 and beta-2 adrenergic receptor-blocking agent (nonselective). It is instilled twice daily. The IOP is lowered between 30 and 70 per cent within 1 to 2 hours. The drug has no effect on size of the pupil, accommodation and visual acuity. It reduces aqueous humour secretion through the inhibition of either the synthesis or the action of adenylyl cyclase of the nonpigmented epithelium of the ciliary body. It is contraindicated in bronchial asthma and cardiac conduction defect or failure.

Betaxolol is a beta-1 antagonist. Its action resembles that of timolol. It is instilled every 12 hours. It has the same pressure lowering effect as other beta-blockers. But it has less deleterious effect on the bronchial system.

Laevobunolol (Betagan) is a nonselective beta-1 and beta-2 adrenergic receptor-antagonist. Its action resembles that of timolol and is equally safe as timolol.

Metipranolol is a nonselective beta-blocker, and its action is similar to that of timolol.

Carteolol (Ocupress) is also a nonselective beta-blocker used twice daily. It is less likely to induce bradycardia.

Carbonic anhydrase inhibitors. Carbonic anhydrase inhibitors agents are described on p. 100.

Acetazolamide is commonly used. It produces its effect 2 hours after oral administration and the maximum effect wanes after 6 hours. 500 mg sustained-release capsules are effective for 12 hours. IV acetazolamide 250 mg causes lowering of pressure with $\frac{1}{4}$ to $\frac{1}{2}$ hours and the action lasts for 4 hours.

Recently, a new topical agent, *dorzolamide*

hydrochloride (Truesopt) 2 per cent has been introduced (see p. 100).

Hyperosmotic agents. Hyperosmotic agents are described on pp. 100–01.

For reducing IOP in acute angle-closure glaucoma, glycerine in lemon juice is given orally. Ocular tension is measured after $\frac{1}{2}$ hour. If it is still high, IV mannitol is given and it starts acting in 10 to 20 minutes, the maximal effect lasting for $\frac{1}{2}$ to 1 hour.

Prostaglandin analogue. Recently, latanoprost (*Xalatan*) in 0.005% concentration is found to cause significant lowering of IOP due to increased uveoscleral outflow.

Alternative drug delivery system in glaucoma.

In some resistant cases the methods described below may be followed:

Soft contact lens. A hydrophilic contact lens (especially bionite), soaked in 1 per cent pilocarpine for 2 minutes if worn for about $\frac{1}{2}$ hours keeps the ocular tension down for 24 hours.

Ocusert. The active drug, usually as free base, is placed within a polymer envelope. It gives a constant and slow release of the drug. Pilocarpine ocuserts are available. It is effective for up to 7 days.

Surgical procedures. The principle of surgical procedure in chronic simple glaucomas is the creation of a new outflow channel for the aqueous humour. Many surgeons advocate trabeculectomy even at diagnosis. Gonioscopy is mandatory in closed-angle glaucoma, while tension recording and tonography are valuable adjuncts in deciding the type of surgical interference. A peripheral iridectomy may be done if peripheral anterior synechiae are not evident or present in minimal degree as in the noncongestive phase, or in the fellow eye as a prophylactic measure. A filtering operation is advocated when more than one-third of the angle is closed by peripheral anterior synechiae and in recurrent closed-angle glaucoma.

Laser therapy. *Laser trabeculectomy* is indicated in uncontrolled POAG despite maximal tolerated medications and argon laser is usually used. After

anaesthetization with a topical anaesthetic the trabecular meshwork is visualized with gonioscopes like Goldmann three-mirror or Rich's lens with the following specifications:

- Spot size—50 millimicrons
- Duration—0.1 second
- Power setting—start with 400 milliwatts, increase if necessary by 100 to 200 mW, maximum 1200 mW.
- Location of the burn at the junction of the pigmented and nonpigmented trabecular meshwork.
- Number of applications—about 50 or 180° and 80 for 360° of angle treatment.

Laser iridectomy is indicated in all cases of angle-closure glaucoma caused by pupillary block. This is performed either with argon, krypton or neodymium:YAG laser. Prior to laser application 1 or 2 per cent pilocarpine and topical anaesthetic are instilled. Abraham contact lens is often used. Iridotomy is often done in the upper part between 10:30 and 1:30 o'clock positions.

Argon laser iridotomy needs the following settings:

- Spot size—50 millimicrons
- Duration—0.2 to 0.5 seconds
- Energy—1000 to 2000 mW

In Nd:YAG laser the power is set between 2 and 8 mJ, and a burst of one or two pulses ranging from 30 nsecs to 20 nsecs is sufficient to perform an iridotomy.

Congenital Glaucoma^{5, 11, 28}

Congenital glaucoma may be genetically determined or nongenetically. The precise mode of inheritance is not known. A multifactorial inheritance is most common. Genetically determined glaucoma may be infantile, juvenile and those associated with ocular and systemic anomalies (Table 44.8). A nongenetic paediatric glaucoma may follow birth injury, inflammation, vascular abnormality and tumour.

Aetiology. There is an obstruction of aqueous outflow due to the presence of an abnormal tissue

Table 44.8

Anomalies Associated with Congenital Glaucoma²⁷

Ocular	Systemic
Anterior chamber cleavage syndrome	Phakomatoses
Posterior embryotoxon	Marfan's syndrome
Rieger's anomaly	Lowe's syndrome
Essential atrophy of the iris	Homocystinuria
Aniridia	Hurler's syndrome
Megalocornea	Down's syndrome
Microcornea	Turner's syndrome
Spherophakia	Trisomy 13-15, 16-18
Myopia	Congenital rubella syndrome

in the angle of the AC. Barkan⁴ had thought of an impermeable membrane covering the angle surface. The various theories of mechanism summarized by Shields²⁸ include incomplete atrophy of the mesoderm of the AC, incomplete resorption of the mesodermal cells by adjacent tissue, incomplete cleavages of the mesoderm in the angle, abnormal anterior insertion of the ciliary muscle, etc.

Clinical features. The affection is typically bilateral.

(a) Excessive watering from the eyes and photophobia appear quite early.

(b) Corneal oedema fluctuates with the rise of tension.

(c) Progressive enlargement of the cornea is especially a characteristic. If buphthalmos develops after three years of age, the eyes usually tolerate distension. If the horizontal diameter of the cornea exceeds 12 mm and tears in Descemet's membrane occur, they are diagnostic.

(d) Deep anterior chamber is due to stretching of the corneoscleral junction.

(e) Glaucomatous cupping and atrophy may appear in untreated cases.

(f) Late signs include gross corneal oedema, iridodonesis, and subluxation of lens. Signs of raised ocular tension may be present during puberty, the condition is called *juvenile glaucoma*. It occurs where in the obstruction at the iridocorneal angle is not complete. About 74 per cent cases can be diagnosed within the first sixth months of life. Fully developed cases are easy to

diagnose. In suspicious cases, the following examinations under general anaesthesia are essential: (i) tonometry; (ii) tonography; (iii) measurement of corneal diameter, and (iv) ophthalmoscopy.

Differential diagnosis. The condition is to be differentiated from: (a) megalocornea (Table 44.9); (b) keratitis; (c) retinoblastoma and secondary glaucoma; (d) high myopia; and (e) metabolic diseases involving the cornea.

Table 44.9
Showing Differences between Buphthalmos and Megalocornea

Points	Buphthalmos	Megalocornea
1. Corneal convexity	Decreased	Increased
2. Ocular tension	Raised	Normal
3. Corneal haziness	Yes	No
4. Anomalies at the angle of Ac	Gross	Minimal
5. Cupping of the disc	Frequent	No
6. Symmetry	Common, but not invariable	Almost invariable
7. Family history	Rare	Common

Treatment. Congenital glaucoma is essentially a surgical problem. Miotics are used preoperatively and are of limited value.

(a) Fizzulising operations are usually ineffective. Trabeculotomy may be tried.

(b) Barkan's goniotomy opens up the passage blocked by persistent embryonic tissue at the iridocorneal angle. The operation consists of incision at the limbus by a specially constructed knife and sweeping round the angle in the opposite segment of the eyeball under gonioscopic contact lens visualization. This operation is probably the best and success may be achieved if the corneal diameter does not exceed 14 mm.

(c) Scheie's goniotomy. The puncture is made by a knife-needle through the corneal margin below the horizontal plane, across the AC and then through the trabecular meshwork until it is seen into the subconjunctival space. The knife is then removed and the AC is filled up with saline.

(d) Trabeculectomy is indicated when all possible trabeculotomy procedures are unsuccessful.

(e) Cyclocryotherapy and laser applications have also been tried.

Absolute Glaucoma

Absolute glaucoma is the final stage of all types of glaucoma. The affected eye is completely blind. The cornea is insensitive; it may show blebs or filaments but may sometimes remain clear. The anterior ciliary veins are dilated. The iris is atrophic. The pupil is dilated and fixed. There is deep glaucomatous cupping. The ocular tension is so very high that the eyeball is hard as stone. The eye is painful. If left as such the eyeball is proptosed with its wall becoming very thin. The sclera may give way causing staphyloma—ciliary and equatorial. Degeneration of the ciliary body may lead to shrinkage of the eyeball.

Treatment. The high tension can be lowered by a cyclodiathermy, while a filtering operation is rarely effective. Pain can be temporarily relieved by a retrobulbar injection of 80 per cent alcohol. A painful blind eye not responding to any of the above measures should be enucleated.

Secondary Glaucomas

Classification. Both open-angle and closed-angle secondary glaucomas can be classified according to the mechanism responsible (Tables 44.10 and 44.11).

Inflammatory glaucomas

Aetiology. There are various causes of inflammation including injury, infection and immunologic process. The disorders associated with glaucoma are uveitis, Fuchs' cyclitis, sarcoidosis, herpetic keratouveitis, juvenile rheumatoid arthritis, scleritis, glaucomatocyclitic crisis, etc.

Glaucomatocyclitic crisis (Posner-Schlossmann syndrome) is a unilateral uveitic glaucoma with

Table 44.10

 Classification of Secondary Open-angle Glaucomas
 Based on Mechanism^{16,17}

Pretrabecular block (membrane occlusion)
Inflammatory
Fibrovascular membrane (neovascular)
Endothelial membrane
Iridocorneal endothelial syndrome
Posterior polymorphous dystrophy
Traumatic
Epithelial downgrowth
Fibrous downgrowth
Trabecular block
Red blood cells
Pigments, e.g. pigmentary glaucoma, exfoliation syndrome, etc.
Ghost cells
Macrophages, e.g. phacolytic glaucoma
Proteins, as in acute anterior uveitis
Steroid-induced
Meshwork swelling, e.g. in uveitis, scleritis, etc.
Enzyme
Viscoelastic
Neoplastic cells
Post-trabecular block (elevated episcleral venous pressure)
Retrobulbar tumours
Carotid cavernous fistula
Cavernous sinus fistula
Sturge-Weber syndrome

Table 44.11

 Classification of Secondary Closed-angle Glaucomas
 Based on Mechanism^{16,17}

Anterior ('Pulling') angle closure
Contraction of inflammatory particles
Contraction of fibrovascular membrane
Contraction of endothelial membrane
Contraction of developmental angle bands
Posterior ('Pushing') angle closure
With pupillary block
Swollen lens
Subluxated lens
Aphakic
Seclusio pupillae
Without pupillary block
Malignant glaucoma
Vitreous herniation in aphakia
Intraocular tumours
Retrolental fibroplasia
Iris and ciliary body cysts
Essential Iris atrophy

minimal signs of uveitis like presence of a few nonpigmented keratic precipitates. The characteristic sign is the recurrent episodes of raised ocular tension between 40–60 mm Hg. Gonioscopy shows normal angle.

Diagnosis. Diagnosis depends on signs of ocular inflammation, slit-lamp examination, tonometry and gonioscopy.

Treatment. The measures include steroids, cycloplegics, flurbiprofen, beta-adrenergic antagonists and acetazolamide.

Lens-induced Glaucomas⁷

There are five types: (a) phacolytic; (b) lens-particle; (c) phacomorphic; (d) lens-induced uveitis with glaucoma; and (e) lens displacement glaucoma.

Phacolytic (lens protein) glaucoma follows senile hypermature cortical cataract in which there is trabecular obstruction by leading lens protein sometimes laden with large histiocytes. Clinical features are those of acute angle-closure glaucoma *except* the following signs

- the angle of the anterior chamber is deep
- the angle is open
- there is no peripheral anterior synechia.

Diagnosis is based on raised IOP, signs of uveitis and presence of hypermature cataract. Treatment consists of medical therapy to control high IOP and inflammation, and this is followed by cataract extraction.

Lens-particle glaucoma is a variant of phacolytic glaucoma (lens protein glaucoma). The most common cause is an extracapsular cataract extraction (ECCE); other causes include traumatic injury to the lens capsule and Nd:YAG laser posterior capsulotomy. The mechanism of glaucoma is same as that of lens protein glaucoma, but the cellular contribution to outflow obstruction is minimal. The signs observed by slit-lamp include dense flare and cells with white cortex in the aqueous. Onset of glaucoma is usually delayed days, weeks or even months after operation. Treatment consists of acetazolamide, cycloplegics,

topical steroids, and surgical removal of the lens particles when high IOP cannot be controlled.

Lens-induced uveitis can lead to glaucoma, see p. 256.

Phacomorphic glaucoma is an acute secondary closed-angle glaucoma following intumescence of the lens. Rapid swelling of the lens occurs in intumescent and hypermature cortical cataract. The rapid swelling is followed by pupillary block or forward shift of the lens-iris diaphragm. Diagnosis is possible by: (a) unilateral advanced cataract; (b) asymmetric central shallowing of the anterior chamber; and (c) raised IOP. Treatment is by reduction of IOP by appropriate medical therapy followed by lens extraction.

Lens-displacement glaucoma. Displacement may be partial or complete, anterior or posterior. In anterior dislocation into the anterior chamber there is an acute secondary angle-closure glaucoma. Posterior displacement into the vitreous may also induce glaucoma. Treatment is started with topical beta-blockers, osmotic agents and acetazolamide. An anteriorly displaced lens is removed, while pars plana lensectomy is recommended if the lens is displaced posteriorly.

Secondary Glaucomas following Ocular Trauma³¹

Glaucomas following trauma may be:

- (a) Early-onset glaucomas following
 - (i) Hyphaema
 - (ii) Contusion
 - (iii) Trabecular disruption
- (b) Late-onset glaucomas which include
 - (i) Angle-recession glaucoma
 - (ii) Ghost cell glaucoma
 - (iii) Lens-induced glaucoma
 - (iv) Glaucoma due to epithelial downgrowth.

Glaucoma following hyphaema

The possible mechanisms of glaucoma are contusion of outflow apparatus, trabecular disruption and blockage of the trabecular meshwork with red blood cells. Unabsorbed total hyphaema

without any treatment for 6 days and with IOP more than 25 mm Hg causes blood staining of the cornea. Re-bleeding occurs in 6 to 33 per cent cases between second and sixth days. Treatment consists of topical steroid, beta-blocker and cycloplegic. If these fail to control high IOP, paracentesis or wash-out of the anterior chamber is recommended.

Angle-recession glaucoma

Though angle recession is very common after blunt ocular trauma, glaucoma is uncommon (about 7–9% cases). Glaucoma ensues months or years after the initial injury. The probable mechanism of glaucoma is decreased aqueous outflow following angle recession. Diagnosis is based on past history of ocular trauma, unilaterality, deep anterior chamber, evidence of injury in ocular structures and gonioscopy. Gonioscopy exhibits deepening of the angle, wider exposed face of the ciliary body, posteriorly displaced iris root and torn ciliary processes. Treatment is at first conventional, and then surgical or laser filtering procedure.

Ghost cell glaucoma

Ghost cells are degenerated red cells. Normal red cells are pliable and hence pass through the trabecular meshwork easily, while the ghost cells are unable to do so because of their rigid nature. Ghost cells obstruct the pores of the meshwork and cause rise of IOP. These cells migrate from the vitreous haemorrhage into the anterior chamber and glaucoma ensues about 1 month after the injury. If it fails to respond to medical treatment, anterior chamber irrigation is often effective. Occasionally a pars plana vitrectomy may be done for complete removal of blood particles from the vitreous.

Neovascular Glaucoma (Haemorrhagic Glaucoma)³³

There are three important causes: (a) central retinal vein thrombosis; (b) diabetes mellitus; and (c) diverse group including carotid artery occlusive disease. Probably angiogenesis factors are

responsible for iris neovascularization. There are three stages of this affection: (a) preglaucoma stage characterized by the presence of rubeosis iridis; (b) secondary open-angle glaucoma, and (c) secondary synechial angle-closure glaucoma. The typical clinical picture in an advanced stage is as follows. Visual acuity is often hand movements, the cornea is steamy, ciliary injection is prominent, ocular tension is 60 mm Hg or higher, the iris shows new vessels, and the eye is painful and photophobic. Anterior segment fluorescein angiography (ASFA) shows leakage from the new iris vessels.

Treatment has been summarized in Table 44.12, though the measures are difficult.

Table 44.12

Suggested Treatment Modalities in Neovascular Glaucoma

Preventive

- CRVT fluorescein angiogram—mandatory
- Ischaemic type—early PRP
- Nonischaemic—careful follow-up
- Diabetes mellitus—control of hyperglycaemia and PRP

Therapeutic

- Early stage
 - PRP
 - Panretinal cryotherapy, if PRP is not possible
 - Goniophotocoagulation
- Late stage
 - PRP
 - Filtration operation
 - Valve implant surgery
 - 5-FU
- End-stage
 - Cyclocryotherapy
 - Cyclodiathermy
 - Alcohol injection retrobulbarly

Glaucoma in Aphakia and Pseudophakia

Such a glaucoma may be either early-onset or late onset, open-angle or closed-angle (Table 44.13).

Treatment is essentially preventive which includes peripheral iridectomy, adequate wound suturing, proper mydriasis and use of steroid.

Table 44.13

Various Types of Glaucoma in Aphakia and Pseudophakia⁵

Open-angle

Early-onset

- Malignant glaucoma
- Preexisting POAG
- Inflammatory glaucoma
- Glaucoma following hyphaema
- Miscellaneous group viscoelastic, pigment, etc.

Late-onset

- Lens-particle glaucoma
- Inflammatory glaucoma
- Ghost cell glaucoma
- Steroid-induced glaucoma
- Vitreous in anterior chamber
- UGH or PUGH syndrome

Closed-angle

Early-onset

- Pupillary block glaucoma
- Preexisting PACG
- Malignant glaucoma

Late-onset

- Pupillary block glaucoma
- Glaucoma associated with peripheral anterior synechia
- Neovascular glaucoma

Therapeutic treatment is by mydriatic-cycloplegic agents and steroids; if this regimen fails, a combined iridectomy (to relieve the pupillary block) and cyclodialysis (to open the angle) is advocated.

Malignant Glaucoma^{16,17} (Syn: Ciliary block glaucoma, aqueous misdirection syndrome)

A classic malignant glaucoma may occur in 0.6 to 4 per cent cases following iridectomy or filtering operation in acute closed-angle glaucoma in phakic patients. This also occurs in aphakia or pseudophakia. Other causes include use of miotics, injury, laser applications, inflammation, etc. The sequence of events in its pathogenesis is as follows: there is a ciliolenticular blockage in phakic or ciliovitreal obstruction in aphakic eye obstructing aqueous circulation forward, decreased aqueous outflow leads to posterior diversion of aqueous and trapping in or behind the vitreous, there is increase

Oops, page PA307 was not yet downloaded :(

24. Posner, A., Gonioscopy. In *Modern Ophthalmology* (2nd ed.), Vol. I. Sorsby, A. (Ed.), Butterworths, London, 1972, p. 623.
25. Primrose, J., Early signs of glaucomatous disc. *Br. J. Ophthalmol.*, **55**:820, 1971.
26. Reese, A.B. and Ellsworth, R., The anterior chamber cleavage syndrome. *Arch. Ophthalmol.*, **75**:307, 1966.
27. Scheie, H.G. and Albert, D.M. (Eds.), *Textbook of Ophthalmology* (9th ed.), W.B. Saunders Co., Philadelphia, 1977.
28. Shields, M.B., *Textbook of Glaucoma* (3rd ed.), Williams and Wilkins, Baltimore, 1992.
29. Smith, R., *Clinical Glaucoma*, Casell, London, 1965.
30. Sood, N.N. and Sihota, R., Primary open angle glaucoma. In *Modern Ophthalmology*, Dutta, L.C. (Ed.), Jaypee Bros., New Delhi, 1994, p. 413.
31. Tingley, D.P. and Shingleton, B.J., Glaucoma associated with ocular trauma. In *Principles and Practice of Ophthalmology: Clinical Practice*, Albert, D.M. and Jacobiec, F.A. (Eds.), W.B. Saunders, Philadelphia, 1994, p. 1436.
32. Tripathi, R., Aqueous outflow pathology in normal and glaucomatous eyes. *Br. J. Ophthalmol.*, **56**:157, 1972.
33. Wand, M. Neovascular glaucoma. In *Principles and Practice of Ophthalmology: Clinical Practice*, Albert, D.M. and Jacobiec, F.A. (Eds.), W.B. Saunders, Philadelphia, 1994, p. 1486.
34. Wilensky, J.T., Glaucoma. In *Principles and Practice of Ophthalmology*, Peyman, G.A. Sanders, D.R. and Goldberg, M.F. (Eds.), W.B. Saunders, Philadelphia, p. 671.

45. DISEASES OF THE RETINA

The retinal diseases are varied and include vascular disorders, inflammations, degenerations, dystrophies, various retinopathies and retinal

detachments. The macular affections are equally varied. There are advanced and sophisticated methods of diagnosis which have been especially introduced during the past two decades.

The Normal Fundus²⁷ (Fig. 45c.1)

Colour. The bright red colour of the fundus depends on: (a) the red component—due to blood in the choroidal vessels; (b) the brown component—due to pigment of the choroid and retina; and (c) type and intensity of the light source used for examination.

Texture. Ocular fundus presents fine stipples especially looser and coarser at the periphery. It is granular in and around the macular area because both choroidal and retinal pigmentation is most dense and uniform at this region. This appearance is most likely due to hexagonal pigment epithelium of the retina.

Pattern. Normally the choroidal vessels are invisible due to density of pigmentation in the retina and compactness of the choriocapillaris. In a young child because of lesser pigment concentration, the colour of the fundus is lighter and the choroidal vessels are visible. In old age, because of progressive fading of the retinal pigments and progressive increase of choroidal pigments, *tesselated* or *tigroid fundus* is common. Tigroid fundus is characterized by visible choroidal vessels and absence of stippling. Tesselation is common in a darkly pigmented individual.

Blood vessels. The four quadrants of the retina are evenly supplied by the branches of the central retinal artery. The retinal arteries are light red, of thinner calibre than the veins, 2:3, and are less tortuous. The retinal veins are purplish, of thicker calibre and are more tortuous. The retinal vessels do not anastomose but present a central reflex streak, while the choroidal vessels anastomose freely but present no central streak.

Optic disc. The term 'disc' is assigned to the ophthalmoscopic view of the head of the optic nerve. It is red in colour but this redness is little

lighter than the rest of the fundus, its temporal part appears relatively paler. It is round or oval. At its centre there is an excavation corresponding to the lamina cribrosa, called the *physiologic cup*, from where originate the retinal vessels. The cup varies in its depth and otherwise. The disc margin is clear. Even under physiologic conditions the margin on its outer aspect shows a pigment ring. The retinal pigment layer and the choroid may cease at a little distance from the margin causing traces of the choroidal vessels and pigment to be visible, called *crescent*.

Macula lutea. This is situated 3 mm or 2 disc-diameters to the temporal side of the disc margin but a little below the horizontal line passing through the centre of the optic disc. The pupil should be dilated to examine this area in details. From its centre a bright reflex, *foveal reflex*, is emitted.

Periphery of the fundus. With full dilatation of the pupil it is feasible to examine even up to the ora serrata with the help of an indirect ophthalmoscope, especially binocular. Scleral depressor may be used in addition for better visualization.

Reflexes. Even under normal conditions the retinal reflexes are widely variable. These are as follows:

Fovea shows a bright reflex while there is also a perimacular reflex. Sometimes there is a fan-shaped reflex radiating from the fovea to the margin of the macula. Blood vessels produce mobile and elusive reflexes. Nerve fibre pattern may be evidenced by striated surface reflex. *Weiss's reflex* occurs due to annular reflex concentric with the disc margin. The posterior parts of the retina may show minute, highly glistening specks known as *Gunn's dots*.

Investigations for Retinal Diseases^{15,27,31}

Investigations for retinal disorders are indicated in Table 45.1.

Table 45.1

Investigations for the Diagnosis of Retinal Disorders

History
Visual acuity
Ophthalmoscopy
Direct
Indirect
Scanning laser
Slit-lamp biomicroscopy
Perimetry and scotometry
Transillumination
Fundus fluorescein angiography
Standardized retinal drawing (cartography)
Ultrasonography
Ophthalmodynamometry
Electrodiagnostic methods
Electrooculography
Electroretinography
Visual-evoked response
Digital imaging

Direct ophthalmoscopy

The ophthalmoscope is an indispensable instrument, and direct ophthalmoscopy is the most commonly used procedure in examination of the retina. However, the diameter of the field of observation is smaller and the retina anterior to the equator is seen with difficulty (Table 45.2).

Indirect ophthalmoscopy. Indirect ophthalmoscopy is better done under full mydriasis and the patient being in a supine position. The extreme periphery of the retina is seen by using a scleral depressor in addition to indirect ophthalmoscopy itself. A stereoscopic indirect ophthalmoscope has three components: (a) the illumination system which provides approximately parallel rays of light; (b) a hand-held lens in dioptric powers varying between +14 D to 33 D, which acts as a condensing lens and forms an inverted image in space; and (c) the viewing system.

Slit-lamp biomicroscopy^{15,16}

The examination is useful in certain conditions like: (a) flat detachment of the retina; (b) central serous retinopathy; (c) posterior vitreous detachment;

Table 45.2
Showing Distinguishing Features of Two Types of
Ophthalmoscopy

Direct ophthalmoscopy	Indirect ophthalmoscopy
Virtual and erect image of the fundus is seen	Inverted and real image of the fundus is seen
Magnification is about 15 times	Magnification is 5 times when a +13D condensing lens is used
There is relatively low brightness	There is relatively greater brightness
Field of observation is about 10° in diameter	Field of observation is 37° in diameter
Image formed is not stereoscopic	Binocular indirect ophthalmoscopy provides better stereopsis
Retina anterior to the equator is not well seen	Retina anterior to the equator is seen better
Scleral indentation is difficult	Scleral indentation can be easily done in binocular indirect ophthalmoscopy
Poor visualization in hazy media	Better visualization

(d) retinal cyst; (e) retinoschisis; and (f) differentiation between a macular cyst and a macular hole. The slit-lamp should have a vertical slit, the facility of bringing in horizontal slit from below (up to 20°), and provision of a vertical tilt. The retina is visualized by the slit-lamp, with the help of Goldmann, Hruby, El Bayadi or Volk lens. The Goldmann contact lens replaces the +45 D of corneal surface refraction by an afocal plane surface. The Hruby lens, -60 D, neutralizes the total refractive power of the eye. The El Bayadi lens, +60 D, produces a large inverted real image of the retina.

Volk lenses of +78 and +90 D may also used. The lens of +90 D having 21.5 mm size is used at a working distance of 6.5 mm from the cornea.

Perimetry and scotometry

Perimetry and scotometry are considered as important investigations especially in conditions like: (a) retinitis pigmentosa which produces typical ring scotoma; (b) retinal detachment, e.g.

an inferior detachment causes a superior field loss and vice versa; (c) central serous retinopathy causes a central scotoma; (d) macular degenerations similarly cause central scotoma; and (e) occlusion of a branch of central retinal artery or vein causes field loss corresponding to the area nourished or drained by the vessel. In thrombosis of a vein, the field changes are proportionately less marked than in an occlusion of an arteriole.

Transillumination

The method can differentiate between an idiopathic retinal detachment and detachment associated with a neoplasm. In case of idiopathic detachment the pupil appears red by transscleral transillumination, while the pupil appears black in case of neoplasm. Pupil dilatation prior to an examination is essential. Photographs can be taken using fibre optics illumination.

Miscellaneous Diagnostic Procedures

Miscellaneous diagnostic procedures include: (a) electroretinography (ERG) records objectively the function of the retina; (b) electrooculography (EOG) is helpful in certain conditions like retinitis pigmentosa, retinopathies and retinal detachment; (c) ultrasonography; (d) ophthalmodynamometry is useful especially in malignant hypertension, papilloedema associated with intracranial hypertension, carotid artery occlusion and pulseless disease; and (e) photostress test or afterimage test involves dazzling the macula and measuring the time for recovery; in optic nerve diseases and tapetoretinal degenerations photostress responses are prolonged.

Electrodiagnostic Methods in Retinal Disorders

Measurement of the electrical responses is possible in the visual system and this forms the basis of the tests of retinal function by EOG and ERG, and those of cortical function by electroencephalogram and visual-evoked response.

Tests of retinal function

There is a steady or corneofundal potential of about 6 millivolts arising from many structures and passing along the optic axis, the cornea being positive compared to the posterior pole of the eye. There are two components: light-insensitive and light-sensitive. The light-sensitive part is able to respond to changes in illumination and this forms the basis of EOG and ERG.

Suitable cases of electrodiagnostic tests²²

Loss of visual acuity. Assessment of macular function is not possible but the tests reveal retinal or cone dysfunction.

Visual field loss. The cause can be detected, e.g. field loss due to an abiotrophy of the retina.

Poor dark adaptation. It is caused among others by tapetoretinal degenerations and essential night blindness. Both EOG and ERG are helpful.

Colour deficiency. Cone dysfunction causing colour deficiency can be assessed by ERG.

Corneal opacity and cataract. If the opacity is too dense to allow examination of the fundus, tests for retinal function are called for.

Equivocal fundus pigmentation. When the symptoms and suspicious signs of tapetoretinal degeneration are present the tests are considered essential.

Assessment of case of an eye injury. This is possible with electrodiagnostic methods.

Examination of a child under anaesthesia. Electrodiagnostic examinations are occasionally preferred.

Electrooculography (EOG)^{11,27}

Electrooculography is the indirect method of measuring the ratio between the maximum potential in the light and the minimum potential in the dark.

Clinical test. Electrodes are placed on both sides of the two eyes, on the skin over the orbital margin opposite each canthus. As the eye moves towards the left, the positive cornea approaches

the left electrode and the negative posterior pole of the eye turns towards the right electrode. The patient is asked to move the eyes repeatedly once every minute. The ocular potential falls to a minimum level after keeping the patient in the dark for about 12 minutes. The eyes are then illuminated and the recordings are continued for another 12 minutes when the ocular potential rises to the maximal level. The measurement of the ratio between the maximal height of the potential in the light, the *light peak*, and the minimal height of the potential in the dark, the *dark trough*, is the basis of EOG. The ratio is expressed after multiplying by one hundred as percentage, called the *Arden ratio*.

Advantages of EOG. The test is painless and it is not affected by corneal opacity or cataract.

Disadvantages of EOG. It is mainly determined by the rods of the retina and the lesions proximal to the receptors can show normal EOG. The response may be variable. The response may be abnormal in an otherwise normal eye.

Electroretinography (ERG)²⁷

In the vertebrate eye, there is a resting potential of about 10 to 12 millivolts, the anterior pole (cornea) being positive with respect to the posterior pole. In 1877 Dewar for the first time recorded the potentials from humans.

By flashing a light stimulus into the eye, the resting potential becomes converted to an action current, and the recording of this action current is called electroretinogram.

The ERG Components. These are shown in Fig. 45.1(a).

Early receptor potential (ERP). This is the initial response which occurs within a few milliseconds. It represents the physiochemical changes evoked by light occurring in the visual pigment molecules.

a-wave. The clinical ERG starts with a negative deflection or a-wave. It is also called *late receptor potential* (LRP). It occurs after 10 milliseconds after the flash. It arises in the rods and cones.

b-wave. A much larger positive deflection then occurs and is known as b-wave. It has two components: b_1 or *photopic* and b_2 or *scotopic*. It arises in the bipolar cells. Four small rhythmic wavelets may be detected on the ascending limb of the b-wave, and they are known as *oscillatory potentials*.

c-wave. Another positive deflection but much slower than b-wave is seen and it is called c-wave. This wave arises in the pigment epithelium.

d-wave. Under certain circumstances as in aphakia, a negative deflection (d-wave) occurs at the cessation of the stimulus.

Clinical ERG may be either scotopic or photopic. The equipments needed for recording ERG are a suitable amplifying and recording system, light source for the stimulus and contact lens electrodes.

Technique. After anaesthetization, the contact lens is placed on the cornea. One electrode is placed on the cornea and another on the forehead (reference electrode) which is in continuity with the posterior pole of the eye. The forehead electrode acts as the negative pole. Following retinal stimulation by light the elicited response reaches the anterior corneal surface by the contact lens. This response is subsequently made to pass through consecutive devices, preamplification and amplification for final display.

The b-wave can be measured in three different ways:

Flicker ERG. The rod system is triggered by flickering stimuli of low frequency and low luminance in the dark-adapted state.

Dynamic ERG. The cone system is stimulated and the rod system suppressed if a strong white light is used, the process is augmented by the use of red stimuli.

Static ERG. A photopic ERG can be recorded as long as necessary if a steady background of high luminance to whole retina is maintained resulting in suppression of the rods.

Types of ERG (Fig. 45.1b)

Normal. An early case of quinine amblyopia may show a normal ERG.

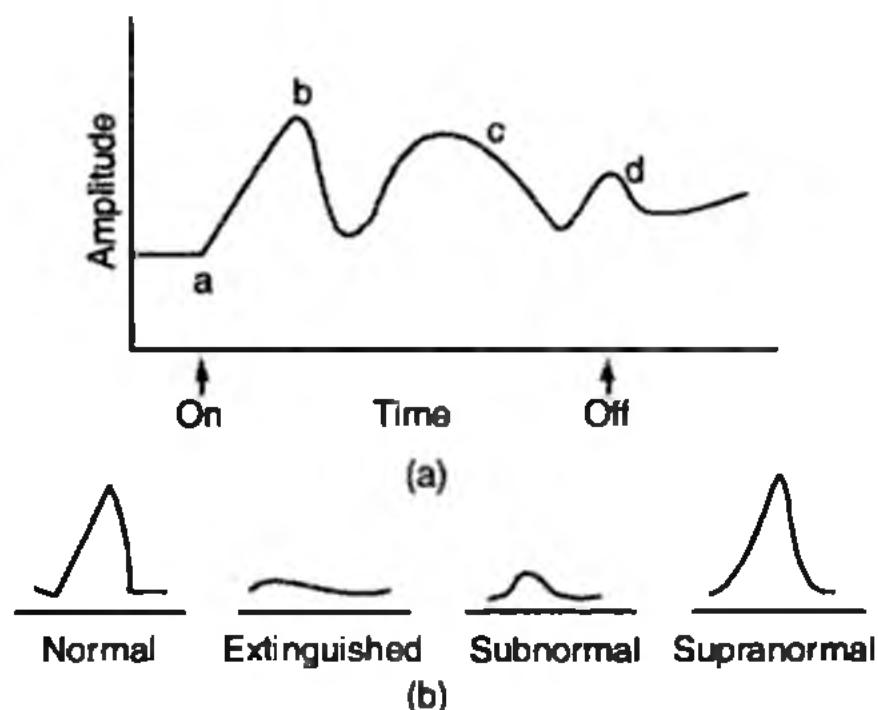


Fig. 45.1 (a) The electroretinogram; (b) types of electroretinogram.

Supranormal. This occurs as in occlusion of a branch of the central retinal artery.

Subnormal. This occurs in conditions like high myopia and in both primary and secondary retinitis pigmentosa.

Negative. This occurs in early phase of occlusion of the central retinal artery.

Extinguished. It occurs in central retinal artery occlusion and retinal detachment.

Electronystagmography

The electrodes placed near the eye can also be utilized to monitor the eye movements as in nystagmus.

Visual-evoked response (VER)^{11,36}

Visual-evoked response is the electroencephalogram (EEG) recorded at the occipital cortex. The VER represents the activity of the visual cortex, evoked by the visual stimuli and recorded by the electrodes placed on the scalp. Each eye is tested separately and both eyes together. The electrodes are connected through preamplifiers to the averaging computer. The light stimulus is either a flash or a pattern presented within a short period of time, say one cycle per second for 100 seconds. There is an initial positive wave, followed by a negative wave, then a large positive wave and

macular colobomata are as follows. In the first type, the choroid is only involved which shows a round pigment patch traversed by the choroidal vessels. Pearly white sclera with its margin pigmented is seen when both choroid and retina are affected. The third type exhibits anomalous vessels.

Cilioretinal vessels

The arteries of this group originate from the posterior ciliary arteries or the circle of Zinn. A cilioretinal artery arises at the temporal border of the disc and courses towards the macular area. In occlusion of the central retinal artery, the incidental presence of this artery retains visual function.

Crescents

Crescent is a white semilunar area at the optic disc margin. There are three types. Developmental crescent does not expand in course of time. This is situated inferiorly. According to Mann,²⁶ the condition appears to be a defect in the development of the walls of the secondary optic vesicle. Myopic crescent is situated on the temporal side of the disc and is always progressive. A senile crescent is a halo of uniform width of a pale depigmented area on the temporal side.

Pseudoneuritis

Pseudoneuritis is usually bilateral. In pronounced cases it is characterized by haziness of the disc margin, swelling and tortuosity of the vessels, and more common in hypermetropia with astigmatism. The appearance is due to heaping up of the nerve fibres in the presence of a small lamina cribrosa.

Anomalies of pigmentation

Anomalies of pigmentation have been discussed on p. 198 of part five.

Vascular disorders of the retina^{9,30}

The retinal blood vessels are prone to be affected in both local disorders and systemic diseases. A

vascular disorder in the retina may be hyperaemia, anaemia, oedema, haemorrhage, vascular anomalies, obstruction of an artery or a vein, neovessels and retrolental fibroplasia.

Hyperaemia

Hyperaemia may be arterial or active and venous or passive. An *arterial hyperaemia* is characterized by fullness and tortuosity of the arteries and occurs in retinitis and uveitis. *Venous hyperaemia* is evidenced by fullness and tortuosity of the veins and occurs due to impeded venous return to the heart. It is present in local conditions like optic neuritis, papilloedema, central retinal vein thrombosis (CRVT), Eales' disease, diabetic retinopathy and glaucoma. It may also follow general venous congestion in such conditions as congenital malformation of the heart, polycythaemia and leukaemia.

Anaemia

Anaemia may be due to local or general causes, and is either slow in onset as in optic atrophy or sudden in onset as in central retinal artery occlusion.

Oedema

Oedema may be diffuse or localized. In mild cases the retina appears granular, while in advanced cases there is swelling obscuring the details of the blood vessels and with ill-defined edges. The favourite site is the macula.

Its aetiology is varied but are mainly divided into two groups: (a) circulatory such as papilloedema, vascular obstruction and retinopathies, and (b) inflammatory such as optic neuritis and retinitis. Pathologically, here are two important features: (a) the passage of fluid owing to increased capillary permeability; and (b) breakdown of large protein complexes into smaller particles.

Evaluation of macular function (Table 45.3)

Projection of rays. Accurate projection of rays

Table 45.3

Tests for Evaluation of Macular Function

Projection of rays
Swinging flash light test
Pin hole
Purkinje vascular test
Two-light discrimination
Maddox rod
Electrodiagnostic tests
Photostress test
Fluorescein angiography
Amsler's grid
Blue field entoptoscopy
Interferometry
Potential acuity meter (PAM)

in all quadrants of the eye indicates good macular function.

Swinging flash light test (see pp. 130–31) detects relative afferent pupillary defect.

Pin hole reduces the area of macular cones and allows only the central rays through it.

Purkinje vascular test. The shadow of the retinal blood vessels can be visualized when a small flash of light is swept across the eyelids.

Two-light discrimination. While sitting in a dark room, two pencil torches are held close to one another and 60 cm away from the patient's eyes. These lights are gradually separated. Macular function is considered normal if the patient perceives these two lights when they are separated for 5 cm.

Maddox rod. The ability to perceive light streaks through Maddox rod indicates normal function. The patient is asked to look at a pen torch through Maddox rod with the other eye closed and a red line is seen. If the macula is affected by disease causing a relative scotoma, this red line exhibits a gap in the middle.

Electrodiagnostic tests include EOG, ERG and VER. These are described on p. 312.

Photostress (afterimage) test differentiates unilateral visual loss following optic nerve disease from retinal disorder. The best corrected visual acuity (BCVA) is recorded. A flash light held about

2 to 3 cm from the eye being tested is shone directly onto the normal uncovered eye for about 10 seconds, while the eye with visual loss is covered. The photostress recovery time is the time in seconds taken by the patient to read any 3 letters of the pretest visual acuity line. The test is repeated in the defective eye while covering the normal eye. The time required for the affected eye to read the appropriate line will be more if the affection is retinal, but will be the same if the disorder is in the optic nerve.

Fluorescein angiography is extremely valuable in many retinal disorders (pp. 523–24).

Amsler's grid (Fig. 45.3) is utilized for testing central visual field and is a rapid screening procedure. Each eye is tested separately. The patient fixates the central dot of the chart held at 33 cm, and any glass for correcting visual acuity must be worn. When the central or paracentral part appears missing it indicates a macular lesion.




Fig. 45.3 Amsler grid.

Blue field entoptoscopy (flying corpuscle test). The visualization of leucocytes moving through the perifoveal capillaries forms the basis of this test. Normally there are 15 or more cells. Macular involvement is suspected when the patient

cannot see any cell or see lesser number of slowly-moving cells.

Interferometry is indicated in eyes with immature cataract. After full mydriasis the light beam is directed into the centre of the pupil. A three-dimensional fringe pattern is formed in the retina by two coherent interferometry light beams.

Potential acuity meter (PAM) consists of a point light source, transilluminated Snellen's chart and a lens. The pupil is widely dilated, then the acuity chart projected and the patient asked to read the letters.

Macular oedema

There is a light grey haze of the macular region which is also elevated. because of the arrangement of the nerve fibres there is often radiating folds in the area, *macular star*. Fluorescein angiography can distinguish between a cystoid oedema and a noncystoid oedema. A cystoid oedema is the result of a deranged blood-aqueous barrier. A noncystoid or amorphous oedema occurs due to damage of the capillaries at this region.

The preference of the retinal oedema to involve especially the macular region is possibly due to: (a) thicker Henle's nerve fibre layer thickest at the disc margin, thus its importance in case of papilloedema and the absorption of more fluid; and (b) avascularity and hence least chance of disappearance. The chief aetiological factors are: (a) vasospastic, e.g. central serous retinopathy; (b) trauma—Berlin's oedema or commotio retinae; (c) papilloedema; and (d) inflammations.

Central Serous Retinopathy (CSR)

Aetiology. The cause is not definitely known. The contributory factors include vasomotor instability, allergy, toxic factors, etc. Recently, its relation with catecholamine has been described.³⁸

Clinical features. Central serous retinopathy is commonly seen in young healthy males. It is greyish (or reddish) circumscribed with distorted or absent foveal reflex with and light reflex encircling the oedema (Fig. 45c.3). The reflexes

reflect from the oedematous anterior margin. The condition is more often unilateral. Visual acuity is often slightly depressed, e.g. 6/9 or so, but definite deterioration occurs when the accumulation is large. Positive scotoma is not uncommon. Sometimes very fine punctate haemorrhages are seen by red-free ophthalmoscopic light. Slit-lamp examination with Hruby lens shows peripheral bulging with central depression. The depressed area is the fovea. Oedema usually clears in a week or two, but sometimes takes longer. Residual picture may be fine pigment stipples at the region. Recurrences are common and each attack leaves behind its trail.

Fluorescence angiography has indicated the pooling of the dye at one or more small focal areas of increased capillary permeability. It also shows leakage of fluid through the defective Bruch's membrane. Possibility of a reversible angiospastic process cannot also be discounted.

FFA. See p. 521.

Treatment. Usually the condition is self-limiting. Argon laser therapy is advocated if CSR remains active for 2 to 3 months and the site of leakage is 500 millimicron or more from the fovea. This treatment reduces serous retinal detachment within 1 to 4 weeks and the recurrence rate.

Complications following laser therapy include accidental foveal burn and choroidal neovascularization.

Central Chorioretinopathy

Klein classified CSR into three types: retinal, retinochoroidal and choroidal. A central chorioretinopathy has the following distinguishing features: (a) involvement of the choriocapillaris in the macular region; (b) more intense oedema appears; (c) haemorrhage may occur along with exudation; (d) greater visual disturbance occurs; (e) pigment disturbance is early; and (f) course is longer.

Cystoid Macular Oedema

Cystoid macular oedema (CMO) is a disorder of the perifoveal capillary network.

Aetiology. The causes of CMO are listed in Table 45.4.

Table 45.4
Major Causes of Cystoid Macular Oedema

Aphakia and pseudoaphakia
Diabetic retinopathy
Central retinal vein thrombosis (CRVT)
Branch vein thrombosis
Retinal vasculitis
Pars planitis
Vitreous loss
Vitreous adhesion to the wound
Ocular hypotony
Hypertensive retinopathy
Age-related macular degeneration
Postphotocoagulation/cryoapplication
Following medications like methyldopa, nicotinic acid, etc.

Pathology. There is leakage from the perifoveal capillary network and accumulation of fluid in the plexiform layers around the foveola.

Diagnosis. Ophthalmoscopy reveals multiple cystoid areas with loss of foveal reflex. Slit-lamp biomicroscopy with the help of a specialized fundus contact lens is helpful. FFA shows vascular leakage from the perifoveal capillaries (*see p. 521*).

CMO occurring usually 1 to 3 months after cataract extraction associated with vitreous adherent to the wound edges is called *Irvine-Gass syndrome*.

Treatment. The condition is self-limited. Systemic steroids are recommended in inflammatory and vascular disorders.

Topical nonsteroidal antiinflammatory drug (NSAID) appears to be promising.

Haemorrhages in the Fundus²⁷

Classification

- (a) Intraretinal:
 - (i) Arterial
 - (ii) Venous
 - (iii) Capillary
- (b) Subhyaloid or preretinal
- (c) Subretinal
- (d) Vitreous

Intraretinal haemorrhages. The haemorrhage is essentially capillary, but sometimes of venous or arterial origin. In case of arterial haemorrhage, the fault may be in the form of seepage of blood such as in atheroma or leakage through the wall such as in acute inflammation. Venous haemorrhage is from the small venules following obstruction to the venous return as in thrombosis of the central retinal vein and Eales' disease. The causes of capillary haemorrhage include: (a) trauma; (b) vascular obstruction; (c) perivasculitis; (d) vascular diseases; (e) toxic state; and (f) haemopoietic diseases. The appearance varies according to the site of extravasation:

(i) Striate and flame-shaped—if the haemorrhage is in the nerve fibre layer, as in CRVT.

(ii) Dot and blot haemorrhage—if the haemorrhage is in the deeper parts, as in BDR.

(iii) Radial and stellate—if it is in the central area.

The course of haemorrhage may be as follows:

- | | | |
|----------------|---|--------------------------------------|
| (a) Absorption | [| Rapid—after haemolysis of RBCs |
| | | Slow—when the haemorrhage is profuse |

(b) *Retinitis proliferans* (Fig. 45.4) is characterized by leash of fibrous tissue associated

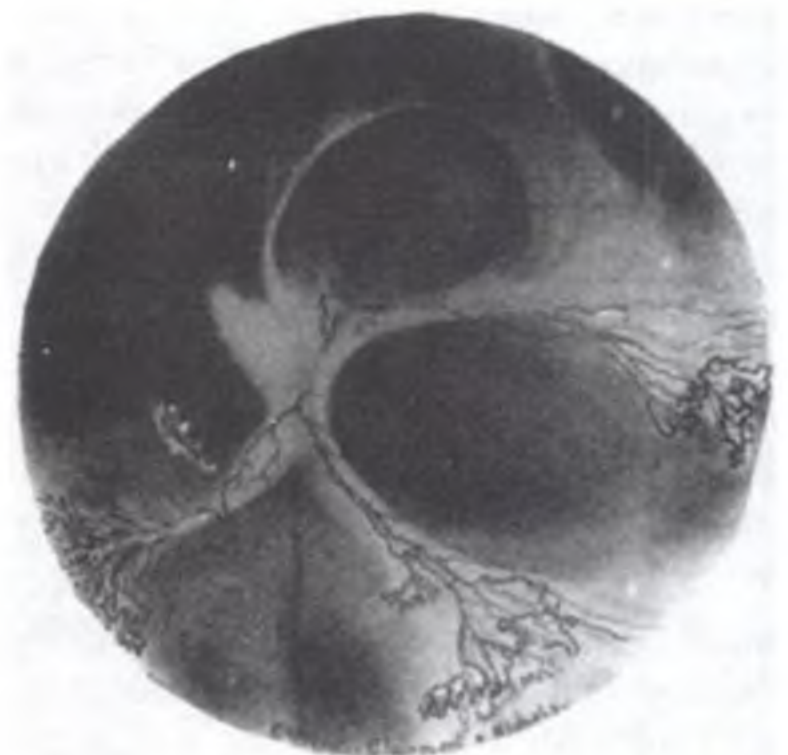


Fig. 45.4 Retinitis proliferans (after Paton, from Trevor-Roper).

Oops, page PA320 was not yet downloaded :(

(c) Disappearance of the nuclei of endothelium and pericytes

(d) Cloudy swelling of the ganglion cells of the retina and their axons leading to coagulative necrosis

(e) Degeneration of the nerve fibres followed by glial proliferation.

Clinical features. The clinical picture of a case of central retinal artery occlusion if due to an embolism is dramatic and the visual loss is sudden, complete and permanent. It is nearly always a unilateral affection. Bilateral affection points to an embolic origin. There may be a veil in front of the affected eye preceded by subjective light and colour phenomenon. There is a possibility of some visual recovery if the circulation is by chance restored and there is no permanent retinal damage.

Pupillary reaction to direct light cannot be elicited, while consensual reaction is present.

Ophthalmoscopically (Fig. 45.5): (i) *Complete obstruction.* Usually within 2 to 3 hours the retina

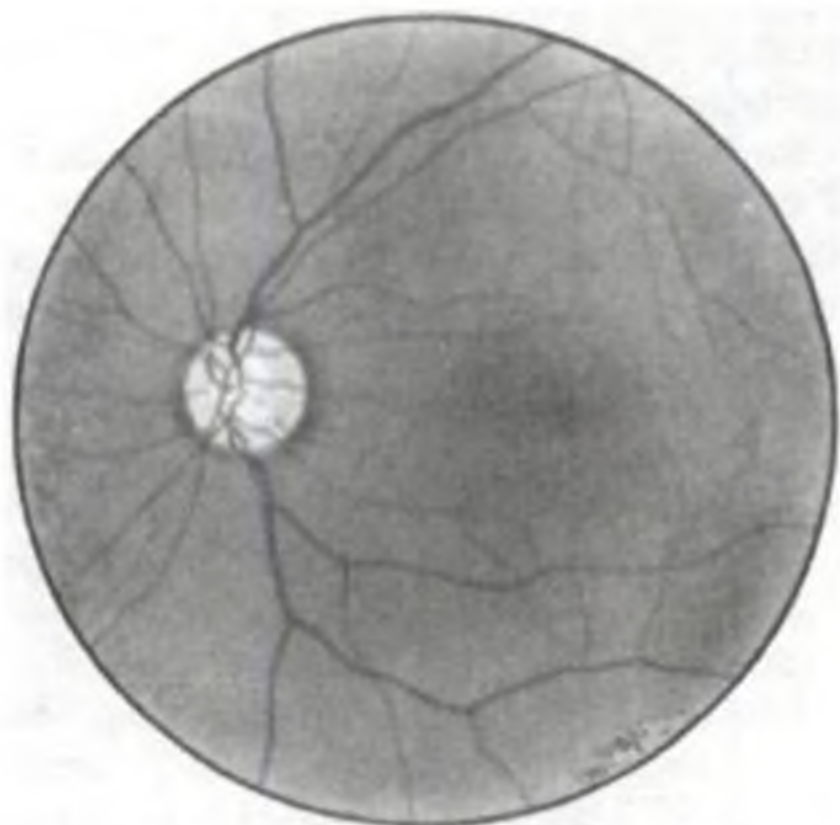


Fig. 45.5 Recent obstruction of the central artery of the retina (May and Worth).

becomes milky-white due to cloudy swelling of the ganglion cells rather than oedema, which becomes dense by the second day and by contrast a 'cherry-red' fovea is seen. The choroid is seen through the thin fovea which appears bright red in

the milky-white background. The disc margins appear blurred and all the arterioles show marked narrowing with no pulsation seen on pressure. The veins remain usually normal but may show slight narrowing. The final picture consists of slow, complete regression of retinal haze, obliteration of the arterioles and vascular optic atrophy.

(ii) *Obstruction of a branch.* It is characterized by sector-shaped retinal haziness and narrowing of one branch of the artery which is obstructed. The disc margin is only blurred when a vessel nearby is affected. The most commonly affected branch is the superior temporal.

(iii) *Obstruction of the central retinal artery in the presence of cilioretinal artery.* Only the cilioretinal artery shows normal filling and there is a zone of normal retina without haziness between the disc margin and the fovea. The central vision is preserved.

(iv) *Incomplete obstruction.* It is characterized by the presence of arterial pulsation induced by gentle pressure on the globe and the 'cattle-truck' appearance of the blood columns, especially in the veins due to fragmentation of the blood column which moves jerkily sometimes in the normal direction of blood flow and sometimes in the opposite one.

FFA. See p. 522.

Treatment. The principles underlying its treatment are to improve the blood supply of the retina, overcome spasm and dislodge the embolus, if present. Improvement of the blood supply may be possible by reduction of ocular tension by IV Diamox (500 mg) combined with massage of the eyeball. Retrobulbar injection of vasodilators like tolazoline, aminophyllin and nicotinic acid may be of help. Paracentesis appears to be risky.

Other measures include injection of fibrinolytic enzyme like urokinase into the supraorbital artery, rapid IV mannitol, inhalation of carbogen (95% oxygen + 5% carbon dioxide) for 10 minutes. Recently, several agents like dextromethorphan, antioxidants, barbiturates and hypothermia have been advocated to protect the retinal tissue from the damaging effects of hypoxia.¹

hypertension, or inflammatory, typically Eales' disease can affect the veins by endothelial proliferation or thrombus formation.

Associated chronic simple glaucoma. The incidence of venous thrombosis is between 11 and 43 per cent in chronic glaucoma. Probably there is venous stasis in the exit veins by raised ocular tension.

Pathology.^{20,39} (i) *Ischaemic.* The obstruction is at or near the lamina cribrosa. Narrowing of the central vein of the retina causes very high venous pressure, the latter being accompanied by low blood pressure at night. This is followed by low perfusion pressure which in turn induces retinal ischaemia and ischaemic capillaropathy. When the blood pressure level reverts to normal or becomes high the retinal circulation is restored but the raised intraluminal pressure in ischaemic capillaries causes ruptures and extensive retinal haemorrhages.

(ii) *Nonischaemic.* The site of obstruction is further posterior to the retrolaminar region, but if this is close to the retrolaminar region the severity of the lesion is less because of available collateral vessels. Following occlusion there is intraluminal narrowing of the central retinal vein leading to raised venous pressure proximal to the site of thrombus. Subsequently there is reduced perfusion pressure and circulatory stasis.

There are extensive haemorrhages at all depths of the retina. If the obstruction is incomplete or gradually developing, there are punctate haemorrhages, the dots being situated in the inner molecular layer of the retina and arranged round the terminal veins or attached to the fine venules. Histologically, there are proliferation of subendothelial connective tissue, thickening of the tunica adventitia, oedema of the retina especially affecting the inner nuclear layer, degeneration of the ganglion cell layer and of the nerve fibre layer, and ultimately ending in glial proliferation.

Sites of venous occlusion. There are four sites: (a) on the optic disc, usually beside the margin of the cup; (b) at the AV crossing; (c) along the main veins as in diabetes; and (d) at the periphery as in Eales' disease.

Clinical features of classic type. The loss of vision is not so sudden as occlusion of the central retinal artery. In a complete obstruction of the central retinal vein the visual acuity may come down to counting finger or so. In some cases the loss of vision is not so pronounced. In branch thrombosis, sector-shaped loss of visual field corresponding to the affected area occurs.

Ophthalmoscopically (Fig. 45c.5) the following signs are present.

In the early stage, there are moderate dilatation of the retinal veins and scattered haemorrhages. In the advanced cases the retinal veins are engorged, tortuous or coiled into loops and enormously dilated. Haemorrhages are numerous extending from the disc margin towards the periphery of the retina. They come in all sizes and shapes, involving all depths of the retina extending into the vitreous. Retinal oedema is caused by leakage of fluid from the capillaries. It is never far-ranging. Occasionally macular stars may be present. The optic disc is hyperaemic and its margins are blurred due to oedema. Exudates sometimes accumulate particularly around the macula causing a picture of circinate retinopathy. Fluorescein angiography demonstrates blockage of flow at the AV crossing and zones of capillary nonperfusion; sometimes the neovessels in the posterior pole are present. In the late stage, haemorrhages gradually disappear and gross exudates persist much longer. Neovessels in the retina are evident and present an attempt to provide collateral circulation to the area of impaired nutrition.

RAPD is detected.

FFA. See p. 521.

Incipient venous occlusion or prethrombosis. This is characterized by the appearance of signs indicating the oncoming venous occlusion which are evident weeks or months before the eventual complete obstruction. The changes are reversible by prompt treatment. The clinical features are as follows:

(a) Engorgement of some or all the retinal veins with occasional oedema alongside the veins or of the affected sector of the disc.

of vision. It occurs about 90 days after the occurrence of CRVT. It is evident in about 20 per cent cases of CRVT. The cause is speculative and may be due to extensive peripheral anterior synechiae, perivascular sclerosis associated with generalised sclerosis, etc.

Prognosis. Visual acuity is worse when the macula is affected. In a complete obstruction the chance of good visual recovery is remote. However, it is relatively better in a branch occlusion provided the macula escapes and also in some cases of incomplete obstruction.

Treatment.¹ Medical treatment is not effective. Drugs include anticoagulants, aspirin and steroids.

Laser therapy is indicated to prevent visual loss due to macular oedema, neovascularization and vitreous haemorrhage. FFA is essential to evaluate the cases before laser therapy. There are three types:

- (a) Grid photocoagulation
- (b) Scatter PRP
- (c) Prophylactic PRP.

Grid photocoagulation is advocated in macular oedema in CRVT causing visual acuity of 6/12 or less. Argon green laser is used throughout the area of fluorescein leakage.

Scatter PRP is recommended in CRVT with neovascularization. Argon blue-green burns of 200 to 500 microns spot size and of 0.1 to 0.2 seconds' duration are applied over the entire extent of capillary nonperfusion.

Prophylactic PRP is indicated in high-risk cases of CRVT before the development of rubeosis iridis.

Probably *anticoagulants* are somewhat effective in incipient venous obstruction, but they appear to be of little value in an established case. Vannus and Raitta³⁷ advocated the use of anticoagulants for better visual acuity, decreased incidence of thrombotic glaucoma and for promoting formation of opticociliary anastomosis.

Aspirin is used as platelet-aggregation suppressor.

Neovascularization of the Fundus Oculi²⁷

Neovessels in the fundus oculi include those vessels appearing under some pathological conditions, but exclude congenital vascular anomalies and persistent fibrovascular sheath except retrolental fibroplasia.

Classification

- (a) Retinal neovessels
 - (i) Intraretinal
 - (ii) Preretinal
 - (iii) In the vitreous
- (b) New vessels on the optic disc
- (c) Choroidoretinal anastomosing vessels
- (d) Subretinal new vessels
- (e) Intramural vessels.

Aetiology. (i) *Retinal neovessels.* They may appear at any part of the retina, but are common near the optic disc. More often they arise from the veins, but occasionally from the arterial vessels. The causes are: (a) occlusion of vein or its tributary; (b) Eales' disease; (c) incomplete arterial or its branch obstruction; (d) diabetic retinopathy; (e) angiomas retinae; and (f) retrolental fibroplasia.

(ii) *On the optic disc.* Affected neovessels are usually veins. The causes are due to: (a) diabetic retinopathy; (b) long-standing glaucoma; and (c) congenital varicosities or anastomoses.

(iii) *Choroidoretinal anastomosing vessels.* The choroidal and the retinal vessels meet due to a breach in Bruch's membrane. They are caused by Coats' disease and retinochoroidal coloboma.

(iv) *Subretinal.* Subretinal vessels do not show any axial reflex while the retinal vessels do. They are narrower than the choroidal vessels. It is characteristically shown in disciform degeneration at the macula.

Inflammation of the Retina⁹

Classification

An inflammation of the retina may be nonspecific or specific, and sometimes may manifest as a vasculitis (Table 45.9).

Table 45.9**Aetiologic and Morphologic Classification of Inflammations of the Retina**

Nonspecific retinitis	
(a) Primary, endogenous	<ul style="list-style-type: none"> — Purulent — <ul style="list-style-type: none"> — Acute suppurative — Subacute focal — Granulomatous
(b) Secondary	<ul style="list-style-type: none"> — Exogenous, purulent — Endogenous, exudative
Specific retinitis	
Bacterial	
Rickettsial	
Viral	
Mycotic	
Parasitic	
Vasculitis	
(a) Retinal perivasculitis	<ul style="list-style-type: none"> — Eales' disease — Secondary to uveitis — Secondary to systemic disease
(b) Granulomatous arteritis	<ul style="list-style-type: none"> — Giant cell arteritis — Thromboangeitis
Of uncertain aetiology	

Pathology. The characteristic changes are:

(a) Vascular changes include congestion, oedema, exudation of inflammatory cells and fibrin, changes in the vessel walls and extravasation of blood

(b) In mild inflammations the nerve fibres, ganglion cells, bipolar cells and then outer neurons are affected

(c) In severe inflammations rapid necrosis of all the neural elements occurs

(d) The pigment epithelium proliferates in chronic inflammations and is destroyed in acute process

(e) Healing is partly by gliosis and partly by proliferation of the mesodermal tissues surrounding the blood vessels.

Nonspecific retinitis. Nonspecific retinitis may be primary wherein the organisms are lodged in the retina directly from the blood stream, or secondary in which the retina is subsequently affected from choroiditis.

Primary retinitis may be: (a) purulent which is

either acute or subacute; and (b) granulomatous. Acute purulent retinitis occurs in course of pyaemia and it leads to metastatic endophthalmitis or to panophthalmitis. A subacute purulent retinitis occurs in course of less virulent infections like subacute bacterial endocarditis and puerperal sepsis; this is characterized by many recurrent haemorrhages with central white spots (*Roth's spots*) in the posterior part of the retina. The examples of granulomatous retinitis are syphilis, sarcoidosis and toxoplasmosis.

Eales' disease⁹ (Syn.: Vasculitis retinae in young adults)

Eales (1882) described the condition which was characterized by intermittent occurrence of haemorrhage in the retina and vitreous, chiefly in males between 20 and 30 years of age.

Aetiology. Perhaps it is an autoimmune process as suggested by serum immunoglobulin abnormalities. It may result from selective sensitization to tuberculoprotein. Other possible causes are focal sepsis, tuberculosis, vascular abnormality and endocrine disturbance.

The causes of vasculitis retinae are:

- (a) Eales' disease
- (b) As a complication of anterior uveitis
- (c) Tuberculosis
- (d) Behçet's syndrome
- (e) Syphilis
- (f) Giant cell arteritis
- (g) Multiple sclerosis. The arteries are never involved. The vein wall is thickened evidenced by white lines visible on each side of the blood column.

Pathology. Sections at an advanced stage have revealed the following characteristics:

- (a) Inflammatory reaction of the wall of the vein, perivenous space and adjoining retina
- (b) Hyalinization and thinning of the vein wall
- (c) Narrowing and obstruction of the lumen
- (d) Endothelial cell proliferation
- (e) Even necrosis, thrombosis and rupture of the vein
- (f) Haemorrhages in the retina and vitreous

(g) Presence of microaneurysms and venous collaterals

(h) In the advanced stage occurrence of retinitis proliferans.

Clinical features. Eales' disease occurs typically in young males between the second and third decades of life. The onset is characterized by sudden loss of vision owing to a vitreous haemorrhage. Bilaterality is more often within five years of onset.

There are two forms of vascular involvement:

(a) Most common—peripheral form

(b) Less common—central form

Peripheral form (Fig. 45c.6) chiefly involves the smaller veins around which small white exudates or patches and small haemorrhages are seen as early signs. Initially, isolated peripheral sectors are involved. Gradually the larger veins are affected with sheathing of both veins and arteries, more widespread haemorrhages and hazy vitreous. Further changes include peripheral retinal neovascularization, further haemorrhages and retinitis proliferans.

Recurrences are common at the intervals of months or years. Loss of vision may occur and is due to massive vitreous haemorrhage, tractional or rhegmatogenous retinal detachment, cataract or secondary glaucoma.

Central form is usually unilateral with the appearance of engorged and tortuous veins with multiple haemorrhages all around or adjoining the disc.

Fluorescein angiography (see p. 521).

Treatment. Treatment is symptomatic and is aimed at:

- (a) reducing the amount of perivasculitis
- (b) reducing associated vitritis
- (c) reducing chances of vitreous haemorrhage
- (d) surgical removal of unabsorbed vitreous haemorrhage.

Many ophthalmologists advocate steroid therapy because of presumed hypersensitivity in this affection. Steroids are used orally, subconjunctivally or periocularly. Anterior retinal transconjunctival cryotherapy has been advocated,

some ophthalmologists combine this procedure with xenon arc photocoagulation. Photocoagulation either with xenon arc or argon laser is advocated after careful fundus examination and FFA. This is probably more useful in cases showing retinal neovascularization without TRD. This is contraindicated if the new vessels are near the macula, over the optic disc or projecting into the vitreous.

Giant cell arteritis^{6,9} (Syn: Cranial or temporal arteritis)

Aetiology. This is a collagen vascular disease.

Pathology. The superficial temporal artery is especially affected. There is a tendency for widespread arterial involvement—the aorta, innominate, subclavian and cranial. There is subacute inflammatory infiltration of the arterial wall leading to necrosis and thrombosis.

Clinical features. Giant cell arteritis occurs in elderly people between the fifth and seventh decades. The predominant symptom is the tenderness of the temporal and occipital regions. It starts with slight fever, malaise, weakness and anorexia. General signs include: (a) tortuous, thickened, tender and nonpulsatile superficial temporal artery; and (b) high ESR, the value over 40 mm/hour is suspicious.

Ocular features. occur in about 40 to 50 per cent cases. The patient may present with evidence of central retinal artery occlusion or ischaemic optic neuropathy.

An occult form is characterized by lack of typical clinical features but with typical unilateral visual loss.

Diagnosis is based on: (a) history; (b) general symptoms; (c) high ESR; and (d) biopsy of an affected artery—confirmatory.

Treatment. The introduction of steroids has been beneficial. The steroid is to be given systematically for 9 to 12 months in high dose of 120 mg of prednisolone daily which is then reduced every three days by 5 mg. It should be continued until ESR remains normal even under cessation of therapy and repeated biopsies are negative.

Acute posterior multifocal placoid pigment epitheliopathy (APMPPE)

This condition, described by Gass in 1968, is usually bilateral but not necessarily simultaneously, and occurs in young adults. There may be a preceding history of an influenza-like affection. It is characterized by the presence of multiple yellowish white placoid lesions at the macular area. At the initial stage fluorescein angiography reveals blockage of choroidal fluorescence. At a later stage the lesions show fluorescence and take up stain. Because of macular involvement visual acuity comes down to 6/60 or less. There is spontaneous resolution with good recovery of vision within 3 to 6 weeks. The final picture is that of alternating pigment areas are not stained but show fluorescence.

Serpiginous, helicoid or geographic peripapillary choroidopathy

It is bilateral and common in middle age. Perhaps some immunologic factor or abiotrophy is responsible. In the early stage it is characterized by yellowish-grey area spreading from the disc region along with retinal oedema. The vitreous reaction is often minimum. Fluorescein angiography reveals hypofluorescence of the affected area. The margins of lesions become a lighter colour and swelling subsides in course of the next three months. At this stage there is hyperfluorescence of the margins of the lesions. After three months there is uniform hyperfluorescence of the lesions. The condition may last for 18 months.

Acute pigment epithelitis

Reported for the first time by Krill and Deutman in 1972, this is a minor affection characterized by an acute onset and resolution in 6 to 12 weeks with full recovery of vision. The lesions are small, dark-grey surrounded by a pale-yellow halo, in clusters of 2 to 4, in the macular region at the level of the RPE. FFA reveals hypofluorescent areas

corresponding to the lesions encircled by hyperfluorescent areas.

Senile Changes in the Retina

The most common change is the senile involutionary sclerosis of the retinal vessels. Other changes include partial regression and partial proliferation of the retinal pigment epithelium (RPE).

Retinal Degenerations

Classification⁵

Retinal degenerations may manifest as:

- (a) Anomalies of pigment pattern:
 - (i) In a normal fundus, (ii) cobblestone or pavingstone degeneration; and (iii) pigment clumping
- (b) Cystic changes:
 - (i) Peripheral cystic degeneration, (ii) giant retinal cyst, and (iii) retinoschisis
- (c) Vascular changes
- (d) Vitreous changes
- (e) Retinal breaks.

Degenerations in the peripheral part of normal fundus^{1,15,31,32,34}

Examination of the peripheral fundus in normal eyes reveals the following possible changes:

- (a) Cystoid degeneration
- (b) Senile retinoschisis
- (c) Cysts of the pars plana ciliaris
- (d) Chorioretinal degeneration
- (e) Chorioretinal atrophy
- (f) Lattice degeneration
- (g) White-with-pressure
- (h) White-without-pressure
- (i) Retinal holes
- (j) Snail track degeneration.

Cystoid degeneration. Cystoid degeneration is universally present in eyes of all adult people, appearing as red dots surrounded by greyish-white area especially in the temporal half of the retina.

The condition is harmless but deteriorates as age advances. Rupture of the inner layer of the cystoid space does not lead to retinal detachment but causes photopsiae. It is visualized by indirect ophthalmoscopy with scleral depression or slit-lamp biomicroscopy with scleral depression.

Senile retinoschisis. Retinoschisis is the separation of the retinal layers. Senile retinoschisis is often bilateral and symmetric, and occurs more in females. The incidence is common after the age of 40 and moderately advanced cases are found in the population of this age-group is about 7 per cent. This appears to be an extension of peripheral cystoid degeneration. It characteristically involves the lower temporal periphery near the ora serrata though it can occur in any part of the retina. It appears as greyish-white and contains white flecks on the inner layers of the retina indicating the presence of Müller's fibres in the inner layer of the retina. The split takes place in the outer plexiform layer. Its progress is very slow, it remains asymptomatic and does not need any treatment. But if the hole develops in both outer and inner layers there is detachment of the retina.

Cysts of the pars plana ciliaris. Cysts of the pars plana ciliaris are usually oval, almost transparent, undistended and irregular, and located on the temporal side.

Chorioretinal degeneration. Chorioretinal degeneration is commonly associated with cystoid degeneration and is seen in about 70 per cent of the normal eyes starting by the age of 40 and progressing as age advances. The changes caused by this degeneration are always predominant in the proximity of the ora serrata. If there is evidence of marked pigment clumps with vitreous it may predispose to a retinal detachment. It appears that peripheral chorioretinal degeneration and cystoid degeneration inhibit each other.

Chorioretinal atrophy, cobblestone or pavingstone degeneration. Chorioretinal atrophy is characterized by the thinning of the affected area along with pigment heaping of the margins, usually involving the region mostly near the ora serrata in

the lower temporal retina. The lesions are small, 0.1 to 1.5 mm, round and flat. There is likelihood of retinal detachment if the lesion is associated with multiple tears.

Lattice degeneration. In 6 to 8 per cent of the normal eyes the condition is encountered and is mostly found in the lower temporal quadrant situated near the ora serrata, but when associated with tears the involvement of the upper temporal quadrant is most common. It is characterized by the presence of interconnecting networks of fine white lines situated at or anterior to the equator. They are cigar-shaped areas of retinal thinning, 0.5 to 2 mm in width and 1.5 mm or more in length, and are located parallel to the limbus. It is usually bilateral, benign and asymptomatic. It may be present at any age above the age of 10. The characteristic histopathologic features include localized retinal thinning, overlying vitreous liquefaction, borders showing increased vitreoretinal adherence, absence of internal limiting membrane and condensation of the vitreous.

White-with-pressure (WWP). The term is used to describe isolated, oblong, white, iridescent patches seen around the cystoid degeneration mostly in the temporal part, and appearing white when pressure is applied by a scleral depressor. Perhaps the retina is unhealthy at the affected area. In normal eyes WWP forms a band situated between the ora serrata and the equator, and parallel to them. The incidence in normal eyes appears to be more than 30 per cent, and is often bilateral.

White-without-pressure (WWOP). The condition is similar to that of WWP. Here the patches are seen as white without any indentation.

Retinal holes. Retinal holes are present in 7 to 8 per cent of normal eyes.

Snail track degeneration. Snail track is the descriptive term in which there are sharply demarcated white areas at or just in front of the equator, commonly in the temporal half of the retina. When vitreoretinal adhesion is found to be associated the snail tracks may precipitate formation of retinal holes.

Developmental Variations in the Peripheral Part of the Fundus

They include: (a) variations of size and shape of bays and teeth of the ora serrata; (b) meridional retinal folds; (c) formation of granular tissue; (d) pigment clumps; and (e) pearls.

Enclosed oral bays

Enclosed oral bays is a developmental anomaly consisting of an island of pars plana due to coalescence of adjacent dentate processes. The condition is to be differentiated from true retinal breaks. The colour, texture and the borders seen during scleral depression can distinguish these two conditions:

(a) Oral bays are brown, granular in appearance and have gradually sloping borders

(b) Retinal breaks are red, smooth in appearance and have sharp borders.

Meridional folds and cystic retinal tufts

Meridional folds and cystic retinal tufts are also developmental variations. The meridional folds are radially oriented, linear elevations of the peripheral retina. The cystic retinal tufts are nodular projections of the retina surrounded by cystic retinal degeneration.

Ora pearls

Ora pearls are bright glistening white pearls in the dentate processes of the ora serrata.

Lesions of the peripheral retina^{1,29,31}

There are two groups of lesions, one predisposing to retinal detachment and another not predisposing to retinal detachment. These lesions are listed (Table 45.10).

Disorders of Bruch's Membrane

Disorders of Bruch's membrane include drusen, angioid streaks, disciform degeneration, high myopia and trauma.

Table 45.10

Lesions of the Peripheral Retina

Lesions predisposing to retinal detachment

- Developmental variations
- Lattice degeneration
- Degenerative retinoschisis
- Vitreoretinal adhesions

Lesions not predisposing to retinal detachment

- Cystoid degeneration
- Cobblestone degeneration
- Equatorial drusen
- White-with-pressure
- White-without-pressure
- Pars plana cyst
- Ora pearls
- Senile reticular pigmentary dystrophy

Drusen or colloid bodies (Fig. 45.6)

Formation of drusen (German, *druse*, nodule) is a significant sign of ageing. These are deposits on the inner surface of Bruch's membrane which cause the retinal pigment epithelium (RPE) to be elevated. The RPE may be weakened in senile eyes with accumulation of phagosomes. The weakened pigment cells are unable to completely phagocytose the ingested phagosomes, and thus liberate them

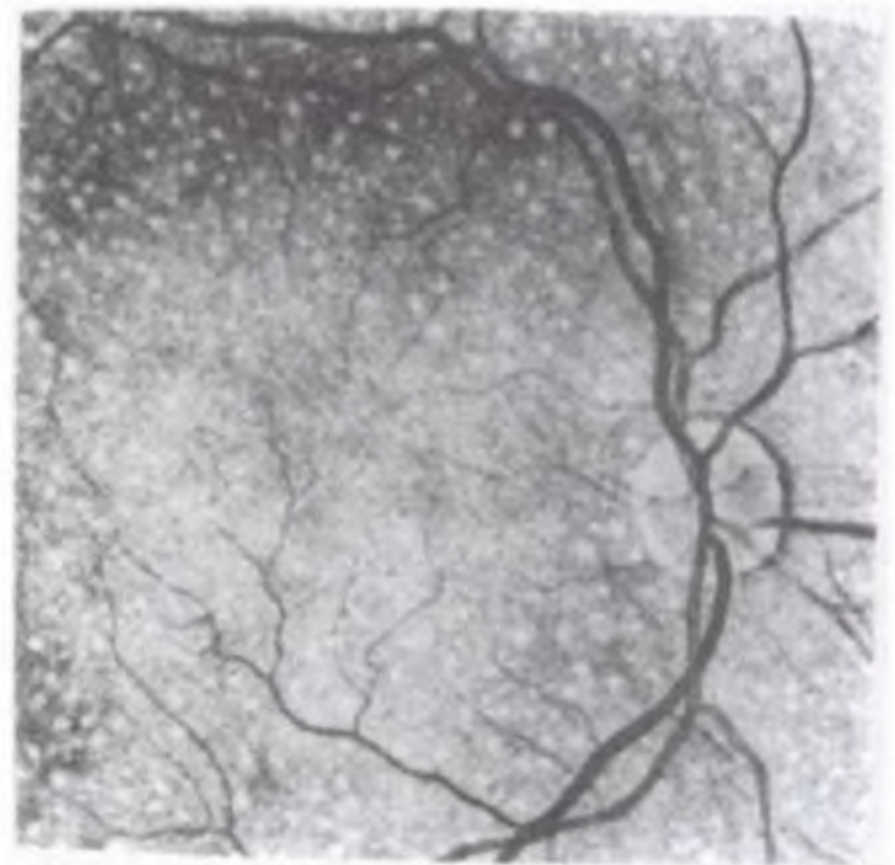


Fig. 45.6 Colloid bodies.

on to the inner collagenous layer of Bruch's membrane. These contribute to the formation of drusen. They appear round, creamy-white, round deposits distributed all over the fundus in each eye, especially in the macular area. As age advances they become larger, confluent and more varied in size and appearance. Dominant familial variety tends to occur in younger age-groups and to involve the area to nasal side of the optic disc.

Angioid streaks (choroidal elastosis)

Angioid streaks are so named because of their resemblance to the blood vessels.

Aetiology. It is more likely to be a primary rather than secondary degeneration of Bruch's membrane. The occurrence of this condition in association with pseudoxanthoma elasticum due to the degeneration of elastic fibres in the deeper part of the skin constitutes a syndrome called *Groenblad-Strandberg syndrome*, which is an autosomal recessive affection.

Age-group varies between 30 and 50.

Clinical features. Pigmented streaks resulting from ruptures in Bruch's membrane the terminal portions of which resemble the blood vessels, usually around the disc and deeper to the retinal vessels are characteristic. They appear bright red when the RPE is missing. The break in Bruch's membrane leads to fibrovascular ingrowth of the choroid and finally macular degeneration. Fluorescein angiography exhibits predominant pattern of hyperfluorescence of the streaks. There may be widespread pseudoxanthoma elasticum but most frequently seen on the neck.

Age-related macular degeneration (ARMD)²⁷

There are two forms of age-related macular degeneration (ARMD):

(a) Nonexudative or 'dry' or senile macular degeneration

(b) Exudative or 'wet' or disciform macular degeneration.

Age-related macular degeneration (ARMD) is a common cause of severe visual loss in people over the age of 50 years. There are three main factors which contribute to the visual impairment: (a) progressive areolar or geographic atrophy of the RPE; (b) serous detachment of the RPE; and (c) choroidal or subretinal neovascularization.

Dry senile macular degeneration (Haab) (Syn. Areolar or geographic macular degeneration)

Pathology. The affection is probably due to sclerosis of the choriocapillaries with chronic choroidal ischaemia leading to degenerative changes in the RPE, Bruch's membrane and choroid.

Clinical features. The affection is bilateral, but one eye may be affected earlier than the other. The earliest symptom is the loss of central vision, and this process is gradual. There are two important features: drusen and geographic atrophy. Drusens may be hard or soft. A geographic or areolar atrophy is evidenced by areas of well-demarcated atrophic RPE. The final picture (Fig. 45.7) is the presence of areas of both reduced and increased

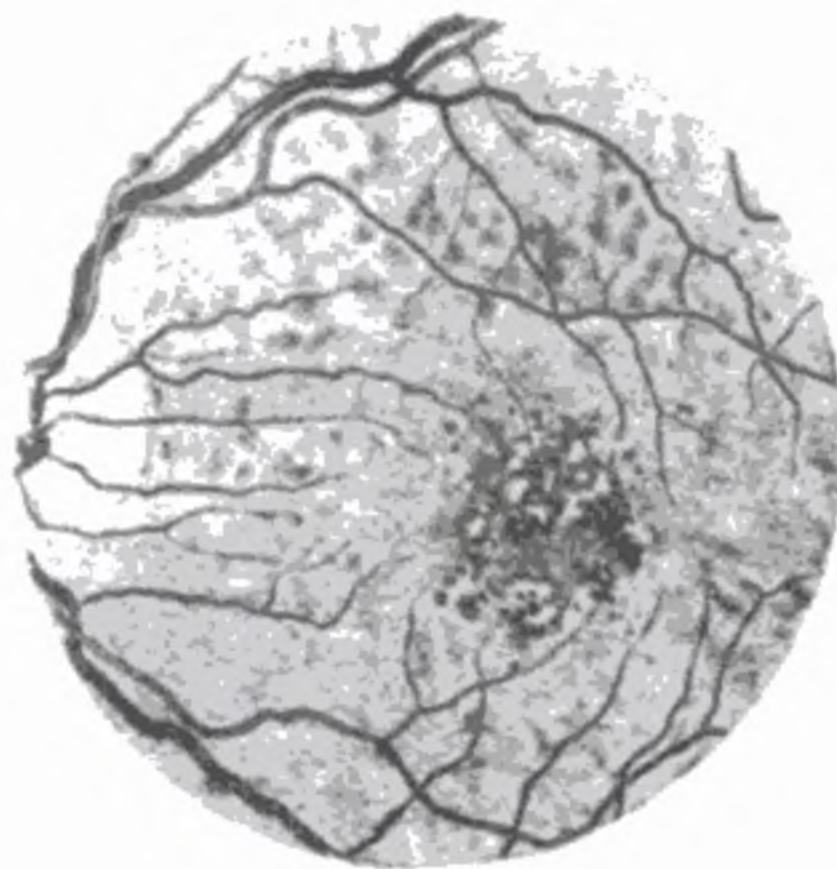


Fig. 45.7 Senile macular degeneration.

macular pigmentation surrounded by colloid bodies.

FFA. Refer to p. 521.

Treatment. There is no definite treatment. Low visual aids may be helpful.

Disciform macular degeneration (Kuhnt-Junius disease) (Syn.: Wet or exudative macular degeneration)

Pathology. Thickening and defects of Bruch's membrane in the macular region are early events. This is followed by transudation between the elastic layer of Bruch's membrane and the RPE, and subsequently there may be serous detachment of the RPE and filling up of the subpigment epithelial space with choroidal blood vessels (choroidal neovascular membrane). Haemorrhages occur from these vessels and lead to formation of subretinal fibrovascular scar.

Clinical features. The affection is eventually bilateral. The onset is characterized by gradual diminution of central vision, sometimes metamorphopsia and occasionally sudden visual loss. The cases may present in the following manners:

(i) *Serous detachment of the RPE.* This appears as a round or oval, yellow orange, sharply demarcated area.

(ii) *Choroidal neovascularization (CNV) or subretinal neovascularization (SRNV)* appears as a round or oval, greyish-grey lesion, and suspicion arises when there is a history of sudden loss of central vision associated with central scotoma. FFA shows two types of angiographic patterns: classic and poorly defined. In the classic type there is a lacy pattern of capillaries. The poorly defined type shows either scattered punctate areas of hyperfluorescence or blocked fluorescence.

(iii) *Haemorrhagic detachment of the RPE* is due to bleeding from the choroidal neovessels.

(iv) *Disciform scar.* The organization of subpigment epithelial haemorrhages leads to a typical subretinal fibrovascular scar in the macular region (Fig. 45c.7).

Recently, a *retinotomy* to surgically remove the disciform scar has been reported.

Vitreous haemorrhage is an extension of subpigment epithelial haemorrhage.

Treatment. Argon blue-green laser after digital indocyanine green videoangiography appears to be effective therapy indicated in both serous detachment of the RPE and CNV *except* in neovascularization at the fovea or closer than 200 millimicrons to the centre of the FAZ. Recently photodynamic therapy (PDT) using low-energy nonthermal diode laser with photosensitive dye, verteporphin has been recommended for treating CNV.

Macular Lesions Secondary to Choroidal Vascular Affections

Hayreh proposed the following classification:¹⁹

(a) Acute choroidal ischaemic lesions:

(i) Elschnig's spot—is a localized choroidal infarct

(ii) Multifocal acute ischaemic choroidopathy or acute multifocal placoid pigment epitheliopathy

(iii) Serpiginous, helicoid or geographic choroiditis

(iv) Postoperative outer retinal ischaemic necrosis

(b) Chronic choroidal ischaemic lesions:

(i) Senile macular degeneration

(ii) Disciform senile degeneration

(c) Associated with choroidal neovascularization

(d) Serous macular detachment

(e) Miscellaneous conditions—include heredomacular dystrophies.

Circinate Retinopathy

Circinate retinopathy occurs in elderly patients and in 50 per cent cases it is unilateral. It is a widespread degeneration affecting the macula and retina around it. Ophthalmoscopy reveals two features, namely the girdle and changed appearance of the macula. The girdle is made up of glistening white punctate exudates around the macula. They are due to aggregation of lipid-laden macrophages. The girdle is considerably large (Fig. 45c.8), greater

than a disc-diameter, appearing in the form of an ellipse open towards the temporal side. It follows the course of superior and inferior temporal vessels. The macula itself shows small exudates and pigments. The disease progresses slowly causing loss of central vision. Treatment is difficult. It consists of identification and subsequent photocoagulation of the area of vascular leakage.

Macular Disorders

Macular disorders are common and they are important as well because it is associated with deterioration of visual acuity, defective colour sense and stereopsis. The advent of fluorescein angiography and different types of laser photocoagulation have improved the prospects of precise diagnosis and proper treatment respectively.

Aetiology. (a) Inflammatory—such as toxoplasmosis, acute multifocal placoid pigment epitheliopathy and acute pigment epithelitis

(b) Vascular—oedema, haemorrhage and maculopathy

(c) Degenerative—such as heredomacular dystrophies of the macula, drusen or colloid bodies, Doyme's honeycomb choroiditis, Tay's guttate choroiditis, angioid streaks, senile macular degeneration, disciform degeneration, circinate retinopathy, cystic degeneration, myopic degeneration and toxic maculopathy following drugs like chloroquine

(d) Traumatic—commotio retinae, solar retinitis and macular hole

(e) Developmental anomalies—like hypoplasia, aplasia, heterotropia and coloboma.

Various macular disorders have been described elsewhere. The remaining few are described.

Doyme's Honeycomb choroiditis and Tay's central guttate choroiditis

Both are essentially colloid bodies deposited in the macular and perimacular region. Doyme observed the familial incidence of the disease in which

colloid bodies are grouped round the macula in a honeycomb fashion. Tay described the central disposition of the colloid bodies in elderly subjects and named it *central guttate choroiditis*. In the initial stage visual acuity is not disturbed. In the advanced stage due to degenerative change there is visual deterioration.

Cystic degeneration of the macula

Cystic degeneration of the macula may follow oedema of the macula following trauma or uveitis, inflammatory conditions, trauma, myopia, senility, vascular lesions, retinal detachment and choroidal tumour.

Chloroquine maculopathy¹

Chloroquine may cause maculopathy, reversible corneal opacities, abnormalities of accommodation and of ocular movements. Central or paracentral scotoma is a characteristic symptom. This may occur in early or midlife.

Maculopathy shows three stages: (a) stage of premaculopathy; (b) bull's eye maculopathy showing irregular hyperpigmentation surrounded by a concentric zone of hypopigmentation, usually horizontally oval occupying the macular area; and (c) geographic atrophy of the RPE but showing no drusen.

Macular hole

Macular hole may be *complete* when it involves the entire thickness, or *lamellar* which is confined to the inner layers. A macular hole occurs spontaneously (idiopathic, senile—more than 80%) or follows trauma.

There are four stages of senile or idiopathic macular hole¹³:

Stage 1—foveal detachment

Stage 2—early hole with central or eccentric opening

Stage 3—full-thickness hole with localized PVD

Stage 4—full-thickness macular hole with PVD. The hole appears round, deep red patch (Fig. 45c.9) seen by slit-lamp biomicroscopy and

(f) The ganglion cells and nerve fibre layers remain relatively undisturbed until a late period.

Michaelson and Yanko described the following five stages:

Stage 1 Functional disability without ophthalmoscopic evidence

Stage 2 Retina showing pigment stippling

Stage 3 Pigment sheathing of the capillaries at their bifurcations in the equatorial zone

Stage 4 Vascular sheathing in the equatorial zone

Stage 5 Sheathing of the veins running towards the centre.

Clinical features. Symptoms start appearing at a young age and the affection incapacitates the patient in later years.

Night blindness may be present for several years before the appearance of pigmentation of the retina.

Visual field. Characteristically there is an annular or ring scotoma always occupying the equatorial region followed by the progress of the scotoma centripetally and centrifugally, till a narrow central field of tubular vision is left behind. The detection of field defect is made easier when such an examination is done in diminished illumination.

Ophthalmoscopically (Fig. 45.8), there are three characteristic features: (a) attenuation of the retinal arterioles—which in the advanced stage appear thread-like; (b) pigmentation—is the most striking



Fig. 45.8 Bone-corporuscle-like pigment deposition in primary pigmentary dystrophy of the retina

feature. In the typical early case they are few and in the equatorial zone. In advanced case they increase in number and size, and invade diffusely. Typical distribution is bone-corporuscle-like and the colour is jet-black; and (c) waxy pallor of the disc is due to glial proliferation and subsequent consecutive optic atrophy.

Visual acuity. When the field is reduced to 10° central field, central vision markedly diminishes.

Dark adaptation. Rod function is diminished and it is absent in advanced stage. Photopic dysfunction also occurs but it is much slower.

ERG. Particularly the scotopic component tends to be diminished or abolished.

EOG. The EOG ratios are substantially abnormal.

Degenerative changes within the vitreous have been reported. In many cases myopia is present.¹¹

Complications and sequelae. The course is slow, chronic and progressive. The macula remains unaffected until an advanced stage. The central vision usually fails in the middle age. The complications include posterior cortical cataract and consecutive optic atrophy.¹¹

Table 45.12 shows its association with systemic diseases.

Table 45.12

Association of Retinitis Pigmentosa²⁷

Laurence–Moon–Biedl syndrome
Refsum's syndrome
Bassen–Kornzweig syndrome
Usher's syndrome
Friedreich's ataxia
Syringomyelia
Mucopolysaccharidoses
Leber's hereditary optic atrophy
Cockayne's syndrome
Keams–Sayre syndrome

This affection shows several variations:

Retinitis pigmentosa sine pigmento. This shows all the features minus pigment distribution.

Retinitis punctata albescens. This is an autosomal recessive affection. The cases are in two forms: (a) progressive type—atypical retinitis pigmentosa, and (b) stationary. It presents same

history as that of retinitis pigmentosa, constriction of the retinal vessels and peripheral field contraction. But there is fairly uniform distribution of numerous small white dots over the whole fundus. Progressive type shows subnormal or extinguished ERG, but in stationary type ERG is normal.

Unilateral. This type is very rare. EOG in the affected eye is abnormal, but ERG responses are minimal or undetectable.

Central or inverse. This is characterized by accumulation of pigments around the macula.

Atypical forms. They may sometimes occur in advanced age. Sometimes there may be variation in the amount, distribution and configuration of the pigment. A sectorial type has also been described.

Differential diagnosis. This can be differentiated from secondary retinal pigmentation (Table 45.13).

Table 45.13

Differentiation Between Retinitis Pigmentosa and Secondary Retinal Pigmentation of Choroiditis

Points	Retinitis pigmentosa	Chorioretinitis with pigmentation
Laterality	Almost always bilateral	Sometimes unilateral
Initial involvement and progress of pigmentation	Equatorial region and then centripetally	May develop in any part and progress irregularly
Distribution of pigment along the vessels and relation of the vessels	Yes, and the vessels are covered up by pigments at places	Normal course of vessels through pigmented areas and the vessels lie superficial to them
Choroidal vessels	Clearly distinguishable	Vaguely distinguishable
Presence of chorioretinal scar	No	Yes
Visual field changes	Ring scotoma and progressive concentric contraction of the field	Irregular scotomas
Involvement of central vision	Often none	Always in macular involvement

Treatment. Ineffective, however, in the following conditions treatment should be tried:

In *Bassen-Kornzweig syndrome*, showing abetalipoproteinaemia treatment consists of fat restriction and supplementation of vitamins A, K, and E.

In *Refsum syndrome* associated with phytanic acid, treatment consists of restriction of green leafy vegetables and milk products for reducing phytanic acid level.

Cone-rod dystrophy. The condition initially starts with cone affection followed later by the affection of the rods. It is functionally inverse of retinitis pigmentosa.

The characteristic clinical features are as follows:

(a) No symptom of night blindness, but complaints of poor visual acuity and colour vision

(b) Ophthalmoscopy reveals ring-like depigmentation around the macula, *bull's eye macula*. This appearance is highlighted by a fluorescein angiogram

(c) Later in the course of the disease the retinal vessels appear narrowed and the optic disc pale

(d) In some cases the picture is one of inverse retinitis pigmentosa.

The EOG is normal, but the cone components of ERG are reduced or absent.

Sex-linked juvenile retinoschisis

Retinoschisis is the condition in which the retina is split into two layers and it may be either *senile* (degenerative) or *juvenile* type.

In sex-linked juvenile type which belongs to inherited vitreoretinal disorders the splitting occurs in the nerve fibre layer. This hereditary affection transmitted as a recessive sex-linked one is bilaterally symmetrical. It is seen in male children.

It is characterized by the following ophthalmoscopic features:

(a) The perifoveal area showing round microcysts

(b) Greyish-white spots at the affected site

(c) Veils in the vitreous with or without enclosed retinal vessels

(d) True retinoschisis occurs in the lower temporal quadrant.

There are relative central and absolute peripheral field defects. On ERG there is selective reduction of b-wave particularly under dark adaptation. EOG is initially normal.

Goldmann–Favre dystrophy

Goldmann–Favre dystrophy is a rare bilateral, autosomal recessive condition characterized by night blindness, atypical pigmentary dystrophy, central and peripheral retinoschisis situated usually in the inferotemporal quadrants, opaque retinal vessels, leakage from the retinal capillaries, microfibrillary degeneration of the vitreous and finally retinal detachment.

Wegener's vitreoretinal dystrophy

The affection is an autosomal dominant dystrophy. It is characterized by the following features:

(a) The patients are myopes, 84 per cent

(b) There are lenticular opacities and almost optically empty vitreous space indicating liquefaction. This space is traversed by fibres or membrane in the vitreous

(c) Retina shows pigmentary dystrophy, paving-stone degeneration, tears and retinal detachment

(d) Visual acuity may be normal or reduced due to associated cataract or retinal detachment

(e) ERG often shows subnormal a- and b-waves. EOG ratios are more often subnormal.

Central areolar choroidal dystrophy

(Syn.: Central choroidal sclerosis)

Central choroidal dystrophy appears to be a better term than central choroidal sclerosis, since in this condition there is disappearance of the choriocapillaris, pigment epithelium and photoreceptors in the affected region. Both autosomal dominant and recessive modes of inheritance are known. It is characterized by visual

deterioration occurring gradually in a subject over 40 years of age. A central scotoma is detected. Ophthalmoscopy and fluorescein angiography are revealing. There is a large round degenerated area traversed by the choroidal vessels and the sclera shines through the macular region and around.

The condition is to be differentiated from a postinflammatory choroidal atrophy. Postinflammatory type is more often unilateral and shows more heavily pigmented areas. Furthermore its onset is less insidious and progress is relatively rapid.

Gyrate or essential atrophy of the retina and choroid

Gyrate or essential atrophy of the retina and choroid is an autosomal recessive affection occurring in myopes and is characterized by the presence of round, discrete or grouped areas of atrophy in the midperiphery and spreading later towards the central part. Recent reports emphasize the presence of increased concentration of ornithine in the plasma.

Choroideraemia or sex-linked tapetochoroidal dystrophy

Choroideraemia is very rare condition in which the affected male shows the characteristic changes and present with night blindness, while female carriers show less distinct fundus picture unaccompanied by night blindness. The affection starts at an early age and is characterized by complete disappearance of both retina and choroid at the affected areas, the midperiphery being especially involved.

Macular dystrophies or heredomacular degenerations

The affection is always bilateral, although one eye may remain normal for sometime. The onset is slow and the progress is equally slow. The disease is of heredofamilial nature. There may or may not be associated CNS involvement. Table 45.14 shows its varieties.

Flecked Retina Syndrome²⁸

The flecked retina syndrome is characterized by the presence of a number of deep, yellow lesions of different shapes and sizes unaccompanied by any vascular or optic nerve abnormalities. Probably they represent pigment epithelium defects.

There are four diseases under this entity:

(a) *Fundus albipunctatus*. This is an autosomal recessive affection. The patients complain of poor night vision. This disorder is stationary. The ophthalmoscopic picture is that of a retinitis punctata albescens. The retinal vessels, optic discs and visual fields are normal.

(b) *Fundus flavimaculatus*. This term was first coined by Franceschetti (1963). It is familial with autosomal recessive inheritance. Onset occurs between 10 and 20 years. More often there is bilateral visual deterioration. It may show abnormal perimacular pigmentation, and in about 50 per cent cases macular dystrophy precedes the appearance of flecks. Stargardt's syndrome and fundus flavimaculatus are probably the same disease.

(c) *Familial drusen*. It may occur as a dominant type of dystrophy.

(d) *Flecked retina*. The ocular fundus shows deep yellow-irregular flecks distributed in the equatorial area. The affection is stationary. Visual fields and EOG are normal, but dark adaptation and ERG are abnormal.

Vascular Retinopathies

Retinopathy indicates the noninflammatory retinal affection as a result of varying causes including vascular diseases and is characterized chiefly by haemorrhages and exudates.

Retinopathies associated with general disease chiefly include, hypertension, metabolic (typically diabetic), blood and collagen diseases.

Arteriosclerosis and hypertension^{3,9,18}

Pathology. Arteriosclerosis. Generalized hypertrophy of the arterial walls with subsequent fibrous replacement occurs.

Atheroma or atherosclerosis. It is degenerative condition characterized by the formation of patches of thickening of the arterial intima associated with fatty change.

Involuntary sclerosis or senile arteriosclerosis. It is characterized by replacement fibrosis of primarily the muscular layer, occurring usually in patients of over 50.

Retinal arterial tree can be conveniently subdivided into two components: true arterial—the central retinal artery and its first branches at or near the optic disc and true arteriolar—away from the disc. Both types of lesions can thus occur in the retina. The changes are shown in Table 45.15.

Table 45.15

Arteriolar Changes Associated with Hypertension³

Proliferative changes are	—	Hyperplastic sclerosis
		Endarteritis fibrosa
Degenerative changes are	—	Hyaline degeneration
		Fibrinoid necrosis

Hyperplastic sclerosis is present in benign chronic hypertension. Thickening of the arteriolar wall is due to muscle hyperplasia in the media and increased fibrous and elastic tissue in the intima.

Endarteritis fibrosa is a characteristic of malignant hypertension which shows thickening of the intima by concentric lamellae of fibroblasts often lying in an abundant mucinous matrix.

Fibrinoid necrosis is considered the hallmark of malignant hypertension and is focal in nature and it chiefly affects the precapillary arterioles.

Retinal Manifestations of Vascular Disease⁹

Retinal manifestations of vascular disease may be enumerated as follows:

- (a) Arteriovenous (AV) crossing changes are:
 - (i) Deflection of the veins out of their normal course (Salus' sign)
 - (ii) Compression of the veins by the rigid artery causing 'banking'
 - (iii) (i) and (ii) are combined to form 'arteriovenous nicking'

- (iv) Tapering of the vein
- (b) Focal vascular narrowing
- (c) Generalized attenuation and straightening of the retinal arterioles
- (d) Tortuosity and engorgement of the vessels
- (e) Changes in the vascular reflex (Fig. 45.9)

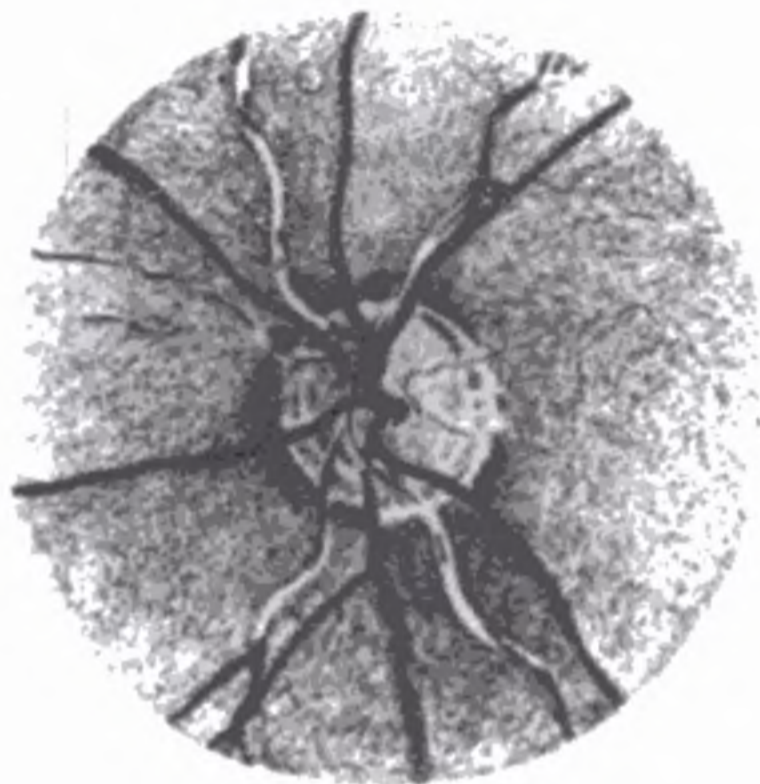

Fig. 45.9 Sheathing of arteries in advanced retinal arteriolar sclerosis (Parr).

They are:

- (i) *Copper wire arteries*. Due to thickening of the arterial wall, the reflex becomes broader and of burnished copper colour
- (ii) *Silver wire arteries*. Great thickening of the arterial walls causes all the light to reflect and the arteries appear white
- (f) **Sheathing**
 - (i) **Parallel** — pale lines appear along two borders of usually larger vessels
 - (ii) **Pipe-stem** — the vessel appears as an opaque strand
- (g) **Vascular complications** include haemorrhages, exudates and occlusion.

Involuntary Sclerosis or Senile Arteriosclerosis

The fundus in patients over sixties shows the following features. The retinal arterioles are narrower, paler, less brilliant and straighter. Other

senile changes like colloid bodies, pigment disturbance and peripheral choroidal degeneration are also present.

The fundus picture in hypertension and involuntary sclerosis can be varied (Table 45.16).

Table 45.16

Leishmann's Classification of Fundus Picture in Hypertension and Arteriosclerosis²⁴

Group 1	Involuntary sclerosis—usually associated with systolic hypertension
Group 2	Involuntary sclerosis—usually associated with benign hypertension
Group 3	Advanced involuntary sclerosis with hypertension, the diastolic pressure is usually higher than that of group 2
Group 4	Normal fundus in youth
Group 5	Early hypertension in youthful vessels—characterized by diffuse hypertonus
Group 6	Malignant hypertension—showing retinopathy and papilloedema and the picture is perhaps due to focal necrosis in the arteriolar wall
Group 7	Severe hypertension with reactive sclerosis—represents severe hypertensive stimulus (hypertonus→hyperplasia→replacement fibrosis) occurring in youthful vessels

Benign hypertension with involuntary sclerosis

The ophthalmoscopic picture is dependent on the degree of fibrosis which has developed. The walls of segments of the arterioles which are fibrosed cause the portions to be wider, deeper coloured and more tortuous. The remaining segments are hypertonic showing a pale, straight and narrow blood column.

Benign hypertension without involuntary sclerosis

Benign hypertension without involuntary sclerosis is characterized by evidence of hypertonus exhibited by pale, narrowed and straight vessels. These vessels regain their normal characteristics with the disappearance of the hypertensive phase. The normal blood vessels are exposed to the effects of high BP for a short period.

Hypertensive retinopathy (Fig. 45c.10)¹⁴

Hypertensive retinopathy can be graded (Table 45.17).

Table 45.17

Grading of Arteriosclerotic—Hypertensive Retinopathy (After Keith, Wagener and Barker, 1939)

Grade	Ophthalmoscopic signs	General symptoms	Cardiorenal functions
I	Mild narrowing or sclerosis of the retinal arterioles	No	Normal
II	More marked arteriolar narrowing, widening of light reflex and AV crossing changes	Marked hypertension	Satisfactory
III	Other changes as those of grade II but more marked and angiospastic retinopathy	Hypertension often high and sustained	Evidence of cardiorenal disease
IV	All signs of grade III plus papilloedema	Malignant hypertension	Marked cardiorenal damage

The development of hypertensive retinopathy depends on the following three factors acting singly or simultaneously: (a) state of the vessel wall; (b) duration of hypertensive state; and (c) level of elevated blood pressure.

Fundus abnormalities include:

- (a) Attenuation of the arteries
- (b) Arteriovenous crossing changes
- (c) Segmental calibre variation in the arterioles
- (d) Haemorrhages
- (e) Exudates:
 - (i) Hard—in more chronic hypertension
 - (ii) Soft—in malignant hypertension
- (f) Papilloedema is present only in malignant hypertension
- (g) Vascular mischiefs are occasional.

Scheie proposed a simpler classification of hypertensive retinopathy (Table 45.18) based entirely on ophthalmoscopy.

Treatment depends on the cause. Energetic treatment with antihypertensive drugs causes remarkable improvement in the fundus picture of malignant hypertension.

Arteriosclerotic retinopathy

The ophthalmoscopic changes should be separated from those of hypertensive retinopathy though both of them are often present simultaneously. Essentially in an arteriosclerosis there are vessel changes following elevated intra-arterial pressure. In hypertensive retinopathy the changes are the result of vasospasm. Any grade of arteriolar sclerosis may be present with any grade of hypertension. Ophthalmoscopic features are shown in Table 45.18.

Table 45.18

Scheie's Grading of Arteriosclerotic and Hypertensive Retinopathies¹³

Grades	Arteriosclerotic	Hypertensive
I	Increased light reflex + minimal AV compression	Narrowing of smaller arterioles
II	Broad light reflex + gross AV compression	More narrowing of the arterioles and focal constrictions
III	Copper wire arteries + more marked AV compression	Changes of grade II + haemorrhages and exudates
IV	Silver wire arteries	Appearance of papilloedema

Renal retinopathy

The term is a misnomer, because secondary hypertension rather than the primary renal disease, e.g. diffuse glomerulonephritis is the contributory factor in its causation. It may occur at any age.

In renal retinopathy, retinal oedema tends to be more extensive causing sometimes exudative retinal detachment and often macular fan is seen. Prognosis is dependent upon impairment of renal function.

Hypotensive retinopathy

Hypotensive retinopathy is the result of tissue hypoxia following arterial hypotension and is characterized by the following signs:

- (a) Slight enlargement of the arterioles
- (b) Few cotton-wool exudates
- (c) Small and round haemorrhages
- (d) Venous microaneurysms
- (e) Segmentation of the blood column.

Two important affections of hypotension are carotid artery occlusion and pulseless disease (Takayasu-Ohnishi syndrome).

Retinopathy in toxæmia of pregnancy

Retinopathy in toxæmia of pregnancy. Occurs in the last trimester of pregnancy. The stages have been described:

Stage of angiospasm. This is due to the toxin in toxæmia of pregnancy. Initially there is narrowing of the retinal arteries, usually the nasal branches first and this is followed by spasmodic contractions.

Stage of sclerosis of vessels. This is dependent on the severity of hypertension.

Stage of retinopathy. This is characterized by haemorrhages, exudates and oedema leading to sometimes globular detachment of the retina.

Treatment. When sclerosis and retinopathy develop, termination of pregnancy is advocated. In the preorganic stage, treatment must be directed to control toxæmia of pregnancy by rest, sedation, salt restriction and mild hypotensive drugs.

Diabetic Retinopathy^{2,9,17,27}

Diabetes mellitus is the major systemic cause of blindness. The factors influencing the natural history of diabetic retinopathy are as follows:

Duration of diabetes. The development of diabetic retinopathy shows a remarkable dependence on the duration of diabetes.

For insulin-dependent diabetes mellitus (IDDM), there is no clinical evidence of retinopathy for 4 to

5 years, 25 to 30 per cent have some retinopathy after 5 to 10 years.

For non-insulin-dependent diabetes mellitus (NIDDM), the incidence of background retinopathy appears to be 23 per cent after 11 to 13 years following diagnosis.

Age and sex. It is so reported that the younger age group usually have IDDM and develop proliferative retinopathy, while older age group have NIDDM and develop macular oedema. Females are more prone to be affected.

Control of diabetes mellitus plays a controversial role, though the improved quality of blood glucose control appears to retard the development of diabetic retinopathy in the early stage of the affection.

Hypertension and hypercholesterolaemia. Both cause deterioration of diabetic retinopathy.

Other factors include genetic factors, pregnancy, and diabetic nephropathy.

Pathology. The changes that occur in the capillaries which show characteristic changes in diabetic retinopathy are:

- (a) There is loss of endothelial cells
- (b) Intramural pericytes are normally seen as ultrastructures between the layers of the basement membrane in the precapillary, capillary and postcapillary vessels in the retina and the CNS. They have phagocytic properties. In diabetic retinopathy, there is selective loss of these pericytes.

Loss of pericytes also occurs in polycythaemia and dysproteinaemia.

This leads to distension of the capillary wall and disruption of the blood-retinal barrier.

(c) Basement membrane shows thickening, lamination and fragmentation

(d) Narrowing of the capillary lumen may be observed.

(e) Microaneurysms result from weakening and dilatation of the capillary wall.

(f) Retinal capillary nonperfusion leads to hypoxia which subsequently causes intraretinal microangiopathy and neovascularization.

(g) Increased vascular permeability causes haemorrhage and oedema.

Ocular lesions

They are listed in Table 45.19.

Table 45.19
Lesions in Diabetic Retinopathy

Retinal microaneurysms
Haemorrhages
Intraretinal
Subretinal
Preretinal
Vitreous
Exudates
Hard
Soft
Venous abnormalities
Dilatation
Beading
Loops
Retinal oedema
Intraretinal microvascular abnormalities (IRMA)
Neovascularization elsewhere (NVE)
Neovascularization on the disc (NVD)
Fibrous tissue
White vessels
Retinal pigment epithelial appearance change

Background (simple) diabetic retinopathy

Background diabetic retinopathy (BDR) shows the following characteristic features (Fig. 45c.11):

Capillary microaneurysms. These constitute the first equivocal evidence of diabetic retinopathy and they are often confused with punctate haemorrhages. They are bright red, one or many, found singly or in small clusters, 75 to 100 microns or larger in size, globular with sharp round edges, and they occur most commonly at the posterior pole in an area in between the superior and inferior temporal vessels. They arise from the venous side of the capillaries and remain unchanged for months or years. They are better displayed by fluorescein angiography. Alone they can rarely cause visual deterioration. They are caused by the thinning of the capillary wall.

Haemorrhages. They are probably due to small occlusions of the venules. Rounded, dark-red

haemorrhages are characteristic and are situated in the deep capillary plexus. Two typical forms, viz. dark 'dot and blot' and light 'sponge mark' haemorrhages are also seen. Individual haemorrhage is severe which may spread to subhyaloid space and into the vitreous.

Exudates. They are characteristically 'hard' and white or yellowish coloured. Three forms, frequently occurring concurrently, are seen: (a) cluster form is not usually associated with aneurysms or haemorrhages; (b) circinate form is usually small and incomplete, and occasionally large and enclose microaneurysms or haemorrhages; and (c) large waxy plaques cause serious visual disability.

All three forms affect the posterior pole.

Venous changes. They include fusiform dilatation, isolated venous loops, coiling and varicosity. Hypertensive and arteriosclerotic changes are frequently associated with diabetic retinopathy.

Fluorescein angiography. See p. 521.

Preproliferative diabetic retinopathy

In preproliferative diabetic retinopathy (PPDR) the lesions are the result of retinal ischaemia. The clinical features include: (a) venous beading and loops; (b) increased capillary occlusion; (c) cotton-wool exudates; (d) superficial flame-shaped haemorrhages; (e) intraretinal neovascularization; and (f) intraretinal microvascular abnormalities (IRMA).

Proliferative diabetic retinopathy

In proliferative diabetic retinopathy (PDR) the newly-formed blood vessels and/or fibrous tissue arise from the retina or optic disc and extend along their inner surfaces or into the vitreous humour. In PDR there is marked ischaemia of the inner retinal layers which provokes neovascularization. There are two types of neovascularisation: (a) neovascularization elsewhere (NVE) Fig. 45.10; and (b) neovascularization on the disc (NVD)

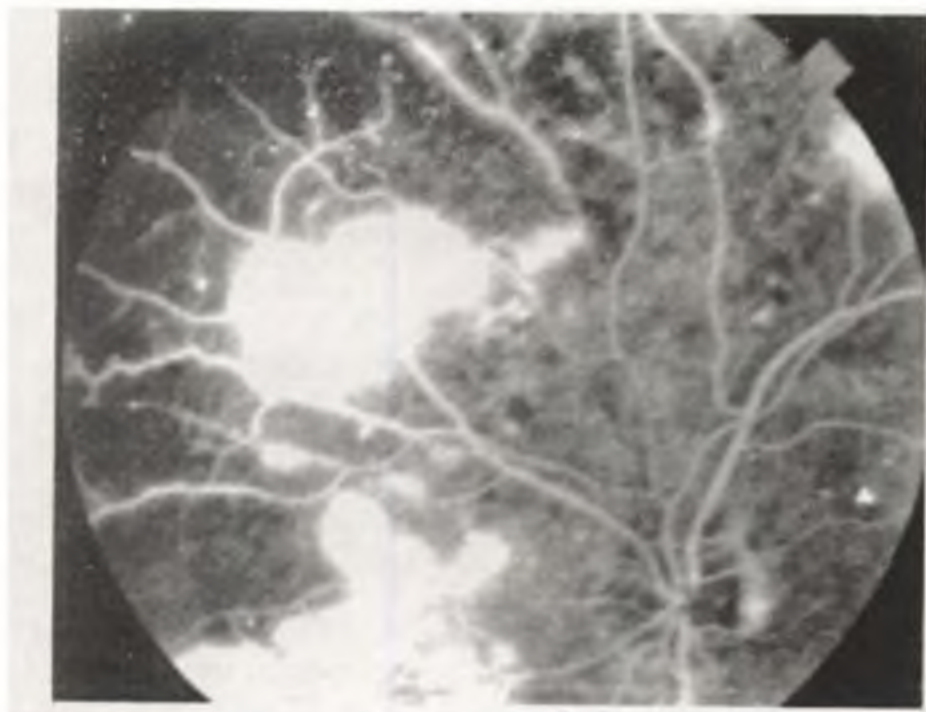


Fig. 45.10 NVE. Profuse leakage of dye from neovessels elsewhere (Dr. S.K. Biswas).

Fig. 45.11. The complications include rubeosis iridis, vitreous haemorrhage, posterior vitreous detachment, tractional retinal detachment and neovascular glaucoma.

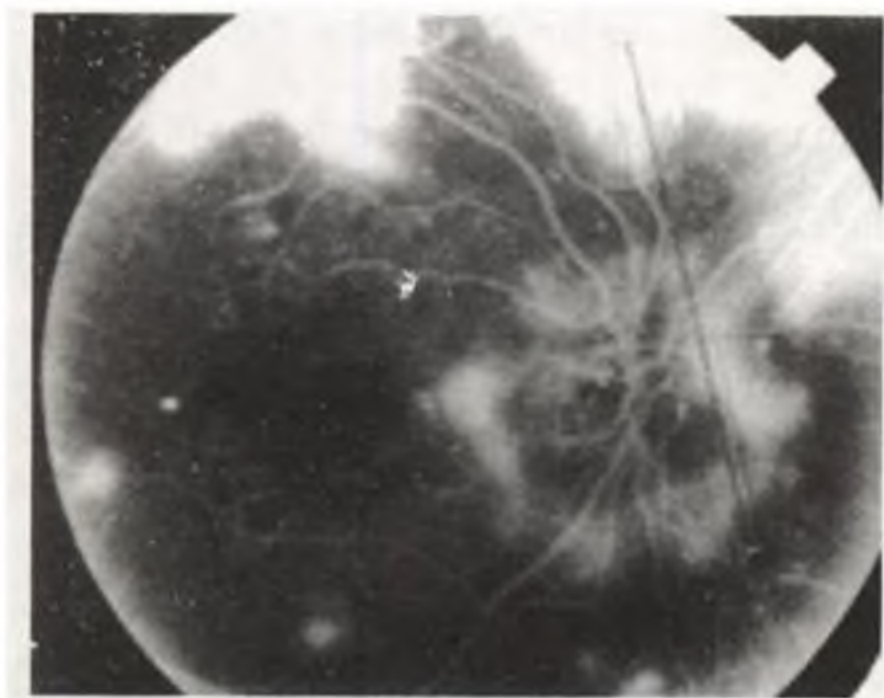


Fig. 45.11 NVD. Extensive dye leakage from neovessels on the optic disc (Dr. S.K. Biswas).

Diabetic maculopathy

There are four types: (a) focal exudative macular oedema; (b) diffuse macular oedema—either central or generalised; (c) ischaemic maculopathy; and (d) mixed forms. Maculopathy is more common in PDR than in BDR.

Clinically significant macular oedema (CSMO) is characterized by one or more of the following signs: retinal oedema within 500 millimicrons of the foveola, hard exudates within 500 millimicrons of the fovea and one-disc diameter or larger retinal oedema within one-disc diameter of the fovea.

Treatment. Prevention or reversal of retinopathy by strict diabetic control appears to be ineffective.

Aspirin or persantine, antiplatelet agent, does not alter the course of retinopathy.

Other modalities in medical management include use of vitamin E and lipid-restricted diet.

Laser photocoagulation offers the best chance of preserving vision. There are three types:

Focal. The early treatment diabetic retinopathy study (ETDRS) recommends focal laser therapy in BDR showing CSMO.

Grid. This is indicated in cases of widespread diffuse areas of leakage from the microaneurysms or capillaries.

Panretinal photocoagulation (PRP) is indicated in PDR. Laser treatment parameters are shown in Table 45.20.

Table 45.20

Laser Treatment Parameters

Direct focal photocoagulation	
Spot size	40–100 millimicrons
Exposure time	0.1 seconds
Power	Just for minimal blanching of RPE
Wavelength	
for blanching RPE	514 nm, 532 nm, 577 nm, 647 nm, 810 nm
for blanching microaneurysms	514 nm, 532 nm and 577 nm
Grid photocoagulation	
Spot size	100–200 millimicrons
Exposure time	0.05–0.1 seconds
Power	Just for minimal blanching of RPE
Wavelength	All except 488 nm
Panretinal photocoagulation	
Spot size	500 millimicrons
Exposure time	0.1 seconds
Power	Start with 250 mw, increase gradually to produce 500 millimicron size spot

Management of advanced PDR is difficult. For these cases, vitrectomy and cyclodestructive procedures may be attempted.

Chronic Arteriolar Capillaropathies in Retina

There are several features and they are as follows:

(a) There is disturbance of the blood flow in the arteries

(b) Evidence of foci of arteriolar occlusion and capillary perfusion impairment of varying degrees are present

(c) Subsequently, there is hypoxia of the blood and tissues

(d) As a result of hypoxia, there are capillary endothelial damage as well as disturbance of the retinal metabolism.

Table 45.21 shows stages and Table 45.22 the classification.

Table 45.21

Michaelson's Stages of Arteriolar Capillaropathies²⁷

Stage I	Arteriopathy
Stage II	Capillaropathy—having two phases:
	(a) Without increased permeability (dry phase)
	(b) With increased permeability (wet phase)
Stage III	Reaction—having two phases:
	(a) Macrophage activity
	(b) Vascular
Stage IV	Regression
Stage V	Complications

Retinal Changes in Blood Diseases

In general, the fundus signs include: (a) generalized pallor of the fundus; (b) venous dilatations; (c) haemorrhages; (d) exudates; and (e) papilloedema.

The blood diseases in which the retinal changes are found include: (a) anaemias; (b) polycythaemia; (c) haemorrhagic diseases; (d) dysproteinaemias; (e) haemoglobinopathies; and (f) leukaemias.

Anaemia

Anaemia is a condition characterized by the falling of haemoglobin concentration in the blood below the normal level for the age and sex of the individual. Broadly, anaemias may be due to:

(a) Diminished red blood cell production:

(i) Due to iron deficiency: the average diameter of the red cell is reduced, microcytic anaemia;

Table 45.22

Classification of Capillaropathies²⁷

Initially vascular, usually arteriolar changes:

- (a) Hypertensive retinopathy
- (b) Diabetic retinopathy
- (c) Central retinal vein thrombosis
- (d) Coats' disease
- (e) Retrolental fibroplasia

Change in the composition of the blood:

- (a) Sickle cell retinopathy
- (b) Leukaemia
- (c) Dysproteinaemia

Extraocular vascular conditions causing hypoxia:

- (a) Carotid insufficiency
- (b) Aortic arch syndrome
- (c) Ischaemic papillopathy

(ii) Due to deficiency of vitamin B₁₂ or folate, e.g. pernicious anaemia due to deficiency of the intrinsic factor, is evidenced by macrocytic anaemia, i.e. the average diameter of the red cells is greater than normal; and

(iii) Deficiency of vitamin C in scurvy.

(b) Excessive destruction of red cells, haemolytic anaemia.

(c) Loss of blood, which may be acute or chronic.

Fundus picture of anaemia is apparent when the concentration of the haemoglobin falls below 35 per cent and in sudden reduction in the haemoglobin level. The signs include flame-shaped haemorrhages, sometimes white-centred haemorrhages, soft exudates, pallor of the arterioles, fullness and tortuosity of the veins, generalized pallor of the fundus and the optic disc, and in severe cases also papilloedema. Treatment of anaemia leads to resolution of the retinopathy but optic atrophy may remain.

Polycythaemia

In this condition there is a high concentration of haemoglobin in the red blood cells. The fundus picture consists of dusky-red or cyanotic fundus, tortuosity and engorgement of the veins which also appear darker, haemorrhages of all types and oedema of the retina.

Haemorrhagic diseases

Haemorrhagic diseases may be due to: (a) defective capillary endothelium, typically vascular purpuras; (b) defective blood platelets as in thrombocytopenic purpura; or (c) defect in the clotting mechanism, typically haemophilia.

Haemophilia and purpura show multiple haemorrhages into the lids, orbit and conjunctiva, hyphaema and haemorrhage into the retina and vitreous. Sometimes the retina also shows exudates.

Dysproteinaemias

There are two types—*macroglobulinaemia* and *cryoglobulinaemia*. The former shows an increase in the serum content of IgM, while the latter shows precipitation of Ig following exposure to cold.

Ocular signs include haemorrhages from the conjunctiva, sludging in the conjunctival and retinal vessels. Retinal haemorrhages, and sometimes gross venous changes such as venous occlusion and engorgement occur. Oedema of the disc and retina also occurs.

Haemoglobinopathies

There are five groups of major ophthalmic interest and they are:

1. Sickle cell anaemia, HbS or SS disease
2. Sickle cell trait, Hb SA disease
3. Sickle cell disease, SC disease
4. Haemoglobin C trait
5. Sickle cell beta-thalassaemia

The erythrocytes become sickle-shaped and they cause mechanical obstruction in the smaller vessels, leading to microvascular infarcts in the bones, brain, lungs, spleen and eyes.

Conjunctival changes are more frequently seen in sickle cell anaemia, while severe retinopathy is encountered in sickle cell disease.

Sickle cell retinopathy. Retinal changes are listed in Table 45.23.

Table 45.23

Retinal Changes in Sickle cell Retinopathy

Nonproliferative

Stage 1: peripheral arterial occlusions

Stage 2: peripheral AV anastomoses

Stage 3: neovessels from anastomoses (*sea-fan retinopathy*)

Stage 4: vitreous haemorrhage

Stage 5: vitreous traction and retinal detachment

Proliferative

Asymptomatic like

Peripheral chorioretinal atrophy (*black sunburst sign*)

Peripheral superficial haemorrhages

Angioid streaks

Symptomatic like

Central retinal artery occlusion

Central retinal vein thrombosis

Occlusions of macular or choroidal arterioles

Leukaemias

Leukaemias are characterized by abnormal proliferation of the leucocytes and their precursors. A leukaemia may be acute or chronic, myeloid or lymphatic.

The clinical features are due to leukaemic deposits and haemorrhages, and they include: (a) subconjunctival haemorrhages; (b) thickening of the lids, conjunctiva and sclera; (c) proptosis especially in children; (d) sometimes greenish infiltrative orbital lesion, *chloroma*; (e) affection of the brain and of the CNS due to leukaemic infiltration of the brain and intracranial haemorrhage; and (f) characteristic retinal changes.

Retinal changes. Retinal haemorrhages are most common, particularly at the peripheral retina. They may be of different shapes and sizes. The site of the haemorrhage may be the nerve fibre layer or the deeper retinal layers. A haemorrhage is retinal, subretinal, preretinal or vitreous. The retinal changes are the result of anaemia and bleeding. Sometimes the haemorrhages appear with pale centres, *Roth's spots*. There may be exudates—hard or soft. Occasionally there may be papilloedema, venous dilatation, non-rhegmatogenous retinal detachment or optic atrophy.

Retinal Changes in Hyperlipidaemia⁸

The important changes include occlusion of the central retinal artery or vein, capillary closure, leakage from the vessels and rarely lipaemia retinalis.

Inflammatory Retinopathy⁸

The causes include acute multifocal posterior placoid pigment epitheliopathy, multiple evanescent white dot syndrome, multifocal choroiditis, birdshot choroidoretinopathy, serpiginous peripapillary choroidopathy and presumed ocular histoplasmosis.

These conditions are described in Chapter 40.

Anomalies of Fundus Pigmentation²⁷

Anomalies of fundus pigmentation may be: (a) congenital or acquired; (b) diffuse or circumscribed; and (c) defect or excess of pigmentation.

At birth and in early childhood, relatively scanty pigmentation of the choroid is seen. In old age, relative loss of pigment in the hexagonal pigment epithelium of the retina and preponderance of pigment in the chromatophores of the choroid are present. Pigmentary disturbance is usually secondary. Pigment cells of the choroid may be affected as in choroidal melanomata. In primary disease of the retina, it is unusual except in retinitis pigmentosa.

Retinal pigmentation may occur at any depth, appears black and is sharply defined. Choroidal pigmentation is rather greyish and ill-defined.

Congenital pigment anomalies may be:

- (a) Albinism—diffuse lack of pigment
- (b) Excessive pigmentation
 - (i) Diffuse
 - (ii) Localized

Acquired pigment anomalies may involve the retina, choroid or both. Retinal pigmentation may be primary or secondary to choroiditis. There factors are probably involved:

- (a) Break through the external limiting membrane
- (b) Spaces in the retina
- (c) Choroidal blood supply.

Retinal Detachment^{27,29,34}

The description is really a misnomer, but it indicates a separation of pigment layer from the rest of the layers, representing a cleavage between the two primitive layers of the retina. *Subretinal fluid* is the fluid between these two.

There are three important factors that maintain retinal opposition: hydrostatic pressure, acid mucopolysaccharide in the subretinal space, and photoreceptor RPE interaction¹

Broadly speaking there are two groups—idiopathic or primary, and secondary.

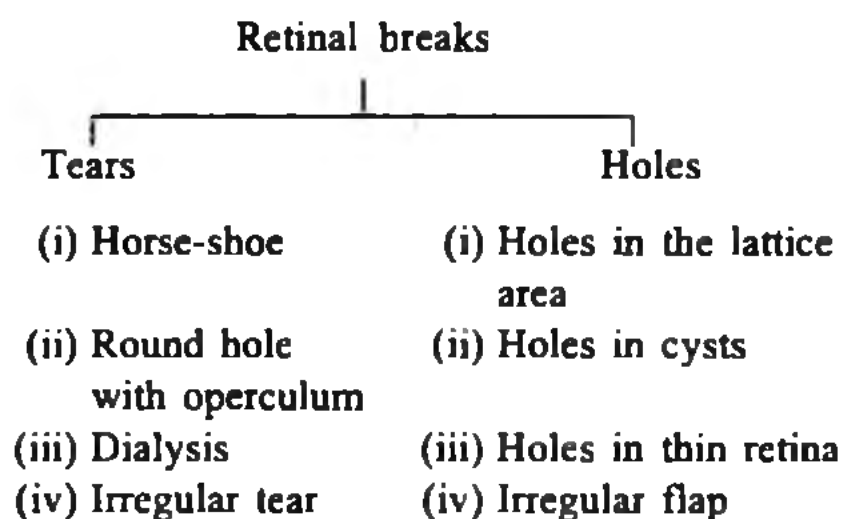
A better classification would be: (a) rhegmatogenous; (b) exudative; (c) tractional, and (d) secondary.

However, the different groups often overlap.

Rhegmatogenous retinal detachment

A retinal detachment is called rhegmatogenous (Gk. *rhegma*, tear; *genos*, origin) when it is due to a retinal break. The term *retinal break* means break in the continuity of the retina. A *retinal hole* is a retinal break not caused by traction, while a break caused by traction is called a *retinal tear*.

The retinal breaks are classified as follows:



Rhegmatogenous detachment are of two types:

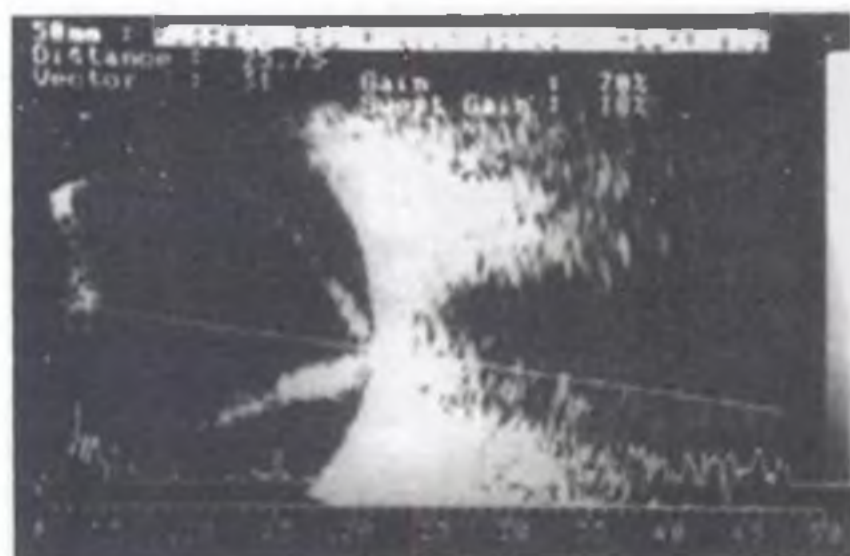


Fig. 45.12 B-scan showing retinal detachment (Courtesy: Eye Care and Research Centre, Kolkata).

Differential diagnosis is indicated in Table 45.24.

Table 45.24

Differential Diagnosis of Rhegmatogenous Retinal Detachment²⁸

-
- A. Developmental defects:
 - Colobomas of retina and choroid
 - Optic nerve—head pit or coloboma
 - Retrolental fibroplasia
 - Retinal dysplasia
 - Retinoschisis: acquired and congenital
 - Persistent hyperplastic primary vitreous
 - Massive retinal fibrosis
 - B. Retinal or choroidal vascular diseases:
 - Angiomatosis retinae
 - Coats' disease
 - Eales' disease
 - Retinal vein or artery occlusion
 - Choroidal haemangioma
 - Post traumatic retinal oedema
 - Central serous choroidopathy
 - Tumours, e.g. malignant melanoma of choroid, retinoblastoma
 - C. Choroidal detachment
 - D. Vitreous opacities
 - E. Inflammatory processes:
 - Diffuse choroiditis
 - Vogt-Koyanagi-Harada syndrome
 - Cyclitic membrane
 - Uveal effusion
 - Parasites
 - F. Systemic diseases:
 - Hypertensive retinopathy
 - Toxaemia of pregnancy
 - Proliferative diabetic retinopathy (PDR)
 - Collagen diseases
 - Haemoglobinopathies
-

Retinal holes. Fison described six types¹² of retinal holes:

1. *Horse-shoe or arrow head tear.* It is seen commonly at the upper half and especially in the temporal sector. Its convexity is directed towards the optic disc and concavity towards the ora serrata. It is commonly single and on occasion in 2 or 3. It is usually found in high myopes with lattice degeneration at the margin of the tear. It has an operculum which is found to move with the movement of the eye, and is also connected with PVD.

2. *Dialysis or disinsertion.* When the retina is disinserted at the ora serrata it is called an *anterior* dialysis. Rarely it is disinserted at the optic disc when it is known as a *posterior* dialysis. Anterior dialysis may follow trauma or cystoid degeneration. It is bilateral, symmetrical and is seen in the lower temporal quadrant.

3. *Holes with free opercula.* When the small portion of the torn retina floats in the vitreous cavity, it is called an *operculum*. Usually one or two, they are not usually large and are caused by vitreoretinal adhesions.

4. *Macular holes.* This may be round or irregular. For detail description, see pp. 333–34.

5. *Giant tears.* These extend 90° or more around the circumference of the globe. They occur in high myopes and are usually progressive.

6. *Holes with lattice degeneration.* Lattice degeneration is bilateral, seen commonly along the upper temporal sector, and is characterized by thinned-out retina and fine white lines. Usually the tears develop along the posterior border of the lattice degeneration. In an advanced stage the vitreous is also liquefied and found to be present in the degenerated area. Prophylactic cryocoagulation of the lattice areas is helpful in averting a retinal detachment.

Finding out of a retinal tear.²⁵ There are two factors which determine the type of retinal detachment: gravity and attachments of the retina at the optic disc and the ora serrata. The site of detachment is dependent upon the position of the retinal tear. Broadly there are two lines, vertical and horizontal, dividing the retina into nasal and

temporal halves above the horizontal line, and into the upper and lower halves respectively.

Upper tears. The characteristics are as follows. The retina is elevated all round the tear. The elevation then extends downwards around the inferior margin of the optic disc and even extends upwards in the other side. The higher level of elevation of the retina indicates the side in which the retinal break is present. If the tear is at 12 o'clock the detachment involves both sides of the disc. Because of gravity there is likelihood of balloon detachment.

Lower tears. Lower tears are those which lie below the horizontal line. They behave in the same fashion as the upper tears, but when the tear is located at 6 o'clock levels of elevation are equal in both nasal and temporal quadrants. The detachment is usually shallow.

Treatment.^{34,36} The basic aims are sealing the retinal breaks, all of which may not need treatment (Table 45.25) and relieving vitreous traction if present. Early detection and prompt surgery are essential in its treatment. There are two chief methods—approximation of the detached part of the retina with the choroid or vice versa. The former can be achieved by cryopexy, diathermy and rarely by photocoagulation. The latter is done by scleral buckling or allied procedures.

Table 45.25

Management of Retinal Breaks
(After Goldbaum et al.)¹⁵

Need close observation

Break in patient with family history of retinal detachment

Break affected by a disease associated with retinal detachment

Break with subretinal fluid of less than 1 disc diameter

Most likely need treatment

Break in aphakic eye

Symptomatic tear with flap

Break with subretinal fluid extending greater than 1 disc diameter

Break greater than 30°

Break with manifest traction

Break in an eye with a previous retinal detachment

Retinal detachment with multiple holes, accompanied by elevation of the tear margin and subretinal fluid essentially needs a scleral buckling and release of subretinal fluid by a fine diathermy needle. Scleral buckling entails the use of silicone plomb which is sutured with the sclera. For isolated holes, plombs should be placed radially, and in multiple holes situated parallel to the equator a circumferential plomb is indicated. The tears lining anterior to the equator are dealt with by cryoapplication with temperature of -70°C at the tip of the probe applied transconjunctivally. Those situated posterior to the equator are sealed by photocoagulation burns encircling them. An aphakic detachment is better treated with an equatorial encirclement with silicone strap.

Exudative retinal detachment²¹

Aetiology. The causes include: (a) inflammations like choroiditis, chorioretinitis, Vogt-Koyanagi-Harada syndrome; (b) tumours like choroidal haemangioma or melanoma; (c) systemic causes like hypertensive retinopathy, toxæmia of pregnancy, renal retinopathy; (d) miscellaneous causes like Coats' disease, uveal effusion, etc.

Pathology. Normally, the blood-retinal barrier keeps the inner retina dehydrated and the outer retina remains dry due to fluid movement across the RPE. In exudative detachment there is accumulation of subretinal fluid (SRF) due to increased subretinal inflow, decreased outflow or the combination of both.

Clinical features. Symptoms include metamorphopsia and dimness of vision. Ophthalmoscopy reveals elevation of the retina and shifting SRF. The retinal surface is smooth and the responsible cause may be detected.

Treatment. The cause is found out and treated accordingly.

Tractional retinal detachment²¹

A tractional retinal detachment (TRD) may follow diabetic retinopathy, Eales' disease, aphakia with

vitreous herniation, etc. Abnormal vitreoretinal adhesion followed by shrinkage of the fibrous tissue causes a TRD. Treatment is called for when there is macular involvement, presence of retinal holes or vitreous haemorrhage.

Coats' Disease³⁸

Coats described three groups of cases: (a) those with massive exudates; (b) those with gross vascular changes; and (c) those with massive exudates, arteriovenous communications and angiomas. The disease is usually common in young males and usually unilateral.

Pathology. There are two characteristics: (a) exudation of albuminous fluid or sometimes blood into the subretinal space, with dilated, thin-walled vessels; and (b) the presence of lipid-laden microglial macrophages along with cholesterol clefts.

Clinical features. The usual picture ophthalmoscopically is the presence of yellowish-white massive exudates with haemorrhages, glistening spots, along with vascular abnormalities namely loops, beading, tortuosity, tuft, sheathing or abnormal anastomoses—all predominantly involving the posterior pole. Fluorescein angiography exhibits dilated capillary networks, irregular aneurysmal dilatations and leakage of fluorescein.

Complications and sequelae. The affection runs a course of resolution and exudation alternating with one another. Ultimately there may be retinal detachment, cataract, iritis and secondary glaucoma.

Treatment. In the early stage, photocoagulation applied to the abnormal vessels may help in resolution of the exudates.

Phakomatoses or Hamartomous Syndromes^{27,38}

Phakomatoses or hamartomous syndromes are congenital tumours involving the eye, skin and

CNS, showing a strong hereditary tendency. The clinical manifestations are widespread. The term is so called because it is derived from *phakos*, greek word meaning 'mother's spot'. There are generally four syndromes—tuberous sclerosis, neurofibromatosis, Sturge-Weber syndrome and von Hippel-Lindau syndrome.

Tuberous Sclerosis or Bourneville's Disease

The name has been derived from multiple cerebral areas of sclerosis which appear as potatoes. The condition is inherited as irregular dominant trait with 50 per cent new mutations. The skin lesions usually are the presenting features in some cases (Fig. 45.13). They are multiple, whitish or yellowish, slightly raised lesions usually distributed in a butterfly pattern around the nasolabial fold. They are called *adenoma sebaceum*. In childhood there is mental retardation. Epileptic fits also occur. The characteristic ocular feature is the presence of single or multiple, smooth or raised, whitish tumours in the retina and optic nerve. These are astrocytic tumours. Tumours are reported to occur in the heart, kidneys, uterus and thyroid gland.

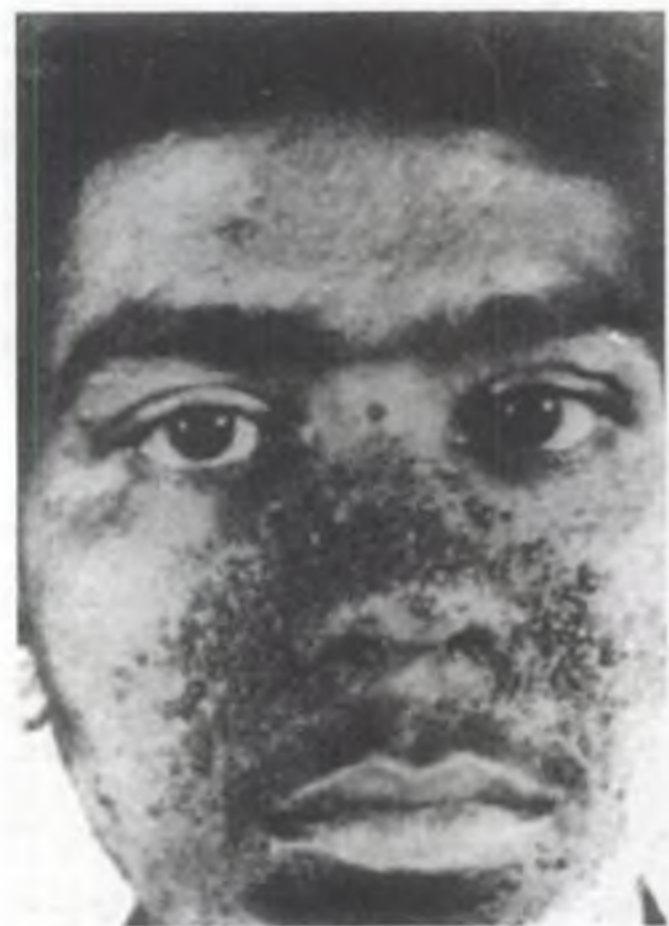

Fig. 45.13 Adenoma sebaceum (Dr. I.S. Roy).

X-rays of the skull may reveal evidence of intracranial calcification. Drusen of the optic nerve is often associated.

Diagnosis is based on family history, general examination, CT and MRI.

Neurofibromatosis or von Recklinghausen's Disease

Neurofibromatosis or von Recklinghausen's disease is transmitted as a dominant trait. There are tumours of the neurilemmal cells of the peripheral nerves. The affection appears at childhood but the manifestations are marked at puberty, during pregnancy and at menopause. Commonly the skin shows spots which are flat, light brown of different sizes with irregular edges distributed on the trunk, eyelids and elsewhere. This *café-au-lait* pigmentation is a characteristic finding. The skin commonly shows innumerable subcutaneous tumours, plexiform neurofibromas, causing either hypertrophied skin folds seen hanging, *elephantiasis neuromatosa*, or pedunculated nodes, *molluscum fibrosum*, due to secondary proliferation of the fibrous tissue.

There may be bone destruction or hypertrophy; this occurs in cranial bones, vertebrae, orbit and extremities. It is often associated with intracranial tumours like meningiomas and gliomas.

Ocular changes are quite common and important. The eyelids show *café-au-lait* pigmentation, single or multiple neurofibromas giving the feeling of a bag of worms, *molluscum fibrosum* and ptosis due to *elephantiasis neuromatosa* (Fig. 45.14). The orbital bones may show erosion or hypertrophy leading to pulsating proptosis or true proptosis. Thickened corneal nerves are occasionally seen. The conjunctiva and the iris may show nodules (Lisch nodules). Buphthalmos is sometimes associated with neurofibroma. Optic nerve gliomas are found in about 15 per cent cases.

Diagnosis is based on family history, EEG and CT.

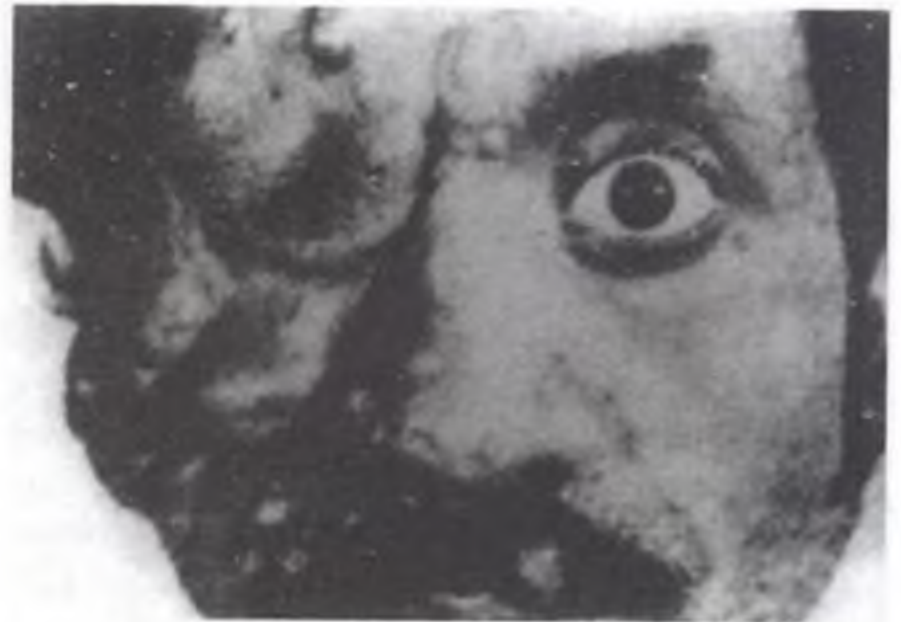

Fig. 45.14 Neurofibromatosis showing lid involvement (Courtesy: Regional Institute of Ophthalmology, Calcutta).

Sturge-Weber Syndrome

Sturge-Weber syndrome is also called *encephalotrigeminal angiomatosis*. The complete syndrome consists of intracranial haemangioma, facial haemangioma and choroidal haemangioma (40%). The intracranial haemangioma involves the meninges on one side of the brain. This is associated with ipsilateral atrophy of the cerebral and cerebellar cortex leading to epileptic fits. X-ray of the skull shows calcification of intracranial haemangioma appearing as fine parallel lines.

The most striking of all the features is the cutaneous angioma called *naevus flammeus* appearing on the face on the same side of the intracranial haemangioma and the area involved is supplied by the first or second division of the trigeminal nerve. In the eye itself buphthalmos is commonly present. Buphthalmos is present on the same side as that of *naevus flammeus* and is due to choroidal haemangioma.

MRI of the brain is helpful.

Treatment consists of control of glaucoma and that of epilepsy.

von Hippel-Lindau Disease

von Hippel-Lindau disease is also called *cerebroretinal angiomatosis*. This condition is

characterized by angiomas of the retina and cerebellum. It is transmitted with irregular dominant trait. The retinal angioma was first reported by von Hippel, while angioma of the cerebellum was reported by Lindau who found it to be associated with retinal angioma. Haemangiomas are also sometimes present in the kidneys, ovaries, pancreas, adrenals, liver and spleen. The chief pathologic characteristic is the formation of the vascular channels due to capillary hyperplasia.

The condition affects both eyes in 35 to 50 per cent.

The stage of vascular dilatation and angiomatous formation (Fig. 45.15) is the most characteristic feature. At first there is fullness of the retinal veins which gradually dilate leading to angiomatous formation, especially on the temporal side. They tend to increase in size until the retina becomes spattered with haemorrhages and exudates. Then a retinal detachment follows. The final picture is one of secondary glaucoma and visual loss.

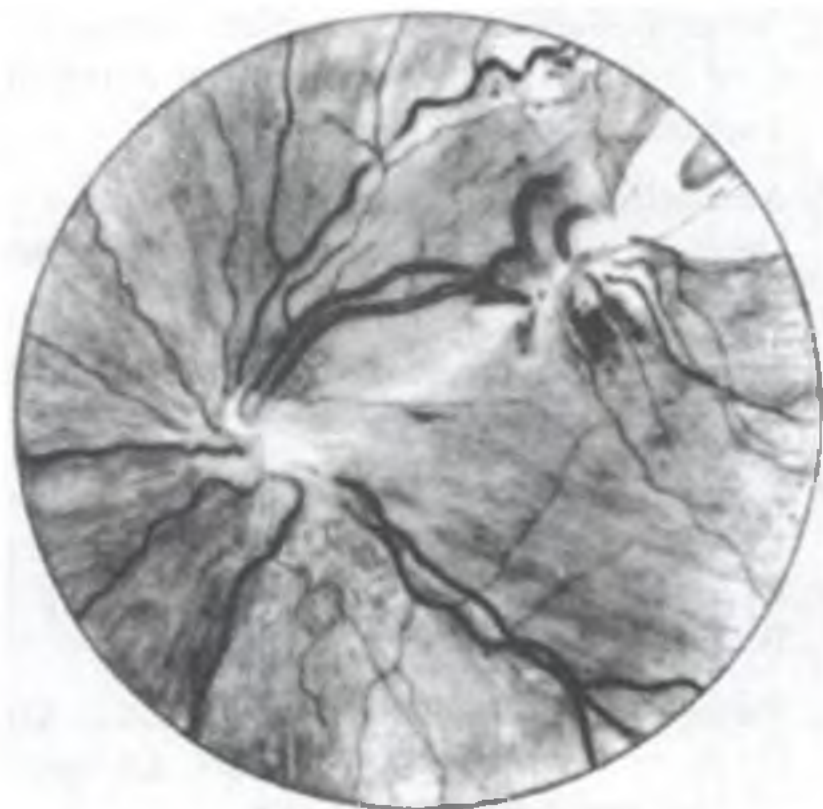


Fig. 45.15 Angiomatosis retinae (von Hippel-Lindau disease) (Trevor-Roper).

Diagnosis is aided by FFA, MRI of the brain and abdomen.

Treatment. Photocoagulation seems to be effective in the early stage. The light should be applied to the tumour itself, but always avoiding the feeding vessels. It should be repeated in small doses at interval of 4 to 6 weeks.

Diathermy coagulation has also been advocated in the early stage. In well-advanced stage, radiation remains the only choice.

In the presence of intracranial angioma, the prognosis is poor.

Cysts of the Retina⁹

Cysts of the retina are rare condition. There are several types:

- (a) Congenital
 - (i) Primary
 - (ii) Secondary—associated with condition like microphthalmos.
- (b) Pseudo or acquired may occur in cystoid degeneration of the retina, long-standing retinal detachment and Coats' disease.
- (c) Traumatic, e.g. postconcussion cyst at the macula, after formation of retinal folds or bands.
- (d) Parasitic. Two of them are known—cysticercus and hydatid.

Further Reading

1. Albert, D.M. and Jacobiec, F.A. (Eds.), *Principles and Practice of Ophthalmology: Clinical Practice*, W.B. Saunders, Philadelphia, 1994.
2. Ariffin, A., Hill, R.D. and Leigh, O., *Diabetes and Primary Eye Care*, Blackwell Scientific, Oxford, 1992.
3. Ashton, N., Eye in malignant hypertension. *Trans. Am. Acad. Ophthalmol. and Otolaryngol.*, 76:17, 1972.
4. Bird, A.C., Bruch's membrane change with age: mini review. *Br. J. Ophthalmol.*, 76:166, 1992.
5. Blach, R.K. and Bedford, M.A., Peripheral retinal degenerations in relation to retinal detachment. *Trans. Ophthalmol. Soc., U.K.*, 86:463, 1966.
6. Cullen, J.F., Occult temporal arteritis. *Br. J. Ophthalmol.*, 51:513, 1967.
7. Deutman, A.F., Retinal dystrophies. In *Scientific Foundations of Ophthalmology*.

- Perkins, E.S. and Hill, D.W. (Eds.), Heinemann Medical, 1977, p. 81.
8. Dodson, P.M., Gibson, L.M. and Kritzinger, E.E., *Clinical Retinopathies*, Chapman and Hall, London, 1995.
 9. Duke-Elder, S., *System of Ophthalmology*, Vol. X: *Diseases of the Retina*, Duke-Elder, S. and Dobree, J.H. (Eds.), Kimpton, London, 1967.
 10. Early Treatment Diabetic Retinopathy Study (ETDRS) Research Group. Photocoagulation for diabetic macular edema. *Arch. Ophthalmol.*, 103:1796, 1985.
 11. Fishman, G., Hereditary retinal and choroidal disease: electroretinogram and electrooculogram findings. In *Principles and Practice of Ophthalmology*, Peyman, G.A., Sanders, D.R. and Goldberg, M.F. (Eds.), W.B. Saunders, Philadelphia, 1980, p. 857.
 12. Fison, L., Retinal detachment. In *Modern Ophthalmology*, Vol. IV (2nd ed.), Sorsby, A. (Ed.), Butterworths, London, 1972, p. 747.
 13. Gass, J.D.M., Idiopathic macular holes: its early stages and pathogenesis. *Arch. Ophthalmol.*, 106:629, 1988.
 14. Gerbrandy, J., Funduscopy and hypertension. In *Perspectives in Ophthalmology*, Henkes. (Eds.), Excerpta Med., 1968, p. 5.
 15. Goldbaum, M.H., Joondeph, H., Huamonte, F.U. and Peyman, G.A., Retinal Examination and Surgery. In *Principles and Practice of Ophthalmology*, Peyman, G.A., Sanders, D.R. and Goldberg, M.F. (Eds.), W.B. Saunders, Philadelphia, 1980, p. 988.
 16. Goldmann, H., The diagnostic value of biomicroscopy of the posterior parts of the eye. *Br. J. Ophthalmol.*, 45:449, 1961.
 17. Hamilton, A.M.P., Ulbig, M.W. and Polkinghorne, P., *Management of Diabetic Retinopathy*, B.M.J. publishing, 1996.
 18. Harry, J. and Ashton, N., The pathology of hypertensive retinopathy. *Trans. Ophthalmol. Soc., U.K.*, 83:71, 1963.
 19. Hayreh, S.S., Macular lesions secondary to choroidal vascular disorders. *Indian J. Ophthalmol.*, 31:158, 1982.
 20. Hayreh, S.S., Retinal vein occlusion. *Indian J. Ophthalmol.*, 42:109, 1994.
 21. Kanski, J.J., *Clinical Ophthalmology* (3rd ed.), Butterworth-Heinemann, London, 1994.
 22. Kelsey, J.H. Electrodiagnostic methods in ophthalmology. *Trans. Ophthalmol. Soc. U.K.*, 87:237, 1967.
 23. Leinfelder, P.J., Ophthalmoscopy: an investigative challenge. *Am. J. Ophthalmol.*, 85:565, 1966.
 24. Leishmann, R., The eye in general vascular disease: hypertension and arteriosclerosis. *Br. J. Ophthalmol.*, 41:641, 1957.
 25. Lincoff, H. and Giesser, R., Finding the retinal hole. *Arch. Ophthalmol.*, 85:565, 1971.
 26. Mann, I. *The Development of the Human Eye* (3rd ed.), British Medical Association, London, 1964.
 27. Michaelson, I.C., *Textbook of the Fundus of the Eye* (3rd ed.), Churchill Living-stone, London, 1980.
 28. Morse, P.H., *Vitreoretinal Disease*, Year Book Medical Publishers, Inc., Chicago, 1979, p. 75.
 29. Namperumalswamy, P., Dwarakanath, D. and Lal, S., Retinal detachment. In *Modern Ophthalmology*, Dutta, L.C. (Ed.), Jaypee Bros., New Delhi, 1994.
 30. Parsons, J.H. *Parsons' Diseases of the Eye* (18th ed.), Miller, S.J.H. (Ed.), Churchill Livingstone, Edinburgh, 1990.
 31. Podos, S.M. and Yanoff, M., *Textbook of Ophthalmology*, Vol. 9: *Retina and Vitreous*, Federman, J.L., Gouras, P., et al. (Eds.), Mosby Year Book, St. Louis, 1994.
 32. Rutnin, U. and Schepens, C.L., Fundus appearance in normal eyes. III peripheral degenerations. *Am. J. Ophthalmol.*, 64:1042, 1967.

33. Scheie, H.G., Evaluation of the ophthalmoscopic changes of hypertension and arteriolar sclerosis. *Arch. Ophthalmol.*, 49:117, 1953.
34. Schepens, C.L., *Retinal detachment and allied disease*, W.B. Saunders, Philadelphia, 1983.
35. Terpstra, J., Treatment of diabetic retinopathy. In *Perspectives in Ophthalmology*, Henkes, P. (Ed.), Excerpta Med., 1968, p. 133.
36. Trevor-Roper, P.D. and Curran, P.V., *The Eye and Its Disorders* (2nd ed.), Blackwell Scientific Publications, Oxford, 1984.
37. Vannus, S. and Raitta, C., Anticoagulant treatment of retinal venous occlusion. *Am. J. Ophthalmol.* 62:874, 1966.
38. Vrabec, M.R. and Floriakis, G.L. (Eds.), *Ophthalmic Essentials*, Blackwell Scientific, Boston, 1992.
39. Wolter, J.R., Retinal pathology after central vein occlusion. *Br. J. Ophthalmol.*, 45:683, 1961.

46. DISEASES OF THE VISUAL PATHWAYS

The optic nerve is really a tract of the CNS rather than a peripheral nerve and it is the continuation from the optic chiasma. Hence the affections of the optic nerve often follow those of the brain. Since the nerve is clothed by the meninges, being in continuity with those of the brain, the nerve may be compressed. The affection leading to degeneration of the nerve fibres leads to blindness.

The important signs for evaluating an optic nerve affection are listed in Table 46.1.

Optic Neuritis^{1,2,11,17}

Optic neuritis is the term used to define inflammation of the optic nerve in any part of its course. Broadly there are two types—papillitis and retrobulbar neuritis. A retrobulbar neuritis may be either acute or chronic. *Papillitis* is the

Table 46.1
Features of Optic Nerve Disorders

-
1. Pain
 2. Loss of visual acuity—variable
 3. Visual field defect—variable
 4. Colour vision defect
 5. Relative afferent pupillary defect—prominent
 6. Optic disc changes
 7. Amaurosis fugax—common
 8. Contrast sensitivity—great loss in midspatial frequency
-

inflammation of the optic nerve-head. *Retrobulbar neuritis* is the inflammation of the part of the optic nerve beyond the globe. When the inflammation spreads from the disc towards the retina it is called *neuroretinitis*.

Aetiology. General conditions are more important and include:

- (a) Demyelinating diseases—typically multiple sclerosis
- (b) Diabetes
- (c) Avitaminosis
- (d) Anaemia
- (e) Giant cell arteritis
- (f) Toxic amblyopia
- (g) Specific conditions like tuberculosis and syphilis.

Of all the causes, demyelinating diseases are most important. In about one-third of the cases of optic neuritis multiple sclerosis is responsible. In all cases of unilateral optic neuritis this should be suspected. Devic's disease is a bilateral optic neuritis along with transverse myelitis. In diabetes mellitus occasionally optic neuritis may occur. In both pernicious anaemia and tobacco amblyopia the inflammation can ensue. In nutritional neuropathy the optic nerves and posterior columns of the spinal cord are affected. Giant cell arteritis may cause an ischaemic optic neuropathy.

Local conditions include uveitis, retinitis, and nasal sinusitis. Even in a severe sinusitis, optic neuritis is uncommon.

Pathology. The inflammation is mostly interstitial and very rarely purulent in nature. The changes occurring in an interstitial neuritis are: (a)

inflammatory infiltration, (b) proliferative changes in the interstitial tissues, (c) loss of myelin sheath, (d) degenerative changes, and (e) finally reactionary gliosis.

Clinical features. *Papillitis* is often unilateral accompanied by rapid loss of vision. The loss of vision often precedes the ophthalmoscopic changes. The symptoms are usually disproportionately more marked than the optic disc changes would suggest. The optic disc shows hyperaemia, blurred margins, distorted and tortuous retinal veins, usually relatively small swelling, less than 2D. It closely resembles papilloedema (Table 46.2). There may be also haemorrhages, exudates in the disc region and macular oedema. But if the lesion is situated in close proximity to the lamina cribrosa the disc oedema may be 6 D or more, this is rather rare.

The optic disc becomes hyperaemic and it is difficult to differentiate it from the surrounding retina. Occasionally oedema spreads around causing a neuroretinitis and in such cases macular stars may be present. Posterior vitreous often shows cloudiness due to fine opacities.

Papillitis is to be differentiated from pseudoneuritis (Table 46.3).

FFA. See p. 521.

Optic disc vasculitis (papillophlebitis)

The cause is obscure but perhaps it is a form of partial CRVT. It occurs in young age. The condition

Table 46.3
Differentiation between Papillitis and Pseudoneuritis

Points	Papillitis	Pseudoneuritis
Loss of vision	Rapid	Usually normal vision with correction
Refractive status	Not characteristic	Usually high hypermetropia with astigmatism
Media	Commonly vitreous opacities	Clear
Colour of optic disc	Red and cloudy	Red but not cloudy
Haemorrhages	Usually present	No
Peripapillary oedema	Present	Absent
Size of blind spot	Enlarged	Smaller than normal average

is evidenced by unilateral disc-oedema accompanied by superficial haemorrhages in the peripheral retina. There is no disturbance of vision, visual field and pupillary reactions. The vasculitis often resolves.⁴

Acute retrobulbar neuritis

Ophthalmoscopically visible changes are not seen unless the lesion is in close proximity to the lamina

Table 46.2
Differentiation between Papillitis and Papilloedema²

Points	Papillitis	Papilloedema
Degree of swelling	Rarely above 2 dioptries	Frequently high
Venous engorgement	Usually less marked	More marked
Haemorrhages	Usually less marked	More marked
Retinal oedema	More marked	Less marked
Macular star	Less prominent	More prominent
Loss of visual acuity	Much more marked and acute	Usually loss is late and gradual
Scotoma	Typically central, especially for colours	Enlarged blind spot
Recovery of vision	May be complete even after development of great visual loss	Visual deterioration continues till the condition is relieved
Pain	May be present	No
Laterality	Often unilateral	Most often bilateral
Vitreous haze	Present	Absent

cribrosa. This condition is an example of symptoms rather than of signs. It is often unilateral. Lack of sustained constriction of the pupil to light is almost pathognomonic of this affection. At first colour vision is impaired. Then the visual acuity is rapidly lost. There is central or centrocaecal scotoma. The patient complains of pain in and behind the eyeball which is the presenting symptom in most cases. It is perhaps the result of oedema of the meninges covering the optic nerve. In large majority of cases ophthalmoscopy reveals a normal fundus. If the lesion is in close proximity to the lamina cribrosa there is some discoedema which is better visible by fluorescein angiography.

Normal VER latency is 100 m secs, but in dysfunction of the optic nerve it is more than 120 m secs.

Differential diagnosis. This includes: (a) compressive neuropathy; (b) ischaemic optic neuropathy; (c) Leber's optic atrophy; (d) tobacco-alcohol amblyopia; (e) basilar meningitis; and (f) retinal disorders.

Complications and sequelae. In both papillitis and acute retrobulbar neuritis the symptoms persist for 2 to 4 weeks, but occasionally the course is longer. They run an acute course, may subside with treatment and may be followed by post-neuritic optic atrophy. Temporal pallor of the disc due to involvement of the papillomacular bundle may occur following acute retrobulbar neuritis. Acute retrobulbar neuritis has a tendency to relapse. Sometimes there is good recovery of vision within 4 weeks. There is usually a residual loss of visual acuity, contrast, brightness and colour.

Treatment. Treatment is directed against the cause. General measures consisting of parenteral or retrobulbar steroids, injections of vitamin B₁₂, etc. are important in acute stage of the disease. Steroids have no effect on final visual activity.

Chronic retrobulbar neuritis

Chronic retrobulbar neuritis is comparatively rare and a characteristic of toxic amblyopia. It is frequently bilateral and it runs a chronic course with more permanent visual deterioration.

Papilloedema

Papilloedema is a noninflammatory oedema of the optic nerve head.

This term is used for swelling of the optic disc due to raised intracranial pressure, otherwise the generic term optic disc oedema is better used.

Aetiology.^{12,15} The causes can be grouped as follows:

1. Due to passive oedema—characterized by little or no loss of vision.
 - (a) With raised intracranial pressure, *plerocephalic oedema*, due to
 - (i) Intracranial tumours—about 80 per cent of them cause papilloedema
 - (ii) Hydrocephalus
 - (iii) Subarachnoid haemorrhage
 - (iv) Benign intracranial hypertension
 - (b) Without raised intracranial pressure as in malignant hypertension.
2. Space-occupying lesions in the orbit—associated with early or late loss of vision such as tumour, cellulitis and severe exophthalmos.
3. Due to focal lesions at or near the disc—characterized by early and obvious loss of vision as in
 - (a) Vascular lesions like thrombosis of the central retinal vein
 - (b) Optic neuritis
 - (c) Posterior uveitis especially near the disc.

Pathology (Fig. 46.1). Normally, the tissue pressure within the intraocular part of the nerve is much higher than that within the retrobulbar portion due to the lamina cribrosa. The disc oedema is either due to diminished tissue pressure in the prelaminar region or due to increased tissue pressure in the retrolaminar region.

Perhaps the acceptable view is the impediment of venous return in the optic nerve. The central retinal vein is occluded in the subarachnoid space due to compression. This results in venous engorgement, transudation of fluid while the exit of fluid is prevented by increased compression in

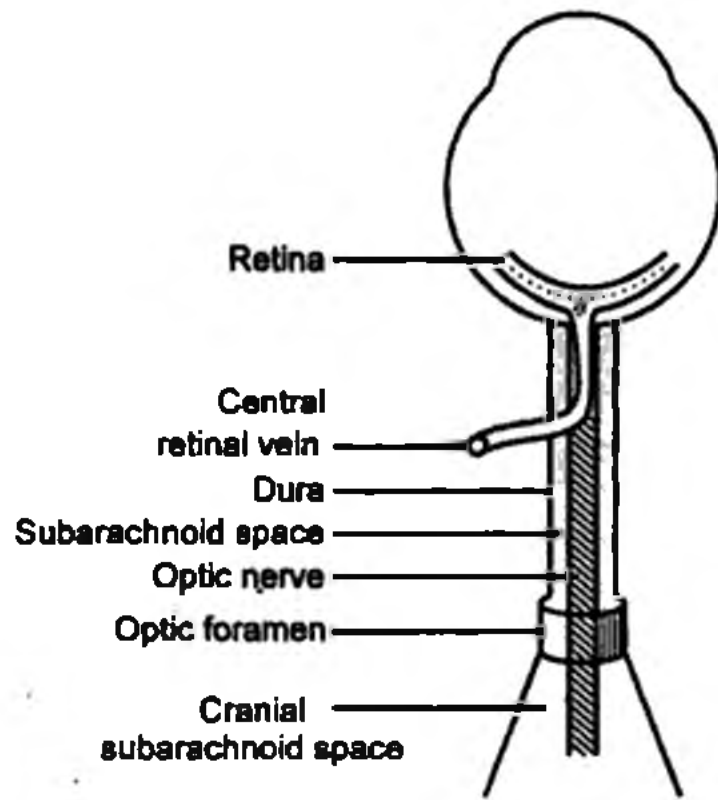


Fig. 46.1 Diagram to show continuity of the subarachnoid space all round the optic nerve and the central retinal vessels crossing this space

the intervaginal space, and finally increased disc oedema. Hayreh⁵ has shown that papilloedema occurs in rhesus monkey with artificially-raised intracranial pressure by introducing intracranial balloons, while the opening of the subarachnoid space in the optic nerve prevents it. So it may be presumed that intracranial space-taking lesions raise the CSF pressure in the subarachnoid space which is transmitted into the optic nerve sheath. Subsequently there is alteration of the pressure gradient across the lamina cribrosa which in turn leads to stasis of axoplasm in the prelaminar region. Axonal oedema is basically an intracellular oedema, and is the initial structural alteration. Axoplasmic stasis causes venous congestion and then an extracellular oedema.¹⁶

The different structures show the following histologic characteristics:

- (a) The optic disc shows
 - (i) Oedema,
 - (ii) Protrusion forwards of the lamina cribrosa and
 - (iii) Obliteration of the physiological cup.
- (b) The nerve fibres in the retina show
 - (i) Oedema
 - (ii) Infiltration
 - (iii) Degeneration

- (iv) Phagocytosis and
- (v) Replacement fibrosis.

(c) The blood vessels of the retina are distended and haemorrhages are frequent.

(d) The outer layers of the retina show minimal affection.

Clinical features. There is hyperaemia due to capillary dilatation, at first affecting the upper and lower poles, then gradually the whole disc. The disc margin becomes blurred—at first upper and lower poles, then nasally and ultimately temporally. Due to oedema there is gross elevation of the disc with disappearance of the physiologic excavation. The retinal veins are usually full and tortuous. All these changes are progressive. Haemorrhages appear usually at the disc margin. Oedema occurs in the retina adjacent to the disc. Exudates may be present at the disc margin or along the vessels.

Ophthalmoscopically there are two groups of signs—mechanical and vascular (Table 46.4).

Table 46.4

Ophthalmoscopic Signs in Optic Disc Oedema¹⁴

Mechanical signs

- Anterior extension of the optic disc
- Blurring of the disc margins
- Filling in of the physiologic cup
- Oedema of the peripapillary nerve fibre layer
- Retinal or choroidal folds

Vascular signs

- Hyperaemia of the optic disc
- Venous dilatation and tortuosity
- Peripapillary haemorrhages
- Exudates in the disc and peripapillary area
- Infarcts of the nerve fibre

When it is due to raised intracranial pressure there may be headache, nausea and vomiting.

Ophthalmoscopic appearance of a fully developed case (Fig. 46c.1) characterized by the presence of multiple haemorrhages; retinal folds and striations; distended retinal veins; and macular oedema, star or fan.

Ophthalmoscopic appearance of subsiding papilloedema may include lessening of oedema, increased pallor of the disc, narrowing of the

arterioles, sheathing alongside the vessels at or near the disc, and finally pale and flat disc. The condition is often asymptomatic. There may be transient attacks of blurred vision and visual field defects.

FFA. See p. 521.

Differential diagnosis. Chiefly differential diagnoses are papillitis and pseudopapilloedema.

Treatment. The case is one of neuroophthalmological emergencies. Even a decompression operation may be necessary to relieve the causal pressure. Oedema starts subsiding within a fortnight of decompression.

Pseudopapilloedema

Table 46.5 shows the causes of this condition.

Table 46.5
Aetiology of Pseudopapilloedema

High hypermetropia
High astigmatism
Medullated nerve fibres
Optic neuritis
Haziness of the media
Drusen of the optic nerve
Epipapillary membrane
Bergmeister's papilla

Unilateral papilloedema

The causes are: (a) ocular or orbital cause; (b) unilateral lowered intracranial pressure; (c) blockage of the intervaginal space on one side due to inflammatory adhesion; (d) excess of the glial tissue on one optic disc; and (e) presence of optic atrophy on one side.

Toxic amblyopia

Toxic amblyopia is the result of absorption of exogenous poisons and causes bilateral effects. It involves the subchiasmal part of the visual path causing permanent visual defect.

Classification of exogenous poisons. Exogenous poisons can be classified as:

(a) Those having affinity for the papillomacular bundle and causing central or centrocaecal scotoma: methyl and ethyl alcohol; tobacco; and drugs like barbiturates, sulphanilamide, isoniazid, streptomycin, chloramphenicol, digoxin, thyroxine, lead, arsenic and aniline.

(b) Those causing a peripheral field contraction: quinine and salicylic acid.

Aetiology. Possible mechanisms are neurotoxic; neuronc degeneration following action on blood vessels; and deficiency of elements—especially vitamin B₁₂.

Pathology. They are chiefly degeneration of the ganglion cells of the retina and the nerve fibres especially in tobacco amblyopia.

Clinical features. Tobacco amblyopia can be detected amongst pipe-smokers of senile age group. It shows normal fundus or slight temporal pallor of the disc, gradual loss of central vision and central field defects. The condition is bilateral.

In acute methyl alcohol poisoning, apart from general symptoms, rapid failure of vision and blurring of the disc margins along with attenuation of the vessels are characteristics.

Later, primary type of optic atrophy sets in.

Treatment. The principles are removal of the cause, use of vasodilators, administration of vitamin B₁₂ to combat its deficiency, and use of steroids in acute stage of optic neuritis.

Optic Atrophy^{2,10,11}

Pallor of the optic disc is not necessarily atrophy. The disc appears paler than the normal pink colour of adults in infants lacking development of rich capillary plexus, in old people because of sclerosis and in high myopia. A diagnosis of optic atrophy should depend on the presence of the following signs: pallor of the optic disc, loss of visual acuity and defect in visual field.

Classification. The following classification may be suggested based on ophthalmoscopic examination: (a) consecutive, i.e. following involvement of the choroid and retina; (b)

glaucomatous; (c) vascular; (d) post-oedematous; and (e) simple

Aetiology. Table 46.6 indicates the causes of optic atrophy.

Table 46.6

Aetiology of Optic Atrophy

Glaucoma	
Optic neuritis	
Papilloedema	
Retinochoroidal affections	<ul style="list-style-type: none"> — Pigmentary dystrophy of the retina — Chorioretinitis — Chorioretinal degenerations
Vascular affections	<ul style="list-style-type: none"> — Occlusion of the central retinal artery — Giant cell arteritis — Occlusion of the internal carotid artery
Haemorrhage, usually repeated	
Toxic factors	<ul style="list-style-type: none"> — Alcohol — Tobacco — Chloroquine — Ethambutol
Metabolic disorders like diabetes mellitus	
Demyelinating diseases	
Tabes dorsalis and GPI	
Meningitis and encephalitis	
Tumours such as optic nerve glioma and meningioma	
Aneurysms	
Bony defects like craniostenosis	
Hereditary such as Leber's optic atrophy	

Pathology. The essential pathologic characteristic of an optic atrophy is loss of the axis cylinders accompanied by overgrowth of the glia and connective tissue septa. The destruction of the nerve fibres and growth of the glial tissue are proportionate to one another unless it is of long duration. In the very advanced stage there is some shrinkage of the optic nerve. The proliferated astrocytes gather in a regular fashion, but in optic atrophy caused by papillitis or following papilloedema these are distributed in a haphazard fashion. The thicker nerve fibres degenerate more rapidly than the thinner ones. In chronic simple glaucoma and chronic progressive vascular insufficiency there is only destruction of the nerve

fibres unaccompanied by any neuroglial proliferation. This results in formation of cavernous spaces occupied by oedematous fluid (*cavernous atrophy*). Optic atrophy may occur following widespread affection of the retinal ganglion cells or involvement of the intracranial or the intraorbital part of the optic nerve. So, pathologically there are three types of optic atrophy: *ascending* or Wallerian degeneration, *descending* or retrograde degeneration and *cavernous*.

Simple optic atrophy (Fig. 46c.2) (Syn. Primary or descending optic atrophy)

Aetiology. Simple optic atrophy is seen in following conditions:

- (a) Acute retrobulbar neuritis
- (b) Temporal arteritis
- (c) Vascular diseases
- (d) Meningitis
- (e) Tabes and GPI
- (f) Head injury
- (g) Pressure on the optic nerve by tumours or bone disease
- (h) Hereditary or Leber's atrophy
- (i) Chronic retrobulbar neuritis, e.g. tobacco amblyopia
- (j) Loss of blood as in haemorrhage from the uterus and stomach

Clinical features. Loss of vision or at times visual deterioration is the presenting symptom. In total optic atrophy the pupil is dilated with loss of direct and consensual reactions in the affected side, while in partial atrophy the reactions are less brisk. The degree of visual defect is proportional to the degree of involvement of the optic nerve and that of visual field. An examination of visual field may show concentric contraction with or without scotomata.

In primary optic atrophy ophthalmoscopy reveals a pale disc. The pallor is due to the destruction of the optic nerve fibres and their replacement with the glial tissues. The disc shows clear-cut margin and often a shallow cupping. The shallow cup is the result of disappearance of the nerve fibres and longitudinal shrinkage of the nerve.

The stipplings of the lamina cribrosa are seen. The minute vessels over the disc disappear. Though the arteries usually show diminished calibre the fundus around the disc appears to be normal.

Clinical features of some of the affections causing primary optic atrophy are now briefly described.

Multiple sclerosis. The temporal half of the optic disc containing the papillomacular bundle is involved in retrobulbar neuritis following multiple sclerosis. There is partial destruction of the myelin sheaths causing greyish-white colour of the disc. In multiple sclerosis, therefore, ophthalmoscopy shows greyish-white pallor of the disc, especially the temporal half. Finally there may be visual regain but there is no restoration of the colour of the disc.

Temporal arteritis. Already described on p. 327.

Vascular diseases. The vascular diseases responsible for optic atrophy include occlusion of the central retinal artery or internal carotid artery, and ischaemic optic neuropathy. Temporal or giant cell arteritis has also been included under this group.

Clinically, apart from the pale disc there is marked attenuation of the arteries. Complete loss of vision occurs in the central retinal artery occlusion.

Meningitis. The distended third ventricle may press the visual pathways and can cause an optic atrophy.

Tabes dorsalis and GPI. In tabes and GPI there is essentially inflammation of the pial sheath as evidenced by perivascular lymphocytic infiltration extending to the septa of the optic nerve. This leads to degenerative changes in the axis cylinders and myelin sheaths. In tabes there is a predominance of slowly progressive degeneration, while in GPI there is predominance of inflammatory signs. Visual loss and optic atrophy may be the presenting signs in about 20 per cent cases of tabes dorsalis. Optic atrophy occurs in about 10 per cent cases of GPI. The atrophy sets in 10 to 15 years after the infection.

Benign intracranial hypertension (pseudotumour cerebri)

Aetiology. Aetiology is unknown. Over 90 per cent of cases are found in women, often obese.

Pathology. There is decreased absorption of CSF due to dysfunction of the absorptive mechanism of arachnoid granulations.

Diagnosis. Diagnosis is based on:

- (a) Features of raised intracranial pressure
- (b) Absence of localizing neurologic signs
- (c) Inability to detect cause of intracranial pressure
- (d) Negative results of CT and MRI.

Treatment. Treatment is determined by the presence or the absence of visual loss. In the absence of visual loss, the measures include control of obesity and symptomatic treatment of headaches, most cases resolve. In the presence of visual loss acetazolamide or frusemide along with steroid may be effective, steroids are given for about 2 months with tapering for next 2 months. Optic nerve-sheath fenestration may have to be recommended in intractable headaches.

Leber's optic atrophy

Leber's optic atrophy is a bilateral optic atrophy occurring usually in adult males and showing characteristics of chronic retrobulbar neuritis. Family history, rapid onset and slow progress are indications of this affection.

Consecutive optic atrophy

Consecutive atrophy means atrophy following diseases of the choroid and retina. It is synonymous with ascending or retinitic optic atrophy. The optic disc appears waxy yellow and the vessels are attenuated.

Postneuritic optic atrophy (Fig. 46c.3)

In this condition optic atrophy occurs after optic neuritis or papilloedema. The pathological features

pituitary adenoma, craniopharyngioma, meningioma, aneurysm and inflammations.

Chiasmal lesions. The pathognomonic visual field change in a chiasmal lesion is a bitemporal hemianopia, although there are other possible variations (see p. 145).

Lesion in optic tract produces incongruous homonymous hemianopia, optic atrophy and hemianopic pupil.

Disorders of Optic Radiations and Visual Cortex

Disorders of optic radiations and visual cortex include occlusion of the middle or posterior cerebral artery. For detail, see retrochiasmal lesions on pp. 145–46.

Symptomatic Visual Disturbances

Symptomatic visual disturbances can be grouped as disturbances of visual sensation and disturbances of visual field. Disturbances of the field are described under visual field. Disturbances of visual sensation include: night blindness, amblyopia, amaurosis fugax, migraine, coloured vision, colour blindness, malingering and hallucinations.

Night blindness. The chief causes include vitamin A deficiency, pigmentary dystrophy of the retina and essential night blindness. The following flow

chart (Fig. 46.2) will be helpful to arrive at a precise diagnosis.

Occasionally it may follow other retinal and choroidal dystrophies, choroideremia, gyrate atrophy and choroidal sclerosis. If the peripheral visual field is lost, as in glaucoma and choroiditis there is also night blindness. Rarely there are functional retinal abnormalities as in essential night blindness and Oguchi's disease. Both are inherited conditions. In Oguchi's disease there is grey discoloration of the fundus which turns to normal colour if the patient remains in the dark for 2 to 3 hours, the *Mizuo's phenomenon*.

Day blindness. This blindness follows affection of the cones.

Amaurosis fugax. It is the sudden and temporary loss of vision as a result of circulatory failure.

The causes are depicted in Table 46.9.

Table 46.9

Causes of Amaurosis Fugax (Transient Loss of Vision)

Postural hypotension
Migraine
Prodromal stage of central retinal artery occlusion
Arteriosclerosis of carotid or vertebral artery
Anaemia
Ischaemic optic neuropathy
Giant cell arteritis

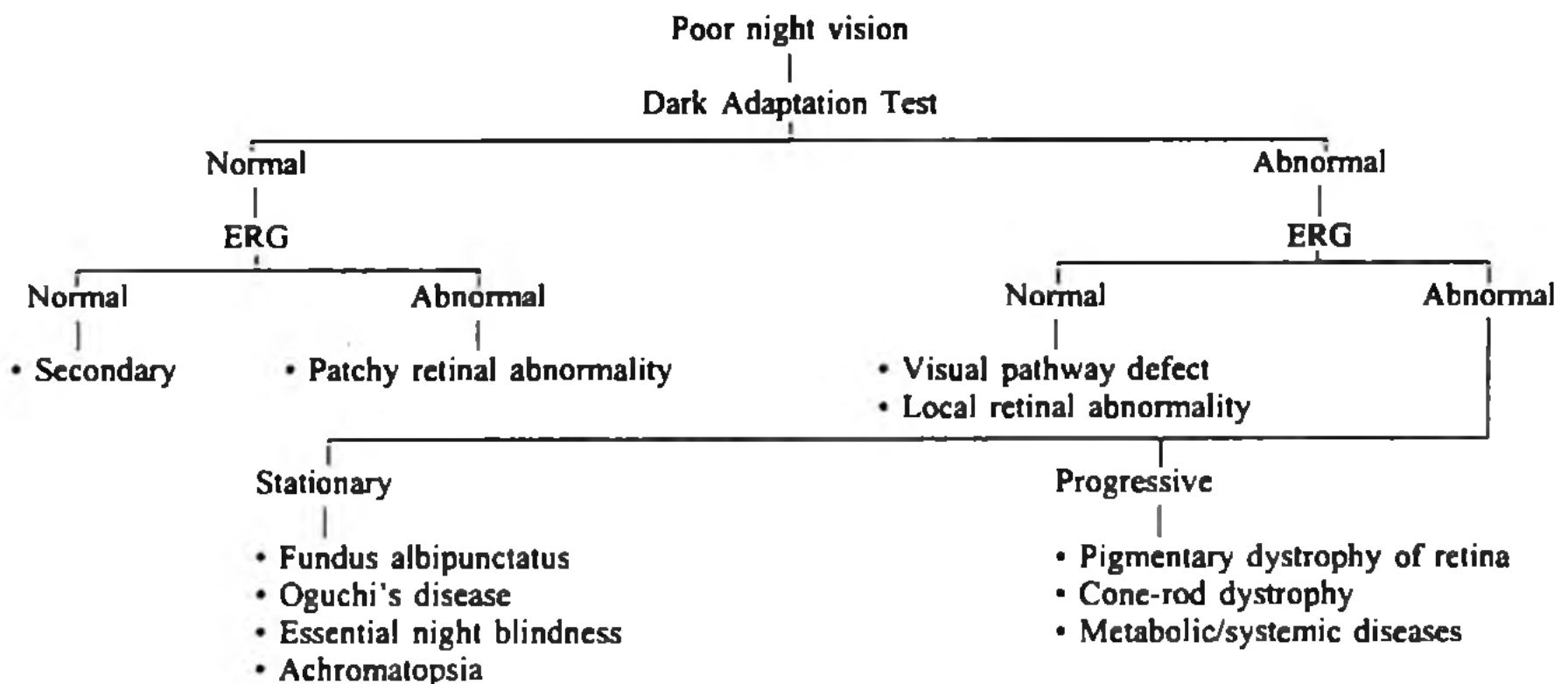


Fig. 46.2 Flow chart for diagnosis of night blindness.

Coloured vision. It is also called *chromatopsia*. The objects appear coloured—red, yellow, blue or green. Red vision or *erythroptopsia* occurs following vitreous or retinal haemorrhage, cataract extraction and iridectomy. Yellow vision or *xanthopsia* occurs in jaundice; after taking drugs like atebriane, santonin, metrazole, streptomycin and sulphonamides. Blue vision or *cyanopsia* occurs following therapy with digitalis, atebriane and in tabetic optic atrophy. Green vision or *chloropsia* occurs after griseofulvin and digitalis therapy.

Acquired colour vision defect

The causes are listed in Table 46.10.

Table 46.10

Causes of Acquired Colour Vision Defect^a

Optic neuritis
Senile macular degeneration
Pigmentary dystrophy of retina
Glaucoma
Myopia
Toxic amblyopia
Chorioretinitis
Following drugs like chloroquine, indomethacin, etc.

Migraine^{2,13}

Migraine is a paroxysmal, recurrent, unilateral hemicrania associated with visual disturbance and vomiting, the condition showing a strong hereditary tendency and occurring in tense and obsessed young people, especially in females with certain predisposing factors like emotion or anxiety, fatigue, digestive upsets and insomnia.

Aetiology. There are possibly vasomotor changes, i.e. vasodilatation followed by vasoconstriction in the brain. There may be excessive autonomic nerve stimulation. Disturbance of serotonin metabolism may occur.

Clinical features. Prodromal symptoms like drowsiness and lassitude may be the early symptoms, while at times the subject feels exceptionally well. The patient has a feeling of impending premonition or *aura*. The typical feature

is the appearance of visual disturbance namely *scintillating scotoma*. These are brilliant coloured shimmering spectral lights expanding towards the periphery and finally fading into a whirling confusion of light. The state lasts for about 15 to 20 minutes. This is followed by intense headache associated with nausea or vomiting.

Ophthalmoplegic migraine. This is a type of migraine accompanied by ocular motor nerve anomalies. In a classic migraine, the neurologic symptoms precede the onset of headache. In ophthalmoplegic type, the ocular motor involvement commonly occurs at the height of headache or just afterward. It occurs in young children.

Basilar migraine. It is common in adolescent girls. Vasospasm involving the basilar artery produces such symptoms as hemianopia, diplopia, ataxia, paresis and paraesthesia.

Treatment. Elimination of predisposing factors appears to be an important consideration.

The drugs for alleviating an acute attack include ergotamine tartrate (1 mg tablet), propranolol hydrochloride (10, 40, 80 mg tablets), flunarizine hydrochloride (5, 10 mg tablets) and tolfenamic acid (200 mg capsules).

Malingering

Wilful pretension of disability sometimes concerns an ophthalmologist. In suspect patient the following tests can be done to detect malingering.

- Place a 0.25 D lens, concave or convex, in front of the so-called defective eye and a +10 D lens in front of the good eye. If there is improvement of distant visual acuity, malingering is suspected.
- The subject is asked to look at a light while he or she wears in a trial frame a prism with base downwards in front of the good eye. If he or she sees two lights malingering is proved.
- Coloured test types alternating green and red, the FRIEND test, are used and the patient is asked to read these letters while wearing a pair of red-green goggles, red

Oops, page PA366 was not yet downloaded :(

Synergistic and antagonistic muscles. In certain ocular movement the eye muscles may act together to cause similar and dissimilar effects, for example SR and IO are synergists (agonists) for elevation, but antagonists for torsion.

Yoke muscles. In co-ordinated eye movements, a muscle of one eye works in unison with a muscle of the opposite eye in six cardinal directions of gaze, namely dextroversion, laevoversion, dextroelevation, laeoelevation, dextrodepression and laevodepression.

Angle kappa (Fig. 47.1). It is the angle between the visual axis and the central pupillary line.

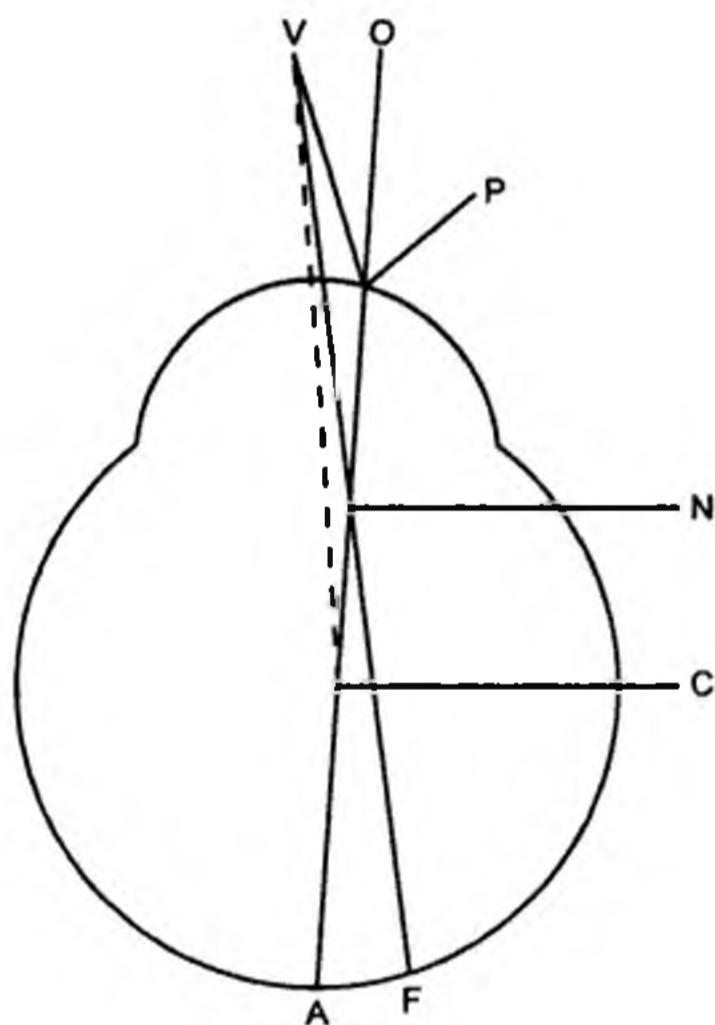


Fig. 47.1 The angle kappa, alpha and gamma. Right eye. OA, the optic axis; VF, the visual axis; P, the midpupillary point; N, the nodal point; C, the centre of rotation; OPV, the angle kappa, ONV, the angle alpha and OCV, the angle gamma.

Normally, it is zero, because while fixing a light both of them coincide. When the visual axis is nasal to the centre of the pupil, there is *positive* angle kappa giving an appearance of exophoria; when temporal it is called *negative* angle kappa, the appearance simulating esophoria.

Angle alpha (Fig. 47.1). It is the angle formed at the nodal point between the optic and visual axes.

Angle gamma. It is the angle formed between the optic axis and the line connecting the centre of rotation with the object of fixation.

Listing's plane. The plane that contains the eyeball in primary position.

Axes of Fick. Each eye has three major axes—horizontal, vertical and anteroposterior. The centre of rotation of the eyeball lies about 13 mm behind the central cornea.

Hering's law of ocular innervation. There is equal and simultaneous flow of innervation from the brain to the muscles of the two eyes during all voluntary movements.

Sherrington's law of reciprocal innervation. While the synergistic muscles are innervated, the antagonists are innervationally inhibited. For example, during convergence both medial recti are innervated and lateral recti are inhibited.

Angle of deviation. It is the objective angle of squint.

Angle of anomaly. It is said to be present if there is a difference between the objective angle of squint and the subjective angle, the latter being the angle at which superimposition of two pictures in a synoptophore is done by the patient.

Optic axis. It is the line which passes through the centre of curvatures of all refractive surfaces (Fig. 47.1).

Pupillary axis. It is a line perpendicular to the cornea passing through the centre of the pupil.

Visual axis. It is a line from the point of fixation to the fovea passing through the nodal point of the eye (Fig. 47.1).

Fixation axis. This is the line connecting the point of fixation to the centre of rotation.

Ocular movements (Table 47.1) may be of two types—voluntary and reflex. Reflex movement is subdivided into optic and postural.

Table 47.1

Classification of Ocular Movements (Fig. 47.2)

Monocular

1. Elevation
2. Depression
3. Adduction
4. Intorsion
5. Extorsion

Binocular (vergence and version)

1. Dextroversion
2. Laevoversion
3. Sursumversion
4. Deorsumversion
5. Dextrocycloversion
6. Laevocycloversion
7. Convergence
8. Divergence
9. Incyclovergence
10. Excyclovergence
11. Right sursumvergence
12. Right deorsumvergence













RIGHT EYE		LEFT EYE		
LR		MR		Dextro version
MR		LR		Laevo version
SR		IO		Dextro elevation
IO		SR		Laevo elevation
IR		SO		Dextro depression
SO		IR		Laevo depression

Fig. 47.2 The cardinal directions of gaze.

Strabismus or Squint⁹

Strabismus is a condition in which the visual axes are not straight in the primary position of the eyes.

The eye which is directed toward the object of fixation is called the *fixing eye*, and the eye which deviates from it is called the *squint eye*.

A strabismus may be constant or intermittent, manifest or latent, unocular or alternating. A manifest squint, or heterotropia or tropia may be concomitant or non-paralytic, and incomitant or paralytic. A concomitant squint may be: (a) horizontal—convergent or esotropia and divergent or exotropia; (b) vertical—hypertropia and hypotropia; and (c) occasionally torsional. Latent squint is also called heterophoria or phoria.

A squint may be periodic, e.g. the degree of squint occasionally varies depending on the distance of the object of fixation. Sometimes there may be an *apparent* or *pseudostrabismus*. The examples of this condition are as follows. A large positive angle alpha simulates esotropia, and a large negative angle alpha simulates exotropia. An epicanthus simulates an esotropia, while wide pupillary distance mimicks an exotropia.

In all cases of strabismus, there are varying degrees of *motor* and *sensory* adaptations. Sometimes there are some motor sequelae as in incomitant strabismus. Motor adaptations may be primary and secondary deviations, as well as compensatory head postures. These head postures may be adopted by the patients to overcome diplopia and minimise confusion. Secondary adaptations include diplopia, confusion, suppression, amblyopia, eccentric fixation and abnormal retinal correspondence (ARC).

Diplopia⁹

Binocular single vision is due to images falling on the corresponding points of the normal retinae.

Diplopia occurs when the visual axes are not directed towards the same object. Diplopia though usually binocular may also be unocular. The causes are shown in Table 47.2.

Diplopia caused by extrinsic muscle palsy may be horizontal, vertical and torsional. When the two images are side by side it is called horizontal diplopia; it may be *homonymous* when the false image is on the same side of the deviating eye,

Table 47.3

Contributory Factors for Development of Amblyopia⁵

Strabismus
Uncorrected isometropia or anisometropia
Uncorrected astigmatism
Combined anisometropia and strabismus
Visual deprivation
Congenital cataract
Congenital ptosis
Corneal opacity
Structural/pathological causes
Macular/perimacular affections
Nystagmus
Coloboma
Achromatopsia
Optic nerve affections
Malingering/hysteria

Table 47.4

Classification of Amblyopia

According to association	With strabismus With anisometropia (straight amblyopia)
According to state of fixation	With centric fixation With eccentric fixation
According to state of development	Amblyopia of arrest Amblyopia of extinction Amblyopia exanopsia
Use of the term in certain clinical states	Toxic amblyopia Hysterical amblyopia

Table 47.5

Relation of Visual Acuity with Age

Age	Visual acuity
Before 1 year	Approximately 6/60
By the age of 2 years	Approximately 6/12
By the age of 3 years	Approximately 6/9
By the age of 5 years	6/6

When vision in an eye is completely impaired in early life as in unioocular cataract or ptosis, remains subnormal even after treatment, the amblyopia is called *amblyopia ex anopsia*. It is also called *stimulus-deprivation amblyopia*.

Strabismic amblyopia. Amblyopia is commonly seen with constant unioocular strabismus. It is the

result of visual inhibition due to overlapping of different foveal images reaching the visual centres. An eccentric fixation is usually found to be associated.

Anisometric amblyopia is more common in anisohypermetropia than in anisomyopia. Generally, the greater the degree of anisometropia, the deeper the amblyopia. A 50 per cent incidence is seen in hypermetropic anisometropia of +2 D and in myopic anisometropia of -5 D. In hypermetropic anisometropia the least hypermetropic eye is used for fixation at all distances, while the more hypermetropic one never receives a clear image. In myopic anisometropia, the less myopic eye is utilized for distance and more myopic one for near.

Diagnosis. Diagnosis depends upon some investigations (Table 47.6).

Table 47.6

Investigations for Diagnosis of Amblyopia

History
Examination of eye
Refractive status
Ophthalmoscopy
Visual acuity
Fixation pattern
Crowding phenomenon
Neutral density filter
Titmus stereotest

Treatment.^{5,12} The various modalities include:

Correction of refractive error is essential for providing stimulus for adequate visual acuity.

Occlusion. Patching is done with leucoplast or plastic. An occlusion may be total or partial, orthodox or inverse. In orthodox (conventional) occlusion, the normally-fixing eye is occluded during all working hours for 2 to 3 months except in infants in whom it is advocated every third or fourth day in order to promote use of the amblyopic eye. Repeated check-up of visual acuity is done at an interval of 4 to 6 weeks, and if there is no visual improvement within 6 to 12 months this treatment is discontinued.

Disadvantages of conventional occlusion are:¹⁰

(a) Some patients cannot tolerate complete occlusion of the sound eye for prolonged period.

(b) There is developmental arrest of binocular vision because of total dissociation of both eyes.

(c) Below the age of two years there is likelihood of precipitating stimulus-deprivation amblyopia.

Penalization aims at forced use of the amblyopic eye. This is done by atropinization of the good eye to discourage its use for near, the near fixation is taken over by the amblyopic eye. This is indicated in anisometric amblyopia without squint. This is tried for 3 to 4 months and there is regain of visual acuity at which occlusion is feasible.

Red-filter treatment is indicated in gross amblyopia with eccentric fixation.

Haidinger's brush appreciation indicates foveal fixation. This may be tried for 3 to 4 weeks by which time visual acuity improves to a level which is suitable for occlusion.

CAM stimulator (Fig. 47.3) is used for 7 minutes daily. Visual acuity improves after 2 to 4 sessions



Fig. 47.3 CAM visual stimulator.

daily or weekly. The visual areas in the brain can respond specifically to rotating gratings of a certain size and spatial orientation since these areas are highly tuned and receptive to such frequencies. In an amblyopic eye an effort has been made to stimulate all the visual neurons by stimulator made up of rotating gratings.⁶

Pleoptics. Active foveal stimulation is indicated in the treatment of eccentric fixation.

Surgical treatment is needed for correction of squint.

Eccentric viewing

Eccentric viewing is a stage midway between central and eccentric fixation.

Eccentric fixation

Eccentric fixation is a condition when the amblyopic eye moves to take up fixation with a point other than the fovea.

The case may be roughly diagnosed by cover test. Either there is no movement of the deviating eye to take up fixation, or there is slight movement of the deviating eye when the fixing eye is covered.

Now-a-days it is accurately diagnosed by visuscope and projectoscope, euthyscope and co-ordinator. Malik and his associates¹⁵ have proposed the following classification using projectoscope with Links star

- (a) Normal or foveal
- (b) Unsteady foveal
- (c) Erratic
- (d) Parafoveal
- (e) Paramacular
- (f) Centrocaecal
- (g) Paracaecal
- (h) Divergent
- (i) Nonfixing.

Treatment. Occlusion should be attempted as the first step. It tends to replace eccentric fixation by foveal fixation. In case of children below the age of 4, a total occlusion of the normally-fixing eye is done for 3 days. After 3 days re-assess the fixation behaviour. If visuscope shows still eccentric fixation, occlusion must be reversed and placed over the amblyopic eye. If the affected child is between 4 and 8 years occlusion of the affected eye, i.e. inverse occlusion, is indicated. Occlusion should be constant and total, with monthly reassessment, for a period extending up to 6 months.

Oops, page PA373 was not yet downloaded :(

(b) Direct injury—causing haemorrhage in the muscle substance, fibrosis following damage or haemorrhage and damage to muscle insertion

(c) Myopathy—may be ocular, thyrotoxic, carcinomatous or iatrogenic following certain drugs, e.g. steroids

(d) Ocular myositis

(e) Myasthenia gravis.

Relative ocular palsy

'Relative' ocular palsy is a result of an orbital lesion. Causes of relative ocular palsy are:

(a) Injury due to damage to the supporters of the eyeball

(b) Fracture of the floor of the orbit and

(c) Space-occupying lesions in or near the orbit such as haemorrhage, endocrine exophthalmos and neoplasm.

Ophthalmoplegia

Ophthalmoplegia is paralysis of the eye muscles. Three common types are:

(a) External—if only the extrinsic muscles are affected

(b) Internal—if only the intrinsic muscles are involved

(c) Total—all the extrinsic and intrinsic muscles are affected.

Certain other forms of ophthalmoplegia which are occasionally met with are:

Nuclear ophthalmoplegia is paralysis of the ocular muscles due to lesion of the third cranial nerve nuclei. They are more often bilateral.

*Acute ophthalmoplegia*¹ may follow these conditions:

(a) Leaking aneurysm of the internal carotid artery or circle of Willis

(b) Ophthalmoplegic migraine

(c) Orbital cellulitis.

Painful ophthalmoplegia may be caused by the following reasons:

(a) Diabetes

(b) Pseudo-tumours of the orbit

(c) Ophthalmoplegic migraine

(d) Sphenoidal fissure syndrome

(e) Orbital apex syndrome

(f) Cavernous sinus thrombosis

(g) Giant cell arteritis

(h) Pituitary apoplexy

(i) Gradenigo's syndrome

(j) Aneurysm of the posterior communicating artery.

Ophthalmoplegic migraine or episodic ophthalmoplegia is characterized by recurrent attacks of headaches associated with paralysis of the third, fourth and sixth cranial nerves. The incidence of involvement of the third cranial nerve is the most common and it persists for days or weeks after the attack. It is often unilateral and tends to become permanent.

Acute and subacute ophthalmoplegia

Aetiology. (a) Acute or subacute ophthalmoplegia may follow acute and subacute inflammatory diseases such as encephalitis, meningitis, sinusitis, tuberculosis, and meningovascular syphilis. Encephalitis of the brainstem leads to nuclear ophthalmoplegia. Basal meningitis (syphilitic or tuberculous) may cause ocular palsies, especially a sixth nerve palsy owing to its long course. Intracranial sinusitis affecting the cavernous sinus causes ocular motor palsies with contralateral sixth nerve palsy. Meningovascular syphilis causes protein manifestations including involvement of the ocular motor nuclei or nerves. The third nerve is most commonly involved, the sixth nerve is less commonly involved, and involvement of the fourth nerve is rare.

(b) In diabetes the common cause is neuritis of the ocular motor nerves.

(c) Vascular lesions include arteriosclerosis, subarachnoid haemorrhage and cerebral aneurysms. Vascular lesions play a main role in the aetiology of ophthalmoplegia. They are as follows.

Arteriosclerosis. In arteriosclerosis a hardened artery tends to compress the ocular motor nerves. It may be remembered that:

(a) the third nerve runs in the narrow space between the superior cerebellar and the posterior cerebral arteries; (b) the fourth nerve crosses over the posterior cerebral artery; and (c) and the sixth

nerve bends sharply round the middle cerebellar artery and then while proceeding forwards runs intimately along the basilar artery. Alternatively, there may be thrombosis or haemorrhage, leading to necrosis and degeneration, finally causing impaired vascular supply.

Subarachnoid haemorrhage. This may be traumatic or nontraumatic in nature and the favourite site of haemorrhage is the anterior half of the circle of Willis. It causes bilateral ocular palsies especially affecting the third and sixth nerves, along with papilloedema and retinal haemorrhages.

Cerebral aneurysms. Aneurysms occurring in connection with the circle of Willis are of two types—subclinoid (or intracavernous) and supraclinoid. Subclinoid type shows involvement of the ocular motor nerves and trigeminal nerve.

(d) An intracranial space-occupying lesion causes ocular palsy either due to direct pressure by the tumour or indirect displacement of the brain tissue

(e) Ophthalmoplegia rarely follows trauma in which peripheral lesions are common and exogenous poisons, e.g. alcohol and drugs.

Chronic and progressive ophthalmoplegia

Chronic and progressive ophthalmoplegia is chiefly due to multiple sclerosis, sometimes due to tabes and GPI. Twenty-five to thirty-five per cent of ocular palsies are ascribed to multiple sclerosis. Not uncommonly the ocular motility disturbance is of a fleeting character.

Paralytic Squint^{9,17}

There is variable deviation with impairment of the movement in the line of the action of the affected muscle.

Clinical features. Diplopia is the most common symptom, in which the false image is less distinct than the true image. The false image is seen by the squint eye and true image by the fixing eye.

Vertigo is sometimes present. It is partly due to diplopia and partly due to false projection. Nausea and uncertain gait are occasionally present.

Deviation. When the eyes are moved towards the field of action of the paralyzed muscle, the affected eye will lag, but the unaffected eye moves normally. There are two varieties of deviation—primary and secondary. *Primary* deviation is the deviation of the affected eye when the normal eye is fixed on a distant object straight ahead. *Secondary* deviation is the deviation of the normal eye in a corresponding direction when the normal eye is covered and the affected eye is fixed on a distant object. Secondary deviation is greater than primary deviation in a paralytic squint but they are equal in concomitant squint. The impulse of innervation required for movement is equally distributed between the paralysed and the synergistic muscles of the unaffected eye, the latter causing overaction.

Compensatory head posture. Compensatory head posture is evident for allaying diplopia if the deviation is not gross. The patient turns his or her head toward the direction of the main action of the paralysed muscle.

There are three components:

(a) a *head turn*—occurring in the direction of the action of the paralysed muscle;

(b) a *chin elevation or depression*—causing compensation for the defective main action of the muscle; and

(c) a *head tilt* to the right or left shoulder which neutralises the vertical and torsional displacement by lowering the image of side towards which there is head tilting.

In case of horizontally-acting muscle, only head turn occurs, while in vertically-acting muscle more than one component are present.

Limitation of movement. It occurs in the affected eye in the direction of action of the paralysed muscle. When the patient is asked to point quickly at an object in front of him or her while closing the sound eye, he or she will direct his or her finger to the side of the object corresponding to the field of action of the paralysed muscle. This is what is called *false projection* and is due to increased innervation for the nerve supplying the paralysed muscle in an attempt to act forcibly.

Complications and sequelae. (a) Overaction of the contralateral synergist; (b) contracture of the ipsilateral antagonist; and (c) secondary palsy of the contralateral antagonist.

Two examples are cited. In a left LR palsy, there is: (a) overaction of the right MR; (b) contracture of the left MR; and (c) secondary palsy of the right LR. In a left SO palsy, there is: (a) overaction of the right IO; (b) contracture of the left IO; and (c) secondary palsy of the right SR.

Treatment.¹¹ Since the aetiology can rarely be pinpointed treatment is rarely feasible.

In recent cases, occlusion of the affected eye prevents diplopia. Otherwise at times orthoptic exercises or suitable prisms afford some relief.

Surgery is only possible when there is no obvious evidence of paralysis. The operation is indicated in bilateral symmetric parietic squints usually and sometimes in unilateral case. Surgery usually consists of recession of the synergistic muscle in the other eye to equalize both eyes. Then the case is to be watched for some months. If necessary, a recession of the antagonistic muscle of the affected eye with an advancement of the paralysed muscle is advised. Rarely, transplantation of a healthy muscle in whole or in part is indicated.

Cranial Nerve Palsy^{17,20}

Three cranial nerves, namely the oculomotor (III), trochlear (IV) and abducent (VI) may be involved simultaneously or singly. The condition may be congenital or acquired. The causes of acquired palsy are shown in Table 47.8.

The third nerve palsy

A congenital palsy never involves the sphincter pupillae and ciliary muscle, while acquired palsy may involve them. It is characterized by ptosis, divergent squint because of unopposed action of the LR and limitation of the ocular movements except abduction and intorsion. Occasionally slight proptosis is due to the lack of tone of the paralysed

Table 47.8

Aetiology of III, IV and VI Cranial Nerve Palsy

Oculomotor
Intracerebral—tumours, basilar artery occlusion, secondary to migraine (vasospasm), Benedict's syndrome and Weber's syndrome
Intracranial—rupture of aneurysm at the base of the brain, migraine and multiple sclerosis
Cavernous sinus syndrome
Superior orbital fissure syndrome
Orbital apex syndrome
Trauma
Trochlear
Intracerebral—haemorrhage in the roof of midbrain, thrombosis of nutrient vessels, aneurysm and tumours
Intracranial—trauma, tumour or aneurysm
Syndromes—cavernous, superior orbital fissure and orbital apex
Miscellaneous—displacement of trochlea due to trauma or operation upon nasal sinuses and adherence between the SR and the SO (adherence syndrome)
Abducent
Intracerebral—thrombosis or aneurysm of nutrient vessels, tumours, Wernicke's encephalopathy, Millard-Gubler and Foville's syndromes
Intracranial—meningitis, skull fracture, carotid artery aneurysm, cerebellopontine angle tumour, increased intracranial pressure, etc.
Syndromes—cavernous sinus, superior orbital fissure and orbital apex

muscles. Also there are dilated and fixed pupil, and paralysis of accommodation in case of acquired palsy.

The fourth nerve palsy

An isolated fourth nerve palsy may occur or it may be involved along with the third nerve. A congenital palsy often presents with compensatory head posture. This consists of a head tilt to the unaffected side, head turn towards the unaffected side and the chin lowered. Tilting the head towards the parietic side causes an elevation and adduction of the affected eye (*Bielschowsky's sign*).

In simultaneous involvement of the third and fourth nerves, examination is done by requesting the patient to look downward. Normally the radial vessels at the upper limbus are watched for intorsion by the SO and extorsion will be observed on attempted elevation.

The sixth nerve palsy

The sixth nerve palsy is the most common of all congenital ocular palsies. Twenty-five per cent of congenital palsies are bilateral. Abduction is limited, the face is turned towards the paralysed side and the eye is turned inwards.

Palsy Involving Extrinsic Ocular Muscles (Table 47.9)

Lateral rectus palsy. This may be congenital perhaps following birth trauma or acquired. Because of its long and exposed intracranial course, the sixth cranial nerve is especially vulnerable to any affection producing raised intracranial pressure. The affected eye is turned inwards and it shows limited abduction. The face is turned towards the affected side.

Inferior rectus palsy. The frequent cause of inferior rectus palsy is a blow-out fracture of the floor of the orbit. The eye is turned upwards and slightly outwards. During abduction the downward movement is limited. The head is tilted to the normal side while the face is rotated towards the affected side. The chin is raised.

Superior oblique palsy. The cause of superior oblique palsy is either an acquired lesion, e.g. displacement of the trochlea during operation on the frontal sinus or occasionally congenital insufficiency. The eye is turned upwards and slightly inwards, while the downward movement is restricted during adduction. The chin is depressed, and the head is tilted and turned towards the normal side.

Inferior oblique palsy. The eye is turned downwards and slightly inwards, while restriction

Table 47.9

Distinguishing Features of Extrinsic Muscle Palsy

Muscle paralysed	Type of squint	Type of diplopia	Diplopia most marked while looking toward
Right LR	Right convergent	Horizontal	Right
Left LR	Left convergent	Horizontal	Left
Right MR	Right divergent	Horizontal	Left
Left MR	Left divergent	Horizontal	Right
Right SR	Left hypertropia	Vertical	Up and right
Left SR	Right hypertropia	Vertical	Up and right
Right IR	Right hypertropia	Vertical	Down and right
Left IR	Left hypertropia	Vertical	Down and left
Right SO	Right hypertropia	Vertical	Down and left
Left SO	Left hypertropia	Vertical	Down and right
Right IO	Left hypertropia	Vertical	Up and left
Left IO	Right hypertropia	Vertical	Up and right

Medial rectus palsy. The eye is turned outwards with restriction of abduction. The face is turned towards the normal side.

Superior rectus palsy. This may be congenital or acquired. The eye is turned downwards and slightly outwards, and it shows restriction of elevation when the eye is abducted. The head is turned towards the affected side, the chin is raised and there is head tilting towards the normal side. It is present with ptosis.

of movement occurs in elevation during adduction. The chin is raised and head turned towards the normal side, while head tilting occurs towards the affected side.

Congenital Paralytic Strabismus

Congenital paralytic strabismus is caused by malinsertion, defective innervation, fibrosis, or occasionally absence of the muscle. Two classical examples are Duane's retraction and superior

oblique syndromes. The various features are given in Table 47.10. Such a case may compensate with or without compensatory head posture. If not compensated it finally causes a concomitant squint. The compensated group again may be decompensated either in childhood or in adult life leading at first to intermittent and then to constant squint.

convergence in excessive hypermetropia. Initially there is intermittent esotropia at the age of 2½ to 3 years when the child starts using the eyes for discerning near objects.

Table 47.11 gives a classification of convergent squint (esotropia).

The characteristics of fully accommodative

Table 47.10
Differentiation between Congenital and Acquired Paralytic Squint

Points	Congenital	Acquired
Onset	From birth	Recent
Aetiology	Rarely known	Definite
Onset of symptoms	Rare and indefinite	Definite symptoms especially diplopia
Diplopia	Intermittent or only in certain directions of gaze	Almost invariable
Compensatory head posture	Intermittent (a) Present, but the subject is not aware of it (b) Ocular torticollis	Grossly evident if the angle of deviation is great The patient is fully aware of its presence
Angle of deviation		
(a) Primary	May be large	May be slight
(b) Secondary	Slightly greater than that of primary deviation	Usually much greater than that of primary deviation
Suppression	Always present	Absent initially, but may be present later
Facial asymmetry	Tendency of facial asymmetry	No tendency
Treatment	Surgery followed by postoperative orthoptics	Conservative treatment and occasionally surgery after about 6 months

Concomitant Squint⁹

In concomitant squint the deviation of the visual axes is constant irrespective in which direction the eyes are moved. It may be horizontal, vertical and torsional, the latter two being rare.

A horizontal squint may be convergent (esotropia) or divergent (exotropia). Occasionally there may be cyclovertical deviations.

Esotropia (Fig. 47.5)

Esotropia is more common in childhood and most frequent in hypermetropes. In *convergence-excess type*, the deviation is significantly greater on near than on distant fixation (Table 47.11).

Fully accommodative esotropia. There is a synkinetic association between accommodation and

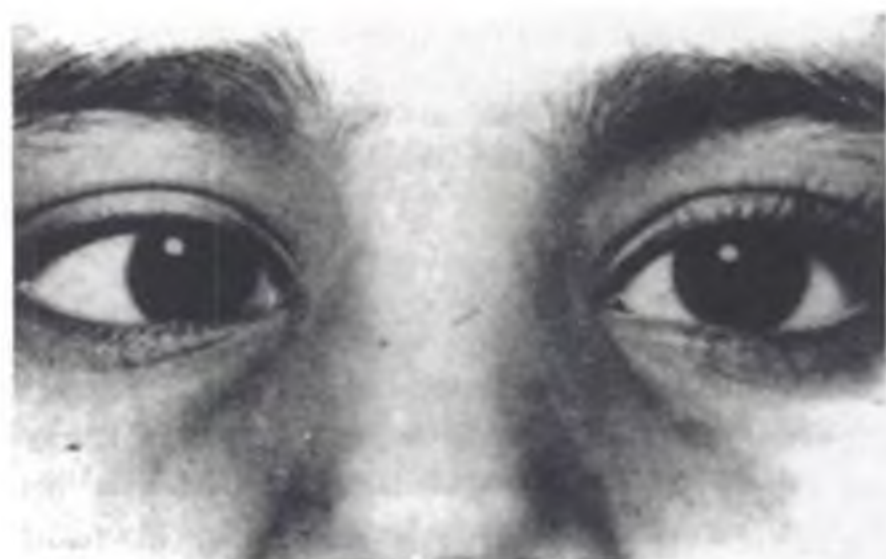

Fig. 47.5 Right esotropia.

esotropia are:⁸ (a) the age of onset is between 2½ to 3 years; (b) cover test without glasses shows constant tropia or the eyes are always equal in both eyes; (c) full hypermetropia correction leads to elimination of tropia with BSV and BVA; (d) AC/A ratio is normal; (e) NPA is normal with

Table 47.11
Classification of Convergent Squint

Accommodative
Fully accommodative (refractive or pure)
Partially accommodative (mixed)
Atypical
Hyperaccommodative (hyperkinetic)
Hypoaccommodative (hypokinetic)
Nonaccommodative
Essential (infantile)
Acquired
Convergence-excess
Divergence-weakness
Basic
Microtropia
Secondary and consecutive

glasses; (f) NPC is to nose with glasses; and (g) the angle is decreased usually after atropinization.

Partially accommodative esotropia. Three subtypes have been described: (a) with normal binocular function; (b) without normal binocular function; and (c) with very weak or anomalous binocular function.

There is manifest esotropia without glasses but substantial elimination of esotropia by wearing hypermetropic correction. This type is designated as 'partial' because of the fact that elimination of accommodation and hypermetropic correction do not fully correct the deviation.

Atypical accommodative esotropia. In this type there is no deviation on distant fixation provided there is no undue effort of accommodation.

In hyperaccommodative type, refractive error plays minor or no role. There is high AC/A ratio.

In hypoaccommodative type, there is no significant refractive error. Accommodation is weak so that the near point is remote, resulting in increased impulses for accommodation and associated exaggerated convergence.

Essential (infantile) esotropia shows the following characteristics:

(a) Onset of deviation occurs before 6 months of age.

(b) The angle of deviation is more than 15 to 30°

(c) Initially the deviation is alternating (*essential alternating convergent squint*)

(d) The angle of deviation is same for both distance and near

(e) Usually there is low degree of hypermetropia

(f) It is commonly associated with amblyopia and defective abduction

(g) There is poor binocular single vision.

Convergence-excess esotropia shows high AC/A ratio, i.e. excessive convergence occurring after a given amount of accommodation, and the deviation is larger for near.

Divergence-weakness esotropia. The deviation is greater on distant fixation than on near fixation. There is low AC/A ratio. It is commonly intermittent.

Basic esotropia. This may develop after 6 months of age. The angle of deviation is same for both distant and near fixation.

Exotropia (Fig. 47.6)

Exotropia is rather common in myopes, often with a late-age onset.

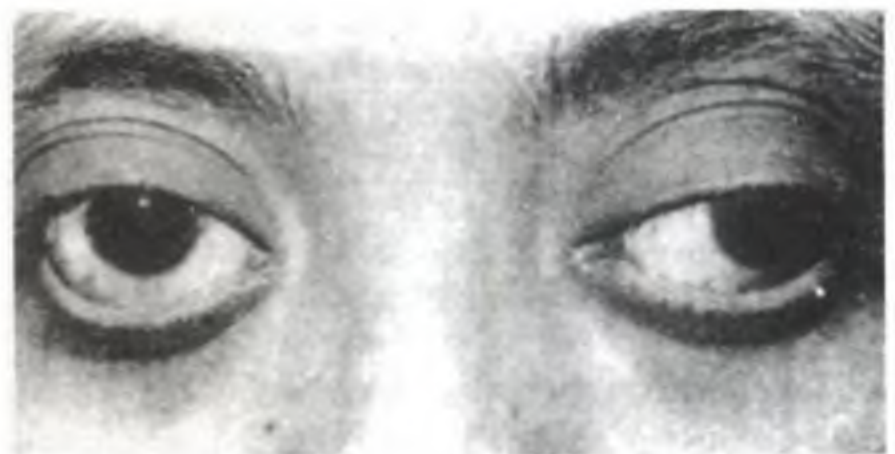

Fig. 47.6 Left exotropia.

Classification. Refer to Table 47.12.

Table 47.12
Classification of Divergent Squint (Exotropia)

Primary
Divergence-excess
Convergence-weakness
Intermittent
Basic
Secondary
Due to sensory obstacle, e.g. opacity of any media
Due to motor obstacle, e.g. paresis of SR or IR
Consecutive

eccentrically-fixing eye. Response to treatment of amblyopia is best before the age of 6 years.

In any severe case of amblyopia, a full course of occlusion is necessary before undertaking orthoptic treatment.

Orthoptic. This aims at overcoming any suppression and ensuring strong fusion and easy stereopsis. Orthoptic exercises may be prolonged and require the cooperation of the child. It may be curative in certain cases such as in a less than 10° deviation and recently developed squint, provided it is carried out systematically and thoroughly. This mode of treatment is a valuable adjunct to the surgery of squint.

Operative. Operation is inevitable: (a) when the angle of squint is 10° or more after correction of refractive error; (b) when orthoptic training has failed; (c) when the child is four or five years old and able to co-operate in postoperative orthoptic treatment; and (d) in all age-groups for cosmetic reason. For details refer to chapter on 'Ophthalmic Surgery'.

Tables 47.15 and 47.16 give a summary of methods of treatment of esotropia and exotropia.

Table 47.15

Treatment of Different Types of Esotropia

Type of esotropia	Mode of treatment
Fully accommodative	Full correction of hypermetropia Occasionally bifocals or 0.125 per cent or 0.325 per cent ecothiophate iodide
Convergence-excess Divergence-weakness	Additional near vision glasses during reading and orthoptic
When all methods fail to control	

Vertical Squint

Classification. Vertical squint is classified as:

- (a) Primary
 - (i) Congenital
 - (ii) Acquired

Table 47.16

Treatment of Different Types of Exotropia

Surgical, in
Large angle of deviation
Divergence-excess type—bilateral LR recession
Basic type—resection of MR + recession of LR on the same eye
Constant uniocular—surgery for cosmetic reason
Orthoptic, in
Convergence-weakness type

(b) Secondary

- (i) Elevation in adduction
- (ii) Elevation of divergent eye

Primary. This may be congenital or acquired. The congenital deviation follows muscle palsy or musculofacial anomaly. The acquired deviation is due to palsy of one or more of the vertically acting extrinsic muscles.

Secondary vertical squints results due to associated horizontal squint, the latter being the predominant of the two.

Cyclovertical deviations^{9,18}

Cyclovertical deviations are associated with a concomitant squint—convergent or divergent. When the eyes are moved directly above or below from the primary position, normally there is no obvious alteration of the relative position of the eyes.

There are five groups of cyclovertical deviation:

- (a) A phenomenon
- (b) V phenomenon
- (c) X phenomenon
- (d) Y phenomenon
- (e) Inverted Y (or lambda) phenomenon.

These are discussed now.

AV phenomenon. In the A phenomenon there is decreased separation of both eyes on elevation, but increased separation of the eyes on depression. In the V phenomenon there is increased separation of both eyes on elevation and decreased separation of the eyes on depression.

Esophoria. It is usually due to an excess of convergence, but may also be due to divergence insufficiency more marked for distant vision. It is usually associated with excessive accommodation and hence common in hypermetropia.

Exophoria. It is usually due to divergence excess more marked for distant vision, and may be due to convergence insufficiency. It is more common in myopes and occasionally in presbyopes. Only decompensated phorias produce symptoms, vague visual upsets and asthenopia.

Investigations include: (a) testing visual acuity; (b) check-up of refraction; (c) cover test; (d) ocular movements; (e) the Maddox wing; (f) the Maddox rod; (g) the measurement of convergence and accommodation on the RAF near point rule; and (h) use of a major amblyoscope.

Treatment. Only symptom-producing phorias require treatment.

Correction of refractive error is the chief treatment, while other measures may include improvement of the general health, orthoptic exercises and rarely surgery. The most effective and simplest exercise in case of convergence insufficiency is a pencil held steadily in one hand and gradually brought closer to the nose until it appears double. This is repeated until there is shortening of the distance at which diplopia occurs. Bilateral recession of both medial recti is advised in esophoria of convergence-excess type. Resection of one or both lateral recti is advocated in esophoria of divergence-weakness type. Symmetrical recession of both lateral recti is done in exophoria of divergence-excess type, whereas resection of one or both medial recti is called for in exophoria of convergence-weakness type.

Gaze Palsy

Gaze palsy is the palsy affecting the paired movements of both eyes in upwards gaze, downward, laterally, in convergence and divergence. The lesion is situated in the: (a) cortical centres; (b) subcortical centres; or (c) central connecting pathways.

Palsy of disjugate movements

Divergence paralysis is due to a lesion such as inflammations, haemorrhage and tumour in the posterior longitudinal bundle near the sixth nerve nucleus. It is essentially characterized by diminished or abolished amplitude of divergence.

Convergence paralysis is principally due to a lesion in the Perlia's nucleus. It is characterized by paralysis of convergence but normal adduction.

Vergence anomalies⁴

Convergence excess is characterized by an esodeviation greater at near than at distance. Convergence insufficiency is characterized by an exodeviation greater at near than at distance.

In divergence excess exodeviation is greater at distance than at near.

In divergence insufficiency esodeviation is greater at distance than at near.

Treatment. (a) Correction of refractive error.

(b) Divergence exercise in convergence excess and divergence insufficiency, and convergence exercise in divergence excess and convergence insufficiency. Base-out prism exercises at near in convergence insufficiency and base-out prism exercises (incorporated in glasses) for distance in divergence insufficiency.

(c) Resection or recession is advocated such as: (i) recession of the MR in convergence excess; (ii) resection of the MR in convergence insufficiency; (iii) recession of the LR in divergence excess; and (iv) resection of the LR in divergence insufficiency.

Orthoptic Instruments^{14,21}

The Maddox rod (Fig. 47.7)

This is indicated in the detection of heterophoria for distant vision. Its principle is to break the fusion. The Maddox rod usually consists of multiple red glass rod cylinders which when placed in front of



Fig. 47.7 Maddox rod.

one eye and the patient looks through the other eye, being seated 6 metres away from a spotlight, converts a 'spot' into a straight line. In case of horizontal deviation the rod should be so placed that the red line is vertical.

Maddox wing (Fig. 47.8)

It is indicated in the detection of heterophoria for near vision and its degree. The patient looks through




Fig. 47.8 Maddox wing.

the slits of the eye pieces. The right eye sees an arrow head, while the left sees a row of numbers graduated in prism dioptres. The number to which the arrow points indicates the measure of the phorias.

Worth's four-dot test (Fig. 32.29)

This consists of 4 lights—the top one is red, the two centre ones are green and the lower is white. A number of possibilities occurs if the patient wears a red glass in front of the right eye and green glass in front of the left.

The patient sees

(a) Four lights—the top one red, the middle two green and the lower one pale red or pale green—normal retinal correspondence

(b) Two red lights—suppression of the left eye

(c) Green lights—suppression of the right eye

(d) Two red or three green lights—alternating suppression

(e) Five lights—two red and three green—paralytic squint

(f) Four lights but in the presence of manifest squint—presence of ARC.

Synoptophore or major amblyoscope (Figs. 47.9 and 47.10).

It is a valuable instrument, consisting of two tubes, each with a mirror and a convex lens, joined by a




Fig. 47.9 Synoptophore.

hinge. It is capable of both convergence and divergence, by means of which two different pictures can be presented one to each eye simultaneously. The synoptophore is an elaborate development of the amblyoscope.

The objective slides are of three classes, i.e. of three different grades of binocular vision.

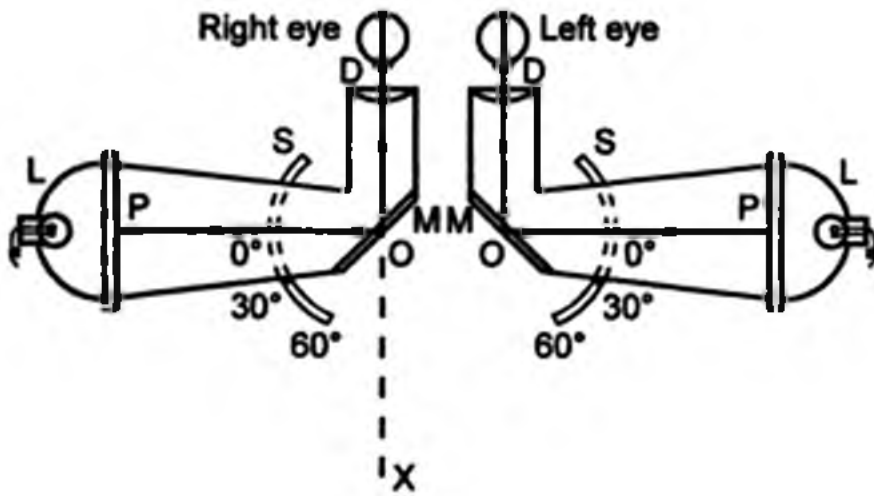


Fig. 47.10 The optical system of the amblyoscope or synoptophore. A ray of light from the picture at P strikes the mirror at O, is reflected in the direction OD and appears to come from a point X, at a distance behind the mirror equal to OP. The eye-piece contains a convex lens, D, the focal distance of which is $DX=(DO+OP)$ so that the image of the test-object slide is situated at the principal focus of the lens. Rays of light emanating from the principal focus will after refraction by the lens, D, emerge as parallel rays; the eye when viewing the image is therefore relaxed or focused for distance, no accommodation being required. D, convex lens in eye-piece; L, lamp house; M, mirrors; O, centre of rotation of arms; P, slide holder; S, scale. (Duke-Elder).

A synoptophore can be used for both diagnostic and therapeutic purposes (Table 47.18).

Table 47.18

Uses of Synoptophore¹³

	Uses of Synoptophore ¹³
Diagnostic	Measurement of the objective and subjective angles of deviation
	Measurement of the angle kappa
	Measurement of primary and secondary deviation
	Measurement of deviation in cardinal directions
	Examination of the status of binocular vision:
	(i) State of retinal correspondence normal/ abnormal/lack of any
	(ii) Presence and type of suppression
	(iii) Presence of fusion and measurement of fusional amplitudes
	(iv) Presence of stereopsis
Therapeutic	Suppression
	Abnormal retinal correspondence (ARC)
	Eccentric fixation
	Accommodative esotropia
	Heterophoria

Hess screen (Fig. 47.11).

This is indicated chiefly in parietic squint. It assesses the degree of false projection in different cardinal directions, by mutually excluding the images of either eye with red-green goggles.

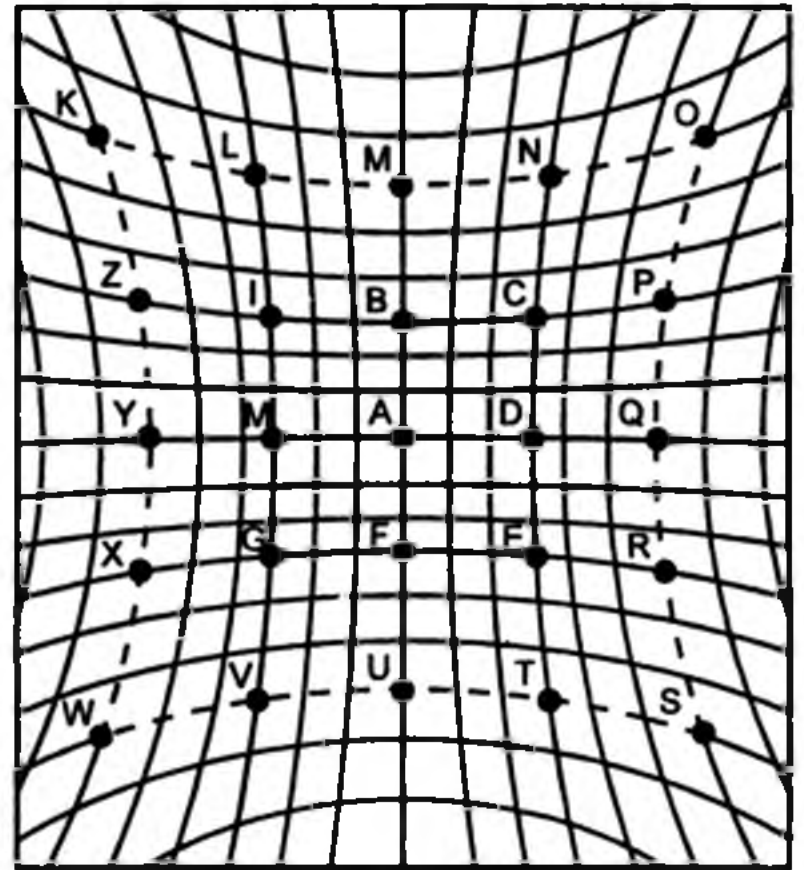


Fig. 47.11 Hess screen.

A tangent black screen is marked in red lines with red spots where the major meridians intersect. The patient seated 1/2 metre away from the screen wearing the red-green goggles, red being in front of right eye, sees the red spots through the right eye while the left can see only a green ring on the end of a black wand held by the patient who is asked to locate the red spots by placing the green ring round the nine red spots. The points on the screen to which the patient projects these dots are charted. The process is repeated by reversing the red-green glasses, i.e. now over the left eye there is red glass and over the right eye green glass.

Nearpoint rule

It measures the near point of accommodation (NPA) and the near point of convergence (NPC). The rule consists of a graduated scale in centimetres with a sliding holder and a card on the holder. The card is slowly brought nearer towards the patient's eyes

Nystagmoid jerks or end-point nystagmus are larger conjugate rhythmic movements, particularly in full abduction, and are due to exaggeration of normal fixation movements. They are not uncommon in normal people in conditions like fatigue and ataxia as in multiple sclerosis, and after taking certain drugs like sedatives. Nystagmus can be evoked in the normal subject by fixation of the eyes on a moving object (optokinetic nystagmus) or by thermal or rotatory stimulation of the labyrinth (vestibular nystagmus).

Clinical examinations in nystagmus include:

(a) Direction of gaze in which it is elicited and more marked. This is divided into several grades: (i) grade I—in this grade nystagmus is confined to the direction of gaze; (ii) grade II—in which oscillation is also present while looking straight ahead; and (iii) grade III—in which there is persistence of nystagmus even when gazing in the opposite direction

(b) Posture of the patient, erect or supine, and effect of change of posture

(c) Type of oscillations—pendular or jerk

(d) Amplitude of oscillation—fine, medium or coarse

(e) Effect of fixation: (i) is it seen on attempted fixation; and (ii) does the fixation suppress or exaggerate nystagmus?

(f) Any special condition provoking the nystagmus, e.g. altered illumination

(g) Evoking nystagmus by optokinetic or caloric stimulation may be needed.

Classification. Nystagmus is classified as in Table 47.19.

Congenital nystagmus or ocular nystagmus is due to congenital visual deprivation. The causes include congenital cataract, macular scarring, albinism, total colour blindness, aniridia, congenital malformations of the eye, etc. Efforts to fix the gaze on an object lead to *pendular* oscillations about the point of attempted fixation. These oscillations are approximately equal in rate in either side.

Latent nystagmus is a type of congenital nystagmus in which occlusion of one eye results in jerk nystagmus in the fellow eye, but there is

Table 47.19

Classification of Nystagmus²²

Pathologic
Congenital (ocular)
Latent
Spasmus nutans
Vestibular
Vertical
Upbeat
Downbeat
See-saw
Horizontal
Gaze-evoked
Periodic alternating
Acquired pendular
Voluntary
Convergence retraction
Physiologic
End-point or end-gaze
Optokinetic
Evoked—rotatory and caloric

steady binocular fixation when both eyes are open.

Spasmus nutans is rare condition in which congenital nystagmus showing both symmetric and asymmetric pendular oscillations associated with head nodding. The condition may resolve by 3 years of age.

Evoked vestibular nystagmus. Displacement of endolymph in the semicircular canals in normal subjects causes nystagmus. This can be elicited either by head rotation (*rotatory*) or caloric stimulation (*caloric*).

In rotatory nystagmus there is jerk nystagmus in the fast phase in the direction of rotation.

In caloric type cold water irrigation produces nystagmus with fast component away from the side of irrigation, while warm water irrigation produces nystagmus with fast component toward the side of irrigation.

Nystagmoid oscillations^{5,19}

Nystagmoid oscillations include ocular bobbing, superior oblique myokymia, ocular dysmetria, ocular flutter, opsoclonus, oculogyric crisis and ocular myoclonus.

Ocular bobbing may be encountered in a comatose patient with pontine lesion. This is characterized by irregular, spontaneous downward jerks of the eyes followed by a slower drift back up to the primary position.

Superior oblique (SO) myokymia. In SO myokymia there are paroxysmal, rapid, small vertical and torsional movements of one eye.

Ocular dysmetria is an overshooting of gaze during change in fixation, seen in cerebellar lesion.

Ocular flutter is evidenced by spontaneous, intermittent bursts of three or four conjugate horizontal microoscillations during maintenance of fixation in primary position. It may be associated with ocular dysmetria.

Opsoclonus is characterized by rapid, involuntary, repetitive, chaotic and multidirectional conjugate ocular movements. This is continuous and persists during sleep.

Oculogyric crisis is a conjugate spasmodic deviation of eyes usually in the vertical plane. This may be seen in postencephalitis, epilepsy, etc.

Ocular myoclonus is a rapid oscillation of the eyes at a rate of 100 to 150 per minute, usually vertical and pendular. The movements persist during sleep.

Vestibular nystagmus is a jerk nystagmus showing two components: slow and fast. The slow phase results from impulses arising in the semicircular canals, while the fast phase is a corrective movement. This is associated with vertigo, tinnitus, deafness and sometimes disorders of gait. The causes include labyrinthitis, Menière's disease, affection of the vestibular nerves and nuclei, and cerebellar lesions.

Upbeat and downbeat nystagmus. In upbeat nystagmus the fast phase is upward, while this is downward in downbeat nystagmus. An upbeat nystagmus is associated with lesions of the posterior fossa, and a downbeat nystagmus is associated with lesion at the cervicomedullary junction.

See-saw nystagmus is a rare type of nystagmus evidenced by rising intorsion of one eye and falling extorsion of the fellow eye, and then the reverse. It is associated with expanding lesions of the area of the third ventricle or with lesions of the upper brain stem.

Gaze-evoked nystagmus (gaze-paretic nystagmus) is a horizontal fast jerk nystagmus occurring in the direction of action of the paresed muscle and a slow movement toward the other side. The causes include upper brain stem lesion, use of anticonvulsants and sedatives.

Acquired pendular nystagmus may be seen in multiple sclerosis. Another example is *miner's nystagmus* occurring due to fixation difficulties in dim illumination.

Convergence retraction nystagmus is characterized by jerk convergence retraction movements occurring either spontaneously or after attempted upward gaze. This is seen in dorsal midbrain syndrome.

End-gaze nystagmus is primarily a horizontal nonsustained nystagmus of small amplitude seen in normal persons when they look toward extreme right or left.

Optokinetic nystagmus is a biphasic jerk nystagmus evoked by seeing objects rapidly moving across the visual field, e.g. looking out of the window of a fast moving train. An optokinetic nystagmus can be elicited by means of a rotating drum painted by black and white bands.

Treatment. Treatment is essentially palliative and consists of correction of refractive error, provision of tinted glass especially in albinism and eradication of the cause if feasible. Surgery is sometimes resorted to if the nystagmus is less jerky in one particular direction of gaze, the aim is to shift the direction in which it is less marked into the straight-ahead position.

Further Reading

1. Abrahamson, I.A. and Horwitz, I.D., Acute ophthalmoplegia. *Am. J. Ophthalmol.*, 38:781, 1954.
2. Ashworth, B., *Clinical Neuroophthalmology*. Blackwell Scientific, Oxford, 1973.
3. Bajandas, F.I. and Kline, L.B., *Neuro-ophthalmology Review Manual* (3rd ed.), Slack (1st Indian ed.), Jaypee Bros., New Delhi, 1989.

4. Bedrossian, E.H., *The Surgical and Non-Surgical Management of Strabismus*, Charles C. Thomas, Springfield, Ill, 1969.
5. Caloroso, E.F. and Rouse, M.W., *Clinical Management of Strabismus*, Butterworth-Heinemann, Oxford, 1993.
6. Campbell, F.W., Hess, R.F., Watson, P. and Banks, R., Preliminary results of a physiologically-based treatment of amblyopia. *Br. J. Ophthalmol.*, 62:748, 1978.
7. Cashell, G.T.W. and Durran, I.M., *Handbook of Orthoptic Principles*, E&S Livingstone, Edinburgh and London, 1967.
8. Dendy, H.M. and Shaterian, E.T., *Practical Ocular Motility*, Charles C. Thomas, Springfield, Ill, 1967.
9. Duke-Elder, S., *System of Ophthalmology*, Vol. VI: *Ocular Motility and Strabismus*, Duke-Elder, S. and Wybar, K. (Eds.) Kimpton, London, 1973.
10. Eggers, H.M., Current state of therapy for amblyopia. *Trans. Ophthalmol. Soc., UK.* 99:457, 1979.
11. Fells, P., Management of paralytic strabismus. *Br. J. Ophthalmol.*, 58:255, 1974.
12. Goel, B.S., Amblyopia: modern concept and management. In *Current Topics in Ophthalmology*, I. Gupta, A.K. (Ed.), B.I. Churchill Livingstone, New Delhi, 1993, p. 145.
13. Hurtt, J., Rasicovici, A. and Windsor, C., *Comprehensive Review of Orthoptics and Ocular Motility*, C.V. Mosby, St. Louis, 1972.
14. Keith Lyle, T.K. and Wybar, K. (Eds.), *Lyle and Jackson's Practical Orthoptics in the Treatment of Squint* (5th ed.) H.K. Lewis, London, 1967.
15. Malik, S.R.K., Gupta, A.K. and Chowdhury, S., Classification of eccentric fixation. *Br. J. Ophthalmol.*, 53:118, 1968.
16. Manley, D.R. Strabismus. In *Pediatric Ophthalmology*, Harley, R.D. (Ed.) W.B. Saunders, Philadelphia, 1975, p. 132.
17. May, C. and Worth, C., *Manual of the Diseases of the Eye* (13th ed.) Keith Lyle, T.K., Cross, A.G. and Cook, C.A.G. (Eds.) Baillière, Tindall and Cashell, London, 1968.
18. von Noorden, G.K., *Atlas of Strabismus* (4th ed.) C.V. Mosby, St. Louis, 1983.
19. Rosenberg, M.A., Neuroophthalmology. In *Principles and Practice of Ophthalmology*, Peyman, G.A. Sanders, D.R. and Goldberg, M.F. (Eds.), W.B. Saunders, Philadelphia, 1980, p. 1917.
20. Rucker, C.W., The causes of paralysis of the third, fourth and sixth cranial nerves. *Am. J. Ophthalmol.*, 67:447, 1966.
21. Schlossman, A., Squint, disturbances of binocular vision and anomalies of the extraocular muscles. In *Modern Ophthalmology* (2nd ed.), Vol. III, Sorsby, A. (Ed.), Butterworths, London, 1972, p. 85.
22. Vaughan, D., Asbury, T. and Tabbara, K.F., *General Ophthalmology* (12th ed.), Appleton and Lange, Connecticut, 1989.

48. OCULAR MANIFESTATIONS OF SYSTEMIC DISEASES

Ocular manifestations may follow affections of the nervous system, endocrine disorders, vascular disorders, metabolic disturbances, infectious diseases, diseases of the blood and reticuloendothelial system, skin and mucous membrane diseases, collagen diseases, diseases of the muscle and nutritional disorders.

Ocular Involvement in Affections of the Nervous System

Ocular involvement occurs in the following groups of affections: (a) intracranial tumours; (b) demyelinating diseases; (c) vascular diseases;

(d) inflammatory lesions of the brain and meninges; (e) degenerative diseases which include Wilson's disease; and (f) injuries.

These are discussed now.

Intracranial Tumours^{4,6,11,15,16}

Intracranial tumours include lesions of both neoplastic and inflammatory origin and they tend to cause a rise in intracranial pressure (ICP). They may be primary or secondary. Primary tumours include: (a) astrocytomas or gliomas which are graded in groups I to IV, the last group being most malignant; (b) supporting cell tumours including medulloblastoma, ependymoma and oligodendroglioma; (c) meningioma; (d) pituitary tumours; (e) perisellar tumours; (f) tumours from the blood vessels; and (g) acoustic neuroma. There may be secondary tumours as carcinomas and sarcomas.

Clinical features in general. The mode of onset is variable. Brain and Walton⁴ classified the modes of onset into five common types, presenting with: (a) progressive focal symptoms such as focal epilepsy, hemiplegia, aphasia and symptoms of increased ICP; (b) symptoms of increased ICP such as headache, vomiting, papilloedema, giddiness and rise of BP; (c) progressive focal symptoms like visual loss and deafness; (d) epileptiform attacks; and (e) an apoplectic episode.

An ophthalmologist suspects a case of an intracranial tumour from the ocular features such as papilloedema, some false-localizing signs, defective visual acuity and visual fields, cranial nerve affections along with disturbances of simple and higher functions.

Papilloedema occurs in about 60 to 80 per cent of all cases of cerebral tumours and is caused by mechanical factor. It is nearly always present in tumours of the cerebellum, fourth ventricle and temporosphenoidal lobes of the cerebral hemispheres. The third ventricle tumours often cause papilloedema. Tumours of the optic thalamus and the midbrain are always accompanied by severe papilloedema. In pontine tumour it may be absent.

Its degree is proportional to the height of ICP and rapidity of the development of raised ICP.

The false-localizing signs are diplopia, pupillary dilatation or constriction, restriction of the movements of the extrinsic muscles, hemianopias, changes in the width of the palpebral fissure and nystagmus. These signs are caused by involvement of the cranial nerves and raised ICP.

Chiasmal tumours

The optic chiasma is much more commonly involved by different types of pituitary tumours excepting a basophil adenoma, by craniopharyngioma and by meningioma. Occasionally other tumours arise from the chiasma and they include glioma, chordoma and cholesteatoma.

Pituitary tumours

The pituitary gland is an ovoid body situated in the hypophyseal fossa of the sphenoid bone, roofed by the diaphragma sellae and related to several important structures. Its anterior lobe secretes a number of vital hormones and contains three types of cells—acidophil or eosinophil, basophil and chromophobe. There are four types of tumours, namely chromophobe adenoma, acidophil adenoma, mixed or transitional adenoma and rarely basophil adenoma. Chromophobe adenoma is the most common type; it is associated with hypopituitarism and often with ocular signs. Acidophil adenoma appears in the young and is associated with hyperpituitarism and is less likely to be associated with ocular signs; gigantism is present if it occurs before the closure of the epiphyses, and acromegaly occurs in adult age-group. Both mixed and basophil types are rare. Adenocarcinoma is also rare.

Clinical features. Depending upon the type there may be hyper- or hypopituitarism. Onset is usually slow. Pressure symptoms are absent in basophil and less common in acidophil types. Characteristic visual field changes occur and there is involvement of the II, III, IV and VI cranial nerves along with radiographic changes.

hyperostosis of the tuberculum sellae with destruction of the anterior clinoid process. Treatment is surgical.

Frontal lobe tumours

Mental symptoms like apathy, irritability and depression are not uncommon, but they may be asymptomatic. Sometimes they may present as Foster Kennedy syndrome in which there is optic atrophy on the affected side and papilloedema on the other side. Though this syndrome is present in any tumour of the frontal lobe, it is particularly common in olfactory groove meningioma. Increased ICP in the advanced stage of the disease accounts for the presence of papilloedema and extrinsic muscle paralysis. The tumour may grow inferiorly to cause direct pressure on the optic nerve and optic atrophy. If the optic chiasma is involved there is a bitemporal hemianopia, and if the optic tract is involved there is a homonymous hemianopia.

Temporal lobe tumours

Presence of temporal lobe tumours is suggested by highly-differentiated visual hallucinations. Due to the damage of the Meyer's loop a homonymous superior defect, either quadrantic or sector-shaped, is present but characteristically there is an incongruous, complete or incomplete, homonymous hemianopia. If the tumour progresses downward it may involve the third cranial nerve by the medial extension of the tumour. Raised ICP may cause sixth nerve palsy.

Parietal lobe tumours

There are several symptoms indicating the disturbances of the higher visual centres. They are *dyslexia* or impairment of reading ability, *agraphia* or inability to write, *alexia* or word blindness and *visual agnosia*, i.e. inability to recognise object shown to the patient. A homonymous hemianopia of the opposite side of the lesion is characteristic in the advanced stage, but in a relatively early stage there is homonymous inferior quadrantanopia.

Occipital lobe tumours

Occipital lobe tumours may be asymptomatic but sometimes the patients may complain of unformed images such as light flashes or jagged lines appearing in the contralateral visual field. These transient visual hallucinations are succeeded by the presence of hemianopias. A complete homonymous hemianopia of the opposite side with the absence of other gross neurologic signs is almost diagnostic. Often there is macular sparing. Computerized tomography and cerebral angiography help in evaluating the lesion.

Olfactory groove meningioma

Olfactory groove meningioma may be noted that a suprasellar meningioma usually occurs in middle-aged woman. It pushes the optic chiasma upwards and backwards, while an olfactory groove meningioma pushes it downwards and backwards. The suggestive features include anosmia, visual field defects, bilateral papilloedema or Foster Kennedy syndrome.

Tumours of the diencephalon

The diencephalon, a forebrain derivative, includes the thalamus and hypothalamus which constitute the lateral wall and floor respectively, of the third ventricle. Tumours may originate from the walls of the third ventricle. These tumours present severe paroxysmal headaches and vomiting due to distended ventricle, gross papilloedema and sometimes hemianopias. The nature of hemianopia is variable depending on whether the optic nerve, the optic chiasma or the optic tract is pressed upon.

Pineal body tumours

The pineal body is situated in the midline rostrally and between the superior colliculi. Teratomas, pinealomas, gliomas and cysts are the tumours present in this region. There are signs of a midbrain lesion, namely defective conjugate deviation usually upward, paresis of convergence, ptosis, dilated pupil, nystagmus, ataxia and sensory loss.

Cerebellar tumours

The clinical features are the result of raised ICP, compression of the fourth and sixth cranial nerves by the tumours, but are mostly due to damage of the cerebellum and its connecting pathways. Intracerebellar tumours frequently involve the children. The signs include papilloedema and nystagmus. The features are variable depending on the location of the tumours, arising from the midline or from the lateral hemispheres. The midline tumours include medulloblastoma, astrocytoma, haemangioblastoma and ependymoma; they cause an early obstruction of the flow of the CSF causing raised ICP. The lateral hemispheric tumours tend to produce ataxia, asynergy, dysmetria and hypotonia of the ipsilateral extremities.

Tumours of the brain stem

The brain stem consists of the midbrain, pons and medulla. The tumours of the brain stem are common in younger age-groups. Raised ICP occurs in the advanced stage. The pupils become dilated and fixed due to involvement of the Edinger-Westphal nuclei. Nystagmus is commonly present.

Tumours of the pons-medulla

Tumours of the pons-medulla produce symptoms like occipital headache, vertigo and diplopia. Lateral rectus paresis may occur in one or both sides. Papilloedema occurs in less than 50 per cent cases. Nystagmus and ataxia are common. General signs include those due to affections of the cranial nerve nuclei and the pyramidal tract. In a pontine tumour the fifth, sixth and seventh cranial nerves are paralysed. The lower four cranial nerves are paralysed in tumours of the medulla.

Cerebellopontine angle tumours

The common tumours at this region is an acoustic neuroma originated from the Schwann cells of the eighth cranial nerve. It usually occurs in middle age. The affection starts with tinnitus and deafness which are followed by loss of corneal sensation

and paraesthesia of the face when a tumour expands to involve the fifth cranial nerve, as well as partial facial palsy. Nystagmus is the most constant sign. In many cases there may be ataxia as well as the fourth sixth nerve palsy. X-ray shows an enlarged internal auditory meatus.

Bilateral vestibular schwannomas are associated with neurofibromatosis. When a tumour expands so much it compresses and displaces the lower brainstem producing dysphagia, dysarthria and nasal regurgitation.

Demyelinating Diseases²⁴

Demyelinating diseases include multiple (disseminated) sclerosis and Devic's disease.

Multiple sclerosis

Multiple sclerosis is an inflammatory demyelinating affection of CNS white matter.

Aetiology. Recent view suggests this to be of autoimmune origin.

Pathology. There are plaques of demyelination, sharply demarcated greyish yellow lesions. About 90 per cent of the plaques are located in the periventricular white matter. Other sites are optic nerve, optic chiasma and optic tract, cerebellar and spinal cord white matters. Remyelination follows demyelination with subtotal recovery of function.

Clinical features. Age-incidence varies between 20 and 40 years. The affection may progress slowly or rapidly. Its severity may be of any degree. Remission is common.

The ocular features are:

(a) *Retrobulbar neuritis (RBN).* Multiple sclerosis is the most common cause of RBN, and RBN is the initial presenting feature in about one-third cases of multiple sclerosis. RBN is commonly unilateral.

(b) *Diplopia.* An episode of unexplained diplopia in a young individual lasting for days or weeks is very suggestive. All varieties of diplopia are met with, but it especially occurs on the lateral

deviation of the eyes. It indicates involvement of the brain stem.

(c) *Ophthalmoplegia*. Perhaps lateral rectus palsy is more common. Total external ophthalmoplegia is very rare.

(d) *Optic atrophy*. It is commonly manifested as temporal pallor and it results from recurrent lesions of the optic nerve leading to gliosis.

(e) *Nystagmus*. It is one of the signs in *Charcot's triad* (nystagmus, intention tremor and scanning speech) which is due to cerebellar involvement in the later stage of the disease. Two special types, considered pathognomonic, are *jelly nystagmus* and *ataxic nystagmus*.

(f) Pupillary changes accompany retrobulbar neuritis (RBN).

(g) Other signs include paralysis of conjugate movements (lateral being commonest), of convergence and internuclear ophthalmoplegia.

The general features are:

(a) Motor weakness involves usually the lower limbs and sometimes one upper limb.

(b) Inco-ordination is manifested as: (i) intention tremor which increases in intensity as in touching the nose with the finger; and (ii) ataxic gait.

(c) Dysarthria is due to involvement of the cerebellar pathways.

(d) Paraesthesias occur in most cases.

(e) There may be impairment of the position and joint sense.

(f) Objective sensory loss occurs in at least 50 per cent cases.

Investigations. These include:

(a) CSF study—elevated protein level, increased gamma globulin and presence of oligoclonal band in the gamma globulin

(b) Visual evoked potentials—unreliable

(c) Neuroimaging—MRI and CT are both employed, but MRI is the most sensitive technique for visualization of plaques of demyelination.

Treatment. Steroids are used to treat optic neuritis, but they have no role of final visual acuity.

Devic's disease (Neuromyelitis Optica)

Synonymous with disseminated myelitis with optic neuritis.

Aetiology. Devic's disease appears to be a variant of multiple sclerosis. Subacute encephalomyelitis evidenced by massive demyelination of the optic nerves and spinal cord are characteristic.

Clinical features. The age of onset varies between 5 and 60 years. The onset is rapid. It is characterized by severe bilateral retrobulbar neuritis and a transverse myelitis. Sometimes this affection starts with blindness and then paraplegia develops, while the process may be reverse in some cases. Fever may be associated with neurologic symptoms arising from lesion of the spinal cord. Immediate prognosis is worse in many cases. Recovery may take place if the patient survives after an acute illness.

Treatment. It consists of intense corticotropin therapy along with usual measures for the care of the skin, urinary and intestinal tracts, and musculature.

Inflammatory Diseases of the Brain and Meninges

The chief inflammatory lesions that can cause ocular signs include meningitis, tabes dorsalis, general paralysis of the insane (GPI) and encephalitis lethargica.

Meningitis or leptomeningitis

Meningitis or leptomeningitis is the inflammation of the pia mater and arachnoid, and three of them cause ocular signs. In acute pyogenic meningitis there are often diplopia, paralysis of one or more motor cranial nerves—the third, fourth and sixth. In an advanced stage of coma the pupils are dilated and fixed. In tuberculous meningitis there is evidence of paralysis of one or more extrinsic muscles, constriction of the pupils in the early and dilatation in the later stages; in the advanced stages there are choroidal tubercles in 25 per cent cases, and sometimes papilloedema may be detected. In a gummatous meningitis, rarely encountered,

bilateral papillitis or papilloedema is common, sometimes third cranial nerve palsy or occasionally fifth cranial nerve palsy may be present.

Tabes dorsalis and GPI

Tabes dorsalis and GPI are two clinical entities of neuro syphilis. In tabes dorsalis, two most characteristic eye signs are: Argyll Robertson pupil (90%) and simple optic atrophy (15 to 20%). Sometimes there are internal ophthalmoplegia and involvement of the third, fourth or sixth cranial nerves. In GPI, simple optic atrophy occurs in about 10 per cent cases and Argyll Robertson pupil in 50 per cent cases.

Encephalitis lethargica

The signs include ocular palsies, unequal and sluggishly reacting pupils, nystagmus and paresis of accommodation.

Endocrine diseases

Endocrine diseases include affection of the pituitary, pancreas, thyroid, parathyroid, adrenal glands and thymus. The affections of the pituitary and thyroid glands have already been described.

Hypoparathyroidism. It usually follows injury or removal of the glands by thyroidectomy. Decreased concentration of blood calcium follows inadequate parathyroid function. This leads to hyperexcitability and tetany. They are often associated with development of lental opacities. Other ocular signs are blepharospasm, keratoconjunctivitis and papilloedema.

Diagnosis is made by low serum calcium, high serum inorganic phosphorus, decreased urine phosphorus and normal urinary alkaline phosphatase.

Two variants, namely *pseudohypoparathyroidism* and *pseudopseudohypoparathyroidism* are reported. There is no parathyroid hormone deficiency in the former. In the latter, the biochemical signs are mild or absent.

Hyperparathyroidism. It is a rare condition causing bony deformities, spontaneous fractures, formation

of renal calculi, and increased excretion of calcium in the urine. A slit-lamp biomicroscopy may exhibit crystals in the bulbar conjunctiva and band-shaped keratopathy due to calcium deposition. Diagnosis is confirmed by the presence of hypercalcaemia and hypophosphataemia.

Tumours of the adrenal medulla

Two of them, neuroblastoma and phaeochromocytoma are of ophthalmic interest.

Neuroblastoma or sympatheticoblastoma. Neuroblastoma occurs in a child and is a potentially malignant tumour of embryonic origin causing bony metastasis. The affected child may present with unilateral or bilateral proptosis in 79.9 per cent cases due to metastasis in the orbit. This is accompanied by swelling on the temporal side of the orbit, ecchymosis of the eyelids, and papilloedema in 29.5 per cent cases.

The condition usually leads to rapid death.

Phaeochromocytoma. Still rarer, this is a benign tumour arising from the chromaffin tissue. The chromaffin cell, a sympathetic nervous system cell, secretes adrenaline and noradrenaline. Due to secretion of adrenaline and noradrenaline there are signs of arterial hypertension, hypermetabolism, headache, hyperglycaemia, weight loss, attacks of flushing and increased sweating.

Ocular signs are secondary to persistent hypertension.

Affections of the adrenal cortex

Two affections, namely Addison's disease due to chronic insufficiency and Cushing's syndrome following excessive production of glucocorticoids produce ocular signs. In Addison's disease apart from weakness and hypotension, pigmentation of the skin and mucous membrane including the conjunctiva occurs. Cushing's syndrome has been described elsewhere.

Vascular Disorders⁴

The vascular disorders include cardiovascular, cerebrovascular, cervical vascular diseases and

other vascular affections occasionally causing ocular manifestations.

Cardiovascular disorders often causing ocular signs are arteriosclerosis, hypertension and other vascular retinopathies. They are described in details under retinopathies.

Cerebrovascular diseases include cerebral atheroma, cerebral embolism, cerebral thrombosis affecting the middle cerebral and posterior cerebral arteries, cerebral haemorrhage, subarachnoid haemorrhage, cavernous sinus thrombosis and intracranial aneurysms.

The intracranial arterial supply is derived from two sources: two internal carotid arteries through the anterior cerebral, middle cerebral and posterior communicating arteries; and two vertebral arteries which unite anteriorly to form the basilar artery, the latter dividing into two posterior cerebral arteries.

Cerebral atheroma

Ophthalmic manifestations are the result of an arteriosclerotic retinopathy and occasionally follow softening affecting the optic radiations or the visual cortex.

Cerebral embolism

Onset is instantaneous. The nature of focal symptoms is dependent upon an embolus lodged in a particular vessel. If such a lesion affects the intracerebral visual paths, the visual defects simulate those of cerebral thrombosis.

Cerebral thrombosis

Cerebral thrombosis follows atheromatous and hyaline changes in the cerebral vessels. The middle cerebral artery or one of its branches is the most common site of affection in two-third of the cases, followed by the posterior cerebral artery which is the next common site. Affection of the middle cerebral artery by thrombosis causes visual agnosia and crossed homonymous hemianopia involving mainly or exclusively the upper quadrants.

The posterior cerebral artery supplies the posterior cerebral hemispheres, the posterior part

of the thalamus, the internal capsule and the major part of the midbrain. Thrombosis of this artery or its branches produces a few important syndromes with ocular features:

(a) Benedict's syndrome.

(b) Weber's syndrome.

(c) The retrothalamic syndrome shows contralateral cerebellar signs with nystagmus *plus* contralateral hemianaesthesia.

(d) The retroocular syndrome is characterized by oculomotor nerve palsy associated with cerebellar ataxia.

(e) Anterior internuclear ophthalmoplegia. An internuclear ophthalmoplegia is a lesion which affects the pathways connecting the three cranial nerve nuclei concerned with ocular movements. It often affects the posterior longitudinal bundle. The common sign is a defective adduction of one eye when the other eye is abducted, associated with ataxic nystagmus in the abducting eye. In anterior internuclear ophthalmoplegia the sign is evident when the eyes are moved from the side of affection.

Cerebral haemorrhage

An intracerebral haemorrhage is commonly due to rupture of an atheromatous artery in a hypertensive subject. During the stage of coma, the pupils become dilated and non-reacting, the larger of the two indicating the side of haemorrhage.

In pontine lesions there are pin-point pupils, absent corneal reflex and deviation of the head and the eye of the affected side. Later on there may be papilloedema due to raised intracranial pressure and homonymous hemianopia due to interruption of the geniculocalcarine pathway.

Subarachnoid haemorrhage

Subarachnoid haemorrhage may be traumatic or spontaneous, involving commonly the anterior half of the circle of Willis. In the spontaneous variety, the haemorrhage is the result of the bursting of a saccular aneurysm of one of the basal arteries.

Apart from the symptoms of rapidly-increasing intracranial pressure and changes in the CSF, there are papilloedema, subhyaloid and retinal

haemorrhages, and paresis of the extrinsic muscles particularly of the lateral rectus of both the eyes. Papilloedema which is of slight degree, is common and rapidly develops.

Intracranial aneurysms

The most common is the congenital, saccular or 'berry' aneurysm occurring in association with the circle of Willis. The circle of Willis (Fig. 48.1) is situated at the base of the brain in the

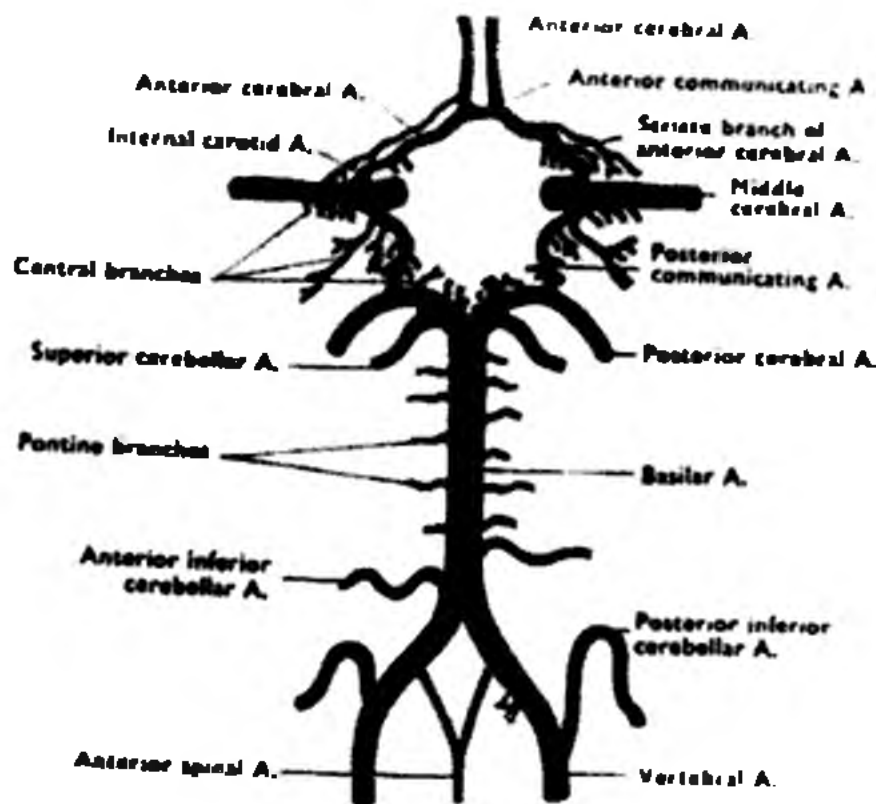


Fig. 48.1 Diagram of the arteries on the base of the brain including the circulus arteriosus (Cunningham).

interpeduncular cistern and formed by the two anterior cerebral arteries joined to each other by the anterior communicating arteries, and by the two posterior cerebral arteries joined to the internal carotid arteries by the posterior communicating arteries. The aneurysms occur at the bifurcations of the arteries. The usual age-group affected is between 20 and 40. Many of them remain asymptomatic.

The next common group is an atheromatous fusiform aneurysm situated on the internal carotid artery. This aneurysm may be: (a) supraclinoid, that is the part after the artery has pierced the dura; and (b) infraclinoid, subclinoid or intracavernous, that is the part lying in the cavernous sinus.

Aneurysm of internal carotid

Clinical features. Intracranial aneurysms essentially depend whether the aneurysm is not yet ruptured or ruptured. The ocular manifestations are the result of mechanical pressure on the structures in proximity, sudden increase in size, periodic slight leakages and rupture.

Effects produced before rupture. The aneurysms of the terminal part of the internal carotid, anterior communicating, posterior communicating and middle cerebral arteries cause visual field changes.

Visual field defects are important considerations but vary widely. The optic nerve may be pressed by an anteriorly-situated supraclinoid aneurysm. Aneurysm of the internal carotid artery typically presses on the outer side of the angle of junction of the optic chiasma and the optic nerves, and produces nasal hemianopia on the affected side and temporal hemianopia of the other side. Sometimes this aneurysm causes bitemporal hemianopia because the internal carotid arteries pass medially under the chiasma. The anterior and middle cerebral arteries situated above the chiasma exert pressure and produce bitemporal hemianopia. If the expansion occurs posteriorly a homonymous hemianopia is present.

When the intracavernous part of the internal carotid artery is involved, the aneurysm presses on the third, fourth, and on the ophthalmic division of the fifth cranial nerves. There are pain, impaired corneal sensibility, pupillary dilatation and extrinsic muscle palsies. Vision is often normal because of non-involvement of the optic nerve. Rarely it expands anteriorly to cause proptosis and loss of vision caused by the compression of the optic nerve in the optic canal.

X-rays show calcification in the walls of the aneurysm, as well as erosions of the sphenoid fissure, optic canal, carotid canal and body of the sphenoid with clinoid processes.

Angiography is the diagnostic choice, but sometimes the shadows may be obscured by those of the vascular trees.

Effects after rupture. Though the majority of the aneurysms are silent and slow-growing, yet a

small number of cases have an abrupt apoplectic onset producing a picture of carotid-cavernous fistula or subarachnoid haemorrhage.

Treatment. Probably the effective treatment is the ligation of the carotid artery proximal and distal to the aneurysm.

Cervical Vascular Diseases¹³

Cervical vascular diseases showing ocular signs include carotid-cavernous fistula (p. 137–38) and occlusion of the internal carotid artery.

Occlusion of the internal carotid artery

Occlusion of this artery may occur in young subjects or elderly patients. In young persons the gradual closure of the arterial lumen does not affect vision and is often asymptomatic because the circle of Willis maintains the supply. In elderly persons the collateral circulation is limited; so in a partial closure the patient complains of fleeting attacks of unilateral blindness, called *amaurosis fugax*, accompanied by contralateral weakness. Usually in a complete closure the clinical features of cerebral infarction appear; there is sudden blindness with presentation of central retinal artery occlusion due to involvement of the ophthalmic artery, the first major branch of the carotid.

The *investigations* are listed in Table 48.1.

Medical treatment includes treatment for hypertension and diabetes, lowering of serum cholesterol level, aspirin as an antiplatelet aggregation agent and sometimes anticoagulant

Table 48.1

Investigations for Carotid Artery Disease¹²

Physical examination

- Gentle palpation of cervical carotid arteries
- Auscultation along the entire length of artery
- Ophthalmodynamometry

Special investigations

- Combined B-scan ultrasonography with Doppler flow analysis
- Digital intravenous subtraction angiography
- Arterial angiography
- Magnetic resonance imaging

therapy. *Surgical treatment* advocated is carotid thromboendarterectomy.

Basilar artery insufficiency and thrombosis

The basilar artery through its two terminal arteries, the posterior cerebral arteries, supplies blood to the posterior part of the optic radiation and the visual cortex. If there is an insufficiency of supply there may be blindness associated with gross signs of involvement of the brain stem and the long tracts. The severity subsides as the collateral circulation improves. Apart from the loss of vision there are other ocular features like third nerve palsy, pupillary dilatation or constriction depending on whether the Edinger-Westphal nuclei or the sympathetic tracts are affected, and nystagmus due to involvement of the vestibular nuclei or their pathways. Complete and sudden thrombosis is always fatal.

Aortic insufficiency

Aortic insufficiency may cause retinal pulsation due to the great difference between systolic and diastolic pressure.

Aneurysm of the aorta

Aneurysm of the aorta may cause Horner's syndrome due to irritation of the cervical sympathetic.

Congenital cyanotic heart disease

The signs are cyanosis of the conjunctiva, and cyanosis and tortuosity of the veins in the retina.

Cardiac insufficiency

Cardiac insufficiency may cause dependent oedema, e.g. lid oedema upon rising in the morning.

Pulseless disease

Pulseless disease is synonymous with aortic arch syndrome and Takayasu's disease. This follows arteriolar narrowing and subsequently inadequate

Type V. *Scheie's syndrome* is characterized by stiff joints, claw hands, aortic regurgitation, corneal clouding, pigment retinopathy and optic atrophy.

Type VI. *Maroteaux-Lamy syndrome* shows stunted growth, severe skeletal changes, hepatosplenomegaly and corneal clouding.

Type VII. *Beta-glucuronidase syndrome* shows corneal clouding.

Table 48.3 summarizes the enzyme defect and inheritance of seven types of mucopolysaccharidoses.

Table 48.3

Enzyme Defect and Inheritance in Mucopolysaccharidoses¹

Type	Syndrome	Enzyme defect	Inheritance
I	Hurler	Alpha-L-iduronidase	Recessive
II	Hunter	Iduronate sulphatase	Sex-linked
III	Sanfilippo		Recessive
	Type A	Heparan-S-sulphaminidase	
	Type B	N-acetyl glucosaminidase	
	Type C	N-acetyl transferase	
	Type D	N-acetyl glucosamine 6-sulphate sulphatase	
IV	Morquio		Recessive
	Type A	N-acetyl galactosamine 6-sulphate sulphatase	
	Type B	Beta-galactosidase	
V	Scheie	Alpha-L-iduronidase	Recessive
VI	Maroteaux-Lamy	Aryl sulphatase	Recessive
VII	Sly	Beta-glucuronidase	Recessive

Table 48.4 lists the ocular and systemic features of mucopolysaccharidoses.

Table 48.4

Ocular and Systemic Features of Mucopolysaccharidoses^{1,20}

Type of MPS	Corneal opacity	Retinal pigmentary degn	Optic atrophy	Mental change	Cardiac defect	Skeletal defect
I	+	+	+	+	+	+
II	-	+	+	+	+	+
III	-	+	+	+	-	+
IV	-	-	+	-	+	+
V	+	+	+	-	+	+
VI	+	-	+/-	-	+	+
VII	+/-	?	?	+	-	+

Albinism

Albinism is a hereditary affection in which the melanocytes are unable to synthesize melanin, due to lack of the enzyme *tyrosinase*. There are two types: ocular and oculocutaneous. Ocular albinism is inherited as a sex-linked recessive trait; the inability to synthesize melanin is restricted to the eye (see p. 262). Biochemically there are two types of albinism: tyrosine-negative and tyrosine-positive.

Homocystinuria

Homocystinuria is an autosomal recessive disorder, and is due to deficiency of *cystathionine-beta-synthetase*, the enzyme responsible for the conversion of amino acid homocystine into cystathionine. Absence of this enzyme leads to elevated plasma levels of homocystine.

Table 48.5 lists the distinguishing features of homocystinuria and Marfan's syndrome.

Table 48.5

Features of Homocystinuria and Marfan's Syndrome

Parameters	Homocystinuria	Marfan's syndrome
Inheritance	Autosomal recessive	Autosomal dominant
Intellect	Decreased	Not decreased
Arachnodactyly	Yes	Yes
Lens subluxation	50% by 30 years, inferonasal	In early life, superotemporal
Urinary nitroprusside	Homocystine in urine	Normal
Vascular complication	Thromboembolic episode	Aortic dissection

Alkaptonuria (ochronosis)

Alkaptonuria is characterized by the deposition of homogentistic acid in the tissues, due to lack of hepatic *homogentisic acid oxidase*. The condition manifests as pigmentation of the conjunctiva and sclera in the equatorial region, accompanied with black urine and darkening of the cartilage of the ear.

Normally phenylalanine combined with tyrosine produces homogentistic acid which in turn converts to melanin.

Oops, page PA405 was not yet downloaded :(

Oops, page PA407 was not yet downloaded :(

Oops, page PA409 was not yet downloaded :(

Oops, page PA411 was not yet downloaded :(

mucosal pemphigoid the blister is subepidermal, while in pemphigus the bullae are within the epithelial layer of the skin and mucous membranes.

The disease primarily causing conjunctival lesion also affects other mucous membranes, and less commonly involves the skin. The conjunctival lesion is usually associated with lesions elsewhere, though the latter may precede or follow ocular manifestations.

At first, the conjunctiva shows perivascular thickening, involving the entire superficial network leading to the formation of vesicles; they are evident in about 25 per cent cases. Because of the very thin walls the vesicles are not obvious, since they disintegrate owing to constant lid movements. New blebs or ulcers appear as the older ones cicatrize. Occasionally there is pseudomembranous conjunctivitis. Due to raw surfaces produced by the rupture of the vesicles there is symblepharon, leading to ankylosis of the lids. There is also obliteration of the lacrimal ducts causing 'dry eye'. Due to cessation of tear formation and lack of complete closure of the eyelids there are corneal complications and parenchymatous xerosis.

Similar vesicular changes occur in other mucous membranes. The lid skin is also affected leading to various complications especially scaly erythematous plaques with peripheral bullae ending in scars.

Instillation of steroid drops appears to be beneficial.

Pemphigus

Pemphigus is a lethal disease, but fortunately the incidence is rare. Pemphigus vulgaris usually occurs in elderly males. Crops of bullae make their appearance without any preceding erythema and in the apparently normal skin and mucous membrane. They dry up within a week or so. Finally the scales disappear completely. Corticosteroids have improved the prognosis of this affection.

Dermatitis herpetiformis

In this affection bullae arise from the inflamed skin. Eruptions tend to occur in groups and are

polymorphic. The lesions are erythematous, papular or pustular. There is intense paraesthesiae.

Epidermolysis bullosa

Epidermolysis bullosa is present since birth with lack of constitutional disturbance. The inheritance is dominant. Development of fresh lesions at the site of injury is characteristic. The bullae affect the skin and heal without scarring. The conjunctiva and lid may be involved.

Behçet's syndrome (*see p. 255*)

Reiter's syndrome (*see p. 205*)

Erythema multiforme (Syn.: Erythema multiforme exudativum, erythema multiforme bullosum, erythema multiforme plurifociale)

There are two types: (a) relatively mild or Hebra type, and (b) more serious or Stevens-Johnson type; in about 75% cases it is associated with HLA-B2.

This affection may be: (a) of idiopathic origin; or (b) secondary, which appears to be a mucocutaneous reaction to infections, drugs and sera. Drugs causing erythema multiforme include sulphonamides, sulphones, para-aminosalicylic acid (PAS), antibiotics, phenylbutazones, iodides and barbiturates.

There is infiltration of subepithelial layers essentially with leucocytes, vascular dilatation and stasis. In more chronic cases there is formation of granulation tissue underneath the mucous membrane.

The affection is common in children and young adults. It commences with malaise, fever, and sometimes swelling of the joints. The disease reaches its peak within a fortnight. The skin eruptions are usually symmetrical. There is development of mucosal lesions in about 25 per cent cases. Ocular complications are common of which the most common is a severe pseudomembranous conjunctivitis, which may lead to symblepharon and even 'dry eye'.

Acne rosacea

Acne rosacea can cause blepharoconjunctivitis; secondary keratitis; and on the face dermatitis, dilated and telangiectasia of the veins, and pustules. Treatment comprises topical steroid and prevention of secondary bacterial infection.

Xeroderma pigmentosum (see p. 176)**Connective Tissue Disorders¹²**

The connective tissue contains ground substance, cells—chiefly fibroblasts, and fibres—collagen, elastin and reticulin. Collagen fibres are made up of the fibrils, the latter being made up of units called tropocollagen. Probably fibroblasts secrete tropocollagen which condenses to constitute the fibrils. Collagen constitutes the principal framework of the fascia, dermis, osteoid and various connective tissue elements of the eye such as the substantia propria of the conjunctiva and sclera, episcleral tissue, extrinsic muscle sheaths and tendons, trabecular meshwork, stroma of the uveal tract, and optic nerve sheaths.

Aetiology is obscure. The chief pathological characteristics are diffuse inflammation and cell destruction with fibrinoid necrosis, cellular infiltration, sclerosis and connective tissue proliferation. There are widespread general manifestations associated with high ESR. Steroids are effective.

Connective tissue disorders of the eye are listed in Table 48.11.

Rheumatological diseases¹²

Rheumatoid diseases include rheumatoid arthritis, juvenile chronic arthritis (JCA) or juvenile rheumatoid arthritis (JRA), ankylosing spondylitis, Behçet's syndrome and psoriatic arthritis.

Rheumatoid arthritis

Rheumatoid arthritis (RA) is a common affection, found more commonly in women between fourth

Table 48.11**Connective Tissue Disorders of the Eyes****Acquired**

Sjögren's syndrome
Rheumatoid arthritis
Juvenile rheumatoid arthritis
Ankylosing spondylitis
Systemic lupus erythematosus (SLE)
Polymyositis—dermatomyositis
Scleroderma
Periarteritis nodosa
Giant cell arteritis
Psoriatic arthritis
Wagener's granulomatosis
Pulseless disease
Others

Hereditary

Marfan's syndrome
Ehlers-Danlos syndrome
Osteogenesis imperfecta
Stickler's syndrome

and fifth decades. Eighty-five per cent of patients are positive for IgM rheumatoid factor.

Clinical features. These include: *systemic features* include arthritis of the extremities, usually symmetrical but always sparing the interphalangeal joints; rheumatoid nodules usually over extensor surfaces of the forearm; vasculitis; pleural effusions, etc.

Ocular features include secondary Sjögren's syndrome, necrotizing scleritis, scleromalacia perforans, peripheral corneal guttering and keratolysis.

Treatment. Treatment consists of physiotherapy, nonsteroidal antiinflammatory drug (NSAID) and those for ocular features.

Juvenile rheumatoid arthritis (JRA)

Juvenile rheumatoid arthritis is an uncommon affection in juvenile age group and the patients are seronegative for IgM rheumatoid factor.

Clinical features. There are three types of presentation:

(a) Pauciarticular, involving 4 or less joints—60%

features are rare, they include cotton-wool exudates in the retina.

Treatment. Treatment may be started with systemic steroids.

Wegener's granulomatosis

Wegener's granulomatosis is a fatal systemic affection of unknown origin. It is a severe type of polyarteritis nodosa in which there is an intense necrotizing granulomatous reaction in and around small- and medium-sized vessels. This affection commonly involves the respiratory organs and kidneys.

Ocular signs are seen in 40 to 50 per cent of the cases. Due to involvement of the orbit there may be proptosis, chemosis, disturbance of ocular motility and papilloedema. Other ocular lesions include inflammations of the conjunctiva, sclera, cornea, uvea and optic nerve.

Diseases of the Muscles

Myasthenia gravis⁴

The recent reports indicate a genetically-determined immunological defect. There is production of autoantibodies which cause destruction of acetylcholine receptors on the muscle cell. There are two types—ocular and generalized. About 80 per cent cases of the ocular type develop generalized muscular weakness. About 50 per cent of patients with generalized myasthenia exhibit ocular symptoms.

Ocular myasthenia usually starts with ptosis and diplopia, the symptoms getting worse towards the evening. Lid twitching is a characteristic sign. This is followed by development of generalized muscular weakness. In the generalized type there is difficulty in swallowing or chewing. Later in the course of the disease there is weakness of the limbs and muscles of respiration.

Myasthenia-myopathic syndrome is found in thyrotoxicosis and bronchogenic carcinoma.

Treatment. One 15 mg neostigmine bromide

tablet is taken initially at a frequency of 4 to 6 hour daily along with 0.5 mg atropine sulphate twice daily. Atropine is given to counteract the muscarinic side effects of neostigmine. Mestinon (60 mg tablet) is given alone or along with neostigmine. Oral steroids gradually increased to 40 mg/day have been advocated in ocular myasthenia.

Myopathy (chronic progressive external ophthalmoplegia)⁴

Myopathy is a generic term used to indicate primary diseases of the muscles showing pathological, biochemical and electrophysiological changes.

It is classified under: (a) genetically determined, i.e. progressive muscular dystrophy and myotonic dystrophy; (b) congenital; (c) metabolic which includes thyrotoxic and steroid myopathy; (d) polymyositis; (e) drug-induced, e.g. clofibrate, beta-blockers, and (f) carcinomatous.

Progressive muscular dystrophy. It is a genetically-determined myopathy characterised by symmetrical wasting and weakness of the muscles.

This is classified as: (a) X-linked; (b) autosomal; (c) facioscapulohumeral; (d) distal; (e) ocular; and (f) oculopharyngeal.

Ocular myopathy. This is a rare variety of progressive muscular dystrophy. It starts either in childhood or in an adult. Dominant heredity has been recorded in some cases. The condition used to be called 'progressive nuclear ophthalmoplegia', but 'progressive external ophthalmoplegia' appears to be more appropriate.

There are progressive bilateral ptosis, total ophthalmoplegia and weakness of the orbicularis oculi. In advanced cases some of the patients may show involvement of the pharynx, larynx, face, neck and muscles of the limb girdle; these cases can be called 'descending ocular myopathy'. Ocular myopathy may be associated with several conditions (Table 48.12).

Table 48.14
WHO Classification of Features of Vitamin A
Deficiency^{26,27}

Classification	Feature
XN	Night blindness
X 1A	Conjunctival xerosis
X 1B	Bitôt's spots
X 2	Corneal xerosis
X 3A	Keratomalacia involving less than one-third of corneal surface
X 3B	Keratomalacia involving more than one-third of corneal surface
XS	Corneal scarring
XF	Xerophthalmia fundus

Table 48.15
Daily Requirements of Vitamin A

Infants	300-400 µgm
Children	250-600 µgm
Adolescents	750 µgm
Women during second half of pregnancy and during first year of lactation	1150 µgm

(b) Bad choice of food article

- (ii) Defective absorption—due to diarrhoea, dysentery, etc. Role of intestinal infestation with helminths should be stressed
- (iii) Increased demand e.g. during growing period, pregnancy and convalescence
- (iv) Defective conversion of carotene into vitamin A in the liver as in kwashiorkor.

Xerophthalmia is more frequent in kwashiorkor, less so in atrophic malnutrition and rare in marasmus.¹⁴

Pathology. The epithelium of the conjunctiva and cornea becomes keratinised, goblet cells are destroyed and there is infiltration of the corneal stroma and degeneration of Bowman's membrane. Later on, there is metaplasia and hyperplasia of the epithelium followed by invasion by microorganisms. Colliquative necrosis of the whole cornea ensues in some cases.

Metaplasia and hyperplasia also occur in the

mucous membranes of the respiratory, gastrointestinal and urinary tracts.

Clinical features. In India keratomalacia is the most common cause of blindness between the third and fourth years of life.

Infants are the most common victims, although children and adults may not escape (Fig. 48.2). The affected infant looks ill. Concomitant evidences of undernutrition or malnutrition are frequently present. The condition is bilateral.

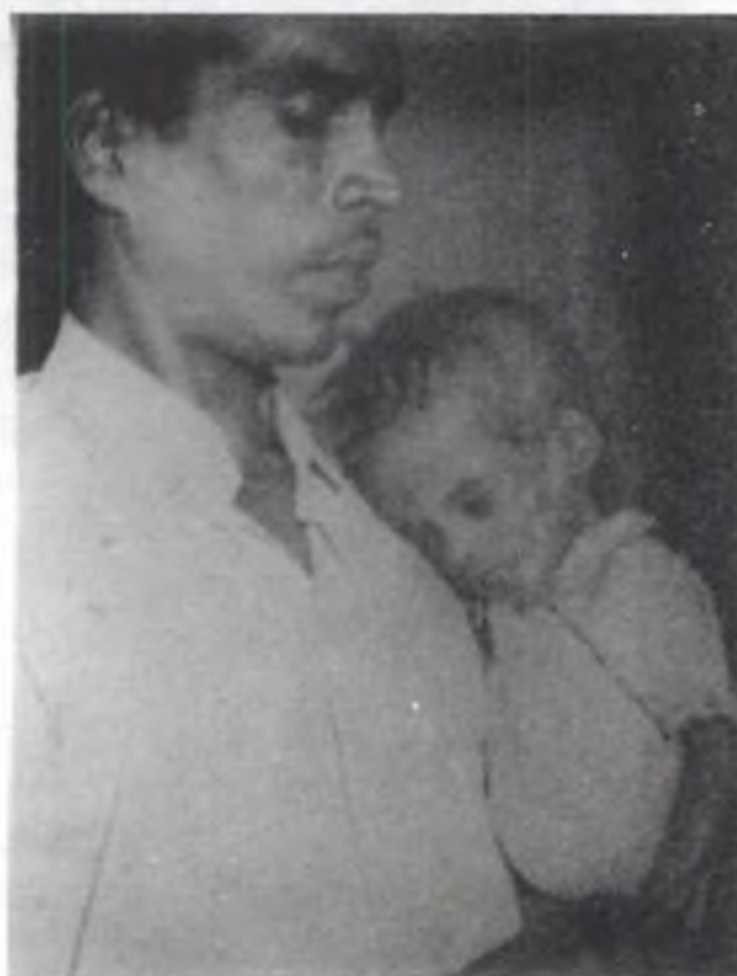

Fig. 48.2 A child with keratomalacia.

Conjunctival xerosis. There is a wrinkling (concentric with the limbus) of the dry, slightly smoky conjunctiva in the equatorial region of the bulbar conjunctiva especially marked on its outer aspect. If this sign is present in an infant, it is almost diagnostic of the condition. But in adults such wrinkling and folding may point to the conjunctival thickening following prolonged irritation and repeated attacks of conjunctivitis. The conjunctiva also loses its wettability though tear production is usually adequate.

Bitôt's spot (Fig. 48.3). It is an important but an equivocal sign of hypovitaminosis A. It is a bilaterally symmetrical, triangular, foamy and dull

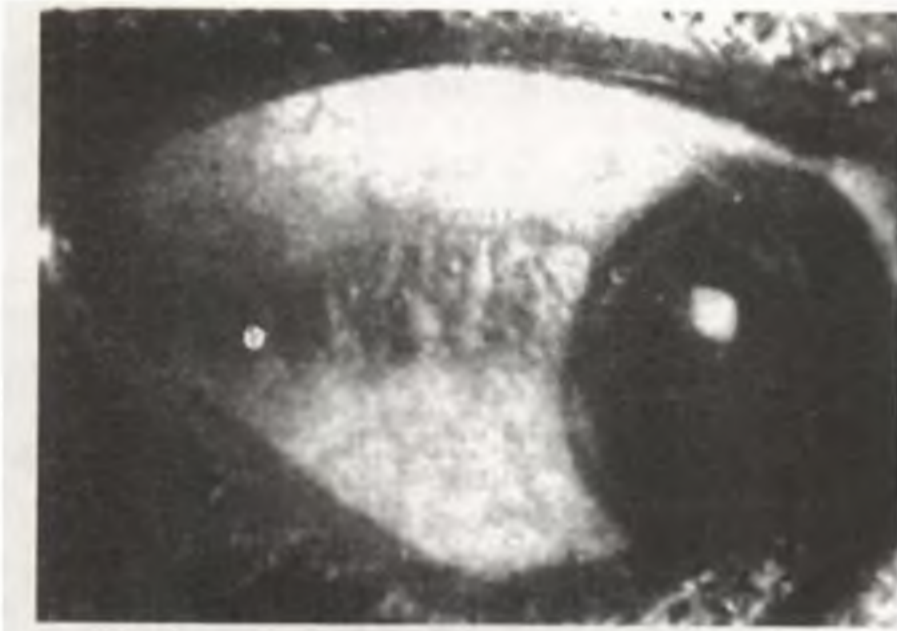

Fig. 48.3 Bitot's spot.

white, patch with its base towards the limbus situated at the same site as described earlier. Microscopic examination reveals epithelial debris, fatty globules and many diphtheroids or xerotic bacilli. Bitot's spots do not disappear necessarily with administration of vitamin A. They may disappear at times, and reappear spontaneously when there is probably poor nutritional state. Xerotic bacilli are in no way related to xerosis. They are so named because they had at first been isolated from xerotic conjunctiva.

Corneal xerosis. This stage is characterized by the appearance of superficial streaks of haziness in the cornea with impairment of sensibility, but unaccompanied by inflammatory signs, i.e. without any pain and without any ciliary congestion. Recent works emphasize that isolated linear streak of epithelial defect in the lower half of the cornea is a typical early picture of avitaminosis A.

Corneal ulceration with xerosis. The necrosis of the cornea occurs following xerosis. Both the conjunctiva and cornea become dry with patchy exfoliation of the epithelium.

Keratomalacia. Initially there are small discrete facets either at the limbus or near the limbus or in the paracentral area of the cornea. The cornea softens and ruptures in one place first and then in another. Finally there is colliquative necrosis of the whole cornea. Most often the onset is acute and the course is fulminating. The affected child is very ill, apathetic and lies almost

motionless. Examination of the cornea is extremely difficult because of its tendency to rupture easily. Following perforation there is iris prolapse. The ulcer itself is characterized by torpidity and absence of inflammatory signs.

There may be localized keratomalacia known by different names such as *malnutritional keratitis*, *keratolysis profunda*, *discrete colliquative keratopathy* and *nutritional myocephalon* in which there is a clean iris prolapse, 2 to 3 mm in diameter close to the lower limbus.

Diagnostic tests include serum vitamin A level, impression cytology and dark adaptation.

Treatment. Not only the 'sick eye' but also the 'sick body' must be taken into consideration while treating keratomalacia. Intramuscular doses of 1 00 000 IU vitamin A is administered on the first day, in conjunction with high oral back-up does if possible. Even 2 to 3 00 000 IU may be given in a very severe case. The intramuscular injections are recommended for three days, after which 50 000 IU are given orally for one week. High protein diet is essential. So if a child can tolerate milk it should be given. Glucose is added to the milk to counteract associated hypoglycaemia. If there is evidence of gross dehydration, infusion may be necessary. Encouragement of breast-feeding up to the age of two years helps in proper growth of the child, and prevents protein energy malnutrition and vitamin A deficiency.

It is also suggested that leaf protein prepared by extraction of fresh green leaves and then by heat precipitation of protein is an acceptable form of protein especially when milk is scarce. The leaf protein is believed to be a rich source of provitamin beta-carotene.¹⁸

Prophylaxis. Newborn infants should receive oral dose of 50,000 IU at birth, subsequently 100,000 IU before reaching 1 year of age and 200,000 IU after 1 year.

Vitamin B deficiency

Vitamin B deficiency manifests itself usually by multiple signs. Vitamin B deficiency may be

associated with ophthalmoplegia and toxic amblyopia. Vitamin B₂ or riboflavine deficiency may be responsible for a corneal vascularization. Vitamin B₁₂ deficiency is possibly related to toxic amblyopia. Treatment consists of administration of vitamin B complex; vitamin B₁ should be 5 to 30 mg/day; riboflavine is to be given 10 to 30 mg/day.

Vitamin C deficiency

Vitamin C deficiency causes haemorrhages at different sites and delayed healing of corneal wound and ulcer. The usual therapeutic dose is 100 to 300 mg/day.

Vitamin D deficiency

Vitamin D deficiency may have some relation with cataract in cases of rickets. The therapeutic dose is 5000 to 10,000 IU/day.

Vitamin K deficiency

Vitamin K deficiency is especially associated with haemorrhagic diseases in the newborn.

Miscellaneous Disorders

Miscellaneous disorders have been described elsewhere, except a few conditions which are described below.

Acne rosacea occurs in elderly women with red spots on the nose and the cheeks, and occasional eye signs (blepharoconjunctivitis, keratitis, etc.).

Acne vulgaris affects face of young adolescents due to sebaceous gland overactivity and may cause blepharoconjunctivitis.

Gout. It is an inborn error of purine metabolism characterized by gouty arthritis, tophi, conjunctivitis, episcleritis, etc.

Further Reading

- Arffa, R.C., *Grayson's Diseases of the Cornea* (4th ed.), Mosby Year Book, St. Louis, 1997.
- Ariffin, A., Hill, R.D. and Leigh, O., *Diabetes and Primary Eye Care*, Blackwell Scientific, Oxford, 1992.
- Ben Ezra, D., The retina in storage diseases. In *Textbook of the Fundus of the Eye* (3rd ed.), Michaelson, I.C. (Ed.), Churchill Livingstone, Edinburgh, 1980.
- Brain, R. and Walton, J., *Diseases of the Nervous System* (7th ed.), Oxford University Press, London, 1980.
- Drachmann, D.A., Ophthalmoplegia plus. The neurodegenerative disorders associated with progressive ophthalmoplegia. *Arch. Ophthalmol.*, 18:654, 1968.
- Duke-Elder, S., *System of Ophthalmology*, Vol XII: *Neuroophthalmology*. Duke-Elder, S. and Scott, G.I. (Eds.), Kimpton, London, 1971.
- Duke-Elder, S., *System of Ophthalmology*, Vol XV: *Summary of Systemic Ophthalmology*, Kimpton, London, 1976.
- Epstein, R.L., Inborn metabolic disorders and the eye. In *Principles and Practice of Ophthalmology*. Peyman, G.A., Sanders, D.R. and Goldberg, M.F. (Eds.), W.B. Saunders, Philadelphia, 1980, p. 1707.
- Gopalan, C., Ramsastri, B.V. and Balasubramanian, S.C., Nutritive value of Indian foods. *National Inst. of Nutrition, ICMR*, Hyderabad, 1976.
- Harley, R.D. (Ed.), *Pediatric Ophthalmology*, W.B. Saunders, Philadelphia, 1975.
- Huber, A., *Eye Symptoms in Brain Tumours*, English Ed., Van Wier (Ed.) C.V. Mosby, St. Louis, 1961.
- Kanski, J.J., Thomas, D., *The Eye in Systemic Disorders* (2nd ed.), Butterworth-Heinemann, London, 1994.
- Knox, D.L., Ocular aspects of cervical vascular disease. *Surv. Ophthalmol.*, 13:245, 1969.
- Kuming, B.S., The evolution of keratomalacia. *Trans. Ophthalmol. Soc., UK*, 87:305, 1967.
- Melen, O. Ophthalmic manifestations of

- brain tumours. In *Principles and Practice of Ophthalmology*, Peyman, G.A., Sanders, D.R. and Goldberg, M.F. (Eds.), W.B. Saunders, Philadelphia, 1980, p. 1982.
16. Nevin, S. and Kiloh, L.G., Organic affections. In *Modern Ophthalmology* (2nd ed.), Vol. II, Sorsby, A. (Ed.), Butterworths, London, 1972, p. 345.
 17. Rodger, F.C. and Sinclair, H.M., *Metabolic and Nutritional Eye Diseases*, Charles C. Thomas, Springfield, III, 1969.
 18. Rodger, F.C. *Eye Diseases in the Tropics*, Churchill Livingstone, Edinburgh, 1981.
 19. Roy, I.S. and Ahmed, E., Hypovitaminosis A from intestinal infestations. In *Documenta Ophthalmologica*, Vol. V: *Public Health Ophthalmology*, Holmes, W.J. (Ed.), Hague, 1975.
 20. Smith, L.H., Inherited metabolic disease with pediatric ocular manifestations. In *Principles and Practice of Ophthalmology: Clinical Practice*, Albert, D.M. and Jacobiec, F.A. (Eds.), W.B. Saunders, Philadelphia, 1994, p. 2777.
 21. Somerset, E.J., *Ophthalmology in the Tropics*, Baillière, Tindall and Cox, London, 1962.
 22. Sommer, A., Assessment of Vitamin A status level by a disc applicator for conjunctival impression cytology. *Arch. Ophthalmol.*, 108:1436, 1990.
 23. Stillerman, M.L., Ocular aspects of diffuse collagen diseases. In *Modern Trends in Ophthalmology* (3rd series), Sorsby, A. (Ed.), Butterworths, London, 1955, p. 158.
 24. Wall, M., Multiple sclerosis. In *Principles and Practice of Ophthalmology: Clinical Practice*, Albert, D.M. and Jacobiec, F.A. (Eds.), W.B. Saunders, Philadelphia, 1994, p. 2682.
 25. Woods, A.C., Ocular tuberculosis. In *Modern Ophthalmology* (2nd ed.), Vol II, Sorsby, A. (Ed.), Butterworths, London, 1972, p. 105.
 26. WHO. *WHO Tech. Rep. Ser.* No: 580, 1975.
 27. WHO. *WHO Tech. Rep. Ser.* No: 590, 1976.

49. TUMOURS

A tumour may be benign or malignant and it may involve the eye as well as the related structures. Most of the tumours are easily seen and can be clinically diagnosed. Intraocular tumours cause visual loss and if malignancy is missed they prove fatal. Biopsies are essential to differentiate between benign tumour and malignant one.

Fine-needle aspiration biopsy (FNAB). Prior to aspiration, peribulbar anaesthesia in adults and general anaesthesia in children are essential. A 25-gauge spinal needle with an obturator is introduced. Aspiration is done by a syringe after taking out the obturator.

For tumours affecting the anterior ocular segment, the needle is introduced through the limbus opposite the site of the tumour.

For posterior segment tumours, a transvitreal route is preferred guided by indirect ophthalmoscopy in case of clear media or by ultrasonography in hazy media. Positive FNAB is diagnostic, while a negative test does not rule out malignancy.

Treatment is basically surgical. If they are not diagnosed early treatment can only be palliative.

The tumours of the orbit, eyelids, lacrimal apparatus, and conjunctiva have been described in the related chapters. The incidence of various tumours has been shown in Table 49.1.

Tumours of the Cornea³

The important neoplasms in relation to the cornea are limbal dermoid, epithelioma, melanoma and intraepithelial epithelioma or Bowen's disease.

Corneal epitheliomata. The notable precursor of carcinoma is the epidermalization of the nearby epithelium with or without dyskeratosis. The incidence of squamous cell versus basal-cell carcinoma is 10:1.

A limbal epithelioma is usually preceded by ulceration, opacification, vascularization or pterygium involving the cornea. To start with there is a small, greyish nodule near the limbus. It

gradually becomes larger, papillary or warty, sessile, intensely vascularized and fixed to the underlying tissues. Eventually it invades the surrounding tissues.

Treatment. Usually excision is enough. In suspicion of scleral spread, radiation/X-ray application may be added. In case of recurrence or the eyeball involved, enucleation is indicated.

The incidence of different ocular tumours has been indicated in Table 49.1.

Intraepithelial epithelioma or carcinoma in situ or Bowen's disease. Intraepithelial epithelioma starts at the limbus and spreads preferentially towards the cornea. It is smooth, opaque and flat growth over the cornea. Histological picture is one of squamous cell carcinoma. In early stage, treatment consists of a careful excision.

Pigmented Tumours⁷

Melanin. It is a protein derivative, liberated from the protoplasm of melanocytes. The melanocytes are mature melanin-forming cells, while melanoblasts are immature cells. Melanophores only carry the pigment.

Genetic classification of melanomas is shown in Table 49.2. Table 49.3 shows pigmented lesions of the conjunctiva.

Pigmented tumours of the lid and conjunctiva^{7,10}

Naevus (Fig. 49.1). Naevus or benign pigmented tumour of the conjunctiva is the most common tumour, most frequently at or near the limbus, present from an early age. Cutaneous pigmented naevi are formed chiefly by the naevus cells derived from proliferation of epidermal melanocytes.

Blue naevus. This rather uncommon, still rare in the conjunctiva, is a benign melanocytic tumour and appears blue because of the filtering effect of the overlying tissues.

Precancerous melanosis. The condition is acquired melanosis occurring in adults not preceded by a naevus. Malignant change follows

Table 49.1

Incidence of Various Related Tumours (1950-1975)

Retinoblastoma	434
Epithelioma of the lid, conjunctiva and limbus	186
Haemangioma	134
Dermoid cyst	115
Papilloma	65
Fibroma	63
Naevus	49
Lymphoma	49
Adenocarcinoma of Meibomian glands	36
Haemangioendothelioma	30
Lipoma	229
Malignant melanoma	28
Mixed tumour of the lacrimal gland	26
Meningioma of the orbit	16
Undifferentiated sarcoma	15
Glioma of the optic nerve	14
Adenoma of the sebaceous glands	12
Neurofibroma	12
Rhabdomyosarcoma	9
Leucaemic deposits in the eyeball	9
Schwannoma	6
Chloroma of the orbit	3
Sympatheticoblastoma	3
Fibrosarcoma	3
Secondary carcinoma of the orbit with primary in the lungs and antrum	3
Reticulum cell sarcoma	2
Lymphangioma	2
Myxoma	2
Hydatid cyst of the orbit	2
Osteoclastoma of the orbit	2
Plasmocytoma of the orbit	2
Adenocarcinoma of the sweat glands	2
Ganglioneuroma	2
Angiosarcoma	2
Metastatic carcinoma of the choroid (Primary—breast and lungs)	2
Adenoma of meibomian gland	2
Teratoma of the limbus	1
Leiomyoma of the ciliary body	1
Diktyoma	1
Myxosarcoma of the lid	1
Osteosarcoma of the orbit	1

Courtesy: Regional Institute of Ophthalmology, Kolkata.

possibly in about 17 per cent while in the rest the lesion either progresses or remains quiescent or regresses.

Cancerous melanosis. Cancerous melanosis is a superficial melanocarcinoma and the distinction

Table 49.2
Genetic Classification of Melanomas

Neurogenic	
From the neural crest	
Uveal	
Blue naevus	
Melanosis oculi and naevus of Ota	
Leptomeningeal melanoma	
From the optic vesicle	
Retina] From the pigment epithelium
Ciliary body	
Iris	
Epitheliogenic	
Melanoma of the skin	
Melanoma of the mucous membrane	

Table 49.3
Type of pigmented lesions of the conjunctiva

Benign Melanosis	—	Epithelial
		Subepithelial
Naevi	—	Epithelial
		Subepithelial
Malignant melanoma		
Epithelial		
Subepithelial		

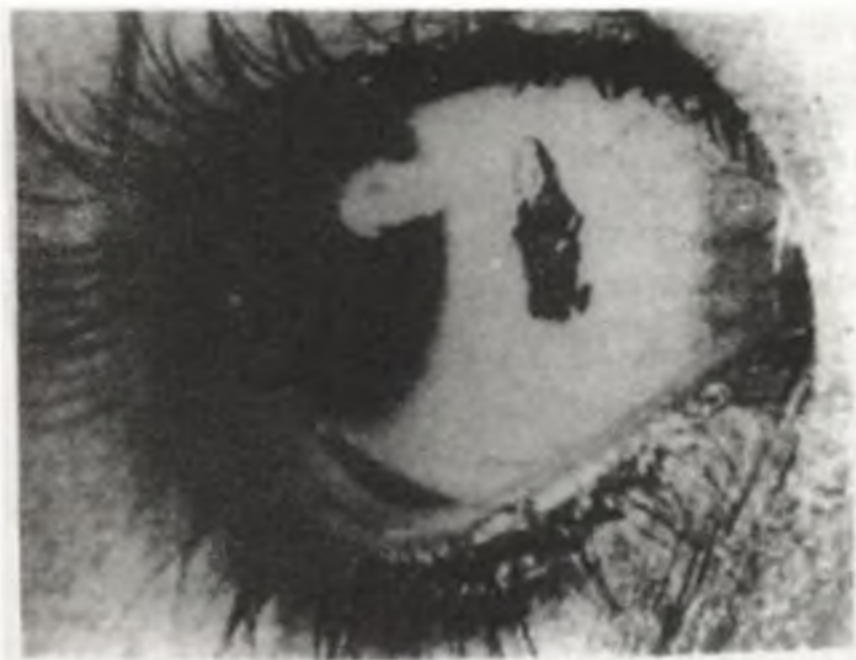

Fig. 49.1 Naevus of left bulbar conjunctiva.

between precancerous and cancerous melanosis is clinically almost impossible. This condition of the conjunctiva or adjacent skin follows a precancerous melanosis or arises spontaneously.

Oculodermal melanocytosis (naevus of ota). Oculodermal melanocytosis is a condition resembling melanosis oculi, unilateral and present from birth, involving periorbital and palpebral skin, episclera, sclera and even uveal tract. In melanosis oculi there is congenital hyperpigmentation of pigment-bearing tissue in and around the eye.

Malignant melanoma. Malignant melanoma of the skin or of the conjunctiva may either develop spontaneously, or occur in a pre-existing naevus or in a precancerous melanosis.

Tumours of the Uveal Tract⁴

Uveal melanocytes are believed to be derived from the neural crest. It is proposed that most melanomas of the choroid and ciliary body originate from the pre-existing naevi.

Classification. (a) Primary

1. Epithelial
 - Benign, e.g. epithelial hyperplasia, adenoma
 - Malignant, e.g. medulloepithelioma and epithelioma
 2. Neuroectodermal
 - (i) Schwannian neurofibroma and neurilemmoma
 - (ii) Melanoma-naevi, benign melanoma and malignant melanoma
 3. Muscular, e.g. leiomyoma
 4. Vascular-haemangiomas
 5. Reticuloses
- (b) Secondary
- (i) Direct—e.g. spread from retinoblastoma
 - (ii) Metastatic, e.g. spread from hypernephroma and chorionepithelioma

Epithelial hyperplasia

Epithelial hyperplasia of the pigmented epithelium occurs following inflammation, degeneration or glaucoma. It consists of proliferated pigmented cells over the front surface of the iris. Epithelial hyperplasia also occurs in the ciliary epithelium; it commonly affects the ciliary processes.

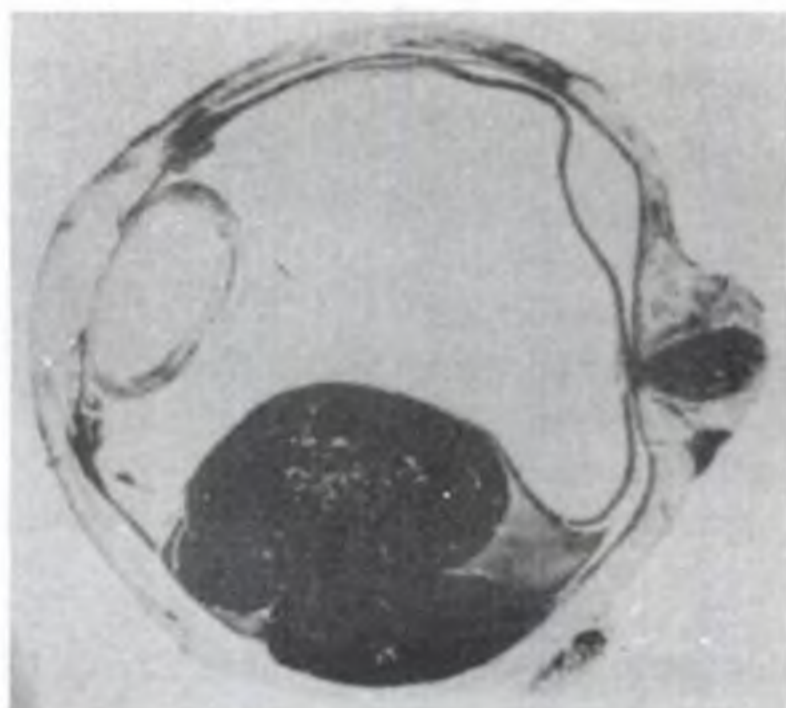


Fig. 49.2 Microphotograph of the eyeball showing malignant melanoma in the posterior half and complete retinal detachment (May and Worth).

because of its high mitotic activity. The test is not reliable in low-grade malignancy and it gives false-positive test. Because of emitting rays, this ^{32}P test is also hazardous.

(b) *Trephine biopsy* is sometimes done, but a direct biopsy of the tumour itself is not indicated because of likelihood of causing widespread dissemination.

(c) *Fluorescein angiography*. See p. 522.

(d) The value of *ultrasonography* in the diagnosis of the tumour even in the presence of hazy media is enormous. Both A-scan and B-scan may be used, but the latter is more useful. Ultrasonography indicates the morphological appearances and acoustic properties of the tumour.

(e) *Magnetic resonance imaging* is of some value in determining the size of the tumour.

(f) *Colour-coded Doppler imaging* exhibits Doppler shifts in choroidal melanoma and haemangioma.

(g) *Examination of the aqueous humour* is sometimes called for evidence of increased lactic dehydrogenase activity as also seen in retinoblastoma. Sediment derived from the subretinal fluid should be examined for detection of the tumour cells.

Even with the best of efforts about 10 per cent cases remain undiagnosed and in them histological

confirmation is possible after the enucleation of the painful and blind eye.

Differential diagnosis.⁹ The condition should be differentiated from:

- (a) Rhegmatogenous retinal detachment
- (b) Detachment of the choroid
- (c) Disciform degeneration at the macula
- (d) Benign melanoma
- (e) Tuberculoma
- (f) Choroidal haemorrhage
- (g) Melanosis oculi
- (h) Choroidal angioma
- (i) Cyst of the choroid
- (j) Metastatic tumours

Rhegmatogenous retinal detachment. Clinical picture is characteristic, the hole is detected while transillumination is negative.

Detachment of the choroid. See p. 475.

Disciform degeneration at the macula. Elevation and pigmentation are present in both disciform degeneration and malignant melanoma of the choroid. The differential diagnosis from malignant melanoma of the choroid. The differential diagnosis from malignant melanoma of the choroid may be made from the following features present in disciform degeneration: (a) deep haemorrhages in and around the lesion; (b) presence of exudates; (c) more often colloid bodies are formed; (d) the surface is irregular; (e) there is evidence of degeneration of the fellow eye; and (f) fluorescein angiography is of great help.

Benign melanoma of the choroid. It may co-exist in the same or fellow eye. Its size, rarely $1\frac{1}{2}$ times bigger than the optic disc, is almost flat, while malignant melanoma (Fig. 56.4) progresses rapidly to form a large protuberant mass. The retina over the lesion is barely affected.

Tuberculoma. There are a few distinguishing points and these are: (a) pearly appearance with presence of mottlings. The mottlings indicate the caseating areas; (b) it is more nodular with sometimes presence of satellite lesions; and (c) the final picture is of atrophy and pigmentation.

Choroidal haemorrhage. It is often a round,

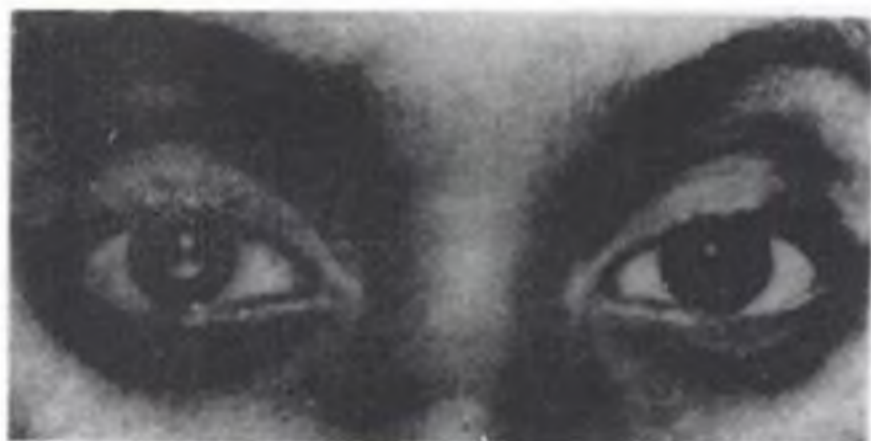

Fig. 49.3 Retinoblastoma showing white reflex at the pupil (Dr. S. Banerjee).

Stage I. Intraocular growth and extension involving: (a) the outer or inner nuclear layer of the retina; and (b) other multiple origins.

The tumour may grow inwards (*glioma endophytum*) towards the vitreous or may grow outwards (*glioma exophytum*) towards the choroid. The ophthalmoscopic appearances are different. If it grows towards the vitreous, polypoid masses with haemorrhages on the surface can be detected. If it grows outwards it causes a secondary retinal detachment. In the rare, diffuse infiltrative type the clinical features are those of uveitis with secondary glaucoma. There may be white flecks due to calcification of the necrosed areas. This stage lasts for about 6 to 12 months.

The extension may be: (a) through the layers of the retina; (b) into the choroid; (c) along the optic nerve; (d) through the sclera; (e) implanation; and (f) metastasis.

Stage II. Secondary glaucoma occurs causing buphthalmos, scleral rupture, proptosis, ulceration and fungation.

This stage lasts for about 6 months.

Stage III. Extraocular extension is by extension through the sclera or along the optic nerve. The spread is along the nerve bundles and rarely goes beyond 10 mm from the optic disc.

Stage IV. Metastasis occurs in the skull bones, the distal bones and the viscera.

Pathology. Retinoblastoma is an intensely cellular tumour. The cells are round with dark-staining nuclei, scanty cytoplasm and closely packed together. There are numerous well-formed blood vessels, but the supply appears to be inadequate to

the needs of the tumour causing patchy necrosis. During this process the cells close to the vessels survive. These perivascular surviving cells become multilayered and form *pseudorosettes*. *Rosettes* are formed by elongated cells arranged radially to an apparently empty lumen, and they are regarded tentatively as a partial differentiation toward rod and cone cells. The necrotic area remains somewhat localized. Hence retinoblastoma may not excite any inflammation. They readily calcify as white flecks and are visible radiologically.

Most retinoblastomas show both undifferentiated, the predominant and the rosetted types of growth. Rarely there is more advanced differentiation of tumour cells and formation of photoreceptor elements.

Lactic dehydrogenase activity is grossly increased in retinoblastoma. This is evidenced by the study of the aqueous humour.

Diagnosis. Diagnosis is aided by the investigations listed in Table 49.5.

Table 49.5

Diagnostic Work-up in Retinoblastoma

1. Direct and indirect ophthalmoscopy after full mydriasis and proper sedation/anaesthesia
2. X-rays of the orbit and skull for evidence of calcification
3. Computerized tomography for assessing intraocular calcification and extraocular extension
4. Magnetic resonance imaging for detection of spread into the optic nerve
5. Aqueous cytology with electron microscopy
6. Aqueous lactic dehydrogenase (LDH) level—grossly increased

Prognosis. There are six groups (Table 49.6).

Treatment. There are four principal categories of cases:

- (a) Unilateral tumour
 - (i) In the moderately advanced or far-advanced case, enucleation is advocated.
 - (ii) In the localized tumour, diathermy or light coagulation may possibly be of some help, but these are not dependable.

Table 49.6
Prognosis of Retinoblastoma¹

Group	Prognosis	Characteristics
1. Most favourable		Solitary and multiple tumours less than 4 disc diameters at or behind the equator
2. Favourable		Solitary and multiple tumours 4 to 10 disc diameters at or behind the equator
3. Average		Any lesion anterior to the equator
4. Unfavourable		Multiple tumours greater than 10 disc diameters
5. Most unfavourable		Massive tumour involving more than half the retina and vitreous seeding
6. Worst		Residual orbital disease, optic nerve involvement and extrascleral involvement

(b) Bilateral tumour

(i) Enucleation of the eye with far-advanced disease may be resorted to.

(ii) Radium and cobalt-60 discs are used. They are sutured in place and kept for the period of time necessary to administer. The recommended dose is 4000 rad to the summit of the tumour in one week.

(iii) Chemotherapy combined with radiation.

(iv) Light coagulation.

(v) Diathermy.

(c) The case with residual tumour tissue, following enucleation should be irradiated.

(d) In extension to the orbit or distal metastasis, the treatment suggested is triethylene melamine (TEM) 0.1 mg/kg body weight.

Astrocytoma

Astrocytoma, a benign tumour occurs in the age-group of 20 to 30 years and arises from the inner layers of the retina affecting the posterior pole. The diagnosis is only possible microscopically after excision of the eyeball.

Haemangiomas

Angiomatosis retinae shows a preference of

involvement for the peripheral retina. Arteriovenous anastomoses may also occur.

Secondary Tumours of the Retina

Most of the emboli that can lodge in the retina are of infectious nature. Rarely carcinoma of the oesophagus, pancreas, liver, rectum, uterus and breast, and sarcoma may cause retinal metastasis.

Tumours of the Optic Nerve and Sheaths⁵

Classification. Tumours of the optic nerve and sheaths may be classified as:

(a) Intracranial, usually the glioma

(b) Intraorbital

(c) Intraocular. This is divided into: (i) primary, e.g. nerve tumours and phakomata; (ii) secondary from the adjacent tissues, e.g. retinoblastoma and malignant melanoma of the choroid.

Clinical features. The intracranial tumour is characterized by progressive loss of vision, optic atrophy and visual field changes.

The intraorbital tumour is characterized by proptosis which is slowly progressive, axial and irreducible, early and rapid visual loss, and radiographic signs.

The intraocular tumour is asymptomatic in the early stage, but later on causes diminution of vision and ophthalmoscopically visible tumour.

Histologically they are classified into three broad groups:

Ectodermal—glioma

Mesodermal—meningioma

Neuroectodermal

Table 49.7 shows the distinguishing features of glioma and meningioma of the optic nerve.

Both meningioma and optic nerve glioma are benign, the only exception being spongioblastoma, *glioblastoma multiforme*, which is the most malignant of the brain tumours.

Treatment consists of an early and complete excision, if possible after an orbitotomy.

Table 49.7

Distinguishing Features of Glioma and Meningioma of the Optic Nerve⁵

Points	Glioma	Meningioma
Nature	Ectodermal	Mesodermal
Histology	Astrocytes or oligodendroglial cells	Endothelium of dural sheath
Association	Neurofibroma	
Age	Early	Usually after 30 years
Visual acuity	Early and serious disturbance	Less marked
Proptosis vs visual loss	Visual loss years before proptosis	Early proptosis
Ocular immobility	Late and not marked	Early and marked
Spread	Directly along the nerve but does not penetrate the dura	Tends to perforate the dura and invade the orbit
X-ray of the optic canal	Enlargement	None
Circulatory disturbance	Less common	Common
Visual field	Not characteristic	More characteristic compression of the nerve *

Further Reading

1. Bedford, M.A., Bedetto, C. and McFaul, P., Retinoblastoma: a study of 139 cases. *Brit. J. Ophthalmol.*, 55:19, 1971.
2. Blodi, F.C., Tumours. In *Modern Ophthalmology* (2nd ed.), Vol. III, Sorsby, A. (Ed.), Butterworths, London, 1972.
3. Duke-Elder, S., *System of Ophthalmology*, Vol. VIII: *Diseases of the Outer Eye*, Part 2: *Cornea and Sclera*, Duke-Elder, S. and Leigh, A.G. (Eds.), Kimpton, London, 1964.
4. Duke-Elder, S., *System of Ophthalmology*, Vol. IX: *Diseases of the Uveal Tract*, Duke-Elder, S. and Perkins, E.S. (Eds.), Kimpton, London, 1966.
5. Duke-Elder, S., *System of Ophthalmology*, Vol. XII: *Neuro-Ophthalmology*, Duke-Elder, S. and Scott, G.I. (Eds.), Kimpton, London, 1971.
6. Greer, C.H., *Ocular Pathology* (3rd ed.), Blackwell Scientific, Oxford, 1979.
7. Reese, A.B., *Tumours of the Eye* (3rd ed.), Harper and Row, New York, 1976.
8. Reese, A.B., Jones, I.S. and Cooper, W.C., Surgery for the tumour of the iris and ciliary body. *Am. J. Ophthalmol.*, 66:173, 1968.
9. Rubenstein, K., Differential diagnosis of malignant melanoma. *Trans. Ophthalmol. Soc. UK*, 87:447, 1967.
10. Vaughan, D. and Asbury, T. (Eds.), *General Ophthalmology*, 7th ed., Lange Medical Publications, California, 1974.

50. OCULAR INJURIES

The eyeball is well protected by the bony walls of the orbit and eyelids. The inferotemporal quadrant of the orbit is least protected. Ocular injuries may be either mechanical or nonmechanical. A mechanical injury may be contusion or concussion, and penetrating. A penetrating or perforating injury may or may not be associated with the presence of an intraocular foreign body. A nonmechanical ocular injury may be due to varied causes.

Conjunctival foreign bodies^{4,5}

Foreign bodies, usually small, may be impacted in the conjunctiva. foreign bodies like coal particle, metal particle, stone chip, grains of corn, husks of seeds and wing cases of insects may stick to the palpebral conjunctiva or lie loose in the lower fornix, and sometimes in the upper fornix and the bulbar conjunctiva. A foreign body impacted in the palpebral conjunctiva may excoriate the cornea by mechanical dragging over the latter. Removal of the loose foreign body is possible by a clean swab or handkerchief. In the upper palpebral conjunctiva, the sulcus subtarsalis is a favourite site of impaction. After surface anaesthetisation removal of the foreign body is not difficult. In

cases of impacted foreign body in the bulbar conjunctiva, removal by a needle after anaesthetization is called for.

Foreign bodies upon the cornea

Foreign bodies upon the cornea may be single or multiple, superficial or deep. They may be wind-blown dust, iron chip, glass fragment or caterpillar hair. They must be removed after instillation of a surface anaesthetic, following which an antibiotic eye ointment is advised. Occasionally a drop of 2 per cent homatropine is instilled after removal of the foreign body. There are certain foreign bodies which get deeply embedded but are non-toxic in nature, and they need not be removed. A typical instance is the fragment of a non-leaded glass. The removal of such a foreign body leads to greater damage than if it is left *in situ*. Accessible foreign bodies should always be removed.

Contusion and Concussion Injuries^{4,6,10}

A contusion injury may result from a direct or an indirect impact. As a result of direct impact over the eyeball and acting anteroposteriorly, there is compensatory distension around the equator of the globe and there are widespread effects. An indirect injury like head injury causes ocular contusion or concussion especially when the eye is already showing pathologic changes. A perforating injury may also reveal effects of contusion or concussion. Table 50.1 gives an account of the investigations necessary to arrive at a precise diagnosis.

Contusion injury of the eyelids

Contusion injury of the eyelid produce gross oedema and ecchymosis of both the lids and conjunctiva, called *black eye*. Treatment is only conservative including application of cold compresses. A black eye may last for 1 to 2 weeks. *Emphysema of the eyelid* is very rare. It is due to the presence of air passing from the nasal cavities of sinuses into the lids. It may follow fracture of the wall of the orbit. A firm dressing is of some

Table 50.1

Diagnostic Evaluation of Ocular and Adnexal Injuries

Visual acuity — uncorrected, corrected and with pin hole
Examination of the skin, face and orbit
Eyelids — look for haematoma, oedema and wound
Conjunctiva — for subconjunctival haemorrhages, chemosis, etc.
Sclera — for foreign body, perforation with or without prolapse of uveal tissue
Cornea — for foreign bodies, haziness, irregularity, wound and staining
Anterior chamber — depth and presence of hyphaema
Pupils — symmetry, size, shape, irregularity and reactions to light
Iris — evidence of injury
Crystalline lens — cataract, lens displacement
Vitreous humour — haze and haemorrhage
Ocular movements — for any restriction
Ophthalmoscopy
Ocular tension
X-rays
CT scan/MRI

help in hastening disappearance of the air. The cornea may show abrasions, deep opacities and rarely a rupture.

Contusion injury of the cornea

Corneal abrasions. These are caused by a minor foreign body or sometimes by contact lens-wear. An antibiotic eye ointment and patching of the eye are essential, occasionally a drop of 2 per cent homatropine is instilled.

Blood staining of the cornea. As a result of a contusion injury hyphaema is not unusual. If hyphaema is associated with secondary glaucoma it may cause a blood staining in which the corneal lamellae are filled with minute particles derived from haemoglobin.

Deep opacities may occur as an after-effect of a contusion injury. They are due to corneal oedema or wrinkling of Descemet's membrane. They generally clear up.

Rupture of the cornea is very rare. Treatment is suturing of the cornea by an atraumatic needle.

Contusion injury of the sclera

Contusion injury of the sclera leads to scleral rupture. A scleral rupture is either direct at the site of impact or indirect frequently occurring in the weak spots in the sclera. The latter is perhaps more common. It is usually near to and concentric with the limbus, in the vicinity of Schlemm's canal and is usually found superonasally following a contusion injury caused from the least protected inferotemporal direction. Marked ocular hypotony is highly suspicious. Other suggestive features include chemosis, blood in the AC, and decreased visual acuity.

Complications include: (a) iris prolapse, ciliary body prolapse, or iridodialysis; (b) subconjunctival dislocation of the lens; (c) hyphaema; (d) vitreous haemorrhage; (e) retinal and subretinal haemorrhage; and (f) retinal detachment.

Injuries of the iris, ciliary body and choroid (Table 50.2)

The possible effects are:

Table 50.2

Effects of Concussion and Contusion Injuries on the Iris, Ciliary Body and Choroid²

<i>On the iris:</i>	<i>On the ciliary body:</i>
Miosis	Spasm of accommodation
Mydriasis	Traumatic cyclodialysis
Hyphaema	<i>On the choroid:</i>
Tear of the sphincter	Haemorrhage
Iridodialysis	Detachment
Irideraemia	Rupture
Iridoschisis	Inflammation

(a) *Traumatic miosis* occurs due to irritation of the nerves occurring as an initial feature of contusion injury of the iris, which is followed by traumatic mydriasis. Constriction of the pupil is marked but usually transient.

(b) *Traumatic mydriasis* similarly follows a contusion injury, perhaps more common, and is probably due to paralysis of the nerve fibres supplying the sphincter and the ciliary muscle.

(c) *Rupture in the pupillary margin*, often minute, is the most common lesion.

(d) *Iridodialysis*. There is separation of the ciliary margin of the iris, not an uncommon condition, presenting a black biconvex area at the periphery of the iris and a D-shaped pupil. Treatment consists of instillation of atropine in the early stage. After a suitable recovery period the extent and effect of iridodialysis are assessed. A grossly dialysed iris is repaired by suturing the torn peripheral margin to a scleral incision just behind the limbus.

(e) *Haemorrhage from the iris* causes hyphaema (Fig. 50c.1) may be mild to severe. If the whole of the AC is filled with blood, the posterior ocular structures are not visible and secondary glaucoma often ensues. A paracentesis is indicated when there is threatening or actual secondary glaucoma. If secondary glaucoma continues with a pressure higher than 25 mm Hg lasting for about a week there is likelihood of developing blood staining of the cornea.

(f) *Rare iris injuries* include *anteflexion* of the iris that is the pigmented back of the iris faces forwards occurring in extensive iridodialysis; *retroflexion* or inversion; and *traumatic aniridia* or *irideraemia*, that is the complete detachment of the iris from its ciliary attachment.

(g) *Rupture of the choroid* results from severe contusion injury or bullet injury passing through the orbit. The immediate result is an extensive vitreous haemorrhage. After absorption of this haemorrhage, the rupture is detected showing these characteristics (Fig. 50c.2):

- (i) Usually it is near the optic disc
- (ii) It is concentric with the disc and is usually on its temporal side
- (iii) It is a yellowish white streak with pigmented edges
- (iv) The retinal vessels cross the streak
- (v) Sometimes multiple ruptures are present.

Treatment consists of atropine eye drops and rest till the blood which is extravasated is absorbed.

(h) *Choroidal haemorrhage* follows a contusion injury.

Concussion injuries of the lens

A concussion injury may cause a cataract,

(d) Retinal detachment secondary to contracture of the organized vitreous tissue

(e) Detachment occurring in eyes having myopia, senile or postinflammatory degeneration in which trauma is the precipitating factor.

Traumatic proliferating chorioretinopathy is prone to develop after a gunshot injury which causes a similar rupture of both the retina and the choroid. This is accompanied by gross vitreous haemorrhage and great loss of vision.

Macular hole (*see pp. 333–34*)

Optic nerve injury

Optic nerve injury may produce rupture and avulsion of the nerve and traumatic optic atrophy. Such injury occurs specially in a fracture of the base of the skull.

Disturbance of ocular tension

Disturbance of ocular tension may present as hypotony or secondary glaucoma. Ocular hypotony occurs in severe concussion injury. Secondary glaucoma due to injury may follow various factors, e.g. dislocation of the crystalline lens, and intraocular haemorrhage.

Perforating Injuries⁴

A perforating injury is always serious because of its effects and the following considerations.

(a) *Introduction of infection.* It sometimes causes disastrous ocular complications like ring abscess of the cornea, purulent iridocyclitis and panophthalmitis.

(b) *Posttraumatic iridocyclitis.* It occurs commonly after a perforating injury. Such an iridocyclitis may be of immediate type following the injury, or delayed type. The initial inflammation passes off to be often followed by recurrent and recalcitrant plastic iridocyclitis.

(c) *Sympathetic ophthalmitis.* This is a rare but very serious type of uveitis, which is bilateral.

A perforating injury of the uvea particularly involving the ciliary body is often the antecedent factor. Three weeks to two months after an injury in one eye, the fellow eye develops uveitis. The injured or the exciting as well as the fellow eye has a tendency to run an indolent course with relapses.

There are two groups of perforating injuries: with the presence of a foreign body and without the presence of a foreign body.

Perforating injuries without the presence of an intraocular foreign body may involve the eyelids, conjunctiva, sclera, lens, vitreous and retina.

Wounds of the eyelids

Wounds of the eyelids may occur after an accidental injury especially in an automobile accident. The good blood supply of the eyelids reduces the risk of tissue necrosis even in cases of lacerated wounds.

A detailed examination is imperative and associated head injury or condition of shock, if present, must be noted. The extent and the type of the wound, injuries to the neighbouring structures namely the lid margins, puncta, canaliculi and lacrimal sac, and the presence of bleeding, are considered before undertaking treatment.

Treatment. Treatment consists of cleaning the dirt or the removal of debris, control of bleeding, measures to combat shock and infection, and repair of the actual wound.

An incised wound may be vertical involving the orbicularis oculi or horizontal. The horizontal wound usually heals without deformity, while the edges of the vertical wound should be apposed by fine silk.

In lacerated wounds, skin grafting or use of sliding flap may be advocated.

Wounds of the conjunctiva

Wounds of the conjunctiva are common. The wounds heal rapidly because of rich blood supply, lymphatic supply, and the presence of reticuloendothelial system readily providing

mononuclear cells and fibrocytes. Granulation tissue in the subepithelial layer forms in 4 to 7 days which forms the scar tissue.

Treatment. If extensive, the edges should be sutured by silk. Protruding granulation tissue should be snipped off by scissors.

Perforating injury of the cornea⁹

A corneal perforation may or may not be associated with retention of an intraocular foreign body. Unless very minute, a corneal perforation is followed by loss of the aqueous from the AC. This is followed by either apposition of the iris with the wound or iris prolapse depending on whether rent is absent or present.

Treatment. The essential step is to exclude an intraocular foreign body by proper radiological investigations. Any prolapsed iris must be abscised and the rent should be repaired by sutures and occasionally covering with a conjunctival flap. The usual steps after repair include introduction of sterile air into the AC, atropine, local and systemic antibiotics.

Perforating injury of the sclera

Perforating injury of the sclera is always serious because of associated intraocular haemorrhage, injury to the lens, vitreous and retina. But if it is clean it should be closed by interrupted 7/0 mild chromic catgut sutures. The prolapsed iris should always be excised. The conjunctiva and Tenon's capsule are also sutured. This treatment is feasible if the portion of the sclera injured is accessible. If the wound is in the posterior part it is treated with diathermy or cryoapplication. A large wound associated with gross injury of the ocular tissues having no chance of recovery of vision should be excised.

Wounds of the lens

Wounds of the lens always cause a traumatic cataract except when a small opening in the anterior

capsule is completely sealed. A rent wound produces rapid opacification and flocculence of the lens matter. This leads to severe iridocyclitis and secondary glaucoma. Sometimes peripheral anterior synechiae form.

Perforating injuries with presence of foreign body^{4,5}

Perforating injuries with the presence of an intraocular foreign body add dangers to the eye because of its mechanical effects, tendency to cause infection and its specific action on the intraocular tissues.

An intraocular foreign body may be retained in the AC (15%), in the lens (8%), in the posterior ocular segment (70%) and in the orbit (7%). It may be metallic or nonmetallic. Metallic foreign bodies include: (a) toxic metals like lead, zinc, iron, nickle, copper and aluminium; (b) nontoxic metals like gold, silver and platinum. Nonmetallic foreign bodies include vegetable matter, stone, glass and plastic material.

The presence of more than one foreign body must always be suspected and looked for.

Mechanical effects. An intraocular foreign body may be located in the AC, in the iris or may pass into or through the lens. It may even reach the vitreous or lodge in the retina and the orbit.

When it is in the AC it may fall into the lower part, and if small it may be retained in the angle of AC. A slit-lamp examination reveals a glass particle with difficulty, because the refractive index of glass is almost equal to that of the surrounding media.

An opening in the iris is a diagnostic sign since it indicates the route of the entrance. Sometimes the foreign body caught in the iris is seen with a loupe but better by a slit-lamp.

Traumatic cataract is produced by the foreign body passing into or through the lens. Rarely the lens is spared if the foreign body passes through the circumlental space.

A foreign body in the vitreous or retina causes degenerative changes. Occasionally it pierces

through the coats of the eye to reach the orbit, called *double perforation*.

Infection. It is a common accompaniment. Some foreign bodies like stone and wood are more prone to cause infection than others like flying metallic particles.

Specific reactions of the ocular tissues. Some of the foreign bodies may be inert such as glass, porcelain and plastics. A few of them like lead and aluminium cause local irritation.

Another group which contains zinc and copper produces suppuration.

Degenerative changes occur in case of iron and copper.

If iron is left in the eye for months, there is electrolytic dissociation of iron into iron salts or free irons. These permeate the ocular tissues and form insoluble toxic products when coming in contact with cellular proteins. Early changes occur in the lens causing rusty brown deposits disposed radially at the periphery of the anterior capsule. The iris becomes at first greenish and then reddish brown. The particles may be deposited in the trabecular meshwork to produce glaucoma. The retina shows a picture of degeneration resembling that of pigmentary dystrophy of the retina. Loss of vision finally ensues because of the involvement of the retina and the lens. The condition described above is called *siderosis bulbi*.

Copper may be pure or heavily alloyed. Pure copper evokes violent suppuration. If it is alloyed it causes *chalcosis*. After electrolytic dissociation the deposition occurs at the periphery of the deeper parts of the cornea known as *Kayser-Fleischer ring* and under the anterior lens capsule to produce a *sunflower cataract* and occasionally in the posterior pole of the retina.

A stone is almost always septic and leads to an endophthalmitis.

Wood chips tend to produce much granulation tissue formation.

Localization of intraocular foreign bodies^{6,7,8}

The methods of localization of an intraocular foreign body can be grouped as:

- (a) Slit-lamp biomicroscopy and gonioscopy
- (b) Ophthalmoscopic examination
- (c) Radiographic examination
- (d) Electroacoustic location
- (e) Ultrasonography.

Slit-lamp biomicroscopy and gonioscopy. Slit-lamp biomicroscopy can detect the site of lodgement of a foreign body in a transparent media, while gonioscopy is especially valuable in detecting minute bodies trapped in the filtration angle.

Ophthalmoscopic examination. It sometimes helps to find out the location of a foreign body when there are clear media.

Radiographic techniques. Several methods can be adopted and they are as follows: (a) direct posteroanterior and lateral exposures in relation to the radioopaque locator are taken.

(b) A few exposures are needed to find out the relative positional changes of the foreign body on rotation of the eyeball in certain directions of gaze.

(c) Geometric projection involves taking of two X-rays, the head and eyes being fixed.

(d) Bone-free method (Vogt) is possible if the foreign body lies in front of the equator. Five exposures are needed while the patient looks in front, up, down, right and left.

(e) The other methods are the stereoscopic method and X-ray after injection of contrast medium into Tenon's capsule.

Limbal ring localization. One-mm thick silver ring with three loops at 3, 12 and 9 o'clock positions is stitched (12 mm diameter) to snugly fit the limbus after adequate anaesthetization. Two exposures are very essential: postero-anterior and lateral.

A line is drawn on the lateral view of the plates backward from the centre of the ring shadow and at right angles to it giving these the following measurements.

(a) The distance of the foreign body situated is deep to the plane of the limbus; if 3 mm are added, it indicates the distance deep to the tangential plane in relation to the midpoint of anterior surface of the cornea.

(b) Distance of the foreign body in mm above or below the horizontal corneal axis.

(c) The third measurement is calculated from the posteroanterior view. The centre of the ring is plotted on the X-ray plate. The vertical corneal axis is obtained by a vertical line passing through the centre of the ring and then the position of the foreign body is assessed, on the nasal or the temporal side by direct measurement (Fig. 50.1).

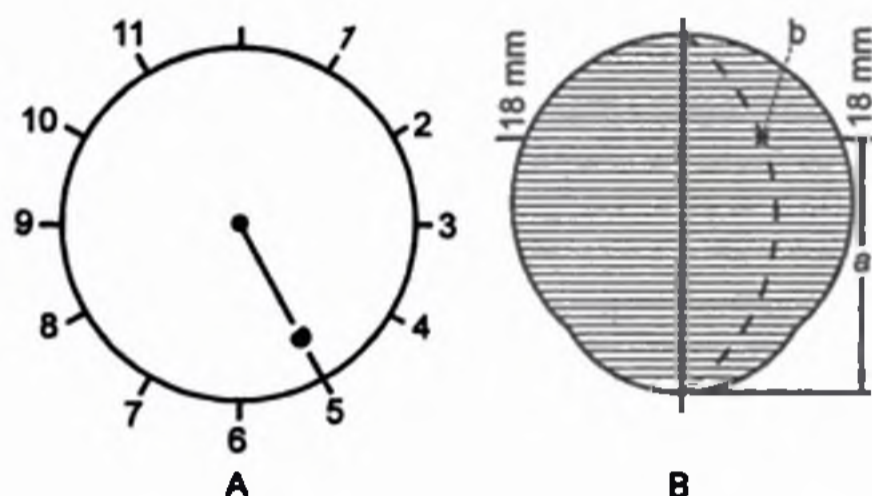


Fig. 50.1 Method of foreign body localization from plane radiographs. The foreign body is placed in its correct meridian by examination of the posteroanterior film (A) (in this case 5 o'clock). The line of the 5 o'clock meridian is then plotted on the plan view of the eye. (B) The distance to the foreign body (a) anterior surface of the cornea, is measured from the lateral film. The foreign body must lie at the position where the 18 mm line intersects the line of the 5 o'clock meridian (b) (Scheie and Albert)

Electroacoustic location. It is possible by electronic apparatus, which can locate both magnetic and nonmagnetic foreign bodies. Roper-Hall has described his recent model of the *electroacoustic metal foreign body locator* in which the instrument gives different signal responses automatically when ferrous or nonferrous metals are present. The response is continuous in case of ferrous, while it is rapidly intermittent in nonferrous metal.

Ultrasonography is able to detect and localize radiotranslucent intraocular foreign body when situated in the anterior orbit, but is not reliable when the foreign body lies deep in the orbit.

Computerized tomography (CT). Both axial and coronal views of CT are very helpful in determination of the precise location of foreign

body. Foreign bodies like lead-free glass, stone, steel and aluminium can be clearly visualized, while CT fails to delineate wooden foreign body.

Magnetic resonance imaging (MRI). It is useful in detecting vegetable matter and wooden foreign bodies. It cannot be used if there is any suspicion of a metallic foreign body.

Treatment. Two factors determine the principle of treatment to be followed: the composition of the foreign body and its magnetic strength. If it is inert and sterile it should be left alone. If the size of the foreign body is very small and very little damage to vision occurs, or if the method of removal is most likely to be followed by loss of vision, removal of the foreign body should not be attempted. A magnetic foreign body can be removed occasionally without difficulty. Hand magnets or hand electromagnets are used if the distance from the particle is very small, less than 2 mm. But if the distance is more than 2 mm a large electric magnet is used.

The use of viscoelastic agent during surgery is of immense benefit.

Removal of a magnetic foreign body^{4,9}

In the AC. A keratome incision is given 3 mm from the limbus. The positive pole of a hand magnet is placed over the foreign body, outside the cornea, and is moved towards the incision till the foreign body is drawn across the AC.

On the iris. The part containing the foreign body should be abscised with de Wecker's scissors.

In the lens. After a few days a curette evacuation is done, and occasionally it is feasible to remove it with a small magnet.

In the vitreous or retina. A large magnet is needed for its removal. There are two routes of removal—anterior and posterior. Posterior route is preferred if the foreign body is large with jagged edges, and this method causes less ocular damage than when the anterior route is employed. Magnetic removal is recommended as soon as possible after the injury.

Anterior route removal. Maximal mydriasis is essential before an operation. The principle is to navigate the foreign body into the AC and then to remove it with a hand magnet. In this technique the terminal of the magnet is placed over the cornea and alternately the current is switched on and off till the foreign body reaches the posterior chamber as evidenced by the bulging of the iris. At this moment the current is switched off; otherwise, the foreign body is caught in the iris. Now the magnet terminal is placed to the opposite point of the limbus which drags the particle from the posterior chamber through the pupil into the AC. The foreign body is then removed by a hand magnet in the manner already described.

Posterior route removal. The essential prerequisite is to reduce the ocular tension by intravenous injection of 250 ml of 20 per cent mannitol one hour before the operation. The sclera is incised as close to the foreign body as possible. A foreign body situated in the anterior vitreous is preferably removed through a pars plana sclerotomy, of adequate size, concentric with the limbus. For more posteriorly-situated foreign bodies, the sclera is incised with preplaced sutures at the edges of the scleral wound. After removal of the particle the wound is closed. A cryoprobe is applied to the edges to reduce the risk of retinal detachment. In the presence of vitreous loss a plombage is also necessary.

Nonmagnetic foreign bodies

Nonmagnetic foreign bodies pose a lot of difficulties. They are removed from the AC or iris with specially-designed forceps after a keratome incision. It can be removed from the lens in the same manner as in magnet extraction but with a plane forceps it is possible after a few days. It is extremely difficult to remove a foreign body from the vitreous and it is better done by vitrectomy instrument. An endoscopic removal is feasible, but it is very traumatizing.

It must be emphasized that retention of an intraocular foreign body is always disastrous, but after-effects of removal of a large foreign body

accompanied by vitreous disturbance are no less serious.

Retention of the foreign bodies in ocular adnexa

A foreign body may be retained in the lid, lacrimal passages or in the orbit. Foreign body retention in the lid is rare. If it is inert as glass particle it lies dormant in the lid; if it is irritant such as wood it may provoke formation of a nonspecific granuloma. Infection is a common complication which leads to suppuration and subsequently fistula formation. Foreign body in the lacrimal passages is rare, an errant eyelash may enter the punctum. Lodgement of a foreign body within the orbit is sometimes missed because the route of entry is not seen properly or the patient may consider the injury as trivial. But usually following an injury proptosis and oedema develop. The patient may complain of diplopia because of the involvement of the extrinsic muscles. There may be loss of vision due to optic nerve involvement when the foreign body reaches the apex of the orbit. Occasionally suspicion arises when there is an obstinate fistula.

Nonmechanical Injuries^{3,5,10}

Nonmechanical injuries include injuries caused by burns, irritants, gases and corrosives. The main causes are shown in the Table 50.3. A burn may be thermal, chemical—acids or alkalis, and radiational.

Table 50.3

Chief Types of Nonmechanical Ocular Injury

Inorganic acids—sulphuric, hydrochloric and nitric
Organic acids—acetic, succinic and maleic
Alkalies—sodium, ammonium and potassium
Metals—iron, copper, aluminium, mercury and lead
Nonmetallic irritants and corrosives—sulphur, silicone and hydrogen peroxide
Irritant and corrosive hydrocarbons—aniline dyes and phenol derivatives
Organic solvents—alcohols, aldehydes and ether
Irritant vegetable and animal products

Thermal burns of the eyelids

Thermal burns of the eyelids may occur following

burn due to hot water and tobacco ashes. These usually involve the eyelids, occasionally the cornea.

Treatment. Treatment depends on the degree of the burn:

In first degree – cleansing and application of saline compress and antibiotic solution are necessary.

In second degree – cleansing and debridement are needed. The vesicles are opened and dead epithelium removed.

The third degree – requires skin grafting to prevent severe contracture and exposure keratitis.

Chemical burns

The severity of chemical burns is dependent on the following factors:

- (a) Physical state and nature of the chemical
- (b) Toxic action of the chemical on the conjunctiva and cornea
- (c) Duration of contact

While the corneal stroma allows the entry of both water-soluble substances and electrolytes, the water-soluble and fat-soluble substances enter the intact epithelium of the cornea, while the corneal stroma allows the entry of both water-soluble substances and electrolytes.

Acid burns

In acid burns, such as that caused by battery acid, there is corneal damage due to precipitation and denaturation of the corneal proteins. Though severe acid burn causes immediate gross corneal injury producing sloughing of the epithelium, further deeper invasion may not occur due to precipitation of corneal proteins. Recent studies show that corneal ulceration is the result of lysis of the corneal collagen fibrils by collagenase.

Alkali burns¹

In alkali burns such as that caused by lime or ammonia, the lesion is more damaging, since there

is denaturation of corneal mucopolysaccharides or release of mucopolyaccharide from the association of collagen and disappearance of the stromal cells.

An alkali burn may cause the following lesions:

(a) In the cornea—extensive loss of epithelium, corneal anaesthesia, and extensive corneal haziness

(b) In the conjunctiva—chemosis and necrosis

(c) In the iris and ciliary body—iridocyclitis may develop within minutes

(d) Later effects—include symblepharon, corneal vascularization and secondary glaucoma.

Treatment. The measures include:

(a) Emergency decontamination which consists of immediate, thorough and copious irrigation with water, and prompt removal of all particles.

(b) Continuous irrigation of conjunctival sac from an infusion set by making a stab wound through the lower lid and irrigating through a polythene tube may also be called for in a severe case.

(c) Mechanical debridement of loose corneal epithelium and necrotic conjunctiva, and in case of removal of necrosed conjunctiva a mucous membrane or sliding conjunctival graft will be needed.

(d) Local treatment with atropine, antibiotic and steroid is essential.

(e) Systemic steroid helps in controlling associated uveitis and preventing symblepharon formation.

(f) Use of protective contact lens.

(g) Other measures include:

- (i) Prophylaxis and treatment of symblepharon
- (ii) Tarsorrhaphy
- (iii) Correction of cicatricial ectropion and entropion
- (iv) Repair of lacrimal passages
- (v) Corneal grafting, etc.

In alkali burn of the cornea topical use of collagenase inhibitors such as EDTA (ethylenediamine tetraacetic acid) salts or cysteine is effective.

Eclipse burn (Solar retinitis or foveomacular retinitis)

While gazing at a solar eclipse, especially a total eclipse, the concentrated light rays, infrared rays having wavelength above 700 millimicrons reach the macula where the visual energy is converted into thermal energy. Emmetropes and hypermetropes are more prone to develop eclipse burn of the macula than are myopes. Eclipse burn or solar retinitis affects the macula. The affection is often unilateral. The visual acuity is disturbed in varying degrees. Following the viewing of solar eclipse, sudden appearance and disappearance of after-image along with central or paracentral scotoma are common. Other symptoms include micropsia, macropsia and chromatopsia.

Ophthalmoscopy reveals macular oedema in the early stage. At first the foveal reflex is surrounded by a red area, and later there is actual oedema. Subsequently fine pigment stipplings are left behind.

Treatment. In the early stage, steroids given orally are found to be somewhat effective.

Orbital Fractures¹⁰

Classification. Following the types of orbital fractures:

- (a) Blow-out or hydraulic fracture of the floor
- (b) Blow-in or elevated fracture of the floor
- (c) Fracture of the medial wall
- (d) Nasoorbital fracture
- (e) Superior orbital fracture
- (f) Fracture of the lateral wall
- (g) Miscellaneous

It may be emphasized that the lower outer quadrant of the orbit is most exposed to a blunt trauma.

Clinical features. Clinical features include diplopia owing to impaired ocular mobility, point tenderness of the affected orbital margin; anaesthesia or hypoaesthesia corresponding to the cutaneous nerves involved; and sometimes other features like epistaxis, crepitations or difficult jaw movement.

Blow-out fracture of the orbit

Blow-out fracture of the orbit is the fracture of the floor of the orbit which is 0.5 to 1 mm thick and is the most vulnerable area, due to sudden increased intraorbital pressure following usually blunt injury of the soft tissue of the orbit. The injury from the front causes backward displacement of the orbital contents, which in turn transmits the increased pressure to the orbital walls and finally there is fracture of the area of least resistance. Following fracture there is some collapse of the floor and herniation of the orbital tissues into the maxillary antrum.

Diagnosis. Diagnosis is difficult in the early stage because the condition is masked by the evidence of a severe trauma. However, there are several features which clinch the diagnosis and these are:

- (a) Diplopia—there is vertical diplopia due to involvement of IR, IO, or both muscles.
- (b) Enophthalmos—first due to herniation of the orbital contents and later due to cicatrix formation.
- (c) Anaesthesia or hypoaesthesia of the affected area is present.

X-ray is of vital significance. Today tomography and computerised coronal tomography are available to assist the diagnosis.

Treatment. Surgery is indicated only when there is severe enophthalmos and gross entrapment of the muscle evidenced by severe diplopia. Within 10 days or so, surgery may be needed which comprises freeing the orbital contents and elevation of the floor. If needed, bone grafting is done, the approach being direct infraorbital.

Head injury

Head injuries often involve multiple structures: the brain, the skull, and the intracerebral vessels. The immediate clinical features are the result of a traumatic neuronal lesion. Evidence of superimposed oedema, haemorrhage or in connection with brain injury—concussion, contusion and laceration indicating whether the degree is minor, intermediate or major. A cerebral

compression may develop due to a meningeal haemorrhage.

Cerebral concussion. Complete recovery occurs after a brief spell of unconsciousness without any organic damage.

Cerebral contusion. Here the loss of consciousness is more prolonged. There are two stages: stage of cerebral shock and then stage of reaction.

Cerebral laceration. In addition to the changes seen in a cerebral contusion there are laceration of the brain substance, and effusion of blood into the CSF.

Cerebral compression. This causes progressive deterioration of the level of consciousness.

Traumatic intracranial haemorrhage. It may be extradural, subdural, subarachnoid and intracerebral.

Fractures of the skull. They may involve the vault or the base and are produced by compression of the sphere, local indentation or tangential injury.

Investigations. The investigations of a case of head injury should include the following examinations:

- (a) Level of consciousness
- (b) Posture, convulsions and twitching
- (c) Pulse, BP, respiration and temperature
- (d) Examination of the head for any wound, haematoma and fracture
- (e) Examination of ear, nose and mouth
- (f) Examination of cranial nerves and reflexes
- (g) Eye examinations
- (h) Skiagram of the skull and other special investigations including ultrasonography and CT scan.

Ocular implications. (See Table 50.4).

Cerebral concussion, contusion or laceration may have dramatic visual implications. During unconsciousness following a head injury the visual axes are not parallel but often show a divergence. But on regaining consciousness this divergence disappears. During cerebral irritation pupils are small and fixed.

Nystagmus indicates disturbance of vestibular apparatus during the period of cerebral shock.

Table 50.4

Ocular Manifestations of Head Injury

Immediate effects

- Haematoma of the lid
- Ecchymosis of the conjunctiva
- Pupillary changes, e.g. traumatic mydriasis
- Extrinsic muscle palsy
- Fracture of the wall or walls of the orbit
- Injury to the ocular motor nerves
- Injury to the visual pathways

Late effects

- Posttraumatic proptosis
- Subarachnoid bleeding
- Raised intracranial pressure

Ocular tension is lowered. In a midbrain injury the pupils are unequal. In fracture of the skull, the pupils are widely dilated and immobile, but typically it is ipsilateral to the affected side. The sixth, second and fourth cranial nerves are affected in a head injury. The other ocular signs include defective convergence and accommodation. The involvement of the visual pathways is common; there may be indirect traumatic optic atrophy, hemianopia and lesions affecting the optic chiasma, optic tract and visual cortex. The signs of cerebral haemorrhages have already been described.

Further Reading

1. Brown, S.I. and Weller, C.A., Collagenase-inhibitors in prevention of ulcers of alkali-burned cornea. *Arch. Ophthalmol*, 83:353, 1970.
2. Duke-Elder, S., *System of Ophthalmology*, Vol. XIV: *Injuries*, Part I. *Mechanical Injuries*, C.V. Mosby, St. Louis, 1972.
3. Duke-Elder, S., *System of Ophthalmology*, Vol. XIV: *Injuries*, Part I. *Non-mechanical Injuries*, C.V. Mosby, St. Louis, 1972.
4. Parsons, J.H., *Diseases of the Eye*, 18th ed. Miller S.J.H. (Ed.), Churchill Livingstone, Edinburgh, and ELBS, 1990.
5. Pavan-Langstone, D. (Ed.), *Manual of Ocular Diagnosis and Therapy* Little, Brown and Co., Boston, 1980.

6. Roper-Hall, M.J., Injuries. In *Modern Ophthalmology* (2nd ed.), Vol. III, Sorsby, A. (Ed.), Butterworths, London, 1972, p. 429.
7. Scheie, H.G. and Albert, D.M. (Eds.), *Textbook of Ophthalmology* (9th ed.), W.B. Saunders, Philadelphia and Igaku Shoin, Tokyo, 1977.
8. Stallard, H.B., *Eye Surgery* (6th ed.) Roper-Hall, M.J. (Ed.), John Wright and Sons, Bristol, 1980.
9. Trevor-Roper, P.D. and Curran, P.V., *The Eye and its Disorders* (2nd ed.), Blackwell Scientific, Oxford, 1984.
10. Zagora, E., *Eye Injuries*, Thomas, Springfield, Ill, 1970.

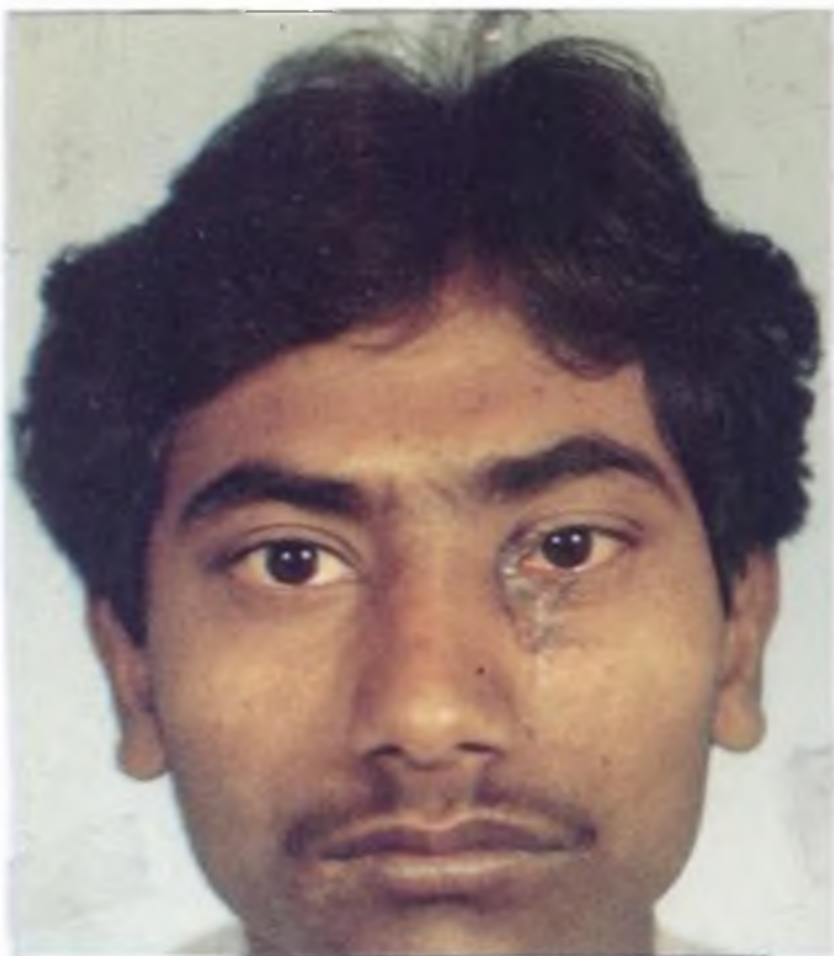

Fig. 35c.1 Ophthalmodermatozoosis.

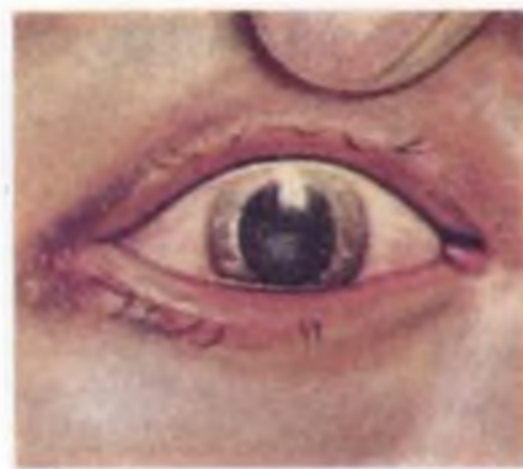

Fig. 35c.2 Chronic ulcerative blepharitis with madarosis (Parsons).

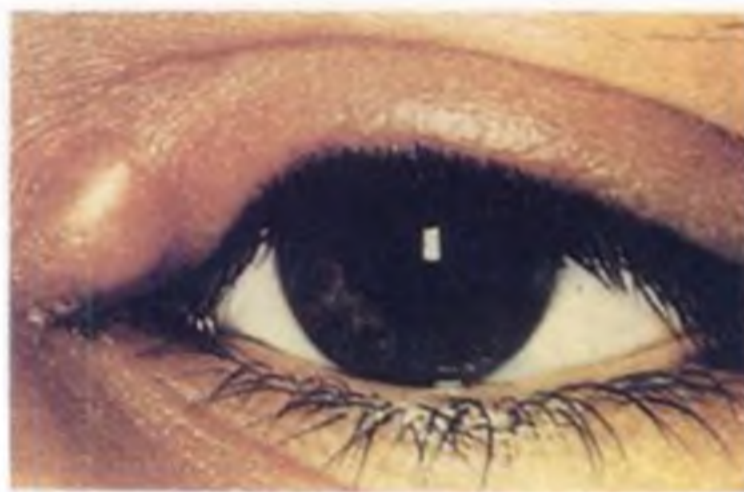

Fig. 35c.3 Stye (A.J. Bron).

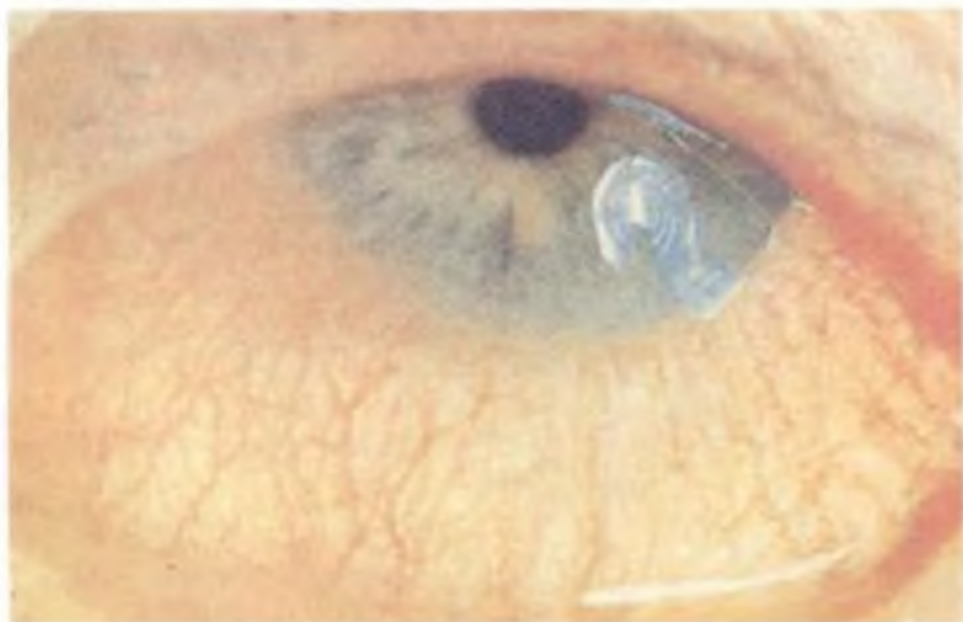


Fig. 37c.1 Conjunctival congestion (A.J. Bron).

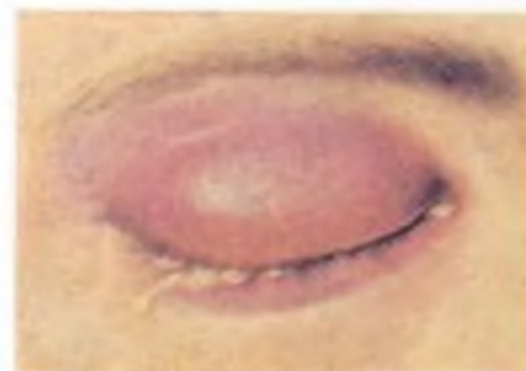

Fig. 37c.2 Purulent (gonococcal) conjunctivitis (Parsons).

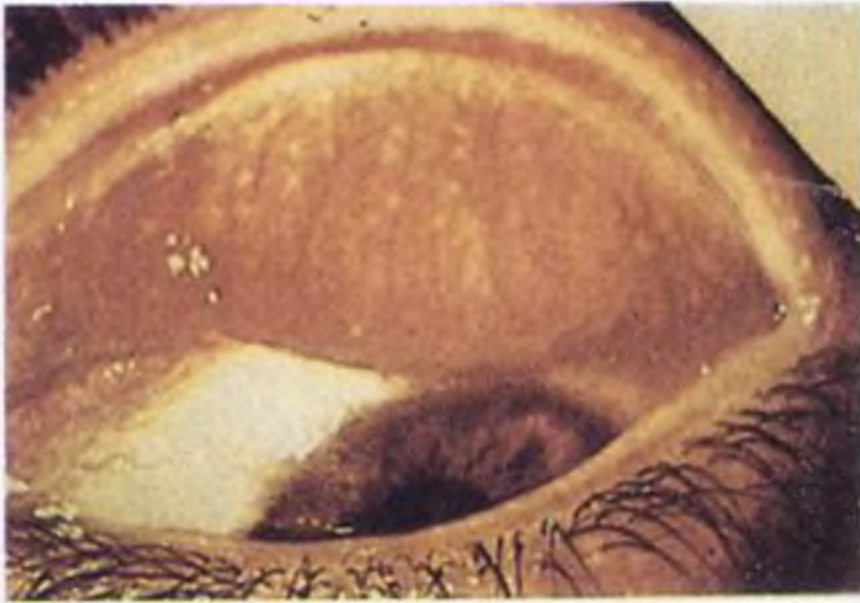


Fig. 37c.3 Follicles in the upper tarsal conjunctiva.

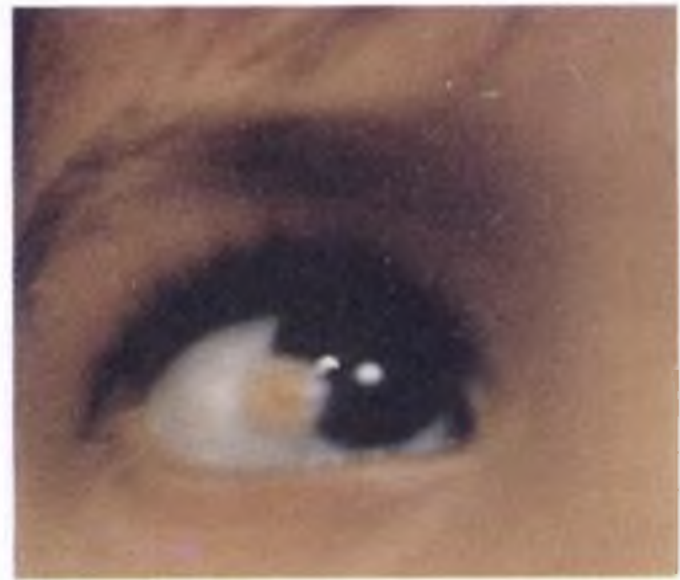

Fig. 37c.6 Dermoid cyst.

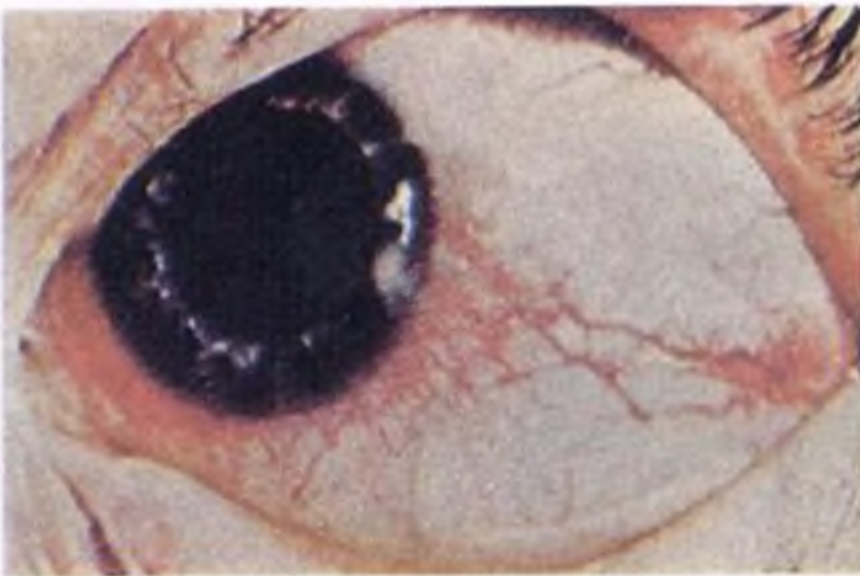

Fig. 37c.4 Phlyctenular conjunctivitis (May).

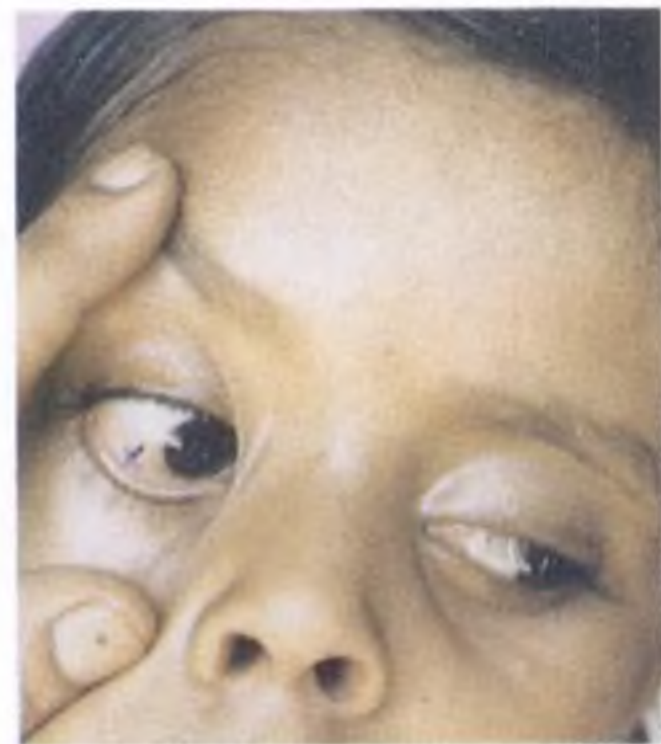

Fig. 37c.7 Dermolipoma.

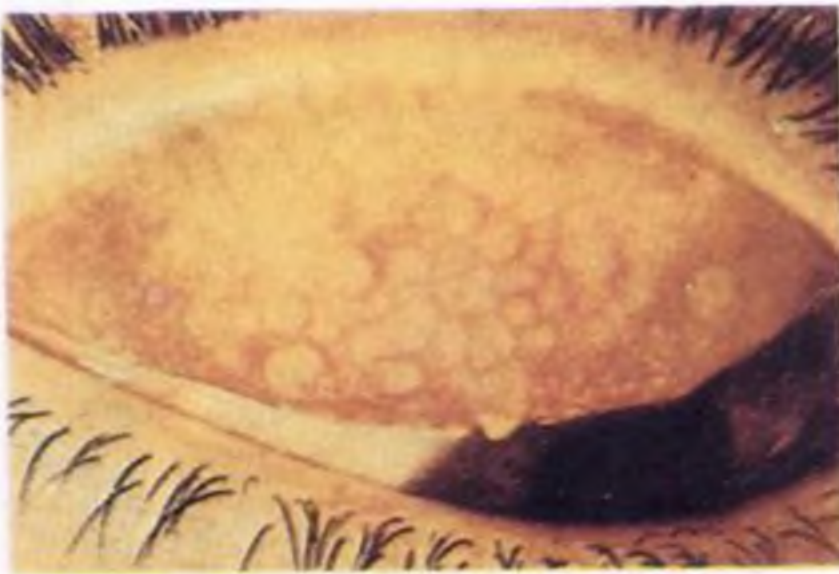

Fig. 37c.5 Giant papillae in vernal conjunctivitis.

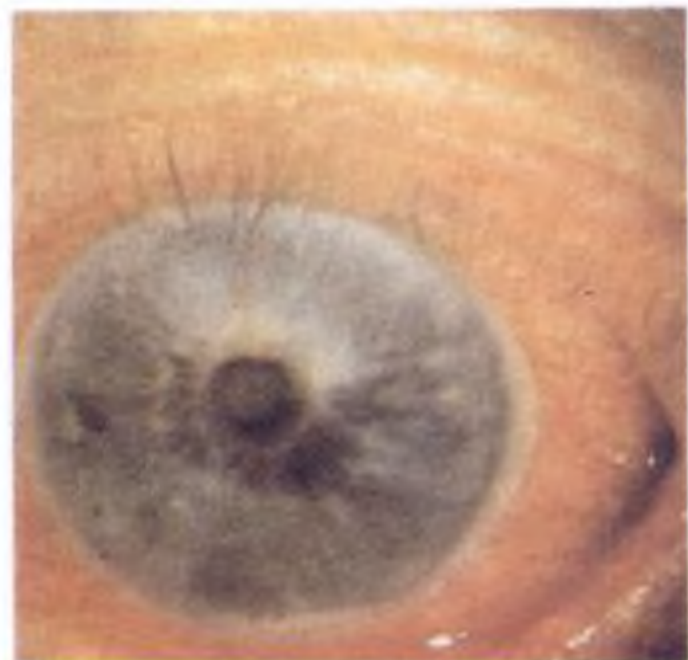

Fig. 38c.1 Hypopyon (A.J. Bron).



Fig. 38c.2 Herpes zoster ophthalmicus.

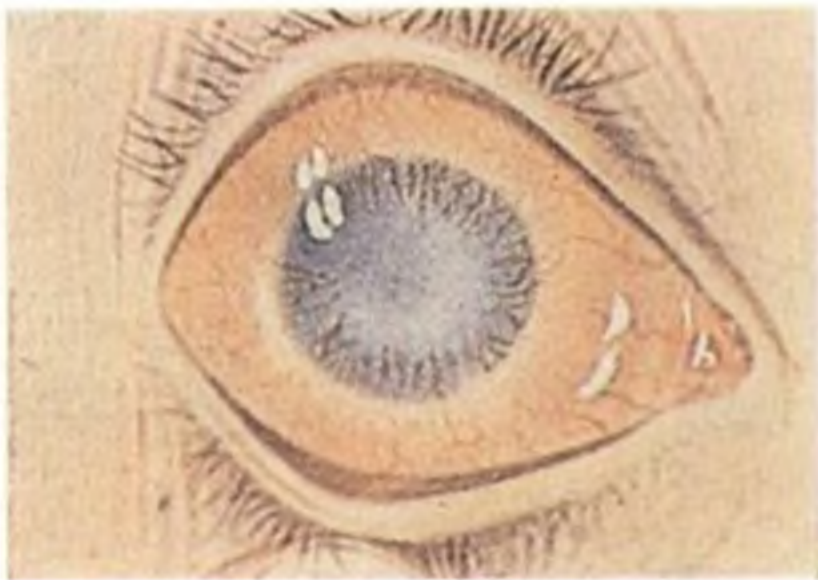

Fig. 38c.3 Interstitial keratitis (Parsons).

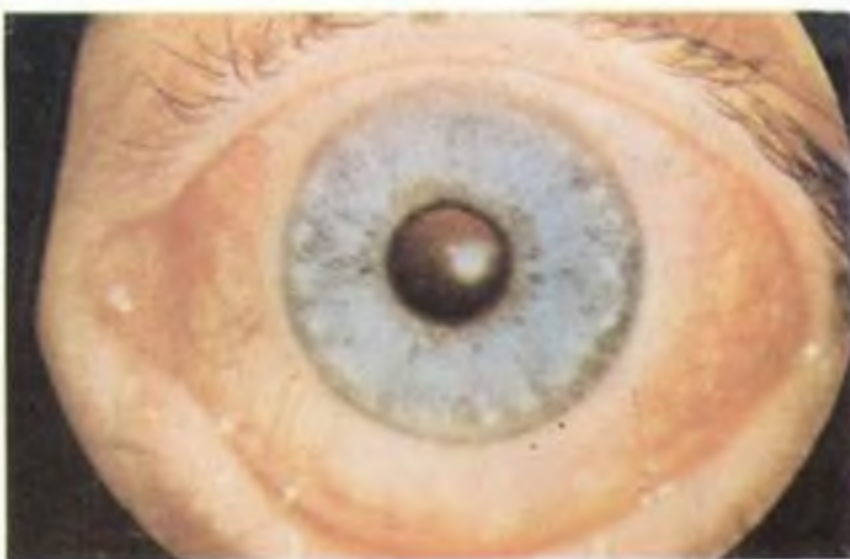

Fig. 39c.1 Episcleritis (A.J. Bron).

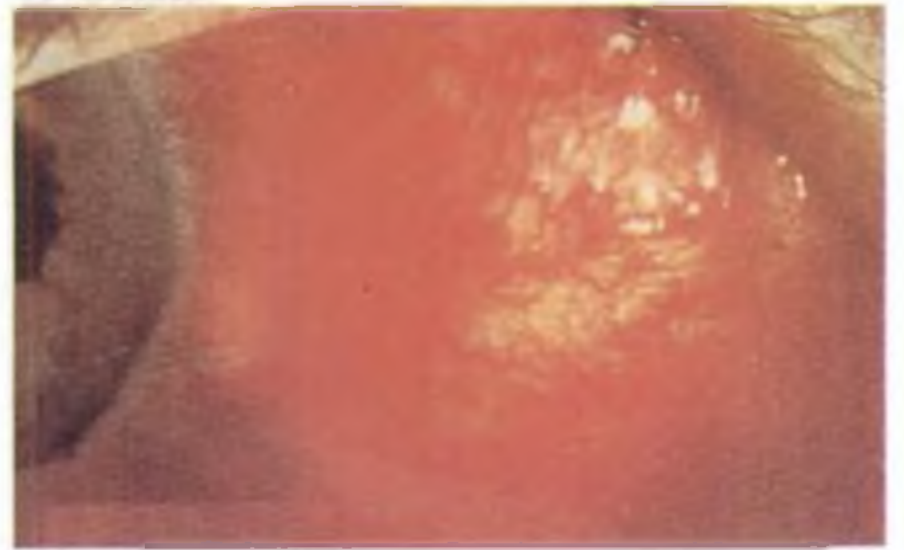


Fig. 39c.2 Scleritis (A.J. Bron).

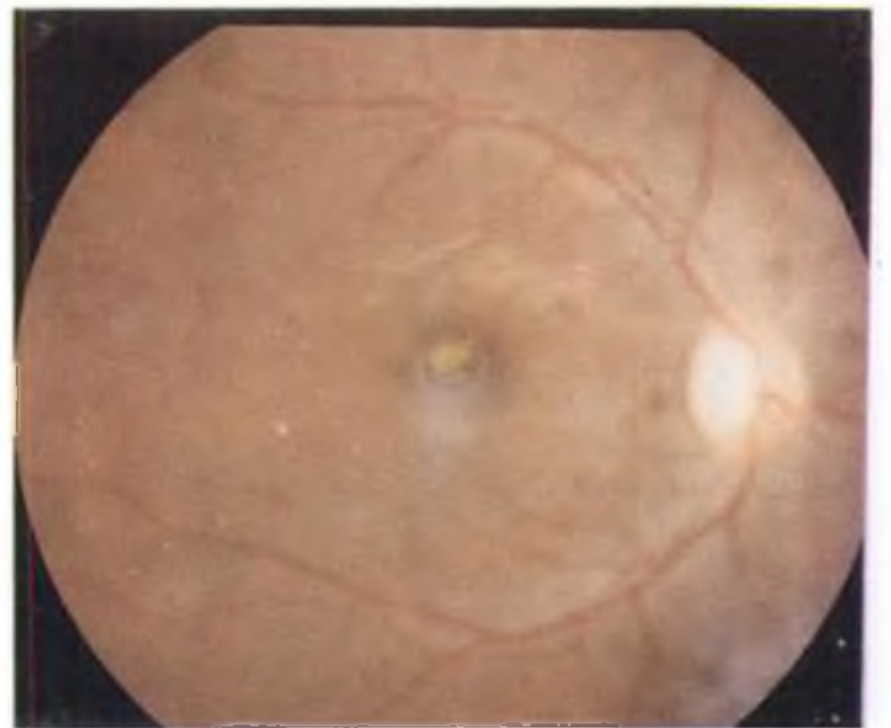


Fig. 40c.1 Healed chorioretinitis

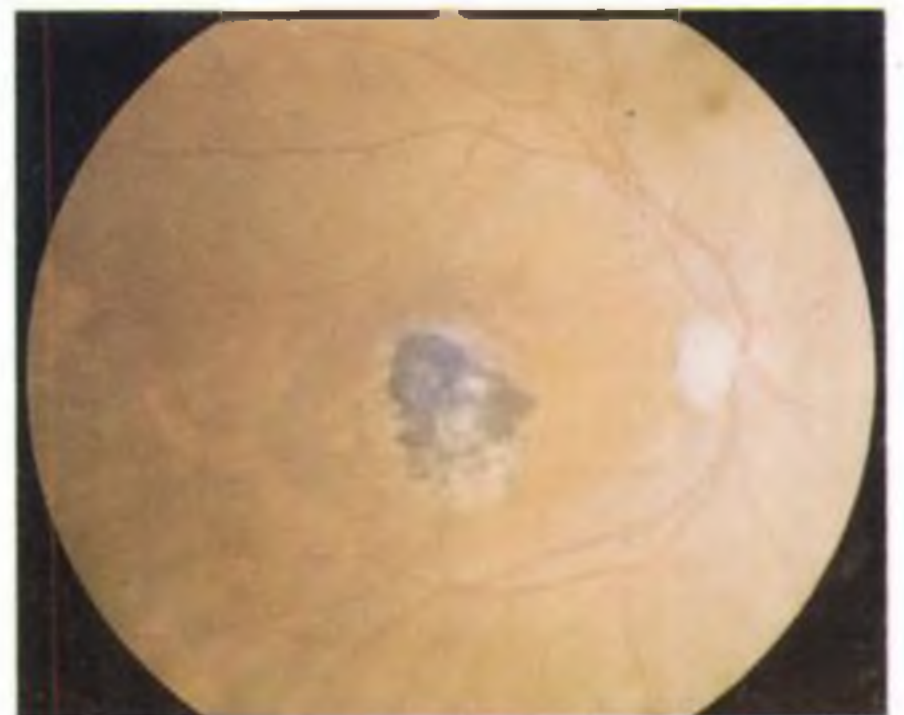

Fig. 40c.2 Toxoplasmic retinochoroiditis

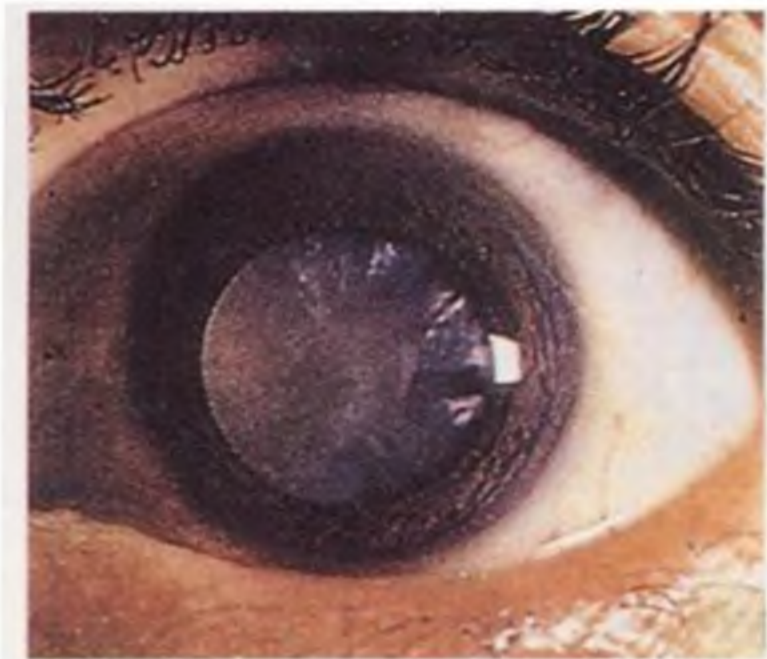

Fig. 42c.1 Mature cataract seen through dilated pupil
(Courtesy: American Ramedies).

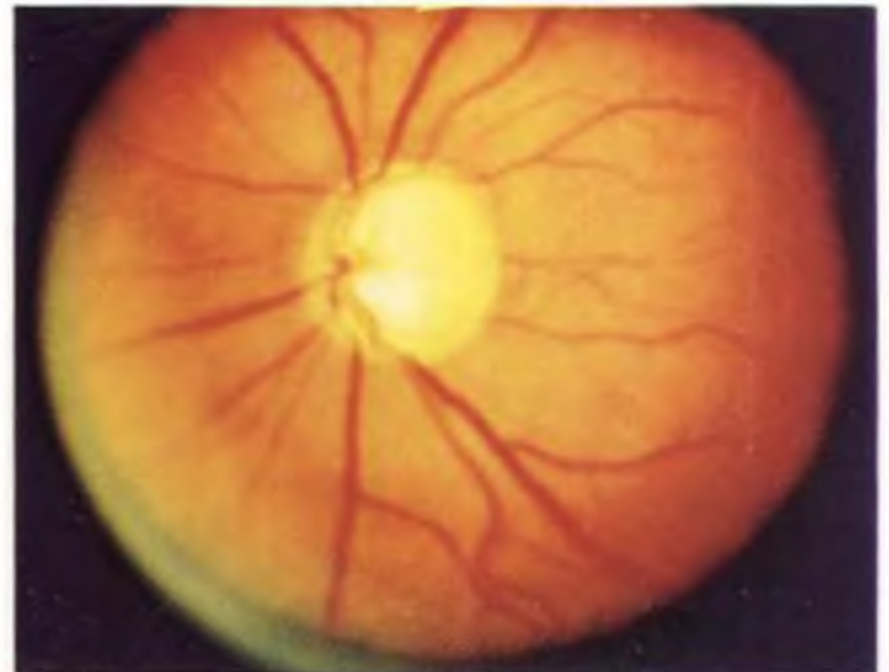


Fig. 44c.1 Glaucomatous cup (Dr. Sumit Chowdhury).

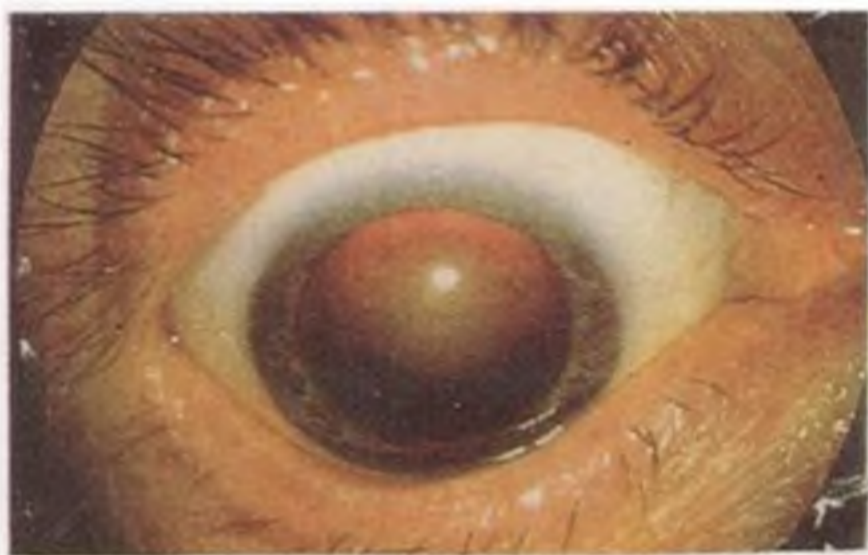

Fig. 42c.2 Nuclear sclerosis (Rousell).

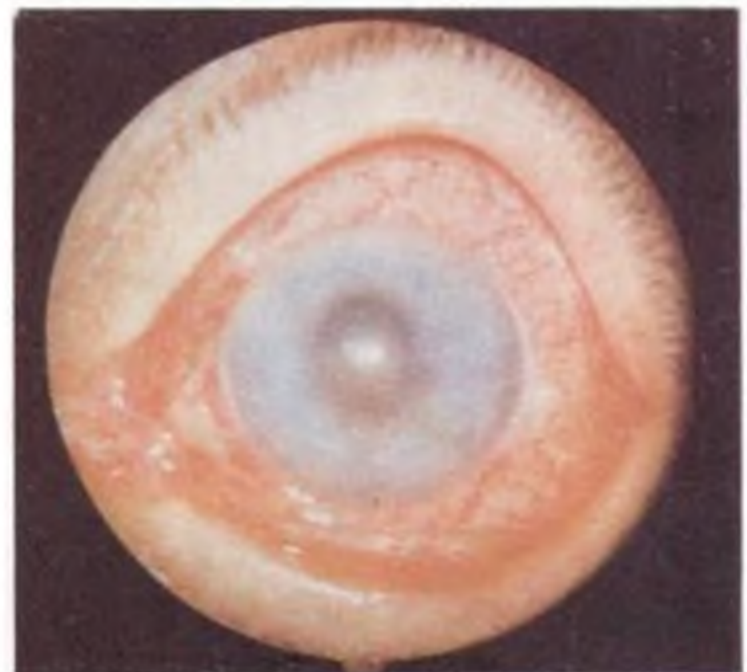

Fig. 44c.2 Acute congestive glaucoma (A.J. Bron).

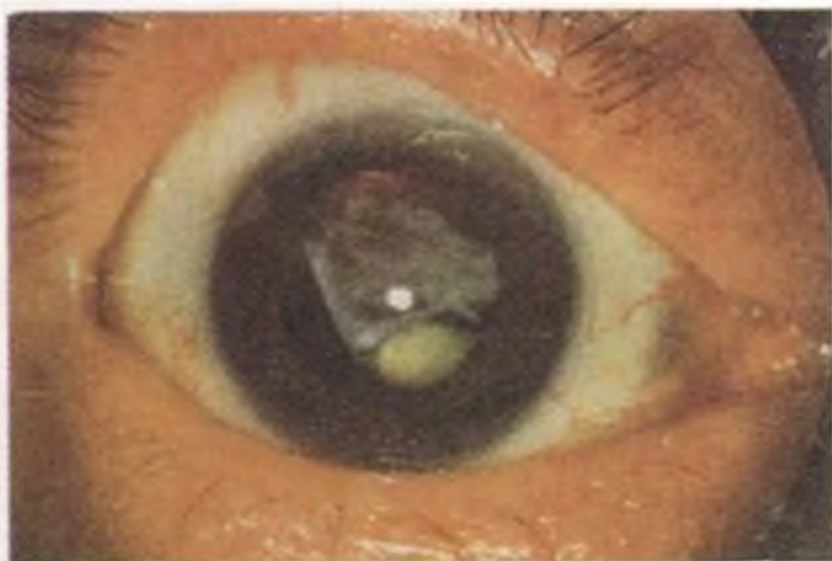


Fig. 42c.3 Traumatic cataract (Rousell).

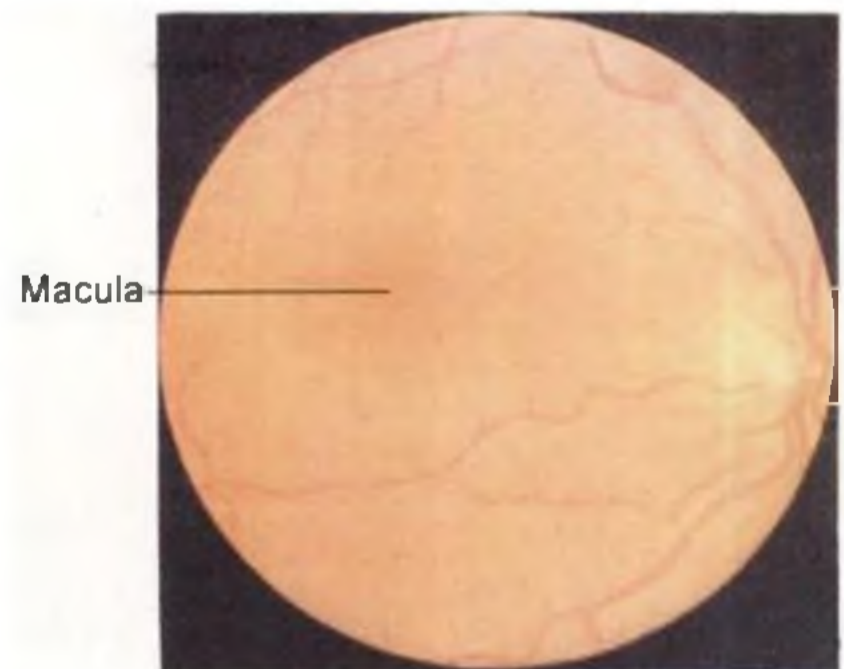


Fig. 45c.1 Normal fundus oculi (A.I. Bron).

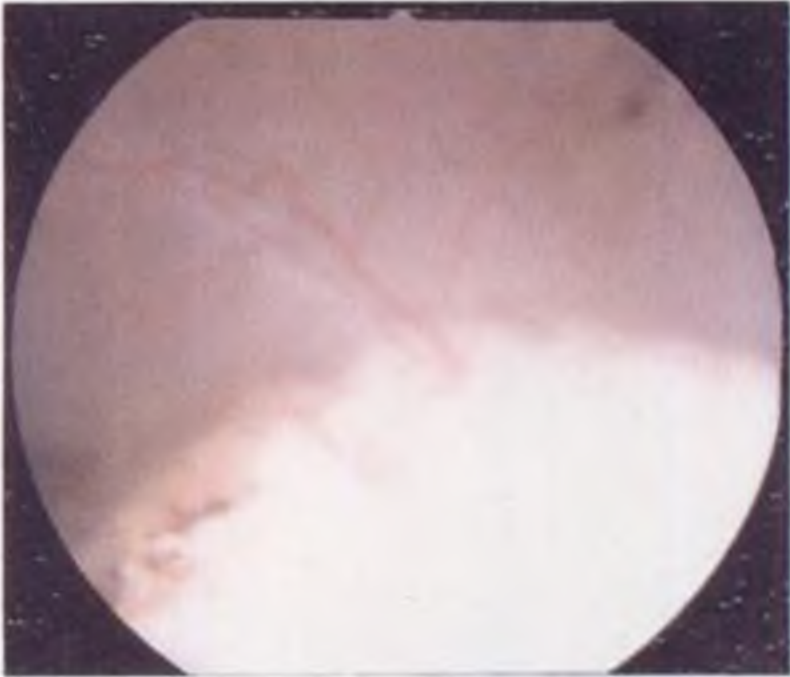


Fig. 45c.2 Congenital coloboma of left fundus.

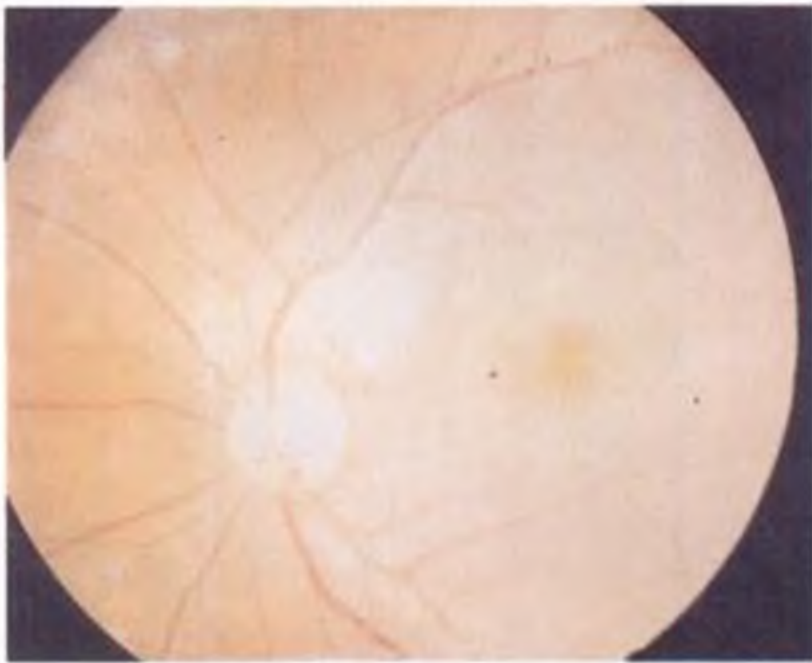


Fig. 45c.3 Central serous retinopathy.

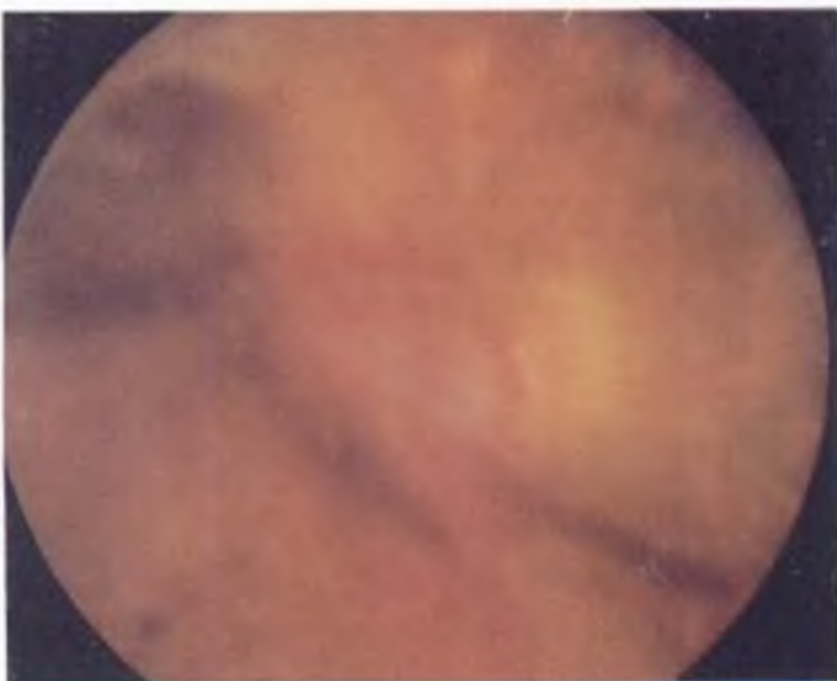


Fig. 45c.4 Subhyaloid haemorrhage.

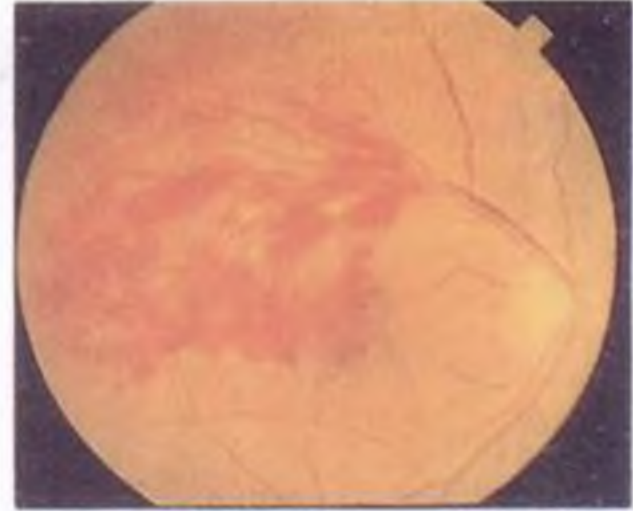

Fig. 45c.5 Branch retinal vein thrombosis (Dr. S.C. Sen and Dr. D. Mondal).

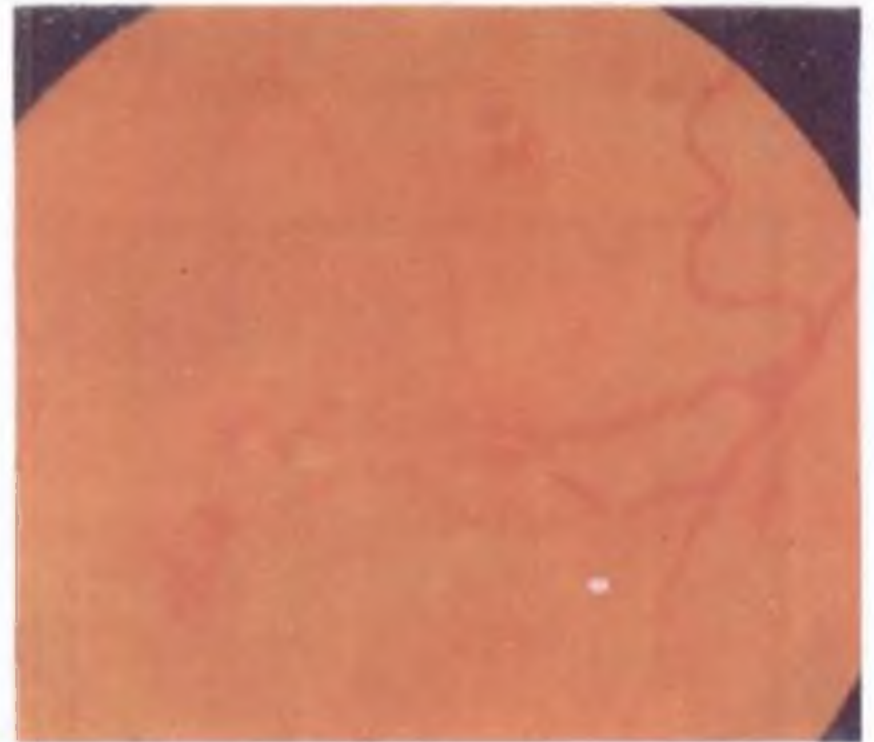


Fig. 45c.6 Eales' disease.

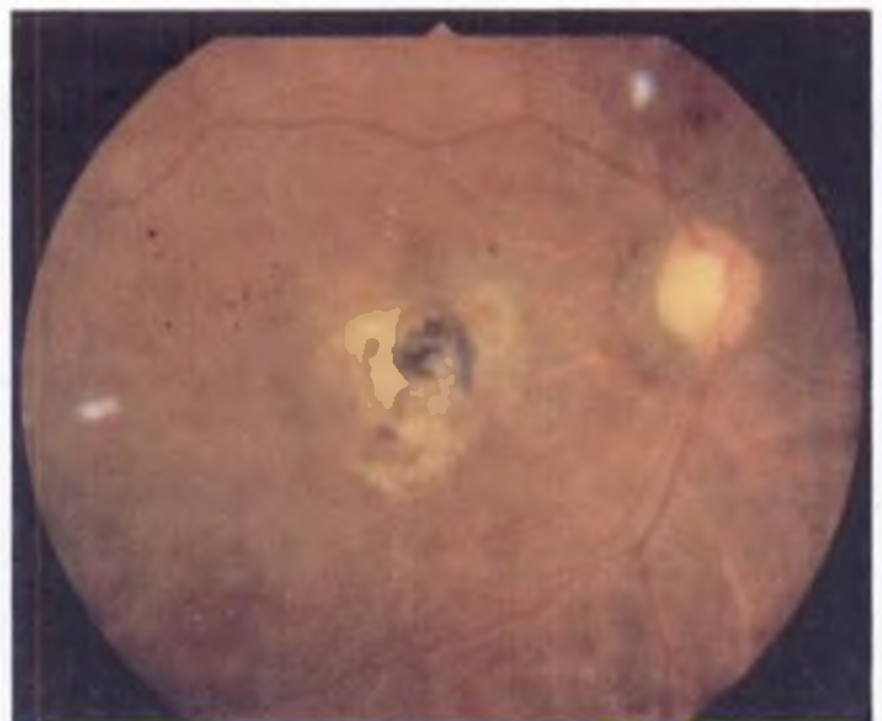


Fig. 45c.7 Disciform degeneration of the macula.

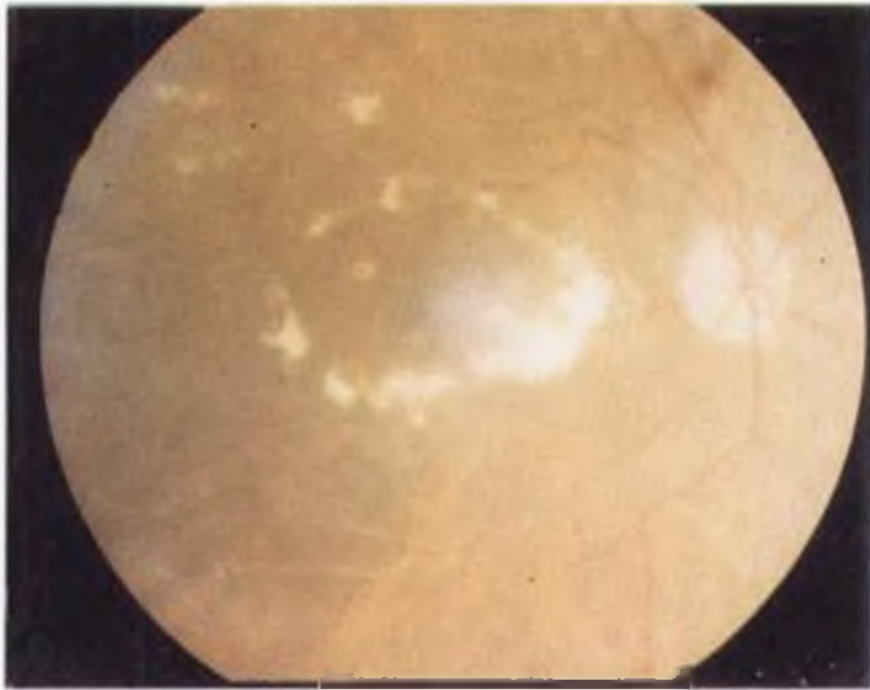


Fig. 45c.8 Circinate retinopathy.

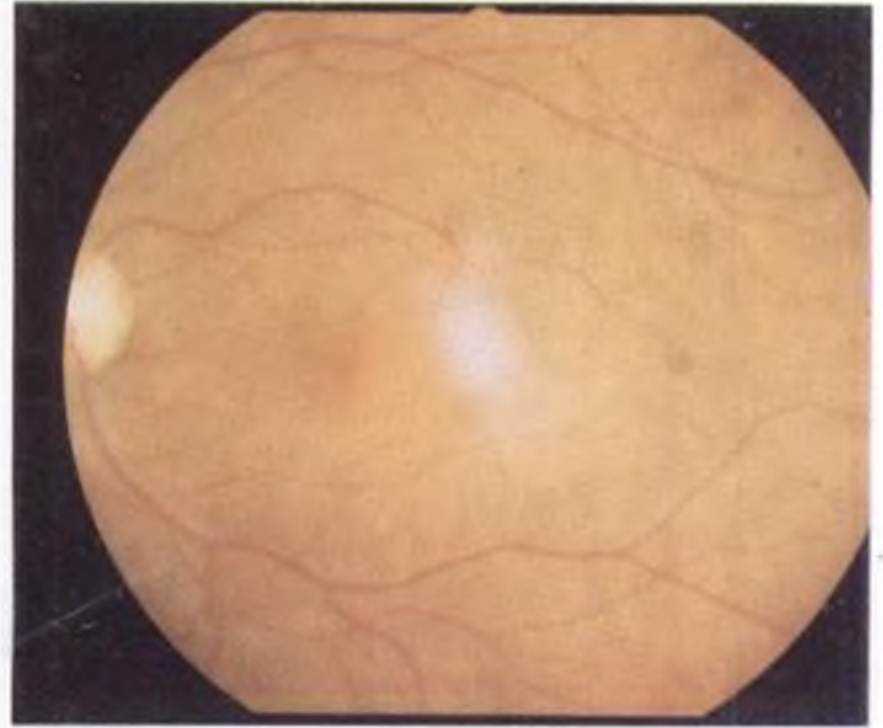


Fig. 45c.11 Diabetic retinopathy.

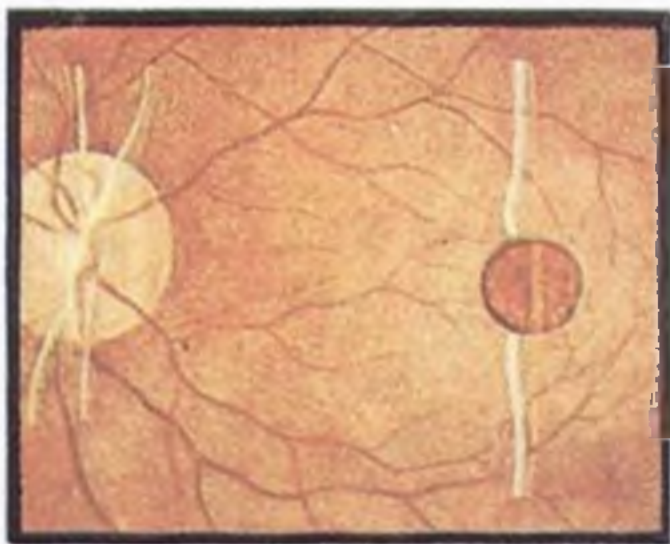


Fig. 45c.9 Slit-lamp examination of the fundus. Hole at the macula (H. Goldman, *Brit. J. Ophthalmol.*).

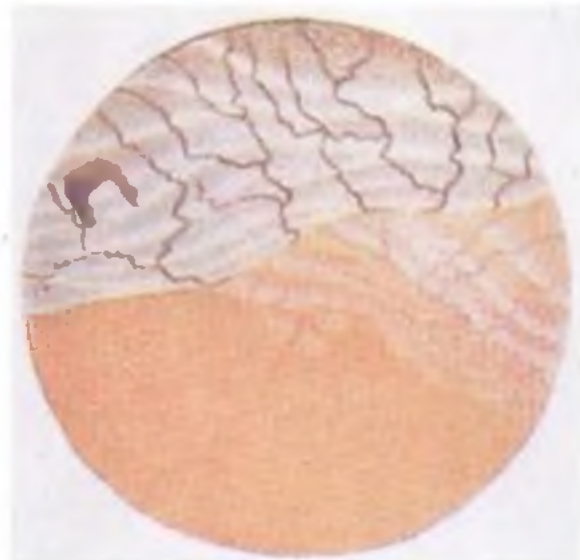

Fig. 45c.12 Retinal detachment (Trevor-Roper).

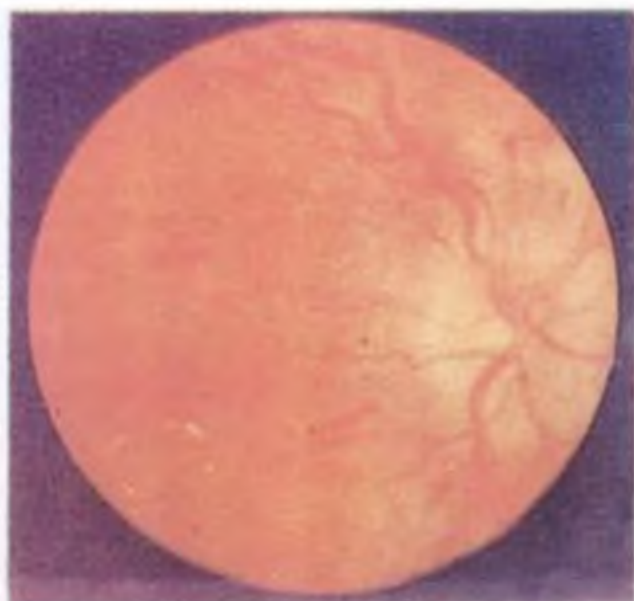

Fig. 45c.10 Hypertensive retinopathy (Parsons).

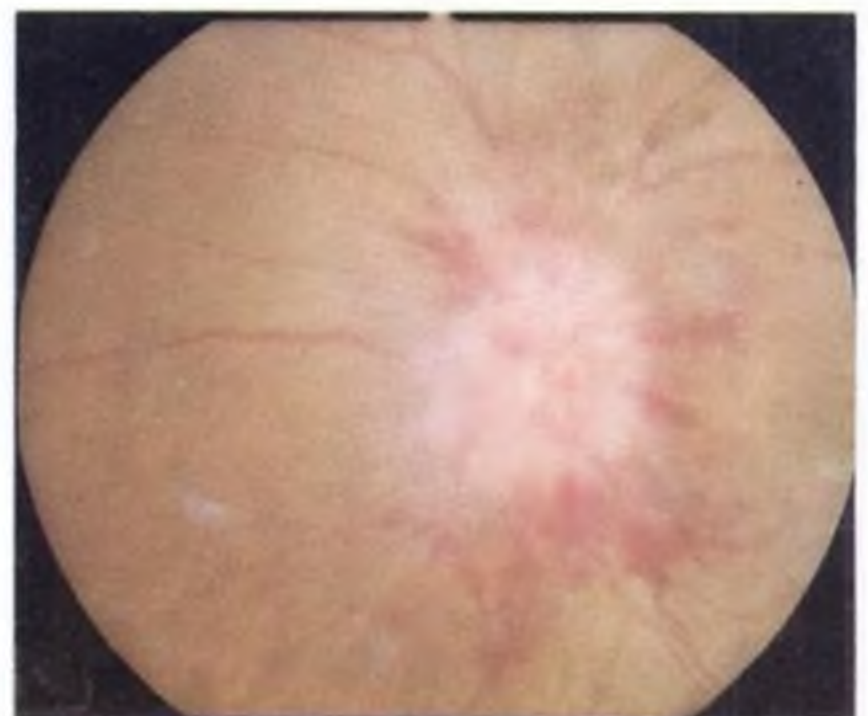


Fig. 46c.1 Papillophlebitis.

Oops, page PA444-IA6 was not yet downloaded :(

Part Six

Surgical Procedures

The various ophthalmic operations have been described and greater emphasis has been stressed on the commoner varieties. This has been done to list the principal steps rather than the exact details of the operations and instruments, as the latter can only be learnt while performing surgery. Techniques vary and only those in common practice have been described while the rarer ones have also been mentioned.

Oops, page PA445 was not yet downloaded :(

motor nuclei. The efferent arc is the vagus nerve to the cardiac muscle. Treatment consists of injection, 0.4 to 0.6 mg intravenously of atropine and cardiopulmonary resuscitation.

Surgery of the Eyelids

Chalazion (Figs. 51.2 and 51.3)



Fig. 51.2 Chalazion clamp and scoop.

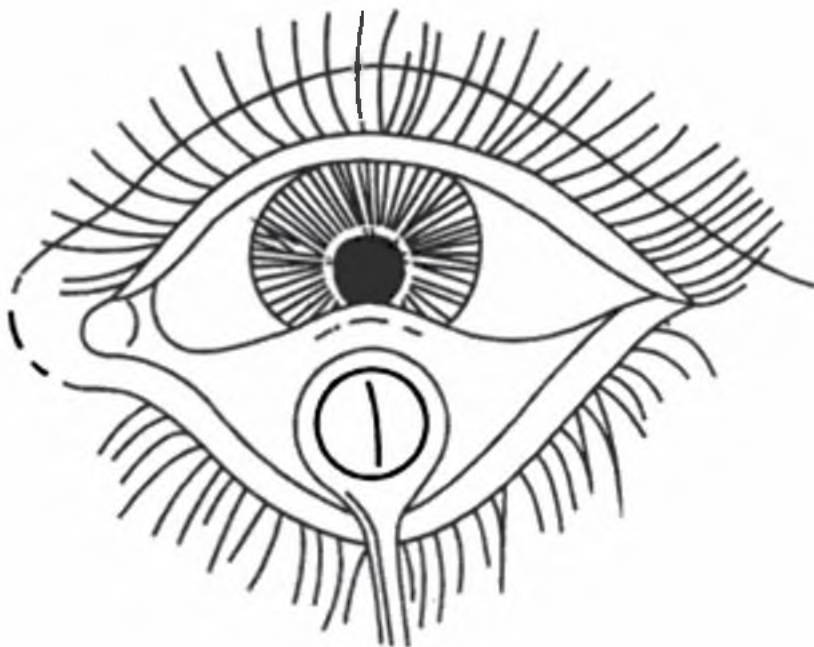


Fig. 51.3 Vertical incision in chalazion.

After instillation of 4 per cent lignocaine or 1 per cent amethocaine and infiltration of the area round the chalazion by 2 per cent lignocaine with adrenaline, a chalazion clamp is applied encircling the chalazion with the fenestrated blade on the conjunctival surface, and the screw is tightened. The lid is then everted. A vertical incision is given on the conjunctiva over the chalazion with a knife such as Beer's knife or No. 11 disposable knife-blade, the point pointing away from the eye. As soon as the incision is completed, the contents peep and the cavity is thoroughly scooped out with a chalazion scoop. After scooping the clamp is released and some oozing occurs usually. An antibiotic eye ointment, pad and bandage are then applied. The pad and bandage are left for 24 hours, and an antibiotic ointment is applied thrice daily for about a week. Rarely in the presence of a thick wall the latter is carefully dissected and removed. Hard consistency but the absence of gelatinous content within a chalazion may suggest a tumour, in which case the excised tissue is sent for a microscopic examination.

Chalazion granuloma. It should be excised following which a curettage may be needed.

Stye

Very rarely an incision 2 to 3 mm long and parallel to the lid margin over the pointing area is called for when the pus oozes out.

Molluscum contagiosum

An incision is given parallel to the lid margin. The molluscum is shelled out after retracting the edges of the incision.

Xanthelasma

Because of cosmetic reason xanthelasma sometimes needs surgical interference. If it is less than 3 mm it is sufficient to undermine the adjacent skin and suture the edges after excision of xanthelasma. If it is more than 3 mm a full-thickness skin graft may be needed after the excision.

Granuloma, papilloma and other benign neoplasms

When these are present on the lid margin they should be treated by electrodesiccation 30 to 40 mA for 3 to 4 seconds.

Entropion^{8.26}

Treatment of entropion has been described earlier. In slight degree of senile or atonic entropion involving the lower lid, cautery punctures may be done over the skin surface 3 mm below and parallel to the lash line. In spastic entropion of the lower lid the operations advocated are: skin-muscle operation; resection of the skin, muscle and tarsus; and modified Wheeler's operation.

In cicatricial entropion of the upper lid two operations are indicated and they are tarsal paring and eversion; and tarsal rotation. Wies' procedure is advocated in both senile and cicatricial entropion of the lower eyelid.

Skin-muscle operation (Figs. 51.4 and 51.5)

The procedure consists of skin incision 3 mm below and parallel to the lid margin; resection of an elliptical area of the skin and a strip of the orbicularis oculi from the central third of the lower lid, the lid being held in an entropion clamp, and then suturing the defect. The result is unsatisfactory.

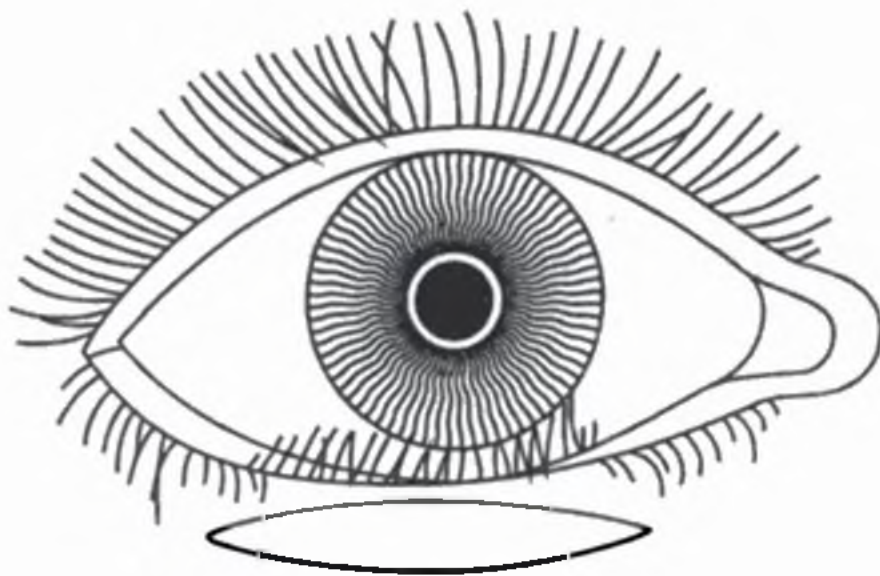


Fig. 51.4 Excision of an elliptical area of the skin and orbicularis oculi.

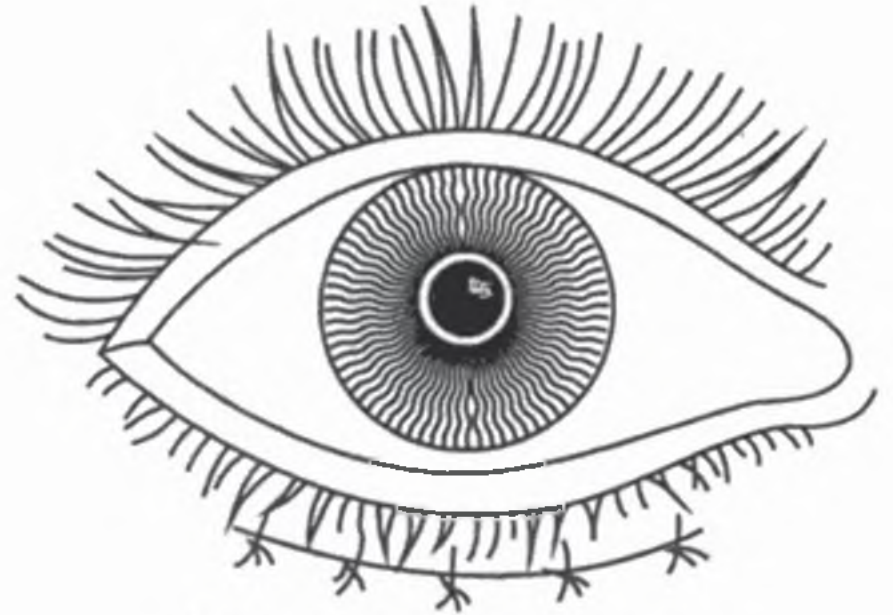


Fig. 51.5 Suturing of the skin.

Resection of the skin, muscle and tarsus

The operation consists of removal of a triangle or quadrilateral of the tarsus, skin and orbicularis. While excising a triangle, 12 mm vertically and 10 to 12 mm at its base, the base should be upwards and 2 mm away from the lateral canthus.

Modified Wheeler's operation

Following infiltration anaesthesia a lid guard is inserted and a skin incision is given 3 mm below and parallel to the lower lid margin for almost its full length. The lower edge of the incision is undermined till it reaches almost the infraorbital margin. After retraction of the wound margin by the sutures a 4 mm wide band of the orbicularis oculi is separated. The band is divided in the midline and the two strips are reflected, nasally and temporally. A triangle of the tarsus with its apex just below the lid margin is excised and then the tarsus is sutured by three 5/0 chromic collagen sutures. The reflected bands of the orbicularis are overlapped and anchored to the orbital septum. The lid guard is removed and the skin incision is closed. Pad and bandage are applied for 24 hours.

Tarsal paring and eversion

This procedure is designed to prevent corneal ulceration. Two traction sutures inserted into the upper lid are passed through the holes one on either side of the lid guard. An incision extending 2 mm

beyond the line of the cilia at the either ends of the lid margin is made 3 mm above the lid margin and through the skin, orbicularis oculi and tarsus leaving 0.5 mm of its posterior part undivided. Then a 4 mm wide band of the orbicularis is removed just above the lid margin throughout the entire length of the incision. Removal of slices of the tarsal plate by a No. 10 disposable knife-blade from its anterior surface starting at its upper border and ending at the deepest part of the incision above the lid margin is performed. Three 5/0 braided polyester sutures are passed through the pared tarsus and brought through the orbicularis muscle and just above the lash line. The skin incision is closed by 6/0 interrupted black silk sutures. The skin sutures are removed on the fourth day and the mattress sutures on the fourteenth day.

Tarsal rotation

Tarsal rotation is indicated in trachomatous cicatricial entropion of the upper lid. An incision is made along the sulcus subtarsalis 3 mm from the upper lid margin and through the whole thickness of the tarsus along the transverse length of the everted upper lid. The incision is made at right angle to the lid surface. A line of cleavage is created in between the anterior surface of the lower end of the tarsus and the posterior surface of the orbicularis oculi. The lower end of the tarsus is rotated through 90° by pulling forward by a Kilner's hook. Three mattress sutures of 5/0 braided polyester are passed through the tarsus in the superior border of the incision, next through the lid margin, and then transversely through the skin 5 mm above the lash line, they are finally tied.

Wies' partial transposition of tarsus

Wies' partial transposition of tarsus is indicated in both senile and cicatricial entropion of the lower eyelid. Wies' procedure consists of a full-thickness horizontal skin incision in the central third of the lower lid 5 mm from the lid margin and passing three 5/0 braided polyester sutures through the palpebral conjunctiva below the incision and then through the lower part of the tarsus, upwards in

front of the tarsus to finally emerge on to the skin 1 mm below the lid margin. Finally the sutures are tied. The skin incision is closed with 6/0 braided silk sutures. The stitches are removed after one week.

Ectropion^{8,20}

Treatment of different types of ectropion has been described.

Kuhnt-Szymanowski operation

(Fig. 51.6)

Kuhnt-Szymanowski operation appears to be best of all the resection operations for senile ectropion. The steps are as follows.

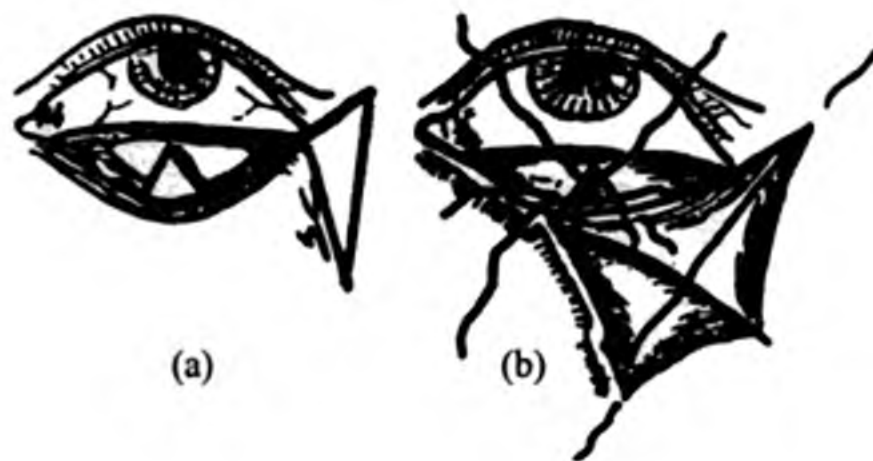


Fig. 51.6 Kuhnt-Szymanowski operation. (a) incision and excision of a triangle of the conjunctiva and the tarsus; (b) suturing of the tarsal plate and skin following skin-resection, conjunctiva, tarsal resection and advancement of the split lateral part of the lower lid.

The lower lid is split along the grey line laterally starting from the junction of the medial and central one-third.

A triangle of the conjunctiva and tarsus with its apex at the lower margin of the tarsus is removed from the central part of the posterior lid flap. The amount of resection is determined by holding the inner end of the incision in close approximation to the eye. Then it is sutured starting from the apex towards the base of the triangle by interrupted 4/0 chromic collagen sutures, inserted 2 mm from the edge of the incision. A triangle of the skin of the same size and shape as that of the excised triangle of the conjunctiva and tarsus with its apex

downward is excised at the outer portion of the lower lid. The anterior lid flap is undermined, slid superolaterally and then sutured by 6/0 braided silk.

Byron Smith prefers to incise the lateral half of the lower eyelid below the lash line.

V-Y operation

V-Y operation is indicated in a slight degree of cicatricial ectropion. A V-shaped incision is given over the lower lid. The margins of the incision are sutured in the form of a Y.

Tarsorrhaphy

Tarsorrhaphy means suturing together of the eyelids. It is either temporary or permanent, lateral or central. Lateral tarsorrhaphy is indicated in atonic ectropion following seventh nerve palsy, and central tarsorrhaphy is indicated in neurotrophic keratitis and anaesthetic cornea. The raw lid margins after de-epithelialization behind the lash line are sutured together by 4/0 silk sutures over a rubber tube. When permanent union occurs after 2 weeks the sutures are removed. In a neurotrophic keratitis tarsorrhaphy may be left undisturbed for 9 to 12 months.

Fascia lata sling

Fascia lata sling is indicated in severe degree of paralytic ectropion. The principle is passing of two separate but short, 15 cm long and 3 mm wide fascia lata slings at the canthi. At the medial canthus it is passed through a fenestration in the tarsus and it is fixed to the medial palpebral ligament. At the lateral canthus it is passed through a fenestration near the lateral end of the tarsus and then through a drill in the lateral orbital margin.

Instead of fascia lata a silicone sling may be used.

Botulinum toxin-induced protective ptosis

This technique is an alternative to tarsorrhaphy. One hundred picograms of the toxin is injected into the levator muscle and ptosis ensues within

72 hours, but this is contraindicated in case of associated active infective keratitis. The action wanes gradually and full levator function returns.

Blepharoplasty

There are varieties of blepharoplasty operations indicated in cicatricial ectropion, but the basic procedure is the removal of the scar tissue and restoration of the normal position and function of the eyelid. Often a skin grafting is necessary.

Ptosis^{5,26,30}

Management of ptosis varies according to the cause and degree of ptosis.

Levator resection

Operations on the levator palpebrae superioris are always worth trying even if there is some degree of function in this muscle. There are two types of approach, conjunctival and skin.

Blaskovics' operation (Figs. 51.7 and 51.8). The conjunctiva ballooned with normal saline and the

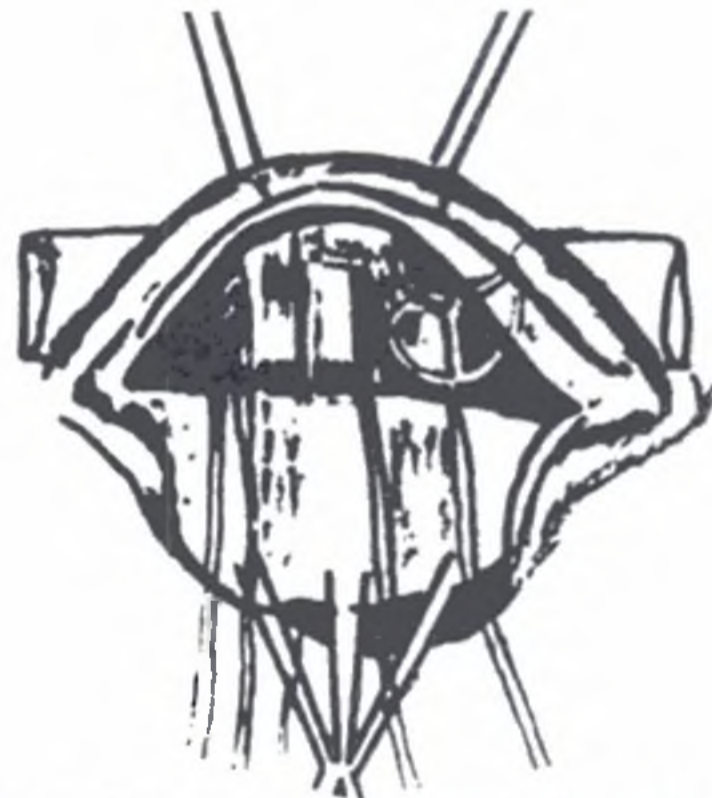

Fig. 51.7 Resection of the levator, the conjunctival approach. A composite diagram showing eversion of the upper lid over a gauze roll and application of two traction sutures, passing of three sutures through the reflected conjunctival flap and passing of three mattress sutures through the levator above its insertion.

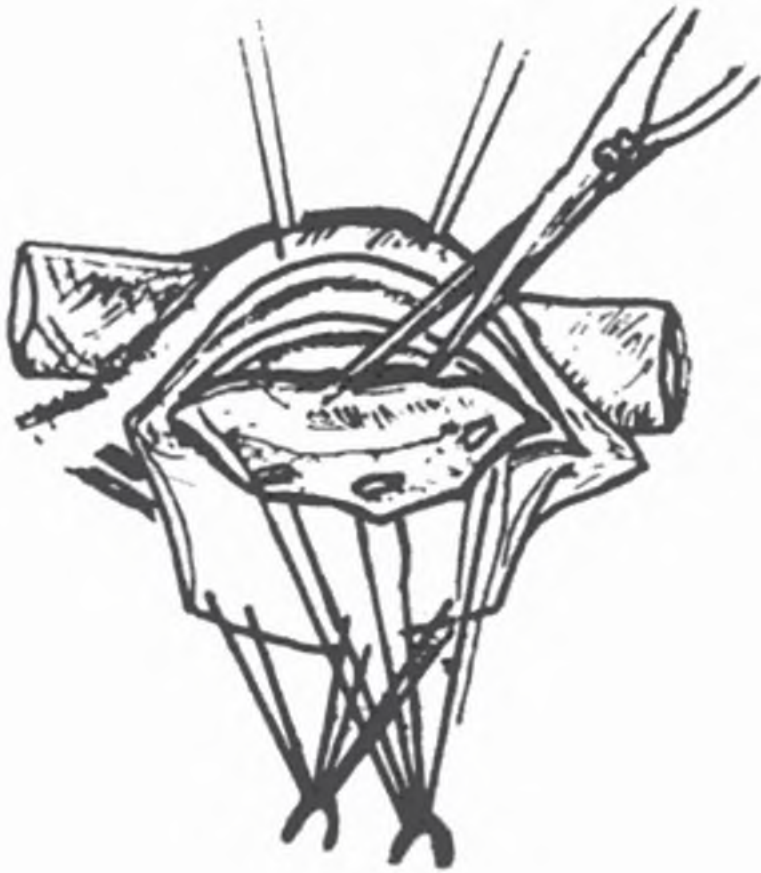


Fig. 51.8 Dissection of the levator from its insertion and the sutures being passed through the conjunctiva, levator and tarsus.

tarsus are incised 1 mm from the upper margin of the tarsus along the whole length of the upper lid after its double eversion over a gauge roll. The conjunctiva is separated from the underlying tarsus up to the upper fornix. Retraction of the conjunctiva downwards is done by three double-armed traction sutures, the sutures passed through the margin of the conjunctival flap and then held by a mosquito forceps.

The levator is dissected from its attachments after retraction by three double-armed traction sutures. The lateral and medial horns of the levator are divided if a large resection is essential.

The tarsus is separated from the pretarsal tissues and a strip of the tarsus is excised. The first row of sutures placed in the conjunctival flap are passed through the levator, 7 to 10 mm from its insertion and the redundant muscle is resected. Greater the degree of ptosis, further behind the sutures are passed. The second row of sutures through the levator 4 to 5 mm apart and 3 mm proximal to the first row, are brought through the skin at the level of superior palpebral furrow. The sutures through the conjunctiva and levator are passed through the cut-edge of the tarsus, orbicularis and finally

emerge 2 mm above the lash line. The sutures are tied over bolsters.

Complications. During operation the levator muscle may be injured while reflecting Müller's muscle with the conjunctiva. While cutting the medial horn the reflected tendon of the superior oblique and occasionally the superior rectus may be injured. Undercorrection is common. Overcorrection tends to disappear with time. There may be temporary weakness of the superior rectus. Other complications are similar to those of the skin approach.

Everbusch's operation (skin approach). The skin approach has the following advantages:

- (a) Better anatomical visualization and more extensive exposure
- (b) Better identification of attachments of the muscle
- (c) The main site of attachment of the levator, i.e. anterior surface of the tarsus is easily accessible
- (d) More of the levator can be excised
- (e) The muscle is less stretched.

A ptosis guard is inserted under the upper lid. A skin incision 6 mm above and parallel to the upper lid margin is given along the whole length. The orbicularis oculi is incised and split. Dissection is done upwards and downwards to the underlying tarsus with attachment of the levator. The muscle belly and tendon of the levator muscle are exposed while its attachment to the orbital septum is freed, and the horns may be separated. Three double-armed mattress sutures with 5/0 chromic collagen are inserted interiorly through the muscle belly forward, passing 2 mm posterior to the line of proposed resection. A resection of about 3 mm of the levator muscle raises the eyelid 1 mm. A minimum 10 mm or maximum 24 mm of the muscle is resected. The upper part of the tarsus may be removed. An ellipse of excess skin is also excised. Finally the sutures are passed through the anterior surface of the tarsus near its distal border and then through the overlying skin.

Complications. There may be injury to the superior oblique pulley while freeing the medial horn on the nasal side and injury to the lacrimal gland during incision of the lateral horn of the levator situated close to the lateral wall of the orbit. Overcorrection may occur and tends to persist. Undercorrection is uncommon. Other complications include uneven positioning of the lid, lid lag, lagophthalmos which is followed by exposure keratitis, ectropion or entropion, and deformity of the lid fold.

Fasanella-Servat operation

Fasanella-Servat operation consists of resecting the upper tarsal border with its attached Müller's muscle and conjunctiva. This procedure is indicated in slight ptosis, less than 3 mm.

After eversion of the upper lid two mosquito forceps are applied at the upper tarsal border which grasps the conjunctiva, tarsus, levator and Müller's muscle. A 6/0 collagen suture is passed through the outer end of the upper lid-fold by making a small skin incision which finally passes through the tarsus and the conjunctiva about 2 mm away from the haemostats towards the lid margin. This suture runs along the whole length of the upper lid. It is positioned behind the mosquito forceps while they are pulled forward. The tissues held by the forceps are resected. The suture then is again passed to close the wound which comes out through the skin incision. Both ends of the suture are then tied and buried under the skin.

Utilization of the superior rectus

There are several procedures for the utilization of the superior rectus. Two of them are briefly mentioned.

Motais' operation. The central part of the superior rectus is freed from its insertion, passed over the upper fornix and upper border of the tarsus and sutured to the anterior surface of the tarsus.

Greeves' operation. Two tongues of the orbicularis oculi are dissected up and fixed to the superior border of the tarsus. These are sutured to the borders of the superior rectus at appropriate sites.

Utilization of the frontalis muscle

Hess' operation. The skin incision is given below the eyebrow and it is undermined over the orbicularis and tarsus through the incision. Three silk sutures are passed from below to emerge above the line of incision and they are tied.

Canthotomy

Canthotomy is a temporary enlargement of the interpalpebral aperture and consists of dividing the outer canthus for a length of about 1 cm. Sutures are omitted.

Canthoplasty

Canthoplasty is a permanent enlargement of the interpalpebral aperture. After canthotomy, adequate suturing of the conjunctiva and lid margin is done. Three sutures are usually needed.

Surgery of the Lacrimal Passages²⁶

History. As early as 1713 Anel recommended probing and irrigation, while dilatation of the punctum and canaliculus had been devised by Bowman in 1851. Toti (1904) described dacryocystorhinostomy (DCR). Dupuy-Dutemps and Bourget (1921) improved the method of suturing the nasal mucosa to the sac. Mosher (1921) described DCR with a combined intranasal and external approach.

Surgical procedures in lacrimal passage disorders

These are indicated in Table 51.2.

Table 51.2

Preferred Surgical Procedure in Lacrimal Passage Disorder

Type of disorder	Choice of operation
Congenital lacrimal obstruction	Syringing and probing
Congenital lacrimal obstruction, after failed syringing and probe on two occasions	DCR or intubation
Punctal stenosis or occlusion	Three-snip
Nasolacrimal duct obstruction	DCR
Medial (mucosal) block of common canaliculus	DCR and tubes
Lateral (fibrous) block of common canaliculus	Canaliculo-DCR

Syringing the lacrimal passages (Figs. 51.9 and 51.10)

Syringing the lacrimal passages is a common and simple procedure. This may be done following negative result of a dye test.

Dye test. One drop of 1 per cent fluorescein or methylene blue is instilled into the conjunctival sac. A cotton-tipped applicator moistened in lignocaine is placed into the inferior meatus of the nose. Wait for 5 minutes to see whether the applicator is stained with the dye.

Technique of syringing. After anaesthetization of the conjunctival sac by a surface anaesthetic,

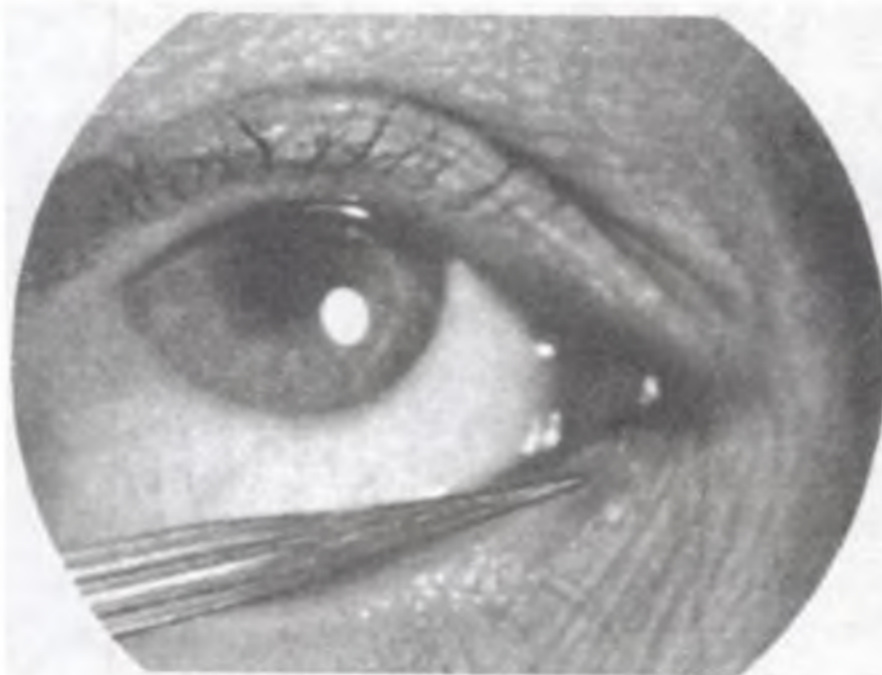

Fig. 51.9 Dilatation of the punctum (Philps and Foster).

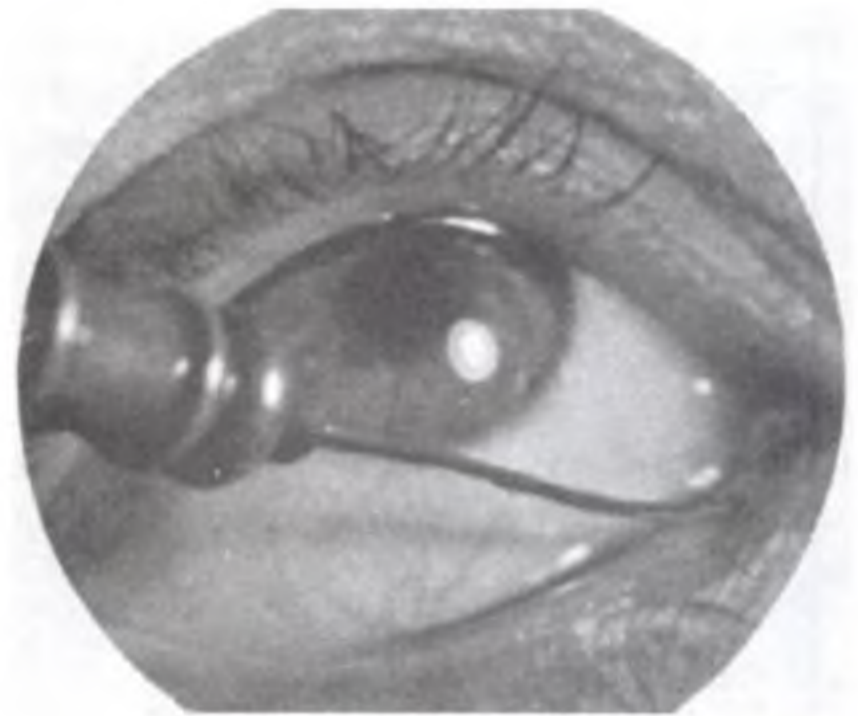


Fig. 51.10 Insertion of the lacrimal canula (Philps and Foster).

dilatation of the lower punctum is done by a punctum dilator. A lacrimal cannula fitted with a syringe filled with irrigating fluid is inserted through this punctum. The fluid is gently syringed. The fluid passes into the nose or it is swallowed by the patient. Any regurgitation through the lower or upper punctum is noted. If the regurgitation is through the lower punctum there is a lower canaliculus obstruction, while if it is through the upper it indicates an obstruction at the junction of the canaliculi and the sac.

Probing of the nasolacrimal duct

Probing of the nasolacrimal duct is indicated during first 6 months of age when conservative treatment with gentle pressure over the sac region followed by instillation of antibiotic drops thrice daily for 4 to 6 weeks fails to relieve the obstruction. In a child it is done under a general anaesthetic.

Dilatation of the upper punctum is done by a punctum dilator. The smallest size probe, 0.6 mm dipped into liquid paraffin is introduced through the upper canaliculus to reach the lacrimal bone. Now the direction of the probe is changed and it is passed downwards, slightly backwards and outwards through the sac. The larger sized probes up to 0.8 mm are subsequently introduced. Irrigation may be tried before but is never advised immediately after probing since it may provoke an

inflammation. *Retrograde probing* done through the nose can also be performed.

Three-snip operation

Three-snip operation is indicated in stenosis or occlusion of the punctum. An attempt is made to dilate the punctum. The first snip is taken vertically downward for 2 to 3 mm, the second inward along the horizontal part of the canaliculus for 4 to 5 mm. The third cut then joins the previous two excising a small triangle of tissue.

In some cases the first snip is sufficient, called *one-snip procedure*. Postoperative treatment consists of punctum dilatation for about 2 weeks.

Dacryocystectomy (Fig. 51.11)

Following infiltration anaesthesia of the lacrimal sac region, the skin is incised along the line of lacrimal crest of the maxilla and down to the bone. The incision is about 20 mm long, starts 3 mm above the medial palpebral ligament and 3 mm to the nasal side of the medial canthus. A self-retaining lacrimal retractor is applied. The orbicularis fascia and muscle are incised along the line of the skin incision. The next step is the identification and division of the medial palpebral ligament.

The sac is now dissected off from its walls. It is resected at the lowest point possible, while drawing it upwards by an artery forceps. The upper

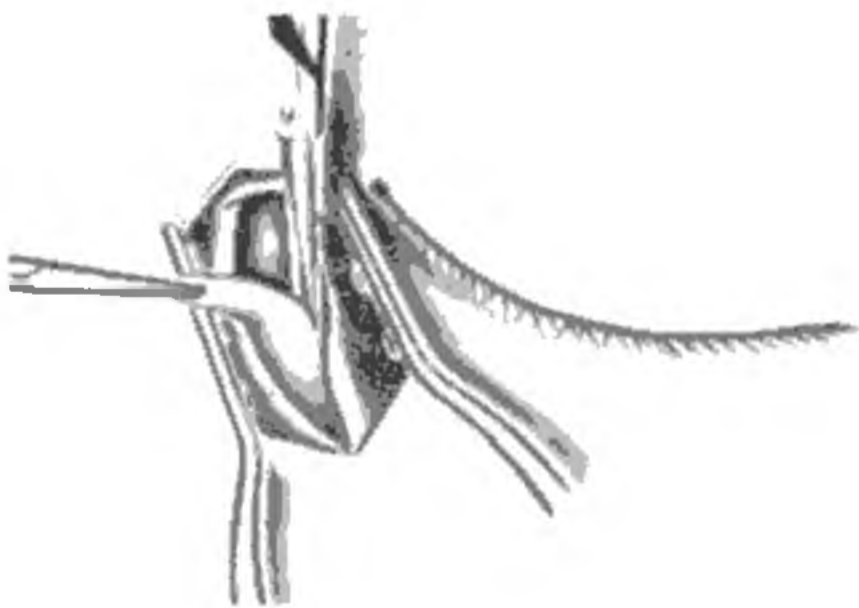


Fig. 51.11 Dissection of the sac from the orbital fascia (Philps and Foster).

part of the nasolacrimal duct is curetted followed by toilet of the wound, suturing and compress dressing.

Complications. Complications can be enumerated as follows:

- (a) Accidental injection of a local anaesthetic into the anterior facial vein occasionally occurs.
- (b) Damage to the neighbouring soft tissues is not unusual.
- (c) Haemorrhage is the greatest complication.
- (d) Spilling of contents following tear of the sac wall occurs if one is not careful during separation of the sac from its walls.
- (e) Remnants of the sac may be left behind.
- (f) There may be failure of curettage of the nasolacrimal duct due to haemorrhage.
- (g) Herniation of fat following opening up of orbital fascia rarely occurs.
- (h) Haematoma is common following surgery.
- (i) Infection is usually the result of improper surveillance.
- (j) Recurrence of troublesome epiphora is an additional complication.
- (k) A disfiguring scar may be left behind. The possible causes are curved incision, buried tissues and incorrect skin approximation.

Dacryocystorhinostomy (DCR) (Fig. 51.12)

Dacryocystorhinostomy (DCR) is always worth a trial since the success rate is high, and there are very few contraindications. It is better to have a rhinological check-up before the operation.

Two important points are emphasized in the preoperative preparation:

- (a) Sedation is preferred when a local anaesthetic is used.
- (b) The nasal cavity is adequately anaesthetised and packed with gauze saturated in an antibiotic ointment.

The first few steps follow the same as dacryocystectomy.

After exposure and retraction of the sac laterally, 2 to 3 mm rim of the anterior lacrimal crest is removed and bone-resection of the lacrimal fossa up to the posterior lacrimal crest by bone-

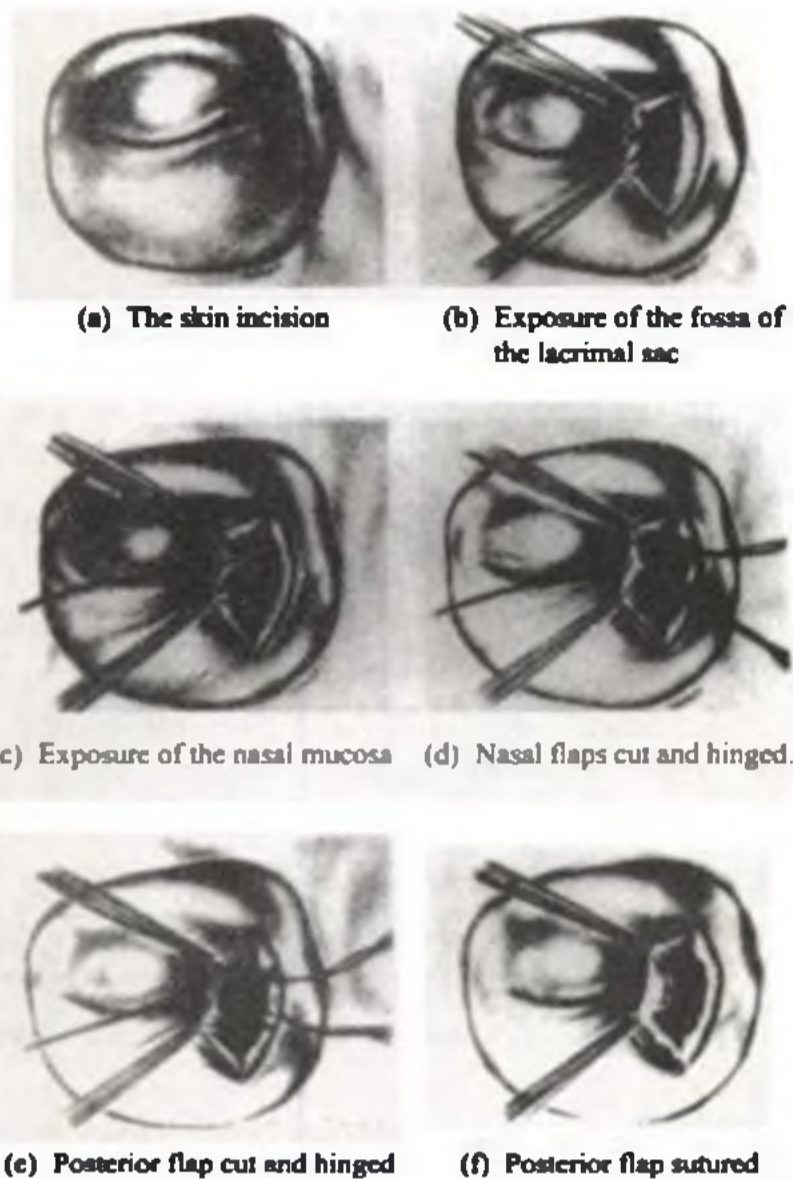


Fig. 51.12 Dacryocystorhinostomy (May and Worth).

nibbling forceps is done. A 10 to 12 mm window is created. The nasal and lacrimal flaps are prepared in the following manner. After a vertical incision in the nasal mucous membrane, right angle incisions at the upper and lower ends of the vertical incision are given to produce anterior and posterior flaps. A probe introduced through the nose can pass freely into the wound. After passing a probe from the upper punctum through the canaliculus into the sac, a vertical incision is made opposite the point of the probe touching the medial wall of the sac and a T-cut is given in this wall as to make anterior and posterior flaps. Subsequently two anterior and two posterior flaps, fashioned from the nasal mucous membrane and the lacrimal sac, are sutured together by 6/0 chromic catgut or 5/0 braided polyester using 10 mm eyeless needle. Closure of the incision is done followed by toileting the wound. Syringing is advocated on alternate days till the 6th postoperative day.

Modifications of DCR operation. The operation can be modified as DCR by intubation—wherein an acrylic tube is used and DCR via the nasal passage.

Other Operations¹¹

Other operations include:

- (a) Canaliculoplasty
- (b) Canaliculo-dacryocystorhinostomy
- (c) Canthocystostomy
- (d) Conjunctivo-dacryocystostomy
- (e) Canaliculorhinostomy
- (f) Conjunctivorhinostomy
- (g) Conjunctivo-dacryocystorhinostomy.

Canaliculoplasty

The various operations have been grouped as under:

- (a) Repair of the recently-divided lower canaliculus between the punctum and the medial canthus can be done by primary suture.
- (b) Repair of the recently-divided lower canaliculus between the medial canthus and the lacrimal sac can be achieved in two ways:

The lacrimal cannula is threaded with a strand of blue nylon. It is passed initially through the upper punctum into the upper canaliculus, then into the lower canaliculus and finally coming out medial to the site of the injury. The ends of the blue nylon strand are passed through a silicone tube and tied over the tube at the medial canthus. The upper end of the thread is attached to the eyebrow and the lower end to the cheek by adhesive tapes.

Alternatively, a retrograde intubation is performed through an incision over the lacrimal sac. The nylon suture is passed through the sac incision into the lumen of the lower canaliculus and then into the wound where it is threaded into the lumen of the canaliculus in the distal end of the canaliculus.

(c) Reconstruction of the lower canaliculus by a conjunctival flap is indicated in the obstruction of the canaliculus between the ampulla and the medial canthus. A strand of blue nylon is passed

through the dilated lower punctum into the lower canaliculus till the site of the obstruction is reached where a vertical incision is done and the fibrous tissue is dissected off. The nylon is then further passed and thus gives a measurement of the graft needed. A conjunctival flap is then rolled over the nylon and secured in place with mattress sutures.

Canaliculo-dacryocystorhinostomy

Indications are: (a) Obstruction at the junction of upper and lower canaliculi, and (b) Obstruction in the lower canaliculus near the sac.

Operation. The principal steps are only enumerated:

(a) A slightly curved incision is given on the side of the nose 3 mm medial to the anterior lacrimal crest and deepened to reach the periosteum. The medial palpebral ligament is then divided, followed by the dissection of the canaliculi

(b) Dacryostomy

(c) Dacryocystorhinostomy

(d) Dacryocanalicular anastomosis

(e) Closure of the DCR.

Transplantation of the upper canaliculus is indicated in extensive obstruction of the lower canaliculus.

Canthocystostomy

Canthocystostomy is indicated in extensive or total occlusion of the lower canaliculus.

Conjunctivo-dacryocystostomy

Stallard's conjunctivodacryocystostomy is indicated in the occlusion of both the upper and lower canaliculi between the medial canthus and the lacrimal sac.

Operation. A 6 mm oblique incision is made through the conjunctiva extending from ampulla of the canaliculus down towards the lacus lacrimalis. Four 7/0 black braided silk sutures are passed through the lips of the incision. The lacrimal sac is exposed through usual steps of the sac

operation. The patency of the lacrimal sac and the nasolacrimal duct is tested through an incision over the fundus of the sac. This is followed by intubation of the lacrimal passages in which a silicone tube of 2 mm in internal diameter is passed through the sac incised down the nasolacrimal duct. Anastomosis of the lacrimal sac and the conjunctiva is the next step. It is done as follows. The lateral wall of the sac is dissected from its fascia for about two-third of its length. The sac is now retracted downwards and forwards. A 6 mm oblique incision is given through the conjunctival incision in the region of the lacus lacrimalis in such a fashion that the fundus of the sac is approximated against the margins of the conjunctival incision. The sac is then retracted outwards and forwards and the orbital septum posterior to the sac is exposed. The septum is then incised vertically so that there is herniation of the orbital fat into the lacrimal fossa, and this pad of fat now remains in the space between the new oblique position of the sac and the bony wall.

Canaliculorhinostomy

Canaliculorhinostomy is indicated in long-standing chronic dacryocystitis with little or no remains of the sac.

The operation is performed in the similar fashion as that of DCR. An oval area of the nasal mucosa is excised with its long axis vertical. The centre of the 5 mm opening made lies in the same line as that of the lower canaliculus. After dissecting off the sac remnants, the flaps of the nasal mucosa are sutured around the opening of the canaliculus which is gradually dilated by increasing-sized probes.

Conjunctivorhinostomy

Communication is made between the conjunctiva at the lacus lacrimalis and the nasal mucosa. Its indications are absence or destruction of the lacrimal sac, and obstruction of the canaliculi and nasolacrimal duct.

Surgery of the Conjunctiva

The operations on the conjunctiva include those for pterygium, peritomy, use of conjunctival hood-flap and excision of new formations. They are described earlier.

Surface and infiltration anaesthesia. Refer to p. 94.

Corneal Surgery

Surgery of the cornea can be essentially grouped into minor and major procedures. Of the minor surgical procedures paracentesis, keratotomy, keratectomy and tattooing are described. The major surgical techniques including keratoplasty have undergone refinements and modifications.

Paracentesis (Fig. 51.13)

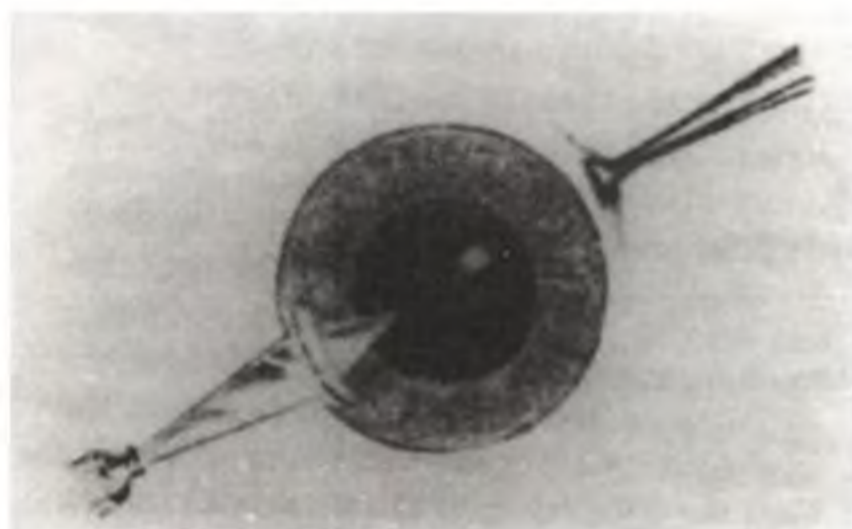


Fig. 51.13 Diagram showing paracentesis of right eye.

Indications. (a) Total hyphaema with no sign of absorption in the first few days.

(b) Recalcitrant corneal ulcer showing no response to conventional treatment, hypopyon with secondary glaucoma, and sloughing corneal ulcer with threatening perforation.

(c) Secondary glaucoma following hypermature cataract, traumatic cataract and iridocyclitis.

(d) For analysis of the aqueous humour which is collected by an Amstler cannula.

(e) Rarely, in central retinal artery occlusion.

Operation. Apart from surface anaesthesia, a retrobulbar injection of 2 per cent lignocaine is occasionally required. A small incision, about 2 mm in length is given just within and concentric with the limbus, in the down and out sector. If frequent irrigation of the anterior chamber is necessary a 5 mm long incision is often useful.

Sato's posterior keratotomy

Sato's posterior keratotomy consists of 3 to 4 mm long incision or incisions made by a special knife through the Descemet's membrane and deeper layers of the substantia propria. It is indicated in keratoconus, keratectasia and high astigmatism. It reduces the corneal curvature.

Saemisch's section of the cornea

Saemisch's section of the cornea is advocated in rapidly-spreading serpiginous ulcer. The cut is made through the floor of the ulcer from the anterior chamber forwards and out through the ulcer.

Delimiting keratotomy

Delimiting keratotomy may have to be done to prevent spread of the ulcer into the central corneal zone. This incision traverses the cornea just in front of the advancing edge, the incision beginning and ending in the healthy cornea parts.

Superficial keratectomy

Superficial keratectomy consists of excision of a superficial corneal scar. It can be combined with covering the raw corneal surface by a conjunctival flap, the corneal surface being made raw by scraping. This is indicated in band-shaped keratopathy, trachoma producing corneal opacity, pterygium and sometimes bullous keratopathy. The area to be excised is outlined by the point of a knife. The incision is started through the healthy cornea to a depth of one-third of its thickness. The margin of the dissected portion is lifted by a Colibri forceps and then excised. In band-shaped keratopathy following instillation of 0.3 per cent ethylene diamine tetraacetic acid (EDTA) in 0.1 per cent sodium bicarbonate wait for about 15 minutes. It dissolves the deposit of calcium.

Tattooing

Tattooing is chiefly a cosmetic procedure to conceal a localized dense corneal opacity.

Scraping of the epithelium is done. A filter paper disc corresponding to the size of the opacity is placed on a watch-glass containing 2 per cent platinum chloride. After allowing the excess of fluid to drop the filter paper is placed over the raw area. After 2 minutes one drop of 2 per cent hydrazine hydrate is instilled, from a pipette and left there for 25 seconds. The eye is immediately irrigated with distilled water. If the colour is not uniform the process is repeated until a grey-black precipitate of platinum is formed. Instead of platinum chloride, gold chloride may be used to obtain a brown precipitate.

Keratoplasty or Corneal Transplantation^{6,19,26}

History. As far back as 1771 Pellier de Quengsy used a transparent material to replace the removed cornea. Reisinger (1818) performed operations on experimental animals and coined the term *keratoplasty*. Zirm (1906) for the first time reported a successful keratoplasty in man. From 1914 to 1930 Elschnig practised full-thickness keratoplasty and obtained good physical and optical results. Filatov apart from evolving newer instruments and techniques, popularized the use of cadaver eyes as donor material. Tudor Thomas, Sourdille, Paufigue, Castroviejo, Franceschetti, Katzin, Rycroft and many others contributed to the enrichment of the surgery.

A corneal transplantation in clinical use is an example of homologous isotopic graft, and the cornea is in a privileged position to accept the graft. A keratoplasty may be *penetrating* (PK) or full-thickness, *lamellar* (LK) or partial thickness or a combination of both, *mushroom* keratoplasty.

In modern-day surgery, virtual control of infection, modern instrumentation, technical perfection and better understanding of graft reaction have combined to achieve better results.

Eye Bank^{6,12,19}

Eye bank is an organization which deals with the retrieval of the eyes from donors immediately after

their deaths, the collection and storage for the purpose of grafting. The donor material may be cornea, sclera and aspirated vitreous.

Suitable donor material

Age. Possibly there is no upper age limit of the donor. Some researchers believe that the eyes of young children are unsuitable because of lack of tissue rigidity, short radius of curvature and rapid imbibition of water.

Ocular pathology. The following donor eyes should not be used, namely those suffering from corneal disease, tumours involving the anterior segment, and showing marked corneal indentation from postmortem hypotony. These donor eyes should not be used, those suffering from septicaemia, leukaemia, syphilis and those who have undergone radiotherapy or antimetabolic therapy.

Interval after death. The donor eye should be placed at 4°C temperature as soon as possible after retrieval. The time-limits for grafting stored donor cornea are:

- For full-thickness grafting—48 hours
- For partial-thickness grafting—5 days

Biomicroscopic assessment of the donor eye. Recent studies have indicated that such assessment is needed for exclusion of the presence of ocular pathology and assessment of corneal viability.

Bacteriology. The chance of bacterial contamination is high. Antibiotic solution, e.g. framycetin sulphate (Soframycin) is used for immersing the donor tissue before surgery. A preoperative bacteriologic study is essential.

Labelling of the container. This should include: (a) age of the donor; (b) sex; (c) date and hour of death; (d) date and hour of enucleation; and (e) possible cause of death.

Storage and preservation. The donor eye should be kept in a sterile glass jar and stored in a temperature between 0 to 4°C. The excised cornea should not be kept in an aqueous solution, since

corneal transparency declines due to hydration of the cornea. The endothelium may be damaged by the use of an antibiotic. The enucleated eye is kept suspended from a glass stopper of a sterilized glass bottle, at the bottom of which moistened gauze is kept to keep the air content of the bottle damp. The glass bottle is packed by ice and placed in a thermoflask and kept in a refrigerator. This particular cornea should not be used for penetrating keratoplasty after 48 hours.

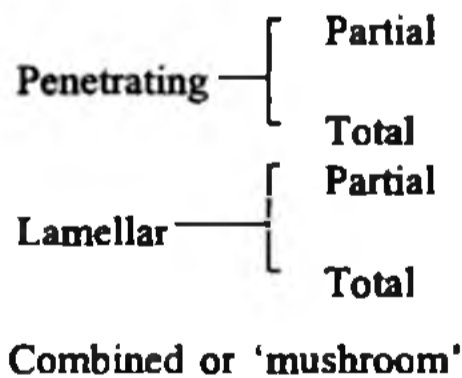
Longer duration of storage. If required for penetrating keratoplasty, the cornea along with a scleral rim is kept in a 12 per cent dimethylsulphoxide (DMSO) solution, cooled down to -80°C in liquid nitrogen and stored at -197°C , for an indefinite period. For use in lamellar keratoplasty sterile 96 per cent glycerol is used as a dehydrating agent.

McCarey and Kaufman (MK) medium offers a duration of 4 days or more for the utilization of the donor material. The sclerocorneal disc is stored in 20 ml culture medium at 4°C .²¹

K-sol medium containing chondroitin sulphate is used for storage of the cornea at 4°C for about two weeks.¹³

Minnesota system of organ culture allows preservation for 35 days.

Classification of corneal grafts



Indications of keratoplasty

Indications of keratoplasty are listed in Table 51.3.

Contraindications of keratoplasty

Contraindications of keratoplasty include: (a) absence of tear; (b) affection of the posterior ocular segment; (c) non-cooperation and mental

Table 51.3

Indications of Keratoplasty

Optical—for improvement of visual acuity
Leucoma
Keratoconus
Corneal dystrophies
Interstitial heratitis
Herpetic keratitis
Chemical burn of the cornea
Preparatory to full-thickness graft
Chemical burn
Therapeutic—to halt or reverse disease process
Uncontrolled corneal infection
Corneal perforation
Chemical burn
Tectonic or structural—to restore corneal integrity
Corneal fistula
Perforating corneal ulcer
Refractive

instability; and (d) in the cornea such as 0.2 to 0.4 mm thinness the fixation of the graft may be difficult or impossible.

Preoperative preparation and treatment

Preoperative preparation and treatment should include all precautions and formalities of any intraocular operation. Some surgeons prefer instillation of drops of miotic prior to operation.

Preoperative treatment consists of detection and if necessary, eradication or control of the following conditions:

(a) Weak orbicularis oculi, entropion, ectropion, trichiasis and symblepharon.

(b) The anterior synechiae must be separated.

(c) The posterior synechiae may need separation or an iridectomy.

(d) Corneal vascularization needs peritomy or a modified operation.

(e) The cause of secondary glaucoma must be found out and treated accordingly. The operation can be performed only when the eye is free from active inflammation. If any other operations are indicated such as synechiotomy, and iridectomy they should be done along with keratoplasty.

Table 51.4 summarizes the main steps in full-thickness or penetrating keratoplasty.

Table 51.4

Key Steps in Full-thickness Keratoplasty

1. Preparation of corneal disc
2. Preparation of recipient bed
3. Trephining and removal of recipient corneal disc
4. Placing donor disc over host bed
5. Direct, edge-to-edge sutures
6. Injection of Miochol into anterior chamber
7. Subconjunctival antibiotic, steroid and mydriatic

After placing the graft on the recipient bed direct edge-to-edge sutures are applied, preferably with 10/0 monofilament polyamide. The graft margin is held with fine Colibri forceps and the first stitch is passed through 6 o'clock position. Twelve to sixteen sutures are required. Continuous perlon sutures may also be used. Sterile air or balanced salt solution (BSS) is injected in the AC. To protect the corneal endothelium healon may be used. Miochol is injected to induce miosis. Subconjunctival injection of gentamicin is advised for preventing post-operative infection.

Postoperative Treatment

The first dressing is done on the next day with steroid-antibiotic preparation. If there is evidence of iridocyclitis a mydriatic is given. In case of irritation, 5 to 10 mg daily dose of systemic steroid is prescribed and continued for about 4 weeks till the irritation subsides. Diamox 250 mg tablet twice daily for 5 days is given. About 4 weeks after the operation alternate direct sutures are removed provided the healing is satisfactory. The remaining sutures are left for 7 to 10 weeks when they are removed as they have become loose and ineffective. Polyamide sutures with buried knots need not be removed unless they cause irritation, vascularization and astigmatism.

Complications

During operation. (a) Off centre and oblique application of the trephine are undesirable,

necessitating a re-grafting. If the trephine is obliquely applied there are complications like iris prolapse, ectasia and anterior synechia.

(b) More often removal of the lens matter is necessary in case of injury to the lens, both dislocation and extrusion.

(c) As a preventive measure in case of threatening loss of vitreous, Flieringa's ring may be fixed to the eyeball prior to the operation.

(d) If the eye collapses it is very difficult to accurately place the graft. Injection of healon into the anterior chamber may be helpful.

Postoperative. Postoperative complications may be early occurring within 2 weeks or late (Table 51.5).

Table 51.5

Complications after Penetrating Keratoplasty

Early

- Shallow anterior chamber
- Secondary glaucoma
- Anterior uveitis
- Oedema and opacification of the graft
- Others—displacement of the graft, iris prolapse, anterior synechia

Late

- Suture irritation
- Graft rejection
- Secondary glaucoma
- Recurrence of the host disease

Shallow anterior chamber may be caused by defective approximation between the graft and the recipient bed, defective suturing and fistulous track around deep suture.

Secondary glaucoma in the early postoperative period is due to deranged outflow facility of aqueous or following large dose of topical steroids.

Oedema and opacification of the graft may be seen within 24 to 48 hours. They are due to damage to the corneal endothelium, defective viability of the endothelium and ocular hypotony.

Suture irritation. There may be loose sutures and they may cause surface disturbance, vascularization and infection following accumulation of mucus on the loops. There may be cellular infiltration in the vicinity of a suture. Resuturing of the wound may be necessary.

Graft rejection, also called *maladie du greffon* may occur. A graft rejection may be epithelial or endothelial. Epithelial rejection is evidenced by the presence of an irregular line or dots on the epithelium.

Endothelial rejection is characterized by the presence of central oedema, keratic precipitates, cells in the anterior chamber and marginal vascular engorgement. Keratic precipitates forming lines is called *Khodadoust line*.

Treatment is by intensive topical and systemic steroids.

Secondary glaucoma occurring after 3 weeks may follow anterior synechia, the latter being dependent upon the size of the graft. If the graft size is 8 mm or more there is likelihood of angle distortion.

Results (Fig. 51.15). The result of the operation should be assessed after about 6 months. Not only success of the implant, but also good corrected visual acuity often improved by myopic astigmatic correction should be the main criteria.

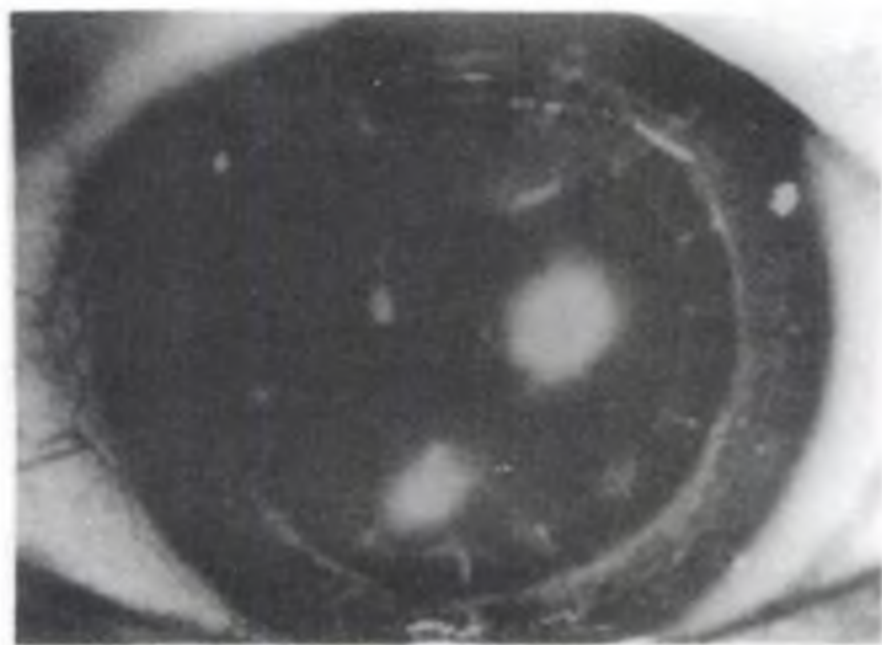


Fig. 51.15 A successful full-thickness keratoplasty.

Penetrating keratoplasty combined with other procedures. The surgical procedures performed with keratoplasty include cataract with or without IOL, trabeculectomy, etc.

Lamellar Keratoplasty²⁵

Indications. (a) Superficial lesions of the cornea

(b) Corneal opacity in an aphakic eye with vitreous in the AC

(c) Preparatory to PK

(d) Therapeutic for halting or reversing a corneal disease process

(e) In restless and mentally unstable patients

Contraindication. The operation is contraindicated in corneal opacity associated with endothelial dystrophy.

Operation. Lamellar keratoplasty is a more difficult procedure than a penetrating keratoplasty. A corneal trephine fitted with a guard to cut a disc of a required depth, about 0.4 mm is used. The edge of the lamellar graft is undermined by a Paufigue's elbowed knife and then the lamella is dissected directly off Descemet's membrane. After trephining, a small paracentesis makes dissection of the deeper layers much safer (Fig. 51.16). A similar procedure is performed on the donor eye. The graft is placed on the recipient bed and sutured. The complications and sequelae during and after a lamellar keratoplasty are almost the same as those of a penetrating keratoplasty.



Fig. 51.16 Lamellar graft. The effect of paracentesis when the scar tissue must be dissected directly off Descemet's membrane (After Paufigue; Philips and Foster).

Postoperative treatment is same as that in penetrating keratoplasty.

Postoperative complications

Postoperative complications are fortunately rare and not serious. They include: (a) oedema; (b) vascularization; (c) opening of the anterior chamber; (d) keratitis; (e) uveitis; and (f) rarely, displacement of the graft, necrosis, haemorrhage and epithelial invasion.

Operation. An incision is made 0.5 mm in front of the limbus and slightly obliquely through the cornea. In *ab externo* the incision is made 2 mm behind the limbus. In narrow iridectomy the iris scissors are placed radially to the section. In broad iridectomy the scissors are placed parallel and tangential to the section. The iris is repositioned with an iris repositor.

Postoperatively, instillation of 1 per cent atropine is continued for about two weeks.

Optical iridectomy

Optical iridectomy is advised in central corneal opacity. However, this condition is better treated by keratoplasty. Before operation test of improvement of visual acuity after full mydriasis, with pin hole or stenopaic slit should be done. Examination of the ocular fundus should show no gross abnormality and the media should be clear. The opacity should be stationary for some months.

The iridectomy is done commonly down and inward provided this region is not affected by opacities; in that case it is done down and outward. It should be ascertained by a stenopaic slit.

A small incision is made (Fig. 51.19) at the selected site just in front of the limbus. A narrow

iridectomy from the pupil margin but not extending up to the iris root is performed by holding the iris scissors radially to the limbus. Reposition of the iris is then done. Refraction is attempted after about four weeks.

During iridectomy problems may arise and they are:

(a) Impairment of the mobility of the iris occurs following severe and recurrent attacks of iritis showing posterior synechiae and atrophy of the iris

(b) The posterior synechiae should be separated

(c) Injury to the anterior capsule of the lens may occur

(d) Haemorrhage is not unusual.

Postoperative complications. These are occasional and they are hyphaema, delayed reformation of the AC, iritis and injury to the lens or vitreous.

Synechiotomy or division of the anterior synechia

A pointed knife is introduced through a scleral incision and is then withdrawn. It is followed by introduction of a cutting knife between the adhesion and the angle of the AC. Finally the synechiae are divided by the cutting knife.

Iridocapsulotomy

Iridocapsulotomy is indicated in after-cataract with total synechiae. A keratome is introduced at the limbus for about 3 mm above the horizontal meridian of the eye. While withdrawing through the temporal incision, the point of the knife is directed inferomedially to enter the iris and the capsule. One blade of de Wecker's iris scissors is passed through the iris incision, while the other blade is in the AC, and a second cut in the iris is done. The scissors are withdrawn and reintroduced from the nasal side, and a third incision is done to join the nasal end of the previous incisions.

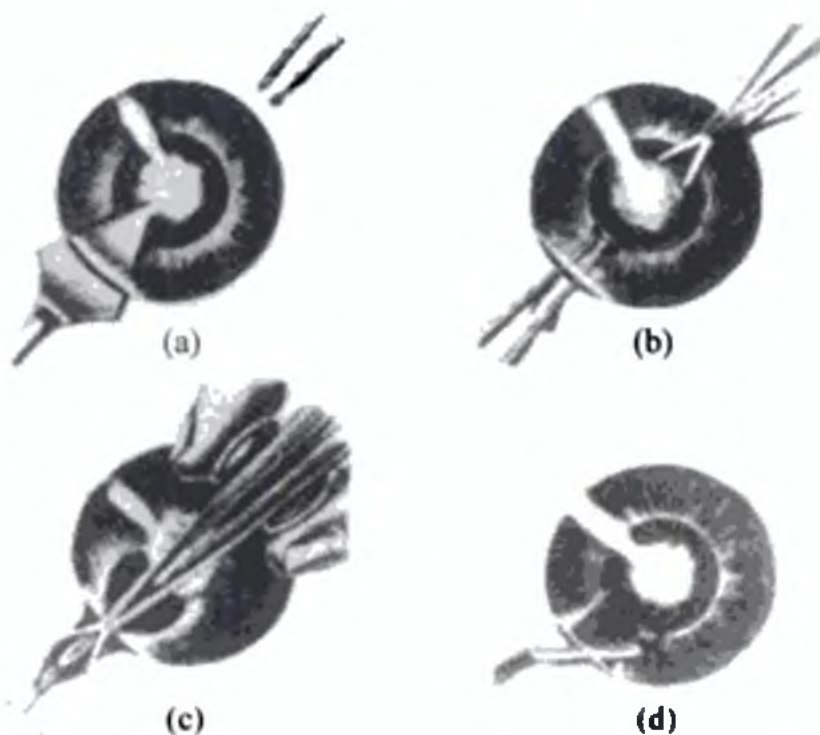


Fig. 51.19 Optical iridectomy: (a) keratome incision; (b) seizing the iris near the pupil margin with Lang's forceps; (c) iridectomy with de Wecker's scissors; (d) replacement of iris. This leaves an eccentric pupil to one side of the scar. (Philps and Foster)

Iridotomy

Iridotomy is an incision in the iris. It is indicated in the

- (a) creation of artificial pupil in *occlusio pupillae*;
- (b) sphincterotomy at 6 o'clock for herniation of the vitreous during cataract operation; and
- (c) occasionally to facilitate delivery of the lens.

Iridotomy in *occlusio pupillae*

A small keratome incision is made at the limbus at the temporal aspect while the point of the keratome is dipped into the iris. After withdrawal of the keratome de Wecker's scissors are inserted to the AC. One of the blades of the inserted scissors is passed behind the iris towards the limbus on the nasal side. The intervening iris is then snipped off. The scissors are now withdrawn and the limbal wound is sutured. After operation the iris opening may not remain intact, because of loss of elasticity of the iris and obstruction by blood and exudate.

Quadruple puncture of the iris

Indication. *Iris bombé* A narrow cataract knife is inserted into the AC entering the cornea 1 mm inside, piercing the iris *bombé* through to the opposite side.

Surgery for Iridodialysis

If small, it is better left alone. If large, surgery is called for. A small limbal-based conjunctival flap is prepared. A needle with a 10/0 monofilament is passed into the iris angle and below the conjunctival flap opposite the dialysis. The needle is introduced to the angle root into the posterior chamber, suturing the margin of the dialysed iris, till it emerges through the cornea. A small keratome incision is done beside the suture and the hook passed through this incision pulls the vertical part of the suture. The suture is drawn out into a loop.

The two ends of the suture are then tied. More than one suture may be required.

Cataract Surgery^{2,10,25,26}

History. Greeks, Romans, Egyptians and Arabians practised couching. The view usually held that Suśruta (bc800) practised couching is wrong. A study of 'Suśruta Samhita'²⁷ suggests that his method was closely allied to present-day extracapsular extraction of the lens. Rhazes and Ammar performed needling and suction of the lens matter.

In 1745 Daviel performed planned extraction through a lower limbal incision. Sharp (1773) performed the first intracapsular extraction by thumb pressure. In 1865 von Graefe devised a knife and advocated iridectomy. In 1867 Williams for the first time used a corneal suture and devised intracapsular forceps. Sutures were also popularized by Mendosa, Liegard, Stallard, Lindner and McLean. In 1910 Col. Smith introduced intracapsular extraction in India through a corneal section, by means of thumb pressure exerted in the lower part of the cornea. Elschmig, Lindner, McLean, Verhoeff, Kirby, Arruga, Stallard and many others improved various aspects of the technique. In 1930 Elschmig recommended retrobulbar injection, while orbicularis anaesthesia was improved by van Lint (1920) and O'Brien (1929). In 1949 Ridley placed an acrylic lens behind the pupil of the aphakic eye. In 1959 J. Barraquer discovered the role of alpha-chymotrypsin on the suspensory ligament of the lens. In 1961 Krwawicz described cryoextraction of the lens. In 1960 Scheie described a procedure for aspirating soft cataract through a small incision. Kelman (1967) introduced phacoemulsification. Binkhorst, Worst, Jaffe, Shearing, Simcoe and many others advocated extracapsular-cataract extraction (ECCE) with intraocular lens (IOL).

Preoperative investigations

Local examinations. The following plan of investigations may be followed:

(a) The lid and conjunctiva are examined for any inflammation and infection.

(b) The lacrimal passages are tested especially by syringing for evidence of obstruction and infection.

(c) The pupil should be examined by a slit-lamp biomicroscope after being dilated by homatropine or cyclopentolate drops.

(d) Ocular tension must be assessed by tonometry.

(e) Tests for perception of light indicating state of the optic nerve and projection of rays indicating state of peripheral parts of the retina are of prime importance.

(f) A brisk response of the pupil to light and similar response in the fellow pupil indicate good optic nerve function.

(g) The patient is asked to fixate a light at a distance of 1/3 metres through a Maddox rod in a trial frame, while the other eye is occluded. A good retinal function is suggested by perception of both vertical and horizontal bar of light. A break or distortion in the centre of the bar points toward a macular lesion.

Other tests for evaluation of macular function have been described on pp. 315–16.

(h) Culture from the conjunctival sac is done for any bacterial growth. Operation is delayed in the presence of pathogenic bacteria. In such a case topical antibiotic is used for a week or so before another bacteriologic examination.

General history and systemic examinations. These include examination of BP; blood sugar; evidence of active infection; chronic straining conditions and skin affections of the face. Other examinations include check-up for dental sepsis; bleeding and coagulation time; and drugs in present use.

Ocular Diseases Posing Problems for Surgery

(a) Control of blepharitis, conjunctivitis and keratitis is necessary.

(b) In leucoma prognosis of probable visual regain should be clarified.

(c) In iridocyclitis no operation is done during activity of the disease, but posterior synechiae are no contraindication for surgery.

(d) In chorioretinitis visual prognosis should be clarified.

(e) Diabetic retinopathy. The level of blood sugar must be normal before and after the operation, but visual prognosis depends on the state of diabetic retinopathy.

(f) Visual prognosis also depends on the state of hypertensive retinopathy.

(g) In recent retinal detachment—the detachment should be tackled first.

(h) In case of manifest rise of ocular tension, possibly antiglaucoma therapy and/or operation will be called for, but when the lens is the cause for glaucoma typically in intumescence of the lens, the cataract extraction perhaps is the only operation needed; occasionally a combined filtering operation and cataract extraction is called for. In case associated with long-standing glaucoma, cataract extraction is indicated, but mydriatics are used cautiously. The presence of a filtering bleb is no bar to cataract surgery, incision in front of the bleb is needed, some surgeons even pass through the bleb.

(i) The use of alphachymotrypsin in myopia especially in younger individuals has considerably reduced the operation risk.

Table 51.6 lists the important tests for prediction of postoperative visual acuity.

Table 51.6

Important Tests for Prediction of Visual Acuity after Cataract Surgery

Contrast sensitivity
Glare assessment
Potential acuity meter
Blue field entoptic test
Interferometry
Electrooculogram
Electroretinogram
Visual-evoked response
Confocal scanning laser ophthalmoscope

Contrast sensitivity. Snellen testing of visual acuity is performed only at high contrast. Contrast

sensitivity function determines the patient's ability to perceive a variety of coarse, intermediate or fine details at variable contrasts relative to the background. Contrast sensitivity may be decreased in patients with cataract.

Glare assessment. There are two types of glare: *discomfort glare* and *disability glare*. Disability glare, in which the patient is not properly able to perform a visual task like reading, is common in patients with cataract.

Confocal scanning laser ophthalmoscope provides a beam of laser light scanned across the retina. The scanning laser ophthalmoscope illuminates one point on the retina at a time.

Other tests have been described on p. 316.

Preoperative preparations

Trimming of the eyelashes and thorough washing of the eye, instillation of antibiotic drops as well as sedative and laxation at bed time are advocated at night before operation. Light breakfast on the morning of operation is allowed. Premedication consists of diazepam, 10 mg for an adult, 2 hours before the operation.

Preliminary surgical procedures include: (a) pupil dilatation not exceeding 6 mm by tropicamide drops to be instilled 10 to 15 minutes before an operation; and (b) anaesthesia. Local anaesthetic is satisfactory and preferable. Surface anaesthesia is induced by 0.5 per cent to 1 per cent amethocaine. After 2 to 3 instillations of amethocaine (tetracaine) there is effective anaesthesia in about 1 minute. It can also be induced by 4 per cent lignocaine (xylocaine or gesicam) hydrochloride. Infiltration anaesthesia is mandatory for akinesia and protective reason.

Infiltration anaesthesia (Figs. 1.6 and 1.11)

Facial block. The facial nerve comes out of the stylomastoid foramen and 5 to 7 mm behind the ramus of the mandible splits in two divisions: temporofacial and cervicofacial. The temporofacial division crosses the neck of the mandible, sometimes lying on it and at times 1.5 to 2.5 cm below it.

Facial block to cause an effective akinesia of the orbicularis is essential to avoid squeezing of the eyelids during an intraocular operation. This is achieved by temporary paralysis of the muscle by injection of 2 to 3 ml 2 per cent lignocaine with adrenaline 1:10000 and hyaluronidase. 0.07 ml of adrenaline in 5 ml of lignocaine is effective. Hyaluronidase is used in the proportion of 150 units per 20 ml of lignocaine.

O'Brien's technique. The condyloid process of the mandible is felt by the finger by asking the patient to open and close the mouth, and the injection is given just in front of the tragus. The needle is inserted up to the inferior margin of the zygomatic arch.

Van Lint's technique. The injection is given across the course of the branches of the facial nerve as they run over the zygomatic bone. Initially, the anaesthesia is deposited at a point 1 cm below and behind the lateral canthus, the needle passes in three directions: (a) upwards towards the temporal fossa; (b) forwards, medially and downwards along the infraorbital; and (c) downwards and backwards along the lower margin of the zygoma.

Retrobulbar block or ciliary block. Retrobulbar block or ciliary block is needed to block the postganglionic fibres of the ciliary ganglion. The injection is given through the skin at the junction of the lateral one-third and medial two-third of the inferior orbital margin. Alternatively, it can be given at the same site through the conjunctiva. A 3.5-cm needle is used to reach the ciliary ganglion. One ml is injected. Immediately after the injection digital pressure is applied over the closed upper lid for about 3 to 4 minutes. This causes lowering of ocular tension.

Peribulbar anaesthesia. This is described on p. 445.

Preliminary steps

After a facial block and a retrobulbar block the patient is placed on the operation table with the head placed in the hollow of a ring acting as a

pillow. The skin of the eyelid and adjoining areas is swabbed with an antiseptic. Surgical draping of the chest and head is done. A face mask with opening over the eye is then placed. Alternatively, adhesive tape may be used. Sutures or fine lid clamp may be used to retract the lids. Sutures are passed through the lids near the lid margins.

A 4/0 white braided silk suture is passed through the insertion of the superior rectus muscle, which rotates the eyeball downwards. This suture is clamped to the head towel by a mosquito forceps.

In the presence of a deep-set eye and short palpebral fissure a lateral canthotomy may be needed.

Some surgeons advocate use of Flieringa's ring made up of stainless steel 0.3 mm thick and 20 to 22 mm in diameter which is sutured between the limbus and the equator of the globe. It is indicated in the presence of a degenerate vitreous or where vitreous loss occurred in the fellow eye.

Conjunctival flap. Some surgeons prefer to prepare a conjunctival flap. A conjunctival flap may be limbal-based or fornix-based. In a limbal-based flap there is good covering in cases of wound separation, iris prolapse and vitreous herniation. The sutures remain completely buried. In a fornix-based flap incision site can be suitably followed and better handling of the instruments in the AC is possible.

Sutures. The sutures may be nonabsorbable or absorbable. They may be preplaced with limbal based flap, preplaced with fornix-based flap, preplaced without a conjunctival flap, postplaced and continuous.

An ideal suture should have enough knot security and high tensile strength. It should keep the wound margins in apposition long enough to cause maximal healing. Present-day synthetic absorbable sutures yield excellent result.

The incision. This is the most important step. It should be adequate, clean and between 3 to 9

o'clock position. To remove a soft or membranous cataract it can be made 1 mm above the central horizontal meridian. The incision may be made by a cataract knife, keratome, scalpel or blade fragment. There are different types of incision: perpendicular, beveled, perpendicular-beveled, beveled-perpendicular, three plane and four plane.

Incision with a cataract knife (Figs. 51.20 and 51.21). The tip of a sharp cataract knife is introduced from the temporal side 1 mm away from the limbus, while the eyeball is held with a fixation forceps in such a fashion that the eyeball

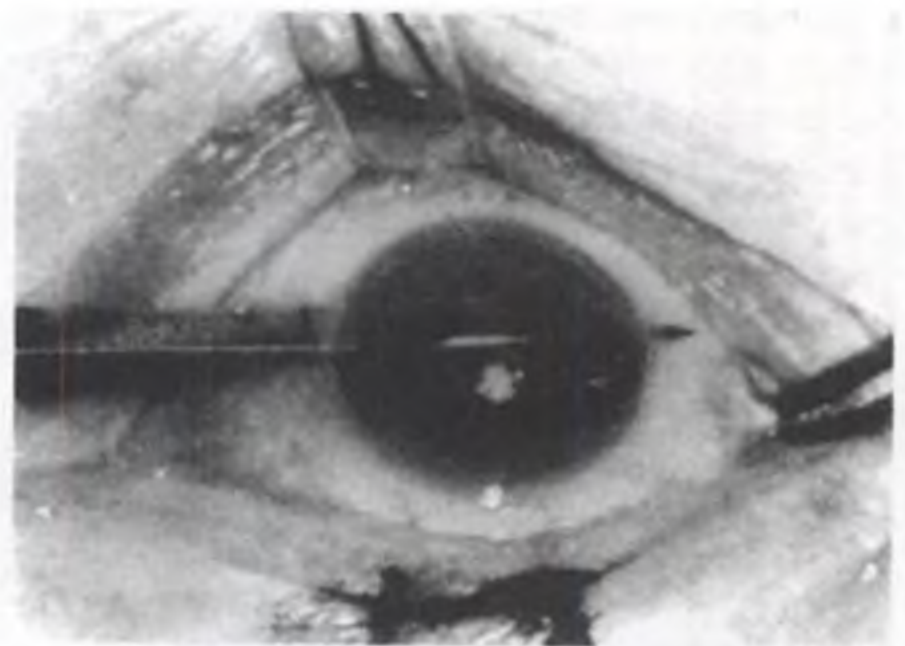


Fig. 51.20 The knife has been inserted just behind the limbus and aimed at the limbus on the other side coming just behind it (Philps and Foster).

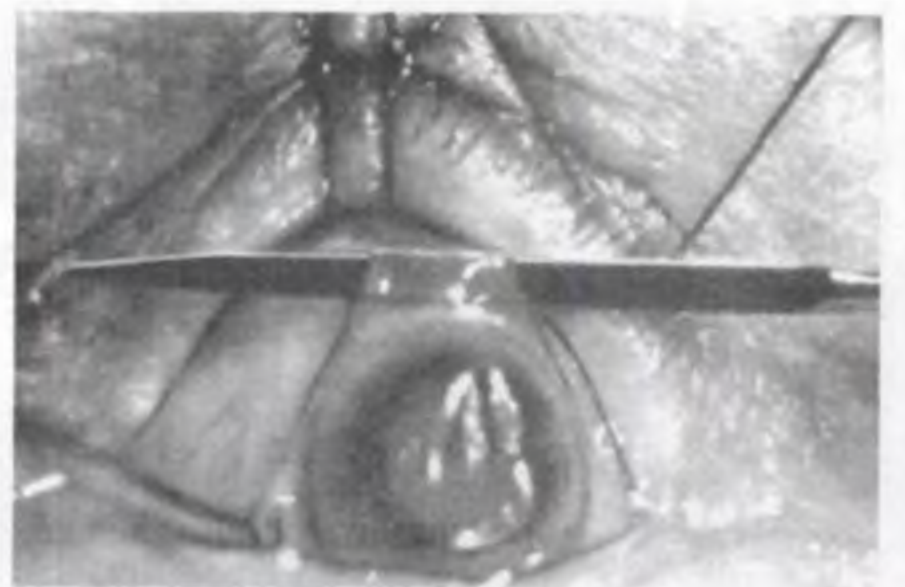


Fig. 51.21 Method of cutting the conjunctival flap (Philps and Foster).

does not rotate. The knife is passed straightway through the anterior chamber till it reaches the point of counterpuncture on the other side, the latter point being exactly opposite to the point of entry. It must be emphasised that confusion may arise as to the point of counterpuncture because of misleading refraction. The knife should touch 1 mm central to the corneal margin to emerge at the limbus. The knife is swept smoothly upwards to finally complete the incision.

Keratome and scissors incision. A keratome is inserted at 12 o'clock for an incision between 11 to 1 o'clock. The incision is enlarged with corneal scissors on either sides.

Ab externo incision. The incision is made from the surface towards the AC. The section can be made with a keratome and scissors, scalpel and scissors, or a razor blade fragment. There are three main stages for a 'stepped' incision meant for the useful securing of the closure of the wound. At first a vertical incision is made, followed by the horizontal splitting of the corneal lamellae. Finally another vertical incision is extended and completed with scissors.

Corneal section. This is ideally performed by a sharp knife under an operating microscope. The wound must be secured by multiple fine sutures or continuous sutures.

Iridectomy. A peripheral (basal) iridectomy is done at 12 o'clock or two iridectomies are done at 11 and 1 o'clock positions. Iridectomy helps in the reformation of the anterior chamber and thus prevents a shallow anterior chamber associated with pupil block from the herniation of the vitreous face. After taking a pinch of the iris root with an iris forceps, it is snipped exactly below the grip of the forceps by a pair of de Wecker's scissors. Instead of a peripheral iridectomy, one may perform a sector (pupil-to-root) iridectomy.

Intracapsular Extraction of the Lens

The *specific indications* for intracapsular cataract extraction (ICCE) are: (a) hypermature cataract with

hard nucleus and wrinkled capsule; (b) subluxated or luxated lens without vitreous involvement; (c) intumescent lens; (d) cataract with presence of foreign body; and (e) severe lens-induced uveitis.

The chief methods are extraction by intracapsular forceps, crysiphake extraction and cryoextraction.

Extraction by intracapsular forceps (Fig. 51.22)

Lower capsule grip. The intracapsular forceps used along with a lens expressor deliver the lens.

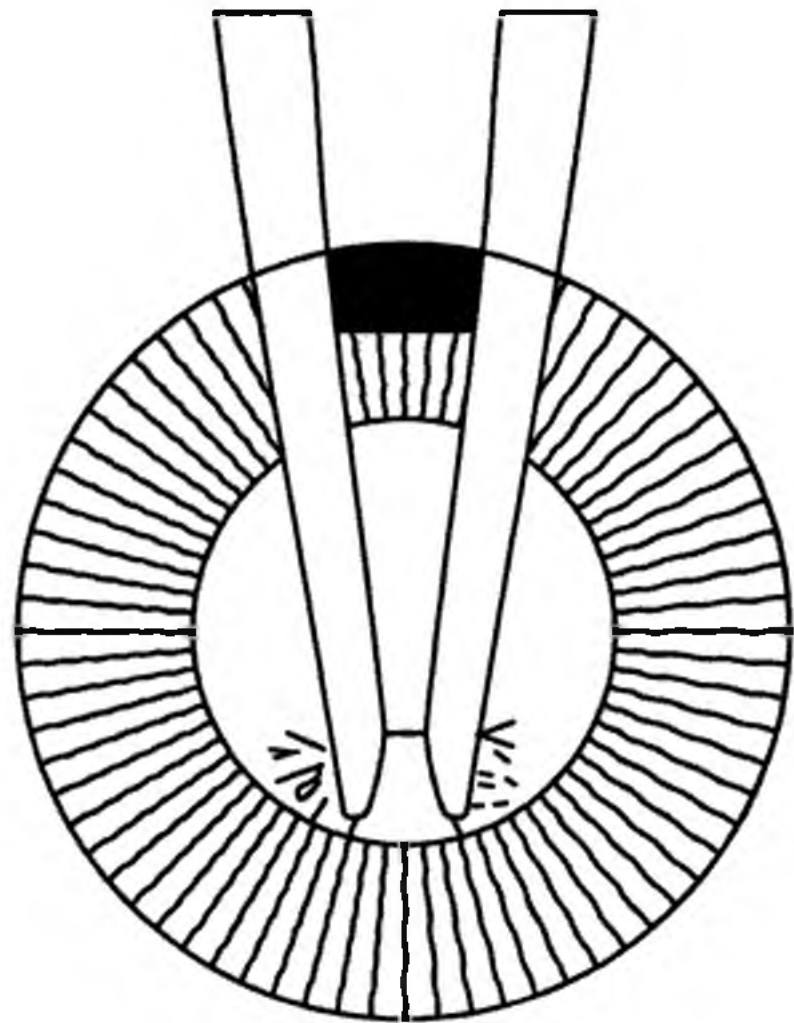


Fig. 51.22 Application of intracapsular forceps at 6 o'clock meridian.

On reaching the pupillary area the closed blades of the forceps are moved over the anterior capsule of the lens till they reach the thickest part of the capsule of the lens just in front of the equator near the lower margin of the lens. The blades are then opened 2 mm to grasp the capsule at 6 o'clock position. The technique is known as the *lower capsule grip* or *tumbling*. After closing the blades of the forceps zig-zag movements of the forceps cause rupture of the suspensory ligament, while

the lens expressor placed horizontally on the lower part of the limbus is providing counterpressure directed backward and slightly upward. When the lower edge of the lens is made free it is tumbled forward. The lens is still held with the forceps but without any pull on it, while the lens expressor is kept below the level of the lower edge of the lens. The final stage of delivery of the lens is slow.

There are three hazards of the lower capsule grip:

(a) Because the hyaloid face cannot be seen properly there is likelihood of damaging it when it is adherent with the posterior capsule of the lens.

(b) The introduction of forceps may damage the corneal endothelium.

(c) Inadvertent iridodialysis poses a problem.

Upper capsule grip or sliding. The lens is delivered more by the traction of the forceps than by the lens expressor. In this technique, after lifting up the corneal flap a gentle pressure is applied at 6 o'clock inside the limbus while the forceps with blades kept horizontally grasp the capsule in the upper-most part just in front of the equator. The lens is gently rotated out of the incision while counterpressure is applied over the cornea. During lens delivery the posterior surface of the lens is held against the posterior lip of the section so as to avert the loss of the vitreous.

Delivery of the lens by an erysiphake

Erysiphake is occasionally used now-a-days. An erysiphake has a cup which is applied just below the centre of the lens. The lens is delivered by rotation and traction of the instrument while counterpressure is maintained.

Cryoextraction of cataract (Fig. 51.23)

Cryoextraction of cataract is a popular method employed in an intracapsular extraction. This is particularly indicated in: (a) hypermature cortical cataract; (b) complicated cataract; (c) chance of rupture of the lens capsule; (d) cataract extraction in a case associated with corneal dystrophy; and (e) sometimes in combined cataract extraction and keratoplasty.




Fig. 51.23 Cryo unit for cataract extraction (Courtesy: Appasamy Associates, Chennai)

In 1961 Krwawicz¹⁷ for the first time described the cryoextraction of intumescent cataract. Today it is an established procedure. It appears to be superior to other methods of intracapsular extraction.

Amoils¹ has proposed the following design for a cryoprobe:

(a) Application of the cryoprobe at room temperature.

(b) Facility for rapid freezing, rapid defrost and rapid re-freeze.

(c) Continuous sustained operation of the unit.

(d) The cryoprobe is constantly visible.

(e) There should be no leakage of gas at the site of operation.

(f) The probe should be small, delicate and well balanced with delicate tip and easily sterilizable.

(g) The cryo unit should be cheap with readily available cryogen.

To avert accidental freezing of the tissues other than the lens there should be a cryoshield probe. It should have an outer and inner cores, the outer

made up of silver and the inner freezing core of stainless steel. The sides are used for retracting the iris to the equator while freezing of the lens is done by the inner core.

The tip of the cryoprobe is applied to the anterior capsule at 12 o'clock meridian between the equator and the anterior pole of the lens, while the iris is well retracted by an iris retractor. An assistant lifts the cornea. The iceball forms at the tip of the cryoprobe at -40°C when the foot switch is pressed upon.

In a *Morgagnian hypermature cataract* while the lens is swollen, and the capsule is taut and slippery, delivery of such a lens by a larger iceball is preferable. This is achieved by longer contact of the probe and instillation of drops of saline on the lens capsule. At first the upper pole of the lens is held and an even traction is applied after 5 seconds. Sometimes to avoid capsular rupture the probe is re applied to the middle or the side of the lens. Care should be taken to do the extraction slowly.

Rupture of the lens capsule can be sealed by the cryoprobe producing a larger iceball.

Cataract and corneal dystrophy. Because there is no chance of trauma to the affected endothelium in a properly done cryoextraction, this is considered to be the best method.

Combined cryoextraction and corneal grafting. When such a combined technique is called for cryoextraction is done while the donor disc is hinged at the 3, 6, and 9 o'clock positions by the sutures but not tied.

Final steps

Closure of the incision is done by drawing the sutures taut. The other steps include repositioning of the iris, tying of the corneoscleral sutures, reformation of the AC by injecting sterile air or better still by sterile physiologic solution, instillation of antibiotic drops, removal of superior rectus suture, and bandaging of the eye. Three types of extraction can be compared (Table 51.7).

Table 51.7

Comparison of Three Types of Lens Extraction

Points	Forceps	Erysiptake	Cryoprobe
1. Instrumentation	Simple	Not so	Complicated
2. Size of the incision	Half the circumference of the cornea	Needs larger incision	Smaller incision will do
3. Grasp on the capsule	Weakest	Better	Best
4. Effect over tense capsule	Difficult	Easier	Best
5. Chance of capsule rupture	Greatest incidence	Less	Least
6. Chance of corneal injury	Least	Most	Least

Alphachymotrypsin

One hundred and fifty units of alphachymotrypsin is dissolved in 5 ml physiologic solution, 1 in 5000, and 0.5 ml of this solution is injected through an iridectomy in between the iris and the anterior capsule of the lens nasally and temporally, and also injected through the pupil. 1 to 2 minutes are sufficient for an elderly patient, though it can act up to $3\frac{1}{2}$ minutes. Then the AC is washed out.

Alphachymotrypsin is a valuable enzyme in intracapsular surgery, particularly in patients under the age of 60.

Extracapsular cataract extraction (ECCE)^{18,24}

An operating microscope of current model is most desirable. Microsurgical instruments especially a few selected ones, needles, sutures and automated mechanical systems (irrigation-aspiration, phacoemulsification and anterior vitreous systems) are of special considerations in ECCE (Fig. 51.24).

Technique. Maximal mydriasis must be achieved and maintained intraoperatively by prostaglandin-inhibitor like flurbiprofen sodium (Flur, Ocuflur). Preoperative sedation, anaesthesia and akinesia and lowering of IOP either by external pressure (either by applying digital pressure for 5 minutes or more by a pneumatic balloon) or hypersomotic agents in high-risk cases are also essential before incision.

The steps of operation are given in Table 51.8.



Fig. 51.24 Vitrectomy + irrigation/aspiration system. (Courtesy: Appasamy Associates, Chennai)

Table 51.8

Steps of Extracapsular Cataract Extraction

Antimicrobial preparation of eyelid, face skin and conjunctiva
Draping of the surgical field
Separation of the eyelids by a wire speculum
Superior rectus traction suture
Groove incision along the upper limbus, then entrance into AC by a sharp blade
Injection of a viscoelastic agent into the anterior chamber
Anterior capsulotomy <ul style="list-style-type: none"> • Can-opening method • Small opening for endocapsular or intercapsular extraction • Continuous curvilinear capsulorhexis (CCC)
Nucleus removal <ul style="list-style-type: none"> • Manual with pressure and counterpressure • Hydrodelivery
Posterior capsule scraping
Iridectomy—not necessary in all cases
Wound closure
Subconjunctival antibiotic, mydriatic and steroids

Incision. Usually a small section of 140 to 160° from 10 to 2 o'clock is adequate. The size of the incision may have to be increased on certain occasions.

Anterior capsulotomy. Three methods are described.

(a) *Can-opening method.* A cystitome can be made by bending a 26-gauge needle. After injecting viscoelastic agent into the anterior chamber the surgeon starts puncturing at 6 o'clock position with

the bent needle and goes on repeating till a 360° circular opening is done. The punctures are at the midperiphery, close to each other and 40 to 50 in number. Thus, approximately 5 to 7 mm diameter circular opening is made.

(b) *Envelope or intercapsular capsulotomy.* A horizontal slightly curved linear incision is given in 10 to 2 o'clock meridian parallel to the pupillary margin by multiple close punctures.

(c) *Continuous curvilinear capsulorhexis (CCC).* The first puncture is made in the midperiphery. The distal edge of the radial tear is lifted with the needle tip that the capsule is everted. Then gradually enlarge the incision round the imaginary circle and remove the anterior capsule.

Nucleus delivery is most commonly done by pressure and counterpressure. The alternative method is hydrodelivery. Balanced Salt Solution (BSS) is injected underneath the anterior lens capsule to separate the lens mass from the anterior capsule (*hydrodissection*). Subsequent injection of BSS reduces the size of the formed nucleus (*hydrodelineation*) and this helps in expressing of the nucleus through a small opening.

Cortical clean-up. This may be achieved either by manual or by automated system of aspiration-irrigation. It is desirable that the anterior chamber remains formed during this stage and for this 3 to 4 interrupted sutures may be used. In manual system, the lens matter is evacuated by aspiration-irrigation using a Simcoe canula with a 5 ml or 10 ml syringe kept inverted and held in left hand (some surgeons prefer 1 ml insulin syringe), while the canula is attached to the drip of Ringer's solution or BSS plus by means of a flexible silicone tube.

Posterior lens capsule polishing. Most of the polishers have rough surface or ring-like edge.

Peripheral iridectomy may be avoided, but it is necessary to add this step when the central AC depth is 2 mm or less, if removal of cortex is not satisfactory and when there is rupture of the posterior lens capsule.

Two methods—intracapsular and extracapsular have been compared (Table 51.9).

Table 51.9

Showing a Comparison between Intracapsular and Extracapsular Extraction²

Intracapsular	Extracapsular
1. Rapid recovery of vision	Not rapid
2. Less chance of postoperative uveitis	More
3. No after-cataract	Common
4. More delicate and more difficult	Easier
5. More chance of vitreous loss	Less
6. More likelihood of the incidence of retinal detachment	Less
7. Without the help of alpha-chymotrypsin, difficult and risky in younger age	Can be done in younger age

Postoperative care

(a) Dressing is done after 24 hours and bandage in the unoperated eye is better left off.

(b) Atropine 1 per cent drops and antibiotic drops are instilled.

(c) Sneezing, coughing and other straining efforts should be avoided.

(d) Regular check-up of the operated eye is an essential feature when treatment consists of atropine and topical steroid.

(e) Sutures are removed after about one week or after.

(f) The patient may be discharged usually after a week.

Complications during operation

(Table 51.10)

'It is indeed true in cataract surgery that a small

Table 51.10

Complications during an Operation^{4, 7}

1. Improper anaesthesia and akinesia
2. Retrobulbar haemorrhage
3. Iris folding over the cutting edge of cataract knife
4. Spontaneous delivery of the lens
5. Failure to grasp the lens capsule
6. Loss of grasp on the lens capsule
7. Rupture of the capsule
8. Luxation of the lens
9. Prolapse of the vitreous
10. Loss of the vitreous
11. Expulsive haemorrhage

error in the beginning may become a great one in the end' (Stallard).

Improper akinesia. When there is incomplete akinesia of the orbicularis oculi, the injection should be repeated. Sometimes an injection into the belly of the superior rectus is needed especially when vitreous loss is suspected.

Retrobulbar haemorrhage. Unless this is severe the operation should not be postponed.

Iris folding over the cutting edge of the knife. If it occurs the iris should be released by lifting the blade of the knife.

Spontaneous delivery of the lens. It rarely occurs with proper anaesthesia and akinesia.

Failure to grasp the lens capsule. The possible factors are tense capsule of an intumescent cataract, defective tips of the blades of intracapsular forceps, and tilting of the forceps or insufficient force.

Loss of grasp on the capsule. It is possibly due to a small section and an inadequate extraction manoeuvre.

Rupture of the capsule. It may occur early during the process of delivery or more commonly just before the completion of the delivery of the lens. The causes of rupture are intumescent cataract; defective intracapsular forceps; a small incision; and inadequate extraction manoeuvre.

Luxation of the lens. Instead of its exit through the wound the lens tends to slip under the scleral lip and then into the vitreous. In such an incident, a complete iridectomy followed by vectis extraction has been advocated.

Vitreous loss and vitreous prolapse.^{15,33} Vitreous loss and vitreous prolapse or herniation occur in about 4 to 5 per cent cases. There are two situations for which the surgeon must be careful. These are *suspected* and *impending* vitreous loss. In suspected vitreous loss there may be history of previous vitreous loss in the other eye or straining conditions, e.g. bronchial asthma and cough. Certain local conditions may be associated with cataract, e.g.

dislocation, glaucoma, and high myopia. The signs of impending vitreous loss are forward protrusion of the lens-iris diaphragm, prolapse of the iris during section, appearance of horizontal tension lines in the cornea, and appearance of beads of the vitreous during lens extraction.

The main causes of vitreous loss and vitreous prolapse are improper akinesia and anaesthesia, and unruly patient. Ocular conditions include luxated or subluxated lens, senescent or diseased vitreous, old iritis and glaucoma.

Vitreous loss and prolapse lead to retinal detachment, updrawn pupil, defective wound healing and corneal opacification.

Prophylaxis. A careful preoperative examination includes special examinations. Proper topical anaesthesia and akinesia should be maintained. Hyaluronidase may be added to retrobulbar injection. Massage of the eyeball for 3 to 4 minutes following retrobulbar injection helps to reduce the ocular tension, and check-up of the tension just before operation is advocated. Pressure during instrumentation is avoided and proper wound suture is ensured.

Treatment. consists of:

- (a) Careful excision of the presented vitreous,
- (b) Complete iridectomy plus sphincterotomy opposite the wound that is in the 6 o'clock meridian,
- (c) Multiple edge-to-edge sutures,
- (d) Instillation of a miotic, and
- (e) Injection of sterile air or BSS into the AC.

Expulsive haemorrhage. It is fortunately rare, but always disastrous. However, it may occur in elderly hypertensive patient. It starts with welling-up of the vitreous and haemorrhage at the depth of the vitreous. Haemorrhage occurs following ruptures of the choroidal vessels. The suprachoroidal blood deposition rapidly expands and forces the ocular contents forward. Thus more and more vitreous, followed by the retina, choroid and accumulated blood are expelled with great rapidity. The eye can be rarely saved but a posterior sclerotomy is worth trying.

Postoperative complications²⁶ (Table 51.11)

Table 51.11

Complications and Sequelae Aftercataract Extraction^{4,7}

1. Striate keratopathy
2. Hyphaema
3. Wound leak
4. Delayed wound healing and reformation of the AC
5. Iris prolapse
6. Pupillary block ————
 ———— Early
 ———— Late
7. Distorted pupil
8. Secondary glaucoma
9. Vitreous changes
10. Macular changes
11. Uveitis
12. Endophthalmitis phacoanaphylactica
13. Detachment of the choroid
14. Retinal detachment
15. Epithelial invasion of the anterior chamber
16. Hypotony
17. Bullous keratopathy

Striate keratopathy. It is quite common and is due to wrinkles in Descemet's membrane causing imbibition of fluid through the corneal edge of the wound. It follows corneal injury, e.g. during incision, during lens delivery, following irrigation and suturing. It affects upper peripheral part of the cornea and is characterized by vertical grey lines. The condition usually clears within one to two weeks.

Hyphaema. It may occur during operation and is found in the AC after 24 hours. It is absorbed within 2 days. But hyphaema of more concern usually occurs between the third and seventh day, the possible explanation being that leakage occurs from the blood vessels which start growing into the wound on about the third postoperative day. Diabetics followed by hypertensives are prone to hyphaema. The possible factors include trauma, defective wound closure, excessively scleral incision and haemorrhage from iridectomy.

Treatment. In less severe cases hyphaema usually clears within about a week. In severe hyphaema with secondary rise of pressure, treatment is by paracentesis and washing out of the AC with urokinase (5,000 units in 5 ml saline).

Wound leak. The various factors responsible include:

- (a) Incarceration of the tissue in the wound
- (b) Irregular, poorly opposed section edges
- (c) Deep sutures may act as drainage wicks
- (d) Poor healing
- (e) Sudden increase of ocular tension, e.g. coughing, sneezing and vomiting

Treatment. This comprises

- (a) Bed rest and bandage.
- (b) In shallow AC with secondary glaucoma treat by diamox.
- (c) If the wound leak is detected by instillation of a drop of fluorescein and noting the tract resuturing the wound and injection of air into the AC are recommended.

Delayed wound healing. After a corneal section coaptation of the endothelium occurs within 24 to 48 hours, healing is firm within 10 to 12 days and is complete by the end of the third week. The causes of delayed healing are generally those of wound leak.

Delayed reformation of the AC. The maximum time the AC takes to reform is usually 5 days. Delayed formation is more common after an ICCE than an ECCE. The causes include: (a) sudden emptying of the content due to straining; (b) jagged section; (c) overriding of the lips of the wound; (d) leakage; and (e) choroidal detachment.

Treatment. In an early case, a light bandage is applied. Diamox is usually helpful. Injection of sterile air into the AC may be tried. If there is no formation within 12 days, choroidal detachment should be looked for and treated accordingly.

Iris prolapse. This may occur within 48 hours of an operation. At least three sutures are needed to accurately coapt corneoscleral wound edges which reduce this complication to less than 2 per cent. It is usually safe to abscise the prolapsed iris and suture the wound margins by edge-to-edge sutures.

Pupillary block.⁴ This may be early and late. In the *early* there is obstruction of the pupil commonly and the iridectomy by the vitreous. It is usually noninflammatory. Ocular pain is suspicious, while these features help in the diagnosis namely shallow AC or AC having an irregular depth, and ocular tension raised leading to oedematous cornea. Medical treatment is by mydriasis. An inferior iridectomy may be needed.

The *late* block is usually due to inflammatory adhesions of the iris to the vitreous and occurs 10 to 20 days after the operation. Diagnosis is made by the presence of a shallow or flat anterior chamber, and usually without evidence of wound leak or choroidal detachment.

Prophylaxis. The measures are:

- (a) Two peripheral iridectomies or complete iridectomy;
- (b) Removal of any tissue remnant;
- (c) Injection of air into the anterior chamber;
- (d) Adequate corneoscleral suturing; and
- (e) Steroids in the postoperative period.

Treatment. This is perhaps more by full mydriasis rather than by strong miosis. If mydriatics are ineffective, an iridectomy is needed. If the angle block is also present, it is to be combined with a cyclodialysis.

Distorted pupil or hammock pupil. The pupil may become drawn up, oval with its peak towards 11 or 1 o'clock. It may be due to anterior synechiae, vitreous incarceration, and adhesion of the iris to capsule remnants.

Treatment. In a grossly deflected pupil, Castroviejo has recommended the separation of

dehiscence which may be due to deep suture and incarceration of fragment of lens capsule or iris in the wound.

Discission for Developmental Cataract

Discission or needling is the classical operative procedure for a developmental cataract. This operation is also indicated in after-cataract (Fig. 51.25). For developmental cataract it can be done most suitably up to the age of 15.

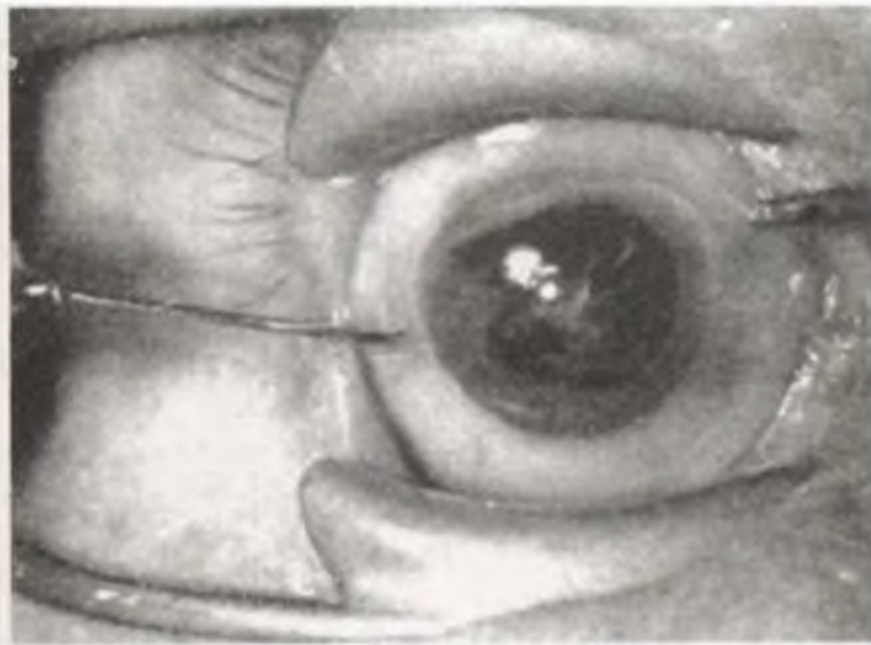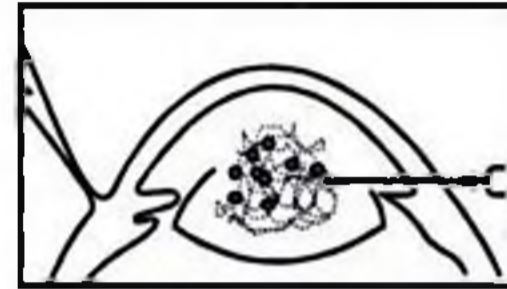


Fig. 51.25 Discission of a thin after-cataract. Ziegler's knife is inserted 1 mm behind the limbus (Philps and Foster).

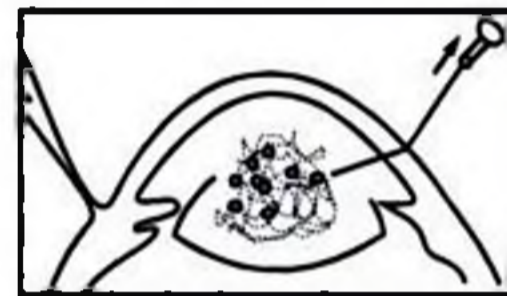
The pupil must be fully dilated with atropine. A general anaesthetic is essential and an operating microscope should be preferably used. After applying an eye speculum the eye is fixed with a fixation forceps near the limbus on the medial side and a discission needle is gently introduced through the conjunctiva just outside the limbus from the lateral side. The needle is passed into the AC through 9 or 3 o'clock in a plane parallel to the iris till it reaches the centre of the pupil. Punctures are made through the anterior lens capsule. The lens matter should be broken. The needle should be withdrawn quickly so that no aqueous is lost. The pupil must be kept well dilated for weeks after the operation. The operation may have to be repeated if residual lens matter is not absorbed.

Discission and aspiration²⁸ (Fig. 51.26)

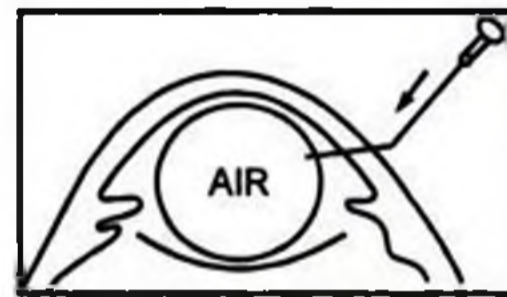
At first a discission is performed. Aspiration is done with a bent hypodermic needle introduced



(a) Anterior capsulotomy with Ziegler's knife



(b) Suction of the soft lens matter



(c) Suction is almost complete

Fig. 51.26 Aspiration of a soft cataract (Dr. I.S. Roy).

into the AC through the track of the discission instrument by an assistant. Physiologic normal saline is gently introduced into the AC to displace the lens floccules. Care must be taken to aspirate as much lens matter as possible and at the same time not to injure the posterior lens capsule and vitreous.

Aspiration is possible by different methods: (a) aspiration by suction; (b) aspiration by alternate suction and irrigation; (c) simultaneous aspiration and irrigation through a double-barreled needle, and (d) simultaneous aspiration and irrigation by separate needles passed through separate openings.

This operation is better than discission alone because it avoids the hazards of repeated needling operations.

Discission for aftercataract or capsulotomy

The procedure is similar to discission with certain modifications. A curved Ziegler's knife-needle is used and it is passed through the capsule. If the capsule is thick two needles are used, one from the temporal and another from the nasal side, and an assistant fixes the eyeball. One needle steadies the capsule while the other cuts through it.

YAG (Yttrium-Aluminium-Garnet) laser is reported to be more effective than a capsulotomy. The YAG laser produces a very short pulse of energy which disrupts the tissues.

Curette Evacuation or Linear Extraction

Although a discission operation is possible up to the age of 30, it is difficult after the age of 15 because of thickening of the lens nucleus. Between 15 and 30 a curette evacuation is indicated in both developmental and traumatic cataracts.

The pupil must be fully dilated with atropine. A 5 mm long incision is given at the 12 o'clock meridian 1 mm within the limbus through the cornea by a keratome. The tip of the instrument passes into the lens. A capsule forceps removes a portion of the anterior capsule. Gentle pressure is exerted upon the posterior lip of the wound by a lens curette, so that the soft lens matter comes out over it. The AC is washed out by thorough irrigation. An iridectomy is sometime done. The iris is repositioned.

Intraocular Lens Implantation

Harold Ridley in 1949 for the first time inserted an intraocular lens after an ECCE. Subsequently Ridley (1960) abandoned the posterior chamber lens implants; the postoperative hazards were reactionary iritis, lens dislocation and glaucoma. Next anterior chamber lens, then iris-supported lens, and finally modern posterior chamber lenses have been introduced. Basically, there are two types of intraocular lenses (IOLs): (a) optic and haptic made up of different materials; and (b) one-piece lens.

Materials used for the optic and haptic of IOL are listed in Table 51.12.

Table 51.12

Materials Used for Optic and Haptic of IOL

For the optic
Polymethyl methacrylate (PMMA)
Silicone
Hydrogel
For the haptic
Polyamide (Perlon)
Polypropylene (Proline)
Polypropylene glycoterephthalate (Mesilene)
Polypropylene terephthalate (Dacron)
Metals like steel, titanium, etc.

Classification of lens implants are shown in Table 51.13.

Table 51.13

Classification of Lens Implants

Ridley's original posterior chamber lens
Anterior chamber lenses
Early (till 1962)
Strampelli tripod
Choyce mark I
Dannheim
Barraquer J loop
Modern (1963 to present)
Choyce Mark VIII and IX
Kelman quadraflex and multiflex
Simcoe C loop
Copeland
Iris-supported lenses
Binkhorst
Worst
Singh
Epstein
Fyodorov
Modern posterior chamber lenses
Shearing J loop
Simcoe C loop
Sinskey J loop
One-piece
Modified Simcoe
Meniscus
Disc
Soft material
Hydrogel
Silicone

Sterilization of IOL. Chemical sterilisation is by soaking the lens in 10 per cent sodium hydroxide solution at 35°C for 3 hours which is washed with sterile distilled water and the residual sodium hydroxide is neutralized with 1 per cent sodium bicarbonate just before use. *Other methods* include gas, thermal or radiation.

Chemical method of sterilisation has now become obsolete.

Calculation of IOL power. A-scan ultrasonography determines the axial length of the globe and AC depth, while keratometry can assess the dioptric power of the cornea. There are various formulae like Sanders-Retzlaff-Kraff (SRK), Binkhorst and Holladay have been developed during past decade.

SRK formula is expressed as

$$P = A - 2.5L - 0.9K$$

where

P = IOL power in D to cause emmetropia

L = Axial length of the eyeball in mm

K = Average of horizontal and vertical keratometric readings in D

A = Specific constant for each lens type and manufacturer.

Indications. An IOL may be suitable in most patients of cataract in whom the surgery is advisable.

The type of IOL advocated especially in cataract associated with primary open angle glaucoma (POAG) or heterochromic cyclitis is only PC IOL.

Contraindications include infants and young children, chronic uveitis, endothelial dystrophy of the cornea, proliferative diabetic retinopathy and rubeosis iridis. AC and iris-supported lenses are contraindicated in cataract associated with chronic simple glaucoma and heterochromic iridocyclitis.

Technique of PC IOL insertion (Fig. 51.27). A PC IOL can be inserted provided the posterior capsule of the lens is intact after a planned ECCE.

In case of *capsular bag fixation*, a viscoelastic agent is injected into the capsular bag which separates the anterior and posterior capsular flaps, thus, creating an adequate space for placement of the IOL. The IOL is introduced into the AC with

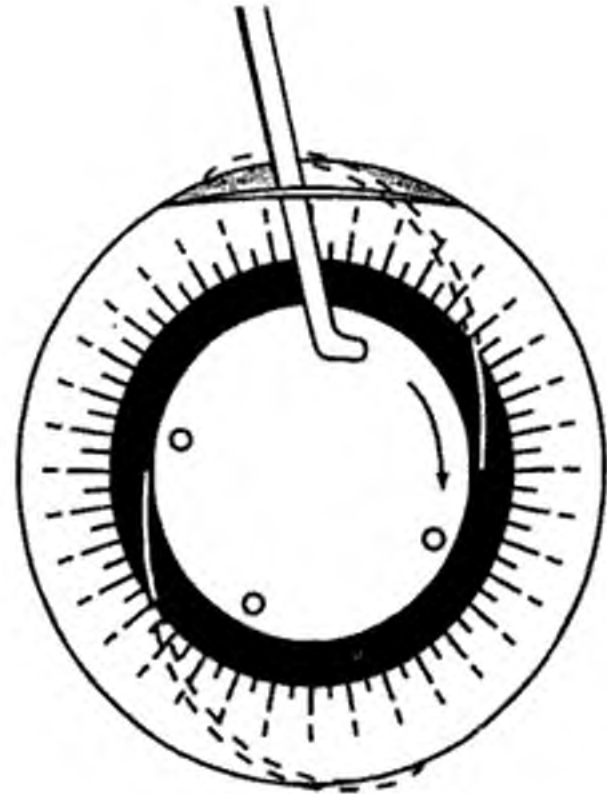


Fig. 51.27 Dialling of an intraocular lens.

the inferior haptic directed into the capsular bag underneath while holding the superior haptic with forceps in the left hand and forceps in right hand grips the proximal part of the optic of the IOL. The optic of the IOL is then dialled by a lens dialling hook until it is positioned in the bag. Then the superior haptic is pushed toward 6 o'clock meridian. Finally the lens is centrally positioned. Miochol is injected into the anterior chamber to constrict the pupil and the anterior chamber is washed with BSS. Continuous suturing is done by 10/0 perlon, subconjunctival injection of gentamicin given and pilocarpine instilled.

Sulcus-fixated IOL technique involves injection of viscoelastic agent into the posterior chamber just behind the iris which causes compression of the anterior and posterior capsule together. The IOL is placed across the anterior chamber in such a fashion that the inferior haptic passes between the iris and the anterior capsule into the sulcus.

Foldable IOL may also be used. This is introduced into the eye through a small 4 mm incision. The lens is placed within the posterior chamber. Now the IOL is allowed to unfold in a controlled manner so that the IOL occupies the capsular bag.

Occasionally *sutured posterior chamber lenses* may be utilized, and this is indicated in: (a) in conjunction with an ICCE; (b) rupture of the

surgically induced astigmatism and early visual rehabilitation. According to Jaffe *et al*, there are five parameters: infusion bottle height, flow, vacuum rise time (the amount of time it takes for the machine to generate maximum vacuum), vacuum and power. The prerequisites are pupil dilatation, ocular decompression, bridle sutures into the insertions of the SR and IR muscles and keeping the eye to be operated under coaxial illumination of the operating microscope.

Technique. A 3.2 to 3.5 mm incision is given at 11 or 1 o'clock position. Then capsulotomy is done using can opening or capsulorrhexis.

Capsulorrhexis. After injecting a viscoelastic into the anterior chamber through a side port incision, a capsulorrhexis is started by making a small cut in the centre of the lens pulling toward 12 o'clock meridian and curving toward left. The capsulorrhexis forceps pulls a freed portion of the capsule in a circular fashion. A bent needle may be used instead of the forceps.

The technique is also called *continuous curvilinear capsulorrhexis (CCC)*. Following capsulotomy, hydrodissection and hydrodelineation are performed.

There are four options and any one of them may be employed:

(a) Kelman technique after dislocation of the lens nucleus into the anterior chamber

(b) Initial removal of the nucleus in the posterior chamber and then removal of the lens fragments in the anterior chamber

(c) Total removal of the nucleus in the posterior chamber

(d) Iris plane phacoemulsification using two-handed technique, the surgeon's dominant hand holding the ultrasonic hand piece and other hand holding the spatula.

The ultrasonic vibrations are utilised for removal of the nucleus and cortex (Fig. 51.28).

Current techniques of phacoemulsification are indicated in Table 51.14.

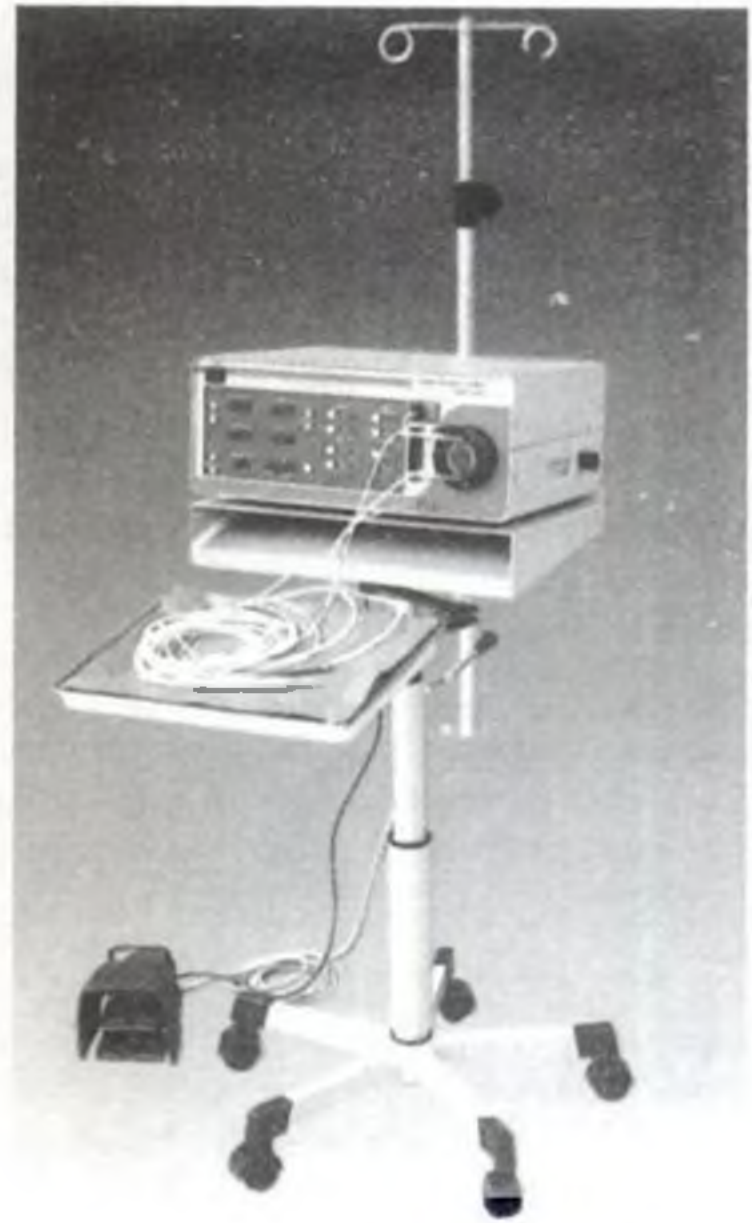

Fig. 51.28 Phacoemulsifier (Courtesy: Appasamy Associates, Chennai).

Table 51.14

Current Techniques of Phacoemulsification (Jaffe *et al*)¹⁰

Crater divide and conquer (Gimbel)
Trough divide and conquer (Gimbel)
Crack and flip technique (Fine)
Phaco chop technique (Nagahara)
Down slope sculpting (Gimbel)
Stop and chop (Koch)

Operations for Glaucoma

History.^{15,26} von Graefe (1856) advocated iridectomy operation for lowering the ocular tension. de Wecker (1871) advised incision of the sclera or sclerotomy. Dianoux (1905) added one more step to sclerotomy, i.e. massage for 12 hours after the operation. Waliker (1894) described an

operation in which tags of the iris had been left behind in iridectomy wound. Herbert (1903) described infolding of the conjunctiva. Holth (1906) was the first to explore deliberate iris inclusion operation systematically, though Bader observed as early as in 1881 the association of iris prolapse and relief of the ocular tension. Herbert (1908) subsequently designed the small-flap of trap-door operation. Lagrange (1905) described the excision of the anterior sclera. Later he concluded that the extent of sclerectomy should be inversely proportional to the degree of rise of tension. Elliot (1912) described classical sclerocorneal trephine. Weve (1933) treated buphthalmos with cyclodiathermy; Vogt (1936) proposed penetrating cyclodiathermy for absolute glaucoma. Barkan (1938) described goniotomy. Redmond Smith (1962) devised a trabeculotomy operation. In 1964 Krasnov described sinusotomy. In 1966 Harms and Dunnheim described trabeculotomy *ab externo*. In 1968 Cairns documented his trabeculectomy operation.

Operations for glaucoma have been listed in Table 51.15.

Table 51.15

Classification of Glaucoma Operations

Surgery to break pupillary block iridectomies:

1. Peripheral
2. Sector
3. Basal
4. Transfixation

Filtering procedures:

1. Iridencleisis
2. Sclerectomy
3. Thermal sclerostomy
4. Sclerocorneal trephine
5. Seton operations

Other surgical procedures:

1. Cyclodialysis
2. Trabeculectomy
3. Trabeculotomy
4. Sinusotomy
5. Cycloanaemization
6. Cyclodiathermy
7. Cyclocryotherapy

Iridectomy (Fig. 51.29)

Two types of iridectomies are done for closed-angle glaucoma, peripheral and complete or sector. Complete iridectomy is occasionally needed. If there is enough peripheral anterior synechia formation in closed-angle glaucoma, iridencleisis operation is preferred.

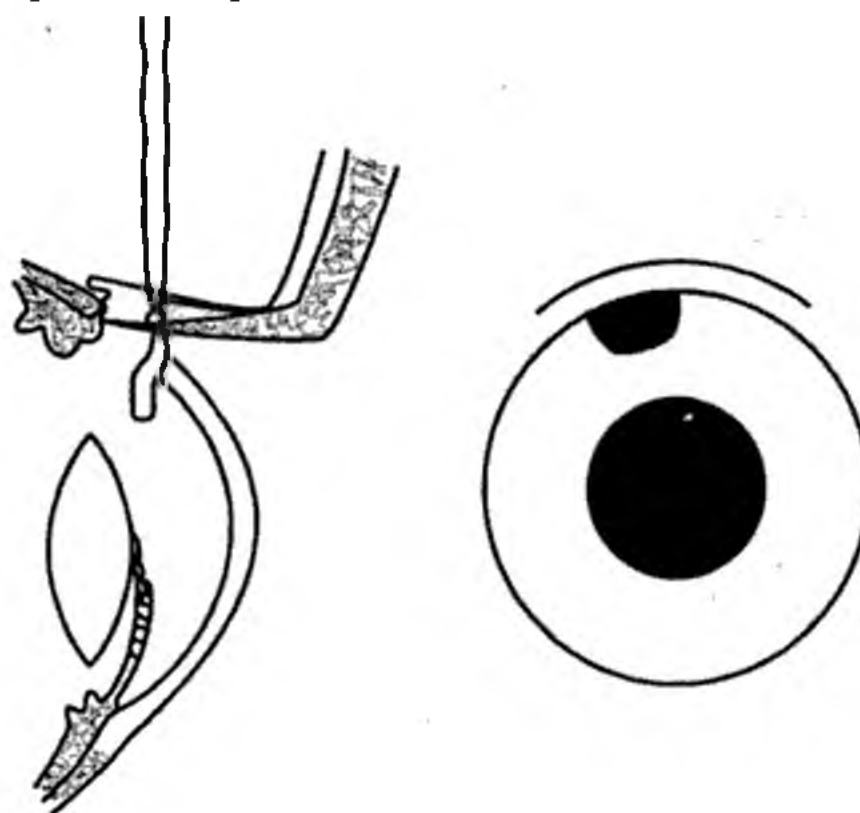


Fig. 51.29 Peripheral iridectomy.

Good sedation and deep regional anaesthesia are essential; occasionally a general anaesthetic may be needed when the patient has great pain. Instillation of a miotic prior to operation is always advocated. A superior rectus stitch is applied before the operation.

A conjunctival incision is given 3 mm away from the limbus between 10 to 2 o'clock; the conjunctiva and Tenon's capsule are retracted down to the limbus. Bleeding points are cauterized. A scleral incision, 2 mm behind the limbus, i.e. *ab externo* incision, is given between 11.30 and 12.30 o'clock to enter the AC. In *Swan's half-lap technique*, after reflection of the conjunctiva and Tenon's capsule a perpendicular 3 to 4 mm slightly curved incision is given which extends about half-way through the stroma at the sclerocorneal junction. Then the iris either presents in the wound or will do so on slight pull on it. In peripheral iridectomy a portion of the iris near its root is abscised. In complete iridectomy it is best done

in the upper temporal quadrant. The iris is seized at one end of the wound and abscised from its root to the pupillary margin; it is then drawn across the other side and freed from its attachment and is then cut by a second snip of the scissors. After iridectomy iris reposition is done. Conjunctival incision is closed by continuous sutures. Atropine is instilled and the eye is bandaged.

Complications may arise from hyphaema, injury to the lens and on occasions intraocular haemorrhages.

Iridencleisis (Fig. 51.30)

Iridencleisis is a popular procedure indicated in both closed-angle and simple glaucomas. The iris is incarcerated in the scleral incision and the atrophied iris acts as a 'wick' to help aqueous drainage into the subconjunctival space. It is contraindicated in case of iris atrophy.

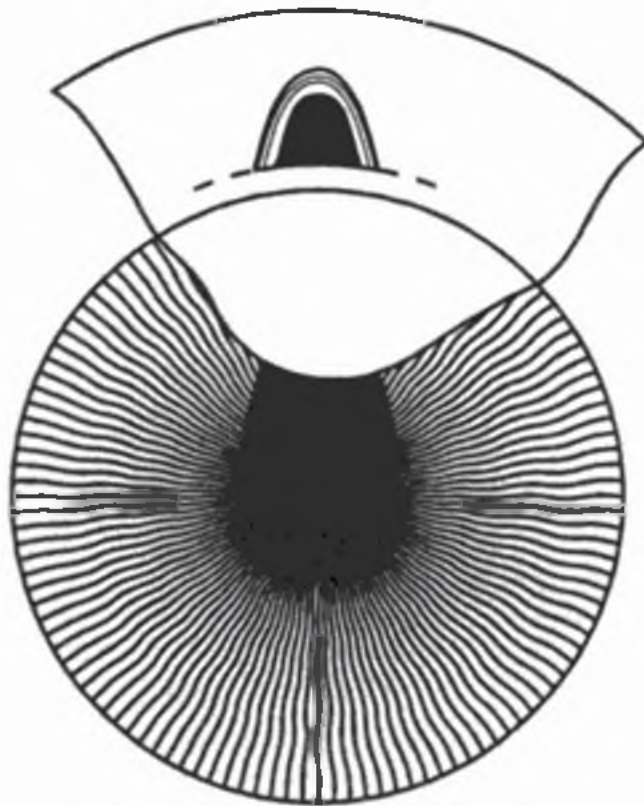


Fig. 51.30 Iridencleisis. The limbal-based conjunctival flap is reflected and an iris knuckle is seen after an *ab externo* incision. The solid line indicates the conjunctival and the dotted line marks the scleral incision.

The steps of turning down the conjunctival flap and scleral incision are the same as in the operation of iridectomy. The iris is seized with an iris forceps near its pupillary margin. For one-pillar iridencleisis a radial cut is made in the iris on one side, while the other side of it is engaged in the scleral incision.

For two-pillar iridencleisis the withdrawn iris is held by two forceps at two ends and is divided vertically from the root to the pupillary border; then the two tongues are separated and interned in opposite ends of the scleral incision. Finally the conjunctiva is closed by continuous sutures.

Anterior flap sclerotomy with peripheral iridencleisis

Anterior flap sclerotomy with peripheral iridencleisis is a modified but much improved iridencleisis operation. After a scleral incision is given its sides are cut laterally so as to prepare a limbal-based scleral flap; sometimes a portion of the flap is excised. The next step is a cyclodialysis. Then plain iris forceps holds the iris about 3 mm above the pupil margin. The iris is gently pulled through the scleral incision. Two button-hole snips, one on the nasal and the other on the temporal sides, are done. The folded tongue of the iris is then placed on the sclera in such a way that 2 mm projects above the upper lip of the scleral incision. The remaining steps are those of iridencleisis.

Scheie's operation (Fig. 51.31)

The steps are those of any filtering operation. After exposure of the sclera the tip of an electrocautery

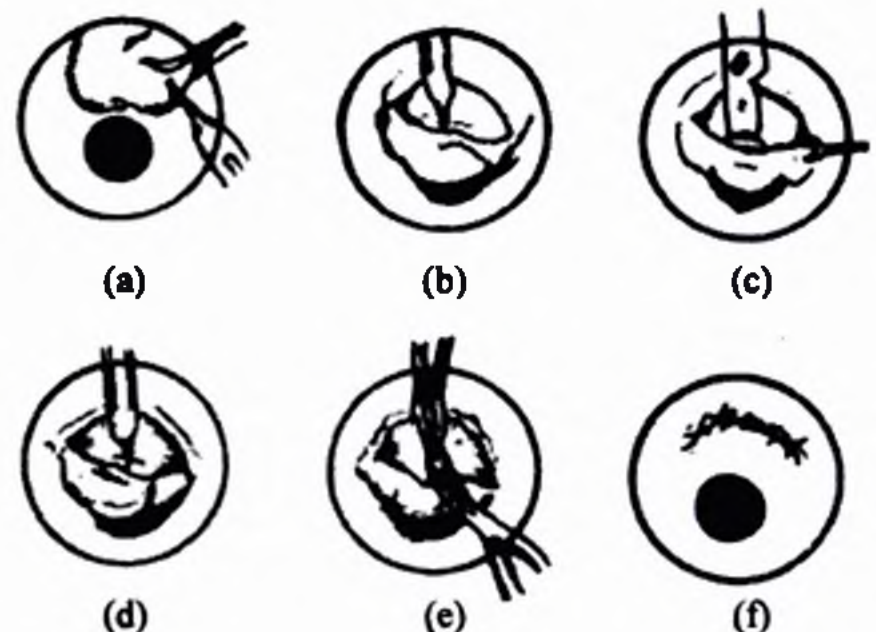


Fig. 51.31 Scheie's operation. (a) incision and reflection of the conjunctiva and Tenon's capsule; (b) application of thermocautery over the sclera; (c) perpendicular scleral incision; (d) application of thermocautery to the lips of the scleral incision; (e) peripheral iridectomy; (f) closure of the wound by suturing.

Oops, page PA484 was not yet downloaded :(

Oops, page PA488 was not yet downloaded :(

Vicryl sutures are used for muscle stitching and fine eyeless needles are preferred.

Recession of the medial rectus (Fig. 51.37)

It is essential to bring the muscle to be operated into the operation field. For that reason a 4/0 black

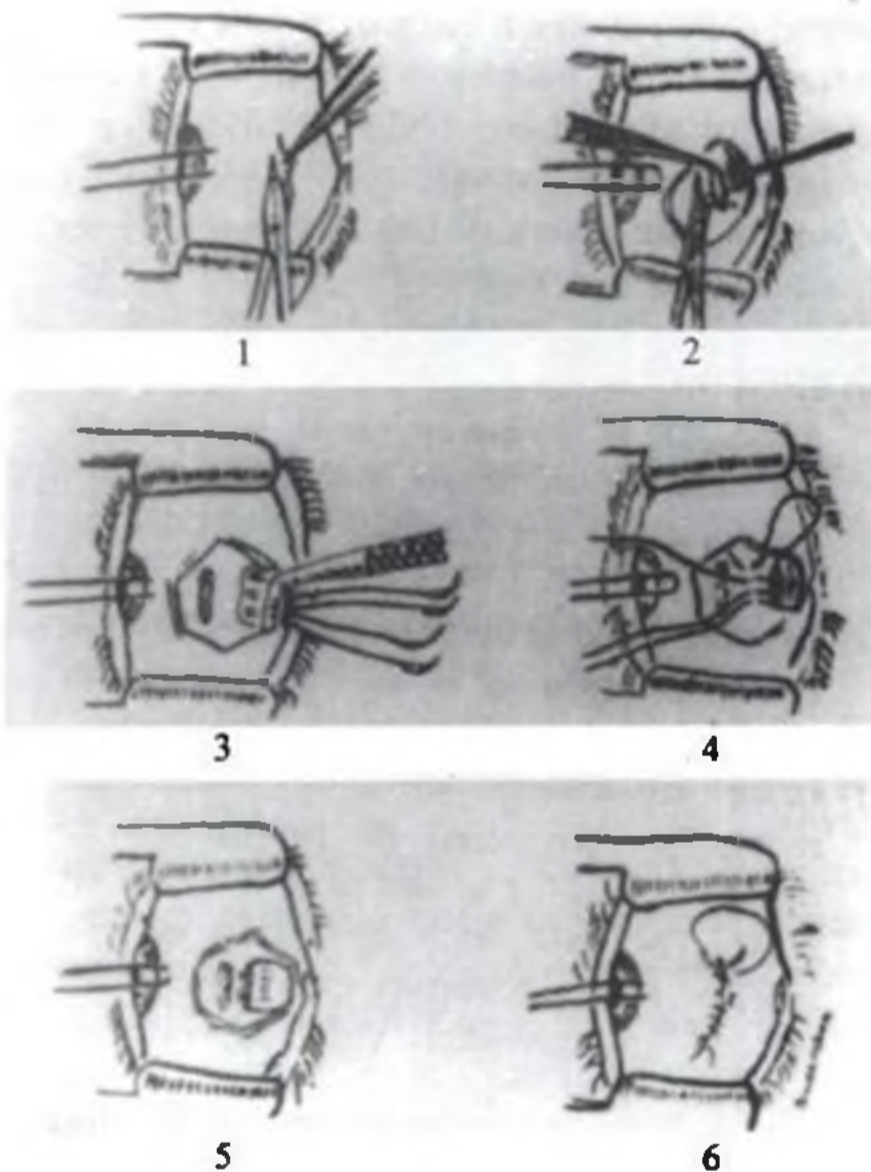


Fig. 51.37 Recession of right medial rectus. (1) incision of the conjunctiva after retraction of the eyeball to the lateral side by means of stay sutures; (2) severing of medial rectus muscle from its insertion after lifting it up by strabismus hook; (3) the sutures are passed through the insertion of the muscle; (4) repositioning of the sutures behind the original insertion; (5) reattachment of medial rectus after recession; (6) suturing of the conjunctiva.

braided silk suture is passed close to the limbus at 3 o'clock position in the right eye and 9 o'clock position in the left, then the two ends of which are pulled to the opposite side by two artery forceps, which rotate the eye. A vertical incision is given in the conjunctiva over the MR muscle 4 mm away from the limbus; then Tenon's capsule is

buttonholed and slit open. The check ligaments near the insertion of the MR is severed. The upper and lower edges of Tenon's capsule incision is preferably retracted by passing a suture through each edge.

The MR is exposed for 7 to 8 mm and its insertion is identified. The exact distance is measured off along the upper and lower margins of the MR by means of a measuring calliper whose one point is set at the insertion and the other on the sclera. The points are suitably marked. A squint hook is passed under the MR and whip stitches of 6/0 vicryl on eyeless needle are passed transversely through 2 mm of the muscle, one at either border of the muscle insertion. The tendon of the MR is severed at its insertion. Then the muscle stitches are attached to the sclera passing superficially through it at right angles to the long axis of the MR at the selected points. After removal of the traction sutures in Tenon's capsule and conjunctiva the conjunctival incision is apposed by continuous 8/0 chromic collagen.

Resection of the lateral rectus (Fig. 51.38)

The eye is rotated medially by passing sutures near the limbus like that in a recession operation. The conjunctival incision, Tenon's capsule incision as well as retraction of its edges and subsequent exposure of the LR follow the same pattern as in a recession operation. The insertion of the LR is detached from the sclera and simultaneously clamped by a muscle clamp. The site of reattachment is marked over the sclera and the amount of resection of the LR is decided. Two whip stitches are passed through the muscle belly as in recession and these stitches are next passed through the superficial layers of the sclera. The redundant muscle is dissected off. Finally the conjunctiva is reapproximated.

Complications. During the operation the appropriate muscle for correction may be improperly exposed and there may be accidental injury to the muscles or perforation of the sclera. Following an operation there may be granuloma, inclusion cyst, persistent oedema and redness at the site of operation.

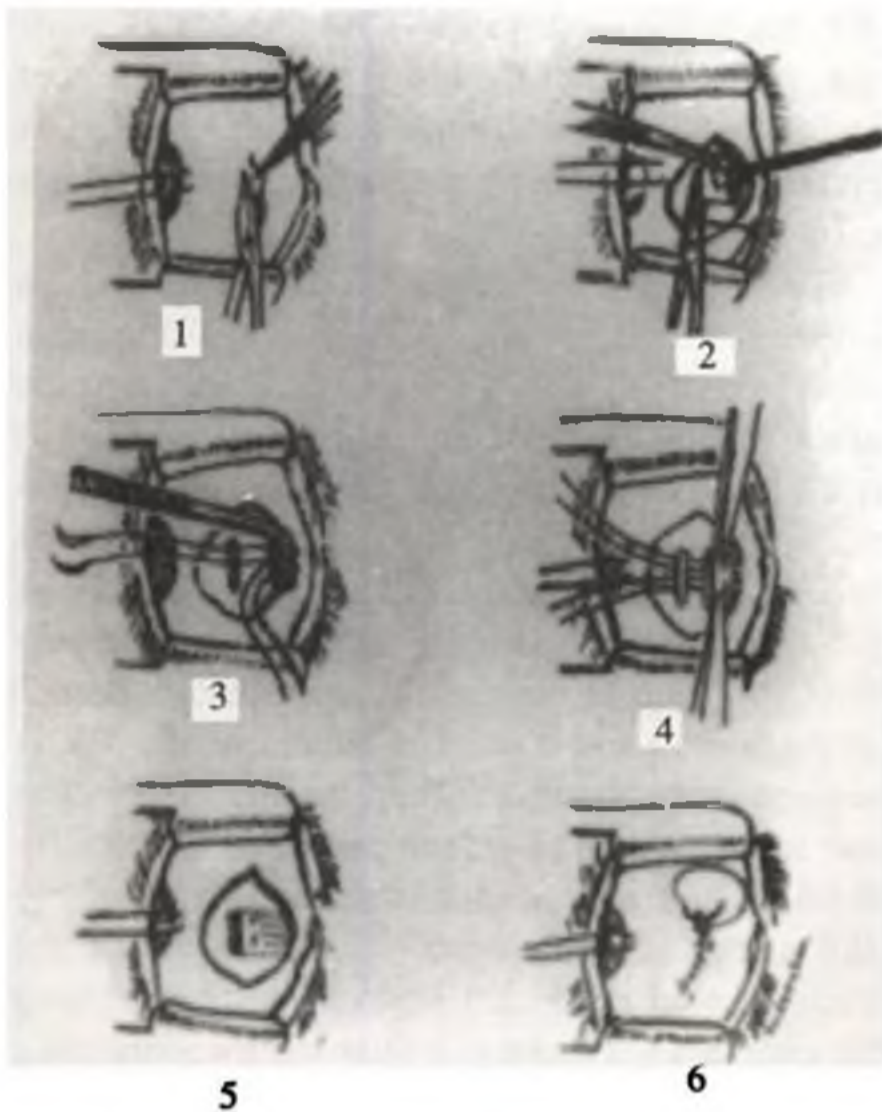


Fig. 51.38 Resection of left lateral rectus. (1) incision of the conjunctiva; (2) grasping the muscle by a muscle clamp and excision of a measured amount from its insertion; (3) passing of sutures behind the muscle clamp after resection of muscle; (4) repositioning of the sutures through the original insertion; (5) reattachment of the resected lateral rectus at its original insertion; (6) final closure of the conjunctiva.

Transplantation of muscle strips

In transplantation of strips of the SR and IR muscles are used for correcting LR and MR palsies. In SR palsy the central third of the normally-acting levator palpebrae superioris is transplanted into a paralysed SR muscle.

Transplantation for LR palsy

Resection of 8 to 10 mm of LR is done. Both SR and IR are split for 12 mm along their long axes equally into temporal and nasal halves. The temporal halves of SR and IR are mobilized down and up respectively and passed through the corresponding halves of the LR tendon stump. Finally the resected LR tendon stump and

transplanted strips are sutured. The conjunctiva is closed.

Faden operation (posterior scleral fixation suture)

The word 'Faden' is German meaning a thread. It is indicated in congenital or longstanding lateral rectus palsy, in which the operation is done in the contralateral medial rectus. It comprises suturing the belly of the rectus muscle directly to the underlying sclera. There are certain risks like damaging the muscle sheath and development of an adhesive syndrome.

Adjustable sutures

They are passed through the scleral anchoring points and a temporary bow knot is given. Following recovery from anaesthesia tightening or loosening of the suture is done to allow final adjustment of the muscle.

Retinal Detachment^{26,29}

The role of tear in the causation of retinal detachment and the effect of closing the tear by electrocautery puncture was not widely accepted till the year 1929, when Gonin established his method of treatment.

The general principles of retinal detachment surgery are as follows:

- (a) Accurate localization of retinal tear or tears
- (b) The edges of the tear and the overlying choroid rendered adhesive by diathermy or cryopexy
- (c) Evacuation of subretinal fluid beneath the detachment
- (d) Relief of traction by shortening the axial length of the globe
- (e) Scleral indentation by which the area of the choroid rendered adhesive presses against the tear.

Transscleral diathermy

The principle is the induction of an aseptic chorioretinitis so that there is approximation of the

detached retina to an area of the choroid. The old methods of diathermy have been replaced by sophisticated, transistorized variety. The output of the radio frequency current is fixed between 0.2 and 0.4 when they are meant for use over a thin sclera. The optimal duration of application with a blunt conical probe gently placed against the sclera is 3 to 4 seconds.

The conjunctiva and Tenon's capsule are reflected over the site of detachment with a break. If the break is small, recent and flat, division of the muscle is often not necessary and diathermy is applied over the affected area. The reaction is verified by indirect ophthalmoscopy. If necessary the subretinal fluid is drained and the ophthalmoscopic examination is repeated which should exhibit apposition of the retina to the choroid. If myotomy is done the muscle should be sutured back in position. The reflected flap is sutured. Both eyes are bandaged.

Scleral shortening procedures (Fig. 51.39)

To relieve intraocular traction and approximation of the retina with the contracted vitreous, a

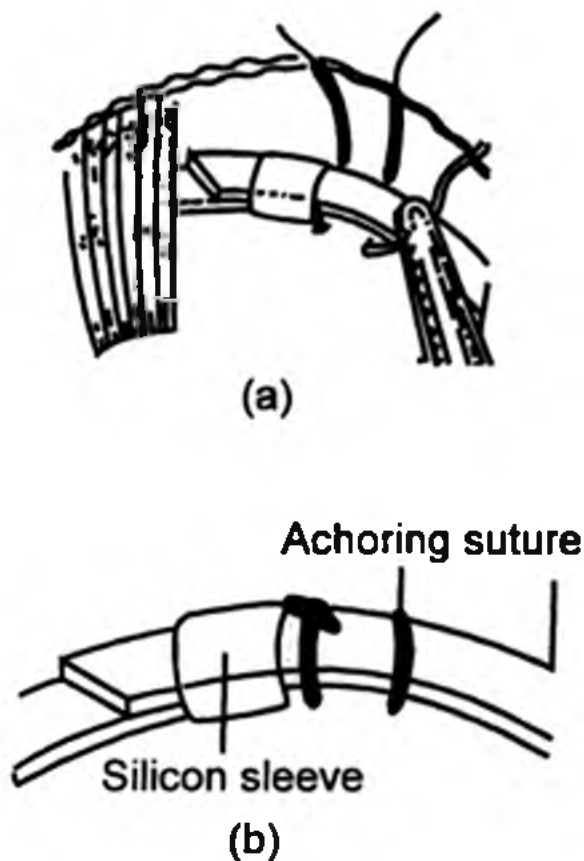


Fig. 51.39 Scleral buckling. (a) Passing a circling silicone band around the eyeball under the attached extrinsic muscles and (b) the ends of the band are fitted into a silicone sleeve and sutures tied.

reduction of the axial length of the eyeball should be done.

The following are the indications:

- (a) Retinal detachment with multiple tears
- (b) Aphakic detachment
- (c) Detachment associated with high myopia
- (d) Multiple peripheral holes
- (e) Detachment associated with vitreous traction and retinitis proliferans
- (f) Reoperation in case of failure.

Scleral overlap. The sclera is incised at an appropriate site around half the circumference of the eyeball and down to the deeper layer of the sclera. The sclera is dissected forward to produce an overlap anterior to the incision. Vertically-placed mattress sutures are applied to fix the overlap.

Lamellar scleral resection. A 4 mm strip of sclera is excised leaving the deepest scleral lamellae intact. After application of diathermy and evacuation of subretinal fluid, the edges are approximated by mattress sutures.

Recently it has been reported that there is no necessity for any scleral dissection, in all cases full-thickness scleral buckles are preferred.

Scleral buckling with a circling element

The steps are listed in Table 51.20.

The operative field is exposed by circumferential incision of the conjunctiva and Tenon's capsule round the limbus, but if 360° encircling band is not necessary the amount of peritomy should be determined by the position of the break and type of procedure planned.

After disinsertion of the recti and passing bridle suture lightly around the muscle, clean and dry the scleral surface to inspect it. Cryopexy or diathermy application is done while examining the fundus with indirect ophthalmoscope, treating all breaks and suspicious areas of the retina.

There are different types of explants available in various sizes (3, 4, 5, 7.5 mm diameter) and various forms (sponge, tyre, strap). They can be attached radially, circumferentially or encircling (Table 51.21).

Table 51.20
Steps of Scleral Buckling Operation

1. Usually local anaesthesia with sedation
2. Draping and exposure of the eye
3. Limbal peritomy
4. Isolation of the recti on sutures, and examination of the sclera for position of the vortex veins and pathological lesions
5. Identification of breaks by indirect ophthalmoscopy
6. Cryopexy and/or diathermy
7. Undermining of sclera and passing of sutures through scleral flaps
8. Placing of circling silicone band around the globe
9. Check-up ocular tension and observe flattening of sclerotomy site
10. Release of subretinal fluid
11. Tying up of sutures
12. Closure of Tenon's capsule and conjunctiva
13. Topical and subconjunctival antibiotic, steroid and atropine
14. Pad and shield

Table 51.21
Types of Buckle Used in Scleral Buckling and their Indications³³

Type	Indications
Radial	Horse-shoe tear Posterior breaks Multiple holes
Circumferential	Dialysis Anterior breaks Multiple holes in different quadrants
Encircling	Breaks not detectable Significant proliferative vitreoretinopathy

SRF should not always be drained. The indications of SRF drainage include immobile retina, inferior detachments, raised IOP, inadequate localization and long-standing detachments.

A single perforation is made behind the undermined area with a diathermy needle to release the subretinal fluid. It is usually performed on either side of the horizontal meridian and near 12 or 6 o'clock position.

Before finally tying the sutures the ocular tension must be checked by a Schiötz tonometer to

ensure that tension is below 10 mm Hg; it is measured once again after tying up the sutures and should be left at a tension no higher than 15 mm Hg.

Custodis' plombage

In this procedure there is production of a local scleral indentation so that the retinal tear lies against the choroid on the summit of indentation.

Indications. These include recent, small, single tear and hole behind the equator.

The silicone 'plomb' is applied to the sclera and fixed by mattress sutures of braided polyester against the tear but without evacuation of the subretinal fluid. But if the ocular tension is abnormally high the fluid needs to be drained.

Equatorial circlage of arruga

A circumequatorial purse-string suture is placed under the four recti, through the superficial layers of the sclera and behind the tear. Drainage of the subretinal fluid is done anterior to the string.

Complications. Equatorial circlage of Arruga causes damage to the zonule and displacement of the lens in the phakic eyes and 'string syndrome'.

Postoperative complications and sequelae. These include:

- Postoperative reaction
- Residual detachment
- Pain—due to pressure on the long ciliary nerves, uveitis, and secondary glaucoma
- Intraocular haemorrhage
- Choroidal detachment
- Secondary glaucoma
- Erosion or implant extrusion

Cryosurgery in Ophthalmology¹

Cryosurgery in ophthalmology is a popular surgical procedure. Freezing which may be slow, rapid or ultrarapid is governed by several factors like

- type of tissue and its constituents;
- time of exposure;

- (c) rate of cooling; and
- (d) hydrostatic pressure.

Three popular cryogens used in eye surgery are halogenated hydrocarbon or 'Freon', carbon dioxide and liquid nitrogen.

Cryomicrosurgery

With the advent of the operating microscope a newly-designed cryoprobe is available which can be used for intravitreal cryomanipulation.

Retinal detachment and cryopexy

Cryosurgery today is an important surgical procedure in the prophylaxis and management of rhegmatogenous retinal detachment and there are several distinct advantages over diathermy. While designing a retinal cryoprobe the minimum tip temperature should be in between -60 and -80°C with provision of automatic defrosting.

The four basic indications of cryopexy are:

(a) For treating peripheral and most equatorial degenerations and breaks unaccompanied by and detachment in the anterior part—a transconjunctival cryopexy is performed.

(b) The cryoprobe is placed around the break or subretinal fluid surrounding the break after adequate local anaesthesia, preferably subconjunctival injection of Xylocaine. To watch the effect an indirect ophthalmoscopy is essential through the dilated pupil. In some cases of equatorial degenerations and nasal posterior tears unaccompanied by retinal detachment—cryo is applied over the intact sclera but after conjunctival incision.

(c) In extensive detachment, cryo is used along with a segmental buckle or encircling buckle, the point of cryo being applied over the intact sclera.

(d) The technique of applying cryoprobe over the scleral bed after a lamellar resection has been discarded.

Cryopexy

For retinal surgery cryopexy using carbon dioxide

gas is preferable. Larger areas of the retina and choroid are destroyed by cryoapplication because of the size of the cryoprobe. There are two techniques: transconjunctival and application on the exposed sclera. The temperature is about -79°C and for 5 to 15 seconds.

Diathermy has given way to cryopexy. Cryopexy may also be done in the prophylactic treatment of anterior and peripheral, and tears over a large ciliary vessel or vortex vein.

The advantages are:

- (a) It can be used through the conjunctiva, episcleral tissues and even through the muscles
- (b) Absence of scleral damage
- (c) Less choroidal damage
- (d) Less chance of vitreoretinal adhesions
- (e) Possibility to spare the vessels
- (f) Greater ease of early reoperation.

Advantages of diathermy over cryopexy are:

- (a) Better control of dosage
- (b) Easier localisation of the affected zones
- (c) Less necessity to add scleral indentation
- (d) Stronger chorioretinitic scar.

In certain other conditions cryotherapy is at times indicated. In trichiasis cryotherapy at a temperature of -20°C destroys the offending eyelash. In a small basal cell carcinoma of an eyelid cryoapplication at a temperature of -30°C is advocated. Haemangioma and xanthelasma can also be treated. Cryoapplication over the vegetation of vernal conjunctivitis appears to be effective. In superficial corneal vascularization it can be tried. In retinal vascular anomalies like Coats' disease and angiomatosis retinae repeated freezing and slow thawing may be tried if the lesions are larger than 2.5 disc-diameter or situated in front of the equator. In a small and circumscribed retinoblastoma not affecting the posterior pole, cryoapplication may be attempted, but the result is not reliable.

Complications of scleroplastic procedures (Table 51.22). Custodis plambage typically causes development of retinal tear near the indentation due to too great pressure.

Photocoagulation

In 1949 Meyer-Schwickerath²² for the first time

Table 51.22

Complications During Scleroplastic Operations

During exposure:	
	Inadequate exposure
	Tear lying far posteriorly
	Difficulty in reoperation
During localization of tear:	
	Corneal haziness
During application of diathermy:	
	Choroidal perforation
	Subchoroidal haemorrhage
During evacuation of subretinal fluid:	
	Haemorrhages—choroidal, subretinal and vitreous
	Perforation of the retina
	Vitreous loss
During the final stages:	
	Inaccurate settling of the tear
	Increased ocular tension

reported light coagulation of the retina using xenon arc. Subsequently various laser photocoagulators have been introduced.

The indications of photocoagulation are as follows:

(a) In Eales' disease the abnormal vessels are destroyed by photocoagulation

(b) In diabetic retinopathy an argon laser is preferred.

The new vessels are photocoagulated. The burns are applied within the vascular arcade above and below the macula. Neovascularisation of the optic disc needs panretinal coagulation.

(c) Other conditions requiring photocoagulation are:

(i) retinal degenerations; (ii) macular hole, (iii) angiomatosis retinae; (iv) retinal tears; (v) angioid streaks; (vi) retinoschistis; (vii) retinal neovascularization following central retinal vein thrombosis, proliferative retinopathy, etc. (viii) iris cyst; (ix) photoiridotomy; and (x) trabeculoplasty.

Xenon arc photocoagulation (Fig. 51.40)

Xenon arc produces radiation whose spectral qualities simulate those of sunlight, but whose energy intensities are many times more than those emitted by the sun. The element xenon flows in high-intensity current and the resulting white light




Fig. 51.40 Carl-Zeiss light coagulation apparatus: 1, Filter disc; 2, Image field diaphragm; 3, Mirror; 4, Release knob; 5, Handle; 6, Cable; 7, Cable connection; 8, Ammeter; 9, Voltmeter; 10, Switch-OFF; 11, Switch-ON; 12, Protective switch; 13, Multi-stage switch for normal load; 14, Selector switch; 15, Multi-stage switch for overload; 16, Door; 17, Door-handle; 18, Optical beam director; 19, Lever for iris diaphragm; 20, Locking lever (Meyer-Schwickerath).

is an unequal mixture of varying wavelengths between 400 and 1100 nm. The beam is polychromatic. About 25 per cent of the energy is absorbed by the transparent ocular media. Total absorption in the retinal pigment epithelium (RPE) is about equal to that in the choroid. But since the choroid is approximately 8 times thicker than the RPE the heat generated in the RPE is much higher. Longer infra red rays, 930 to 1030 nm, are absorbed by the refractive media, while the shorter infrared rays are most effective for light coagulation occurring at the site of absorption.

Technique. After full dilatation of the pupil and a retrobulbar injection light coagulation treatment is given after viewing the fundus through an aperture in an inclined mirror. The optimum focal distance for projection of the light beam is 5 cm from the cornea. The duration of application varies between 0.2 and 1 second. As a rule not more than one quadrant of the retina is coagulated. The treatment is repeated after 3 to 4 days if so required. In high myopia the light is projected on the healthy retina round the margin of the degenerate retina otherwise there is risk of the development of retinal break following contraction.

Effects on the retina. Six hours after photocoagulation there is a localized whitish swelling surrounded by a pinkish ring. After 24 hours the ring turns brownish and the pigments appear in the centre of the oedematous area between the 2nd and 7th day. In mild burn the main coagulative effect is in the inner choroidal and outer retinal layers. In intense burn the retina, the choroid and part of the sclera are involved. So longer infra red rays should be used in intraocular tumours and telangiectatic tumours.

Complications and sequelae of photocoagulation. These include keratopathy, iritis, iris atrophy, cataract, intraocular haemorrhages, vitreoretinal adhesion, retinal break, exudative retinal detachment and macular fibrosis. However they are rare and can be avoided.

Instrumentation in vitreoretinal surgery. Various instruments used are listed in Table 51.23.

Table 51.23

Instruments Used in Vitreoretinal Surgery²³

Coaxial microscope with
Gross and fine focus facilities
Zoom adjustment
X-Y coupling
Attachment of a filter assembly for an endolaser, etc.
Vitreous probe
Full function probes containing
Infusion
Cutting, oscillating and guillotine
Illumination
Suction ocutome
Divided system
Separate port systems for infusion, illumination and vitrectomy instrument
Myringotome or microvitreoretinal blade
Infusion cannulas
Vitreous probes
Endoilluminator
Membrane pics and hooked needles
Vitreous forceps
Vitreoretinal scissors
Endodiathermy
Endocryopexy
Endophotocoagulation
Neutralizing contact lens
Indirect laser ophthalmoscope

Intravitreal Procedures^{3,23}

The procedure is applied when vitreous traction is the cause of retinal detachment. Vitrectomy is done to break the traction of the retina together with vitreous supplementation with liquid silicone, which acts as an internal support.

Pars Plana Surgery³ (Table 51.24)

A transcorneal illumination is essential to choose a blood vessel-free area. The incision should be

Table 51.24

Pars Plana Surgical Procedures and their Indications

Lensectomy
Complicated cataract
Developmental cataract
Traumatic cataract
Membranectomy
Aftercataract
Cyclitic membrane
Updrawn pupil
Vitrectomy
Varied—see-details under vitrectomy
Lens extraction with vitrectomy for vitreous haemorrhage
Immature cataract + vitreous haemorrhage
Diabetic retinopathy + cataract

3.5 mm away from the limbus, but a 3 to 9 o'clock meridian is avoided because of the risk of injuring the long posterior ciliary artery and nerves.

The following instruments are essential: operating microscope, ocutome with control unit and probe, neutralizing contact lens, fibre optic illumination system, lens fragmentor, infusion system and aspiration needle.

Lensectomy

After selecting a proper site, a myringotomy knife is introduced through the sclera into the lens. A second sclerotomy is needed for the infusion. After withdrawal of the knife from the lens a fragmatome is introduced towards the centre of the lens and fragmentation started. The fragmatome is withdrawn after fragmentation is complete and through the same opening an ocutome is introduced.

by removal of the contents of the eyeball, till the sclera is seen clearly. It is better to excise a greater part of the sclera leaving only the posteriormost part around the optic nerve (frill excision).

Contracted socket

The main causes are:

- (a) Obliteration of the fornices by symblepharon
- (b) Shelving the lower fornix with ectropion
- (c) Atrophy of the orbital fat and retraction of the socket floor
- (d) Depression of the orbital floor
- (e) Maldevelopment of orbital walls
- (f) General contraction of socket lining, fornices too shallow and inadequate to retain a prosthesis.

Contracted sockets are difficult to remedy. In bad cases treatment consists of dissecting away the remaining conjunctiva and fibrous tissue followed by skin grafting with the insertion of a stout acrylic mould.

Orbitotomy

Exploration of the orbit can be done by three different routes.

Anterior orbitotomy. Anterior orbitotomy is indicated in lesions which can be palpated through the eyelids. The incision is given through the eyelid and orbital septum, the line of incision passing either along the upper or lower margin of the orbit depending on the situation of the lesion.

Lateral orbitotomy (Krönlein's Operation). The operation is especially called for in lesions located in the lateral and posterior parts of the orbit; it provides a good exposure.

The modified Krönlein operation may be described as follows. After closing the medial halves of the eyelids by sutures and retraction of the lateral rectus by traction suture, an incision is given through the skin along the lateral orbital margin from the centre of which the incision is extended laterally. Lateral canthotomy is then done. The periosteum of the lateral orbital wall is incised and separated. The contents of the orbit are retracted away from the bony margin. The

bone is incised and a quadrilateral part of the bone of the lateral wall is removed, exposing the contents of the orbit. After removal of the mass or tumour the periosteum is sutured and the bone flap is replaced in position.

Transfrontal orbitotomy (Naffziger's Operation). A quadrilateral opening is made in the frontal bone. The orbit is then approached by the removal of a portion of the roof after exposing the frontal lobe of the brain. It is indicated in lesions of the upper and posterior parts of the orbit.

Exenteration

Exenteration involves removal of the whole contents of the orbit. Exenteration of the orbit may be done with or without a split-thickness skin graft. Post-operative irradiation, if given in large amount, may induce sloughing of the graft.

After suturing the eyelids an incision is given below the eyebrow inside the orbital margin. The periosteum is elevated and separated by a periosteal elevator.

The trochlea is detached and the canthal ligaments are severed. But while separating the periosteum from the medial wall great care should be exercised because of the fragile ethmoid bones.

The contents of the orbit are removed, the bleeding points are cauterized and if indicated a skin graft is applied.

Further Reading

1. Amoils, S.P., *Cryosurgery in Ophthalmology*, Pitman Medical, London, 1975.
2. Arruga, H., *Ocular Surgery*, 3rd ed. Translation from 4th Spanish ed. by Hogan, M.J. and Chaparro, L.E., McGraw-Hill, New York, 1962.
3. Badrinath, S.S., Pars plana surgery, *Indian J. Ophthalmol.*, 30:409, 1980.
4. Barraquer, J., Troutman, R.C. and Rutlan, J., *Surgery of the Anterior Segment of the Eye*, Vol. I, McGraw-Hill, New York, 1964.
5. Beard, C., *Ptosis*, C.V. Mosby, St. Louis, 1969.

will be borne only by the female and can be partially or fully borne by the male. In the recessive state the disorders are inherited through the genes.

The criteria for diagnosing sex-linked recessive hereditary traits are:

(a) The trait is seen more often in male than female.

(b) The affected male is usually affected by the affected mother.

(c) An affected mother will give birth to 50 per cent affected males and 50 per cent daughters which will bear the affection.

(d) The affected male will never transmit the disorder to any of his or her sons, but all his or her daughters will inherit the diseases.

(e) Only when an affected female is born, consanguinity is suspected.

Ocular affections showing sex-linked inheritance. These include:

(a) Dominant—such as nystagmus and xeroderma pigmentosum.

(b) Intermediate—such as ocular albinism, choroideraemia and retinitis pigmentosa.

(c) Recessive—such as night blindness, haemophillia, Fabry's syndrome, Laurence-Moon-Biedl syndrome and Lowe's syndrome.

Chromosomal Aberrations

In 1959 Lejeune and Turpin for the first time demonstrated that in mongolism there were 47 chromosomes instead of the normal 46. Since then, there have been many further reports of chromosomal anomalies and structural abnormalities.

Identification of the entire diploid set of chromosomes in dividing cells of selected body tissues has been made possible by microscopic study of suitable material such as the culture preparation of the peripheral blood.

New techniques have been introduced for the analysis of chromosomes. These include autoradiographic tagging, quinacrine fluorescent analysis and Giemsa banding.

Disorders of chromosomal number and structure^{4,8}

Disorders of chromosomal number and structure include trisomy 21 or mongolism, trisomy 18 or Edwards' syndrome, trisomy 13 or Patau's syndrome and Turner's syndrome.

Trisomy 21 has been described under syndromes (see p. 539).

In *trisomy 18*, the ocular features are microphthalmos, ptosis, blepharophimosis, epicanthus, hypertelorism, strabismus, cataract, optic atrophy and glaucoma; and the systemic findings include congenital heart disease, mental deficiency, long narrow skull, malformed ears, small mouth and mandible. Majority of the patients die before 1 year of age.

In *trisomy 13*, the ocular findings include coloboma, microphthalmos, formation of cartilage within the eye, defective angle development, glaucoma, retinal dysplasia and cataract. The systemic features are congenital heart disease, malformation of the viscera, cleft palate, and polydactyly.

Turner's syndrome or gonadal dysgenesis occurs in females whose cells exhibit a male sex chromatin. About 8 per cent of the patients are colour blind. Other ocular features are antimongoloid slant of the palpebral fissure, ptosis, epicanthus, strabismus, pigment dystrophy of the retina and eccentric pupils. These patients are short with webbed neck, sexual infantilism and congenital heart disease.

Disorders of deletions of chromosomes

Disorders of deletions of chromosomes occur due to the loss of genetic material from specific chromosomes. The deletion syndromes include cri-du-chat or chromosome 5-deletion, chromosome 18 deletion and others.

Paediatric Ophthalmology

Paediatric ophthalmology should cover anomalies and affections occurring at any time between the intrauterine life and young age. There are some

variations in anatomical features and physiologic functions of the eyes from those of adult eyes. Investigations thus naturally differ in young children.

Anatomical variations. The orbits are smaller and closer to one another. At birth the palpebral fissure is 18 mm, and attains 30 mm in the adult. In the newborn the sclera is slightly blue, the horizontal diameter of the cornea is 10 mm and the pupils are small. The optic discs appear paler than those in adults and the maculae appear redder than the rest of the retina.

Physiological variations. Tear secretion is scanty, accommodation—convergence reflex appears at 6 months, and pupils do not dilate well with atropine.

Presenting features in childhood disorders.⁷ The important features with which an affected child may present are as follows:

(a) Excess watering of the eye as in lacrimal obstruction, lodgment of a foreign body and occasionally buphthalmos

(b) Proptosis

(c) Ptosis

(d) Red eye as in acute conjunctivitis, phlyctenular conjunctivitis, keratitis, injury and trachoma

(e) Strabismus

(f) Nystagmus—as in macular coloboma or scar, macular dystrophies and achromatopsia

(g) Cloudy cornea—as in buphthalmos, CHED, interstitial keratitis (IK) and mucopolysaccharidoses

(h) White reflex at the pupil

(i) Subluxated lens—as in Marfan's syndrome, Marchesani syndrome and homocystinuria

(j) Optic atrophy—as in demyelinating disease, hereditary optic atrophy, craniopharyngioma and secondary to retinal degenerations.

Investigations^{4,6}

The methods of investigations are not much

different than in adults. Emphasis must be on the following points:

History. Apart from others, history related to birth and developmental defects must be elicited from the parents. Family history, past history and general health of the child are taken into account.

It should also include prenatal and perinatal history. It is useful to remember the milestones of both motor and visual system (Table 52.1).

Table 52.1

Motor and Visual Milestones in Infancy

Age	Functions
<i>Motor</i>	
4 months	Prone to supine position
6 months	Crawling
12 months	Walking
<i>Visual</i>	
3 months	Fixation to nearby object
3–4 months	Full accommodation
3–5 months	Onset of stereopsis
6 months	Fixation to distant object
3 years	Subjective visual acuity possible

Clinical examination and testing of visual acuity.

In the newborn pupil reactions, size and transparency of the cornea, and glimpse of the ocular fundus can be noted. In infancy, eye movements following objects and visual acuity can be tested in addition to possible investigations in the newborn. By 1 to 2 months most of them can follow light, and at 2 to 3 years most of them are able to respond to subjective test of visual acuity.

Assessment of visual acuity is often difficult and occasionally impossible.

From birth to 3 years of age. The clinically useful test is the ability to follow and to fix a target. Preferential looking and visual evoked response are quantitative tests for assessment of visual acuity.

From 3 to 6 years of age. In developmentally normal children a subjective acuity can be obtained.

(a) **Cover test.** It shows the presence or absence of a manifest deviation. The cover-uncover test also reveals heterophoria.

(b) *Ocular movements.* They should always be tested, unilaterally and binocularly.

(c) *Refraction under atropine ointment.* Cycloplegia refraction is a routine procedure in most cases.

(d) *Examination with a synoptophore.* It is indicated in assessment of binocular vision and evaluation of strabismus.

(e) *Examinations under a general anaesthetic.* They include:

- (i) Ophthalmoscopic examination,
- (ii) Tonometry,
- (iii) Gonioscopy, and
- (iv) Keratometry.

(f) *General physical examinations* include alertness, height, weight and thorough examination of various systems.

Defects of the Globe as a Whole^{2,4,8}

Anophthalmos

It is the absence of the eyeball and it is rarely total. It has an autosomal recessive inheritance. It is commonly associated with other systemic anomalies. Thalidomide-induced anophthalmos has been reported.

Microphthalmos

The size of the eyeball is abnormally small. It may be a pure microphthalmos, colobomatous microphthalmos and microphthalmos associated with cyst. Pure microphthalmos is of either dominant or recessive inheritance. It is unilateral or bilateral and often other ocular anomalies like spherophakia, microphakia, cataract, glaucoma and macular hypoplasia are present. In the colobomatous type colobomas of the iris, choroid and retina are present. The cyst associated with this condition is usually felt through the lower lid, the wall of which is derived from the sclera.

Colobomas

Coloboma occurs as a result of the failure of a

portion of the foetal fissure to close. Their inheritance is autosomal dominant and they are more often bilateral. A coloboma may affect the iris, lens, ciliary body, choroid, retina, optic nerve and macula.

Cycloopia

It is extremely rare. It presents a single eye situated in the midline. It is associated with severe systemic anomalies.

Buphthalmos

5 to 13 per cent of blindness in school children occur to buphthalmos. Early recognition and adequate surgical treatment can control 80 per cent of the cases.

Abnormal Skull and Face Development

Craniofacial dysostoses

These include oxycephaly or tower skull, Crouzon's disease, Apert's syndrome and hypertelorism. All of them are already described except hypertelorism. In *hypertelorism* the distance between the two puncta is excessive stretching into 50 mm, normally the distance is 30 to 33 mm. The lateral displacement of the puncta, blepharophimosis, heterochromia iridis, fusion of the eyebrows in the midline, white forelock and congenital deafness may be associated with hypertelorism. These constitute *Waardenburg's syndrome*.

Mandibulofacial dysostoses

These include Franceschetti's syndrome, Goldenhar's syndrome and Meyer-Schwickerath syndrome.

Meningoencephalocele

This is the protrusion of the meninges and the brain substance through a bony defect in the skull; there may be only protrusion of the brain substance, encephalocele. Meningoencephalocele is found usually as a naso-orbital lesion.

Abnormalities of the eyelids, lacrimal apparatus and conjunctiva

The conditions are described in details under their respective chapters.

Abnormalities of the cornea

Microcornea. This is characterized by having a corneal diameter of less than 10 mm. It frequently causes myopia. It is inherited as an autosomal dominant trait. It is seen either as an isolated anomaly or is seen to be associated with other ocular anomalies including coloboma, cataract and strabismus. In 20 per cent cases it is associated with glaucoma.

Megalocornea. This is a stationary congenital enlargement of the corneal diameter, exceeding 13 mm. It may be as large as 18 mm. The cornea remains clear. It needs to be differentiated from a buphthalmos. It is usually inherited as sex-linked recessive trait. Ninety-two per cent of the cases are in males. It may be a part of general megalophthalmos.

Cornea plana. It shows a flattened cornea, an ill-defined limbus and stromal opacities. Other ocular anomalies are co-existent. It is inherited as an autosomal recessive trait.

Abnormalities of the anterior ocular Segment

Axenfeld's syndrome of posterior embryotoxon. The inheritance is either autosomal dominant or recessive. The classic features form a triad of: (1) an enlarged line of Schwalbe; (2) forward placement of the line of Schwalbe; and (3) prominent iris processes traversing the angle of the AC from the root of the iris to the line of Schwalbe. It may be associated with glaucoma.

Rieger's syndrome of mesodermal dysgenesis. The hereditary trait is autosomal dominant. In addition to the triad of Axenfeld's syndrome there are other features like hypoplasia

of the anterior stroma of the iris, bluish sclera or sclerilisation of the cornea, posterior defect of the cornea, corectopia, slit-pupil and glaucoma. Rieger's syndrome is also accompanied by facial, dental and bony abnormalities. The syndrome is to be differentiated from essential progressive iris atrophy, buphthalmos and oculodentodigital dysplasia.

Peter's anomaly. It is also called *mesodermal-ectodermal dysgenesis of the cornea*. This exhibits central posterior corneal defect, iris adhesions to the border of the corneal defect and central corneal capacity. The inheritance is autosomal recessive. About 20 per cent cases are unilateral. The pathogenesis is obscure.

Abnormalities of the iris and the pupil

Abnormalities of the iris and the pupil include aniridia, persistent pupillary membrane, aplasia or hypoplasia of the mesodermal stroma, hypoplasia or hyperplasia of the pigment epithelium, heterochromia, coloboma, anisocoria, polycoria, corectopia, naevus, albinism and ectropion of the uvea.

Aniridia. Aniridia or the absence of the iris is rarely complete, usually bilateral and frequently associated with glaucoma and other ocular anomalies like nystagmus, glaucoma and cataract.

Persistent pupillary membrane

In the intrauterine life the vascular arcades which surround the foetal lens cross the pupil. With the development of the eye these vascular arcades disappear and the pupillary area is free from any one of them. But the disappearance may cease at any stage of intrauterine life and this leads to persistent pupillary membrane. The incidence is relatively common. The inheritance is irregular autosomal dominant. Persistent pupillary membrane extends from one portion of the iris collarette to another, while posterior synechiae extend from the pupil margin to the lens.

include toxoplasmosis, syphilis and occasionally rubella.

Congenital toxoplasmosis. Most of the ocular toxoplasmosis lesions are congenital. It is characterized by bilateral, central, circumscribed retinochoroiditis and sometimes accompanied by nystagmus or strabismus. It is also associated with intracranial calcification and hepatosplenomegaly. In a severe case the eyes may be microphthalmic.

Congenital syphilis. Typically there is an interstitial keratitis (IK) which is bilateral. This is often accompanied by stigmata of congenital syphilis such as frontal bossing of the skull, saddle nose, Hutchinson's teeth, and sabre tibia. Though also evident at birth an IK usually manifests between the ages of 10 and 15.

Congenital rubella infection. The ocular findings include nuclear cataract, glaucoma and sometimes microphthalmos.

Neonatal Infections

Neonatal infections include neonatal herpes simplex, gonorrhoea and rarely inclusion conjunctivitis.

Neonatal herpes simplex. There may be skin blisters, fever, conjunctivitis with or without keratitis, and sometimes CNS manifestations.

Gonorrhoea. The classic picture of ophthalmia neonatorum is produced mostly by gonococci.

Paediatric Inflammations

Most inflammations affecting adults may occur to children, but children are more prone to these inflammations.

Phlyctenular keratoconjunctivitis. This occurs in children between 8 and 15 years. It is essentially characterized by formations of nodules at or near the limbus and is allergic in nature.

Vernal keratoconjunctivitis. This occurs due to an exogenous allergy in children with the typical

symptom of itching. In the tarsal type, there are typical cobblestone vegetations of bluish-white colour. In the limbal type the perilimbal vegetations appear smoky in colour.

Interstitial keratitis. This has been described on p. 225.

Pseudotumours of the orbit. These have been described on pp. 154-55.

Iridocyclitis in juvenile rheumatoid arthritis. Iridocyclitis in such an affection is chronic associated with minimal clinical features. Band-shaped keratopathy is a common sequel. Cataract may follow.

Iridocyclitis associated with ankylosing spondylitis. Ankylosing spondylitis is more common in males, occurs in association with iridocyclitis.

Pars planitis. A careful examination of the peripheral part of the retina is essential to arrive at diagnosis (see p. 252).

Endophthalmitis. This occurs at any age. In children this may follow infections following injury or operation, otitis media and meningitis.

Orbital cellulitis. This is usually due to the extension of inflammation from the nasal sinuses. In infants it may spread from the teeth.

Inherited Metabolic Disorders

See inborn errors of metabolism on p. 401.

Miscellaneous Disorders

These include achromatopsia, albinism, abetalipoproteinaemia, galactosaemia and hepatolenticular degeneration.

Connective tissue disorders

The inherited connective tissue disorders include Marfan's syndrome (see p. 270), Ehlers-Danlos syndrome (see p. 540) Groenblad-Strandberg

syndrome, osteogenesis imperfecta and Paget's disease.

Osteogenesis imperfecta is characterized by fragile bones, blue sclera and thin cornea.

Paget's disease is characterized by the thickening of the bones especially the skull bones. The ocular features include angioid streaks and optic atrophy. The conditions are described earlier.

Abnormalities of the crystalline lens

These include developmental cataract, abnormal shape or size of the lens, coloboma, and rarely congenital absence of the lens.

Glaucoma in Childhood

Hepatolenticular Degeneration or *Wilson's disease* is inherited as an autosomal recessive (see also p. 301). There are evidence of hepatic and progressive neurologic diseases. The affection is due to copper deposition in different tissues including the basal ganglia of the brain, the cornea and the anterior lens capsule. Ceruloplasmin, which is responsible for binding copper in the serum is low. Ocular manifestations include Kayser-Fleischer's ring in the cornea and brownish discolouration of the anterior lens capsule.

Phakomatoses

There are four phakomatoses and basically they are hamartomas. A hamartoma is an abnormal mixture of tissues ectopically situated, with excess of one or more of these tissues. Hereditary pattern of all these affections is of autosomal dominant trait, but in Sturge-Weber's syndrome sometimes this is uncertain. They are described on p. 351.

Tumours in Childhood

Tumours are described under the corresponding chapters. Tumours occurring in childhood include retinoblastoma, rhabdomyosarcoma, neuroblastoma, optic nerve glioma, leukaemia, craniopharyngioma,

medulloblastoma (diktyoma), and juvenile xanthogranuloma.

Retinoblastoma. Forty per cent cases of retinoblastoma are inherited as an autosomal dominant. This is the most common tumour in childhood. The typical presenting sign is a white reflex at the pupil.

Rhabdomyosarcoma. Though its incidence is rare it is the most common primary orbital tumour in childhood. It is characterized by rapidly-spreading proptosis pushing the globe upward or downward. The clinical features resemble those of an acute orbital cellulitis. Radiation with or without chemotherapy is probably the most effective therapy.

Neuroblastoma. It takes origin from the paraspinal sympathetic chain or the adrenal glands. It frequently metastasises in the orbit and presents clinically as a proptosis.

Optic nerve glioma. Most often it has a benign course. There is usually an axial irreducible and marked proptosis.

Leukaemia. The usual variety of leukaemia encountered in childhood is acute lymphatic leukaemia.

Craniopharyngioma. It is a childhood affection characterized by typical bitemporal hemianopia, evidence of hypopituitarism and calcification in the suprasellar region.

Diktyoma. It is a rare embryonic epithelial tumour affecting the ciliary body. It may be benign or malignant.

Prematurity and Ocular Abnormalities

Three ocular conditions are commonly met with myopia, cataract, and retrolental fibroplasia.

Retrolental fibroplasia [Syn.: Retinopathy of prematurity (ROP)]

Pathology. Retinopathy of prematurity is a complex disease of abnormal retinal vasculature

in premature infants of low birth weight (LBW), less than 1500 gms. Its pathogenesis is not fully understood, though oxygen therapy appears to be an important contributory factor. Normally, the precursors of the retinal vasculature: the spindle cells and the primitive endothelial cells migrate from the optic disc toward the retinal periphery. The nasal retina is first vascularized due to close approximation of the disc with the nasal retina, while the temporal retina is vascularized later after birth. Vasoproliferation following excess oxygen therapy affects usually the temporal retina because of relatively delayed vascularization.

Clinical features. The committee for 'Classification of Retinopathy of Prematurity' (1984)¹ proposed the following five stages:

Stage 1: demarcation line between the posterior vascular and the peripheral avascular retina

Stage 2: ridge

Stage 3: ridge with extraretinal fibrovascular proliferation

Stage 4: subtotal retinal detachment

Stage 5: Total retinal detachment.

Treatment. Difficult. Recently, indirect argon diode laser photocoagulation has been suggested. Retinal detachment is treated by scleral buckling.

White pupil

One of the important paediatric problems is the presence of white reflex at the pupil or *leucokoria*. Sometimes exact diagnosis becomes extremely difficult. Three important conditions are: developmental cataract, retinoblastoma and pseudoglioma. The causes of white reflex at the pupil is shown in the Table 52.2.

The different conditions are described under pupillary disorders.

Strabismus and amblyopia

Convergence prevails in infants and children, while divergence prevails in the adults. Normally a child's

Table 52.2

Causes of White Reflex at the Pupil

1. Cataract
2. Retinoblastoma
3. Endophthalmitis
4. PHPV
5. Retrolental
6. Coats' disease fibroplasia
7. Persistent pupillary
8. Coloboma of the choroid and retina membrane
9. Tumours other than retinoblastoma
10. Retinal detachment
11. Retinal dysplasia
12. Retinoschisis
13. Organized vitreous haemorrhages
14. Occlusio pupillae
15. Parasite in the vitreous
16. Larval granulomatosis
17. Phakomatoses

eye is hypermetropic, a condition needing more accommodation and thus more convergence. That is the reason why an accommodative esotropia is so common in children, its average age of onset being 2½ years. Esotropia is also common in infants and children when there is associated poor vision in one or both eyes. In the myopic child accommodation is not required to see near objects clearly. This causes weak or absent convergence and thus a tendency for exotropia. Poor visual acuity in one eye is more likely to develop into strabismus than a case where visual acuity is either equal or poor in both eyes. Unilateral esotropia in a child should arouse suspicion for visual loss in that eye and need investigation for other ocular lesions such as high refractive error, cataract and retinoblastoma.

About 50 per cent of all children with strabismus may have a positive family history.

Amblyopia may lead to strabismus or vice versa. When amblyopia is due to strabismus it is called strabismic amblyopia; which appears around the age of 4 years. Due to strabismus the child favours using one eye to avert confusion or diplopia. He or she thus suppresses the image received by one eye and that eye ultimately becomes amblyopic.

Further Reading

1. The Committee for the Classification of Retinopathy of Prematurity. *Arch. Ophthalmol.*, 102:1130, 1984.
2. Duke-Elder, S., *System of Ophthalmology*, Vol. III, *Normal and Abnormal Development*, Part 11: *Congenital Deformities*, Kimpton, London, 1964.
3. Francois, J., *Heredity in Ophthalmology*, C.V. Mosby, St. Louis, 1961.
4. Harley, R.D. (Ed.), *Paediatric Ophthalmology*, W.B. Saunders, Philadelphia, 1975.
5. Keith, J.H., *Genetics and Ophthalmology*, E&S Livingstone, Edinburgh, 1978.
6. McKeon, C.A., The paediatric eye examination. In *Principles and Practice of Ophthalmology: Clinical Practice*, Albert, D.M. and Jacobiec, F.A. (Eds.), W.B. Saunders, Philadelphia, 1994.
7. Pavan-Langstone, D. (Ed.), *Manual of Ocular Diagnosis and Therapy*, Little, Brown and Co., Boston, 1980.
8. Scheie, H.G. and Albert, D.M. (Eds.), *Textbook of Ophthalmology* (9th ed.), W.B. Saunders, Philadelphia, 1977.

53. IMMUNOLOGY RELATED TO OCULAR DISORDERS

Immunology today occupies an important position in ophthalmology as significant numbers of ocular affections appear to be related to disorders of the immune mechanism.

Cellular Components^{2,5}

Cellular components are listed in Table 53.1.

Antigen (immunogen) is a substrate, protein in nature, which causes an immune response when it comes in contact with an organism. There are four

Table 53.1

Cellular Components in the Immune System

Lymphocytes
T-lymphocytes
Helper inducer
Suppressor
Cytotoxic
Mediator of delayed hypersensitivity
Memory
B-lymphocytes
Non-T-lymphocytes
Non-B-lymphocytes (null cells)
Killer (K) cells
Non-killer (NK) cells
Neutrophils
Eosinophils
Basophils
Mast cells
Platelets
Macrophages

types: homologous, heterologous, organ specific and species specific.

Autoantigens are body's own proteins and these under normal conditions do not evoke an immune response.

Adjuvants are substances which when mixed with antigens enhance immune response.

Immune response occurs by production of antibodies, cell mediated immunity (CMI) or immunologic tolerance.

Antibody or immunoglobulin. The sequence of events in antibody formation is as follows: ingestion of a foreign body by a macrophage → produces information RNA → stimulates helper T lymphocytes to produce lymphokines → sends nonspecific signals to the attenuated antigen → these combined signals then trigger B lymphocytes to produce antibody.

Immunoglobulins (Ig) are of five classes: Ig A, Ig E, Ig G, Ig M and Ig D. Their characteristics are depicted in Table 53.2.

Human Leucocyte Antigens (HLAs)

The genetically-determined antigens, the surface glycoproteins on the nucleated cells of almost all

combining with antigen-specific lymphocytes (T-cells) but without participation of any antibody. Table 53.4 lists the ocular affections caused by hypersensitivity responses.

Table 53.4

Ocular Affections due to Hypersensitivity Responses

Type I

Vernal conjunctivitis
Atopic keratoconjunctivitis
Giant papillary conjunctivitis
Insect bite
Contact hypersensitivity

Type II

Mooren's ulcer
Cicatricial pemphigoid

Type III

Disciform keratitis
Rheumatoid arthritis
Systemic lupus erythematosus (SLE)

Type IV

Phlyctenular keratoconjunctivitis
Corneal graft rejection
Herpetic stromal keratitis
Sympathetic ophthalmitis

Type V. The example of type V or stimulatory hypersensitivity is LATS.

Type VI. This type is known as *antibody-dependent cell-mediated cytotoxic (ADCC) response*.

Autoimmune Diseases

Autoimmunity is a condition in which one's own tissues are prone to be affected by the deleterious effects of the immunological system.

There are two groups of autoimmune disorders: organ specific and non-organ specific. *Organ specific* disorders are related to organs like thyroid, adrenal cortex, kidney and nervous system. *Non-organ specific* disorders include connective tissue diseases.

Immunologic Aspects of Certain Ocular Affections

Vernal conjunctivitis. This affection is a typical

example of type I immune response. Tear histamine is four times normal. Steroids are highly effective, while disodium cromoglycate is a good adjuvant.

Mooren's ulcer. An example of type II immune response, there is basically an autoimmune lysis of the corneal epithelium accompanied by liberation of collagenolytic enzymes.

Disciform keratitis. This is probably due to an antigen-antibody reaction following HSV infection. Hence, combined IDU-steroid therapy is recommended in its treatment.

Corneal graft rejection.⁵ Immune-associated (Ia) antigens associated with HLA-DR locus may play the key role in its pathogenesis. So in its management apart from intensive steroid therapy, use of small graft and removal of donor epithelium which reduce the antigenic load are advocated.

Uveitis. The cause of many cases of uveitis remains obscure, but immunology plays a definite role in some of these. HLA B27 is definitely linked with ankylosing spondylitis and it is present in 42 per cent of patients with acute anterior uveitis in the absence of associated disease.⁴ The other typical examples of immunologic disorders are lens-induced uveitis, sympathetic ophthalmitis and toxoplasmic retinochoroiditis.

Retinal vasculitis. This represents non-specific clinical features of a number of infective and probably toxic conditions. It includes Eales' disease, sarcoidosis, SLE and Behcet's syndrome. Immune complexes have been found to be present in some cases.⁴

Ocular tumours.³ There are two types of tumour-associated antigens (TAA): tumour-specific transplantation antigen (TSTA) and tumour-specific cytoplasmic antigen (TSCA). Both antigens, TSTA and TSCA, are involved and cause an immune reaction. The cell damage is caused by the immune reaction on the surface of the tumour cell. TSCA in combination with antibodies results in an immune-complex-mediated inflammation and necrosis, or T-cell blockade and tumour enhancement.

Further Reading

1. Arffa, R.C., *Grayson's Diseases of the Cornea* (4th ed.), C.V. Mosby, St. Louis, 1977, p. 485.
2. Foster, C.S., Basic immunology. In *Principles and Practice of Ophthalmology: Basic Sciences*, Albert, D.M. and Jacobiec, F.A. (Eds.), W.B. Saunders, Philadelphia, 1994, p. 754.
3. Rahi, A.H.S., The immunological aspects of ocular tumours. In *Scientific Foundations of Ophthalmology*, Perkins, E.S. and Hill, D.W. (Eds.), Heinemann Medical, London, 1977, p. 119.
4. Sanders, M.D. and Graham, E.M., Medical ophthalmology. In *Recent Advances in Ophthalmology*, No. 6, Davidson, S.I. (Ed.), Churchill Livingstone, Edinburgh, 1983, p. 59.
5. Smolin, G., Basic immunology in the anterior segment. In *The Cornea: Scientific Foundations and Clinical Practice* (3rd ed.), Smolin, G. and Thoft, R.A. (Eds.), Little, Brown and Co., Boston, 1994, p. 305.

Table 54.1WHO Classification of Blindness¹

Category	Visual acuity in both eyes	Professional independence	Social independence
1.	6/18 to 6/60	Yes	Yes
2.	6/60 to 3/60	No	Yes
3.	3/60 to 1/60	No	No
4.	1/60 to PL	No	No
5.	No PL	No	No
6.	Undetermined	—	—

training and education of technicians and paramedicals to socioeconomics and co-ordinating units.

Eye care and treatment in rural areas^{2,4,5}

To extend eye care and treatment in rural areas one must be conversant with the problems encountered in the villages.

In India the great majority of the people live in the villages, where almost no facility for eye care and treatment exists. Dirth of ophthalmologists and lack of hospitals coupled with poverty and native superstition have led to more blindness in the villages than in the cities.

About 40 per cent of the blindness is preventable and another 40 per cent is curable particularly by surgery.

Prevention should ideally start from the postnatal stage if there is a suspicion of defects. Routine check-up at the school-going age should be made mandatory. Examination of refraction of all age-groups are essential. In the adult and elderly the eyes should be examined for evidence of cataract, glaucoma and systemic diseases such as diabetes and cardiovascular diseases which may lead to ocular complications.

During childhood. The affections which can be prevented include ophthalmia neonatorum and retrolental fibroplasia. Prenatal check-up of the mother, strict asepsis during labour and instillation of antibiotic drops soon after birth have virtually eliminated ophthalmia neonatorum. For preventing retrolental fibroplasia, oxygen concentration in an incubator not exceeding 30 to 35 per cent is used.

54. PREVENTION AND REHABILITATION OF BLINDNESS

Blindness is defined by WHO Expert Committee on Health Statistics as 'inability to do any kind of work, industrial or otherwise, for which sight is essential.' For practical purposes, registration of blindness, economic blindness, may be considered when visual acuity is less than 3/60 or the visual field is reduced to a small area around the fixation point. Table 54.1 shows WHO classification of blindness.

Preventive Ophthalmology¹⁻⁵

Preventive ophthalmology is a multidiscipline field which ranges from epidemiology, vital statistics,

Both congenital cataract and glaucoma can be treated by surgery. The factors like ill-sanitation, dirty clothes and flies are associated with the spread of trachoma which is specially contacted during childhood. These factors should be prevented to avoid its spread.

Vitamin deficiencies are common in this age-group. Breast-feeding is encouraged to prevent vitamin deficiencies. Food habit should also be looked in for prevention of other deficiency diseases such as protein-calorie malnutrition (PCM).

During school age. Apart from physical injuries to the eyes, the major problem is refractive error. Most cases of refractive errors are correctable.

In adult life. The common causes of blindness include gross refractive error, injury, neurologic diseases and iatrogenic disorders. Refractive errors need adequate correction. Injury can happen at home or at work and is rarely an eclipse burn. Treatment of neurologic disease is mandatory to prevent blindness. Long-continued use of drugs like ethambutol can cause optic neuritis and amblyopia. Sometimes Stevens-Johnson syndrome causing ocular lesions may follow intake of antibiotics or sulphonamides.

During old age. The causes of blindness include cataract, glaucoma, retinopathies and occasionally macular degenerations. The first two conditions are treated by operations.

In modern developed countries it is estimated that there is one ophthalmologist per 20,000 population, but in India there is one ophthalmologist for 1.2 lakhs people. The city and district hospitals can cope with only 50 per cent operations. Because of this grim situation the government as well as private sector services are cooperating to control blindness caused by cararact.

Eye camps

Eye camps are temporary field hospitals located far away from a city hospital. Any spacious place is suitable for an eye camp. Cooperation from the local people is absolutely essential. Other options are a mobile eye unit related to well-equipped

ophthalmic institution and a mobile unit related to a rural hospital but under the supervision of a city hospital. Under all circumstances improved surgical techniques must be employed, strict asepsis followed and proper postoperative measures taken. Disastrous results occur if these are not followed.

Health education including eye health should be introduced in the villages. Parents should be instructed to seek early treatment for their children and teachers should be conversant with elementary eye hygiene and prevention of contaminating diseases.

Blindness in India

In India there are about 9 million blind people and 45 million visually-handicapped individuals. The causes are indicated in Table 54.2.

Table 54.2
Causes of Blindness in India³

Causes	Percentage
Cataract	55
Trachoma and infections	20
Small pox	3
Nutritional deficiencies	2
Injuries	1.20
Glaucoma	0.50
Others	18.30

Rehabilitation of the blind

Individual adjustment of visually-handicapped or blindness is dependent on several factors, such as

- age at onset,
- educational standard of the affected subject,
- economic resources and,
- adaptability to newer circumstances.

Blind people may adjust to various jobs, such as

- typing,
- business methods,
- training in manual work,
- machine manipulation,
- imparting of instruction in Braille and
- Gaining of auditory and tactual experience.

56. MODERN ADVANCES IN OPHTHALMOLOGY

During the recent past newer clinical entities, improved diagnostic facilities, effective therapeutic measures and sophisticated surgical procedures have been introduced. In the field of science new happenings are frequently reported and what appears recent may not be really so within the next few years.

Improved Diagnostic Facilities

In orbital disorders. The introduction of B-scan ultrasonography, computerized tomography (CT) and magnetic resonance imaging (MRI) has revolutionized the diagnosis of several orbital disorders like tumours, pseudotumours, vascular lesions, optic nerve affections and extrinsic muscle involvement.

Radioactive arteriography has been used in the diagnosis of vascular tumours and arteriovenous communications. Holography, a special laser photographic method, has been employed for detecting a metallic foreign body. Radioimmunoassays are used increasingly for diagnosis dysthyroid disorders.

(a) *In affections of lacrimal apparatus*, newer laboratory tests for the diagnosis of dry eye (refer to pp. 183–84) and evaluation of the lacrimal passages by dacryocystography and radiosintillography (see p. 187) have been already described.

(b) *In corneal diseases* the investigations like pachymetry, fluorometry, specular microscopy, computer-assisted keratometry, photokeratoscopy and tests for evaluation of precorneal tear film are increasingly employed.

Tissue-typing may be recommended in repeated rejection of the grafts and vascularized corneas. Interesting techniques like adhering cultured endothelial cells to the denuded Descemet's membrane of a graft and growth of new corneal endothelium from the non-corneal vascular endothelium have been reported.

For investigation of a case of *scleritis* or

episcleritis one should carry out tests to find out the possible cause. They include full immunological tests including the presence of circulating antibodies to immunoglobulin molecules.

(c) *In uveal diseases* though hosts of new laboratory tests can be employed (Table 40.7) only a few of them are advocated according to the need of the cases which are recurrent, persistent or resistant to treatment.

(d) *In glaucoma* the improved diagnostic methods include automated perimetry and optic nerve-head imaging.

(e) *In retinal diseases* there are several modern advances like fundus fluorescence angiography (FFA), indocyanine green (ICG) angiography, use of high-powered aspheric lenses, specialized contact lenses, digital fundus imaging, scanning laser ophthalmoscopy (SLO) and confocal scanning laser ophthalmoscopy (CSLO). Tests for evaluation of macular function have been described on pp. 315–16.

(f) *In strabismus*. For assessment of motor functions forced generation tests, forced duction test and saccadic tracking using EOG are employed. For assessment for sensory aspect, Bagolini striated glasses, phase difference haploscope, photorefractometer, etc. may be recommended.

In diseases of the optic nerve the following investigations are helpful to arrive at a diagnosis of an optic nerve affection: fluorescence angiography, ERG, VER and neuroradiologic techniques including CT.

Pachometry (Pachymetry)

Corneal thickness is measured with an optical device, *pachometer*. There are three methods: (a) pachometer attached to the slit-lamp; (b) use of specular microscope with automatic digital display; and (c) ultrasonographic, this being commonly employed.

Fluorophotometry

The increased exchange of fluorescein between the

aqueous humour and the cornea after ingestion or IV injection of fluorescein suggests a breakdown of corneal endothelial barrier function.

Specular Microscopy

Direct visualization of the corneal endothelium is possible by specular microscope.

In 1968 Maurice photographed the corneal endothelium of enucleated rabbit's eye, while Laing (1975) produced a photograph of the corneal endothelium in a living human subject.

There are two types: contact and noncontact. The examination is possible with corneas *in vitro* and *in vivo*. Both regular and wide field specular microscopy have been described. The study of the corneal endothelium is of vital significance because

(a) corneal transparency is dependent on the integrity of the endothelium

(b) the endothelium is the site of metabolic process which maintains the deturgescence state of the cornea

(c) the effect of drug therapy can be judged

(d) pre- and postoperative picture of corneal grafting can be assessed.

Both quantitative and qualitative analysis of the corneal endothelium are made possible.

Computer-assisted Keratometry

Computer-assisted keratometry provides a colour-coded topographic map of the cornea using 18 concentric Placido rings as the illuminated target (or 32-ring collimated video keratoscope). The video screen captures the reflected images and this is followed by computer analysis.

Specialized Contact Lenses in Fundus Examination

Panfunduscopy lens facilitates fundus examination through poorly dilated pupils and is used during laser photocoagulation. This gives an inverted, real and reduced image. However, the view through the peripheral part of this lens is not excellent.

Mainster lens produces less reduced minification

and more reduced field of view than panfunduscopy lens. This lens is especially useful to detect macular oedema.

High-power Plus Lenses¹⁸

These lenses (+60, +78 and +90) are usually used. The lens is held in front of the cornea along with the slit-lamp for performing binocular indirect ophthalmoscopy. A real image is formed several cms in front of the patient's eye and this aerial image is magnified by the slit-lamp optics.

Transillumination Ophthalmoscopy⁹

Transillumination ophthalmoscopy is a combination of indirect ophthalmoscopy and transillumination. The light source, usually a *fibre optic probe* is placed against the sclera in a darkened room. During the examination the illuminating ophthalmoscope light is turned off.

Equator Plus Ophthalmoscope and Camera^{20,21}

Equator plus ophthalmoscope and camera have been designed by Pomerantzeff and associates. They require the use of a specially-designed contact lens and cover an angle ranging between 175 and 203° according to the method of illumination. The field of observation is 10° in diameter in direct and 37° in diameter in indirect ophthalmoscopy.

Scanning Laser Ophthalmoscope²⁵ (SLO)

A narrow flying beam of weak laser light is utilized for visualization of the ocular fundus. Its main advantages are as follows:

(a) 100-10000 times less light is required to illuminate the fundus than in conventional ophthalmoscopy

(b) Ophthalmoscopy is possible without pupil dilatation because of less light needed

(c) It is possible to examine one point at a time because of monochromatic property of the laser

(d) A sharper image is seen because of less scattering of light.

The light emerging from the pupil is collected by a lens system and photomultiplied. Subsequently this is observed on a television screen. Both video cassettes and hard copies can be made. With the illuminating beam flying across the fundus there is synchronous electron beam flying across the television screen.

Confocal Scanning Laser Ophthalmoscope (CSLO)²⁵

Confocal scanning laser ophthalmoscope is a variant of SLO. The laser light beam is scanned across the retina specially delivering all of its energy briefly to one point. This is essentially a combination of SLO and confocality.

Optic Nerve-head Imaging

Optic nerve-head imaging has been made possible by

1. *Photography.* An improved fundus camera can take excellent photographs of the optic disc with the help of slit-lamp along with 90 D plus lens.

2. *Digital imaging* is the method in which the images can be digitally captured, stored, retrieved, analyzed and displayed. Two instruments—Topcon imagenet and Rodenstock optic nerve-head analyzer can be used.

Sensory Diagnostic Tests in Strabismus

Some recent tests are described below.

Bagolini's striated glasses. These are optically plano lenses with faint striations ruled on them. These striations produce a light streak when the point-source of light viewed by the patient wearing the glasses, as they do not blur the view. These lenses are worn in a trial frame and placed in front of the correcting lens. The rows of cylinders forming the lenses are similar to those of Maddox rod. The lenses are so placed, one before each

eye, that the lines correspond to the 45° axis in the right eye and to the 135° axis in the left eye. The subject sits at a distance of 6 metres from the point-source of light. The test is repeated at 33 cm distance. If he or she sees an X, that is a symmetrical cross and the cover test shows no shift, NRC is present and the fixation is central. If there is a break in one of the lines of the cross this is indicative of suppression. If the cover test shows a shift but the patient sees an X, it indicates the presence of harmonious ARC. In unharmonious ARC the centre of the X does not apparently pass through the point-source of light (Fig. 56.1).

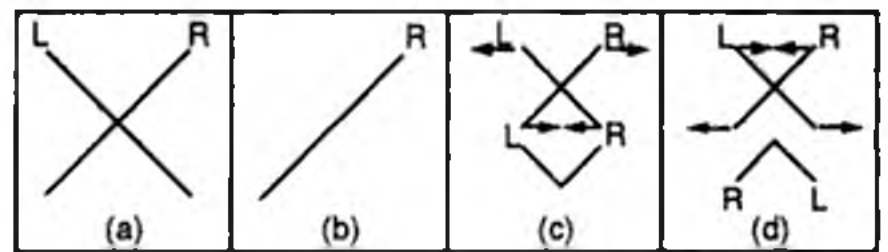


Fig. 56.1 Bagolini's striated glasses: (a) a cross is perceived in orthophoria with NRC; (b) a patient with squint and large angle suppresses and sees one line; (c) a V is seen with esotropia and uncrossed diplopia; and (d) A-type of configuration is seen by a patient with exotropia and crossed diplopia.

Neutral density filter test. For differentiation between an organic and a functional amblyopia this test is advised. These filters, from Kodak No 96; ND 2.00 and 0.50, reduce vision in a normal eye from 6/6 to 6/12. If such a filter is placed in front of an amblyopic eye, the visual acuity may be remarkably reduced which indicates an organic amblyopia. If on the other hand, the visual acuity remains unaffected or slightly improved, it is usually indicative of a functional amblyopia.

Haidinger's brushes. This is an entoptic phenomenon and it results from the effect of the polarized light on Henle's fibres at the fovea. The effect is transient and it is prolonged by rotating the axis of polarization so that the brushes also rotate. The effect is enhanced by a blue light background. Its recognition indicates a foveal fixation.

Projectoscope. This is used for the diagnosis and treatment of eccentric fixation. This is a modified

Miscellaneous conditions. A fluorescence angiogram is helpful in certain conditions. These are sickle cell retinopathy, macular degenerations, retinal detachment, retinitis pigmentosa, cystoid macular oedema and anomalies of the optic nerve-head.

Iris angiogram. This is possible following the same technique as for fundus fluorescence photography.

Indocyanine Green Angiography¹⁵

Fundus fluorescein angiography using sodium fluorescein has some limitations because this dye rapidly leaks from choriocapillaries causing a diffuse background fluorescence thus obscuring the details of the choroidal vessels.

The dye *indocyanine green (ICG)* has some advantages over sodium fluorescein and these are:

(a) Ninety-eight per cent of ICG is bound to plasma protein and probably it does not leak from the choriocapillaries

(b) Better visualization of the choroidal vessels is possible because the dye remains longer than fluorescein.

(c) Better fluorescence is possible through blood, exudate and melanin

(d) The patient tolerates better because of near infra red light causing fluorescence of ICG.

Indications. This is indicated in age-related macular degeneration subretinal neovascular membrane, bird shot choroidoretinopathy and during diode laser photocoagulation.

Technique. Twenty mg of indocyanine green in 1 ml of aqueous solvent is rapidly injected through the antecubital vein. The introduction of laser ophthalmoscope and retinal digital imaging has improved the quality of the image.

Ultrasonography (Scintillography)^{4,26}

When the frequency of the sound wave is over 18,000 cycles per second it is beyond the auditory range of human ear and this is called *ultrasound*. This ultrasound can be measured and assessed in

terms of amplitude and velocity. Ultrasonography related to ophthalmology, first reported in 1956, utilizes high-frequency ultrasonic waves.

Properties of ultrasonic waves

(a) All the diagnostic ultrasonic instruments make use of the piezoelectric effect where mechanical vibrations are converted into electrical potentials.

(b) The waves can penetrate all the tissues whether they are transparent or opaque.

(c) Some part of the waves are reflected and others refracted.

(d) Increased temperature causes increased velocity of the wave.

(e) There is an *impedance discontinuity* as the wave meets the structural changes within the tissues. Here some of the waves are reflected towards its source and the proportion of the reflected towards its source and the proportion of the reflected wave gives an index of discontinuity between the original and the new media. In the human eye there are several impedance discontinuities.

Components of an ultrasonic instrument (Fig. 56.6)

There are three important components. The



Fig. 56.6 Combined A/B scan for ultrasonography with console (lower right corner) and printer (upper right corner) (Courtesy: Eye Care and Research Centre, Kolkata).

transmitter provides the electrical energy. The *transducer* is a vital component through which the electrical effects are metered. The *display unit* is usually a cathode-ray oscillograph. The interval between the transducer and the point at which the beam of the transducer starts diverging is called the *near field*. Beyond this is called the *far field*. Very high-frequency waves, about 500 megacycles per second, are used from a probe placed over the cornea through a waterbath. The oscilloscope shows the pulsations arising from the ocular tissues.

Technique. An anaesthetic agent coupled with viscous agent is instilled into the conjunctival sac. The motorized transducer is placed over the eyelid or is held in direct contact with the globe. The tip of the transducer oscillates near tip of the probe in case of B-scan.

A-scan or time amplitude display. The echoes are displayed as spikes or vertical deflections from the base, while the height of the spike indicates the strength of an echo. The typical example is biometry (Fig. 56.7).

B-scan or brightness intensity-modulated

display is a two-dimensional display and the echoes are displayed as dots, and the brightness of the dot indicates the size of the received echo. There are three probe orientations: transverse, longitudinal and axial. (Fig. 56.8).

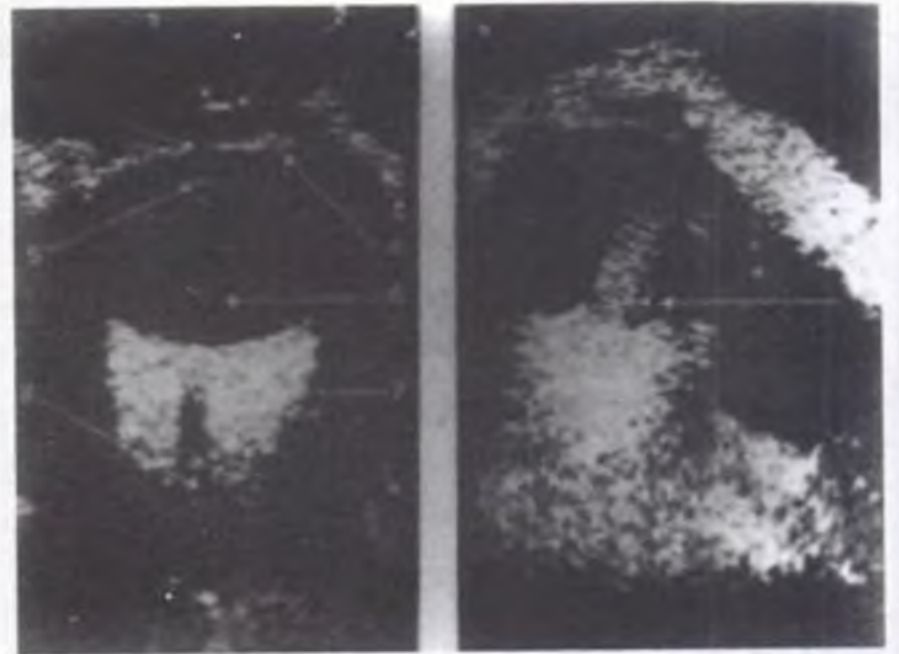


Fig. 56.8 (Left) Linear horizontal B-scan through normal eye and orbit, showing partial outline of globe. Areas shown include: 1, anterior corneal surface; 2, posterior corneal surface; 3, pupil; 4, iris; 5, posterior lens surface; 6, vitreous; 7, orbital fat; and 8, optic nerve. (Right) Ultrasonic scan of malignant melanoma of the choroid (arrowed) (Trevor-Roper and Curran).

SRK II Emmetropia/Ametropia		Aug. 4, 1998		12:56 p.m.																																																	
IOL #1	NO IOL DESCRIPTION	IOL #2	4																																																		
Patient:	MRS. MAJIDAN BIBI	Type:	dense cat.																																																		
Physician:	DR E AHMED IMPLANT HOUSE	Eye:	left																																																		
Vit. Velocity:	1532m/s	Aphakic Spectacle Power:	11.04D																																																		
Lens Velocity:	1629m/s	Aphakic Contact Lens Power:	12.47D																																																		
Avg. Velocity:	1552m/s	<table border="1"> <thead> <tr> <th>IOL #1</th> <th>RFER #1</th> <th>IOL #2</th> <th>RFER #2</th> </tr> <tr> <th>=====</th> <th>=====</th> <th>=====</th> <th>=====</th> </tr> </thead> <tbody> <tr><td>17.00D</td><td>1.26D</td><td>19.00D</td><td>1.02D</td></tr> <tr><td>17.50D</td><td>0.86D</td><td>19.50D</td><td>0.52D</td></tr> <tr><td>18.00D</td><td>0.46D</td><td>20.00D</td><td>0.22D</td></tr> <tr><td>18.50D*</td><td>-0.06D*</td><td>20.50D*</td><td>-0.18D*</td></tr> <tr><td>19.00D</td><td>-0.34D</td><td>21.00D</td><td>-0.58D</td></tr> <tr><td>19.50D</td><td>-0.74D</td><td>21.50D</td><td>-0.98D</td></tr> <tr><td>20.00D</td><td>-1.14D</td><td>22.00D</td><td>-1.38D</td></tr> <tr><td>20.50D</td><td>-1.54D</td><td>22.50D</td><td>-1.78D</td></tr> <tr><td>21.00D</td><td>-1.94D</td><td>23.00D</td><td>-2.18D</td></tr> <tr><td>21.50D</td><td>-2.34D</td><td>23.50D</td><td>-2.58D</td></tr> </tbody> </table>				IOL #1	RFER #1	IOL #2	RFER #2	=====	=====	=====	=====	17.00D	1.26D	19.00D	1.02D	17.50D	0.86D	19.50D	0.52D	18.00D	0.46D	20.00D	0.22D	18.50D*	-0.06D*	20.50D*	-0.18D*	19.00D	-0.34D	21.00D	-0.58D	19.50D	-0.74D	21.50D	-0.98D	20.00D	-1.14D	22.00D	-1.38D	20.50D	-1.54D	22.50D	-1.78D	21.00D	-1.94D	23.00D	-2.18D	21.50D	-2.34D	23.50D	-2.58D
IOL #1	RFER #1					IOL #2	RFER #2																																														
=====	=====	=====	=====																																																		
17.00D	1.26D	19.00D	1.02D																																																		
17.50D	0.86D	19.50D	0.52D																																																		
18.00D	0.46D	20.00D	0.22D																																																		
18.50D*	-0.06D*	20.50D*	-0.18D*																																																		
19.00D	-0.34D	21.00D	-0.58D																																																		
19.50D	-0.74D	21.50D	-0.98D																																																		
20.00D	-1.14D	22.00D	-1.38D																																																		
20.50D	-1.54D	22.50D	-1.78D																																																		
21.00D	-1.94D	23.00D	-2.18D																																																		
21.50D	-2.34D	23.50D	-2.58D																																																		
ACD:	3.32mm																																																				
ALX:	23.88mm																																																				
K1:	43.120																																																				
K2:	42.500																																																				
A const #1:	116.80																																																				
A const #2:	118.50																																																				
B constant:	2.50																																																				
C constant:	0.90																																																				
REFR:	0.00D																																																				
IOL #1 Emmetropia:	18.58D																																																				
IOL #2 Emmetropia:	20.28D																																																				

Fig. 56.7 A biometry printout.

C-scan or coronal section display is indicated in examination of the soft tissues in the coronal plane of the orbit. A 4-cm square aperture in the centre of the eye is selected and the focal plane of the transducer is placed over this plane. The display is similar to that of B-scan except that it is exclusively present in the coronal plane.

D-scan or deflection modulation display is the superimposition of A-scan amplitude on B-scan image. Colour-coded B-scan is an enhancement imaging technique.

M-scan or motion display shows the motion characteristics of the tissues. This is a dot format in which both transducer and object remain stationary, but the oscilloscope trace moves vertically.

Doppler method is utilized for assessment of the direction of flow within blood vessels, especially the carotid system but sometimes vessels in the globe and orbit. The Doppler effect is caused by movement of blood either away from or toward the transducer.

Indications of ultrasonography

These are described as follows:

Axial length measurement of the globe or biometry. This is the most common application of ultrasonography in ophthalmology. A-scan offers accurate calculation of power for an intraocular lens. 0.25 to 0.30 mm of axial length corresponds to 1D refractive power for IOL (Fig. 56.7).

Tumours of the orbit. Ultrasonography of different types of tumours shows the following characteristics:

(a) **Solid tumours** show round, well-defined contours. They have poor sound transmission and variable internal reflection depending on the consistency of the tumour.

(b) **Cystic tumours** seen on B-scan have sharply defined, round borders with good sound transmission. There is clear definition of the posterior wall of the lesion of tissues behind the tumour.

(c) **Angiomatous tumours** produce extremely high amplitude echoes and strong internal echoes from the connective tissue septa.

(d) **Infiltrative lesions** show irregular variable shape, poor sound transmission and minimal internal echoes.

Pseudotumours of the orbit are usually diffuse and their shape is irregular. They produce low to medium internal reflection and weak sound attenuation accompanied by other features like thickening of the extrinsic muscles and oedema of Tenon's space.

Dysthyroid ophthalmopathy. B-scan exhibits gross size and contour of the extrinsic muscle, while A-scan gives precise measurement of muscle thickness.

Vascular lesions of the orbit. Doppler imaging is particularly valuable.

Vitreoretinal disorders. Normal vitreous in young age does not produce any echo. Echoes are present in the following conditions.

Vitreous opacities. B-scan shows dots or short lines. Larger echoes are detected in synchysis scintillans and asteroid hyalopathy because of higher density.

Vitreous haemorrhage. B-scan can determine the density and location of haemorrhage. More dense the haemorrhage the greater will be the number of dots or short chains.

Malignant melanoma of the choroid. Both A-scan and B-scan are necessary. A-scan shows a solid echo, and B-scan shows a marked internal 'shadowing', i.e. absorption of sound by the tumour causing attenuation of sound at the back part of the eye. (Fig. 56.8).

Ultrasonic holography

Holography is a photographic method of producing a three-dimensional image of the object like a metallic foreign body in a single exposure. Ultrasonic holography appears to be a more sophisticated method than A-scan or B-scan.

Computed Tomography²⁸

CT is a valuable noninvasive computer-assisted tomography. This uses thin X-ray beams to obtain tissue-density values and these values are processed by computer which provide cross-sectional images.

CT can visualize various orbital compartments, bones, orbital fat, nerves, muscles, orbital walls as well as intracranial lesions.

In the original technique the area to be scanned is subdivided into cubes $3 \times 3 \times 13$ mm and an average absorption value for each tube is calculated. The head is subjected to scanning by narrow beam of X-rays and 160 readings are taken for each position of the scan. The X-ray source of the protector are rotated through 1° and the scan repeated. In this manner 180° are covered and 28,000 (180×160) readings obtained. The data is analysed by computer and calculation of X-ray absorption values for each cube of tissue is done. Either the paper record of the computer printout of the absorption coefficients or cathode-ray tube display of the processed information from the memory chip shows the result.

In orbital diagnosis the original scanner displays and 80×80 matrix. The latest displays a matrix of 160×160 , which has improved resolution of details of cells by reducing the dimension of each cell to 1.5×1.5 mm and increased the number of picture points from 6400 to 25,600.

Computerized axial tomography (CAT) shows medial and lateral walls of the orbit, while a *computerized coronal tomography (CCT)* shows all the walls. Hence, a combined CAT and CCT give a three-dimensional accurate view. IV contrast-enhanced CT (CECT) scans are recommended in patients with vascular lesions, malignant tumours, extraocular extension and inflammatory disease.

Magnetic Resonance Imaging (MRI)

Also called *nuclear magnetic resonance (NMR)*, this technique has the ability of multiplanar imaging capabilities. This is a noninvasive and nonionizing radiation technique.

The principles are as follows. There is rearrangement of hydrogen nuclei when the tissues are exposed to a short electromagnetic pulse. The electromagnetic echoes are picked up by sensitive receivers. The results are analyzed by computer and finally displayed as cross-sectional image of the observed area. Other variants are: (a) gadolinium enhancement; (b) gradient echo images with limited flip angles; and (c) MRI angiography.

Table 56.2 gives a differentiation between CT and MRI.

Table 56.2
Comparison between Computed Tomography and
Magnetic Resonance Imaging⁷

Computed tomography	Magnetic resonance imaging
1. Evaluation of bony details and calcium containing lesions better	1. Poor bony details and calcium demonstration
2. Modality of choice in presence of magnetic foreign body	2. Cannot be employed
3. Not so	3. Better in detection of lesions in and around the apex of the orbit
4. Difficult to evaluate early extension of retinoblastoma through the eyeball or into the optic nerve	4. Evaluation easier
5. Difficult to differentiate	5. Melanotic melanoma and subretinal fluid can be differentiated
6. Cannot differentiate between benign and malignant lesion poor soft tissue contrast resolution	6. Much superior

Improved Modes of Treatment

Medical treatment. Availability of newer antibiotics, antivirals, antifungals, beta-blockers, collagen inhibitors, viscoelastic agents and nonsteroidal antiinflammatory drugs (NSAIDs) has made the treatment more effective.

Surgical methods. It includes various types of refractive corneal surgery, lensectomy,

phacoemulsification, pneumatic retinopexy and adhesives.

Laser applications.

Laser Therapy

The term *laser* is an acronym for *light amplification by stimulated emission of radiation*. The light produced by laser is composed of photons of same wavelength (monochromatic), waves parallel to each other (collimated) and travelling in phases, and waves running in the same direction (coherent).

Various types of ophthalmic lasers are shown in Table 56.3.

Table 56.3

Types of Ophthalmic Lasers

Used in photocoagulation
Argon blue-green
Argon green
Krypton red
Krypton yellow
Tunable dye
Diode
Neodymium: Yttrium-aluminium-garnet (Nd:YAG)
Used in photodisruption
Nd:YAG
Used in photoablation
Carbon dioxide
Excited dimmers (Excimer)

Components of laser. A laser is composed of: (a) lasing medium solid, liquid or gas; (b) energy source—light in solid or dye laser, and electricity in lasers like argon or krypton; and (c) two sides—one reflective mirror on one side and partially reflective mirror on the other side of the lasing medium.

Modes of application. They may be: (a) continuous wave; and (b) pulsed—either Q switched or mode locking.

Possible laser effects. When the lasing medium is excited it causes production of excited atoms and finally exponential increase in the release of light.

There are four laser tissue-interactions: reflection, scattering, transmission and absorption. The tissue effects depend upon:

- (a) The amount of energy absorbed, dependent on amount of pigment
- (b) The wavelength
- (c) The exposure time
- (d) The energy delivered
- (e) The size of the laser spot.

Principal wavelengths of ophthalmic lasers are listed in Table 56.4.

Laser photocoagulation. Table 56.5 lists the possible indications of laser photocoagulation.

Table 56.4

Wavelengths of Different Ophthalmic Lasers

Type of laser	Wavelengths (nm)
Argon blue-green	488
Argon green	514.5
Krypton red	647.1
Krypton yellow	568.2
Ruby	694
Nd:YAG	1064
Tunable dye	570–630
Diode	780–850
Carbon dioxide	9000–11000
Excimer	
Argon fluoride	195
Krypton fluoride	248
Krypton chloride	222
Xenon chloride	308
Xenon fluoride	351

Table 56.5

Indications for Laser Photocoagulation

Diabetic retinopathy
Central retinal vein thrombosis
Branch retinal vein thrombosis
Eales' disease
Subretinal neovascular membrane
Age-related macular degeneration
Retinal detachment
Retrolental fibroplasia
Miscellaneous
Sector iridectomy
Neovascular glaucoma
Repositioning of the pupil

Xenon arc and laser photocoagulation compared (Table 56.6) gives an account of two major types of radiant energy in eye surgery.

Radial keratotomy²⁷

Radial incisions for correction of myopia were introduced by Sato and his associates in early 1950s, this technique of *posterior keratotomy* failed.

Fyodorov and Durnev¹⁰ introduced incisions in the anterior peripheral cornea.

There are two techniques for radial keratotomy (RK): front cutting (Russian) and back cutting (American). Both may be combined.

Indications. RK is indicated in myopia of less than 8 D. Usually the patients are over 18 or 21 years of age with stable refraction with regular astigmatism, if any.

Informed consent. The patient must be briefed about benefits and risks as well as unpredictable result in the postoperative period.

Preoperative assessment consists of refraction, ultrasonic pachmetry and computer-assisted corneal topographical analysis.

Technique. (Fig. 56.11) RK is mostly done under local anaesthesia. The centre point of the cornea is marked. An optical zone marker, 3.5 mm diameter, is applied concentrically round the centre point. Four or eight radial, deep (ideally 80–90% thickness of the cornea) incisions are given in the paracentral and peripheral cornea with a diamond or metal blade. Finally the cuts are gently irrigated with BSS. An antibiotic eye ointment is applied and light pressure bandage is advocated for four hours.

Postoperative complications. Refer to Table 56.9.

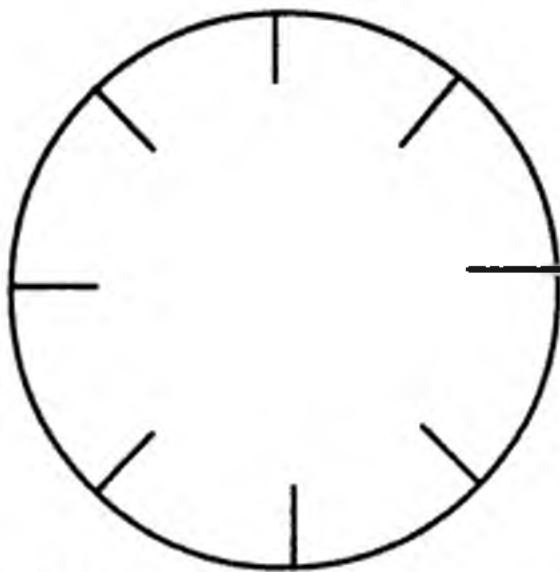


Fig. 56.11 Incisions in radial keratotomy.

Table 56.9

Postoperative Complications of Radial Keratotomy

Transient
Pain
Photophobia
Permanent without visual loss
Undercorrection
Overcorrection
Diurnal fluctuations of visual acuity
Mild glare
Ghost images
Permanent with loss of vision
Disabling glare
Irregular astigmatism
Infective keratitis
Corneal perforation
Corneal vascularization
Endophthalmitis

Astigmatic keratotomy²⁷

Astigmatic keratotomy (AK) aims at correction of regular astigmatism. AK is of two main types:

- (a) Those causing flattening of the steeper meridian
 - (i) Transverse incisions
 - (ii) Arcuate incisions
 - (iii) Trapezoidal incisions
 - (iv) Corneal relaxing incisions
- (b) Those causing steepening of the flatter meridian
 - (i) Wedge resections
 - (ii) Compression sutures.

Transverse cuts are made in pairs, not longer than 3 mm, along the steepest meridian. A single pair of transverse cuts 5 mm apart flattens the incised meridian by 1 D while steepening the cornea 90° away by an equal amount. The addition of second pair of cuts 2 mm away will further correct astigmatism up to 0.50 D.

Arcuate incisions remain at uniform distance from the optical centre throughout their length and have greater effect than transverse cuts of the same length and optical zone.

Keratomileusis

Barraquer, J. introduced this procedure in 1961.

Both severe hypermetropia and myopia can be corrected.

Technique. A lamellar disc or lenticule is removed from the patient's cornea by a microkeratome, frozen and reshaped on a cryolathe.

In hypermetropic keratomileusis the central cornea is steepened. This is achieved by lathing in such a way that the peripheral part of the lenticule is thinner than the central part.

In myopic keratomileusis the anterior corneal curvature is flattened. This is done by lathing in such a fashion that the peripheral part of the lenticule is thicker than the central part.

Complications. During operation the disc is made too thick, too thin or irregular. The postoperative complications include deposition of foreign matter in the interfaces, epithelial ingrowth into the lamellar space and irregular astigmatism.

Laser keratorefractive surgery²⁷

Laser keratorefractive surgery includes the following procedures (Table 56.10).

Table 56.10

Laser Keratorefractive Procedures and their Indications

Type of procedure	Indications
Radial keratotomy (RK)	Myopia
Transverse keratotomy	Astigmatism
Photorefractive keratectomy (PRK)	Myopia, hypermetropia and astigmatism
Phototherapeutic keratectomy (PTK)	Myopia, hypermetropia
Laser-assisted <i>in-situ</i> keratomileusis (LASIK)	Myopia, hypermetropia and astigmatism
Intrastromal photodisruption	Myopia

Photorefractive keratectomy (PRK) involves large area ablation. For correction of myopia the tissue is ablated maximum in the central zone and less so in the periphery. An opposite pattern is followed in case of hypermetropia.

Phototherapeutic keratectomy (PTK) performed by excimer laser diminishes corneal opacities by changing the contour of the anterior surface of the cornea.

Laser-assisted in-situ keratomileusis (LASIK) is indicated for correction of high myopia. A microkeratome is used to mobilize a partial thickness anterior corneal flap attached at one end. Now the excimer laser is used to ablate the exposed stromal bed. Then the corneal flap is replaced.

Keratoprosthesis^{5,8}

Keratoprosthesis or *artificial cornea* involves replacement of the full thickness of the cornea by material like polymethylmethacrylate (PMMA). It is a nontoxic material which forms optical portion. For anchoring skirts materials like Dacron and siliconized Teflon are preferred.

Osteo-odonto-keratoprosthesis has been described in which bone and teeth from the same patient are used to hold the prosthesis.

Hydrogels and other materials are reported to offer promising results.

Indications. The procedure is considered in bilateral corneal blindness. The patient must be briefed and told about possible high rate of complications.

Types of keratoprosthesis are indicated in Table 56.11.

Table 56.11

Types of Keratoprosthesis

Glued-on contact lens (epikeratoprosthesis)
Buried membranes and prosthesis
Intrastromal membrane
Membrane with posterior stem (mushroom)
Artificial endothelium
Penetrating
Through-and-through prosthesis with intrastromal anchoring plate
Prosthesis with anterior and posterior plates (collar button)
Nut and bolt keratoprosthesis
Sandwich

Epikeratoprosthesis (EKP) is the bonding of a thin contact lens to the anterior. Stroma of the

cornea after removal of the scarred and vascularized epithelium, the contact lens having fine grooves at the periphery of its back surface. This is also called *artificial epithelium*.

Buried membranes and prosthesis involve the use of inert and transparent materials like silicone rubber and PMMA which are impermeable to water. A silicone rubber may be placed against the corneal endothelium and held by sutures, called *artificial endothelium*.

Collar button prosthesis consists of anterior and posterior plates connected by the stem.

Nut and bolt prosthesis. The optical 'bolt' is inserted into the central hole or 'nut'.

Sandwich prosthesis involves the use of two plates, smaller anterior and larger posterior with peripheral holes, and surgical adhesive. The preserved piece of corneal stroma, at first dehydrated and rehydrated just before surgery, is sandwiched between the two plates. The plates are interconnected by perlon sutures.

Postoperative complications include tissue necrosis around the prosthesis, retroprosthetic membrane and secondary glaucoma.

Keratophakia

Keratophakia is a lathing technique that uses a prelathed plus power donor corneal tissue to correct an aphakic refractive error. An anterior stromal disc is dissected from the cornea by a microkeratome. Then a lenticule is placed in the interlamellar space of the host cornea. This procedure thus steepens the radius of curvature of the patient's cornea. The complications are similar to those of keratomileusis, but they are less commonly met with.

Epikeratophakia

Epikeratophakia a technique in which a piece of donor cornea is frozen, lathed and finally sutured to the surface of the cornea after removal of its epithelium. The chief complications include epithelialization, dehiscence of the graft, infection and persistent haziness of the lenticule.

Corneal wedge resection

Corneal wedge resection reduces 10 to 20 D corneal astigmatism found after keratoplasty or cataract operation. Removal of a wedge from the flatter corneal meridian causes its steepening. The excision of the wedge of tissue extends almost to Descemet's membrane.

Corneal relaxing incisions

Corneal relaxing incisions are at times indicated in postkeratoplasty astigmatism which reduces 5 to 10 D. The principle is to flatten the steeper meridian and subsequently steepen the opposite meridian.

Adhesives in Ophthalmology¹⁷

Cyanoacrylate adhesives, methyl, n-heptyl, n-octyl and isobutyl cyanoacrylates, were introduced in ophthalmic practice in the year 1963. Human eyes are reported to tolerate these adhesives better than experimental animals. The toxic effects are the result of the breakdown of their products and also the rate at which they are broken.

The probable uses of adhesives are:

- (a) Sealing of small perforations—especially corneal
- (b) Sutureless ocular surgery;
 - (i) Corneoscleral incisions
 - (ii) Scleral incisions
 - (iii) Temporary tarsorrhaphy
 - (iv) Postoperative fistula
- (c) Adhesives for attaching alloplastic material to ocular tissues:
 - (i) Glued-on contact lens or EKP
 - (ii) Keratoprosthesis
 - (iii) Artificial endothelium
- (d) Adhesive used in intracapsular extraction of the lens.

Sealing of small corneal perforation. The glue is preferably used if the perforation is 1 mm or less. The area is debrided, cleaned and the surrounding surface is dried with a swab. The adhesive is applied with an applicator against the ulcer with a moderate pressure for 10 to 15

seconds. Within minutes the AC reforms and the adhesive is left there up to 5 weeks or more, depending upon the spontaneous detachment. If it is not loosened after about 5 weeks, it is removed with fine forceps. A larger perforation is at first sealed by a small patch graft and then glued.

Sutureless ocular surgery. It has been reported that adhesive has been used in the reattachment of the extrinsic muscles to the episclera in filtration operations to prevent conjunctivoscleral adhesions, gluing scleral flaps, fixation of implants in various surgical techniques such as evisceration, exenteration and orbital surgery.

Restoration of the AC in case of postoperative leakage or fistula has been made possible.

Adhesive for attaching alloplastic material. The optical correction, if needed, is incorporated in the sterilised lens whose posterior surface at the periphery is grooved for the placement of the glue and is then applied to the cornea whose epithelium has been denuded specially.

Adhesive used in intracapsular extraction. Nagpal¹⁷ reported a new method of an intracapsular extraction of the lens by means of a blunted and bevelled plastic knitting needle whose end was painted with half a drop of Histoacryl-N. The needle is placed at the 12 o'clock position for a minute and the lens can be delivered.

Pneumatic Retinopexy³

Pneumatic retinopexy relies exclusively on gas internal tamponade to seal retinal breaks.

Cibis and associates first used silicone IOL in complicated retinal detachment. Silicone IOL is toxic to the retina and hence not popular today.

Air and other gases (sulphur hexafluoride, perfluoromethane, perfluoroethane and perfluoropropane) are inert, colourless, odourless with purity levels exceeding 99 per cent.

Indications. Perhaps it is best indicated in anterior retinal break or group of breaks located between 8° and 4° clock meridian.

Technique. After a retrobulbar and surface anaesthesia a lid speculum is applied and betadine is instilled over the conjunctiva and cornea.

Gas is withdrawn into a syringe through two tandemly-placed sterile millipore filters; the first aspirate is discarded. A needle is placed 3 to 4 mm from the limbus and the injection is given. A cotton-tipped applicator is applied upon withdrawal of the needle.

Postoperative care. Apart from analgesics the prone position is advised to prevent pupillary block, corneal endothelial touch and touch with the lens. Retinal break is now most superiorly located. This position is continued 12 to 18 hours a day for 5 days and by this time the size of the bubble reduces.

Postoperative complications. There may be fresh breaks, bubble entrapped in the vitreous base, secondary glaucoma, subretinal gas accumulation, failure of resorption of subretinal gas and endophthalmitis.

Further Reading

1. Aaberg, T.M., Fluorescein angiography and acquired macular disease. In *Principles and Practice of Ophthalmology*, Peyman, G.A., Saunderson, D.R. and Goldberg, M.F. (Eds.), W.B. Saunders, Philadelphia, 1980, p. 905.
2. Belchar III, C.D. and Greff, L.J., Laser therapy of angle closure glaucoma. In *Principles and Practice of Ophthalmology: Clinical Practice*, Albert, D.M. and Jacobiec, F.A. (Eds.), W.B. Saunders, Philadelphia, 1994, p. 1597.
3. Brinton, M.G. and Hilton, G.F., Pneumatic retinopexy. In *Recent Advances in Ophthalmology*, Vol. VIII, Davidson, S.I. and Jay, B. (Eds.), Churchill Livingstone, Edinburgh, 1992, p. 149.
4. Byrne, S.E. and Green, R.L., *Ultrasound of the Eye and Orbit*, Mosby Year Book, St. Louis, 1992.

27. Talamo, J. and Steinert, R.E., Keratorefractive surgery. In *Principles and Practice of Ophthalmology: Clinical Practice*, Albert, D.M. and Jacobiec, F.A. (Eds.), W.B. Saunders, Philadelphia, 1994, p. 342.
28. Wright, J.E. Lloyd, G.A.S. and Ambrose, J. Computerized axial tomography in the detection of space occupying lesions. *Am. J. Ophthalmol.*, 80:78, 1975.

57. SYNDROMES IN OPHTHALMOLOGY

There are numerous syndromes which are encountered in ophthalmology.¹⁻³

Acquired immuno deficiency syndrome (AIDS) (see pp. 410-11)

Adie's syndrome (Holmes-Adie Syndrome) (see p. 268)

Aircardi's syndrome

Aircardi's syndrome is a sex-linked dominant affection showing colobomata of the optic disc and multiple lacunar defects in the retinal pigment epithelium.

Albers-Schönberg syndrome
(Osteopetrosis; marble-bone disease)

Albers-Schönberg Syndrome is a rare hereditary anomaly of osteogenesis in which resorptive process does not occur. This presents chiefly a thickening of the cartilages and bones. Radiography displays increased density of the bones with the absence of normal trabecular pattern. Due to compaction of the optic nerve during its course through the optic canal, there may be optic atrophy. Orbital and maxillary involvement leads to development of proptosis and divergent squint. Spontaneous fractures are common.

Alport's syndrome

This affection showing sex-linked dominant inheritance exhibits both ocular and systemic features. The characteristic ocular feature is anterior lenticonus. Systemic features include acute haemorrhagic nephropathy and deafness.

Alstörm's syndrome

The affection is autosomal recessive. Ocular features include retinal degeneration, loss of central vision and nystagmus. Systemic features include nerve deafness, diabetes and obesity in childhood.

Anton's syndrome (or cortical blindness)

Anton's syndrome or cortical blindness is characterized by blindness in both eyes with normal pupillary reactions. The patient denies blindness. There are bilateral occipital cortical lesions.

Apert's syndrome (acrocephalosyndactyly) (see p. 162)

Axenfeld-Rieger syndrome

Axenfeld-Rieger syndrome is an autosomal dominant affection. Also known as *mesodermal dysgenesis of the cornea and iris*, this shows bilateral ocular anomalies including posterior embryotoxon, broad iris processes inserted onto the embryotoxon (*Axenfeld's anomaly*), hypoplasia of the iris stroma, pupillary abnormalities, peripheral anterior synechia and secondary glaucoma. Systemic anomalies are found in face and teeth.

Bassen-Kornzweig syndrome

Bassen-Kornzweig syndrome is an autosomal recessive affection. The affection is due to the absence of gene responsible for absorption and transport of lipid causing abetalipoproteinaemia. It is characterized by ataxia, muscle weakness, steatorrhea, crenated RBCs (acanthocytosis) along

with ocular features. The ocular features include atypical pigmentary dystrophy of the retina, ophthalmoplegia, optic atrophy, squint and nystagmus.

Batten–Mayou syndrome (*see p. 338*)

Batten–Spielder–Vogt syndrome (*see p. 404*)

Behçet's syndrome (*see p. 255*)

Behr's syndrome

Behr's syndrome is a heredofamilial affection transmitted as an autosomal recessive and is chiefly characterized by optic atrophy and pyramidal tract involvement.

Benedict's syndrome (tegmental syndrome)

Benedict's syndrome is due to simultaneous involvement of the oculomotor nucleus and the red nucleus due to a lesion of the dorsal part of the peduncle. It is clinically evidenced by ipsilateral oculomotor palsy with contralateral tremor of the face and limbs.

Benson's syndrome (asteroid hyalopathy) (*see p. 278*)

Best's syndrome (vitelliform macular dystrophy)

Best's syndrome is an autosomal dominant affection. It starts in infancy and is characterized by bilateral egg yolk-like lesions in the macular area.

Bourneville's syndrome (or tuberous sclerosis) (*see p. 351*)

Brown's superior oblique sheath syndrome

Superior oblique (SO) tendon sheath syndrome occurs due to shortening of the SO tendon

sheath, typically congenital but occasionally acquired. This shows gross limitation of elevation in adducted position because during adduction the sheath becomes taut. There may be downshoot of the affected eye during adduction. During abduction the restriction of elevation decreases. In a typical case there is no underaction of the ipsilateral SR. Forced duction test is positive. The face is slightly elevated and turned to the opposite shoulder.

Carpenter's syndrome (acrocephalopolysyndactyly)

Oxycephaly is found to be associated with brachysyndactyly of the hand, polydactyly of the feet, and mental retardation.

Chandler's syndrome

Chandler's syndrome is characterized by endothelial dystrophy of the cornea, mild degree of iris atrophy and rise of ocular tension.

Charlin's syndrome

Following neuritis of the nasociliary nerve this condition develops. This is associated with: (a) inflammation of the anterior ocular segment; (b) unilateral neuralgia involving the root of the nose and ala nasi; and (c) profuse rhinorrhoea.

Chédiak–Higashi syndrome

Chédiak-Higashi syndrome is a type of oculocutaneous albinism of tyrosinase-positive type along with fatal reticuloendothelial incompetence.

Chiasmal syndrome

Chiasmal syndrome is evidenced by bitemporal visual field defects, optic atrophy and often endocrine disturbance.

Claude–Bernard syndrome

Claude-Bernard syndrome follows sympathetic irritation causing widened palpebral aperture,

dilated pupils, mild degree of exophthalmos, and hyperhydrosis of the face and forehead on the affected side.

Cockayne's syndrome (trisomy 20 syndrome)

Cockayne's syndrome is a heredofamilial syndrome with autosomal recessive transmission. The syndrome consists of dwarfism, deafness, mental retardation, and epidermolysis bullosa, exhibiting ocular features such as pigmentary dystrophy of the retina, external ophthalmoplegia and consecutive optic atrophy.

Cogan's syndrome (I) (Keratocochlear syndrome)

Cogan's syndrome is clinically characterized by nonsyphilitic IK, vertigo, tinnitus and progressive nerve deafness.

Cogan's syndrome (II)

Congenital ocular motor apraxia.

Cogan-Reese syndrome

The most characteristic feature is the presence of nodular pigmented lesions of the iris. Occasionally there are other iris and corneal defects. This appears to be a variant of ICE syndrome.

Cri-du-chat syndrome

Cri-du-chat syndrome is a chromosomal disorder showing antimongoloid obliquity, epicanthus, squint and iris coloboma. Because of anomaly of the larynx, the child presents with and shrill cry (cat-cry).

Crocodile tear syndrome

Residual facial paralysis due to a lesion central to the geniculate ganglion may cause profuse lacrimation during eating.

Crouzon's syndrome (see p. 162).

Cushing's syndrome (I)

Cushing's syndrome is due to excessive activity of adrenal cortex following a neoplasm in the adrenal or pituitary gland. It is characterized by adiposity, hirsutism in the female and impotence in the male. Hypertension associated with features of pituitary tumour is present. Ocular manifestations include exophthalmos, pigmentation of the eyelids and hypertensive retinopathy.

Cushing's syndrome (II) (cerebellopontine angle syndrome) (see p. 394)

Devic's syndrome (neuromyelitis optica) (see p. 395)

Down's syndrome (mongolism, trisomy 21 syndrome)

Down's syndrome is due to chromosomal abnormality. It is characterized by mental retardation, stunted growth, mongoloid facies associated with important ocular signs, namely hypertelorism, narrow palpebral fissure with downward and inward obliquity, epicanthus, keratoconus, cataract and speckling of the iris (*Brushfield's spots*).

Duane's retraction syndrome (Stilling-Turk-Duane syndrome)⁴

It is unilateral, though bilateral cases have also been reported. The aetiology is controversial—it is due either to a defect in the development or insertion of the lateral rectus muscle or tendon; or to a defect in the innervation of the lateral rectus muscle. This syndrome (Fig. 57.1) is characterized by (a) complete absence of abduction; (b) retraction of the globe with narrowing of the palpebral fissure on attempted adduction; (c) widening of the palpebral fissure on attempted abduction; (d) upshoot inwards or downshoot inwards of the eyes during attempted adduction; and (e) loss of convergence.

Foville's syndrome

Foville's syndrome is due to a pontine lesion at or just above the level of the sixth cranial nerve nucleus. The syndrome exhibits an ipsilateral lateral rectus palsy with loss of conjugate deviation to the same side, and contralateral hemiplegia.

Franceschetti's syndrome (mandibulofacial dysostosis) (see p. 162)

François syndrome (dermochondrocorneal dystrophy)

François syndrome is due to defective metabolism of polysaccharides. This is characterized by central corneal dystrophy associated with skeletal and cutaneous anomalies.

Fröhlich's syndrome (dystrophia adiposogenitalis)

Fröhlich's syndrome is seen to be present from birth, more often in boys than in girls, the child being obese with marked genital hypoplasia and is associated with pigmentary dystrophy of the retina.

Gaucher's syndrome (glucosyl ceramide lipidosis) (see p. 404)

Goldenhar's syndrome (Oculoauriculovertebral dysplasia)

Goldenhar's syndrome (Fig. 57.2) is characterized by epibulbar dermoids or lipodermoids, accessory auricles, pretragal fistula and vertebral anomalies. Other features sometimes present include coloboma of the upper lid (usually involving the outer half), antimongoloid slant of the palpebral fissure, hypoplasia of the mandible, and macrostomia.

Gradenigo's Syndrome

Gradenigo's syndrome is due to extension of the middle ear infection to the inferior petrosal sinus

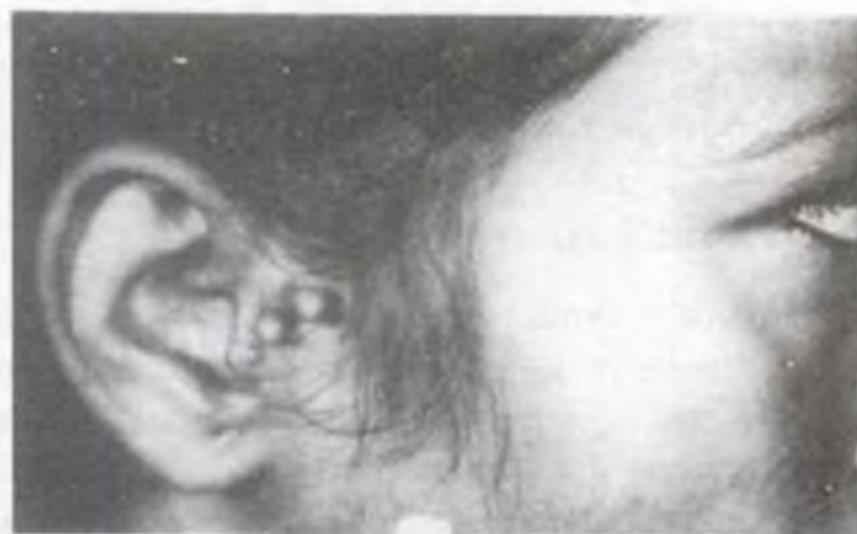

Fig. 57.2 Goldenhar's syndrome showing accessory auricles.

and is characterized by sixth cranial nerve palsy with or without trigeminal neuritis.

Greig's syndrome

Greig's syndrome is characterized by hypertelorism which is the excessive distance between the two orbits, divergent squint and optic atrophy. This is perhaps due to an enlargement of the lesser wing of the sphenoid.

Grönblad-Strandberg syndrome (pseudoxanthoma elasticum)

Grönblad-Strandberg syndrome is a recessive inherited, degenerative connective tissue disorder. There is premature degeneration of the elastic fibres of the dermis leading to the thickening, wrinkling and discolouration of the skin especially near the flexures, abdomen, chest and neck. Grönblad and Strandberg were the first to observe its association with angioid streaks occurring due to degeneration of Bruch's membrane.

Hallermann-Streiff syndrome

Also known as mandibulo-oculo-facial dysmorphia, this shows hypoplasia of the mandible with a bird-like facies, microphthalmos, congenital cataract and glaucoma.

Hand-Schüller-Christian syndrome (diabetic exophthalmic dysostosis)

Hand-Schüller-Christian syndrome is characterized

Marcus Gunn syndrome (*see p. 170*)

Marfan's syndrome (Fig. 42.1, p. 270)

Marie–Strümpell syndrome

Uveitis is associated with ankylosing spondylitis.

Maroteaux–Lamy syndrome (*see p. 402*)

Meyer Schwickerath syndrome
(Oculodentodigital dysplasia)

It is characterized by microphthalmos, polydactyly, syndactyly, and dental defects.

Mikulicz syndrome (*see p. 182*)

Millard Gubler syndrome

Millard Gubler syndrome is characterized by homolateral facial palsy and lateral rectus palsy in association with contralateral hemiplegia. The affection is due to a lesion in the lower part of the pons where the supranuclear pathway for conjugate lateral gaze escapes.

Möbius syndrome

Möbius syndrome is characterized by the bilateral loss of abduction with bilateral facial palsy due to the lack of development of the sixth cranial nerve nuclei.

Morquio's syndrome (*see p. 401*)

Naffziger's syndrome (cervical rib syndrome)

Naffziger's syndrome is due to compaction of the brachial plexus and subclavian artery against the first thoracic vertebra by the scaleneus, the anticus muscle or by the accessory cervical rib. The clinical features are weakness of the upper limb, ptosis and miosis.

Niemann–Pick syndrome (*see p. 404*)

Orbital apex syndrome (superior orbital fissure syndrome) (*see p. 159*)

Parinaud's syndrome

Parinaud's syndrome follows usually a pineal body tumour and is characterized by mid-dilated pupils, poor upgaze light near dissociation and convergence-retraction nystagmus.

Parinaud's oculoglandular syndrome

Parinaud's oculoglandular syndrome is caused by a virus infection such as lymphogranuloma venereum and is characterized chiefly by an unilateral conjunctivitis associated with preauricular and submandibular lymphadenopathy.

Patau's syndrome (trisomy 13) (*see p. 504*)

Pierre Robin's syndrome

Pierre Robin's syndrome exhibits micrognathia, abnormal smallness of jaws, cleft palate, high myopia, congenital glaucoma and retinal detachment.

Refsum's syndrome

This is characterized by pigmentary dystrophy of the retina with diffuse polyneuritis, ichthyosis and deafness. This appears to be due to deposition of phytanic acid. Diagnosis is also dependent on plasma lipid analysis. Treatment includes prolonged dietary management.

Reiter's syndrome (*see p. 205*)

Rendu–Osler–Weber syndrome

Rendu-Osler-Weber syndrome shows multiple haemorrhagic telangiectasia in the bulbar conjunctiva, the retina, the skin and the mucosa. It is a hereditary condition.

Retroocular syndrome (*see p. 397*)

Retroththalmic syndrome (*see p. 397*)

Rieger's syndrome (mesodermal dysgenesis of the cornea and iris)

Rieger's syndrome, caused by mesodermal dysgenesis involving the trabeculae, is characterized by prominent posterior embryotoxon, prominent Schwalbe's ring, hypoplastic iris, aniridia and peripheral anterior synechia. These signs are associated with dentofacial abnormalities.

Romberg's syndrome

Romberg's syndrome shows progressive hemiatrophy involving the skin muscles and bones of the face.

Rothmund's syndrome

Rothmund's syndrome is an autosomal recessive disorder showing juvenile cataract, saddle nose, hypogonadism as well as atrophy and pigmentation of the skin.

Sanfilippo's Syndrome (*see p. 401*)

Scheie's syndrome (*see p. 402*)

Schilder's syndrome (diffuse sclerosis)

Schilder's disease is a sex-linked recessive affection, a leucodystrophy. The affection starts in young age with blindness and is fatal. The features include optic atrophy, slurring speech, ataxia, deafness and mental retardation.

Sjögren's syndrome (*see p. 183*)

Sjögren-Larsson syndrome

Sjögren-Larsson syndrome is an autosomal recessive condition characterized by the

presence of pigmentary retinal dystrophy, ichthyosis, mental retardation, speech defects and short stature.

Sorsby's syndrome

Sorsby's syndrome consists of bilateral macular coloboma associated with apical dystrophy of the extremities.

Stargardt's syndrome (*see p. 338*)

Stevens-Johnson syndrome (*see p. 205*)

Stickler's syndrome

Stickler's syndrome is perhaps due to a defect in collagen metabolism. Ocular features include high myopia, anomalies of the angle of the anterior chamber and cataract. Systemic features include premature degeneration, joint laxity, bony enlargement of ankle, knee and wrist as well as dental anomalies.

Sturge-Weber syndrome (*see p. 352*)

Takayasu's syndrome (pulseless disease, aortic arch syndrome)

The syndrome, perhaps resulting from a non-specific arteritis, is characterized by loss of pulsation in the radial, carotid and axillary arteries. Syncope and paresis are evident in ischaemia. Ocular features are a maurosis fugax, microaneurysms, and haemorrhages in the retina.

Tay-Sachs syndrome (*see p. 338*)

Tolosa-Hunt syndrome (painful ophthalmoplogia)

This syndrome is characterized by severe unilateral periorbital pain followed by ophthalmoplegia, sensory loss along the first division of the fifth

cranial nerve, pupillary dysfunction and visual loss. This follows a chronic inflammation at the apex of the orbit, superior orbital fissure or cavernous sinus. Most cases respond to oral steroid.

Treacher–Collins syndrome (franceschetti syndrome) (*see p. 179*)

Turner's syndrome (gonadal dysgenesis) (*see p. 446*)

Usher's syndrome

Usher's syndrome, a recessively inherited condition, consists of retinitis pigmentosa, deafness and occasionally deaf-mutism.

van der Hoeve syndrome

A hereditary condition, it is characterized by blue sclera, abnormal fragility of the bones and deafness.

Vogt–Koyanagi–Harada syndrome (*see p. 255–56*)

von Gierke's syndrome (*see p. 401*)

von Hippel–Lindau syndrome (*see pp. 352–53*)

von Recklinghausen's syndrome (Neurofibromatosis) (*see p. 312*)

Waardenburg's syndrome (*see p. 188*)

Weber's syndrome

Weber's syndrome is characterized by the features of oculomotor paralysis with contralateral hemiplegia due to neoplastic or vascular lesions of the cerebral peduncles, pons and medulla.

Wernicke's syndrome

Seen in chronic alcoholics this is due to deficiency of thiamine. The affection is characterized by disturbance in ocular motility, pupillary alterations, nystagmus, ataxia and tremors.

Wilson's syndrome (heptolenticular degeneration)

Wilson's syndrome is due to inborn error of copper metabolism, and is characterized by cirrhosis of the liver, tremors, rigidity along with Kayser-Fleischer ring.

Wyburn–Mason syndrome

Wyburn-Mason syndrome shows arteriovenous malformations in the cerebral cortex, retinal arteriovenous angioma, facial angioma and mental retardation.

Zellweger's syndrome (Cerebrohepatorenal syndrome)

Zellweger's syndrome is an autosomal recessive disorder. This exhibits muscular hypotony, liver enlargement, craniofacial abnormalities, cataract, glaucoma, corneal opacity and various other anomalies.

Further Reading

1. Duke-Elder, S., *System of Ophthalmology*, Vol. XV, *Summary of Systemic Ophthalmology*, Kimpton, London, 1976.
2. Geeraets, W.J., *Ocular Syndrome* (2nd ed.), Lea and Febiger, Philadelphia, 1969.
3. Nema, H.V., *Ophthalmic Syndromes*, Butterworths, London, 1973.
4. Roy, I.S. and Ahmed, E., Bilateral Duane's retraction syndrome, XXII. *Concil Ophthalmol., Paris*, Vol. II, 1974, p. 875.

10. Flurometholone-neomycin (FML-Neo) suspension. Each ml contains
- | | |
|-------------------|--------|
| flurometholone | 1 mg |
| neomycin sulphate | 3.5 mg |
11. Prednisolone-sulphacetamide suspension
- | | |
|----------------|------|
| prednisolone | 0.2% |
| sulphacetamide | 10% |
12. Betamethasone-gentamicin drops (Genticyn B, Genoptic B)
- | | |
|--------------------------------|------|
| betamethasone sodium phosphate | 0.1% |
| gentamicin sulphate | 0.3% |
13. Hydrocortisone-gentamicin drops
- | | |
|------------------------|------|
| hydrocortisone acetate | 1% |
| gentamicin sulphate | 0.3% |
14. Dexamethasone-framycetin (Sofracort) drops
- | | |
|--|--------|
| dexamethasone sodium metasulphobenzolate | 0.116% |
| framycetin sulphate | 1% |
15. Dexamethasone-chloramphenicol-polymyxin (Ocupol D) drops/ointment
- | | |
|--------------------------------|----------------------------------|
| dexamethasone sodium phosphate | 1 mg/ml in drop; 1 mg/g in oint. |
| chloramphenicol | 5 mg in drop; 10 mg in oint. |
| polymyxin B sulphate | 50000 i.u. |
16. Triamcinolone (Kenalog-S) ointment
- | | |
|-------------------------|------------|
| triamcinolone acetonide | 0.1%, 1 mg |
| gramicidin | 0.25 mg/g |
| neomycin sulphate | 2.5 mg/g |

Nonsteroidal antiinflammatory drugs

1. Flurbiprofen sodium (Flur, Ocuflur) drops 0.03%
2. Sodium cromoglycate drops 2%
3. Diclofenac sodium drops 0.1%
4. Ketorolac tromethamine (Ketlur, Acular) drops 0.5%
5. Indomethacin suspension 1%

Antihistamine-decongestant drops

1. Naphazoline hydrochloride (Clearine, Mezol) drops 0.05%, 0.1%
2. Phenylephrine hydrochloride (Ocurest) drops 0.12%
3. Pheniramine maleate drops 0.3%

4. Tetrahydrozoline hydrochloride (Visine) 0.05%
5. Antazoline phosphate drops 0.05%
6. Oxymetazoline hydrochloride (Oxylin) drops. Each ml contains oxymetazoline 0.25 mg

Mydriatics-cycloplegics

1. Atropine sulphate drops/ointment 1%
2. Homatropine hydrobromide drops 1%, 2%
3. Cyclopentolate hydrochloride (Cyclomid) drops 0.5%, 1%
4. Phenylephrine hydrochloride (Drosyn) drops 5%, 10%
5. Tropicamide (Tropicacyl) drops 1%
6. Tropicamide + phenylephrine (Tropicacyl plus, Tropifrin) drops
7. Scopolamine (Hyoscine) drops 0.25%

Miotics

1. Pilocarpine nitrate or hydrochloride drops 1%, 2%, 4%
2. Pilocarpine + epinephrine drops 1–4%
3. Physostigmine salicylate (Eserine) drops 0.25%, 0.5%
4. Carbachol drops 0.75–3%

Adrenergic drugs

1. Epinephrine borate/bitartrate/hydrochloride drops 0.5%, 1%
2. Dipivalyl epinephrine (Dipivefrin, Propine) drops 0.1%
3. Apraclonidine drops 1%

Adrenergic-blocking agent

1. Thymoxamine 0.1–0.5%

Beta-blockers

1. Timolol maleate drops (Iotim, Glucomol, Timolet) 0.25%, 0.5%
2. Betaxolol (Betoptic, Iobet, Gluoptic) drops 0.5%

Appendix II: Ophthalmic Instruments (Plates 1–5)

1. *Anterior chamber washing canula*. This is a small canula having a flat and slightly bent end. It is connected with an undine by means of a rubber tube. The undine contains the irrigating fluid and the tip is introduced into the AC.
2. *Beer's knife*. It has a triangular blade at the end of a handle. The blade has only one cutting edge having a sharp pointed end. It is used for incision over a chalazion.
3. *Blade breaker and holder* (Plate 4, Fig. 2) can hold a small triangular fragment from the edge of a thin and hard steel blade after breaking it.
4. *Bone punch* (Plate 3, Fig. 11) contains two blades and a spring handle. The upper blade is meant for cutting the bone edges and lower one for holding the bone fragments in dacryocystorhinostomy.
5. *Bowman's discission needle*. Its tip is sharp, triangular and pointed. It is used in needling operation.
6. *Bowman's lacrimal probes* (Plate 3, Fig. 3). They are thin and malleable, and are used for probing the naso-lacrimal passages.
7. *Broad needle*. It has a lance-shaped blade showing a sharp point and two cutting edges. It is used in paracentesis.
8. *Caliper* (Plate 5, Fig. 3) has open tips and calibrated scale in mm. This is used to measure corneal diameters, amount of tissue to be resected in lid surgery, length of the muscle to be resected in resection operation, and mark the point on the sclera during recession and retinal detachment surgery, etc.
9. *Capsulotomy forceps* (Plate 2, Fig. 13). It is a small forceps having 3×4 teeth at the tips of the blades. It is used for removal of the anterior lens capsule.
10. *Cat's paw retractor* (Plate 3, Fig. 5) showing terminals bend downward from fork-like instrument at the end of a handle, is used for retraction of the skin and ligament during operation on the lacrimal sac.
11. *Chalazion clamp or forceps* (Plate, Fig. 3). It has got two limbs and screw. One limb has a circular solid end, while the other shows a fenestrated round ring. It is used for fixation and haemostasis in a chalazion operation. The fenestrated ring is placed around the chalazion on the conjunctival surface and the screw is tightened and kept as such till the operation is completed.
12. *Chalazion scoop* (Plate 1, Fig. 4). There is a tiny depression with sharp margin which is used to scoop out the content of chalazion.
13. *Chisel* (Plate 3, Fig. 10) has a flat tapering blade attached to a strong metallic handle and is used to chisel the bone during dacryocystorhinostomy.
14. *Colibri forceps* (Plate 4, Fig. 3) has small toothed (1×2) curved ends. This is used to hold the edges of the corneal and scleral incisions during passing of sutures.
15. *Conjunctival scissors*. It is a straight fine scissors with pointed tips. It is a commonly-used instrument used in various operations like cataract, glaucoma, squint and retinal detachment for incising and dissection of the bulbar conjunctiva.
16. *Corneal forceps* (Plate 2, Fig. 6), tiny with narrow limbs showing 1×2 teeth at the tip, is used to hold the corneal margin to retract the cornea during cryoapplication.
17. *Cyclodialysis spatula* (Plate 1, Fig. 7). This is a spatula, 15 mm long making an angle of 100° with a handle. This is indicated to separate the ciliary body from its attachment to the scleral spur.
18. *Cystitome with curette* (Plate 1, Fig. 12). At one end of a handle a tiny sharp needle like point situated at right angle to the long axis, while at the other end there is a spoon lying longitudinally. By the sharp end of the cystitome the anterior lens capsule is incised, and the curette is either used to give

35. *Intracapsular forceps*. Chiefly there are two types—Arruga's and Elschmig's. *Arruga's forceps* (Plate 2, Fig. 7) shows knobs having shallow concavity in the inner surface near its tips. In *Elschnig's forceps* (Plate 2, Fig. 8) there is a double bend near its tips and the tips are blunt and pointed. An intracapsular forceps grasps the anterior capsule of the lens usually at 6 o'clock position near the equator, during an intracapsular extraction.
36. *Iris forceps* (Plate 2, Fig. 5). It is a tiny forceps like capsulotomy forceps but having 1 × 2 teeth. It is meant for seizing the iris during an iridectomy.
37. *Iris repositor*. This has two narrow flat limbs at two ends of a handle. Each end is bent and its edges and tips are blunt. It is used for toileting the iris after an iridectomy or cataract extraction.
38. *Iris retractor* (Plate 3, Fig. 19) contains a small wire loop bent in a *H*-fashion at the end of a tiny metallic handle. This is used to retract the upper edge of the pupil as during cryoapplication to the anterior lens capsule.
39. *Kelman-Mcpherson forceps* (Plate 4, Fig. 4) is used for holding an intraocular lens implant and placing the superior haptic of the lens.
40. *Keratome* (Plate 1, Fig. 2). This has a triangular cutting blade bent at an angle of 60° with its handle, both edges of the blade being sharp cutting. It is used for section as in paracentesis, curette excacuation and sometimes in cataract operation.
41. *Lacrimal cannula* (Plate 3, Fig. 2). It is thin, slightly bent with a round tip. It is fitted with a syringe containing irrigating fluid. It is used for syringing of the lacrimal sac. The cannula is introduced in the same manner as a punctum dilator after dilating the lower punctum and canaliculus.
42. *Lacrimal dissector and curette* (Plate 3, Fig. 6). The pointed end is the dissector and there is an elongated groove, the curette at the other end. The dissector is used to open up the upper end of the naso-lacrimal duct and the curette is meant for scraping off the epithelial remnants from the upper end of the nasolacrimal duct.
43. *Lacrimal sac knife*. This has a short, straight cutting edge. It is meant for incision over the sac region.
44. *Lens expressor* (Plate 2, Fig. 17). This has a flat corrugated handle with a rounded limb bent at right angle 10 mm from its tip. While the forceps grasps the capsule, the tip of the expressor placed at 6 o'clock on the cornea ruptures the suspensory ligament of the lens. Next when the forceps rotates the lens side-to-side the expressor merely supports the lens. Finally, both the forceps and the expressor are gently utilized, the former holding and lifting the lens and the latter supporting as well as expressing the lens to come out through its exit.
45. *Lens holding forceps* (Plate 5, Fig. 13) is used for holding an intraocular lens implant.
46. *Lid spatula* (Plate 1, Fig. 12). About 4 inches long, its both ends are round and convex showing fenestrations parallel to the long axis of the spatula. It is placed under the lid and its support is utilized in operations like entropion and ptosis.
47. *Müller's haemostatic retractor* (Plate 3, Fig. 4). It is a self-retaining retractor whose two limbs contain two claw-like hooks and has a screw. It is used for retraction and haemostasis during a lacrimal sac operation. After incising the skin the hooks are engaged at the incising margins.
48. *Muscle clamp* (Plate 5, Fig. 7) shows 4 × 4 teeth in the angled end of the forceps with a locking device. This is used for holding the muscle during squint operation.
49. *Needle holder* (Plate 2, Fig. 20 and Plate 6, Fig. 6). Needle holders come in different varieties, with or without lock, small or large.
50. *Periosteal elevator* (Plate 3, Fig. 7) having a narrow limb and rectangular blunt blade is used to separate the nasal mucosa from the adjoining bone during dacryocystorhinostomy.
51. *Simcoe irrigation-aspiration canula* (Plate 4, Fig. 7) is connected with a silastic tube through

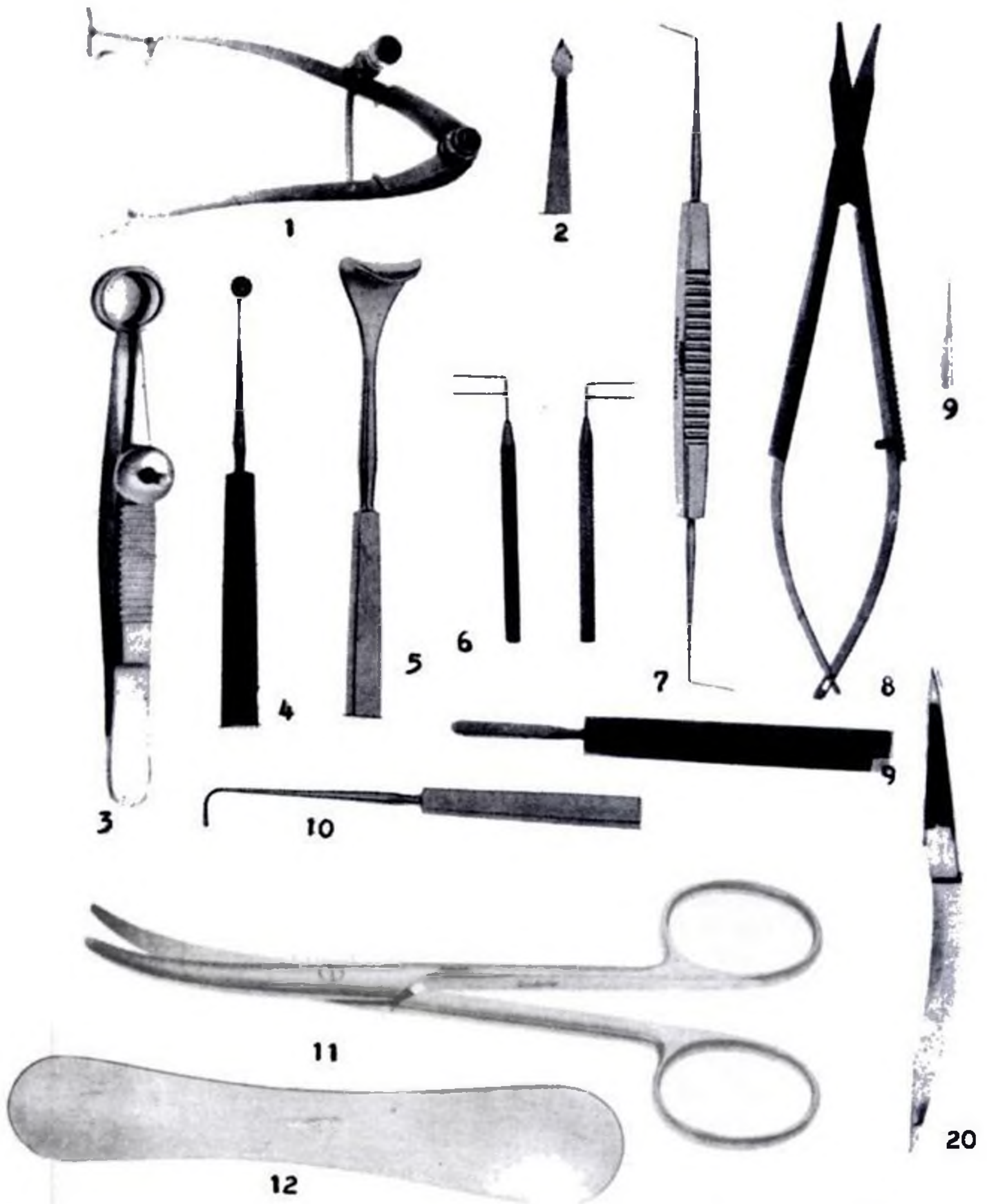

Plate 1 1, Universal eye speculum; 2, Keratome; 3, Chalazion clamp (forceps); 4, Chalazion scoop; 5, Desmarres lid retractor; 6, Marm's trabeculotomy probes; 7, Cyclodialysis spatula; 8, Westcott tenotomy scissors; 9, Tooke's knife; 10, Strabismus (muscle) hook; 11, Enucleation scissors; 12, Lid spatula (Courtesy: Modern Surgicals, Kolkata).

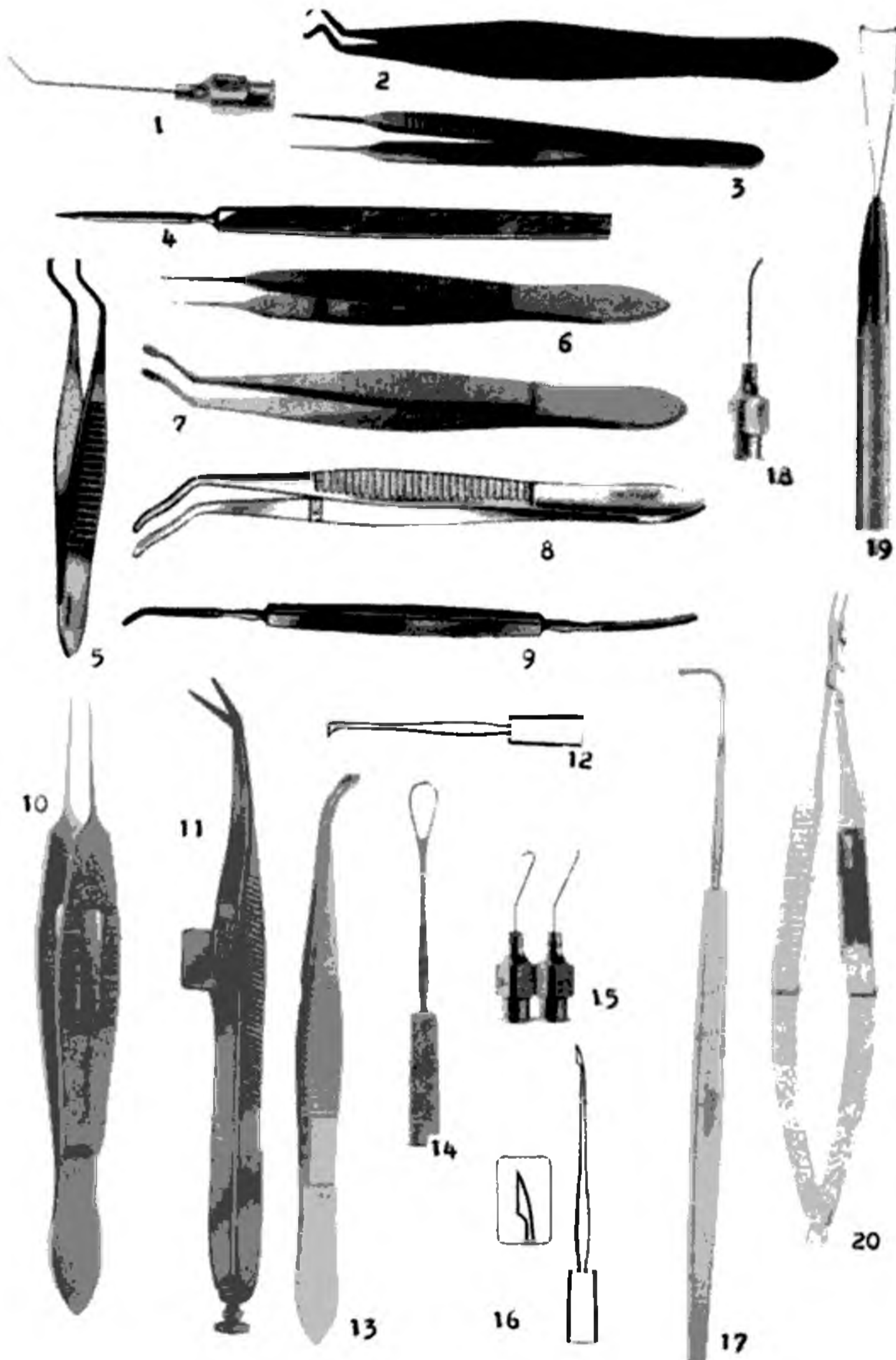


Plate 2 1, Aspirating canula; 2, Superior rectus forceps; 3, Fixation forceps; 4, von Graefe cataract knife; 5, Iris forceps; 6, Corneal forceps; 7, Arruga intracapsular forceps; 8, Elschmig intracapsular forceps; 9, Iris retractor; 10, Suture tying forceps; 11, Dewecker iris scissors; 12, Cystitome; 13, Capsulotomy forceps; 14, Vectis; 15, Irrigating canula; 16, Ziegler knife-needle; 17, Lens expressor; 18, Air injection canula; 19, Iris retractor; 20, Needle holder (*Courtesy*: Modern Surgicals, Kolkata).

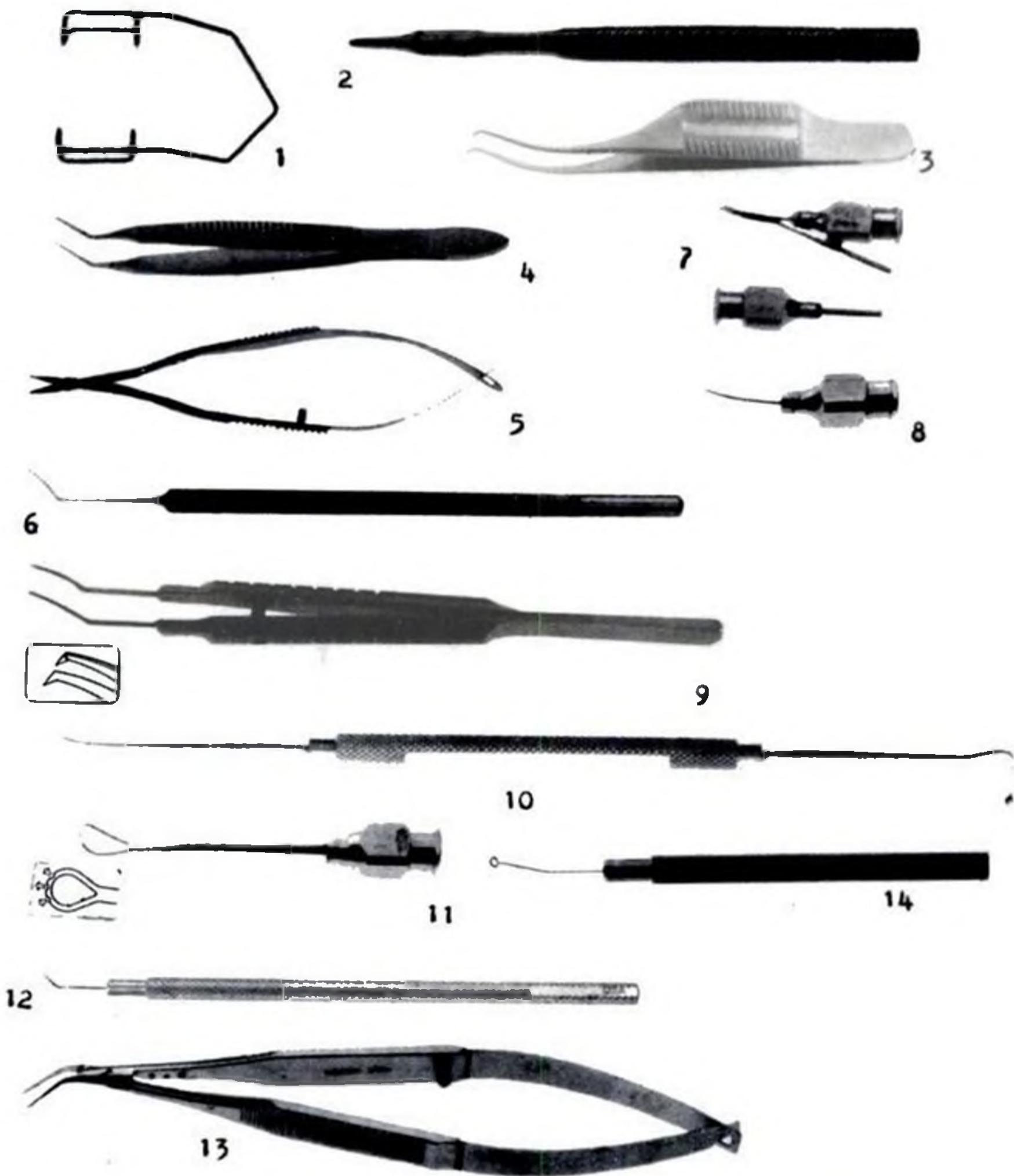


Plate 4 1, Wire speculum; 2, Blade breaker and holder; 3, Colibri forceps; 4, Kelman-Mcpherson forceps; 5, Vannus capsulotomy scissors; 6, Iris spatula; 7, Simcoe irrigation-aspiration canula; 8, Hydodissection canula; 9, Capsulorrhexis forceps; 10, Lens loop and muscle hook; 11, Irrigating vectis; 12, Sinsky lens manipulating hook; 13, Lens holding forceps; 14, Capsule polisher (*Courtesy: Modern Surgicals, Kolkata*).

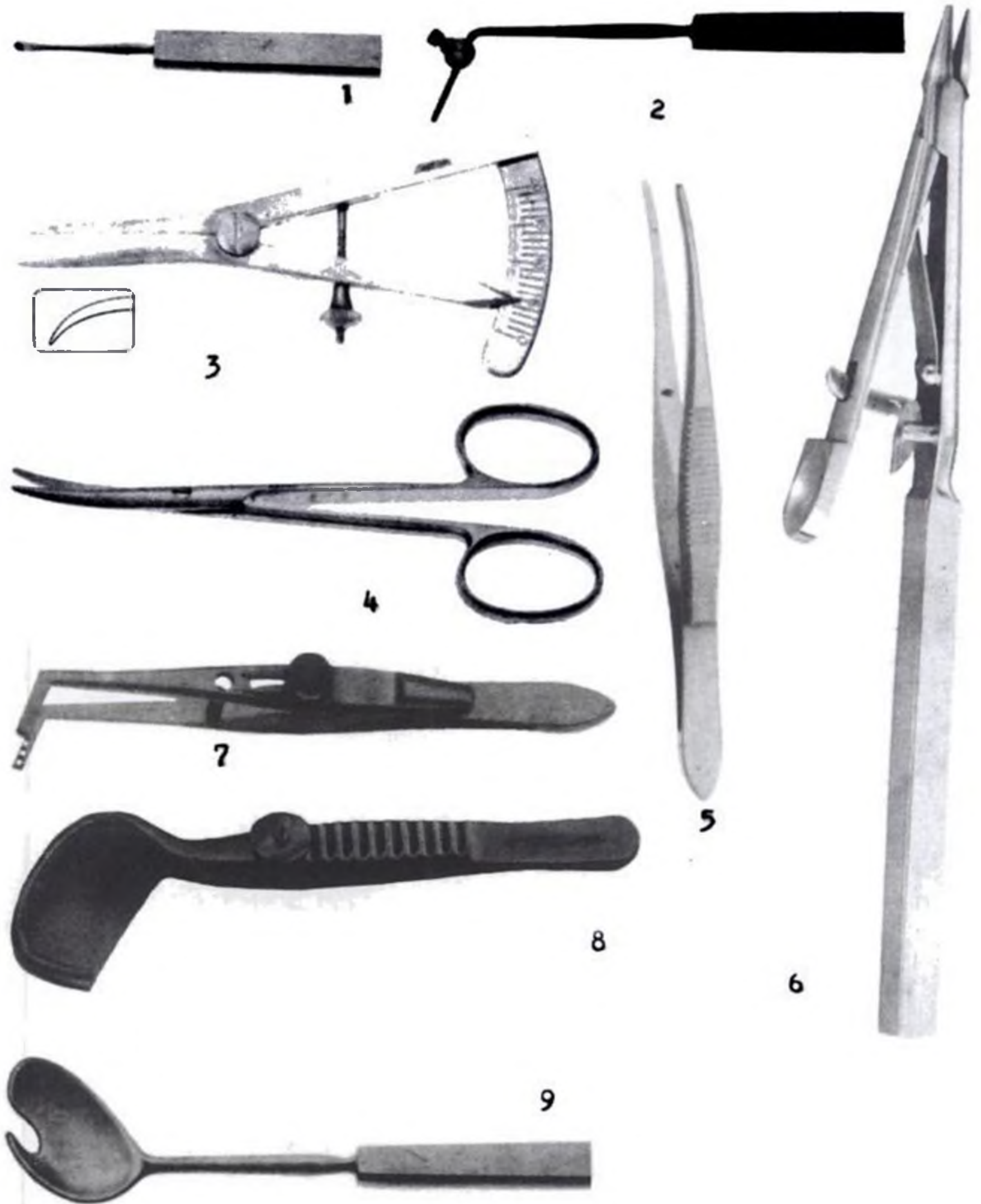


Plate 5 1, Foreign body spud; 2, thermocautery; 3, Caliper; 4, Strabismus scissors; 5, Epilation forceps; 6, Silcock needle holder; 7, Muscle clamp; 8, Entropion forceps; 9, Enucleation spoon (Courtesy: Modern Surgicals, Kolkata).

Glossary

- abduction:** outward movement of one eye
- abetalipoproteinaemia:** absence of beta-lipoprotein, the main carrier of carotenoid
- abiotrophy:** an inborn defect which manifests sometimes in adult life
- ablatio falciformis congenita:** synonym for persistent hyperplastic primary vitreous
- ablepharon:** absence of the eyelids
- abnormal retinal correspondence (ARC):** conditions in which the fovea of the fixing eye is used simultaneously with the fovea of the deviating eye.
- harmonious:** the angle of anomaly is the same as the angle of squint
- unharmonious:** the angle of anomaly is less than the angle of squint
- acanthocytosis:** presence of malformed erythrocytes with horny projections
- acantholysis:** loss of cohesion between epithelial cells
- acanthosis:** thickening of the prickle cell layer of the skin
- accommodation:** the ability of the eye to increase its covering power for obtaining a clear image of a near object
- accommodative esotropia:** inward ocular deviation more marked for near than for far
- achromatopsia:** colour blindness, often complete
- acrocephaly:** oxycephaly
- adamantinoma:** craniopharyngioma
- adaptometer:** a device for measuring the rate and amount of increased sensitivity of the retina to light
- adduction:** inward movement of one eye
- Adie's pupil:** often unilateral, dilated pupil not reacting to light but showing slow tonic constriction while the patient is asked to look at near object
- advancement operation:** placing of the insertion of the muscle further away
- after cataract:** remnant of the lens matter following extracapsular extraction, needling or curette evacuation
- after image:** persistence of the visual sensation after cessation of the stimulus
- agnosia:** inability to recognize objects by sight in the presence of intact visual acuity
- agonist:** synergic groups of muscle acting together to rotate the eye in the same direction
- agraphia:** inability to write
- alexia:** inability to read
- allele:** or partner, situated at the same site on the homologous chromosome
- amaurosis fugax:** temporary loss of vision
- amblyopia:** impaired form of vision unaccompanied by any detectable organic lesion:
- ex anopsia:** stimulus-deprivation amblyopia
- strabismic:** amblyopia in the squint eye
- ametropia:** refractive error
- Amsler grid:** grid chart for rapid screening of the central field
- anaplasia:** anomalous appearance of nuclei in malignant tumours
- angioid streaks:** irregular jagged lines resembling the retinal vessels due to ruptures in Bruch's membrane
- angiосcopy:** ophthalmoscopic observation of the passage of the dye, generally fluorescein
- angioscotometry:** refined technique of scotometry to detect extended blind spot due to blocking of vision by the large retinal vessels
- angle alpha:** angle between the visual axis and the optic axis
- angle gamma:** the angle located between the optic axis and the fixation axis at the centre of rotation of the eye
- angle kappa:** the angle between the visual axis and the pupillary line at the nodal point
- angle lambda:** the angle between the visual axis and the optic axis at the centre of the pupil
- angle of anomaly:** angle between the visual axis and the abnormal direction of alignment of an eye having suppression
- angström (Å):** unit of wavelength equal to 10^{-10} m
- aniridia:** absence of the iris

- black sunburst sign:** chorioretinal scars seen ophthalmoscopically in sickle cell haemoglobinopathy
- blepharochalasis:** redundant upper lid skin occurring in old age due to atrophy and loss of elasticity of the skin
- blepharoclonus:** involuntary rhythmic contractions of the orbicularis
- blepharoclonus:** narrowed palpebral fissure
- Blessig-Iwanoff cysts:** microcystic peripheral retinal degenerations
- blind spot:** the insensitive area in the visual field corresponding to the optic disc having no photoreceptors
- blue field entoptoscopy:** uniform illumination of about 20° of the retina of a patient sitting in a dark room by blue light
- bobbing:** intermittent, rapid downward rotation of the eyes followed by slow return to primary position
- break phenomenon:** in retinoscopy when the pupillary reflex band is not in alignment with the streak
- Brooke's tumour:** trichoepithelioma of the eyelid
- Brücke's muscle:** the longitudinal fibres of the ciliary muscle
- Brushfield's spots:** golden specks running round the periphery of the iris seen in mongolism
- Busacca nodules:** nodules over the anterior surface of the iris elsewhere than at the pupillary margin seen in sarcoid uveitis
- campimeter:** Bjerrum's screen
- canal of Cloquet:** central area in the vitreous extending from the back of the lens to the optic nerve-head
- canal of Petit:** triangular space between the suspensory ligament of the lens
- canal of Schlemm:** annular sinus situated in the posterior part of the internal scleral sinus
- canthotomy:** division of the canthus
- canthus:** angle at the either end of the palpebral fissure
- capsulopalpebral muscle of Hesser:** nonstriated muscle of orbit
- capsulotomy:** surgical incision of the lens capsule
- carcinoembryonic antigen:** antigen related to carcinoma-associated substance present in embryonic tissue
- cardinal directions of gaze:** six positions of gaze utilized to test the primary field of actions of the six extrinsic muscles
- cardinal points:** six points of an optical system—two each of the principal, nodal and focal points
- caruncle:** roundish elevation at the medial angle of the palpebral fissure
- cataracta glaucomatosa:** opaque sheets of anterior subcapsular epithelium of the lens following an acute glaucoma.
- cataracta nigra:** nuclear cataract showing excessive pigment accumulation
- centrad:** unit of measurement of the prism power along the arc of a circle
- cerclage:** an operation for retinal detachment using an encircling band around the sclera behind the insertions of the recti muscles
- chalcosis:** degenerative condition of the eye due to retention of copper
- Charcot's triad:** a triad of nystagmus, intentional tremor and scanning speech found in late stage of demyelinating disease
- chemosis:** oedema of the conjunctiva
- Chievitz, layer of:** embryonic plexiform layer between the outer and the inner neuroblastic layers of the retina
- choked disc:** papilloedema
- chlorolabe:** green-sensitive pigment in the retinal cones
- cholesterolosis bulbi:** synonym for sychisis scintillans
- choristoma:** congenital tumour-like growth containing normal tissue in abnormal location
- choroideraemia:** an abiotrophic condition showing absence of a part of the choroid
- chromatopsia:** coloured vision
- chromosomes:** bodies present in the nuclei of all cells. They contain about 20,000 to 40,000 different pairs of genes
- chrysiasis:** deposition of gold within the ocular tissues
- circle of Haller-Zinn:** an arterial circle lying within the sclera adjacent to the optic disc

- macula adherentes:** synonym for desmosomes
- maculopathy, cellophane:** acquired idiopathic preretinal fibrosis; other synonyms are macular pucker, spontaneous surface wrinkling retinopathy and vitreoretinal interface retinopathy
- madarosis:** loss of eyelashes
- Maler, sinus of:** the dilated terminal canal of union of the upper and lower canaliculi
- Marcus Gunn pupil:** pupil dilatation on the side of the lesion of the optic nerve or retina
- margin limbal distance (MLD):** the distance from the 6'o'clock limbus to the midpoint of the upper lid margin when the patient fixates a light in extreme upper gaze
- margin reflex distance (MRD):** the distance in mm from the corneal light reflex to the centre of the upper or lower lid margin with the patient's eyes are in the primary position
- massive preretinal retraction (MPR):** synonym for massive vitreous retraction (MVR)
- melanosis bulbi:** congenital hyperpigmentation of an eye
- metamorphopsia:** distortion of vision
- meniscus lens:** lens having one concave and another convex surface
- morning glory syndrome:** dysplastic coloboma of the optic disc resembling morning glory flower
- metre angle (ma):** unit of convergence
- Meyer's loop:** the detour around the ventricle caused by the fibres arising on the outer aspect of the lateral geniculate body
- microprria:** the object appears smaller in size
- microtropia:** small degree of squint, about 5°
- Mittendorf's dots:** light grey opacities at or near the posterior pole of the crystalline lens due to the presence of remnants to tunica vasculosa lentis
- Mizuo–Nakamura phenomenon:** regaining of the normal colour of the ocular fundus with prolonged dark adaptation as in Oguchi's disease
- monochromatism:** total colour blindness
- monosomy:** presence of only one chromosome instead of the normal two, e.g. Turner's syndrome
- mesopic:** intermediate illumination between photopic and scotopic
- mural cells:** cells found in the outer aspect of the endothelial basement membrane of the retina
- mutation:** change in the genetic material
- myiasis:** infection of tissues or cavities of the body by larvae of dipterous insects
- myoclonus:** twitching of a muscle or group of muscles
- myodiotres:** the unit to estimate the physiologic power of the ciliary muscle by altering the curvature of the lens by 1 dioptre
- myokymia in orbicularis oculi:** fluttering contractions of some fibre bundle usually near the outer canthus
- myotomy:** surgical incision into or across the belly of a muscle
- Nadbath akinesia:** the injection for facial akinesia given behind the pinna of the ear
- naevus flammeus:** skin angioma situated in the area supplied by the first or second division of the fifth cranial nerve
- nanometer:** synonym of millimicron
- nanophthalmos:** congenital smallness of an eyeball
- near point:** the nearest point at which small objects can be clearly distinguished
- neuronal ceroid lipofuscinosis (NCL):** hereditary affection showing excessive accumulation of ceroid lipofuscin in neurons
- neuroretinitis:** inflammation of the optic nerve and retina
- nicking, AV:** compression of a vein by an arteriosclerotic arteriole
- nodal point of an eye:** the apex of all the angles subtended by any object situated in front of the posterior surface of the crystalline lens
- nyctalopia:** night blindness
- occluder:** a cover for the eye
- ocular bobbing:** irregular spontaneous downward jerks of the eyes followed by slower upward movement toward primary position
- oculogyrric crisis:** conjugate, spasmodic, tonic or clonic, usually upward ocular deviations
- oculus dexter (OD):** right eye
- oculus sinister (OS):** left eye
- oculus uterque (OU):** both eyes
- ophthalmodynamometer:** instrument for measurement of BP of the ophthalmic artery

ophthalmometer: synonym for keratometer

opsin: protein of the light-sensitive pigment of retinal rods and cones

opsoclonus: multiple, involuntary, repetitive, chaotic multidirectional conjugate ocular movements

optic vasculitis: synonym for central retinal vein thrombosis without ischaemia

optometer: synonym for lensometer

oral bays: convex curves lying between the dentate processes of the ora serrata

orbitometry: measurement of the ease of displacement of an eye into the orbit

orthophoria: perfect parallelism of both eyes

orthoptics: techniques used in the diagnosis and management of latent or manifest squint

pachometer: a device for measuring the thickness of the cornea

palinopsia: persistence or recurrence of images after removal of the stimulus from the visual field

Panum's area: a circular area in which fusion is possible by the stimulation of disparate points

pannus: superficial vascularization of the cornea with cellular infiltration

panophthalmitis: generalized suppurative inflammation of an eye

papillophlebitis: synonym for central retinal vein thrombosis without ischaemia; other synonyms are venous stasis retinopathy and optic vasculitis

parafovea: 2.1-mm belt round the fovea

parakeratosis: retention of nuclei in the superficial keratin layer of the skin

pectinate ligament: vestigial strands connecting the periphery of the iris with the anterior wall of the angle occasionally found in man

penalization treatment, in amblyopia: a method of treatment without occlusion by advising the patient to use one eye for distance and the other for the near

pendular nystagmus: nystagmus in most positions of gaze has oscillations equal in speed and amplitude

pericytes: see mural cells

peritomy: excision of a collar of conjunctiva round the limbus

phacoemulsification: ultrasonic fragmentation and aspiration of cataract

phacolytic glaucoma: secondary glaucoma following liquefaction of the lens

phagolysosomes: combination of phagosomes with lysosomes in the retinal pigment epithelium

phagosomes: fragments of outer segments of rods and cones entering the vacuoles

phakomatosis: developmental and hereditary tumour-like malformations in the organs like the eye, skin and CNS

phenotype: signifies the physical manifestations of a characteristic trait

phonoangiography, carotid: method of visual analysis of carotid bruit

phorometer: instrument for measuring muscular balance

photons: quanta of light energy

photopsia: flashes of light due to retinal irritation

pits: incomplete coloboma of the optic disc

plagiocephaly: lopsided skull due to asynchronous fusion of the cranial bones

plateau iris: anterior insertion of the iris on the ciliary body

pleoptics: method of re-establishment of foveal fixation

poliosis: loss of pigment in the hairs

polycoria: multiple pupils, present as a developmental anomaly

posterior embryotoxon: see *Axenfeld syndrome*

posterior keratoconus: dome-shaped posterior excavation of the cornea

proband of propositus: the patient who seeks advice and evokes study of family tree

prostaglandins: fatty acid compounds liberated within the eye in inflammation

protanopia: red-green colour blindness with greatest loss of sensitivity for red

Psammoma bodies: proliferated nests of menigothelial cells within the arachnoid, commonly found in optic nerve meningioma

pseudorosettes: viable tumour cells arranged circumferentially round the blood vessels seen in retinoblastoma

pseudotumour cerebri: synonym for benign intracranial hypertension

punctum proximum: synonym for near point
punctum remotum: synonym for far point
pupillary escape phenomenon: synonym for Marcus Gunn pupil
pupillary ruff: curling of a narrow ridge of the posterior pigment epithelium of the iris at the pupillary margin
pupillometer: a device for measuring the diameter of the pupil
Purkinje images: the images reflected from the anterior and posterior surfaces of the cornea and the lens
Purkinje phenomenon: the shift in relative colour values from photopic to scotopic vision
Purtscher's retinopathy: retinopathy following severe crushing injury of the chest

quadrantanopia: a sector-shaped defect bounded by the vertical and horizontal radii

recession operation: retroplacement of the insertion of the muscle from its normal position
recessive: when the mutant gene are inherited from both parents and the individual is homozygous for the gene, the trait is known as recessive
reduced eye: concept of treating the optical system of the eye as a single ideal refracting surface
resection operation: shortening of the muscle tendon
resolving power of the eyes: synonymous with minimum separable; the smallest angle subtended at the nodal point of the eye by two points that still allows them to be seen distinctly
retinal hole: a round opening unaccompanied by attached retinal flap in most cases
retinal rivalry: a conflict between the two retinae due to superimposition of the two dissimilar images
retinopathy: noninflammatory affection of the retina with haemorrhages and exudates
retinopexy: surgical procedure of correction of retinal detachment by means of diathermy
retinoschisis: split of the sensory retina usually in the outer plaxiform layer
retinotomy: surgical removal of scar-like disciform scar from the retina

rhegmatogenous: with hole formation
rhodopsin: light-sensitive photopigment of rods
Riolan, muscle of: pars ciliaris component of the pretarsal part of the orbicularis oculi
Roth's spots: white-centred haemorrhages in the retina as in leukaemia
rubeosis Iridis: iris neovascularization

saccades: rapid conjugate ocular movements
Salus' sign: deflection of the course of the vein
Sattler's layer: layer of large vessels in the choroid
Sattler's veil: corneal haze following contact lens overwear
scaphocephaly: boat-like skull due to premature closure of the sagittal sutures
Schwalbe's contraction furrows: numerous little radial furrows starting 1 mm from the pupillary margin
Schwalbe's line: circular bundle of fibres at the terminal portion of Descemet's membrane
scintillating scotoma: unformed visual hallucinations with brilliantly coloured shimmering lights, usually in migraine
scleral spur: specialized scleral fibres enclosing the posterior pole of Schlemm's canal
scleromalacia perforans: degenerative thinning of the sclera leading to necrosis and perforation
sea-fan neovascularization: tufts of new vessels in the retina in conditions like Eales' disease and sickle cell retinopathy
Seidel's scotoma: a small nerve fibre bundle field defect adjacent to the blind spot
Seidel's test: the leaking aqueous humour washes the dye from the wound site visualized by a slit-lamp
septum orbitale: the fascia extended from the orbital rim to the tarsus
sex chromosome: there is only one pair of human sex chromosomes
sex-linked (or X-linked): when the gene is situated on the X-chromosome
sib or sibling: brothers and sisters
shadow test: synonym for retinoscopy
Sherrington's law of reciprocal innervation: when a muscle is stimulated its antagonist is simultaneously and equally inhibited

situs inversus, of the disc: an inversion of the disc vessels accompanied by an inferior crescent

skew deviation: an ocular movement disorder seen as irregular spontaneous downward jerks of the eyes followed by a slower upward movement toward the primary position

Snellen's fraction: visual acuity is expressed in terms of Snellen's fraction

Soemmerring's ring: peripheral ring of lens capsule and cortex after an extracapsular extraction

spasmus nutans: acquired condition in infants with nystagmus, head-nodding and torticollis

Stähli-Hudson line: an iron line in the cornea in old age

stereocampimetry: an instrument for measuring central visual field of each eye separately with each eye fixing

Stiles-Crawford' effect: the light rays entering the eye obliquely are less efficient stimuli than those entering from in front

Stocker's line: vertical arc in front of a filtering bleb due to iron

supraduction (sursumduction): upward movement of one eye

sursumversion: simultaneous upward movement of both eyes

synchysis scintillans: golden yellow vitreous opacities made up of cholesterol in degenerate vitreous

tapetoretinopathy: hereditary degeneration of the retinal pigment epithelium and sensory retina

teichopsia: various colours in zig zag fashion seen by patients with migraine

telecanthus: outward displacement of the medial canthi

Tenon's space: episcleral space

Titmus test: test for three-dimensional vision and retinal correspondence is the observation large housefly with wings having nine sets of circles through polarising spectacles, patients with good vision and normal retinal correspondence (NRC) see all of them, while those with abnormal retinal correspondence (ARC) see only the housefly.

tenotomy: incision across the muscle tendon

toric lens: meniscus lens with a cylinder on one surface

tomography, computed (CT): a noninvasive method of cross-sectional imaging applied to the skull and orbit using a scanner

tonography: method of determination of the coefficient of aqueous outflow

tonometry: measurement of the ocular tension

torsion: rotation of the eye around the anteroposterior axis

trait: characteristic determined by any gene

translocation: the displacement of part or all of one chromosome to another

trisomy: presence of three chromosomes instead of the normal two e.g. trisomy 23 or mongolism

tucking: folding of the tissue of an extrinsic muscle

tunica: vascular network surrounding the foetal lens

ultimeter: synonym for lensometer

Uthoff's sign: exacerbation of visual symptoms, ataxia and extremities by heat and exercise in multiple sclerosis

valve of Hasner: a valve of mucous membrane at the lower end of the nasolacrimal duct

venous stasis retinopathy: central retinal vein thrombosis without ischaemia

vergence: dysjugate ocular movements

Verhoeff's membrane: a light microscopic picture showing MPS occupying space between the junctional zones of the pigment epithelium of the retina

version: conjugate ocular movements

vertometer: synonym for lensometer

visual angle: the angle subtended by the object at the nodal pint

visual-evoked response (VER): electroencephalography recorded at the occipital region

visuscope: a modified ophthalmoscope to assess the fixation pattern of the eye

von Michel's spurs: synonym for Fuchs' spurs

VISC: vitreous infusion suction cutter

Vossius' ring: pigment ring over the anterior capsule of the lens following contusion

wall eye: exotropia

Wernicke's pupil: diminished or absent pupillary response on the blind side of the retina of the patient with homonymous hemianopia but normal pupillary responses on the seeing-half

Whitnall's tubercle: a small elevation on the orbital surface of the zygomatic bone

white-without-pressure (WWOP): iridescent whitening of the fundus oculi seen ophthalmoscopically without pressure exerted by a scleral depressor

white-with pressure (WWP): the above picture seen after exerting pressure by a scleral depressor

Wieger's ligament: condensation of the fibrils

forming a circular attachment of the lens in young age

xanthopsia: yellow vision

yoke muscles: they are those muscles paired in such a manner that they are used in coordinated ocular movements

zonulae adherentes: junctions between the cells leaving behind some spaces seen electronmicroscopically

zonulae occludentes: tight junctions between the cells seen electron microscopically

Index

- Abducent nerve, [8](#), [9](#), [10](#)
palsy, [377](#), [378](#)
- Abduction, [44](#), 366
- Aberrations
chromatic, [112](#)
peripheral, [112](#)
spherical, [110](#)
- Abetalipoproteinaemia, 403, [559](#)
- Abiotrophy, [559](#)
- Ablatio falciformis congenita, [559](#)
- Ablepharon, 179, [559](#)
- Abnormal retinal correspondence (ARC), 372
harmonious, 372
paradoxical, 372
unharmonious, 372
- Abrasions, corneal, [210](#), [430](#)
- Abscess
corneal, [215](#)
lacrimal sac, 186
vitreous, [252](#)
- Acanthamoebiasis, [86](#)
- Acanthocytosis, [559](#)
- Acantholysis, [559](#)
- Acanthosis, [559](#)
- Accessory ciliary ganglion, [7](#)
- Accommodation, 63–65
amplitude of, 64
anomalies of, 64–65
aphakia, absence in, [119](#), [120](#)
and asthenopia, 64
excess of, 65
far point of, 64
in hypermetropia, [113–114](#)
ill-sustained, 65
insufficiency, 65
lens changes in, 63, 64
mechanism of, 63–64
near point of, 64, 386
nervous pathway of, 64
paralysis of, 65
physical, 64
physiological, 64
range of, 64
spasm of, 65
strabismus and, 379–380
theories of, 64
- Accommodative convergence/accommodation (AC/A)
ratio, 64
- Accommodative esotropia, 379–380
- Acetazolamide, 100, 300
- Acetylcholine, [91–92](#)
- Acetylcysteine, 181, [184](#)
- Achromatic lens, [110](#)
- Achromatopsia, [559](#)
- Acne rosacea, [413](#), [419](#)
- Acne vulgaris, [419](#)
- Acanthamoebiasis, [86](#)
- Acquired immuno deficiency syndrome (AIDS),
410–411
- Acrocephalosyndactyly, *see* Apert's syndrome
- Acrocephaly, *see* oxycephaly
- Acromegaly, 391
- Actinomycosis, [70](#), [185](#), [246](#)
- Action potentials, [70](#)
- Acute posterior multifocal placoid pigment epitheliopathy
(APMPPE), [328](#)
- Acute retinal pigment epithelitis, [328](#)
- Acycloguanosine or acyclovir (Zovirax), 97
- Adamantinoma, [559](#)
- Adaptation, [73](#), [135](#)
- Adaptometer (Phorometer), [73](#), [135](#)
- Addison's disease, [396](#)
- Adduction, [44](#), 366
- Adenocarcinoma
of lacrimal gland, [182](#)
Meibomian, 174
- Adenoma
of ciliary body, 423
pituitary, [145](#), 391–392
pleomorphic of lacrimal gland, [182–183](#)
sebaceum, [351](#)
- Adenosine arabinoside (Vidarabine), 97
- Adenoviral keratitis, [223](#)
- Adenoviral keratoconjunctivitis, [196](#), [197](#)
- Adenoviruses, 80, 81
- Adhesives in ophthalmology, [534–535](#)
- Adie's pupil, [268](#), [269](#)
- Adjustable, sutures, [490](#)
- Adjuvants, 512
- Adrenaline (epinephrine), 92, 93
- Adrenergic drugs, 92, 93, 299–300
- Adrenocorticotrophic hormone (ACTH), 98
- Advancement operation, 487, [559](#)
- Aesthiometer, [212](#)
- Aftercataract, [276](#), 477
- Afterimages, [72](#), [559](#)
- Age changes
in accommodation, 64
in cornea, [23](#)
in lens, 29, 65, [274](#)
in retina, [328](#)
in sclera, [24](#)
in uvea, [261–262](#)
in vitreous, [138](#), [277](#), [278](#)

- Age-related macular degeneration (ARMD), [331–332](#)
 Agnosia, visual, [599](#)
 Agonist (synergistic muscles), 369, [559](#)
 Agraphia, [323](#), [599](#)
 Aicardi's syndrome, [537](#)
 Air puff tonometer, [284](#)
 Akinesia of facial nerve, 466
 Alacrima, [188](#)
 Albers-Schönberg syndrome, [537](#)
 Albinism, [262](#), [402](#)
 Alcohol
 amblyopia, 103, 359
 retrobulbar injection of, [302](#)
 Alexia, 393, [559](#)
 Alkaptonuria (ochronosis), [235](#), [402](#)
 Alkylating agents, 101
 Alleles, [589](#)
 Allen-Thorpe gonioscopy lens, [285](#)
 Allergic conjunctivitis, [202–205](#)
 Allergic dermatitis of eyelids, 164
 Allergic reactions, [202](#)
 Alopecia, uveitis with, [256](#)
 Alpha-blocker, 298, 299
 Alphachymotrypsin, 100
 Alpha-receptors, 92
 Alport's syndrome, [559](#)
 Alström's syndrome, [559](#)
 Amacrine cells, 36
 Amantadine, [95](#)
 Amaurosis fugax, 363
 Amaurotic cat's eye, [266–268](#), 411
 Amaurotic family idiocy, 338
 Amaurotic pupil, [268](#)
 Amblyopia, 369–371
 anisometropic, 379
 of arrest, 369
 classification of, 369
 defined, 369
 diagnosis of, 370
 ex anopsia (stimulus deprivation), 370
 of extinction, 370
 hysterical, 370
 strabismic, 370
 tobacco, [144](#), 359
 toxic, 359
 treatment of, 370–371
 Amblyoscope, *see* synoptophore
 Amethocaine (tetracaine), [94](#)
 Ametropia, [113](#)
 Amikarin, [96](#)
 Aminoacidopathies, 403
 Aminoglycosides, [96](#)
 Amoebiasis, 85
 Amoxicillin, [96](#)
 Amphotericin B (Fungizone), 98
 Ampicillin, [96](#)
 Amsler grid, [316](#)
 Amyloidosis, 403
 Anaemia, retinal changes due to, [315](#), [345](#)
 Anaesthesia dolorosa, [223](#)
 Anaesthesia in ophthalmology, 93–94
 Anaesthetics, local, [94](#)
 Anaplasia, [559](#)
 Anatomy of
 abducent nerve, [8](#), [9](#), [10](#)
 anterior chamber, [31](#)
 cavernous sinus, [153](#), [154](#)
 choroid, [27–28](#)
 ciliary arteries, 28
 ciliary body, [26–27](#)
 ciliary ganglion, [7](#)
 conjunctiva, [18–21](#)
 cornea, 22–24
 extrinsic muscles, [43–45](#)
 eyelids, [11–14](#)
 facial nerve, [10–11](#)
 intrinsic muscles, [1](#), [26](#)
 iris, [25–26](#)
 lacrimal apparatus, [15–18](#)
 lens, crystalline, 29–30
 oculomotor nerve, [8–9](#)
 ophthalmic artery, [5–6](#)
 optic nerve, [38–40](#)
 orbit, [3–11](#)
 retina, 33–38
 sclera, [24](#)
 Tenon's capsule, [7–8](#)
 trigeminal nerve, [9–10](#)
 trochlear nerve, [8–9](#)
 uvea, [25–28](#)
 visual pathways, [38–42](#)
 vitreous humour, [30–31](#)
 Ancylostomiasis (Hookworm), 409–410
Ancylostoma duodenale, 409
 Aneurysm
 cerebral, [376](#)
 of circle of Willis, [398](#)
 of internal carotid artery, [398](#)
 micro-, in retina, 319, [343](#)
 Angiogenesis, [305](#)
 Angiography
 carotid, [151](#)
 indocyanine green, 525
 Angioid streaks, [331](#)
 Angioscopy, [559](#)
 Angiotensin-converting enzyme (ACE), [249](#), 255
 Angle
 alpha, 367
 of anomaly, 367
 cerebellopontine, 393
 critical, 106
 of deviation, 367

- filtration, [32](#)
- gamma, [367](#)
- kappa, [367](#)
- lambda, [559](#)
- metre, [65](#)
- of the prism, [108](#)
- of squint or deviation, [367](#)
- visual, [570](#)
- Angle-recession glaucoma, [304](#)
- Ångström (Å), [559](#)
- Angular conjunctivitis, [195](#)
- Angular vein, [14](#)
- Aniridia, [507](#)
- Aniseikonia, [119](#)
- Anisocoria, [266](#), [267](#)
- Anisometropia, [119](#)
- Anisometropic amblyopia, [379](#)
- Ankyloblepharon, [167](#), [179](#)
- Ankylosing spondylitis uveitis, [414](#)
- Annular scleritis, [242](#)
- Annulus tendinous communis of Zinn*, [4](#)
- Anomaloscope, [72](#)
- Anophthalmos, [506](#)
- Antagonistic muscles, [367](#)
- Anterior axial embryonic cataract, [271](#)
- Anterior chamber
 - anatomy of, [31](#)
 - angle of, [32](#)
 - gonioscopic classification of, [286](#)
 - main features of gonioscopy in [286](#), [287](#)
 - blood in, [212](#)
 - deep, [31](#)
 - delayed re-formation of, [474](#)
 - depth of, [31](#), [130](#)
 - implants in, [479](#)
 - lens matter in, [4](#)
 - paracentesis, [456](#)
 - shallow, [31](#)
- Anterior membrane corneal dystrophy, [231](#)
- Anterior polar cataract, [272](#)
- Anterior sclerectomy, [483](#)
- Anterior scleritis, [242](#)
- Anterior staphyloma, [216](#)
- Anterior uveitis, *see* iridocyclitis
- Antibiotics, [95](#)
 - subconjunctival injections of, [96](#)
 - systemic administration of, [95](#)
- Antibodies *see* immunoglobulins
- Anticholinesterase agents, [91](#)
- Anticoagulants, [100](#)
- Antidiphtheric serum, [194](#)
- Antifungal agents, [98](#)
- Antigen-antibody complement-mediated keratitis, [221](#)
- Antigens (immunogens), [512](#)
- Antimetabolites, [101](#)
- Antinuclear antibodies (ANA), [249](#)
- Antiseptics, [91](#)
- Antithyroid drugs, [157](#)
- Antiviral agents, [95](#), [97](#)
- Anton's syndrome, [537](#)
- Aortic aneurysm, [398](#)
- Aortic arch syndrome, *see* pulseless disease
- Aortic insufficiency, [398](#)
- Apert's syndrome, [162](#)
- Aphakia, [119](#)
 - congenital, [270](#)
 - contact lenses in, [120](#)
 - and glaucoma, [305](#)
 - hypermetropia and accommodation in, [119](#), [120](#)
 - optical conditions in [119–120](#)
 - treatment of, [120](#)
- Aphakic glaucoma, [305](#)
- A-phenomenon, [382](#), [383](#)
- Applanation tonometry, [283](#)
- Apraclonidine, [92](#), [300](#)
- Apraxia, [560](#)
- Aqueous humour
 - circulation of, [55–56](#)
 - composition of, [55](#)
 - drainage of, [56](#)
 - lactic dehydrogenase, [427](#)
 - slit-lamp biomicroscopy of, [138](#)
 - theories of formation of, [55](#)
- Aqueous influx, [56](#)
- Aqueous misdirection (diversion) syndrome, *see* malignant glaucoma
- Arachidonic acid, [99](#), [102](#)
- Arachnodactyly, [270](#)
- Arboviruses, [80](#)
- Arcuate scotoma, [292](#)
- Arcus juvenilis (anterior embryotoxon), [560](#)
- Arcus senilis (gerontoxon), [229](#)
- Arden ratio, [312](#)
- Area(s)
 - 8 or aculogyric, [65](#)
 - [17–19](#) of Brodmann, [43](#)
 - of Martegiani, [30](#)
- Argemone mexicana*, [306](#)
- Argon laser, [530](#)
- Argyll Robertson pupil, [269](#), [560](#)
- Argyrol, [91](#)
- Arlt's line, [491](#)
- Arteriovenous (AV) banking retinal, [339](#)
- Arteritis, giant cell, [327](#)
- Artery/arteries
 - anterior cerebral, [40](#), [41](#)
 - anterior choroidal, [42](#)
 - anterior ciliary, [6](#), [20](#), [21](#)
 - anterior communicating, [40](#), [41](#)
 - anterior conjunctival, [21](#)
 - central retinal, [37](#)
 - cilioretinal, [20–21](#)

- of conjunctiva, 20
- copperwire', 340
- dorsal nasal, 6
- external striate (artery of cerebral haemorrhage), 42
- of eyelids, 14
- hyaloid, 30, 50
- infraorbital, 5
- of lacrimal gland, 16
- of lacrimal passages, 18
- ophthalmic, 5–6
- palpebral, 14
- posterior cerebral, 42
- posterior communicating, 42, 43
- posterior conjunctival, 20, 21
- retinal, 6, 37
- short posterior ciliary, 28
- 'silverwire', 340
- supraorbital, 6
- supratrochlear (frontal), 6
- of uveal tract, 28, 39, 41, 42
- of visual pathways, 43
- zygomatic, 6
- Arthropod infections, 87, 166
- Artificial drainage devices, 486–487
- Artificial eye, 497
- Artificial tear, 181
- A-scan, 526
- Ascariasis, *see* roundworms
- Ascorbate, 101
- Ascorbic acid
 - in aqueous humour, 55
 - in cornea, 59
 - in lens, 61
- Aspergillus fumigatus*, 80
- Aspiration, 476
- Aspirin
 - in central retinal vein thrombosis, 325
 - in diabetic retinopathy, 344
 - toxic effects of, 103
 - in vernal conjunctivitis, 204
- Asteroid hyalopathy (Benson's disease), 278
- Asthenopia, 65, 560
- Astigmatic fan, 118
- Astigmatic keratotomy, 532
- Astigmatism, 116–118
 - aetiology of, 116
 - against-the-rule, 116
 - bioblique, 117
 - compound, 116
 - contact lens in, 118
 - curvature, 116
 - defined, 116
 - diagnosis of, 117–118
 - hypermetropic, 116
 - irregular, 117
 - mixed, 116
 - myopic, 116
 - oblique, 116–117
 - optical conditions in, 116
 - regular, 116
 - simple, 116
 - treatment of, 118
 - with-the-rule, 116
- Astringents, 91
- Astrocytoma, retinal, 428
- Atenolol, 299
- Atherosclerosis, retinal, 339
- Atopic kerato conjunctivitis, 204–205
- Atopy, 559
- Atrophy
 - cavernous, 360
 - choroidal, 261–262
 - iris, 247
 - lacrimal gland, 182
 - optic nerve, *see* optic atrophy
- Atropine, 93, 103
 - acute poisoning, 93
- Autoantigens, 512
- Autokeratoplasty, 560
- Automated perimetry, 293
- Automated refraction, 132
- Autonomic drugs, 91–93
- Autosomes, 560
- AV crossing changes, retinal, 339
- AV nicking, retinal, 339
- AV ratio, retinal, 339
- AV syndrome, 382
- Axenfeld–Rieger syndrome, 507, 537
- Axenfeld's nerve loop, 560
- Axis
 - Fick's 367
 - fixation, 367
 - optic, 367
 - pupillary, 367
 - visual, 367
- Azathioprine, 101
- Azidothymidine (Zidovudine), 97
- Azithromycin, 96

- Bacitracin, 79
- Background (simple) diabetic retinopathy, 343
- Bacterial conjunctivitis, 191
- Bacterial corneal ulcers, 214–217
- Bacterial endophthalmitis, 259
- Bacterial flora of conjunctiva, 191
- Bacterial retinitis, 326
- Badal's principle, 93
- Bagolini striated lenses, 520
- Ballet sign, 156
- Ballooned sella, 392

- Barany's nystagmus, 560
 Barr bodies, 560
 Basic eye movements, [45](#)
 Bassen-Kornzweig syndrome, [537–538](#)
 Batten-Mayou syndrome, 338
 Batten-Spielder-Vogt syndrome, 404
 Beal's syndrome, [196](#)
 Bedsonia, 560
 Behcet's syndrome, 255
 Behr's pupil, 560
 Behr's syndrome, [538](#)
 Bell's phenomenon, [179](#)
 Benedict's (tegmental) syndrome, [538](#)
 Bengal glaucoma, *see* epidemic dropsy glaucoma
 Benign intracranial hypertension, 361
 Benign mucosal pemphigoid, 411–412
 Benson's disease, *see* asteroid hyalopathy
 Benzalkonium chloride, [91](#)
 Benzyl penicillin (penicillin G), 96, 97
 Bergmeister's papillae, 508
 Beri-beri, *see* epidemic dropsy glaucoma
 Berlin's oedema (commotio retinae), 432
 Berman's syndrome, 405
 Bernheimer-Seitelberger syndrome, 404
 Best's vitelliform dystrophy, 338, [538](#)
 Beta-blockers, 92, 299
 Betamethasone (Betnesol), 98
 Beta-receptors, 92
 Betaxolol (Betoptic), 92, 300
 Bielschowski's sign, [377](#)
 Bielschowsky-Jansky's syndrome, 404
 Binocular diplopia, 369
 Binocular ocular movements, 368
 Binocular vision
 anatomical factors, in [67](#)
 grades of, [67–68](#)
 physiological factors in, [67](#)
 Biomicroscopy, slit-lamp, *see* slit-lamp biomicroscopy
 Bipolar cells 33, 35
 Birdshot retinochoroiditis, [257–258](#)
 Black eye, 430
 Black sunburst sign, [346](#)
 Blaskovics-operation, 449–450
 Blepharoconjunctivitis, [194](#)
 Blepharitis, [165–166](#)
 Blepharochalasis, [179](#)
 Blepharoclonus, [77](#)
 Blepharophimosis, [179](#)
 Blepharoplasty, [449](#)
 Blepharospasm, 177
 Blindness
 classification of, WHO, 515
 colour, [71–72](#)
 cortical (Anton's syndrome), [537](#)
 defined, 515
 in India, 516
 transient, 363
 Blinking, [178](#)
 Blood staining of cornea, [212–213](#)
 Blood vessels, new, in iris, *see* rubeosis iridis
 Blow-in fracture of orbit, [439](#)
 Blow-out fracture of orbit, [439](#)
 Blue sclera, 244
 Bobbing, ocular, [491](#)
 Bonnet sign, [156](#)
 Botulinium toxin, [449](#)
 Boumeville's syndrome, [315, 316](#)
 Bowen's disease (intraepithelial epithelioma), 421
 Brachycephaly, [162](#)
 Break-up time (BUT) of tear film, [183](#)
 Brimonidine, 92, 300
 Bromovinyl deoxyuridine (BVDU), 97
 Brown's syndrome, [538](#)
 Brücke's muscle, [23](#)
 Bupivacaine (Marcaine), [94](#)

 CAM vision stimulator, 371
 Canaliculodacryocystorhinostomy, 455
 Canaliculoplasty, 454
 Canaliculorhinostomy, 455
 Canal(s)
 optic, [4](#)
 Petit's, [491](#)
 supraorbital, 5
 zygomatic, 5
Candida albicans, [84](#)
 Canthi, [11](#)
 Canthoplasty, [451](#)
 Canthotomy, [451](#)
 Capsids, 80
 Capsomers, 80
 Carbachol, [91, 299](#)
 Carbon dioxide laser, 158, [162](#)
 Carbonic anhydrase inhibitors, 100
 topical, 100–101
 Carcinoma of eyelids, 175–176
 Caroticocavernous fistula, [161](#)
 Carotid angiography, [151](#)
 Carpenter's syndrome, [538](#)
 Carteolol (ocupress), 300
 Cataract
 acquired, [273–276](#)
 black, 274
 classification of senile, [273](#)
 complicated, 275
 complications and sequelae of cortical, 274
 cortical, senile, [273–274](#)
 cuneiform, [273](#)
 cupuliform, [273](#)
 defined, [271](#)
 developmental, [271–272](#)
 anterior axial embryonic, [271](#)
 anterior polar, [272](#)

- blue-dot (punctate), [272](#)
- Coppock's (central pulverulent or embryonal nuclear), [272](#)
- coronary, [272](#)
- floriform (coralliform), [272](#)
- posterior polar, [272](#)
- sutural, [271](#)
- treatment of, [272](#)
- zonular (lamellar), [271](#)
- diabetic, [275](#)
- diagnosis of senile, [274](#)
- drugs and poisons causing, [276](#)
- history related to [270](#)
- hypermature
 - inspissated, [273](#)
 - Morgagnian, [273](#)
- in hypothyroidism, [275](#)
- iatrogenic, [276](#)
- immature (intumescent), [273](#)
- incipient, [273](#)
- mature, [273](#)
- metabolic, [274](#)
- in mongolism, [275](#)
- in myotonic dystrophy, [275](#)
- nuclear, [274](#)
- in parathyroid deficiency, [275](#)
- posterior cortical, [273](#)
- saucer-shaped, [273](#)
- secondary, [274](#)
- senile, [273–274](#)
 - aetiology of, [273](#)
 - clinical features of, [273](#)
 - pathology of, [273](#)
 - physiochemical changes in, [273](#)
- sunflower, [236](#)
- surgery
 - anaesthesia in, [466](#)
 - complications during, [472–473](#)
 - complications, postoperative, [473](#)
 - extracapsular extraction, [470–471](#)
 - history of, [464](#)
 - intracapsular extraction, [468–470](#)
 - preoperative investigations in, [464](#)
 - preoperative preparation in, [466](#)
 - problems associated with, [465](#)
 - traumatic, [432](#)
- Cataracta
 - glaucomatosa, [561](#)
 - nigra, [561](#)
- Catoptric images, *see* Purkinje–Sanson images
- Cat's eye reflex, [266–268](#), [411](#)
- Cavernous sinus
 - anatomy of, [153](#), [154](#)
 - thrombosis, [153–154](#)
- Cells
 - basal, of cornea, [12](#)
 - colour, [71](#)
 - goblet, [20](#)
 - wandering, [22](#)
 - wing, [22](#)
- Cellulitis, orbital, [152](#), [153](#)
- Central artery of retina, [5](#), [37](#)
- Central crystalline dystrophy, corneal, [332](#)
- Central retinal artery occlusion (CRAO), [144](#), [320–322](#)
- Central retinal vein thrombosis (CRVT), [144](#), [322–325](#)
- Central serous retinopathy, [144](#), [317](#)
- Cephalexin, [96](#)
- Cephalocele, orbital, [163](#)
- Cephalosporins, [96](#)
- Cephalothin, [96](#)
- Cephazolin, [96](#)
- Cephotaxime, [96](#)
- Cerebellar tumours, [394](#)
- Cerebellopontine angle tumours, [393](#), [394](#)
- Cerebral aneurysms, [376](#)
- Cerebral arteries
 - atheroma, [397](#)
 - embolism, [397](#)
 - haemorrhage, [397](#)
 - thrombosis, [397](#)
- Cerebroside lipidoses, *see* Gaucher's syndrome
- Chalazion, [166–167](#)
 - operation, [446](#)
- Chamber
 - anterior, anatomy of, [31](#)
 - posterior, [31–32](#)
- Chandler's syndrome, [538](#)
- Charcot's triad, [395](#)
- Charlin's syndrome, [538](#)
- Chediak–Higashi syndrome, [538](#)
- Chemosiis, [190](#)
- Chemotactic factors, [202](#)
- Chievitz, layer of, [81](#)
- Chlamydia trachomatis*, [81–82](#), [197](#)
- Chlorolabe, [70](#)
- Chloroma, [346](#)
- Chloroquine, [333](#)
- Choked disc, *see* papilloedema
- Cholesterolosis bulbi, *see* synchysis scintillans
- Cholinergic agents, [91](#), [92](#)
- Chorioretinal atrophy (cobblestone or pavingstone degeneration), [329](#)
- Chorioretinal degeneration, [329](#)
- Choroid/choroidal
 - anatomy of, [27–28](#)
 - atrophy, [261–262](#)
 - degenerations, [261–262](#)
 - detachment, [475](#)
 - development, [50](#)
 - inflammations, *see* choroiditis
- Choroideremia (sex-linked tapetochoroidal dystrophy), [337](#)

- Choroiditis, [123](#), 216
 Foerster's 407
 juxtapapillary, 407
 pathology of, 245
 Tay's guttate, [261](#)
- Choroidopathy, serpiginous (helicoid or geographic), [328](#)
- Chromatic aberration, 111
- Chromatopsia, 364, [561](#)
- Chromihydrosis, [561](#)
- Chromosome, 503
 aberrations, [504](#)
- Ciliary arteries, 28
- Ciliary body, anatomy of, [26–27](#)
- Ciliary ganglion, [7](#),
- Cilioretinal vessels, [315](#)
- Ciprofloxacin, 96
- Circinate retinopathy, [332–333](#)
- Circle of Willis, aneurysm of, 146
- Climatic keratopathy, 230
- Clindamycin, 409
- Clonidine, 299
- Coats' disease, [267](#), 351
- Cocaine hydrochloride, [94](#)
- Cockayne's syndrome, [539](#)
- Cogan–Reese syndrome, [539](#)
- Cogan's rule, 562
- Cogan's syndrome, [539](#)
- Coloboma, 506, 508
 of eyelid, [179](#)
 of macula, 314–315
 of retina, 314
- Colour Doppler imaging, [161](#)
- Colour(s)
 complementary, [70](#)
 deficiency, [71–72](#)
 primary, [70](#)
 sense, [72](#)
 shift, [70](#)
 vision, [70–72](#)
 theories of, [70–77](#)
- Commotio retinae, 432
- Compensatory head posture, [376](#)
- Compressive optic neuropathy, 362
- Computerized tomography (CT), 528
 coronal tomography (CCT) 528
- Concomitant strabismus, 379–382
- Concretions (lithiasis), [206](#)
- Concussion injuries, *see* injuries
- Cone-rod dystrophy, [336](#)
- Confocal scanning laser ophthalmoscope (CSLO), 520
- Confusion, 369
- Congenital cataract, *see* developmental cataract
- Congenital ectropion, [179](#)
- Congenital entropion, [179](#)
- Congenital hereditary endothelial corneal dystrophy (CHED), 239
- Congenital oculomotor nerve palsy, [377](#)
- Congenital paralytic strabismus, 378–379
- Congenital syphilis, 407, 509
- Congenital toxoplasmosis, 408, 509
- Congestion, ciliary vs conjunctival, [189](#)
- Conical cornea, *see* keratoconus
- Conidiophore, 82
- Conjunctiva/conjunctival,
 allergy of, 202–205
 anatomy of, 18–21
 arterial supply of, 20, 21
 bacterial flora of, 191
 bleeding from, [190](#)
 congestion (hyperaemia), [189](#)
 cysts, [209](#)
 degenerative conditions of, 205–207
 dermoid cyst of, [209](#)
 dermolipoma of, [209](#)
 development of, [48](#)
 essential shrinkage of, 205
 examination, 130
 fornix, [19](#)
 fungi, in healthy, 191
 glands, 20
 inflammations, *see* conjunctivitis
 lymphatic drainage, 21
 marginal, 18–19
 nerve supply of, 21
 oedema, [190](#)
 orbital, [19](#)
 palpebral, 18–19
 pigmentation, [210](#)
 scarring, 205
 tarsal, [19](#)
 tuberculosis of, 201–202
 tumours, [209–210](#)
 ulcers of, 202
 veins of, 21
 wounds of, [213](#), [433](#)
- Conjunctivitis
 acute, 191–194
 adenoviral, [196](#)
 allergic, 202–205
 angular, [195](#)
 bacterial,
 catarrhal, acute, 191
 chronic, [194](#)
 classification, 191
 diphtheritic, [194](#)
 follicular, [195–196](#)
 gonococcal, [193](#)
 haemorrhagic, epidemic, [196–197](#)
 infective, aetiological types of, 191
 Koch–Weeks, [192](#)
 lacrimal, [195](#)
 ligneous, [195](#)

- Meibomiana, [195](#)
- membranous, [193–194](#)
- mucopurulent, acute, 191–192
- petrificans, [195](#)
- phlyctenular, 202–204
- pneumococcal, 191
- purulent, acute, [192–193](#)
- staphylococcal, 191
- tuberculous, 201–202
- vernal (spring catarrh), 201, 204
- viral, 191, [196](#)
- Conjunctivodacryocystostomy, 455
- Conjunctivorhinostomy, 455
- Connective tissue diseases, 413–415
- Contact lens, [120–122](#)
 - in aphakia, [120](#), [121](#)
 - in astigmatism, 118
 - central posterior curve (CPC) of, [121](#)
 - complications, [122](#)
 - fitting of, [121](#)
 - haptic, [121](#)
 - hard or conventional, [121](#)
 - indications of, [120](#)
 - K reading in, [121](#)
 - in myopia, 115
 - optical principles in, [120](#)
 - soft, [122](#)
- Contrast sensitivity, 465
- Contusion, effects on
 - cornea, [212](#), 430
 - eyelids, 430
 - iris, 431
 - lens, 430
 - macula, 432
 - vitreous, 432
- Convergence, 65–67
 - accommodation, relation with, [66](#)
 - amplitude of, [66](#)
 - anomalies, [66](#)
 - excess, [66](#), 381, 384
 - far point of, [66](#)
 - insufficiency, [66](#), 381, 384
 - measurement of, 65
 - near point of, [66](#), 386
 - negative, [66](#)
 - pathway, 65
 - positive, [66](#)
 - range of, [66](#)
- Convergent squint, *see* esotropia
- Coordinator, 387
- 'Copper-wire' arteries, [340](#)
- Coppock's cataract, [272](#)
- Corectopia, 508
- Cornea/corneal
 - abrasions, [212](#), [450](#)
 - abscess, [215](#)
 - anatomy of, 21–24
 - blood staining, [212–213](#), 430, 431
 - congenital anomalies involving cornea, 238–239
 - congenital opacification, 239
 - conical, *see* keratoconus
 - contusion, [212](#)
 - desiccation, [224](#)
 - degenerations, [227–230](#)
 - amyloid, [229](#)
 - hyaline, [228](#)
 - lipoid, [229](#)
 - pigmentary, [228](#)
 - pullucid, [229](#)
 - Salzmann's nodular, [228](#)
 - Terrien's, [229](#)
 - dystrophies, 230–234
 - anterior membrane, 231
 - bleb-like, 231
 - central crystalline, 232
 - Cogan's microcystic or finger-print map-dot, 231
 - congenital hereditary endothelial, 239
 - ectatic, *see* keratoconus
 - epithelial basement membrane, 231
 - fleck or speckled 231
 - Fuchs' endothelial, 232–233
 - granular or Groenouw type, 232
 - Grayson–Wilbrandt, 231
 - juvenile epithelial, 231
 - lattice, 232
 - macular or Groenouw type II, 232
 - polymorphic, 231
 - Reis–Bückler's, 231
 - Schnyder's, 231
 - vortex, 231
 - diagnosis, [215](#)
 - diplobacillary, [218](#)
 - erosions, recurrent, 230
 - farinata, [228](#)
 - healing of wounds of, [213](#)
 - history related to diseases of, [211](#)
 - hypopyon, 217
 - inflammations, *see* keratitis
 - injury of, 430, 431
 - marginal, 217
 - metabolism, [59–60](#)
 - metastatic, [218](#)
 - Mooren's, [229–230](#)
 - morphologic classification of, 217
 - mycotic, [226–227](#)
 - nerve supply of, [23–24](#)
 - nutrition, [59](#)
 - oedema, 236–237
 - opacities, [211](#)
 - pathology of, [214](#)
 - perforation, [215](#)
 - permeability, [60](#)

