


Nicola Maffulli  
Mark Easley  
*Editors*



**Minimally Invasive  
Surgery for Achilles  
Tendon Disorders in  
Clinical Practice**



Springer

Minimally Invasive  
Surgery for Achilles Tendon  
Disorders in Clinical Practice



Nicola Maffulli • Mark Easley  
Editors

# Minimally Invasive Surgery for Achilles Tendon Disorders in Clinical Practice

 Springer

*Editors*

Nicola Maffulli  
Mile End Hospital  
London  
United Kingdom

Mark Easley  
Duke Health Center  
Durham  
North Carolina  
USA

Originally published as part of Minimally Invasive Surgery of the Foot and Ankle (ISBN-978-1-84996-417-3) in 2011.

ISBN 978-1-4471-4497-7      ISBN 978-1-4471-4498-4 (eBook)  
DOI 10.1007/978-1-4471-4498-4  
Springer London Heidelberg New York Dordrecht

Library of Congress Control Number: 2012951635

© Springer-Verlag London 2013

This work is subject to copyright. All rights are reserved by the Publisher, whether the whole or part of the material is concerned, specifically the rights of translation, reprinting, reuse of illustrations, recitation, broadcasting, reproduction on microfilms or in any other physical way, and transmission or information storage and retrieval, electronic adaptation, computer software, or by similar or dissimilar methodology now known or hereafter developed. Exempted from this legal reservation are brief excerpts in connection with reviews or scholarly analysis or material supplied specifically for the purpose of being entered and executed on a computer system, for exclusive use by the purchaser of the work. Duplication of this publication or parts thereof is permitted only under the provisions of the Copyright Law of the Publisher's location, in its current version, and permission for use must always be obtained from Springer. Permissions for use may be obtained through RightsLink at the Copyright Clearance Center. Violations are liable to prosecution under the respective Copyright Law.

The use of general descriptive names, registered names, trademarks, service marks, etc. in this publication does not imply, even in the absence of a specific statement, that such names are exempt from the relevant protective laws and regulations and therefore free for general use.

While the advice and information in this book are believed to be true and accurate at the date of publication, neither the authors nor the editors nor the publisher can accept any legal responsibility for any errors or omissions that may be made. The publisher makes no warranty, express or implied, with respect to the material contained herein.

Printed on acid-free paper

Springer is part of Springer Science+Business Media ([www.springer.com](http://www.springer.com))

# Preface

The tendo Achillis, the largest and strongest tendon in the body, is the most frequently injured. Overuse and acute injuries plague it, their management is complex, the results not guaranteed. A few things, however, hold true: there is not much scientific evidence behind what we do, and there is much controversy about anything we do in this particular field. Also, the rate of complications of traditional surgery is staggeringly high: in the management of tendinopathy, traditional techniques result in 10 % of patients experiencing a complication related to skin healing. It is therefore not surprising that less invasive techniques have been advocated. In this book, we illustrate the most advanced minimally invasive techniques: they can be hard to master, but they are for the benefit of the patients.



# Contents

<b>1 Endoscopic Assisted Percutaneous Achilles Tendon Repair</b> .....	1
Mahmut Nedim Doral, Murat Bozkurt, Egemen Turhan, and Ozgür Ahmet Atay	
<b>2 Percutaneous Repair of Acute Achilles Tendon Ruptures: The Maffulli Procedure</b> .....	15
Nicola Maffulli, Francesco Oliva, and Mario Ronga	
<b>3 Minimally Invasive Semitendinosus Tendon Graft Augmentation for Reconstruction of Chronic Tears of the Achilles Tendon</b> .....	25
Nicola Maffulli, Umile Giuseppe Longo, Filippo Spiezia, and Vincenzo Denaro	
<b>4 Minimally Invasive Achilles Tendon Reconstruction Using the Peroneus Brevis Tendon Graft</b> .....	35
Nicola Maffulli, Filippo Spiezia, Umile Giuseppe Longo, and Vincenzo Denaro	
<b>5 Free Hamstrings Tendon Transfer and Interference Screw Fixation for Less Invasive Reconstruction of Chronic Avulsions of the Achilles Tendon</b> .....	45
Nicola Maffulli, Umile Giuseppe Longo, Filippo Spiezia, and Vincenzo Denaro	



<b>6 Percutaneous Longitudinal Tenotomies for Chronic Achilles Tendinopathy</b> .....	55
J.S. Young, M.K. Sayana, V. Testa, F. Spiezia, U.G. Longo, and Nicola Maffulli	
<b>7 Minimally Invasive Stripping for Chronic Achilles Tendinopathy</b> .....	69
Nicola Maffulli, Umile Giuseppe Longo, Chandrasekar Ramamurthy, and Vincenzo Denaro	
<b>Index</b> .....	77

# Chapter 1

## Endoscopic Assisted Percutaneous Achilles Tendon Repair

**Mahmut Nedim Doral, Murat Bozkurt, Egemen Turhan,  
and Ozgür Ahmet Atay**

The Achilles tendon is the strongest tendon in the human body [1]. Hippocrates said “this tendon, if bruised or cut, causes the most acute fevers, induces choking, deranges the mind and at length brings death” [2]. Achilles tendon rupture has been the focus of many studies since Ambroise Paré initially

---

M.N. Doral, M.D. (✉)

Department of Orthopedics and Sports Medicine, Faculty of Medicine,  
Hacettepe University, Sıhhiye, Ankara 06100, Turkey

Sports Medicine Department, Hacettepe University,  
Ankara, Turkey

e-mail: mn-doral@bim.net.tr, ndoral@hacettepe.edu.tr

M. Bozkurt

Department of Orthopedics and Traumatology,  
Ankara Etlik Training Hospital, Ankara, Turkey

E. Turhan

Department of Orthopedics and Traumatology, Faculty of Medicine,  
Karaelmas University, Zonguldak, Turkey

O.A. Atay

Department of Orthopedics and Sports Medicine,  
Faculty of Medicine, Hacettepe University,  
Sıhhiye, Ankara 06100, Turkey

described it in 1575 [3]. Achilles tendon ruptures are the third most frequent major tendon ruptures, following rotator cuff and quadriceps ruptures [4, 5]. Nevertheless, there is no consensus on the optimal management, and management is still determined by the preferences of the surgeon and the patient. Cast immobilization may lead to suboptimal healing, with elongation of the tendon, reduced strength of the calf muscles, and an unacceptably high rate of re-rupture [6–10].

Open surgical repair of the Achilles tendon carries specific risks including adhesions between the tendon and the skin, infection, and particularly wound breakdown [11–14]. Although Ma and Griffith introduced the percutaneous repair technique to avoid these complications, percutaneous repair may not achieve satisfactory contact of the tendon stumps and adequate initial fixation [15]. In addition, sural nerve entrapment is a reported complication of this technique [16, 17]. Only recently have safe and sound techniques been developed, and some are described in other chapters of this book by Prof Maffulli.

Percutaneous repair has become popular. The advantages of the operative and conservative methods are combined in minimally invasive percutaneous repair techniques, but these techniques do not allow direct visualization of the tendon ends (Fig. 1.1). This may be overcome by performing the percutaneous repair under endoscopic control [18–27].

## 1.1 The Technique of Endoscopy Assisted Percutaneous Repair

The operation is performed with the patients in prone position with infiltration of local anesthesia in the area to be operated on. No tourniquet is used, and we do not use antibiotic or anti-thrombotic prophylaxis. Before starting the procedure, the rupture site is marked (Fig. 1.2). Then, to minimize local bleeding, proximal (about 5 cm) and distal (about 4 cm) to the palpated gap, the skin, subcutaneous tissues, and peritendon are infiltrated with 20–50 mL 0.9 % saline solution with local anesthetic

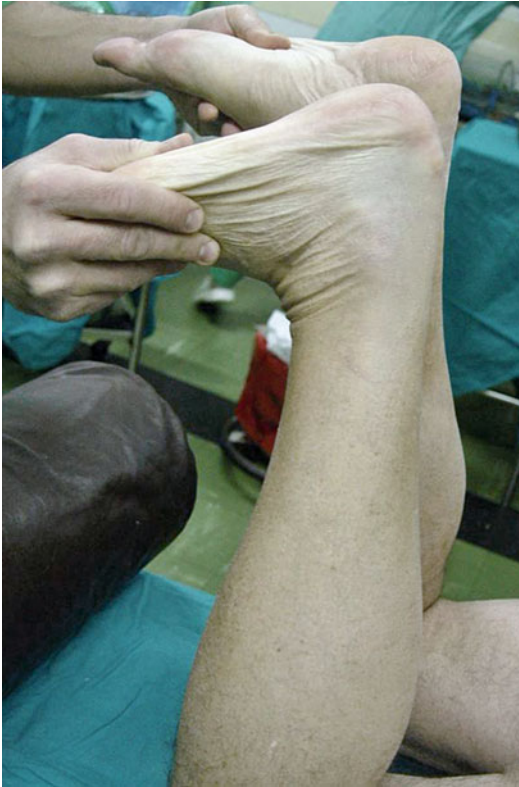

FIGURE 1.1 Greater dorsiflexion on the ruptured side than on the healthy side

(1 % Citanest® 5 mL+0.5 % Marcain® 5 mL) around the 8 planned stab wounds, 4 medial and 4 lateral to the tendon, distributed evenly proximally and distal to the rupture (Fig. 1.3), These stab wounds are later enlarged with the nick and spread technique, and used for needle entry. Special attention is paid to the area lateral to the Achilles tendon, especially proximally, where the sural nerve lies close to and crosses the Achilles tendon. The patient is prompted to report any paresthesiae or pain in the area of distribution of the sural nerve at any time

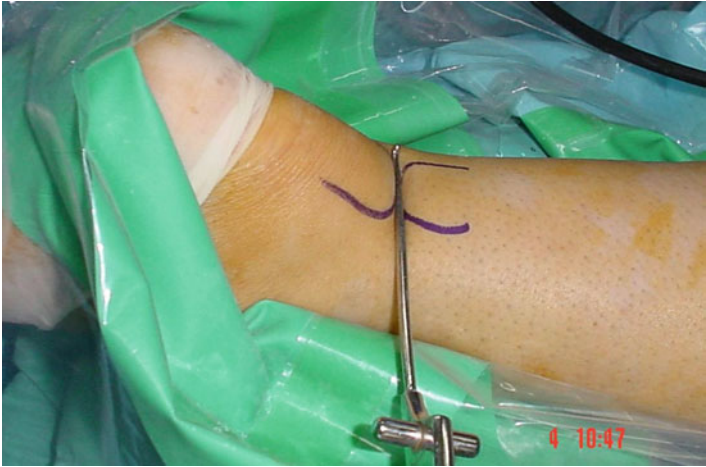

FIGURE I.2 Palpation of the gap between the ruptured tendon ends using an arthroscopic probe

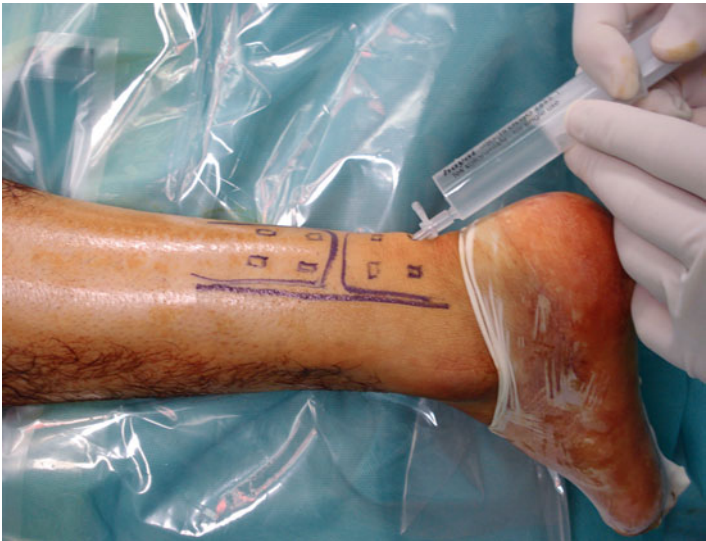

FIGURE I.3 Local anaesthetic injection to the subcutaneous tissues from the stab incisions

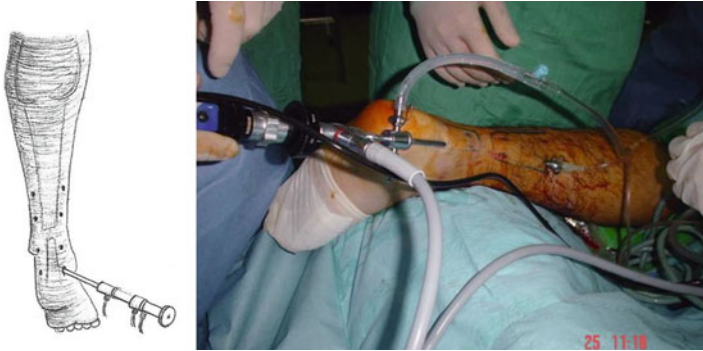

FIGURE 1.4 The placement of the arthroscope from distal medial incision

during the injection of local anaesthetic or during the procedure. If this is experienced, the injection site is moved 0.5–1 cm toward the midline. The injured foot is positioned in approximately  $15^\circ$  of plantar flexion. The tendon and paratenon are examined with a  $30^\circ$  arthroscope (Smith-Nephew, London) via the distal medial incision (Fig. 1.4). After the level of the rupture has been determined, the continuity of the surrounding tissues together with their consistency and vascularization are evaluated. The torn ends of the Achilles tendons are inspected, and, if necessary, are manipulated within the paratenon. The passing of the suture through the Achilles tendon is also controlled with the scope. We use an Ethibond No.5 or PDS No. 5 (Ethicon Inc, Johnson & Johnson, Somerville, NJ) suture with a modified Bunnell configuration.

The needle with the PDS or Ethibond suture is first introduced through the upper medial portal (shown as '1' in Fig. 1.5a). The Achilles tendon is gently palpated between the thumb and the index finger of the opposite hand to make sure that it is caught fully by the needle. This first bite is a transverse one, and the needle emerges from the upper lateral portal (shown as '2' in Fig. 1.5a). The needle is then retrieved, introduced again through it and passed through the upper lateral portal towards portal 3. The procedure is repeated in a proximal to distal direction going from portal 3 to portal 4, from portal 4 to portal 5,

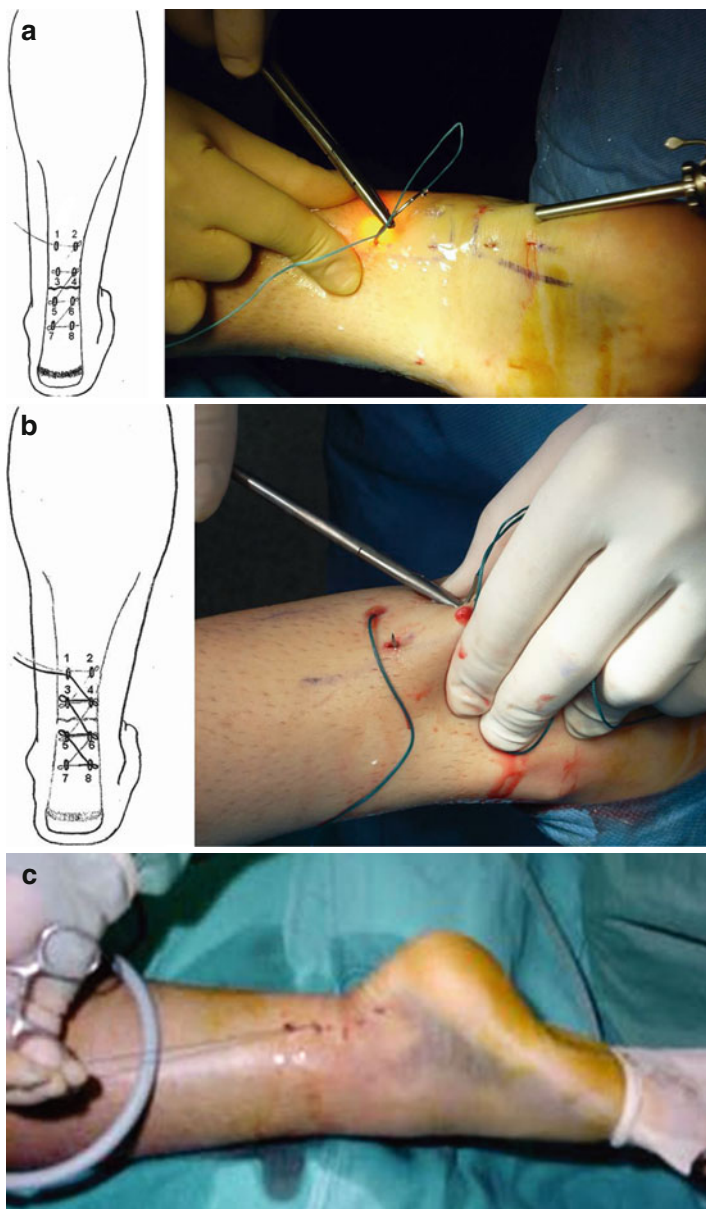


FIGURE 1.5 (a, b) Schematic diagram of the percutaneous technique (please refer to the text for details). (c) The sutures are tied with the ankle in the neutral position

from portal 5 to portal 6, from portal 6 to portal 7, and from portal 7 to portal 8, the distal most lateral portal. At this point, the needle is retrieved from portal 8, introduced through it and passed through the distal most lateral portal towards portal 5, and the procedure described above repeated backward in a distal to proximal direction until the needle is finally returned to the upper medial portal (shown as '1' in Fig. 1.5b).

First, we pass the suture from the proximal medial incision and out from the medial incision just above the ruptured tendon, making sure that the body of the proximal stump of the tendon is squeezed between the thumb and index (Fig. 1.5a). Second, we pass the suture from the same incision and out from the lateral stab incision just above the tendon (Fig. 1.5a). Finally, as in the first step, the suture is passed through this stab incision and out from the distal medial side (Fig. 1.5a).

During suture passage, the arthroscope is placed alternatively in the various entry portals, and the Achilles tendon is inspected from the medial and lateral aspects, and the proximal and distal stumps are inspected from proximal and distal to make sure that the tendon stumps are juxtaposed. Also, through the endoscope we make sure that the sutures are introduced in the tendon at different levels on the coronal plane, so that the chance of them cutting through during the process of tensioning is minimized.

Finally, the sutures are tensioned, and tied in the proximal medial entry portal with the ankle in neutral position whilst checking the tendon approximation through the arthroscope. Before tying the sutures with the ankle in neutral position, the patient is instructed to actively dorsi- and plantar-flex the ankle with the knee at 90° of flexion (Fig. 1.5c) to make sure that appropriate tension is imparted to the suture. A final check is performed, and the suture is knotted fully.

The skin stab incisions are closed with subcutaneous suture and steristrips are used for initial dressing, and a walking brace with the ankle in neutral is applied for at least 3 weeks (Fig. 1.6).

Immediate weight-bearing as tolerated with a walking brace is initiated (for 3 weeks only), alternating with passive range of motion exercises. Physiotherapy includes electrical stimulation of the gastrosoleus complex; cryotherapy and therapeutic ultrasound are applied around the Achilles tendon



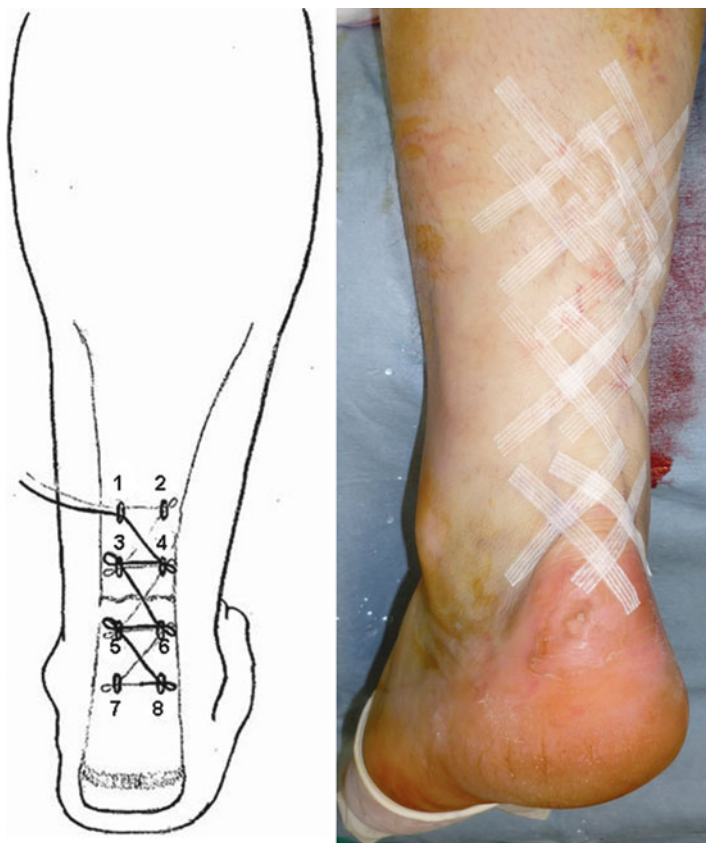


FIGURE 1.6 Final stab wound closure with steristrips

for reduction of edema. Transverse friction massage is used to promote scar and tendon re-formation.

Patients are instructed to move the ankle four times a day between  $20^{\circ}$  of plantar flexion and  $10^{\circ}$  of dorsiflexion. The patients complete gentle isometric, eccentric and concentric exercises of the ankle several times a day, with flexion and extension of the toes in a supine position, and full plantar flexion and dorsiflexion of the ankle to neutral in a supine position; extension of the knee in a sitting position; flexion of the knee in a prone

position; and extension of the hip in a prone position within first 3 weeks. The walking brace is discontinued after 3 weeks. From the sixth week to tenth week, rehabilitation progresses to using elastic resistance bands; rotation of the ankles; standing on the toes and heels; ankle stretching exercises to flexion with the help of a rubber band; stretching of the calf muscle by standing with the leg to be stretched straight behind and the other leg bent in front and leaning the body forward, with support from a wall or physiotherapist; stretching exercises for the toes and ankle against manual resistance in a sitting position; balance and proprioception exercises on different surface progress from bilateral to unilateral; controlled squats, lunges, bilateral calf raise (progressing to unilateral), toe raises, controlled slow eccentrics vs. body-weight. After 10 weeks, patients start training jogging/running, jumping and eccentric loading exercises, non-competitive sporting activities, sports-specific exercises, and return to physically demanding sports and/or work.

#### Rehabilitation process

---

0–3 weeks:	Range of motion: 20° of plantar flexion and 10° of dorsiflexion
0–6 weeks:	Gentle isometric, eccentric and concentric exercises with flexion and extension of the toes, full plantar flexion and dorsiflexion of the ankle to neutral in a supine position; extension of the knee in a sitting position; flexion of the knee in a prone position; and extension of the hip in a prone position
6–10 weeks:	Resistance exercises, rotation of the ankles; standing on the toes and heels; ankle stretching exercises for calf muscles, the toes and ankle, balance and proprioception exercises on different surface progress from bilateral to unilateral; controlled squats, lunges, bilateral calf raise (progressing to unilateral), toe raises, controlled slow eccentrics vs. body-weight
10–↑ weeks:	Start training jogging/running, jumping and eccentric loading exercises, non-competitive sporting activities, sports-specific exercises, and return to physically demanding sports and/or work

---

Endoscopy-assisted percutaneous repair allows direct observation of the process of suturing the Achilles tendon. This eliminates some of the disadvantages of the percutaneous repair techniques, especially the evaluation of the juxtaposition of the torn ends [18, 30–32]. Endoscopy-assisted percutaneous repair allows early active ankle mobilization and weight bearing after a short period of cast immobilization and thereby, prevents complications due to the prolonged immobilization such as arthrofibrosis, joint stiffness, calf atrophy, damage to the articular cartilage, and deep vein thrombosis. Buchgraber and Pässler [28] compared the results of immobilization and functional postoperative treatment after percutaneous repair of Achilles tendon rupture and found that functional postoperative rehabilitation with early weight-bearing was associated with significantly less severe calf muscle work by the injured leg than postoperative immobilization. Considering these advantages, endoscopy-assisted percutaneous repair of AT may prevent some of the negative issues associated with open, conservative, or percutaneous techniques. Also, this technique could help to prevent the risk of damage to the sural nerve by allowing its direct visualization. However, we stress that knowledge of the local anatomy is necessary to place the stab wounds in the areas less likely to damage this nerve [29, 33].

In endoscopic repair, the paratenon is protected, providing a biological advantage to the mechanical strength of the repair furnished by the suture material. Also, preservation of the paratenon decreases the gliding resistance of the extrasynovial tendons after repetitive motion *in vitro* [33]. Achilles tendoscopy allows direct observation of the hematoma and the stab wounds, and controlled juxtaposition of the tendon ends without damaging the paratenon [34, 35].

Any technique may result in lengthening of the Achilles tendon, possibly from not having closely approximated the tendon ends. Carmont and Maffulli recommend a mini open technique, with a 1.2–1.5 cm transverse incision at the level of the rupture, to directly observe that appropriate juxtaposition of the ruptured tendon ends had been achieved [36].

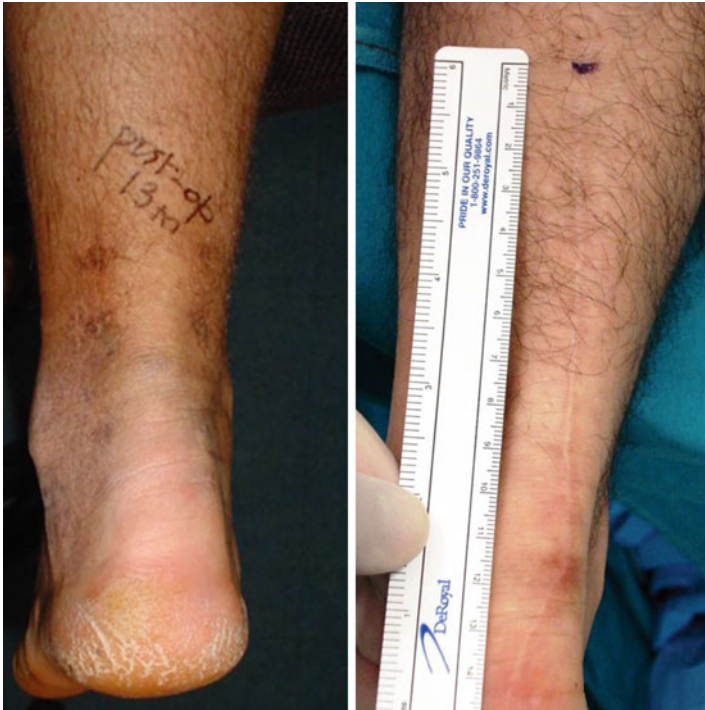

FIGURE 1.7 Bilaterally operated patient of AT rupture. *Left side* is operated with percutaneous method and *right side* was operated with open surgery previously. The appearance of the wound is cosmetic with percutaneous method

Direct visualization of the tendon ends by endoscope through the stab incisions allows this without any additional incision.

Obviously, the procedure requires experience in soft tissue endoscopy. Percutaneous repair of the Achilles tendon under endoscopic control results excellent wound appearance (Fig. 1.7), This technique resulted in a cosmetic wound appearance, endurable to early-active mobilization and satisfactory clinical recovery without any severe complication. Furthermore, this procedure protects the paratenon, and should enhance biologic recovery. Direct visualization and

manipulation of the tendon ends also provide stable repair that allows early weight-bearing and ambulation, and we have used in athletic individuals. Percutaneous repair is likely more cost effective than open techniques, and, in some settings, endoscopic control carries no additional costs [37].

**Acknowledgement** We would like to thank to Professor Nicola Maffulli for his support and Dr. M. Ayvaz and Dr. G. Dönmez for archiving and pictures.

## References

1. Maffulli N. Rupture of the Achilles tendon. *J Bone Joint Surg Am.* 1999;81:1019–36.
2. Carden DG, Noble J, Chalmers J, et al. Rupture of the calcaneal tendon. The early and late management. *J Bone Joint Surg Br.* 1987; 69:416–20.
3. Cetti R, Christensen SE, Ejsted R, et al. Operative versus nonoperative treatment of Achilles tendon rupture. A prospective randomized study and review of the literature. *Am J Sports Med.* 1993;21:791–9.
4. Hattrup SJ, Johnson KA. A review of ruptures of the Achilles tendon. *Foot Ankle.* 1985;6(1):34–8.
5. Weiner AD, Lipscomb PR. Rupture of muscles and tendons. *Minn Med.* 1956;39(11):731–6.
6. Edna TH. Non-operative treatment of Achilles tendon ruptures. *Acta Orthop Scand.* 1980;51:991–3.
7. Fierro N, Sallis R. Achilles tendon rupture: is casting enough? *Postgrad Med.* 1995;98:145–51.
8. Inglis AE, Scott WN, Sculco TP, et al. Ruptures of the tendo Achillis. *J Bone Joint Surg Am.* 1976;58:990–3.
9. Jacobs D, Martens M, Van Audekercke R, et al. Comparison of conservative and operative treatment of Achilles tendon ruptures. *Am J Sports Med.* 1978;6:107–11.
10. Leppilahti J, Puranen J, Orava S. Incidence of Achilles tendon rupture. *Acta Orthop Scand.* 1996;67:277–9.
11. Aoki M, Ogiwara N, Ohta T, Nabeta Y. Early active motion and weightbearing after cross-stitch achilles tendon repair. *Am J Sports Med.* 1998;26(6):794–800.
12. Bhandari M, Guyatt GH, Siddique F, et al. Treatment of acute Achilles tendon ruptures a systematic overview and meta-analysis. *Clin Orthop.* 2002;400:190–200.
13. Kangas J, Pajala A, Siira P, et al. Early functional treatment versus early immobilization in tension of the musculotendinous unit after

- Achilles rupture repair: a prospective, randomized, clinical study. *J Trauma*. 2003;54:1171–80.
14. Mortensen NHM, Skov O, Jensen PE. Early motion of the ankle after operative treatment of a rupture of the Achilles tendon: A prospective randomized clinical and radiographic study. *J Bone Joint Surg Am*. 1999;81:983–90.
  15. Ma GWC, Griffith TG. Percutaneous repair of acute closed ruptured Achilles tendon. A new technique. *Clin Orthop*. 1977;128:247–55.
  16. Klein W, Lang DM, Saleh M. The use of the Ma-Griffith technique for percutaneous repair of fresh ruptured tendo Achillis. *Chir Organi Mov*. 1991;76(3):223–8. English, Italian.
  17. Rowley DI, Scotland TR. Rupture of the Achilles tendon treated by a simple operative procedure. *Injury*. 1982;14(3):252–4.
  18. Tang KL, Thermann H, Dai G, Chen GX, Guo L, Yang L. Arthroscopically assisted percutaneous repair of fresh closed Achilles tendon rupture by Kessler's suture. *Am J Sports Med*. 2007;35(4):589–96.
  19. Thermann H, Tibesku CO, Mastrokalos DS, Pässler HH. Endoscopically assisted percutaneous achilles tendon suture. *Foot Ankle Int*. 2001;22(2):158–60.
  20. Assal M, Jung M, Stern R, Rippstein P, Delmi M, Hoffmeyer P. Limited open repair of Achilles tendon ruptures: a technique with a new instrument and findings of a prospective multicenter study. *J Bone Joint Surg Am*. 2002;84-A(2):161–70.
  21. Barfred T. Experimental rupture of the Achilles tendon. Comparison of various types of experimental rupture in rats. *Acta Orthop Scand*. 1971;42(6):528–43.
  22. Kannus P, Józsa L. Histopathological changes preceding spontaneous rupture of a tendon A controlled study of 891 patients. *J Bone Joint Surg Am*. 1991;73(10):1507–25.
  23. Inglis AE, Sculco TP. Surgical repair of ruptures of the tendo Achillis. *Clin Orthop Relat Res*. 1981;156:160–9.
  24. Kannus P. Etiology and pathophysiology of chronic tendon disorders in sports. *Scand J Med Sci Sports*. 1997;7(2):78–85.
  25. Zantop T, Tillmann B, Petersen W. Quantitative assessment of blood vessels of the human Achilles tendon: an immunohistochemical cadaver study. *Arch Orthop Trauma Surg*. 2003;123(9):501–4.
  26. Nistor L. Surgical and non-surgical treatment of Achilles tendon rupture. A prospective randomized study. *J Bone Joint Surg Am*. 1981;63:394–9.
  27. Bradley JP, Tibone JE. Percutaneous and open surgical repairs of Achilles tendon ruptures. *Am J Sports Med*. 1990;18:188–95.
  28. Buchgrabber A, Pässler HH. Percutaneous repair of Achilles tendon rupture. Immobilization versus functional postoperative treatment. *Clin Orthop*. 1997;341:113–22.
  29. Gorschewsky O, Vogel U, Schweizer A, et al. Percutaneous tenodesis of the Achilles tendon. A new surgical method for the treatment of

- acute Achilles tendon rupture through percutaneous tenodesis. *Injury*. 1999;30:315–21.
30. Halasi T, Tállay A, Berkes I. Percutaneous Achilles tendon repair with and without endoscopic control. *Knee Surg Sports Traumatol Arthrosc*. 2003;11(6):409–14.
  31. Rebeccato A, Santini S, Salmaso G, Nogarin L. Repair of the achilles tendon rupture: a functional comparison of three surgical techniques. *J Foot Ankle Surg*. 2001;40(4):188–94.
  32. Webb JM, Bannister GC. Percutaneous repair of the ruptured tendo Achilles. *J Bone Joint Surg Br*. 1999;81:877–80.
  33. McClelland D, Maffulli N. Percutaneous repair of ruptured Achilles tendon. *J R Coll Surg Edinb*. 2002;47(4):613–8.
  34. Momose T, Amadio PC, Zobitz ME, Zhao C, An KN. Effect of paratenon and repetitive motion on the gliding resistance of tendon of extrasynovial origin. *Clin Anat*. 2002;15(3):199–205.
  35. Doral MN, Tetik O, Atay OA, Leblebicioğlu G, Oznur A. Achilles tendon diseases and its management. *Acta Orthop Traumatol Turc*. 2002;36 Suppl 1:42–6.
  36. Carmont MR, Maffulli N. Modified percutaneous repair of ruptured Achilles tendon. *Knee Surg Sports Traumatol Arthrosc*. 2008;16(2):199–203.
  37. Ebinesan AD, Sarai BS, Walley GD, Maffulli N. Conservative, open or percutaneous repair for acute rupture of the Achilles tendon. *Disabil Rehabil*. 2008;30(20):1721–5.

# Chapter 2

## Percutaneous Repair of Acute Achilles Tendon Ruptures: The Maffulli Procedure

**Nicola Maffulli, Francesco Oliva, and Mario Ronga**

### 2.1 Introduction

The Achilles tendon (AT) is the strongest tendon in the human body, but despite its strength, is the most frequently ruptured tendon in the body. Ruptures usually occur between 2 and 6 cm of its insertion into the superior surface of the calcaneus, a relatively hypovascular area [7, 17]. The major

---

N. Maffulli, M.D., M.S., Ph.D., FRCS (Orth) (✉)  
Centre for Sports and Exercise Medicine, Barts and The London  
School of Medicine and Dentistry, Mile End Hospital, Queen Mary  
University of London, 275 Bancroft Road, London E1 4DG, UK

Department of Trauma and Orthopaedic Surgery,  
Keele University School of Medicine, University Hospital  
of North Staffordshire Hartshill, Thornburrow Drive,  
Stoke-on-Trent, Staffordshire, ST4 7QB, UK  
e-mail: n.maffulli@qmul.ac.uk

F. Oliva, M.D., Ph.D.  
Department of Trauma and Orthopaedic Surgery,  
University of Rome “Tor Vergata”, Viale Oxford 81, Rome, Italy

M. Ronga, M.D.  
Department of Orthopaedic and Trauma Surgery,  
University of Insubria, Varese, Italy

N. Maffulli, M. Easley (eds.), *Minimally Invasive Surgery  
for Achilles Tendon Disorders in Clinical Practice*,  
DOI 10.1007/978-1-4471-4498-4\_2,  
© Springer-Verlag London 2013



blood supply to tendons is from the mesotendon, and the largest supply is from the anterior mesentery [2]. The tendon is at the greatest risk of rupture when it is obliquely loaded, the muscle is contracting maximally, and tendon length is short [12]. This usually occurs as a result of pushing off with the foot against resistance, and occurs most frequently in males in their fourth decade.

The diagnosis of acute AT rupture is generally made clinically. There is usually a palpable defect in the AT. Patients will often report that they felt as though they had been struck at the back of the heel and may have heard a snapping sound. They are usually unable to weight bear on the affected limb because of pain and/or weakness. If some time has elapsed since the rupture, the diagnosis can be more difficult, as the gap fills in with edema and palpation is unreliable. Various tests can be employed to aid diagnosis [11, 13, 14], such as calf squeeze test [14], the Matles test can also be used [11], and the needle test. The neurovascular status of the limb should be assessed, in particular the sensation over the distribution of the sural nerve, and documented

Open surgical management of patients with ruptured ATs allows accurate apposition of the ruptured tendon ends, earlier motion, has a low risk of re-rupture, but is associated with a significant rate of wound healing problems.

Advocates of minimally invasive AT surgery cite faster recovery times, shorter hospital stays, and improved functional outcomes as the principal reasons for adopting these new approaches when compared to traditional open techniques.

In this chapter we describe a minimally invasive technique to repair acute AT rupture.

## 2.2 Surgical Technique

The patient is positioned prone [3]. Areas 4–6 cm proximal and distal to the palpable tendon defect and the skin over the defect are infiltrated with 20 mL of 1 % Lignocaine. 10 mL of

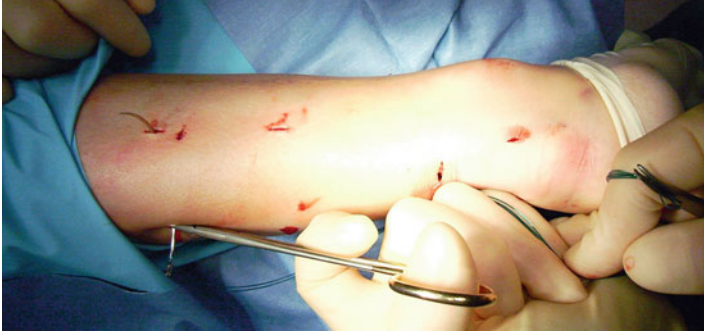

FIGURE 2.1 A 9 cm Mayo needle (BL059N, #B00 round point spring eye, B Braun, Aesculap, Tuttlingen, Germany) is threaded with two double loops of Number 1 Maxon (Tyco Healthcare, Norwalk, CT), and this is passed transversely between the proximal stab incisions through the bulk of the tendon

Chirocaine 0.5 % are infiltrated deep to the tendon defect. A calf tourniquet, skin preparation and steridrapes are applied.

A 1 cm transverse incision is made over the defect using a size 11 blade. Four longitudinal stab incisions are made lateral and medial to the tendon 6 cm proximal to the palpable defect. Two further longitudinal incisions on either side of the tendon are made 4–6 cm distal to the palpable defect. Forceps are then used to mobilize the tendon from beneath the subcutaneous tissues. A 9 cm Mayo needle (BL059N, #B00 round point spring eye, B Braun, Aesculap, Tuttlingen, Germany) is threaded with 2 double loops of Number 1 Maxon (Tyco Healthcare, Norwalk, CT), and this is passed transversely between the proximal stab incisions through the bulk of the tendon (Fig. 2.1). The bulk of the tendon is surprisingly superficial. The loose ends of the suture are held with a clip. In turn, each of the ends is then passed distally from just proximal to the transverse Maxon passage through the bulk of the tendon to pass out of the diagonally opposing stab incision. A subsequent diagonal pass is then made to the transverse

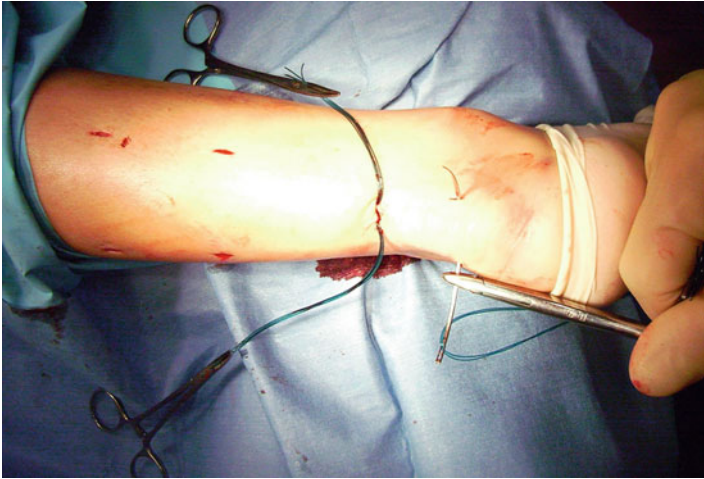


FIGURE 2.2 Another double loop of Maxon is then passed between the distal stabs incisions through the tendon

incision over the ruptured tendon. To prevent entanglement, both ends of the Maxon are held in separate clips. This suture is then tested for security by pulling with both ends of the Maxon distally. Another double loop of Maxon is then passed between the distal stabs incisions through the tendon (Fig. 2.2), and in turn through the tendon and out of the transverse incision starting distal to the transverse passage in a half Kessler configuration (Fig. 2.3). The ankle is held in full plantar flexion, and in turn opposing ends of the Maxon thread are tied together with a double throw knot, and then three further throws before being buried using the forceps. A clip is used to hold the first throw of the lateral side to maintain the tension of the suture.

A subcuticular Biosyn suture 3.0 (Tyco Healthcare) is used to close the transverse incision, and Steri-strips (3M Health Care, St Paul, MN) are applied to the stab incisions. Finally, a Mepore dressing (Molnlycke Health Care, Gothenburg, Sweden) is applied, and a bivalved removable scotch cast in full plantar flexion is applied being held in place with Velcro straps.

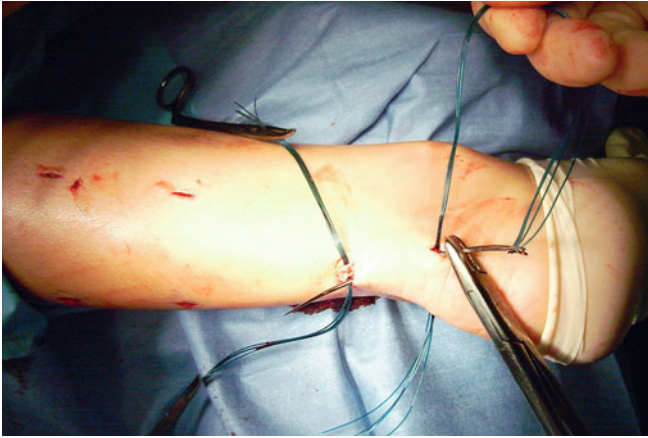


FIGURE 2.3 The double loop of Maxon is passed in turn through the tendon and out of the transverse incision starting distal to the transverse passage

## 2.3 Postoperative Regimen

The patient is allowed home on the day of surgery, and fully weight bears as able in the cast in full plantar flexion. At 2 weeks, the wounds are inspected, and the back shell is removed allowing proprioception, plantar flexion, inversion and eversion exercises. The front shell remains in place for 6 weeks to prevent forced inadvertent dorsiflexion of the ankle.

## 2.4 Discussion

Several percutaneous repair techniques have been described [4, 5, 9, 15, 16]. Ma and Griffith described a technique of percutaneous repair of the AT in 18 patients using stab incisions over the tendon [9]. The suture was passed through stab incisions and crisscrossed through the tendon.

Gorschewsky et al. described a technique using barbed suture wires passed from proximal to distal to pull the retracted

proximal stump distally and approximate the ruptured tendon ends. Fibrin glue was then applied to the repair. The wires were removed at 3 weeks. At 1 year follow-up in 20 patients there was one re-rupture and no other complications [5].

Webb and Bannister described a new percutaneous technique that reduced the potential risk to the sural nerve by placing the most proximal of the incisions to the medial side, away from the nerve [14]. We described a percutaneous technique of repair of the ruptured ATs similar to that described by Webb and Bannister [15], but using a more secure suture configuration. Recently, several authors reported on the Achillon mini-incision technique, comparing the basic mechanical properties of the tendon suture performed using the Achillon method with those of the Kessler method, and assesses whether the strength of the repair was related to tendon diameter. The Achillon repair had comparable tensile strength to the Kessler repair. When compared to the Achillon repair the present technique [3] is cheaper, and allows a stronger repair, as it allows to use a greater number of suture strands (eight) for the repair of the AT.

Complications of this surgery can be early, intermediate or late, and are outlined in Table 2.1.

Early possible post-operative complications of this surgery are sural nerve damage and hematoma formation.

Hockenbury and John noted sural nerve entrapment in 3 of 5 cases treated using a percutaneous technique in cadaveric specimens with divided ATs [2]. The positioning of the incisions and the configuration of the stitch reduces the risk of damage to the sural nerve.

TABLE 2.1 Complications which can occur following a ruptured AT

Early (peri-operative)	Sural nerve damage Hematoma
Intermediate (<6 weeks)	Infection Wound healing complications
Late (6 weeks to 6 months)	Re-rupture of tendon

TABLE 2.2 Key points of rupture and repair

---

Patient selection
Prone position
Local anesthesia
Incisions made to avoid sural nerve
Four and if necessary eight strand repair
Splintage to protect repair for total of 6 weeks

---

The risk of hematoma formation is reduced as the procedure is carried out without tourniquet so that the surgeon will be able to deal with any bleeding at the time of operation.

Intermediate superficial and deep wound infections can occur. Open repair is associated with a significant risk of wound breakdown. Percutaneous repair reduces this risk (Table 2.2).

The most important late complication is re-rupture.

Bradley and Tibone [1] reported a higher risk of re-rupture in percutaneous repairs compared with open repair. Lim et al. more recently, however, in a prospective multicentre randomized controlled study comparing open and percutaneous repair techniques reported a higher rate of re-rupture in patients treated by an open technique (6 vs 3 %, using a percutaneous technique). The difference, however, was not statistically significant. Bradley and Tibone [1] compared 15 patients treated with a gastrocnemius fascial graft and 12 patients treated using a percutaneous technique. Strength, power and endurance measurements of both groups showed no statistical difference. Two of 12 (13 %) percutaneous repairs re-ruptured up to a follow-up of 1.8 years, compared with none in the open repair group (follow-up 4.6 years). They recommended percutaneous repair in the recreational athlete and open repair in the competitive athlete. Martinelli [10] reported 30 cases of percutaneous repair of ATs in which all athletes returned to preinjury levels of sport by 150 days

post-injury. Wound healing problems associated with open repair can be reduced by using percutaneous techniques, and the incidence of adhesion of the skin to the underlying tendon, as can occur in open repair, is also lower with percutaneous techniques [8, 15].

Kauranen and Leppilahti [6] reviewed the motor performance of 90 patients following operative repair (mean of 3.1 years post surgery) of a ruptured AT. They observed the performance of the unloaded lower extremity, and compared the operated limbs with the unoperated side, and to age and gender-matched control subjects. They found no statistical difference between any of the groups, and concluded that the motor performance of the unloaded lower limb had fully recovered in the tested parameters.

## References

1. Bradley JP, Tibone JE. Percutaneous and open surgical repairs of Achilles tendon ruptures. A comparative study. *Am J Sports Med.* 1990;18:188–95.
2. Canale ST. *Campbell's operative orthopaedics.* 9th ed. St Louis: Mosby; 1998.
3. Carmont MR, Maffulli N. Modified percutaneous repair of ruptured Achilles tendon. *Knee Surg Sports Traumatol Arthrosc.* 2008;16:199–203.
4. Cretnik A, Zlajpah L, Smrkolj V, et al. The strength of percutaneous methods of repair of the Achilles tendon: a biomechanical study. *Med Sci Sports Exerc.* 2000;32:16–20.
5. Gorschewsky O, Vogel U, Schweizer A, et al. Percutaneous tenodesis of the Achilles tendon. A new surgical method for the treatment of acute Achilles tendon rupture through percutaneous tenodesis. *Injury.* 1999;30:315–21.
6. Kauranen KJ, Leppilahti JI. Motor performance of the foot after Achilles rupture repair. *Int J Sports Med.* 2001;22:154–8.
7. Lagergren C, Lindholm A. Vascular distribution in the Achilles tendon. *Acta Chir Scand.* 1958;116:491–5.
8. Lim J, Dalal R, Waseem M. Percutaneous vs. open repair of the ruptured Achilles tendon – a prospective randomized controlled study. *Foot Ankle Int.* 2001;22:559–68.
9. Ma GW, Griffith TG. Percutaneous repair of acute closed ruptured achilles tendon: a new technique. *Clin Orthop Relat Res.* 1977;(28):247–55.

10. Martinelli B. Percutaneous repair of the Achilles tendon in athletes. *Bull Hosp Jt Dis.* 2000;59:149–52.
11. Matles AL. Rupture of the tendo Achilles. Another diagnostic sign. *Bull Hosp Joint Dis.* 1975;36:48–51.
12. McMaster P. Tendon and muscle ruptures: clinical and experimental studies on the causes and location of subcutaneous ruptures. *J Bone Joint Surg.* 1933;15:705–22.
13. O'Brien T. The needle test for complete rupture of the Achilles tendon. *J Bone Joint Surg (A).* 1984;66:1099–101.
14. Simmonds FA. The diagnosis of the ruptured Achilles tendon. *Practitioner.* 1957;179:56–8.
15. Webb JM, Bannister GC. Percutaneous repair of the ruptured tendo Achillis. *J Bone Joint Surg Br.* 1999;81:877–80.
16. Webb J, Moorjani N, Radford M. Anatomy of the sural nerve and its relation to the Achilles tendon. *Foot Ankle Int.* 2000;21:475–7.
17. Williams PL, Warwick R, Dyson M, Bannister LH. *Grays anatomy.* 37th ed. Edinburgh: Churchill Livingstone; 1989.



# Chapter 3

## Minimally Invasive Semitendinosus Tendon Graft Augmentation for Reconstruction of Chronic Tears of the Achilles Tendon

**Nicola Maffulli, Umile Giuseppe Longo, Filippo Spiezia,  
and Vincenzo Denaro**

### 3.1 Introduction

The management of chronic ruptures of tendo Achillis often requires augmentation techniques. These can be performed using a turn down flap, a tendon transfer, tendon graft, or synthetic materials. Open procedures on the Achilles tendon can lead to difficulty with wound healing because of the tenuous

---

N. Maffulli, M.D., M.S., Ph.D., FRCS (Orth) (✉)

Centre for Sports and Exercise Medicine, Barts and The London School of Medicine and Dentistry, Mile End Hospital, Queen Mary University of London, 275 Bancroft Road, London E1 4DG, UK

Department of Trauma and Orthopaedic Surgery,  
Keele University School of Medicine,  
University Hospital of North Staffordshire, Hartshill,  
Thornburrow Drive, Stoke-on-Trent, Staffordshire ST4 7QB, UK  
e-mail: n.maffulli@qmul.ac.uk

U.G. Longo • F. Spiezia • V. Denaro  
Department of Orthopaedic and Trauma Surgery,  
Campus Biomedico University, Via Alvaro del Portillo, 200,  
Trigoria, Rome 00128, Italy

N. Maffulli, M. Easley (eds.), *Minimally Invasive Surgery  
for Achilles Tendon Disorders in Clinical Practice*,  
DOI 10.1007/978-1-4471-4498-4\_3,  
© Springer-Verlag London 2013

blood supply and increased chance of wound breakdown and infection. In this chapter we describe a method of minimally invasive semitendinosus reconstruction for the Achilles tendon. This technique uses one proximal para-midline incision and one distal midline incision preserving skin integrity over the site most prone to wound breakdown. The first incision is a 5 cm longitudinal incision, made 2 cm proximal and just medial to the palpable end of the residual tendon. The second incision is 3 cm long and is also longitudinal but is 2 cm distal and in the midline to the distal end of the tendon rupture. The distal and proximal Achilles tendon stumps are mobilized. After trying to reduce the gap of the ruptured Achilles tendon, if the gap produced is greater than 6 cm despite maximal plantar flexion of the ankle and traction on the Achilles tendon stumps, the ipsilateral semitendinosus tendon is harvested. The semitendinosus tendon is passed through small incisions in the substance of the proximal stump of the Achilles tendon, and it is sutured to the Achilles tendon. It is then passed beneath the intact skin bridge into the distal incision, and passed from medial to lateral through a transverse tenotomy in the distal stump. With the ankle in maximal plantar flexion, the semitendinosus tendon is sutured to the Achilles tendon at each entry and exit point. This minimally invasive technique allows reconstruction of the Achilles tendon using the tendon of semitendinosus preserving skin integrity over the site most prone to wound breakdown, and can be especially used to reconstruct the Achilles tendon in the presence of large gap (greater than 6 cm).

### 3.2 Surgical Technique

The patient is positioned prone with a calf tourniquet. Skin preparation is performed in the usual fashion, and sterile drapes are applied. Pre-operative anatomical markings include the palpable tendon defect and both malleoli. Two skin incisions

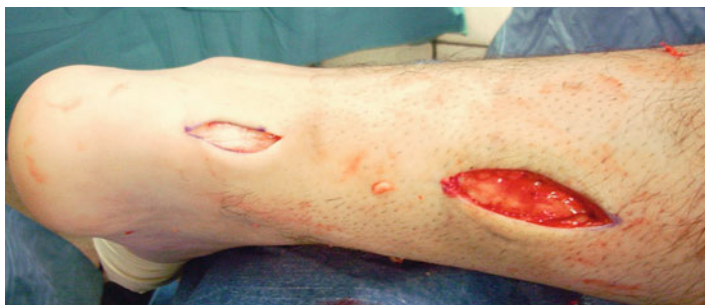

FIGURE 3.1 Two skin incisions are made. The first incision is a 5 cm longitudinal incision, made 2 cm proximal and just medial to the palpable end of the residual tendon. The second incision is 3 cm long and is also longitudinal but is 2 cm distal and in the midline over the distal end of the tendon rupture

are made (Fig. 3.1), and accurate hemostasis by ligation of the larger veins and diathermy of the smaller ones is performed. The first incision is a 5 cm longitudinal incision, made 2 cm proximal and just medial to the palpable end of the residual tendon. The second incision is 3 cm long and is also longitudinal but is 2 cm distal and in the midline over the distal end of the tendon rupture. Care is taken to prevent damage to the sural nerve. At the level of the Achilles tendon insertion, the sural nerve is 18.8 mm lateral to the tendon but, as it progresses proximally, the nerve gradually traverses medially crossing the lateral border of the tendon 9.8 cm proximal to the calcaneum [6]. Thus, the second incision avoids the sural nerve by being placed medial and posterior to the nerve.

The proximal and distal Achilles tendon stump are mobilized, freeing them of all the peritendinous adhesions. It should be possible to palpate the medial tubercle of the calcaneum. The ruptured tendon end is then resected back to healthy tendon, and a Number 1 Vicryl (Ethicon, Edinburgh) locking suture is run along the free tendon edge to prevent separation of the bundles (Fig. 3.2).

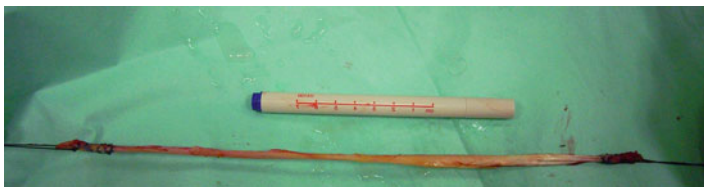

FIGURE 3.2 A locking suture is run along the free tendon edge to prevent separation of the bundles

The proximal tendon is then mobilized from the proximal wound, any adhesions are divided, and further soft tissue release anterior to the soleus and gastrocnemius allows maximal excursion, minimizing the gap between the two tendon stumps. A Vicryl locking suture is run along the free tendon edge to allow adequate exposure and to prevent separation of the bundles.

After trying to reduce the gap of the ruptured Achilles tendon, if the gap produced is greater than 6 cm despite maximal plantar flexion of the ankle and traction on the Achilles tendon stumps, the ipsilateral semitendinosus tendon is harvested through a vertical 2.5–3 cm long incision over the pes anserinus (Fig. 3.3). The semitendinosus tendon is passed through a small incision in the substance of the proximal stump of the Achilles tendon (Fig. 3.4), and it is sutured to the Achilles tendon at the entry and exit point using 3–0 Vicryl (Polyglactin 910 braided absorbable suture; Johnson & Johnson, Brussels, Belgium). The semitendinosus tendon is then passed beneath the intact skin bridge into the distal incision and passed from medial to lateral through a transverse tenotomy in the distal stump (Fig. 3.5). With the ankle in maximal plantar flexion, the semitendinosus tendon is sutured to the Achilles tendon at each entry and exit point using 3–0 Vicryl (Polyglactin 910 braided absorbable suture; Johnson & Johnson, Brussels, Belgium). The repair is tensioned to maximal equinus.

One extremity of the semitendinosus tendon is then passed again beneath the intact skin bridge into the proximal incision, and passed from medial to lateral through

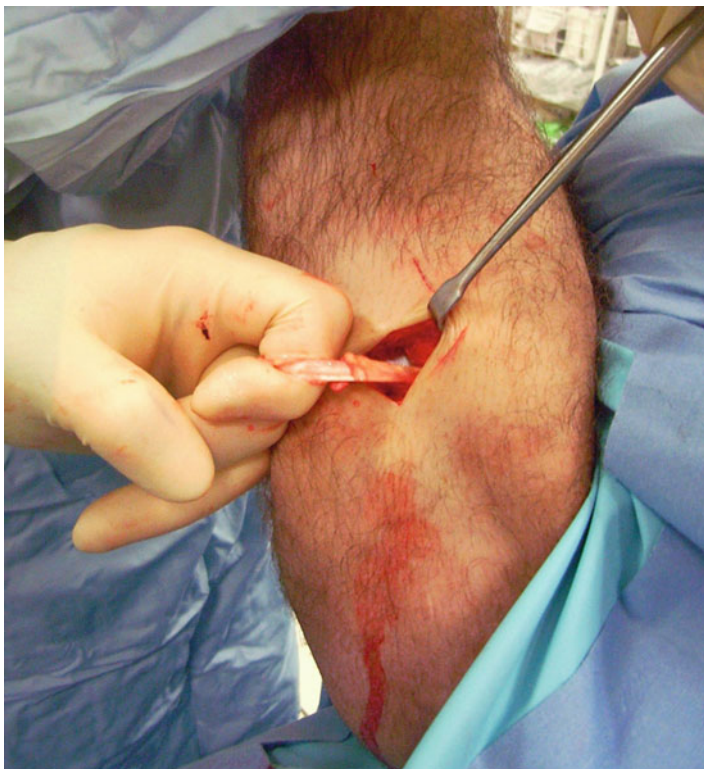

FIGURE 3.3 The tendon of the semitendinosus is harvested through a vertical, 2.5–3 cm longitudinal incision over the pes anserinus

a transverse tenotomy in the proximal stump (Fig. 3.6). The other extremity of the semitendinosus tendon is then passed again from medial to lateral through a transverse tenotomy in the distal stump. The reconstruction may be further augmented using a Maxon (Tyco Health Care, Norwalk, CT) suture. The wounds are closed with 2.0 Vicryl, 3,0 Biosyn (Tyco Health Care, Norwalk, CT) and Steri-strips (3M Health Care, St Paul, MN) (Fig. 3.7). A previously prepared removable scotch cast support with Velcro straps is applied.

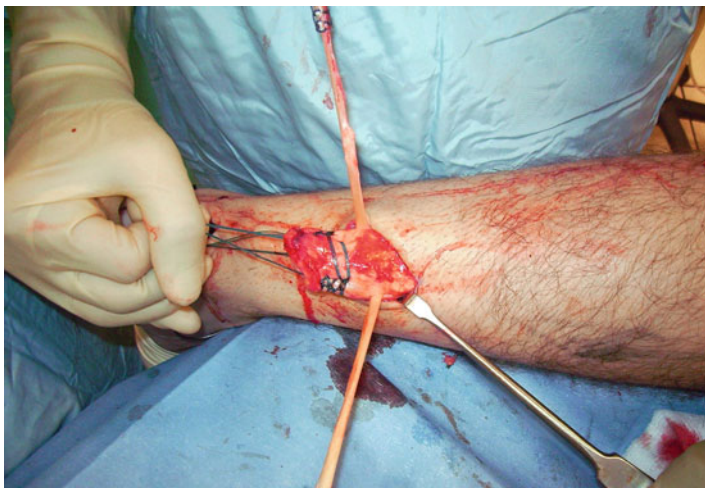

FIGURE 3.4 The semitendinosus tendon is passed through a small incision in the substance of the proximal stump of the Achilles tendon

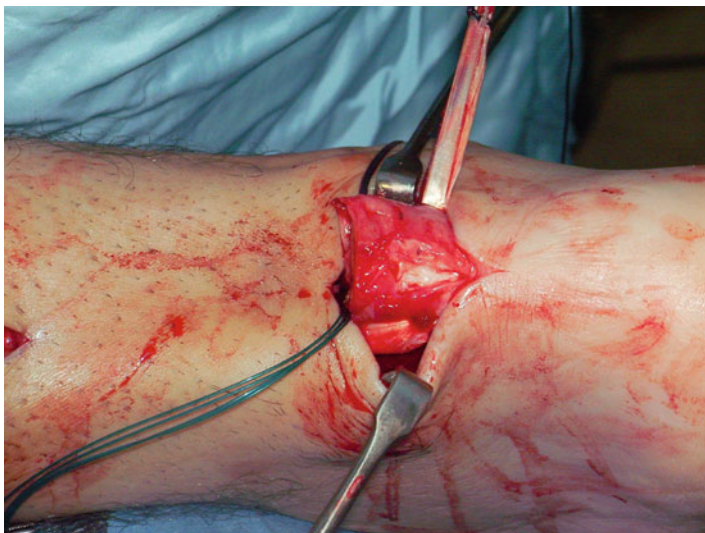


FIGURE 3.5 The semitendinosus tendon is passed from medial to lateral through a transverse tenotomy in the distal stump

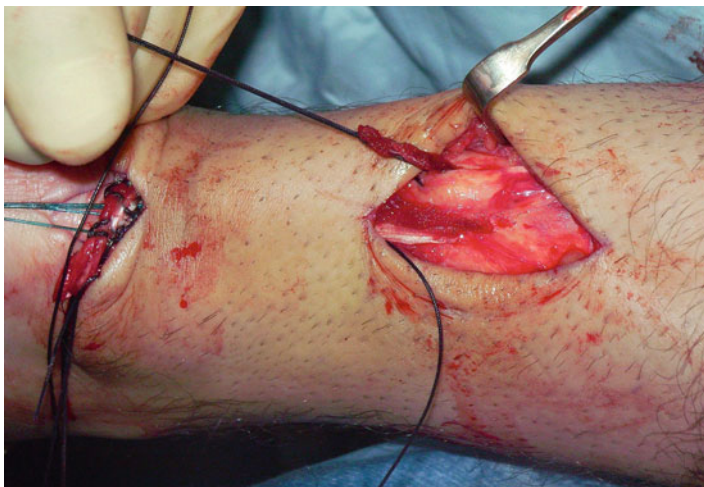


FIGURE 3.6 One extremity of the semitendinosus tendon is passed from medial to lateral through a transverse tenotomy in the proximal stump

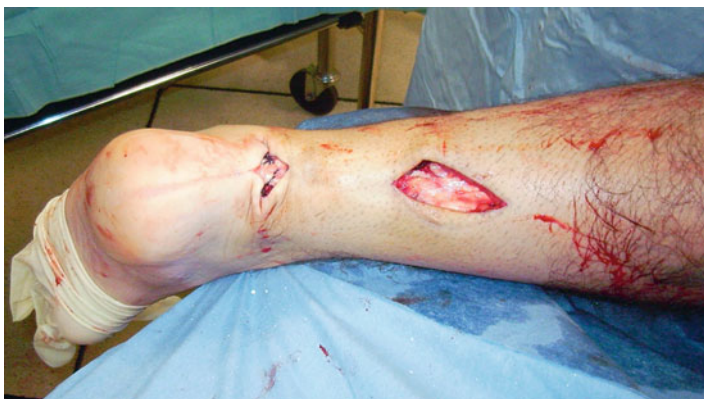

FIGURE 3.7 The final result

### 3.3 Postoperative Management

Post operatively, patients are allowed to weight bear as comfort allows with the use of elbow crutches [2,3]. It would be unusual for a patient to weight bear fully at this stage. After 2 weeks, the

back shell is removed, and physiotherapy is commenced with the front shell *in situ* preventing dorsiflexion of the ankle, focusing on proprioception, plantar-flexion of the ankle, inversion and eversion [2, 3]. During this period of rehabilitation, the patient is permitted to weight bear as comfort allows with the front shell *in situ* although full weight bearing rarely occurs on account of balance difficulties and patients usually still require the assistance of a single elbow crutch as this stage. The front shell may be finally removed after 6 weeks. We do not use a heel raise after removal of the cast, and patients normally regain a plantigrade ankle over 2 or 3 weeks [2, 3].

### 3.4 Discussion

The main complication the surgeon may encounter is sural nerve injury. Care is taken to prevent damage to the sural nerve. At the level of the Achilles tendon insertion, the sural nerve is 18.8 mm lateral to the tendon but, as it progresses proximally, the nerve gradually traverses medially crossing the lateral border of the tendon 9.8 cm proximal to the calcaneum [6]. Thus, the second incision avoids the sural nerve by being placed medial to the nerve.

Wound breakdown is a challenging complications in Achilles tendon reconstruction surgery, with open techniques having a 9 % superficial infection rate [5]. The great advantage of this technique is that it allows to perform a semitendinosus tendon augmentation in a minimally invasive fashion, preserving skin integrity. In patients with chronic ruptures, the skin over the gap retracts over several weeks, and remains so until the operation. In open surgery, this skin is incised, and is then stretched out in a relatively acute fashion to accommodate the reconstructed tendon. Therefore, following the reconstruction, the skin over the gap may well be stretched so much that vascular supply is impaired [4]. The reconstructed gastrosoleus Achilles tendon complex will stretch with increased loading and range of movement exercises during rehabilitation [1]. Preservation of skin cover during reconstruction



procedures is clearly an advantage, as the skin is not injured by the operation, and protects the reconstruction beneath. As with all surgery performed through minimally invasive incisions, this procedure is technically demanding. Careful incision placement is required together with skin retraction to allow visualization of the tendon ends and to permit the reconstruction. This technique is designed to preserve skin cover of the reconstruction site, and, although reconstruction is always risky, it may extend the indications for surgery in patients prone to wound complications such as vasculopathies and diabetics who present with a large gap.

In conclusion, this technique allows minimally invasive reconstruction of the Achilles tendon using semitendinosus tendon preserving skin integrity, and can be especially used to reconstruct the Achilles tendon in the presence of large gap (greater than 6 cm).

**Competing Interests** The authors declare that they have no competing interests.

## References

1. Carmont MR, Maffulli N. Less invasive Achilles tendon reconstruction. *BMC Musculoskelet Disord.* 2007;8:100.
2. Maffulli N, Tallon C, Wong J, et al. Early weightbearing and ankle mobilization after open repair of acute midsubstance tears of the achilles tendon. *Am J Sports Med.* 2003;31:692–700.
3. Maffulli N, Tallon C, Wong J, et al. No adverse effect of early weight bearing following open repair of acute tears of the Achilles tendon. *J Sports Med Phys Fitness.* 2003;43:367–79.
4. McClelland D, Maffulli N. Neglected rupture of the Achilles tendon: reconstruction with peroneus brevis tendon transfer. *Surgeon.* 2004;2:209–13.
5. Pintore E, Barra V, Pintore R, et al. Peroneus brevis tendon transfer in neglected tears of the Achilles tendon. *J Trauma.* 2001;50:71–8.
6. Webb J, Moorjani N, Radford M. Anatomy of the sural nerve and its relation to the Achilles tendon. *Foot Ankle Int.* 2000;21:475–7.

# Chapter 4

## Minimally Invasive Achilles Tendon Reconstruction Using the Peroneus Brevis Tendon Graft

**Nicola Maffulli, Filippo Spiezia, Umile Giuseppe Longo, and Vincenzo Denaro**

### 4.1 Introduction

Minimally invasive peroneus brevis reconstruction for the Achilles tendon (AT) overcome the problems with an open procedure, namely difficulty with wound healing because of the tenuous blood supply and increased chance of wound breakdown and infection. In this chapter we presented a technique which uses two para-midline incisions preserving skin integrity over the site most prone to wound breakdown.

---

N. Maffulli, M.D., M.S., Ph.D., FRCS (Orth) (✉)  
Centre for Sports and Exercise Medicine, Barts and The London School of Medicine and Dentistry, Mile End Hospital, Queen Mary University of London, 275 Bancroft Road, London E1 4DG, UK

Department of Trauma and Orthopaedic Surgery,  
Keele University School of Medicine, University Hospital  
of North Staffordshire, Hartshill, Thornburrow Drive,  
Stoke-on-Trent, Staffordshire ST4 7QB, UK  
e-mail: n.maffulli@qmul.ac.uk

F. Spiezia • U.G. Longo • V. Denaro  
Department of Orthopaedic and Trauma Surgery,  
Campus Biomedico University,  
Via Alvaro del Portillo, 200, Trigatoria, Rome 00128, Italy

N. Maffulli, M. Easley (eds.), *Minimally Invasive Surgery for Achilles Tendon Disorders in Clinical Practice*,  
DOI 10.1007/978-1-4471-4498-4\_4,  
© Springer-Verlag London 2013

This minimally invasive technique allows reconstruction of the Achilles tendon using the tendon of peroneus brevis preserving skin integrity over the site most prone to wound breakdown, and can be especially used to reconstruct the Achilles tendon in the presence of gap less than 6 cm.

The ideal candidate to minimally invasive semitendinosus tendon graft augmentation is a patient with a chronic tear of the Achilles tendon with a gap, during surgery less than 6 cm with the ankle kept in maximal plantar flexion and traction on the AT stumps [7]. This technique is designed to preserve skin cover of the reconstruction site, and, although reconstruction is always risky, it may extend the indications for surgery to patients prone to wound complications such as those with peripheral vasculopathy and diabetes who present with a tendon gap. Gap greater than 6 cm are better managed with semitendinosus transfer [3].

There are no specific contraindications exist for minimally invasive ipsilateral tendon transfer. Obviously this is not possible in patients previously undergone peroneus tendon harvesting for other procedure.

## 4.2 Surgical Technique

The patient is positioned prone with a calf tourniquet. Skin preparation is performed in the usual fashion, and sterile drapes are applied. Pre-operative anatomical markings include the palpable tendon defect, both malleoli, and the base of the fifth metatarsal.

Three skin incisions are made, and accurate hemostasis by ligation of the larger veins and diathermy of the smaller ones is performed. The first incision is a 5 cm longitudinal incision, made 2 cm proximal and just medial to the palpable end of the proximal stump. The second incision is 3 cm long and is also longitudinal, but is 2 cm distal and lateral to the distal stump. Care is taken to prevent damage to the sural nerve by making this incision as close as possible to the anterior aspect

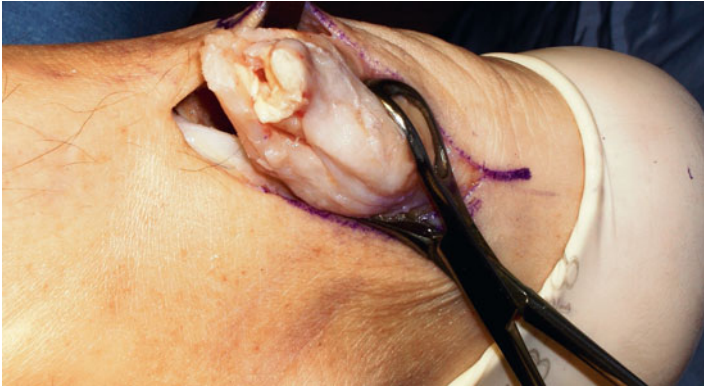

FIGURE 4.1 The distal Achilles tendon stump is mobilized, freeing it of all the peritendinous adhesions

of the lateral border of the Achilles tendon to avoid the nerve. At the level of the Achilles tendon insertion, the sural nerve is 18.8 mm lateral to the tendon but, as it progresses proximally, the nerve gradually traverses medially crossing the lateral border of the tendon 9.8 cm proximal to the calcaneum. Thus, the second incision avoids the sural nerve by being placed on the lateral side of the Achilles tendon but posterior to the nerve. The third incision is a 2 cm longitudinal incision at the base of the fifth metatarsal.

The distal Achilles tendon stump is mobilized, freeing it of all the peritendinous adhesions, particularly on its lateral aspect (Fig. 4.1). This allows access to the base of the lateral aspect of the distal tendon close to its insertion. It should be possible to palpate the medial tubercle of the calcaneum. The ruptured tendon end is then resected back to healthy tendon, and a Number 1 Vicryl (Ethicon, Edinburgh) locking suture is run along the free tendon edge to prevent separation of the bundles.

The proximal tendon is then mobilized from the proximal wound, any adhesions are divided, and further soft tissue release anterior to the soleus and gastrocnemius allows

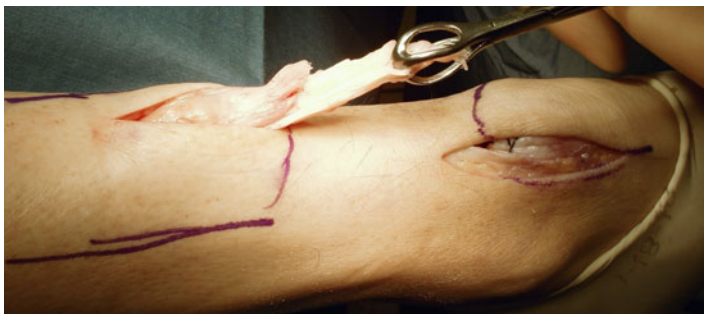


FIGURE 4.2 The proximal tendon is then mobilized from the proximal wound, any adhesions are divided, and further soft tissue release anterior to the soleus and gastrocnemius allows maximal excursion, minimizing the gap between the two tendon stumps

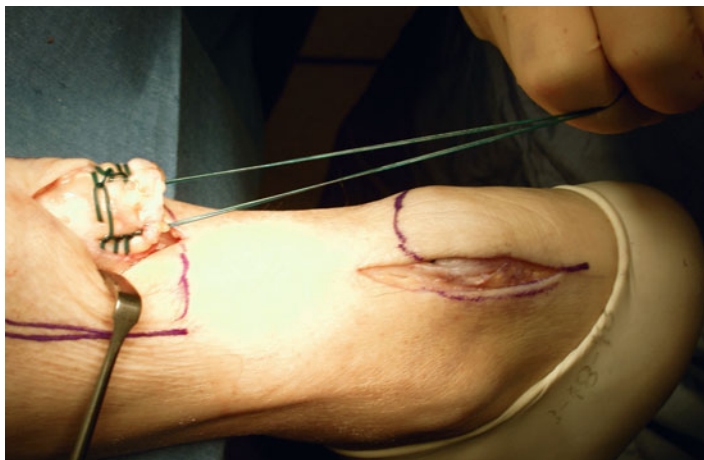


FIGURE 4.3 A Vicryl locking suture is run along the free tendon edge to allow adequate exposure and to prevent separation of the bundles

maximal excursion, minimizing the gap between the two tendon stumps (Fig. 4.2). A Vicryl locking suture is run along the free tendon edge to allow adequate exposure and to prevent separation of the bundles (Fig. 4.3).

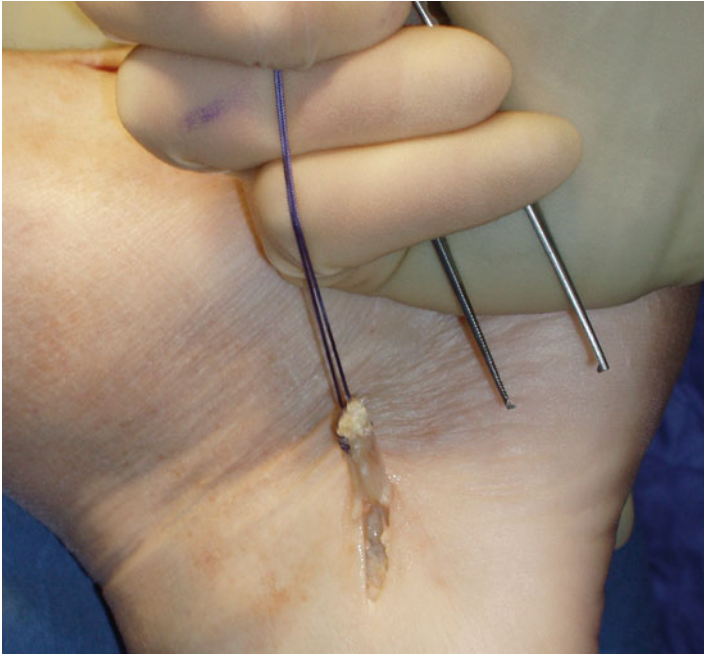


FIGURE 4.4 The tendon of peroneus brevis is harvested

The tendon of peroneus brevis is harvested (Fig. 4.4). The tendon is identified through the incision on the lateral border of the foot at its insertion at the base of the fifth metatarsal. The tendon is exposed, and a No.1 Vicryl locking suture is applied to the tendon end before release from the metatarsal base. The tendon of peroneus brevis is identified at the base of the distal incision of the Achilles tendon following incision of the deep fascia overlying the peroneal muscles compartment. The tendon of peroneus brevis is then withdrawn through the distal wound (Fig. 4.5). This may take significant force, as there may be tendinous strands between the two peroneal tendons distally. The muscular portion of peroneus brevis is then mobilized proximally to allow increased excursion of the tendon of peroneus brevis.

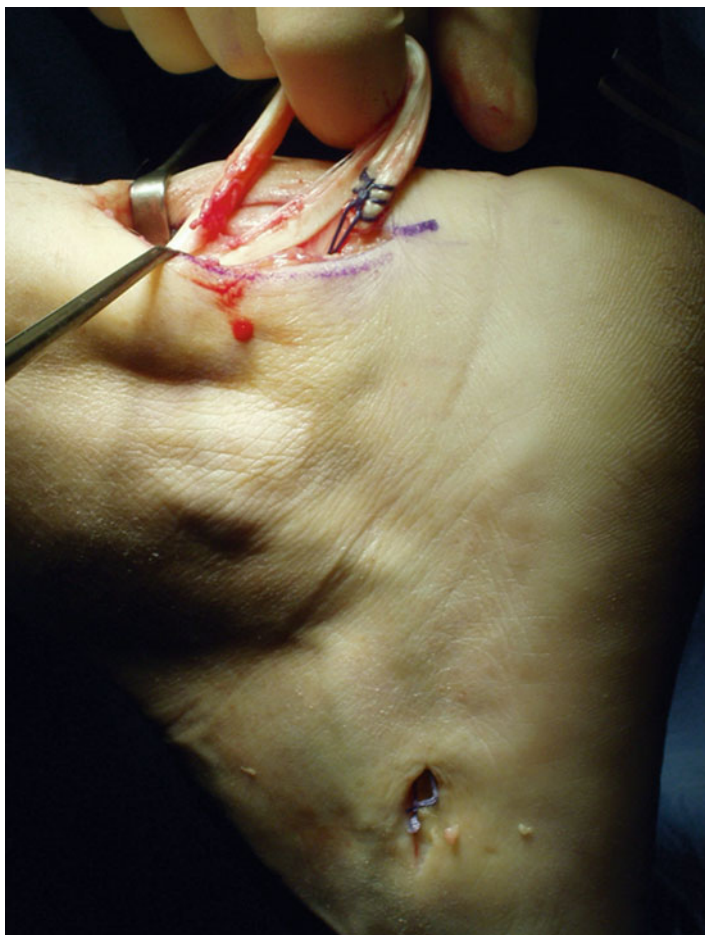

FIGURE 4.5 The tendon of peroneus brevis is then withdrawn through the distal wound

A longitudinal tenotomy parallel to the tendon fibers is made through both stumps of the tendon. A clip is used to develop the plane, from lateral to medial, in the distal stump of the Achilles tendon, and the peroneus brevis graft is passed through the tenotomy (Fig. 4.6). With the ankle in maximal plantar flexion, a No.1 Vicryl suture is used to suture the peroneus brevis to

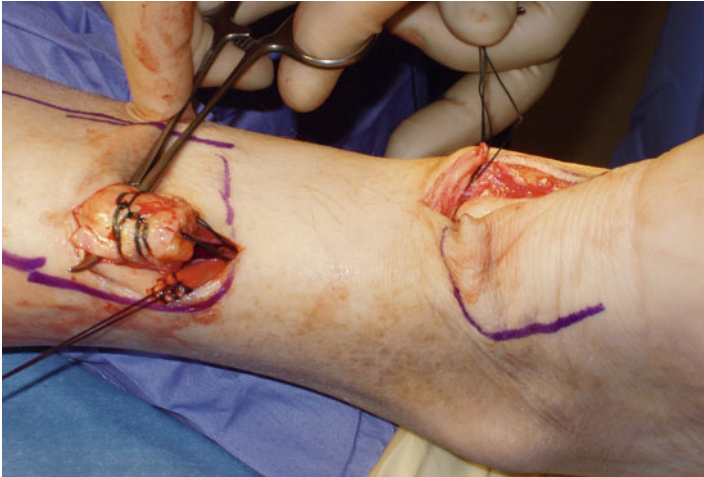


FIGURE 4.6 A clip is used to develop the plane, from lateral to medial, in the distal stump of the Achilles tendon, and the peroneus brevis graft is passed through the tenotomy

both sides of the distal stump. The tendon of peroneus brevis is then passed beneath the intact skin bridge into the proximal incision, and passed from medial to lateral through a transverse tenotomy in the proximal stump, and further secured with No 1 Vicryl. Finally, the tendon of peroneus brevis is sutured back onto itself on the lateral side of the proximal incision. The reconstruction may be further augmented using a Maxon (Tyco Health Care, Norwalk, CT) suture.

The wounds are closed with 2.0 Vicryl, 3.0 Biosyn (Tyco Health Care, Norwalk, CT) and Steri-strips (3M Health Care, St Paul, MN), taking care to avoid the risk of post operative hematoma and minimize wound breakdown. A previously prepared removable scotch cast support with Velcro straps is applied.

### 4.3 Postoperative Management

Post operatively, patients are allowed to weight bear as comfort allows with the use of elbow crutches [9, 10]. It would be unusual for a patient to weight bear fully at this stage. After



2 weeks, the back shell is removed, and physiotherapy is commenced with the front shell *in situ* preventing dorsiflexion of the ankle, focusing on proprioception, plantar-flexion of the ankle, inversion and eversion [9, 10]. During this period of rehabilitation, the patient is permitted to weight bear as comfort allows with the front shell *in situ*, although full weight bearing rarely occurs on account of balance difficulties and patients usually still require the assistance of a single elbow crutch as this stage. The front shell may be finally removed after 6 weeks. We do not use a heel raise after removal of the cast, and patients normally regain a plantigrade ankle over 2 or 3 weeks [9, 10].

## 4.4 Discussion

The main complication the surgeon may encounter is sural nerve injury. Care is taken to prevent damage to the sural nerve. At the level of the AT insertion, the sural nerve is 18.8 mm lateral to the tendon but, as it progresses proximally, the nerve gradually traverses medially crossing the lateral border of the tendon 9.8 cm proximal to the calcaneum [13]. Thus, the second incision avoids the sural nerve by being placed medial to the nerve.

Wound breakdown is a challenging complications in AT reconstruction surgery, with open techniques having a 9 % superficial infection rate [12]. The great advantage of this technique is that it allows to perform a peroneus brevis tendon augmentation in a minimally invasive fashion, preserving skin integrity. In patients with chronic ruptures, the skin over the gap retracts over several weeks, and remains so until the operation. In open surgery, this skin is incised, and is then stretched out in a relatively acute fashion to accommodate the reconstructed tendon [1]. Therefore, following the reconstruction, the skin over the gap may well be stretched so much that its vascular supply is impaired [11]. The reconstructed gastro-soleus AT complex will stretch with increased loading and range of movement exercises during rehabilitation [2].

Preservation of skin cover during reconstruction procedures is clearly an advantage, as the skin is not injured by the operation, and protects the reconstruction beneath [4–6, 8]. As with all surgery performed through minimally invasive incisions, this procedure is technically demanding. Careful incision placement is required together with skin retraction to allow visualization of the tendon ends and to permit the reconstruction. This technique is designed to preserve skin cover of the reconstruction site, and, although reconstruction is always risky, it may extend the indications for surgery in patients prone to wound complications such as vasculopathy and diabetics who present with a tendinous gap.

In conclusion, this technique allows minimally invasive reconstruction of the AT using peroneus brevis tendon preserving skin integrity, and can be especially used to reconstruct the AT in the presence of gap less than 6 cm.

**Competing Interests** The authors declare that they have no competing interests.

## References

1. Ames PR, Longo UG, Denaro V, et al. Achilles tendon problems: not just an orthopaedic issue. *Disabil Rehabil.* 2008;30:1646–50.
2. Carmont MR, Maffulli N. Less invasive Achilles tendon reconstruction. *BMC Musculoskelet Disord.* 2007;8:100.
3. Crisp T, Khan F, Padhiar N, et al. High volume ultrasound guided injections at the interface between the patellar tendon and Hoffa's body are effective in chronic patellar tendinopathy: a pilot study. *Disabil Rehabil.* 2008;30:1625–34.
4. Longo UG, Ramamurthy C, Denaro V, et al. Minimally invasive stripping for chronic Achilles tendinopathy. *Disabil Rehabil.* 2008;30:1709–13.
5. Longo UG, Ronga M, Maffulli N. Achilles tendinopathy. *Sports Med Arthrosc.* 2009;17:112–26.
6. Longo UG, Ronga M, Maffulli N. Acute ruptures of the achilles tendon. *Sports Med Arthrosc.* 2009;17:127–38.
7. Maffulli N, Ajis A, Longo UG, et al. Chronic rupture of tendo Achillis. *Foot Ankle Clin.* 2007;12:583–96, vi.
8. Maffulli N, Longo UG, Ronga M, et al. Favorable outcome of percutaneous repair of achilles tendon ruptures in the elderly. *Clin Orthop Relat Res.* 2010;468(4):1039–46. Epub 2009 Jun 19.

9. Maffulli N, Tallon C, Wong J, et al. Early weightbearing and ankle mobilization after open repair of acute midsubstance tears of the achilles tendon. *Am J Sports Med.* 2003;31:692–700.
10. Maffulli N, Tallon C, Wong J, et al. No adverse effect of early weight bearing following open repair of acute tears of the Achilles tendon. *J Sports Med Phys Fitness.* 2003;43:367–79.
11. McClelland D, Maffulli N. Neglected rupture of the Achilles tendon: reconstruction with peroneus brevis tendon transfer. *Surgeon.* 2004;2:209–13.
12. Pintore E, Barra V, Pintore R, et al. Peroneus brevis tendon transfer in neglected tears of the Achilles tendon. *J Trauma.* 2001;50:71–8.
13. Webb J, Moorjani N, Radford M. Anatomy of the sural nerve and its relation to the Achilles tendon. *Foot Ankle Int.* 2000;21:475–7.

# Chapter 5

## Free Hamstrings Tendon Transfer and Interference Screw Fixation for Less Invasive Reconstruction of Chronic Avulsions of the Achilles Tendon

**Nicola Maffulli, Umile Giuseppe Longo, Filippo Spiezia,  
and Vincenzo Denaro**

### 5.1 Introduction

Chronic avulsions of the Achilles tendon from the calcaneus are infrequent [1, 13, 19, 26]. Achilles “sleeve” avulsions are a surgical challenge, as the Achilles tendon sleeves from its insertion into the calcaneus leaving virtually no tendinous

---

N. Maffulli, M.D., M.S., Ph.D., FRCS (Orth) (✉)

Centre for Sports and Exercise Medicine, Barts and The London School of Medicine and Dentistry, Mile End Hospital, Queen Mary University of London, 275 Bancroft Road, London E1 4DG, UK

Department of Trauma and Orthopaedic Surgery,  
Keele University School of Medicine, University Hospital  
of North Staffordshire, Hartshill, Thornburrow Drive,  
Stoke-on-Trent, Staffordshire ST4 7QB, UK  
e-mail: n.maffulli@qmul.ac.uk

U.G. Longo • F. Spiezia • V. Denaro

Department of Orthopaedic and Trauma Surgery, Campus Biomedico University, Via Alvaro del Portillo, 200, Trigatoria, Rome 00128, Italy

N. Maffulli, M. Easley (eds.), *Minimally Invasive Surgery  
for Achilles Tendon Disorders in Clinical Practice*,

DOI 10.1007/978-1-4471-4498-4\_5,

© Springer-Verlag London 2013

tissue on the posterior calcaneus to facilitate a repair to the free end of the Achilles tendon [22]. So reconstruction of chronic avulsions of the Achilles tendon can be technically difficult. Hence can be necessary a tendon graft because may be not possible to directly reattach the Achilles tendon. The free hamstrings tendon transfer and interference screw fixation for less invasive reconstruction of chronic avulsions of the Achilles tendon is less invasive technique using a free semitendinosus tendon graft with interference screw fixation in the calcaneus through a Cincinnati incision. This approach permits a wide exposure of the insertion of the Achilles tendon, preserving the integrity of the skin overlying the site most decreasing the risk of wound breakdown.

Open reduction and fixation is possible only when a large bony fragment is avulsed.

Bibbo et al. [2] described a transcalcaneal suture technique for repair of the Achilles tendon sleeve avulsion, through a longitudinal extensile incision. This technique, to be used in patients without a large tendon defect, allows reinsertion of the tendon to the calcaneus. However, when a large tendon defect is present, the surgeon must consider a tendon graft to bridge the gap and produce a strong construct [8, 12, 14, 25, 28]. Moreover, open procedures on the Achilles tendon can lead to difficulty with wound healing because of the tenuous blood supply and increased chance of wound breakdown and infection [20, 21, 24]. The broad exposure given by open procedures may cause extensive iatrogenic disruption of the subcutaneous tissues and paratenon, increasing the potential for peritendinous adhesions [10, 11]. For this reason, less invasive surgical approaches have been developed [4, 6, 9, 15, 18, 27]. Advocates of less invasive AT surgery cite faster recovery times, shorter hospital stays, and improved functional outcomes as the principal reasons for adopting these new approaches when compared to traditional open techniques [4, 6, 7, 9, 18].

This technique uses one proximal para-midline incision and one distal Cincinnati incision to respectively expose the proximal Achilles tendon stump and the Achilles tendon insertion. Using

this approach, a wide exposure of the insertion of the Achilles tendon is possible.

## 5.2 Surgical Technique

The patient is positioned prone with a calf tourniquet. Skin preparation is performed in the usual fashion, and sterile drapes are applied. Pre-operative anatomical markings include the palpable tendon defect and the tuberosity of the calcaneus. Two skin incisions are made, and accurate hemostasis by ligation of the larger veins and diathermy of the smaller ones is performed. The first incision is a 5 cm longitudinal incision, made 2 cm proximal and just medial to the palpable end of the residual tendon. The second incision is 5–7 cm semicircular Cincinnati skin incision [5], made over the area of Achilles tendon insertion.

The proximal and distal Achilles tendon stumps are mobilized, freeing them of all the peritendinous adhesions. After trying to reduce the gap of the ruptured Achilles tendon, if the gap does not allow the tendon to reach the bone despite maximal plantar flexion of the ankle and traction on the AT stump, the ipsilateral semitendinosus is harvested through a vertical 2.5–3 cm long incision over the pes anserinus. The tendon is prepared in the usual fashion [15].

A cannulated headed reamer corresponding to the grafts diameter is used to perforate the calcaneus to allow the passage of the double-looped semitendinosus tendon graft (Fig. 5.1). A wire is then passed through the tunnel (Fig. 5.2).

The proximal tendon is then mobilized from the proximal wound, any adhesions are divided, and further soft tissue release anterior to the soleus and gastrocnemius allows maximal excursion, minimizing the gap between the two tendon stumps. The semitendinosus tendon is passed through a small incision in the substance of the proximal stump of the AT (Fig. 5.3), and it is sutured to the AT at the entry and exit point using 3-0 Vicryl (Polyglactin 910 braided absorbable suture; Johnson & Johnson, Brussels, Belgium).

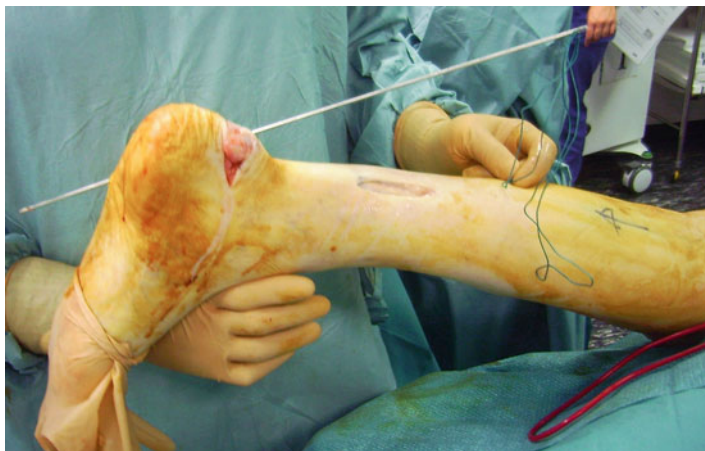


FIGURE 5.1 A cannulated headed reamer corresponding to the grafts diameter is used to perforate the calcaneus to allow the passage of the double-looped semitendinosus tendon graft

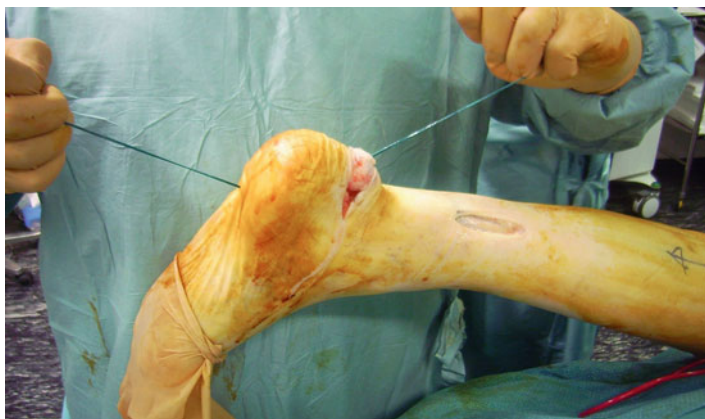

FIGURE 5.2 A wire is passed through the tunnel

The semitendinosus tendon is then passed beneath the intact skin bridge into the distal incision, and then through the calcaneus tunnel (Fig. 5.4). With the ankle in maximal plantar flexion, the semitendinosus tendon is fixed to the calcaneus

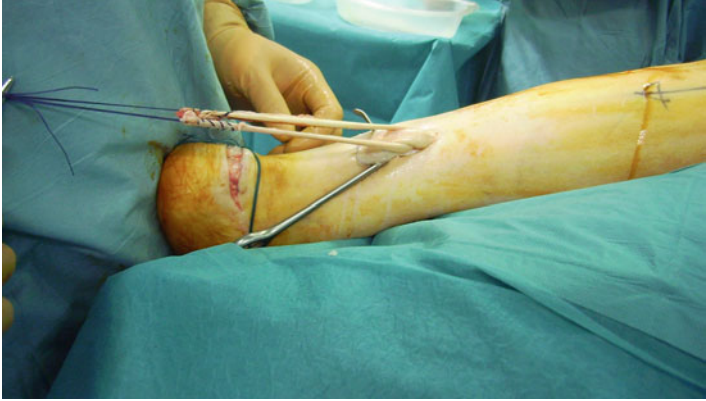

FIGURE 5.3 The semitendinosus tendon is passed through a small incision in the substance of the proximal stump of the AT

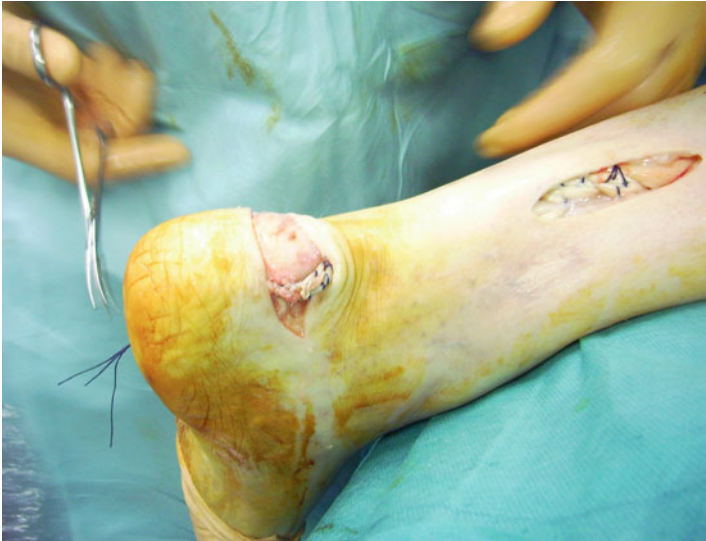

FIGURE 5.4 The semitendinosus tendon is passed into the calcaneus tunnel



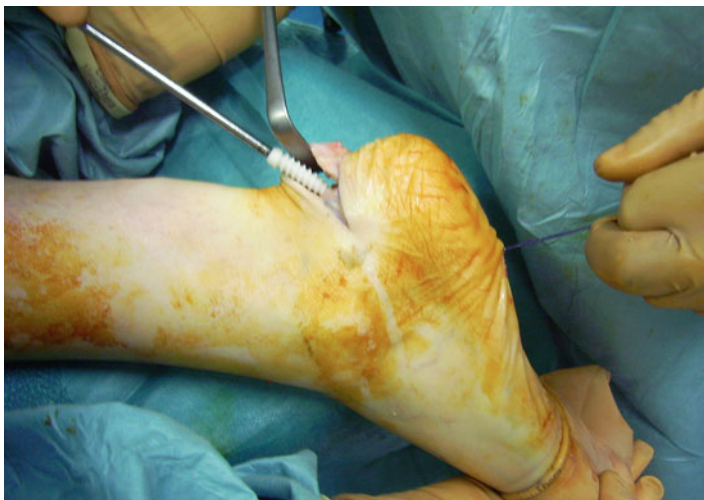

FIGURE 5.5 The bioabsorbable interference screw is inserted over a guide wire

using a bioabsorbable interference screw (Fig. 5.5) inserted over a guide wire into the calcaneus.

### 5.3 Postoperative Regimen

The patient immobilized in a below knee weight bearing synthetic cast boot. Post-operatively, patients are allowed to weight bear as comfort allows with the use of elbow crutches [16, 17]. It would be unusual for a patient to weight bear fully at this stage. After 2 weeks, the cast is removed and an Aircast boot with five heel wedges (XP Walker, DJO Ltd, Guilford, England) is applied, and physiotherapy is commenced preventing dorsiflexion of the ankle, focusing on proprioception, plantar-flexion of the ankle, inversion and eversion [16, 17]. During this period of rehabilitation, the patient is permitted to weight bear as comfort allows with the boot *in situ*, although full weight bearing rarely occurs and patients usually still require the assistance of a single elbow crutch as this

stage. One heel wedge is removed every other week, and the boot may be finally removed after 6 weeks. We do not use a heel raise after removal of the boot, and patients normally regain a plantigrade ankle over 2 or 3 weeks [16, 17].

## 5.4 Discussion

Wound breakdown is a challenging complications in AT reconstruction surgery, with open techniques having a 9 % superficial infection rate [23]. To minimize the rate of infection after AT reconstruction, 2 less invasive techniques of reconstruction of AT have been already described using peroneus brevis [4] and semitendinous autologous tendon graft [14].

These techniques allow reconstruction of the AT using tendon autografts preserving skin integrity, and can be especially used to reconstruct the AT in the presence of previous surgery [4]. When occurs a chronic avulsion at the tendon insertion, a reconstruction of the enthesis is required. When the tendon avulses from the posterior calcaneus, it may do so without bony element. The tendon of semitendinosus is long and strong, and provides a robust reconstruction to the AT. It has showed good integration rate when used in anterior cruciate ligament surgery with interference screws [29]. A free semitendinosus graft does not deprive the knee of motor strength and power, is safe, and, given its length, can be used to bridge large gaps [3]. The great advantage of this technique is that it allows to perform a semitendinosus tendon transfer preserving skin integrity.

Preservation of skin cover during reconstruction procedures is clearly an advantage, as the skin is not injured by the operation, and protects the reconstruction beneath. As with all surgery performed through small incisions, the procedure is technically demanding. Careful incision placement is required together with skin retraction to allow visualization of the tendon ends and to permit the reconstruction. This technique preserve skin cover of the reconstruction site, and, although reconstruction is always risky, it may extend the

indications for surgery in patients prone to wound complications such as vasculopathy and diabetic patients who present with a large gap.

## References

1. Ames PR, Longo UG, Denaro V, et al. Achilles tendon problems: not just an orthopaedic issue. *Disabil Rehabil.* 2008;30:1646–50.
2. Bibbo C, Anderson RB, Davis WH, et al. Repair of the Achilles tendon sleeve avulsion: quantitative and functional evaluation of a transcalcaneal suture technique. *Foot Ankle Int.* 2003;24:539–44.
3. Capuano L, Hardy P, Longo UG, et al. No difference in clinical results between femoral transfixation and bio-interference screw fixation in hamstring tendon ACL reconstruction. A preliminary study. *Knee.* 2008;15:174–9.
4. Carmont MR, Maffulli N. Less invasive Achilles tendon reconstruction. *BMC Musculoskelet Disord.* 2007;8:100.
5. Carmont MR, Maffulli N. Management of insertional Achilles tendinopathy through a Cincinnati incision. *BMC Musculoskelet Disord.* 2007;8:82.
6. Carmont MR, Maffulli N. Modified percutaneous repair of ruptured Achilles tendon. *Knee Surg Sports Traumatol Arthrosc.* 2008;16:199–203.
7. Elliot RR, Calder JD. Percutaneous and mini-open repair of acute Achilles tendon rupture. *Foot Ankle Clin.* 2007;12:573–82, vi.
8. Franceschi F, Longo UG, Ruzzini L, et al. Soft tissue tenodesis of the long head of the biceps tendon associated to the Roman Bridge repair. *BMC Musculoskelet Disord.* 2008;9:78.
9. Longo UG, Ramamurthy C, Denaro V, et al. Minimally invasive stripping for chronic Achilles tendinopathy. *Disabil Rehabil.* 2008;30:1709–13.
10. Longo UG, Ronga M, Maffulli N. Achilles tendinopathy. *Sports Med Arthrosc.* 2009;17:112–26.
11. Longo UG, Ronga M, Maffulli N. Acute ruptures of the Achilles tendon. *Sports Med Arthrosc.* 2009;17:127–38.
12. Lui TH. Endoscopic assisted flexor hallucis tendon transfer in the management of chronic rupture of Achilles tendon. *Knee Surg Sports Traumatol Arthrosc.* 2007;15:1163–6.
13. Maffulli N, Ajis A, Longo UG, et al. Chronic rupture of tendo Achillis. *Foot Ankle Clin.* 2007;12:583–96, vi.
14. Maffulli N, Longo UG, Gougoulas N, et al. Ipsilateral free semitendinosus tendon graft transfer for reconstruction of chronic tears of the Achilles tendon. *BMC Musculoskelet Disord.* 2008;9:100.

15. Maffulli N, Longo UG, Ronga M, et al. Favorable outcome of percutaneous repair of achilles tendon ruptures in the elderly. *Clin Orthop Relat Res.* 2010;468(4):1039–46. Epub 2009 Jun 19.
16. Maffulli N, Tallon C, Wong J, et al. Early weightbearing and ankle mobilization after open repair of acute midsubstance tears of the achilles tendon. *Am J Sports Med.* 2003;31:692–700.
17. Maffulli N, Tallon C, Wong J, et al. No adverse effect of early weight bearing following open repair of acute tears of the Achilles tendon. *J Sports Med Phys Fitness.* 2003;43:367–79.
18. Maffulli N, Testa V, Capasso G, et al. Results of percutaneous longitudinal tenotomy for Achilles tendinopathy in middle- and long-distance runners. *Am J Sports Med.* 1997;25:835–40.
19. Maffulli N, Testa V, Capasso G, et al. Surgery for chronic Achilles tendinopathy produces worse results in women. *Disabil Rehabil.* 2008;30:1714–20.
20. Nilsson-Helander K, Thurin A, Karlsson J, et al. High incidence of deep venous thrombosis after Achilles tendon rupture: a prospective study. *Knee Surg Sports Traumatol Arthrosc.* 2009;17(10):1234–8. Epub 2009 Feb 24.
21. Paavola M, Orava S, Leppilähti J, et al. Chronic Achilles tendon overuse injury: complications after surgical treatment. An analysis of 432 consecutive patients. *Am J Sports Med.* 2000;28:77–82.
22. Pavlou G, Roach R, Salehi-Bird S. Repair of the achilles tendon sleeve avulsion: a transcalcaneal suture technique. *Foot Ankle Int.* 2009;30:65–7.
23. Pintore E, Barra V, Pintore R, et al. Peroneus brevis tendon transfer in neglected tears of the Achilles tendon. *J Trauma.* 2001;50:71–8.
24. Saxena A, Maffulli N, Nguyen A, et al. Wound complications from surgeries pertaining to the Achilles tendon: an analysis of 219 surgeries. *J Am Podiatr Med Assoc.* 2008;98:95–101.
25. Sebastian H, Datta B, Maffulli N, et al. Mechanical properties of reconstructed achilles tendon with transfer of peroneus brevis or flexor hallucis longus tendon. *J Foot Ankle Surg.* 2007;46:424–8.
26. Silbernagel KG, Nilsson-Helander K, Thomee R, et al. A new measurement of heel-rise endurance with the ability to detect functional deficits in patients with Achilles tendon rupture. *Knee Surg Sports Traumatol Arthrosc.* 2010;18(2):258–64. Epub 2009 Aug 19.
27. Testa V, Capasso G, Benazzo F, et al. Management of Achilles tendinopathy by ultrasound-guided percutaneous tenotomy. *Med Sci Sports Exerc.* 2002;34:573–80.
28. Wagner E, Gould JS, Kneidel M, et al. Technique and results of Achilles tendon detachment and reconstruction for insertional Achilles tendinosis. *Foot Ankle Int.* 2006;27:677–84.
29. Weiler A, Peine R, Pashmineh-Azar A, et al. Tendon healing in a bone tunnel. Part I: biomechanical results after biodegradable interference fit fixation in a model of anterior cruciate ligament reconstruction in sheep. *Arthroscopy.* 2002;18:113–23.

# Chapter 6

## Percutaneous Longitudinal Tenotomies for Chronic Achilles Tendinopathy

**J.S. Young, M.K. Sayana, V. Testa, F. Spiezia,  
U.G. Longo, and Nicola Maffulli**

### 6.1 Introduction

Athletic tendinopathy is an overuse condition causing pain and swelling in and around tendons [8], not only restricted to athletes, but 25–30 % of patients are nonathletes [1].

---

J.S. Young • M.K. Sayana

Department of Trauma and Orthopaedic Surgery,  
Keele University School of Medicine, University Hospital  
of North Staffordshire, Hartshill, Thornburrow Drive,  
Stoke-on-Trent, Staffordshire ST4 7QB, UK

V. Testa

Department of Sports Medicine, Angri, Italy

F. Spiezia • U.G. Longo

Department of Orthopaedic and Trauma Surgery, Campus Biomedico  
University, Via Alvaro del Portillo, 200, Triglia, Rome 00128, Italy

N. Maffulli (✉)

Department of Trauma and Orthopaedic Surgery,  
Keele University School of Medicine, University Hospital  
of North Staffordshire, Hartshill, Thornburrow Drive,  
Stoke-on-Trent, Staffordshire ST4 7QB, UK

Centre for Sports and Exercise Medicine, Barts and The London School  
of Medicine and Dentistry, Mile End Hospital, Queen Mary University  
of London, 275 Bancroft Road, London E1 4DG, UK  
e-mail: n.maffulli@keele.ac.uk

N. Maffulli, M. Easley (eds.), *Minimally Invasive Surgery  
for Achilles Tendon Disorders in Clinical Practice*,  
DOI 10.1007/978-1-4471-4498-4\_6,  
© Springer-Verlag London 2013

The Achilles tendon is commonly affected by this condition, due to continuous prolonged intense functional demands imposed on it especially in sportsman [2, 14, 17, 23]. Surgery is recommended for patients in whom non-operative management has proved ineffective for at least 6 months. 24–45.5 % of the patients with Achilles tendon problem fail to respond to conservative treatment and eventually require surgical intervention [3, 6, 12].

Each patient should be managed on an individual basis, and appropriate work up for theatre should be instituted. All patients should have a full history and examination and the diagnosis of Achilles tendinopathy should be established.

Patients can complain of burning pain in the posterior aspect of the calf and ankle, often worse at the beginning of a training session, and after exercise. Some patients have difficulty taking the first few steps in the morning. Pain during activities of daily living, include prolonged walking and stair climbing. Clinical diagnosis is mostly based on palpation and on the use of the painful arc sign [21]. In paratendinopathy, the area of tenderness and thickening remains fixed in relation to the malleoli when the ankle is moved from full dorsiflexion into plantarflexion. If the lesion lies within the tendon, the point of tenderness and any swelling associated with it move with the tendon as the ankle is brought from full dorsiflexion into plantarflexion. In mixed lesions, both motion and fixation of the swelling and of the tenderness can be detected in relation to the malleoli [10, 19].

## 6.2 Surgical Technique

There are different surgical techniques for tendinopathy [4, 5, 11, 15, 16, 18, 20], but the objective is to excise fibrotic adhesions, remove degenerated nodules and make multiple longitudinal incisions in the tendon to detect intratendinous lesions and to restore vascularity, and possibly stimulate the remaining viable cells to initiate cell matrix response and healing [13].

Management of paratendinopathy includes releasing the crural fascia on both sides of the tendon. Adhesions around the tendon are then trimmed; the hypertrophied adherent portions of the paratenon are excised [3]. In tenolysis, classically longitudinal tenotomies are made along the longitudinal axis of the tendon in the abnormal tendon tissues, excising areas of mucinoid degeneration. Reconstruction procedure may be required if large lesions are excised [7].

The paratenon and crural fascia are incised and dissected from the underlying tendon. If necessary, the tendon is freed from adhesions on the posterior, medial and lateral aspects. The paratenon should be excised obliquely as transverse excision may produce a constriction ring, which may require further surgery [21]. Areas of thickened, fibrotic and inflamed tendon are excised. The pathology is identified by the change in texture and color of the tendon. The lesions are then excised, and the defect can either be sutured in a side-to-side fashion or left open. Open procedures on the Achilles tendon can lead to difficulty with wound healing due to the tenuous blood supply and increased chance of wound breakdown and infection. Hemostasis is important, since the reduction of postoperative bleeding speeds up recovery, diminishes the chance of wound infection and diminishes any possible fibrotic inflammatory reaction.

In patients with isolated Achilles tendinopathy with no paratendinous involvement and a well-defined nodular lesion less than 2.5 cm long, multiple percutaneous longitudinal tenotomies can be used when conservative management has failed. An ultrasound scan can be used to confirm the precise location of the area of tendinopathy.

In this chapter two techniques for the percutaneous management of Achilles tendinopathy are discussed [10, 20]. Although the techniques reported in this article are performed under local anesthesia, there is a small chance that general anesthesia may be necessary, and therefore baseline investigations such as blood tests, ECG and chest radiographs should be undertaken if deemed necessary. Patients should have DVT prophylaxis. Valid informed consent should be achieved prior

to the operation, and the patient should be aware of risks of infection, bleeding, wound and scar problems, operation failure, and that further surgery may be required.

### 6.3 Multiple Percutaneous Longitudinal Tenotomies

Patients are operated as day cases. The patient lies prone on the operating table with the feet protruding beyond the edge, and the ankles resting on a sandbag. A bloodless field is not necessary. The tendon is accurately palpated, and the area of maximum swelling and/or tenderness marked, and checked again by US scanning. The skin and the subcutaneous tissues over the Achilles tendon are infiltrated with 10–15 ml of plain 1 % lignocaine (Lignocaine Hydrochloride, Evans Medical Ltd, Leatherhead, England).

A number 11 surgical scalpel blade is inserted parallel to the long axis of the tendon fibers in the marked area(s) with the cutting edge pointing cranially. Keeping the blade still, a full passive ankle dorsi-flexion movement is produced. After reversing the position of the blade, a full passive ankle plantar-flexion movement is produced. A variable, but probably in the region of 3 cm long, area of tenolysis is thus obtained through a stab wound. The procedure is repeated 2 cm medial and proximally, medial and distally, lateral and proximally and lateral and distally to the site of the first stab wound. The five wounds are closed with steristrips, dressed with cotton swabs, and a few layers of cotton wool and a crepe bandage are applied.

### 6.4 Ultrasound Guided Percutaneous Tenotomy

Patients are operated as outpatients. The patient lies prone on the examination couch with the feet protruding beyond the edge, and the ankles resting on a sandbag. A bloodless



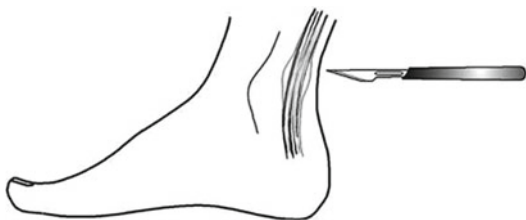

FIGURE 6.1 11-scalpel blade inserted into the predetermined area with sharp edge pointing caudally

field is not necessary. The tendon is accurately palpated, and the area of maximum swelling and/or tenderness marked, and checked by US scanning. The skin is prepped with an antiseptic solution, and a sterile longitudinal 7.5 MHz probe is used to image again the area of tendinopathy. Before infiltrating the skin and the subcutaneous tissues over the Achilles tendon with 10 ml of 1 % Carbocaina (Pierrel, Milan, Italy), 7 ml of 0.5 % Carbocaina are used to infiltrate the space between the tendon and the paratenon, to try and distend the paratenon and break the adhesences that may be present between the tendon and the paratenon.

Under US control, a number 11 surgical scalpel blade (Swann-Morton, England) is inserted parallel to the long axis of the tendon fibers in the centre of the area of tendinopathy, as assessed by high resolution US imaging (Fig. 6.1). The cutting edge of the blade points caudally, and penetrates the whole thickness of the tendon (Fig. 6.2a, b). Keeping the blade still, a full passive ankle flexion is produced (Fig. 6.3). The scalpel blade is then retracted to the surface of the tendon, inclined 45° on the sagittal axis, and the blade is inserted medially through the original tenotomy (Fig. 6.4). Keeping the blade still, a full passive ankle flexion is produced. The whole procedure is repeated inclining the blade 45° laterally to the original tenotomy, inserting it laterally through the original tenotomy (Fig. 6.4). Keeping the blade still, a full passive ankle flexion is produced. The blade is then partially retracted to the posterior surface of the Achilles tendon, reversed 180°, so that its cutting edge now points cranially,

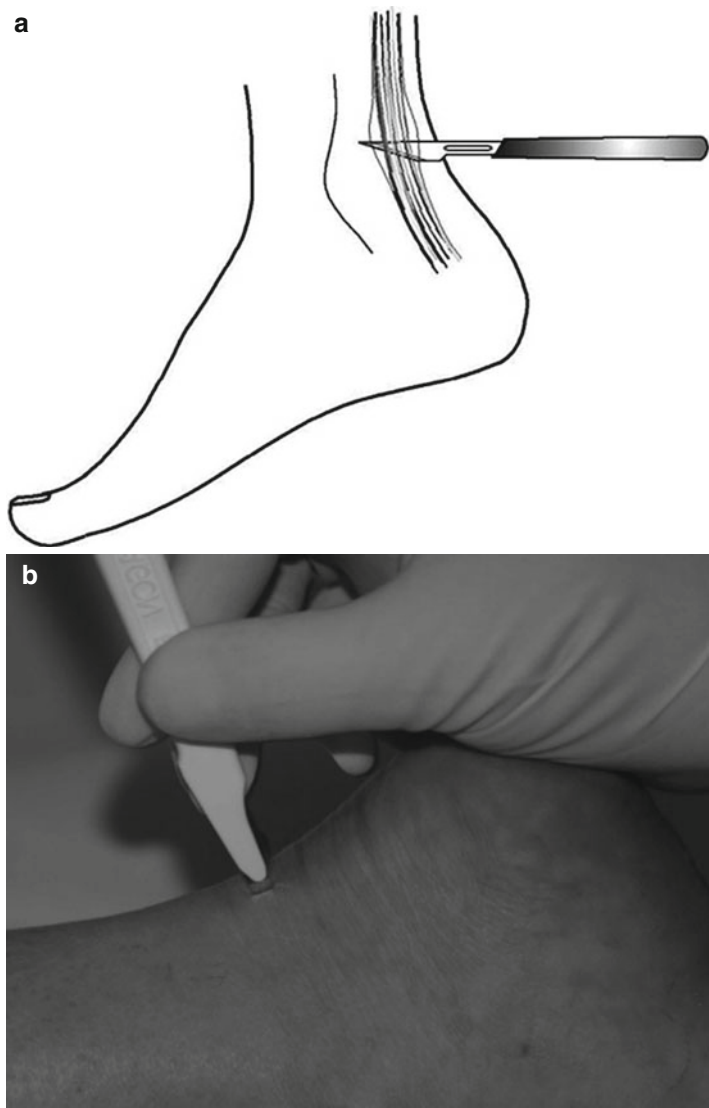
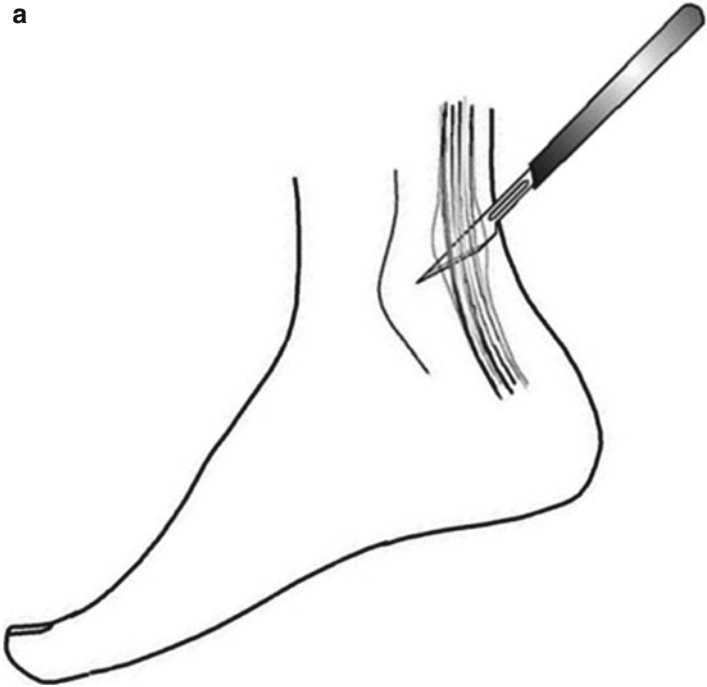


FIGURE 6.2 (a, b) The blade penetrating the whole thickness of the Achilles tendon

**a**



**b**

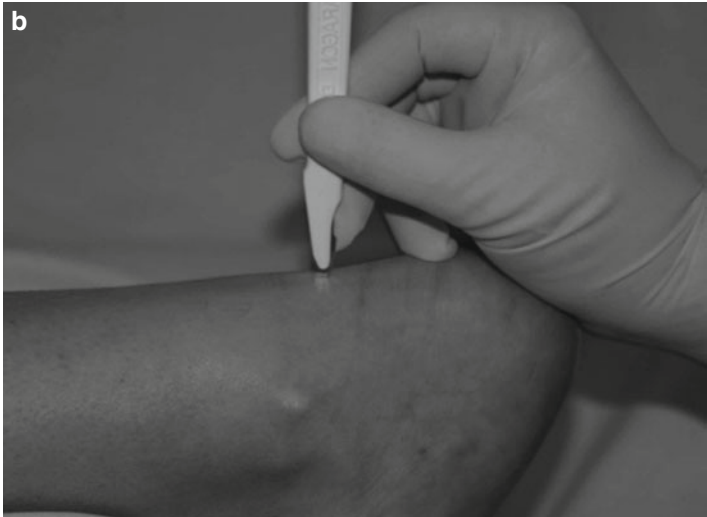
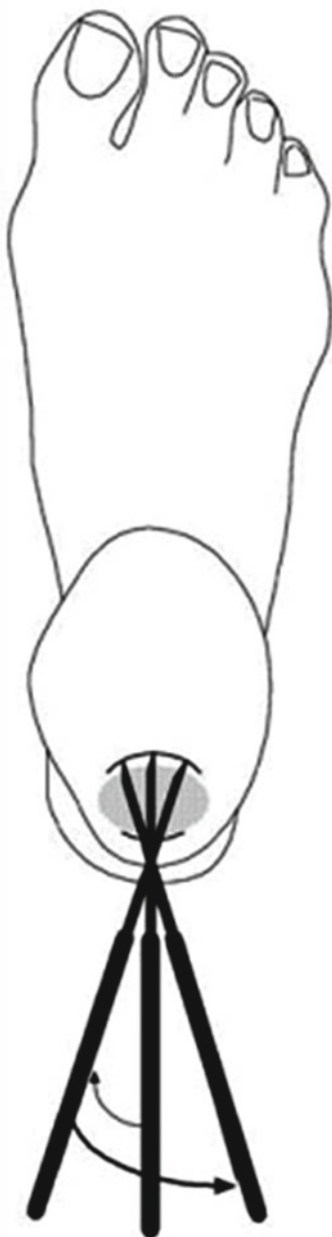

FIGURE 6.3 (a, b) Passive ankle flexion is produced

FIGURE 6.4 Procedure repeated with blade inclining the  $45^{\circ}$  medial and  $45^{\circ}$  lateral to the original tenotomy



and the whole procedure repeated, taking care to dorsiflex the ankle passively (Figs. 6.5a, b and 6.6a, b). Preliminary cadaveric studies showed that a tenotomy 2.8 cm long on average is thus obtained through a stab wound in the main body of the tendon [10]. A steristrip (3M United Kingdom PLC, Bracknell, Berkshire, England) can be applied on the stab wound, or the stab wound can be left open [9]. The wound is dressed with cotton swabs, and a few layers of cotton wool and a crepe bandage are applied.

## 6.5 Post-operative Management

On admission, patients are taught to perform isometric contractions of their triceps surae. Patients are instructed to perform the isometric strength training at three different angles, namely at maximum dorsi-flexion, maximum plantar flexion and at a point midway between the two.

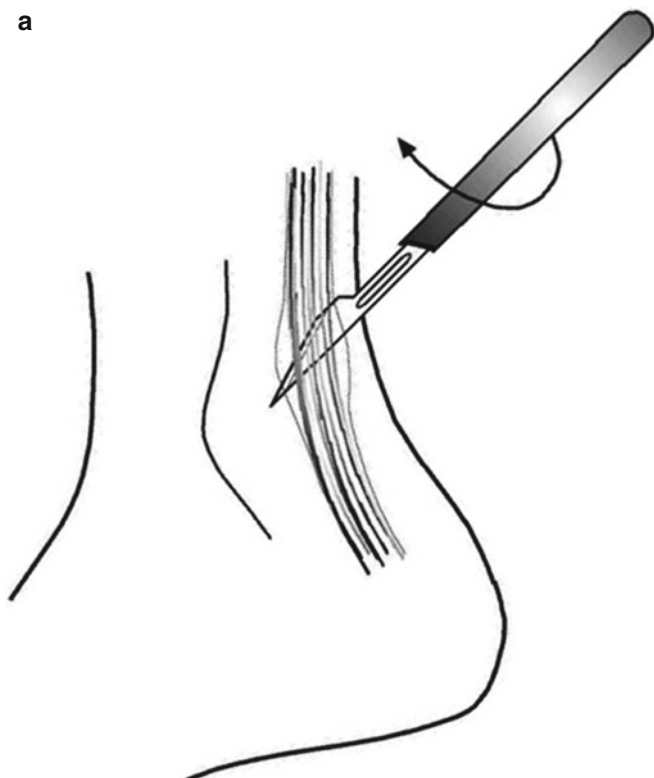
The foot is kept elevated on the first postoperative day, and non-steroidal anti-inflammatory medications are given for pain control. Early active dorsi- and plantar-flexion of the foot are encouraged [22]. On the second postoperative day, patient are allowed to walk using elbow crutches weight-bearing as able. Full weight-bearing was allowed after 2 or 3 days, when the bandage is reduced to a simple adhesive plaster over the wounds. Stationary bicycling and isometric, concentric and eccentric strengthening of the calf muscles are started under physiotherapy guidance after 4 weeks. Swimming and water running are encouraged from the second week. Gentle running is started 4–6 weeks after the procedure, and mileage gradually increased.

Patients normally discontinue physiotherapy by the sixth post-operative month.

## 6.6 Discussion

The management of Achilles tendinopathy aims to return the patient to a similar level of activity prior to acquiring tendinopathy in the shortest possible time without significant

**a**



**b**

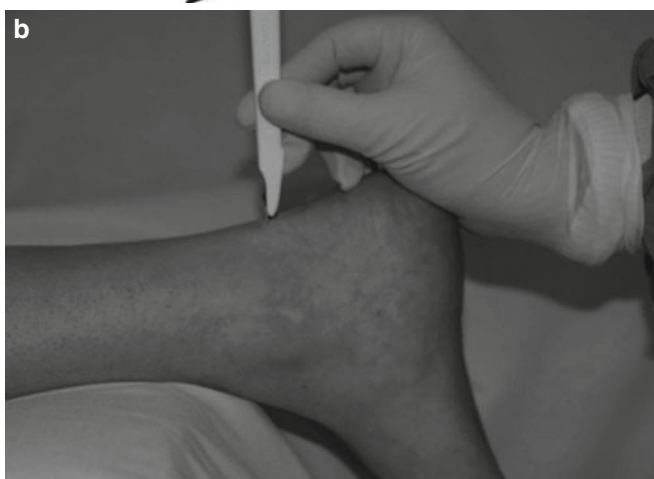


FIGURE 6.5 (a, b) The blade is reversed 180°

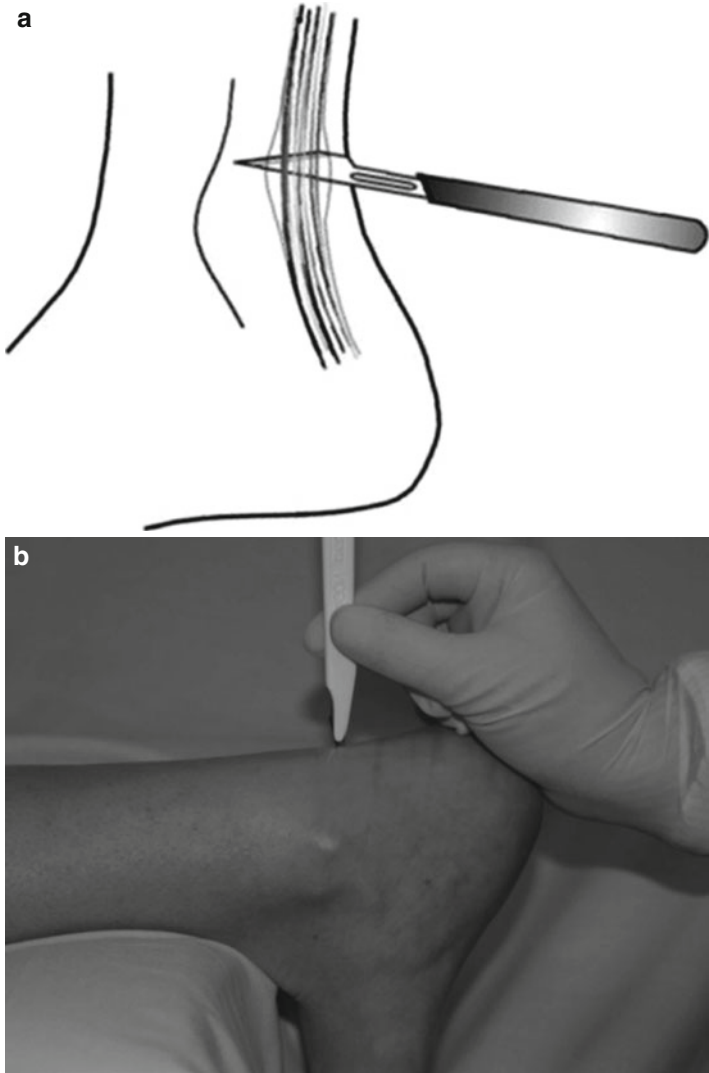


FIGURE 6.6 (a, b) The sequence of tenotomies repeated with ankle dorsiflexion and the 45° medial and 45° lateral inclination to the initial tenotomy

residual pain. Physiotherapy and conservative treatment should be the first form of management.

If conservative measures fail, percutaneous longitudinal tenotomy is simple, requires only local anesthesia, and can be performed without a tourniquet. If post-operative mobilization is carried out early, preventing the formation of adhesions, this will allow the return to high levels of activity in the majority.

## References

1. Astrom M. Partial rupture in chronic achilles tendinopathy. A retrospective analysis of 342 cases. *Acta Orthop Scand.* 1998;69:404–7.
2. James SL, Bates BT, Osternig LR. Injuries to runners. *Am J Sports Med.* 1978;6:40–50.
3. Kvist M. Achilles tendon injuries in athletes. *Sports Med.* 1994;18:173–201.
4. Leach RE, Schepsis AA, Takai H. Long-term results of surgical management of Achilles tendinitis in runners. *Clin Orthop Relat Res.* 1992;(282):208–12.
5. Leadbetter WB, Mooar PA, Lane GJ, et al. The surgical treatment of tendinitis. Clinical rationale and biologic basis. *Clin Sports Med.* 1992;11:679–712.
6. Leppilahti J, Orava S, Karpakka J, et al. Overuse injuries of the Achilles tendon. *Ann Chir Gynaecol.* 1991;80:202–7.
7. Ljungqvist R. Subcutaneous partial rupture of the Achilles tendon. *Acta Orthop Scand.* 1967;Suppl 113:1+.
8. Maffulli N, Khan KM, Puddu G. Overuse tendon conditions: time to change a confusing terminology. *Arthroscopy.* 1998;14:840–3.
9. Maffulli N, Pintore E, Petricciuolo F. Arthroscopy wounds: to suture or not to suture. *Acta Orthop Belg.* 1991;57:154–6.
10. Maffulli N, Testa V, Capasso G, et al. Results of percutaneous longitudinal tenotomy for Achilles tendinopathy in middle- and long-distance runners. *Am J Sports Med.* 1997;25:835–40.
11. Nelen G, Martens M, Burssens A. Surgical treatment of chronic Achilles tendinitis. *Am J Sports Med.* 1989;17:754–9.
12. Paavola M, Kannus P, Paakkala T, et al. Long-term prognosis of patients with achilles tendinopathy. An observational 8-year follow-up study. *Am J Sports Med.* 2000;28:634–42.
13. Rolf C, Movin T. Etiology, histopathology, and outcome of surgery in achillodynia. *Foot Ankle Int.* 1997;18:565–9.
14. Rovere GD, Webb LX, Gristina AG, et al. Musculoskeletal injuries in theatrical dance students. *Am J Sports Med.* 1983;11:195–8.



15. Schepsis AA, Leach RE. Surgical management of Achilles tendinitis. *Am J Sports Med.* 1987;15:308–15.
16. Subotnick SI, Sisney P. Treatment of Achilles tendinopathy in the athlete. *J Am Podiatr Med Assoc.* 1986;76:552–7.
17. Teitz CC, Garrett Jr WE, Miniaci A, et al. Tendon problems in athletic individuals. *Instr Course Lect.* 1997;46:569–82.
18. Testa V, Capasso G, Maffulli N, et al. Ultrasound-guided percutaneous longitudinal tenotomy for the management of patellar tendinopathy. *Med Sci Sports Exerc.* 1999;31:1509–15.
19. Testa V, Capasso G, Benazzo F, et al. Management of Achilles tendinopathy by ultrasound-guided percutaneous tenotomy. *Med Sci Sports Exerc.* 2002;34:273–80.
20. Testa V, Maffulli N, Capasso G, et al. Percutaneous longitudinal tenotomy in chronic Achilles tendonitis. *Bull Hosp Joint Dis.* 1996;54:241–4.
21. Williams JG. Achilles tendon lesions in sport. *Sports Med.* 1986;3:114–35.
22. Williams JG, Sperryn PN, Boardman S, et al. Post-operative management of chronic achilles tendon pain in sportsmen. *Physiotherapy.* 1976;62:256–9.
23. Winge S, Jorgensen U, Lassen Nielsen A. Epidemiology of injuries in Danish championship tennis. *Int J Sports Med.* 1989;10:368–71.

# Chapter 7

## Minimally Invasive Stripping for Chronic Achilles Tendinopathy

**Nicola Maffulli, Umile Giuseppe Longo,  
Chandrasekar Ramamurthy, and Vincenzo Denaro**

### 7.1 Introduction

The etiology of pain in Achilles tendinopathy is widely debated, with recent evidence that neo-vascularization and neo-innervation may be responsible [2, 4, 5, 9, 11, 13, 16]. Neo-vascularization is often present in patients with tendinopathy, and the area in which patients perceive most pain correlates with the area

---

N. Maffulli (✉)

Department of Trauma and Orthopaedic Surgery,  
Keele University School of Medicine, University Hospital  
of North Staffordshire, Stoke on Trent ST4 7LN, UK

Centre for Sports and Exercise Medicine, Barts and The London  
School of Medicine and Dentistry, Mile End Hospital, Queen Mary  
University of London, 275 Bancroft Road, London E1 4DG, UK  
e-mail: n.maffulli@keele.ac.uk

U.G. Longo • V. Denaro

Department of Orthopaedic and Trauma Surgery, Campus Biomedico  
University, Via Longoni, 83, Rome 00155, Italy

C. Ramamurthy

Department of Trauma and Orthopaedic Surgery,  
Keele University School of Medicine, University Hospital  
of North Staffordshire, Stoke on Trent ST4 7LN, UK

where most neo-vascularization occurs on power Doppler ultrasound scan (US) [16].

During eccentric calf-muscle contraction, the flow in the neovessels disappears on ankle dorsiflexion [2]. The good clinical effects with eccentric training may result from the interference on the neovessels and accompanying nerves. Also, local anaesthetic injected in the area of neovascularisation outside the tendon resulted in a pain-free tendon, indicating that this area is involved in pain generation [2, 17].

A pilot study injecting a commercially available sclerosing agent into and around the neo-vessels [2, 15] significantly reduced pain in eight of ten patients. A similar study of patellar tendinopathy, which has a similar histological picture to Achilles tendinopathy, gave equally encouraging results [1, 3].

Recently, the same group has developed an arthroscopic approach to this issue. They proposed arthroscopic shaving of the area with neovessels and nerves on the posterior aspect of the patellar tendon in patients with patellar tendinopathy [19].

In this chapter we describe a minimal invasive technique of stripping of neovessels from the Kager's triangle of the AT is performed. This achieves safe and secure breaking of neo-vessels and the accompanying nerve supply.

## 7.2 Surgical Technique

The patient undergoes local or general anesthesia, according to surgeon or patient preferences. The patient is positioned prone with a calf tourniquet which is inflated to 250 mmHg after exsanguination. Skin preparation is performed in the usual fashion.

Four skin incisions are made. The first two incisions are 0.5 cm longitudinal incisions at the proximal origin of the Achilles tendon, just medial and lateral to the origin of the tendon. The other two incisions are also 0.5 cm long and longitudinal, but 1 cm distal to the distal end of the tendon insertion on the calcaneus.

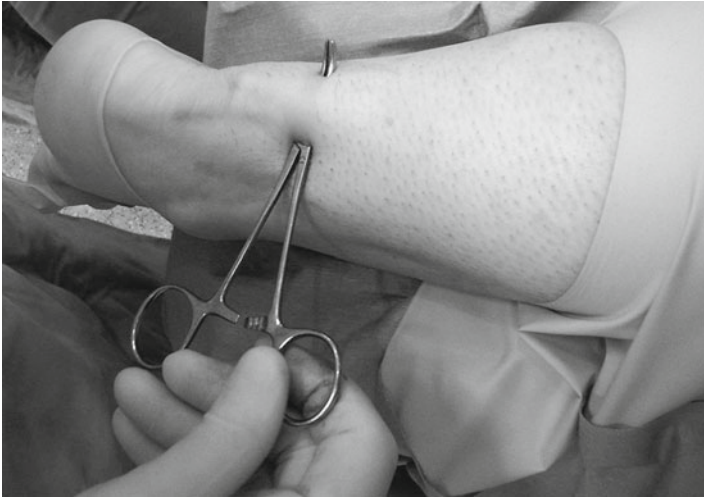

FIGURE 7.1 A mosquito is inserted in the proximal incisions

A mosquito is inserted in the proximal incisions (Fig. 7.1), and the Achilles tendon is freed of the peritendinous adhesions. A Number 1 unmounted Ethibond (Ethicon, Somerville, NJ) suture thread is inserted proximally, passing through the two proximal incision (Fig. 7.2). The Ethibond is retrieved from the distal incisions (Fig. 7.3), over the posterior aspect of the Achilles tendon. Using a gentle see-saw motion, similar to using a Gigli saw, the Ethibond suture thread is made to slide posterior to the tendon (Fig. 7.4), which is stripped and freed from the fat of Kager's triangle.

The procedure is repeated for the posterior aspect of the Achilles tendon.

If necessary, using an 11 blade, longitudinal percutaneous tenotomies parallel to the tendon fibers are made [10, 14, 18].

The subcutaneous and subcuticular tissues are closed in a routine fashion, and Mepore (Molnlycke Health Care, Gothenburg, Sweden) dressings are applied to the skin.

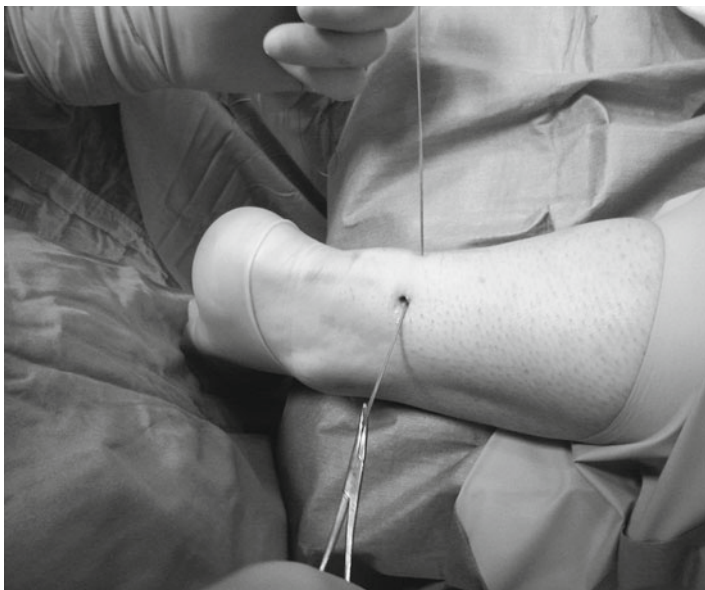

FIGURE 7.2 A Number 1 Ethibond (Ethicon, Somerville, NJ) is inserted proximally, passing through the two proximal incision over the anterior aspect of the Achilles tendon

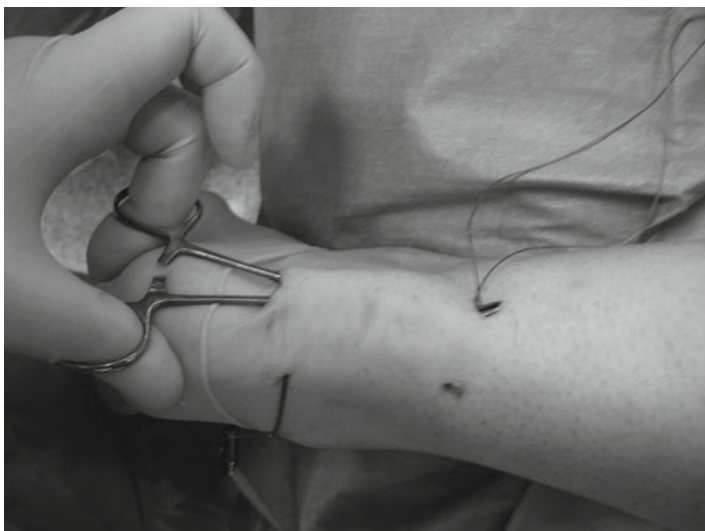


FIGURE 7.3 The Ethibond is retrieved from the distal incisions

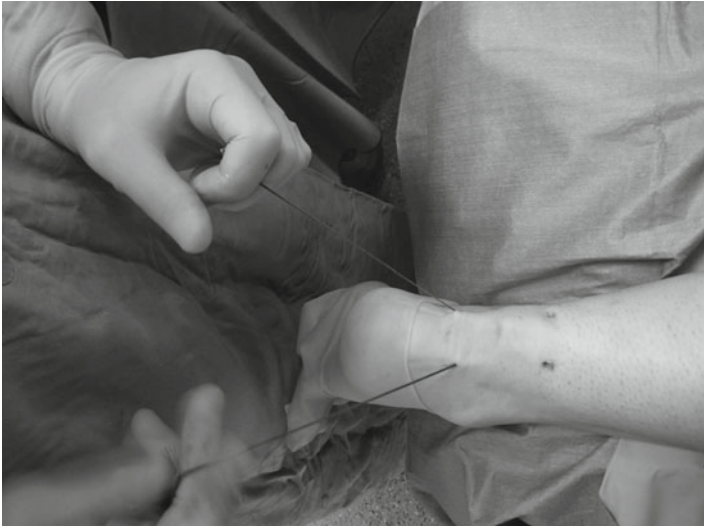

FIGURE 7.4 The Ethibond is slid over the anterior aspect of the Achilles tendon with a gentle see-saw motion. The whole process is repeated over the posterior aspect of the tendon

A removable scotch cast support with Velcro straps can be applied if deemed necessary.

### 7.3 Postoperative Regimen

Post-operatively, patients are allowed to mobilize fully weight bearing. After 2 weeks, the cast, if used is removed, and physiotherapy is commenced, focusing on proprioception, plantar-flexion of the ankle, inversion and eversion.

### 7.4 Discussion

The source of pain and the background to the pain mechanisms associated with chronic AT have not been scientifically clarified [9].

In ATs with chronic painful tendinopathy, but not in normal pain-free tendons, there is neovascularization outside and inside the ventral part of the tendinopathic area [1, 2, 9, 11, 13].

The pathogenetic significance of the neovascularisation is unknown, but several theories can be proposed. The increased vascularization often seen in biopsies from patients with AT who underwent surgery is a part of a reparative response in the tendon [7, 11, 12]. Reparative processes associated with neovascularisation are probably inadequate [1, 2].

Surgery should be offered to patients with chronic recalcitrant tendinopathy [8].

The percentage of patients requiring surgery is around 25 % [6], depending on poorly understood biochemical and molecular events leading to AT [9]. Surgery is successful in up to 85 % of patients [7], even though postoperative ultrasound examination often shows a widened tendon with hypo-echoic areas. This has led to hypotheses of a possible denervation of the tendon as one of the explanations to the frequently favorable effect of surgery [7].

The rationale behind this technique is that the sliding of the Ethibond breaks the neo-vessels and the accompanying nerve supply, therefore decreasing the pain in patients with chronic Achilles tendinopathy.

Classically, open surgery for midsubstance tendinopathy of the AT has provided good results [9]. However, wound complications can occur with these procedures [9]. One possible advantage of this minimal invasive technique could be reduction of infection risks. It is, furthermore, technically easy to master, and inexpensive. It may provide greater potential for the management of recalcitrant AT by breaking neo-vessels and the accompanying nerve supply to the tendon. It can be associated with other minimally invasive procedures to optimize results.

## References

1. Alfredson H, Ohberg L. Neovascularisation in chronic painful patellar tendinosis – promising results after sclerosing neovessels outside the tendon challenge the need for surgery. *Knee Surg Sports Traumatol Arthrosc.* 2005;13:74–80.
2. Alfredson H, Ohberg L, Forsgren S. Is vasculo-neural ingrowth the cause of pain in chronic Achilles tendinosis? An investigation using

- ultrasonography and colour Doppler, immunohistochemistry, and diagnostic injections. *Knee Surg Sports Traumatol Arthrosc.* 2003; 11:334–8.
3. Kannus P. Structure of the tendon connective tissue. *Scand J Med Sci Sports.* 2000;10:312–20.
  4. Knobloch K, Kraemer R, Lichtenberg A, et al. Achilles tendon and paratendon microcirculation in midportion and insertional tendinopathy in athletes. *Am J Sports Med.* 2006;34:92–7.
  5. Kristoffersen M, Ohberg L, Johnston C, et al. Neovascularisation in chronic tendon injuries detected with colour Doppler ultrasound in horse and man: implications for research and treatment. *Knee Surg Sports Traumatol Arthrosc.* 2005;13:505–8.
  6. Kvist M. Achilles tendon injuries in athletes. *Ann Chir Gynaecol.* 1991;80:188–201.
  7. Maffulli N, Kader D. Tendinopathy of tendo Achillis. *J Bone Joint Surg Br.* 2002;84:1–8.
  8. Maffulli N, Kenward MG, Testa V, et al. Clinical diagnosis of Achilles tendinopathy with tendinosis. *Clin J Sport Med.* 2003;13:11–5.
  9. Maffulli N, Sharma P, Luscombe KL. Achilles tendinopathy: aetiology and management. *J R Soc Med.* 2004;97:472–6.
  10. Maffulli N, Testa V, Capasso G, et al. Results of percutaneous longitudinal tenotomy for Achilles tendinopathy in middle- and long-distance runners. *Am J Sports Med.* 1997;25:835–40.
  11. Maffulli N, Testa V, Capasso G, et al. Similar histopathological picture in males with Achilles and patellar tendinopathy. *Med Sci Sports Exerc.* 2004;36:1470–5.
  12. Maffulli N, Testa V, Capasso G, et al. Surgery for chronic Achilles tendinopathy yields worse results in nonathletic patients. *Clin J Sport Med.* 2006;16:123–8.
  13. Maffulli N, Wong J, Almekinders LC. Types and epidemiology of tendinopathy. *Clin Sports Med.* 2003;22:675–92.
  14. Maffulli NA, Almekinders LC. The Achilles tendon. New York: Springer; 2007. p. 83–92.
  15. Ohberg L, Alfredson H. Ultrasound guided sclerosis of neovessels in painful chronic Achilles tendinosis: pilot study of a new treatment. *Br J Sports Med.* 2002;36:173–5; discussion 6–7.
  16. Ohberg L, Lorentzon R, Alfredson H. Neovascularisation in Achilles tendons with painful tendinosis but not in normal tendons: an ultrasonographic investigation. *Knee Surg Sports Traumatol Arthrosc.* 2001;9:233–8.
  17. Sayana MK, Maffulli N. Eccentric calf muscle training in non-athletic patients with Achilles tendinopathy. *J Sci Med Sport.* 2007;10:52–8.
  18. Testa V, Capasso G, Benazzo F, et al. Management of Achilles tendinopathy by ultrasound-guided percutaneous tenotomy. *Med Sci Sports Exerc.* 2002;34:573–80.
  19. Willberg L, Sunding K, Ohberg L, et al. Treatment of Jumper's knee: promising short-term results in a pilot study using a new arthroscopic approach based on imaging findings. *Knee Surg Sports Traumatol Arthrosc.* 2007;15:676–81.



# Index

## A

- Achilles tendon (AT) repair
  - adhesions, 2
  - advantages, 2
  - arthroscope placement, distal
    - medial incision, 5
  - bilaterally operated patient, AT rupture, 11
  - cast immobilization, 2
  - description, 1–2
  - direct visualization, 10
  - disadvantages, 10
  - dorsi-and plantar-flex the ankle,
    - knee at 90° of flexion, 6–7
  - dorsiflexion, healthy side, 2, 3
  - early weight-bearing and ambulation, 11–12
  - endoscopy technique, 1–2
  - final stab wound closure with steristrips, 7, 8
  - immobilization and functional postoperative treatment, 10
  - isometric, eccentric and concentric exercises, 8
  - local anaesthetic injection,
    - subcutaneous tissues, 3, 4
  - patient's activities, 9
  - PDS/Ethibond suture,
    - upper medial portal, 5–6
  - physiotherapy, 7–8
  - rehabilitation progress, 9
  - repetitive motion *in vitro*, 10
  - ruptured tendon ends palpation,
    - arthroscopic probe, 2, 4
    - suture passage, 7
    - sutures tied, neutral position, 6–7
- Acute AT ruptures
  - age and gender-matched control subjects, 22
  - cadaveric specimens, 20
  - calf squeeze and Matles test, 16
  - 9 cm Mayo needle threading, 17
  - complications, AT rupture, 20
  - description, AT, 15
  - distal stabs incisions, double loop
    - of Maxon passage, 18–19
  - Fibrin glue, 20
  - foot vs. resistance, males, 16
  - intermediate superficial and deep wound infections, 21
  - Kessler method, 19
  - pain and/or weakness, limbs, 16
  - percutaneous technique, AT rupture, 19
  - post-operative complications, 20
  - postoperative regimen, 19
  - risk, hematoma formation, 21
  - rupture and repair, 21
  - stab incisions and tendon crisscrossing, 19

Acute AT ruptures (*cont.*)

- subcuticular Biosyn suture 3.0, 18
- wound healing problems, 16, 22

Aircast boot with heel wedges, 50

**C**

Calf squeeze test, 16

Carbocaina, 59

Careful incision placement, 33

Cast immobilization, 2

Chronic Achilles tendinopathy. *See*  
Percutaneous longitudinal  
tenotomies

Chronic avulsions, invasive

reconstruction

advantages, 51

careful incision placement, 51

description, 45

double-looped semitendinosus  
tendon graft, 47, 48hamstrings tendon transfer and  
screw fixation, 46

iatrogenic disruption,

subcutaneous tissues and  
paratenon, 46

insertion, bioabsorbable

interference screw, 50

para-midline and one distal

Cincinnati incision, 46–47

postoperative regimen, 50–51

pre-operative anatomical markings,  
skin, 47proximal and distal Achilles tendon  
stumps, 47semitendinosus tendon, proximal  
stump and calcaneus tunnel,  
47–49

skin integrity and AT

construction, 51

transcalcaneal suture technique, 46  
in vasculopathy and diabetic  
patients, 51–52

wire passed through tunnel, 47, 48

wound breakdown risk, 46, 51

Cincinnati incision, 46, 47

**E**

Ethibonds

description, 71

gentle see-saw motion, 71, 73

insertion, 71, 72

neo-vessels breakage, 74

retrieval, distal incisions, 71, 72

**F**

Fibrin glue, 20

**H**

Hemostasis, 57

**K**

Kessler method, 19

**M**

Matles test, 16

Minimally invasive peroneus brevis

tendon graft

advantages, 42

and AT, clip, 39, 40

careful incision placement, 43

chronic tear, 36

description, 35

distal Achilles tendon stump, 37

distal wound, 39, 40

gastro-soleus AT complex, 42

harvesting, 39

postoperative management, 41–42

pre-operative anatomical markings,  
skin, 36

proximal tendon, 37–38

reconstruction, AT, 36

stages, skin incisions, 36–37

sural nerve injury, 42

transverse tenotomy, 41

Vicryl locking suture, 38

wound complications, 36

Multiple percutaneous longitudinal  
tenotomies, 58

**N**

- Neo-vascularization
  - power Doppler ultrasound scan, 69–70
  - tendinopathy, patients, 69

**P**

- Para-midline incision, 46
- Paratendinopathy management, 57
- Percutaneous longitudinal tenotomies
  - athletic tendinopathy, 55
  - blood tests, ECG and chest radiographs, 57
  - continuous prolonged intense functional demand, 56
  - DVT prophylaxis, 57
  - fibrotic adhesions, 56
  - hemostasis, 57
  - history, examination and diagnosis, 56
  - multiple (*see* Multiple percutaneous longitudinal tenotomies)
  - pain, calf and ankle, 56
  - paratendinopathy management, 57
  - paratenon and crural fascia, 57
  - post-operative management, 63
  - post-operative mobilization, 66
  - ultrasound guided (*see* Ultrasound guided percutaneous tenotomy)
  - ultrasound scan, 57
- Peroneus brevis tendon graft
  - advantages, 32
  - careful incision placement, 33
  - closed wounds, 29, 31
  - description, 25
  - harvested, vertical, 2.5–3 cm longitudinal incision, 28, 29
  - incisions, 26
  - locking suture, bundles separation, 27, 28
  - longitudinal and medial incisions, 27
  - medial to lateral, transverse tenotomy, 28, 30
  - one extremity passed, transverse tenotomy, 29, 31

- postoperative management, 31–32
- pre-operative anatomical markings, 26
- proximal stump,
  - Achilles tendon, 28, 30
  - proximal tendon, 28
  - reconstruction, Achilles tendon, 26
- vasculopath and diabetics, 33
- Vicryl locking suture, 28
- Pre-operative anatomical markings,
  - skin, 26, 36, 47

**S**

- Semitendinosus tendon
  - calcaneus tunnel, 48, 49
  - cannulated headed reamer, 47, 48
  - proximal stump, AT, 47, 49
  - skin integrity preservation, 51
- Stripping, chronic AT
  - arthroscopic approach, 70
  - eccentric calf-muscle contraction, 70
  - Ethibonds, 71–73
  - etiology, pain, 69
  - Kager's triangle, AT, 70
  - mosquito, proximal incisions, 71
  - neo-vascularization, 69–70
  - pathogenetic significance, neovascularisation, 74
  - postoperative regimen, 73
  - preparation and incisions, skin, 70
  - reparative process, 74
  - subcutaneous and subcuticular tissues, 71
  - Velcro straps, 73
  - wound complications, 74
- Subcuticular Biosyn suture 3.0, 18
- Sural nerve injury, 42

**T**

- The Maffulli procedure. *See* Acute Achilles tendon ruptures
- Transcalcaneal suture technique, 46
- Transverse tenotomy, 41

**U**

Ultrasound guided percutaneous tenotomy  
ankle dorsiflexion, 45° medial and 45° lateral inclination, 63, 64  
blade inclining, 45° medial and 45° lateral, 59, 62  
blade penetration, Achilles tendon, 59, 60  
Carbocaina, 59  
outpatients, 58  
passive ankle flexion, 59, 61

reversed 180°, blade, 63, 64  
11-scalpel blade insertion, sharp edge pointing caudally, 59

**V**

Velcro straps, 73  
Vicryl locking suture, 28, 38

**W**

Wound healing problems, 16, 22